48

I

JOURNAL OF ANATOMY

CAMBRIDGE UNIVERSITY PRESS
C. F. CLAY, Manager
LONDON: FETTER LANE, E.C. 4

H. K. LEWIS & CO., LTD., 136, GOWER STREET, LONDON, W.C. 1
CHICAGO: THE UNIVERSITY OF CHICAGO PRESS
(AGENT FOR THE UNITED STATES AND CANADA)
BOMBAY, CALCUTTA, MADRAS: MACMILLAN & CO., LTD.
TOKYO: THE MARUZEN-KABUSHIKI-KAISHA

JOURNAL OF ANATOMY

ORIGINALLY THE JOURNAL OF ANATOMY AND PHYSIOLOGY

CONDUCTED ON BEHALF OF THE ANATOMICAL SOCIETY
OF GREAT BRITAIN AND IRELAND BY

PROFESSOR EDWARD FAWCETT UNIVERSITY OF BRISTOL
PROFESSOR J. P. HILL UNIVERSITY OF LONDON
PROFESSOR ARTHUR ROBINSON UNIVERSITY OF EDINBURGH
PROFESSOR G. ELLIOT SMITH UNIVERSITY OF LONDON
PROFESSOR ARTHUR KEITH ROYAL COLLEGE OF SURGEONS
LINCOLN'S-INN-FIELDS, LONDON, W.C. 2

VOLUME LV

OCTOBER 1920—JULY 1921

CAMBRIDGE
AT THE UNIVERSITY PRESS
1921

CONTENTS

FIRST PART—OCTOBER, 1920

PAGE

A Contribution to the Morphology of the Corpus Striatum. By Raymond A. Dart . . . 1

The Basal Arteries of the Forebrain and their functional significance. By Joseph L. Shellshear . . . 27

Fusion-lines of Bones. By Zachary Cope . . . 36

Note on the Vertebral Epiphyseal Discs. By Prof. A. Francis Dixon . 38

On the Pacchionian Bodies. By W. E. Le Gros Clark, F.R.C.S. (Eng.) 40

Note on the Lachrymal Gland of the Hedgehog. By E. W. Hurst, B.Sc. 49

The Exact Distribution of the Gastric Glands in Man and in Certain Animals. By Y. Miyagawa, M.D. . . . 56

Parthenogenesis in the Water Vole, *Microtus amphibius*. By G. S. Sansom, B.Sc. . . . 68

Reviews. Selected Lectures and Essays (including Ligaments, their Nature and Morphology). Sir John Bland-Sutton. 4th edition, 1920 . . . 78

The Principles of Anatomy as seen in the Hand. Frederic Wood Jones, D.Sc., M.B. . . . 78

The X-Ray Atlas of the Systemic Arteries of the Body. H. C. Orrin, O.B.E., F.R.C.S. (Edin.) . . . 78

SECOND AND THIRD PARTS—JANUARY AND APRIL, 1921

The Distribution of Nerves in the Upper Limb, with reference to Variabilities and their Clinical Significance. By Eric A. Linell, M.D. (Manch.) . . . 79

On the Development of the Fissural and Associated Regions in the Eye of the Chick, with some Observations on the Mammal. By I. C. Mann, M.B., B.S. . . . 113

The Evolution of the Vertebrate Endoskeleton. An Essay on the Significance and Meaning of Segmentation in Coelomate Animals. By W. B. Primrose, M.B., Ch.B. . . . 119

Odontological Essays. By L. Bolk, M.D. . . . 138

The Primordial Cranium of *Tatusia novemcincta* as Determined by Sections and Models of the Embryos of 12 millimetre and 17 millimetre c.r. Length. By Prof. Fawcett, M.D. (Edin.) . . . 187

FOURTH PART—JULY, 1921

PAGE

Odontological Essays. By L. Bolk, M.D. 219

On Rarer Ossifications seen during X-Ray examinations. By Chas. Thurstan Holland 235

Tactile Localisation. By John S. B. Stopford, M.D. 249

On Sesamoid and Supernumerary Bones of the Limbs. By A. H. Bizarro, F.R.C.S. (Eng.). 256

The Auriculo-Ventricular Bundle in Mammals. By A. Hillyard Holmes, M.D., M.R.C.P. 269

Bifurcate Clavicle. By Henry Rutherfurd, M.B., C.M. 286

Abnormal Disposition of the Intestinal Tract. By N. Pan 288

The Superior Olive in Ornithorhynchus. By Marion Hines, Ph.D. . 290

The Embryonic Cerebral Hemisphere in Man. By Marion Hines, Ph.D. 292

Index 298

JOURNAL OF ANATOMY

A CONTRIBUTION TO THE MORPHOLOGY OF THE CORPUS STRIATUM

By RAYMOND A. DART,
Demonstrator of Anatomy, University College, London

INTRODUCTION

For a recapitulation of the essential features in the divergent conclusions of investigators who have studied this problem, we are indebted to the recent paper by Elliot Smith ('20) in which he pointed out the nature of the corpus striatum in *Sphenodon*, and indicated the morphological relationships of its several parts.

For some time past I have been studying a series of sections of the brain of the highly specialised Marsupial Mole, *Notoryctes typhlops*, which was very kindly placed at my disposal by Prof. Elliot Smith. As might be anticipated, in this creature devoid of any visual apparatus, the olfactory and closely associated striatal areas play a dominant rôle in its cerebral constitution—features already described by Elliot Smith in his communication to the Royal Society of South Australia ('95). In attempting to elucidate the significance of these structures I have investigated more primitive forms in the biological series; and I have to acknowledge the generosity of Professors A. Dendy of King's College and J. P. Hill of University College for the free access to their important collections, which has made possible an extensive comparative study. It is primarily for the purpose of abbreviating the account of the brain of *Notoryctes* that this preliminary note upon the striatal region is submitted; but the problem of the evolution of the corpus striatum is sufficiently important to call for this separate treatment.

If a transverse section of the brain of *Notoryctes* be studied in the region of the anterior commissure and foramen of Monro (e.g. A. 2. 7. of this series) (fig. 1), the pallial formation is recognisable as a continuous cell layer from the region of the fascia dentata and hippocampus dorso-medially, to the upturned lateral margin of the pyriform lobe ventro-laterally. Medial to this point (where the pyriform area is turned up to become continuous, through a scattered cell zone, with the denser structure of the claustral area lateral to the corona radiata) there are to be seen in section remnants of the lenticulo-striate artery (claustral artery of Shellshear, '20) whose significance as a guide to the morphology in this region has been indicated by Elliot Smith ('19). Medial to this vessel are to be seen the "scattered islands of Calleja" which constitute the "cortical" formation known as the tuberculum olfactorium. Medially this formation becomes continuous without any sharp break with the grey matter of the hypothalamic region—the constricting influence of the optic tract in strongly separating these two formations being absent in this brain.

It is important to recognise that the tuberculum olfactorium is a cap-like structure surrounding the enormously expanded striatal region ventrally. Laterally this close relationship of Calleja's "islands" to the corpus striatum is preserved into the depth of the section as far as the anterior commissure, and indeed actual remnants of the tubercular cortex appear to be intermingled with the commissure itself. Certainly islets are to be observed deep to the lateral part of the claustral region and the upturned part of the pyriform lobe and the associated lenticulo-striate artery.

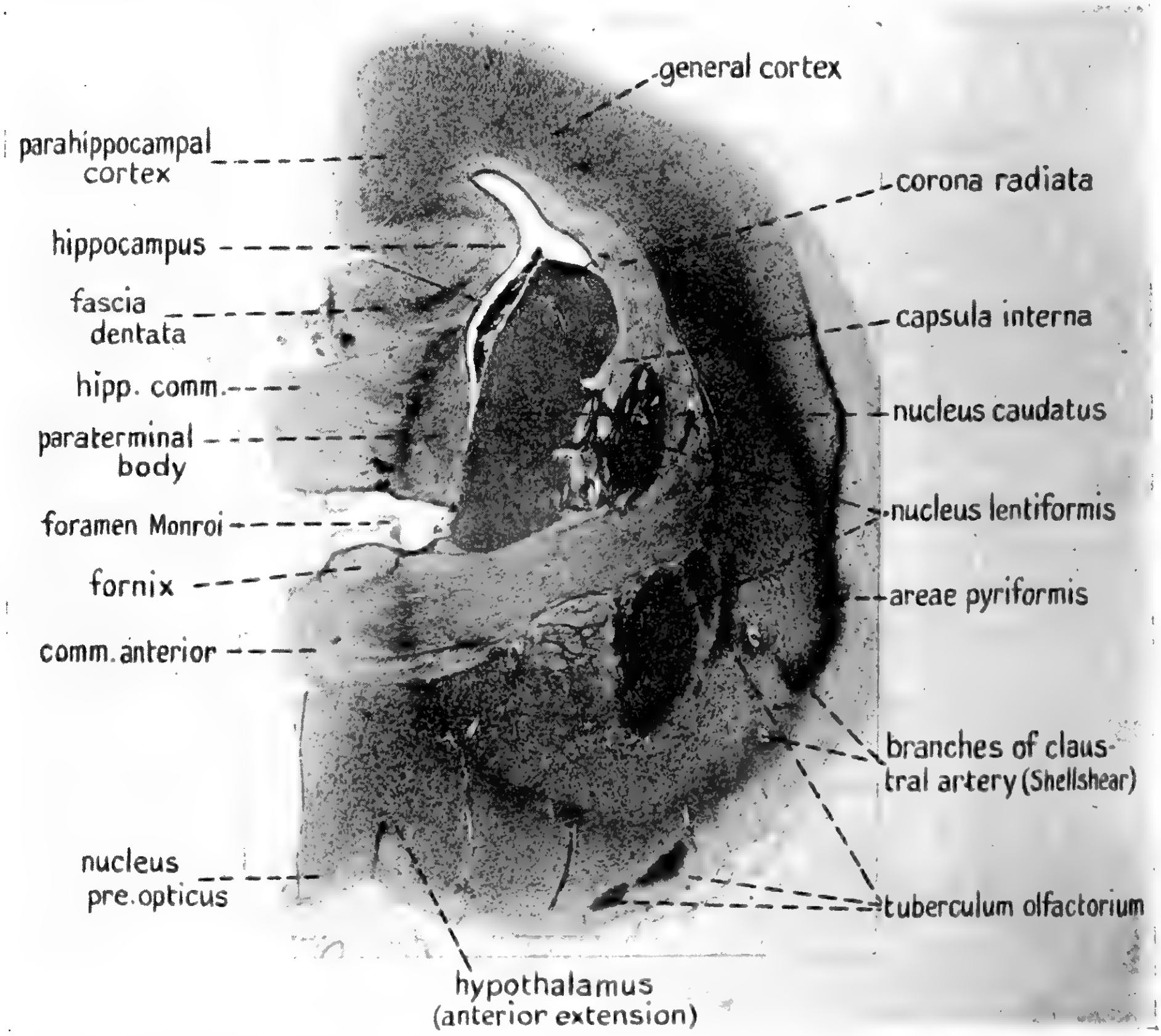

Fig. 1. Transverse section of cerebrum of *Notoryctes typhlops* (A. 2. 7. of this series) to show the scattered islands of Calleja and the lateral relationships of the tuberculum olfactorium.

Ramon y Cajal (*Histologie du Système Nerveux*, tome II, 1911, p. 730) has remarked concerning this region: "Son aspect varie beaucoup avec l'orientation et la place des coupes ainsi qu'avec l'espèce animale. Cet amas atteint ses plus grandes dimensions chez le chien, chez lui ses bords plongent jusque dans les couches profondes et projettes des cordons et des bandelettes ramifiées et anastomosées." Hence it is not to be wondered at if in a creature much more dependent for its livelihood upon its sense of smell than is the dog, an even more remarkable development of this component should be present.

Sagittal sections corroborate these observations concerning an apparently "inrolled" tubercular cortex: figs. 2 and 2 *a* (representing Section V. 2. 5. of this series) portray the same facts, viz., a pyriform cortex turned in above a lenticulo-striate artery to become continuous with the claustrum, while below the artery the tubercular cortex is continued in its characteristic interrupted fashion till it meets the corona radiata and the anterior commissure.

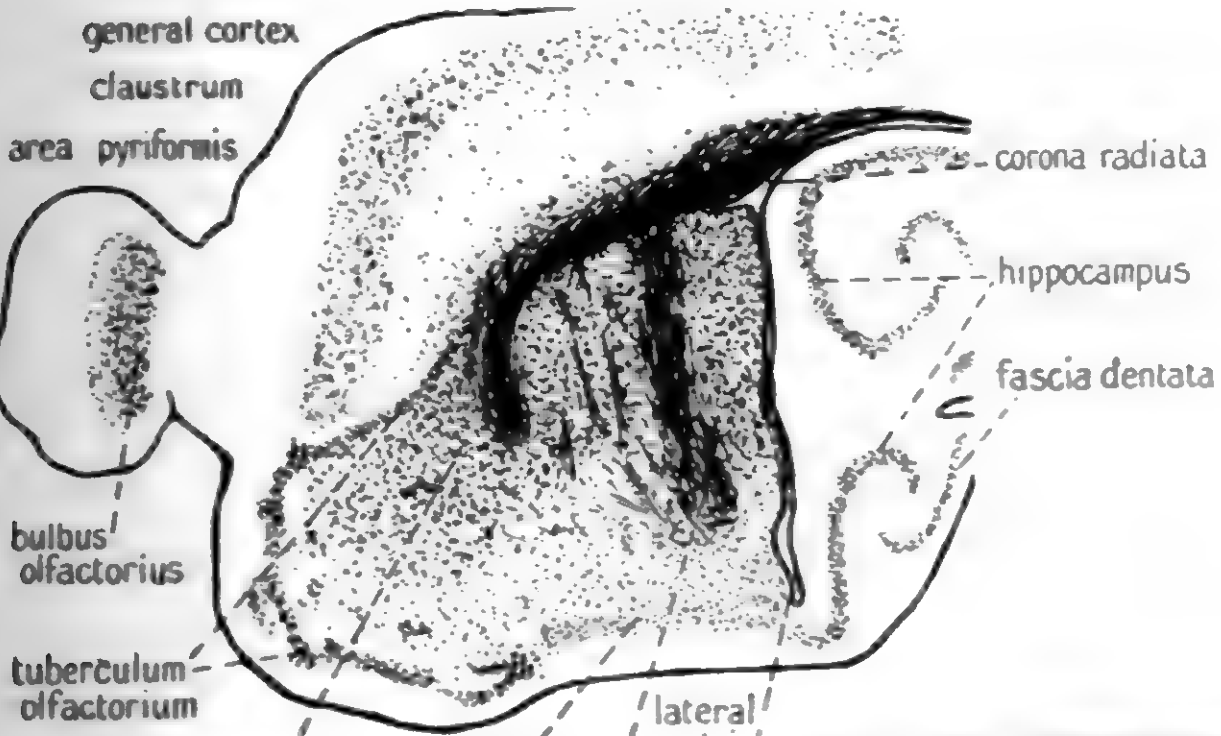

Fig. 2.

Figs. 2 and 2 *a*. Sagittal section of cerebrum of *Notoryctes* (Section V. 2. 5. of this series) to illustrate "embracing" relationship of the tuberculum olfactorium to the corpus striatum, and the continuous "cortical cap" of this body.

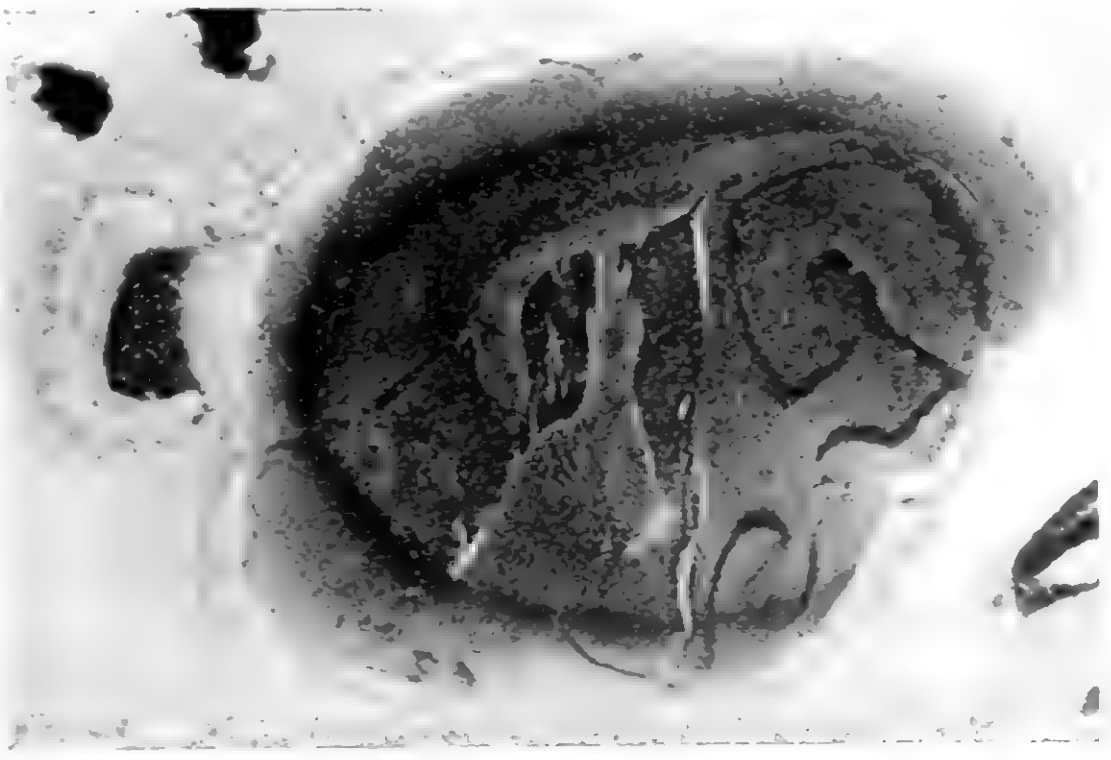

Fig. 2 *a*.

Not every section illustrates these phylogenetic vestiges so diagrammatically as the two to which reference has been made; but despite the disturbing factors which have influenced the structure of this lowly Metatherian brain, a clear conception can be adduced of the primitive anatomical relationships of the region.

It is definite then that both ventrally, laterally, and anteriorly the tuberculum olfactorium in *Notoryctes* bears a definite "embracing" relationship to the striatal region. The same longitudinal section (fig. 2) shows that this "cortex" is continuous posteriorly with a formation which is equally entitled to the appellation of "cortex," and later in this paper it will be proved to be composed of those elements known as the nucleus of the diagonal band of Broca (*nuc.d.b.b.*) and the amygdaloid nucleus.

Johnston ('13) has shown in detail the morphology of the tuberculum olfactorium on the medial side, his work being an extension of Beccari's ('11) results. In *Notoryctes* it is clear that in front of the region where it is continuous with the hypothalamus it forms the lateral boundary of the homologue of the preoptic nucleus (of many writers). Still further anteriorly it again penetrates deeply, separating the so-called paraterminal body (nucleus septalis of some writers) from the nucleus accumbens of Ziehen. This nucleus accumbens is a portion of the palaeostriatum, and it is therefore separated from the paraterminal region by islets of Calleja. This is clearly portrayed in Johnston's ('13) figures one of which I reproduce here as fig. 3 depicting the state of affairs in *Didelphys*. While her specimens obviously (e.g. her diagrams 6, 7 and 8) illustrate this cell grouping, Crosby ('16–'17) does not recognise the patent fact. The confusion which obtains in the nomenclature of this region is a token of the uncertainty concerning its interpretation. The tubercular formation is not well developed in Reptilian forms and it is curious that where its islet formation is clearly marked, viz., in the cortical islets capping the anterior end of the palaeostriatum (the caudate nucleus of Johnston in the turtle, '15), writers (such as Johnston, '15, and Crosby, '17) should choose to dignify it with the distinctive title of anterior olfactory nucleus. No useful purpose can be served by unnecessarily

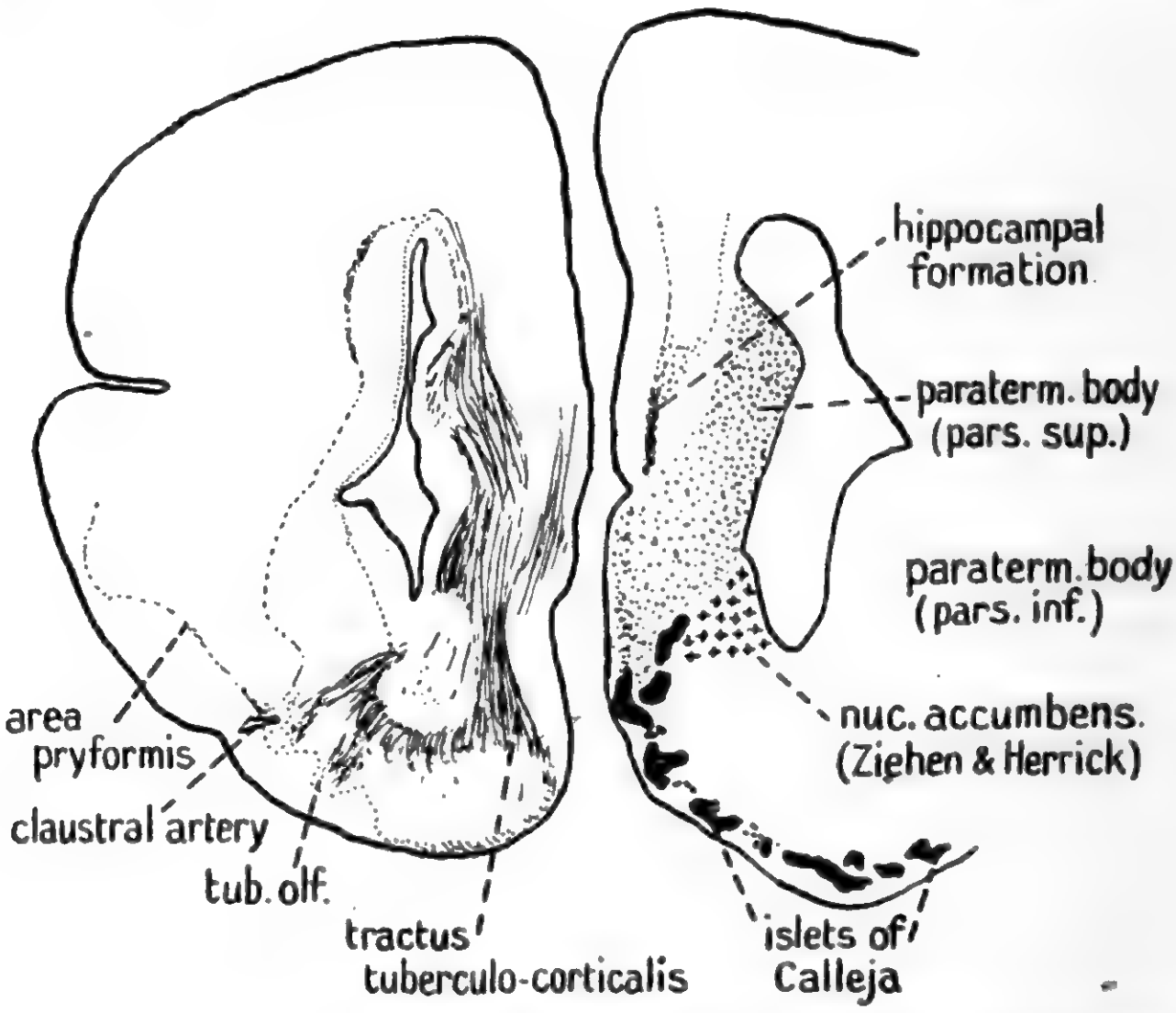

Fig. 3 (after fig. 27, Johnston, '13). To illustrate relationship of tuberculum olfactorium medially, anterior to the commissures.

adding to the already unwieldy and cumbersome accumulation of anatomical terms. The structure in question is merely the most obvious portion of the tuberculum present in Reptiles.

Before entering into the discussion of the morphology it is necessary to refer to a further conclusion insisted upon by Johnston ('13), and previously recognised by Elliot Smith (e.g. '02). This is the careful discrimination between a supra- and infra-foraminal portion of the paraterminal body (or commissure bed) of Elliot Smith (see fig. 5). This discrimination has unfortunately led to the use by Johnston of the term "primordium hippocampi" invented by Elliot Smith for a wholly different structure. Whether, as he contends, there is any justification for this gratuitous transference of terminology and incidental confusion remains to be proved. Apart from the question of priority of usage, the appellation "primordium" as applied to any structure is meaningless unless that structure gives rise later in phylogeny to the tissue of which it is called the primordium. And this Johnston has failed to show. For the purposes of this paper I prefer to use the terminology of Elliot Smith. It will therefore appear that the infra-foraminal portion of the commissure bed corresponds with the medial parolfactory nucleus (so-called) which is stated to meet its fellow of the opposite side in the nucleus of the anterior commissure, and is continuous behind with the nucleus preopticus. I am not wholly in accord with the interpretation of the cell masses found by Röthig ('12) in this region: otherwise I would gladly have utilised his terms "pars dorsalis et ventralis."

THE ORIGIN OF THE HYPOPALLIUM

The brain of *Lepidosiren* presents with almost diagrammatic clearness the simplest arrangement of cortical cell groupings in the cerebrum. In the absence of definite knowledge concerning the arrangement of its fibre tracts our interpretation of its forebrain is not yet conclusive. It has been described by Elliot Smith ('08). Figs. 4 and 5 have been taken from his work, in which the double constitution of the commissure bed was pointed out. This conclusion has been questioned by Herrick ('10). Apart from this however, there are two outstanding characteristics of its forebrain which merit special attention in a study of the striatal region. The first relates to the tubercular cortex, which is seen (figs. 4 and 5) completely to surround a cellular area ventral to the ventricle. This cellular mass below the ventricle is the palaeostriatum (of Kappers) and, as has been shown by various authors, its limits are indicated by sulci in the ventricular wall; that is to say, the sulci are opposite the medial and lateral limits of the tubercular cortex.

The primitive morphological relationship for the vertebrate palaeostriatum then, is that it should lie within a cortical structure, which we may term provisionally the "palaeostriatal cortex," a portion of which we recognise as the tuberculum olfactorium. This tuberculum olfactorium is a very obvious

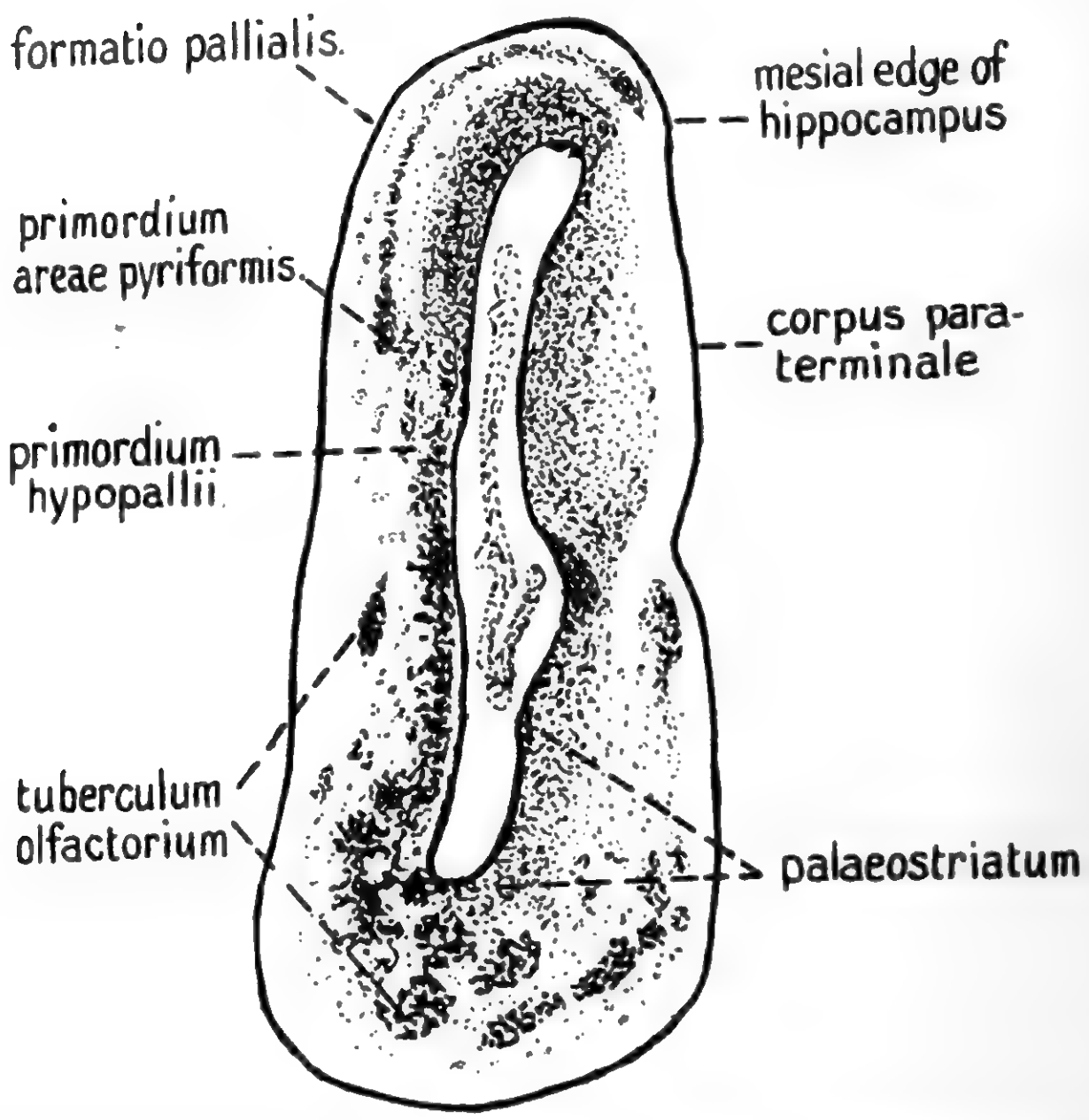

Fig. 4. A coronal section through the left cerebral hemisphere of an adult *Lepidosiren paradoxa* Fitz., a short distance in front of the lamina terminalis (Graham Kerr's section 148 c. 37. 2.). × *circa* 10. (Reproduced from Elliot Smith's paper on "The Cerebral Cortex in *Lepidosiren*.")

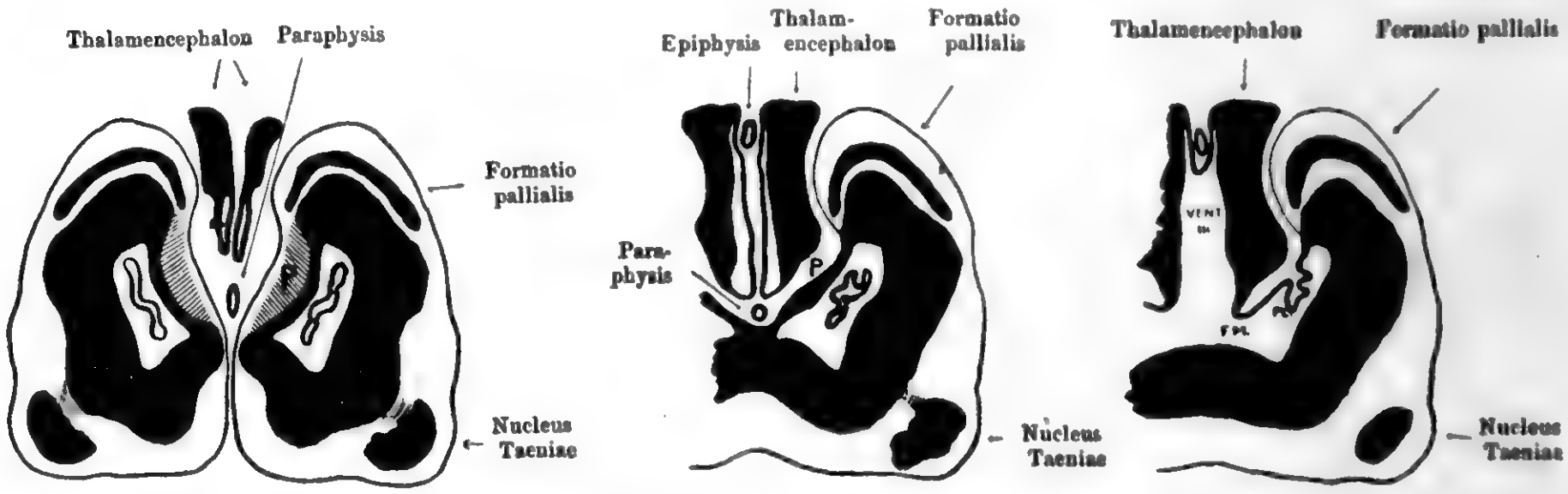

15. 16. 17.

Fig. 5 consists of the three figs. 15, 16 and 17 taken from Elliot Smith's article upon "The Cerebral Cortex in *Lepidosiren*," and here reproduced to reinsist upon his interpretation of the paraterminal region in that form and to show the relationship of the "nucleus taeniae" so-called to the palaeostriatal region. His description of the figs. is appended.

Fig. 15. A diagram of another section (20. 2. 4.) of the same series cut immediately in front of the lamina terminalis. (140 A. 20. 2. 4.) × *circa* 20.

Fig. 16. Here the lower parts of the paraterminal bodies have fused to form the commissure bed or matrix for the cerebral commissures. The dorsal portion of the paraterminal body, marked *P* in fig. 15, has now become attenuated to form an epithelial membrane *P*. (140 A. 20. 3. 6.) 70 μ behind the section represented in fig. 15.

Fig. 17. Diagram of a section 40 μ behind that shown in fig. 16. (140 A. 21. 1. 2.) The paraterminal lamella (*P* in fig. 16) has now given place to the lamina chorioidea, which is invaginated into the lateral ventricle to form the choroid plexus (*PL.*).

F.M. Foramen of Monro. *vent. III* third ventricle.

feature in certain fishes, and also as we have seen in Mammalia, but may be inconspicuously developed in certain reptilian forebrains. But the palaeostriatum is always enclosed by a cortex of some kind; and I find myself in strong disagreement with the statements of certain authors (e.g. Johnston, '15) who find that the striatal areas are sometimes covered by, and sometimes free from, a migrating olfactory area. The palaeostriatum presents a typical arrangement throughout the vertebrate series, it is encapsulated by a "palaeostriatal cortex." Hence it is apparent that the tubercular cortex found in *Notoryctes* represents the remnants of that completer arrangement shown in primitive vertebrates such as the Dipnoi.

A second characteristic to be noted in the Dipnoan cerebrum (cf. fig. 4) is a certain area of cortex lying between the lateral boundary of the so-called "formatio pallialis" of Elliot Smith and the lateral boundary of the tuberculum olfactorium. It conforms to all the known criteria of the region called "hypopallium" by Elliot Smith in reptilian forms: for it lies between the above-stated regions and already shows a "bending-in" which has affected the contour of the ventricular wall. It is the part of the primordial cortex first to be affected by the stimuli arriving from diencephalic centres, and by neurobiotactic influence comes to assume a deeper position. It may be regarded as the forerunner of the claustrum and part of the corpus striatum of still higher forms, and is therefore the "primordium hypopallii."

In this communication I have deliberately refrained hitherto from discussing the Elasmobranch forebrain (which is perhaps the most unspecialised primitive vertebrate form known to us) because that structure has been analysed by Johnston ('11). I intend at a later date to give an account of the Selachian forebrain in which I shall enter into a detailed criticism of that author's conclusions, but in this communication I shall refer only to certain points directly relevant to the matters under discussion here. *Lepidosiren* presents us with an indubitable homology on account of the macroscopical clearness of its tuberculum olfactorium, its definite relation to the simple palaeostriatum and the obvious meaning of the remaining cell masses.

Exactly the same formations are, however, to be seen in the Selachii and even in the specialised and retrogressive Amphibia. A comparison of Johnston's own figures ('11 and '13), and the distribution of the cell areas as depicted by J. Stuart Thomson ('18–'19), with fig. 6 will disclose this fact unappreciated by either of these authors, which is all the more remarkable since Röthig had pointed out this "rudiment of the epistriatum" in 1912. After discovering this rudiment as figured in his paper ('12), it is surprising that Röthig himself should have had any doubt concerning the cortical nature of the epistriatum (cf. his figures for *Hynobius*, *Cryptobranchus*, etc.). Prior to my examination of the *Lepidosiren* cortex I was quite unaware of Röthig's facts, and although there is not in the Amphibia (owing to its retrograde development) the same degree of cortical differentiation that one finds in the Dipnoan, the homology of the several parts is precise and unquestionable.

Preparations of the Selachian forebrain stained by the Weigert or Bielschowsky methods exhibit the nature of the factors actually at work in the production of this so-called "Epistriatum-Anlage" or as I have already named it "primordium hypopallii." In a transverse section (stained by the Weigert method) through this brain in the region of the distribution of the lateral olfactory tract (fig. 7) it will be seen that, medial to this nucleus of the lateral olfactory tract (*nuc.lat.olf.tr.*) there is a mass of fibres which have a different direction, for they course upwards and laterally, as if issuing from the main forebrain bundle, and are distributed to an area abutting upon the ventricular wall and forming the hypopallial ridge.

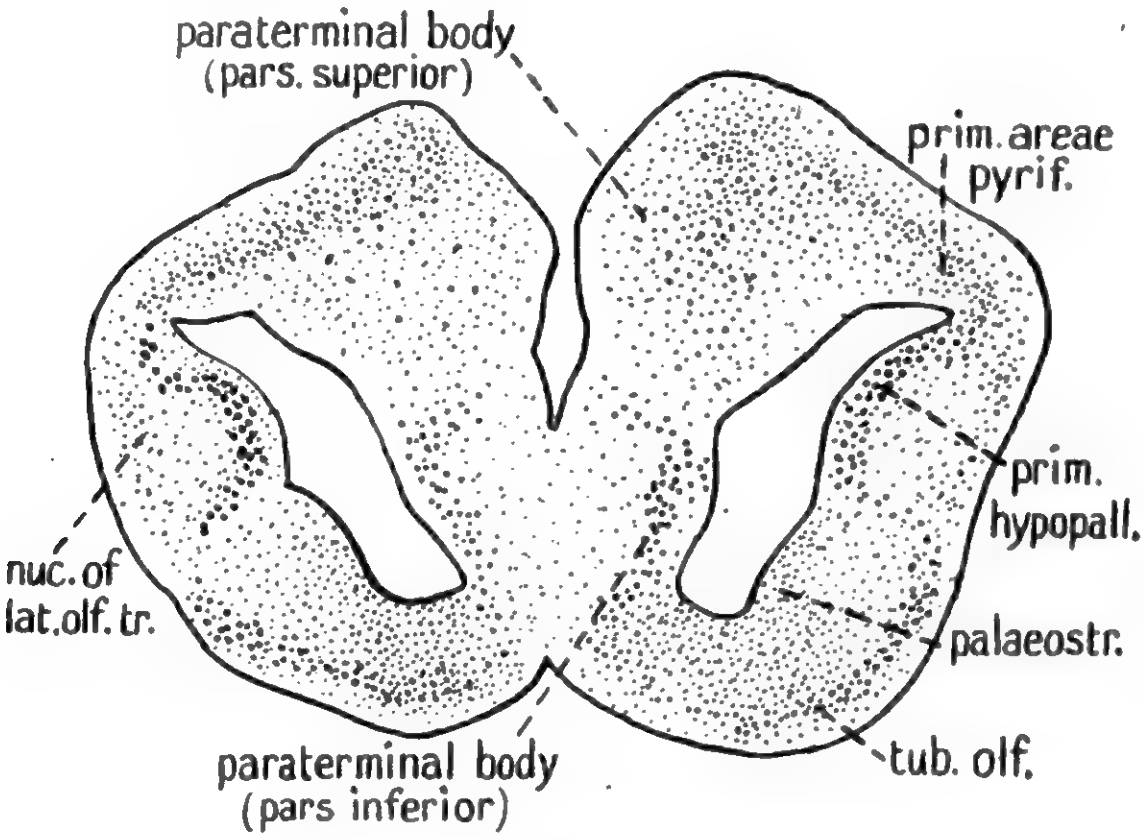

Fig. 6

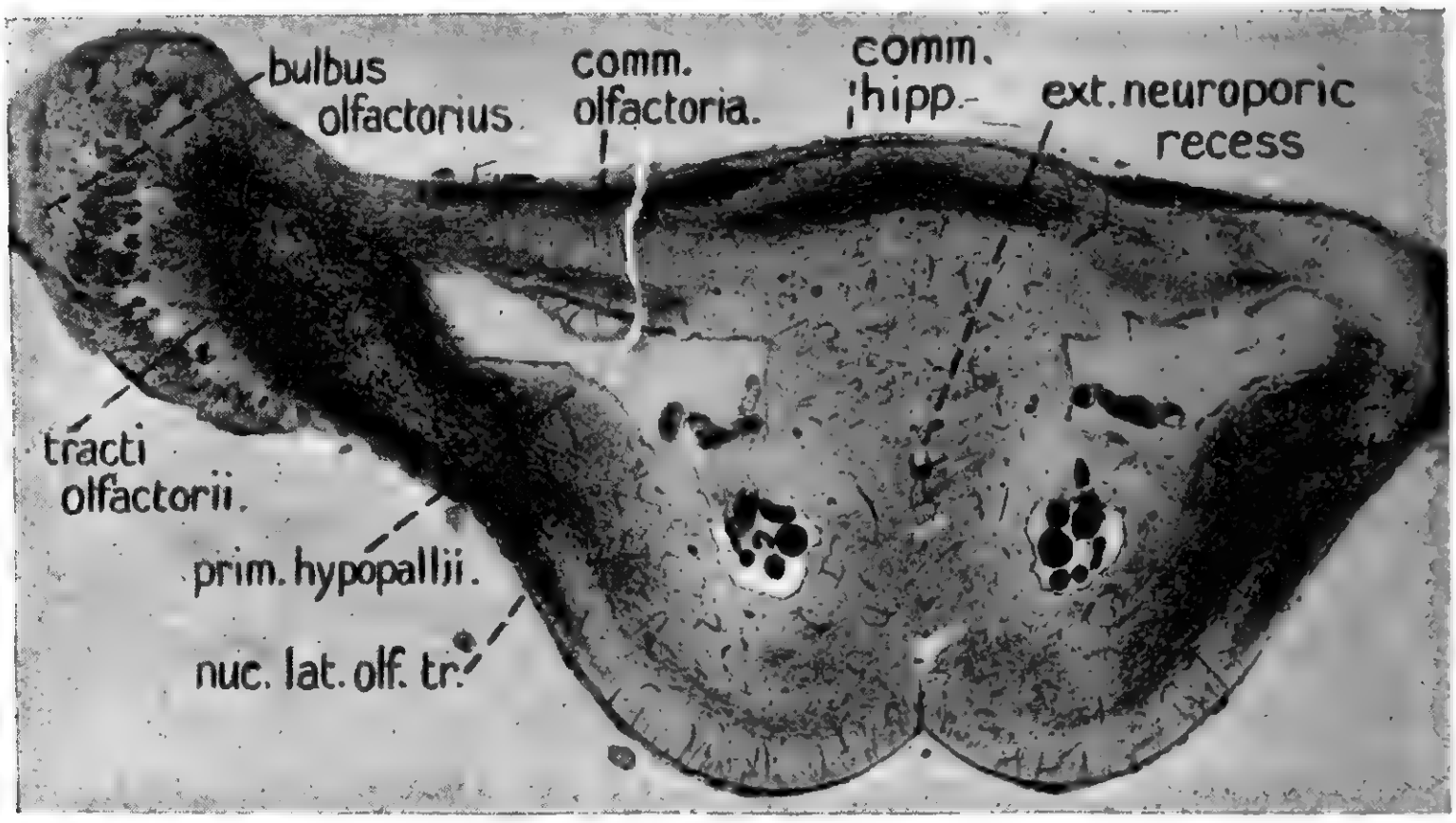

Fig. 7. Actual photograph of a transverse section of cerebrum of *Scyllium* (prepared by the Weigert method) to demonstrate the distribution of the fibre tracts in the region. *comm. olfactoria* = the so-called "corpus callosum" of Johnston.

If the cell masses of the same form are now considered in the light of what has already been shown it is clear from fig. 6 (copy of lantern slide taken from an actual photograph by Elliot Smith) and figs. 8 and 9, which show the distribution of the cell masses in an embryo of *Scyllium*, that the ventral part of the forebrain is a palaeostriatum ensheathed by a definite cortex, which is the tuberculum olfactorium, although the typical "islet" formation is not very characteristically developed, probably owing to its primitive lack of differentiation. Immediately lateral to the limits of this palaeostriatum, as indicated by the ventricular sulcus, there is a bulging in of the ventricle corresponding to a cellular mass continuous dorsally with the pallial formation. But this very definite cell mass lies deep to a cortical differentiation, which is the cellular area serving as the receptive nucleus of the lateral olfactory

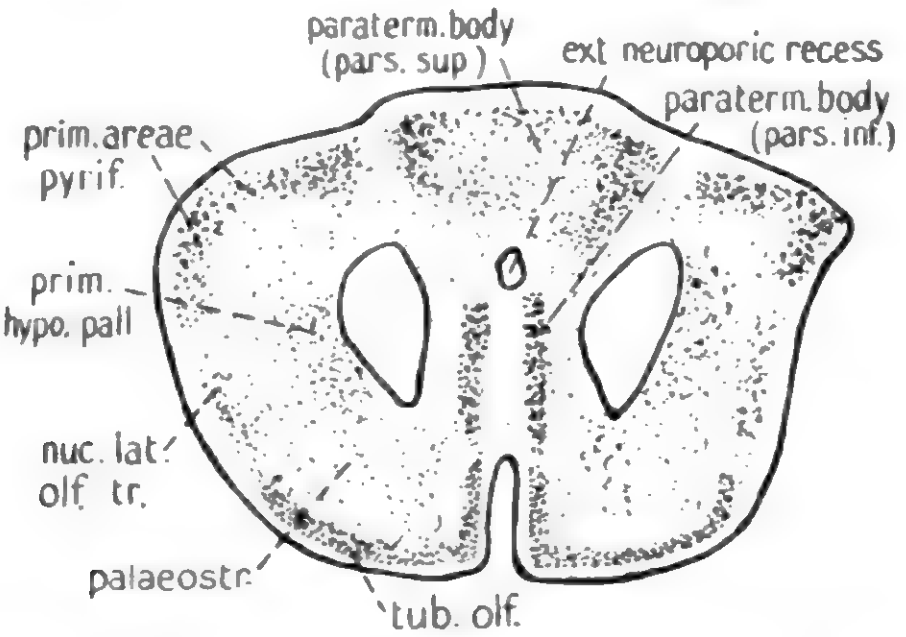

Fig. 8. Transverse section of cerebrum of developing *Scyllium* anterior to third ventricle to illustrate the cell-mass distribution.

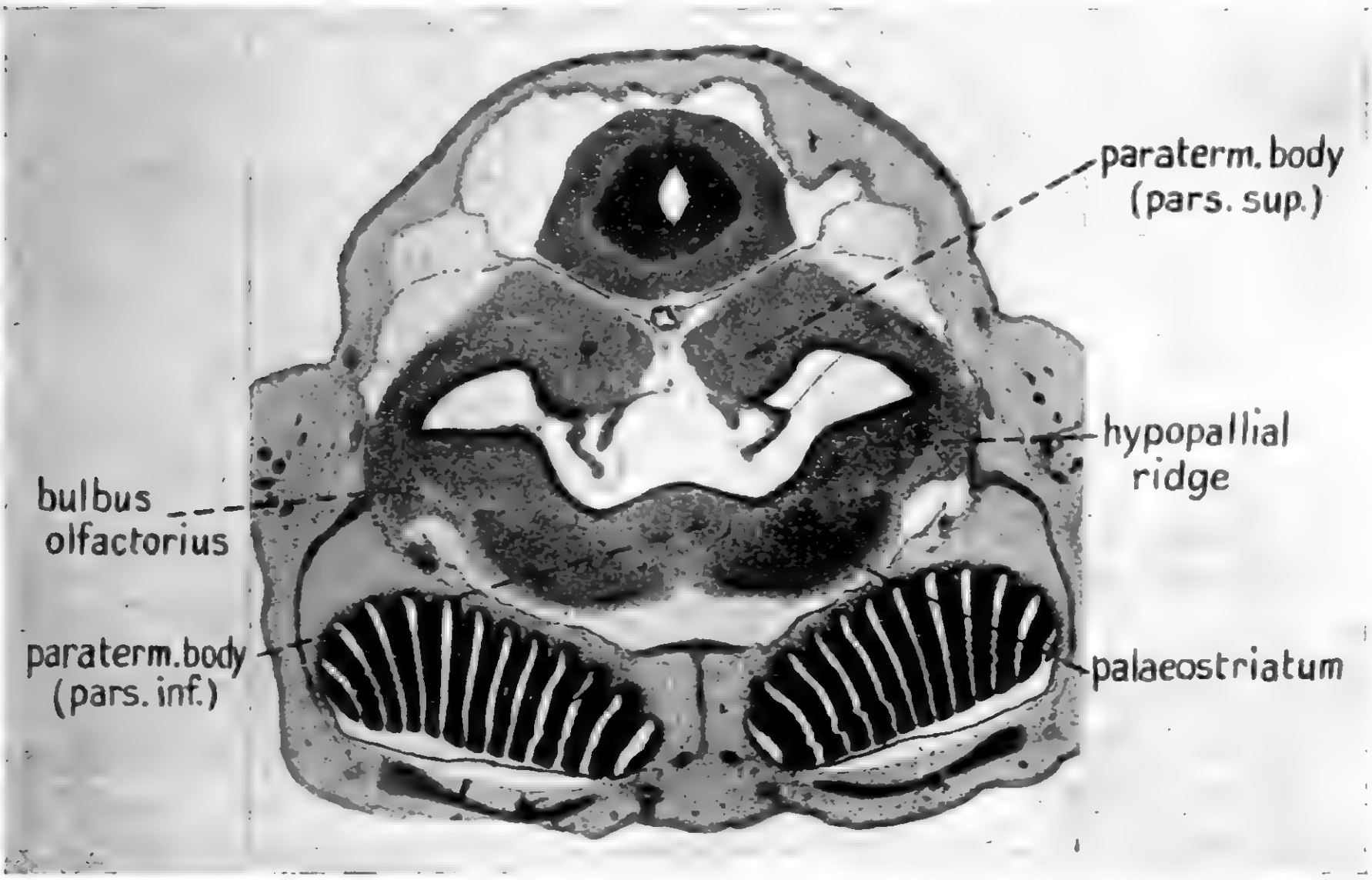

Fig. 9. Photograph of transverse section of developing *Scyllium* in region of attachment of the olfactory bulb. Note nucleus of lateral olfactory tract and the hypopallial ventricular bulging lateral to the palaeostriatum which is covered by the tubercular cortex.

tract as we have already observed. The distinctive nature of the structures referred to is thus shown diagrammatically in the foetal brain (figs. 8 and 9) where the disturbing influence of the developing tracts has not, as yet, reached its full expression. The common point where the primordium hypopallii and the lateral olfactory tract nucleus meet the pallial formation dorsally is to be recognised as the primordium of the pyriform lobe of higher forms. The deduction that we have in *Scyllium* the beginning of that process of a "dragging in" of a cortical structure to form those portions of the striatal complex known as the hypopallium in reptiles is obvious, and we have further an ocular demonstration of the activity of the factors in that process, viz., a superficial set of impulses (lateral olfactory tract) retaining at the surface (on Äriens Kappers's principle of neurobiotaxis) a cellular layer clearly definable as the nucleus of the lateral olfactory tract, and a deep set of impulses coming in by way of fibres closely associated with the forebrain bundle, which, attracting the deeper cortical cells towards the source of their stimulus, cause the formation of the ventricular bulging, in a way exactly homologous to that shown by Johnston for the turtle ('15).

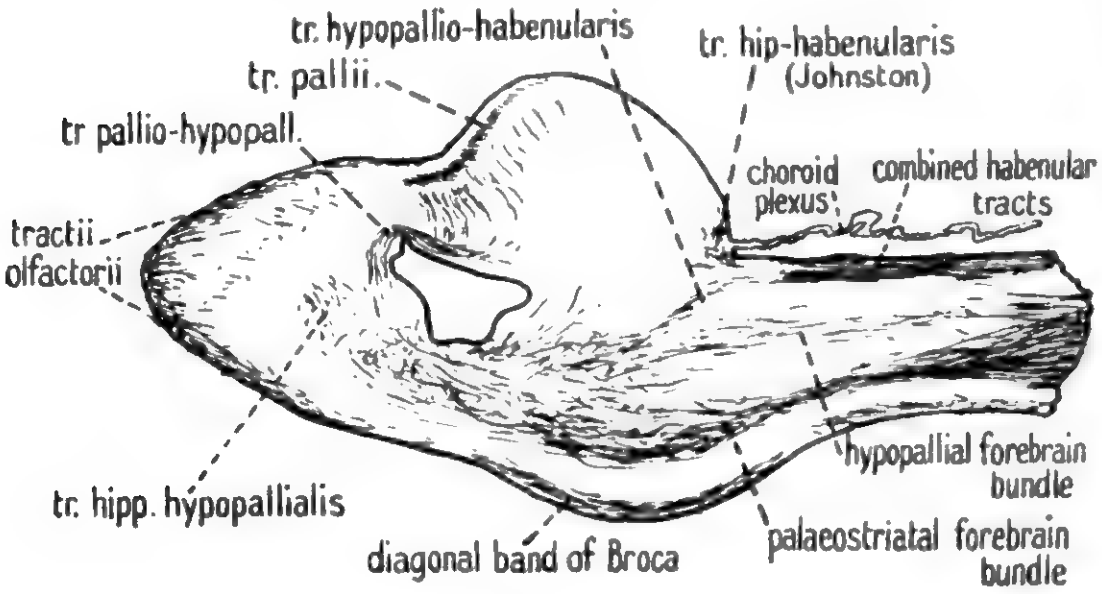

Fig. 10.

Fig. 10 *a*.

Fig. 10 *a*. Photograph of the section from which fig. 10 was drawn to show the relation of the diencephalon and mesencephalon to the cerebral hemisphere in *Scyllium*.

The probable source of this deep set of fibres associated with such an important modification of the originally simple pattern of the pallium will undoubtedly be discovered by a fuller study of the Selachian brain. My own studies of three series of specimens stained by the Weigert method, (transverse, sagittal and horizontal) controlled by the examination of Bielschowsky series, have convinced me that the forebrain bundle in *Scyllium* has two distinct components; one is the ordinary basal bundle constituents, which has long been recognised, while the other concerns the most dorsal and lateral portion. In both sagittal (fig. 10) and horizontal (fig. 11) series, this element of the forebrain bundle is seen to be quite distinct from the basal portion and its goal has been determined as the region I have described as the hypopallial primordium. I have no doubt (from my series) that it is a dorsal thalamic tract and it seems also to receive accessions direct from the tectum opticum. These accessions correspond with the "strio-tectal" tract found by Franz ('12) in various bony fishes. Johnston has described in the Selachian forebrain a so-called "somatic area," and Judson Herrick accepts this reading, as is shown by his retention of this conception in his *Introduction to Neurology*—though elsewhere ('17) he has recognised the striatal nature of Johnston's "somatic area." I have been unable to find any specialised area corresponding with Johnston's description, and more particularly I cannot admit that the structure defined by him is the special site of termination of the more recent thalamic and tectal tracts that appear in this cerebrum. Undoubtedly the hypopallial formation extends a long way posteriorly; but it can everywhere be distinguished from such unrelated elements as the tractus taeniae, which Johnston also traces to his "somatic area." But this and other divergent results I shall discuss in a future communication. That the recognition of the fallacy of these views is of crucial importance is evident from an examination of the deductions made by Johnston from his data. He has reopened the classical dispute concerning the presence of callosal fibres in the hippocampal commissure, and in support of his thesis has claimed to have discovered a so-called "corpus callosum" in the Selachian forebrain. A study of his diagrams (or better still actual specimens of Selachian brains) will show that the fibres he has termed callosal take their origin in an area including the lateral olfactory tract and the lateral part of the tubercular cortex. I have therefore termed it the *commissura olfactoria* (see fig. 7). Specialised commissural connections of these primitive olfactory regions cannot be homologised with a structure so dissimilar functionally as the corpus callosum. This is derived from the neopallium

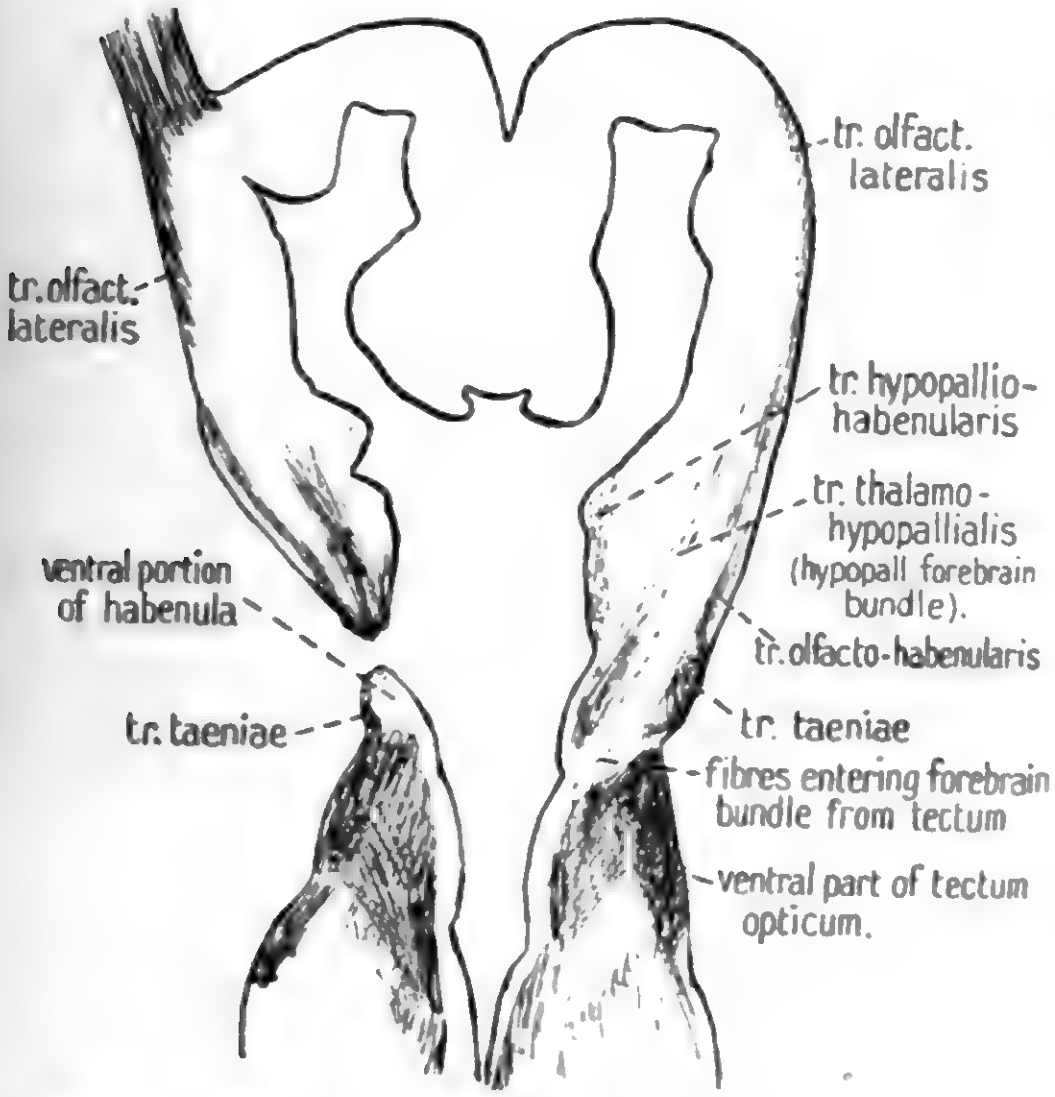

Fig. 11. Diagram of horizontal section of brain of *Scyllium* to illustrate in particular the afferent and efferent paths of the hypopallial primordium.

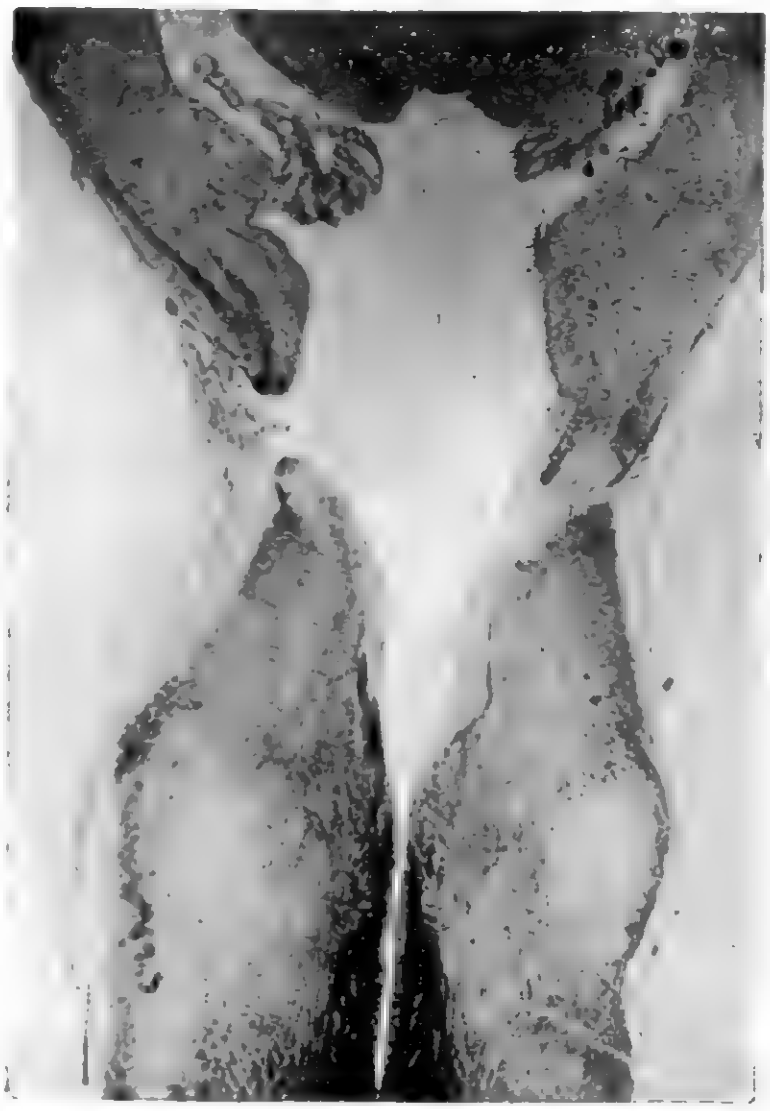

Fig. 11 *a*. Actual photograph of the section from which fig. 11 was drawn.

which is not yet differentiated in fishes. As we now know, the neopallium appears definitely for the first time in the Reptilia and the site of its origin is closely related with the anterior end of the hypopallial region. The appearances in this particular part of the Selachian forebrain are highly interesting and suggestive of a foreshadowing of the neopallium: but their consideration will have to be deferred to my later communication. Meantime it is to be recognised that this anterior extremity of the hypopallium has no relationship whatever to Johnston's fictitious "corpus callosum."

THE FATE OF THE NUCLEUS OF THE LATERAL OLFACTORY TRACT

Reference to figs. 6 and 8 shows how this nucleus bears a very precise relationship to the hypopallial primordium. This is an anatomical arrangement concerning the nature of which I was for a long period greatly exercised, seeing that Elliot Smith had described the continuity of the hypopallium with the pyriform cortex, but had not entered into other problems concerned in the process of evolution of the striatal complex. The study of the tract-distribution has however given the clue, and obviously the study of the cerebrum of *Sphenodon*—in order to understand what had become of this lateral olfactory nucleus—was of considerable moment. Owing to the liberality of Prof. A. Dendy I had the opportunity of studying the development of its striatal complex. This study revealed a continuous series, from the simple form resembling the condition found in the Selachian brain to the fully developed adult described by Elliot Smith. During development (e.g. fig. 12) there is to be recognised a small, though definite rudiment of this nucleus perforated by the lenticulo-striate artery, and even in the adult *Sphenodon* some scattered nuclei, representative of this primitive structure, are to be recognised. In the course of his paper ('20) Elliot Smith corrected his earlier conception and pointed out that the lateral edge of the pyriform primordium is continued into the hypopallium "without any disturbance of the superficial layer of the pallium, which still remains in unbroken continuity with the surface of the palaeostriatum, but without the intervention of any furrow." It will be seen that my interpretation of the facts (as illustrated by this comparative study) is that the infolding of hypopallium is merely the expression of an exuberant

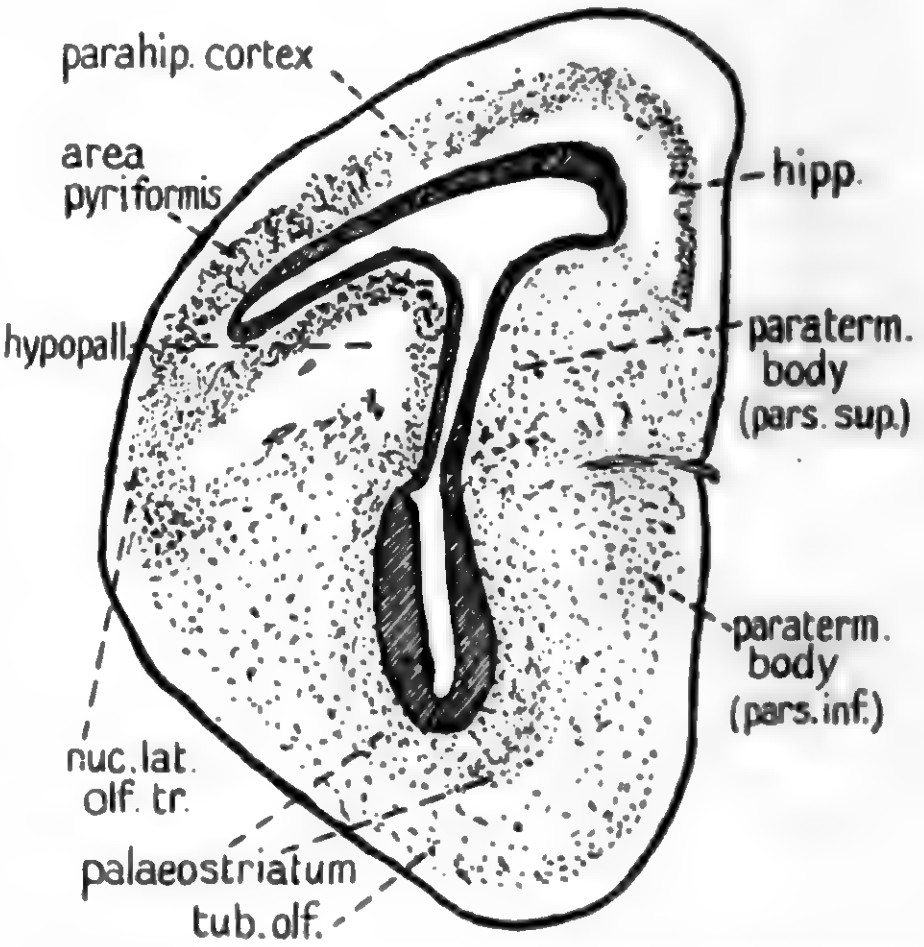

Fig. 12. Transverse section of brain of *Sphenodon* (stage *R*) to show condition of the nucleus of the lateral olfactory tract (*L.O.T.*) at this stage.

growth of the internal layer of the "primordium hypopallii" in the Reptilia, which has caused a bulging inwards of the ventricular wall, while the unbroken contour of the surface is merely the exhibition of the influence of the fibres of the lateral olfactory tract in keeping a small cellular layer at the surface.

It would have been unnecessary to have emphasized this fact were it not that many Reptilia fail to demonstrate the diagrammatic "cortical" continuity of the hypopallium of *Sphenodon*, or of *Lacerta* as figured by De Lange. It is apparent from the study of the turtle (Johnston, '15) and the alligator (Crosby, '17) that there are in these forms certain anomalous conditions of the striatal complex not easily reconciled with that of more archaic forms. The same is true of the striatum in snakes and monitors. What the exact explanation of all the forms of striatum exhibited by these families is we are not yet in a position to say. In some reptiles, such as *Varanus* (e.g. Elliot Smith's paper, '20), there is a very diffuse scattering of the hypopallial cells, in others it does not seem unlikely that there is a spreading out laterally of the palaeostriatum, to separate the hypopallium and the nucleus of the lateral olfactory tract (Johnston, '15); and in these it would seem that the division of the original cortical cell mass and the entrance of the fibres causing the differentiation of the hypopallium, have supplied the path for the spreading referred to. Further, much of the complexity of this interesting site is to be understood, when it is recognised that the adjacent superficial areas (pyriform lobe, superficial layer or nucleus of lateral olfactory tract, and tuberculum olfactorium) are subject to the influence of identical stimuli—hence a tendency to closer grouping of the masses, and homogeneity of structure, with an obscuring of the phylogenetic landmarks. That the embryological history, however, depicts the several stages in the phylogenetic development of these structures has been demonstrated by Elliot Smith even for man.

THE AMYGDALOID COMPLEX

With the historical aspect of this problem I do not intend to deal, for it has been well summarised by Völsch ('06) who has pointed out the conclusions arrived at by Meynert ('67), Mondino ('85), Ganser ('82), Honegger ('90), Ziehen, Kölliker, Cajal and other observers whose researches are for the most part restricted to the mammalian orders. In 1867 Meynert insisted upon the close relationship between the claustrum and the amygdala, but despite our advance in knowledge of the fibre tracts and the means of investigating them, the amygdaloid complex has remained unravelled.

To keep the issues clear, this division of the corpus striatum is considered separately. The first striking observation in regard to this portion of the striatum in *Notoryctes* which confronted me, was that in any typical section of the region (e.g. fig. 13—Section C. 3. 5. of this series) there was very definite evidence of a "cortical" layer of cells covering all parts of the corpus striatum, including the region known as the amygdala. Further the amygdaloid complex has a very definite location between the hippocampus medially and the pyriform lobe laterally, and the transition from subiculum to amygdala is not very apparent. From Johnston and Crosby's descriptions it is obvious that essentially the same relationships hold good for this region in the turtle and the alligator, where the so-called amygdala is treated as a complex of the homologue of the nucleus of the tractus pallii (in fishes) together with the projection tracts of the lateral olfactory nucleus and pyriform lobe. The homology of the tractus pallii with a specific portion of the stria terminalis (olfactory projection tract of Cajal) may be regarded as established. It will therefore be evident, that if the homologues of the various components of the amygdaloid nucleus of higher forms can be isolated in the Selachian forebrain, we are in a position (owing to the definite homologies existing between the reptilian and mammalian forebrain) to explain the mammalian modifications.

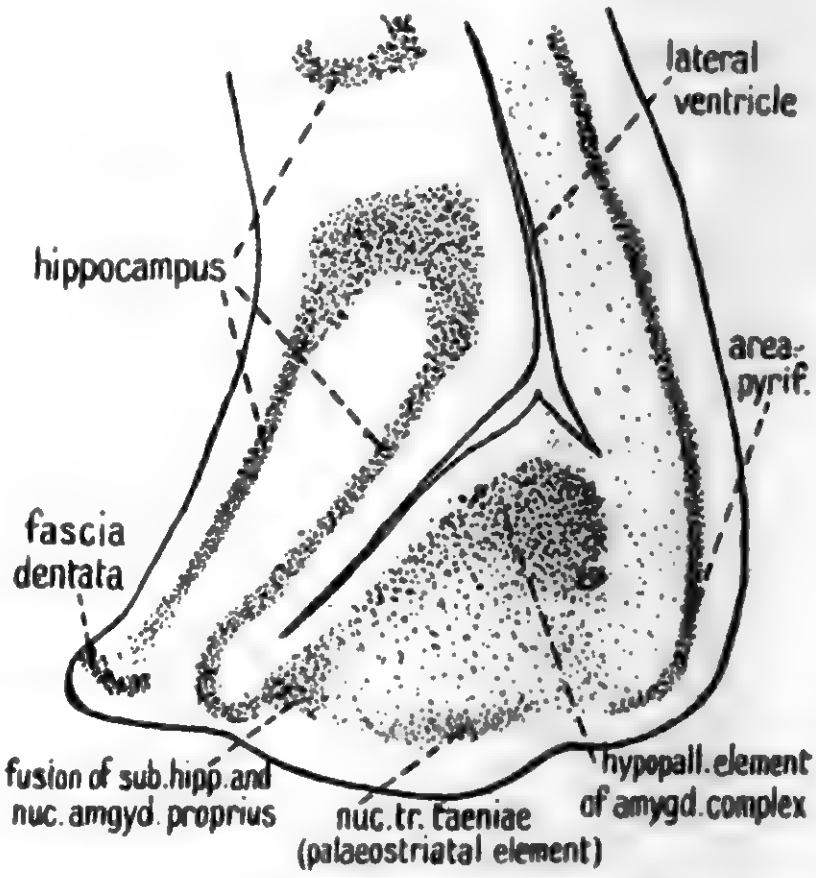

Fig. 13. Ventral half of a transverse section. (C. 3. 5. of this series) of the cerebral hemisphere in *Notoryctes typhlops* to illustrate the components of the amygdaloid complex at this level.

THE ELEMENT *A*

The destination of the tractus pallii in the Selachian forebrain is the posterior and lateral part of the roof of the forebrain. Its situation is very definite—between Johnston's "primordium hippocampi" medially and the primordium of the pyriform lobe and nucleus of the lateral olfactory tract laterally—in short it corresponds with at least part of the region I have indicated in *Notoryctes*. This cortical area in *Scyllium* (fig. 14) is situated very deeply abutting upon the dorsolateral aspect of the "posterior arm of the ventricle" and is to be distinguished by the shower-like appearance of the fibres of the tractus pallii as they pass in from the superficial tract. It is to be noted that the region is quite separate from and unrelated to the other elements grouped with it in higher forms

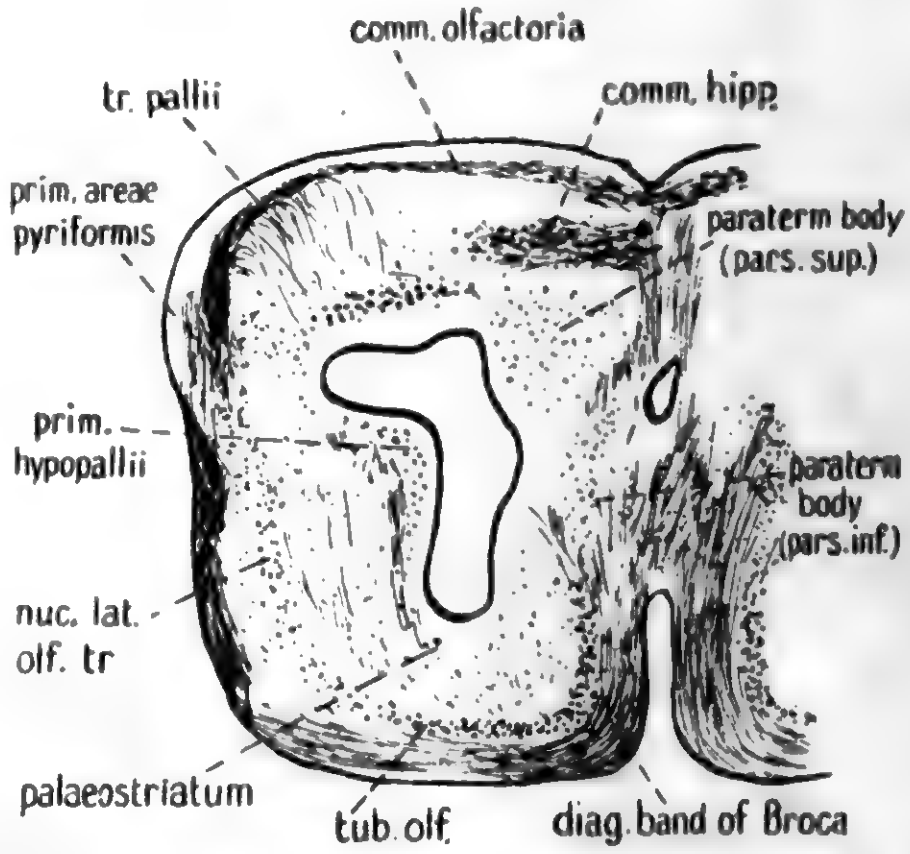

Fig. 14. Transverse section of cerebrum of *Scyllium* (adult) to show the distribution of the tractus pallii and the situation of its nucleus. Drawn from specimen stained by Bielschowsky method.

as the "amygdaloid complex." In this posterior part of the forebrain (cf. fig. 9) the palaeostriatal region is mainly occupied by the forebrain bundle, and is continuous with its fellow of the opposite side through the nucleus preopticus. The hypopallium is relatively small, and is found to be the site of origin of a descending tract. But its cellular layer is continuous laterally with the region into which the tractus pallii discharges. The posterior limits of the pyriform and lateral olfactory tract elements are hard to distinguish, but these with the palaeostriatal cortex of this region (i.e. the nucleus taeniae) are the site of origin of important habenular connections.

Practically the same arrangement is found by Johnston for the turtle, and *Sphenodon* presents a diagrammatic relationship of the constituents in this region (fig. 15) the hypopallium and nucleus tracti pallii (*Sph. I.* 33. 1. 3) still preserving their ventricular position and their relationship to one another and to the hippocampus. The isolated character of "the large-celled medial nucleus" constituent of the complex has been insisted upon by Johnston in his description of the cell masses in the turtle. It may be referred to as the "amygdala proper" (Johnston's medial large-celled nucleus, Crosby's ventro-medial nucleus—though the latter author's failure to separate the subiculum hippocampi from the ventro-medial nucleus, throws some doubt upon the exactitude of her delimitation of this region). At the same time, Johnston's identification of the medial large-celled nucleus in diagrams 15 and 16 in his paper ('15) is incorrect. This region is not a portion of the amygdala proper, but is the palaeostriatal cortex, here quite distinct, and as is evident in fig. 15 of this paper, forms the nucleus tracti taeniae.

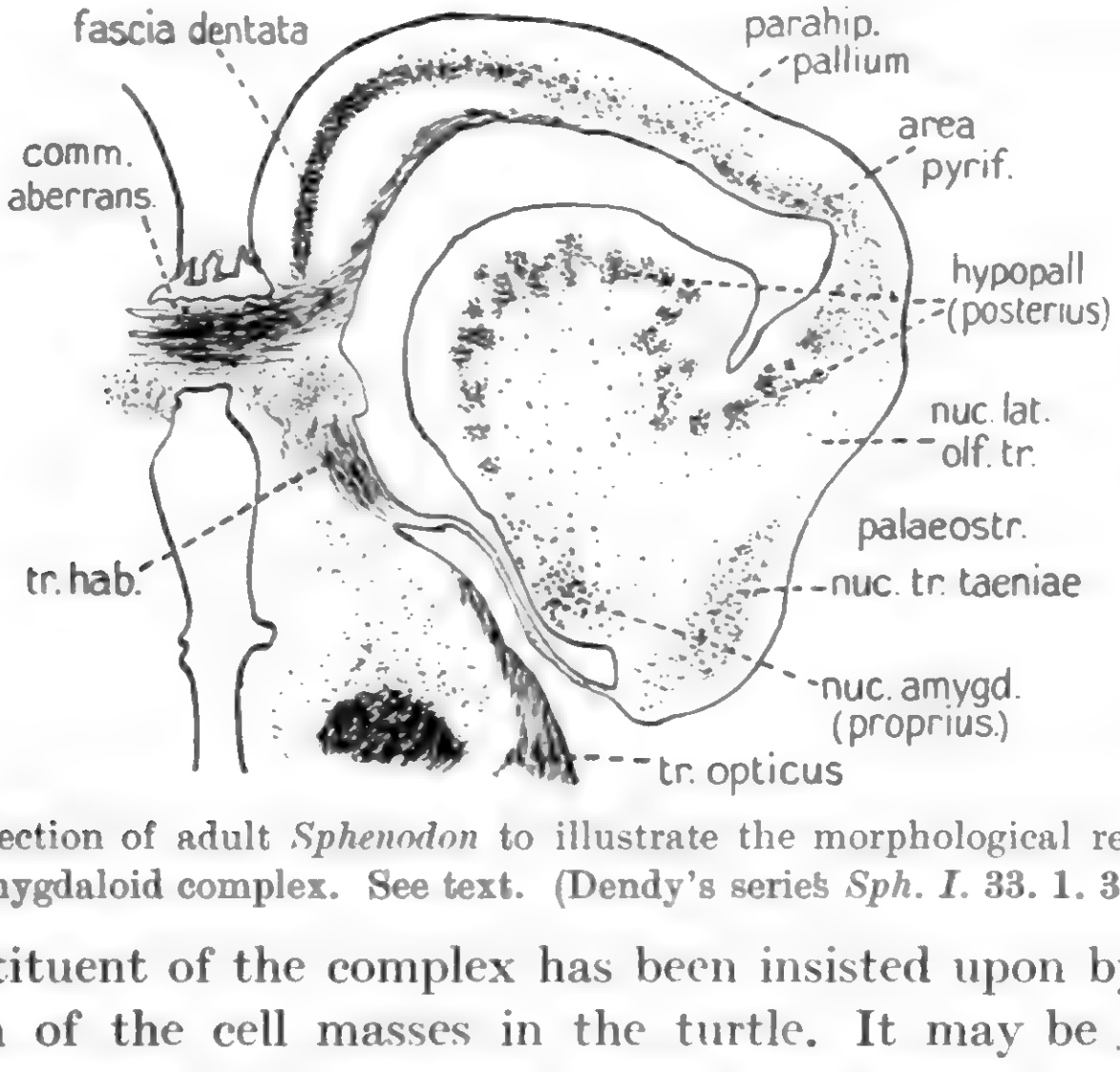

Fig. 15. Lateral section of adult *Sphenodon* to illustrate the morphological relationship of the amygdaloid complex. See text. (Dendy's series *Sph. I.* 33. 1. 3.)

In their *Anatomical Guide to Experimental Researches on the Rabbit's Brain*, Drs Winkler and Potter (fig. xi, reproduced here as fig. 16) have identified three separate cell-masses lying in the space between the pyriform lobe and the tractus opticus, terming them respectively the nucleus amygdalae, subiculum cornu ammonis and zona presubicularis.

This complex has also been the subject of an extensive and painstaking research by Max Völsch ('06 and '10–'11): but, as his investigations were limited to the Mammalia, he found little more than a progressive differentiation in this area when traced through the series. His work has been of significance however in determining that for all mammals the amygdaloid complex can be roughly divided into the three components outlined by Winkler and Potter and insisted upon in this paper.

Accepting then the fundamental division of the complex into three regions, it is the "zona presubicularis" of Winkler and Potter or "basaler Spitzenkern" of Völsch that corresponds with the "large-celled medial nucleus" of Johnston (amygdala proper) and seems to be the homologue of the nucleus of the tractus pallii in fishes.

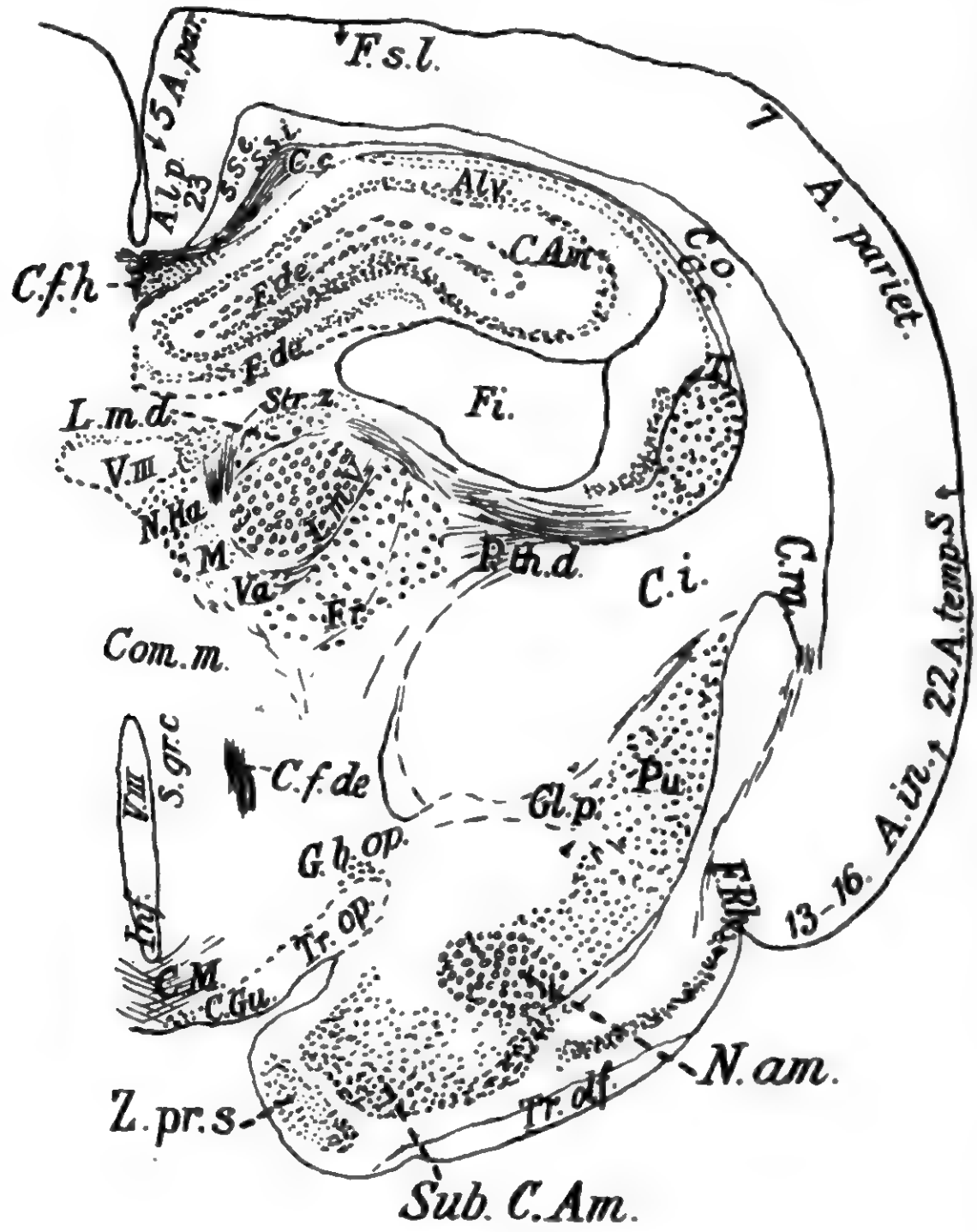

Fig. 16

It is well to recollect that Cajal (p. 723) states for mammals that: "Le noyau amygdalien (the amygdala proper) émet très certainement des fibres qui vont au taenia (semicircularis) mais jusqu'à présent il nous a été *impossible de constater le fait* de visu." Further, although Kölliker ('96) regarded the tract of the so-called taenia semicircularis as arising from the pyriform lobe, lenticular nucleus and amygdaloid nucleus, he nevertheless considered it as an annex of the striatal region, and not an olfactory tract of the third order as did Déjerine. Kölliker's interpretation agrees with Cajal's. Two points concerning Cajal's observations are of the highest importance in the present discussion. First, that direct olfactory tracts never enter the amygdaloid nucleus proper, and second, that he was unable at any time to find a portion of the taenia semicircularis fibres *arising* from its cells, although he carefully searched for such a constituent. He did however believe that some fibres arose from the "cortical" part of the amygdala proper and entered the taenia.

There is no doubt that the one and only area conforming to such a criterion in the Selachian forebrain is this area of distribution of the tractus pallii. The tractus pallii takes origin in the hypothalamus in the cells lining the walls of the large tuber cinereum of these forms, and after extensively decussating just behind the optic chiasma travels partly superficially to, and also amongst, the optic tract fibres to take up a position laterally in the telencephalon medium, until it is distributed (in the manner described above) to the dorso-lateral part of the posterior portion of the telencephalic wall and roof.

Kappers and Theunissen ('07) and Kappers and Carpenter ('08) have confirmed the important finding of Wallenberg by a study of degeneration experiments, that "there is one ascending hypothalamic bundle, and one only to the forebrain of animals with a normal forebrain."

Johnston indeed ('09) states that the "tractus lobo-epistriaticus in fishes is believed to carry up gustatory impulses to the epistriatum from the tertiary gustatory centres in the hypothalamus," and has therefore concluded "that the 'epistriatum' must be regarded as a correlating centre for smell and taste and so be a forerunner of the smell-taste cortex." This use of the unfortunate term "epistriatum" can only be deplored, for by the "tractus lobo-epistriaticus" Johnston undoubtedly refers to the one definite tract associating the hypothalamus with the cortex, and this in fishes is the tractus pallii. In Reptilia and Mammalia it is a very definite constituent of the taenia semicircularis which goes to a restricted portion of the so-called "amygdaloid complex"—it is the nucleus amygdalae proper.

There must be some fibre tract which carries into the vertebrate forebrain those impulses, which, when transmitted upwards from their receptive nucleus in the medulla oblongata, are interpreted as sensations of taste. Such a component in the forebrain of fishes would necessarily be large, as taste is one of their dominant senses. Seeing that the tractus pallii is the only ascending tract from the hypothalamus to which Herrick has traced relays from the primary gustatory end nuclei in the medulla, the inference is justifiable that the primary importance of this tract in fishes and the persistence of its homologue throughout the vertebrate series, is due to this function which it subserves. In the Selachian, there is a large correlation bundle connecting the area of distribution of the tract possibly with the hippocampus and certainly with the anterior end of the hypopallial formation. It may be that this latter region is the primary seat of those disturbances which presaged the birth of the neopallial primordium.

Landau ('19) has pointed out that even in the human brain the cells of the nucleus amygdalae are continuous with those of the hippocampus. This is certainly true in Selachians and the reptiles and hence there is a further link here in the chain of phylogenetic evidence. He states that there is a tract connecting the two, and though this may be the case in the Selachian brain, the most apparent connection of the amygdala (nucleus tracti pallii) anteriorly is with the anterior end of the hypopallium (see fig. 10, tractus pallio-hypopallialis).

If the tractus pallii is the bearer of those impulses which are interpreted as sensations of taste in the cerebrum, we are justified in interpreting the amygdaloid nucleus proper and the amygdaloid tubercle associated with it (first named by Kölliker in the rabbit), as the site where these afferent impulses terminate in the mammalian brain.

The superficial position of this element of the complex, which the work of Völsch has shown to have little or no relation to the ventricle in most mammals, calls for some explanation. Indeed he has named it the "basaler Spitzenkern." Apart from those stresses operating in this region, to which I shall be later drawing attention, two facts are to be noted; first, that the nucleus is under the neurobiotactic influence of a superficially placed tract (tractus pallii), second, that Völsch himself has shown how pure mechanical factors of growth can result in the movement of large areas (his nuclei *M* and *T*) from a ventricular situation. It is of some significance that Völsch was unable to confirm the statement of Ganser "that there is a contribution from this nucleus to the anterior commissure," and further that he, too, could not determine whether it was an efferent nucleus. Such then is the status of the element *A*, which may also be termed the "pallial element" of the amygdaloid complex.

In putting forward this hypothesis I am not unaware of the contentions of the American School of neurologists. Far from being deterred by the "epistriatal" hypothesis (of '09) to which I have already referred, they have insisted that taste impulses are carried to the forebrain in the medial forebrain bundle by a tract as yet undiscovered, that this tract discharges into the hippocampal formation, and therefore the hippocampus, being connected by relays of neurones with so-called "visceral" centres in the lower parts of the brain, is an olfacto-visceral correlation centre. Smell is claimed to be a "visceral" sense; and so, in contradistinction to a so-called "somatic" cortex, the American neurologists refer to a "visceral" representation in the cerebrum. These series of gratuitous assumptions are so utterly devoid of any justification that it hardly seems worth while to embark upon an exposure of their fallacy. By the method of argument adopted by Johnston—classifying any mass connected by a fibre tract directly or indirectly with a visceral or somatic nucleus—it would be possible to present a case for the view that any part of the central nervous system whatsoever was either visceral or somatic, as it suited the predilection of the arguer at the moment. In many fishes the taste buds are ectodermal, and satisfy all the requirements of an exteroceptive sense. At most, a taste-organ is a borderland mechanism which, although the balance of evidence may be in favour of such a conclusion, cannot be definitely accepted in the present state of our knowledge as visceral. Finally if the reasoning adopted leads not only to this assumption and those already mentioned, but also, when we have traced our "visceral" relays into the cerebrum, exercises its magic to such a degree as to make us interpret a thorough-going somatic, ectodermal and exteroceptive sense (viz., smell) as a specialised visceral sense, the limit of paradox is undoubtedly reached.

Roughly outlined, this is the obscurantist aspect of the above hypothesis, which has led to the search for a somatic cortex where it did not exist and has created difficulties that have prevented the appreciation of the full significance of the neopallial primordium. The names "visceral" and "somatic" reduce forebrain terminology to an absurdity, and should be completely discarded if the issues are to remain unclouded.

THE ELEMENT *B*

The second element in the constitution of the so-called amygdaloid complex is a cortical layer of cells which includes the nucleus of the diagonal tract of Broca, which in Selachians and even in *Ornithorhynchus* seems inseparable from the cortex I have termed tubercular (Johnston's area superficialis basalis). This tract travels antero-medially to be distributed to the paraterminal region. The remaining constituents of this element are the areas of origin of efferent tracts such as the cortico-habenular tracts (which are represented in *Scyllium* by efferent tracts first from the posterior part of the "primordium hippocampi" of Johnston, second from the nucleus of the lateral olfactory tract, and third the tractus taeniae, which, arising from a specialised part of the postero-lateral portion of the tubercular cortex adjacent to the optic chiasma, passes dorso-posteriorly (the most lateral structure in this region of the telencephalon medium) and runs to the habenula. It is to be recognised that the anterior commissure is a scattered structure in *Scyllium* and that the stria terminalis as a distinctive structure is not observable therein, though it is probably represented by some few fibres, as also is the poorly developed "fornix" system. The characteristic line of olfactory discharge is ostensibly through the habenular system. There may also be a small efferent system in the tractus pallii itself, but of this nothing certain is known. At any rate it must be clearly understood that these efferent paths adjacent to the pallial tract (amygdaloid) cortex only secondarily enter into the constitution of the so-called amygdaloid complex. The nucleus of the diagonal band of Broca (when distinct from the tuberculum olfactorium) and the nucleus taeniae (site of origin of the tractus taeniae) are definite cortical areas.

In Selachians the site of origin of the tractus taeniae (somatic area of Johnston) is so clearly cortical as to have misled Johnston. It covers the palaeostriatum. Throughout phylogenesis this relationship of the nucleus of the tractus taeniae is preserved. Fig. 15 illustrates that this is true for *Sphenodon* and this "Rindenabtheil" of the amygdaloid complex of Völsch is the area which in the turtle Johnston has failed to distinguish from his "large-celled medial nucleus." The habenular tract arising in this nucleus (a true cortex in Selachians) overlying the palaeostriatum is to be regarded probably as the most primitive efferent path through the habenula. When a true olfactory cortex in the shape of a pyriform and a nucleus of the lateral olfactory tract appeared lateral to the palaeostriatum, its posterior efferent fibres utilised the path laid down by the tractus taeniae. These areas lying adjacent to one another and subserving similar functions are to be recognised in the Reptilia but not as clearly as in Selachians. In the Reptilia too, the problem is complicated by the fact that many of these efferent fibres utilise the more direct path to the hypothalamic region, omitting the synapse in the habenula. They appear to have found the path to the hypothalamus along the line of the tractus pallii which they accompany and would undoubtedly utilise the path of the efferent portion of this tract if such exists. This would explain how the more primitive habenular efferent system characteristic of Selachians may give rise to the taenia semicircularis and stria terminalis systems which are found from the Reptilia onwards.

What natural tendency there is for these similarly-functioning areas to come closer together is heightened in the Reptilia by two factors; first, actual stretching of their axones in the so-called "olfactory projection tract of Cajal" to form the characteristic taenia semicircularis; and second, the expansion of the cortex represented now by a definitely developed hippocampal formation, a true pyriform and a nucleus of the olfactory tract, a huge parahippocampal cortex and lastly the primordium neopallii.

The net result of all these factors of a mechanical nature and undoubtedly also active neurobiotactic influence is to heap the primitive palaeostriatal cortex into a nuclear mass: but even in the specialised mammalian classes it will be recollected that Cajal found fibres arising from that region called by him "cortical part of the amygdala". An examination of his text and figures (*op. cit.*) shows that this region corresponds with that termed subiculum hippocampi by Drs Winkler and Potter. It is indeed continuous in Mammalia (owing to the "extrusion" of the "nucleus amygdalae proprius" from its ventricular position as the nucleus tracti pallii in the Selachian forebrain) with the subiculum on the medial aspect and the pyriform laterally. This region discharging into the same areas as the posterior part of the pyriform lobe and lateral olfactory tract is homologous with the nucleus tracti taeniae. Like that region—so clearly differentiated in Dipnoi and other fishes—it is continuous anteriorly with the cortex of the tuberculum olfactorium and nucleus of the diagonal band of Broca, and is the relic of probably the most primitive lines of discharge of correlated olfactory impulses through the habenula, and in higher forms through the hypothalamus also. It may be regarded as the most posterior portion of the "palaeostriatal cortex."

The work of Völsch has shown that this mass is a "Rindenabtheil." This area he has copiously described and figured and we can unhesitatingly regard it as the structure termed the "subiculum cornu Ammonis" by Drs Winkler and Potter, the element *B* of both this paper and that of Völsch, or what may be far better designated as the "palaeostriatal element" of the amygdaloid complex.

That this association of fundamentally differing parts has not been clearly conceived is shown by the fact that it is dealt with "en bloc" by certain writers (e.g. Kappers, '08, in stating that the "secondary epistriatum which is closely related with the tertiary smell-cortex comes to take a wholly caudal and basal situation as the nucleus amygdalae"). This "secondary epistriatum" of birds is probably a far more highly differentiated area than, but is entirely homologous with, the "hypopallium posterius" of this article. Its relationships are most distinct, and will receive immediate attention.

THE ELEMENT *C*

There is a conspicuous element in this morphologically posterior part of the forebrain which, as far as my knowledge goes, has either been unrecognised or wrongly interpreted by previous investigators. If horizontal sections of the brain of *Scyllium* (fig. 11) be examined in series it will be discovered that in a region, corresponding in situation with the hypopallial rudiment posteriorly, a tract takes origin. It is difficult to distinguish in specimens prepared by the method of Weigert exactly where the posterior limit of the afferent tracts to, and the anterior limit of the efferent tracts from, this longitudinally differentiating hypopallial rudiment, are to be set. In short the most anterior region is mainly an afferent nucleus while the posterior is mainly efferent. In *Scyllium* this posterior efferent part of the hypopallium gives rise to fibres which become bunched together forming the most medial fibre constituent of the region. It later meets the other efferent tracts with which it ascends to the habenula. It appears to be the main discharge mechanism for the newly differentiating hypopallial region.

Sphenodon provides us with a remarkable confirmation of this tentative explanation. The hypopallium in *Sphenodon* has a very definite double constitution for while the anterior part is solid in cell formation the posterior part has a scattered arrangement—a thing which is most conspicuous in longitudinal sections. Here we find also (figs. 17 and 17 *a*) that there has been a crumpling at the line of differentiation between the two portions of hypopallium. The study of the fibre tracts shows that while the anterior portion (figs. 17 and 17 *a*) is the goal of the afferent system from the thalamus, the posterior region discharges by a tract which runs at any rate for the most part to the habenula. It may also discharge in part to the hypothalamus in Reptilia. This hypopallio-habenular constituent, then, is clearly marked in fishes and in reptiles, and evidently must have its homologue in Mammalia.

The habenula gradually decreases in relative importance in phylogenesis and as has been pointed out an increasingly large portion of the efferent system utilises the more convenient passage through the hypothalamic region.

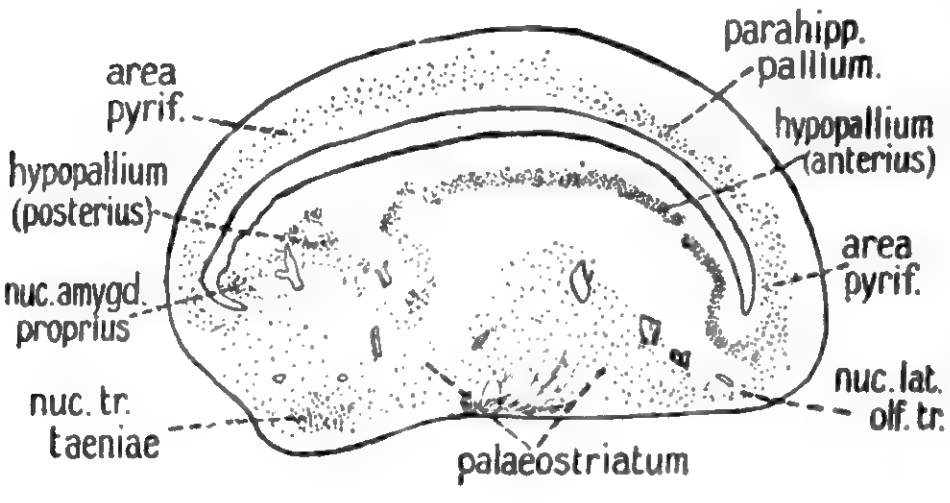

Fig. 17.

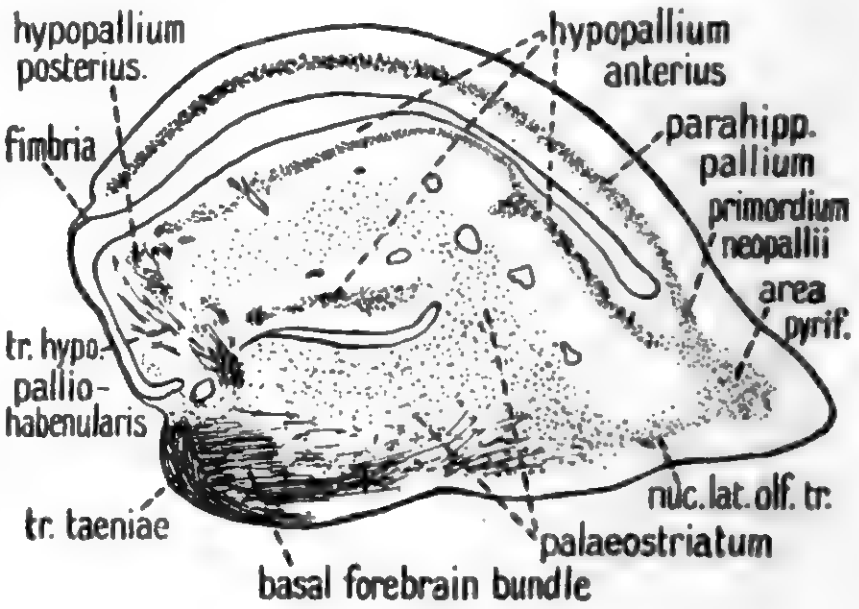

Fig. 17 *a*.

In the diagram reproduced (fig. 16) from the work of Winkler and Potter I have not discussed that element of the amygdaloid complex termed by them the "nucleus amygdalae." From what has been written it is clear that this portion of the complex corresponds in every detail with that posterior region of the hypopallium which discharges (in Selachii and Reptilia) through the habenula for the main part. It only becomes related secondarily to that portion of the palaeostriatal cortex which we have identified as the nucleus tracti taeniae and is very distinct in Selachians, being continuous with the hypopallial bulging into the ventricle. It has apparently been compressed during phylogeny owing to the mechanical changes affecting the expanding cortex and corpus striatum but must be recognised as originally a hypopallial and not a palaeostriatal constituent. It has therefore been designated as such in fig. 18, taken from the *Notoryctes* series, somewhat anterior to fig. 13.

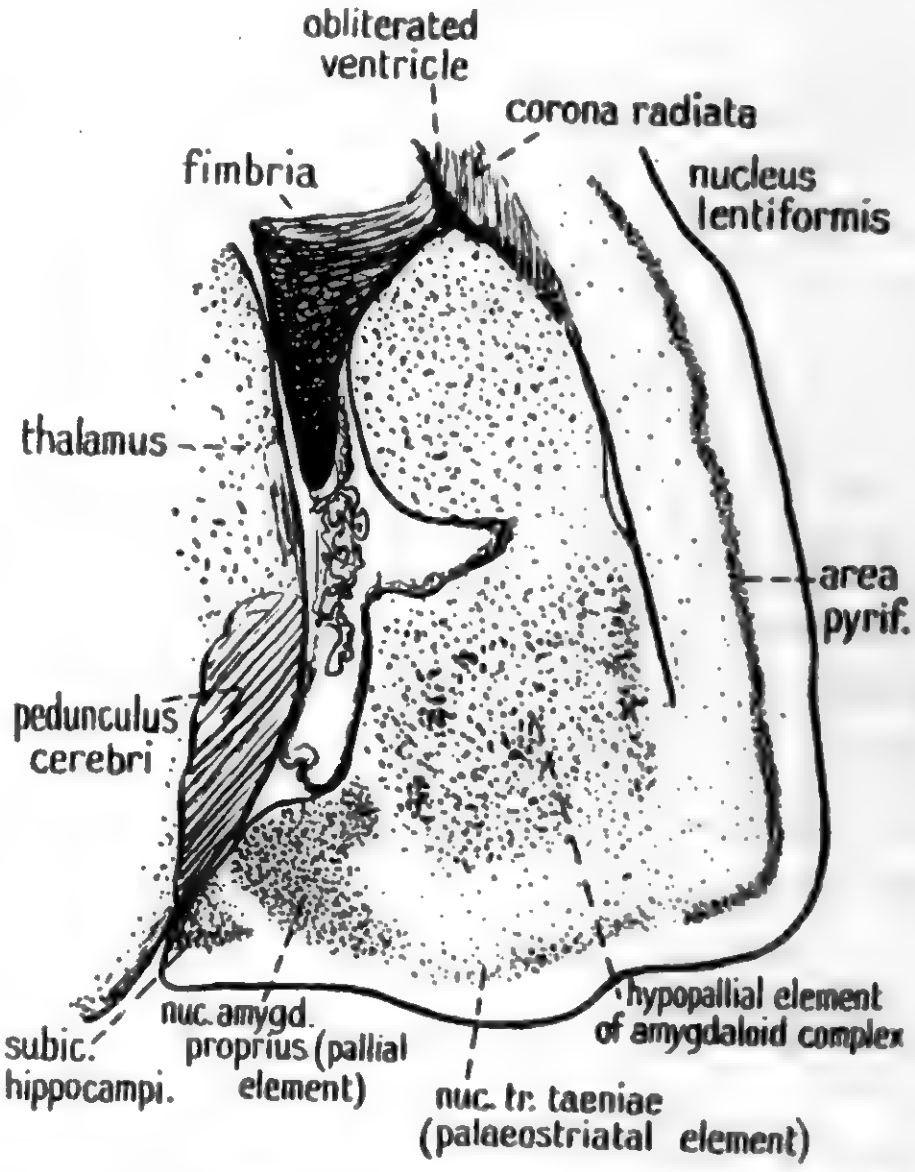

Fig. 18. Ventral half of transverse section of brain of *Notoryctes* some sections anterior to that represented in fig. 13 of this paper. Note the relationships of the three elements of the amygdaloid complex.

In his painstaking monograph Völsch has closely observed this region: "the nucleus amygdalae of Ganser," which he himself has termed the "Areas *M* and *T*." He has shown how in certain classes of Mammalia this mass in ontogeny is forced away from its ventricular position "by the development of the stria and the corpus striatum," and further, that its identity is rendered distinct by a kind of capsular formation, presumably of fibrils. Such a separate element of the amygdaloid complex is certainly the "nucleus amygdalae of Winkler and Potter," which has been regarded (as Völsch has shown) by some as portion of the lentiform nucleus, but by cytological structure and fibre connections it is an element of the amygdaloid complex. It is as clearly too the homologue of the hypopallium posterius (mihi) in Reptilia and forms the element *C* or more suitably the "hypopallial element" of the amygdaloid complex.

It is not part of my scheme here to criticise the work of Völsch. That it shows obvious fallacies has been recently exposed by Landau ('19) and as Elliot Smith has himself shown ('19) the claustrum is cortical; and so the views of Meynert ('67) to-day find confirmation. He (Völsch) thinks that the amygdaloid complex arises by a "sinking in" of what he has called the "intermediate area" of the pyriform lobe, and insists on the corroborative evidence of the two sulci to be found in this region. Such a view would rather naturally follow (see figs. 13 and 18) from researches which, as I have already stated, are confined to the Mammalia. It was the recognition of this that drove me from the study of *Notoryctes* to that of *Scyllium*. The phylogenetic history of this site of early transformations is to be sought in the lowliest and not the more highly organised Vertebrata. His insistence upon the finer cytology of the three constituent elements of the complex which he himself has discovered to be fundamental may have some justification when we are more fully acquainted with the causal factors in the production of its more intimate fibre connections. In the solution of this problem, the Reptilia may afford valuable evidence: for the hypopallium anterius of Reptilia is not a uniform structure. It shows a degree of differentiation which it should be possible to correlate with the different types of stimulus reaching it from the thalamus and it is to be expected that the hypopallium posterius is correspondingly complex. Here lies the key not only to the proper appreciation of the differentiation of cell structure within the three groups found in the mammalian amygdaloid complex by Max Völsch, but also to the understanding of the curious development of the striatal regions in Aves.

It must further be remembered that in the amygdaloid region deep to the "Rindenabtheil" (cortical part of the palaeostriatum) there are scattered cells of the palaeostriatum itself filling up the space between the three elements but not obscuring their identity.

A RETROSPECT

(the terms basal and cortical)

For the last quarter of a century and more, the attention of morphologists has been directed to the elucidation of the so-called basal regions of the forebrain. Nothing has done more towards a correct evaluation of the components in this district than the researches of Elliot Smith upon the nature of the "paraterminal body" and "commissure bed," which cleared the way for the appreciation of the hippocampus throughout the vertebrate series. His differentiation between a rhinencephalon and neopallium has been an illuminating conception for the whole of neurological phylogeny. But within the rhinencephalon itself there had been transformations of an exceedingly intricate character long before a neopallium emerged. And these were the changes concerned in the evolution firstly of the palaeostriatum and later of the hypopallium. What was the character of those impulses that first impinged upon the original simple olfactory reception centre, which later grew to be the dominant mechanism of the body, is difficult to say with certainty. They were probably imperfectly differentiated impressions coming up from the massively-responding thalamus of the primitive vertebrate. These newly entering impulses stimulated cell formation in the deeper part of the primitive cortex. The cells by neurobiotactic influence naturally tended to aggregate in the ventral and juxta-thalamic region, while the dorsum of the primitive vesicle remaining freer from disturbing influences became the seat of the formation of a true pallium (cortex).

The nature of the disturbances in a primitive olfactory mechanism caused by this early entrant tract is well illustrated in a diagram (fig. 19) taken from Kappers (*Anat. Anz.* Bd. XXXIII. 1908): but in that figure the more salient example of his neurobiotactic principle is exemplified, not by those cells migrating towards the source of stimulus in the olfactory bulb, but rather by those heaped up round the newly entering tract from below. Such a degenerate Amphibian forebrain shows practically no palaeostriatal differentiation, but in the more clearly differentiated brain of the Selachian the pallium in the region of the palaeostriatum is represented by a cortical formation which rapidly became variously modified for particular purposes. The process of differentiation of this "palaeostriatal cortex" has advanced to the degree recognised in its various elements as we know them, though all the steps in their history are still far from clear. It is probably, broadly-speaking, true that the tuberculum olfactorium proper is a receptive centre for olfactory impulses, that the diagonal tract of Broca is a correlation mechanism between the various olfactory cortices and that the tractus taeniae is an olfactory efferent tract, but there is just as probably much more. The Selachian forebrain also shows us how these earlier cortices developed out of an apparently homogeneous formation lying over the palaeostriatum. But it shows us more, for already we discover an additional disturbing element in the mechanism

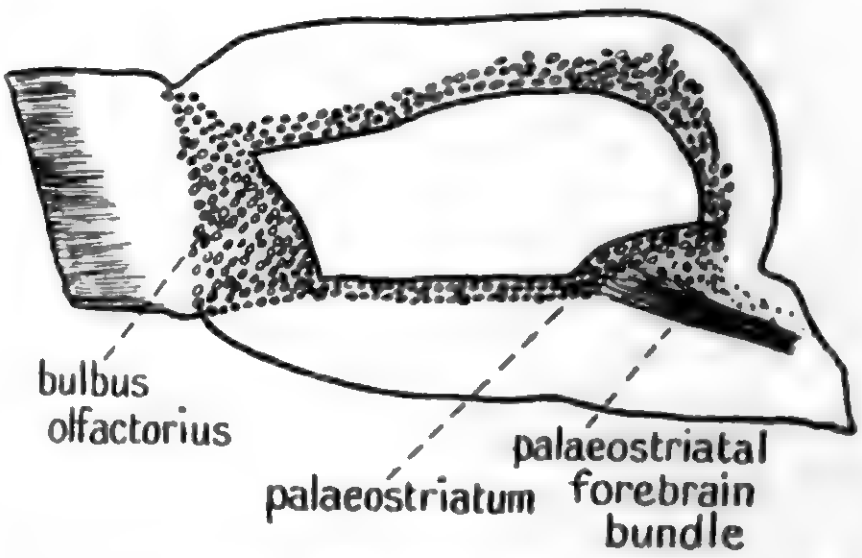

Fig. 19. Taken from Kappers (*op. cit.* '08) to illustrate the possible nature of the conditions arising by the entry of the first "thalamic" impulses leading to the differentiation of a palaeostriatum in the primitive olfactory receptor. Sagittal section of forebrain of *Axolotl*.

which we are now in a position to term a forebrain. It is the only ascending tract we know from the hypothalamus; and in Selachians it has reached a portion of the primitive pallium by a course through, and lateral to, the optic chiasma. It is the tractus pallii the relationships of which have already been discussed. It is possibly the bearer of impulses interpreted by this primitive forebrain as taste and it has its homologue throughout the vertebrate series as the "nucleus amygdalae proprius."

But by far the most significant event in the history of the vertebrate phylum is the entrance for the first time into the forebrain of the Selachian of that dorsal thalamic and presumably also tectal group of fibres, which, passing through the palaeostriatum, invade the pallial formation beyond it and lead to its differentiation into two definite regions, which we have recognised as the hypopallium and nucleus of the lateral olfactory tract respectively. Concerning the impulses borne by this fibre tract we are still ignorant, but it is probable that they are concerned with some degree of tactual discrimination, and the coarser appreciation of sight and sound. And significant is the fact that, together with the changes accompanying the entrance of this tract, there is a specialisation for the discharge by a particular path of the correlated response. This is conceivably by way of the tract here described as the hypopallio-habenular and its homologues.

The origin of the neopallial primordium is a further advance which affects the anterior portion of the hypopallium. It is apparently foreshadowed in the Selachian but it is very clearly present in reptiles, as has been shown by Crosby, Elliot Smith, and Woollard (in a paper read before the Cambridge meeting of the Anatomical Society), and, as I have personally observed, even in the archaic *Sphenodon*. It is a striking fact that these successive modifications of the original olfactory mechanism have affected successively more and more anteriorly lying portions of the forebrain, and that then, the expansion of the region invaded has led to large alterations in shape and relationship of the various areas.

It is clear from these remarks that the usage of the terms "basal" and "cortical" will need definition if they are to remain intelligible expressions of neurological terminology.

Throughout the whole vertebrate series known to us there is no such thing as a pure rhinencephalon; in that primitive vertebrate which possessed a palaeostriatum only, this structure was an addition, a well-defined correlation mechanism composed of gross afferent and efferent elements. Even some term such as "archipallium" which was introduced by Edinger is quite inadequate without definition. There are four definite stages (and perhaps five—if we regard the entrance of the tractus pallii as a stage) in the development of the forebrain—an original olfactory receptor, or placodal stage, a palaeostriatal stage, a pallial stage, a hypopallial stage and a neopallial stage, and the terminology of the forebrain can only be rational when based upon this wide phylogenetic survey.

REFERENCES

Beccari, Nello. "Le sostanza perforate anteriore e i suoi rapporti col rinencephalo nel cervello dell' uomo." *Archivo di Anat. e di Embriol.* vol. x. 1911.

Cajal, S. Ramon y. *Histologie du Système Nerveux.* Paris, 2 vols. (translated from the Spanish by Dr L. Azoulay), 1909–11.

Crosby, Elizabeth C. "The Forebrain of *Alligator mississippiensis.*" *Journ. Comp. Neurol.* 1917.

Gisi, Julia. *Inaugural Dissertation zur Erlangung der Doctorwürde Universität.* Basel, 1907.

Herrick, C. Judson. "On the Centers for Taste and Touch in the Medulla Oblongata." *Journ. Comp. Neurol. and Psych.* 1906.

—— "On the Phylogenetic Differentiation of the Organs of Taste." *Journ. Comp. Neurol. and Psych.* 1908.

—— "Morphology of the Forebrain in Amphibia and Reptilia." *Journ. Comp. Neurol.* 1910.

—— "Midbrain and Thalamus of Necturus." *Journ. Comp. Neurol.* 1917.

Johnston, J. B. "The Brain of Petromyzon." *Journ. Comp. Neurol.* 1902.

—— "Morphology of Forebrain Vesicle in Vertebrates." *Journ. Comp. Neurol.* 1909.

—— "The Evolution of the Cerebral Cortex." *Anat. Record,* 1910.

—— "Telencephalon of Selachians." *Journ. Comp. Neurol.* 1911.

—— "Morphology of the Septum, Hippocampus and the Pallial Commissures in Reptiles and Mammals." *Journ. Comp. Neurol.* 1913.

—— "The Cell Masses in the Forebrain of the Turtle." *Journ. Comp. Neurol.* 1915.

Kappers, C. V. Ariens. "Die Phylogenese des Corpus Striatum und der Vorderhirn-Commissuren." *Folia Neurobiologica,* 1908.

—— "Weitere Mittheilungen über die Phylogenese des Corpus Striatum und des Thalamus." *Anat. Anzeiger,* Bd. xxxiii. 1908.

—— "Die Phylogenese der Paläeocortex und der Archicortex vergleichen mit der progressiven Entwickelung der Sehrinde. *Deutsch. Zeitschrift für Nervenheilkunde.*" Bd. xxxvi. 1908.

Kappers and Theunissen. "Zur vergleichenden Anatomie des Vorderhirns der Vertebraten." *Anat. Anzeiger,* Bd. xxx. 1907.

Kappers and F. W. Carpenter. "Das Gehirn von Chimaera monstrosa." *Folia Neurobiologica,* 1908.

Landau, E. "The Comparative Anatomy of the Nucleus Amygdalae, the Claustrum and the Insular Cortex." *Journ. of Anat.* (together with a note on Prof. Landau's Memoir by G. Elliot Smith), 1919.

Lange, S. J. de. "Das Vorderhirn der Reptilien." *Folia Neurobiol.* 1911.

—— "L'évolution phylogénétique du corps strié." *Le Nevraxe,* vol. xiv. 1913.

—— "Das Zwischenhirn und das Mittelhirn der Reptilien." *Folia Neurobiol.* Bd. vii. 1913.

Sheldon, R. E. "The Olfactory Tracts and Centers in Teleosts." *Journ. Comp. Neurol.* 1912.

Smith, G. Elliot. Catalogue of Physiol. Series of Comp. Anat. Museum of Royal Coll. of Surgeons of England, vol. ii. 2nd edition, 1902.

—— "The Cerebral Cortex in Lepidosiren." *Anat. Anzeiger,* Bd. xxxiii. 1908.

—— "The Arris and Gale Lectures." *The Lancet,* Jan. 1, 15 and 22, 1910.

—— *The Central Nervous System in Cunningham's Anatomy,* 3rd edition, 1913.

—— "A Preliminary Note on the Morphology of the Corpus Striatum and the Origin of the Hypopallium." *Journ. of Anat.* vol. liii. 1919.

Thomson, J. Stuart. "Morphology of Prosencephalon of Spinax, etc." *Trans. Roy. Soc. of Edin.* vol. lii. Part ii. 1918–19.

Tretjakoff, D. "Brain of Ammocoetes." *Archiv für Mikr. Anat. und Entwick.* Bd. lxxiv.

Völsch. "Anatomie des Mandelkerns, etc." *Archiv für Mikr. Anat.* 1906.

—— "Zur vergleichenden Anatomie des Mandelkerns, etc." *Archiv für Mikr. Anat.* 1910–11.

THE BASAL ARTERIES OF THE FOREBRAIN AND THEIR FUNCTIONAL SIGNIFICANCE

By JOSEPH L. SHELLSHEAR,

Demonstrator of Anatomy, St Bartholomew's Hospital, London

THE recent important investigations of Professor Elliot Smith in reference to the phylogenesis of the corpus striatum, and more especially to the particular significance which he has attached in that paper (1919) to the vessel which he has termed the lateral striate artery in Reptiles, has made it obvious that a more searching investigation than has hitherto been made into the nature of the blood vascular supply of the so-called basal regions of the cerebral hemispheres might supply corroborative evidence in the elucidation of these morphological problems.

At his suggestion I undertook this investigation in the Anatomical Department of St Bartholomew's Hospital.

The research has not only justified these anticipations, but in addition has revealed some important discrepancies in the work of previous investigators in this field.

But further, when viewed in the light of Stopford's contribution to the study of the "Blood Supply of the Pons and Medulla," it has strongly confirmed the opinion of Hilton that the arteries of the body are laid down with remarkable precision, and that their distribution is closely associated with the function of the part supplied. For these reasons I have felt, that, despite the incomplete nature of the data in my hands, a record should be made of the results obtained to serve as a stimulus to further investigation, since circumstances have rendered it impossible for me to carry this work to a more complete stage at the present time.

TECHNIQUE

The methods employed in this work are the same as those used by Beevor (1909) except that it was found more convenient to use a record syringe instead of Beevor's pressure apparatus to inject the basal vessels.

THE ARTERIAL SUPPLY OF THE CLAUSTRUM

In his paper, previously referred to, Elliot Smith suggests that the claustrum is represented in Reptiles by the hypopallium, where it turns in from the pyriform area. Now if the arterial blood supply is to be of any value as a phylogenetic criterion, then the claustrum should be supplied by the lateral striate group of arteries, unless perchance John Hunter's view is correct that "the course of the arteries is such as will convey the blood most conveniently....whoever, therefore, discovers a new artery, vein, or lymphatic, adds little to the stock of physiological knowledge."

Dealing with the actual question of the arterial supply of the claustrum. In his investigation of the blood supply of the brain Duret realised the phylogenetic importance of the vessels and made use of his findings in an attempt to confirm the then existing views on the origin of the claustrum.

He states: "The claustrum receives some fine arterioles which penetrate the convolutions of the Island of Reil. It is supplied exclusively by these vessels and ought not to be included in the circulation of the corpus striatum. One knows moreover that this grey band is only a detached portion of the grey matter of the neighbouring convolutions. We have never seen any anastomosis between these arteries and those of the corpus striatum." Beevor (1909) confirms the findings of Duret, stating that: "The claustrum and external capsule are supplied by the cortical arteries which penetrate from the insula and that there is no connection between the arteries to these structures and those of the adjoining lenticular nucleus."

The observation of both these investigators, that no anastomosis occurs between the vessels to the claustrum and those to the lenticular nucleus, is a very important one, as we shall see shortly, and it is interesting in that it confirms the opinion of John Hunter (the first to describe end arteries) that the arteries entering the brain substance do not anastomose with one another. My own work also confirms this observation. In contrast with Duret's statement, however, I would point out that, in his illustration here reproduced (fig. 1), he shows the claustrum as being supplied in part by branches of the lateral striate artery.

Unfortunately Beevor's specimens, showing his injections of the claustral region, are not accessible, but a careful study of his memoir and of his beautiful specimens in the Museum of the Royal College of Surgeons, has impressed me with the accuracy and value of his work.

I was surprised therefore to find, when I injected the middle cerebral artery at its origin and clamped off the vessels to the insular cortex, that the claustrum was clearly injected together with the lenticular nucleus, whilst the insular cortex was not injected. This I repeated in three other cases with the same result.

In my cases there is no communication between the vessels of the insular cortex and those of the claustrum.

In the cases described by Beevor and Duret there is no communication between the vessels of the lenticular nucleus and those of the claustrum.

The discrepancy in the two results is explained by the fact that on examination of my specimens one sees a separate and distinct series of fine vessels passing through the limen insulae to reach the claustrum. These are basal branches of the middle cerebral, arising more laterally than the commonly named lateral striate arteries.

The ligatures applied by Duret and Beevor must have been placed on the medial side of this series of vessels, and they had presumably regarded any vessels arising lateral to the lateral striate as cortical. This view is at once true and false: phylogenetically the claustrum is cortical, but as it is a definite part of the corpus striatum, from the point of view of blood vascular relationship, it may be considered quite as definitely basal.

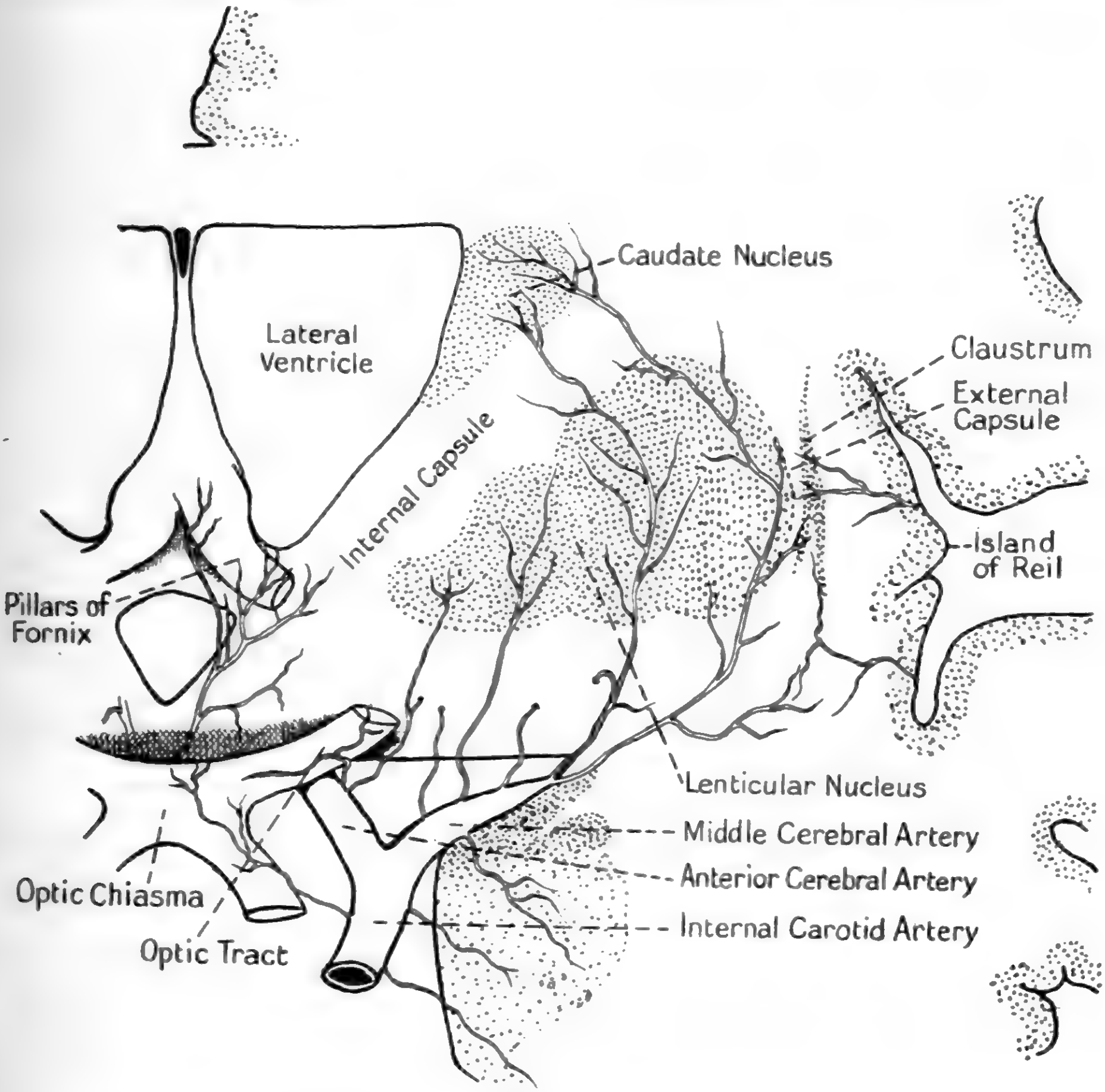

Fig. 1

In order to demonstrate this series of vessels I placed a cannula in the middle cerebral artery at its origin and applied a ligature medial to the claustral arteries. I next placed a cannula distal to the claustral arteries but proximal to those of the insular cortex. I then injected the proximal segment of the middle cerebral in red and the distal segment in blue, with the result that the insular cortex was unstained, the claustrum stood out as a blue crescent and the portion of the lenticular nucleus injected stood out in red.

Unfortunately this specimen was not ready when this paper was read before the Society. It is however to be seen in the Museum of the Royal

College of Surgeons, where it provides a vivid demonstration of the discrete character of the blood supply to all three parts.

It is thus perfectly clear that the claustral arteries are not branches of the lateral striate, but arise as a special group in series, on the one hand with the cortical vessels of the island, and on the other hand with those arteries which have been identified as the special arteries of cerebral haemorrhage by Charcot.

In this connection it is interesting to relate the following statement by Charcot (1881): "The Thalami together with the Corpora Striata are the most common seats of haemorrhage; and yet certain authors have announced the opinion that in the majority of cases the haemorrhage takes place outside the corpus striatum. This is an exaggeration rather than an error, for next to the opto-striate bodies the spot most frequently attacked by haemorrhage is the claustrum."

The recent contribution to the morphology of the corpus striatum by Elliot Smith, and the still more recent paper by Dart in this Journal on the same subject, seem to give peculiar significance to the fact already emphasized that the arteries in this region are end-arteries and in series with the cortical arteries of the insular cortex. Elliot Smith has explained the appearance and origin of the hypopallium as an infolding of the cortex and Dart has shown that the folding follows the differentiation of the deeper layer of that cortex whose superficial layer is the nucleus of the lateral olfactory nucleus in Selachians. These changes have taken place lateral to the palaeostriatum which is covered by the tuberculum olfactorium.

If this differentiation and increase of the nature of a hypertrophy occurs, then in the place of a primitive even distribution of cortical end-arteries, one would expect to find an enlargement of the end-arteries at the place where hypertrophy has occurred. This occurs at the site immediately lateral to the palaeostriatal region (as was phylogenetically deduced by Elliot Smith) and not from the insular cortex. It must however be recognised that the artery which he termed lateral striate in Reptiles is not the lateral striate of human anatomy. The lateral striate of human anatomy, as Charcot pointed out, passes into the lentiform nucleus and is probably palaeostriatal, because it is much more medial in position than the claustral (or hypopallial) arteries, which I consider correspond with the lateral striate in Reptiles. I have therefore named these vessels accordingly in fig. 2.

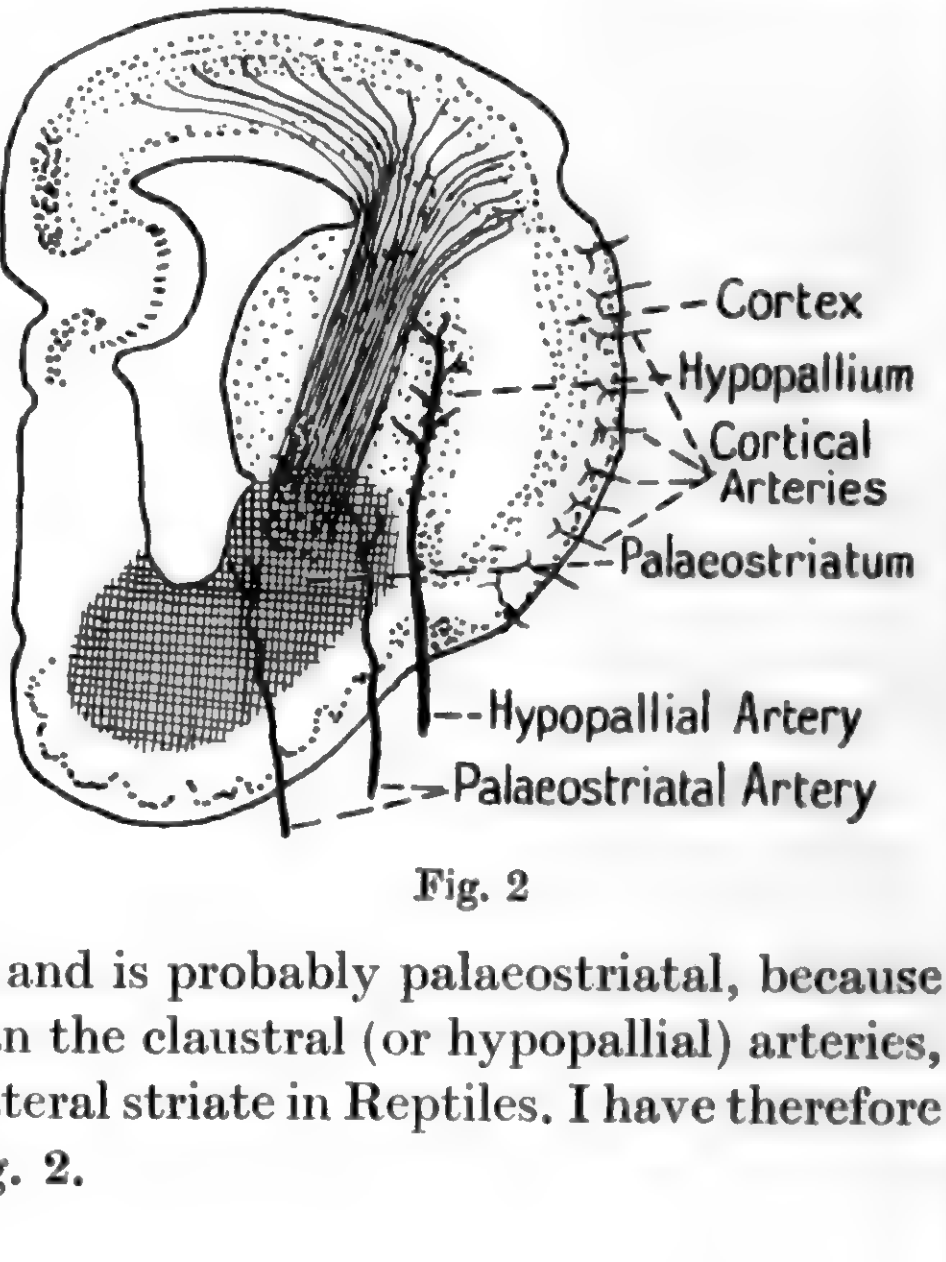

Fig. 2

There is little necessity to stress further than Charcot has done the clinical significance of such large cortical end-arteries as we have here represented.

THE DISTRIBUTION OF THE VESSELS IN RELATION TO THE ANTERIOR PERFORATED SPOT

The usual descriptions and illustrations given in text-books of these vessels have become so diagrammatic from continual repetition that it is difficult to reconcile what is actually found with the descriptions given.

Figs. 3 *A*, *B* and *C* show the appearance of three typical specimens of the anterior perforated spot.

A row of perforations lies in close relation to the endorhinal fissure placed postero-internal to the lateral olfactory stria.

Except at the lateral angle of the space, where there are bunched together five or six perforations larger than the remainder, these perforations are arranged in a row roughly in two series.

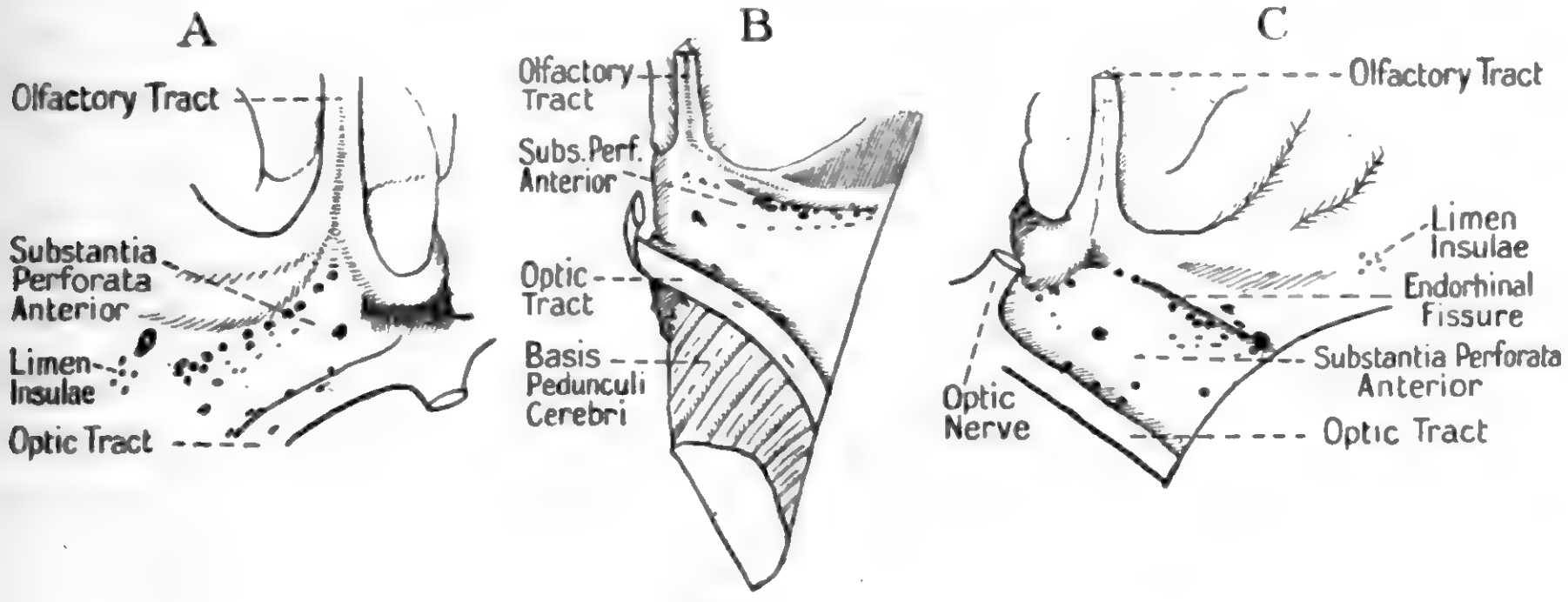

Fig. 3

Laterally to these perforations can be seen the fine perforations on the limen insulae caused by the claustral arteries.

The perforations in relation to the olfactory stria average from 18 to 20 in number.

The usual description of these basal arteries is as follows: the anterior cerebral artery gives off antero-mesial basal branches which pierce the inner part of the anterior perforated spot and the lamina terminalis. The middle cerebral supplies antero-lateral basal branches perforating the anterior perforated spot. These antero-lateral branches are further divided into mesial and lateral striate arteries.

To correspond therefore with the perforations the antero-lateral branches of the middle cerebral artery should be approximately 18 in number. An examination however of an injected brain, sectioned horizontally just above the anterior perforated spot, shows that of the 18 openings the outer 5 are middle cerebral, and of the remainder only 4 or 5 are middle cerebral, the others being anterior cerebral branches.

Of the two rows of openings the anterior is occupied by the anterior cerebral branches, the posterior by the middle cerebral.

It is very interesting to observe that a section through the anterior commissure in this specimen shows that, at this level, the corpus striatum in front of the commissure, together with the commissure itself, is supplied by the anterior cerebral artery, the area lateral and postero-lateral by the middle cerebral. Finally the area postero-mesial to it is supplied from without inwards by the anterior choroidal, the posterior communicating and the posterior cerebral arteries. Thus the anterior commissure is the dividing line between five different arteries, and this I have confirmed in one of Beevor's specimens.

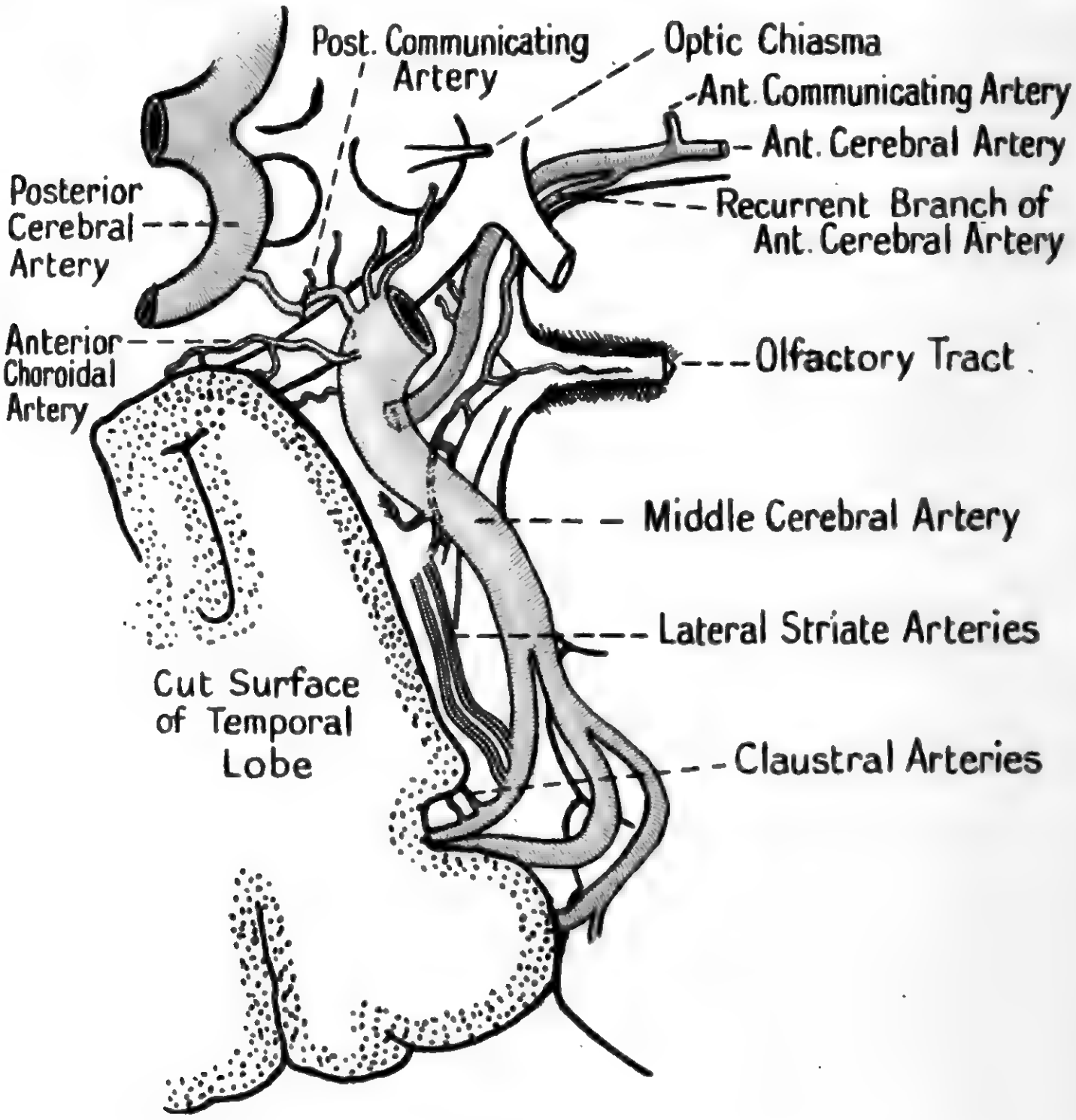

Fig. 4

When one considers with this fact the complicated phylogenetic changes which have taken place round this area, it seems clear that arteries are laid down in no haphazard fashion.

A reference to fig. 4 explains the supply of the anterior cerebral artery, and also impresses the necessity for a revision of the nomenclature of these vessels. The anterior cerebral gives off, in all the specimens I have examined, a recurrent vessel in the neighbourhood of the anterior communicating artery, and in one case distal to it. This vessel passes backwards and outwards to the lateral angle of the space, and there enters the brain substance closely related to the lateral striate group of the middle cerebral.

Contrary to Duret's observations, and in confirmation of Beevor's, I have been unable to find any supply to the optic thalamus from the lateral striate arteries, and consider that the name lenticulo-optic artery should be omitted from anatomical nomenclature.

It is of interest here to observe the angles at which these vessels come off from the anterior and middle cerebral arteries. Text-book illustrations show them as a neatly arranged row coming off at right angles, whereas I have noticed that the larger the vessel entering the substance of the brain, the more acute is the angle it makes against the direction of the current; and to attain this end both sets from the anterior and middle cerebral leave the parent trunk at a considerable distance from the place of entry into the anterior perforated spot. It is strange that no reference to this fact, which must have an important clinical bearing, can be found in the literature, except in *John Hunter's Works*, p. 220. He states:

"I have already observed that the angles at which the branches of an artery arise may either retard or allow a freer motion of the blood; but nature appears to have taken still more care in retarding the blood's motion when velocity might do mischief. She seems also to have taken more care about the blood's motion in some parts than in others; as for example, in the brain, a part which probably cannot bear the same irregularity, in quantity or velocity of the blood, as many other parts of the body."

Directly posterior to the division of the olfactory tract, and lying immediately in front of the optic tract, is a well marked perforation into which passes a branch of the anterior cerebral artery. In the specimen from which fig. 3 *B* was taken there was a line of very fine perforations leading from this perforation to the lateral angle of the space. Except for this opening the only other perforations are of insignificant size.

The precise nature of the distribution of the anterior and middle cerebral arteries is also to be found in the other vessels of the brain.

Thus I find that the posterior cerebral and posterior communicating arteries are so precisely distributed in my specimens that the description given by Beevor of the arterial supply of the optic thalamus could well have been made from my specimens.

I would refer my readers to his paper for a more detailed description of the blood supply of this structure. It is sufficient here to say that the anterior nucleus is supplied by the posterior cerebral, and the injected nucleus stands out as an island in the rest of this part of the thalamus; and roughly speaking, that, of the remainder of the thalamus, the anterior portion is supplied by the posterior communicating, and the posterior portion, including the pulvinar and the external geniculate body, is supplied by the posterior cerebral artery.

A reference to Sachs's investigations on the function of the thalamus in *Macacus*, reveals the fact that the subdivision of the thalamus into functional areas by him very closely coincides with the areas of blood vascular distribution as found by Beevor and myself.

Thus he found that the anterior nucleus was extremely unexcitable to electrical stimulation, and further we know that into this nucleus passes the fasciculus mammillo-thalamicus, and there is reason to associate this nucleus with the sense of smell.

Similarly the distribution of the other basal branches of the posterior cerebral is closely associated with vision.

That this association between blood vascular distribution and function, so suggestive in the thalamus, is no mere coincidence, is clear from the complete and exact account of the blood supply of the pons and medulla oblongata by Stopford and from the distribution of the blood vessels in other parts of the body in their relation to function first clearly demonstrated by John Hilton.

Stopford's clear-cut areas in the medulla oblongata demarcating the hypoglossal nucleus in the case of the anterior spinal artery, the trigonum vagi in the case of the vertebral artery, and the trigeminal nucleus in the case of the posterior inferior cerebellar artery, are so similar in type to the areas of the corpus striatum shown by me, and the optic thalamus by Beevor, that we are justified in using the blood supply as confirmatory evidence in investigation of function.

Furthermore, when one considers the ingenious experiments on brain function by such investigators as Sherrington, it seems to be within the range of practical experimentation to determine function by cutting off the blood supply to known areas.

The morphological and functional importance of the distribution of arteries receives a further significance from Blackburn's report on the abnormal median anterior cerebral artery, as found among the insane. He finds that this abnormality is much more frequent among the insane, and states that the frequent variations of this system of vessels suggest instability of ontogeny and phylogeny.

It seems possible to enunciate the two following principles:

(1) That arteries are laid down with a definite relation to function.

(2) That the distribution of arteries obeys some definite ontogenetic and phylogenetic law.

This problem, which was before me throughout, viz., the relation of blood supply to function, is far from its full explanation, and yet there is one aspect of it which deserves special consideration, as it arises directly from the material provided by this investigation. There is a free capillary anastomosis between the cortical and hypopallial arteries on the one hand, and the hypopallial and palaeostriatal arteries on the other hand, and yet no opening up of this capillary network to form connecting arterial channels takes place.

Such an arrangement provides us with a critical problem in the question of the relationship of arterial supply to function, for we are now in such a position of precise knowledge as to the origin of the claustrum that the fact of the preservation of the original reptilian type of blood supply, throughout the mammalian series (as shown in fig. 2), illustrates that arteries once laid down, maintain their anatomical and presumably functional integrity throughout phylogeny.

The only hypothesis which I can suggest to explain this precision of distribution is the following: In an evolutionary sense it must be to the advantage of the organism that the blood supply to a part or parts of its structure concerned with some special function should be capable of being adjusted to its requirements at any given time.

Such a co-ordinating and accommodating mechanism for the blood supply is found in the vasomotor system. When a particular area, such as the hypopallium, develops and differentiates, its vascular supply, although more elaborate, remains under the influence of the same controlling apparatus.

Perhaps no more beautiful illustration of this could be found than in the blood supply of the palate.

Hilton says: "Curiously enough, this soft palate receives six arteries, three on each side: one from the facial, one from the ascending pharyngeal and one from the internal maxillary, the true 'masticatory artery.'

Here then is a simple piece of anatomy, which shows the precision and purpose of the distribution of arteries which seem to be associated with three different important functions: one in relation to respiration, the facial artery; another in relation to deglutition, the ascending pharyngeal artery; and a third in relation to mastication receiving its supply from the masticatory artery."

In conclusion I wish to express my thanks to Dr Macphail of St Bartholomew's Hospital for his assistance in this work, to Mr R. Keene for the drawings he has made for me, and to the Pathological department of the same institution for the supply of material used in this investigation.

REFERENCES

Elliot Smith. *Journal of Anatomy*, vol. LIII. 1919.
Stopford. *Journal of Anatomy*, vol. L. pt III. 1916.
Beevor. *Phil. Trans. Roy. Soc.* vol. CC. 1909.
Duret. *Arch. de Physiol.* 1873 and 1874.
Charcot. *Lectures on Senile Diseases*, 1881.
John Hunter. *The Works of John Hunter*, vol. III.
Sachs. *Brain*, Part CXXVI. 1909.
Blackburn. *Journ. of Comp. Neur. and Psych.*
John Hilton. *Rest and Pain*, 1880.

FUSION-LINES OF BONES

By ZACHARY COPE

In a previous communication on the internal structure of the sphenoidal sinus I stated that there is evidence to show that the bone formed at the line of fusion of bony centres may be and often is of a denser and more resistant material than the tissue on either side of the line.

Though I believe evidence to support this statement must be known to all those who have made a study of the internal structure of the long bones yet I have thought it an interesting investigation to see in what parts of the skeleton such fusion-lines can be recognised and at what age they become indistinguishable from the neighbouring bone.

For this purpose I have examined sections of fully-developed dried bones and radiograms of fully-grown individuals of different ages. The conclusions arrived at, and illustrated by the accompanying radiograms and photographs, are as follows:

The lines of fusion between the epiphyses and diaphyses of the long bones can be recognised in many cases until a late period of life. The fusion-line persists as a somewhat irregular line of thin compact tissue, or as a narrow belt of cancellous tissue denser than the bone on either side. The lines are best seen and most persistent in the bones of the lower extremity where the stress is greatest. The junction of the great trochanter and the head of the femur with the diaphysis are usually distinct years after the bone is fully grown (fig. 1). The most remarkable persistence is seen at the site of the epiphyseal lines at the lower end of the femur and the upper end of the tibia, for a thin but dense line of bone can be seen in these situations in patients who are sixty and even seventy years of age (figs. 2, 3, 4). Radiograms show this line fairly constantly and one would be likely to take the bone as that of a much younger person unless aware of the fact of persistence of the fusion-line (fig. 5). The lines at the lower end of the tibia and fibula persist for some years but not so definitely.

In the upper extremity the fusion-lines are not so persistent. At the upper end of the humerus the position of fusion between the head and shaft (morphological neck) can usually be distinguished in a fully ossified bone as two denser lines of bone enclosing an obtuse angle between them. At the lower end of the humerus a transverse fusion line may be seen frequently, but the bones of the forearm seldom show very definite indication of such a line.

The metacarpal and metatarsal bones and the phalanges not uncommonly show some, though seldom very definite, evidence of denser bone at the epiphyseal junction-line.

g. 1. Section of upper end of femur from a full grown adult (R.C.S. Museum).

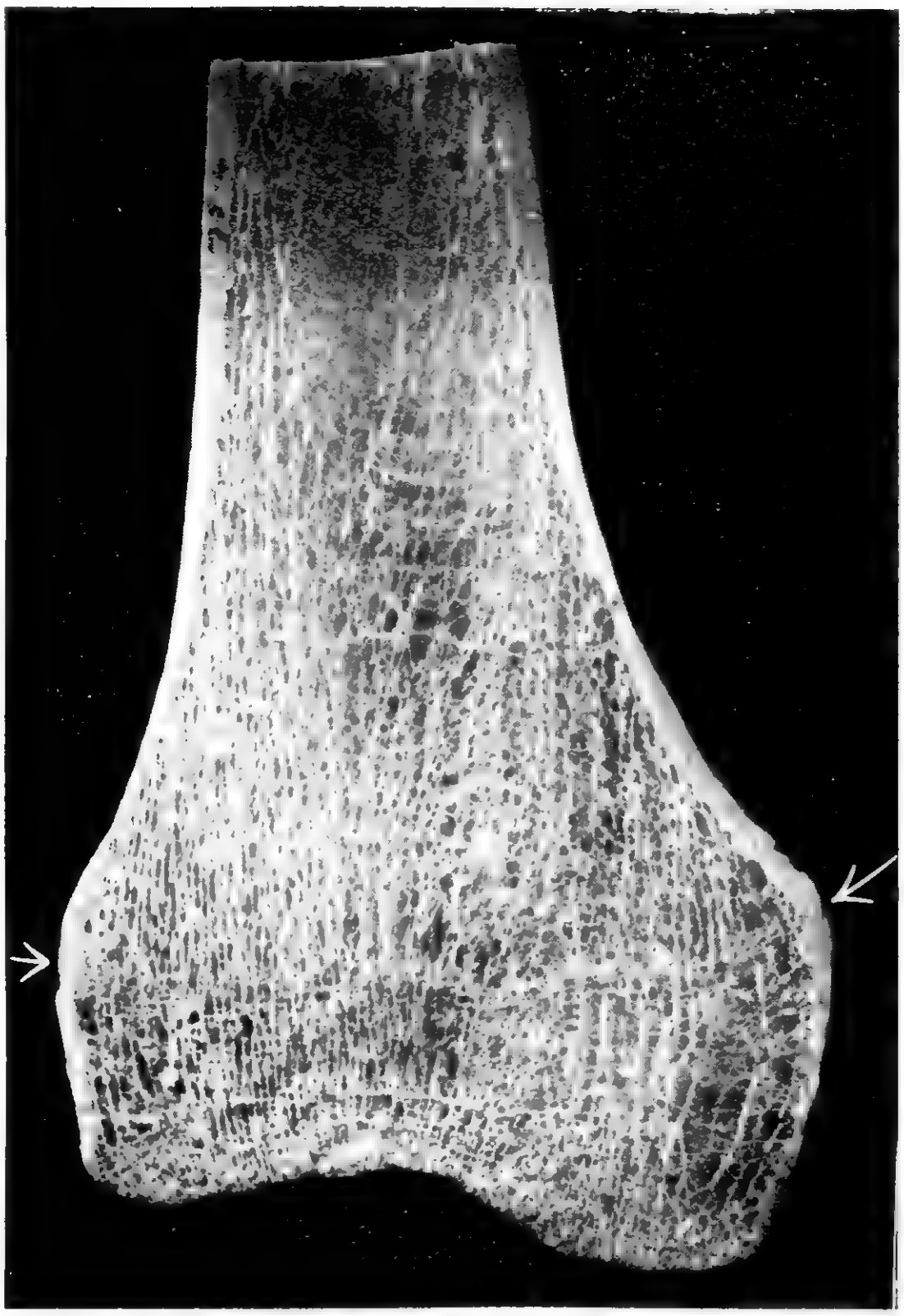

Fig. 2. Coronal section of lower end of femur from a full grown adult (R.C.S. Museum).

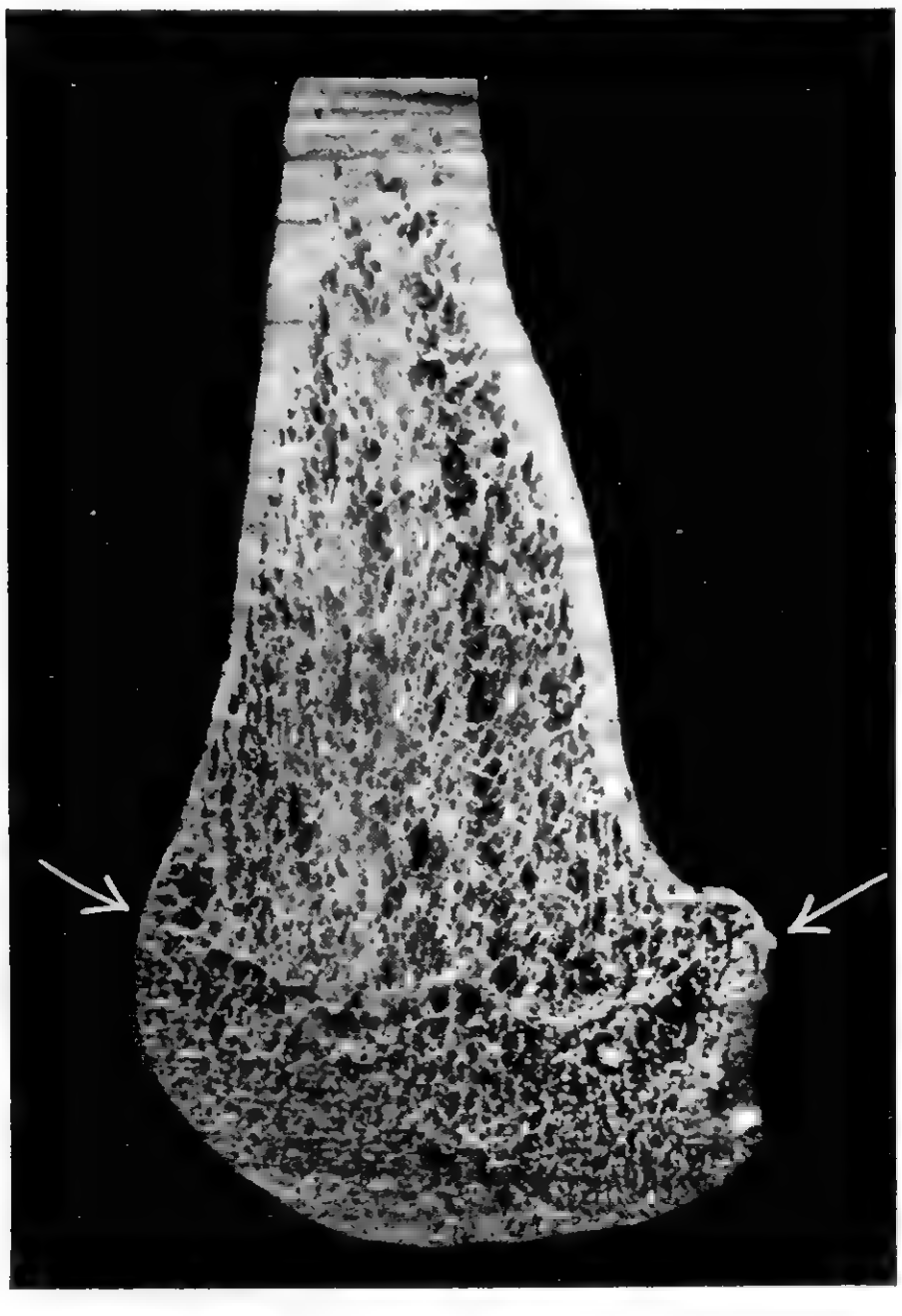

Fig. 3. Sagittal section of lower end of femur from a full grown adult (R.C.S. Museum).

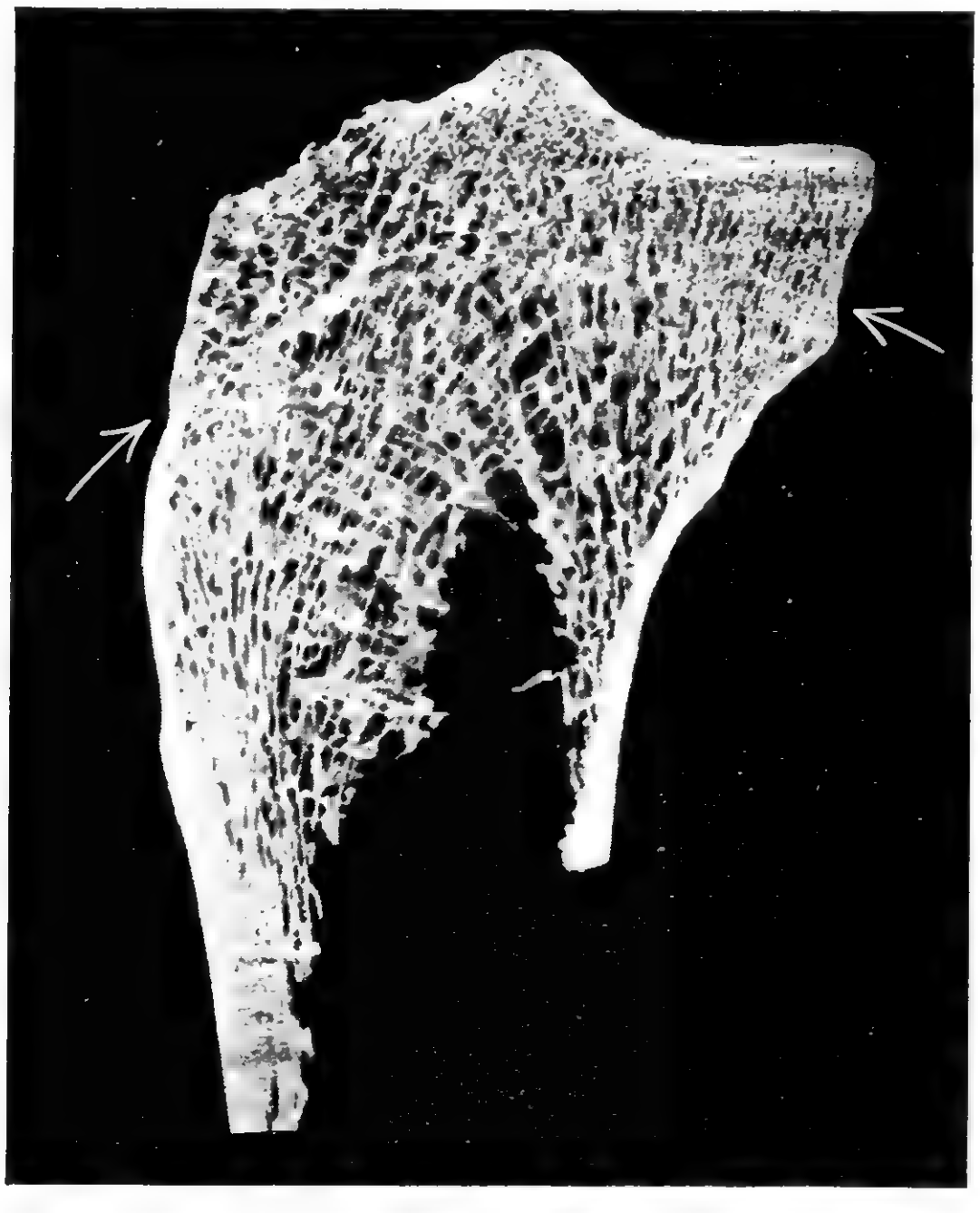

Fig. 4. Section of upper end of tibia from a full grown adult (R.C.S. Museum).

Fig. 5. X-ray of upper end of tibia in a patient aged 60 years, showing fusion-line.

Fig. 6. Sagittal section of skull showing fusion-line between basi-occipital and basi-sphenoid (R.C.S. Museum).

In the skull base the junction between the basi-occipital and the basisphenoid can frequently be observed as a band of dense cancellous tissue (fig. 6). The fusion between the segments of the sacrum and of the sternum is also denoted by lines of denser bone. The above facts are sufficient to support the statement made in my former communication.

It is doubtful whether the epiphyseal fusion-line has much clinical importance. It is well known that the cartilaginous epiphysis presents a barrier to the progress of infection and malignant disease, but so far I have been able to find very little evidence that the bony fusion-line acts in a similar manner. In several femora, however, taken from subjects with osteitis deformans, I have noted that the osteoporotic process either stopped short at or left unaffected, the narrow band of denser bone at the junctions of the diaphysis with the epiphyses. That the denser bone has an influence on the formation of air sinuses is easily understood and not difficult to demonstrate.

NOTE ON THE VERTEBRAL EPIPHYSEAL DISCS

By Professor A. FRANCIS DIXON,
Trinity College, Dublin

As is well known the vertebral epiphyseal discs in man are feebly developed structures in comparison with those found in lower animals, and possess an annular and not a complete disc-like outline. A careful examination shows, however, that in one remarkable detail the human epiphyseal plates exhibit an almost complete agreement with those of lower forms.

If a number of young human subjects are examined it will be found that, in the thoracic region, the vertebral epiphyseal plates tend to become first fused to the vertebral bodies in the neighbourhood of the costal facets. In stages a little earlier in development it will be seen that the edges of plates not only cover the upper and under aspects of the vertebral bodies but that they send downwards, or upwards, as the case may be, thin scale-like prolongations to cover the costal articular facets. Even in the three lower thoracic vertebrae, where the costal facets lie far from the upper and lower edges of the vertebral bodies, a slender spicule of bone may often be recognised connecting the articular surface for the head of the rib with the upper epiphyseal vertebral plate of the vertebra.

In this way it can be shown that the costal articular facets, seen in the adult to lie in the vertebral bodies, do not actually belong to those bodies, but are extensions of the vertebral epiphyseal plates. The heads of the ribs articulate not with the bodies of the vertebrae but with their epiphyses. The reason that this fact has been so often overlooked seems to be that the condition is only clearly seen in man for a very short period in the developmental history of the vertebra, and that the fusion of the plate with the vertebral body takes place in the first instance in that part which covers the costal facet. Fig. 1 illustrates the condition in man just at the time when it is best marked.

When we examine the thoracic vertebrae in lower animals the arrangement is much more distinct. The epiphyseal plates are seen to possess wing-like extensions which cover over, and indeed form, the costal facets. The heads of the ribs articulate the epiphyseal plates only (fig. 2). This plan appears to be universal in all animals in which the heads of the ribs reach the main part of the vertebral axis. Man as we have seen is no exception.

One other point is of interest. The annular outline of the human epiphyseal plate arises from a want of ossification in the central part of the cartilage covering the surface of the vertebral body. In such an animal as the baboon we seem to have an intermediate condition between the human type and that which obtains in quadruped Mammals. In the baboon, as fig. 3 shows, the annular epiphyseal plate is well developed, but in addition a second centre of ossification is seen on the upper and under aspect of the vertebral body, occupying the space enclosed within the annulus. At a stage a little later in development there may appear to be a complete disc, very thin however in its central portion. Possibly it is the failure of this central ossific islet, *C* in fig. 3, which is responsible for the typical annular form assumed by the human epiphyseal vertebral plates.

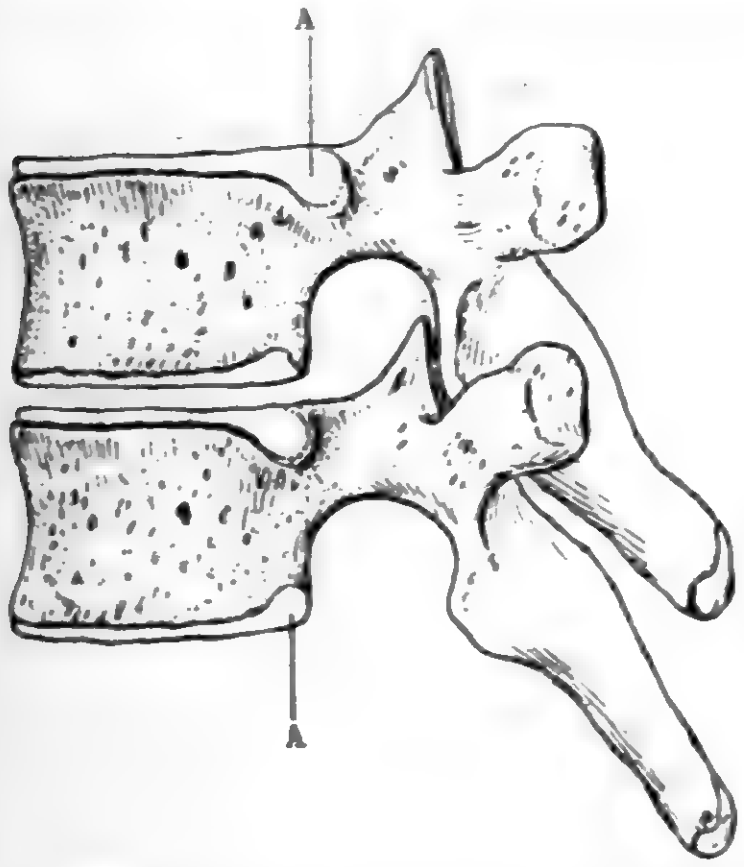

Fig. 1. Two young human thoracic vertebrae. The extension of the vertebral epiphyseal plates to form the costal facets is shown at *A*.

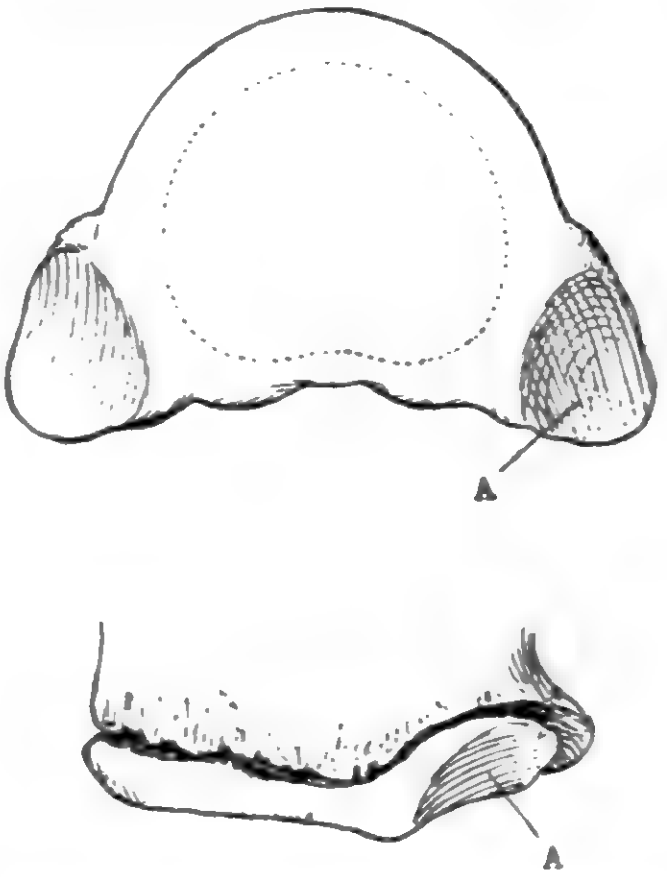

Fig. 2. Vertebral epiphyseal plate from a young Zebu seen from below and from the side. The wing-like extension which forms a part of the articulation for the head of a rib is seen at *A*.

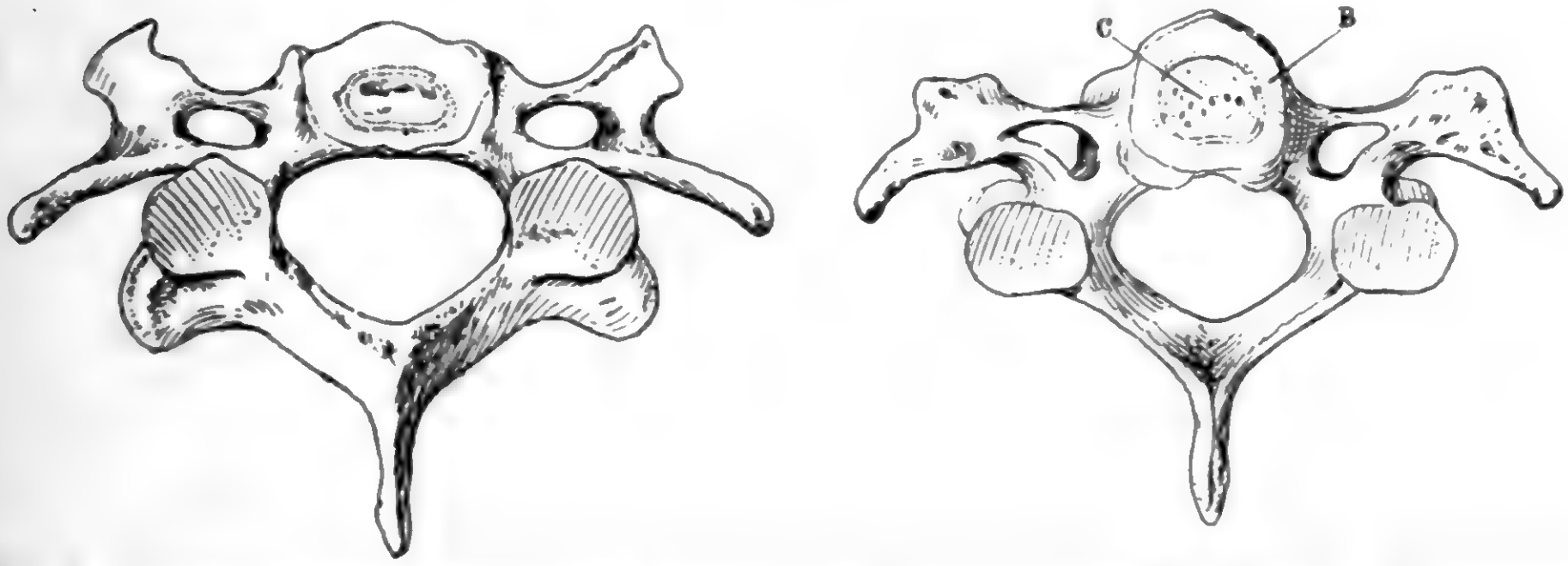

Fig. 3. Cervical vertebra from a young baboon; seen from above and from below. The annular vertebral epiphysis is indicated by *B*, and the ossific islet which arises inside this ring-like epiphysis by *C*.

ON THE PACCHIONIAN BODIES

By W. E. LE GROS CLARK, F.R.C.S.,

St Thomas's Hospital Medical School, London

The villous outgrowths of the arachnoid membrane in the neighbourhood of the intracranial venous sinuses, which were originally described in detail by Pacchioni (1) in 1721, have for a long time attracted the curiosity of anatomists and physiologists. Investigations of these granulations have almost always been approached from the experimental point of view, and there are surprisingly few observations recorded on their anatomical structure and relations.

Originally referred to as "glandulae" by the old anatomists, the Pacchionian bodies were later regarded as passive filters through which the cerebrospinal fluid drained from the subarachnoid space into the intracranial venous sinuses. This view was strongly supported by the classic work of Key and Retzius (2), and received further corroboration from a number of investigators (3), (4) who approached the problem by different methods of experimental injection.

Latterly, the observations made by Weed (5) enable one to accept, though in a somewhat modified form, the filtration hypothesis as being fully confirmed.

Luschka (6) first pointed out that the Pacchionian bodies are hypertrophied arachnoid villi which are normally present in all brains, but which are microscopic in character. If this is so, then what is the significance of the hypertrophy?

Some authors, among whom are Weed and Rokitansky, regard the granulations as definitely pathological formations. This view appears untenable when consideration is given to the constant presence of the granulations in human brains above a certain age, and to their presence in the brains of certain lower mammals. Weed says that "undoubtedly the Pacchionian granule must be considered as a large hypertrophic villus becoming evident on macroscopic examination in *most*[1] adults." I have never seen an adult in which they were absent.

In order to arrive at a satisfactory solution of the question, it is necessary to enquire more closely into the morphological features of the Pacchionian bodies, and to this aspect of the subject I shall confine myself in the present communication.

The intimate relation—physiological and anatomical—between the development of the arachnoid outgrowths and the venous system is well known, and it is clear that the two must be studied in conjunction.

---

[1] Italics mine.

During the course of my investigations, I have found that the arrangement of the meningeal venous sinuses and the cerebral veins differs fundamentally in several points from the orthodox description as given in current text-books of anatomy. I propose first to deal with these points, and subsequently to give an account of the macroscopic and microscopic features of the Pacchionian bodies.

A. THE VENOUS SYSTEM IN RELATION TO THE PACCHIONIAN BODIES

1. *The Superior Cortical Veins*

The general course and distribution of these veins have lately been described in some detail by Sargent(7). In common with modern text-books, he describes these veins as sometimes opening into the sagittal sinus directly, and sometimes opening into the lacunae laterales. This statement, I believe, is incorrect, and is based on a misconception of the true nature of the lacunae laterales, as I shall indicate.

If the cortical veins are carefully dissected out, either in injected or uninjected specimens, they will be found always to open directly into the sinus, and never into the cavities of the lacunae. Where they come into relation with the lacunae, the cortical veins pass beneath them. Such at least is the result of my observations which are based on the examination of over 40 brains. It is evident, therefore, that a cerebral vein opening into a lacuna lateralis is a very rare and abnormal occurrence.

In many cases the vein, immediately before opening into the sinus, undergoes a dilatation, and this may be mistaken for a lacuna lateralis. These two structures are, however, situated in different planes, and, moreover, differ in their naked-eye appearance and in their mode of formation.

The floor of the vein is throughout lined by a smooth endothelial membrane which is only very exceptionally perforated by an isolated Pacchionian body near its termination.

The floor of a lacuna, on the other hand, presents a fasciculated appearance, and is usually perforated by numerous arachnoid protrusions, while the cavity is crossed by innumerable fine dural strands. The membrane separating the lumen of the vein from the lacuna may be extremely thin, and is thus readily torn.

2. *The Lacunae Laterales*

These structures develope pari passu with the growth of the Pacchionian bodies, but it is impossible to say precisely when these lacunae—as such—appear in the human brain.

If the intracranial venous system of a new-born child be injected with coloured gelatine, and if the dura mater be then removed, dehydrated with alcohol and cleared in xylol, the following arrangement will be well seen.

Alongside the sagittal sinus is a coarse plexus formed by the anastomosis of the terminal arborizations of the meningeal veins, the diploic veins which run from the parietal bones to the dura in this region, and the small lateral tributaries of the sagittal sinus.

This plexus occupies precisely the position of, and is formed in exactly the same way as, the lacunae laterales of the adult. As growth proceeds, the venous network becomes more complex, and by the attenuation of the dural meshes and the corresponding widening and coalescence of the venous channels, "lacunae" of variable number and extent are formed.

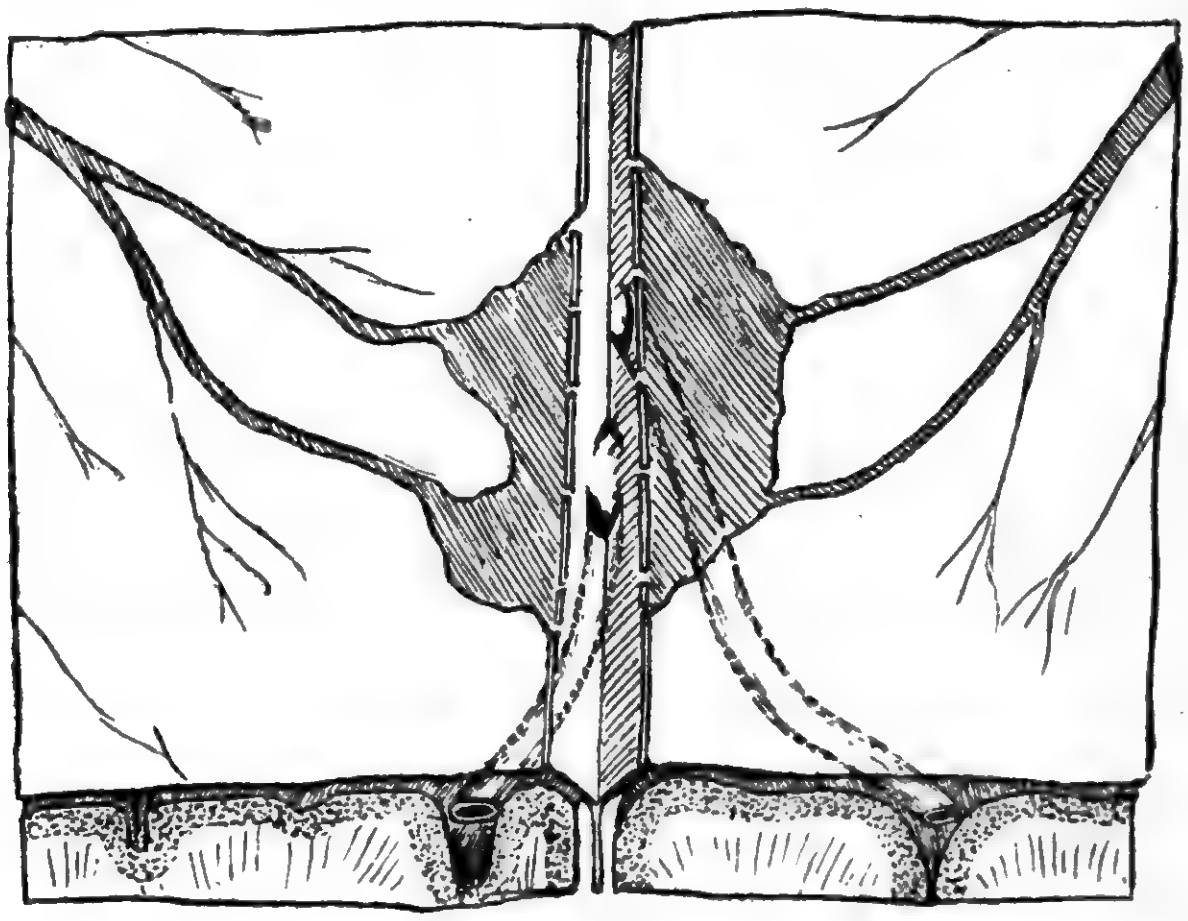

Fig. 1. Diagram illustrating the relations of the cortical and meningeal veins to the lacunae laterales.

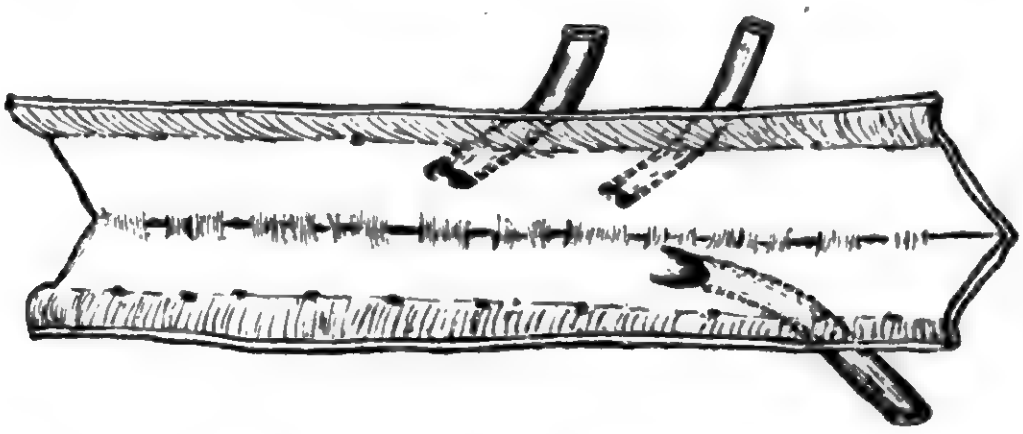

Fig. 2. Diagram illustrating the sagittal sinus laid open from above, to show the openings of the cortical veins and the dural venous plexus.

These lacunae should not be described as well-defined single cavities—diverticula of the sagittal sinus—but rather as a complicated meshwork of veins. If they are studied by dissection, or, better still, microscopically by means of serial sections, it will be seen that the superior terminations of the meningeal veins drain into the outer border of this meshwork, while the diploic veins enter it on its upper aspect. Internally, the meshwork opens by a series of small foramina into the sagittal sinus, i.e. through the venous tributaries of the sinus mentioned in connection with the venous plexus found at birth. The position of these openings is shown with diagrammatic clearness in the sinus of a new-born child, and the accompanying illustration shows their relation to the openings of the cortical veins.

A glance at the calvarium of an adult will show the very numerous diploic foramina scattered alongside the groove for the sagittal sinus, indicating the extent to which the diploic veins enter into the formation of the lacunae laterales.

Faivre (13), indeed, appears to have regarded the lacunae as being formed wholly in association with the diploic veins, for he speaks of "les lacunes, des sinus secondaires qui reçoivent le sang des veines diploïques."

Incidentally, it is perhaps worth while drawing attention to the inadequate description of the openings of the diploic channels as given in anatomy textbooks. These descriptions lead the student to suppose that the diploic veins leave the diploë at very few and limited points.

The lacunae, as they increase in size, form small smooth depressions in the frontal and parietal bones on either side of the groove for the sagittal sinus. These are commonly described as "depressions for the Pacchionian bodies." They are more correctly regarded as depressions for the lacunae laterales, for they are frequently well-developed before the Pacchionian bodies are large enough to make an impression on the bone. As the Pacchionian bodies grow, however, they may become lodged in well-defined and sharp-edged pits which can be easily recognised and distinguished by their characteristic appearance. The arrangement of the other cerebral veins and dural sinuses accord well with the usual description. Sargent has recorded the presence of a dilatation at the commencement of the straight sinus, i.e. at the junction of the great vein of Galen and the inferior longitudinal sinus. This dilatation he terms a lacuna, but it is clear that it differs fundamentally in its anatomical relations and mode of formation from the lacunae laterales. This dilatation is especially well marked at birth, when it forms a relatively very large cavity.

B. MACROSCOPIC ANATOMY OF THE PACCHIONIAN BODIES

1. *Development*

The Pacchionian bodies appear at a much earlier age than is generally supposed. At birth they are imperceptible even on examination with a hand lens. At the age of six months they are still invisible, but by 18 months they are quite obvious on close inspection. They appear in the first instance in the regions where the parieto-occipital and central veins open into the sagittal sinus. From these nuclei they spread forwards and backwards along the superior margin of the cerebral hemispheres, and at the age of three they are disseminated over a considerable area. By this time they are often to be seen along the lateral sinuses, on the margin of the cerebellum. At four they project well into the sagittal sinus, forming conspicuous nodules in the lumen of the sinus[1].

---

[1] Faivre (13) states: "c'est vers la dixième année que ces produits (Pacch. bodies) commencent à se montrer, bien qu'on en puisse trouver avant cette époque." I cannot explain this discrepancy.

2. *Distribution of Pacchionian bodies in Adult*

According to Key and Retzius, the Pacchionian bodies occur in the following situations in order of frequency: sup. longitudinal sinus, transverse sinus, cavernous sinus, sup. petrosal sinus, and venae meningiae mediae. I have also found them in connection with the sphenoparietal and straight sinuses. In all these situations, they tend to congregate in the regions where the cerebral veins open into the sinuses.

In the neighbourhood of the sagittal sinus, the granulations are most numerous in the floor of the lacunae laterales. As these latter increase in extent, the granulations also spread, and, with advancing age, they tend to crawl down the middle meningeal veins. Elliot Smith (8) has recorded an extreme instance of this latter arrangement.

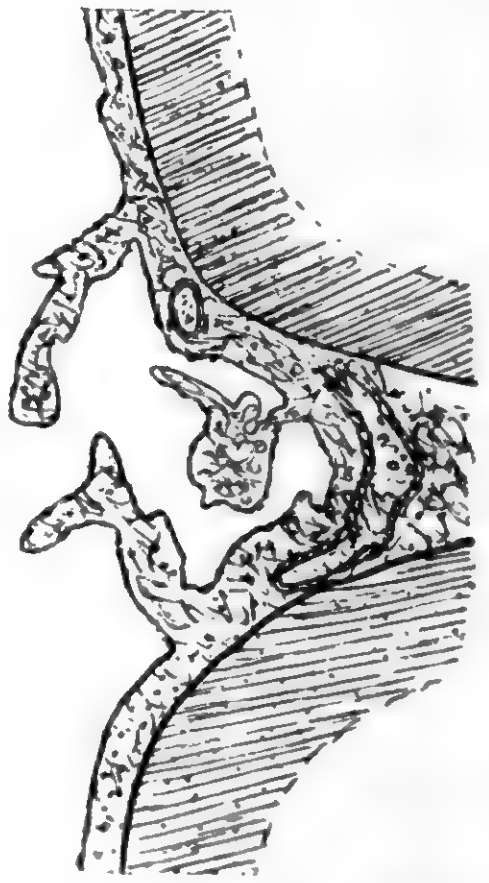

Fig. 3. Section showing Pacchionian bodies in the region of the parieto-occipital fissure in a child aet. 2½.

The bodies that project into the lumen of the sinus are found in the floor and lateral walls. Quite frequently, a small clump of granulations is found on the floor of the sinus at the mouth of one of the cerebral veins, so that they are bathed by the blood as it is poured from this vein into the sinus.

The Pacchionian bodies in relation to the lateral sinus are practically always confined to the surface of the cerebellum—that is to say, they project into the sinus from below. Very rarely are they found on the surface of the cerebrum in this situation. They are most numerous at the point where the inf. cerebellar veins open into the lateral sinuses on either side of the Torcular Herophili, and from this point they gradually fade away laterally.

The Pacchionian bodies are much less frequently seen in relation to the other venous sinuses, and these become conspicuous only in certain conditions, such as senility.

The precise relation of the Pacchionian bodies to the venous spaces with which they are associated is of some interest. The impression is gained from most descriptions that the Pacchionian bodies are formed by a pouching out of the arachnoid membrane, which eventually finds its way into a venous sinus, i.e. that the body, when it first appears, is not connected with a venous space in the dura. This idea can be readily demonstrated to be erroneous. If the brain, either of an adult or a child, be examined, and if the dura mater be lifted up from the underlying arachnoid with the utmost care, it will be found that every granulation of the arachnoid—even the most minute—is directly attached to the under surface of the dura mater. If this adhesion be broken down and the dura inspected, it will be seen that the point of attachment at the dura is marked by a minute aperture, and with appropriate pressure, blood can be squeezed out through this aperture from the dural sinuses. This observation—in conjunction with histological evidence to be presently produced—indicates that the arachnoid granulations come into direct contact with the blood of the venous spaces from their first appearance. Poirier (9) wonders "comment functionnent celles qui ne sont pas dans une cavité veineuse." The answer is that they all reach a venous cavity.

Other points in the naked-eye anatomy of the granulations are well-known, and need not be detailed here.

C. MICROSCOPIC ANATOMY OF THE PACCHIONIAN BODIES

Histologically, a Pacchionian body or arachnoid granulation (Arachnoidealzotte of German authors) appears as a diverticulum of the subarachnoid space penetrating into the interstices of the dura mater. It is thus covered by a layer of arachnoid mesothelium, and contains a prolongation of the subarachnoid space.

The arachnoid mesothelium consists of a single layer of flattened cells, with lightly staining cytoplasm and large oval nuclei. The subarachnoid space consists of a reticulum of fine fibrous tissue in which are scattered a number of connective-tissue cells. These cells are most numerous, and the fibrous stroma more dense, immediately beneath the arachnoid mesothelium, and on the surface of the brain. Between these two areas, bundles of fine fibrous tissue predominate and the cellular element is very scanty. In children, these connective-tissue cells are found in very much larger numbers, and intertrabecular spaces are very much less marked than in adults.

Incidentally, it may be noted that the pia mater is merely a condensation of the subarachnoid trabecular tissue, and is not a definite membrane comparable to the arachnoid. The density of the subarachnoid tissue in the Pacchionian bodies as a rule is greater at the periphery than at the centre of the structure, and this difference is more marked in the larger granulations.

Although not usual, it is by no means uncommon to find a small capillary blood-vessel in the cavity of a granulation, and in some cases a capillary may be observed to leave the granulation by passing through the arachnoid mesothelium and subdural space to reach the surrounding dura mater. In the Pacchionian bodies of adults, and more so in advanced age, there are frequently found small calcareous nodules. These may be either spherical or cylindrical in shape. They appear to arise by the calcification of small collections of endothelial cells arranged in a concentric formation. My sections show these latter structures undergoing various degrees of hyaline and calcareous changes to form ultimately calcareous nodules. The origin of the primary endothelial formation is, however, not clear. Some sections would appear to indicate their origin in connection with capillary blood-vessels by a proliferation of the endothelium. In other sections they are found in the epithelial cap on the summit of the Pacchionian body, as described below. Their interest lies in the close resemblance of their structure to that of endotheliomatous tumours in this region, and this fact lends support to the suggestion—originally put forward by Schmidt (11) with detailed evidence—that the so-called endotheliomata of the dura mater are really arachnoidal tumours. The calcareous changes in these endotheliomata leading to the formation of psammomata are well-known.

If the arachnoid mesothelium of a Pacchionian body be followed throughout the structure by means of serial sections, it will be found that at the summit of the granulations the mesothelial cells proliferate to form a multilayered cellular cap, and this cellular formation penetrates the surrounding dura mater to come into direct continuity with the endothelial lining of the intradural venous sinuses. At this point, that is to say, there is no subdural space or layer of dura mater intervening between the arachnoid and the venous sinus.

Fig. 4. Section 49, showing tip of Pacchionian body projecting into a venous sinus. The arachnoid has completely blended with the vascular endothelium, and the subdural space is obliterated. 1. Epithelial cap. 2. Arachnoid mesothelium. 3. Subdural space. 4. Dura mater.

This mesothelial cap is evidently identical in structure with the cellular tuft described by Weed in connection with the microscopic arachnoid villi of lower animals, and corresponds to the "Epithelzapfen" of German authors (10, 11). Moreover, Weed (5) has demonstrated that it is through this structure that the cerebro-spinal fluid passes from the subarachnoid space into the venous sinuses.

Except for this point of fusion between the arachnoid and the vascular endothelium (which can be demonstrated by serial sections), the arachnoid covering the Pacchionian bodies is surrounded by the subdural space and the dura mater. The latter—covered on its cerebral aspect by a layer of endothelium—is invaginated into the venous sinus by the protrusion of the arachnoid granulation. In most sections of a Pacchionian body it appears to be completely surrounded by the subdural space, but, as pointed out above, this is not so.

Histological evidence indicates that the Pacchionian bodies are developed in the following way. Opposite the point where an intradural venous sinus approaches the cerebral surface of the dura mater, the arachnoid cells proliferate to form a cell cluster (Epithelknoten of German authors). The cellular tuft thus formed finds its way through the interstices of the thin layer of dura mater separating it from the sinus, and fuses with the endothelial lining of the latter. In so doing, it pulls out a stalk of arachnoid membrane containing a diverticulum of the subarachnoid space. This early stage is shown in the accompanying illustration.

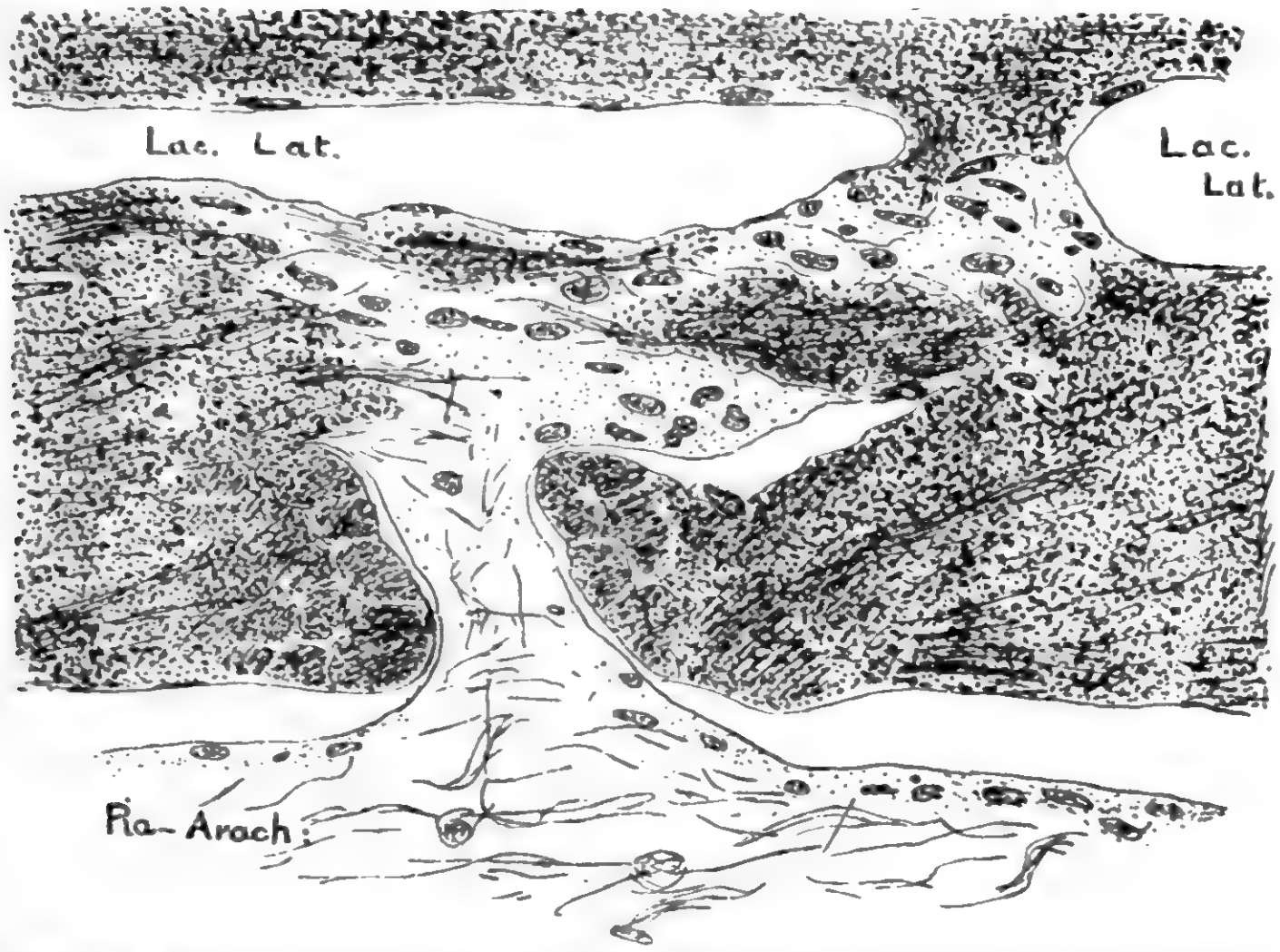

Fig. 5. Section 102, showing the first formation of an arachnoid villus.

Thus is formed the microscopic arachnoid villus normally present in all brains. Subsequent growth, leading to the formation of the macroscopic arachnoid granulation, appears to take place almost entirely by the dilatation of the subarachnoid space in the pedicle of the microscopic villus.

D. SIGNIFICANCE OF THE PACCHIONIAN BODIES

The assumption that the Pacchionian bodies constitute the essential mechanism of filtration of the cerebro-spinal fluid is nullified by Weed's researches. He has shown that the cerebro-spinal fluid reaches the venous channels by means of the microscopic arachnoid villi. It therefore remains to ascertain the precise relation of the Pacchionian bodies to the villi.

Microscopic examination gives the Pacchionian bodies the appearance of arachnoid villi which have been distended and herniated into the cavity of the venous sinuses by the pressure of the cerebro-spinal fluid. And it is, in fact, suggested that the size and number of the Pacchionian bodies are an indication of the cerebro-spinal fluid pressure. If this is the case, then an examination of the brain of an individual who has died with an abnormally high cerebro-spinal fluid pressure should reveal an unusual development of the Pacchionian bodies. This indeed appears to be the case. It is well known that an autopsy of a case of Dementia Paralytica reveals an increase in the number and size of the Pacchionian bodies (Stoddart(16)). This is correlated with an increased pressure of the cerebro-spinal fluid, for an examination of the brain also shows that "the sulci are distended with fluid" (Mott(14)).

Similar changes are to be found in cases where the intracranial pressure is raised by the presence of tumours. I have lately seen the post-mortem examination of a case of cerebral tumour in which there was evidence of increased intracranial pressure of two years standing. In this case, the Pacchionian bodies were very clearly larger and more numerous than in a normal person of the same age and sex.

Again, the Pacchionian bodies are always found to be very well developed —sometimes to an extraordinary degree—in patients suffering from chronic nephritis and arterio-sclerosis. In these cases, the arterial blood-pressure is abnormally high, and it has been shown that the cerebro-spinal fluid pressure is dependent to a certain extent upon the blood-pressure (Becht(15)). If the development of the Pacchionian bodies is indeed an expression of the cerebro-spinal fluid pressure, then the increase in number and size of these bodies with advancing age receives a satisfactory explanation. For the blood-pressure increases with age, and presumably therefore the pressure of the cerebro-spinal fluid also rises.

It is thus seen that the Pacchionian granule is not so much an hypertrophy as a distension of the arachnoid villus, and it appears that Pacchioni was correct in his implication: "In senibus vero glandulae albescentes et magis turgidae cernuntur."

REFERENCES

(1) Pacchioni. *Dissertationes Physico-anatomicae de Dura Meninge Humana.* 1721.
(2) Key and Retzius. *Anatomie des Nervensystems und des Bindesgewebe.* Stockholm, 1876.
(3) Leonard Hill. *Physiology and Pathology of the Cerebral Circulation.* 1896.
(4) Spina. "Experimentelle Untersuchungen über die Bildung des Liquor cerebrospinalis." *Arch. f. d. gesammte Physiol.* LXXVI. 1899.
(5) Weed. *J. of Medical Research,* XXXI. 1914.
(6) Luschka. *Die Adergeflechte des Menschlichen Gehirns.* 1855.
(7) Sargent. "Some Points in the Anatomy of the Intracranial Blood Sinuses." *J. of Anat. and Phys.* XLV.
(8) Elliot Smith. *Rev. Neur. and Psych.* March, 1905.
(9) Poirier and Charpy. *Traité d'Anatomie humaine.* 1907.
(10) Bluntschli. *Verhandl. Gesellsch. deutsch. Nat. Aertz. Verein.* 80 Th. 2 Hälfte, 2, p. 363, 1909.
(11) Schmidt. "Ueber die Pacchionischen Granulationen und ihr Verhältniss zu den Sarcomen und Psammomen der Dura Mater." *Arch. f. Path. Anat.* Berlin, 1912, CLXX. 429.
(12) Cushing. *Am. J. of Med. Sciences,* CXXIV. No. 3, 1902.
(13) Faivre. "Les granulations méningiennes." Collection des Thèses. *École de Médecine.* Paris, 1853.
(14) Mott. *General Pathology* (ed. by Pembrey and Ritchie). 1913.
(15) Becht. *Amer. Journ. of Physiology,* LI. No. 1, 1920.
(16) Stoddart. *Mind and its Disorders.*

NOTE ON THE LACHRYMAL GLAND OF THE HEDGEHOG

By E. W. HURST, B.Sc.

From the Physiological Laboratories of the University of Birmingham

METHODS OF PREPARATION

The animals were killed with coal gas and portions of the tissues fixed in one of the following fixatives:

Mann's solution (B) (7),
Flemming's Chromo-osmo-acetic acid,
Mercuric chloride.

Subsequently sections were made from these by the methods in common use, and stained with well-known dyes.

LITERATURE

Langley (5) describes the lachrymal of the rabbit as corresponding to the infra-orbital. He states that it is difficult to distinguish between the two, but that they are not usually active at the same time. The cells show an outer clear and an inner granular zone during activity.

Dahlgren and Kepner (3) describe the lachrymal of the mouse as appearing on first sight like the sebaceous tissue of the chicken's rump. The cells, however, form a single layer, and there is no obvious method of renewal. The secretion appears in little globules or vacuoles in the proximal end of the cell and moves through or with the cytoplasm to the distal end, where it is set free with a disintegrating part of the cytoplasm, the nucleus remaining at the proximal end of the cell. The secretion stains black with osmic acid, but is not a true fat because it is soluble in water.

Szymonowicz (10) states that the ducts consist of a basement membrane surrounded by star-shaped cells that form a network around it: they are lined by cylindrical epithelium, which is prolonged into the acini.

Dogiel (4) says that the basement membrane of the tubules is surrounded by a basket work of nerve fibres, from which finer fibres pierce the membrane to form a network around the bases of the cells, and another between the cells.

Thanhoffer (11) maintains that the lachrymal gland is wanting in those vertebrates that have no eyelids, but is present in serpents.

Lowenthal (6) mentions in his work on the development of the orbital glands that in the hedgehog the lachrymal and the infra-orbitals develop from the conjunctival sacs, but in the guinea-pig the latter develops from the lachrymal.

Schäfer (9) in *Quain's Anatomy* describes the gland as compound tubulo-racemose with the tubules enlarged at the closed ends (Marziarski). The cells are situated upon a basement membrane of flattened cells, outside which again there is plain muscle in both ducts (Zimmermann (12)) and alveoli (Kolossow). The cells lining the ducts are columnar, but do not exhibit any rodding, which is such a characteristic feature of salivary duct cells. In old age the interglandular tissue becomes crowded with lymph cells.

According to Noll (8) there are two kinds of cells present in the lachrymal gland, one of which stains lightly and exhibits an evident cell network, the other staining darkly and so obscuring the cyto-reticulum which is no doubt there however; there are also cells present which in staining lie intermediate between the two extremes. He finds that on stimulating the glands, the cells undergo certain marked changes and exhibit droplets of fat that stain with osmic acid and intensely red staining small granules often in increasing number. The cell network, so evident in the resting gland cell, is absent from most of them after stimulation.

DISSECTION

The orbit of one animal was carefully dissected to expose its contents, when the eyeball was seen to be surrounded by four glandular masses distinctly separated from one another. These have been designated in the accompanying figure as *A*, *B*, *C*, *D*; of these *A* only is a true lachrymal, and even to the unaided eye differs in appearance from the others, as it presents a smooth surface; the others *B*, *C*, *D* are lobulated and are of the nature of salivary glands, so constituting the orbital gland of this animal.

After being photographed each gland mass was carefully removed and placed in a separate receptacle, in which it was fixed and taken through the usual processes for microscopical examination, in order to determine its nature, with the result already stated.

Fig. 1. Dissection of the orbit of a hedgehog to show the position of the various gland masses. *A*. Lachrymal. *B, C, D*. Orbital.

Sufficient attention does not appear to have been paid by some authors to this difference in the gland masses present in the orbit and so some confusion has arisen in the descriptions they have given of lachrymal cell structure.

STRUCTURE OF THE LACHRYMAL GLAND

In the resting condition

In most of the animals examined the glands were active, but in one killed during hibernation the glands were certainly in a resting condition.

In the hedgehog the gland differs from that of all other animals examined by me in its diffuse appearance (fig. 2), which is caused by the tubules being arranged either singly or in twos and threes, widely separated from one another by adipose tissue, the fat of which reacts acid to nile blue, as the fat of adipose tissue elsewhere in the body does.

Surrounding the whole gland is a thin fibrous capsule, that lies in close relation to the orbital glands and muscles. From this capsule septa pass inwards into the gland to unite with prolongations of the capsule carried in around the vessels and ducts.

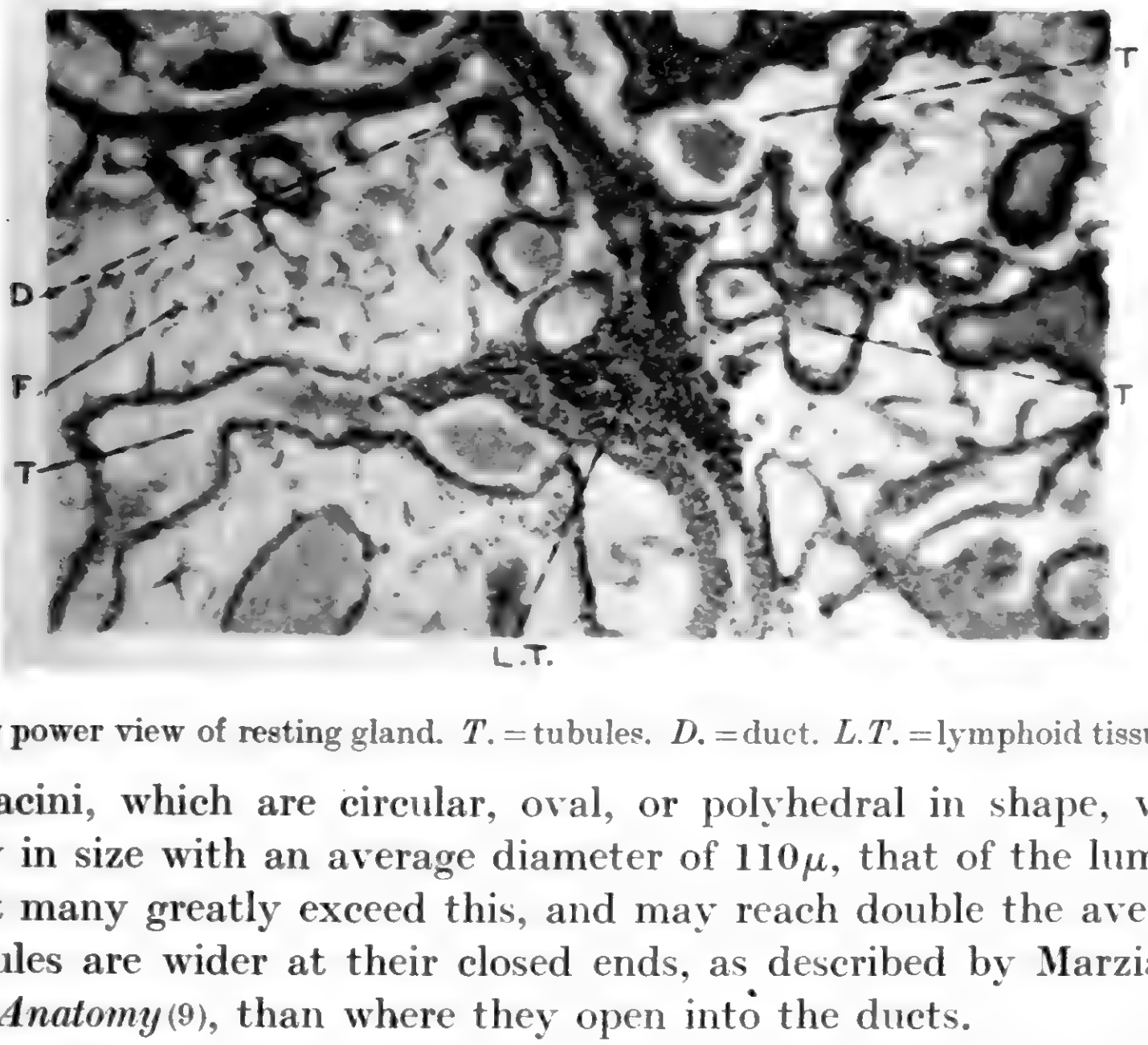

Fig. 2. Low power view of resting gland. *T.* = tubules. *D.* = duct. *L.T.* = lymphoid tissue. *F.* = fat.

The acini, which are circular, oval, or polyhedral in shape, vary considerably in size with an average diameter of 110μ, that of the lumen being 75μ: but many greatly exceed this, and may reach double the average size. The tubules are wider at their closed ends, as described by Marziarski, see *Quain's Anatomy* (9), than where they open into the ducts.

In many cases the wide lumen of the acinus is filled with a coagulated mass of protein nature, containing large droplets that stain black with osmic acid, and nuclei derived from the cells are often present in it. The cells lining the acini are of cubical or low columnar shape, measure 13μ in height, and present flattened extremities to the lumen (fig. 3). Their cytoplasm is cloudy and the cell outlines indistinct. With methyl blue eosine (7) many small eosinophile granules are seen in the neighbourhood of the nucleus, as described in *Quain* (9), and in addition some larger clearer bodies (described in the same article as clear granules with no definite affinity for stains) are present in some number near the free end of the cell, but vary greatly both in size and number in different cells. The spherical nucleus which lies in the centre and outer part of the cell is of comparatively large size, measuring 6μ in diameter, which is half that of the cell itself. Its chromatin content lies chiefly at the periphery, which gives it a clear appearance, and it often contains a nucleolus. In cases in which the accumulated secretion has distended the acinus (storage secretion) the lining cells are reduced to flattened squames. The cells are arranged in a single layer and stand upon an endothelial basement membrane, which, in many cases, seems to be the only fibrous structure present. The supporting wall of the acinus is therefore often of extreme tenuity, and the tubule must depend for its support largely upon the fatty tissue in which it lies, though the fatty tissue may equally well be considered as having been developed from the walls and fibrous tissue between the acini.

Fig. 3. Lachrymal gland of hedgehog in the resting condition.

The larger ducts are lined by a single layer of columnar cells with oval nuclei of considerable size, the chromatin content of which is greater than in those of the acini. Here and there among them are one or two well marked goblet cells, an occurrence which does not seem to have been hitherto recorded and which may not be found in the same situations in other animals. This may be merely another case in which mucous secreting structures are present in the hedgehog in an unusual place, for have not mucous glands been described by Carlier (1) in the pancreatic duct of this species!

The smaller ducts are lined by cubical cells, among which there do not appear to be any goblet cells. Where the ducts join the acini the cells seem to be prolonged into them for some little distance, as described by Szymonowicz (10). There is an endotheloid basement membrane outside the lining epithelium of all the ducts, but of the stellate cells mentioned by Szymonowicz (10) no trace can be found. Outside the basement membrane is ordinary connective tissue, containing here and there a few non-striped muscle fibres circularly disposed as mentioned in *Quain* (9). Thick walled vessels and, occasionally, some lymphoid tissue may be seen in the fibrous sheaths.

In the active condition

When the animals become active after hibernation and throughout the early summer the gland tubules appear more numerous and more closely packed together, probably because there is then less fat in these animals than during their long winter sleep. When the glands secrete, the lining cells of the acini become much higher, measuring on an average 30μ, which is about two and a half times their former height, and their free extremities become very ragged, giving to the lumen an irregular outline. Many vacuoles, varying much in size, are present in the cytoplasm, producing a honeycomb appearance, more nearly resembling those seen in mammary gland cells than those of the lachrymal cells of the rabbit and guinea-pig, in which animals the vacuoles, being nearly all of one size, produce a beautiful reticulate appearance throughout the cell (fig. 4). When treated with osmic acid their contents stain a blackish colour, as noted by Dahlgren and Kepner (3), who state that the blackened substance is soluble in water, and therefore cannot be of a fatty nature. This would also appear to be the case here, as it does not react in the least to nile blue and other specific fat stains.

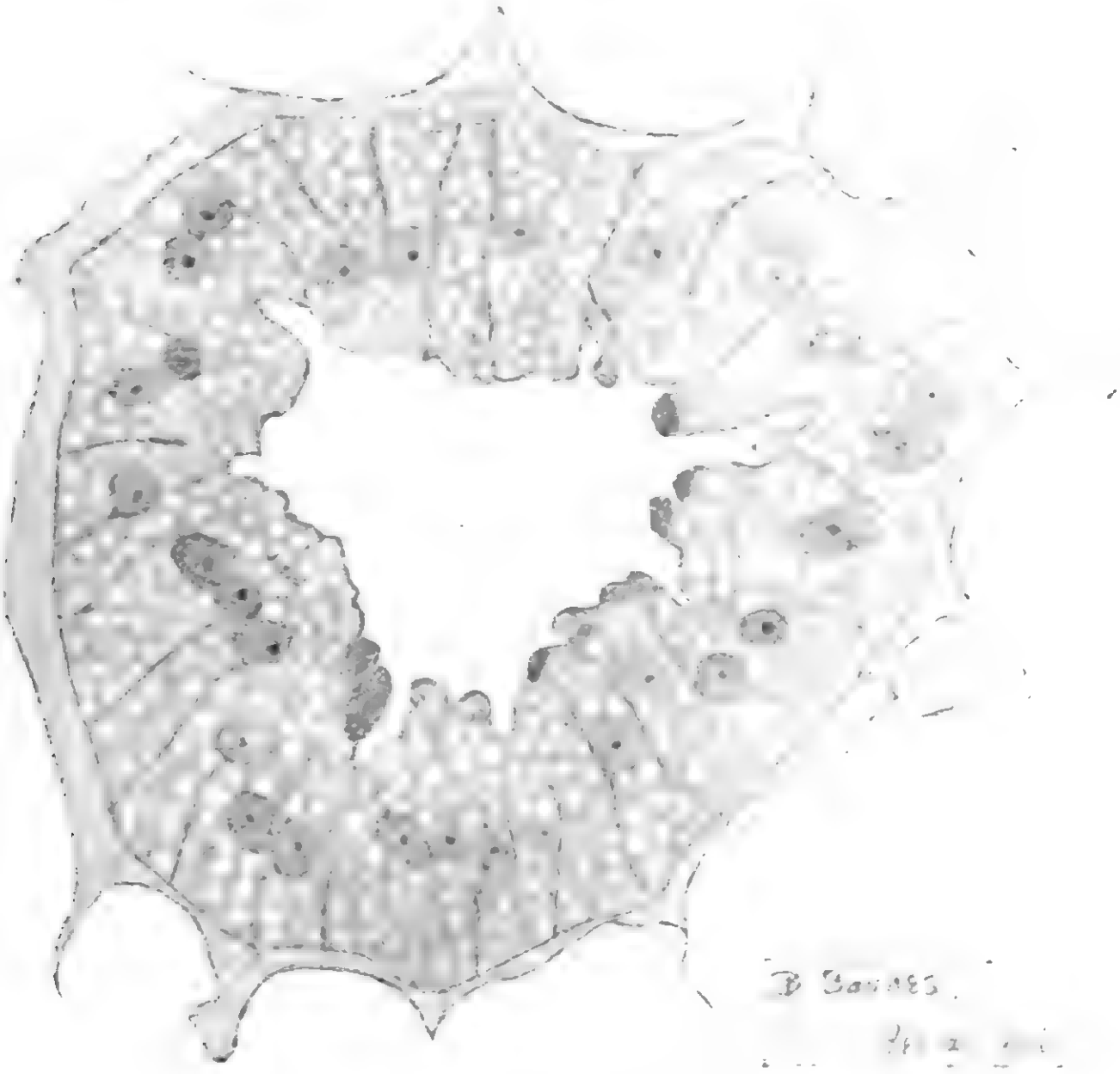

Fig 4. Lachrymal gland of hedgehog in full activity.

Both kinds of granules found in the resting cells seem to disappear from the cytoplasm during secretion, and the cell outlines become distinct. Here and there portions of the cell, sometimes vacuolated, sometimes not, can be seen breaking off and passing into the lumen of the acinus. These disrupted parts stain more deeply than the remainder of the cell, as described by Dahlgren and Kepner (3). This peculiarity further increases the resemblance which these cells bear to those of an active mammary gland.

During this activity the nuclei are slightly swollen, measure 7μ in diameter, appear clouded and come to lie close to the lumen. They react differently to methyl blue eosine, some uniting with the blue and others with the red stain. This may merely indicate that all the cells are not in the same state of activity at the same time; probably they work in relays, or it may indicate various stages of nuclear exhaustion as described by Carlier (2). With other dyes such as iron alum haematoxylin, different nuclei stain with different intensity. The nucleoli are larger and more numerous than in the resting condition and some may be seen bodily extruded into the cytoplasm where they break down.

There seems to be no evidence of the two distinct kinds of cells in the glands of the hedgehog, described by Noll (8) as present in lachrymal glands generally, though as pointed out by him, cells the cytoplasm of which does not stain uniformly may be seen in some acini mingled with the others. This appearance would seem to be due to a less even distribution of the clear granules throughout the cell, than usually obtains.

In the gland masses *B*, *C*, *D* (orbital gland) two kinds of cells, the one clear, and the other dusky, are readily seen and present different affinities for the various dyes, the cytoplasm of the clear being distinctly eosinophile whilst that of the dusky ones seems to contain a basophile material within it.

No trace of the secretion canals described by Schäfer (9) could be found, but lymph corpuscles are numerous, forming patches of various sizes here and there in the connective tissue around the vessels. The ducts show little change beyond an occasional vacuole in the free extremity of the lining cells.

OTHER OBSERVATIONS

In the lachrymal gland of one of the hedgehogs examined a few tubules were found among the others lined not by lachrymal cells, but by serous cells identical with those lining the tubules of the neighbouring orbital gland. This may be merely due to an inclusion of a minute portion of the orbital in the lachrymal during development, but in one single acinus lachrymal and orbital gland cells were placed side by side which would rather point to a common origin for all the glands of the orbit, as suggested by Lowenthal (6), with subsequent differentiation of one of them to form a lachrymal.

REFERENCES

(1) **Carlier.** "The Pancreas of the Hedgehog." *Journ. Anat. and Phys.* vol. xxx. p. 334.

(2) —— "Concerning the Secretion of Ferments by the Liver Cells." *La Cellule,* vol. xxii. p. 431.

(3) **Dahlgren** and **Kepner.** *Textbook of the Principles of Animal Histology.* New York, 1908.

(4) **Dogiel.** *Archiv f. Mikro. Anat.* vol. xliv. 1895.

(5) **Langley.** "The Infra-orbital Gland of the Rabbit and the Lachrymal Gland of the Rabbit." *Journ. of Physiol.* vol. ii. pp. 274–75, 1879–80,

(6) **Lowenthal.** "Drüsenstudien. IV. Beitrag z. Kenntnis d. Entwicklung d. Augenhöhlendrüsen." *Archiv f. Mikro. Anat.* vol. lxxix. p. 464, 1892.

(7) **Mann,** G. *Physiological Histology. Methods and Theory.* Oxford, 1902.

(8) **Noll.** "Morphologische Veränderungen der Thränendrüse bei der Secretion." *Archiv f. Mikro. Anat.* vol. lviii. p. 487.

(9) **Schäfer** and **Symington.** *Quain's Anatomy,* vol. iii. Part ii. p. 181, 1909.

(10) **Szymonowicz.** *Lehrbuch der Histologie und der Mikroskopischen Anatomie mit besonderer Berücksichtigung des menschlichen Körpers einschliesslich der mikroskopischen Technik.* Würzburg, 1901, p. 360.

(11) **Thanhoffer.** *Grundzüge der vergleichenden Physiologie und Histologie.* Stuttgart. 1885.

(12) **Zimmermann.** "Beiträge zur Kenntniss einiger Drüsen und Epithelien." *Archiv f. Mikro. Anat.* vol. lii. p. 552.

THE EXACT DISTRIBUTION OF THE GASTRIC GLANDS IN MAN AND IN CERTAIN ANIMALS

BY Y. MIYAGAWA, M.D.,
Assistant Prof. of the Med. Faculty of the Imperial University, Tokio

From the University College Hospital Medical School, London

INTRODUCTION

THE gastric glands in man and in lower animals are generally classified into three groups, namely: cardiac, fundus and pyloric. The cardiac gland is however not always considered as an independent kind of gastric gland, but as belonging to the fundus group. Some authors describe a few mucous glands, principally in the prepyloric area. The pyloric and fundus glands are the most important forms, from both the pathological and the physiological points of view. The usual statement made with regard to the localization of these forms of gastric glands is that the pyloric glands occupy the pyloric region, the fundus glands the fundus and the body of the stomach, and the cardiac a narrow area surrounding the cardiac orifice. I cannot however find any description which deals with their *exact* distribution. To know this is of capital importance from both physiological and pathological standpoints; for example, from the point of view of the study of the gastric secretion with regard to hydrochloric acid and the ferments, or from that of the study of the localization or genesis of gastric ulcers and of carcinoma, and of their relationship to the various types of gastric glands. The observation of Pawlow, Heidenhain, Edkins and Starling mark epochs in the study of the gastric secretion, but in those researches apparently no definite attention has been paid to the exact distribution of the gastric glands.

In the present investigation I have mapped out the exact distribution of these three types of gastric glands in the stomachs of two adults and one infant, and also in the guinea-pig, rabbit and cat.

METHOD OF INVESTIGATION

The stomach used in this observation was opened in luke-warm physiological salt solution, its contents removed and the mucous membrane thoroughly washed in that solution. It was then stretched and pinned out on cork, thus obliterating the folds of the mucous membrane, and after fixation in 8 per cent. formalin solution was cut into serial sections and stained with haematoxylin and eosin, iron haematoxylin and Van Gieson, methylen blue and fuchsin. For the systematic microscopical examination, the posterior wall of the stomach was divided into longitudinal strips, each 1 cm. broad and each strip was then cut into blocks 2 cm. long. The blocks were cut into sections in the *longitudinal* direction with a microtome by the paraffin method. The anterior wall was divided into squares as in fig. 1, the number varying according to the size of the animal. These blocks were cut into sections in the *transverse* direction. All the blocks were numbered as in fig. 1 for identification and each block was cut as described above into a complete series of serial sections.

(I) THE EXACT DISTRIBUTION OF THE GASTRIC GLANDS IN THE GUINEA-PIG

A guinea-pig weighing about 350 grams, after twenty hours starvation, was killed by a blow on the neck. Its stomach was examined exactly as above described.

Microscopic Appearances

There was no difference between the distribution of the gastric glands on the anterior and posterior walls, so that they were found to be perfectly symmetrical on the two sides.

The length of the lesser curvature of the stretched stomach used in this experiment was 3·5 cm. and the entire distribution length of the pyloric glands on the lesser curvature,—in which no fundus glands were seen,—was about 1·7 cm. from the pyloro-duodenal border. The ratio of the entire distribution length of the pyloric glands to the total length of the lesser curvature was therefore as 17/35 (approximately 5/10 (+)). The length of this distribution on the greater curvature was practically the same as that on the lesser curvature.

Intermediate zone

The intermediate zone between the pyloric and the fundus glands was nearly 1 mm. in width and took the form of a slight curved line. There was formed in this way a triangle on both the anterior and the posterior walls, corresponding to the area of the pyloric glands.

There was a sudden decrease in the number of the fundus glands and a sudden increase in that of the pyloric glands in the intermediate zone. The gland cells of both kinds were never found intermingled in the same gland tubule, each tubule remaining either entirely of the pyloric or of the fundus type.

OXYNTIC CELLS

In the pyloric gland area

These were never found in group form, but always occurred irregularly in the body of a pyloric gland, taking a parietal position between the ordinary gland cells, exactly as in the case of the cardiac glands. Contrary to the usual teaching, isolated oxyntic cells were found scattered throughout the whole pyloric gland area.

In the fundus gland area

Oxyntic cells were found of course in the fundus glands in group form as usual, but mostly abounded in the corpus gastricum and prepyloric part, being smaller in number at the fundus extreme.

In the cardiac gland area

The cardiac glands were found in a narrow area in two or three groups immediately surrounding the cardiac orifice and the ordinary gland cells of this part always included a few oxyntic cells.

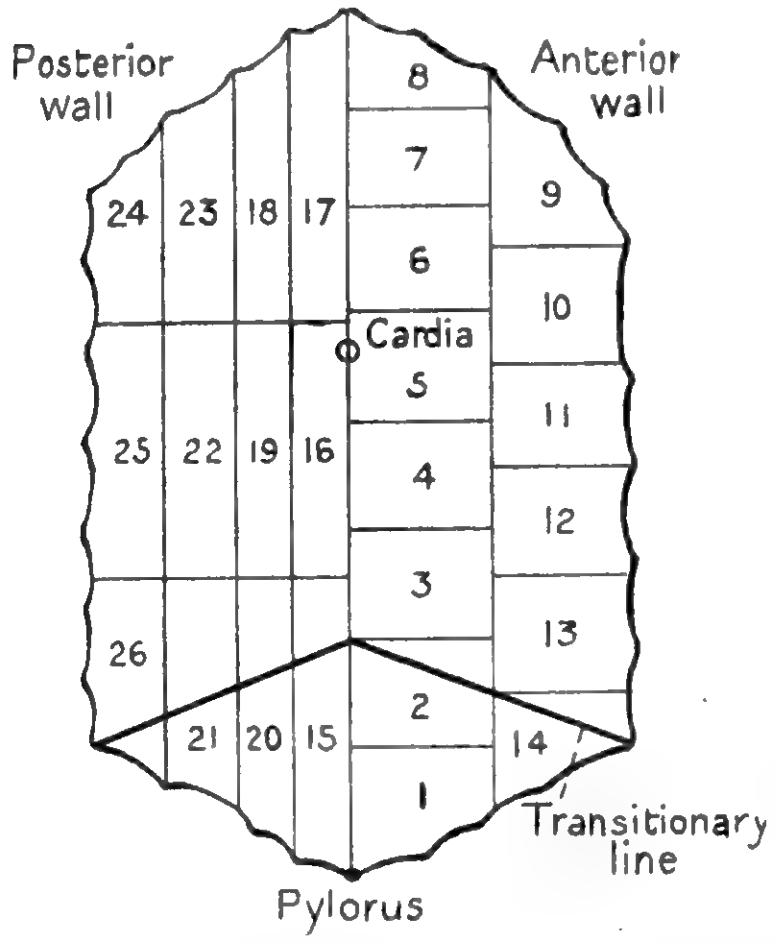

Fig. 1. The stretched stomach of a guinea-pig (divided into areas).

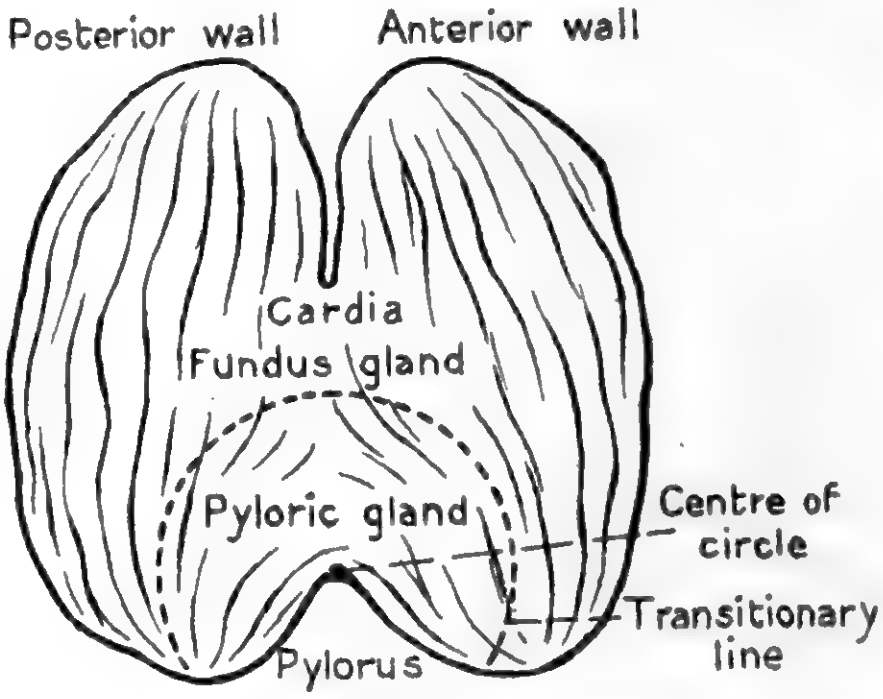

Fig. 2. The stomach of a guinea-pig (opened in luke-warm saline solution).

Macroscopic appearances

The macroscopic appearances of the two parts occupied by the pyloric and fundus glands showed the following characteristics. The area occupied by the former glands was much pinker, the mucous membrane being thicker and tougher and more intimately adherent to and more firmly connected with the underlying tissue than that of the fundus gland area. The lines of the rugae in the mucous membrane are longitudinal and particularly marked along the lesser and greater curvatures in the fundus and the gastric body; but, in the area of the pyloric glands, they are much more oblique or even circular near the pyloric sphincter.

The mucous membrane in the area of the fundus glands is thinner and softer, being of dark brown pink colour, especially in the centre of the body, and its separation from the underlying tissue is quite easy, large lamellae being formed.

The mathematical determination of the distribution area of the pyloric glands

The distribution area of the pyloric glands can be mathematically determined by drawing a circle, having its centre at the pyloric end of the lesser curvature and having a radius equal to the distance from this centre to the mid-point of the lesser curvature. This circle represents the distribution area of the pyloric glands.

(II) THE EXACT DISTRIBUTION OF THE GASTRIC GLANDS IN A NORMAL RABBIT

A large rabbit after 24 hours starvation was killed by a blow on the neck and its stomach opened in luke-warm physiological salt solution. The stomach was stretched and pinned out on cork. After fixation it was cut into serial sections and stained, the same methods being employed as in the case of the guinea-pig.

Microscopic appearances

There was no difference between the distribution of the gastric glands on the anterior and posterior walls,—thus, as in the case of the guinea-pig, they were found to be perfectly symmetrical on the two sides. The lesser curvature in the stretched stomach of this rabbit was 6·5 cm. long and the entire distribution length of the pyloric glands on the lesser curvature—in which no fundus glands were seen,—was about 4·5 cm. from the pyloro-duodenal border. The ratio of the entire distribution length of the pyloric glands to the total length of the lesser curvature may be calculated therefore as 45/65 (approximately 7/10 (+)). The length of this distribution on the greater curvature was practically the same as that on the lesser curvature. The intermediate zone between the pyloric and fundus glands area was nearly 1 mm. in width, taking the form of a line as in the guinea-pig. The distribution area of the pyloric glands is therefore proportionately greater than that of the other animals examined and also of man.

Oxyntic cells. A few isolated oxyntic cells were as in the guinea-pig found in the pyloric glands, never in group form as in the case of the human being, but always in the body of the glands, taking a parietal position between the ordinary gland cells. The same statement applies to the cardiac glands. Oxyntic cells were found as usual in group form in the fundus glands being most abundant in the corpus gastricum and the prepyloric part of the stomach.

The cardiac glands. The condition of the cardiac glands was found to be practically the same as that of the guinea-pig.

The macroscopical characteristic appearances of the distribution area of the pyloric glands

The distribution area of these glands as seen after washing the stomach in salt solution immediately after killing the animal was more whitish-pink in colour than that of the fundus glands area, which was much darker and brownish-pink in colour. The course of the folds in the mucous membrane was similar to that in the stomach of the guinea-pig. This part had a higher chromaffinity as shown by staining with Müller than that of any other region, especially in the region of the lesser curvature. This region of high chromaffinity extended along the lesser curvature to within 0·5 cm. of the cardia. Furthermore the blood was much more easily washed out from this area than from the fundus gland area, by transfusion of physiological salt solution into the aorta thoracalis. This facility of washing out the blood depends upon the smaller amount of blood in the part and upon the shortness of the vessels supplying it. The mucous membrane was thicker, harder and its separation from the muscularis mucasae was much more difficult than that of the fundus gland area, its connection to the underlying tissue being much firmer.

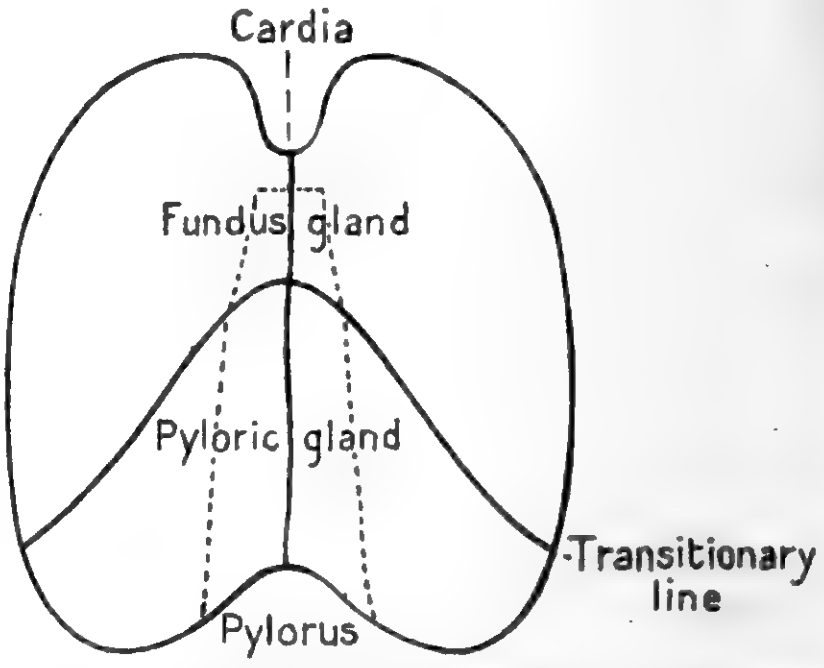

Fig. 3. The stretched stomach of a rabbit. The area shown in dotted line has high chromaffinity.

The mathematical determination of the distribution area of the pyloric glands

The distribution area of the pyloric glands can be mathematically determined by describing a circle, its centre being at the pyloric end of the lesser curvature and its radius equal to a distance of 7/10 of the total length of the lesser curvature. The distribution area represents the area covered by the circle.

(III) THE EXACT DISTRIBUTION OF THE GASTRIC GLANDS IN THE CAT

I have examined the stomach of a large cat by practically the same method as described above. I found the area of distribution of the pyloric glands to extend for a distance of 5 cm. along the lesser curvature from the pylorus and nearly the same length along the greater curvature. In this particular stomach, the total length of the lesser curvature was 12 cm. after stretching and fixation in 8 per cent. formalin solution. The ratio of both lengths may be calculated consequently as 5/12 (approximately 4/10 (−)).

Oxyntic cells. The oxyntic cells were found scattered in small numbers and not in group formation in both the pyloric and the cardiac glands, as described above for the guinea-pig and rabbit. The greater number of the oxyntic cells abounded as usual in the corpus gastricum and the prepyloric part in group formation.

Cardiac glands. The cardiac glands were found in from two to four groups in a narrow area, which surrounded the cardiac orifice. The secreting tubule was much smaller than that of the fundus and the pyloric glands and the ordinary gland cells were columnar and moderately high, being filled with fine granules, which could be always much more intensively stained with dyes than those of the principal cells in the fundus glands. Between the gland cells were found a few oxyntic cells, which were much more numerous than those in the herbivora. Haane's (1) description of the cardiac glands in the cat is as follows: "Bei der Katze liegen die Verhältnisse ungefähr so wie beim Hunde, doch sah ich hier gleich am Oesophagus echte Fundusdrüsen und so kann man wohl annehmen, dass die Katze eine reine Cardiadrüsenzone besitzt, sondern eine intermediäre Zone....Fleischfresser haben eine ganz kleine Cardiadrüsenzone an der Speiseröhrenmündung oder nur eine intermediäre Zone, wo Cardiadrüsen mit Fundusdrüsen gemischt sind. Letztere ist auch dann vorhanden, wenn zugleich eine reine Cardiadrüsenzone zugegen ist. In diesen Zonen kommt noch eine ganz besondere Art von Drüsen vor, nämlich solche, welche mit acidophilen Zellen ausgerüstet sind, aber daneben auch Belegzellen enthalten."

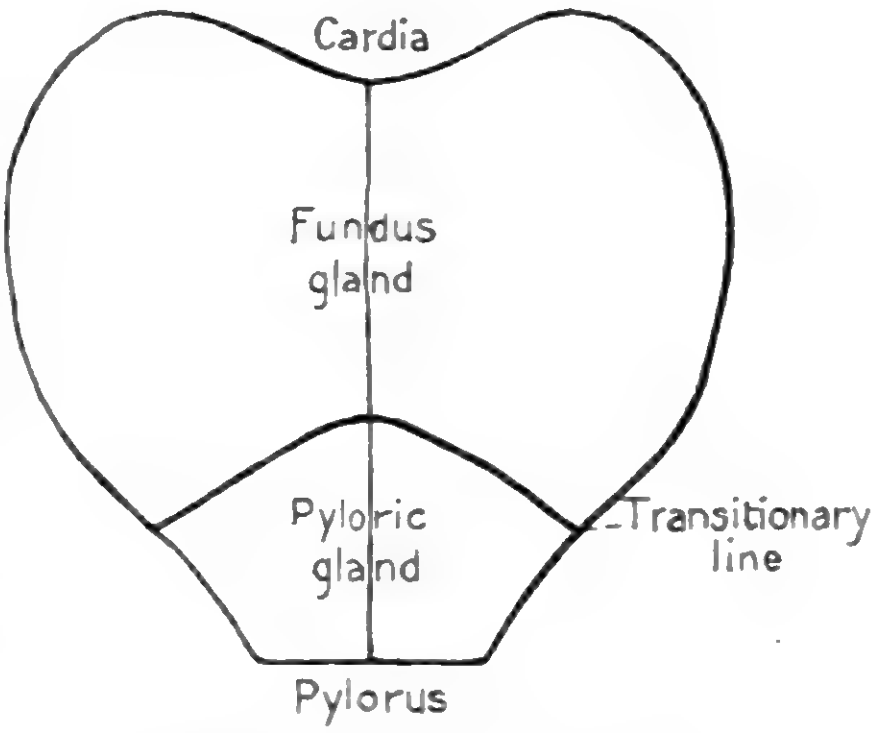

Fig. 4. The stomach of a cat.

At any rate, I have not the slightest doubt in my own mind that the cardiac gland in the cat is an independent kind of gastric gland, because of the staining properties and formation of the tubules.

The macroscopical characteristic appearances of the distribution area of the pyloric glands and its mathematical determination

The colour, toughness and the course of the folds of the mucous membrane in this area were quite similar to the herbivora described above. One can easily determine mathematically this distribution area by use of the ratio 4/10 (+) as described above.

(IV) THE EXACT DISTRIBUTION OF THE GASTRIC GLANDS IN MAN

I have examined three human stomachs, two adults,—one fresh and the other a preserved specimen—and a fresh stomach of a six weeks old infant. There was a slight difference in the gland distribution area between the adults and the infant.

A. (i) The Adult Stomach (*fresh specimen*)

The total length of the lesser curvature was 19 cm. in the freshly stretched and fixed stomach examined and the entire distribution length of the pyloric glands from the pyloric end-point of the lesser curvature was 5·5 cm. on this curvature. The ratio between these lengths may be therefore estimated as 55/190 (approximately 3/10 (+)).

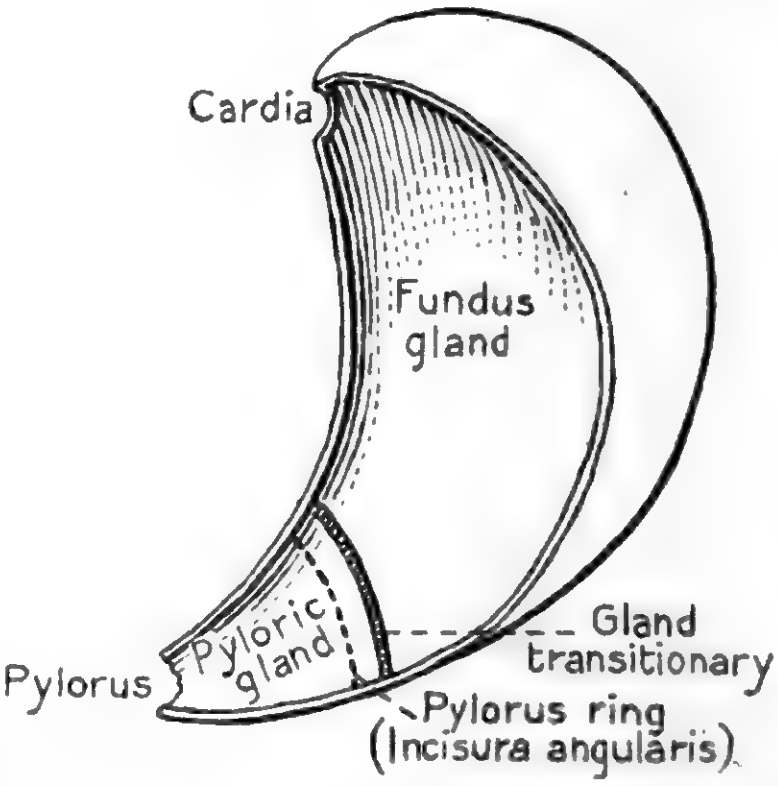

Fig. 5. The human stomach (adult).

The distances from the middle points of the pyloric sphincter on the anterior and posterior walls to the limit of the pyloric gland area on the lesser curvature were the same as the distances from those two points to the limit of the pyloric gland area on the greater curvature. There was no difference between the distribution of the gastric glands on the anterior and posterior walls, so that they were found to be completely symmetrical on both sides.

The intermediate zone. The intermediate zone between the pyloric and fundus gland areas was nearly 1 cm. in width. The pyloric glands were gradually decreased and the fundus glands gradually increased in number in this part, both types of glands being intermingled. Therefore this part may be called the "transitional gland area." In this specimen this transitional gland area on the lesser curvature was 6·5 cm. distant from the pyloro-duodenal border. Even in this area the gland cells of both kinds were never found intermingled in the same gland tubules, which always maintained their independent characteristics of either fundus or pyloric glands. The same condition was found on the transitional area between the pyloric and duodenal glands. The change of the glands here was much more sudden than that between the pyloric and fundus glands. Piersol (2) described it as follows: "The transitional or intermediate zone connecting the pyloric and adjoining portions of the stomach contains forms of glands, those of the fundus variety with parietal cells being intermingled with the pyloric type. Towards the intestine the change of the pyloric glands into those of the duodenum is gradual, the gastric tubules sinking deeper until, as the glands of Brunner, they occupy the submucous coat of the intestine."

The transitional area between the pyloric and fundus glands lies on the small curvature about 1–2 cm. beyond the pyloric ring or incisura angularis, which is 4–5 cm. distant from the pyloro-duodenal border (see fig. 5).

A. (ii) The Adult Stomach (*preserved specimen*)

The distribution areas of both the pyloric and fundus glands were found to be precisely the same as in the fresh specimen.

B. THE STOMACH OF AN INFANT OF SIX WEEKS

The total length of the lesser curvature of this stomach after stretching and fixation was about 8 cm. and the length of the entire distribution area of the pyloric glands on the lesser curvature was nearly 3 cm. The ratio between these lengths can be calculated thereupon as 3/8 (approximately 3·8/10 (+)). The width of the "transitional gland area" was about 1 cm., which is comparatively wider than that of the adult. The length of the pyloric gland distribution area on the greater curvature was equal to that on the lesser curvature, so that the distribution area of the pyloric glands in the infant stomach is much larger in proportion, being longer and wider than that of the adult stomach.

The oxyntic cells were found also in the pyloric glands, being fewer in comparison with those in the adult.

The conditions regarding the cardiac glands were the same in the infant stomach as in those of the adult.

The cardiac glands in the human stomach

The glands of the cardia were first described in the kangaroo by Schäfer and Williams (3), in which animal they are simple tubules; and subsequently in various other animals by Ellenberger and Hofmeister (4). The glands of the cardia in man are found by Schäfer (5) to form a zone, which surrounds the cardiac orifice and is generally very small, but may be 3 cm. broad. I have found them in three human specimens in a narrow zone, which was about 0·5 cm. in width as in Piersol's (6) description, being adjacent to the cardiac orifice and forming two to three groups of glands. These secreting gland tubules may be divided into two forms, simple and compound.

The tubules of simple form are composed of moderately high, columnar epithelium, which is filled with granules, always staining intensively with dyes and resembling those of the mucous glands. The gland cells are a little smaller and lower than those of the pyloric and fundus glands.

The cells of the compound forms are found to be of the tubulo-racemose type, resembling rather Brunner's gland of the duodenum than the pyloric. The gland cells are high, columnar and poor in granules. Intermingled with these secreting gland cells are found a few acidophile cells,—especially in the gland body,—which take a parietal position between the ordinary gland cells.

In some animals these glands constitute a much wider zone, as in the hog, in which they occupy almost a third of the entire stomach. It is described by Haane (8) as follows: "Durch Eosin werden die Drüsen der Cardia stark roth gefärbt. Diese Färbung kommt in ihrer Intensität der Rothfärbung der Belegzellen der Fundusdrüse nahe, welche wir an diesen bei Färbung mit Eosin wahrnehmen." These glands are regarded by Oppel as modified fundus glands, since they possess similar epithelium, usually including a few parietal cells. But I consider that the cardiac gland is an independent kind of gastric gland, having similar epithelium to the pyloric and Brunner's glands and being associated with a few oxyntic cells.

The oxyntic cells and their distribution in the human stomach

(A) *In the pyloric and in the cardiac glands.* The fact that a small number of oxyntic cells are to be seen in the pyloric glands is already described by Nussbaum(9), etc.: "There are also a few isolated cells (Nussbaum), which resemble in structure and in their behaviour to anilin dyes the parietal cells of the fundus glands." Stöhr(10) described it as follows: "Beim Menschen finden sich auch hier (Pylorus) vereingelte Belegzellen, bei Tieren z. B. beim Hunde, einzelne dunklere kegelförmige Zellen, die ihr Aussehen einer durch Nachbarzellen bewirkten Kompression verdanken." Schäfer(11) says: "Amongst the ordinary cells of these glands (pyloric glands) some are here and there found, which stain with osmic acid much more deeply than the rest. The nature and function of these cells,—which were described by Nussbaum,—is not known. They are not identical with the parietal cells of the fundus glands. Occasionally, true parietal cells have been found in the pyloric gland and even in Brunner's glands in the duodenum."

As above described, a few acidophile cells have already been found in the pyloric glands. But it has not been determined, whether they have the same function as those of the fundus glands from a physiological point of view. From the anatomical and the histological standpoint, I cannot find any difference between them, regarding their reaction to dyes, their positions in the glands, their size and form. But there is one and only one difference between them, in the pyloric glands the number of the oxyntic cells is relatively smaller than that in the fundus glands. I consider that these acidophile cells in the pyloric glands and those in the cardiac glands are both of the same nature as those of the fundus; they should be therefore the so-called "oxyntic cells."

The distribution of the oxyntic cells in the pyloric glands was found by me to be as follows. Within a few millimetres of the pyloro-duodenal border, they were very rarely seen, being isolated here and there in the gland body (as was seen in the case of the cardiac glands). They were sometimes found in Brunner's glands of the duodenum. At a distance of 0·5 cm. away from the pyloro-duodenal border, many oxyntic cells were found already in group form, each tubule often containing 15 cells or so. Many secreting tubules were found here without oxyntic cells, which tubules were intermingled with the other tubules containing oxyntic cells. Nearer the transitional area of the pyloric and fundus glands, the oxyntic cells increased in number, so that nearly all the tubules contained more or fewer oxyntic cells, as if they had been one of the physiological and anatomical elements. The number of these cells in this part of the human stomach was incomparably in excess of those in the animals above described. Consequently the results attained from the experiments made on the animals are not immediately applicable to the study of the secretion of the human pyloric glands.

(B) *In the fundus glands.* In the fundus glands, the oxyntic cells were for the most part numerous in the gastric body and the prepyloric part, especially near and on the lesser curvature. Howell's (12) description of it is as follows: "From a physiological standpoint it is important to remember that the parietal cells are massed, as it were, in the glands of the middle or prepyloric region of the stomach, that they are scanty in the fundus and absent in the pyloric region. This fact is indicated to the eye by the deeper red or brownish colour of the mucous membrane in the prepyloric region." By Grützner (13) it is found that the digestion of foods occurs mostly in the prepyloric part, the food being impregnated first with pepsin and then with acid, and the fundus part being simply a filling organ for the food. He described it as follows: "Nämlich, dass sich der Mageninhalt in ganz gesetzmässiger Weise schichtet, indem der leere Magen, dessen Wände sich berühren, so aufgefüllt wird, dass im allgemeinen die spaeteren Nahrungsmittel in die Mitte der alten gelangen und so zunächst vor der Berührung mit der Magenwand geschutzt werden. Der linke Theil des Magens, der sog. Fundus oder die Pars splenica, ist das eigentliche Auffüllungsorgan. Hier ruhen die Speisen namentlich in der Tiefe stundenlang, ohne auch nur mit Spur Magensaft in Berührung kommen. Während dieser Zeit aber vollzieht sich die Wirkung des Speichels—die amylotische Wirkung. Zu gleicher Zeit, nicht aber durchweg spaeter, wie man bisher glaubte, wird in dem rechten Abschnitt des Magens, dem präpylotische und pylorische Theile, tüchtig peptisch verdaut, indem die hier gelegenen Nahrungsmittel im Verein mit den von rechts her oberflächlich abgewichten und gewöhnlich reichlich mit Pepsin beladenen Nahrungsmitteln mit stark saurem und peptischem Saft durchtränkt und zugleich kräftig durchknetet werden. Auf diese Weise wird der Inhalt grösstenteils verdaut und das verdaute sofort aus dem Magen befördert."

This distribution of the oxyntic cells is very interesting with reference to the digestion of food and the genesis of chronic gastric ulcer. Grützner said: "An jedem Abschnitt der Magenschleimhaut geht streng genommen etwas ander vor, sowohl secretorisch wie motorisch. Die Zusammensetzung des Mageninhaltes ist, wenn man es genau nimmt, nirgend ganz gleich....Man darf deshalb nicht, wie es z. B. Pawlow thut, ein bestimmtes Stück Magenschleimhaut ein seiner Thätigkeit ohne weiteres als das Spiegelbild—wenn ich so sagen darf—der ganzen übrigen Magenschleimhaut, ansehen und den von ihm zu bestimmten Zeiten gelieferten Magensaft dem an anderen Stellen der Magenschleimhaut abgesonderten Saft gleichstellen. Das ist sicher nicht der Fall; der Magensaft in der Regio prepylorica ist sicherlich im Durchschnitt viel sauerer als der aus der grossen Curvatur oder gar der dem Fundus." This is of great importance and contains much valuable information for the study of the genesis of chronic gastric ulcer and of the situations for the formation of different strengths of the gastric juice in acid and ferments, especially of the gastric acid in connection with the distribution of the oxyntic cells.

Another kind of gastric gland in man

Besides the above described three types of the gastric glands here and there were found a great number of mucous glands, especially near the transitional part of the pyloric and fundus glands. In certain parts of the stomach were found the so-called "true crypts of Lieberkühn," which are similar in all respects to those of the small intestine. These were generally numerous in the transitional part of the pyloric-fundus glands and a few were found quite close to the pylorus and to the cordia. From a physiological point of view it has not been determined what function these islands of the mucous membrane have.

(V) THE RATIOS OF THE DISTRIBUTION LENGTH OF THE PYLORIC GLAND AREA TO THE TOTAL LENGTH OF THE LESSER CURVATURE

Guinea-pig	5/10
Rabbit	7/10
Cat	4/10
Human being (adult)	3/10
„ „ (infant)	4/10

The distribution area of the pyloric glands in herbivora is wider than that in carnivora. Consequently the carnivora have relatively wider distribution area of the fundus glands.

(VI) GENERAL CONCLUSIONS

(1) The distribution area of the pyloric glands can be mathematically determined by describing a circle, its centre being at the pyloric end of the lesser curvature and its radius equal to a certain proportion of the length of the lesser curvature, e.g. 5/10 guinea-pig, 7/10 rabbit, 4/10 cat, 3/10 (adult human), and 4/10 (infant human). The distribution area of the pyloric glands represents that covered by the circle; the distribution area of the fundus glands can be determined from this.

(2) There is no difference between the distribution areas of the gastric glands (pyloric and fundus) on the anterior and posterior walls; so that they are found to be completely symmetrical on the two sides.

(3) The transitional area of the pyloric fundus glands forms a line in the guinea-pig, the rabbit and cat, and is 1 cm. in width in man. The pyloric glands are gradually decreased in number and the fundus glands gradually increased, both types of glands being intermingled; but the gland cells of both kinds are never found intermingled in the same gland tubule.

(4) The distribution area of the pyloric glands in the guinea-pig and

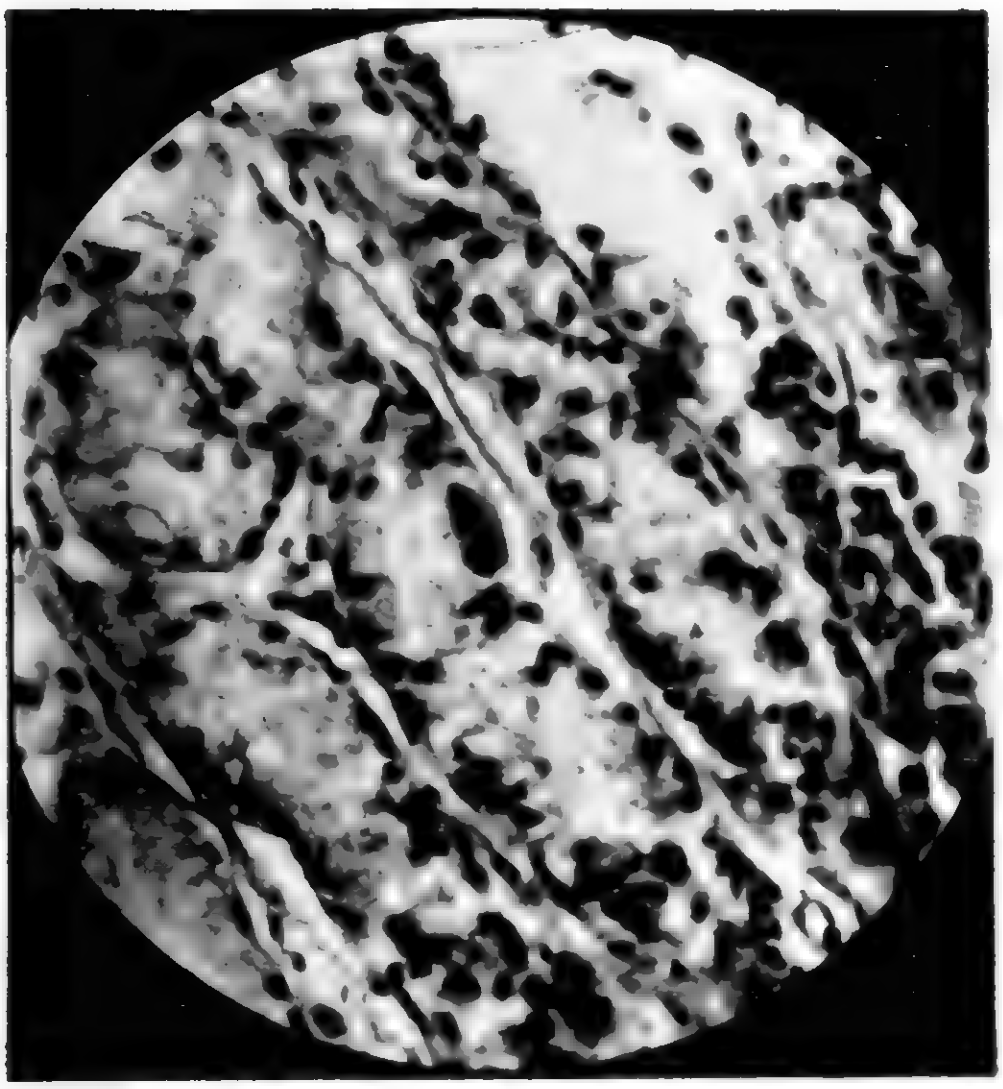
Fig. 6.


Fig. 7.

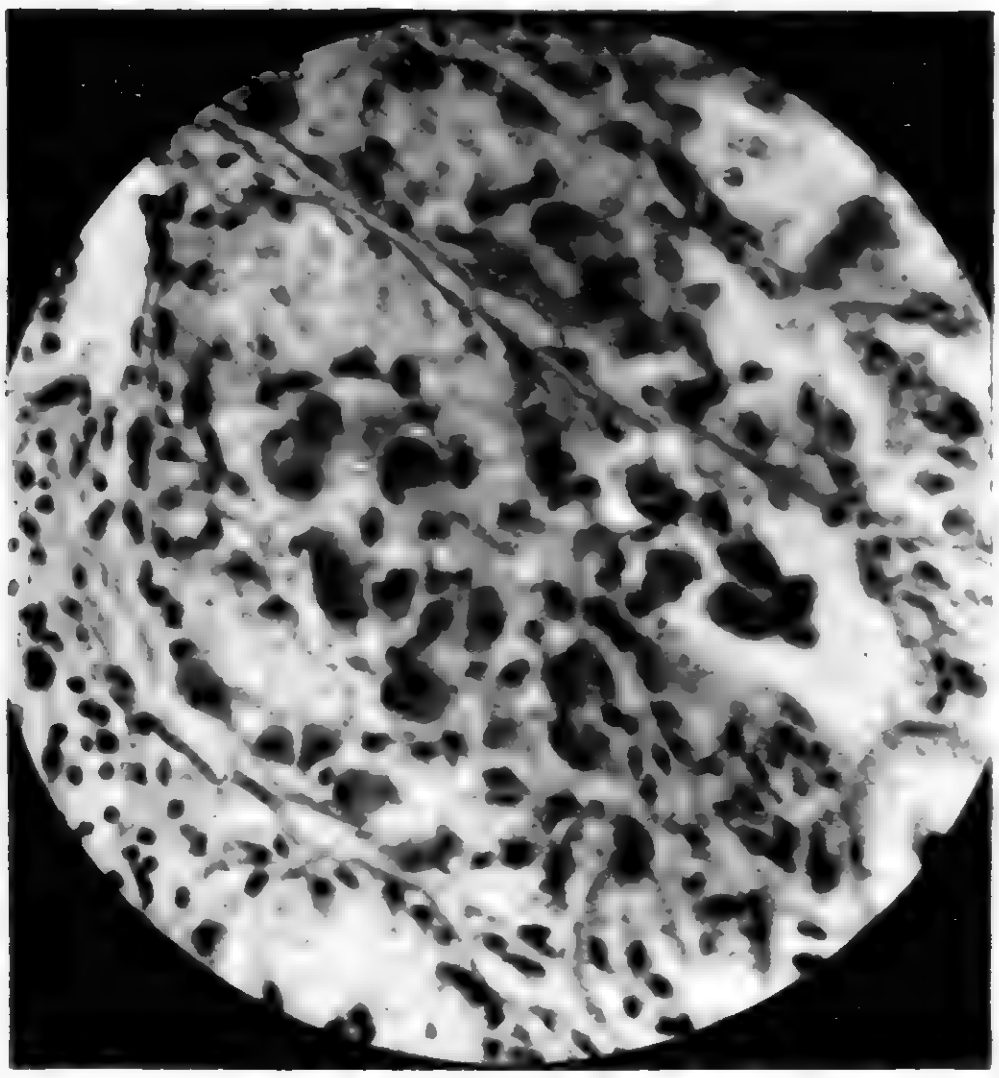
Fig. 8.

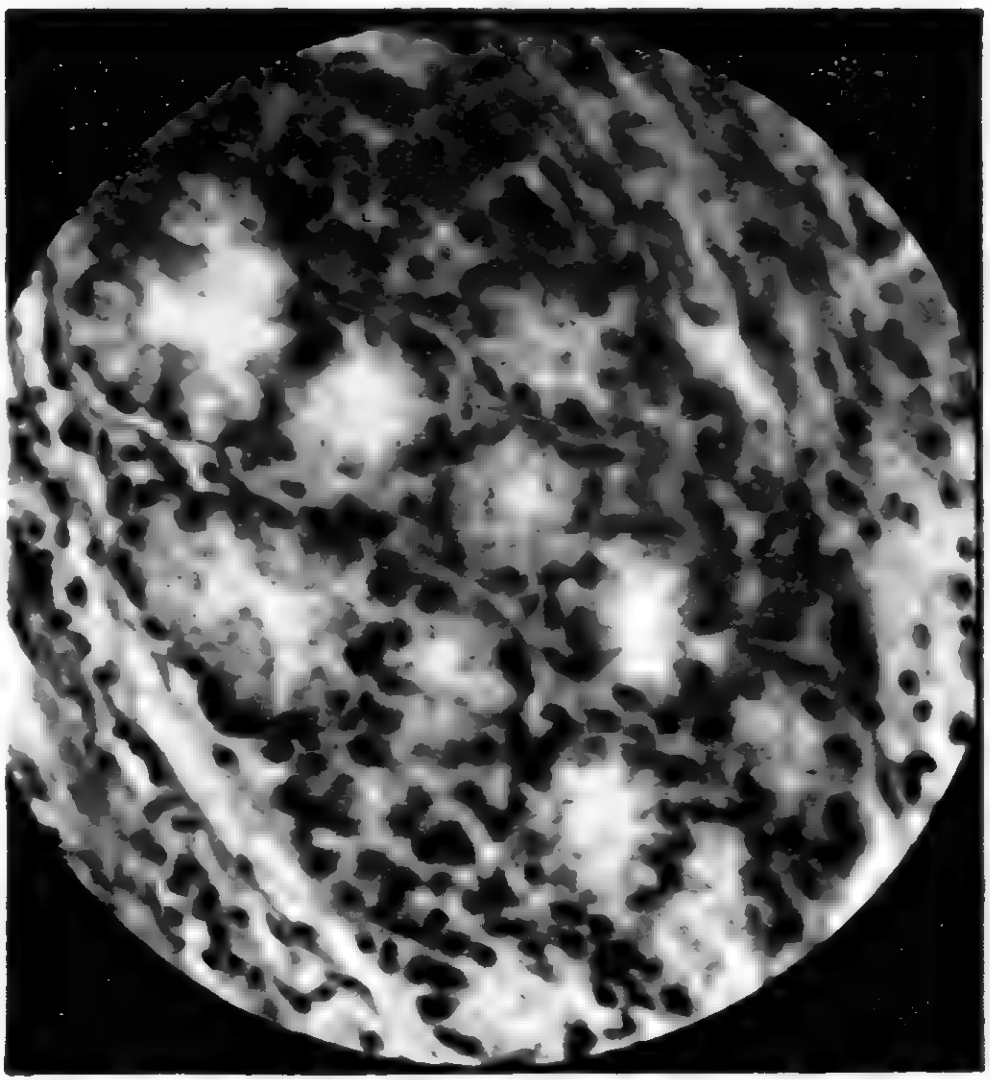
Fig. 9.

rabbit is much wider than that in the cat and man. The cat and man have consequently a comparatively wide distribution area of the fundus glands.

(5) The oxyntic cells from the histological and the anatomical standpoints are always found in both the pyloric and cardiac glands; in the human pyloric glands, they are found especially numerous, as if they were one of its physiological and anatomical elements.

(6) In the fundus glands, the oxyntic cells are most numerous and characteristic particularly in the gastric body and the prepyloric part, and especially near and on the lesser curvature.

(7) The cardiac glands in the above described animals and in man are always found in a narrow area in groups of from two to four, which surrounds the cardiac orifice. But I consider that they are an independent kind of gastric gland.

(8) A great number of mucous glands and so-called "crypts of Lieberkühn" are found here and there.

I desire to express my best thanks to Dr C. Bolton, F.R.S., for his kindness in my research. The expenses have been met by a grant from the Graham Research Fund of the University.

REFERENCES

(1) **Haane.** *Archiv f. Anatomie,* 1905.
(2) **Piersol.** *Human Anatomy,* 1918.
(3) **Schäfer** and **Williams.** *Proc. Zool. Soc.* 1876.
(4) **Ellenberger** und **Hofmeister.** *Arch. f. wiss. u. prakt. Tierheilk.* 1885.
(5) **Schäfer.** *Quain's Elements of Anatomy.*
(6) **Piersol.** *Human Anatomy,* 1918.
(7) and (8). **Haane.** *Archiv f. Anat.* 1905.
(9) **Nussbaum,** refer. **Kemp.** *Diseases of the Stomach, Intestine and Pancreas,* 1917.
(10) **Stöhr.** *Handbuch d. Histologie,* 1906.
(11) **Schäfer.** *Quain's Elements of Anatomy.*
(12) **Howell.** *Textbook of Physiology,* 1918.
(13) **Grützner.** *Arch. f. Physiologie,* von Pflüger, Bd. 106, 1905.

DESCRIPTION OF PLATE III

Fig. 6. Two oxyntic cells in the pyloric gland (guinea-pig).
Fig. 7. Four oxyntic cells in the pyloric gland (rabbit).
Fig. 8. Many oxyntic cells in the pyloric gland (human adult).
Fig. 9. Cardiac gland, simple tubular form (human adult).

PARTHENOGENESIS IN THE WATER VOLE, *MICROTUS AMPHIBIUS*

By G. S. SANSOM, B.Sc.,

Hon. Research Assistant, Dept. of Zoology and Comp. Anatomy, University of London, University College

There is already a considerable amount of literature dealing with the segmentation of ovarian ova in the mammalia but authorities are not yet in agreement as to the interpretation of the various conditions obtaining in the ova contained in atretic follicles. It is hoped that the present paper will throw further light on the subject.

In 1899 Bonnet reviewed all the literature dealing with this subject and came to the conclusion that none of the mitoses seen in ovarian ova were cleavage mitoses, but that they were abnormal maturation processes, and that the multicellular eggs described by various workers were purely the result of degenerative fragmentation. Since then Spuler has described mitotic figures centrally situated in ova with one polar body and maintained that they were cleavage spindles, on the ground that ovulation normally occurred prior to this stage of development. He also described one egg with two polar bodies and centrally located spindle. This does afford some evidence in favour of parthenogenesis but the two polar bodies may have been, and indeed probably were, formed by the division of the first. This latter process appears to occur exceedingly frequently in the ova of the Water Vole. Van der Stricht in 1901, working on the ovary of the bat, produced far stronger affirmative evidence of parthenogenesis. He found ovarian eggs with two equal blastomeres yet he interpreted them as oocytes with abnormally large polar bodies. Loeb in the same year figured multicellular eggs with one blastomere dividing mitotically. The spindle was devoid of astral rays and similar in dimensions to a polar spindle and, for this reason, Newman considers this to be a case of polar body formation in an egg undergoing degenerative fragmentation, although in 1913 he himself produced strong evidence in favour of parthenogenetic cleavage in the Armadillo. Rubaschkin in 1906, working on Cavia, came to the conclusion that all mitoses in ovarian ova were more or less abnormal maturation divisions. Athias in 1908 and 1909 also reviewed all the evidence then available and inclined to the negative view. The present author has attempted to give a comparative account of the maturation and cleavage stages occurring in normal eggs and those in atretic follicles, and to show that in *Microtus amphibius* parthenogenesis does occur to a limited extent.

This work was undertaken by me at the suggestion of Prof. J. P. Hill, F.R.S., to whom I am greatly indebted for much valuable assistance and advice.

MATERIAL AND METHODS

The water voles, living in the wild state, were killed during the spring breeding season, March and April, and the ovaries and uteri immediately removed and placed in fixing fluids. Of the latter the following gave the best results: (i) Bouin's Picro Formol Acetic, (ii) a modification of Carnoy's fluid containing 60 per cent. absolute alcohol saturated with mercuric chloride, 30 per cent. chloroform and 10 per cent. glacial acetic.

The ovary of the water vole is completely invested in a tough capsule into the interior of which opens the fimbriated end of the Fallopian tube. The capsule is rich in fat and this rendered the employment of a fixative with great penetrative power necessary.

The ovaries and Fallopian tubes were cut together in serial sections mostly 10μ, some 8μ, in thickness and stained with Erhlich's Haematoxylin or Iron Haematoxylin and Eosine. The plates accompanying this paper were made from photomicrographs for assistance in the preparation of which I am indebted to Mr F. J. Pittock of University College.

NORMAL MATURATION STAGES

A longitudinal section through a mature ovary of *Microtus* is represented in Pl. IV, fig. 1 which shows the investing capsule into the interior of which the ripe ova are discharged on the bursting of the follicles. This ovary was taken from a non-pregnant female killed during the breeding season. Two large ripe follicles and many smaller degenerating ones are present. In the normal ripe follicle the outer wall projects from the surface of the ovary and is exceedingly thin. The ovum, surrounded by cells of the corona radiata, lies free in the liquor folliculi. It is invested in a clear zona, exhibiting no radial canals, to which the corona radiata cells are attached by fine filaments. The ovum possesses a single polar body with scattered chromosomes whilst those of the egg are in a compact group. The diameter of the oocyte is ·048 mm., that of the polar body ·019 mm., the thickness of the zona ·003 mm. Fig. 2 is a high power view of the same egg, the plane of section nearly coincides with the plane of separation of the polar body.

In the same ovary there occurs a similar normal ripe follicle containing an ovum with two polar bodies (fig. 3). The chromosomes in both polar bodies and also in the egg are in compact groups and it seems highly probable that the first polar body has divided into two, since the chromosomes are normally scattered and the two polar bodies present are each considerably smaller than the average first polar body. There are no signs of the second polar spindle.

The next stage obtained was found in the other ovary of the same female.

In this the follicle has burst and the ovum, surrounded by its zona and numerous adherent cells of the corona radiata, is free in the ovarian capsule. This ovum is apparently not yet fertilised and although large numbers of sperms occur in the Fallopian tube none are to be seen in the capsule. Its diameter is ·052 mm., it has a single polar body with scattered chromosomes, whilst those of the oocyte are in a compact group. No spindle is visible. The follicle from which this egg was discharged has a fairly extensive cavity containing comparatively few free follicular epithelial cells. The gap in the follicle wall is closed by a plug of structureless coagulum.

MATURATION STAGES IN ATRETIC FOLLICLES

Follicular atresia has been dealt with very fully by various workers and it is unnecessary to describe it for *Microtus*. The conditions obtaining in atretic follicles agree very closely with those figured by Flemming for the rabbit ovary.

The first polar spindle at the time of its formation lies close to the surface of the oocyte and nearly tangential to that surface. The bivalents have the form of dumb-bell shaped rods arranged in a fairly compact mass on the equatorial plate of the spindle.

During the metaphase the spindle apparently swings round and ultimately comes to lie in a radial position. The chromosomes divide and pass towards the poles of the spindle. The fibres of the latter do not come to a very sharp focus and the whole spindle is usually rather shorter and broader than the second maturation spindle. No cases of spindle fibres splitting and giving rise to pseudoasters, as described by Kingery for the ova of the white mouse, were observed in the case of the water vole. The spindle persists until the polar body is completely constricted off. Fig. 4 shows the separation of the first polar body with the persistent spindle fibres. Immediately the spindle disappears the chromosomes become scattered throughout the cytoplasm of the polar body, fig. 5, as in normal eggs, compare fig. 2. The number of chromosomes, so far as I have been able to determine it, is probably twelve. Those in the polar body vary in size and shape but mostly have the form of pear-shaped rods. The eggs in these follicles vary in size from ·048 to ·074 mm. in diameter, the polar bodies vary from ·02 to ·04 mm. As Van der Stricht has stated, the first polar bodies given off by oocytes in atretic follicles are often far larger than those met with in normal maturing oocytes. According to him they are occasionally the same size as the secondary oocyte itself. This may be the case in *Vesperugo* and *Vespertilio* but it is certainly not so in *Microtus*. In this mammal it is not possible to regard the two-celled eggs met with in atretic follicles as secondary oocytes with abnormally large polar bodies.

The separation of the first polar body probably occurs very rapidly after the formation of the spindle, as large numbers of eggs were found with the first polar body but comparatively few with the spindle alone. On completion of the first maturation division the nucleus of the secondary oocyte is not reconstituted, the chromosomes remaining in a compact group until the formation of the second spindle. This agrees with the conditions which obtain in normal oocytes as represented in fig. 3.

In a large number of cases the first polar body exhibits signs of mitotic division prior to the formation of the second polar spindle. Spindle fibres make their appearance in the cytoplasm of the polar body, sometimes irregularly arranged as in fig. 6, sometimes in typical form as in fig. 7.

The chromosomes appear irregularly arranged along the fibres but soon separate into two well defined groups and the polar body divides into two. In fig. 7 the first polar body is in process of division, while in fig. 8 the division is completed and the second polar spindle formed. The latter almost invariably appears nearly radial in position; with one pole directed towards the periphery of the first polar body. It is usually longer and narrower than the first spindle and its fibres come to a sharp focus. Pl. V, fig. 9 represents it typically, with the chromosomes arranged in an equatorial plate. Its length is about ·022 mm. and its diameter ·004 mm.

No stages have been obtained showing the completion of the second maturation division either in normal eggs or in ovarian eggs contained in atretic follicles. This agrees with Van der Stricht's observations: "Jamais il ne nous a été donné d'observer le détachement d'un second globule d'un œuf à l'intérieur de l'ovaire, pas même d'oocytes de second ordre en apparence normaux, retenus dans un follicule dont la déhiscence ne s'est pas opérée."

All the eggs described above resemble one another in size and in optical and staining properties, the normal ovum and that from a follicle in the early phase of atresia being indistinguishable. The condition of the follicular cells however enables one to say whether the follicle is normal or in process of atresia.

The first signs of atresia are characteristic changes in the cells of the membrana granulosa and discus proligerus. Some of these cells lose their connection with the remainder, become rounded off and their nuclei stain intensely black with haematoxylin. They float free in the liquor folliculi and have been described by various workers as phagocytic in character. A comparison of figs. 2 and 3 with figs. 5 and 6 clearly demonstrates these typical changes.

Some of the atretic ova are devoid of a zona while others possess it, but the presence or absence of a zona pellucida around an egg is conditioned by the fixing agent employed. In ovaries fixed in Bouin's fluid it is sometimes present, more often absent, while in those fixed in Carnoy Corrosive Mixture or any other fixative containing mercuric chloride it is invariably present.

In a few atretic eggs there occurs in the cytoplasm a small spherical body staining deeply with eosine. It possibly represents the yolk nucleus of Balbiani.

CLEAVAGE OF NORMAL EGGS IN THE FALLOPIAN TUBE

No stages are available of fertilisation or of ova with male and female pronuclei. The first normal stage in the cleavage process obtained is that of the two-celled egg represented in fig. **10**. Two equal blastomeres are present, apparently identical in character and size, still surrounded by a thick intact zona, inside of which there is no sign of the polar bodies. This egg measures ·054 × ·045 mm. in diameter, the thickness of the zona is ·003 mm. Both nuclei are centrally situated and in the resting condition. Several two-celled stages were obtained, all very similar to the one figured. In none of them are there present any definite polar bodies, but in one there are certainly indications of the presence of possible remnants of the same in the cleavage plane of the egg.

The next normal stage obtained is an eight-celled egg lying free in the upper portion of the uterus. The zona is still present and almost intact. No polar bodies are present. All the cells and their nuclei appear similar, the latter being in the resting condition. The diameter of the egg is ·074 × ·053 mm.

Two 13-celled stages were obtained, in one the egg measured ·074 × ·056 mm. It is completely surrounded by a zona and consists of twelve blastomeres arranged peripherally and one central cell, which is not recognisably different in character from the others, and which reaches the surface on one side. This suggests the occurrence of a process of epibole or overgrowth. It is possible this central cell has not divided since the second cleavage and that the mode of arrival at the present number of blastomeres is as follows:

$$1 \rightarrow 2 \rightarrow 3 + 1 \text{ (future central cell)} \rightarrow 6 + 1 \rightarrow 12 + 1 \text{ central cell.}$$

CLEAVAGE OF OVARIAN EGGS

The first cleavage occurs in a plane at right angles to the plane of separation of the polar body. Fig. 11 is a drawing of a section through an egg contained in a small atretic follicle. This egg has no investing zona but the vitelline membrane is well defined. Two polar bodies are present one much larger than the other. The chromosomes in the smaller are in a compact mass, in the larger a resting nucleus has been reconstituted (fig. 8). The sectional plane coincides with the plane of separation of the polar bodies and also with the long axis of the cleavage spindle, i.e. the first cleavage is at right angles to the plane of separation of the polar bodies. This cleavage spindle is far larger than a polar spindle; it measures ·03 mm. in length and ·007 mm. in diameter. The fibres come to a sharp focus, centrosomes are probably not present, astral radiations are certainly absent. The chromosomes are arranged irregularly along the spindle fibres, they have the form of thick curved rods. The egg cytoplasm is not homogeneous, it contains several very granular areas staining more deeply with eosine, and around the outer thirds of the spindle are two spherical clear areas of cytoplasm.

Spuler in 1901 and Newman in 1913 both figured cleavage spindles with centrosomes and astral radiations and laid special emphasis on the fact that asters are never associated with maturation spindles. In the egg represented in fig. 11 there are certainly no asters visible yet it seems far less probable that the spindle is a second polar spindle than that it is a cleavage spindle. Its length is ·03 mm. and its diameter ·007 mm. whereas the second polar spindles vary in length from ·02 to ·015 mm. and in diameter from ·005 to ·004 mm. No second polar spindles occur centrally situated, they are invariably close to the surface, with one polar directed towards the margin of the first polar body or its daughter cell. This spindle is not only central but lies in a plane almost parallel to the plane of separation of the polar bodies. Moreover in all the numerous ovarian eggs exhibiting second polar spindles which I have examined the chromosomes are situated in a compact mass on the equatorial plate, whereas here they are scattered irregularly along the fibres.

It seems highly probable that in the parthenogenetic development of ovarian eggs the second polar body is suppressed, the second polar spindle either degenerating or being converted directly into the first cleavage spindle.

The completion of the first cleavage in an ovarian egg is represented in fig. 12. The egg is lying free in the liquor of the atretic follicle. It is invested in a zona and consists of two equal blastomeres with resting nuclei. One or possibly two small polar bodies are situated inside the zona in the cleavage plane. At the opposite side is a non-nucleated body which is probably deutoplasmic in character, the extrusion of such deutoplasmic material by segmenting eggs being not improbable. This egg measures ·056 × ·051 mm. in diameter.

No stages with the second cleavage spindles were obtained, but in one two-celled egg the nucleus of one of the blastomeres has divided unequally into two, one large, and one quite small, daughter nucleus being formed, the plane of division being at right angles to the first cleavage plane. Lying inside the zona in the cleavage plane are two small non-nucleated bodies which may be deutoplasmic or may be the remains of the polar bodies.

Mention may be made here of a two-celled stage found in the ovary of the mouse. This egg, represented in fig. 16, which is a reproduction of a beautiful drawing by the late F. J. Bridgman of University College, is actually in process of division. Unfortunately Mr Bridgman left no description of this stage and the original slide from which the drawing was made is not available. Apparently the conditions obtaining are very similar to those described for *Microtus*. One polar body with scattered chromosomes is present. The clear areas of cytoplasm around the ends of the spindle as in fig. 11 are very marked and the general characteristics of follicular atresia are well shown.

The completion of the second cleavage in a plane perpendicular to the first and to the maturation division is shown in fig. 13 which represents a section through a four-celled stage. This egg has a diameter of ·059 mm.

The zona has disappeared and no polar bodies are recognisable. The four blastomeres are grouped in two pairs showing the typical cross-shaped arrangement. One pair is larger than the other. Each blastomere possesses a large nucleus in the resting condition, but in addition several small supernumerary nuclei are present. At one pole are two small non-nucleated bodies, which are probably of a deutoplasmic character.

Another four-celled stage occurs in the same ovary. In this the blastomeres are differently arranged to those in the preceding egg. Three of them lie in one plane, the dividing lines being radial and meeting at 120° in the middle, the fourth blastomere lies in a plane parallel to that of the other three and occupies the entire opposite pole of the egg, the whole forming a pyramid. Several small supernumerary nuclei are present close to the normal nuclei, two of them possess discreet chromatin masses. A small non-nucleated, probably deutoplasmic, body is present at the outer junction of the three symmetrical blastomeres. This egg, represented in fig. 14, measures ·063 × ·056 mm.

No egg with more than four blastomeres was found in atretic follicles. A large number of eggs undergoing degenerative fragmentation occur in nearly all the ovaries examined, but these are entirely different in character from the segmenting parthenogenetic eggs described above, and are dealt with in the next section.

DEGENERATIVE FRAGMENTATION

The above heading is the term adopted by many writers to cover the parthenogenetic cleavages of ovarian eggs.

Janosik, however, in 1897 described in the rabbit and guinea-pig two entirely different conditions obtaining in dividing ovarian eggs.

"4. Es kann die Theilung aber auch zur Bildung von Segmenten führen, welche untereinander ungleich gross sind, die aber alle Kerne besitzen und somit den Charakter von Zellen haben. 5. Neben diesen wirklichen Theilungen kommen auch vielfach nur Fragmentirungen der Eizelle vor (welchen Vorgang man besonders bei älteren Thieren vorfindet) oder es kann auch die Eizelle schollig zerfallen."

These two conditions which Janosik described also occur in the ovary of the water vole, and some of the preparations figured by him bear a striking resemblance to some of mine. Compare fig. 14 in this paper with Janosik's fig. 5. There seems little doubt that Janosik's material was very similar to my own, though he found ovarian eggs with many more blastomeres than have been seen in *Microtus*. He also described and figured small bodies in contact with the blastomeres of the three and four-celled stages and interpreted them as polar bodies, it seems probable however that some of them were deutoplasmic in origin.

The cleavage stages represented in figs. 12, 13 and 14 bear little resemblance to eggs which are obviously undergoing degenerative fragmentation. The latter have been described very fully by various workers, Flemming in 1885 and Kingery in 1914, and it is unnecessary to describe them in detail for the water vole, suffice it to say that fragmenting eggs have quite distinctive characters. The zona, which is nearly always present, stains very deeply with eosine as does the egg cytoplasm. The latter contains several (in late stages many) small nuclei and a variable number of cells characterised by intensely dark staining nuclei and scanty cytoplasm. These cells may be formed inside the egg, but are more probably wandering phagocytic cells from the follicular epithelium. The contents of the egg in fact resemble a syncytium, the cytoplasm of which may fragment into a number of irregularly shaped pieces with or without nuclei. Distinct cell walls such as are visible in figs. 12, 13 and 14 never occur in these fragmenting eggs and mitotic figures also are invariably absent. Fig. 15 represents a typical degenerating egg. It is not possible to determine whether such eggs, prior to their present condition, were undergoing parthenogenetic cleavage or not but owing to the comparative scarcity of cleavage stages it is safe to assume that the majority of eggs undergoing degenerative fragmentation never completed their first cleavage.

SUMMARY

From a study of the ovary in the water vole one is led to believe that true parthenogenesis does occur to a limited extent and that it is quite distinct from the degenerative processes which result firstly, in the production of multinucleate masses and secondly, fragmentation of the cytoplasm. This is the fate of all eggs which either fail to reach maturity owing to the unfavourable situation of the follicle in the ovary, leading to insufficient nutrition, or which reach maturity but fail to be discharged from their follicles owing to lack of the requisite stimulus to cause ovulation. Whether or not ovulation can take place independently of copulation in *Microtus* is uncertain but it seems improbable. Some mature females killed during the height of the breeding season were not pregnant and examination of their ovaries showed that all the larger follicles were undergoing atresia and that the Fallopian tubes contained no sperms. Some of the accompanying figures are made from ovaries of non-pregnant females killed during the breeding season, but the same phenomena are met with in the ovaries of pregnant females and of those which have recently given birth to young. Unfortunately only one stage was obtained of the ripe ovum immediately after ovulation and in this case sperms were present in the tubes. The evidence though slight therefore favours the view that ovulation only occurs after copulation.

The course of events in this parthenogenetic development appears to be as follows. The vitality of an egg enclosed in an atretic follicle persists for a variable time and, despite the fact that the follicle contains an enormous number of degenerating cells, enables the egg to carry out the earlier stages of development. The first polar body is separated off and divides mitotically into two unequal portions, the second polar spindle is formed but owing to

lack of the stimulus normally afforded by penetration of the sperm, the second polar body fails to separate. The first cleavage spindle then arises either from the second polar spindle or *de novo*, and the first cleavage takes place, resulting in the formation of two equal blastomeres in a plane at right angles to the plane of separation of the first polar body. These two blastomeres then divide giving rise to the four-celled stage. Meanwhile the blastomeres eliminate a variable number of small deutoplasmic bodies which together with the polar body are absorbed or destroyed by the follicular cells. By this time the conditions of atresia in the follicle are so acute that further development is impossible. Cytolysis, nuclear degeneration and fragmentation set in, probably hastened by penetration of phagocytic cells, with the result that the degenerating egg comes to consist of a deeply staining mass, imbedded in which are numbers of more or less degenerate nuclei. In the great majority of eggs the atresia gains the upper hand long before the first maturation division is completed.

Newman (1913) states that the parthenogenetic cleavage stages, which he found in the Armadillo, were probably not preceded by maturation divisions, no polar bodies being given off from those eggs destined to undergo parthenogenetic development. He gives no reasons to support this view and in the case of *Microtus* such suppression of the first polar body certainly does not occur, though as already stated the second polar body is probably not extruded by unfertilised eggs. There is a reasonable explanation, whether sound or not I cannot assert, for suppression of the second polar body, but it is difficult to find a satisfactory one to account for the absence of the first.

Janosik (1897) stated that in his opinion such parthenogenetic development probably occurred in unfertilised ova in the Fallopian tube. No such stages have been observed in *Microtus*. It might be mentioned that one egg was found in the upper part of the Fallopian tube of a female killed shortly after parturition. It is surrounded by a thin zona, entirely free from any corona radiata cells and possesses a single small polar body with chromosomes in a compact mass, while those of the ovum are thin curved rods closely grouped together. The condition of the follicle from which it was shed suggests that ovulation occurred some days previously. No sperms are present in the Fallopian tube. If parthenogenesis occurs in the Fallopian tube, it might well have happened in this case.

Precise information as to the breeding habits of the water vole is not available, but it seems probable that after the spring breeding season there is a resting period of several months.

REFERENCES

Athias. "Les phénomènes de division de l'ovule dans les follicules de De Graaf en voie d'atrésie." *Anat. Anz.* Bd. xxxiv. 1909.

Bonnet. "Giebt es bei Wirbeltieren Parthenogenesis?" *Erg. Anat. u. Ent.* Bd. ix. 1899.

Flemming. "Ueber die Bildung von Richtungsfiguren in Säugethieren beim Untergang Graafschen Follikel." *Archiv f. Anat. u. Phys. Anat. Abth.* 1885.

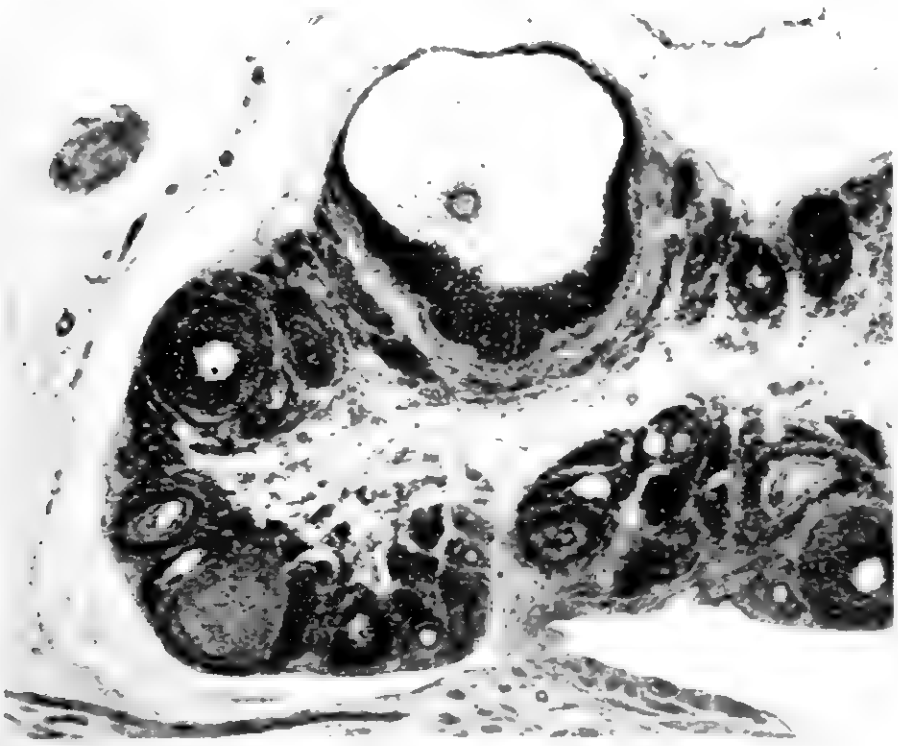

Fig. 1.

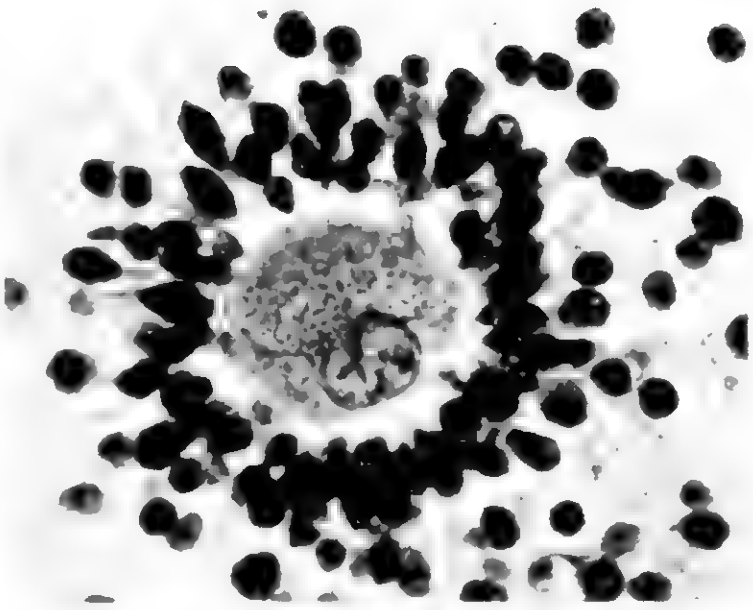

Fig. 2.

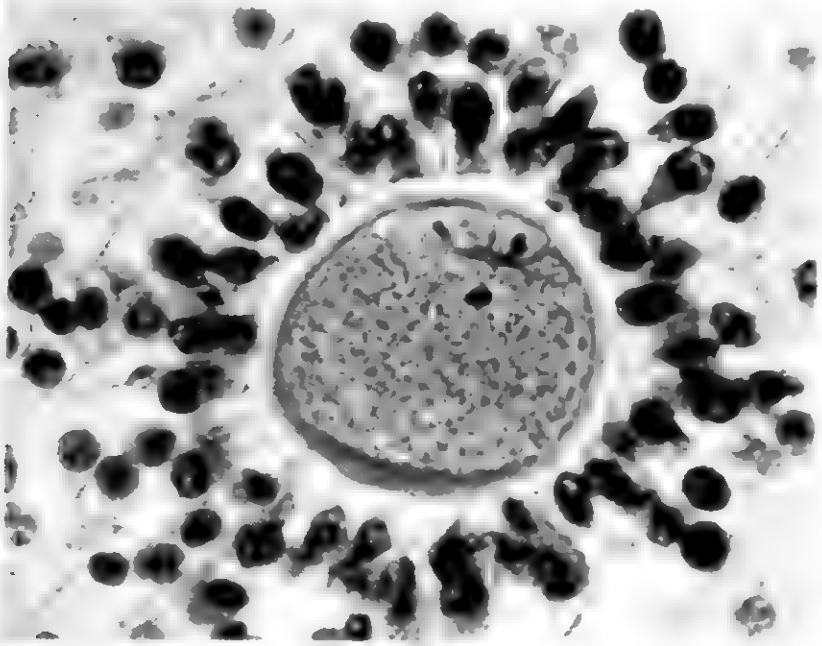

Fig. 3.

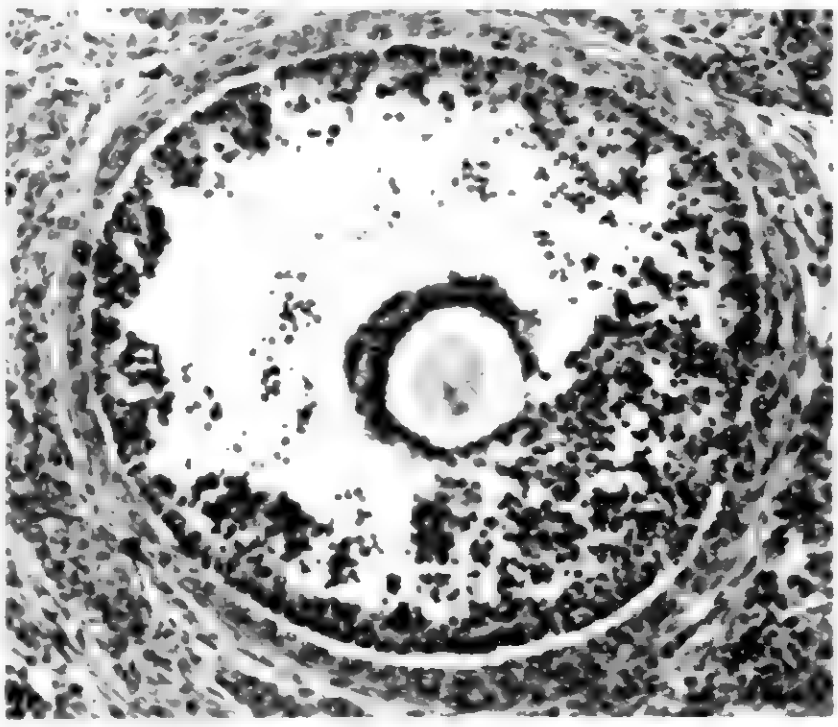

Fig. 4.

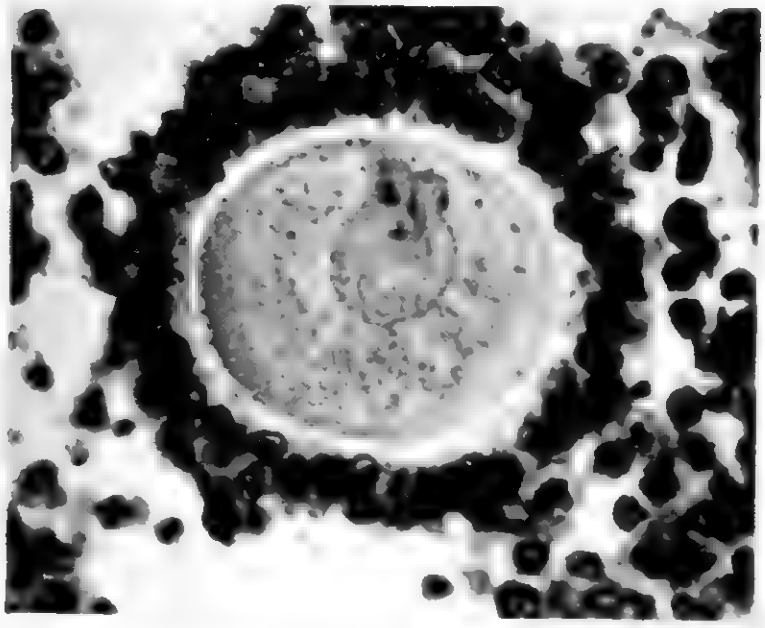

Fig. 5.

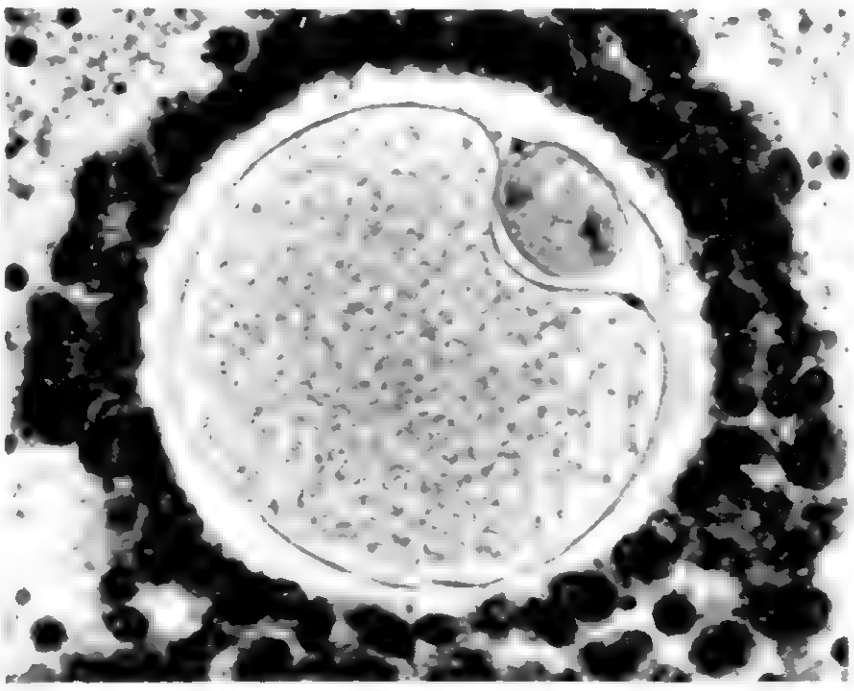

Fig. 6.

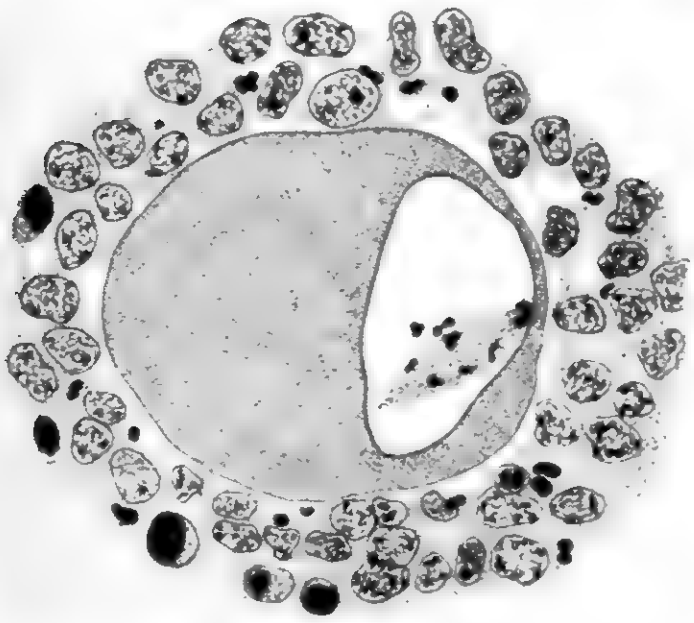

Fig. 7.

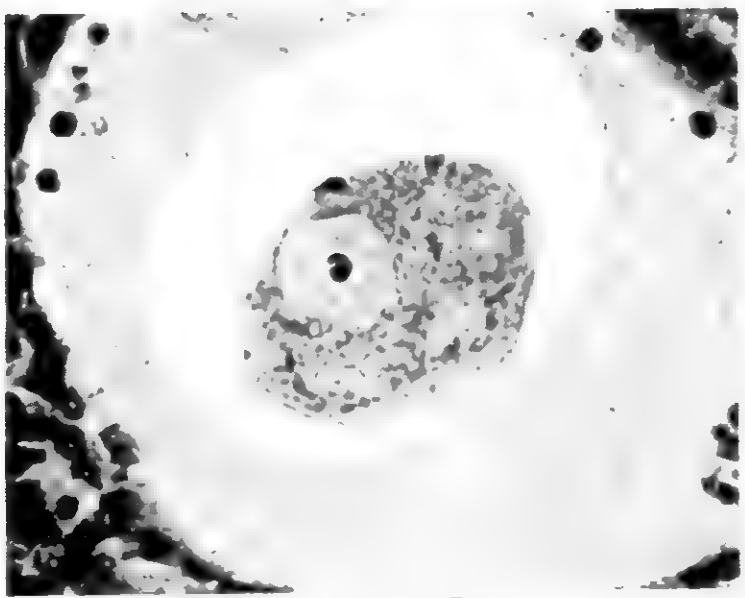

Fig. 8.

Heape. "Ovulation and Degeneration of Ova in the Rabbit." *Proceedings of the Royal Society,* vol. 76 B, 1905.

Janosik. "Die Atrophie der Follikel." *Archiv f. Mikros. Anat.* Bd. XLVIII. 1897.

Kingery. "So-called Parthenogenesis in the White Mouse." *Biological Bulletin,* vols. XXVII. and XXVIII. 1914 and 1915.

Kirkham. "Maturation of the Mouse Egg." *Biological Bulletin,* vol. XII. 1907.

Kirkham and **Burr.** "Breeding, Maturation and Ovulation in the White Rat." *American Journal of Anatomy,* vol. XV. 1913–1914.

Marshall. *The Physiology of Reproduction.*

Newman. "Parthenogenetic Cleavage of the Armadillo ovum." *Biological Bulletin,* vol. XXV. 1913.

Rubaschkin. "Über die Veränderungen den Eier in den Zugrunde gehenden Graafschen Follikeln." *Anat. Hefte,* Bd. XXXII. H. 97, 1906.

Schottländer. "Ueber den Graafschen Follikel u. Beitrag zur Kenntniss der Follikelatresie." *Archiv f. Mikros. Anat.* Bd. XXXVII. 1891 and Bd. XLI. 1893.

Sobotta. "Die Befruchtung u. Furchung des Eies der Maus." *Archiv f. Mikros. Anat.* Bd. XLV. 1895.

—— "Die Bildung der Richtungskörper bei Maus." *Anat. Hefte,* Bd. XXXV. 1907.

Spuler. "Über die Teilungserscheinungen der Eizellen in degenerierenden Follikeln des Säugerovariums." *Anat. Hefte,* Bd. XVI. H. 51, 1901.

Van der Stricht. "L'atrésie ovulaire et l'atrésie folliculaire du follicule de De Graaf dans l'ovaire de chauve-souris." *Verhand. d. Anat. Gesellsch.* 15 Versamml. Bonn, 1901.

EXPLANATION OF PLATES IV, V

Fig. 1. Photomicrograph of longitudinal section through the ovary of a mature female, killed just prior to ovulation. One large ripe follicle is visible. Magnified 30 diameters.

Fig. 2. High power view of ripe ovum from the follicle shown in fig. 1. Ovum, surrounded by follicular cells, possesses first polar body with scattered chromosomes. × 500.

Fig. 3. Normal ripe ovum surrounded by follicular cells. The first polar body has divided into two. The second polar spindle has not yet formed. × 500.

Fig. 4. Large follicle in the early phase of atresia. Some cells of the membrana granulosa have broken away from the follicle wall and lie free in the liquor folliculi. The egg exhibits the first polar spindle, the first polar body is in process of extrusion. × 200.

Fig. 5. Atretic follicle containing an egg with first polar body. The chromosomes of the first polar body are scattered. × 500.

Fig. 6. Atretic follicle containing an egg with first polar body. The latter is in process of division, the chromosomes are in two groups and the cytoplasm shows irregularly arranged spindle fibres. × 500.

Fig. 7. Line drawing made with camera lucida, of section through the egg shown in fig. 9. The first polar body possesses a typical spindle and is in process of division. × 750.

Fig. 8. Section through an egg contained in a small atretic follicle. The first polar body has divided into two unequal portions, the larger of which contains a resting nucleus. This egg possesses the first cleavage spindle (see fig. 11). × 450.

Fig. 9. The second polar spindle of an egg contained in an atretic follicle. This egg has a first polar body in process of division (fig. 7). × 500.

Fig. 10. Section through the Fallopian tube of a pregnant female. Typical normal two-celled egg, enclosed in its zona. × 220.

Fig. 11. Line drawing made with camera lucida of egg contained in a small atretic follicle. The first cleavage spindle is present. A section through the same egg is shown in fig. 8. × 630.

Fig. 12. Section through a two-celled egg in an atretic follicle. The zona is still intact. × 500.

Fig. 13. Section through a four-celled stage in an atretic follicle. The four blastomeres lie in one plane with a typical cross-shaped arrangement. One nucleus is not in the sectional plane. × 500.

Fig. 14. Section through a four-celled stage in an atretic follicle. Three blastomeres occupy one plane, the fourth occupies the opposite pole of the egg. × 500.

Fig. 15. Section through an egg undergoing degenerative fragmentation. The zona is still intact but the egg consists of a multinucleate deeply staining mass, exhibiting no trace of cell walls. × 450.

Fig. 16. Line drawing of a section through an atretic follicle of the mouse. The ovum is in process of division into two. The cytoplasmic division is not yet completed. One polar body is shown. The original drawing was made by the late F. J. Bridgman of University College, London.

REVIEWS

Selected Lectures and Essays (including Ligaments, their Nature and Morphology). By Sir JOHN BLAND-SUTTON. 4th edition, pp. 309, figs. 111. Price 15*s*. (London: Heinemann. 1920.)

Sir John Bland-Sutton was one of the original members of the Anatomical Society of Great Britain and Ireland and did much, during the earlier years of its existence, to further its life and prosperity. Many of its members regretted that a busy professional life made it necessary for him to resign his connection with the society. The present volume will show his former colleagues that his interests in anatomical pursuits are still alive and fruitful at the end of forty years spent at the Middlesex Hospital as student, anatomist and surgeon. The opening essays, on the Nature of Ligaments, are already well known to anatomists and need no comment here. In the essays and lectures which follow, such as those on peculiar mechanisms in the orbit, on the structure of the gizzard and ruminant stomach, on misplaced and missing organs and on hermaphroditism he has original observations to record and inferences to draw. We note that the evidence he has collected points to the ovum being transmitted along the Fallopian tube, not by the action of cilia lining it, but by the contraction of its muscular walls. The essays are written in the clear, incisive, piquant style which characterises everything that Sir John Bland-Sutton has written. The essays are illustrated by 111 illustrations drawn and engraved on wood.

The Principles of Anatomy as seen in the Hand. By FREDERIC WOOD JONES, D.Sc., M.B., Professor of Anatomy in the University of Adelaide. pp. 325, 2 plates and 123 text-figures. Price 15*s*. (London: Churchill. 1920.)

In this work Prof. Wood Jones has used the structure of the hand as a means of exemplifying the principles underlying the construction of the human body and has thereby provided medical students with an excellent introduction to their anatomical studies and teachers of anatomy with new facts and novel interpretations of structural problems. He is known to the readers of this Journal as a gifted draughtsman and has illustrated this work by 123 of his original drawings. All through the work the essential primitiveness of the structural characters of the human hand is emphasised while the complexity of its nervous machinery is acutely realized and graphically described. This volume is one which should be on the book-shelves of every thinking anatomist.

The X-Ray Atlas of the Systemic Arteries of the Body. By H. C. ORRIN, O.B.E., F.R.C.S. (Ed.). Large Quarto, with Text and 33 original illustrations. Price 13*s*. 6*d*. net. (London: Bailliere, Tindall and Cox. 1920.)

The author of this atlas while engaged at a military hospital as civil surgeon felt the need of plates which would depict the distribution and relationship of the arteries of the body as revealed by the aid of X-rays. The excellent plates published in this atlas were prepared by the author to meet this need. With one exception all of them are taken from a very successfully infected full-time foetus. The atlas has been prepared for the use of students of anatomy, surgical anatomy and operative surgery, but one would also commend it to the notice of teachers and investigators for some of the plates bring out certain facts—particularly in the course and distribution of abdominal arteries—which are worthy of further study. A useful series of stereoscopic radiographs are added at the end which should prove very serviceable. The price seems to us extremely moderate.

79

THE DISTRIBUTION OF NERVES IN THE UPPER LIMB, WITH REFERENCE TO VARIABILITIES AND THEIR CLINICAL SIGNIFICANCE[1]

By ERIC A. LINELL, M.D. (Manch.)
(*Late Leech Fellow, University of Manchester*)

1. INTRODUCTION.

This investigation was undertaken with the following objects:

(1) To assist the clinician, by means of measurements, as to the position of origin of important branches of the nerves of the arm and as to the limits within which he may expect to find variations of these branches;

(2) to give average positions for the entry of muscular nerves into their respective muscles, and also the variabilities to be expected;

(3) to determine the positions at which the larger sensory branches become cutaneous;

(4) to study, as far as dissecting-room subjects will permit, the communications taking place between cutaneous nerves;

(5) to point out any anatomical anomalies and variabilities found in the nerve supply of the upper limb which may be of significance in helping to elucidate various problems presented clinically by soldiers wounded during the war. Clinical investigation and the surgical treatment of the very numerous cases of peripheral nerve injury has shown that a more precise knowledge than is to be found in the standard anatomical textbooks was required about the above points.

For this reason 26 adult and eight foetal limbs have been examined. The method employed has been to take measurements accurate to ·5 cm. between convenient bony points of the limbs examined. The bony points used were the tip of the acromion process and the tip of the external condyle of the humerus for upper arm measurements, and the tip of the external condyle and the tip of the styloid process of the radius for measurements in the forearm, the limb being always adducted to the side with the forearm supinated. The level at which the branch of the nerve under examination arose from its parent trunk, entered a muscle, became cutaneous, etc., was marked off on a vertical scale stretching between the two bony points used. For example, if the distance in an upper arm was found to be 30·0 cms. between the tip of the acromion process and the tip of the external condyle of the humerus and the branch of the musculo-cutaneous to the biceps was found to enter this muscle at the

---

[1] This thesis was submitted for the degree of M.D. at Manchester in May 1920, and was awarded commendation.

level of 15·5 cms. along this scale, that measurement was noted under that limb as $\frac{15·5}{30·0}$. This fraction expressed as a decimal or ratio is ·52. From a series of such ratios obtained by the measurement of numerous limbs an average ratio can be obtained, as shown in column 3 of the Tables in section 11. This average ratio is a constant for all limbs. The average length of the upper arm is found to be 30·5 cms. and so the application of this figure to the constant, or average ratio, gives an average distance in centimetres for the entry of the nerve to the biceps in an upper arm of average length. In correcting the distance for any particular arm under examination, e.g. for one 33·5 cms. long, all that is required is an application of the constant to this figure, ·52 × 33·5. This, within slight limits of variability to be described later, will give a definite position at which the clinician may confidently expect to find the branch of the musculo-cutaneous nerve entering the biceps.

It is to be carefully noted that all measurements refer to horizontal *levels* and bear no relation to the actual length of the nerve unless, between two measurements, the nerve happens to pass vertically down the limb and in one vertical plane.

The dissections of foetal limbs have not been included in this series of measurements. The average ratio or constant was found to correspond with that of the adult series, but the great disparity of length between foetal and adult limbs so lowered the average length measurements as seriously to affect the average readings of the positions taken.

The foetal limbs have however been of value, particularly in studying the brachial plexus and the distribution of cutaneous nerves.

The application of this principle to about forty important definite points in the course of the nerves of the upper limb has resulted:

(1) in a series of average measurements from which the course of the various nerves can be accurately mapped out, and

(2) in a series of average ratios or constants (column 3, Tables, section 11) from which the clinician can obtain the above series of average measurements in any limb he is investigating provided he knows the length of that limb.

In the subsequent descriptions the brachial plexus will first be dealt with and then will follow an account of each of its branches of distribution to the limb with the exception of the lesser internal cutaneous, which did not seem to be of sufficient clinical importance to warrant its inclusion.

The gross anatomy of the parts will not be considered except where it is necessary in order to explain any points of interest or anomalous conditions which may require description. Anomalies will be described under the various nerves in the course of which they occur. Variabilities in position of branches of distribution will also be considered under their respective nerves and these variabilities will be given in their corrected form. To explain this the nerve supply to the biceps may be again taken as an example. Let us suppose that the muscle-entry of this nerve is found to vary between 12·0 and 18·0 cms. in various arms. This may be termed *gross variability* and would be inaccurate as the upper arm giving the first measurement was found to be 28·0 cms. long, and that giving the second 34·0 cms. The ratios in these cases were therefore $\frac{12 \cdot 0}{28 \cdot 0}$ and $\frac{18 \cdot 0}{34 \cdot 0}$ or ·42 and ·53. This therefore reduces the variability to ·11, which, taking the average upper arm as 30·03 cms. in length, is 3·3 cms. The *corrected variability* of this branch would therefore be 3·3 cms.

The figures used in this example are not accurate, but they will serve to explain the principle of these measurements. The subject will be referred to again when the actual figures are considered.

2. BRACHIAL PLEXUS

The gross anatomy of the formation of the trunks and cords of the brachial plexus has been found to correspond so accurately with the description in the textbooks that it need not be mentioned here.

The branches of the brachial plexus are generally divided into a supraclavicular and an infraclavicular set. This is indefinite and inaccurate, and is consequently of little clinical value. To substantiate this statement the position of origin of the external and internal anterior thoracic nerves has been observed with some care. These branches are described as infraclavicular in origin. In the fully abducted position of the limb, when the outer end of the clavicle is considerably raised with reference to its level in the orthodox "anatomical position," the external anterior thoracic is found to arise distinctly above the clavicle and the internal anterior thoracic has at least a postclavicular if not a supraclavicular origin. In the anatomical position, therefore, with the arm adducted to the side, these branches must be even more supraclavicular in origin due to the dropping of the outer end of the clavicle. In view of this inaccuracy and of the lack of definition in using the clavicle as a line of subdivision on account of the considerable excursion of this bone with motion of the limb, it has seemed advisable to look for some definite line by which may be effected a subdivision which is not dependent on the vagaries of the moving clavicle (1).

In the fully abducted position of the limb, the trunks, cords and their terminal divisions, may be described as passing horizontally from the root of the neck into the limb. It is found that the point of junction of the three posterior divisions of the trunks to form the posterior cord is constant. If now a vertical line be drawn through the plexus cutting this point, a definite line of division of the plexus is obtained which is constant for all limbs, showing only very slight variations proportionate with the dimensions of the individual subject. A series of measurements of 21 limbs has established this line as being on an average 7·75 cms. from the lateral border of the lower cervical vertebral bodies (fig. 1). In the living, the pulsations of the common carotid artery will form a better landmark and 6·75 cms. horizontally outwards from the lateral border of the common carotid at the root of the neck will give the same line of division. This line, where it cuts the plexus, is definitely distal to the clavicle.

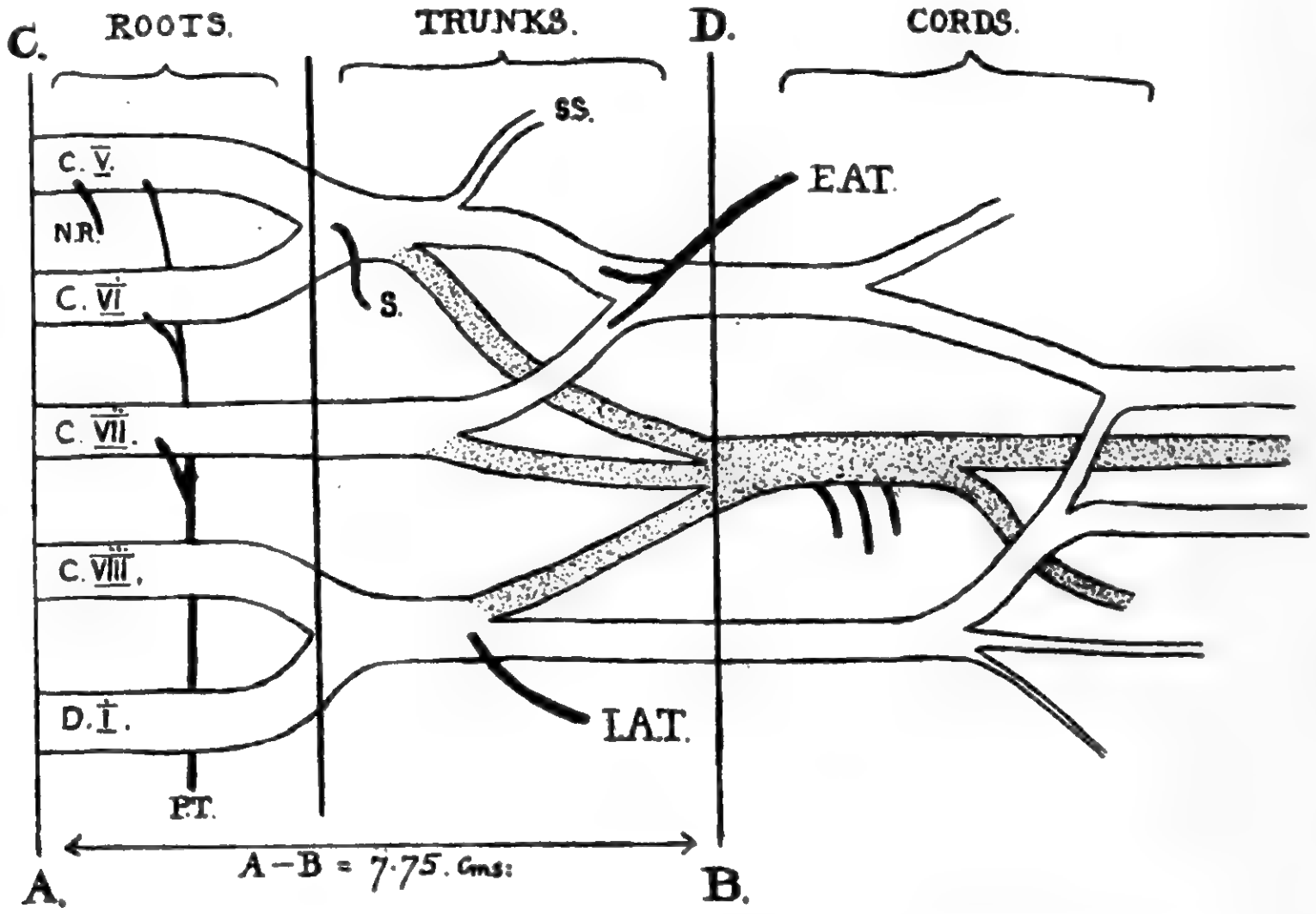

Fig. 1. Brachial plexus (left).

C.A. = line of lateral borders of bodies of lower cervical vertebrae.
D.B. = subdivisional line separating trunks from cords.
S.S. = suprascapular nerve.
S. = nerve to subclavius.
N.R = nerve to rhomboids.
P.T. = posterior thoracic nerve.
E.A.T. = external anterior thoracic nerve.
I.A.T. = internal anterior thoracic nerve.

The use of this line should simplify the nomenclature of the branches of the plexus, besides eliminating the clavicle from consideration in this respect. The branches would be classified as

(*a*) branches of the roots,
(*b*) branches of the trunks,
(*c*) branches of the cords.

The line would divide the trunks from the cords. The branches of the roots would remain as before, as would those of the cords. The trunk branches as at present described are two, the suprascapular and nerve to the subclavius, both from the upper trunk. To these would have to be added the two anterior thoracic nerves and such an addition appears to be justifiable. An examination of the origins of these nerves in 25 subjects (including foetuses) shows the following points.

Internal anterior thoracic nerve. This nerve arises from the plexus at a higher level than is compatible with its origin from the inner cord. Gray (2) recognises this high origin by describing it as a posterior relation of the first part of the axillary artery, which portion of the vessel is always considered as an inferior relation of the three trunks of the plexus. The actual origin of the nerve is occasionally directly from the anterior aspect of the lower trunk. Generally, however, it arises from the anterior aspect of the trunk immediately distal to the origin of its posterior division which is going to assist in the formation of the posterior cord. It is customary to say that the lower trunk divides into an anterior and posterior division but the anterior division is not considered as a separate entity, in other words the inner cord is described as beginning immediately the posterior division of the lower trunk has arisen. It would seem better to give the anterior division of the lower trunk a definite length and to consider it as extending downwards to the dividing line described (*BD*, fig. 1), distal to which line it could justifiably be called the inner cord. The internal anterior thoracic nerve does therefore belong definitely to the trunk branches and should be considered as arising from the anterior division of the lower trunk.

External anterior thoracic nerve. This should also be considered as a branch of the brachial nerve trunks. Observations on the origin of this nerve have been taken in a series of 21 adult and four foetal limbs. The nerve has been found to arise either by two separate roots from the anterior divisions of the upper and middle trunks, or by a single root placed exactly at the angle where these two anterior divisions join to form the outer cord. In 60 per cent. the origin was by two roots from the anterior divisions of the trunks, and in the remainder the single root origin so obviously came from these two divisions, immediately after their union, that only technically could the nerve be considered as a branch of the outer cord.

When the anterior divisions of the upper and middle trunks join they are classically considered as forming the outer cord immediately. If, now, we consider this cord as being formed at the level of the dividing line, *BD* in fig. 1 as suggested, the external anterior thoracic will, in any case, be included as a trunk branch and will be rightly described as arising from the anterior divisions of the upper and middle trunks.

The anterior thoracic nerves should therefore be considered, from both anatomical and clinical points of view, as branches of the brachial nerve trunks, and not as branches of the outer and inner cords as usually described. The dividing line here suggested will place them both in this category.

Passing now to the segmental constitution of the cords, a variability has been observed which has not been sufficiently emphasised in English textbooks, but which is of very considerable clinical significance.

The inner cord is generally described as drawing its fibres solely from the eighth cervical and first dorsal roots. In a very considerable proportion of cases the seventh cervical root also gives fibres to the inner cord in the following manner:

The outer head of the median contains fibres from the sixth and seventh cervical roots. This nerve bundle joins the inner head of the median to form the median trunk.

Frequently, however, a considerable bundle of fibres from the inner aspect of the outer head of the median becomes separated off immediately above the formation of the median trunk. This bundle, consisting of seventh cervical fibres, runs obliquely downwards and inwards behind the inner head of the median to enter the ulnar nerve. Hence the ulnar nerve frequently contains fibres from the seventh cervical root in addition to its eighth cervical and first dorsal fibres (fig. 2). The significance of this distribution of fibres will be discussed when dealing with the ulnar nerve.

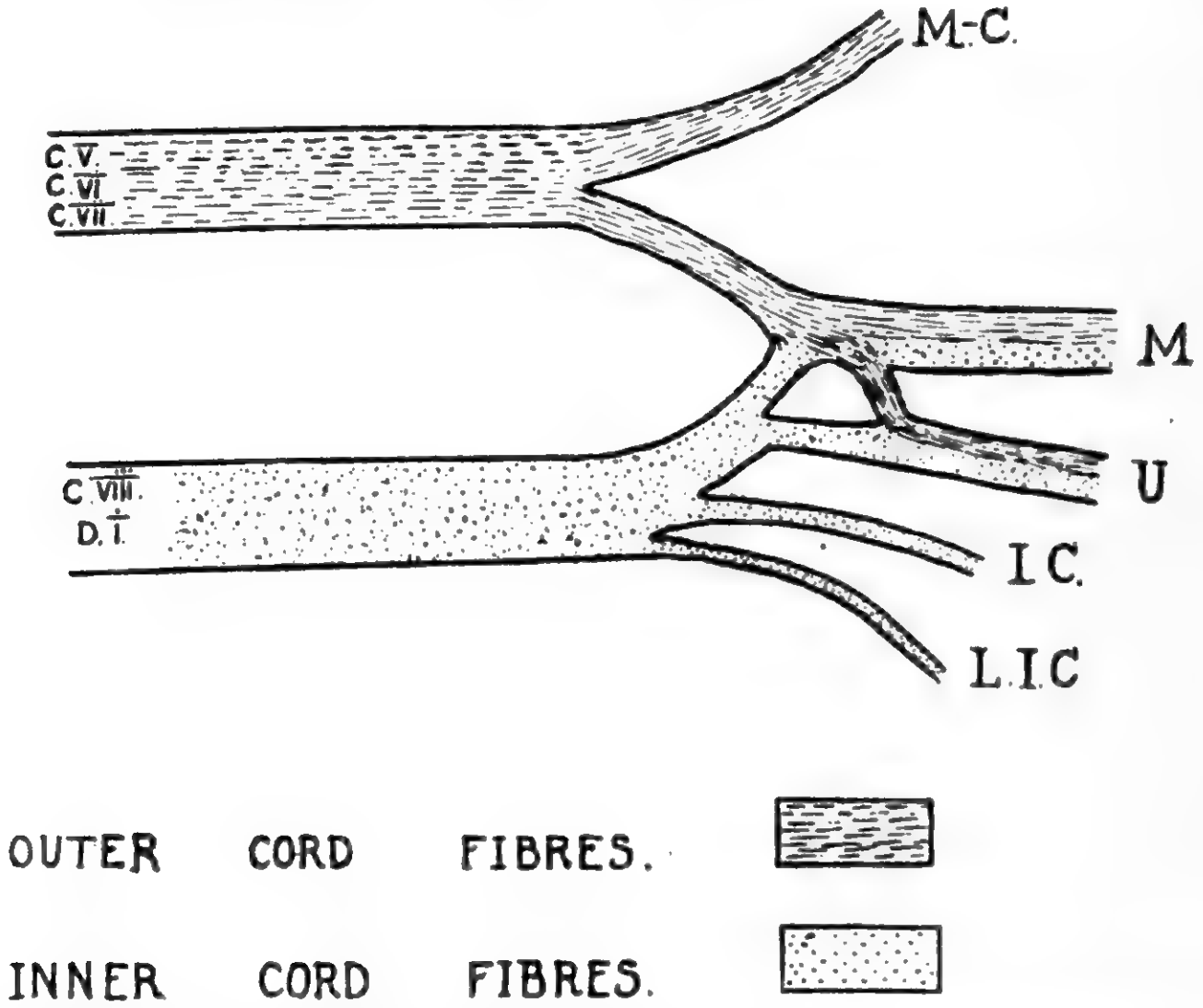

Fig. 2. Communication between outer and inner cords. Right brachial plexus (from behind).
M.C. = musculo-cutaneous nerve.
M. = median nerve.
U. = ulnar nerve.
I.C. = internal cutaneous nerve.
L.I.C. = lesser internal cutaneous nerve.

This interchange of fibres between the outer and inner cords has been looked for in 21 foetal and adult subjects and has been found to be present in 57 per cent.

Wilfred Harris (3) in his paper on the true form of the brachial plexus gives a positive result in 86 per cent. of the 30 subjects examined. He includes in this percentage a number of cases in which, by careful dissection of excised brachial plexuses removed at postmortems, he was able to trace a bundle of fibres down the outer head of the median, up its inner head and thence down again into the ulnar nerve.

Whatever the exact percentage may be, my estimate of 57 per cent., in which the condition was quite obvious without minute dissection, may be taken as a minimum. This variability is consequently well worthy of emphasis in textbooks, especially in view of its clinical significance in helping to explain variabilities in the cutaneous distribution of the ulnar nerve.

3. MUSCULO-CUTANEOUS NERVE

Origin. This nerve shows considerable variability in its origin from the outer cord.

In four out of the 26 cases the outer cord did not split into two divisions and the muscular branches of the musculo-cutaneous arose direct from the lateral aspect of the outer cord. The cutaneous division of the nerve was separated from the cord about the junction of the middle and lower thirds of the arm, from which point it proceeded downwards and outwards between the biceps and brachialis anticus to its normal distribution. This anomalous origin of muscular branches did not affect the average level at which the coraco-brachialis, biceps and brachialis anticus are normally supplied.

Another anomaly occasionally found in this region was a musculo-cutaneous trunk containing fibres destined to join the median. These fibres were given off in a bundle to join the median trunk at a variable distance down the upper arm. The size of this anomalous nerve bundle, which has been noted by several other workers, varies inversely with the size of the outer head of the median, and this bundle appears to consist merely of a variable number of "median" fibres which have descended for a short distance in the trunk of the musculo-cutaneous nerve.

Distribution. In describing the distribution of the nerves the numbers given will refer to horizontal levels down the average upper arm or average forearm.

The average upper arm is found to measure 30·5 cms. from the tip of the acromion process to the tip of the external condyle of the humerus. The average forearm, measured from the latter bony point to the tip of the styloid process of the radius, is 24·04 cms. long. These two numbers should, therefore, be borne in mind throughout the subsequent description of the individual nerves.

I. Muscular distribution

In such an average upper arm (30·5 cms.) the levels at which muscular branches arise from the musculo-cutaneous nerve trunk and enter their respective muscles will be shown by the following figures:

Nerve to coraco-brachialis	arises	4·76	cms.	(·156)
,, ,,	enters	7·35	,,	(·241)
Nerve to biceps	arises	12·99	,,	(·426)
,,	enters	15·28	,,	(·501)
Nerve to brachialis anticus	arises	17·32	,,	(·568)
,, ,,	enters	20·27	,,	(·665)

Nerve to coraco-brachialis. A slender bundle of fibres arising from the lateral aspect of the nerve trunk high up in the upper arm. After a course of about 2·5 cms. it ends by entering the medial aspect of the muscle just above the point at which the coraco-brachialis is pierced by the main musculo-cutaneous trunk.

Nerve to biceps. A stout branch arising from the nerve trunk as this is proceeding obliquely distally and laterally between biceps and brachialis anticus. After a short course distally and forward it divides into two branches, one entering the deep surface of each belly of the muscle at the same horizontal level. The above figures bring out two points. First, the nerve to the biceps is very short and secondly it enters the muscle immediately below the middle of the brachium $\left(\frac{15\cdot28}{30\cdot50}\right)$.

Nerve to brachialis anticus. This nerve arises from the inferior aspect of the main trunk while it is lying between biceps and brachialis anticus. Its extra-muscular course is longer than that of the nerve to the biceps and it ends by breaking up into four or five large branches which penetrate the anterior aspect of the muscle over a considerable area. From the measurements it will be observed that this branch arises only about 2 cms. below the middle of the upper arm and that it enters the muscle approximately at the junction of the middle and lower thirds of the brachium.

From these points it follows (i) that a lesion of the musculo-cutaneous trunk below 17·32 cms. of the upper arm will result in an anaesthesia of the musculo-cutaneous area uncomplicated by any muscular paralysis, and (ii) that however extensive any lesion of the upper arm may be, provided its upper limit is distal to 20·27 cms., the branch to the brachialis anticus will be uninjured and consequently a simple sensory lesion will again be the result in so far as the musculo-cutaneous nerve is concerned.

II. Cutaneous distribution

It will be noticed that the musculo-cutaneous gives off its last motor fibres higher up in the arm than is generally realised, 17·32 cms. This is of interest in view of the fact that a lesion of the musculo-cutaneous trunk a very short distance below the middle of the brachium will result in an uncomplicated sensory lesion. Stopford states that an uncomplicated sensory lesion of this nerve is five times as common as a mixed lesion.

Of the two cutaneous divisions of this nerve the anterior is the larger. The posterior division seldom reaches to the wrist, generally ending on the back of the lower part of the forearm. Occasionally this division ends by anastomosing with the lower external cutaneous branch of the musculo-spiral (fig. 4).

The anterior division can always be traced beyond the wrist and terminates by supplying a variable portion of skin over the thenar eminence. This division is in close relation with the radial nerve, which is becoming cutaneous in the lower part of the forearm by appearing behind the supinator longus tendon. In this region, therefore, there is frequently a communication between the musculo-cutaneous and radial nerves, which is a matter of clinical importance as probably explaining the slightness or absence of sensory disturbance in cases of section of the radial nerve above the lower third of the forearm (4). An attempt has consequently been made to find how often this anastomosis occurs, but there have been obvious difficulties in studying limbs dissected by students who do not reverence cutaneous nerves. In only seven limbs was it possible to be certain whether or not this anastomosis occurred, and these seven gave five positive results. In the other two no trace of a communication could be found, although the dissection was carefully performed. Two of these anastomoses are shown in figs. 3 and 4. It will be seen from these figures that the size and complexity of the anastomosis vary greatly. In fig. 3 two large bundles of fibres are seen entering the radial nerve, whereas in fig. 4 the anastomosis consists only of two small filaments and the latter is the condition more frequently met with.

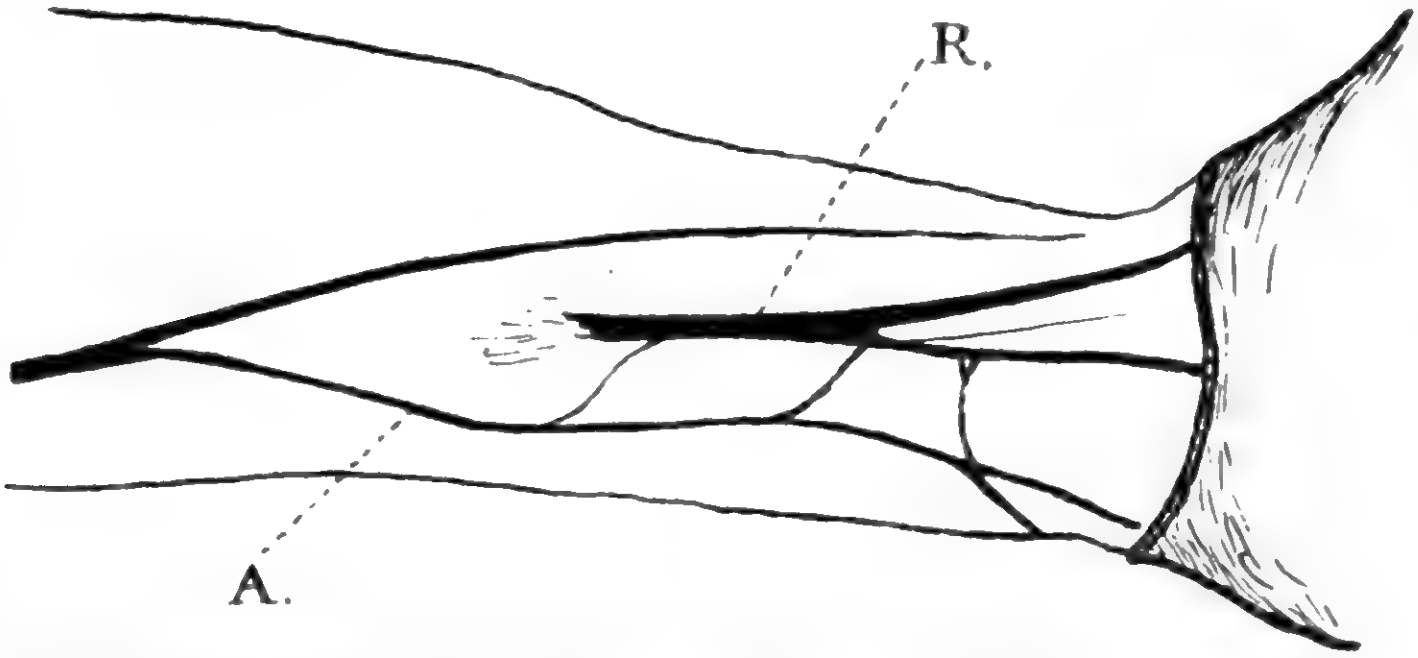

Fig. 3. Communication between musculo-cutaneous and radial nerves.
R = radial nerve.
A = anterior division of musculo-cutaneous nerve.

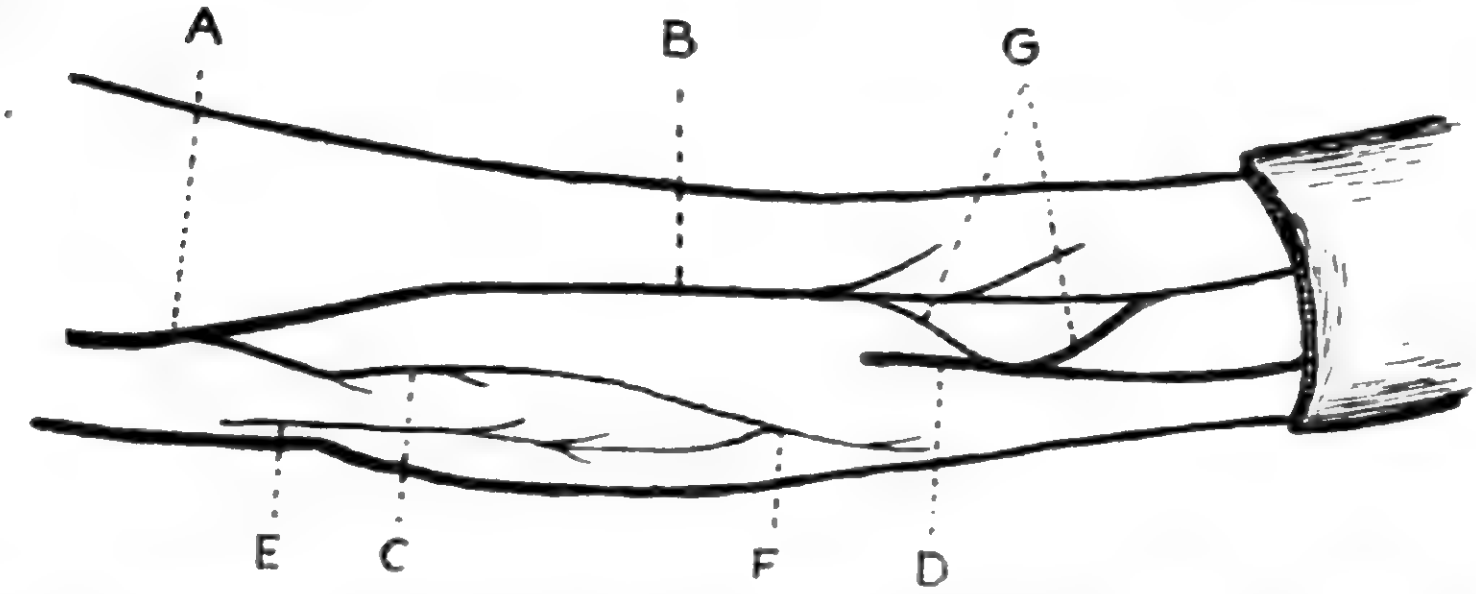

Fig. 4. Communications between musculo-cutaneous, musculo spiral and radial nerves.
A = musculo-cutaneous nerve trunk.
B = anterior division of musculo-cutaneous.
C = posterior division of musculo-cutaneous.
D = radial nerve.
E = lower ext. cut. branch of musculo-spiral.
F = communication between lower ext. cut. branch of musculo-spiral and post. div. of musculo-cutaneous.
G = communication between ant. div. of musculo-cutaneous and radial nerves.

An attempt to find this communication in foetuses was unsuccessful, the filaments being too minute to trace with any accuracy in these small limbs.

The interchanged fibres become inextricably bound up with the radial nerve and are presumably distributed in the branches of the latter.

It is of some clinical importance to remember that this communication may not be present.

4. MEDIAN NERVE

The median trunk is normally formed to the lateral side of the proximal part of the brachial artery by the union of its outer and inner heads, the outer head being slightly the larger.

This origin is subject to some variation. The fibres composing the inner head are constant, but those forming the outer head may be partially, or completely, carried down in the musculo-cutaneous trunk to be given off from that trunk to the inner head, and thus form the median nerve, at variable distances down the upper arm. This low origin was found in three of my cases. In one of these the nerve was only formed at the junction of the fourth and lowest fifth of the upper arm. Occasionally only some of the fibres of the outer head join the inner head in the normal position, the remainder joining it, *via* the musculo-cutaneous trunk, at a lower level. On both sides of one body the median nerve passed deep to the brachial artery to get from its lateral to its medial side.

Distribution

Muscular. The multiple muscular branches of the median immediately distal to the elbow show such tremendous variability and come off so close together that estimations of their average levels must be only approximate. The nerve to the pronator radii teres can be distinguished as a separate branch but the supplies of flexor carpi radialis, palmaris longus and flexor sublimis digitorum have been classed as one nerve bundle. In the average forearm 24·04 cms. long the

Nerve to pronator radii teres arises 1·0–2·0 cms. approx.
,, ,, enters 1·5–2·0 ,, approx.
Nerve bundle to the common flexor mass, upper limit of origin = 2·08 cms. (·086)
,, ,, upper limit of entry = 2·76 ,, (·115)
,, ,, lower limit of entry = 5·05 ,, (·210)
Anterior interosseous nerve arises 5·24 cms. (·218)

Nerve to pronator radii teres. This is the first branch of distribution of the median. Although its origin may be given as approximately 1·0–2·0 cms. below the tip of the external condyle this point varies greatly in both directions. As a general rule it arises below the external condyle, but it has been found coming from the trunk as much as 4 cms. above this bony point. Its direction is medially and slightly distally. As it approaches the muscle it commonly divides into an anterior and a posterior branch, the anterior entering the lateral aspect of the condylar head of the muscle and the posterior supplying the coronoid head at its origin from the ulna. The level of the entry to the muscle is approximately from 1·5–2·0 cms., therefore its direction is practically horizontal, the posterior branch descending a little to gain the coronoid head. Occasionally the nerve to the coronoid head of the muscle arises by a separate branch just below that for the condylar head, and in one case such a branch entered the coronoid head as low as 6·0 cms. down the forearm. It is therefore anatomically possible to have paralysis of either of the heads of the muscle alone in lesions of the anterior or posterior branches when these arise from a common trunk. When these branches arise independently, section of the median between their points of origin will paralyse the coronoid head leaving the condylar head intact. It is doubtful whether this point is of clinical value as the coronoid head of pronator radii teres is generally very small and its reactions cannot be tested clinically apart from those of the condylar head.

Frequently the nerve supply to the condylar head arises by two distinct roots.

Bundle to the common flexor mass. A large bundle of fibres arising from the antero-medial aspect of the nerve trunk at about 2·0 cms. down the forearm. This bundle proceeds forwards and medially towards the muscles it supplies, expanding as it goes into a triangular sheet of fibres. The highest fibres are directed medially and a little distally to reach the flexor carpi radialis. The lower fibres descend more and more obliquely to reach the palmaris longus and flexor sublimis digitorum. The expanded base of this triangular sheet of fibres is formed where they enter the muscles, the upper limit of entry being 2·75 cms. and corresponding to their entry into flexor carpi radialis and the lower limit, or point of entry into palmaris longus and flexor sublimis digitorum being a little more than 5 cms. down the forearm. The base of this triangle has therefore a vertical length of nearly an inch. In accordance with this increasing obliquity of nerve fibres a lesion involving the supply to the flexor sublimis digitorum is more likely to injure the median trunk than is damage to the nerve to flexor carpi radialis.

The flexor sublimis digitorum does not, however, receive all its nerve fibres in this situation. In 11 cases out of this series of 24 I was able to find a branch of the median mentioned by Quain (5), which arises in the lower part of the forearm, while the nerve is lying between the superficial and deep flexor muscles, and which proceeds practically horizontally forwards with a slight inclination distally to end in the posterior aspect of the index or occasionally of the medius belly, of the flexor sublimis digitorum. The level at which this branch arises is not sufficiently constant to give anything of a reliable average measurement. Its height of origin in my cases varies between 9·0 cms. and 22·5 cms. down the forearm, but in the majority of cases it was below 12·0 cms. It entered the muscle belly, on an average, 1·0 cm. below its origin. The paralysis of this branch may help to explain weakness of flexion confined to the index finger in median injuries in the second quarter of the forearm.

Clinically this branch seems to have been very constant. Professor Stopford tells me that in all of nine patients in whom complete division of the median in the middle of the forearm was verified at operation, the belly of the flexor sublimis digitorum to the index finger was paralysed. This nerve may, then, be the sole supply of the index belly of the muscle.

Anterior interosseous nerve. This is the next distinct branch of the median. It arises 5·24 cms. down the forearm and proceeds distally and dorsally to reach the interosseous membrane and lie between the flexor profundus digitorum and flexor longus pollicis. Just before it reaches the interosseous membrane it gives a branch from its medial side to the lateral portion of the flexor profundus digitorum and, at about the same level, one from its lateral side, which enters the upper extremity of the flexor longus pollicis. In the proximal part of its course on the interosseous membrane it supplies a few additional twigs to the upper ends of these muscles and then, greatly reduced in size, runs vertically downwards. At the junction of the third and lowest quarters of the forearm it disappears under the pronator quadratus, which muscle it supplies on its deep aspect.

This completes the muscular distribution of the median in the forearm, as the branch to the index belly of the flexor sublimis digitorum has been described in connection with that muscle.

Muscular distribution in hand

The median nerve is classically described as supplying abductor pollicis, opponens pollicis and the superficial head of flexor brevis pollicis. It has been found clinically, however, that the superficial head of flexor brevis pollicis may react well to faradic stimulation in cases of median paralysis, although the abductor and opponens pollicis do not respond. The difficulty, as Wood-Jones (6) points out, appears to be principally one of nomenclature, and the problem resolves itself into the answer to the question "What exactly is the superficial head of flexor brevis pollicis?" If the answer to this question is "That portion of flexor brevis pollicis which obtains insertion to the radial sesamoid and to the radial side of the base of the proximal phalanx of the thumb" an electrical response will be obtained from this "superficial head." Wood-Jones shows that this slip of muscle attached to the radial side of the first phalanx of the thumb is divisible into a superficial and deep portion. The superficial portion, which arises practically entirely from the anterior annular ligament, is supplied by the median nerve. The deeper portion gets its nerve supply from the ulnar and it is this portion of the "superficial head" of flexor brevis pollicis which reacts to stimulation when the median nerve is paralysed.

Cutaneous distribution

Palmar cutaneous. A minute twig arising a variable, and generally considerable, distance proximal to the wrist-joint. It runs down on the anterior surface of the main trunk to appear at the wrist-joint between palmaris longus and flexor carpi radialis. Then, running over the anterior annular ligament, it terminates by supplying a small area of skin over the middle of the proximal part of the palm.

Cutaneous supply to fingers. This supply varies inversely with variations in the palmar digital distribution of the ulnar nerve, and to save re-duplication of description the nerve supply of the fingers will be discussed when dealing with the ulnar nerve.

5. CIRCUMFLEX NERVE

This branch of the brachial plexus arises from the posterior cord as this is lying on the subscapularis muscle. The nerve runs distally to the lower border of this muscle when it turns backwards through the quadrilateral space. In this situation it is a somewhat intimate relation of the inferior aspect of the capsule of the shoulder-joint and it gives an articular branch upwards to penetrate this aspect of the capsule. Immediately behind the quadrilateral space it ends by dividing into an anterior and posterior division. The level of this division is 6·98 cms. down the arm.

The *anterior division* runs horizontally round the surgical neck of the humerus in contact with the deep aspect of the deltoid muscle. It is exhausted in supplying numerous short twigs of supply to this muscle and ends just short of its anterior border. The terminal twigs described as perforating the muscle to have a cutaneous distribution were not seen.

The *posterior division.* This division takes up a definitely lower level than the anterior one. It gives off, close to its origin, a short stout branch which proceeds upwards and medially to sink into the teres minor muscle. The remaining fibres then wind round the posterior border of the deltoid muscle and immediately pierce the deep fascia to become cutaneous. This division takes a horizontal course on the superficial surface of the deltoid similar to, but at a somewhat lower level than, that of the anterior division on its deep surface. By means of ascending and descending branches it supplies the skin over the distal half or more of the deltoid and cannot be traced further forwards than the anterior border of this muscle.

6. ULNAR NERVE

The ulnar is the lowest nerve-trunk split off from the medial aspect of the inner cord of the brachial plexus. It is constant in its level of origin in front of the teres major muscle, lying immediately medial to the termination of the axillary artery and separating this structure from its accompanying venae comites.

In describing the brachial plexus it has been observed that the ulnar nerve obtains fibres from the seventh cervical root, in at least 57 per cent. of cases, by means of a communication established between it and the outer head of the median nerve.

The course of the ulnar follows very constantly the accepted description in the textbooks. It leaves the brachial artery at the middle of the brachium by dipping backwards into the posterior muscular compartment. Here it runs distally in contact with the posterior aspect of the internal inter-muscular septum to the interval between the olecranon and internal condyle of the humerus. Entering the forearm between the two heads of flexor carpi ulnaris it comes to lie on the flexor profundus digitorum, and this deep relation it maintains to the wrist-joint. Passing superficial to the anterior annular ligament the nerve ends at the lower border of this ligament under cover of palmaris brevis muscle by dividing into a superficial and a deep division.

The ulnar has no branches of distribution until it arrives in the region of the elbow-joint. In one case a communicating filament from the internal cutaneous nerve trunk was observed to join the ulnar about the middle of the arm. The first branch of distribution of the ulnar is an *articular branch* to the posterior aspect of the elbow-joint. This is a twig of considerable size, variable in its origin, but seldom coming off higher than 1 cm. proximal to the tip of the external condyle. In one anomalous case this nerve arose as high as the junction of the middle and lower thirds of the arm, and ran distally along with the main trunk for a length of about 12 cms. to reach its distribution to the elbow-joint. Generally, however, this nerve was extremely short and ran practically horizontally outwards to its distribution.

The next series of branches of the ulnar trunk are for the supply of the flexor carpi ulnaris and flexor profundus digitorum.

Nerves to flexor carpi ulnaris. There are, as a rule, two distinct nerves to this muscle, but frequently three and occasionally four separate branches may be seen.

I and II. The two primary and almost constant branches arise from the main trunk, one immediately below the other, and just before the ulnar trunk disappears between the two heads of flexor carpi ulnaris. The level of origin of these two branches was, in this series, ·90 cm. and 1·62 cms. distal to the tip of the external condyle. In two cases (which are not included in this average) the levels of origin of the highest muscular branch were 1·0 cm. and ·5 cm. respectively, proximal to the external condyle. It is exceptional, therefore, for any muscular branch to arise from the ulnar above the elbow-joint or, more accurately, above the tip of the external condyle.

These two primary branches run distally. The upper one is the shorter and ends 2·08 cms. down the forearm by piercing the inner aspect of the olecranon head. The lower branch enters the lateral aspect of the condylar head at 2·99 cms. down the forearm. Tabulated, the measurements of these two nerves are as follows:

Nerve to olecranon head arises	·90 cm.	(·037)
,, ,, enters	2·08 cms.	(·087)
Primary nerve to condylar head arises	1·62 ,,	(·067)
,, ,, enters	2·99 ,,	(·125)

III. The next branch, which is not constant but is frequently present, may be spoken of as the secondary nerve to the condylar head. The average measurements are:

Secondary nerve to condylar head arises	2·25 cms.	(·093)
,, ,, ,, enters	4·88 ,,	(·203)

This secondary nerve will be seen from these figures to arise a little more than ·5 cm. below the primary branch to this head of the muscle. It will also be observed to have a much longer extra-muscular course than either of the preceding branches. It arises from the medial aspect of the ulnar trunk, runs down with this trunk between the two heads of the muscle and then proceeds obliquely distally and medially on the deep surface of the condylar head to enter the anterior surface of this head at its medial border after an extra-muscular course of over an inch (2·63 cms.).

Poirier and Charpy (7) describe this branch as having an extremely long extra-muscular course and state that it enters the muscle in the lower third of the forearm. Nothing comparable with this length of course was found in any of this series.

IV. The fourth nerve to the flexor carpi ulnaris is a short, inconstant twig which arises from the ulnar after it has disappeared between the two heads of the muscle. It runs forward to enter the deep aspect of the muscle at approximately the same level of entry as the secondary branch to the condylar head.

It has seemed of value to describe this nerve supply fully as the books are vague on the subject, and it is one of clinical importance since injuries to the ulnar nerve in the region of the elbow have been encountered so frequently and displacement of the nerve trunk in front of the internal condyle of the humerus is now a fairly common surgical manœuvre, which permits end-to-end suture to be performed, even when a large defect is found. The freeing of the nerve trunk necessary to allow of this anterior displacement can generally be performed without sacrifice of any of the branches to the flexor carpi ulnaris. The articular branch to the elbow-joint has, however, to be cut as a rule.

To summarise: Four distinct branches may be found arising from the ulnar to supply the flexor carpi ulnaris. In their order of origin these are:

(i) Nerve to olecranon head.
(ii) Primary nerve to condylar head.
(iii) Secondary nerve to condylar head.
(iv) Branch entering muscle immediately below the junction of its two heads.

An analysis of 23 limbs showed the following:

2	cases had	4	branches	(i), (ii), (iii) and (iv).
3	,,	3	,,	(i), (ii) and (iii).
12	,,	2	,,	(i) and (ii).
6	,,	1 branch.		

(i) and (ii). 17 out of 23 subjects, therefore, had these two branches so that this seems to be the usual method of nerve supply to the muscle.

(iii). Five cases showed this additional branch to the condylar head. This branch, although only present in approximately 20 per cent., is of importance for two reasons. First, on account of the length of its extra-muscular course and secondly, because it may, exceptionally, be the only branch to the condylar head of the muscle. In one case this nerve entered as low as 8·0 cms. down the forearm.

(iv). The fourth branch is obviously exceptional.

The six cases, in which only one branch was found, showed this branch entering at the junction of the two heads. Its filaments were not traced into the muscle.

The last point to notice in connection with this nerve supply is that the ulnar gives off the first three of these nerves between the average horizontal levels of ·9 cm. and 2·25 cms. down the forearm.

Nerve to flexor profundus digitorum. This branch arises high in the forearm, a short distance below the origin of the lowest nerve to the preceding muscle. The following are its average measurements:

Origin 3·07 cms. (·127),
Entry 5·54 cms. (·230).

The nerve arises from the ulnar trunk while this is lying on the upper fibres of flexor profundus digitorum deep to flexor carpi ulnaris. It is a stout bundle of fibres which runs down on the anterior surface of its muscle for nearly an inch before entering it.

The remaining branches of distribution of the ulnar nerve in the forearm are two, both of which are probably entirely sensory in function.

Dorsal cutaneous branch of ulnar. Two measurements have been taken to fix this branch:

(*a*) its position of origin, 17·06 cms. (·709);

(*b*) the level at which it becomes cutaneous by appearing at the mesial border of the flexor carpi ulnaris muscle, 20·95 cms. (·871).

The measurement of the level of origin shows very marked variation (see Tables, section 11). From its average level of 17·06 cms. the nerve runs distally and very obliquely inwards under flexor carpi ulnaris to gain its second fixation point at the medial border of this muscle. Here it becomes cutaneous at an average level of 20·95 cms. down the forearm and this measurement showed little variability. In the average forearm of 24·04 cms. length the dorsal branch of the ulnar may therefore be considered to become cutaneous a little over 3 cms. proximal to the tip of the styloid process of the radius, and this is therefore a measurement of importance for purposes of localisation in connection with injuries in the neighbourhood of the ulnar side of the wrist-joint.

This is a lower level than is usually given in textbooks. Fig. 5 shows this branch winding round the wrist below the styloid process of the ulna. This is anomalous and is therefore not included in these estimates.

The distribution of this nerve to the dorsum of the hand and fingers has been carefully worked out and will be considered later.

Palmar cutaneous branch. This, the last branch of the ulnar trunk, is a slender twig arising in the lower third of the forearm. It runs down on the anterior aspect of its parent trunk superficial to the annular ligament to be distributed to the skin over the hypothenar eminence.

The ulnar nerve ends at the distal border of the anterior annular ligament under cover of the palmaris brevis muscle, by dividing into a superficial and a deep division.

The *deep division* dips down between abductor minimi digiti and flexor brevis minimi digiti to supply all the intrinsic muscles of the hand, except those which are innervated by the median and have already been considered.

The superficial division. This is a purely sensory nerve supplying branches to the skin of the ulnar half of the palm and then dividing into terminal branches for the palmar aspect of the ulnar digits. The exact distribution of this nerve will now be considered.

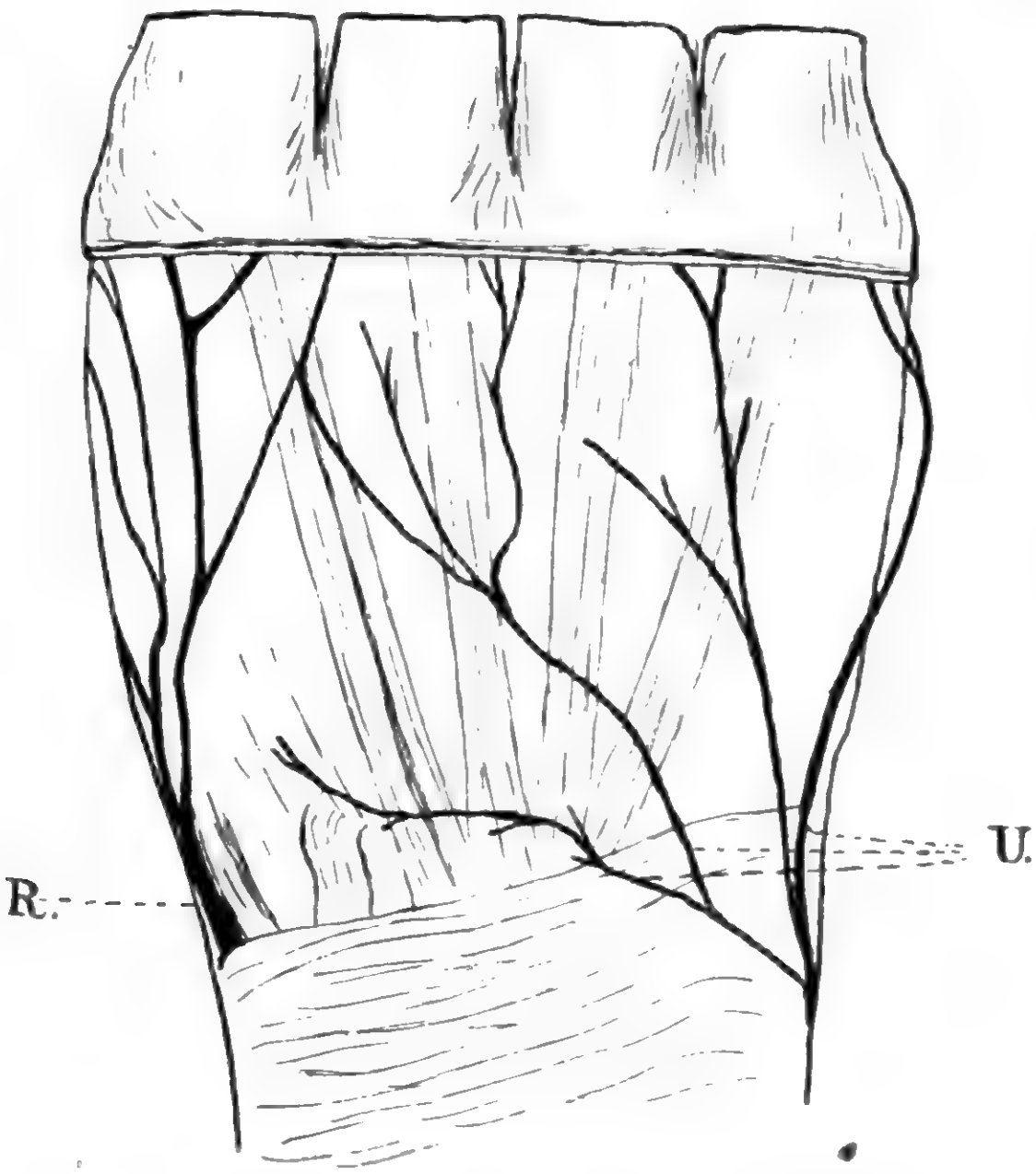

Fig. 5. Dorsal digital distribution of ulnar nerve (Rt).
U. = dorsal cutaneous branch of ulnar nerve.
R. = radial nerve.

Digital cutaneous distribution of ulnar nerve. The ulnar nerve is usually described as supplying the fifth and the ulnar half of the fourth digit on their palmar and dorsal aspects. Anomalies found clinically have called in question the accuracy of this classical description.

Consequently I have attempted in a series of dissections to arrive at some conclusions as to the variabilities which may be expected to be met with in the cutaneous supply to the fingers.

The ulnar nerve has been taken as the basis in these dissections as, from a complete display of this nerve, it has been considered justifiable to deduce the digital supply of the median to the palmar aspect and of the radial to the dorsal aspect of the remaining fingers.

In order to supplement observations on dissecting-room subjects a careful dissection of eight foetal ulnar nerves has been performed.

In all, 36 observations have been made—20 on the palmar digital and 16 on the dorsal digital distribution of the nerve.

Palmar digital distribution of ulnar nerve. In the 20 cases of this series, 16 showed the classical supply to the little finger and the ulnar side of the ring finger. Of the remaining four, one supplied the whole of the two ulnar digits and the remaining three had an additional distribution to the ulnar side of the middle finger.

Dorsal digital distribution of ulnar nerve. Of 16 cases, only two showed the classically described distribution to the little finger and the inner half of the ring finger. In eleven cases the distribution was to the little, ring and the ulnar half of the middle fingers. Of the remaining three, one supplied the fingers as far laterally as the ulnar side of the index and two supplied both sides of the two ulnar fingers.

Counting from the ulnar margin of the hand these results may be put in a concise form as follows:

Palmar Digital Distribution

1½	fingers in	16 cases	= 80 %
2½	„	3 „	= 15 %
2	„	1 case	= 5 %
		20	100 %

Dorsal Digital Distribution

1½	fingers in	2 cases	= 12·5 %
2	„	2 „	= 12·5 %
2½	„	11 „	= 68·75 %
3½	„	1 case	= 6·25 %
		16	100 %

These figures show, therefore, that, while the palmar digital distribution corresponds with the description in the textbooks, the branches of the dorsal cutaneous branch of the ulnar very frequently supply the whole of the inner two fingers and the ulnar side of the middle finger (fig. 5). Stopford from clinical data comes to the conclusion that "the radial nerve only rarely appears to supply the extensive area of skin usually described, as in about 70 per cent. it does not extend medially beyond the second metacarpal bone (4)."

The dorsal digital branches of the ulnar nerve cannot be traced distally beyond the head of the first phalanx.

In connection with this distribution of the dorsal cutaneous branch of the ulnar it is of interest to remember, as again suggested by Stopford, that the middle is the axial finger of the limb. The seventh cervical is the axial nerve root of the limb. In discussing the brachial plexus the ulnar nerve was found to obtain fibres from the seventh cervical root by a communication from the outer head of the median in at least 57 per cent. of cases. The dorsal branch of the ulnar supplies the middle finger in 75 per cent. (68·75 per cent. + 6·25 per cent.) of cases. The seventh cervical fibres may be then distributed as a whole, or in part, in this nerve to supply the middle or axial finger.

7. INTERNAL CUTANEOUS NERVE

With the exception of the lesser internal cutaneous this is the highest branch given off from the inner cord of the brachial plexus. It may be considered as arising immediately distal to the lower border of pectoralis minor. It takes up a position on the anterior aspect of the third part of the axillary and the proximal part of the brachial arteries. As a general rule the nerve divides into anterior and posterior divisions in the upper third of the arm.

These divisions run down and pierce the deep fascia close together about the middle of the antero-medial aspect of the arm. Immediately after piercing the fascia the anterior division supplies a constant branch which runs transversely outwards and divides into ascending and descending twigs to supply the skin over the biceps, the descending twigs being traceable as far as the elbow-joint. In two of my cases the internal cutaneous did not divide until it reached the lower third of the arm and, in these, the supply to the skin over the biceps came from the main trunk.

In one case there was a considerable communication between the anterior division and the ulnar in the lower third of the arm.

The anterior division is somewhat larger than the posterior. At the elbow-joint it is an anterior relation to the bicipital fascia and thus to the termination of the brachial artery. It is distributed as low as the lower third of the forearm.

The posterior division diverges from the anterior in the superficial fascia to gain the internal condyle in front of, or occasionally behind, which it proceeds to gain the lateral and posterior aspect of the forearm. It is the smaller of the divisions and can seldom be traced below the middle of the forearm.

The communication described (2) between the internal cutaneous and ulnar nerves at the wrist-joint was never found in this series of cases, and neither of the divisions appeared to get far enough down the forearm to make such an exchange of fibres possible.

As has just been noted a communication may occur between these two nerves in the upper arm and this may be of clinical value.

8. MUSCULO-SPIRAL NERVE

This is the largest of the terminal branches of the brachial plexus. It is best considered as a continuation into the arm of the posterior cord of the plexus. The lowest branch of the posterior cord, the circumflex, arises as the cord is lying upon the subscapularis, and the musculo-spiral may therefore be said to start immediately below this point. From this point of origin, which was found to be very constant, the nerve proceeds vertically downwards in front of the lower fibres of subscapularis, the latissimus dorsi and teres major muscles to leave the axilla and enter the arm, where it is first placed in front of long head of triceps. It now inclines posteriorly and laterally between the long and inner heads of triceps to gain the musculo-spiral groove. Here it lies directly in contact with the bone and is covered by the outer head of the triceps and a fibrous arch thrown over the groove from the deep aponeurosis of this head. The musculo-spiral groove conducts the nerve obliquely distally and laterally to the external inter-muscular septum, which it pierces at the junction of the middle and lower thirds of the arm to appear between the supinator longus and brachialis anticus muscles. A vertical course thence, deeply between the supinator longus and extensor carpi radialis longior on its outer and the brachialis anticus on its inner side, carries it to its termination, which shows very considerable variation. In 23 measurements the variability of termination of this nerve was from 4·5 cms. above to 4·0 cms. below the tip of the external condyle. In nine cases it was above this point and in eleven below it. In the remaining three the nerve split into its two terminal divisions immediately in front of the tip of the external condyle.

This bony landmark therefore gives a good average position of termination of this nerve (2), but it should be remembered that it has a variability of approximately 4 cms. above and below this point.

Distribution

Muscular. Up to the point where the musculo-spiral pierces the external inter-muscular septum, i.e. in the upper two-thirds of the arm, the muscular branches of distribution are those to the triceps and anconeous muscles.

Nerve supply of triceps (fig. 6). The triceps is supplied by four distinct bundles of nerve fibres from the musculo-spiral and their average positions will be seen from the following table:

I.	Nerve to long head arises	7·11	cms.	(·233)
	,, ,, enters	11·30	,,	(·370)
II.	Ulnar collateral arises	9·53	,,	(·312)
	,, ,, enters	18·17	,,	(·595)
III.	Nerve to outer head arises	10·13	,,	(·332)
	,, ,, enters	14·62	,,	(·479)
IV.	Nerve to inner head arises	11·21	,,	(·368)
	,, ,, enters	18·26	,,	(·599)

There is one general point about the branches of the musculo-spiral which will be most conveniently referred to here. The nerve bundles are arranged and receive their individual sheaths of perineurium a considerable distance above the point where they are given off as branches. These branches are bound to the main trunk merely by the epineurium and are consequently easily split up from the nerve to some distance above their normal point of origin. This discretion of nerve bundles in the main trunk was observed to some extent in all the nerves but it is so marked in the case of the musculo-spiral as to deserve special mention. The dissection was carried out to avoid this splitting up as far as possible, as the object of these measurements is to show where the nerve actually leaves the main trunk, but its recognition is of practical importance particularly

(1) in the operation of fascicular suture,

(2) in explaining certain dissociated paralyses.

Fig. 6. Nerve supply of Triceps
A = long head of Triceps.
B = outer head of Triceps.
C = inner head of Triceps.

Nerve to the long head of triceps. This bundle of fibres is the first branch of the musculo-spiral. It arises while the main trunk is still in contact with the posterior axillary wall at 7·11 cms. After a course of over 4 cms. distally and medially it ends by piercing the anterior surface and lateral border of the long head of the muscle at 11·3 cms. A point to emphasise is the height of its origin. The internal cutaneous branch of the musculo-spiral generally arises in common with this muscular bundle. The bundle splits into numerous branches some distance before it gains the muscle and these terminal branches enter the long head over a considerable area, the highest at least a centimetre above the lowest. The figure of entry, 11·3 cms., is a mean measurement.

Ulnar collateral nerve. This branch arises at 9·53 cms., which corresponds approximately to the lower border of teres major. It is the inner and smaller nerve to the inner head of the triceps. It has a long extra-muscular course distally and slightly medially, first resting on the ulnar nerve and then on the internal inter-muscular septum which it pierces about 18·0 cms. down the arm to sink immediately into the inner head of triceps. It has the longest extra-muscular course of any of the branches to the triceps. This nerve is therefore sometimes injured in lesions of the ulnar nerve, but it has not been found clinically to be of importance as a nerve supply of this head of triceps (Stopford).

Nerve to the outer head of triceps. A bundle of fibres arising about half a centimetre below the ulnar collateral and the last of the branches coming off definitely on the medial side of the arm. Its general direction is laterally with an inclination distally. As it approaches the muscle it divides into numerous subdivisions which enter the medial aspect of the outer head of the muscle over an area with a vertical depth of half to one centimetre. The mean level of its entry is 14·62 cms.

Frequently this nerve arises by a large common trunk, which includes the nerve to the inner head of triceps and the lower external cutaneous branch of the musculo-spiral.

Nerve to the inner head of triceps. This is a branch of considerable size arising just as the main trunk is entering the musculo-spiral groove at an average level of 11·21 cms. It proceeds distally and very slightly laterally and, after an extra-muscular course of 7·0 cms., it enters the fibres of the inner head of the triceps. The terminal filaments of this nerve run through the triceps to supply the greater part of the anconeous muscle. This nerve is definitely larger than the ulnar collateral so that, although a few of its fibres end in the anconeous, it is probably the more important nerve of supply to the inner head of triceps. This observation seems to get confirmation from clinical evidence of lesions of the ulnar collateral nerve.

As previously mentioned this bundle of fibres sometimes arises by a common trunk with the fibres destined for the outer head of the muscle and, more frequently, with those which eventually go to form the lower external cutaneous branch.

In connection with the nerve supply of the triceps there are certain points of special significance. The musculo-spiral is most vulnerable while it lies in the musculo-spiral groove. The musculo-spiral groove corresponds in vertical length with the middle third of the upper arm. All the nerves to the triceps except the nerve to the inner head arise in the upper third of the arm, i.e. above the musculo-spiral groove. The nerve to the inner head arises just at the upper limit of the groove. No other muscular branches arise while the main trunk is in the groove. Consequently (i) an uncomplicated lesion of the trunk in the musculo-spiral groove is very unlikely to affect the nerve supply of the triceps, and (ii) when the surgeon is operating on the musculo-spiral in the groove there are no important muscular branches for him to look for and establish the integrity of. The only important branch which generally arises definitely in the groove is the lower external cutaneous. A piece of clinical evidence confirming these anatomical facts is found in the statement that in 25 cases of injury to the musculo-spiral in the middle third of the brachium, in which complete division of the main musculo-spiral trunk was proved at operation, there was no paralysis of any head of triceps (Stopford).

The remaining muscular branches arise well within the lower third of the upper arm after the trunk has pierced the external inter-muscular septum. They are distributed to brachialis anticus, supinator longus and extensor carpi radialis longior in that order proximo-distally.

Nerve to the brachialis anticus. This branch is by no means constant. When present it arises about 24·0 cms. down the upper arm. It has a very short course running transversely inwards, sometimes with an inclination upwards, to enter the superficial aspect and lateral border of the muscle. Electrical stimulation of this branch on the operating table has shown no effect on the muscle, from which it is considered probable that this nerve is an afferent nerve-path (H. Platt).

Nerve to the supinator longus.

Arises 25·23 cms. (·827).
Enters 28·26 ,, (·927).

This branch arises from the anterior aspect of the musculo-spiral and, after proceeding vertical downwards for about 3 cms., terminates in the inner surface of its muscle. This branch is frequently duplicated. In two of my cases it entered the muscle as low as the tip of the external condyle (30·5).

Nerve to the extensor carpi radialis longior. This nerve was extremely constant in its origin at an average of 26·79 cms. down the arm, roughly 1½ cms. below the origin of the nerve to supinator longus. It proceeds distally and slightly laterally, somewhat deep to the preceding nerve, to enter the medial border of its muscle. As an average level of entry into its muscle a point should be taken immediately above the tip of the external condyle. In 22 measurements the nerve entered the muscle, in the upper arm in 11, in the forearm in seven and directly opposite the tip of the external condyle in four cases. The highest level of entry noted was 2 cms. above, and the lowest, 2·5 cms. below the condyle. These figures exclude an anomalous case in which the nerve arose from the posterior interosseous trunk and entered the muscle as low as 5·5 cms. below the external condyle.

Cutaneous. Three cutaneous nerves are generally described as arising from the musculo-spiral trunk:

(i) Internal cutaneous.
(ii) Upper external cutaneous.
(iii) Lower external cutaneous.

Internal cutaneous. This branch arises in the axilla, generally from one of the muscular branches to the long head of triceps (7·11 cms.). After effecting communications with the intercosto-humeral nerve and the lesser internal cutaneous it winds round the medial border of the long head of triceps to gain the back of the brachium. It runs vertically downwards in the superficial fascia of the posterior aspect of the arm and its terminal filaments can generally be traced as far as the olecranon.

Upper external cutaneous. This nerve though described in the textbooks was very seldom found, and it was not considered of sufficient importance to warrant any records being taken of it.

Lower external cutaneous. Arises 13·95 cms. (·457). (Fig. 6.)

A large nerve trunk, of interest as being the only branch of importance arising from the musculo-spiral trunk in the musculo-spiral groove. Its point of origin is so extremely variable (7·11 cms.–28·87 cms.) that the average is of little value. This variability is largely due to the fact that this nerve is the branch of the musculo-spiral most easily "split up" from the main trunk. Probably the nerve fibres are arranged in their own sheath of perineurium in the axilla in all cases. This bundle has frequently been observed to arise in common with the nerve to the outer or inner heads of triceps or even in common with both these branches.

From its origin it proceeds down the musculo-spiral groove in company with the main trunk, and at the lower end of the groove it turns outwards to pierce the deep fascia immediately behind the external inter-muscular septum. Exceptionally it becomes cutaneous by piercing the lower and outer fibres of the triceps. After piercing the deep fascia it runs obliquely distally and medially to gain the middle of the posterior aspect of the forearm. It then runs vertically down the forearm and can be traced as far as the posterior aspect of the wrist-joint. The position of the nerve on the posterior aspect of the forearm varies between the radial border and the axial line. The nearer it runs to the radial border of the forearm the more likely it is to communicate with the posterior division of the musculo-cutaneous (see fig. 4).

9. RADIAL NERVE

This is the smaller of the two terminal divisions of the musculo-spiral and arises, therefore, where this nerve terminates on the anterior aspect of the outer side of the elbow on an average horizontal level with the tip of the external condyle. It runs down the forearm along a line continuous with that of the terminal portion of the musculo-spiral trunk. Just below its origin it is in intimate relation with the front of the elbow-joint and the head of the radius. From its origin it lies under the supinator longus muscle, which relation it maintains to a point ·5 cm. above the junction of middle and lower thirds of the forearm. There, on account of the slight lateral obliquity of its course, it appears behind the posterior border of the supinator longus tendon and almost immediately afterwards pierces the deep fascia. It then proceeds vertically downwards in the superficial fascia to its cutaneous termination in the hand and fingers. This cutaneous distribution has been considered in the description of the sensory supply of hand and fingers when the ulnar nerve was dealt with.

Some interesting anomalies were found in connection with this nerve:

(*a*) On both sides of one body the radial was completely absent.

(*b*) In another case the supinator longus muscle was inseparably fused with the extensor carpi radialis longior and the tendon of the combined muscles was inserted into the base of the second metacarpal bone. Here it was noticed that the nerve pierced the fused tendons marking off the portion of the tendon corresponding to the supinator longus superficially from that portion corresponding to the extensor carpi radialis longior deep to the nerve.

(*c*) In three cases the motor branch to the extensor carpi radialis brevior arose from the radial trunk.

(*d*) One radial nerve was observed to wind round the mesial margin of supinator longus opposite the elbow-joint and to pass down the forearm superficial to this muscle.

The most important point, for practical purposes, in the course of this nerve is that at which it becomes cutaneous by appearing from under the tendon of the supinator longus. This point was found to average 15·53 cms. down the average forearm of 24·04 cms. length, i.e. 8·5 cms. above the tip of the radial styloid process, which will be seen to be just above the junction of middle and lower thirds of the forearm. This point varied between 12·52 cms. and 18·28 cms.

The communications of the radial nerve at the wrist-joint have been discussed in section 3, when describing the musculo-cutaneous nerve.

10. POSTERIOR INTEROSSEOUS NERVE

This nerve normally contains all the motor fibres remaining in the musculo-spiral nerve when it divides in front of the external condyle of the humerus. These fibres are distributed by the posterior interosseous nerve to all the muscles on the back of the forearm, except in the anomalous cases mentioned, in which the radial supplies extensor carpi radialis brevior.

The following measurements have been taken to fix the course of this nerve:

In the average forearm of 24·04 cms., posterior interosseous arises 0·0 (average)

Nerve to extensor carpi radialis brevior arises	1·82 cms.	(·076)
,, ,, enters	6·10 ,,	(·254)
Posterior interosseous enters supinator brevis	4·05 ,,	(·169)
,, leaves ,,	7·09 ,,	(·295)
Dips below extensor longus pollicis	13·69 ,,	(·570)

Two minor anomalies of this nerve are worthy of mention:

(1) In three cases the motor fibres to the extensor carpi radialis brevior

were carried down in the radial nerve for a short distance before being given off to the muscle.

(2) In three cases the posterior interosseous, in its course down the back of the forearm, crossed the superficial aspect of the extensor longus pollicis instead of dipping down normally at the upper border of this muscle to reach its deep aspect.

Nerve to the extensor carpi radialis brevior. This is the first branch of the posterior interosseous nerve and the only one arising on the front of the forearm. As just mentioned, this nerve may occasionally come from the radial trunk. It arises 1·82 cms. down the forearm and proceeds distally and very obliquely laterally. Just before it reaches the muscle it splits into numerous bundles of fibres which enter the anterior border of the muscle along a vertical line of considerable extent. The horizontal level of this point of entry is 6·10 cms.

Nerves to the supinator brevis. These are numerous short branches which arise while the posterior interosseous trunk is in relation to the anterior, lateral and posterior aspects of the neck and upper part of shaft of the radius. The nerve trunk takes this course amidst the fibres of the supinator brevis, thus dividing this muscle into a superficial and a deep portion.

The posterior interosseous leaves the supinator brevis on the back of the forearm a considerable distance above the lower border of that muscle. Its exit is bounded above by the lower margin of a well-defined tendinous arch which is developed on the posterior surface of the supinator brevis.

The course of this nerve through the supinator brevis muscle is of clinical importance. It is firmly bound down in this region to the neck and upper part of the shaft of the radius by the superficial fibres of supinator brevis and consequently can hardly escape injury in fracture of this portion of the radius. This relationship to bone is maintained from the point where the nerve enters the muscle on the anterior aspect of the forearm to the point where it leaves it on the posterior aspect. The vertical distance between these two points is over 3 cms. and so the posterior interosseous nerve is extremely vulnerable in lesions of the radius anywhere between 4·04 and 7·09 cms. down the forearm.

The posterior interosseous leaves the supinator brevis 7·09 cms. down the forearm as a flat band of nerve fibres of considerable width. Almost immediately after its appearance this band gives off the majority of its fibres as a bundle which runs horizontally backwards to sink into the deep aspect of the superficial extensor muscles.

This large posterior leash of nerve fibres may therefore be considered as arising 7·5 cms. down the forearm. Before it reaches its muscles it breaks up into at least four distinct branches. Two of these sink immediately into extensor communis digitorum. One, slightly longer than its companions, has a short oblique course downwards and medially to end in extensor minimi digiti. The last of the four constant branches has a short but distinct course practically horizontally inwards to end in extensor carpi ulnaris. Very inconstantly a fifth branch may be traced still further inwards to terminate in the lower fibres of the anconeous muscle. On account of their practically horizontal direction backwards these branches are very short and their level of entry to their muscles practically corresponds with their level of origin as a bundle from the main trunk (7·5 cms.). As an exception to this general rule, the nerve to the extensor minimi digiti, by the obliquity of its direction, enters its muscle at a slightly lower level.

The main trunk of the nerve, reduced to less than half its size, now runs vertically down the forearm between the superficial and deep extensor muscles as far as the upper border of the extensor longus pollicis. It lies in this portion of its course well to the radial side of the axial plane of the forearm and rests from above downwards on the lower fibres of the supinator brevis, extensor ossis metacarpi pollicis and extensor brevis pollicis.

Nerves to the extensor ossis metacarpi pollicis. These are generally two short stout branches which arise from the main trunk as it is lying on the muscle, and consequently they have practically no extra-muscular course.

Nerve to the extensor brevis pollicis. A fine filament arising from the main trunk as it lies on the muscle, which sinks into the muscle immediately.

The main trunk reaches the upper border of extensor longus pollicis 13·69 cms. down the forearm and normally dips below this muscle to gain the interosseous membrane. It has already been mentioned that in three of the dissections it continued its downward course superficial to this muscle.

Nerve to the extensor longus pollicis. This is a bundle of fibres of some size, which arises just before the nerve passes deep to the muscle. The branch breaks up into two or three filaments which enter the upper (or lateral) border of the muscle over an area of considerable vertical extent.

Nerve to the extensor indicis proprius. This muscle is supplied by a slender filament which arises from the posterior interosseous nerve whilst this trunk descends on the interosseous membrane. This branch runs backwards to enter the deep surface of its muscle. The nerve to the extensor indicis proprius is always described as the last muscular branch of the posterior interosseous, but the posterior interosseous may occasionally have still another muscle to supply. In three cases of this series a muscle has been observed which may be called the extensor medii proprius. This muscle when present receives the last motor fibres of the posterior interosseous nerve and, on account of its size and its possible clinical significance, seems worthy of description.

Extensor medii digiti proprius muscle (fig. 7). This muscle has been found in three out of the 26 adult limbs examined in this work.

It arises from the posterior and lateral surfaces of the ulna below the extensor indicis proprius and from the inter-muscular septum separating it from the extensor carpi ulnaris. In one case its fleshy belly of origin was partially fused with that of extensor indicis, but in the other two it was quite distinct. The fleshy belly gives place to a tendon which runs under the posterior annular ligament in company with the extensor communis and extensor indicis tendons. The tendon then passes obliquely over the dorsum of the hand medial to that of extensor indicis and deep to the extensor communis tendons, and gains its insertion by joining the ulnar side of the dorsal expansion of the long extensor tendon to the middle finger.

This muscle, judging from the description of its insertion, is the musculus Manieux described by Le Double (8), but this author described its origin as from the back of the carpus and in no description have I read of its possible origin from the ulna.

It is of morphological interest, since it may be considered either (1) as the reappearance of an atavistic short extensor of the middle finger, or (2) as an example of what Wood-Jones (6) describes under the term of "progressive variabilities." A quadruped, such as the cat, has a special short extensor to each of the digits of its forelimb and these are used as muscles of progression. In bipedal man the forelimb is not used for progression and therefore these short extensors lose their function. Those to the middle and ring fingers disappear and the remaining three are retained and modified to subserve other uses. The medius is probably the next in importance to the thumb, index and little fingers and would therefore be the next most likely to require an individual short extensor. It is just possible then, that the reappearance of this special short extensor of the medius may be a progressive

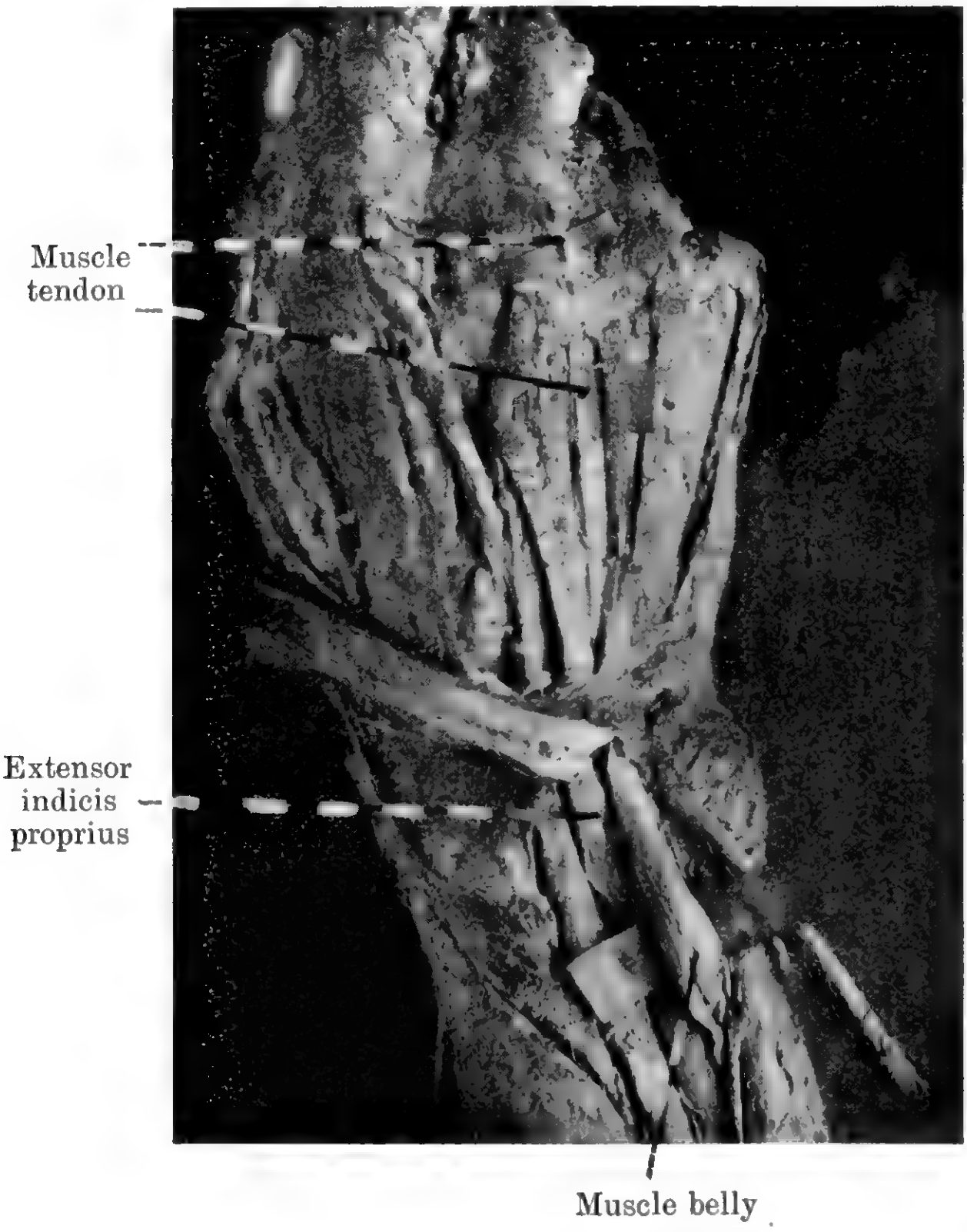

Fig. 7. Extensor medii digiti proprius muscle.

stage in the development of the human hand. The well-defined appearance of this muscle three times in 26 cases seemed to me a somewhat excessive percentage for a pure atavism.

The posterior interosseous nerve terminates on the dorsum of the carpus in a swollen extremity from which appear small filaments for the supply of the carpal joints.

Tables of Measurements

It is hoped that these Tables may prove of clinical value. They are compiled from over 700 measurements of 25 adult limbs. Extreme anomalies, which would invalidate the ratios, have been excluded.

The principle of these measurements has been explained in the introduction and little more remains to be said.

Two vertical measurements have been taken. One, from the tip of the acromion process to the tip of the external condyle of the humerus, for nerves of the upper arm, may conveniently be spoken of as the "A measurement"; the second, from the tip of the external condyle to the tip of the styloid process of the radius, which may be called the "B measurement," and is for nerves in the forearm.

In the 25 limbs under consideration

The average length of A measurement = 30·5 cms.
" " B " = 24·04 "

Column 3 gives the average ratio of the total A or B measurement where the important point on the nerve is situated. Column 1, which gives the horizontal level of this point down the average arm or forearm, is obtained, therefore, by multiplying column 3 by 30·5 or 24·04 as the case may be.

Columns 4 and 5 give the maximum proximal and distal variabilities found of the average ratio, column 3.

The clinical value of these tables can best be shown by an example.

The clinician may wish to know as accurately as possible where the nerve to the supinator longus arises. He measures the upper arm of his patient and gets an "A measurement" of 32·0 cms. He multiplies this by the average ratio, ·827 in this case,

$$\cdot827 \times 32 = 26\cdot46 \text{ cms.}$$

Therefore, he will expect to find the nerve to the supinator longus arising in this patient at a horizontal level 26·46 cms. vertically below the tip of the acromion process.

He has however to take into account the variabilities of this origin. Applying his A measurement to the maximum proximal and distal variabilities he gets

$$\cdot742 \times 32 = 23\cdot74 \text{ cms.}$$
$$\cdot900 \times 32 = 28\cdot80 \text{ cms.}$$

The variability in this case is, therefore, 5·06 cms. or approximately 2 inches.

Before leaving this section I wish to acknowledge the great assistance I have obtained from Mr Burnet, a student of Engineering at the University of Manchester. His work of averaging and checking the mass of figures, which the compilation of these tables entailed, has been very helpful.

11. TABLES OF AVERAGE MEASUREMENTS AND THEIR VARIABILITIES

	Average distance in cms.	Arm (A) or fore-arm (B)	Average ratio	Variability of ratio	
				From	To
I. *Musculo-cutaneous Nerve:*					
Nerve to coraco brachialis ... ... arises	4·76	A	·156	0·0	·283
,, ,, ,, ... enters	7·35	A	·241	·096	·410
Nerve to biceps ... ... arises	12·99	A	·426	·357	·533
,, ,, ... enters	15·28	A	·501	·426	·616
Nerve to brachialis anticus ... ... arises	17·32	A	·568	·400	·650
,, ,, ,, ... enters	20·27	A	·665	·616	·746
Cutaneous division ... ... arises	17·32	A	·568	·400	·650
II. *Median Nerve:*					
Nerve to pronator radii teres ... ... arises	1·0–2·0	B	Variability too great to give reliable ratios. See text		
,, ,, ,, ... enters	1·5–2·0	B			
Nerve bundle to common flexor mass:					
Upper limit of origin	2·08	B	·086	0·0 (B)	·213
,, ,, entry	2·76	B	·115	·037	·340
Lower limit of entry	5·05	B	·210	·143	·425
Branch to index belly flexor sublimis digitorum arises	12·0 +	B		See text	
Anterior interosseous ... ... arises	5·24	B	·218	·130	·314
III. *Circumflex Nerve:*					
Supplies deltoid	6·98	A	·229	·161	·290
IV. *Ulnar Nerve:*					
Branches to flexor carpi ulnaris:					
(i) Nerve to olecranon head ... ... arises	·90	B	·037	0·0 (B)	·115
,, ,, ... enters	2·08	B	·087	·020	·200
(ii) Primary nerve to condylar head ... arises	1·62	B	·067	·020	·120
,, ,, ,, ... enters	2·99	B	·125	·060	·204
(iii) Secondary nerve to condylar head ... arises	2·25	B	·093	·087	·100
,, ,, ,, ... enters	4·88	B	·203	·193	·213
Nerve to flexor profundus digitorum ... ... arises	3·07	B	·127	·040	·225
,, ,, ,, ... enters	5·54	B	·230	·128	·311
Dorsal cutaneous nerve ... ... arises	17·06	B	·709	·420	·854
,, ,, ... Appears behind flexor carpi ulnaris	20·95	B	·871	·700	·960
V. *Musculo-spiral Nerve:*					
Branches to triceps:					
(i) Nerve to long head ... ... arises	7·11	A	·233	·161	·333
,, ,, ... enters	11·30	A	·370	·308	·441
(ii) Ulnar collateral ... ... arises	9·53	A	·312	·179	·419
,, ,, ... enters	18·17	A	·595	·431	·800
(iii) Nerve to outer head ... ... arises	10·13	A	·332	·293	·393
,, ,, ... enters	14·62	A	·479	·342	·643
(iv) Nerve to inner head ... ... arises	11·21	A	·368	·300	·467
,, ,, ... enters	18·26	A	·599	·517	·800
Lower external cutaneous nerve ... ... arises	13·95	A	·457	·233	·750
				See text	
Nerve to supinator longus ... ... arises	25·23	A	·827	·742	·900
,, ,, ... enters	28·26	A	·927	·855	0·0 (B)
Nerve to extensor carpi radialis longior ... arises	26·79	A	·878	·786	·935
,, ,, ,, ... enters	Average immediately proximal to tip of external condyle. See text				
Musculo-spiral nerve ... ... ends	Average level is tip of external condyle. See text				
VI. *Radial Nerve:*					
Appears from under tendon of supinator longus	15·53	B	·646	·521	·761
VII. *Posterior Interosseous Nerve:*					
Nerve to extensor carpi radialis brevior ... arises	1·82	B	·076	0·0	·130
,, ,, ,, ... enters	6·10	B	·254	·160	·339
Posterior interosseous trunk enters supinator brevis	4·05	B	·169	·120	·245
Posterior interosseous trunk leaves supinator brevis	7·09	B	·295	·240	·358
Trunk dips below extensor longus pollicis ...	13·69	B	·570	·456	·667

12. SUMMARY AND CONCLUSION

An attempt has been made in the text of this paper to emphasise points of clinical importance in the distribution of the nerves of the upper limb. In many cases it has been possible to support the anatomical findings by analyses of clinical groups of cases kindly given me by Prof. J. S. B. Stopford. Most of these analyses have been referred to in the text, so that it is only necessary to give a very brief tabulated summary of the main conclusions arrived at from these observations.

I. Variability of Distribution of Nerve Branches

As the nerve branches show such marked individual variability in their distribution no rules can be laid down. Each branch of each nerve must be taken separately and its variability worked out from the Tables before any accurate conclusion can be arrived at as to its variability. It is interesting to note that the minimum variability of any branch is 4·5 to 5·0 cms., which represents approximately a variation between an inch above and an inch below the point obtained for the average ratio. Variations so extreme as to fall under the heading of anomalies have been excluded from the Tables.

A clinical matter of importance, in which these measurements should be of assistance, deals with the question of prognosis in nerve injuries. It is often difficult to judge by clinical examination before operation as to the length of nerve involved in and devitalised by callus or scar tissue, etc. Upon the length of nerve which will require to be resected at operation depends the important question as to whether or not end-to-end suture will be possible. Reference to the Tables will, in many cases, give the surgeon a definite idea in centimetres of the length of nerve likely to require removal.

II. Subdivision of the Brachial Plexus

The brachial plexus may be subdivided by a vertical line drawn 7·75 cms. from the lateral borders of the lower cervical vertebral bodies or by a similar vertical line 6·75 cms. lateral to the common carotid artery at the root of the neck. Such a line, where it cuts the plexus, divides the trunks from the cords with certain modifications of the usual nomenclature as described in the text. This line has the great advantage of excluding the clavicle as a basis of subdivision.

III. Anterior Thoracic Nerves

Both these nerves have a very high origin from the brachial plexus and should be considered anatomically and clinically, as branches of the nerve trunks and not of the nerve cords.

IV. Communication between the outer and inner cords

In at least 57 per cent. of cases the ulnar nerve obtains fibres from the seventh cervical root by means of a communication which it receives from the inner aspect of the outer head of the median.

V. Anomalies of Musculo-cutaneous Nerve

In a small proportion of cases the branches of this nerve arise direct from an undivided outer cord.

VI. Muscular Distribution of the Musculo-cutaneous

This is completed in the upper two-thirds of the brachium. A lesion of the main trunk distal to 2·0 cms. below the middle of the upper arm will cause no paralysis. Clinical evidence shows that a sensory lesion of the musculo-cutaneous is five times as common as a mixed lesion.

VII. Communication between Musculo-cutaneous and Radial Nerves at the Wrist-Joint

This was absent in two out of seven cases and was seen to vary extremely in size when found. The interchanged fibres are presumably distributed in the branches of the radial nerve.

VIII. Anomalies of Origin of Median Nerve

The position at which the outer head joins the inner head of this nerve shows marked variability but, generally, at least a number of the fibres of the outer head join the inner head at the normal level.

IX. Nerve to pronator radii teres

This nerve seldom arises proximal to the elbow-joint.

X. Nerve to index belly of flexor sublimis digitorum

A branch, frequently present, which arises in the lower half of the forearm and sinks into the deep aspect of this belly. Occasionally it supplies the medius belly of the muscle.

XI. Muscular Distribution of Median Nerve in the hand

Besides supplying the abductor and the opponens pollicis muscles this nerve also supplies the superficial slip of that portion of flexor brevis pollicis which is inserted into the radial sesamoid bone and the radial side of the base of the first phalanx of the thumb.

XII. Circumflex Nerve

The most constant nerve of the upper limb in origin, course and distribution. Its anterior terminal division is purely motor to the deltoid. The posterior division takes up a lower horizontal level than that maintained by the anterior division.

XIII. Nerves to flexor carpi ulnaris

These vary from two to four in number. They all enter the muscle high up in the forearm, the point of entry of the lowest being 4·88 cms. Only occasionally does the highest of these branches arise in the upper arm, but this infrequent high origin will account for those exceptional cases in which the flexor carpi ulnaris is only paretic after an injury to the ulnar nerve trunk, where it lies between the olecranon process and the internal condyle.

XIV. Nerve to flexor profundus digitorum

A single stout trunk, with an extra-muscular course of about an inch, and not the two distinct bundles of fibres, one for each ulnar belly of the muscle, as described by Poirier (7).

XV. Dorsal Cutaneous Branch of Ulnar Nerve

Origin very variable. Point where it becomes cutaneous at the medial border of the flexor carpi ulnaris reasonably constant and just over an inch proximal to the tip of the styloid process of the radius, i.e. approximately half an inch above the styloid process of the ulna.

XVI. Digital Cutaneous Distribution of Ulnar Nerve

On the palmar aspect the ulnar nerve gives the classical supply of 1½ fingers in 80 per cent. of cases.

The dorsal cutaneous branch of the ulnar supplies 2½ fingers in 75 per cent. of cases.

XVII. Communication between Ulnar and Internal Cutaneous Nerves

These nerves have been seen to communicate in the upper arm but not in the region of the wrist-joint.

XVIII. Termination of Musculo-spiral

Variability from approximately 4 cms. above to 4 cms. below the tip of the external condyle. This bony point gives a good average level of termination.

XIX. Nerve-supply of triceps

This muscle has four distinct bundles of fibres from the musculo-spiral nerve. For practical purposes they all arise in the upper third of the arm before the main trunk enters the musculo-spiral groove. The two nerves for the inner head have the longest extra-muscular course.

XX. Discretion of bundles of Nerve fibres in the Musculo-spiral

The individual bundles of fibres of this nerve are arranged and receive their own sheaths of perineurium in the lower part of the axilla. Consequently the branches of the musculo-spiral are very easily split up from the main trunk, and suture of individual bundles ought to be easily practicable.

XXI. Ulnar Collateral Nerve

This is the smaller and less important branch to the inner head of the triceps.

XXII. Branch of Musculo-spiral to Brachialis Anticus

Probably an afferent nerve-path.

XXIII. Cutaneous Branches of Musculo-spiral

Internal cutaneous branch generally arises from one of the nerves to the long head of triceps.

Upper external cutaneous branch was very seldom found.

Lower external cutaneous branch supplies the skin of the back of the forearm as far as the wrist. It occasionally communicates with the musculo-cutaneous. It is the branch of the musculo-spiral most easily split up from the main trunk.

XXIV. Radial Nerve

This becomes cutaneous as a rule just above the junction of middle and lower thirds of the forearm, approximately 3½ inches proximal to the tip of the radial styloid process.

XXV. Nerve to the Extensor Carpi Radialis Brevior

Occasionally this motor nerve arises from the radial trunk.

XXVI. Relation of the Posterior Interosseous Nerve to Radius

The posterior interosseous nerve is an intimate relation of this bone throughout its course through the supinator brevis muscle. As its relation to the muscle has a vertical extent of over 3 cms. it can hardly escape injury in fracture of this portion of the radius.

XXVII. Extensor Medii Digiti Proprius Muscle

A well-defined muscle-belly present in three out of 26 cases.

REFERENCES

(1) Todd, T. W. "Descent of Shoulder after Birth." *Anat.* Anzeig, 1912.
(2) Gray's *Anatomy*, 1918.
(3) Harris, W. "The true form of the brachial plexus." *Journal of Anatomy and Physiology*, 1904.
(4) Stopford, J. S. B. "The Variation in distribution of the cutaneous nerves of the hands and digits." *Journal of Anatomy*, vol. liii. Part I, October, 1918.
(5) Quain's *Anatomy*, vol. iii, Part II, 1909.
(6) Wood-Jones, F. *The Principles of Anatomy as seen in the human hand*, 1920.
(7) Poirier and Charpy's *Traité d'anatomie*, ed. II; *Système Nerveux*, 1901.
(8) Le Double, F. A. *Variations du système musculaire de l'homme.* Tome ii. ed. 1897.

ON THE DEVELOPMENT OF THE FISSURAL AND ASSOCIATED REGIONS IN THE EYE OF THE CHICK, WITH SOME OBSERVATIONS ON THE MAMMAL

By I. C. MANN, M.B., B.S.,

Research Student in the Institute of Pathology and Research, St Mary's Hospital

From the Department of Anatomy and Embryology

It is a well-known fact that in embryonic eyes, both avian and mammalian, the point of attachment of the optic stalk and of the early optic nerve is to the extreme lower part of the optic cup, while in the grown eye it is practically half-way up the posterior surface of the globe. What then is the mechanism whereby the lower portion of the retina is formed? There is evidence to show that growth takes place below the level of the optic stalk, and that in the formation of the lower portion of the retina the choroidal fissure and para-fissural regions are concerned. The closure of the choroidal fissure takes place very early in the mammalian eye, but in the large eye of the chick embryo the process is relatively slower and can be more easily observed.

In the eye of the chick embryo the choroidal fissure is at first very short and directed vertically downwards. Its margins apparently come together first in the intermediate portion, leaving the proximal part open for the ingrowing vascular mesoderm. This mesoderm, which in differentiation very soon shows one or two definite thin-walled blood vessels, at first occupies the whole of the interval between the intermediate closed portion and the upper end of the fissure, and, after traversing the lower part of the globe, passes out again at the distal opening in the fissure at the pupillary margin.

The growth of the lower part of the retina apparently takes place by extension of the margins of the cleft and neighbouring areas in the form of two processes or cornua which extend downwards, curving of course outwards with the retinal concavity to reach the pupillary margin. Further, it appears probable that the growth of these two cornua is not exactly equal, the posterior or malar one increasing slightly more rapidly than the anterior, with the result that the line of the fissure becomes altered as growth proceeds. The direction is at first vertically downwards, but in the adult bird the line of the fissure, which is represented by the line of nerve fibres entering the so-called *cauda* of the nerve, runs downwards and forwards. In a series of chick embryos of increasing age this alteration in direction can be seen to take place gradually, the angle decreasing in successive specimens from a right angle in the earliest embryos examined to about 70° with the horizontal in the adult bird. It is also noteworthy that the nerve fibre layer of the developing retina appears first in the region above the optic stalk, namely in the oldest part of the retina, and thence extends gradually downwards on either side of the fissure, the area possessing nerve fibres being at one stage slightly more extensive on the malar side of the cleft than on the nasal.

The adult bird, however, differs from the mammal in that in the former the blood vessels enter the eye some distance below the nerve attachment, and also in that some of the nerve fibres pass out of the globe below the nerve attachment and run up to this on the back of the eye: these constitute the *cauda*. The fissure in the bird, however, as will be apparent later, originally exists proximal to the point of entry of the vessels, and, as in the mammal, the upper end of the fissure is included in the nerve attachment.

At an early age in the chick, possibly as a result of quicker growth of the inner, non-pigmented, layer of the optic cup, this layer becomes everted, so to speak, in the lips of the fissure. This condition is shown in fig. 1, which represents a section through the eye of a chick embryo of about four days. The fissure is still open in its entire length and, though very little pigment is as yet present in the outer layer of the cup, the everted portion of the inner layer at the margins of the cleft can be recognised by its similarity in thickness and type of cell to the true inner layer. This eversion occurs in the upper part of the cleft first, and is always more marked here. The everted area elongates with the elongation of the fissure, but not co-extensively with it and so never reaches the pupillary margin. At first the entering vessels occupy the whole of the region of the fissure bordered by this everted area, but later, as the margins of the fissure come together, the entering vessels lie towards the lower end of the area. From their point of entrance they pass forwards in the vitreous, forming a vascular septum stretching across the lower part of the globe to their original point of exit from the cleft just below the pupillary margin. This distal portion of the fissure soon closes and the vessels are cut off here and gradually become shorter. Their subsequent fate will be discussed later.

The upper part of the cleft must now be considered. It is easily seen that when this upper part closes fusion takes place, owing to the eversion just described, between two portions of the non-pigmented inner layer only. After obliteration of the cleft there remains an area of non-pigmented (originally inner) layer on the outer surface of the globe, this area being directly continuous at its edges with the true outer pigmented layer some little distance away from the fissural line. This condition is shown in fig. 2, which is a transverse section (from a slightly older chick) through a portion of the back of the globe including the margins of the cleft in the region between the point of attachment of the optic stalk above and the entering vessels below. It will be seen that fusion takes place between comparatively large areas of inner layer, so that two projections or ridges are formed by the heaping up of this layer, one, anterior, projecting into the globe, the other, more marked, on the posterior surface, continuous at its base with the pigment layer. Fig. 3 shows the mode

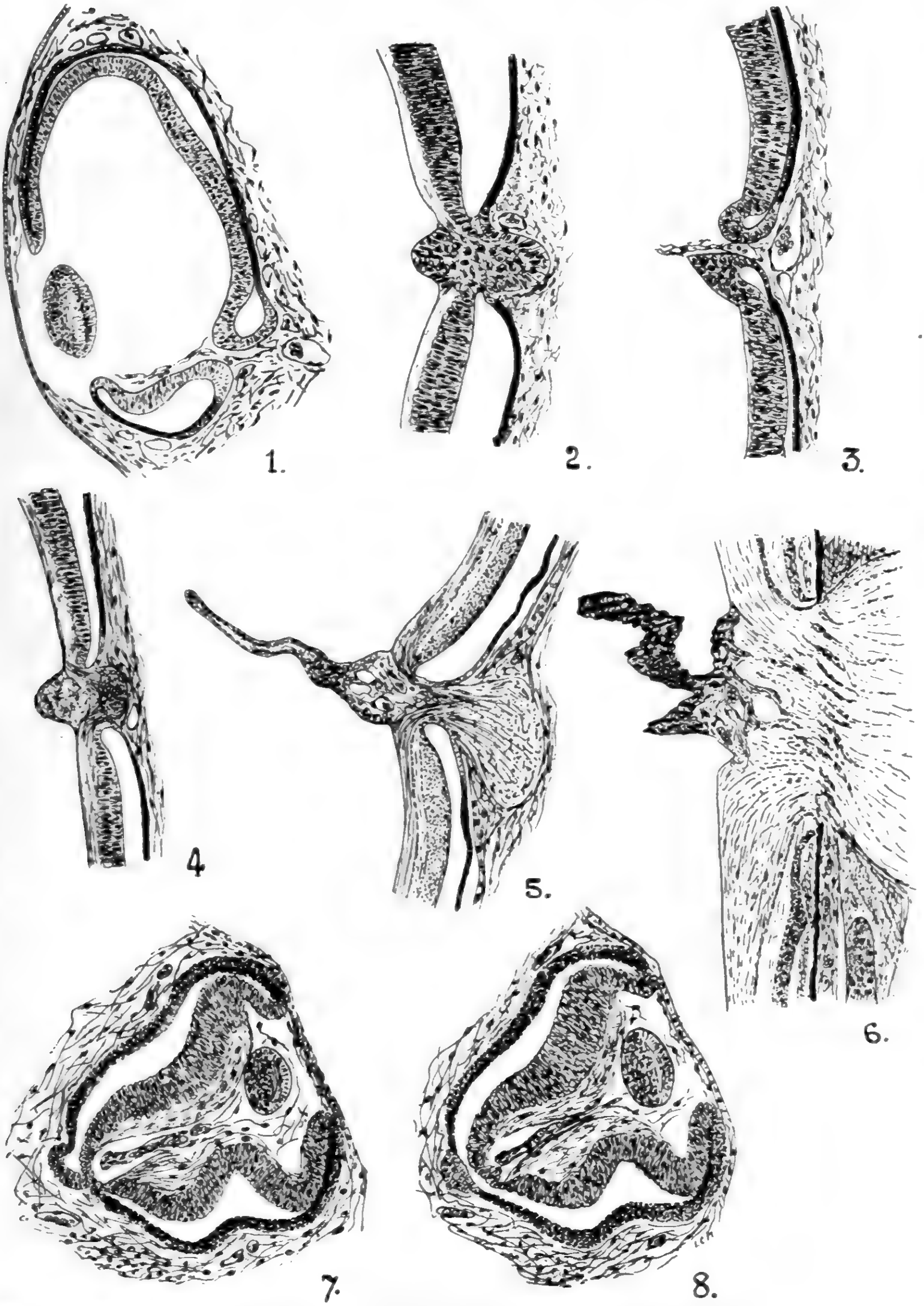

Figs. 1–5. Sections through embryonic chick eyes. Fig. 6. Adult hen. Figs. 7 and 8. 15 mm. human embryo. (From camera lucida drawings.)

of fusion of the lips of the cleft in the region of the entering vessels. It will be seen that the overgrowth of the inner layer is not sufficiently marked here to give rise to definite eversion and the formation of a posterior ridge, but that it is great enough to form the anterior projection and that here, as in fig. 2, the fusion occurs between two non-pigmented areas only. The anterior prominence fades away below the vessels. Thus it comes about that in a fresh chick embryo the line of the fissure stands out as a white streak on the superficial surface of the large pigmented eye. Developing nerve fibres adjacent to the sides of the fissure will grow into this posterior non-pigmented area since it is in origin directly continuous with the fibre-bearing inner retinal layer. This morphological continuity is well seen in early chicks where there is some attempt at the formation of a rod and cone layer to be seen in the everted portion. This is indicated in fig. 2. This appearance is of short duration since the cells are soon obliterated by the ingrowing nerve fibres, which become visible as bundles running up on the back of the globe to the nerve attachment, thus later forming the *cauda* of the adult nerve.

Fig. 4 shows a later stage through the same region as in fig. 2. The nerve fibres can be seen passing into the projection on the posterior surface, which now consists of bundles of fibres forming the *cauda* and running up to the nerve attachment.

These phenomena of closure as seen in the upper part of the cleft are intimately connected with the development of the *pecten* and some mention must be made of this in explaining the subsequent fate of the margins of the fissure. It has already been shown that the posterior projection of the non-pigmented layer in the upper part of the fissure provides the path for the fibres of the *cauda* of the nerve.

The fate of the anterior ridge remains to be dealt with. The lower portion of this, below the entering vessels, very soon after fusion of its two component lips and before the appearance of nerve fibres in this region, becomes flattened and takes on the character of the retina on either side of it and no trace of the situation of the ridge can be subsequently demonstrated.

The upper portion (fig. 2), which will be referred to as the *crista intraocularis*, behaves differently. When the developing nerve fibres grow towards the region of the cleft (figs. 2 and 4) they do not reach the posterior everted projection by remaining on the surface and entering along the line of fusion, but they begin to sink into the substance of the inner (retinal) layer along the base of the *crista* and so by taking a more direct route they cut off, as it were, the portion of the inner layer which forms the ridge, and separate it from the deeper strata. The cells of the *crista intraocularis* never show any attempt at differentiation into nervous retinal elements. At first (before the appearance of the nerve fibre layer) the tissue appears to be spongioblastic in nature. Later, as the ridge becomes cut off by the ingrowing nerve fibres, it takes on a more reticular appearance, the cells becoming smaller and somewhat stellate and the whole structure appearing as a loose meshwork of cells and fibrils covered and limited on its free or vitreous surface by the *membrana limitans interna* and in relation on the inner side of this again with the hyaloid membrane, which is always firmly adherent to the ridge.

By this time a change has taken place in the arrangement of the blood vessels entering the eye. The vascular septum which at first passed through the lower part of the globe entirely disappears. The proximal portion of the vessel however remains and now enters the eye at the lower end of the *crista intraocularis.* This ridge of loose reticular tissue, described above, now becomes vascularised by branches of the vessel running in its substance towards the upper end. These branches increase in number and the *crista* becomes more marked and develops a sharp apex. The ridge now shows in its lower part as the primitive unplicated pecten. Growth proceeds from below up and the pecten develops as a septum growing out into the vitreous (the hyaloid membrane being always firmly attached to its sides and apex) and consisting of ramifications of the proximal part of the original choroidal vessels enclosed in a loose stroma, neuroglial in nature, derived from the portion of the fused lips of the fissure cut off by the growing nerve fibres. This condition can be seen in fig. 5, which should be compared with the preceding figure, where the precursor of the pecten can be clearly seen in the form of the *crista intraocularis.* Later the pecten grows rapidly, becomes many times folded upon itself in a complicated manner, and pigment is developed in it. Fig. 6 shows a section through the extreme upper end of the pecten in an adult hen's eye. It can be easily seen that it occupies the position of the *crista intraocularis* in the embryonic eye and that its "roots," if the term may be used, are directly continuous with the supporting neuroglial septa of the optic nerve, in which, however, there is no pigment. It is in this way easy to understand that the pecten *ex origine* is attached along a line extending between the optic nerve and the entering vessels.

Examination of various embryos shows that the earlier stages in development of the chick's eye have their parallel among the mammalia. The eversion of the inner layer in the upper part of the cleft occurs in mammals but to a much less extent than in the bird. The position of the *arteria centralis retinae* shows that this eversion must be of the lips of the fissure. Figs. 7 and 8 show the condition in the 15 mm. human embryo. Fig. 7 shows the cleft with the entering vascular tissue. It will be seen that the out-turning of the inner layer is marked. Fig. 8 shows the condition immediately below that shown in fig. 7 in the same embryo. The two everted inner layers have come together and fused, forming a small mass of non-pigmented cells continuous with the outer pigmented layer (the parallel of the larger structure in the chick). These non-pigmented cells do not appear connected with the inner layers here since in man no nerve fibres grow into this everted region and no *cauda* is formed to the optic nerve.

The condition can be seen best in human embryos of 13 mm. and 15 mm. It is extremely small in the 16 mm. embryo and in the 18 mm. it has practically disappeared. It is very well marked in early mouse embryos. There is no trace of the formation of a true *crista intraocularis* in the mammalian eye. It is true that when the inner layers of the retina fuse below the *arteria centralis retinae* in the mammal the site of fusion remains for a very short period as a slight projection into the vitreous which, like the similar area below the vessels in the chick, soon becomes flattened and indistinguishable from the retina on either side of it. There is, however, no sign of a *crista* above the vessels, and the nerve fibres pass into the nerve head on the inner surface of the inner layer and do not sink deep to it in any place.

The possible causes of this difference of behaviour of the avian and mammalian cleft margins are of course somewhat obscure, but may be associated with relative differences in dimensional growths of the lower portions of the retinal fields and also with the relation in time between the appearance of nerve fibres in various areas and the closure of the cleft. It is hardly necessary to say that the eversion of the inner layer must occur while the cleft is, potentially at least, still open.

In conclusion, I wish to express my thanks to Professor Frazer both for the loan of much valuable material and for his encouragement and advice in the preparation of this paper.

THE EVOLUTION OF THE VERTEBRATE ENDOSKELETON

AN ESSAY ON THE SIGNIFICANCE AND MEANING OF SEGMENTATION IN COELOMATE ANIMALS

By W. B. PRIMROSE, M.B., Ch.B.,
Lately Senior Demonstrator of Anatomy in the University of Glasgow

THE EVOLUTION OF THE VERTEBRATE ENDOSKELETON

When investigating the morphology of the vertebrate head, I found it necessary to discover the morphological principles on which the segmentation of the body is founded. This essay is one of the results of this investigation, and its object is to show what has determined the segmented form in vertebrate animals. It will be seen that the segmented form in vertebrates results from a condition which at no time occurs in vertebrate animals. This condition is a form of skeleton found only in animals lower in the scale of organisation than vertebrates, and has the characters of a space containing water. This space is the Coelomic Cavity. The coelomic cavity is the key to the formation of the segmented structure of the body, and is the structure that determines the vertebrate form.

The coelomic cavity is present in a well defined state from the Annelida upwards, so that in annelides it is performing the functions for which a coelom was evolved. It is, however, necessary to observe the conditions prevailing among still lower forms to see why a separate cavity was formed in animals, which became the means of raising them in the scale of organisation, and ultimately leading to the evolution of the vertebrate animal.

I therefore propose to trace the steps in evolution by which, I presume, the coelomic cavity originated, and then show how it or its modifications have been the basis on which the whole vertebrate structure of animals is founded. In demonstrating this the various steps or stages in the evolution of the vertebrate endoskeleton will be indicated clearly.

In the evolution of the vertebrate endoskeleton five distinct stages occur. These are:

1. The Hydroskeleton.
2. The Hydrostatic skeleton.
3. The Sclerotome skeleton.
4. The Neural skeleton. (Notochord.)
5. The Neuro-muscular skeleton. (Vertebrate skeleton.)

1. THE HYDROSKELETON

In the large and lowest group of the Metazoa, namely the Coelenterata, we, for the first time find animals possessing three distinct kinds of tissues. The outer of these is the ectoderm, and is more or less epithelial. This is a protective and receptive layer of cells which are modified in many ways to perform both of these functions. In all animals those structures which keep the animal informed about its surroundings, and which control its reactions to them, are derived from this layer. The middle layer or mesoglea is a somewhat structureless tissue developed to very different degrees of organisation in different Coelenterates. It represents the mesoderm of higher animals in which it comes to form the bulkiest portion of the animal tissues. The inner layer is the endoderm. It is the layer that nourishes the animal, and it lines a cavity called the enteron. The cells of this layer are principally digestive, but some are arranged for entrapping and killing the animalculae upon which these animals feed, and which are drawn into the enteric cavity with the circulating water. The enteric cavity is the digestive and respiratory organ of the animal and it only possesses one opening which serves both for mouth and anus. Around this opening there are muscle fibres arranged to act as a sphincter. This cavity is always kept filled with water, which however, is being constantly changed by the activities of the animal for metabolic purposes. In addition to the physiological characters of this cavity and its contained fluid, we recognise a fact of great morphological importance. This is that the water contained in the enteric cavity has the essential characters of a skeleton. Thus it gives form to the animal, and maintains this form. Being an incompressible fluid it gives the animal's muscle fibres a resisting body to act upon, and so allows of alterations of shape, and in free swimming forms allows of propulsion through the water. When the water, which is the skeleton of the animal, is removed from its enteric cavity, the supporting structure is gone and the animal loses its shape just as when it is dead. This is the hydroskeleton and is the first stage in the evolution of the vertebrate endoskeleton. Fig. 1 shows the conditions present in a hydra polyp where we find the three layers of tissues mentioned above, and the enteric cavity. Where the oral tentacles are hollow the enteric cavity extends into them so that they likewise derive their support from the water in the enteric cavity, and their movements depend upon its presence. Fig. 2 shows the disposition of parts in a medusa form where the umbrella or under surface of the animal contracts upon the water in contact with it as a means of propulsion.

Fig. 3 shows the arrangement of parts in a sea-anemone. The same three layers are present and the enteric cavity; also hollow or solid tentacles. The mouth opening is present and leads down into the enteric cavity through a tubular invagination called the oesophagus. The enteric cavity is incompletely subdivided by a number of longitudinal septa passing from the body wall towards the centre ending in a free margin. Certain of these septa, however, attach themselves to the oesophagus forming incomplete compartments in the enteric cavity. These cavities extend into the hollow tentacles. On these septa are placed the reproductive glands which discharge their cells into the enteric cavity. These animals also depend upon the water contained in the enteric cavity for the maintenance of their form and for providing a means for their muscles to produce movements, so that here again we find the hydroskeleton in the enteric cavity. This type of skeleton is evidently efficient in its principle, namely, that water is dense and incompressible, but the structure of the animal limits the efficiency of the hydroskeleton by allowing the water to escape easily, which is necessary, as frequent change of water is required by the animal for metabolic purposes.

The enteric cavity here contains the skeleton, digestive, respiratory, excretory and reproductive systems. These are all represented in a very simple form, while in higher animals these systems all become differentiated and specialised.

Fig. 1

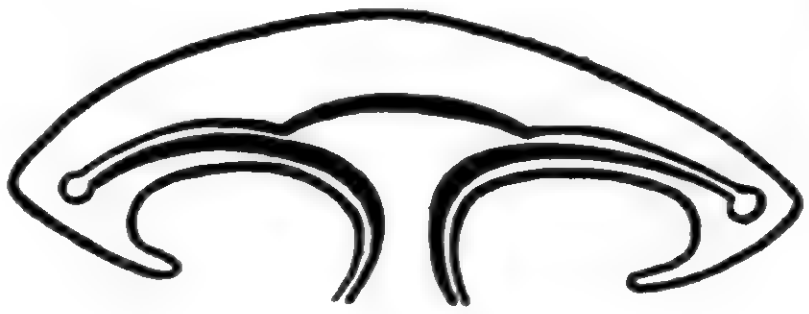

Fig. 2

Fig. 3

Fig. 1. Diagram of hydra polyp showing enteric cavity which contains the hydroskeleton.
Fig. 2. Diagram of the same parts in a medusa.
Fig. 3. Section through the oesophagus of a sea-anemone showing enteric spaces and mesenteries. After Shipley and MacBride.

In concluding the remarks on the hydroskeleton of coelenterate animals, I would again point out that the skeleton is the water contained in the body of the animal. It is this water that maintains the form of the animal, and it is upon this water that the muscles of the animal act in order to effect movements of parts of the body on one another, or the propulsion of the animal as a whole. The skeleton being the water within the body of the animal, and the body cavity never being shut off from the water in which the animal lives, it is not very efficient as a skeleton, and dooms the whole class of coelenterate animals to an aquatic existence. So soon as the animal is removed from the water its skeleton is lost, and it has then no means of maintaining its form, and still less has it any means of continuing its existence.

2. THE HYDROSTATIC SKELETON

In the next stage in the evolution of the vertebrate endoskeleton, the chief disadvantages of the hydroskeleton are overcome by confining the water which forms the skeleton in an enclosed space. This is effected by the complete separation of the enteric pouches from the enteric cavity. The arrangement of the mesenteric septa in relation to the oesophagus or stomodaeum in actinian forms strongly suggests how this could be accomplished as in fig. 3. The continuance of the process by which enteric pouches are formed would result in the complete separation of these pouches from the enteric cavity. This would form a new set of enclosed spaces situated between and separating the enteric cavity from the body wall. I do not propose to do more than suggest such a method of producing these perienteric spaces, for we find a different method obtaining in some other animals. In coelomate animals we are presented with this condition as an accomplished fact. It is this condition that makes animals coelomate, and separates these entirely from the whole group of Coelenterates. It is therefore a condition of the highest importance in the evolutionary history of animals.

These perienteric cavities are present in some form in all animals higher in the scale of organisation than Coelenterates, and the reproductive cells are always produced in their walls, just as they are in the sea-anemone. There may be pores in the body wall of the actinozoon, and also in hollow tentacles, by means of which the reproductive cells can escape to the exterior of the body. In the higher forms more efficient means are adopted for the same purpose.

We have now to deal with coelomate animals which are characterised by having a perienteric space separating the body wall from the enteric cavity which now forms the gut wall. The lowest annelid shares this common character with the highest vertebrate. This perienteric space is the coelomic cavity, and this cavity is of the first importance as a skeletal structure, or, more accurately, as a space containing the skeleton, and it with its derivatives will be described from this point of view. This skeleton of water being enclosed in the coelomic space may be called a hydrostatic skeleton.

The lowest animals possessing this coelomic space are the Annelida, and the most primitive of these present this coelomic space well formed and containing the watery skeleton, which gives these animals definite shape, and upon which its body muscles can act and produce movements and locomotion. In addition, this space is used for purposes of excretion, for which its boundaries are suitably modified, and, as before stated, reproductive cells are shed into it and are subsequently allowed to pass from it to the exterior of the body.

In adult archiannelids, this coelomic space is broken up into two series of compartments. There are two different arrangements for dividing these spaces into compartments. One set consists of two compartments which are antero-posterior or cephalo-caudal in direction, and present a coelomic cavity on either side of the gut from end to end of the animal. The walls of these spaces form the dorsal and ventral mesenteries of the alimentary tube throughout its entire length in the middle line, while they are related to the body wall peripherally.

This form of coelomic spacing is not found on account of the fact that long flexible tubes of water cannot withstand lateral strain. Some animals, however, do present such a coelom, but it is reduced in comparison with the thickness of the body wall, and it does not contain water.

To prevent lateral strain from distorting the animal, these two coelomic spaces become divided transversely at short intervals by septa, so that there are now many compartments whose antero-posterior length is not much greater, if any, than their diameter. These sacs containing fluid are completely shut off from each other, and are arranged in two rows, one on each side of the gut. Figs. 4 and 5 show this. Each enclosed compartment or sac is the exact likeness of those adjacent. They are all serially homologous, for they all have the same fundamental structures; and are all derived in the same way from the same structures. These spaces are always kept filled with water, which forms a permanent endoskeleton, and it acts as such as long as the animal lives. When the animal dies, the water disappears and the form is lost.

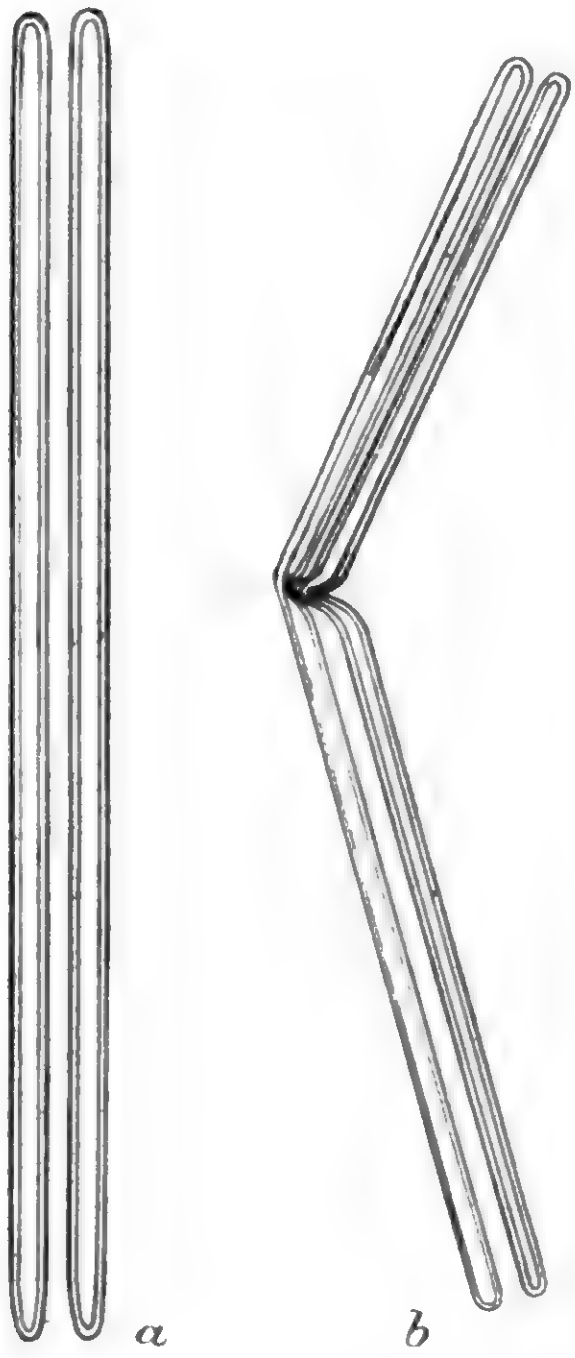

Fig. 4

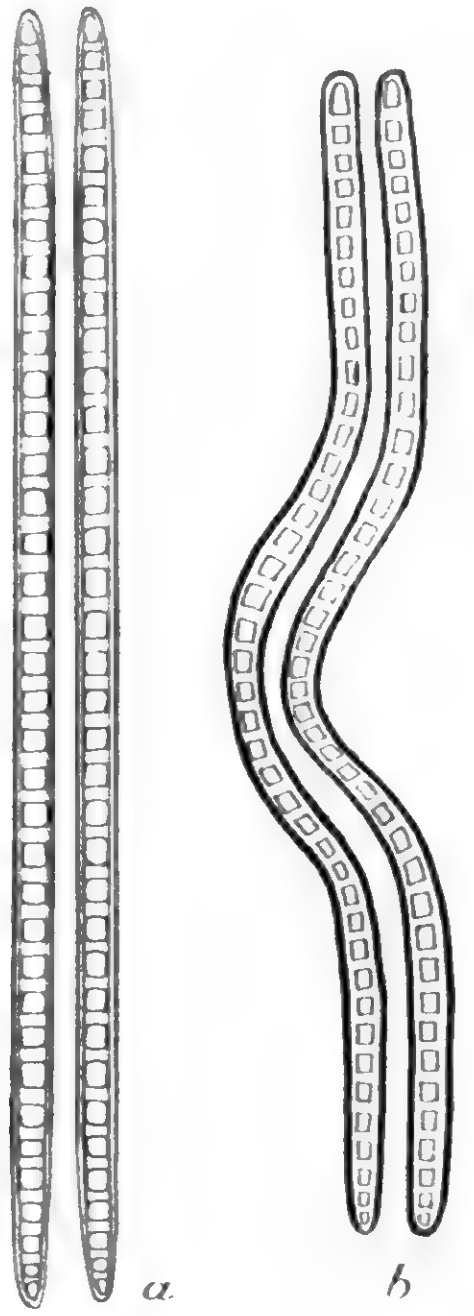

Fig. 5

Fig. 4. (*a*) Supposed primitive coelomic spaces without transverse septa; (*b*) result of such an arrangement in a lateral flexion.

Fig. 5. (*a*) Segmentation of the coelomic space by septa; (*b*) result of lateral flexion under segmented conditions.

The transverse division of the large coelomic cavity into compartments is in obedience to mechanical principles that relate to tubes and their stresses. For a certain thickness of tube wall, support requires to be repeated at certain intervals according to the pressure the tube has to withstand, so that we find coelomic sacs of different diameter and of different antero-posterior length in different animals.

This is the first appearance of what is called Segmentation of the Body in animals. The beginning of this segmentation is this division of the hydrostatic skeleton into segments. This secondarily involves the other tissues in relation to the coelomic spaces, namely, excretory organs, muscular and neural structures, etc.

The segmentation of the hydrostatic skeleton is of the greatest importance to animals possessing such an organ, for we can see that with a skeleton in the form of a long unsegmented tube filled with water the animal would be liable to kink its body after the manner of a flexible tube, and thus produce strangulation of the part of its body behind the distortion. This is prevented by breaking up the skeleton into parts or segments, of which the antero-posterior length is usually less than the diameter.

The segmentation of the hydrostatic skeleton by its influence on other tissues leads to a distinct morphological arrangement, which is a repetition of similar parts. This segmented arrangement allows of a degree of evolution that unsegmented animals do not attain. Thus among coelomates of the chordate class we find mammals have evolved in the highest degree; and among coelomates of the non-chordate class we find the highest degree of evolution presented by the highest group of arthropods.

This segmental arrangement of tissues so necessary in animals with a hydrostatic skeleton is not lost even when the hydrostatic skeleton has been replaced by a more rigid skeleton. Indeed it is retained by the tissues in all the vertebrates, although in no vertebrate animal does a hydrostatic skeleton ever exist. For this reason we find segmentation of the body presented by animals as lowly organised as the simplest annelids, and as highly organised as man.

As secondary morphological changes resulting from the segmentation of the hydrostatic skeleton, we find that each segment of the hydrostatic skeleton is separately related to that part of the gut wall, and that part of the body wall which corresponds with it in position and extent. The gut wall always retains its unsegmented character and may lose all relation with the segment by change of position as in the tail region. On the other hand, the muscular part of the body wall undergoes definite changes. There is at first a longitudinal band of muscle fibres extending from end to end of the animal's body. This becomes segmented or broken up into separate pieces of the same length as the sections of the hydrostatic skeleton to which it corresponds and with which it coincides, and the ends of these separate pieces of muscle attach themselves to the circumference of the septa which separate the segments of the hydrostatic skeleton from one another, as shown in fig. 6.

The ectodermal tissues, like the gut wall, are never segmented in this manner, but again like the gut wall, they get their nervous and vascular systems arranged on the segmental plan. This plan is determined by the arrangement of the hydrostatic skeleton and the mesoblastic tissues of the body wall in sections with septa between, which make each section more or less a separate compartment. From the longitudinal blood-vessels and nerve cords branches pass off into each of these compartments for the supply of all the tissues related to the skeleton of each segment. Nephridial organs are also repeated serially in every coelomic cavity for the drainage of these cavities after the manner of excretory organs.

All these structures are called "segmental" because they follow the arrangement of the skeleton which is "segmented," and this of course means that the coelomic space containing the hydrostatic skeleton is also segmented. It must be clearly understood what the difference is between structures that are segmental and those that are segmented. The latter determine the former: that is, the condition of a space controls the arrangement of the animal's tissues and organs.

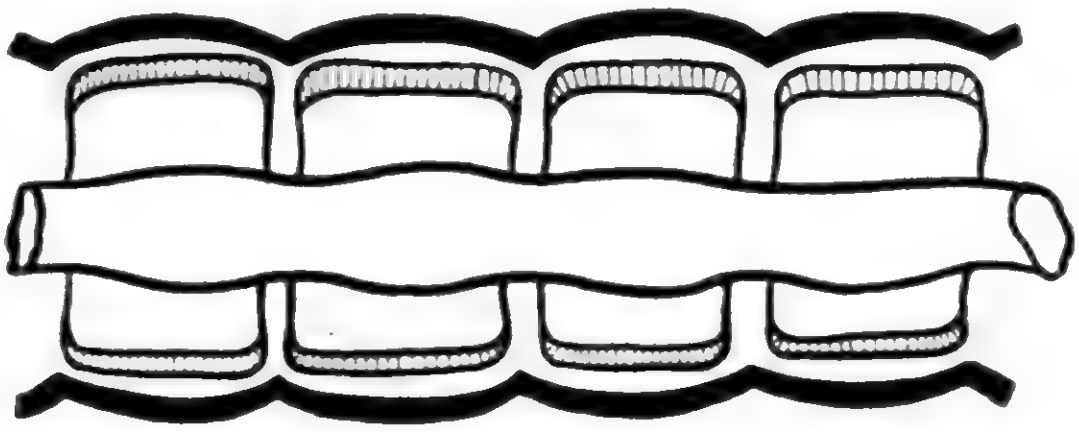

Fig. 6. This shows the attachment of the somatic mesoderm to the boundaries of the coelomic sacs before and behind, and the unsegmented condition of the splanchnic mesoderm. Between the coelomic sacs is a certain amount of blastemal tissue.

Before proceeding further, we shall define what is meant when we speak of a mesoblastic segment and a metameric segment.

A *mesoblastic segment* consists of that portion of the mesoderm that is related to one coelomic cavity, and is repeated in every unmodified metameric segment in the body.

A *metameric segment* consists of all the structures of epiblastic, hypoblastic and mesoblastic origin related to one coelomic cavity, and its segmented and segmental structures are repeated serially in every unmodified metameric segment in the body.

The development of the archiannelid Polygordius illustrates the process of segmentation so well that a description of it will be of advantage.

Polygordius is a typically segmented annelid (fig. 7), and its development has been worked out in the greatest detail. Its larva (fig. 8) is free swimming and called a trochophore. This trochophore larva is roughly spherical in shape with an equatorial mouth and a ciliated groove called the prototroch, and a polar anus near another ciliated structure called the telotroch, with an oesophagus, stomach and intestine extending from the mouth to the anus. The space between the ectoderm and the endoderm is filled with blastemal tissue, and in it are strands of mesoderm with contractile properties passing between the poles of the larva. An archinephridium drains this space. At the upper pole of the larva is a cap of ectoderm with some nervous tissue underlying it and sending out radiating nerves. There is no cavity corresponding to coelomic cavity, so there is no segmentation present in the trochophore larva. Correlated with this, we find the nephridia do not have ciliated funnels, but have instead solenocytes which can drain the blastemal tissue or blastocoele of its body.

When metamorphosis occurs, this larva commences to grow out a tail-like process from its lower hemisphere, which is formed at first of gut tube, ectoderm and blastocoele with its blastomal tissue. This goes on extending until a length of animal is formed, having an anus at the tip of this tail-like structure. This is the body of the animal, and has the same essential parts as the trochophore larva, but these are now disposed in a cylindrical form.

Fig. 7



Fig. 8

Fig. 7. *Polygordius Neapolitanus.* After MacBride[1].
Fig. 8. Larva of *Polygordius* metamorphosing. After MacBride

A later stage shows the mesodermic bands of the larva being continued into the body of the animal owing to the activities of certain mesoderm cells in the region of the lower pole. Two such mesodermic bands are formed and pass into the blastemal tissue of the cylindrical body, one on either side of the gut. The body is now a cylindrical rearrangement of the structures forming the trochophore, and so far shows no sign of segmentation (fig. 9).

The next change in the animal is the appearance of cavities in the mesodermic bands at certain regular intervals, so that there is always a pair at any particular level of the animal. This is the stage of segmentation, and we see only segments of a general mesodermic cavity. The mesoderm itself is still unsegmented, and is lying in the blastocoele having no relation either to ectoderm or gut wall, and a cavity has appeared in it which we call the coelomic cavity, and from its first appearance this cavity is segmented.

---

[1] *Text-book of Embryology.* Vol. I. (Macmillan and Co. 1914.)

Coincidently with the appearance of these cavities, communications are being established with the exterior, and these communications are going to give rise to nephridia of which one part at least is going to become a nephrostome or ciliated funnel operating in conjunction with these coelomic spaces.

These coelomic cavities go on enlarging until they meet above and below the gut, and come into contact with each other before and behind, forming mesenteries to the gut and also transverse septa from the thinned out walls of the mesodermic bands in which they appeared (fig. 10).

The next stage represents the segmentation of these mesodermic bands into belts, each of which is the extent of the underlying pair of coelomic sacs. The reason for this breaking up of this uniform mesoderm into belts is to allow the body muscle to get attachment and purchase upon the water skeleton as far as possible. The muscle therefore attaches itself as far as it can to the anterior and posterior boundaries of the sac containing the water or, in other words, to the septa separating coelomic cavities from each other; and in this way, the muscle obtains a hold upon the skeleton, which greatly increases the efficiency of the body muscle. From now onwards, we find this condition always shown as somites in developing coelomate animals of segmented type.

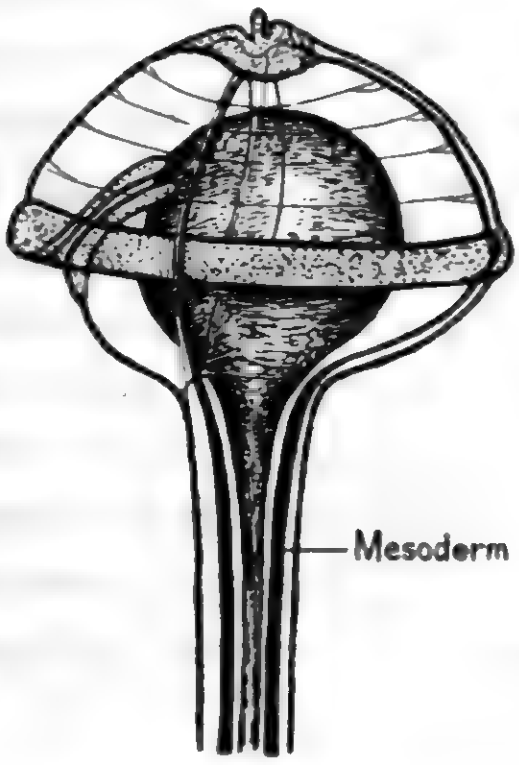

Fig. 9. *Polygordius*: unsegmented mesoderm growing into body. After MacBride.

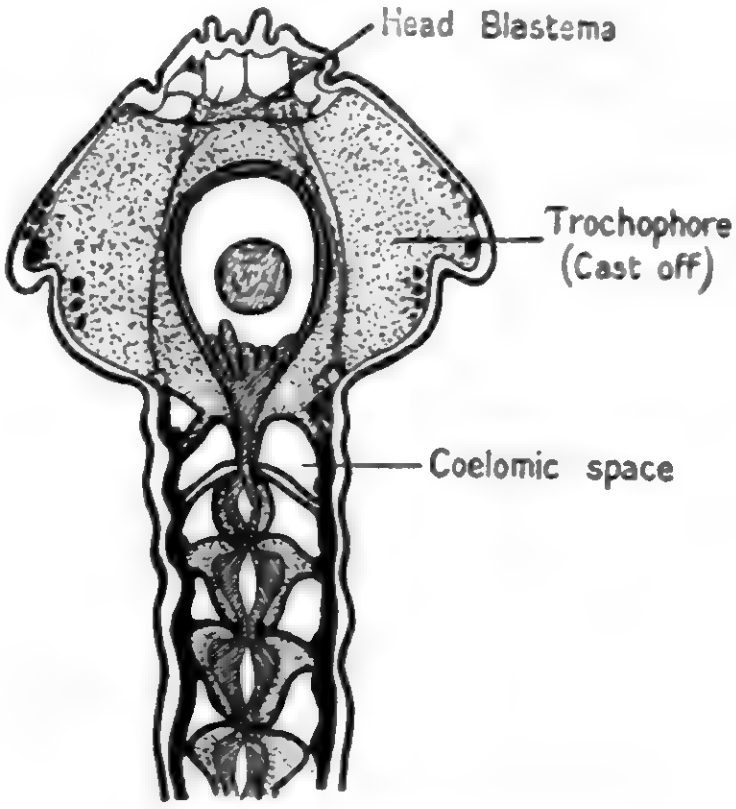

Fig. 10. Mesoderm segmenting. After MacBride.

The muscular part of the gut wall is also derived from the unsegmented mesoderm, but this never segments although it has a similar relation to coelomic spaces. The gut tube does not require any improvement upon the movement performed by unsegmented muscle, which condition we find constant in all splanchnic muscle. The hydrostatic skeleton is therefore not related to the gut wall in anything like the manner in which it is related to the body wall, the muscle of which it causes to be segmented in physiological correspondence with its own form.

While this has been going on, changes have been taking place in the trochophore. The stomach is dissolved and the mesodermic bands now retract the "oesophagus" down to the anterior end of the gut which is in the first trunk segment. Other mesodermic bands, attached to the upper pole of the trochophore, pull this down like a lid upon the first trunk segment. This lid, which consists of the remains of the trochophore, contains the brain and the heart, and its cavity is blastocoele. It contains no gut. All other structures of the trochophore are detached from the animal and disappear. In this way the adult segmented Polygordius comes into being. Its last segment has the anal orifice of the gut, and its first segment has the mouth. The part in front of the first trunk segment is the "face" and is derived from the blastemal tissue of the trochophore covered by ectoderm. It contains the brain or supraoesophagal ganglion and the special vascular organ. There is no coelomic cavity in the face, but there is mesoderm which is observed to remain unsegmented.

After discussing the hydroskeleton of Coelenterate animals we came to the conclusion that it was impossible for any Coelenterate to exist after its removal from the water, as it then lost its skeleton, and with this its form and its ability to move or to procure nourishment to keep it alive. The hydrostatic skeleton has at least overcome this defect, though we shall see that it too is not the ideal skeleton. It is heavy and bulky in proportion to the amount of muscle there is to work upon it; but in the case of an annelid with a hydrostatic skeleton and whose habitat is the sea bottom, being washed ashore and left there by the tide, it could at least live in the littoral or the terrestrial environment, and possibly adapt itself to the new conditions. Indeed something of this kind is supposed to have taken place after coelomates were evolved, in order to account for coelomate animals becoming terrestrial and spreading all over the globe.

3. THE SCLEROTOME SKELETON

Many of these animals, both on land and in the sea, got rid of the water of their bulky hydrostatic skeleton. The direct result of this change was that the place of the hydrostatic skeleton was taken by a skeleton of fibrous tissue. This is the Sclerotome skeleton. It consists of the walls of the coelomic cavities from which the water has been lost; especially the stronger portions formed by the septa separating these cavities, to the margins of which the muscles are already attached.

The sclerotome skeleton is entirely a muscular skeleton. The muscles of the body wall are segmented in correlation with the arrangement of the coelomic cavities, and the muscles depend on this skeleton for their leverage.

The sclerotome skeleton is of great morphological importance, and has allowed of the greatest amount of evolutionary change; but physiologically it is very inefficient. The advantages gained by the loss of water from the skeleton are more than counterbalanced by the disadvantages due to the loss of rigidity. Indeed a rigid skeleton is now the imperative need of the animals that have arrived at the stage in their evolution when it would be an advantage to get rid of their water skeleton. The evolutionary problem for these animals is how to get rid of their bulky, heavy water skeleton, and acquire a rigid skeleton to supplement the sclerotome skeleton that takes its place. We shall see that this problem has been solved in two distinct and different ways by segmented coelomates. How this has been accomplished we shall now endeavour to illustrate.

The structures that are evolved to supply the rigidity so deficient in the sclerotome skeleton are both formed in connection with ectodermal structures. One is formed in the skin as an exoskeleton, the other is formed from the gut wall to support the dorsal nerve tube, and is a Neural skeleton.

Exoskeleton

One of these acquired rigid structures is the exoskeleton of segmented coelomates. This is formed in the skin of the animal, and is arranged segmentally in correspondence with the segmented form of the particular animal. This is well illustrated in the case of the arthropods. These animals have evolved an exoskeleton which gives the animal the rigidity necessary to maintain its form and also gives additional leverage to the muscles of its body wall. Animals that have acquired a rigid exoskeleton to take the place of incompressible water lost from their coelomic cavities, have probably departed from the line of evolution which leads to the vertebrate form; but they have been able to attain a high degree of specialisation, and a very wide distribution both on land and in the sea. It will be interesting to look at the process involved in this rearrangement of skeletal structures which is illustrated in such an animal as Peripatus.

Peripatus is a typically segmented coelomate which has both annelidan and arthropodan characters, and neither of these characters is typical of either group, as the coelom containing a certain amount of hydrostatic skeleton is much reduced, and the newer exoskeleton is imperfectly formed. Peripatus seems to represent a transitional stage in the evolution of arthropods from annelids.

During its development, which is embryonal and not larval, mesoblastic segments are formed along the sides of the elongated gastrular opening, which is elongated until its sides meet and leave an anterior and posterior opening as primitive mouth and anus. These segments become hollow, and the hollows are coelomic cavities. The coelomic cavities remain small and become filled with water after the manner of annelids generally. Nephridia appear in correspondence with the annelidan plan. The whole body is formed of these segments, so that there is no part anterior to the first segment to which the name "face or preoral part" can be applied. As development proceeds, the anterior segment leaves the gut to assume a preoral position, and a further move in this direction by other segments gives rise to the arthropodan head (fig. 11).

In correlation with this arthropodan form of exoskeleton, the watery endoskeleton decreases as the exoskeleton increases in amount. This exoskeleton is said to be partly formed of matter which in the annelid is excreted by the nephridia from the spaces containing the skeleton. This exoskeleton is segmental, and its segmental arrangement follows the segmented arrangement of the body. In this way the annelid form may change to the arthropod form of animal, and replace its hydrostatic skeleton with a more rigid, and for many purposes, a more efficient exoskeleton. In all segmented coelomates, the coelom must appear in its primitive condition very early before any segmentation can take place. When this takes place, the coelom may become modified to any degree short of disappearance.

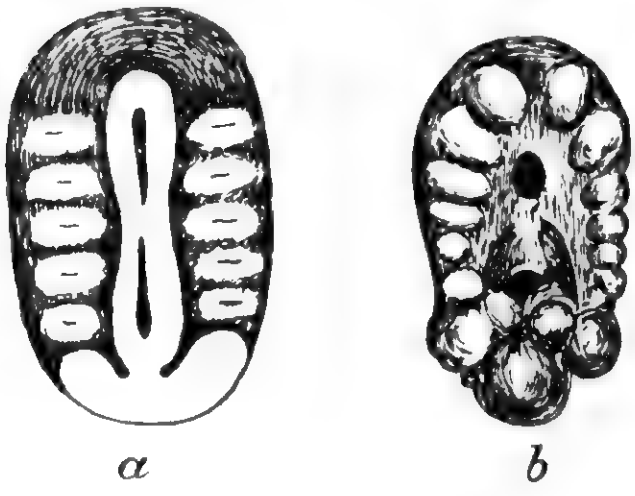

Fig. 11. Two stages in the development of *Peripatus capensis*. The anterior somite in (*a*) is perioral in position, whereas in (*b*) it has moved forward to a preoral position to form the antennary or preoral segment. After MacBride.

4. THE NEURAL SKELETON

The other acquired structure that supplies rigidity to the segmented coelomate that is dispensing with the water of its endoskeleton is the notochord. This is a neural skeleton, in the sense that it is correlated to the nerve tube on the dorsal surface of the animal. It supports the tube and maintains its tubular form during lateral flexion of the body. As the nerve tube is essentially a non-segmented structure, the notochord, formed primarily for its support, is also unsegmented. It is a solid column of cells that gives rigidity to the animal, but it has no relations to the muscles of the body wall. This is a condition we first meet with in the chordate animals, such as Amphioxus. This animal is developed from a larva which forms its coelom from three pairs of sacs derived directly from the archenteron. The first of these pairs forms a face or preoral part for the animal, and the second pair forms the collar or perioral segment. The third pair of coelomic sacs extends the length of the rest of the body, and the mesoderm of its outer wall becomes segmented in the manner we have seen occurring in the annelids. In the body there is thus formed a large number of coelomic spaces with their myotomes, but these spaces do not contain water. In other words, they have lost their hydrostatic skeleton, and have only retained the rigid parts of the coelomic cavities, to which the segmented muscles are now attached. All the other parts of these spaces break down, and a large coelomic cavity or peritoneum results from these changes. The rigid parts of the walls of the coelomic spaces to which the muscles are attached, form a connective tissue skeleton, and these inter-muscular septa are called sclerotomes. Each myotome is separated from the adjacent myotomes by a sclerotome or connective tissue skeleton.

The loss of the hydrostatic skeleton has reduced the bulk of the animal to such an extent, that the body of the animal is now no longer cylindrical, but is flattened from side to side. The object aimed at is evidently to attain such a condition as later on in evolution we find in fishes, where the animal can keep itself off the sea-bottom, and move from place to place by the lateral movement of the hinder part of its body. In Amphioxus, the reduction of bulk of the body and its flattening from side to side has also resulted in a loss of leverage for the muscles; and this is added to the fact that the muscles, though strong enough for creeping along the bottom of the sea, are not sufficiently developed for propelling its body through the water away from the bottom.

The fate of all the chordates is that they can never leave the bottom of the sea. Thus in the case of Balanoglossus, the hydrostatic skeleton of the body is replaced by an endoskeleton of thickened basement membranes, which being formed from unsegmented epithelial structures are themselves unsegmented (fig. 12). Segmentation of the body does not exist apart from the collar region, and since the mechanics of this form do not meet the requirements, all hope of a free-swimming life is gone. Under these circumstances, Balanoglossus, having a coelomic cavity filled with water in its proboscis, makes of this part a muscular organ for burrowing in the sea-bottom. The cephalochordate Amphioxus retains the segmented structure of the body, but free lateral movement is interfered with by the rigid notochord, which is a new unsegmented skeleton that has been formed and gives support to the new dorsal nerve tube.

Fig. 12. Diagram of anterior part of Balanoglossus.

In the urochordate animals, where the organisation of structures is in many respects the highest that had at that time been evolved, the mechanical arrangements of the skeleton were so defective that these animals have all given up their freedom of movement with their larval existence, and become sessile and degenerate creatures.

It is probably from a form like Amphioxus that the vertebrate animals have evolved. We saw that when its body lost its hydrostatic skeleton, there were still two great defects which prevented it from being a success as a free-swimming animal. These were:

(1) That its muscles were not powerful enough to keep it away from the bottom.

(2) That they were prevented from acting efficiently by the rigid notochord.

Two great changes mark the transition from non-chordate to chordate characters in animal evolution:

(1) The nervous system which was situated on the ventral aspect of the body now comes to be developed on the surface of the dorsal aspect of the body, and a rigid notochord is formed from the enteron which serves to support it.

(2) The hydrostatic skeleton which occupied the closed coelomic spaces disappears and is replaced by the sclerotome skeleton.

As the notochord persists in the chordates, we have to trace the evolution of the vertebrate endoskeleton in vertebrate animals themselves, as it is here that all the changes occur which transform the notochord into an efficient segmented endoskeleton. This notochord is found in all chordates as an epithelial rod related to the neural tube and acting as a support to it, and, for this reason, we call it the Neural skeleton.

5. THE NEURO-MUSCULAR SKELETON

(Vertebrate endoskeleton)

In the next group of animals—the vertebrates—we find the defects in the structure of the Chordates overcome.

Fishes present us with an enormous increase in the bulk of the muscle in proportion to the size of the skeleton of the animal, so that this defect is readily overcome. The rigidity of the notochord is a more difficult problem.

We have seen that chordates fail very largely on account of this, so do certain chordate fishes, and even the lowest fishes (cyclostomes) try to get rid of the notochord. The anterior end of the notochord begins to break down soon after it is formed, and forms a loose mesenchyme within its sheath. This was observed by Agar in dipnoan fishes, and might be interpreted as an attempt at the removal of the notochord.

This effort at the removal of the notochord does not seem to be satisfactory, probably because by this time the notochord is necessary for the support of the dorsal nerve tube which is developing greatly in this region. The notochord therefore grows again and attains its former length.

As it is found inadvisable to remove the rigid notochord itself, means are taken to overcome its rigidity, and these means can be traced in the formation of a segmental skeleton which is of greater strength, and possesses greater flexibility, in the vertebrate animals. This new skeleton displaces the notochord as a continuous and rigid structure; and in its complete form, is the true segmented vertebrate axial skeleton, or more strictly endoskeleton.

We must now consider the phases presented by different groups of vertebrates, of the formation of a skeleton to take the place of the notochord. The cyclostome fishes present the first effort in this direction. This is very imperfect and consists of little pieces of hyaline cartilage applied to the sheath of the notochord. They are called arcualia because they are the rudiments of arches, which will later attach themselves to the bodies of vertebrae and surround the neural tube.

It is necessary to recall the primitive coelomic conditions to indicate the relations these arcualia bear to that very important structure, or space, the coelom. In all vertebrate animals, the coelomic cavities appear in somites. Each coelomic cavity has an anterior and a posterior wall. The anterior and posterior walls of adjacent cavities are separated from each other by blastemal tissue (fig. 6). The muscle of the myotome is attached by its anterior end to the anterior wall of the coelomic cavity and by its posterior end to the posterior wall of the same coelomic cavity. The ventral root of the spinal nerve gives rise to the motor nerve of each myotome, and this nerve passes direct from the spinal cord to the myotome. The dorsal root of the spinal nerve gives rise to the sensory nerve of the body segment, and this nerve passes between two myotomes to get to the skin of its segment. At this stage the motor and sensory nerves belonging to the same body segment are separated by an interval of the extent of half a myotome, and their roots leave the spinal cord in a like manner, that is a ventral root alternating with a dorsal root, about the extent of half a myotome apart (fig. 13).

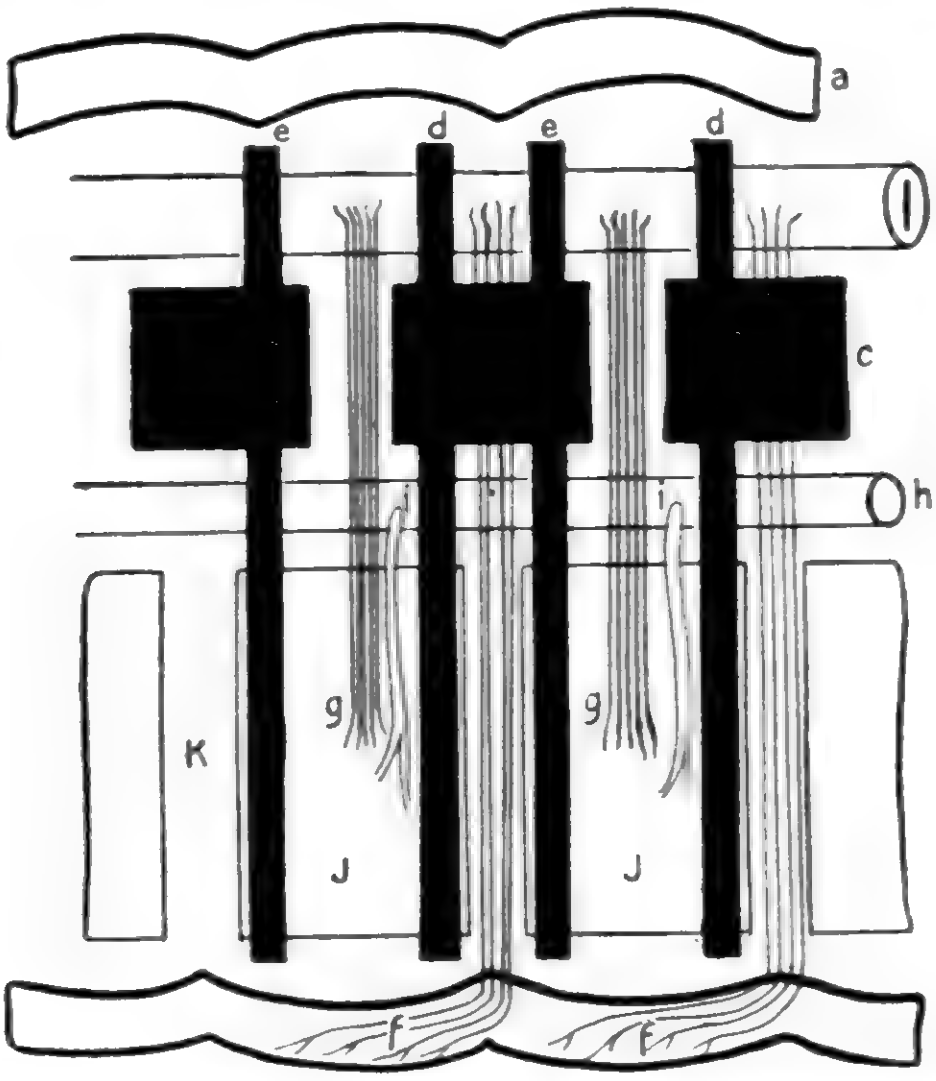

Fig. 13. Diagram of the arrangement of somatic arches in relation to vertebrae and myotomes with segmental arteries and nerves: *a*, skin; *b*, dorsal nerve tube; *c*, vertebral bodies; *d*, anterior neural arches of vertebral relation; *e*, posterior neural arches of vertebral relation; *f*, dorsal or sensory nerves passing in sclerotomes to the skin; *g*, ventral or motor nerves passing to the myotomes; *h*, aorta; *i*, segmental arteries; *j*, myotomes, intervertebral in position; *k*, sclerotomes.

The small cartilaginous bodies, or arcualia, which are the beginnings of vertebral arches, appear in relation with the walls of the coelomic cavities, one at the anterior wall and another at the posterior wall. In this manner there are two arcualia formed in relation with each myotome, and these may be called the anterior and the posterior arcualia. When vertebral bodies are formed they do not correspond in position with the myotome. A vertebral body alternates with a myotome; so that the middle of a vertebral body is placed opposite a sclerotome, which is in the interval between two myotomes, and the nerve of a myotome is opposite an intervertebral space. In the course of development the arcualia pass round the notochord, and then encircle the spinal cord. In this manner they each form a haemal arch and a neural arch. On account of the myotome and the vertebral body alternating with one another, the anterior neural and haemal arches arising in connection with the anterior wall of a myotome, come into relation with the posterior end of a vertebral body when these appear, and the posterior neural and haemal arches come into relation with the anterior part of the vertebral body following. In this way, there are formed two pairs of arches to each vertebra, and these may be called anterior neural and haemal arches respectively (although in relation to myotomes, they would be named in the reverse order).

Recalling the arrangement of the two nerves to each segment as being separate and alternating with one another, it will be evident that the ventral motor nerve and blood-vessel will now pass between posterior and anterior arches of vertebral relation from before backwards, or be intervertebral in position, while the dorsal roots pass between anterior and posterior arches of similar vertebral relation, and are intravertebral in position, so that the motor nerve and blood-vessel pass straight to the muscle from between two vertebrae, while the sensory nerve passes over a vertebra through the space between two myotomes. Thus we have a morphological reason for this double arrangement of arcualia and the separation of sensory and motor nerves in each segment.

As mentioned above, these arcualia are the rudiments of arches and are related to the notochordal sheath, which in cyclostomes is unmodified. These rudiments are related to the notochord so as to form dorsal arcualia which assume a relation to the overlying nerve tube, and ventral arcualia which are the rudiments of the so-called haemal arches. In Myxinidae, these arcualia are extremely rudimentary, and even in Petromyzontidae, they form very imperfect arches, even in relation to the nerve tube.

In cyclostomes we find then, a persistent notochord with additional cartilaginous rudiments developed in relation with the anterior and posterior walls of the coelomic spaces. It is among gnathostomatous fishes that we find the further steps in the evolution of the vertebrate endoskeleton, and we shall proceed to indicate what they are. We now find alterations in the notochordal sheath following upon the presence of the cartilaginous arcualia mentioned. These begin to invade the sheaths of the notochord, and later break up these structures into segments or vertebrae; and from the facts of this process of invasion of the notochordal sheaths by cartilage, we should infer that the vertebral column would be formed after the neural and haemal arches (and this appears to be the case in man), so as to give these arches and the nerve tube increased support. The notochord by itself is probably limited as to the degree to which it is capable of acting as a support in the increasing size of animal forms, and the notable increase in the amount of nerve tissue. This is expressed by the fact that the notochord sheaths tend to chondrify and to replace the notochord itself, so as to form at first a tube, and later a broken or segmented rod of hyaline cartilage.

In the Dipnoi, we find forms with a notochordal sheath uniformly chondrified. This cartilage is entirely free from segmentation. In other words, segmental form has impressed itself upon the muscles and nerves, but not upon the chondrified notochordal sheath.

The next step appears to be represented by the Holocephali, where the notochord sheath is chondrified in the form of a series of rings, several such rings being formed in each segment of the body. This distribution of cartilage cannot be called segmental. It probably only expresses the manner in which support must be given to a tube containing the notochordal cells under pressure and is a distinct advance, mechanically and functionally, upon the uniformly chondrified sheath mentioned above, as the arrangement allows of a certain degree of flexibility of the notochord.

The anterior arcualia now begin to disappear, and the primitive condition in which two neural arches (anterior and posterior) and two haemal arches (anterior and posterior) were present in each segment, becomes replaced by a condition in which we find only one neural arch and one haemal arch in each segment. This latter condition allows of the ventral nerve and the dorsal nerve of the same segment coming together to form a mixed nerve, an arrangement of the segmental nerve which is adhered to in all the higher vertebrates. These mixed spinal nerves are always accompanied by the segmental blood-vessels.

All vertebrate skeletons above that of Holocephali show secondary segmentation following that of the somatic mesoderm, and the notochordal sheath is modified to form the axial part of the axial skeleton, either by sheath formation or by peri-sheath formation, from the bases of the segmental arcualia. By the time vertebral bodies are being formed, this disappearance of the anterior neural and haemal arches is becoming evident, with the above-mentioned changes in the arrangement of the spinal nerves. The resulting condition for vertebrates generally, is that for each segment there is a corresponding intersegmental vertebra, with one intersegmental neural and haemal arch, while the mixed nerve is now segmental, and myotomic in position.

Having shown that the sclerotome is the skeleton of the myotome, and having pointed out the morphological relation of arcualia to the issuing nerves, it will be evident from the various forms of arcualia among the lower fishes, that such cartilage elements appear primarily in relation to the nerve tube and not to muscle, although they are placed in the intermyotomic intervals or sclerotomes.

In the fishes, where cartilage first appears as an organised skeleton, two facts are to be noted:

(1) The enormous development of muscle.
(2) The slight development of axial skeleton.

The disproportion in amount between these tissues is so great, that it is difficult to believe that any primary relation exists between them.

The true skeleton of the myotome is, as before stated, the sclerotome skeleton, which is always found developed to the extent required by myotomes for their attachment. The sclerotome skeleton is the only structure in fishes that is capable of standing the strain of their powerful muscles. Fishes are the most muscular animals that exist, evolution of muscular tissue having been carried to an extreme degree. This is an adaptation to life in a dense medium: the water they live in absorbs the work of the muscles, and being so dense and difficult to displace, this muscular development is necessary for propelling these animals through this medium.

Passing down the peritoneal aspect of each sclerotome in fishes is a slender rib with its accompanying nerve. It cannot be imagined that such a rib is acting as a skeletal support to the adjacent myotomes, unless to the stratum of fibres of corresponding thickness to the rib. For this purpose the rib would be quite useless, yet the rib being a rigid structure, the muscle attaches itself as far as it can to it and in this way we get an intercostal arrangement of muscles. The rib is, however, really a process of a vertebra and is always accompanied by the segmental nerve. In air-breathing vertebrates, the relation of skeleton to muscle increases. Thus we find in the animals from Amphibia upwards, living generally in a rarer medium than water, that there is again a change, namely,

(1) reduced amount of muscle;
(2) increased amount of skeleton;

both of which are now well specialised.

The muscular relations established in fishes with neural and haemal arches is now exaggerated, so that in higher vertebrates large bones are formed, muscles are relatively reduced and specialised, and their fibrous sclerotomes almost disappear in the adult forms.

This last relation of muscle to skeleton need not be enlarged upon. We are all familiar with the specialised forms of the muscles in the highest vertebrate, and with the way they have taken advantage of almost every particle of the skeleton to give the leverage necessary for the actions of such highly specialised muscles.

In the evolution of the vertebrate skeleton we have seen that archiblastic tissues have the power of providing themselves with a skeleton for protection or support. It is evidently not so with muscle, for we have seen during its whole history, that this tissue had to take advantage of anything it could find to help it to do its work, or to enable it to do it more efficiently. Thus in the coelenterates, the muscle fibres act on the fluid contained in the enteric cavity and that within the bell of the medusa, because it is the only resisting body they can find to act upon. It is for this reason we call this fluid the hydroskeleton.

In the annelid, the coelomic spaces appear and are full of water. Here the muscles take advantage of an improved condition, namely, an enclosed mass of water instead of an unenclosed mass, and arrange their attachments according to the changed conditions. Then when transverse septa are formed, they again take advantage of the firm circumferential parts of the septa and attach themselves to them, and in doing so, get broken up into sections which can act more or less independently of one another to the great advantage of the animal.

When the septa of the coelomic cavity disappear, and this no longer contains fluid as in Amphioxus, the muscles retain the circumference of the septa as sclerotomes which serve them as a skeleton until something better is evolved. This next thing is the skeleton which gives support to the nerve tube, and we find the muscles acquiring relations of attachment to this skeleton in fishes. As we ascend in the vertebrate scale these relations are extended until it would appear that they are more important than the relations of the skeleton to nervous system.

The skeleton we have been discussing as the vertebrate skeleton is a neuro-muscular skeleton. It was primarily neural as we have seen, and secondarily muscular; then in its highest form it is neuro-muscular. It forms the skeletal support of the dorsal nervous system. It is also the skeleton of the somatic muscles, and it is segmented in conformity with the body segmentation.

The neuro-muscular skeleton is, as we have seen, formed round the notochord which is a structure of hypoblastic origin. This is therefore unsegmented, and it is entirely superseded by the neuro-muscular skeleton, and almost entirely removed by it. The neuro-muscular skeleton may therefore be described as of mesoblastic origin, not only being formed from mesoblastic tissue, but its structure being determined by the arrangement of the mesoblastic somites, which in turn were determined by the arrangement of the coelomic cavities. In other words, it arose as an extension of the sclerotome skeleton which remained after the disappearance of the hydrostatic skeleton, and is therefore the result of mesoblastic segmentation depending upon the segmentation of coelomic cavities.

ODONTOLOGICAL ESSAYS

By L. BOLK, M.D.,

Director of the Anatomical Institute of the University of Amsterdam

FIRST ESSAY

ON THE DEVELOPMENT OF THE PALATE AND ALVEOLAR RIDGE IN MAN

It seems desirable, not to say necessary, as a general introduction to the following essays, to record briefly the results of my researches upon the development of the palate, tooth-band and alveolar ridge in man. The communication of these results is justified by the consideration that it brings out some ontogenetical principles, which will find their application in the following essays, and further that it shows that some of the readings of the development of this part of the human mouth which are adopted in textbooks of Embryology are not entirely true.

Upon the earliest stages of the development of the human palate until the complete separation of cavum oris and cavum nasi by the coalescence of the two palatine processes, I have nothing to say; the purpose of this essay is to elucidate the developmental phenomena in the palate after the uniting of the processus palatinus in the middle-line.

The starting-point of our research is the palate of a fetus of five months, the oral surface of which is outlined in fig. 1. One may distinguish two regions in this palate, a central part and a surrounding border. I denominate the first *Tectum oris*, the second, *Zona marginalis*.

The tectum oris is egg-shaped, and is continued backwards as the soft palate, of which the outline is lacking in this figure. The tectum oris as a whole is concavely vaulted, its lateral parts are in this stage of development, but slightly prominent. I will distinguish these prominences as *Tectal ridges.* Between the tectal ridges and the zona marginalis there runs an uninterrupted furrow. The surface of the tectum oris is still characterised by a number of well marked rugae palatinae, extending from the middle-line, to the groove separating the tectal ridges from the zona marginalis. This fact is of some importance in regard to the interpretation of the anatomical conditions in earlier stages.

In its foremost part the median line of the tectum oris is occupied by the papilla palatina which is connected with the papilla labii superioris by a fold of the mucous membrane, which will be distinguished as the *Fraenum tecto-labiale.*

The zona marginalis is horseshoe-shaped, and surrounds the tectum oris.

In the front part of the mouth it lies between the latter and the lip, laterally between the cheeks and the tectum. It is separated from lips and cheeks by a rather deep furrow—the vestibular groove—interrupted in the median line by the fraenum already referred to. The internal boundary line of the zona marginalis is a somewhat more complicated one. A furrow, which separates the zona from the tectum, begins at the fraenum tecto-labiale and deepens as it passes outward and backward. A little behind the mouth this furrow turns obliquely outward, finally fusing with the vestibular groove. Thus the zona marginalis is divided into an anterior and a posterior part. The latter is separated from the tectum oris by a special furrow which is apparently a backward prolongation from the furrow in the front part of the palate. On grounds, which will become intelligible in the course of this essay, I shall distinguish the first furrow—that ending the vestibular groove—as the *internal alveolar furrow*, that limitating the posterior part of the zona marginalis on the inner side as the *transitory palatine furrow*.

The posterior part of the internal alveolar furrow divides the zona marginalis into two parts, whose significance in the future development of the palate is quite different. For the anterior part is the alveolar ridge, in this phase but partially developed, whereas the posterior part has nothing to do with this ridge; being, as development advances, incorporated in the tectum oris by the disappearance of the transitory palatine furrow. This fusion with the tectum is as a rule already complete when the fetus is full grown: so that in the new-born child only some small fragments of the furrow persist on the inner side of the alveolar ridge, which by this time has extended considerably further backward. The different signification and behaviour of the two parts of the zona marginalis necessitate the application of a special name to each; the anterior part, as the true alveolar ridge, shall retain that name, the name *pseudo-alveolar ridge* being appropriate to the posterior part in the light of its later development. In fetuses, more advanced in development than that of fig. 1, the alveolar ridge has penetrated between the cheek and the pseudo-alveolar ridge.

The surface of the pseudo-alveolar ridge is smooth, that of the alveolar on the contrary is rugged; small irregular prominences indicating the spots where the teeth are lying under the surface of the gum.

In a fetus in an earlier stage of development, anatomical conditions are met with, which prove that the above described configuration of the palate does not originate by a simple enlargement, but by a development of very particular nature. This becomes obvious by a comparison of fig. 1 with fig. 2, in which the palate of a fetus from the fourth month is outlined.

The most striking difference between the palate sketched in fig. 1 and that of the younger subject drawn in fig. 2, is that in the earlier stage the zona marginalis is incomplete, being represented only by its anterior and posterior extremities. The anterior part, the alveolar ridge, is narrower and sickle-shaped, lying between the lips and the tectum oris. The corrugations by which it is characterised in the older fetus have not appeared, its surface being smooth. In the median line it is divided into two halves by the Fraenum tecto-labiale. The papilla palatina and papilla labii superioris lie closer to one another, and are connected by the short and broad Fraenum. A little behind the corner of the mouth the internal alveolar furrow and the vestibular furrow unite, forming a common groove, which runs backwards between the cheek and the tectum oris. Examination of the rugae palatinae makes it clear, that the tectum oris in this stage extends laterally as far as the cheeks, for the rugae reach these lateral walls of the mouth. In this region therefore the zona marginalis is lacking. In the most posterior part of the palate it reappears, the pseudo-alveolar ridge intercalating itself between the cheek and the tectum oris, being bounded internally by the transitory palatine furrow, and externally by the vestibular groove.

Summarising, one finds that in a younger stage of development the zona marginalis is wanting in part, and the tectum oris extends laterally as far as the cheeks. Moreover the lateral parts of the tectum project more considerably, and the palate is therefore more strongly vaulted from side to side.

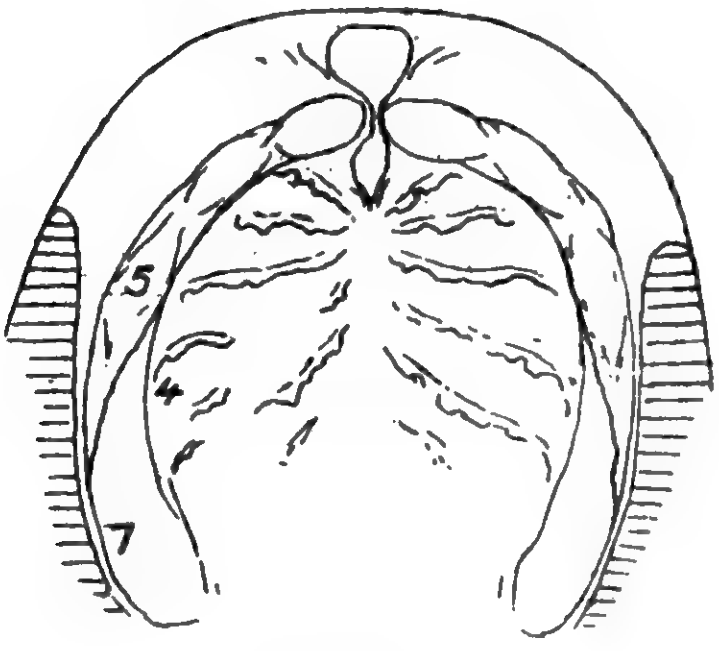

Fig. 1

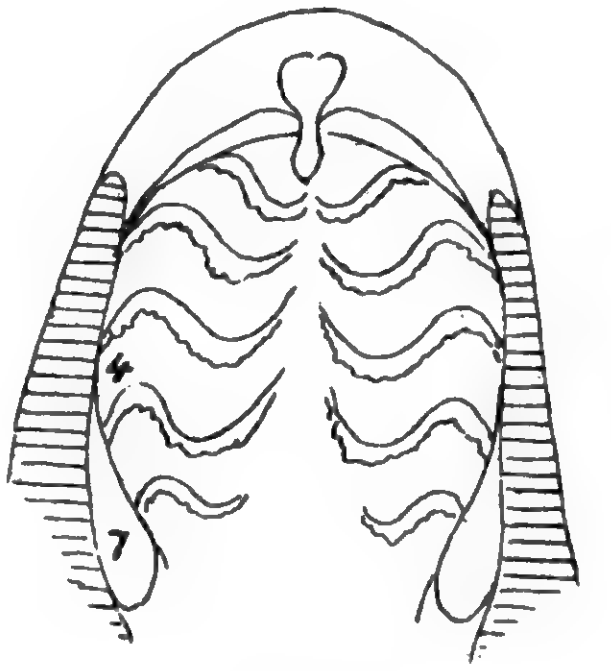

Fig. 2

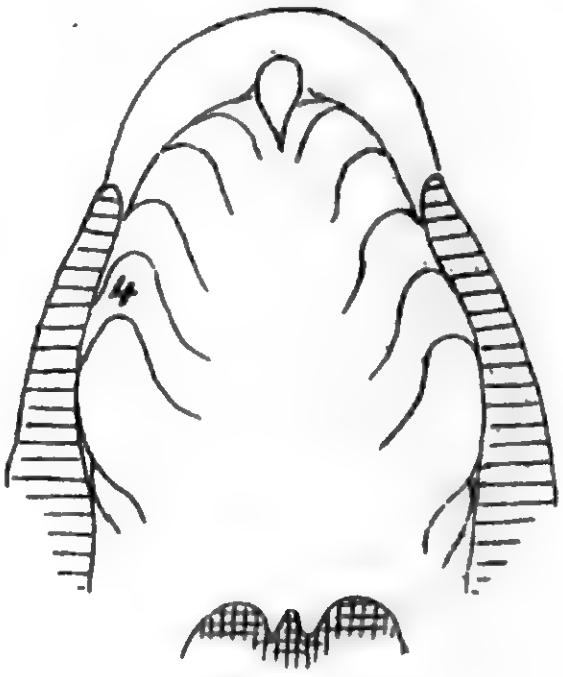

Fig. 3

Knowledge of the structure at this stage of development facilitates the understanding of the conditions in a still earlier stage, drawn in fig. 3. This is characterised by the total absence of the zona marginalis, the palate being represented in this subject solely by the tectum oris. In the front part of the mouth the latter reaches the lips; laterally along its whole length it touches the cheeks. That such is really the case is proved by the fact, that the rugae palatinae on the front part of the palate reach the furrow bounding the lip, and posteriorly extend outwards to the groove between the cheeks and the palate. If the lateral groove in this stage is called the vestibular groove, stress must be laid on the fact that its anatomical value is not the same as the vestibular groove in the stage represented in fig. 1. The conditions in the two subjects are quite different. For in the elder stage this groove runs between the zona marginalis and the cheeks and lip, whilst in the younger it separates these from the tectum oris. Therefore it is advisable to distinguish the groove in the latter case by a special name at the labio-tectal and bucco-tectal furrow. The total absence of the zona marginalis in fig. 3 involves lack of the internal alveolar furrow and the transitory palatine furrow.

A very remarkable phenomenon is presented by the eminence lying in the front part of the palate. In older stages two papillae are situated in the median line: a papilla palatina and a papilla labii superioris, which are connected with each other by the Fraenum tecto-labiale. In the present case both papillae are represented by a single egg-shaped eminence, the Fraenum being still undeveloped.

The three stages of development above described, enable us to explain the history of the differentiation of the human palate after the fusion of the two palatinal processes. I wish to emphasise the fact that this description applies only to the development of the palate in man, and must not be extended to other mammals. I am aware of the circumstance that the developmental history of this part of the mouth in some other mammals differs not inconsiderably from that in man, especially so far as it concerns the alveolar ridge. In the following paragraphs I will try to give a short summary of this history.

The so-called secondary palate is formed by the fusion in the middle line of the left and right palatine processes, the resulting plate separating the primitive cavum oris into an upper and a lower cavity. This secondary palate is in man transitory, representing only that part of the definitive palate which lies within the alveolar ridge. It is thus not identical with the final palate, which includes this ridge and may therefore be distinguished as the *tertiary palate.*

The secondary palate is strongly vaulted from side to side, the lateral parts forming two prominences, along the inner surface of the cheeks, from which they are separated by the labio-bucco-tectal furrow. In the median line this furrow is interrupted by a rather large papilla: the labio-tectal papilla. The two prominences, just referred to, may be distinguished as *tectal ridges.*

The tertiary palate arises from this by the growing up of a ridge, which originates from the bottom of the labio-bucco-tectal furrow, and sandwiches itself between the tectal ridges on the inner side, and the lip and cheeks on the outer side. This ridge embraces the secondary palate like a horse-shoe. Two divisions of the palate so constituted are to be distinguished: a central part—the true roof of the mouth—tectum oris, and a border, the zona marginalis which surrounds it. This zona originates in each half of the palate from two centres, an anterior and a posterior one. The latter becomes visible before the former. The anterior part of the zona makes its first appearance at the surface immediately laterally to the tecto-labial papilla, and extends gradually backwards to touch the posterior part. The two parts however do not unite with each other as a rather deep furrow remains between them after their contact. This furrow is the continuation of that between the tectum oris and the frontal part of the zona marginalis.

The two parts of the zona have different relation to the set of teeth, and it is therefore necessary to give them different names, the anterior part I call the alveolar ridge, whilst the posterior part may be distinguished as the pseudo-alveolar ridge. The former is bounded by the vestibular groove and the internal alveolar furrow, the latter by the vestibular groove and the transitory palatine furrow.

The surface of the alveolar ridge shows some prominences, caused by the developing teeth, the pseudo-alveolar ridge on the contrary remains smooth and flattens gradually as the transitory palatine groove disappears. At birth, therefore, the limits of this part of the zona marginalis are difficult to determine. The main cause of this difficulty is the backward extension of the alveolar ridge which insinuates itself between the cheek and the pseudo-alveolar ridge, so as to give that prominence an internal position, where, on the total disappearance of the transitory palatine furrow it becomes fused with the tectum oris. In an early stage of development the foremost part of this median line of the palate is interrupted by a small eminence, the papilla tecto-labialis. In consequence of the growing up of the alveolar ridge between the lip and the tectum, this papilla is divided into an anterior labial papilla and a posterior tectal papilla, united by a mucous fold, the Fraenum tecto-labiale. Till shortly before birth the presence of this fraenum is easy to demonstrate. After birth this fold is partly flattened by the gradually accentuated prominence of the alveolar ridge, and only the anterior part—known as the Fraenum labii superioris—persists. In some Prosimiae (Lemur, e.g.) the whole Fraenum is persistent, running between the two central incisors from the lip to the palate. It seems to me not impossible that the diastema sometimes occurring in man in the median line of the set of teeth is caused by the persistence of this fraenum during a longer period than usual.

I have controlled and completed this developmental history of the human palate based on its surface anatomy in fetuses of different ages by the microscopical researches with which the following account deals. It is obvious that the value and significance of such a microscopical investigation are greater ones than those of a purely macroscopical study. For this research ought also to include the genetical and topographical phenomena concerning the teeth and the dental lamina and their relation to the superficial furrows above described.

I have examined by means of serial sections a large number of human fetuses with regard to the anlage and further development of teeth and palate, from these I choose for description five specimens varying in age from the second till the fifth month of development. The youngest embryo measured 25 mm. whole length.

I begin with this embryo, which is represented in figs. 4–7. As shown by these figures in this embryo the separation between the cavum oris and the cavum nasi is not yet formed, the palatine processes still lying lateral and ventral to the dorsum of the tongue. Figs. 6 and 7 are drawn from transverse sections behind the corner of the mouth, figs. 4 and 5 from similar sections in front of this corner. In this embryo there is not the minutest trace of the teeth-germs. In figs. 4–7, as well as in all those which follow, the interesting epithelial formations are indicated by dotting. In fig. 4 one sees nearly in the middle of the surface of the common anlage for lip and palate a shallow furrow (fig. 4, 1) which may be distinguished as the labio-tectal furrow. Below, with this furrow an epithelial thickening has grown into the subjacent tissue, which shows two offshoots, a medial and a lateral one. I shall call the medial the dento-gingival sheet (fig. 4, 2) and the lateral the labio-gingival sheet (fig. 4, 3). These names indicate the future significance of these epithelial formations; from the former are differentiated the enamel-organs of the teeth, whilst in addition a part of the gum takes origin from it; the latter gives rise to the epithelium on the inner surface of the lip and furthermore to a part of the gum. I lay stress upon the fact that neither of these sheets is distinguished by me as dental lamina, being convinced that such a name is too restricted, as I shall show in the course of the present paper.

The two epithelial sheets above described separate three ridges of mesenchyme. Of these the medial one will be called the tectal ridge (fig. 4, 4), in the later parts of this paper, the middle the alveolar ridge (fig. 4, 5) and the lateral one the labial ridge (fig. 4, 6). The appropriateness of these names will be shown by the behaviour of the ridges in later embryos.

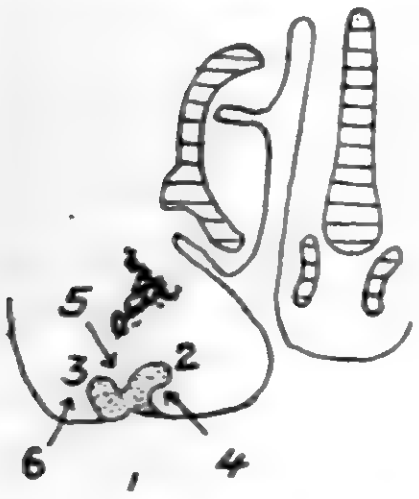

Fig. 4

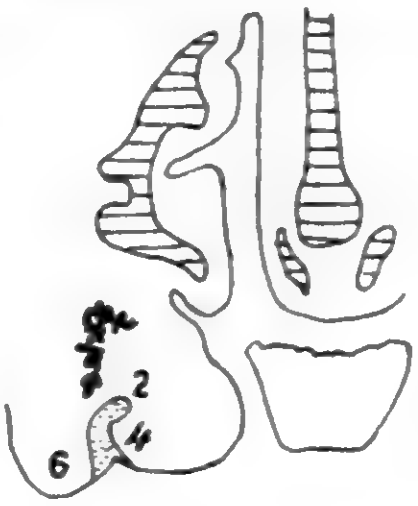

Fig. 5

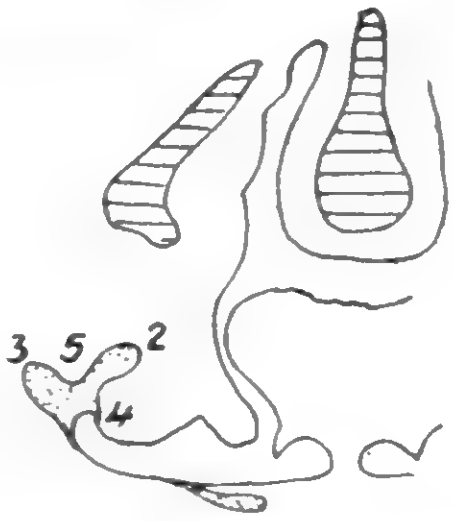

Fig. 6

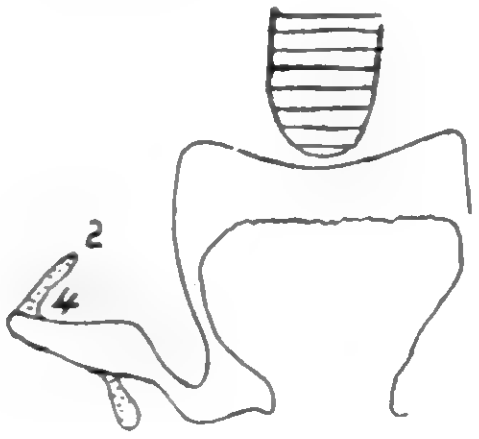

Fig. 7

The conditions of these ridges do not alter much as they are traced backward through the serial sections until at a point a little in advance of the corner of the mouth, the labio-gingival sheet disappears and the common epithelial mass is carried inward only by the dento-gingival sheet, which is slightly inclined medially (fig. 5). That this is a normal structure and not an individual peculiarity of the embryo is shown by conditions in later stages. The region where the labio-gingival sheet is absent is short because it reappears immediately behind the corner of the mouth (see fig. 6).

As this region is in the cheek the name labio-gingival must be replaced by bucco-gingival. The whole epithelial formation in this region arises from the surface epithelium forming the lateral border of the cavum oris, the labio-tectal furrow has disappeared, and the groove between the tectal ridge (fig. 6, 4) and the cheek may be distinguished as the bucco-tectal groove.

Further back the bucco-gingival sheet becomes lower and finally disappears (fig. 7) and the dento-gingival sheet above is continued to the posterior part of the mouth where it disappears.

The conditions in a fetus of 40 mm. are shown in figs. 8, 9, 10 and 11. The cavum oris in this specimen is separated from the cavum nasi, the secondary palate is complete and the germs of all the milk teeth are present. In fig. 8 a section is drawn between the germ of the lateral incisor and the canine tooth, nearly the same level as the section drawn in fig. 4 of the younger embryo. The changes which have taken place may be recognised in the easiest manner by a comparison of the two figures.

Fig. 8

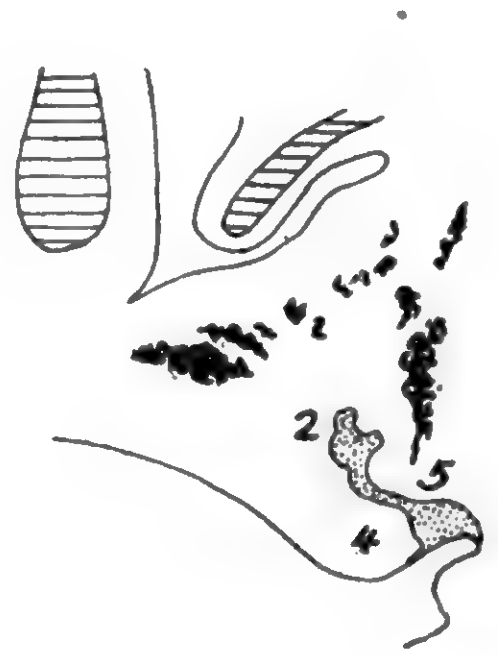

Fig. 9

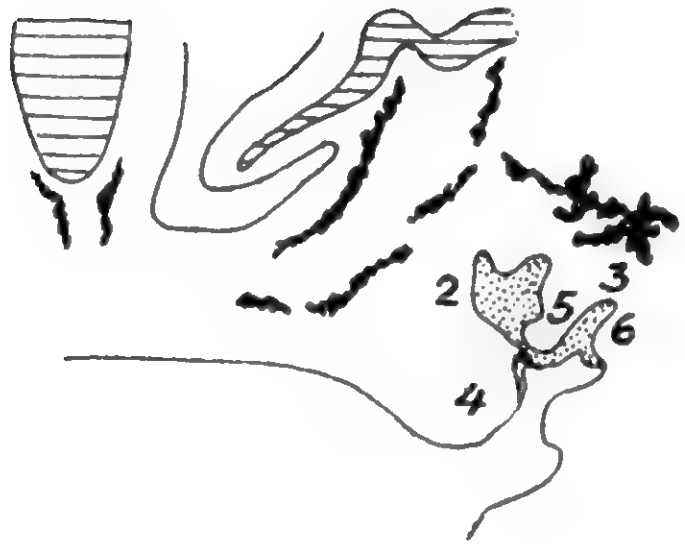

Fig. 10

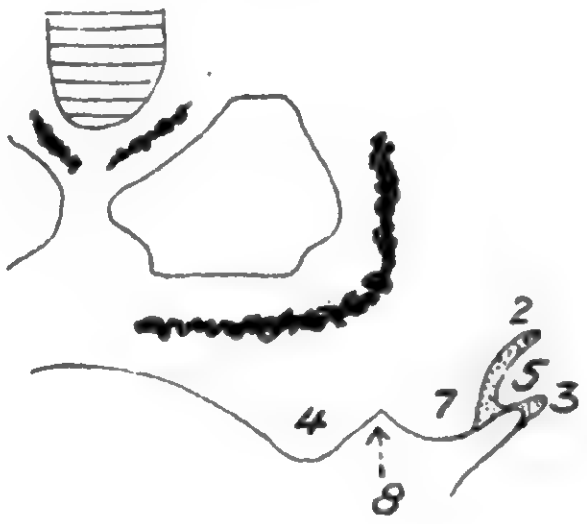

Fig. 11

The labio-tectal furrow has deepened, so that the lip becomes more prominent and acquires a free inner surface. A considerable heaping up of epithelium separates the labial ridge (6) from the tectal ridge (4) and from this common epithelial strand the dento-gingival sheet (2) goes out in a mesial direction, whilst the labio-gingival sheet is directed upwards and laterally. By the considerable elongation of both sheets the alveolar ridge is much broadened.

The section represented in fig. 9 runs through the germ of the canine tooth; at this level the upper and lower lip are united with each other. This section corresponds nearly with that in fig. 5.

There is a rather broad bucco-tectal cleft and between the cheek and tectal ridge (4) is intercalated the backward prolongation of that large epithelial mass, which in the preceding figure is shown to separate the tectal and labial ridges. In the present section as in that of fig. 5 there is but a single offshoot going out from this thickening of the surface epithelium, namely the mesially inclined dento-gingival sheet (2), carrying at its free edge the germ of the canine tooth. As in the younger fetus the bucco-gingival sheet is absent in the region of this tooth. Hence a lateral limitation of the alveolar ridge (5) is lacking in this region.

A little further backwards this sheet reappears, as is shown by fig. 10, which section runs through the germ of the first milk molar. The cleft between the cheek and the tectal ridge is deepened and widened out. This bucco-tectal groove cannot be identified with the vestibulum oris, for the vestibular cavity is not in existence in the present stage of development. The cleft between the cheek and the tectum oris is only of short duration, it disappears in the course of the further development, as will be demonstrated in older embryos.

The section drawn in fig. 10 is taken through nearly the same region as that of the younger embryo which is the original of fig. 6. It shows a new feature which is worthy of special notice. This is that the dento-gingival sheet no longer arises from the lateral edge of the tectal ridge (4) but originates more laterally. Fig. 11, which represents a section through the posterior part of the palate, shows that this condition is accentuated as the structures are followed backward. In it the bucco-gingival sheet (3) has become very low, penetrating only a little way into the subjacent tissue. The dento-gingival sheet (2) has still a considerable depth. On the surface of the palate the tectal ridge (4) is much flattened, and the tecto-buccal cleft, although considerably broadened, has become very shallow. Between the cheek and the tectal ridge a new ridge is formed (7) which has nothing to do with the alveolar ridge (5). For the dento-gingival sheet extends laterally from this new formation. The ridge in question is that described by me earlier in this paper as pseudo-alveolar ridge, it is separated from the tectal ridge (4) by the shallow furrow which I have distinguished as the transitory palatine furrow (8).

I choose an embryo of the age of two and a half months as a third stage. The figs. 12, 13, 14 and 15 are drawn from it.

The section in fig. 12 cuts the germ of the lateral incisor, and corresponds therefore with those in figs. 4 and 8. There is an enormous heaping up of epithelium between the tectal ridge (4) and the labial ridge (6). By this considerable thickening of the epithelium these ridges are pushed away from each other and in consequence the alveolar ridge (5) is broadened. By the penetration of the labio-tectal furrow into this mass of epithelial cells the lip becomes more and more independent and acquires a free inner surface.

The deepening of this furrow is due to an atrophy of the cells which fill the interior of the epithelial mass. The dento-gingival sheet (2) is strongly inclined mesially, so as to take nearly a horizontal direction. The labio-gingival sheet (3) bounding the alveolar ridge (5) along its lateral edge, is also thickened and penetrates more deeply into the mesenchyme.

The section drawn in fig. 13 cuts through the enamel organ of the canine, being therefore comparable with figs. 9 and 5. This section lies behind the corner of the mouth. At this level there is, more anteriorly, a considerable thickening of the epithelium between the cheek and the tectal ridge (4), pushing these parts away from each other. From the medial upper edge of this epithelial mass, the dento-gingival sheet arises, terminating in the germ of the canine. Lateral of this lamina extends the alveolar ridge (5), which is continuous with the mesenchyme of the cheek, because in this embryo, as in the two already described, the bucco-gingival sheet is wanting at this level. The bucco-tectal cleft is widened and deepened, owing to the atrophy of the superficial cells.

Fig. 12

Fig. 13

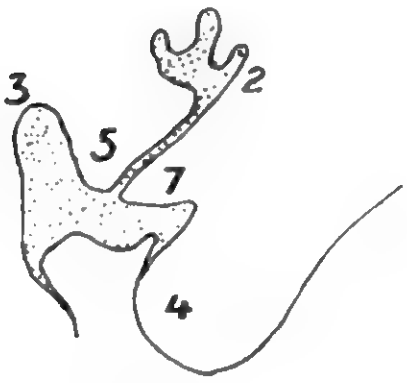

Fig. 14

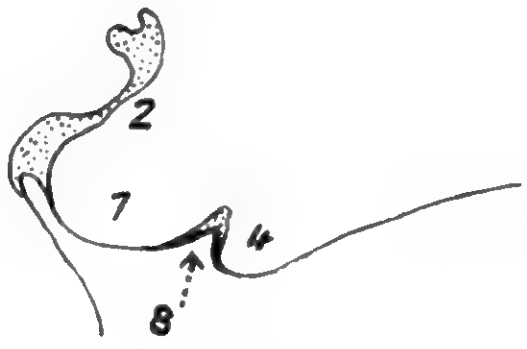

Fig. 15

Further back the dento-gingival sheet shows the same behaviour as in the earlier embryo. It no longer takes origin from the medial upper edge of the common epithelial mass, but it is pushed laterally, approaching the bucco-gingival sheet, which has reappeared at this level, as demonstrated by fig. 14, passing through the posterior part of the enamel-organs of the first milk molar. By this change of position the alveolar ridge (5) becomes thinner, and medial of it, the pseudo-alveolar ridge (7) appears, its surface covered by a thick epithelial layer. This layer forms the bottom of the bucco-tectal cavity, which is very broad and in consequence of the strong projection of the tectal ridge also very deep.

Further back the conditions change gradually in the following manner (fig. 15). The dento-gingival sheet gradually moves laterally, coming at first into relation to and finally fusing with the bucco-gingival sheet. From this point the dento-gingival sheet forms the dividing band between the cheek and the palate. By the shifting of the dento-gingival sheet, and its fusion with the bucco-gingival, the alveolar ridge gradually disappears, whilst the pseudo-alveolar ridge develops and broadens. By the flattening of the bucco-tectal groove it finally appears on the surface, being covered with a thin layer of epithelium. The section shown in fig. 15 cuts through the enamel-organ of the second milk molar. And it is obvious that in this region the alveolar ridge has not yet developed. The specimen from which the sections outlined in figs. 12–15 are taken, was nearly in the same stage of development as that whose palate is represented in fig. 2. And a comparison, specially of the figs. 14 and 15 with fig. 2 will greatly facilitate an understanding of these developmental conditions.

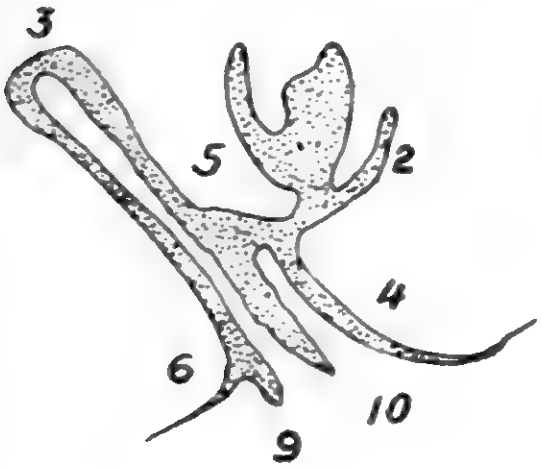

Fig. 16

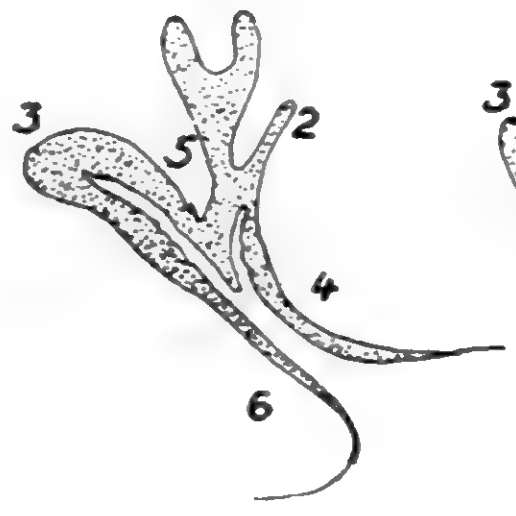

Fig. 17

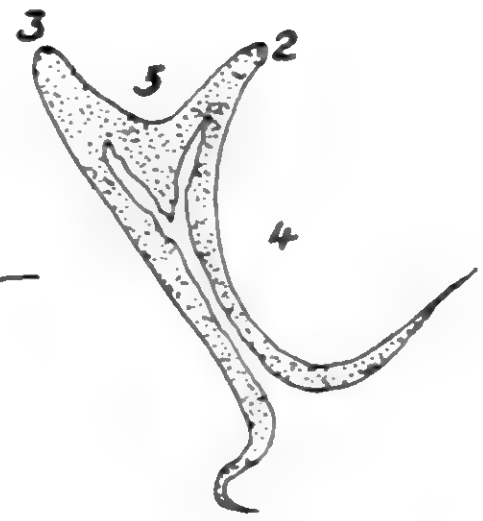

Fig. 18

Fig. 19

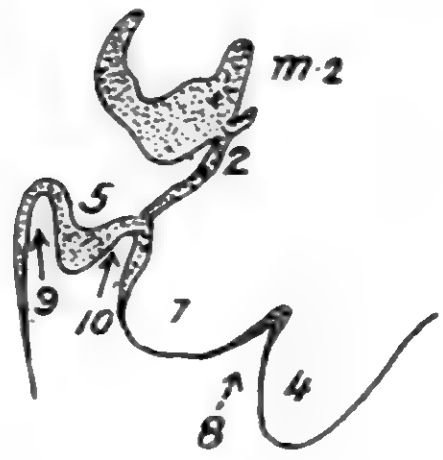

Fig. 20

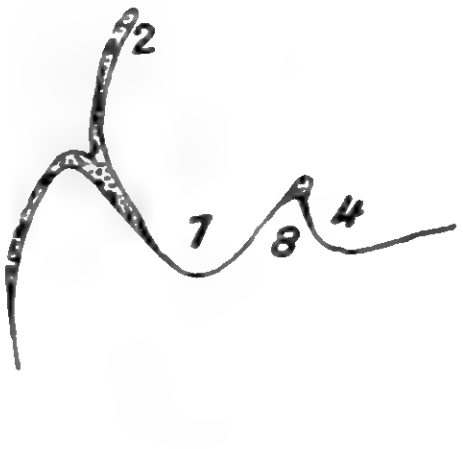

Fig. 21

Figs. 16 to 21 represent six sections from a series of an embryo at the end of the fourth month. This stage of development is characterised by the final separation of lip and palate, and the ingrowth between these of the alveolar ridge.

The section drawn in fig. 16 cuts through the enamel-organ of the lateral incisor. Comparison of this section with fig. 12 will give a clear idea of the changes which have happened in the interval between these two embryos. The changes are very considerable. In the stage, prior to the present, a cleft was formed in the epithelial mass between the lip and the tectal ridge. Now in this older stage, this cleft not only has broadened but is also complicated in a typical manner. It is duplicated, or, more exactly, in penetrating more deeply the epithelial mass, it has bifurcated into a lateral and a medial cleft. This enlargement of the groove is due principally to an outgrowth of the epithelial lamina into the mesenchyme, joined with an atrophy and loosening of their interior cells.

The lateral cleft, having pushed into the labio-gingival sheet (8) to its upper extremity, the lip has become fully free, whilst the alveolar ridge has acquired a free outer surface. This lateral cleft is therefore in its deeper part the true vestibular groove (9), for it separates the lip and the alveolar ridge (5) from each other. The latter however, as clearly shown by fig. 16, does not yet reach the surface, it remains under the level of tectum oris and lip.

The epithelial mass building up the labio-gingival lamina is, as now stated, divided into two layers, one lining the oral surface of the lip, the other lining the gum on the outer surface of the alveolar ridge. This behaviour justifies our denomination: "labio-gingival sheet."

The medial cleft (10) penetrates less deeply than the lateral and is inclined to the base of the dento-gingival sheet but without pushing into the latter. In the foregoing description of the surface anatomy of the palate in human embryos, I distinguished this cleft as internal alveolar furrow. Between this and the vestibular groove there is situated a cup-shaped investment of epithelium cells upon the alveolar ridge, which reaches the surface between the lip (6) and the tectal ridge (4). In fig. 2 this mass is seen on both sides of the tecto-labial papilla. The section in fig. 16 demonstrates clearly that in the frontal part of the mouth the alveolar ridge (5) gets its free labial surface before its palatinal, for in this stage the dento-gingival sheet is still solid, being not yet hollowed out.

The elucidation of the present section renders the following easier to understand. In fig. 17 a section through the germ of the canine is outlined. As the tectal ridge (4) is here nearly in contact with the lip, a very narrow but deep tecto-labial groove is formed. This groove bifurcates and the lateral continuation penetrates into the labio-gingival sheet. This is the vestibular groove, whilst the mesial continuation—the internal alveolar furrow—pushes into the dento-gingival sheet, as far as the neck of the enamel-organ of the canine. This section proves that the dento-gingival sheet (2) is partly hollowed out by atrophy and loosening of its interior cells, the remainder forming the epithelial layer covering the inner surface of the alveolar ridge (5).

This process becomes yet more evident in sections a little further back in the spatium interdentale between the canine and the first milk molar, as shown in fig. 18. The great prominence of the tectal ridge (4) in the region in question forms a very deep but narrow bucco-tectal groove, branching out at its extremity into a short vestibular groove, pushed into the bucco-gingival sheet (3), and a similar short internal alveolar furrow penetrating the dento-gingival sheet (2). The alveolar ridge is already well shewn at this level, as a broad prominence between the cheek and the tectal ridge (4).

In the region of the first milk molar the condition becomes more complicated by the appearance of the pseudo-alveolar ridge. Fig. 19 gives an outline of a section cutting through the enamel-organ of this molar. The bucco-tectal cleft has widened, acquiring a broad roof. This roof shows two prominences: a larger lateral and a smaller medial one. The lateral prominence is the alveolar ridge (5) covered by a thick layer of epithelial cells, and bounded by the vestibular groove (9) as a lateral continuation of the bucco-tectal cleft, and the internal alveolar furrow (10). The lower medial prominence is the pseudo-alveolar ridge (7). It must be noticed that the line of attachment of the dento-gingival sheet (2) to the covering epithelial layer corresponds with the internal alveolar furrow, and that the pseudo-alveolar ridge (7) is introducing itself as a new formation between the tectal ridge (4) and the alveolar ridge (5).

The latter condition is demonstrated yet more obviously in the section through the enamel-organ of the second milk molar, outlined in fig. 20. The tectal ridge (4) has moved considerably from the cheek, the bucco-tectal cleft becoming in consequence a widely opened shallow cavity with an irregular bottom, showing two eminences. The medial one is the much broadened pseudo-alveolar ridge (7), the lateral one is the alveolar ridge (5). In a bucco-lingual direction the following furrows are cut in the bottom of this cavity: the vestibular groove (9), the internal alveolar furrow (10) and, finally, the transitory palatine furrow. The second again corresponds with the line of attachment of the dento-gingival sheet (2) to the superficial epithelium.

This section proves in a conclusive manner the fact that the pseudo-alveolar ridge (7) cannot be a formation which later enters into relation to the set of teeth. For if such was really the case, the second as well as the first molar, would, in the course of their further development have to perforate the dento-gingival sheet. And we know that the enamel-organs of all teeth develop lateral of this lamina.

The reduction of the alveolar and the increase of the pseudo-alveolar ridge continue backwards, till at last, behind the gum of the second milk molar, the former has totally disappeared, and the bottom of the cavity between the tectal ridge and the cheek is formed only by the vaulting of the pseudo-alveolar ridge as is shown by fig. 21. In this region the dento-gingival sheet is shifted laterally as far as possible.

To get an idea of the developmental phenomena in this hindmost part of the palate, one may compare fig. 19 with fig. 14, and the figs. 20 and 21 with fig. 15. From this comparison one learns that the anatomical conditions in fig. 15—representing a section through the second milk molar in a younger embryo—are very likely those in fig. 21, giving a section behind the second milk molar in an older embryo. Also the comparison of fig. 15 with fig. 20 is very instructive. Both sections cut through the enamel-organ of the second milk molar. But in the younger specimen (fig. 15) there is not yet a vestige of an alveolar ridge lateral to the dento-gingival sheet (2), in the older embryo;

on the contrary, it is already well developed in this region. Hence, it follows that the alveolar ridge elongates during the development.

Thus the present embryo demonstrates in an unquestionable manner that the alveolar ridge of man is a quite new formation taking its origin in the gap between the secondary palate and the surrounding soft parts: lip and cheeks, in fact that this ridge is not a differentiation of an external border of the secondary palate. In detail the origin of this ridge differs slightly in its anterior and posterior part, but the main outlines are uniform throughout.

Finally, I give in the figs. 22, 23 and 24 three sketches of sections of an embryo of five months. In fig. 23 a section is reproduced going through the lateral incisor. To get an idea of the developmental changes which have occurred in this region one has to compare this figure with fig. 16. The most striking change relates to the alveolar ridge. In the younger stage, sketched in fig. 16, this ridge did not yet reach as far as the surface, it was but of a minute development, lying in the gap between the lip (6) and the tectal ridge (4) and only its lateral side had a free surface. In the older embryo this ridge has considerably developed, the thick layer of epithelium cells, which covered it, is thrown off, and it has grown out so strongly between the lip and the tectal ridge, that it has pushed these two formations entirely away from each other. It now even projects a little above the tectal ridge (4). The vestibular cleft (9) as well as the internal alveolar furrow (10) have deepened and widened, so that the alveolar ridge has now a free internal surface. The deepening of the latter furrow is achieved by the atrophy and throwing off of the internal cells of the dento-gingival sheet. This is proved by the fact that in this stage of development the neck of the enamel-organ of the second incisor is attached to the oral epithelium in the internal alveolar furrow, whilst originally this organ was attached to the dento-gingival sheet, quite at its free edge, as shown by fig. 12. On comparing the latter figure with fig. 22, it becomes evident that the internal alveolar furrow has penetrated into the dento-gingival sheet, as far as the spot where the germ of the incisor takes origin. Therefore the so-called dental lamina of authors—a term intentionally not

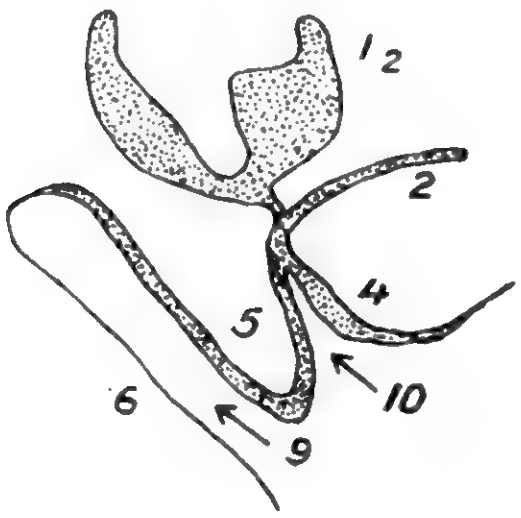

Fig. 22

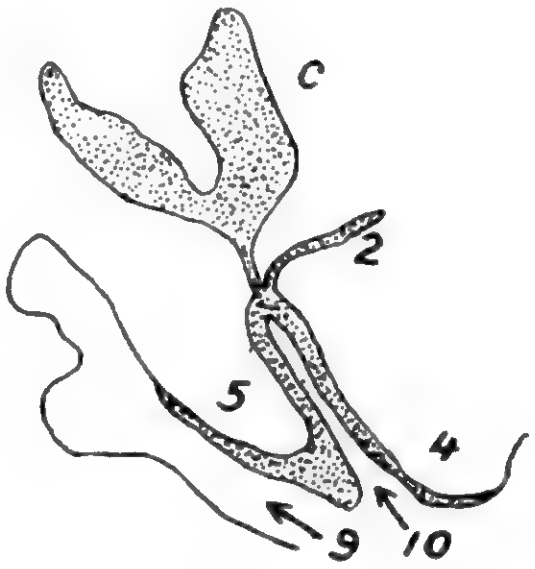

Fig. 23

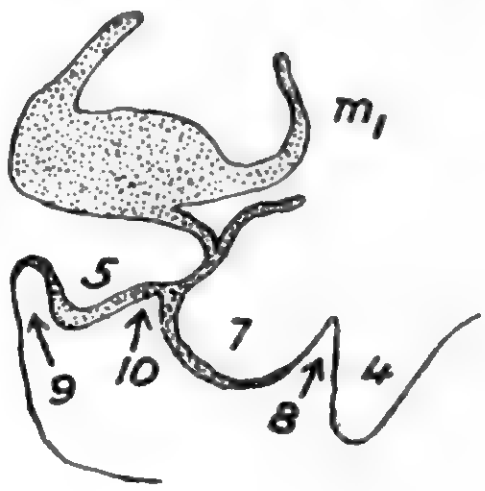

Fig. 24

used by me—is an epithelial band, which forms not only the germs of the teeth, but also the gum on the inner surface of the alveolar ridge. After comparing fig. 12 with fig. 22 there cannot remain the least doubt upon this fact. Hence my distinguishing of this band as dento-gingival sheet.

Fig. 23 is a drawing of a section through the germ of the canine. This figure should be compared with fig. 17, showing a section through the same tooth in a younger embryo. The differences between these sections are in the main identical with those in the front part of the mouth. In the older stage the alveolar ridge (5) nearly fills up the cleft between the tectal ridge (4) and the cheek, its internal surface has become free by the hollowing out of the dento-gingival sheet, as far as the neck of the enamel-organ of the canine. For the rest this figure asks no further explanation.

Finally, fig. 24 shews a section of the same embryo, going through the enamel-organ of the first milk molar. This figure is to be compared with fig. 19. Such a comparison shows that the tectal ridge (4) in the older embryo has relatively increased in size; the cavity between the cheek and the alveolar ridge, originally deep and narrow, is now very wide and shallow, the bottom of it is formed by the broad pseudo-alveolar ridge (7) and the also broadened alveolar ridge. This bottom is incised by three furrows: the transitory palatine furrow (8) between the tectal and the pseudo-alveolar ridge; the internal alveolar furrow (10) between the alveolar and pseudo-alveolar ridge, and the vestibular groove in its well-known situation.

After the description of the five stages of development now given, it is very easy to reproduce by means of some simple diagrams the main features in the developmental history of the human palate, specially the origin of the alveolar ridge and its genetical relation to the epithelial formations growing into the mesenchymatous tissue of the palate. Before doing so, it seems necessary to me to remark, that I have never met in human embryos with the considerable heaping up of epithelium extending along the length of the jaw, distinguished as "Zahnwall" by the German authors. I have had under observation a large number of serial sections of the mouth of human embryos. But, as shown by figs. 5 and 6, even in the youngest stage there is no trace of an outward thickening of the epithelium. On the contrary, from the outset, the surface of the jaw shows a shallow furrow, marking the position of the ingrowing epithelium. In this matter I agree with Leche, that this heaping up of epithelium does not represent an occurrence typical of all mammals. At all events it does not occur in man.

In fig. 25 five diagrams are reproduced, showing the manner in which in man the alveolar ridge develops, and also the origin of the gums. I specially lay stress upon the fact that this ridge is a new formation, and that the gums are differentiated in consequence of a splitting of a primitively solid epithelial lamina. For the rest the diagrams don't need any special explanation; to the reader who has taken cognizance of the preceding descriptions they are undoubtedly sufficiently intelligible.

Finally, the question as to the significance of the pseudo-alveolar ridges must be considered. These organs which in a young stage form the very prominent posterior half of the zona marginalis on both sides of the palate, are, as already sufficiently indicated, transitory. In the older stages they are surrounded by the alveolar ridges, prolongating backwards, and become incorporated in the central part of the palate, which I distinguished as tectum oris. To solve the question of their significance seems to me a rather difficult matter. Klatch, after having confirmed the occurrence of these organs first described by me in human embryos, is perhaps right, when he considers them as rudimentary organs, inherited by us from our marsupial ancestors, where they may have assisted the young in holding on to the nipple.

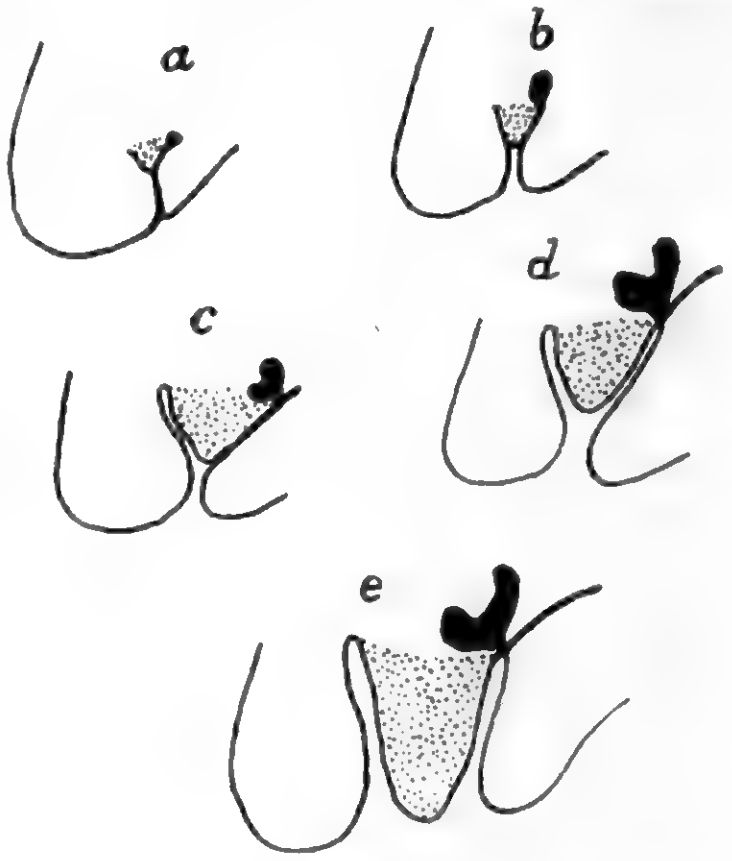

Fig. 25

SECOND ESSAY

ON THE DEVELOPMENT OF THE ENAMEL-GERM

To write a special essay upon the development of the enamel-germ, worth reading, may seem a somewhat bold endeavour. For the development of this part of the tooth-germ has already so often been the subject of investigations, that it may be considered as improbable that particularities of some importance are as yet unknown. However, at the very outset of this essay it must be said that the descriptions of the development of the enamel-germ as given in the textbooks of Anatomy or Embryology are incomplete.

So simple a matter as the development and internal structure of the enamel-germ is without exception described in an incomplete manner. This is the case not only in the textbooks written in English, but also those written in German and French. And often during my researches upon this subject, I have wondered at the fact, that phenomena so simple and appearances so easily observable as those described in the present paper, are still unknown. For the facts referred to occur with such a regularity and are so unmistakable, that they may easily be verified by anyone desirous to do so. But a prime requisite for such a study is the examination of complete serial sections of several subjects of different ages. Only in this way does it become possible to survey the relation between the changes in the succeeding stages, and to build up the complete history of the development of the enamel-organ.

Not without intention, at the outset of this essay, I lay stress upon the value of the facts to be described hereafter, for they are of primary significance as a starting point to the dental theory which will be gradually developed in the succeeding essays. In saying so, I remember, that in my own mind, the first conception of the principles of this theory was founded on observations of some phenomena during the development of the enamel-organ in embryos of man and monkeys.

The facts to be dealt with in the present paper, possess therefore a double signification: as ontogenetic phenomena and as the principal elements of a theoretical construction. In this latter significance they can only be utilised later on, in connection with facts and meanings, worked out in succeeding essays. Therefore in the present communication, I confine myself to the facts alone.

The first principal fact which I intend to demonstrate in the present essay is as follows: enamel-organs are, during a certain phase of their development, connected with the tooth-band or dental lamina by means of *two* strands, a lateral and a medial one. The large number of embryological series of man and monkeys at my disposal has led me to use these primates and especially man as the basis of my investigations. Therefore I will begin by trying to justify the above assertion by observations made upon the teeth of man and other Primates; after that I will give a number of examples to prove that this assertion holds good also with regard to other mammals. In fig. 26 ten successive sections are reproduced through the inferior lateral incisor of a human embryo of 39 mm. whole length. This embryo is registered in the collection as: Homo *Y*. The thickness of the sections is 10 μ. After the 10th section there followed three more through the same tooth showing a gradual diminishing of the enamel-organ. It was not necessary to reproduce these also.

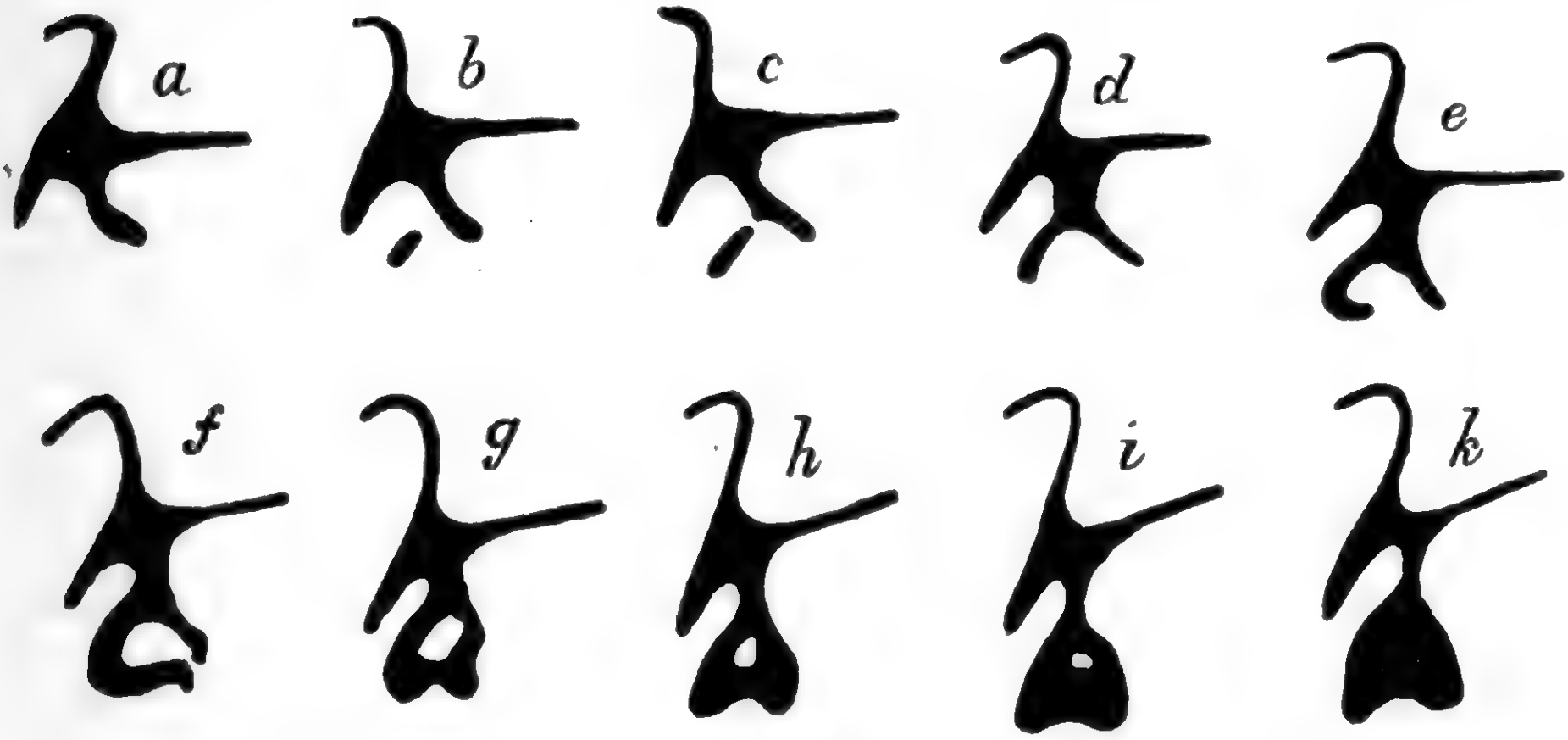

Fig. 26

In looking over the figures, it seems to me that the last of the series (fig. 26) is intelligible without further explanation, the enamel-organ possessing the well-known form and being connected with superficial epithelial layers by means of the dental lamina.

Lateral from this the labio-gingival sheet (cf. the first essay for the meaning of this term) penetrates into the subjacent tissue.

The drawn sections show the form of the anterior half of the enamel-organ. In the first section (fig. 26 *b*) there is as yet no trace of the enamel-organ, only the dental lamina is cut through[1]. In the second section (fig. 26 *b*) there appears lateral to the dental lamina a heaping up of epithelial cells, which enlarging in the succeeding section (fig. 26 *c*) fuses in the fourth section (fig. 26 *d*) with the centre of the dental lamina, forming with this a crescentic epithelial formation at the end of the tooth-band.

This section is a very misleading one, for if some one had under observation only this section, he would be inclined to interpret it as a bell-shaped enamel-organ into the cavity of which the dental papilla was already deeply pushed. This interpretation, though a false one, becomes intelligible by the unquestionably existing agreement of the present section with that of a real bell-shaped enamel-organ. For the latter, when viewed in section, is also somewhat crescentic as that in fig. 26 *d*. And also in this stage of development of this enamel-organ the inner horn of the crescent seems to be formed by the terminal end of the tooth-band, while the outer bends outwards from it. Yet, the mistake in this interpretation of fig. 26 *d* is immediately shown by the next section. For here, from the end of the outer horn of the crescent, an offshoot emerges in a horizontal direction, approaching the end of the medial horn (fig. 26 *f*) and, finally, uniting with the same (fig. 26 *g*). By this process an enamel-organ is formed, ring-shaped in transverse section, the centre of which is filled up by mesenchymatous tissue. In the two next sections this centre gradually decreases (fig. 26 *h*, *i*) to disappear finally in the last section (fig. 26 *k*). The enamel-germ has now acquired the well-known form of a Florence flask. Immediately behind the section represented in fig. 26 *k*, the enamel-organ rapidly diminishes in size, as has already been mentioned.

This description of the structure of the enamel-organ in a very early stage of development differs somewhat from that usually found in odontological literature. Yet I wish to emphasise the fact that the structure described is not at all an exception or a special case, but is a phase of development which is passed through by every tooth in Primates as will be demonstrated later on. Only the details of it are not in all teeth so easy to observe as in the example chosen.

Recognition of this more complicated form of the enamel-organ is of fundamental value for the right understanding of the succeeding stages of development. And therefore we must try to get a clear and complete conception of it. This can be performed by building up in our mind the enamel-

---

[1] I wish to follow the custom in calling this epithelial formation the dental lamina. But as demonstrated in the first essay, its real signification is wider, because the gum at the oral surface of the alveolar ridge is produced by it.

organ represented in fig. 26 by superposition of the sections. On doing so, the enamel-organ presents itself as a low flask-like organ, with a broad base, slightly concave and with a niche-shaped dimple in its front side. In the present case the niche is still very shallow, only the three sections, *g*, *h*, *i* of fig. 26 running through it; but the whole organ is as yet a very minute one. This niche shall be distinguished henceforth as *enamel-niche.*

Now our first task is to demonstrate that the enamel-niche is a regularly occurring formation in an early stage of development of teeth in general, after which a description of its further destiny will follow and a discussion of its signification. To demonstrate the occurrence of the enamel-niche in the germ of the lower medial incisor, I give in fig. 27 six diagrams of sections through this tooth in a Macacus cynomolgus. Intentionally I choose this example, not only because it is in a somewhat further state of development than the preceding specimen, but also because, by using promiscuously preparations of man and monkeys the facts to be stated are demonstrated for the whole order of the Primates at once.

After the description of the diagrams in fig. 26, those in fig. 27 do not require detailed discussion. The question whether there is in this case also an enamel-niche is not a dubious one, it is clearly shown by diagrams *d* and *e*.



Fig. 27

This series of diagrams enables us to demonstrate the necessity of basing the study of the development of teeth always upon uninterrupted series of sections. In this case, for instance, the diagrams *b* and *c* might give rise to a quite incorrect interpretation. If any one had only these two sections at his disposal, he would take them for the germ of a milk tooth, and medial from this the dental lamina with the first trace of the germ of the successional tooth. That such an interpretation is a false one is at once demonstrated by the diagram *d*, though it must be admitted that the images are very misleading ones. The epithelial strand, interpreted as the dental lamina, is indeed the medial wall of the enamel-niche, not yet connected with the body of the enamel-organ.

Furthermore these diagrams illustrate unquestionably that the medial wall of the enamel-niche is in reality formed by the dental lamina itself. We will return to this question when we discuss the mode in which the enamel-niche is formed. For the present our purpose is only to demonstrate its occurrence.

Concerning the two next teeth I return to the genus Homo. In fig. 28 eight diagrams are represented from sections through the upper canine of the human embryo, registered in my collection as: Homo *d. R.*, and in fig. 29 ten diagrams of sections through the germ of the lower canine from the human fetus registered in my collection as Homo *A*. I preferred to select for these teeth distinct embryos, because, by doing so, the proof is furnished that the occurrence of the enamel-niche is a general phenomenon, happening not occasionally in some fetuses. The embryo *A* to which the figure 29 relates was older than the embryo *d. R.* of fig. 28. The number of sections through the inferior canine of the former was therefore larger than that through the superior canine of fig. 28. Therefore in fig. 29 all the sections through the frontal part of the tooth-germ are not reproduced. I choose such as are necessary to give a sufficient idea of the manner in which the enamel-niche is formed in this tooth and—as must be emphasised—in the present stage of development. For, as will be demonstrated, in this stage of development the enamel-niche has already passed from its first stage into that in which it is commonly found, being transformed from a niche into a tunnel.

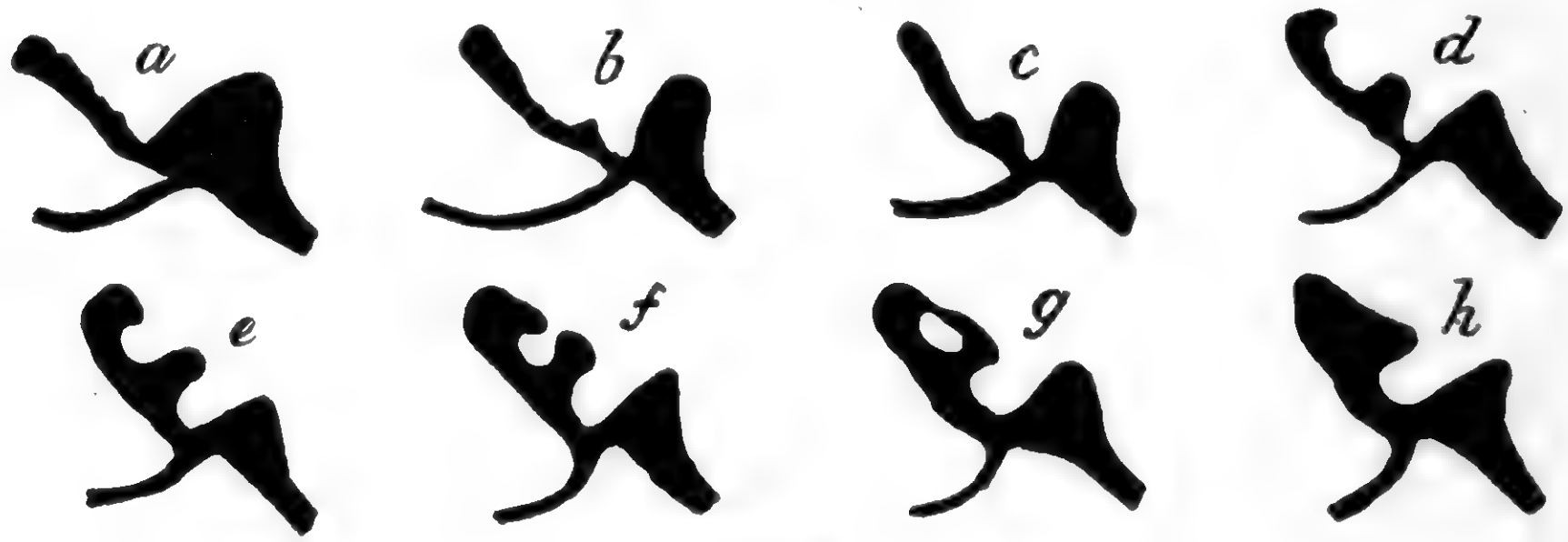

Fig. 28



Fig. 29

That the enamel-niche occurs also in the upper canine is undoubtedly settled by fig. 28. The thickness of the sections being $15\,\mu$, it becomes evident that the niche in this case was but a very shallow dimple. This circumstance is a very lucky one, for it gives us an insight into the very first stage of the niche, and we shall make use of this case in our discussion of the mode of formation of the niche.

A somewhat different state of the niche is shown by the diagrams in fig. 29, relating to the inferior canine of man. The sections also had a thickness of $15\,\mu$, and between the first and last diagram there were in reality still ten sections which are not represented. When the diagrams of fig. 29 are examined and compared with the description of the enamel-organ in its succeeding stages of development as commonly met with in literature, it is not easy to understand their meaning. The diagram *a* showing only the dental lamina connected with the surface epithelium is intelligible without any explanation. On the contrary the diagram *b* offers a difficulty. For, lateral from the dental lamina a second strand of cells has grown into the mesenchyme, going out from the surface epithelium, close to the spot where the base of the dental lamina is attached to the superficial epithelium. And this latter, lateral strand, elongates until it becomes even larger than the true dental lamina, as shown by the diagrams *c* and *d*. If one had only these two sections at his disposal, surely it would be quite impossible to understand them. In diagram *e* two changes have occurred: from the lateral band a horizontal process—already seen in the diagram *d*—has sprung, and by the union of this with the free edge of the dental lamina, the enamel-niche is formed. There is besides a considerable thickening at the outer side of the lateral strand. It is clear that in this stage of development the outer wall of the enamel-niche is formed by the lateral strand of cells, whilst the inner wall is formed by the dental lamina, a fact already known to us. Now it is very interesting to notice the position of the niche in the sections behind, as shown by the diagrams *f*, *g* and *h*. The niche is narrowed gradually, but at the same time it moves upwards and laterally, till finally its outer wall is formed by a thin layer of epithelial cells, as seen in diagram *h*. In the next diagram this wall is burst and the niche has opened on the outer side of the enamel-organ. In this stage of development there is in reality no longer question of an enamel-*niche*, for its backwall is perforated and it is transformed into a short tunnel running through the anterior half of the enamel-organ in a slightly oblique direction. This fact is of fundamental significance. For in consequence of the perforation of the backwall of the niche, the enamel organ has got a double junction with the dental lamina; a medial and a lateral one. The medial is formed by the dental lamina itself, and the lateral by a thin band of epithelial cells originally participating in the building up of the enamel-organ. It is necessary to distinguish the bands, connecting the enamel-organ with the dental lamina, by distinct names. The lateral band I will denominate *the outer enamel-band* and the medial *the inner enamel-band*. In the sequel of this essay these bands will be amply discussed. But I must first return to the enamel-niche in its original state.

We have stated its occurrence in the lower incisors and in the canines. As to the superior incisors it is somewhat more troublesome to demonstrate their presence in an early stage of development of man and monkeys. For, the niche being a dimple in the medial side of the enamel-organ, transverse sections are not the most suitable to demonstrate its presence in these teeth, owing to the fact that they are transversely implanted in the premaxillary bone, and the germs already occupy this position. In older stages, when the niche is transformed into a tunnel, and the whole germ of the tooth is enlarged, this difficulty is removed. As a more suitable demonstrating object I choose the enamel-organ of the superior incisors of a Prosimian, in which these teeth are implanted in a more sagittal plane. In fig. 30 nine diagrams are represented of sections through the second superior incisor of a Propithecus (series *B* of my collection) and in fig. 31 six diagrams of sections through the third incisor of a Lemur melanocephalus (series *A* of my collection). By these figures it is proved that the enamel-organs of these teeth also are provided with an enamel-niche. But that it is, under favourable circumstances, not at all impossible to observe the niche in the upper incisors of man is proved by fig. 32, showing six diagrams of sections through the enamel-organ of the lateral upper incisor of a human fetus (series *B* of my collection, thickness of the sections: 25 μ). The plane of section in this case was slightly oblique.



Fig. 30

Fig. 31

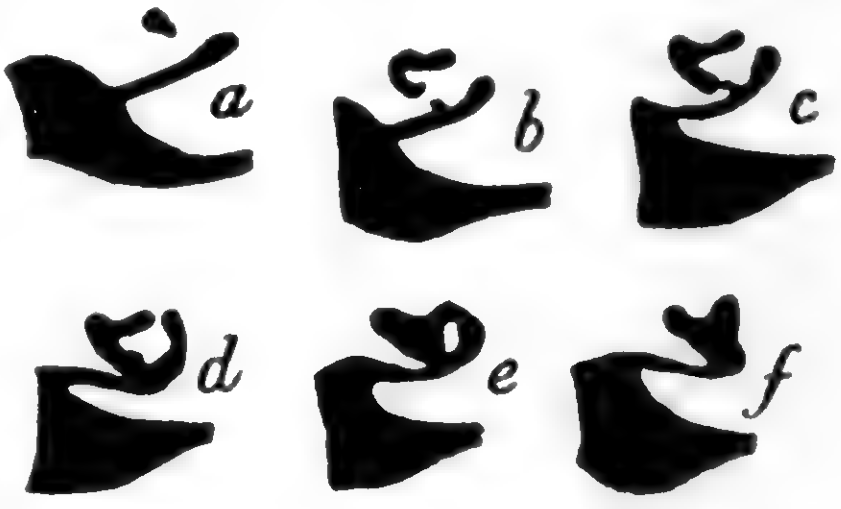

Fig. 32

From the foregoing it may safely be concluded that the enamel-niche is met with in the germ of all the monocuspidate teeth of the milk-dentition of Primates. It would be very easy for me to supply more examples, but the foregoing are, I believe, sufficient to prove the niche to be a normal phenomenon in the development of the teeth. Besides, any one possessing suitable material and uninterrupted series may produce further proofs himself. The establishment of the niche in its primitive state in the enamel-organs of molars is not so easy a matter as in the monocuspidates. For as a rule the germs of the molars are situated close to the surface epithelium, the dental lamina being shorter; it even happens not seldom that in the region of the germ of a molar the dental bond seems to be absent totally, the germ taking origin directly from the surface epithelium. This fact renders the interpretation of the appearances often somewhat troublesome. Moreover, the niche itself in the enamel-organ of molars behaves so as to render its demonstration rather difficult. Firstly it seems to exist in these tooth-germs only a very short time, passing rapidly into its second state, namely the canal or tunnel already alluded to.

And secondly, it seems that in the germs of molars, the niche is not always situated in the mesial or frontal side of the germ, but occasionally the dimple appears at the posterior side of the germ. This variability in the situation of the niche is a very indifferent fact, for whether beginning at the front side or at the back side of the organ it is in all cases soon transformed into a canal by perforating the organ either in a forward or in a backward direction.

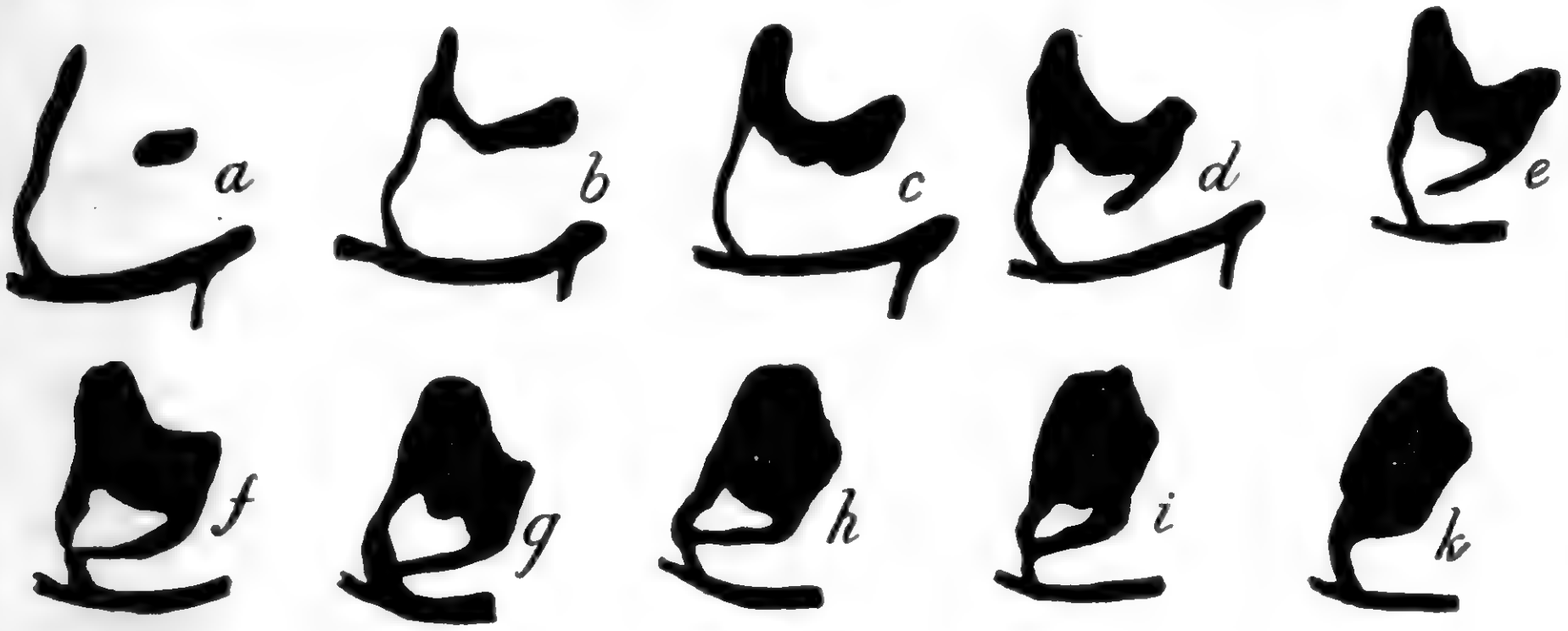

Fig. 33

The above facts are illustrated by figs. 33 and 34. In fig. 33 ten sections are represented through the enamel-organ of the second superior milk molar of an embryo of Mycetes (Mycetes *A* of my collection) and in fig. 34 eight sections through the enamel organ of the third superior milk molar of the same object. Now in both figures the presence of the enamel-niche is obvious. But on comparing the figures it becomes clear that in the second milk molar (fig. 33) the entrance to the niche is situated at the front side of the organ. The sections figured are taken from the anterior half of the germ. And in this part of the germ the niche diminishes in size, as it is traced backward until it finally disappears. The germ of the third milk molar on the contrary (fig. 37) shows no trace of a niche in its anterior half, till behind the middle of the germ the niche appears as a small opening in the centre of the organ which increases in size and has its entrance at the back side of the organ. In the beginning of my investigation when my attention had only recently been drawn to this formation, the variable situation of the niche in the enamel-



Fig. 34

organs of molar teeth rendered the phenomena not always easy to understand, the object being not always in the most suitable state of development to procure a clear insight into the relations. But in examining a larger number of series this point became more intelligible to me. I thought it necessary to intercalate this remark as a warning to the reader anxious to check the correctness of my description, that he must procure himself a rather numerous series of specimens of different ages. Only in this manner will he be able to observe all the particular facts described above.

As a last example of an enamel-niche in its first and simple state in a molar, I give in fig. 35 nine sections through the anterior half of the first superior molar of a human embryo (series *A* of my collection).

After the preceding descriptions these diagrams do not require a particular elucidation. They prove that in human molars also the niche is present during a certain stage of development of these multicupidates.



Fig. 35



Fig. 36

I have already made allusion to the fact that in some Primates a true dental lamina is absent, the germs of the teeth originating immediately from the deep layer of the surface epithelium. Such a Primate is, for instance, the Semnopithecus. Now it is a fact worthy of note, that in such cases also the enamel-niche makes its appearance. For by such cases it is proved that the niche is not a formation of the dental lamina, but that it belongs exclusively to the enamel-organ, being characteristic of an early stage of its development. In case of absence of the dental lamina the niche is of a somewhat irregular form and its mode of formation is also not a typical one. Fig. 36 gives a sufficient illustration of such a case.

The diagrams show a number of sections through the enamel-organ of the first inferior molar tooth of a Semnopithecus maurus in an early stage of development.

By the foregoing facts I believe to have succeeded in my attempt to prove that the development of the enamel-organ of teeth in Primates is not so simple a fact as may be concluded from the descriptions given in the textbooks of

Anatomy. In none of these have I met with any allusion to the formation of the enamel-niche. In German literature it was recognised at nearly the same time by myself[1] and by Ahrens[2].

This author, however, had restricted his investigation to human teeth only, whereas I have examined a large number of other mammals and have demonstrated that the niche is a common appearance in the organ of nearly all the objects studied by me.

The examples given all agree in one point, namely, that they relate to milk teeth of the Primates. And the question arises, whether this appearance is restricted to this set of teeth only, or if in the enamel-organ of the successional teeth a niche is formed. The answer to this question must be in the affirmative but the demonstration of the correctness of this assertion is not easy. For it is a rather troublesome matter to obtain an uninterrupted series of sections through the germs of these teeth, and having succeeded in it, it is a mere chance that the object was in the proper stage of development.

Yet, I have been able to gather some examples out of my collection of preparations of which I now will give a brief account.

In figs. 37, 38 and 39 three examples of the niches in the enamel-organ of permanent teeth are represented. Fig. 37 relates to the lower permanent canine of a Galeopithecus (series *B* of my collection). Fig. 37*a* gives a general view of the situation of the enamel-organ of this tooth. The surface epithelium is already differentiated and the germ of this tooth lies free in the mesenchyme of the jaw. Lateral to it the fang of the milk canine is cut as a cap of dentine, containing pulp-mass. The germ of the permanent canine is of a conical form with a ring-shaped top. To get a more detailed idea of this niche in fig. 37*b*, *c*, *d* and *e*, four sections through this enamel-organ are drawn on a magnified scale. And from these figures it becomes obvious that the niche was no longer in its primitive state of development, fig. 37 *e*, showing the perforation of the lateral wall of the niche. Instead of a niche, we have here already to do with the enamel-canal. This detail, however, is of no importance. In general the study of my series has convinced me that in the germs of the successional teeth the enamel-niche in its simple state is small and of short duration, being soon transformed into a canal.

This is illustrated by the four outlines of fig. 38, showing sections through the enamel-germ of the superior medial permanent incisor of man (series 2 of my collection). I have represented the germs of both sides *in situ*, and included in the figures also the enamel-organs of the milk incisor, situated lateral to those of the successional teeth. It is obvious that in the permanent incisors the enamel-niche appears in a very early stage of development, the whole organ being still very minute. This circumstance renders the establishment of the

---

[1] L. Bolk, *Odontologische Studien I, Die Ontogenre der Primatenzähne.* Zena. Gustav Fischer. 1913.

[2] H. Ahrens. "Die Entwicklung der menschlichen Zähne," *Anat. Hefte*, Band 48. Wiesbaden. 1913.

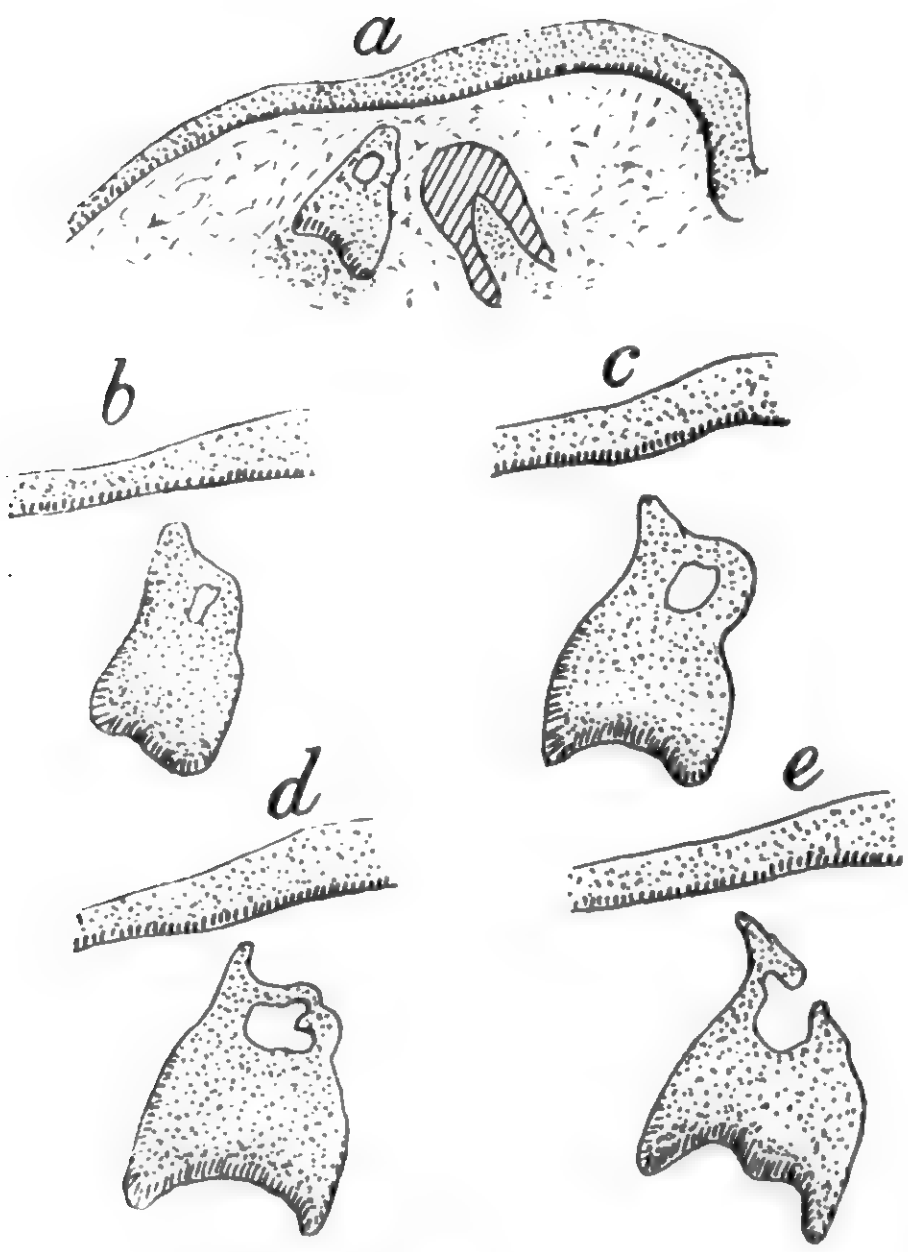

Fig. 37

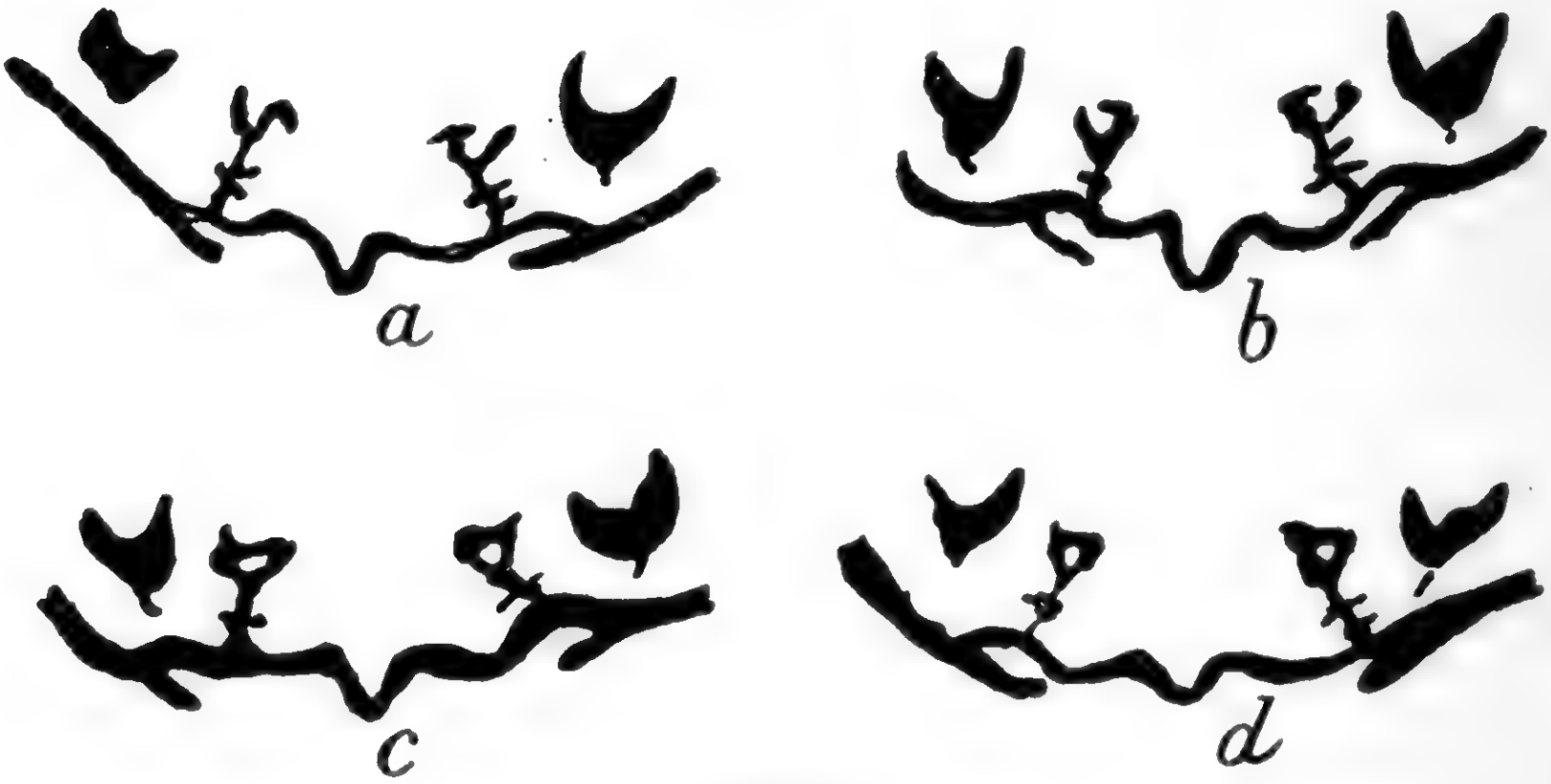

Fig. 38



Fig. 39

presence of the niche in such organs rather difficult. A very fine specimen of an enamel-niche in the germ of a permanent tooth is finally represented in fig. 39, showing a number of diagrams of succeeding sections through the enamel-organ of the inferior first permanent molar of Mycetes (series *B* of my collection). The diagrams are arranged in vertical rows. In this case we have to do with a niche whose backwall is already perforated, as shown by the two diagrams of the last row.

With regard to theoretical considerations upon the morphological signification of the enamel-niche, the statement of its occurrence in the organ of permanent teeth is of the utmost interest. And therefore I will here add that Sicher has lately demonstrated the presence of an enamel-niche in the permanent teeth of the mole[1].

From the foregoing it may safely be concluded that the development of the enamel-organ in Primates (and as will be demonstrated later on also in other mammals) does not happen in such a simple manner as would be concluded from the descriptions given in the textbooks of Embryology. It is of a more complicated nature, and owing to the appearance of the enamel-niche, the relation between the enamel-organ and the dental lamina becomes somewhat more intricate than would be concluded from the current descriptions. Our first task will now be to demonstrate this by dealing with the principal points in the further behaviour of the enamel-niche.

There was already occasion in the foregoing discussion to remark that the enamel-niche as such is but of short duration. For, by penetrating gradually deeper into the enamel-organ, its backwall becomes successively thinner, until at last it is perforated and instead of a niche the enamel-organ is provided with a canal of conical form.

An organ in which the perforation has just been completed is but rarely seen. Yet, amongst my series of human embryos, I have found some examples of this process, two of which are represented in figs. 40 and 41. The diagrams in fig. 40 relate to the first upper milk molar of man (series *C* of my collection) and those in fig. 41 to the lower canine of man (series *V*). In both figures the diagrams are arranged in horizontal rows, and in both the last diagram but one is that of the section just passing through the very point where the niche perforates its backwall. The opening is still a very narrow one.

But even if such stages were not found, the transformation of the niche into a canal cannot be at all dubious, for, in all stages of development that have proceeded somewhat further than these, of which a description has been given, it is a very easy matter to observe the canal-shaped formation alluded to passing through the enamel-organ. Only, to get a complete idea of this formation, it is necessary to have at our disposal a considerable collection of preparations, for the enamel-canal also undergoes great changes in the course of its own development, and owing to the enlargement of the enamel-organs.

To depict the history of the enamel-canal in a brief and simple manner, it

---

[1] Harry Sicher, "Die Entwicklung des Gebisses von Talpa europaea," *Anat. Hefte*, Band 54.

seems sufficient to me to base my explanation upon a series of figures, showing different stages of development of enamel-organs.

It is superfluous to figure all sections through an organ of these older stages. I will confine myself to representing the figures necessary to understand the course of development.

In its earliest state the enamel-niche appears as a dimple situated in the top half of the enamel-organ—at this time still conical. And during the time immediately after the perforation of its backwall this is still nearly the case.


Fig. 40


Fig. 41

In the course of the further development the first change concerning the enamel-canal is its often considerable widening, connected in most cases with a change in its position. In the earlier stages the niche or the canal is situated not infrequently rather symmetrically in the enamel-organ. But in older stages it has a more asymmetrical position and is situated as a rule in the lingual half of the enamel-organ. This is clearly shown by the figs. 42, 43, 46 and 47. This situation is due to the fact that the proper enamel-organ is developing and enlarging principally in a buccal direction.

That this mode of development does however not always take place is shewn by the figs. 44, 45, 48 and 49, to which I will return later on. By the dilatation of the enamel-canal the character of the whole germ is very much changed. For the canal is now enclosed between a very thin lingual wall, which is indeed the prolongation of the dental lamina, and the enamel-organ itself.

This condition is very clearly demonstrated by fig. 42, representing a section through the medial upper incisor of Mycetes (Mycetes *A* of my collection) and by fig. 43 representing a section through the same tooth of an older embryo of this genus (Mycetes *B*). If one takes into consideration that in both cases there exists a real canal running through the enamel-germ, and that the thin lingual wall of this canal is the prolongation of the dental lamina, it is obvious that one may describe this state as an enamel-organ having not a single, but two connections with that lamina, a lateral and a medial one. That the lingual wall of the canal is really a part of the dental lamina is demonstrated by figs. 46 and 47, the former being a transverse section of a milk molar of Mycetes *A*, and the latter a sagittal section through the germ of the upper medial incisor of a human embryo (series *M*). For at the point at which the dental lamina is connected with the lingual side of the enamel-organ, an epithelial outgrowth may be seen, and without doubt this outgrowth is the commencement of the germ of the successional tooth. Now for the sake of intelligibility and to facilitate further description it is necessary to introduce some morphological expressions. In describing the tooth-germs in figs. 46 and 47, one may distinguish the enamel-organ proper and a system of epithelial strands.

The existence of these epithelial strands is partly due to the formation of the enamel-niche as a predecessor of the enamel-canal. Now the niche, as well as the canal, are differentiations formed in the primitive enamel-organ; in an earlier stage the walls of the canal took part in the building up of the enamel-organ. And so in the history of the development of the enamel-organ two phases must be distinguished: the primitive state in which there is not yet an enamel-niche and *a fortiori* no enamel-canal and a secondary state in which it is obvious that the enamel-organ represented in figs. 46 and 47 is not identical with the organ in its earliest state. For, in the latter the walls of the enamel-canal are differentiated. This fact requires us to distinguish a primitive from a secondary enamel-organ. The primitive is the club-shaped thickening of the tooth-band before the dimple of the enamel-niche has made its impression into it. By the formation of the enamel-canal this primitive organ is differentiated into the secondary enamel-organ and a system of strands. These strands—a fact not to be forgotten—are built up from elements, which originally belonged to the primitive organ.

This point settled, we will proceed to consider the system of strands. The diagrams represented in figs. 46 and 47 show relations very typical of a certain stage of development of the teeth, and easily to be found in embryos of appropriate ages. First there is an epithelial strand, emerging from the surface epithelium and bifurcating into two strands, which unite with the secondary enamel-organ. So the strand-system is composed of three elements which may be demonstrated by distinct names. The strand which emerges from the surface epithelium to its point of bifurcation is the true dental lamina, which I will further distinguish as *common dental band*. The two other strands are special formations, belonging, as having taken their origin from the primitive enamel-organ, to a distinct enamel-germ. I shall distinguish these two strands as the "lateral" and the "medial" enamel strand. The latter is the prolongation of the common dental band, at least in younger stages of development.

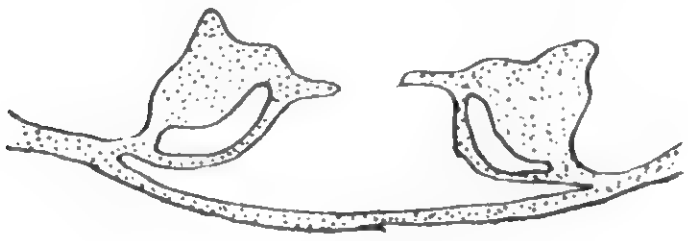

Fig. 42

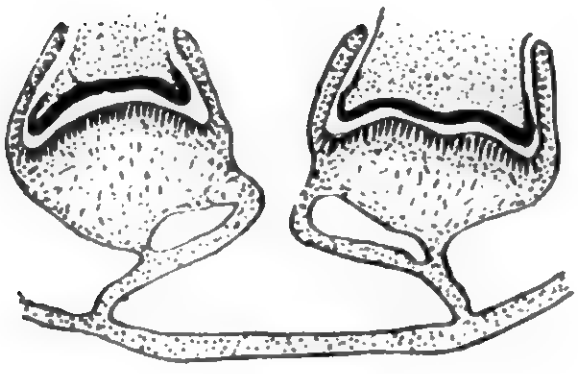

Fig. 43

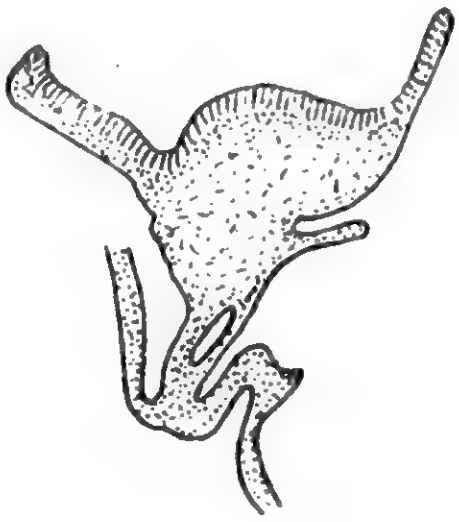

Fig. 44

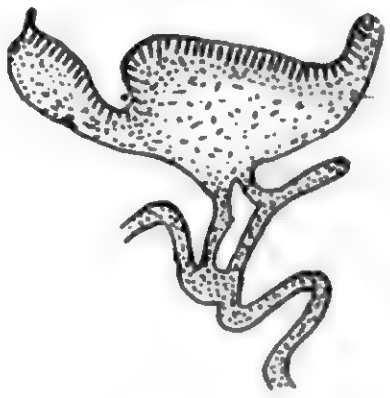

Fig. 45

Fig. 46

Fig. 47

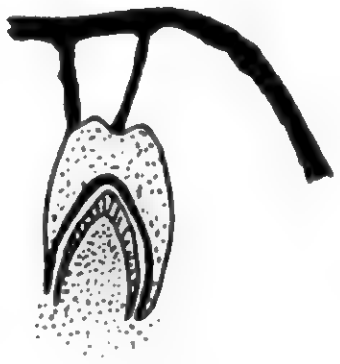

Fig. 48

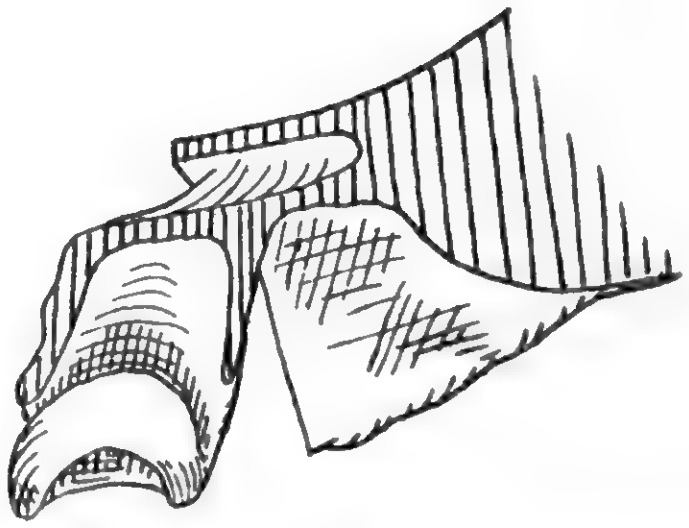

Fig. 49

The proposed nomenclature, which facilitates the further description in no mean degree, is, I believe, a rational one, making due allowance for the morphological value and genetical signification of each of the elements. Returning to our proper subject, the sections seen in figs. 44 and 45 require a closer consideration. Both figures represent sections through the enamel-organ of the first upper molar tooth of man, the specimen in fig. 45 being somewhat further developed, as derived from an older embryo (fig. 44, series *T*, and fig. 45, series *G* of my collection). To understand these figures, I remind the reader of the fact, already mentioned, that the primitive dental lamina of molar teeth is frequently very short, the primitive enamel-organ of these teeth being therefore attracted immediately to the surface epithelium.

Taking this fact into consideration the conditions in figs. 44 and 45 are easily understood. The common dental band being absent, the top of the primitive enamel-organ reached to the surface epithelium. And, as amply demonstrated, the enamel-niche begins as a dimple in the top part of the organ. Thus this niche, and also the enamel-canal, is situated immediately beneath the surface epithelium. Such a case is represented by fig. 44. And because during the further development the canal is enlarging itself, it becomes partly limited by the surface epithelium as shown in fig. 45. In such cases the secondary enamel-organ is attached to this epithelial layer by the two distinct strands, without the agency of a common dental band.

The conditions just described do not occur only in molar teeth, but now and then also in front-teeth as, for instance, the American monkey, Chrysothrix, may prove. Fig. 48 gives a section through the germ of $\bar{i}$, of this animal[1]. The enamel-canal in this case is very large, and were one ignorant of the development process of the organ, as described in the foregoing pages, it would be very difficult to understand this figure. I suppose I have now proved in a sufficient manner the fact that the evolution of the enamel-organ in Primates is not so simple a matter as usually described in literature.

As the principal fact, added to our present knowledge, I consider the circumstance that in this evolution two phases must be distinguished: that of the primitive and that of the secondary enamel-organ, the former being differentiated into the latter and a system of bands.

To get a more complete idea of the shape of the secondary enamel-organ with its epithelial bands, I have constructed in the well-known manner some wax models, two of which are represented in the figs. 49 and 50. The figure 49 shows the wax reconstruction of the enamel-organ of $\bar{i}$, of a human embryo. In this rather young stage there is not yet an enamel-canal; above the secondary enamel-organ one looks into the hollow of the enamel-niche. A stage of further development is represented by figs. 50*a* and 50*b*, being the reconstruction of the $\bar{M}_3$ of a Chrysothrix. In this case there is a well formed enamel-canal with a complete system of bands, the common dental band emerging from the layer of surface epithelium and dividing into the internal and external enamel strand. In fig. 50 *a* the reconstruction is seen from the front side, in fig. 50*b* from the buccal side. By the latter figure it is clearly shown that the external enamel strand is a special one, it is confined to the enamel-organ, whereas the internal strand is a real part of the common tooth-band.

The further history of the system of bands can be shortly exposed with the aid of figs. 52*a* and 52*b*. While the secondary enamel-organ is gradually enlarging, and the well-known histogenetical transformations take place into

---

[1] I wish to give here a short explanation of the manner in which the elements of dentition will be indicated in this and all following essays. The teeth of the milk-dentition are indicated by the minuscules $\underline{i}$, $\underline{c}$, $\underline{m}$; the permanent teeth by the *majuscules* $\underline{I}$, $\underline{C}$, $\underline{P}$, $\underline{M}$. A tooth of the lower jaw is recognisable by a dash above the symbol, those of the upper jaw by a dash beneath it. Thus, for instance, the second milk incisor of the lower jaw is written as $\bar{i}_2$, the third permanent molar of the upper jaw is $\underline{M}_3$.

it, the enamel-canal becomes more and more spacious. And in those cases in which the lateral enamel strand was attached near to the base of the organ, the top of the enlarging organ vaults into the widening canal. By this filling up of the canal, its outer wall—that is the lateral enamel strand—approaching gradually the lateral side of the organ, finally covers the same, as clearly shown by fig. 52 *b* representing a section through the $\underline{m}_3$ of a Canis familiaris (series *A*). Now, in the meanwhile this outer wall has been the seat of considerable changes. These changes were of a degenerative nature. Instead of being a flat and complete sheet, it becomes cribriform. The surrounding mesenchymatous tissue penetrates it in an abundant manner, so that at last the lateral enamel strand is broken up into a large number of fragments or epithelial islets. In this condition it acquires contact with the outer side of the enamel-organ, the fragments are situated immediately against its external epithelium and appear as a layer of irregular excrescences, projecting from the buccal side of the organ. Now and then, however, a more primitive condition persists, the lateral enamel strand remaining independent of the outer side of the organ, and extending as a layer of epithelial islets at some distance from it, reaching from

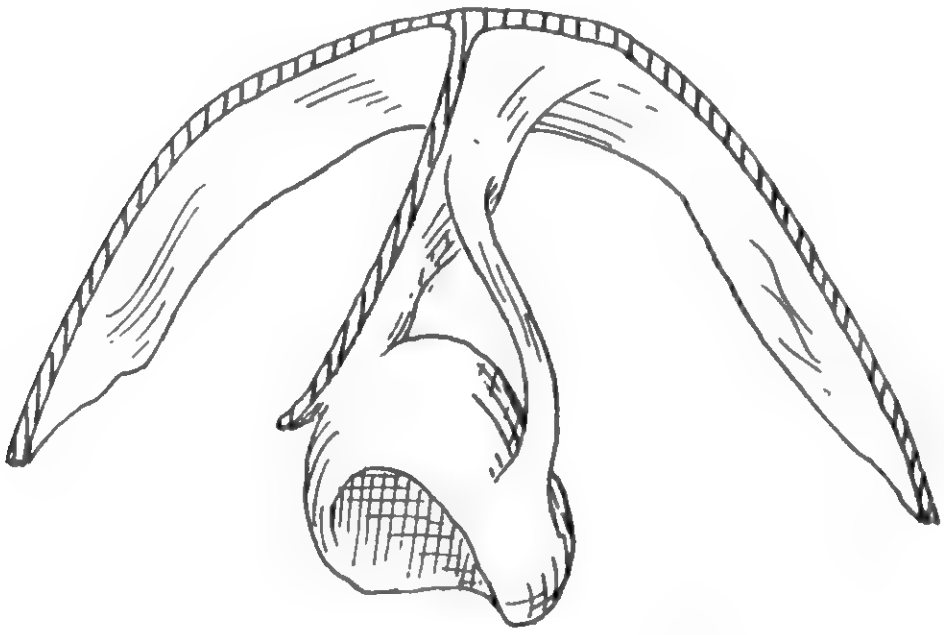

Fig. 50 *a*

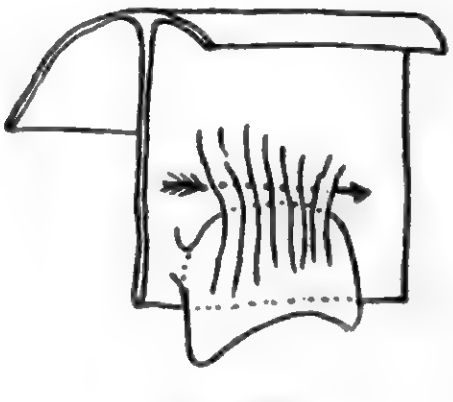

Fig. 50 *b*



Fig. 51

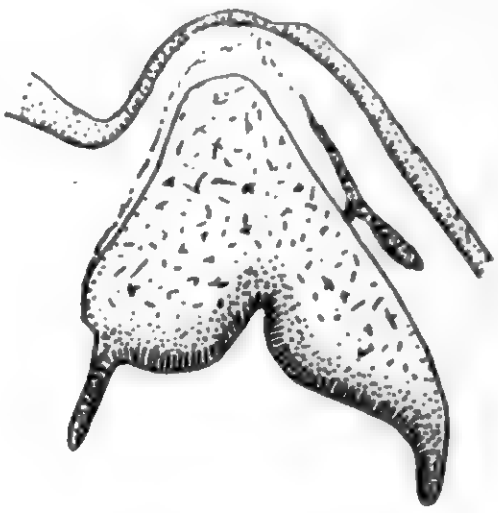

Fig. 52 *a*

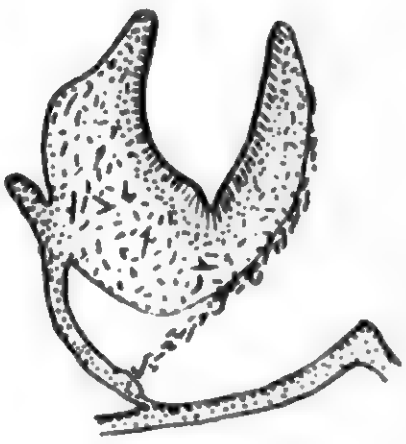

Fig. 52 *b*

the base of the organ to the common dental band. This condition is shown by fig. 52*a* ($\overline{m}$, of a Mycetes) and fig. 58 ($\bar{\imath}$ of Equus caballus, series *D*).

In the course of the further development, the common dental band and its prolongation, the medial enamel strand, degenerate and atrophy. The manner in which this process goes on is similar to that in the lateral enamel strand. In the meantime the organ recedes from the medial enamel strand; during a short time it is still connected with it by a narrow line of cells, by the interruption of which the organ becomes quite independent of the system of bands. To our knowledge of this well-known process, I have nothing to add.

As pointed out before, we intended, after the description of the earlier stages of tooth-genesis in Primates in a more detailed manner, to prove that the ontogenetical conditions, which we have met with in this group of mammals, occur also in the other groups. As we can do so in a brief account, there is no need of the pointing out afresh of all observations which I have made concerning these points, and I will confine myself to giving some examples from different groups, which I choose among my considerable collection of series of mammalian embryos. In doing so I accomplish, as I believe, my purpose: to demonstrate that the enamel-niche and canal are universal phenomena in the tooth-genesis of mammals. The conviction, however, that the enamel-organ, during a short period of tooth-genesis, has a double connection with the tooth-band, can only be acquired by examining a large number of mammalian embryos of different species and different ages. For it may be repeated that the recognition of the presence either of the niche or of the canal is not always very easy, the development of both being often rudimentary. Of the general occurrence of niche and canal I was so strongly convinced, that it was a very interesting and surprising fact to me, to find that there are forms in which any trace of a niche or canal is wanting. I will advance two examples of these exceptions. The first concerns the milk teeth of Cheiroptera. Of this group I have studied a number of series, in close stages of development, of the Malayan form: Roussettus amplexicaudatus. And it is very interesting, that while I looked in vain for an enamel-niche or canal in the organs of the set of milk teeth, the organs of the successional teeth behave quite regularly, as may be seen in fig. 56, showing a section through the anlage of P_2 (series *C* of my collection) in which the double connection between tooth-band and enamel-organ is obvious. There is a short enamel-canal running in the typical manner through the top part of the organ.

This case is a very welcome one from another point of view, for it is a further proof of the occurrence of the enamel-canal in the organs of permanent teeth.

I believe I know the reason of this lack of an enamel-niche in the milk teeth of Cheiroptera, but I think it is premature to advance my opinion upon this point, before I have given a plain and integral exposition of my views upon the genetical signification of the enamel-canal in general. And so I will return to the facts later on.

The second exception concerns the dentition of Marsupials. Here also the attempt to find an enamel-niche or canal is sometimes in vain. As in many other features so in this point the Marsupialia behave in a very peculiar manner. For while in one tooth the smallest vestige of a canal or a niche is absent, the succeeding tooth may show either in a most excellent manner. This is demonstrated, for instance, by fig. 54, in which three sections are drawn of I_3 of Perameles nasuta. I will not insist upon these phenomena in this place, because the dentition of Marsupialia will be, in the following essays, more than once an object of special inquiry, and on one of these occasions the above-mentioned peculiarity will be taken into detailed consideration.

Now we will proceed to give some examples of an enamel-niche or canal in other mammals. The first "anlage" of the niche in the enamel-organ of the cow is sketched in fig. 53. The diagrams represent eight successive sections through the organ of m_1. As clearly shown, this molar has taken origin in the ordinary way immediately from the surface-epithelium, whereby the niche—being still rather shallow—is bounded partially by this layer. The figs. 51 and 58 are drawn after preparations of embryos of the horse. Fig. 51 shows the entrance to the niche in the enamel-organ of $\bar{i}$ and fig. 58 a section through the enamel-canal of an $\bar{i}$, of an older fetus. The lateral dental strand of the horse attaches itself to the secondary organ very near to its base, that is to say the enamel-niche does not develop as usually in the apex of the primary organ, but is situated in its buccal part.

This is to be seen in the diagrams of fig. 51. And during the further development—in which the canal is much enlarged and partially filled up by the secondary organ—the lateral enamel strand does not lay itself against the outer side of the secondary organ, but there always remains a cleft-shaped space between the organ and the strand. This condition, clearly shown by fig. 58, was met with—as already referred to—also in some monkeys. A somewhat different condition, corresponding more to the normal state in monkeys, is offered by the dog. In this animal the niche develops, as is the rule in Primates, in the apex of the primary enamel-organ, and the two special strands therefore attach to the secondary organ in a more symmetrical manner as shown by figs. 55 *a* and 55 *b*. Similar conditions are offered by the teeth-germs of Hyrax. In fig. 55 *c* a section is represented through the germ of $\underline{i}_2$ of this animal. Also in Ovis the canal is present as is demonstrated by the section through $\overline{m}_2$, drawn in fig. 57.

In the foregoing, I think, sufficient proofs are furnished, to establish the truth of my assertion that the development of an enamel-niche and the transformation of it into a canal is a process proper to all mammals save some exceptions. And on account of the universality of these phenomena it can hardly be doubted that they are of prime significance in the phylogenetical history of mammalian teeth. This supposition is strengthened by the fact that during the development of the teeth of lower vertebrates, including reptiles,



Fig. 53

Fig. 54



Fig. 55 *a*

Fig. 55 *c*

Fig. 55 *b*

Fig. 56

Fig. 57

Fig. 58

not the least trace of a niche or canal is to be seen. It is a phenomenon restricted to the tooth-genesis of mammals and therefore in some way or other it must be a consequence of the manner in which the evolution from reptilian to mammalian tooth happened.

After the systematical description of the enamel-niche and canal, and the special epithelial strands bounding the latter, at present only a few lines can be devoted to the question whether these formations are really entirely unknown in literature. The answer to this question can be very short. The development of the enamel-niche and its transformation into a canal as a typical phenomenon in the tooth-genesis of mammals was quite unknown; it is a new fact added to our knowledge.

But the rudimentary fragments of the lateral enamel strand have already been observed by many investigators (Woodward, Kükenthal, Adloff). And by these authors the fragments are interpreted as vestiges of a supposed hypothetical pre-milk-dentition which will be the subject of a thorough enquiry in one of the succeeding essays and therefore I will not enter into a discussion of the value of this hypothesis, restricting myself for the present to a mention of this view.

The second phenomenon to which I wish to draw attention in the present essay is very different from the foregoing. It concerns the histogenetical differentiation of the enamel-organ. This process may be supposed to be generally well-known. Soon after the investment of the top of the dental papilla by the enamel-organ, the rounded undifferentiated cells, which build up the latter, begin to arrange themselves. Immediately upon the papilla is formed the layer of cylindrical ameloblasts, the superficial more flattened cells arrange themselves as the layer of external epithelium covering the mass of still undifferentiated cells, from which the layer of intermediate cells and finally the stellate reticulum or pulp-mass will take its origin.

Now it is to the last mentioned process—the formation of the stellate reticulum—that I wish to draw special attention, because the mode of origin of this mass, as observed by me, does not agree with the current opinion about it. This opinion is expressed very well in p. 140 of the 7th edition of Tomes' *Manual of Dental Anatomy*, where we read as follows: "The cells on the periphery of the enamel organ remain prismatic, but those in the centre become transformed into a stellate network. This conversion of the cells into a stellate reticulum is most marked quite in the centre of the enamel organ. The transformation of the cells occupying the centre and constituting the bulk of the enamel organ into a stellate reticulum goes on progressing from the centre outwards, but it stops short of reaching the layer of columnar cells which constitute the surface of the enamel organ, next to the dentine papilla. A narrow layer of unaltered cells remains between the stellate cells and the columnar enamel cells and is known as the 'stratum intermedium.'"

From this quotation I wish to emphasise the fact that according to this description there should be in the enamel-organ but a single point where the transformation into a stellate reticulum begins, and from which the process would progress. This point is situated in the centre of the organ.

My observations disagree with this opinion. I have found that as a rule there is not a single centre, but that there are two centres in the enamel-organ from which the transformation into the tissue of stellate cells radiates. According to their situation these centres may be distinguished as a lingual and a buccal one. In dealing with and representing a number of my observations concerning this phenomenon I hope to furnish sufficient proofs of this assertion.

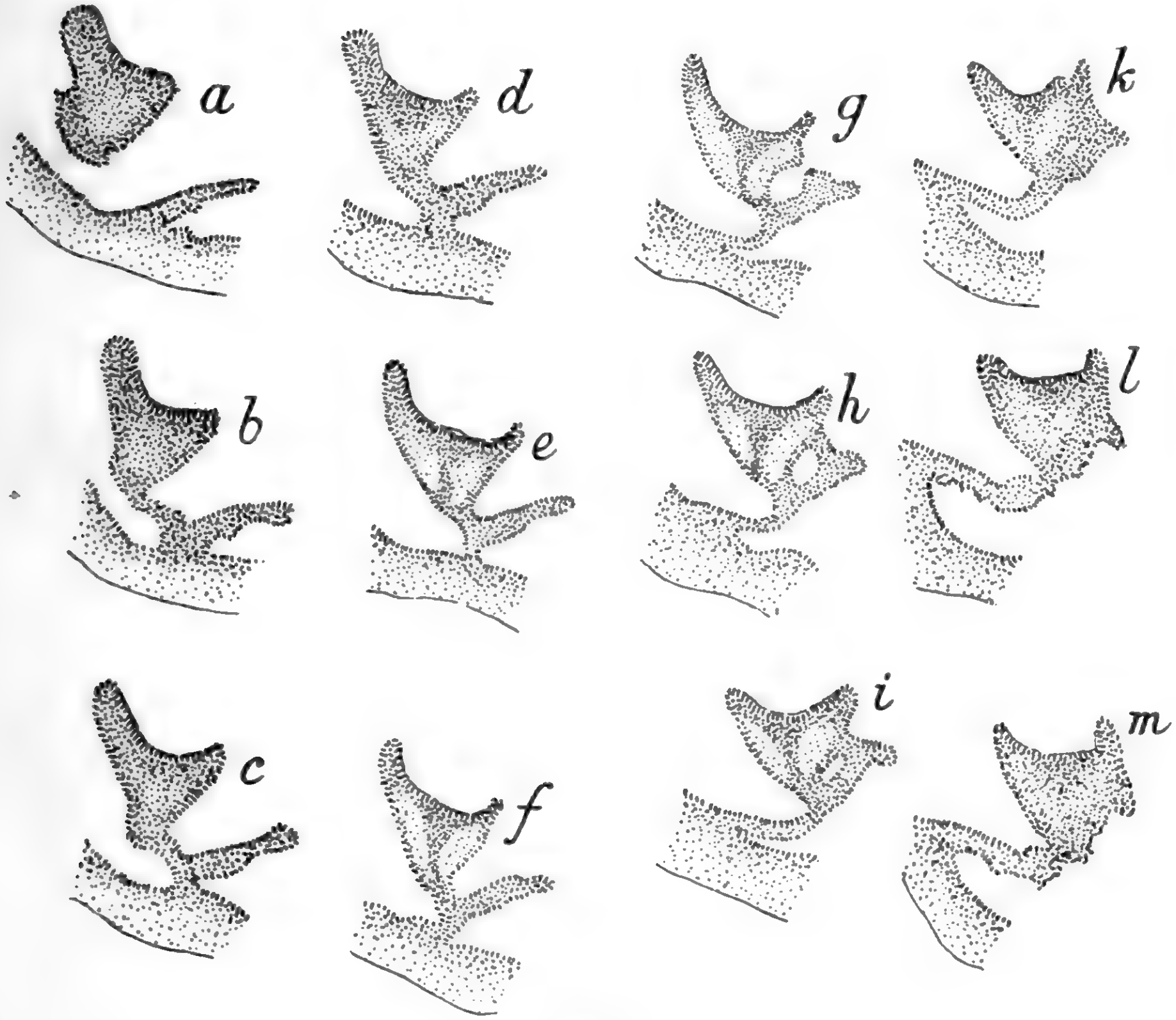

Fig. 59

I begin by communicating some observations made upon human embryos, because it was on this material that I made my first observations, and further, because human embryological material certainly is at hand in every anatomical or embryological institute, rendering my assertions easily controlable.

The starting point of the discussion may be furnished by the three series of sections through the tooth-germs of man in figs. 59, 60 and 61. Fig. 59 concerns the enamel-organ of an $\underline{i}$, fig. 60 that of a $\overline{m}_1$, and fig. 61 that of a $\underline{c}$. Each of these figures shows also the presence of the enamel-niche, to which point however I do not wish to return. In looking over the first series of diagrams drawn in fig. 59, it is clear that the histological differentiation of the enamel-organ is still in its beginning. There is a well differentiated layer of columnar cells or ameloblasts, but for the rest the cells of the organ and of the dental lamina still possess their primitive rounded form. The first three sections of fig. 59 do not offer any particularity, but in the fourth section of the series (fig. 59 *d*) there appears in the centre of the organ a clearing up of the tissue, the heaping up of the nuclei becoming here somewhat less dense. Without doubt this is to be considered as the very beginning of the transformation into the stellate reticulum. In the next section (fig. 59 *e*) this clearing up is more pronounced but now it becomes obvious that the cellular elements, lying in the axes of the organ, do not participate in this process, so that there remains a layer of densely packed nuclei extending from the apex of the organ to the middle of its base. By this layer the centre of clearing is divided into two parts, a lingual and a buccal one.

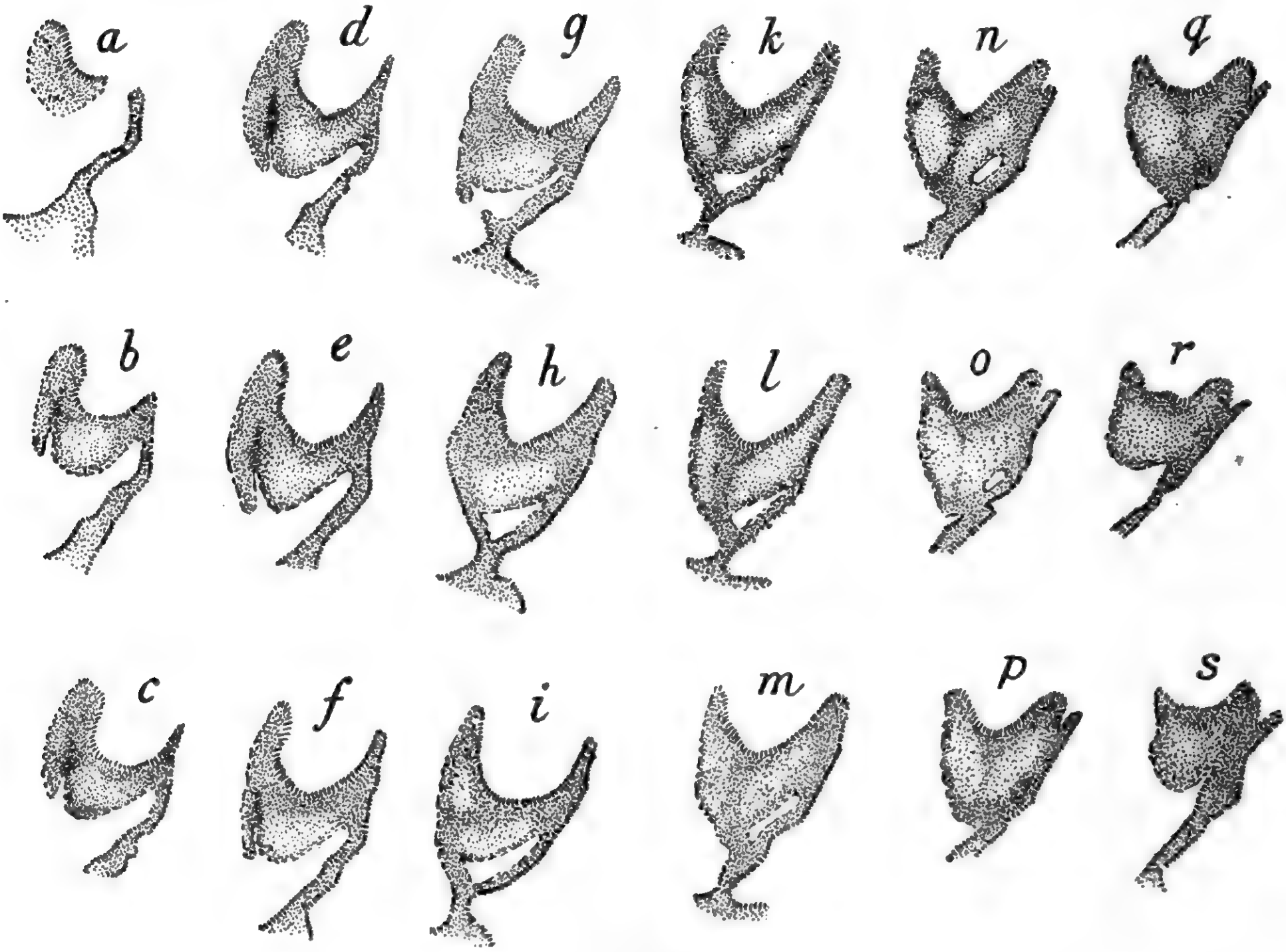

Fig. 60

Examining the succeeding sections it is evident that this compact layer of cells extends through the enamel-organ in a sagittal direction, disappearing in its posterior part, in which the organ is constituted anew by a very dense mass of cells.

I think the drawings in fig. 59 prove in a very clear manner this pulp-formation as not beginning at a single central point of the organ, but from two centres, whereas it is exactly the central or axial elements of the organ that do not participate in this process, remaining on the contrary a more dense formation.

This compact layer of cells constitutes a separating wall or septum between the two centres of pulp-formation and accordingly in the sequel will be denominated as *enamel-septum.*

Now before beginning the inquiry about the further development and peculiarities of this septum, I wish to demonstrate its presence in man and in some other mammals by some other examples.

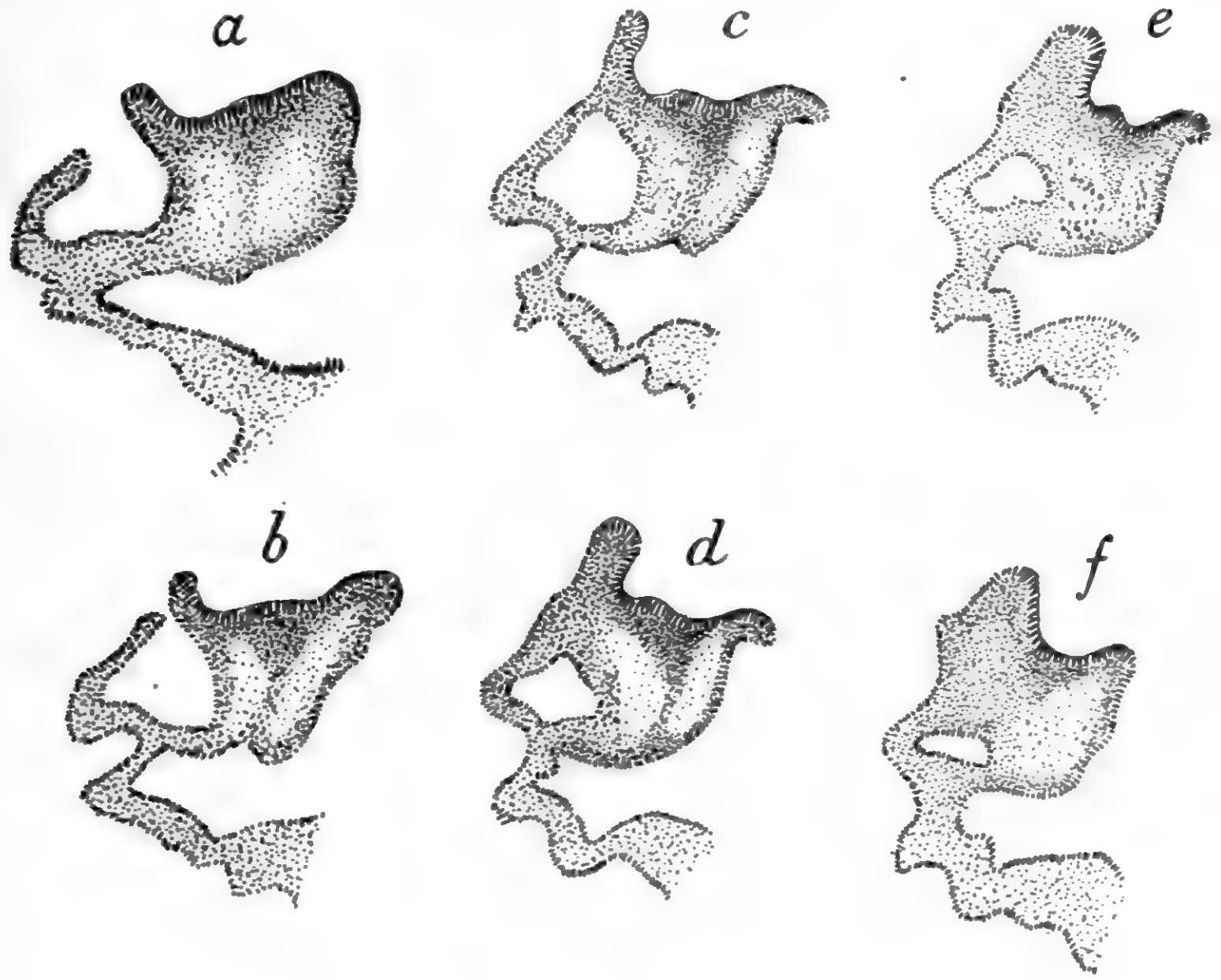

Fig. 61

In fig. 60 eighteen succeeding sections through the germ of $\overline{m}_1$ of a human embryo are sketched. And these sketches too show that there are two centres in which the pulp-formation begins. In the sketches 60 *c* to 60 *h* there is but one centre to be seen, situated somewhat excentrically in the lingual part of the organ. In fig. 60 *e* a second centre appears in the buccal half of the organ quite independent of the former. From fig. 60 *k* to fig. 60 *q* both centres are separated from each other by the enamel-septum. In the last mentioned figure the lingual centre disappears and only the hindmost part of the buccal is to be seen in the two last sketches. It is obvious that in this case the septum had a somewhat oblique direction, with the result that in the anterior part only the lingual and in the posterior part of the organ only the buccal centre was cut through.

The fact that in this case also there is still an enamel-niche and not yet an enamel-canal, proves that the organ is still in a very early stage of its development. I lay stress upon this fact for—as will soon be demonstrated—the septum is not a persistent formation of the enamel-organ, it is of a transitory nature. Therefore to observe it, one must select the material with care.

As a third example of the double pulp-centre in the enamel-organ of man, six sections through the organ of *c* are sketched in fig. 61. This specimen was selected in order to draw attention to a peculiarity of the external form of the organ, often observed in connection with the septum.

In figs. 61*b* and 61*e* a dimple is visible in the apex of the organ corresponding with the attachment of the septum. The surface of the organ seems to be retracted somewhat inwards by the attachment of the septum. In the present case this dimple—which I will distinguish in the sequel as *enamel-navel*—is but a shallow one.

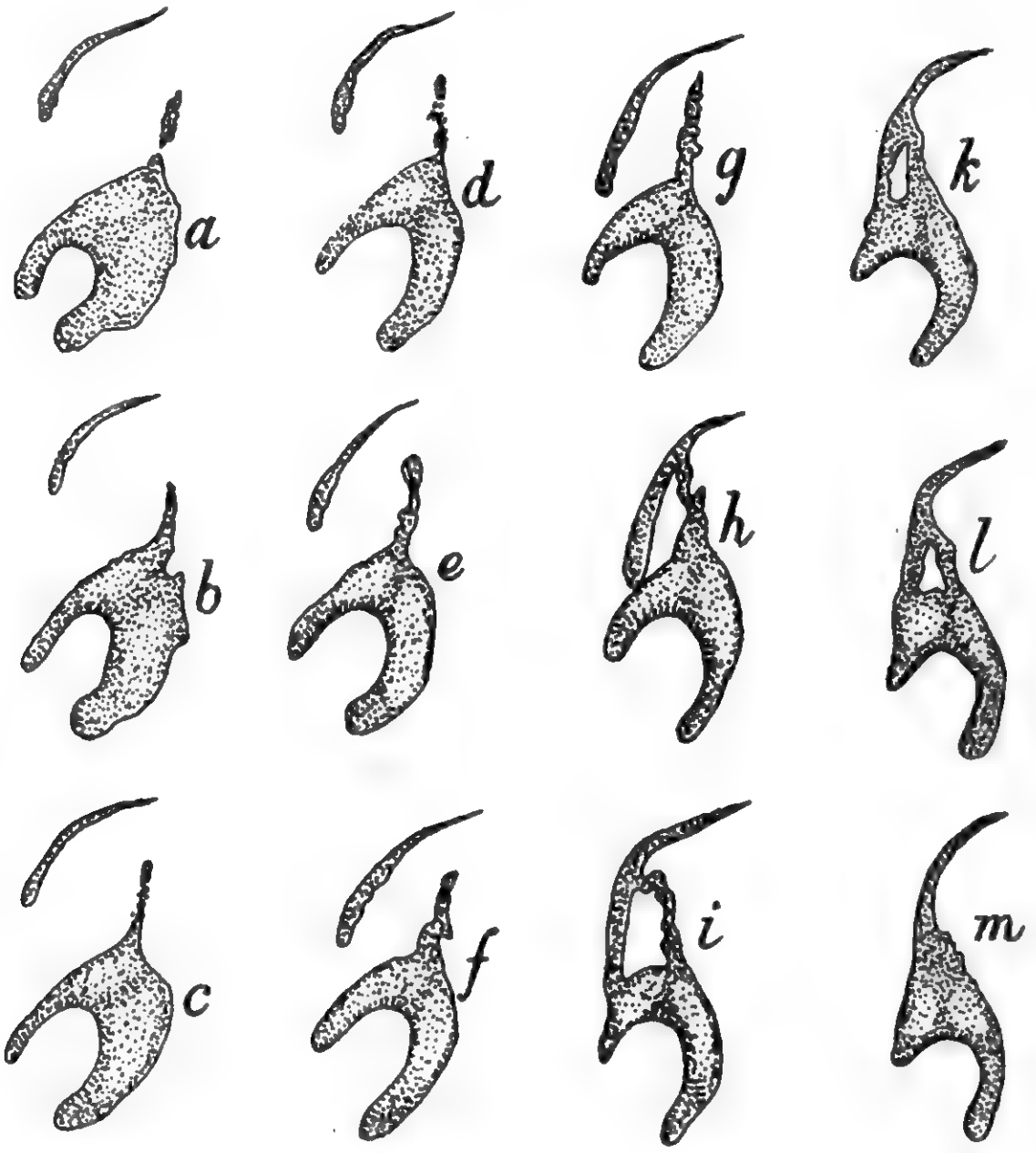

Fig. 62

After having demonstrated the occurrence of two centres of pulp-formation in the enamel-organ of human embryos, some examples may follow to prove that in other mammals the histogenetical differentiation proceeds in similar manner.

In fig. 62 a number of successive sections through the enamel-organ of $\bar{i}_2$ of a cow are drawn (series *A* of my collection). It is obvious that in this specimen the organ has still its enamel-niche, an indication of its rather early stage of development.

Furthermore it is not at all dubious that there are two points at which the transformation into pulp-mass is beginning, one in each half of the organ. They are separated from each other by the layer of undifferentiated cells, known already as enamel-septum. The enamel-niche has not yet been formed.

The latter formation was very well developed in the following case, drawn in fig. 63, which concerns the enamel-organ of $\bar{i}$ of a sheep (series *Z* of my collection). In the sheep the enamel-organs are directed in a somewhat unusual manner, the base being directed medially and the dental papilla pushing into it, from this side. There exists in this case—as commonly in the sheep—a very wide enamel-niche, with spacious aperture. The presence of two pulp-centres, separated by the septum also in this case is not subject to any doubt. In fig. 63 *e* a very fine enamel-navel is visible.

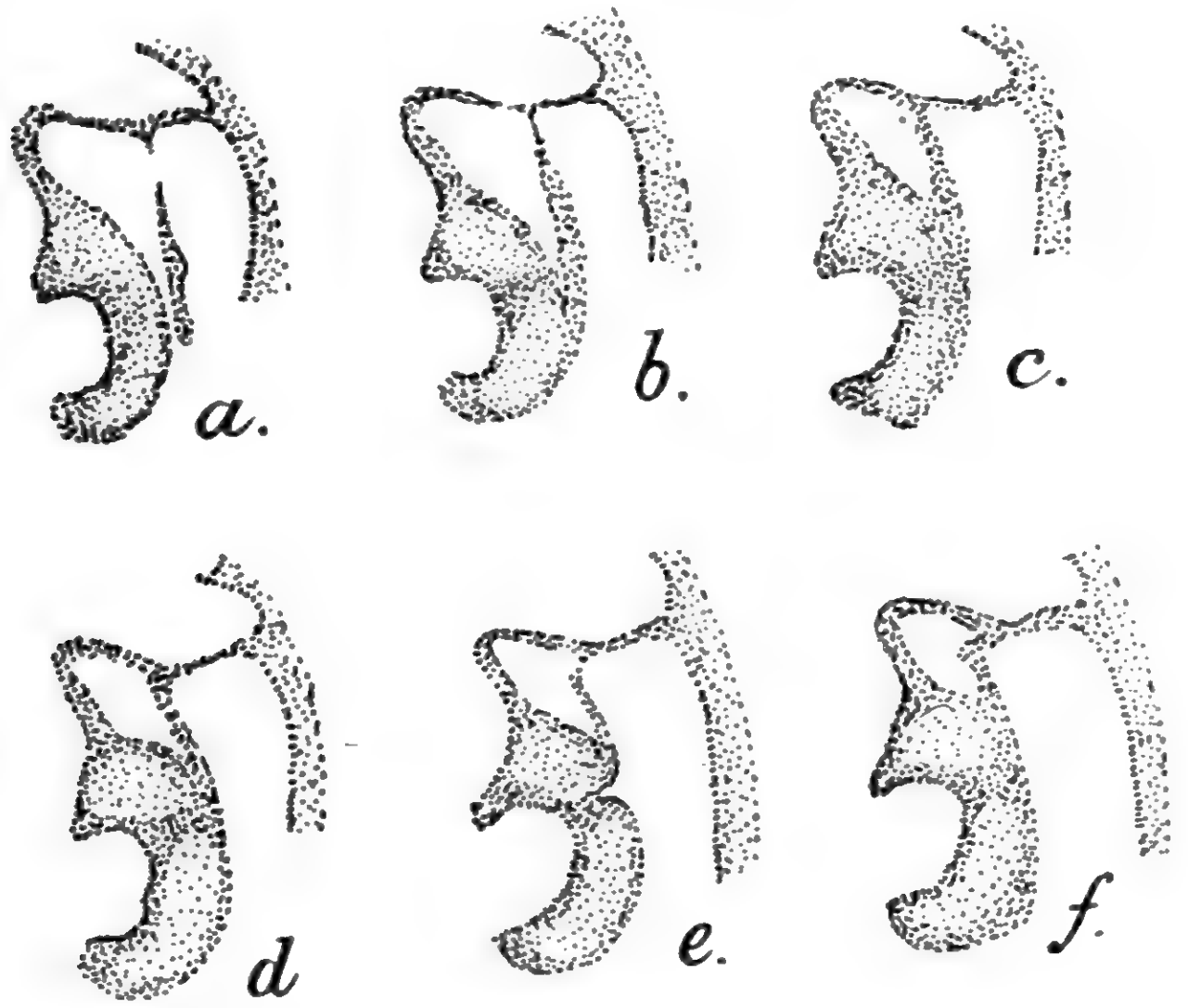

Fig. 63

That in Marsupials the genesis of the stellate reticulum does not differ from that in placental mammals is proved by fig. 64, representing four sections through the germ of an $\underline{m}_2$ of Dasyurus viverrinus (series *E* of my collection). In two of these sections the enamel-navel is also visible.

Finally fig. 65 shows the occurrence of a double pulp-centre in the enamel-organ of the horse. The drawings represent six sections through the germ of $\bar{i}_2$ of this animal (series *D* of my collection).

I think the correctness of my assertion that in mammals there are two centres of pulp-formation and not one single, to be sufficiently proved by the foregoing examples.

Now we will proceed to examine the further behaviour and development of the enamel-septum. In the first place we intend to inquire into the relation between the septum and the other components of the organ.

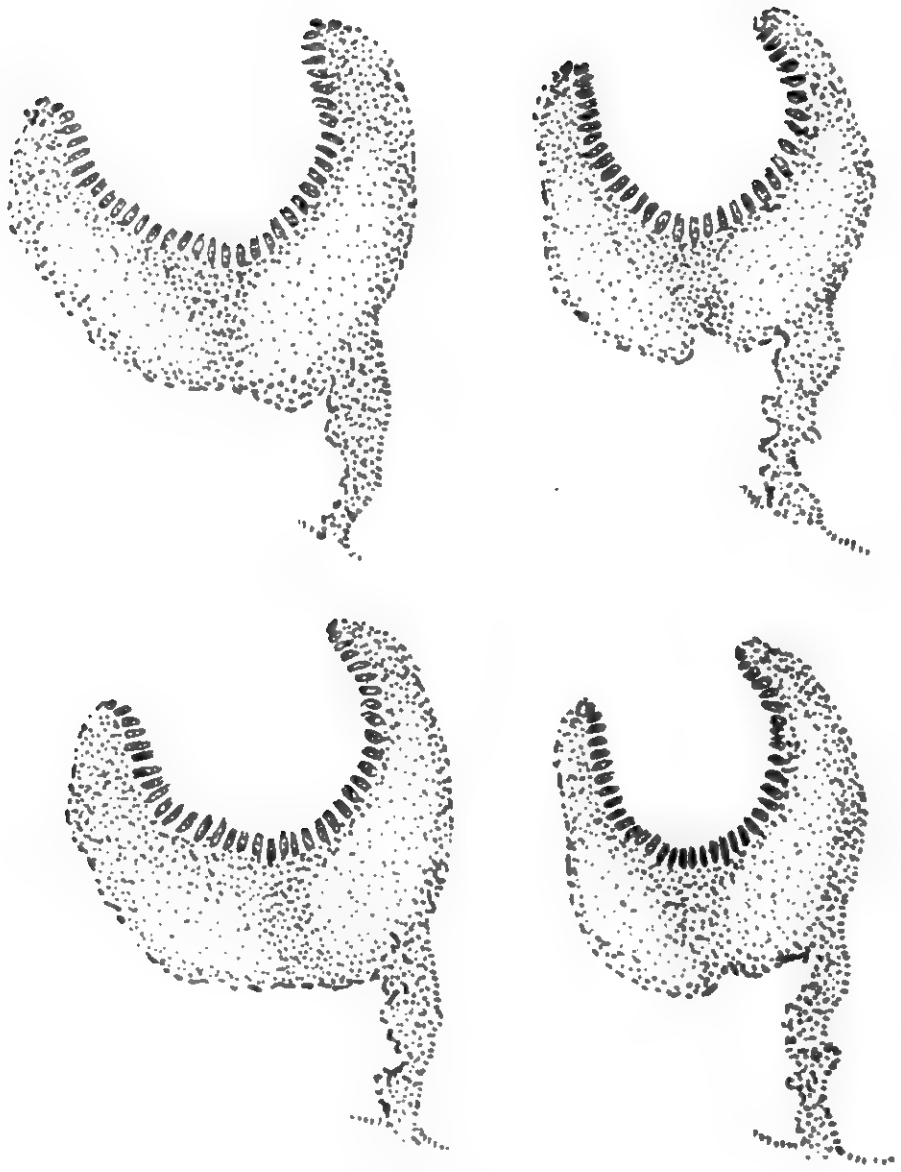

Fig. 64

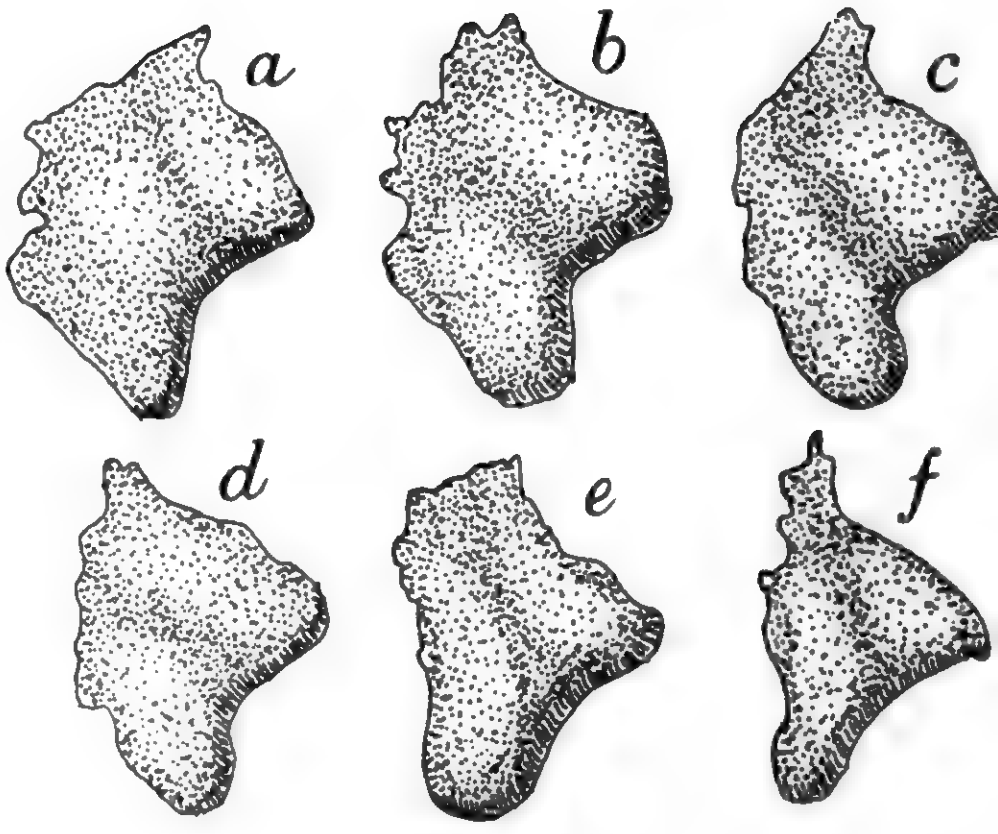

Fig. 65

Fig. 66

The fact has already been mentioned that the cells of the septum keep their indifferent character. Now there exists still another layer in the organ which behaves in the same manner, namely the layer of intermediate cells. And in examining the relation between the septum and the layer in a much differentiated organ, the former appears on longitudinal sections as a conical outgrowth of the latter directed to the apex of the organ. This is demonstrated in figs. 66, 67, 68 and 69, showing sections through the enamel-organs of different mammals in which the relation between the septum and the layer of intermediate cells gradually becomes more evident. Moreover these figures

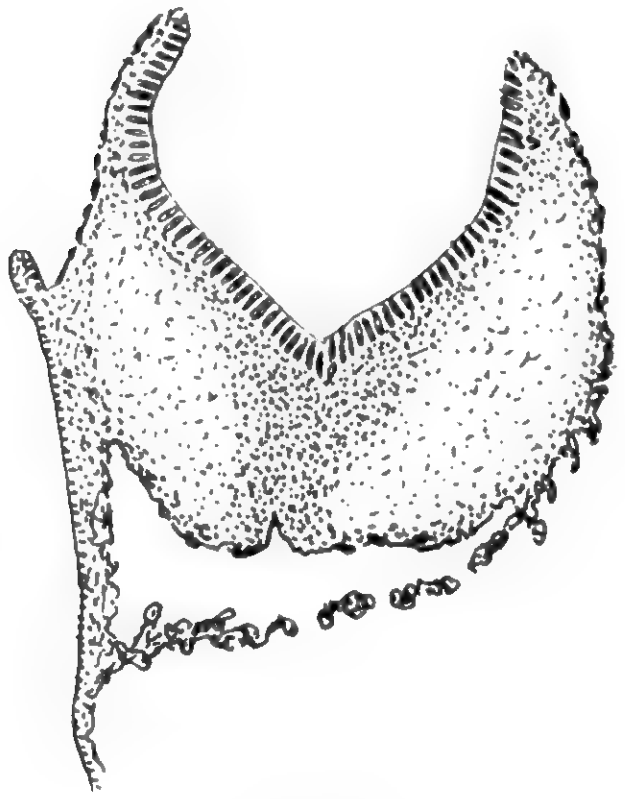

Fig. 67



Fig. 68

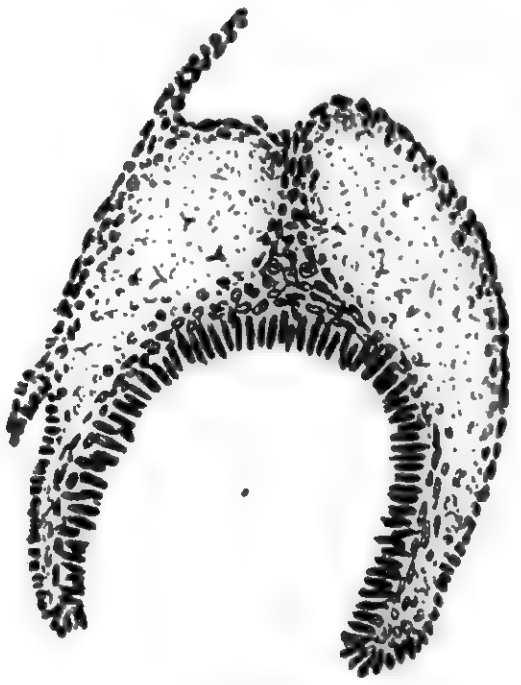

Fig. 69

give an instructive survey of the histological differentiation of the septum. In fig. 66, showing a section through $\overline{m}_1$ of Mustela erminia there is not yet a clear difference between the elements of the pulp-masses and those of the septum; the centres are recognisable only by a lesser density of the nuclei, being evidently the cell-bodies somewhat swollen up. In fig. 67, representing a section through $\underline{m}_1$ of Hyrax syriacus the pulp-formation has proceeded further. Some stellate cells are to be recognised; already the layer of ameloblasts, as well as the superficial epithelium are recognisable without difficulty, while the layer of intermediate cells, covering the ameloblasts, has become sharply bounded. Now this layer prolongs itself into the middle of the organ as a broad partition wall, attaching at the top of the organ, where a well developed enamel-navel is visible.

A further stage of development is shown by fig. 68, representing a section through $\underline{m}_1$ of Canis familiaris (series *T* of my collection).

In both centres of pulp-formation the cells acquire the typical stellate form, the nuclei of the cells of the stratum intermedium are enlarged and the elements of the septum, extending through the organ from the stratum intermedium to the very well developed enamel-navel show quite the same character.

In fig. 69, representing a section through $\overline{m}_2$ of Macacus cynomolgus, a slight difference becomes visible. While the nuclei of the cells of the intermediate layer preserve their original more rounded form, those of the septum become more oblong, stretched out parallel to the axis of the organ.

The latter phenomenon I have observed but rarely. A very fine case of it I found in the molars of Bos taurus.

In a more advanced stage of development of these teeth, in which the internal differentiation of the organ was finished, the enamel-septum appears as formed by much elongated and flattened cells as may be seen in fig. 70, in which a section through $\overline{m}_2$ of Bos taurus (series *E*) is represented. One has, of course, the opportunity of observing an image as represented in fig. 70 only, when the section through the organ agrees with the direction in which the cells are lengthened. If such is not the case, the cells being cut through obliquely or transversely, appear in the section as rounded elements and seem to have preserved their original form.

On the evidence of fig. 70 we may arrive at the conclusion, that the elements of the septum during the further develop-

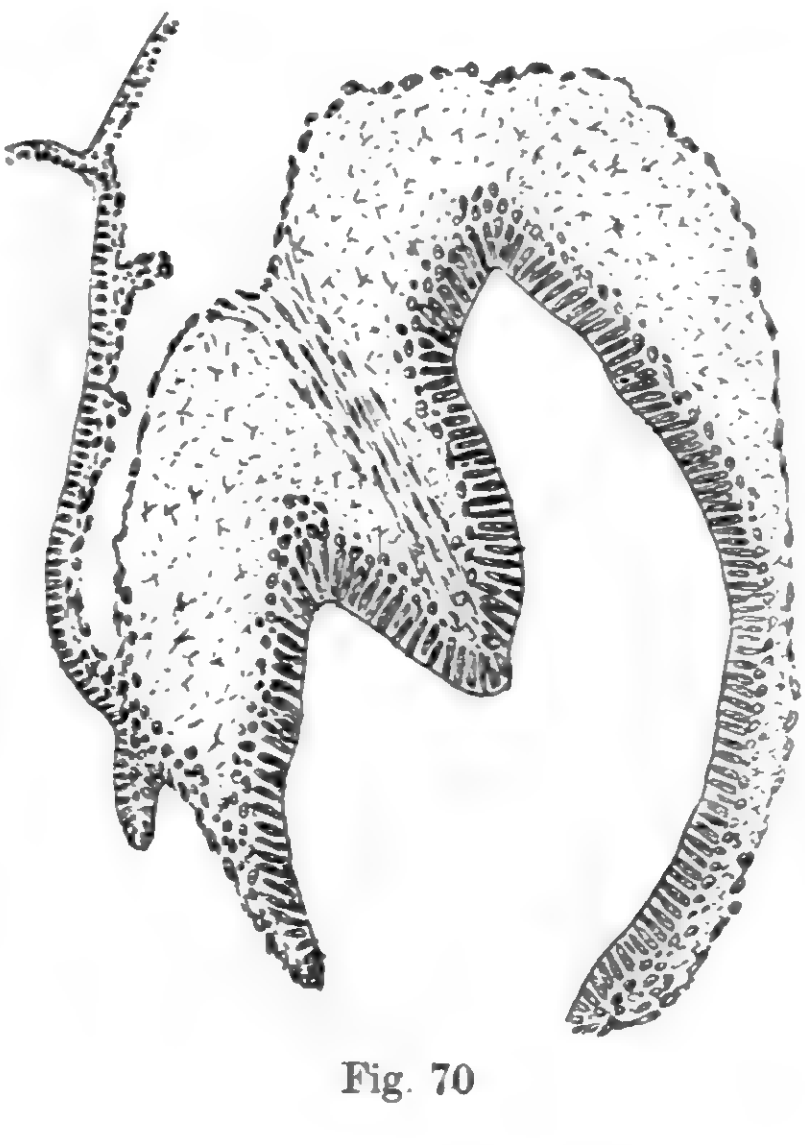

Fig. 70

ment of the organ are not transformed into stellate cells: in this figure their form being already specialised so far in another direction, the possibility of transformation into stellate cells may be considered as wholly excluded.

The septum is not always as strongly developed as in the preceding examples. Sometimes it becomes very narrow, existing only as a double line of cells. A very instructive example of this condition is seen in fig. 71, in which a part of the organ of $\underline{i}_2$ of Propithecus diadema (series *A*), is represented much magnified. This figure may serve also to draw attention to a phenomenon in my opinion of no mean value with regard to the morphological and phylogenetical signification of the septum. On considering carefully the surface epithelium in fig. 71, one will note its failure at the spot where the septum is attached.

Fig. 71

The elements of this epithelium are characterised by the power to become stained very intensively. This fact facilitates the statement that this layer of external epithelium curves inwards to form the septum. The discontinuity of the covering epithelium in the navel of this enamel-organ was very obvious.

Corresponding phenomena may be observed in the enamel-organs of the molars of Marsupials, an example of which is given in fig. 72. This figure represents a section through an $\overline{m}_3$ of Dasyurus viverrinus (series *F*). The covering epithelium, forming a very deep navel, curves inwards to the layer of intermediate cells. The section drawn in fig. 72 resembles much that of a Macropus Cillardieri, figured by Hopewell Smith and Tims in the *Proc. Zool. Soc.*, London, 1911, Pl. XLVII, fig. 4, and described by the authors as follows: "Figure 4 shows the subdivision of an enamel-organ into two parts, by an epithelium septum passing from the outer enamel epithelium to the inner, where the latter lies over the apex of the dental papilla. This occurs in more than one cheek-tooth and may be seen on both sides. We have never met with anything of the kind before. We can offer no other suggestion than that it is a double enamel-organ taking part in the formation of a single tooth."

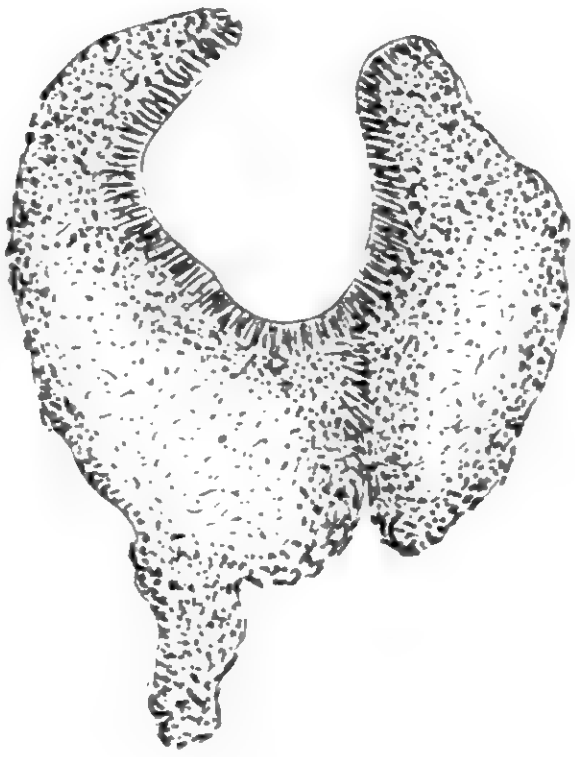

Fig. 72

Not without intention I intercalcate this quotation, because as will be pointed out in one of the next essays, I agree with the authors as to the interpretation of the appearance.

I have once had the opportunity of observing a very particular function of the enamel-septum, which I will shortly mention. As to the question whether the enamel-organs are vascularised or not, the discussion is not yet closed. There are authors who assert that the organs contain no vessels at all, on the other hand there are investigators who state that a vascular network lies in the stratum intermedium. Personally I have failed to detect any vessel in the organ of mammals, except in one case. And the vascularity of the organ was in this case so obvious, that it seemed necessary to me to deal with my observation in a special paper (*Anatomischer Anzeiger*, vol. XLVIII. 1915). This communication concerns the enamel-organs of Phascolarctos cinereus, of which I have given in the above mentioned paper a series of illustrations, proving in an unquestionable manner the vascularity of these organs. In a somewhat advanced state of development the well-known stratum intermedium is lost in the enamel-organ, a very dense network of vessels covering the layer of ameloblastic cells. Now, in relation to the point discussed in the present paper it is very interesting to see in what manner the vessels enter the organ. This is illustrated by fig. 73, in which a part of a section through the organ of $\underline{T}_2$ of Phascolarctos is represented. The formation of dentine and enamel had commenced already, a thin layer of these hard tissues covered the apex of the dentinal papilla. Now fig. 73 shows how from the surrounding mesenchyme vessels enter into the enamel-organ by the way of the enamel-septum. To illustrate this fact I have chosen intentionally a section in which a vessel lies within the septum, while another in the navel of the organ is on the point of penetrating it.

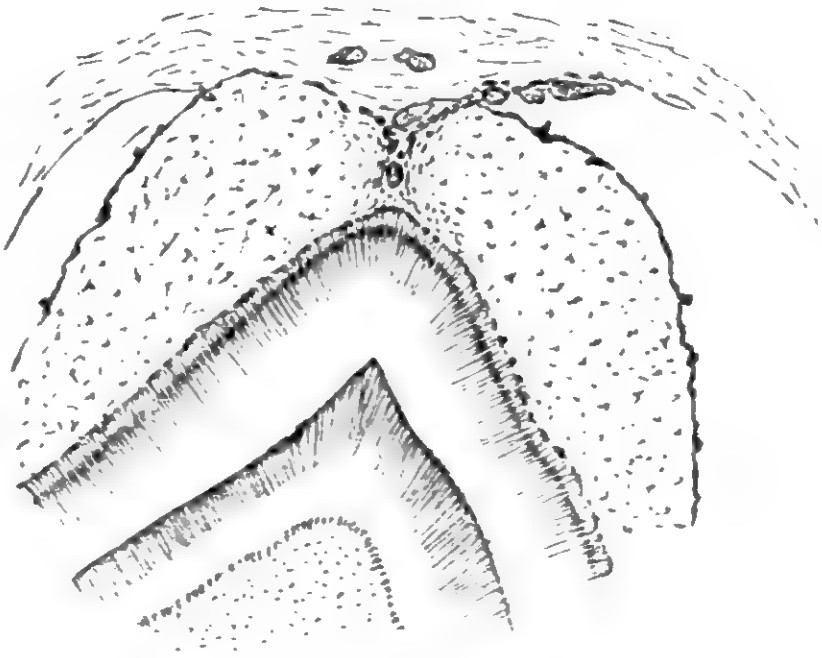

Fig. 73

As to the manner in which these vessels form the network in the enamel-organ, I refer the interested reader to my above-mentioned paper in the *Anatomischer Anzeiger*. For the present it was only my purpose to mention this particular function of the enamel-septum.

So far on the participation of the septum in the structure of the enamel-organ. Now we will go on in discussing its morphological and topographical particularities. The knowledge of these particularities will render intelligible the fact that this formation is nearly unknown in the odontological literature, though it may have been observed already by many embryologists, but not recognised by them in its real significance, and considered as an accidental appearance without any genetical importance.

The denomination of the formation as an enamel-septum or partition wall holds good only for the very first phase of development of the enamel-organ. Only in very young stages does the septum extend from the front to the back wall, entirely separating the two centres of pulp-formation from each other. Now concerning the relation between the septum and these two centres, it must be emphasised that the beginning in two spots of the transformation into reticular cells, is the essential point, the septum being only the necessary consequence of it. Nevertheless, the fact that the elements of the septum acquire in a further stage of development a typical specialised form, is to be appreciated as a hint that the septum has also a history of its own, and that it may not be considered exclusively as a consequence of the double centres of pulp-formation. This view is strengthened by the fact that rudiments of the septum are to be found even in enamel-organs in a very advanced stage of development.

The morphological history of the septum may be now summarised as follows.

It has already been mentioned that only in very young stages of development is the septum a real complete partition wall, dividing the inner mass of the enamel-organ in a lingual and buccal half. This state is a transitional one, for in the growing and increasing enamel-organ the two centres of pulp-formation soon fuse together in the anterior as well as in the posterior part of the organ, so that the septum, surrounded by reticular tissue becomes reduced to a central formation of conical form. This reduced form in which it is usually met with, may be considered as the main reason that it is scarcely known in literature, and that its original nature has not yet been recognised.

Intentionally I have laid much stress upon the original character of the formation as a real complete partition wall, dividing the organ into two halves. For after my first publication of it in the German language, Ahrens has expressed doubt about this assertion. He describes the formation as being not a septum, but, from the very beginning, a strand (emailstrang) running from the layer of intermediate cells to the top of the organ. The difference between our views is relatively of no importance, for the principal point—the fact that the pulp-formation does not begin in the centre of the organ—is accepted even by Ahrens whose view of the septum I have shown to be erroneous[1]. And truly the mentioned fact is of the greatest significance as to the morphological value of the enamel-organ, as will be demonstrated later on.

After being surrounded by reticular tissue the concentration of the septum

---

[1] "Ueber die Entstehung des Schmelzseptums," *Anat. Anzeiger*, vol. XLVIII. 1915.

to a conical strand progresses more and more. And when in somewhat older enamel-organs the level of the section runs obliquely with regard to the direction of the septum, the latter appears as a rounded heaping up of un-

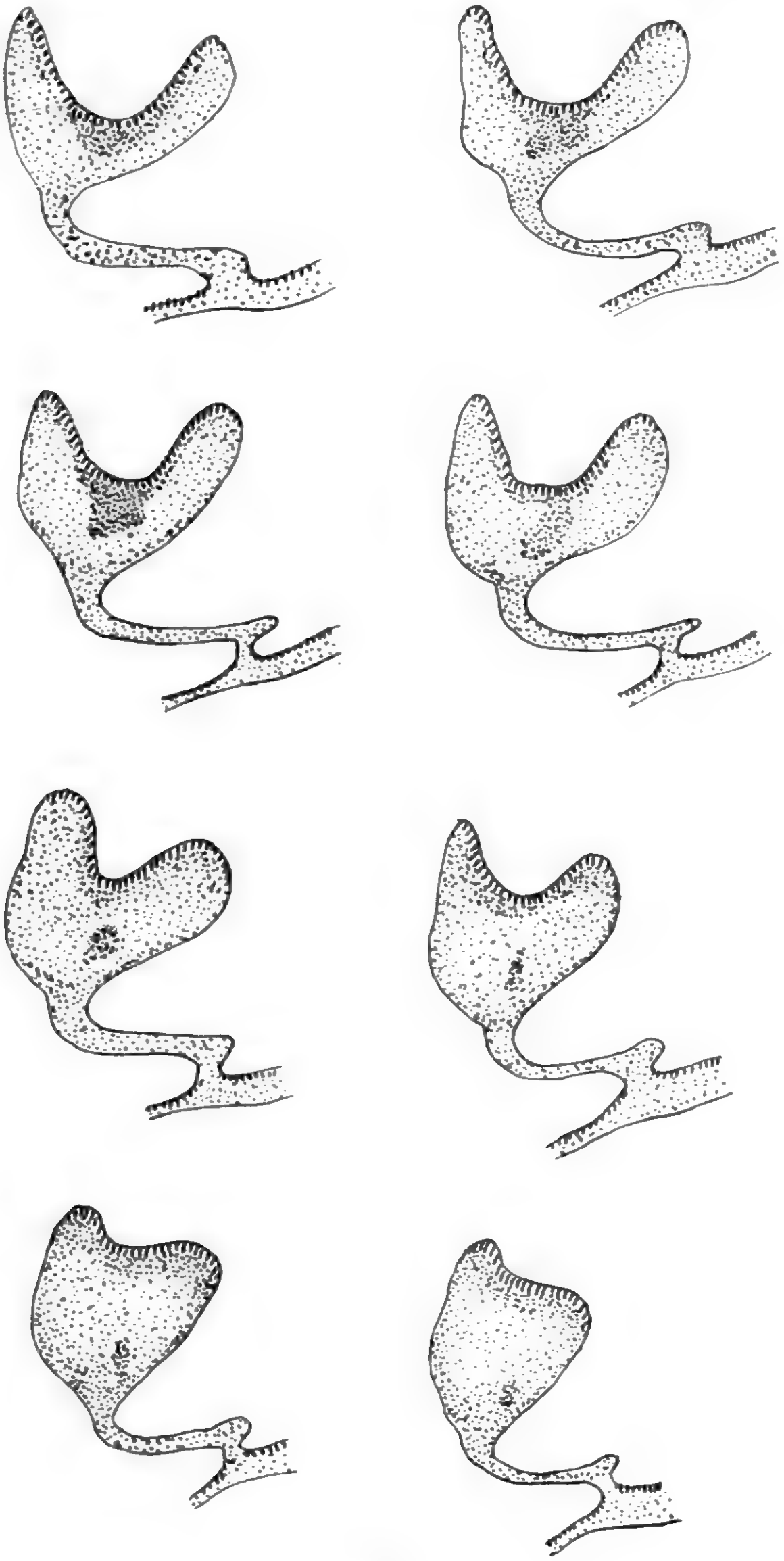

Fig. 74

differentiated cells, wholly enclosed by reticular cells. A very fine example of such a condition is given in fig. 74, showing eight sections through the organ of $\underline{m}_2$ of Macacus cynomolgus. It is obvious that the septum in this case is reduced to a cylindrical strand, passing through the pulp-mass from the base to the top.

In this reduced form the septum is already known in literature, but not generally. The French histologist, Renaut, has given, as far as I am aware, the first short description of it[1] and calls it the "directing enamel-cone (cône adamantin directeur)," because he thought that this strand determined the direction in which the apex of the tooth will push through the enamel-organ. Now it is true that in monocuspidate teeth the septum—as I will continue to call it, even in its reduced strand-shape form—extends from the apex of the tooth to the outer epithelium at the top of the organ, as illustrated by the figs. 66, 67 and 68 for instance, and accordingly indicates the way which the pushing tooth shall take. This is, however, not an absolute necessity, as is proved by fig. 70, the septum terminating here, between the two cusps of the molar tooth.

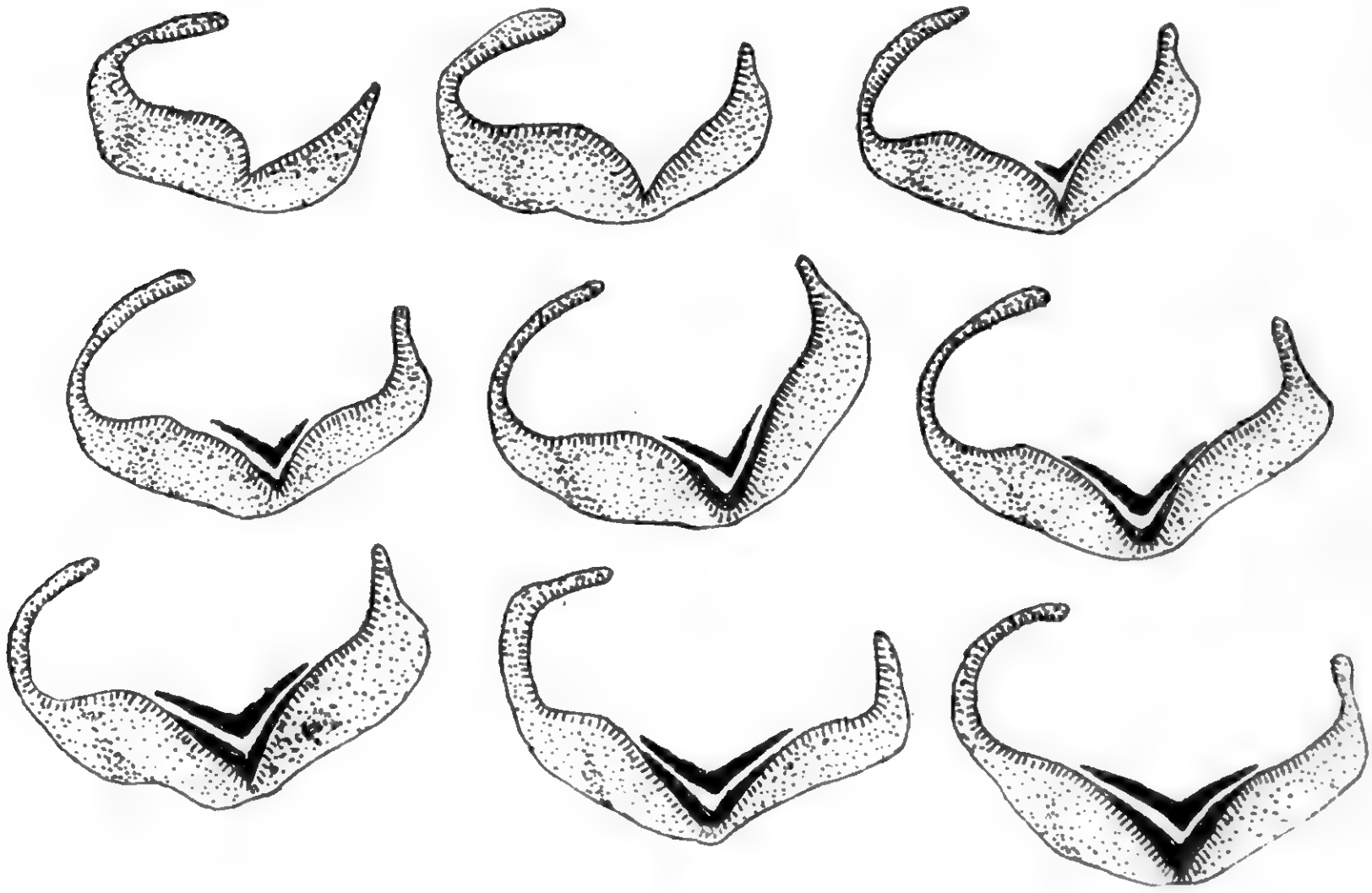

Fig. 75

It is obvious, furthermore, that, though in many cases the direction in which the tooth perforates the organ is indicated by the septum, this fact ought not to be taken into consideration in a discussion upon the significance of the septum. For it would be an error to take as subject of this discussion the septum in its reduced cylindrical shape, instead of in its original form as a real complete partition wall.

A conclusive proof that the enamel-septum is independent from the apex dentis and therefore unfit to accomplish the task of directing element is given in fig. 75, in which some sections are represented through the anterior part of the germ of $\underline{m}_2$ of Galeopithecus, on which the formation of enamel and dentine has already begun. The septum is situated in this specimen very eccentrically,

---

[1] *Traité d'histiologie pratique*, p. 248. Paris, 1897.

without any topographical relation with the apex of the tooth, which has nearly reached the outer epithelium of the enamel-organ.

Such an eccentric situation is met with very seldom and finally in fig. 76 there is reproduced yet another case of it, being a section through $\overline{m}_3$ of Chrysothrix sciurea.

With this case I wish to finish the description of the enamel-septum. It is—as mentioned already—my intention to restrict myself in the present paper to the communication of my observations only, putting off the discussion upon their significance to one of the next essays. Yet it seems to me not wholly out of place to anticipate some general considerations.

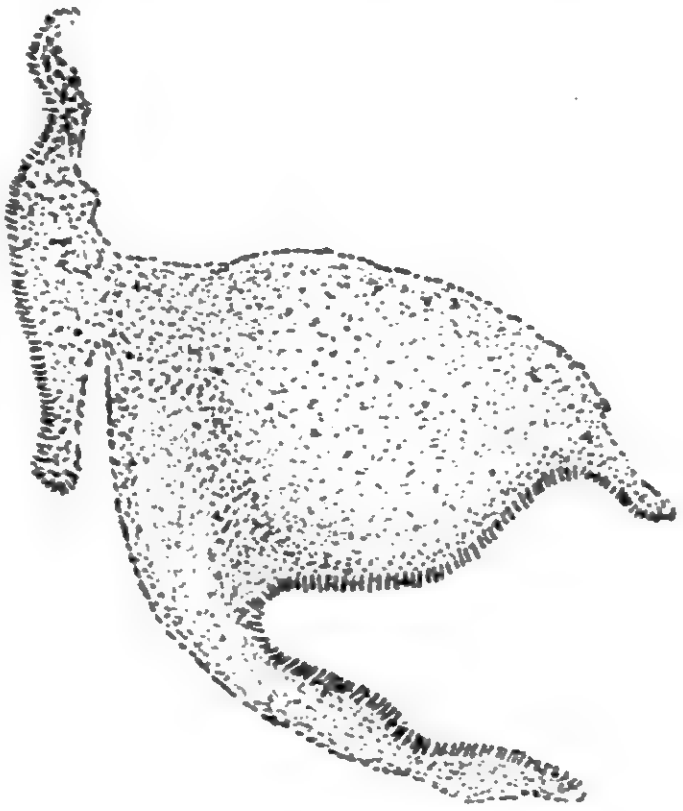
Fig. 76

A first remark concerns the septum. It is of great importance, as bearing on the significance of this formation, that it is met with exclusively in the enamel-organs of mammals. I have examined the genesis of the teeth in reptiles as thoroughly as that of mammals. And I have never seen in any enamel-organ of this group of vertebrates the smallest trace of an enamel-septum. It may be stated as a matter of fact that the septum is a formation typical of the teeth of the highest class of the vertebrates, and in some way or other its origin must be the consequence of the manner in which the teeth of the mammalia have taken origin from those of reptiles. For that the dentition of mammals must be derived from that of reptiles is no longer subject to any doubt, only as to the manner in which this evolution has taken place are the opinions of the authors not unanimous. A special essay will be devoted to my own views upon this subject.

Now one may remember that after my description of the external developmental appearances of the enamel-organ, I made the remark that the enamel-niche and canal fail in the tooth-genesis of reptiles, appearing exclusively during the development of mammalian teeth. And the conclusion at which I arrived was necessarily the same as that just given: the enamel-niche must be a result of the manner in which the evolution of the mammalian teeth took place. Therefore a relation must exist between the external developmental and the internal histogenetical phenomena, for both result from the same cause, and an attempt to solve the problem of the evolution of mammalian teeth must demonstrate at the same time the origin of the enamel-niche (canal) as well as that of the enamel-septum as a consequence of this process.

Now a very striking agreement between both phenomena may be pointed out here, by which a main morphological character of the mammalian enamel-organ comes to light.

Our researches have taught us, firstly, that in the tooth-genesis of mammals there is a common dental band from which two special bands emerge, attaching themselves at the buccal and lingual sides respectively of the enamel-organ. In reptiles on the contrary, there is but one single connection between the organ and the dental lamina. This fact gives rise to the question whether the enamel-organ of the mammals is a single organ, or a compound one, being homologous with two organs of reptiles and not with a single one. If this point of view were true, the mammalian organ should be, so to say, a twin-organ, in which the constituent elements are situated as a buccal and a lingual one.

Now, this point of view is surely strengthened by our second observation, described in the present paper. We have demonstrated that in the organ of mammals there is not a single centre of pulp-formation, arising in the middle of the organ, but there are two centres, one in its buccal and one in its lingual half. This fact too is favourable to the appreciation of this organ as a double one, built up by two elementary organs, a buccal and lingual one.

I confine myself to throwing simply this light upon the morphological nature of the enamel-organ of mammals, the working out of this idea is to be put off to one of the next essays, after the exposition of some details on the origin of teeth in reptiles.

Yet I cannot end this essay without pointing out a consequence of the above view concerning the teeth. If, in reality, the mammalian enamel-organ be a compound one, the tooth itself also must be of the same nature, built up by two elements each homologous with a reptilian tooth. The buccal cusps of the mammalian tooth should represent then the one, and the lingual cusps the other reptilian tooth. The mammalian tooth should be then, what I will call a "dimer" tooth.

This consequence forms the fundamental point of my hypothesis upon the morphological value of the mammalian tooth and its relation to the teeth of reptiles.

THE PRIMORDIAL CRANIUM OF *TATUSIA NOVEMCINCTA* AS DETERMINED BY SECTIONS AND MODELS OF THE EMBRYOS OF 12 MILLIMETRE AND 17 MILLIMETRE C.R. LENGTH[1]

By Professor FAWCETT, M.D. (Edin.),
University of Bristol.

The embryos of which the crania are to be described were kindly given to me by Professor Wood Jones, and were cut into sections of 15 microns thick and stained with Mallory's triple connective tissue stain.

The 12 mm. stage will be described first.

THE PRIMORDIAL CRANIUM OF A 12 MM. *TATUSIA NOVEMCINCTA* EMBRYO
(Pls. VI, VII, VIII, IX)

Following the methods I have previously adopted in regard to the description of the primordial cranium, I will consider it here as consisting of the following parts. First a neural cranium, second a visceral cranium.

The osseous skeleton will be described separately.

The Neural Cranium may be divided into the following parts, viz.:

1. A central stem.
2. Appendages to the central stem.
3. Commissures which connect the central stem with the appendages.
4. Lateral structures.
5. Commissures connecting the lateral structures.
6. Dorsal structures, i.e. structures which lie dorsal to the encephalon and form a cartilaginous roof to the cavum cranii.

1. The Central Stem.

The central stem is at a very important morphological stage, because it shows three independent elements which are from behind forwards:

(*a*) The *pars chordalis.*
(*b*) The *pars trabecularis.*
(*c*) The *pars interorbito-nasalis.*

The condition recalls that of the mole at the 10–11 mm. stage in which similar cartilaginous elements are present and independent of one another (Noordenbos and Fawcett); but in Tatusia the independence of the pars

---

[1] The expenses of this research were to a large extent borne by the University of Bristol Colston Research Society.

trabecularis and pars interorbito-nasalis is maintained later than in the mole. The condition is of interest because it has hitherto been assumed that the nasal septum is formed by forward prolongation of the pars trabecularis. This is certainly not the case either in Tatusia or Talpa[1].

(*a*) *The pars chordalis.*

The pars chordalis is of considerable length and posteriorly of considerable breadth. In general form as viewed from above it is quadrilateral, but narrower in front than behind. It may be regarded then as having four borders which are anterior, posterior, and two lateral.

The posterior border is at least twice as wide as the anterior; it forms the anterior margin of the primary foramen magnum, is concave towards that foramen and the concavity is deepest at the middle line where a well-marked *incisura anterior* is formed in which the cartilaginous dens is lodged. The lateral limit of the posterior border may be taken as at an antero-posterior line drawn obliquely from within forwards and outwards through the medial margin of the hypoglossal canal.

The anterior border is narrow from side to side and concave forwards. Its extremities therefore project forwards towards the pars trabecularis from which it is separated by dense cellular tissue in which is lodged the *chorda dorsalis.*

The lateral borders are the longest and may be described as consisting of two parts, viz. a posterior and an anterior. The posterior part is somewhat shorter than the anterior part, and it forms the medial margin of a large space which will later become the *foramen jugulare*: the anterior part is in close relation with the medial side of the "cochlear" segment of the pars cochlearis of the auditory capsule, and it is in its whole length connected with this by a certain amount of cellular tissue. At a later stage this cellular tissue will in great part be replaced by cartilage, but a small vacuity will persist as the basi-cochlear fissure (Pl. X).

At the junction of the various borders with one another angles are found, thus, a postero-lateral angle lies at the junction of each lateral border with the outer end of the posterior border. This postero-lateral angle is directly continuous with the ex-occipital cartilage, the site of the continuity being perforated by the hypoglossal canal. At junction of the lateral borders with the anterior border antero-lateral angles are formed which form the horns of the crescentic anterior border of the pars chordalis.

The surfaces of the pars chordalis are superior or caval, and inferior. The superior surface is markedly concave from side to side, but near its anterior end this concavity is replaced by a transverse convexity under which the chorda dorsalis runs. Save at this spot the chorda dorsalis in its forward course from the dens lies on the caval surface of the pars chordalis.

The inferior surface is broad in its posterior half flattened or even slightly

---

[1] What I have termed pars trabecularis Noordenbos calls the *lamina polaris.* "Ueber die Entwickelung des Chondrocraniums der Säugetiere," *Petrus Camper*, vol. 3, 1906.

concave, but in its anterior half or so, it is narrow and convex from side to side and tends to project especially at its anterior half in the form of a keel.

(*b*) *The pars trabecularis.*

This element of the central stem is of comparatively small size and may be described as a pentahedral plate of cartilage perforated centrally by the hypophyseal duct. It is pointed anteriorly, straight posteriorly. Its borders are two antero-lateral, two lateral and one posterior.

The antero-lateral borders commence at the pointed anterior extremity, and diverge from one another rapidly as they are traced backwards. They form the postero-medial boundaries of the incomplete sphenoidal fissure.

Each lateral border is subtended by a mass of cellular tissue which is divisible into three parts, viz. an anterior which is continued out to the cartilaginous *ala temporalis*, an intermediate which is continued outwards in front of the foramen caroticum, then lateral to that foramen to fuse with the cochlear capsule, and is the primordium of the *anterior trabeculo-cochlear commissure*, a posterior which passes outwards behind the foramen caroticum as the posterior trabeculo-cochlear commissure to fuse with the cochlear capsule.

The posterior border is raised up to form a transverse crest which is the *crista transversa.*

The surfaces of the pars trabecularis are two in number, viz. a superior or caval, and an inferior. The superior surface is concave and at the deepest part of the concavity is perforated by the hypophyseal duct. The inferior surface is convex from side to side and marked in its middle by an antero-posterior keel-like ridge, which is perforated at its middle by the hypophyseal duct.

A large vacuity separates the pars trabecularis from the pars chordalis as viewed from below in the model, because the connective tissue has not there been modelled in order that the chorda dorsalis which makes a curious hook-like bend downwards into the vacuity may be brought into view.

(*c*) *The pars interorbito-nasalis.*

The pars interorbito-nasalis is separated from the pars trabecularis by a V-shaped fissure which laterally is confluent with the sphenoidal fissure of the corresponding side. The interorbital part of this segment of the central stem is very short and commences behind in a curious way. It looks, in fact, as if formed by the fusion of two common masses on each side of the middle line which have resulted from the junction of the pre- and post-optic limbs of the medial angle of the ala orbitalis, medial to the foramen opticum (Pl. VI). These two common masses fuse together at an acute angle and so seem to form the hinder part of the *inter-orbital septum*, viz. that part between the optic foramina; that part of the interorbital septum immediately in front of this fusion forms the medial boundary of the orbito-nasal fissure on each side of it. It is very low in height. The remainder of the pars interorbito-nasalis, which lies in front of the interorbital septum is the *septum nasi.*

The septum nasi consists of two parts, viz. a *subcerebral* and a *precerebral.* The subcerebral part has a superior or caval border which is comparatively thin and continued forwards in the plane of the floor of the cavum cranii. The inferior border (Pl. VII) is thicker and is continued forwards almost parallel with the upper border. It however does diverge somewhat from the upper border when traced forwards and as a result the septum nasi gradually deepens from behind forwards. The precerebral part of the septum nasi is characterised by the fact that it on each side gives off a lateral expansion which forms the roof of the corresponding narial passage, and is later continued downwards as the lateral wall of the nasal capsule. The inferior border as traced forwards gradually rises towards the superior border but soon runs straight forwards parallel with that border, so that a very obtuse angle is formed between the two segments of the inferior border of the precerebral segment of the septum nasi. On each side of the anterior segment of the inferior border of the precerebral segment of the inferior border lies an *anterior paraseptal cartilage,* which in great part and from behind forwards is separated from the septum nasi by a narrow fissure, the *septo-paraseptal fissure,* but in front of this fissure is directly continuous apparently with the septum. Each anterior paraseptal cartilage is connected by its inferior border and near its anterior end by a cellular *lamina transversalis anterior,* with the lateral wall of the nasal capsule. The anterior end of the septum nasi was not chondrified and has not been represented in the model.

2. APPENDAGES TO THE CENTRAL STEM (Pls. VI, VII, VIII, IX).

These from behind forwards are:

(*a*) The ex-occipital cartilages.
(*b*) The auditory capsules.
(*c*) The alae temporales.
(*d*) The alae orbitales.
(*e*) The lateral nasal capsules.

(*a*) *The ex-occipital cartilages.*

Each ex-occipital cartilage is a massive bar which passes backwards and outwards from the corresponding postero-lateral angle of the pars chordalis of the central stem. It may be regarded as springing by an anterior and a posterior root between which the hypoglossal canal is enclosed. It runs outwards and backwards practically parallel with the pars canalicularis of the auditory capsule and comes to an end posteriorly at a level corresponding with that of the pars canalicularis. If cut across coronally it is seen to be triangular in section; one face of the triangle is directed forwards and upwards towards the infero-medial surface of the pars canalicularis of the auditory capsule. This face or surface is formed on the *lamina alaris* and is separated from the auditory capsule by the recessus supra alaris which medially is continuous with the foramen jugulare, and laterally opens out to the exterior.

At no point at this stage is there any direct connection between the ex-occipital cartilage and the pars canalicularis of the auditory capsule. Another face of the ex-occipital is directed towards the cavum cranii looking somewhat obliquely upwards and inwards, and its lower margin forms the lateral boundary of the incomplete primary foramen magnum. The remaining surface which is infero-lateral is concave, being overhung by the lamina alaris (Pl. VII).

(*b*) *The auditory capsules.*

These are of very great size and at the present stage lie more in the floor of the cavum cranii than in the lateral margin. Each may be divided into two primitive parts, viz. a more lateral which containing the semicircular canals is the *pars canalicularis*, and a more medial which is termed the *pars cochlearis*, and this latter is sub-divisible into a vestibular and a cochlear segment.

At this early stage the auditory capsule as a whole is naturally but imperfectly chondrified, the pars canalicularis as is usual being more perfectly chondrified than the pars cochlearis, which in fact is only chondrified at its antero-inferior and postero-medial parts.

The whole auditory capsule at this stage has a very isolated position and has no cartilaginous connection with any other region of the chondro cranium. It is connected with the central stem by connective tissue only, no part of which shows at this stage any sign of chondrification.

The pars canalicularis. This is the lateral part of the auditory capsule and so named because it contains the semicircular canals which determine to a large extent its form. Its lateral aspect forms part of the lateral surface of the neural chondro cranium, whereas antero-medially it is directly continued into the pars cochlearis.

As a whole the pars canalicularis presents for examination four free surfaces of which one is lateral, another is anterior, another supero-medial, and the remaining one infero-medial.

The *lateral* surface is most conveniently regarded as being triangular in shape with base forwards, and with apex opposite, forming the so-called cupula. The borders of this triangular lateral surface are anterior or basal, superior and inferior and will be considered before the surface itself is described.

The anterior or basal border is very slightly convex in the forward direction. It commences above at the superior basal angle, which may perhaps be the representative of a later-forming tegmen tympani, though such a structure cannot be recognised at the stage now being described. Below this basal angle a slight notch is met with which, because it is caused by the crus breve of the incus cartilage is called the fossa incudis. Some distance below and medial to the fossas incudis a slight projection (to which the, at this stage, cellular processus styloideus is attached) is found and is from the fact that the processus styloideus is attached to it, the *crista parotica.* Below this comes the inferior somewhat rounded basal angle which is the *processus mastoideus.*

The superior border commences anteriorly at the superior basal angle and runs backwards and slightly downwards to the end of the cupula. From its anterior half there springs the *lamina parietalis*, a plate-like structure of which more will be said in the proper place. Behind the lamina parietalis the superior border is free and at this time forms part of the brim of the cranium. This part of the superior border is semi-cylindrical and caused by the superior or anterior semicircular canal and it forms part of the *prominentia semicircularis anterior*.

The *inferior* border commences at the inferior basal angle, passes backwards and upwards to the end of the cupula. It is semi-cylindrical and caused by the posterior semicircular canal, hence it is the *prominentia semicircularis posterior*.

The lateral surface—itself of triangular outline—is convex, and a special convex ridge runs across it from about the middle of the prominentia semicircularis posterior to the middle or thereabouts of the base. This ridge is the *prominentia semicircularis lateralis*, and is caused by the lateral semicircular canal.

The anterior surface is narrow from side to side, but deep in the vertical direction, it forms the posterior wall of the primary tympanic cavity. It is marked by the sulcus facialis which pursues a somewhat curved course along it, lying at first supero-medial then later as traced downwards more lateral. To the medial side of the lower end of the sulcus facialis a hollow is found which lodges the stapedius muscle and is therefore termed the *fossa musculi stapedii*.

The supero-medial surface looks more medialwards than upwards. It is bounded above by the prominentia semicircularis anterior, below by a semi-cylindrical elevation which is directed backwards and upwards towards the cupula and from the fact that it contains the crus commune of the semicircular canals (anterior and posterior) is the *prominentia cruris communis*. A small perforation exists in this prominence which is due to non-chondrification. It does not transmit anything and is filled with connective tissue. There is an anterior border to the supero-medial surface which at the same time forms the lateral margin of the meatus auditorius internus. At about the centre of the supero-medial surface a slight hollow is met with, which, because it is surmounted by the prominentia semicircularis anterior is termed the *fossa subarcuata anterior*. It is also termed the floccular fossa, but at this stage the flocculus does not rest in it; above and anterior to this fossa an elevation caused by the ampulla of the anterior semicircular canal is visible, and is indented by backward and outward extension of the upper lateral angle of the meatus auditorius internus. This elevation is the *prominentia utriculo ampullaris anterior*.

The *infero-medial* surface (Pl. VI) is of comparatively large size and concave in all directions. The concavity is not a deep one nor is it specially localised to one spot as, say, in the seal. It is the *fossa subarcuata posterior* and is bounded below and laterally to a certain extent by the *prominentia semicircularis* *posterior*. Somewhat infero-anteriorly to the hollow a rounded prominence the *prominentia utriculo-ampullaris* marks the site of the ampulla of the posterior semicircular canal. The greater part of the infero-medial surface is directed towards the lamina alaris and it therefore forms the roof of the *recessus supra-alaris*, which medially is continuous with the foramen jugulare.

The pars cochlearis. The pars cochlearis is divisible into two parts, viz. "vestibular" and a "cochlear." The "vestibular" segment contains parts of the utricle and of the succule and corresponds roughly with the vestibule of the temporal bone. It is characterised at this stage mainly by the fact that medially it is perforated by the meatus auditorius internus and laterally by the *foramen vestibuli*, and by the fact that it is crossed superiorly by the facial nerve. At this stage it is in a very incomplete state of development, and the meatus auditorius internus is of enormous size owing to this incomplete chondrification; it is in fact so large that it practically takes up the whole of the medial or caval wall of the vestibular segment. Not only is the medial wall deficient but the roof of the upper wall of this segment likewise shows a great gap below the facial nerve, and there is therefore no cartilaginous sulcus facialis in this region. The inferior wall too of the vestibular segment is almost wholly occupied by the large conjoined foramina perilymphaticum and cochleae. The lateral wall is however more complete and is perforated by the comparatively small *foramen vestibuli* into which is fitted the foot of the *stapes* cartilage. This wall forms the upper part of the medial wall of the primitive tympanic cavity.

The "cochlear" segment of the pars cochlearis is only chondrified at this stage to a very slight extent at its infero-medial aspect, all the rest is in a dense cellular condition but it is of considerable size and is connected with the central stem in the manner already indicated above (see pars trabecularis). Its surfaces are supero-medial, antero-lateral and inferior. The supero-medial surface forms a considerable part of the floor of the posterior cranial fossa and is much flattened. Except at its postero-medial part this region is quite unchondrified and is represented in Plate VI stippled. The antero-lateral surface is in relation with the Gasserian ganglion and somewhat flattened, no chondrification is observable here. The inferior surface, which is markedly convex, is oval in form with its long axis directed from behind forwards and medialwards. It is crossed along its long axis by the internal carotid artery. At its hinder part the common foramen (foramina cochleae and perilymphaticum) is found, above which lies the *promontorium* caused by the initial part of the *ductus cochlearis*.

(*c*) *The alae temporales* (Pls. VI, VII).

Each ala temporalis is of very simple form being a mere curved rod of cartilage placed some distance below the plane of the general floor of the cavum cranii, and projected into the large *spheno-parietal* fontanelle partially dividing that fontanelle into an anterior segment which will become the sphenoidal fissure and a posterior segment, the *foramen pro-oticum* proper. Its medial extremity is connected with the lateral border of the pars trabecularis of the central stem by connective tissue and from this medial extremity there projects in a downwards direction a short blunt process which is the *processus pterygoideus.* Amongst other structures the ophthalmic and maxillary divisions of the fifth nerve pass forwards above the ala temporalis to the cavity of the orbit. The mandibular division of the fifth nerve descends behind it.

(*d*) *The alae orbitales.*

These are exceedingly interesting in Tatusia. Each is a triangular plate which overhangs and forms the roof of the orbital cavity. Each consists of a body or main mass with a base which forms part of the cranial brim. By its basal angle important relations are established. Thus, the anterior basal angle is connected by a well chondrified bar with the frontal prominence of the pars intermedia of the paries nasi, the bar in question being the *spheno-ethmoidal commissure,* which forms the lateral boundary of the *orbito-nasal fissure.* The posterior basal angle is joined by connective tissue only with the anterior extremity of the *lamina parietalis,* an important point in the phylogeny of the lamina parietalis. The apex of the ala orbitalis bifurcates into two long limbs which enclose and meet medial to the foramen opticum, a foramen which is of large size and oval in shape. Of these two limbs the anterior or preoptic is the more slender, each being cylindrical in form. Union between the two limbs having been established the common mass curves forwards and medialwards to join the corresponding postero-lateral part of the pars interorbito-nasalis, the appearance presented giving the impression that this pars interorbito-nasalis bifurcates when traced backwards. From about the middle of the ventral surface of the post-optic limb of the apex of the ala orbitalis a well marked process projects laterally. This gives attachment to the rectus system of muscles of the eyeball and is the *ala hypochiasmata* (Pl. VII). From the examination of a younger stage, viz. that of 10 mm. C.R. length it seems evident that the ala hypochiasmata chondrifies independently of the post-optic limb of the ala orbitalis and is to be considered as part of the pars interorbito-nasalis. In the body of the ala orbitalis somewhat lateral to the foramen opticum a small foramen is met with which transmits a blood vessel from the cavum cranii to the orbital cavity (I have queried this in Plate VII as foramen epiopticum).

(*e*) *The lateral nasal capsules.*

These structures will be described later under the nasal capsule.

3. COMMISSURES CONNECTING THE CENTRAL STEM WITH THE APPENDAGES.

As these structures are all unchondrified their description will be deferred until the 17 mm. stage is described.

4. Lateral Structures.

These are in this case the lamina parietalis and the ala orbitalis. No supra-occipital cartilages are as yet chondrified.

The *lamina parietalis* is a plate-like cartilage which springs from the anterior half of the superior border of the pars canalicularis of the auditory capsule. Each is directed upwards and forwards for a short distance, it then turns wholly forwards arching over the spheno-parietal fontanelle and ends in close contact with the posterior basal angle of the ala orbitalis but is separated from it by a narrow interval filled by connective tissue.

The *ala orbitalis* having been previously fully dealt with need not further be described.

5. Lateral Commissures.

The only complete lateral commissures are the spheno-ethmoidal; the orbito-parietal commissures are not complete since the lamina parietalis is not fused with the posterior basal angle of the ala orbitalis.

The *spheno-ethmoidal* commissure (Pls. VI, VIII, IX) on each side is a strong bar well chondrified connecting the anterior basal angle of the ala orbitalis of its side with the frontal prominence of the pars intermedia of the paries nasi. It forms the lateral boundary of the orbito-nasal fissure.

The nasal capsule.

The nasal capsule is not perfectly chondrified at this stage, the anterior extremity being wholly in a cellular condition, only so much as consists of cartilage has been modelled. What is chondrified forms a relatively enormous structure which consists of a subcerebral and precerebral part.

When viewed from above it presents a pear-shaped form, the large bulbous end of the pear being posterior. So much as can be seen from the front consists then of a narrower anterior part, the *pars anterior* and a much wider though shorter posterior part, the *pars intermedia.* The *pars posterior* is seen from the caval aspect and it is to a certain extent overlapped by the alae orbitales, though separated from them by the orbito-nasal fissure.

The subcerebral part which forms the anterior part of the floor of the cavum cranii shows two large vacuities on each side of the septum nasi no lamina cribrosa having been developed at this stage; and the plane of the septal wall together with the upper margin of each lateral part of the nasal capsule is practically that of the floor of the cavum cranii generally, but the plane of the upper or dorsal surface of the precerebral part is almost at right angles with that of the subcerebral part (Pls. VIII, IX).

The precerebral part as seen from above and in front is almost complete save for a small foramen at the junction of the pars anterior and the pars intermedia. This foramen, the *foramen epiphaniale,* lies near the upper end of the sulcus *antero-lateralis* which separates the pars anterior from the pars intermedia. It transmits the lateral branch of the nasal nerve. In the middle of the precerebral part an antero-posterior sulcus is seen—the *sulcus dorsalis nasi* and on each side of this lies a longitudinal antero-posterior semi-cylindrical elevation which is the roof of the corresponding narial passage.

The lateral wall (Pls. VIII, IX) of the nasal capsule is incomplete in front, but is divisible into a pars anterior, a pars intermedia and a pars posterior. The *pars anterior* is separated from the pars intermedia by a well-marked curved sulcus which commencing above and behind not far from the antero-lateral margin of the subcerebral part curves forwards then downwards and finally somewhat backwards towards the lower margin of the lateral wall (paries nasi). The sulcus is the *sulcus antero-lateralis.* It corresponds with the crista semicircularis on the medial surface of the lateral wall. The *pars intermedia* is separated from the pars posterior by the *sulcus lateralis posterior*, which commencing above opposite the attachment of the spheno-ethmoidal commissure to the nasal capsule curves downwards then somewhat backwards and finally forwards to reach the lower margin.

Considering these parts in detail and taking first the *pars anterior*, one notices that it is deeper behind than in front, that above it is continuous with the roof of the corresponding narial passage whilst below it is free but incurved to form the cartilaginous maxillo-turbinal; the *pars intermedia* is of great height and lateral projection. It is divisible at this stage into two well-marked subdivisions of which the upper part is the *prominentia frontalis* and gives attachment to the spheno-ethmoidal commissure; the lower prominence is the *prominentia maxillaris* and it as usual gives attachment at about its most prominent part to the inferior oblique muscle of the eyeball[1]. These prominences correspond with recesses on the medial side of the lateral wall, the frontal prominence with the *recessus frontalis*, the maxillary prominence with the *recessus maxillaris*; the *pars posterior*, which is separated from the pars intermedia by the sulcus lateralis posterior—a sulcus which corresponds with the line of attachment of the main root of the first primary ethmo-turbinal on the medial aspect of the lateral wall of the nasal capsule—is the smallest segment of the lateral wall. It is narrow from above downwards and curved backwards and inwards towards the septum nasi. Its hinder small end forms the cupula nasi posterior. Its upper border forms the lower or anterior boundary of the orbito-nasal fissure through which the nasal nerve gains the orbital cavity. Its lower border is free but is not sufficiently incurved posteriorly at this stage as to form a lamina transversalis posterior. The lateral surface of the pars posterior forms the antero-medial wall of the orbital cavity and is the *planum antorbitale.*

The *medial* aspect of the lateral wall of the nasal capsule is extremely simple at this stage. It is divisible into the same segments as the lateral aspect. Its pars anterior is sharply marked off posteriorly in its upper half by the crista semicircularis but in its lower half it is only separated from the pars

---

[1] Dotted lines leading back to a dotted circle (the eyeball) indicate the inferior oblique muscle (Pl. VIII).

intermedia by a low rounded ridge.—The lower margin of the pars anterior is incurved to form the *maxillo-turbinale,* and at its anterior end the margin is much inbent and continued towards the anterior paraseptal cartilage by a connective tissue representative of the lamina transversalis anterior. The pars intermedia is deeply recessed and bounded posteriorly by the first *primary ethmo-turbinal,* which stretches from the upper to the lower margin of the medial aspect of the lateral wall and so cuts the pars intermedia completely off from the pars posterior. The cavity of the pars intermedia may be divided into an upper and a lower recess, the upper being the *recessus frontalis* which produces the prominentia frontalis on the exterior, the lower being the *recessus maxillaris* which produces the prominentia maxillaris on the exterior, there is no visible line of separation between these two recesses at this stage. In the anterior part of the recessus maxillaris the lateral nasal gland is lodged. The *pars posterior* is the smallest segment of the region under consideration. It lies behind the first primary ethmo-turbinal. No lamina transversalis posterior is developed at the present time. As regards the first primary ethmo-turbinal, it may be described as a triangular plate which projects inwards and forwards towards the septum and crista semicircularis; by its base it is attached to the entire depth of the medial aspect of the lateral wall, and its line of attachment corresponds with the sulcus lateralis posterior on the exterior. Its apex is free and turned forwards towards the crista semicircularis. The septum nasi has already been described (see pars interorbito-nasalis). The solum nasi at this stage save for the connective tissue lamina transversalis anterior is entirely wanting, but it is interesting to note that the connective tissue lamina transversalis anterior is upcurved about its middle to form an *atrio-turbinal.*

6. THE VISCERAL CARTILAGES (Pls. VIII, IX).

These from before backwards are arranged in five pairs corresponding with five visceral arches.

The cartilaginous skeleton of the first arch is represented from behind forwards by the *incus* cartilage, the *malleus* cartilage and by Meckel's cartilage. The *incus* cartilage is remarkable for its great size. It consists of a relatively small body which is keyed into the back of the head of the malleus cartilage and projects upwards slightly above the latter as a small somewhat conical knob. The crura which arise from this body are of unusual length, the *crus posterior* or *breve* is of great length and runs almost straight backwards to reach the fossa incudis to the outer side of the basal border of the lateral surface of the pars canalicularis of the auditory capsule. The *crus anterior* or *longum* descends parallel with the manubrium mallei and is also of great length, to the medial side of its lower end the stapes cartilage is attached by dense connective tissue. This crus is at its lower part separated from the manubrium mallei by the chorda tympani nerve.

The *malleus* cartilage is remarkable for the small size of its head and very large size of its manubrium. The head articulates behind with the body of the incus cartilage and sends outwards a considerable wing-like expansion to the front and lateral aspect of the body of the incus. The manubrium is very long and incurved at its lower end; along the medial side of its upper half the chorda tympani nerve ascends.

Meckel's cartilage starts from the body of the malleus cartilage and runs forwards as a simple cylindrical rod almost parallel with the plane of the precerebral plane of the dorsum nasi; at about the middle of its course it bends somewhat sharply medialwards then runs forwards gradually converging on its fellow, but as it is not completely chondrified at this stage it does not meet its fellow in the middle line.

The cartilages of the *second* arch are from behind forwards the stapes and the hyoid cartilage (Richert's). The stapes cartilage is comparatively small, is perforated by a stapedial artery and by its foot fitted into the foramen vestibuli; by its opposite extremity it is connected with the crus longnum of the incus by dense cellular tissue, and it still retains a connective tissue connection (interhyale) with the hyoid cartilage. The hyoid cartilage springs from the crista parotica of the pars canalicularis by connective tissue (laterohyal), around whose lateral aspect the facial nerve winds, soon becoming cartilaginous it continues as such towards the middle line which it does not quite reach, as it suddenly bends downwards to articulate with the top of the anterior extremity of the thyro-hyal, and with the corpus hyale or basibranchial of Parker.

The cartilaginous part of this rod shows no sign of segmentation.

The cartilage of the *third* arch—thyro-hyal—is comparatively short and lies in a plane almost parallel with that of the under surface of the main part of the neural cranium; from behind where it commences in a pointed extremity it is directed medialwards and ends not far from the middle line by articulating above with the hyoid cartilage, and in front with the corpus hyale. The cartilage to which I have referred as the corpus hyale is of small size and when viewed from the front triangular in shape, its base being downwards. By its lateral margins it articulates with the hyoid cartilage and with the thyro-hyal.

The cartilage of the *fourth* arch, viz. the thyroid cartilage is of great interest at this stage, lying in its hinder two-thirds in a plane parallel with that of the thyro-hyal and being of considerable depth it suddenly contracts owing to a deep notch which indents its upper margin and having suddenly harrowed it bends upwards to reach a plane posterior to the corpus hyale and there fuse with its fellow in the middle line. At a later stage the deep notch in the upper border becomes closed over from above and a comparatively large foramen takes its place (Pl. XIII). There is no cartilaginous connection at this stage between the thyro-hyal and the thyroid cartilage.

The cartilage of the *fifth* arch is represented by the cricoid which presents the usual form, save that the ring is not chondrified in front and medially.

The arytenoid cartilages are not yet chondrified.

7. The Osseous Skeleton (Pl. IX).

This at this stage is in an extremely simple condition, only two bones having appeared, viz. the maxilla and the mandible.

The *mandibula* is a large splint-like membrane bone placed lateral to the anterior half of Meckel's cartilage. It shows no sign of condyle or alveolar processes at this stage.

The *os maxillare* has just commenced to ossify, and is placed some distance behind the inferior margin of the pars anterior of the nasal capsule.

It is a tribute to the value of Mallory's connective tissue stain that one is able to model the maxilla at this early stage. Mall, who spoke disparagingly of stains as a means of detecting bone at early stages cannot have used Mallory's stain for that purpose, for in my experience the very finest spicules of bone are brought out by it. I agree that the commonly used haemaloxylin and eosin stain is very unreliable in such matters.

THE PRIMORDIAL CRANIUM OF THE 17 MM. C.R. STAGE OF *TATUSIA NOVEMCINCTA*

(Pls. X, XI, XII, XIII, XIV, XV)

At this stage the chondro cranium has become much more complete, especially in regard to the following regions and structures. A well chondrified and large supra-occipital cartilage is present, which is fused with its fellow dorsal to the cavum cranii to form a large tectum cranii posterius, which additionally is fused with the ex-occipital cartilage of its side, and with the lamina parietalis. The auditory capsule has become more or less elaborated and is now definitely fused with the central stem by the three usual commissures, viz. chordo-cochlear, anterior and posterior trabeculo-cochlear. Between the posterior trabeculo-cochlear commissure and the chordo-cochlear commissure a small basi-cochlear fenestra persists. The meatus auditorius internus has become divided by a crista falciformis into an upper and lower part respectively foramen acusticum superius and foramen acusticum inferius, but the foramen acusticum superius is only complete so far as concerns the nerves for the ampullae of the anterior and lateral semicircular canals, the utricle and the upper nerve to the saccule. There is no foramen faciale, the facial nerve leaving the skull by a sulcus facialis on the upper part of the "vestibular" segment of the auditory capsule.

The fossa subarcuata anterior interna is reduced in size till it is a narrow deep pit which leads into the interior of the pars canalicularis. A well marked tegmen tympani is present.

The ala temporalis now appears fused with the middle of the anterior surface of the anterior trabeculo-cochlear commissure.

The pars trabecularis as viewed from the caval aspect is continuously fused with the pars chordalis of the central stem, but when viewed from below a large transverse gap separated them, the gap being occupied by the down-turned chorda dorsalis. The pars trabecularis however still retains its independence of the pars interorbito-nasalis. Its cranio-pharyngeal canal has closed up. The alae orbitales whilst very generally retaining the form shown at the 12 mm. stage, have made some advances. Thus the post-optic limbs have sent backwards an anterior clinoid process. The pre-optic limbs have developed on the medio-anterior wall of the optic foramen a small spur for the attachment of the obliquus superior of the eyeball, and the optic foramen has become relatively reduced in size. The posterior basal angle has fused with the lamina parietalis forming now a continuous orbito-parietal commissure. The foramen lateral to the foramen opticum observed at the 12 mm. stage has increased in size (may it represent the foramen epiopticum of reptiles?).

Perhaps the most striking changes are observable in regard to the nasal capsule, which though as yet not completely chondrified is of enormous size—especially in length. The actual length of the pars interorbito-nasalis in the model amounts to 13 inches, whilst the length of the pars trabecularis and pars chordalis combined amounts to only 6½ inches. A cupula posterior with tectum nasi completum posterius is now developed, a lamina transversalis posterior is well chondrified, an anterior and a posterior paraseptal cartilage are present. The lamina transversalis anterior although not yet chondrified is easily made out and the medial aspect of the lateral wall of the nasal capsule has much increased in complexity mainly however by increased growth of the parts seen in it at the 12 mm. stage, very little in the way of new structure having appeared. No cartilaginous lamina cribrosa is as yet developed.

In the visceral chondro cranium certain advances have been made. Both the incus and the malleus cartilages are of enormous size and the crus posterior (breve) of the former lies as before on the lateral aspect of the lateral surface of the pars canalicularis of the auditory capsule. Meckel's cartilages have been fused together at their anterior extremities. The hyoid cartilage has had segmented off from it anteriorly a definite cerato-hyal, which at 12 mm. stage was directly continuous with the root of the hyoid cartilage. The thyro-hyals have now come into contact with the posterior margin of the ala of the thyroid cartilage but are still unfused with it. The deep notch in the upper margin of the ala of the thyroid cartilage is now converted into a foramen.

The osseous skeleton has naturally made considerable advance.

The two bones—*mandibula* and *maxilla*—have grown considerably, the mandibula being of great length and covering the greater part of the Meckel's cartilage laterally and reaching almost from the malleus posteriorly to the anterior fused ends of Meckel's cartilage. The maxilla seems to have ossified from two centres, a more medial which covers the lateral aspect of the maxillo-turbinal cartilage and a more lateral covering the prominentia maxillaris of the pars intermedia of the nasal capsule.

The *incisivum* is only represented by a small splint-like centre which lies on the medial aspect of the anterior end of the anterior paraseptal cartilage and which may be called the pars paraseptalis of the incivisum (Broom's "Pre-vomer").

The *zygomaticum* is present lateral to the processus coronoideus of the mandibula and a palatinum lies below the pars posterior of the nasal capsule. Finally a well developed frontale covers the postero-lateral aspect of the prominentia frontalis of the pars intermedia of the nasal capsule, and is continued backwards along the outer side of the orbito-parietal commissure for a considerable distance.

The *vomer* is not yet ossified but its primordium is easily recognised occupying its usual position, i.e. at the medial aspect of the hinder end of the anterior paraseptal cartilage as well as at the medial aspect of the anterior end of the posterior paraseptal cartilage (Pl. XV).

We may now consider in more detail the primordial cranium of the 17 mm. stage taking first the

1. CENTRAL STEM (Pls. X, XI).

This consists of the usual parts from behind forwards, viz. the pars chordalis, the pars trabecularis and the pars interorbito-nasalis. Of these parts the pars interorbito-nasalis is almost twice as long as the other two taken together. As viewed from the caval aspect the pars cochlearis and the pars trabecularis are completely fused with one another, but a glance at the inferior surface shows that this fusion is entirely at the upper aspect as a large transverse gap is visible from below between the two containing the chorda dorsalis. This gap although transverse to the long axis of the central stem is seen to run obliquely backwards so that if continued through into the cavum cranii it would appear at the anterior margin of the basi-cochlear fenestra which is the usual position. This obliquity suggests that during the mutual growth of the pars trabecularis and the pars chordalis the former has been thrust back over the latter and the crumpled up condition of the chorda dorsalis which occupies this gap supports this view.

(*a*) *The pars chordalis* (Pls. X, XI).

The pars chordalis stretches from the anterior margin of the foramen magnum to the afore-mentioned gap below or to an imaginary transverse line drawn through the anterior margin of the basi-cochlear fissures—or even, perhaps, a little in front of this. It is a quadrilateral plate whose antero-lateral angles fuse with the posterior trabeculo-cochlear commissures, whose postero-lateral angles are continued outwards beyond the hypoglossal canals to become the ex-occipital cartilages. The borders are anterior, posterior and lateral. The anterior border is narrow and only visible as such from below where it forms the posterior boundary of the *chorda-trabecular fissure*. The posterior boundary is deeply concave and at the deepest part of its concavity forms the *incisura anterior* which lodges the dens of the axis cartilage. This border forms the anterior boundary of the foramen magnum.

Each lateral border may be traced from the postero-lateral angle, i.e. to the anterior part of the basi-cochlear fissure. It may be divided into three parts, viz. a posterior, an intermediate and an anterior. The posterior part is free and forms the medial boundary of the foramen jugulare. It is directed from behind forwards and medialwards. The intermediate part of the lateral border is fused with the pars cochlearis of the auditory capsule to form the *chordo-cochlear commissure*, and this commissure is of great antero-posterior width. The anterior segment of the lateral boundary is the shortest. It is free and forms the medial boundary of the basi-cochlear fissure.

The surfaces of the pars chordalis are superior or caval, and inferior. The superior or caval surface is wider behind than in front and is concave from side to side and the chorda dorsalis rests on almost the whole length of this surface in the middle line from before backwards, only sinking through to the under aspect at the anterior limit of the upper surface of the pars chordalis. The inferior surface is wide posteriorly, narrow interiorly. It is convex from side to side, but from end to end shows a concavity under its broad part. The under aspect of the narrow anterior segment projects downwards almost keel-like. In front of this keel-like projection the chordo-trabecular fissure is seen to contain the downbent anterior end of the chorda dorsalis.

(*b*) *The pars trabecularis.*

The pars trabecularis at this stage retains to a considerable extent its independence. As already mentioned, as viewed inferiorly the chordo-trabecular fissure (remnant of the basi-cranial fenestra) marks it off from the pars chordalis whilst anteriorly it is quite independent as yet of the pars interorbito-nasalis whether viewed from above or below. As in the younger stage described above it is of pentahedral form, pointed anteriorly where it juts into the notch at the back of the pars interorbito-nasalis, straight behind where confluent above with the anterior margin of the pars chordalis. Its borders are two antero-lateral, two lateral and one posterior. The antero-lateral borders are free and separated from the neighbouring hinder edges of the post-optic limbs (? alae hypochiasmatae) of the alae orbitales by a narrow fissure. The lateral borders give attachment from before backwards to the alae temporales, the anterior and posterior trabeculo-cochlear commissures, between which two latter the foramen caroticum is found. The posterior trabeculo-cochlear commissure is of great antero-posterior width. The posterior border of the pars trabecularis is only free as viewed from below and then only medially where it forms the anterior boundary of the chordo-trabecular fissure. The surfaces are caval or superior, and inferior. The caval surface is slightly concave from side to side and lodges the hypophysis. There is nothing bounding it behind which one could call a crista transversa, and there is no cranio-pharyngeal canal at this stage. The hypophysis is of small size. The inferior surface is markedly convex from side to side, and marked by a keel-like median antero-posterior ridge which is deeper behind than in front.

(*c*) *The pars interorbito-nasalis.*

This region and structure is of enormous length, being in actual measurement of the model 13 inches in length—and almost twice as long as the combined partes trabecularis and chordalis. Comparatively low in height so long as it lies between the optic foramina which it separates, it suddenly increases in height between the orbito-nasal fissures which it also separates (Pl. XV). From this point onwards as nasal septum it consists of a subcerebral and a precerebral part and its height varies very little, perhaps it is greatest just behind the junction of the subcerebral and precerebral segments where its upper border is thickened to form a *crista galli*, from this region forwards there is a very slight fall in height, but there is a sudden increase in height at about the junction of the anterior and middle thirds of the precerebral parts. This increase is however more apparent than real as it is here that the processus lateralis ventrales are given off, and as they descend almost in the same vertical plane as the septum nasi the apparent depth or height of the septum is much diminished. More will be said regarding the septum nasi when the nasal capsule is described.

2. APPENDAGES TO THE CENTRAL STEM.

(*a*) *The ex-occipital cartilages.*

In general form and direction these cartilages have changed but little on becoming older, but each cartilage at its posterior extremity is now almost completely fused with the neighbouring supra-occipital cartilage, slight notches median and lateral only remaining to indicate the site of their original separation (Pls. XII, XIII). Each ex-occipital cartilage leaves the corresponding postero-lateral angle of the pars chordalis by two roots which embrace the hypoglossal canal, each passes, at first backwards and outwards, lying parallel almost with the infero-medial surface of the pars canalicularis of the auditory capsule from which it is separated by the recessus and fissura supra-alaris, then it turns suddenly upwards by the side of the foramen magnum of whose lateral margin it forms a considerable part. It ends by fusing with the postero-lateral angle of the supra-occipital cartilage. The first stage is thick and strong and triangular in section. Its surfaces are, supero-medial, antero-lateral and inferior. The supero-medial surface is directed towards the foramen magnum and the cavum cranii. The antero-lateral surface is triangular in shape, is formed on the lamina alaris whose apex juts forwards under the pars canalicularis. The inferior surface is concave owing to the forward curve of the lamina alaris. Upon the anterior-lateral surface of the lamina alaris rest the sinus venosus transversus and the ganglia of the vagus and glossopharyngeal nerves.

(*b*) *The auditory capsules* (Pls. X, XI, XII, XIII).

These are of a very large relative size—and divisible into the two main parts, viz. pars cochlearis and pars canalicularis of which the former is subdivisible into vestibular and cochlear segments. Although by no means completely chondrified considerable advance has been made in that direction.

The cochlear part of the pars cochlearis is practically fully chondrified and is now attached to the central stem by three cartilaginous commissures which are from before backwards, the anterior trabeculo-cochlear, the posterior trabeculo-cochlear and the chordo-cochlear. The two latter are of great antero-posterior width, hence the basi-cochlear fissure which lies between them is of small antero-posterior length.

The vestibular segment of the pars cochlearis is not yet completely chondrified but the meatus auditorius internus is now divided by the crista falciformis into a small foramen acusticum superius and a large foramen acusticum inferius. There is no commissura supra-facialis so that a facial canal is not present and the facial nerve rests in a sulcus facialis whose floor is only imperfectly chondrified and as a result opens into the foramen acusticum superius. The foramina cochleae and perilymphaticum are still unseparated from one another.

The pars canalicularis now shows a well-developed tegmen tympani which projects forwards over the incus-malleus joint. The fossa subarcuata interna is small in area but very deep, being at this stage a foramen opening into the interior of the pars canalicularis.

There is a fossa subarcuata on the infero-medial surface which likewise has an imperfectly chondrified floor. The foramen endo-lymphaticum is of large size and leads backwards into a long groove which lodges the ductus endo-lymphaticus after its exit from the foramen. These are the main points of distinction between this stage and that at 12 mm., and as the former has been fully described, no more detailed description of this stage is necessary so far as it concerns the auditory capsule.

(*c*) *The ala temporalis* (Pls. X, XI).

This cartilage still retains a simple form but is now united by cartilage both to the lateral border of the pars trabecularis and the anterior surface of the anterior trabeculo-cochlear commissure from which it passes laterally then makes a curve convex forwards, outwards, upwards, and backwards to end in a blunt point. In the concavity the mandibular division of the fifth nerve lies.

(*d*) *The ala orbitalis.*

The ala orbitalis shows a few growth changes, but retains to a large extent its form of the 12 mm. stage. The post-optic limb of the apical angle has developed a backwardly projected process (Pl. X) which has all the appearances of an anterior clinoid process, and the pre-optic limb sends backwards towards the medial side of the foramen opticum a small triangular spur from which the musculus obliquus superior takes origin. The foramen opticum has become relatively smaller than at its 12 mm. stage, but what I have ventured to call the foramen epiopticum is of larger size. The posterior basal angle is now completely fused with the anterior limb of the lamina parietalis so that a complete orbito-parietal commissure is formed. The anterior basal angle is as it was at the 12 mm. stage fused with the prominentia frontalis of the pars intermedia of the nasal capsule forming the spheno-ethmoidal commissure. The foramen epiopticum is well shown at this stage.

3. Lateral Structures.

These from behind forwards are the supra-occipital cartilage, the parietal plate, the ala orbitalis and the commissures which bind these lateral structures together.

The *supra-occipital cartilage,* which is now fused below with the upper end of the ex-occipital, is triangular in form, with base upwards (Pls. XII, XIII).

By its apex it is fused with the ex-occipital, by its anterior-basal angle it is joined to the parietal plate through what I shall term the *occipito-parietal commissure* and by its posterior or internal basal angle it joins that of the opposite cartilage to form the tectum cranii posterius vel synoticum.

The *parietal plate* is a somewhat quadrilateral curved plate of cartilage attached by its lower border to the anterior half of the upper border of the pars canalicularis of the auditory capsule. Its anterior border is continued to and fused with the posterior basal angle of the ala orbitalis under the designation *orbito-parietal commissure.* Its posterior border is joined by the supra-occipital cartilage as the occipito-parietal commissure. The upper border is free and forms part of the free upper lateral margin of the cranial cavity.

It may be well to say that for the most part the terms anterior and posterior borders of the parietal plate are artificial or imaginary borders drawn from the anterior and posterior limits of the spring of the plate from the auditory capsule.

The *ala orbitalis* has already been described.

The commissures are occipito-parietal, orbito-parietal and spheno-ethmoidal (orbito-nasal).

The occipito-parietal is the anterior attenuated basal angle of the supra-occipital cartilage which, arching forwards over the upper margin of the pars canalicularis of the auditory capsule and separated therefrom by the anterior part of the common *occipito capsular fissure,* joins the parietal plate.

The orbito-parietal commissure which connects together the parietal plate and the posterior basal angle of the ala orbitalis is an important site of origin of the musculus temporalis. It forms at this time the outer boundary of the spheno-parietal fontanelle and developmentally is a forward growth of the parietal plate to the posterior basal angle of the ala orbitalis as was seen in the stage previously described.

The orbito-nasal (spheno-ethmoidal) commissure has a twofold origin, viz. from the anterior basal angle of the ala orbitalis and a backwardly directed process from the prominentia frontalis of the pars intermedia of the auditory capsule. It bounds the orbito-nasal fissure laterally.

The *tectum cranii posterius* is of considerable size and is formed by the fusion of the medial basal angles of the supraoccipital cartilages of the two sides with one another. It is deepest centrally and it forms the hinder (upper) boundary of the primary foramen magnum.

The nasal capsule.

This truly enormous structure is as long as the remainder of the chondro cranium. It consists of the usual parts, viz. a septum, a roof, a lateral wall and a floor.

The septum nasi is that part of the pars interorbito-nasalis of the central stem which is included within the nasal capsule. It consists of two parts, viz. a subcerebral and a precerebral. The subcerebral part is of large size or perhaps one had better say of great length, almost equal in fact to the length of the precerebral part. It is almost uniform in height, but is a little higher at a short distance from the front than behind. This augmentation is the crista galli. Its superior margin separates the two subcerebral vacuities of the nasal capsule from one another, and there is as yet no sign of any lamina cribrosa. The inferior margin of the septum is much thicker than the superior, and it is especially thick posteriorly. Infero-lateral to its subcerebral part is on each side a *posterior paraseptal* cartilage. This is separated by a narrow *septo-paraseptal fissure* from the septum nasi. The precerebral part of the septum, like the subcerebral, may be described as having a superior and an inferior margin. The superior margin does not however project freely, or at all events it is connected directly with the lateral nasal capsule by the tectum nasi anterius. In its posterior half this part of the upper border may be said to be flush with the superior surface of the tectum nasi (Pl. X), but in its anterior half it is sunk below the level of the tectum at the bottom of the *sulcus dorsalis.*

The inferior border is thicker than the superior one and is convex from side to side. It has on each side of it in the greater part of its extent the anterior paraseptal cartilages which are separated by a narrow septo-paraseptal fissure from the septum; more anteriorly, i.e. is near the anterior end of the lower margin of this segment of the septum, the lamina transversalis anterior passes directly outwards from the septum to the lateral wall. This lamina, which will be described in detail later, may here be said to be continuous by its hinder border with the anterior paraseptal cartilage of its side, and in front with the processus lateralis ventralis (Pl. XIV). The main mass of the septum is for the most part of uniform thickness save near its anterior end. Here it greatly thickens below the level of the tectum anterius, a condition which is like that in mole, hedgehog, and in Miniopterus, forming the basis of a septo-turbinal. There is no septal foramen, and the anterior border of the septum is an oblique one, looking downwards and backwards.

The *roof* (tectum nasi) consists of two parts, viz. a tectum posterius and a tectum anterius. At this stage no lamina cribrosa is developed so that the subcerebral part of the roof is represented only by the tectum nasi posterius which is the forwardly curved dorsal part of the cupula nasi. This tectum posterius is at this stage quite free of the upper margin of the septum. Although the lamina cribrosa is not present, and although the cribro-ethmoidal crest is likewise absent, the olfactory nerves can be seen to leave the interior of the nasal capsule in the usual arrangement, viz. an antero-lateral and a postero-median group. The antero-lateral supply especially the interior of the recessus frontalis of the pars intermedia, whilst the postero-median supply the septum and the interior of the pars posterior. From the anterior part of the recessus frontalis a *cribro-ethmoidal canal* runs forwards through the tectum anterius and ends at the *foramen epiphaniale.*

The precerebral part of the roof (Tectum nasi anterius) is long, broad and convex on each side of the septum. It may be said to be wider in front than behind, flat behind, but in front longitudinally grooved in the middle, the groove being the sulcus dorsalis nasi. Laterally the tactum runs more abruptly than usual into the lateral wall of the capsule, anteriorly the tectum forms a very slight projection—the spina cupularis.

The *lateral wall* (*paries nasi*) (Pls. XII, XIII) is divisible into three parts which are from behind forwards, the pars posterior pars intermedia and pars anterior. The pars posterior is separated from the pars intermedia by the *sulcus postero-lateralis,* the pars anterior is separated from the pars intermedia by the *sulcus antero-lateralis.* The sulcus postero-lateralis commences above at about the middle of the lateral boundary of the olfactory vacuity in the subcerebral segment of the nasal capsule, it descends to the inferior margin of the paries nasi after running a course convex backwards. Its upper end perhaps may be more precisely stated as at the hind edge of the attachment of the spheno-ethmoidal commissure.

The antero-lateral sulcus is very well marked. It commences above at a deep depression into which opens the anterior (external) orifice of the foramen epiphaniale. It descends with a curved course convex forwards and ultimately bifurcates to enclose a triangular area which corresponds externally with the recessus glandularis internally, the two limbs of bifurcation can be traced to the lower margin of the paries nasi. These two sulci which are such important external landmarks are of equal importance with reference to the medial aspect as they correspond with projections on the medial aspect of the lateral wall, thus the antero-lateral sulcus corresponds with the crista semicircularis and the postero-lateral with the first primary ethmo-turbinal.

The *pars posterior*, that part of the paries nasi which lies behind the postero-lateral sulcus is, as seen from the side, triangular in form with base forwards at the sulcus lateralis posterior. The apex is directed backwards towards the taenia preoptica of the ala orbitalis and separated from it by the orbito-nasal fissure. This apical region can be traced medialwards towards the septum nasi, but it is not fused therewith. The upper border of the pars posterior ends freely as the lateral margin of the subcerebral olfactory vacuity (Pl. X). The inferior margin is curved medially and takes a large part in the formation of the *lamina transversalis posterior*, but that part of it which lies anterior to the lamina transversalis posterior ends freely and helps to bound laterally the fenestra basalis of the solum nasi (Pl. XI).

The *pars intermedia*, as seen from the lateral aspect, is very large and prominent. It consists of at least three parts, viz. a superior to which is attached the spheno-ethmoidal or orbito-nasal commissure, the *prominentia frontalis* (v. superior), an inferior which in the recent condition is concealed in part at this stage by the maxilla and is the *prominentia maxillaris* (v. inferior); an anterior which is perhaps the most striking of all, and is the forward continuation of the prominentia of the frontalis. This is the *prominentia anterior* (Pl. XI).

To the hinder aspect of the prominentia maxillaris the *musculus obliquus inferior oculi* is attached as usual.

The pars anterior is almost as long as the pars intermedia and the pars posterior taken together. It is deep behind where it is bounded by the sulcus antero-lateralis but gradually tapers in front and is smallest at the anterior extremity where it is slightly incurved to form a small cupula anterior, and a blunted cartilaginous process, the processus cupularis projects downwards from this cupular region. The inferior margin of this region is in great part incurved to form the *maxillo-turbinal*, but not far from its anterior end it is continuous with the outer edge of the lamina transversalis anterior, the site of continuity being bent upwards into the interior of the nose to form the *atrio-turbinal*, and in the concavity of this junctional region is found the *naso-lacrimal duct* (Pl. XI). No trace of a dorsal fenestra was found in the pars anterior.

Interior of the nasal capsule.

The lateral wall (Pl. XV).

This shows very beautifully the typical division into three segments, viz. the pars posterior (v. ethmoidalis), the pars intermedia (v. maxillo-atrio-turbinalis) and the pars anterior. Of these parts the pars posterior and the pars intermedia are of about equal size, though very different in form; the pars anterior, on the other hand, is greater in extent than the other two taken together. At this stage too the internal aspect of the lateral wall is exceedingly simple and bears out the statements of Voit, Seydel and Paulli.

The *pars posterior* appears as a roughly pentagonal concavity ending in the cupula posterior behind. It has the following boundaries, a posterior or postero-medial, an anterior (divisible into antero-superior and antero-inferior segments), a supero-lateral and an infero-medial.

The postero-medial border is short, lies in the sagittal plane, is placed in almost immediate contact with the septum nasi, but it is not anywhere fused therewith. It is so curved as to be concave forwards. The anterior border consists of two segments, one an antero-superior, the other an antero-inferior segment. These two meet in front at a very acute angle and form the free edges of the first ethmo-turbinal—a structure to be described later. The antero-superior segment of the anterior border commences above and behind at the anterior end of the supero-lateral boundary of the pars posterior, just where this part joins the pars intermedia. It passes forwards and downwards with a somewhat wavy course to the acute angle above mentioned. The antero-inferior segment of this border springs from the anterior end of the infero-medial boundary of the pars posterior, runs forwards and upwards in a curve concave, downwards to reach and fuse with the antero-superior segment at the above mentioned acute angle. The two segments taken together form the anterior border of the pars posterior and at the same time the posterior boundary of the pars intermedia and the acute-angular region projects so far forwards as to reach into the pars anterior. The supero-medial border is free, concave upwards and medialwards. It stretches from the posterior boundary to the hinder end of the superior boundary of the pars intermedia, and forms the antero-inferior wall of the orbito-nasal fissure (Pl. X).

The infero-medial border is divisible into two segments, viz. the hinder which, rather less in length than the more anterior segment, is the median free edge of the lamina transversalis posterior. It comes into very close relation with the nasal septum but is nowhere fused with it. The remainder of this border is free and forms the hinder part of the lateral boundary of the fenestra basalis of the solum nasi (Pl. XI).

The medial surface of the pars posterior is concave and at this stage uninterrupted by the projection of any turbinals, the sole turbinal present being the first primary ethmo-turbinal in this region and that at the anterior limit of the pars posterior.

The *pars intermedia* is of large size and its long axis is placed at right angles to that of the pars posterior and pars anterior, and if the latter be looked upon as approximately horizontal the long axis of the pars intermedia may be regarded as vertical. It is completely shut off by the first primary ethmo-turbinal from the pars posterior, whereas it is for the upper half or so of its extent shut off from the pars anterior by the crista semicircularis. Below the crista semicircularis the pars intermedia is in direct continuity with the pars anterior. The pars anterior is so projected outwards as to cause enormous prominences on the paries nasi and these projections have already been described as the prominentia superior, prominentia anterior and prominentia inferior. Corresponding with these prominences on the exterior are hollows or recesses in the interior. These are a recessus superior or frontalis, a hollow which is bounded above by the superior margin of the pars intermedia, below and anteriorly by the anterior root of the first primary ethmo-turbinal, below and posteriorly by the freely projecting part of that turbinal. Anteriorly, the pars frontalis communicates directly with a very deep and anteriorly projected recess, the recessus anterior, whilst below it is continuous over the free edge of the anterior root of the first primary ethmo-turbinal with the recessus inferior (v. maxillaris). The floor of the recessus frontalis is practically uniformly concave, as it as yet has no frontal turbinals developed in it.

The recessus inferior v. maxillaris is very deep and largely hidden from medial view by the overhanging first primary ethmo-turbinal. It is in the recent condition almost completely occupied by the lateral nasal gland, whose duct can be traced forwards almost to the front of the pars intermedia. Anteriorly and superiorly the recessus inferior (v. maxillaris) is continued without interruption into the recessus anterior which is of great depth. Inferiorly the recessus inferior is bounded by the incurved lower margin of the pars intermedia, whilst anteriorly the recessus inferior is directly continuous with the pars anterior below the level of the crista semicircularis. The *recessus anterior* is unusually large, and overhung from the front by a very deep crista semicircularis. It forms the prominentia anterior of the exterior, communicates supero-posteriorly with the recessus superior and infero-posteriorly directly with the recessus inferior.

From the posterior third of the superior margin of the pars intermedia the orbito-sphenoidal (nasal) commissure passes backwards.

The pars anterior of the medial aspect of the lateral wall is by far the largest segment of this aspect being as 6 : 5 to the length of the pars intermedia and pars posterior taken together. Posteriorly it is bounded in part by the crista semicircularis, but below this runs without line of demarcation into the pars intermedia, anteriorly it ends at the incisura narina, superiorly it is bounded by the tectum nasi anterius, whilst the inferior boundary is formed by the maxillo-turbinal in greater part, but near the front by the atrio-turbinal. The general outline of this region tends to the triangular the base being backwards and the apex at the incisura narina.

This region apart from its length is characterized by the presence of three turbinals, viz. the naso-turbinal, the maxillo-turbinal and the atrio-turbinal, but the two latter are confluent at this stage so that the term *maxillo-atrio-turbinal* is appropriate for the conjoined mass.

The naso-turbinal is very low in height, little more in fact than a slightly rounded elevation commencing behind at the crista semicircularis in its upper half, and running downwards and forwards for a short course to die away.

The maxillo-atrio-turbinal is of great length and the maxillary part specially so. It commences behind as the incurved lower margin of the pars intermedia and continues forwards as far as the hinder edge of the lamina transversalis anterior where it is confluent with the atrio-turbinal. It is so curved inwards and upwards that a well-marked gutter runs along its upper aspect in its whole expanse, the sulcus supra-conchalis. On its under aspect in the hinder half is the maxilla, whilst below it in its anterior half runs the naso-lacrimal duct. The atrio-turbinal segment of the maxillo-atrio-turbinal is practically caused by a folding of the floor of the anterior segment of the capsule over the underlying naso-lacrimal duct, This folding takes place along the line of junction of the lamina transversalis anterior with the under margin of the lateral wall of the nasal capsule. It is directly continued behind with the maxillo-turbinal, no incisura such as Voit describes in the rabbit being present at this stage.

In front of the maxillo-atrio-turbinal the inferior border of the lateral wall is also slightly incurved and at the same time curved upwards and medially.

It ends at an angular process which is formed by the junction of this border with the anterior border of the pars anterior.

The upper border of the pars anterior gradually slopes downwards from behind. It is formed by the tectum nasi anterius which is of very great thickness in its whole length.

Now a word or two may be said regarding the two great projections into the nasal cavity from the medial aspect of the lateral wall, viz. the first primary ethmo-turbinal and the crista semicircularis. These are of fundamental importance because they are the means of dividing the lateral wall into its three main divisions.

The first primary ethmo-turbinal is of great size and forms the boundary between the pars anterior and the pars intermedia and not only that but by its medial surface forms a considerable part of the lateral wall of the pars posterior, whilst its lateral surface forms the medial wall of the pars intermedia. It springs in the usual way from the lateral wall, viz. by three roots, the main root springs from the lateral wall along the curved line corresponding precisely with sulcus postero-lateralis on the exterior. This primary root is joined at right angles at its middle and on its lateral aspect by the anterior or third root (which in Tatusia is unusually large), forming a floor to the recessus frontalis and a roof to the recessus maxillaris. It passes forwards and upwards to end in the lateral wall of the recessus anterior.

After resolution from its three roots, the first primary ethmo-turbinal projects forwards and inwards and comes to an end in a pointed extremity which conceals from view part of the entry into the pars intermedia and even projects forwards far enough to reach the pars anterior.

The crista semicircularis, which partially separates the pars intermedia from the pars anterior commences at the upper portion of the pars intermedia and passes at first downwards and forwards, then downwards and backwards dying away gradually at its lower end. It forms the medial wall of the prominentia anterior and corresponds at its attached border with the sulcus antero-lateralis on the exterior. On the medial side of its upper end is found the inner end of the foramen epiphaniale.

Septum nasi (Pl. XV).

This is the forward continuation of the interorbito-nasal septum, is of great length, longer than the combined length of the pars trabecularis and pars chordalis, and though of considerable height, that height is altogether dwarfed by its great length. It consists of two parts, viz. a posterior which is subcerebral and an anterior which is precerebral. The two parts are of about equal length.

The subcerebral part projects freely above into the cavum cranii and as yet is unconnected laterally with any lamina cribrosa and at its hinder border is only connected with the cupula nasi posterior by connective tissue. The upper margin of this segment then plays the part of a crista galli. The lower margin is much thicker than the upper one and is thicker behind than in front. It has appended to it on each side a narrow cylindrical posterior paraseptal cartilage, which seems to have chondrified independently of the lamina transversalis posterior (Pls. XI, XV). This cartilage is co-extensive with the length of the under border of the subcerebral part of the nasal septum and it ceases abruptly at the anterior limit of this part of the under border, a connective tissue bridge alone connecting it with the hinder end of the anterior paraseptal cartilage.

The precerebral segment of the septum has upper and lower and anterior borders. The upper border in its whole length is united with the lateral wall of the nasal capsule through the tectum nasi anterius and not far from its anterior end becomes greatly thickened, the thickening extending some distance from the septum. This thickening is the basis of a septo-turbinal.

The lower border is for the most part free and somewhat arched from behind forwards, anteriorly it is directly fused with the lamina transversalis anterior and through it connected with the lateral wall of the capsula nasi. Along the infero-lateral aspect of the free part of the under border lies the anterior paraseptal cartilage but this is separated from the septum itself by a narrow septo-paraseptal fissure.

The anterior border of the septum nasi is oblique and extends forwards and upwards from the anterior end of the lower border. At its lower hinder part it gives off on each side a small processus lateralis ventralis. There is no internarial foramen in the septum such as is met with in the rabbit (Voit), Microtus (Fawcett).

The solum nasi (Pl. XI) is relatively imperfect, though of great antero-posterior length. Posteriorly the solum nasi is represented by a lamina transversalis posterior which, considering the large size of the nasal capsule is extremely small; moveover, it is not so flat inferiorly as is usually the case. It is, however, pointed posteriorly. Anteriorly the lamina ends in a very oblique margin which is directed obliquely from within forwards and outwards and connected with its commencement by fibrous tissue is the posterior paraseptal cartilage. The medial edge of the lamina transversalis posterior is free of the septum nasi, being separated from it by a narrow fissure which is the backward continuation of the septo-paraseptal fissure. The anterior edge of the lamina transversalis posterior is the hinder boundary of the long fenestra basalis.

The lamina transversalis anterior, another constituent of the solum nasi, is of small size and at this stage perhaps more pro-cartilaginous than cartilaginous. It may be traced from the infero-lateral margin of the septum nasi in a downward direction at first separated only by a narrow fissure from its fellow of the opposite side. It then curves outwards, being convex downwards, next it bends suddenly upwards, vertically and rebends downwards over the underlying ductus naso-lacrimalis to form the atrio-turbinale after which it joins the lower margin of the lateral wall of the nasal capsule. The lamina transversalis anterior forms at once the anterior boundary of the fenestra nasalis and the posterior boundary of the incisura narina. From the medial part of its hinder edge the anterior paraseptal cartilage is projected backwards.

The paraseptal cartilages (Pls. XI, XV).

These are anterior and posterior, and so far as I know they do not unite to form a common paraseptal cartilage.

The *anterior paraseptal cartilage* commences in front as a backward continuation of the median part of the hinder edge of the lamina transversalis anterior and is continued backward along the infero-lateral aspect of the lower border of the precerebral segment of the septum nasi in almost the whole extent of the latter. From its very commencement anteriorly it is in the form of a plate concave outwards and very soon the concavity lodges the organ of Jackson which is of great length. At the hindmost end of this organ the paraseptal cartilage becomes cylindrical and rod-like and soon comes to an end. By its lateral aspect the anterior paraseptal cartilage forms a considerable part of the medial wall of the fenestra basalis. Its medial aspect anteriorly is separated from that of its fellow by a narrow interval only, but further back and in fact for the remainder of its extent the gap between the two cartilages is considerable. From the septum nasi the anterior paraseptal cartilage is separated by a fissure—the septo-paraseptal fissure. On the infero-medial aspect of the anterior part of the anterior paraseptal cartilage is placed the independently ossified paraseptal process of the os incisivum; more will be said of this later.

The posterior paraseptal cartilage, not quite so long as the anterior is placed at the infero lateral aspect of the inferior margin of the subcerebral part of the septum nasi from which it is separated by a narrow septo-paraseptal fissure. It is a cylindrical rod-like structure, not continuous with the anterior paraseptal cartilage but separated by a small gap from it, medial to which lies the primordium of the vomer, which is not yet ossified. Posteriorly the posterior paraseptal cartilage reaches, but does not fuse with, the lamina transversalis posterior. This cartilage forms part of the medial boundary of the fenestra basalis.

The cartilaginous skeleton of the visceral arches (Pls. XII, XIII).

That of the first arch is represented from behind forwards by the incus, malleus and Meckel's cartilage.

The *incus* is of enormous size, consisting of a body, and two processes. The posterior process or processus brevis is very large and passes backwards from the body along the outer aspect of the pars canalicularis of the auditory capsule lying in a sulcus, the sulcus incudis, below the tegmen tympani and the prominentia semicircularis anterior. It is completely uncovered, so lies freely at the lateral aspect of the auditory capsule. The processus longus is very large, but perhaps actually shorter than the processus brevis; it descends from the corpus incudis, is facetted anteriorly and keyed in the usual way to the malleus cartilage, but the connection between the two is by means of dense cellular tissue, for no joint cavity is as yet developed.

The *malleus* cartilage, placed directly in front of the incus cartilage, is like the latter, of enormous size. It consists of the usual parts. The manubrium is very thick antero-posteriorly and at its lower end bends sharply towards the pars cochlearis of the auditory capsule, and the musculus tensor tympani is attached to its medial side just above the bend above mentioned. The posterior surface of the body of the malleus cartilage is articulated to the incus in the way already mentioned. From the front of the body projects the third element in the first arch, viz. Meckel's cartilage.

Meckel's cartilage is here represented as a long cylindrical rod which runs a somewhat sinuous course forwards till it arrives opposite the lamina transversalis anterior of the nasal capsule, when it fuses with its fellow of the opposite side and comes to an end.

Traced forwards from the malleus cartilage it runs at first an arched course upwards and forwards; then it descends gradually for some distance, at the same time going somewhat medially. It then arches upwards, then downwards, again upwards slightly, and finally runs straight forwards to fuse with its fellow; during the whole of this sinuous course it is making inwards.

On the outer side of the anterior three-fourths or so the ossified mandible lies, but this does not quite reach forwards to the anterior extremity of the cartilage, so that a part of the lateral surface of the latter remains uncovered by bone.

No bone appears on its medial aspect, not even a geniale at its posterior end, though it may later, as there seems to be a collection of densely aggregated cells which suggest a goniale. The chorda tympani nerve runs through this mass and for some distance accompanies Meckel's cartilage forwards.

The cartilages of the *second* visceral or *hyoid arch* are the stapes, processus styloideus, and cerato hyal at this stage.

The stapes is of comparatively large size, perforated by a large opening through which a very small stapedial artery runs. Its foot rests against the cellular lateral wall of its vestibular cavity whereas its head articulates by dense cellular tissue with the inturned lower extremity of the processus longus of the incus cartilage. The musculus stapedius is inserted into the hinder lower aspect of its neck, and the main mass of the cartilage is separated from the anterior surface of the pars canalicularis by the nervus facialis. It has lost all connection with the processus styloideus.

The processus styloideus commences in a posterior hook-like piece (Pls. XII, XIII) which is bent down in front of the crista parotica but is still separate from the latter although connected to it by cellular tissue which is in process of chondrification. From the hook-like bend the processus styloideus descends almost vertically and parallel with the line of the manubrium mallei, then it suddenly bends forwards slightly upwards and slightly inwards and runs forwards and inwards to near the middle line where it comes to an end. At right angles to this anterior extremity is placed the cerato-hyal which is connected to the processus styloideus by dense cellular tissue. The cerato-hyal lies with its long axis in the sagittal plane, supero-laterally it is connected with the anterior extremity of the processus styloideus whilst inferiorly it rests on the junctional region of the thyro-hyal and the basi branchial.

The cartilage of the third or thyroid arch is long, rod-like and almost cylindrical. It commences behind in a somewhat pointed extremity which rests upon a very small superior cornu of the corresponding ala of the thyroid cartilage. It runs forwards and inwards gradually increasing in thickness and near the middle line is jointed on to the side of the basi branchial. The basi branchial (body of hyoid) is somewhat wedge-shaped as seen from the front, the thin edge of the wedge being downwards, and the whole mass is wedged in between the anterior extremities of the thyro-hyals. As above said, on the junctional region of thyro-hyal with basi branchial, the cerato-hyal rests.

The cartilage of the *fourth* visceral arch, viz. the ala of the thyroid cartilage, is of considerable size. It is in the form of a quadrilateral plate curved from behind forwards and inwards towards the middle line, where it fuses with its fellow. At each of its posterior angles a small cornu is developed by which, in the case of the upper posterior angle, it articulates with the hind end of the thyro-hyal, and by means of the lower angle or cornu articulates with the cricoid cartilage. About its middle the ala is perforated by a foramen whose origin has been described in the account of the 12 mm. embryo. The symphyseal region of the two alae is the narrowest in vertical height of the parts of the thyroid cartilage. It is overlapped from above and in front by the basi branchial cartilage.

The cartilage of the *fifth* arch, viz. the cricoid, is well formed and for all practical purposes complete. On its summit are perched in the usual manner the arytenoid cartilages.

4. THE OSSEOUS SKELETON (Pls. XI, XIII).

Only covering or membrane bones are ossified at this stage, and being stained by Mallory's method are very easily located and modelled. The bones ossified at this stage are the os incisivum (paraseptal process only), the maxillare, palatinum, frontale, zygomaticum and mandibula.

The *os incisivum* is, as above said, only developed so far as its paraseptal process is concerned, and this lies on the infero-medial aspect of the anterior part of the anterior paraseptal cartilage a short distance behind the junction of the latter with the lamina transversalis anterior. Below the septum nasi and opposite the gap between the anterior and posterior paraseptal cartilages, a collection of densely aggregated cells is seen which I take to be the primordium of the vomer, but no trace of ossification is visible here at this stage.

The *os maxillare* is of great interest at this stage, and consists of two almost independent parts, the junction between them being by a very narrow bridge of bone. The appearance is highly suggestive of double ossification, a condition I have never previously met with.

The two parts in question are a medial and a lateral.

The median part is an elongated mass of bone which lies on the under aspect of the maxillo-turbinal reaching from a point about opposite the middle of the anterior paraseptal cartilage in front to the lowest point of the maxillary prominence of the pars intermedia behind; cut coronally it shows three surfaces, viz. a lateral free or facial surface, a medial surface directed towards the nasal capsule and an inferior or buccal surface. Along the anterior third of its upper border the naso-lacrimal duct runs forwards. The lateral part is a leaf-like plate of bone separated for the most part by a wide gap from the median part but connected by a narrow stalk with the latter anteriorly. It conceals from lateral view the maxillary prominence of the pars intermedia of the nasal capsule.

The *os zygomaticum* is placed some distance behind the lateral part of the maxillare and below the eyeball. It is a long splint-like bone which covers from the side the upper part of the hinder fourth of the mandibula, from which however it is separated by a considerable interval.

The *os palatinum* lies in its usual position, viz. below the lamina transversalis posterior. Seen from behind it is a somewhat triangular plate whose base is directed forwards, and whose median basal angle is likewise slightly projected somewhat forwards over the antero-median part of the lamina transversalis anterior. Its outer side is curved in a downward direction whilst its apex is directed backwards below the maxillary division of the fifth nerve.

The *os frontale* is an elongated plate-like bone which commences anteriorly at the hinder part of the prominentia frontalis of the pars intermedia of the nasal capsule, and is continued back over the lateral aspect of the spheno-ethmoidal commissure and the basal region of the ala orbitalis, ceasing at a line drawn transversely through the optic foramen.

The *mandibula* is by far the largest of the bones ossified and forms a plate-like bone commencing in an anterior pointed extremity not far from the conjoined anterior extremities of Meckel's cartilages; it runs backwards on the lateral side of that cartilage as far back as or perhaps a little beyond the plane of the zygomaticum where it comes to an end in a pointed posterior extremity. Its upper margin deep to the zygomaticum rises to form a coronoid process into whose medial side the musculus temporalis is inserted.

The medial alveolar wall is developed as an upgrowth from the medial aspect of the main mass opposite the second fourth of Meckel's cartilage from the front. It commences as a plate-like offshoot of the main mass and insinuates itself between that and Meckel's cartilage, but further back it runs more like a splint along the lateral aspect of the cartilage. The anterior end of the main mass of the mandible is much fenestrated and through one of these fenestrae the mental nerve issues.

The vomer is not yet ossified, but its fibrous primordium can be seen occupying the interval between the anterior and posterior paraseptal cartilages (Pl. XIV). Its position raises an interesting point in regard to this bone, a point which has already been dealt with in this Journal.

The models from which these descriptions are taken were made some five years ago, but publication has been delayed for many reasons. I had hoped to be able to obtain specimens of 25 mm. and 30 mm. total length, but have been unable to do so. Such specimens, I think, would have brought to light several obscure points. Details have already been described of the anterior end of the nasal capsule at the 60 mm. stage (os septo-maxillare in this Journal, vol. LIII. July, 1919).

SUMMARY

The points of special interest which the models above described bring out are:

1. The formation of three independent masses of cartilage in the central stem, viz. the chordal plate, the trabecula, and the interorbito-nasal septum. I have not found double chondrification of the trabecula in these stages.
2. The large size of the incus and malleus cartilages.
3. The apparent independent chondrification of the posterior paraseptal cartilages, i.e. independent of the lamina transversalis posterior.
4. The late union of the parietal plate (lamina parietalis) with the ala orbitalis to form an orbito-parietal commissure.
5. The presence of a foramen (? epioptic) in the ala orbitalis lateral to the optic foramen.
6. The curious mode of union of the pre- and post-optic limbs of the ala orbitalis with the interorbito-nasal septum.
7. The independent chondrification of the ala hypochiasmata, and its subsequent fusion with the interorbito-nasal septum or with the post-optic limb of the ala orbitalis.
8. The mode of formation of a somewhat high type of ala of the thyroid cartilage from the simple form like that of the mole, 4th arch, and the foramen in connection therewith.
9. The curious bent condition of the anterior end of the chorda dorsalis, suggesting intershifting of the pars chordalis and the trabecular part of the central stem.
10. The independent ossification of the paraseptal process (Broom's "Prevomer") of the incisivum.
11. The probable double ossification of the maxilla.

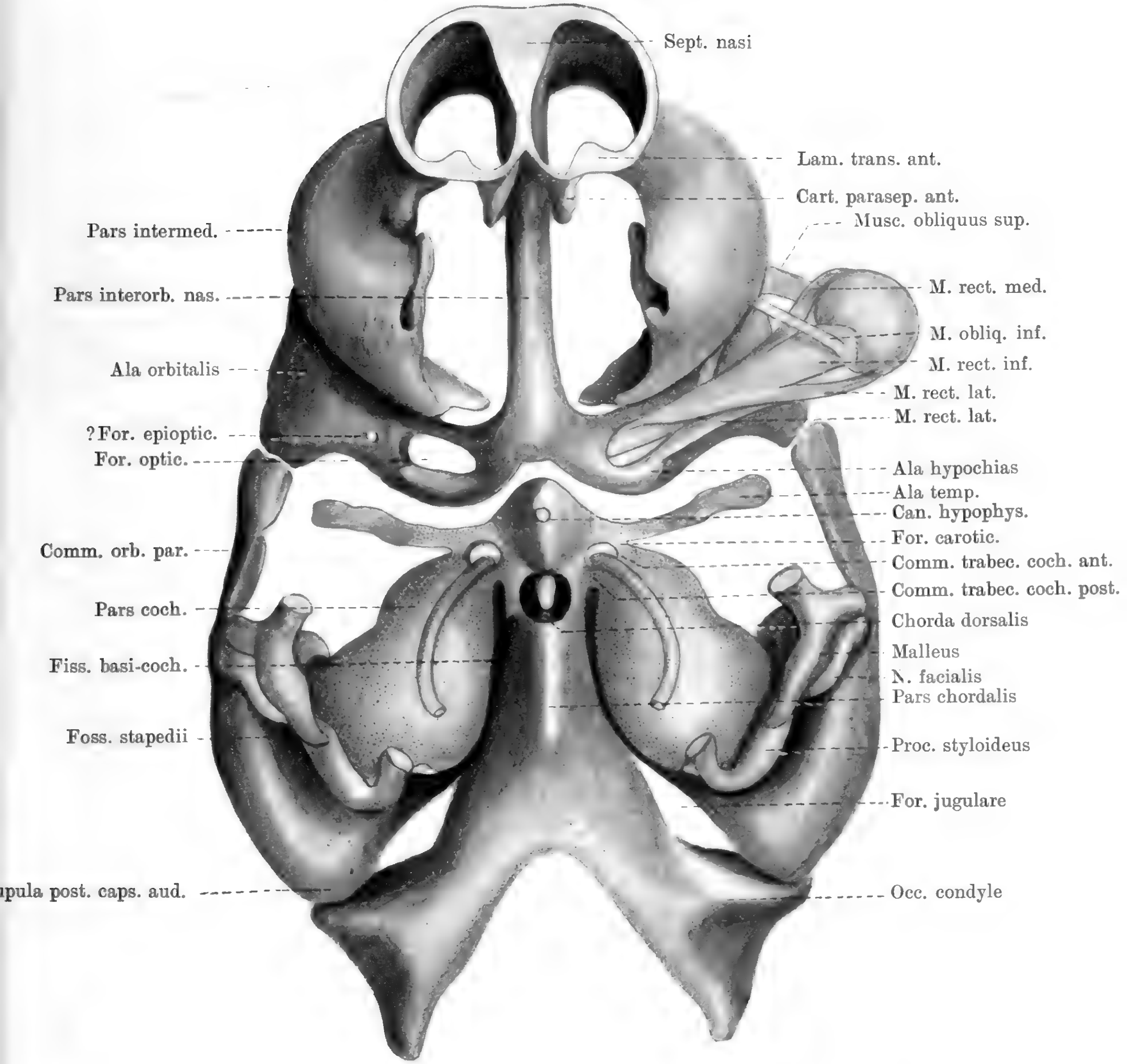

Tatusia Novemcincta. Chondrocranium of 12 mm. (Wood-Jones) embryo, from below. The parts dotted are unchondrified, the lamina transversalis anterior and the anterior paraseptal cartilages are procartilaginous.

218³

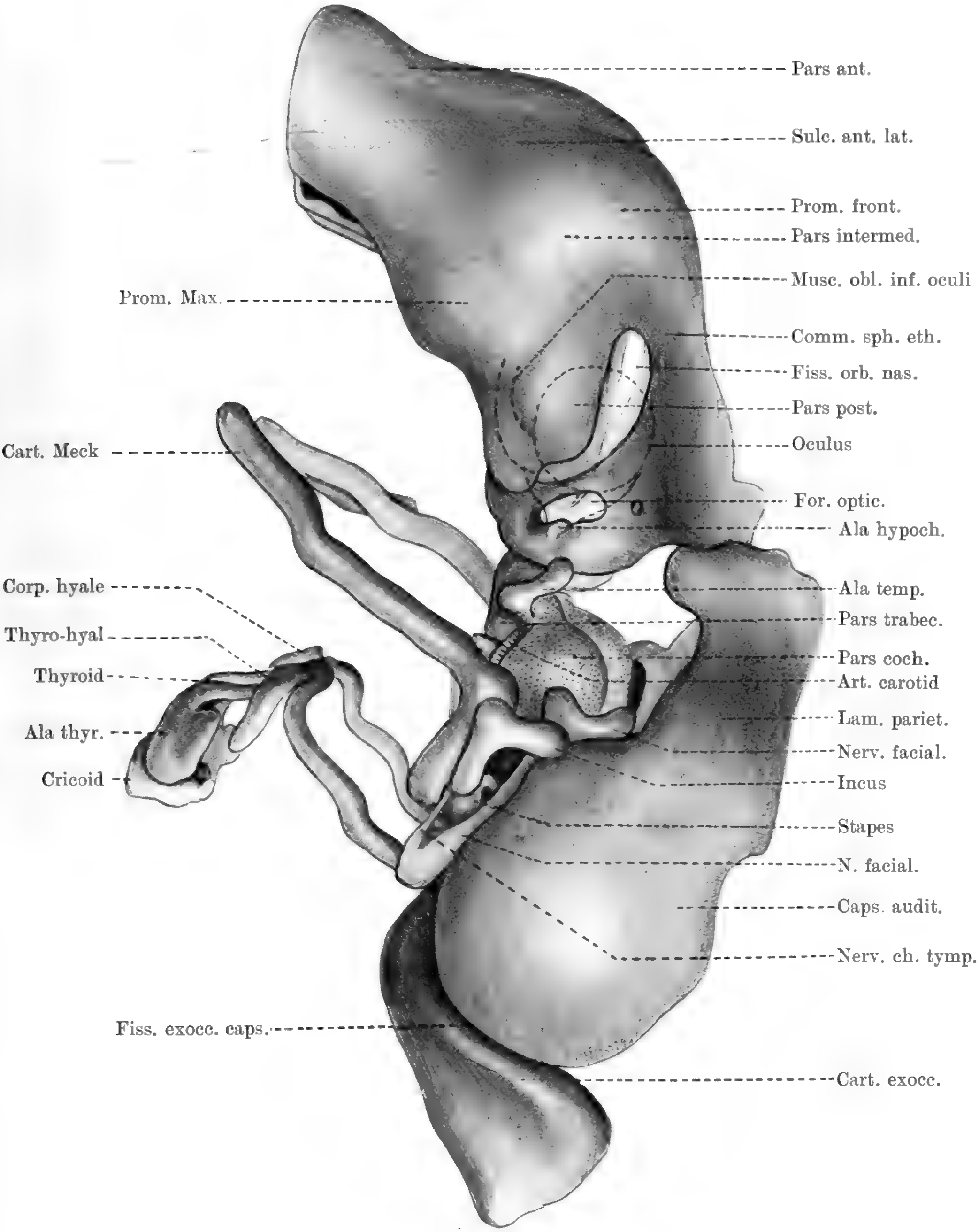

Tatusia Novemcincta. 12 mm. (Wood-Jones) embryo. Chondrocranium from left side.

218^{4}

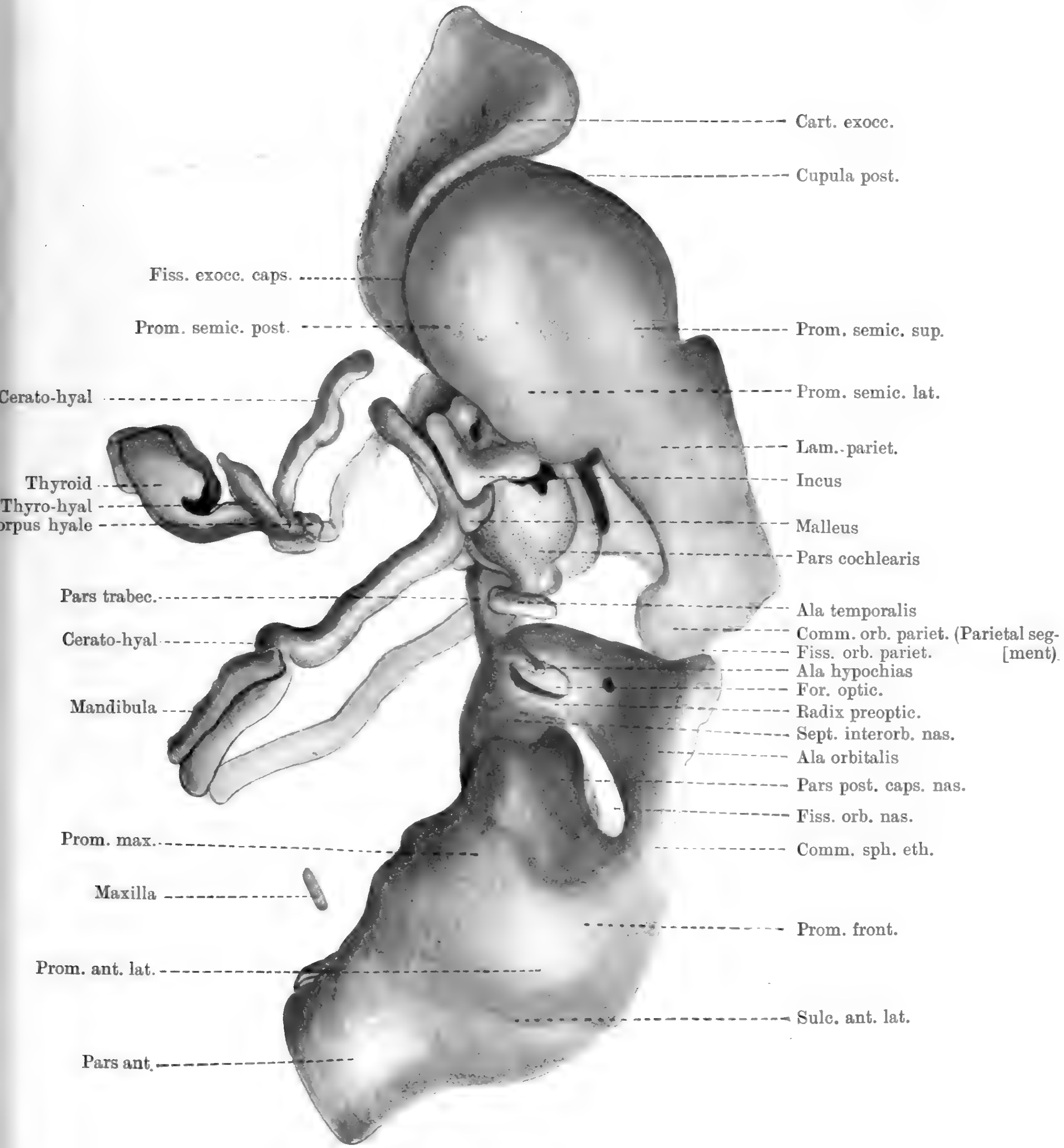

Tatusia Novemcincta. 12 mm. (Wood-Jones) embryo from right side. Unchondrified parts are dotted.

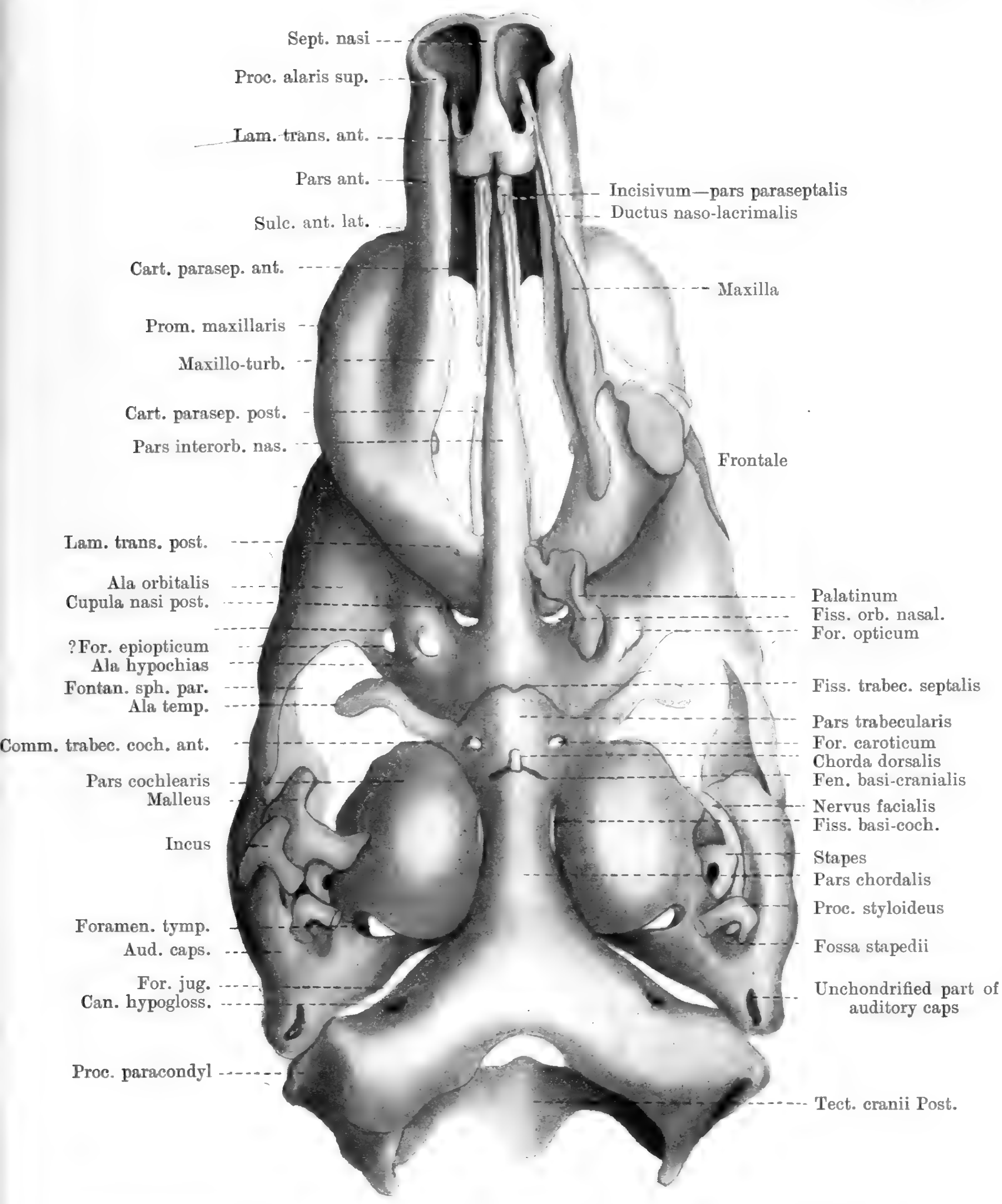

Tatusia novemcincta. Chondrocranium of 17 mm. (Wood-Jones) embryo, from below. The lamina transversalis anterior is unchondrified.

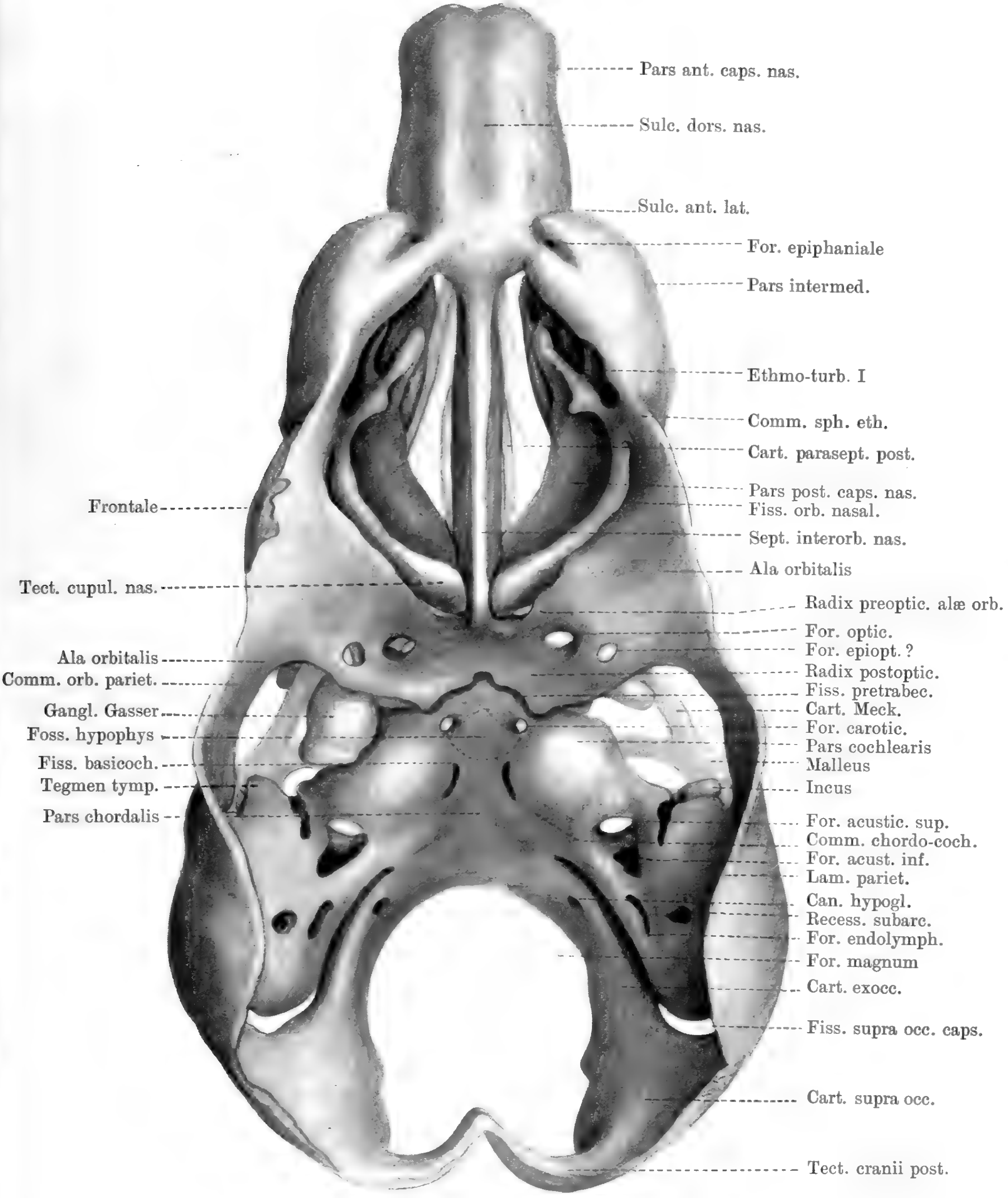

Tatusia novemcincta. 17 mm. (Wood-Jones) embryo. Chrondrocranium from above.

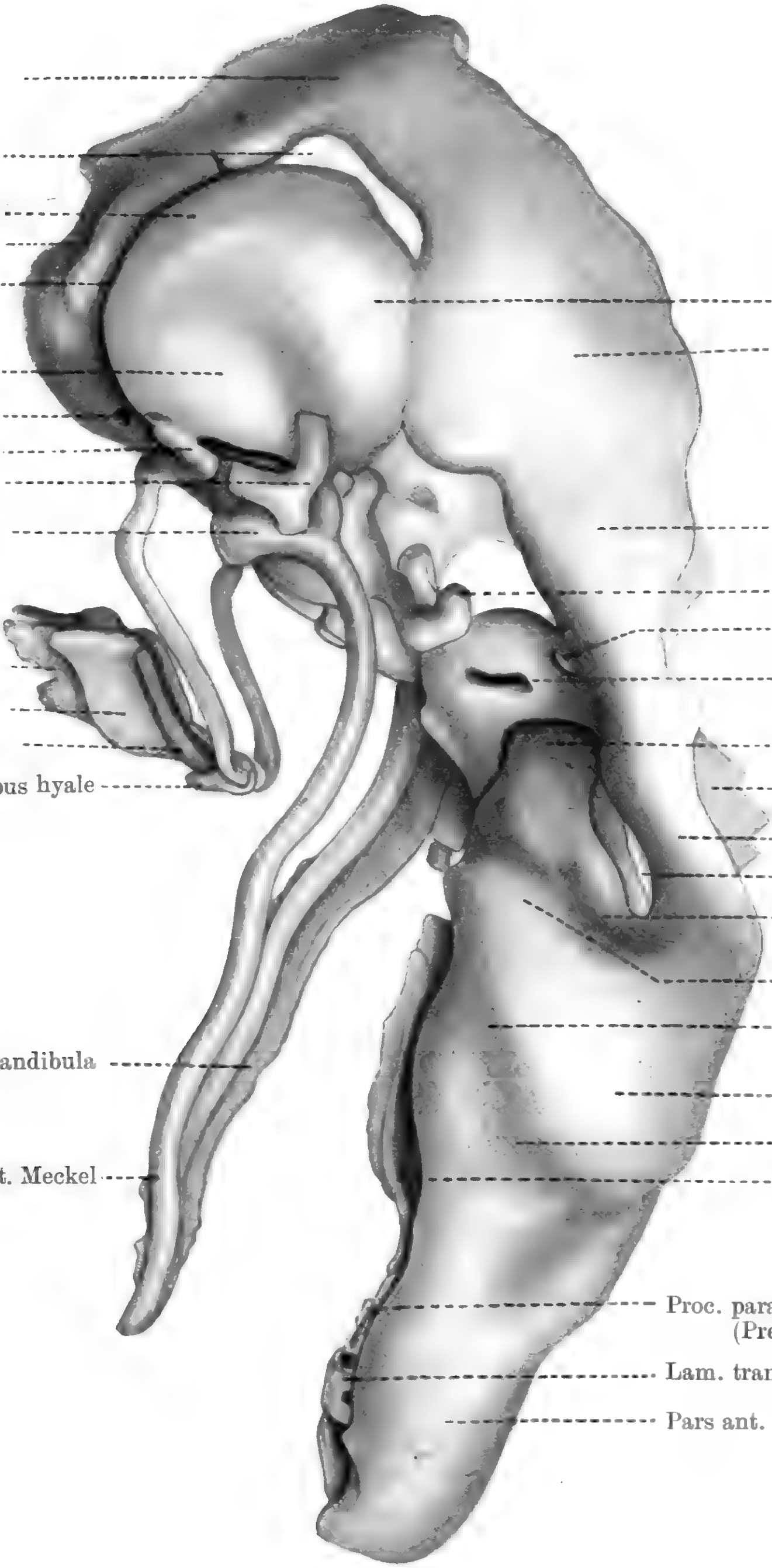

Tatusia novemcincta. 17 mm. (Wood-Jones) embryo. Chrondrocranium from right side.

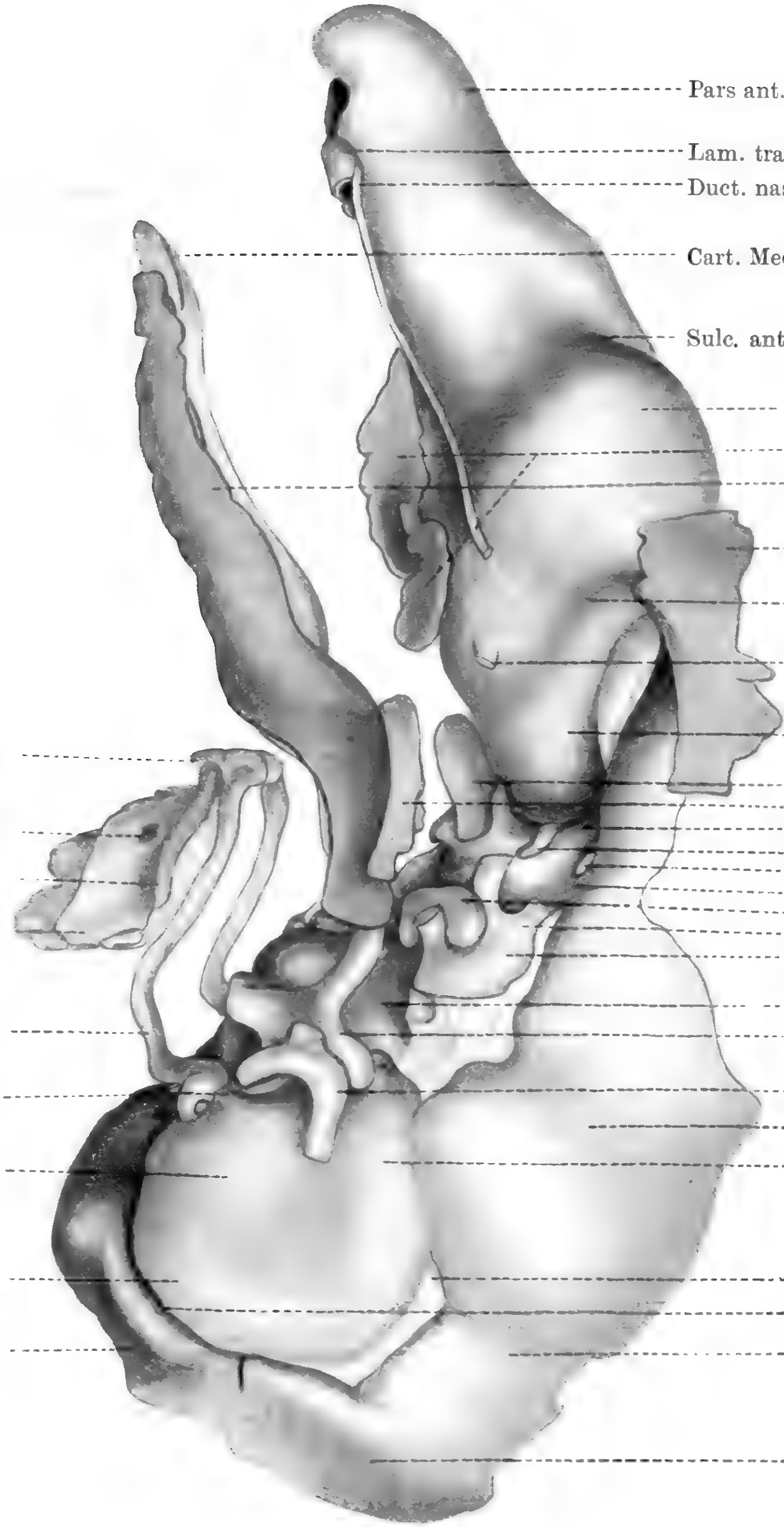

Tatusia novemcincta. Chondrocranium of 17 mm. (Wood-Jones) embryo, from left side.

Journal of Anatomy, Vol. LV, Parts 2 & 3 *Plates XIV and XV*

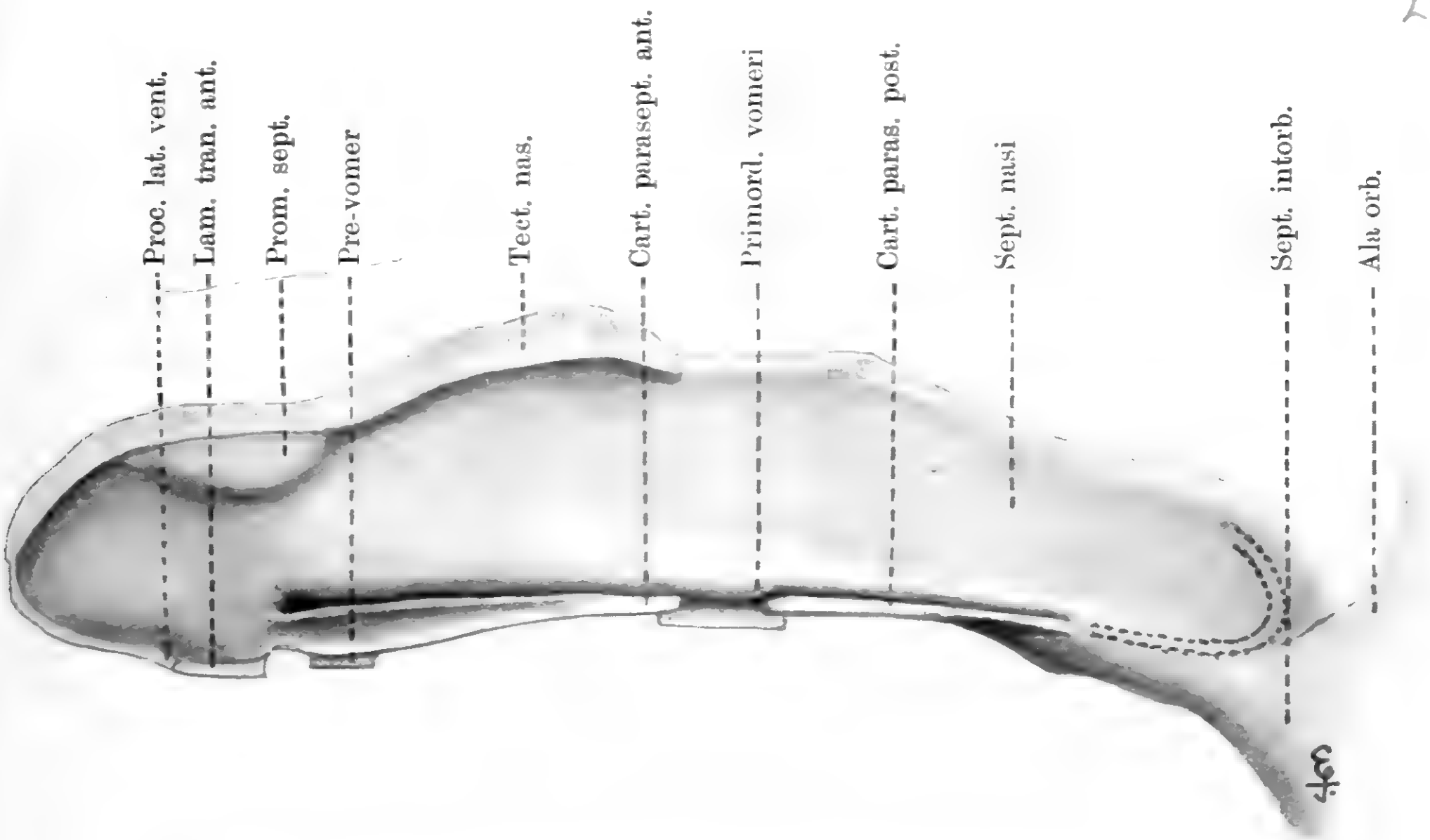

Plate XIV. *Tatusia novemcincta.* 17 mm. Septum nasi and appendages seen from left side.

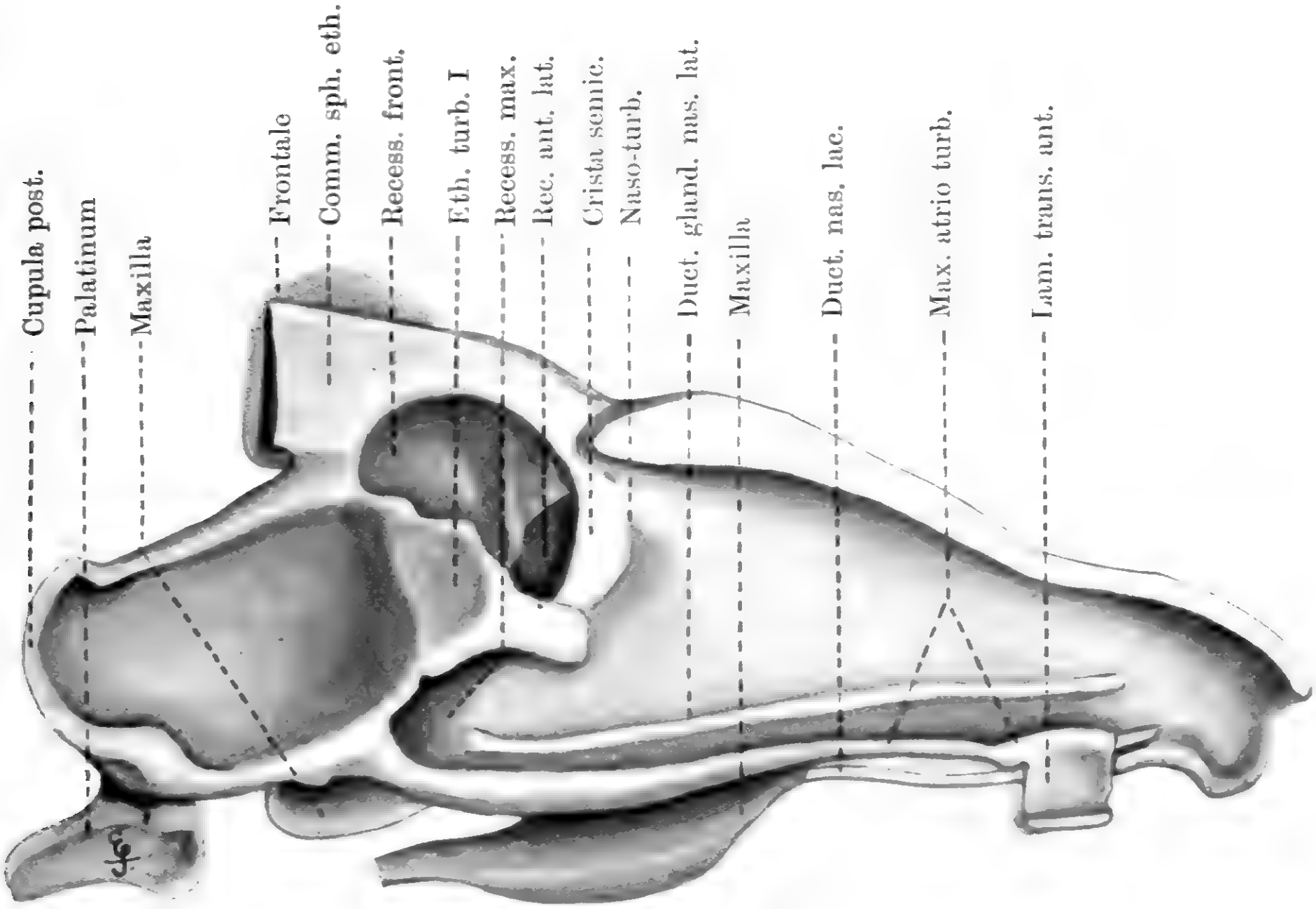

Plate XV. *Tatusia novemcincta.* 17 mm. Left wall of nasal capsule from within.

ODONTOLOGICAL ESSAYS

By L. BOLK, M.D.,
Professor of Anatomy, University of Amsterdam

THIRD ESSAY

ON THE TOOTH-GLANDS IN REPTILES AND THEIR RUDIMENTS IN MAMMALS

For a proper discussion of the phenomena described in the previous number of this *Journal*, it is necessary to draw attention to another phenomenon, which I came across in the course of my investigation. The meaning of this has caused me much difficulty. I will begin by stating the facts, and then discuss their significance.

As pointed out in the previous essay I began my odontological researches in embryos of man and other Primates, and the ontogenetical peculiarity which is the subject of the present essay was first observed in a human embryo.

In examining the series of human embryo *D* of my collection, I was struck by a phenomenon quite unknown to me. At the interval between the anlage of m_1 and m_2, the superficial epithelium sends a strand-like outgrowth into the subjacent tissue buccal to the dental lamina, and independent of the latter. The formation was seen on both sides and in both jaws.

ACCESSORY BAND

This *accessory band*, as I will term it provisionally, was shorter than the dental lamina. On tracing the series in a backward direction the accessory band gradually approaches the dental lamina and finally both bands arise close together from the oral epithelium. Further back, the origin of the accessory band is moved to the buccal side of the base of the dental lamina, as is represented in fig. 77. Fig. 77 *a* represents the condition in the lower jaw. The section passes through the posterior part of the germ of m_2. Fig. 77 *b* is from the upper jaw, behind the anlage of this tooth. In neither jaw has the development of M_1 set in. The accessory band in the lower jaw joins the dental lamina at an acute angle. The structure of both bands is perfectly identical. In tracing the series further back, it becomes evident that the accessory band

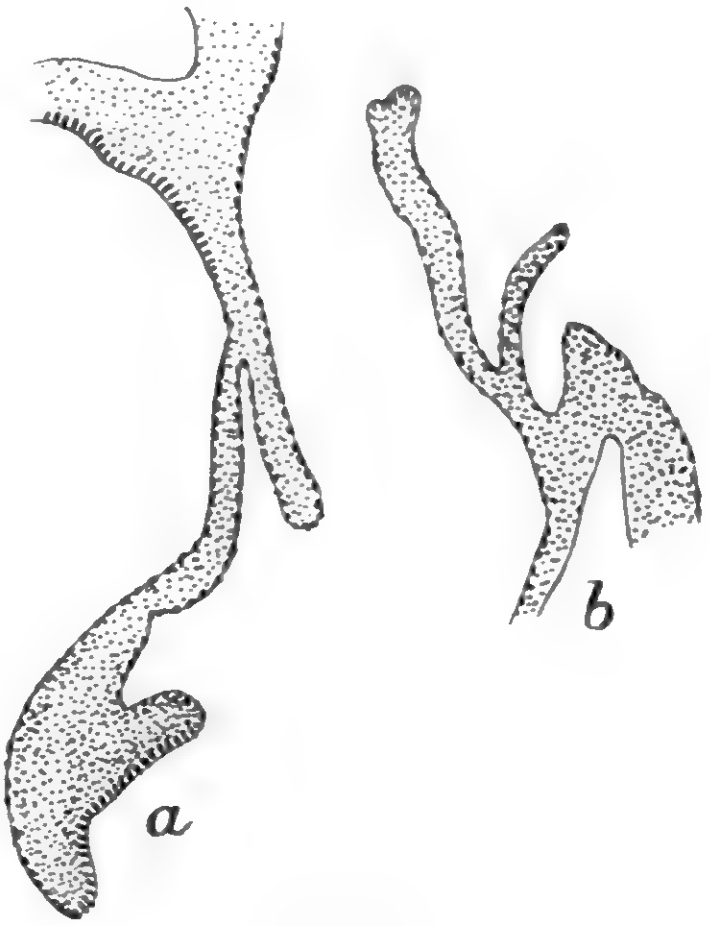

Fig. 77

extends to the hinder end of the dental lamina. However, its behaviour, especially its relation to the dental lamina, is somewhat different in the two jaws, as may be seen on comparing fig. 78 with fig. 79. In the upper jaw (fig. 78) the accessory band, gradually shortening, moves towards the free border of the dental lamina, ultimately disappearing a short distance from its posterior end. On account of this behaviour, one may conclude that there is a relation between this band and the dental lamina.

This supposition is strengthened by the relationships of the accessory band in the lower jaw as shown in fig. 79. After the union of the accessory band with the base of the dental lamina, the former does not shift to the free border of the latter, as happens in the upper jaw, but remains in connection with this base. The base is severed from the superficial epithelium, just above the point of junction with the accessory band. Thus the epithelial formation, now lying free in the mesenchyme, has become hook-shaped. It should be noted that this hooked formation represents not only the dental lamina. It is compound in nature, the short leg, directed nearly horizontally, being the posterior end of the accessory band. This somewhat different relation of the two bands in the upper and lower jaws has no fundamental significance. The discovery of an accessory band in the human embryo *D* induced me to search for its possible occurrence in the other series at my disposal. I could thus determine whether I had to do with an accidental or with a normal phenomenon. To my surprise I found this formation occurred regularly in all human embryos examined. However, it is not always so strongly developed as in embryo *D*. In some the formation was very rudimentary.

Fig. 78

Fig. 79

Further examination of my human embryological material revealed peculiarities of the accessory band which possess some morphological significance. Fig. 80 will serve as a starting point for the description of these peculiarities. Both drawings (fig. 80) are from an embryo (Series *U*) older than the embryo *D*, from which figs. 77, 78 and 79 have been taken. For, while in embryo *D* the development of the first permanent molar had not yet commenced, in the embryo *U* the enamel-organ of this tooth has reached a further stage of development, as shown in fig. 80 *b* which represents a section through this organ. When comparing fig. 77 with fig. 80, the difference in age must be taken into consideration. Fig. 80 *a* represents a section at the interval between upper m_2 and M_1. The dental lamina, and the accessory band on the buccal side of the lamina are easily recognised. The band shows a noteworthy feature. Its free border is bifurcated, terminating in short buccal and lingual branches. Undoubtedly this section of the accessory band possesses more than a superficial resemblance to the first stage of development of an enamel-organ. The two branches are connected with the oral epithelium by a short dental lamina. The resemblance to an enamel-organ merits special mention, for it is possible that an investigator, observing this formation, and having but a restricted amount of embryological material at his disposal, and therefore not in a position to control his observations, may suppose that he sees a rudimentary anlage of a tooth buccal to the normal set of teeth. Yet this supposition would be an erroneous one, for the resemblance is not real but only apparent.

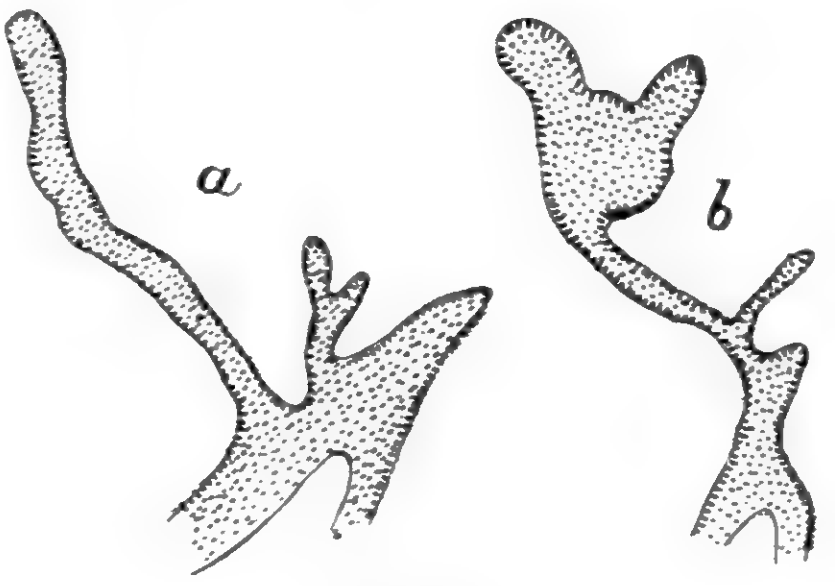

Fig. 80

That there is no question of an anlage of a tooth is proved by the fact that there is not the slightest indication of a dental papilla, the mesenchyme surrounding the bifurcated border of the accessory band showing no heaping up or concentration of nuclei. I draw attention to this fact because an investigator might mistake these outgrowths of the accessory band for rudimentary germs of the so-called prelacteal teeth. Now—as will be demonstrated later—the accessory band and its outgrowths have nothing to do with the hypothetical premilk-dentition.

Fig. 80 *b* represents a section at a more posterior point, one running through the enamel-organ of M_1. The accessory band is present and its origin has shifted towards the base of the dental lamina. The bands approach each other as the series is followed backwards, as occurred in the previous specimen. The section in fig. 80 *a* lies anterior to that in fig. 80 *b*, and shows the accessory band emerging from the oral epithelium, buccal to the dental lamina. The bands are independent of each other, as in section shown in fig. 80 *a*. In the posterior part of the dental lamina, behind the germ of M_1, the accessory band gradually shortens and approaches the free border of the dental lamina, as already depicted in fig. 78.

On comparing fig. 77 with fig. 80, an important fact concerning the growth of the accessory band comes to light. Fig. 77 *b* represents a section through the upper jaw of a younger embryo behind the germ of $\underline{m}_2$. Here the accessory band takes origin from the buccal side of the dental lamina. Fig. 80 *a* gives a section through the corresponding point of an older embryo. A comparison shows that the accessory band, in the older embryo, no longer takes its origin from the dental lamina, as in the younger, but emerges from the superficial epithelium. Fig. 80 *b* clearly shows that in the older embryo the attachment to the dental lamina takes place at a more posterior point.

From this comparison one may conclude that there exists a genetical relation between the dental lamina and the accessory band, both being elongated during growth in a posterior direction. This conclusion is supported by the fact that the bands are extended together not independently. The epithelial formation, known as the dental lamina, is of a composite character on its buccal aspect, containing there not only the formations from which the germs of the molars arise—the dental lamina *sensu strictiori*—but also giving rise to the accessory bands. For this band is an outgrowth from the buccal side of the dental lamina, gradually decreasing in size as it passes backwards, almost to the posterior end of the lamina itself. Both bands progress backwards simultaneously, only topographical relations being changed during development. In the upper jaw the accessory band shifts its attachment to the base of the dental lamina and subsequently into the superficial epithelium. In the lower jaw it arises direct from the base, so that there is no possibility of any displacement towards the buccal side of the dental lamina.

This fact explains why the accessory band in a younger embryo is attached to the dental lamina, whereas in an older one it appears at a corresponding point as an outgrowth from the superficial epithelium. Having thus given a survey of the occurrence and of the developmental peculiarities of the accessory band in man, I shall proceed to discuss whether this formation is only a human peculiarity or is of more general occurrence. Anticipating the results of my inquiry, I may say that I have met with this band in a large number of different mammalian embryos both in the upper and in the lower jaw. I begin by describing its presence in other Primates.

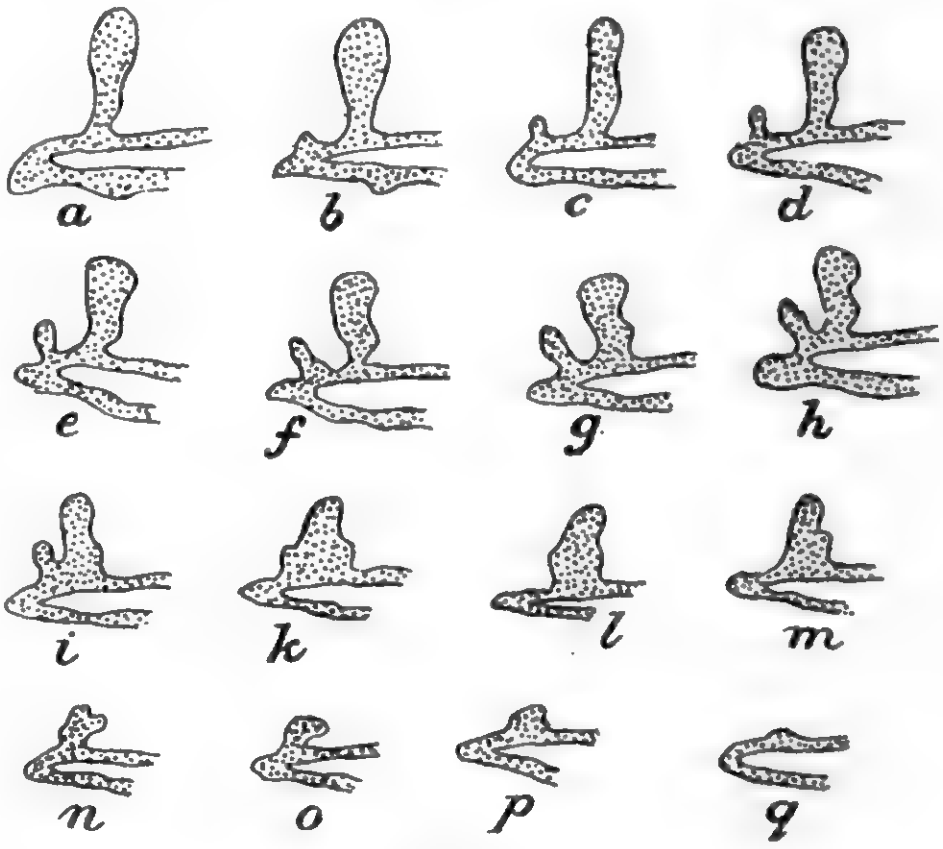

Fig. 81

In fig. 81 is represented a series of sections through the posterior end of the dental lamina of Tarsius spectrum. The thickening of the band indicates that the sections have passed through the germ or anlage of $\underline{m}_2$. In fig. 81 *b* the accessory band appears buccal to the dental lamina, as a slight outgrowth of the superficial epithelium. As shown by the succeeding sections this outgrowth gradually approaches the dental lamina. In fig. 81 *h* both formations are in close proximity and fuse in the next section, exactly in the same manner as has been demonstrated in man. After this fusion the dental lamina rapidly diminishes in size as followed backwards.

Another example of the occurrence of an accessory band in lower Primates is illustrated in fig. 82, which represents a series of sections of the dental lamina in the lower jaw of Mycetes. The series begins with a section a short distance in front of the enamel-organ of M_1; the last section runs through the middle of the enamel-organ of this tooth.

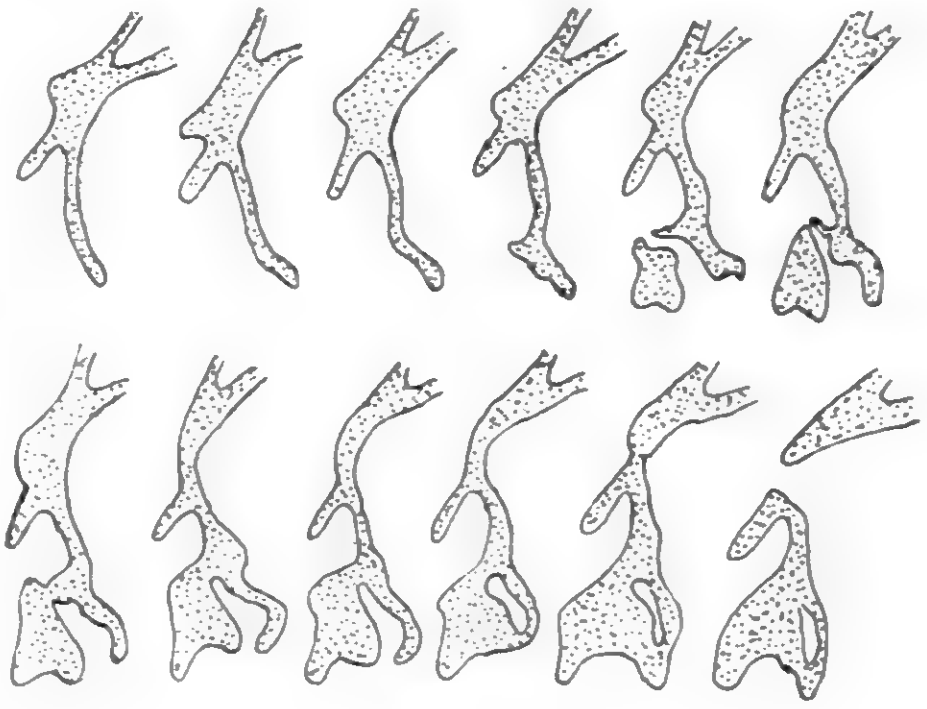

Fig. 82

I have already drawn attention to the fact, that the relation of the two bands differs somewhat in the lower and upper jaws. This is the case not only in man, but also in other Primates. As demonstrated by fig. 82, the base of the accessory band is attached to the base of the dental lamina, both bands originating conjointly from the superficial epithelium. This topographical relation holds all along the dental lamina. The separation of the laminar formation from the superficial epithelium takes place by the bands becoming free conjointly. The displacement of the dental lamina towards the buccal side in the upper jaw does not take place in the lower. This difference, however, is of little importance, resulting from the different manner in which the vestibular groove is formed in each of the jaws, a point which I need not dwell on now.

I could demonstrate the occurrence of the accessory band in other Primates which I have examined, but I shall restrict myself to the examples already given, remarking only that in Semnopithecus, Hapale, Chrysothrix and Pithecia this band is present. The accessory band may therefore be considered as a normal occurrence in the development of Primates.

I will add here a short description of an important peculiarity met with in one of my human embryos. Fig. 83 represents six sections through a part of the upper dental lamina of a Macacus cynomolgus. In the first three drawings the posterior part of the enamel-organ of $\underline{i}_1$ is to be seen. Now in fig. 83 *a* the accessory band, buccal to the dental lamina, is very well developed, growing out from the surface epithelium some distance from the dental lamina. In fig. 83 *b* the accessory band is strongly developed, and exhibits a bifurcated free end. By this bifurcation the accessory band undoubtedly shows some resemblance to the section of a normal tooth-germ at a very early stage of development.

In the succeeding sketches the bifurcation diminishes gradually, the accessory band itself decreasing in size. We have already drawn attention to a similar modification in a human fetus (represented in fig. 80) and I may repeat the remark made *à propos* of that case: that the resemblance to an enamel-organ is a very superficial one, concerning only the external form. In the bifurcated part of the accessory band, there is not the slightest vestige of internal differentiation. There is no indication of ameloblastic cells. The surrounding mesenchyme shows no indication of a dental papilla.

The sections in fig. 83 are proof of the occurrence of an accessory band in the front part of the mouth. The accessory formation occupied the whole interval between $\underline{i}_1$ and $\underline{i}_2$. Behind the enamel-organ of the latter incisor a second vestige appeared and buccal to $\underline{m}_1$ a third. Behind the germ of this tooth the band approaches the dental lamina to fuse with it in the manner already described. The two epithelial formations in the front part of the mouth of this Macacus should be regarded as fragments of a single structure, for their situation and relation to the dental lamina are quite the same as in the posterior part of the mouth, where the band possesses a still more primitive character. The examination of embryological serial sections of other mammals has convinced me that the accessory band is not restricted to the group of the Primates, but is a formation appearing so often in the development of mammalian embryos, that it may be considered as almost a normal appearance. It is superfluous to enumerate all my observations concerning this point, for it has been described by other authors, such as Woodward in Erinaceus and Sicher in Talpa. None of these authors, who confined their attention to isolated specimens (to one species, Sicher, to one group of mammals, Woodward), has been able to ascertain whether or not the accessory band is a usual occur-

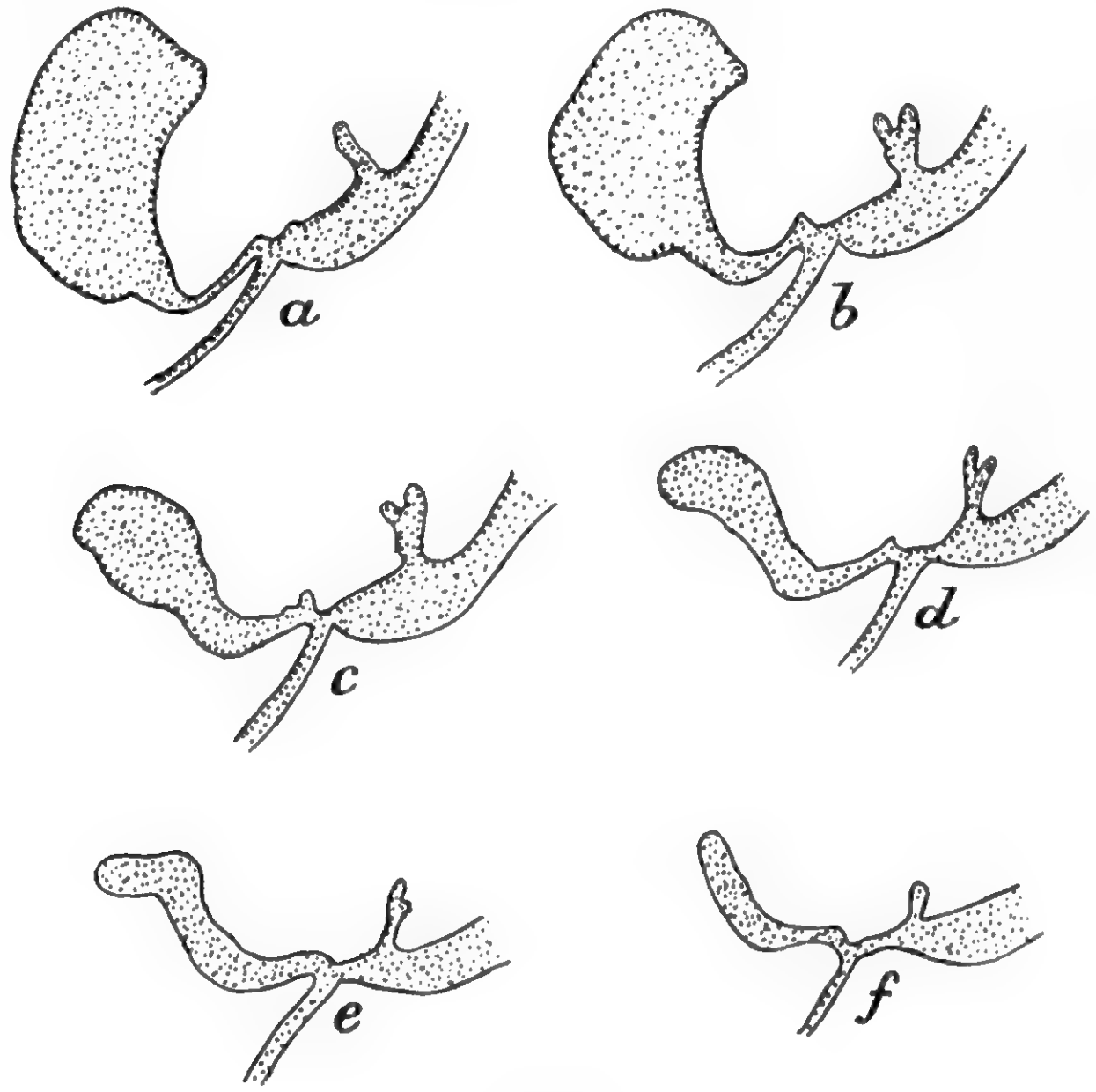

Fig. 83

rence. Although I do not venture to assert that the accessory band occurs in all mammalian embryos, its occurrence nevertheless is so frequent that a description of its development should have a place in every systematic treatise. Now the accessory band, as will be pointed out later, is a rudimentary organ, possessing a striking relation to the tooth-band, but having nothing to do with the development of the mammalian dentition. Therefore conditions are not always favourable for determining its presence. It may happen that the embryo examined is one in which it is very rudimentary or perhaps wholly wanting, as is the case in all organs undergoing regression. On the other hand one may light on an embryo of the same species in which it is strongly developed.

I will give some idea of the variability of the accessory band in mammalian embryos by relating some of my observations.

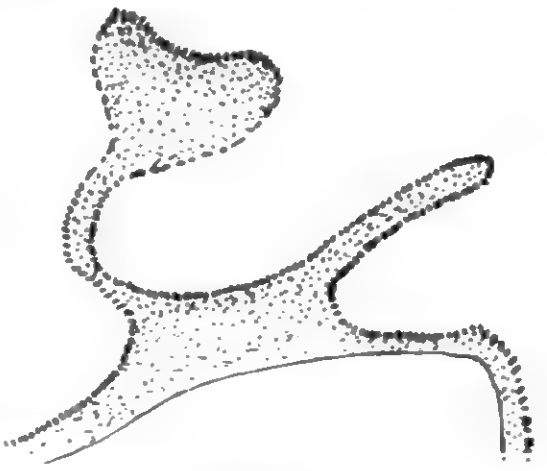

Fig. 84

I select, first of all, a case in which the band was extraordinarily strongly developed. It is drawn in fig. 84, which represents a section through $\underline{m_2}$ of a Tragulus javanicus. The specimen was still in an early stage of its development, as proved by the enamel-organ, in which the formation of stellate reticulum has just commenced. A short distance from the dental lamina, and buccal to it, the deeper layer of the oral epithelium sends down a process, inclining laterally, into the subjacent tissue. This process—which is even longer than the dental lamina itself—is the accessory band. It shows its proper relation to the latter lamina by both processes taking a common origin from a thickening of the surface epithelium, the dental lamina at the lingual border, the accessory at the buccal. This circumstance is important as a means of explaining the nature of the accessory band. This thickening is very often met with. As a second example I give a section through the anlage of $\underline{m_1}$ of an embryo of Sus scrofa (Series *R*) in fig. 85 in which the thickening of the

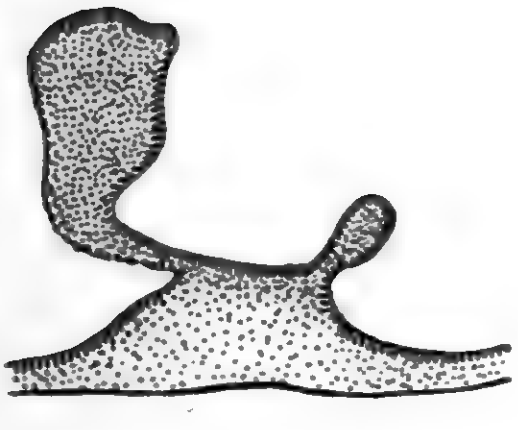

Fig. 85

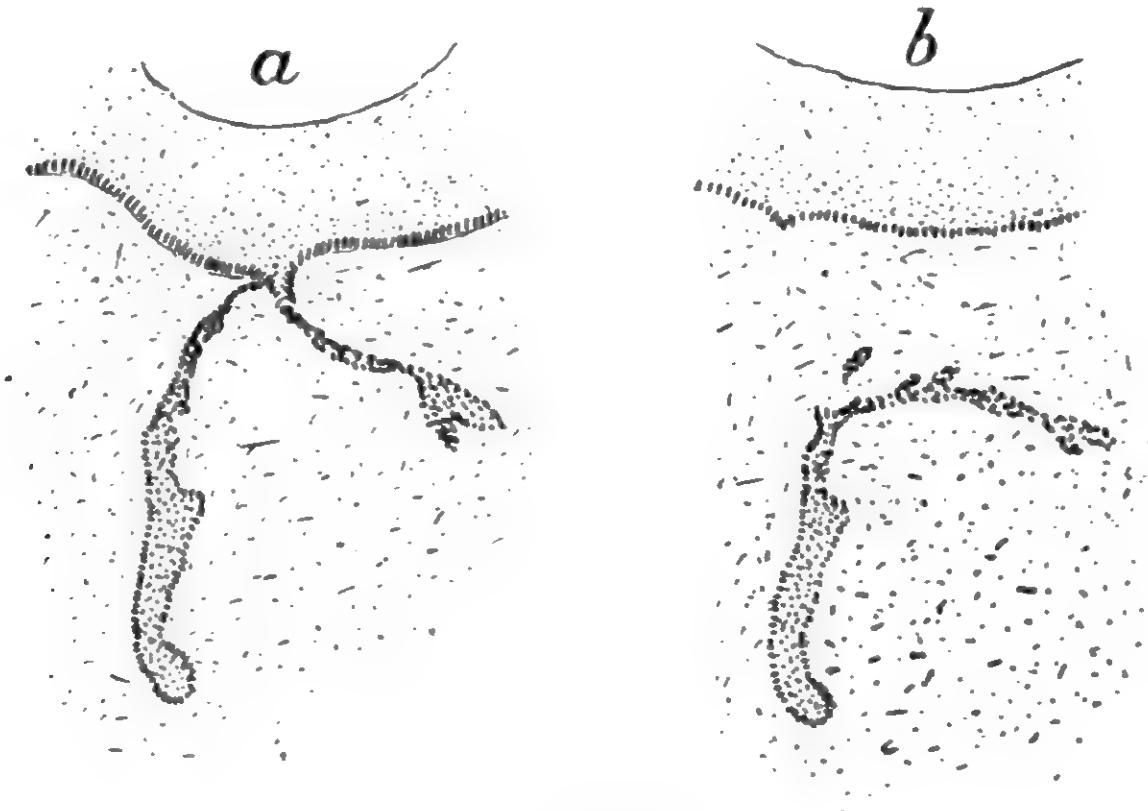

Fig. 86

superficial epithelium between the dental lamina and the accessory band (in this case bud-like) is very well demonstrated. As this figure shows, the deeper layer of cylindrical cells of the thickened plate of the oral epithelium passes continuously from the dental lamina to the accessory band.

The embryos of Equus caballus are very instructive regarding the nature of this band. I have found that the accessory band is rather strongly developed in this mammal, especially in the lower jaw. This is to be seen in fig. 86 in which are represented two sections through the posterior part of the dental lamina in the lower jaw of the embryo *D* of my collection. In section *a* the dental lamina and accessory band are still connected with the superficial epithelium; in section *b*, taken a little further back, the whole laminar formation lies free in the mesenchymatous tissue, and both parts of the well-known hook-shaped mass (cf. figs. 79 and 82). Fig. 86 *a* merits special attention. The free end of the accessory band bears the epithelial thickening already described in man and Macacus, and is not unlike the young stage of an enamel-organ.

The interpretation of such a thickening as a rudimentary tooth-germ becomes very attractive, particularly when the accessory band terminating in such a thickening is very short and emerges from the base of the dental lamina or even from the neck of a real enamel-organ. Such a case I have met with in Roussettus (Xantharpyia) amplexicaudatus, a bat of the Malayan Archipelago. In fig. 87 a representation of this formation is given from each jaw.

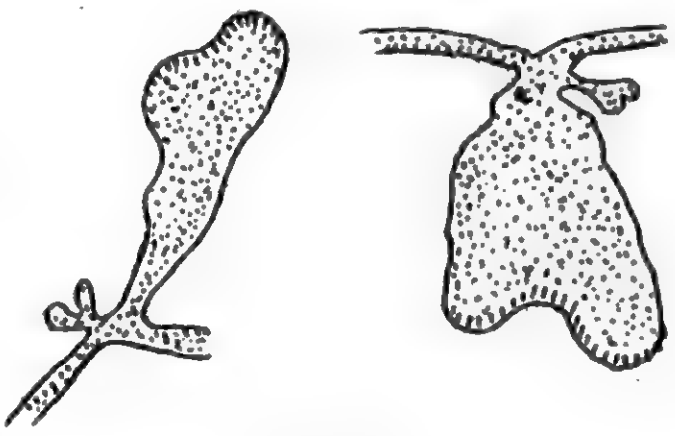
Fig. 87

The rather numerous representations which I have given of this thickening at the free border of the accessory band, may give rise to the idea that it is common. Yet, this is not the case. On the contrary, they are uncommon, not to say rare. The cases described and depicted in this paper are, with the exception of one, of which mention will be made later, all that I have observed in the course of my investigations. It seemed necessary, however, to give a brief account of all of these cases, in view of the discussion on the significance of the accessory band. Its interpretation has given me much labour and it was only after a thorough consideration of the different possibilities and after the discovery of some new facts in the development of teeth in reptiles, that I reached a definite solution of its meaning.

Of the possibilities to be taken into consideration I will discuss here only two. In the first period of my researches, when the accessory band was still a rather new and unknown phenomenon to me, I reflected on the possibility of it being identical with the lateral enamel-strand, which has been fully discussed in my previous paper. I thought it possible that in some cases the formation of the enamel-niche might occur in an irregular manner, so that its outer wall—the lateral enamel-strand—arising from the superficial epithelium, failed to reach and become attached to the enamel-organ. This idea of an incomplete enamel-niche is not unlikely. Firstly this niche and the lateral enamel-strand are rudimentary formations, and we know that often such formations develop irregularly or in a defective manner. Moreover, the accessory band, lying buccal to the enamel-organ, is situated so near to the latter that the topographical relations of this band and the lateral enamel-strand do not differ much. Finally I recall the fact dealt with in my previous paper, that in the germ of the molars the enamel-niche is not infrequently situated immediately beneath the oral epithelium, so that the lateral enamel-strand is not attached to the dental lamina but to this epithelial layer. Now in such a case one has only to imagine that the attachment to the enamel-organ is broken away and a condition is produced resembling in all respects an enamel-organ with an accessory band.

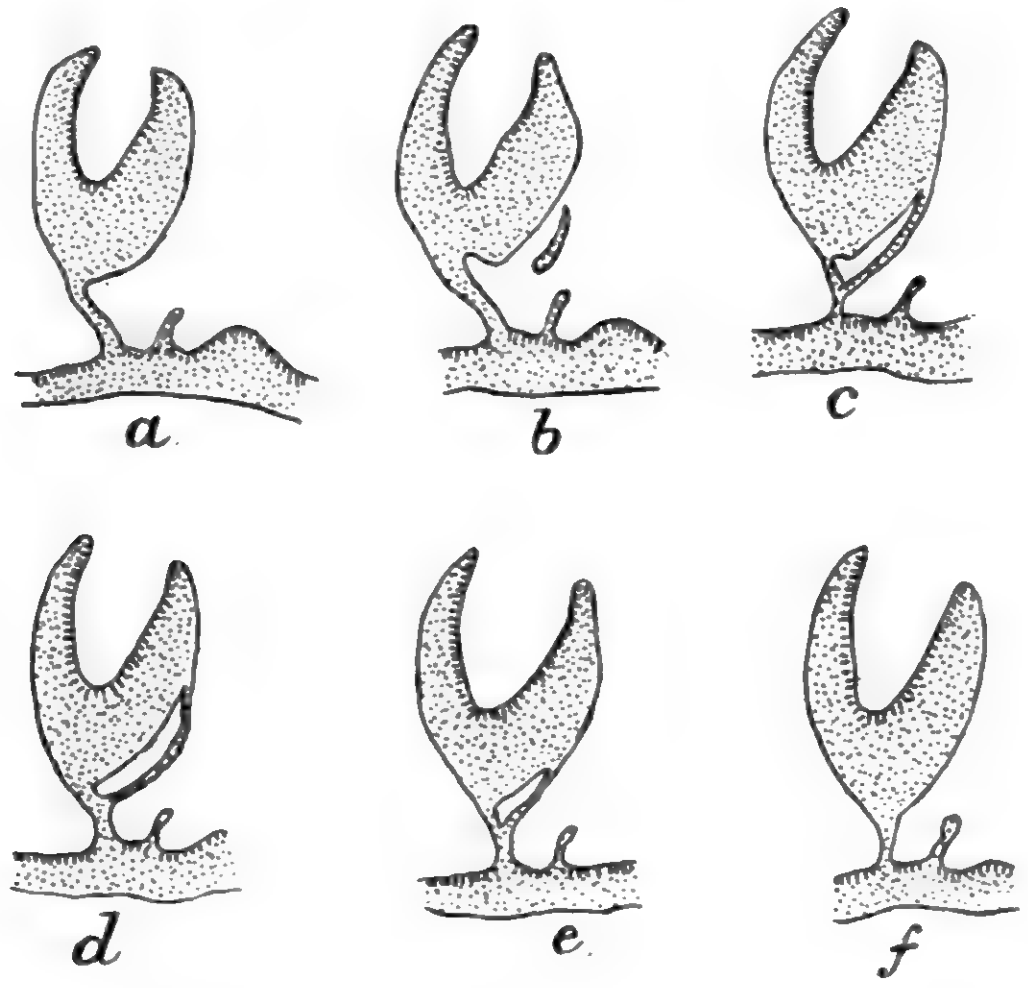

Fig. 88

Continued researches have convinced me however that this interpretation of the accessory band is quite erroneous. For if such an interpretation were right, the possibility of a section showing both a complete enamel-niche with the lateral enamel-strand and an accessory band, should be positively excluded. Now such cases do occur, and I have had the good fortune to examine a number of them.

A very fine instance is represented in fig. 88. Here are sketched six sections through the germ of $\underline{m}_1$ of an embryo of Sus scrofa (Series *W*). In fig. 88 *a* an accessory band is seen arising from the oral epithelium, buccal to the tooth-germ. In fig. 88 *b* the lateral enamel-strand appears, which, becoming complete in the next section, closes the enamel-niche laterally. Then the enamel-niche grows narrower and disappears in the last section. Now, these sections prove that there is no identity nor even an anatomical relation between the accessory band and the lateral enamel-strand. Both formations exist at the same time quite independent of each other.

In order to establish this fact still more conclusively, I have reconstructed in wax a portion of the dental lamina with a tooth-germ and the accessory band of the lower jaw of Mycetes. The reconstruction is represented in fig. 89 and establishes unmistakably the fact that the accessory band and the lateral enamel-strand are two independent formations.

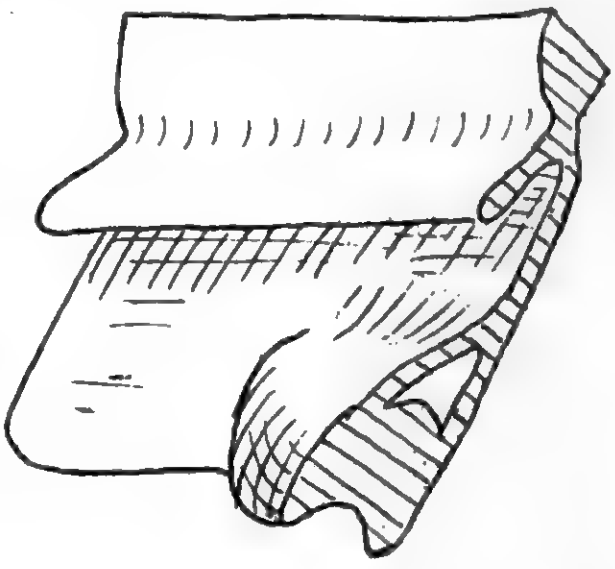

Fig. 89

Furthermore this model enables us better than any series of sections can do to get a good idea of the anatomical features of the accessory band. And this is necessary in view of the discussion relating to my second interpretation.

The accessory band is not described in the present paper for the first time. Several writers have observed and described it before. It is, however, the first time that its relative frequency and generality have been pointed out, most authors confining their attention to isolated cases and consequently considering that the accessorial formations were accidental. Not uncommonly such a formation has been regarded as a rudiment of the hypothetical so-called premilk-dentition, and certainly this view seems specially justified in those cases where the free border of the accessory band is thickened, bearing on section some resemblance to a young stage of enamel-organ. I have already given some examples of this condition.

The above view is discussed in the seventh edition of Tomes' *Dental Anatomy*. On p. 353 of this work a section is figured through the tooth-germ of a pig, showing a lateral outgrowth from the dental lamina. The author, however, expresses himself with some reserve with regard to this outgrowth. "If it is to be regarded as an aborted tooth-germ the writer expresses the opinion that it must be referred to a premilk-series. It is not definitely accepted as representing a tooth-germ by Marett Tims and others who have studied this specimen." I agree with this denial, for the outgrowth is a well-developed accessory band.

A somewhat divergent opinion is expressed by Woodward[1]. This author describes the accessory band in Erinaceus as follows (*l.c.* p. 563): "We find a slight but constant labial outgrowth from that portion of the dental lamina connecting the enamel-organ of the functional molar with the oral epithelium," and his conception of these formations becomes clear by what he writes on p. 583: "These labial growths in the molar regions are the last indications of an earlier set of teeth." The author, however, does not identify this earlier set of teeth with the hypothetical premilk-dentition, but, considering the functional molars as belonging to the replacing set of teeth, he concludes that these labial outgrowths of the dental lamina represent the much reduced milk-dentition (*l.c.* p. 584).

---

[1] "Contributions to the Study of Mammalian Dentition." Part D, Insectivora. *Proc. Zool. Soc.* London, 1896.

Thus while one group of investigators interpret the accessory band as a rudiment of the hypothetical premilk-dentition, another consider this formation as the reduced milk-dentition. Both agree as to the accessory band being a rudiment of a reduced set of teeth, either the premilk- or the milk-set. With this interpretation I do not agree.

Though accepting Woodward's view that the permanent molars belong to the replacing set of teeth, for I consider the milk predecessors of these elements as reduced, I cannot accept this author's opinion of the accessory band, which I consider erroneous. This is proved by the fact that this band appears not only in the region of the permanent molars but also—indeed very often—in that of the milk molars. I have already described and figured some cases of a well-developed accessory band buccal to a milk molar. These facts contradict Woodward's interpretation. Moreover I recall the fact, that in Macacus (*vide* fig. 83) there are rudiments of this band even in the frontal part of the mouth, buccal to the milk incisors.

On the other hand these facts seem to favour the interpretation of the accessory band as a rudiment of a premilk-dentition. Before entering into a discussion of this view, I will state my own standpoint relative to the problem of a premilk-dentition. Not only am I no partisan of such a dentition but on the contrary I strongly oppose both this conception and the possibility of a fourth or post-permanent dentition. For the present I cannot discuss these problems further—I intend to do so in a subsequent paper—and therefore I will confine myself to a brief statement. If we consider the phenomenon of the dentition in mammals as being identical with that in reptiles, then the hypothesis of a premilk-dentition as well as that of a post-permanent dentition seems probable enough, for reptiles usually have an indefinite succession of teeth. But in a future paper I hope to show that the processes of dentition in mammals and in reptiles are two quite different and heterogeneous processes, the similarity being only apparent.

Setting aside for a moment my general objection to the identity of the accessory band and the hypothetical premilk-dentition, I would direct attention to the special facts dealt with in the present paper. I lay stress upon the accessory as being a real band, extending uninterruptedly in a backward direction, being prolonged during the growth of the embryo in this direction, together with the dental band. If there was any relation at all between the epithelial formation in question and the premilk teeth, one would expect to find not a continuous band but isolated germs. And these germs should alternate with those of the milk-dentition. In view of the fact that in mammals the elements of the milk-dentition and those of the successional set of teeth alternate regularly, it seems to me necessary, if accepting a premilk-dentition at all, that equal topographical relations must have existed once between the elements of the milk- and premilk-dentitions. According to my observations this is not the case. This discrepancy I count of no importance as I repudiate wholly the hypothesis of a premilk-dentition.

I will state my own views as briefly as possible as to the significance of the accessory band. As mentioned already my conclusions are based on researches on the development of the teeth in reptiles.

In the course of this inquiry my attention was drawn to the very interesting relationship existing between the origin of teeth and the system of glands, which is often so profusely developed in the mouth of these animals. As is well known the system comprises several groups. There is one group, which takes origin from the palatinal epithelium and is therefore situated medial to the teeth. These glands—glandulae palatinae—are of no importance to us here. A second group is situated lateral to the teeth. These glands, known in literature as glandulae labiales (a denomination which, as will be shown, is not quite correct), are developed usually in both jaws, but may be absent in the upper jaw.

The first anlage of these glands is represented in fig. 90. This figure shows a transverse section through the epithelium of the lower jaw of a young Hemidactylus frenatus. Whilst this epithelium is built up in general by a single layer of cells, there is a zone, corresponding to the upper margin of the jaw, in which the oral epithelium is thicker, consisting of two layers of cells. This thickened zone is continued medially into the dental lamina, bearing at its free border in fig. 90 an enamel-organ in a young stage of development. Laterally this thickened zone penetrates the subjacent mesenchymatous tissue, forming a short band situated labial to the dental band. This epithelial formation will produce the glands, and should be distinguished as the "glandular band." In the stage shown in fig. 90, there is nothing to be seen of a differentiation of glandular organs, the band extending as far backward as the dental lamina. It is very obvious that the dental band and the glandular band are formations of the same matrix and that there exists a close relationship between them. The layer of very typical cylindrical cells, composing the dental lamina, is continued—as demonstrated by the figure—uninterruptedly into the glandular band.

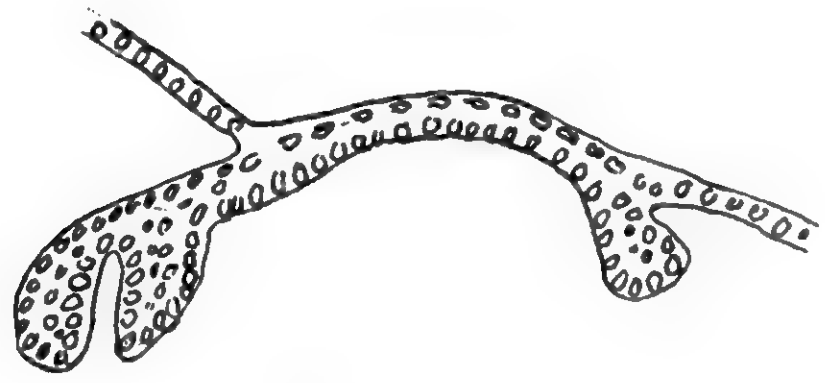

Fig. 90

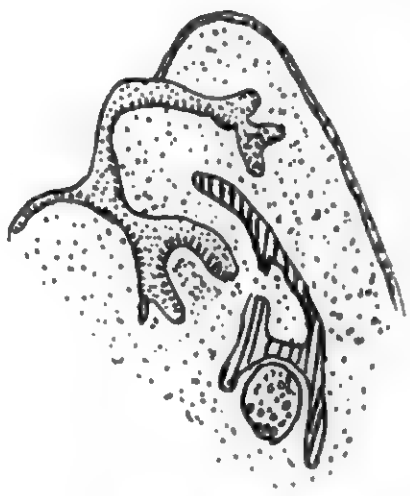

Fig. 91

A somewhat older stage of development is shown in fig. 91, in which a section is reproduced from the lower jaw of a young Lacerta agilis. The relation of the dental lamina to the glandular band has grown more distinct. The covering epithelium still consists of a thin layer, but in this case, as in the previous one, there is a thickened middle zone, the medial border of which penetrates deeply, forming the dental lamina, which bears at its buccal side a well-developed enamel-organ. The dental lamina and enamel-organ are situated lingual to the os dentale. The glandular band is also present, emerging from the lateral border of the thickened region. It penetrates rather deeply into the mesenchymatous tissue. In this section (fig. 91) the lamina terminates in two bud-like thickenings, the first indications of a gland. The glandular band extends buccal to the os dentale.

In fig. 92 a further stage of development is shown by a section through the lower jaw of Cyclodus Boddaertii. The thickened epithelial plate has grown narrower, by which fact the difference between this epithelial zone and the epithelial layer covering the other parts of the jaw is more accentuated. In consequence the contrast between both epithelial bands—the dental and the glandular—has become still more evident. They appear as buccal and lingual prolongations of the thickened plate, while sunk into the depth of the underlying soft tissue. A rather large and ramified gland emerges from the glandular band. This gland corresponds topographically to the tooth on the dental lamina, and effects a close relationship with the latter in the course of further development.

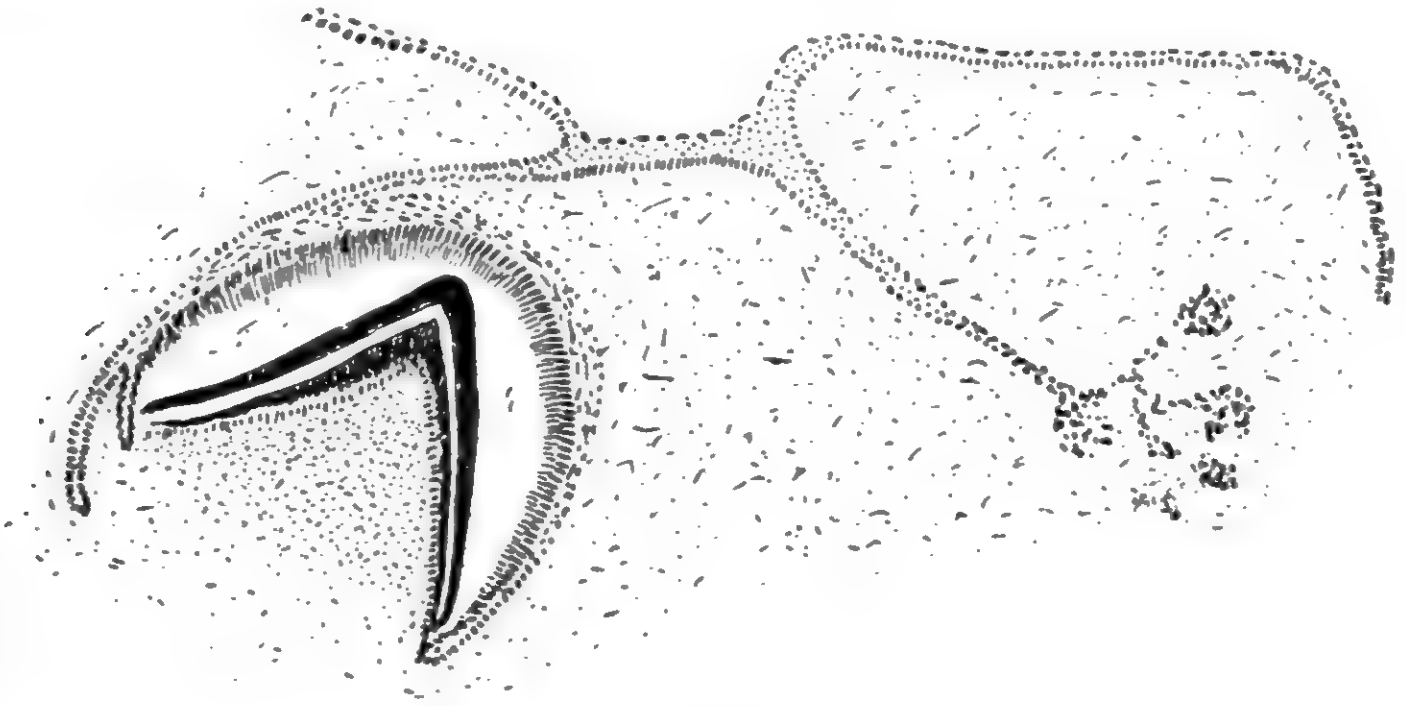

Fig. 92

Finally I give in fig. 93 a section through the lower jaw of Draco volans, to demonstrate once more the topographical relations between the dental lamina and the glandular band at a more advanced stage of development, and specially to draw attention to the relation of both bands to the os dentale.

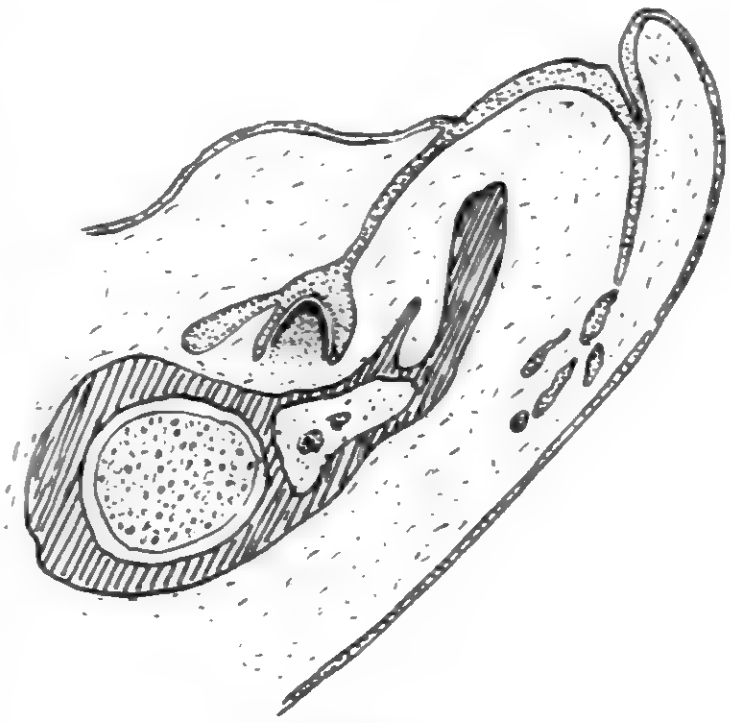

Fig. 93

Figs. 90, 91, 92, 93 establish beyond doubt that in reptiles the development of the glandular band, from which the so-called glandulae labiales take origin, is closely connected with that of the dental lamina. Both proceed from a common epithelial matrix. And therefore it seems to me preferable to distinguish the glands shooting off from the band described above as tooth-glands and not as lip-glands, as is usually done. For even without laying stress upon the fact that lips, in the accepted sense, are wanting in reptiles, the further history of these glands justifies the name I propose. It has been mentioned already that the glandular band gives rise to the development of a gland opposite to every tooth formed from the dental band. Therefore there are as many glands as teeth, whilst the interglandular parts of the band degenerate and disappear. Thus the glands become separate organs, each with its own excretory duct. Originally the excretory ducts open on the surface in all reptilian embryos. This condition may persist during life, in which case a groove is usually formed, bounded on the medial side by the os dentale, laterally by a fold of soft tissue, on the bottom of which the excretory ducts open. By the development of this protecting wall of soft tissue there comes about an anatomical condition, not unlike that in mammals with real lips. Hence the naming of these glands, glandulae labiales.

In most cases, however, the thickened plate between the dental lamina and the glandular band is converted into special sheaths around the teeth. In consequence of this the excretory duct of a gland, belonging to a tooth, opens into the narrow cavity between the tooth and its sheath. The topographical relation between tooth and gland then becomes a very close one. Such a condition occurs in the Iguanidae, as may be seen in fig. 94, showing a section through the upper jaw of a young Iguana sapidissima. This figure needs no further explanation.

Fig. 94

Having given this short summary of the development of the glandular band in reptiles and established the genetical relation between this band and the tooth-band, we return to the proper subject of the present paper: the accessory band, which appears in connection with the dental band in mammalian fetus. I think the foregoing facts throw light upon the true nature of this band.

I have already given my reasons for not accepting the current opinion of the significance of this band. Personally I think this accessory band is the rudimental homologon of the glandular band in reptiles. To prove this absolutely is not possible, as in so many problems of the same nature. My conviction is founded upon the several corresponding points between both bands. On the other hand I lay stress upon the fact that the opinions of other writers, too, are mere suppositions, and none I think is so broadly based on fact as this inference of mine.

An important analogy is the common anlage of tooth-band with accessory band in mammals, and tooth-band with glandular band in reptiles. In reptiles the glandular band appears as an outgrowth from an epithelial mass, from which also the tooth-band emerges, so in mammals the accessory band arises from the mass, which gives origin to the tooth-band. This thickened superficial plate between the two bands, which is so characteristic of reptiles, is sometimes fairly well seen in mammals. In fig. 85 (Sus) and fig. 84 (Tragulus) the intermediate plate is clearly demonstrated. A comparison of these figures with figs. 91, 92 will serve to strengthen the homology of accessory and glandular bands. The only difference between the anatomical conditions in mammals and reptiles in these four figures is the absence of glandular ramifications at the free border of the accessory band. This fact may indeed be utilized as an argument against the proposed homology. But the suggestion is not a sound one. For, what I was unable to observe in Sus and Tragulus, was seen by me in other mammals. Special mention has been made already of all cases in which thickenings and vestigial ramifications came under observation at the free margin of the accessory band. I refer the reader to figs. 80 (Homo), 83 (Macacus), 87 (Roussettus), and 86 (Equus). I am convinced that these thickenings are really vestigial glands, degenerating during later development. Besides, the whole accessory band atrophies.

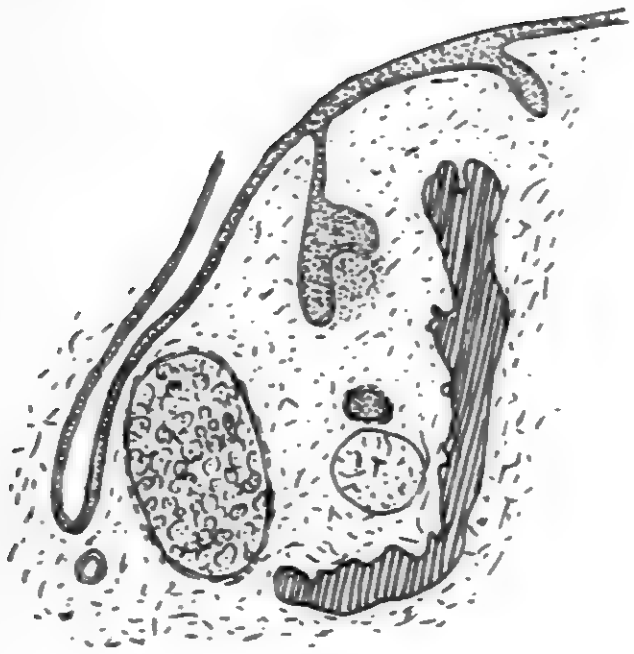
Fig. 95

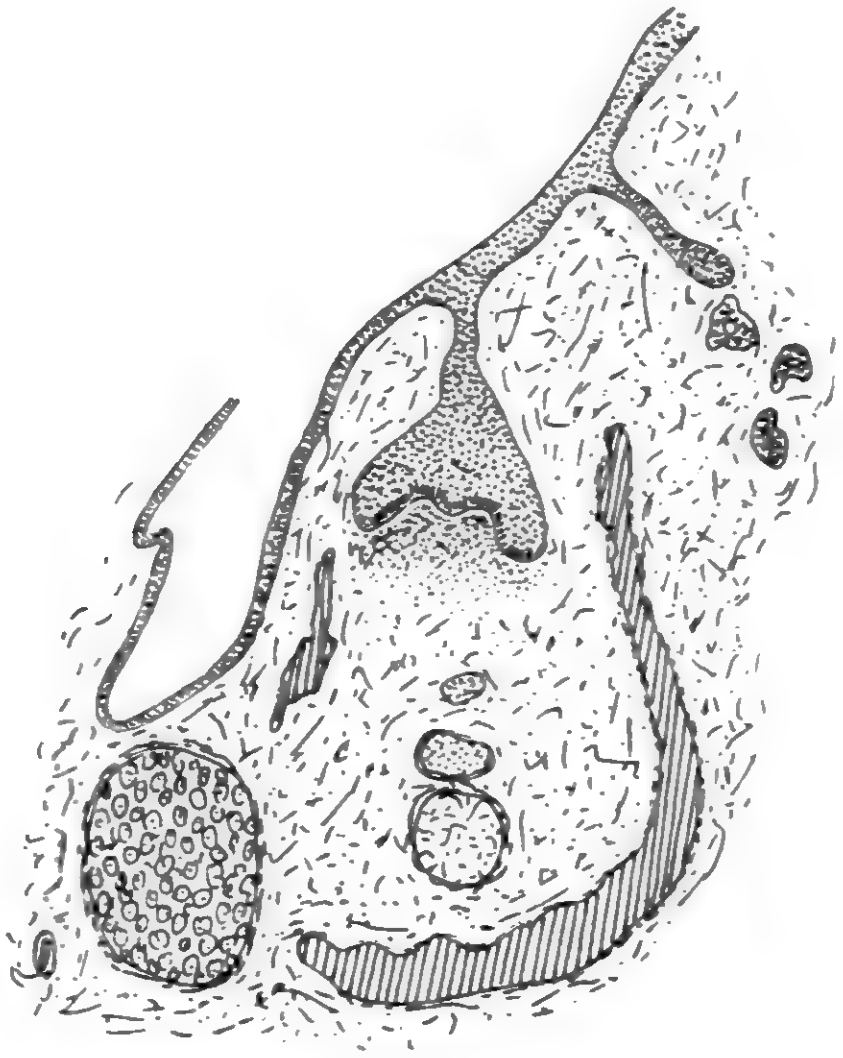
Fig. 96

There exists between the accessory band of mammals and the glandular band of reptiles a similarity in a genetical, topographical and functional sense.

The similarity from a functional point of view is proved in only an imperfect manner. For it is only a supposition of my own that the thickenings at the margin of the accessory band are vestigial glands. Fortunately, however, I am in the position to establish the correctness of my assertion, having had the good fortune to come across a mammal in which this band shows unmistakably real glandular ramifications. This happens in the mole. In this animal the accessory band is strongly developed and apparently is not atrophying so rapidly as in the other mammalian embryos studied by me. In its general features and relation to the dental lamina it very much resembles the glandular band of the reptiles, as is apparent from fig. 95, representing a section through the lower jaw of a somewhat older embryo of the mole (Series *N* of my collection). Both bands emerge separately from the superficial epithelium, and the zone of the covering epithelium, extending between both bands, is thickened as in reptiles. The section in fig. 94 runs through the germ of $\overline{M}_2$. In this stage of development, the accessory band possesses still an undifferentiated free border.

A more advanced stage of development is represented in fig. 96 (Series *NN*). This section, too, runs through the enamel-organ of $\overline{M}_2$. The figures are drawn at corresponding points, and are therefore directly comparable. In both, the Meckelian cartilage with the os dentale are to be seen. In the concavity of the latter, the Arteria mandibularis is situated with the accompanying nerve.

The changes which have taken place concern principally the accessory band. It has penetrated more deeply into the mesenchymatous tissue. Now, though it terminates in the section shown (fig. 95) in a free border, there are three sections of a tubule to be seen situated close to the free edge. On studying the succeeding sections it became evident that this tubule is really an outgrowth from the margin of the accessory band.

We have thus a direct proof that the accessory band in mammals can still produce glands or at least glandular organs. In addition, the very close resemblance of fig. 96 from a mammal, to fig. 94 obtained from a reptile, should banish all doubts and prove conclusively *that the reptilian glandular band and the mammalian accessory band are homologous structures.*

The further developmental history of the glands in the mole is unknown to me. I do not know whether they become functional organs in the adult or atrophy after birth. The embryo *NN*, from which fig. 96 was obtained, was the oldest specimen in my possession, and it was certainly in the last phase of its intrauterine development.

In the publication of the present paper I have aimed at a double purpose. Firstly to make known new facts concerning the development of the dentition in mammals and reptiles, and secondly to enable odontologists to obtain a more exact knowledge of the so-called vestigial premilk-teeth. For I am convinced that many epithelial formations in a mammalian embryo described in literature as vestigial premilk-tooth, are in reality rudiments of the reptilian glandular band.

ON RARER OSSIFICATIONS SEEN DURING X-RAY EXAMINATIONS[1]

By CHAS. THURSTAN HOLLAND,
Liverpool

ROUTINE examination of the body, particularly of such parts as have been the seat of accident, often raises doubts concerning whether the appearances seen are the results of force or of development. This is particularly the case as regards the foot. It is true that the accurate researches carried out by the late Prof. William Pfitzner[2] in the closing decade of last century give as complete an account as we may ever hope to have of the abnormal ossifications and bones as seen during the examination of anatomical material. The radiologist, however, encounters such ossifications under very different conditions and it is with the view of placing the problem of abnormal ossifications of the foot from the radiologist's point of view that I now place on record some of my more recent observations.

The accessory bones of the foot are of very special importance from a medico-legal point of view, and the frequency of the presence of some of them, as shown by radiography, is somewhat surprising. The accessory bones of the hand are, I believe, very much less common and of far less importance.

There are some ten or eleven of these accessory foot bones altogether[3], but some of them are not of much importance owing to their extreme rarity, and some which do not lend themselves to a definite display by X-rays.

The first one I depict is one of the most common (fig. 1)—it is known usually as the "tibiale externum," and it is situated on the posterior and external side of the tuberosity of the scaphoid. It has been demonstrated by radiography at the early age of three years, but those I have seen have been usually in adults. It is a definite skeletal bone; and as it is never enclosed in the tendon of the tibialis posticus it is not a sesamoid bone.

The presence of this bone may give rise to tarsalgia and even local manifestations of inflammation, and it may, radiographically, be mistaken in cases

---

[1] Abstract of a paper read at the Liverpool Medical Institute, Feb. 3rd, 1921.

[2] "Beiträge zur Kenntniss des menschlichen Extremitätenskelets," *Morphologische Arbeiten*, 1891–2, Bd I. pp. 1–120; pp. 517–760 (on sesamoids); 1894–5, Bd IV. pp. 347–570 (on special ossifications of hand); 1896, vol. VI. pp. 245–514 (on special and uncommon ossifications of foot). See also Dr M. Lupo, *La chirurgia degli organi di movimento*, 1920, vol. IV. p. 141 (abnormal ossifications of foot); *Biometrika*, 1921, vol. 13, p. 133 (sesamoids of knee).

[3] List in Quain's *Anatomy*, 1915: (1) Os trigonum; (2) os sustentaculum proprium; (3) calcaneus accessorius; (4) calcaneus secundarius; (5) ossiculum trochleae; (6) tibiale externum; (7) cuboides secundarium; (8) os intercuneiforme; (9) sesamum peronaeum; (10) os intermetatarsum; (11) os Vesalianum.

of injury for a fracture of the tuberosity of the scaphoid. To assist in making the exact diagnosis the other foot should always be examined, and in the large majority of cases it will be found to be also present in this other foot (figs. 1 and 2). A similar condition in both feet would obviously put fracture practically out of court.

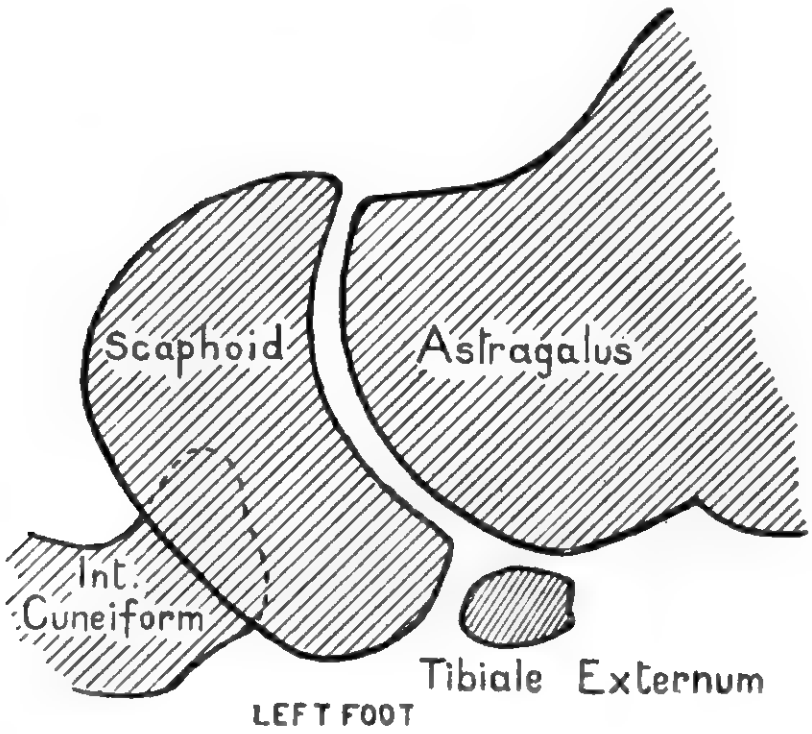

Fig. 1. Tibiale externum of left foot.

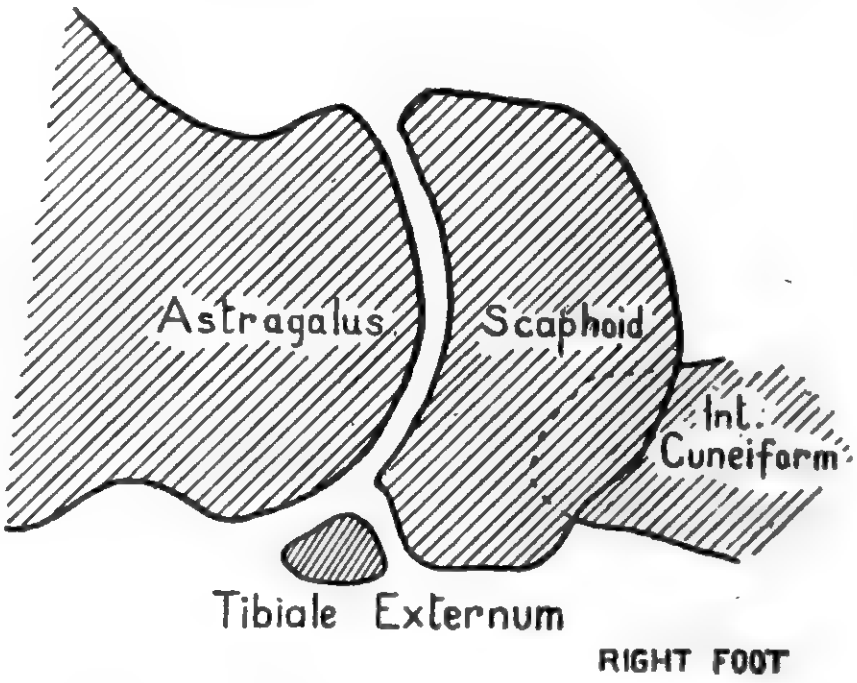

Fig. 2. Tibiale externum of right foot.

Further, in making a differential diagnosis, the appearance of the edges of the bones is valuable, as in cases of injury the edges of a fractured bone will almost certainly be irregular, whilst on the other hand the lines of both it and the adjacent scaphoid will be quite normal and well-defined when the condition is that of an accessory bone.

Before passing on to the consideration of some others of these definite bones, let me depict here some of the true sesamoid bones.

The first one is that usually known as the sesamoid bone in the tendon of the peroneus longus, and it was first described by Vesalius in 1555. It lies, as is shown in the radiograph, posterior to the base of the 5th metatarsal and in close proximity to the edge of the cuboid.

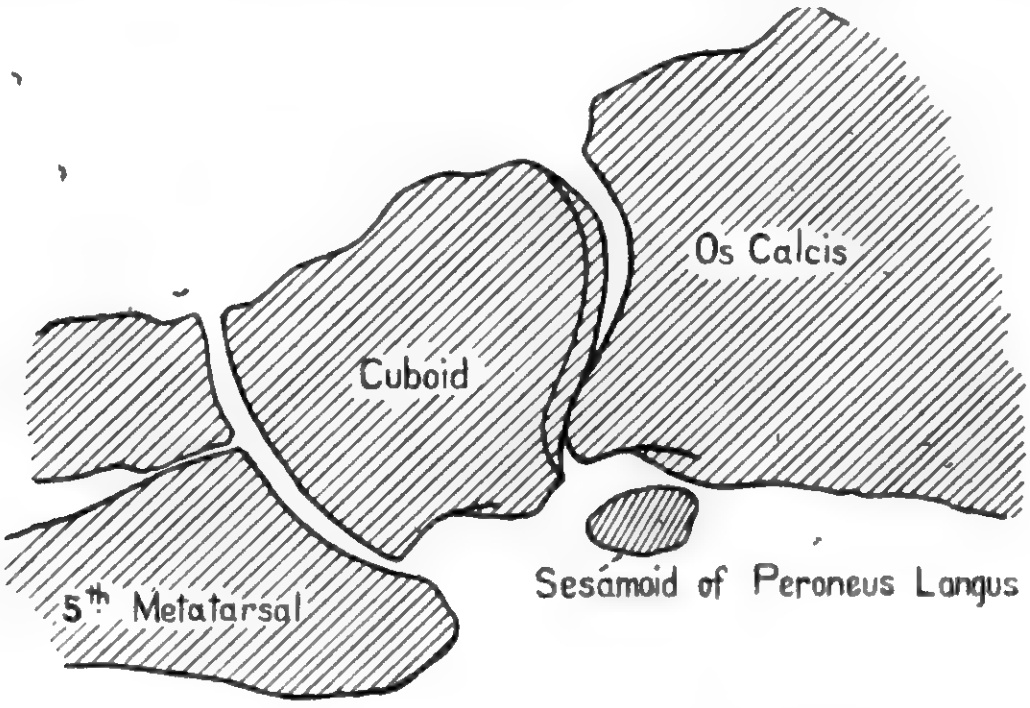

Fig. 3. Sesamoid on peroneus longus.

Comparatively it is very common and varies very much in size and shape, and the fact that it may be present should be known when considering the radiographical appearance in cases of injury. Apart from its situation, shape, clear cut edges and so on, a comparison with the other foot will almost invariably show a similar bone on the other side.

The two other prominent sesamoids of the foot are those beneath the distal end of the first metatarsal in the tendons of the flexor hallucis brevis.

These appear as somewhat oval shadows lying side by side. Developmentally, and by X-ray examination, it has been noticed that the inner one may be in two, three, or even (very rarely) in four separate bony pieces. It is somewhat curious that this departure from the normal so rarely affects the outer sesamoid; even Dwight[1] had only once seen it in two pieces, and personally I do not ever remember seeing it so in a radiograph. One point to be specially noted is that when these bones are in two pieces the line of cleavage is always transverse to the length of the bone.

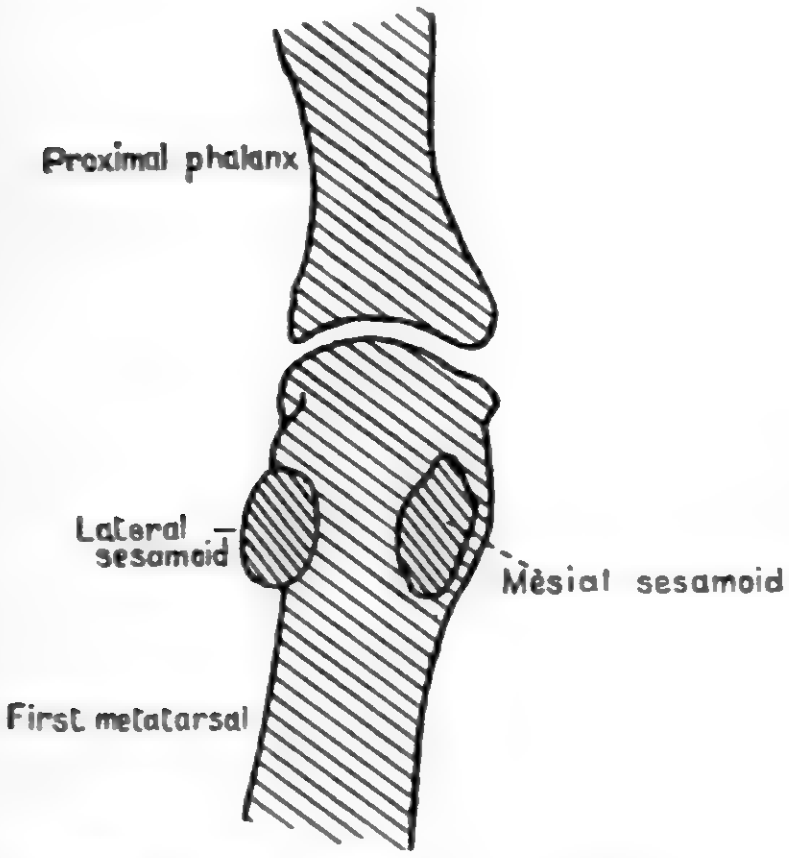

Fig. 4. Sesamoids of 1st (hallucial) metatarsal bone.

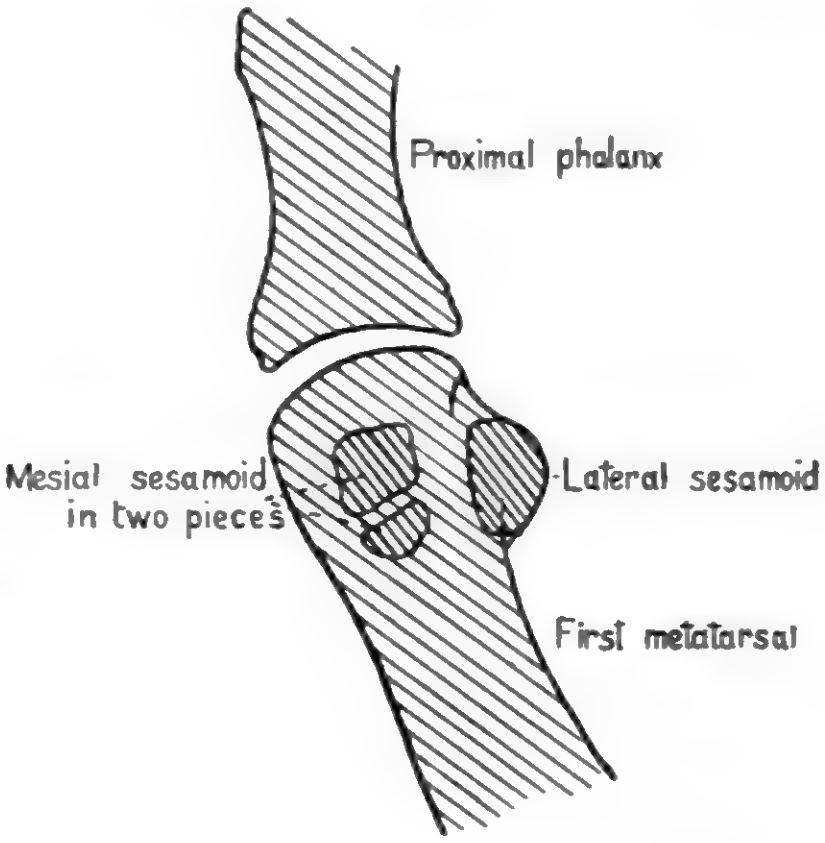

Fig. 5. Division of mesial hallucial sesamoid.

Many times such a bone, shown radiographically, has been described as fractured, more especially in those cases in which there is a history of a foot injury; in my experience this fracture must be a very rare occurrence, and most of the so-called fractures are really nothing of the kind. Seen on the radiograph the lines of separation of the two halves are very clearly defined and quite regular, the spacing being quite even. If a bone is cracked across one rarely sees radiographically such a straight and even line of fracture, associated with a definite regular space between the two halves. The great point, however, in differential diagnosis is the radiograph of the other foot, a symmetrical appearance, which is the rule, should negative fracture.

To return to the true accessory bones. In injuries about the ankle joint the os trigonum is of importance. Radiographically the shadows of the posterior part of the astragalus vary considerably according to (*a*) the shape

---

[1] Prof. Th. Dwight, "Variations in Bones of Hands and Feet," *Clinical Atlas.* 1907.

of the bone, which is variable, and (*b*) according to the exact angle in which the radiograph is taken. Normally the posterior part of the astragalus is

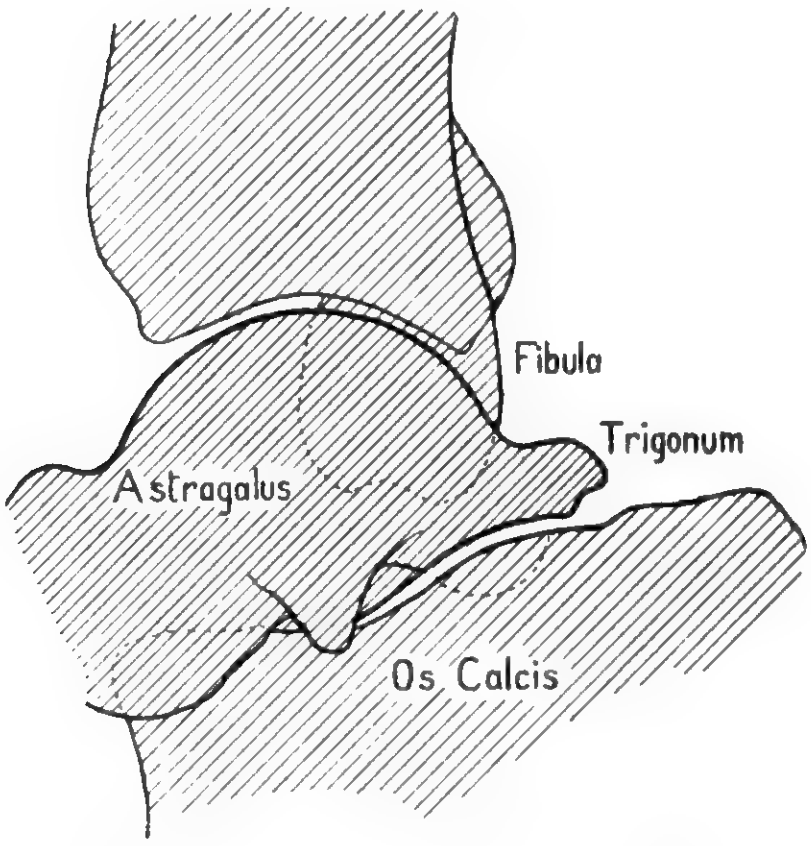

Fig. 6. Os trigonum fused with astragalus.

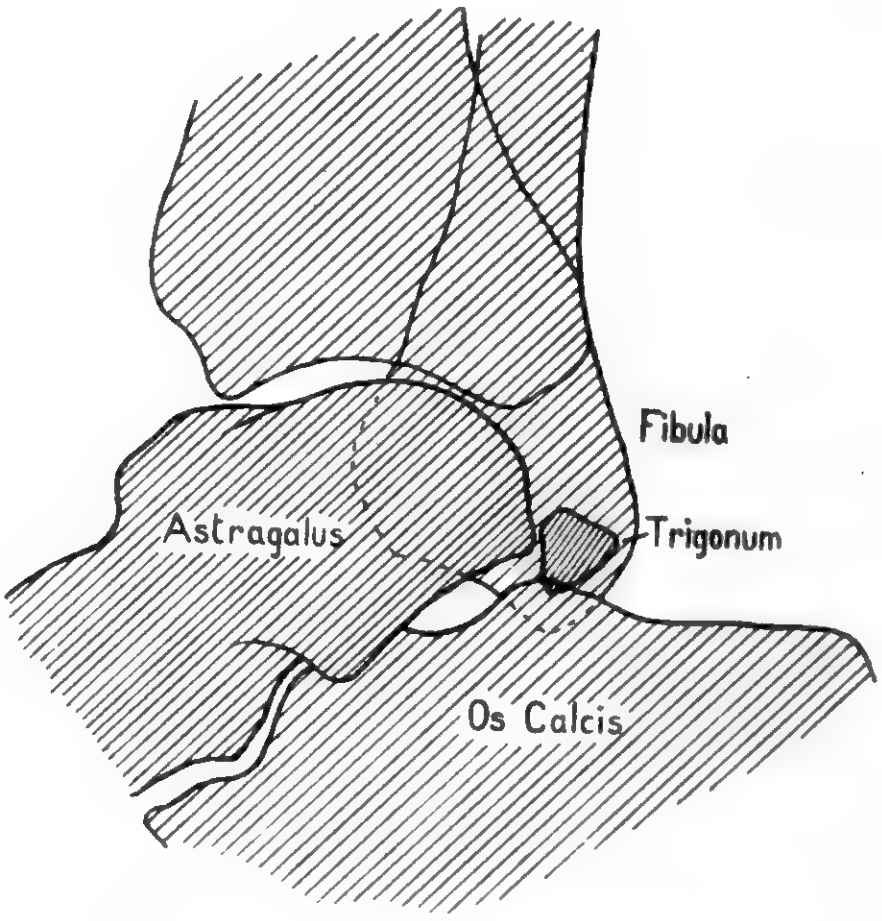

Fig. 7. Os trigonum separate from astragalus.

drawn out backwards into a projection, and in some radiographs, for instance in fig. 7, shows very prominently. Now the os trigonum when present is situated just at the back of the upper surface of the astragalus, and radiographically shows in such a position that it may simulate a fracture of this projecting piece of the bone. There is no doubt but that it is a distinct bone and Dwight has found it distinct in cartilage at birth. It is not known ever to give rise to any symptoms. Apart from the X-ray appearance already described as helping to distinguish a true bone from a fracture at the posterior end of the astragalus, the true bone is usually symmetrical and should be seen in the other foot.

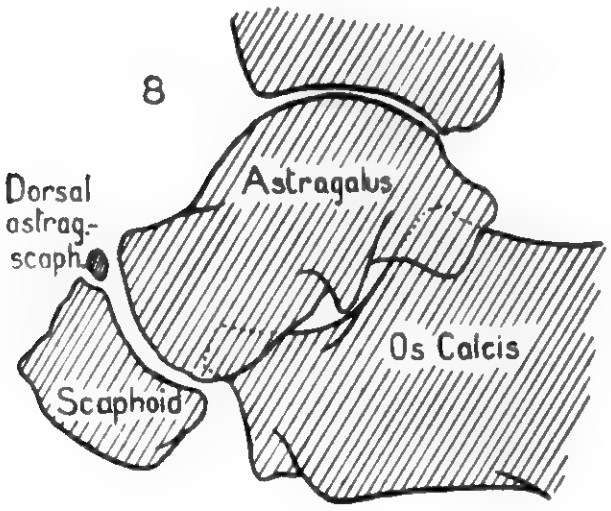

Fig. 8. Dorsal astragalo-scaphoid ossicle.

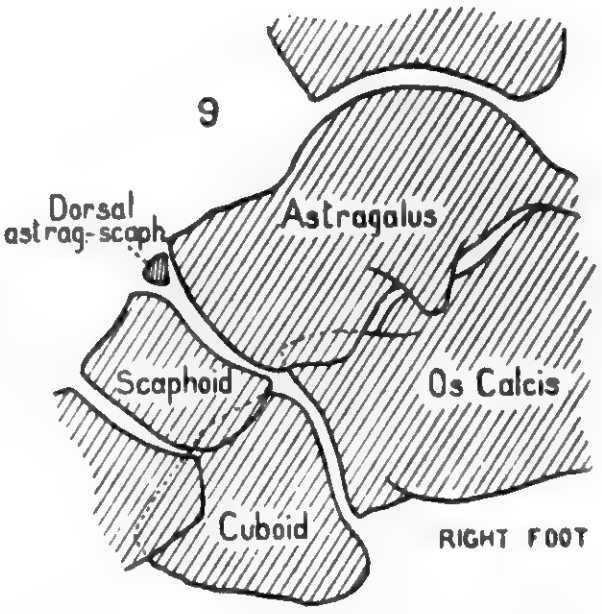

Fig. 9. Dorsal astragalo-scaphoid ossicle (right foot).

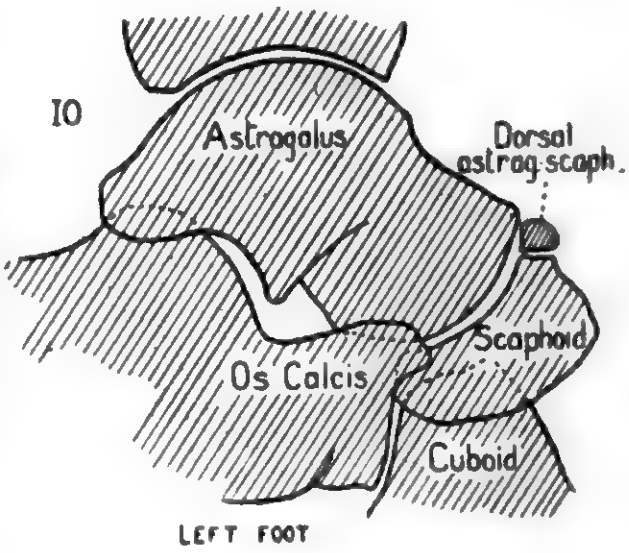

Fig. 10. Dorsal astragalo-scaphoid ossicle (left foot).

A further addition to our knowledge of these extra bones was made by Pirie in 1919 when he described a little ossicle, which he had met with in eight cases, lying between the upper surfaces of the astragalus and scaphoid. In most of his cases again it was symmetrical and present in each foot. On referring his discovery to Professor Robinson of Edinburgh the latter said that he had never seen or heard of such a bone, but had suspected that it might exist as he had once seen an articular surface for such a bone on a scaphoid.

I have met with a few cases; its proper recognition is essential in view of injuries in this region, and also in view of the fact that certain painful conditions are not unfrequent in this part of the foot.

I next come to the most interesting of all these bones, namely the one known as the os Vesalianum, or the "bone of Vesalius." It lies at the base of the 5th metatarsal.

Referring to the description of this bone by Vesalius in the 1725 edition (of which there is a splendid copy in the library of the Liverpool Medical Institute) we find a picture—a beautiful drawing of the bones of the foot, and at the base of the 5th metatarsal and close to the cuboid is figured a small bone. Translated into English the description is: "A small bone, opposite to the outer side of the joint, and placed proximally to the little toe, and *probably articulating with the cuboid*[1]."

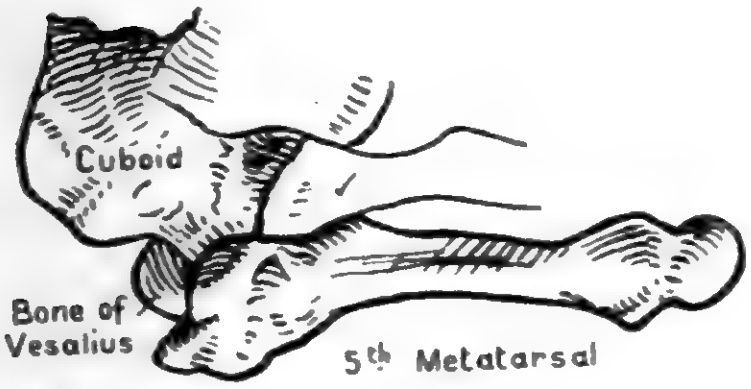

Fig. 11. Tracing from Vesalius of the bone named after him by Pfitzner.

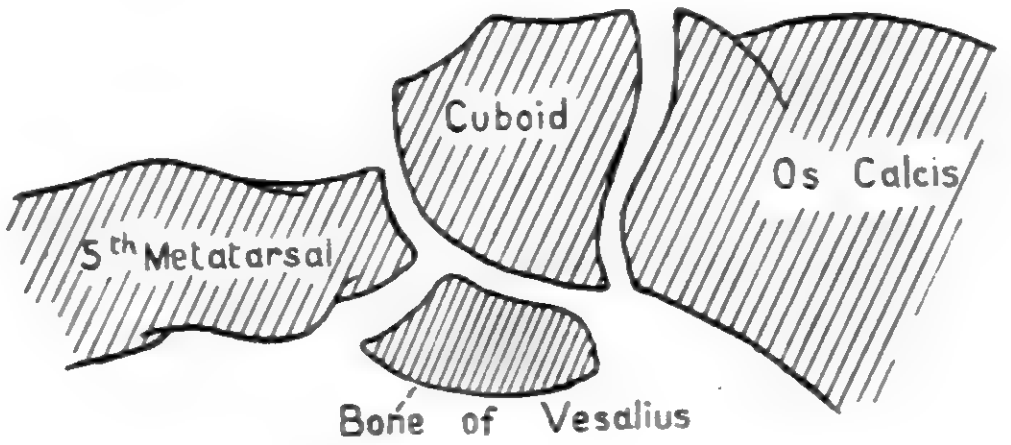

Fig. 12. Tracing from print given by Laquerrière and Drevon.

I have been in communication with Professor Keith[2] as regards this and other bone abnormalities and he writes me that "he considers that Vesalius describes really the sesamoid of the peroneus longus." There are other grounds for considering that this is probably the case as Dwight describes the bone of Vesalius (os Vesalianum) as the proximal and lateral part of the tuberosity of the 5th metatarsal, states that it is excessively rare, and that he has never seen it in the macerated foot of an adult. (The drawing in the book of Vesalius is that of an adult foot, and the position of the extra bone does not correspond with that of Dwight.) Dwight also mentions that Spronck has seen it at birth, and that he himself had seen it in a girl of 12 years of age. He also quotes

---

[1] This "probably articulating with the cuboid" is the key to the situation, as the peroneus tendon is in a groove in the cuboid at this spot and it is here that the sesamoid is found. Sometimes a bursa intravenes. This bone may be very large—up to 2 cm. in length.

[2] "Lately I have examined more closely Pfitzner's account of this bone and I fear I have misled Mr Thurstan Holland. An element, other than the peroneal sesamoid does occur at the base of the 5th metatarsal and in contact with the cuboid, but there is reason to doubt that this—which represents the os Vesalianum according to Pfitzner—can be reduced so as to become a mere epiphyseal plate on the base of the 5th metatarsal."—A. Keith.

Gruber as having seen a proximal epiphysis, not to be confounded with the os Vesalianum, distinct, in *an adult*[1].

There is also a paper by Laquerrière and Drevon in which are figured two cases, present in both feet. In one a very tiny piece of separate bone is seen exactly behind the tip of the base of the 5th metatarsal. This case is not of much importance; but the second shows a very large separate bone at the base of the metatarsal in both feet together with a metatarsal in which the usual tuberosity appears to be wanting. This is described as a true bone of Vesalius: on the other hand it looks like a complete separation of the tuberosity of each metatarsal, and in this case it would mean that the tuberosities were developed from separate centres and had not joined on. This case is an adult.

Lupo in his paper says "that the utmost confusion exists with regard to the os Vesalianum, and that he recognises a definite bone, and also an epiphysis at the base of the 5th metatarsal."

Again I have had his paper translated and in my opinion he merely adds confusion to confusion, as the only illustration he reproduces he describes as showing an undoubted accessory bone of Vesalius, and yet it is obviously typical of what is really an epiphysis. This author also states that this bone is excessively rare (i.e. of course the one he pictures).

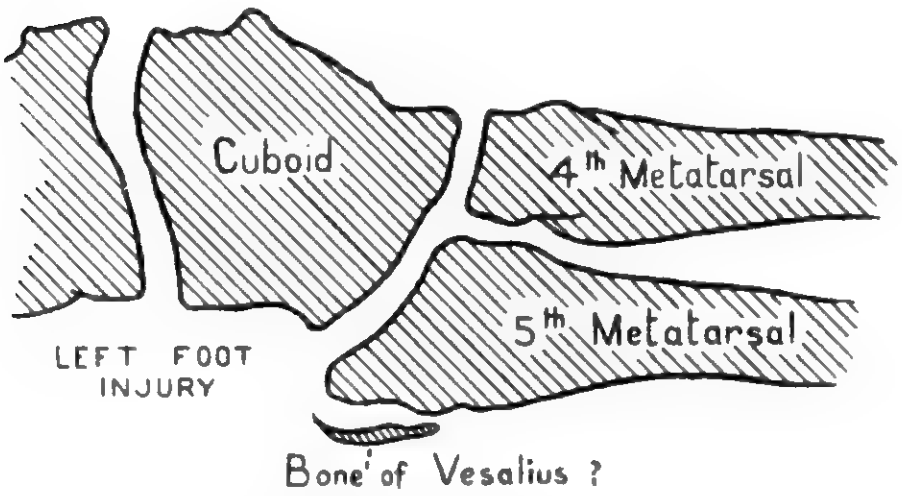

Fig. 13. Tracing from plate of left foot of boy aged 16 years.

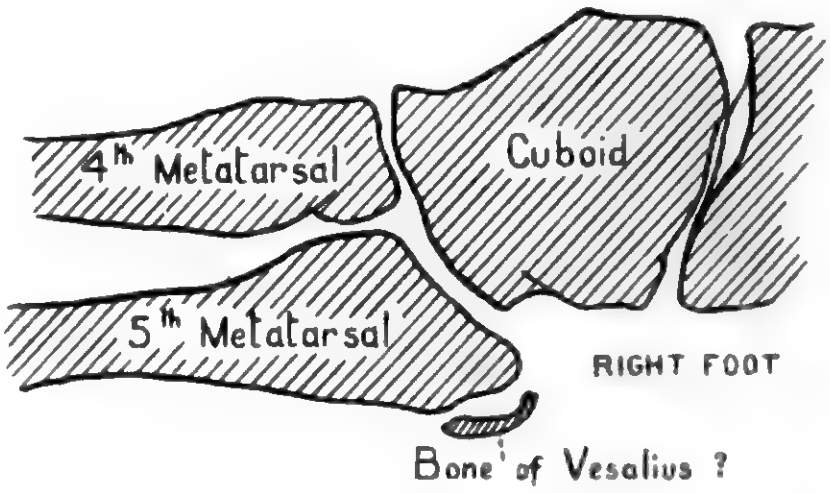

Fig. 14. Tracing from plate of right foot.

Dwight reproduces one radiograph only—that of the foot of a child, probably a girl, about 13 years of age. He describes it as an example of the bone of Vesalius. Again it is to my mind obvious that it is merely an epiphysis. I will show you later radiographs of my own which might have been the originals of both these cases as they are like them in all details.

During the past year I have seen six cases, and it was the first one of these which called my attention to this bone.

A radiograph was brought to me at the Royal Infirmary, Liverpool, one afternoon of the left foot of a boy of 16 years of age who had been run over by a motor, the wheel of which passed over the dorsum of the foot. Looking at this one sees a thin strip of bone lying outside the base of the 5th metatarsal.

---

[1] I have had made for me a translation of this paper of Gruber's but it appears to me to be somewhat involved, and I am not satisfied that he was actually describing such a separate bone in an adult.

What struck me was the regularity of this strip of bone, that everywhere it lay equidistant from the main bone, and that altogether from its appearance it did not look like a fracture. It then came to my memory that I had read somewhere something about a bone of Vesalius, and I asked for a radiograph of the other foot. The other foot was examined and showed the same strip of separated bone. A further examination of the injured foot showed that there was no pain or tenderness over the base of the 5th metatarsal, and it became quite clear that we were not dealing with a fracture, but with the so-called bone of Vesalius.

The condition is bilateral, is precisely the same in the two feet, and the appearances are exactly those one would expect if it were an epiphysis: also that injury is eliminated (*a*) by its presence in both feet, (*b*) by the fact of there being no pain or tenderness over it on the injured foot.

These radiographs are practically identical in appearance with the one shown by Lupo in his paper already referred to: and which he described as being the true bone of Vesalius as opposed to an epiphysis at the base of the 5th metatarsal.

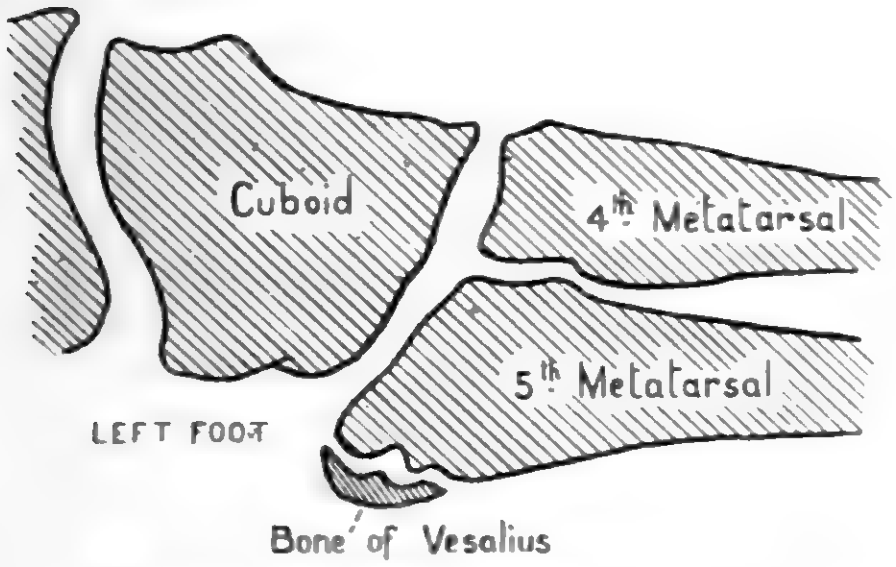

Fig. 15. Tracing of plate of left foot of boy $13\frac{9}{12}$ years.

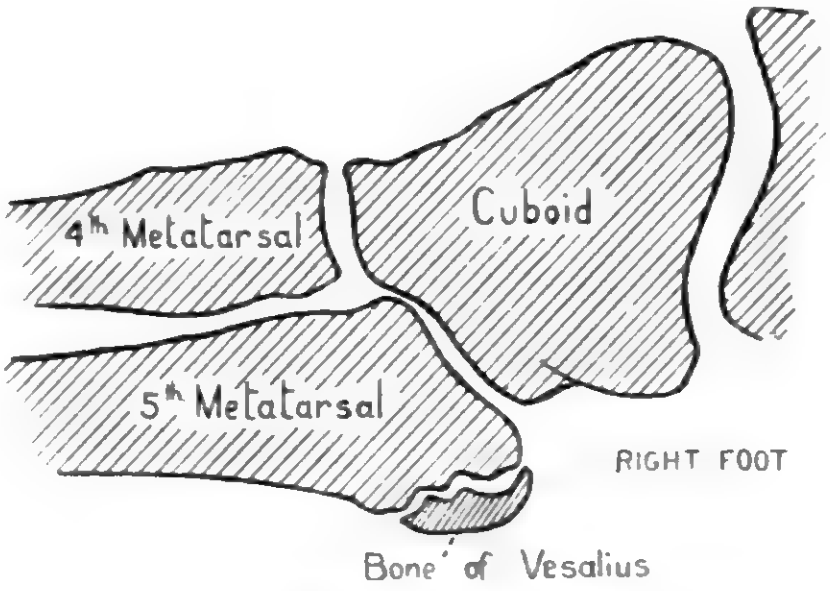

Fig. 16. Tracing of plate of right foot of boy $13\frac{9}{12}$ years.

One month later a boy of $13\frac{9}{12}$ years, again radiographed for a foot injury, showed similar appearances at the base of his 5th metatarsals. These radiographs reproduce identically the only one shown by Dwight, described by him as the bone of Vesalius.

Again you will notice the complete symmetry, and it is obvious that they must be epiphyseal—it is clear that unless this is the case, and taking them away altogether, then the bases of the metatarsals are quite abnormal, as if a piece of bone had been cut off from each.

A little more than one month later a boy of 16 years was radiographed for a foot injury, but it was the great toe which had been injured 18 months previously. Again a "bone of Vesalius" and obviously again an epiphysis. We failed to trace him to get a radiograph of his other foot, but in view of the other cases it appears to be pretty obvious. Four months later a girl, $13\frac{10}{12}$ years old, came with an injury to her left foot, and she proved to be a case of very great interest inasmuch as she showed definitely a small fracture of the base of the metatarsal in addition to the bone of Vesalius, and it corresponded with a painful and tender area. Compare the two feet and the first, the uninjured, shows an obvious bone of Vesalius of the epiphyseal type; whilst the second shows the presence of the same bone in the injured foot and in addition a triangular chip torn from the proximal end of the 5th metatarsal.

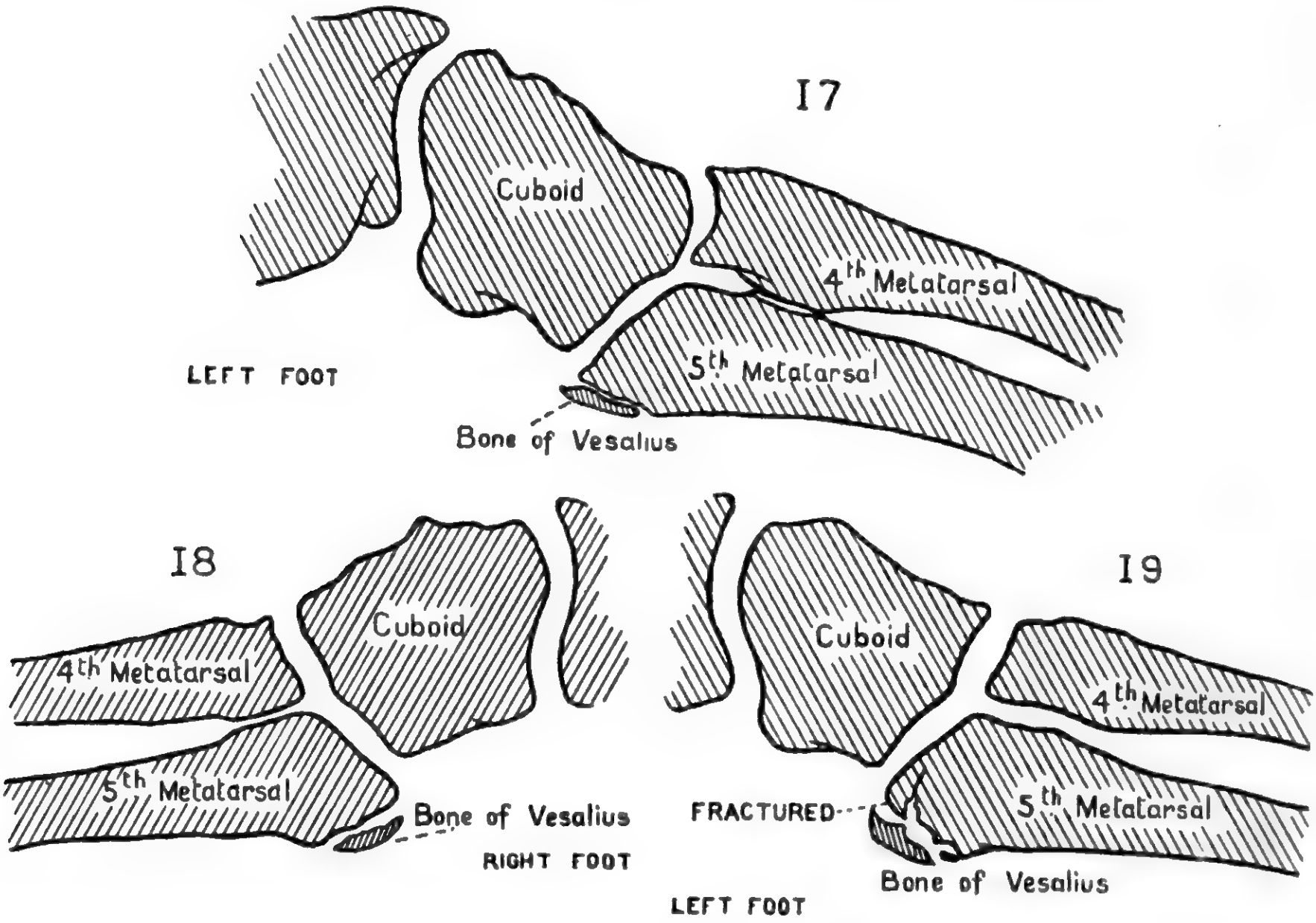

Fig. 17. Tracing from plate of left foot of boy aged 16 years.
Fig. 18. Tracing from plate of right foot of girl aged $13\frac{10}{12}$ years.
Fig. 19. Tracing from plate of left foot of girl aged $13\frac{10}{12}$ years.

Less than one month later a boy of $17\frac{1}{2}$ years came for examination, a waggon wheel having passed over his right foot one day previously. There was considerable swelling on the dorsum of the metatarsus and tenderness over the 1st metatarsal: whilst there was no tenderness over the 5th. A bone of Vesalius is again present, and this one is of interest inasmuch as it is ossifying from three centres—a condition not altogether unusual in similar epiphyses, for instance the one at the back of the os calcis. It was rather unfortunate that a careful search for this boy—even to the extent of putting the police upon his track—ended in a failure to find him. We should have had the other foot; however, I think it is clear that even without this, this is a definite example of still another bone of Vesalius.

My series was completed to date three weeks later when my friend Mr Prosper Marsden brought his little girl aged 12 years for examination of one foot, not for any injury. By radiographing both feet we found a fine example of this celebrated bone in each.

These are my six cases: and I think I am entitled to draw some conclusions from them.

Dwight states that it is excessively rare: he has never seen it in the macerated foot of any adult. He and Spronck have seen it at birth. The only X-ray Dwight reproduces is, in view of this series of mine, an obvious epiphysis.

Lupo, although most dogmatic as to the epiphysis and the true "bone of Vesalius" being two different things, produces no evidence of this; and the only X-ray he produces of his own—again in view of my series—is an obvious epiphysis, and this although (and this is important) he describes it as "clearly showing the real bone of Vesalius."

All my series, without an exception, suggest from the X-ray appearances that the true explanation is that they are epiphyses[1].

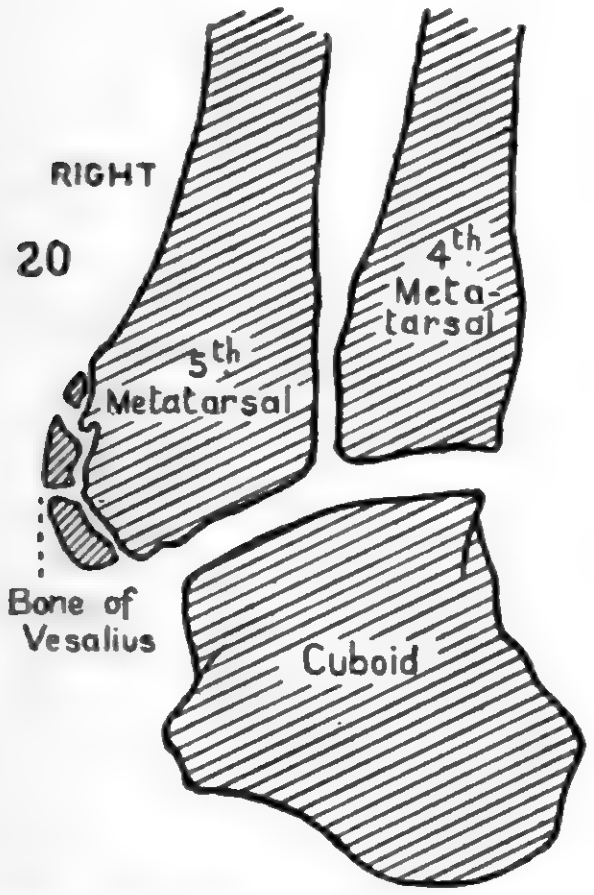

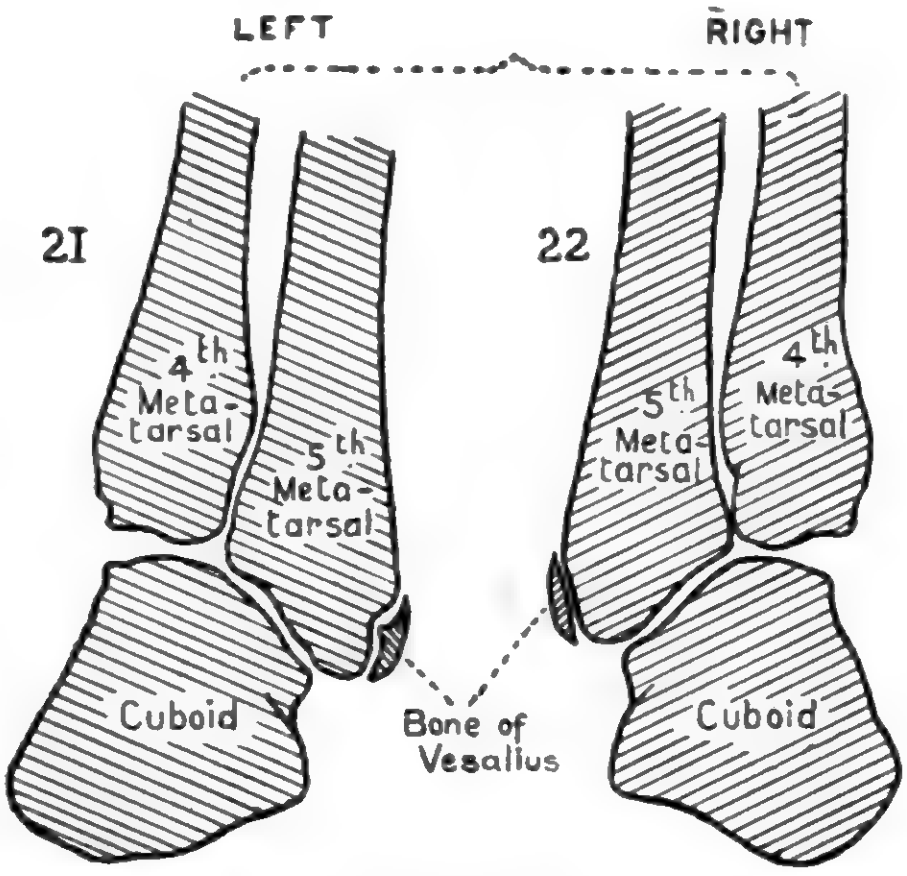

Fig. 20. Tracing of plate of right foot of boy 17½ years, three centres of ossification over tuberosity of 5th metatarsal.

Fig. 21. Tracing of plate of left foot of girl aged 12 years.

Fig. 22. Tracing of plate of right foot of girl aged 12 years.

I have never seen anything separate in any of the adult feet I have ever examined. All my cases are in young people—before the age of the complete formation of the skeleton. There is, as far as I know, no record of an adult radiograph showing such a separate bone, *with the base of the metatarsal at the same time well formed.*

I will therefore venture the opinion that the true "bone of Vesalius" does not exist as a distinct and separate bone. That Vesalius described the sesamoid of the peroneus longus and if any name is to be attached this is the "bone of Vesalius." That which is commonly described as the "bone of Vesalius" is in reality an epiphysis at the base of the 5th metatarsal which usually joins on or before adult life, but in one form may remain separate in the adult. This form—the very rare one—is seen in the case of Laquerrière, a diagram of

---

[1] "I agree with Mr Holland that the ossification represented is an epiphyseal one. Pfitzner however in six cases did find a separate element at the base of the 5th metatarsal bone as a separate cartilage and as a cartilage partly conjoined with the 5th metatarsal. Pfitzner was in error when he regarded this separate element and the epiphyseal plate as identical structures."—A. Keith.

which I have shown you, drawn from the radiograph of one of the two feet of his case. It is an example, which associated with the shape of the base of the 5th metatarsal, means that it is in fact the whole tuberosity, ossified from a separate centre, and remaining separate.

That all these examples of Dwight, Lupo, and myself—and others—are really an "epiphysis." Further I will also suggest that this epiphysis as shown by us is comparatively a common one, and that it is frequently present, but missed in the radiograph, owing to the position in which the foot is usually examined—the usual position being a direct one with the sole down on the plate. In our examination of the tarso-metatarsal region we adopted a position in which the inner side of the foot is on the plate whilst the outer is tilted upwards from the plate to an angle of about 15–20 degrees—a position for which I am indebted to my late assistant at the Royal Infirmary, Mr Woods. This brings the base of the 5th metatarsal with the epiphysis—if it is present—well into the field. I have tested this in some of my cases in which the epiphysis showed plainly. In this in the direct sole down position the epiphysis either did not show at all, or showed so slightly that it would have been overlooked without the tilted, semi-lateral view, as this epiphysis is on the under and outer side of the base of the 5th metatarsal bone.

There is a disease of the scaphoid bone of the foot which occurs in very young people and which was first described by Köhler of Wiesbaden in 1908 and is known as "Köhler's disease of the scaphoid." It is comparatively rare, less than 20 cases having been described in literature up to 1919, and it is entirely an X-ray discovery.

The symptomatology is that a young child is noticed to have some pain in his or her foot, and is limping. Examination discloses on the dorsum of the foot an area of tenderness, swelling, and possibly some redness, over the inner side of the tarsus. Usually I take it the cause would be put down as due to the rubbing of a boot. The foot is X-rayed and shows a remarkable condition. Whilst all the other bones show normal ossification, that of the scaphoid is quite abnormal. As compared (1) with the amount of ossification of the other bones there is an arrest of the process in the scaphoid, and (2) that area already ossified is abnormally opaque to the X-rays.

Whilst the X-ray appearances are quite typical, the exact pathology is at the present time uncertain. Tubercle, syphilis, defective ossification caused by fracture, trauma, or osteitis have all been put forward by one or other observer as possible explanations. Owing to the results of treatment the two former can I think be excluded. The exact cause is still a matter of doubt but I suggest that pressure or rubbing from foot gear causing a chronic irritation of the part may possibly have something to do with it. Be this as it may the result of treatment, or even in the absence of treatment, the symptoms disappear and the child becomes apparently quite well. Rest seems to be the only thing required—and this even for only a short period of time.

Two typical cases of this disease are shown in figs. 23 and 26, and I can also show the radiological appearances at a later date when all symptoms had entirely disappeared.

The first is the foot of a girl of 3½ years of age and it is typical. It will be seen that the ossification of the scaphoid is arrested and that the density to X-rays of the part ossified is great when compared with the rest of the tarsal bones. Only the one foot was radiographed in this case. Two years and three months later I re-examined the foot and also took a picture of the other foot. Now the scaphoid of the affected side, whilst showing that ossification generally has caught up to the normal, still shows an area of great density. At this time no symptoms of any kind were present.

23.

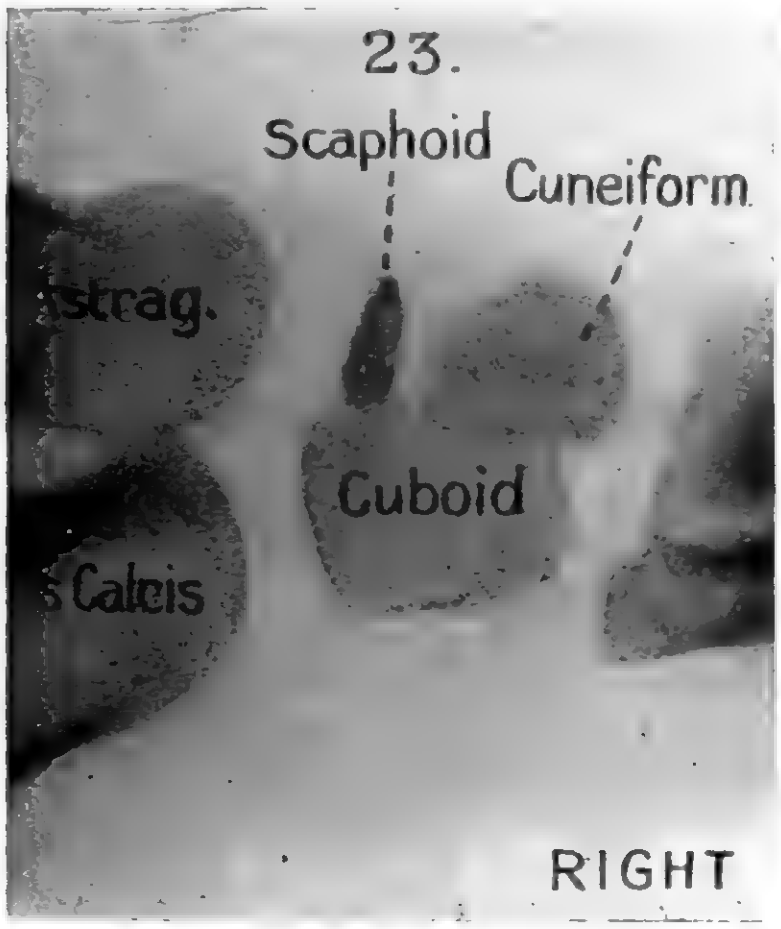

24.

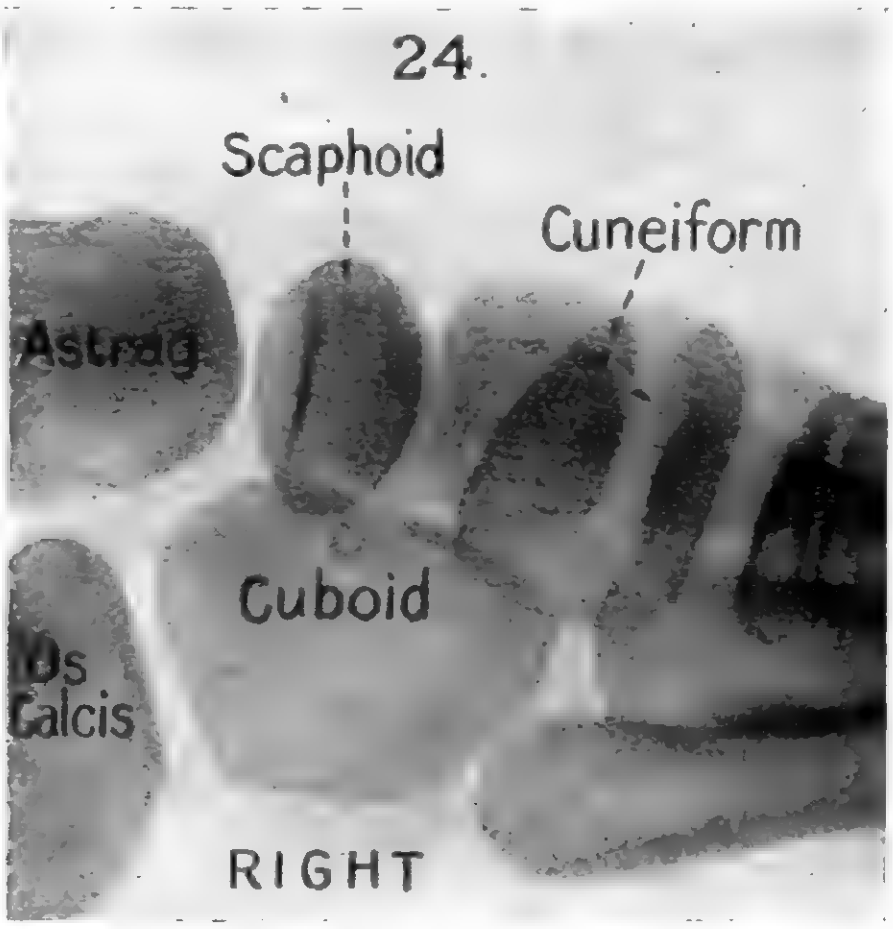

25.

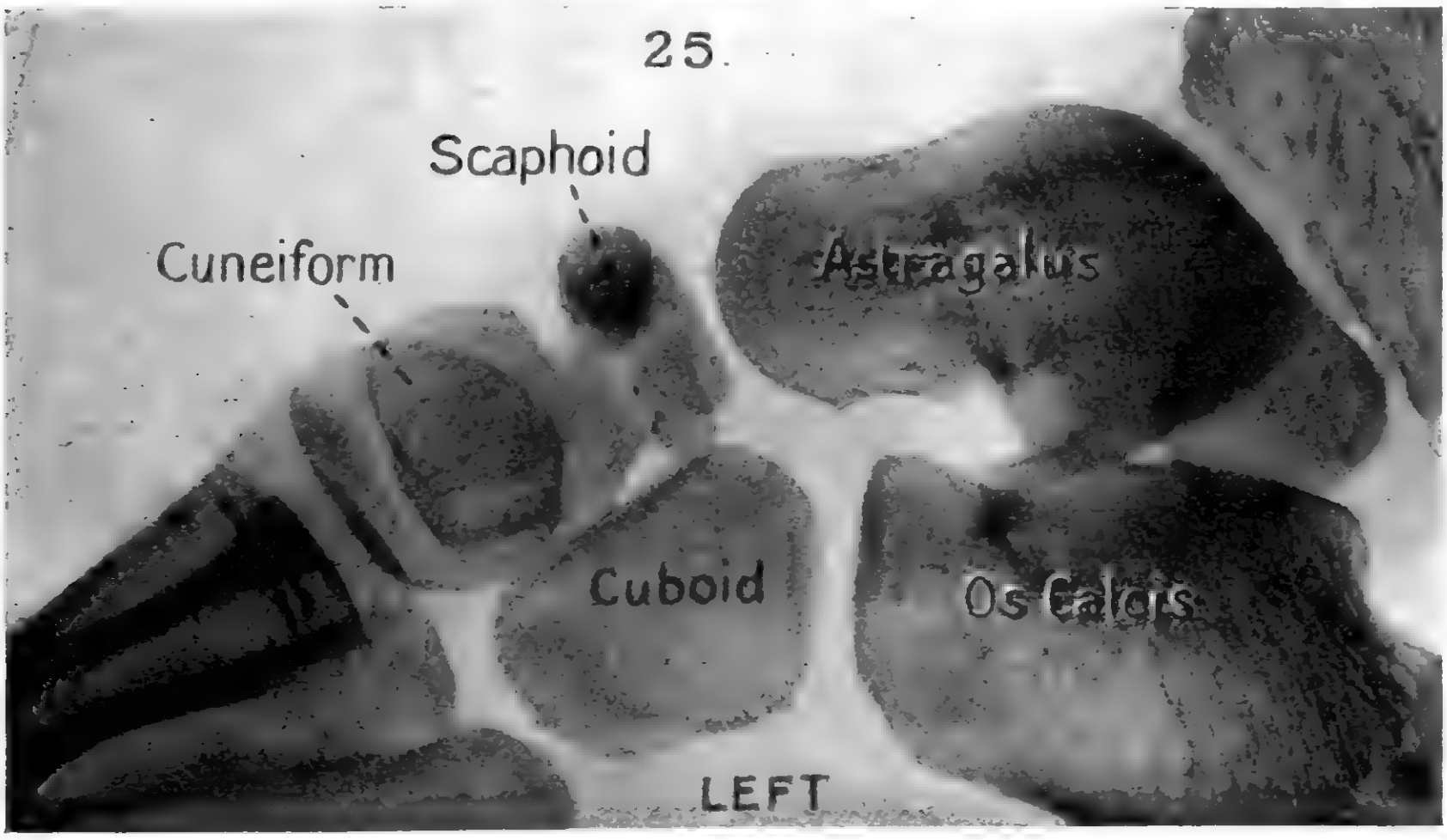

Fig. 23. X-ray plate of mid-tarsal region of right foot of girl aged 3½ years.
Fig. 24. X-ray plate of mid-tarsal region of right foot of same girl aged 5¾ years.
Fig. 25. X-ray plate of mid-tarsal region of left foot of same girl aged 5¾ years.

In the other case—a boy 9 years of age—both feet were examined at the first and the contrast between the two scaphoids is obvious and again typical. Twenty months later, all symptoms having disappeared, the affected side is still slightly more opaque than the other, otherwise there is no difference.

Neither case had any special kind of treatment other than rest.

I now come to my last abnormality—a very rare one—probably the rarest of all those I have described—one affecting the patella.



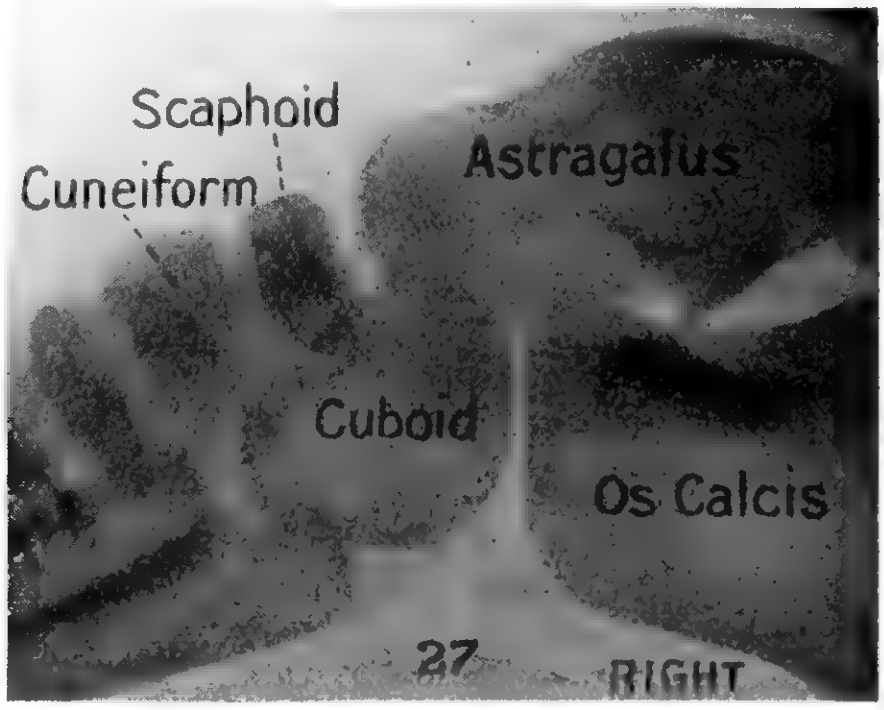

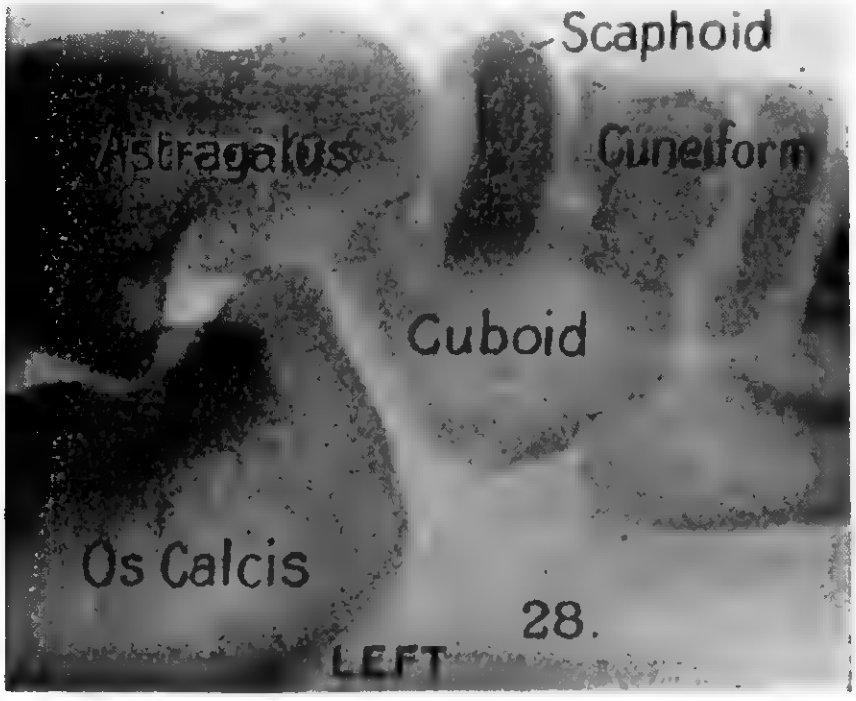

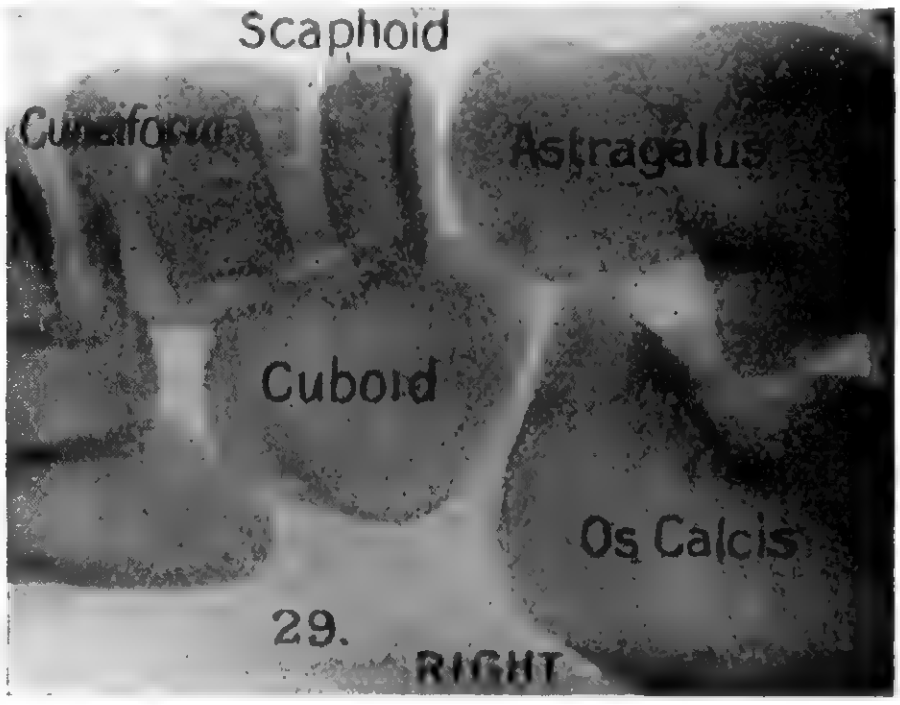

Fig. 26. X-ray plate of left foot of boy aged 9 years showing arrest in ossification of scaphoid.
Fig. 27. X-ray plate of right foot of boy aged 9 years showing normal ossification.
Fig. 28. Same foot as in fig. 26, twenty months later.
Fig. 29. Same foot as in fig. 27, twenty months later.

In radiographing one knee of a boy of 18 years of age who had rickets, knock-knee, inability to completely straighten the knee joint, etc., we found a curious condition of the patella (fig. 30). It was perfectly formed and ossified with the exception that at its upper and outer margin there was a completely separated piece of bone, much as if it had been fractured, but there was no history of any injury at any time.

It was known that a patella sometimes ossifies from two centres placed side by side, but these radiographic appearances do not suggest this as the explanation. I came to the conclusion that we had some quite abnormal condition to deal with and had the other knee X-rayed (fig. 31). This showed a somewhat similar appearance in the same region, but the piece of bone was not entirely separate on this side but was joined on to the rest of the patella at its upper end.

We then decided that we had to deal with a condition of the patella in which there were separate centres of ossification at the upper and outer borders in the nature of epiphyses.

The literature is very small, but Mouchet in 1919 published a somewhat similar case and I reproduce drawings from his illustrations—these drawings being made for him from his radiographs (figs. 32 and 33). These show epiphyses which he describes as being analogous to that seen at the posterior border of the os calcis and elsewhere. He refers also to three other writers, two of whom found a similar condition in adults when making autopsies, whilst the third had found it in the traumatic knees of adults.

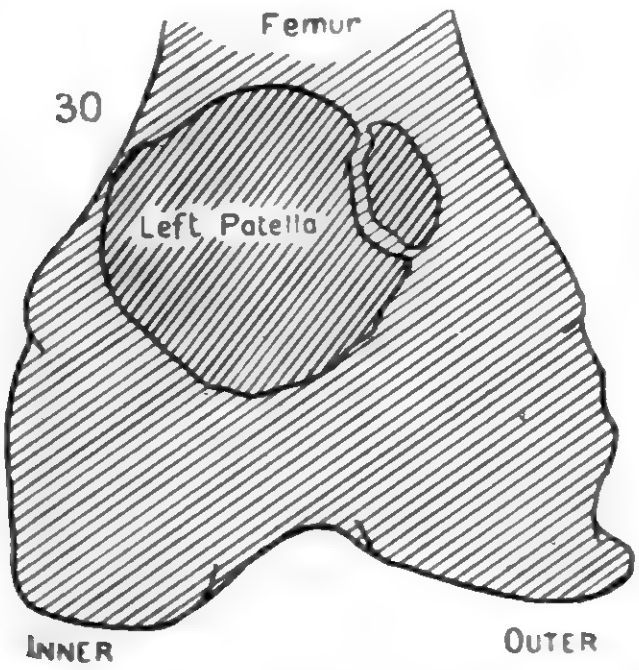

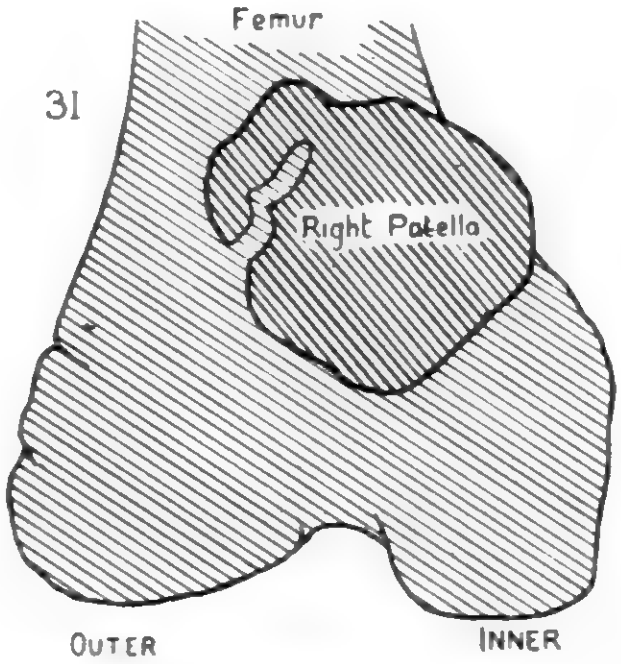

Fig. 30. Tracing from X-ray plate of left patella of a lad aged 18 years.
Fig. 31. Tracing from the right knee showing a corresponding anomaly of patella.

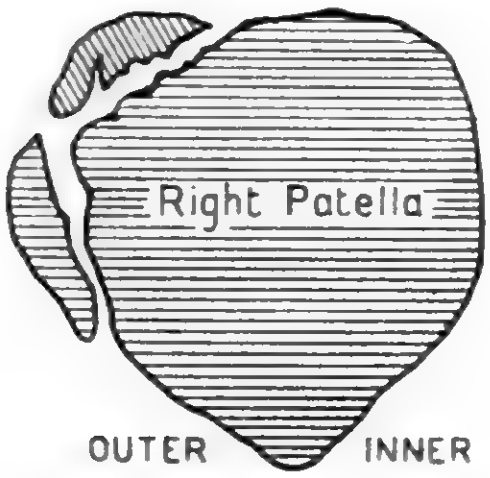

Fig. 32. Right patella in Mouchet's case.

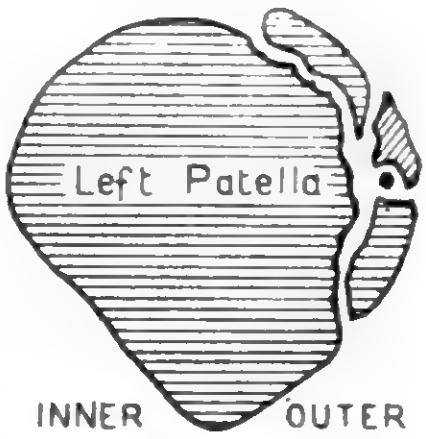

Fig. 33. Left patella in Mouchet's case.

As I wrote at the beginning of my paper these, and many similar, conditions have become of first class importance in view of two things: (1) the question of accidents and compensation, (2) the demonstration of these conditions by radiography.

In the earlier days of radiography even experts made many mistakes in interpretation owing to the fact that all this was new work which had to be learnt gradually by experience. Even at the present time, when so much X-ray work is done by men without any special training, there is still a great chance that many of these rarities will pass unrecognised, or if they are recognised of being wrongly described. These must be my excuses for inflicting this paper upon you.

REFERENCES

Accessory Bones and Sesamoids of Feet

Dwight, Thomas. "Variations of the bones of the Hands and Feet." *Clinical Atlas*, 1907.
Quain's *Anatomy*, vol. iv. Part I. 1915.
Pfitzner. "Die Sesambeine des menschlichen Körpen." *Schwalbe's Morphologische Arbeiten*, Bd. i. 1892.
—— *Die Variation in Aufbau des Fussskelets, ibid.* Bd. vi. 1896.
Spronck. *Anat. Anzeiger*, Bd. ii. 1887.
Gruber. *Arch. für Anat. und Phys.* S. 48. 1875.
Stieda. *Beiträge zur klin. Chirurgie*, 1904.
Pirie. *Arch. Rad. and Electrology*, p. 93, 1919.
Scott. *Ibid.* p. 224, 1918.
Vesalius. 1725 edition, p. 120.
Lupo. *La Chirurgia degli organi di movimento*, vol. iv. fasc. 2, 1920.
Shillington Scales. *Arch. Rad. and Elect.* p. 83, 1918.
Dennis. *Ibid.* p. 253, 1918.
Johnston. "Epilunar and hypolunar ossicles, etc. etc." *Journ. of Anat. and Phys.* p. 59, 1906.
Laquerrière and Drevon. "On the Vesalian bone." *Jour. Rad. and Elect.* (French), p. 395, 1916.

Köhler's Disease

O'Brien. *Bost. Med. and Surg. Journ.* p. 445, 1919.
Köhler. *Münch. Med. Woch.* vol. 55, ii. p. 1923, 1908.
Pfahler. *Surg. Gaz. Obst.* 625, 1913.
Rotch and George. *Roentgen ray in Pedriatics*, 1910.
Stumme. *Fortschr. a. d. Geb. d. Roentgenstrahlen*, Hamburg, ii. xvi. 342, 1910.
Schultz. *Arch. für klinische Chir.* No. 2, p. 341, 1912.
Wohlauer. *Zeit. für orth. Chir.* Bd. xxxi. ii. 1913.
Fassett. *Journ. A.M.A.* lxii. 1155, 1914.
Hetzel. *Amer. Journ. Orth. Surg.* xv. No. 3, 1917.
Preiser. *Berlin. klin. Woch.* xlviii. 593, 1911.
Haenisch. *Münch. Med. Woch.* vol. 55, ii. No. 44, 2285.
Bertoletti. *Rad. Med. Turino*, ii. 400, 1915.

Knee

Mouchet. *Bull. et Mém. Soc. Anat. de Paris*, No. 11, p. 452, 1919.
—— *Bull. et Mém. Soc. de Chir.* I. xlv. No. 26, p. 1215.
Gruber. *Virchow's Arch.* Bd. 94, p. 358, 1883.
Joachminstal. *Arch. für klin. Chir.* Bd. 67, 342, 1902.
Reinbold. *Revue méd. de la Suisse romande*, No. 4, p. 653, 1917.

TACTILE LOCALISATION

By JOHN S. B. STOPFORD, M.D.,
Professor of Anatomy, University of Manchester

From a review of studies in sensation it is at once apparent that no perfectly satisfactory method for accurately testing tactile localisation has been evolved. Almost all the methods at present practiced only demonstrate very gross defects and fail to furnish measurable results. The tests most frequently used in the investigation of tactile localisation only show such a gross defect as failure to recognise correctly the segment of the digit upon which the pressure has been applied, a defect which in this research has been found to occur several times in apparently normal individuals.

In the course of an investigation of sensation, particularly with reference to the disturbances found in peripheral nerve injuries, it became necessary to decide upon some method which would supply more accurate information about the power of localisation and also provide measurable results. In this paper the most useful method and the results of the application of this method to normal individuals, so as to provide a normal standard for localisation, are described. Although the findings recorded in this work do provide a standard to be considered when testing pathological states, it is necessary to state that the provision of such a standard does not abolish the necessity for comparing the results of the same test upon normal and abnormal parts of the same patient.

METHOD

The method found to be most serviceable was a slight modification of that described as Henri's, but unfortunately it has not been possible for me to procure the original description of his method. The patient, having the part to be tested obscured from his vision, marked upon a life-sized diagram the position of the point he felt to be stimulated, whilst the observer recorded on another similar diagram the exact spot touched. The tactile pressure was made by a blunt instrument about ·2 cm. in diameter. After a sufficient number of points had been localised the two diagrams were superimposed and the two points recorded in each test were marked on one diagram, in different colours or by distinctive signs, and then the error in each case was measured off with a scale. From these measurements, if a sufficient number of points have been localised, the average error for the whole or individual parts—as each finger—may be determined. In the latter part of the investigation only one chart was used, the observer recording the exact point stimulated after the person examined had marked the point where he felt the stimulation, and this simpler procedure proved as successful and apparently as reliable as the more tedious original form.

Head (1) in a criticism of Henri's method points out the one great disadvantage of this test when he states that "many patients find a difficulty in translating an image of the part tested on to a diagram which can show only two planes of space"; but in practice I have only encountered this difficulty in the case of the thumb, and find the method perfectly reliable for testing the power of localisation on the fingers and palm of the hand, which are the parts where, for the purposes of clinical and scientific investigation, accurate information is most frequently and most urgently required.

Before commencing each examination instructions were given that on no account was the hand to be moved whilst the pressure was being applied, as of course such a procedure would render the results fallacious.

The examinations were all undertaken under similar conditions, with absolute freedom from any disturbance. The necessity for this and the importance of undivided attention was very marked in the recent examination of a patient. The examination was continued after a third person had come into the room and entered into conversation with me; up to the time of the entrance of the intruder the average error was ·5 cm., during the time the distraction occurred the error increased to considerably over a centimetre, and then returned to ·5 cm. again with the re-establishment of quietness.

The investigations into the normal power of localisation in the hand and fingers have been divided into three series.

SERIES I

In this series ten members of the medical profession provided the subjects for examination, eight of these were either surgical colleagues or members of the staff of the anatomical department, and all were familiar with the diagrams used for the charting of disturbances of sensation. This series was undertaken for two chief reasons. In the first place it was thought that any possible fallacy due to unfamiliarity with the diagrams would be reduced to a minimum, and secondly such a series would provide valuable information at the outset with regard to the introspective aspect of this form of sensation. All were right-handed and took great interest in the work, and proved excellent subjects for my purpose as they exhibited keen competition to show the best result. Most of the tests in this series were carried out by the two chart method so that no suggestion as to progress or type of errors could be extended to the person under examination until the completion of all the tests. The palmar and dorsal aspects of each hand and digits were explored in turn. Twelve stimulations on each surface were made, eight or nine of which were on the digits and the rest on the palm or dorsum of the hand. The digits and hand were not tested separately in this series or the next, because my original object was to arrive at a normal standard for comparison when testing patients suffering from injuries to such nerves as the median and ulnar. From the early results it became apparent that the error on the palmar and dorsal surfaces of the hand was considerably greater in most individuals than on the digits, and therefore to permit comparisons the proportion of stimulations on the hand and digits has been maintained practically constant throughout series I and II.

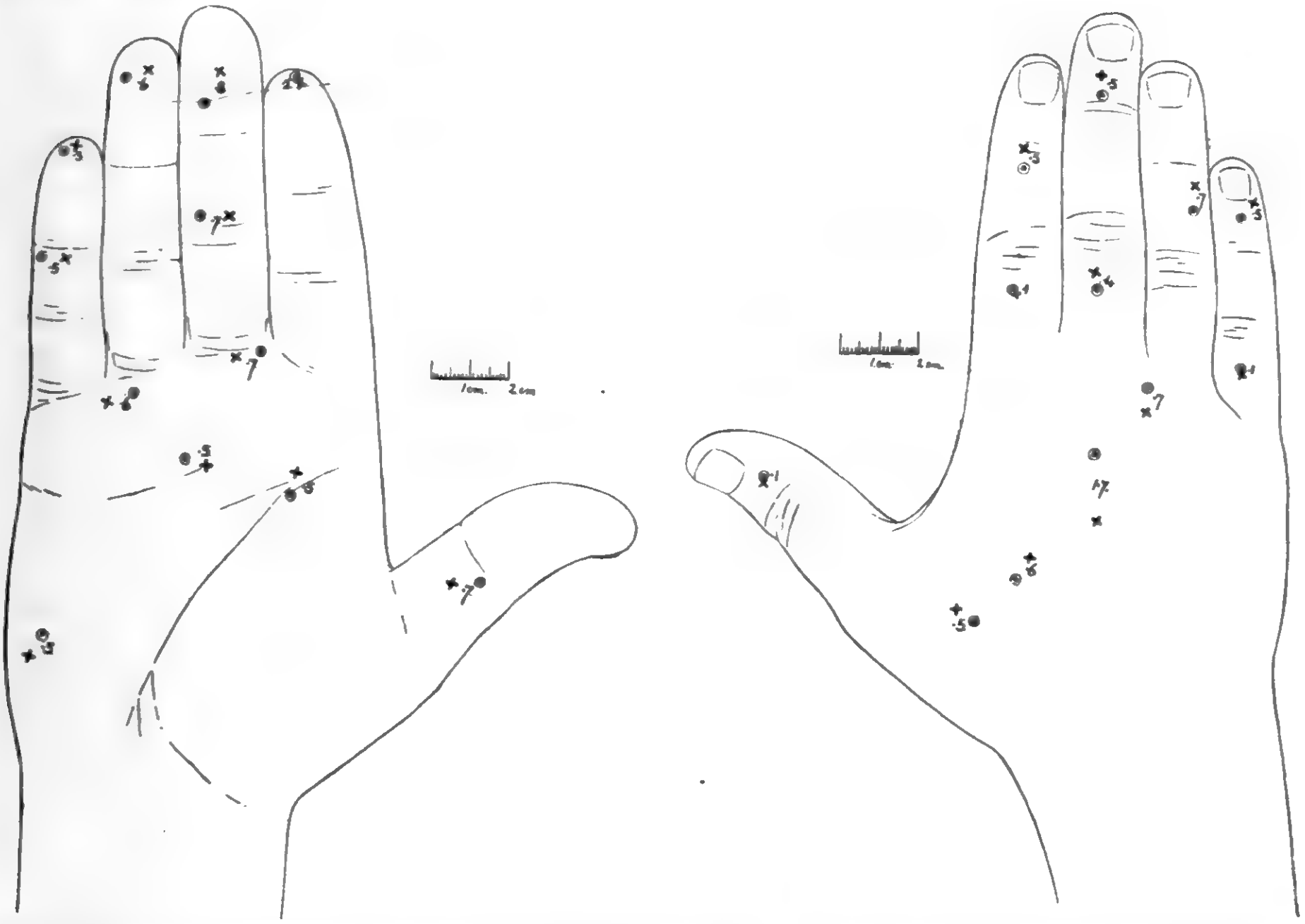

Fig. 1. Charts for the right hand of D. K. S. (Series I). × = precise point stimulated; ⊙ = point localised by D. K. S. The figures represent the error in each test measured in centimetres.

Table I.

	Right hand and fingers		Left hand and fingers		Errors proximal and distal
	Palmar surface	Dorsal surface	Palmar surface	Dorsal surface	
S. L. ...	·4 cm.	·5 cm.	·6 cm.	·6 cm.	Prox. 53 %
R. L. N.	·4	·5	·6	·5	Prox. 65
D. K. S.	·5	·5	·8	·8	Prox. 52
S. J. ...	·7	·6	·5	·6	Distal 66
H. P. ...	·8	·8	·8	1·0	Distal 63
W. H. W.	·4	·5	·5	·6	Distal 64
J. D. B.	·5	·4	·6	·4	Distal 53
C. E. B.	·6	·5	·6	·5	Prox. 63
E. A. L.	1·0	·9	·8	·5	Distal 71
G. J. ...	·6	·3	·4	·3	Prox. 61
Average	·6	·5	·6	·6	Distal 52

Table I shows the average errors in the four examinations of the ten subjects.

For the right palm and palmar surface of the digits the average error varied between ·4 cm. and 1·0 cm. (average for the ten = ·6 cm.), and the same surface of the left hand and digits showed an average error varying between ·4 cm. and ·8 cm. (average for the ten = ·6 cm.). On the dorsal surface of the right hand and digits the average error varied between ·3 cm. and ·9 cm. (average for the ten = ·5 cm.), and on the left hand from ·3 cm. to 1·0 cm. (average for the ten = ·6 cm.). It is rather striking that on both the right and left hands in five the error was greater on the palmar surface. The explanation of this became quite clear as the work proceeded, since all agreed at the termination of the examination that they could localise the point much more readily when the pressure was applied over bone, and of course the phalanges and metacarpal bones are much more exposed on the dorsal than on the palmar surface. Tactile pressure over the metacarpal bones was usually more accurately localised than similar stimulation in an interosseous space. In the case of the digits alone greater accuracy of localisation on the dorsal surface was quite definitely found in nine out of the ten people examined in this series.

On the palmar surface the most accurate results were obtained when the point stimulated was upon one of the permanent creases, and several, who remarked upon the difficulty they experienced in localising a spot upon the palm, stated that they were much happier if the point was situated upon one of the creases. In six the power of localisation was definitely more exact on the right hand than on the left, in three the reverse was found, whereas in the other one there was no obvious difference in accuracy on the two sides.

E. A. L. localised one point on the wrong segment of the palmar surface of the left middle finger, and made a similar error on the dorsum of the right index finger. C. E. B. made a similar mistake on the palmar surface of the index and middle fingers. Three others localised on the wrong segment once, S. L. on the dorsal surface of the left little finger, H. P. on the dorsum of the left ring finger, and S. J. on the palmar surface of the left little finger. As will be seen from the last column of Table I the errors occurred in a proximal and distal direction in almost equal proportions.

SERIES II

In this series ten non-medical people were taken and only the palmar surfaces of the hands and digits of the two sides explored. The ten were composed of clerks, departmental stewards, porters and second year students. All were right-handed except H. G., who is ambidextrous. Reference to Table II shows that for the right palm and palmar surface of the digits the average error varied between ·4 cm. and 1·0 cm. (average for the ten = ·6 cm.), and on the left side it varied between ·4 cm. and 1·3 cm. (average for the ten = ·7 cm.). Except in the case of the left hand of R. M. P. (average 1·3 cm.) the results corresponded with those found in Series I. No explanation could be discovered for the gross errors found in R. M. P.'s left hand.

R. M. P. localised the point on the wrong segment of the finger three times on the right hand and four times on the left and repeated these mistakes when some of these points were restimulated (without R. M. P.'s knowledge that

Table II.

	Palmar surface Right hand and fingers	Palmar surface Left hand and fingers	Errors proximal and distal
A. F. C. D.	·5 cm.	·6 cm.	Prox. 52 %
H. H. ...	·7	·7	Prox. 55
H. G. ...	·7	·7	Distal 59
W. S. ...	1·0	·7	Distal 70
J. A. ...	·6	·7	Prox. 68
R. M. P....	·8	1·3	Distal 52
R. F. ...	·5	·5	Distal 76
N. P. ...	·5	·6	Prox. 59
M. C. ...	·5	·6	Prox. 55
P. G. ...	·4	·4	Distal 57
Average	·6	·7	Distal 52

the same spots were being again tested) at the end of the examination. W. S. localised the wrong segment of the finger once on the right hand and H. H. once on each hand. H. G. localised one point on the wrong finger of the left hand. In five the power of localisation was more accurate on the right hand and in two on the left, whereas in the other three there was no difference in the degree of accuracy on the two hands. As in the previous series errors were found in a proximal and distal direction in almost equal proportions. The close similarity in the results in Series I and II is rather remarkable, and shows that any error due to unfamiliarity with the charts, at any rate for the palmar surface of the hand and digits, must be very slight.

SERIES III

This series was undertaken to discover the average error for the individual fingers and to find out if there was usually any variation in the power of localisation in the different fingers; information on these points being of considerable importance in view of the recent additions to our knowledge made by Head (2) on patients suffering from injuries of the cerebral cortex. Two people were chosen from each of the two former groups and twelve stimulations (six on the palmar and six on the dorsal surface) were made on each finger. As far as possible two stimulations were made on both surfaces of each segment of each finger.

From these results, which are shown in Table III, it appears that the power of localisation does not vary to any obvious extent in the four fingers.

Table III.

	Index finger			Middle finger			Ring finger			Little finger		
	Both surfaces	Palmar surface	Dorsal surface	Both surfaces	Palmar surface	Dorsal surface	Both surfaces	Palmar surface	Dorsal surface	Both surfaces	Palmar surface	Dorsal surface
S. L. ...	·4 cm.	·5 cm.	·4 cm.	·5 cm.	·4 cm.	·5 cm.	·3 cm.	·3 cm.	·3 cm.	·4 cm.	·4 cm.	·4 cm.
S. J. ...	·6	·8	·4	·4	·4	·3	·4	·5	·4	·4	·4	·4
P. G. ...	·2	·3	·2	·3	·4	·2	·4	·5	·3	·3	·2	·3
A. F. C. D.	·4	·4	·3	·3	·4	·3	·4	·6	·2	·3	·4	·2
Average ...	·4	·5	·3	·4	·4	·3	·4	·5	·3	·3	·3	·3

Greater accuracy of localisation on the dorsal surface was found in all four on the index finger, in three on the middle and ring fingers, and in one on the little finger; in only two fingers (middle in **S. L.** and little in **P. G.**) out of the sixteen examined was there more exact localisation on the palmar surface. Only twice in the 192 tests was the point localised on the wrong segment of the finger.

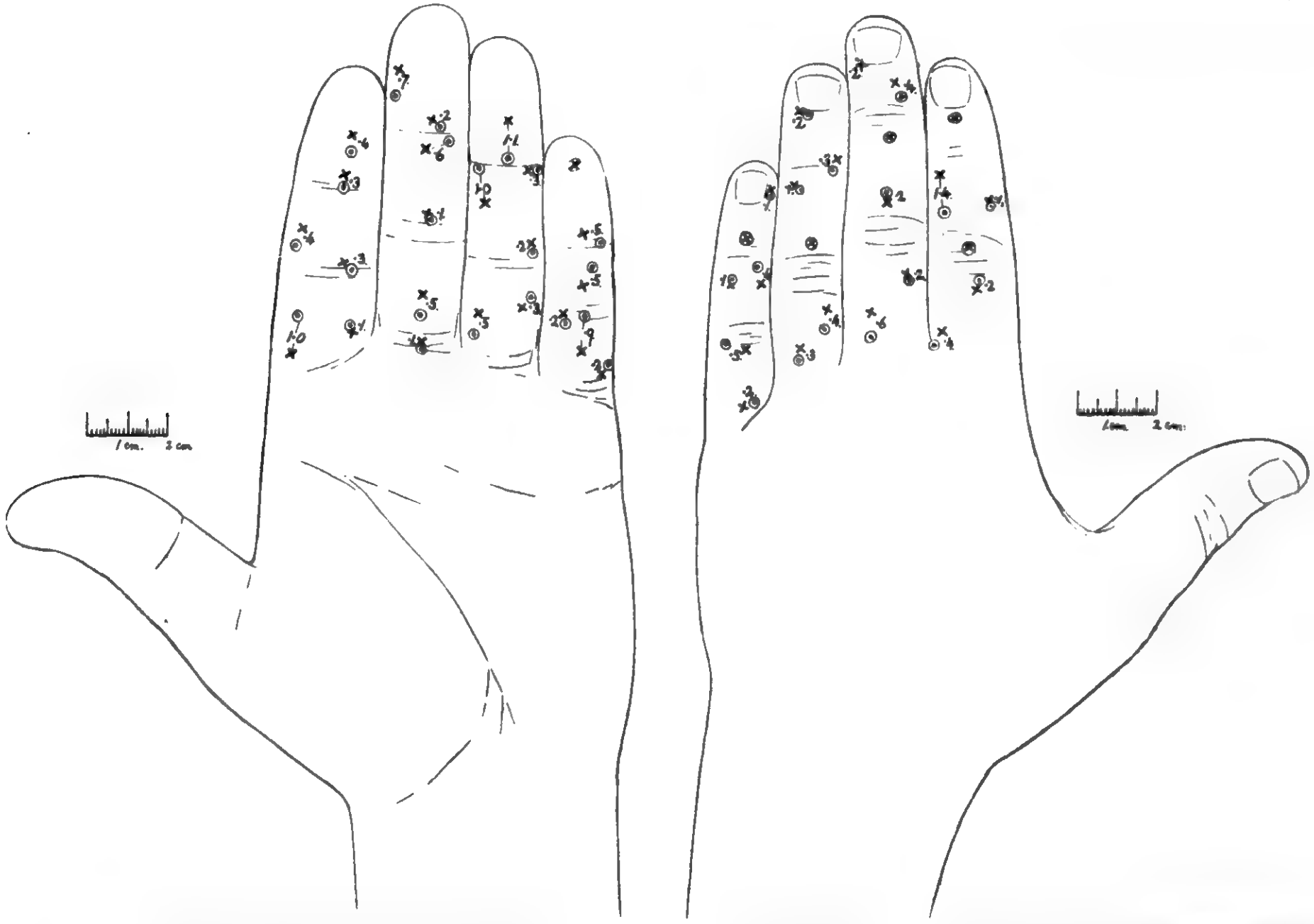

Fig. 2. Charts for localisation on fingers of A. F. C. D. (Series III). × = precise point stimulated; ⊙ = point localised by A. F. C. D.; ⊗ = correct localisation. The figures represent the error in each test measured in centimetres.

It was found that rather more difficulty was experienced in localising a point on the middle segment than on either the proximal or distal segments of the fingers.

Table IV.

	Index	Middle	Ring	Little
Right hand (normal) ...	·3 cm.	·5 cm.	·6 cm.	·5 cm.
Left hand	·6	1·3	2·1	1·2

The application of this method of measuring tactile localisation to pathological states will be considered as part of a subsequent paper, but for the purposes of comparison Table IV shows the results of testing the two hands in a patient who was suffering from a gunshot wound of the head in the right parietal region.

Some experiments were undertaken to investigate the power of localisation in the foot and toes by this method. Two practical difficulties were at once encountered, first owing to the necessity of having to transpose in the case of the sole and plantar surface of the toes, and secondly on the dorsum owing to the difficulty, already referred to with regard to the thumb, experienced from a diagram only being able to show two planes of space. But these practical difficulties in themselves did not absolutely prohibit the application of a measurable test for localisation to the foot and toes, if the power of localisation in most normal individuals had been sufficiently well-developed in this region to warrant the application of a delicate test. It was rather astonishing to find that the normal people tested were unable with any degree of accuracy to state even which toe had been stimulated when the pressure was applied to the second, third and fourth toes.

On the great and little toes the point could be localised fairly accurately, an average error of about one centimetre being found.

In view of these results no further effort was made to estimate any standard for localisation in the toes, and from the above experiences it would seem that the foot and digits could not be used for any accurate investigation of localisation.

CONCLUSIONS

1. It is possible, at any rate for the hand and fingers, to obtain fairly accurate information about the power of localisation and to express the result of the tests numerically.

2. The average error for the hand and fingers appears to be about ·6 cm., but may vary between ·4 cm. and 1·0 cm.

3. The power of localisation is generally more accurate on the digits than on the hand.

4. Most people have less difficulty in localising tactile pressure when it is applied over bone than over such softer tissues as muscle, and this accounts for the greater accuracy of localisation on the dorsal than on the palmar surface of the fingers.

5. It was found that many individuals can localise a point stimulated more readily when it is applied on one of the permanent creases.

6. There is no obvious difference in the power of localisation in the different fingers of the same hand.

7. Localisation on the wrong segment of a finger may occasionally occur in apparently normal individuals who show no other disturbance of sensation, and consequently many of the tests at present in use, which only show gross errors, may lead to mistakes.

8. The foot and toes cannot be used for any accurate investigation of localisation.

REFERENCES

(1) HEAD, H. *Studies in Neurology*, I. 1920.
(2) —— "Sensation and the Cerebral Cortex." *Brain*, XLI. Pt II. 1918.

ON SESAMOID AND SUPERNUMERARY BONES OF THE LIMBS

By A. H. BIZARRO, F.R.C.S. (Eng.),
London

The study of the sesamoid structures forms an interesting chapter of anatomy. Owing to their size and frequent variations, they have attracted but little attention and are deemed undeserving of mention in many surgical text-books and anatomical treatises.

Nor have they been of great medico-legal interest, and for these various reasons these little bones have usually met with a neglect which has probably been increased by the absence of a systematised knowledge and correct classification.

I propose to give in this article a short account of the result of a radiological investigation and a summary of our present state of knowledge about these structures.

Hand

The sesamoid bones of the hand have been seen distributed as follows in 112 skiagrams (fig. 1). The percentages given in this diagram do not show a great variation from others found by other authors. The percentage (22·3) of the interphalangeal sesamoid of the pollex is much lower than Pfitzner's and Fawcett's figures. On the other hand the third and fourth digits metacarpo-phalangeal sesamoids appear, in my series, to be more frequent than other authors have indicated. It is remarkable to observe the great rarity of the interphalangeal sesamoids of the hand; as an X-rays structure, I could not find them in these 112 plates, and remember to have previously seen it once only in the joint between the primi and secundi phalanges of the index.

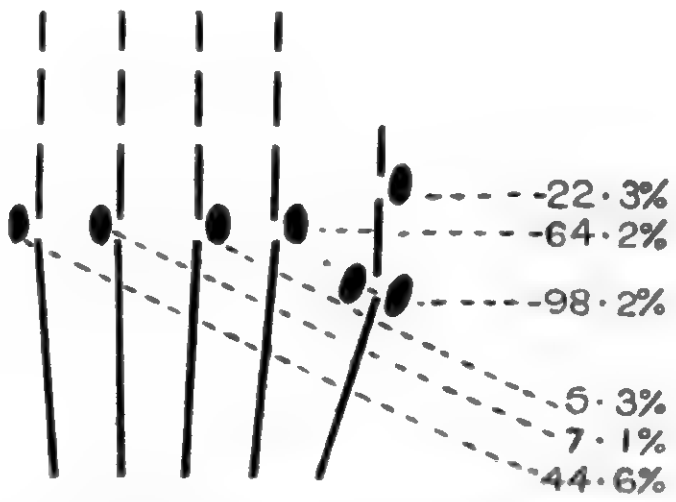

Fig. 1. Percentages of the hand sesamoids in my series.

The ages of the cases of this series were distributed as follows:

Between 15 and 25 years, 54 cases.
,, 25 and 35 ,, 36 ,,
,, 35 and 45 ,, 22 ,,
Total 112 ,,

102 were males and 10 females.

The metacarpo-phalangeal sesamoids of the pollex were found missing in two cases. In one case it appeared as a single bone on the ulnar side, and in all the rest two bones were present. The interphalangeal sesamoids of the pollex appeared double in one single case.

The metacarpo-phalangeal sesamoids of the other digits appeared as a single formation. It is difficult to ascertain in a skiagram the side that these bones occupy. It appears that the radial side is more commonly seen to be the case of the index and medium fingers, and the ulnar that of the auricular and ring digits.

In one case I found the 3rd digit metacarpo-phalangeal sesamoid as a double structure, one bone being placed at the ulnar side of the metacarpal head and the other in the centre of the interval between the head of the metacarpal bone and base of the phalanx. In another case the index sesamoid appeared as a double structure.

It is curious to note that when the antero-posterior skiagram reveals the absence of the sesamoids of the fingers, the lateral plate will show them to be either too small or the metacarpal heads will reveal an abnormal ventral cornual like projection. This interesting projection seems to take the place of the sesamoid.

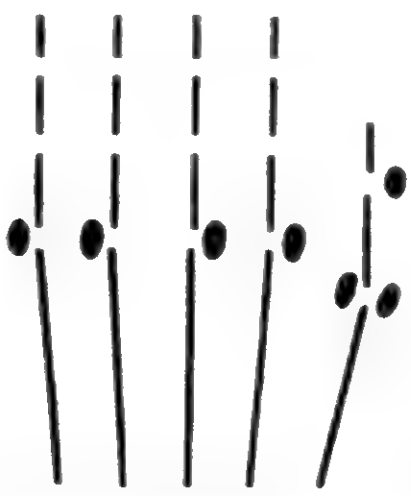

Fig. 2. Maximum number of sesamoids seen in one skiagram.

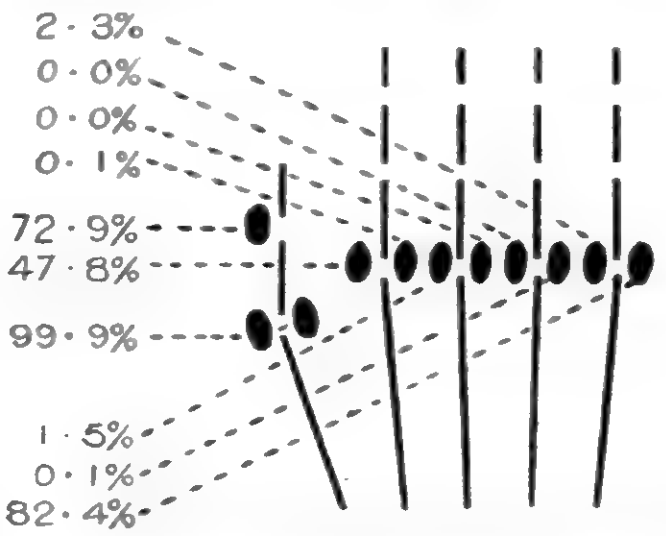

Fig. 3. Percentages of the hand sesamoids in Pfitzner's series.

The more numerous sesamoids seen in one skiagram in this series were distributed as shown in fig. 2.

In none of the cases was I able to find any evidence of bipartition of the pollex sesamoids.

It is noteworthy how disuse seems to affect the sesamoids of the hand, which reveal the same increase of transparency as the rest of the skeleton. Bony disease, such as rheumatoid arthritis, appears to affect these little bones as well.

Pfitzner in his dissections of the hand found the percentages shown in fig. 3, which are of exceptional importance owing to the considerable number of cases examined.

Fawcett, Stieda, Skillern and Retterer cases are of interest owing to the great variety and irregularity of distribution of the sesamoids. Retterer has dissected the hands of a man and found five bony and fourteen fibro-cartilaginous and vesiculo-fibrous palmar sesamoids on the right, and three bony and sixteen fibro-cartilaginous and vesiculo-fibrous on the left. In both hands there were fourteen fibrous dorsal sesamoids.

The pollex sesamoids more commonly, and rarely the others, are said to show two or more centres of ossification.

The centre of the sesamoids may be osseous, and the periphery fibro-cartilaginous. They may be larger in one hand, and appear as a bony formation in one side and a fibro-cartilaginous nucleus in the opposite.

Foot

The distribution of the sesamoid bones in 100 skiagrams of feet was as shown by the following percentages (fig. 4). These figures agree, on the whole, with the percentages found by other authors. The metatarso-phalangeal sesamoids form a constant feature of the skeleton of the human foot. The metatarso-phalangeal sesamoid of the 5th toe is the next in importance in this series. It was very difficult to determine whether it was a tibial or a fibular formation, as it very often appeared directly opposite the centre of the head of the metatarsal.

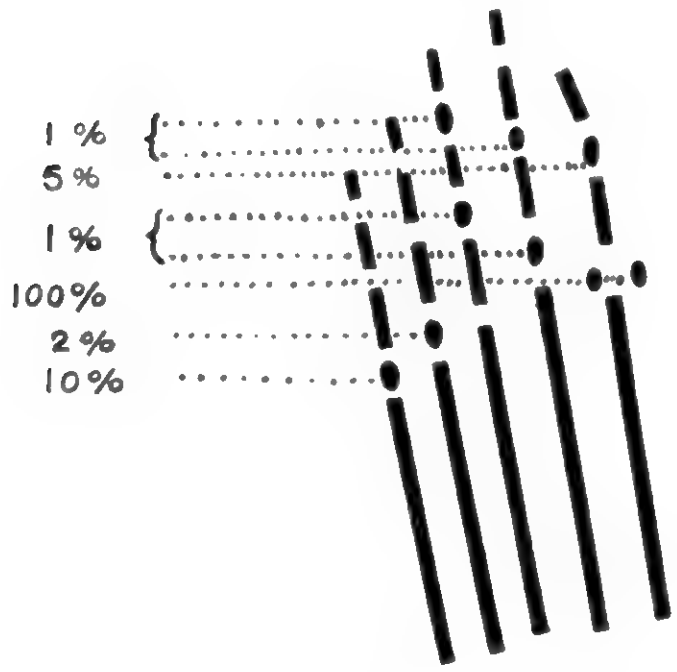

Fig. 4

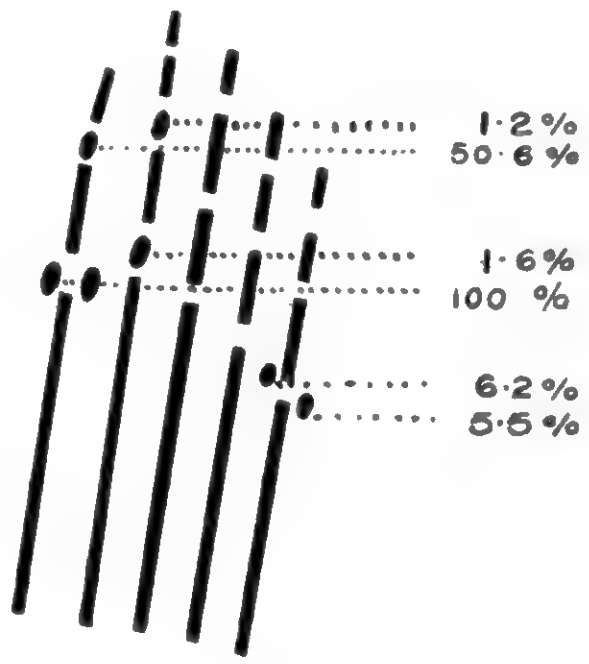

Fig. 5

Fig. 6

Fig. 4. Percentages of the foot sesamoids in my series.
Fig. 5. Percentages of the foot sesamoids in Pfitzner's series.
Fig. 6. Maximum number of sesamoids seen in one skiagram.

The age distribution of these cases was as follows:

Between 15 and 25 years, 46 cases.
,, 25 and 35 ,, 29 ,,
,, 35 and 45 ,, 25 ,,
Total 100 ,,

91 being males and 9 females.

The interphalangeal sesamoid of the hallux is very rarely seen in this series, compared with higher figures found by other writers. The great irregularity in the distribution of the more uncommon sesamoids seen in the series is worthy of note. They show more variety of distribution than is the case in the hand. The maximum number of sesamoids found in a single case of the series is shown in fig. 6.

Pfitzner gave the percentages of the commoner podal sesamoids shown in fig. 5. It is to be noted that his figure of the frequency of the two sesamoids of the metatarso-phalangeal of the 5th toe is almost identical with the percentage of my series; and, on the other hand, the interphalangeal sesamoid of the hallux appears to be 45 per cent. commoner than in the skiagrams examined by me.

Stieda describes three skiagrams of feet which show a great variety of distribution of the sesamoids.

From what has been said previously, it is clear that the metatarso-phalangeal sesamoids of the hallux are the most important and constant in the foot.

The tibial sesamoid of the hallux appears to be more commonly the seat of normal anatomical alterations, a fact of great importance in dealing with the traumatology of these bones. In four cases the tibial sesamoid appeared divided as in fig. 7. This shows a very irregular distribution of the line of division, and it should be mentioned that there was neither evidence nor history of fracture in any of these cases.

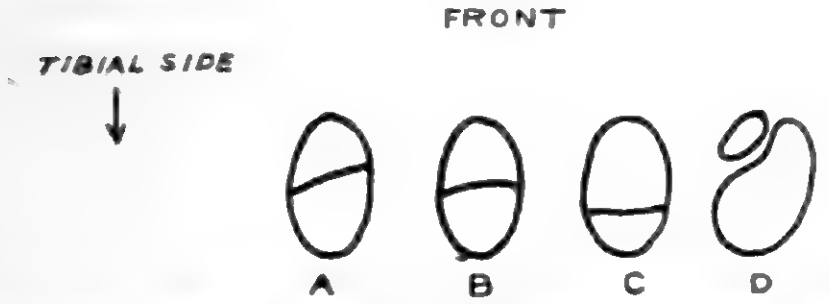

Fig. 7. Four cases of congenital division of the tibial sesamoid of the hallux. Cases *A*, *B*, *C* of transverse, and *D* of antero-posterior bipartition.



Fig. 8. A case of supernumerary sesamoid of the hallux. It differs from Fig. 7 *D* because the larger fragments show an outline without concavity.

In one case (fig. 8) a third small sesamoid was present between the two constant ones, similar to a case described by Gillette.

In one case there was a fracture dislocation of the peroneal sesamoid of the hallux. The sizes of the metatarso-phalangeal sesamoids vary in both feet, and several times it was possible to detect such differences in our series. On the other hand any alteration in the alignment of the phalanx and metatarsal bones upsets the position of these structures. A marked valgoid position of the toe is always followed by a lateral displacement of the peroneal sesamoid towards the outer side.

Some of these data are confirmed by Geist, Gillette, Malgaigne, Momburg, Nesbitt, Pfitzner, Scott and Stieda findings.

CARPUS

The carpal series very rarely displays any anomaly to be seen radiographically. In 100 skiagrams of the wrist, in one case there was a small dorsal bony formation at the wrist opposite the semilunar. This nodule was of the size of a radial metacarpo-phalangeal sesamoid and was clearly seen in the lateral view. It is not clear whether it was a capsular formation, a radialis brevior sesamoid or the "epilunatum" (fig. 9 (1)). The fusiform and the uncinate process show very marked differences in size; and the projected surface of the latter in the antero-posterior view forms, in some cases, a well-marked radiographic detail. I found no evidence of "os hamuli" or of secondary pisiform being present.

In one case there was a small, bony nodule on the flexor surface and opposite the base of the first metacarpal, which may have been the "pretrapezium" (fig. 9 (2)).

In one case there was a small bone, corresponding to the secondary "os triquetrum" or the "ulnare antebrachii" (fig. 9 (3)), below the ulnar styloid process. In another case I met with a possible bipartition of the navicular (fig. 9 (4)), as I could not find any history of trauma.

There was no evidence in any skiagram of any anomaly of the metacarpal bases.

All the cases referred to above were unilateral.

Fig. 9. Diagram showing the distribution of the carpal anomalies seen in this series: (1) epilunatum, 1 %; (2) pretrapezium, 1 %; (3) ulnare antebrachii or triquetrium secundarium, 1 %; (4) (?) naviculare bipartitum, 1 %.

TARSUS

The tarsal series shows frequent and curious bony formations. A clear knowledge of these bones seems to be of some practical importance, as they occur with considerable frequency. In 100 skiagrams of the tarsus 21 abnormal bony formations were found as follows:

Os trigonum (intermedium) (fig. 10 (1)). It was present in seven skiagrams, in one being of very large size, and the rest of medium size. They were all single, except in one case in which the bone appeared to have been fractured by a piece of shrapnel. It is sometimes very difficult to state whether the bone is quite a separate and independent piece in the skiagram. The os trigonum was described by Rosenmüller in 1804, and found by Bardeleben in the embryo as a cartilaginous nucleus. It may have one, two or more nuclei of ossification. Keith says that it represents the semilunar. Eight per cent. has been the figure found by other authors.

Os peroneale (accessory cuboid, sesamum peroneum) (fig. 10 (2)). It was found in five plates. In one case it was bilateral. In all the cases it appeared as a small single bony formation. Sometimes it is placed slightly behind the cuboid ridge, which appears to be due to the posterior part of the os peroneale becoming ossified earlier. This bone is cartilaginous in children and later becomes fibro-cartilaginous and osseous. Heavy work appears to precipitate such an alteration. I had an opportunity of confirming Retterer's findings. It may be said that the upper portion of the structure is cartilaginous, the lowermost tendinous and the intervening layer osseous. The os peroneale is developed in the peroneus longus tendon, and is the representative of the bony piece found at the angulated portion of the tendon Achilles of the frog. An analogous structure, seen in the long plantar of the rabbit and dog, which in these animals glides over the os calcis, has an identical phylogenetic significance (Retterer). It was first described by Vesale in 1555. It was found in 7, 8 and 10 per cent. of cases respectively by Geist, Pfitzner and Dwight.

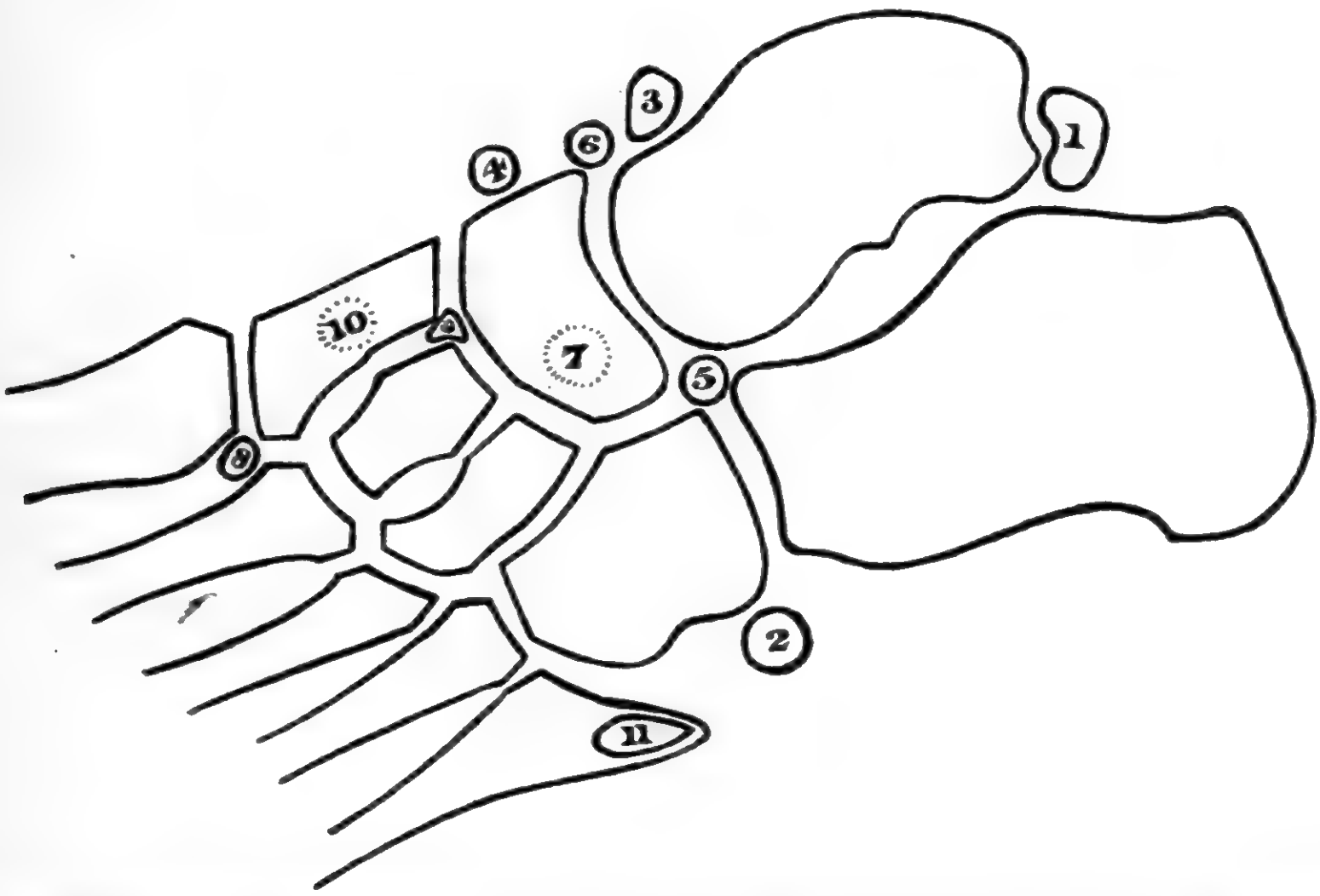

Fig. 10. Diagram showing the distribution of the tarsal supernumerary bones and sesamoids: (1) os trigonum, seen in 7 % of cases; (2) os peroneale, seen in 5 % of cases; (3) trochlear talar process, seen in 5 % of cases; (4) os tibiale, seen in 2 % of cases; (5) secondary os calcis, seen in 1 % of cases; (6) supra navicular (inter talo-scaphoid), seen in 1 % of cases; (7) secondary cuboid; (8) intermetatarseum; (9) intercuneiform; (10) division of first cuneiform; (11) os vesalii. The last five were not seen. This diagram also shows that the majority of the tarsal supernumerary bones are seen around the navicular.

Trochlear process of talus (fig. 10 (3)). This is a small bony formation found in the dorsum of the head and neck of the talus. It was seen in 5 per cent. of our cases. In one plate it was a very well-marked bony spicule and was present in both feet. The patient, a man 24 years old, only complained of pain while walking and due to a corn in the sole of the foot. He could wear boots. The other four cases were intermediate stages of development of the trochlear talar process. The X-ray appearance of this formation, well seen in the lateral view, does not resemble an exostosis, and it was not possible to find evidence of disease in any other part of the skiagrams.

Os tibiale externum (fig. 10 (4)). It was seen in 2 per cent. of the cases of this series. It forms a very interesting feature of the skeleton of the tarsus.

This bone has a cartilaginous nucleus in the second month embryo, and corresponds to the tubercle of the scaphoid common in some mammals. I found this bone well represented in the tarsal range of the sea-lion. It is found sometimes divided as if by a fracture. It is said it may be one of the causes of painful foot, and that it represents either the first cuneiform or a traumatic division of the navicular centre of ossification. Lupo brings forward the debated view which regards the scaphoid as resulting from the fusion of the tibiale externum, navicular and accessory scaphoid centres. The cases referred to in my series were men of 27 and 31 years of age. In one case the presence of the os tibiale was associated with a sesamoid of the metatarso-phalangeal joint of the 5th toe, and with division of the tibial metatarso-phalangeal sesamoid of the hallux. The pathology of the so-called Köhler's tarsalgia will be more clearly understood when a better understanding is reached of the morphology and ossification of the interesting human scaphoid.

Secondary os calcis (fig. 10 (5)). This little structure is to be found between the os calcis, cuboid and talus. It was seen as a small nucleus in one case only. It was found in a man of 32 years of age and it was associated with a vestige of supra-trochlear process of the talus, interphalangeal sesamoid of the hallux, and metatarso-phalangeal sesamoid of the 2nd and 5th toe. The secondary os calcis must not be mistaken for a *secondary cuboid* (fig. 10 (7)), which was not seen in any case of my series, and it is very seldom seen by means of X-rays. When present it is situated below the scaphoid which may show a connection with it. The secondary cuboid is still a debated anatomical entity.

In one case I was able to find a small independent bony formation between the talus and scaphoid (fig. 10 (6)); it was well seen in the lateral external skiagram on the dorsum of the foot. I cannot state whether this little bone was a sesamoid in a tendon or in the talo-navicular capsule.

Intermetatarseum (fig. 10 (8)). This bone is placed between the bases of the 1st and 2nd metatarsal bones, in the intermetatarsal cleft. It is said to represent a real metatarsal, and it has been found better developed in polydactylic cases. I was not able to see it among any of the skiagrams of the series and in seven special plates of polydactylia. I venture to suggest that this bone is identical with the so-called sesamoid described by Stieda. The intermetatarseum has been seen by Pfitzner and Dwight in 10 per cent. of cases.

Intercuneiform (fig. 10 (9)). Is to be found between the 1st and 2nd cuneiforms and the scaphoid.

Division of first cuneiform (fig. 10 (10)). This is an extra bony piece found in the plantar surface of the cuneiform.

Os vesalii (fig. 10 (11)). This appears, as in the hand, as a division of the base of the 5th metatarsal. Some authors claim it to be an epiphyseal irregularity; others maintain that this rare structure is a fracture of the metatarsal base.

Peroneal tubercle. It was described in one case by Pfitzner as an indepenent structure.

The *infra-tibial*, mentioned by Lupo, is to be found occasionally beneath the internal malleolus.

The last six of the varieties of tarsal formations described above have not been met with in this series, and usually they can very rarely be identified by means of X-rays.

UPPER LIMB

Small bones are in some rare cases to be seen in the *upper limb*.

Thus the *bicipital tendon* showed a small bony formation opposite the radial tuberosity in one case. This bone was of the size of a small metacarpo-phalangeal sesamoid. I have already referred to a sesamoid possibly developed in the *radialis brevior* tendon, opposite the wrist.

The much debated *tricipital sesamoids* and the *supinator brevis* described by Macalister were not seen in any of the 80 plates I have examined.

LOWER LIMB

In the lower limb the outer head of the *gastrocnemius* showed a sesamoid behind the femoral condyle in one plate out of 50. This was not very large, and radiographically it is noteworthy the great variety of sizes that this small bone exhibits. The internal gastrocnemius and the popliteus sesamoids are very rarely seen. The last named appears to be common in felids and the orang. The gastrocnemii sesamoids are well illustrated in a dried femur of "cynocephalus anubis" of the osteologic collection of the Royal College of Surgeons.

The psoas magnus, gluteus maximus, gracilis, long plantar claimed sesamoids have not been seen by me in any skiagram yet.

The patella forms another subject of much interest. In 100 consecutive plates of the knee I have not been able to find any "patella bipartita." This curiosity so well defined by Mouchet, Moreau and others requires a more prolonged study of this subject. The bilaterality of the anomaly does not appear to my mind to exclude the possibility of a traumatic origin of this curious condition. It is remarkable that the patella, though the largest sesamoid, very rarely shows any anomalies of ossification. The best position in which to detect patellar deformities and injuries by means of the X-rays is the antero-posterior with the knee and thigh flexed to 30 or 40 degrees and oblique exposure from behind. The thigh should be flexed as well as the leg. This position widens the tibio-femoral space and allows the lower portion of the patella to be seen directly in that interval.

SOME POINTS ON MORPHOLOGY

The morphological information regarding these structures is unfortunately still very inconclusive and lacking in precision.

The variations which these bones exhibit in shape and size in the mammalian series are well illustrated in the excellent osteologic collection of the Royal College of Surgeons of England.

The skeletons of the grizzly bear—*Ursus horribilis*—the deer hound, koodoo, elk, cervus show the distribution of these bones in the hands and feet, and the depth of the grooves in which they play. The same point is well shown in the limbs of the *Rhinoceros unicornis*, Sumatran rhinoceros, and hippopotamus.

The race horse Orlando of aristocratic and regal tradition, and the plebeian Spanish horse near it, display very little difference as regards the structure of their sesamoids, and this notwithstanding the turf career of agility and alacrity of the former, in marked contrast with the leisurely contemplative life probably led by the latter.

The skeletons of the *Bos Taurus*, *Tapirus indicus*, giraffe and elephant show the sesamoids in the four limbs, and in the latter animal one is struck by the size of its patella. The dried hand and feet skeletons of the armadillo, ant eater, badger, kangaroo, hedgehog, rabbit, hare and dog show an interesting degree of evolution of the sesamoids.

Specimen H. 26. 1 shows the hemisection of a horse's foot in which one of the upper sesamoids has been cut in a vertical direction. Here it can be seen how the tendon is attached, and contrary to what has been maintained by some authorities, the fibres of the tendon seem to run in the posterior surface of the sesamoid, while a few appear to end in this bone. The articular surface is smooth and plays in the groove of the phalanx and head of the metacarpal. Its appearance is exactly like that of the rest of the joint surface.

In making this rapid survey of the sesamoids of animals differing so greatly in size, weight and habits one is surprised to find that these bones do not appear to be related to the size of these skeletons in any definite proportion. In fact one may extend the dictum of Aeby by saying that the habits and size of a mammal seem to have no influence on the anatomical characters of their sesamoids.

In all, however, one fact is constant: they all seem to enlarge the articular surface of the joint, and in all they run in a well-formed groove. These grooves are subdivided by a central ridge similar to that seen in the head of the 1st human metatarsal, for instance.

Retterer recently studied these bones in the lion and cat, and states that, as in the dog, these animals have metacarpo- and metatarso-phalangeal and primi-secundii-phalangeal dorsal sesamoids. They are capsular thickenings, and are not ossified but fibro-cartilaginous.

CLASSIFICATION

The etymology of the word sesamoid shows how untrue is the exact up-to-date meaning of the word. It is rather inconsistent to compare bones of the size of a patella on the one hand, and the almost microscopical nodules of the articular phalangeal capsules on the other hand, to the grains of sesame of Galen. If size alone is to be the basis of classification the small supernumerary bones of the skeleton would be included in this class notwithstanding their recognised anatomical ancestry.

Cruveilhier (1881) proposes to confine the name sesamoid to the patella.

Gillette classified the sesamoids into *peri-articular* and *intratendinous*. Pfitzner divided them into *real* and *false*. The former are those that cannot be grouped in any other known category of bones. The false are bony or calcareous new formations of pathological origin, supernumerary bones of the carpal or tarsal range, little bony pieces in or in close contact with some tendons.

Poirier has grouped the sesamoids into *constant* and *inconstant*. The former being only the metacarpo- and metatarso-phalangeal sesamoids of the pollex and hallux. The latter being any others. Retterer proposes a histological classification, dividing these structures into four different groups: (1) *Fibrous*, (2) *Vesiculo-fibrous*, (3) *Cartilaginous*, and (4) *Osseous*.

To my mind, if Nesbitt and Thilenius' deductions are accepted, there is only the phylogenetic factor as a basis of classification. Then, whether these structures be bony or fibrous, they are all of the same nature as Retterer's claims. Evidently any accidental pathological finding has to be excluded. Many details, however, in the science of phylogeny need to be filled in before an accurate classification of the sesamoid structures can be achieved. Such is the reason that forces me to divide them into *supernumerary bones* and *sesamoids*. The former having a well-defined phylogenetic meaning, and the latter being those which have an unknown anatomical pedigree.

ANATOMO-PHYSIOLOGY

It is difficult to give a reason for the existence of the sesamoid structures in the human body.

If function is accepted as the cause of the formation of these structures, as parts of anatomical systems, it becomes necessary to state what physiological duties they have to perform.

If, on the other hand, the phylogenetic theory is to be accepted, it still remains to find the reason for so many individual variations.

Again, it has been fully demonstrated that the sesamoid structures have an evolution resembling that of other bones. In fact, they present definite evolutionary stages, starting as a mesoblastic core and ending in some cases as real bony structures.

The sesamoid problem comprises two separate questions, as follows: (*a*) why should these structures appear; and, (*b*) when once formed, what are the functions that they have to fulfil? In fact the sesamoids are not an accidental formation. They are not due to a mere ossification in a tendon; they are real bones, having a definite cartilaginous nucleus—Nesbitt, Gillette, Thilenius.

Bradley expresses the opinion that these bones have a phylogenetic origin.

Monro stated that the causes of sesamoids are manifold. They are to be found where tendons and ligaments are firmest, muscular action strongest, and compression greatest.

In Gray's anatomy it is stated that the sesamoids have a phylogenetic reason of existence; and that their functions probably are to modify pressure, to diminish friction, and occasionally to alter the direction of the pull of the muscle. Parsons suggests that "some traction epiphysis were once sesamoid bodies."

Wood-Jones thinks that the manual sesamoids are ossicles in the tendons of a fluctuating group of intrinsic muscles which produce flexion of the metacarpo-phalangeal joints.

On the other hand their functional importance in animals has been long recognised. Youatt gives in his book the following description of the sesamoid function in the horse: "in proportion as the pastern is oblique or slanting, two consequences will follow, less weight will be thrown on the pastern, and more on the sesamoid...and in that proportion concussion will be prevented."

Assuming for a moment that the phylogenetic theory is accepted, it remains to find the reason for the variations of the sesamoids. The two metacarpo-phalangeal sesamoids of the pollex are developed by the strong movements of opposition which will produce pressure in the palmar surface of the capsule. The metacarpo-phalangeal joints of the pollex, index and auricular appear to be the seat of maximum pressure when the hand grasps an object. The heads of the corresponding metacarpals even show alterations of shape due to the same pressure—Gillette, Retterer. In these three places one finds with comparative frequency the pollex, index and auricular sesamoids, as it was demonstrated.

The metatarso-phalangeal sesamoids of the hallux are a constant feature of the human foot. They appear to be placed at a point of maximum pressure and friction of the base of the anterior pillar of the internal arch of the foot. It is on this point that the strong flexor of the hallux plays, at an angle, in walking. The elevation of the body, in taking a step, is preceded by a strong metatarso-phalangeal and ankle extension. Whenever the line between the metatarsal and the phalanx of the hallux varies, as in abduction of the toe, the two sesamoids alter their position as well. In such movements the X-ray examination will reveal these structures displaced outwards, and the peroneal sesamoid appearing in the cleft between the 1st and 2nd metatarsals. Frazer says that the sesamoids of the hallux with the soft tissue covering are responsible for the plantar prominence of the ball of the toe.

The other sesamoids of the hands and feet never attain large dimensions, and are all extremely inconstant as far as ossification is concerned. They appear to be always present at the flexor and extensor surfaces of the capsules of all the joints but in a vestigial stage only.

The so-called articular sesamoids appear to enlarge the joint surface and to render the articular movements conformable to the condylarthrosis type of articulation. In fact, extension and flexion appear to be the dominating or sole types of motion exhibited.

Taking the pollex and hallux as instances, it will be found that more complex movements will take place at the carpo-metacarpal and tarso-metatarsal articulations. In the case of the pollex, the trapezio-primi-metacarpal joint is an epiphiarthrosis, which supplements the mechanical deficiency of motion of the metacarpo-phalangeal articulation. The same can be said of the very elaborate reniform arthrosis of the primi cuneiform metatarsal.

On the other hand, it is noticeable that the sesamoids generally appear close to the seats of muscular insertion, and there are very few exceptions to this rule. The great majority of sesamoids are not only situated near a joint, but are always found in close contact with other bones.

The heads of the metacarpals appear to show, as it has already been said, by means of the lateral view of the X-rays a cornual-like projection, whenever the sesamoids of the corresponding joints fail to appear as independent structures.

Age seems to have a definite influence in sesamoid ossification. Sex in our experience does not appear to be of any significance.

Pressure, traction and friction alone are not the cause of the formation of sesamoids.

Pressure usually produces cartilaginous formations, or a curious adipose-like tissue, seen for instance in the Haversian formation of the hip.

Traction, by itself, brings the mesoblastic core to a line, and stretching orientates the cells in a direction parallel to the line of force, as in a tendon for instance.

Friction, on the other hand, places the cells, as it were, in an oblique or vertical direction to the gliding motion. This has been well shown by Retterer.

Pressure combined with the complex series of movements of circumduction, displayed by an enarthrosis, as in the hip or shoulder, appears to originate a further anatomical element. The interesting ligamentum teres of the hip, and the long head of the biceps at the shoulder, with the cartilaginous brim of the cotyloid surface, probably owe their kinetic origin to these forces.

If a condylarthrosis has to perform gliding movements, these seem to give rise to a special element, the intra-articular fibro-cartilages. This structure follows the antero-posterior movements of the joint by gliding in a similar direction.

If the gliding motion is combined, as in the knee with a rotatory movement, the menisci become cartilaginous or, in some mammals, bony.

It seems, therefore, that every articulation of the types of enarthrosis or condylarthrosis, requires the presence of intra- and peri-articular elements of a sesamoid nature, produced either by motion or its consequence.

Phylogeny and function combined appear to be the two causes of sesamoid formation and development. The former originates and plants, as it were, the seeds for their formation, and the latter, acting daily and with every movement, promotes the increase in size of these structures.

It is hardly possible to accept either of these theories separately, and the only obscurity remaining lies within the elastic boundaries indicated by the term phylogeny.

My thanks are due to the Council of the Royal College of Surgeons for free access to the material in their Museum.

NOTE. The traumatology of these bones will be given in the *Annals of Surgery*.

BIBLIOGRAPHY

AEBY. *Arch. für Anat. u. Phys.* p. 261, 1875.
BARNES. *New York Med. Journ.* vol. 102, p. 940, 1915.
BRADLEY. *Anat. Anzeiger*, vol. 28, p. 528, 1906.
DWIGHT *Anat. Anzeiger*, vol. XX. p. 465, 1902.
—— *A Clinical Atlas*, 1907.
FAWCETT. *Journ. of Anat. and Phys.* vol. XXXI. p. 157, 1897.
FRAZER. *The Anatomy of the Human Skeleton.* Lond. 1920.
GEIST. *Amer. Journ. of Orth. Surg.* vol. XII. p. 403, 1915.
GILLETTE. *Journ. d'Anat. et Phys.* vol. VIII. p. 506, 1872.
GRAY. *Anatomy*, 1920.
KEITH. *Human Embryology and Morphology.* Lond. 1913.
LUPO. *La chir. degli org. di mov.* vol. IV. p. 141, 1920.
MACALISTER. *Journ. of Anat. and Phys.* vol. III. p. 108, 1869.
MONRO. *Anat. of the bones.* Edin. 1726; *Collected Papers.* Edin. 1781.
MOMBURG. *Deut. Zeit. f. Chir.* vol. LXXXVI. p. 382, 1907.
MOREAU. *Presse méd.* p. 374, 1920.
NESBITT. *Human Anatomy.* Lond. 1736.
PARSONS. *Journ. of Anat. and Phys.* vol. XIII. p. 248, 1904.
PFITZNER. *Morphol. Arbeit.* vol. I. p. 1, 1892.
—— *Ibid.* vol. IV. p. 347, 1895.
—— *Ibid.* vol VI. p. 245, 1896.
—— *Zeit. f. Morph. u. Anthro.* vol. II. p. 77, 1900.
POIRIER. *Anatomie*, vol. I. 1899.
RETTERER. *Journ. d'Anatomie*, vol. XX. p. 467, 1884.
—— *Comp. rend. soc. biol.* vol. LXXI. p. 7, 1911.
—— *Ibid.* vol. LXXXI. pp. 353, 630, 829, 1918.
SCOTT. *Arch. of rad. and elect.* vol. XXIII. p. 224, 1918.
SKILLERN. *Ann. Surg.* vol. LXII. p. 297, 1915.
STIEDA. *Münch. med. Woch.* vol. LIII. p. 1954, 1906.
—— *Beit. z. Klin. Chir.* vol. XLII. p. 237, 1904.
THILENIUS. *Anat. Anzeiger*, vol. IX. p. 425, 1894.
—— *Morphol. Arbeit.* vol. V. pp. 309, 462, 1896.
WOOD-JONES. *Principles of Anatomy as seen in the Hand.* Lond. 1920.
YOUATT. *The Horse.* Lond. 1866.

THE AURICULO-VENTRICULAR BUNDLE IN MAMMALS

BY A. HILLYARD HOLMES, M.D., M.R.C.P.
Honorary Physician to Ancoats Hospital,
Honorary Assistant Physician, Manchester Royal Infirmary,
Lecturer in Applied Anatomy (Medical) in the University, Manchester

(*From the Departments of Anatomy and Pathology, the University, Manchester.*)

THE Auriculo-Ventricular Bundle with its connections is best seen, both by the naked eye and microscopically, in the heart of Ungulates, and for this reason a description of the appearances in the sheep will first be given, to serve as a standard with which other hearts may be compared.

SHEEP AND OX—MACROSCOPIC FINDINGS

If the endocardium be stripped off the right side of the ventricular septum from the junction of the septal and infundibular cusps of the Tricuspid valve to the base of the Moderator Band (which in the sheep and ox is always present, passing from the lower and fore part of the septum to the base of the anterior papillary muscle), a white strand will be seen about ½–1½ millimetres in width according to the size of the heart. This is the Right Branch of the A.V. Bundle (fig. 1). It can be followed by dissection along the Moderator Band, but not easily further than this. Tracing it backwards by removing the cusps, the endocardium, and a thin layer of muscle from the auricular septum, a definite fusiform expansion is reached, which is the A.V. Bundle itself (fig. 1). Careful dissection will bring into view another deeper strand of similar pale tissue, directed towards the left side of the septum, and taking origin from the A.V. Bundle. This is the Left Branch of the Bundle (fig. 1). It is seen as a definite pale strand through the endocardium on the left side of the septum, in a line from the junction of the Right coronary and non-coronary cusps of the Aortic valve to the apex of the ventricle, first appearing ½–1 inch below the cusps. It does not reach the apex but divides into several strands, the largest of which crosses in a false chord to the base of the anterior papillary muscle; another strand passes similarly to the posterior papillary muscle, and a third may often be seen continuing down the septum towards the apex.

If the A.V. Bundle itself be traced backwards on the auricular septum, it will be found to diminish in size, and finally disappear as a definite tract a few millimetres in front of the orifice of the Coronary Sinus. It is overlaid by muscle and endocardium of the auricular septum, and deep to it is the fibrous tissue known as the central fibrous body, or in some hearts, the os cordis, because of the bone developed in this region. This prolongation backwards from the fusiform expansion of the Bundle is the A.V. Node. In the sheep it is not defined from the Bundle as seen by the naked eye, but in larger hearts, as the ox, the tract first narrows behind the Bundle and then expands again into the Node. The ramifications of the Right and Left Branches of the Bundle under the endocardium of the ventricles are too fine to be traced by ordinary dissection, but may be very strikingly demonstrated by injecting each Branch with Indian ink. This ink is better for the purpose than Prussian blue, which does not photograph so well, and is apt to wash out of the tissues as they are prepared for paraffin sections. The best injection was obtained in the heart of an ox, which was well washed while quite fresh in running water for several hours, then opened and left on a dish for 3 days, covered by a glass shade which admitted plenty of air. The left ventricle was opened to be viewed from the front; the right ventricle was cut so as to be viewed when open from behind; these incisions allow of the best access for injection and the most complete view of each ventricle.

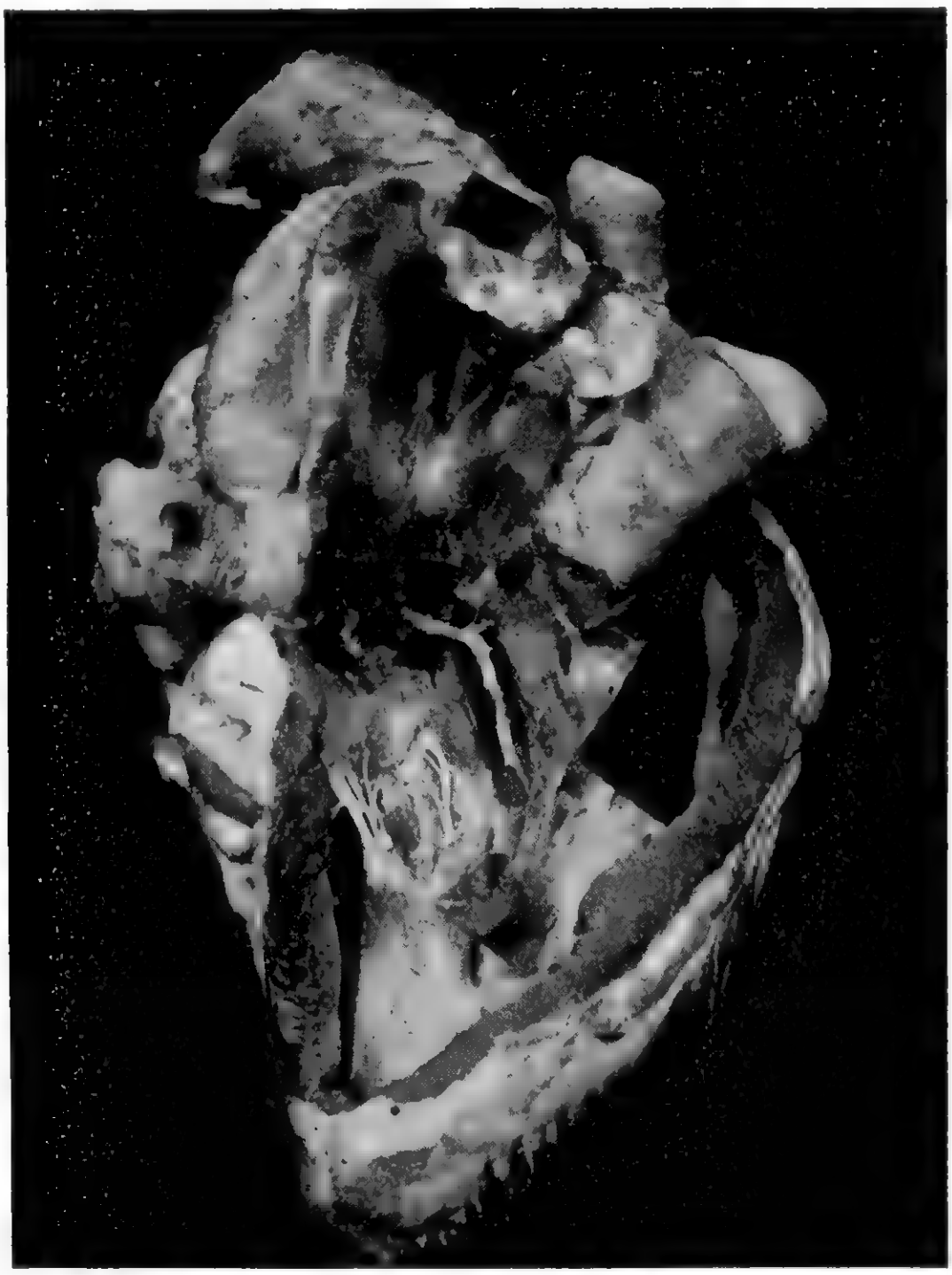

Fig. 1. Heart of a Sheep, with most of the Right Auricle and Right Ventricle cut away. Black arrows in the venous orifices and Pulmonary Artery. The A.V. Bundle and its Right Branch dissected, seen against black papers. The Left Branch is shown for about one-eighth of an inch. A piece of the anterior wall of the Right Ventricle is left hanging from the Moderator Band. (× $\frac{2}{3}$ nat. size.)

With very little pressure from the 5 c.c. syringe the ink ran readily into a network covering the bulk of the interior of both ventricles, reaching to the base of the valves and the apex of each cavity. Much more of the network appeared on the left side of the septum than on the right. Attempts to inject each Branch upwards into the Bundle and Node were not successful, no ink reaching these parts, as shown by later dissection. No ink ever flowed to the endocardium of the auricles or to the epicardium of any part of the heart.

SHEEP AND OX—MICROSCOPIC FINDINGS

A.V. Bundle and Branches

The minute structure of the Bundle and of the Right and Left Branches and their ramifications is similar in almost every detail. For convenience of preparing sections and studying these details, the Moderator Band is most useful, and the description of the Right Branch as it courses along this Band, or "true" chord, will serve as the type of Purkinje tissue throughout the ungulate heart. In transverse sections of the Moderator Band (fig. 2) the Right Branch of the Bundle is readily distinguished as an oval or circular mass of muscle, staining much less deeply with eosin than the ordinary muscle, and well marked off from the latter by a sheath of connective tissue. What appear to be the individual fibres of Purkinje tissue are very much larger than the fibres of the ordinary myocardium. They are apparently divided into compartments, three to six in number, by ill-defined dots taking the eosin tint more deeply than the main cytoplasm; these dots also often form a fringe for each Purkinje fibre (fig. 3). One or two rounded nuclei surrounded by granules may occupy a comparatively clear space in one or more compartments of each fibre.

A longitudinal section through the Purkinje tissue makes it very clear that the dots seen in a transverse section are simply the cross sections of fibrils which course along the Purkinje fibres (fig. 4). These fibrils are cross striated, just as are those of an ordinary myocardial fibre, but they by no means fill the Purkinje fibre as they do the ordinary fibre, being usually seen only at their periphery, and running obliquely, or almost transversely across them. It is obvious that if the Purkinje fibre were packed with fibrils, each of which takes the eosin stain deeply, the whole fibre would not appear pale when contrasted with the ordinary heart muscle similarly stained. It is the differentiated part of the protoplasm, the fibril, which takes the eosin tint deeply. The fibres of the Purkinje type branch and anastomose just as do those of the ordinary muscle, forming a syncytium, but one Purkinje fibre is 10–20 times the length of an ordinary fibre, and in cross section may be 50–100 times the area of an ordinary fibre, a single one of its compartments being perhaps 10 times the diameter of a myocardial fibre.

Connective tissue everywhere forms a sheath, not only for the whole tract of the Right Branch of the Bundle, but for each Purkinje fibre (fig. 3); it is this which gives the naked eye pallor to the Branch, which makes its dissection

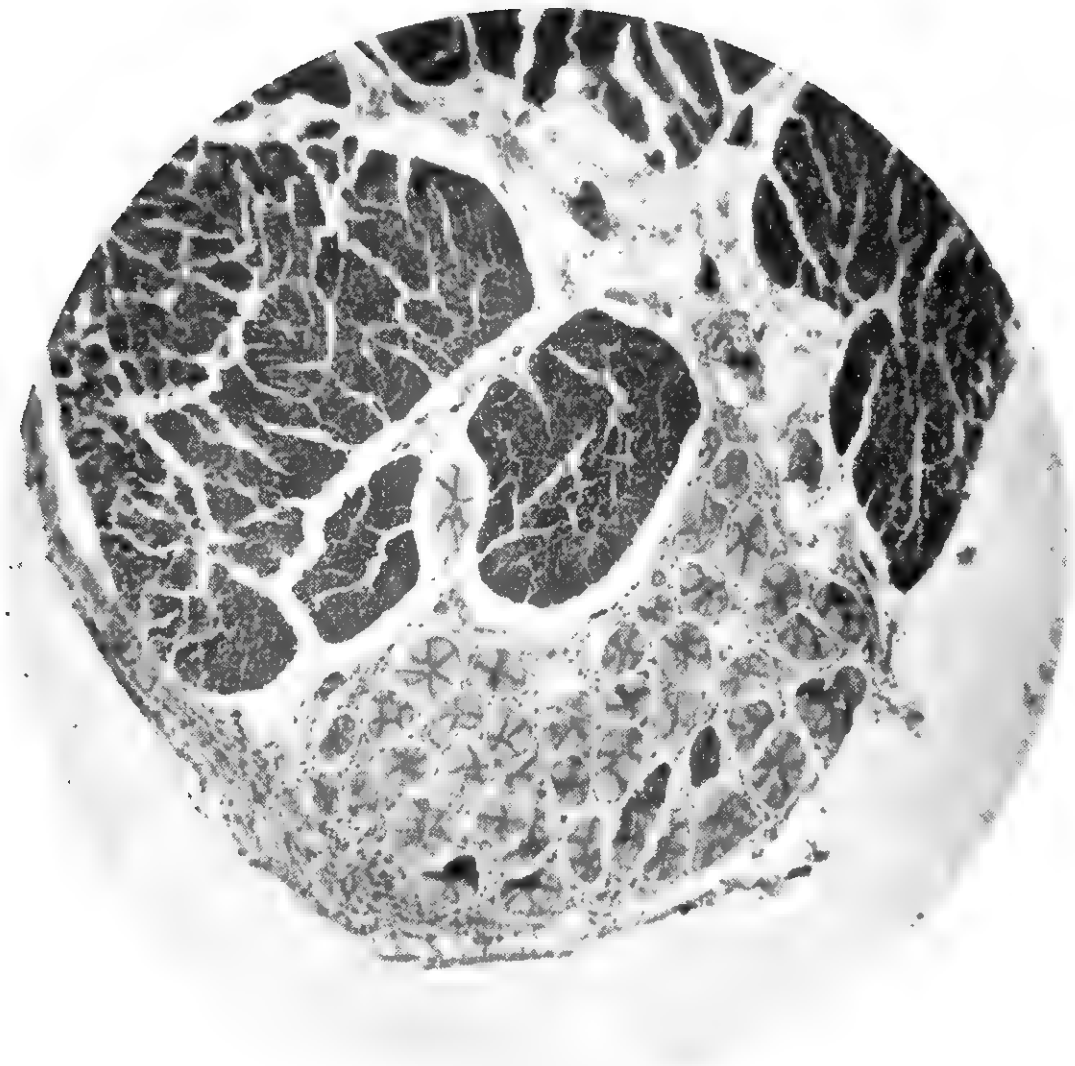

Fig. 2. Half the Moderator Band of a Sheep, in transverse section, showing the Right Branch of the A.V. Bundle. Purkinje fibres. (Low power.)

Fig. 3. Portion of Fig. 2, showing ordinary heart muscle, connective tissue sheath of the Purkinje fibres, the space round each fibre, the subdivision of each fibre into compartments by fibrils. (High power.)

Fig. 4. Longitudinal section of part of the Moderator Band of the sheep, showing Right Branch of A.V. Bundle. Purkinje fibres subdivided by longitudinal fibrils; connective tissue sheath for each fibre. Ordinary heart muscle. (High power.)

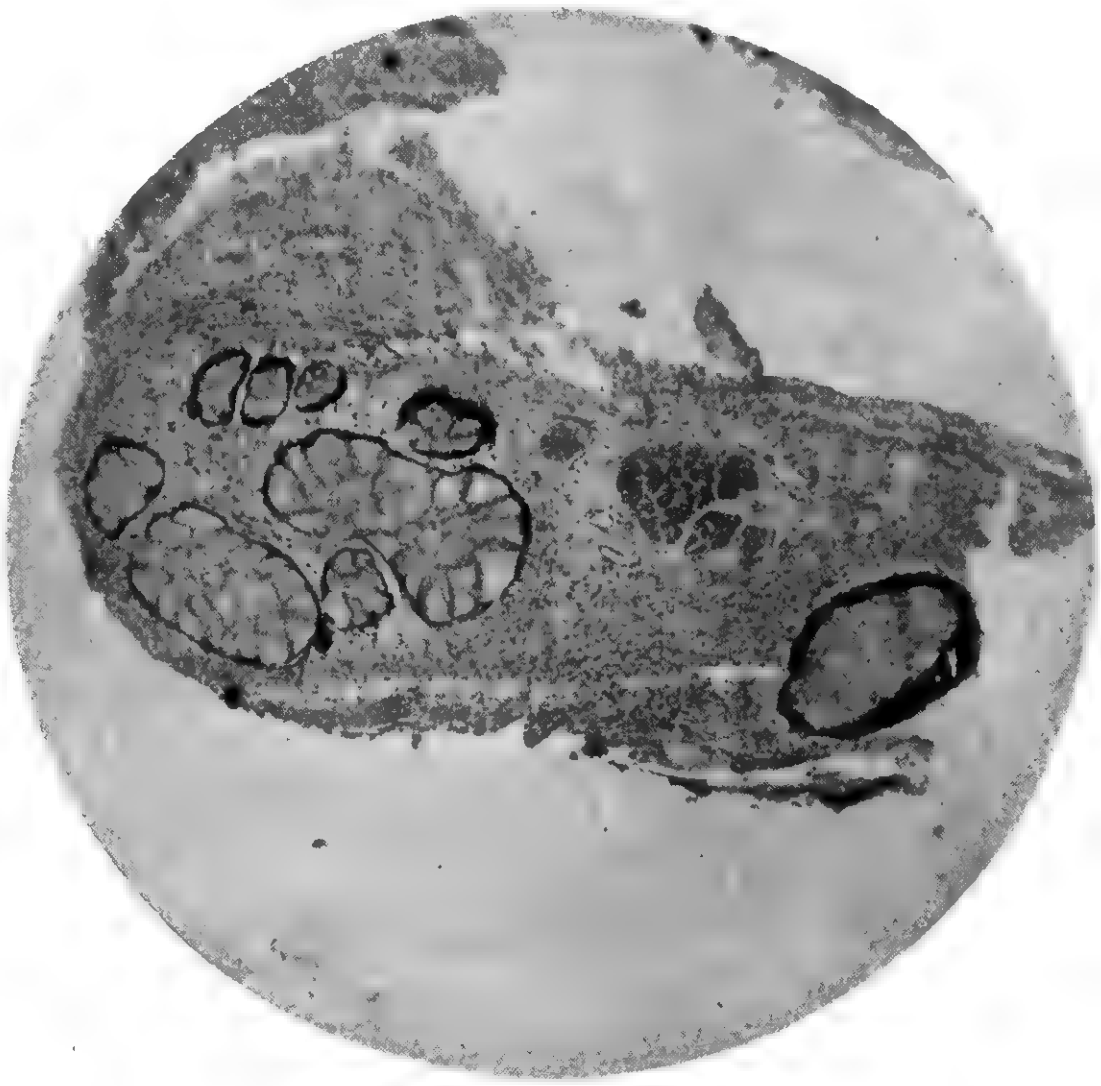

Fig. 5. Section across chorda of Left Ventricle from septum to anterior papillary muscle, in an Ox. Indian ink was injected into this chorda and flowed in a network under the endocardium of the outer wall of the ventricle. The ink surrounds each Purkinje fibre. A small bundle of ordinary heart muscle fibres is seen. (Low power.)

possible. But the connective tissue never penetrates into the walls of the compartments, as is readily understood when the fibrillar nature of these walls is realised. Often a space can be seen between the Purkinje fibre and its sheath, and in places a definite lining of very flat cells with elongated nuclei can be defined in this space. It is this space into which the Indian ink runs when the main Branch is injected, as microscopic sections clearly show in any part of the injected inner wall of the ventricle (fig. 5); again the true nature of the divisions of a Purkinje fibre into compartments is clearly seen, for no ink ever runs into the walls of the compartments.

Small non-medullated Nerves may readily be found in sections of either Branch of the Bundle, prepared and stained by ordinary methods (fig. 6); these Nerves may be seen within the outer sheath of the Branch, between the separate Purkinje fibres. Occasionally small groups of ganglionic Nerve cells are found in the closest proximity to the Purkinje tissue.

In the walls of the Ventricles the Purkinje fibres penetrate in places to a third or half the thickness of the wall; they were never found in the outer third, nor under the epicardium. As they leave the endocardium they usually follow a small artery, and become progressively smaller in all dimensions, till finally they are scarcely to be distinguished from an ordinary myocardial fibre, with which they can sometimes be seen to be in direct continuity. A definite sheath of connective tissue, and often small non-medullated Nerves, mark out the course of the Purkinje tissue.

In serial sections it is seen that the Bundle may either pass through the central fibrous body or round its right side; in the latter case it has to perforate the fibrous attachment of the septal cusp of the Tricuspid valve to the body, in order to reach the top of the ventricular septum. In Man the Bundle runs just below the pars membranacea septi; in those animals which show no membranous portion of the septum, the Bundle runs forwards and downwards just behind the angle of union of the septal and infundibular cusps of the Tricuspid valve.

The A.V. Node

The structure of the A.V. Node in the Sheep and Ox is quite different from that of the Bundle and its Branches (fig. 7). There is no distinct sheath of connective tissue but a fine reticulum of this tissue pervades the Node. The muscle fibres of the Node are more slender than those of the myocardium, in marked contrast with Purkinje fibres. They are multinucleated and stain less deeply with eosin than the myocardial fibre, but somewhat deeper than a Purkinje fibre. They show no undifferentiated cytoplasm, but consist of one to four fibrils running longitudinally through the fibre; the fibrils are often marked with cross striae. The fibres do not run in one direction but curve and anastomose freely, forming a syncytium in plexiform manner. Non-medullated Nerves are plentiful in the immediate vicinity of the Node, and in the Sheep and Ox are found actually within the Node and Bundle (figs. 8–10). Ganglia of Nerve cells are usually found several millimetres behind the Node (fig. 9).

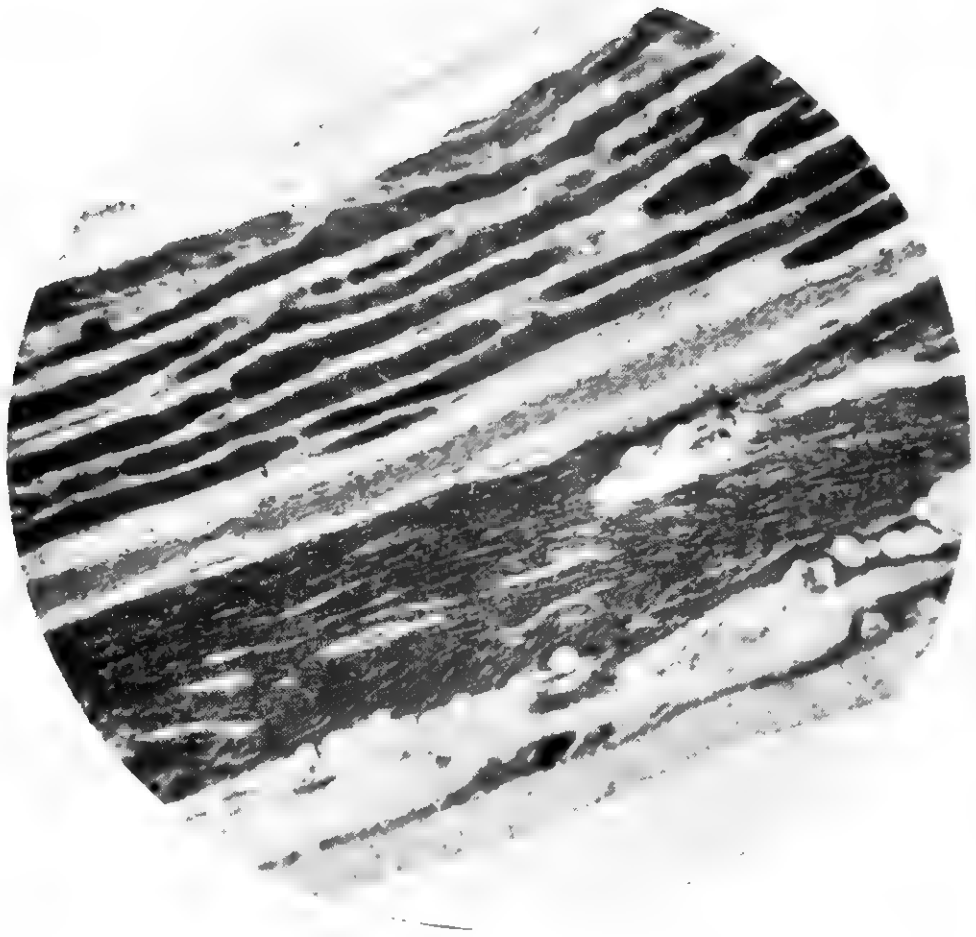

Fig. 6. Longitudinal section of the Moderator Band of a Sheep, showing a Nerve between the ordinary heart muscle and the Purkinje tissue which forms the Right Branch of the A.V. Bundle. The Nerve traverses the centre of the photograph. (Low power.)

Fig. 7. Transverse section of the A.V. Node in a Sheep showing a syncytium of multinucleated fibres. (Low power.)

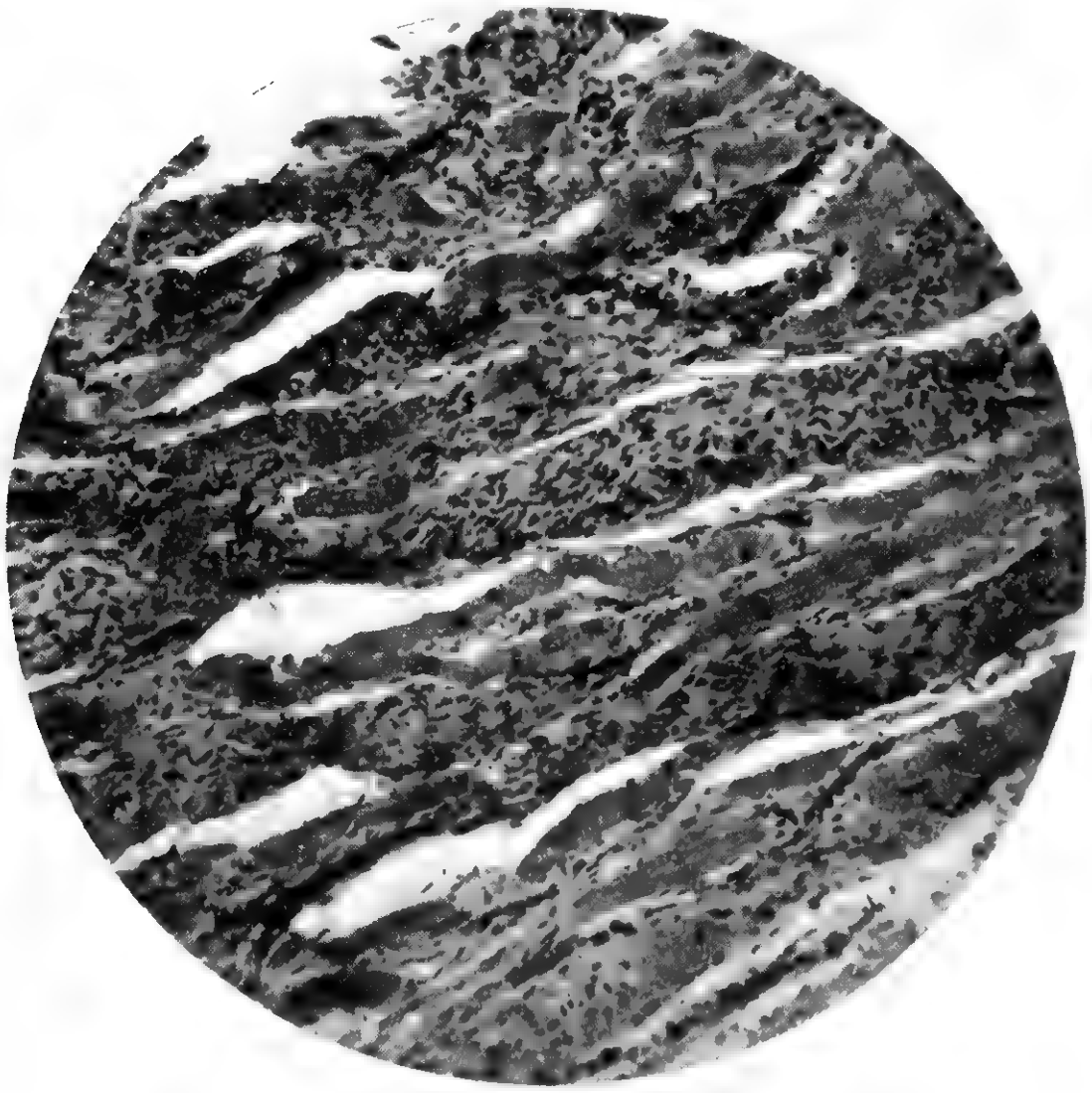

Fig. 8. Longitudinal section of the A.V. Bundle in a Calf, showing a profusion of Nerves among the Purkinje fibres. The densely nucleated strands are the Nerves. (Low power.)

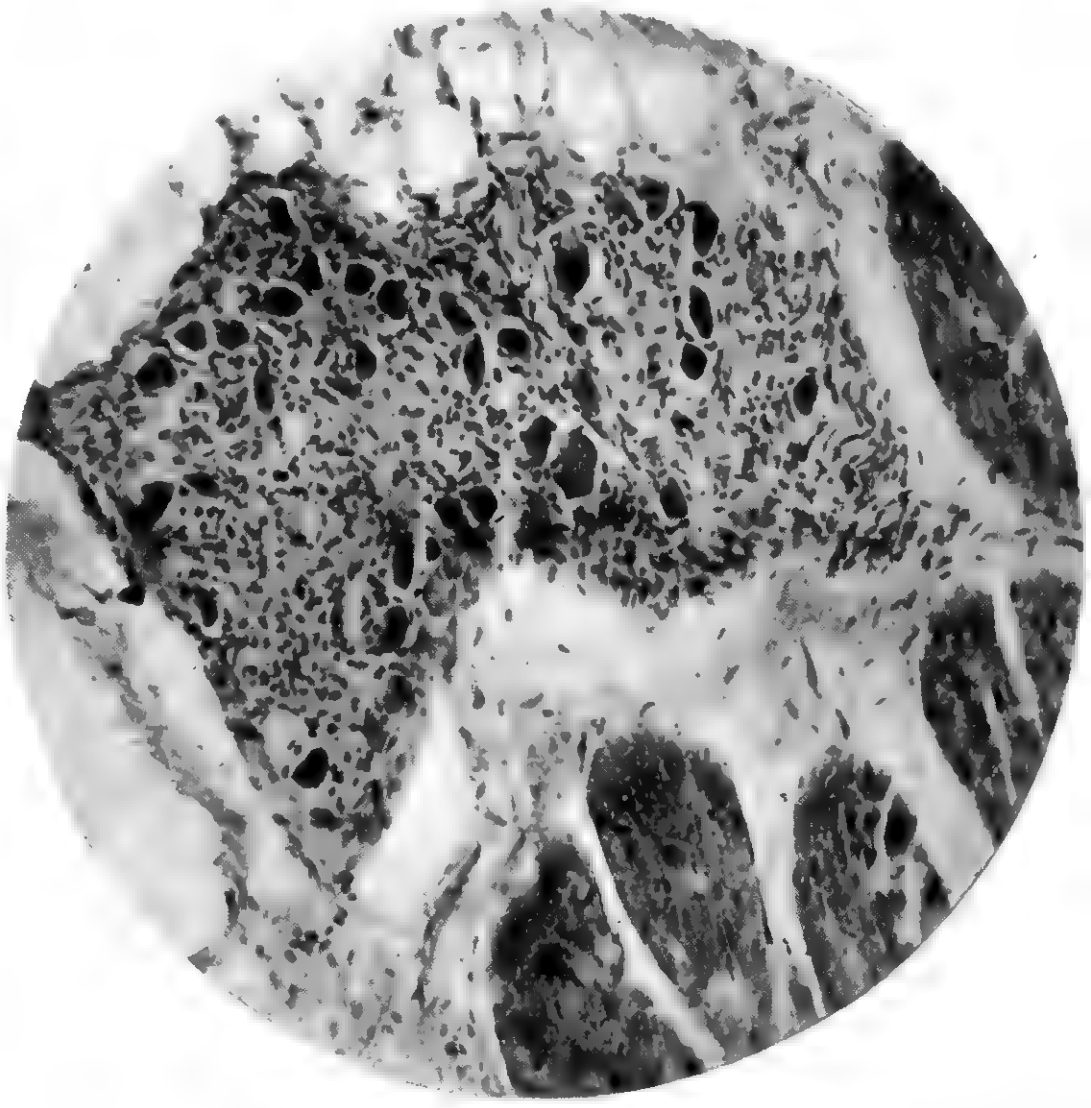

Fig. 9. Large ganglion of Nerve cells situated 4 mm behind the posterior end of the A.V. Node in a Lamb (High power.)

The adjacent auricular muscle fibres appear to fade gradually into the Node, but the continuity was not definitely established; in size and depth of staining the similarity may become so close that in places where a little connective tissue does not intervene, it is impossible to define just where auricular myocardium ends and Node begins. Anteriorly the fibres of the Node may be seen directly continuous with the Purkinje fibres of the Bundle (fig. 11), three or four Node fibres passing into one Purkinje fibre, which then widens out like a pear from its stalk, and shows fibrils in its periphery, with a clear central cytoplasm. Nerves are plentiful in the Bundle in the heart of the Calf, where they may be seen directly continuous with those of the Node in serial longitudinal sections. Occasionally there is an extension of the Node towards the base of the septal cusp, but this fades away in the fibrous tissue and does not form an accessory connection with the ventricle (cf. Curran(7)).

The S.A. Node

An exhaustive search of the auricles for Purkinje tissue has generally proved fruitless, but Keith and Flack(16) found a mass of tissue differing markedly from the rest of the auricles, and somewhat resembling the A.V. Node. This is situated to the right of the orifice of the Superior Vena Cava, in the upper part of the groove known as the Sulcus Terminalis. A comparative study led them to regard this specialised tissue as the remnant of the ring of tissue joining Sinus Venosus and Auricle in early foetal life, and hence it was called the Sino-Auricular Node.

The S.A. Node is elongated, being broadest above and tapering to a thin tail below. In its centre is an artery, around which the peculiar tissue of the Node is readily identified in transverse sections of the upper part of the Sulcus Terminalis (fig. 12). The amount of connective tissue is relatively greater than in the A.V. Node; the muscle fibres are smaller, and do not form such a clearly interlacing network; they are multi-nucleated and contain fibrils which at times clearly show cross striation. Though Nerves and small ganglia of Nerve cells are in close proximity to the Node, they are rarely seen within the Node to the same extent as in the A.V. Node.

Direct continuity of auricular and nodal fibres was not seen; at the margin of the Node the auricular fibres are in most places sharply delimited in bundles, but in other places it is difficult to define where the ordinary myocardium ends and the Node begins.

FINDINGS IN OTHER HEARTS

Lamb and Calf. The gross and microscopical anatomy is exactly the same as in the adult Sheep and Ox. Serial sections through the A.V. Node and Bundle *in situ* show very clearly the gradual transition from the ordinary myocardial fibres into the Node fibres; there is no sign of a connective tissue sheath isolating the Node. Nerves are plentiful in the Node, and Nerve cells in the immediate vicinity.

The striking fact about all the regions examined in the Calf was the abundance of Nerve structures; Nerves were readily found in both Nodes, in the

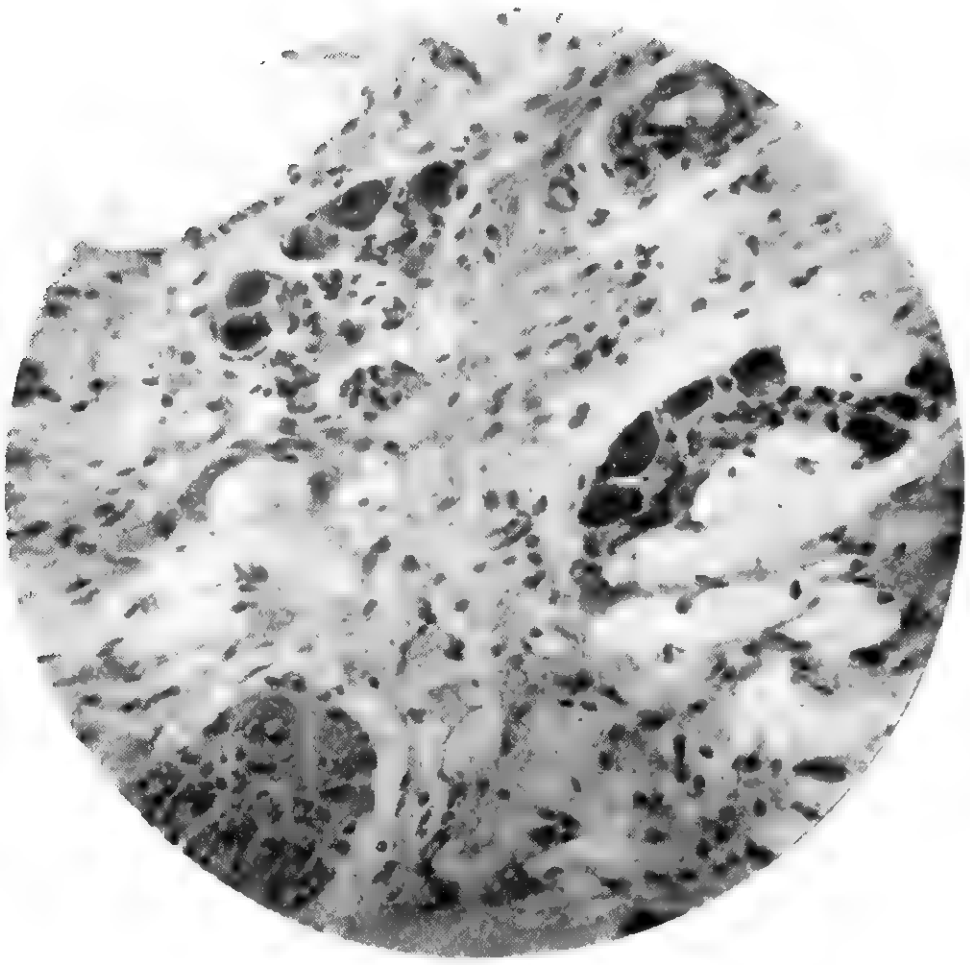

Fig. 10. Nerve cells and part of a non-medullated Nerve at the inferior margin of the A.V. Node of a Sheep. Nerve in left lower part of photo. (High power.)

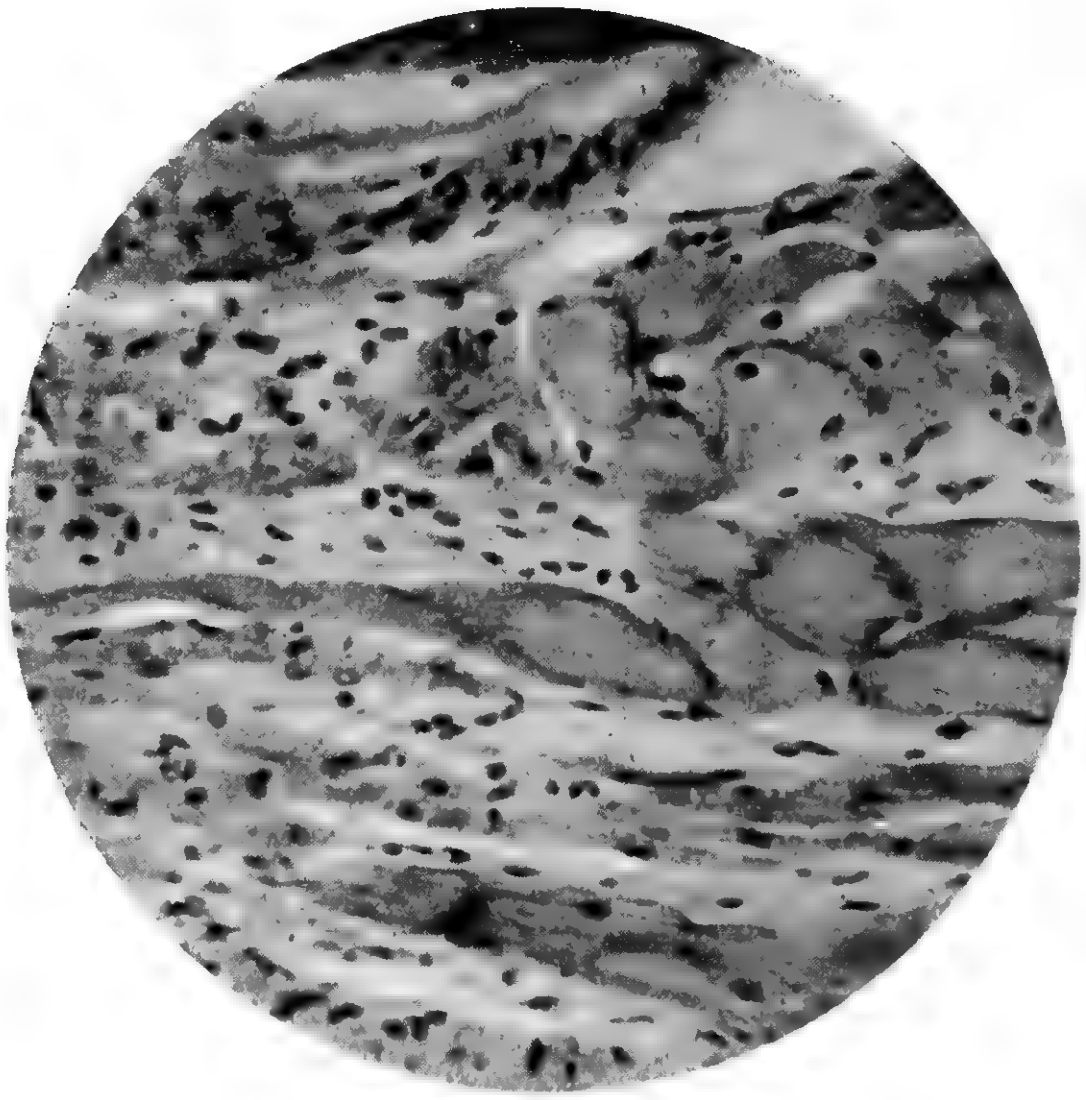

Fig. 11. Longitudinal section through the junction of the A.V. Node and A.V. Bundle in a Sheep. In the centre of the photo a Node fibre is seen expanding into a Purkinje fibre of the Bundle. (High power.)

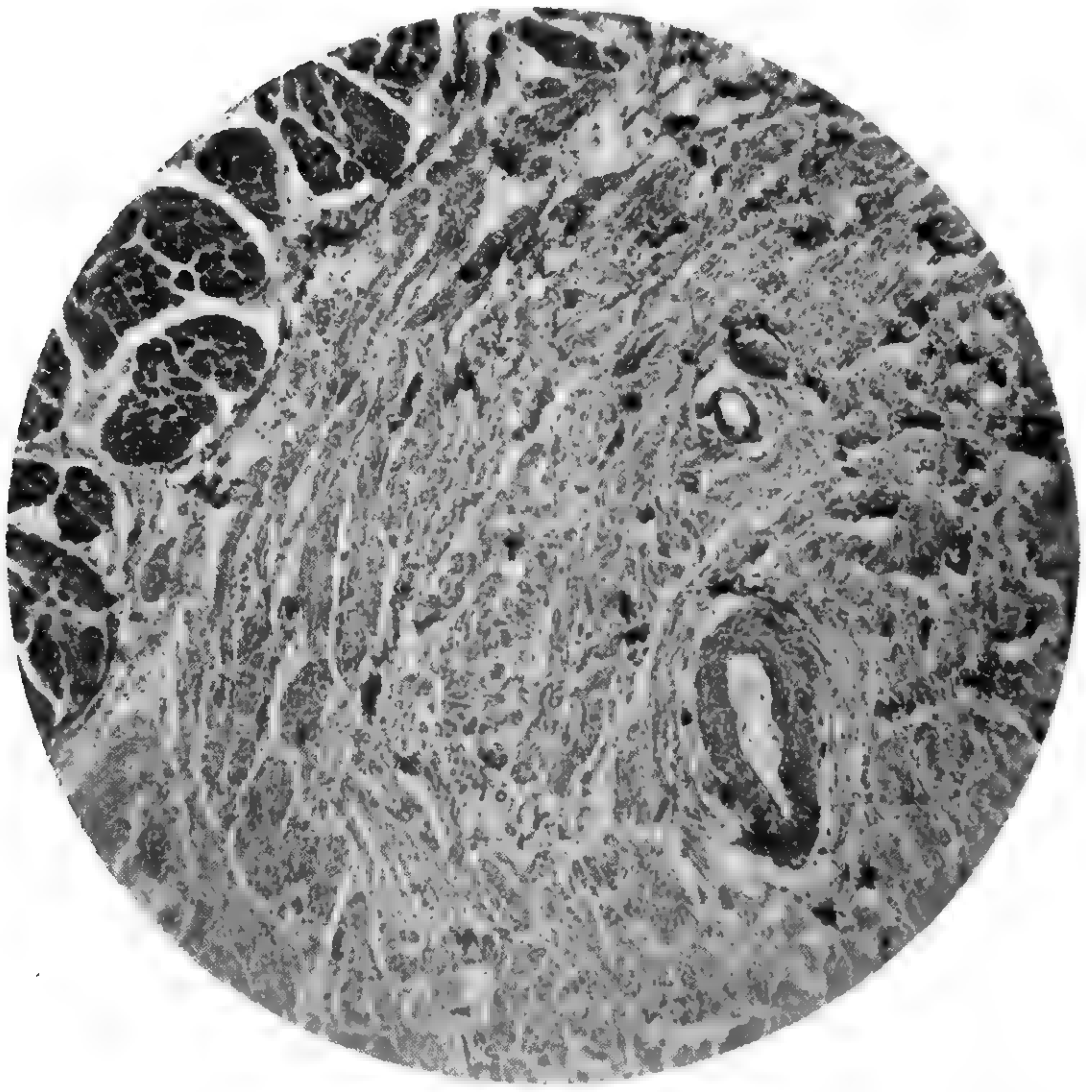

Fig. 12. Transverse section through the Sino-Auricular Node in a Calf. The central artery of the Node, and ordinary heart muscle adjoining the Node, are shown. (Low power.)

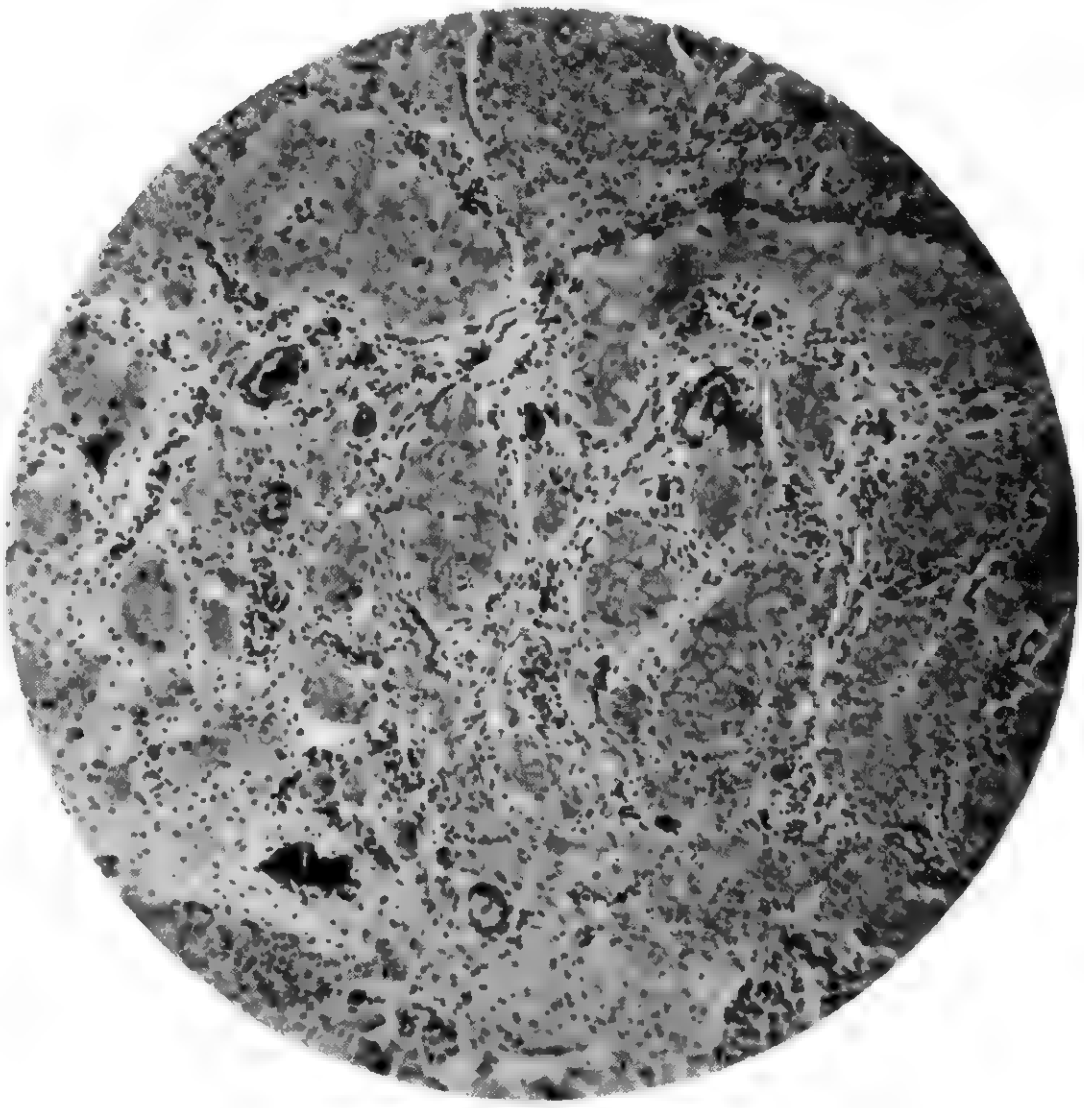

Fig. 13. Purkinje tissue in one of the Columnae carneae of the Right Auricle of a Calf—one of the only two instances in which Purkinje tissue was found in the auricles of any mammal. (Low power.)

Bundle, and in both main Branches of the Bundle. In two of the blocks taken from the Right *Auricle* of calves there appeared Purkinje tissue as distinct as in the Bundle or its Branches; one of these showed a small clump near the Superior Vena Cava, the other showed two columnae carneae in the roof of the Auricle consisting very largely of Purkinje tissue (fig. 13). These findings are notable as being the only mammalian Auricles in which any Purkinje tissue has been found by the writer.

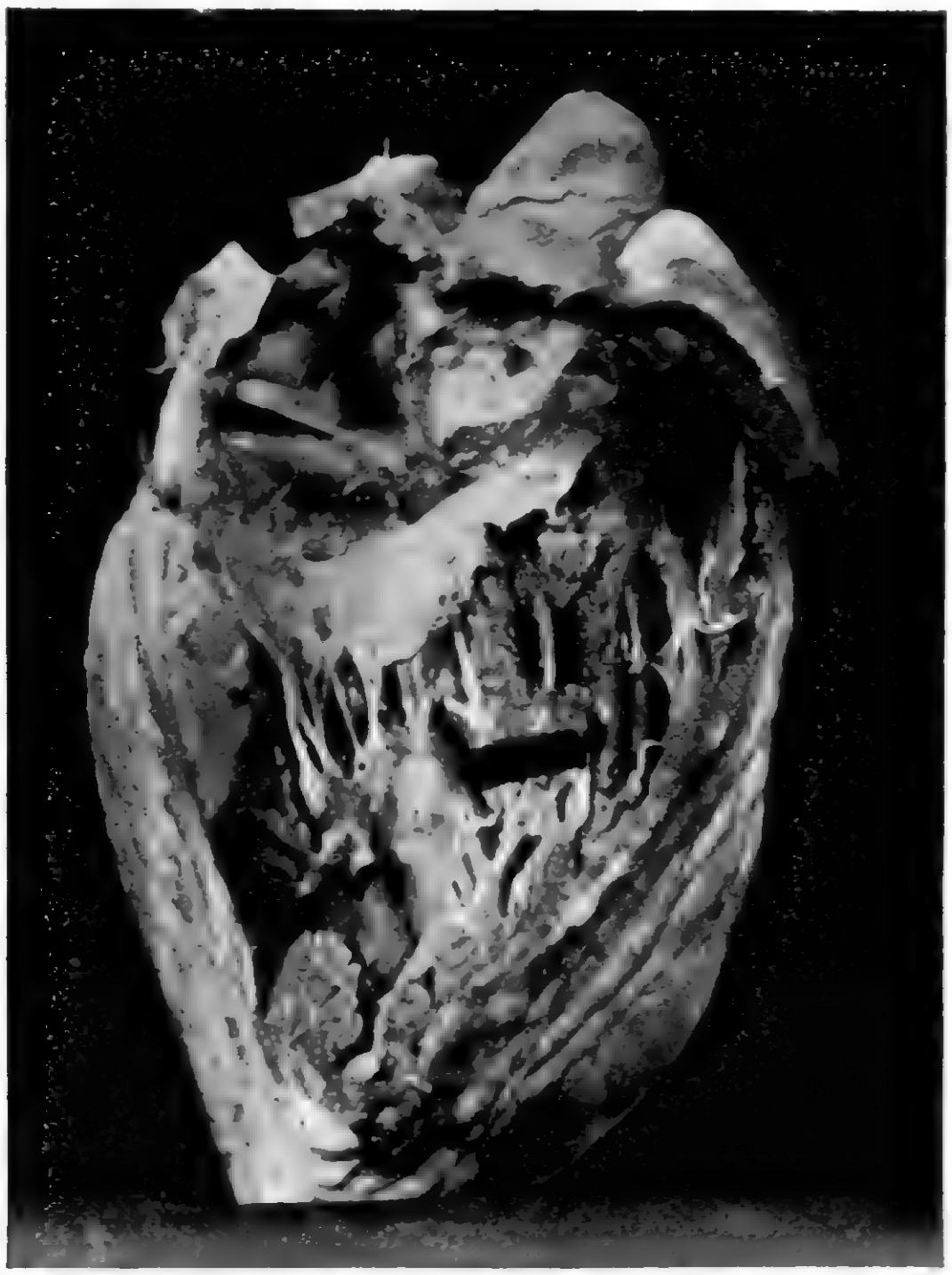

Fig. 14. Human heart, dissected to show Right Branch of A.V. Bundle; a short portion is seen lying on black paper. Compare with fig. 1. A strip of black paper is lying in the gap left by cutting out the block from which the section shown in fig. 15 was taken. (× $\frac{2}{3}$ nat. size.)

Pig. Both Nodes, the Bundle, and its Branches show the same structure and distribution as in the Sheep, but the compartments of a Purkinje fibre are usually smaller than those seen in the Sheep.

Gazelle. The same applies to the Gazelle. Both in the Pig and in the Gazelle the Nerve structures were less in evidence than in the Sheep.

Camel. Sections of the Right Branch of the Bundle as it ran along the Moderator Band showed great increase of connective tissue, with marked vacuolation of the Purkinje fibres, which were otherwise like those of the Sheep.

Man and Child. The topography of the Bundle and its Branches in the human heart cannot with certainty be determined by dissection alone, nor yet by injection methods. Attempts to dissect even the main Bundle and Right Branch are often fruitless. Histology reveals the topography as following closely that in the Sheep and Ox, and also explains the difficulty of gross dissections and injections.

In the human heart there is rarely a distinct Moderator Band; the prominent Trabecula Supraventricularis represents the Band, and somewhere on the surface of this runs the Right Branch of the Bundle in its course from the septum to the anterior papillary muscle of the Right ventricle (fig. 14). Transverse sections of this Trabecula show a differentiated strand of muscle, totally unlike the Purkinje tissue of the Ungulate heart, but certainly representing that tissue; for serial sections show the continuity of this strand with the A.V. Bundle itself, and in the *A.V. Node* of the Sheep and Man there is very close agreement both in topography and minute structure. Very rarely the course of the Right Branch can be seen through the endocardium when the heart is opened, on account of its pallor which is mainly due to its sheath of connective tissue.

The Right Branch of the Bundle (figs. 15–17) is of varying shape as seen in transverse section of the Trabecula Supraventricularis; it may be distinctly ovoid and compact, triangular, or long and narrow. There is always more connective tissue around and within it than is found with a bundle of ordinary myocardial fibres, but no clear space is evident around the muscle fibres such as the space which contains the injection material around the Purkinje fibres of the Sheep. Nerve fibres are much more scarce than in the Sheep and Ox; Nerve cells were not seen in any of these sections. The muscle fibres themselves, totally unlike the Purkinje fibres of the Sheep, are very little larger than the ordinary myocardial fibres and often are actually smaller than these. They take the eosin less deeply on account of their cytoplasm being incompletely fibrillated. This scarcity of fibrils often gives them the appearance of being granular, and in many fibres the granules, which are fibrils in transverse section, are limited to the periphery of the cell, just as they are in the Purkinje fibres of the Sheep.

The left Branch of the Bundle is found in blocks from the left side of the ventricular septum, taken from half to one inch below the junction of the R. Coronary and non-Coronary cusps of the Aorta. It is never so compact as the Right Branch, but is of the same structure (fig. 19).

In sections from the outer wall of the ventricles it is rarely possible to identify the arborisations of the Branches of the Bundle. Sometimes small groups of cells like those in the main branches may be found just under the endocardium, but often not even a few small, pale, "granular" cells are seen, which cells might reasonably be considered as belonging to the Bundle system of fibres.

A number of blocks were cut from the Right Ventricle across the path of the Right Branch of the Bundle down the septum, at various places between

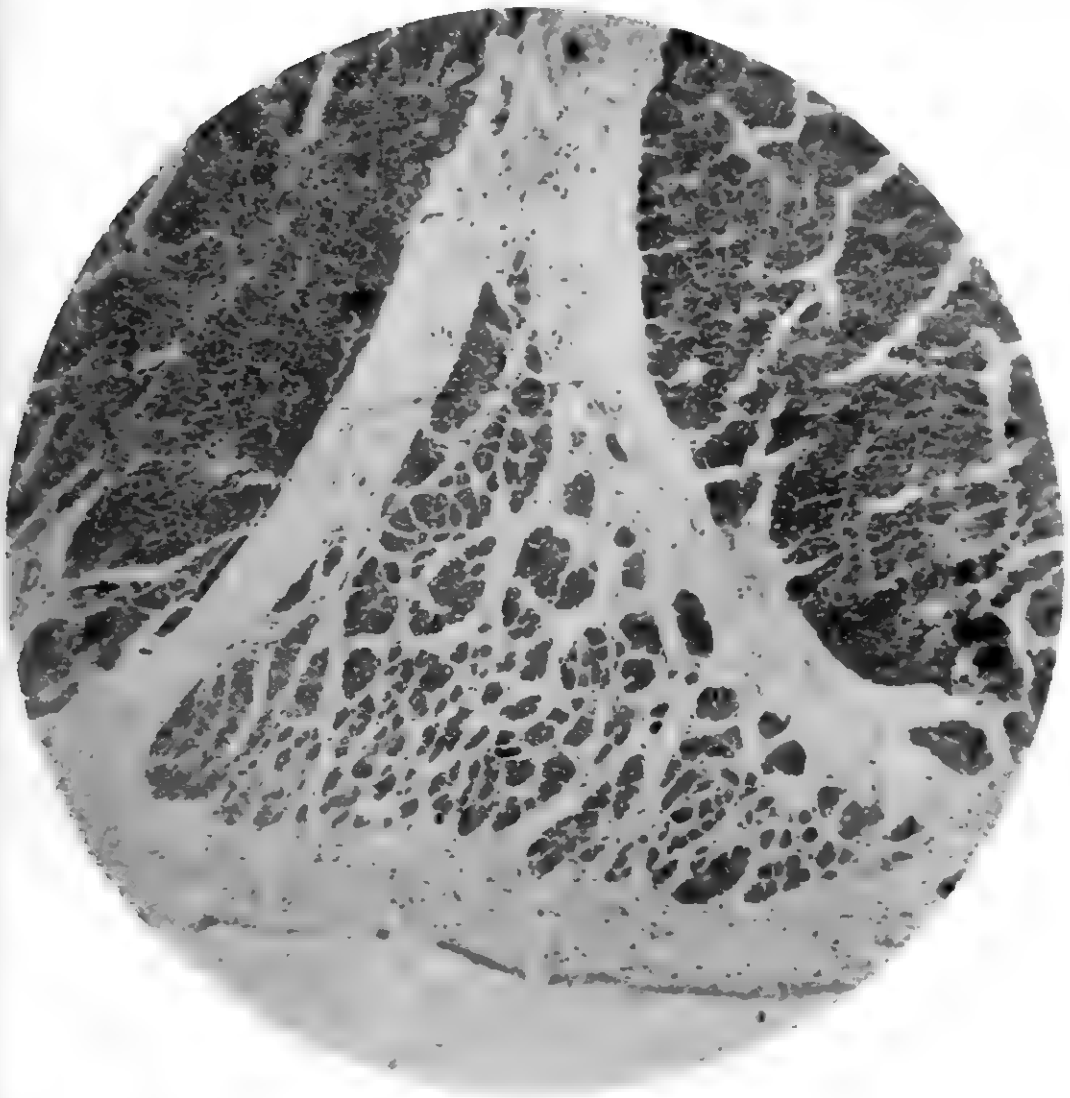

Fig. 15. Transverse section of R. Branch of A.V. Bundle in Man, on the trabecula supraventricularis, showing the connective tissue sheath, and the slight differentiation from ordinary heart muscle. The site of the block from which this section was cut is shown in fig. 14. (Low power.)

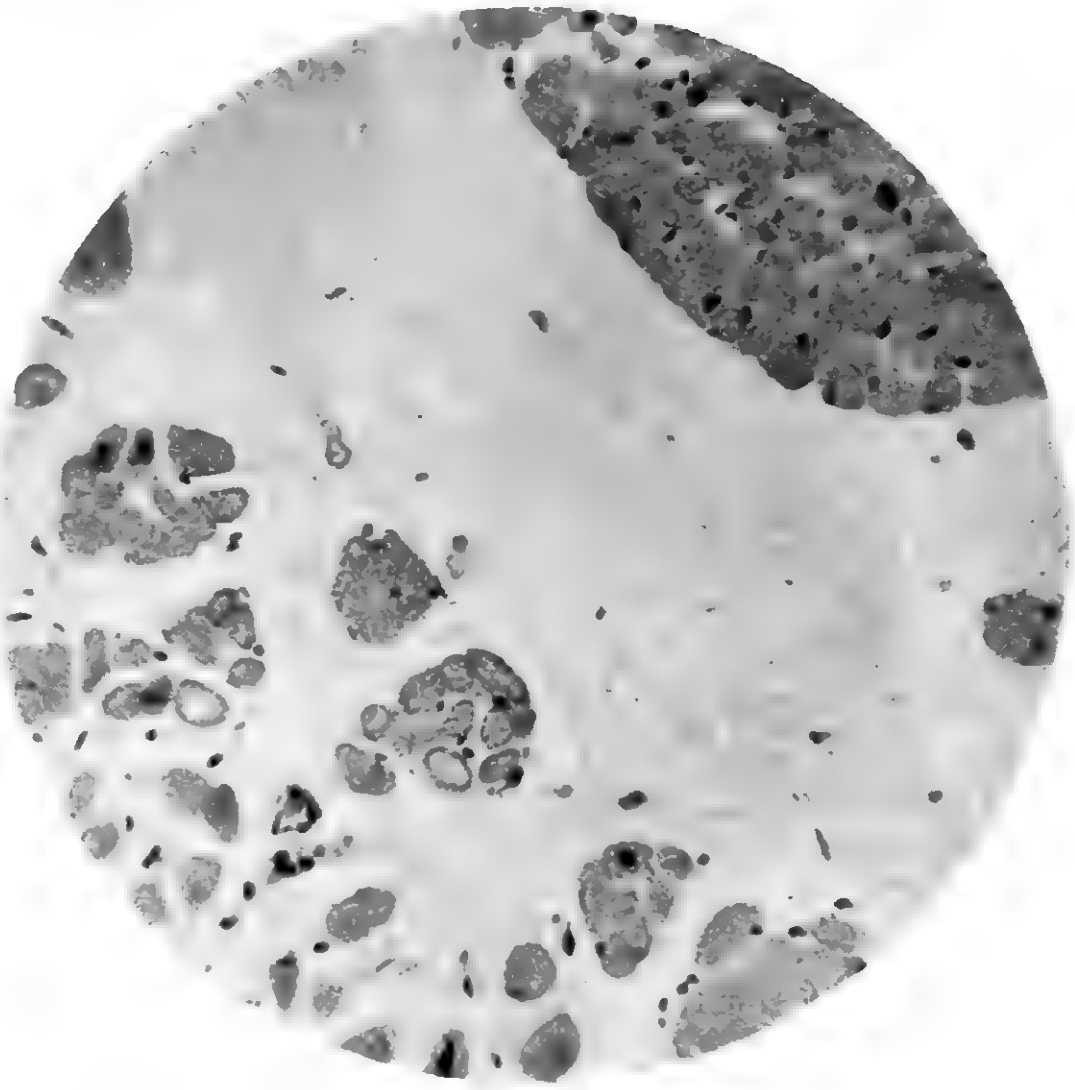

Fig. 16. Portion of fig. 15 more highly magnified to show the granules at the periphery of some of the fibres of the R. Branch of the A.V. Bundle—the human type of Purkinje fibre. (High power.)

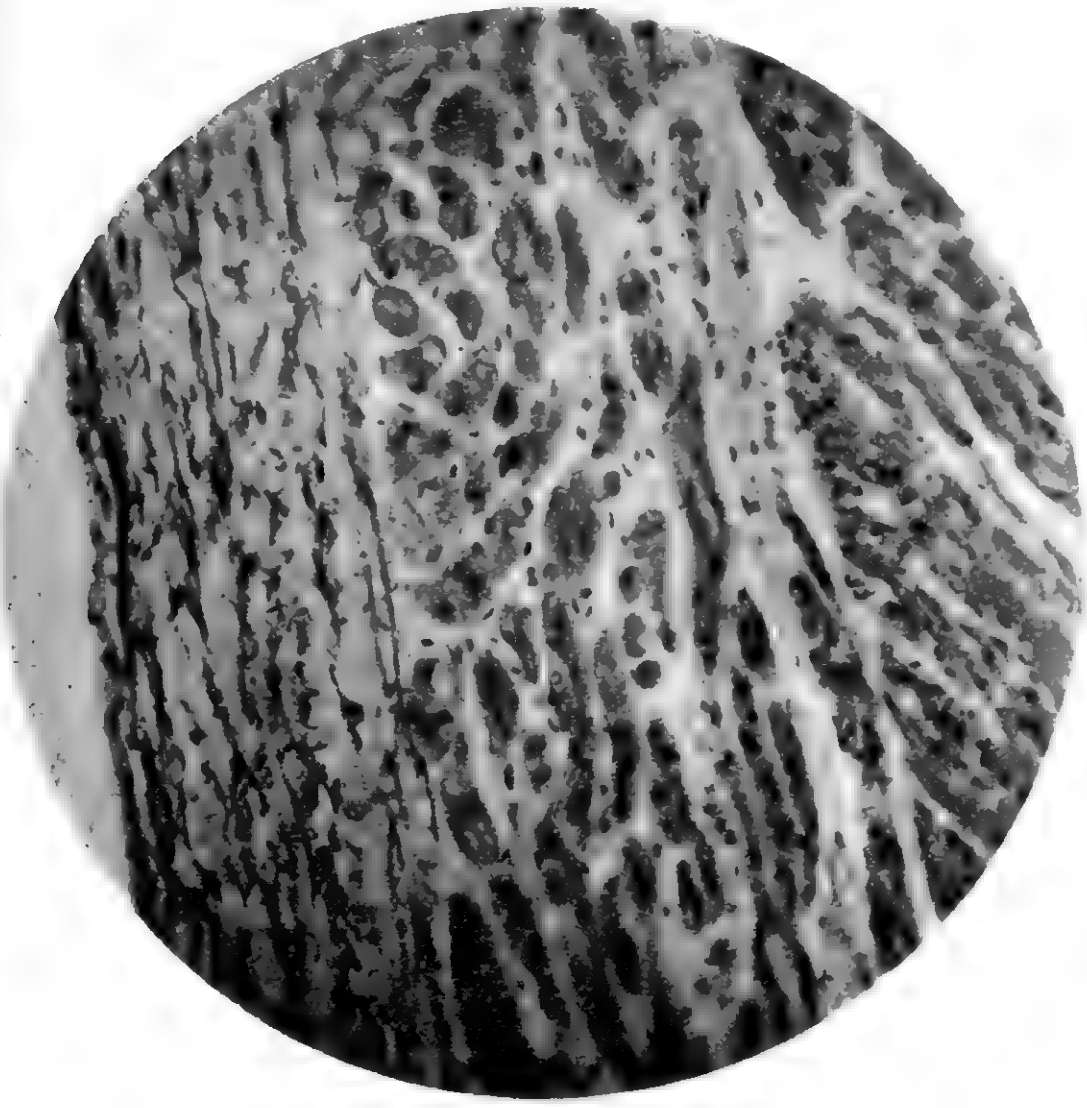

Fig. 17. Transverse section of the trabecula supraventricularis in Man, showing a broad strand of Purkinje fibres (human type) under the endocardium, bounded and intersected by loose areolar tissue. The size, pallor, and clear centre of many of these fibres of the Right Branch of the Bundle form a marked contrast with the ordinary fibres of the myocardium. (High power.)

Fig. 18. Transverse section of the Right Branch of the A.V. Bundle in a Child, half an inch from its origin. The muscle in the centre of the photo, surrounded by open areolar tissue, and showing two veins, is the Right Branch. The photo illustrates the difficulty of identifying the Branches in Man, except by a study of serial sections in which the Branches are traced from the Bundle. (Low power.)

the pars membranacea septi and the origin of the Moderator Band or its homologue. In many of them no definite tract could be identified as the Right Branch, though the blocks were $\frac{1}{2}$–$\frac{3}{4}$ inch broad, and allowed for considerable variation in the course of the Branch. These hearts were compared with those human hearts which showed a definite Right Branch in sections from the same region, and with Sheep and Calf hearts in which the Branch was dissected, so that there is good reason for concluding that in some cases the Right Branch fades off into the appearance of normal muscle, without a sheath, soon after it has left the main Bundle (fig. 18).

In serial sections through the A.V. Bundle and its Branches in the heart of a child (Block LXXI) the Right Branch could only be followed for a distance of 2 millimetres. Frequently nothing but a study of serial sections enables one to identify the Branches of the Bundle 5–10 millimetres distant from their origin.

The A.V. Node and Bundle are best studied in serial sections of a block of tissue containing the adjacent portions of the auricular and ventricular septa, beginning just in front of the orifice of the Coronary Sinus, and ending in front of the pars membranacea septi. The Bundle is broader from side to side than from above downwards, so that it is more easily found in transverse than in longitudinal sections; the block is best cut from behind forwards.

There is no clear distinction between Node and Bundle in the human heart such as the change from Nodal to Purkinje tissue in the Sheep. The Node begins a few millimetres in front of the Coronary Sinus opening, its fibres becoming gradually differentiated from the auricular myocardium which overlies it, by their smallness, their pallor, their closely interwoven reticular arrangement, and their many nuclei (fig. 21). Traced forwards this type of muscle fibre becomes a somewhat oval mass lying between the auricular muscle and the central fibrous body. Into the latter mass are inserted the aorta, the aortic cusp of the Mitral valve, and the septal cusp of the Tricuspid valve. The Node either pierces the central fibrous body or runs round its right side; in the latter case it pierces the fibrous insertion of the septal cusp of the tricuspid valve. It then runs beneath the pars membranacea septi, and bifurcates beneath the anterior end of this structure (fig. 20).

The Sino-Auricular Node in the human heart is identified in sections of the upper part of the Sulcus Terminalis, chiefly by the position of a fibro-muscular mass around a large artery; the artery runs along the Sulcus and forms the landmark for the Node (fig. 22). The fibrous tissue of the Node is more abundant even in the Child's heart than it is in the Node of a Sheep, and the muscular fibres are less numerous; they do not form a distinct network, but appear to be intersected in very short lengths by the abundant connective tissue. Their fibrils may be seen to be cross striped. Non-medullated Nerves and small ganglia of Nerve cells are numerous in the vicinity of the Node, and in some sections ordinary stains reveal Nerves actually within the Nodal area. There is no definite boundary to the Node, but this fibro-muscular area fades off

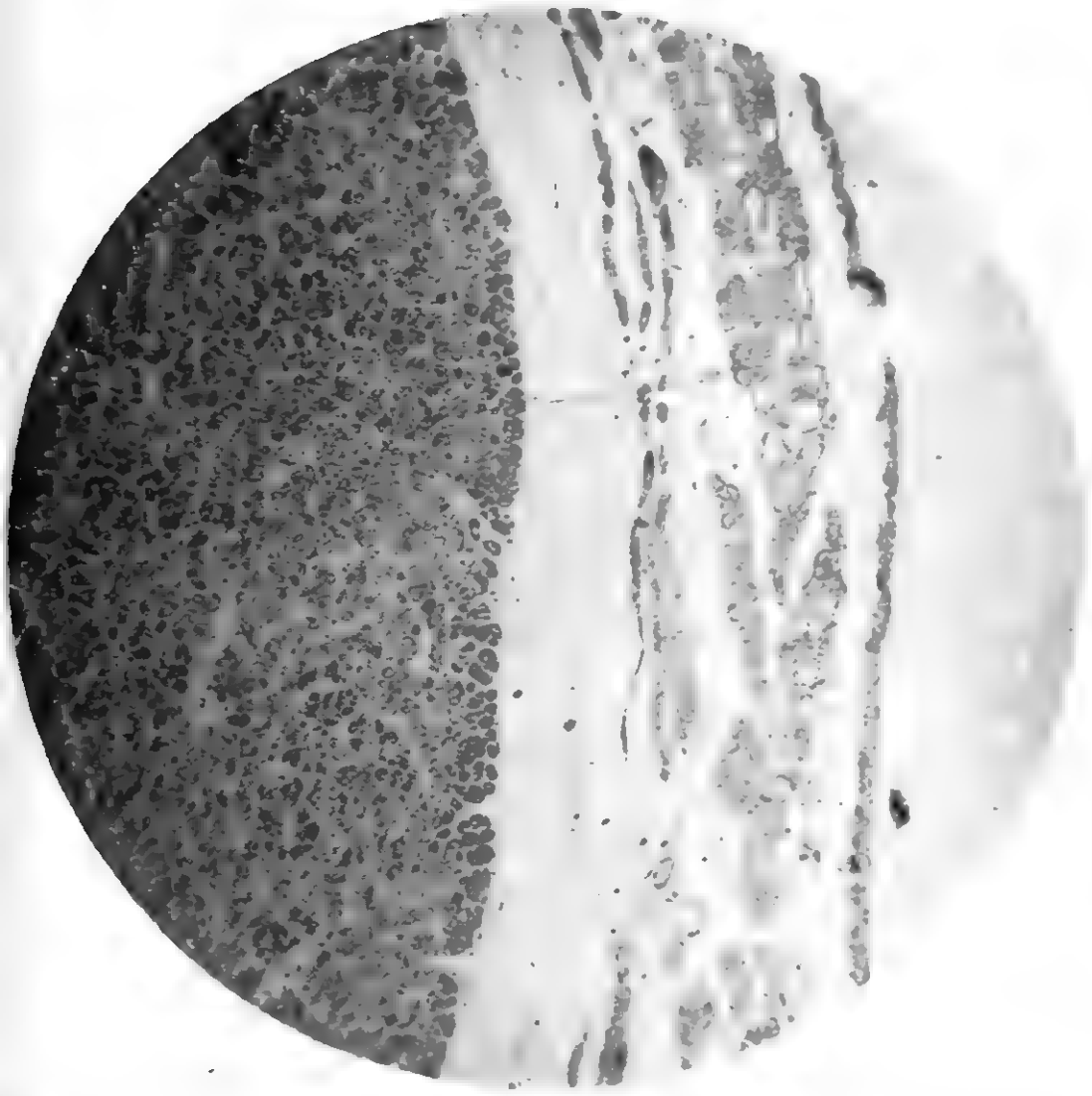

Fig. 19. Longitudinal section of the Left Branch of the A.V. Bundle in a Child. Purkinje tissue of human type is seen between endocardium and myocardium. (Low power.)

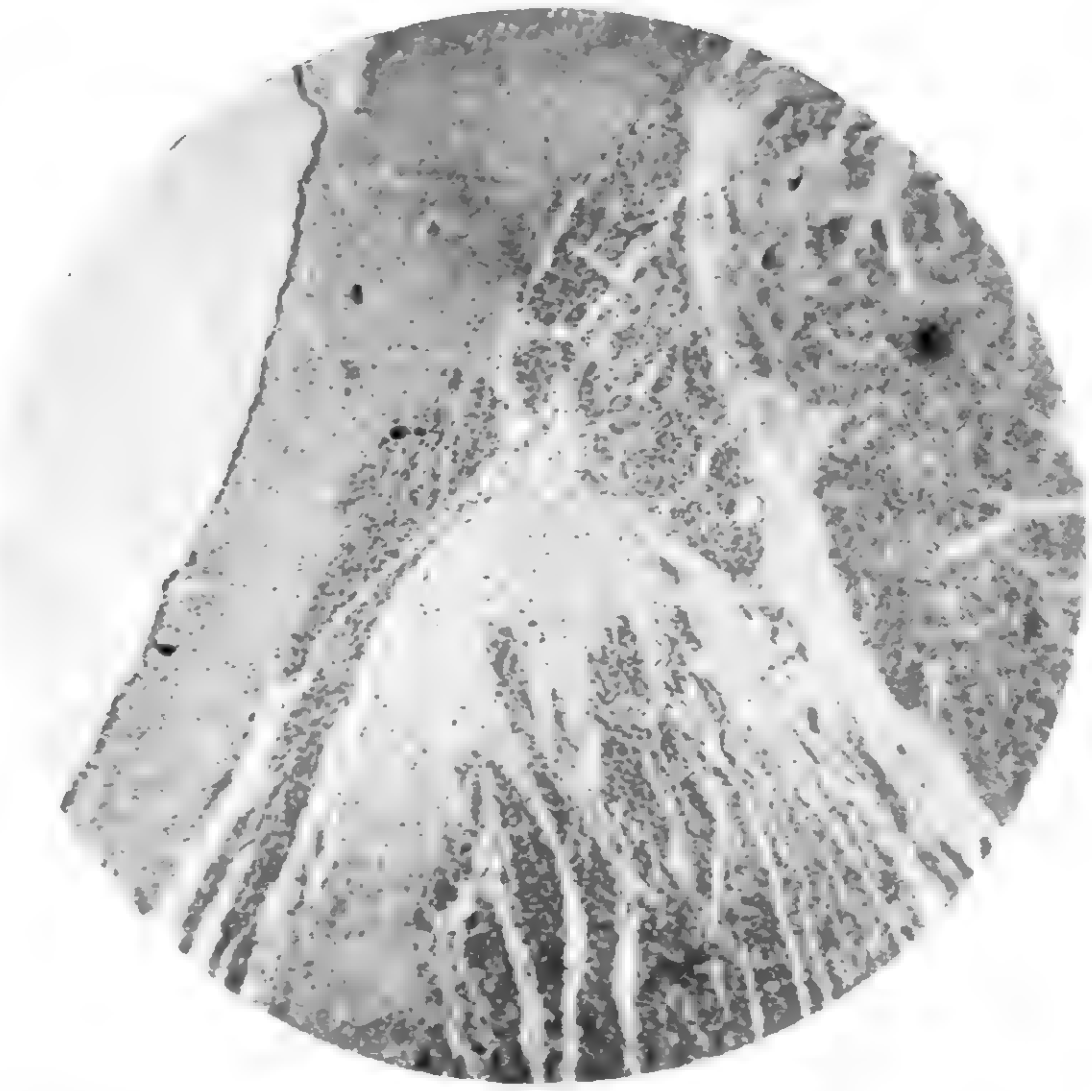

Fig. 20. Vertical section of the bifurcation of the A.V. Bundle in a Child. The section is just anterior to the pars membranacea septi. The aortic wall is seen on the left. The Bundle bestrides the fibrous summit of the Ventricular septum. The Left Branch of the Bundle extends to the margin of the photo. (Low power.)

Fig. 21. Transverse section of the A.V. Node in a Child. The close network of multinucleated fibres lies between the central fibrous body of the septa and the septal musculature of the Right Auricle. (Low power.)

Fig. 22. Transverse section of the S.A. Node in Man. The central artery of the Node is surrounded by a dense mass of fibrous tissue in which are delicate muscle fibres. Ordinary myocardium is seen in the left lower part of the photo; epicardial fatty tissue on the opposite side. (Low power.)

gradually into the ordinary myocardium of the Auricle, the typical fibres of which are larger than the typical muscle fibres of the Node.

Rabbit. In serial sections through a Rabbit's heart the A.V. Node was identified topographically and structurally. There was more fat and less connective tissue than in the heart of Sheep or Man. The muscular fibres were small, pale, and rich in nuclei, but did not form so clear a network as in the hearts already described. No Nerves were recognised in the Node, but the inter-auricular septum, and region between the Pulmonary Artery and Aorta, were rich in Nerves and small collections of Nerve cells.

Under the endocardium of both ventricles many of the muscle fibres were smaller than usual, with less complete fibrillation, and stained less deeply; these closely resembled the smaller cells of the Branches in the human heart, though only in one place on the left side of the septum was there a collection of them that could be looked upon as the Left Branch; no Right Branch could be identified. Similar cells formed the bulk of several fine chordae crossing the Left Ventricle. They also occurred under the epicardium of both Auricles and Ventricles, a position in which Purkinje tissue was not found in Ungulates. Their relation to the A.V. Bundle is therefore very doubtful.

Guinea Pig. The differentiation of Nodal and Purkinje tissue was no more distinct than in the Rabbit. The Left Branch of the Bundle could be identified and also the A.V. Node.

Cat. The A.V. Bundle and its Right Branch were recognised rather from the topography of slightly differentiated strands than from any resemblance in structure to those of the Sheep. Their recognition was easier in the Kitten than in the Cat.

Monkey. The A.V. Node is readily recognised in serial sections, being very similar to the Node in the Sheep. No Nerves were found in the Node. The Right Branch was not identified, but the Left Branch was located by the same points as distinguished it in the Rabbit and Guinea Pig.

Hedgehog. The A.V. Node was very similar to that of the Sheep. Unlike the small hearts above described, the Bundle could be distinguished from the Node by the appearance of Purkinje tissue with very small compartments. The two Branches could only be identified by tracing their connection with the Bundle in serial sections.

REFERENCES TO THE LITERATURE

Prior to 1892 no muscular connection between the Auricles and Ventricles of the Mammalian Heart was known to exist. Kent's work was published in 1893 (1) in the same year that His (2) made known similar findings and gave his name to the Auriculo-Ventricular Bundle. In 1906 Tawara (3) published an exhaustive account of the Bundle in Mammals, and proved that the network of Purkinje fibres, which had been known since 1846 to exist under the endocardium of the sheep's ventricles, was in direct connection with the Bundle of His through its Right and Left Branches. It was Tawara who emphasised the structure of that portion of the Bundle known as the A.V. Node.

Keith (4) and Keith and Flack (5) made a detailed study of the muscular connection between the various chambers of the vertebrate heart, which investigation led to the discovery of the Sino-Auricular Node.

The difficulty of dissecting the Bundle and Branches in Man is emphasised by several writers. Both Keith, and Curran (7) describe the fading away of the Right Branch on the septum until it cannot even be recognised by the microscope.

Josué (8) and Dietrich (9) give summaries of the early literature. Coloured figures and photos are given by Tawara (3), Fahr (10) and Monrad-Krohn (11). Miss de Witt's excellent reconstruction in wax of the Bundle and its arborisations is reproduced as a stereoscopic plate (12).

With the exception of Thorel quoted by Dietrich (9), no one has succeeded in demonstrating a specialised tract joining the S.A. Node and the A.V. Node; the fibres of the Nodes fade gradually into the ordinary auricular fibres as described by Cohn (13), Keith and Ivy Mackenzie (14), and Retzer (15).

The central artery of the S.A. Node comes from the Right Coronary Artery; no artery is found in the centre of the A.V. Node, but a special branch to the Node has been traced by Curran (7), Keith and Flack (16) and Monrad-Krohn (11) from the Right Coronary Artery. The present writer traced a branch to the Bundle from the Right Coronary Artery near its origin, and a branch to the Node running forwards in the Auricular septum from the Right Coronary Artery as it lies in the posterior A.V. Groove.

Nerves are not obvious in the Nodes and Bundle of Man, but those who have employed special methods, as de Witt (12), Morison (17) and Meiklejohn (18), have found a few small Nerves and some Nerve cells in the Bundle. In Ungulates, Nerve cells and Nerve fibres are more plentiful, as figured by Wilson (19), Engel (20), and Oppenheimer (21).

Robinson and Draper (22) found in Man that the Right Vagus is more powerful to affect the heart beat than is the Left Vagus, and that the Right Vagus seemed to control the rate, while the Left Vagus had more power over conductivity; and they surmised that possibly the Right Vagus is chiefly related to the S.A. Node, and the Left Vagus to the A.V. Node—a relation which I. Mackenzie (30) stated as very probable on the grounds of comparative anatomy and embryology.

The sheath of the Purkinje tissue has been specially studied by Curran (7), Lhamon (23), and Cohn (24). No injection results have been achieved in the human heart comparable with those in the beef heart.

Nagayo (25) found glycogen in the Nodal and Purkinje tissue of the lower mammals and Man; it is most plentiful in Ungulates.

The A.V. Node and Bundle was found by Tandler (26) in a 19·75 mm. human embryo: by Mall (27) in 10·20 mm. embryo; Mall found Nerves in the Bundle in a 13 mm. human foetus.

The comparative anatomy and embryology of the Bundle system has been studied by Keith and Flack (5) and by Ivy Mackenzie (28, 30). Malformations of the Septum, and arrested development of the Bulbus, give rise to variations in the precise position of the Bundle, which serve to illustrate its mode of development (Keith (4, 29)).

No reference has been found to the presence of Purkinje tissue in the auricles of any mammal, such as is shown in fig. 13 of the present article.

Search has repeatedly been made for a muscular connection between Auricles and Ventricles other than the A.V. Bundle. Keith and Flack (16), Ivy Mackenzie (30) and Braeunig (31) failed to find a second muscular connection, but Kent in 1893 maintained that such existed, and has repeatedly demonstrated what he terms the Right lateral connection across the A.V. Groove (1, 32, 33, 34). He brings also experimental evidence in support of his histological findings. There is considerable evidence for such a connection in the clinical, experimental and pathological work of many writers, of which a full bibliography is given by Lewis (35).

My best thanks are due to Professor Elliot Smith, Professor Stopford and Professor Dean, in whose Departments this work has been done; and also to Mr H. Gooding of the Anatomy Department for the microphotographs.

REFERENCES

(1) Kent, A. F. S. "Researches on the structure and function of the mammalian heart." *Journ. of Phys.* xiii. pp. xxiii–xxiv; xiv. 233–254, 1893.

(2) His, Wm. Jr. "Die Thätigkeit des embryonalen Herzens und deren Bedeutung für die Lehre von der Herzbewegung beim Erwachsenen." *Arb. a. d. med. klin. zu Leipz.* 14–49 (cited by Tawara), 1893.

(3) Tawara, S. *Das Reizleitungssytem des Saugetierherzens*, etc. 8vo. Jena, 1906.

(4) Keith, A. "The auriculo-ventricular bundle of His." *Lancet*, i. 623–624, 1906.

(5) Keith, A. and Flack, M. W. "The form and nature of the muscular connections between the primary divisions of the vertebrate heart." *Journ. Anat. and Phys.* xli. 172–189, 1907.

(6) Lewis, T. *The pacemaker of the mammalian heart.* 17th International Congress of Medicine, London, 1913, Section I, pt i. 107–119.

(7) Curran, E. J. "A constant bursa in relation with the bundle of His, with studies of the auricular connections of the bundle." *Anat. Record*, iii. 618–631, 1909.

(8) Josué, O. *Les localisations cardiaques.* 17th International Congress of Medicine, London, 1913, Section I, pt i. 1–105.

(9) Dietrich, A. *Die Elemente des Herzmuskels.* 8vo. Jena, 1910.

(10) Fahr, Dr. "Ueber die muskulare Verbindung zwischen Vorhof und Ventrikel (das Hissche Bündel) in normalen Herzen und beim Adams-Stokesschen Symptom-Komplex." *Virchow's Archiv.* clxxxviii. 562–578, 1907.

(11) Monrad-Krohn, G. H. "Le faisceau atrio-ventriculaire dans le cœur humain." *Arch. du Mal. du Cœur*, iv. 350–357. Paris, 1911.

(12) De Witt, L. M. "Observations on the sino-ventricular connecting system of the mammalian heart." *Anat. Record*, iii. 475–497, 1909.

(13) Cohn, A. E. "On the auriculo-nodal junction." *Heart*, i. 167–176, 1909–10.

(14) Keith, A. and Mackenzie, I. "Recent researches on the anatomy of the heart." *Lancet*, i. 101, 1910.

(15) Retzer, R. "Ueber die musculose Verbindung zwischen Vorhof und Ventrikel des Saugethierherzens." *Arch. f. Anat. u. Phys.*, Anat. Abth. 1–14, 1904.

(16) Keith, A. and Flack, M. W. "The auriculo-ventricular bundle of the human heart." *Lancet*, ii. 359, 1906.

(17) **Morison, A.** "On the innervation of the sino-auricular node (Keith-Flack) and the auriculo-ventricular bundle (Kent-His)." *Journ. of Anat. and Phys.* XLVI. 319–327, 1911–12.

(18) **Meiklejohn, J.** "On the innervation of the nodal tissue of the mammalian heart." *Journ. of Anat. and Phys.* XLVIII. 1–18, 1913–14.

(19) **Wilson, J. G.** "Nerves of the atrio-ventricular bundle." *Proc. Roy. Soc.* LXXXI. London, 1909.

(20) **Engel, J.** "Beiträge zur normalen und pathologischen Histologie des Atrio-ventrikularbündels." *Beitr. zur path. Anat.* XLVIII. 499–525, 1910.

(21) **Oppenheimer, B. S.** and A. "Nerve fibrils in the sino-auricular node." *Journ. of Exper. Med.* XVI. 613–619, 1912.

(22) **Robinson, G. C.** and **Draper, G.** "Studies with the electro-cardiagraph on the action of the vagus nerve in the human heart." *Journ. Exper. Med.* XV. 14–47, 1912.

(23) **Lhamon, R. M.** "The sheath of the sino-ventricular bundle." *Amer. Journ. of Anat.* XIII. 55–70, 1912.

(24) **Cohn, A. E.** "Observations on injection specimens of the conduction system in ox hearts." *Heart,* IV. 225–227, 1913.

(25) **Nagayo, M.** "Pathologisch-anatomische Beiträge zum Adams-Stokesschen Symptomenkomplex." *Zeits. f. klin. Med.* LXVII. 495–514, 1909.

(26) **Tandler, J.** "The development of the heart." In *Manual of Human Embryology,* Edited by F. Keibel and F. P. Mall, vol. II. 8vo. Philadelphia, 1912.

(27) **Mall, F. P.** "On the development of the human heart." *Amer. Journ. of Anat.* XIII. 249–298, 1912.

(28) **Mackenzie, I.** "Zur Frage eines Koordinationssystem in Herzen." *Verhandl. d. Deutsch. Path. Ges.* 90–118, 1910.

(29) **Keith, A.** "The Hunterian Lectures on malformations of the heart." *Lancet,* II. 359, 433, 519, 1909.

(30) **Mackenzie, I.** *The excitatory and connecting muscular system of the heart.* (A study in comparative anatomy.) 17th International Congress of Medicine, London, 1913, Section I, pt I. 121–150.

(31) **Braeunig, K.** "Ueber musculose Verbindungen zwischen Vorkammer und Kammer bei verschiedenen Wirbelthierherzen." *Arch. f. Anat. u. Physiol.* Suppl. Bd 1–19. Leipzig, 1904.

(32) **Kent, A. F. S.** "The structure of the cardiac tissue at the A.V. junction." *Journ. of Physiol.* XLVII, p. xvii. 1913.

(33) —— "Observations on the auriculo-ventricular junction of the mammalian heart." *Quart. Journ. of Exper. Physiol.* VII. 193–195, 1913–14.

(34) —— "Neuro-muscular structures in the heart." *Proc. Roy. Soc.* Ser. B, vol. 87, 594.

(35) **Lewis, T.** *The Mechanism and Graphic Registration of the Heart Beat.* 8vo. London, 1920

BIFURCATE CLAVICLE

By HENRY RUTHERFURD, M.B., C.M.,
Glasgow

The subject of this abnormality was a youth of 16 years admitted under my care in the Royal Infirmary on 27th August last. He was said to have been assaulted the night before, and to have been struck a heavy blow on the left shoulder. There was swelling and ecchymosis of the posterior triangle of the neck in its lower part, and it seemed not unlikely that the clavicle had been broken.

There was also found some enfeeblement of both upper and lower limbs on the left side, and this was said to date from a depressed fracture of the skull eight months before. This is represented by a depressed scar in the right upper temporal region.

Fig. 1. X ray photograph taken with patient supine, plate in front of shoulder.

As the swelling over the shoulder subsided, a bony projection could be felt standing up from the line of the clavicle. Over this the skin could be slid smoothly, and it was thought that this might be the clavicle itself, or a displaced fragment of that bone. But there was no characteristic droop of the shoulder or disablement such as would have been expected had this been the explanation.

Skiagraphs showed that there were two clavicles or rather that the clavicle was bifurcate in its outer half, the upper branch running upwards and backwards from the middle of the normal one, which passed outwards to the acromion. That there is such a gap in the skiagraph between clavicle and acromion is to be accounted for by the cartilaginous condition of that process; ossification only beginning in the epiphysis there at 15 to 16 years.

On the 6th November the upper limb of the clavicle was removed by operation, its root on the main stem being easily cut with bone forceps. To the best of my judgment the part removed (now preserved in the Museum of the Royal College of Surgeons, England) presents the normal form of the clavicle in its external or lateral half, the conoid tubercle and ridge for the trapezoid ligament being represented on the undersurface. This in itself precludes our regarding the structure as an exostosis; to which is to be added the fact that its root was no nearer the sternal (epiphyseal) end than the acromion.

Splitting of the bone or detachment of its periosteum at the time of the earlier or later injury does not seem a reasonable explanation of the facts in view of the conformity to normal of the redundant part.

Skiagraphs of the opposite shoulder and of the pelvis show nothing abnormal.

A distinguished anatomist notes on the skiagraph which I sent him that the scapula is not normal, the coracoid being of more than normal thickness.

I know of no duplications of the long bones if the phalanges of the fingers and toes be excluded, that is to say, except in the extremities.

Professor Fawcett has shown that the inner and outer parts of the clavicle arise from separate centres. In this case the outer centre seems to have been duplicated and with the duplication appeared certain anomalies of the scapula. The condition is a rare one and we have been unable to find any previous record of the kind.

ABNORMAL DISPOSITION OF THE INTESTINAL TRACT

By N. PAN,

Professor of Anatomy, Medical College, Calcutta, India

Certain abnormalities were found in the disposition of the intestinal tract of an adult male subject brought into the dissecting room of the Medical College, Calcutta. As such abnormalities are rare, I am publishing a short note of them.

The stomach was very small and was normal in position. The superior and descending portions of the duodenum were normally placed, but the latter terminated abruptly in the jejunum on the right side of the third lumbar vertebra (see fig.). The mesentery crossed the vertebral column obliquely

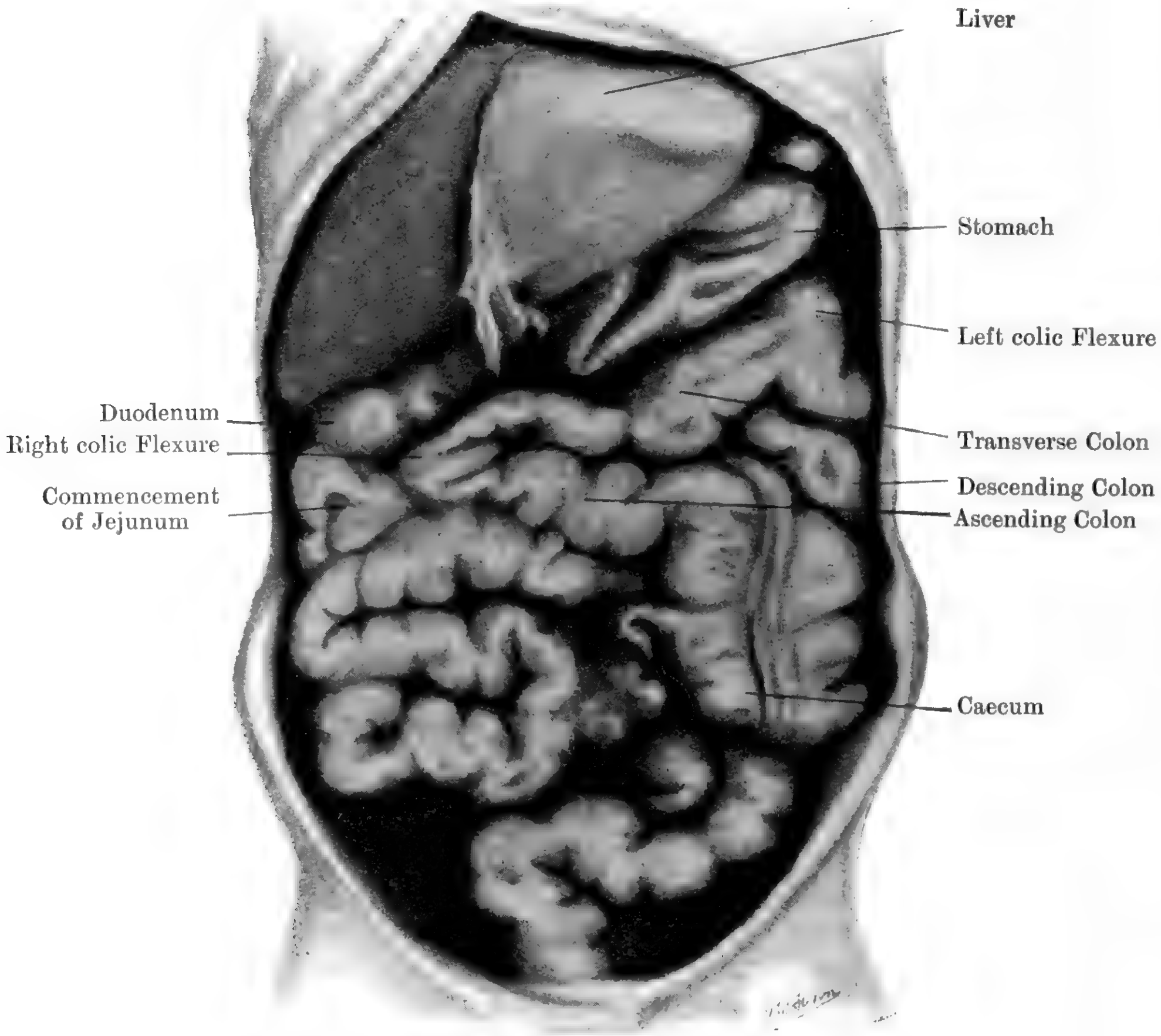

from the right to the left. The ileum terminated at the caecum situated in the left iliac fossa. The ascending colon crossed the vertebral column from the left to the right and ended in right colic (hepatic) flexure to the left of the descending portion of the duodenum. The transverse colon ended in the left colic (splenic) flexure and from there the descending colon was continued to the left iliac fossa concealed by the caecum on its left side.

This abnormal disposition of the intestinal tract was not associated with transposition of the thoracic or other abdominal viscera. The abnormal position of the vermiform process in the left iliac fossa is noteworthy from a clinical point of view as appendicitis occurring in such an individual would mislead the surgeon.

THE SUPERIOR OLIVE IN ORNITHORHYNCHUS

By MARION HINES, Ph.D.,
University of Chicago

In a splendid monograph (1) upon the bulb and midbrain of Ornithorhynchus published in 1901, Koelliker identified two larger nuclei in the medulla oblongata as the dorsal and ventral motor nuclei of the seventh nerve. He thought that a small nucleus lying midway between his "ventral nucleus of the seventh," and most medial part of the nucleus sensibilis of the fifth, was the superior olive. Consequently fibres which lay upon the outer part of the nucleus sensibilis and entered this nucleus he called the "trapezoid body." Ziehen (2), a few years later, wrote in the same sense, with the exception that he described a part of the trapezoid fibres as running laterally and dorsally to the nucleus sensibilis of the fifth. He also insisted that these fibres were the trapezoid body and not the pons, as Elliot Smith had identified them (3).

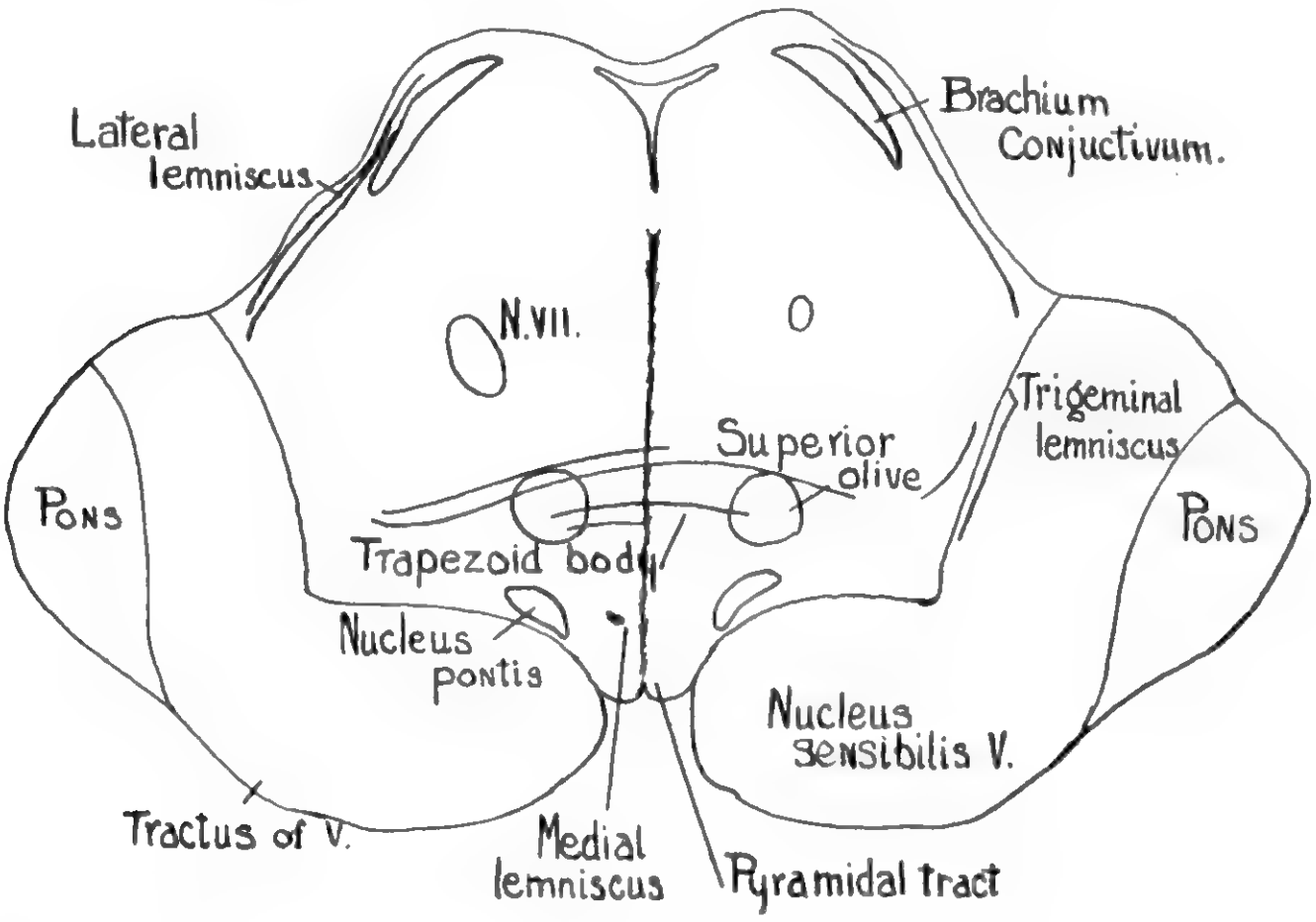

By a careful study of two excellent transverse series of this brain, one belonging to Professor Elliot Smith and the other to Professor J. T. Wilson, the following analysis was made. Koelliker's ventral nucleus of the seventh is the superior olive. Fibres connecting the two nuclei may be identified as the trapezoid body. The stria medullaris fibres may be traced from the larger dorsal nucleus of the eighth running with the root fibres of the seventh nerve. Fibres connecting the two nuclei can be identified. The stria medullaris runs from the larger dorsal nucleus of the eighth with the root fibres of the seventh nerve to the genu of the seventh and then turn ventral-ward to the body of the olive. From this body the trapezoid fibres cross to the outer side lying dorsal to the nucleus sensibilis of the fifth. They are continued in this position as the lateral lemniscus until they reach the region of the inferior colliculus, when, turning dorsal-ward, they end in that body or, sweeping more lateral-ward, they are lost in the nucleus of the thalamus. The lateral lemniscus is interrupted by two nuclei. These nuclei, the lateral lemniscus and the colliculus, were beautifully demonstrated by Koelliker.

On the other hand Koelliker's "trapezoid body" is the pons and his "superior olive" one of the larger nuclei of that body (see fig., Nucleus pontis).

The accompanying outline, at the level of the superior olive and nucleus of the seventh nerve, will delineate the relations described above.

I would like to thank Professor Elliot Smith and Professor J. T. Wilson for the use of their material.

REFERENCES

(1) KOELLIKER. *Die Medulla Oblongata und die Vierhügelgegend von Ornithorhynchus und Echidna*, Leipzig, 1901.

(2) ZIEHEN. "Das Centralnervensystem der Monotremen und Marsupialier." Semon's *Zool. Forschungsreisen, Jenaische Denkschrift.*

(3) ELLIOT SMITH. *Journ. of Anat. and Physiol.* XXXIII. 325 (giving the history of this remarkable controversy, pp. 325–330).

THE EMBRYONIC CEREBRAL HEMISPHERE IN MAN

By MARION HINES, Ph.D.,
University of Chicago

The medial wall of the cerebral hemisphere of embryos 16 mm. to 30 mm. in length is not perfectly smooth. Its otherwise even contour is broken by a shallow groove, which extends from the olfactory bulb to the tip of the temporal pole. This is the fissura hippocampi, the "Bogenfurche" of His. The primordial hippocampus can be identified in embryos about 10 mm. in length by a thicker wall, a narrower matrix, and a more clearly defined marginal velum than the area immediately contiguous to it laterally. This region is separated from the area epithelialis by a sulcus limitans hippocampi.

The fascia dentata arises in the matrix of the ventral limb of the hippocampus as a group of deeply-stained cells, which migrate dorsal-ward into its marginal velum. The telencephalon medium is divided into terminal plate and roof by the angulus terminalis. The area epithelialis contiguous to the midplane-region differentiates into three characteristic areas, the septum ependymale, the area intercalata and the lamina epithelialis; that which lies contiguous to the main body of the lamina terminalis forms the septum.

In embryos of 16 mm. in length the ventro-lateral region of the hemisphere is very thick, containing two slight elevations, the medial and lateral roots of the corpus striatum. At this age the medial hillock is larger than the lateral. But in embryos of 20 mm. they are approximately equal in length and depth; and in those of from 27 mm. to 43 mm. the lateral hillock is the greater.

In early stages the cerebral hemisphere expands by intrinsic growth of each particular sector and especially by a marked extension of neopallial tissue. It elongates by acceleration of mid-line growth in the region of the lamina terminalis and the di-telencephalic fold, and by the expansion of areas of new tissue, which form the frontal, parietal and temporal poles. A study of histological differentiation in the early development of the telencephalon in man gives a method of measuring the relative growth of its several parts and thus of contributing to our knowledge of its intrinsic development.

INDEX

Alveolar ridge and palate in man, development of, Odontological Essays, I, L. Bolk, M.D., 138
Animals, exact distribution of the gastric glands in man and, Y. Miyagawa, M.D., 56
Arteries, basal, of the forebrain and their functional significance, Joseph L. Shellshear, 27
Auriculo-ventricular bundle in mammals, A. Hillyard Holmes, M.D., M.R.C.P., 269

Bifurcate clavicle, Henry Rutherfurd, M.B., C.M., 286
Bizarro, A. H., F.R.C.S. (Eng.), on sesamoid and supernumerary bones of the limbs, 256
Bland-Sutton, Sir John, Selected lectures and Essays (including ligaments, their nature and morphology), 4th ed., 1920, Review, 78
Bolk, L., M.D., Odontological Essays, 138, 219
Bones, fusion-lines of, Zachary Cope, 36
— of the limbs, sesamoid and supernumerary, A. H. Bizarro, F.R.C.S. (Eng.), 256

Cerebral hemisphere in man, embryonic, Marion Hines, Ph.D., 292
Chick, eye of, development of the fissural and associated regions of, with some observations on the mammal, I. C. Mann, M.B., B.S., 113
Clark, W. E. Le Gros, F.R.C.S. (Eng.), on the Pacchionian bodies, 40
Clavicle, bifurcate, Henry Rutherfurd, M.B., C.M., 286
Coelomate animals, significance and meaning of segmentation in, W. B. Primrose, M.B., Ch.B., 119
Cope, Zachary, fusion-lines of bones, 36
Corpus striatum, contribution to the morphology of, Raymond A. Dart, 1
Cranium, primordial, of *Tatusia novemcincta*, as determined by sections and models of the embryos of 12 millimetre and 17 millimetre C.R. length, Prof. Fawcett, M.D. (Edin.), 187

Dart, Raymond A., a contribution to the morphology of the Corpus striatum, 1
Dixon, Prof. A. Francis, note on the vertebral epiphyseal discs, 38

Enamel-germ, development of, Odontological Essays, II, L. Bolk, M.D., 152
Endoskeleton, vertebrate, evolution of, W. B. Primrose, M.B., Ch.B., 119
Epiphyseal discs, vertebral, note on, Prof. A. Francis Dixon, 38
Eye of Chick, development of the fissural and associated regions of, with some observations on the mammal, I. C. Mann, M.B., B.S., 113

Fawcett, Prof., M.D. (Edin.), the primordial cranium of *Tatusia novemcincta* as determined by sections and models of the embryos of 12 millimetre and 17 millimetre C.R. length, 187
Forebrain, basal arteries of, and their functional significance, Joseph L. Shellshear, 27
Fusion-lines of bones, Zachary Cope, 36

Gastric glands in man and in certain animals, exact distribution of, Y. Miyagawa, M.D., 56

Hedgehog, lachrymal gland of, note on, E. W. Hurst, B.Sc., 49
Hines, Marion, Ph.D., the superior olive in Ornithorhynchus, 290
— The embryonic cerebral hemisphere in man, 292
Holland, Chas. Thurstan, on rarer ossifications seen during X-ray examinations, 235
Holmes, A. Hillyard, M.D., M.R.C.P,. the auriculo-ventricular bundle in mammals, 269
Hurst, E. W., B.Sc., note on the lachrymal gland of the hedgehog, 49

Intestinal tract, abnormal disposition of, N. Pan, 288

Jones, Frederic Wood, D.Sc., M.B., the principles of anatomy as seen in the hand, 1920, Review, 78

Lachrymal gland of the hedgehog, note on, E. W. Hurst, B.Sc., 49
Limb, upper, distribution of nerves in, with reference to variabilities and their clinical significance, Eric A. Linell, M.D. (Manch.), 79
Limbs, sesamoid and supernumerary bones of, A. H. Bizarro, F.R.C.S. (Eng.), 256
Linell, Eric A., M.D. (Manch.), the distribution of nerves in the upper limb, with reference to variabilities and their clinical significance, 79
Localisation, tactile, John S. B. Stopford, M.D., 249

Mammals, auriculo-ventricular bundle in, A. Hillyard Holmes, M.D., M.R.C.P., 269
— development of the fissural and associated regions in the eye of the chick, with some observations on the mammal, I. C. Mann, M.B., B.S., 113
— tooth-glands in reptiles and their rudiments in, Odontological Essays, III, L. Bolk, M.D., 219
Man, embryonic cerebral hemisphere in, Marion Hines, Ph.D., 292
— gastric glands in, and certain animals, exact distribution of, Y. Miyagawa, M.D., 56

Man, palate and alveolar ridge in, development of, Odontological Essays, I, L. Bolk, M.D., 138

Mann, I. C., M.B., B.S., on the development of the fissural and associated regions in the eye of the chick, with some observations on the mammal, 113

Microtus amphibius, water vole, parthenogenesis in, G. S. Sansom, B.Sc., 68

Miyagawa, Y., M.D., the exact distribution of the gastric glands in man and in certain animals, 56

Nerves in the upper limb, distribution of, with reference to variabilities and their clinical significance, Eric A. Linell, M.D. (Manch.), 79

Odontological Essays, L. Bolk, M.D., 138, 219

Olive, superior, in Ornithorhynchus, Marion Hines, Ph.D., 290

Ornithorhynchus, superior olive in, Marion Hines, Ph.D., 290

Orrin, H. C., O.B.E., F.R.C.S. (Edin.), the X-ray atlas of the systemic arteries of the body, 1920, Review, 78

Ossifications, rare, seen during X-ray examinations, Chas. Thurstan Holland, 235

Pacchionian bodies, W. E. Le Gros Clark, F.R.C.S. (Eng.), 40

Palate and alveolar ridge in man, development of, Odontological Essays, I, L. Bolk, M.D., 138

Pan, N., abnormal disposition of the intestinal tract, 288

Parthenogenesis in the water vole, *Microtus amphibius*, G. S. Sansom, B.Sc., 68

Primrose, W. B., M.B., Ch.B., the evolution of the vertebrate endoskeleton, an essay on the significance and meaning of segmentation in Coelomate animals, 119

Reptiles, tooth-glands in, and their rudiments in mammals, Odontological Essays, III, L. Bolk, M.D., 219

Reviews, selected lectures and essays (including ligaments, their nature and morphology). By Sir John Bland-Sutton, 4th ed., 1920, 78

— The principles of anatomy as seen in the hand. By Frederic Wood Jones, D.Sc., M.B., 1920, Review, 78

— The X-ray atlas of the systemic arteries of the body. By H. C. Orrin, O.B.E., F.R.C.S. (Edin.), 1920, Review, 78

Rutherfurd, Henry, M.B., C.M., bifurcate clavicle, 286

Sansom, G. S., B.Sc., parthenogenesis in the water vole, *Microtus amphibius*, 68

Sesamoid and supernumerary bones of the limbs, A. H. Bizarro, F.R.C.S. (Eng.), 256

Shellshear, Joseph L., the basal arteries of the forebrain and their functional significance, 27

Stopford, John S. B., M.D., tactile localisation, 249

Tactile localisation, John S. B. Stopford, M.D., 249

Tatusia novemcincta, primordial cranium of, as determined by sections and models of the embryos of 12 millimetre and 17 millimetre C.R. length, Prof. Fawcett, M.D. (Edin.), 187

Tooth-glands in reptiles and their rudiments in mammals, Odontological Essays, III, L. Bolk, M.D., 219

Vertebral epiphyseal discs, note on, Prof. A. Francis Dixon, 38

Vertebrate endoskeleton, evolution of, W. B. Primrose, M.B., Ch.B., 119

Vole, water, *Microtus amphibius*, parthenogenesis in, G. S. Sansom, B.Sc., 68

X-ray examinations, rarer ossifications seen during, Chas. Thurstan Holland, 235

CAMBRIDGE: PRINTED BY J. B. PEACE, M.A., AT THE UNIVERSITY PRESS

JOURNAL OF ANATOMY

CAMBRIDGE UNIVERSITY PRESS
C. F. CLAY, MANAGER
LONDON: FETTER LANE, E.C. 4

H. K. LEWIS & CO., LTD., 136, GOWER STREET, LONDON, W.C. 1
WHELDON & WESLEY, LTD., 28, ESSEX STREET, LONDON, W.C. 2
CHICAGO: THE UNIVERSITY OF CHICAGO PRESS
(Agent for the United States and Canada)
BOMBAY, CALCUTTA, MADRAS: MACMILLAN & CO., LTD.
TOKYO: THE MARUZEN-KABUSHIKI-KAISHA

JOURNAL OF ANATOMY

ORIGINALLY THE JOURNAL OF ANATOMY AND PHYSIOLOGY

CONDUCTED ON BEHALF OF THE ANATOMICAL SOCIETY
OF GREAT BRITAIN AND IRELAND BY

PROFESSOR EDWARD FAWCETT	UNIVERSITY OF BRISTOL
PROFESSOR J. P. HILL	UNIVERSITY OF LONDON
PROFESSOR ARTHUR ROBINSON	UNIVERSITY OF EDINBURGH
PROFESSOR E. BARCLAY-SMITH	UNIVERSITY OF LONDON
PROFESSOR SIR ARTHUR KEITH	ROYAL COLLEGE OF SURGEONS LINCOLN'S-INN-FIELDS, LONDON, W.C. 2

VOLUME LVI

OCTOBER 1921—JULY 1922

CAMBRIDGE
AT THE UNIVERSITY PRESS
1922

PRINTED IN ENGLAND

56

CONTENTS

FIRST PART—OCTOBER, 1921

PAGE

The Nerve Supply of the Interphalangeal and Metacarpo-Phalangeal Joints. By John S. B. Stopford, M.D. 1

Report on an Anencephalic Embryo. By J. Ernest Frazer, F.R.C.S. 12

The Skull and Some Related Structures of a Late Embryo of Lygosoma. By Helga S. Pearson, B.Sc. 20

A Note on the Post-Coronal Sulcus, with Dissections of the Epicranial Aponeurosis in Two Cases of its Occurrence. By Duncan M. Blair, M.B., Ch.B. 44

The Nerves of the Human Larynx. By T. F. M. Dilworth, M.B., B.Ch. 48

Abnormal Position of the Iliac and Pelvic Colons. By Naguib Effendi Nicola 53

Reviews. The Origin of Milk Glands: The Mammary Apparatus of the Mammalia, in the Light of Ontogenesis and Phylogenesis. By Ernst Bresslau, M.D. 55

Initiative in Evolution. By Walter Kidd, M.D., F.R.S.E. . . 55

SECOND PART—JANUARY, 1922

A Case of Early Human Ovarian Pregnancy. By John I. Hunter, M.B., Ch.M. 57

The Origin of the Motor Neuroblasts of the Anterior Cornu of the Neural Tube. By Raymond A. Dart, M.Sc., M.B., Ch.M. and Joseph L. Shellshear, M.B., Ch.M. 77

Absence of the Lens occurring in the Human Embryo. By Ida C. Mann, M.B., B.S. 96

A Suggestion as to the Cause of the Aspermatic Condition of the Imperfectly Descended Testis. By F. A. E. Crew, M.D., D.Sc. . 98

Odontological Essays. By L. Bolk, M.D. 107

Correlation between Habit and the Architecture of the Mammalian Femur. By G. de M. Rudolf, M.R.C.S. (Eng.), L.R.C.P. (Lond.), D.P.H. 137

On Certain Normal Irregularities in the Vertebral Column in its Lower Dorsal Area. By Edgar F. Cyriax, M.D. (Edin.) 147

The Myodome and the Trigemino-Facialis Chamber in the Coelacanthidae, Rhizodontidae and Palaeoniscidae. By Edward Phelps Allis, Jr 149

PAGE

A Human Foetus exhibiting Iniencephaly and other Abnormalities. By William Ivon Hayes, M.B. (Melbourne) 155

Reviews. Studies in the Palaeopathology of Egypt. By Sir Marc Armand Ruffer, C.M.G., M.D. 160

Anatomie des Menschen: ein Lehrbuch für Studierende und Ärzte. Von Hermann Braus 161

Hereditary Disease. By Hermann W. Siemens 162

Obituary Notice of Dr Peter Thompson. By Arthur Robinson . . 164

THIRD AND FOURTH PARTS—APRIL AND JULY, 1922

What are Viscera? By C. Judson Herrick 167

The Misuse of the Term "Visceral." By Raymond A. Dart, M.Sc., M.B., Ch.M. 177

The Cranial Anatomy of Polypterus, with Special Reference to *Polypterus bichir*. By Edward Phelps Allis, Jr 189

On the Hypotrochanteric Fossa and Accessory Adductor Groove of the Primate Femur. By A. B. Appleton 295

A New Interpretation of the Bones in the Palate and Upper Jaw of Fishes. By H. Leighton Kesteven, D.Sc., M.D., Ch.M. . . . 307

On Truncated Umbilical Arteries in Some Indian Mammals. By Basanta Kumar Das, M.Sc. (Allahabad) 325

Early Development and Placentation in *Arvicola* (*Microtus*) *amphibius*, with Special Reference to the Origin of Placental Giant Cells. By G. S. Sansom, B.Sc. 333

Anatomical Notes on the Accessory Organs of the Eye of the Horse. By Maj.-Gen. Sir Frederick Smith, K.C.M.G., C.B. 366

Appointment 390

Index 391

JOURNAL OF ANATOMY

THE NERVE SUPPLY OF THE INTERPHALANGEAL AND METACARPO-PHALANGEAL JOINTS

By JOHN S. B. STOPFORD, M.D.,
Professor of Anatomy, University of Manchester

The numerous examples of injuries, incurred during the war, to the peripheral nerves have offered us a unique opportunity of studying the distribution of these nerves from a functional aspect, and consequently of widely supplementing a knowledge which had been obtained chiefly by dissection. The most careful and deliberate dissections of the peripheral nerves fail to provide information about the function of the constituent fibres, and yet it is exactly this knowledge which is often most urgently required in the clinical investigation of a patient.

In this paper it is my endeavour to describe the distribution to the interphalangeal and metacarpo-phalangeal joints of the thumb and fingers of the nerve fibres which conduct sensory impressions that determine a consciousness of passive movement, and impulses which enable us to recognise posture. It will become obvious that such investigations as are described in this paper cannot possibly give any information about those fibres which conduct from the joints to the cerebellum impulses, which of course make no appeal to consciousness.

A precise knowledge of this subject is fundamental for any research upon sensation, is also of considerable importance for the purposes of diagnosis and prognosis and is becoming of increasing significance in the late treatment of peripheral nerve injuries by methods of muscle re-education and training (1).

The patients selected for this investigation were those in which definite peripheral nerves of the upper extremity were known to be completely severed, and in which there was no complication such as division of tendons or any limitation of mobility in the joints; since it has been proved clinically that a number of afferent fibres subserving the recognition of pressure reach their distribution by such structures as tendons, and of course any limitation of movement of the joints would interfere seriously with the performance of the tests.

The examination was first made on the normal side in order to make the patient quite familiar with the method and what was expected of him, secondly to provide a control and standard for comparison, and thirdly to enable me to test the reliability and attention of the patient. It is surprising how few patients need to be discarded as unreliable if sufficient time is taken to make quite clear to them what is wanted and enough patience is expended. A large number of patients, who were otherwise quite suitable, had to be omitted on account of arthritic adhesions, a complication unfortunately very frequently encountered in peripheral nerve lesions. Each segment of the digit, above and below the joint to be examined, was grasped firmly by the lateral borders and then the joint was gradually and evenly flexed or extended. The segments of the digit must be grasped firmly, as Head(2) has pointed out, so that the additional pressure required to move the joint shall not be distinguishable and thus lead to the recognition of movement from other impressions than those arising from the articular structures. The movement of the joint must also be made as far as possible at a uniform rate and not too slowly.

The patient was requested to state when he first felt any movement, and on answering was further asked at which joint it occurred and also the apparent direction of the movement. The latter two questions were soon found to be of fundamental importance for any accurate investigation of the appreciation of passive movement in a *joint*, since it was found that patients were able frequently to recognise movement of a particular digit without possessing any knowledge of the joint at which it occurred or the direction in which it was moved. Investigation of the earlier cases showed that this recognition of mere movement of a digit was obviously dependent upon alteration in tension or position of the tendons, and did not arise from any stimulation of afferent nerve terminals in the region of the joint. Fortunately this source of fallacy was discovered at an early stage in the investigation, and errors arising from it were consequently prevented. From ~~a~~ review of other work on this aspect of sensation it seems possible that fallacies may have arisen in the past from this cause. Another source of possible error which was soon discovered arose from the difficulty patients had in expressing the joint at which the movement was experienced. Such a term as the "first joint" is apt to be very misleading, as some referred this to the proximal interphalangeal joint and others to the distal: consequently it was found necessary at the outset of each examination to have a clear understanding with the patient as to the terminology he adopted for the various joints. In all, 51 patients have been examined and they are composed of the following and will be considered in this order:

Division of ulnar	20 (in arm 5, in forearm 11, at wrist 4).
Division of median	12 (in arm 5, in forearm 5, at wrist 2).
Division of musculo-spiral ...	14.
Division of median and ulnar	4 (in forearm 3, at wrist 1).
Division of median and radial	1 (in forearm).

For greater ease of comparison the left hand is represented in all the figures.

ULNAR NERVE

In all 20 an absolute loss of all appreciation of passive movement was found in the two interphalangeal joints and the metacarpo-phalangeal joint of the little finger, but the extent of the supply from the ulnar to the articulations of the ring finger was subject to considerable variation. In eight the power of perception of movement in all three joints of the ring finger was definitely impaired (fig. 1 *A*), and this was particularly striking on comparing the same joint on the two sides. In one of the eight in addition there was also defective recognition of movement at the metacarpo-phalangeal joint of the middle finger (fig. 1 *B*). Four other patients failed to recognise any movement at the two interphalangeal joints of the ring finger, in three of these a defect was also found at the metacarpo-phalangeal joint of the same finger (fig. 1 *C*), and in the fourth a similar defect at the metacarpo-phalangeal joint of the ring, middle and index fingers (fig. 1 *D*). In five no objective or subjective evidence of any ulnar supply to any joint of the ring finger could be demonstrated (fig. 1 *E*). This accounts for 17 out of the 20, the condition found in the remaining three is shown in fig. 2, *A*, *B* and *C*.

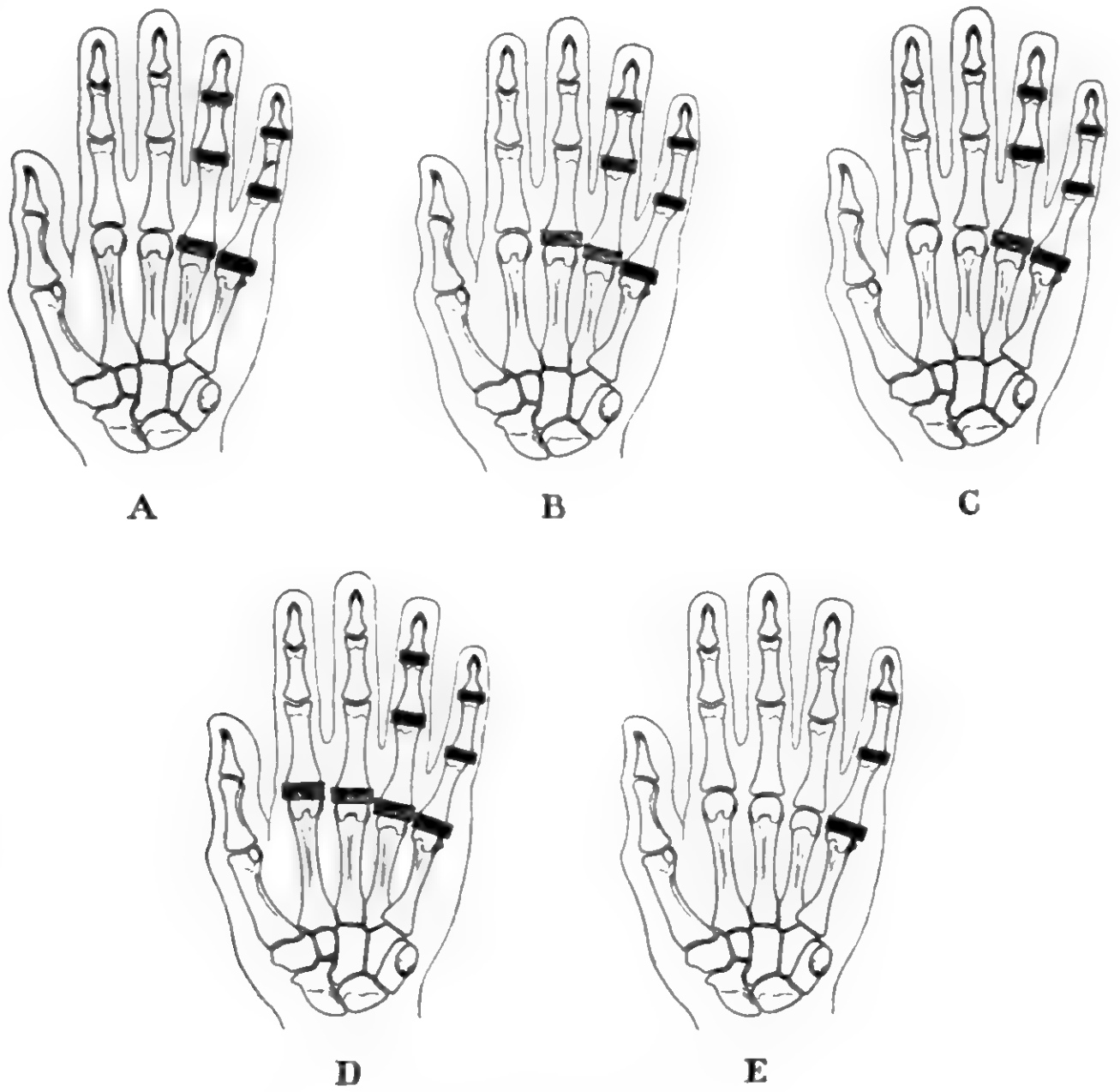

Fig. 1. Division of ulnar nerve.

■ = Complete loss of appreciation of passive movement.

▨ = Impaired recognition of passive movement.

Type *A* = 7 patients. Type *D* = 1 patient.
„ *B* = 1 patient. „ *E* = 5 patients.
„ *C* = 3 patients.

The explanation of the variation in distribution of the ulnar to the joints of the ring finger is readily appreciated on reference being made to the variation already described in the cutaneous distribution of this nerve (3), since it was discovered that a more profound loss of the appreciation of movement was present in those patients where the supply to the skin of the fingers was found to be more extensive than that usually described. A very intimate and significant relation between the extent of the distribution to the joints and the skin of the fingers was discovered throughout this series.

The supply to the metacarpo-phalangeal joint of the index in one patient could not be explained in this way and it must be consequently presumed that the distribution to this joint, in the one patient, was through the deep palmar branch.

It is of the greatest importance to notice that no modification in distribution to the articulations of the fingers was produced by section of the nerve at different levels in the limb, precisely similar results being found whether the nerve was severed in the upper arm, forearm or at the wrist; fuller reference to the significance of this will be made at a later stage after the distribution of the various nerves to the joints has been discussed.

From these results it may be deduced that normally the ulnar conducts afferent impulses that excite consciousness from all the three joints of both the little and ring fingers, it invariably provides the sole pathway in the case of the former, but in the latter finger considerable variation is found; broadly speaking in most people it provides the principal course for the transmission of impulses from the three articulations of the ring finger.

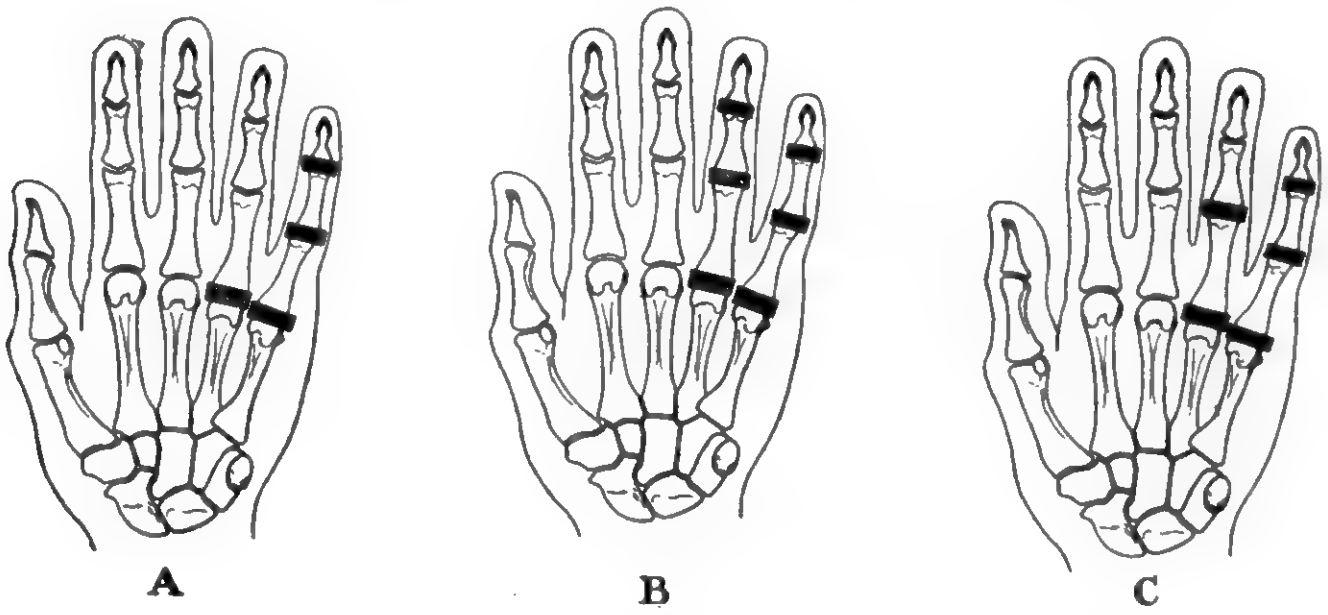

Fig. 2. Division of ulnar nerve.
▬ = Complete loss of appreciation of passive movement.
▨ = Impaired recognition of passive movement.
One patient showing each type = *A*, *B* and *C*.

MEDIAN NERVE

Most variation in the median distribution was discovered in the supply to the joints of the thumb (fig. 3), and the reason for this will be quite apparent after we have considered the distribution of the radial. Only in one patient out of the twelve examined was no impairment of the perception of movement found in the two joints of the thumb. Two patients were unable to recognise any movement of either joint, and in two others the power of appreciation of movement was definitely diminished in the two joints. In the remaining seven the condition in the two articulations of the thumb differed. In four defective recognition, and in another complete loss, was found in the interphalangeal joint, whereas the metacarpo-phalangeal was unaffected; in the other two there was failure to recognise movement in the interphalangeal joint and some disturbance at the metacarpo-phalangeal joint.

Loss of appreciation of movement in both interphalangeal joints of the index and medius was the rule in all twelve; complete failure to recognise movement in any joint of the index was discovered in four and a similar condition in the medius in six. Of the remaining eight, as regards the metacarpo-phalangeal joint of the index, five manifested imperfect perception and three showed no clinical evidence of any distribution to this joint from the median. Of the six, which remain to be considered with reference to the metacarpo-phalangeal joint of the middle finger, four showed imperfect perception and in two no disturbance could be detected.

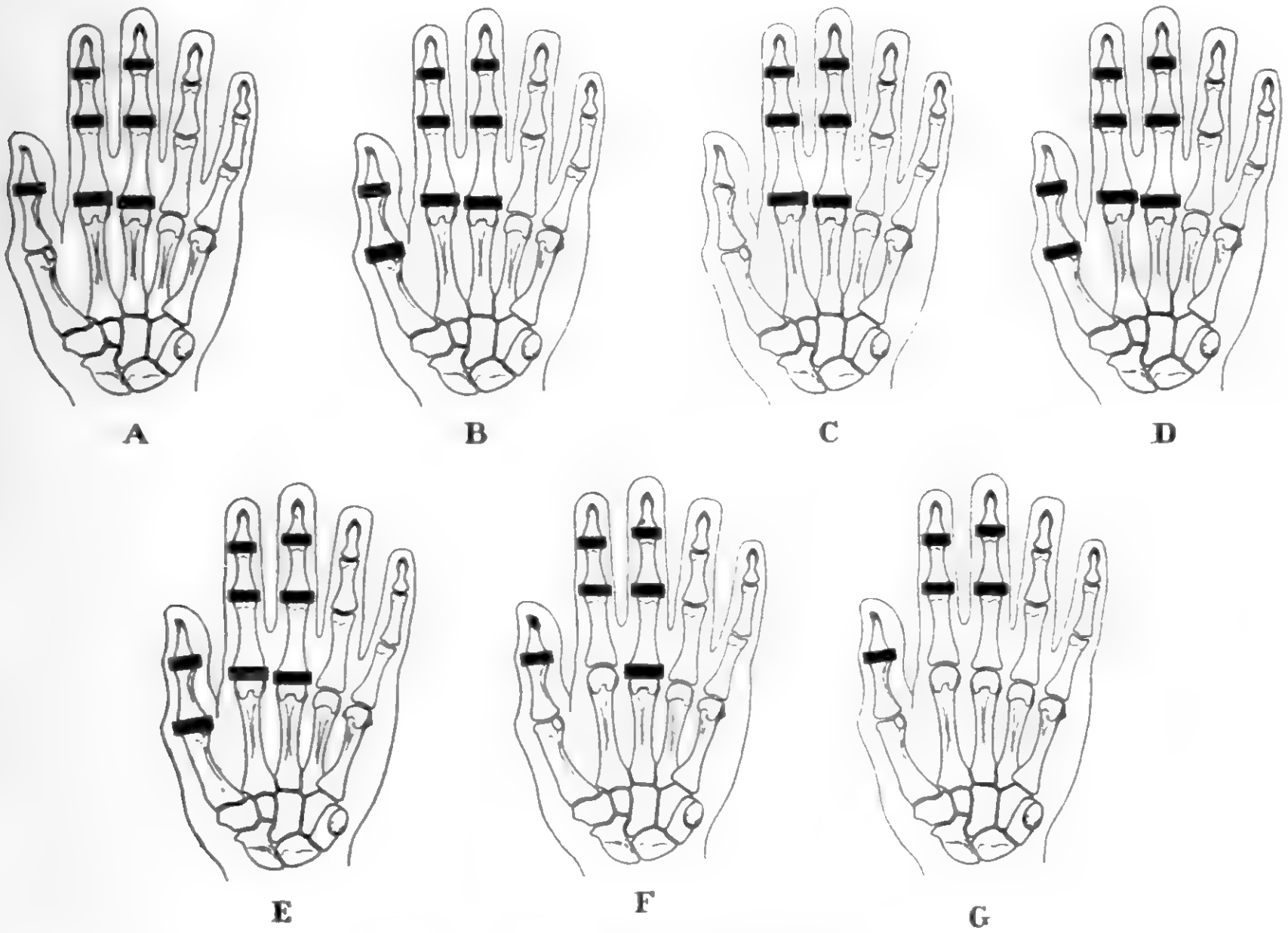

Fig. 3. Division of median nerve.
▬ = Complete loss of appreciation of passive movement.
▨ = Impaired recognition of passive movement.

Type *A* = 4 patients.
,, *B* = 1 patient.
,, *C* = 1 patient.
,, *D* = 2 patients.
Type *E* = 1 patient.
,, *F* = 1 patient.
,, *G* = 2 patients.

In no patient was I able to discover any subjective or objective sign of any distribution from the median to the articulations of the ring finger, although the results found after division of the ulnar anticipate some evidence to this effect, but it must be remembered that we decided that the ulnar appeared to provide the principal supply to the joints of this finger. Consequently it seems probable that in the 12 patients examined the ulnar provided the main supply to the joints of the ring finger, and the distribution from the median was insufficient to be appreciated by clinical tests.

From these results it appears that the median normally provides the sole pathway for the transmission of afferent impulses from both interphalangeal joints of the index and medius fingers, is the principal pathway from the metacarpo-phalangeal joints of these two fingers and the interphalangeal joint of the thumb, and provides frequently a route for the passage of these impulses from the metacarpo-phalangeal joint of the thumb. We have no direct evidence from the examination of these 12 patients, but it may be surmised that the median supplements the distribution of the ulnar to the articulation of the ring finger.

The fact must be again emphasised that the level of division of the nerve in the limb did not in any way control the extent of the distribution of afferent fibres conveying sensory impressions from the joints.

MUSCULO-SPIRAL NERVE

Fourteen patients were examined in which this nerve had been severed, but of course the study of these patients really resolves itself into an investigation

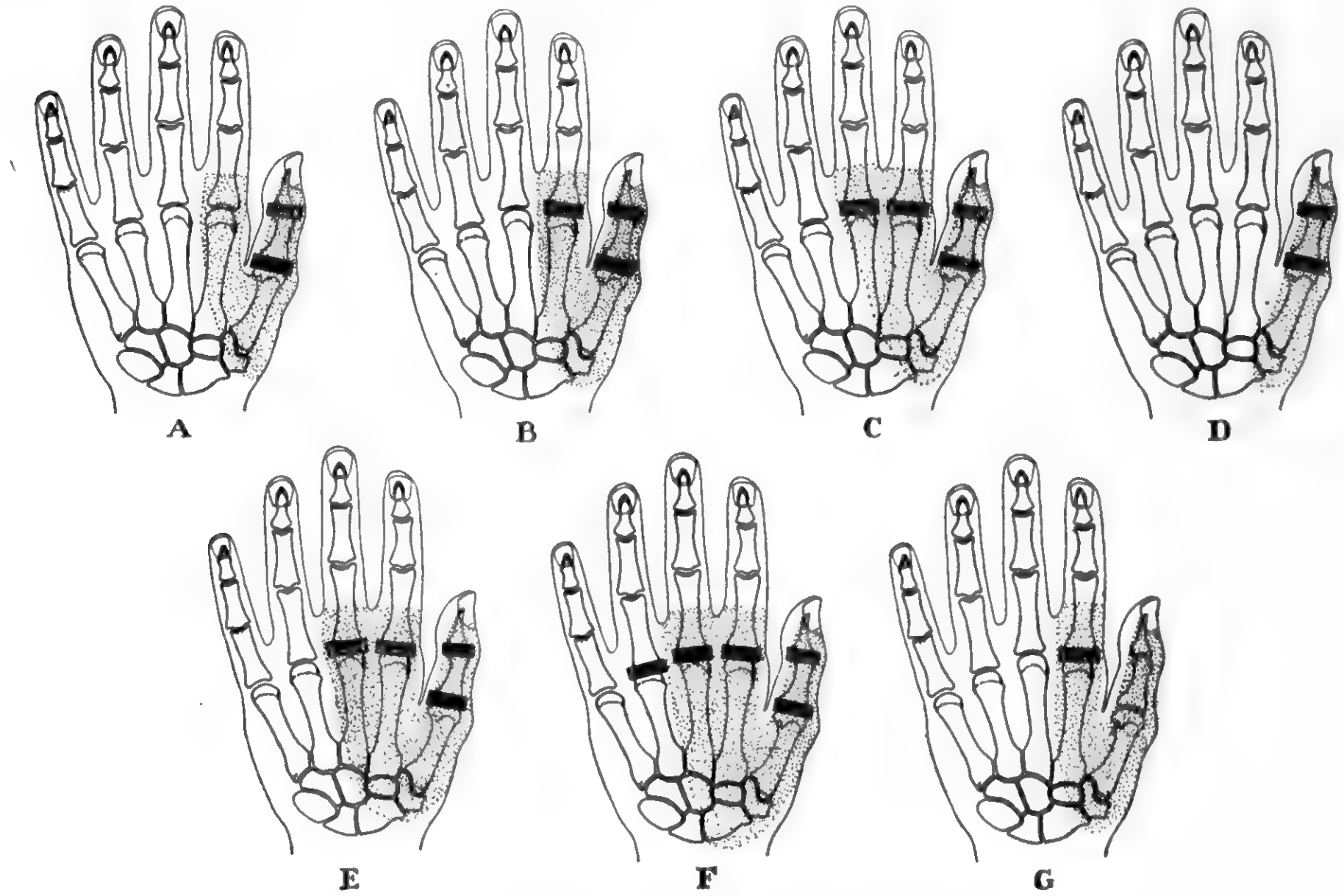

Fig. 4. Division of the musculo-spiral nerve.

▬ = Complete loss of appreciation of passive movement.

▨ = Impaired recognition of passive movement.

▒ = Extent of anaesthesia to lightest possible stimulations.

Type *A* = 1 patient.
,, *B* = 4 patients.
,, *C* = 3 patients.
,, *D* = 1 patient.
Type *E* = 1 patient.
,, *F* = 1 patient.
,, *G* = 1 patient.

of the distribution of the radial and lower external cutaneous branches of the musculo-spiral to the joints.

In two the recognition of passive movements appeared to be perfect in all the joints, but in the remainder one or more articulations of the thumb or fingers were affected, and the extent of this distribution was found to be subject to considerable variation. It is of interest to remember that there was no disturbance of the perception of passive movement in Head's historical experiment (4), upon which depends a good deal of our present conception of deep sensibility; and it seems possible from the fact that a similar result was found in only two patients out of 14 that this form of distribution is the exception rather than the rule.

The simplest way of demonstrating the disturbances found in this series has been to represent the conditions found in the 12 patients graphically in fig. 4. As in the case of the ulnar a close relationship was maintained between the extent of the distribution of the radial to the skin and to the joints. The results also explain quite definitely the variations which have been described in the distribution of the median to the two joints of the thumb and the metacarpo-phalangeal joints of the index and middle fingers. The investigation has proved that the radial as a rule supplements the supply of the median to the two joints of the thumb (frequently providing the chief supply to the metacarpo-phalangeal joint of the thumb), and the metacarpo-phalangeal joint of the index; the radial may be the sole supply to the metacarpo-phalangeal joint of the thumb and not infrequently supplements the median distribution to the metacarpo-phalangeal joint of the middle finger.

MEDIAN AND ULNAR NERVES

The examination of four patients with division of both the median and ulnar (fig. 5) nerves supported the results found in the case of section of the individual trunks. In two there was an absolute loss of appreciation of passive movement

A **B** **C**

Fig. 5. Division of median and ulnar nerves.
▬ = Complete loss of appreciation of passive movement.
▨ = Impaired recognition of passive movement.
Type $A = 2$ patients.
,, $B = 1$ patient.
,, $C = 1$ patient.

in all three joints of the little, ring and middle fingers and in the two interphalangeal joints of the index, whilst in the two joints of the thumb and the metacarpo-phalangeal joint of the index the perception was markedly diminished. The condition found in the other two patients only differed very slightly from the foregoing; in one the only difference was loss instead of defective perception at the interphalangeal joint of the thumb, and in the other loss instead of defective perception at the metacarpo-phalangeal joint of the index finger.

From the residual sensation it is easy to see that branches of the musculo-spiral contributed to the supply of the interphalangeal joint of the thumb in three out of the four, to the metacarpo-phalangeal joint of the thumb in all four and to the metacarpo-phalangeal joint of the index in three—results which are in precise agreement with the conditions found after division of the musculo-spiral.

MEDIAN AND RADIAL NERVES

An opportunity was offered of investigating one patient who suffered from division of both the radial and median nerves in the middle of the forearm. There was complete loss of appreciation of movement in both joints of the thumb and all three joints of the index and middle fingers; no disturbance could be detected in any of the joints of either the ring or little finger (fig. 6).

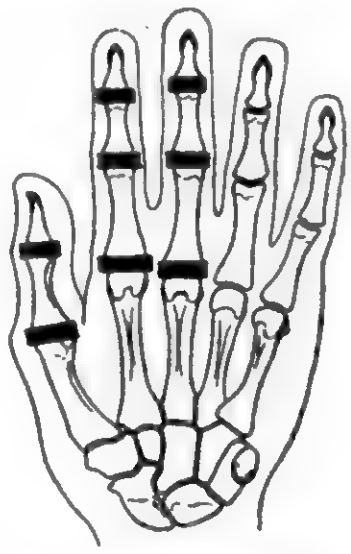

Fig. 6. Division of median and radial nerves.

COMMENTARY

From an analysis of the investigations recorded in this paper it appears possible to work out the regular source of supply of afferent fibres, conveying sensory impressions, to the joints of the fingers and thumb and also to establish the principal variations in distribution. The findings have been summarised in the table opposite. An attempt has been made to work out in percentages the occurrence of the commoner irregularities, but it ought to be stated that these figures can merely be considered as approximately accurate since only 51 patients were examined. The exact frequency of the various forms of distribution is not of any great practical service in clinical work; what appears to be more useful and of greater importance to the clinician, is to realise the intimate relationship between variations in the cutaneous and articular distributions of the various nerves. It is easy accurately to define and chart the former, and from this it is possible fairly accurately to forecast the distribution of that particular nerve to the joints. This relationship is of real value when endeavouring to estimate the extent of recovery in a patient who has not been examined previously, and whose form of distribution is not known unless previous clinical records are forthcoming. In the past too little attention has been directed to the examination of the power of appreciating passive movements

Thumb		Index			Medius			Ring			Little		
Inter-phal.	Met.-phal.	Distal Inter-phal.	Prox. Inter-phal.	Met.-phal.	Distal Inter-phal.	Prox. Inter-phal.	Met.-phal.	Distal Inter-phal.	Prox. Inter-phal.	Met.-phal.	Distal Inter-phal.	Prox. Inter-phal.	Met.-phal.
1. Median chiefly Radial supplementary	1. Radial chiefly Median supplementary	Median	Median	1. Median chiefly Radial supplementary	Median	Median	1. Median chiefly Radial supplementary	1. Ulnar	1. Ulnar	1. Ulnar	Ulnar	Ulnar	Ulnar
		(invariably)			(invariably)			(Probably supplemented by median)			(invariably)		
2. Median alone 42 %	2. Radial alone 15 %			2. Median alone 25 %			2. Median alone 42 %	2. Ulnar alone 25 %	2. Ulnar alone 25 %	2. Ulnar alone 5 %			
	3. Median alone 16 %			3. Radial alone 8 %			3. Radial alone 8 %			3. Very rarely branches from radial			
				4. Very rarely some branches from ulnar			4. Rarely some branches from ulnar						

in patients suffering from injury to, or disease of, the peripheral nerves, and yet full information about this aspect of sensation is required in every case if the disability is to be assessed accurately and muscle training advised on a sound scientific basis for each individual patient.

It is not uncommon to discover, especially after suture of the median, that all the muscles—when tested individually—have recovered voluntary power, and yet the hand is of slight practical service when the patient attempts purposive movements. Further, it has been a frequent experience to hear patients complain, after an apparently successful suture of the median, that they find they lose the grip of their tools when they make an effort to work; and on further enquiry it is discovered that they can use the hand fairly well as long as they concentrate upon the movements, but it ceases to function satisfactorily as soon as they take their eye off it. Such patients also frequently inform you that the hand is useless in the dark, or when they cannot observe what they are trying to do with it. These complaints may be heard even when cutaneous sensibility has made a fair recovery and all the muscles, tested individually, exhibit a good range of voluntary movement. It seems clear that such disabilities are due to the loss of afferent stimuli from joints, muscles, tendons and other deep structures: but it is only really practicable to investigate directly the function of fibres conveying conscious impressions from such deep structures as joints. It was to obtain a knowledge of the normal distribution of these fibres, and the commoner variations, that the work described in this paper was originally undertaken. The application of these results, in the examination of the patients making the complaints just described, has shown that there is at the best a very defective recognition of passive movement in the joints supplied by the injured nerve, even when three years have elapsed since the time of the suture.

The further these investigations have progressed the more I have been impressed with the importance of an examination of the afferent nerve supply of the joints in all patients suffering from nerve injuries of the upper extremity, to be assessed for pensions; since the routine investigations of voluntary power and cutaneous sensibility do not, in themselves, provide sufficient information to determine the real functional capacity of the hand.

Previous reference has also been made to the significance of a knowledge of the power of appreciation of passive movement in all patients with disabilities of the hand to be treated by muscle re-education; the loss of this form of sensibility in peripheral nerve injuries offers a serious obstacle to the efficient application of this form of treatment—an obstacle which is probably insufficiently realised. Before the war our chief experience of muscle training was derived from the treatment of infantile paralysis, and consequently many who are responsible for the supervision of the administration of this form of treatment are content merely to develop an increased range of movement of the individual muscles, and fail to appreciate the very different problem which arises in peripheral nerve lesions. After injuries to the peripheral nerves there is usually a serious loss of those afferent stimuli which are so necessary for the perfect performance and adjustment of the finer and more delicate movements, and consequently in the latter part of the treatment every effort must be made to develop those purposive and more complex movements which the particular patient will require when he returns to a suitable civil occupation.

To all who are familiar with the brilliant researches of Head upon the afferent system one result stated in this paper must appear astonishing. Head maintains that there is no loss of the sense of appreciation of movement in any joints when the median or ulnar nerves are divided at the level of the wrist, provided the nerve injury is not complicated by any division of tendons; since he holds the view that fibres subserving what he terms "deep sensibility" run mainly with the motor nerves and must pass to such deep structures as joints along the tendons and possibly the blood vessels. To uphold Head's contention with regard to deep sensibility the digital branches of the median and ulnar must be considered as cutaneous nerves, and yet a simple dissection of these nerves will clearly demonstrate branches passing to the periosteum of the phalanges and the interphalangeal articulations. It may be presumed that these branches of the digital nerves are either afferent or vaso-motor in function. The examinations recorded in this paper of patients suffering from division of the median or ulnar at the wrist and uncomplicated by any injury to the tendons, appear to show conclusively that some of these branches are afferent in function and transmit information which enables us to appreciate the site and direction of passive movement. As was pointed out at an earlier point in this paper, patients suffering from division of the median or ulnar nerve at the wrist are able frequently to recognise "movement" of a finger, probably as a result of alteration of tension or movement of the long tendons, but if care is taken it can be demonstrated easily that this knowledge is not produced by stimulation of afferent terminals in the neighbourhood of the joint.

My investigations fully support the view that some afferent fibres, distributed to subcutaneous structures, do pass probably along such channels as tendons, since a patient suffering from division of the median or ulnar is able to appreciate the application of pressure even on the digits. The significance and bearing of these results upon our conception of sensation must be dealt with fully in a subsequent paper.

REFERENCES

(1) Stopford, J. S. B. "The anatomical and physiological principles of muscle training, particularly with reference to peripheral nerve injuries." *Journ. of the Incorp. Soc. of Trained Masseuses*, Jan. 1920.

(2) Head, H. *Studies in Neurology*, vol. i, London, 1920.

(3) Stopford, J. S. B. "The variation in distribution of the cutaneous nerves of the hands and digits." *Journ. of Anat.* vol. liii, Oct. 1918.

(4) Rivers, W. H. R. and Head, H. "A human experiment in nerve division." *Brain*, vol. xxxi, 1908.

REPORT ON AN ANENCEPHALIC EMBRYO

BY J. ERNEST FRAZER, F.R.C.S.,
St Mary's Hospital

THE specimen which forms the subject of this report is a human embryo measuring some 17 mm., and presenting the condition of anencephaly. The stage of development, however, places the embryo among those of about 27 or 28 mm., and the details of its structure, apart from the abnormal regions, are quite comparable with those in a normal 28 mm., which I have consequently adopted as the standard by which the specimen is judged. I need not go into these particulars, and it will be enough, I think, to say that the specimen is one of anencephaly in a human embryo near the end of the second month; so far as I am aware, no record exists of a similar specimen of this age.

An outline reconstruction of the embryo is shown in fig. 1. It can be seen that, with the exception of the head, the general appearance of the embryo exhibits nothing unusual. It was divided into 10 μ serial sections, and these have been examined with a view to the discovery of any concomitant abnormalities.

(*a*) *Urinogenital System.* The anal end of the gut reaches the surface between the hinder extremities of the inner genital folds. The Müllerian ducts run down normally as far as the place where they cross over the Wolffian ducts, i.e. about the pelvic brim. Here, on the left side, the former duct apparently runs into the latter, while the right Müllerian duct disappears, though it cannot be definitely traced into the Wolffian duct. It may be remarked that examination of the genital glands suggests that the embryo is a male, whereas the 28 mm. "control" is female.

(*b*) *Alimentary and Respiratory Systems.* With the exception of the minor displacement of the terminal situation already noticed, nothing abnormal was found. The proximal limb of the U-loop was partly in the abdomen, and displaced above the distal limb and mesentery, but this was, I think, evidently accidental and referable to the preparation of the specimen: otherwise, the loop was normally in the umbilical sac.

(*c*) *Circulatory System.* Nothing abnormal found except in the head.

(*d*) *Skeletal System.* The cartilaginous skeleton appears normal, though there is a suggestion that the neural arches in the lumbar region, and perhaps elsewhere, are not quite as "thick" as in the 28 mm. sections. The impression of being thinner applies to all the tissues lying dorsal to the spinal cord, but there is absolutely no indication of any giving way or stretching to be observed.

(*e*) *Special senses.* The inner ear has reached a stage of development similar to that in the normal 28 mm. specimen, but the whole organ is rather smaller: the cells are probably smaller also, and, in the region of the proximal part of the cochlear duct, they are destroyed or absent on the left side, possibly injured during sectioning. The tubo-tympanic region is normal.

The eyes are present, and present no evident abnormalities in the sections, but models show that the line of the choroidal fissure can be still appreciated, although the fissure itself is of course closed. It also seems likely that the formation of nerve-fibres is largely inhibited in these eyes, but no methods of special staining were used.

Fig. 1. Linear reconstruction of anencephalic embryo. The shaded areas in the head indicate certain nerve positions. *V, V,* the fifth nerve and its attached root; *IX, X, XII* are corresponding nerves. Some nerve remnants lie along the ventral surface of the elongated hind-brain stem. *Pit.*, marks the situation of the pituitary rudiment. *M.C.* is the upper end of Meckel's cartilage.

The nasal cavities are only apparently abnormal in their shape: this is projected on the drawing in fig. 1 by a dotted line, giving a somewhat triangular outline. The upper angle is prolonged into a small tube of epithelium, drawn out to reach the meningeal level of the skull-base. The anterior nares lead into the cavities through elongated canals. The palate folds lie above the tongue, not in contact with each other: it is probable, I think, that this position had been acquired after death.

Spinal cord. This appears to be quite normal, similar in size and structure to that in the 28 mm. embryo, and extends to the tail region, as shown in the figure. The spinal nerves also call for no comment; the position of the first cervical nerve is indicated in the figure, and it may be said that in this case there was a tendency to separation of the nerve filaments from the cord.

Head and brain. The brain is represented (see figure 1) by an elongated portion of the hind-brain, ending fairly abruptly above, and by a pituitary body (*X* in the figure) and optic stalks and eyes. The pituitary body is smaller than in the 28 mm. specimen, but is almost as well developed, presenting a posterior lobe with the antero-lateral cornua growing up on each side of its stalk. There are cellular outgrowths from the lower part of the glandular portion, and the infundibulum is broken and ragged. The two pituitary organs are shown in fig. 2. The optic stalks begin in front of, and lateral to, the pituitary, from a small chaotic mass of *quondam* brain-tissue, and run outwards and downwards to the eyes: they are hollow for some distance.

All the cranial nerves are present in position below the base of the skull. Some of them are indicated in fig. 1, where the shaded projections give the positions of the trigeminal ganglion (*V*), ninth, tenth, and eleventh nerves. Traced proximally, all the nerves reach the meninges, where they come to an end, evidently torn: it may be pointed out here that the optic nerve does the same, and the olfactory fibres, quite apparent in their lower parts, are lost in the meningeal level with the upward tube-like prolongations of the nasal cavities. On comparison of the nerves with each other, there is found a marked difference between the third nerve and other nerves in the same sections of the orbit, the former nerve being little more than a vacuolated framework: this, for want of a better term, might conveniently be called degeneration. Muscles supplied by the nerve did not appear to be changed. No "degeneration" was found in the fourth nerve, and no change was apparent in the facial after giving off the chorda tympani—in fact no change could be certainly made out in any cranial nerve other than the third.

A space exists above and behind these broken ends of the cranial nerves on the meningeal aspect of the skull-base, and separates them from the remnant of the hind-brain. This space has evidently resulted from the straightening out of the hind-brain, which should, of course, occupy this region of the cranial cavity by its pontine flexure. The cavity presents occasionally in the sections a certain amount of débris, which in some cases is evidently nervous, and in others no doubt is meningeal.

The only part of the brain which remains—with the exception of the infundibular remnant and the basal débris—is the lower portion of the hind-brain. Reference to fig. 1 will show that the spinal cord is carried up to the head and becomes continuous there with an elongated column of nervous tissue which is directed upwards and forwards, ends somewhat abruptly above, and is surrounded dorso-laterally in its upper part by a broken mass of folded layers which are evidently remnants of the roof-plate of the rhombencephalon: a well-formed choroid plexus[1] is recognisable as being made by the dorsal and upper part of these layers. The neural cavity begins to show a dorsal broadening shortly after passing into the skull, and, some little distance further up, opens out rapidly, so that this part of the brain-stem is widely open dorsally when it has extended up half the distance shown in the figure. The open "ventricle" is, of course, roofed by the layers already referred to, but the attachment of these to the stem is only occasionally visible, possibly owing to changes in this upper end during preparation.

The whole structure is related, on its ventral aspect at any rate, to membranes in which are vessels and remnants of nerves. These nerves cannot be traced into the stem, consist of groups of fibres and ganglionic masses, and may run through several slides. No indication is found, however, to point to the different nerves represented, and it may be said at once that none of the lower cranial nerves can be found attached to the stem. These remains of nerves are represented in the figure by a few shaded areas along the ventral side of the main stem, and among them is a large ganglionic mass lying above the trigeminal ganglion: it does not seem, however, to be a portion of that ganglion, and its real value, like that of the other remains, is doubtful.

When we come to the upper end of the main stem, however, there is, on each side, a large nervous attachment ventro-laterally, and this can be recognised (*V* in fig. 1) with certainty as the superficial origin of the fifth nerve. The recognition was made first from its size and general relations to the other parts, and was clinched by examination of its deep strands and relations within the stem.

It is only a short stump on each side, and has apparently been carried away from its ganglion by extension of the main stem. The stem comes to an end a little distance above the situation of this nerve stump.

Miss I. C. Mann made a reconstruction model for me of this piece of the brain-stem, which confirms the short account just given. The dorsal view of the model, however, is of sufficient interest, I think, to merit further investigation. It is shown, after removal of the folds of the roof plate, in fig. 2, with a drawing of the hind-brain of the 28 mm. embryo, seen from the left. Dealing first with the normal specimen, the dorsal portions of the spinal cord are seen to end in the dorsal tubercles *D* (paired), and in front of this the widely open rhombencephalic cavity is covered by the broad roof-plate, of which the attached edge only is shown. Within this cavity the dorsal lamina of the front limb of the pontine flexure (metencephalon) is thickening as a cerebellar plate (*Cbm*). Caudal to this, just behind the angle of the flexure, is a small but well defined area, *A*, in evident connection with the auditory nerve, while the paired prominences of the myelencephalic floor of the cavity lie caudal to these auditory areas. The positions of origin of the fifth, eighth, ninth and tenth nerves

---

[1] It is commonly stated that the choroid plexuses are formed in the fourth month. This is not correct: they begin to appear at or just after the middle of the second month, and grow steadily after this. When I speak of the plexus as "well-formed" in this specimen, I am of course referring to its proper stage of development.

are also shown. Turning now to the abnormal brain, the dorsal tubercles are recognised at once at *D*, and the open region above these is the rhombencephalic cavity, the floor of which is exposed as a result of removal of the roof-plate. But the rounded and prominent masses seen in this floor, *V*, are not metencephalic, such as would be their value if seen from a dorsal view of such a brain as that of the 28 mm. specimen: they are the floor masses of the myelencephalon, brought up above the level of the dorsal tubercles as a result of the straightening out of the flexure. Thus, cranial and lateral to them, we recognise the auditory area *A*, from which a groove extends upwards and inwards and probably marks the line of the flexure.

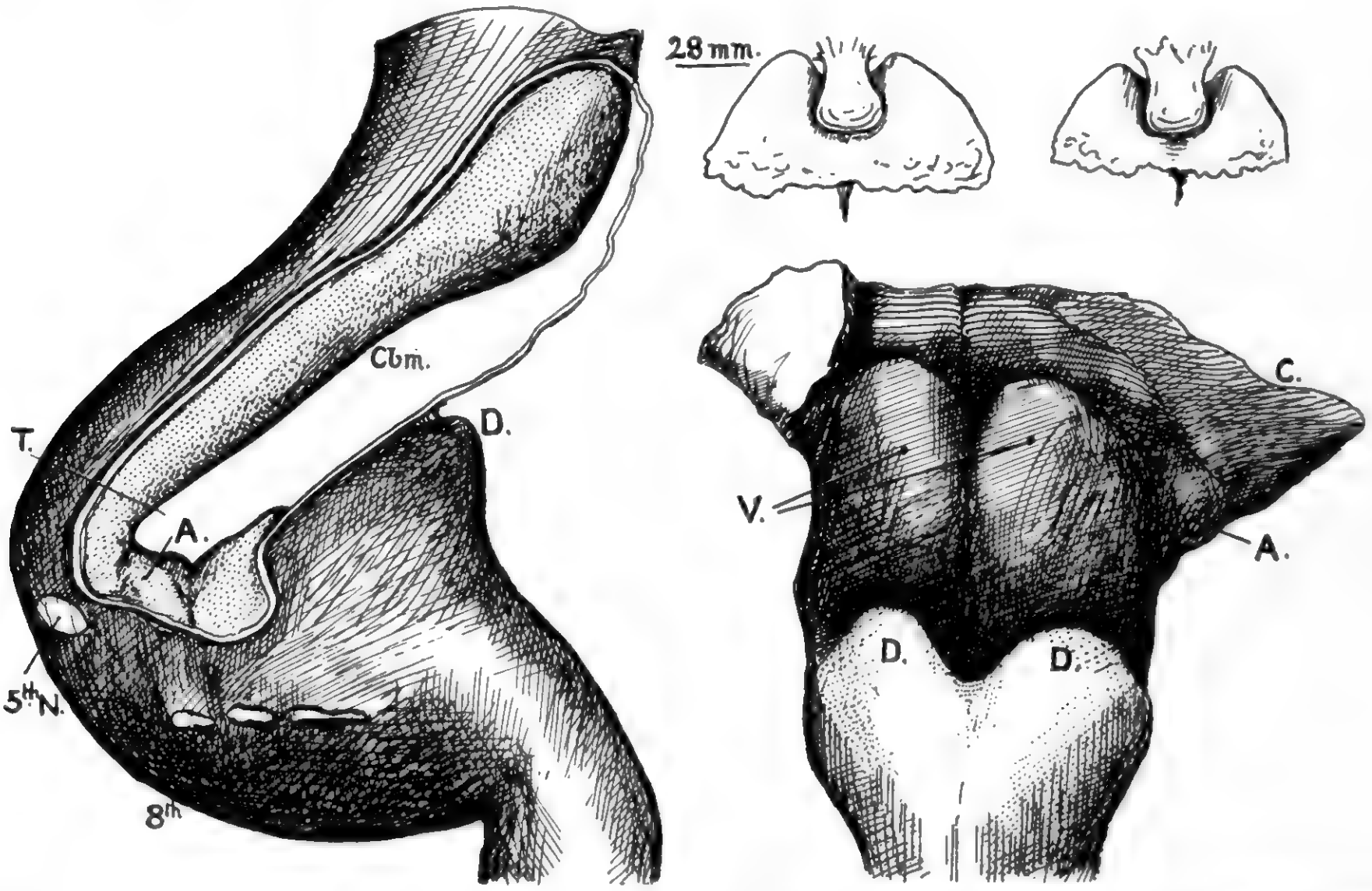

Fig. 2. On the left is a side view of the hind-brain of the 28 mm. embryo. On the right a dorsal view of the brain stump in the anencephalic specimen. The small figures above this are from reconstructions of the pituitary bodies in these two embryos. *A*, the auditory area; *C*, the everted cerebellar plate; *Cbm*, the same plate in normal position; *D*, the dorsal tubercles in both brains; *V*, the ventral laminae of the myelencephalon; and *T*, the approximate level of destruction.

Further up and further out, the dorsal lamina or cerebellar ridge (*C*) is present in part on one side, while it is folded in on the other side. This reading of the condition present is in accord with the previous description of the origin of the fifth nerve, which is now seen to bear exactly similar relations to the various parts of the hind-brain in the two specimens. We thus reach the conclusion that the brain-stem of the anencephalic embryo comes to an end at a level which might be represented on the normal 28 mm. reconstruction by the line *T*, drawn through the lower part of the metencephalon.

Inferences to be drawn from the conditions in this embryo which have been described are that there has been a secondary separation of the cranial nerves from their attachments to the brain, and that the remnant of the brain, free from controlling forces holding it down in position, is no longer bent but has straightened itself and grown up in a direct line with the cord. I do not think there can be reasonable doubt that a brain existed: the presence of eyes, of a neural pituitary outgrowth, of third and fourth nerves, and incidentally of the nervous débris found in the cranium, indicate this very clearly. If, then, we start with the conception of a brain being present, it follows that this must have undergone destruction at a later period, and I think that this catastrophe might reasonably be referred to primary and secondary causes. We must, I think, assume the previous presence of the brain, but we cannot and ought not assume that this brain was normal. The present specimen gives no hint about the nature of that fundamental abnormality, but no doubt the tendency would be to place it in the dorsal laminae or roof-plate, or, taking what is only an intercurrent effect, to assume the existence of an embryonic hydrocephalic condition. As just said, the specimen does not appear to give any clue to this, and it remains open to anyone to maintain his own views as to this primary fault. The ventral laminae were evidently able to form third and fourth nerves: further than that it does not seem possible to go in drawing inferences as to their condition, except that they appear perfectly good, so far as they exist, in the stump of the hind-brain.

But whatever the nature of the primary fault, it is clear that it must result in destruction of the continuity of the brain-stem at some point or points. In the present specimen I have the impression—to which I will refer again—that this destruction of the continuity of the tube occurred in the fore-brain, about the region of the rudiments of the corpora mammillaria: it is easy to formulate theories connecting this situation with deficiencies in dorsal and cerebral development. With this necessary solution of the tube, it seems to me that the action of the primary cause may be considered to have reached its acme and now, by virtue of this primary result, the secondary causes come into play and complete the destruction of that part of the brain affected by them.

Some years ago (*Lancet*, 1916) I described the pituitary region of the brain as the most "fixed" place within the skull, and referred the formation of the mid-brain flexure to the forward growth of the hind-brain acting against this fixed point. I have no wish to put forward any far-reaching morphological argument on this point, which I simply advance for what has always seemed to me to be its mechanical value: the definite adhesion of stomodaeal and neural ectoderm at this place, and their association with the upper end of the bucco-pharyngeal membrane, Seessels' pocket (when present), and the adherent notochord, seem to me to give a guarantee of fixation, supported by every sagittal section, which must influence the shape of a brain growing up against its fixation here. The brain, growing more rapidly than the skull-base, piles itself up into curves, so to speak, and these then owe their existence, mechanically, and at least in part, to this fixation of the fore-brain. So, if the continuity of the brain is destroyed behind this fixed region, there is not the mechanical fixation or point of resistance against which the growing brain can produce or maintain curves, and the result is that there is a tendency for the stem to become straight behind the site of the destruction. This is seen in the straight stump left in this specimen, and would reasonably be certainly expected to occur in the mid-brain curve, if the destruction takes place anterior to this. But the straightening out of these curves involves rupture of all structures which pass between them and fixed points in their neighbourhood, and thus we come to secondary rupture of nerves and vessels.

So far as concerns the nerves, there are at least two possible explanations of the nerves being found broken off short at the meningeal level—they may have been ruptured by the straightening out of the curves, or they have been left free as a result of destruction of their sites of origin, without being previously separated from the stem. In this connection it is interesting to consider the hind-brain. Here we find the great fifth nerve evidently torn and yet with its torn root still in position in the brain, and the lower nerves, also torn, have certainly suffered this fate before the destruction of the brain-stem. Hence we can conclude that the rupture of nerves as a result of straightening of the brain can certainly take place, and is probably easier to accomplish than we perhaps imagine, influenced no doubt largely by our experience of adult nerves. This is suggestive, but of course not conclusive, for the third and fourth nerves: we can leave the matter there for the moment, and turn now to the vessels.

The internal carotids are large vessels, of normal appearance and running a normal course up to the origin of the ophthalmic arteries. These branches are of normal size, and the carotids go on after their origin for a little distance, and then abruptly come to an end, with open mouths. It is evident that they have been torn across, and it would seem that this is a result of the same processes which have torn the nerves. The vertebral arteries, lying in the meningeal tissues on the ventral side of the hinder stump of the brain, join here to form a basilar artery, and this is drawn out on the ventral surface of the stump, practically to its upper end: probably this is the end of the artery, but its division could not be absolutely demonstrated, as the membranes get very ragged at the upper end. This system is composed of vessels of good size, giving off good-sized branches. If we can judge from the remains of the carotid and vertebral systems, there was nothing wrong with these to account for the primary failure in development, but they have been secondarily affected as a result of the primary failure.

The position of the rupture of the carotids seems to me to suggest that the solution of continuity of the brain-stem took place not very far away—in fact, it was an important factor in forming my opinion that this destructive lesion occurred just above the infundibular outgrowth, the other considerations having mainly to do with the structure of this part and its connections with cerebral and other dorsal derivatives. A rupture in this place fits in well with the conditions that were found, want of fixation of the brain-tube behind the situation leading to rupture of nerves, and failure of blood supply leading to disappearance of tissue. In accordance with this is the fact that the pituitary and eyes, whose vascular supplies remain, are still present, while the cerebral system supplied by the carotids above this level has utterly disappeared: also the hind-brain remains as far as the vascular supply is present and then ends abruptly, although there is nothing in the structure, examined microscopically, to distinguish this from any other hind-brain of the same stage and at the same level.

A reconstruction of the skull-base showed that it was comparable in development with the 28 mm. skull in its post-pituitary portion, except that the otic capsules showed a tendency, perhaps, to stand up more from the level of the floor, suggesting that there had not been any hind-brain structures lying on this floor for some little time: but, in front of the infundibular region, the base was narrowed and shortened, giving the impression of belonging to an earlier stage, although its cartilaginous and other details were in keeping with those of the "control." The eyes projected out for a considerable distance beyond the side levels of the front part of the skull. The frontal wall of the cranium was folded back sharply over the front of the base, and turned down here, ending in a thinned edge; there were no indications of the occipital sinking so noticeable in older anencephalics.

To sum up, this specimen appears to me to suggest that, although the original and primary cause of anencephaly may be some local defect, limited perhaps to the fore-brain region, or may be of different nature in different cases, secondary causes of the condition ultimately found may also occur: that these secondary conditions result from rupture of the brain-stem and consequent loss of fixation of the front end of this growing stem: that as a result of this the curves tend to straighten out: that consequently the nerves and vessels connected with it give way: and that the brain tissue, as a result of the vascular starvation, breaks up and disappears up to the limits of the remaining blood supply. The specimen does not appear to offer any explanation of the nature of the primary fault.

THE SKULL AND SOME RELATED STRUCTURES OF A LATE EMBRYO OF LYGOSOMA

By HELGA S. PEARSON, B.Sc.,

Assistant in the Department of Zoology, University College, London

The skull described in this paper is that of an embryo *Lygosoma* of unknown species belonging to the collection of Prof. J. P. Hill. The accompanying text-figures are of a wax plate model constructed from drawings of the transversely-sectioned head of the embryo, the actual length of which was about 4·8 mm. The model represents a magnification of approximately 100 in the transverse plane but only of about 75 in length, and this telescoping is of course reproduced in the drawings. The left half of the brain was included as a support.

The model was made at the suggestion and under the direction of Mr D. M. S. Watson, who helped in the construction of it and has throughout given advice, criticism and assistance. It was intended to serve as a basis of comparison for fossil skulls, certain blood-vessels, nerves and muscles being included in order to demonstrate more clearly the relations of the hard parts: it may be analogised with the standard solution of the chemist.

OTIC REGION

This region of the cranium is very largely ossified, the various bony elements having nearly attained their adult relationships, though still separated from each other by larger or smaller strips and blocks of cartilage into which no bone has yet extended. One such strip runs right along the ventral surface of the ear capsule, separating the basisphenoid and basioccipital below from the pro-otic, opisthotic and exoccipital above. The pro-otic, opisthotic and supraoccipital are also separated from each other by cartilaginous areas. Between the exoccipital and opisthotic alone no cartilage remains and the suture is difficult to determine, but the foramen for the tenth nerve, which passes out of the cranium immediately behind the ear capsule, appears to lie between the two bones.

Anteriorly the processus anterior inferior (figs. 1 and 2, *P.A.I.*) of the pro-otic extends forwards in front of the ear capsule beneath the big pro-otic notch for the fifth nerve as a thin sheet of bone leaning outwards from the brain below the gasserian ganglion, its upper edge rolled over scrollwise where it affords attachment for the protractor pterygoid muscle. This process, like the ventral edge of the rest of the pro-otic, is still continuous with the strip of cartilage mentioned above as forming the lateral boundary of the basisphenoid; ossification is extending downwards into the cartilage from the pro-otic and upwards into it from the basisphenoid. The process ends at about the level of the back wall of the pituitary fossa.

On the inner side of the ear capsule the pro-otic extends back to the foramen acusticum posterius which it almost, but not quite, surrounds, the postero-ventral boundary of the foramen being still cartilaginous. Behind this foramen the supraoccipital extends nearly half way down the inner wall of the capsule, enclosing the foramen endolymphaticum, while the ventral half is now formed by the opisthotic. This is the region of the sinus superior utriculi of the membranous labyrinth.

On the outer side of the ear capsule the pro-otic extends back above the fenestra vestibuli to the region where the supra-temporal pushes in between the upper end of the quadrate and the prominence for the external horizontal canal. This is just anterior to the paroccipital process (crista parotica of Gaupp[1]) which is itself still cartilaginous.

The anterior extremity of the opisthotic on the outer side of the ear capsule is below and just anterior to the fenestra vestibuli and paroccipital process.

The supraoccipital extends forwards to a point above the foramen acusticum posterius. It completely surrounds the posterior extremity of the anterior vertical semicircular canal and reaches down on the inner surface of the ear capsule to enclose the foramen endolymphaticum (as described above), while on the outer surface of the capsule it extends half way across the dorso-lateral wall till it meets the cartilaginous region surrounding the external semicircular canal and continuous with the paroccipital process. It completely surrounds the anterior extremity of the posterior semicircular canal and in this region arches over the cranial cavity, the tectum synoticum being ossified except for a cartilaginous core continuous in front with the anteriorly projecting processus ascendens. Behind the tectum, in the region where the posterior semicircular canal is passing outwards and downwards, the supraoccipital is rapidly excluded from the wall of the canal, the bone narrowing to its posterior extremity which is just above Gaupp's orificium posterius of the external semicircular canal.

In the floor of the brain case the basioccipital runs forwards as a very thin plate of bone bounded at the sides by the thick cartilaginous strip which separates it from the exoccipital and otic bones. Posteriorly it broadens out into the cancellous condylar portion, sheathed in cartilage. Anteriorly, just in front of the anterior end of the cochlear canal, it thins out in the membrane which separates it from the basisphenoid. This membrane closes the reduced basicranial fenestra (fig. 1, *B.F.*), the thin bony plates bounding it in front and behind probably having been formed by extension into an originally much larger membranous area such as is present in Gaupp's 31 mm. *Lacerta* and stage 5 of Rice's[2] *Eumeces*.

There is no trace of the notochord within the cranial region.

The thin plate of basisphenoid in front of the fenestra does not extend back quite to the level of the posterior edge of the pro-otic notch. Passing forwards

[1] Gaupp, 1900, *Anatomische Hefte*, Bd. xv, Heft 3.

[2] Rice, 1920, *Journal of Morphology*, vol. xxxiv.

beneath the fore-brain it rapidly thickens dorso-ventrally and narrows from side to side, forming a cancellous bony plate below the notch, but still separated from the pro-otic by a strip of unossified cartilage which continues forwards in front of the processus anterior inferior of that bone along the edge of the plate to its anterior extremity.

At either edge of the ventral surface of this plate the palatine branch of VII and the internal carotid artery (fig. 1, VII, P^1 & *I.C.A.*) lie in a groove which runs anteriorly for a short distance and then plunges into the substance of the bone to form the Vidian foramen. The place of exit of the latter is on the anterior edge of the plate just mesial to the root of the basipterygoid process (fig. 1, VII, P^2 & fig. 3, *V.F.*).

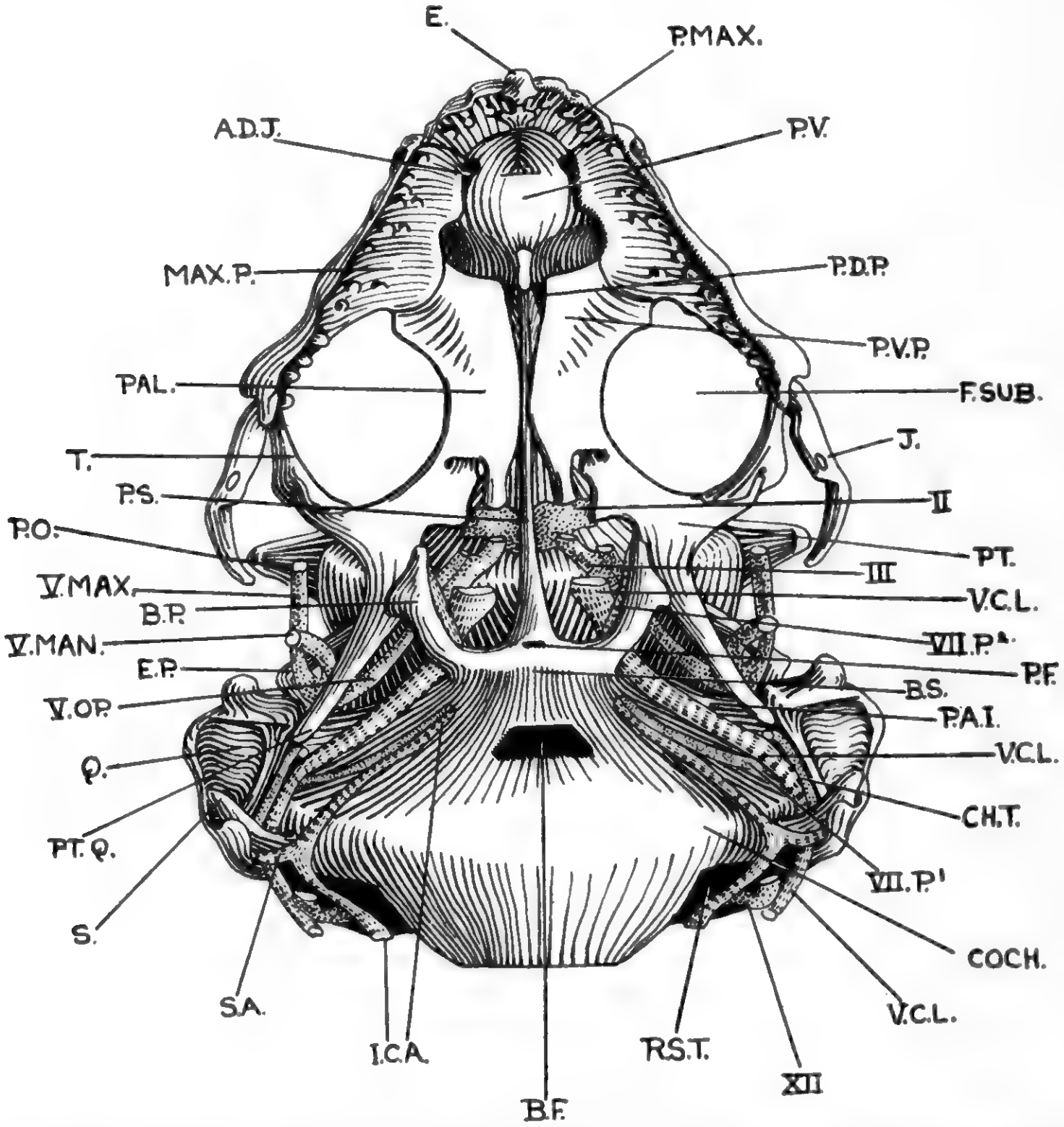

Fig. 1. Palatal aspect of wax plate model of skull. × $\frac{1}{4}$. Nerves and blood-vessels dotted. Jaw, hyoid and muscles removed. (Brain included in model for support.)

Anteriorly the plate is scooped out between the two Vidian foramina to form the pituitary fossa, in which the proximal ends of the posterior rectal eye muscles, attached to the floor of the fossa, may be seen lying on either side of the hypophysis cerebri.

Immediately after entering the Vidian foramen the internal carotid artery branches, one small branch running forwards with the palatine of VII in the foramen, while the main branch passes into the pituitary fossa and upwards through that to the ventral surface of the brain.

The N. abducens, running forwards below the brain, enters the basisphenoid from above, just behind the place where the palatine of VII and the internal carotid artery enter it from below. It runs forwards in the bone for a short distance and enters the pituitary fossa lateral to the internal carotid artery as that vessel passes up to the brain. The nerve at once comes into contact with the proximal end of the posterior rectus and seems to enter that muscle before it passes out of the pituitary fossa.

On either side of the pituitary fossa the basisphenoid still retains its thick cancellous nature but over the floor of the fossa it consists of a very thin bony plate. Towards the anterior end of the hypophysis the fossa shallows out, the thicker lateral portions of the basisphenoid approach each other in the mid-line, and the anterior extremity of the thin floor between them is perforated by the very small membrane-closed pituitary foramen (fig. 1, *P.F.*).

SUMMARY OF NERVE EXITS

V. The trigeminal, after a short forward course within the cranium, passes out through the pro-otic notch. The big gasserian ganglion (fig. 2, *G.G.*) is sheltered dorsally by the anterior end of the ear capsule, postero-ventrally by the outwardly bent processus anterior inferior of the pro-otic (fig. 2, *P.A.I.*), so that it lies almost intra-cranially. From the ganglion the three main branches of the nerve run forwards, the ramus ophthalmicus (figs. 1 and 2, V, *OP.*) inwards mesial to the epipterygoid, the rami mandibularis (V, *MAN.*) and maxillaris (V, *MAX.*) outwards laterally to that bone.

VII. The facial nerve arises by the same root as V but passes straight out of the cranium so that its foramen lies at a short distance posterior to the pro-otic notch and slightly more ventral. The foramen is very small, piercing the pro-otic immediately under its capsular portion. The geniculate ganglion lies just in front of the foramen, and from it the ramus palatinus (fig. 1, VII, *P.*) passes downwards and forwards close to the cranial wall, the ramus hyomandibularis backwards along the outer surface of the ear capsule.

VIII. The root of the auditory nerve lies immediately posterior to and above that of VII. The foramen acusticum anterius for the vestibular branch perforates the pro-otic above the anterior end of the cochlear canal. The foramen acusticum posterius for the cochlear branch lies at the extreme postero-median limit of the pro-otic, part of the posterior and ventral boundaries of the foramen being still cartilaginous.

IX. The glossopharyngeal does not pass out of the cranium through the foramen which leads into the recessus scala tympani (figs. 1–4, *R.S.T.*) as in *Lacerta* (Gaupp), *Varanus bivittatus* (Watkinson[1]), and some of the stages of *Eumeces* observed by Rice, but has a separate small foramen immediately above and in front of this and also leading into the recessus. Possibly, earlier

---

[1] Watkinson, *Morphologisches Jahrbuch* Bd. xxxv.

in development, the two were confluent as in *Lacerta*, their separation being due to the extension of the cranial wall in this region—a continuation of the process of extension which earlier still divides the originally single metotic fissure into a posterior "foramen jugulare" and an anterior perilymphatic foramen.

These foramina pierce the opisthotic at its antero-ventral extremity, just posterior to the pars cochlearis of the ear capsule (figs. 1–4, ***COCH.***).

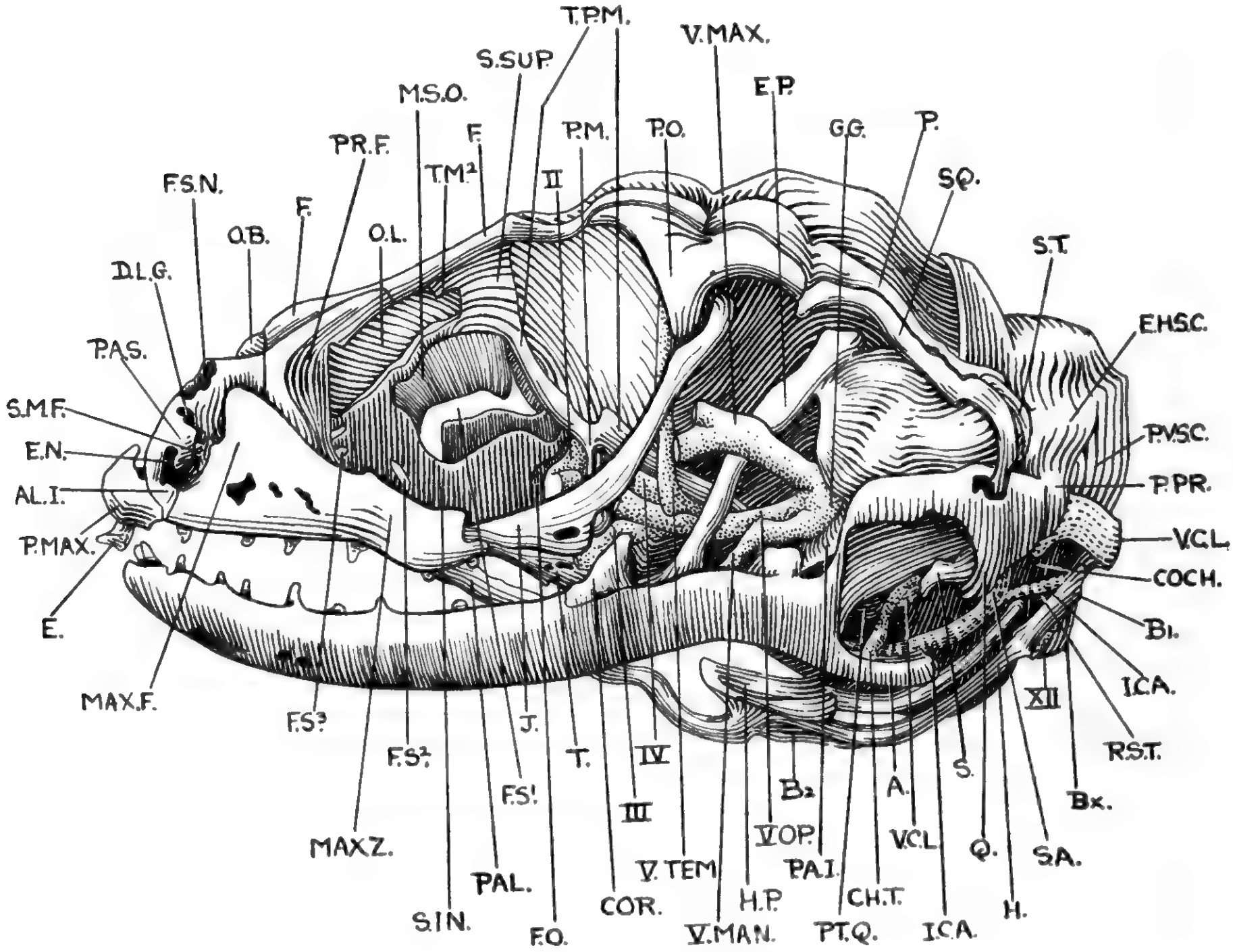

Fig. 2. Left lateral view of same model. ×½.

The glossopharyngeus runs back along the dorso-medial border of the recessus scala tympani to pierce the membranous wall of the latter at its posterior extremity. Outside the recessus it comes into contact with the hypoglossus and vagus, at the point where these two cross each other, and is joined by a branch of the hyomandibular of VII.

X and XII. The several small roots of the vagus join to form one large nerve which leaves the cranium at the back of the ear capsule between the opisthotic and exoccipital. Ventral to this the exoccipital is pierced by two foramina for the roots of the hypoglossal, one immediately in front of the vagal foramen and beneath the posterior end of the ear capsule, the other a little behind it.

The anterior root of XII runs straight out laterally under the ear capsule; the posterior root, after being joined by a branch of the first spinal, runs forwards to meet the anterior root. At the point where these roots unite the hypoglossal turns forwards and is crossed by X which loops back beneath it.

RECESSUS SCALA TYMPANI AND RELATED FORAMINA

The conditions in that region of the ear where the perilymphatic duct—of which the scala tympani is phylogenetically a modified portion—passes from it and into the cranium cannot be homologised directly in lizards and mammals, but must be referred to a common Cotylosaurian ancestor. The mammals appear not only to have evolved further in this respect but also along a rather different line. Therefore it is difficult to apply the mammalian nomenclature of fenestra cochleae or rotunda, and aqueductus cochleae, to the structures present in a lizard. Neither, however, will the nomenclature used by Gaupp for *Lacerta* and, with modifications, by Rice for *Eumeces*, fit in with the very definite arrangement found in *Lygosoma*, the stage here described being evidently later in development.

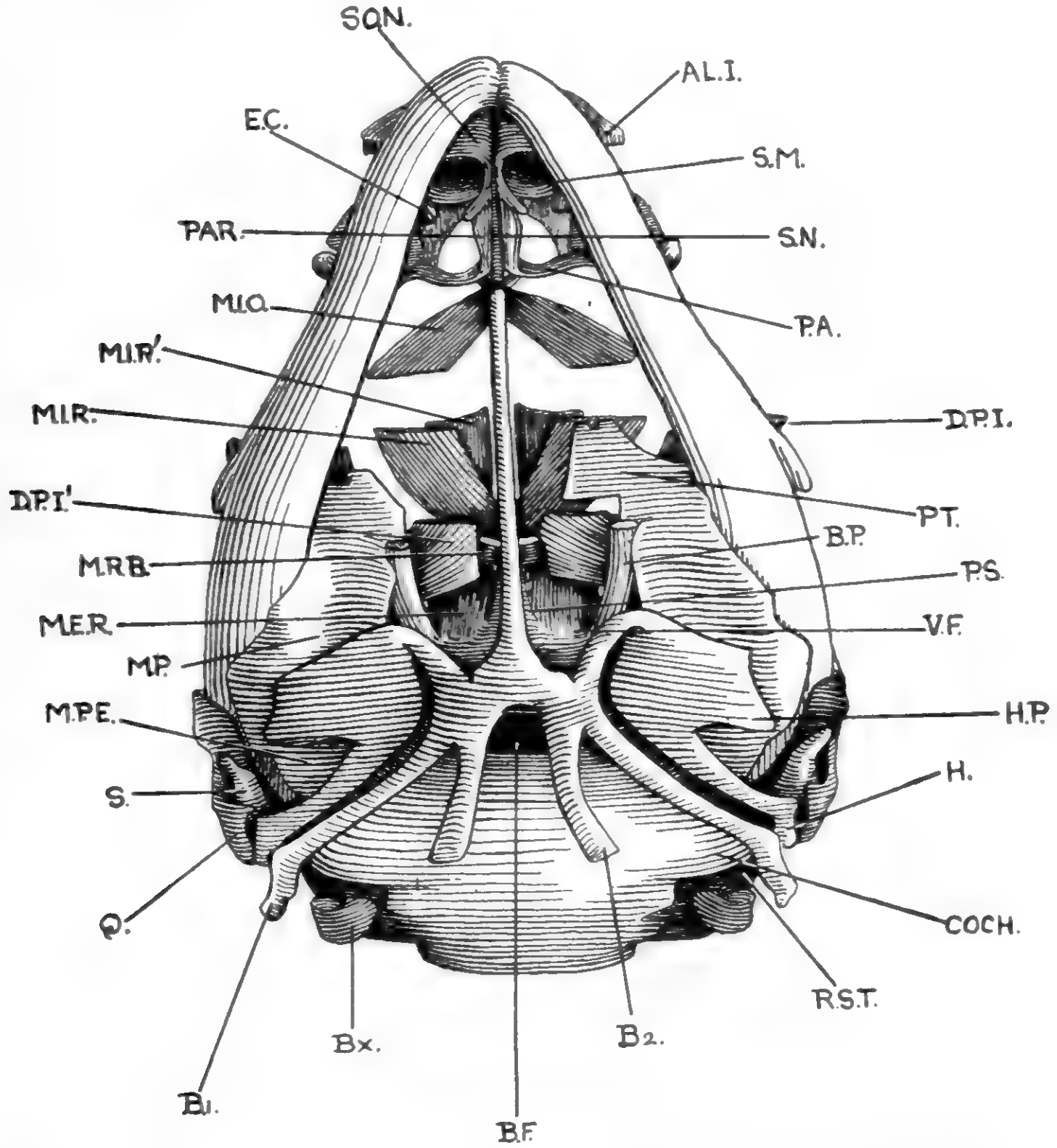

Fig. 3. Ventral view of same model. × ½. Most of palate removed to show muscles. Nerves and brain omitted.

In this lizard the recessus scala tympani (figs. 1–4, *R.S.T.*) is a well defined chamber lying beneath the ear capsule immediately behind the cochlear prominence (*COCH.*). The perilymphatic duct enters this chamber by a foramen in its roof and swells out into a big saccus perilymphaticus; from this, perilymphatic tissue passes into the cranial cavity through a foramen in the mesial wall of the chamber just below the one in its roof. In front of these two foramina, which lie in the same transverse plane as the paroccipital process and thus well in front of the foramen for the Xth nerve, the back of the cochlea prominence projects down to form the anterior wall of the chamber; behind them the latter stretches back for some distance. The concave ventro-lateral wall of the chamber is formed throughout by a very definite, clearly-defined membrane, which stretches from just above the cartilaginous strip of basal plate separating opisthotic from basioccipital upwards and outwards to the ventro-lateral edge of the ear capsule. This membrane also arches up behind to form the back wall of the chamber.

Gaupp's name of "medial aperture of recessus scala tympani" may be applied to the foramen through which the perilymphatic duct enters the cranium, but the whole of the extensive ventro-lateral and posterior walls of the recessus can hardly be referred to as its lateral aperture, in spite of its being composed of membrane only.

ORBITO-TEMPORAL REGION

At the level of the small pituitary foramen (fig. 1, ***P.F.***) the basisphenoidal plate (fig. 1, ***B.S.***) ends abruptly, passing over into the presphenoidal cartilage (figs. 1 and 3, ***P.S.***) in the mid-line, and the basipterygoid processes (figs. 1 and 3, ***B.P.***) laterally. The origin of the presphenoidal bar from paired trabecular cartilages is evident at its root, which is a double structure, the two halves (corresponding to the longer "trabeculae" of *Lacerta*) being continuous with the just ossifying block of cartilage on either side of the pituitary foramen.

This presphenoidal cartilage runs right forwards through the orbital region and is continued into the base of the septum nasi (figs. 3, 4 and 6, ***S.N.***). It lies well above the bony palate and is itself simply the ventral edge of the neural cranium in the orbito-temporal region—a region which is here, as in all lizards, much fenestrated, and compressed between the eyes into a narrow interorbital septum in correlation with the enormous size of these organs. The reduction of the chondrocranium in this region has proceeded even further than in the stage modelled by Gaupp (1900) and is perhaps intermediate between the conditions in stage 2 and stage 5 of *Eumeces* figured diagrammatically by Rice (1920) but does not quite correspond to either.

Of the cartilaginous bars in the temporal region resulting from this fenestration, the following, after Gaupp's nomenclature, are present in part or whole.

1. *Taenia marginalis.* This is only represented at its extreme posterior (fig. 4, ***T.M.***[1]) and anterior (fig. 2, ***T.M.***[2]) ends. Posteriorly as a slender rod of cartilage arising from the dorsal surface of the ear capsule in the cartilaginous region which separates the supraoccipital and pro-otic ossifications, and projecting forwards for a short distance above and parallel to the ridge for the anterior vertical semicircular canal (fig. 4, ***A.V.S.C.***). Anteriorly as a

similar but even shorter projection from the antero-dorsal edge of the solum supraseptale (figs. 2 and 4, *S.SUP.*) (just as in Gaupp's model) and under cover of the lateral edge of the frontal (fig. 2, *F.*).

2. *Taenia parietalis media* (figs. 2 and 4, *T.P.M.*). This is present throughout its whole length, forming the dorsal margin of the fenestrae optica (fig. 2, *F.O.*) and metoptica, and lying close against the antero-ventral wall of the fore-brain, between that and the posterior eye-muscles.

3. *Pila pro-otica* (fig. 4, *P.P.*). This is simply represented by the blindly ending posterior extremity of the taenia parietalis media, bent round at right angles to the rest of the latter so as to point caudally, and quite failing to reach the basis cranii. From its ventro-median border originates the depressor palpebrae inferioris muscle, which passes forwards and divides into two, a small group of fibres (fig. 3, *D.P.I.*^{1}) passing inwards to the soft palate and a broad thin sheet (figs. 3 and 4, *D.P.I.*) passing forwards and outwards under the eye to be inserted in the lower eyelid and on the posterior edge of the membrane covering the suborbital fenestra (fig. 1, *F.SUB.*).

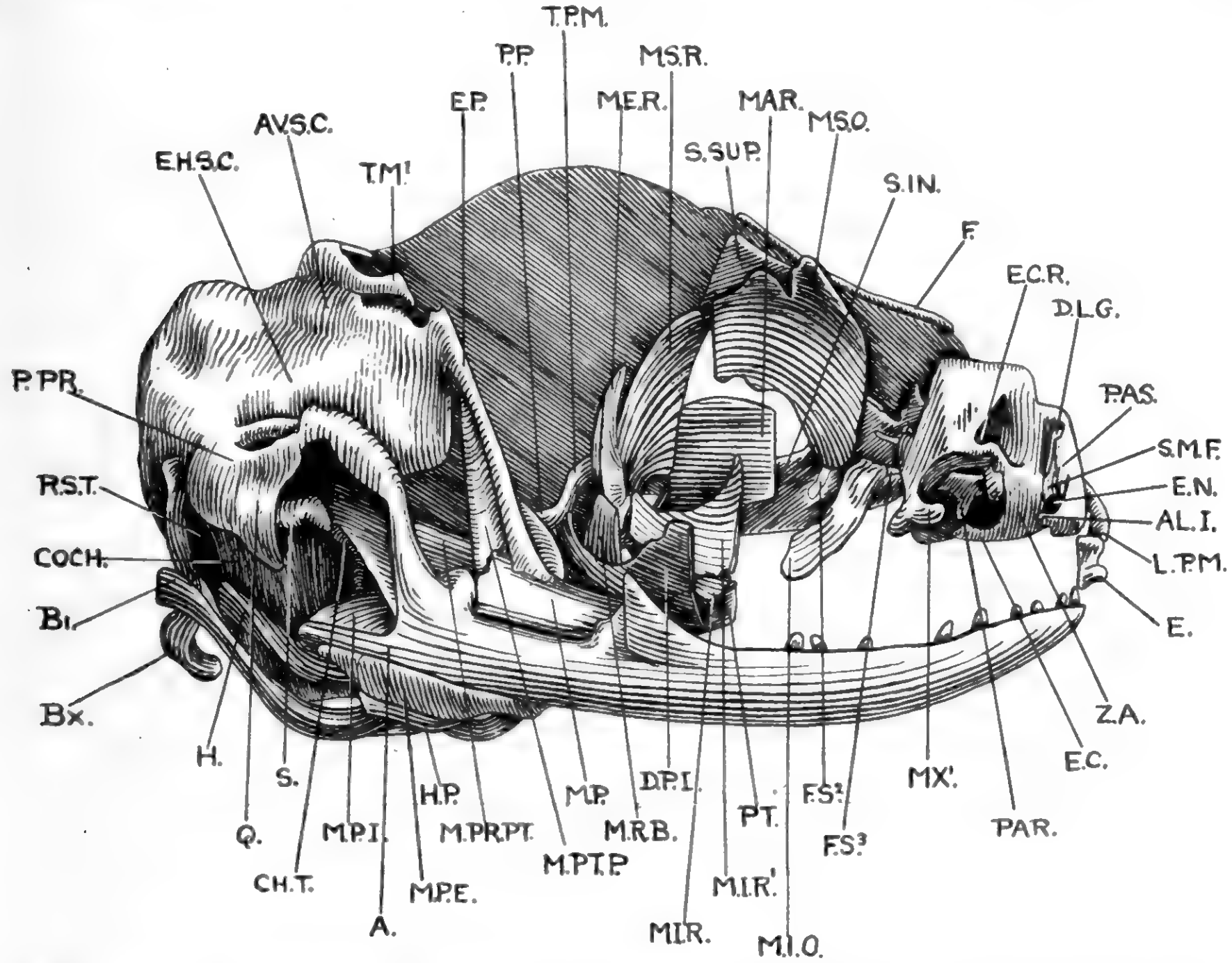

Fig. 4. Right lateral aspect of same model. × ¼. (The left half of the brain is included in the model for support.)

4. *Pila metoptica* (fig. 2, *P.M.*). This is complete, lying close against the antero-ventral surface of the fore-brain, at right angles to the taenia parietalis media and the presphenoidal cartilage, and forming the posterior margin of the fenestra optica.

The pila of either side meets its fellow below the optic chiasma and the single bar thus formed bends straight down away from the brain to join the presphenoidal cartilage. The superior recti muscles take origin from either side of the place of union of the two pilae, while the inferior recti arise immediately in front of them from the posterior edge of the joint bar. The retractor bulbi muscles arise from the dorsal surface of the presphenoidal cartilage posterior to the region where this bar joins it.

The pila accessoria is entirely lacking.

Of the fenestrae of which these cartilaginous remnants form the boundaries, the fenestra optica (fig. 2, ***F.O.***) is complete and transmits the optic nerve (figs. 1 and 2, II) only. The fenestra metoptica is confluent with the "fenestra" pro-otica at its postero-ventral corner owing to the pila pro-otica being incomplete. Gaupp's fenestra epioptica is entirely lacking, owing to the absence of a taenia marginalis in this region and of a pila accessoria. The "fenestra" pro-otica itself has no dorsal boundary, also owing to the absence of a taenia marginalis above the greater part of it.

The pro-otic space transmits the trigeminal nerve, the big gasserian ganglion (fig. 2, ***G.G.***) lying in the usual notch in the pro-otic (incisura pro-otica of Gaupp). From the ganglion the maxillary (figs. 1 and 2, V, ***MAX.***) and mandibular (figs. 1 and 2, V, ***MAN.***) branches of the nerve pass outwards, laterally to the epipterygoid (figs. 1 and 2, ***E.P.***), while the ophthalmic (figs. 1 and 2, V, ***O.P.***) branch runs more medially, keeping near to the ventro-lateral surface of the brain, between that and the pterygoid muscles (fig. 4, ***M.PR.PT.*** and ***M.PT.P.***) and above the edge of the basisphenoid; it runs along the ventral surface of the pila pro-otica (fig. 4, ***P.P.***) and anteriorly to this gives off a small branch (ramus temporalis) (fig. 2, V, ***TEM.***) which passes forwards with the main one for a short distance and then bends abruptly upwards along the lateral surface of the brain, crossing over the taenia parietalis media (figs. 2 and 4, ***T.P.M.***). The main maxillary branch still runs forwards, keeping near to the ventro-lateral surface of the brain and coming into contact with the oculomotor (figs. 1 and 2, III), with which it runs parallel between the brain and the eye-muscles as far as the pila metoptica (fig. 2, ***P.M.***).

From its origin on the dorsal wall of the mid-brain the trochlear nerve (fig. 2, IV) runs forwards and slightly downwards, and keeping very close against the brain wall it comes into contact with the taenia parietalis media (fig. 2, ***T.P.M.***), lying at first dorsal to the latter and then ventral, and crossing it on its medial surface. In this part of its course it runs above and within the oculomotor and the maxillary ramus of V. Together with these it passes laterally to the pila metoptica (fig. 2, ***P.M.***).

Thus, as in *Lacerta* and *Eumeces*, the three branches of the trigeminal pass out of the cranium through the fenestra pro-otica (incomplete dorsally), the trochlear and oculomotor through the fenestra metoptica, and the optic nerve through the fenestra optica.

ORBITAL REGION PROPER

The anterior part of the ethmoidal cartilage is represented solely by the fenestrated septum (figs. 2 and 4, *S.IN.*) between the eyes and a small dorsal portion, (solum supraseptale of Gaupp), (figs. 2 and 4, *S.SUP.*) still clasping the posterior end of the elongated olfactory lobes (fig. 2, *O.L.*). The ventral edge of the septum is confluent with the anterior end of the presphenoidal cartilage (fig. 1, *P.S.*). The septum is perforated by three membrane-closed fenestrae, a very large postero-dorsal (figs. 2 and 5, *F.S.*[1]) and two smaller antero-ventral (figs. 2 and 5, *F.S.*[2] & *F.S.*[3]). The lower half of its posterior border is curved forwards, forming the anterior edge of the fenestrae opticae (fig. 2, *F.O.*) while the upper half is a simple bar, triangular in section, supporting the antero-ventral surface of the fore-brain and bounding the large septal fenestra behind. This bar is directly continuous with the anterior ends of the taeniae parietales mediae (fig. 2, *T.P.M.*) which indeed seem not to fuse completely on joining it, as the bar appears double in section. Antero-dorsally, above the large septal fenestra, each half of the bar expands into a flat wing which runs up to meet the lateral edge of the frontal bone (fig. 2, *F.*) of that side, the short trough-shaped tunnel (figs. 2 and 4, *S.SUP.*) thus formed surrounding the olfactory lobes (fig. 2, *O.L.*) at their posterior end. The cartilaginous part of the tunnel is the solum supraseptale of Gaupp.

[The taeniae marginales (fig. 2, *T.M.*[2]) constitute in this region a dorsal extension of the side wall of the tunnel. The ventral edge of the trough is continued forwards and slightly downwards as a narrow bar below the anterior end of the olfactory lobes; this joins the anterior part of the septum in front of the big septal fenestra, of which it forms the dorsal boundary.

In the region where the taenia parietalis media of either side joins the posterior edge of the septum, above the place where the two optic nerves separate from one another, is the more dorsal of the two origins of the internal rectus eye-muscle (figs. 3 and 4, *M.A.R.*), which runs anteriorly in a vertical plane between the septum and the back of the eye. The ventral origin of this muscle is on the dorsal surface of the presphenoidal cartilage below the optic fenestra. The two parts join each other immediately in front of the place of separation of the optic nerves.

The more posterior of the two small septal fenestrae (figs. 2 and 4, *F.S.*[2]) lies immediately in front of and below the large fenestra (*F.S.*[1]). On the anterior part of its closing membrane the superior oblique eye-muscle (figs. 2 and 4, *M.S.O.*) has origin. The more anterior of the two fenestrae (*F.S.*[3]) lies just behind the planum antorbitale (figs. 3, 6 and 7, *P.A.*) where the much narrowed interorbital septum (figs. 6 and 7, *S.IN.*) passes into internasal septum (*S.N.*); the closing membrane of this fenestra gives origin to the inferior oblique eye-muscle (figs. 3 and 4, *M.I.O.*). In Gaupp's *Lacerta* embryo there is only one fenestra in this anterior region of the septum. Rice finds that in *Eumeces* the extent of fenestration depends on the age of the embryo and the degree of resorption of the cartilage.

SUMMARY OF EYE-MUSCLES

Fig. 5 is a diagrammatic representation of the orbito-temporal region of the cranium in which the places of origin of these muscles are indicated by cross-hatching.

1. *External Rectus* (figs. 3 and 4, *M.E.R.*). Origin: on floor of pituitary fossa at side of hypophysis and forwards along dorsal surface of presphenoidal cartilage until replaced by fibres of retractor bulbi. Muscle passes forwards close to brain and then spreads out in front of the taenia parietalis media (fig. 4, *T.P.M.*) into a flat sheet at back of eye. Before doing this it gives off a large clump of fibres, a few of which pass up to join the superior rectus, the remainder passing forwards and downwards to form an accessory inferior rectus (figs. 3 and 4, *M.I.R.*^{1}) lying closely within and above the other one but never fusing with it.

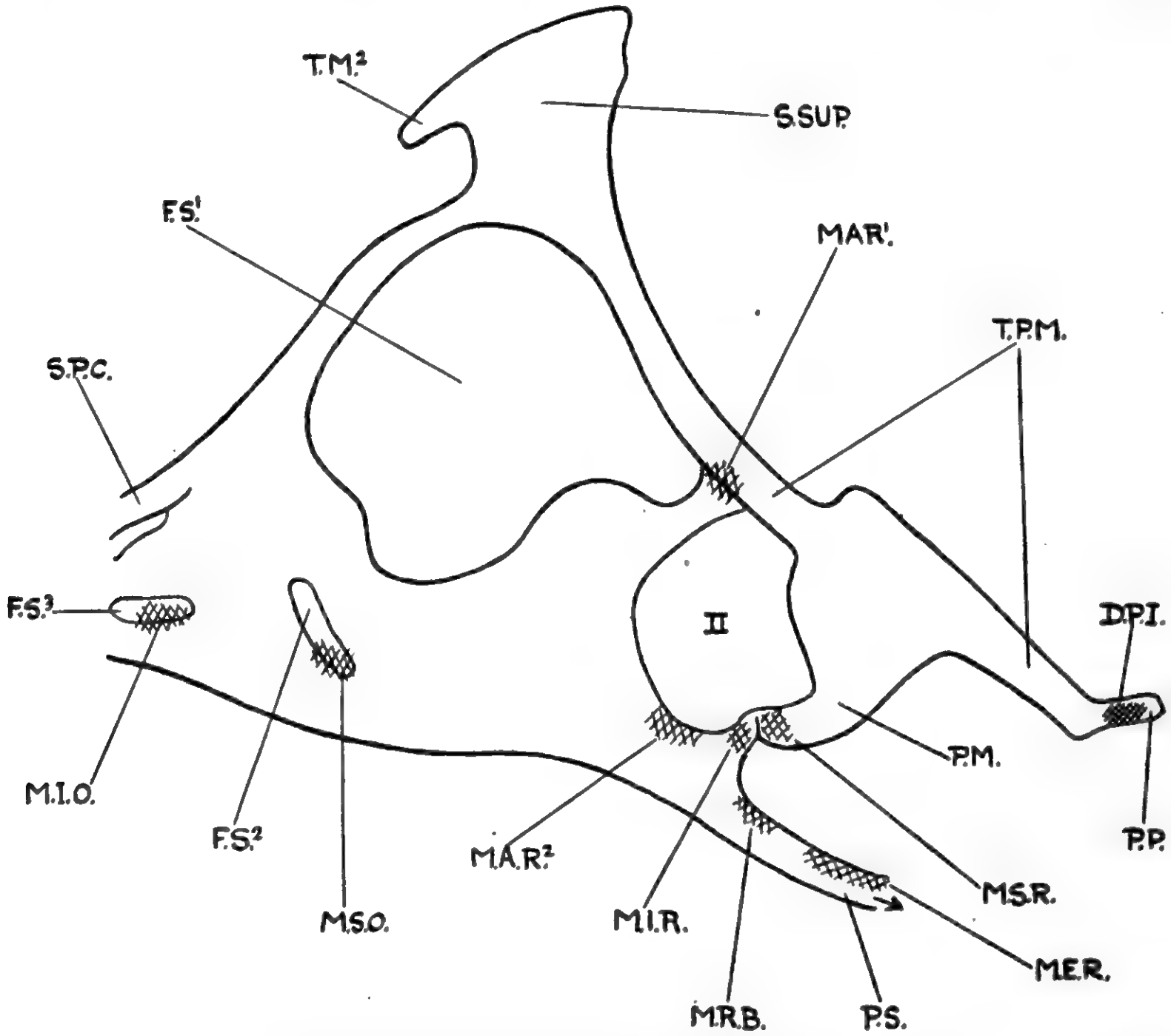

Fig. 5. Diagrammatic lateral view of orbito-temporal region of cranium to show eye-muscle insertions (cross-hatched). $\times \frac{1}{2}$.

2. *Superior Rectus* (fig. 4, *M.S.R.*). Origin: on pila metoptica at the place where it meets its fellow beneath the brain at back of optic chiasma. Muscle runs forwards and upwards at side of latter against anterior surfaces of pila metoptica and taenia parietalis media, and is joined beneath its insertion by a few fibres from the external rectus.

3. *Inferior Rectus* (figs. 3 and 4, *M.I.R.*). Origin: just in front of superior rectus on short bar formed by union of pilae metopticae above and joining them

to presphenoidal cartilage. Muscle passes forwards and outwards in a horizontal plane just below edge of septum.

4. *Internal Rectus* (figs. 4 and 5, *M.A.R.*). Origin: (*a*) by fibres arising from place where taenia parietalis media joins the cartilage bounding the big fenestra septi behind and representing posterior edge of septum; (*b*) by fibres on dorsal surface of presphenoidal cartilage below optic fenestra. The two groups join together in front of optic nerve, the main body of the muscle running straight forwards between eye and septum.

5. *Retractor Bulbi* (figs. 3 and 4, *M.R.B.*). Origin: partly on dorsal surface of presphenoidal cartilage anterior to the fibres of external rectus, but mainly further forwards on this cartilage below the origin of inferior rectus described above. Muscle is a slender one running straight out to side to be inserted on eye just below and in front of insertion of posterior rectus.

6. *Superior Oblique* (figs. 2 and 4, *M.S.O.*). Origin: on anterior part of membrane closing hindermost of the two small septal fenestrae (*F.S.*^{2}). Muscle passes upwards and backwards along surface of septum and of membrane closing big posterior septal fenestra, being inserted on eye in region of solum supraseptale.

7. *Inferior Oblique* (figs. 3 and 4, *M.I.O.*). Origin: on closing membrane of foremost of the two small septal fenestrae (*F.S.*^{3}).

OLFACTORY REGION

Incomplete as are the walls of the nasal capsule, the olfactory organs are well protected on all sides owing to the development of membrane bones over those regions where cartilage is lacking. In general plan the capsule itself agrees fairly closely with that of *Lacerta*, the differences being principally a matter of proportion and degree of fenestration. The large fenestra lateralis nasi described and figured by Gaupp in the wall of the extraconchal recess is, as in *Eumeces*, entirely lacking, while, also in agreement with stage 5 of *Eumeces*, the small fenestra superior nasi of Gaupp is so large that it occupies about half of the antero-dorsal slope of the nasal capsule and is separated from its fellow by little more than the dorsal edge of the septum (figs. 2 and 7, *F.S.N.*). This latter fenestra is completely covered in by the as yet somewhat ill-defined nasal bone, while the extraconchal recess (fig. 4, *E.C.R.*), a deep pit due to the inpushing of the lateral wall of the capsule to form the concha (figs. 6 and 7, *CO.*) and housing the big lateral nasal gland, is itself covered in at the side by the overlapping facial portions of the maxilla and prefrontal (fig. 2, *MAX. F.* & *PR.F*); a gap is left anteriorly however, where the facial sheet of the maxilla ceases somewhat abruptly, for the outward passage of the duct of this gland, which runs forwards to open into the nasal cavity just behind the external naris (figs. 2 and 4, *D.L.G.*).

Below and behind the extraconchal recess the facial plate of the maxilla forms a cover to the naso-lachrymal duct as it runs forwards from the orbit. The lachrymal foramen through which this duct leaves the orbit is bounded on the outer side by the posterior edge of the facial plate of the maxilla and the very small lachrymal bone lying in contact with it, on the inner side by the outer edge of the prefrontal, which bone stands transversely across the front of the orbit.

Passing through this foramen the duct crosses above the maxillary processes of the nasal capsule (figs. 4, 6 and 7, MX^1 & MX^2) and, keeping in close contact with the inner surface of the maxilla, runs forwards to open into the top of the choanal fissure below the extraconchal recess (fig. 4, ***E.C.R.***).

At the back of the nasal capsule the big olfactory fenestra on either side (figs. 6 and 7, ***F.OLF.***) is blocked by the olfactory bulb (fig. 2, ***O.B.***), which projects into it above the sphenethmoidal cartilage (figs. 6 and 7, ***SP.C.***) and planum antorbitale (figs. 3, 6 and 7, ***P.A.***), the only representatives of a cartilaginous capsular wall in this region. The two olfactory bulbs form one mass supported in the mid-line, within the capsule, by the nasal septum (figs. 3, 6 and 7, ***S.N.***), on either side of which the olfactory nerves run down. Below and external to each olfactory bulb the nasal capsule is shut off from the orbit by the prefrontal bone (fig. 2, ***PR.F.***), met below by the dorsal plate of the palatine and laterally abutting on the inner surface of the maxilla. The dorsolateral edge of the prefrontal is bent forwards over the roof of the capsule for a short distance, meeting the anterior end of the frontal above and the facial plate of the maxilla below; these three together form a continuous curved surface which is continued anteriorly over the roof of the capsule by the as yet ill-defined nasal.

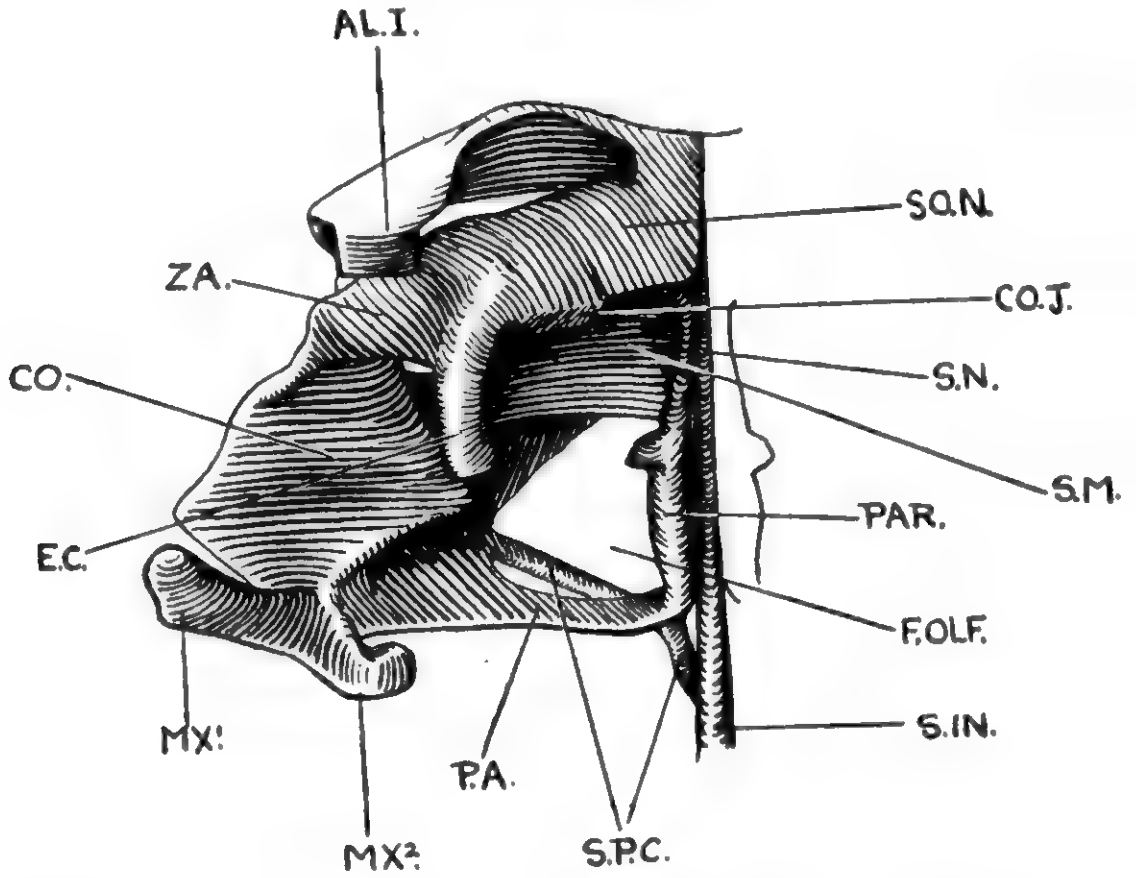

Fig. 6. Ventral view of right half of nasal capsule. × ½.

The anterior face of the prefrontal is in contact with the planum antorbitale and covers in the gap between this and the sphenethmoidal cartilage, sending in a bony projection between the two. The ethmoidal branch of the fifth nerve passes out of the antero-mesial corner of the orbit into the nasal capsule between this projection and the sphenethmoidal cartilage; it then passes forwards at the side of the olfactory bulb, among the roots of the olfactory nerve, and soon divides into two—a ramus lateralis passing out to the side and leaving the capsule by the foramen epiphaniale above the mouth of the extra-conchal recess, and a ramus medialis which keeps close to the bulb wall and in front of that to the septum just above the septomaxilla; this latter branch leaves the capsule by a foramen (f. apicale) in its extreme antero-mesial wall.

Viewed from the ventral surface the nasal capsule is nearly completely hidden by the premaxillae (fig. 1, *P.MAX.*) in front, the fused prevomers (fig. 1, *P.V.*) and the maxillae (fig. 1, *MAX.P.*) behind. Between these latter bones, on either side, is the cleft-like opening of the choanal fissure. These fissures are continuous behind the prevomer with the canal-like naso-palatine groove (described in connection with the palatine bone); each at first, as it runs forwards under the planum antorbitale, retains a common aperture onto the palate ventral to the prevomer, but further forwards, within the olfactory region, this bone develops a ventrally directed ridge which divides the common aperture into two; further forwards still the prevomer expands ventrally into two curved plates embracing the organs of Jacobson, and the apertures of the choanal fissures swing outwards away from one another and become widely separated.

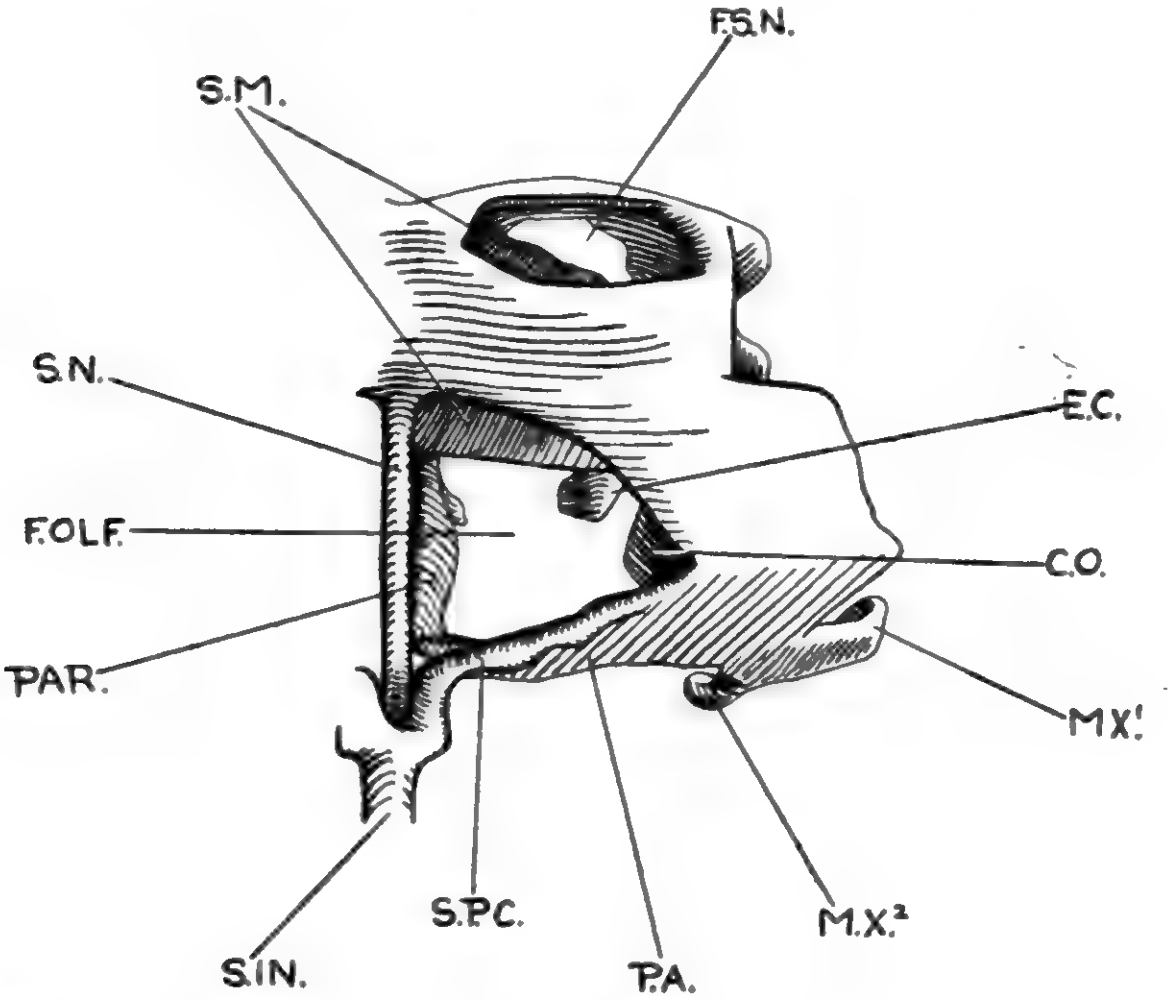

Fig. 7. Dorsal view of right half of nasal capsule. × ½.

Each fissure is a cleft-like space running outwards and upwards from the buccal cavity against the inner surface of the maxilla. The ectochoanal cartilage (figs. 3, 4, 6 and 7, *E.C.*) projects back from the solum nasi along the free inner edge of the palatal sheet of the latter. Posteriorly, however, in front of the abruptly ending ventral plate of the palatine (fig. 1, *P.V.P.*) and before the fissure has swung out to the side round the organ of Jacobson, this palatal sheet of the maxilla does not extend inwards as far as the entrance of the fissure, here right in the centre of the palate, but its place is taken by a thick mass of dense glandular tissue lying between the palatal epithelium and the ventral epithelial wall of the fissure, and probably acting as a valve for closing the latter.

So nearly in front of the anterior end of the fissure as almost to open onto the palate together with it is the duct of Jacobson's organ (fig. 1, ***A.D.J.***). Immediately in front of this, below the posterior edge of the solum nasi, the prevomer and the anterior end of the maxilla approach one another. In front of this again the maxilla is replaced by the premaxilla (fig. 1, ***P.MAX.***), which forms a floor to the nasal capsule in the region of the external naris and sweeps forwards and inwards round the edge of the prevomer to meet its fellow in the mid-line below the anterior extremity of the nasal septum; the palatal portions of the premaxillae thus form a horseshoe-shaped plate at the anterior end of the palate. This plate projects well in front of the nasal capsule to support the big egg-crushing tooth (figs. 1, 2 and 4, ***E.***) ventrally, and dorsally to give rise to the small facial part of the premaxilla which is deflected back over the sloping anterior face of the capsule to meet the nasal.

SEPTOMAXILLA AND JACOBSON'S ORGAN

In relation to the nasal capsule there still remains to be described the septomaxilla. This membrane bone is mainly intracapsular, dividing the nasal cavity into two chambers, a smaller antero-ventral one containing Jacobson's organ and a much larger postero-dorsal one for the principal olfactory organ. The bone also possesses a very small facial portion.

The intracapsular portion (figs. 3, 6 and 7, ***S.M.***) forms a sloping, slightly arched shelf over the dorsal surface of Jacobson's organ. This shelf is deflected downwards anteriorly to form a front wall also to that organ. The mesial edge of the shelf spreads out into a narrow plate at right angles to the main part and applied to the internasal septum about half-way up the side of the latter. From this edge the shelf slopes outwards and slightly downwards to rest on the inner surface of the ventro-lateral capsular wall (part of Gaupp's zona annularis) present in this region.

In front of the zona annularis arises from this outer edge of the shelf, just before the latter narrows and curves down in front of Jacobson's organ, the facial portion of the bone (figs. 2 and 4, ***S.M.F.***). This is a small vertical projection running upwards to meet the processus alaris superior of the capsule (figs. 2 and 4, ***P.A.S.***) and together with this completely separating the external nareal aperture (figs. 2 and 4, ***E.N.***), which lies immediately below and in front of it, from another aperture (figs. 2 and 4, ***D.L.G.***), which lies immediately above and behind. This latter aperture is that by which the duct of the lateral nasal gland, coming forwards along the outer surface of the capsule, enters this in order to open into the nostril (an entrance place employed among mammals by the naso-lachrymal duct).

Lygosoma at this stage does not possess a complete zona annularis such as that in Gaupp's model of *Lacerta*, but it is more nearly complete than in

Eumeces, stage 5. Corresponding to the lateral portion of Gaupp's cartilaginous ring is that region of the capsular wall (figs. 4 and 6, *Z.A.*) which projects downwards and inwards in front of the concha, with a straight posterior edge lying against the anterior extremity of the choanal fissure and an outer surface resting against the maxilla in the position occupied further back, below the concha, by that fissure itself. From the ventral edge of this part of the capsular wall projects back the ectochoanal cartilage (figs. 4 and 6, *E.C.*) described above in relation to the palatal aperture of the fissure; anteriorly its ventral edge becomes confluent with the solum nasi (figs. 3 and 6, *SO.N.*), the sole representative of a cartilaginous floor to the capsule, and thus completes the ventral part of the zona annularis; dorsally however the latter is interrupted owing to the extension of the big fenestra superior nasi (fig. 7, *F.S.N.*) into this region.

The solum nasi lies on each side on the concave dorsal surfaces of the fused prevomers and separates those bones from the downwardly bent anterior ends of the septomaxillae. Anteriorly it arises as two outwardly projecting horns from the ventral edge of the septum, but further back, within the chamber of Jacobson's organ, it becomes detached from the septum as two separate plates, from the dorsal surfaces of which arise the cartilaginous knobs constituting the conchae of the organs of Jacobson (fig. 6, *CO.J.*). The medial edges of these plates are continued back into the two paraseptal cartilages (figs. 3, 4, 6 and 7, *PAR.*) which pass back on either side of the ventral edge of the septum to the posterior extremity of the capsule, where they swing abruptly outwards and expand into the plani antorbitalia (figs. 3, 6 and 7, *P.A.*). In front of the duct of Jacobson's organ the solum nasi stops abruptly and that organ is floored in by the prevomer alone. The posterior and postero-lateral walls of the chamber are formed by the rising up of the prevomer to meet the posterior edge of the septomaxillary shelf.

Jacobson's organ is thus enclosed in a box, the walls of which are constituted as follows. The roof and anterior wall by the septomaxilla. The admedial wall: in front by the septum nasi alone, behind by the septum above and the medial ridge of the fused prevomers below. The floor: in front by the solum nasi resting on the prevomer, behind by the prevomer alone. The lateral wall: quite anteriorly by the septomaxilla, centrally by the ventro-lateral part of the zona annularis resting on the maxilla, quite posteriorly by the prevomer (in the region where the posterior end of Jacobson's organ lies mesial to the anterior end of the choanal fissure). The only apertures in this box are (*a*) for the duct of Jacobson's organ which runs onto the palate between the prevomer and the zona annularis (fig. 1, *A.D.J.*), and (*b*) for the fibres of the olfactory nerve which innervate the organ and gain access to it posteriorly between the septomaxilla and the septum nasi.

TEMPORAL AND CIRCUM-ORBITAL MEMBRANE BONES

Parietal (fig. 2, *P.*). The parietal at this stage is a narrow strip of bone lying along the dorso-lateral surface of the brain. Its posterior end forks above the taenia marginalis, one portion passing outwards to end in contact with the anterior end of the supra-temporal over the depression between the external and anterior semicircular canals, the other, which is much shorter, keeping close to the surface of the brain above the latter and terminating in the fibrous tissue which stretches back in this region to the tectum synoticum.

In front of the supra-temporal the parietal lies just mesial to the squamosal posteriorly and the postorbital anteriorly, no temporal fossa being present as yet. The anterior end of the parietal is overlapped by the frontal.

Supra-temporal (fig. 2, *S.T.*) and *squamosal* (fig. 2, *SQ.*). These are also narrow strips of bone. Their posterior ends will be dealt with in connection with the quadrate. From that bone they curve upwards and then forwards in the same connective tissue sheath. The supra-temporal, or the innermost of the two bones, terminates shortly in front of the posterior end of the parietal which lies in the same sheath. The squamosal, or outermost of the two bones, runs forwards for some way along the lateral edge of the parietal until it is separated from that bone by the posterior end of the postorbital.

Postorbital (figs. 1 and 2, *P.O.*). This is a stout triangular plate of bone forming the posterior boundary of the orbit and with the angles drawn out into processes which lie respectively along the upper edge of the jugal, the outer edge of the frontal, and the upper edge of the squamosal.

Jugal (figs. 1 and 2, *J.*). This is a slender rod of bone encircling the orbit and meeting the postorbital behind, the transverse and maxilla in front. It is met by these last two bones about half way round the orbit but continues forwards to the front of the latter in a groove on the inner surface of the maxilla as a very slender bar which terminates between this bone and the lachrymal. Behind the point where it is met by the transverse and just above the coronoid process (fig. 2, *COR.*) of the lower jaw the jugal broadens a little and is perforated by a foramen for a small branch of the maxillary of V.

Frontal (figs. 2 and 4, *F.*). The anterior halves of the two frontals form a roof to the olfactory lobes. Behind these the bones diverge widely from each other round the back of the orbit as narrow strips overlapping the anterior ends of the parietals and meeting the post-orbital. Anteriorly they are met by the nasals in the middle line and by long backward projections of the prefrontals along their outer edges.

Prefrontal (fig. 2, *PR.F.*). The prefrontal has already been described in connection with the olfactory region. It is met by the frontal, nasal, maxilla and palatine.

Lachrymal. This is an exceedingly small plate of bone lying at the antero-lateral corner of the orbit between the naso-lachrymal duct and the inner surface of the facial portion of the maxilla at its posterior edge. It rests in front on the planum antorbitale and is met behind by the jugal. It does not come into contact with the prefrontal.

JAW ATTACHMENT

Quadrate and Stapes. The quadrate (figs. 1 and 4, *Q.*) is a large plate-like bone lying at the side of the otic region of the cranium and articulating behind with the paroccipital process (figs. 2 and 4, *P.PR.*), in front with the lower jaw. Its anterior, dorsal and posterior edges are bent over to form a semicircular rim across which is stretched the tympanic membrane. The tympanic cavity occupies the space between this membrane and the mesial plate-like surface of the quadrate, and passes downwards and inwards under the ventral edge of the latter to open into the pharynx between the pro-otic and the posterior ends of the branchial arches. The stapes (figs. 1–4, *S.*), its head inserted in the centre of the tympanic membrane, lies across the back of the tympanic cavity and passes inwards and backwards under the ventral edge of the quadrate to the fenestra vestibuli which lies in the cartilaginous region between pro-otic and opisthotic.

In its articular regions the quadrate is not yet ossified. Posteriorly it abuts on the cartilaginous paroccipital process (crista parotica) (figs. 2 and 4, *P.PR.*), but is separated from that by the posterior end of the supra-temporal (fig. 2, *S.T.*) and by a short cartilaginous spur which arises from the outer extremity of the process and projects forwards, enclosing the inpushing end of the supra-temporal between itself and the wall of the external semicircular canal. This spur corresponds to the "processus pro-oticus" of *Lacerta* and *Eumeces* (intercalare of Versluys[1]) but there is considerably less of it present in this stage of *Lygosoma*; a stout strand of fibrous connective tissue joins it to a backward projection (processus dorsalis?) of the stapes.

Shortly in front of this articular region the rolled-over dorsal edge of the quadrate is perforated by a rectangular fenestra filled with dense connective tissue into which projects the downwardly-bent posterior end of the outermost of the two temporal bones ("squamosal") (fig. 2, *SQ.*). A film of fibrous connective tissue passes from that portion of the innermost temporal bone ("supra-temporal") which is wedged between the quadrate and ear capsule forwards and outwards over the surface of the quadrate to meet the squamosal at this spot.

Just mesial to this fenestra is another smaller one, also filled by connective tissue and transmitting nothing.

From the mesial and dorsal surfaces of the quadrate and from the ventral surfaces of the squamosal and postorbital takes origin the big temporal muscle (M. capiti-mandibularis) which lies posteriorly in the cleft between the quadrate and ear capsule and passes forwards and downwards to its insertion on the lower jaw. Here may also be mentioned a smaller muscle (pterygoideus of Bradley[2], pterygoideus internus of Sanders) which is not always distinguished from the capiti-mandibularis but which in *Lygosoma* is recognisable as a separate entity inserted on the lower jaw more mesially than the above,

---

[1] Versluys, 1898, *Zoolog. Jahrbuch. Anat. u. Ontog.*, Bd. XII, H. 2.

[2] Bradley, 1903, *Zoolog. Jahrbuch. Anat. u. Ontog.*, Bd. XVIII.

embracing the outer surface of the epipterygoid, and taking origin from the parietal.

The nerves and blood-vessels in the region of the stapes have the usual relations to that element, to the quadrate and to the paroccipital process. The vena capitis lateralis (figs. 1 and 2, *V.C.L.*) and the hyomandibular branch of VII lie side by side in the usual groove under the paroccipital process. Just in front of the latter, ventral to the inturned end of the supra-temporal, the chorda tympani (figs. 1, 2 and 4, *CH.T.*) comes off from the hyomandibular of VII, passes out to the ventral edge of the quadrate, runs forwards in contact with this above the stapes, and finally runs down into the lower jaw near the anterior end of the quadrate in contact with the posterior extremity of the quadrate ramus (figs. 1 and 2, ***PT.Q.***) of the pterygoid.

In the gap between the ramus hyomandibularis of VII, the recurrent chorda tympani, and the stapes crossing below them, runs up the stapedial artery (carotis facialis Rathke) (figs. 1 and 2, *S.A.*), a branch of the internal carotid (figs. 1 and 2, *I.C.A.*); it passes between the quadrate and the external semicircular canal and runs forwards along the ventral surface of the squamosal.

The strand of fibrous tissue connecting the processus pro-oticus with the stapes also passes down to the latter between the chorda tympani and the ramus hyomandibularis of VII; it lies in close contact with the chorda just after that nerve has branched off.

That end of the quadrate which articulates with the lower jaw is only just beginning to ossify. It lies closely applied to the dorsal surface of the articular region of Meckel's cartilage (figs. 2 and 4, *A.*), which is also only just beginning to ossify. The posterior end of the quadrate ramus of the pterygoid (figs. 1 and 2, ***PT.Q.***) lies just mesial to the quadrate in this region and is connected with the ventral edge of that bone immediately behind the articular region by connective tissue; the extreme tip projects freely however, and lies in close contact with the chorda tympani, which is here just entering the pterygoideus muscle on its way to the lower jaw.

This muscle (pterygoideus Versluys, pterygo-mandibularis Bradley) (figs. 3 and 4, *M.P.*) represents the pterygoideus externus plus the pterygoideus internus; these are fused together anteriorly but separate posteriorly, where they are inserted respectively on the ventral (figs. 3 and 4, *M.P.E.*) and dorsal (fig. 4, *M.P.I.*) surfaces of the lower jaw, on the angular and posterior part of the articular. The muscle has its origin on the dorsal surface of the quadrate ramus of the pterygoid in front of the epipterygoid, on the outer surface of the base of the epipterygoid, and on the outer surface of the pterygoid more posteriorly.

The other muscles related to the quadrate ramus of the pterygoid are those which connect it with the cranium. These are the protractor pterygoidei Versluys (pterygo-sphenoidalis posterior Bradley) (fig. 4, *M.PR.PT.*) and the pterygo-parietalis (fig. 4, *M.PT.P.*).

Some of the fibres of the former take origin from the middle of the basipterygoid process, the rest from the dorsal edge of the outwardly leaning processus anterior inferior of the pro-otic (figs. 1 and 2, *P.A.I.*), below the gasserian ganglion, and from the cartilaginous region of the basal plate below and in front of the processus. It is inserted along the inner surface of the pterygoid from behind the base of the epipterygoid to the posterior end of the quadrate ramus.

The pterygo-parietalis takes origin from the centre of a thickish strip of membrane which runs obliquely down the side of the brain from that part of the parietal which is level with the top of the epipterygoid to the taenia parietalis media level with the base of the latter. The muscle ensheathes the mesial and posterior borders of the epipterygoid at its lower end and is inserted along the pterygoid from the level of the anterior edge of the basal plate, forwards above the insertion of the protractor pterygoidei, to the anterior extremity of the epipterygoid; some fibres are also inserted on the ventral surface of the latter just before it reaches the pterygoid.

PALATE

Basipterygoid Processes (figs. 1 and 3, *B.P.*). From the antero-lateral corner of the basisphenoidal plate the basipterygoid process of either side runs outwards and forwards as a stout rounded bar to its articulation with the pterygoid. It reaches the latter immediately in front of the base of the epipterygoid (figs. 1, 2 and 4, *EP.*), here forms a laterally directed elbow, and before terminating bends forwards for a short distance along the ventro-medial surface of the pterygoid, with which, however, it never comes into very close contact.

Where it leaves the basis cranii the basipterygoid is completely ossified, but this ossification does not extend out as far as the elbow, the distal half of the process being completely cartilaginous. At its proximal end the process is crossed by the big vena capitis lateralis (fig. 1, *V.C.L.*), which runs outwards and upwards above it as it passes back from the infra-orbital sinus. The palatine branch of VII (fig. 1, VII, P^2) having issued from the Vidian foramen just mesial to the base of the basipterygoid, runs forwards and outwards along the dorso-medial surface of the latter onto the dorsal surface of the palate.

Pterygoid (figs. 1 and 3, *PT.*). In front of its articulation with the basipterygoid the pterygoid spreads out into a thin plate below the back of the eye and forms the hinder margin of the bony ring surrounding the large suborbital fenestra (fig. 1, *F.SUB.*), a ring completed by the transverse, maxilla and palatine. The pterygoid forms about a third of the inner boundary of the fenestra and then meets the palatine and narrows to form a short process inserted between the upper and lower plates of the latter.

Palatine (figs. 1 and 2, *PAL.*). When the skull is viewed from below the palatines are seen as two sheets of bone running side by side down the centre of the palate between the suborbital fenestrae, and swinging out round the anterior margins of these to meet inward projections of the maxillae. The inner edges of these plates approach each other very closely in the mid-line and form a kind of secondary palate, since they almost completely shut off the naso-palatine groove from the main part of the buccal cavity, and indeed the flaps of buccal epithelium in which they lie extend beyond the bone and actually overlap each other, appearing to form a kind of valve. This inner edge of either palatine is continued back behind the pterygoid articulation as a narrow bar diverging somewhat from its fellow and lying alongside the inner edge of the pterygoid but separated from that bone by a cleft filled with connective tissue. This bar and the medial edge of the pterygoid alongside it, and for a short distance behind it, both lie in a backward extension of the epithelial flaps mentioned above, but the flaps in this region do not nearly approach each other, the naso-palatine groove being in wide communication with the buccal cavity.

From the upper surface of each of the ventral palatine plates described above arises another thin bony plate arching upwards and inwards at an angle of about 45° over the naso-palatine groove and making the palatine bone Y-shaped in transverse section. This dorsal plate of the palatine (fig. 1, ***P.D.P.***) becomes more and more prominent as it passes forwards and here forms a flat surface with the outer, suborbital edge of the palatine (the limb of the Y), whereas the ventral plate in the secondary palate appears as a slightly bowed downward projection of this surface.

The palatine branch of VII (figs. 1–7, VII, P^2), running forwards along the dorsal surface of the pterygoid and palatine, passes gradually from the outer to the inner edge of the latter and, towards the front of the orbit, comes to lie in a groove formed by the bending upwards of the mesial edge of the dorsal palatine plate on either side of the base of the interorbital septum. Right at the anterior extremity of the orbit the floor of this groove becomes bent down to form a regular gutter.

At the level of the planum antorbitale both dorsal and ventral plates of the palatine cease abruptly, but a slender process from the mesial edge of the former runs forwards for some way in a canal in the prevomer and thus supports the palatine anteriorly at its inner edge, the maxillary articulation supporting it at its outer edge; the choanal fissure opens into the naso-palatine groove between these two articulations.

Transverse (figs. 1 and 2, *T.*). The transverse is a small plate of bone running inwards and backwards from the maxillo-jugal articulation to the pterygoid and forming with the short transverse ramus of the latter the postero-lateral boundary of the large suborbital fenestra. Its articulation with the pterygoid is of the type characteristic of the whole palate, inasmuch as it forms a sheath round the narrow distal extremity of the transverse ramus of that bone.

Maxilla. The zygomatic part of this bone (fig. 2, ***MAX.Z.***), forming the anterior half of the zygoma and the antero-lateral border of the suborbital fenestra, is met behind by the transverse and jugal. A double row of teeth extends right along the outer edge of the bone to its posterior end in this region. In the palate the maxilla does not play any very great part, its palatal portion (fig. 1, *MAX.P.*) being a rather narrow strip projecting inwards as a thin shelf from the tooth-bearing region; this shelf meets the palatine in front of the suborbital fenestra and thence runs forwards with a free inner edge to meet the premaxilla anteriorly; at its extreme anterior end, in front of the duct of the Organ of Jacobson and immediately behind the palatal portion of the premaxilla, it comes into contact with the prevomer.

The facial portion of the maxilla (fig. 2, *MAX.F.*) extends upwards in front of the orbit as a thin sheet forming an outer wall to the extraconchal recess (fig. 4, *E.C.R.*). The posterior edge of this portion comes into contact with the prefrontal (fig. 2, *PR.F.*) which stands at right angles to it as the front wall of the orbit; the naso-lachrymal duct passes through a gap between the two bones.

The relations of the maxilla to the nasal capsule and choanal fissure have been dealt with in more detail elsewhere.

Prevomer (fig. 1, *P.V.*). The two prevomers are completely fused at this stage. They form a rather complex bone occupying the central part of the palate anteriorly, between the palatal apertures of the choanal fissures. Posteriorly they articulate with the palatines as described above, anteriorly they meet the premaxillae. The dorsal surface of the joint bone has a complex arrangement of grooves and ridges in relation to the other structures in contact with it—i.e. to the articulatory processes of the palatines, the nasal septum, the paraseptal cartilages, and the Organ of Jacobson.

Premaxilla (figs. 1 and 2, *P.MAX.*). The palatal portions of the premaxillae form a horseshoe-shaped plate round the anterior edge of the fused prevomers. The limbs of the horseshoe meet the maxillae behind. Anteriorly the right premaxilla supports the big egg-crushing tooth (figs. 1, 2 and 4, *E.*), and as this lies symmetrically in the mid-line the right premaxilla in this region encroaches on the left side and the palatal exposure of the left premaxilla is narrower anteriorly than that of the right.

HYOID AND BRANCHIAL ARCHES

These are essentially similar to those of the 47 mm. *Lacerta* embryo figured by Gaupp[1]. The free dorsal extremity of the hyoid bar (figs. 2, 3 and 4, *H.*) lies well below the posterior end of the quadrate at this stage, and has no connection with either stapes or paroccipital process. The plate-like expansion of the hyoid arch (figs. 2, 3 and 4, *H.P.*) just posterior to the point where it bends sharply back after a short forward course from the mid-ventral line is even larger than in *Lacerta*: the outer edge of the plate is in contact with the ventral surface of the big pterygo-mandibularis muscle (fig. 3, *M.P.* and fig. 4, *M.P.E.*) enfolding the lower jaw in this region.

The first branchial arch (figs. 2, 3 and 4, *B.* 1.) is slightly longer than the hyoid; their dorsal ends are in close proximity. This arch is ossified or beginning

---

[1] Gaupp, 1905, *Hertwig's Handbuch*, Bd. III. ii. Die Entwickelung des Kopfskelets.

to ossify along the greater part of its length. The second branchial arch (figs. 2 and 3, *B.* 2.) is, as in *Lacerta*, very short.

The same additional sickle-shaped piece of cartilage (figs. 2, 3 and 4, *Bx.*) as Gaupp interprets as the separated dorsal extremity of the second branchial arch is present in the branchial region, lying just posterior to the dorsal ends of the hyoid and first branchial. It does not lie parallel to these but rather within and at an angle to them, with its upper, handle-like end directed straight upwards close against the opisthotic where that forms the outer wall of the posterior ampullary recess—i.e. some way behind the paroccipital process.

The hypoglossal nerve (figs. 1 and 2, XII) leaves the skull just posterior to this cartilaginous bar and runs downwards and forwards along its outer surface, giving off a branch which loops round the back of it to the genio-hyoid muscle. The main hypoglossal nerve runs on in front of this cartilage close to the first branchial arch, first on its ventral and then on its lateral surface.

The vena capitis lateralis (figs. 1 and 2, *V.C.L.*) crosses external to the upper end of the accessory branchial cartilage, the internal carotid artery internal to its lower end in the loop of the sickle.

LOWER JAW

The lower jaw is of the normal lacertilian type. Meckel's cartilage, except in the articular region, is at this stage already entirely sheathed by membrane bones. The dentary supports a double row of teeth, similar to those on the maxilla, the inner row alternating as there with the outer row, which are the larger.

In conclusion I wish to express my thanks to Prof. J. P. Hill for enabling me to carry out the work during my tenure of the Percy F. Macgregor Scholarship in Zoology, and for allowing me free access to his embryological material for comparative purposes.

To Mrs D. M. S. Watson, D.Sc. I am much indebted for constant help and advice.

My thanks are also due to Mr F. J. Pittock who undertook the laborious and unpleasant task of making the wax plates for the model and gave other practical assistance.

LIST OF ABBREVIATIONS USED IN FIGURES

A. articular; *A.D.J.* aperture for duct of Jacobson's organ; *A.L.I.* processus alaris inferior; *A.V.S.C.* anterior vertical semicircular canal; *B.*1. 1st branchial arch; *B.*2. 2nd branchial arch; *Bx.* accessory branchial cartilage; *B.F.* basicranial fenestra; *B.P.* basipterygoid process; *B.S.* basisphenoid; *CH.T.* chorda tympani; *CO.* concha; *CO.J.* concha of Jacobson's organ; *COCH.* pars cochlearis of ear; *COR.* coronoid; *D.L.G.* entrance place of duct of lateral nasal gland; *D.P.I.* and *D.P.I.*^{1} depressor palpebrae inferioris; *E.* egg-tooth; *E.C.* ectochoanal cartilage; *E.C.R.* extraconchal recess; *E.H.S.C.* external horizontal semicircular canal; *E.N.* external naris; *EP.* epipterygoid; *F.* frontal; *F.O.* fenestra optica; *F.OLF.* fenestra olfactaria; *F.S.*^{1}, *F.S.*^{2}, *F.S.*^{3} fenestrae septi; *F.S.N.* fenestra superior nasi; *F.SUB.* fenestra suborbitalis; *G.G.* gasserian ganglion; *H.* hyoid arch; *H.P.* hyoid plate; *I.C.A.* internal carotid artery; *J.* jugal; *L.P.M.* left premaxilla; *M.A.R.*, *M.A.R.*^{1}, *M.A.R.*^{2} internal rectus; *MAX.F.* facial sheet of maxilla; *MAX.P.* palatal sheet of maxilla; *MAX.Z.* zygomatic part of maxilla; *M.E.R.* external rectus; *M.I.O.* inferior oblique; *M.I.R.*, *M.I.R.*^{1} inferior rectus; *M.P.* pterygoideus; *M.P.E.* external insertion of pterygoideus; *M.P.I.* internal insertion of pterygoideus; *M.PR.PT.* protractor pterygoidei; *M.PT.P.* pterygo-parietalis; *M.R.B.* retractor bulbi; *M.S.O.* superior oblique; *M.S.R.* superior rectus; *MX.*^{1}, *MX.*^{2} maxillary processes; *O.L.*, *O.B.* olfactory lobes; *P.* parietal; *P.A.* planum antorbitale; *P.A.I.* processus anterior inferior of pro-otic; *PAL.* palatine; *PAR.* paraseptal cartilage; *P.A.S.* processus alaris superior; *P.D.P.* dorsal plate of palatine; *P.F.* pituitary foramen; *P.M.* pila metoptica; *P.MAX.* premaxilla; *P.O.* postorbital; *P.P.* pila pro-otica; *P.PR.* paroccipital process; *PR.F.* prefrontal; *P.S.* presphenoidal cartilage; *PT.* pterygoid; *PT.Q.* quadrate ramus of pterygoid; *P.V.* prevomer; *P.V.P.* ventral plate of palatine; *P.V.S.C.* posterior vertical semicircular canal; *Q.* quadrate; *R.S.T.* recessus scala tympani; *S.* stapes; *S.A.* stapedial artery; *S.IN.* septum interorbitale; *S.M.* septomaxilla; *S.M.F.* facial process of septomaxilla; *S.N.* septum internasale; *SO.N.* solum nasi; *SP.C.* sphenethmoidal cartilage; *SQ.* squamosal; *S.SUP.* solum supraseptale; *S.T.* supra-temporal; *T.* transverse; *T.M.*^{1} posterior end of taenia marginalis; *T.M.*^{2} anterior end of taenia marginalis; *T.P.M.* taenia parietalis media; *V.C.L.* vena capitis lateralis; *V.F.* Vidian foramen; *Z.A.* lateral part of "zona annularis."

Nerves. II, III, IV, V *OP.*, V *MAX.*, V *MAN.*, V *TEM.* (r. temporalis maxillaris), VII *P*^{1} and VII *P*^{2} (r. palatinus), *CH.T.* chorda tympani, XII.

A NOTE ON THE POST-CORONAL SULCUS, WITH DISSECTIONS OF THE EPICRANIAL APONEUROSIS IN TWO CASES OF ITS OCCURRENCE

By DUNCAN M. BLAIR, M.B., Ch.B.,
Demonstrator of Anatomy, Glasgow University

In connection with the collection of West Scottish Skulls preserved in the Anatomical Museum of Glasgow University and previously described by Dr Matthew Young (1), it was known that a feature of the series was the presence in many specimens of a post-coronal sulcus running transversely across the skull behind the bregma. On reviewing the whole series with a view to determining the frequency of its occurrence, I find the groove to be present in 238 cases out of a total of 710 crania examined—i.e. in 33½ per cent. The incidence does not appear to vary to any appreciable extent in the two sexes, but is much greater among metopic skulls and the groove is on the average more pronounced in skulls of this type. In 40 adult metopic skulls the groove is present in 27 cases (67½ per cent. occurrence). In 480 adult non-metopic skulls, 147 or 30⅝ per cent. are grooved.

What is the cause of this sulcus? In his book on the muscles of the trunk, Eisler (2) describes the presence of transversely-running bands of fibres in the epicranial aponeurosis, and he suggests in passing, without however giving any proof of this view, that the presence of such fibres may cause grooving of the cranial vault. Under the direction of Professor Bryce, I undertook dissections of the scalp in order to obtain first-hand evidence regarding the course of the fibres in the epicranial aponeurosis, and in particular to find if any causal relationship could be established between the presence of transverse bands and the post-coronal sulcus. Mounted needles were largely used in cleaning the fibres, and the dissection was aided by a stereoscopic magnifier.

In the first specimen dissected there was no trace of a post-coronal groove, but a fine band of fibres was found crossing the mid-sagittal line transversely in the position in which the groove occurs. The question then was whether such a band, only more pronounced in character, occurred in cases of post-bregmatic grooving.

Subsequently, two subjects with well-marked grooves came into the Anatomy Rooms, and their scalps were dissected (specimens *A* and *B* illustrated). In both cases, strongly-marked transverse fibres occupied the post-coronal sulcus, the antero-posterior limits of the depression coinciding with those of the pronounced transverse tendinous band. After the dissection had been completed in each case, the skull-cap, with scalp attached, was removed in order to determine whether the groove on the outer side was reflected in any way on the inner table, and in one case (specimen *A*) a plaster-cast was made of the interior of the skull-cap. In neither case was there any definite marking within corresponding to the groove without.

The following is a detailed account of the dissections, and for purposes of contrast a description of the normal (non-grooved) specimen is first given (Plate I, fig. 1).

The main band of aponeurotic fibres sprang from the upper margin of the occipitalis muscle on either side, and passed upwards and forwards over the parietal eminence with a distinct medial inclination. The fibres became finer as they passed forwards, and a short distance in front of the parietal eminence each band expanded somewhat. The bulk of the fibres ran forwards into continuity with the muscle fibres of the frontalis (the longest fibres of which reached practically to the coronal suture), so that the main "run" of the aponeurotic band was in an oblique line from behind, forwards and inwards, with a slight medial convexity. In addition, on the lateral but especially on the medial side of each band, other fibres took divergent courses. On the lateral side posteriorly, some fibres turned with a shorter medial convexity so as to run into the auricularis posterior muscle, while further forwards the fibres from the auricularis superior appeared to sweep forwards, joining the main aponeurotic band. On the medial side, several bunches of fibres turned inwards towards the middle line, but only one band actually crossed over to be continued into a corresponding band from the other side. This band, less than half an inch in antero-posterior width and composed of very delicate fibres, crossed the middle line just behind the coronal suture. In the case of the other medially-turned bundles, the fibres spread out from each other and terminated at varying distances from the middle line, being more firmly attached to the overlying fascia towards their free ends. As these bands were dissected out, the appearance was exactly as if a thin sheet of fibres crossing the vertex from side to side had been burst, except at the one point, by the cranial expansion. Behind, between the occipitales muscles and the posterior ends of the lateral tendinous bands, the interval was filled by a layer of soft dark red fibrous tissue, the fine fibres running antero-posteriorly.

Specimen A. (Plate I, figs. 2, 3.) The skin and superficial fascia of the scalp were very much finer than in the previous specimen; there was a well-marked post-coronal depression. As before, the aponeurotic layer commenced posteriorly on either side as a broad band springing upwards from the occipitalis muscle. A more distinct accession of forwardly-turning fibres from the auricularis superior muscle was present. Only a small part of each lateral band became continuous with the frontalis muscle, the greater part turning medially, forming a broad transverse band crossing the vertex in the middle line from about $\frac{1}{2}$ in. in front of the coronal suture to about 3 inches behind it. The fibres crossing in the depression formed a distinctly firmer band about 1 inch in width, and interlaced in the middle line. Immediately in front of the coronal suture the transverse fibres abruptly thinned off, and less abruptly behind, where a fine, smooth band about 2 inches broad swept over from side to side without any marked interweaving in the middle line. Numerous small spindle-shaped slits occurred in the transverse band, transmitting minute blood-vessels. The transverse band was not fixed to the underlying bones, and could be made to glide over the skull in a lateral or antero-posterior direction. (This mobility has disappeared since preserving the specimens in alcohol.) Anteriorly, a distinct band of fibres passed from the adjacent borders of the frontalis and auricularis muscles medially and slightly posteriorly, deep to the main antero-posterior band, to take part in the formation of the transverse band lying in the post-coronal sulcus. Except for the gap between the occipitales muscles, the appearance in this subject was rather that of a continuous band of muscle fibres running from the periphery upwards towards the vertex. The frontales muscles were very distinctly confluent across the middle line, and their longest fibres reached to within 1¼ inches of the coronal suture. On removing the skull-cap, the dura mater was observed to be rather more adherent than usual to the cranial vault. No transverse ridge corresponding to the groove outside was found on the inner table of the bone, and a plaster-cast taken of the interior of the skull showed an uninterrupted convexity along the mid-sagittal line.

Specimen B. (Plate II, figs. 4, 5.) The occipitalis muscle was rather broader than usual, and towards the auricle blended with the auricularis posterior. As in the other specimens, a band of relatively coarse aponeurotic fibres, about 2 inches broad, passed upwards, forwards and inwards from the upper border of the occipitalis, sweeping over the parietal eminence, the fibres becoming finer as they went forwards. At that point the fibres on the inner border of the band turned more abruptly inwards and disappeared towards the middle line of the head. Further forwards, the band was broadened by the addition of finer fibres passing upwards and forwards from the auricularis superior muscle, and about an inch in front of the parietal eminence the aponeurotic fibres diverged into two streams. One passed obliquely forwards and inwards, radiating out into a fan-shaped expansion attached to the upper border of the frontalis muscle. The other band of fibres, about 2 inches broad, passed transversely over the top of the cranium, continuing into the corresponding fibres of the other side, and decussating slightly in the middle line. It occupied a transverse groove, the floor of which was deepest anteriorly just behind the coronal suture and gradually rose posteriorly to resume the general convexity of the cranium at a point mid-way between the parietal eminences. In front of the coronal suture was a rounded eminence lying in the triangle formed by the anterior border of the transverse band and the inner borders of the anterior radiations. The dura mater was even more adherent to this skull-cap than in specimen *A*. The inner table showed a very irregular surface and, in spite of an elongated bulging along the anterior part of the sagittal sinus groove, displayed no ridge corresponding to the depression on the outer table.

Fig. **1.** Normal (non-grooved) skull, viewed from above.

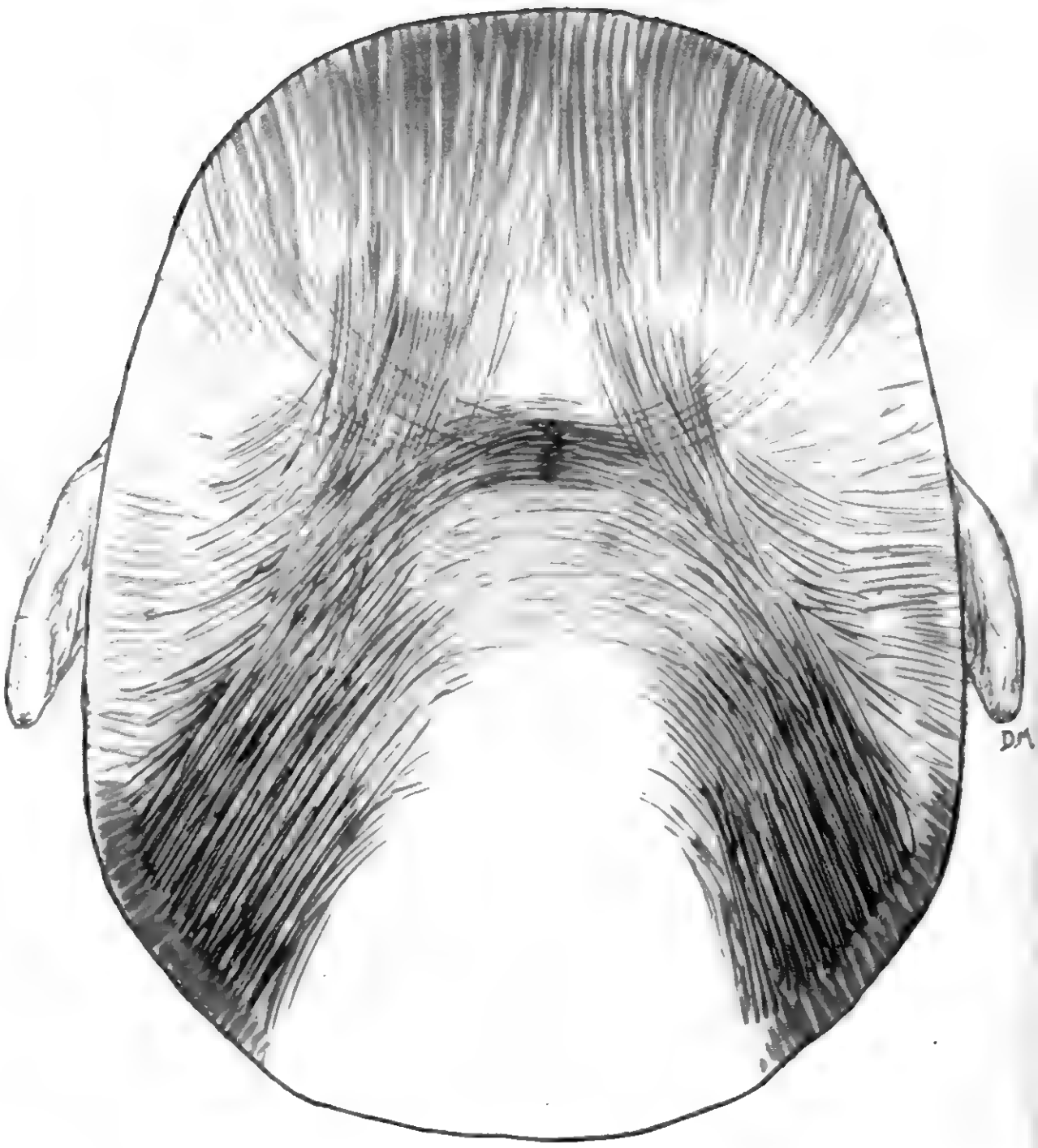

Fig. 2. Skull with narrow groove (specimen *A*), viewed from abov

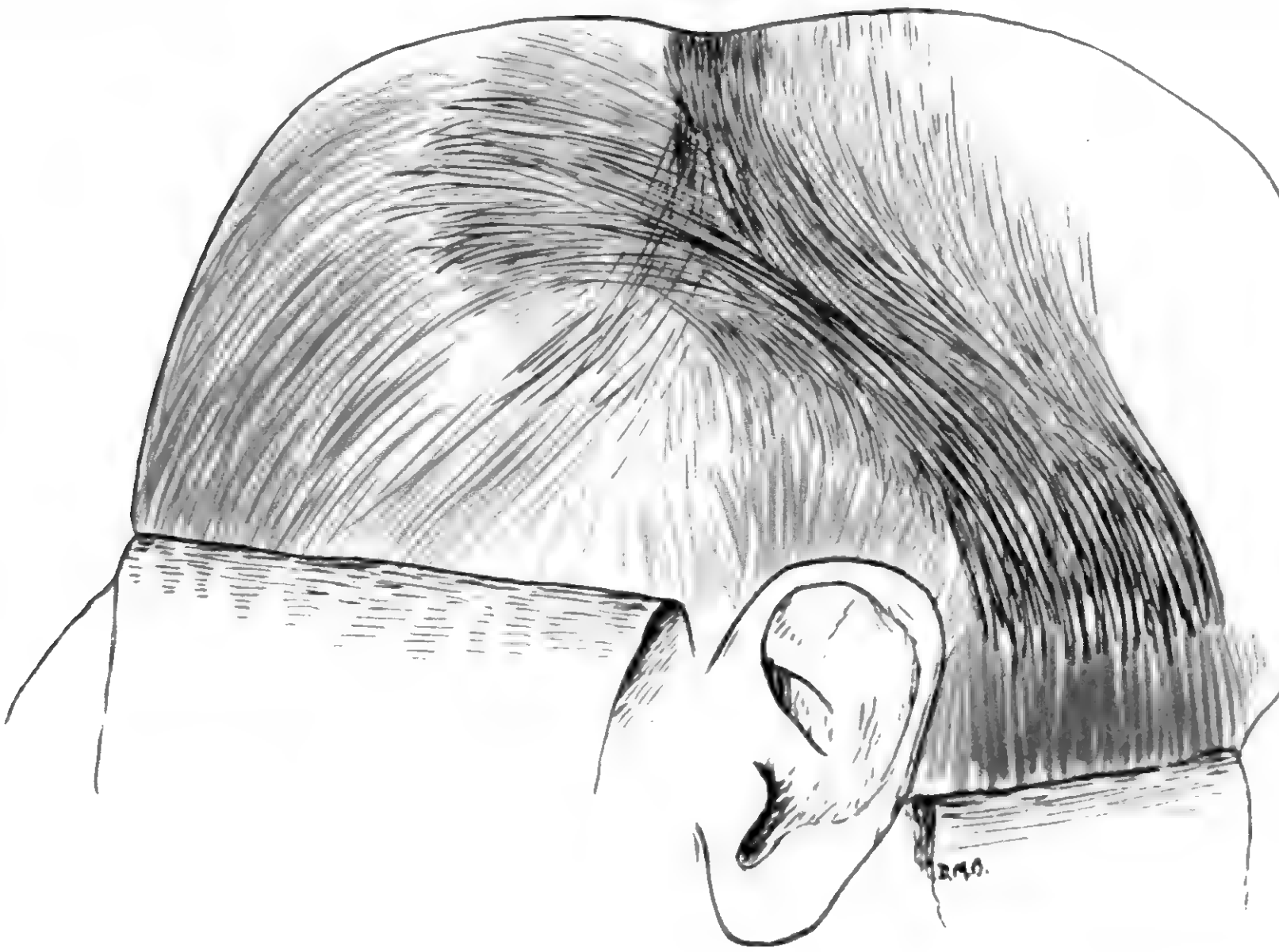

Fig. 3. Skull with narrow groove (specimen *A*), viewed from the side.

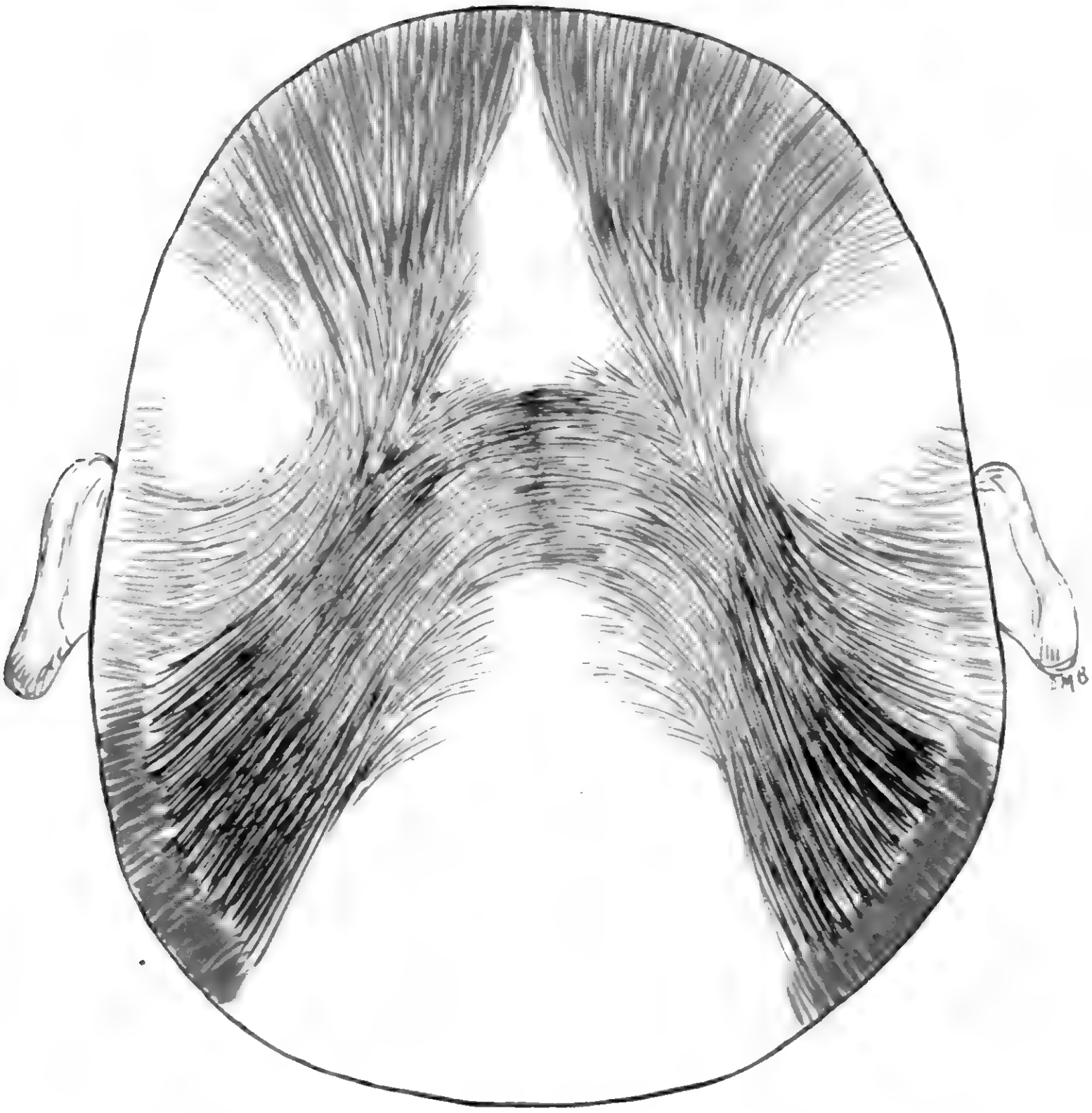

Fig. 4. Skull with broad groove (specimen *B*), viewed from above.

Fig. 5. Skull with broad groove (specimen *B*), viewed from the side.

Were the post-coronal sulcus due to an intra-cranial cause, it would be reasonable to expect an exaggerated reversal within of the groove on the outside, but in both the specimens dissected, the smooth, transverse depression appears to be purely a feature of the outer table of the skull, and it is therefore suggested that its presence may be caused by the persistence of the unusually strong transverse band of the epicranial aponeurosis which, in both these cases, was found to be within it.

It is interesting to note the prevalence of this post-coronal sulcus in skulls of the West Scottish type, as exemplified in the Glasgow University Collection. The greater incidence among metopic skulls is also a striking feature. As already pointed out, the depression occurs in the majority of such skulls and more than twice as frequently as in the non-metopic variety.

REFERENCES

(1) Dr Matthew Young. "A Contribution to the Study of the Scottish Skull." *Trans. Roy. Soc. Edin.* vol. LI, Part II (No. 9), 1916.
(2) Eisler. "Die Muskeln des Stammes," p. 187. *Bardeleben's Handbuch der Anatomie.* 1912.

[The cost of publishing the illustrations to this article has been met by a grant from the Carnegie Trust.]

THE NERVES OF THE HUMAN LARYNX

By T. F. M. DILWORTH, M.B., B.Ch.,
Demonstrator of Anatomy, St Thomas's Hospital

In 1884 Exner published a paper on the nerves of the larynx. It was based on experimental work and on dissection. His experiments were of two types: they consisted of (1) cutting the laryngeal nerves of dogs and rabbits and months later killing the animals and noting what muscles had degenerated. (2) Stimulating the nerves and noting what muscles contracted. His dissections consisted of the microscopic examination of three larynxes of newly-born children. One of these he cut into 150 serial sections and the other two he used for determining minute or obscure points.

On this work he showed that the innervation of the larynx was much more complicated than had been previously thought. He showed that the superior laryngeal nerve was not a purely sensory nerve and that the inferior laryngeal was not purely motor. He furthermore discovered in rabbits a new nerve which he called the middle laryngeal.

His results were opposed by Onödi, whose work I have not been able to use. But Nicolas in Poirier and Charpy (1903) follows Exner's description, even reproducing two of his diagrams.

Exner's description seems to be the popular one on the Continent; on the other hand, English speaking anatomists follow the older and more classical description.

The differences between the two descriptions are very great. The classical description restricted the internal laryngeal to a purely sensory function. The other teaches that each laryngeal muscle has a double nerve supply from the superior and from the inferior laryngeal nerves.

The description given here is based on naked eye dissections of 33 adult larynxes. Ten of these were used for microscopic work after the nerve supply of the arytenoideus had been worked out (Bielchowsky's method was used), but as this work did not give satisfactory results, the remaining 23 were not sectioned. The distribution of the other nerves was worked out in addition to the arytenoideus in these specimens.

THE EXTERNAL LARYNGEAL NERVE

A branch of the superior laryngeal, variable in size, generally small. It runs downwards and forwards, deep to the sterno-thyroid and close to this muscle's attachment to the thyroid cartilage. The corresponding artery is superficial to the muscle.

At first it lies on the inferior constrictor, but as it approaches its termination it passes deep to the inferior constrictor and lies on the thyroid cartilage.

The nerve passes under those fibres of the inferior constrictor which are attached to the inferior tubercle of the thyroid cartilage.

The nerve winds closely round this tubercle, enters the crico-thyroid muscle on its superficial surface where it breaks up into its filaments for the supply of the muscle. There are two possible explanations of its close relationship to the inferior papilla. (1) That the nerve is pulled round this to supply the reflected part of the muscle which is attached to the internal surface of the thyroid cartilage; (2) that filaments go to join the inferior laryngeal nerve. In two specimens I have found such filaments, but they are exceedingly small and difficult to find; they join the inferior laryngeal as it passes over the crico-arytenoideus lateralis.

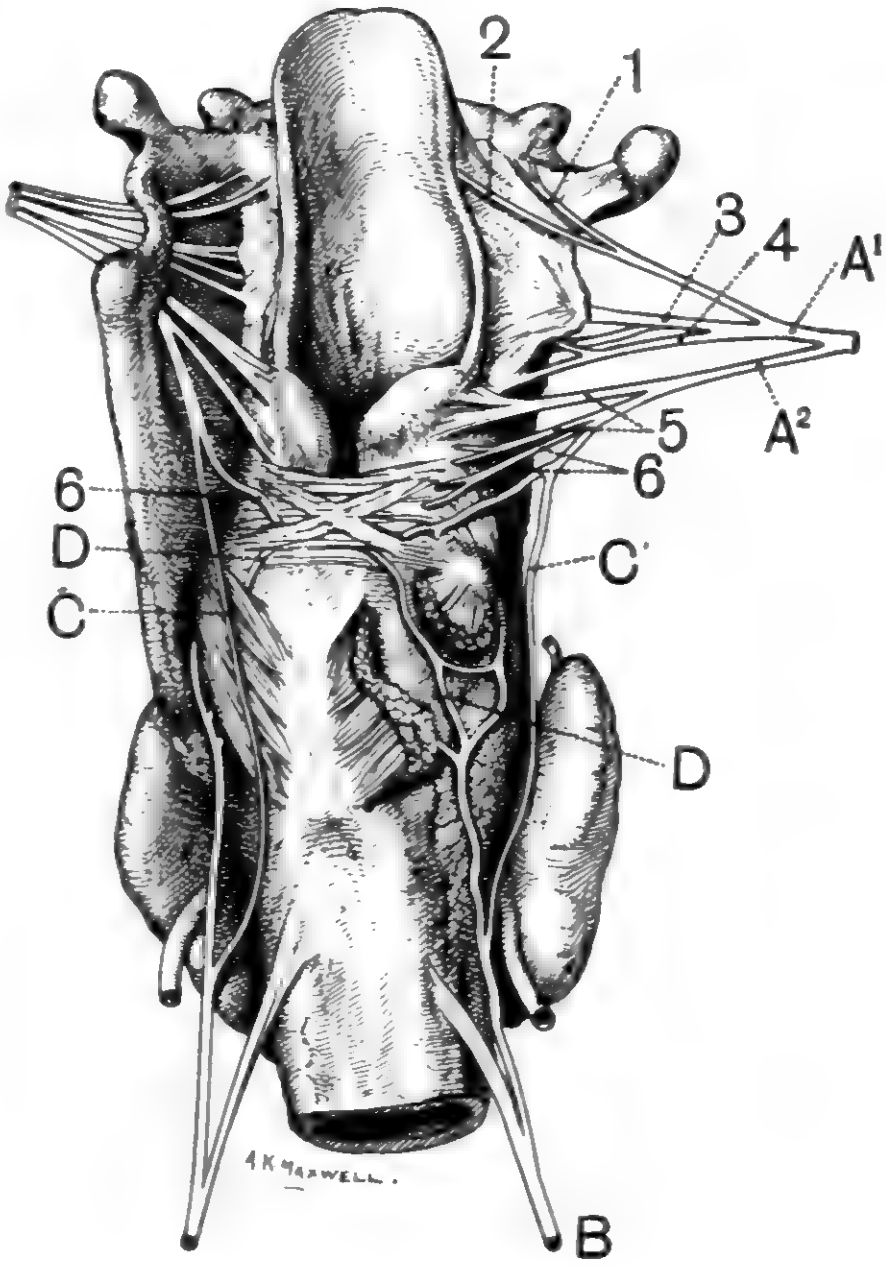

As the nerve passes deep to the inferior constrictor muscle, it gives off a constant twig to the muscle and two other inconstant twigs.

(1) To the apex of the lateral lobe of the thyroid gland.

(2) A branch which passes upwards to the region of the superior tubercle of the thyroid cartilage. In three larynxes out of 23 this nerve passed through a foramen in the cartilage. In two it ended in the cartilage and no foramen was found.

This foramen was present twice on the left side, once on the right. In a fourth specimen it was present on both sides and in this specimen it contained an artery. The foramen in this specimen was larger than in the other cases. The artery was apparently that branch of the superior thyroid which is stated to accompany the internal laryngeal nerve, but which really enters the larynx through the thyro-hyoid membrane on a lower plane quite close to the thyroid cartilage. When the nerve passed through the foramen it joined the internal laryngeal nerve.

THE INTERNAL LARYNGEAL NERVE (fig.: A^1 and A^2)

The internal laryngeal nerve enters the larynx through the thyro-hyoid membrane. As already mentioned, the artery enters the larynx on a lower plane quite close to the superior border of the thyroid cartilage and separately from the nerve.

While it is in this membrane it divides into two main divisions. One, the larger, runs horizontally inwards towards the mesial plane (fig.: A^1). The other runs downwards through the sinus pyriformus, in the aryteno-epiglottic fold deep to the mucous membrane (fig.: A^2).

This latter branch is the one usually called the internal laryngeal but it is less than half the internal laryngeal. The other is referred to as a leash or sheaf of fine filaments. This sheaf can be reduced to a simple and fairly constant plan. It will be found to consist of four main twigs which give off many secondary twigs (fig.: 1, 2, 3, 4).

The first turns upwards immediately it gets through the membrane. Sometimes it appears before the main nerve pierces the thyro-hyoid membrane. It runs upwards in the membrane to be distributed to the mucous membrane of the lateral wall of the pharynx and lateral to the glosso-epiglottic fold. The second passes mesially and upwards to sink into the anterior surface of the epiglottis just mesial to the attachment of the glosso-epiglottic fold. It supplies the mucous membrane in the vallecula.

The third runs horizontally inwards and ends on the anterior surface of the epiglottis quite close to its fellow of the opposite side. The epiglottis is getting narrow at this level which is just below the superior border of the thyroid cartilage. This twig gives branches to the mucous membrane of the vestibule.

The fourth passes downwards and mesially to end on the anterior surface of the epiglottis close to the attachment of the thyro-arytenoid and thyro-epiglottic muscles. It supplies the mucous membrane of the false vocal cord and the region just above it.

Three of these twigs, it will be noted, end definitely on the epiglottis.

THE DESCENDING DIVISION OF THE INTERNAL LARYNGEAL
(fig.: A^2)

This runs down in the mesial wall of the sinus pyriformis giving off two or three branches, to the muscles in the aryteno-epiglottic fold, to the mucous membrane, and to the mucous glands on the posterior surface of the arytenoid cartilage (fig.: 5).

Then it gives one and sometimes two branches to the inter-arytenoideus muscle. This branch was present in 31 out of 33 specimens—so I venture to say it is quite constant. It sinks into the posterior surface of the muscle just above the oblique part of the muscle, arising from the arytenoid cartilage of the same side (fig.: 6).

It goes right through the muscle and can be found to end on the posterior surface of the cartilage; before it does so, it gives definite twigs to the muscle and frequently a little twig to join the branch coming to this muscle from the recurrent laryngeal nerve. The nerve is then continued down on the posterior surface of the arytenoideus posticus deep to the mucous membrane, lying in a well-marked layer of connective tissue; here it gives off many fine twigs to the mucous membrane but none to the posterior surface of the crico-arytenoideus posticus as Exner states.

It ends by piercing the inferior constrictor and joins the inferior laryngeal outside the larynx. This is usually described as being the ramus communicans superior joining the ramus communicans inferior of the recurrent laryngeal. But it is difficult to say where one begins and the other ends. There is no anastomosis to mark out their junction and I describe it as above to suggest a continuous nerve. On the other hand, it might be looked on as a continuation of the inferior laryngeal upwards (fig.: *C*).

THE INFERIOR OR RECURRENT LARYNGEAL NERVE (fig.: *B*)

The right nerve lies more anteriorly on the trachea than the left, but on each side they enter the larynx at the same place. Each nerve gives off branches to the trachea and oesophagus in its course upwards.

About an inch before it enters the larynx it divides into two divisions and also at about the same place it gives off two other fairly constant fine twigs. One goes to the thyroid gland where this is attached to the trachea, the other makes for the oesophagus just below its angle of junction with the pharynx.

Of the two main divisions, one is the branch which unites with the internal laryngeal. It is the branch already described as the continuation of the internal laryngeal. It can be picked up before it enters the larynx. It is the smaller of the two. It enters the larynx by piercing the inferior constrictor at the angle of junction of the oesophagus with the pharynx. The larger division lies more laterally. This pierces that part of the inferior constrictor which arises from the cricoid cartilage, immediately behind the articulation of the inferior cornu of the thyroid with the cricoid. It is the muscular division of the nerve. Branches of the inferior thyroid artery are in close relation with the nerve, as it enters the larynx, the artery being on a more anterior plane but some of its branches may pass behind the nerve.

In the Larynx:

The course of the smaller division has already been described.

The larger division, or muscular division.

It runs upwards at the lateral border of the crico-arytenoideus posticus muscle as far as its attachment to the muscular process of the arytenoid cartilage. In this part of its course it first of all gives off a branch to the crico-arytenoideus posticus muscle which enters the deep surface of the muscle. It then gives off a twig which passes deep to the crico-arytenoideus posticus muscle to appear at its upper border and then enter the posterior surface of the inter-arytenoideus muscle. This is the branch of supply from the inferior laryngeal nerve. As it lies deep to the arytenoideus posticus, it is joined by a twig which winds round the groove on the posterior surface of the cricoid cartilage immediately below the crico-arytenoid articulation. This twig comes from the main part of the recurrent nerve (fig.: *D*). In this way it is seen that the inter-arytenoideus muscle gets a double nerve supply on each side. The branch from the recurrent laryngeal is frequently joined to the branch from the internal laryngeal of the same side. Neither nerve goes across the mesial plane to the opposite side.

The twig from the inferior laryngeal nerve ends in a different manner to that of the internal laryngeal. It breaks up very quickly into its filaments of distribution and does not go through the muscle to end on the cartilage. This nerve can be quite easily picked up as it appears at the upper border of the crico-arytenoid posticus, in the little triangular space bounded by the mesial plane, the crico-arytenoid and inter-arytenoideus muscles. As already stated this double nerve supply seems to be constant.

The inferior laryngeal nerve then lies on the superficial surface of the crico-arytenoideus lateralis. Here I have twice seen it joined by a small twig from the external laryngeal nerve. It gives fine twigs to this muscle and then ends by sinking into the thyro-arytenoid muscle. Here I have seen it joined by a twig from the internal laryngeal nerve.

To sum up there are four ways of looking at the laryngeal nerves:

(1) The classical way, following Luschka, that they are separate sensory and motor nerves.

(2) The school of Exner which says they are mixed motor and sensory nerves and that each muscle receives a double nerve supply.

(3) An obvious middle way which says that the nerves are mixed nerves but which denies that all the muscles have a double nerve supply. This is what I found: that the arytenoideus was supplied by the internal and recurrent laryngeal nerves, but that the rest including the crico-arytenoideus posticus had only a supply from the recurrent laryngeal. This fits in with the pathological facts.

(4) It seems to me however that such an explanation does not fit in with all the facts. For example, the connections between the various nerves. So I suggest that the laryngeal nerves are really a plexus of nerves. Just as the vagus breaks up into its various plexuses in the body, it does the same in the larynx. It is a highly modified plexus. I would further suggest it arose by the larynx separating a strand of fibres from the vagus—that this strand is represented by the continuous nerve joining the internal and recurrent laryngeal, and that the separation from this strand of further fibres forms the various nerves of the larynx.

REFERENCES

Exner. "Die Innervation des Kehlkopfes." *Sitzungsb. der Kais. Akad. der Wissensch.* 1884, Bd. lxxxix, Abth. iii, p. 63.

Kanthack. "The myology of the larynx." *Journal of Anatomy and Physiology*, 1892, vol. xxvi, p. 279.

Nicolas. *In Poirier and Charpy's Traité d'Anatomie Humaine*, 1903, tome iv, 2e fascicule, Deuxième Édition Revue, p. 461.

Piersol. *Human Anatomy.* Philadelphia and Lond. 1907, p. 1827.

Russell. "The abductor and adductor fibres of the recurrent laryngeal nerve." *Proc. Roy. Soc.* Lond. 1892, vol. li, p. 102.

Semon and Horsley. "On the central motor innervation of the Larynx." *B.M.J.* 1890, vol. i, p. 175.

—— *Transactions of the Royal Society*, 1891, vol. 181.

ABNORMAL POSITION OF THE ILIAC AND PELVIC COLONS

By NAGUIB EFFENDI NICOLA,
Egyptian Government School of Medicine, Cairo

During the dissection of the abdomen in a Sudanese negro the following remarkable displacement of the iliac and pelvic portions of the colon was discovered.

The descending colon occupied its normal position and measured 24 cms. in length.

About 1½ inches above the anterior superior spine of the ilium, the colon bent sharply upon itself and ascended parallel to the descending portion and overlying it, so that the descending colon was quite hidden in the undisturbed condition. This ascending portion passed upwards as high as the transverse colon, close to the lower border of the spleen, where it once more turned upon itself and again descended parallel and medial to the ascending part just described, and passing over the pelvic brim became continuous with the rectum. The combined length of these two parts, which may be considered to represent the iliac and pelvic portions of the normal colon, measured 58 cms. and both were covered by the general peritoneal layer of the posterior abdominal wall, which formed a short mesentery, continuous with the peritoneum covering the descending colon proper, and passing thence over the ascending portion of the loop, dipping between it and the descending part of the loop where it was attached to the posterior abdominal wall, and then crossing this descending part to become continuous with the peritoneum forming the mesentery of the small intestine. Both these portions of bowel were uncovered posteriorly and were loosely attached by connective tissue to the posterior abdominal wall.

The upper end of this great loop was attached by extra-peritoneal tissue to the transverse meso-colon, and medially to the duodenum at its junction with the jejunum.

At the point in the left iliac fossa where the descending colon proper terminated, the taeniæ coli gave place to a continuous layer of longitudinal muscular fibres, which were carried uninterruptedly throughout the remainder of the bowel into the longitudinal muscle of the rectum.

The attached sketch illustrates the appearance and position of the loop, except that in the undisturbed condition, the descending colon proper was completely hidden by the ascending part which overlaid it. The loop was evidently of congenital origin and not due to secondary adhesions.

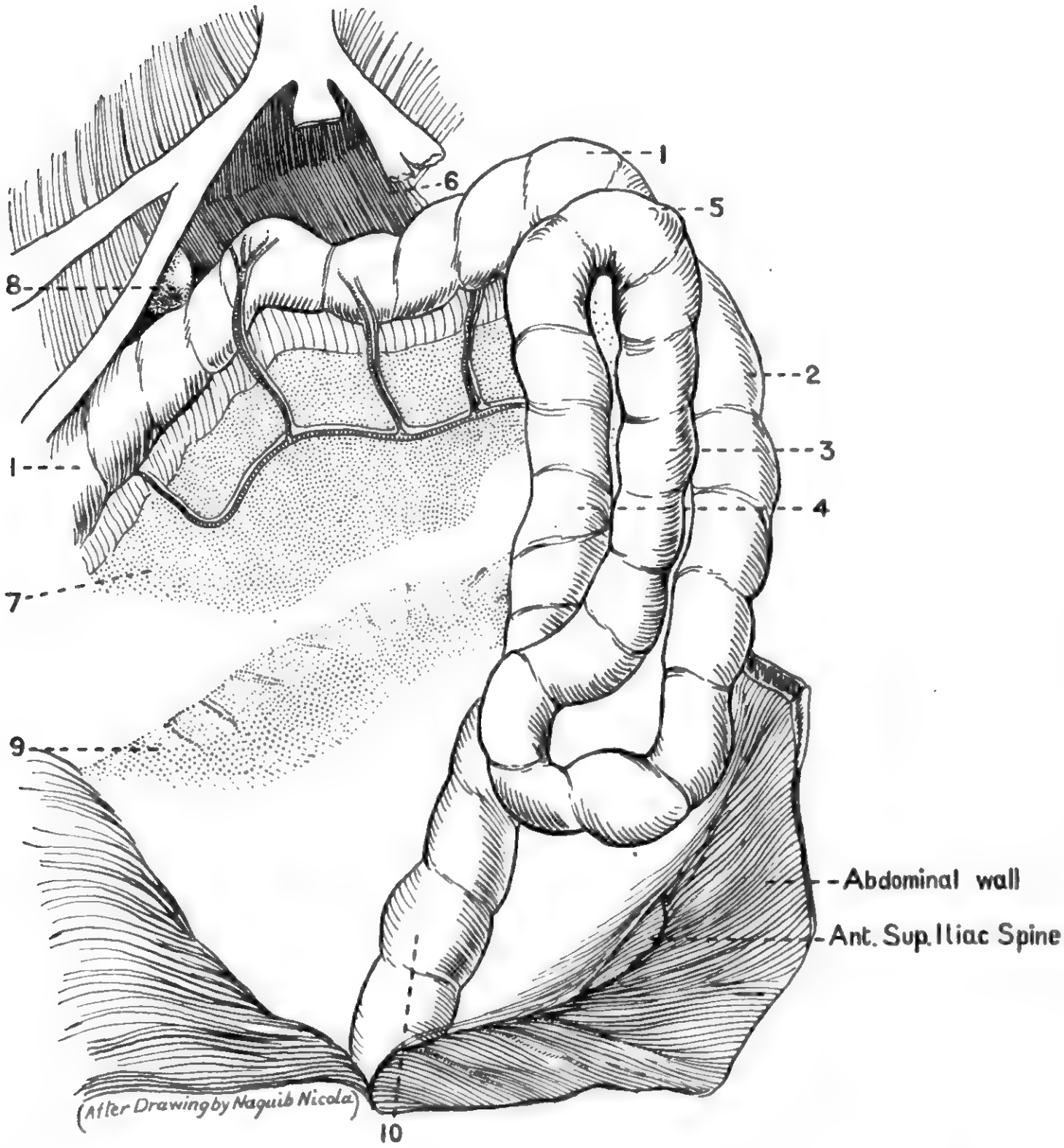

Diagram to show an abnormal position of the Sigmoid Flexure. 1 Transverse Colon, 2 Descending Colon, 3 and 4 Iliac and Pelvic portions of Large Intestine, 5 Sigmoid Flexure, 6 Exposed portion of Liver, 7 Transverse Meso-colon, 8 Fundus of Gall-bladder, 9 Remainder of mesentry of Coils of Small Intestine, 10 Going to Rectum.

REVIEWS

The Origin of Milk Glands: The Mammary Apparatus of the Mammalia, in the Light of Ontogenesis and Phylogenesis. By ERNST BRESSLAU, M.D., late Professor of Zoology in the University of Strassburg. With a Note by Prof. J. P. HILL, F.R.S. pp. 145. Figs. 47. (London, Methuen and Co., Ltd.) 1920.

Prof. J. P. Hill, in a note introducing the above volume to English readers, makes the statement that this work of Professor Bresslau's has lost nothing of its value by its corrected proofs having to wait six years before being issued from the press. With this statement we agree most cordially. For the first time a rational and simple explanation of the origin of milk glands is given—one founded on a prolonged investigation of original material. This book, which contains the substance of three lectures given by Prof. Bresslau at University College, London, in the spring of 1913, traces the origin of the mammary apparatus of monotremes, marsupials and Eutherian mammals to a common source—the brooding organs of the primitive mammalian ancestry. The story is clearly and fully told with the result that a chaotic mass of facts has been given an orderly sequence. We commend this work to the attention, not only of all anatomists but of all medical men.

Initiative in Evolution. By WALTER KIDD, M.D., F.R.S.E. 80 original illustrations. pp. 262. (London, H. F. and G. Witherby.) 1920. Price 15*s.* net.

If this notice of Dr Walter Kidd's greatest contribution to our knowledge of the hair patterns of mammals is somewhat belated, the delay is in no way due to a lack of appreciation of its importance and worth. On the contrary, no one can give serious attention to the new facts which are set out in the *Initiative in Evolution* without recognising its author as a student and investigator of the best kind—one who has made himself master of a definite field of knowledge. It may be thought that hair patterns—the directions in which the hairy coverings of mammals are arranged—is a somewhat limited subject to engage the industrious application of a life-time. But we agree with Dr Kidd in thinking that the man who can give a rational explanation of the origin of hair patterns has solved the fundamental problems of evolution. Nowhere are manifest and complex *adaptations* to be seen and studied so readily as on the surface of the vertebrate body—whether it be the arrangements of scales on fishes, feathers on birds, hairs on mammals, or the flexure lines on the palms and soles; all are developed in the young to answer exactly to the movements of the fully grown body and the habits of the living animal. For Dr Kidd there is only one possible way in which such adaptations could arise—by inheritance of effects produced in the adult or growing body by movement and posture.

His exact position—as well as the humour and gentleness of his style—may be best illustrated by the following passage:

"It will be remembered that a single example was given of a short-haired dog in which its common habit of lying was associated with a definite pattern of hair. This introduces and illustrates the very wide conception of a moulding process undergone by an organism. It is one familiar to biologists....I therefore claim nothing new when, with the temerity of certain persons treading where others are said to fear to do so, I invent an inclusive term and propose to call the two fundamental factors of organic evolution—Plasto-diēthēsis, in which the conceptions of mould (i.e. Lamarckism) and sieve (i.e. natural selection) are included and hyphenated....It has at any rate the merit of having a meaning clear to all friends and opponents alike of Lamarckism. It will be observed that the two words are placed in what I take to be their natural order as expressive of the Alpha and Omega of the story of organic evolution....So the banns between Lamarck and Darwin are published and not for the first time of asking."

Therein Dr Kidd states the result of all his labour—that use and wont mould the animal body and produce its pattern and that the suitable patterns are selected and survive. Whether his readers be followers of Weismann or of Lamarck he has them equally on the horns of a dilemma. For if they are Lamarckists, where is the machinery which transfers the effects of use—wont to the ova—to the spermatozoa? or if they be Weismannites—how do such complex and exact adaptations arise? Perhaps a fuller knowledge of the mechanism of growth and development may solve the conundrum of ages and show that both Lamarck and Weismann were wrong and also that both were right.

This at least is true; Dr Walter Kidd has tabulated and put at the disposal of his biological colleagues a great series of new observations which will materially help in getting at the nature of the machinery of evolution.

A CASE OF EARLY HUMAN OVARIAN PREGNANCY

By JOHN I. HUNTER, M.B., Ch.M.
Associate Professor of Anatomy, University of Sydney.

The present paper comprises a complete description of a specimen of primary ovarian pregnancy, of which I have already published a preliminary account ('21). The specimen was presented to me by Professor J. T. Wilson, who had received it from the Royal Prince Alfred Hospital, Sydney, diagnosed as a case of primary ovarian pregnancy. I desire to express my great indebtedness to Professor Wilson for the opportunity he has given me to describe this interesting specimen. My investigations confirm the original diagnosis. They also demonstrate, as the clinical records of the case indicate, that the pregnancy is at a very early stage of development. This fact renders the specimen of considerable value and justifies the present detailed description because it helps to throw light upon the process of imbedding and the phenomena occurring in the early stages of primary ovarian pregnancy which are still imperfectly known (cf. Ray '21).

The specimen appears in the embryological collection of the Anatomy Department, Sydney University, under the catalogue number H 153, and it will be referred to throughout this account under this designation.

HISTORY OF THE CASE

The patient was under the care of Mr Joseph Foreman, Honorary Gynaecologist of the Royal Prince Alfred Hospital, who directed that the ovary removed at operation should be examined for ovarian pregnancy.

The patient (G.R. aet. 37) on admission on 1.7.14, complained of pain in the hypogastrium of 12 hours' duration. She had experienced a similar attack seven days previously in which the pain was accompanied by vomiting, rigor and perspiration. Her last menstrual period had appeared 22 days previously (9.6.14). Her periods were quite regular of the 28 day type, and consisted of a scanty flow of 3 days' duration. The patient, who had been married five years, had two children; the first was four years of age, the second two and a half years. There had been no miscarriages. On 3.7.14 four days before the next period was due, an operation for ectopic pregnancy was performed. The abdomen was opened in the median line and clotted blood was found in the pelvic peritoneal cavity. The right ovary appeared to be a mass of blood clot, and was deemed necessary to remove. The tubes were apparently normal. The mesovarium was crushed by an angioclast and the free tissue was removed with a scalpel.

The outstanding feature of this account is the regular menstrual history. Operation was performed four days before the time of commencement of the menstrual period which, in all probability, would have been missed. In this respect the history resembles that of the cases reported by Lea ('10) and Chiene ('13). In neither of the above-mentioned cases, however, were embryonic structures recovered and exact comparison with H 153 in which an embryonic papilla was found within an intact chorionic vesicle, is impossible. The chorionic vesicle of H 153 was greatly compressed. Its internal dimensions were 10 × 4·7 mm. and the villi varied from 2–4 mm. in length. Histological examination of the sections obtained revealed a damaged embryonic papilla. The amniotic sac was found to be collapsed and ruptured. Blood from the intervillous space had apparently infiltrated into the embryonic papilla and invaded the yolk sac. The distorted papilla measures approximately 3·5 mm. in length (fig. 7). No details of embryonic structure can be ascertained. The abdominal stalk and the wall of the yolk sac contain blood vessels within which nucleated red blood corpuscles may be seen. The general features indicate that the stage of development approximated to, but was probably earlier than, that of Graf von Spee's embryo "Gle."

H 153 greatly resembles the ovarian pregnancy described by Bryce, Teacher and Kerr ('08). In this case there was a history of seven weeks' amenorrhoea. The chorionic vesicle measured approximately the same as H 153 and the villi were 2–3 mm. in length. There was a fragmentary papilla, the general characters of which resembled the "Gle" embryo. The dimensions indicate that the stage of development is approximately the same as in H 153.

It seems probable that H 153 is the result of fertilisation after the last menstrual period and if so the duration of gestation would be less than 20 days. However, as in Bryce, Teacher and Kerr's specimen retardation of the growth of the vesicle and embryo has probably occurred on account of the abnormal environment, or differentiation may have ceased after the first attack of intra-peritoneal haemorrhage, so that the condition of the embryonic structures is not a true guide of the exact time of duration of gestation.

NAKED EYE DESCRIPTION OF THE SPECIMEN

The specimen removed at operation had been divided longitudinally and consequently both external and cut surfaces were presented for inspection. It consisted of an ovary (4 × 1·5 cms.) from the surface of which, in proximity to one pole, there projected a dark haemorrhagic mass of rounded contour measuring 3 cms. supero-inferiorly and 2 cms. antero-posteriorly (figs. 1 and 2).

This mass rested upon the ovary for the distance of 2·5 cms. In its neighbourhood the ovary contained a corpus luteum of pregnancy measuring 14 × 8 mm. The opposite pole of the ovary was occupied by a large atresic follicle. In one situation a mass of blood projected from the otherwise smooth surface of the haemorrhagic swelling; the smoothness of the surface of the swelling was due to the presence of an investing fibrous capsule which could be traced into continuity with the ovarian stroma. At the point of junction it attained its maximum thickness (1 mm.). It became extremely thin upon the surface of the haemorrhagic swelling and was apparently ruptured where the extravasation of blood was still represented by the projection of blood clot. The original cut had passed through the chorionic vesicle. In either portion of the specimen this structure could be seen lying excentrically in the haemorrhagic swelling. An examination of the blood clot in the vicinity of the chorionic vesicle revealed the presence of villi in section. Also several branching villi were seen lying free in the crumbled blood clot. The villi could

Fig. 1. Photograph of the ovary and the contained haemorrhagic swelling (× 1⅓).

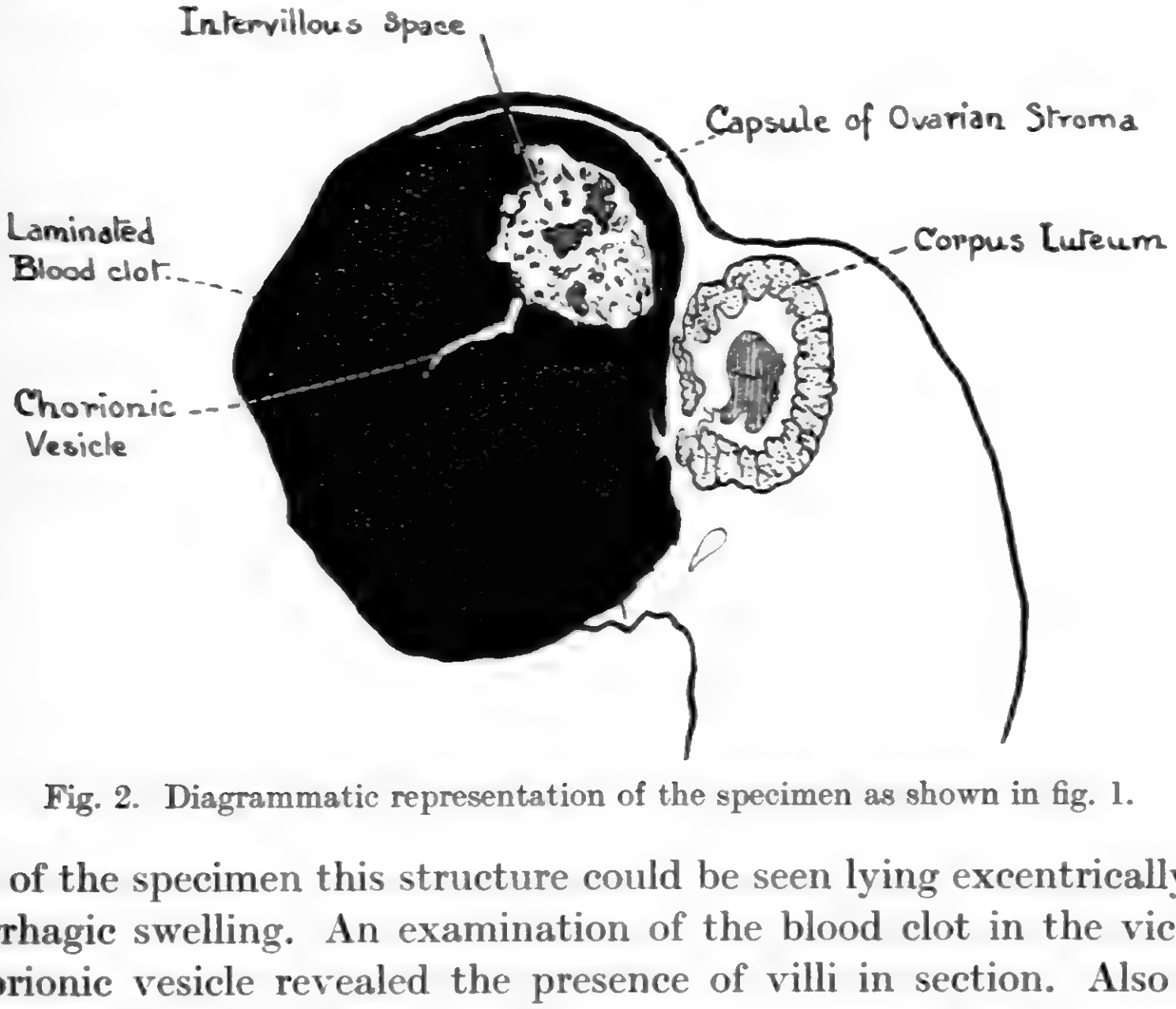

Fig. 2. Diagrammatic representation of the specimen as shown in fig. 1.

be traced towards the wall of the chorionic vesicle. The interior of the vesicle was comparatively smooth, but at this stage (infiltration with celloidin was already in progress) no embryonic papilla was detected.

The evidence so far obtained is sufficient to establish H 153 as a genuine case of primary ovarian pregnancy.

THE CRITERIA OF PRIMARY OVARIAN PREGNANCY WITH REFERENCE TO THE FULFILMENT OF THE REQUIREMENTS BY H153

The arrival of the definite diagnosis of primary ovarian pregnancy is greatly facilitated by the early stage of development of H 153. As Norris ('09) states, "it is much easier to make a positive diagnosis of primary ovarian pregnancy prior to the sixth or eighth week, than it is later after the gestation sac has grown to such proportions as to change its relation to the surrounding parts." Freund and Thomé ('06), Webster ('04), Young and Rhea ('11) and Caturani ('14) have also stressed this fact.

It is necessary to exclude the following conditions which may closely simulate cases of primary ovarian pregnancy:

(*a*) Haematoma of the ovary due to a bleeding corpus luteum.

(*b*) Pregnancy in an accessory tube or in a diverticulum from the tube (cf. Webster, '02).

(*c*) Implantation upon the fimbria ovarica; or upon an accessory fimbria which may become detached from the tube; or upon the fimbriated extremity of the tube.

(*d*) A ruptured tubal pregnancy in the intraligamentous position.

Until full and careful histological descriptions were available of early cases difficulty was experienced in ruling out the existence of all these conditions. In 1898, in his Ingleby Lectures, J. W. Taylor states that "early rupture of a tube from a pregnancy of two, five or six weeks standing is a special phenomenon of extra-uterine pregnancy which has as yet not received the recognition it deserves." Now early operative treatment for ectopic pregnancy provides the best opportunities for securing such specimens as H 153, and in the absence of early stages the scepticism of Lawson Tait and Bland Sutton as to the existence of genuine cases of primary ovarian pregnancy was justifiable. Lawson Tait ('88) asserted that all so-called cases were primarily tubal. In an editorial upon the subject in 1900 the British Medical Journal declared that Webster, P. W. Taylor and Bland Sutton had adduced evidence which tended to confirm this opinion. Bland Sutton ('96) had stated that "ovarian dermoids and calcified foetuses from tubal ruptures into the broad ligament have been mistaken for primary ovarian pregnancy." In discussing Croft's fatal case (Croft, '00) in which a four months' foetus was removed and in which the ovary could not be found on the side of the tumour Bland Sutton reiterated these views. He stated that Croft's case was too far advanced to discuss dogmatically, but he would only be convinced of the possibility of the occurrence of primary ovarian pregnancy, if he were shown "an early embryo and its membranes contained in a sac within the ovary." He was convinced of the genuineness of Van Tussenbroek's classical specimen in 1901. After having made a special journey to Amsterdam to investigate the sections, he declared that he was convinced that this form of ectopic gestation was now possible (Bland Sutton, '01).

In consequence of the difficulties of accurate diagnosis of primary ovarian pregnancy criteria have been laid down by various authors who regard the fulfilment of these conditions as essential to a positive diagnosis of ovarian pregnancy. German writers had accepted the possibility as early as 1850, and in 1878 Spiegelberg laid down his well-known criteria, viz.

(i) That the tube on the affected side must be intact.

(ii) That the foetal sac should occupy the position of the ovary.

(iii) That the sac should be connected to the uterus by the round ligament.

(iv) That ovarian tissue must be found in the wall of the sac.

Williams ('08) modified the last condition by stating that ovarian tissue must be found at several different sites in the wall.

Jacobson ('08) added two further requirements, viz.

(i) That an organic connection between the foetus and ovary must be demonstrated. This condition is sufficiently covered by the demand of Williams.

(ii) That the foetus should be visible in the cavity of the ovum.

The latter condition, which is reminiscent of the statements of Bland Sutton ('00) and Mayo Robson ('02), is unwarranted, as Meyer and Wynne have pointed out (John Hop. Hosp. Bull. No. 338, 1919), because the development of the embryo is retarded by its abnormal environment and is often not recovered after rupture of the gestation sac. In Holland's case ('11), in which the gestation had been of six weeks' duration, the foetus had become converted into an amorphous mass. No embryo was found in 24 out of 43 cases collected by me from the literature. This series included only those cases usually regarded as positive and in which I could satisfy myself, from the descriptions at my disposal, of the presence or absence of the embryo.

Heincke (quoted by Caturani, '14) adds the presence of placental tissue within the ovarian tissue as an additional criterion. But plasmodium may be formed independently of pregnancy, e.g. in cases of chorion-epithelioma of the ovary, sarcoma of the testis, and a dermoid cyst of the anterior mediastrium. Whitehouse ('10), who quotes the above examples, points out, however, that in them plasmodium did not occur alone. This is unlike his case, which he concludes is probably an example of ovarian pregnancy.

Norris ('09) emphasises the importance of examining the corresponding tube microscopically to exclude cases of tubal abortion. He states, "the tube should not only be intact, but should be microscopically free from any evidence of gestation." Chiene ('13) disagrees with this statement and maintains that the removal of the corresponding tube as in his case may not be clinically essential or desirable. Lockyer ('17) nevertheless accepts Chiene's case as a genuine example of primary ovarian pregnancy. Further Caturani ('14) maintains that a decidual reaction may be present in the corresponding tube in cases of primary ovarian pregnancy.

Of the requirements detailed above, those fulfilled by H 153 are as follows:

(i) The tube on the affected side was intact (macroscopically).

(ii) The tumour is part of the ovarian mass which was connected to the uterus by the ligament of the ovary.

(iii) The ovarian stroma encapsulates the chorionic vesicle or blood clot.

(iv) Chorionic villi are abundantly present.

(v) An embryonic rudiment is visible within the cavity of the ovum.

The condition of Norris that the corresponding tube should be examined microscopically is unfulfilled. However, tubal abortion is not difficult to exclude. The ovarian stroma completely encapsulates the haemorrhagic swelling which contained the chorionic vesicle, and the ovary was quite free from surrounding structures so that at operation the specimen could be removed by the application of an angioclast to the mesovarium.

In this connection it may be pointed out that in van Tussenbroek's classical case the tube was not subjected to microscopic examination. Bryce, Teacher, and Kerr ('08) state in reference to this specimen that "the Fallopian tube was in no way attached to the ovary and, being normal, was obviously not the primary seat of implantation of the ovum." In an editorial of the British Medical Journal (1900, p. 922) the statement is made that van Tussenbroek's specimen proves that ovarian impregnation is a fact no longer to be denied. The existence of a considerable mesovarium and the absence of adhesions are facts stressed in this summary. These desiderata are present in the case of H 153.

DESCRIPTION OF THE SECTIONS

The following description is based upon incomplete celloidin sections 10μ in thickness and complete celloidin sections 40μ to 50μ in thickness. The thick sections proved of considerable value in presenting the topographical relationship of tissues upon which certain conclusions which follow are partly based.

The ovarian capsule.

The capsule is everywhere composed of fibrous tissue. In many parts the nuclei are sparse and the stroma cells can be seen to be arranged in concentric laminae around the blood clot similar to the specimen described by Hewetson and Jordan-Lloyd ('06). In addition there are considerable patches of connective tissue in which the nuclei are abundant. Both types of connective tissue abound throughout the ovary. As already revealed by naked-eye examination the capsule of ovarian tissue was ruptured for the extent of 9 mm. from which blood clot projected. The capsule was fragmentary for some distance beyond the site of rupture. The superficial aspect of this part of the capsule was covered by a thin layer of blood. It is evident that the rupture of the capsule caused the intraperitoneal haemorrhage found at operation. Such a rupture is probably brought about by a considerable increase of blood surrounding the chorionic vesicle so thinning the capsule until it finally gives way under the internal pressure.

Lea ('10) has pointed out that intraperitoneal haemorrhage in cases of primary ovarian pregnancy may be produced by the penetration of the ovarian capsule by syncytial elements, especially when the implantation cavity is in a superficial position. This occurs relatively infrequently. Examples of its occurrence are provided by the cases described by Boesebeek ('04), Norris and Mitchell ('08), Banks ('12), and Freund and Thomé ('06).

The chorionic villi.

The chorionic villi are to be seen on all aspects of the compressed chorionic vesicle although they are especially abundant at one pole adjacent to the ovary. Here the intervillous spaces are intact. A similar distribution occurred in the cases described by van Tussenbroek ('99), Hewetson and Jordan-Lloyd ('06), and Bryce, Teacher, and Kerr ('08).

Fig. 3. Chorionic villus and wall of the chorionic vesicle showing embryonic blood vessels (×75).

The villi consist of a loose connective tissue core composed of elongated spindle-shaped cells with well-defined oval nuclei. This connective tissue is continuous with the extra embryonic mesoderm composing the wall of the chorionic vesicle (fig. 3). Blood vessels containing nucleated red blood corpuscles occur in both these situations. The usual double covering of the connective tissue core is present. The cyto-trophoblast consists of a distinct layer of cubical cells—Langhan's layer. The outer layer consists of plasmodi-trophoblast in which nuclei staining darkly with carm-alum are often to be seen arranged in successive rows. Irregular plasmodial processes are also present, some of which abut against the extravasated blood (fig. 4).

The relationship of the villi to the ovarian tissue.

It has already been pointed out that in some cases syncytial elements perforate the capsule of ovarian tissue and so produce intraperitoneal haemorrhage. In Freund and Thome's case ('06) the perforated capsule was 1–2 cm. in thickness. In the cases of Thompson ('02), Young and Rhea ('11), Hannes ('12), and Caturani ('14), the villi had invaded the surrounding stroma without causing perforation. H 153 is, on the other hand, to be included with the specimens described by Norris ('09), Mall and Cullen ('13), Kelly and

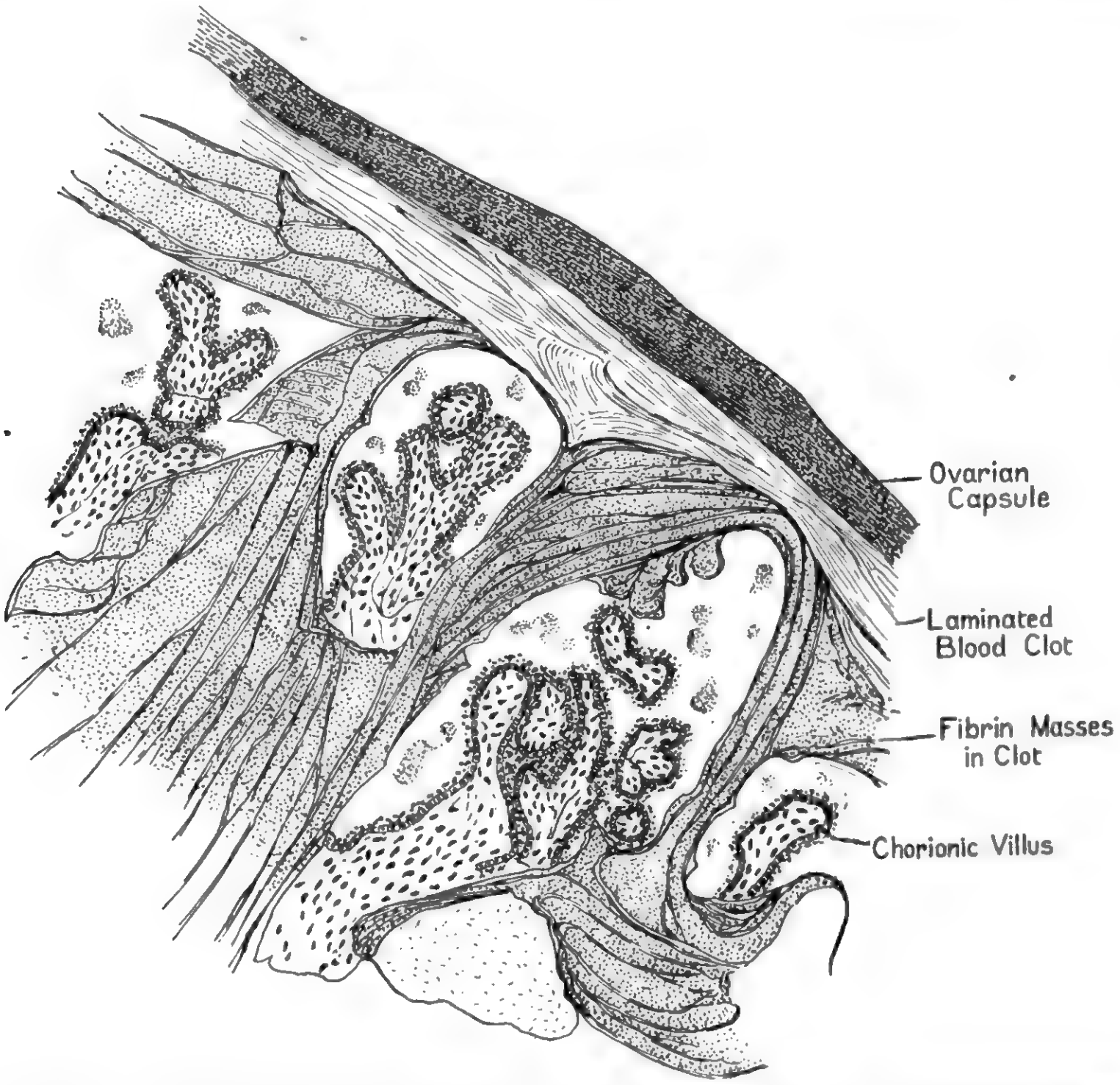

Fig. 4. Showing villi on the external aspect of the chorionic vesicle imbedded in fibrin which separates them from the capsule of ovarian stroma (× 35). (D. J. Farrell, del.)

McIlroy ('06), Leon and Holleman ('02), Hewetson and Jordan-Lloyd ('06), Chiene ('13) and Lea ('10), in which the villi do not invade the stroma. A laminated blood clot separates the villi from the capsule of ovarian tissue. Weigart's fibrin stain reveals in H 153 masses of fibrin surrounding the villi, while a firmer laminated clot abuts against the capsule (fig. 4). Holland ('11) ascribes such a condition in the case described by him to recurrent haemorrhages. Recurrent haemorrhages with a very slow circulation of blood in the implantation cavity would account for the appearance in H 153 also. This blood clot in most situations closely surrounds the villi. In one position, viz. where the villi were found to be most abundant, intervillous spaces are still preserved (fig. 5).

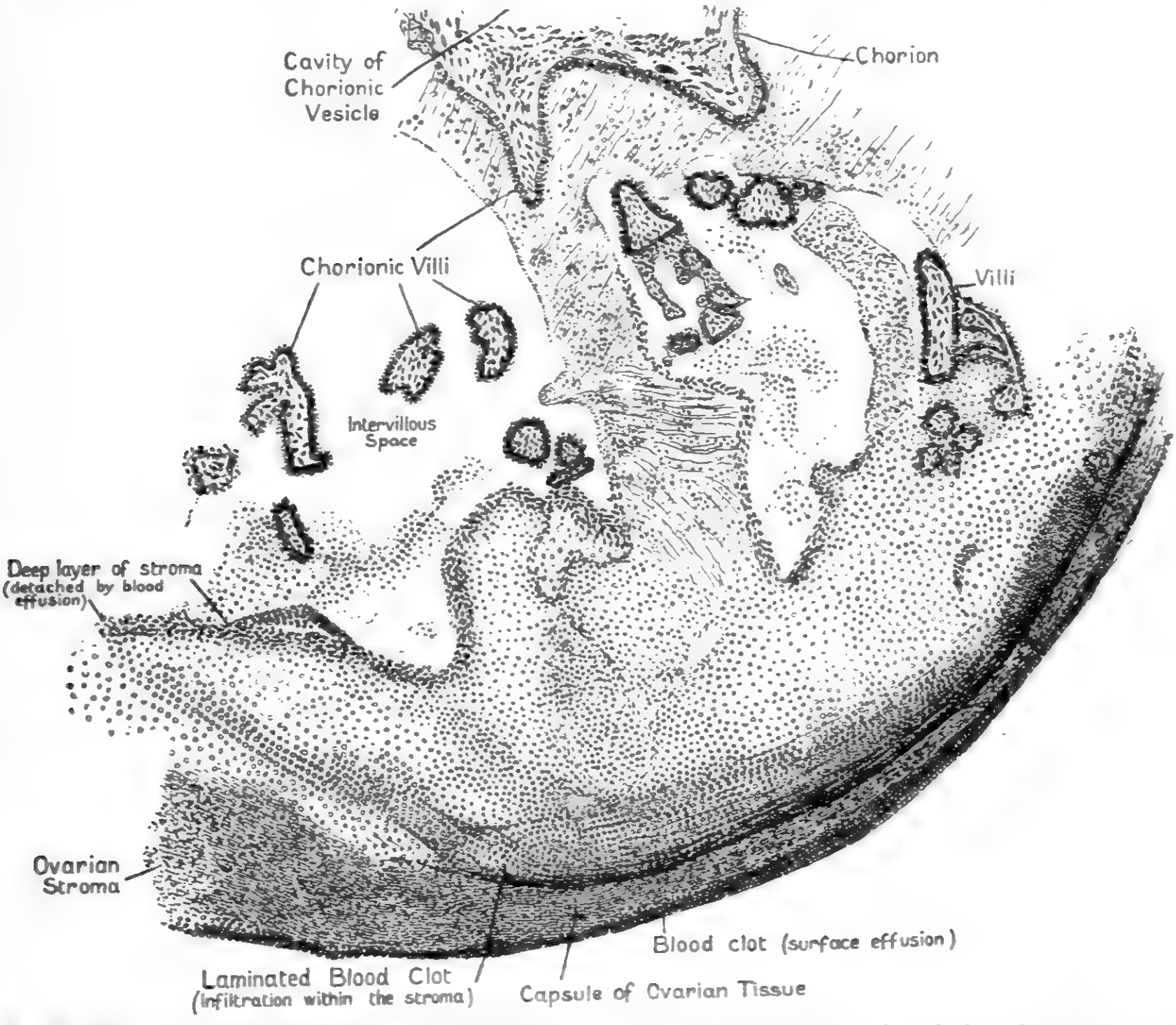

Fig. 5. Showing the intervillous spaces which are preserved at one pole of the chorionic vesicle. Between the surface and the spaces are to be seen three layers, viz. the capsule of ovarian tissue, blood extravasation, and a zone of barrier decidua-like cells (× 20). (D. J. Farrell, del.)

These spaces are bounded by a zone of cells which walls off the laminated blood clot. I believe that this layer originally belonged to the capsule of ovarian tissue. Separation has apparently been effected by an infiltration of blood into the ovarian capsule. Consequently, where the intervillous spaces are present, they will be bounded by a thin necrotic zone of tissue. This zone consists of decidua-like cells. It is separated by a blood-filled interval, 2 to 5 mm. in width from the main mass of ovarian capsule. Therefore, three zones intervene between the intervillous spaces and the surface of the haemorrhagic swelling, viz. the ovarian capsule, a laminated blood clot, and a barrier zone of decidua-like cells (fig. 5).

An important aspect of this condition is that the deep layer of stroma is very thin. It is on this account that the villi do not establish a firm connection with the stroma, for, in effect, their original connections have been torn away by the blood extravasated into the stroma which encapsulates the implantation cavity. This haemorrhage has distended and eventually ruptured the capsule in H 153, so producing the intraperitoneal haemorrhage which led to operative interference. In the specimen described by Bryce, Teacher, and Kerr ('08) a similar separation of the villi from the capsule has been effected, although in one situation villi came into direct relation with the stroma of the ovary. The authors state that "it is apparent from a study of the sections that considerable haemorrhage has taken place shortly before the operation, and that the blood has more extensively infiltrated the tissue intervening between a layer of necrotic tissue immediately applied to the villi and the more healthy living ovarian tissue forming the outer lamella of the wall of the cavity. A large coagulum was thus formed round the chorionic vesicle and the whole constituted a "fleshy mole" which would doubtless, in short time, have been extruded from the ovary into the peritoneal cavity." This describes accurately the condition found in H 153. Webster ('07) stated that haemorrhage had occurred in the ovarian stroma in his specimen of ovarian pregnancy especially near the placental site. In the Bryce-Teacher uterine ovum a similar haemorrhage was found in the decidua but no extensive infiltration had ensued (cf. Bryce and Teacher ('08), Pl. III).

The marked disturbances of the circulatory mechanism in cases of ovarian pregnancy account, I believe, for the frequency in which the embryo is degenerated or absent. As Kelly and McIlroy ('06) point out the embryo is likely to perish at an early age although the envelopes go on living. Consequently retardation of development of the embryo is not infrequent (cf. Holland ('11), van Tussenbroek ('99), Bryce, Teacher, and Kerr ('08)). Freund and Thomé ('06) believe that the embryo develops normally or not according to the size of the vessels in the region of the implantation cavity and regard the vicinity of the hilum as being the most favourable site. But, on the other hand, a profuse extravasation of blood into the ovarian stroma in the manner shown to have occurred in H 153 would clearly interfere with normal intervillous blood flow and so retard development. Where the intervillous spaces are not preserved degenerating villi are to be found, while the fewness of villi in these situations indicates that some have already been absorbed. In the ovary, as in the tube, lack of decidual reaction has been cited as the cause of the abnormal circulatory condition in the vicinity of the ovum. In a specimen so young as H 153 it is a matter of great interest to determine if there is any definite decidual reaction to be found.

THE REACTION OF THE MATERNAL TISSUES

In H 153 there is a general increase in vascularity of the ovarian stroma which is highly cellular in character. There are hosts of leucocytes in the blood clot against which the villi abut. A similar infiltration of leucocytes has been observed by Mall and Cullen ('13) and Hewetson and Jordan-Lloyd ('06). In general the condition found in H 153 agrees with the statement of Kelly and McIlroy ('06) that the reaction of the ovary in ovarian impregnation resembles that of the uterus in uterine pregnancy. But these authors conclude their discussion of this subject by stating that "nowhere throughout the specimen can tissue be found which has taken upon itself the function or appearance of a decidual layer." They state that lutein cells are present in the fibrin layer which together with some connective tissue cells separate the foetal tissues from the corpus luteum. These decidua-like cells, they believe, are the cells which have been mistaken for true decidual cells by some writers. van Tussenbroek ('99) found large granular necrotic cells which she first interpreted as being due to a decidual reaction. Later she was convinced that these cells were lutein and connective tissue cells. Banks ('12) and Graham ('12) interpret the decidua-like cells present in their specimens as being at least partly trophoblastic in origin.

Only a small minority of observers admit that the decidua-like cells may be the result of a maternal reaction. Bryce, Teacher, and Kerr ('08) acknowledge that many of the large mononuclear cells spread out in the ovarian stroma in their specimen may be maternal in origin. Whitehouse ('10) found similar cells. Caturani ('14) described an attempt at decidual reaction especially around the blood vessels of the stroma. Webster ('04) found a definite decidual reaction lining the intervillous spaces. He denies, however, that ovarian tissue itself is responsible for this change and attributes the reaction to embryonal inclusion of Mullerian tissue in the ovary. In Giles and Lockyer's case ('14) the ovarian stroma contained many large blood vessels and showed decidual reaction in the medulla and cortex. Norris ('09) states that in the specimen described by Franz ('02) there were a few small groups of decidual cells immediately around the ovum. Norris concluded, however, that a study of the literature proved that few authors record "the presence of decidua-like cells and in these the identification is somewhat doubtful." Williams ('08) who also summarised the literature upon this subject was also convinced that a definite decidua was absent in cases of ovarian pregnancy.

The survey of the literature given above, illustrating as it does that the majority of observers speak against a decidual reaction, would tend to convey the impression that the conclusion arrived at by Williams and Norris is a correct one.

After an investigation of H 153 with reference to the occurrence of a true decidual reaction, I am convinced that this condition does occur in the early stages of ovarian pregnancy, so confirming the conclusion of Giles and Lockyer

('14). In discussing the relationship of the chorionic villi to the maternal tissues, the appearances were interpreted by supposing that blood had infiltrated into the ovarian stroma, so separating a thin layer of cells from the main mass and tearing this and the villi away from their connexions with the capsule of connective tissue. This conclusion is based upon the presence of a definite layer of cells which is found to bound the maternal aspect of the intervillous spaces (fig. 6). This layer is most perfectly seen where the intervillous spaces are best preserved. If it be followed, it is found to form an imperfect barrier of cells. This is interrupted at various points on account of the haemorrhage in the stroma being in many situations continuous with the blood in the

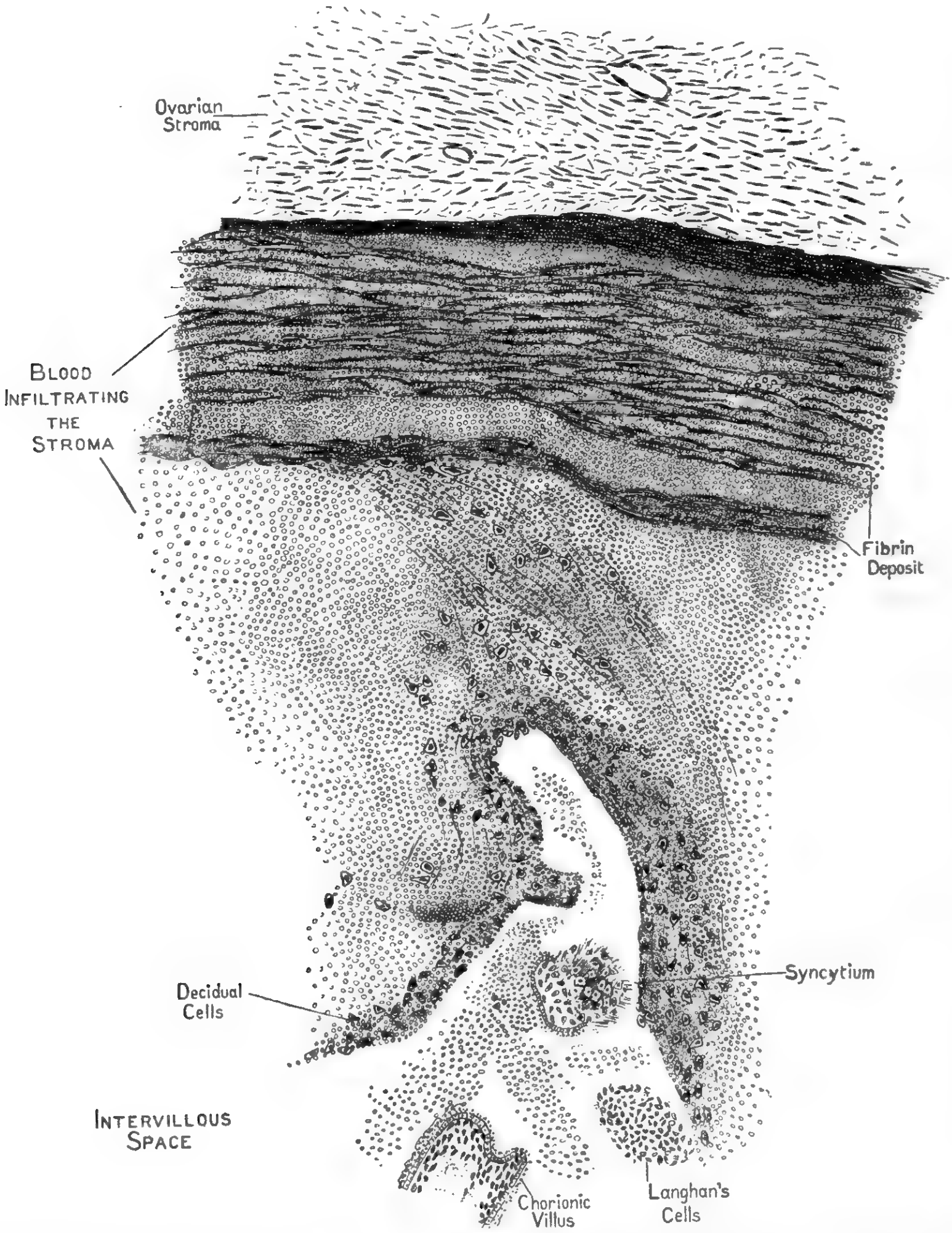

Fig. 6. The barrier cell zone is shown separated from the ovarian stroma by means of an extravasation of blood (× 60). (D. J. Farrell, del.)

intervillous spaces. There is no interruption of the barrier layer in one position for the extent of 8 mm. and the layer can be followed on the opposite side of the blood clot which has broken through it (fig. 5). On the external aspect of the chorionic vesicle, it is only represented here and there by groups of cells, which still show the barrier arrangement. But here the intervillous space is imperfect, being continuous to a considerable extent with the blood within the stroma. This is the site at which the villi have already been noticed in a state of degeneration.

The barrier is made up of large elongated, polygonal, oval and pearshaped cells. These are mainly placed concentrically around the intervillous space. The cytoplasm of the cells is stained uniformly with carm-alum and the nuclei are large and conspicuous. With haematoxylin the nuclei are again deeply stained in some of the cells. In others the nucleus is large, oval and more faintly stained.

The decidua-like cells are imbedded in a fibrin layer, scattered cells extending outwards towards the ovarian stroma. In a few sections the ovarian stroma surrounding the implantation cavity has not been infiltrated with blood, and consequently the barrier zone and ovarian stroma are, in these sections, found to be continuous with one another for the extent of 3 mm. Here there is a definite decidual reaction of the stroma and transition stages are to be seen between large darkly staining cells bounding the intervillous space and fusiform connective tissue cells. Similar transition forms were noticed in Hewetson and Jordan-Lloyd's case ('06). This indicates the origin of the large cells from the ovarian stroma. These cells correspond in arrangement, shape and staining reactions with the cells of the barrier layer which lines the intervillous spaces elsewhere. The tissue formed by these cells though not extensive represents an ovarian decidua.

I believe that H 153 illustrates a retrogressive phase with regard to the development of the decidua. The infiltration of blood into the stroma which has separated the barrier zone from the capsule proper has also led to the partial disintegration of this deep zone. Consequently in some situations it is only represented by isolated groups of cells. Extreme difficulty would have been encountered in distinguishing these groups from trophoblastic masses if the continuous lamina of cells forming the ovarian decidua in H 153 had been wholly destroyed.

The difficulty of distinguishing these two types of cells from one another would also have been increased because the stroma of the capsule in H 153, where it has been isolated from the villi in the intervillous space by a considerable blood filled interval, does not present the intermediate stages in the formation of the large decidual cells. These facts probably explain why the decidual reaction in other specimens is less marked than in H 153. It may also explain why isolated decidua-like cells have been found in many specimens which have been interpreted as being wholly foetal in origin. The truth is that the uterus is imitated by the ovary in its reaction not only by leucocytic infiltration, by increased vascularity and by increased cell formation, but by the formation of true decidual tissue. However, the badly regulated blood flow in the ovary brought about when the plasmodium invades the vessels, leads, in many cases, to bleeding beyond the intervillous space into the ovarian stroma. If this is not arrested, the inner layer of decidua cells becomes stripped away from the stroma and destroyed, and the enlarging cells in the latter resume their normal size, being no longer subject to the direct influence of the trophoblast. As already shown, the uterine decidua surrounding the Bryce-Teacher ovum exhibits a similar infiltration, but this is not extensive, though its effect in this case also was to strip off a zone of maternal tissue. In the ovarian pregnancy of Bryce, Teacher, and Kerr ('08), the infiltration was of a much greater extent than in the uterine decidua, and this fact probably accounted for the relatively few decidua cells found.

Caturani ('14), in speaking of van Tussenbroek's specimen, believes that the lack of decidual reaction accounts for the considerable haemorrhage between the maternal tissue and the oval sac. But I have presented another aspect of the case, viz. that the invasion of comparatively large vessels imbedded in fibrous tissue will probably lead in cases of ovarian pregnancy to relatively profuse haemorrhage independently of the degree of decidual reaction at this stage. I have endeavoured to show that this haemorrhage ploughs up the decidual tissue and separates the villi from their close connexion with the ovarian stroma and consequently the degree of decidual formation is greatly reduced.

A priori, there is no reason why the ovarian stroma cannot react in a manner similar to that of the endometrium. Indeed, decidual reaction has been found on the surface of the ovary in cases of uterine pregnancy as part of the condition called by Taussig ('06) "ectopic decidua formation."

It has been noted above that some observers, e.g. van Tussenbroek ('99), regard decidua-like cells described by them as being lutein in nature. The following description of the corpus luteum and of the relationship of the implantation cavity to it, makes this explanation untenable in the present case.

THE RELATIONSHIP OF THE CHORIONIC VESICLE TO THE CORPUS LUTEUM

A corpus luteum corresponding to the duration of gestation as indicated by the clinical history and confirmed by the degree of development of the chorionic vesicle, is situated within the ovary adjacent to the implantation cavity. It consists of a plicated lamina of large, lightly staining polygonal cells with faintly staining nuclei. On three aspects the lutein lamina is uniform in size. The lamina is infiltrated by connective tissue septa which are already vascularised. Within the lamina of lutein cells there is a delicate connective tissue layer enclosing a central blood clot. A second group of lutein cells form the walls of that part of the corpus luteum which is adjacent to the implantation cavity (fig. 7). These cells also constitute a plicated lamina which is only one-third of the thickness of the more extensive layer. Externally an uninterrupted layer of connective tissue separates the thinner lutein lamina from the implantation cavity. This layer contains decidua-like cells. Beyond each end of the lamina the internal and external layers of connective tissue become continuous with one another. Lutein cells are absent over considerable areas of these uniting bridges of connective tissue.

There is no direct relationship between the chorionic vesicle and the corpus luteum adjacent to it. The separation of the corpus luteum from the implantation cavity by a layer of connective tissue makes it unlikely that any lutein cells are spread out in the wall of the gestation sac. Certainly they cannot be present in sufficient numbers to produce the zone of cells found bounding the intervillous spaces described as representing an ovarian decidua.

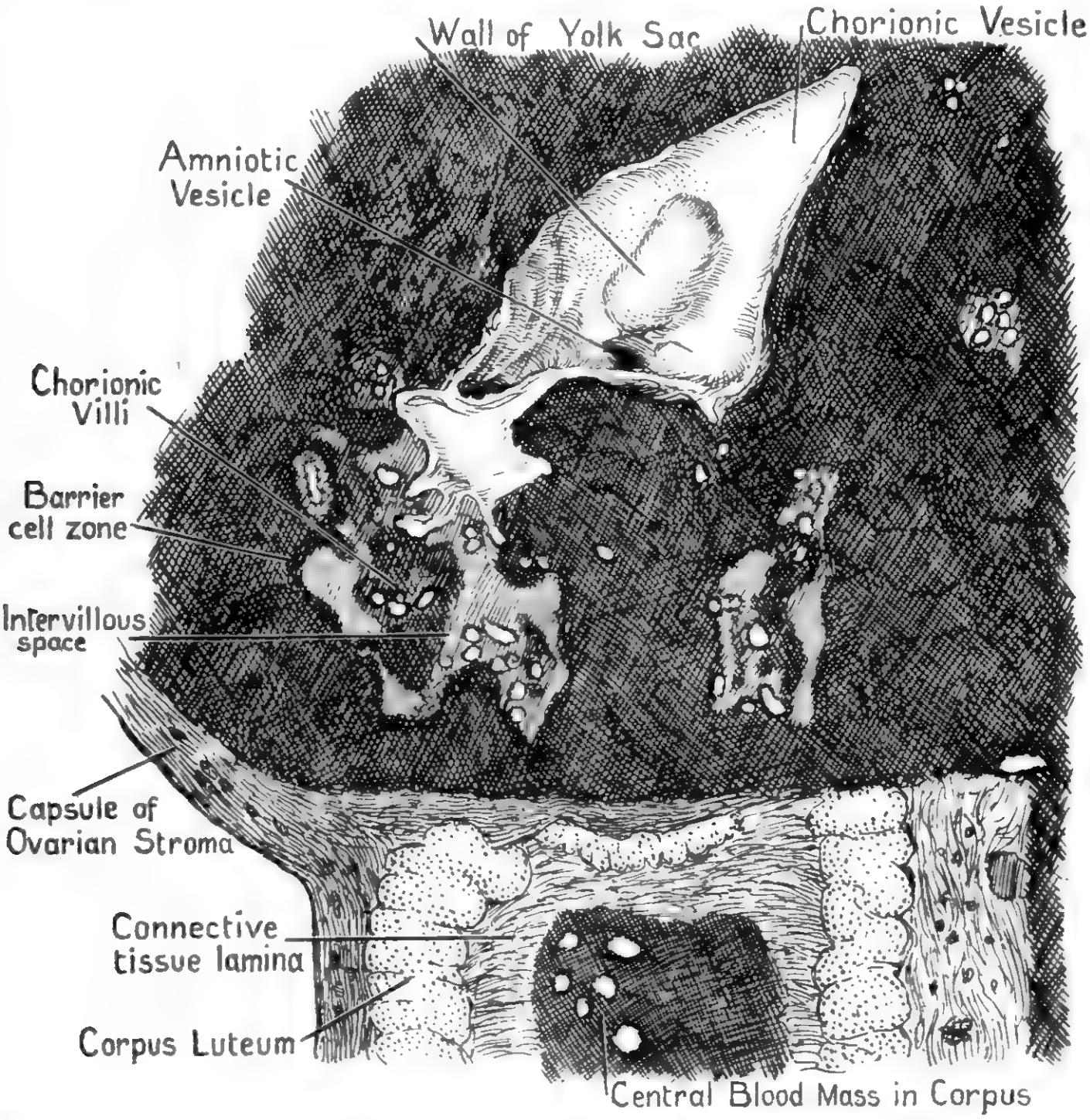

Fig. 7. Drawing from a photograph of a wax plate reconstruction of the chorionic vesicle and embryonic papilla of H 153 showing the relations of surrounding parts. The corpus luteum is shown to be separated from the implantation cavity by a layer of connective tissue (× 5).

H 153 is an addition to that class of ovarian pregnancy in which the chorionic vesicle lies wholly outside the corpus luteum. This condition is exhibited in the specimens described by Hewetson and Jordan-Lloyd ('06), Thompson ('02), Webster ('04), Franz ('10), and Bryce, Teacher, and Kerr ('08). Whitehouse ('10) also described a specimen in which plasmodial masses were situated wholly outside a cystic corpus luteum.

The problem is to account for the extra-follicular position of the ovum in these cases.

A summary of the views of various authors in regard to the imbedding of the ovum is given by Graham ('12). This writer is himself of the opinion that imbedding occurs in an epithelial lined tubule cut off from the fimbriated extremity of the Fallopian tube and that the ovum is attracted towards the corpus luteum. Webster ('04) believes that the fertilised ovum is imbedded in Mullerian duct inclusions which react to form a decidua, and that imbedding is extra-follicular. The wide distribution of ectopic decidua in cases of uterine pregnancy proves that such inclusions are unnecessary to provide a decidual reaction. Moreover, the large epithelial cells described by Graham and Webster are not consistently found in cases of ovarian pregnancy. In H 153 there is no justification for the view that the decidua cell barrier has arisen from Mullerian tissue. On the contrary, its connective tissue origin is displayed in those sections where the ovarian stroma directly bounds the intervillous spaces. In Hewetson and Lloyd's specimen a layer of connective tissue completely separates the implantation cavity from the corpus luteum as in H 153. The authors believe that the ovum was fertilised after extrusion from the Graafian follicle, and that the fertilised ovum then invaded the ovary at a higher level. They suggest that the grafting on the ovary may be due to the retention of the fertilised ovum in a crypt or by adhesions. Such cases are distinguished by Spiegelberg as epiovarian. Although the possibility of such an occurrence cannot be excluded it is unlikely. However, the presence of inflammation of the ovary has been mentioned by Caturani as a possible aetiological factor in the production of ovarian pregnancy. Inflammatory processes of the ovary and in some instances of the tube in cases of ovarian pregnancy have been described by Caturani ('14), Norris ('09), Lockyer ('17), Young and Rhea ('11) and Bandel ('02). No adhesions were to be found in the case of H 153. Yet, in order to invade the ovary from without, it must be supposed that in some way the fertilised ovum was retained in the vicinity of the ovary until its trophoblastic layer was developed. Bryce, Teacher, and Kerr ('08) while admitting the possibility of such an invasion in Hewetson and Jordan-Lloyd's specimen suggest an alternative explanation for the occurrence of such cases in which connective tissue surrounds the implantation cavity. They believe that the ovum was primarily imbedded in the thin layer of connective tissue within the corpus luteum and that it burrowed through the wall of the corpus to reach its extra-follicular position. Although the chorionic vesicle was extra-follicular in the specimen described by Bryce, Teacher, and Kerr ('08), a gap was present in that part of the wall of the corpus luteum which adjoined the implantation cavity. A similar gap occurred in the specimen described by Franz ('02). Bryce, Teacher, and Kerr state, in describing their specimen, that at the site of interruption of the corpus luteum, "the gestation sac is directly continuous with the interior of the corpus luteum by a band of tissue of doubtful character and more or less in a state of necrosis."

They interpret this strand as being comparable to the cone of fibrinous material occupying the point of entrance of the Bryce-Teacher ovum. Their conclusion is, therefore, that the ovum had been fertilised within the follicle and while only about ·2 mm. in diameter migrated through the wall of the corpus luteum to become imbedded in the surrounding vascular connective tissue.

However, Bryce, Teacher, and Kerr admit a second possibility, viz. "that the ovum was arrested between the lips of the wound of the follicle, was there fertilised, and was then imbedded in the vascular stroma outside the follicle." As they point out, this may explain Thompson's case ('02) which lay "in the splayed out mouth of the follicle with no lutein tissue either on its free surface or between it and the corpus luteum." However, since in their younger specimen the chorionic vesicle was wholly outside a corpus luteum they favour the first alternative. They state that if the vesicle had continued to grow the corpus luteum would have been invaded and destroyed as in Thompson's case. They regard the migration theory as a more complete analogy to the conditions found in uterine implantation. They believe that all cases may be explained by assuming that they were primarily intra-follicular and only vary from one another in the degree of penetration of the connective tissue. They agree with van Tussenbroek that in her case the ovum imbedded itself excentrically in the connective tissue within the lutein lamina. If such an ovum progressed, the final result would again be destruction of the corpus luteum. This explanation adheres to van Tussenbroek's original definition that "ovarian pregnancy means pregnancy in an ovarian follicle."

A study of H 153 which is at least in the same age period as the specimen described by Bryce, Teacher, and Kerr has convinced me that it is possible for the fertilised ovum to become primarily implanted in the connective tissue surrounding the mouth of the ruptured follicle. This is the alternative explanation which is dismissed by Bryce, Teacher, and Kerr. There is no cone of necrosed tissue joining the gestation sac with the interior of the corpus luteum in H 153 as in their specimen. Moreover, although the size of the lutein layer adjacent to the implantation cavity is reduced, it is nevertheless a well-formed plicated lamina. The reduction in size is readily explainable by the probability that the vascularisation of the area in which it is growing is interfered with due to the proximity of the implantation cavity.

The appearance in H 153 suggests that the ovum, together probably with cells of the discus proligerus still attached to it, was entrapped in the blood clot closing the wound of the ruptured follicle. Spermatozoa probably fertilised the ovum while lying in this situation as the coagulum formed. After the development of the trophoblast the ovum seems to have imbedded itself in the connective tissue surrounding the original opening and here development proceeded. In this case the growing ovum has formed for itself a capsule consisting of a thin outer layer of stroma, and a deep layer of connective tissue, separating the implantation cavity from the corpus luteum.

With the data presented by H 153 the early ovarian pregnancy of Bryce, Teacher, and Kerr no longer occupies a unique position. In H 153 the cone of necrosed tissue described by Bryce, Teacher, and Kerr is not present. If their explanation that it is formed by the outward migration of the ovum were correct, it should be still visible in this specimen of corresponding age if this migration had taken place. Moreover, another explanation may be given to the necrosis of the lutein wall described by these authors, viz. that invasion of the corpus luteum by a growing ovum primarily implanted outside the follicle is in progress. They themselves state that "only at one point does the chorion come close to the ovarian stroma and that is opposite a gap in the wall of the corpus luteum."

The further progress of development of a growing chorionic vesicle primarily imbedded outside the follicle would be identical with that described by Bryce, Teacher and Kerr for specimens which have secondarily invaded that tissue, viz. the corpus luteum will be invaded and finally will disappear. It is thus not unlikely, as suggested by Webster in 1904, that many cases obtained at a comparatively late stage of development described as follicular because of the presence of lutein cells in the gestation sac, may have been imbedded in the first instance in the thecal connective tissue and not in the follicle at all. In this connexion it is interesting to note that the extra-follicular specimens so far described are early specimens which suggest that extra-follicular imbedding is not uncommon. Probably, as suggested by Thomson ('19), ovarian pregnancy may be produced by fertilisation of an ovum which has not been expelled from the follicle, and some cases are to be explained in this way. But it is certain that van Tussenbroek's original definition which includes only such cases must be replaced by a more comprehensive statement to include primary imbedding outside the follicle as well.

SUMMARY AND CONCLUSIONS

The specimen described in this paper (H 153, Anat. Dept. Collection, Sydney University) has been shown from clinical and histological data to be an example of primary ovarian pregnancy of less than 20 days' duration. The embryonic papilla (3·5 mm. in length) was enlarged by the infiltration of maternal blood into the yolk sac through the body stalk. The compressed chorionic vesicle measured 10 × 4·7 mm. The specimen is of special value due to the early period of development. The following conclusions were derived from a consideration of its features.

(1) That a decidual reaction probably always occurs in early stages of ovarian impregnation.

(2) That the decidual tissue in H 153 is ploughed up by infiltration of the ovarian stroma by blood from the intervillous space; this infiltration has detached the villi from their attachments and probably led to retardation of growth of the chorionic vesicle and embryonic rudiment.

(3) That the ovum was fertilised as the closing coagulum was formed in the mouth of the Graafian follicle and proceeded to develop in the con-

nective tissue in this situation, imbedding itself *ab initio* outside the growing corpus luteum of pregnancy. It appears that ovarian pregnancy may result from the fertilisation and imbedding of an ovum within its follicle or at any point of its course in its progress outwards.

In conclusion I wish to express thanks to Messrs Schaeffer, Burfield and Bagnall of the University of Sydney for the technical assistance rendered me in the preparation of this account.

REFERENCES

('01) Anning, G. P. and Littlewood, H. "A Case of Primary Ovarian Pregnancy." *Trans. Obstets. Soc.* xliii, p. 14. London, 1901.

('10) Barrows, C. C. "Ruptured Ovarian Pregnancy." *Amer. Journ. Obstet.* lxii, pp. 1078–1081. New York, 1910.

('12) Banks, A. G. "A Case of Ovarian Pregnancy." *Journ. Obstet. Gyn. Brit. Emp.* xxi, pp. 216–219. 1912.

('02) Bandel, R. *Beitr. z. Klin. Chir.* xxxvi, p. 657. 1902.

('96) Bland Sutton. *Surgical Diseases of the Ovaries and Fallopian Tubes*, p. 35. 1896.

('01) —— *Brit. Med. Journ. Vide* Discussion of Anning and Littlewood's specimen. 1901.

('04) Boesebeek. *Monat. f. Geb. u. Gyn.* Berlin, 1904. *Vide* Norris ('09).

('10) Bondi, Josef. *Wiener Klinische Wochenschrift*, p. 774. 1910.

('08) Bryce, Teacher and Monro Kerr. *Dev. and Imbedding of Human Ovum. An Early Ovarian Pregnancy.* Glasgow, 1908.

('14) Caturani, M. "Ovarian Pregnancy with Report of a Case." *Amer. Journ. of Obstets.* lxix, pp. 409–428. 1914.

('13) Chiene, G. "Ruptured very early Ovarian Pregnancy." *Obstet. Trans. Edin.* xxxviii, p. 96. 1913. Also *Edin. Med. Journ.* x, p. 316.

('00) Croft. "On an Anomalous Case of Extra-uterine Pregnancy probably Ovarian." *Trans. London Obstet. Soc.* xlii, p. 316.

('02) Franz, K. "Ueber Einbettung und Wachstum des Eies im Eierstock." *Hager's Beiträge z. Geb. u. Gyn.* vi. 1902. *Vide* Bryce, Teacher and Kerr ('08).

('06) Freund, H. W. and Thomé, R. *Virchow's Archiv f. Path. Anat.* Bd clxxxiii, Heft i. 1906. *Vide* Kelly and McIlroy ('06).

('14) Giles, A. E. and Lockyer, C. "A Case of Ovarian Pregnancy." *Proc. Roy. Soc. Med.* viii, pp. 2–10. 1914–15.

('12) Graham, G. S. "A Case of Ovarian Pregnancy." *Journ. Med. Res.* xxvi, pp. 499–512. 1912.

('13) Grimsdale, T. B. "Case of Ovarian Pregnancy with Full Time Foetus." *Journ. Obstet. and Gyn. of Brit. Emp.* xxiii, pp. 115–117. 1913.

('12) Hannes, W. "Ovarian-Gravidität." *Zeitschrift für Geburtsch. und Gynäkologie*, lxxii, pp. 269–271. 1912.

('09) Hastings, Tweedy. "A Specimen of Ovarian Pregnancy." *Proc. Roy. Soc. Med.* iii, pt. 2. 1909–10.

('06) Hewetson and Jordan-Lloyd. *Brit. Med. Journ.* ii, p. 568. 1906.

('11) Holland, Eardley. "A Case of Ovarian Pregnancy probably Bilateral." *Journ. Obstet. and Gyn. of Brit. Emp.* xx, pp. 295–298. 1911.

('21) Hunter, J. I. "A Case of Early Primary Ovarian Pregnancy." *Med. Journ. Australia*, ii, No. 13, p. 233. 1921.

('08) Jacobson, S. D. *True Primary Ovarian Pregnancy. Contributions to the Science of Medicine and Surgery, New York Post Grad. Med. School and Hosp.* p. 241. 1908.

('06) Kelly, J. K. and McIlroy. *Journ. Obstet. and Gyn. of Brit. Emp.* ix, p. 389. 1906.

('08) Kerr, J. M. M. "Case of Ovarian Pregnancy associated with an Intra-uterine Pregnancy." *Proc. Roy. Soc. Med.* i, No. 9, p. 268. 1908.

('10) Lea, A. W. W. "A case of Ovarian Pregnancy with Diffuse Intraperitoneal Haemorrhage." *Journ Obstet. and Gyn. of Brit. Emp.* xv, pp. 182–187. 1910.

('12) LENDON, A. A. *Aust. Med. Gaz.* XXXI, p. 492. 1912.

('02) LEON, M. DE and HOLLEMAN. *Rev. de Gyn.* June, 1902. *Vide* KELLY and MCILROY ('06).

('17) LOCKYER, C. "Two Cases of Primary Ovarian Pregnancy." *Proc Roy. Soc. Med.* x, No. 8, p. 169. June, 1917.

('15) MALL, F. P. "Tubal Pregnancy." *Surg. Gyn. Obstet.* XXI, pp. 289–298. 1915.

*('13) MALL, F. P. and CULLEN, E. K. "An Ovarian Pregnancy located in the Graafian Follicle." *Surg. Gyn. Obstet.* XVII, pp. 698–703. 1913.

('02) MAYO ROBSON. "Primary Ovarian Gestation." *Trans. Lond. Obstet. Soc.* XLIV, p. 215. 1902. Also *Brit. Med. Journ.* II, p. 1447. 1902.

('08) NORRIS, C. C. and MITCHELL, C. B. "Primary Ovarian Pregnancy with Report of a Case." *Surg. Gyn. Obstet.* p. 460. May, 1908.

('09) NORRIS, C. C. "Primary Ovarian Pregnancy. The Report of a Case combined with Intrauterine Pregnancy." *Surg. Gyn. Obstet.* IX, p. 123. 1909.

('13) OLDFIELD, C. "Ovarian Gestation." *Journ. Obstet. Gyn. Brit. Emp.* XXIII, pp. 41, 42. 1913.

('21) RAY, H. M. "Primary Ovarian and Primary Abdominal Pregnancy: Their Morphological Possibility." *Surg. Gyn. Obstet.* XXXII, No. 5, p. 437. 1921.

('78) SPIEGELBERG, OTTO. *Arch. f. Gyn.* VIII, p. 73. 1878. Also "Text-book of Midwifery," *New Sydenham Soc. Trans.* p. 429.

('06) TAUSSIG. "Ectopic Decidua Formation." *Surg. Gyn Obstet.* p. 292 March, 1906.

('98) TAYLOR, J. W. "Ingleby Lectures." *Lancet,* p. 1447. May, 1898.

('02) THOMPSON, J. F. *Trans. Amer. Gyn. Soc.* XXVII, p. 338. 1902. Quoted by KELLY and MCILROY ('06).

('19) THOMSON, ARTHUR. "Rupture of the Graafian Follicle." *Journ. of Anat.* LIV, Pt 1. 1919.

('99) VAN TUSSENBROEK, CATHERINE. *Annales de Gyn. et Obstet.* Dec. 1899. Quoted by BRYCE, TEACHER, and KERR ('08).

('12) VERCO, W. A. "Ovarian Pregnancy." *Aust. Med. Gaz.* XXXI, p. 491. 1912.

('02) WEBSTER, J. C. *Amer. Journ. Obstet.* XLV, p. 302. 1902.

('04) —— "Study of Ovarian Pregnancy." *Amer. Journ. Obstet.* L, pp. 28–50. 1904.

('07) —— *Trans. Amer. Gyn. Soc.* XXXII, p. 122. 1907.

('10) WHITEHOUSE, B. "Remarks on a case of Probable Ovarian Pregnancy." *Brit. Med. Journ.* I, pp. 1276–1280. London, 1910.

('08) WILLIAMS, WHITRIDGE. *Kelly and Noble's Gynaecology,* 1908.

('17) —— *Text-book of Obstetrics,* 1917.

('11) YOUNG, E. B. and RHEA, L. J. "Ovarian Pregnancy: Report of a Case." *Boston Medical and Surgical Journ.* CLXIV, p. 264. 1911.

[* *Note.* Since this article has been in the press *Contributions to Embryology,* Vol. XII, No. 56, Washington, 1921, which includes "Ovarian Pregnancy" by F. P. Mall and A. W. Meyer, has become available.]

THE ORIGIN OF THE MOTOR NEUROBLASTS OF THE ANTERIOR CORNU OF THE NEURAL TUBE

By RAYMOND A. DART, M.Sc., M.B., Ch.M.

AND

JOSEPH L. SHELLSHEAR, M.B., Ch.M.

Demonstrators of Anatomy, University College.

INTRODUCTION

The foundation of His' conception lies in the ectodermal or neural tube origin of motor neuroblasts. It is essential therefore to analyse carefully the evidence of those who have actually dealt with this phase of the question. With few exceptions the His conception has been given a false appearance of certainty by writers having assumed this neural tube origin from the results of His, Ramón y Cajal, and Schaper.

As recently as 1921 Neal writes "That neuraxones develop as processes of ganglion cells scarcely admits of reasonable doubt in the light of the evidence now in our possession. Few to-day would challenge the truth of Harrison's assertion that the work on the cultivation of tissues may be said without reserve to have completely proved the correctness of the conception of His and Ramón y Cajal."

Coordinated movements occur in the embryo at a time antedating the first appearance of ganglion cells and at a stage in development before those stages on which His, Ramón y Cajal, and Schaper worked. Such being the case the problem must be reinvestigated, for the origin of any structure or mechanism must go back to the ultimate beginnings, and these certainly antedate the stages which these men describe.

His depicts no stages earlier than Pristiurus of 4·5 mm. in length and Cajal makes his deductions from chicks at stages from 72 hours onwards.

The work of Harrison on the cultivation of tissues is undoubtedly a demonstration of the protoplasmic activity of nerve cells in general, but upon the subject of the site of origin of the cells we are particularly dealing with, it gives us no information whatever. Further, as Harrison stated in one of his papers, "There is nothing in the present work which throws any light upon the process by which the first connection between the nerve fibres and its end organ is established." We must therefore emphasise at this point that, no matter how instructive researches and experiments may be on the development of axonic processes, if the somites are so functioning as to give rise to movements in the embryo before nerve-fibres, or even ganglionic cells, are demonstrable in the embryo, such researches as these can give us no certain information as to the *origin* of the mechanism concerned in the production of these movements.

Some consider neuro-fibrillae to be the first evidence of "effector" activity, but the demonstration of these in an embryo after the advent of coordinated movements merely points to a later differentiation going on in a mechanism already established.

Our aim is to demonstrate the origin of these motor neuroblasts from the myotomes and to establish the principle of both functional and structural continuity between the nervous system and the other systems which it controls.

TERMINOLOGY

The motor neuroblast is frequently referred to as the effector neuroblast or neurone when referring to the elements in the reflex arc.

On the sensory side, as Huxley so clearly pointed out, we have (1) the *receptor*, a modified epithelial organ, (2) the nerve and ganglion or cell *transmittor*, and (3) the *sensorium*; whereas on the effector side we have only the term *effector* used, in some cases distinctly referring to the neurone itself, in others to the structure effected, or the two elements as a whole unit. In this paper the term "*effector*" is used for the motor neuroblast (or neurone) and we propose to introduce the term "*expressor*" for the organ acted upon by the effector neurone, be it muscle, electric organ, or other structure; and thus the term "*expressor*" on the motor side is similar in use to the term "*receptor*" on the sensory side.

Thus we could describe a simple reflex arc in the following terms: *receptor, transmittor, sensorium, effector, expressor.* The old term *neuro-muscular*, revived by Parker and others, in the case of undifferentiated primitive tissue is open to great objection because such tissue is neither neural nor muscular in that it is undifferentiated. Although the meaning of the term may be clear, in many cases its ambiguity becomes obvious when the undifferentiated tissue of the myotomes, or of the embryonic heart, is directly compared with adult fully differentiated muscle. The substitution here of the term *effector-expressor* seems to us less open to objection. Furthermore it clarifies the general conception of the so-called "independent-effectors" by dividing them into two obvious classes: *independent expressors* and *independent effector-expressors.*

EVIDENCE OF COORDINATED ACTIVITY

Recent work on unicellular organisms shows that the cilia, the *expressors* are coordinated by impulses from *receptors* in the cirri and we thus find the earliest expression of complicated coordination even in the unicellular organism. Parker shows in Invertebrata a definite *effector-expressor* (neuro-muscular) undifferentiated tissue. Obviously we have need of a conception sufficiently broad to comprehend these activities as well as those of higher forms. By such a conception the components of the *effector-expressor* mechanism are traced back to their sources, or, better still, common source in the single *indifferent* cell.

We ourselves have observed movements of a coordinated character with abduction and adduction in embryos before the appearance of sensory neuroblasts, and when the apparent relationship between the neural tube and the myotome is one of contact. Such evidence has been to hand since Balfour, who, in his famous monograph on Elasmobranch fishes, states,

"Before the appearance of the third visceral cleft in a part of the innermost layer of each protovertebra (which may be called the splanchnic layer from its being continuous with the mesoblast of the splanchnoplane) opposite the bottom of the neural tube, some of the cells commence to become distinguishable from the rest and to form a separate mass. This mass becomes much more distinct a little later, its cells being characterised by being spindle shaped and having an elongated nucleus which becomes deeply stained by reagents. Coincidently with its appearance the young dog-fish commences spontaneously to move rapidly from side to side with a kind of serpentine motion, so that, even if I had not traced the development of this differentiated mass of cells till it becomes a band of muscles close to the notochord, I should have had little doubt of its muscular nature. It is indicated by the letters *mp* (in figs. 11, 12, and 13). Its early appearance is most probably to be looked upon as an adaptation consequent upon the respiratory requirements of the young dog-fish necessitating movements within the egg.

Shortly after this date, at a period when three visceral clefts are present, I have detected the first traces of the spinal nerves." Cf. fig. 1 of this paper.

Wintrebert (1904), and Paton (1906), have confirmed this demonstration of Balfour's. Furthermore, Paton points out that the primitive movements of abduction and adduction of the body begin at a time when these phenomena "may as yet neither be designated as myogenic or neurogenic in origin." So, Paton describes for the vertebrate embryo phenomena comparable with those designated by Parker as *neuro-muscular* in lower invertebrates.

If the His conception is correct, there is, at this stage, no connection whatever between the neural tube and the myotomes. The *effectors* are in the neural tube and have not yet grown out to the *expressor* organ. How then are there coordinated movements of abduction and adduction?

Of those who stand for discontinuity between the neural tube and myotome, Balfour alone would appear to have appreciated the significance of this question. Keen student of phylogeny as he was, he saw the origin of the *effector-expressor* mechanism from a common source (as also did Gaskell) and he failed to account for the apparently insurmountable difficulty in any other way than by a pathologic-like lesion.

Before describing in detail the actual histological appearance of various embryos at this age, it is expedient to quote Balfour in full on this point:

"General considerations. One point of general anatomy upon which my observations throw considerable light is the primitive origin of the nerves. So long as it was admitted that the spinal and cerebral nerves developed in the embryo independently of the central nervous system, their mode of origin always presented to my mind considerable difficulties. It never appeared clear how it was possible for a state of things to have arisen in which the central nervous system as well as the peripheral termination of nerves, whether motor or sensory are formed independently of each other; while between them a third structure was developed, which, growing out either towards the centre or towards the periphery, ultimately brought the two into connection. That such a condition could be a primitive one seemed scarcely possible.

...It is possible to suppose that in their primitive differentiation contractile and sensory systems may, as in Hydra, have been developed from the protoplasm of even the same cell.

...When such a condition as that was reached the sensory portion of the cell would be called a ganglion cell, or, terminal sensory organ, the connecting process a nerve, and the contractile portion of the cell a muscle cell. When these organs were in this condition, it might not impossibly happen for the general developmental growth, which tended to separate the ganglion cell and the muscle cell, to be so rapid as to render it impossible for the growth of the connecting nerve to keep pace with it and that thus the process connecting the ganglion cell and the muscle cell might become ruptured. Nevertheless the tendency of the process to grow from the ganglion cell to the muscle cell, would remain, and when the rapid developmental growth had ceased, the two would become united again by the growth of the process which had previously been ruptured."

From our present knowledge of the origin of sensory neuroblasts, of the constitution of the neurones, and of primitive neuro-epithelial and neuromuscular cells, it is evident that to establish His' conception, the demonstration of some pathologic-like lesion is logically necessary, but even then the presence of coordinated movements of abduction and adduction would be entirely unexplained.

THE HISTOLOGICAL APPEARANCE OF THE EMBRYO AT THE TIME OF THE FIRST APPEARANCE OF COORDINATED MOVEMENTS

Fig. 1 is a section of a drawing of *Squalus acanthias* (No. 1498, Sect. 110, 8μ) from the embryological collection at Harvard inaugurated by Dr C. Sedgwick Minot.

This embryo is described as being 3·8 mm. in length and shows the actual appearance of the embryo when the first movements occur. It corresponds almost exactly with Balfour's figures. The myotome shows the differentiation and thickening of the inner wall (fig 1 *b*). In the interval between the myotome and notochord is to be seen the commencement of the so-called *breaking-down* of the inner wall of the myotome. The relationship between the myotome and neural tube is certainly one of *contact*, but it is not possible in this specimen to determine continuity.

Fig. 2, *Squalus acanthias*, 4·0 mm. (H. C.) (No. 7050 *a*, Sect. 106, 10μ) shows a further stage in the differentiation of the myotome.

Protoplasmic continuity between the myotome and neural tube is now very definitely established.

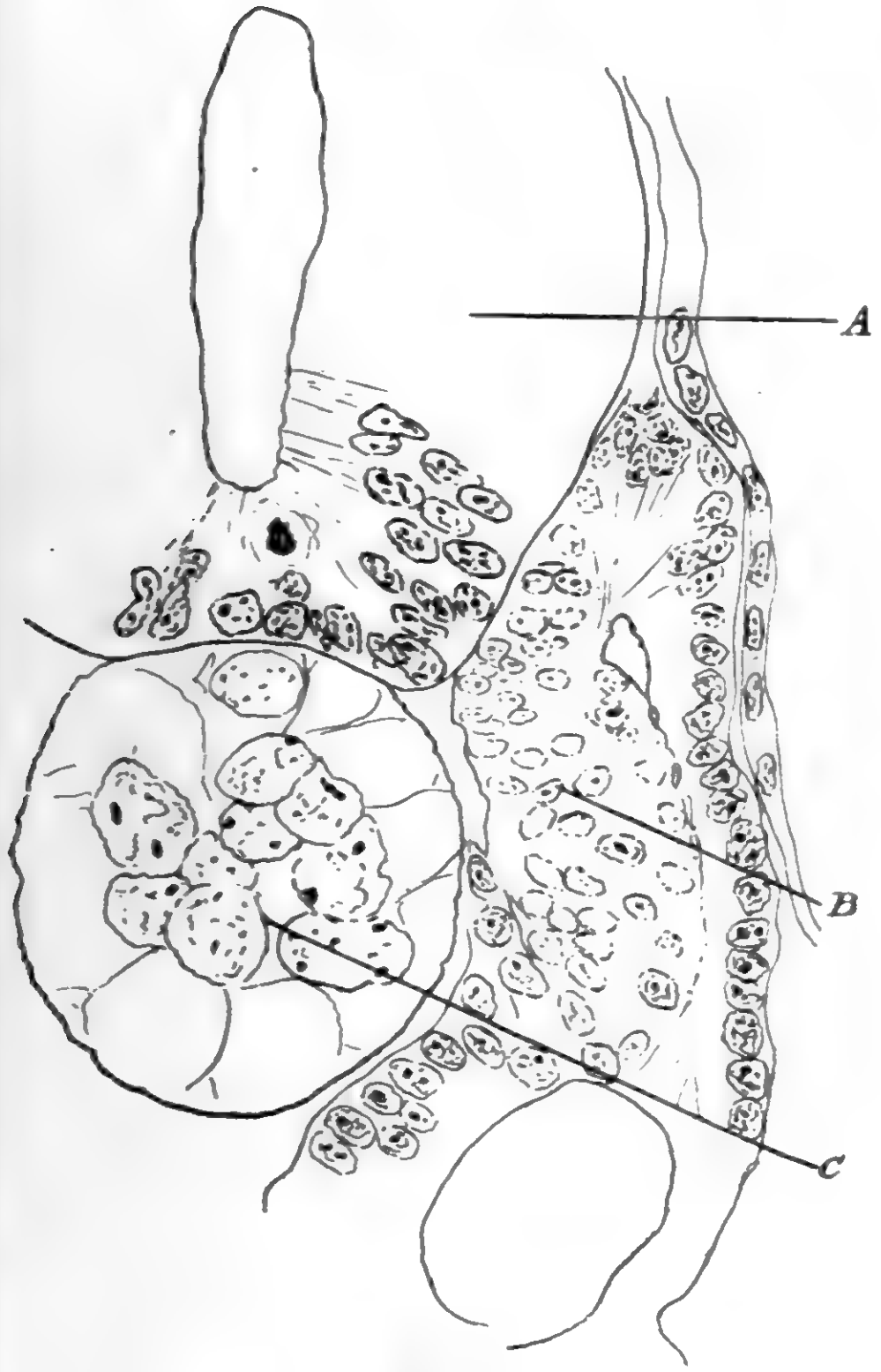

Fig. 1.

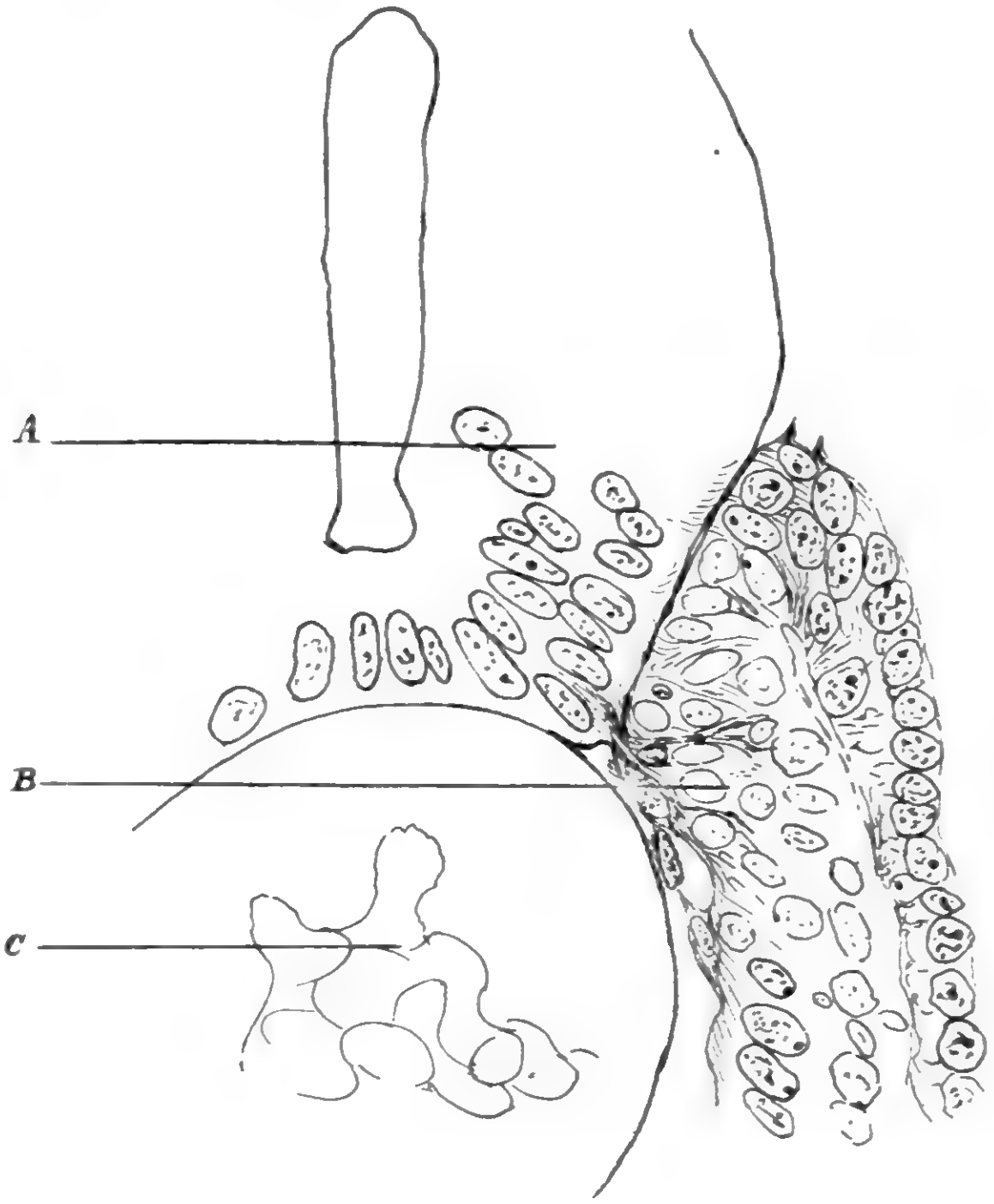

Fig. 2.

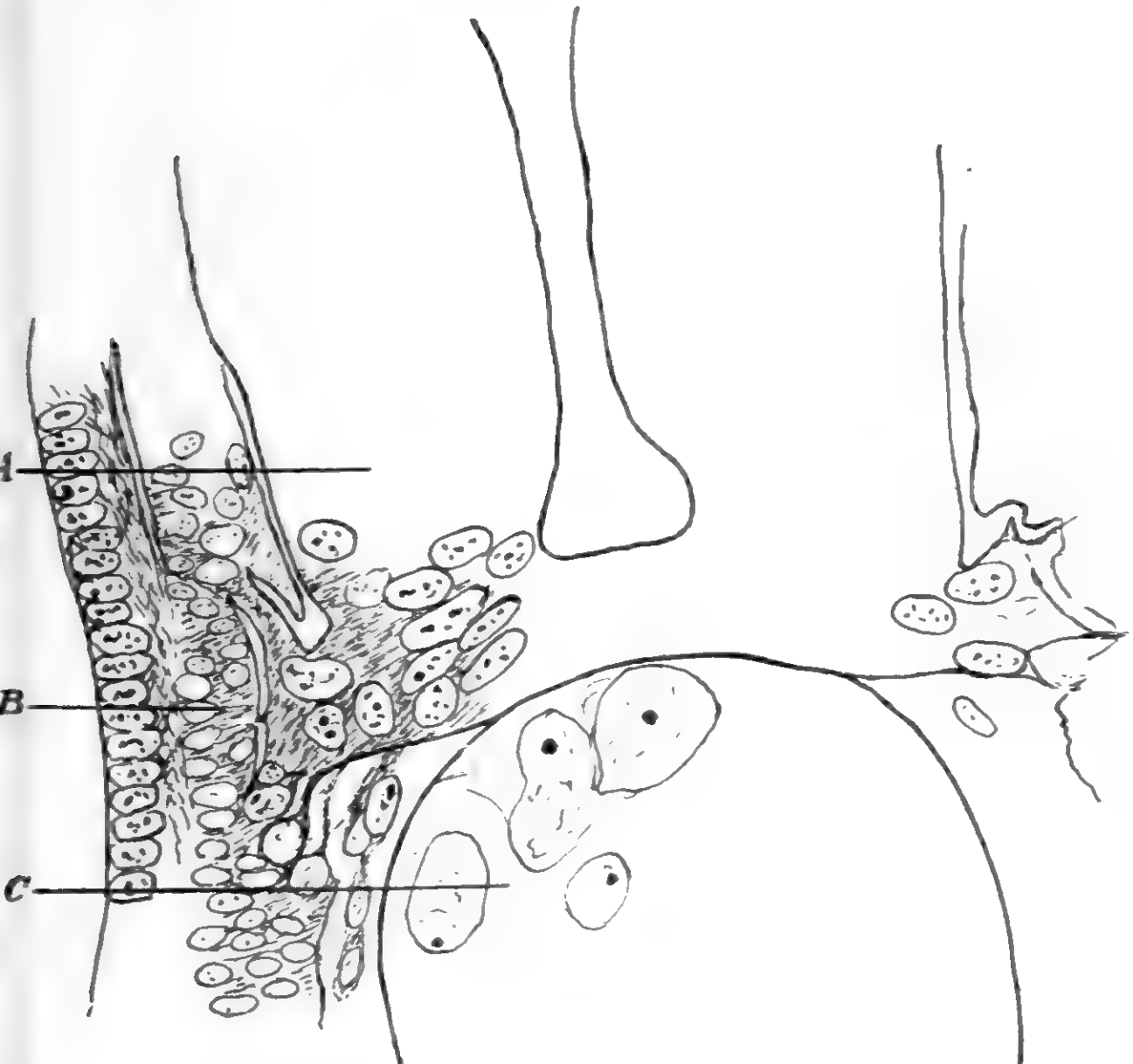

Fig. 3.

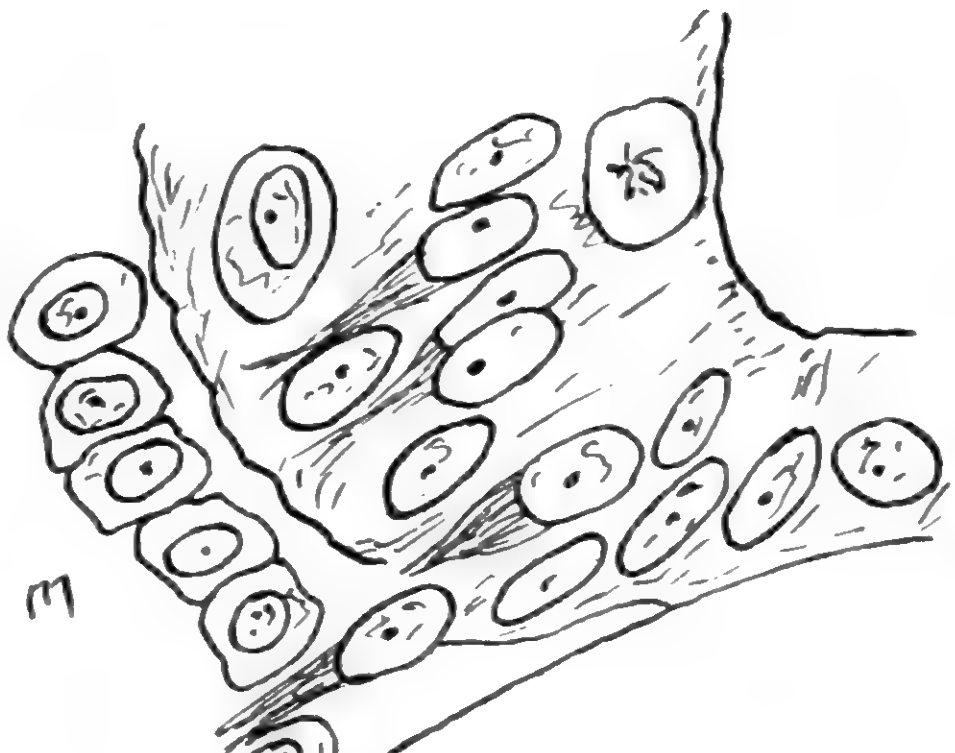

Fig. 4.

The differentiation of the inner wall reveals the type of tissue shown in fig. 1, for we see the beginnings of the division of the *effector-expressor* mechanism of the myotome into its two components *effector* and *expressor*. As to which of the cells lying outside the neural tube are motor neuroblasts, there is nothing in the specimen to tell. The cells are *indifferent*.

Fig. 3. *Squalus acanthias*, 5·2 mm. (H. C.) (No. 1355 *a*, Sect. 251) shows a later differentiation. For further evidence as to the nature of these cells readers are referred to Held's monograph in which similar stages are clearly depicted.

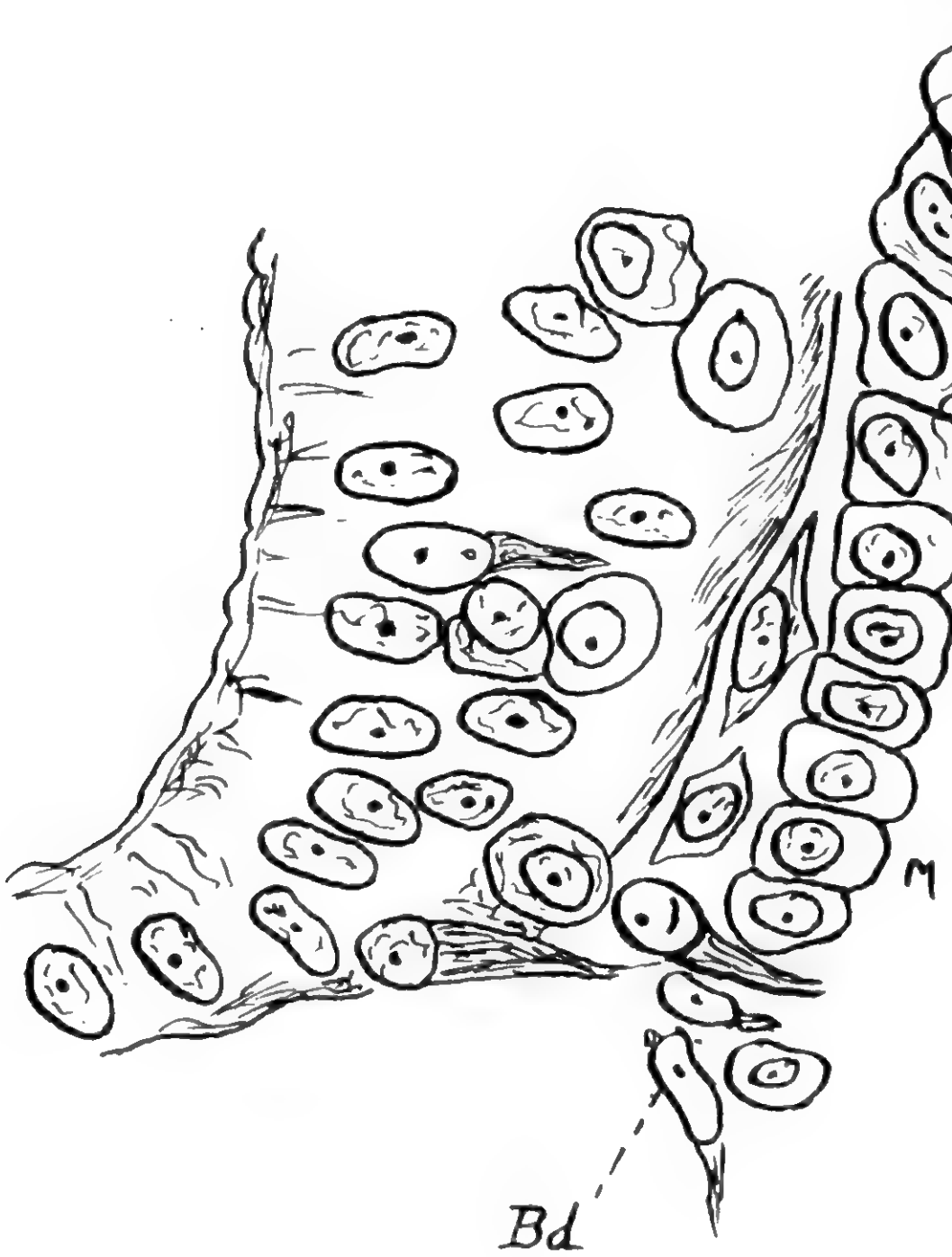

Fig. 5.

His publishes in his paper on the development of neuroblasts numerous pictures of *Pristiurus* in the same stages. He regarded the myotome of so little account that in all but a few pictures he leaves it out altogether. Comparing his pictures, however, of embryos of 4½ mm. with fig. 2, we note a striking similarity between his figs. 38 and 39. He depicts a *breaking-down* of the myotome in the same area as fig. 2. We do not desire to fall into the error of assigning to the so-called sclerotome a purely neuroblastic function. We are alive to the outcome of this having been done in the case of the "neural crest." Placodes give rise to neuroblasts and connective tissue. We consider that the inner wall of the myotome belongs to this *placodal* type of structure. But whereas we do not at this stage commit ourselves as to which cells are neuroblasts in the figures of this paper, His did commit himself and depicts neuroblasts outside the neural tube at this early period. The study of his figures leaves the impression that these cells have come from the myotome. His' figs. 38 and 39 are reproduced as figs. 4 and 5. His proof that these motor neuroblasts are derived from the germinal layer of the neural tube will be found on pages 323 and 324 of his paper, "Die Neuroblasten und deren Entstehung im Embryonalen Mark."

Briefly stated, his proof rests on two facts:

(1) That the site of origin of the motor neuroblasts is the germinal layer, for when he sees the motor neuroblasts (in the outer part of the neural tube) present, there are holes in the ependymal layer from which they have sprung.

(2) That the cubic capacity of a protoplasm of a germinal cell allows of sufficient volume of material to stretch from the neural tube to the myotome:

"das Volum	der Gesammtzelle	697 cub. μ
,,	des Kernes	65 ,,
,,	des Zellenleibes ohne den Kern	632 ,,

Die Breite eines Axencylinders beträgt (mit einem Nadelzirkel am Projectionsbilde des Zeichnungsprismas gemessen) ca. 0·9 μ. Aus obigen 632 cub. μ Protoplasma würde demnach eine Faser von rund 250 μ Länge gebildet werden können."

Our criticism is not simply captious, for it is remarkable that His was able to determine so much with material showing such obvious lacunae after preparation. But surely the time has come for a reconsideration of this problem, and with evidence other than that used seriously by His.

Figs. 6 and 7 are, respectively, *Squalus acanthias*, 6 mm. (No. 293, Sect. 208, 10 μ) and 7·5 mm. (No. 149, Sect. 404, 8 μ), both (H. C.). They show the further changes in the myotome and region between the myotome and neural tube. These figures illustrate the banking up of the nuclei lying in the protoplasm between the neural tube and the myotome. The inner wall of the myotome is reduced in thickness and in the number of rows of nuclei, whether due to growth of the embryo or to change in position of nuclei it is difficult to express an opinion. For comparison with figs. 3, 6 and 7, we represent figs 8, 9 and 10, which are a continuation of His' pictures. If histological evidence is our criterion, these pictures clearly point to a centripetal rather than a centrifugal movement, for the neuroblasts are outside the neural tube in the early stages and inside in the later stages although no explanation of the relative change in position of the motor neuroblasts is offered by His.

DISCUSSION OF EVIDENCE

On the evidence so far as we have represented it, certain facts stand out:

(1) A mechanism capable of coordinated movements is in existence in very early stages in the embryos of those vertebrates which take on a free existence at an early stage in ontogeny.

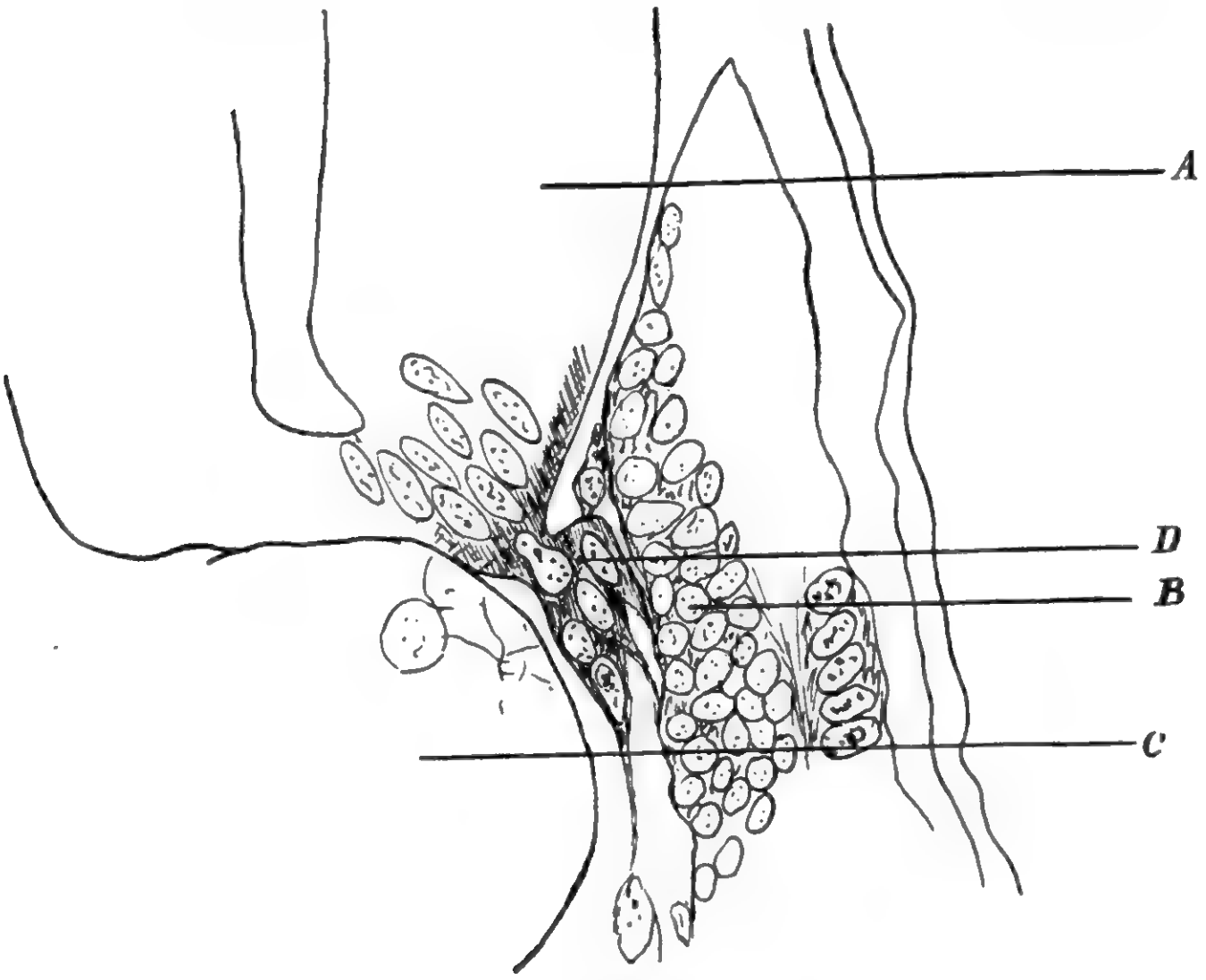

Fig. 6.

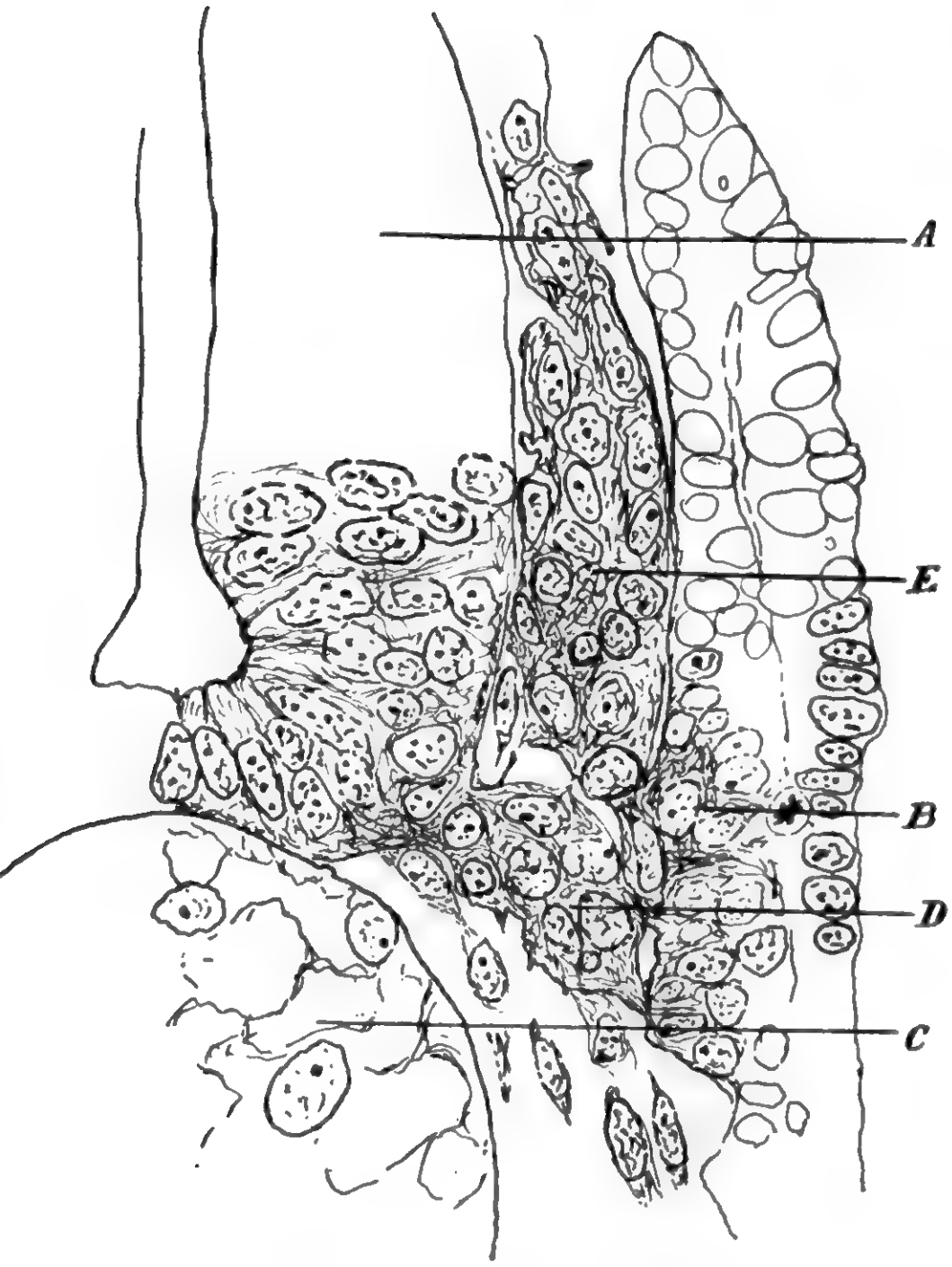

Fig. 7.

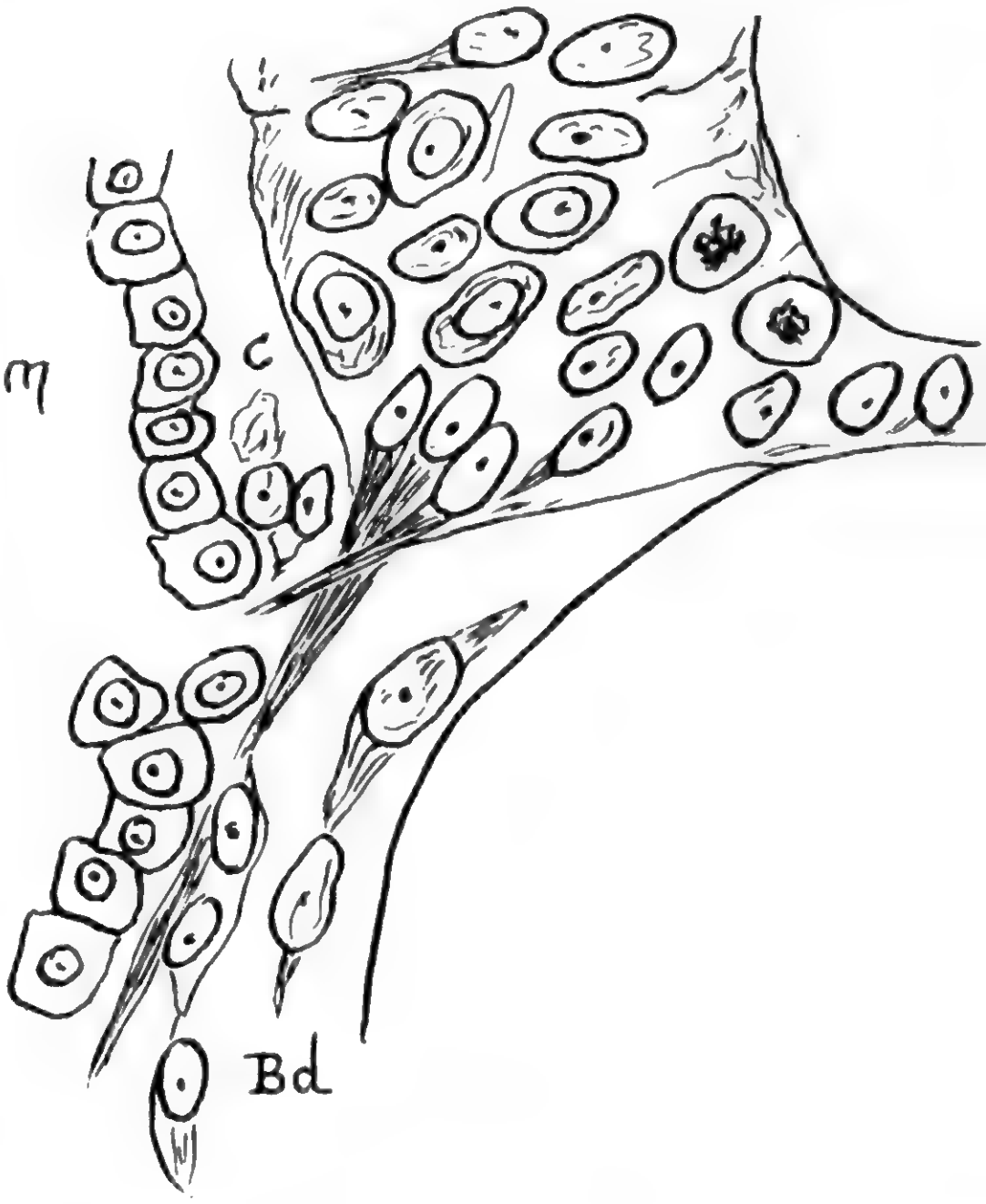

Fig. 8.

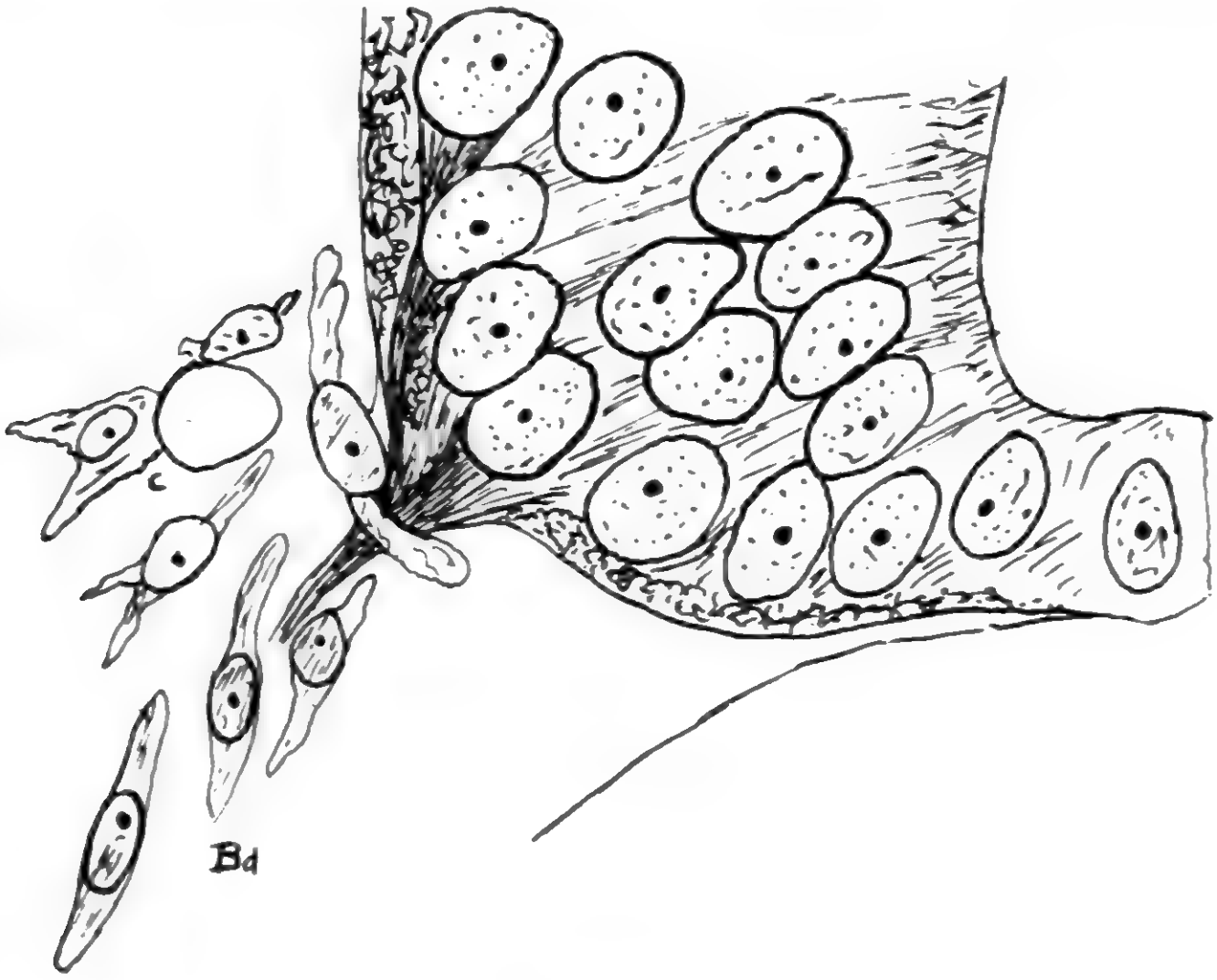

Fig. 9.

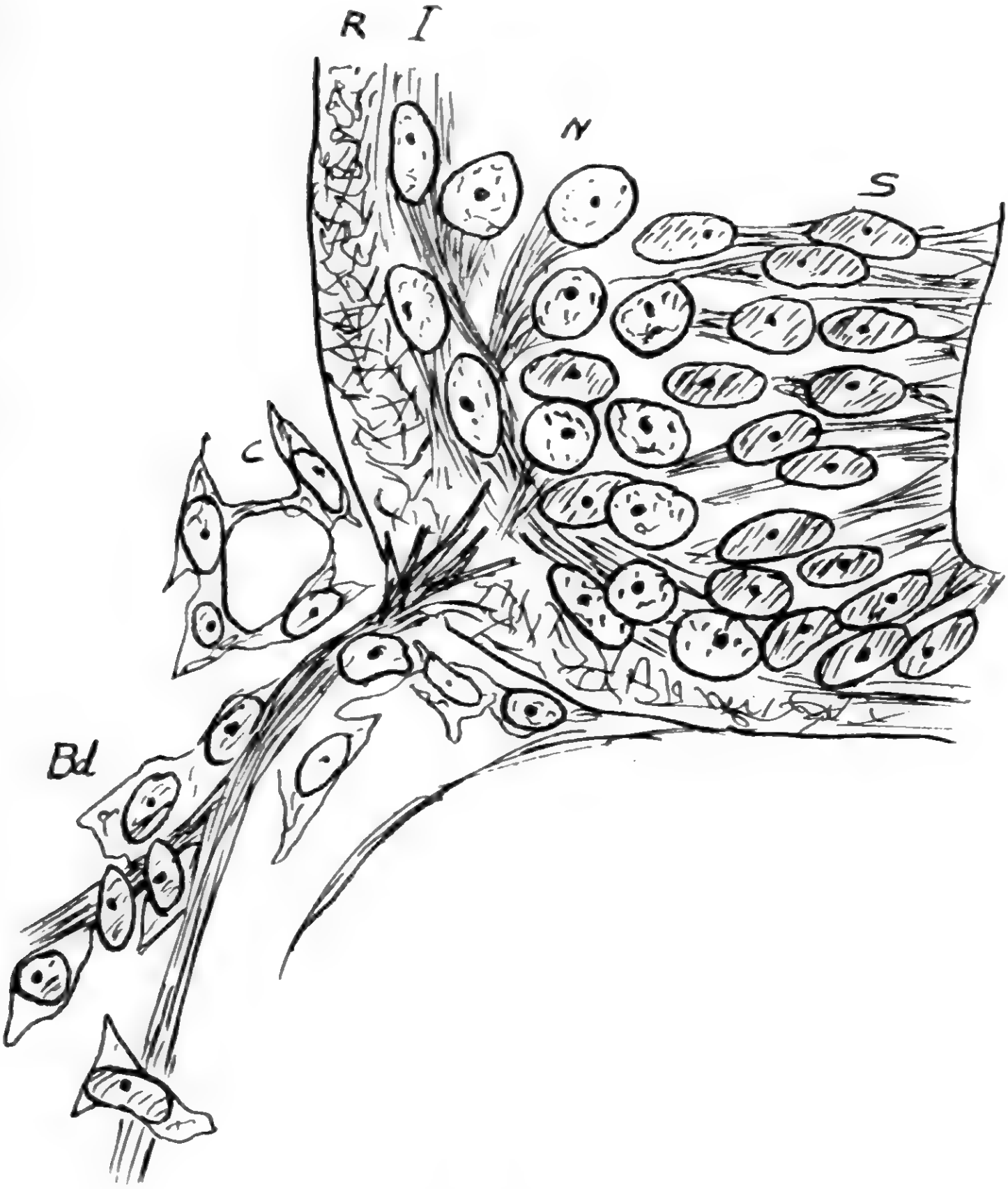

Fig. 10.

(2) This mechanism is in the myotome itself, and the subsequent differentiation of the myotome reveals the stage of development chosen by most investigators for the solution of the problem.

(3) If there is no protoplasmic continuity between the myotome and the neural tube at these earliest stages, and if the motor neuroblasts are in the neural tube, His' hypothesis can give us no explanation of the behaviour of the embryo unless we suppose that the adult mechanism has no relationship with the primitive embryonic mechanism.

(4) In *Squalus acanthias* the motor ganglion outside the neural tube is seen in fig. 7 to be in the same stage of development as the so-called neural crest (in the sense of recent text-books).

Thus the nuclei belonging to the motor neurones would seem to be differentiated from the myotome at a time which synchronises with the formation of sensory neuroblasts from neuroepithelium. This is no chance circumstance, but it reveals to us a definite phylogenetic story. We have developed an *effector-expressor* mechanism to respond to a *receptor-transmittor* mechanism. In brief, we have a vivid demonstration of the fact that the myotomic mechanism was developed in response to the exteroceptive side of the reflex arc.

By the development of the segmentally repeated reflex arc, characterised by its "invariability of response," the animal kingdom becomes to a greater extent the master of its environment; the development of such a mechanism is the common characteristic of all animals with a segmented mesoderm, i.e. of the Annulata and higher Invertebrata and of the Vertebrata. The neural tube (or *sensorium*) itself is the later and typically vertebrate achievement in phylogeny developed for more accurate coordination and association.

So far the problem has been approached from the standpoint of the lack of protoplasmic connection between the neural tube and the myotome, and also a type has been used where the collection of anterior cornual nuclei embedded in protoplasm seems to arise from the myotome *en masse*. Both Balfour and Beard refer to Löwe's statement that the cells of this mass are, in part, of myotomic origin, and remark that this statement is a "gratuitous assumption." Surely it is likewise a gratuitous assumption to derive them from the neural tube. If they have wandered out from the neural tube, what are they? And why do they wander out?

With regard to the question of protoplasmic continuity! We were very interested in the question of fixation and felt that, whatever certain *fixed* specimens showed, there is a living connection between the myotome and the neural tube. Observing very many embryos in the course of fixation, we found that with a very great variety of fixatives the invariable response was violent contractions of the embryo extending over quite an appreciable interval of time, and this sometimes after preliminary chloretone treatment.

Despite such violent contractions during fixation, we have found obvious continuity between the neural tube and myotome at very early stages. Our observations confirm those of Graham Kerr, Hensen and others on this point.

Urodele material in our possession for which we are indebted to Dr Landacre of Ohio State University show unbroken lines of yolk and pigment passing between the neural tube and myotome, and by this fact leave no doubt of absolute protoplasmic connection. To our knowledge continuity, by virtue of a study of the disposition of the mitachondrial elements, has not been urged previously.

What is the nature of this connection? It is surely a protoplasmic pathway between the neural tube and the myotome. Graham Kerr (fig. 12, *a*, *b*, *c*) says "The nerve trunk is lengthened out and externally is continued into the muscle cell of the myotome." There is no doubt he means motor nerve trunk (*m.n.r.*). There is no proof that there is a differentiated motor nerve trunk at so early a stage, meaning by nerve trunk the *effector* axon. Again, muscle cells have not been seen at this stage. The cells to which he refers are at that time primitive types in the process of differentiation, and many changes are going to take place on the inner wall of the myotome before there are seen muscle cells differentiated out of the cells of which he speaks.

Assuming for the moment that these connections could be motor nerves, then it would mean that the neuroblast itself has differentiated in ontogeny at a time antedating any known differentiation of neuroblasts, and, furthermore, that the *effector-expressor* mechanism has differentiated long before the *ganglion-receptor* differentiation in association with which it undoubtedly arose in phylogeny. We will return to this question in the next section of our paper dealing with migration.

THE MIGRATION OF NERVE CELLS

The phenomenon of cell migration is accepted by all as being of fundamental importance in questions of development. The movements of blood cells, of phagocytic cells of various kinds, of mesenchyme cells are real, that these cells do move is amply shown by the examination of living embryos. Dr Sabin's work on the chick and the Clarks' on the tadpole are illustrative of the phenomenon.

It is not surprising therefore, in the face of a familiar parallel instance, that practically all writers on the origin and development of the peripheral nervous system have given expression to some conception of migration in the case of the nerve cell, perhaps the most extreme example being that of Neumayer, who speaks of cells passing out of the neural tube and then being "fetched back" again. No one has actually seen the migration of a nerve cell in its entirety in the living embryo and without some selective method of intra-vitam staining such demonstration would be almost impossible.

What do we mean by migration of the nerve cell?

If a movement of the complete cell occurs from a place x to a place y, then it is legitimate to speak of the migration of that cell in its entirety. Evidence of such migration requires to a certain extent that those structures in the vicinity of the cell, by which we determine the relative alteration in position of the cell, should be fixed in position and in time. Again to show migration of a cell, in the sense in which we speak, requires that we demonstrate a movement of the whole cell and, since we ourselves in an extensive study of embryos, have never been able to define cell boundaries in their entirety, we hold that despite the suggestive appearances offered, the question is not proved either way from purely histological methods.

To illustrate our meaning, let us refer to figs. 3 and 7. It could be granted, for the sake of argument, that the nuclei are moving either towards or away from the neural tube, but, if the protoplasm under the influence of any particular nucleus is, on the one hand, fixed in relation to the neural tube and, on the other hand, to the myotome, the cell as a whole does *not* move with reference to these structures if those relations are maintained. *The nucleus may move however*, and we believe it does do so. It is conceivable further, that, without any alteration in the relative position of the cell, the nucleus may be in earlier periods in relation to the myotome and in later periods become absorbed into the neural tube. Such an interpretation is justified not only from the figures of Selachian embryos we here produce, but also from His' own figures despite the fact that they bear only the faintest resemblance to the embryos they are designated to depict.

Assuming, then, that the nuclei may migrate, is there any other way in which the nuclei of motor neuroblasts may find themselves in the ventral horn of the neural tube and yet be primarily extraneural in origin?

There are three possible lines of approach to this problem.

(1) The examination of a close series of embryos.

(2) The experimental method.

(3) By the observation of living embryos in such a manner as Drs Sabin and Clark have done for cells of other types.

THE SERIAL METHOD

This method is recognised by all to have its serious limitations, and for this reason has been supplanted at various times by newer fashions, such as the culture method and the experimental method. These in their turn have limitations just as serious if not more so.

The serial method seems to us to give an almost complete answer to this problem and yet with many observers has not only failed, but has led to erroneous interpretations for the reason that an elementary law of topographical survey has been disregarded.

The fundamental principle in surveying is that the "base line" or "datum line," from which subsequent measurements are taken in order to determine the relative position of objects, must be *fixed in space*. No surveyor takes the shore line of a beach which is continually silting up for this purpose. For, should he do so, his map would soon have little value. The "datum line" which has been used by embryologists consciously or otherwise, has been the external limiting membrane and so any cells within the membrane have been stated to come from the neural tube itself.

If we take any embryo in early stages we find, as His depicts in his fig. 39 (fig. 5 of this paper), blood forming cells (*Bd.*) just outside the external limiting membrane—in brief, the rudiment of a branch of the anterior spinal artery. We find this artery takes a constant position. We refer readers to current text-books of embryology, to His' own work, to Hensen's pictures and others. We reproduce different embryonic stages of this vessel, figs. 12, 13 and 14, showing its constancy with relation to adjacent structures.

The order of structures from within outwards is:

(1) The original neural tube which is in most cases clearly distinguishable.

(2) Commissural fibres running from the posterior horn to the anterior horn of the opposite side.

(3) The blood vessel in question.

(4) The motor nuclei and also that which formed at the same time the included portion of the neural crest designated by Balfour as the commissure of the neural crest.

The longitudinal connection between successive sensory segments has become included at the same time and so is laid the foundation for the columns of Goll and Burdach. The transference of the posterior root from a dorsal to a lateral position in the cord, so puzzling to Balfour, is explained by the increasing prominence of these longitudinal columns.

This fact of *inclusion into the neural tube* is borne out by the studies of Kolliker upon reptilian and avian forms, where the process of *inclusion* is incomplete and motor cells lie extra-neurally even in the adult. That these cells are somatic motor cells is shown by the later work of Sterzi and is indicated in fig. 14, of a toad fish embryo, here provided. It seems reasonable to assume, concerning these pictures, that the differentiation of motor neuroblasts is relatively later in these particular animals.

We are now in a position to discuss the observations of Ramón y Cajal. The earliest stage in which he could obtain a result with his method of staining was a 72 hour chick. His figure is reproduced as fig. 15.

Upon our hypothesis the neuroblast designated as motor is already included. Cajal's picture gives explanation of the true status of the so-called "motor nerve fibres" of Graham Kerr, previously referred to. These may well be the protoplasmic bridges in which the *intercalated axones* (*sensorium* of Huxley) are formed, and at this stage these axones, as depicted by Cajal, are becoming completely included into the neural tube.

As motor neuroblasts are differentiated before the 72 hour stage is reached, and before a silver reaction can be secured, it is obvious that Cajal's work can give us no certain information concerning their origin.

So far we have demonstrated the fact that motor neuroblasts and other cells may become incorporated into the neural tube without having to call

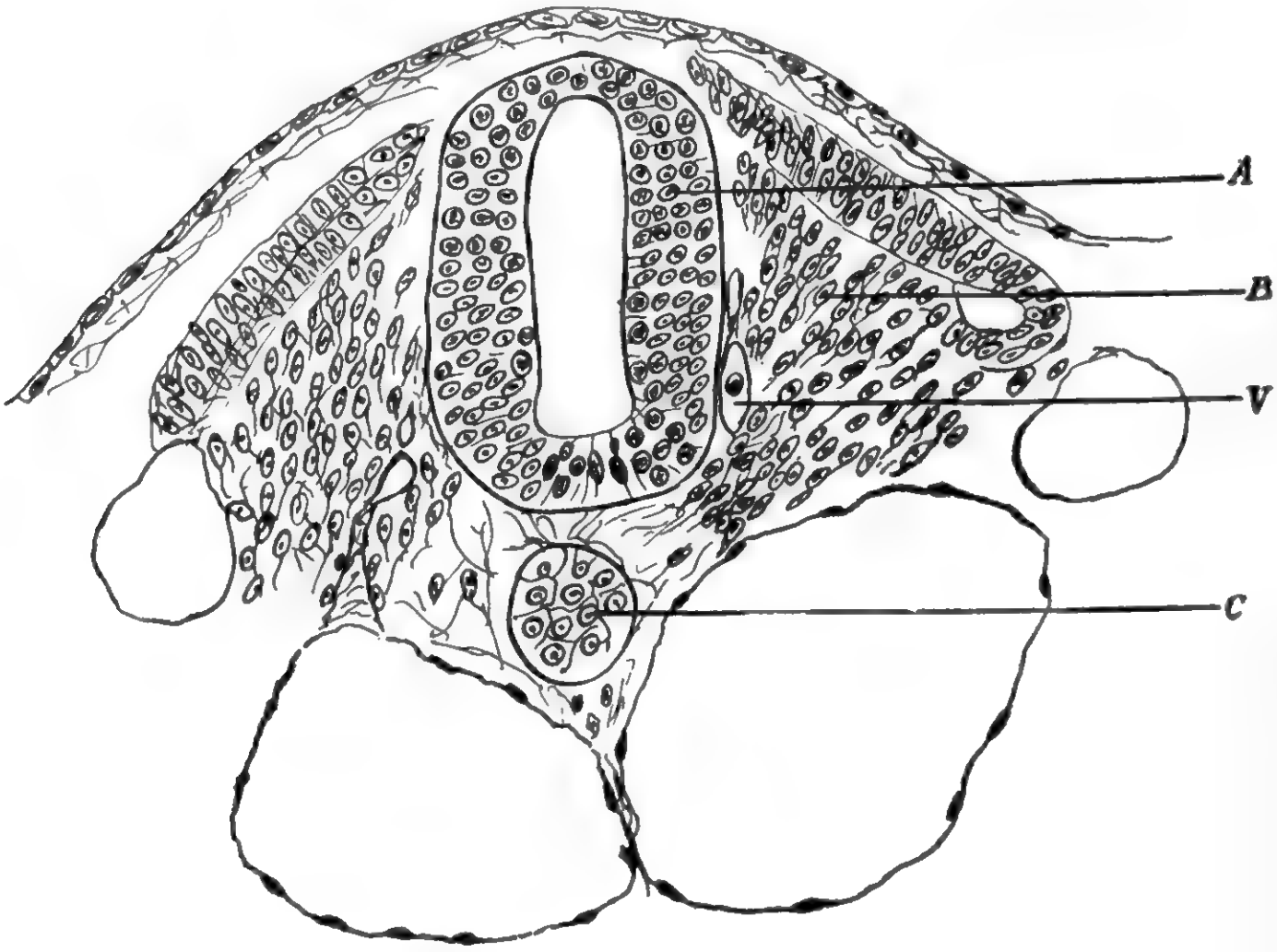

Fig. 11.

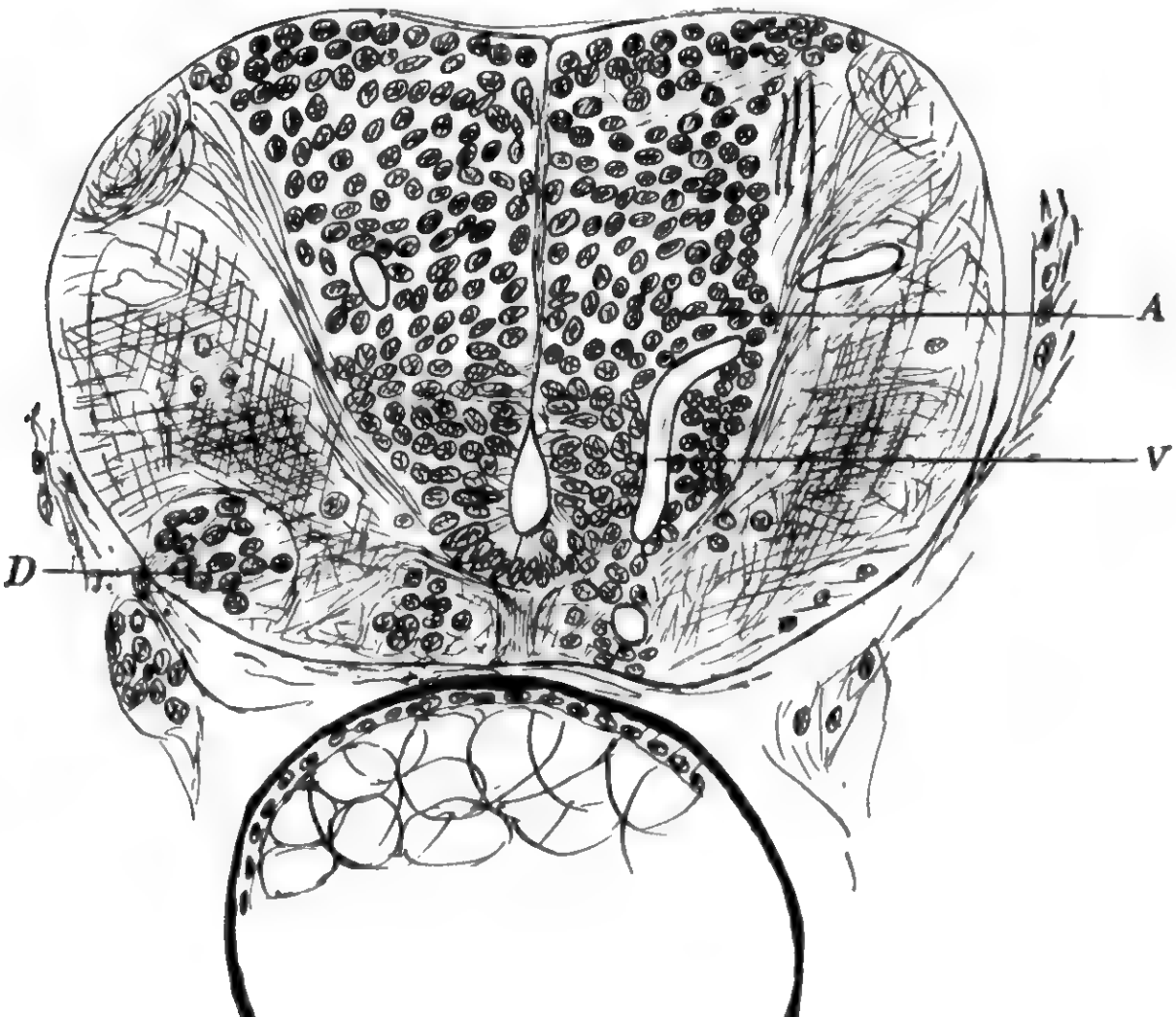

Fig. 12.

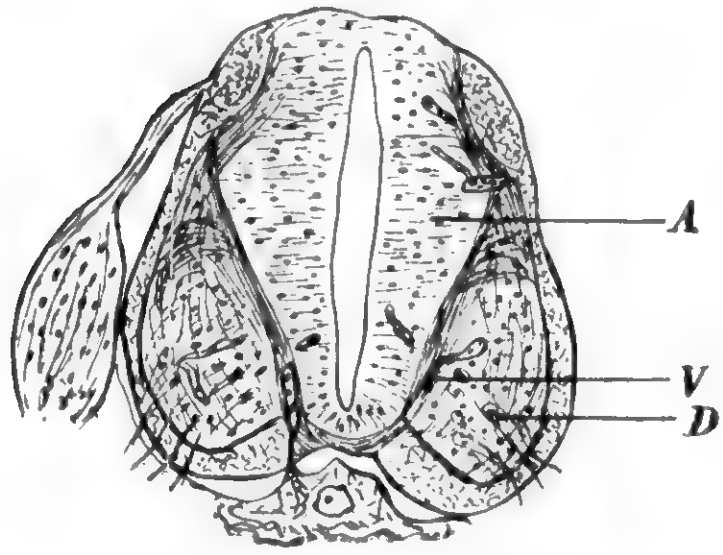

Fig. 13.

in the aid of complete cell migration as a factor. We are nevertheless in accord with Ariens Kappers that neurobiotaxis is a real thing. Ariens Kappers has shown that the position of the motor nuclei in the medulla oblongata is in great part determined by the particular sensory tracts that predominate. If such is the case and motor nuclei are attracted thereby, centripetal rather than centrifugal movements on the part of motor neuroblasts should be

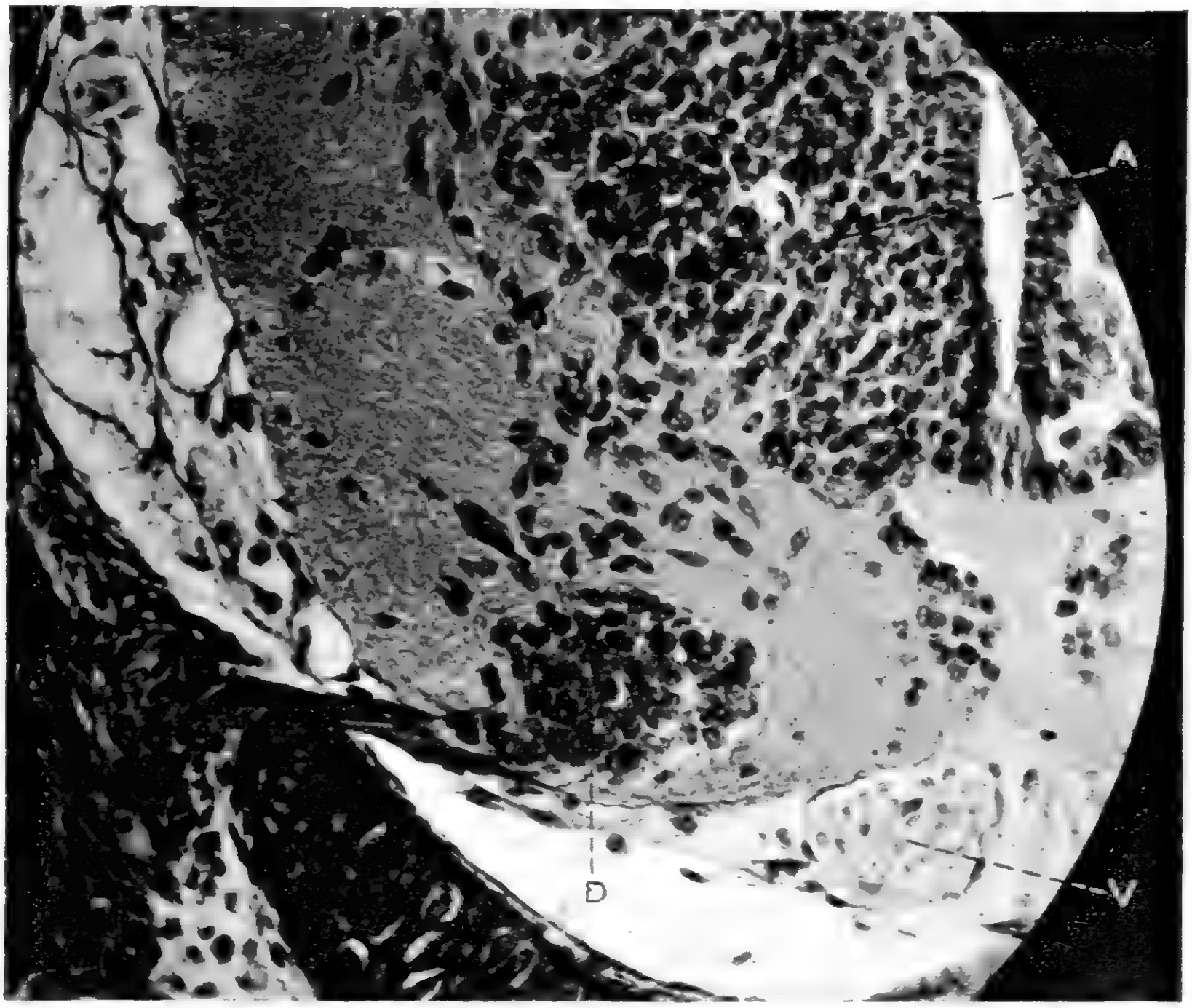

Fig. 14.

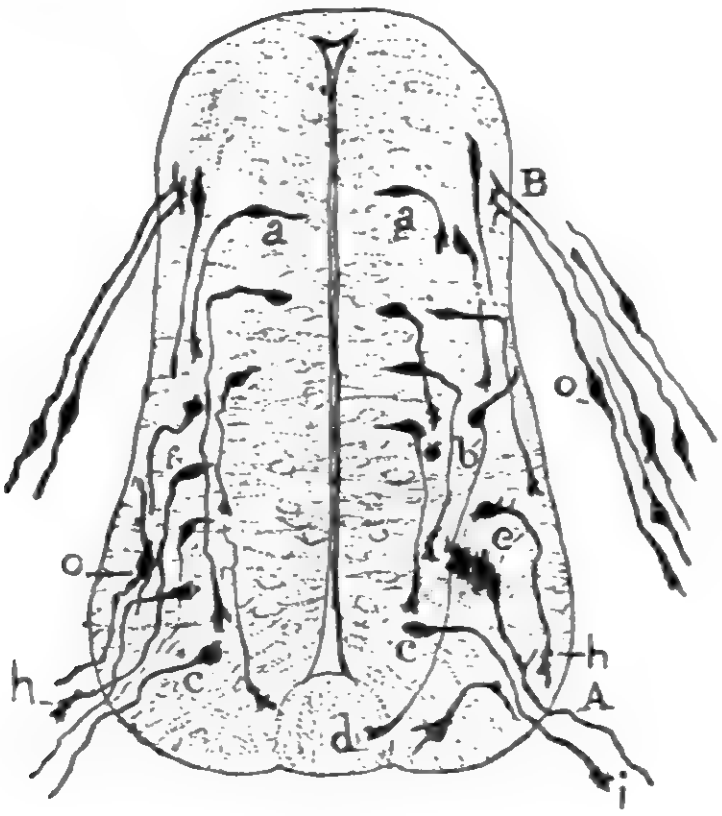

Fig. 15.

expected. Consequently the inclusion of the motor cells of the anterior cornu in the neural tube forms the most striking verification of the neurobiotactic conception of Kappers.

We have so far dealt with the problem of the origin of the motor neuroblast from fixed serially sectioned material and from the physiological side.

EVIDENCE FROM THE EXPERIMENTAL METHOD OF APPROACH

A considerable volume of experimental work has been done on the problem of the behaviour of nerve cells and the questions of development generally. But that the experimental method gives results capable of antagonistic explanations is shown by the anomalous findings in the works of Shorey and Harrison. It is instructive at the same time to compare the experimental results of Kuntz and Eric Muller on the origin of the sympathetic system.

At Wood's Hole, during the summer, we subjected the early developing tadpole of the Bull Frog to treatment with ·7–·8 per cent. NaCl as suggested to us by Dr Streeter.

Stockard from the experimental side, and Murk Jansen from the clinical side have shown that, if embryos are exposed to certain influences at definite times in development, certain definite defects or arrests in development follow. Anencephalia and amyelia are examples of such *developmental arrests.*

In these particular experiments, careful histological examination showed that we were not successful in producing complete absence of the neural tube, i.e., complete anencephalia and amyelia. However, many cases histologically approached very closely this condition. In these embryos with defective neural tubes the myotomes developed and became fused with their fellows of the opposite side. Collections of ganglionic cells also developed ventral to, and, in many places, separated from, the neural tube in the substance of the fused myotomes. These embryos were capable of "vortex" movements. We reproduce fig. 16, a type of such specimens, which are certainly confirmatory of our histological investigation in normal embryos; for if neuroblasts develop from the substance of the myotome, such an extra-neural situation of motor cells is to be anticipated where the neural tube is incomplete.

Sherrington states that the anencephalic foetus suckles at the breast. Accurate information concerning the activities of such monsters is difficult to secure, but in Cincinnati we received first-hand information concerning the behaviour of an anencephalic monster. The mother gave birth to twins, of which the second was an anencephalic monster. The doctor and nurse placed it on one side and attended to the other child. Shortly afterwards the nurse called the doctor's attention to the fact that the monster was moving its limbs about and gasping for breath. A cast of the head of this foetus, preserved at the Cincinnati hospital, leaves no doubt as to its anencephalic character.

The explanation of these "reflex" phenomena is not yet apparent, but as in the tadpoles discussed, may well be bound up with the phenomenon of the inclusion of extra-neural elements into the neural tube. They are certainly inexplicable upon the His hypothesis. It is hoped that when the attention of obstetricians is called to these facts, still more precise evidence will be forthcoming concerning the neuro-physiology of these curious monsters.

The remarks of Andral concerning teratomata are of great interest: "The progress, which has recently been made in the cultivation of embryology and comparative anatomy, has taught us that the greater number of the organs are much more independent of each other in their respective formation, than was for a long time supposed; and that consequently any arrest in the development of one organ, but seldom necessarily produces a similar arrest in the development of others. For instance, we now know that the nerves may be perfectly developed independently of the existence of the brain or spinal cord; as has been abundantly proved in several cases of anencephalia and amyelia. It appears that the nerves are primarily formed in those organs, which it is their office to connect with the centres of the nervous system; and that they do not unite with these centres for a considerable time after their first rudiments are perceptible. Where these organs are deficient, the nerves are likewise deficient; so that the existence of the nerves depends much more on the development of the organ which they are destined to supply, than on that of the nerve centres.

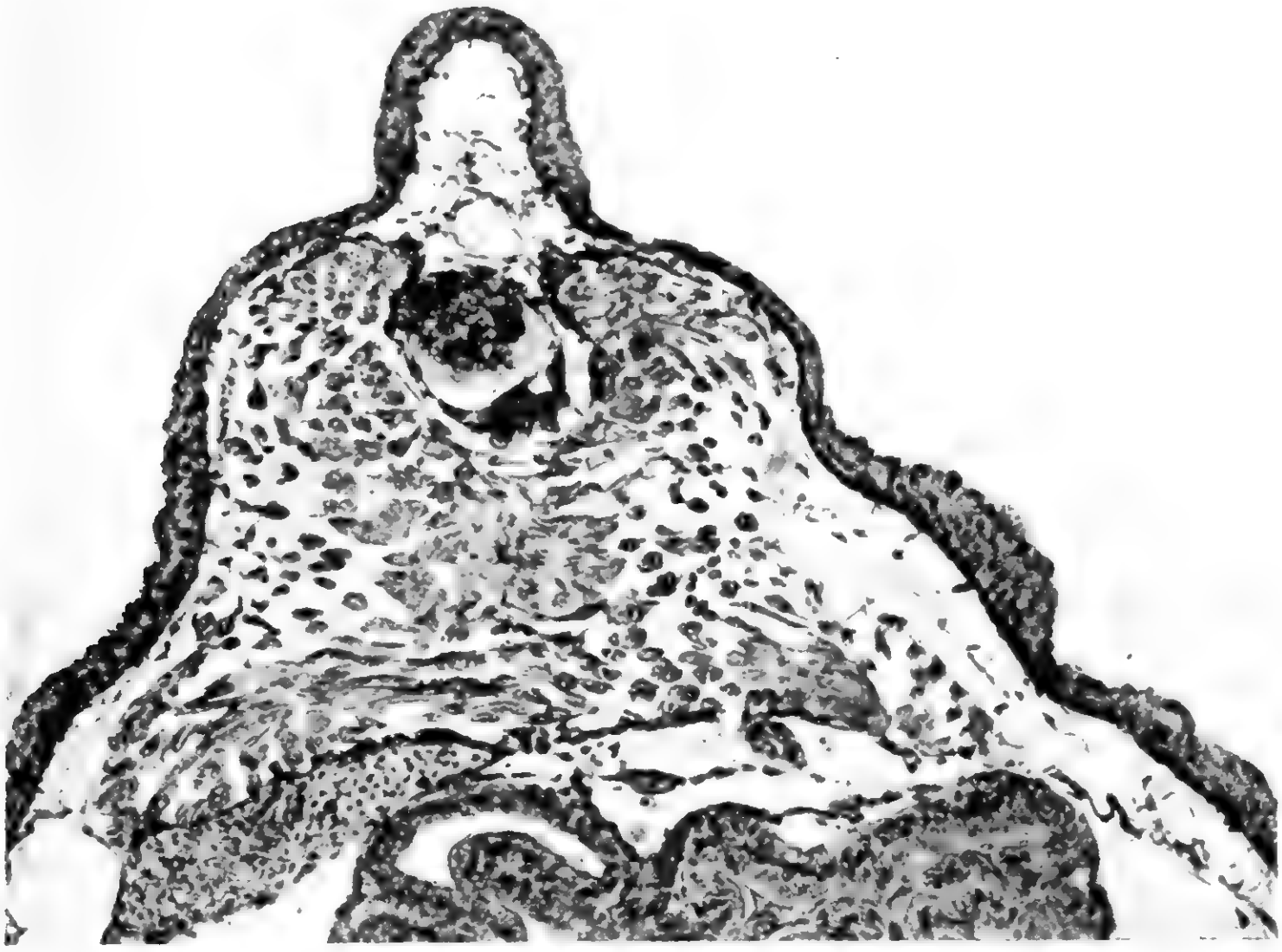

Fig. 16.

M. Serres has recorded a remarkable illustration of this fact in the case of a monster with two brains and a single body in which case there were only two pneumogastrics found, arising one from the external side of each brain. In this case there were only two pneumogastric nerves, because there was only a single pulmonary and digestive apparatus for them to supply. In other cases on the contrary, which M. Serres has cited, when these organs were double, and the brain single, there were two sets of nerves destined for the two sets of organs" (1832).

It is consequently clear that the revival of so ancient a conception can scarcely be regarded as revolutionary. The most modern views concerning developmental teratology and neurology found support in very salient evidence almost a century ago.

In conclusion we desire to express our deep sense of indebtedness to Professor Grafton Elliot Smith for his generous advice and assistance in the preparation of this paper and to Professor Frederic T. Lewis of Harvard for placing the Minot Embryological Collection at our disposal during our stay in Boston.

DESCRIPTION OF FIGURES

A. Neural tube.
B. Inner wall of myotome.
C. Notochord.
D. Ventral ganglion.
E. Dorsal ganglion.
V. Vessel.

Figs. 1, 2, 3, 6, 7, see text.

Figs. 4 and 5. (His' figs. 38 and 39.) *Pristiurus*-embryo von 4½ mm. Länge. Neuroblasten aus der Markfläche hervorbrechend. *M.* Myotomozellen. *Bd.* Bindegewebszellen.

Fig. 8. (His' fig. 40.) *Pristiurus* von 6 mm. Länge. Gruppe von Neuroblasten, ihre Fortsätze an eine vordere Wurzel abgebend. Gekreuzer Verlauf der Fasern, die zum Ramus dorsalis und die zum R. ventralis gehen. *C.* Gruppe von Bindegewebszellen an der Stelle, wo später ein Blutgefäss liegt.

Fig. 9. (His' fig. 43.) *Pristiurus*-embryo von 8 mm. Länge. Randschnitt eines Wurzelstämmchens. Das von einer kleinen Neuroblastengruppe ausgehende Stämmchen endet in kurzer Entfernung vom Mark schräg abgeschnitten. *Bd.* längs und quer gelagerte Bindegewebszellen in dessen Umgebung. Bei *C.* ein capillares Längsgefäss.

Fig. 10. (His' fig. 44.) *Pristiurus*-embryo von 14 mm. Länge. Der Randschleier ist deutlicher ausgebildet, die Intermediärschicht vorhanden. Die vordere Wurzel zeigt einen cylindrischen axialen Strang, von einzelnen Bindegewebszellen umlagert. Innerhalb des Marks sind einige Fasern durch den Randschleier hindurch bis zur Intermediärschicht verfolgbar, andere treten schon vorher aus der Schnitt-fläche heraus. Bei dieser und bei der vorigen Figur sind die reifen Neuroblasten an ihren hellen Kernen erkennbar. Bei *C.* das Längegefäss.

Fig. 11. Chick No. 2. 49 hours, sect. 7. 2. 4, illustrating the position of the anterior spinal artery in an earlier stage than fig. 12.

Fig. 12. Toad fish embryo, No. 638, sect. 13. 2. 7, to illustrate the branch of the anterior spinal artery and the outlying group of motor cells.

Fig. 13. Pig embryo 8 mm.

Fig. 14. Toad fish embryo, to illustrate laterally placed motor ganglion. Note position of blood vessel entering the neural tube.

Fig. 15. (Ramón y Cajal's fig. 7 *a.*) Coupe de la moëlle d'embryon du poulet au 3^{e} jour de l'incubation.

Fig. 16. Bull frog embryo after treatment with ·8 per cent. NaCl.

LITERATURE CITED

Andral, G. (1832). *A Treatise on Pathological Anatomy*, translated from the French by Richard Townsend and Wm. West. New York, Samuel Wood and Sons, 261, Pearl St.

Balfour, F. M. (1876). "The development of elasmobranch fishes." *Journ. of Anat. and Physiol.* vols. x and xi.

Beard, J. (1888). "Morphological Studies. II. The development of the peripheral nervous system of vertebrates. Part 1. Elasmobranchii and Aves." *Quart. Journ. Micr. Sci.* vol. 29.

Clark, E. R. (1912). "Further observations on living growing lymphatics: their relation to the mesenchyme cells." *Amer. Journ. of Anat.* vol. xiii, No. 3.

Harrison, R. G. (1907). "Observations on the living developing nerve fibre." *Anat. Rec.* vol. i, No. 5.

Held, H. (1909). *Die Entwickelung des Nervengewebes bei den Wirbelthieren.* Barth, Leipzig.

Hensen, V. (1903). *Die Entwickelungsmechanik der Nervenbahnen im Embryo der Säugetiere.* Kiel and Leipzig.

His, W. (1889). "Die Neuroblasten und deren Entstehung im Embryonalen Mark." *Abh. sachs. Gesell. Wiss.* Leipzig. Math.-phys. Cl., Bd. 15, No. 4.

Kerr, Graham J. (1902–3). "The development of Lepidosiren paradoxa." *Quart. Journ. Micr. Sci.* vol. xlvi.

Kolliker, A. (1902). "Ueber die oberflächlichen Nervenkerne im Marke der Vögel und Reptilien." *Zeitschrift f. wissen. Zool.* lxxii. 1.

Kuntz, Albert and **Bateson**, O. V. (1920). "Experimental observations on the histogenesis of the sympathetic trunks in the chick." *J. Comp. Neur.* vol. xxxii.

Muller, Eric and **Ingvar, Sven**, (1921). "Ueber den Ursprung des Sympathicus bei den Amphibien." *Upsala Läkäref. förh.* Ny följd. Bd. xxvi, H. 5–6.

Neal, H. V. (1903). "The development of the ventral nerves in Selachii. 1. Spinal ventral nerves." *Mark Anniversary Volume*, Article XV.

—— (1921). "Nerve and plasmodesma." *J. of Comp. Neur.* vol. xxxiii, No. 1.

Neumayer, L. "Entwickelungsgeschichte der Wirbelthiere." *Hertwig*, vol. ii, Teil 3.

Parker, G. H. (1918). "The elementary nervous system." *Monographs on Experimental Biology.* J. B. Lippincott & Co., Philadelphia.

Paton, S. (1908). "The reactions of the vertebrate embryo to stimulation and the association changes in the nervous system." *Mitt. aus der Zool. Stat. zu Neapel*, Bd. 18.

Ramón y Cajal (1890). "A quelle époque apparaissent les expansions des cellules nerveuses de la moëlle épinière du poulet?" *Anat. Anz.* vol. v, p. 638.

Sabin, F. R. (1917). "Origin and development of the primitive vessels of the chick and the pig." Contributions to Embryology, vol. vi. *Carnegie Instit. Wash. Pub.* 226.

Schaper, A. (1897). "Die frühesten Differenzirungsvorgänge im Centralnervensystem." *Archiv f. Entwick. mech. der Organismen*, Bd. v, Heft 1.

Sherrington, C. S. *Schäfer's Text-book of Physiology.*

Shorey, M. S. (1909). "The effect of the destruction of peripheral areas on the differentiation of the neuroblasts." *Journ. of Exper. Zoology*, vol. vii, No. 1.

Sterzi, Andrea I. (1904). "I gruppi cellulari periferici della midolla spinale dei rettili." *Inst. Anat. della Regia Univ. di Pisa.*

Wintrebert, M. P. (1904). "Sur l'existence d'une irritabilité excito-matrice primitive indépendante des voies nerveuses chez les embryons ciliés des Batraciens." *Comptes Rendus de la Soc. de Biol.* vol. lvii.

ABSENCE OF THE LENS OCCURRING IN THE HUMAN EMBRYO

By IDA C. MANN, M.B., B.S.

From the Department of Anatomy and Embryology, St Mary's Hospital.

The subject of this communication is a human embryo (one of Professor Frazer's collection) which, as far as I know, is unique in that it shows failure of development of both lenses: the optic cups are of normal size and the rest of the embryo shows no evident malformation with the exception of the state of the brain shortly noticed below.

After sectioning, the embryo measured 8·64 mm. It was compared with a normal 13 mm. human embryo (measuring 8·67 mm. after sectioning) with regard to its general development and they were found to have reached the same stage as evidenced by the condition of the submaxillary outgrowth (just appearing in both) and the situation of the posterior nares. The embryo was not in good histological condition and the sections were considerably fissured. The thin walls of the intracranial portion of the central nervous system were much folded, as might be expected in an embryo not in perfect condition, but in addition to this—without going into details—there is, I think, clear evidence of some dilatation of the cavities. The cerebral vesicles are clearly recognisable in their normal hinder portions, but do not appear to have grown in front so that they cannot be definitely marked off from the telencephalon. In spite of these peculiarities the general structure of the substance of the brain appears to be that normal for the stage.

The condition of the eye is the same on both sides. The optic cups occupy their normal position on the side of the head. Their invagination and differentiation have proceeded normally, but the choroidal fissure, which does not extend quite into the optic stalk, has not yet closed, whereas in the normal 13 mm. embryo it has closed except for a notch at the pupillary margin. The hyaloid vessel is present and is well developed and full of blood. It breaks up into numerous blood spaces in the pupil and these drain into scattered channels in the surrounding mesoderm and into a vessel larger than normal running in the line of the cleft outside the optic cup. There is no lens whatever, and the only suggestion of it is the presence of a small blunt-pointed epithelial projection from the deep layer of the surface ectoderm almost opposite the centre of the pupil. This may represent an abortive lens thickening which has failed to differentiate.

The case is interesting both on account of the confirmatory evidence it offers on the subject of independent differentiation of the optic cup (shown experimentally by Lewis, Spemann and others) and also as throwing some light on the clinical controversy as to the possibility of the occurrence of congenital aphakia in an otherwise normal eye. Rabl has described an Amblyostoma embryo which showed unilateral failure of development of the lens, but there was also extensive failure of other ectodermal structures. A few cases in man have been reported clinically, but were not verified by microscopical examination and were generally associated with microphthalmos.

REFERENCES

Adams (1915). "Congenital aphakia with microcornea." *Ophth. Rec. Chicago*, vol. XXIV. p. 581.
Bach. "Pathol. Anat. Studien über verschiedene Missbildungen des Auges." *Archiv für Ophth.* vol. 45, Pt. 1, p. 1.
Baker (1887). "Congenital aphakia." *New York Med. Journ.* vol. XLVI. p. 595.
Cherryholmes (1902). "Congenital aphakia with microphthalmos." *Ophth. Rec. Chicago*, vol. XI. p. 198.
Hardy (1915). "Congenital aphakia." *Ophth. Rec. Chicago*, vol. XXIV. p. 347.
von Kupffer (1896). *Verhandl. der Anat. Gesellsch. auf der zehnten Versammlung in Berlin.*
Lewis, W. H. "Expt. Study of Devel. of Eye in Amphibia." *Amer. Journ. Anat.* vol. III. p. 505, 1904 and vol. V. p. 9, 1906.
Ochi (1919). "Experimental Study of Histogenesis of eye abnorm. in chick embryos." *Brit. Journ. Ophth.* vol. III. p. 433.
Rabl (1898). "Ueber den Bau u. Entwicklung der Linse." *Zeitschr. f. wiss. Zool.* vol. 63.
Sherer (1915). "Congenital aphakia, a clinical report." *Journ. Missouri Med. Ass. St Louis*, vol. XII. p. 478.
Spemann (1901). *Anat. Anz.* vol. 19, suppl. p. 61.
Wiegels, H. (1900). *Arch. f. Ophth.* vol. 50, p. 369.

A SUGGESTION AS TO THE CAUSE OF THE ASPERMATIC CONDITION OF THE IMPERFECTLY DESCENDED TESTIS

By F. A. E. CREW, M.D., D.Sc.

(*Paper from the Animal Breeding Research Department, The University, Edinburgh.*)

In all Vertebrates the testes are developed in contact with the ventral surface of the kidneys, behind the peritoneum covering the body-cavity. In some they remain permanently in this situation, but it is characteristic of the majority of mammals that during the course of development they leave their primitive lodgment and migrate posteriorly and ventrally to the terminal periphery where they protrude at the surface of the body-wall. This protrusion constitutes the scrotum which varies in character from that of a pair of small ill-defined slightly elevated areas to that of a capacious, definite, pedunculated sac.

A survey of the Vertebrates will show that the testes in different cases are found in positions which mark the stages in a complete migration from the primitive position near the kidneys to the peripheral scrotum. It will also be seen that the scrotal situation of the testis is characteristic of the more impulsively active mammals. In the case of the human, in whom the migration has been most thoroughly studied, it provides a very complete example of the manner in which ontogeny repeats and condenses phylogeny in whole or in part.

There is much diversity of opinion as to the exact mechanism of the migration and it is probable therefore that not one but several factors are involved. The process possibly may be explained thus. Mechanical forces resulting from the changing methods of progression compelled the dense, compact, suspended testis to pass from the primitive position towards the inguinal region of the abdominal cavity (Woodland). There it naturally came to lie in the line of the lymph-sinuses described by Sabin. With increasing impulsiveness of movement and with increased intra-abdominal pressure consequent upon the development of the diaphragm, the testis was forced along the lymph-track so that it came to occupy a sub-integumental position in the groin (Bramann, Eberth, Keith). Here the testis found itself in a situation which in several ways was different from the interior of the abdomen and it was obliged to adapt itself to the new conditions. But, owing to its decreased mobility and to the injurious effects of active flexion of the thigh upon the abdomen, it suffered repeated attacks of inflammation. The local peritoneum with the mesorchium became involved in this inflammation with the result that adhesions and bands were produced. The overlying skin became thinned and stretched. Then further increase of impulsive activity and of intra-abdominal pressure produced a hernia of the testis. So the scrotum and the inguinal fold could have been produced. The position of the testis was equivalent to the sub-integumental one in the groin but the organ was now secure from injury by muscular movements since its mobility had been restored.

This process would be repeated in every generation until at last variation succeeded modification, or, by adaptation, the migration became incorporated in the life-processes of the individual and anticipated by the development of a mechanism which would produce the descent of the testis during foetal life.

"Originally, the descent of the testes did not occur until sexual maturity in all cases, but in many Mammalia (e.g. Marsupials, Ungulates, Carnivores, Primates), the process has gradually become shifted backwards ontogenetically to earlier periods, so that the formation of the scrotum takes place independently in the embryo in the form of the external genital folds." WIEDERSHEIM.

In the modern mammals in which the migration occurs, the testis is united to a mammary area—supra-pubic, inguinal, perineal, or scrotal, at first by the inguinal fold and later by the gubernaculum—the canal-former, the guide of the testis—which is attached by its upper end to the Wolffian duct, the epididymis, and at the point where the globus minor and vas deferens meet, and by its lower end to the subcutaneous tissues in the groin, the scrotum, the root of the penis, and on the pubis.

The gubernaculum is an actively growing mass of fibro-muscular tissue which, starting from the muscular stratum in the mesorchium and inguinal fold in the inguinal fossa, invades the abdominal wall, every layer of which it carries with it as a prolongation within the scrotum. Upon the peritoneum thus drawn down the testis is dragged like a log upon a sledge. The gubernaculum forms the inguinal canal by the growth of its wedge-shaped end along the line of the lymph-sinuses, The canal is formed before the testis passes.

The final situation of the testis is decided in great part by the relative development of the different gubernacular insertions.

There is no physiological reason why the testis should not leave its primitive position. It does not stand in the same relation to the general economy of the individual as do the other organs of the body. It belongs to the race rather than to the individual, for though there cannot be an actual isolation yet there is distinctly an apartness of the germ-cells and the body is but the carrier of the testes. The migration to the periphery does not disturb the general economy for this reason and just as reproduction itself consists of a separating off of a portion of the organism so the organs of reproduction become separated, in consequence of their migration, from the viscera which belong entirely to the individual.

It is too difficult to conceive that the migration has imparted any advantage to the organism: the process bears no great relation to either advantage o disadvantage, though the scrotal position would appear to be one much exposed to danger, for the ease with which the scrotum is attacked and the devastating effects of contusion of the testes make of this region a veritable Achilles' heel.

"...there remain many unsolved problems. Take, as an instance, the descent of the testis in the Mammalia. Neither direct nor indirect equilibration accounts for this. We cannot consider it an adaptive change, since there seems no way in which the production of sperm-cells, internally carried on in a bird, is made external by adjustment to the changed requirements of mammalian life. Nor can we ascribe it to the survival of the fittest; for it is incredible that any mammal was over-advantaged in the struggle for life by this changed position of these organs. Contrariwise, the removal of them from a place of safety to a place of danger would seem to be negatived by natural selection. Nor can we regard the transposition as a concomitant of re-equilibration, since it can hardly be due to some change in the general physiological balance." HERBERT SPENCER.

There certainly appears to be no compensatory physiological advantage offering benefits which outweigh the physical disadvantage and it would seem that the migration is, as suggested, but the inevitable concomitant of some other constant feature of the animal's existence, and that it has not arisen in relation to ulterior ends.

A study of the conditions in which the testis fails to complete its migration will show that the testis has become so modified that while it will function perfectly when within the scrotum, it is incapable of producing spermatozoa when situated elsewhere. This would indicate that the conditions within the scrotum are different from those of the interior of the abdominal cavity.

"The descent of that testicle is very slow which is not complete before birth, often requiring years for that purpose; and it sometimes never reaches the scrotum, especially the lower part of it. There is oftener, I believe, an inequality in the situation of the two testicles than is commonly imagined; and I am of the opinion that the lowest is the more vigorous, having taken the lead readily, and come to its place at once.

"It is not easy to ascertain the cause of this failure in the descent of the testicle; but I am inclined to suspect that the fault originates in the testicles themselves. This, however, is certain, that the testicle, which has completed its descent is the largest, which is more evident in the quadruped than in the human subject; as in these we can have the opportunity of examining the parts when we please, and can determine how small in comparison with the other that testicle is which has exceeded the usual time of coming down; it never descends so low as the other.

"When one or both testicles remain through life in the belly, I believe that they are exceedingly imperfect, and probably incapable of performing their natural function, and that this imperfection prevents the disposition for descent from taking place." JOHN HUNTER.

"Arrest of descent is commonly regarded as a symptom of arrest of testicular development. John Hunter regarded arrested descent of the testicle as due to an imperfection in its development; all recent observations support his opinion." KEITH.

"It is commonly believed that the imperfection of an undescended testicle is due to its failure to reach the scrotum. This I believe to be an error. An undescended testis fails to reach the scrotum because of its imperfection." BLAND-SUTTON.

In spite of the great weight of these opinions it is difficult to accept them without question since it is generally understood that the testis plays but a passive rôle in the migratory process. Imperfection of the local peritoneum during the development of the inguinal fold and mesorchium; of the gubernaculum; of the inguinal canal; or of the scrotum, these conditions also must lead to imperfect descent.

The long mesorchium may allow the testis to hang too freely in the abdominal cavity; there may be a deficiency or abnormality of the upper attachment of the gubernaculum; intra-uterine peritonitis may have caused adhesions which limit the mobility of the testis; shortness of the vas deferens and of the blood-vessels, though more likely to be an effect, may also be a cause of imperfect descent; the inguinal canal may be imperfectly formed or the scrotum ill-developed so that passage thereinto may be hindered. Overaction of the cremaster may be another possible cause, for in infants and children the action of this muscle occasionally draws the testicle up even beyond the external ring. Murard records a case in which the testis periodically disappeared into the abdominal cavity.

Imperfection of the testis most certainly can be a potent cause of its non-descent, but unless it is of such a size or of such a shape that it cannot pass along the passage prepared for it, surely the fault must lie with the powers, or with the passage, but not with the passenger.

"It is certain that in the majority of cases the imperfectly or abnormally descended testicle is functionless, at any rate as regards spermatogenesis. But though the function of spermatogenesis is absent, that of producing the internal secretion necessary for the development of the secondary sexual characters of the male is generally, but not always, carried out. That the function of spermatogenesis is lost is shown by the fact that such persons are unable to beget offspring and is also confirmed by the histological examination of retained testes after removal.

"In rare cases the spermatogenetic function is not lost, even when there is a double imperfect descent with very small testes, or when both organs are arrested within the abdominal cavity; this has been proved both by the presence of normal tubules and active spermatozoa, and also by the fact that these persons have proved capable of procreation. Many examples of this are recorded in medical literature. There is, however, evidence that those in which spermatogenesis is normally carried out are young men mostly under thirty years of age. In men over this age the imperfectly descended testis is nearly always functionless. In the majority of cases under thirty the spermatogenetic function is absent and the proportion of functional organs is probably small." TURNER, P.

"After careful observations extending over many years I only once found spermatozoa in an undescended testis." BLAND-SUTTON.

"It is not rare to find spermatozoa in testicles which have remained in the lower part of the inguinal canal, but in those in the upper part, and in those taken from the abdomen, this is exceptional." HOBDAY.

"In mammals the testes fail at times to pass through the inguinal canal, and, in consequence of their retention in the body-cavity, the germ-cells fail to develop. On the other hand, the interstitial cells of the testis develop normally. Cryptorchid individuals show the normal secondary sexual characters of their species." MORGAN.

M'Fadyean, who examined a series of twenty-five imperfectly descended testes for Hobday, found that out of fourteen from the abdominal cavity, only two contained spermatozoa, and that of eleven from the inguinal canal—three being from the upper part—only five were capable of functioning. Gurlt failed to find spermatozoa in testes removed from the abdomen; Wesche found that testes from the inguinal canal were capable of producing functional spermatozoa; Paugoué records the case of a stallion in which both testes were undescended yet who sired many colts of which, however, five suffered from the same condition; Dollar states the opinion that testes retained within the abdomen contain degenerate spermatozoa or none at all.

As a result of the examination of a series of imperfectly descended testes from the horse, placed at my disposal by the courtesy of Mr Wm. Brown of the Veterinary Department, Marischal College, I am able to demonstrate the fact that the nearer the testis comes to lie to the normal scrotal position, the more likely it is that functional spermatozoa will be found therein. Testes removed from the lower part of the inguinal canal, though smaller in size than the normal and inclined to be of an unusual shape, are in the majority of cases imperfectly functional; testes removed from the abdominal cavity, so far as my experience goes, are invariably the seat of tumour growth, benign or malignant, even in the case of two-year old horses; testes removed from the upper part of the canal are usually atrophic and normal spermatozoa can be found therein only very exceptionally.

Russell Howard records that of twenty-seven cases of malignant disease of the testis, nine had occurred in imperfectly descended glands.

It would seem that when the testis occupies its normal position in the scrotum, the conditions are such that the activities of the other component tissues of the gland are restrained by the dominating activity of the germinal epithelium, but that when the testis is brought to rest in an abnormal situation, the function of spermatogenesis being in abeyance, the other tissues of the gonad take on an uncontrolled growth.

Griffiths, in an experimental investigation on dogs, found that when the testes of the puppy were replaced within the abdominal cavity they developed normally up to the time of puberty but that they never produced spermatozoa, and that when the testes of grown dogs were similarly replaced within the abdomen they invariably atrophied and never remained functional.

In those mammals in which the testis periodically passes into a scrotum during the breeding period, it is found that they are spermatic only when in the scrotum, and aspermatic when within the abdomen.

To explain the relation between imperfect descent and imperfect functioning there are two theories: one, that the imperfection in functioning is the cause of the imperfect descent, the other, that it is the result. The first postulates that there is some abnormality of the germinal epithelium which prevents the normal development and migration. If this is so, then obviously no operative treatment can possibly restore the spermatogenic function. The second explanation is that full growth and development of the testis up to the time of puberty is possible in an abnormal situation, but that at the time when the final stages of spermatogenesis should occur, the abnormal situation reacts upon the testis in some way so that these stages cannot occur and atrophy of the testis ensues while various pathological processes easily attack the gland leading to degeneration and tumour growth. If the fault lies with the situation and not with the testis, if the absence of the spermatogenic function is the result of the malposition, then the operation of Orchidopexy should restore this function. It may be accepted that if an immature imperfectly descended testis is secured within the scrotum without operative injury it will complete its development and function normally.

But if the final stages of spermatogenesis are effected in one situation, the scrotum, and not in another, the abdominal cavity, there must exist some great difference between these two situations.

Such a difference does exist. It is that the temperature within the tunica vaginalis is appreciably lower than that within the general abdominal cavity.

It was known to John Hunter that the temperature of the body is not the same throughout; he demonstrated this fact by several most ingenious experiments on mice and dogs. But more recently, and with much more critical methods, Benedict and Slack have shown that there is a temperature gradient of some 5° C. between the temperature of the abdominal cavity and that of the surface of the body. The temperature rises in proportion to the depth to which the thermometer is inserted until at 6–8 cms. a constant temperature is reached.

The testis within the scrotum is not exposed to the same temperature as that of the primitive position within the abdomen. Moreover, a consideration of the peculiar structure of the scrotum will show that this is a very specialised area of body surface extremely well equipped with a mechanism for local temperature-regulation.

The scrotum is a pouch composed of skin and the dartos tunic. It is divided on its surface by a median raphe into two lateral portions. The skin is very thin, of a brownish colour, and is usually thrown into rugae. It is well supplied with sebaceous follicles, the secretion of which has a peculiar odour, and is beset with thinly scattered crisp hairs, the roots of which are visible through the skin.

The dartos tunic is a thin layer of non-striated muscle, continuous around the base of the scrotum with the two layers of superficial fascia of the groin and of the perineum. It sends inwards a septum which extends between the median raphe and the under surface of the penis, as far as its root, and divides the scrotum into two cavities for the testes. It is closely applied to the skin externally and is connected with the subjacent parts by a delicate areolar tissue upon which it glides with the greatest facility. There is no fat in this areolar tissue; the scrotum is fat-free even in the fattest of entire animals. But in the castrate the scrotum is loaded with fat and the butcher's test for prime beasts is the amount of fat in the scrotum.

Klaatsch has shown that in many mammals the site of the future scrotum is marked out by a certain area of skin, evident both by its naked-eye and microscopic characters. White and Martin state that in cases of ectopy in which, owing to an over-development of an insertion of the gubernaculum other than the usual, the testis comes to occupy a position beneath the skin of the perineum, the overlying skin assumes the peculiar characters of that of the scrotum.

The appearance of the scrotum varies with different conditions of atmospheric temperature. Under the influence of warmth, and in the debilitated and old, it is elongated and flaccid; under the influence of cold, and in the young and robust, it is short, corrugated, and closely applied to the testes. The amount of surface exposed is controlled by the action of the dartos.

The scrotum stands well away from the body and is in an area where transpiration is well marked. The temperature within it is not only considerably lower than that within the general cavity but its regulation is controlled by a most efficient mechanism.

That the scrotum itself, by reason of its specialised structure, is concerned in the functioning of the testis is shown by the results of certain diseases in which the scrotal integument becomes very much thickened and inelastic, as in *Elephantiasis arabum*, for the testes become deformed and atrophied. The testis within such a scrotum is in a situation equivalent in many ways to the interior of the abdominal cavity.

John Hunter, Ashworth, Child, Marshall, Reamur, Semper, Graham Kerr, Bles, Spallanzani, Meek, Turner, C. L., and many others have produced considerable evidence which goes to show that reproductive activity is intimately related to external temperature in the case of the lower orders. In the fish, for example, it has been shown that the beginning of the annual decline in temperature is contemporaneous with the seasonal volumetric increase in the testes of the Perch, and that the beginning of the seasonal decrease in the testes is contemporaneous with the beginning of the seasonal rise in the temperature. It can be accepted that growth and reproduction vary in length and periodicity with temperature and though, undoubtedly, other factors also are concerned, it is sufficient to recognise that temperature itself is a factor.

In the case of the testiconda it is possible that some of the pharyngeal derivatives, such as the thymus, the function of which is not definitely known, control the activities of the testes throughout the individual's whole lifetime, whereas in the case of the mammals whose testes normally migrate to the scrotal position, the action of the internal secretion of this gland has become restricted to inhibiting the too active development of the testis up to the time of puberty, when the body is sufficiently grown so that it can entertain the demands of spermatogenesis. The thymus is so situated that it can readily appreciate changes in the environmental temperature and its intimate association with the activities of the testes is acknowledged. In the case of the scrotal testis, the situation is such that the optimum temperature for spermatogenesis can be maintained throughout the year because of the development of the local temperature-regulating mechanism. The thymus becomes unnecessary after puberty and consequently atrophies.

But be it as it may, the fact remains that the testes of the testiconda, and of the other Vertebrates in which their normal position is abdominal, have never been required to adapt themselves to function in a situation in which the local temperature is markedly different to that of the general abdominal cavity. This also applies to the ovaries of all the Vertebrates. They are so organised as to function quite satisfactorily in an intra-abdominal situation, and so far as can be ascertained, should an ovary come to occupy an ectopic position, it does not produce functional ova. This great distinction between ovary and testis in the case of the higher mammals has a very direct bearing upon the question of hermaphroditism in the human and renders the postnatal reversal of the sex-organisation, such as occurs in the case of the Amphibians, for example, utterly impossible.

Since the capacity for functioning within a scrotum has been of the nature of an adaptation, it is not extraordinary that exceptionally an imperfectly descended testis should produce functional spermatozoa.

SUMMARY

1. In the more impulsively active mammals the testis leaves its primitive position to pass into the scrotum. The process of migration has been shifted back ontogenetically so that now the formation of the inguinal canal and of the scrotum occurs in anticipation of the descent of the testis. The process bears no great relation to either advantage or disadvantage; it is but the inevitable concomitant of other constant features of the animal's existence and has not arisen in relation to ulterior ends.

2. The testis has become adapted to function in a situation, the conditions of which are markedly different from those of the general abdominal cavity. It can no longer function in the primitive position. The great difference between the two situations is one of temperature. The temperature within the tunica vaginalis is considerably lower than that within the abdomen. The scrotum

is so constructed that it is exceedingly well equipped with a temperature-regulating mechanism. The final stages of spermatogenesis occur at a certain optimum temperature which is that within the scrotum and not that within the abdominal cavity.

3. The imperfectly descended testis is aspermatic because the temperature of the abnormal position is not that at which the final stages of spermatogenesis occur.

BIBLIOGRAPHY

ANNANDALE. *See* MARSHALL.
ASHWORTH. *See* MARSHALL.
BENEDICT, F. C. and SLACK, E. P. (1902). *Public. Carnegie Instit.* No. 153.
BLAND-SUTTON, J. *See* HOBDAY.
BLES. *See* MARSHALL.
BRAMANN (1884). *Arch. f. Anat.*
CHILD. *See* MARSHALL.
DOLLAR, J. A. W. (1902). *The Practice of Veterinary Surgery.* Edinburgh.
EBERTH (1904). *Die männlich. Geschlechtsorgane.* G. Fischer, Jena.
ECCLES, MCADAM (1903). *The Imperfectly Descended Testicle.* London.
GRIFFITHS. *See* WHITE and MARTIN.
GURLT. *See* DOLLAR.
HART, BERRY (1910). *Journ. Anat. and Physiol.* vol. 43, p. 244; vol. 44, p. 4.
HARTUNG, E. (1875). *Ueber einen Fall von* Mamma accessoria. Erlangen.
HOBDAY, F. T. G. (1914). *Castration and Ovariotomy.* Edinburgh.
HOWARD (1907). *Practitioner.*
HUNTER, JOHN (1837). *Works*, vol. 4. Palmer edit.
KEITH, A. (1921). *Human Embryology and Morphology.* London.
KINGSLEY, J. S. (1919). *Comparative Anatomy of Vertebrates.* London.
KLAATSCH (1890). *Morph. Jahrb.* vol. 16.
LOCKWOOD, C. B. *See* BERRY HART.
MARSHALL, F. H. A. (1910). *Physiology of Reproduction.* London.
MEEK, A. (1920). *Nature*, vol. 106, No. 2669, December 23rd.
MIGHON and PORTE (1920). *Lyon. Chir.*, Nov.–Dec.
MORGAN, T. H. (1902). *Public. Carnegie Instit.* No. 285.
MURARD (1919). *Lyon. Chir.* No. 16.
OWEN, R. (1866). *Comparative Anatomy and Physiology of Vertebrates.* London
PAUGOUÉ. *See* DOLLAR.
REAMUR. *See* MARSHALL.
SABIN. *See* BERRY HART.
SPALLANZANI. *See* MARSHALL.
SPENCER, H. (1866). *Principles of Biology*, vol. 1, p. 573.
TURNER, C. L. (1919). *Journ. Morphol.* vol. 32, No. 3.
TURNER, P. (1919). *Inguinal Hernia.* London.
WESCHE. *See* DOLLAR.
WHITE and MARTIN. *Genito-urinary Surgery.* Lippincott edit.
WIEDERSHEIM (1906). *Vergleichen. Anatomie d. Wirbeltiere.* Jena
WOODLAND (1903). *Proc. Zool. Soc. Lond.* p. 319.

ODONTOLOGICAL ESSAYS

By L. BOLK, M.D.,

Director of the Anatomical Institute of the University of Amsterdam.

FOURTH ESSAY

ON THE RELATION BETWEEN REPTILIAN AND MAMMALIAN TEETH

OF the many varied problems of Odontology, no one is more interesting and fascinating than the origin of the complicated tooth form found in Mammals. The simplest mammalian tooth is believed not to be primitive but to have been evolved from a very simple prototype. Furthermore, this prototype must be sought for in the Reptiles as they are generally regarded as the ancestors of the Mammals. If this be granted the problem resolves itself into tracing the derivation of the complicated mammalian tooth from the simpler ancestral reptilian form.

The solution of the problem demands in the first place a recognition of the features of the type form from which the mammalian tooth is derived; and in the second place a knowledge of the changes which this type form has undergone whereby the complicated tooth of the mammal is the result.

The literature on the subject evidences that as regards the first point opinion is practically unanimous. In spite of the unanimous support accorded to it I hope to prove this popular opinion to be incorrect.

The second point involves a question which is far from easy to answer. Many morphologists have attempted to do so, but opinion is notably diverse and no two investigators are in complete agreement thereon. Writers on the subject may be classified into groups according to the principles upon which their views are founded.

Some hold that the mammalian tooth results from the concrescence of a varying number of simple conical reptilian teeth, a single cusp of the former corresponding to a complete tooth of the latter.

This, the *concrescence theory*, implies that a mammalian tooth is homologous with several reptilian teeth. Many odontologists accept this theory although their application of the principle varies considerably.

Others hold an entirely opposite opinion and consider that every mammalian tooth, even the most complicated, represents a single reptilian tooth: the originally simple conical crown becoming complicated by the superaddition of new cusps. The special nature of the food and the relative position of the tooth in the jaw are regarded as the stimuli determining the growth of new cusps. This view is known as the *differentiation theory.*

It is not my intention to review the two theories methodically and in chronological order or to summarise the different principles assigned to them. This would entail a criticism of the opinions and assertions of other investigators. As previously mentioned in a foregoing essay I wish to avoid a polemical discussion as far as possible. My chief purpose is to communicate certain new and hitherto unknown facts and further to propound the views at which I have arrived as the result of my observations. It is my intention in this essay to present my personal views as to the relationship existing between reptilian and mammalian teeth.

In so doing the meaning of the developmental phenomena—the enamel-niche and the enamel-septum—described in the second essay will become clear. As a consequence the present paper is more theoretical in character than its predecessors.

A summary of the essential points of my theory regarding the relationship existing between reptilian and mammalian teeth will prove instructive as such a summary will facilitate the understanding of my general argument. Further, a knowledge of my views will render the reader familiar with the value I attach to certain definite phenomena and will acquaint him with the conclusions at which I have arrived.

The principal points of my theory can be summarised in the following theses:

Thesis 1. The reptilian tooth from which that of the mammals evolved was not of a simple conical or styloid form, as is the current opinion, but possessed a crown with three cusps; a main cone, with anterior and posterior accessory cusps upon its slopes. The three cusps are placed in an antero-posterior linear series. (Hypothesis of Triconodonty.)

Thesis 2. Every mammalian tooth, with certain exceptions presently to be mentioned, is homologous with two reptilian teeth. The outer half of the mammalian tooth with the series of buccal cusps represents one of these teeth, the inner half with the series of lingual cusps represents the other. These two parts of the mammalian tooth may be distinguished as: the *protomere* (buccal part) and the *deuteromere* (lingual part). (Hypothesis of Dimery.)

Thesis 3. The mammalian tooth was not evolved from two reptilian teeth by means of a real coalescence of two separate and independent elements, but in consequence of a concentration of the anlage of two reptilian teeth. (Hypothesis of Concentration.)

Thesis 4. The elements of a mammalian set of teeth are all morphologically and genetically equivalent. The terms monocuspidate and multicuspidate possess only a descriptive-anatomical value and do not indicate morphogenetic differences. The differences in shape exhibited by the teeth are solely of a quantitative nature. The anlage of every tooth possesses the potentiality of developing all the cusps found in the most complicated tooth of the set. Complication is to be regarded as completeness. Simplicity of a tooth is explained by the fact, that the anlage of a tooth develops its potentialities in a more or less incomplete manner. (Hypothesis of Equivalency.)

These theses form the basis of my theory regarding the relationship between reptilian and mammalian teeth. The theory may be termed the "Dimer theory." In discussing these theses the terms protomere and deuteromere are now intelligible.

In the second thesis I have alluded to certain exceptions. This thesis is not applicable to the grinding teeth of the elephant and in all probability not to the teeth of the extinct Multituberculata. A future essay will be specially devoted to the results of an inquiry into the ontogenesis of the teeth of Elephas, the result of the study of the foetus of an *Elephas Africanus*, which I had the good fortune to acquire. I have made very interesting observations regarding the elephant's odonto-genesis, which in some points differs radically from that of other mammals, and which renders the morphology of the teeth of Proboscidea intelligible.

I will now discuss the question as to the type of reptilian tooth from which the mammalian tooth is evolved. The opinion of authorities upon this point is, as I have already remarked, unanimous, the form of the primitive tooth being invariably regarded as conical or styloid. For instance Marett Tims[1], in a communication upon this subject, expresses himself as follows: "The type of primitive tooth was the haplodont or simple cone; and the object of the present paper is an endeavour to trace the evolution of the complex crowns of the mammalian cheek-teeth from such a pattern" (*l.c.* p. 133). I will restrict myself to this one quotation from an English author.

I may commence with a criticism of the arguments advanced in favour of this view. Undoubtedly a conical tooth is the simplest imaginable. It is also true that many reptiles are endowed with a set of these very simple teeth. Finally, mammals may be provided with a purely haplodont dentition. These facts are all well known, but that they afford a reliable basis to the assertion, that the conical or styloid tooth is the primitive type from which that of mammals must be derived is questionable. From my point of view the assertion is untrue and I will endeavour to establish the ground of my disbelief.

If the shapes of the teeth of a large number of reptiles be examined, it will be found that only in a minority of these vertebrates do the teeth possess a conical or styloid form. This simple form must therefore be regarded as exceptional. In most cases, the teeth of reptiles are compressed from side to side and present sharp edges. The pattern of the teeth depends largely on the character of the food and on the development of the jaws. The latter factor is of no small importance.

That the conical teeth of the Crocodilia represent the prototype from which the complicated tooth of the mammals is to be derived is the current view. For instance, Osborn[2] expresses himself as follows: "The principle of growth was the regular addition of new parts to the simple cone." Is it beyond all reasonable doubt, that the teeth of Crocodilia are in reality primitive? Is

---

[1] "The evolution of the teeth in the Mammalia." *Journ. of Anat. and Phys.* vol. XXXVII, 1903.

[2] *American Naturalist*, 1888.

it not possible that the conical teeth are not primitive forms at all, but are simplified forms evolved from the commoner type of tooth compressed from side to side and provided with sharp edges? This question is fundamental, and its solution must be the starting point of any theory dealing not only with the relationship between the teeth of the reptiles and those of the mammals, but also with the respective dentitions of the two vertebrate groups. Authoritative views regarding this question are remarkable for their absence in the literature on the subject and the real value of the dogma that the styloid tooth is the prototype of the mammalian tooth has never been properly estimated. This I will endeavour to do as briefly as possible.

That certain mammals, namely the Odontoceti, are provided with a purely haplodont dentition is a well known fact. According to the commonly accepted view, this haplodont set of teeth is not primitive, but the simple conical teeth in these mammals have been acquired as an adaptation to the function of the very elongated jaws, being most suitable organs for seizing the prey. In jaws with such a function a large number of sharp conical teeth is obviously a very efficacious arrangement for piercing and retaining the prey. The investigations of Kükenthal prove that, not only are the styloid teeth of Odontoceti secondary formations, but enlighten us as to the manner in which the simplification of the elements of this dentition has occurred. The process was mainly the result of considerable elongation of the jaws. That a similar explanation of the dentition of the Crocodilia has never been propounded is somewhat surprising. In these animals, as in Odontoceti, the jaws are markedly elongated and are thereby adapted for seizing the prey and retaining it. To consider the conical teeth of Odontoceti as simplified forms while those of the Crocodilia are to be regarded as primitive does not seem to be a logical conclusion. I have endeavoured to collect sufficient data to enable me to form a conclusion on this most interesting question by studying the development of the teeth of *Crocodilus porosus*. My observations seem to have a most important bearing on the problem, as I have been able to establish the fact, that the elements comprising the first row of teeth appearing in the young embryo of this reptile are by no means of a conical form, as are those in the newly born animal, but are compressed from side to side, as is the case in the functional teeth of most of the Lacertilia. These small teeth, however, never cut the gums and become functional, they atrophy and disappear before the embryo is full grown. One of my assistants made an elaborate investigation of the development of the teeth of reptiles and has confirmed this fact[1].

This observation justifies the conclusion that the Crocodilia have origin from an ancestral form provided with compressed sharp edged teeth resembling those in the majority of reptiles. My observations therefore do not allow me to accept the current opinion as to the value of the Crocodilian tooth as a prototype from which the mammalian tooth is to be derived, as this tooth,

---

[1] M. Woerdeman. "Beiträge zur Entwicklungsgeschichte von Zähnen und Gebiss der Reptilien." *Archiv für mikroskopische Anatomie*, vol. 92, 1919.

like the tooth in the Odontoceti is apparently the result of a secondary simplification.

There is a noteworthy difference, however, as to the manner in which the Odontoceti and the Crocodilia have acquired their respective haplodont dentitions. Kükenthal has demonstrated that the young embryo of Odontoceti possesses complicated teeth and at a later stage these teeth cleave; as a final result, one originally complicated tooth gives rise to a very restricted number of styloid teeth. In Crocodilia on the other hand, a set of complicated teeth which do not cut the gums appears and these are succeeded by a second set of styloid teeth. It is obvious that this difference in origin of the haplodont teeth in Odontoceti and Crocodilia is closely correlated with the diphyodonty of the mammals and the polyphyodonty of the reptiles.

The assertion that the prototype from which the mammalian tooth took origin was styloid may now, I think, be considered as based on insufficient evidence. Further, it must be kept in mind that the assertion is not the outcome of observations or deductions but is consequent on the hypothesis that every tubercle of the mammalian tooth corresponds to a reptilian tooth. This was the dogmatic basis of the concrescence theory of Röse and Kükenthal.

Thesis 1 contains both a denial of the truth of this dogma and my own point of view, namely, that the mammalian tooth is evolved from a tricuspid reptilian tooth, with a main middle cone and two side cones, and not from a styloid tooth. I shall now state my reasons for taking this view.

One of these has already been stated, namely, that such tricuspid teeth are found in many reptiles whereas the styloid form occurs as an exception only and as a result of adaptation to the elongation of the jaws.

The matter may be viewed from another standpoint as evidence regarding the form of the teeth in the more primitive mammals may be gleaned from Palaeontology. The American palaeontologist Osborn is undoubtedly the greatest authority on, and possesses a most extensive knowledge of, the teeth of the mesozoic mammals. Cope, who shares responsibility with Osborn for the well known tritubercular theory, presents in the first chapter of his book, *The Evolution of Mammalian Teeth*[1], several reproductions of the jaws of primitive mammals. The more primitive of these is the Upper Triassic Microconodon and Dromatherium, two genera still possessing molars with imperfect division of the fangs, a purely reptilian character. The crown of the molars of Dromatherium is not conical at all but "narrow and lofty, the general pattern of the crown consisting of a single main cone with a high anterior and a lower posterior accessory cusp upon its slopes." As regards Microconodon the author states (*l.c.* p. 21), "the molars have that regular tricuspid division of the crown, which is first observed in the genus Amphilestes of the English lower Jurassic, and characterises a large number of the Jurassic mammals."

Judging from the figures of Jurassic mammals reproduced by the author, tricuspidity is the prevalent form. The two accessory tubercles are not always strongly developed, and in these cases one would be inclined to believe that

---

[1] New York, London, 1907.

they represent simplified forms. This is, however, rarely met with as, for example, in the lower jaw of the Stylodon, reproduced by the author (*l.c.* p. 28). Cope himself deduces the tritubercular tooth—the elementary type of his odontological system—from a triconic predecessor.

Palaeontology therefore affords no support to the opinion that the prototype of the mammalian tooth is styloid.

Osborn admits this as he represents the evolution of the tritubercular type in the following manner (*l.c.* p. 39).

I. *Haplodont Type.* A simple conical crown. *This type has not as yet been discovered among the primitive mammals.*

II. *Triconodont Type.* The crown elongated and trifid, with one central cone and two distinct lateral cones. The fang is double. Example: Triconodon.

III. *Tritubercular Type.*

This scheme is practically an admission that Osborn regards a haplodont dentition in the primitive mammal as purely hypothetical, the type consisting of a crown with three cones placed in a row representing the earliest known form. That this form has been inherited from reptilian ancestors is a justifiable assumption. It is a tooth form often met with in Cynodontia, extinct reptiles which are closely related to mammals.

Such are my reasons for assuming that the prototype of the mammalian tooth is triconic. As far as Osborn's scheme is concerned it is a matter of small moment whether the primitive mammalian tooth is to be regarded as haplodont or tricuspidate, where the latter form is regarded as transitional, and whether this tricuspidate type has been transmitted from reptiles to the primitive mammals, or has been secondarily acquired by the latter. This remark also holds good if Osborn's tritubercular theory be accepted, but it is an entirely different matter should the mammalian tooth result from a process of concrescence as is my contention. Should the prototype from which the mammalian tooth developed by concrescence be styloid, as is the general view, every cusp of a mammalian tooth will correspond to one reptilian tooth. If, as I maintain, the prototype be tricuspid, then a group of cusps, disposed in a row, will correspond to one reptilian tooth and the number of elements taking part in the formation of a mammalian tooth will be considerably lessened.

Granting the truth of the latter view the concrescence theory is reduced to a simpler form while the origin of the teeth and their processes of development become less complicated. Further several phenomena which do not fall in line with the concrescence theory are now explicable.

Before the further consideration of the process of concrescence, I wish to draw attention to a phenomenon which is directly associated with my view concerning the fundamental nature of the mammalian tooth.

In the heterodont dentition of mammals the teeth have not all attained the same degree of development. Especially is this the case with the incisors and canines, which exhibit the least differentiation. It is noteworthy, however, that the so-called monocuspidate teeth are in reality provided with three cusps. The three cusps vary in the extent of their development. In the case of the canine, the central cusp as compared with the two accessory cusps is usually the largest. Moreover the stage of development attained by the accessory cusps varies considerably in different individuals of the same species. In the case of the incisors on the other hand, the central tubercule is sometimes the broadest, sometimes the smallest, or the three tubercles may be equal in size; the last condition being the most frequent. This difference in degree of development of the three cusps observable in mammals, can also be detected in the teeth of reptiles, as is shown in fig. 97 in which parts of the dentition of *Tupinambus nigropunctatus* are represented. The intermaxillary teeth are shown in the top figure, each tooth possessing three cusps of equal size. The lower figure represents the hinder teeth which also possess three cusps, the central being the largest. That tricuspidity is a fundamental property of the incisors, is demonstrated by a frontal section through such a tooth (fig. 98), whereby it is apparent that these cusps are not due to a local thickening of the enamel layer only, the dentine also taking part in their formation. This proves that the presence of the three cusps is a result of the growth activity of the tooth-papilla, for were this not the case the limit of the dentine would present a straight edge.


Fig. 97.

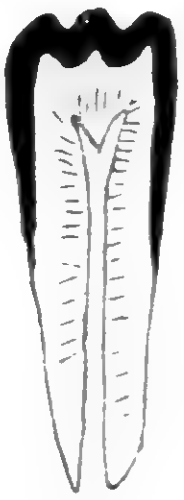
Fig. 98.

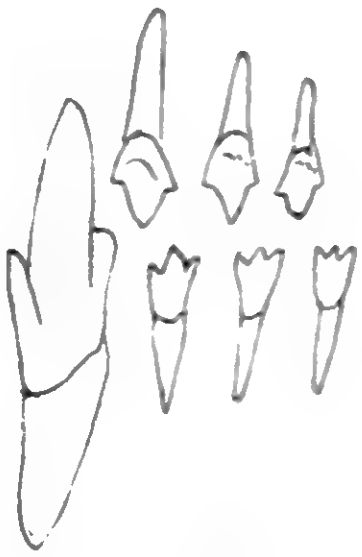
Fig. 99.


Fig. 100.

Special attention must be drawn to the fact that neither tricuspidity of the crown of incisors and canines in mammals, nor that of the teeth in reptiles, is caused by a concrescence of three adjoining but originally independent small teeth. Scales often exhibit three cusps; hairs are also often trifid consisting of one main and two accessory hairlets, and the tricuspidity under discussion is to be regarded as a similar phenomenon.

This primary property of the mammalian tooth, inherited from the reptilian tooth, controls—as will be shown in a later essay—the further differentiation of the mammalian tooth, and is the fundamental character in the pattern of even the most complicated tooth. This character is conserved most purely in those teeth whose function corresponds most nearly to that of the teeth of reptiles, namely the incisors and canines, which are chiefly concerned in seizing and retaining the prey. This is elucidated by the following facts. A tricuspid form is often distinctly recognisable in the incisors and canines of Carnivora and Primates, as is demonstrated by the following figures. Fig. 99 represents the incisors of the milk-set of a *Felis leo*, fig. 100 the permanent incisors of *Canis lupus*. There are differences in detail, but both figures clearly show the tricuspid form of these teeth.

As an example of Primate dentition the crown of the human incisor, before it has been subject to use, is tricuspid, this being the case in the lower as well as in the upper jaw. "In recently erupted teeth, the thin cutting edge presents three slight tubercles, which soon wear down and disappear apparently by use" (Tomes, *Dental Anatomy*, p. 9). This is also true for the Primates generally. In this connection certain facts are worthy of note. In the case of the human tooth the three tubercles are equal in size. This is not always the case in other Primates, and it is remarkable that when reduction occurs it is always the central tubercle which suffers. This is evidenced by fig. 101, a reproduction of I_1, and I_2, of *Semnopithecus maurus*, as seen from the lingual side. The central tubercle is in this case the smallest. The reduction may sometimes lead to complete disappearance. This process can be easily followed in the genus Cebus, as shown in fig. 102, representing three upper medial incisors of *Cebus capucinus*, in (*a*) the tubercle is very small, in (*b*) it is absent, a notch and furrow indicating the seat of its disappearance, whereas in (*c*) the crown is partly split, on account of a still further increase in depth of the notch.

Fig. 101.

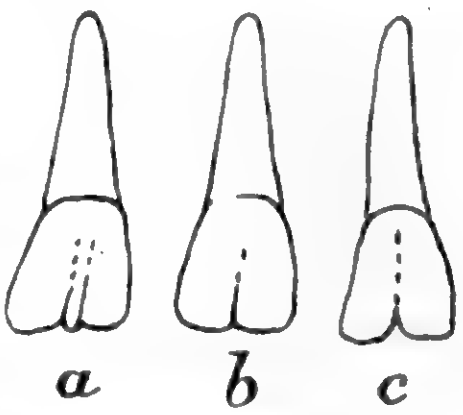

Fig. 102.

The disappearance of the central tubercle explains the splitting and duplication of the incisors, a not at all uncommon phenomenon. In a further essay, where I hope to deal with the causation of supernumerary teeth, I shall include such variations under the title *schizogenetic*.

That tricuspidity is a fundamental character of the incisors, is proved by the fact, first demonstrated by Margitol[1] as early as 1883, and subsequently confirmed by Schwalbe[2], that the crown of the incisors of permanent teeth in man, develops from three enamel tubercles, which originally separate, soon unite with one another. This fact makes the formation of crowns as shown in fig. 102 intelligible. The central tubercle in the medial incisors of Primates is, as has already been pointed out, in a condition of reduction. If this tubercle undergoes complete reduction, the lateral tubercles will unite; this will occur at a somewhat late stage of development, when they have already acquired

---

[1] *Journ. de l'Anat. et de Phys.* 1883, p. 59.
[2] *Morphologische Arbeiten*, vol. III, p. 491.

a certain altitude and as a consequence the crown will be more or less deeply incised.

So far the hypothesis formulated in Thesis I has not been elucidated and the next question concerns the morphological relationship between the triconodont prototype and the more complicated mammalian tooth. The answer to this is found in the same thesis, and I shall now set down the facts and considerations by which I was led to formulate it.

From what has been stated above it is evident, that, in my opinion, the prototype from which the mammalian tooth is derived corresponds to a phase in the Cope-Osborn tritubercular theory and so far we are on common ground. Cope and Osborn formulated their scheme as a result of palaeontological research. Their principal conclusion was that, as a result of further evolution, the central or main cusp, the so-called "protoconus" moved lingually in the upper, and buccally in the lower jaw. In this way the tritubercular tooth with the triangular crown was developed, the base being situated buccally in the upper, and lingually in the lower, jaw. This theory has but few supporters; the embryological researches of Woodward, Marett Tims and Tucker have proved the theory untenable. Gregory, originally a supporter of this part of the Cope-Osborn theory, rejected it in a later essay[1].

Although the embryological investigations of Woodward, Marett Tims and others have shown the fallacy of the Cope-Osborn theory, these investigators do not arrive at any definite conclusion as a result of their positive inductive reasonings. I venture to suggest that the embryological investigation explained and discussed in the second of these essays sheds a new light on the phylogeny of the mammalian tooth. In order to make the matter clear it will be advisable to recapitulate the essential points and descriptions recorded therein. This can be done most conveniently by means of a scheme showing the structure of the dental lamina and the enamel-organ as completely as possible (fig. 103). Especial attention must be drawn to the fact that this scheme is not hypothetical, but is the result of observations fully dealt with in the same essay. On the other hand I must confess that the investigator can but seldom hit upon the particular phase in the development of the enamel-organ, showing clearly and completely all the relations of the details in the scheme as they are represented.

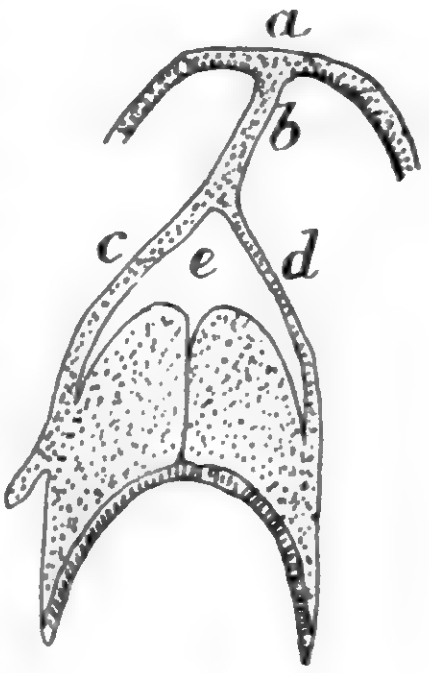

Fig. 103.

The scheme may be shortly described as follows. From the external epithelium of the mouth (*a*), a lamina (*b*), the "dental lamina" as it is usually termed, arises; this I designate the general dental lamina to distinguish it from others. This general dental lamina has a double connection to the enamel-organ. The real dental lamina is joined to the lingual side of the enamel-organ. This junction I term the "internal enamel-strand" (*c*). The second junction

---

[1] *Bull. Amer. Museum of Nat. Hist.* vol. xxxv, p. 239, 1916.

extends from the buccal side of the general dental lamina to the buccal side of the enamel-organ. This I term the "lateral enamel-strand" (*d*). These two bands and the upper surface of the enamel-organ enclose a canal—the enamel-canal (*e*). As this canal is closed behind at an earlier stage, a niche-like space "the enamel-niche" is formed. The way in which this niche develops and the enamel-canal is formed, have been discussed in detail in the second essay.

At an early stage of development a septum subdivides the enamel-organ into two halves, a buccal and a lingual. This I distinguish as the enamel-septum. It comes into being as the result of the development of two centres of pulp formation, one situated in the buccal and the other in the lingual half. Where the enamel-septum is attached to the external epithelium of the enamel-organ, the surface is often retracted, and thus a deepening, which I term the "enamel-navel," is formed. In the organ itself the enamel-septum is continuous with the layer of intermediate cells.

This description applies to what may be termed an ideal scheme of a fully developed enamel-organ. Further developmental details are given in my second essay.

The outstanding morphological characteristic of the enamel-organ is obvious. The complete toothgerm is in reality a duplicate organ, the two components of which lie side by side in a bucco-lingual direction. This is evidenced both by the double connection of the enamel-organ with the epithelial lamina from which the teeth are developed and by the two centres of pulp formation. It was pointed out in my second essay that the enamel-septum does not develop secondarily by an ingrowth of the external epithelium, but is a result of the formation of pulp derived from two centres, a lingual and a buccal. At an early stage the septum consists of undifferentiated cells disposed in the middle of the enamel-organ. These cells assuming a somewhat different form to those of the reticulum—as appears from some of the figures reproduced in the second essay—proves that the septum is essentially something more than a mere undifferentiated cell mass. An additional proof is provided by the fact that in some Marsupials blood-vessels enter into the septum from the outside.

The double nature of the toothgerm is evidenced not only by the system of "enamel bands" (an external and an internal) and by the structure and differentiation of the enamel-organ, but further by a third and no less important feature, namely, the layer of ameloblastic cells. This layer demonstrates the double nature of the toothgerm in two ways. Ahrens[1] has made the most important observation, that at a very early stage of development, the layer of ameloblastic cells is separated into buccal and lingual parts, and the elements of the enamel-septum between the two appear to be continuous with the tissue of the papilla. In this stage there is therefore no continuity between the ameloblast layers of the buccal and the lingual halves of the enamel-organ.

Thus the double nature of the toothgerm is proved by the enamel bands,

---

[1] *Die Entwicklung der menschlichen Zähne.* Habilitationsschrift, Wiesbaden.

by the enamel pulp and by the ameloblastic layer; in short, by the three components of the enamel-organ.

The duplicity of the ameloblastic layer is made evident in still another way, in that the formation of enamel begins independently in the buccal and lingual halves of the enamel-organ.

This holds good not only for the multicuspidate teeth, but even for the monocuspidate, where the so-called *Tuberculum dentis*, arising from a separate centre on the lingual side of the papilla, becomes secondarily united to the main cusps on the buccal half.

As all the component parts of the toothgerm, viz. the lamina-system, the enamel-organ and the layer of ameloblasts are apparently composed of two parts, a lingual and a buccal, I would term the toothgerm a "dimeric" organ, each one of its two constituents containing the elements necessary for the "anlage" and development of a complete tooth.

Embryology drives us to the conclusion, that the mammalian tooth is a composite organ built up from two parts, each of which alone is capable of developing into a complete tooth. When it is realised that herein lies the essential difference between a toothgerm of a reptile and that of a mammal the great importance of this fact becomes obvious. A detailed study of the development of teeth in reptiles appeared in my third essay. I stated that in lower vertebrates there is no question of a double junction of the toothgerm with the dental lamina, there is no enamel-septum and the layer of ameloblasts is absolutely single. Thus the toothgerm of reptiles is a single organ as is also the tooth which is formed from it. I therefore term the reptilian tooth "monomerous" in contra-distinction to the dimerous mammalian tooth.

Some new terms may now be conveniently introduced. The toothgerm of mammals is a dimerous organ, composed of a buccal and a lingual half. These halves I shall term "Odontomeres." It is advisable to designate the odontomeres by separate names. In future I will refer to the buccal as the "Protomere,"while the lingual odontomere will be termed the "Deuteromere." Why these terms have been chosen will be explained later.

The toothgerm of reptiles being monomerous, while that of mammals is dimerous, makes it clear that the dimery of the mammalian tooth is a property acquired in consequence of the manner in which the mammalian tooth evolved from that of the reptilian ancestor. The toothgerm of mammals is not homologous with that of reptiles, the former being homologous with two germs of the latter. The mammalian tooth evidently corresponds to two reptilian teeth, represented by the protomere and the deuteromere respectively.

Before drawing attention to certain characteristics of full-grown mammalian teeth, made intelligible by the dimerous nature of the tooth, enquiry may be made as to the conclusions that can be drawn by combining the first and second theses. (Hypotheses of Triconodonty and Dimery.)

According to the first thesis the reptilian tooth from which the mammalian is derived, was not monocuspidate but possessed three conules, a larger middle conule and two accessory cusps, anterior and posterior respectively. It is obvious that if a mammalian tooth is formed by the fusion of two such elements, the fundamental type of the tooth must have six cusps. In this sexitubercular tooth the outer or buccal three cusps represent the protomere, the three inner or lingual cusps the deuteromere. In order to interpret the morphological value of the cusps correctly, it must be kept in mind that the middle cusp of each row is potentially the strongest, and is therefore the most important. These facts may be represented by a simple formula.

The typical protomere of the mammalian tooth possesses one main and two accessory cusps. As I shall distinguish the former by the letter ***P***, and the accessory cusps by the numbers 1 and 2, the protomeric element of the tooth may be represented as

$$1\,P\,2.$$

Similarly the deuteromere has a main cusp, which I shall distinguish by the letter ***D***, and the two accessory cusps to be distinguished by the numbers 3 and 4. Thus the general structure of this part of the tooth may be indicated by

$$3\,D\,4.$$

Therefore the symbols for the buccal row of cusps are 1 ***P*** 2, whereas those for the lingual row are 3 ***D*** 4. By combining the two a "crown-formula" may be constructed and accordingly the crown-formula of the type form of the mammalian tooth is expressed as

$$\frac{1\,P\,2}{3\,D\,4}.$$

The dividing line indicates the distinction between the protomerous and deuteromerous elements of the crown.

The use of crown-formulae greatly facilitates odontological description, as the pattern of a tooth is expressed in a very simple and suggestive manner. This is not the case when special terms are used, as for instance in the Cope-Osborn system. Furthermore crown-formulae may be used to distinguish the teeth of the milk from those of the permanent dentition, capital letters being used for the latter, small type for the former, e.g.

$$\frac{1\,p\,2}{3\,d\,4}$$

represents the crown-formula of a milk-tooth.

A cusp resulting from the fusion of two primitively independent cusps may be indicated by placing their symbols in brackets, e.g.

$$\left(\frac{P}{D}\right).$$

In order to demonstrate the usefulness of this system of crown-formulae, I intercalate a table demonstrating the formulae of the post-canine teeth in the upper jaw of Prosimiae, Platyrrhinae and Katharrhinae. I do not intend to discuss the contents of these tables, which will serve as examples only.

Further information regarding the morphological value of these tables may be obtained by consulting my *Odontologische Studien*, II. 128–181 (Gustav Fischer. Jena, 1914).

In this publication I have demonstrated that the main cusps of the protomere, *P*, may, as the result of further differentiation, be subdivided into two daughter-cusps, which I have distinguished as *Pa* and *Pp*, since they occupy anterior and posterior positions relatively to one another. This subdivision is characteristic of the molars, but may occur also as a rare exception in premolars, as, for example, in the genera Galago and Hemigalago.

Crown-formulae of the upper post-canine teeth of Primates.

	P_1	P_2	P_3	M_1	M_2	M_3
Tarsius	$1\,P\,2$	$\frac{1\,P\,2}{D}$	$\frac{1\,P\,2}{D}$	$\frac{1\,Pa\,Pp\,2}{D}$	$\frac{Pa\,Pp}{D}$	$\frac{Pa\,Pp}{D}$
Stenops	$1\,P\,2$	$\frac{1\,P\,2}{D\,4}$	$\frac{1\,P\,2}{3\,D\,4}$	$\frac{1\,Pa\,Pp\,2}{3\,D\,4}$	$\frac{1\,Pa\,Pp\,2}{3\,D\,4}$	$\frac{1\,Pa\,Pp}{D\,4}$
Nycticebus	$1\,P\,2$	$\frac{1\,P\,2}{D}$	$\frac{1\,P\,2}{D\,4}$	$\frac{1\,Pa\,Pp\,2}{D\,4}$	$\frac{1\,Pa\,Pp}{D\,4}$	$\frac{1\,Pa\,Pp}{D}$
Cheirogaleus	$1\,P\,2$	$1\,P\,2$	$\frac{1\,P\,2}{D}$	$\frac{Pa\,Pp}{D\,4}$	$\frac{Pa\,Pp}{D\,4}$	$\frac{Pa\,Pp}{D}$
Galago	$1\,P\,2$	$\frac{1\,P\,2}{D}$	$\frac{1\,Pa\,Pp\,2}{3\,D\,4}$	$\frac{1\,Pa\,Pp\,2}{3\,D\,4}$	$\frac{1\,Pa\,Pp\,2}{3\,D\,4}$	$\frac{1\,Pa\,Pp}{D\,4}$
Hemigalago	$1\,P\,2$	$\frac{1\,P\,2}{D}$	$\frac{1\,Pa\,Pp\,2}{3\,D\,4}$	$\frac{1\,Pa\,Pp\,2}{3\,D\,4}$	$\frac{1\,Pa\,Pp\,2}{3\,D\,4}$	$\frac{1\,Pa\,Pp}{3\,D\,4}$
Avahis	—	$1\,P\,2$	$1\,P\,2$	$\frac{1\,Pa\,Pp\,2}{3\,D\,4}$	$\frac{1\,Pa\,Pp\,2}{3\,D\,4}$	$\frac{Pa\,Pp}{D}$
Propithecus	—	$1\,P\,2$	$\frac{1\,P\,2}{D}$	$\frac{1\,Pa\,Pp\,2}{3\,D\,4}$	$\frac{1\,Pa\,Pp\,2}{D\,4}$	$\frac{Pa\,Pp}{D}$
Indris	—	$1\,P\,2$	$\frac{1\,P\,2}{D}$	$\frac{1\,Pa\,Pp}{3\,D\,4}$	$\frac{1\,Pa\,Pp}{D\,4}$	$\frac{Pa\,Pp}{D\,4}$
Lemur	$1\,P\,2$	$\frac{1\,P\,2}{D}$	$\frac{1\,P\,2}{D}$	$\frac{1\,Pa\,Pp}{D}$	$\frac{1\,Pa\,Pp}{D}$	$\frac{Pa\,Pp}{D}$
Hapale	$\frac{1\,P\,2}{D}$	$\frac{1\,P\,2}{D}$	$\frac{1\,P\,2}{D}$	$\frac{Pa\,Pp}{D}$	$\frac{Pa\,Pp}{D}$	—
Chrysothrix	$\frac{1\,P\,2}{D}$	$\frac{1\,P\,2}{D}$	$\frac{1\,P\,2}{D}$	$\frac{Pa\,Pp}{D\,4}$	$\frac{Pa\,Pp}{D\,4}$	$\frac{Pa}{D}$
Mycetes	$\frac{1\,P\,2}{D}$	$\frac{1\,P\,2}{D}$	$\frac{1\,P\,2}{D\,4}$	$\frac{1\,Pa\,Pp\,2}{D\,4}$	$\frac{1\,Pa\,Pp\,2}{D\,4}$	$\frac{Pa}{D}$
Cebus	$\frac{P}{D}$	$\frac{P}{D}$	$\frac{P}{D}$	$\frac{1\,Pa\,Pp\,2}{D\,4}$	$\frac{Pa\,Pp}{D\,4}$	$\frac{Pa}{D}$
Ateles	$\frac{P}{D}$	$\frac{P}{D}$	$\frac{P}{D}$	$\frac{Pa\,Pp}{D\,4}$	$\frac{Pa\,Pp}{D\,4}$	$\frac{Pa}{D}$
Nyctipithecus	$\frac{P}{D}$	$\frac{P}{D}$	$\frac{1\,P\,2}{D}$	$\frac{Pa\,Pp}{D\,4}$	$\frac{Pa\,Pp}{D\,4}$	$\frac{Pa}{D}$
Cercopithecidae	$\frac{P}{D}$	$\frac{P}{D}$	—	$\frac{Pa\,Pp}{D\,4}$	$\frac{Pa\,Pp}{D\,4}$	$\frac{Pa\,Pp}{D\,4}$
Anthropoidae	$\frac{P}{D}$	$\frac{P}{D}$	—	$\frac{Pa\,Pp}{D\,4}$	$\frac{Pa\,Pp}{D\,4}$	$\frac{Pa\,Pp}{D\,4}$
Homo	$\frac{P}{D}$	$\frac{P}{D}$	—	$\frac{Pa\,Pp}{D\,4}$	$\frac{Pa\,Pp}{D\,4}$	$\frac{Pa\,Pp}{D\,4}$

This essay must convince the reader that I am no upholder of the theory that a mammalian tooth is homologous with a reptilian tooth and that the complicated structure of the former is to be interpreted as merely a reaction to its functional activities. At the same time I would urge that function is a factor of great importance in modelling the crown of the mammalian tooth. However, my views on this problem differ fundamentally from those generally held, in that I am of the opinion that every toothgerm possesses the potentiality of forming all the cusps present, in what may be termed the mammalian "standard tooth," namely, three cusps on the protomere and three cusps on the deuteromere. In my opinion the significance of function, as a factor influencing cusp formation, is that those cusps which are necessary to fit the tooth for the particular rôle it has to play in the general dentition are developed, the other cusps remaining latent. In other words, function exercises a selective influence in cusp-forming potentialities, some being stimulated while others are repressed. This view is the application of my hypothesis of a primary equivalency of all teeth composing a mammalian dentition.

My view as to the origin of the mammalian tooth is therefore intermediate between the pure differentiation theory and the pure concrescence theory, as will be set out in detail later. The manner in which I conceive the complicated nature of the mammalian tooth and its dimerous character came about must first be explained. With this object in view my third thesis, the hypothesis of concentration as I have designated it, must now be discussed.

In upholding the view that every mammalian tooth is homologous with two reptilian teeth, I am open to the accusation of supporting the concrescence theory. This, however, is not the case, as, according to this theory, a complicated mammalian tooth is formed by the concrescence of as many reptilian teeth as there are cusps in the crown of the tooth, each cusp representing a reptilian tooth. Against this view I bring two fundamental objections. In the first place a real concrescence of two or more elements situated in an antero-posterior direction has never been observed and has never been proved. Comparative anatomy and comparative embryology furnish no evidence whatever that such a concrescence has taken place as a preliminary stage for the evolution of the mammalian tooth, which is composite in a buccolingual direction only.

My second objection concerns the idea of "concrescence" itself. The notion the term concrescence conveys is, that two or more independent, disconnected organs are fused into one indivisible whole. A multiplicity becomes a unity. This notion of concrescence is either tacitly accepted or explicitly stated in odontological literature. In my opinion this notion is the weakest point in the concrescence theory, both in its actual form and in its various applications. In the first place, no observations have as yet been published, proving the appearance of a concrescence of two separate teeth into one tooth. It is true that developmental phenomena are described, which are interpreted as proving such a concrescence, but these cases are not conclusive, as the phenomena can be explained in an entirely different way. Kükenthal in particular, a firm adherent of the concrescence theory, has published and given diagrams of a number of very interesting observations on the teeth of Cetaceae, which he regards as evidencing concrescence. These cases, which I will discuss later on, do not prove concrescence, but may be explained as stages of incomplete scission.

The dimerous tooth of the mammals is not, in my opinion, the result of a real concrescence of two originally independent teeth. Were this the case one would expect to find indications of it either in such reptiles as the Cynodontia which are considered to be the direct ancestral forms of the mammals—or in the triassic mammals. Such indications, however, are entirely wanting.

If the dimerous mammalian tooth is not the result of the concrescence of two reptilian teeth in a bucco-lingual direction, how is this type of tooth to be accounted for? To answer this question I must discuss in detail the process of development of reptilian teeth, and mention a few facts serving as a starting-point of the subject of the next essay, in which the relation between the dentitions of the reptiles and of the mammals will be considered. One of the chief differences between the dentitions of the reptiles and of the mammals, is that the former are polyphyodont, the latter diphyodont. In mammals there is but one succession of teeth, in reptiles on the contrary there is an indefinite number of successions. The intensity of this process varies greatly in reptiles; some forms exhibiting very intensive tooth-change, while in others the process happens but rarely. The duration of the existence of a tooth must therefore vary very considerably in the different reptiles. In both reptiles and mammals the teeth are formed by the so-called tooth-band. I may anticipate the subject-matter of my next essay, wherein its morphological nature will be described, by pointing out the general relation of the tooth-band to the teeth.

The potentiality of tooth-formation in the dental lamina of the reptiles is apparently concentrated in a larger or smaller number of circumscribed centra arranged in two rows. Such a centrum I call a "tooth-matrix." A tooth-matrix is a circumscribed mass of epithelial cells, surrounded by inactive epithelium. When the embryonic tooth-band has grown into the subjacent mesenchymatous tissue, the various tooth-matrices begin to function.

A survey of the development of the teeth of the reptiles may be given by the aid of the diagrams in fig. 104. The first diagram illustrates the dental lamina with a swelling at the free border, the first indication of a toothgerm. The tooth-band of reptiles shows in a particularly clear way a structure which can also be observed in mammals, but much less clearly and only for a comparatively short period. The tooth-band of reptiles is a fold derived from the surface-epithelium pushing its way into the subjacent mesenchymatous tissue. This band consists of two laminae, buccal and lingual, continuous with one another at its free or distal border. Both laminae are composed of cylindrical cells, continuous with the deep layer of cylindrical cells of the surface-epithelium. Intervening between the buccal or outer and lingual or inner lamina of cylindrical cells, is a thin layer of more indifferent epithelium. From its commencement the toothgerm projects in a buccal direction, the tooth papilla pushing into it, as is shown in diagram 2. While the odontoblasts are being differentiated in the papilla and the ameloblasts, reticular cells and external epithelium are appearing in the enamel-organ, the toothgerm migrates to the buccal side of the tooth-band. As a result the originally free border of the tooth-band, in which the enamel-organ takes origin, reappears as is shown in diagram 3. Diagram 4 indicates a further stage of development. The enamel-organ has migrated surfacewards, i.e. towards the base of the dental lamina. The connection of the organ with the dental lamina is now entirely on the outer side of the tooth-band, and it seems as if the external epithelium of the enamel-organ takes origin from the buccal lamina of the tooth-band. The enamel-organ is, in fact, not completely closed; the reticular tissue is continuous with the tissue of indifferent cells between the outer and inner laminae of the tooth-band. In the meantime the formation of the dentine and enamel has commenced.

In its further development the tooth begins to push its way between the two laminae of the tooth-band, as may be seen in 5 and 6 (fig. 104). In so doing the apex of the tooth is inclined towards the base of the dental lamina. As the attachment of the organ to the lamina is displaced towards its base, the tooth-band gradually re-acquires its original form. Finally the apex of the tooth reaches the surface as shown in 7 (fig. 104). Consequently the tooth does not really break through the surface epithelium as its apex appears between the two laminae of the tooth-band.

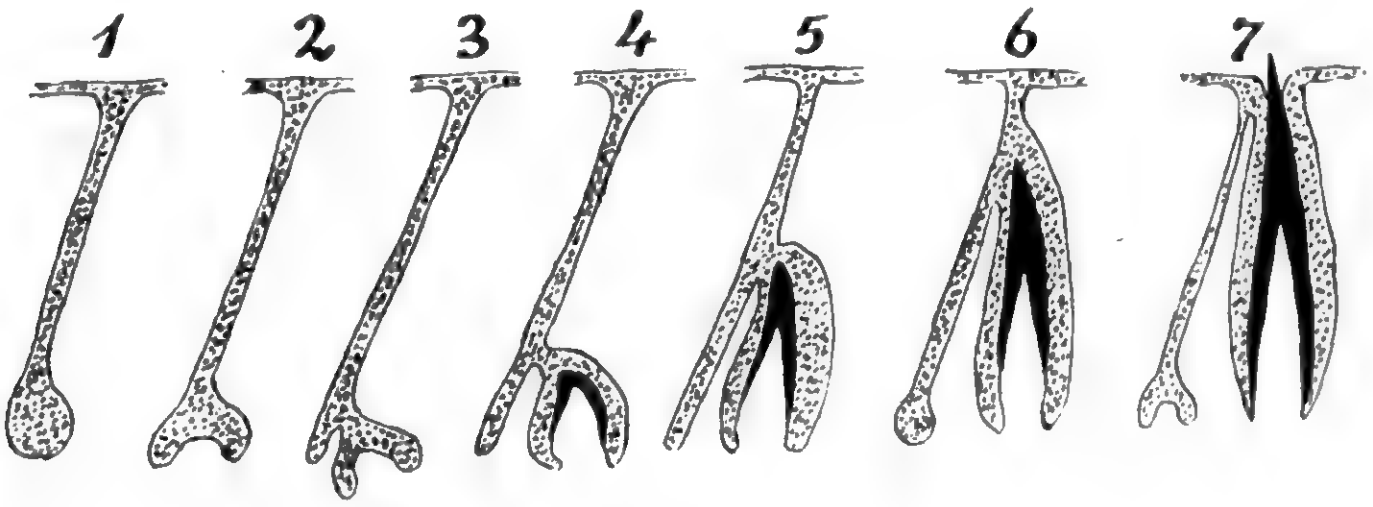

Fig. 104.

Such, in brief, is the story of events usually happening in reptiles. Variations do occur, but they can easily be explained as modifications of the generalised method of development.

It must be realised that the reptiles have in reality no free enamel-organs, and in addition this organ is incompletely closed, its reticular tissue remaining in continuity with the indifferent tissue between the two laminae of the tooth-band. In the next essay the manner of development of the teeth of the reptiles will be proved to be derived from that of the sharks, and it will then become evident that in this respect the Selachii and the Reptiles have much in common. Further the morphological significance of the tooth-band will become intelligible.

Returning again to the diagrams in fig. 104, it will be noticed that when the enamel-organ has reached the surface, and the tooth-band has re-acquired its original shape, the free border of the latter begins to swell again at the same spot at which the first enamel-organ took origin. This is shown in diagram 6. The second toothgerm develops and behaves exactly like its predecessor. When the second tooth reaches the surface it pushes out and replaces the first.

From the above description I hope I have made it clear that the teeth of the reptiles are the products of a matrix. The tooth-band swells again and again at its free border, each new tooth as it is formed, migrates upwards towards the surface and replaces its predecessor. The enamel-organ of a replacing tooth does not take origin from the enamel-organ of its predecessor, but two succeeding teeth are formed independently of one another from one and the same matrix, situated in or near to the free border of the dental lamina. The relationship between a tooth and its successor is therefore not that of mother and child, but as that between two children of one mother, one born after the other.

In such manner a tooth-matrix produces a large number of teeth during the life span of the individual. I shall distinguish all teeth formed from one and the same matrix as a "tooth family" of which every individual succeeding tooth is regarded as a generation.

The number of matrices in the tooth-band of the reptiles varies in different genera, but this is, for the moment, a matter of minor importance. Of greater importance is the fact that the productivity of the matrices differs greatly in different genera.

In certain forms, e.g. Lacerta and Hemidactylus, the matrices functionate very intensively, the interval between two generations being very short. In such cases the tooth-families are rich in generations and frequently three generations in successive stages of development are found in addition to the functioning tooth. In other cases the interval between two generations is prolonged, the matrix has a limited power of production, and the generations of a tooth-family are few in number. A case in point is Calotes in which a search through the two jaws failed to find a single replacing tooth.

A knowledge of the tooth-genesis of reptiles is a necessity in order to understand the relationship between the teeth of the reptiles and those of the mammals, and further to understand the dimerous nature of the latter. The producing activity of the tooth matrices in different reptiles is such that the interval between two succeeding generations varies considerably. This interval, however, is sufficiently long in all reptiles for the last produced tooth to have reached a certain completion and independence before the matrix begins to produce the next generation. It is conceivable that the interval between two generations may be so shortened that the matrix produces a new generation before the preceding generation has attained its independence; in short, a method of tooth formation where the interval between two generations is lacking. As a consequence, two generations will be intimately associated with one another during development, the younger generation instead of pushing out and replacing its predecessor fuses with it and a compound tooth, consisting in reality of two teeth, is the result. The conception may be extended to as many as ten tooth generations after the production of which the matrix becomes exhausted. In such a case a tooth homologous, not with a single reptilian tooth, but with a whole tooth-family is formed. Such teeth occur in mammals, e.g. in the extinct group of the Multituberculata and further in recent Proboscidea. In the latter every lamella of the tooth is homologous with a tooth or tooth-generation of the reptiles, the intervals between successive generations are lacking and generations are all so intimately associated with one another that the whole tooth-family forms but one large tooth. The morphological value of this extraordinary tooth-form, found in *Elephas Africanus,* upon which I am writing a special treatise, serves as a clue to the understanding of the tooth-form in the ordinary mammal.

The grinder of the elephant is homologous with a large number of reptilian tooth-generations, the potentiality of tooth production being very strongly developed in the matrix of this tooth. Such a tooth may be described as "polymeric." To understand the tooth-form normally occurring in mammals we may suppose that the productivity of the matrix is so limited, that after the production of two generations, the producing power is exhausted. Thus a tooth will be formed, homologous with two reptilian teeth, the whole tooth-family consisting of two generations only, coherent from their very commencement. Such a tooth may be described as "dimeric."

Although no interval occurs between the production of the two generations, nevertheless an older and a younger generation can be distinguished. The older generation forms the buccal part of the tooth, the younger the lingual, the two parts which I distinguish as the "Protomere" and the "Deuteromere" respectively. The Heterodonty of the mammalian dentition will be shown later to be due to the fact that the development of the deuteromere is very variable, and may even be entirely suppressed, as is the case for instance in the incisors and canines of some mammals.

I hope I have now proved to the satisfaction of the reader that the typical mammalian tooth is homologous with a reptilian tooth-family capable of producing a very limited number of generations.

An objection might be urged against my theory of multiple generations of a tooth-family being applied to the polymerous teeth of the Proboscidea and Multituberculata in that the successive generations are disposed not in a bucco-lingual direction as is the case in other mammals, but in an antero-posterior series. In such teeth the more anterior lamella represents the older generation, the hindmost lamella being the youngest. This apparently contradictory arrangement is to be explained, as I shall show in a forthcoming treatise on tooth-genesis in the elephant, by the toothgerm undergoing a twist whereby the buccal side is displaced forwards and the lingual side backwards.

As, according to my view, the relationship between the dimerous teeth of the mammals and the reptilian teeth is such, that the former cannot be regarded as resulting from the coalescence of two independent entities of the latter, but rather as being due to the permanent association of two teeth which in the reptile would have succeeded one another and are derived from one and the same matrix, the process may be defined as one of "Concentration" in contra-distinction to "Concrescence." Hence I have entitled my view the "Concentration Theory."

The phenomena observed in the ontogeny of the mammalian tooth and fully described in the second essay, viz. the enamel-septum, the enamel-canal and the double connection of the enamel-organ with the general tooth-band, are now open to interpretation. The phenomena can be explained by reference to fig. 103, in which a complete mammalian enamel-organ is delineated. Attention has been already drawn to the fact that the enamel-septum and the double connection of the toothgerm with the dental lamina afford a twofold proof of the composite nature of the mammalian tooth. It is conceivable that each half of the enamel-organ is identical with the germ of a reptilian tooth, the mammalian toothgerm containing the anlage of two teeth. The formation of the enamel-canal (fig. 103, *e*), bordered by the internal and external dental lamina (fig. 103, *c* and *d*), is simply the manifestation of the special connections of the two anlage with the general dental lamina (fig. 103, *b*). The canal is not so much the essential feature as are its buccal (*d*) and lingual (*c*) walls, since the buccal wall (or external dental lamina) is the special connection of the buccal component, the lingual wall (or internal dental lamina) the special connection of the lingual component, of the toothgerm to the general dental lamina (*b*).

The composite nature of the toothgerm is manifested by the double centre of the pulp formation and by the enamel-septum with the enamel-navel (clearly shown in fig. 103), both indicating undeniably that the two components, lingual and buccal, take part in the construction of the germ. The fact that in some Marsupials bloodvessels enter into the enamel-septum (*vide* Essay II) may be considered as evidence that connective tissue primitively existed between and marked the independence of the two parts of the enamel-organ.

Although the composite nature of the layer of odontoblastic cells is scarcely demonstrable, yet it is conceivably so since Ahrens has discovered that this layer is discontinuous (*vide* Essay II).

The developmental history of the mammalian tooth clearly demonstrates its dimerous character and further it seems as if there is still some tendency for the two components of the tooth to become free and independent of one another and to re-acquire their respective individualities.

This tendency may be much stronger in some teeth than in others with a result that the composite nature of the tooth becomes manifest, its protomerous and deuteromerous components being more or less independent. Such variations occur chiefly in those teeth in which the deuteromere is normally greatly reduced, e.g. in the incisors and the canines. Although I am anticipating some future considerations, I may remark here that the so-called *Tuberculum dentis* of the incisors and canines is the deuteromerous component of these teeth and occasionally appears as a small free tooth. In such cases the two generations concerned with the building of the tooth are independent, and represent a condition normally existing in the reptiles. In other cases the deuteromere, though still connected with the protomere, attains a considerable degree of independence. Cases exemplifying this condition are represented in fig. 105, where two human medial upper incisors are shown. In (*a*) the deuteromere is so well developed that it appears as a free conical cusp arising from the lingual aspect of the crown. In (*b*) a supernumerary tooth is apparently adherent to the lingual side of the normal incisor. A case in which the protomere and the deuteromere are completely independent is shown in fig. 106. This example is reproduced from Selenka, *Die Menschenaffen*, I. Lieferung, p. 141. It represents the frontal part of the upper jaw of a Gorilla with a so-called superfluous canine. Two grooves on the lingual aspect of the normal canine clearly differentiate the protomerous and the deuteromerous components of the tooth. These may be seen on the left canine. On the right side, two canines, a larger buccal and a smaller lingual, are present. The normal grooves on the lingual aspect of the larger buccal tooth are absent, clearly indicating that the two components of the normal tooth have developed independently. This case is quoted with intent, as a possibility of a superfluous canine is frequently denied and it disproves the statement that more than one canine never occurs in the functional dentition of the mammal. Supernumerary canines do occur, and are logically explained by my theory of the dimery of the mammalian tooth.

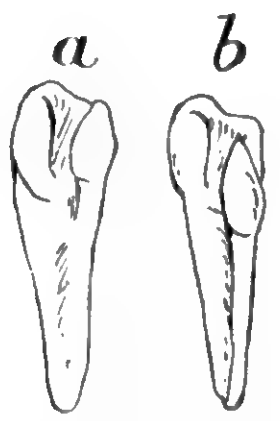

Fig. 105.

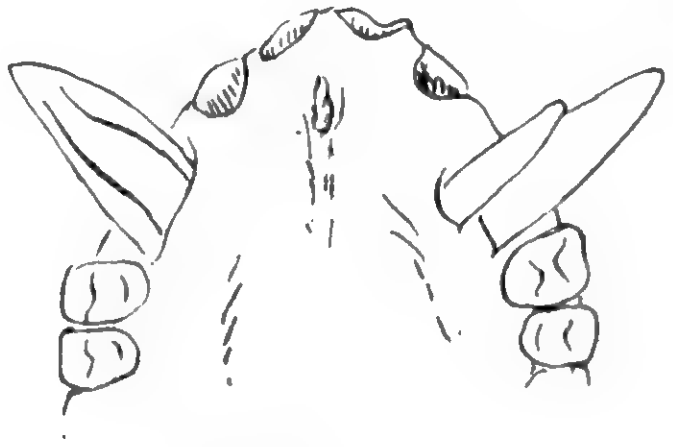

Fig. 106.

Further examples from the literature on the subject and from specimens in my own collections could be produced, but the two examples described will suffice as evidence of the dimery of the mammalian tooth.

Cases similar to these are frequently used by authors as proving the concrescence-theory. For instance, Kükenthal[1] defends the point of view as a result of his researches on the teeth of Cetaceae. I will discuss his researches

---

[1] *Denkschriften der medisch-naturh. Gesellsch. zu Jena*, III. Bnd

at some length, since in my opinion, they afford most excellent proof of my own theory. That the teeth of Cetaceae exhibit many phenomena in the direction of reduction, is a well known fact. The result of this reduction in the Odontoceti is an almost complete haplodont dentition. This reduction has progressed so far in the Mystacoceti that no functional teeth are developed at all.

In Kükenthal's opinion the teeth of Cetaceae are homologous with the milk-dentition of mammals. This assertion I do not intend to criticise, but the arguments he advances in favour of it prove, in my opinion, something entirely different.

Kükenthal describes a tooth with a prominent cusp on its lingual aspect as not infrequently occurring in Phocaena. Such a tooth is represented in fig. 107 (*a*) (Kükenthal, *l.c.* fig. 81). This cusp may even be provided with its own root, as represented in fig. 107 (*b*) (Kükenthal, *l.c.* fig. 82). Kükenthal interprets these cases as due to a growing together of a replacing tooth with a milk-tooth, and considers such teeth as evidence in favour of his assertion that the functionating teeth of the Cetaceae represent the milk-dentition, while the permanent teeth have undergone reduction. This interpretation can be easily refuted. Kükenthal's contention might have some weight if the process of tooth-change in the mammal were identical with that in the reptile and the milk-teeth and replacing teeth of the mammal stood in the same genetic relationship to one another as two tooth generations of the reptile. There is, however, as I shall show in my next essay, a fundamental difference between the process of tooth-change as it occurs in reptiles and in mammals. For this reason a concrescence of a milk-tooth with a permanent tooth is an impossibility.

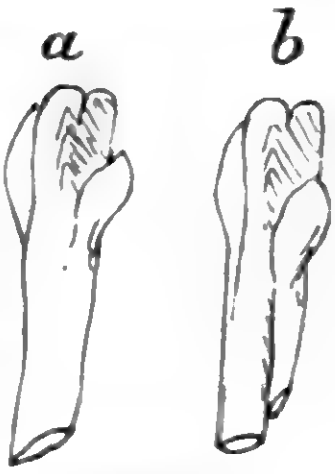

Fig. 107.

Another striking argument against Kükenthal's interpretation can be adduced by comparing figs. 107 and 105. The remarkable resemblance between the two is obvious. Fig. 105 represents two permanent incisors with very strongly developed tubercula dentis. A precisely similar condition is represented in fig. 107. This identity in pattern, proves conclusively to my mind, that Kükenthal is in error in stating that the teeth of the Odontoceti are milk-teeth, and that the occasional supernumerary cusp on its lingual aspect represents a replacing tooth. The additional cusp in the Cetacean tooth must have the same significance as the additional cusp in the human tooth. In my opinion human incisors or Cetacean teeth provided with supernumerary cusps are in either case uncommonly strong evidence of the dimerous nature of the mammalian tooth and are due to unusually strong development of the deuteromere. If the fact that the teeth of Cetaceae are in a state of reduction be taken into consideration, the phylogeny of their tooth formation being regressive, this occasional dental modification is easily interpreted. As the dimerous mammalian tooth results from the concentration of two generations of a reptilian tooth family, the products of a twofold activity of the toothmatrix persisting in intimate association, it is conceivable that in these anomalous cases the concentration is incomplete and a short interval occurs between the productions of protomere and deuteromere; as a result the latter acquires a certain degree of independence.

In the process of reduction to which the tooth of the Cetaceae has been subject, the second generation of the tooth family, the deuteromere, is lost first. The tooth of the Odontoceti consists in my opinion of a single generation only, viz. the protomere. This explains the resemblance between these teeth and those of the crocodile, to which they are, in fact, morphologically equivalent.

The fourth thesis does not present any further view, but formulates explicitly a fact necessarily sequential to the first and second theses.

According to the first thesis, the primitive element constituting the mammalian tooth is tricuspidate. The second thesis gives vent to the opinion that the mammalian tooth is the outcome of a union in a bucco-lingual direction of two reptilian teeth. Two conclusions may be drawn from these theses. In the first place, the primitive form of the mammalian tooth is sexicuspidate provided with three buccal and three lingual cusps, secondly every tooth of the set, however simple, is derived from this fundamental plan. The toothgerm of every tooth must therefore possess what Driesch calls the prospective potentiality of developing a sexi-cuspidate tooth. All toothgerms are equivalent in their morphogenic properties. Hence this thesis is designated the "Hypothesis of Equivalency."

The question as to whether or no all toothgerms are equivalent as concerns their prospective potentialities has no interest for the supporter of a concrescence theory, in which every cusp is considered as identical with a reptilian tooth. A corollary of the concrescence theory demands potential differences of a quantitative nature between the toothgerms, an idea incompatible with equivalency.

The question of equivalency must appeal to disciples of the differentiation theory, as set forth by Cope and Osborn. However, equivalency has never been propounded as a necessary qualification of the theory. On the contrary, its consideration exposes the weakness of the theory, at any rate when it was first promulgated, since the molars were regarded as fundamentally different from the other teeth. The tritubercular theory was applied at first to the molars only, a different method of development being tacitly assumed for the antemolars. Later a conformity in the patterns of the crowns of premolars and molars was conceived and considered to be the result of convergence. For instance, Osborn (*Evolution of mammalian molar teeth,* p. 195) states: "This premolar metamorphosis into the molar pattern is a very gradual process, and from the biological standpoint most interesting as illustrative of convergence, since forms exactly similar to the molars are finally attained from somewhat dissimilar beginnings."

The rest of the teeth, the incisors and canines, are left out in the cold and are not included within the scope of the Cope-Osborn theory. The "Premolar analogy" theory rests on a broader basis, as premolars and molars are considered together from a common point of view, but does not connote any idea of equivalency in tooth origin. Like the theory of Cope and Osborn it seeks to establish the homology of the cusps of the various teeth.

The concrescence theory, the tritubercular theory of Cope and Osborn, and the "premolar analogy" theory have one aim in common in that they all endeavour to explain how a numerical increase of dental cusps may be attained by some modification or other of a simpler form. As a consequence the discovery of factors determining the formation of new cusps to be superadded to those already in existence is a necessity. The fallacy of such a line of investigation is exposed in the latest (seventh) edition of Tomes' *Dental Anatomy* (pp. 366 *et seq.*).

Similar objections cannot be urged against my suggestion since the development of the various dental patterns is considered from an entirely opposite standpoint. The concrescence and the tritubercular theories are forced to explain the formation of new cusps by some evolutionary process whereby more complex forms are derived from less complex. If my views are accepted the various tooth-forms are to be explained in an entirely different manner. The problem resolves itself into determining the particular tooth-form in which all the potentialities possessed by the toothgerm are completely developed and which is, as a consequence, provided with the greatest possible number of cusps: further, should a tooth be provided with cusps smaller in number than the greatest possible, in determining which particular potentialities of the toothgerm are latent.

My theory therefore implies an involutionary principle applicable to all the teeth, and does not necessitate any artificial subdivision of the teeth into groups.

I lay no claim to absolute originality for the general idea underlying this principle. Ameghino introduced it, but applied it to the molars only. He was of the opinion that the primitive molar possessed six cusps, the number he found in Proteodidelphys, and that the molars of other mammals are derived from this form by a process of cusp reduction. Palaeontological observation led Ameghino to the same opinion as my own, but by an entirely different route. The molars of Proteodidelphys representing, as I opiniate, the fusion in a bucco-lingual direction of two reptilian tricuspidate teeth are the ideal realisations of my conclusions regarding the origin of mammalian teeth. Ameghino, on the other hand, is of the opinion that the sexicuspidate molar of Proteodidelphys resulted from a concrescence of six reptilian teeth. This opinion cannot be justified, since it implies a concrescence, partly at all events, in an antero-posterior direction. As I have mentioned already there is no particle of evidence to prove that a concrescence in such direction ever occurred in the course of evolution.

The teeth of the extinct Multituberculata have also served as a basis from which the tooth-forms of the recent mammals are to be derived. Taking into consideration that the Multituberculates are most primitive mammals, and that their molars possess a multiplicity of cusps, Forsyth Major supposes that the tritubercular molar is derived from a multitubercular by a process of cusp reduction.

Forsyth Major and Ameghino apply this principle of reduction to the molars, and are, in this restricted application, in agreement with the supporters of the tritubercular theory.

My theory differs essentially from the foregoing in that it applies to all the teeth comprising a dental set; all the teeth having had a similar developmental history are equivalent, the developmental potentialities of the front teeth as compared with the back teeth being to a great extent latent.

By summarising and combining all the different views regarding the form relations of the various teeth comprising a dental set, a result harmonising with my own particular view can be obtained. One group of investigators consider incisors, canines and premolars to be modifications of one original type, the molars being regarded as a group *sui generis.* A second group derive the premolars and molars from one common primitive type. Therefore some authorities include the premolars in one and the same group as the molars; others group them with the incisors and canines.

Opinion being at variance whether to put the line of demarcation between the canines and premolars, or between the premolars and molars, is fairly strong evidence that such demarcation is really non-existent and that all the teeth are modifications of one and the same fundamental type.

The form relationship between premolars and molars, was first advocated by Huxley. "In Centetes," writes this author, "it is easy to trace the successive changes by which the simple and primitive character of the mammalian cheek-tooth exhibited by the most anterior premolar passes into the complex structure of the crown of the posterior teeth[1]."

Topinard expresses a similar opinion: "Il y a donc," says the author, "unité d'origine des molaires supérieures et inférieures. Un type commun s'est différentié dans deux voies, qui se sont divisées et ont abouti l'une aux prémolaires, l'autre aux molaires[2]."

These views indicate a common ground plan for both premolars and molars. The opinion that the premolars and the front teeth may also have a common origin has also frequently found expression. For instance, Stehlin[3] expresses himself very definitely regarding the dentition of Suidae. The canine he believes is derived from a bicuspidate, biradical premolar tooth. As for the incisors, the author states "An den oberen Incisivi blickt die Prämolarenstructur noch

---

[1] *Collected Papers,* vol. IV, p. 450.

[2] "De l'Evolution des molaires et prémolaires chez les Primates et en particulier chez l'homme." *L'Anthropologie,* p. 670, 1892.

[3] "Über die Geschichte des Suidengebisses." *Abh. Schweiz. Palaeont. Gesellschaft,* vol. XXVI, 1899.

so deutlich durch, dasz sie sich am besten direct als modifizierte Prämolaren beschreiben lassen."

The upper incisors are found to resemble the premolars in shape in the Primates as well as in the Suidae. The lateral upper incisor of the genus Cebus, for instance, has a crown bicuspidate to such degree that the tooth may be easily mistaken for a premolar. The upper incisor of Siamanga syndactylus has a posterior cusp nearly as large as the anterior.

According to Zucherkandl, the canines and premolars are modifications of one and the same original form[1].

Finally, to quote d'Eternod[2] who comes to the conclusion that: "Toutes les dents humaines sont des bicuspides modifiées."

Summarising the opinions of these several investigators the idea of a uniformity of plan underlying the conformation of all the teeth seems definitely to exist. This conclusion is arrived at as a result of comparing the crown-patterns of the adult teeth. I arrive at identically the same conclusion as a consequence of the manner in which, in my opinion, the mammalian tooth takes origin, viz. by a concentration of the germs of two tricuspidate reptilian teeth. It was only *a posteriori* that I examined in detail the teeth of Primates, in order to learn how far facts were in accordance with this principle. The results of this investigation have already been published in detail[3].

Some further points which can be elucidated by my theory may now be considered. According to my theory mammalian teeth are identical with two generations of a reptilian tooth-family together forming a morphological unit, no interval occurring between two successive producing activities of the tooth-matrix. Of the two generations, the first or protomere represented by the buccal row of cusps, is the older; the deuteromere represented by the lingual row of cusps, is the younger.

When all the potentialities of a toothgerm are not developed, it is naturally the deuteromere which is incomplete or entirely absent. Such is the case with the incisors and canines. The deuteromere is usually completely suppressed in the incisors of the lower jaw, in the upper jaw, on the other hand, it is present and is represented by the so-called *Tuberculum dentis.* Primitive triconodonty is very often clearly indicated in the protomere and may be occasionally seen in the deuteromere of the incisors.

The canines of the Primates vary considerably as regards the degree of development of their fundamental morphological characters. In the human canines as well as in those of other Primates in which these teeth are not well developed, the deuteromere is completely suppressed, any indication of its presence on the lingual side of the crown being absent. In the well-developed canines of Gorilla, Cynocephalidae and Cebidae on the other hand, two longitudinal grooves on the lingual side of the crown are the lines of demarcation

---

[1] *Anatomie der Mundhöhle.* Wien, 1891, p. 44.

[2] *Verhandl. Anat. Gesellsch.* Leipzig, 1911.

[3] *Odontologische Studien* II. *Die Morphogenese der Primatenzähne.* Jena, 1913.

between the larger protomerous and the smaller deuteromerous elements of the tooth. The protomere of the less specialised human canine sometimes exhibits its primitive triconodonty in a very beautiful manner.

The marked reduction of the deuteromere is a common characteristic of incisors and canines, and the potentiality of development of this part of the tooth remains more or less latent in the germ, but may become active, as has been previously shown by some very instructive cases.

The deuteromere is usually more strongly developed in the premolars, although its degree of development varies considerably. It is as a rule relatively less well developed in the first premolar, but it may be so large in the last premolar that protomere and deuteromere are equal in size. Accessory cusps are also more evident in the premolars than in the incisors and canines.

A feature, enabling us to understand the pattern of the molars, can be observed in the hindmost premolar of Primates. In the early part of this essay I suggested a crown-formula for the teeth, and may remind the reader that the principal cusp of the protomere is indicated by the symbol *P*, the accessory cusps by 1 and 2; the main cusp of the deuteromere by the symbol *D*, and the accessory cusps by 3 and 4. A premolar in which the two main cusps alone are developed is indicated by the crown formula;

$$\frac{P}{D}.$$

As regards the extents of their several developments, the premolars of the Primates usually present a progressive series from before backwards. The hindmost may be so strongly developed that the principal cusp of the protomere is subdivided into anterior and posterior cusps. This is indicated in the crown-formula by writing two symbols: *Pa* and *Pp* in place of *P*. Such a subdivision is found, for instance, in the hindmost premolar of the lower jaw of Galago, Hemigalago and Avahis, and in the upper jaw of Galago and Hemigalago. The hindmost premolar of these genera exhibits a pattern similar in all respects to that of the first molar, and is judged to be a premolar, not from the conformation of its crown, but from its position in the series. A similar appearance, but in a somewhat less degree, is seen in the second lower premolar of Inuus, Cynocephalus and even Gorilla and Chimpanzee, and in the third premolar of Hapale. The subdivision of *P* into *Pa* and *Pp* is associated with a very strongly developed *D*.

In tracing the developmental features of the teeth constituting a dental series from before backwards, it is now obvious that the essential feature is the progressive increase of the deuteromere culminating in the molars. As the principal cusp of the deuteromere becomes strongly developed, the main cusp of the protomere lengthens and when associated with a more strongly developed deuteromere may be subdivided into two daughter-cusps.

In some cases the deuteromere of the premolars of Primates may be provided with a strongly developed posterior accessory cusp, to be indicated by the symbol 4. As a rule this cusp attains such a degree of development in the molars as to equal in size the main cusp of the deuteromere. Consequently the general crown-formula of the Primate-molar is as follows:

$$\frac{Pa\ Pp}{D\ 4}.$$

In addition one or more of the three remaining accessory cusps (1, 2 or 3) may be present.

This brief account will make clear what I mean by the equivalency of all the teeth. The germs of all teeth possess the potentiality of developing a sexicuspidate tooth. This potentiality is a consequence of the modus in which the mammalian tooth was evolved. Two possibilities may eventuate, either all potentialities may activate or one or more may be latent. As a rule the whole deuteromere is latent in the incisors and canines or when present is a mere vestige. In general the development of all the accessory cusps is much more variable than that of the two main cusps.

I consider all the teeth as having had origin from an equivalent matrix. From this standpoint the incisors and canines as compared with the premolars and molars are not to be considered as teeth which have undergone reduction. No question of a real reduction is involved, since the cusp-forming potentialities in the germs of these teeth are, in contradistinction to the molars, incompletely developed. Hence my definition in Thesis 4: complication is coincident with completeness.

Finally, two features, viz. the *Tuberculum impar* or cusp of Carabelli and the Cingulum both of which have some bearing on my theory of the origin of the mammalian tooth will be considered. The *Tuberculum impar,* to which comparatively little attention is paid by English writers, will be considered first.

This tubercle has a very important bearing on the problem of the homology of the cusps characterising the Primate dentition. I have already alluded to the fact that the main cusp of the protomere *P*, usually simple in the premolars, is subdivided in the molars into two daughter-cusps, distinguished as *Pa* and *Pp*. Homologising these cusps is of such importance that further evidence must be adduced in support of this assertion. That two cusps on one tooth are together homologous with a single cusp on another is a somewhat bold and novel statement. However, such a view helps to solve the difficulty of homologising the cusps of the premolars with those of the molars.

I was led to this opinion by comparing the pattern of the hindmost premolar in Primates with that of the first molar. The factor causing the cusp *P* to be subdivided into the cusps *Pa* and *Pp* is the very strong development of the adjacent cusp *D*. Evidence supporting this supposition can be drawn from direct morphological observations made on the hindmost premolars of some Primates, and the *Tuberculum impar,* which is not infrequently met with in man, is a further convincing proof. I have had the opportunity of examining this supernumerary cusp in some thousands of molars.

The genetic and morphological significance of the *Tuberculum impar* must first be proved and I shall show, subsequently, that the excessive development of this cusp, situated on the lingual side of *D*, is a factor causing the latter to subdivide into two daughter cusps, *Da* and *Dp*, in precisely the same way as the excessive development of *D* compels the main cusp of the protomere *P* to subdivide into the daughter cusps *Pa* and *Pp*.

The genetic importance of the *Tuberculum impar* may be explained as follows. The mammalian tooth is a dimerous organ homologous with two generations of a reptilian tooth-family, which as the protomere and the deuteromere, both take part in the building of the tooth. Normally the mammalian tooth-matrix is endowed with the potentiality for producing two generations only, which are intimately associated with one another as a result of concentration. Primitively a tooth-matrix possesses the potentiality of producing more than two generations. Should the matrix be capable of producing a third generation the result would appear on the lingual side of the principal cusp of the deuteromere, and a little eminence or even a cusp in this situation may be considered as the indication of the principal cusp of the third generation. In such case, the tooth is not a dimerous organ but is in reality trimerous and the manifestation of a third generation can therefore be distinguished as the "Tritomere" its cusp being indicated by the symbol *T*. The cusp *T* is commonly denoted the *Tuberculum impar* or the cusp of Carabelli. This cusp is simply a manifestation of a third generation of the mammalian tooth-family, in persistent association with the second generation in precisely the same manner as the latter is associated with the first generation. The crown-formula of a molar provided with a *Tuberculum impar* is therefore

$$\frac{\frac{Pa\ Pp}{D\ 4}}{T}.$$

The *Tuberculum impar* has been found associated at one time or another with every tooth of the upper jaw in man, but not so frequently with some teeth as with others. I will not present the results of my investigations upon the frequency of this cusp, but the following figures prove that I have had ample opportunity of studying it. In 300 $m\ 2$, the cusp was present 54 times; in 2325 M_1, 407 times; in 2072 M_2, 144 times. I intend to publish shortly a detailed account of an investigation on this cusp found in Primates other than man. Certain information concerning and some diagrams illustrating this cusp may be found in a treatise already published[1]. From the figures given above it is apparent that this cusp is not rare in man, where it is found more frequently in M_1 than M_2.

When the cusp *T* is well developed, it has a marked influence on the cusp *D*. I have been able to trace the gradual effect of this influence. The cusp *D* first widens then a shallow furrow is formed incompletely subdividing the cusp.

---

[1] "Das Carabellische Höckerchen," *Schweiz. Vierteljahrschrift für Zahnheilkunde*, vol. xxv, 1915.

Finally, when T is very strongly developed the furrow becomes so deep that the cusp is completely split into two daughter-cusps, which may be distinguished as Da and Dp. The crown-formula of such a molar is

$$\frac{\dfrac{Pa\ Pp}{Da\ Dp\ 4}}{T}\,.$$

As a matter of detail the crown of such a molar is somewhat irregular.

I must emphasise the importance of the foregoing description of the behaviour of the cusp D as it makes the general crown pattern of the molar teeth intelligible. The cusp T must be considered as the main cusp of a third generation, participating in the building up of a tooth. It is adjacent to cusp D. In those cases, in which this cusp T is strongly developed, the cusp D is sub-divided into two daughter-cusps. This process elucidates the homology of the premolar and the molar patterns. In the premolar the cusp D, adjacent to the cusp P is moderately developed; in molars, on the other hand, it is as a rule strongly developed and as a consequence the cusp P is sub-divided into two daughter-cusps.

In my opinion the pattern of the molar teeth does not result entirely from concentration as I use the term, but is also partly due to differentiation.

I cannot close this essay without briefly discussing the theory of the origin of the premolar pattern as formulated by Marett Tims[1].

He thinks the cingulum is of great importance in the genesis of the premolars, the molars being considered as formed by a concrescence of two premolars. With the latter opinion I cannot agree, as there is no evidence of a concrescence of teeth in an antero-posterior direction ever having taken place as a normal evolutionary process, but I am more inclined to agree with him respecting the importance of the cingulum.

Marett Tims makes a great point of the so-called "internal cingulum" possessing the faculty of forming cusps, e.g. the protoconus of the premolars. Translated into my own nomenclature the "Protoconus" is cusp D, the principal cusp of the deuteromere, and I fully agree with him that a genetic relationship exists between the internal cingulum and this cusp D. I consider the cingulum to be the manifestation of the deuteromere. When very slightly developed, the latter does not exist as a cusp, but as a small inconspicuous eminence, as is the case, for instance, in the deuteromere of the upper incisors. Marett Tims' observation that all intermediate conditions between a simple cingulum and a well-developed cusp may be met with is obviously true.

The same applies to the tritomere. This may be slightly developed as a low ridge, and also exhibits progressive increase, ultimately attaining the dignity of a true cusp.

Odontological problems of vast importance concerning the relationship between mammalian and reptilian teeth and the causes of Heterodonty have

---

[1] "The Evolution of the Teeth in Mammalia," *Journ. of Anat. and Phys* vol. XXVII, 1903.

been discussed in this essay. My conceptions run counter to current opinion and will, doubtlessly, be subjected to criticism. I would plead, however, that considered judgment be suspended until the appearance of my fifth essay, in which the second great odontological problem, viz. the relationship between the diphyodonty of mammals and the polyphyodonty of reptiles will be discussed. I hope to prove that the processes of tooth-change in reptiles and mammals are two entirely different phenomena and that the reason for the appearance of the dimerous tooth in the mammal is to be sought for in the profound change which has affected the primitive features of tooth replacement.

As the two fundamental odontological problems are closely inter-related and both come within the compass of my general conceptions, the complete evidence upon which my theory stands or falls has yet to be unfolded.

CORRELATION BETWEEN HABIT AND THE ARCHITECTURE OF THE MAMMALIAN FEMUR

By G. de M. RUDOLF, M.R.C.S. (Eng.), L.R.C.P. (Lond.), D.P.H.

King's College.

The object of the investigations undertaken is the study of the architecture of the upper end of the femur and the relationship which this bears to the habits of its owner.

With this object in view, coronal sections were made through the upper ends of femora of various animals.

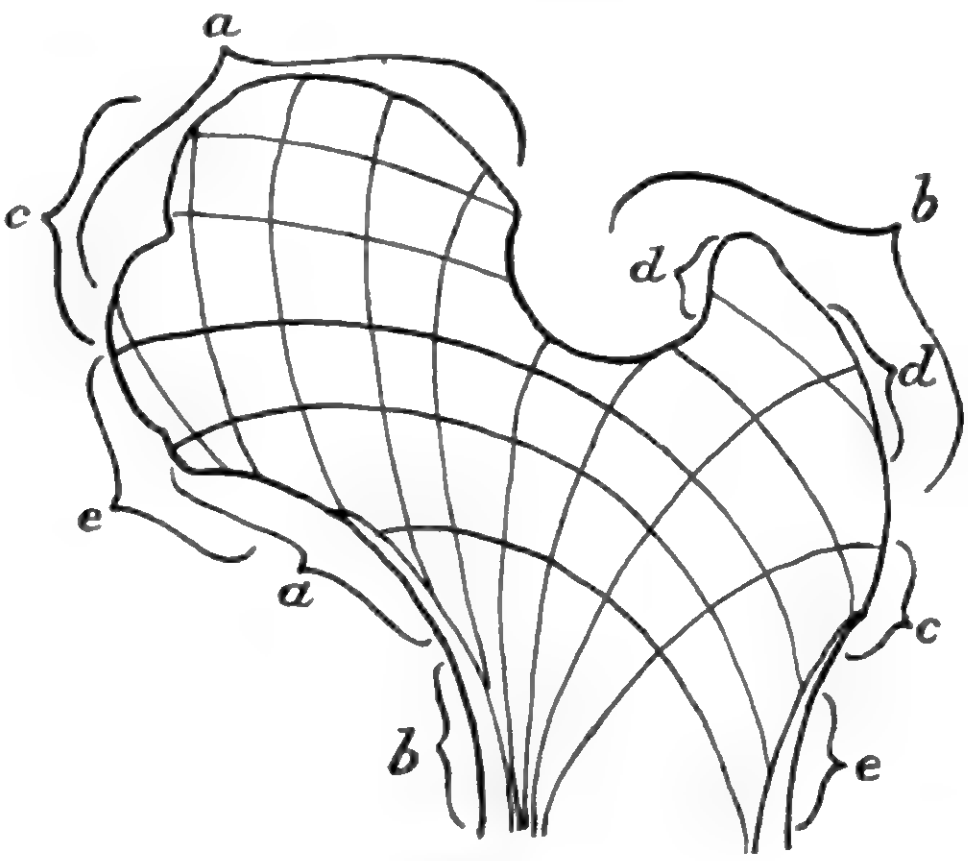

Fig. 1.

As a standard of comparison the human femur will be taken as the type. Koch (5) classifies the lamellae exhibited by a coronal section of the upper end of this bone in five groups (fig. 1). For convenience of description these groups are marked *a*, *b*, *c*, *d*, *e*. The characteristics of these groups are as follows:

(*a*) Principal compressive group. The lamellae are closely packed. They are the thickest found in the upper end of the femur and are mainly prolonged from the inner wall of the shaft. The lamellae exhibit no change as they cross the epiphysial lines.

(*b*) Secondary compressive group. Trabeculae thin. Intervening spaces wide.

(*c*) Principal tensile group. Lamellae thinner and more widely spaced than those of group (*a*).

(*d*) Secondary tensile group. Lamellae very thin and poorly defined.

(*e*) Group of tensile lamellae situated below, and parallel to group (*c*).

According to Wolff's law the arrangement of the lamellae may be regarded as a response to the normal stresses and strains to which the part of the bone is subject. Consequently, this arrangement will depend upon the use made of the bone by its owner, and thus is an index of the habits of the creature. Murk Jansen (4), however, believes, contrary to Wolff's law, that lamellae are never laid down as the result of tension, but only of pressure. He also believes that "functional pressure" is not the only factor determining bone formation, but that there are other factors which make themselves felt in the formation of bone.

The mammalian femora providing the material for this thesis can, for descriptive purposes, be divided into three main classes:

I. Compact class. The femora in this class contain a large number of closely packed lamellae.

II. Loose class. The femora contain a small quantity of widely spaced lamellae.

III. A class characterised by the appearance of two new sets of lamellae, *f* and *g*. These converge towards one another in the substance of the great trochanter, crossing each other at angles varying in different animals.

Each class may be further divided into two sub-classes, 1 and 2. In sub-class 2 of class I the lamellae are more widely spaced and less numerous than in sub-class 1. In sub-class 1 of class II the lamellae are closer and more numerous than in sub-class 2. In class III, sub-class 1 consists of aquatic mammals, sub-class 2 of creatures with leaping habits.

The femora examined, and their classification, are as follows:

Class I. Compact class.
  Sub-class 1. (i) Aard-Vark (*Orycteropus*).
    (ii) Brown Bear (*Ursus arctos*, var. *isabellina*).
    (iii) Great Anteater (*Myrmecophaga jubata*).
    (iv) Domesticated Horse (*Equus caballus*).
      (*a*) Cart-horse.
      (*b*) Carriage-horse.
      (*c*) Pony.
    (v) Man (*Homo sapiens*).
    (vi) Domesticated Pig (*Sus*).
  Sub-class 2. (i) Domesticated Sheep (*Ovis aries*).
Class II. Loose class.
  Sub-class 1. (i) Domesticated Dog (*Canis familiaris*).
    (ii) Three-toed Sloth (*Bradypus tridactylus*).
  Sub-class 2. (i) Domesticated Cat (*Felis domesticus*).
    (ii) Diademed Sifaka (*Propithecus diadema*).
    (iii) Stoat (*Mustela erminea*).
    (iv) Brown Rat (*Mus decumanus*).
Class III.
  Sub-class 1. (i) European Beaver (*Castor fiber*).
    (ii) Monk-Seal (*Monachus albiventer*).
    (iii) Northern Sea-Bear (*Otaria ursina*).
  Sub-class 2. (i) Great Grey Kangaroo (*Macropus giganteus*).

The individual bones will now be considered.

Aard-Vark. This animal, being very heavy for its size, needs a strong femur. The lamellae are very closely packed and numerous. The aard-vark is a creature that lives on hard ground and is an expert at rapid digging, being able to dig a hole sufficiently large to bury its entire body in a few minutes. The hole is dug by means of the fore-feet, the clods of earth being passed backwards between the hind-limbs (8). Thus the animal must support itself for short spaces of time upon its hind-limbs alone. These considerations, combined with the knowledge that the femora of the creature must, when the animal is trotting, be continually receiving sudden shocks on coming into contact with the hard ground, would lead to the assumption that the lamellae would be not only numerous and closely packed, but also arranged in definite and well-marked groups. The femur, however, only exhibits two main groups of lamellae, namely *a* and *c*, and these are not so distinct as is the case in femora of other animals. Possibly this is due to the relationship of the aard-vark to the anteaters of South America. Lydekker states that it is "urged that during the connection of America with Africa the latter country received from South America the ancestors of its pangolins and aard-varks (10)."

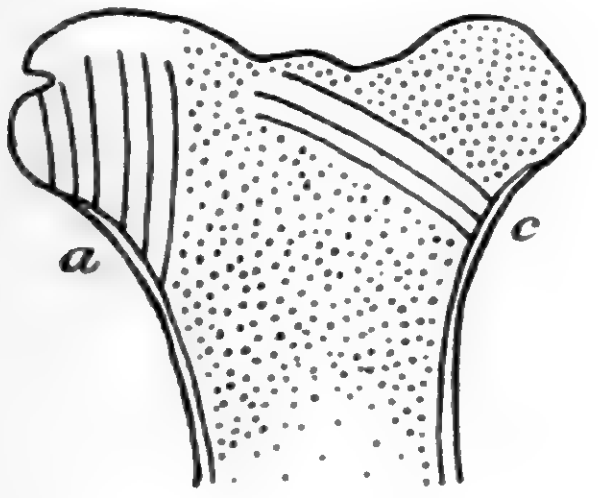

Fig. 2. Aard-Vark.

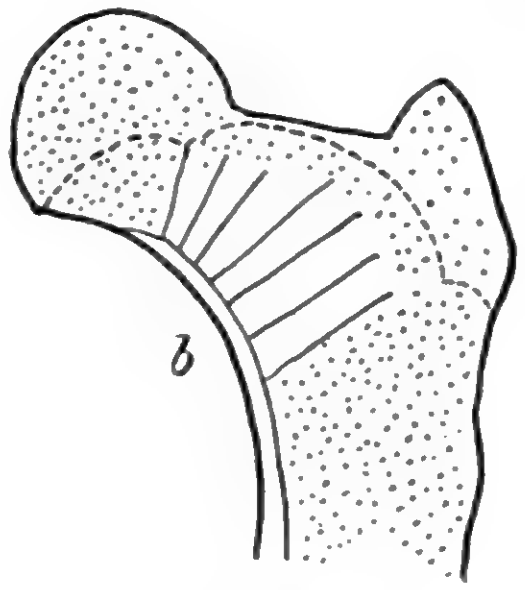

Fig. 3. Bear.

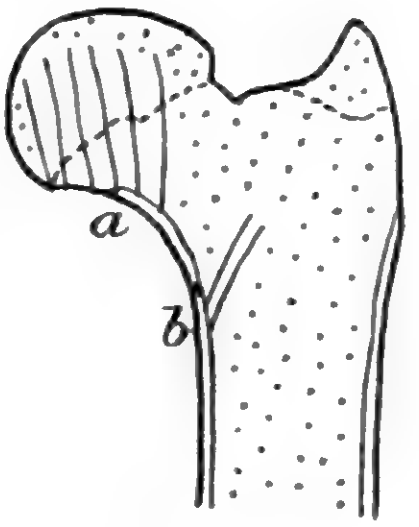

Fig. 4. Anteater.

Brown Bear. The species examined is another heavy animal and inhabits wooded hilly districts in the Himalayas. Its food consists of insects, fruit, etc. (6). In order to reach the vegetarian part of its diet, the bear must ascend the trees. As the animal commences to climb, it must first raise itself up on its hind-limbs and place its fore-paws up the trunk of the tree. In this position the hind-limbs must support nearly the whole weight of the body. To enable the femora to withstand this enormous strain the lamellae are very closely packed. Group *b* is particularly well-marked. Possibly the reason for this may be found in the manner in which the animal walks. A bear does not move its hind-foot forwards in a straight line, but swings the foot forwards in the arc of a circle, convex outwards. Towards the end of this swinging movement the foot is moving forwards and inwards. Consequently the inner side of the foot bears the brunt of the sudden impact with the ground, and the inner part of the limb must be proportionately strong in order to withstand the immense strain put upon it.

Anteater. The femur of this animal has only one well-marked group of lamellae, group *a*, although group *b* is distinguishable. The anteater lives in wet, swampy districts(11), and, owing to the yielding nature of the ground on which the animal walks, the femur is not often subject to loads applied suddenly. The immediate effect of stresses applied suddenly is approximately double that of the same force applied gradually(5). From this it follows that the groups of lamellae in the femur of the anteater need not be so well-marked as would be necessary if the animal lived upon hard ground. The lamellae are fairly closely packed, though not to the extent found in the femur of the aardvark. This can be explained not only by the consistency of the surface upon which the animal walks, but also by the fact that as the anteater is not a burrower, it does not support itself upon its hind-limbs alone. The only digging performed by the animal is confined to opening the nests of termites(11), and this can be done with one fore-paw alone.

Horse. The femur of the domesticated horse must be exceedingly strong, for not only is this animal heavy, but also it lives on hard roads, over which certain types, e.g. the carriage-horse, move rapidly. The speed at which an animal travels may make a great difference in the lamellae of the femur, for the load borne by the femur during running is much greater than that borne during walking. In the case of Man, the load is 1·6 of the body weight during running, and only ·8 of the same weight during walking(5). This is another form of the statement already made that stresses applied suddenly are double those produced gradually. The load in walking is so cushioned by ligaments, etc., that it equals a load applied gradually, whereas in running the ligaments are not sufficient to break the force of the load, with the consequence that the stresses are applied suddenly.

(*a*) Cart-horse. The femur of this animal is very massive compared with that of the pony. There is a large amount of closely packed lamellae. Groups *a* and *e* are well-marked, the former being the more prominent. The upper surface of the great trochanter is at a level higher than that of the head of the bone. This is, perhaps, connected with the manner in which the horse rises from the ground. The animal first sits on its haunches in the same way as a cat, and then springs suddenly on to its hind-feet, not rising in the more leisurely fashion of the carnivore. This movement of springing on to the hind-feet is similar to that of jumping, and, as will be shown later, jumping habits are associated with a high great trochanter. The reason for this association in all probability lies in the circumstance that an extended great trochanter increases the leverage about the axis of the neck of the femur and so enables a greater movement to be performed without too great an expenditure of energy. There is a certain amount of flattening of the head of this femur. This is perhaps partly due to the pressure exerted by the head upon the acetabulum when the horse rises from the sitting position.

(*b*) Carriage-horse. As would be expected, the lamellae are not so closely packed as are those of the heavier cart-horse. Group *a* is very prominent, as is also group *c*. There is a large quantity of cancellous tissue, extending some distance down the shaft.

(*c*) Pony. The lamellae of group *a* are well-marked, although those of group *e* are not very prominent. The walls of the bone are relatively thicker than in either the cart-horse or the carriage-horse. Apparently, in the smaller, active animals strength is obtained by an increase in the amount of compact bone, the cancellous tissue being relatively scanty.

The femora of these three types of the same species demonstrate two facts, (*a*) that the compactness of the lamellae varies directly with the intensity of the stresses and strains to which the femora is subject, and (*b*) that the height of the great trochanter bears a direct relationship to the agility of the animal. That this is the case is shown by the observations that the lamellae are most closely packed in the cart-horse and least so in the pony, and that the great trochanter of the cart-horse is relatively shorter than that of the pony. The carriage-horse occupies an intermediate position both as regards the compactness of the cancellous tissue and the height of the great trochanter.

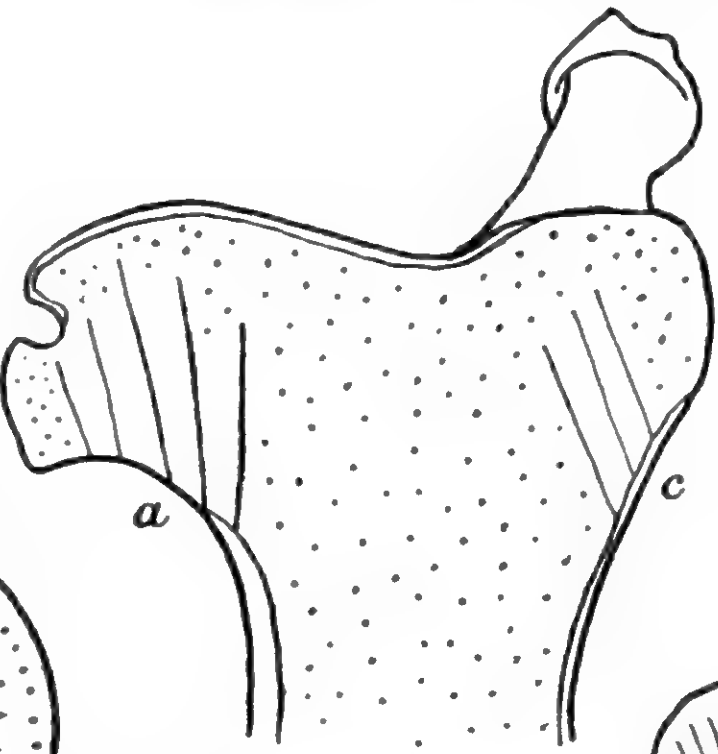

Fig. 6. Carriage-horse.

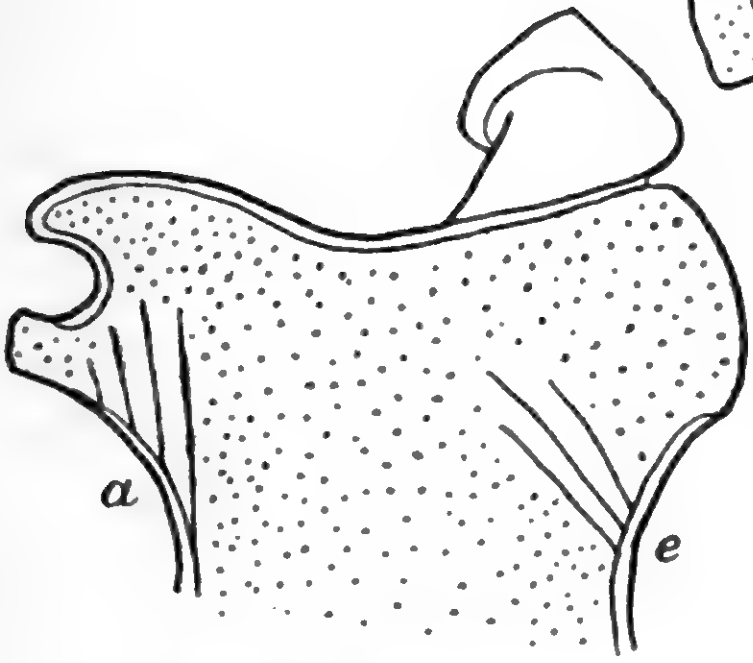

Fig. 5. Cart-horse.

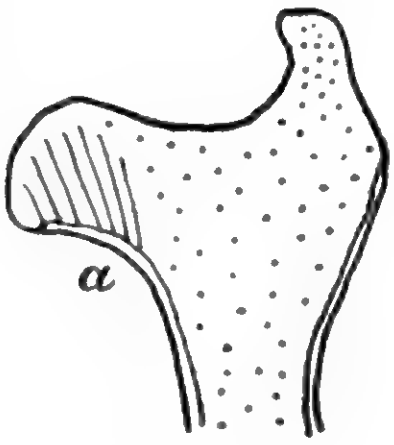

Fig. 7. Pony.

Pig. The femur of this animal contains a moderate quantity of cancellous tissue. The lamellae are very closely packed as might be expected when the weight of the animal is considered. The walls of the bone are thick. The lamellae of group *a* are very well-marked. Group *e* is the only other group at all prominent. The absence of many well-marked groups agrees with the habits of the pig, for this animal lives upon soft ground and is rather inactive. The prominence of group *a* is probably caused by the relatively huge weight of the animal, whereas the prominence of group *e* is no doubt due to the position of the bone when the animal is standing. As in Man, the femur is obliquely inclined, the distal end being nearer the middle line than the proximal.

Consequently, the greater part of the weight supported by the femur will be transmitted along the lateral part of the bone. On this account there is more cancellous tissue laterally than medially, and group *e*, along which a large part of the weight is transmitted, is prominently marked.

Sheep. The cancellous tissue is more open in this bone than in any of the preceding members of the class. The amount is relatively less than in the femur of the pig. Group *a* can be seen, while groups *b* and *e* are barely recognisable. The upper surface of the head is flattened, and the summit of the great trochanter is at a higher level than that of the head. This latter characteristic is probably due to the habits of the sheep, for, although the modern domesticated sheep is not as a rule very active, the wild sheep and the domesticated sheep allowed to run wild are very agile animals. The flattening of the head of the bone is possibly caused by the great weight of the creature at certain periods of its life, combined with the small amount of circumduction possible in the movements of the hind-limbs. Neither the high great trochanter nor the flattening of the head can be due, as in the case of the horse, to the manner in which the sheep rises from the ground, for the latter raises its hind-quarters first, and then gradually straightens out its fore-limbs. Thus there is no great pressure exerted upon the head of the bone in this movement, nor is there any need for a great deal of leverage.

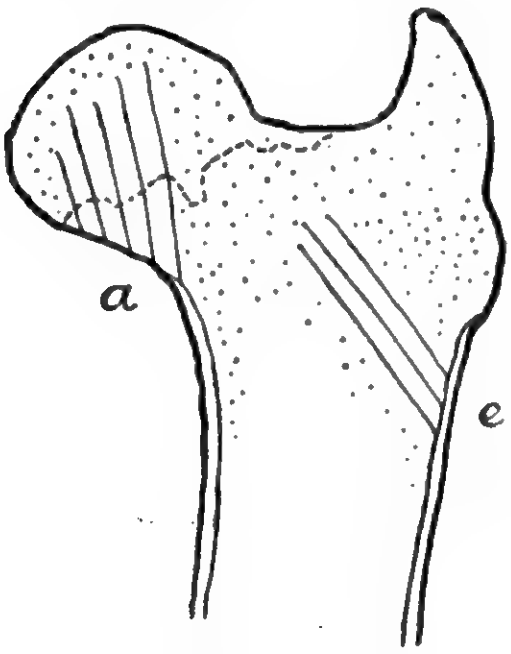

Fig. 8. Pig.

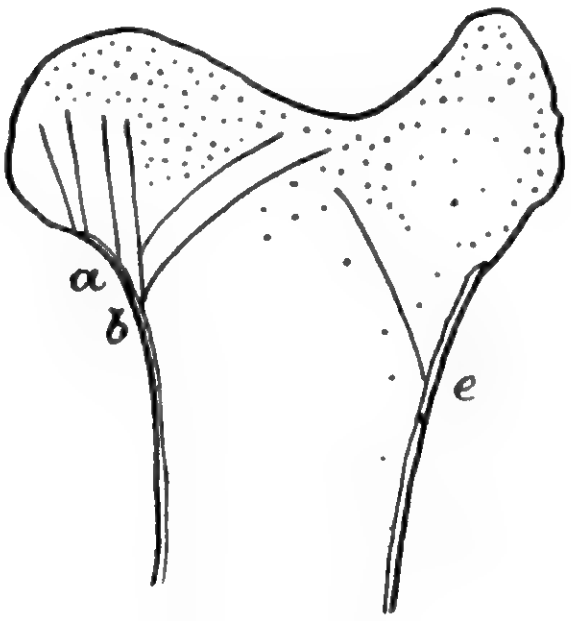

Fig. 9. Sheep.

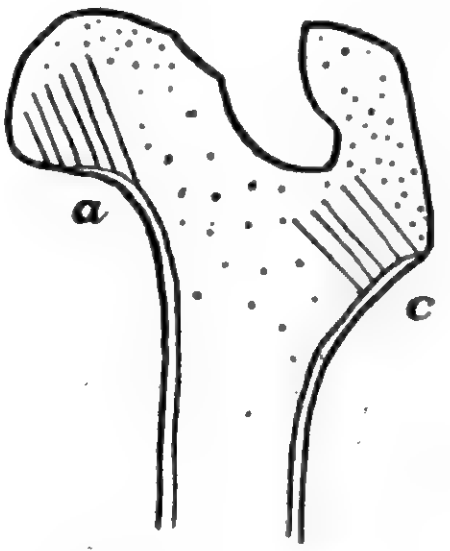

Fig. 10. Dog.

Dog. This animal is a representative of class II in which very few lamellae are present. In the femur of the dog, that of a fox-terrier being the bone described, the lamellae are fairly widely spaced. Groups *a* and *c* are well-marked, although neither is very prominent. The wall of the bone is thick. The top of the great trochanter is level with the upper surface of the head of the bone. This might suggest that, although the dog is able to jump, it is not primarily built for that purpose.

Sloth. The lamellae of this femur are less closely packed than are those of the dog. The compact bone on the superior aspect of the head is thin, and the neck forms a very wide angle with the shaft. The sloth passes most of its life hanging by its feet from boughs in an inverted position. Thus the neck and the shaft of the femur tend to be pulled into one straight line, for the weight of the animal will be supported by the leg and thigh. Flower states that the neck of the femur of this animal is nearer the axis of the shaft of the bone than in most other animals (1). The habitual attitude of the animal involving no pressure upon the proximal end of the femur, the compact bone investing the head is thin. There are three well-marked groups of lamellae, *a*, *c* and *d*. As the sloth hangs from the bough there is a tendency for the neck of the femur to be pulled into the line of the shaft, and also a component pressure force tending to press the head of the bone against the acetabulum. Group *c*, situated in the head of the bone, is well-marked and obviously resists this flattening tendency. Group *a* is probably well-marked in order to support *c* to prevent the latter from "buckling." The slight prominence of group *d* may be accounted for by the fact that the muscles attached to the great trochanter must, to some extent, support the weight of the body from the bough, and the group referred to may resist a tension strain.

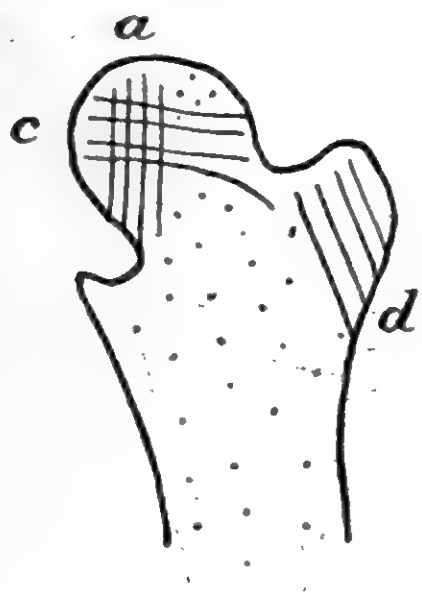

Fig. 11. Sloth.

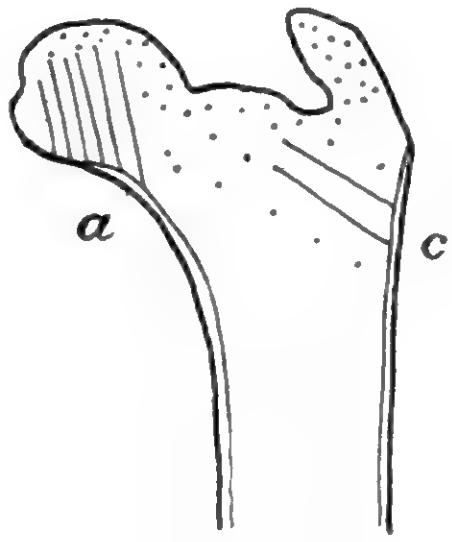

Fig. 12. Cat.

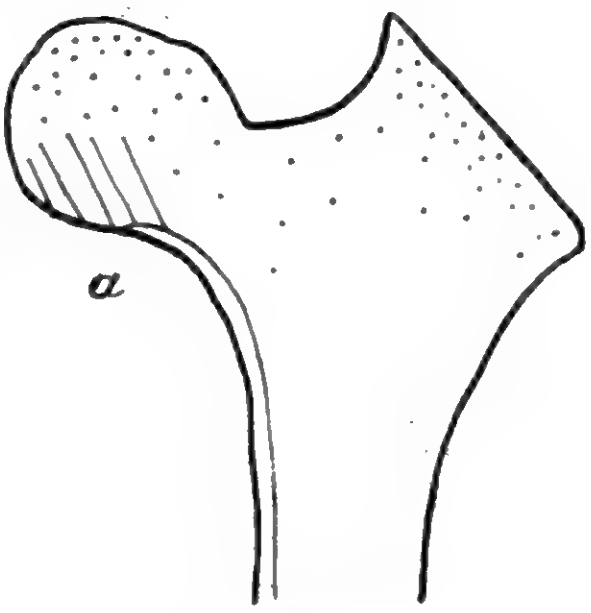

Fig. 13. Sifaka.

Cat. The amount of cancellous tissue is even less in this femur than in that of the sloth. The only group of lamellae readily distinguished is group *a*, although group *c* can just be recognised. As the cat is an active animal it might be expected that the various groups would be well marked. The animal is adapted, however, not only for agile movements, but also for stealthy and silent tread. The feet are therefore well-padded and the ligaments allow a certain amount of "play." The full force of a fall is not received by the femur, the ligaments and pads acting as disseminating cushions. The strength of the bone mainly depends on the compact tissue, the walls being comparatively thick.

Sifaka. The sifaka, or propitheque, is one of the lemurs. The cancellous tissue in this femur is very slight indeed. The sifaka is an exceedingly active animal. It spends most of its life in the trees, rarely coming to the ground; there is therefore a reduction in the amount of the cancellous tissue. When on the ground the sifaka progresses by means of long leaps of about ten yards, not using the fore-limbs at all (3). The requisite strength of the femur is obtained by the walls of the bone being relatively thick. The great trochanter rises slightly above the level of the head of the bone. This is no doubt associated with the leaping habits of the animal.

Stoat. This is another active animal whose light weight facilitates its rapid movements. Little cancellous tissue is present. Group *a* is fairly distinct, enabling the femur to resist the sudden shocks to which it is subject.

Rat. This femur contains relatively less cancellous tissue than does that of the stoat. This is presumably associated with the agility of the rat, for this animal can not only run rapidly, but also climb and swim. As would be expected from the habits of this creature, group *a* is fairly prominent.

Beaver. The beaver is included in class III. In this class two additional groups of lamellae (*f* and *g*) are found. The lamellae in the femur of the beaver are very closely packed. The reason for this is not far to seek, the animal being very heavy, and the weight mainly disposed in the hind-quarters. A beaver may weigh as much as 60 lbs. while the length of the body is only 30 ins. Swimming being almost entirely performed by the hind-limbs (7), the muscles of these extremities are very large, accounting for the great weight of the caudal end of the body. Groups *f* and *g* meet one another at an angle of about 45°. The great trochanter rises slightly above the superior aspect of the head of the bone.

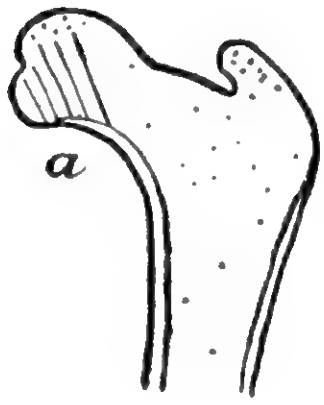

Fig. 14. Stoat.

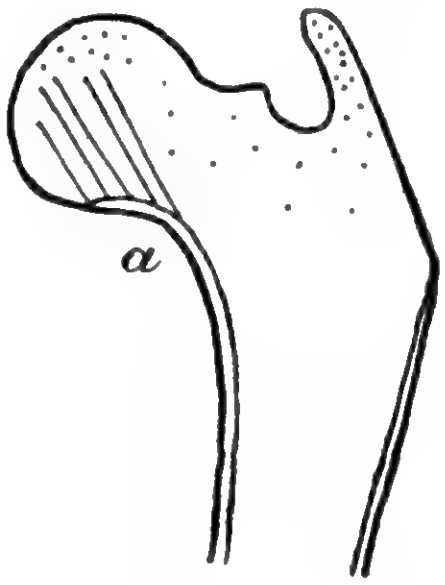

Fig. 15. Rat.

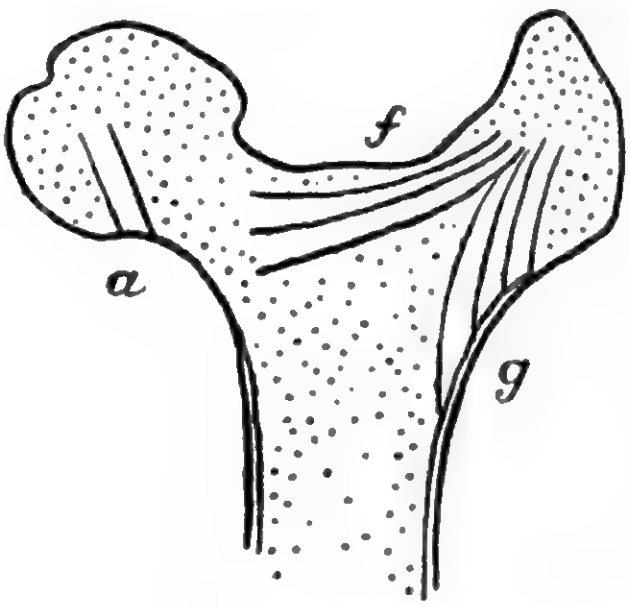

Fig. 16. Beaver.

Monk-Seal. As in the beaver, there is a large amount of cancellous tissue, although the lamellae are not so closely packed. As the seal does not support itself upon its hind-limbs at all, but only uses them as a rudder, a very strong femur is not a necessity. Consequently, the cancellous tissue is not very closely packed. Groups *f* and *g* converge towards one another at an angle of about 90°. (In fig. 17 this angle is represented as being greater than it actually is.) Groups *a* and *b* can just be recognised. The great trochanter rises to about the level of the upper surface of the head of the bone.

Northern Sea-Bear. This creature is one of the eared seals. The femur exhibits a large amount of cancellous tissue. The walls are thick, more especially the lateral one. This is explained by the oblique disposition of the shaft of the bone, more marked than in the case of the sheep. The bone must of necessity be stronger than that of the monk-seal, for the sea-bear supports its body on its hind-limbs, as well as using them as a rudder. The great trochanter does not reach to the level of the superior surface of the head.

Groups *f* and *g* meet one another at an angle which is slightly greater than a right angle.

Kangaroo. The great trochanter in this animal is exceedingly prominent, being exaggerated by the flattening of the superior surface of the head. Group *f* converges towards group *g* at an angle of about 70°. The flattening of the head of the bone is probably partly due to the jumping habits of the animal combined with its great weight. Towards the end of a leap, when the hind-limbs reach the ground, the body is carried forwards for an instant by its own momentum until it is stopped, partially at any rate, by the impact of the acetabulum on the head of the femur. The Great Grey Kangaroo weighs about 14 stone, while the length of the head and body is only 5 ft. 3 ins.(9), consequently the impact between the acetabulum and the head of the bone must be very great. This probably accounts for the flattening of the head. Group *a* is fairly well developed in order to resist this tendency to flattening. The upper surface of the head of the bone is provided with a thick cap of compact bone. This is presumably protective and caused by hypertrophy of the compact bone due to the severe intermittent pressures to which this part of the bone is subject.

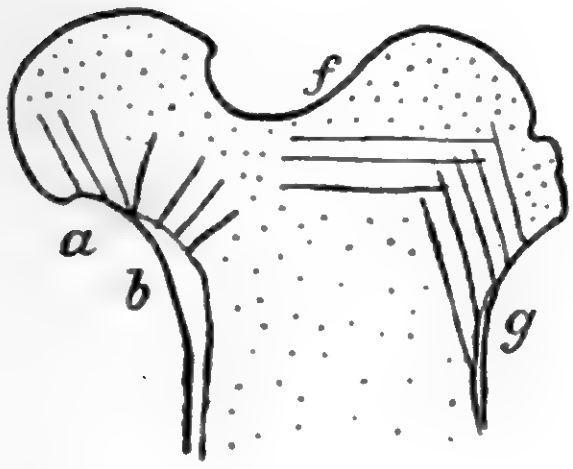

Fig. 17. Monk-Seal.

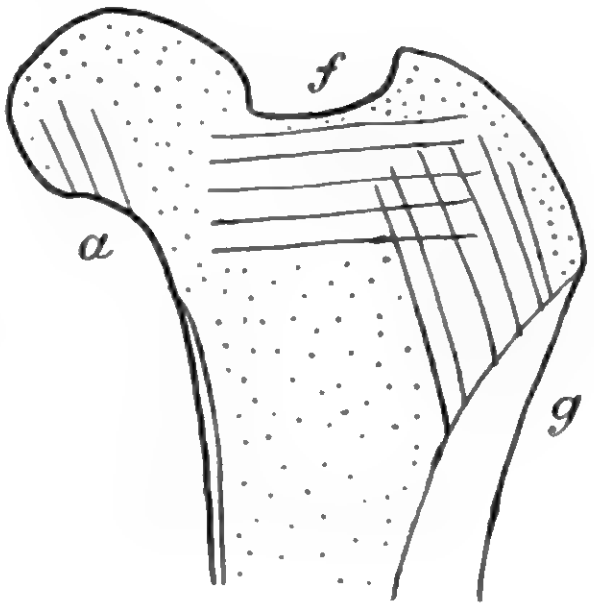

Fig. 18. Sea-Bear.

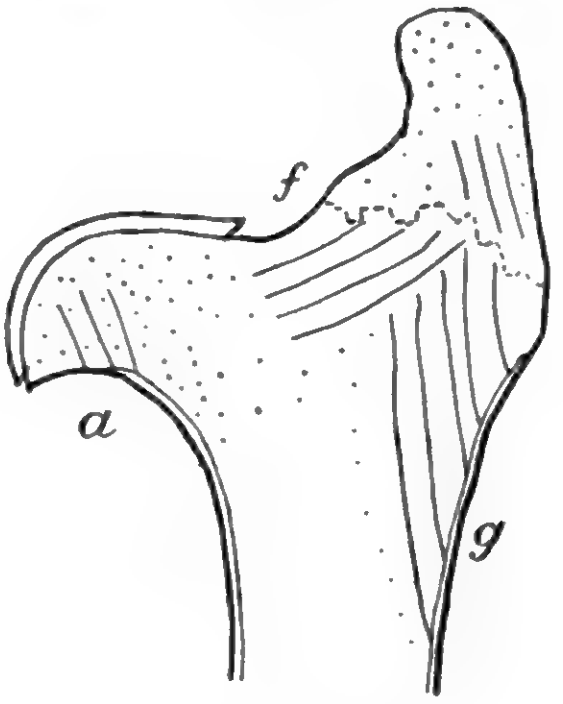

Fig. 19. Kangaroo.

SUMMARY

The facts given in this paper would suggest that there is a definite correlation between the habits of the animal and the structure of the upper end of the femur.

The characteristics of the upper end of the femur in association with the habits can be summarised as follows:

(*a*) If the upper limit of the great trochanter is above the level of the upper surface of the head of the femur, the animal is able to jump or leap, or to perform similar movements, such as rising rapidly from the sitting posture, as exemplified by the horse. The use of the hind-limbs for swimming is also apparently associated with a high great trochanter.

(*b*) Flattening of the superior surface of the head of the bone appears to be associated with the receiving of relatively great stresses on this surface.

(*c*) The thickness of the walls of the femur depends upon at least two, and perhaps three, factors, namely, (1) the amount of cancellous tissue present, this varying inversely as the thickness of the walls; (2) the intensity of the stresses and strains acting on, and through, the femur; and possibly (3) the histological structure of the bone, for Foote has shown that the histology of the femur varies with the race and species of the animal (2).

(*d*) The quantity of cancellous tissue varies directly with the relative weight of the animal. Therefore the lighter animals tend to have little cancellous tissue and thick walls. The quantity of cancellous tissue may be associated with the histological character of the bone.

(*e*) Groups of lamellae are well-marked if the stresses and strains borne by the groups are large.

(*f*) The two groups of lamellae *f* and *g* are not found in the human femur, but when present in a femur of one of the lower animals would appear to indicate the use of the hind-limb for the purpose of swimming, leaping or similar movements.

In conclusion, I feel I must thank most sincerely all who have assisted in the preparation of this article. In particular I must thank Professor E. Barclay-Smith and Dr R. J. Gladstone of King's College, London for their invaluable advice and help. I also wish to thank all those who so kindly supplied me with material, especially Mr W. P. Pycraft and Dr A. Smith-Woodward of the British Museum (Natural History), also Professor Shave of the Royal College of Veterinary Surgeons, Sir Charlton Briscoe, M.D., of King's College Hospital, and Dr G. W. Robinson.

REFERENCES

(1) FLOWER, W. H. (1885). *Osteology of the Mammalia*, p. 336.
(2) FOOTE (1916). "A contribution to the comparative histology of the femur." *Smithsonian Contributions to Knowledge*, 35, No. 3.
(3) GRANDIDIER (1894). Quoted in LYDEKKER, *Royal Natural History*, 1, p. 207.
(4) JANSEN, M. (1920). *On Boneformation*, p. 107.
(5) KOCH. *Amer. Journ. Anat.* 21, No. 2.
(6) LYDEKKER, R. (1894). *Royal Natural History*, 2, p. 12.
(7) —— *Ibid.* 3, pp. 96–100.
(8) —— *Ibid.* 3, p. 234.
(9) —— *Ibid.* 3, p. 241.
(10) —— *Encyclopaedia Britannica*, Edit. 10, 33, p. 941.
(11) MIVART, St G. 1894). *Types of Animal Life*, p. 255.

ON CERTAIN NORMAL IRREGULARITIES IN THE VERTEBRAL COLUMN IN ITS LOWER DORSAL AREA

By EDGAR F. CYRIAX, M.D. (Edin.),

London.

When a subject is lying face downwards, palpation of the spinous processes of the lower dorsal vertebrae will frequently reveal irregularities; in some cases they are even obvious to mere inspection. These irregularities, though normal in the site mentioned, would be indicative of disease or trauma if encountered elsewhere in the vertebral column; due appreciation of these facts is therefore of importance.

These irregularities seem up to the present to have escaped detection; I have never seen them depicted in diagrams or described in the text in anatomy books. They are as follows:

(1) The spinous process of D 10 is slightly shorter than those of the bones immediately above and below it; differences of $\frac{1}{8}$ inch are quite common. Thus the spinous process will apparently be depressed and will lie in front of the line joining the spinous processes of D 9 and D 11; a forward displacement of D 10 will thus be simulated. In rarer cases the above will be found in D 11 instead of D 10.

(2) The spinous process of D 10 is situated at a slightly higher level than normal as regards the body of its vertebra. Thus the space between it and the spinous process immediately above it becomes considerably reduced. A tilt of the vertebra or possibly a fracture of the spinous process with displacement upwards will thus be simulated. In rarer cases the above will be found in D 9 or D 11. This appearance of a displacement is often accentuated by the fact that the interspinous ligament uniting the spinous processes of the irregular vertebra to that of the bone immediately below it is somewhat curved (i.e. concave when viewed from behind) instead of being practically a straight line, thus simulating the ligamentous atrophy which is so common an accompaniment of vertebral displacement[1]. This ligamentous irregularity, though generally confined to the one interspinous space mentioned, may also be found in one or more of the spaces below it as far as the sacrum.

One or other of the above irregularities is found, roughly speaking, in about 20 per cent. of all subjects. The close proximity of two dorsal spinous

---

[1] Cyriax, *Journ. de chir.* xv. 472, 1919.

processes seems to be peculiar to man, but the shortness of the spinous process of D 10 (or corresponding vertebra) is also found in many mammals, though not to the same extent. Thus in the galleries of the South Kensington Museum, I found it in the following:

Great cave bear (France)	as regards	D 11
Cervus giganteus	,,	D 12
Brindled gnu	,,	D 12
Okapi	,,	D 10
Clouded leopard	,,	D 11
African rhinoceros	,,	D 15
St Simon (thoroughbred stallion)	,,	D 13

THE MYODOME AND THE TRIGEMINO-FACIALIS CHAMBER IN THE COELACANTHIDAE, RHIZODONTIDAE AND PALAEONISCIDAE

By EDWARD PHELPS ALLIS, Jr.,
Menton, France.

In a recent and excellent work on the *Triassic Fishes from Spitzbergen,* Stensiö (1921) describes what he considers to be the myodome and the trigemino-facialis chamber in certain of the Coelacanthidae and Palaeoniscidae, but his identification of these structures seems to me to be in certain respects incorrect. To properly present my views, the palatoquadrate of these early fishes, as described in the few works I have at my disposal, must first be considered.

Huxley, in 1866, described, in certain of the Coelacanthidae, a great triangular plate of bone which he considered to represent the hyomandibula, quadrate and pterygoid, and he called it the pterygo-suspensorium. The hyomandibula was considered to form the dorsal portion of the somewhat thickened posterior border of the bone, this portion projecting dorsally above the remainder of the bone and having a wide dorsal edge which is said to articulate with a superior process of the prootic, and also with "the roof of the skull." In Macropoma, a process which arises either from the opisthotic or parasphenoid is said to be directed outward from near the base of the skull, and to end "in a free obtuse surface against which the middle of the hyomandibular suspensorium abuts." This process, and a vertical ridge-like process that arises from it, together look so much like the ascending process of the parasphenoid of Polypterus that, in an earlier work (Allis, 1919 *c*), I came to the conclusion that it must represent that process, the trigemino-facialis chamber then lying directly above it, in a depression between it and the dorsal end of the superior process of the prootic of Huxley's descriptions. This conclusion must, however, be wrong, for Stensiö says (1921, p. 62) that the parasphenoid is without ascending processes in all of the Coelacanthidae.

Reis (1888–9), in referring to Huxley's descriptions of these fishes, says that the inclusion of the hyomandibula in the so-called pterygo-suspensorium has been a much contested point, and he himself concludes (*l.c.* p. 18) that that element forms no part of the latter bone. He calls the suspensorium the pterygoid and considers the thickened posterior portion to represent the dorsal half of the mandibular arch, the anteriorly projecting, plate-like portion of the bone having been formed by the fusion with it of dermal, tooth-bearing plates similar to those found in the branchial arches of many fishes. In *Libys* *polypterus*, the dorsal end of the thickened hind edge of the bone is shown (*l.c.* Pl. III, fig. 1) apparently articulating with the lateral edge of the posterior portion of the frontal, but in *Macropoma speciosum* it is said to articulate with a dorsal process of the prootic, as Huxley had previously stated to be the case for *Macropoma mantelli.* The dorso-mesial edge of the anterior, plate-like part of the pterygoid is shown, in one of the figures given, articulating with the lateral edge of the parasphenoid. Posterior to the pterygoid, and articulating with the so-called postfrontal and squamosal bones, Reis finds (*l.c.* p. 41) what he considers to be a hyomandibula. There is said to be no epihyal, the ceratohyal being bound to the hyomandibula by ligament, as it is also said by Reis to be in the Sirenidae.

Stensiö, in the work referred to in the opening paragraph of this article, calls the pterygo-suspensorium the palatoquadrate, and says that it contains four independent ossifications, a large dermal one which lies on the internal surface of the apparatus, and three substituent ones which lie external to the dermal one. The dermal ossification he calls the pterygoid and the three substituent ones the quadrate, metapterygoid and palatine. The quadrate and metapterygoid are said to have been quite certainly connected by cartilage, and the metapterygoid is said to articulate, by its dorsal edge, with what Stensiö calls the basipterygoid process of a median basisphenoid bone, this latter bone being the paired prootics of Huxley's and Reis' descriptions. In *Wimania sinuosa* this so-called basipterygoid process apparently extends so far dorsally that it comes into contact with the dermosphenotic portion of the fronto-dermosphenotic bone, and also closely approaches, if it does not actually reach, the lateral edge of what would seem to be a piscine parieto-pterotic, but is called by Stensiö the parieto-intertemporal. This process of Wimania thus has approximately the position that the corresponding process has in Huxley's figures of Macropoma, but in *Axelia robusta* it is said by Stensiö to extend much less far dorsally.

In *Rhizodopsis sauroides*, Watson and Day (1916) find the "pterygoidal element" articulating, in its orbital portion, with the lateral edge of the parasphenoid, while the vertical posterior portion of the bone "rises to the top of the skull, so as nearly or quite to come into contact with the cranial roof." A quite large hyomandibula is found, and Watson and Day say that it "seems to be extremely feebly ossified, the bone forming a mere skin." It articulates with the otic region of the chondrocranium, near its dorsal edge, and is pierced, just below its head, by a foramen. Traquair (1881) also describes a hyomandibula in this same fish.

From the above references to descriptions of these fossil Crossopterygii, it is evident that the so-called pterygo-suspensorium is simply a palatoquadrate, for both in Libys and Rhizodopsis a hyomandibula has been found lying posterior to it and wholly independent of it. The palatoquadrate of these fishes differs, however, from that in any other known Teleostome in one very important respect, for in addition to having articulation with the lateral edge of the parasphenoid, it has a posterior and important one with a part of the lateral surface of the neurocranium that would seem to correspond to the postorbital process of recent fishes, notwithstanding that Stensiö says (*l.c.* p. 140) that a real postorbital process is absent in these fishes. This postorbital articulation is considered by Stensiö to be a basipterygoid one, and it is said (*l.c.* p. 126) to be a very old formation, and doubtless a character common to all of the Crossopterygii (*l.c.* p. 71). It is said (*l.c.* p. 71) to correspond essentially to the palatobasal articulation of the Selachii, and each of these articulations is said to probably represent the primary articulation of the mandibular arch with the neurocranium. My work leads me to quite different conclusions, and the relations of the nervus trigeminus and the vena jugularis to the dorsal process of the palatoquadrate and to the so-called basipterygoid process are important in this connection, those of the vena jugularis in particular.

According to Stensiö (*l.c.* pp. 58–60) the ramus ophthalmicus profundus probably issued from the cranial cavity through a canal that traverses the dorsal portion of an anterior process on either side of the median bone that he considers to be a basisphenoid. This anterior process forms the lateral boundary of the fossa hypophyseos, and the external opening of the profundus canal lies ventral to the dorsal end of the basipterygoid process of the basisphenoid, and unquestionably ventral also to the surface of articulation, with that process, of the so-called palatobasal process of the palatoquadrate. The nervi trigeminus and ophthalmicus lateralis are said to issue through an incisure at the base of the posterior edge of the basipterygoid process, and the rami maxillaris and mandibularis trigemini to have presumably passed outward behind that process, or over its posterior part, in a lateral direction. The ophthalmicus lateralis is said to have run forward over the process, close to the lateral wall of the brain case, and the vena jugularis to have had a similar course. This course for the vena jugularis seems wholly improbable for several reasons: first, such an extremely dorsal course would be most exceptional for this vein; second, there is practically no room for its passage dorsal to the basipterygoid process in either Wimania or Macropoma, the dorsal end of the process being, in each of these fishes, practically in contact with the dermal bones of the roof of the skull; and third, as the hyomandibula is evidently of the teleostoman type, the vein must have passed internal to it (Allis, 1915), and to have reached that position after passing dorsal to the so-called basipterygoid process, and hence morphologically external to the articulating process of the palatoquadrate, would require a course so devious and indirect that it is wholly improbable. The vein must accordingly have had a more ventral course and have passed internal to the process of the palatoquadrate. The latter process could not then be a palatobasal one, and if it has its homologue in any process of the palatoquadrate of recent fishes, that process must be either the otic process of the Dipneusti, or the processus muscularis of the Selachii, Holostei and Teleostei; and the wide distribution of the latter process, together with the facts that the process of the Coelacanthidae ossifies as a piscine metapterygoid bone, as it does in the Holostei and Teleostei, and that it articulates with the cranium in the postorbital region, as in the Notidanidae, instead of fusing with it, as in the Dipneusti, all indicate that it is a processus muscularis, a process frequently, but wrongly, called the otic process. The trigeminus nerves would then all run forward internal to this process instead of outward posterior to it, as Stensiö suggests (*l.c.* p. 70), and this is in accord both with the position of the ophthalmicus profundus as shown by Stensiö himself, and with Huxley's statement that the foramina of the trigeminus nerves lie on either side of the root of his so-called superior process of the prootic, which is Stensiö's basipterygoid process of the basisphenoid. Some part of the space between this process and the cranial wall would then represent either the entire trigemino-facialis chamber, or, as in the Notidanidae, the pars jugularis only, the pars ganglionaris being represented in a recess or cavity in the cranial wall.

In the Palaeoniscidae the conditions are quite different from those above described in the Coelacanthidae and Rhizodontidae. In these fishes the processus muscularis of the palatoquadrate, if present, does not articulate with the neurocranium, and the parasphenoid has ascending processes. In *Birgeria mougeoti* there is, on either side, at the base of the hind edge of the latter process, between it and the lateral edge of the body of the bone, a large foramen which Stensiö (1921, pp. 176–9) says is the posterior opening of a canal which transmits the nervus facialis. He says that it must still be considered an open question whether the root of this nerve, as it issued from the cranial cavity, accompanied the trigeminus roots and so entered the posterior end of a postorbital cavity, described immediately below, or pierced the cranial wall posterior to that cavity; the latter assumption conclusively showing that Stensiö did not consider the canalis facialis and postorbital cavity to be necessarily continuous with each other, or to be primarily in any way related. The postorbital cavity is paired, and is said to presumably correspond to a great extent both to the trigemino-facialis chamber and the myodome of recent fishes, the former chamber lying dorso-lateral to the myodome and the two probably being separated by either membrane or cartilage. The mesial wall of the trigemino-facialis part of the cavity is said to probably correspond to the mesial wall of the pars jugularis of my descriptions of this chamber in the Teleostei, the ascending process of the parasphenoid accordingly forming the external wall of that part of the chamber. The myodome part of the cavity is said to presumably represent a small part only of the dorsal compartment of my descriptions of the myodome of the Teleostei, and it is said to have been invaded not only by the musculus rectus externus, but also more or less by the three other recti muscles. The posterior portion of this so-called myodome forms a longitudinal groove on the posterior portion of the ventro-lateral surface of a sphenoid bone which resembles that of Polypterus but extends somewhat farther posteriorly. The grooves of opposite sides are separated from each other by what Stensiö calls the parachordal portion of the sphenoid bone, and the anterior ends of the grooves are connected by a cross-canal which traverses the postero-ventral end of the pituitary fossa and is called by Stensiö the canalis transversus. A longitudinal slit in the roof of the groove is said to have probably given passage to the nervus abducens (*l.c.* p. 170). This groove, or so-called myodome, is said (*l.c.* p. 166) to have been closed posteriorly partly by the parachordal plate and partly by cartilage that forms the anterior portion of the labyrinth region. No connection whatever with the canalis facialis is suggested. The widely separated myodomic cavities of opposite sides are assumed to have gradually approached each other and finally fused to form the median myodome of modern fishes, the conditions in the Palaeoniscidae thus representing a very primitive phylogenetic condition.

With these interpretations of the conditions in these fishes, so fully and excellently described by Stensiö, my work leads me to disagree, and here, as with the Crossopterygii, it is the course of the vena jugularis that is of prime importance. According to Stensiö (*l.c.* p. 178), this vein, running posteriorly, probably entered the anterior end of the so-called myodomic part of the postorbital cavity, but soon turned upward into the trigemino-facialis part, the latter part of the cavity lying between the ascending process of the parasphenoid and the lateral wall of the sphenoid and, as already stated, being considered by Stensiö to correspond to the pars jugularis of the trigemino-facialis chamber of the Teleostei. The further course of the vein is not given, but as the so-called trigemino-facialis chamber has no posterior opening, the vein must, in Stensiö's opinion, either have run posteriorly external to the ascending process of the parasphenoid, or have entered the cranial cavity through the foramen trigeminum. The latter one of these two assumptions seems wholly improbable; and if the vein passed external to the ascending process, the latter process would necessarily be similar to that in Cottus and Amiurus and would correspond to the inner wall of the pars jugularis of the trigemino-facialis chamber of other fishes (Allis, 1909, 1919 *a*), instead of to its external wall, which is in itself improbable and is furthermore contrary to the homology proposed by Stensiö himself. The vein must accordingly have passed internal to the ascending process, and this assumption is confirmed by a comparison with the conditions in Polyodon, a fish much more closely related to the Palaeoniscidae than either Cottus or Amiurus. In Polyodon the vena jugularis (Allis, 1911, p. 291) traverses a canal in the cranial wall that Bridge (1879) described as the facial canal. The nervus facialis issues from the posterior opening of this canal, accompanied by the vena jugularis, and before entering the canal the latter vein receives a branch from the pituitary body. The ganglion of the nervus trigeminus lies largely within the cranial cavity, and the several branches of the nerve pierce the cranial wall slightly anterior to the anterior opening of the facial canal. These conditions in this fish thus so closely resemble those described by Stensiö in Birgeria that it seems practically certain that the so-called myodomic groove, or fossa, of the latter fish is simply a part of a jugular canal similar to the facialis canal of Polyodon. The conditions in the two fishes are then strictly comparable, the so-called myodome of Birgeria becomes the canalis facialis of Polyodon, and there is no functional myodome in either of these fishes.

LITERATURE CITED

ALLIS, E. P. Jr. (1909). "The Cranial Anatomy of the Mail-cheeked Fishes." *Zoologica*, Bd. 22. Stuttgart.

—— (1911). "The Pseudobranchial and Carotid Arteries in *Polyodon spathula*." *Anat. Anz.* Bd. 39. Jena.

—— (1915). "The Homologies of the Hyomandibula of the Gnathostome Fishes." *Journ. Morphol.* vol. 26. Philadelphia.

—— (1918). "On the Origin of the Hyomandibula of the Teleostomi." *Anat. Rec.* vol. 15. Philadelphia.

—— (1919 *a*). "The Myodome and Trigemino-facialis Chamber of Fishes and the corresponding Cavities in higher Vertebrates." *Journ. Morphol.* vol. 32. Philadelphia.

—— (1919 *b*). "On the Homologies of the Auditory Ossicles and the Chorda Tympani." *Journ. Anat.* vol. 53. Cambridge.

—— (1919 *c*). "The Homologies of the Maxillary and Vomer Bones of Polypterus." *Amer. Journ. Anat.* vol. 25. Philadelphia.

BRIDGE, T. W. (1879). "Osteology of *Polyodon folium*." *Phil. Trans.* vol. 169. London.

HUXLEY, T. H. (1866). "British Fossils. Illustrations of the Structure of the Crossopterygian Ganoids." *Mem. Geol. Survey of the United Kingdom.* Decade XII, Scientific Memoirs.

KINDRED, J. E. (1919). "The Skull of Amiurus." *Illinois Biological Monographs.* vol. 5.

POLLARD, H. B. (1894). "Suspension of the Jaw in Fishes." *Anat. Anz.* vol. 10. Jena.

REIS, O. M. (1888–9). "Die Coelacanthinen mit besonderer Berücksichtigung der im Weissen Jura Bayerns vorkommenden Arten." *Palaeontografica.* Bd. 35. Stuttgart.

STENSIÖ, ERIK A:SON (1921). *Triassic Fishes from Spitzbergen.* Vienna.

TRAQUAIR, R. H. (1881). "On the Cranial Osteology of Rhizodopsis." *Trans. Roy. Soc.* vol. 30. Edinburgh.

WATSON D. M. S. and DAY, H. (1916). "Notes on some Paleozoic Fishes." *Mem. and Proc. Manchester Lit. and Phil. Soc.* Session 1915–16.

A HUMAN FOETUS EXHIBITING INIENCEPHALY AND OTHER ABNORMALITIES

By WILLIAM IVON HAYES, M.B. (Melbourne),
Trinity College, Dublin.

Through the kindness of the Master of the Rotunda Hospital, Dublin, I was permitted to examine the unusual foetus here described. I am unable to find any previous record of a similar foetus having occurred in the practice of the hospital, and certainly none such has been seen there within the last ten years.

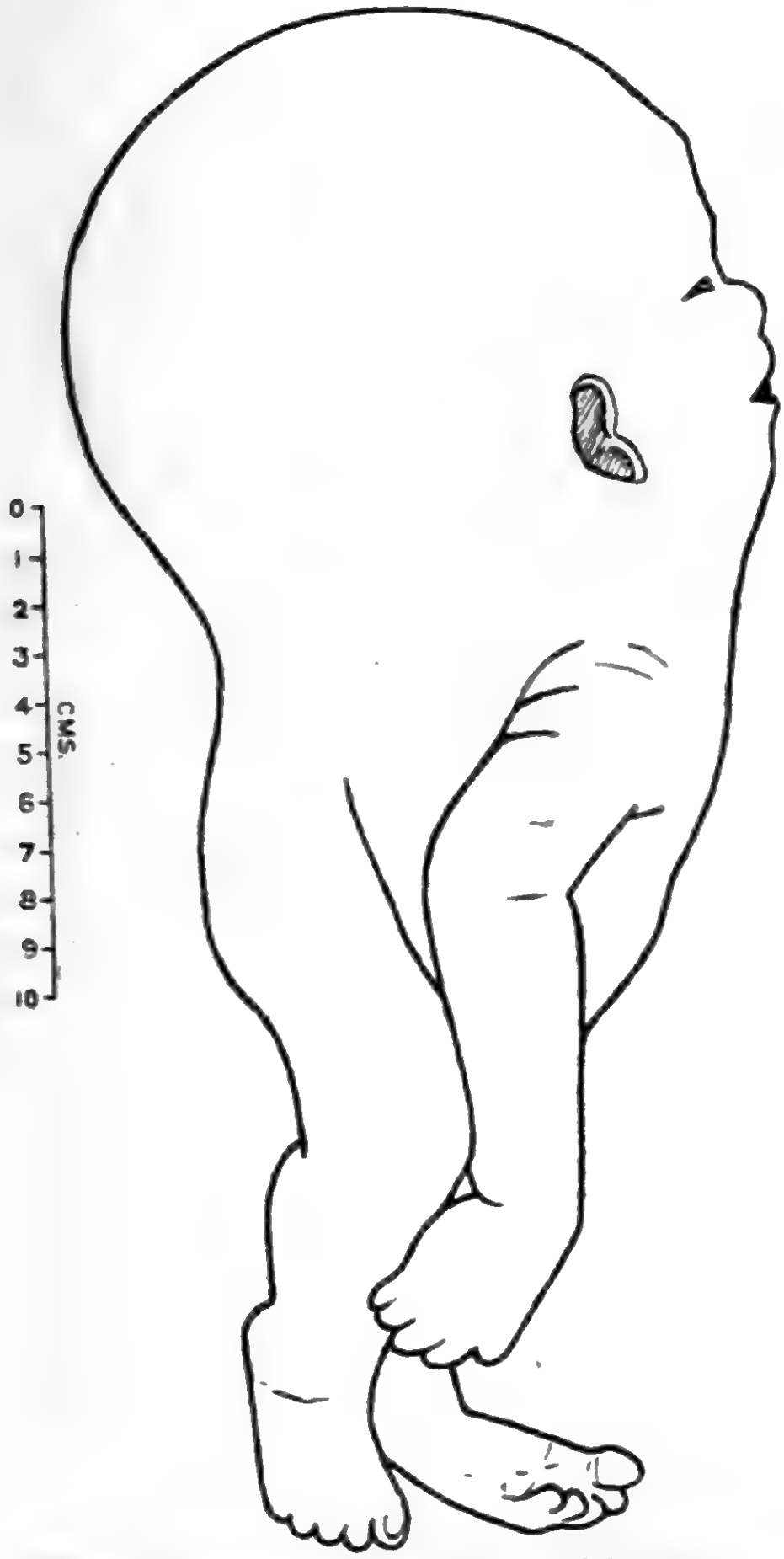

Fig. 1. Camera lucida drawing of foetus, from right side.

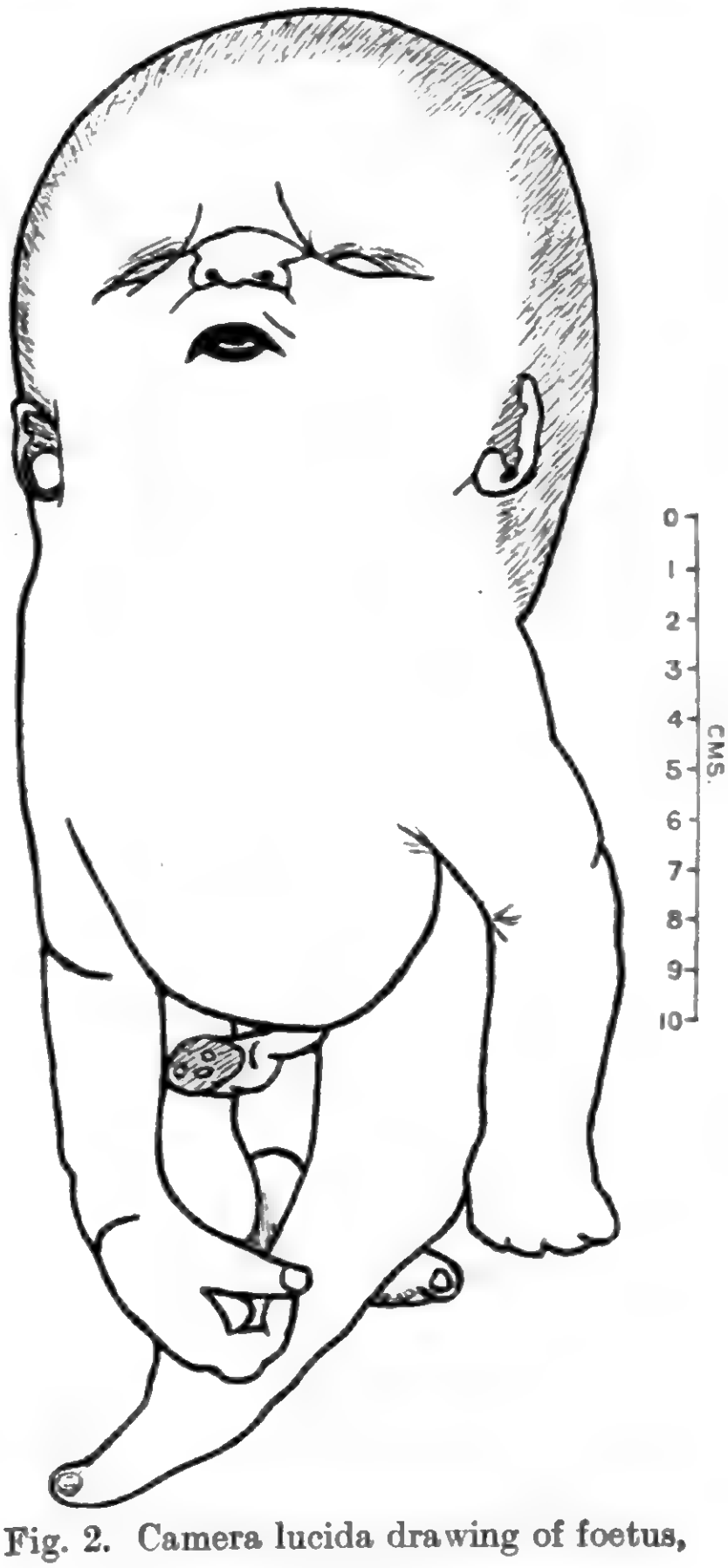

Fig. 2. Camera lucida drawing of foetus, from front.

The foetus is full time. The hair is about half an inch long on the head, the nails project just beyond the finger tips and unusually large centres of ossification are present at the lower end of the femur, and the upper end of the tibia.

The head is slightly enlarged, measuring 38 cms. in greatest circumference, and the face looks slightly upwards. Owing to the increase in size of the vault of the skull, the ears, which are both somewhat deformed, seem to be set more anteriorly than normal. The head is imperfectly separated from the body by an ill-defined neck, so that the contour of the head is almost directly continuous with that of the body. The abdomen is protuberant, with the umbilicus looking downwards, while the back, between the occiput and the nates, is greatly decreased in length. The combined length of the head and body is 23 cms., while the length of the entire foetus measures 38 cms. There is no external sign of any protrusion of the contents of the spinal canal, and the integument of the occiput passes uninterruptedly down over the back and sacrum. Owing to the shortness of the back, the lower limbs are attached dorsally, while the arms are attached ventrally and only slightly above them, so that the fingers reach down almost to the feet.

On mesial sagittal section, it is at once seen that the deformity is due to malformation of the cranio-vertebral axis, which is much shortened, and forms practically a straight line from the nasal septum to the sacrum. The viscera are consequently pushed downwards and forwards. On the left side a pseudo-hernia is present, part of the liver and some intestines passing through the diaphragm into the left pleural cavity, where they lie lateral to the left lung. The herniated viscera are not enclosed in a peritoneal hernial sac. Owing to the presence of this hernia, the pericardium and the heart lie wholly on the right side of the medial plane. The various viscera appear normal. The thymus is almost spherical and is placed in the neck just above the sternum. The internal genitals, which are female, are well developed. The suprarenals and the pituitary were both examined microscopically, and were found to be normal.

The cranio-vertebral axis, passing from the anterior end of the nasal septum to the last piece of the sacrum measures 16 cms. and forms practically a straight line, except for a short anterior convexity at about its middle. At its cephalic end can be distinguished the mesethmoid, presphenoid, basi-sphenoid, basi-occipital, and the cartilaginous anterior arch of the first cervical vertebra. More caudally, in the region of the anterior convexity, there is a mass, in which there are a number of irregular malformed centres of ossification. Here the different vertebrae are indistinguishable. Following this irregular mass, may be seen a number of well formed vertebræ, and the 11th thoracic to the 5th sacral may be distinguished. The 5th lumbar vertebra is partly fused with the first sacral. The reduction in length of the vertebral column is thus due to an irregular fusion, or, more correctly, a failure in separation of the cervical and thoracic vertebrae. The vertebral neural arches are all deficient, none of them uniting posterior to the spinal cord.

The foramen magnum is of large size, measuring 6 cms. antero-posteriorly. It is formed in front by the basi-occipital, and laterally by the ex-occipitals, to which are united the neural arches of the fused vertebrae. Posteriorly the foramen is completed by the supra-occipitals, which are united behind the spinal cord, opposite the 4th lumbar vertebra. Caudal to this, the remainder of the vertebral canal is covered by the meninges and integument alone. The

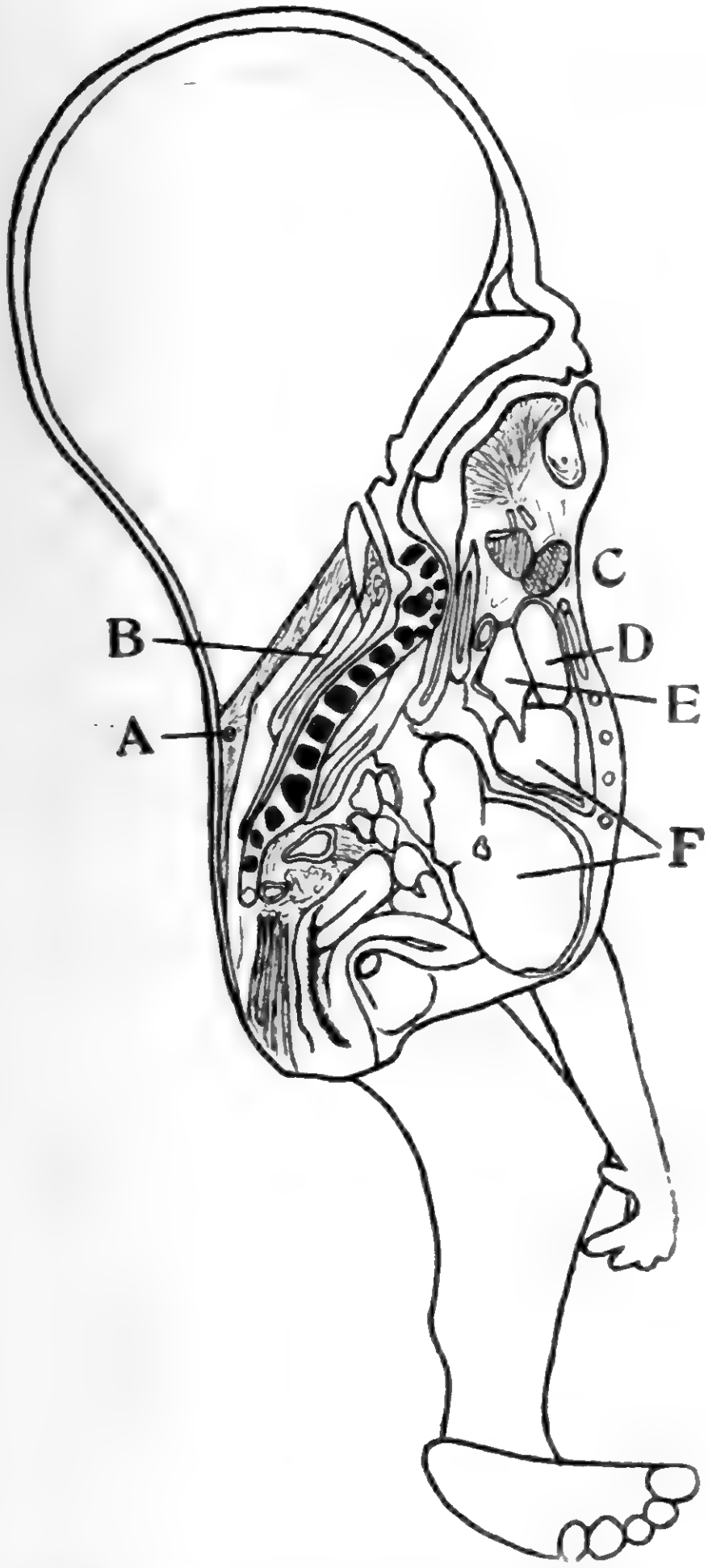

Fig. 3. Median section showing left side.
A, supra-occipital; B, spinal cord; C, thymus; D, intestine; E, lung; F, liver.

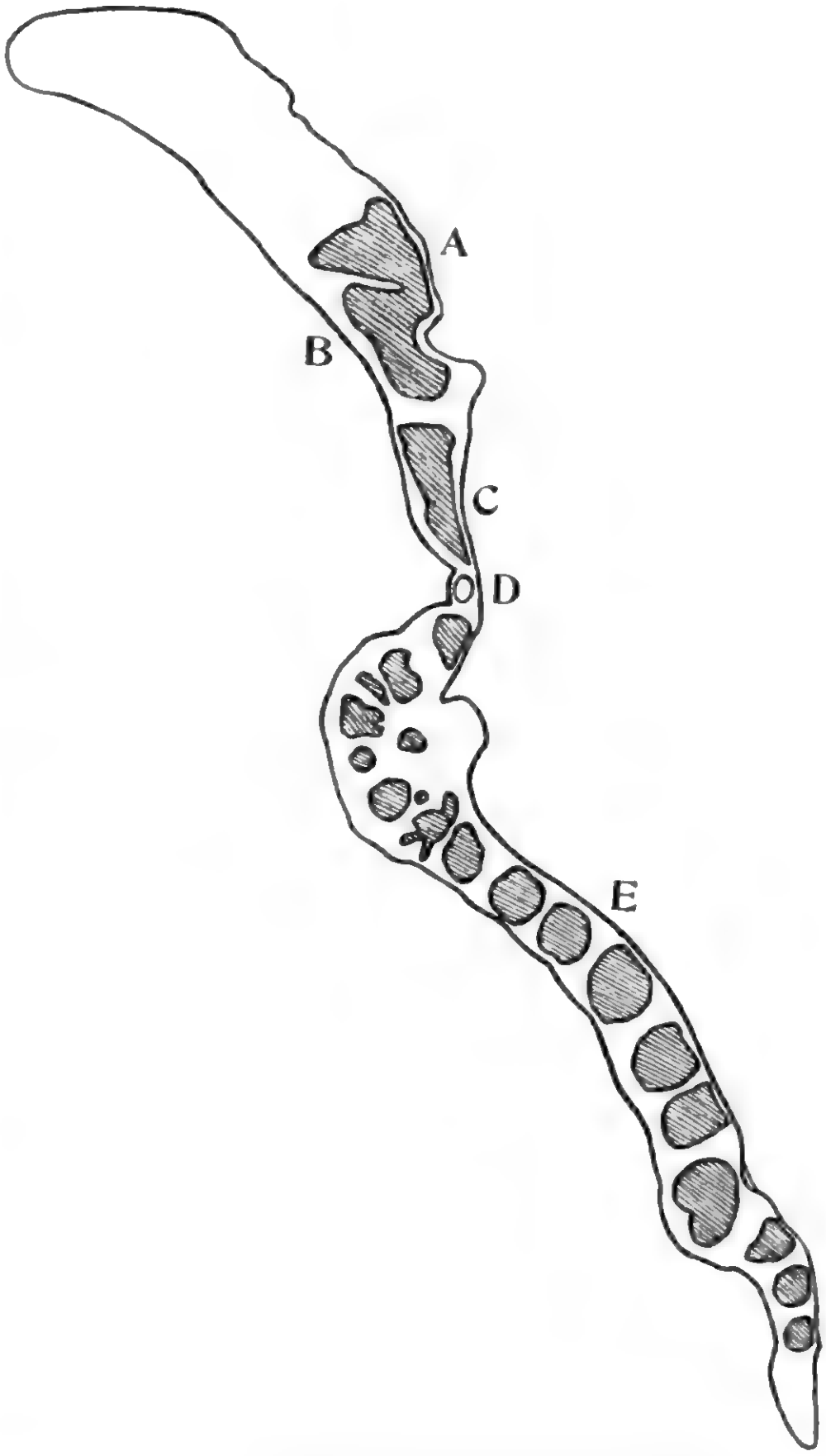

Fig. 4. Section of Cranio-vertebral Axis, from left side.
A, presphenoid; B, basi-sphenoid; C, basi-occipital; D, anterior arch of atlas; E, first lumbar vertebra.

Owing to the section not being exactly mesial, the centre of ossification of the 5th sacral vertebra is not seen.

inter-parietal part of the occipital bone is unossified, but the other membrane bones of the skull are well developed.

The ribs, which are eleven in number on each side, are, in their dorsal parts, fused to one another, and to the vertebrae from which they arise.

The central nervous system was much injured during delivery. There is a mass of nervous tissue, representing the pons and cerebellum, beneath the tentorium cerebelli. Its different parts cannot, however, be distinguished. From this mass a spinal cord runs downwards to the level of the third sacral vertebra.

The cranial nerves are normal, in number and plan. All the spinal nerves are present, and the great plexuses are normal in their constituents and mode of formation, except that the lowest trunk of the brachial plexus is formed by the union of the division of the 8th cervical nerve, the whole of the first thoracic and the greater part of the second thoracic nerves. The remainder of the 2nd thoracic nerve formed the nerve of the first intercostal space, and the succeeding thoracic nerves are each anteposed one space, the 12th thoracic nerve lying below the last, or 11th, rib.

The musculature appeared normal, but the dorsal muscles are very thin.

The more interesting points of the specimen are:

1. The absence of the neck.
2. The condition of hydrocephalus.
3. The deformity of the vertebral column.
4. The unclosed vertebral neural arches.
5. The large size and the formation of the foramen magnum.
6. The diaphragmatic hernia.

Following the classification of Ballantyne (1), the above points would lead us to place the monster in the class, iniencephaly. The cardinal characteristics of this type, are a backward bending of the vertebral column with a varying degree of spina bifida, and imperfect formation of the occiput in the region of the foramen magnum. In most cases it is usual to meet with an occipital encephalocele, or a spina bifida with a protrusion of the spinal meninges. Schwalbe (2) would classify the condition under the term Rachischisis. He finds that it is very rare to have all the vertebral neural arches ununited, and that the commoner type is accompanied by a cleavage of the occipital region of the skull. Schwalbe also lays stress on the very interesting feature of the ex-occipitals being fused with the vertebrae. The foetus under examination exhibits this latter condition very well, and also has the rarity of a complete vertebral cleavage with an uncleft occiput. Wheeler (3) describes in detail a most interesting iniencephalic foetus, but her case appears to be of the more common type, and presents a well marked encephalocele.

The condition of iniencephaly is uncommon, nevertheless, Ballantyne had met with seven cases up to the year 1904. The sex is apparently usually female (4).

The etiology is not quite clear. The malformation of the spine is apparently the primary condition, and the closure of the vertebral arches appears to be prevented by the dorsal displacement of the occiput. The absence of the neck is directly due to the shortening of the spinal column, and the diaphragmatic hernia probably results from the same cause. The malformation of the spine may be due, either to the pressure of the amniotic fluid, or where that is deficient, to the pressure of the uterus itself. More probably it is due to a malformation of the foetus, and not the result of external pressure.

Quite recently Stockard (5), by experimental methods, has shown that most monsters are caused by arrests in development. If we assume that iniencephaly is also due to an arrest, we must look for an embryonic stage in which there is a dorsal concavity of the vertebral axis. Such a stage is represented by His' embryo 3·2 mm., aged about 3 weeks. Inasmuch as embryos with this dorsal thoracic concavity are themselves regarded as abnormal, we can readily understand that, if iniencephaly is the result of an arrest in this stage, it must of necessity occur but rarely.

REFERENCES

(1) **Ballantyne**, J. W. *Antenatal Pathology and Hygiene.*

(2) **Schwalbe.** *Die Morphologie der Missbildungen des Menschen und der Tiere* (III. Teil, 1. Lieferung, 1909).

(3) **Wheeler, Theodora.** "Study of a human spina bifida monster with Encephaloceles and other abnormalities." Contributions to Embryology, No. 22. *Public. Carnegie Instit. Wash.* 227, pp. 87–110.

(4) **Lewis**, H. F. *Amer. Journ. Obstet.* XXXV, 11, 1897.

(5) **Stockard, Charles.** "Developmental and Structural Expression, etc." *Amer. Journ. Anat.* vol. 28, No. 2. Jan. 1921.

REVIEWS

Studies in the Palaeopathology of Egypt. By Sir MARC ARMAND RUFFER, C.M.G., M.D., Late President of the Quarantine Council of Egypt. Edited by ROY L. MOODIE, PH.D., Associate Professor of Anatomy in the University of Illinois. pp. 372. Plates LXXI. (Chicago University Press.)

This stately volume contains studies by the late Sir Marc A. Ruffer on the diseases of historic and prehistoric peoples—a branch of medical knowledge to which he gave the name of Palaeopathology. In an introductory note to the eighteenth study or paper of the series contained in this volume, Lady Ruffer writes as follows: "When starting in December, 1916, on a mission which was evidently attended by dangers and which finally proved fatal to my husband, he left with me instructions as to the various unfinished papers at which he and I had worked together."

To say that a voyage across the Mediterranean from Egypt to Salonika in the winter 1916–1917 was attended with "dangers" is an inadequate expression of the murderous success which then attended the submarine campaign. Ruffer, having given his medical aid in Salonika was torpedoed on his way back to Egypt and gave his own life to save that of a fellow passenger. He was then 57 years of age, 20 of which he had spent in Egypt as pathologist and as President of the Sanitary Council. He was one of the first British pupils of Pasteur and Metchnikoff. He was a master of microscopical technique which he applied to the investigation of the tissues and diseases of ancient Egyptians. These studies occupied intervals stolen from his official duties.

The papers deal with the histology of Egyptian mummies; a case of spinal caries of 1000 B.C., the detection of *Bilharzia haematobia* in mummified kidneys, arterial lesions, skin eruption resembling variola, dwarfs and deformed persons found in ancient tombs or records. The chief papers deal with chronic arthritis and diseases of the teeth and jaws.

This memorial volume has many interests for anatomists for the examination of ancient human remains usually falls to their province. Sir Marc A. Ruffer, almost in every page, acknowledges his indebtedness to Professor Elliot Smith and Professor Wood Jones, who made the *Reports of the Archaeological Survey of Nubia* a mine of wealth for pathologists as well as for anthropologists and anatomists for many years to come. Further, the volume has been ably edited by an anatomist, Professor Roy L. Moodie. The volume forms a fitting remembrance of a handsome, gallant, engaging and gifted personality.

New German Text-book of Human Anatomy.

Anatomie des Menschen: ein Lehrbuch für Studierende und Ärzte. Von Hermann Braus, Professor an der Universität, Direktor der Anatomie, Heidelberg. Erster Band, Bewegungsapparat. pp. 835. Figs. 400 (mostly in colour). (Berlin, Julius Springer.) 1921. Price not stated.

The appearance of this work is evidence that a revolution is taking place in the outlook of teachers of human anatomy in Germany. Its prototype is to be sought for in the *Handbuch der Topographischen Anatomie* of Professor Merkel rather than in the great *Handbuch der Anatomie des Menschen* edited by the late Professor Karl von Bardeleben. In its conception, execution and arrangement, this new work differs from both of these. Merkel and Bardeleben, in their several ways, designed their books to serve as encyclopaedias to meet the needs of professional anatomists; for the progress of anatomy the publication of such books is absolutely essential. These great modern text-books are framed on too large a scale for the education of young men who are to spend their lives in studying the living human body in health and its treatment in disease. Dr Braus, the Professor of Anatomy in the University of Heidelberg, regards the needs of the medical student and practitioner as identical and has framed his text-book to meet their common needs. Instead of displaying the human body to the student in topographical regions or in structural systems he seeks to present it as a working whole. He has brought to bear in his presentation all modern sources of knowledge; well modelled drawings and photographs of the living body, and of its various parts in action, help the student to translate his dead dissections into live anatomy; he has drawn freely on radiology to illustrate his text. Comparative anatomy and embryology are made to illuminate the origin and nature of structural arrangements. Microscopical anatomy is interwoven with descriptive anatomy. The illustrations are numerous and of high finish. Above all, form is studied to throw light on function; his chief aim is to emphasise the use rather than the form of parts.

Alas! the book has no index; only an elaborate table of contents. The opening chapter gives an account of the size, form of the body and of the structural elements which make up its component parts. The author then passes on to consider the structure and origin of the tissues concerned in the movements of the body. The vertebral column and its muscles are the first regional parts to be dealt with; the musculature of the trunk is treated as a whole which is as it should be, for in their action the various muscles of the trunk make a single complex. A description of the origin, form and mechanism of the skeletal parts and muscles of the limbs and of the head complete the present volume.

Anatomy is here presented as a single-author survey; authorities are rarely quoted; references to original papers or recent literature are seldom made; the author places before the reader what he believes, in the light of twenty years of teaching, will prove most useful in the pursuit of medicine. Although the manner in which muscles carry out the action of the body is dealt with at great length yet there is a lack of perspective in the method of treatment. When we seek to obtain a working picture from the author's text of how the vertebrae are kept balanced one upon the other in the standing or sitting posture, or of the movement of ribs and action of muscles in quiet respiration or the part played by muscles in maintaining the arch of the foot, we find it hard to come by. There is a prolixity, as well as a force, in the author's style. It is clear, too, that this text-book, when completed, will be too bulky to serve as a manual for the ordinary student of medicine.

Hereditary Disease. By HERMANN W. SIEMENS. "Einführung in die allgemeine Konstitutions- und Vererbungspathologie." pp. 229 + vii. Julius Springer. Berlin, 1921.

Professor Siemens states in the introduction to his book that his aim has been to select from the literature on the subject of Heredity those parts which have a medical interest and which bear on the problems of hereditary diseases. This he has accomplished in a work, compact and clearly written, and neither submerged in complex abstractions nor overburdened with an abstruse technical terminology.

In the first, the theoretical, part, the author deals with the broad general conceptions of the endogenous factors in disease, and defines with considerable clearness the scope of such terms as "malformations," "anomalies," "constitutional disease" and "hereditary predisposition." A short description of Mendelian principles is given, and this is followed by an analysis of the cytological bases of hereditary transmission. The chromosome theory and its corollary, the purity of the gametes in respect of their qualities as attained in maturation, are accepted, while the problems of the determination of sex are held to be solved in the heterochromosomes—full notice being given to the non-correspondence of the sex-proportion of births and the distribution of the X and Y bodies; and the author's conclusion in this respect, therefore, is, "eine willkürliche Bestimmung des Geschlechtes beim Menschen erscheint wohl für ewig unmöglich." In the second, the practical, part of the work, the usual methods of investigation are described, and an extensive critical analysis is then made of the actual findings in transmitted disease and a comparison instituted with the postulates of the Mendelian laws. This is the longest part of the book, and with full tables of an interesting group of conditions—many of them personal observations—discussed from many points of view, the close correspondence of transmitted disease, as dominants or recessives, to the theoretical requirements is established. There is an interesting inquiry into the meaning of hereditary disease, centred round the question as to whether the anlage of disease may be established through external factors, alcoholism for example, becoming influences which may act on the germ plasm and be causative of idioplasmic variation. A chapter on the possible method of control and elimination of hereditary disease, scientifically orthodox but put forward in a manner not over dogmatic, concludes the book, apart from an appendix on a tentative classification of hereditary diseases, a glossary of the biological terms used in works on Heredity, and a bibliography of the more important works on the subject.

The book forms an admirable introduction to the study of hereditary diseases, and its wide scope and the suggestive manner in which it is written should make it a distinct stimulus to further inquiry.

OBITUARY NOTICE

Dr Peter Thompson, Professor of Anatomy in the University of Birmingham, died at Penmaenmawr, after a long illness, on Nov. 16th, 1921.

Professor Peter Thompson

He studied medicine at Owens College, Manchester, and graduated, in 1894, when he was 22 years old, as M.B., Ch.B., in the Victoria University.

In the following year he was appointed junior demonstrator of Anatomy in the Victoria University and shortly afterwards became senior demonstrator and lecturer.

In 1901 he was elected to the Lectureship in Anatomy in the Medical

School of the Middlesex Hospital, London, and obtained thereby the full control of a department.

Four years later, in 1905, he became Professor of Anatomy in King's College, London, and in 1909 was transferred to his last anatomical post, the Professorship of Anatomy in the University of Birmingham.

The son of a successful Lancashire business man he inherited business capabilities which, combined with an abundant enthusiasm, account for much of his success.

As concerns Anatomy it accounts for the detailed thoroughness of his work, and for the fact that he extracted the utmost amount of information from every specimen that fell into his hands. It also accounts for his cautious estimation of the value of results and for his restrained judgment concerning the probable line of research which the results might suggest.

The influence is still more markedly illustrated by his success as a manager and organiser, not only as the head of an anatomical department, but also as an officer in the Victoria University Volunteer Corps; as Secretary, Vice-President, and President of anatomical sections of British Medical Association Meetings; as Secretary, Treasurer and Vice-President of the Anatomical Society; and as Dean of the Medical Faculty both at King's College, London, and at Birmingham.

He was essentially a social person, always anxious and glad to take part in the organisation of meetings, either for the promotion of social pleasure or for the advancement of knowledge, and the occurrence and success of many important meetings were due to his initiative, his tireless efforts and his intense energy.

He was a fluent, lucid and impressive speaker, who possessed the invaluable capability of grasping and carrying with him the interest of his audience, whilst, at the same time, he impressed upon it the importance of the subject dealt with.

His purely anatomical work was morphological and embryological.

In the earlier period, when he was at Manchester, he investigated the structure and morphology of the pelvic floor and illuminated his results with questions of medical and surgical importance.

In London he became interested in the embryological aspect of morphology and his subsequent publications were mainly descriptions and discussions of reconstructions of embryos, which threw considerable light on many phases of development previously obscure, and which brought into prominence facts not previously noted.

He was, however, much more than an anatomist, an organiser and a teacher, he was a stimulating lovable man, willing to offer and share pleasures, always ready to help, encourage and sympathise, and his death has deprived many of us not only of a pleasant colleague but also of a faithful and invaluable friend.

ARTHUR ROBINSON.

WHAT ARE VISCERA?

By C. JUDSON HERRICK,

From the Hull Laboratory of Anatomy, The University of Chicago

WORDS in commonest use are often most difficult of definition. And the projection of an inquiry into new fields is sometimes followed by strange and confusing applications of familiar terms. Certain soft and messy parts of the body we all agree are viscera, the brain has been termed a viscus, but there is also a visceral skeleton sanctioned by hoary usage. Visceral reactions are unconsciously performed; so are many others and some undoubtedly visceral muscles are under voluntary control. Visceral muscles in general are supplied by the sympathetic nervous system, but not the muscles of the visceral skeleton; and what is the sympathetic nervous system?

Our accounts of the visceral nervous system are especially confused, and the reason is obvious—the thing itself is inextricably intertwined with everything else in the body. Descriptive anatomy alone can help but little, though under the guidance of sound physiological analysis it may contribute much. And it is to this phase of the question that I wish to direct attention.

The usual formulation of Bell's law does scant justice to its gifted author's acumen; for Bell not only demonstrated that dorsal roots are sensory and ventral roots motor, but he distinguished a third category of nerve fibres which we would now call visceral. Gaskell later amplified Bell's idea into a four-root scheme of the spinal nerves, somatic and visceral afferent and somatic and visceral efferent. The details of his scheme have been greatly modified, but the fundamental distinction between somatic and visceral systems of nerve components and centres has been more and more evidently justified as time passed on.

Some thirty years ago a group of American zoologists, following lines suggested by Prof. Osborn's work on the amphibian brain, began an analysis of the functional components of the cranial nerves of vertebrates by the microscopic method, which is still in process and is exerting a profound influence. One of the early fruits of these labours was a more accurate description and a clearer analysis of the visceral systems, both peripheral and central. In short, a "visceral brain" can now be recognised and its limits defined and the analysis of its internal structure is far advanced. Appropriate physiological control has been applied and the analysis carried farther in some directions experimentally. The anatomical method can penetrate into some regions not as yet accessible to experiment, for, given an accurate knowledge of the limits and functional values of the primary sensory and motor centres of the brain stem, the further functional connections of these centres can be deduced as soon as the courses of the related central fiber tracts are adequately known.

These studies have demonstrated a remarkable uniformity of pattern of reflex mechanisms of the head throughout the vertebrate series when viewed broadly, though with great variation in the details, and these modifications present some difficult problems to which specific reference will be made shortly. In view of the divergencies of usage, especially in Europe, which are growing out of the further study of these ambiguous cases, it seems expedient to formulate the views of the so-called American school and some of their implications.

If, now, we look at the matter from the physiological standpoint, it is possible to frame a definition of viscera in general which, though not free from objections and confusing exceptions, is nevertheless serviceable and probably on the whole the most generally useful.

Sherrington, building on the foundation laid by Gaskell, has divided the receptive organs into exteroceptors, interoceptors and proprioceptors. The related afferent nerves and their central connections readily fall into the corresponding classes, and if to each of these systems we join the neuromotor mechanisms most directly related, the way is opened up for a fundamental analysis of all the organs of the body.

The exteroceptors and related neuromotor apparatus are primarily concerned with the adjustment of the body or its members to external conditions. Since this usually involves a change in the relations of the body as a whole to its environment, these systems in the aggregate may be called somatic.

The interoceptors and related neuromotor apparatus, on the other hand, are primarily concerned with internal adjustments of the body, its conservation and reproduction. The mechanisms here employed are, in the main, those classed as viscera in the dissecting room, and, accordingly, these are called the visceral or splanchnic systems.

The proprioceptors ensure the coordinated or synergic action of the motor apparatus. They are internally excited, but not necessarily visceral. By far the larger part of the proprioceptive system is ancillary to the skeletal musculature and is, therefore, somatic in type as we have defined this term. Any proprioceptors which are excited by the action of visceral muscles, by the same token, would have to be classed with the visceral systems.

The distinction here made between somatic and visceral systems of organs is most fundamental. It cuts down through the entire body and conforms as closely as any single criterion can to current usage. Of course, it cannot be applied inflexibly because the body is not made that way and numerous puzzling questions arise in applying this or any other analytic procedure. Moreover, the somatic and visceral systems do not work independently, but each serves the other and structurally they are intimately knit together.

The non-nervous organs of the human body can, for the most part, readily be classified as somatic or visceral in accordance with this principle; but when the matter is examined comparatively momentous questions arise, for in numerous cases undoubtedly visceral organs of primitive species have, in the course of evolution, assumed somatic functions and conversely. These transformations are often recapitulated in human embryological development, and such organs in the human adult usually bear the hall-marks of their genetic relationships. Now, in the case of primitively visceral structures which have secondarily acquired somatic functions one must choose whether to classify them as visceral along with their homologues in lower forms in accordance with their genetic relationships or as somatic, recognising only their status in the definitive stage. Good arguments can be adduced for both courses.

In the nervous system we always set off a visceral part over against the remainder, but the limits of the visceral system have been variously drawn. The sympathetic ganglionic plexuses are unquestionably visceral by all commonly accepted standards. But how shall we define the sympathetic nervous system? We now know that many efferent fibres which enter these ganglionic plexuses arise within the central nervous system and that some (if not all) of the afferent visceral fibres are outgrowths of neurons of the spinal and cranial ganglia.

In view of the existing confusion[1] it would seem desirable to abandon the term autonomic nervous system altogether, for it has been defined in so many different ways as to have no generally accepted meaning. Let us retain the word sympathetic nervous system in the good old-fashioned sense as the name of that portion of the visceral nervous system which in the gross can be recognised as such. Those visceral ganglionic plexuses which can be separated in the dissecting room from the cranio-spinal nervous system[2] comprise from time immemorial the sympathetic system. So let the matter rest.

In the more precise usage demanded by microscopic anatomy and physiology, the general[3] visceral nervous system will, then, be defined as comprising all of the neurons directly concerned in the reactions of the viscera as here physiologically determined, whether their cell bodies lie in the sympathetic system (in the restricted sense), in the central nervous system, or in the cranio-spinal ganglia. These neurons which form the visceral nervous system can be accurately localised anatomically and their physiological

---

[1] Ranson, S. W. 1917. "On the use of the word 'sympathetic' in anatomical and physiological nomenclature." *Anat. Rec.* vol. XI. pp. 397–400.

[2] I say cranio-spinal system, instead of the usual term cerebro-spinal system, in the interest of a more consistent nomenclature. If the lower division of the main neural axis (medulla spinalis) is defined in terms of the enclosing skeleton, the upper division, or encephalon, may well be similarly designated. This is especially important in view of the confusion introduced in the BNA tables by a definition of the word cerebrum at variance with both the classical meaning (synonymous with encephalon) and the modern custom of denoting by it the cerebral hemispheres, or these with the thalamus. The designation of the nerves of the head as cerebral nerves in the BNA tables is inconsistent with the definition of cerebrum there adopted and should be avoided. Cranial nerves and cranio-spinal nervous system are satisfactory terms.

[3] General visceral, in distinction from certain highly specialised visceral nervous systems found only in the head.

characters can be determined experimentally. The efferent route of the general visceral system leading away from the cranio-spinal axis is by a two-neuron path, with preganglionic and postganglionic neurons separated by a synapse. The cell bodies of the afferent neurons lie chiefly (perhaps wholly) in the cranio-spinal ganglia. The peripheral ganglionic plexuses, such as the myenteric and submucous plexuses, are of course included in the general visceral system.

It is common practice nowadays to enlarge the ancient meaning of the word sympathetic system to include all neurons in their entirety which lie wholly or in part in the peripheral sympathetic nervous system in the narrower sense above defined. Here would then be included neurons which lie wholly in sympathetic ganglionic plexuses, preganglionic neurons whose cell bodies lie in the spinal cord and brain and whose axons enter rami communicantes, and also those neurons of spinal and cranial ganglia whose peripheral processes pass out into rami communicantes. This would not be objectionable if the prevailing ambiguity in the use of the term sympathetic could be avoided.

Langley limits the term sympathetic to the efferent elements of the thoracic-lumbar visceral system and applies the term autonomic to the efferent cranio-spinal visceral system as a whole. Certain continental writers, on the other hand, restrict the term autonomic to the cranio-sacral efferent visceral system in contact with the thoracic-lumbar. Still other variant usages are current, and the confusion is so great that some physiologists advise that the terms autonomic, sympathetic and para-sympathetic be eliminated from our nomenclature altogether. If, however, the preganglionic efferent neurons are included in the enlarged definition of the sympathetic system, then the visceral sensory neurons of the spinal ganglia whose peripheral processes enter the rami communicantes should also be included.

In the head the situation is far more complex than in the trunk. Here, in addition to general visceral organ systems arranged essentially as in the trunk, there are special systems concerned primarily with feeding and respiration. These physiologically are intermediate between the general visceral and the somatic organs, for they are concerned with the incorporation into the body of materials from outside. It is, therefore, not surprising to find that structurally also, they occupy an intermediate position.

The bony framework of the jaws, hyoid and branchial arches (and their derivatives in adult mammals) constitutes a true visceral skeleton, as has long been recognised. The related muscles are striated and voluntary and their nerves are in no way related with the sympathetic nervous system. The muscles of the jaws, hyoid and branchial arches were clearly primitively visceral (but neither non-striated or supplied by sympathetic neurons), though the jaws as prehensile organs are also none the less truly somatic. Some of the muscles derived from the embryonic musculature of the visceral arches persist as visceral in the adult man. Others have secondarily acquired typical somatic functions, such as those of the larynx and the mimetic facial musculature, and there is certainly room for difference of opinion as to their classification. In the current American usage these muscles and their nerves are usually called special visceral in conformity with their genetic relationships. Certain English anatomists, on the other hand, have called them special somatic muscles in accordance with their functional and (adult) anatomical characteristics. This difference in nomenclature is a matter of small importance, for the muscles do occupy an ambiguous position (compare the variability of striation in the oesophageal musculature). The essential thing is the recognition of their *special* character, in contrast with both the general visceral and the typical somatic neuro-muscular systems.

In all vertebrate animals the muscles of this special series in the head are supplied by motor nerves arising from the brain in a lateral series (V, VII, IX, X and XI pairs), clearly separated from the more ventral nerves of the somatic muscles (III, IV, VI and XII pairs). This topographic separation of the somatic and visceral series of motor nerves at their superficial origins applies also to their nuclei of origin in the brain stem, and the intracranial centres of the somatic and visceral sensory systems are similarly distinct. In human embryos and in the adults of the more generalised fishes, where these primary sensory and motor centres make up the greater part of the medulla oblongata, this part of the brain is obviously divisible on each side into four well defined longitudinal columns whose characters are determined chiefly by their peripheral connections. Enumerating them from ventral to dorsal borders, these columns are: somatic motor, visceral motor, visceral sensory, and somatic sensory. To these primitive sensori-motor centres there is added in the adult human brain a much larger volume of correlation mechanisms and long conduction paths, such as the olives, pons, pyramidal tracts, etc.

This method of analysis of the bewildering complexity of the human brain has so clarified the subject that it has been widely adopted, and its pedagogic value has been tested with thousands of medical students. A number of years ago the late Prof. Edinger wrote me with reference to it that he saw its merit, but added: "I fear I am too old a dog to learn the new tricks." But Edinger was of the type that does not grow old, and a few months later I was interested to notice that this plan in its essential features appeared in the next edition of his *Vorlesungen*.

Largely by the comparative study of the functional composition of the cranial nerves and their centres the morphological pattern of the medulla oblongata has been definitely established, and this pattern is found to be in fundamentals surprisingly uniform throughout the vertebrate series. It is always recognisable, even when distorted by exaggerated development of certain systems to a degree almost unbelievable in some species of fishes.

In the higher levels of the brain, where correlation tissue so largely overshadows the primary sensori-motor apparatus, the application of these principles becomes naturally more difficult, and here there is room for wide divergence of opinion and usage.

Let us now turn to a more detailed consideration of some of these puzzling cases where secondary changes have led to confusion of somatic and visceral types of structure. No simple arbitrary standards can be established for these organs. Their phylogeny, ontogeny, structure and function must be analysed and each treated on its own merits. Uniformity of usage is probably not possible here, for each student will evaluate these matters in accordance with his own ideas of fitness. The principles already laid down can, however, readily be applied as soon as all the necessary facts are known.

Seeking and capturing food is obviously a somatic reaction, but mastication, insalivation, swallowing, and further treatment of this food equally clearly must be classed as visceral, and the mechanisms employed are viscera. Taste is a visceral sense as truly as is hunger, though it is reckoned as a special sense. Its nerves peripherally have no connection with the sympathetic nervous system, but the primary centre for taste in the medulla oblongata is anatomically intimately joined (in the nucleus of the solitary bundle) with the centres for hunger and other visceral senses served by the vagus.

But where taste buds are developed both in the mouth and in the outer skin, as in the carp and catfish, the cutaneous organs of taste at once become exteroceptors and, as we know from experiment, they are used in the search for food and they call forth somatic reactions. This is a secondary or derived condition, for the internal (visceral) taste buds are more primitive than the external. In the catfish the primitive visceral gustatory centre for mouth-tasting is a greatly enlarged portion of the nucleus of the solitary bundle known (somewhat inappropriately) as the vagal lobe. In front of this lobe there is another gustatory centre which is likewise an enlargement of the nucleus of the solitary bundle and is termed (quite properly) the facial lobe, for it receives all of the fibers from the cutaneous taste buds, which enter the brain through the facial nerve. The facial lobe is, therefore, a somatic sensory centre by a strict application of our formula. It is, however, genetically derived from the nucleus of the solitary bundle, a visceral centre, and it is functionally so intimately bound up with the sense of taste served by the internal taste buds that it has usually been termed visceral. In the codfish I have described a very similar situation, where the somatic nature of the centre for cutaneous taste buds is much more clearly evident both structurally and physiologically. Thus, though taste is primitively and typically a visceral sense, it may in some animals acquire somatic characters and develop end-organs and intracranial centres of somatic type.

The sense of smell presents a still more puzzling case, for its twofold nature is always in evidence in all classes of vertebrates. The phylogenetic origin of the organs of taste and smell is obscure, for there are no extant documents which preserve for us the details of their history. In all living vertebrates smell, whatever its origin, is a true exteroceptive sense, concerned with locating objects at a distance and calling forth locomotor reactions of a somatic type. This is the dominant function throughout the vertebrate phylum. Nevertheless there is a visceral phase of olfactory reactions equally widespread and probably more primitive, namely, their part in the processes of internal preparation of food, such as the excitation of jaw-movements, flow of saliva, etc. This question I have examined in some detail in 1908[1] and I have more recently[2] endeavoured to show that with the opening of the posterior nasal aperture in air breathing vertebrates the visceral or "mouth-smelling" function of the nose took on a new phase with which was correlated the development of the vomero-nasal organ (of Jacobson) and its cerebral centres, the accessory olfactory bulb and amygdala. So intimately bound together, however, are the somatic and visceral functions of the nose that we ourselves are incapable of determining without special laboratory tests whether we are smelling or tasting various articles of food.

In the interest of an adequate understanding of the olfactory organ and the related neuromotor apparatus it is indispensable that these two phases of its functional activity be clearly apprehended. Whether it be called a visceral or a somatic organ is not of so much consequence, for clearly it is both, that is, it is viscero-somatic.

The respiratory mechanisms present another interesting series of transformations which have caused confusion. In fishes the gills are obviously visceral structures concerned primarily with respiration, with an important part to play in the feeding reactions also. Their muscles, unlike the visceral muscles of the trunk, are striated and are not supplied by sympathetic nerves. In mammalian embryos the branchial apparatus, after passing through an ichthyopsid stage, is highly modified in most diverse ways, some parts retaining visceral functions and others, like the larynx, acquiring typical somatic characters. Whether these latter are classed as somatic or visceral will depend upon whether emphasis is placed upon adult relations or upon embryologic or phylogenetic origin. The current American usage, which classes the gills and all their derivatives as visceral, has the merit of simplicity, but requires some explanation and qualification as applied in the human body.

In the course of the transition from water breathing to air breathing vertebrates an entirely new respiratory mechanism was developed, largely from pre-existing skeletal muscles of the thoracic region. Genetically these muscles are somatic and they are commonly so classified. The primary innervation of these muscles of the somatic type from the spinal cord was preserved. But it is interesting to note that the respiratory centre which controls the rhythm of breathing, even in man, does not lie in the spinal cord in relation with the sources of the phrenic and intercostal nerves, but is retained in the vagus region of the lower medulla oblongata, its primitive position in fishes where branchial breathing is in vogue. The appropriation for respiratory purposes of certain structures innervated from the spinal cord has not in-

---

[1] Herrick, C. Judson. 1908. "On the phylogenetic differentiation of the organs of smell and taste." *Jour. Comp. Neur.* vol. XVIII. pp. 157–166. In this paper will be found also references to the original sources of the statements made above relating to the gustatory centres of fishes.

[2] Herrick, C. Judson. 1921. "The connections of the vomero-nasal nerve, accessory olfactory bulb and amygdala in Amphibia." *Jour. Comp. Neur.* vol. XXXIII. pp. 213–280.

volved the abandonment of the primitive visceral respiratory centre in the brain.

The most extreme instances of secondary transformation of a primitive visceral neuromotor apparatus is perhaps furnished by the spinal accessory nerve and the related trapezius and sternocleidomastoid muscles. These are apparently typical somatic muscles, and their innervation from the lateral or special visceral motor centres presents a serious problem which has been resolved by an application of the comparative method.

The trapezius muscle is found in most groups of vertebrates, though sometimes called by different names (levator scapulae, humeromastoid, cucullaris, capiti-dorso-clavicularis, etc.), and often more or less united with the sternocleidomastoid. The muscles of this group are regarded by comparative anatomists as partially homologous throughout the vertebrate series. They typically have a double innervation, partly from the XI (or X) cranial nerves and partly from the spinal nerves. In elasmobranchs the trapezius muscle is supplied by the "accessorius" branch of the vagus[1] and is regarded by Vetter as a derivative of the superficial constrictor system of the gill region, whose function is to contract the gill chamber. In teleosts the muscle named trapezius is, in some species, innervated from the X cranial nerve and in other species from the spinals. It is probable that two muscles morphologically distinct are combined in the trapezius of higher vertebrates where both innervations occur.

The trapezius is developed in Scyllium, Gallus and Lepus[2] from the mesoderm of the gill arches. In Teleostemi, Ceratodus and Amphibia it is differentiated from the levatores arcuum branchialium and this is regarded by Edgeworth as the primitive condition. Its materials are derived embryologically from the mesoderm of five branchial arches in Scyllium, four in Chrysemys, two in Gallus and three in Lepus.

Kappers[3] in discussing the relations of the spinal accessory nerve shows that both phylogenetically and embryologically (in the sheep) the nucleus of this nerve as seen in the mammals is independent of both the ventral gray column of the spinal cord and the nucleus ambiguus of the medulla oblongata, with both of which it has in the past often been related. The same relations have since been described in the new-born human[4].

In fishes there has usually been described a single large-celled motor vagus nucleus under the name nucleus ambiguus, from the caudal end of which the fibres for the trapezius muscle are derived, in cases where this muscle is inner-

---

[1] Fürbringer, M. 1897. "Spino-occipitale Nerven." *Festschr. f. Gegenbaur*, Bd. III. Norris and Hughes. 1920. "The cranial, occipital and anterior spinal nerves of the dogfish, *Squalus acanthias.*" *Jour. Comp. Neur.* vol. XXXI. pp. 293–402.

[2] Edgeworth, F. H. 1911. "On the morphology of the cranial muscles in some vertebrates." *Q.J.M.S.* vol. LVI. pp. 167–316.

[3] Kappers, C. U. A. 1912. "Weitere Mitteilungen über Neurobiotaxis." VII. *Folia Neurobiol.* Erg.-Heft 6, pp. 3–142.

[4] Black, D. Davidson. 1914. "On the so-called 'bulbar' portion of the accessory nerve." *Anat. Rec.* vol. VIII. pp. 110–112.

vated from the vagus. In the carp[1] and probably in other fishes there is also a dorsal small-celled motor vagus nucleus. This more dorsal nucleus, which forms the motor layer of the vagal lobe, probably as in mammals supplies smooth visceral muscle fibres through the sympathetic nervous system, while the large-celled motor nucleus is known to supply the striated branchial musculature, including the trapezius when present.

The large-celled motor vagus nucleus lies much farther dorsally in fishes than in mammals and is called the dorsal vagus nucleus by Kappers. It is possible that in most fishes and amphibians the true dorsal nucleus is united with the large-celled nucleus to form the "dorsal nucleus" of Kappers, though in the carp, where the vagus is greatly enlarged, the two motor vagus nuclei are clearly separate. The "dorsal vagus nucleus" of Kappers in fishes occupies a position corresponding with that of the dorsal small-celled (general visceral) nucleus in mammals, and Kappers shows that in the phylogenetic series from fishes to mammals there has been a migration ventralward from this "dorsal" nucleus in two directions, one forward and downward to form the nucleus ambiguus supplying the striated muscles of the pharynx and larynx, and one backward and downward to form the accessorius nucleus (spinal nucleus of the XI nerve).

It seems probable, therefore, that the trapezius (or that portion of it in higher vertebrates which is innervated from the XI cranial nerve) was originally a respiratory muscle. The same holds true for the sternocleidomastoid, which has a similar double innervation.

In Sauropsida and Mammalia the demand for greater mobility of the shoulder has apparently incorporated the trapezius and sternocleidomastoid muscles into the complex connected with the shoulder girdle for participation in general shoulder and arm movements. Nevertheless in mammals the respiratory function of these muscles has not been entirely lost. Their twofold relationships were clearly pointed out by Charles Bell[2], and this has since been many times confirmed. Bell reports the case of a hemiplegic who was quite unable to elevate the shoulder on the affected side by an act of will, but who was able in forced inspiration to elevate both shoulders equally, the respiratory function of the trapezius being unimpaired by the failure of the other functions.

Our conclusion is that the trapezius muscle (and the sternocleidomastoid, which appears to have a common origin with it) is in part a derivative of the branchial musculature of primitive fishes, originally respiratory in function. In some fishes it derives its motor innervation from the lower vagal region and this innervation persists in all higher animals.

In Sauropsida and Mammalia, however, a union of the primitive trapezius, of branchial origin innervated from the vagus region, with a slip of the dorsal

---

[1] Herrick, C. Judson. 1915. "The central gustatory paths in the brains of bony fishes." *Jour. Comp. Neur.* vol. xv. pp. 375–456.

[2] *Phil. Trans.* 1822, pp. 284–312; and *The Nervous System,* 3rd ed. 1844.

musculature innervated from the spinals took place for the double purpose of facilitating movements of the shoulder (with the head fixed) and of the head and respiratory muscles (with the shoulder fixed). The former (which is the dominant function) is a typical somatic movement, and to bring the nucleus of origin of the trapezius muscle into closer relations with the other motor nerves involved in the synergic muscular complex of the shoulder the nucleus of the **XI** nerve in the course of vertebrate phylogeny has migrated backward into the cervical spinal cord, this being an illustration of Kapper's principle of neurobiotaxis. During this evolution, however, the connection of the trapezius and sternocleidomastoid muscles with the central mechanism of respiration was not lost, and both of these muscles may cooperate as important accessory muscles of respiration. The somatic and visceral (respiratory) functions have separate central nervous pathways leading into the nucleus of the accessorius, and of these the respiratory may be left intact after the loss of the more recently acquired voluntary motor path in certain cases of hemiplegia.

We conclude, then, that in a functional analysis of the animal body three classes of organs must be recognised: (1) visceral, (2) somatic, and (3) ambiguous or transmutant cases, in origin belonging to one of the two primary types but secondarily transformed wholly or in part into the other. The third class cannot be eliminated or ignored, for organisms are not static, but are ever in flux and old materials may be transformed and put to new uses quite at variance with any formal rules which we may lay down in our logical systems.

THE MISUSE OF THE TERM "VISCERAL"[1]

By RAYMOND A. DART, M.Sc., M.B., Ch.M.,
Senior Demonstrator of Anatomy; University College, University of London

INTRODUCTION

"What names are applied to these systems is a relatively unimportant matter, but it is necessary to bear in mind that the olfactory system itself is a complex in which visceral (interoceptive) and somatic (exteroceptive) elements are always present. To deny or ignore this dual nature of the sense of smell is to close the door to further progress." (Herrick, *Jour. of Comp. Neur.* 1921.)

That inherent qualities do not necessarily find expression in terminology is a fact of which men had long been cognisant before Shakespeare delivered himself of his immortal statement concerning the independence of "sweetness" and nomenclature. But such is the limitation of the scientific method that we may only proceed from definition to definition, so names are apt to assume an exaggerated importance and often become the index of the exactitude of our information or of the clearness of our thinking.

In a previous publication (1921) I dissented from the teaching, current amongst certain neurologists, that "smell" is a "specialised visceral sense" and insisted that it was "a thorough-going somatic, ectodermal and exteroceptive sense." In view of Herrick's restatement of the situation, it will be the purpose of this paper to trace briefly the outstanding historical incidents in the production of a glaring confusion in modern neurological and physiological literature, arising out of an unrestrained use of the term "visceral."

The confusion is one of gradual growth. The term "visceral," as first utilised in anatomical literature, was undoubtedly in the adjectival sense of "pertaining to a viscus" (*L. visceralis*), and it is in this original sense that time has justified its use in general anatomical description as opposed to "parietal"—in referring, for example, to the reflections of the abdominal or of the pleural serosa. Further, the term "visceral," as applied to the unstriated, endodermal musculature of the gut or of the other viscera, has afforded, in the past, a suitable distinction between this musculature and that which causes erection of the hair, etc.—the so-called "dermal" (ectodermal) musculature. Although both systems of musculature are innervated and controlled by the vegetative nervous system (systema nervorum sympatheticum) and consequently form a physiological unity, it is true that for descriptive purposes the antithetical character of the two germ layers provided a sufficiently valid phylogenetic background for such a distinction.

---

[1] Editorial Note. This paper was received by the acting editor, Feb. 9th, 1922. Sixteen days later Prof. Herrick's welcome article (p. 167), dealing with the same subject, arrived, the covering letter bearing the date Feb. 10th, 1922.

THE TERM "VISCERAL" IN THE SKELETAL SYSTEM

An entirely theoretical and artificial force, however, was given to the designation with the appearance of C. Reichert's (1836) inaugural dissertation, "de embryonum arcubus sic dictis branchialibus." To H. Rathke (1825) is due the discovery of the "branchial arch mechanism" in mammalia. This publication together with his succeeding papers (1828–1832) established beyond all question the validity of his contention concerning the presence of the "gill-arch mechanism" in Amniota and by him it was correctly described as "Kiemenapparat." Reichert extended the observations of Rathke; but, being dominated by the conception that "die Visceralhöhle des Kopfes aus Bogen gebildet werde," he re-named the "*branchial arches*" of his far-sighted predecessor "*visceral arches*" (Visceralbogen) purely because of their adaptation to what he was pleased to term the "visceral cavity of the head."

This use of the term "visceral" has become fairly firmly grounded in osteological literature because it afforded a convenient distinction between the cranial skeletal elements developed in apparent adaptation to the digestive tube and its requirements (viscero-cranium) and those in adaptation to the sense organs and the neural tube (neuro-cranium). The distinction so clearly embodied in the work of Reichert, was rendered classical by Huxley's famous Croonian Lecture (1858). Through the advances in morphological interpretation made by Gegenbaur and so many others, it was crystallised in Gaupp's account of the comparative anatomy of the skull. (Hertwig's *Entwickelungslehre*, 1906.)

Valuable as the distinction drawn by Reichert certainly is, it is equally valid to regard, with Gegenbaur, the ribs and other skeletal parts, which are developed for the protection of the gut, as "visceral." This is the accepted terminology in certain quarters, for Dorland's *Medical Dictionary* tells us that the "visceral" skeleton is "that portion of the skeleton which protects the viscera, as the sternum, ribs and innominate bones." It remains to be demonstrated that such a teaching is groundless. Hence it is unfortunate that the term "visceral" should have been selected by Reichert, or that the wider application of his principle should not have been met by suitable adjustments in the nomenclature used by his successors. In the sense of Reichert (as interpreted by Gegenbaur) the "parietally" situated ribs should be called "visceral" structures. Further, the admirable summary of Landacre (1921) and the experimental work of Stone (1921) have clinched a dramatic series of brilliant researches by many workers demonstrating that the so-called "visceral" arches themselves are "dermal" (ectodermal) in origin.

Sufficient will have been said to indicate the deplorable inadequacy of the term "visceral" in osteological literature and to justify a rigid adherence to the fundamental and earlier classification of Rathke where the cranium is concerned.

THE TERM "VISCERAL" IN THE MUSCULAR SYSTEM

For the next important application of this word in terminology we must note the appearance of Schneider's (1879) early attempt at a comparative myology of Chordata, because it formed the then accepted, though erroneous basis upon which Gaskell later built up his morphological scheme. Schneider divided the musculature of Chordata into the *smooth* and *striated* varieties quite correctly; but he sub-divided the striated musculature into two subsidiary groupings, viz. body or "parietal" musculature and "visceral" musculature. His division is based apparently on the statements: (p. 59) "Die visceralen Muskeln sind die Muskeln der Kiemen, des Kopfes, Mundes, des Velum, der Zunge; man kann sie als die Fortsetzung der glatter Muskelfasern des Darmes betrachten. Beide entstehen aus derselben Schicht."

Such a classification should include all musculature innervated by cranial motor nerves and an appreciable part of the neck musculature also. But Schneider is not obstinate in his contention. He finds (p. 116) that the so-called sterno-pharyngeal muscles of Ganoids and Teleosts are "parietal" muscles. Nevertheless, "Sie entsprechen den Sterno-branchiales, welche wir weiter unten auch bei den Elasmobranchiern finden werden, und dort gehören sie nachweisbar zur *visceralen* Muskulatur." When he comes to deal with amphibian, reptilian and avian forms he is far from confining his "visceral" terminology either to the head and tongue region or even to the limits of his embryological conception, but includes under that heading the Transversus groups (pp. 134, 137, 142, etc.) and the diaphragm.

Such a classification, lacking even in internal harmony, is morphologically worthless. It was unfortunate that Gaskell (1908) should have regarded Schneider's proposals so seriously. Not appreciating the whole extent of the flaws, he seized upon the conception as an elucidation of his theory of vertebrate origin and strove to harmonise this faulty division with van Wijhe's discoveries concerning the segmentation of the Selachian head. When Gaskell differed from Schneider by restricting the term "visceral" to the branchial musculature, his use of the term might have been expected to apply to all of the musculature attached to the skeletal elements described by Reichert as "visceral." This was not so, for in order to adapt it to his theory, Gaskell (p. 172) separated out the hypoglossal musculature as a "spinal somatic" and the eye musculature as a "cranial somatic" group. According to him, these were the only muscles innervated by cranial nerves which were at all comparable with the other striated muscles of the body, forming with them the "somatic" as opposed to the "visceral" musculature.

Quite apart from the philological objection to an antithesis of Greek and Latin terms, the artificiality of Gaskell's arrangement of the musculature constitutes sufficient reason for not adopting it, for it is at variance with the embryological evidence, which it was supposed to elucidate.

If we trace the history of embryological terminology this is abundantly clear. We find that Pander (1817) was the first to distinguish clearly the three-layered blastoderm in the following terms: "serous" or outer, "vascular" or middle and "mucous" or inner. Shortly afterwards Von Baer substituted the terms "animal" and "vegetative" for the outer and inner layers respectively, and did not recognise the middle layer as a separate entity. Remak, however (1850–1855), reverted to the conception of Pander in a modified form, calling attention to the morphological significance of the "split" in the middle layer, whereby the coelomic space is formed and is so bounded externally in the embryo by a "Hautfaserblatt" and internally by the "Darmfaserblatt." The two mesodermal layers became known as the "somatopleure" and "splanchnopleure" respectively, and the terms were established in embryological literature by Balfour's work (1885) as the "*somatic*" and "*splanchnic*" layers. Meantime, in the year when Darwin's *Origin of Species* appeared, the genius of Huxley (1859) elucidated the homology of Pander's serous and mucous layers in Mammalia with the "ectoderm" and "endoderm" of Coelenterata. The year 1859 consequently saw a complete basis provided for embryological generalisation.

The embryological facts concerning the origin of striated muscles were tersely stated by Balfour (*loc. cit.* p. 671) as follows: "The first changes of the mesoblastic somites and the formation of the muscle-plates do not, according to existing statements take place on quite the same type throughout the Vertebrata, yet the comparison which has been instituted between Elasmobranchs and other Vertebrata appears to prove that there are important common features in their development, which may be regarded as primitive, and as having been inherited from the ancestors of Vertebrata. These features are (1) the extension of the body cavity into the vertebral plates, and subsequent enclosure of this cavity between the two layers of the muscle plates; (2) the primitive division of the vertebral plate into an outer (somatic) and an inner (splanchnic) layer, and the formation of a large part of the voluntary system out of the inner layer, which in all cases is converted into muscles earlier than the outer layer."

And p. 673: "Thus both layers of the muscle plate are concerned in forming the great longitudinal lateral muscles, though the splanchnic layer is converted into muscles very much sooner than the somatic."

The Hertwigs, Rabl and Maurer go even further and state that the whole of the "parietal" musculature arises from the inner or "splanchnic" layer of the somite.

The first consideration that emerges from these statements is that all somites are homologous in giving rise to striated ("parietal," "somatic") musculature from the medial or "splanchnic" lamella; consequently the term "splanchnic" as used by Balfour in embryology cannot be correlated in any way with "visceral" (its Latin translation) as employed by Gaskell. Secondly, it is no distinctive feature of the "branchial" musculature (as Maurer, *Hertwig's Entwickelungslehre*, p. 47, appears to believe) that "Aus dieser medialen

Lamelle welche der Splanchnopleura entspricht, bildet sich die Muskulatur der einzelnen Kiemenbogen aus."

It would be entirely misleading to assume that the embryologists of the same period (Cf. Maurer, *loc. cit.*) were in harmony with Gaskell's arbitrary division of the cranial musculature. Hatschek, with admirable penetration, recognised that if the musculature of the branchial arches was to be called "visceral" then the embryologically homologous muscles supplied by the oculomotor and abducens nerves are "visceral," a view which Maurer himself extends to the trochlear muscles as well. All of these muscles have their origin in somites—somites which, in certain cases, are giving rise simultaneously to musculature (e.g. masticatory muscles) that is *visceral* in the senses of both Reichert and Gaskell. The same mesodermal origin is so well known in the case of the striated musculature innervated by the glossopharyngeal, vagus, accessory and hypoglossal nerves, that to mention it is to become trite—all belongs embryologically to the type called *somatic* by Gaskell.

The only rational way in which the term "visceral" could possibly be applied to a portion of the striated musculature (and then only as a descriptive term), is in the sense defined by Reichert, where it is synonymous with the term "branchial," as was first clearly indicated by the researches of Rathke on the "Kiemenapparat." Even so, the term introduced by Reichert is objectionable as applied to the musculature, because it tends to exaggerate the real distinction between the gill-arch musculature and the general body musculature. Consequently the discarding of this application of the word would eliminate an element of confusion from the literature relating to the striated musculature. The descriptive, and earlier, term "branchial" (of Rathke) is not open to this objection; but it, too, is of value only as long as the embryologically homologous character of all muscles with the visual muscles on the one hand, and with the so-called parietal muscles on the other, are clearly recognised. Since all of these are now known to arise from segmented mesoderm, they may be grouped together morphologically as the *mesodermal* musculature.

It must not be presumed that, in criticising Gaskell's division of the striated musculature, any attempt is being made to minimise the emphasis which his work placed upon the fundamental anatomical and physiological distinction to be drawn between the *striated* and *unstriated* musculature. However clearly anatomists had recognised the distinction between the two systems, it remained for Gaskell and his followers in physiology—more especially Cannon—to provide the evidence necessary to show that the involuntary unstriated musculature, with its characteristic innervation, presented a unity phylogenetically older and more widespread than that of the so-called striated or voluntary muscular system.

The most significant aspect of these revelations, from the morphological point of view, is that they laid bare this ancestral unstriated muscular system which is equally distributed in the tissues derived directly from the ectoderm and endoderm. Now the endodermal portion of this musculature is very obvious, because of its activity in all vital phenomena of digestion, circulation, excretion and generation. The application of the term "visceral" to this *endodermal* musculature has both a descriptive and a morphological value. But the extension of the term (as has been common in some quarters) to embrace the whole of the vegetative (sympathetic) nervous system has had the unfortunate effect of causing the somewhat less obvious ectodermally-arising unstriated musculature to be frequently under-valued and sometimes even entirely neglected in morphological terminology. Yet, this *ectodermal* musculature comprises the pilo-motor, glandular and vaso-motor mechanisms of the general body surface and such specialisations as the ciliary and Müllerian muscles in the eyeball region. It is found in all Vertebrata; but most essential of all, it is supplied along with the endodermal musculature by the vegetative nervous system, forming with it, as has been stated, a physiological unity.

The ectodermal musculature arises *in situ* directly from the ectodermal tissues, and the endodermal from the endoderm. This is known (cf. W. H. Lewis, 1910; Brachet, 1921) by actual observation and must follow from phylogenetic considerations if we may trust the work of Darwin and Huxley. The ectoderm and endoderm of Metazoa are homologous layers, or else embryology has gone astray since the time of Pander.

Now the analogies existing between the peristalsis of the gut in Mammalia and the reactions of the "diffuse nerve-net" system of Invertebrata have been admitted by the physiologists, but the homologies of the underlying anatomical mechanisms have not been recognised by morphologists. So far as the homologies of the layers go, the homologies of these derivatives must follow. Consequently, the "endodermal-ectodermal" (or more simply, "*dermal*") system of unstriated musculature in creatures with a segmented mesoderm is homologous with the entire musculature of Coelenterata, Echinodermata, Platyhelminthes and of Mollusca—in brief, of all forms with unsegmented mesoderm. Characterised by undulatory contraction of slow velocity of propagation, long reaction time and low rate of metabolism (however modified this may be in forms with higher specialisations than those of Coelenterata), this muscular apparatus is well adapted for the mechanical propulsion of fluids within tubular cavities (peristalsis), but ill-adapted to respond to the demands for progression upon land (e.g. flat worms, slugs); although a fairly high degree of facility may be achieved in a fluid medium (e.g. octopus and squid families) in the presence of the specialisation of certain organs of higher sense (e.g. eyes).

The *mesodermal* (somatic) musculature is characteristic of all animals with a segmented mesoderm (Annelida, Arthropoda and Chordata) and of these only. When present, this musculature represents an addition to, and not a replacement of, the *dermal* (endodermal-ectodermal) musculature. It is consequently not found so widely distributed in nature; and as contrasted with the diffuse "dermal" musculature, the "mesodermal" is bilaterally segmented and adapted primarily to one end only—that of propulsion of the body as a whole. It is a system characterised by great velocity of propagation of the wave of contraction, swift reaction time and high rate of metabolism, which has been elaborated for a particular locomotive (animal) want and not for the distribution of nutriment (vegetative) to the tissues.

This antithesis, already inherent in the neurological nomenclature of Meckel (1811) (Das Cerebralsystem mit dem sympathischen oder das animalische mit dem vegetativen), was rendered serviceable to myology by the terms "voluntary" and "involuntary." The discovery that voluntary muscle so-called was "striated" and that involuntary muscle was "smooth," seemed to afford evidence that the physiological antithesis was reflected in the microscopical structure of the tissue.

This division of the musculature upon the basis of its histological structure, valuable as it is, is rendered inadequate by the fact that striation is evident in cardiac musculature and in other "involuntary" musculature such as that of the salamander's mesentery (Schaper) and the muscles that close the shell in certain molluscs (Dahlgren and Kepner). In short, as the latter authors remark, "striation is evidently a feature that belongs to no particular set of muscle cells but may appear in any of them."

To the terms "voluntary" and "involuntary" there are just as cogent objections. A vast number of the actions of the striated skeletal muscles are involuntary reflex actions. Further, as Langley (1921) says, "the fundamental drawback to the use of the word 'involuntary' is that it makes subjective sensations the criterion of classification. It is inappropriate in a science based on objective observation."

But Langley's own substitute "autonomic" is scarcely more happy; for not only does the word "autonomic"—as he himself has confessed (*loc. cit.*)—"suggest a much greater degree of independence of the central nervous system than in fact exists, except perhaps in that part which is in the walls of the alimentary canal," but the word "autonomic" is hopelessly inadequate to describe the musculature of the nervous system of the molluscs and certain worms where the whole neural or "*receptor-expressor*" apparatus is "dermal" in type. (*Vide* Dart and Shellshear, 1922.)

Meanwhile, in a question of nomenclature, we must not overlook Gaskell's confusion. We have considered the unfortunate application of the term "visceral" to a portion of the "striated" (mesodermal) musculature. But the same term "visceral" was also used to apply to the "involuntary" system as a whole and so came to be applicable equally to the "ectodermal" musculature. Now, however tolerant embryology may be toward the designation of endodermally-arising musculature as "visceral," only violence to the meaning of the word can follow its application to the "ectodermal" musculature.

For these reasons the term "*dermal*" has been suggested to apply to the "ectodermal-endodermal" system, as a whole. The term "dermal" has already been applied by Gaskell to some of the strictly endodermally-arising muscles. It would be of great value to give to this general term "dermal" its complete significance—by including both all the ectodermal and all the endodermal derivatives—not merely to contrast morphologically with the term "mesodermal," but also, emancipating ourselves from subjectivity altogether, to provide for the physiologist and anatomist a rational embryological basis in myological and neurological nomenclature. Thus:

MUSCLE	DERMAL (unstriped)	ECTODERMAL ENDODERMAL
	MESODERMAL (striped)	DORSAL (EXTENSOR) VENTRAL (FLEXOR)

The Term "Visceral" in the Nervous System

If these ontogenetic and phylogenetic facts concerning the bony and muscular tissues are appreciated, their application to the study of the nervous system as a whole is apparent immediately.

The unstriated musculature has been recognised as a physiological unity by virtue of its innervation by the ancestral "nerve-net" (or vegetative nervous system) in both segmented and unsegmented animals. We find in addition, in creatures with segmented mesoderm, a characteristically specialised nervous apparatus for the supply of the segmented musculature. This nervous apparatus forms a second unity of entirely different character, for it is always essentially segmented and bilaterally symmetrical. It is a nervous system characterised by the neurone of Waldeyer, by synapses, and by fixed segmental paths with their well-defined reflex arcs and "invariability of response." In short, it is the elaboration of this segmental anatomical system of skeletal parts, muscles and nerves coincidentally in phylogeny which provides a physical basis for the functional complex known to the physiologist as "voluntary." These form his "voluntary" systems.

I urged this view in putting forward "a new interpretation of the morphology of the nervous system" on behalf of Dr Shellshear and myself at the Philadelphia (1921) meeting of the American Anatomists. At the same meeting Kuntz demonstrated the presence of sympathetic elements developed in the chick after "destruction of the *neural crests and the dorsal portions* of the neural tube," to prove the origin of sympathetic neurones from the ventral lamina of the neural tube. In the same year, Erik Müller and Sven Ingvar published the results of experiments upon Amphibian embryos in which they discovered that the removal of the *ventral half* of the neural tube does not interfere with the production of sympathetic elements. By these ingeniously designed experiments, a beautiful corroboration is afforded of the view enunciated by Weber (1851) that the sympathetic system develops *independently of the neural tube altogether.*

It is evident that the facts afford no substantiation whatever of the conception that the sympathetic system is derived from the neural tube, but rather present the evidence necessary to show that the vegetative nervous system is the fundamental mechanism upon which the segmented system is later superimposed.

The "additional" or "superimposed" character of the voluntary (or segmented) system has been strikingly demonstrated in the work of Agduhr and Boeke (*vide* J. T. Wilson, 1921) for it has been shown that striated muscle, even in mammals, receives a double innervation. Various views have been put forward by physiologists concerning the significance of this phenomenon, but to the morphologist the universal occurrence of the sympathetic innervation in the body and the limitation of voluntary innervation (and then only in conjunction with a sympathetic innervation) demonstrate beyond all possible doubt the validity of the conception urged here.

Now, Gaskell recognised the presence of segmentation, but believing in the "outgrowth" doctrine of the origin of the vegetative system he imagined that the "visceral" system was an equally segmented system. He overlooked the fact that any segmentation, arising within the ancestrally unsegmented, reticular, vegetative nervous system, was *secondary to* the "neural tube—mesodermal" segmentation. In consequence, he postulated a segmentation for his "visceral" system, coincident with the "somatic" segmentation and represented with the latter in the constitution of the segmented neural tube. According to this postulate, we should find in addition to so-called "somatic" motor and sensory elements, certain "visceral" motor and sensory specialisations within each neural tube segment.

Gaskell applied the theoretical conclusions deduced from his (and Schneider's) study of the musculature to the motor nuclei of cranial nerves, where the bilateral double-column arrangement of these nuclei seemed to lend colour to his classification. The splitting of the "motor column" of nuclei, however, corresponds with certain modifications that have taken place, not in the *gut musculature* itself but in the *segmented mesoderm* which secondarily becomes associated with the gut. However intimately associated with the gut the musculature has become and to whatever degree it has abrogated its original condition to comply with "rhythmical" demands necessitated by the development of increasingly complicated movements of mastication, deglutition and respiration within the animal series, it is recognisable as a "mesodermal" (somatic) musculature of true segmental type. Morphologically speaking, it has nothing whatever to do with the "dermal" system of musculature and only secondarily becomes very intimately correlated with it for obvious economic reasons.

But if confirmation of the "mesodermal" (somatic) character of this musculature were needed, what could possibly be more convincing than the histological investigations of Malone (1913). Even in the most advanced mammalian types the unmistakable "somatic" cellular arrangements are discoverable. No chapter in neurological histology is more clear than this. The cells are typical large *somatic* motor cells, with their characteristic Nissl substance, the axons are thick and *coarsely medullated*, the nerve-endings are *somatic* in type and the muscle is *striated*. We do not call the motor nucleus of the phrenic nerve "visceral" because the diaphragm moves involuntarily and even rhythmically, nor again the motor nuclei of the V, VII, IX, X or XI cranial nerves which go to mesodermal musculature, whether they respond voluntarily or involuntarily to given stimuli. For theoretical reasons the III, IV, VI and XII nuclei escaped this "visceral" fate at Gaskell's hands, although the XIIth nerve is concerned with the "visceral" function of swallowing food material and supplies "branchial arch" musculature and the others are in segmental series with it. In cases of this character an appeal to physiological criteria is invalid because of the contradictory nature of the answers provided, but the evidence of histology, ontogeny and phylogeny are complete and final.

Although the application of the term "visceral" to these nuclei of cranial nerves has been a feature of American (with the important exception of Malone) and Continental (*vide* Kappers, 1921) neurology, this movement was not countenanced by Elliot Smith (Cunningham, 1914). To my knowledge the statements of Elliot Smith and Malone represent the only remonstrance yet raised against the acceptance of Gaskell's system so far as it concerns the innervation of striated musculature, i.e. the motor side.

The removal of these segmental nuclei (the "special visceral efferent" nuclei of American authors) from the "visceral" category reveals the slender basis upon which the "four-columned" theory was raised, despite J. B. Johnston's (1915) claim to have demonstrated the necessary "viscero-motor" and "viscero-sensory" segmental elements even in the spinal cord of Amphioxus. The "afferent" connection of the vegetative nervous system through the vagus with the central nervous system in the medulla oblongata is well known. Other representation of "afferent visceral" elements in the cerebrospinal axis is inadequately demonstrated anatomically and rests, for the most part, on clinical and physiological induction.

In any case, the term "visceral" (afferent or efferent) can have no morphological significance in neurology apart from its limitation to the vegetative innervation of the endodermal lining of the *archenteric tube* and its derivatives. As such it may include presumably "afferent" elements, by means of which the viscera are brought into more or less intimate connection with the central nervous system. But as soon as the "visceral" (endodermal) elements become entangled in description with the "ectodermal" portion of the vegetative nervous system in supposed contradistinction to the so-called "somatic" nervous system, confusion is bound to result, and particularly in considering the "afferent" or sensory side.

Most productive of harmful results is the extension of the "*visceral afferent*" conception to the study of the special sense organs, which arise in the *ectoderm*. It is evident, *prima facie*, that to call any such ectodermal mechanism "visceral" is to indulge in a loose terminology which neglects all embryological considerations. Even in the case of taste, which appears to have endodermally arising receptors and ganglion cells in all higher forms, it is definitely known that portion of the mechanism is ectodermal—and not "visceral"—in certain fishes.

Even if the contentions concerning the "visceral" character of taste were to be admitted in the present incomplete nature of our information, it is obvious that no such reasoning can be applied to smell. Tretjakoff (1913) put the facts lucidly enough when he stated "Die rezeptorischen Zellen des Olfaktorius sind den somatisch-rezeptorischen Zellen der Haut der Wirbellosen so ähnlich, dass sie für eine visceralsensorische Komponente zu halten kein Grund vorliegt."

Herrick's criterion, "the relation of the sense to selection and digestion of food" is equally inadmissible. With a full appreciation of the underlying physiological principles involved, it would be possible to make out as good a case for the "visceral" character of the musculature and innervation of the diaphragm, the levator ani and the perineal musculature because of their relation to respiration, defaecation and generation.

CONCLUSION

It is therefore reiterated that far from admitting any claim for the "visceral" nature of smell, restraint should be exercised even in the case of taste, which has been spoken of previously (1920) as a "border-land mechanism." There is certainly no justification in morphological considerations either for a "*visceral cortex*" or for the latest form in which we have the conception appearing when Kappers (1921) calls the striatum a "*sympathisches Gebiet.*"

BIBLIOGRAPHY

BAER, C. E. VON. *Ueber Entwickelungsgeschichte der Tiere.* 1828, 1837.

BALFOUR, F. M. *Comparative embryology.* 1885.

BRACHET, A. *Traité d'embryologie des Vertébrés.* Paris. 1921.

DAHLGREN and KEPNER. *Principles of Animal Histology.* New York. 1908.

DART, RAYMOND A. "A contribution to the morphology of the corpus striatum." *Jour. of Anat.* vol. LX. Part I. 1920.

DART, RAYMOND A. and SHELLSHEAR, J. L. "A new interpretation of the morphology of the nervous system." *Anat. Record,* vol. XXI. No. 1, p. 54. 1921.

—— —— "The origin of the motor cells of the anterior cornu." *Jour. of Anat.* vol. LVI. Pt. II. Jan. 1922.

DARWIN, CHARLES. *Origin of species.* 1859.

ELLIOT SMITH, G. "The central nervous system." *Cunningham's Anatomy,* 3rd edition. 1913.

GASKELL, W. H. *The origin of vertebrates.* London. 1908.

GAUPP, E. *Hertwig's Entwickelungslehre.* Bd. III. 3ter T. 1906.

GEGENBAUR, C. *Untersuch. z. vergl. Anat. d. Wirbelth.* Hft. 3. "Das Kopfskelett der Selachier u. s. w." Leipzig. 1872.

HATSCHEK, B. "Die Metamerie des Amphioxus und des Ammocoetes." *Verhandl. d. anat. Ges. Wien.* 1892.

HERRICK, C. JUDSON. "The connections of the vomero-nasal nerve, accessory olfactory bulb and amygdala in Amphibia." *Jour. of Comp. Neur.* vol. XXXIII. No. 3. 1921.

HERTWIG, O. and R. *Die Coelomtheorie, Versuch einer Erklärung des mittleren Keimblattes.* Jena. 1881.

HUXLEY, T. H. "On the theory of the vertebrate skull." (The Croonian Lecture, 1858.) *Proc. of Roy. Soc. Lond.* vol. IV. 1859.

JOHNSTON, J. B. "Cranial and spinal ganglia and the viscero-motor roots in Amphioxus." *Biol. Bull.* vol. IX. No. 2. 1915.

KAPPERS, C. U. ARIENS. *Vergleichende Anatomie des Nervensystems.* Abschnitt II. Haarlem. 1921.

KUNTZ, A. "Peripheral migration and distribution of medullary cells in the absence of spinal ganglia and dorsal nerve roots in embryos of the chick." *Anat. Record,* vol. XXI. No. 1, p. 70. 1921.

LANDACRE, F. L. "The fate of the neural crest in the head of urodeles." *Jour. of Comp. Neur.* vol. XXXIII. No. 1. 1921.

LEWIS, W. H. "Muscular System." *Manual of Human Embryology.* Keibel and Mall. 1910.

MALONE, E. "Somatic motor chain of nerve cells." *Anat. Record,* vol. VII. 1913.

MAURER, F. *Hertwig's Entwickelungslehre,* Bd. III. 1ter T. 1906.

MECKEL, J. F. *Beiträge zur vergleichende Anatomie.* Leipzig. Bd. I. 1808; Bd. II. 1811.

MÜLLER, ERIK and INGVAR, SVEN. "Ueber den Ursprung des Sympathicus bei den Amphibien." *Upsala Läkareförenings förhandlingar.* Ny följd. Bd. XXVI. H. 5–6.

PANDER, C. H. *Beiträge z. Entwick. d. Hühnchens im Ei.* Doktordissertation. 1817.

RABL, C. "Ueber die Differenzierung des Mesoderms." *Verh. d. Anat. Ges. Würzburg.* 1888.

RATHKE, H. *Anat.-philos. Untersuch. über d. Kiemenapparat u. d. Zungenbein d. Wirbelth.* Riga u. Dorpat. 1832.

REICHERT, C. *De embryonum arcubus sic dictis branchialibus.* Dis. inaug. ord. med. Berolini. 1836.

—— "Ueber d. Visceralbogen d. Wirbelth. Im algem. u. d. Metamorph. b. d. Vögeln u. Säugethieren." *Müller's Arch.* 1837.

SCHNEIDER, A. *Beiträge zur Anat. und Entwick. d. Wirbelth.* Berlin. 1879.

STONE, L. S. "Experiments on the development of the cranial ganglia and the lateral line sense organs in Amblystoma." *Anat. Record,* vol. XXI. No. 1, p. 85. 1921.

TRETJAKOFF, D. "Die zentralen Sinnesorgane bei Petromyzon." *Arch. f. mikr. Anat.* Bd. 87. 1913.

WEBER, E. H. *Arch. f. Anat. Phys. und wissensch. Medizin.* 1851.

VAN WIJHE. "Ueber die Mesodermsegments des Rumpfes u. d. Entwickelung des Exkretionssystems bei Selachiern." *Arch. f. mikr. Anat.* Bd. XXXIII. 1889.

WILSON, J. T. "The double innervation of striated muscle." *Brain,* vol. XLIV. Pt. II. 1921.

THE CRANIAL ANATOMY OF POLYPTERUS, WITH SPECIAL REFERENCE TO *POLYPTERUS BICHIR*

By EDWARD PHELPS ALLIS, Jr,
Menton, France.

CONTENTS

PAGE
INTRODUCTION 189
NEUROCRANIUM 190
NASAL SAC AND NASAL APERTURES . . 198
OSTEOLOGY 199
  Parieto-dermopterotic 200
  Frontal 201
  Nasal 202
  Accessory nasal 203
  Os terminale 203
  Ethmoid 203
  Infranasal and infraorbital bones . . 204
  Spiracular ossicles 205
  Supratemporals and Posttemporal . 205
  Basi-exoccipital 206
  Aortic canal 209
  Aortic canal and occipital region in the 75 mm. *Polypterus senegalus* . . 211
  Opisthotic 218
  Postfronto-sphenotic 220
  Parasphenoid 222
  Sphenoid 226
  Ectethmoid 230
  Visceral arches 231
  Basal line 231
  Branchial arches 232
  Hyal arch 235
  Opercular and cheek bones . . . 238
  Palatoquadrate 240
  Mandible 245
  Maxillary 248
  Premaxillary 249

PAGE
LATERO-SENSORY CANALS 250
MYOLOGY 252
  Eye muscles 252
  Muscles innervated by the nervus trigeminus 252
  Muscles innervated by the nervus facialis 256
  Muscles innervated by the nervi glossopharyngeus and vagus . . 257
  Longitudinal ventral muscles . . 259
ANGIOLOGY 260
  Vena jugularis 260
  Afferent and efferent arteries . . 264
  Carotid arteries 266
  Trigemino-facialis chamber . . . 268
NEUROLOGY 269
  Nervus and lobus olfactorius . . 269
  Nervus terminalis 270
    ,, opticus 270
    ,, oculomotorius 270
    ,, trochlearis 271
    ,, abducens 271
    ,, profundus 271
    ,, trigeminus 273
    ,, facialis 279
    ,, acusticus 283
    ,, glossopharyngeus . . . 283
    ,, lineae lateralis vagi . . 286
    ,, vagus 286
SUMMARY 289
LITERATURE CITED 292

INTRODUCTION

The present work was begun in 1899, on two large specimens of *Polypterus bichir* purchased in Germany, but it was soon found that they would not suffice for the work contemplated. Several large specimens from the material collected by N. R. Harrison in Abyssinia, and said to also be of *Polypterus bichir*, were later sent me by Professor Bashford Dean, of Columbia University, and still later Professor Dean sent me three heads of *Polypterus ornatipinnis* from the collections at the American Museum of Natural History, New York

City. In addition to this adult material I have had four specimens from 29 cm. to 32 cm. in length, which, as they had only 8–12 finlets, were probably of *Polypterus Lapradei* though said to be of *Polypterus bichir*; and three larvae of *Polypterus senegalus*, 73 mm. to 83 mm. in length, kindly sent me by Professor J. Graham Kerr from the material collected by J. S. Budgett in the Gambia. The dissection of the adult specimens was confided to my assistant, Mr Jugiro Nomura, and the drawings used for the accompanying illustrations are all by him. The three larvae were sectioned, and the one series that proved of any value was given to my assistant, Mr John Henry, with instructions to carefully trace the nerves and blood vessels. While waiting, at different times, for additional material the work was necessarily interrupted, other work undertaken in the meantime still further delayed it, and before it was fully completed and controlled both Mr Nomura and Mr Henry died.

The work has thus not been limited to a single species, which is unfortunate, and it has not been carried through to the extent that was intended, this applying particularly to the nervous system. While it has been in progress I have published several works in which certain of the features of the cranial anatomy have been more or less fully described and discussed, and just as the work is ready for publication I have received a copy of the *Zeitschrift für angewandte Anatomie und Konstitutionslehre* in which there is an important article by Dr Charlotte Lehn, published in Berlin in 1918 and describing the neurocranium of a larva of *Polypterus senegalus*, 76 mm. in length. As my descriptions relate largely to the adult, and include the visceral arches, muscles, nerves and blood vessels as well as the neurocranium, the manuscript is sent to press with but little alteration beyond frequent reference to Lehn's work. Many features referred to, and more or less fully described, in my earlier works are here again described, in order to make the work complete.

NEUROCRANIUM

The neurocranium of one of the large specimens from Abyssinia, shown in figs. 7–14, has approximately the proportions of that of the 30 cm. specimen of *Polypterus Lapradei* described by Bridge (1888), but is relatively longer, and less tall and wide than that of the small specimen of *Polypterus* (presumably *senegalus*) described by Traquair (1871) and of the 21 cm. specimen (species not given) described by Pollard (1892). Its dorsal surface is formed by the paired parieto-dermopterotics, frontals, nasals, accessory nasals, ossa terminalia, and premaxillaries, by a single median ethmoid, and by a small portion of the postfronto-sphenotic of either side which is exposed along the lateral edge of the posterior portion of the frontal. Its ventral surface is formed by the premaxillaries, the large median parasphenoid, a small portion of the basi-exoccipital that is exposed between the diverging hind ends of the parasphenoid, and by three small portions of the ethmoid cartilage which appear anterior and lateral to the anterior end of the latter bone.

The orbital fossa is long and low, and occupies about two-fifths of the total length of the neurocranium. Its anterior half, only, is occupied by the eyeball, the posterior half lying internal to the postorbital and prespiracular bones and being completely filled by what Pollard calls the pterygoid and temporal divisions of the musculus adductor mandibulae. The external opening of the fossa leads into the part occupied by the eyeball, and is bounded dorsally by the frontal, posteriorly by the postorbital, ventrally by the lachrymal and the latero-sensory component of the maxillary, and anteriorly by the lachrymal and the antorbital process of the premaxillary. The postorbital process lies at a considerable distance posterior to the hind edge of the external opening of the fossa, and the mesial wall of the posterior half of the fossa corresponds, morphologically, to the hind wall of the orbits of Amia and most of the Teleostei; the flattening out and consequent lengthening of this part of the orbit of Polypterus being an important factor in giving to the entire neurocranium its unusual length.

The nasals, accessory nasals, and ossa terminalia can all be readily removed in alcoholic specimens, but the frontals and parieto-dermopterotics could not be removed, intact, in any of my specimens, without injury to the underlying cartilage. The latter bones could, however, when filed very thin, be stripped off the underlying cartilage without injury to it. The ascending processes of the parasphenoid apparently include the proötics, as will be later explained, and this part of each process could not be removed without breakage of the cartilage.

The primordial cranium, or so-called chondrocranium of the adult is almost entirely of cartilage in the otic and ethmoidal regions, but almost entirely of bone in the orbitotemporal and occipital regions. There is, in the orbitotemporal region, a large perforation of the basis cranii, and directly dorsal to it a still larger perforation of the tegmen cranii. The perforation of the basis cranii may be called the basicranial fontanelle, a name already given to it by other authors, but it is apparently the strict homologue of the fontanelle that I have recently (Allis, 1919*b*, p. 228) called, in Amia and the Teleostei, the fenestra ventralis myodomus. It is closed ventrally by the parasphenoid, and will be further considered when describing the sphenoid bone. The perforation of the tegmen cranii is the supracranial fontanelle. It is roofed by the frontals and parieto-dermopterotics, and is closed, in the natural state, by membrane; and in this membrane, at the posterior third or quarter of the length of the fontanelle, and between the hind ends of the vertical plates of the sphenoid, there was, in the one specimen examined in this respect, the small thin round plate of cartilage described by Pollard, perforated by a small hole. In my 75 mm. specimen of *Polypterus senegalus* there is here a complete bridge of cartilage, as there also was in the larvae described by Budgett (1902) and Lehn (1918). On either side of the supracranial fontanelle there is, in the adult, a large supraorbital fontanelle, which perforates the roof of the posterior portion of the orbital fossa. It is closed dorsally by the frontal, and the temporal division of the musculus adductor mandibulae here has its insertion on the ventral surface of that bone. In my 75 mm. specimen, and in that described by Lehn, the cartilage of the chondrocranium is also here perforated, but in Budgett's 30 mm. larva it is shown as simply hollowed out on its ventral surface, but not perforated, the definitive perforation thus apparently being caused by the insertion of the musculus temporalis.

In Budgett's 30 mm. larva the highest point of the median line of the dorsal surface of the chondrocranium lies between the postorbital processes, in Lehn's 76 mm. specimen it lies somewhat posterior to that point, and in my adults still farther posteriorly, at the hind end of the dorsal surface of the chondrocranium; this change in position of this highest point apparently being caused by a gradual thickening of the cartilage from the hind end of the supracranial fontanelle to the hind end of the dorsal surface of the chondrocranium. From this highest point in the adult, the dorsal surface slopes antero-ventrally at a slight angle, the posterior surface sloping postero-ventrally at an angle of about 30° to the horizontal plane. From the hind edge of the dorsal surface a small flat crista occipitalis, which is horizontal instead of vertical in position, projects posteriorly and slightly overhangs the dorsal edge of the posterior surface.

In the otic region, the median portion of the dorsal surface of the chondrocranium is nearly flat, and on either side of this flat portion there is a large, but non-functional temporal groove. Each postero-lateral corner of the flat surface forms the hind end of the mesial bounding edge of the temporal groove of its side, and corresponds exactly, in topographical position, to the epiotic process of Amia and certain of the Teleostei. The temporal groove has a Y-shaped hind end, one limb of this Y running postero-laterally onto the dorsal surface of the postero-lateral portion of the opisthotic, and the other limb running postero-mesially and then postero-ventrally onto the posterior surface of the chondrocranium. The lateral limb of the Y is a slight depression, only, and lies antero-lateral to the posterior semicircular canal, the mesial limb crossing that canal; the two limbs thus corresponding to the two branch depressions described by me (Allis, 1920*a*) at the hind end of the temporal depression on the dorsal surface of the chondrocrania of Lepidosteus and Rana. The slight depression of the lateral limb lodges the postero-lateral corner of the parieto-dermopterotic, that part of that bone enclosing the hind end of the main latero-sensory canal. The depression of the mesial limb lodges a postero-ventral process of the parieto-dermopterotic, and between this limb and the lateral one, the posterior process of the parieto-dermopterotic projects directly posteriorly. The temporal groove, itself, is almost completely filled by a rounded ridge on the ventral surface of the parieto-dermopterotic.

The dorsal end of the sinus utriculus superior lies considerably mesial to the temporal groove, not far from its fellow of the opposite side. The anterior semicircular canal runs antero-laterally from there, lying mesial to the temporal groove and always enclosed in the cartilage of the chondrocranium.

The posterior semicircular canal runs postero-laterally, anterior to the epiotic process, and then beneath and across the base of the mesial limb of the Y-shaped prolongation of the temporal groove, its course there being marked by a low rounded ridge which forms the boundary between the dorsal and posterior surfaces of the chondrocranium, and the canal lying partly in the cartilage of the chondrocranium and partly in the opisthotic bone. The lateral semicircular canal lies in part internal to, and in part ventro-posterior to the articular facet for the hyomandibula, and traverses both the cartilage of the lateral wall of the chondrocranium and the opisthotic bone, its canal in the latter bone lying internal to the descending arm of the posterior semicircular canal and being in part confluent with that canal.

The anterior end of the lateral semicircular canal lies posterior to the curved descending limb of the anterior semicircular canal, and between these two portions of these two canals there is a marked re-entrant angle in the dorso-lateral edge of the chondrocranium. The anterior edge of the spiracular canal lies in the point of this angle, and the ramus oticus lateralis issues on the dorsal surface of the chondrocranium almost directly mesial to it. The angle is thus a fossa spiracularis, and corresponds to that depressed region on the dorso-lateral edge of the chondrocranium of 14 mm. embryos of Lepidosteus to which I have referred (Allis, 1920*a*) as probably lodging the recessus dorsalis spiracularis. This depressed region of the chondrocranium of embryos of Lepidosteus later becomes spanned by cartilage, and so gives rise to the spiracular canal, the lateral edge of this spanning cartilage forming a connection between the primarily independent sphenotic and pterotic ridges. The chondrocranium of Polypterus thus here remains in the stage of development shown in the 14 mm. Lepidosteus, and a spheno-pterotic ridge such as is found in the adults of the Holostei and Teleostei, is never developed, its two component parts persisting as independent ridges; and this is apparently the condition in mammals, the fossa spiracularis of Polypterus corresponding to some portion of the fossa epitympanica of mammals.

The dorsal portion of the posterior surface of the chondrocranium extends from the hind edge of its dorsal surface to the dorsal edge of the foramen magnum, sloping postero-ventrally at an angle of about 30° to the horizontal plane. This part of the posterior surface is, in reality, the dorsal surface of the occipital portion of the chondrocranium, and its lateral edge, which separates it from the lateral surface of the chondrocranium, is formed by a lateral occipital ridge similar to that found in many of the Teleostei, this ridge starting from the base of the posterior process of the opisthotic, and running along the dorsal margin of the foramen vagum to the ventro-posterior portion of the exoccipital part of the basi-exoccipital. Dorso-mesial to this ridge is a ridge which forms the lateral boundary of the postero-mesial prolongation of the temporal groove, and mesial to this latter ridge is another ridge which forms the mesial boundary of the same prolongation, this latter ridge running dorso-anteriorly into the epiotic process. Between this latter ridge and its fellow of the opposite side the dorsal surface of the chondrocranium is slightly concave. The conditions in Polypterus thus here resemble those in Amia (Allis, 1897), Scomber (Allis, 1903), and the mail-cheeked fishes (Allis, 1909), excepting in that, in all these latter fishes, the lateral bounding ridge of the posterior prolongation of the temporal groove is confluent with the lateral occipital ridge, the two together forming the bounding edge between the posterior and lateral surfaces of the chondrocranium.

On the lateral surface of the postorbital portion of the neurocranium there is a large articular facet for the hyomandibula, the antero-ventral portion of this facet lying on the lateral surface of the chondrocranium, but its dorso-posterior portion on the lateral edge of the parieto-dermopterotic, and hence actually above the chondrocranium. The antero-ventral end of the facet lies external (lateral) to the anterior portion of the lateral semicircular canal, but its posterior portion dorsal to that canal. The dorsal edge of the facet is formed by a sharp curved ridge which, as described in an earlier work (Allis, 1920*a*), lies partly on the cartilage of the chondrocranium but mainly on the lateral edge of the parieto-dermopterotic, the hollow of the curve presented ventro-posteriorly. That part of this ridge that lies on the chondrocranium is continued posteriorly, on that cranium, internal to the parieto-dermopterotic, and is continuous with the lateral edge of the dorsal surface of the opisthotic, the entire ridge thus forming the pterotic portion of the spheno-pterotic ridge of the chondrocranium. Ventral to the posterior portion of the facet for the hyomandibula there is another ridge, which lies wholly on the opisthotic, and ventral to it is the opisthotic ridge, which begins at about the middle of the lateral edge of the postorbital process, immediately dorsal to the definitive foramen faciale, and runs postero-dorsally across the opisthotic to the hind end of the posterior process of that bone. Between these two ridges there is, on the opisthotic, a concave and roughened surface which gives insertion to the musculi adductor hyomandibularis, adductor operculi, and levatores arcuum branchialium. Ventral to the opisthotic ridge there is a groove, the sulcus jugularis, which lodges the vena jugularis after it issues from the definitive foramen faciale; and ventral to this sulcus there is a large bulla acustica. From the bulla acustica a broad but low ridge runs posteriorly and slightly ventrally, ventral to the foramen vagum and parallel to the lateral occipital ridge, and between these two ridges there is a deep groove which lodges the nervus vagus after it issues from its foramen.

In Budgett's 30 mm. larva the dorso-lateral edge of the otic portion of the chondrocranium is formed by a large ridge, which is said to enclose the lateral semicircular canal and is hence a prominentia semicircularis lateralis. It is called by Budgett the pterotic ridge, and the hyomandibula articulates with its lateral surface. In my 75 mm. specimen this prominentia is found in similar position, and the hyomandibula here also articulates with its lateral surface, but a secondary ridge of cartilage forms the dorsal boundary of the surface of articulation, and it is this secondary ridge that forms the dorso-lateral edge of this part of the chondrocranium, and is, therefore, the pterotic ridge properly so called, the hyomandibula at no place extending dorsal to it. Mesial to this pterotic ridge, the dorsal surface of the prominentia semicircularis lateralis forms a low and rounded ridge which separates the temporal groove into lateral and mesial portions, the mesial portion lodging the main latero-sensory canal. The parieto-dermopterotic extends laterally beyond this part of the prominentia, its lateral edge resting upon the summit of the pterotic ridge and at no place forming part of the articular facet for the hyomandibula, as it does in the adult. Immediately posterior to the facet for the hyomandibula, the prominentia semicircularis lateralis becomes narrower and more rounded in serial transverse sections, and the pterotic ridge on its dorso-lateral corner gradually vanishes. The prominentia still forms the dorsal boundary of the jugular groove, and the anterior edge of the adductor hyomandibularis is now cut in the sections, this muscle being inserted on the prominentia dorsal to the vena jugularis, between that vein and a large lymph space which extends forward internal to the hyomandibula. Proceeding posteriorly in the sections, a ridge develops on the summit of the prominentia, immediately dorsal to the lymph space above mentioned, this ridge lying ventral to the line prolonged of the pterotic ridge and evidently being, notwithstanding that it lies posterior to the facet for the hyomandibula, that marked ridge on the opisthotic of the adult that forms the ventral boundary of the posterior portion of that articular facet; this ridge vanishing, in the 75 mm. specimen, on the dorsal surface of a posteriorly projecting portion of the otic capsule which lodges the vertically descending portion of the posterior semicircular canal. In the adult the hind end of this ridge forms a slight process on the lateral surface of the posterior process of the opisthotic, as seen in the posterior view of the chondrocranium (fig. 14). The dorsal, or supratemporal branch of the nervus glossopharyngeus runs upward across the surface of insertion of the musculus adductor hyomandibularis, there traversing that muscle, and then perforates the ridge just above described, to reach the dorsal surface of the chondrocranium. In the adult, that part of this nerve that, in this embryo, lies along the external surface of the surface of insertion of the adductor hyomandibularis has become entirely enclosed in the opisthotic.

Lehn (1918, p. 365) considers the ridge just above described on the dorsal surface of the prominentia semicircularis lateralis to be the crista parotica, but as the ridge to which Gaupp (1893) first gave that name, in Rana, forms the dorsal edge of the jugular groove, it seems more probable that it is represented in the entire posterior portion of the opisthotic ridge of Polypterus, as already suggested in an earlier work (Allis, 1920*a*, p. 264).

The cranial cavity occupies about two-thirds of the full length of the chondrocranium, extending from the foramen magnum forward between the orbits to a median wall that separates the foramina olfactoria from each other and that is formed by the mesial portions of the articulating anterior ends of the vertical laminae of the sphenoid. In the orbito-temporal and occipital regions the bounding walls are entirely of bone, but in the auditory region entirely of cartilage excepting where they are perforated by the large openings that lead into the labyrinth recesses, these openings doubtless being closed by membrane though none could be detected in the dissections. The anterior and posterior portions of the floor of the cavity lie in approximately the same horizontal level, and between them, extending from the foramina optica to the postclinoid wall (proötic bridge), is the large pituitary fossa, this fossa lodging the lobi inferiores in its anterior portion, the hypophysis in its middle portion, and the saccus vasculosus, called by Waldschmidt (1887) the glandular portion of the hypophysis, in its posterior portion, beneath the proötic bridge. The floor of the fossa is perforated, its full length, by the basicranial fontanelle, which is closed ventrally by the parasphenoid. At about the middle of the length of the fontanelle there is, on the dorsal surface of the parasphenoid, a slight median hypophysial depression. The sides of the fontanelle are nearly parallel, and are formed, in the adult, by the basal portions of the vertical laminae of the sphenoid, but in the 75 mm. larva by the cartilaginous trabeculae. The cranial cavity is of approximately equal width throughout the auditory and orbito-temporal regions, and the brain extends its full length. Dorsal to the foramen opticum of either side there is a large but slight depression in the lateral wall, this depression marking the position of the fore-brain.

The ventral portion of the labyrinth recess of either side is occupied by a deep fossa which runs postero-laterally and is separated by a slight and rounded transverse ridge into a small anterior and a large posterior portion. The former lodges the sacculus and the latter the lagena, the thin ventral wall of the latter fossa bulging outward and forming the bulla acustica on the external surface of the chondrocranium. Dorsal to the fossa lagenae there is a fossa in the postero-lateral wall of the recess, this fossa lying in the opisthotic, in the hollow of the curve of that portion of the lateral semicircular canal that projects posteriorly into the hollow of the curve of the posterior semicircular canal, as described by Retzius (1881). The dorsal end of the lagena doubtless lies in this fossa, but I could not definitely determine this in my specimens. Dorsal to the anterior portion of this fossa lagenae there is a small depression which doubtless lodges the saccus endolymphaticus. Antero-lateral to the dorsal edge of the fossa sacculi there is a fossa, slightly double, which lodges the recessus utriculi and the ampullae anterior and lateralis, and antero-lateral and postero-lateral to this fossa are the openings, respectively, of the anterior and lateral semicircular canals. Postero-mesial to the dorsal edge of the fossa lagenae there is a small fossa which lodges the ampulla posterior, and dorso-lateral to this is the ventral opening of the posterior semicircular canal. Two little grooves, which diverge anteriorly and posteriorly from near the median line of the roof of the labyrinth recess, lead into the dorsal ends of the canals for the anterior and posterior semicircular canals, and the little fossa that lodges the dorsal end of the saccus endolymphaticus lies ventro-lateral to the posterior one of these two grooves.

The walls of the labyrinth recess are traversed by all three of the semicircular canals, the part so traversed by the anterior canal lying wholly in the cartilage, internal to the postfronto-sphenotic, while the parts traversed by the lateral and posterior canals are in part enclosed in the opisthotic. The nervi facialis, glossopharyngeus, and ophthalmicus superficialis all enter the labyrinth recess before perforating the cartilaginous wall of the cranium. The nervus facialis, having entered the recess, perforates its cartilaginous wall near the mesial end of the ridge between the fossa sacculi and the fossa that lodges the recessus utriculi and the ampullae anterior and lateralis, and passing ventral to the recessus utriculi opens into the jugular canal, which will be described in connection with the parasphenoid. The foramen for the ophthalmicus superficialis lies slightly anterior to the foramen faciale, close against the ridge of cartilage that forms the mesial wall of the anterior portion of the labyrinth recess, and traverses the cartilage ventro-mesial to the ampulla anterior. The canal for the nervus glossopharyngeus begins in the ventral wall of the labyrinth recess mesial to the mesial end of the ridge between the fossa lagenae and the fossa for the ampulla posterior, and running ventral to the latter ampulla issues at the ventro-posterior edge of the bulla acustica.

Retzius did not find a canalis utriculo-saccularis in the adult specimens he examined. In my 75 mm. larva the large sac formed by the sacculus and lagena was connected by a narrow canal with the basal portion of the sinus utriculi superior, the canal opening into the sacculus-lagena on its mesial surface close to the base of the ductus endolymphaticus.

From the above general description it is seen that the cranium of Polypterus is strictly platybasic in type. The cavum cranii differs markedly, in its general lines, from that of Amia and all of the Teleostei I know of excepting only Amiurus and Silurus, and it as markedly resembles that of many of the Selachii. The resemblance is particularly marked with that of Scymnus, as shown by Gegenbaur (1872, fig. 3, Pl. 4), and slightly less so with that of Chlamydoselachus as described by me (Allis, 1914). In both these latter fishes there is, as in Polypterus, a large pituitary fossa which lodges the lobi inferiores and the pituitary body, the anterior end of the fossa being formed by a presphenoid bolster and the posterior end by a postclinoid wall. The nervus opticus perforates the cranial wall dorsal to the presphenoid bolster in Chlamydoselachus, as it does in Polypterus, and but slightly posterior to that bolster in Scymnus. The pituitary foramen perforates the side wall of the fossa in all three fishes, but differs slightly in position in each of them, perforating the side wall near the middle of the length of the fossa in Polypterus, at its hind end in Chlamydoselachus, and apparently perforating the hind wall in Scymnus. The arteria carotis interna perforates the floor of the fossa by a median foramen, in Chlamydoselachus and Scymnus, while in Polypterus it enters the cranial cavity anterior to the fossa, through the foramen opticum, but this is probably not an important difference, for as the artery in Chlamydoselachus and Scymnus quite undoubtedly runs forward a certain distance between the cartilage of the fossa and its lining membrane, it lies morphologically anterior to the fossa. In Chlamydoselachus the brain extends forward nearly to the level of the presphenoid bolster, and in embryos doubtless extended onto the bolster, as it does in the adult Polypterus. In Scymnus there is a large presphenoid shelf, as in Polypterus, but it is not said how far forward the brain extends. The anterior end of the cavum cranii is formed, in all three fishes, by a narrow median column which separates the foramina olfactoria from each other, and in the Selachii this column is said by Sewertzoff (1899) to be formed by the trabeculae fused to form what he has called the rostral stalk. A septum nasi, where found, as in Galeus and Mustelus, lies ventral to that stalk. In Polypterus the septum apparently lies dorsal to the trabeculae. But, however this may be, it is evident that the nasal capsules must lie morphologically dorsal to the trabeculae in all these fishes, for the nervi olfactorii always run outward dorsal to the latter cartilages.

NASAL SAC AND NASAL APERTURES

In my 75 mm. larva of *Polypterus senegalus*, and also in one adult specimen from Abyssinia, the only ones examined in this respect, the nasal sac is divided into five sectors by five longitudinal septa which radiate outward from the axis of the sac. Waldschmidt (1887) also found but five sectors and septa in the 25 cm. to 30 cm. specimens of *Polypterus bichir* examined by him, as did also J. Müller (1846) in what were probably older specimens of the same fish. Wiedersheim (1906), however, says that there are six sectors and six septa in this fish.

In my 75 mm. larva, one of the five septa is horizontal in position and extends mesially from the horizontal axis of the sac to its periphery, the other septa extending dorso- and ventro-mesially and dorso- and ventro-laterally. The nervus olfactorius lies in the horizontal axis of the sac, but it does not enter the sac in the line of that axis, entering it by passing ventro-antero-laterally across the hind end of that sector of the sac that lies immediately dorsal to the horizontal septum, that sector not extending as far posteriorly as the others. The two mesial sectors both extend forward slightly beyond the other three, and there lie mesial to an open space into which they and the other three sectors all open. The ventral one of the two mesial sectors is prolonged anteriorly beyond this space, and there lies in a slight recess in the nasal cartilage. In the adult this projecting anterior end of this sector becomes somewhat separated from the remainder of the nasal organ and forms the "Nebenriechorgan" said by Waldschmidt to have been described by Wiedersheim in a work I have not been able to consult. It is innervated, as Waldschmidt says, by a simple terminal branch of the nervus olfactorius.

Into the open space, above referred to, that lies lateral to the anterior ends of the two mesial sectors of the nasal sac, the anterior nasal tube opens, the base of the tube projecting a certain distance into the space, and being slit a certain distance upward along its lateral surface. Slightly posterior to this tube, in the lateral portion of the space into which it opens, the posterior nasal passage begins, and runs posteriorly in a slight depression on the lateral surface of the antorbital process of the premaxillary bone. This depression lies between the lateral edge of the nasal bone above and tube 5 of the infraorbital latero-sensory canal below, and the nasal passage opens posteriorly in a crescentic and slit-like aperture which lies slightly anterior to the anterior edge of the orbit. The anterior nasal tube was, in certain of my preserved specimens, folded back onto the external wall of this posterior nasal passage, and, pushing in that wall, was half imbedded in the groove that lodges the passage.

In one of my large specimens, the only one examined in this connection, the two nasal passages had the same relations to each other and to the nasal sac that they had in the 75 mm. larva, but in a 30 cm. specimen the two nasal apertures both opened into a space that was partially separated from the nasal chamber by a membranous partition, and that was apparently the "Vorhöhle" of Waldschmidt's (1887) description. A large opening led from this atrial chamber into the nasal chamber, and was incompletely bridged by a process of membrane which projected dorso-posteriorly from its antero-ventral edge and touched, but was not fused with, the opposite edge of the opening. Nothing resembling the arrangement here described by Waldschmidt was found in either of the three specimens examined.

The nasal epithelium of Polypterus would thus seem to be a special development of the rosette form found in certain of the Teleostei and in Chimaera, and it is usually assumed that it has arisen from that form as a result of a thickening of the sensory epithelium and a concomitant deepening of the nasal sac. The nasal capsule cannot, however, have arisen by the simple deepening of a shallow pit, for the terminal branches of the nervi ophthalmicus and maxillaris trigemini both perforate the wall of that capsule and then run forward between it and the nasal sac to issue through the fenestra nasalis. These terminal branches of these nerves both contain latero-sensory fibres, and hence must necessarily have primarily passed external to the nasal capsule, and a simple deepening of the capsule could not have included them within it. There must then have been a forward growth of the lateral wall of the capsule, and it is possible that a similar growth of the primitive sac and nasal epithelium has also taken place.

OSTEOLOGY

The bones that form the skull of Polypterus are, as is well known, in part so-called primary ones (ossa substituentia) and in part secondary, or dermal ones (ossa investiantia), and certain of them are apparently the equivalents of two or more bones usually found separate and independent in the Holostei and Teleostei. Whether this is due to the invasion, by one bone, of the territory usually occupied by one or more other bones, or is due to the actual fusion of two or more primarily independent bones, cannot be determined from my material, for, even in my 75 mm. specimen, there is no positive indication, in any of the bones concerned, of two or more separate centres of ossification. It nevertheless seems proper, in certain cases, to assume the fusion of two bones, and to indicate the two components by the use of a compound term.

Parieto-dermopterotic. This bone was called by both J. Müller (1846) and Traquair (1871) the parietal. Van Wijhe (1882) later called it the squamoso-parietal, because of its assumed formation by the fusion of the squamosal and parietal bones of the Teleostei, and I adopted this term in my work on the latero-sensory canals of this fish. The bone, however, only includes the dermal component of the squamosal of the Teleostei, and as the latter bone is currently called by English authors the pterotic, I shall call the bone of Polypterus the parieto-dermopterotic.

The two parieto-dermopterotics, one on either side of the head, are each somewhat rectangular in shape, and they together form the posterior portion of the flat dorsal surface of the neurocranium, extending from the orbito-temporal to the occipital regions and lying upon the otic portion of the chondrocranium. Each bone articulates, in the median line, with its fellow of the opposite side, and articulates anteriorly either with the frontal of its side, alone, or with both that bone and the postero-mesial corner of the frontal of the opposite side, the sutural line between the frontals not always being in line with the suture between the parieto-dermopterotics. The anterior end of each bone rests upon the dorsal surfaces of the postfronto-sphenotic and the vertical plate of the sphenoid, and between these two bones it roofs the hind end of the supraorbital fontanelle. Mesial to the sphenoid it roofs one half of the hind end of the median supracranial fontanelle.

Along the lateral edge of the anterior portion of the bone there is a depressed region which extends forward slightly onto the hind end of the frontal. The anterior portion of this depression lodges the mesial half of the anterior spiracular ossicle. The posterior portion of the depression is deeper than the anterior portion, and lodges the anterior portion of the dorsal end of the spiracular canal, this part of the depression extending downward across the lateral edge of the bone. Posterior to this there is, on the lateral edge of the bone, a concave depression which forms the dorsal portion of the articular facet for the hyomandibula, the dorsal edge of this depression forming a sharp ridge which runs dorso-posteriorly in a curved line from the ventral edge of the lateral edge of the bone, at about the middle of its length, to the posterior end of its dorsal edge.

The postero-lateral corner of the bone rests upon the dorsal surface of the opisthotic, and from the deeper layers of this part of the bone a stout process, directed posteriorly along the dorso-lateral surface of the trunk muscles, gives insertion to a fascia-like formation related to the muscle fibres of the most anterior segment of the trunk muscles that is seen in dorsal views. This process apparently belongs wholly to the dermopterotic portion of the bone, and corresponds to that posterior process of the pterotic that is found in many of the Teleostei. In Salmo this process is said by Gaupp (1905, p. 678) to be developed in relation to the primary, and not the dermal component of the pterotic, and, furthermore, in all of the Teleostei it is with what is considered to be the primary component of this bone, and not the dermal one, that the hyomandibula articulates. The process of Polypterus is, nevertheless, certainly not of primary origin, and it has quite certainly been developed, like the corresponding process of Scomber (Allis, 1899, p. 55), in relation to the fibrous tissues to which it gives insertion. From the base of this process of Polypterus, and from the ventral surface of the parieto-dermopterotic immediately mesial to it, another process arises which is directed ventro-posteriorly and slightly mesially and lies in that shallow depression on the posterior surface of the chondrocranium that forms a postero-ventral continuation of the mesial arm of the Y-shaped temporal groove. This depression lies immediately lateral to the epiotic ridge, its lateral half lying upon the dorso-posterior surface of the opisthotic, and its mesial half in part upon the cartilage of the chondrocranium and in part upon the dorsal surface of the single median basi-exoccipital bone. Mesial to this ventro-posterior process of the parieto-dermopterotic, the hind end of that bone projects posteriorly somewhat beyond the hind edge of the dorsal surface of the chondrocranium, and there lies upon the dorsal surface of the trunk muscles. The hind edge of the bone is nearly transverse in position, and is slightly bevelled where it is overlapped externally by the anterior edges of the two mesial ones of the three supratemporal bones of its side.

The pterotic portion of the bone is traversed its full length by the main infraorbital latero-sensory canal, the part of the bone so traversed forming a rounded ridge on the ventral surface of the bone which completely fills the temporal groove on the dorsal surface of the chondrocranium. The bone lodges two sense organs of the canal that traverses it, and a tube of the canal issues through the bone slightly posterior to the middle of its length. Immediately posterior to the opening of this tube there is a slight depression which lodges the middle head-line of pit organs.

Frontal. The frontal lies immediately anterior to the parieto-dermopterotic and is the largest bone on the dorsal surface of the cranium. Its mesial edge is nearly straight, and articulates with the corresponding edge of the frontal of the opposite side. Its anterior edge is deeply cut out by a rounded or angular incisure into which the hind end of the nasal fits, the latter bone overlapping externally the frontal. The frontal thus has pointed antero-mesial and antero-lateral corners. The antero-mesial corner rests upon the hind end of the dorsal surface of the median ethmoid. The antero-lateral corner rests upon the flattened dorsal edge of the antorbital process of the premaxillary. Posterior to the latter process the frontal rests upon a portion of the dorsal edge of the ectethmoid, the surface of contact with the latter bone lying slightly mesial to the lateral edge of the frontal. Mesial to these two surfaces of articulation the frontal rests directly upon the cartilage of the chondrocranium, but between the frontal and the cartilage there is, along the lateral edge of the chondrocranium and underlying the supraorbital latero-sensory canal, a shallow groove which lodges the nerves that supply the sensory organs of that canal.

Posterior to the antorbital process of the premaxillary, the lateral edge of the frontal runs postero-laterally in a more or less wavy line, about one half of the width of the bone here overhanging the orbit. When the bone reaches the postfronto-sphenotic it rests upon and is firmly bound to the dorsal surface of that bone, the lateral edge of the frontal here turning postero-mesially in a rounded angle. The larger, mesial portion of the dorsal surface of the postfronto-sphenotic is slightly hollowed out to receive the frontal, the remaining, lateral portion of the bone forming a slight ridge along the lateral edge of the frontal. On the lateral edge of this part of the frontal there is a small rounded incisure which gives passage to the double tube infraorbital 10—supraorbital 7 of the latero-sensory system (Allis, 1900*a*). Posterior to this tube the frontal roofs for a short distance the main infraorbital latero-sensory canal, that canal lying in a groove on the dorsal surface of the postfronto-sphenotic. The frontal then overlaps externally the anterior edge of the parieto-dermopterotic, and is itself overlapped externally by the anterior corner of the anterior spiracular ossicle, the latter ossicle lying in a slight depression on the hind end of the frontal and being loosely bound to it by tough dermal tissues. Anterior to this spiracular ossicle the lateral edge of the frontal is in articular contact with the posterior one or two prespiracular ossicles, and anterior to all of the prespiracular ossicles it is in articular contact with the postorbital bone.

Mesial to the postfronto-sphenotic the frontal roofs the large supraorbital fontanelle, then rests upon the dorsal edge of the vertical plate of the sphenoid, and mesial to the latter bone, roofs, with its fellow of the opposite side, the median supracranial fontanelle. Along the line where the frontal rests upon the dorsal edge of the vertical plate of the sphenoid, there is a ridge on its ventral surface, this ridge being Y-shaped at its anterior end. Beneath the hind ends of the frontals, in the membrane that closes the supracranial fontanelle, there is the small, round and thin median plate of cartilage already referred to.

The frontal is traversed, the greater part of its length, by the supraorbital latero-sensory canal, but is not traversed by any part of the main infraorbital canal. It lodges three sense organs of the supraorbital canal, and two of the tubes of that canal issue on the dorsal surface of the bone. Beginning mesial to the posterior one of these two tubes, and extending postero-mesially, there is a short and slight depression on the dorsal surface of the bone, which lodges the anterior head-line of pit organs.

Nasal. The nasal is a somewhat oval bone which lies upon the cartilaginous roof of the nasal capsule. Its posterior end is bluntly pointed and lies in the re-entrant angle in the anterior edge of the frontal, overlapping that bone externally and being firmly bound to it by dermal tissues. Its mesial edge overlaps externally, and rests upon the dorsal surface of the posterior process of the median ethmoid, and is there in contact with, or closely approaches, the corresponding edge of its fellow of the opposite side. Its lateral edge is free, and lies upon the dorsal surface of the antorbital process of the premaxillary. The anterior edge of the bone is straight, or slightly re-entrant, and articulates with the accessory nasal bone.

The nasal is traversed by the supraorbital latero-sensory canal, and lodges the third sense organ of that line. The third supraorbital tubule traverses a notch in the anterior edge of the bone, the fourth tubule traversing a notch in its latero-posterior edge.

Accessory nasal. This bone is a small and somewhat triangular one, immovably bound to the anterior end of the nasal. Its small anterior end rests upon and is bound to the dorso-posterior end of the ascending process of the premaxillary. Its mesial edge fits into a slight groove on the postero-lateral surface of the thickened anterior portion of the median ethmoid, and lateral to the latter bone it rests directly upon the cartilaginous roof of the nasal capsule. Its lateral edge is in contact with the movable os terminale of Traquair's descriptions. The bone is traversed by the supraorbital latero-sensory canal, and lodges the second sense organ of that line. The external surface of the bone lies deeper than the corresponding surface of the nasal, and has not the rugous markings of the latter bone. On one side of the head of the two specimens examined it was found in two pieces.

Os terminale. This bone is a small, curved, somewhat comma-shaped bone traversed by the supraorbital latero-sensory canal and lodging the first sense organ of that line. It is a movable bone, lies in the tough dermis along the postero-mesial edge of the base of the nasal tube, and overhangs the dorsal edge of the fenestra nasalis. It lies along the lateral edge of the accessory nasal, its antero-mesial end resting upon, or adjoining, the dorsal end of the ascending process of the premaxillary. Like the accessory nasal it lies deep in the dermis, and has not the rugous markings of the nasal.

The nasal, accessory nasal and os terminale, together, quite certainly represent the single nasal bone of Amia, as fully explained in my work on the latero-sensory canals of this fish (Allis, 1900*a*).

Ethmoid. The ethmoid is a median bone and is included by Traquair among the primary ossifications. It is said by him to be "a median ossification in the front of the septum narium," and to send "backwards beneath the nasal bones a flat narrow process which is ossified in the membrane superficial to the cartilage." Pollard (1892, p. 400), without making reference to Traquair, says that, "There is no ossification of the cartilage in front of the nasal septum." In all my specimens, from the 75 mm. larva to the largest adult, the bone is strictly a dermal one, lying everywhere external to the cartilage and separated from it by a layer of connective tissue.

The bone has a thickened anterior end and a thinner, plate-like posterior portion, and lies on the dorsal surface of the chondrocranium, in a median depression between the nasal capsules which is much more pronounced beneath the anterior portion of the bone than beneath its posterior portion. The thickened anterior end of the bone lodges the anterior section of the infraorbital latero-sensory canal of either side of the head, the two canals anastomosing with each other in this bone, in the median line, but without leaving the slightest indication, even in the 75 mm. larva, of a median tube where the anastomosis has taken place. The bone lodges two sense organs, one belonging to either canal, and the thickened portion of the bone that is traversed by this so-formed cross-commissural canal lies in a groove that has a curved course, convex posteriorly, and crosses transversely the dorsal surface of the rostral process of the chondrocranium immediately anterior to the fenestrae nasales. The rostral process of my adult specimens projects forward slightly beyond the anterior edge of the ethmoid and abuts against the slightly concave posterior surfaces of the premaxillaries. The ethmoid is accordingly not exposed on the ventral surface of the chondrocranium, between the premaxillaries, as Traquair says that it was in his specimen.

Each half of the anterior edge of the ethmoid abuts against and is firmly bound to the premaxillary of its side, and immediately lateral to this surface of contact, the short ascending process of the premaxillary projects posteromesially in a groove on the lateral surface of the ethmoid, the latter bone thus being held between the two premaxillaries. The ascending process of the premaxillary does not extend the full length of the groove on the lateral surface of the ethmoid, the groove posterior to that process lodging the lateral edge of the accessory nasal, the anterior end of the latter bone resting upon the dorso-posterior end of the ascending process of the premaxillary. The frontal and nasal of either side both overlap externally the hind end of the ethmoid, this being the relations that these bones have to the ethmoid in the Characinidae and Cyprinidae (Sagemehl, 1884 and 1891), but the reverse of the relations that the frontals have to the supra-ethmoid of Parker's (1873) descriptions of *Salmo salar*.

The ethmoid of Polypterus thus corresponds to that middle portion of the dermal ethmoid of Amia that lodges the anterior sense organ of the main infraorbital canal of either side. The lateral portions of the bone of Amia, each of which lodges a second sense organ of the related infraorbital canal, have each fused, in Polypterus, with the premaxillary of its side, as fully explained in my work on the premaxillary and maxillary bones of this fish (Allis, 1900*b*).

Infranasal and infraorbital bones. These bones are usually all described as the infraorbital chain, but the anterior ones are definitely preorbital and infranasal in position and not infraorbital, and they are developed in relation to a definitely preorbital part of the main infraorbital latero-sensory line. The infranasal bones, which correspond to the lateral portion of the median ethmoid and the antorbital bone of Amia, have both fused with the premaxillary, and the infraorbital bones, excepting the anterior and posterior ones, have fused with the maxillary (Allis, 1900*b*).

The anterior infraorbital bone corresponds to the lachrymal of Amia, but is called by Traquair the anterior suborbital. It is a triangular bone the base of which is directed anteriorly and abuts in large part against the hind edge of the antorbital process of the premaxillary, but partly also against the lateral border of the anterior edge of the ectethmoid. Its dorsal edge forms the antero-ventral margin of the orbit. Its ventral edge rests upon the dorsal edge of the maxillary. It is traversed by the main infraorbital latero-sensory canal and lodges one sense organ of that canal.

The next two bones of the chain are suborbital ones, each containing a single sensory organ of the line, and they have both completely fused with the maxillary.

The next, or posterior bone of the chain is called by Traquair the posterior suborbital, but as it forms the posterior margin of the orbit it is a postorbital. Its dorsal edge is in contact with the lateral edges of the frontal and post-fronto-sphenotic, its ventral edge in contact with the dorsal edge of the posterior portion of the maxillary, and its hind edge overlapped externally by the one or two anterior prespiracular ossicles. It is traversed by the main infraorbital canal and lodges one sense organ of that canal.

Spiracular ossicles. In my 49 cm. specimen of *Polypterus bichir* (figs. 5 and 6) there were 7–8 prespiracular ossicles, 2 spiracular ossicles, and 3–5 postspiracular ones, this agreeing approximately with the number of these ossicles shown by J. Müller (1846) in his figure of this fish, and with the number described by Bridge (1888) in that one of his two specimens that had fourteen dorsal finlets. In one of my small specimens, which had 8–12 finlets, there were nine of these ossicles in all, on either side of the head, this agreeing approximately with the number in the specimens described by Traquair, which also had 8–12 finlets, and with the number in that one of two specimens described by Bridge that also had this same number of finlets. This difference in the number of these spiracular ossicles is thus probably a specific character.

Supratemporals and posttemporal. There are three supratemporal bones on either side of the head in all of my specimens, two of them lying in transverse line immediately posterior to the parieto-dermopterotic, and the third one lying posterior to the lateral portion of the lateral one of the other two. The two bones transversely placed are traversed by the supratemporal latero-sensory canal and each lodges one sense organ of that canal, the postero-lateral bone being traversed by the main infraorbital canal and lodging one sense organ of that canal. These three bones, together, thus correspond to the single large supratemporal (extrascapular, Sagemehl) bone of Amia, as fully explained in my work on the latero-sensory canals of this fish.

The posttemporal is a relatively large, plate-like bone in contact anteriorly with the hind edges of the two transversely placed supratemporals, and laterally with the median edges of the postero-lateral supratemporal and the posterior postspiracular ossicle. From the ventral surface of the lateral edge of the bone, at about the middle of its length, a short stout rod-like process projects antero-ventrally and slightly mesially and gives insertion to a stout ligament which has its origin on the posterior process of the opisthotic. From the base of this process of the posttemporal a slight ridge runs postero-mesially across the ventral surface of the bone, and on reaching its mesial edge turns posteriorly and becomes a stout posterior process which gives insertion to a large fascia-like tendon related to the muscle fibres of that segment of the trunk muscles that is the third one seen in dorsal view of the adult.

Basi-exoccipital. The basi-exoccipital, the occipital bone of earlier descriptions, is, as Traquair has stated, formed by the fusion of the median basioccipital and the two exoccipitals of the Holostei and Teleostei. It has exposed dorsal, ventral, lateral, posterior, and cerebral surfaces. Anteriorly it is everywhere bounded by cartilage. Its dorsal and lateral surfaces are separated from each other by the lateral occipital ridge, already described, this ridge lying wholly on the exoccipital portion of the bone. Its lateral and ventral surfaces are separated by a rounded edge which starts posteriorly on the lateral edge of the vertebra-like hind end of the bone and, lying wholly on the basioccipital portion of the bone, runs anteriorly and slightly ventrally to its anterior end. This edge of the bone is not exposed in the prepared cranium, being covered, throughout its entire length, by the lateral edge of the parasphenoid.

The posterior surface of the bone is formed by the hind end of its basioccipital portion and the hind edges of its exoccipital portions. The hind end of the basioccipital portion is oval in shape, the vertical axis of the oval being slightly less than half as long as its horizontal axis. It is slightly concave, and gives articulation to the first free vertebra. The hind edges of the exoccipital portions of the bone form the lateral and dorsal boundaries of the foramen magnum, and are bound by membrane to the anterior edges of the occipital vertebral arch.

The lateral surface of the bone, formed largely by its exoccipital portion, is about twice as tall at its anterior as at its posterior end. Its anterior edge is deeply notched, at about the middle of its height, to form the posterior border of the foramen vagum, and from this foramen a deep groove runs postero-ventrally and gradually vanishes toward the hind edge of the lateral surface of the bone. The dorsal edge of this groove is formed by the lateral occipital ridge, its ventral edge by the ridge, already described, that runs posteriorly from the bulla acustica. Both dorsal and ventral to the foramen vagum the anterior edge of the bone is overlapped externally by, and articulates with, projecting processes of the opisthotic, these processes extending posteriorly along the external surfaces of the anterior ends of the lateral occipital and subvagus ridges.

Posterior to and in line with the foramen vagum there are two foramina, one of which transmits, as Lehn has stated, the posterior occipital nerve (z^v) of Fürbringer's (1897) descriptions and the other the ventral root of his anterior occipito-spinal nerve (a^v); the internal openings of these two foramina lying considerably anterior to their external openings. The external opening of the anterior one of the two foramina lies in the vagus groove on both sides of the head of the one specimen examined, the posterior foramen lying at the dorsal edge of that groove on one side of the head, but, on the other side, definitively on the lateral occipital ridge. A slight groove runs postero-ventrally from each foramen, and ends, postero-ventrally, either in a slight depression, in a relatively deep pit, or in a short canal leading into the bone. Each groove lodges the related nerve for a short distance after it issues from its foramen, the pit, or canal, at its hind end apparently giving passage to an artery, as explained below. Dorsal to and slightly anterior to the posterior one of these two foramina, and dorso-mesial to the lateral occipital ridge, there is a small foramen for the dorsal root of the anterior occipito-spinal nerve (a^d), the internal opening of this foramen lying considerably posterior to the internal opening of the foramen for the ventral root of the same nerve.

The two ventral occipital foramina above described thus correspond almost exactly, in general position, to the foramina for the first and second occipital nerves of my descriptions of Amia, and as the nerves that issue through these foramina in Amia are called by Fürbringer the nerves *z* and *a*, as are also the corresponding nerves in Lepidosteus, the two nerves and their foramina in these three fishes are, in all probability, homologous. The foramina in these fishes are, however, apparently not the homologues of the occipital foramina of Scomber (Allis, 1903) and the mail-cheeked fishes (Allis, 1909), for the foramina in these latter fishes all lie either directly on the lateral occipital ridge, or definitely dorso-posterior to that ridge, this being in accord with Fürbringer's conclusion that the nerve that issues through the anterior one of the foramina in these fishes is the second occipito-spinal one (nerve *b*), and hence the nerve next posterior to the one that issues through the posterior foramen in Polypterus and Amia.

Antero-ventral to the anterior occipital foramen, between it and the transverse plane of the foramen vagum, there is on each side of the head what appears like a simple imperfection in the bone, but a bristle can be pushed into it for a considerable distance. This canal lies in the line prolonged of the two little pits, or canals, at the hind ends of the two grooves that lead postero-ventrally from the two occipital foramina, and in the adult nothing could be found entering either of them. In the 75 mm. larva a branch of an intervertebral artery penetrated the bone in a position corresponding to that of each of the two posterior canals, but nothing was found entering the bone in the position of the anterior canal. The two intervertebral arteries here concerned arose as a single artery from the dorsal aorta immediately after that artery issued from the hind end of the aortic canal, each artery first sending a branch into the canal in the basioccipital, then one into the cranial cavity through the foramen for the related occipital nerve, and then continuing onward, doubtless in relation to a muscle septum, but this was not traced. From the posterior one of these two intervertebral arteries, previous to the branch sent into the cranial cavity, a branch was sent posteriorly, and from this branch a branch was sent into the cranial cavity through that foramen in the occipital neural arch that gives passage to the ventral root of the related spinal nerve (nerve b^v). No separate artery arising directly from the aorta was found in relation to this neural arch, but one was found in relation to the first, third and fourth free vertebrae. Between the arteries sent to the first and third vertebrae an artery arose from the dorsal aorta, but it was apparently not distributed to the segment of the second vertebra, this vertebra being supplied by a posterior branch from the artery to the first vertebra.

The dorsal surface of the basi-exoccipital forms the ventral portion of the gently sloping posterior surface of the chondrocranium. For a short distance immediately anterior to the foramen magnum, the mid-dorsal line of this surface is nearly horizontal in position, the bone here forming an arch above the medulla. Anterior to this short horizontal portion the surface widens gradually and slopes gently upward to the anterior edge of the bone. The two epiotic ridges, one on either side, are prolonged slightly onto the basi-exoccipital, and separate the exposed portion of its dorsal surface into three regions, one median and two lateral, each of which is slightly concave and is prolonged dorso-anteriorly in a corresponding depression on the cartilaginous portion of the posterior surface of the chondrocranium. Each lateral depression forms the mesial portion of that shallow depression on the posterior surface of the cranium that forms the ventro-mesial arm of the Y-shaped temporal groove and lodges the ventro-posterior process of the parieto-dermosphenotic. The median depression is apparently formed by what Lehn (1918, p. 360) calls the supratemporal grooves, but as the depression ends dorso-anteriorly at the hind edges of the parieto-dermosphenotics it corresponds to the postero-ventral prolongations of the supratemporal grooves of my descriptions of Scomber (Allis, 1903) and not to those grooves themselves, the grooves lying on the dorsal surface of the cranium.

The hind edges of the exoccipital portions of the basi-exoccipital form the lateral and dorsal boundaries of the foramen magnum, the lateral edges of the foramen inclining upward and forward. The basioccipital portion of the bone projects posteriorly, beyond its exoccipital portions, a distance equal to about one half the thickness of the first free vertebra, and its dorsal surface is here slightly concave, transversely, on either side of the median line. In these concavities the rounded bases of a pair of free dorsal neural arches rest, the anterior edges of the arches resting against and being connected by membrane with the hind edges of the exoccipital portions of the basi-exoccipital. These two arches, one on either side, are fused with each other in the median line dorsal to the spinal cord, and a short dorsal neural spine articulates with, and is firmly bound to, the dorsal portions of their posterior edges. The neural arch of either side is perforated by the ventral root of a spinal nerve, and either perforated, or notched on its anterior edge, by the dorsal root of the same nerve. The next posterior, or second pair of dorsal neural arches are fused with the first free vertebral centrum, the arch of either side being perforated by both roots of the related spinal nerve. The first neural arch is accordingly an occipital arch, related to a vertebral centrum that has fused with the basi-exoccipital, and the nerve that perforates it is actually the posterior occipital nerve. It is however called by Fürbringer (1897) the second spinal nerve.

The rounded edge that separates the lateral and ventral surfaces of the basi-exoccipital, and the larger portion of the ventral surface of that bone, are covered externally by the hind end of the parasphenoid, the two bones being so firmly anchylosed that they could not be separated without breakage even in an alcoholic specimen that had been long macerated. In a fresh specimen they could probably be separated, for the two bones are wholly separate and distinct in my 75 mm. larva. In the hind edge of the parasphenoid there is a large and deep V-shaped incisure, which extends about one half the length of the basi-exoccipital, and a corresponding portion of the ventral surface of the basi-exoccipital is exposed between the limbs of the V. In the middle line of this exposed surface there is a large foramen which leads into the aortic canal, and on either side of this foramen there is a round depression which lies partly on the basi-exoccipital and partly on the parasphenoid and gives origin to a stout ligament which runs almost directly laterally and is inserted on the shoulder girdle.

Aortic canal. The aortic canal of Polypterus was, so far as I know, first particularly described by Bridge (1888), and he refers to it, in the plural, as the basicranial canals. Of these canals he says: "In both specimens the somewhat massive bone occupying the basioccipital region and continuously surrounding the foramen magnum, and possibly including also the centrum of the first vertebra, is perforated near the posterior end of its under surface, at the extremity of the parasphenoid, by a small median foramen. Traced forwards this foramen leads into two divergent canals, which at first lie between the basioccipital above and the parasphenoid below, but more anteriorly, between the last mentioned bone and the cartilaginous basis cranii. Finally, after perforating the roots of the lateral wings of the parasphenoid, the canals open into the orbit near the postero-inferior angles of the lateral plates of the sphenethmoid, and below the notch for the second and third divisions of the fifth nerve. The median foramen apparently transmits the dorsal aorta, and it is probable that the divergent canals are traversed by either the internal or external carotids, or possibly by both arteries during a portion of their course. Although the eye muscles in Polypterus are not in any way related to these canals, it is by no means improbable that the latter represent the orbital canals so characteristic of many Teleostean fishes."

Pollard (1892) says of this canal: "The dorsal aorta runs both forwards and backwards. The precardiac portion penetrates immediately into the skull passing into the body of the last vertebra which takes part in the formation of the cranium. Further forwards it lies between the cranium and the parasphenoid dividing and passing out with each wing of the latter to join the efferent 1st branchial. The common trunk thus formed runs on as the ophthalmic artery on each side." In one of his figures (fig. 12, Pl. 28) he shows the canal lying between the basi-exoccipital and the parasphenoid, while in another (fig. 23, Pl. 28) he shows it wholly enclosed in the basi-exoccipital.

Budgett (1902) does not particularly describe this canal in his 30 mm. larva of *Polypterus senegalus*, but he describes a so-called subaortic bridge of cartilage which projects ventrally beneath the hind ends of the parachordals and encloses a short section of the aorta. Of this bridge he says: "The basioccipital region does not completely envelope the anterior end of the notochord, but is composed of two halves (the parachordal cartilages) abutting on two sides of the front end of this structure. Posteriorly these two masses of cartilage send wings ventrally which meet and fuse beneath the dorsal aorta, enclosing it in a short canal which is roofed in by the notochord itself. Anteriorly to the bifurcation of the aorta, the basioccipital cartilages fuse below the notochord, sending forward a narrow medial plate of cartilage which underlies the tip of the notochord."

In a figure giving a lateral view of the occipital portion of a reconstructed skull, Budgett (*l.c.* fig. 4, Pl. 33) shows the aorta turning dorso-anteriorly immediately anterior to his subaortic bridge and there being immediately hidden from view by the parachordal cartilage, and as the parachordals are said, in the quotation just above given, to be here separated from each other by the anterior end of the notochord, it would seem as if the aorta must lie in a deep groove on the ventral surface of the basal plate. The descriptions and figures are, however, not in accord as to this, and it would furthermore seem as if there must be some error either in the figures or in the descriptions of them. In the fig. 4 above referred to, the subaortic bridge is shown lying considerably posterior to the hind end of the otic capsule, and, anterior to the bridge, the parachordals run dorso-anteriorly at a considerable angle to the ventral surface of the notochord. Fig. 1 on the same plate is said to give a lateral view of the same reconstructed primordial cranium with the exoccipital region cut off, and figs. 2 and 3 to give posterior and anterior views of the same. The subaortic bridge of fig. 4 should accordingly be excluded from figs. 1, 2 and 3. The aorta is however shown, in each of these three figures, enclosed within an arch of cartilage, and in figs. 2 and 3 this arch is said, by index letters, to be the subaortic bridge. It must then be that the aorta is again enclosed in a canal in the parachordal cartilage after it has traversed the canal formed by the bridge at its hind end, but this is in no way indicated in the descriptions. In fig. 4 the notochord is shown decreasing rapidly in size as it approaches the subaortic bridge, but in a cross-section through it, shown in fig. 2, and hence presumably close to the hind end of the otic capsule, the notochord has not diminished in size and is even approximately as tall, in cross-section, as it is in the region of the aortic bridge.

In the adult Polypterus, I find the aortic canal penetrating the ventral surface of the basioccipital immediately anterior to its vertebra-like hind end, between the diverging hind ends of the parasphenoid. The canal then turns forward and, wholly enclosed in the basioccipital, extends to the anterior end of that bone. There it bifurcates, the bifurcations passing outward, on either side, in the cartilage of the basis cranii and opening in the canal enclosed between the lateral, ventral and mesial plates of the lateral wings of the parasphenoid. The cartilage in which these bifurcations lie extends the full length of the basal portion of the labyrinth region, and separates the anterior end of the aortic canal from the hind end of the pituitary fossa. This cartilage is thick in the median line, but thinner on either side, and raised portions of the parasphenoid there support the anterior walls of the bifurcations of the aortic canal.

The aortic canal and occipital region in the 75 mm. Polypterus senegalus. In my 75 mm. specimen of *Polypterus senegalus* I find no trace of the cartilaginous subaortic bridge of Budgett's descriptions, nor does Lehn describe it in her 76 mm. one. There is, however, on the ventral surface of the basal plate of the chondrocranium, a groove, with ventro-laterally projecting edges, which lodges the dorsal aorta and its diverging branches (the lateral dorsal aortae), and hence is an aortic groove.

The floor of the postpituitary portion of the cavum cerebrale cranii begins anteriorly in a narrow transverse bridge of cartilage which extends from one cranial wall to the other and is the homologue of the cartilago acrochordalis of Sonies's (1907) descriptions of embryos of the chick and duck. It represents, at this age, the proötic bridge of the adult and has concave anterior and posterior edges, the widened base of the bridge forming, on either side, a ridge on the cerebral surface of the lateral wall of the cranium. Anteriorly this ridge vanishes on the cranial wall opposite the line of the cerebral sulcus that lies along the dorsal edge of the lobus inferior. Posteriorly it descends gradually and becomes continuous with the dorsal edge of the thick cartilage that forms the lateral boundary of the posterior portion of the basicranial fontanelle, and this posterior part of the ridge is connected by membrane, throughout its entire extent, with its fellow of the opposite side, this membrane and the cartilaginous proötic bridge forming the roof of the posterior portion of a dorsal, but non-functional myodomic cavity (Allis, 1919*b*) which lodges the large pituitary body. The dorsal portion of the thick cartilage that forms the posterior boundary of the basicranial fontanelle thus forms the posterior boundary of a fenestra basicranialis posterior, the ventral portion of the cartilage forming the posterior boundary of a fenestra ventralis myodomus (Allis, 1919*b*). What Waldschmidt (1887) calls the nervous portion of the hypophysis lies beneath the cartilaginous proötic bridge, the glandular portion lying beneath the membrane posterior to that bridge. Waldschmidt says that this so-called glandular portion of the hypophysis of this fish is in no sense a saccus vasculosus such as is found in the Teleostei, but as the two structures evidently are, as Waldschmidt says, genetically related, it may be called the saccus. The pituitary vein of either side perforates the lateral wall of the myodomic cavity beneath the anterior portion of the proötic bridge and immediately falls into the infraorbital branch of the vena jugularis. The perforation of the roof of the cavum sacci vasculosi, the fenestra basicranialis posterior above referred to, is described by Lehn (1918, p. 364) in her 76 mm. specimen, but it is not the fenestra basicranialis posterior of her descriptions, which lies posterior to this and will be referred to later.

The basicranial fontanelle ends slightly posterior to the hind end of the saccus vasculosus, and from there as far back as the tip of the notochord, the basal plate is an unbroken plate of cartilage. From that point, posteriorly, to the point of bifurcation of the aortic groove, the basal plate encloses the anterior end of the notochord and is somewhat thickened in the median line, but the cartilage is imperfect in places both dorsal and ventral to the notochord, the parachordal plates of opposite sides not yet having completely fused around it. This thickening of the cartilage here forms a median ridge on the ventral surface of the basal plate, this ridge increasing in height posteriorly and, at the point of bifurcation of the aortic groove, projecting ventrally below the level of the ventral surface of the aorta. The lateral surfaces of the ridge are here scooped out to form grooves which are directed postero-mesially and lodge the lateral dorsal aortae, and when these grooves unite with each other in the median line, the ventral portion of the ridge is pinched off and projects posteriorly as a short process which extends to the point where the lateral dorsal aortae join the median aorta. This little process may be called the median subaortic process. It is not shown or mentioned by Budgett in his descriptions either of his 30 mm. larva or of the older ones examined by him, but is described by Lehn (1918, p. 257) in her 76 mm. specimen. Pollard (1892) shows it in two of the sectional views of his 21 cm. specimen, and of it he says: "In front of the vertebral elements which have been drawn into the base of the skull there occurred in the youngest specimen of Polypterus a small oval block of cartilage curiously surrounded by a thin shell of bone and above it lay the thread-like termination of the notochord." This would seem to mean that Pollard found the projecting hind end of the process of my larva as an independent piece of cartilage, but Winslow (1898), who examined drawings made by Kingsley of Pollard's sections of this same specimen says: "A peculiar rod of cartilage projects a short distance backward from beneath the middle of the basilar plate."

Anterior to the median subaortic process, the lateral aortic groove of either side diverges from the median ridge on the ventral surface of the basal plate, and its mesial boundary is then formed by a sharp cartilaginous ridge which diverges from the median one. The lateral boundary of the groove is here at first formed by an anterior prolongation of the lateral bounding ridge of the median, posterior portion of the aortic groove, but this ridge gradually vanishes on the rounded ventro-mesial edge of the otic capsule, the groove then lying in the angle formed where that capsule is joined by the parachordal plate, and there gradually vanishing anteriorly. Posterior to the subaortic process, the lateral aortic grooves of opposite sides fuse to form a median groove which lies directly beneath the notochord, the notochord here lying against the ventral surface of the basal plate and projecting ventrally beneath it into the groove. Proceeding posteriorly, the ventrally projecting ridge that forms, on either side, the lateral boundary of the groove gradually diminishes in height, and the parachordal cartilages there recede slightly from the notochord, thus leaving a small fenestration in the parachordal plate which lies approximately in the transverse plane of the anterior edge of the foramen vagum, and hence in that of the hind ends of the otic capsules, and is the fenestra basicranialis posterior of Lehn's descriptions. This fenestra is spanned, at about the middle of its length, by a bridge of membrane bone which encloses the notochord. Posterior to the fenestra the dorsal edge of the mesial edge of each parachordal is in contact with the lateral surface of the notochord, the notochord, enclosed in bone, lying between the parachordals with exposed dorsal and ventral surfaces which form, respectively, the median portion of the floor of this part of the cavum cranii, and the roof of the here shallow aortic groove on the ventral surface of the basal plate.

Up to the point where the lateral aortic canals unite with each other in the median line, there is no indication of ossification in relation to the cartilage that surrounds the notochord, and even in the adult the cartilage still persists in this region. In my sections, which were double stained in Weigert and magdala-red fluids, a superficial layer of the cartilage is everywhere stained a reddish colour which is much deeper in certain regions than in others. This layer contains occasional cells, found singly and somewhat separated from each other, and coloured lines extend inward from it between the cells of the deeper portion of the cartilage, certain of these lines occupying the entire space between adjoining cells, while others are completely surrounded by a less deeply staining matrix which separates the cells. In certain places these lines seem to be fibrous, but in others they are certainly simply a staining of the matrix of the cartilage. Superficial to this layer there is, on the cerebral surface of the cartilage, a thin membranous layer which is in most places closely applied to the cartilage, but in certain places separated from it. This membrane is quite certainly the dura mater, or a part of it, and where it has separated from the cartilage scattered cells are found in the intervening space. On the external surface of the cranium fibrous lines separate, in certain places, from the external surface of the deeply staining superficial layer of the cartilage and are continuous with the perichondrial fibrous tissues that lie external to it. Throughout the notochordal portion of the region there is, internal to and concentric with the superficial reddish layer on the cerebral surface of the cartilage, a second layer of strictly similar appearance, and between the two layers there is a layer of cells which look like the cartilage cells found in places where the cartilage is undergoing resorption. Beginning somewhat anterior to the base of the median subaortic process, the cells in that portion of the cartilage of the basis cranii that lies dorsal (cerebral) to the notochord are encircled, in groups of one or more, by the reddish lines above described, and in the transverse plane of the tip of the subaortic process these cells all become separated from the remainder of the cartilage by a prolongation of the inner one of the two reddish layers above referred to. A median portion of the cartilage, which lies directly upon the dorsal surface of the notochord and which is concavo-convex in transverse section is thus here incompletely separated from the parachordals, and as the latter cartilages do not here reach the notochord, and as the fenestra basicranialis posterior of Lehn's descriptions begins immediately posterior to the median cartilage, the latter cartilage fills the anterior end of the fenestra and apparently represents a stage in the occlusion of it. This little cartilage is described by Lehn (1918, p. 363) in her specimen, and is there said to be continuous anteriorly with the cartilage of the basis cranii.

In the basioccipital region resorption cavities are forming in the cartilage, and they lie, in certain places, internal to the reddish superficial layer of the cartilage, but in others include that layer. Where perichondrial bone has been formed it occupies exactly the place of this reddish layer, and it is difficult to tell where bone ends and the unossified tissue begins. The tissue thus cannot be cartilage, for perichondrial bone is said never to be formed by direct ossification of cartilage. It is however skeletogenous tissue of some sort, and it lies directly upon the cartilage without a recognisable intervening layer of tissue of any sort, the conditions here thus seeming to be similar to those described by Schauinsland (1906, p. 445) in the neural arches of Amia, where the first-formed bone is said to develop in the perichondrium (im Perichondrium). Nowikoff (1909) says that, in the tibia of the new-born mouse, the first-formed bone develops external to the perichondrium, but Schäfer (1893, p. 275) makes the general statement that true membrane-bone (that is, perichondrial bone), "lies underneath the perichondrium, and closely investing the surface of the cartilage." There is thus difference of opinion as to how this bone develops.

The parasphenoid, in the region of the subaortic process, underlies the cartilage of the basis cranii, separated from it by dense fibrous tissue, and its lateral edges project laterally on either side so as to partly floor the related diverging branch of the aortic groove. Posterior to the point where these diverging branches unite with each other in the median line, and as far back as the point where the lateral dorsal aortae fuse with each other to form the median dorsal aorta, the notochord lies on the ventral surface of the cartilage of the basis cranii, directly dorsal to the median subaortic process. Around the subaortic process a layer of perichondrial bone is forming, and laminae of bone are sent outward from it to the inner surface of the dense fibrous tissue that lies between it and the parasphenoid, this perichondrial bone and the related laminae forming part of the basioccipital. The lateral edges of the parasphenoid here extend upward, on either side, to the cartilaginous lateral edge of the aortic groove and abut directly against that cartilage, with a somewhat broad and flattened edge, the aortic groove of more anterior sections thus becoming a canal the ventral portions of the walls of which are formed by the parasphenoid. From here the aortic groove extends posteriorly to the hind end of the parachordal cartilage, the cartilaginous lateral edges of the groove projecting ventrally as slight ridges which increase somewhat in height at the hind end of the cartilage.

Posterior to the hind end of the median aortic process, that portion of the basioccipital bone that develops in relation to that process still continues, but it is here a purely membrane bone, developed internal to the dense fibrous tissues in which the parasphenoid is imbedded, and having no relations whatever to the cartilage of the chondrocranium. Farther posteriorly, in the transverse plane of the anterior edge of the foramen vagum, this portion of the basioccipital extends upward on either side, internal to the parasphenoid, until it reaches the cartilage of the basis cranii, where it fuses with the layer of perichondrial bone developed in relation to that cartilage, the dorsal aorta thus here being wholly enclosed in the basioccipital, that part of the bone that forms the roof of the canal being developed in relation to the parachordal cartilages, but the part that forms the floor and lateral walls of the canal being developed in relation to fibrous tissue and in no relation whatever to existing cartilage.

At the hind end of the otic capsule, the parachordal of either side, as seen in transverse sections, is directed dorso-laterally, and immediately posterior to the capsule its dorsal edge forms the ventral boundary of the foramen vagum. From that point it diminishes gradually in height and ends slightly posterior to the foramen for the anterior occipital nerve (the nerve z^v of Fürbringer's descriptions), that foramen lying immediately dorsal to the hind end of the cartilage, in membrane bone that forms part of the exoccipital. Posterior to this the notochord increases rapidly in size, is circular in transverse section, and is completely surrounded by a layer of deeply staining tissue that looks like bone and includes the outer layer of the fibrous portion of the notochordal sheath. From this deeply staining layer, processes of bone of membrane origin project outward along the dorso-lateral and ventro-lateral lines of the notochord. The dorso-lateral processes extend posteriorly to the hind end of the skull, form the posterior portions of the exoccipitals, and end dorsally in connective tissues that here form the roof of the cranial cavity. The ventro-lateral processes are short, and correspond in position to the aortic supports of Budgett's descriptions of the vertebrae in his 90 mm. larva of this fish. They are continuous, at their outer ends, with that portion of the basioccipital, of membrane origin, that forms the lateral and ventral bounding walls of the aortic canal, and this bone is now beginning to break through on its ventral surface preparatory to the exit of the aorta from its canal. This portion of the basioccipital still lies wholly internal to the dense fibrous tissue that separates it from the parasphenoid, the latter bone here being represented only by its two projecting hind ends, one on either side, these ends lying external to thickened portions of the basioccipital that correspond to those slightly raised and pad-like portions of the bone which, in Amia (Allis, 1897), give support to the parasphenoid. Irregular laminae of membrane bone extend between the dorso-lateral and ventro-lateral processes of either side.

Slightly posterior (7 sections) to the hind ends of the parachordals, cartilage appears within the basal portions of the dorso-lateral bony processes and extends posteriorly through about 25 sections, the bases of these cartilaginous processes resting directly upon the deeply staining outer layer of the notochord and their sides being lined by perichondrial bone which is continuous with that layer, and is prolonged dorsally beyond the cartilaginous processes to form the dorsal portions of the exoccipitals. The ventral roots of the second pair of occipital nerves (nerves a^v, Fürbringer) issue from the cranial cavity immediately dorsal to these cartilaginous processes, there perforating the membrane-bone portions of the exoccipitals, the dorsal roots of these nerves issuing, almost directly dorsal to the ventral roots, across the hind edges of the exoccipitals. These cartilaginous processes are thus evidently the dorso-lateral vertebral processes of a vertebra that has fused with this part of the cranium. They are described by Lehn (1918, p. 351) in her 76 mm. specimen, and are said to be continuous, in a 55 mm. specimen, with the parachordal cartilages anterior to them. The processes are continuous posteriorly, as Lehn has stated, with a thin cartilaginous ring which surrounds the notochord, lying between its deeply staining outer layer and a concentric ring of bone that develops external to it. This thin ring of cartilage would seem to be similar to the one described by Schauinsland (1906, p. 444) in Amia and there called by him the skeletoblastic layer. Immediately posterior to this ring, there is a second pair of dorso-lateral cartilaginous processes, and they form the basal portions of the free occipital arches. Their bases break through the ring of bone concentric with the notochord and rest directly upon its outer, deeply staining layer. The third, and posterior, pair of occipital nerves, the second spinal nerves of Fürbringer's descriptions, perforate the membrane-bone portions of these arches.

Comparing the conditions above described in my 75 mm. larva with those described and figured by Budgett in his 30 mm. one, it is first to be remarked that the notochord, as shown in Budgett's fig. 4, Pl. 33, would seem to end considerably posterior to the otic capsules. Its mid-dorsal line is shown curving rapidly ventrally, and as Budgett says that the notochord tapers "suddenly...anteriorly...towards its termination," one naturally concludes that this tapering is here represented, and that it continues uninterruptedly to the anterior end of the chord. This is however not the case, for Budgett says that the tip of the notochord reaches the hind end of the membrane that closes the "very large fontanelle in the posterior end of which lies the hypophysis." The notochord must accordingly extend forward a considerable distance beyond the point where it is shown, in Budgett's figure, passing between the hind ends of the parachordal cartilages, and it must there run upward and forward at a considerable angle to the vertebral part of the chord. The post-auditory portions of the parachordals also run dorso-anteriorly at a considerable angle to the auditory portions, thus leaving a marked depression in the mid-dorsal line between the hind ends of the otic capsules and the second neural arch of this larva. No such depression can be noticed in my transverse sections, and it is not shown in the median section of Lehn's specimen (1918, fig. 4).

The subaortic bridge of Budgett's descriptions is shown by him lying immediately posterior to the point where the notochord passes upward between the hind ends of the parachordals, and directly beneath the expanded base of the exoccipital cartilage of his descriptions. The nerve XI of his descriptions, my anterior occipital nerve, issues across the anterior edge of the exoccipital cartilage, the first spinal nerve of his descriptions, my second occipital, issuing across the posterior edge of that cartilage. The subaortic bridge of this 30 mm. larva must then be represented, in my 75 mm. larva, by the little ventrally projecting processes on the extreme hind ends of the parachordal cartilages, and as these little processes do not extend ventrally beyond the level of the dorsal surface of the aorta, the bridge of Budgett's larva must have undergone considerable resorption, the part so resorbed being replaced by membrane bone that forms part of the basioccipital. Anterior to this point, a similar resorption of cartilage, and its replacement by membrane bone, must also have taken place, for at no place does cartilage bound the entire lateral surface of the aorta.

Anterior to the bifurcation of the aorta, the parachordal cartilages of opposite sides are said by Budgett to fuse with each other beneath the notochord, this apparently being represented, in my larva, by the basal portion of the median subaortic process. From this point Budgett says that a narrow median plate of cartilage is sent forward as far as the tip of the notochord. There must then be an open space on either side of this median band, between it and the ventral edge of the otic capsule of its side. No such space exists in my larva, the cartilage of the basis cranii here being complete, and the tip of the notochord lies at a considerable distance (40 sections of 15μ thickness) posterior to the hind edge of the basicranial fontanelle.

The so-called exoccipital cartilage of Budgett's larva is evidently represented, in my larva, by the anterior dorso-lateral vertebral process, for these two cartilages have similar relations of the nerves. In Budgett's larva the so-called first lateral vertebral process is shown by him attached to the base of the exoccipital cartilage, and there is no corresponding so-called ventral vertebral process. The second lateral process of his larva lies postero-ventral to the base of the first free spinal neural arch, and there is a corresponding ventral process. In my larva the first dorsal rib is attached to the second dorso-lateral vertebral process, in relation to which the free occipital arch is developed, and there is no corresponding ventral rib. The second dorsal rib and the first ventral one are both attached to the first free vertebra. The anterior lateral and anterior ventral vertebral processes of Budgett's larva are accordingly not represented by ribs in my larva, and must either have both disappeared or be represented, one or both, in the large ligament which, in the adult, extends from the ventral surface of the hind end of the basioccipital to the shoulder-girdle. This ligament is well developed in my 75 mm. larva, arising from the lateral surface of that portion of the basioccipital that forms the hind end of the aortic canal and there being continuous with the tough fibrous tissue that lies between the basioccipital and the parasphenoid.

The first free neural arch of Budgett's larva is thus the free occipital arch of the adult, and the related lateral vertebral process must have acquired connection with it by a continuation of the dorsal shifting of these lateral processes that is evident in Budgett's larva. Two vertebral centra and one neural arch have then fused with the hind end of the cranium during the ontogenetic development of this fish. In my 75 mm. larva the wholly enclosed portion of the aortic canal lies anterior to the anterior one of these two vertebrae, the posterior opening of the canal lying ventral to that vertebra and in a nearly horizontal position. In transverse sections through this opening, the processes of the basioccipital closely resemble the haemal processes shown by Budgett in sections through both the anterior and posterior portions of the body of his 90 mm. and 130 mm. specimens of this fish, and the raised, pad-like portions of the basioccipital which, both in my larva and in the adult, support the lateral margins of the parasphenoid, lie dorsal to these processes of the basioccipital and hence in the positions of the bases of the lateral vertebral processes.

Opisthotic. The opisthotic, so named by Traquair, was considered by him to represent both the opisthotic and epiotic of the Teleostei. It has both primary and membrane components and is a much more important bone than in any of the Holostei and Teleostei. It is of irregular shape, forms the dorso-postero-lateral corner of the chondrocranium, and has both external and internal surfaces, the latter forming a posterior portion of the labyrinth recess of the cranial cavity. Its dorsal surface is in articular contact with the ventral surface of the postero-lateral portion of the parieto-dermopterotic, the mesial portion of its posterior surface in contact with the internal surface of the ventro-posterior process of the same bone, and the stout posterior process of the parieto-dermopterotic projects posteriorly between these two articular surfaces. The anterior portion of the dorsal surface of the bone forms the floor of the posterior portion of the temporal groove, and the anterior edge of the bone here shows two directions of growth, one forward along the ridge that forms the lateral wall of the temporal groove and the other antero-mesially across the hind end of that groove and along the outer surface of a slightly raised portion of the chondrocranium which marks the course of the posterior semicircular canal.

Postero-ventrally the opisthotic articulates with the external surface of the basi-exoccipital, a deep and rounded incisure in this edge of the bone forming the anterior boundary of the vagus foramen. The anterior edge of the bone articulates, in its middle third, with the proötic portion of the ascending process of the parasphenoid, and there forms the posterior boundary of the foramen faciale. The dorsal and ventral thirds of this edge of the bone are both continuous with the cartilage of the chondrocranium, the ventral third being thin and covering the dorso-posterior portion of the small but pronounced swelling of the bulla acustica. This latter part of the bone is perforated, not far from its ventral edge and at the ventro-posterior edge of the bulla, by the foramen glossopharyngeum. A strongly developed opisthotic ridge extends dorso-posteriorly from the anterior edge of the bone to the hind end of its posterior process, and apparently corresponds to the crista facialis and crista parotica, combined, of mammals (Allis, 1920*a*). Dorsal to this ridge there is another, which forms the ventral boundary of the posterior portion of the articular facet for the hyomandibula, this ridge ending posteriorly in a slight process which apparently corresponds to the hind end of the pterotic ridge of the Holostei and Teleostei. Between this ridge and the opisthotic ridge there is a large and slightly concave surface which gives origin to the musculi adductor hyomandibularis, adductor operculi, and levatores arcuum branchialium. The stout posterior process of the bone projects posteriorly in the line prolonged of this concave surface, and gives origin to a stout ligamentous formation which is in part inserted on the distal end of the ventro-anterior process, or so-called pedicel, of the suprascapula, and in part on the dorsal end of the supraclavicula. Ventral to the opisthotic ridge, between it and the bulla acustica, is the large jugular groove. Dorsal to the anterior portion of the opisthotic ridge the lateral surface of the opisthotic forms the ventral portion of the articular facet for the hyomandibula.

On the internal, or cerebral, surface of the opisthotic there are two recesses, a small ventro-posterior one which lodges the hind end of the sinus utriculi posterior, and a large dorso-anterior one which lies in the hollow of the curve of the hind end of the lateral semicircular canal. The lateral and posterior semicircular canals both traverse the bone, the bony canals being in communication with each other at the point where the lateral membranous canal passes internal to the posterior canal. The bone is also traversed by the dorsal, or supratemporal branch of the nervus glossopharyngeus, this nerve entering the bone immediately ventral to the opisthotic ridge and leaving it on its dorsal surface.

In my 75 mm. specimen the opisthotic is but slightly developed. The primary portion of the bone is represented by a thin layer of perichondrial bone which covers that projecting hind end of the otic capsule that lodges the vertically descending portion of the posterior semicircular canal. A few short laminae of bone, of membrane origin, project outward from this perichondrial bone into the surrounding tissues, and on its hind end there is a short posterior process, of membrane origin, which is imbedded in fibrous tissues which extend from there to the overlying dermal bones.

The opisthotic of Polypterus thus has the topographical position of the opisthotic of other fishes, but it has a much greater extent than that bone has in any other recent fish I know of, having invaded the regions occupied, in those fishes, by the autopterotic, proötic, and epiotic. Pollard (1891) says of this bone that: "In brief the bone is not an opisthotic or intercalare of fish but corresponds to the 'Petrosum' of Urodeles." In a later work, he (1892) still calls this bone the Petrosum in his text, but refers to it in a figure given as the opisthotic. In *Wimania sinuosa*, one of the Coelacanthidae, it is an even larger and more important bone than in Polypterus, and it has been fully described and discussed by Stensiö (1921) both in that fish and in *Bergeria mougeoti*, one of the Palaeoniscidae, Stensiö considering it to be there formed by the fusion of the opisthotic and proötic of the Teleostei and calling it the proötico-opisthotic. Stensiö also discusses (1921, p. 156) the bone in Polypterus, but does not consider that it there contains the proötic.

There is no epiotic in this fish.

What I consider to represent the proötic will be discussed when describing the parasphenoid.

Postfronto-sphenotic. This bone was called by Traquair the postfrontal, and by Bridge and Pollard the sphenotic. It is said by Traquair to consist of two portions, "a posterior, yellowish and spongy-looking, placed like a little vertical plate projecting down from the posterior external angle of the frontal bone; and an anterior part, white and compact, flattened horizontally, and closely applied to the lower part of the frontal, along its external margin behind the orbit." All three of these authors show the bone in figures said to give dorsal views of the cranium with the dermal (investing) bones removed, the bone thus being considered, by all of them, to be a primary ossification.

In my adult specimens the bone is as shown by Traquair, but there is a distinctly evident line along its lateral surface, between the two components noted by Traquair, this line vanishing near the anterior edge of the bone beneath a projecting corner of its superficial component. That part of the bone that lies ventral to this line is of primary origin and represents the sphenotic bone of the Holostei and Teleostei, the part that lies dorsal to the line being of dermal origin and representing the postfrontal of those fishes. Anterior to the anterior end of the line separating these two components, the long anterior process of the bone is also partly of primary and partly of dermal origin, but there is no line of demarcation between the two components.

In my 75 mm. larva the supraorbital band of cartilage forms, as in Budgett's and Lehn's larvae, the entire lateral boundary of the large supraorbital fontanelle. In its posterior portion it is V-shaped in transverse section, as shown in Budgett's figure, the hollow of the V directed dorsally and lodging the anterior end of the otic portion of the main infraorbital latero-sensory canal, which here lies beneath the overhanging lateral edge of the frontal. Posterior to the base of the supraorbital band, the latero-sensory canal is roofed by the anterior end of the parieto-dermopterotic, short laminae of bone being sent down on either side of the canal, thus partly enclosing it. The parieto-dermopterotic is here completely covered, externally, by the hind end of the lateral edge of the frontal. Immediately anterior to the parieto-dermopterotic, at the base of the supraorbital band, a layer of perichondrial bone has formed on the dorsal edge of the lateral arm of the V-shaped band. From this perichondrial layer, bony laminae, of membrane origin, are sent upward and give insertion, on their lateral surface, to the anterior edge of the musculus levator arcus palatini. These laminae belong to the dermal, or postfrontal component of the bone, and bound laterally the main infraorbital canal, that canal here lying on the dorsal surface of the supraorbital band and being roofed by the lateral edge of the frontal. Continuing forward, in the sections, the main infraorbital canal is soon joined by the hind end of the supraorbital canal (Allis, 1900*a*), and at this point a nerve perforates the supraorbital band and sends a branch to a sense organ that lies in the main infraorbital canal anterior to the point where it is joined by the supraorbital canal, the infraorbital canal here still lying on the dorsal surface of the supraorbital band and not yet being wholly enclosed in the postfrontal component of the postfronto-sphenotic. Continuing forward, the infraorbital canal leaves the dorsal surface of the supraorbital band and acquires a position along its ventro-lateral edge, and it is now wholly enclosed in dermal bone which is continuous with the perichondrial layer developed in relation to the supraorbital band. The supraorbital canal here lies in the frontal, directly above the supraorbital fontanelle. From here forward the infraorbital canal always lies ventro-lateral to the supraorbital band, enclosed in dermal bone that is continuous with the perichondrial layer enclosing that band, and the lateral edge of the frontal overlaps the band externally. The infraorbital canal then leaves the postfronto-sphenotic, to run downward posterior to the orbit, but the supraorbital band continues onward, lying beneath the frontal and without either dermal or perichondrial bone related to it. The two components of the postfronto-sphenotic are thus apparently completely fused with each other from their very inception, and not simply anchylosed in later stages of development.

In the adult Polypterus the sphenotic component of the postfronto-sphenotic has roughly the shape of a tetrahedron, the base of the tetrahedron directed dorsally and its posterior surface directed postero-mesially and everywhere in primary relation to the cartilage of the chondrocranium. The latter surface nowhere comes into direct relation to the labyrinth recess, but it lies dorso-anterior to the dorso-anterior portion of the anterior semicircular canal. The other two surfaces of the bone are directed the one antero-ventro-mesially and the other laterally, the angle that separates them being presented antero-ventrally and forming the dorso-posterior boundary of the orbital fossa. This edge of the bone is continued forward, as a slight rounded ridge, along the ventral surface of the anteriorly projecting portion of the bone, the latter portion of the bone lying along the lateral edge of the roof of that posterior part of the orbital fossa that is filled by the musculus adductor mandibulae, its anterior end reaching almost to the hind edge of the external opening of the fossa. The dorsal surface of the bone is large, and has a slightly raised portion along its lateral edge, the deeper-lying portion of the surface lodging and giving support to both the frontal and the parieto-dermopterotic, the former bone occupying approximately the anterior three-quarters of the surface and the latter bone its posterior quarter. The raised and thickened lateral edge of the bone projects laterally slightly beyond the edges of the frontal and parieto-dermopterotic and forms part of the dorsal surface of the skull. Anterior to this raised edge, the bone is entirely covered by the frontal, the lateral edges of the two bones coinciding. The main infraorbital canal, coming up from its course beneath the orbit, enters the bone on its lateral edge at about the anterior quarter of its entire length, and issues from it on its dorsal surface slightly posterior to the middle of the length of that surface. At this point the compound tube 10 infraorbital–7 supraorbital is given off, this tube running antero-laterally, in a curved line, in a groove on the dorsal surface of the bone and issuing through a notch in the lateral edge of the frontal. From the point where this tube is given off, nearly to the hind edge of the bone, the infraorbital canal lies in a deep groove on its dorsal surface, roofed dorsally, in its anterior portion, by the frontal, and posteriorly by the antero-lateral corner of the parieto-dermopterotic, both of these bones resting on the dorsal surface of the postfronto-sphenotic on either side of the canal. In a specimen used in relation to my earlier work on this fish, I found the infraorbital canal enclosed in the postfronto-sphenotic for a short distance posterior to the infraorbital tube 10, a point of bone projecting mesially from the lateral edge of the groove that lodges the canal and fusing with the mesial edge of the groove, thus forming a narrow bridge across it.

Parasphenoid. The parasphenoid is a large and complex bone, and Traquair says that it has been considered to contain, in its anterior portion, the vomer, and in its ascending processes both the proötics and the alisphenoids. He himself concludes that it does not contain either of these three bones, and that it is strictly comparable to the parasphenoid of other fishes. The proötic is said by him to be wholly wanting.

The parasphenoid consists, as in the Holostei and Teleostei, of what may be called a body, and an ascending process on either side, but each ascending process encloses a large canal which, as stated in an earlier work (Allis, 1919*b*, p. 313), corresponds to the canalis parabasalis of the Teleostei. The mesial wall of this canal corresponds to the ascending process of the parasphenoid of Amiurus, and the ventral and lateral walls to the ascending process of Amia and Scomber, and as the process is triangular in transverse section, these three walls may be called the mesial, ventral and lateral plates of the process.

The body of the parasphenoid is a large flat horizontal plate which covers the larger part of the ventral surface of the chondrocranium, the ventral plate of each ascending process projecting laterally and slightly ventrally from it at about the posterior third of its length. Anterior to these processes the lateral edges of the bone converge slightly throughout the full length of the orbital region, the lateral portions of the bone here forming the floor of the deeper portions of the orbits. Anterior to the orbits the bone widens slightly, and, lying upon the ventral surface of the ethmoidal cartilage, articulates with the hind ends of the palatal plates of the premaxillaries. The extreme anterior end of the bone varies in width in different specimens, and there may here be, on either side, bits of bone that have not yet fused with it. Posterior to the ascending processes, the body of the bone widens slightly to its hind end, and in that end there is a large V-shaped incisure which extends about half the length of this part of the bone. The posterior portion of the basi-exoccipital projects ventrally between the two arms of this incisure, the arms lying along the rounded lateral edges of the basi-exoccipital and extending posteriorly slightly beyond them, there appearing as short processes which project posteriorly along the lateral edges of the first vertebra.

Extending from close to the anterior end of the bone to the level of its ascending processes, there is a well-defined pad of minute thickly-set teeth. This pad has a large anterior end, with an evenly rounded anterior edge, and there occupies the full width of the parasphenoid, but it tapers rapidly and evenly from there to its hind end, where it forms a narrow median band which separates into two curved bands, one on either side, each band running latero-posteriorly along the ventral surface of the curved anterior edge of the ventral plate of the ascending process of its side, and extending nearly to the outer end of that plate. This pad has evidently been developed in relation to the teeth it bears, and the dermal bone so formed has apparently fused with an underlying bone of distinctly different, membrane origin. Between the lateral edges of these two parts of the bone there is a large and rounded groove which receives and gives movable articulation to the dorso-mesial edge of the entopterygoid.

On the dorsal surface of the body of the parasphenoid there is a large median groove, which extends its full length but is somewhat constricted in the pituitary region. At the middle of the length of the pituitary fossa there is a slight median pit, and in a specimen that had been long macerated the bone was here perforated, this thus probably indicating where the epidermal stalk of the hypophysis formerly passed. In the region of the aortic groove the bone is thin in the median line, and in the macerated specimen above referred to this part of it had disintegrated, leaving two long diverging hind ends to the bone. The anterior end of the space between these two ends lies beneath the point where the aortic canal separates into its diverging anterior ends, and hence represents the point where the subaortic process is found in the 75 mm. specimen. For a short distance anterior to this point the parasphenoid is considerably thickened on either side, and this thickened portion is traversed by a deep groove which lodges the basal portion of the related lateral dorsal aorta, the anterior edge of the groove arching posteriorly and forming a partial roof to the groove. This groove runs antero-laterally and opens into the posterior portion of the large canal through the ascending process of the bone.

From near the postero-mesial end of the groove, a small groove leads postero-laterally and opens on the lateral edge of the bone. Anterior to the ascending processes of the bone, each lateral edge of the median groove on its dorsal surface forms a thin ridge which articulates, in its anterior portion with the ectethmoid, and posteriorly with the ventral edge of the sphenoid. At its hind end this ridge curves postero-laterally and is continuous with the anterior edge of the mesial plate of the ascending process of the bone, a large and rounded notch in the latter edge forming the ventral boundary of the anterior opening of a canal in the chondrocranium which I have called, in earlier works, the facialis portion of a trigemino-facialis chamber, but which is more properly called the jugular canal.

The ventral plate of the ascending process of the parasphenoid is triangular in shape, with a convex anterior edge and a concave posterior one. The anterior portion of the anterior edge of the plate is attached by tough connective tissues to the dorsal surface of the dorso-mesial border of the entopterygoid, and it and the lateral edge of the body of the bone anterior to it form the mesial wall and roof of a groove in the dorsal surface of the buccal cavity which leads posteriorly into the oral opening of the spiracular canal, the posterior portion of the edge of the process forming the mesial boundary of the latter opening. The lateral plate of the ascending process rises from the dorsal surface of the anterior edge of the ventral plate, and, projecting dorso-mesially, abuts against and fuses with the external surface of the mesial plate of the process. The mesial plate lies directly upon the cartilage of the chondrocranium, and, in the 75 mm. specimen, is much wider at its base than at its dorsal end, the latter end extending upward along the external surface of the outer wall of the jugular canal and being but slightly wider than it, its hind edge projecting posteriorly slightly beyond the opening of the canal. In the adult this plate still lies along the outer surface of the cartilage that encloses the jugular canal, and, after its fusion with the lateral plate, extends upward until it nearly reaches the ventral edge of the sphenotic portion of the postfronto-sphenotic, the two bones there being separated by a narrow band of cartilage with which they both, apparently, have similar primary relations. In the ventral portion of the hind edge of the plate there is a large incisure, which embraces the anterior edge of the bulla acustica, and anterior to this incisure, or confluent with it, the plate is perforated by a foramen which bounds the anterior opening of the lateral aortic canal of its side. On the mesial surface of the posterior half or two-thirds of the plate, along the line where it fuses with the lateral plate, two flanges of bone have developed, one projecting dorso-mesially along the ventro-mesial surface of the posterior half of the jugular canal and the other dorso-mesially along its lateral and dorsal surfaces, the two flanges arching toward each other and nearly enclosing this portion of the canal (fig. 15). The hind end of each of these flanges projects posteriorly and overlaps externally, and articulates with, the anterior edge of the opisthotic, thus forming the lateral boundary of the foramen faciale. The mesial surface of the ventro-mesial flange, and the dorsal and lateral surfaces of the dorso-mesial flange, are both in direct contact with the cartilage of the cranial wall, and between the dorso-mesial flange and the dorsal portion of the entire ascending process there is a thick mass of cartilage, that portion of this cartilage that lies anterior to the two flanges being traversed by the anterior portion of the jugular canal. No layer of connective tissue could anywhere be distinguished between these several parts of the bone and the cartilage upon which they lie.

The ascending process of the parasphenoid of the adult Polypterus thus differs greatly from that of the 75 mm. specimen. In the latter specimen all parts of the process are definitely of either membrane or dermal origin, whichever it may be, for the mesial plate of the process is everywhere separated from the cartilage of the chondrocranium by connective tissue, and the ventral and lateral plates have no relations to the cartilage, lying, respectively, internal to the lining membrane of the buccal cavity and to that of the spiracular canal. In the adult, the mesial plate has apparently, in places, acquired primary relations to the cartilage, and the flanges that partly enclose the jugular canal replace, if they do not actually represent the proötic of other fishes, and they probably represent the small and independent bone which both van Wijhe (1882, p. 257) and Stensiö (1921, p. 157) find in this region and which they consider to be a proötic. No part of the bone would seem to contain any part of the alisphenoid.

The canal through the ascending process of the parasphenoid transmits the common carotid artery, a lymph vessel, pharyngeal branches of the nervi glossopharyngeus and vagus and a sympathetic nerve, and the ramus palatinus facialis, after issuing from the jugular canal, runs antero-ventrally across its anterior opening. The canal is thus not the strict homologue of the canalis parabasalis of Amia and the Teleostei, but it certainly represents a part of that canal. The dorsal ends of the efferent arteries of the external hyal gill and the first branchial arch enter the posterior portion of the canal and there fall into the lateral dorsal aorta. The dorsal end of the pharyngo-branchial of the first branchial arch enters the hind end of the angle between the lateral and ventral plates of the process, and is there strongly attached by fibrous tissues; and the pointed posterior corner of this angle gives attachment to a stout ligament which runs posteriorly and is inserted on the dorsal end of the first ceratobranchial. The bulla acustica projects laterally beyond the level of the external opening of the aortic canal, and there closely approaches, and in certain cases touches, the dorsal surface of the parasphenoid, enclosing, in the latter case, a canal between the otic capsule and the parasphenoid. No vessel or nerve was found traversing this canal in the adult, but it is possible that it may be traversed by small arteries related to the thymus. What I consider to be the suprapharyngeal process of the epibranchial of the first branchial arch articulates with the dorsal surface of the bulla, this branchial cartilage being called by Lehn (1918, p. 365) the "Pharyngobranchiale inferius."

The jugular canal is a canal through the cartilaginous postorbital process which transmits the jugular vein and also a general sensory branch of the nervus trigeminus which joins the truncus hyomandibularis facialis. The primary foramen of the nervus facialis opens into this canal near its hind end, and there may be, anterior to this foramen, an independent foramen for the ramus palatinus facialis. The ramus hyomandibularis issues from the canal through its hind end, the ramus palatinus through its anterior end. The canal thus lies approximately between the primary foramina of the trigeminus and facialis nerves, and hence corresponds to the posttrigeminus portion of some part of the trigemino-facialis chamber of other fishes, and probably to some part of the pars jugularis only of that chamber. The trigeminus part of the chamber lies immediately anterior to this canal, in a recess in the cranial wall that lies beneath the anterior end of the anterior semicircular canal and opens directly into the hind end of the orbital fossa, the posterior portion of the recess being closed externally by the anterior edge of the ascending process of the parasphenoid. The conditions here thus closely agree with those described by Stensiö (1921, p. 177) in *Bergeria mougeoti*—but somewhat differently interpreted by him (see Allis, 1922)—excepting in that the ascending process of the parasphenoid of Bergeria consists of but a single plate of bone, and hence corresponds either to the mesial plate alone of the process of Polypterus, or to the three plates fused so as to appear as a single one. The trigeminus chamber and the jugular canal are both described by Lehn in her 76 mm. specimen, and I, still earlier, described them in a work relating to the arteries of this fish (Allis, 1908*b*).

Sphenoid. The sphenoid bone of Polypterus was so named by Traquair, and was considered by him to be a median bone which occupied the space filled, in the teleostean skull, by the bones called by Huxley the orbitosphenoids, the postsphenoids, and the wings of the latter bones. The bone was said to consist of two vertical laminae connected with each other, posteriorly, by a narrow horizontal plate which formed part of the floor of the cranial cavity. Bridge accepted for this bone the name given to it by Traquair, but Pollard called it the orbitosphenoid. As it certainly contains more than the latter bone, I retain the name given by Traquair.

The internal surface of each vertical lamina of the bone is slightly concave, its outer surface slightly convex. The dorsal edge of the lamina flares slightly (fig. 10), and articulates by dentated suture with the ventral edge of a longitudinal ridge on the ventral surface of the frontal, this latter ridge beginning at the posterior end of the frontal and extending forward, along its mesial third or quarter, nearly its full length. At about the middle of its length this ridge gives off a mesial branch which extends forward a short distance and then curves abruptly to the mesial edge of the bone. When the dorsal edge of the sphenoid reaches the point where this ridge is given off, it expands both laterally and mesially, the lateral portion extending forward but a short distance and there ending abruptly with a straight transverse edge, while the mesial portion curves mesially, widens antero-posteriorly, and, after completely encircling the nervus olfactorius, meets in the median line its fellow of the opposite side, the two laminae, one on either side of the head, here suturating with each other their full heights. The anterior end of the dorsal edge of each lamina, as seen in the prepared skull, lies on a level with, and is continuous with, the cartilage of the chondrocranium, but ventral to this visible edge the bone continues onward, beneath the cartilage, in an antero-lateral direction, and articulates by suture, at its anterior end and lateral to the canalis olfactorius, with the hind end of the ectethmoid (prefrontal, Traquair). The anterior surface of the bone is everywhere bounded by cartilage, excepting only where it articulates with the ectethmoid.

The surface by which each vertical lamina of the bone articulates, anteriorly, with its fellow of the opposite side is somewhat V-shaped, the V placed horizontally, with its point directed forward (fig. 11). The ventral arm of this V is longer than the dorsal one, and extends to the transverse plane of the foramen opticum, where it curves ventrally and ends in a straight horizontal edge which rests upon the dorsal surface of the parasphenoid. The articulation of the two laminae with each other forms a narrow median wall which lies between the nervi olfactorii and forms the anterior boundary of the median portion of the cranial cavity. Immediately lateral to both the dorsal and ventral arms of this V-shaped median wall, the cerebral surface of each lamina of the bone is slightly hollowed out, this hollow lodging the lobus olfactorius and leading forward to the canalis olfactorius. The floor of this hollow lies above the level of the floor of the pituitary fossa, in the level of the floor of the postpituitary portion of the cranial cavity, and the hind edge of the floor forms, with its fellow of the opposite side, the anterior wall of the pituitary fossa, this raised portion of the cranial floor thus being the homologue of the presphenoid bolster of Gegenbaur's (1872) descriptions of the Selachii.

The ventral edge of each vertical lamina flares somewhat, as its dorsal edge does, but this edge is grooved to form an inverted V, the mesial arm of which is considerably longer than the lateral arm. The hollow of this V rests upon the longitudinal ridge that forms the lateral boundary of the median groove on the dorsal surface of the parasphenoid, the long mesial arm of the V everywhere reaching and resting upon the dorsal surface of that bone, but its external arm not everywhere reaching that surface, the lateral surface of the ridge on the parasphenoid forming, in places, a ventral portion of the mesial wall of the orbital fossa. The lateral arm of the V extends forward to the anterior end of the bone. The mesial arm is abruptly tenoned in the transverse plane of the external opening of the foramen opticum, the V in the ventral edge of the bone anterior to this point being much larger and deeper than it is posterior to it.

The hind edge of each vertical lamina is nearly vertical, inclining slightly anteriorly, and it is everywhere continuous with the cartilage of the chondrocranium excepting at its ventro-posterior corner, where it articulates with the anterior edge of the mesial plate of the ascending process of the parasphenoid. In this hind edge of the lamina there are two rounded incisures, the dorsal one of which may become entirely enclosed in the bone. The dorsal incisure forms the anterior margin of a foramen which transmits a meningeal vein coming from the dorsal surface of the brain. The ventral incisure forms the anterior margin of the foramen trigeminum, this foramen opening in the cranial cavity dorsal to the proötic bridge (postclinoid wall), slightly anterior to the middle of its width, and being frequently almost entirely, but never entirely, enclosed in the bone. This foramen lies immediately anterior to the anterior wall of the labyrinth recess, and there is here a slight recess on the cerebral surface of the sphenoid. Dorso-posterior to this foramen, the foramen ophthalmicum perforates the cartilage that lies between the sphenoid and the postfronto-sphenotic, and enters the anterior end of the labyrinth recess. From the latter foramen a groove runs dorso-anteriorly along the external surface of the orbital wall, between the sphenoid anteriorly and the postfronto-sphenotic posteriorly, and lodges the ramus ophthalmicus superficialis trigemini, that nerve giving off, while in the groove, the ramus oticus, which pierces the overhanging end of the otic capsule, traverses the canal for the anterior semicircular canal of the ear, and then again perforates the cartilage to issue on the roof of the chondrocranium. Immediately ventral to the ventral edge of the foramen trigeminum, there is a more or less pronounced and rounded notch on the outer surface of the hind edge of the sphenoid, and the nervus abducens, coming from the orbit, traverses this notch and enters a relatively long canal in the cartilage, this canal opening on the floor of the cranial cavity immediately posterior to the base of the postclinoid wall. Anterior to the foramen trigeminum, and in line with it, the sphenoid is perforated by a foramen which transmits the nervi oculomotorius and ophthalmicus profundus, and in a line running dorso-anteriorly from this foramen there are two foramina, the ventral one transmitting the nervus trochlearis and the dorsal one a second meningeal vein from the dorsal surface of the brain. Postero-ventral to the foramen profundo-oculomotorium is the foramen for the pituitary vein, this foramen lying near the ventral edge of the sphenoid and entering the cranial cavity slightly anterior to the anterior edge of the postclinoid wall. In the specimen that was macerated this foramen could not be found on either side of the head. These several foramina were all described in an earlier work (Allis, 1908*b*), and Lehn (1918) describes them in her 76 mm. specimen.

Slightly anterior to the middle of the orbital fossa, at the hind edge of that part of the fossa that is occupied by the eyeball, there is a large notch in the ventral edge of each vertical lamina of the sphenoid. This notch is imperfectly divided into anterior and posterior portions, and it lies beneath a slight swelling on the external surface of the sphenoid. From this notch a canal leads inward in the bone and opens on its cerebral surface dorsal to the hind edge of the presphenoid bolster. This canal transmits the nervus opticus and the internal carotid artery, and a groove on the internal surface of the sphenoid leads posteriorly from it and marks the further course of the nervus opticus. On both sides of the head of the macerated specimen, a small canal perforated the mesial wall of this canal for the nervus opticus and opened on the internal surface of the sphenoid immediately anterior to the opening of the main canal, this small canal doubtless being traversed by one of the two divisions of the internal carotid. This little canal did not exist in the specimen used for the figures.

Anterior to the anterior end of that portion of each vertical lamina of the sphenoid that lies lateral to the canalis olfactorius, there are, on each side of the head of the specimen used for illustration, two little plates of bone which lie between the sphenoid and the ectethmoid, and there is nothing to definitely show to which one of these two bones they belong. Traquair shows them forming part of the ectethmoid (prefrontal, Traquair), and, following him, I have already referred to the dorsal one of the two as forming part of the ectethmoid. Both plates will accordingly be considered when describing the latter bone.

The hind ends of the two vertical laminae of the sphenoid are connected by the horizontal plate described by both Traquair and Bridge, this plate forming the postclinoid wall and corresponding to the proötic bridge of the Holostei and Teleostei. The dorsal surface of this bridge inclines slightly postero-ventrally, and its ventral surface still more so, the bridge being thicker at its posterior than at its anterior end. Its anterior edge is concave and its posterior edge convex, as Bridge has stated, the hind edge of the bridge projecting posteriorly beyond the hind edges of the vertical laminae of the bone and there being everywhere bounded by cartilage. The hind ends of the vertical laminae are not in contact with each other beneath this bridge, being there separated from each other by cartilage that forms the posterior boundary of the basicranial fontanelle. This fontanelle is large, extends the full length of the pituitary fossa, and corresponds to the fenestra ventralis myodomus of Amia.

In my 75.mm. larva the non-cartilaginous portion of the orbital wall has practically the extent that is shown in Budgett's figure of his 30 mm. larva, extending from near the hind edge of the nasal capsule to a certain distance posterior to the foramen opticum. In Budgett's specimen this portion of the wall was wholly membranous. In my specimen, the posterior and larger portion of this membranous wall has already undergone ossification as membrane bone, and where this membrane bone adjoins the surrounding cartilage, the cartilage is breaking down preparatory to being replaced by bone. There is nowhere any indication either of calcification or of direct ossification of the cartilage. The proötic bridge is, in this larva, a narrow transverse bridge of cartilage which extends the full length of the nervous portion of the pituitary body but does not cover its glandular portion, that portion of the organ being separated from the cranial cavity by membrane only. The conditions in this larva are thus here similar to those in embryos of

Amia, Lepidosteus and certain of the Teleostei (Allis, 1919*b*). The glandular portion of the pituitary body extends to the hind end of the basicranial fontanelle, this hind end lying considerably anterior to the tip of the notochord. In Budgett's 30 mm. larva the fontanelle extended to the tip of the notochord, and the proötic bridge was wholly of membrane. In Budgett's 90 mm. specimen this bridge had become entirely chondrified, and he says that in this specimen the tubules of the glandular portion of the hypophysis are still in communication, by a duct, with the cavity of the mouth. No indication of such a duct was found in my 75 mm. larva, but there is, in the adult, as already stated, a median depression on the dorsal surface of the parasphenoid slightly anterior to the anterior edge of the proötic bridge which doubtless represents the place where the duct has disappeared. Lehn describes (1918, p. 364) this duct in her 76 mm. specimen.

The so-called sphenoid of this fish thus occupies approximately the region of the orbitosphenoids, alisphenoids and median basisphenoid of the Ganoidei and Teleostei, and in addition forms the proötic bridge, which in the Ganoidei and Teleostei is usually (always?) formed by processes of the proötics. What seems to be a strictly similar bone is found in *Bergeria mougeoti* (Stensiö, 1921), one of the Palaeoniscidae, but, singularly enough, is not found in the Coelacanthidae, which are supposed to be much more closely allied to Polypterus. In the Coelacanthidae the proötic bridge is formed by what were formerly considered to be the paired proötics but which Stensiö considers to be a median basisphenoid comparable to that bone of higher vertebrates and hence in no way comparable to the similarly named bone of the Teleostei. Polypterus further resembles the Palaeoniscidae, and differs from the Coelacanthidae, in that its parasphenoid has well-developed ascending processes which lie external to a trigeminus chamber and jugular canal.

Ectethmoid. The ectethmoid (prefrontal, Traquair) is, in the specimen used for illustration, formed by a large and irregular bone which forms the anterior wall of the orbital fossa, and two smaller bones which lie posterior to it. In Traquair's specimen these three bones were apparently fused to form a single bone. The larger bone forms part of the lateral wall of the nasal cavity, and its dorsal surface forms part of the dorsal surface of the primordial cranium, but as the dorso-posterior end of the antorbital process of the premaxillary rests upon it and conceals it, it is not seen in the accompanying fig. 10. The dorsal one of the two smaller bones also forms part of the dorsal surface of the primordial cranium, there lying directly posterior to the larger bone and posterior also to the antorbital process of the premaxillary. Between this small bone and the larger one the preorbital canal leads from the dorso-anterior end of the orbital fossa into the hind end of a short groove on the dorsal surface of the nasal capsule along the mesial edge of the antorbital process of the premaxillary, this groove lodging the ramus ophthalmicus superficialis trigemini, the ramus ophthalmicus profundus, and an accompanying vein and artery. Between the ventral one of the two smaller bones and the ventro-anterior corner of the vertical lamina of the sphenoid dorsally, and the parasphenoid ventrally, there is the external opening of a small canal which leads into the canalis olfactorius as it leaves the sphenoid bone to enter the nasal capsule, this canal transmitting the terminal portion of the orbito-nasal artery. The ventral surfaces of the ectethmoid and the ventral one of the two smaller bones are covered by cartilage, these bones thus not being exposed on the ventral surface of the chondrocranium. Along the orbital edge of this covering cartilage there is a groove which is continuous with the groove along the lateral edge of the parasphenoid and gives articulation to the articular surface on the anterior edge of the autopalatine.

Visceral arches. There are in Polypterus a mandibular, a hyal, and four branchial arches, and they have been figured and described, in all or in part, by Agassiz (1833–43), Müller (1846), Traquair (1871), van Wijhe (1882) and Pollard (1892). Budgett (1902) has described these arches in a 30 mm. embryo, and I have described the maxillary and premaxillary bones and the labial cartilages in the adult (Allis, 1900*b*, 1919*c*).

Basal line. There is but one piece in the basal line of this fish, the basibranchial of van Wijhe's (1882) descriptions. It is relatively large, and has a flat dorsal and a somewhat concave and irregular ventral surface (figs. 16–19). Its posterior quarter, approximately, is of cartilage and gives articulation to the third and fourth branchial arches. The remainder of the element has become entirely ossified excepting at its anterior end, where it gives articulation to the hyal arch, and at two points on each lateral edge, where it gives articulation to the first and second branchial arches.

The articular facets for the hyal arches occupy the entire anterior end of the element, excepting a narrow median line which separates them. They are oval in shape, the long axis of each facet directed dorso-anteriorly, and they give articulation, through the intermediation of a pad of tough connective tissue, to the hypohyals. The basibranchial is considerably thickened, dorso-ventrally, in the planes of the long axes of these facets, and it is similarly, but less pronouncedly thickened in relation to the articular facets for the second and third branchial arches. Ridges on the ventral surface of the bone run from each of these thickened points toward the middle portion of its anterior third, and there vanish, the ventral surface of the bone thus being concave both longitudinally and transversely. Between the ridges of opposite sides there is a longitudinal groove, which is relatively deep both anteriorly and posteriorly but vanishes in the middle of the length of the bone. Lateral to the ridges of either side, the lateral edge of the bone is much thinner than in its middle portion, and the articular cap for the first branchial arch lies on this thin lateral edge, between the caps for the hyal and second branchial arches; the cap having a shallow facet which is presented laterally and slightly antero-ventrally and gives articulation to the postero-mesial corner of the first hypobranchial. In the specimen used for illustration, this cap was connected with the cap for the hypohyal by a narrow line of cartilage along the lateral edge of the element. The articular cap for the second branchial arch lies at about the middle of the length of the element, extends from the dorsal to the ventral surface of the element, is slightly 8-shaped, and the facet on its outer surface is presented postero-laterally and gives articulation to the distal end of the second hypobranchial. The posterior, cartilaginous portion of the element is twice as broad and thick in its anterior portion as in its posterior, and is concave transversely on its ventral surface. On either side of its hind end it gives articulation to the fourth ceratobranchial, and on either side of its thickened anterior portion there are two articular facets, separated by a slight groove, which gives articulation to the two articular ends at the distal end of the third hypobranchial.

Branchial arches (figs. 16–21). The hypobranchial of the first branchial arch is, roughly speaking, a thick flat semicircular plate with a stout process arising from the straight edge that forms the diameter of the semicircle, and it is shown in dorsal and ventral views in figs. 20–21. The straight edge forms the distal edge of the element, and the postero-mesial half of the curved edge articulates in part with the ceratobranchial of its arch and in part with the related articular facet on the basibranchial. The process of the element arises from the ventral edge of its straight distal edge, and the ossification of the entire element has apparently proceeded from this point as a centre, semicircular plates of perichondrial bone developing on both sides of the element and giving to it its semicircular appearance. The process is capped with cartilage and strongly attached by ligamentous tissues to the edge of the pad of connective tissue that lies between the articulating surfaces of the hypohyal and basibranchial.

The second hypobranchial has enlarged distal and proximal ends, the longer axes of these ends lying at right angles to each other. The anterior end of the element articulates with the 8-shaped articular facet at the middle of the length of the basibranchial, its posterior end articulating with the ceratobranchial of the arch.

The third hypobranchial resembles the second one in general shape, but has two articular heads on its distal end, these two heads corresponding to the two parts of the 8-shaped articular head of the second hypobranchial, and articulating with the two articular facets at the anterior end of the posterior, cartilaginous portion of the basibranchial.

There is no fourth hypobranchial, as van Wijhe has stated, but the distal portion of the ceratobranchial of this arch forms, in general appearance, a serial continuation of the preceding hypobranchials.

The first ceratobranchial is a stout, strongly curved and flattened bone, capped at each end with articular cartilage. Its distal end lies in a nearly horizontal position, and articulates with the hypobranchial of the arch. Its ventro-lateral (external) edge is not grooved in my large specimens, but is grooved in the 30 cm. ones, and on either side of this edge of the bone there is a row of branchial rays which are wholly of cartilage in my 75 mm. specimen, but partly calcified in the adult. The bases of these branchial rays tend to fuse with each other, as shown in fig. 22, and the presence of a double row of rays in this fish, and of but a single row in the Selachii, suggests that the extrabranchials of the latter fishes have been derived either from the basal portions of the anterior row of branchial rays, or from those dorsal and ventral rays of the posterior row that were primarily related to the pharyngeal and hyal elements of the arch. This was explained in a recent work (Allis, 1918*c*, p. 264), but by typographical error a part of the sentence was omitted.

The second ceratobranchial is only about two-thirds as long as the first one, and is less strongly curved. The outer surface of the curve is presented ventrally and is deeply grooved throughout the larger part of its length, the groove lying postero-mesial to an angular process on the antero-lateral edge of the bone, near its distal end. This process is capped with cartilage, and is related to the surface of insertion of the musculus interarcualis ventralis of its arch. The groove on the ventral (external) edge of the bone lodges the afferent artery of the arch.

The third ceratobranchial has much the shape of the second one, but is somewhat shorter and more slender, and the ventro-anteriorly directed process near its distal end is less strongly developed.

The fourth ceratobranchial has strikingly the appearance of being formed by a ceratobranchial and hypobranchial which have not been separated from each other by transverse segmentation. There is no process, capped with cartilage, near the distal end of the ceratobranchial part of the bone, but there is, at that point, a rounded angle on the anterior edge of the bone. Both ends of the bone are capped with cartilage, the distal end articulating with the facet on the hind end of the cartilaginous portion of the basibranchial, and the proximal end articulating, by its anterior corner, with the posterior corner of the cartilaginous cap on the proximal end of the third ceratobranchial. The ceratobranchial part of the bone is grooved on its external edge, exactly as the other ceratobranchials are, but in order to reach this groove the afferent artery of the arch runs postero-laterally across the dorsal surface of the bone, in a groove on that surface, and then turns upward across the posterior surface of the bone, passing through a large opening between it and a series of dermal toothed plates which have fused with it, along the posterior edge of its dorsal surface. The probable explanation of this twisting of the artery around the ceratobranchial is given on a later page.

The epibranchial of the first arch is the bone called by both van Wijhe and Pollard (1891) the suprapharyngobranchial of that arch. Both ends of the element are capped with cartilage, the cap on the distal end being large and articulating by one corner with the proximal end of the ceratobranchial of the arch, and by the other with the so-called infrapharyngobranchial of the arch. An independent bit of cartilage interposed between the epibranchial and ceratobranchial, such as is shown by van Wijhe in his figure and called by him the epibranchial of the arch, was found in certain of the adult specimens but not in others. In the 75 mm. specimen there is here a little process of the epibranchial, and it is probable that the head of this process sometimes becomes detached, and is found as an independent piece.

The large cartilaginous cap on the distal end of the epibranchial quite unquestionably represents the primitive element, the ossified portion being a process on its postero-mesial edge which corresponds to the suprapharyngobranchial process of the epibranchial of the first branchial arch of Amia (Allis, 1897). This process of the epibranchial of Polypterus forms the principal portion of the element, and it articulates, by its proximal end, with the bulla acustica, there lying in normal position ventral to the vena jugularis. The so-called infrapharyngobranchial is quite certainly simply the pharyngeal element of the arch and is, in the adult, a slender rod of bone which is frequently immovably anchylosed with the epibranchial and apparently has primary relations to the proximal corner of the cartilage that caps that bone and which I consider to represent the primary epibranchial. Between it and the epibranchial, on the external surface of the arch, there is a deep groove, which lies wholly on the epibranchial and lodges the efferent artery of the arch. In the 75 mm. larva, the pharyngobranchial is a slender and wholly independent rod of cartilage which articulates movably with the epibranchial. It lies imbedded in the lateral surface of the thymus, its anterior end extending into the hind end of the angle between the lateral and horizontal plates of the ascending process of the parasphenoid, and there being attached by fibrous tissues. A stout ligament has its origin on the point of that angle, and running postero-laterally, parallel to and slightly ventral to the pharyngobranchial, is inserted on the dorsal end of the ceratobranchial of the arch. In the middle of its length this ligament is, for a short distance, wholly muscular, thus apparently corresponding to that interarcualis dorsalis muscle of the Selachii that extends between the first branchial and hyal arches. The levator muscle of the arch is inserted mostly on the pharyngobranchial, but partly also on adjacent portions of the epibranchial. Comparison of these two elements of this arch of Polypterus with the similarly named elements of the arch in Amia (Allis, 1897), would seem to leave no possible doubt as to their being respectively homologous, the posterior corner of the proximal end of the epibranchial of Amia having, in Polypterus, acquired articulation with the cranial wall instead of with the proximal end of the infrapharyngobranchial of the second branchial arch.

In the second and third branchial arches of Polypterus the epibranchial and pharyngobranchial have fused with each other and are usually both wholly of cartilage. The part that corresponds, in position and in its relations to the efferent artery of the arch, to the epibranchial of the first arch is greatly reduced in length, and its dorso-anterior and dorso-posterior edges have arched toward each other dorsal to the efferent artery of the arch and fused, so forming a short canal through which the efferent artery passes. The pharyngobranchials of these two arches are directed antero-mesially, approximately parallel to the bony process on the epibranchial of the first branchial arch, and not, as van Wijhe says, posteriorly. In the specimen used for illustration the pharyngobranchial of the second arch had undergone partial ossification.

In the fourth arch there is neither epibranchial nor pharyngobranchial, the anterior corner of the cap of cartilage on the proximal end of the ceratobranchial simply forming a slight process which articulates with the proximal end of the third ceratobranchial.

The branchial arches of this fish are thus strictly comparable to those in Amia. In both fishes the so-called infrapharyngobranchials are simply pharyngobranchials, and there are no independent suprapharyngobranchials in either fish.

The cartilaginous branchial rays (fig. 22) have been referred to in an earlier work (Allis, 1918*c*), and the probable significance of the dorsal ends of the rods formed by the fusion of their bases there considered.

Hyal arch. The hyal arch of Polypterus consists, as currently described, of a hypohyal, ceratohyal, interhyal, and hyomandibula. The symplectic is always said to be wanting. The so-called accessory hyomandibula of certain descriptions was considered by van Wijhe, and since him by other authors, to be one of the series of spiracular ossicles that has become secondarily attached to the hyomandibula.

The hypohyal is a disk-shaped piece, the antero-mesial surface of which is slightly convex and the postero-lateral surface slightly concave. It lies in a nearly vertical plane and its distal edge, which is directed postero-mesially, articulates with the facet on its side of the anterior end of the basibranchial. On its ventral edge, and the postero-lateral surface of that edge, the deeper part of the stout tendon of the musculus sternohyoideus has its insertion, and ossification of the element takes place from the point of attachment of this tendon as a centre, perichondrial plates of bone developing on both surfaces of the element and advancing toward its dorsal edge, the latter edge remaining cartilaginous even in my adult specimens. The superficial portion of the tendon of the sternohyoideus runs forward across the ventral edge of the basihyal and becomes a tough ligamentous formation which envelops the distal end of the ceratohyal, and attached to this ligamentous formation there is a little circular pad of tough tissue which lies between the antero-lateral edge of the hypohyal and the mesial corner of the distal end of the ceratohyal and forms an articular pad between the articulating surfaces of the two elements.

The ceratohyal is a stout flat slightly curved bone with a large distal end, triangular in cross section, and a flat and expanded proximal end which has a long and convex edge. The proximal end of the bone lies in a nearly horizontal position, immediately mesial to and in the horizontal plane of the ventral edge of the hind end of the mandible, but not extending quite to the hind end of that bone. The anterior end of the bone curves slightly dorsally, the ventral surface of the bone thus being slightly convex longitudinally.

Both ends of the bone are capped with cartilage in my small specimens, but in the larger ones ossification tends to extend over the middle portion of the long convex proximal edge of the bone, cartilage persisting only at either end of the edge. The mesial portion of the proximal edge of the bone is covered by a tough pad of fibrous tissue which extends laterally and envelops the distal end of the interhyal of current descriptions, a bone which must represent either the epihyal alone, or both that element and the pharyngohyal (Allis, 1918*c*), and which I shall hereafter call the epihyal. This tissue binds these two bones firmly, but flexibly, together, and certain ligaments have their origins or insertions in it. One of these ligaments is a short one which extends to the internal surface of the gular plate. Another is a relatively narrow band which arises from the ventral portion of the hind edge of the dentary and from the dermarticular immediately posterior to it, and from there runs posteriorly across the ventral surface of the pad on the proximal end of the ceratohyal, there being strongly attached to it. It then turns proximally (here laterally) along the dorsal (internal) surface of the epihyal, and running along that bone, strongly attached to it, reaches and is inserted on the internal surface of the hyomandibula. Beneath (internal to) this ligament is a wider and stouter one which arises from the ventral surface of the dermarticular and running postero-mesially separates into two parts, the mesial one of which is inserted in the pad of fibrous tissue on the proximal end of the ceratohyal, while the lateral one turns dorso-mesially over the lateral portion of the proximal end of the ceratohyal, is there strongly attached to it, and then continues onward and is inserted on the internal surface of the metapterygoid. Beneath this ligament, the hind edge of the fold of epithelial tissue that lies between the floor of the buccal cavity and the ventral surface of the tongue of the fish, is attached, by connective tissue, to the proximal end of the ceratohyal. Beneath the deeper one of the two ligaments above described, and as a part of it, a stout ligament arises from the ventral surface of the articular, and, turning dorsally over its hind edge, is in part inserted on the internal surface of the mandible, but in part continues upward as a short stout ligament which has its insertion on an angular ridge on the internal surface of the quadrate. This ligament and the one inserted on the internal surface of the metapterygoid both pass between the external and internal branches of the ramus mandibularis facialis.

The epihyal is, as shown in figs. 50–52, a small and somewhat cylindrical bone, both ends of which are capped with cartilage. It lies, when the mouth is closed, in a nearly horizontal position, directed postero-laterally and slightly dorsally immediately posterior to the hind end of the mandible. The distal end of the element articulates with the lateral portion of the proximal end of the ceratohyal, and slightly proximal to this articular end of the epihyal there is, on its hind edge, a slight process which gives attachment to the ligamentous formation that binds the two elements together. The summit of this process was of cartilage in one specimen, this seeming to indicate that this process and the actual articular end of the bone together form its distal end, and that this entire end articulated with the ceratohyal before the two elements acquired the inclined relations to each other that they actually have. The proximal end of the element articulates with the ventro-mesial surface of a process of the cartilage that caps the ventral end of the hyomandibula, the two elements there lying nearly at right angles to each other.

The hyomandibula is, as shown in figs. 29 and 30, a stout flat bone, with two portions which lie nearly at right angles to each other, the dorsal portion directed, from above, ventro-posteriorly, and the ventral portion ventrally and slightly anteriorly. Slightly dorsal to the angle between these two portions, the opercular process projects posteriorly and slightly dorsally, is capped with cartilage, and articulates with an articular facet on the internal surface of the operculum, this facet being lined with cartilage, as van Wijhe has stated. A stout ligament arises from the dorsal edge of the process and is inserted on the ventral edge of the large posteriorly projecting portion of the accessory hyomandibula of Traquair's descriptions. A large depressed region on the anterior portion of the lateral surface of the hyomandibula marks the surface of insertion of the musculus adductor mandibulae. Posterior to this depressed region, the preoperculum lies upon the lateral surface of the bone, and is bound to it by connective tissues.

Both ends of the hyomandibula are capped with cartilage. The dorsal cap articulates with the lateral surface of the cranium in the large hyomandibular facet, the dorsal end of the bone there projecting dorsally beyond the level of the dorsal edge of the large cheek-plate and lying directly internal to the dorsal end of the spiracular canal. The ventral cap has two articular surfaces, one on the ventro-mesial surface of a short pointed process on the posterior end of the cap, and the other on the anterior edge of the anterior end of the cap. The former surface gives articulation to the proximal end of the epihyal. The other surface is a facet which gives articulation to a short process, capped with cartilage, which projects posteriorly from the internal surface of the posterior portion of the quadrate. Dorsal to this latter articulation, the ventral portion of the anterior edge of the hyomandibula fits into a slight groove on the hind edge of the metapterygoid and is bound to it by connective tissues.

There is no independent symplectic, but it is possible that that element is represented in that short articular process of the quadrate that articulates with the anterior surface of the cartilaginous cap on the ventral end of the hyomandibula. This will be discussed when describing the quadrate.

The so-called accessory hyomandibula is a small bone which sits saddle-like on the hind edge of the dorsal arm of the hyomandibula, extending downward from the dorsal end of the arm to the base of the opercular process. The two bones are tightly bound together, and cannot be separated in my non-macerated specimens. The posterior portion of the dorsal end of the bone is exposed on the outer surface of the skull, there lying immediately anterior to the anterior postspiracular ossicle. The dorsal edge of the bone articulates with the skull in the dorso-posterior portion of the large hyomandibular facet, the articulation being wholly with the lateral edge of the parieto-dermopterotic. The articulating edge of the process was not capped with cartilage on one side of the head of the one adult specimen examined, this being as van Wijhe found it in his specimen. On the other side of the head of my specimen the process was capped with cartilage, this being as Traquair shows it in his figure. On both sides of the head of my 75 mm. specimen there was here a little independent piece of cartilage lying along the dorsal edge of the bone.

The accessory hyomandibula bounds part of the hind end of the spiracular opening, as van Wijhe has stated, and it was considered by him to be one of the series of spiracular ossicles, a conclusion that has been accepted by both Bridge and Pollard. The presence of a bit of cartilage in the articular edge of the bone is decidedly against this supposition, and, as fully discussed in an earlier work (Allis, 1918*c*), I consider this bit of cartilage to represent the dorsal end of the bar formed by the fusion of the bases of the posterior row of branchial rays of the hyal arch, here not completely differentiated to form a posterior articular head to the hyomandibula such as is found in the Teleostei. The ligament that connects the bone that encloses this cartilage with the opercular process represents the ventral portion of the posterior articular head of the teleostean hyomandibula, and the shank of the accessory hyomandibula is a secondary formation of membrane origin. The articular head of the hyomandibula is the homologue of the anterior articular head of the teleostean hyomandibula, and it is derived from the dorsal end of the bar formed by the fusion of the bases of the anterior row of branchial rays of the hyal arch. The ramus hyoideus facialis runs outward between these two heads of the hyomandibula, thus having normal relations to them, but the ramus mandibularis facialis runs outward anterior to the anterior head, which is, so far as I know, an exceptional position in fishes.

Opercular and cheek bones. The larger part of the cheek of this fish is covered by a large and irregular dermal plate which was called by both Müller (1846) and Agassiz (1833–43) the preoperculum. Huxley (1861) says that this bone has two parts, one of which he calls the supratemporal and the other the hyomandibula, and he says that he is much inclined to doubt the existence of a true preoperculum in any crossopterygian fish. Traquair (1871) calls the bone the cheek-plate, and says that the presence of anything corresponding to the preoperculum is somewhat doubtful. Collinge (1893) considers it to be the homologue of the infraorbital bones of Lepidosteus grafted upon the preoperculum, and says that in young skulls these two components of the bone are separated dorsally by a distinct groove, and ventrally by a suture. Pollard (1892) adopts the name preoperculum, but says that the bone consists, as Agassiz first showed, of two parts which correspond to the preoperculum and the lower postorbital of Amia.

This bone of my adult specimens has, as Huxley, Pollard and Collinge all say, decidedly the appearance of being formed of two components, a large plate-like superficial one, and a deeper one which lies along the mesial surface of the hind edge of the superficial component and projects ventrally beyond it as a stout flat process. There is, however, no suture, at any place in any of my several specimens, separating the two components from each other.

The superficial component is less wide anteriorly than it is posteriorly, its dorsal and ventral edges inclining forward toward the dorsal and ventral edges of the hind end of the maxillary. The more or less convex dorsal edge of the bone is overlapped externally by the series of spiracular ossicles. In the anterior edge of the bone there is a V-shaped incisure which varies in depth but occupies the full length of the edge, the anterior end of the bone thus having two pointed processes, the dorsal one of which overlaps externally the hind end of the maxillary, while the ventral one is overlapped externally by the latter bone. Immediately posterior to the point of the angle in this edge of the bone there is, on the external surface of the bone, a short oval groove which lodges the anterior horizontal cheek-line of pit organs, and both dorsal and ventral to this groove there are slight depressions which, in the fresh specimen, are filled with dermal tissues. In the horizontal line of this groove there is, at the hind edge of the bone, another short groove, which lodges the posterior horizontal cheek-line of pit organs, and perpendicular to the ventral edge of this groove there is a short groove for the vertical line of pit organs. The hind edge of the superficial component forms a slight ledge which runs postero-dorsally in a curved line along the external surface of the deeper component, the dorsal end of the ledge running either into the groove that lodges the vertical cheek-line of pit organs, or, posterior to that groove, into the hind end of the groove that lodges the posterior horizontal cheek-line. The conditions here vary greatly, and it is probably these vertical and horizontal grooves that led Collinge to say that the two components of the bone were separated from each other by a groove. The superficial component of the bone is not traversed by the infraorbital latero-sensory canal and is accordingly the homologue of the so-called squamosal of Glyptopomus and Osteolepis, and not of the postorbitals of Amia (Allis, 1919*e*).

The deeper component of the bone corresponds to the preoperculum of Amia and the Teleostei. Its ventral end is formed by the ventral process of the entire bone, and from there it extends upward along the mesial surface of the superficial component to about one third the distance between the posterior horizontal cheek-line of pit organs and the dorsal edge of the entire bone, where it has the appearance of ending abruptly, with a concave dorsal edge which lies approximately in the level of the axis of the opercular process of the hyomandibula. Up to this point the hind edge of this deeper component lies upon, and is bound by dermal tissues to, the hind edge of the lateral surface of the hyomandibula, and its hind edge is grooved to receive the anterior edges of the operculum and suboperculum. Dorsal to this point the internal surface of the cheek-plate is hollowed out to receive the articular end of the operculum and to give passage to the musculus dilatator operculi, and dorsal to this hollow, the dorsal edge of the entire bone is somewhat thickened, and forms an eminence, or short process, which is directed dorso-postero-mesially and gives attachment to tissues of the region.

The preoperculo-mandibular latero-sensory canal enters the ventral end of the process-like ventral end of the cheek-plate, and runs upward in the plate to its dorsal edge, thus passing upward beyond its thickened, preopercular portion. At the dorsal end of the ventral, process-like portion of the bone, tube No. 7 of the line is given off, tube No. 8 being given off directly posterior to the posterior horizontal cheek-line of pit organs. Dorsal to the thickened, preopercular portion of the bone, the canal turns dorso-anteriorly and traverses the superficial, plate-like portion of the bone, approximately along the bottom of the hollow that lodges the articular end of the operculum and the musculus dilatator operculi. This part of the canal contains no sensory organ, the dorsal organ of the line lying in the dorsal end of the deeper, thickened part of the bone. That part of the canal that lies dorsal to this thickened portion has thus apparently been secondarily enclosed in a part of the entire bone that does not belong to the preoperculum.

The bone *Y′* of Traquair's descriptions I do not find in any of my specimens, unless it be that it is represented in the anterior prespiracular ossicle.

The bone *Y″* is always present, and in all my large specimens there is a second and similar bone posterior to it, as shown in Müller's (1846) figure of this fish, the external surfaces of both bones being tuberculated. In the small specimens of *Polypterus Lapradei* the anterior bone, only, was found, this being as shown in Traquair's figure of his specimen of *Polypterus senegalus*. The two bones usually lie ventral to the ventral edge of the cheek-plate, but may somewhat overlap that edge.

The operculum (fig. 33) is a large bone with a rounded hind edge marked with concentric lines. The ventral portion of the anterior end of the bone fits into the groove on the hind edge of the deeper component of the cheek-plate, and immediately dorsal to this part of the bone is the facet for the opercular process of the hyomandibula. This facet is lined with cartilage and is presented antero-mesially, this being the only bony fish I know of in which this facet is said to be lined with cartilage, excepting only Alepocephalus (Gegenbaur, 1878). The operculum projects anteriorly somewhat beyond this facet, and is there hollowed out on its internal surface. On the internal surface of the anterior edge of this part of the bone the tendon of the musculus dilatator operculi has its insertion. The dorsal edge of the operculum is overlapped externally by the ventral edges of the postspiracular ossicles, the dorsal edge of the operculum being slightly grooved, on its external surface, to receive them.

The suboperculum articulates, along its anterior edge, with the hind edge of the cheek-plate, its dorso-posterior edge being overlapped externally by the antero-ventral edge of the operculum.

Palatoquadrate. The palatoquadrate (figs. 29 and 30) is an elongated structure, traversed its full length by a band of cartilage which is bounded dorsally, ventrally and internally by bone, its external surface alone being exposed. The dorsal edge of the apparatus is strongly convex and lies in a nearly horizontal position, its anterior two-thirds fitting into the groove on the lateral edge of the orbital portion of the parasphenoid, between its membrane and tooth-bearing components, and being bound to it by connective tissues, and its posterior third turning outward and lying along the lateral surface of the ventral end of the spiracular canal. The hind end of the apparatus is double, the two ends being parallel and separated by a slight groove, but their hind edges lying at a considerable angle to each other. The internal one of these two edges extends downward from the dorsal edge of the apparatus to about the middle of its width, and abuts against and is firmly bound to the anterior edge of the ventral portion of the hyomandibula. The external one of the two edges extends the full width of the apparatus, inclining antero-ventrally and overlapping externally, at its dorsal end, the anterior edge of the hyomandibula. The posterior portion of the ventral edge of the apparatus is bent outward at approximately a right angle to the anterior portion, lies in a transverse position, and forms the articular surface for the mandible. Starting from the outer end of this bent-out edge, a ridge runs upward on the external surface of the apparatus, approximately in the transverse plane of the anterior edge of the postorbital process of the chondrocranium, and marks both the posterior limit of the surface of origin of the deeper portion of the musculus adductor mandibulae, and the anterior limit of the surface of origin of the superficial portion. Immediately anterior to this ridge, and slightly ventral to the middle of its length, there was, in two of the four specimens examined, but not in the other two, the external opening of a canal which ran dorso-posteriorly in the apparatus. It did not issue on the internal surface of the apparatus, and nothing was found entering it. The bending outward of the ventral edge of the apparatus forms a deep depression on its external surface, the anterior edge of the depression being marked by a lateral process on the ectopterygoid. The transverse plane of the angle of the gape lies immediately posterior to this process, between it and the anterior edge of the ascending process of the splenial, and when the mouth opens and shuts, the splenial, with the attached labial cartilage and related tissues, has a sliding dorso-ventral motion on the hind edge of the lateral process of the ectopterygoid. The anterior end of the cartilaginous core of the apparatus has ossified as the autopalatine, and this bone, capped with cartilage, articulates with the cartilage that covers the ventral border of the orbital surface of the ectethmoid.

The quadrate was, in the specimen particularly examined, so firmly bound to the metapterygoid that the two bones could not be separated without breakage. The bone is quadrantal in shape, with one edge lying in a horizontal plane and the other directed dorso-postero-mesially, and its external surface is crossed by the ridge, above described, that forms the boundary between the surfaces of insertion of the deeper and superficial portions of the adductor mandibulae. The ventral edge of the bone is curved, with its posterior portion transverse in position, and this part of the edge articulates with the autarticular in a transverse groove on the dorsal surface of that bone, neither of the articular surfaces being capped with cartilage so far as could be determined from my specimens.

On the internal surface of the bone there is a pronounced ridge which begins, ventrally, at the mesial end of the articular edge of the bone, and runs dorso-posteriorly nearly to its dorsal edge. There it turns posteriorly, or postero-ventrally, and extends to the hind edge of the bone, there forming the ventral end of the mesial one of the two diverging hind edges of the dorsal portion of the entire apparatus. Between this ridge and the hind edge of the bone there is a deep depression which receives the hind end of the autarticular when the mouth is widely opened. That part of the ridge that forms the ventral end of the mesial one of the diverging hind edges of the apparatus is capped with cartilage that is continuous with the cartilaginous core of the apparatus, and, as already stated, it articulates with the anterior edge of the cartilaginous cap on the ventral end of the hyomandibula. The ramus mandibularis externus facialis passes external to this process-like part of the quadrate, the ramus mandibularis internus passing internal to it, the process thus having to these two nerves and to the hyomandibula and quadrate, the relations that the teleostean symplectic would have if it were to fuse with the quadrate instead of with the hyomandibula; and it is quite probable that it represents some part of that element of the hyal arch.

The convex dorsal edge of the quadrate is everywhere bounded by cartilage. Its internal surface, anterior to the ridge across it, is completely covered by the metapterygoid and ectopterygoid, these two bones resting directly upon it, and the metapterygoid being firmly anchylosed with it in the one specimen examined.

The metapterygoid has, in my adult specimens, decidedly the appearance of being wholly an investing bone, and in the 75 mm. specimen it at no place has primary relations to the cartilage of the apparatus, this thus confirming van Wijhe's and Pollard's conclusions regarding it. It lies mainly upon the internal surface of the apparatus, but its dorsal edge embraces the dorsal edge of the cartilaginous core and projects somewhat above it, there being exposed on the lateral surface of the apparatus. The anterior portion of this dorsal edge is grooved on its dorso-lateral surface, and there receives and articulates with the hind end of the entopterygoid. On the mesial surface of the apparatus the bone articulates anteriorly with both the ectopterygoid and entopterygoid, and ventrally with the quadrate, overlapping the mesial surface of the latter bone to a considerable extent and being itself overlapped mesially by the entopterygoid, the latter bone fitting into a sharply marked depression on the mesial surface of the metapterygoid.

The hind edge of the bone is slightly thickened and grooved, and lodges part of the cartilage, already referred to, that forms the ventral portion of the mesial one of the two hind edges of the entire apparatus. The dorso-posterior corner of that part of the bone that overlaps externally the dorsal edge of the cartilage of the apparatus is either perforated by a foramen, or deeply notched in its hind edge. This foramen, or notch, is traversed by the ramus mandibularis internus facialis, that nerve then running downward between the cartilage of the apparatus and the internal plate of the metapterygoid and issuing at the ventral edge of the latter bone, between it and that process of the quadrate that apparently corresponds to the symplectic. The dorso-anterior portion of the mesial surface of the bone is roughened with minute tooth-like eminences.

The entopterygoid is a long thin dermal bone which forms the larger part of the dorso-mesial edge of the apparatus, there projecting considerably beyond the cartilage of the apparatus. Ventral to this wide projecting edge, the bone rests upon the mesial surfaces of the metapterygoid and ectopterygoid, lying in a sharply marked depression along the dorsal edges of those bones, and being separated, by them, from all contact with the cartilaginous portion of the palatoquadrate. The anterior half of the dorso-mesial edge of the bone is loosely bound to the lateral edge of the parasphenoid, between its membrane and tooth-bearing components, the posterior half lying against the external surface of the spiracular canal. The anterior end of the bone is thin, and extends forward onto the ventral surface of the posterior portion of the ethmoidal cartilage, there being covered by tough connective tissues. Its hind end is somewhat pointed, curves postero-laterally, and rests upon the dorso-external surface of the dorsal edge of the metapterygoid. Its mesial surface is completely covered with small tooth-like eminences, excepting that part of its anterior end that extends forward beneath the ethmoidal cartilage.

The ectopterygoid is a thin dermal bone which lies directly upon the mesial surface of the cartilage of the palatoquadrate, its dorsal edge coinciding with the dorsal edge of that cartilage, but its ventral edge extending ventrally beyond the cartilage. The mesial surface of the bone is everywhere covered with small tooth-like eminences, these eminences becoming small sharp teeth along the anterior half of its ventral edge and there forming a posterior continuation of the teeth on the oral surface of the mesial dermo-palatine, the so-called vomer of earlier descriptions. The dorsal edge of the bone is overlapped to a considerable extent by the ventral edge of the entopterygoid, as just above explained. Its hind end overlaps slightly the anterior edges of the metapterygoid and quadrate.

The anterior end of the ventro-lateral edge of the ectopterygoid is somewhat thickened, apparently by dermal accretions to its external surface, this giving rise to what appears like a short antero-laterally projecting process, this process and the remainder of the bone being separated by a narrow V-shaped space which receives the hind edge of the palatine process of the maxillary. The anterior end of the body of the ectopterygoid, which forms the ventro-mesial boundary of this V-shaped space, articulates with the hind end of the mesial dermopalatine, the antero-laterally projecting process giving support, on its dorsal surface, to the autopalatine. This little process may accordingly be called the palatine process of the ectopterygoid, and posterior to it, at the hind end of the row of small sharp teeth on the anterior portion of the ventral edge of the bone, there is a second process, which I have above referred to as the lateral process of the bone. This process is directed laterally and has a flat and somewhat spreading outer end which abuts against, and is firmly bound to, the ventral portion of the internal surface of the maxillary, immediately posterior to the toothed part of that bone (Allis, 1900*b*). The posterior edge of the process is slightly hollowed and gives sliding articulation to tissues attached to the anterior edge of the ascending process of the splenial. Dorso-anterior to the base of this process there is a large semicircular notch in the ventral edge of the cartilage of the palatoquadrate, the lateral surface of the ectopterygoid there being exposed. This notch lies beneath the eyeball, and is apparently caused by the wearing action of that organ. The bone is here traversed by a small canal which begins at the dorsal edge of the palatoquadrate cartilage and issues near the ventral edge of the ectopterygoid, the canal transmitting a branch of the ramus palatinus facialis, which thus has the course of the ramus palatinus posterior facialis of Amia. In Amia that nerve runs antero-ventrally across the external (dorso-lateral) surface of the entopterygoid, passes internal to the cartilage of the palatoquadrate, and then internal to the autopalatine, between it and the dermopalatine, sometimes perforating the autopalatine in part of its course. The conditions in Polypterus would accordingly arise if the autopalatine of Amia were to be pushed forward beyond this nerve, and the nerve were then to become enclosed in the dermopalatine, this suggesting that the dermopalatine of Amia is represented in the anterior portion of the ectopterygoid of Polypterus.

The autopalatine is a small bone of primary origin which develops in the anterior end of the palatoquadrate cartilage, that end of the cartilage here turning slightly antero-laterally. The bone rests upon the dorsal surface of the palatine process of the ectopterygoid, and was not, as van Wijhe found it, fused with that process in any of my specimens. Its slightly concave dorsal surface is capped with cartilage and articulates with the cartilage that covers the ventral surface of the ectethmoid. The ethmopalatine ligament of Pollard's descriptions (1892, p. 413) arises from the cranium posterior to this articular surface and, running postero-laterally and spreading considerably, is inserted along the dorso-mesial edge of the cartilaginous core of the palatoquadrate. Pollard says that this cartilaginous core projects forward beyond the autopalatine, and that this anterior portion is the homologue of the prepalatine cartilage of his descriptions of the Siluridae. No such projecting portion of the cartilage was found in any of my specimens.

Van Wijhe (1882, p. 253) found the autopalatine fused with the anterior end of the ectopterygoid, as above stated, and because of this he concluded that this anterior portion of the latter bone fulfilled the function of a dermopalatine, and was hence probably, genetically (in der Entwickelungsgeschichte), an independent bone, the equivalent of the dermopalatine of the Ganoidei, a conclusion which the relation of the ramus palatinus posterior facialis to the bone seems to fully confirm, as just above explained.

The mesial dermopalatine (figs. 23–27), the so-called vomer of earlier authors, forms a direct anterior prolongation of the ventro-lateral portion of the ectopterygoid. It is furnished with small sharp teeth, and its posterior portion lies upon and is firmly bound to the ventral (oral) surface of the palatine process of the maxillary, its anterior end projecting forward beyond that process and lying upon the ventral (oral) surface of the palatine process of the premaxillary, but only loosely bound to it. This end of the bone is somewhat wider than its posterior portion, and curving mesially meets and articulates, in the median line, with its fellow of the opposite side. The curved external edge of the bone is concentric with the line of the premaxillo-maxillary teeth, and separated from them by a groove which I have called the primary alveolo-labial sulcus (Allis, 1919*c*). Along the postero-mesial edge of the bone there is a slight furrow in the lining membrane of the roof of the buccal cavity, and I formerly, but erroneously, considered the anterior edge of this groove to represent the maxillary breathing-valve of the Teleostei. This bone thus being a mesial dermopalatine, the dermopalatine of Amia, which is represented in the anterior portion of the ectopterygoid of Polypterus, must be a lateral dermopalatine.

Mandible. The mandible contains the four bones described by Traquair, and also the mento-Meckelian ossicle described by van Wijhe. No bone corresponding to the angular of van Wijhe's descriptions was found in any of the specimens examined, nor was there any indication of such a bone having fused with the dermarticular.

The dentary is a long and rather slender bone, the anterior end of which curves mesially. It bears on its dorsal edge a single row of sharp stout teeth. Its mesial surface is deeply grooved its entire length, the anterior half of this groove being relatively narrow, with an enlarged anterior end, and lodging the anterior portion of Meckel's cartilage and the mento-Meckelian ossicle. The posterior portion of the groove is deeper than the anterior portion, and widens gradually to the hind end of the bone, there occupying its entire width and lodging the anterior portion of the dermarticular. The mesial surface of the dorsal edge of the groove is flat and articulates with the lateral (aboral) surface of the ventral half of the anterior portion of the splenial, the latter bone projecting dorsally above the articulating surface with the dentary and forming a pronounced ridge which lies parallel to the outer, tooth-bearing edge of the dentary and is separated from it by a deep groove which lodges the ramus mandibularis internus facialis and a branch of the ramus mandibularis trigemini that I consider to represent part of the ramus posttrematicus internus of the nerve. In the hind edge of the dentary there is a large V-shaped incisure, the sharp dorsal and ventral edges of the incisure resting upon the external (lateral) surface of the dermarticular. The anterior end of the bone is thickened, turns slightly mesially, and has a large flat surface which articulates with its fellow of the opposite side. The ventral edge of this part of the bone is flattened and projects slightly ventrally as a sharp ridge, but there is no indication that this part of the bone was, as van Wijhe suggests, a primarily independent predentary that has fused with the dentary.

The dentary is traversed its full length by the mandibular latero-sensory canal, the canal entering the bone on its external surface, close to the symphysis, and leaving it at the re-entrant point of the large V-shaped incisure in its hind edge. Two tubes leave the canal as it traverses the bone, and the bone lodges three sense organs of the line. The ramus mandibularis externus facialis runs forward ventral to the groove that lodges Meckel's cartilage, and three short canals give passage to the branches sent to the three sense organs lodged in the bone.

The dermarticular is a stout dermal bone, with a long and sharply pointed anterior end which fits into the posterior portion of the groove on the mesial surface of the dentary, the outer surface of the dermarticular being excavated to receive the diverging hind ends of the dentary. Posterior to the dentary the ventral edge of the bone is thin, and on the external surface of this edge, immediately posterior to the hind end of the dentary, there is a small pit-like depression which is presented ventrally and forms part of the surface of origin of the long ligament that has its insertion on the proximal (posterior) end of the ceratohyal. On the mesial surface of the bone there is a groove to receive the posterior portion of Meckel's cartilage, and this groove is crossed by a smaller groove which lodges the ramus mandibularis externus facialis and the ramus mandibularis trigemini as those two nerves run forward onto the mesial surface of the dentary. Dorsal to the posterior portion of this latter groove there is a depression which forms the surface of insertion of a part of the musculus adductor mandibulae. Ventral to the hind end of Meckel's cartilage the ventral edge of the groove that lodges it rises as a ridge-like process, the mesial surface of which is flat and roughened and articulates with the aboral surface of the ventral edge of the splenial. Posterior to this, the mesial surface of the dermarticular articulates with the lateral surface of the autarticular, the dorsal edge of the bone projecting upward beyond this surface of articulation and there articulating with the ventral edge of the lateral plate of the ascending process of the splenial.

The dermarticular is traversed by the posterior portion of the mandibular latero-sensory canal, and lodges two organs of that line. The canal enters the bone on its external surface at the point of the V-shaped incisure in the dentary, and leaves it near its dorsal edge close to its hind end, one tube leaving the canal as it traverses the bone. Slightly dorso-anterior to the opening by which the canal leaves the hind end of the bone, there is a notch in the edge of the bone, this notch leading into a canal which runs forward, at first between the dermarticular and the autarticular and then through a portion of the former bone to reach and enter the little groove that crosses the groove that lodges Meckel's cartilage, this canal transmitting the ramus mandibularis externus facialis.

The autarticular (figs. 38 and 39) is an irregular bone which lies between the hind ends of the dermarticular and splenial, articulating with the former bone by its entire lateral surface excepting only a narrow dorso-posterior edge, and with the splenial by the anterior third or half of its mesial surface. The hind end of Meckel's cartilage abuts against the anterior end of the bone, and is in primary relations to it. At about the middle of the length of the dorsal surface of the bone there is a transverse hour-glass shaped groove which is lined with connective tissue and not with cartilage and gives articulation to the articular edge of the quadrate. These two articulating surfaces are thus neither of them lined with cartilage. Anterior to this articular groove, the dorsal surface of the autarticular is deeply grooved, this groove occupying the entire dorsal surface of the bone and inclining antero-ventrally into the hollow of the mandible. Posterior to the articular groove the bone narrows abruptly and then tapers to a rounded hind end which is capped with a pad of tough connective tissue which looks somewhat like cartilage and rubs against the anterior edge of the epihyal. On the mesial surface of the bone, immediately ventral to the mesial end of the articular facet for the quadrate, there is the external opening of a short canal which traverses the bone and transmits the ramus mandibularis internus facialis.

The mento-Meckelian ossicle is a small cylindrical, or knob-shaped bone which extends from the anterior end of Meckel's cartilage forward to the symphysis, where it articulates with its fellow of the opposite side. It lies in the enlarged anterior end of the longitudinal groove on the mesial surface of the dentary and is not seen in either lateral or anterior views of the latter bone.

Meckel's cartilage is a rod-shaped piece which extends from the autarticular to the mento-Meckelian ossicle. In its posterior portion it is flat, and there lies against the mesial surface of the dermarticular. Anteriorly it becomes gradually rounded, and there lies in the longitudinal groove on the mesial surface of the dentary.

The splenial (fig. 28) is a long dermal bone which is best described as formed of two thin plates, one lateral and the other mesial, the lateral plate being narrower than the mesial one and not extending as far posteriorly. In the anterior half of the bone the two plates have a common dorsal edge and are completely fused with each other. Posteriorly the ventral portions of the two plates diverge from each other, but their dorsal edges remain fused, and the two plates are produced dorsally to form the tall ascending process of the bone. The lateral surface of the mesial plate here rests upon the flattened mesial surfaces of the autarticular and dermarticular, the ventral edge of the lateral plate resting upon the dorsal edges of the lateral surfaces of those same bones. The ascending process is thus deeply grooved both ventrally and posteriorly, and straddles the posterior opening of the ramus of the mandible, the floor of that opening being formed by the concave dorsal surface of the prearticular portion of the autarticular. Anterior to the ascending process, the mesial plate of the splenial rests against the mesial surface of the ridge that forms the dorsal edge of the groove in the dentary that lodges Meckel's cartilage, the ventral edge of the lateral plate resting upon the dorsal surface of that ridge. Anterior to the anterior end of the splenial there are the two little dermal and toothed plates described by van Wijhe, and these plates and the dorsal edge of the splenial form the mesial boundary of the deep groove that is bounded laterally by the tooth-bearing edge of the dentary, that groove extending from the anterior edge of the base of the ascending process forward to the symphysis and there being continuous with the groove of the opposite side. The mesial surface of the splenial, and the base of its ascending process are covered with minute tuberosities.

The ascending process of the splenial, together with the labial cartilage and related tissues, has sliding articulation with the posterior edge of the lateral process at the middle of the length of the ectopterygoid. On its dorsal and posterior edges it gives insertion to the masseter division of the musculus adductor mandibulae, and anterior to that muscle to the tough connective tissues that envelop the labial cartilage. There is no cartilage whatever in the process, even in my 75 mm. specimen, and I can see no reason to assume, as van Wijhe has suggested was probable, that any part of it is, or has been derived from, a primary ossification. The process would seem to correspond strictly to the coronoid (operculum) bone of certain reptiles (Baur, 1895, fig. 3), and is certainly in no way related to the cartilaginous coronoid process of Amia.

Maxillary. This bone of the adult Polypterus has been formed by the fusion of two suborbital latero-sensory ossicles with a dental bone that quite certainly corresponds to the maxillary component of the superior maxillary bone of mammals (Allis, 1900*b* and 1919*c*). Projecting mesially from the mesial surface of the anterior portion of the bone there is a long and thin palatine process which rests directly upon the ventral surface of the ethmoidal cartilage, but is only loosely bound to it. The mesial half of the ventral (oral) surface of this process supports, and is immovably attached to, the posterior two-thirds, approximately, of the mesial dermopalatine and to the anterior end of the ectopterygoid. The bone bears a single row of stout sharp teeth, and the hind end of this tooth-bearing part of the bone rests against the antero-ventral edge of the lateral process of the ectopterygoid, the lateral end of the latter process resting against the mesial surface of the maxillary dorso-posterior to this point, and being firmly but not immovably bound to it by a short stout ligament. All movements of the palatoquadrate are thus impressed upon the maxillary, and *vice versa.*

The maxillary articulates anteriorly with the premaxillary and lachrymal, and posterior to those bones forms the larger part of the ventral boundary of the orbit. Its dorso-posterior corner is overlapped externally by, and loosely attached to, the postorbital bone and the anterior spiracular ossicle.

The dorsal portion of the hind end of the bone projects posteriorly as a long and pointed process which fits against the internal surface of the large cheek-plate, the ventral portion of the bone projecting as a shorter process which lies against the external surface of the cheek-plate. These two bones and the palatoquadrate and hyomandibula are thus all firmly but apparently not immovably bound together. The anterior one of the two bones *Y''* lies external to the ventro-posterior corner of the maxillary.

The dorsal portion of the maxillary is traversed by the infraorbital latero-sensory canal, that canal entering the bone close to its dorsal edge, at the hind end of the lachrymal, and issuing from it on its external surface near its dorsal edge and immediately ventral to the postorbital bone. One primary tube is given off as the canal traverses the bone, and issues from it dorsal to the hind end of the line of maxillary teeth. The bone lodges two sensory organs of the line.

Premaxillary. This bone, like the maxillary, is formed by the fusion of latero-sensory and dental components, and also like the maxillary it has a flat palatine process, of membrane origin, which rests upon the ventral surface of the ethmoidal cartilage. This palatine process projects posteriorly and articulates with the anterior edge of the parasphenoid, and between it and its fellow of the opposite side there is a small exposed portion of the ventral surface of the rostral process of the chondrocranium. The internal surface of the premaxillary rests against the anterior edge of the rostral process, the bone projecting dorso-posteriorly above that process, and the internal (here posterior) portion of its dorsal edge there articulating with the anterior edge of the median ethmoid. Lateral to the latter bone the premaxillary sends a small ascending process dorso-postero-mesially, this process lying in the groove along the lateral surface of the head of the ethmoid and giving support, on its dorsal end, to the antero-mesial corner of the nasal, and partly also to the mesial end of the os terminale. Lateral to this process, the dorsal surface of the premaxillary is slightly hollowed out and forms the ventral edge of the fenestra nasalis, this part of the premaxillary lying beneath the antero-lateral portion of that atrial chamber of the nasal sac from which the anterior and posterior nasal tubes have their origins. Lateral and posterior to the fenestra nasalis the premaxillary has a stout antorbital process which projects dorso-posteriorly along the lateral edge of the fenestra nasalis, there lying against the lateral surface of the nasal capsule and giving support, on its dorsal end, to the lateral edge of the nasal and the antero-lateral corner of the frontal. Postero-ventrally the process articulates both with the ectethmoid and the lachrymal, and ventral to the latter bone with the anterior end of the maxillary. The bone has a single row of stout sharp teeth which apparently correspond to the premaxillary teeth of mammals (Allis, 1919*c*).

The premaxillary is traversed by the preorbital portion of the infraorbital latero-sensory canal, that canal entering it on its dorsal surface at the lateral edge of the median ethmoid, and leaving it at the anterior edge of the lachrymal. Two primary tubes leave the canal as it traverses the bone, the lateral one lying dorsal to the hind end of the row of premaxillary teeth. The bone lodges three organs of the infraorbital line, which correspond to those in the antorbital and the lateral half of the median ethmoid of Amia.

LATERO-SENSORY CANALS

These canals were fully described in an earlier work (Allis, 1900*a*), and as their relations to the individual cranial bones have already been given in the present work, and the manner of their innervation will be given when describing the nerves, it will suffice to here give simply their general course and disposition.

The accompanying fig. 1 gives a full length view of a 44 cm. specimen of *Polypterus bichir*, and shows the external openings of the primary tubes of the cranial canals, the line of little grooves that mark the positions of the sensory organs of the lateral line of the body, and other similar grooves that mark the positions of other lines of surface organs. Figs. 2, 3 and 4 give enlarged lateral, dorsal and ventral views of the same specimen. Comparing these figures with those of the prepared skull of the 49 cm. specimen (figs. 5 and 6), it is seen that most of the surface pores of the canals lie in a thick dermis which completely covers all those bones the external surfaces of which are without rugous markings, and also the smooth and bevelled edges of certain of the other bones.

The supraorbital canal begins at a pore that lies immediately posterior to the base of the nasal tube, approximately in the line prolonged of the three suborbital pores of the main infraorbital line. From there the canal enters and traverses the os terminale, and at its antero-mesial end anastomoses with the second primary tube of the main infraorbital canal, there forming the double tube and pore 2 inf.–2 sup. Turning posteriorly from there the supraorbital canal enters and traverses, successively, the accessory nasal, nasal and frontal, issuing from the latter bone near the hind end of its lateral edge and there anastomosing with the main infraorbital canal to form the double tube and pore 10 inf.–7 sup. There are six sensory organs in the line, and seven primary tubes and pores.

The main infraorbital canal begins in the median line on the top of the snout, and is there in direct continuation with its fellow of the opposite side of the head. There is no median pore marking the point of fusion of these two canals, this probably being due to the fact that the anterior sensory organ of each line lies so close to the median line, that the two organs were enclosed simultaneously in the process of involution that gave origin to the canal, no primary tube ever forming between them. Starting from this point the canal traverses the ethmoid, and on issuing from that bone anastomoses with the supraorbital canal to form the double tube and pore 2 inf.–2 sup. The canal then enters and traverses, successively, the premaxillary, lachrymal, maxillary, postorbital and postfronto-sphenotic, and on the dorsal surface of the latter bone becomes a groove which is roofed in its anterior portion by the frontal and in its posterior portion by the parieto-dermopterotic. Slightly anterior to the line between these two latter bones the canal anastomoses with the hind end of the supraorbital canal, a single double tube and pore, **10** inf.–**7** sup. marking the point of fusion. Posterior to this point the canal enters the parieto-dermopterotic, traverses that bone and then the second and first supratemporals and the posttemporal, at the hind end of which it comes to the surface and ends. While traversing the second supratemporal, or between that bone and the first supratemporal, it anastomoses with the lateral end of the supratemporal cross-commissure, so forming the double tube and pore **12** inf.–**1** supratemporal. There are 13 sense organs in all in the line, and 13 primary tubes and pores, the anterior tube and pore of the line not being present.

The supratemporal commissure traverses the second and third supratemporal bones, and anastomoses in the median line with its fellow of the opposite side, a single median pore marking the point of fusion. There are two sense organs in the line, and three primary tubes and pores, counting the two terminal ones.

The preoperculo-mandibular canal begins at the symphysis of the mandibles, at a median pore common to it and its fellow of the opposite side. From there the canal runs posteriorly through the dentary and dermarticular, traverses the dermis between the latter bone and the ventral end of the preoperculum, and then turns upward in the latter bone, traversing it and ending at a pore that lies on the external surface of the cheek-plate near its dorsal edge. The canal does not reach and anastomose with the main infraorbital canal, this doubtless being related to the presence of the line of spiracular ossicles. There are eight sense organs in the line, five in the mandible and three in the preoperculum, and there are nine primary tubes, but in the specimen used for illustration the external openings of the fifth and sixth tubes had fused to form a single pore, there thus being but eight surface pores along the line. In an adult specimen of *Polypterus ornatipinnis* this anastomosis of these two pores had not taken place, and there were accordingly nine primary pores related to the line. In the specimen used for fig. 30, there were four nerves entering the canal as it traversed the preoperculum, but whether there were three or four sensory organs was not determined.

The lateral line of the body begins posterior to the posttemporal bone, and is represented by longitudinal grooves on the external surfaces of successive scales, the grooves on the first seven rows of scales forming three short lines, the first one of which lies in the line of the hind end of the cranial canal, the next one slightly ventral to the first one, and the third one still farther ventrally. The next groove lies slightly ventral to the third short line, and from there the line of grooves continues in an unbroken line to the base of the tail fin, there being one groove on each successive scale. Dorsal to this line, approximately in the line of the dorso-anterior one of the three short lines, there is another line of sense organs, the positions of which are indicated by a somewhat irregular line of grooves placed transversely on every third or fourth scale; and dorsal to this line there is, along the ventral edge of the dorsal fin, a line of short longitudinal grooves, approximately one on each successive scale.

On the head there are six short lines of surface organs, each marked by a slight depression on the external surface of the underlying bone: an anterior head-line on the dorsal surface of the frontal, mesial, or postero-mesial to pore 6 supraorbital; a middle head-line on the parieto-dermopterotic, mesial, or postero-mesial to pore 11 infraorbital; an anterior horizontal cheek-line on the cheek-plate somewhat posterior to pore 8 infraorbital; a posterior horizontal cheek-line on the cheek-plate immediately anterior to pore 8 preoperculo-mandibular; a vertical cheek-line on the cheek-plate immediately ventral to the posterior horizontal cheek-line; and a transverse line on the ventral surface of the gular plate.

MYOLOGY

Eye muscles. The recti superior, inferior and externus arise from a short tendinous stalk that has its origin on the sphenoid, near its ventral edge and immediately posterior to the foramen opticum, its position and its relation to these muscles suggesting the eye stalk of the Selachii. The rectus internus has its origin directly upon the sphenoid, near its ventral edge and anterior to the foramen opticum, between that foramen and the foramen for the orbito-nasal artery. The obliquus superior arises from the ectethmoid, on the edge of, and partly within, the preorbital canal, the obliquus inferior arising from that same bone, near its ventral edge.

The innervation of these muscles is as in Amia (Allis, 1897), excepting in that the inferior division of the nervus oculomotorius passes dorsal, instead of ventral, to the rectus inferior.

Muscles innervated by the nervus trigeminus. These muscles have been described by both Pollard (1892) and Luther (1913).

The musculus adductor mandibulae, the masseter of Pollard's and Luther's descriptions, has, in my adult specimens, the superficial (upper) and deeper (lower) portions described by Pollard but not found by Luther. In the 75 mm. specimen both portions are also found, but not so distinctly separated from each other as in the adult. The superficial portion is the larger, and has its origin in part on a line of tough connective tissue that is attached to the internal surface of the dorsal border of the cheek-plate, in part on the external surface of the dorsal portion of the hyomandibula, and in part on the external surface of that part of the palatoquadrate that lies posterior to the ridge that runs upward across the quadrate from the outer end of its articular edge. The dorsal edge of the muscle is thin, and along a part of this edge is the line of tough connective tissue, above referred to, which is firmly attached to the dorsal edge of the cheek-plate and hence serves in part as surface of origin of the muscle, and in the 75 mm. specimen this is the only origin that the muscle has. The surface of origin on the palatoquadrate covers parts of the quadrate, entopterygoid and metapterygoid, and that on the hyomandibula the anterior portion of that bone from the dorsal edge of the palatoquadrate upward to the line of the opercular process, the fibres of the muscle all having their origins on a tough membrane that covers these several bones, and not directly on the bones themselves. A slip of that part of the membrane that covers the surface of origin on the palatoquadrate extends posteriorly, external to the ramus mandibularis facialis, and is inserted on the hyomandibula posterior to that nerve (fig. 46). The fibres of the muscle converge toward the ascending process of the splenial, running antero-ventrally, anteriorly, and even antero-dorsally, and the dorsal and larger part of them are inserted on the dorsal edge of that process and along the internal surface of its hind edge, the ventral fibres passing directly into the ramus of the mandible and there being inserted on the internal surface of the dermarticular.

The deeper portion of the adductor arises from that part of the quadrate that lies anterior to the ridge that runs upward from the outer end of its articular edge, these fibres, like those of the superficial portion of the muscle, arising from a membrane that covers the quadrate and not directly from that bone. The fibres of this portion of the muscle run antero-ventrally and are inserted, mostly tendinous, on the internal surface of the dermarticular, the tendinous ends of the muscle passing mesial, or in part lateral and in part mesial, to the ramus mandibularis trigemini. Associated with this part of the adductor there is a short muscle which corresponds to the mandibular portion of the muscle of Amia and certain of the Teleostei. The fibres of this latter muscle arise from the stout flat tendon of the musculi temporalis and pterygoideus, to be described below, and running ventro-anteriorly are inserted on the dorsal surface of the hind end of Meckel's cartilage.

The musculus temporalis has its origin from the ventral surface of the postfronto-sphenotic, from the supraorbital band of cartilage, and from that part of the ventral surface of the frontal that roofs the supraorbital fontanelle, the surface of origin of the muscle extending forward to the transverse plane of the foramen opticum. From this long surface of origin, the fibres of the muscle run postero-ventrally, ventrally and antero-ventrally, and passing external to the rami ophthalmicus profundus and ophthalmicus superficialis trigemini, and internal to the rami maxillaris and buccalis trigemini, are all inserted on the external surface of a tendinous band which lies between it and the musculus pterygoideus and which gives insertion, on its internal surface, to the fibres of the latter muscle. This tendinous band passes internal to the ramus mandibularis trigemini and, diminishing in width, is inserted on the internal surface of the dermarticular.

The musculus pterygoideus arises from the postero-ventral portion of the lateral surface of the sphenoid and from adjacent portions of the mesial plate of the ascending process of the parasphenoid, there lying between the nervus trigeminus dorsally and the common carotid artery, the ramus palatinus facialis, and the vena orbitalis inferior ventrally. It is a wide stout muscle, runs ventro-laterally and slightly anteriorly along the external surface of the palatoquadrate, and has its insertion on the tendinous band, just above described, that gives insertion on its external surface to the musculus temporalis.

The musculi temporalis and pterygoideus apparently together correspond to the first and second divisions of the levator maxillae superioris of my descriptions of Amia (Allis, 1897).

The single primitive levator arcus palatini has been more or less completely differentiated into four muscles; the levator arcus palatini of Luther's descriptions (levator maxillae superioris of Pollard), the protractor hyomandibularis of Pollard's descriptions, the dilatator operculi, and the musculus spiracularis (Luther). These muscles, excepting the spiracularis, all arise together from the lateral surface of the postfronto-sphenotic, there forming practically a single muscle but separated from each other by an aponeurotic formation. The fibres of the levator arcus palatini run postero-ventrally and, spreading somewhat, are inserted on a curved tendinous band which is concave postero-ventrally. This band crosses the external surface of the protractor hyomandibularis at about the middle of its length, and has its ventro-anterior end inserted on the dorsal edge of the entopterygoid, and its dorso-posterior end on the external surface of the hyomandibula in the horizontal line of its opercular process. The dilatator operculi lies along the dorsal edge of the levator arcus palatini, and runs posteriorly and slightly laterally. Its fibres are all inserted on a long tendinous formation which extends the full length of the muscle, along the middle line of its external surface, and has its insertion on the internal surface of the anterior edge of the operculum. The musculus spiracularis lies along the dorsal edge of the dilatator operculi, and in the adult has its origin on the hind edge of the frontal bone, as Luther states. Pollard calls it a slip of the dilatator, but even in my 75 mm. specimen it is wholly independent of that muscle. It runs posteriorly along the lateral edge of the spiracular opening, and apparently has its insertion on the wall of that opening. It lies directly beneath the spiracular ossicles and is attached to them by fibrous tissues, but not inserted on them. The protractor hyomandibularis lies internal to the levator arcus palatini, and is a much stouter muscle. Its fibres run postero-ventrally and most of them are inserted on a membrane that covers and forms part of the lateral wall of the spiracular canal, that membrane having its attachment, ventrally, to the dorsal edge of the palatoquadrate and, posteriorly, to the anterior edge of the hyomandibula, the longest fibres of the muscle, which are the external ones, only extending to the edges of those two skeletal elements and not overlapping them. The muscle thus has an action upon the suspensorial apparatus that is strictly similar to that of the so-called levator arcus palatini, and, in addition, an action of some sort on the spiracular canal.

There is no muscle comparable to the intermandibularis of Amia, but there are two muscles strictly comparable to the geniohyoidei inferior and superior of that fish, and I have described them in an earlier work (Allis, 1919*d*). The geniohyoidei inferior and superior of this fish are called by Pollard the intermaxillares anterior and posterior, the former being said to be innervated by the ramus mandibularis trigemini and the latter by the ramus hyoideus facialis. Holmqvist (1910) calls the anterior one of these two muscles the intermandibularis, and the posterior one the protractor hyoidei, and he says that the latter muscle, as an independent structure, is found only in the bony fishes and in Amia, the term bony fishes, as employed by him, evidently meaning the Teleostei only. In a later work (1911), Holmqvist calls the intermandibularis of his earlier descriptions of Polypterus the intermandibularis II, in order to distinguish it from an intermandibularis such as is found in Amia, which latter muscle is called the intermandibularis I; and these two muscles, where found, are both considered by him to be innervated by the ramus mandibularis trigemini. The protractor hyoidei, which is the geniohyoideus superior of my descriptions of Amia, is, on the contrary, considered by him to be innervated by the ramus hyoideus facialis. In the Teleostei the homologue of this latter muscle of Polypterus is said (1910, p. 12) to have added to it certain fibres derived from the constrictor of the mandibular arch, the anterior portion of the muscle then being innervated by the nervus trigeminus and its posterior portion by the nervus facialis. It is said that, in both Polypterus and Lepidosteus, none, or but few, of these trigeminus fibres have as yet been acquired by the protractor, and Holmqvist's descriptions would seem to indicate that he did not consider them, where found, to have been derived from the intermandibularis II (geniohyoideus inferior). Where they are considered to have come from is not clear. Luther (1913), following Holmqvist's earlier work, calls the two muscles of Polypterus the intermandibularis and protractor hyoidei, and he says that the former muscle is derived from the ventral portion of the constrictor of the mandibular arch, and is innervated by the ramus mandibularis trigemini, while the protractor hyoidei is derived from the ventral portion of the constrictor of the hyal arch and is innervated by the ramus hyoideus facialis.

The contraction of either of these two muscles would evidently have similar effect upon either the mandible or the hyal arch, and in my work on Amia, I said (Allis, 1897, p. 562) that this action must be either that of an adductor (more properly protractor) of the hyal arch or a retractor of the mandible, according as the one or the other of these two structures was fixed and stationary. If then the principal action of the posterior muscle is that of a protractor hyoidei, as Holmqvist's descriptions would seem to establish, that must be the action also of the anterior muscle. The two muscles, in fact, become, in certain of the Teleostei described by Holmqvist, simply anterior and posterior portions of a single muscle, but apparently always separated from each other by a more or less developed aponeurotic line. If one of them is called a protractor hyoidei, the other should then also be so called, one being an anterior protractor and the other a posterior one. I have however thought best, for the sake of conformity in my several works, to continue to use for them the names employed in my descriptions of Amia and Scomber.

The geniohyoideus inferior, thus defined, is a muscle strictly similar to that of Amia, arising in the median line from a median aponeurotic raphe common to it and its fellow of the opposite side, and running antero-laterally to be inserted mainly upon the mesial surface of Meckel's cartilage, immediately ventral to the ventral edge of the splenial, but partly also along the ventral edge of the latter bone. The geniohyoideus superior arises, as in Amia, from the proximal (posterior) end of the ceratohyal, and, running anteriorly and somewhat mesially, has its mesial fibres inserted on a posterior continuation of the median raphe that gives insertion to the geniohyoideus inferior, while the lateral fibres pass internal (dorsal) to the geniohyoideus inferior and are inserted on the dorsal portion of the raphe that gives insertion to the fibres of that muscle. The fold of the mucous membrane of the mouth cavity that lies beneath the tongue, lies between the lateral portions of the two geniohyoidei.

The mesial edge of the geniohyoideus superior is in contact with the lateral edge of the hyohyoideus inferior, the two muscles there forming a single and practically continuous sheet. The two muscles are however certainly innervated, as fully explained in my recent work (Allis, 1919*d*), the one by the nervus trigeminus, and the other by the nervus facialis, and the fibres of the one pass ventral, and those of the other dorsal, to a fold of the dermal tissues that extends inward between the two muscles and spreads laterally on either side, thus forming a short fold, or pocket, between the two muscles. This pocket opens, superficially, into a long and narrow median space formed by the infolding of the dermis inward and laterally beneath the mesial edge of each gular plate, this space extending anteriorly nearly to the anterior edge of the geniohyoideus inferior.

Muscles innervated by the nervus facialis. The adductor hyomandibularis and adductor operculi, called by Pollard the retractor hyomandibularis and the opercularis, form a single continuous muscle which has its origin on the large concave surface on the dorso-lateral surface of the posterior portion of the opisthotic ridge, and the anterior portion of the muscle is inserted on the internal surface of the hyomandibula and the posterior portion on the internal surface of the operculum.

The hyohyoideus has inferior and superior portions similar to those of Amia, the inferior portion being called by Pollard both the mantle muscle and the muscle of the jugular plate. Of it he says: "Behind the intermaxillaris is a separate muscle which arises from a median raphe of its own, and proceeds to the postero-internal angle of the jugular plate. Some fibres pass on into the mantle." Starting from this median aponeurotic raphe, which is common to it and its fellow of the opposite side and lies internal to the raphe of the geniohyoidei, the muscle runs posteriorly in the gill cover and becomes a wide thin sheet the lateral edge of which is contiguous with the mesial edge of the geniohyoideus superior, as already explained. Slightly posterior to the hind end of the latter muscle, the hyohyoideus ends as a continuous muscle sheet, but separate bundles are continued onward in the gill cover and form the hyohyoideus superior. No fibres of either division of the muscle have any attachment to the gular plate. The hyohyoideus superior continues upward in the gill cover, as a series of small and somewhat stringy muscle bundles, the anterior bundles all ending at the ventral edge of the operculum, but the posterior ones extending the full length of the gill cover, as shown in fig. 45. In my 75 mm. specimen certain bundles of these fibres have undergone specialisation in relation to the external gill, and form a relatively large muscle which lies ventral to the external gill and sends branches into it. The hind end of the ventral edge of the adductor operculi lies dorsal to the external gill, and doubtless also acts upon it, the base of the gill lying between it and the large bundle of the hyohyoideus above referred to.

Muscles innervated by the nervi glossopharyngeus and vagus. The levator muscle of the first branchial arch arises by two independent heads, one of which has its origin on the opisthotic ridge immediately dorsal to the foramen faciale and the other on the lateral plate of the ascending process of the parasphenoid ventral to the latter foramen. The truncus hyomandibularis facialis and the efferent artery of the hyal arch pass between these two heads, the one to enter the jugular canal and the other the canalis parabasalis. Beyond this nerve and artery the two heads of the muscle unite to form a single muscle, which runs postero-ventrally and has its insertion in part on the pharyngobranchial of the first branchial arch and in part on the epibranchial of that arch. The stout ligament that extends from the ventro-postero-lateral corner of the ascending process of the parasphenoid to the dorsal end of the ceratobranchial of the first branchial arch passes across the external surface of that part of the muscle that is inserted on the pharyngobranchial.

Posterior to this muscle there are four levator muscles, all of which have their origins on the large concave surface on the dorso-lateral aspect of the posterior portion of the opisthotic ridge, their surfaces of origin lying ventral to those of the adductores hyomandibularis and operculi. The levatores all run postero-ventrally, each one overlapping externally, to a considerable extent, the next posterior muscle. The levators of the second and third branchial arches are each inserted on the epi-pharyngobranchial of their arch, the levator of the fourth arch being inserted on the dorsal end of the ceratobranchial of its arch. Wiedersheim (1904) says that this latter levator is in large part inserted on a tendinous line which separates it from part of the transversus ventralis, but it was not so found in my specimens. The fifth, and last levator is inserted on the anterior edge of the clavicle, and varies considerably in importance in different specimens, being wholly wanting in certain of them. The first four levators are each innervated by a branch of the nerve of its arch. The innervation of the fifth levator was not determined in the one fish examined in which the muscle was well developed. In a second fish, in which the muscle had the appearance of being a small slip of the fourth levator, it was innervated by a branch of the nerve of that arch. It represents the musculus trapezius of the Plagiostomi (Allis, 1917). The dorsal end of the clavicle is enclosed in a sheath-like formation of connective tissue, and certain fibres of the trunk muscles, inserted on it, have somewhat the appearance of a rudimentary trapezius, but they do not represent that muscle.

There are, as Pollard states, no interarcuales dorsales and no adductores arcuum branchialium.

The interarcualis ventralis of the first branchial arch arises from the ventral surface of the ceratobranchial of its arch, near its distal end, and running almost directly forward is inserted, by tendon, on the dorsal surface of the ceratohyal, near its distal end.

The interarcualis ventralis of the second branchial arch is somewhat separated, at its origin, into two parts. One of these parts forms the postero-mesial portion of the entire muscle and has its origin immediately distal to the little process, capped with cartilage, near the distal end of the ceratobranchial of its arch. The other part forms a wide muscle-sheet which has its origin partly on the distal end of the ceratobranchial and partly on the hypobranchial of the arch, but mostly on a ligamentous band which has its origin on the ceratobranchial of the first arch and from there extends postero-mesially and is in part inserted on the second arch, and in part either passes between the two parts of the interarcualis of that arch, or passes ventral to both of them, and reaches the ventral wall of the pericardial chamber, where it continues onward in that wall and, entering the tough connective tissue that lies between the two sternohyoidei, is inserted on the clavicle. From these several surfaces of origin, the fibres of the muscle run anteriorly and antero-mesially and are all inserted on a ligamentous band which is attached, anteriorly, to the dorsal edge of the distal end of the ceratohyal, contiguous to and continuous with the tendon of the interarcualis of the first arch. From there the band extends postero-mesially dorsal to the afferent arteries of the hyal and first branchial arches, and, posterior to the common trunk of those two arteries, turns mesially ventral to the truncus arteriosus and is continuous with its fellow of the opposite side.

The interarcualis ventralis of the third arch has its origin on the ceratobranchial of its arch immediately distal to the little process, capped with cartilage, near the distal end of that element. It lies internal (dorsal) to the interarcualis of the fourth arch, and is largely concealed from view until that muscle is removed. It runs antero-mesially and is inserted on the lateral edge of the posterior, cartilaginous portion of the large basibranchial. It is innervated by branches of the nerve of its arch.

The interarcualis ventralis of the fourth arch has its origin on the ceratobranchial of its arch, dorsal to that distal portion of the bone that corresponds to the hypobranchials of the more anterior arches. Running forward and but slightly mesially, ventral and hence superficial to the interarcualis of the third arch, it is inserted on the ligamentous formation that serves as surface of origin for the anterior portion of the interarcualis of the second arch. It is innervated by the nerve of its arch, and not by the nervus hypoglossus, as Pollard thought probable.

The pharyngo-clavicularis is, at its origin, a single continuous muscle which arises from the anterior edge of the ventral portion of the clavicle. It runs almost directly forward, but slightly dorsally and mesially, and separates into two parts which are inserted, one on that part of the fourth ceratobranchial that corresponds to the ceratobranchial of the more anterior arches and the other on the part that corresponds to the hypobranchial, the two parts straddling the afferent artery of the arch. In *Polypterus ornatipinnis* the muscle fibres are inserted directly on the ceratobranchial. In *Polypterus bichir* the two parts each become tendinous and the tendons are inserted on the ceratobranchial at a considerable distance from each other. The muscle is innervated by branches of the pharyngeal branch of the nervus vagus, as stated in one of my earlier works (Allis, 1917, p. 358). This muscle is not described by Pollard.

The transversus ventralis is a large muscle-sheet which arises, on either side, from the fourth ceratobranchial and has its insertion in a median aponeurotic raphe common to it and its fellow of the opposite side, as Pollard states. It lies directly internal (dorsal) to the pericardial chamber, and is continuous, posteriorly, with the constrictor oesophagei. It is innervated by branches of the pharyngeal branch of the nervus vagus. Wiedersheim (1904) calls it the constrictor pharyngis, and says that its anterior portion is an adductor of the fourth branchial arches.

Longitudinal ventral muscles. There are but two of these muscles, the sternohyoideus and branchiomandibularis.

The sternohyoideus, called by Pollard (1892) the coracohyoideus, has its origin on the dorso-anterior surface of the ventral portion of the clavicle. It is a stout muscle crossed by two aponeurotic septa which extend entirely through it. It ends anteriorly in a stout tendon which passes dorsal to the afferent arteries of the hyal and first branchial arches and is inserted mainly on the hypohyal, but partly also in the tough connective tissues that cover the ventral surface of the tongue. The tendon of the muscle encloses, near its mesial edge, a small bone, and a slender median Y-shaped bone lies between the muscles of opposite sides, enclosed in tough connective tissue that lies between the muscles near their dorsal surfaces. This tough tissue is attached to the ventral surface of the pericardial chamber and encloses the two ligaments, one on either side and already described, that have their origins on the ventral ends of the ceratobranchials of the first and second branchial arches.

The branchiomandibularis, called by Pollard the "branchiomandibularis sui geniohyoideus," arises mostly from the distal end of that part of the third hypobranchial that forms the ventral one of the two heads by which it articulates with the basibranchial, but certain of its fibres have their origins on the anterior wall of the pericardial chamber. It runs at first ventro-antero-mesially and passes, with its fellow of the opposite side, between the basal portions of the tendons of the sternohyoidei, the two branchiomandibulares there being closely pressed together. The muscle then passes ventral to the afferent arteries of the hyal and first branchial arches, and, spreading somewhat, runs directly forward, dorsal (internal) to the hyohyoideus inferior and to both divisions of the geniohyoideus, and is inserted on the dentary close to the symphysis. Near their insertions, the muscles of opposite sides are separated by a tough median septum of fibrous tissue which spreads laterally, on either side, both dorsal and ventral to the muscles, there lying between them and the adjacent portions of the external epidermis and the lining membrane of the mouth cavity.

The muscle is innervated by a branch of the spino-occipital nerves.

ANGIOLOGY

Vena jugularis. The vena jugularis of Polypterus is formed by the union of two veins, one of which is supraorbital and the other infraorbital in position. The former corresponds to the orbito-nasal vein of Allen's (1905) descriptions of the mail-cheeked fishes, but as it closely accompanies the ophthalmic artery and the ramus ophthalmicus superficialis trigemini it may be called the ophthalmic vein. The infraorbital vein closely accompanies the orbito-nasal artery, and it might, accordingly, be called the orbito-nasal vein, but to avoid confusion it seems best to call it simply the infraorbital vein. It apparently has no homologue in Allen's descriptions, for the vein called by him the facialis-maxillaris is said to accompany the ramus maxillaris trigemini in the posterior portion of its course through the orbit. These veins and their several branches were traced in the 75 mm. specimen, and not in the adult, and the following descriptions relate to them as there found.

The ophthalmic vein has its origin in numerous little branches on the dorsal surface of the anterior end of the snout, some of these branches running posteriorly along the dorsal surface of the nasal capsule and others entering that capsule through the fenestra nasalis. These latter branches unite to form a single vein which runs posteriorly along the dorsal surface of the nasal sac, between it and the roof of the nasal capsule, there being accompanied by a branch of the ophthalmic artery, a branch of the ramus ophthalmicus profundus, and the terminal portion of the ramus ophthalmicus superficialis trigemini, the latter nerve containing the latero-sensory fibres that innervate the sense organs in the os terminale and the accessory nasal bone. While in this position the vein receives one large, and possibly other smaller branches coming from the nasal sac, and the vein so formed, together with the accompanying nerves and artery, perforates the roof of the nasal capsule and issues at the anterior end of a groove on its dorsal surface. This groove is short, leads posteriorly into the preorbital foramen, and through that foramen into the dorso-anterior portion of the orbit. While in this short groove the vein receives a vein formed by the fusion of the branches, above referred to, that arise on the anterior end of the snout and run posteriorly along the external surface of the nasal capsule, and the so-formed vein then traverses the foramen preorbitalis and enters the orbit along with the accompanying nerves and artery.

The short groove above described is shown in the accompanying fig. 10, of the chondrocranium of the adult; is shown in Pollard's figure giving a dorsal view of the chondrocranium of his 21 cm. specimen of Polypterus; is apparently shown in Budgett's figure of his 30 mm. larva as a slit-like opening that lies immediately anterior to the preorbital foramen; and is described by Lehn (1918, p. 388) as a large opening (grosse Öffnung) which leads into a canal which opens into the orbit and is considered by her to be an anterior eye-muscle canal. Pollard shows a foramen at the anterior end of the groove and calls it the canalis ethmoidalis, this name seeming to indicate that he here found a canal and that he considered it to be the homologue of the similarly named canal in Gegenbaur's (1872) descriptions of the Selachii. There is no canal here in my 75 mm. specimen, but conditions found in the adult indicate that the anterior end of the groove might become roofed by cartilage and so be converted into a short canal. This canal would, however, not be the homologue of the canalis ethmoidalis of Gegenbaur's descriptions of the Selachii, for that canal simply traverses the cartilage of the nasal capsule from its dorsal to its ventro-lateral surface without at any point entering or communicating with the cavity of the capsule. In Heptanchus I find this canal traversed by an important vein which connects the ophthalmic and infra-orbital veins, but the canal is not traversed either by the ophthalmic artery or by the lateralis branches of the ophthalmicus superficialis trigemini, these latter structures running forward on the dorsal surface of the nasal capsule without at any point perforating it. The canal of Heptanchus and the groove or canal of Polypterus are thus not homologous, and I have accordingly called the groove of Polypterus the antero-mesial ethmoidal groove, to distinguish it from the postero-laterally situated canal of Heptanchus.

Having entered the orbit, the ophthalmic vein runs posteriorly in its dorsal portion and, in the 75 mm. specimen, receives several branches: one from the musculus obliquus superior; two from the dorsal surface of the cranium through foramina that perforate the roof of the orbit; two from the cranial cavity, each branch issuing through an independent foramen in the cartilaginous portion of the orbital wall; a branch formed by the fusion of one vein coming from the musculus rectus superior and another from the eyeball, accompanying the nervus ciliaris longus; a branch from the temporal and pterygoid divisions of the musculus adductor mandibulae; and one that is formed by branches from the masseter division of the adductor, from the levator maxillae superioris, and from the mandible. The latter one of these several branches is evidently the mandibular vein, for it is the only branch from the mandible that reaches the jugular vein. It accompanies, in its course, the ramus mandibularis trigemini, and receives a branch that accompanies the ramus maxillaris trigemini. It is accordingly a maxillo-mandibular vein, and will be so referred to.

After receiving these several branches, the ophthalmic vein has become what I wrongly called, in an earlier work (Allis, 1908*b*), the external jugular, and the posterior one of the two branches received from the cranial cavity was there said to probably be the encephalic vein of Allen's (1905) descriptions of the Loricati. In favour of the latter assumption is the fact that the vein receives branches from the region of the hypophysis, but, as noted in my earlier work, its foramen of exit has a markedly different position from that of the encephalic vein of the Loricati.

The ophthalmic vein, in its course through the orbit, lies along the mesial wall of the orbit, internal to the musculus temporalis and dorsal to the nervi opticus, oculomotorius and profundus. When it reaches the hind end of the orbit it lies beneath the overhanging anterior portion of the postorbital process, and there passes between the ganglia formed on the lateralis-communis and general sensory-motor roots of the nervus trigeminus, ventral to the former and dorsal to the latter. These ganglia are both extracranial in position, and they and the ophthalmic vein all lie beneath the overhanging postorbital process, that process here enclosing the dorso-anterior portion of the anterior semicircular canal. Posterior to this, the vein and ganglia lie in a recess in the cranial wall, closed externally by the lateral plate of the ascending process of the parasphenoid, the chamber so formed being "the trigeminus portion of a perfectly typical trigemino-facialis chamber" (Allis, 1908*b*, p. 220), and strictly similar to the trigemino-facialis chamber of Stensiö's (1921) descriptions of *Birgeria mougeoti*. The general sensory-motor root of the trigeminus now soon perforates the mesial wall of this chamber, its foramen lying, in the adult, at the bottom of a small but marked recess on the cerebral surface of the cranial wall. Posterior to this, the lateralis-communis root traverses the cranial wall through a short canal which opens into the anterior end of the labyrinth recess, the ophthalmic vein continuing posteriorly external to the cranial wall and dorsal to the general sensory-motor root, and being joined, posterior to the latter root, by the infraorbital vein to form the vena jugularis.

The infraorbital vein arises in the tissues at the anterior end of the snout, and runs posteriorly along the ventral surface of the nasal capsule, no branches, so far as could be traced, entering the nasal capsule and running posteriorly between that capsule and the nasal sac, as is the case with the ophthalmic vein. Near the hind end of the nasal capsule it receives a large branch from the nasal sac, and another from the labial fold. The branch from the nasal sac traverses a foramen in the floor of the nasal capsule together with a branch of the maxillary artery and a branch of the ramus maxillaris trigemini, and in the nasal sac it forms anastomoses both with the ophthalmic vein and with a vein that comes from the cranial cavity through the foramen olfactorium. The infraorbital and ophthalmic veins are thus here connected with each other, but this connection is by branches that traverse the nasal sac, instead of, as in the Selachii, by a branch that passes outside the nasal capsule.

The infraorbital vein, after receiving these two branches, runs posteriorly along the floor of the orbit, receiving branches from the maxillary region, from the musculi obliquus inferior, rectus internus, rectus inferior and rectus externus, and one from the eyeball that accompanies the nervus ciliaris brevis. Close to this latter vein it apparently receives a branch that comes from the large orbital lymph sinus, that sinus also apparently being connected with that branch of the ophthalmic vein that accompanies the nervus ciliaris longus. The infraorbital vein here lies ventral to the musculus pterygoideus, along the lateral edge of the parasphenoid and immediately dorsal to the common carotid artery, and when it reaches the hind end of the orbit, it passes dorsal to the anterior edge of the horizontal plate of the ascending process of the parasphenoid, and, lying in the angle between that plate and the mesial plate of the process, receives the pituitary vein, which issues from the pituitary fossa through the pituitary foramen. The infraorbital vein then runs upward posterior to the general sensory-motor root and ganglion of the trigeminus, and falls into the ophthalmic vein, as above described.

From this description of these two veins it is evident that, in this fish, the basal portion of the vena ophthalmica is formed by that portion of the vena capitis lateralis that lies anterior to the nervus facialis, and the vena infraorbitalis by the corresponding portion of the vena capitis media plus the posttrigeminus commissure between that vein and the vena capitis lateralis. The conditions seem to indicate that a pretrigeminus commissure between the venae capitis media and lateralis primarily existed, and that the vena maxillo-mandibularis acquired connection with it. The commissure then lost its connection with the vena capitis media, but retained that with the vena capitis lateralis and so became the basal portion of the vena maxillo-mandibularis. The vena infraorbitalis retained its connection with the primitive vein (cardinalis anterior), as did also the pituitary vein. This would fully explain the conditions actually found, and the vena jugularis, instead of beginning anterior and ventral to the nervus trigeminus, begins posterior and dorsal to it, this being, so far as I know, exceptional in fishes, and an excellent example of how difficult it is to give names to these veins of fishes that will definitely indicate their homologies.

The vena jugularis, formed, as above set forth, by the union of the ophthalmic and infraorbital veins, at first lies internal to that portion of the lateral plate of the ascending process of the parasphenoid that lies dorso-anterior to the line of fusion with the mesial plate of that process, and then enters that short canal in the cartilaginous side wall of the cranium that has been already referred to as the jugular canal. Posterior to the anterior opening of this jugular canal, the lateral and mesial plates of the ascending process of the parasphenoid fuse with each other, and the projecting dorsal end of the so-formed plate lies against the outer wall of the jugular canal. The jugular vein is accompanied, as it enters its canal, by the ramus palatinus facialis and a general sensory branch sent from the trigeminus ganglion to the truncus hyomandibularis facialis. The ramus palatinus facialis soon falls into the communis root of the nervus facialis, that root perforating the mesial wall of the jugular canal along with the lateralis and motor roots of the nerve. This foramen is thus the foramen primitivum faciale, and it lies ventral to the vena jugularis. Shortly posterior to this foramen, the jugular canal opens on the external surface of the chondrocranium, but it is still, for a few sections, closed externally by the fused dorsal ends of the mesial and lateral plates of the ascending process of the parasphenoid. The mesial plate of the ascending process then vanishes in the sections, and the vein and the nervus hyomandibularis facialis lie in a groove in the cartilaginous lateral wall of the cranium, still enclosed externally, for a short distance, by the hind edge of the lateral plate of the process. The posterior opening of the jugular canal is accordingly the foramen faciale of the skull of the adult. Posterior to this foramen the vein lies in the jugular groove on the lateral surface of the cranium, and there receives venous vessels from the hyal and each of the branchial arches, and also the vena jugularis interna, which issues from the cranial cavity through the foramen vagum.

Afferent and efferent arteries. The truncus arteriosus (figs. 51–54) gives off, immediately after issuing from the pericardial chamber, a large vessel on either side which runs laterally anterior to the musculus branchiomandibularis, at its point of origin, and immediately separates into two parts, one ventral to the other, which are, respectively, the afferent artery of the second branchial arch and the united trunks of the afferent arteries of the third and fourth arches.

The afferent artery of the second branchial arch runs outward internal (dorsal) to the interarcualis ventralis of the fourth arch, and posterior both to the head of the hypobranchial of its own arch and to the interarcualis ventralis, and reaches the ventral surface of the ceratobranchial of its arch.

The trunk formed by the united afferent arteries of the third and fourth branchial arches turns posteriorly, passes between the two articular heads at the distal end of the third hypobranchial, then internal (dorsal) to the interarcualis ventralis of the third arch, at its insertion, and at the hind edge of that muscle separates into its two parts, the afferent arteries of the third and fourth arches. The afferent artery of the third arch turns laterally and reaches the ventral surface of the ceratobranchial of its arch. The afferent artery of the fourth arch continues posteriorly, passes across the dorsal (internal) surface of the fourth ceratobranchial, in the marked groove on that surface and between that bone and the related dermal plates, and turning dorso-laterally across the hind edge of the ceratobranchial, passes between the inferior and superior divisions of the musculus pharyngo-clavicularis and reaches the ventral (external) surface of its ceratobranchial. This artery thus has the relations to the distal end of its ceratobranchial that the artery of the third arch has to the ventral one of the two articular heads at the distal end of its hypobranchial, which suggests that these parts of these two bones may be homologous, for otherwise it would be difficult to explain how the artery has come to twist completely around the branchial bar of its arch in order to reach its ventral (external) surface.

After giving off this large branch on either side, the truncus arteriosus continues forward, and approximately in the level of the articular head of the hypobranchial of the first arch gives off a large branch on either side and then continues onward as a small and unimportant median artery which could be traced a short distance in the adult, but was not even evident in the 75 mm. specimen. The large branch on either side lies dorsal (internal) to the musculus branchiomandibularis, and soon separates into the afferent arteries of the hyal and first branchial arches. The latter (fig. 52) runs laterally across the ventral surface of the tendon of the musculus sternohyoideus and ventral to the interarcualis of its arch, and reaches the ventral surface of the ceratobranchial of its arch. The afferent hyal artery runs posteriorly along the ventral surface of the musculus sternohyoideus and reaches the ventro-mesial edge of the ceratohyal, near its proximal end, where it turns dorso-laterally along the posterior surface of the epihyal and the corresponding edge of the hyomandibula, and becomes the efferent artery of the arch.

The median dorsal aorta, running forward, reaches the hind end of the cranium, and there enters the aortic canal in the basis cranii. Running forward in that canal it separates into its two branches, the lateral dorsal aortae, each of which issues from the aortic canal into the canalis parabasalis in the ascending process of the parasphenoid. Immediately before entering the aortic canal, the dorsal aorta receives the efferent artery of the second branchial arch, and immediately posterior to that artery the efferent arteries of the third and fourth branchial arches, these two latter arteries usually being fused to form a single trunk. Posterior to these several arteries the dorsal aorta gives off a single artery which runs posteriorly beyond the head region and was not traced, and then the subclavian arteries. Immediately after issuing from the aortic canal, the lateral dorsal aorta of either side receives, close together, the efferent arteries of the hyal and first branchial arches, and then continues onward as the common carotid.

The afferent and efferent arteries of the branchial arches all lie between the two rows of branchial rays of their respective arches, the efferent artery lying internal to the afferent artery and each of them receiving, at the level of the dorsal end of the ceratobranchial, a relatively large branch which comes from those branchiae that lie dorsal to this point. The efferent artery of the hyal arch comes upward along the hind edge of the hyomandibula, and passes, with the ramus hyoideus facialis, between the hyomandibula and the ligament that extends from its opercular process to the accessory hyomandibula.

The efferent arteries were not farther traced in the adult, but in the 75 mm. specimen the artery of each of the first three branchial arches falls, at the ventral end of its arch, into a ventral longitudinal commissure which lies internal to all the afferent arteries and hence is an internal lateral hypobranchial artery (Allis, 1912). The efferent artery of the fourth arch does not fall into this commissure, but the subclavian artery does, this latter artery being, in fact, a direct posterior continuation of the commissure. From the efferent artery of the fourth arch a large branch is given off near the proximal end of the ceratobranchial of the arch, and sends branches to the oesophagus, to the air-bladder and to the heart. Between the roots of the second and third afferent branchial arteries, the lateral hypobranchial receives a small branch from the truncus arteriosus, and, continuing onward beyond the first efferent artery, passes internal to the afferent hyal artery and, turning mesially, enters the thyroid gland. There it separates into two parts, one of which continues mesially and joins its fellow of the opposite side, the other turning anteriorly and forming an anterior prolongation of the hypobranchial. The latter artery soon gives off two branches, one of which runs upward along the ventromesial (morphologically external) edge of the ceratohyal, and the other in similar relation to Meckel's cartilage, the former lying posterior to the ramus mandibularis internus facialis and the other anterior to that nerve. These two arteries are, the one the anterior efferent hyal artery and the other either the afferent mandibular artery, or the posterior efferent artery of that arch (Allis, 1916), and dorsal to the ramus mandibularis internus facialis they fuse with each other, and then immediately fall into a cross-commissural vein which extends from the efferent hyal artery to the mandibular branch of the carotid artery, the anterior portion of this commissure running forward along the external surface of the ventro-lateral edge of the palatoquadrate. Dorsal to the commissure the anterior efferent hyal artery continues upward, accompanies the ramus hyoideus facialis as it passes inward across the hind edge of the hyomandibula, and internal to the latter element falls into the epibranchial longitudinal commissure, described immediately below. Anterior to this artery a small artery arises from the cross-commissure and runs upward along the external surface of the palatoquadrate, between it and the overlying muscles, and apparently represents a dorsal continuation of the afferent mandibular artery.

Anterior to the afferent mandibular artery, the lateral hypobranchial artery continues onward, is joined by the terminal branches of the mandibular branch of the carotid, and then ends in a cross-commissural vessel which connects it with its fellow of the opposite side.

A dorsal, or epibranchial longitudinal commissure arises, in my 75 mm. specimen, by three roots, two from the median dorsal aorta before it enters the aortic canal, and one from the lateral dorsal aorta after it issues from that canal, a branch of this latter root going to the thymus.

Carotid arteries. The main branches of the carotid arteries were described by me in 1908, and brief reference to them was made in a later work (Allis, 1916). In the work published in 1908, and also in a work published in that same year on the pseudobranchial and carotid arteries of Amiurus (Allis, 1908*a*), the descriptions are, in certain places, greatly confused, and I am unable to account for it excepting on the assumption that there was some resetting of the type after the proofs had been corrected. I was unfortunately absent from my laboratory at the time, and the proofs were corrected and returned by an assistant.

In my 75 mm. specimen the lateral dorsal aorta of either side issues from the aortic canal into the posterior portion of the canalis parabasalis, and there immediately receives the efferent arteries of the hyal and first branchial arches. It then becomes the common carotid, and runs forward in the canalis parabasalis accompanied by a lymph vessel, a sympathetic nerve, and a communicating branch from the nervus glossopharyngeus to the ramus palatinus facialis which would seem to represent, in this fish, Jacobson's anastomosis. No branch of the common carotid is sent into the jugular canal, but immediately anterior to the anterior opening of that canal a branch is sent upward posterior to the general sensory ganglion of the nervus trigeminus and then forward dorsal to that ganglion but ventral to the related lateralis-communis ganglion, this branch corresponding to the ophthalmic branch of the external carotid of Amia and the Teleostei. A branch is sent upward from this artery along the anterior surface of the spiracular canal, and other branches to the musculi pterygoideus, masseter, temporalis and obliquus superior, and to the dorsal surface of the head, the artery then traversing the foramen preorbitalis and accompanying the branches of the vena ophthalmica, as already described. Approximately in the transverse plane where this ophthalmic artery separates from the common carotid, the communicating branch from the nervus glossopharyngeus falls into the ramus palatinus facialis, the latter nerve then passing dorso-lateral, and hence posterior, to the ophthalmic artery.

After giving off this ophthalmic branch the remainder of the common carotid issues from the canalis parabasalis and then runs forward in the groove on the lateral edge of the body of the parasphenoid, accompanied by the lymph vessel that traverses the canalis parabasalis with it, and also by the ramus palatinus facialis, and when it reaches the hind edge of the foramen opticum it gives off the maxillo-mandibularis artery. That part of the carotid that lies between the latter artery and the ophthalmic artery thus contains both the internal carotid and a large part of the external carotid of the non-siluroid Teleostei, but, because of its position, so similar to that of the internal carotid of Amiurus (Allis, 1908*a*), it was given that name in my earlier work. It seems, however, better to consider it as still a part of the common carotid, the internal carotid being that part of the artery that remains after the maxillo-mandibular artery is given off.

The maxillo-mandibular artery runs ventro-laterally and soon separates into its maxillary and mandibular portions. The maxillary artery runs forward through the orbit, giving off certain branches, and then traverses the foramen by which the nasal branch of the vena maxillaris issues from the nasal capsule. Inside that capsule a branch is sent into the nasal sac to join and fuse with a terminal branch of the orbito-nasal artery, the remainder of the artery running forward between the sac and the wall of the nasal capsule to issue through the fenestra nasalis. The mandibular artery runs ventrally and reaches a point that lies slightly posterior to the angle of the gape of the mouth, where it gives off a number of little branches which form the "much vasculated tissue" referred to in my earlier work (Allis, 1916, p. 116), one of these branches being the hyomandibular cross-commissural vessel there described. The mandibular artery then sends a branch into the labial fold, where it supplies both external and internal surfaces of the labial cartilage, and itself continues onward into the mandible and separates into two terminal branches, both of which fall into the lateral hypobranchial artery. The much vasculated tissue above referred to lies somewhat dorsal to the ventro-lateral edge of the palatoquadrate, and mesial to the bottom of the longitudinal groove on the dorsal surface of the buccal cavity that I have recently described as the secondary superior alveolo-labial furrow (Allis, 1919*c*).

The internal carotid artery, after it separates from the maxillo-mandibular artery, immediately gives off two branches, arising close together, one of which goes to the choroid gland and hence corresponds to the arteria ophthalmica magna of other fishes. The other branch is the posterior cerebral artery, which perforates the cranial wall immediately posterior to the nervus opticus and turns posteriorly in the cranial cavity, giving off as it traverses the cranial wall, a branch which goes to the eyeball and is apparently the arteria centralis retinae. The internal carotid artery then immediately gives off the anterior cerebral artery, which perforates the cranial wall between the posterior cerebral artery and the nervus opticus and supplies the anterior portion of the cranial cavity, a terminal branch traversing the foramen olfactorium and entering the nasal sac. The remainder of the artery is now the orbito-nasal artery, which continues onward, sends a branch to the choroid gland, another to accompany the ramus palatinus facialis and others to certain of the muscles of the eyeball, and then itself passes over the lateral edge of the cartilage of the basis cranii and penetrates the basal portion of the membranous lateral wall of the cranial cavity. Running forward in this membrane, it enters the cranial cavity, and then, always lying in, or external to the lining membrane of that cavity, and hence never entering the cavum cerebrale cranii, it reaches and enters the nasal capsule through the foramen olfactorium.

The internal carotid of my 75 mm. specimen of this fish, like that artery of Amiurus, thus passes lateral and then dorsal to the trabecula in order to enter the cranial cavity, instead of passing ventral and then mesial to the trabecula as it does in all other fishes that I know of.

Trigemino-facialis chamber. From the above descriptions of the veins, arteries and nerves of this region, it is evident that the canal in the cranial wall traversed by the vena jugularis represents some part of a trigeminofacialis chamber, and it is probable that it represents the pars jugularis, and that part only of the posttrigeminus portion of the chamber. The pars ganglionaris of this part of the chamber must then be represented either in the short canal by which the nervus facialis traverses the cartilage of the cranium, or in some part of the anterior portion of the labyrinth recess. The trigeminus part of the chamber is represented in the space, between the lateral wall of the chondrocranium and the ascending process of the parasphenoid, that lodges both the trigeminus ganglion and the vena jugularis, and it would seem as if it must represent the entire chamber notwithstanding that it is not closed externally by cartilage. This condition of the chamber is apparently primitive, for it closely resembles that described by Stensiö in the Palaeoniscidae, as already stated.

NEUROLOGY

Nervus and lobus olfactorius. The nervus olfactorius of the adult is long, has a long intracranial course, and arises from a bulbus olfactorius that is separated from the remainder of the telencephalon by a slight constriction only, as Bing and Burckhardt (1905) have stated. The rhinocele extends about half the length of the bulbus.

In my 75 mm. specimen the nervus olfactorius is short, while the bulbus is relatively long, as it is shown to be in Bing and Burckhardt's figure of a 16·5 cm. specimen. The bulbus extends forward to the foramen olfactorium, and from its anterior end two bundles of fibres arise, one from its dorsal and the other from its ventral half, the dorsal half of the bulbus projecting forward slightly beyond the ventral one. These two bundles form the nervus olfactorius, which runs ventrally and but slightly antero-laterally, and enters the nasal capsule on the dorso-mesial aspect of its hind end. The bulbus is entirely separate from its fellow of the opposite side, but closely pressed against it, as far back as the line of attachment of the anterior edge of the tela choroidea.

There is, as shown in Bing and Burckhardt's figure of a median sagittal section of an 18 cm. specimen, a deep median fold in the tela choroidea, but the anterior end of the bottom of that fold, as there shown, lies at a much higher level than in my 75 mm. specimen, where it descends almost to the level of the floor of the third ventricle. The floor of the latter ventricle is here thin, and in the transverse plane of the foramen interventriculare rises slightly in the median line, so that it has, in transverse sections, the shape of an inverted V, the top of this inverted V meeting the bottom of the median fold of the tela. Anterior to this point there is, on either side, a tall and narrow anterior prolongation of the ventricle, which forms a sort of diverticulum extending through 10 sections of 15μ each. The dorsal end of each diverticulum is enlarged, and is prolonged anteriorly as a short projecting pocket which lies on the dorsal surface of the related bulbus. Venous vessels that come from the nasal sacs with the nervi olfactorii lie, some in the dorsal and some in the ventral angle between the bulbi of opposite sides, and becoming united at the hind ends of the diverticula by dorso-ventral commissures, continue posteriorly in the hollow of the fold of the tela, and form the choroid plexus. The conditions in my 75 mm. specimen thus here so closely resemble those shown by Johnston (1911, figs. 1 and 45) both in a median view of the brain of the adult Amia and in a median sagittal section of a 25 mm. embryo of the same fish, that it is probable that the lamina supraneuroporica has a similar position in each of them, and if Johnston is correct in placing this lamina ventro-posterior to the anterior end of the bottom of the median fold of the tela in his 25 mm. Amia, it must form the anterior portion of what is actually the floor of the third ventricle of Polypterus, and not, as Bing and Burckhardt (1905) concluded, the anterior portion of the bottom of the median fold of the tela, which forms the median line of the roof of the third ventricle.

The dorsal edge of the lateral wall of the telencephalon has been everted, and there is an external sulcus extending the full length of the primordium hippocampi, approximately at the middle of the height of the lateral wall of the telencephalon, and it is particularly deep in its middle portion. The lateral edge of the tela choroidea is everywhere attached to the ventral edge of this everted portion of the lateral wall.

Nervus terminalis. What seems to be the nervus terminalis of either side is found, in my 75 mm. specimen, as two nervous strands which are wholly separate and independent of each other up to the point where they enter the nasal capsule. One of these strands arises from the dorso-lateral surface of the bulbus olfactorius, and the other from its ventral and ventro-lateral surfaces. Each strand arises by two or more rootlets which look, in sections, like protruding portions of the superficial layer of the bulbus, and each strand runs forward along the related surface of the bulbus to its anterior end. Each strand then follows the related root of the nervus olfactorius, and, as it enters the nasal capsule, fuses with its fellow. No ganglion cells could be recognised in any part of the nerve.

Nervus opticus. There is a well developed optic chiasma which lies upon the dorsal surface of the parasphenoid slightly anterior to the slight depression that lodges the hypophysis. The chiasma forms the anterior end of a marked ridge, formed by the hypothalamus, on the ventral surface of the brain, and the base of the ascending tract of the opticus is, in lateral view, separated from the chiasma by a slight furrow. From there the nervus opticus runs antero-laterally and slightly dorsally and traverses the sphenoid bone through the foramen opticum, passing, in my 75 mm. specimen, dorsal to the cartilaginous trabecula. The nerve then gradually curves somewhat more laterally and penetrates the sclerotic ventro-posterior to its central point. It is a solid nerve, without any indication of folding of any sort.

Nervus oculomotorius. This nerve, after its origin from the base of the brain, runs antero-laterally and issues from the cranial cavity through a foramen in the sphenoid common to it and the radix profundi (Allis, 1908*b*;

Lehn, 1918), the oculomotorius there lying anterior to the radix profundi. The oculomotorius then runs forward between the profundus ganglion and the cranial wall, closely pressed against the dorso-mesial surface of the ganglion, and there separates into its superior and inferior divisions. There is no slightest indication of an anastomosis with the profundus, such as Lehn found in her specimen. The superior division runs upward mesial to the ramus ophthalmicus profundus and innervates the rectus superior. The inferior division runs forward ventral to the nervus profundus and comes into intimate contact with the ciliary ganglion, there unquestionably being connected with that ganglion by strands which form the radix brevis. The nerve then continues onward, passing ventro-lateral to the rectus superior and mesial to the rectus externus and sends a branch to the rectus inferior. It then passes dorsal to the latter muscle and ventral to the nervus opticus, sends one or two branches to the rectus internus, and then passes ventral to the latter muscle and terminates in the obliquus inferior.

The course and distribution of this nerve is thus as it is in Amia excepting in that the inferior division of the nerve passes dorsal instead of ventral to the rectus inferior, this relation of the nerve to the latter muscle being, so far as I know, exceptional in the gnathostome fishes. The recti inferior and externus arise close together from the tendinous stalk that gives origin to them and also to the rectus superior, and the oculomotorius passes close to their points of origin from that stalk. A slight shifting of the point of origin of the inferior muscle would make it creep, at its origin, across the nerve, and it would then lie dorsal to it, as it does in Amia, without having either cut through the nerve or been cut through by it.

Nervus trochlearis. This nerve has the usual origin, and after a relatively long intracranial course issues from the cranial cavity through its foramen in the sphenoid. It then runs forward and becomes closely applied to the ventro-mesial surface of the ramus ophthalmicus superficialis trigemini, passes ventral to that nerve but dorsal to all the other nerves of the orbit, and enters the obliquus superior near its point of origin from the cranium.

Nervus abducens. This nerve arises, in the 75 mm. specimen, by two rootlets quite near the mid-ventral line of the brain, and from there runs antero-laterally and issues from the cranium with the nervus trigeminus through a large perforation of the cranial wall which is closed by fibrous tissue which surrounds the nerves and completely separates them from each other. That part of this tissue that encloses the abducens later undergoes chondrification, and the nerve then traverses a short canal in the cranial wall which lies postero-ventral to the foramen trigeminum and opens on the floor of the cranial cavity immediately posterior to the base of the postclinoid wall.

After issuing from its foramen the nerve runs antero-laterally ventral to the nervus trigeminus and enters and supplies the musculus rectus externus.

Nervus profundus. The root of the nervus profundus issues from the medulla, in the adult, anterior to but in contact with the root of the trigeminus, while in the 75 mm. specimen it issues from the medulla slightly anterior to the anterior rootlet of the trigeminus. Its point of origin from the medulla indicates that its fibres are quite certainly all general cutaneous ones. The root runs forward in the cranial cavity and, in the 75 mm. specimen, traverses a perforation of the cartilaginous cranial wall that is common to it and the nervus oculomotorius and that lies anterior to the foramen trigeminum. As the two nerves traverse this perforation of the cranial wall, they are separated from each other by membrane, their two foramina, at this age, thus not being actually confluent, the primordial membranous cranial wall simply not having undergone either chondrification or ossification between the two nerves. Having issued through this foramen, a ganglion immediately forms on the root of the profundus, the nervus oculomotorius lying between this ganglion and the cranial wall and the nervus abducens lying immediately ventral to the ganglion. No communicating branch is received from the trigeminus ganglion, and no sympathetic nerve could be traced to it. There is, as already stated, no anastomosis with the nervus oculomotorius.

The radix longa arises, in the 75 mm. specimen, from the ventral surface of the profundus ganglion, and running forward enters a small ciliary ganglion which lies directly against the inferior division of the nervus oculomotorius, at the point where the branch of that nerve to the musculus rectus inferior is given off, and is there unquestionably connected with the oculomotorius by fibres that represent the radix brevis. The radix longa is not described by Lehn, but it is probably represented in that anastomosis of the profundus and oculomotorius to which she refers. From the ciliary ganglion the ramus ciliaris brevis arises, and passing between the recti superior and externus and dorsal to the rectus inferior, has a course approximately parallel to the latter muscle and perforates the sclerotic between the point of insertion of that muscle and the point where the nervus opticus enters the eyeball. Close to, or coincident with, the point where this nerve perforates the sclerotic, that cartilage is also traversed by a branch of the orbito-nasal artery and a branch of the infraorbital vein.

Anterior to the point of origin of the radix longa from the profundus ganglion, either a single branch arises from that ganglion, or two branches arise close together, the one or two branches forming the portio ophthalmici profundi shown by van Wijhe (1882) in his figure of this fish. Branches of this nerve, or nerves, run upward and forward, some passing mesial and others lateral to the ramus ophthalmicus superficialis trigemini, and, accompanying branches of the latter nerve, are distributed to tissues on the dorsal surface of the head in the region of organs 5 and 6 supraorbital. No complete anastomosis of any of these branches with the ramus ophthalmicus superficialis was noticed.

From the anterior end of the profundus ganglion the ramus ophthalmicus profundus and the ramus ciliaris longa arise, either close together or as a single trunk. The ciliaris longa runs forward between the recti superior and externus, and passing dorsal to the nervus opticus perforates the sclerotic dorso-lateral to that nerve, between it and the point of insertion of the rectus superior, there being accompanied by a branch of the orbito-nasal artery. Lehn found this nerve arising from the ramus ophthalmicus in the transverse plane of the foramen opticum.

The ramus ophthalmicus profundus runs forward between the recti superior and externus, there lying between the superior and inferior divisions of the nervus oculomotorius, and then continues onward dorsal to the nervus opticus. A branch is here sent upward to join, but not fuse with, the ramus ophthalmicus superficialis trigemini, this branch and the main nerve both traversing a large orbital lymphatic space. Branches of this branch of the profundus perforate the roof of the orbit and are distributed to tissues on the dorsal surface of the head in the region of organ 4 supraorbital, one branch accompanying the lateralis branch to that organ. After giving off this branch the ramus ophthalmicus profundus continues onward and upward, passes ventral to the nervus trochlearis, and, in the 75 mm. specimen, ventral to the musculus obliquus superior, close to its origin in the preorbital canal. In one adult specimen that was examined the nerve also passed ventral to the obliquus superior, but in the specimen used for illustration, the nerve passes ventral to the trochlearis but dorsal to the obliquus superior. Beyond this point the nerve traverses the preorbital canal with the ophthalmicus superficialis trigemini, and on issuing from that canal lies in the antero-mesial ethmoidal groove. A branch is there sent to tissues in the region of organ 3 supraorbital, the terminal portion of the nerve then traversing the perforation in the roof of the nasal capsule at the anterior end of the ethmoidal groove and running forward in the nasal capsule accompanied by the terminal portion of the ophthalmicus superficialis trigemini and a vein and artery, as already described. As the nerve traverses the capsule one or two branches are sent upward through its roof to the region of organ 2 supraorbital, and on issuing from the capsule through the fenestra nasalis the remainder of the nerve is distributed to tissues in the region of organ 1 supraorbital, and to the extreme anterior end of the snout.

The nervus profundus of this fish thus sends branches to the entire region that, in most teleosts, is innervated by general cutaneous branches of the ramus ophthalmicus superficialis trigemini. This has been fully discussed in an earlier work (Allis, 1918*b*), and it was there said that the portio ophthalmici profundi and the ramus ophthalmicus profundus of this fish were quite certainly the homologues, respectively, of the frontal and nasal branches of the ophthalmic nerve of higher vertebrates.

Nervus trigeminus. The nervus trigeminus is currently considered to contain only general sensory and motor fibres, the communis and lateralis fibres that are associated with it being assigned to the nervus facialis. As so conceived, this nerve of the adult Polypterus arises from the medulla by a single root common to it and the nervus profundus. In the 75 mm. specimen these two roots are wholly independent, and the nervus trigeminus arises by two rootlets, one of which is motor and the other apparently wholly general cutaneous. The root of the trigeminus, so formed, runs antero-laterally, traverses the foramen trigeminum, and then immediately swells into a large ganglion which is apparently wholly general cutaneous, the motor component of the nerve lying imbedded in the ventral surface of the ganglion. The root of the nerve, as it traverses its foramen, is accompanied by the nervus abducens, but not by any recognisable vein or artery. The ganglion lies in the trigeminus portion of the trigemino-facialis chamber, immediately anterior to that portion of the infraorbital vein that runs upward between the nervi trigeminus and facialis to fall into the ophthalmic vein, the latter vein passing dorsal to the ganglion. Dorsal to this ganglion and separated from it by the ophthalmic vein, is a ganglion formed by the fusion of two ganglia, one of which is formed on a lateralis root and the other on an intracranial branch from the communis root of the nervus facialis. The larger part of the ganglion on the lateralis root lies in the trigemino-facialis chamber, while the ganglion of the communis root is largely intracranial in position and is continuous with the intracranial portion of the facialis ganglion. The roots and ganglia of this fish thus resemble those in Scorpaena (Allis, 1909, p. 81), excepting in that the communis fibres issue from the cranial cavity with the lateralis fibres instead of with the general cutaneous ones.

From the lateralis-communis ganglion three nerves arise, the rami ophthalmicus superficialis, buccalis, and oticus, and in addition to these nerves two separate bundles of fibres are sent to the general cutaneous ganglion. The ramus ophthalmicus superficialis contains both lateralis and communis fibres, but no general cutaneous ones could be traced to it either from the general cutaneous ganglion itself, or from any of its branches. The nerve is accordingly neither an ophthalmicus facialis, an ophthalmicus lateralis, nor an ophthalmicus superficialis trigemini, as those terms are currently employed, for the two former terms are considered to designate a nerve formed exclusively of lateralis fibres, and the latter a nerve that contains a considerable proportion, at least, of general cutaneous fibres. There is also the further question as to whether the lateralis and communis fibres contained in this nerve belonged primarily to the trigeminus or to the facialis. I have accordingly thought best, as fully explained in an earlier work (Allis, 1918*b*), to readopt for this nerve the time-honoured term ramus ophthalmicus superficialis trigemini, referring, when necessary, to the lateralis or communis fibres as the lateralis or communis trigemini. Lehn calls this nerve the ramus supraorbitalis ophthalmici lateralis, and considers it to be a branch of a nerve which she calls the nervus ophthalmicus lateralis, the other branches of which are the rami infraorbitalis ophthalmici lateralis, maxillaris ophthalmici lateralis, and mandibularis externus ophthalmici lateralis. She says that an independent ramus ophthalmicus superficialis trigemini, comparable to that found in other fishes, is wanting in Polypterus.

The ramus ophthalmicus superficialis trigemini, thus defined, runs forward internal to the musculus temporalis and dorsal to all the nerves of the orbit, traverses the preorbital canal at the dorso-anterior corner of the orbit, and enters the antero-mesial ethmoidal groove on the dorsal surface of the nasal capsule. At the anterior end of that groove the nerve traverses the foramen that there perforates the roof of the nasal capsule, and runs forward in that capsule between its cartilaginous roof and the lining membrane of the nasal sac. As it traverses the orbit branches are sent upward through its roof to supply the anterior head-line of pit organs and organs 6, 5 and 4 of the supraorbital latero-sensory canal, these organs all lying on, or in, the frontal bone. As the nerve traverses the ethmoidal groove a branch is sent to organ 3 supraorbital, which lies in the nasal bone, and as it traverses the nasal capsule a branch is sent upward through the roof of the capsule to organ 2 supraorbital, which lies in the accessory nasal. The nerve then issues through the fenestra nasalis, and its lateralis component terminates in organ 1 supraorbital, which lies in the os terminale. Communis fibres doubtless accompany the lateralis fibres in all these branches of the nerve, and the branches are accompanied by general cutaneous branches of the nervus ophthalmicus profundus, as already described.

The ramus buccalis trigemini arises, like the ramus ophthalmicus superficialis, from the lateralis-communis ganglion and contains both lateralis and communis fibres. The nerve runs forward external to the musculus temporalis and then along the floor of the orbit until it reaches its anterior end. There it perforates the ventro-lateral portion of the wall of the nasal capsule, runs forward in that capsule, between its cartilaginous wall and the lining membrane of the nasal sac, passes along the dorsal surface of the ventral border of the fenestra nasalis, and, mesial to that fenestra, perforates the wall of the capsule and issues on its external surface.

Seven branches are given off by the ramus buccalis after its origin from its ganglion, this making, with the terminal branch, eight branches in all to the nerve. Two other branches, which arise directly from the lateralis-communis ganglion, belong morphologically to it, and each of these ten branches doubtless contains both lateralis and communis fibres. The terminal branch of the nerve, the one that issues from the nasal capsule antero-mesial to the fenestra nasalis, innervates organ 1 infraorbital, which lies in the median ethmoid bone. The second and third branches issue through the fenestra nasalis and innervate organs 2 and 3 infraorbital, both of which lie in the premaxillary. The fourth branch is given off just before the nerve leaves the orbit to enter the nasal capsule, and running outward innervates organ 4 infraorbital, which also lies in the premaxillary. The fifth, sixth, seventh, and eighth branches innervate the corresponding infraorbital organs, which lie, organ 5 in the lachrymal, organs 6 and 7 in the maxillary, and organ 8 in the postorbital bone. The ninth branch arises from the anterior portion of the lateralis-communis ganglion, and running upward perforates, in my 75 mm.

specimen, that overhanging portion of the dorsal end of the postorbital process of the chondrocranium that later ossifies as the sphenotic portion of the postfronto-sphenotic, and innervates organ 9 infraorbital, that organ lying in the postfrontal portion of the postfronto-sphenotic. The tenth branch of the nerve is the so-called ramus oticus facialis. It arises from the lateralis-communis ganglion, and, running upward, immediately perforates the cranial wall and enters the auditory capsule beneath the ampulla of the anterior semicircular canal. Passing ventro-lateral to that ampulla, it again enters the cartilage of the chondrocranium and issues on its dorsal surface to enter the parieto-dermopterotic bone and innervate organ 10 infraorbital, which lies in the anterior portion of the latter bone. This ramus oticus contains communis as well as lateralis fibres, but no general cutaneous ones could be traced to it, and it is not accompanied by any branch arising from the general cutaneous ganglion of the nerve.

The general cutaneous ganglion receives two bundles of communis fibres from the lateralis-communis ganglion, as above described, and still another bundle of similar fibres from a part of the facialis ganglion that lies at the base of the ramus palatinus facialis, this latter bundle forming the anastomosis described by Lehn and running upward ventro-mesial to the maxillo-mandibular vein. All of these communis fibres apparently traverse the general cutaneous ganglion and go both to the ramus mandibularis trigemini and to certain branches that have independent origin from the ganglion but belong morphologically to that nerve.

From the proximal end of the ganglion a bundle of general cutaneous fibres is sent posteriorly into the jugular canal to there join the truncus hyomandibularis facialis, and issue with it through the posterior opening of the canal. This bundle of fibres thus has a course which lies morphologically posterior to the outer wall of the jugular canal, and as that wall is probably formed (Allis, 1918*a*) by the posterior branchial-ray bar of the mandibular arch, the nerve has to the bar the relations of a facialis nerve and not of a trigeminus one. This bundle of fibres thus probably belongs to the nervus facialis, and must, accordingly, represent the primitive general cutaneous component of that nerve, a component which is otherwise wanting, and its issuing from the medulla with the general cutaneous fibres of the trigeminus, instead of as a part of the root of the facialis, is of secondary origin, and due to central condensations.

The rami maxillaris and mandibularis trigemini arise from the anterior end of the general cutaneous ganglion, and from the ganglion, close to the bases of these nerves, several small branches have their origin, these branches all containing motor fibres and hence undoubtedly belonging, morphologically, to the ramus mandibularis.

The ramus maxillaris contains only general cutaneous fibres, and runs forward through the orbit, closely accompanying the ramus buccalis throughout its entire course. Branches are sent from it to tissues of the region traversed, and they apparently present no features of special importance. One branch enters the maxillary portion of the labial fold, toward its anterior end, and sends branches anteriorly and posteriorly in it.

The ramus mandibularis and the several smaller associated branches all contain motor, communis and general cutaneous fibres. The proximal one of the smaller branches runs antero-dorsally and in large part penetrates, on its internal surface, the muscle-mass formed by the levator arcus palatini and its derivatives, certain of the branches, however, passing outward across the anterior edge of the levator and then posteriorly a short distance along its external surface. The next one or two branches arise in the angle between the rami maxillaris and mandibularis and are sent the one to the musculus temporalis and the other to the pterygoideus, the branch to the temporalis penetrating it on its internal surface and that to the pterygoideus penetrating it on its dorso-external surface. The next two branches arise from the base of the ramus mandibularis and not directly from the ganglion, and are the one largely motor and the other wholly sensory. The motor branch goes to the large superficial portion of the adductor mandibulae, entering it on its internal surface. The sensory branch runs outward across the anterior edge of the superficial portion of the adductor and then postero-ventrally along its external surface, some of its branches penetrating the muscle, this branch thus apparently corresponding to the ramus posttrematicus externus anticus of the more posterior arches.

After giving off these several branches, which doubtless vary somewhat in different specimens, the ramus mandibularis runs downward along the dorso-external surface of the musculus pterygoideus, and while in that position sends a branch to the deeper portion of the adductor, the branch entering the muscle on its external surface. The nerve then passes internal to the deeper portion of the adductor, crosses the internal surface of that muscle, and then turns forward, there either passing over the hind edge of the muscle, onto its external surface, or traversing the muscle near its hind edge and close to its origin (figs. 42–44). The nerve then enters the ramus of the mandible, there lying, in my 75 mm. specimen, internal to those fibres of the superficial portion of the adductor that pass directly into the ramus of the mandible, but external to the tendon of insertion of the musculi temporalis and pterygoideus, and also external to those fibres of the mandibular portion of the adductor that have their insertions on the latter tendon. Luther (1913, p. 21) shows this nerve passing internal to this tendon and muscle, but it was not so found in any of my specimens. No motor fibres going to the mandibular portion of the adductor could be traced in the sections of my 75 mm. specimen, but the nerve, in this part of its course, sends a small sensory branch outward to join the ramus mandibularis internus facialis as that nerve traverses its canal in the dermarticular.

As the ramus mandibularis here passes between the two parts of the adductor, it gives off a branch which is wholly sensory and soon separates into two parts. One of these parts runs forward dorsal to that ridge on the internal surface of the dentary that forms the dorsal edge of the groove that lodges Meckel's cartilage and gives support to the dorsal edge of the splenial, and is there joined by the ramus mandibularis internus facialis, not shown in the figures, the two nerves lying in the groove between the dentigerous edges of the dentary and splenial. The other part of the branch runs forward ventral to the ridge, above referred to, on the mesial surface of the dentary, there lying along the dorsal surface of Meckel's cartilage and soon entering a canal in the dentary which begins at about the anterior quarter of the entire length of the mandible. A branch is there at once sent outward through the bone, and entering the mandibular portion of the labial fold turns posteriorly in it. The remainder of the nerve then continues onward in the canal in the dentary, accompanied by an arterial vessel, and sends branches to the dentary teeth. Both portions of this branch of the ramus mandibularis thus have a course dorsal to Meckel's cartilage, that is, morphologically along its internal surface. The branch is accordingly the ramus posttrematicus internus trigemini and corresponds strictly in its relations to the dentary and to Meckel's cartilage to the inferior dental nerve of human anatomy (Bryce, 1915, fig. 92).

After giving off this branch, the remainder of the ramus mandibularis runs antero-ventrally across the external (morphologically anterior) surface of Meckel's cartilage, in the groove on the internal surface of the dermarticular that was described when describing that bone, and is there joined by the ramus mandibularis externus facialis, the two nerves then running forward ventral (morphologically external) to Meckel's cartilage, in a groove on the mesial surfaces of the dermarticular and dentary, and being accompanied by a branch of the mandibular artery. The two nerves here pass ventral to the musculus geniohyoideus inferior, close to its line of origin, but are not seen in ventral views because of the underhanging ventral edge of the mandible. As the ramus mandibularis passes over the hind edge of the geniohyoideus inferior it gives off either a single branch which immediately separates into two branches, or two branches arising close together. These two branches contain some sensory fibres and all the remaining motor fibres of the nerve, and they run antero-mesially along the ventral surface of the geniohyoideus inferior, and then turn, the one anteriorly and the other posteriorly, each of them sending branches into the muscle to innervate it. The anterior branch does not continue beyond the muscle. The posterior branch continues posteriorly beyond it and reaches the ventral surface of the geniohyoideus superior, where it breaks up into branches which penetrate that muscle and innervate it. The terminal branch of the nerve usually, but not always, runs directly into a branch of the ramus hyoideus facialis, the two nerves there forming a continuous circuit, as the corresponding nerves do in Amia and Scomber. This has been fully discussed in a recent work (Allis, 1919*d*), and it was there shown that the fibres of the ramus mandibularis trigemini are all sent to the geniohyoideus, and that the musculus hyohyoideus is innervated wholly by the nervus facialis. After giving off this important branch to the two divisions of the geniohyoideus, the ramus mandibularis continues onward in the groove on the mesial surface of the dentary, sending branches outward with each of the branches of the mandibularis externus facialis to the latero-sensory organs of the mandibular canal, the branches of the trigeminus innervating the general sensory tissues of the region.

This terminal portion of the ramus mandibularis thus corresponds, in its relations to Meckel's cartilage and its terminal distribution, to the nervus mylohyoideus of human anatomy (Bryce, 1915, fig. 92), but there is no branch that corresponds to the nervus lingualis unless it be that part of the ramus posttrematicus internus that runs forward in the groove between the dorsal (oral) edges of the dentary and splenial; and the fact that that part of the nerve is accompanied by the mandibularis internus facialis seems to indicate that it is the lingualis.

Nervus facialis. The nervus facialis arises, in the adult, by a single root which issues from the medulla slightly posterior to the root of the trigeminus and in contact, posteriorly, with the root of the nervus acusticus. In the 75 mm. specimen it arises by four rootlets, two lateralis, one communis, and one motor, the two lateralis rootlets furnishing, the one the lateralis fibres to the nervus trigeminus and the other those to the nervus facialis. The communis root soon becomes ganglionated, and then separates into two parts, one destined to the nervus trigeminus and the other to the nervus facialis. Those parts of the lateralis and communis roots that are destined to the nervus trigeminus run forward in the cranial cavity, and, joining the root of the latter nerve, issue with it through the trigeminus foramen. These two bundles of fibres thus here definitely belong, both in their point of exit from the cranial cavity and in their peripheral distribution, to the nervus trigeminus, and, as already stated, I consider them to belong to that nerve and not to the nervus facialis.

After giving off these two bundles of fibres to the nervus trigeminus, the remainder of the facialis root, composed of lateralis, communis and motor fibres, traverses the primary facialis foramen and enters the jugular canal in the lateral wall of the cranium, there lying ventral to the vena jugularis. Ganglion cells then immediately appear in the lateralis component of the root, and the communis component, which is still ganglionated, separates into two parts, one of which extends forward in the jugular canal and the other posteriorly in it. The anterior portion of this communis ganglion gives origin to the ramus palatinus, and to the bundle of communis fibres, already referred to, that is sent to the general cutaneous ganglion of the nervus trigeminus, and it is connected, by an extracranial communicating branch, with the communis ganglion of the nervus glossopharyngeus. The fibres that arise from the posterior portion of the ganglion join the lateralis and motor fibres of the nervus, and together form the truncus hyomandibularis, this truncus receiving the communicating branch from the general cutaneous ganglion of the trigeminus, already described. Sympathetic fibres are sent from the main sympathetic chain both to that portion of the communis ganglion that is related to the truncus hyomandibularis and to the part related to the ramus palatinus.

The ramus palatinus, or more properly ramus anterior facialis, issues through the anterior opening of the jugular canal and enters the trigeminus chamber, where it turns sharply downward onto the dorsal surface of the horizontal plate of the ascending process of the parasphenoid, passing dorso-lateral to the ophthalmic branch of the common carotid artery, close to its point of separation from the latter artery. The nerve, still containing ganglion cells, then runs forward dorso-lateral to the common carotid artery, and after receiving the communicating branch from the nervus glossopharyngeus, gives off the communicating branch to the general cutaneous ganglion of the nervus trigeminus. The latter branch runs upward, dorso-lateral to the infra-orbital branch of the vena jugularis, and as its fibres apparently all go to the ramus mandibularis trigemini, as already stated, it is the ramus pretrematicus externus of the facialis. The ramus palatinus, still ganglionated, here becomes slightly enlarged, thus forming a slight ganglion at the base of the nerve, and ganglion cells are not continued forward beyond this point. From the anterior end of this small ganglion, or from the base of the ramus palatinus immediately anterior to it, a branch is given off which runs forward a short distance parallel to the palatinus, in the dense connective tissues that bind the palatoquadrate to the ventral surface of the lateral edge of the parasphenoid, there lying dorso-lateral to the dorso-mesial edge of the entopterygoid. It then separates into two branches both of which run ventrally between the entopterygoid and the palatoquadrate cartilage and are distributed to the ventro-mesial surface of the latter cartilage. This branch must therefore be a ramus pretrematicus internus facialis, as that nerve is defined by Sewertzoff (1911), but if it contains fibres derived from the communicating branch from the nervus glossopharyngeus, it would be, in part, also a ramus pharyngeus glossopharyngei corresponding to that nerve as described by me in Amia (Allis, 1897, p. 685).

The ramus palatinus then continues onward along the dorsal surface of the lateral edge of the parasphenoid, lateral to the common carotid artery and ventral to the musculus pterygoideus, until it reaches the anterior edge of the latter muscle. There it passes downward over the lateral edge of the parasphenoid, and runs forward, at first immediately dorsal to the connective tissue that binds the palatoquadrate to the parasphenoid, and then enclosed within that tissue, there lying considerably dorso-mesial to the dorso-mesial edge of the palatoquadrate cartilage. The nerve then gives off a branch which runs antero-latero-ventrally along the internal surface of the palatoquadrate cartilage, between it and the entopterygoid and ectopterygoid, and, beyond the lateral edge of the palatoquadrate cartilage, enters a canal in the entopterygoid and issues from that bone near its lateral edge. There it continues forward and can be traced a certain distance, communicating branches connecting it with the ramus maxillaris trigemini. This branch of the palatinus thus corresponds to the ramus palatinus posterior of Amia, and as it lies internal to the palatoquadrate cartilage it would seem as if it must be a ramus pretrematicus internus facialis, there thus being two of these nerves in this fish, one anterior and the other posterior.

After giving off this branch, the remainder of the nerve becomes the ramus palatinus anterior, or ramus pharyngeus facialis, and runs forward, in the tissues dorsal to the entopterygoid, to the anterior end of that bone. It then passes beneath the nasal capsule, there lying at first in the tissues immediately mesial to the mesial dermopalatine (the so-called vomer), and then dorsal to the latter bone. It is accompanied, throughout this part of its course, by a small vein and artery.

The truncus hyomandibularis facialis runs posteriorly in the jugular canal and issues through its posterior opening, being joined, while in the canal, by the communicating branch of general cutaneous fibres from the trigeminus ganglion. The truncus then runs outward ventral to the vena jugularis, and soon separates into its rami mandibularis and hyoideus, the ramus opercularis being a branch of the latter nerve.

The ramus mandibularis contains all of the lateralis fibres of the nerve, some of the communis fibres, and, so far as could be judged from my sections, a considerable portion of the general cutaneous fibres received from the trigeminus ganglion, but no motor fibres. The nerve runs postero-ventrally along the mesial wall of the spiracular canal, there lying at first dorsal and then lateral to the efferent artery of the hyal arch, the nerve and artery both lying in a fold of the mucous tissues that projects ventrally between the posterior portion of the spiracular canal, externally, and the dorso-anterior end of the first gill cleft internally. At the hind edge of the spiracular canal the nerve turns ventro-laterally across that edge, between it and the anterior edge of the hyomandibula and then downward along the lateral surface of the canal, there lying along the line of insertion of the musculus protractor hyomandibularis, and internal to the superficial division of the adductor mandibulae, between the latter muscle and the external wall of the dorso-anterior diverticulum of the first gill cleft. There the nerve gives off its first branch, which runs ventro-posteriorly and supplies both the dorsal one of the three laterosensory organs in the preoperculum, and the organs of the posterior horizontal and vertical cheek-lines of pit organs. Fibres that are not lateralis ones certainly form part of this branch and go to tissues of the region, but whether they are communis or general cutaneous ones could not be definitely determined, and the same is true for the other branches of the nerve. A second and similar branch is then sent to the seventh preoperculo-mandibular organ, and approximately at the point of origin of this branch the ramus mandibularis separates into its external and internal branches.

The ramus mandibularis externus contains all of the lateralis fibres of the ramus mandibularis and also some of the other fibres of that nerve and is apparently the ramus posttrematicus externus anticus facialis (Allis, 1920*b*). It runs downward internal to that part of the superficial division of the adductor mandibulae that has its origin on the hyomandibula, but external to the tough membrane that here covers the latter bone, and then passes internal to that slip of the tough membrane that covers the external surface of the palatoquadrate that has its insertion on the hyomandibula. Ventral to that slip it sends a branch to the sixth preoperculo-mandibular organ, the non-lateralis fibres related to this branch sometimes appearing as a separate and independent branch. The main nerve then turns ventro-anteriorly along the hind edge of the palatoquadrate, and passing external to the quadrato-hyomandibular articulation, and posterior and external to the quadrato-mandibular articulation, reaches the hind end of the mandible, where it enters the canal that lies, at first, between the dermarticular and autarticular, but farther forward entirely in the former bone. While in that canal two branches are sent outward, one going to the fifth and the other to the fourth preoperculo-mandibular organs, these two organs both lying in the dermarticular. The nerve then issues from the canal in the dermarticular and enters that groove on the mesial surface of the dentary that first passes external to Meckel's cartilage and then forward along the ventral edge of that cartilage and lodges also the ramus mandibularis trigemini. There branches are sent to the third and second organs of the preoperculo-mandibular canal, the terminal branch of the nerve going to the first organ of that canal.

The ramus mandibularis internus, which is the posttrematicus internus facialis, turns antero-ventrally after its separation from the ramus externus and either passes through a notch, or a foramen, at the dorso-posterior corner of the metapterygoid. It then continues onward along the hind edge of the palatoquadrate, passing internal to the quadrato-hyomandibular articulation and postero-ventral to the quadrato-mandibular articulation, and reaches the mandible. There it enters the short canal that begins on the mesial surface of the autarticular, directly ventral to the mesial end of the articular facet for the quadrate, and issues from that canal onto the mesial surface of the hind end of Meckel's cartilage. There it runs antero-dorsally across Meckel's cartilage and enters the groove between the splenial and the dentigerous edge of the dentary, where it runs forward to the anterior end of the mandible, accompanying that branch of the ramus mandibularis internus trigemini that also occupies that groove. This nerve of Polypterus thus has to Meckel's cartilage the relations of the chorda tympani of human anatomy (Bryce, 1915, fig. 92), which is further evidence that it is the homologue of that nerve.

The ramus hyoideus facialis runs posteriorly internal to the hyomandibula, and immediately gives off its ramus opercularis, which contains both sensory and motor fibres, the former apparently being communis ones. This ramus runs posteriorly mesial to the hyomandibula and dorsal to the opercular process of that bone, receives a communicating branch from the ramus anterior glossopharyngei, and then reaches the external surfaces of the musculi adductor hyomandibularis and adductor operculi, where it runs posteriorly, sending branches to both those muscles and to tissues of the region. A terminal branch of the nerve runs directly into a terminal branch of the supratemporal branch of the nervus vagus, the two nerves forming a continuous circuit which is topographically similar to that in Amia (Allis, 1897), but different from that in Menidia (Herrick, 1899). Lehn found this nerve lying ventral to the opercular process of the hyomandibula.

After giving off the ramus opercularis, the ramus hyoideus turns outward across the dorsal edge of the opercular process of the hyomandibula, there passing between the hind edge of the latter bone and the stout ligament that extends from the opercular process upward to the accessory hyomandibula. The nerve then runs ventrally in the gill cover, lying slightly posterior to the hyomandibula and epihyal and sending branches posteriorly and posteroventrally internal to the opercular bones, these branches innervating the musculus hyohyoideus superior and tissues of the region. At the level of the proximal (posterior) end of the ceratohyal the nerve passes onto the external surface of the hyohyoideus inferior, and is distributed to that muscle and adjacent tissues. One branch of the nerve passes onto the external surface of the geniohyoideus superior and usually there anastomoses with that terminal branch of the trigeminus that innervates the latter muscle, another branch passing internal to the geniohyoideus superior and anastomising with a branch of the ramus posttrematicus glossopharyngei.

Nervus acusticus. This nerve arises by a large root which lies immediately posterior to, and in contact with, the lateralis root of the nervus facialis. In the adult this root may issue from the medulla as two separate roots, a ramus anterior (vestibularis) and a ramus posterior (cochlearis). The ramus anterior, when found as a separate root, separates into two parts, one of which supplies the maculae of the ampulla anterior, ampulla externa, and recessus utriculi, and the other the maculae sacculi and neglecta. The ramus posterior supplies first the macula lagenae and then the macula of the ampulla posterior. I thus find this nerve as described by Retzius (1881), excepting in that the ramuli said by him to go to the maculae sacculi and neglecta form part of the anterior, instead of the posterior ramus of the nerve.

Nervus glossopharyngeus. This nerve arises, in the adult, as well as in the 75 mm. specimen, by two rootlets which lie close together, ventral and slightly posterior to the root of the nervus lineae lateralis vagi. One of the rootlets contains the motor, and the other the sensory fibres of the nerve, the latter fibres apparently all being communis ones. This root soon receives a bundle of lateralis fibres from the root of the nervus lineae lateralis vagi, and, running postero-laterally, enters and traverses the recessus sacculi, there passing ventral to all parts of the membranous ear and to all branches of the nervus acusticus. The nerve then issues from the cranium through the glossopharyngeus foramen, there lying ventral to the vena jugularis and being accompanied, as it traverses its foramen, by a delicate branch of that vein, a similar but much larger branch issuing with the nervus vagus through its foramen.

Immediately after issuing from its foramen the nervus glossopharyngeus gives off, in the 75 mm. specimen, a branch which contains both communis and lateralis fibres, and an independent ganglion, involving both components, immediately forms upon it. From this ganglion a ramus supratemporalis arises, this nerve containing all the lateralis fibres of the glossopharyngeus and a part of the communis fibres. It runs dorsally along the lateral surface of the cranium, passes mesial to the vena jugularis, and then traverses a canal in the opisthotic and issues on the dorsal surface of that bone. There it separates into two branches, one of which penetrates the parieto-dermopterotic and innervates organ 11 of the main infraorbital canal, the other anastomosing with two branches of the ramus supratemporalis vagi and going to the organs of the middle head-line of pit organs. The latter branch of the glossopharyngeus apparently contains only communis fibres, while the vagus branches apparently contain lateralis fibres, and if this be correct the middle head-line of pit organs would be innervated by the vagus.

After giving off this branch, the nervus glossopharyngeus receives a communicating branch from the first vagus ganglion and then runs dorso-laterally across the postero-mesial edge of the epibranchial of the first branchial arch, and reaches the dorsal surface of that element. There it swells into an elongated ganglion which lies along the lateral surface of the cranium, ventral to the vena jugularis. From the hind end of this ganglion the ramus posttrematicus glossopharyngei arises, and from its anterior end the ramus anterior glossopharyngei.

The ramus anterior lies, in the 75 mm. specimen, along the dorsal surface of the thymus, but gives off a small branch which traverses that gland and rejoins the main nerve at its anterior end. The ramus anterior there gives off a branch which runs posteriorly between the two heads of the levator muscle of the first branchial arch and then along the external surface of that muscle, and reaches the external surface of the ceratobranchial of its arch, where it runs downward in the arch, always lying anterior to the ramus posttrematicus glossopharyngei. This branch of the ramus anterior is accordingly the ramus posttrematicus externus anticus. As it passes over the hind edge of the levator of the arch, it crosses, externally, a ramus posttrematicus internus, to be later described, and may there anastomose with that nerve, these nerves and the ramus anterior then forming a loop around the levator. After giving off this branch, the ramus anterior gives off, in the 75 mm. specimen, two branches, both of which run postero-ventrally, one lying along the ventral surface of the musculus adductor hyomandibularis and dorsal to the efferent artery of the hyal arch, and the other ventral to that artery, close to the ramus mandibularis facialis. The dorsal one of these two branches is connected, by an anastomosing branch, with the ramus opercularis facialis, the anastomosing branch passing across the anterior edge of the adductor hyomandibularis. These two branches of the nerve both lie immediately lateral (internal) to the mucous lining membrane of the lateral wall of the dorsal, pocket-like end of the first branchial cleft, and hence are both pretrematic nerves, the ventral one being a pretrematicus internus and the other apparently a pretrematicus externus. The remainder of the ramus anterior, which is now the ramus pharyngeus glossopharyngei, runs forward through the canalis parabasalis in the ascending process of the parasphenoid—there lying ventral to the efferent artery of the hyal arch and lateral to the common carotid artery—and fuses with the small ganglion at the base of the ramus palatinus facialis, slightly proximal to the point of origin of the communicating branch from that ganglion to the general cutaneous ganglion of the nervus trigeminus. This branch of the glossopharyngeus is described by Lehn as the ramus palatinus, and it would seem to represent Jacobson's nerve, but it fuses entirely with the palatinus portion of the geniculate ganglion, instead of receiving a branch from that ganglion and then continuing onward to end in an otic ganglion. Furthermore, the nerve apparently contains only communis fibres, and Norris says (1908, p. 547) that Jacobson's nerve is largely composed, in the Amphibia, of general cutaneous fibres, with but few communis and sympathetic ones.

The ramus posttrematicus, immediately after its origin from the hind end of the glossopharyngeus ganglion, sends a motor branch to the levator muscle of the first branchial arch, and then runs outward posterior to that levator. It then immediately gives off a sensory branch which passes internal to the ramus posttrematicus externus anticus, and may, as already stated, anastomose with that nerve. This branch then perforates, from its external surface and near its dorsal edge, the stout ligament that extends from the latero-ventro-posterior corner of the ascending process of the parasphenoid to the dorsal end of the first ceratobranchial, and reaches the internal edge of the latter ceratobranchial, where it runs downward in its arch, lying close to, or fusing with, the ramus pretrematicus internus of the first vagus nerve. This branch of the glossopharyngeus is thus a ramus posttrematicus internus. Soon after giving off this sensory branch, the ramus posttrematicus crosses the external surface of the epibranchial of the first branchial arch, there lying in the groove between that element of the arch and the pharyngobranchial, and reaches the external surface of the ceratobranchial, where it lies between the bases of the two rows of cartilaginous branchial rays. There it is joined by the ramus pretrematicus externus of the first vagus nerve, this branch apparently being a general cutaneous one and fusing completely with the ramus posttrematicus glossopharyngei. The trunk so formed continues downward in the arch, and soon sends a branch to the tissues of the arch, this branch apparently containing motor fibres destined to innervate certain small muscles related to the gill filaments. Near the ventral end of the arch two branches are sent to the musculus interarcualis ventralis of the arch, and between these two branches the ramus posttrematicus forms an anastomosis with a branch of the ramus hyoideus facialis, as already described. Beyond this point the nerve anastomoses completely with the terminal portion of the ramus pretrematicus internus of the first vagus, the nerve so formed continuing onward along the internal surface of the tissues that form the floor of the buccal cavity.

Nervus lineae lateralis vagi. This nerve arises from the medulla slightly dorsal and anterior to the root of the glossopharyngeus, and immediately sends a branch to the latter root. The root then becomes imbedded in the lateral surface of the large intracranial vagus ganglion and issues from the cranial cavity through the vagus foramen with the vagus nerve and a large venous vessel which joins the vena jugularis. As the root issues through the vagus foramen it separates into two parts and a ganglion forms on each of them, one being the ganglion of the ramus supratemporalis and the other that of the nervus lineae lateralis. The latter nerve was not further traced. The ramus supratemporalis passes ventro-anterior to the venous vessel that issues through the vagus foramen, and then runs dorso-laterally mesial to the posterior process of the opisthotic, in the hollow between that process and the body of the bone. Branches are sent by it to organs 12 and 13 of the main infraorbital laterosensory canal, which lie the one in the first supratemporal bone and the other in the posttemporal (suprascapular), then two separate branches to the middle head-line of pit organs, and the nerve then terminates in branches to the two supratemporal organs, which lie in the second and third supratemporal bones.

Nervus vagus. The nervus vagus arises by several rootlets which contain motor, communis and general cutaneous fibres. A large intracranial ganglion forms on the general cutaneous fibres and protrudes partly through the vagus foramen, and two extracranial ganglia are formed on the communis fibres of the nerve, one in relation to the fibres destined to the first vagus nerve and the other on the remaining fibres of the nervus.

The ramus supratemporalis vagi of the 75 mm. specimen arises by two roots from the dorsal surface of the protruding, extracranial portion of the general cutaneous ganglion, each root receiving a bundle of communis fibres. One root runs upward dorso-posterior, and the other ventro-anterior to the vein that issues through the vagus foramen, the two then fusing with each other and joining the ramus supratemporalis of the nervus lineae lateralis. The nerve is in part distributed to tissues on the dorsal surface of the head, but two important branches run laterally over the dorsal edge of the musculus adductor operculi, and then ventrally along the external surface of that muscle. One of these branches fuses with the ramus opercularis facialis, the other passing external to that nerve and being distributed to tissues in the gill cover, this distribution of this branch of the vagus evidently showing that that cover was not developed wholly in relation to the hyal arch.

The first vagus nerve arises, with the other vagus nerves, from the ventral portion of the intracranial ganglion, and separates from the other vagus nerves while they are all traversing the vagus foramen, the first vagus there lying ventral to the other nerves, and all of them lying ventral to the distal end of the general cutaneous ganglion of the complex. The nerve consists mainly of motor and communis fibres, but some general cutaneous fibres must certainly enter it, for, as there are certainly general cutaneous tissues in the arch the nerve traverses, there must be nerve fibres to innervate them. Furthermore, although no general cutaneous fibres could be definitely traced into this nerve, they were traced into the nerves sent to the more posterior arches. After the nerve has separated from the other nerves of the complex, a small and independent ganglion is formed in relation to its communis fibres, this ganglion forming, as in Amia (Allis, 1897, fig. 59), a knob-like swelling on the anterior surface of the main trunk of the nerve. From this ganglion, in the 75 mm. specimen, four nerves arise, and the descriptions that follow, of this nerve and the other vagus nerve, apply largely to this specimen.

One of the nerves that arise from the first vagus ganglion is a communicating branch to the nervus glossopharyngeus, and it has already been referred to when describing that nerve.

A second nerve separates into two parts. One of these parts immediately joins and fuses with the main sympathetic nerve, but the nerve so formed soon separates into two parts, one of which is certainly largely composed of sympathetic fibres and the other largely of communis fibres. Both of these nerves run forward and traverse the canalis parabasalis in the ascending process of the parasphenoid, the sympathetic nerve then falling into the trigeminus ganglion and the communis one joining and closely accompanying the ramus palatinus facialis proximal to the point where the communicating branch is sent from that nerve to the trigeminus ganglion, this nerve thus being the ramus pharyngeus of the first vagus nerve. The other part of this second nerve of the first vagus perforates the thymus, and while in that gland receives a communicating branch from the communis nerve just above described. The nerve so formed then enters the first branchial arch and reaches the internal surface of that arch, where it joins and fuses with the ramus posttrematicus internus glossopharyngei. This branch of the first vagus is thus the ramus pretrematicus internus of that nerve, and the nerve formed by its fusion with the ramus posttrematicus internus glossopharyngei is the ramus internus of the first branchial arch. This nerve runs downward along the internal surface of the arch, and, at its ventral end, joins and fuses with the terminal portion of the ramus posttrematicus glossopharyngei, as already described.

The third nerve that arises from the first vagus ganglion runs outward between the levator muscles of the first and second branchial arches, and separates into two parts. One of these parts is the ramus pretrematicus externus of the first vagus, and joins the ramus posttrematicus glossopharyngei on the external surface of the first arch. The other part is the ramus posttrematicus externus anticus of the first vagus, and it has a course, in its arch, similar to that of the corresponding branch in the glossopharyngeus arch.

The remaining branch that arises from the first vagus ganglion is the ramus posttrematicus. This nerve first sends a motor branch to the levator muscle of its arch, and then both in my 75 mm. specimen and in one adult that was examined, runs outward through that muscle. On issuing from the muscle it gives off its ramus posttrematicus internus, which immediately joins and fuses with the ramus pretrematicus internus of the second vagus. The main nerve then receives, and fuses with, the ramus pretrematicus externus of the second vagus, and, running downward in its arch, gives off first a branch which contains motor fibres, apparently destined to muscle fibres related to the gill filaments, then a branch which is apparently wholly sensory, and then a third branch which innervates the musculus interarcualis ventralis of its arch. The remainder of the nerve then separates into two branches, each of which anastomoses with the ramus internus of the arch.

The second vagus nerve arises from the main extracranial ganglion of the vagus complex, and contains motor, communis, and a few general cutaneous fibres. It immediately gives off a motor branch to the levator muscle of its arch, and a communis branch which goes to the dorsal surface of the branchial chamber in the region of the basioccipital, and then runs outward anterior to the levator muscle of its arch. The nerve then gives off, in succession, a ramus pretrematicus internus, a ramus pretrematicus externus, a ramus posttrematicus externus anticus, and a ramus posttrematicus internus; all of these nerves having courses similar to those of the corresponding nerves in the preceding arches. The remainder of the nerve is then the definitive ramus posttrematicus, which runs downward in its arch, gives off branches similar to those of the first vagus, and then separates into two parts, each of which fuses with one of two terminal branches of the ramus internus of the arch.

The third vagus nerve arises from the extracranial ganglion of the complex and soon sends a motor branch to the levator muscle of its arch. It then runs outward anterior to that levator and gives off, in succession, a ramus pretrematicus internus, a ramus pretrematicus externus, a ramus posttrematicus externus anticus, and a ramus posttrematicus internus, these nerves all having courses similar to those in the preceding arches, excepting in that the ramus posttrematicus externus anticus fuses completely with the ramus posttrematicus throughout the larger part of its course. The ramus posttrematicus runs downward in its arch giving off branches similar to those in the preceding arches, and finally anastomosing with the ramus posttrematicus internus of its own arch, exactly as, in the more anterior arches, it anastomoses with that nerve fused with the ramus posttrematicus internus of the next posterior arch. No pharyngeal branch was found related to this nerve.

The remaining vagus nerve, the ramus intestinalis, was not traced beyond its origin from the extracranial ganglion of the complex, but branches of the nerve innervate the superior and inferior pharyngo-claviculares, and the transversus ventralis.

SUMMARY

The cranium of Polypterus is platybasic, and several of the cranial bones correspond, in topographical position and relations, to two or more of the bones of recent Holostei and Teleostei. These several bones are the basi-exoccipital (basioccipital + exoccipitals), the parieto-dermopterotic (parietal + dermopterotic), the postfronto-sphenotic (autosphenotic + dermosphenotic), the premaxillary (premaxillary + antorbital + $\frac{1}{2}$ dermoethmoid), the maxillary (maxillary + suborbitals), the cheek-plate (preoperculum + cheek-plate), and the sphenoid (orbitosphenoids + alisphenoids + piscine basisphenoid + proötic bridge). The nasal, accessory nasal and os terminale, found wholly separate in this fish, are usually represented by a single bone in other fishes. There is a large opisthotic, which is partly of primary and partly of secondary origin and invades somewhat the regions occupied, in other fishes, by the epiotic, autopterotic and proötic, the two former bones, as independent ossifications, being wholly wanting in this fish, and the proötic either also wanting, being found as a small and unimportant bone, or, possibly, found fused with the ascending process of the parasphenoid.

The opisthotic, so well developed in this fish, is found as a dermal, and often unimportant, bone in the Holostei and most of the Teleostei; the epiotic, absent in Polypterus, is found in both the Holostei and Teleostei; and the autopterotic, also absent in Polypterus, is found in the Teleostei but not in the Holostei. In the Teleostei there are thus five otic bones, the sphenotic, pterotic, epiotic, proötic and opisthotic, but the opisthotic is tending to disappear, this apparently being correlated to the development of the autopterotic. In the Tetrapoda, a proötic, alone, is found in the Batrachia (Gaupp, 1905), a proötic and opisthotic in Reptilia, a proötic, opisthotic and epiotic in Aves, and several otic bones in the Mammalia, Huxley giving three, but Vrolik six. A sphenotic, found in Polypterus and in the Holostei and Teleostei, is not described as such in any of the Tetrapoda, but one of the centres of ossification ascribed to the proötic in man has markedly the position of the piscine autosphenotic, for it is said to appear on the dorso-lateral aspect of the otic capsule, over the superior (anterior) semicircular canal, to form the "border" over the nervus facialis, and to extend into the tegmen tympani from above, all of which would be characteristics of an enlarged autosphenotic and not of the piscine proötic.

The dental arcade is apparently similar to that in the Mammalia, and, in fishes, this arcade is known only in the Crossopterygii. The superior maxillary bone has certain striking resemblances to that of the Mammalia.

The trigemino-facialis chamber consists of a trigeminus chamber and a jugular canal, the latter canal apparently representing a primitive condition of the facialis part of the entire chamber. The lateral wall of the trigeminus chamber is formed by the ascending process of the parasphenoid, instead of, as in the Holostei and Teleostei, by the proötic.

The hyomandibula corresponds to the prefacialis portion of the holostean and teleostean hyomandibula, the postfacialis portion of the latter element being represented by ligament.

The common carotid artery traverses the canalis parabasalis through the ascending process of the parasphenoid and enters the ventral portion of the trigeminus chamber, where it gives off an ophthalmic branch, which accompanies the ramus ophthalmicus superficialis trigemini. The remainder of the artery issues into the orbit and there runs forward along the lateral edge of the parasphenoid, in the position of the orbito-nasal artery of the Teleostei, but the artery still contains the equivalents of the internal carotid, of a part of the external carotid, and of the orbito-nasal artery of the latter fishes. As this artery approaches the foramen opticum it gives off first a maxillo-mandibularis branch, and then two branches which enter the cranial cavity posterior to the nervus opticus and are, the one the arteria cerebralis posterior and the other the arteria cerebralis anterior. The remainder of the artery is then the orbito-nasal artery. The internal carotid of this fish thus enters the cranial cavity by passing dorsal, instead of ventral, to the trabecula, a condition which is also found in Amiurus (and hence probably in others of the Siluridae) but in no other fish that I know of.

The jugular vein is formed by the union of supraorbital and infraorbital veins, the supraorbital one accompanying the ramus ophthalmicus superficialis trigemini, and receiving, at its base, the maxillo-mandibularis vein, while the infraorbital one accompanies the common carotid and orbito-nasal arteries.

The nervus terminalis is apparently represented by two nervous strands that arise from the bulbus olfactorius and accompany the nervus olfactorius into the nasal sac.

The eye-muscles are innervated as they are in the Ganoidei and Siluridae, excepting in that the inferior division of the nervus oculomotorius passes dorsal, instead of ventral, to the musculus rectus inferior.

The radix profundus, which apparently contains only general sensory fibres, issues from the cranial cavity with the nervus oculomotorius, and a ganglion then immediately forms upon it. No branches from other nerves could be traced to this ganglion, and from it three nerves arise: the radix longa, which runs forward with the nervus oculomotorius and enters the ciliary ganglion, which is sessile on the inferior division of the nervus oculomotorius; a ramus ophthalmicus profundus, which runs forward between the two divisions of the oculomotorius and then ventral to the nervus trochlearis and joins, but does not fuse with, the ramus ophthalmicus superficialis trigemini as it traverses the preorbital foramen; and a portio ophthalmici profundi, which runs forward in the orbit, but not beyond it, lying ventral to the ramus ophthalmicus superficialis trigemini and sending branches to the dorsal surface of the head, accompanying branches of the latter nerve. The profundus nerve of this fish thus sends branches to the entire region that, in most teleosts, is innervated by branches of the ramus ophthalmicus superficialis trigemini, its ramus ophthalmicus corresponding to the ophthalmic nerve of man and its portio ophthalmici to the frontal branch of that nerve.

The nervus trigeminus contains motor, general sensory, communis, and lateralis fibres, the communis and lateralis fibres arising from the medulla with the corresponding roots of the nervus facialis. These fibres all issue from the cranial cavity through the foramen trigeminum and enter the trigeminus chamber, where two separate ganglia form, one on the general sensory fibres and the other on the lateralis-communis ones. From the lateralis-communis ganglion the rami oticus, ophthalmicus superficialis and buccalis arise, all of which contain both lateralis and communis fibres, and important bundles of communis fibres are also sent to the general sensory ganglion. The latter ganglion also receives communis fibres from the ramus palatinus facialis, and it sends a bundle of general sensory fibres into the jugular canal to there join and fuse with the truncus hyomandibularis facialis. From the general sensory ganglion the rami maxillaris and mandibularis arise, the former apparently containing only general sensory fibres, and the latter motor, general sensory and communis ones.

The radix facialis apparently contains only motor, lateralis, and communis fibres, but it receives the bundle of general sensory fibres just above mentioned from the nervus trigeminus. The radix issues from the cranial cavity into the jugular canal, and a ganglion forms on it which is partly intracranial and partly extracranial in position. From this ganglion the rami palatinus and hyomandibularis arise, the palatinus containing only communis fibres and running forward in the jugular canal, while the hyomandibularis contains motor, communis and lateralis fibres and runs posteriorly in that canal. The ramus palatinus sends a communicating branch to the general sensory ganglion of the trigeminus, and receives one from the nervus glossopharyngeus. The ramus hyomandibularis receives a general sensory bundle from the trigeminus ganglion, and sends its ramus mandibularis outward anterior to the hyomandibula and its ramus hyoideus outward posterior to that element, between it and a ligament that represents its postfacialis portion.

The nervus glossopharyngeus contains motor, communis and lateralis fibres, and apparently no general sensory ones, and it has a dorsal branch and all the ventral branches typical of a branchial nerve.

The nervus vagus contains motor, general sensory, communis, and lateralis fibres, the latter fibres all entering the ramus supratemporalis vagi and the nervus lineae lateralis. The first and second vagus nerves each has all the typical ventral branches, but in the third nerve these branches are less definitely evident.

PALAIS DE CARNOLÈS,
MENTON, FRANCE.
Nov. 29th, 1921.

LITERATURE CITED

AGASSIZ, L. (1833–1843). *Recherches sur les poissons fossiles.* Neuchâtel.

ALLEN, W. F. (1905). "The Blood Vascular System of the Loricati, the Mail-Cheeked Fishes. *Proc. Wash. Acad. Sci.* vol. VII.

ALLIS, E. P. JR (1889). "The Anatomy and Development of the Lateral Line System of *Amia calva.*" *Journ. Morph.* vol. II.

—— (1897). "The Cranial Muscles, and Cranial and First Spinal Nerves in *Amia calva.*" *Journ. Morph.* vol. XII.

—— (1899). "On certain homologies of the Squamosal, Intercalar, Exoccipitale and Extrascapular bones of *Amia calva.*" *Anat. Anz.* Bd. XVI.

—— (1900*a*). "The Lateral Sensory Canals of *Polypterus bichir.*" *Anat. Anz.* Bd. XVII.

—— (1900*b*). "The Premaxillary and Maxillary Bones, and the Maxillary and Mandibular Breathing Valves of *Polypterus bichir.*" *Anat. Anz.* Bd. XVIII.

—— (1903). "The Skull, and the Cranial and First Spinal Muscles and Nerves in *Scomber scomber.*" *Journ. Morph.* vol. XVIII.

—— (1908*a*). "The Pseudobranchial and Carotid Arteries in *Amiurus.*" *Anat. Anz.* Bd. XXXIII.

—— (1908*b*). "The Pseudobranchial and Carotid Arteries in *Polypterus.*" *Anat. Anz.* Bd. XXXIII.

—— (1909). "The Cranial Anatomy of the Mail-Cheeked Fishes." *Zoologica,* Bd. XXII.

—— (1912). "The Branchial, Pseudobranchial and Carotid Arteries in *Heptanchus* (*Notidanus*) *cinereus.*" *Anat. Anz.* Bd. XLI.

—— (1914). "The Pituitary Fossa and Trigemino-facialis Chamber in Selachians." *Anat. Anz.* Bd. XLVI.

—— (1916). "The so-called Mandibular Artery and the Persisting Remnant of the Mandibular Aortic Arch in the Adult Selachian." *Journ. Morph.* vol. XXVII.

—— (1917). "The Homologies of the Muscles related to the Visceral Arches of the Gnathostome Fishes." *Q.J.M.S.* vol. LXII. Pt. 3.

—— (1918*a*). "The Myodome and Trigemino-facialis Chamber of Fishes and the Corresponding Cavities in Higher Vertebrates." *Proc. Nat. Acad. U.S.A.* vol. IV. No. 8. (An abstract.)

—— (1918*b*). "The Ophthalmic Nerves of the Gnathostome Fishes." *Journ. Compar. Neurol.* vol. XXX.

—— (1918*c*). "On the Origin of the Hyomandibula of the Teleostomi." *Anatom. Rec.* vol. XV.

—— (1919*a*). "The Lips and the Nasal Apertures in the Gnathostome Fishes." *Journ. Morph.* vol. XXXII.

—— (1919*b*). "The Myodome and Trigemino-facialis Chamber of Fishes and the Corresponding Cavities in Higher Vertebrates." *Journ. Morph.* vol. XXXII.

—— (1919*c*). "The Homologies of the Maxillary and Vomer Bones of *Polypterus.*" *Amer. Journ. Anatomy,* vol. XXV.

—— (1919*d*). "The Innervation of the Mandibularis and Geniohyoideus Muscles of the Bony Fishes." *Anatom. Rec.* vol. XVI.

—— (1919*e*). "On the Homologies of the Squamosal Bone of Fishes." *Anatom. Rec.* vol. XVII.

—— (1920*a*). "On Certain Features of the Otic Region of the Chondrocranium of *Lepidosteus,* and Comparison with other Fishes and Higher Vertebrates." *Proc. Zool. Soc.* 1919. London.

—— (1920*b*). "The Branches of the Branchial Nerves of Fishes, with special reference to *Polyodon Spathula.*" *Journ. Compar. Neurol.* vol. XXXII.

—— (1922). "The Myodome and the Trigemino-facialis chamber in the Coelacanthidae, Rhizodontidae and Palaeoniscidae." *In press.*

BAUR, G. (1895). "Ueber die Morphologie des Unterkiefers der Reptilien." *Anat. Anz.* Bd. XI.

BING, R. and BURCKHARDT, R. (1905). "Das Centralnervensystem von *Ceratodus forsteri.*" *Jenaische Denkschriften,* Bd. IV.

BRIDGE, T. W. (1888). "Some Points in the Cranial Anatomy of *Polypterus.*" *Proc. Philos. Soc. Birmingham,* vol. VI.

BRYCE, T. H. (1915). *Quain's Anatomy.* 11th ed. vol. IV, Pt. 1. London.

BUDGETT, J. S. (1902). "On the Structure of the Larval *Polypterus.*" *Trans. Zool. Soc. London,* vol. XVI.

Collinge, W. E. (1893). "Note on the Lateral Canal System of *Polypterus*." *Proc. Philos. Soc. Birmingham*, vol. viii, Pt. 2.

Fürbringer, M. (1897). "Ueber die spino-occipitalen Nerven der Selachier und Holocephalen und ihre vergleichende Morphologie." *Festschrift f. Carl Gegenbaur*, vol. iii. Leipzig.

Gaupp, E. (1893). "Primordial-Cranium und Kieferbogen von *Rana fusca*." *Morph. Arbeiten*, Bd. ii. Jena.

—— (1905). "Die Entwickelung des Kopfskelets." *Handbuch d. vergl. u. experim. Entwickelungslehre d. Wirbeltiere*, von Oscar Hertwig, 1906, Bd. iii, Th. 2.

Gegenbaur, C. (1872). *Das Kopfskelet der Selachier: Untersuchungen zur vergleichenden Anatomie der Wirbeltiere*, Hft 3. Leipzig.

—— (1878). "Ueber das Kopfskelet von *Alepocephalus rostratus*." *Morph. Jahrb.* Bd. iv. Sup.

Herrick, C. J. (1899). "The Cranial and First Spinal Nerves of Menidia: A Contribution upon the Nerve Components of the Bony Fishes." *Journ. Comp. Neurol.* vol. ix.

Holmqvist, O. (1910). "Der Musculus Protractor Hyoidei und der Senkungsmechanismus des Unterkiefers bei den Knochenfischen." *Lunds Universitets Arsskrift*, N.F. Afd. 2, Bd. vi, Nr. 6. Lund.

—— (1911). "Studien in der von den NN. Trigeminus und Facialis innervierten Muskulatur der Knochenfische." *Lunds Universitets Arsskrift*, N.F. Afd. 2, Bd. vii, Nr. 7. Lund.

Huxley, T. H. (1861). "Preliminary Essay upon the Systematic Arrangement of the Fishes of the Devonian Epoch." *Memoir Geol. Survey of United Kindom*, Decade 10. London.

Jaquet, M. (1898). "Recherches sur l'anatomie et l'histologie du *Silurus glanis*, L." *Arch. d. Sciences Médicales*, Tome iii. Paris.

Johnston, J. B. (1911). "The telencephalon of Ganoids and Teleosts." *Journ. Comp. Neurol.* vol. xxi, No. 6.

Kerr, J. G. (1907). "The Development of *Polypterus*." *Proc. Royal Physical Soc. Edinburgh*, vol. xvii, No. 2.

Kindred, J. E. (1919). "The Skull of *Amiurus*." *Illinois Biol. Monographs*, vol. v, No. 1.

Lehn, **Charlotte** (1918). "Beitrag zur Kenntnis des Primordialschädels von *Polypterus*." *Zeitsch. f. angewandte Anat. u. Konstitutionslehre*, Bd. ii, Hft. 4–6.

Luther, A. (1913). "Ueber die vom N. trigeminus versorgte Muskulatur der Ganoiden und Dipneusten." *Acta Soc. Sc. Fenn.* Tome xli, No 9.

Müller, J. (1846). *Ueber den Bau und die Grenzen der Ganoiden, und über das natürliche System der Fische*. Berlin.

Norris, H. W. (1908). "The Cranial Nerves of *Amphiuma means*." *Journ. Comp. Neurol.* vol. xviii.

Nowikoff, M. (1909). "Untersuchungen über die Structur des Knochens." *Zeit. Wiss. Zoologie*, Bd. xcii.

Parker, W. K. (1873). "On the Structure and Development of the Skull in Salmon (*Salmo salar*, L.)." *Phil. Trans Royal Soc. London*, vol. clxiii.

Pollard, H. B. (1891). "On the Anatomy and Phylogenetic Position of *Polypterus*." *Anat. Anz.* Bd. vi.

—— (1892). "On the Anatomy and Phylogenetic Position of *Polypterus*." *Zool. Jahrb. Abt. f. Anat. u. Ontog. d. Thiere*, Bd. v.

Retzius, G. (1881). *Biologische Untersuchungen.* IV. Das Membranöse Gehörorgan von *Polypterus bichir*. Geoffr. und *Calamoichthys calabricus*, J. A. Smith. Stockholm.

Sagemehl, M. (1884). "Beiträge zur vergleichenden Anatomie der Fische. III. Das Cranium der Characiniden nebst allgemeinen Bemerkungen über die mit einem Weber'schen Apparat versehenen Physostomen Familien." *Morph. Jahrb.* Bd. x.

—— (1891). "Beiträge zur vergleichenden Anatomie der Fische. IV. Das Cranium der Cyprinoiden." *Morph. Jahrb.* Bd. xvii.

Schäfer, E. A. (1893). *Quain's Elements of Anatomy*, vol. i, Pt. 2. 10th ed. London.

Schauinsland, H. (1906). "Die Entwickelung der Wirbelsäule nebst Rippen und Brustbein." *Handbuch d. vergl. u. experim. Entwickelungslehre d. Wirbeltiere*, von Oscar Hertwig. Bd. iii, Abth. 2.

Sewertzoff, A. N. (1899). "Die Entwickelung des Selachierschädels. Ein Beitrag zur Theorie der correlativen Entwickelung." *Festschrift C. von Kupffer*.

Sewertzoff, A. N. (1911). "Die Kiemenbogennerven der Fische." *Anat. Anz.* Bd. xxxviii.

Sonies, F. (1907). *Ueber die Entwickelung des Chondrocraniums und der knorpeligen Wirbelsäule bei den Vögeln.* Petrus Camper. Deel iv.

Stensiö, E. A. (1921). *Triassic Fishes from Spitzbergen,* Part 1. Adolf Holzhausen. Vienna.

Traquair, R. H. (1871). "On the Cranial Osteology of *Polypterus.*" *Journ. Anat. and Phys.* vol. v. London.

Waldschmidt, J. (1887). "Beitrag zur Anatomie des Centralnervensystems und des Geruchsorgans von *Polypterus bichir.*" *Anat. Anz.* Bd. ii.

Wiedersheim, R. (1904). "Ueber das Vorkommen eines Kehlkopfes bei Ganoiden und Dipnoern sowie über die Phylogenie der Lunge." *Zool. Jahrb.* Sup. Bd. vii.

—— (1906). *Grundriss der Vergleichenden Anatomie der Wirbeltiere.* Jena.

Wijhe, J. W. van (1882). "Ueber das Visceralskelet und die Nerven des Kopfes der Ganoiden und von *Ceratodus.*" *Niederl. Arch. f. Zool.* Bd. v.

Winslow, G. M. (1898). "The Chondrocranium in the Ichthyopsida." *Tufts College Studies,* No. 5.

ABBREVIATIONS IN PLATES

aa^{1-4}, afferent arteries of first to fourth branchial arches; *ab,* nervus abducens; *abfr,* foramen for nervus abducens; *ac,* aortic canal; *A.HM,* accessory hyomandibula; *ah,* afferent artery of hyal arch; Am^{1}, superficial division of musculus adductor mandibulae; Am^{2}, deeper division of musculus adductor mandibulae; Am^{3}, mandibular division of musculus adductor mandibulae; *ANA,* accessory nasal; *Ao,* musculus adductor operculi; ART^{a}, autarticular; ART^{d}, dermarticular; *AUP,* autopalatine; *ba,* bulla acustica; *BB,* basibranchial; *BEO,* basi-exoccipital; *Bm,* musculus branchiomandibularis; CB^{1-5}, ceratobranchials of first to fifth arches; *cf,* canal for nervus hyomandibularis facialis; *CH,* ceratohyal; *cj,* canal for vena jugularis; *cl,* ramus ciliaris longus; *CP,* cheek plate; *cpf,* canal for ramus palatinus facialis; *D,* dentary; *dl,* dorsal body-line of pit organs; *Do,* musculus dilatator operculi; EB^{1}, epibranchial of first branchial arch; *ECP,* ectopterygoid; *ECT,* ectethmoid; *eg,* antero-mesial ectethmoidal groove; *EH,* epihyal; *ENP,* entopterygoid; *ETH,* ethmoid; *ffr,* foramen for nervus facialis; *Ghi,* musculus geniohyoideus inferior; *Ghs,* musculus geniohyoideus superior; *glfr,* foramen for nervus glossopharyngeus; HB^{1-2}, hypobranchials of first and second branchial arches; *hf,* ramus hyoideus facialis; *HH,* hypohyal; *Hhi,* musculus hyohyoideus inferior; *Hhs,* musculus hyohyoideus superior; *HM,* hyomandibula; *il,* intermediate body-line of pit organs; *ioc,* infraorbital latero-sensory canal; ip^{1-11}, pores of infraorbital line; $i^{2}s^{2}p$, double pore at point of union of supraorbital and infraorbital canals; $i^{10}s^{7}p$, double pore at point of union of supraorbital and infraorbital canals; Iv^{1-4}, musculi interarcuales ventrales; *LA,* lachrymal; Lab^{1-5}, levator muscles of first to fifth arches; *Lap,* musculus levator arcus palatini; *ll,* lateral line of body; *M,* Meckel's cartilage; *MDP,* mesial dermopalatini; *mdt,* ramus mandibularis trigemini; *mef,* ramus mandibularis externus facialis; *mf,* ramus mandibularis facialis; *mif,* ramus mandibularis internus facialis; *MM,* mentomeckelian ossicle; *MP,* metapterygoid; *MX,* maxillary; *mxt,* ramus maxillaris trigemini; *NA,* nasal; *nll,* nervus lineae lateralis; *nt,* nasal tube; *o,* nervus opticus; *ocfr,* foramen for oculomotorius and ophthalmicus profundus; *ocm,* nervus oculomotorius; *ofr,* foramen for nervus opticus and internal carotid artery; *oi,* musculus obliquus inferior; *onfr,* foramen for orbito-nasal artery; *opf,* ramus opercularis facialis; *opp,* nervus ophthalmicus profundus; *OPS,* opisthotic; *opt,* ramus ophthalmicus trigemini; *os,* musculus obliquus superior; *OT,* Os terminale; *otfr,* foramen for ramus ophthalmicus trigemini; *PA,* parieto-dermopterotic; PB^{1}, pharyngobranchial of first branchial arch; *Pc,* musculus pharyngo-clavicularis; *pfr,* foramen for pituitary vein; *Pg,* musculus pterygoideus; *Ph,* musculus protractor hyomandibularis; *pmp,* preoperculo-mandibular pores; *PMX,* premaxillary; *pna,* posterior nasal aperture; *pq,* palatoquadrate; *PS,* parasphenoid; *PSF,* postfrontosphenotic; *PT,* posttemporal; *Q,* quadrate; *re,* musculus rectus externus; *rif,* musculus rectus inferior; *rit,* musculus rectus internus; *rs,* musculus rectus superior; *s,* spiracle; *Sh,* musculus sternohyoideus; *SP,* sphenoid; *Sp,* musculus spiracularis; sp^{1-6}, pores of supraorbital canal; *SPL,* splenial; *ST,* supratemporals; *ta,* truncus arteriosus; *tfr,* foramen for nervus trigeminus; *Tp,* musculus temporalis; *trfr,* foramen for nervus trochlearis; *Tv,* musculus transversus ventralis; *vfr,* foramen for nervus vagus.



Fig. 1a

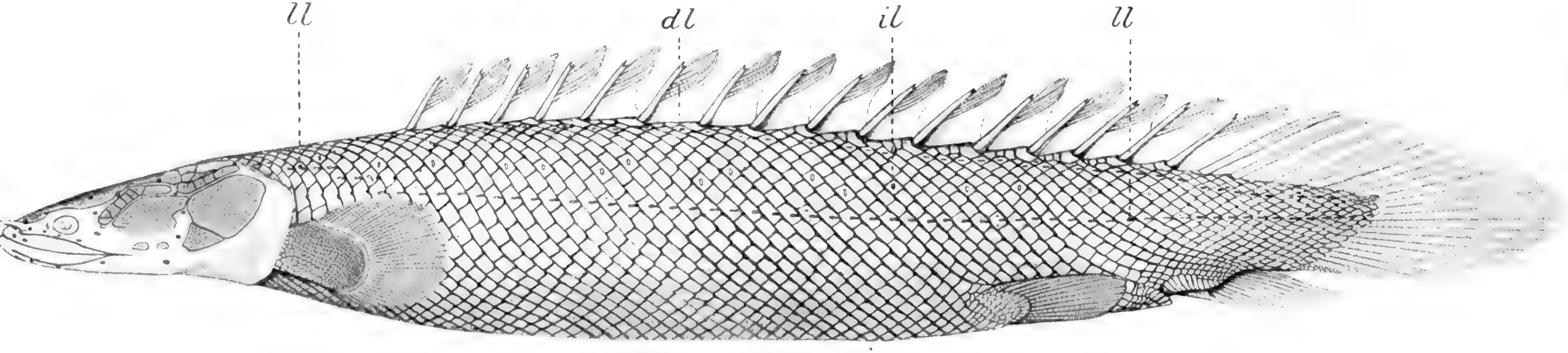

Fig. 1

Fig. 1b

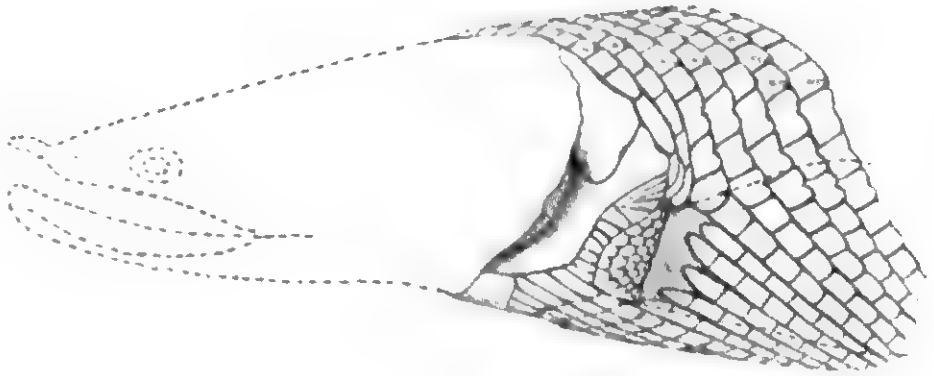

Fig. 1c

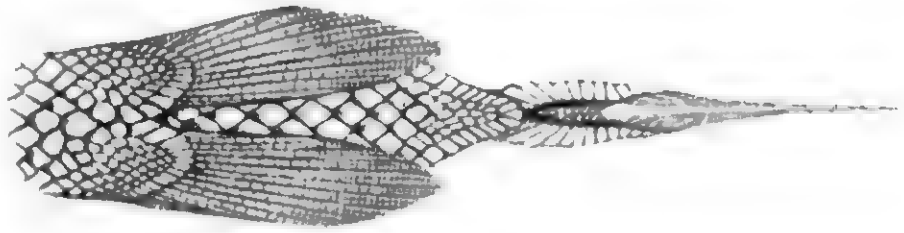

Fig. 1. Full length lateral view of 44 cm. *Polypterus bichir*. × 1.
Fig. 1*a*. Dorsal view of mid-dorsal line of same. × 1.
Fig. 1*b*. Lateral view of anterior portion of trunk of same, with pectoral fin removed. × 1.
Fig. 1*c*. Ventral view of anal fins of same. × 1.

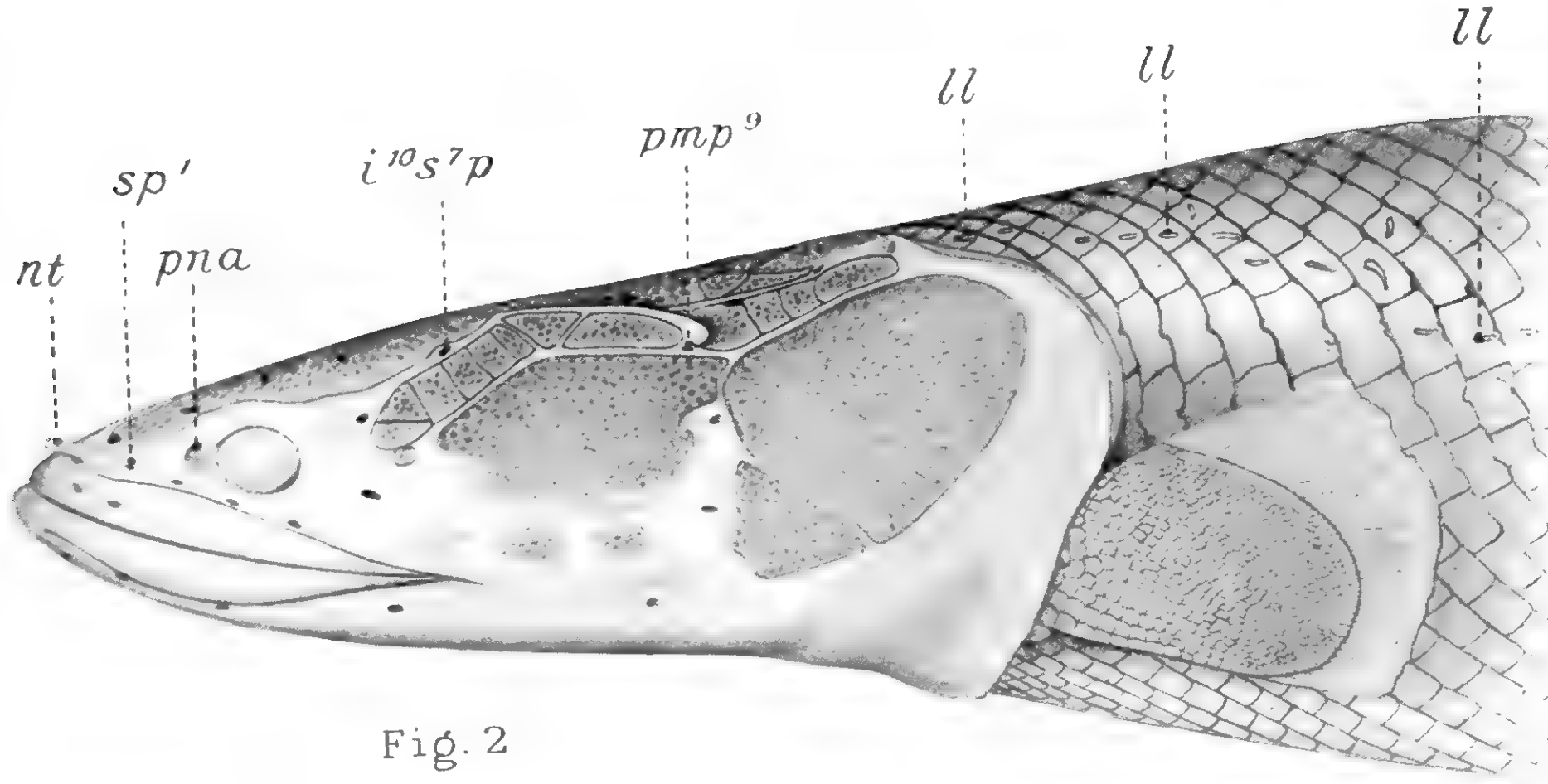

Fig. 2

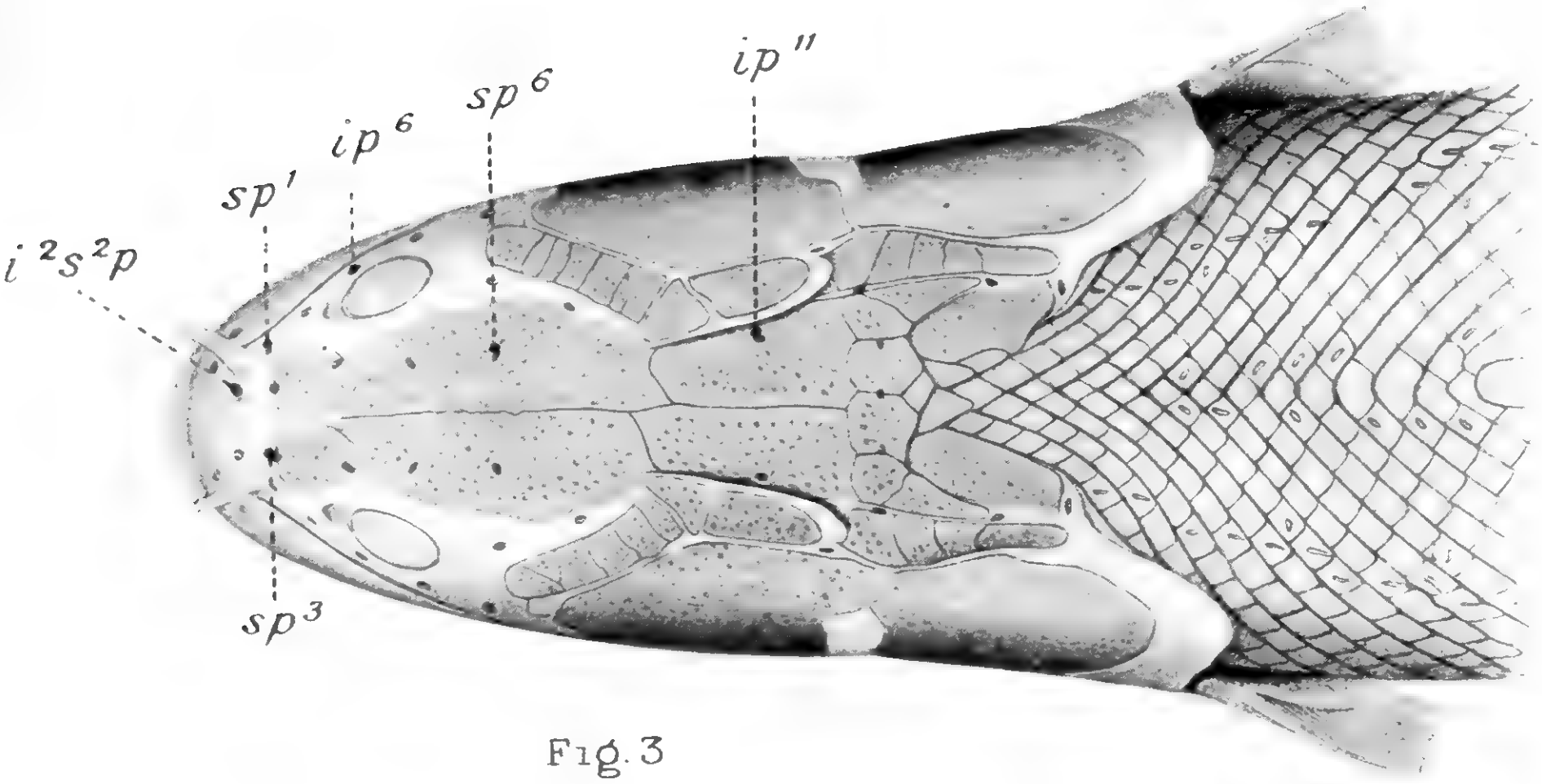

Fig. 3

Fig. 4

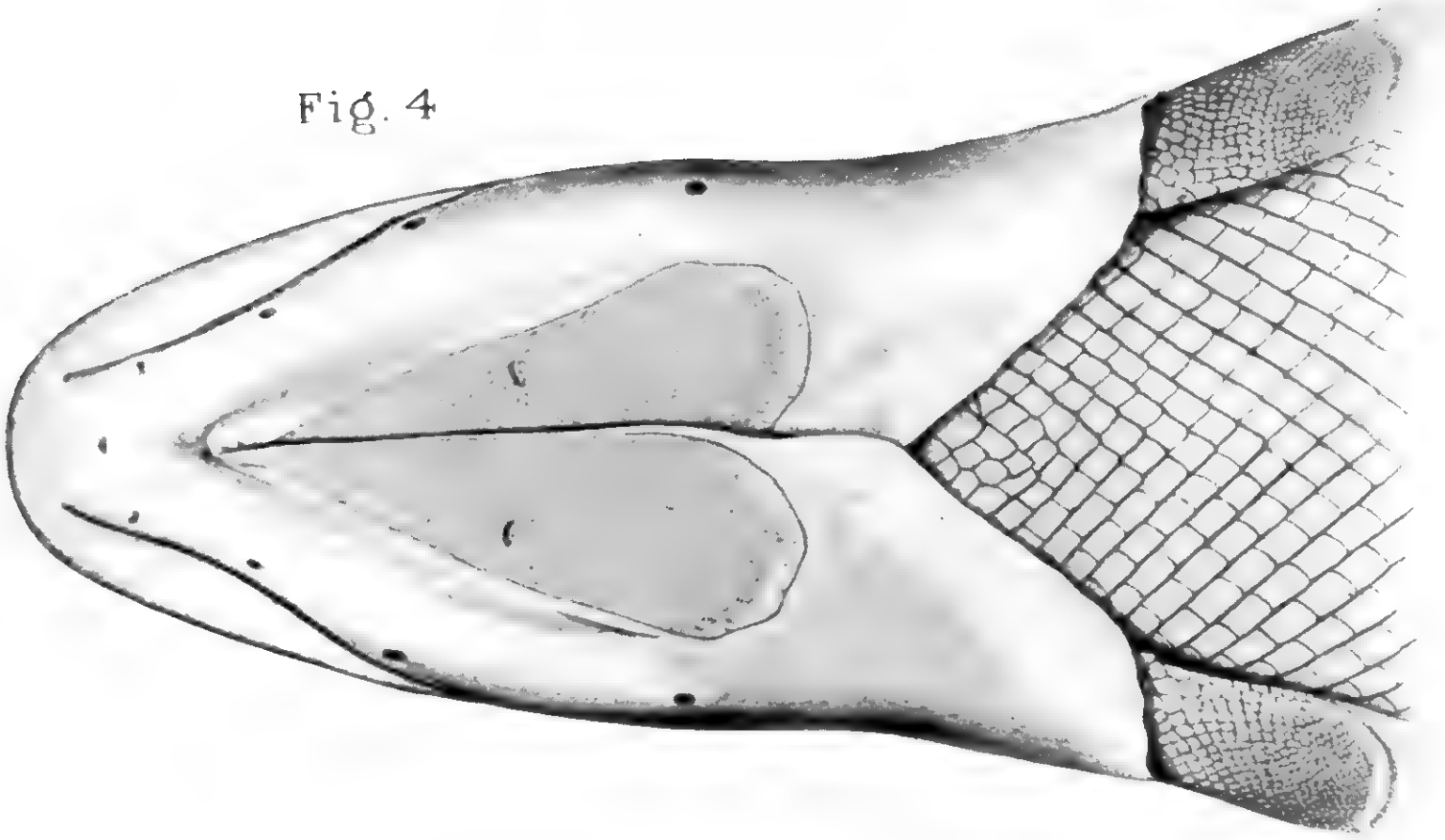

Fig. 2. Lateral view of head of 44 cm. *Polypterus bichir.* ×2.
Fig. 3. Dorsal view of head of same. ×2.
Fig. 4. Ventral view of head of same. ×2.

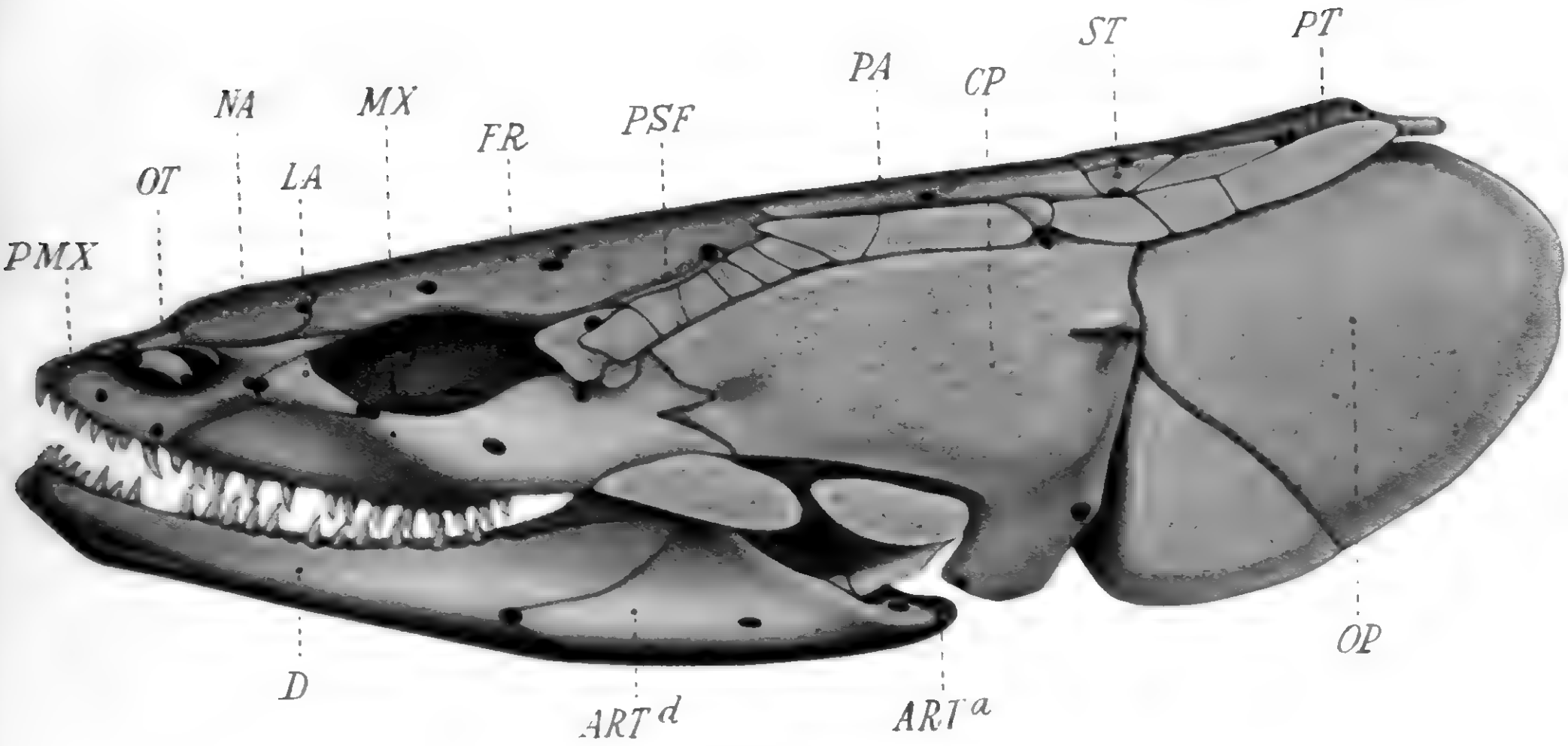

Fig. 5

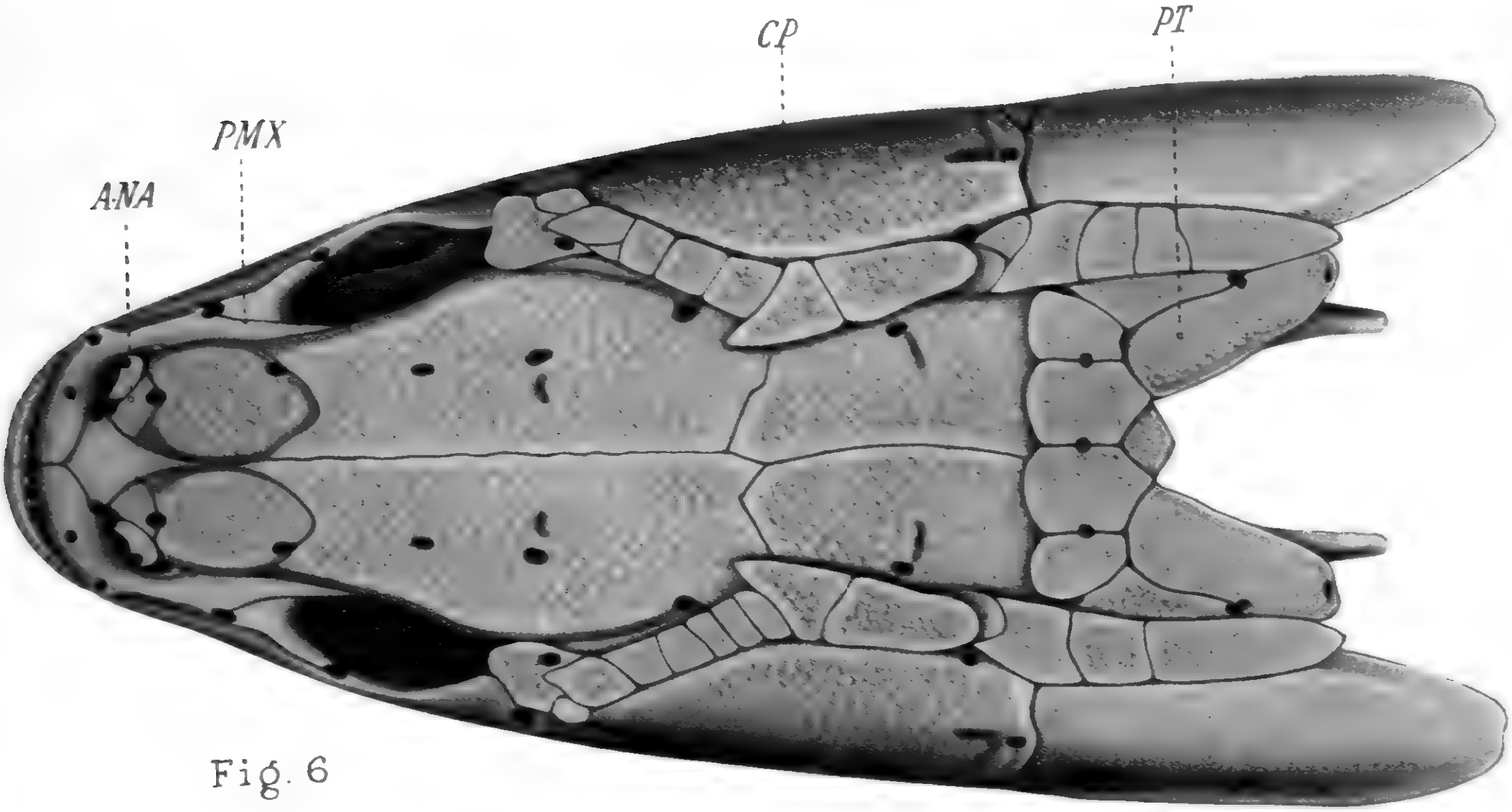

Fig. 6

Fig. 5. Lateral view of entire skull of a 49 cm. *Polypterus bichir.* ×2.
Fig. 6. Dorsal view of same. ×2.

Fig. 7

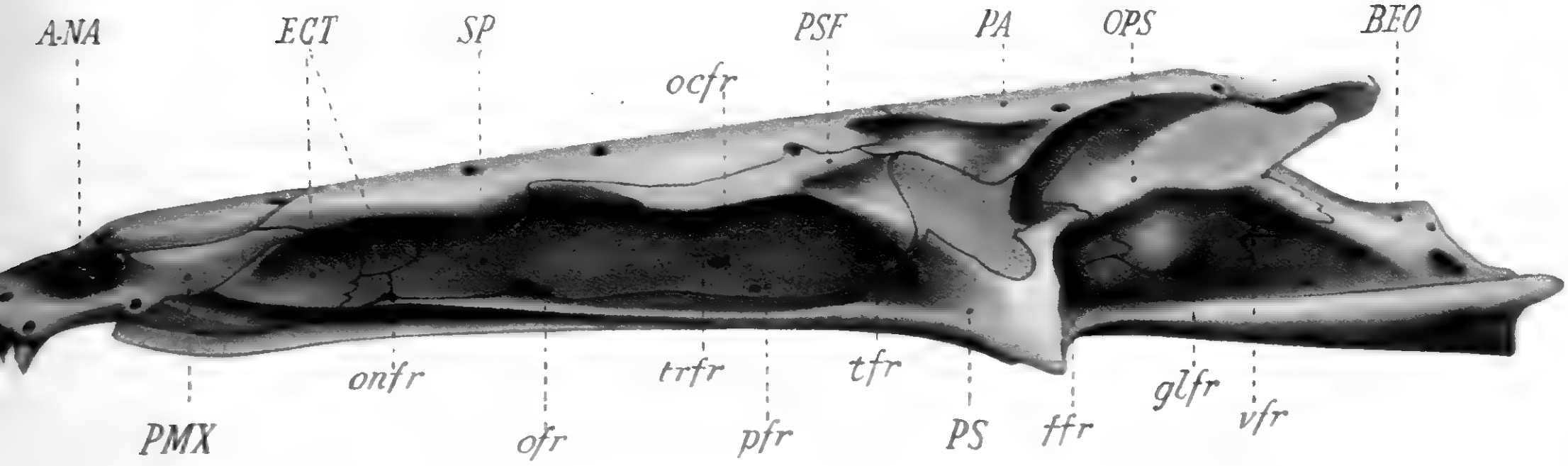

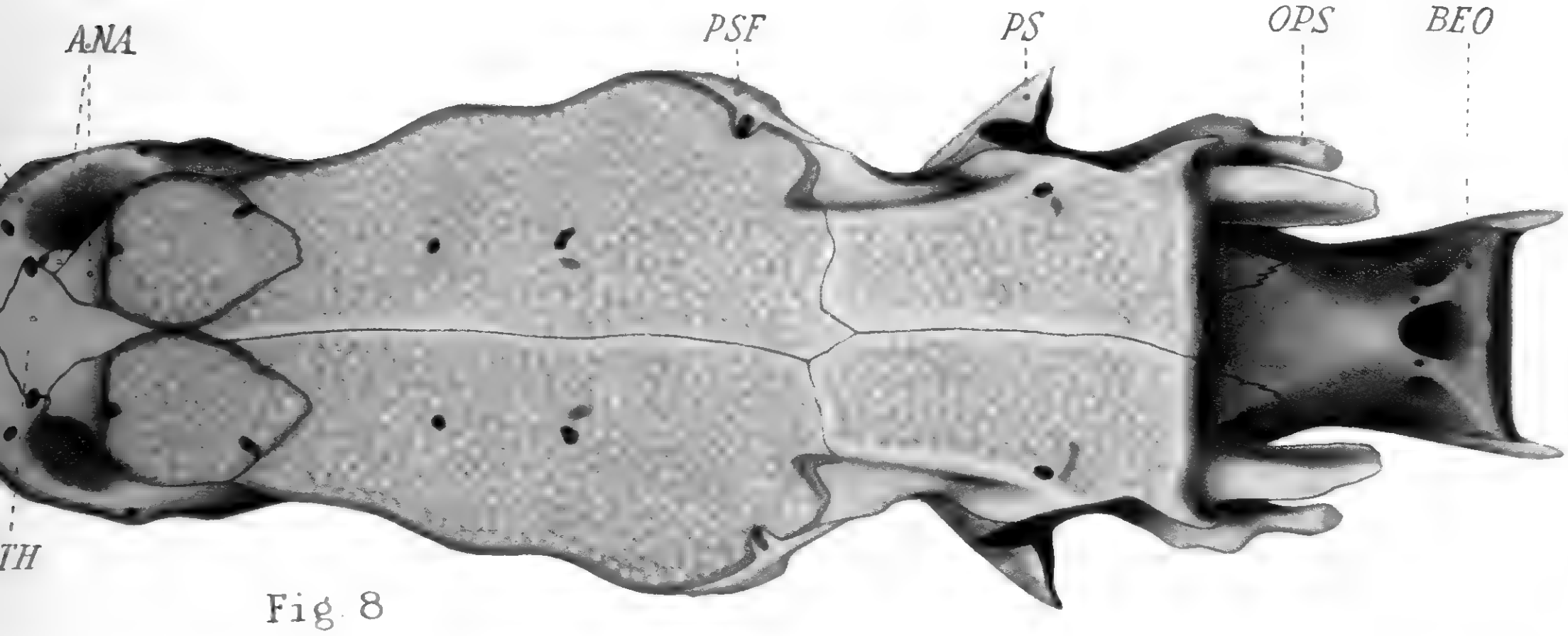

Fig. 8

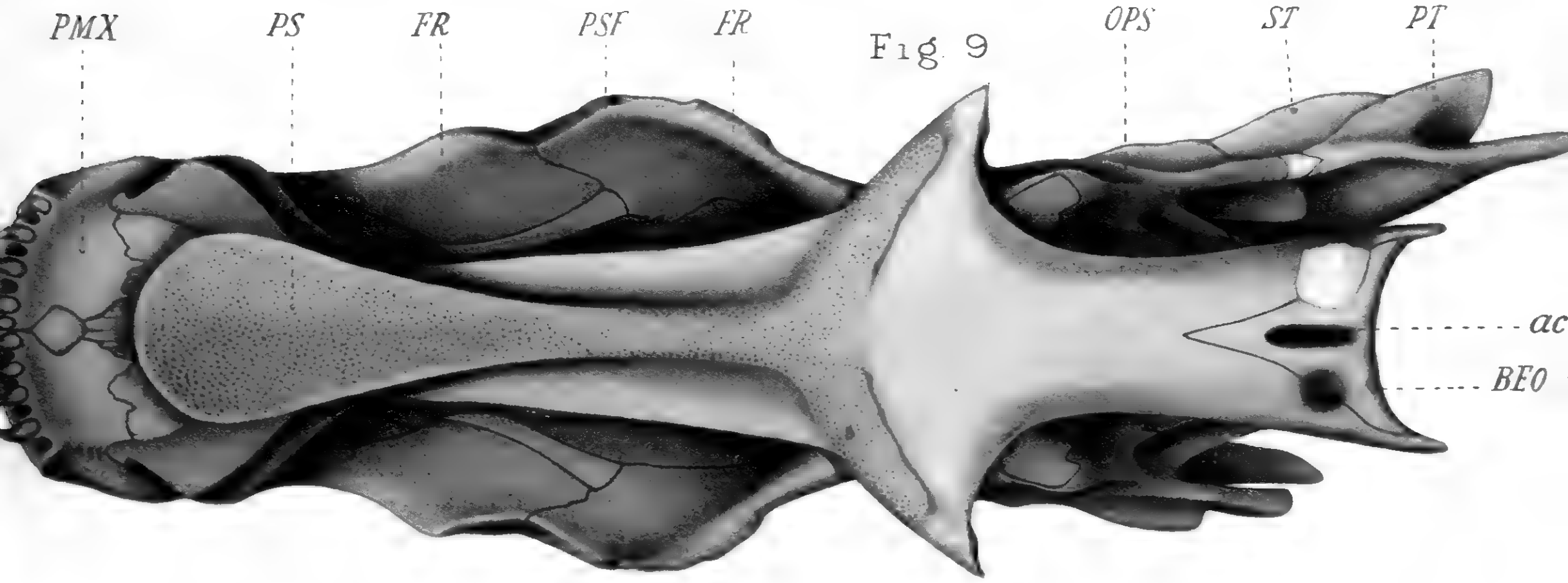

Fig. 9

Fig. 7. Lateral view of neurocranium of large specimen of *Polypterus bichir* from Abyssinia. ×2.
Fig. 8. Dorsal view of same. ×2.
Fig. 9. Ventral view of same. ×2.

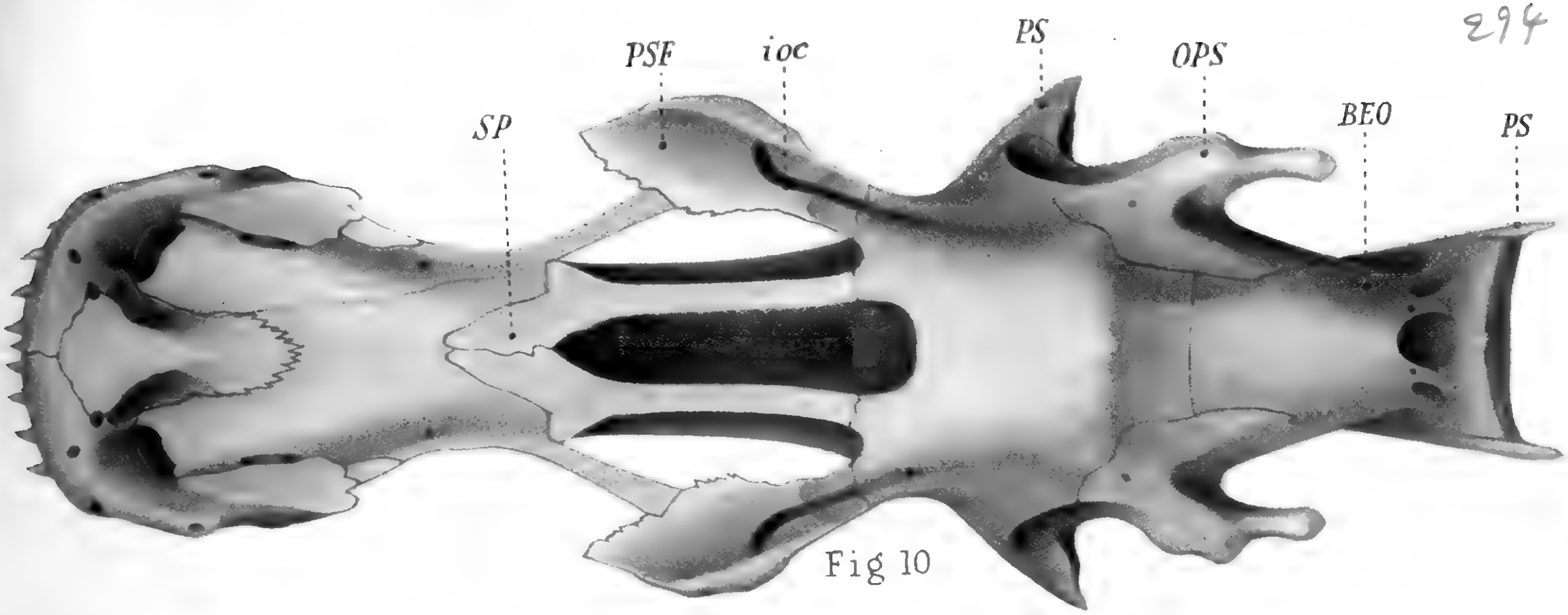
Fig 10

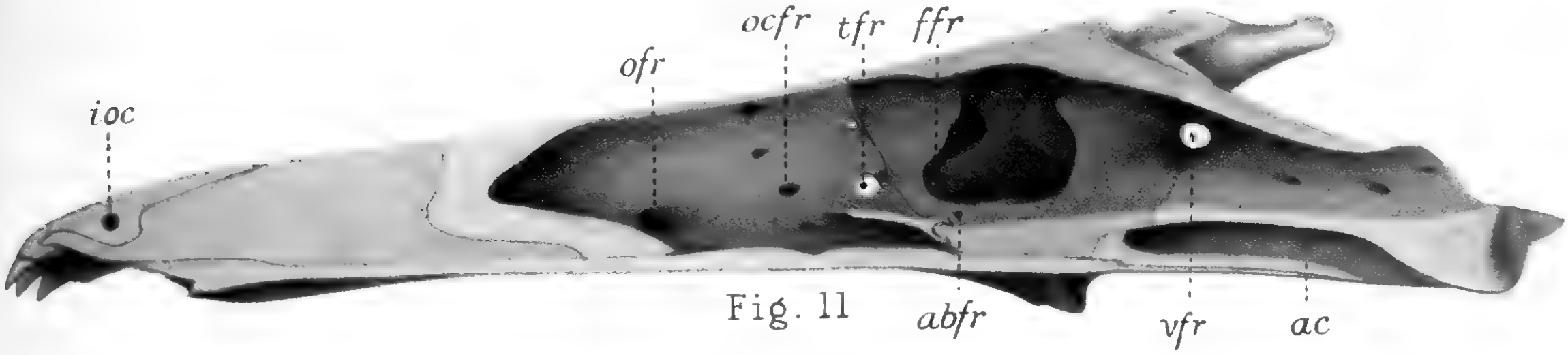
Fig. 11

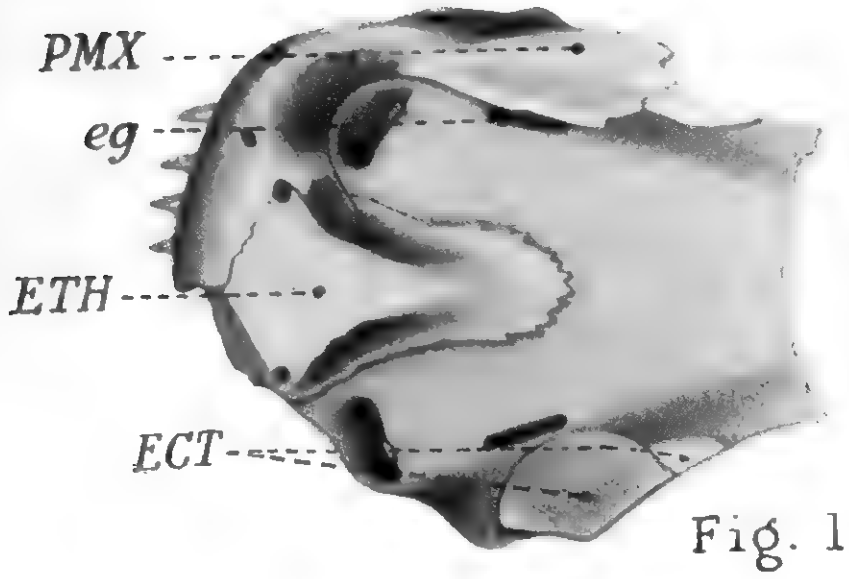
Fig. 12

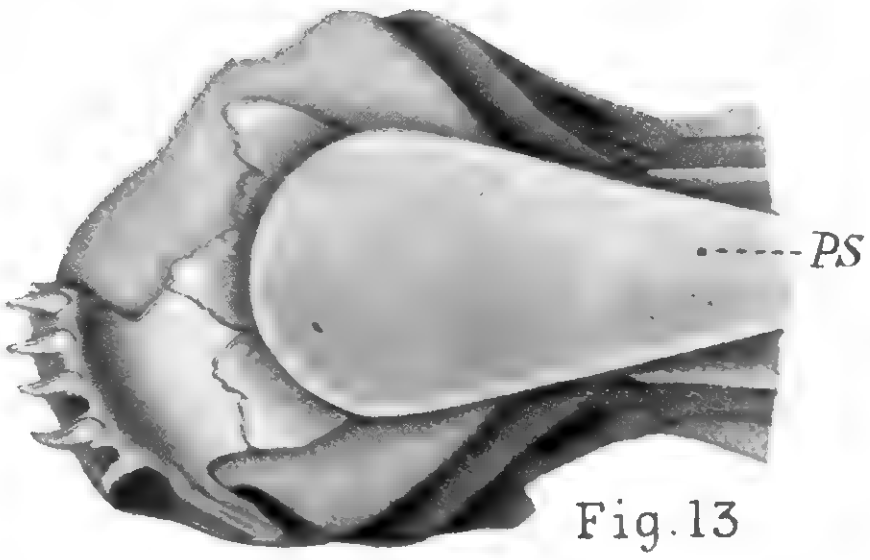
Fig. 13

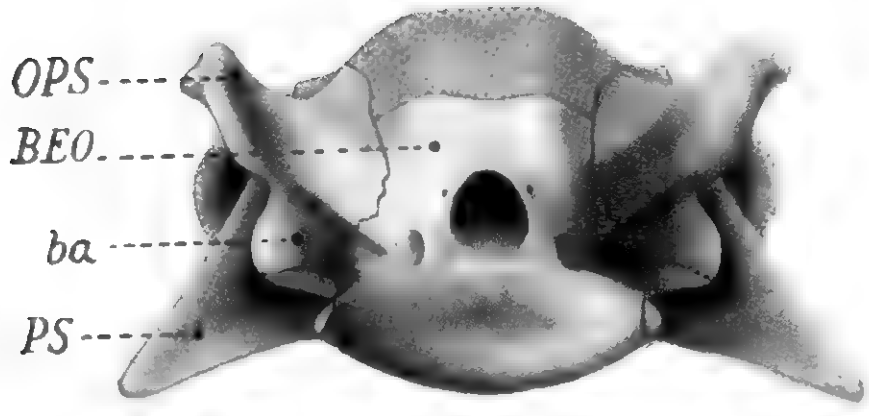
Fig. 14

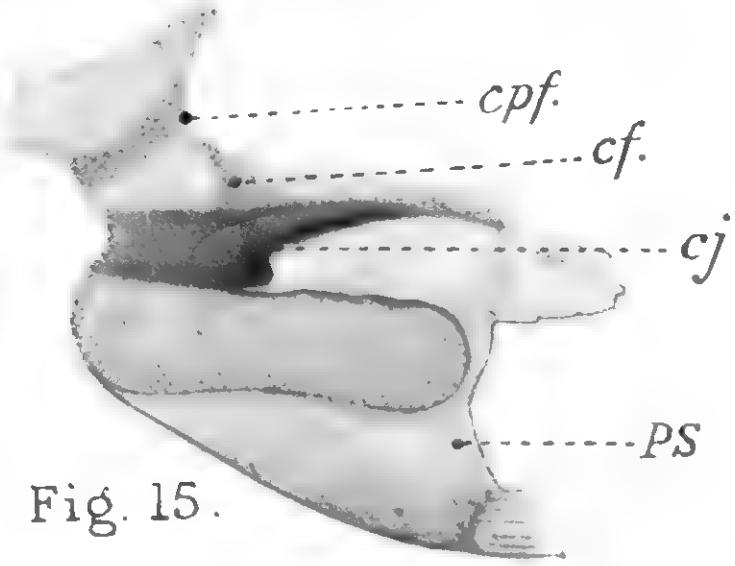
Fig. 15.

Fig. 10. Dorsal view of neurocranium of large specimen of *Polypterus bichir* from Abyssinia with dermal bones removed. × 2.

Fig. 11. Median view of bisected skull of same. × 2.

Fig. 12. Dorsal view of ethmoidal region of same, with left premaxillary removed. × 2.

Fig. 13. Ventral view of same. × 2.

Fig. 14. Posterior view of neurocranium of same. × 2.

Fig. 15. Dorsal view of section through jugular canal. × 3.

Fig. 16

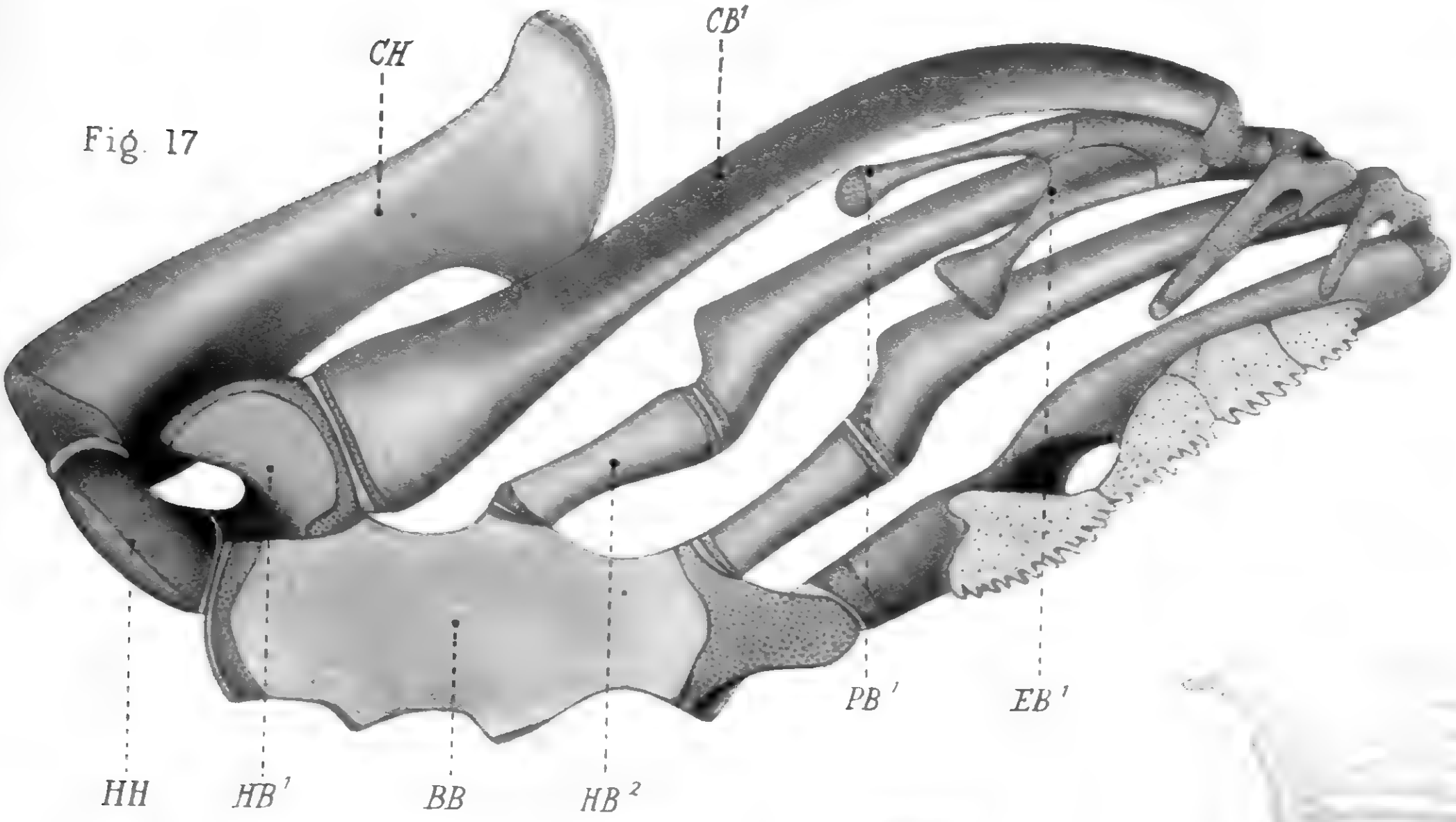

Fig. 17

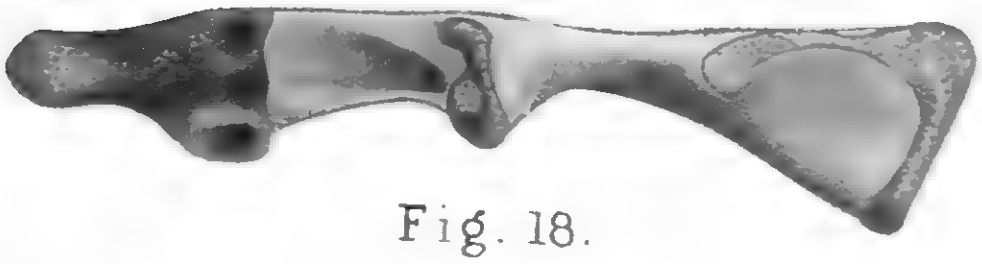

Fig. 18.



Fig. 20



Fig. 19

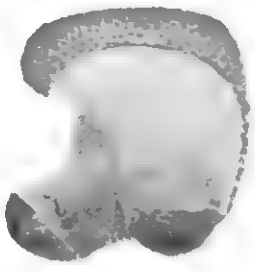

Fig. 21.

Fig. 22

Fig. 16. Ventral view of hyal and branchial arches of large specimen of *Polypterus bichir* from Abyssinia. ×2. Fig. 17. Dorsal view of same. ×2. Fig. 18. Lateral view (right side) of basibranchial of same. ×2. Fig. 19 Ventral view of same. ×2. Fig. 20. Ventral view of first hypobranchial of same. ×2. Fig. 21. Dorsal view of same. ×2. Fig. 22. Lateral view of branchial rays of second branchial arch. ×4.



Fig. 27

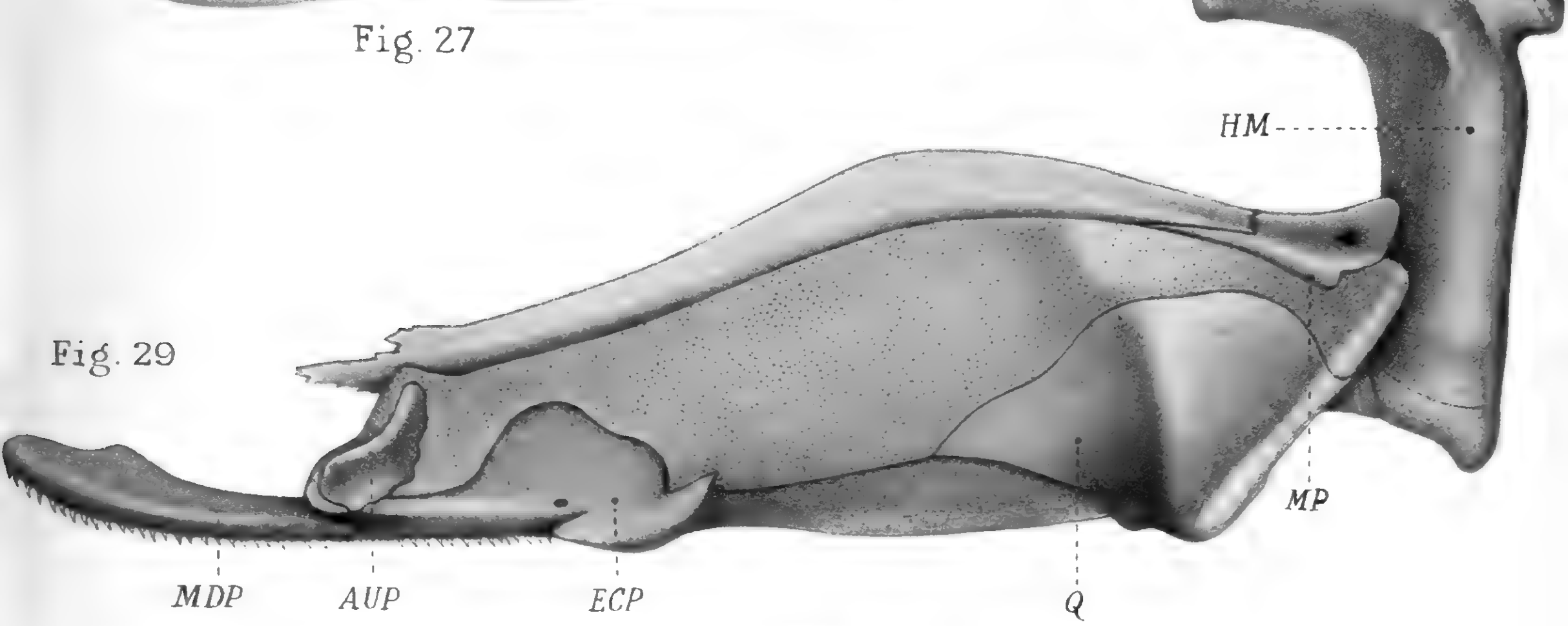

Fig. 29

Fig. 28

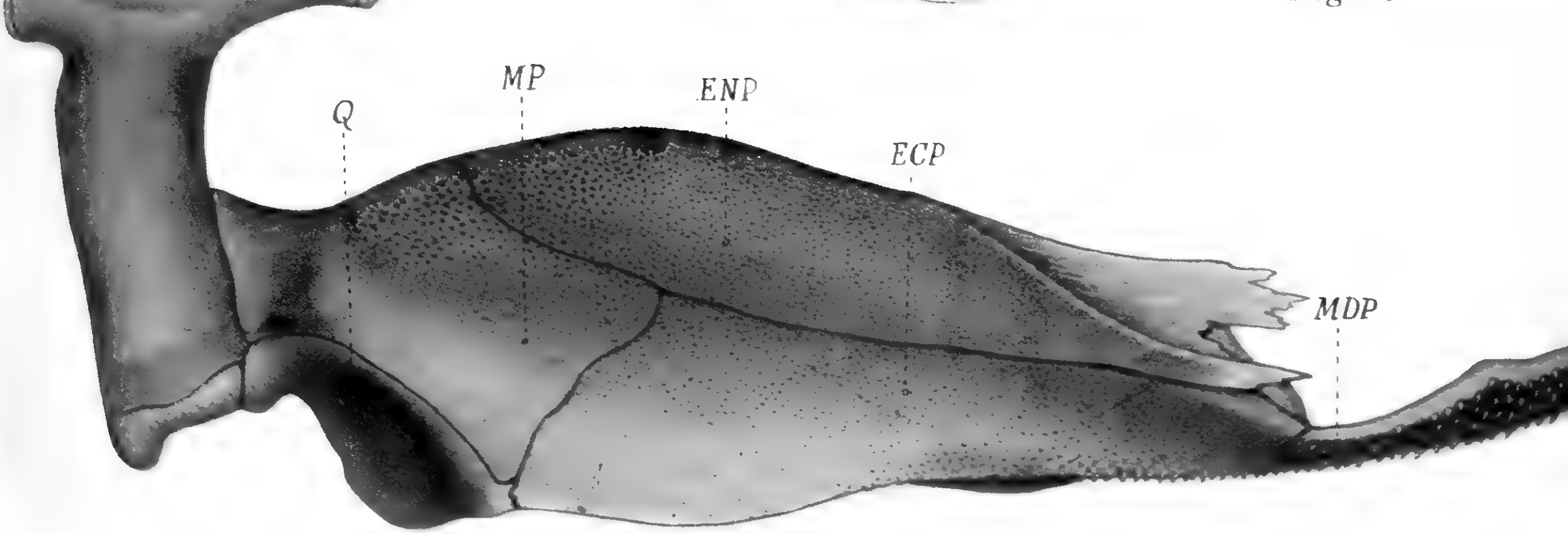

Fig. 30

Fig. 27. Ventral view of right maxillary of a 27 cm. specimen of *Polypterus Lapradei*. ×6.
Fig. 28. Lateral view of splenial of large specimen of *Polypterus bichir* from Abyssinia. ×2.
Fig. 29. Lateral view of hyomandibula and palatoquadrate of same. ×2.
Fig. 30. Median view of same. ×2.

Fig. 31

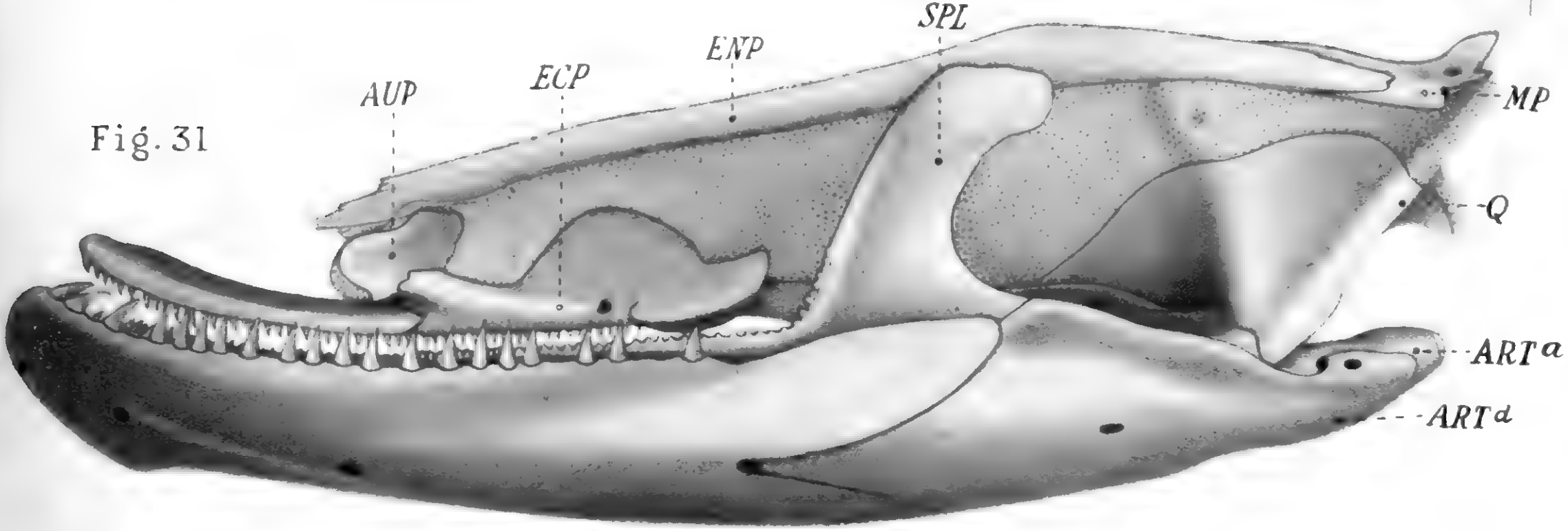

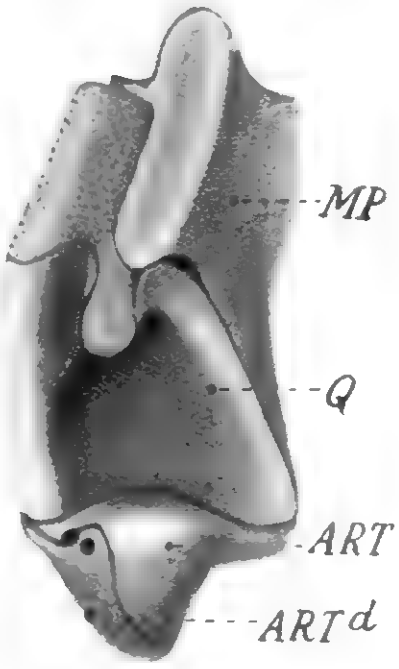

Fig. 32

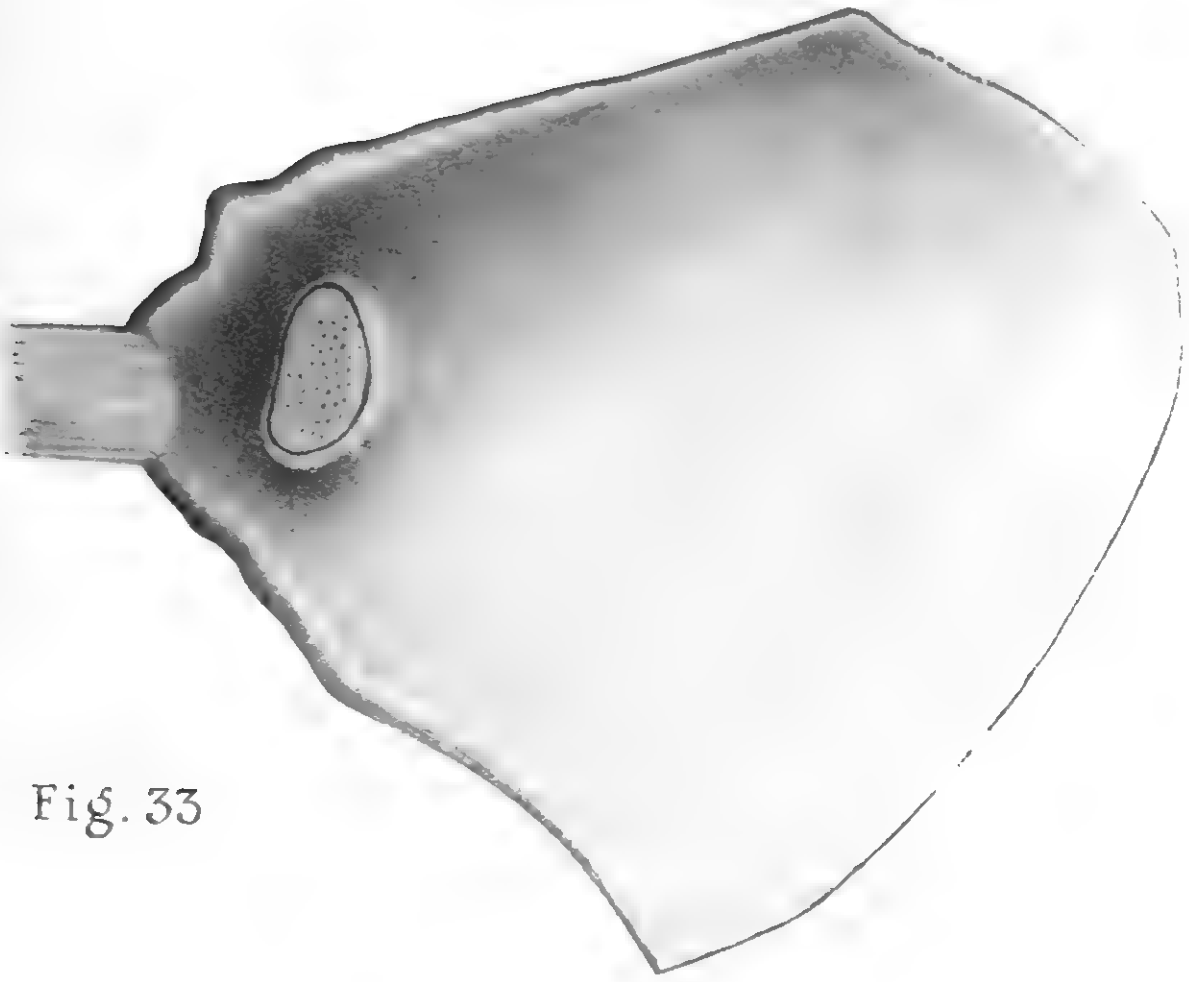

Fig. 33

Fig. 34

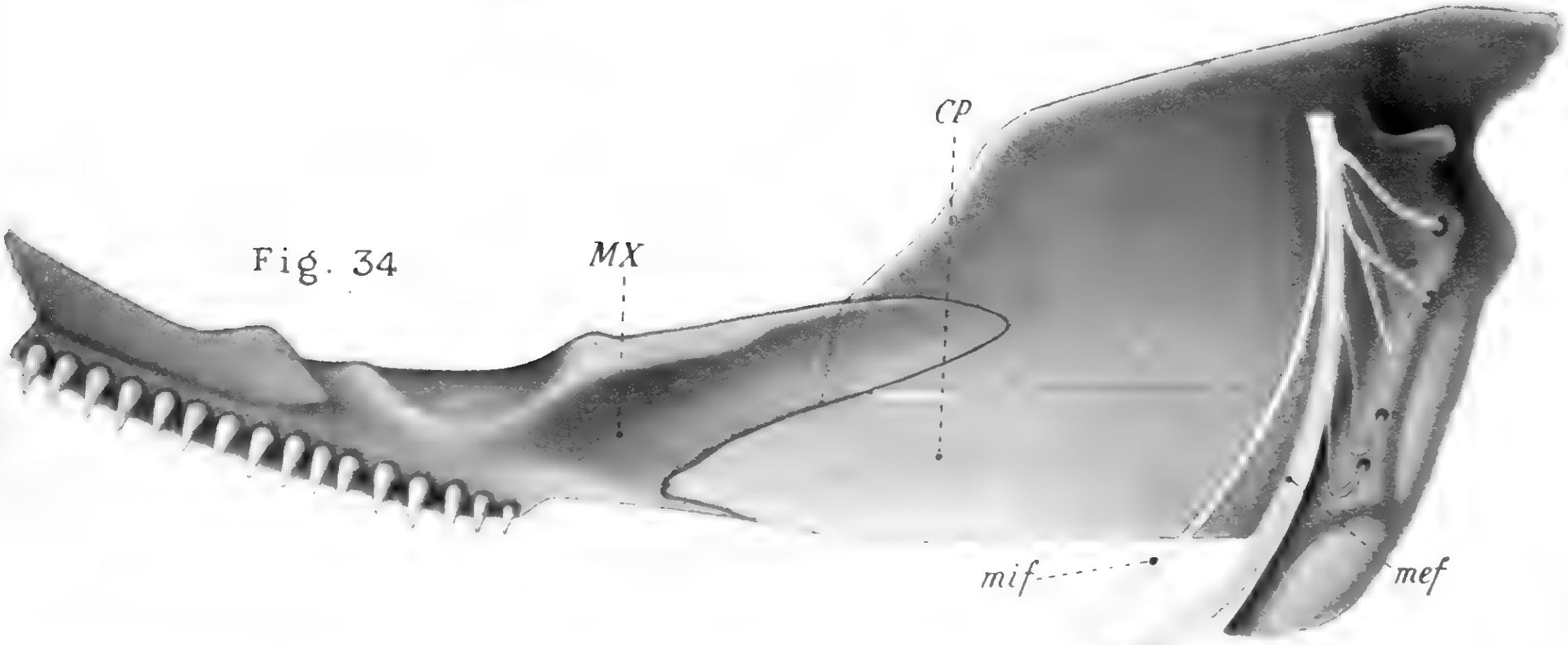

Fig. 31. Lateral view of palatoquadrate and mandible of large specimen of *Polypterus bichir* from Abyssinia. × 2.

Fig. 32. Posterior view of same. × 2.

Fig. 33. Internal view of operculum of same specimen. × 2.

Fig. 34. Internal view of cheek-plate and maxillary of same specimen. × 2.

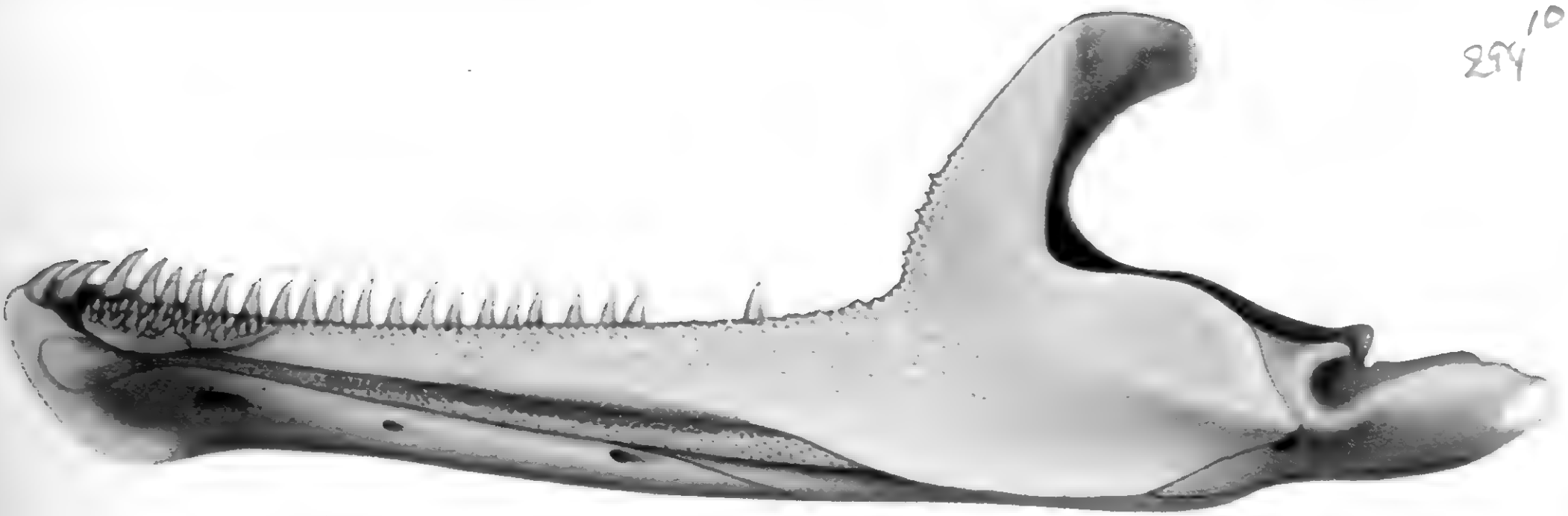

Fig. 35

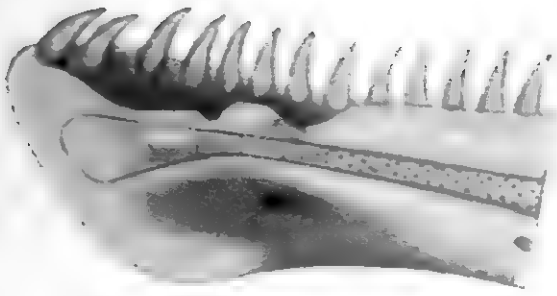

Fig. 35a



Fig. 39



Fig. 38

Fig. 36

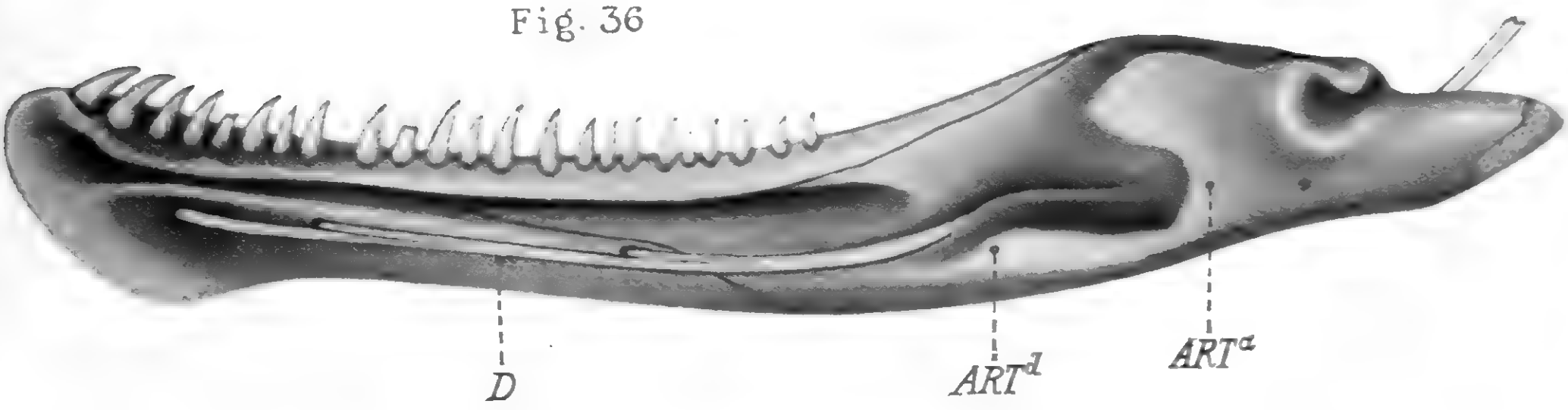



Fig. 37

Fig. 35. Internal view of left mandible of large specimen of *Polypterus bichir* from Abyssinia. ×2.

Fig. 35*a*. Anterior end of the same with dermal ossicles removed. ×2.

Fig. 36. The same with splenial removed. ×2.

Fig. 37. Dorsal view of the same. ×2.

Fig. 38. Dorso-mesial view of the autarticular. ×2.

Fig. 39. Lateral view of the same. ×2.

294''

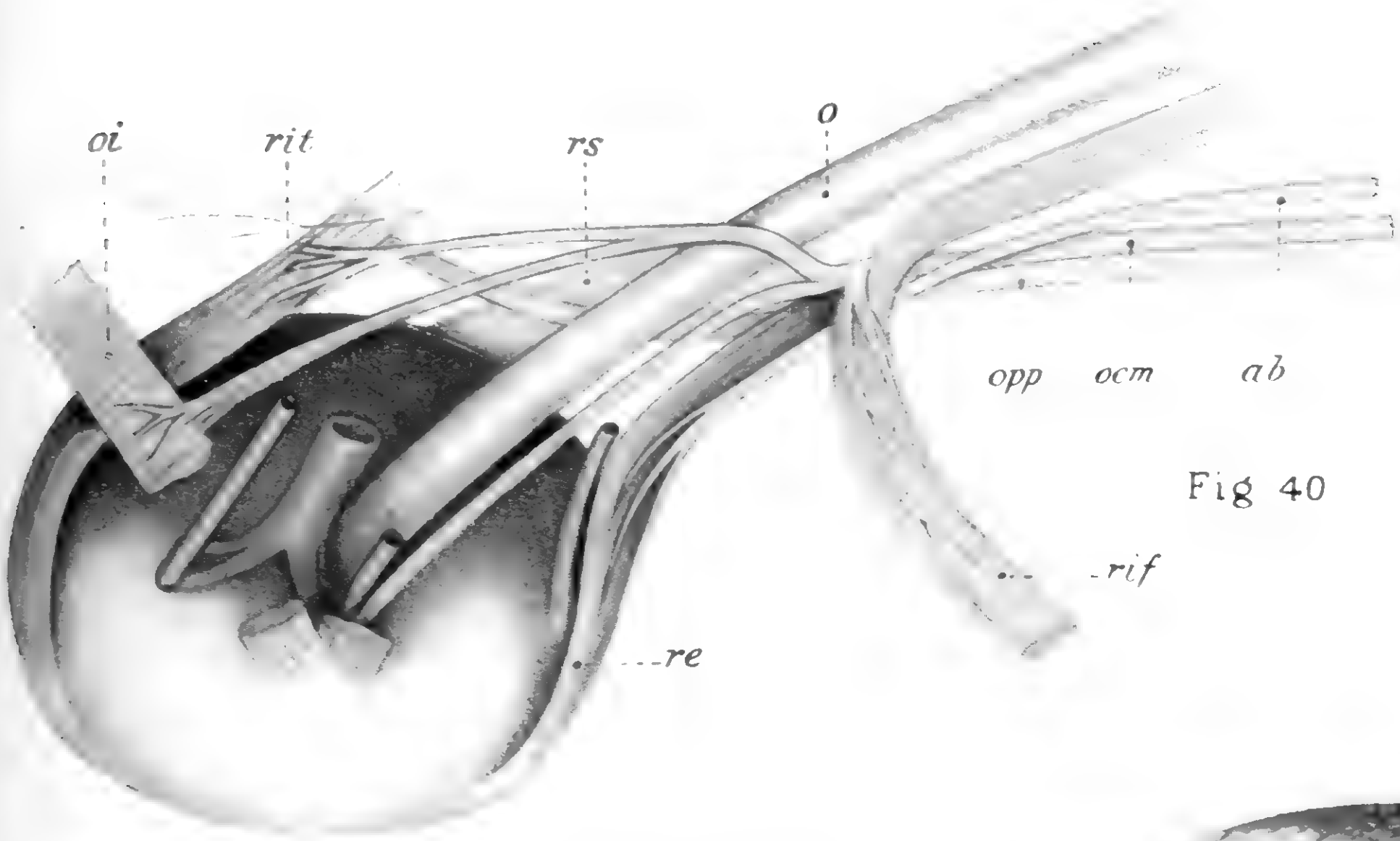

Fig 40

Fig. 42

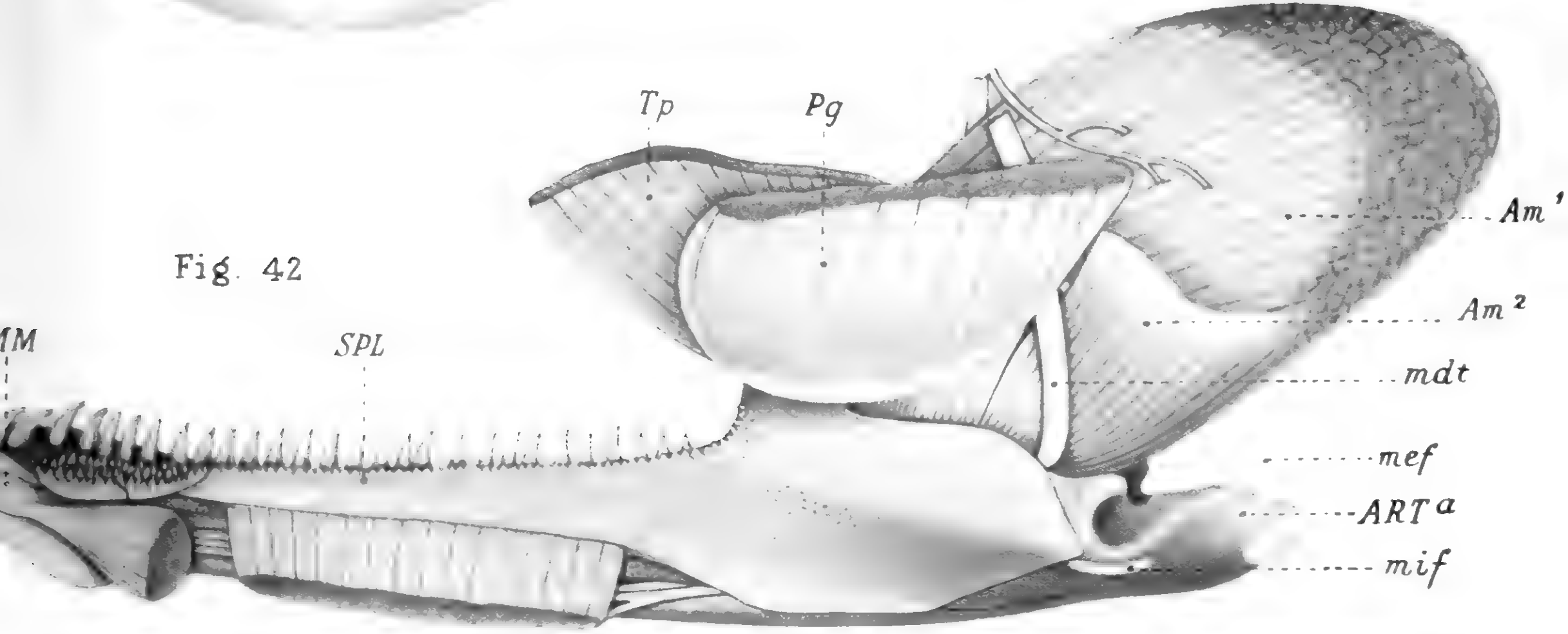

Fig. 43

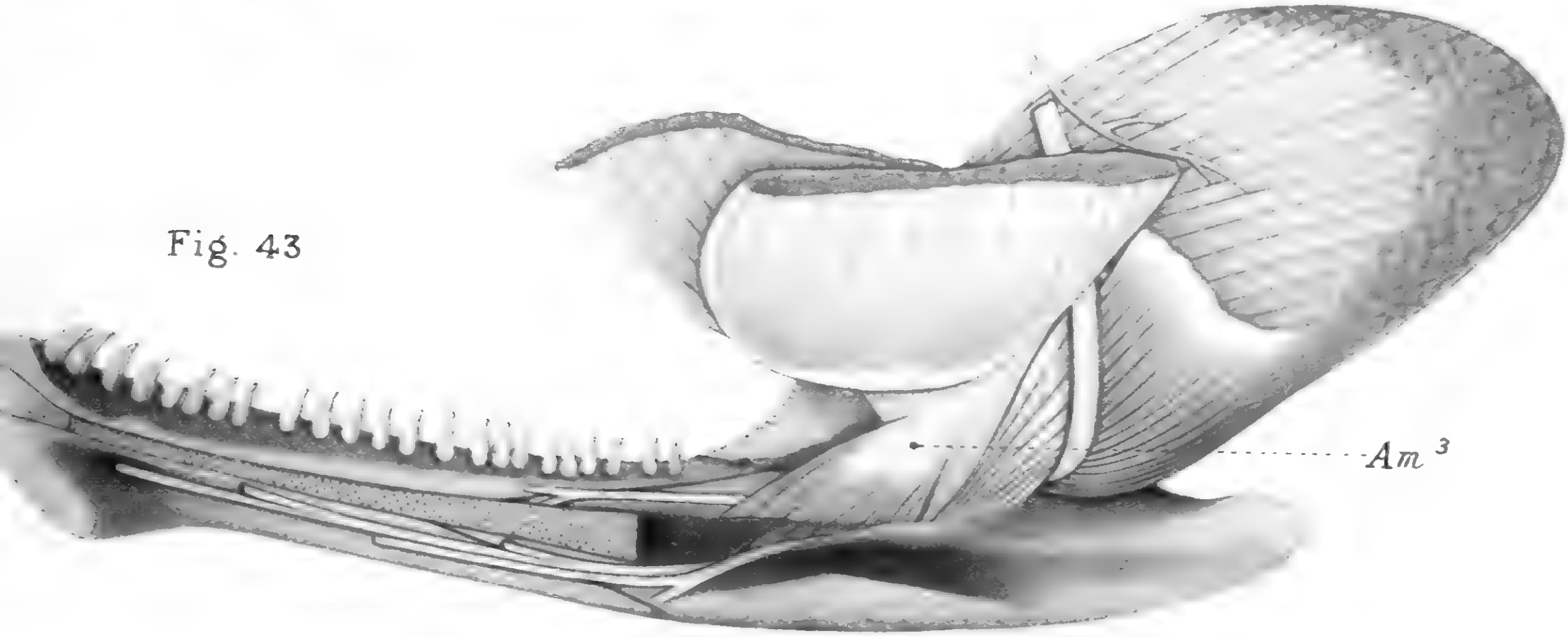

Fig. 40. Ventral view of right eyeball of large specimen of *Polypterus bichir* from Abyssinia. ×6.
Fig. 42. Internal view of mandible with muscles attached. ×2.
Fig. 43. The same, with splenial removed. ×2.

Fig. 41

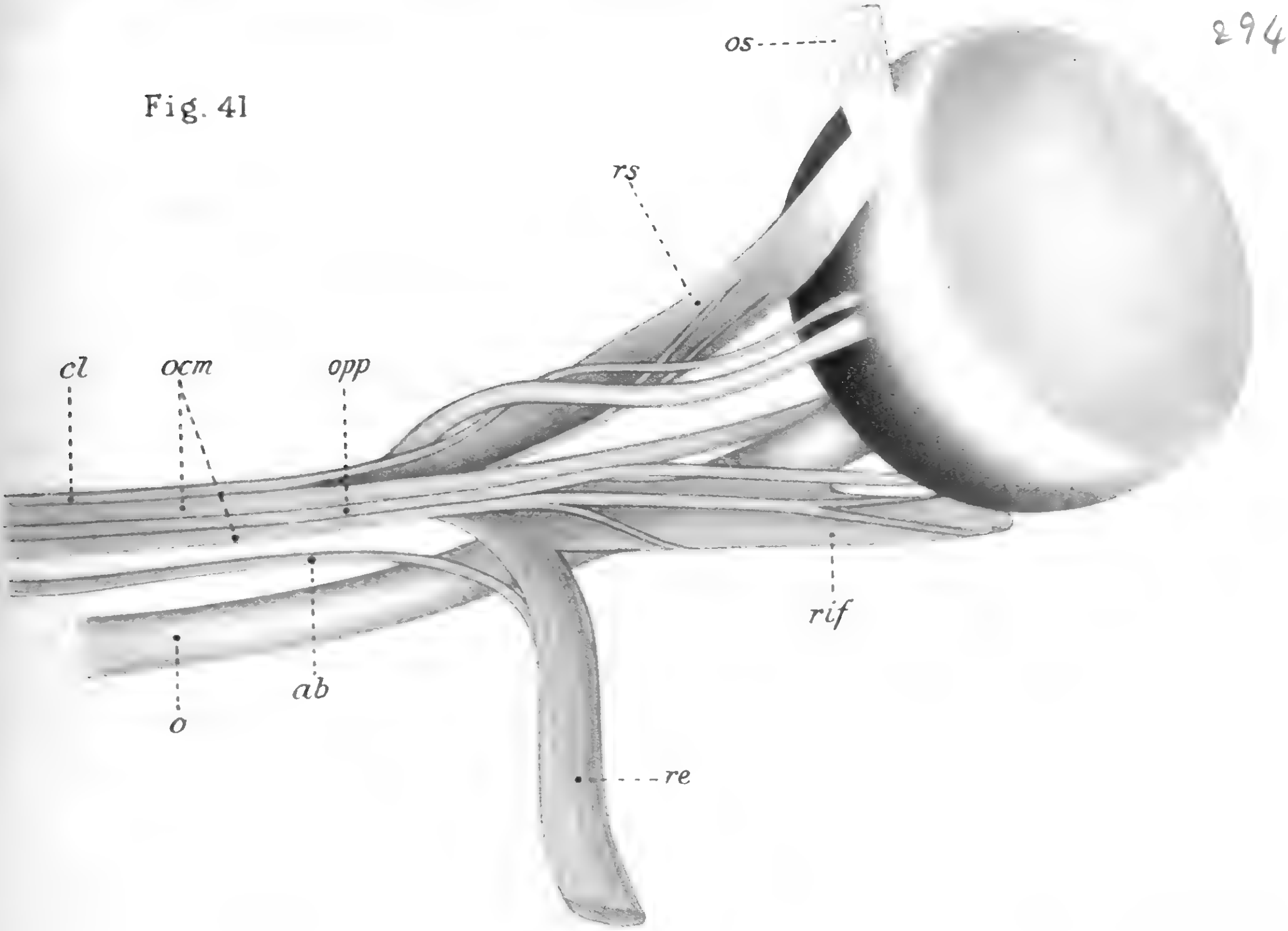

Fig. 44a

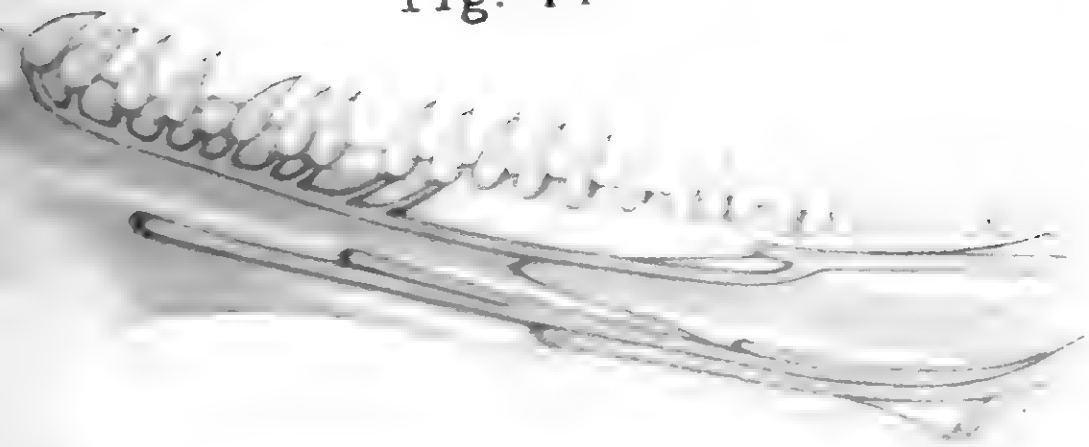

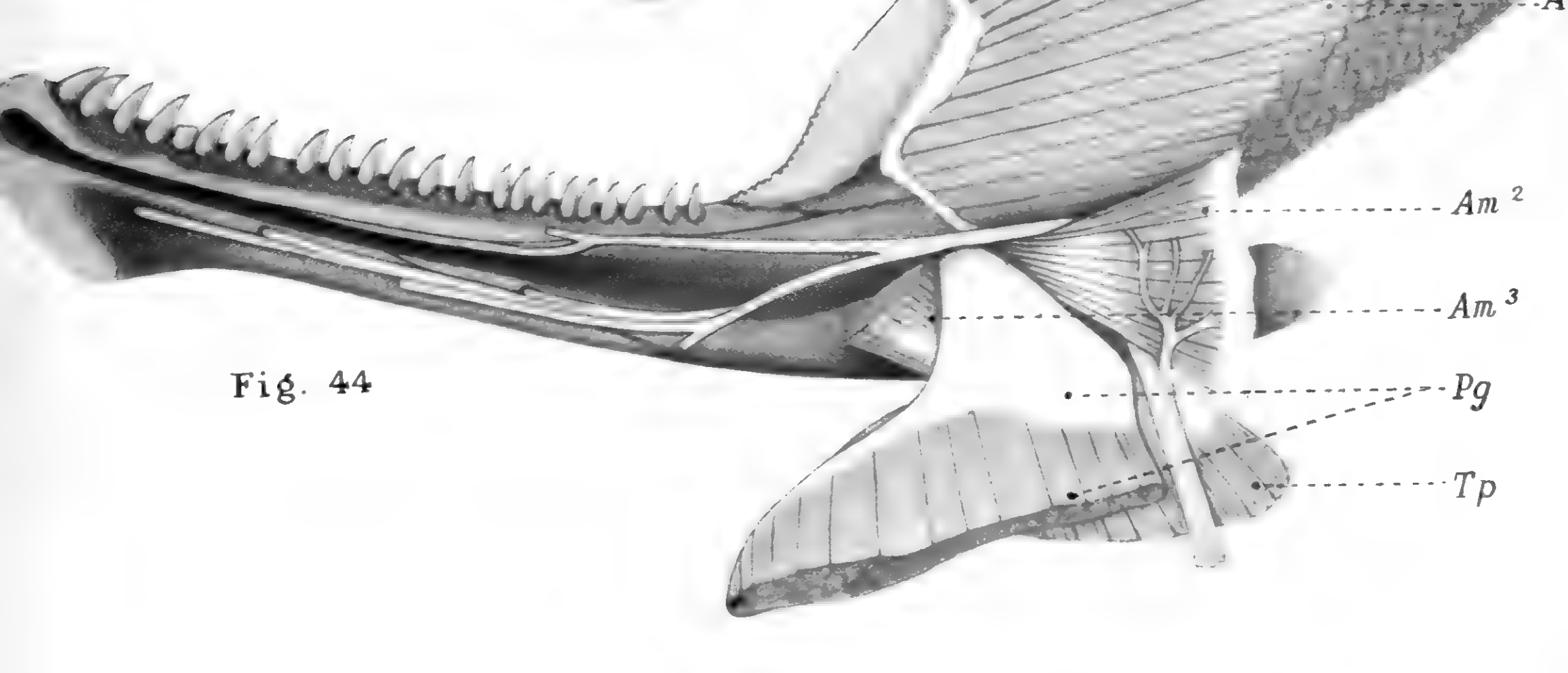

Fig. 44

Fig. 41. Lateral view of right eyeball of large specimen of *Polypterus bichir* from Abyssinia. ×6.
Fig. 44. Internal view of mandible with musculi temporalis and pterygoideus turned downward. ×2.
Fig. 44*a*. Anterior end of the same, showing innervation of the teeth. ×2.

294 13

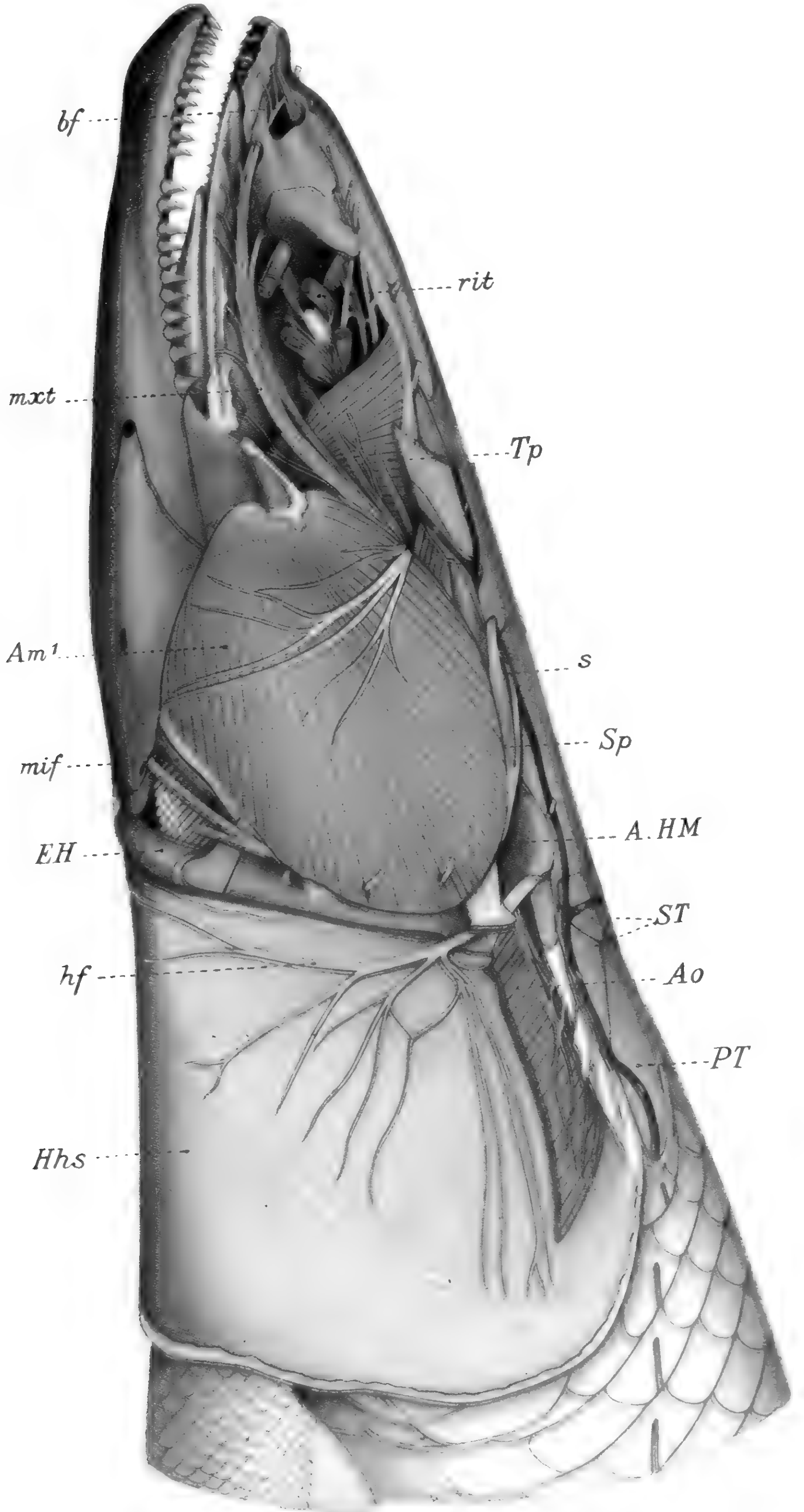

Fig. 45. Lateral view of head of large *Polypterus bichir* from Abyssinia, with skin and eyeball removed. ×2.

256 14

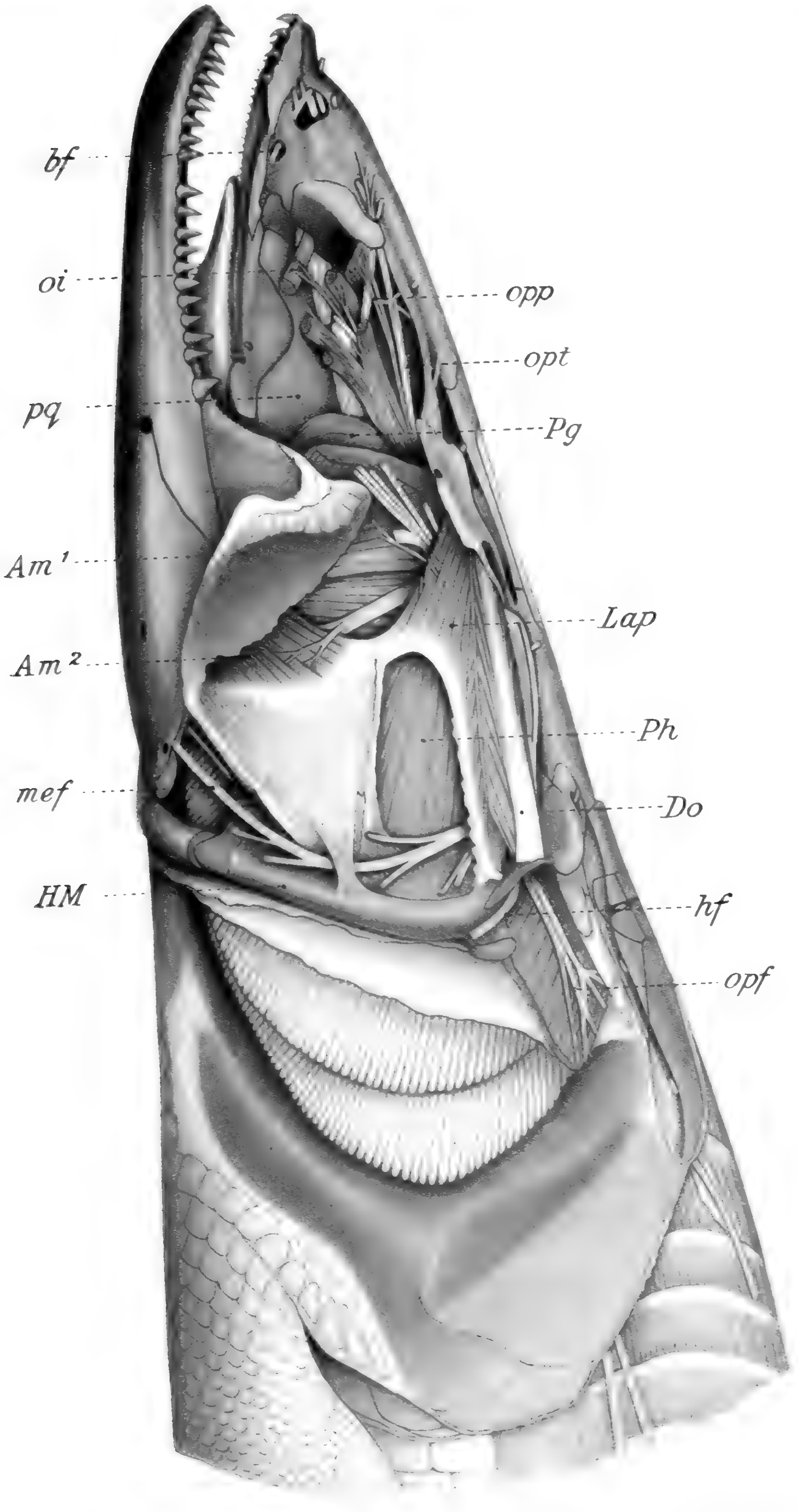

Fig. 46. Lateral view of head of large *Polypterus bichir* from Abyssinia, with musculus masseter removed. × 2.

294 (5'

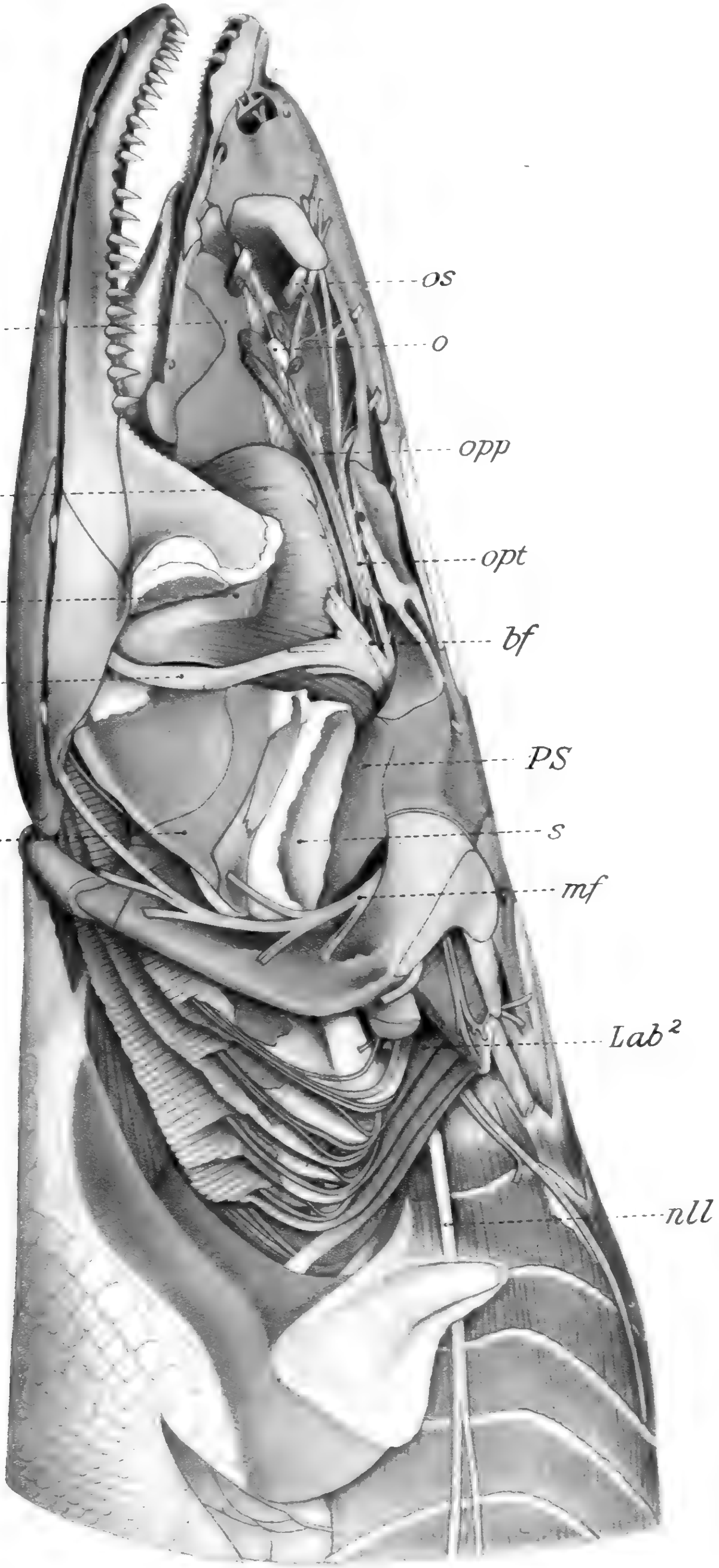

Fig. 47. A deeper dissection of head of large *Polypterus bichir* from Abyssinia. × 2.

294¹⁵

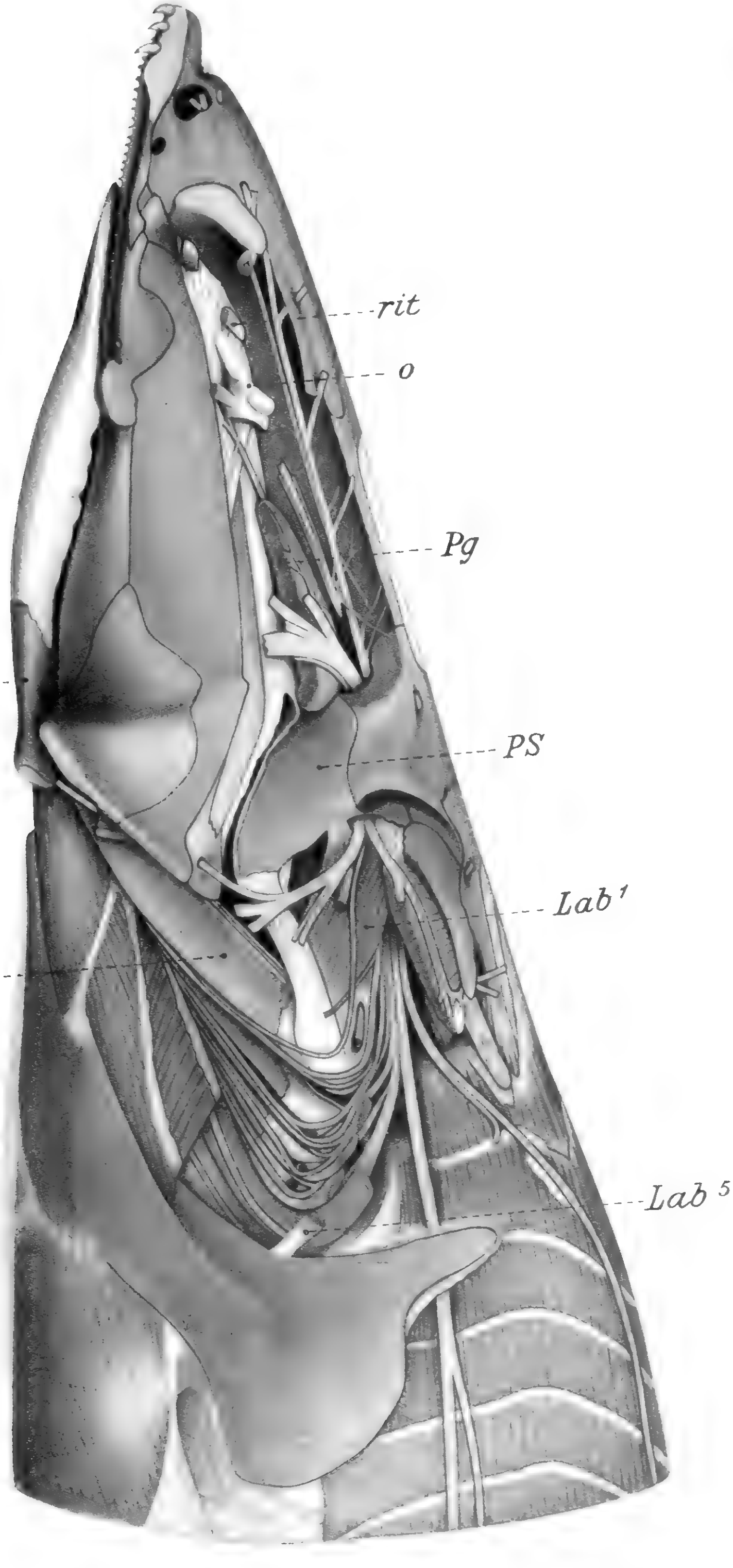

Fig. 48. A still deeper dissection of head of large *Polypterus bichir* from Abyssinia. × 2.

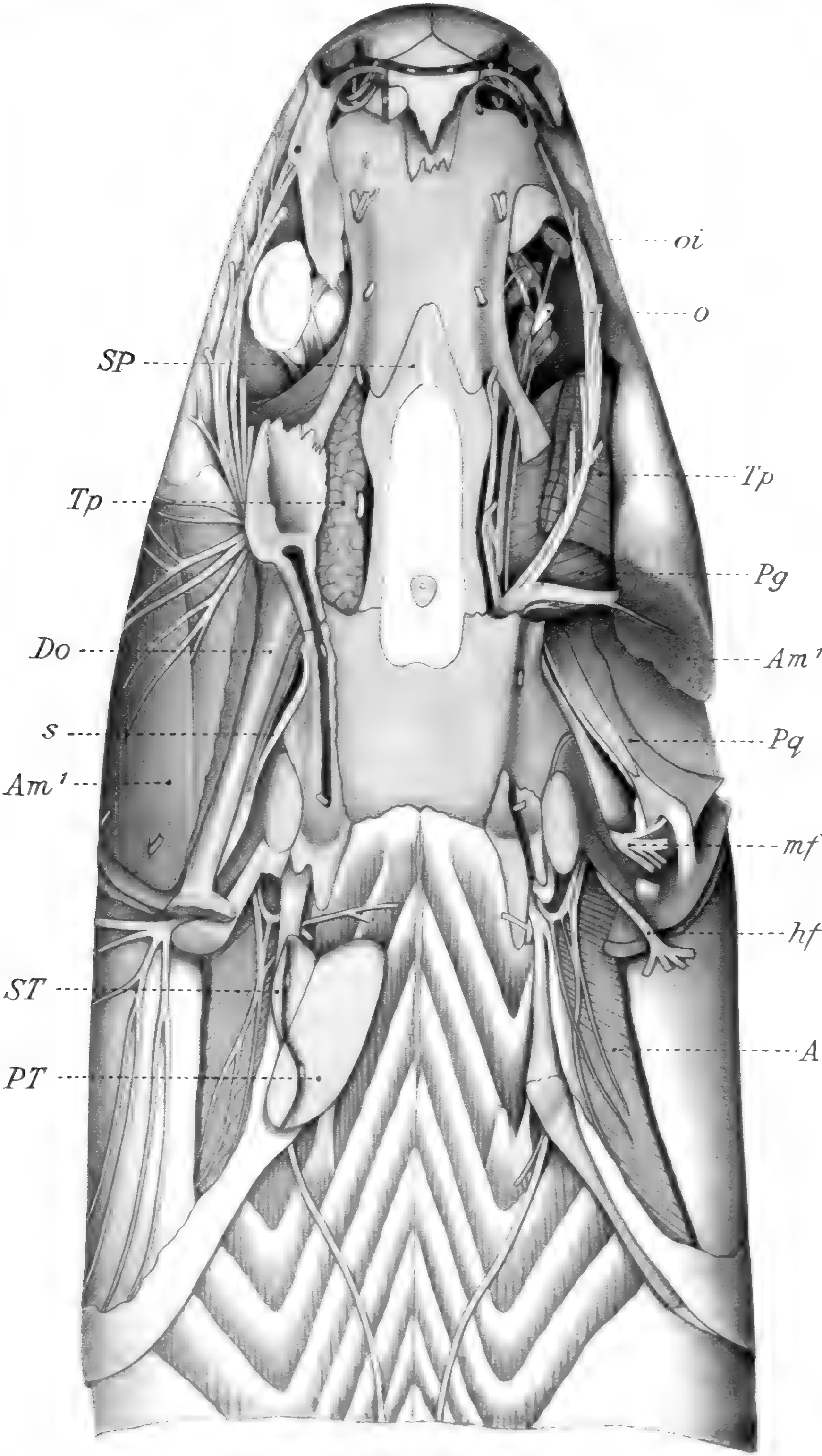

Fig. 49. Dorsal view of head of large *Polypterus bichir* from Abyssinia, with skin and dermal bones removed. × 2.

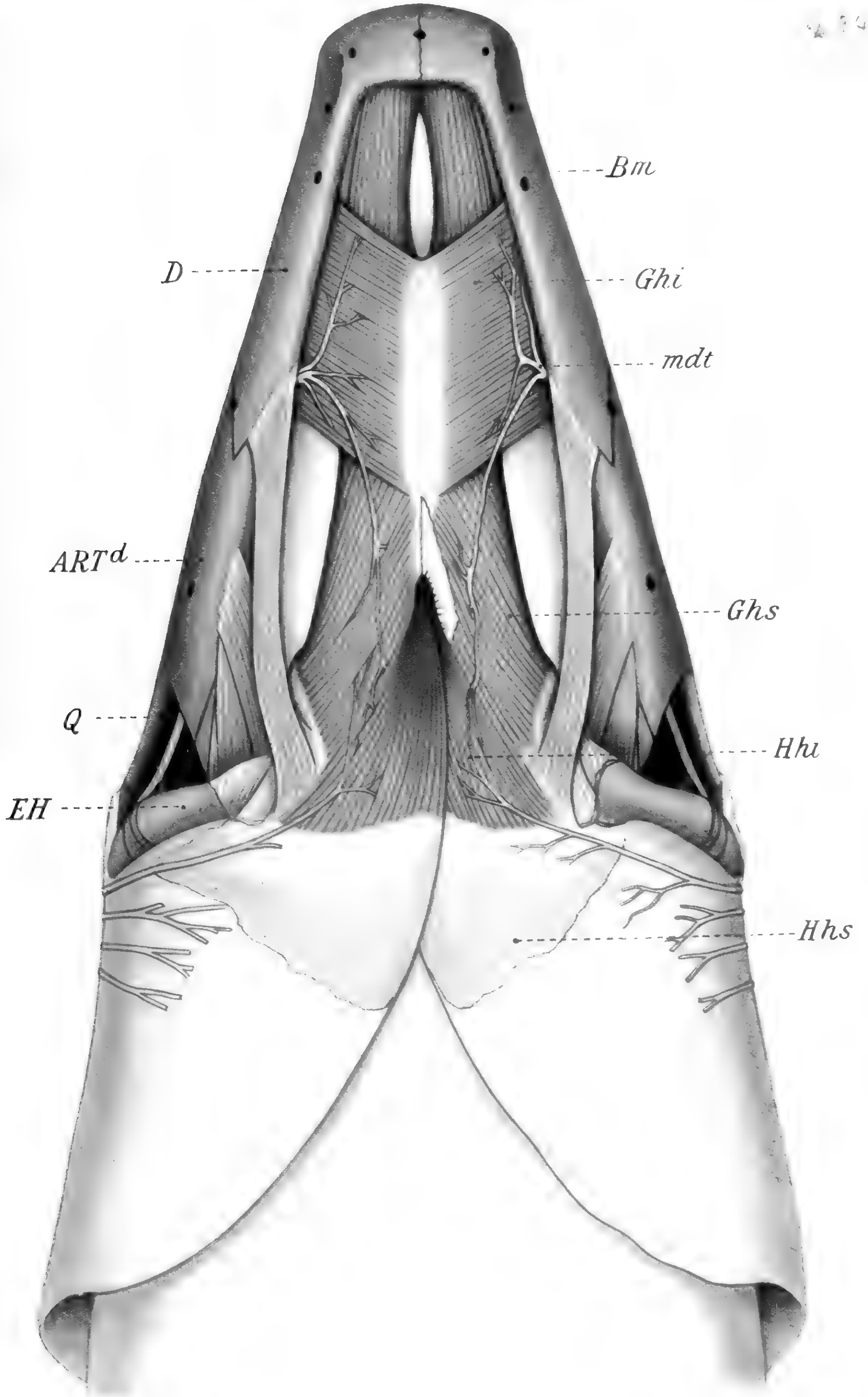

Fig. 50. Ventral view of a second head of large *Polypterus bichir*, with skin removed. × 2.

19
194

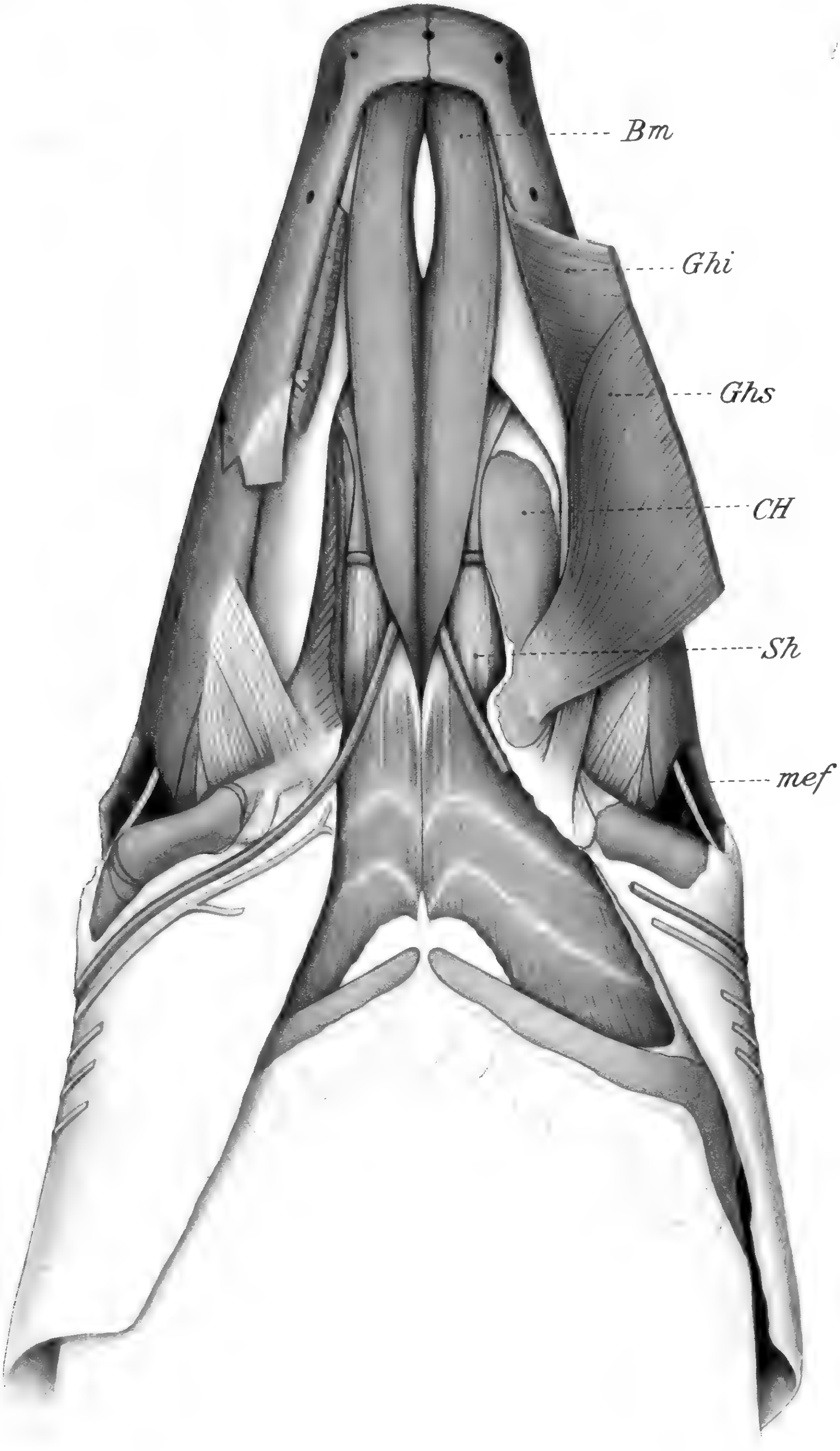

Fig. 51. A deeper dissection of a second head of large *Polypterus bichir*. ×2.

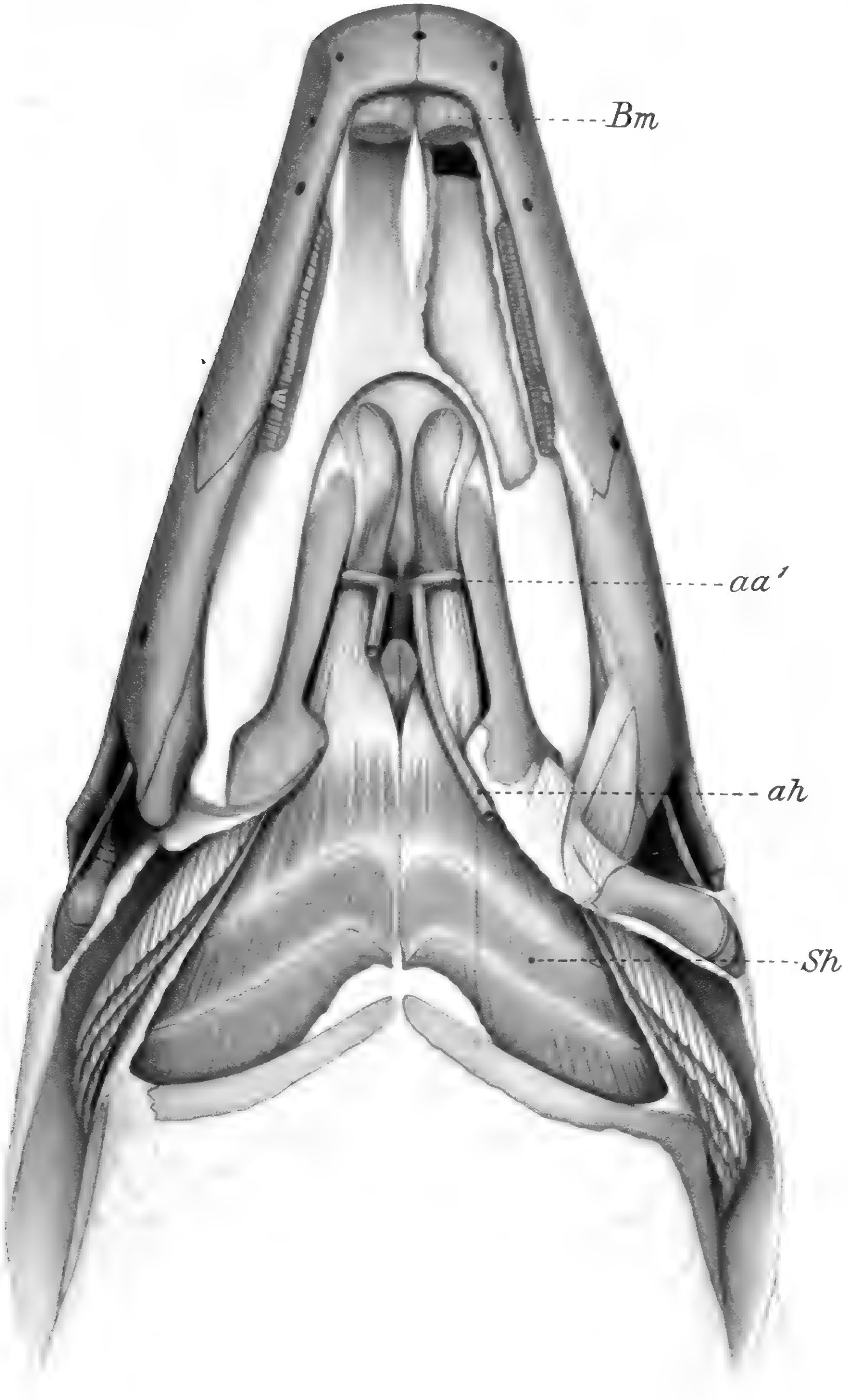

Fig. 52. A still deeper dissection of a second head of large *Polypterus bichir*. × 2.

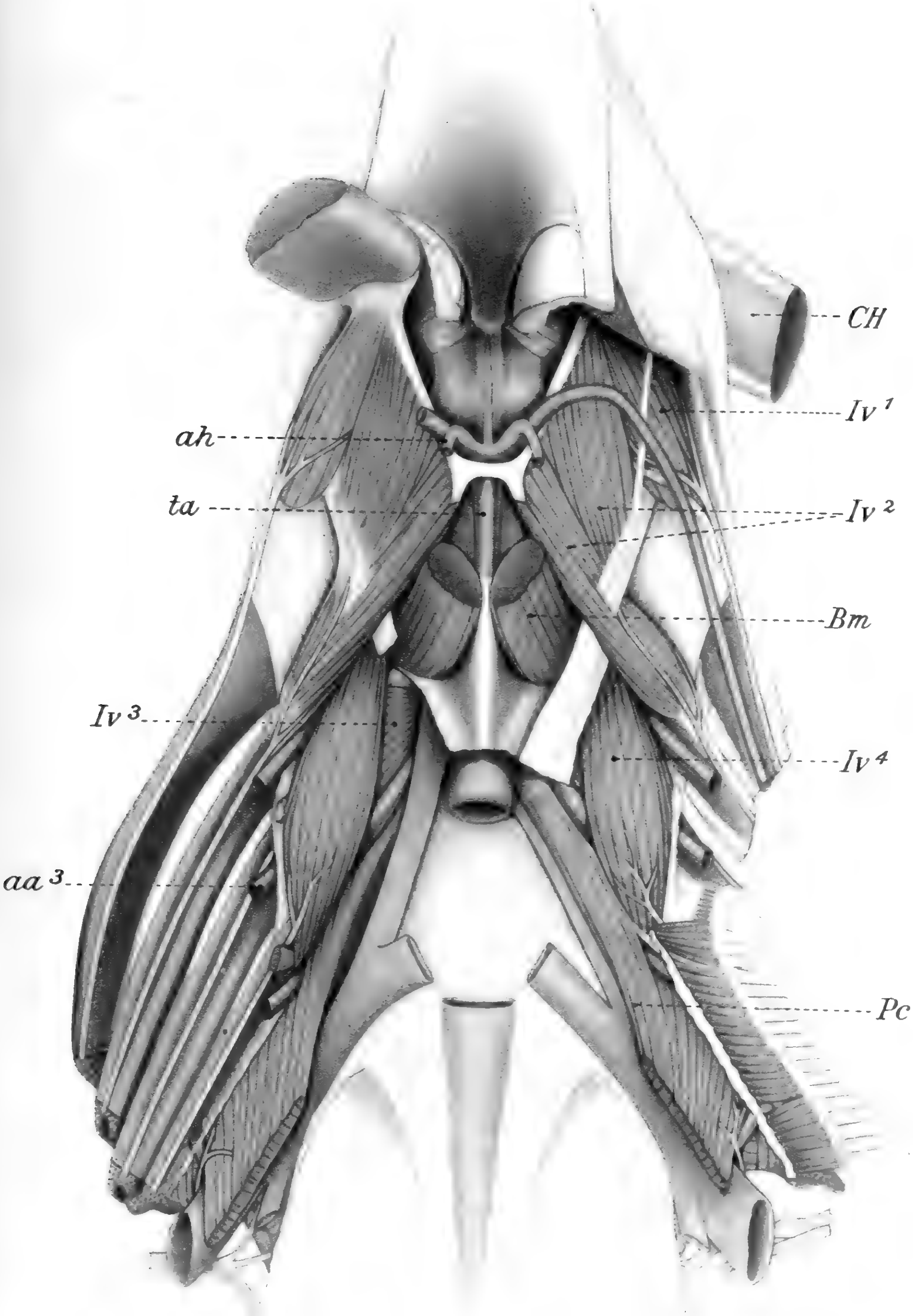

Fig. 53. Ventral view of the hyal and branchial arches of *Polypterus ornatipinnis*, with muscles attached. × 2.

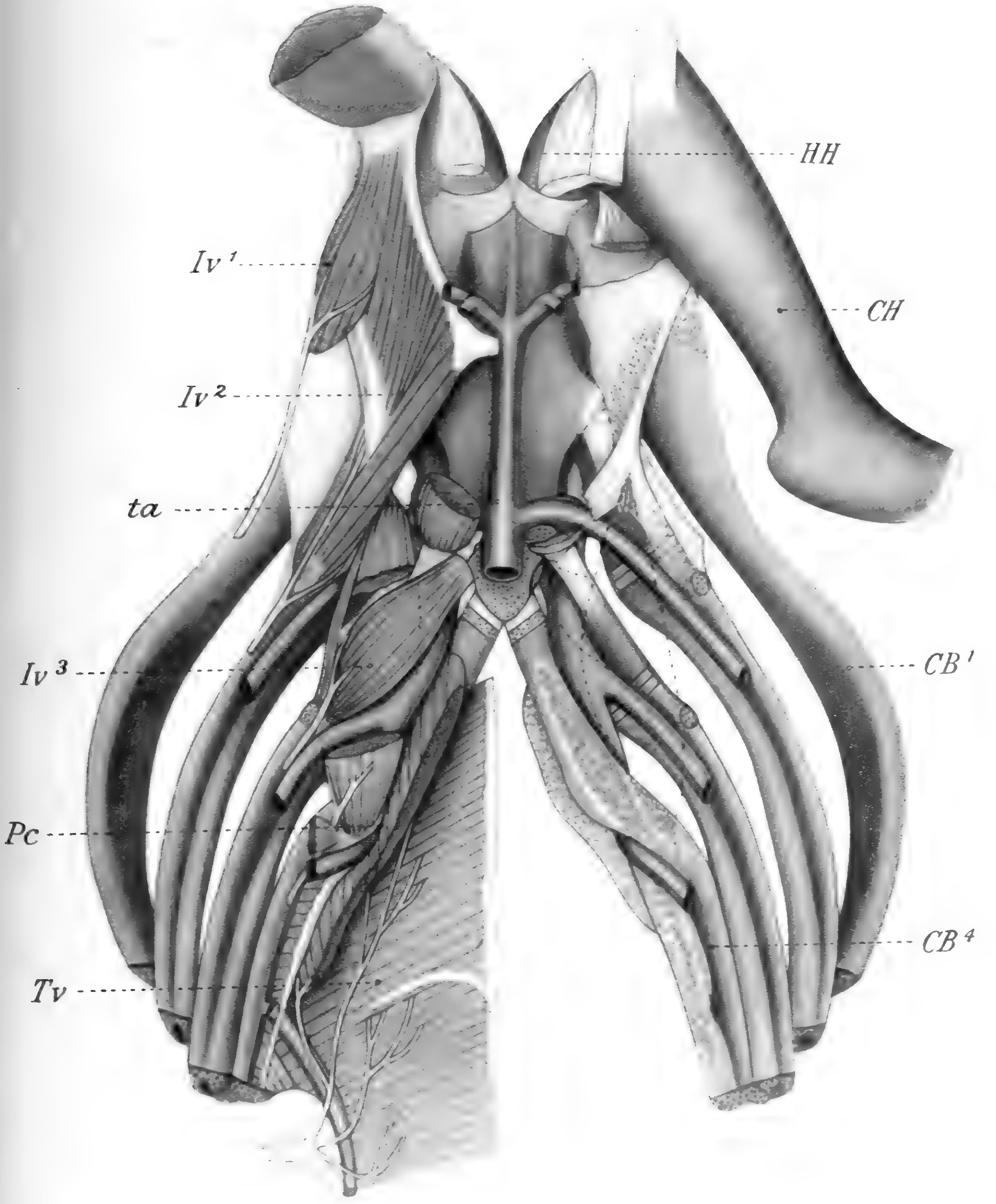

Fig. 54. A deeper dissection of the hyal and branchial arches of *Polypterus ornatipinnis*. × 2

ON THE HYPOTROCHANTERIC FOSSA AND ACCESSORY ADDUCTOR GROOVE OF THE PRIMATE FEMUR

By A. B. APPLETON.

Houzé, in 1883, drew attention to the occasional replacement in Man of the gluteal ridge by a fossa which he named the *fossa hypotrochanterica*.

It is the purpose of this paper to point out the presence of certain fossae in a similar position on other primate femora, which cannot be identified with the *fossa hypotrochanterica* of Man, since they are of a totally different nature.

In particular, a fossa is present on the femur of the Gorilla, Chimpanzee and Orang-outan, named in this paper the "**accessory adductor groove**[1]," which superficially resembles the *fossa hypotrochanterica* of Man. The homologue of the latter, however, is found in these apes in another situation, viz. on the outer aspect of the shaft well below the level of the lesser trochanter.

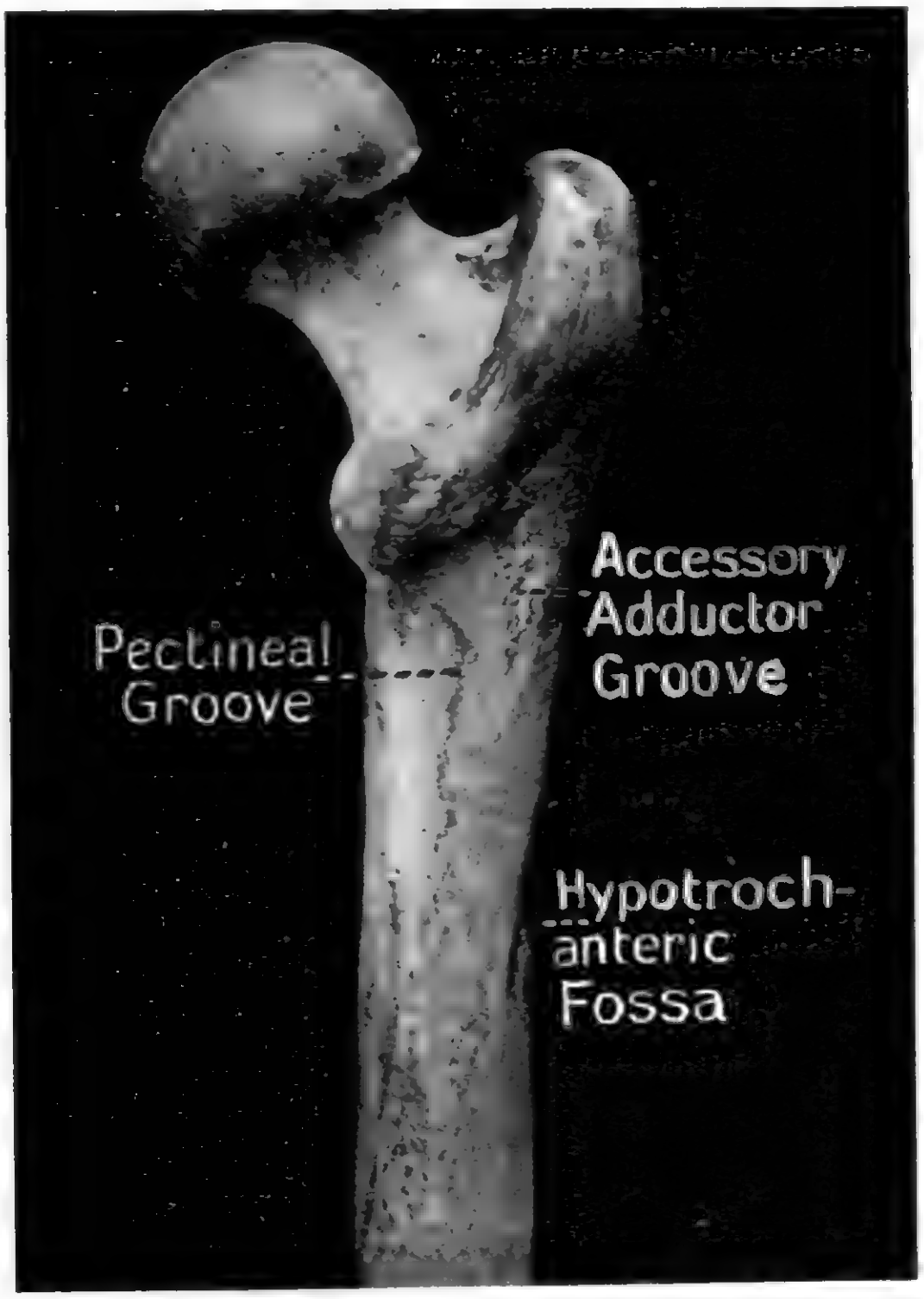

Fig. 1. Femur of Orang-outan (W.L.H.D). Posterior aspect of proximal end.

The resemblance between the *fossa hypotrochanterica* of Man and the accessory adductor groove of these apes is such that it may well be doubted

---

[1] *Vide* also fig. 2, showing a pair of such grooves in *Macacus nemestrinus*.

whether they would be distinguishable if we were not in a position to dissect the animals and demonstrate the muscular attachments. If all these femora belonged to fossil genera known to be closely related, one could hardly avoid the mistake of confusing the fossa and the groove.

Pearson and Bell, in their monograph on the femur (1), have confused the fossa and the groove in the Chimpanzee and Orang (p. 66, footnote 2).

The identity of the *fossa hypotrochanterica* is defined for us by Houzé as the site of insertion of *M. gluteus maximus* and in this sense later writers have dealt with it (von Török, Costa and Pearson).

The accessory adductor groove is the site of insertion of certain small muscle-slips belonging to the adductor musculature; these are supplied by small twigs from the obturator nerve. A detailed discussion of their morphology is reserved to another paper, but it is desirable to anticipate the conclusion that they are derived from the *MM. adductores longus, brevis* and *magnus*. They are accordingly named "accessory adductor muscles." They are apparently present in *all* Primates; and muscles which resemble them are found in other orders of mammals, e.g. *Carnivora* (*Canis*) and *Marsupialia* (*Perameles*).

The accessory adductor muscles (fig. 4) are situated between *M. obturator externus* on the one hand, and *MM. adductores longus, brevis* and *magnus* on the other hand, both at origin and insertion. The most caudad of the series is the homologue of the human *M. adductor minimus* and has a muscular insertion to the lateral lip of the accessory adductor groove. A common aponeurosis usually provides insertion for the remaining muscle-slips, of which there may be one (Man, Gorilla and Chimpanzee), two (Orang), or as many as four (*Cercopithecidae* and *Hapalidae*). This aponeurosis is attached to the floor of the accessory adductor groove; a reduplication of the groove sometimes occurs, corresponding to a reduplication of the aponeurosis (e.g. *Macacus nemestrinus*: II, W.L.H.D.).

In Man, the "upper belly" of *M. adductor brevis* is homologised as a part of the accessory adductor musculature of other *Primates*. It either shares insertion with *M. pectineus*, or it gains attachment somewhere between the pectineal line and *M. adductor minimus*. No accessory adductor groove is found at its insertion in Man.

ATTACHMENT OF *M. GLUTEUS MAXIMUS* TO FEMUR

Man: gluteal ridge, 3rd trochanter or *fossa hypotrochanterica*[1].

Gorilla, Chimpanzee and Orang-outan: a spiral fossa on the *lateral* aspect of the femoral shaft; this is the *fossa hypotrochanterica* of these animals[2]. It is the largest and most distally placed in the Gorilla.

---

[1] Pearson and Bell call attention to the frequency with which all types of Primogenial Man exhibit this fossa (1, p. 453).

[2] This is the fossa which Pearson and Bell named *fossa angulolateralis*, clearly distinguishing it from their "*fossa hypotrochanterica*" (accessory adductor groove); for they note "the presence of a ridge between" them in the Chimpanzee and Orang (1, p. 66, footnote 2).

Gibbon: gluteal ridge, opposite lesser trochanter.

Cercopithecidae: gluteal ridge, replaced or accompanied occasionally by a *fossa hypotrochanterica* (e.g. *Cercopithecus sab.* Juv. (Z.M.C. E 7788) and *Papio. ham.* Z.M.C.

The fossa takes the form of a groove in these two named specimens. A mere flattening is present in *Nasalis larv.* (A.D. 1 and R.C.S. 107), a slight groove in *Nas. larv.* Juv. (W.L.H.D. 1). It sometimes takes the form of a faint pit, with prominent medial lip. (*Semnopith. crist.* R.C.S., *Cynopithecus niger*, R.C.S. 175.)

A rough line forms a downward continuation of the gluteal ridge, or of the medial lip of the hypotrochanteric fossa when this is present.

Cebidae: two extreme types are found. On the one hand a very conspicuous gluteal ridge may be present, prolonged for some distance down the shaft; it is found in *Cebus* and *Mycetes*. On the other hand, there may be no projection at all (*Ateles*), but an extensive flattened area, of which the postero-medial margin is a little prominent; it extends considerably below the level of the lesser trochanter and recalls the spiral, laterally situated hypotrochanteric fossa of *Simiidae*.

Intermediate conditions between the two extreme kinds of gluteal attachment are found in *Brachyurus* and *Pithecia*. *Brachyteles* exhibits both a rough area pitted proximally, and a ridge on its medial side, both distal to the lesser trochanter.

Hapalidae: gluteal ridge is prominent.

Prosimiae: 3rd trochanter.

POSITION OF ACCESSORY ADDUCTOR GROOVE

Man: absent.

Gorilla, Chimpanzee and Orang-outan: about level with lesser trochanter, well to the lateral part of the posterior aspect. It is deepest and most proximally situated in the Chimpanzee.

Gibbon: small shallow groove (inconstant), midway between gluteal ridge and lesser trochanter.

Cercopithecidae: between gluteal ridge (or hypotrochanteric fossa) and lesser trochanter. Its proximal end is opposite the lesser trochanter, and it extends distally somewhat beyond the commencement of the pectineal groove. At least half of the pectineal groove is situated distally to the accessory adductor groove. These grooves approach one another as they proceed distally.

An *additional* accessory adductor groove is found in *Macacus nemestr.* and in *Semnopithecus*, marking the insertion of *M. adductor minimus*. It is situated slightly more distally than the customary accessory adductor groove, between it and the gluteal ridge. Dissection demonstrates the presence in both these species of an aponeurosis on the deep surface of *M. adductor minimus*, this aponeurosis being attached to the additional groove[1]. The accessory adductor groove has the least proximal extent in *Papio*. It is situated closer to the hypotrochanteric fossa in *Papio* and *Cynopithecus* than in *Macacus, Semnopithecus, Cercopithecus* and *Nasalis*.

In one specimen of *Semnopithecus hosei* (W.L.H.D. 1) an "**accessory adductor ridge**" is present, replacing the customary groove. In a specimen of *Semnopithecus crist.* a short ridge is placed lateral to the groove (R.C.S. 100).

It is necessary to distinguish a faint depression which is frequently present at the insertion of *M. quadratus femoris* from an accessory adductor groove. It is immediately adjacent to the proximal end of the latter.

Cebidae: in many specimens no accessory adductor groove is present. One or more faint grooves are sometimes to be found in *Ateles, Cebus* and *Brachyteles*.

Hapalidae: a faint groove is placed close to the distal part of the gluteal ridge.

Prosimiae: absent (*vide infra*).

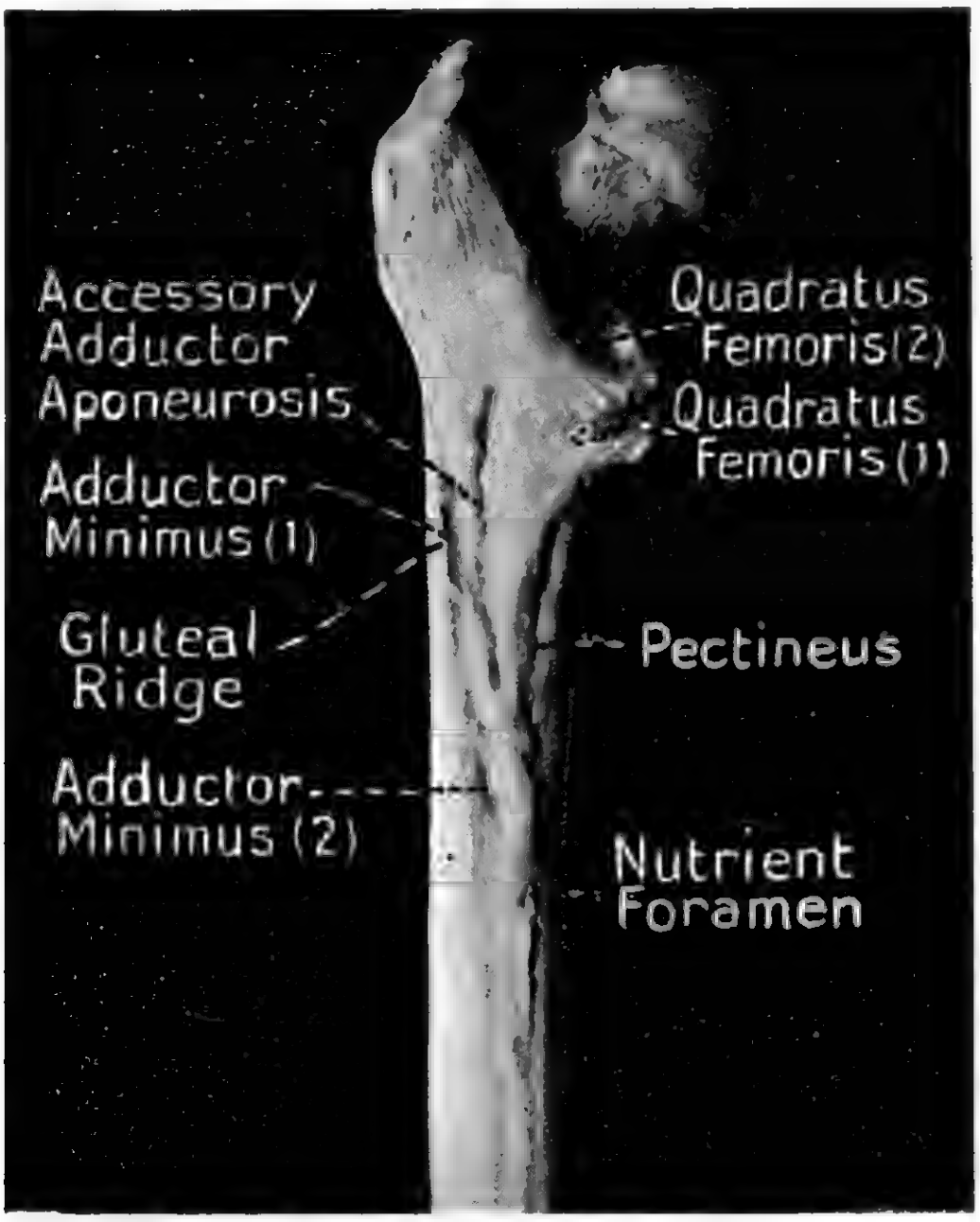

Fig. 2. Femur of *Macacus nemestrinus* (W.L.H.D.). Posterior aspect of proximal end.

Other grooves are present on the posterior aspect of the primate femur: besides the hypotrochanteric fossa and the accessory adductor groove (sometimes reduplicated). In most Primates a groove is present at the insertion of *M. pectineus*. The lateral lip is frequently raised and rough (especially in

---

[1] As a distinct condition it is to be noted that at the site of attachment of *M. adductor minimus* an apparent groove is sometimes formed between the prominent adjacent lips of hypotrochanteric fossa and accessory adductor groove (e.g. *Nasalis larvat.* Juv. W.L.H.D. 1; and *Cynopithecus niger*, R.C.S. 175) (cf. fig. 3).

certain *Cercopithecidae*) so that the attachment has more the character of a ridge than a groove. Of *Simiidae*, the Gorilla and *Hylobates* present the best marked grooves in the specimens examined: of *Cercopithecidae*, a *Colobus vell.* and a *Nasalis larv.* (Juv.) exhibit the most obvious grooves, while it is generally evident in *Platyrrhinae.*

The presence of this pectineal.groove must be remembered in the identification of the accessory adductor groove. The distal ends of the two grooves approach one another, but the former is situated more distally, being always entirely *distal* the level of the lesser trochanter. Still another groove is frequently found marking the site of attachment of *M. vastus medialis.* It occurs sporadically throughout Primates, replacing (at the level of the pectineal line) the ridge to which *M. vastus medialis* is elsewhere attached. It is conspicuous in a femur of *Nasalis larvatus* Juv. (W.L.H.D. 1). It is mentioned only to distinguish it from the pectineal groove.

Dissection shows that the *MM. adductores longus* and *brevis* in *Cercopithecidae* are attached to a groove which occupies the middle one-third of the posterior aspect of the femur. It is called the "posterior fossa" by Pearson and Bell, and is present in most specimens both in their series and mine.

It is not continuous with either the hypotrochanteric fossa or the accessory adductor groove, and if attention is paid to the position of the foramen for the nutrient branch of *A. perforans prima* (where this is present) it will be found that the "posterior fossa" stops short of it. Now this artery always passes between the accessory adductor muscles on the one hand and *MM. adductores longus* and *brevis* on the other. It marks a distinct interval between two muscle masses, corresponding to which there are two separate grooves for their insertions on the femur.

One is the accessory adductor groove; for the more distal groove a more descriptive name would be the "**adductor groove.**" The adductor groove may be indeed duplicated (e.g. a *Cercopithecus sab.* Juv.), correspondingly with the sometimes independent aponeuroses of insertion of *MM. adductores longus* and *brevis.* Its lateral lip is in *Cercopithecidae* the more prominent, and to it is attached *M. adductor magnus.* It takes part in the maximum antero-posterior diameter of the femoral shaft, and its development must therefore be considered in a study of the pilastric index of these animals. The backward projection of this lip allows of such an attachment for *M. adductor magnus* as will minimise friction against the aponeurosis of the other two adductor muscles. A similar arrangement is seen in many *Artiodactyla* (e.g. *Cervus*) and most *Carnivora.*

Turning to Man and the Simiidae, this "posterior fossa" (or "adductor groove" as I prefer to call it) is said by Pearson and Bell to be absent. Evidently they have not recognised the downward displacement of the adductor insertions in the Gorilla, Chimpanzee and Orang. In all of these an adductor groove is a discernible feature distal to the "apex" of the popliteal space along its medial side. The groove in them is rough, and tends in the Orang to become a ridge. In *Hylobates* the adductor groove is situated on the middle part of the shaft, as in *Cercopithecidae*. Man differs from all these in the possession of a projecting ridge on the middle one-third of the shaft, to which these two adductor muscles (as well as other muscles) are attached: this projection appears to have attained a maximum in Cromagnon man.

In *Platyrrhinae* a slight adductor groove is present. It occupies the middle part of the shaft, and is usually limited above and below by foramina for nutrient arteries to the femur.

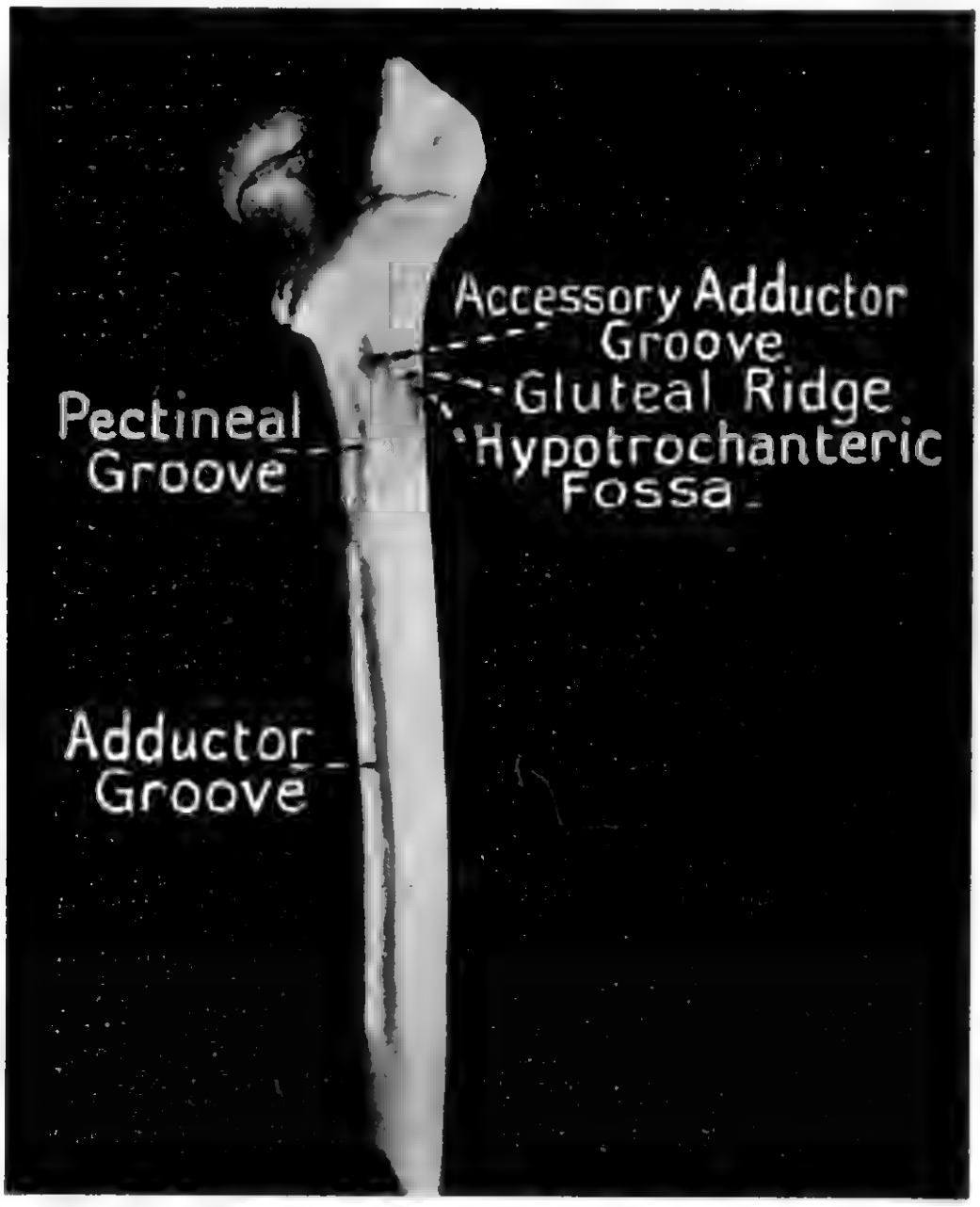

Fig. 3. Femur of young *Nasalis larvatus* (W.L.H.D.). Posterior aspect of proximal end.

POSITION OF ADDUCTOR GROOVE

Man: absent.
Gorilla, Chimpanzee and Orang-outan: shallow and rough: on proximal part of medial supracondylar line.
Gibbon: region of mid-shaft, between approximated septal lines of linea aspera.
Cercopithecidae: as in Gibbon, but longer and usually deeper (especially in *Nasalis* and *Semnopithecus*).
Platyrrhinae: similar to Gibbon.
Prosimiae: immediately below pectineal ridge.

Prosimiae present a great contrast to **Primates** in the disposition of muscular attachments on the posterior aspect of the femur.

They are indeed like the giant apes in the possession of *M. femorococcygeus*, attached along the lateral margin of the femur; and in the possession of a broad "interseptal" space on the femur between the attachments of the lateral and medial intermuscular septa (4). They differ (5), however, from most Primates in the presence of *M. caudofemoralis*[1], which is attached to a ridge (or rough area) at mid-shaft on the posterior aspect; and in the extensive insertion of *M. quadratus femoris* on the hollowed space between the lesser and 3rd trochanters. These two features constitute a most significant resemblance to *Insectivora* (e.g. *Tupaia*). *Prosimiae* are nevertheless distinguished from some *Insectivora* at least in the possession of an accessory adductor musculature. This is absent from *Tupaia*, and, so far as other *Insectivora* are concerned, Leche gives no hint of ever having seen it (6). Dobson (7, p. 81), however, detected its existence in Centetes and Solenodon, recording it under the name "adductor quartus."

A comparison of the femora of a Lemur and of a Primate is scarcely profitable without a special examination of the insertions of adductor and accessory adductor muscles. The accessory adductor muscles are attached in *Lemur* and *Tarsius* to the *medial* side of the shaft of the femur, below the lesser trochanter. They share attachment with *M. pectineus* to the pectineal ridge, and there is therefore no accessory adductor groove.

The pectineal ridge is, in *Lemur*, continued downwards for a short distance by a groove, to which *MM. adductores longus* and *brevis* are attached. This groove then is the adductor groove. It is homologous with the adductor groove on the middle third of the femur of *Cercopithecidae* and on the medial limit of the popliteal space of *Simiidae*. It is in *Prosimiae* placed above the mid-point of the shaft. In certain *Prosimiae* no adductor groove is present (*Tarsius* and *Galago*); in *Propithecus diad.* a tuberculated "**adductor ridge**" replaces it. In *Prosimiae* there is no *fossa hypotrochanterica*, for *M. gluteus maximus* is attached to the 3rd trochanter. The mode of attachment is not unlike that in *Hapalidae*.

The changes in site of attachment of muscles to the posterior aspect of the femur as we pass from *Insectivora*, through *Prosimiae* to the higher *Primates*, may be briefly indicated.

Along with enormous elongation of the femoral shaft as we pass from an Insectivore like *Tupaia* to *Prosimiae*, we find proximal shifting of the insertions of *MM. adductores longus* and *brevis*, and the differentiation of accessory adductor muscles which are attached still more proximally; they are all so far displaced that they are situated medially to the extensive attachment of *M. quadratus femoris* (fig. 5) instead of being medial to the insertion of *M. adductor magnus* (as in *Insectivora*, e.g. *Tupaia*). In passing from *Prosimiae* to *Primates* we note the disappearance of *M. caudofemoralis*, and of *M. femorococcygeus* (except in *Simiidae*). A reduction in the area of attachment of *M. quadratus femoris* is associated with considerable changes in the shape of

---

[1] This muscle is present in Hapalidae, at least.

the upper end of the femur and a lateral migration of the insertion of ***MM. adductores accessorii.*** This migration could hardly take place so long as *M. quadratus femoris* was attached to the whole of the space lateral to the pectineal groove (or ridge). The lateral situation of the attachment for accessory adductor muscles which is rendered possible by the restriction of *M. quadratus femoris* in *Primates* confers on those muscles a strong external rotatory action (*vide* fig. 4). The accessory adductor groove is thus found in *Primates* within the area formerly (in *Prosimiae* and *Insectivora*) occupied by the insertion of *M. quadratus femoris.*

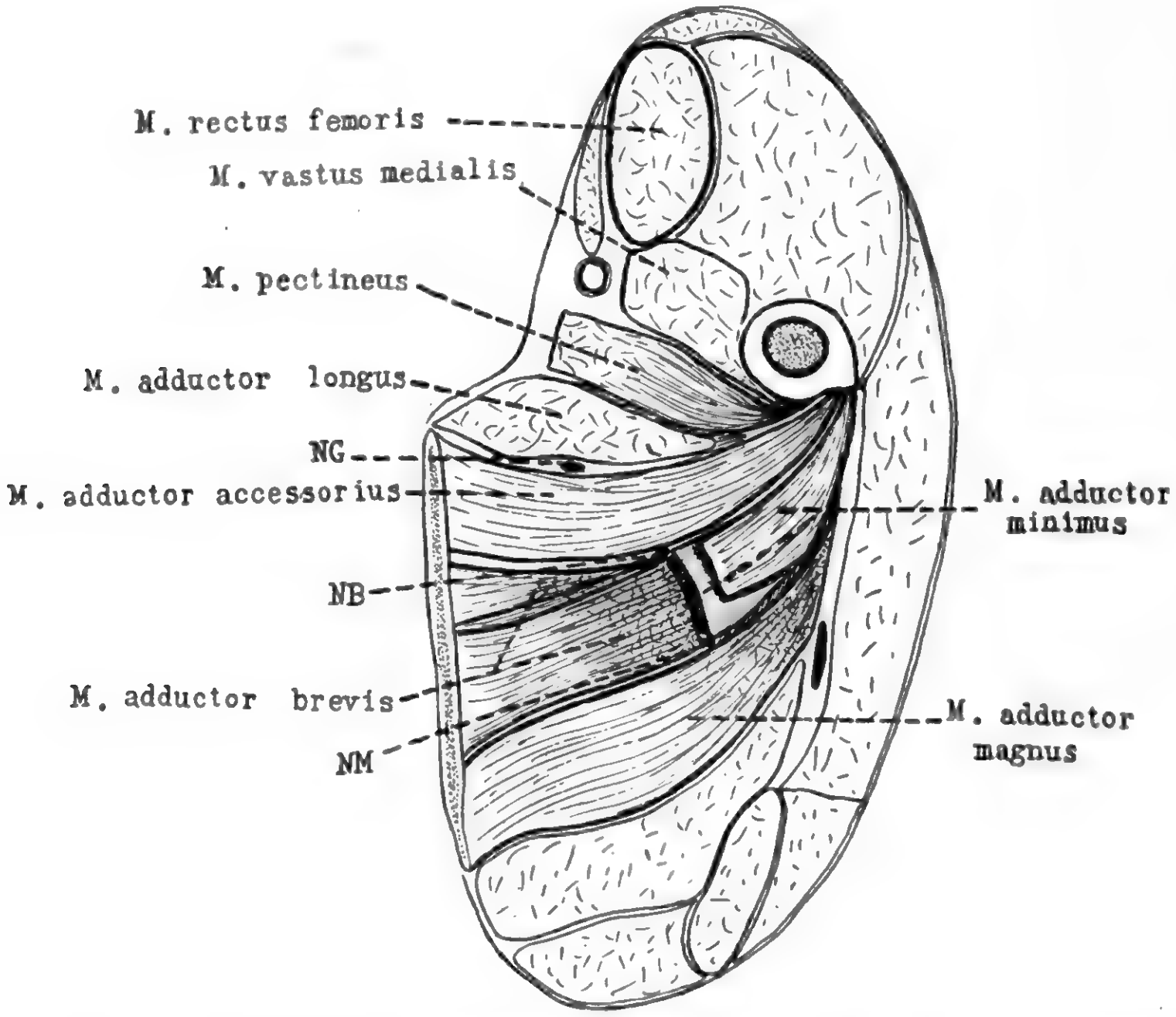

Fig. 4. Oblique Section of Thigh, *Macacus nemestrinus*, through pubic symphysis and accessory adductor groove. *NG* = Nerve to *M. gracilis*; *NB* = Nerve to *M. adductor brevis*. *NM* = Nerve to *M. adductor magnus*.

The retreat of *M. quadratus femoris* was associated also with an important change in *M. adductor magnus*. This muscle extended its femoral attachment proximally, and the proximal portion has, to a variable extent, become differentiated as *M. adductor minimus*. This, the most caudad accessory adductor muscle, is attached laterally to the accessory adductor groove. In certain *Primates* (e.g. *Macacus nemestr.*) its deep (ventral) surface is aponeurotic near its insertion, and a second accessory adductor groove marks its site of attachment. In *Primates* the proximal displacement of *MM. adductores longus* and *brevis*, which occurs in *Prosimiae* is not reproduced. They are even attached *distally* to the middle of the shaft in the Gorilla, Chimpanzee and Orang. It is probable that proximal displacement in *Prosimiae* and distal displacement in the *Simiidae* named is a function of the relative length of the femur (to pelvis). The more proximal attachment in the Gibbon supports this view (*vide* also Appleton 4, p. 385).

The position of *A. perforans prima* is worthy of attention, not only because it pursues a singularly constant course amid all the muscular changes. For the present study it is of special interest because it so frequently provides a nutrient branch to the femur, and the corresponding foramen is found also to exhibit some constancy in its position on the femur. It provides a land-

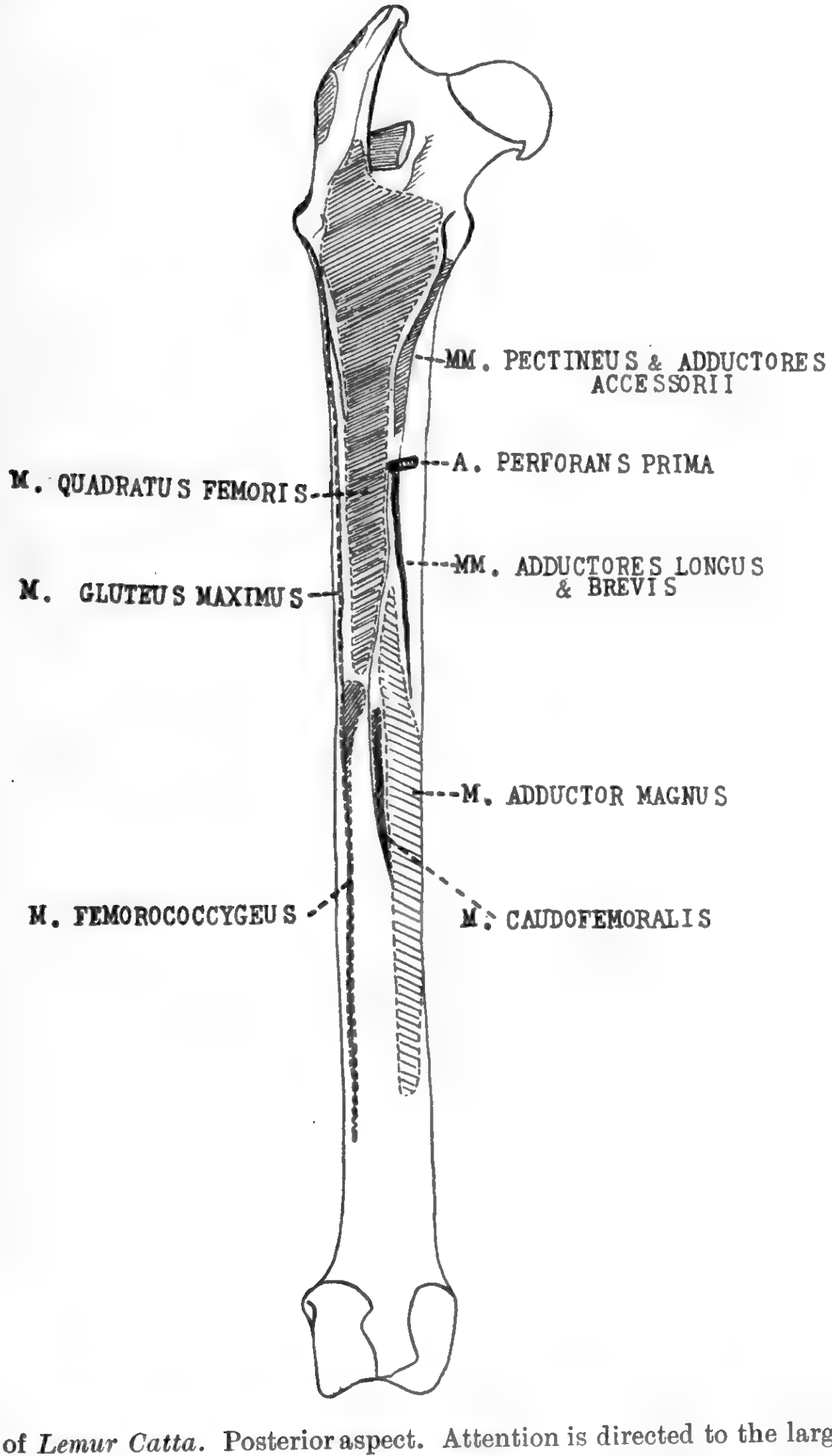

Fig. 5. Femur of *Lemur Catta*. Posterior aspect. Attention is directed to the large flattened area of insertion of *M. quadratus femoris*; the proximal limitation of *M. adductor magnus*; and the medially situated insertion of the *MM. adductores accessorii* on the pectineal ridge.

mark on the bone which exhibits far greater constancy than the muscular attachments around it. In *Tupaia* this artery runs proximally to the whole of the adductor musculature. In *Primates*, on the other hand, it passes through the interval between the adductor muscles proper, and the accessory adductor musculature. The appearance of the latter has in no wise disturbed the course of the artery across the bone. *Lemur* exhibits an interesting intermediate stage; for the most caudad of the accessory adductors is not yet differentiated. The artery, therefore, after passing[1] between the partially differentiated accessory adductors and *MM. adductores longus* and *brevis*, reaches the interval between *M. quadratus femoris* and *M. adductor magnus*. It then passes proximally to the whole *M. adductor magnus*. The *Primates* differ from this condition in the retreat of *M. quadratus femoris* to an intertrochanteric ridge, and the differentiation of a *M. adductor minimus* (from *M. adductor magnus*) with an insertion *proximal* to the *A. perforans prima*. *M. adductor minimus* has come between the artery and *M. quadratus femoris*.

The foramen for the nutrient branch of *A. perforans prima* is accordingly found in *Primates* when present[2] between the adductor groove and the accessory adductor groove. These grooves mark the site of attachment of distinctly differentiated muscle-groups, and this nutrient foramen is definitely related to the interval between them. The foramen is sometimes placed similarly in *Prosimiae*, but there is no accessory adductor groove proximal to it: instead of this Primate feature we find only a pectineal ridge and a hollowed or flattened space on which *M. quadratus femoris* is attached.

In this paper no attempt is made at discussing the significance of ridges and of fossae at the site of muscular attachments.

Facts established in this paper, however, suggest caution in the employment of the *fossa hypotrochanterica* for the natural classification of *Primates*. Pearson and Bell discuss the relationships among *Primates*, partly on the basis of the occurrence of this fossa, and of the alternative 3rd trochanter (1, pp. 83, 342, 483, 501). Apart from their failure to identify this fossa correctly in the large *Simiidae*, they apparently make the assumption that *Primates* exhibiting this fossa are to be considered mutually related forms: while a bony projection is to be regarded as a sign of affinity between animals (*op. cit.* p. 483).

Now the distribution of fossa and of the alternative gluteal ridge (when large, known as a 3rd trochanter) is an argument against this assumption. A classification based upon the presence of fossa or ridge is quite unlike the usually accepted natural classification of *Primates*. If we accept, as a particular case[3], the association of the genera *Ateles* and *Cebus*, in the same sub-family,

---

[1] In a *Galago* the foramen was situated medially to the pectineal ridge.

[2] When absent, a nutrient foramen is usually found just below mid-shaft. In *Ateles ater*, both nutrient foramina are sometimes present.

[3] Another such case is provided by the *Semnopithecinae*. In certain of these an accessory adductor ridge is a conspicuous feature, but in *Nasalis larv.* it is usual to find an obvious accessory adductor *groove*.

Cebinae (accepted by Pearson and Bell, *vide* Atlas, Table II), we must doubt the validity of their assumption. *Cebidae* as a whole indeed present great variety in the nature of the insertion of *M. gluteus maximus* to bone; but the two genera named, which belong to the *same* sub-family, present us with the two extreme conditions. In *Cebus* a very prominent ridge (properly described as a 3rd trochanter) is found: in *Ateles*, a rough hollowed, pitted or flattened area is found. Intermediate conditions of all stages are presented by *other* Cebidae. Among *Cercopithecidae* there is less variety; but here also we sometimes find a groove whereas in most of them a ridge occurs like that in *Cebus* (e.g. *Macacus*). *Hylobates* presents a distinct ridge: while the other *Simiidae* have a conspicuous fossa on the *lateral* aspect of the shaft which is more like the condition in *Ateles* than that of any nearer relatives.

Until more is known of a possible functional significance for the appearance of a fossa at the site of insertion of *M. gluteus maximus*, it must be precarious to argue[1] as to the nature of that insertion, whether fossa or ridge, in the common ancestor of *Hylobates*, the other *Simiidae* and Man.

The replacement of the pectineal groove by a ridge in certain individuals of certain species: the occurrence of a groove in some *Primates* at the origin of *M. vastus medialis*: the occurrence of an "accessory adductor ridge" in some *Semnopitheci* (conspicuous in *S. hosei* W.L.H.D. 1) instead of the more customary Primate groove: these facts are all suggestive of a problem akin to that of the occurrence of conspicuously "marked" bones in non-muscular human beings, and *vice-versa*. Individual variations in the production of bone-tissue at muscle-attachments seem to occur in Man: and it is uncertain at what point to describe the condition as pathological. We must reckon with the possibility of similar inter-special variations. The influence of age as a factor in the production of ridges at the sites of these fossae has not been investigated: it may be stated, however, that among the bones of *Cercopithecidae* examined, grooves mostly occurred in the immature bones, but were not confined to them.

In this paper attention is directed to the following points:

(1) The name *fossa hypotrochanterica* is conveniently reserved for a fossa, groove or pit at the site of insertion of *M. gluteus maximus* on the femur.

(2) In addition to this depression there occurs another groove on the posterior aspect of the Primate femur, in the neighbourhood of the lesser trochanter. It provides attachment for a specialised portion of the adductor musculature, and is given the name of "accessory adductor groove." With the specialisation of *two* accessory adductor aponeuroses in certain Catarrhinae, two corresponding grooves make their appearance on the femur.

(3) Grooves are also present in many *Primates* at the sites of attachment of *MM. pectineus, adductores longus* and *brevis*.

(4) All of the above-mentioned fossae and grooves may be replaced by ridges; the frequency of which varies in different species.

---

[1] See Pearson and Bell, 1, p. 483.

(5) The femur of *Prosimiae* is widely separated from that of *Primates* by differences of markings and muscular attachments. It presents a closer approach to that of *Insectivora*.

(6) Among *Primates* the hypotrochanteric fossa presents considerable variety of situation; an extreme condition is presented by the large *Simiidae*.

(7) With the reduction of the accessory adductor musculature in Man, there is an absence of any special groove or ridge for its attachment.

(8) In Man the hypotrochanteric fossa occupies a position approximating to that of the accessory adductor groove in other *Primates*.

My thanks are due to Prof. Wilson for valuable advice and criticism. Dr Duckworth generously placed many animals at my disposal for examination; and I am indebted to Sir A. Keith and Mr Forster Cooper for their kind permission to examine femora under their care.

Sources of specimens particularised in this paper:

Anatomy School, Cambridge ...	A.D.
Dr Duckworth, Private Collection ...	W.L.H.D.
Museum, Royal College of Surgeons	R.C.S.
Museum of Zoology, Cambridge ...	Z.M.C.

REFERENCES

(1) Pearson and Bell. *Drapers' Company Research Memoirs.* A Study of the Long Bones of the English Skeleton. Biometric Series, x. and xi. The Femur. 1919.

(2) Von Török, A. *Anat. Anz.* Jahr. i. S. 169–178. 1886.

(3) Houzé, E. *Bull. de la Soc. d'Anthr. de Brux.* Tom. i. pp. 21–54. 1883.

(4) Appleton, A. B. *Proc. Cambridge Philos. Soc.* vol. xx. pp. 374–387. 1921.

(5) —— *Proc. Cambridge Philos. Soc.* vol. xx. Gluteal Region of Tarsius Spectrum, pp. 466–474. 1921.

(6) Leche, K. *Svensk. Vet.-Akad. Handl.* 20 Bd. *The Pelvic Region of Insectivora,* pp. 374–387. 1883.

(7) Dobson, G. E. *Monograph of the Insectivora.* London, 1882.

A NEW INTERPRETATION OF THE BONES IN THE PALATE AND UPPER JAW OF FISHES

PART I

By H. LEIGHTON KESTEVEN, D.Sc., M.D., Ch.M.

HUXLEY'S *Elements of Comparative Anatomy* bears the date 1864, and, with alterations in the form only of the terminology, his description of the bones of the fish palate and upper jaw as exemplified in the pike (*Esox lucius*) and the interpretations which his terminology implies have passed practically unchallenged to the present day. It is therefore only after long deliberation, under the impulse of a very real conviction, and with a full sense of the responsibility, that I now venture to question the whole of those interpretations, and offer an almost entirely new concept of the significance of the bones in the fish palate and upper jaw.

My reading leads me to recognise that I am not alone in feeling unconvinced by the old interpretations, and I am emboldened to advance my somewhat startling ideas, because I have reason to believe that the majority of investigators have based their descriptions of the structure and development of fish skulls on the assumption that the interpretations involved in their terminology were already sufficiently established, whereas this is not so. Huxley's defence of his interpretations is, in the light of our more intimate knowledge of structures and development, quite inadequate, and no serious defence of those interpretations has been advanced since. Especially have they not been analysed in the light of our knowledge of the development of the palate and chondrocranium not only of the fishes but of the vertebrata generally.

Throughout the following discussion the adult form and relations of the various bones are dealt with first, because the opinion is held that those factors in such problems as it is here attempted to solve are of primary importance. It appears to the writer that there is a tendency at the present time to abandon the cadaver and the scalpel entirely in favour of the wax plate model and the microtome, and that arising out of this tendency is another, that of allotting to adult form and structural inter-relationships less value than is their due. These tendencies are traceable directly to the reorientation of many of our ideas which resulted from the brilliant embryological studies of the latter end of last century and the early years of this. It was then demonstrated that adult form and position may disguise fundamental relationships which are obvious in the early stages of development. In each case, however, the demonstration has been that the fundamental condition has been truly retained, and being pointed out may always be recognised in the adult.

It is a truism that the boy is father to the man, and in our embryology we have recognised that he is often more nearly the son of his father than is the man he becomes. It were, however, well not to lose sight of the fact that the man is the direct descendant of the boy, and whatsoever the man hath, that must he have inherited from the boy.

Hence it is believed that, armed as we now are with the facts of embryology, and applying the knowledge of those facts all the time, it is permissible and, indeed, desirable to base our comparisons on the adult skulls first, and then, if need be, to test or modify them by an analysis of the ontogeny of the bones involved in the comparisons. The method has the added value that it lends itself to clarity of exposition—and brevity of discussion.

For a basis of comparison I have chosen as a typical teleostean palate that of *Promicrops*, a member of the Serranidae (one of the families of the Acanthopterygii), and in no way unique. It was selected primarily because, conforming in all essential respects to *Salmo*, *Scomber*, etc., it translated the vertical relations of the side bones of the palate and upper jaw arch, into horizontal relations, which permit of readier comparison with the palatal aspect of the skulls of tetrapods. *Promicrops* was preferred to *Platycephalus* and one or two other forms that were at my disposal, and in which the flattening towards one plane of the bones of palate and jaw is carried to a further degree, because the large size of the *Promicrops* skull made it exceedingly easy to disarticulate and determine with confidence the intimate relation of the various bones and their respective limits. Accordingly the following description of the upper jaw and palate has been carefully checked by the study of each bone separately, and by rearticulation of the disarticulated components.

THE UPPER JAW AND PALATE OF PROMICROPS

(Figs. 1 and 2.)

The premaxilla articulates with one bone only, the maxilla of its own side. Each is a tapering, slightly curved rod, presenting on the ventro-mesial aspect of the curve an attenuated isosceles triangular area closely set with strong sharp conical teeth. In the midline the bones unite one with the other by a fibro-cartilaginous union, and on either side of this symphysis send upward a pyramidal process. This solid pyramidal process is notched above, and its central portion stands up as a spur, which by the intermediary of a goodly thickness of cartilage and fibrous tissue comes to be connected to the upper surface of the mesethmoid and upper end of the anterior surface of the ethmo-vomer. The pyramidal process is that which in other forms has been designated the ascending process of the premaxilla. Its central portion may be termed the processus medialis, and the lower portion to the outer side of the notch the processus lateralis. Each medial process lies just medial to the medial border of the os nasalis, and is in the same plane therewith, being bound to it by fibrous tissue, and both lying immediately under the skin. The lateral process, shorter and stouter than the medial, is overlapped at its upper and lateral border by the anterior flange of the premaxillary articular cup of the head of the maxilla. A low triangular lamina rises from the postero-mesial edge of the dorsal surface of the distal one-third of the premaxilla. This flange rising abruptly from the bone at its own mesial limit tapers distally, and in its upper part lies behind the shaft of the maxilla.

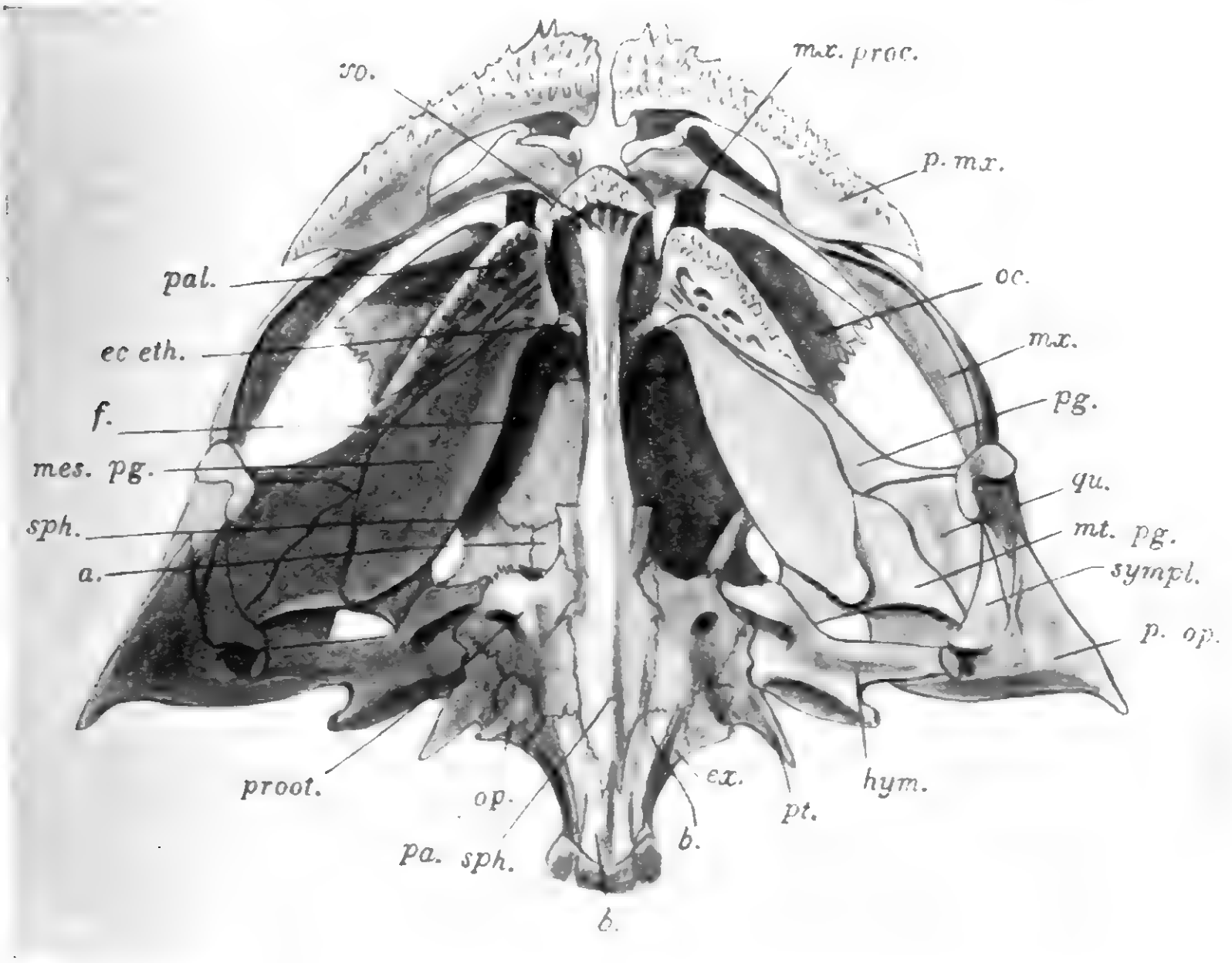

Fig. 1. *Promicrops itaiara*, palatal view of the complete skull.

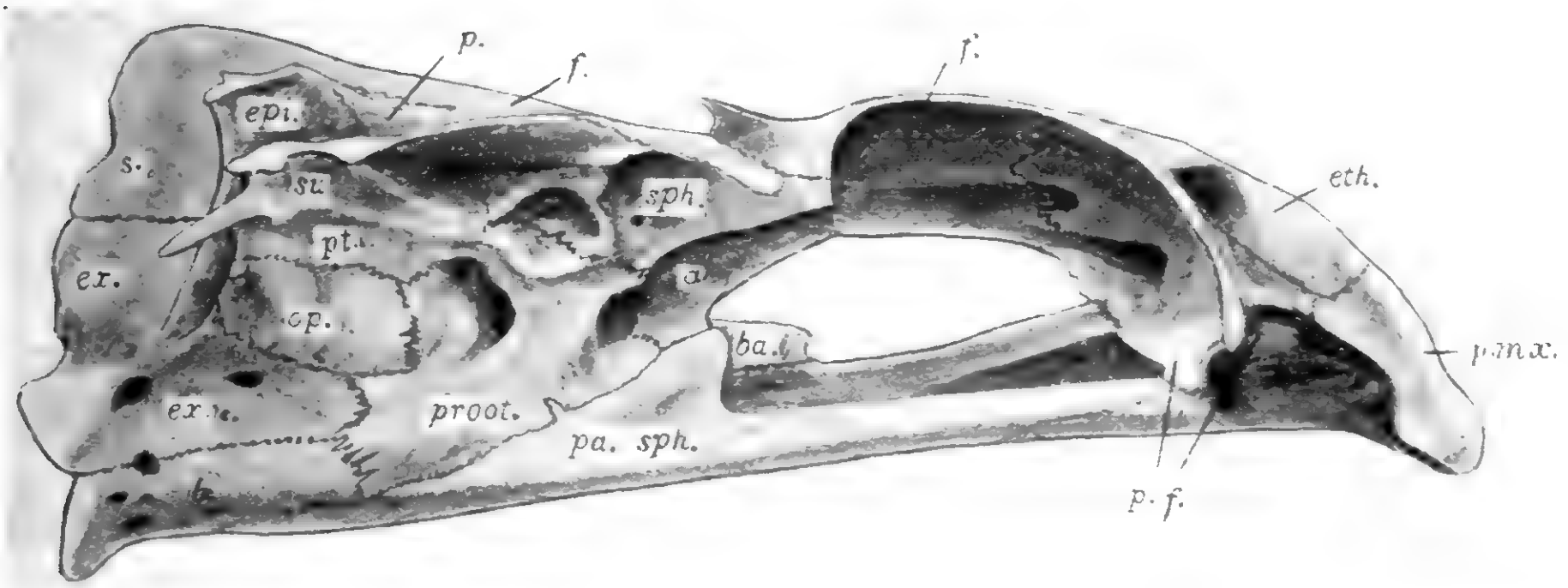

Fig. 2. *Promicrops itaiara*, side view of the cranium and bones derived from the chondrocranium.

The maxilla may be conveniently described as being composed of a head, a shaft and a distal spatulate portion. The swollen head of the bone lies for the most part behind the base and lateral process of the ascending process of the premaxilla, being extensively hollowed out to articulate therewith. It may be that there is a small joint cavity behind the base of the ascending process, but certainly for the most part the space between the two bones is filled in with tough fibrous tissue, fibro-cartilage and hyaline cartilage. Particularly strongly developed is a curved rod of cartilage which is attached above in front to the posterior surface of the medial process of the premaxilla, below and laterally to the inner edge of the articulate cup of the maxilla, and behind in its upper portion to the ridge developed down the centre of the mesethmoid and upper part of the anterior surface of the ethmo-vomer.

It is well to emphasise the fact that the premaxillae articulate with the maxillae only, these latter with a process of the palatine found in no other vertebrate, and that for the rest these two jaw bones are hung to the skull by fibrous tissue only.

The vomer presents an enlarged body and a tapering laminate posterior process. The body is armed with teeth on the anterior portion of the oral surface, it articulates above with the mesethmoid and parethmoid. The posterior process lies beneath the anterior end of the parasphenoid. The upper portion of the anterior surface of the body of the vomer together with the anterior surfaces of the mesethmoid and parethmoids constitute the sloping posterior bony wall of the nasal organs.

The parasphenoid presents the usual shape and relations posteriorly. Anteriorly it becomes laterally compressed and extends far forward above the posterior process of the vomer to articulate not only with the hinder aspect of the ascending portion of the body of that bone, but also with the mesethmoid, and with the inner edges of the parethmoids. The articulations of the parasphenoid and the cranial components are shown in fig. 2, and call for no detailed description.

The palatine bone articulates with the parethmoid in two places, and bears two facets for these articulations. As viewed from the palatine aspect, the bone is triangular in outline. The shortest side of the triangle forms with the midline of the skull an angle a little less than a right angle. This angle is open anteriorly, and at its apex the palatine articulates with the palatine process of the parethmoid, the palatine facet being, of course, on the dorsal surface of the bone. Above this and slightly in front of it, there is a second facet of articulation with the parethmoid. This latter facet is born on the inner and upper aspect of the posterior end of a short, stout process, which, projecting forward and diverging from the midline, parallel with the short antero-medial edge of the bone, comes to overlie the head of the maxilla just lateral to the premaxillary articular cup. This process is that already referred to as providing the only bony attachment for the jaw bones. The palatine bone bears teeth along a narrow area close to the outer border of the bone. The postero-mesial border of the bone articulates with the mesopterygoid along the anterior one-third, and with the pterygoid for the rest of its length.

The pterygoid is a roughly boomerang-shaped bone, but with a short, comparatively broad spur standing out in a postero-mesial direction from near the centre of the convex edge. Behind the palatine the outer border is free. The inner edge articulates with the mesopterygoid as far back as the tip of the spur, and behind this with the quadrate. The blunt tip of the spur reaches the metapterygoid.

The general shape and articulations of the mesopterygoid, metapterygoid, quadrate, symplectic and hyomandibular are sufficiently clear in the drawing to need no description.

The mesethmoid, situated immediately above the ascending face of the vomer, suturates with the parethmoid on each side, and also forms a squamous suture with the antero-mesial edges of the frontals, the latter bone being the superficial element in the suture.

The irregularly shaped parethmoid besides its two articulations with the palatine, suturates with the vomer, the anterior end of the parasphenoid, the mesethmoid and the frontal, and articulates with the most anterior of the subocular bones. The sutures are all sutura notha, and the articulations, allowing of a very limited, but definite movement, were perhaps better termed amphiarthroses.

Having now figured and briefly described a typical teleostean palate, in accordance with general usage with the idea of providing a standard for comparison, the new interpretations of the components are stated briefly, and in the following pages are analysed in detail.

THESIS

(1) The maxillae and premaxillae of the majority of teleostean fish constitute an adventitious jaw, and are not homologous with the similarly named bones in other vertebrates.

(2) The labial cartilages well developed in most Elasmobranchs, present in one teleostome, and evanescent in amphibia, are structures homologous with the teleostean maxillae and premaxillae.

(3) The vomer of teleosts is homologous with the premaxillae of other vertebrates, it is certainly not the vomer of other vertebrates.

(4) The anterior portion of the parasphenoid of the teleosts is the homologue of the vomer of other vertebrates.

(5) The palatine of the teleostean skull is the homologue of the maxilla of other vertebrates.

(6) The mesopterygoid is the palatine.

(7) The pterygoid is the quadrato-jugal or jugal.

(8) The quadrate has been correctly homologised.

(9) The metapterygoid is the amphibian pterygoid.

(10) The parasphenoid corresponds to the vomer and pterygoids of the reptile.

(11) The parethmoid is the homologue of the reptilian prefrontal.

In fig. 3 the palate described above is reproduced in outline, bereft of the adventitious jaw. In this drawing the bones have been named in accord with my thesis. The figure is, as it were, a pictorial presentation of the thesis.

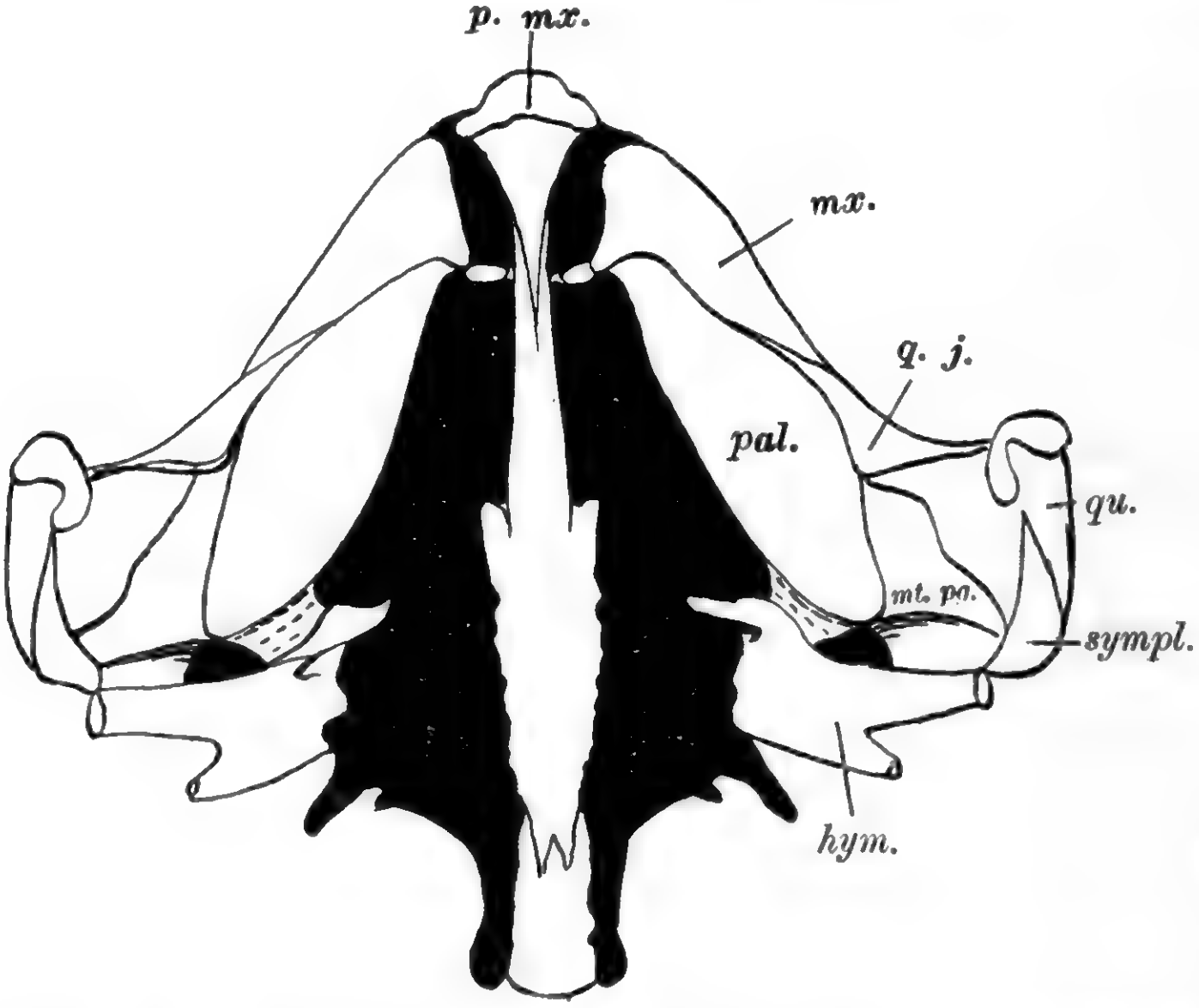

Fig. 3. *Promicrops itaiara*, outline of palate with adventitious jaw bones removed.

Fig. 4 is offered in support of the thesis, it is the same palate deprived of two of the suspensory bones, viz. the hyomandibular and the symplectic. Suspension is now depicted as being affected directly by the quadrate, which is drawn attached in the usual position to the side of the cranium. The metapterygoid has with the rest of the bones in the palate been approximated to the midline, and comes to underlie the parotic region. The palatine has been reduced in extent to create a subocular vacuity and to emphasise the position of the jugal and its relation to the maxilla and to the quadrate. The premaxilla has been provided with a median suture.

This drawing is, of course, hypothetical, but most of the innovations are present in some members of the bony fishes. Thus the approximation of the palatine to the midline is paralleled in *Platycephalus*. In *Lepidosteus* we find the upper jaw attached to the skull by the metapterygoid, and although a hyomandibular and a symplectic are present, it will be shown later that the attachment by the so-called metapterygoid approximates to the attachment shown in the hypothetical drawing. In *Amia* the vomer is paired, as also are premaxillae which are not homologous with the premaxillae of teleostei. In the muraenid eels maxillae and premaxillae are not developed.

Fig. 4, though, as stated, hypothetical, is not merely a figment of the imagination, and may fairly be compared on the one hand with fig. 3, and on the other with amphibian and reptilian palates. It resembles most nearly the amphibian type, and when it is compared therewith one is struck by the absence of the prevomers, so well developed in the amphibian palate, and by the large size of the palatines.

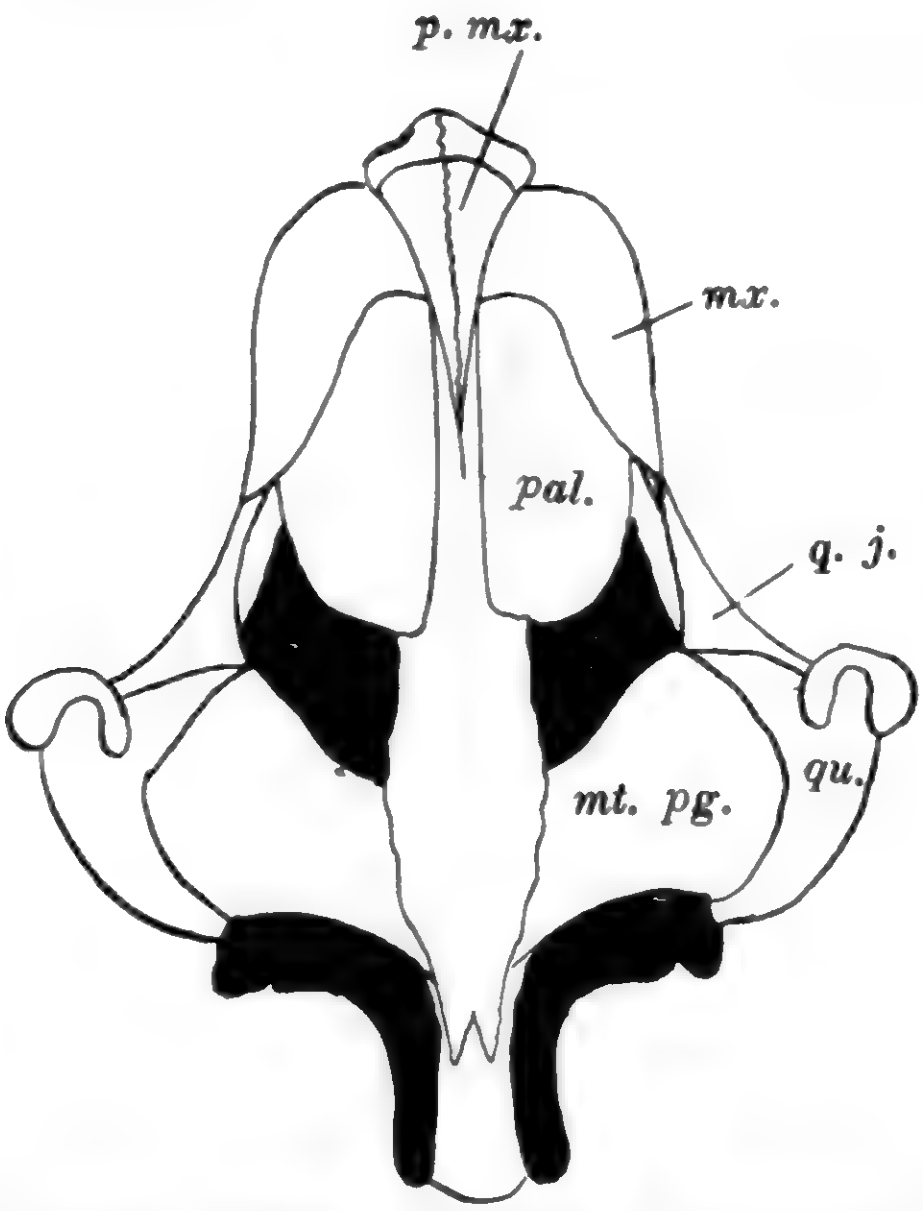

Fig. 4. *Promicrops itaiara*, hypothetical modification of fig. 3.

Fig. 5. *Chelonia midas* (*seu viridis*), median bones of facial skeleton from the side.

A comparison such as suggested serves to emphasise the fact that, granted the new interpretations are correct, the piscine palate falls into line with that of the rest of the vertebrata in all essential respects, with the exception of the suspension by hyomandibular and symplectic. The essential fact which these new interpretations present is that the fish does not differ from other palates in the number of bones which enter into its composition.

The established interpretation of the piscine palate assumed the presence of two bones developed in relation to the subocular arch, whose origin and disappearance phylogenetically was quite inexplainable. They simply come and go in the bony fishes, and are not represented in any way whatever in any other vertebrates.

On the other hand, as soon as we recognise the two jaw bones as peculiar, adventitious jaws, their origin from the labial cartilages of the Elasmobranchs and Cyclostomes is at once comprehensible, and their disappearance may be studied in the various bony fishes and seen in their last stages in that class of vertebrates which probably next most nearly resembles their common ancestor, namely the Amphibians. Moreover, when we study the bones of the palate and attempt to trace them through the vertebrates, we do not now find ourselves with a superabundance of bones developed in relation to the subocular arch, but can trace all the bones through at least two other vertebrate classes.

This general defence of the thesis, admittedly, only stands if the bones, as now interpreted, conform in their adult relations and in their development to the similarly named bones in the rest of the vertebrata, but if in some respects that conformity be not as perfect between piscine and other palates as between those other palates *inter se*, then it is contended that the general considerations just advanced, must give confirmation to what might, in the absence of those considerations, be doubtful homologies.

In short, the general argument advanced is that the fishes, being descended from the same common ancestor as the other vertebrates, the palates of all are builded on a common plan.

Turning again to the established interpretation, we find labial cartilages present in Cyclostomes and Elasmobranchs, *absent* in bony fishes except Polypterus, present in Amphibia and absent in all other vertebrates. This then is a negative discontinuity in the serial homologies no less striking and incomprehensible than the positive discontinuity presented by the *presence* of the two extra pterygoid bones.

It is, moreover, a very emphatic coincidence that in *Polypterus* the only bony fish to retain a labial cartilage in the adult, Allis has argued that the maxillae and premaxillae are not homologous with the similarly named bones of other bony fish, but are homologous with the maxillae and premaxillae of other vertebrates.

THE INDIVIDUAL BONES

1. *Teleostean Maxilla and Premaxilla*

There is no doubt whatever that among the bony fishes the term maxilla has been applied to bones which are not homologous. In *Accipenser* (Parker,

1882) and in *Polyodon* (Bridge, 1878) a bone developed in relation to the subocular arch has been termed the maxilla. Inasmuch as there is no such relationship in the development of the so-called maxilla in the teleostean fishes the two bones cannot be homologous.

The contention that the teleostean maxillae and premaxillae are homologous with the labial cartilages in the elasmobranch fish is based on the relation of both structures to the fore part of the skull and to the lips. Both occupy labial folds which are in front of and lateral to the mouth border proper.

It is true that in teleostean embryos labial cartilages have been described (Parker, *Salmo.* 1873), but their relation to the development of maxillae and premaxillae has not, so far as I am aware, been determined. Their situation is, however, such that they may be generically related to the bones, and, moreover, in certain cases the developing jaw bones are found to have a lamina of cartilage on the posterior surface. In the Cyprinidae Sagemehl describes the development of a bony ossicle, the "os rostrale," in relation to this posterior covering of the premaxilla.

However, whatever be the genetic relation of the teleostean jaw bones to the embryonic labial cartilages, those cartilages are evancescent and in the adult their place is taken by the central ends of the jaw bones.

The similarity in situation of the labial cartilages is best illustrated in those elasmobranch fishes in which the two upper labial cartilages are best developed, and amongst these *Squatina* is a particularly useful example to quote, because the material for comparison is not difficult to obtain, and because there are excellent figures of the skull in Huxley's *Elements* and in Kingsley's *Comparative Anatomy of Vertebrata.* The two drawings are particularly fortunate in that they show not only the position of the cartilages with the jaw closed (Kingsley), but also the manner in which they are drawn down, exactly as do the premaxilla and maxilla, when the jaw is opened, owing to both being situated in the labial folds. It will be seen at once that in *Squatina* if the cartilages were carried forward, or if the snout were a little shorter, the situation of the cartilages would be exactly that of the two jaw bones in the teleostean fishes.

If, in the following pages, it is demonstrated that the piscine vomer and palatine bones are homologous with the maxillae and premaxillae of the tetrapods, that becomes at once an added reason for regarding the piscine maxillae and premaxillae as the homologues of elasmobranch labial cartilages.

2. *The Teleostean and Tetrapod Vomer and Premaxillae*

The premaxillae of the tetrapods present the following features of form and position. Occupying the front segment of the upper jaw they suturate one with the other medially and each with the maxilla laterally. They develop a palatine process which contributes to the formation of the antero-median portion of the bony palate and floor of the nasal organ, this process may or may not suturate with the vomer above, it generally suturates with the prevomers when they are present. In front the premaxillae may (Lacertilia, Ophidia, Aves and Amphibia) or may not (Chelonia, Crocodilia and Mammalia) send a process upward between the anterior nares, anterior nasal process (processus praenasalis, Gaupp), or they may bound the nostril laterally by an ascending posterior nasal process (processus extranasalis, Gaupp). The processus praenasalis suturates with the nasal bones which lie to either side of them. The processus extranasalis is separated from its fellow by the anterior nares, and above it is wedged in between the nasal bone to its inner side and the ascending facial process of the maxilla.

The so-called premaxilla of the teleosts presents one single bony contact, that with the maxilla. This contact is in no sense a suture, but is an amphiarthrosis in which, it may even be, an actual joint cavity is present. This articulation is not situated like the suture in the tetrapods at the lateral edge, but is between the back of the pyramidal process of the premaxilla, and a glenoid cavity on the front of the body of the maxilla, so that the latter bone intervenes between the premaxilla and the rest of the skull.

It may be thought that the medial process of the premaxilla is directly comparable with the tetrapod processus praenasalis. The processus medialis is united by firm fibrous and cartilaginous tissue to its fellow and the two are similarly bound to the central ridge of the mesethmoid, they lie in the same plane as the nasal bones, and in their upper portion lie between the divergent anterior ends of these bones, there is, however, no suture formed, and the interval, which may be quite marked, is filled in by loose connective tissue.

In the tetrapods the nasal bones are situated above the nares and at times extend forward to form their outer border in its upper portion. In the bony fish the nasal bones lie between and, where they are juxtaposed to the processus medialis, are for the most part anterior to the nares.

The processus praenasalis of the tetrapods is by its inner margin in contact with the cartilaginous septum nasi, and in the fish the cartilage which binds the two medial processes to the median ridge of the mesethmoid might be regarded as the homologue of the nasal septum. This, however, is not so, for though it lies between the two nasal sacs it is a secondary fibro-cartilaginous inter-osseous union and is no part of the primary chondrocranium. The structures are analogous but not homologous.

The resemblance between the processus medialis and the processus praenasalis is then purely topographical and not one of true similitude.

The teleostean premaxilla possesses no suture with neighbouring bones, it is separated from the rest of the craniovisceral skeleton by the maxilla and there is no relation to the palatine or vomer. In all these features it differs fundamentally from the tetrapod premaxilla.

It is proposed to compare the teleostean vomer with the tetrapod premaxilla, it will, therefore, be convenient to institute that comparison before dealing with the development of the bones, and then discuss all three together.

Broom has, I believe, satisfactorily established the identity of the mammalian vomer with the reptilian parasphenoid, and I have advanced reasons for regarding the latter as a derivative of the anterior end only, of the amphibian parasphenoid. If these contentions, or if Broom's alone be accepted, the vomerine nature of the teleostean "vomer" is at once disproven. Wilson's masterly analysis of the relations of the prevomer, dumbell bone, in *Ornithorhynchus* (Wilson, 1894) and Broom's own description of the prevomers in *Miniopterus*, would seem to have so sufficiently established the duality of prevomers and vomers and the parasphenoid origin of the true vomer, that it is with surprise that one reads Kingsley's statement that "more evidence is needed on these points" (Kingsley, *l.c.*). However, in view of that statement it would appear advisable to assume for the moment that the application of the name vomer to the teleostean bone signifies homology with the bones that in recent years we have learned to term prevomers. In the reptilia these bones are developed in relation to the inner side and under surface of the paraseptal cartilage. When as in the Chelonians the attachment of the paraseptal cartilage to the lower edge of the septum nasi takes place early and rapidly becomes extensive, the prevomers are developed in relation to the sides of the lower edge of the septum. In the Amphibians there is no paraseptal cartilage, and the floor of the nasal capsule is very early completed, the lower edge of the septum nasi being quite early expanded laterally. Under these conditions the prevomers develop on the under surface of the nasal floor medial to the widely separated nares.

In all these forms the bone is situated under the nasal floor, which in the midline anteriorly is similarly supported by the palatine plates of the premaxillae. In no case does the prevomer extend forward to the anterior limit of the nasal floor.

On the other hand the piscine vomer is situated beneath the most anterior portion of the ethmoid cartilage, which is the homologue in the fish of the nasal floor in the tetrapod. In some cases, Acanthopterygii, actually ossifying the whole of that portion of the cartilage.

There can be little doubt that the piscine vomer is a more anterior element than the tetrapod prevomer and the two structures are not homologous.

In the arrangement of an argument such as the present, wherein each section, being proven, lends support to the contention of the next, there is a tendency to rely upon that support. I am anxious not to fall into such a fallacious method of argument, for though I believe that the reasons advanced are sufficient to justify the view adopted, I am fully aware that the nature of the problem attacked does not admit of absolute proof of the verity of that view, and that the last appeal will always be to the personal equation.

Let us then for the moment *assume* either that the above contention constitutes proof that the piscine jaw bones together form an adventitious jaw not present in the tetrapods, or that no such bones are present in piscine skull, and then examine the situation of the vomer. (See figs. 2 and 3.)

Situated in the centre of the gap in front, it develops a strong median palatine process. Its upper surface forms the floor of the anterior portion of the nasal organ. Its antero-ventral margin is tooth bearing. It is flanked by, and at times suturates with (***Esox***, ***Platycephalus***, ***Sebastodes***) a bone having a palatine lamina, a tooth-bearing border and at times a facial process (***Esox***). In these relations the vomer resembles the tetrapod premaxilla. There is another feature wherein the resemblance is marked. The anterior end of the parasphenoid laterally compressed, vomerine in situation and form, suturates with the upper surface of the palatine plate of the vomer in the midline, and, as already stated, we have strong reasons for believing that anterior portion of the parasphenoid to be the true tetrapod vomer.

The vomer possesses no ascending facial process and there is therefore no suture or articulation with the nasals.

Turning next to the development of these three bones. The teleostean premaxillae are developed as paired ossifications from a membranous stroma, perhaps in relation to the embryonic labial cartilages, quite independently of the chondrocranium, in front of the ethmonasal cartilage.

The teleostean vomer is developed as a single ossification, in membrane as an ectochondral bone to the anterior portion of the ethmonasal cartilage, or endochondrally replacing that cartilage in its anterior portion.

The tetrapod premaxilla is developed in membrane in relation to the front and anterior portion of the floor of the cartilaginous nasal capsule.

Now, of course, if the two bones in front are true premaxillae then the vomer cannot be, but we have seen that they may be quite reasonably regarded as constituting an adventitious jaw derived from the labial cartilages. The relation, situation, and development of the vomer all resemble those of the tetrapod premaxilla, with the single exception of the absence of the premaxilla-nasal suture. It is reasonable to regard the bones as homologous. The vomer is certainly not the vomer of tetrapods and if it be not the tetrapod premaxillae, *then it would appear to be a bone present in the bony fishes and unrepresented in all other vertebrates.*

3. *The Teleostean Maxilla and Palatine, and the Maxilla of the Tetrapods*

In the tetrapods the maxillae present the following features. Situated on either side of the premaxillae they constitute the greater part of the gape. They suturate with the premaxillae in front and with the jugal behind. Its extensive palatine lamina suturates with that of premaxilla, with the palatine bone and commonly with the prevomers. A well developed ascending facial process forms more or less of the side wall of the nasal organ, and suturates with the processus extranasalis of the premaxilla, the nasal bone, and with the frontal or prefrontal. Above the jugal and below the frontal suture the maxilla commonly articulates with the lachrymal. Mesial to the lachrymal, there may be union with the ethmoid. There is a maxillo-vomerine suture along the inter-maxillary suture for more or less of the length of the palatine plates, when these meet in the midline and a true vomer is present. Though in man and the apes the maxilla participates in the boundary of the orbit, this is unusual in Mammalia, but the rule in the rest of the tetrapods.

The teleostean maxilla does not suturate with any bone. By amphiarthrosis as we have already seen it articulates with the back of the pyramidal process of the premaxilla and by fibrous and cartilaginous tissue it is loosely but firmly bound to the vomer and mesethmoid. Also by amphiarthrosis it articulates with the maxillary process of the palatine. This latter articulation is in no way similar to the sutural connection between palatine laminae of the maxillae and palatine bones in the tetrapods.

Comparing these two brief descriptions it is apparent that there are no features of similitude in their relations. True, both bear teeth and both may be said to be situated in the gape. I would contend that the teleostean bone is morphologically outside the gape.

The palatine bone of the teleosts articulates with the parethmoid of its side by two fibro-cartilaginous amphiarthroses, and by amphiarthrosis or suture with the lateral edge of the vomer. The root of the maxillary process forms an incomplete, low side wall for the nasal cavity. It will be shown later that there are very real reasons for regarding the parethmoid as the homologue of the prefrontal of the reptiles[1]. Though there is no articulation of the palatine with the frontal or nasal, there is yet in its situation and relation to other elements sufficient evidence to justify the statement that it is more probably homologous with the tetrapod maxilla than is the so-called teleostean maxilla. Especially is this so if it be admitted that the so-called vomer is in truth a premaxilla.

This statement appears to receive further support from the development of the three bones.

The teleostean maxilla is developed, as has already been stated, quite independently of and not in juxtaposition with the chondrocranium.

The teleostean palatine is the most anterior of the bones developed in relation to the outer side and under surface of the palatine portion of the subocular arch, is, in fact, developed around the place of attachment of that arch to the lateral expanse of the ethmoid.

The tetrapod maxilla is developed in relation to lateral plates of the ethmonasal cartilage, and to the anterior attachment of the subocular arch, when that is present.

The teleostean palatine and tetrapod maxilla in their developmental history present much greater similitude than do the latter bone and the teleostean maxilla.

In view of all the facts it is reasonable to regard the teleostean palatine and the tetrapod maxilla as homologous bones.

---

[1] This is not a new idea. Sagemehl is quoted by Allis (1898) as applying the name prefrontal to the parethmoid in Amia. Allis himself adopts the name in the explanation of his figures in the Scomber paper, 1903.

4. *The Teleostean Mesopterygoid and the Palatine of the Tetrapods*

If the homologies arrived at in the last section hold good, then it becomes necessary to seek in the fish palate for the homologue of the tetrapod palatine. A similar statement might be made at the beginning of each section of the analysis of the topography and development of the individual bones, but would make the whole argument hinge on section 1. For that reason this form of argument is not stressed in any other section, though believed to be good.

The tetrapod palatine is found in the palate, suturating with the palatine plates of the maxilla, between and behind which they are placed. There is a median inter-palatine suture. There is commonly sutural connection with the prevomer in front. The vomer when present as a separate entity suturates with both palatines along the dorsal aspect of the inter-palatine suture.

The palatine may suturate with the vomerine anterior end of the parasphenoid, or with the anterior end of the pterygoids. There is commonly a suture along the posterior border of the bone with the os transversum, when that bone is present.

Now, it will be found that, unless the conclusions of the previous and subsequent sections of this analysis be accepted as presenting the correct interpretations and homologies of the bones in the fish palate, then the adult mesopterygoid does not possess one single relation to surrounding bones in common with the palatine of the tetrapods. This, however, is the only homology argued which is dependent in the adult condition on the acceptance of the other sections. Even here, moreover, the new idea is supported by the development of the two bones.

The palatine bone of the amphibians is developed in relation to the ventral and medial surface of the anterior end of the subocular arch, extending thence across the under side of the posterior region of the expanded nasal floor.

The mesopterygoid of the fish is developed in relation to the same portion of the subocular arch, there being no expansive nasal floor, that relation does not occur, and the bone extends medially and backward to contribute largely to the formation of the bony palate, and in this *situation* it resembles strongly the palatine of the reptiles.

5. *The Teleostean Metapterygoid, the Amphibian Pterygoid and the Reptilians Os Transversum*

I have in an unpublished paper argued the homology of these bones and need not again canvass the subject. It is sufficient to state here that the arguments then adduced in favour of the homologies were and are quite independent of anything advanced in the present contribution. It is intended here to regard those homologies as already established.

6. *The Teleostean Pterygoid and the Quadrato-Jugal of the Tetrapods*

The pterygoid bone in the fishes suturates with the quadrate, with the metapterygoid, the mesopterygoid and the palatine. In the tetrapods the quadrato-jugal is sutured to the quadrate behind and to the maxilla or jugal in front, and at times just reaches the hinder end of the palatine. Both bones are developed ectochondrally in relation to the subocular arch immediately in front of the quadrate. (Compare especially the development in the amphibian skull.)

The situation of the two bones is essentially the same, such differences as are present are directly due to the expansive development of the other two pterygoid bones, which, meeting one another and the pterygoid, fill in the area where, in the tetrapods, we find the suborbital vacuity. If one imagine an amphibian in which, to the condition present in the *Ichthyophis*, there were added the broad posterior portion of the pterygoid present in *Branchiosaurus*, then would the quadrato-jugal be in contact along its length with the quadrate, the pterygoid, the palatine and the maxilla. That is to say with the quadrate behind, the maxilla in front, and the other two bones developed in relation to the subocular arch between these two. On the other hand, if we imagine the reverse process applied to the fish palate, and devise a subocular vacuity, then we have a quadrat-jugal suturing with the quadrate behind and with the two bones developed in relation to the inner and outer aspect of the point of attachment of the subocular arch to the ethmo-nasal cartilage.

If, finally, we add to these arguments those advanced in the previous sections, then the weight of probability lies with the contention that the piscine pterygoid is the homologue of the tetrapod quadrato-jugal.

7. *The Teleostean Parethmoid, the Reptilian Prefrontal and the Mammalian Lacrymal*

As previously indicated the name prefrontal has already been applied to the parethmoid by more than one writer. Thus Swinnerton (1902, p. 531) says: "In the higher vertebrates the squamosal, post frontal and *prefrontal* are purely dermal bones, but the bones in the teleostean skull to which these names are frequently applied, viz. pterotic, sphenotic and *parethmoid*, are cartilage bones with a possible dermal origin." I am not aware of any extended defence of the homology assumed by the procedure, and therefore believe that an analysis of their development and relations is desirable. The nomenclature has not found acceptance in the text books. Kingsley gives it qualified acceptance. In the text the bone is referred to as the ectethmoid, and in the explanation of the drawing of Scomber skull he follows Allis and terms it the prefrontal.

In the adult skull (fig. 2) the piscine parethmoid is sutured to the vomer, the mesethmoid, the frontal and the front of the parasphenoid. The vomer is below it in front, the mesethmoid is to its inner side and in advance of it, the frontal is above and behind it, whilst the parasphenoid suturates with its lower medial edge. Its situation relative to the orbit behind and the nasal organ in front is, as in the case of the reptilian, prefrontal. It forms the anterior perpendicular wall and anterior moiety of the roof of the orbit and the posterior wall of the cavum nasi. The superior naso-tectal process which in the reptiles forms the posterior portion of the roof of the cavum nasi is, however, not developed to protect the teleostean nasal capsule, and there is no articulation with the nasal bone medially above the organ. The olfactory nerve reaches the olfactory sac by passing forward through a sulcus on the inner margin of the bone, or it perforates the inter-orbito-nasal plate of the bone near its inner margin. Sensory branches of the fifth and seventh nerves pass forward to the snout through a foramen or a sulcus on the inner margin of the same plate above the olfactory nerve. Below, the parethmoid presents two facets for the articulation of the palatine, and one for the anterior periocular scute, (subocular bone).

In most of these features the resemblance to the reptilian prefrontal is very striking, especially is this so if it be kept in mind that a greater or lesser degree of dissimilarity must result from the increasing size and complexity of the nasal organ.

In the reptiles the prefrontal is sutured to the frontal above, and with the ascending, facial, process of the maxilla below. It may suturate with the nasal in front of the frontal. The lower margins of the inter-orbito-nasal plates suturate with the palatines.

The olfactory nerve enters the sac by passing forward against the upper end of the inner margin of the inter-orbito-nasal plate. The sensory fibres of V and VII also pass that margin as they enter the bony nasal capsule, on their way to the front of the snout.

The large reptilian nasal capsules have, as it were, been excavated out of solid sub-, retro-, and inter-nasal ethmoidal cartilage, which in the fish either remains as such encased in mesethmoid, parethmoid, and vomer, or is replaced by these as massive bones. The mesethmoid bone has gone, and is represented by the hinder portion of the cartilaginous nasal septum, later to reappear in the mammals as the perpendicular plate of the ethmoid.

If in the fish skull the mesial portion only of the mesethmoid were present, there would be no contact of that bone with the two parethmoids, and an inter-parethmoidal vacuity would result, absolutely comparable with the inter-prefrontal vacuity in the hinder wall of the cavum nasi of the reptiles.

If, further, in the fish skull the expanding nasal organs should excavate the ethmoid cartilage right down to the dorsal surface of the bony palate, and at the same time develop large anterior nares at that level, the portion of the vomer which articulates with the parethmoid would be abolished.

Under these circumstances the piscine parethmoids would suturate with the frontals above and with the parasphenoid below.

The suture with the vomerine anterior end of the parasphenoids reproduced in the crocodilian skull, where the conjoint pterygoids retain the archaic parasphenoid features and the prefrontal bones articulate with the vomerine portion of the bone (Kesteven, 1919).

As against so many features of similarity, the fact stated by Swinnerton (*l.c.*) that the parethmoid is a cartilage bone with a possible dermal origin, whilst the reptilian prefrontal is a purely dermal bone, cannot be conceded the greater weight. From several investigators, more especially Sewertzoff, Sagemehl and Gaupp, we have learned that more than one of the cartilage bones is phylogenetically of dermal origin.

It is to be concluded then that the piscine parethmoid and the reptilian prefrontal are in all probability homologous bones.

Fig. 5 is offered for comparison with fig. 2.

In view of the facts and observations advanced by Gaupp it would appear that the bone which palaeo-osteologists have designated prefrontal in the Cynodonts would be more correctly termed preorbital, and that the prefrontal is really that which has been designated lacrymal. I would endorse Gaupp's conclusion that the reptilian prefrontal is the homologue of the mammalian lacrymal, and accept his term "adlacrymal" for the variable "lacrymal" of the reptilian skull.

It was intended to offer some observations on several of the more aberrant piscine palates, but material which I had hoped for has failed to reach me, and this matter is therefore reserved for a future contribution, when I shall have had an opportunity of dissecting heads of *Amia*, *Lepidosteus*, Accipenserids, and perhaps, if one of my confreres reading this will assist me, also *Protopterus*.

BULLAH-DELAH,
NEW SOUTH WALES.
January 1921.

BIBLIOGRAPHY

ALLIS (1897). "The cranial muscles and cranial and first spinal nerves in *Amia calva*." *Jour. Morph.* vol. XII. No. 3, p. 487.

—— (1898). "The morphology of certain bones of the cheek and snout of *Amia calva*." *Jour. of Morph.* vol. XIV. No. 3, p. 425.

—— (1903). "The skull and the cranial and first spinal nerves and muscles in *Scomber scomber*." *Jour. of Morph.* vol. XVIII. Nos. 1 and 2, p. 45.

BRIDGE (1879). *Phil. Trans. Roy. Soc.* (On *Polyodon*), vol. CLXIX. p. 683.

BROOM (1896). "On the Homology of the Palatine Process of the Mammalian Premaxillary." *Proc. Linn. Soc. N.S.W.* vol. X. p. 477.

—— (1902). "On the Mammalian and Reptilian vomerine bones." *Proc. Linn. Soc. N.S.W.* vol. XXVII. p. 545.

GAUPP, E. (1905). "Neue Deutungen auf dem Gebiete der Lehre vom Saugetierschädels." *Anat. Anz.* Bd. XXVII. p. 273.

KESTEVEN, H. L. (1916). "The relations of the Amphibian Parasphenoids." *Jour. of Anatomy and Physiology*, vol. L. p. 303.

Kesteven, H. L. (1919). "The pterygoids in Amphibia and Reptiles and the parasphenoids." *Jour. of Anat.* vol. LIII. p. 223.

Kingsley, J. S. (1919?). *Comparative Anatomy of the Vertebrates.* (2nd edition). London. Undated.

Parker, W. K. (1873). "On the structure and development of the skull in the Salmon." *Phil. Trans. Roy. Soc.* vol. CLXIII. p. 95.

—— (1882). "On the structure and development of the skull in the Sturgeon." *Phil. Trans. Roy. Soc.* vol. CLXXIII. p. 139.

Sagemehl (1891). "Das Cranium der Cyprinoiden." *Morph. Jahrb.* Bd. XVII. Hft. 4, p. 489.

Swinnerton, H. H. (1902). "A contribution to the morphology of the teleostean head skeleton." *Quart. Jour. Micr. Sci.* vol. XLV. p. 503.

Wilson, J. T. (1894). "Observations on the anatomy and relations of the dumb-bell bone in Ornithorhynchus." *Proc. Linn. Soc. N.S.W.* vol. IX. p. 129.

ABBREVIATIONS

a. alisphenoid; *b.* basi-occipital; *ba.* basi-sphenoid; *ec.eth.* ect-ethmoid; *epi.* epi-otic; *eth.* mesethmoid; *ex.* ex-occipital; *f.* frontal; *hym.* hyomandibular; *mes.pg.* mesopterygoid; *mt.pg.* metapterygoid; *mx.* maxilla; *mx.proc.* maxillary strut of the palatine; *oc.* anterior periocular; *op.* opisthotic; *p.* parietal; *p.f.* prefrontal; *p.mx.* premaxilla; *p.op.* preopercular; *p.vo* prevomer; *pa.sph.* parasphenoid; *pal.* palatine; *pg.* pterygoid; *proot.* prootic; *pt.* pterotic; *q.j.* quadrato-jugal; *qu.* quadrate; *s.* supraoccipital; *sph.* sphenotic; *su.* sulcus hyomandibularis (for attachment of the hyomandibular bone); *sym.* symplectic; *vo.* vomer.

ON TRUNCATED UMBILICAL ARTERIES IN SOME INDIAN MAMMALS

By BASANTA KUMAR DAS, M.Sc. (Allahabad),
Zoological Department, Muir Central College, Allahabad, U.P., India.

In Volume LIV of this *Journal*[1] Dr W. N. F. Woodland described and figured, as an unique anatomical fact, the blindly-ending umbilical arteries of the common Indian goat. As he remarked, it is difficult or impossible to call to mind "any other instances in Vertebrates of arteries ending blindly in this fashion." In February of this year I was engaged in examining a very abnormal female puppy (pariah dog) and I noticed that the umbilical arteries also ended blindly in this type. Dr Woodland then suggested to me that it might be worth while to examine systematically as many Indian mammals as I could obtain to ascertain if these truncated umbilical arteries are the rule in India. Acting on this suggestion I have examined 28 species of Indian mammals, and in 26 of these truncated umbilical arteries were found to exist.

Roughly speaking, these truncated umbilical arteries can be separated into two groups: (1) those which are of approximately uniform diameter from their origin to their extremity, and (2) those which diminish in diameter to some extent towards their extremity.

THE YOUNG DOMESTIC PIG (*SUS CRISTATUS*, DOMESTICATED) AN EXAMPLE OF A MAMMAL POSSESSING TRUNCATED UMBILICAL ARTERIES OF UNIFORM DIAMETER.

Each truncated umbilical artery (text-fig. 1, *TUA*) in the very young domestic pig (one ♂ specimen, about four days old, examined) arises, as usual, as the external division of the two branches into which the dorsal aorta bifurcates at its posterior limit. The diameter of these arteries, near the point of their origin, is approximately three times that of the internal iliac arteries (*INTIL*)—a superiority in size which is apparently found in all *young* mammals and in them only: in all adult mammals the internal iliacs are either equal in calibre to the umbilical arteries or larger. These truncated umbilical arteries, invested by the peritoneal folds, become, after a short course, slightly dilated (here giving off the small arteries—*UMA*—to the uterus masculinus) and then, reverting to their original diameter (which is maintained throughout their length), run straight backwards to the bladder (*B′*), to the wall of which they are loosely attached. Vesical arteries (*VESA*), two on each side, are given off from the upper half and on the inner side of each umbilical artery.

---

[1] Part 4, p. 309, 1920.

OTHER EXAMPLES OF TRUNCATED UMBILICAL ARTERIES OF UNIFORM DIAMETER

Bos bubalus and *Bos indicus*.

The only particular in which the truncated umbilical arteries of the buffalo, *Bos bubalus* (half a dozen specimens examined, three ♂ and three ♀), and the bullock, *Bos indicus* (half a dozen specimens examined, three ♂ and three ♀) differ from those of the young pig is that the arteries, instead of running straight backwards, have, unlike those of the pig, a slightly sinuous course and do not come into contact with the bladder, as shown in text-fig. 2. Curiously enough, in these species, three to four very fine vesical arteries (text-fig. 2, *S*) are given off from the very extremity of the umbilical arteries and run close together in the peritoneal folds on their way to the bladder. The equal calibres of the internal iliacs and umbilical arteries are clearly shown.

Boselaphus tragocamelus.

There is one interesting feature to be noted in the nilgai or blue bull, *Boselaphus tragocamelus* (two specimens examined, both ♂). The vesical arteries (text-fig. 3, *VESA*), five to ten in number, soon after their origin from the truncated umbilical arteries, anastomose to a slight extent, as represented. The truncated umbilical arteries are slightly narrower in external diameter than the internal iliacs, and the left one (*LTUA*) in an abnormal male specimen was nearly twice the length of the right one (*RTUA*), but in normal individuals both the truncated arteries are equal in length (the normal condition is shown on the left-hand side of the figure, *RTUA*), and do not come into contact with the anterior part of the bladder, as is also the case in the bullock and the buffalo. In the abnormal umbilical artery (*LTUA*) the truncated end was continued on as a tag-like muscular process (*M*) in which ran two small arteries (*G* and *H*), given off from the hinder end of the left truncated artery. I did not ascertain the connections of the muscular process or the contained arteries. A couple of very fine twigs (*D* and *E*) was given off from one (*H*) of these small arteries to supply the posterior wall of the left truncated artery, as shown.

Felis torquata (domesticated).

The truncated umbilical arteries of the bazaar cat, the domesticated *Felis torquata* (four specimens examined), are very similar to those of the young pig, the only point of difference being that the truncated vessels (of the same diameter as the internal iliacs) do not pursue a straight course, but curve round (over a fatty mass lying in contact with the urinogenital organs) in the manner shown in text-fig. 4. Six vesical arteries are given off from their lower extremities. I might also add that under certain abnormal conditions both the truncated umbilical arteries, as well as the internal iliacs, may be given off from a single main vessel arising either from the right division of the dorsal aorta (as found in an abnormal ♂ specimen) or from the left division (as found in an abnormal ♀ specimen).

Felis pardus.

In the panther, *Felis pardus* (two ♂ specimens examined), the truncated umbilical arteries (smaller in calibre than the internal iliacs) run almost straight down to the bladder, the blind extremity of each artery being slightly dilated, and from the inner side of each dilated end a fine vesical artery (text-fig. **5**, ***T***), in addition to a main vesical artery (*VESA*) coming off from its upper half, is given off to the bladder.

Platanista gangetica.

The truncated umbilical arteries of the Gangetic dolphin, *Platanista gangetica* (one ♀ specimen examined), are of the same diameter as the internal iliacs at their origin, run towards the bladder in a slightly curved course (as observed in a preserved specimen and represented in text-fig. 7) and are intimately connected with the anterior end of the bladder, differing in this last respect, from the arteries of the pig, the cat and the panther. Two vesical arteries (*VESA*), as well as from one to four uterine arteries (*UTA*), are given off from the truncated umbilicals. Other noteworthy facts are that there are no external iliac arteries (due to the absence of the posterior limbs) and that the caudal (*CA*), as well as the internal iliac arteries (*INTIL*), soon after their origin, break up into the well-known arterial "retia mirabilia" (*PA*), the caudal plexus being continued into the wide haemal canal.

Canis familiaris (Pariah dog).

The truncated umbilical arteries in the adult pariah dog pursue a straight course for the greater part of their length, but are much convoluted towards their extremity, in which region they are also intimately connected with the bladder wall. It is important to note that in the pariah dog puppy the umbilical arteries are at least equal in diameter to the internal iliac arteries, but that in the adult they are distinctly smaller. The same fact is seen in the pig as already stated, and has also been observed in the young porcupine.

Another important feature to note concerning the umbilical arteries of the Indian dog is that in both the puppy (three examples) and the adult (two examples) the blind terminal portions have the lumen largely filled with hard greenish translucent granular matter—like sand in consistency. In the puppy the granular matter occupied about the last fifth of the blind artery; in the adult the granule-occupied region was relatively smaller. This granular matter was non-crystalline and was found to be insoluble in chloroform, alcohol, glacial acetic acid and even in aqua regia, though the last caused the granules to disintegrate and to evolve a small quantity of gas (CO_2?). The origin and nature of this refractory granular matter are at present undetermined, but the deposit must be a result of the separation-out from the blood of the blood pigments—a process which, occurring as it does in the living animal, is in itself of considerable physiological interest. It remains to be mentioned that the wall of the portion of the artery containing the granular matter was deeply tinged with brown colouring matter, and that I have found no other instances of this granular matter in the umbilical arteries of other Indian mammals.

Macacus rhesus.

I have figured (text-fig. 6) the condition of the umbilical arteries in the common brown monkey, as an example of a primate.

Camelus dromedarius.

In the single-humped camel, *Camelus dromedarius* (one ♂ specimen examined), the truncated umbilical arteries appear to be similar to those described for the young domestic pig, save that, in the specimen examined (which I think was abnormal), the right truncated umbilical artery and the right internal iliac artery take their origin separately from the posterior end of the dorsal aorta. Both the truncated arteries are, as usual, smaller in calibre than the internal iliacs and do not reach the bladder, although the posterior end of the left truncated artery was continued on as a muscular process (as in the abnormal nilgai already described above) which was attached to the wall of the bladder.

Pteropus medius and *Vespertilio muricola.*

It is interesting to note that in two of the common representatives of the Indian cheiroptera, e.g. the Indian fruit-bat or "flying-fox," *Pteropus medius* (five specimens examined, all females) and the mustachioed bat, *Vespertilio*

DESCRIPTION OF FIGS. 1—8

Fig. 1 (× 2): ventral aspect of the truncated umbilical arteries of uniform diameter in the young domestic pig, *Sus cristatus*, domesticated; fig. 2 (× 1): the same in the bullock, *Bos bubalus*; fig. 3 (× 1): the same in the abnormal male nilgai or blue bull, *Boselaphus tragocamelus*; fig. 4 (× 3): the same in the bazaar cat, *Felis torquata*, domesticated; fig. 5 (× 1): the same in the panther, *Felis pardus*; fig. 6 (× 2): the same in the brown monkey, *Macacus rhesus*; fig. 7 (× 3): the same in the Gangetic dolphin, *Platanista gangetica* (in this figure the umbilicals are represented as having been pulled to the left of the median line); fig. 8 (× 1): ventral aspect of the truncated umbilical arteries (with diminishing calibre) in the doe of *Antilope cervicapra* ("black buck").

B, bladder (contracted); *B′*, contracted bladder turned backwards; *CA*, caudal artery; *CIL*, common iliac artery; *D*, small artery given off from the vessel *H*; *EXIL*, external iliac artery; *FA*, small artery to the fat body; *G* and *H*, small arteries running along the muscular process; *INTIL*, internal iliac artery; *LTUA*, left truncated umbilical artery; *M*, muscular process attached to the posterior extremity of the left truncated umbilical artery; *MA*, small artery to the mesentery; *PA*, arterial plexus of the caudal and the internal iliac arteries; *PM*, posterior mesenteric artery; *PMS*, artery supplying the muscles of the pelvic cavity; *PT*, artery supplying the proximal region of the thigh; *PTD*, posterior trunk of the dorsal aorta; *RTUA*, right truncated umbilical artery; *S*, small vesical arteries from the posterior extremities of the truncated umbilical arteries; *SPM*, spermatic artery; *T*, small vesical artery given off from the dilated extremity; *TUA*, truncated umbilical artery; *UMA*, artery to the uterus masculinus; *UTA*, uterine artery; *VESA*, vesical artery; *VGA*, vaginal artery. The centimetre scale indicates the amount of reduction in size that has occurred in reproducing the figures.

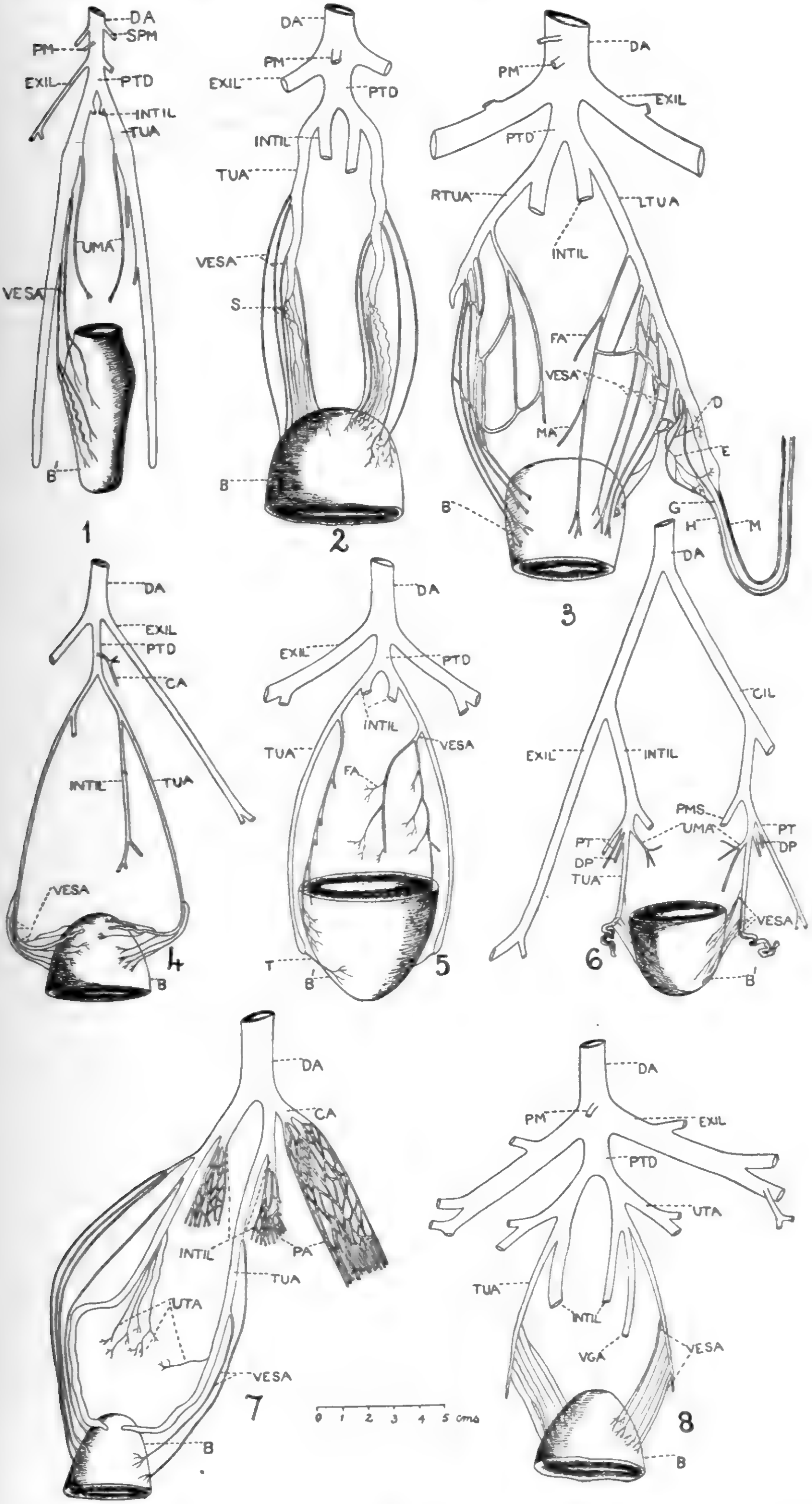
DA
SPM
PM
EXIL
PTD
INTIL
TUA
UMA
VESA
B
1
DA
PM
EXIL
PTD
INTIL
TUA
VESA
S
B
2
DA
PM
EXIL
PTD
RTUA
LTUA
INTIL
FA
VESA
MA
D
E
G
H
M
B
3
DA
EXIL
PTD
CA
INTIL
TUA
VESA
B
4
DA
EXIL
PTD
INTIL
TUA
VESA
FA
T
B
5
DA
CIL
EXIL
INTIL
PMS
UMA
PT
DP
TUA
VESA
B
6
DA
CA
INTIL
PA
TUA
UTA
VESA
B
7
0 1 2 3 4 5 cms
DA
PM
EXIL
PTD
UTA
TUA
INTIL
VGA
VESA
B
8

Figs. 1—8

muricola (two specimens examined, both males) the umbilical arteries are of the usual truncated type[1]. They are slightly smaller in calibre than the internal iliacs and do not reach the bladder. The vesical arteries are apparently given off from their hinder extremities.

Equus caballus (India), *Equus asinus* (India) and *Ovis vignei.*

The only other types which I have examined and which are to be included among those possessing the truncated umbilical arteries of uniform diameter are the Indian horse, ass and sheep, and the truncated umbilical arteries in these types require no special description, the vesical arteries not arising from the extreme tip of artery.

TRUNCATED UMBILICAL ARTERIES WHICH DIMINISH IN DIAMETER DISTALLY

Antilope cervicapra.

As an example of the second type of truncated umbilical arteries it may be mentioned that in the doe of *Antilope cervicapra* ("black buck"—one specimen examined) the two arteries (text-fig. 8, *TUA*), smaller in calibre than the internal iliacs, gradually taper from the point of origin towards their posterior extremities which are loosely connected with the wall of the bladder. These truncated arteries have terminally a slightly sinuous course and give off six to seven vesical arteries. It is a curious fact that the left internal iliac artery (near the origin of the common vaginal artery) is much narrower in calibre than the right internal iliac (on which side there is no vaginal artery).

Semnopithecus entellus.

In the langúr or hanúmán monkey, *Semnopithecus entellus* (one ♀ specimen examined) the truncated umbilical arteries, instead of gradually diminishing in calibre, become slightly dilated at about two-thirds of the distance from their origin and then suddenly become very narrow (and convoluted) before terminating. A single vesical artery arises from each umbilical in the latter third of its length.

Some common local rodents.

In some common local rodents (except the common Indian rat) such as the hare, *Lepus ruficaudatus* (four specimens examined, two ♂ and two ♀), the palm-squirrel, *Sciurus palmarum* (two specimens examined, both ♂) and the porcupine, *Hystrix leucura* (four specimens examined, one adult ♂, two young ♂ and one young ♀) the truncated umbilical arteries (smaller in diameter, as usual, than the internal iliac arteries in the adult) have gradually tapering extremities which are so intimately associated with the wall of the bladder that (save in the hare) they are not easily visible with the naked eye. Strange

---

[1] In most cases the truncated umbilical arteries in these cheiroptera are wholly or only partially covered with black pigment cells.

to say, in the common Indian rat, *Mus rattus* (six out of eight specimens examined, one adult and two young ♂, and three adult and two young ♀) the truncated umbilical artery was present on the *right* side only, there being *no truncated artery on the left side.* This remarkable truncated umbilical artery of the right side (slightly smaller in calibre than the right internal iliac artery) was a thread-like structure white in colour save for its posterior extremity, which was tinged with deep brown pigment. On the left side, however, a small vesical artery was given off from the left internal iliac artery, which evidently capillarised over the wall of the bladder, the latter being also supplied by several minute vesical arteries, as usual, given off from the truncated umbilical artery. Lastly, I must state that in two rats (one ♂ and one ♀) I was unable to detect any truncated umbilical artery on either side.

Other types.

In addition to the preceding mammals possessing tapering truncated umbilical arteries the following may be mentioned without special description: the Indian wild boar, *Sus cristatus*[1] (one adult ♂ specimen examined), the jackal, *Canis aureus* (two specimens examined, one adult ♂ and one young ♂), the Indian fox, *Vulpes bengalensis* (one ♀ specimen examined), the Indian palm-civet, *Paradoxurus niger* (two specimens examined, one adult ♂ and one young ♀) and the common Indian mongoose, *Herpestes mungo* (two specimens examined, one ♂ and one ♀).

TWO INDIAN MAMMALS NOT IN POSSESSION OF TRUNCATED UMBILICALS

Pteromys inornatus.

In one badly preserved male specimen of a less common rodent, viz. the large red flying-squirrel, *Pteromys inornatus*, from the Simla Hills, I could detect no truncated umbilical arteries, though such may exist.

Crocidura caerulea.

In the common Indian insectivore, the grey musk shrew or musk-rat, *Crocidura caerulea* (four specimens examined, two ♂ and two ♀), I was unable to detect any truncated umbilical artery, but small vesical arteries were given off from one of the branches of the internal division of the common iliac artery.

FEATURES IN THE HISTOLOGY OF THE TRUNCATED UMBILICAL ARTERY

(1) The lumen of the truncated umbilical artery is much smaller relative to that of such a normal artery as the internal iliac: e.g. in the jackal the diameter of the umbilical artery at its anterior end is only 1/31 of that of

---

[1] Probably the adult domesticated pig has also tapering truncated umbilical arteries, so differing from the young individual.

the internal iliac, in the porcupine 1/25, civet cat 1/13, pariah dog 1/10, "black buck" 1/6, langúr monkey ¼, mongoose 1/3, panther and *Macacus rhesus* 1/25 and the bullock ½.

(2) As a general rule the walls of the umbilical arteries are thicker (absolutely) than those of the internal iliac arteries (from 1·2 to 3·5 times as thick); only in the porcupine, *Hystrix leucure*, were the walls of the two arteries of the same thickness. The thickening in some cases occurs in the middle coat (*tunica media*) of the artery (jackal, camel, panther, civet cat); in others in the outer coat (*tunica adventitia*) of the artery ("black buck," nilgai, horse, ass, bullock, wild boar, cat); in others both coats thicken (macacus, langúr monkey and dog). In the porcupine the walls of the umbilical artery are not thicker than those of the internal iliac. All these statements are founded on accurate measurements of transverse sections of the arteries.

(3) Posteriorly the lumen of the truncated umbilical artery gradually narrows and becomes broken up into small intercommunicating spaces which finally terminate towards the tip, the centre of the artery being occupied with a core of muscle.

CONCLUSION

The presence of these truncated thickened umbilical arteries in such a large number of Indian mammals is of considerable interest to the student of embryology and possibly of physiology. It is possible that this feature is correlated with existence in a tropical climate, but we cannot assume this until it is known whether mammals in other tropical countries possess similar umbilical arteries. It is difficult to suppose that these persistent embryonic structures perform any function in connection with the bladder, though it would be pleasing to imagine that they had something to do with the conservation of the water of the urine. It is probable that these umbilical arteries are merely conspicuous embryonic vestiges and have no particular function, and this view is supported by the facts that in young mammals they are very much larger, relative to the internal iliacs, than those found in adults, the lumen in the adult umbilical artery being very reduced in size.

In conclusion I wish to express my great indebtedness to Dr W. N. F. Woodland for his kind criticisms and advice, and the keen interest he has taken in my work. My best thanks are also due to him for assistance in writing up this paper.

EARLY DEVELOPMENT AND PLACENTATION IN *ARVICOLA* (*MICROTUS*) *AMPHIBIUS*, WITH SPECIAL REFERENCE TO THE ORIGIN OF PLACENTAL GIANT CELLS

By G. S. SANSOM, B.Sc.

Honorary Research Assistant, Department of Anatomy, University College, London.

INTRODUCTION

This work was begun in 1913 at the suggestion of Professor J. P. Hill, partly on material belonging to him and partly on that collected by myself. At that time we had no early stages in our possession and it was not until the Spring of 1919 that I was able to obtain a sufficiently complete series.

The water voles, in the wild state, were killed during the months of March and April when their first breeding season occurs. The ovaries and uteri were, in every case, removed immediately after death and placed in fixing fluids. Of the latter, the following gave the most satisfactory results:

(i) Bouin's picro-formol acetic.

(ii) Alcohol sublimate-acetic mixture, consisting of 60 parts absolute alcohol, saturated with $HgCl_2$, 30 parts chloroform, 10 parts glacial acetic acid.

One of the finer cytological fixatives would have been most valuable but, owing to the nature of development in these rodents, the embryo is shut off from the uterine lumen by a considerable thickness of compact tissue and a fixing agent of great penetrative power was essential.

The ovaries and uteri were cut in serial sections, some at 8μ some at 10μ. Where, as in later stages, a complete series was not necessary, some sections were cut at 5μ thickness.

Throughout the work I am very greatly indebted to Professor J. P. Hill for much kind assistance, advice and encouragement.

I am also indebted to Mr F. J. Pittock of University College for advice on photographic matters connected with my preparation of the photomicrographs.

The early development and placentation of *Microtus amphibius* does not appear to have been worked out hitherto, but with the material now available it is possible to form a clear view of the general course of events.

In the allied species of voles, *Arvicola agrestis* and *Arvicola arvalis*, a certain amount of work has already been published, but my own observations are not in complete agreement with those of Disse as regards the uterine changes and origin of the giant cells, which latter form such a conspicuous feature in the placentae of these rodents. Kupffer and Biehringer have described for the Field Vole and Water Vole respectively, the so-called "inversion of the germ layers," the reason for, and significance of, this "inversion" is now so well understood that I shall not do more than refer to this aspect of development in the water vole. Considerable space, however, is devoted to a description of the origin and significance of the giant cells which play such an important rôle in the placentation of Microtus.

CHANGES IN THE UTERINE TISSUES PRIOR TO ATTACHMENT

Externally little change is visible to indicate the presence of early developmental stages. A number of voles killed during the breeding season exhibited localised dilatations of the uteri, which suggested the presence of blastocysts, but examination of the ovaries and Fallopian tubes in section indicated that the uteri were not pregnant. In some cases the ovaries contained ripe follicles with undischarged ova, in others corpora lutea were present, but the eggs were still situated in the Fallopian tubes. Moreover, the ovary in the water vole is surrounded by a tough closed capsule which obscures the details and renders difficult the determination of the condition of the ovarian follicles when examined in the fresh or fixed state.

These localised dilatations of the uteri are indicative of changes undergone by the maternal tissues preparatory to the attachment of the embryos, hence it would appear that the sites of attachment of the blastocysts to the uterine mucosa are predetermined before the eggs reach the uteri at all.

Examination of these special areas of the uterus was rendered more difficult owing to the fact that after fixation and embedding the dilatations were no longer recognisable. Examination of many complete series of sections through uteri possessing these localised swellings demonstrated that the latter were due to a considerable increase in size and number of the superficial blood vessels. These vessels contract on fixation far more than the conjunctive tissue, hence it comes about that the uterus, which in the fresh state exhibited marked dilatations, appears after fixation to be of a more or less uniform diameter throughout, and those areas where the swellings occurred are only recognisable from the hypervascularity of the outer layers.

This increase in vascularity of the uterus is chiefly noticeable in the external layer of longitudinal muscle fibres and between it and the inner circular layer, where large blood sinuses occur. It seemed probable that these localised areas indicated the future sites of attachment of the eggs, and with a view to ascertaining the causes which conditioned the attachment at certain points and the fairly uniform spacing out of the embryos in the uteri, a large number of serial sections of uteri in which these local dilatations occurred, but in which the eggs had not reached the uteri, were examined in detail. The results were mainly negative; no definite changes could be detected either in the shape of the uterine lumen, or in the character of the lining epithelial cells, which marked off these areas as predetermined spots for the attachment of the eggs.

It is of course possible that these dilatations indicated the places where embryos were attached during a preceding pregnancy. From material collected, as this was, in the wild state, it is not possible to determine whether a female had already had young.

Many workers have studied this question which, however, still remains unanswered. Widakowich noted that the mucosa became more vascular before the attachment of the embryos occurred, but he apparently made no reference to the presence of local dilatations. He states, however, that cilia appear on certain areas of the uterine epithelium shortly after copulation and that they disappear after a short time. Other workers have confirmed this observation. I have not detected cilia either in the Fallopian tubes or uterine lumen of Microtus but it is possible that transitory ciliated areas occur.

It is not easy to imagine how cilia can cause the attachment of the eggs, but it is quite conceivable that they might prevent it. If that were the case one would expect to find large tracts of uterine epithelium provided with cilia and localised areas on the antimesometrial side devoid of them, the latter areas being the appointed places of attachment.

An alternative arrangement for arresting the eggs in certain regions of the uteri, and one moreover for which I have some slight evidence, is that in which the uterine epithelium contracts around the egg, closing above it temporarily until the remaining eggs are all attached. One can imagine that certain areas of the uterine epithelium on the antimesometrial side become hypersensitive, these hypersensitive areas corresponding to those of hypervascularity, and that they react to the presence of eggs in the lumen by closing above them. If such a condition obtains, then the eggs nearest the Fallopian tubes become enclosed first, the remainder passing over the enclosed eggs and becoming arrested in turn as they reach the successive sensitive areas.

The eggs while in the Fallopian tube are often crowded together, two or more often occurring in the same section, hence it is obvious that some such mechanism must exist in the uterus to prevent several embryos from lodging in one fold of the epithelial wall, for if such were to occur, it would be impossible for them all to reach maturity and examination of the ovaries of females in late stages of pregnancy reveals that there are no corpora lutea in excess of the number of developing embryos, hence one can assume that eggs do not become attached to the uterine epithelium so close together that one or more fail to develop.

An examination of the uterine epithelium in the neighbourhood of the blastocyst shown in Pl. XXV, fig. 1 reveals the fact that the latter is lying in a crypt or groove of the antimesometrial uterine lumen. Study of the serial sections in this region indicates that this groove was, at the time of preservation, or shortly prior thereto, shut off from the main lumen mesometrically to it. In fig. 1 a break is seen in the uterine epithelium on the right side, from which three or four cells have disappeared, while on the left side, there is, attached to the intact epithelium, a triangular mass consisting of these missing cells. This clearly indicates that these epithelial layers were at one time in contact. The condition here figured is traceable in the sections over a distance of nearly ·4 mm.

One may therefore conclude that the crypt containing the blastocyst, becomes temporarily separated off from the remainder of the uterine lumen by the close adherence of the uterine epithelium forming its lips.

It might be suggested that this closure of the uterine lumen was an artefact, brought about by mechanical pressure after death. This, however, seems very improbable, for if such were the case, one would expect to find signs of lateral compression of the uterus in this region. No indications of such compression are recognisable; the diameter of the uterus in the region where this adhesion occurs is almost precisely the same as in other areas and the serous coat exhibits no signs of injury.

There is, moreover, collateral evidence that this adhesion was initiated prior to death, for the epithelial cells in that region are more columnar than those of the neighbouring portions of the epithelium. **Pl. XXV, fig. 1.**

SEGMENTATION OF THE OVUM

As has been described in a previous publication, the oocyte of Microtus gives off the first polar body while it is still in the Graafian follicle and this polar body divides mitotically into two. The outer wall of the follicle which has, by this time, become exceedingly thin, then ruptures and the secondary oocyte, surrounded by its zona and the cells of the corona radiata, passes into the fluid filled cavity of the capsule into which the fimbriated end of the Fallopian tube opens.

Unfortunately no stages of fertilisation were obtained, but from the fact that numerous sperms occur in the ovarian capsule it seems probable that fertilisation occurs therein. The oocyte, invested in its zona, then gives off the second polar body and passes into the Fallopian tube.

The first cleavage occurs in a plane at right angles to the plane of separation of the polar bodies and results in the formation of two blastomeres, which are apparently identical in size and character.

The average measurement of the two-celled egg is ·054 mm. × ·045 mm.; the thickness of the zona is ·003 mm. The latter, under minute examination, shows no signs of radial canals. In some of the two-celled stages in my possession there are indications of the presence of degenerating polar bodies lying underneath the zona in the cleavage plane, but in the majority of cases they are not recognisable.

No stages were obtained showing the completion of the second cleavage, but an ovarian segmenting egg, which has been described in a paper dealing with parthenogenetic cleavage in the water vole, shows the four blastomeres arranged in a cross shaped manner which is known to be typical of these rodents.

The second cleavage therefore probably results in the formation of the typical cross-shaped arrangement of the four cells, after which stage the segmentation appears to occur irregularly, for in the eight-celled stage, which measures ·074 × ·053 mm. there is no definite arrangement of the blastomeres. The zona is still intact and the cells appear similar in size and character, though had more precise cytoplasmic fixatives been employed, it is possible that some differentiation between the cells would have been recognisable. Unfortunately none of these eggs are really well preserved as they were fixed *in situ* in the Fallopian tubes.

Several stages with 12 or 13 cells were obtained. These morulae vary in size somewhat, the largest measuring ·074 × ·056 mm. and the smallest ·069 × ·056 mm. It will be seen therefore that during these early cleavages the egg has not materially increased in size. In the best preserved egg of this stage thirteen nuclei are present, one of which is situated in a central cell, which is, however, exposed to the surface on one side, thus suggesting a condition of epibole. This egg lies free in the upper portion of the uterus near the junction of the latter with the Fallopian tube; it has not yet reached its site of attachment. The zona is still present but appears to be in process of degeneration.

FORMATION OF THE BLASTOCYST

This irregular segmentation continues and leads to the formation of a more or less spherical blastocyst, having the form of a thin walled vesicle, at one side of which is a globular mass of cells projecting into the cavity (Pl. XXV, figs. 1 and 2). This mass of cells constitutes the embryonal knot and denotes, what I shall call, the upper pole of the egg, i.e. that portion which will become directed towards the mesometrium. The thin wall of the vesicle is the Trophoblast or extra-embryonal ectoderm; it is apparently at this stage quite distinct from, though in intimate contact with, the cells of the embryonal knot, at the upper pole of the egg.

The blastocyst shown in fig. 1 measures ·08 × ·07 × ·07 mm. of which the inner cell mass, or embryonal knot, measures ·05 × ·04 × ·04 mm. The one shown in fig. 2 measures ·09 × ·075 × ·06 mm., the embryonal knot ·05 × ·06 × ·04 mm. These blastocysts have apparently reached their definite sites of attachment to the uterus, but they are not yet correctly orientated although they are attached by a mucous secretion to the epithelium. These stages correspond in development to Sobotta's mouse egg at the end of the fourth day or Huber's rat egg of the fifth day after fertilisation.

The blastocyst represented in fig. 2 shows signs of differentiation of the cells of its embryonal knot into an outer layer of more or less uniform granular cells enclosing two rather larger cells, with pale staining less granular, cytoplasm. This apparent differentiation of the embryonal knot is not recognisable in the blastocyst shown in fig. 1, which is cut almost horizontally, the next section of the series passing through the embryonal knot above the level of the blastocyst cavity.

It is, however, possible that the two pale-staining cells visible in Pl. XXV, fig. 2, are simply the products of a recent cell division. The two daughter cells resulting from a division are often rather different in appearance to neighbouring cells which have not so recently divided. The appearance of the nuclei in this case does not afford much guide.

The trophoblastic cells constituting the outer wall of the vesicle are somewhat elongated and flattened. Their cytoplasm is pale-staining and coarsely granular with ragged free surfaces.

At this time the uterine tissues exhibit very characteristic changes. The uterine lumen is wide and simple in character, the convolutions and diverticula, which are present prior to pregnancy, having disappeared in these regions where the blastocysts are located. The uterine glands are large but simple in character and their epithelium has undergone marked changes, the cells, normally columnar, are more cubical and the nuclei appear spaced out in a peculiar manner (Pl. XXV, fig. 1). This histological change is also recognisable in the uterine epithelium itself, but more especially in that portion of the anti-mesometrial wall neighbouring on the blastocysts. There the epithelial cells are very pale-staining and their nuclei small and widely separated, the cytoplasm around them appearing quite colourless and free from granularity.

In view of the fact that these cells are destined, at an early date, to degenerate and disappear, one might suppose that these histological changes were the preliminary processes leading up to that degeneration, but an examination of other sections in this, or in similar, series shows that tracts of uterine epithelial cells with identical characters occur in several other places, even on the mesometrial side of the lumen; it would appear therefore that these changes are in no wise conditioned by the presence of blastocysts in the uterus and that they do not necessarily indicate those regions in which the uterine epithelium is destined to disappear.

The connective tissue cells of the mucosa exhibit no marked change, but leucocytes are present in considerable numbers and capillaries are more numerous. As regards vascularity, however, by far the greatest change is noticed in the superficial layers of the uterus. Numerous and extensive blood vessels occur in the outer muscular coat. These vessels have contracted very considerably during fixation and subsequent treatment, with the result that the outer wall of the uterus has in most cases been thrown into numerous folds.

BLASTOCYST STAGES AND THEIR RELATIONS TO THE DECIDUAL CAVITY

The blastocyst, having reached its definitive position on the antimesometrial side of the uterine lumen, becomes orientated with its upper pole, containing the embryonal cell mass, directed towards the mesometrium. The cells of the uterine epithelium, around the sides and lower pole of the blastocyst, flow together with the formation of a symplasma layer. This breaks down and disappears, with the result that the egg comes to lie in a narrow cleft, the implantation crypt, bounded laterally and antimesometrially, by the stroma cells of the uterine mucosa.

Text-fig. 1 illustrates this stage. The blastocyst lies in the implantation crypt, the opening of which into the narrow uterine lumen is closed by a plug of necrotic tissue, consisting of degenerating red blood corpuscles, leucocytes and portions of symplasma derived from the uterine epithelium. The blastocyst, which has the form of a slightly flattened sphere, measuring ·11 mm. in transverse diameter and ·06 mm. in the future long diameter, consists of an outer trophoblastic layer, which is in contact at the mesometrial pole with a rounded mass of compact cells, which constitutes the embryonal knot. The cavity of the blastocyst is fairly extensive and contains several pale-staining cells which are mostly in close contact with the lower surface of the embryonal knot. These cells represent the future entoderm.

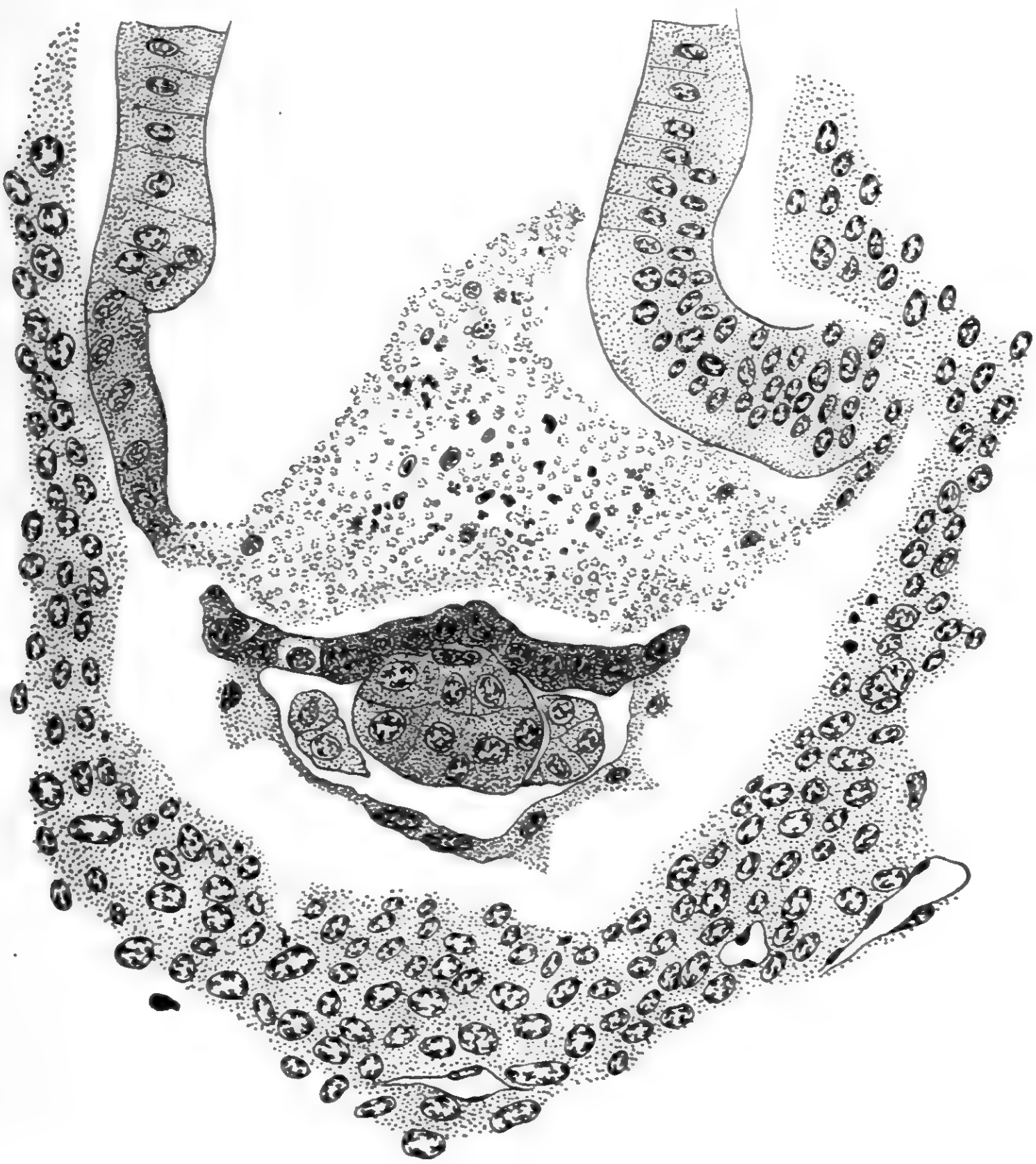

Fig. 1

The outer wall of the vesicle appears to have contracted away from the uterine tissue during fixation or subsequent treatment. Its cells possess digitiform processes which during life no doubt penetrated into the spaces between the stroma cells. These irregular cells, constituting the outer wall of the blastocyst, serve to attach the latter to the maternal tissue lining the implantation crypt, they are usually regarded as purely trophoblastic in character and as being formed from the original trophoblastic wall of the unattached blastocyst. There is, however, a strong probability that in *Arvicola amphibius* the outer wall of the blastocyst at this time is not a purely embryonal structure, but that certain maternal cells have become incorporated in it.

Later, when dealing with the subject of giant cells, I shall produce evidence in support of this view, which appears at first sight improbable.

The cells of the mucosa surrounding the implantation cavity have lost their normal character, their nuclei are crowded together and cell outlines are in places unrecognisable. Numerous leucocytes are present, both in the superficial and deeper layers. The capillaries have increased in number to an enormous extent, particularly in the lateral and antimesometrial portions of the mucosa. A few of the endothelial lining cells of these capillaries are enlarged and stain very deeply.

The next stage in development is represented in text-fig. 2. The blastocyst measures ·074 × ·09 mm. and roughly corresponds to the six day rat embryo figured by Huber. The embryonal knot is distinctly separated from the covering layer of trophoblast. It has the form of a very compact ovoid mass of rather pale-staining cells measuring ·053 × ·04 mm. At the mesometrial end the covering trophoblast forms a curved disc, the margins of which bend upwards towards the mesometrium. It is in intimate contact with, but everywhere recognisable from the embryonal ectoderm and its constituent cells, which are cubical in character, stain more deeply than those of the latter. The margins of this trophoblastic plate extend outwards and upwards in contact with the uterine tissues of the implantation crypt, which communicates with the uterine lumen, mesometrially to it, by a comparatively narrow channel filled with necrotic tissue, degenerating epithelial cells and blood corpuscles. This trophoblastic plate is the primordium of the Träger of Salenka, or Ectoplacental Cone of Duval.

The parietal trophoblastic wall of the vesicle is continuous with the ectoplacental plate at its margins and extends around the implantation cavity in very intimate contact with the maternal tissue. It apparently consists of rather large irregular cells united by strands, but, as I have already stated, there is reason to believe that some at least of these cells are of maternal origin.

The entoderm has the form of a continuous layer of elongated, spindle-shaped cells, loosely investing the lower surface of the embryonal ectodermal mass. This layer of cells constitutes the visceral or inner yolk sac wall; between it and the ectoderm there are present one or two isolated cells which are probably entodermal cells which have not become incorporated in the layer.

The differentiation of the uterine tissues has proceeded still further; the vascularisation of the outer, muscular layers has resulted in the formation of numerous and extensive blood sinuses between the longitudinal and circular muscle layers. From these sinuses many capillaries extend into the mucosa and give the latter, with the exception of that portion immediately surrounding the uterine lumen, a loose spongy character. The uterine glands are greatly reduced, both in size and number.

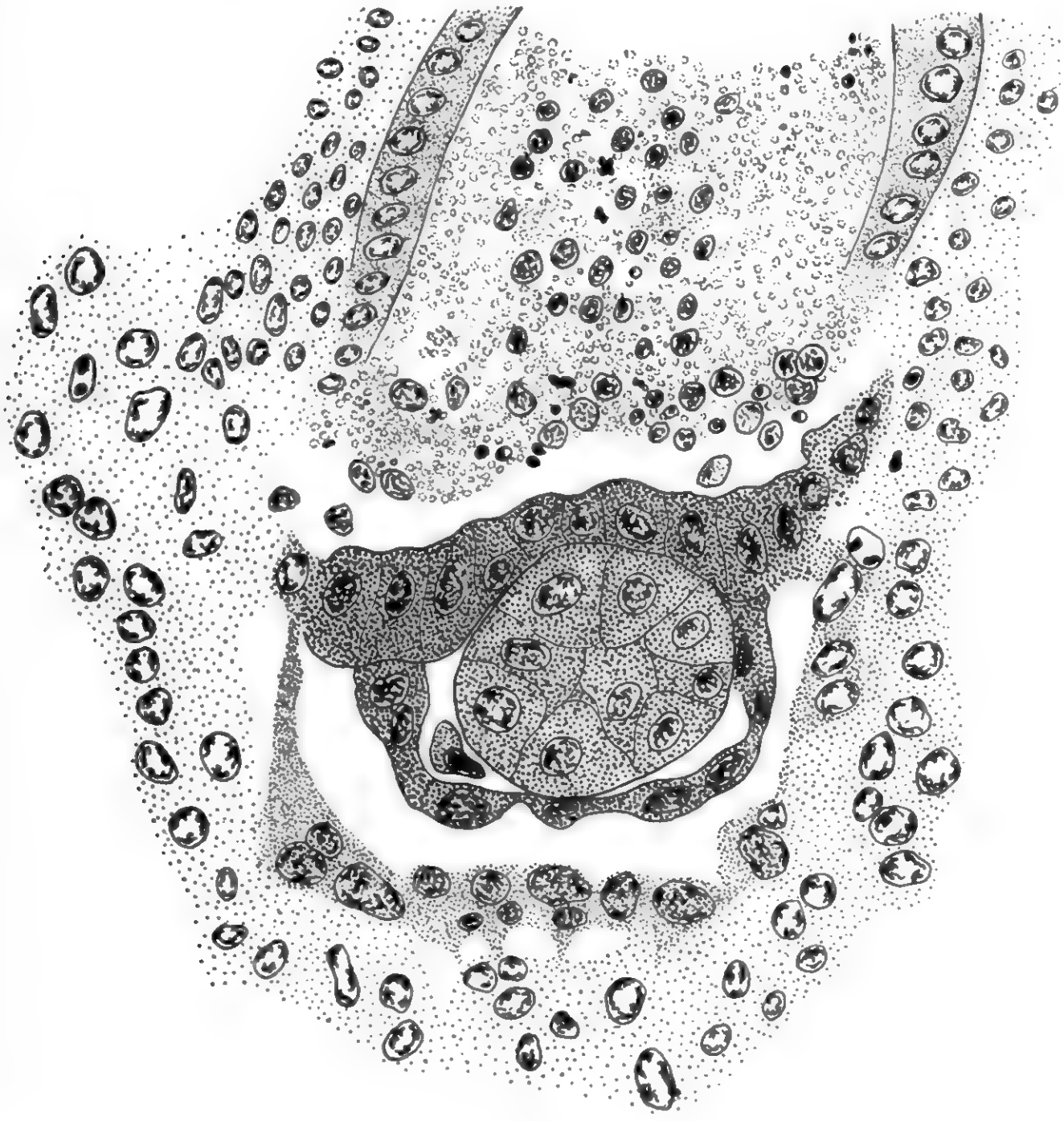

Fig. 2

This uterus, in the fresh state, exhibited well marked localised dilatations, corresponding, presumably, to the sites of attachment of embryos, but after sectioning, the variations in diameter, between the embryonal and inter-embryonal regions, were quite insignificant. The plications in the outer wall of the uterus indicated the extent of the contraction during fixation and subsequent treatment.

A considerable advance in embryonal development is shown in text-fig. 3 Here the blastocyst measures ·11 × ·11 mm., of which the embryonal ectodermal mass measures ·04 × ·04 mm. The ectoplacental trophoblast or Träger has thickened at its edges, where it is in contact with the walls of the implantation cavity, and appears to be in a state of active proliferative growth. The ectodermal mass has the form of an almost spherical solid structure composed of rather pale-staining cells. The entoderm, in this stage, forms a closed vesicle, consisting of elongated, deeply-staining spindle-shaped cells with ovoid nuclei. The upper wall of this entodermal vesicle is applied to the lower surface of the ectodermal mass and constitutes the visceral yolk-sac wall; it is continuous with the parietal yolk-sac wall which is at this time intact, the yolk-sac cavity being shut off from the cavity of the blastocyst. This outer yolk-sac entoderm is destined to disappear as an intact layer at an early date, though its cells continue to divide and remnants of the layer persist throughout the whole gestation period.

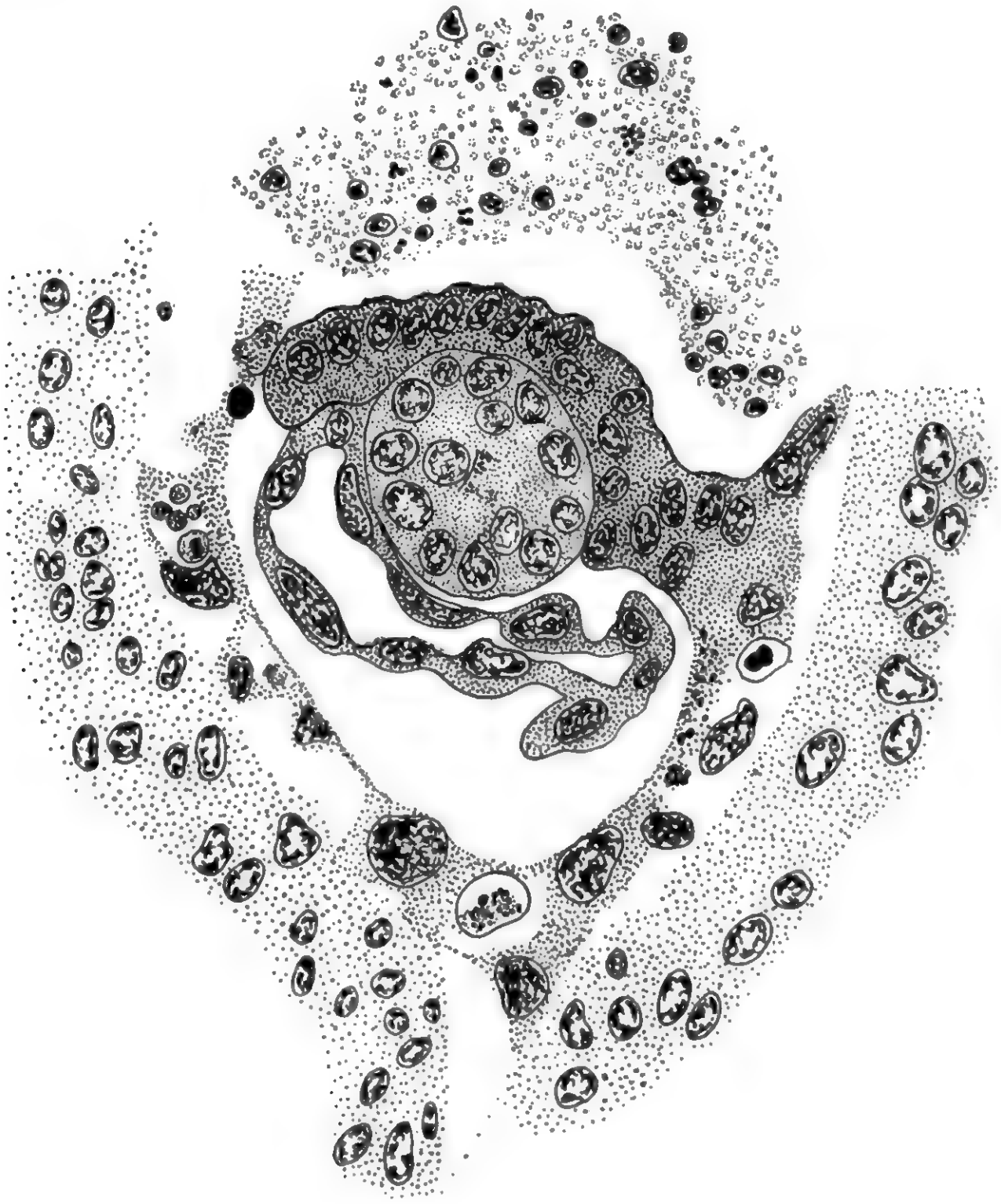

Fig. 3

The peripheral or parietal wall of the vesicle consists, over its extent, of a single layer of large cells with very vacuolated cytoplasm united by fine strands. The nuclei of these cells are, on the average, far larger than those of the ectoplacental trophoblast and their cytoplasm is prolonged into irregular processes which pass into the decidual tissue surrounding the implantation cavity. These cells appear to be actively phagocytic, for many red blood corpuscles and dark-staining granules are present in them.

Similar cells, at the antimesometrial end of the early blastocyst, have been described by Sobotta, Duval and Melissinos in the Mouse, and by Widakowich and Huber in the Rat. Considerable discussion as to their significance has taken place; I shall revert to this question when describing the origin of the placental giant cells.

The next stage in development is represented in text-fig. 4. The blastocyst now measures ·16 mm. in length and ·11 mm. in diameter. The embryonal ectodermal mass measures ·048 × ·048 × ·06 mm. The ectoplacental trophoblast has the form of a slightly curved plate of deeply-staining cells, considerably thicker than in the preceding stage. Marginally it is continuous with a fine structureless membrane which is in contact with the wall of the implantation cavity. This membrane, which represents the parietal trophoblastic wall of the blastocyst, is Reichert's membrane. In intimate union with this membrane are large cells with vacuolated cytoplasm, similar to those described in the last stage.

Fig. 4

The embryonal ectoderm has the form of an almost spherical solid mass of pale-staining cells in contact with, but sharply marked off from, the ectoplacental trophoblast. The increase in thickness of the latter over its middle region has forced the embryonal ectoderm downwards into the cavity of the blastocyst, with the result that the underlying layer of entoderm has become invaginated. This visceral or splanchnic entoderm is mostly in close contact with the lower surface and sides of the embryonal ectoderm. It consists of a single layer of very regular, dark-staining, spindle-shaped cells with ovoid nuclei. At the point of junction of the ectoplacental trophoblast and embryonal ectoderm this layer is reflected downwards into the cavity of the blastocyst as the parietal entoderm, but it no longer constitutes a continuous membrane. Over the lateral walls of the cavity it is complete and its cells similar in character to those of the visceral layer, but around the lower pole of the blastocyst it has already broken down and is only represented by a few scattered cells. These cells, however, continue to divide and form an attenuated layer in contact with Reichert's membrane.

The maternal tissues have undergone further changes. The cells of the mucosa around the implantation cavity have increased in size and assumed the character of typical decidual cells. They are compactly grouped together and cell outlines are in many places unrecognisable. Numerous capillaries are present in these masses of decidual cells, and their endothelial lining cells are often large and darkly staining. The implantation cavity is still in open continuity with the uterine lumen, but the epithelium of the latter shows signs of degeneration over a considerable area at the antimesometrial end, the cell walls having disappeared with the formation of a symplasma layer, which is destined to degenerate at an early date.

Between the stages already described and that represented by text-fig. 5 there is, unfortunately, a considerable gap in the material, but a stage which we possess of the Field Vole, the development of which appears to agree closely with that of the Water Vole, serves to bridge the gap fairly well.

The blastocyst in question has the form of an elongated hollow cylinder measuring ·55 mm. in length and ·15 mm. in diameter. It corresponds roughly with that represented by Huber's fig. 27*c* of the eight day rat embryo.

One can distinguish three areas of this egg cylinder. First a hemispherical, cup-shaped, region at the antimesometrial end, constituted by the embryonal ectoderm. The cells forming the wall of this deep cup, which appears almost horse-shoe shaped in vertical section, are very closely crowded together and are in a state of active proliferation, numerous mitoses being present. The lips of this cup are in continuity with, but fairly sharply defined from, the extra-embryonal ectoderm which constitutes the middle region of the egg cylinder. There the cells are less crowded together than in the embryonal region and mitoses, though present, are far less numerous. At the mesometrial end this layer passes rather abruptly into the tissue of the Träger, which is, by this time, a cone-shaped structure of considerable size, composed of rather large pale-staining cells with almost spherical nuclei. The cells of the Träger are irregularly disposed in groups, between which are present masses of maternal blood corpuscles. The Träger projects upwards into the still persistent uterine lumen the epithelium of which has disappeared in the antimesometrial portion, while over the remainder, with the exception of a small area at the mesometrial end, it has broken down with the formation of a symplasma layer. Mingled with the cells of the advancing edge of the Träger are a number of large cells united by cytoplasmic filaments. The spaces between these cells, and the cytoplasm of the cells themselves, contain maternal blood corpuscles, which also occur amongst the trophoblastic cells of the Träger. These cells, which are

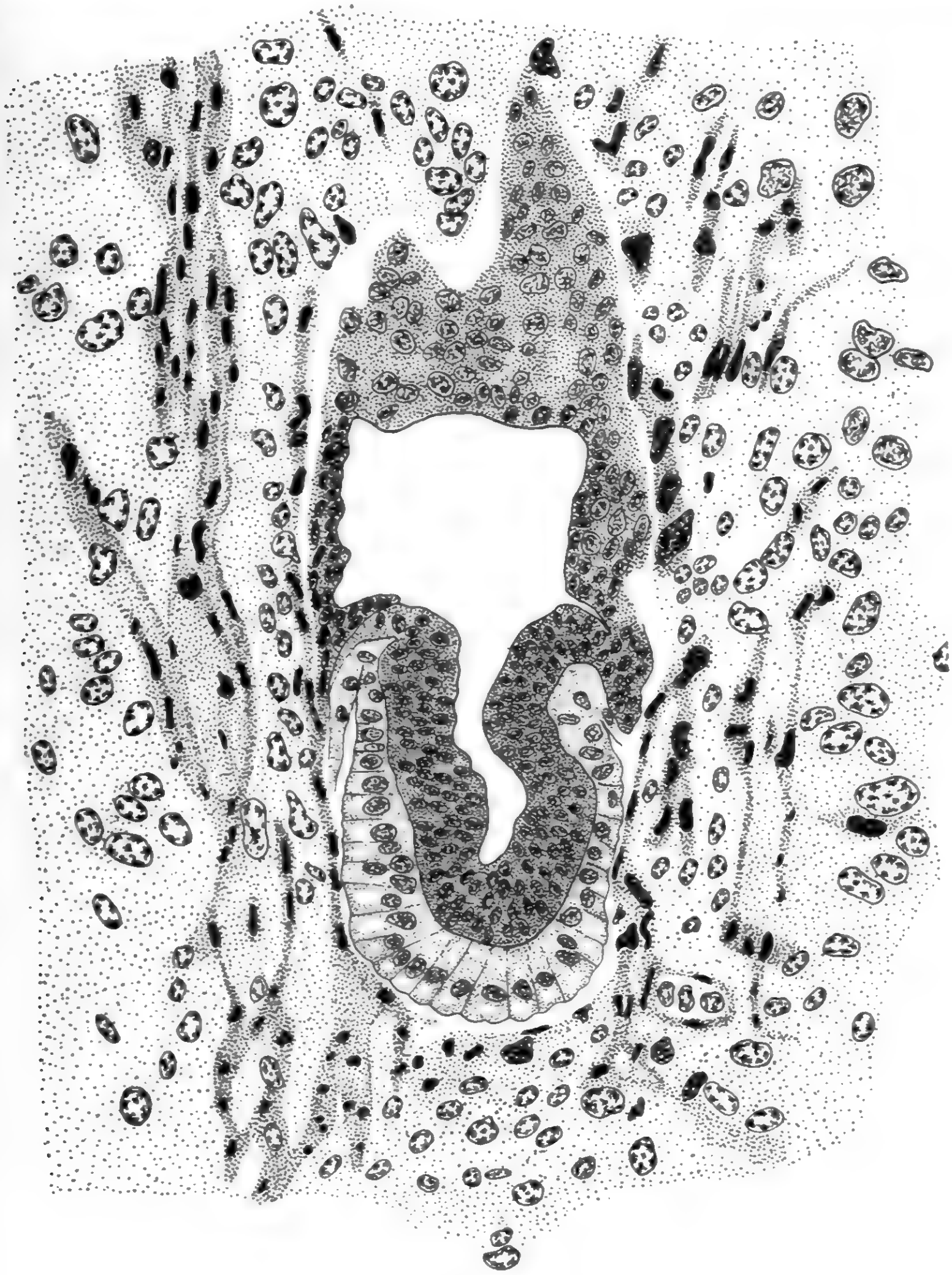

Fig. 5

in reality small giant cells, are held by some workers to be trophoblastic in origin, but as will be seen later they are actually of maternal origin.

The parietal trophoblastic wall of the egg cylinder is continuous at the mesometrial end with the cells of the Träger, but it has the form of a thin structureless membrane in intimate contact with the walls of the implantation cavity. This membrane—Reichert's membrane—has adherent to its inner surface a few scattered isolated cells, mostly fusiform in shape, which represent the parietal yolk-sac entoderm.

The egg cylinder itself is clothed externally by a layer of splanchnic or visceral entoderm. Over the embryonal ectodermal cup it has the form of a single layer of fusiform or ovoid cells, constituting the embryonal entoderm, whilst over the extra-embryonal ectoderm it is composed of very large columnar cells, in which the nuclei are situated basally. The cytoplasm of these cells is very coarsely granular and in places vacuolated, but I cannot detect the haemoglobin granules which Sobotta described and figured in the outer portions of the cells of the visceral entoderm in the Mouse. As this layer approaches the mesometrial end of the cylinder the cells become more cubical in character and at the junction of the extra-embryonal ectoderm and the Träger it disappears as a continuous membrane and is only represented by the scattered cells in contact with Reichert's membrane, referred to above.

As regards the maternal tissues, a considerable advance in differentiation has taken place. All the cells of the mucosa antimesometrially and laterally to the implantation cavity have become converted into typical decidual cells with large vesicular, pale-staining, nuclei. These masses of decidual cells are penetrated by numerous extensive blood sinuses, the endothelial cells of which are large and deeply-staining. Around the walls of the implantation cavity and extending upwards therefrom, in contact with the symplasma layer formed from the degenerating uterine epithelium, is a belt of deeply-staining spindle-shaped cells with dark elongated nuclei. These cells I regard, for reasons which I shall state later, as the endothelial cells of maternal capillaries, the lumina of which have disappeared owing to apposition of the vessel walls.

Coming now to the stage of *Arvicola amphibius* represented by text-fig. 5, we find the blastocyst completely embedded in maternal tissue, the uterine lumen being restricted to a very narrow passage, with fine radial canals, at the mesometrial side of the decidual swelling. It measures ·3 mm. in length and ·15 mm. in breadth and is of the cylindrical form, characteristic of rodents with inversion of the germinal layers.

The ectoplacental cone is now greatly enlarged and consists of a mass of rather pale-staining cellular tissue and is of irregular shape, being prolonged into digitiform processes which extend upwards into the decidual tissue mesometrially to it. The nuclei of these trophoblastic cells are smaller than those of the maternal cells and react to stains in a rather different manner. The Träger forms the roof of a cavity of considerable size, the primitive amniotic cavity, which later becomes subdivided into the amniotic cavity proper and the ectoplacental or false amniotic cavity. The embryonal ectoderm now has the form of a deep cup, the lip of which is continuous with the tissue of the Träger, its walls being composed of narrow columnar cells which increase in number towards the lower pole, where the layer is considerably thicker. Externally, this embryonal ectoderm is invested by the splanchnic yolk-sac entoderm, which consists of a single layer of long columnar cells with pale-staining vacuolated cytoplasm. The inner ends of these cells are often densely granular, but here again, I am unable to detect the presence of haemoglobin granules. At the junction of the embryonal ectoderm and the trophoblast, the entoderm is reflected back, but it almost immediately loses its character as a distinct cell layer and is only represented by a few scattered cells lying in contact with the outer wall of the vesicle formed by Reichert's membrane. This now has the form of an exceedingly thin structureless membrane, in intimate contact with, and difficult to distinguish from, the maternal tissues lining the implantation cavity. These tissues have by this time undergone marked changes. An intense cell proliferation has taken place around the implantation cavity with the result that the decidual swelling has become converted into a compact tissue, composed of large cells, with rather pale-staining nuclei, subdivided by numerous fine blood channels lined by endothelium. The lumina of these capillaries are often exceedingly narrow, indeed the endothelial walls are frequently so closely apposed that the lumen appears completely obliterated. The nuclei of these endothelial cells are long and narrow, stain intensely dark with haematoxylin, whilst the cell cytoplasm stains deeply with eosine. These narrow capillaries, with their modified endothelial lining, form a very well marked annular zone around the implantation cavity, and a belt of these cells constitutes the actual lining of the cavity around the antimesometrial end and lateral regions of the embryo. They are apparently fused with Reichert's membrane, with the result that the latter is scarcely recognisable.

It will be seen from the above that this early blastocyst of Microtus differs somewhat from the corresponding stage of the Mouse and Rat. In the latter forms, the ectodermal cylinder is completely invested, except at the upper pole, by the splanchnic yolk-sac entoderm, whereas in *Microtus amphibius* the junction of the embryonal ectoderm and the trophoblast, i.e. the region from which the amnion folds will later arise, marks the limit of upward extension of the yolk-sac entoderm. In later stages, however, this condition no longer obtains. The visceral entoderm gradually extends in a mesometrial direction, so that a similarity with the typical murine condition is re-established.

The next stage available is represented in Pl. XXV, fig. 3. The blastocyst measures 1·4 mm. in length and ·63 mm. in diameter, excluding the trophoblast of the Träger, the limits of which are difficult to determine for purposes of measurement. The blastocyst now exhibits the form typical for rodents with inversion; it contains three extensive cavities: the one nearest the mesometrium is purely trophoblastic and constitutes the false amniotic or ectoplacental cavity. Its roof is continuous with the tissue of the Träger; its floor, together with a layer of mesoderm, constitutes the roof of the extra-embryonal coelom, the so-called "chorion." Its lateral walls are clothed externally with a layer of splanchnic entoderm, the visceral yolk-sac wall having, by now, extended upwards almost to the junction of the Träger with the lateral walls of the ectoplacental cavity. The middle and largest cavity of the blastocyst is the extra-embryonal coelom, which is lined by an exceedingly fine layer of fusiform mesodermal cells. Its roof, as already described, consists of a layer two or three cells thick of cubical trophoblastic cells, lined internally with mesoderm, and constitutes the "chorion." Its lateral walls are clothed with columnar entodermal cells, while the floor, which is extremely thin, is constituted by the amnion, consisting of two closely apposed fine layers of ectoderm and mesoderm. The embryonal ectoderm has the form of a thick curved plate, the medullary plate, composed of elongated columnar cells. The visceral entoderm in which the vesicle is invested is not of the same character throughout. Below the embryonal ectoderm the entodermal cells are partly cubical, partly fusiform and constitute a thin compact layer. In the middle region of the egg cylinder, around the extra-embryonal coelom, the entoderm consists of very tall columnar cells, in which the nuclei are situated basally. The cytoplasm of these cells is vacuolated, coarsely granular, and prolonged into irregular processes. This layer gradually thins down as it approaches the Träger, and before reaching the latter it is reflected back as the parietal yolk-sac wall, which is represented by isolated cells, lying in contact with Reichert's membrane. The latter is continuous with the tissue of the Träger at its margins and forms a very distinct lining to the implantation cavity; it has already increased somewhat in thickness as compared with the previous stage and would appear to have a protective function. It prevents the passage of maternal blood, particularly leucocytes, into the yolk-sac cavity, and limits the destructive and phagocytic activities of the giant cells or megalokaryocytes to the maternal tissues. It persists throughout the gestation period and increases very considerably in thickness in later stages.

The uterine swellings in which the embryos are situated are at this stage of considerable size. They are egg-shaped, the narrow end, in which the embryo is located, being antimesometrial in position. They average 4 mm. in diameter and 5·5 mm. in length (Pl. XXV, figs. 3 and 4).

The original uterine lumen on the mesometrial side has almost disappeared, being represented by an exceedingly fine passage, but its former connection with the implantation cavity is usually marked by an extensive blood sinus, which serves to assist the rapid penetration of the foetal trophoblast of the Träger. The decidual tissue is everywhere extremely vascular. On the mesometrial side, the cells are small and densely crowded together, with numerous large blood sinuses lined by endothelium. On the antimesometrial side the cells are large and pale-staining, having the character of typical decidual cells;

blood sinuses are equally abundant, but far smaller than those at the mesometrial end. The implantation cavity itself is considerably larger than the embryonal formation, the space between Reichert's membrane and the decidua being occupied by extensive blood lacunae, enclosed in the meshes of a fine network, the strands of which are united by very large cells with densely-staining nuclei. The origin and nature of these cells is discussed later.

I do not propose to describe the further development of the embryo, or the origin of the mesoderm, as detailed accounts of the development of other rodents are available and from the rather limited number of stages of Microtus at hand, it is not possible to follow the development in detail. I shall therefore proceed to describe the placentation, and origin of the placental giant cells.

PLACENTATION AND ORIGIN OF THE GIANT CELLS

The general character of the placentation in *Arvicola amphibius* does not appear to differ markedly from that of the Rat or Mouse, and the ripe placenta is very similar. In all three forms the blastocyst comes to lie excentrically in a crypt on the antimesometrial side of the uterine lumen. The uterine epithelium surrounding it degenerates and disappears, with the result that the trophoblastic wall of the vesicle is brought into direct contact with the stroma of the uterine mucosa. The cells of the latter immediately around the blastocyst become destroyed by the agency of giant cells, while those more remote become converted into decidual cells. The ectoplacental trophoblast at the mesometrial end of the blastocyst thickens rapidly and grows forwards through the uterine tissues which thus become penetrated by a coarse network of trophoblastic cells, which destroys the endothelial lining of the maternal blood vessels. The blood extravasations thus formed become enclosed in trophoblastic tissue. At a later stage the mesodermal allantois fuses with the "chorionic" mesoderm underlying the trophoblast and when vascularisation of the allantois is initiated, the allanto-chorionic mesenchyme, carrying foetal capillaries, extends into the trophoblast, which by this time has the form of a complex system of lamellae, honeycombed with narrow channels in which the maternal blood circulates. In this way the definitive allantoic placenta is established.

Although the placentation of *Arvicola amphibius* is similar to that of other murine rodents, there are considerable differences in detail.

Before describing the development of the placenta, however, it seems desirable to give an account of the origin of the giant cells.

Origin of the Giant Cells.

A very characteristic feature of Rodent placentae is the presence of numerous large cells, Riesenzellen, Megalokaryocytes or Giant Cells as various authors have designated them. They occur abundantly in the Rat, Mouse and Field Vole but do not appear to attain the number or dimensions that they do in the placenta of the Water Vole.

If one examines a section through the fairly late placenta, such as is represented in Pl. XXXII, fig. 27, one sees that the margins of the placental disc consist almost exclusively of these giant cells, while very many others occur in the decidual tissues, particularly in the region just beyond the limit of penetration of the trophoblast, that is to say, in the area which has been termed the "Umlagerungszone." These giant cells make their appearance soon after the egg has become attached to the uterine tissues, and a considerable time before the allantoic outgrowth is recognisable. In stages corresponding to that represented in Pl. XXV, fig. 3, one finds a few large isolated giant cells of very considerable size embedded in the decidual tissues, not necessarily adjacent to the implantation cavity, in fact often close to the muscularis.

The question as to the origin of these cells has occupied the attention of a number of workers but the conclusions arrived at are by no means in agreement.

According to Jenkinson, Duval, Sobotta and Hubrecht, these giant cells are of foetal origin, being derived from the trophoblast. These writers affirm that certain cells of the parietal trophoblast of the early blastocyst, become detached, penetrate the maternal tissues, and grow in size by ingulfing decidual cells and maternal blood.

According to Disse, who worked on *Arvicola arvalis*, the giant cells are purely maternal in derivation. He states that they appear prior to the attachment of the egg to the uterine epithelium and that their origin from maternal tissue is therefore beyond question. He ascribes their formation to some stimulus, derived from the fertilised egg, but in no wise limited to the immediate neighbourhood of the egg, since large giant cells and symplasma masses occur deep down in the uterine tissues, far from the implantation cavity. The course of events according to Disse is as follows: Some stimulus from the fertilised egg causes certain maternal cells to flow together with the formation of symplasma masses, while others increase in size, by ingulfing decidual cells and symplasma masses already formed, until they come into contact with the walls of maternal capillaries. They destroy the endothelial walls and pass into the lumen of the vessels, whence they are carried to the implantation cavity and deposited on the wall thereof. In this way, Disse explains the presence of the giant cell network which surrounds the embryonal formation in the earlier stages and which persists around the margin of the placenta throughout the whole period of gestation.

Disse supports his statements with numerous figures representing these Riesenzellen ingulfing decidual cells, symplasma masses and maternal blood. He also shows them in contact with, and, according to him, destroying, by phagocytosis, the endothelial walls of maternal capillaries and ultimately lying free in the lumen of the vessels.

Otto Grosser, in his more recent description of the placenta of the Rat, expresses agreement with the observations of Duval and Sobotta. He states that cells from the transitory trophoblastic wall of the vesicle penetrate the mucosa and grow into giant cells, which serve to enlarge the implantation cavity by destroying the decidual cells which constitute its wall. According to him, the superficial layer of the trophoblast of the Träger also becomes, in later stages, converted into giant cells and constitutes the Umlagerungszone. He says:

"In etwas späteren Stadien (figs. 118 and 119) ist diese Veränderung der peripheren Trägerzone gleichfalls kenntlich; von Degeneration der Zellen ist aber nur mehr wenig zu sehen, die Zellen sind in intensiver resorbierender Tätigkeit begriffen und vielfach mit aufgenommenen mütterlichen Blutkörperchen beladen. Die Zellen sind bedeutend grösser als die übrigen Trophoblastelemente, sie wandeln sich in die Riesenzellen älterer Placenten um." He holds, however, that a certain number of giant cells are of maternal origin being formed from decidual cells which, under the influence of the invading trophoblast, flow together with the formation of symplasma masses: "Unter seinem (Träger) Einfluss, der vielleicht anfänglich mehr in einer Fermentwirkung wie in einem aktiven Vordringen der Zellen besteht, gehen die oberflächlichen Deciduaschichten zugrunde, zum Teil nach Symplasmabildung (mütterliche Riesenzellen)."

Jenkinson, in his account of the histology and physiology of the placenta of the Mouse, also supports the trophoblastic origin of the giant cells.

All these workers are of opinion that the giant cells are essentially migratory in character. Sobotta, Duval, Jenkinson and Grosser maintain that they migrate from the trophoblastic wall of the vesicle into the decidua, while Disse, on the other hand, maintains that they are formed in the decidua remote from the blastocyst and migrate to the wall of the implantation cavity.

My own observations on the placenta of *Arvicola amphibius* do not confirm either of these theories. I am in agreement with Disse as regards the maternal character of these giant cells but differ from him as to their time of first appearance and as to their origin. There is, moreover, no evidence that these cells in the placenta of Microtus are migratory.

In the stage represented by text-fig. 5 the implantation cavity is surrounded by an annular zone of tissue which, owing to its peculiar reaction to stains, is sharply differentiated from the remainder. It consists of a belt of maternal capillaries, the lumina of which are greatly reduced, with the result that the endothelial walls are almost in apposition. The cytoplasm of these endothelial cells stains intensely with eosine, while the nuclei stain black with haematoxylin.

Capillaries with such a modified endothelial lining are present in many parts of the decidual swelling, but they reach their maximum number in the area surrounding the lateral walls of the implantation cavity.

It is these endothelial cells, I maintain, which give origin to the giant cells or megalokaryocytes of the Microtus placenta.

Figs. 5–16 (Pls. XXVI, XXVII and XXVIII) are reproductions of photomicrographs illustrating the successive stages in giant cell formation. They are not selected from progressive developmental stages, since it is unnecessary to do so, for the transformation of endothelial cells into giant cells is a continuous process, which lasts until the placenta is fully formed. It is moreover a rapid metamorphosis, for quite large giant cells are present in early stages such as Pl. XXV, fig. 3.

Pl. XXVI, fig. 5 represents a portion of the decidual capsule around the embryo shown in text-fig. 5. The dark coloured strands are endothelial cells lining maternal capillaries, the lumina of which are greatly reduced. The cells are somewhat enlarged and their cytoplasm stains intensely with eosine.

In Pl. XXVI, fig. 6 is shown, under a higher magnification, one of these capillaries traversing typical decidual tissue. It will be seen that the endothelial lining is quite intact but that many of the cells have undergone characteristic changes. Their nuclei stain intensely dark and are considerably enlarged. The cytoplasm is increased in amount and appears fibrillar.

In Pl. XXVI, fig. 7 is seen an enlarged capillary or sinus, the endothelial wall of which is everywhere recognisable yet in which certain cells have increased enormously in size. The nuclei are large and vesicular with irregular black chromatin masses and fine reticulum. The cytoplasm is finely fibrillar in character with very irregular ragged free surfaces.

In Pl. XXVI, fig. 8 is shown a similar stage. The cells though profoundly changed are still unmistakably endothelial. The deeply-staining cytoplasm, which formed the characteristic annular zone around the implantation cavity in text-fig. 5, is clearly visible.

A later stage is represented in Pl. XXVII, fig. 9; here the cells have increased in thickness and their outer surfaces are in more intimate contact with the surrounding decidual cells; it is in fact difficult to determine their limits, for their cytoplasm is prolonged into irregular processes which pass between the neighbouring cells.

In the next stage, Pl. XXVII, fig. 10, the cells have increased in size still further and are unmistakably giant cells, yet they still retain their endothelial character.

In Pl. XXVII, fig. 11, but for the fact that the enlarged cells form a more or less continuous layer, enclosing a space filled by maternal blood, one would hardly recognise them as transformed endothelial cells. Their cytoplasm is vacuolated and in many cases contains fragments of decidual cells and blood corpuscles.

The maximum development is shown in Pls. XXVII and XXVIII, figs. 12 and 13. Their cytoplasm is coarsely fibrillar, vacuolated and contains much foreign matter. The cells remain quite distinct from one another, they do not form a syncytium or symplasma, the cell outlines between neighbouring giant cells being clearly defined, but where their cytoplasm comes into contact with decidual tissue it appears to be actively phagocytic, ingulfing the decidual cells and symplasma masses formed therefrom. Numerous brown granules are present around the periphery of some of these cells (Pl. XXVIII, fig. 14). They possibly represent a haemoglobin derivative, for numerous red blood corpuscles in various stages of degeneration are present in the cytoplasm. These cells are actively phagocytic, their cytoplasm usually containing large vacuoles and fragments of maternal cells. The fixatives employed have not permitted me to determine the occurrence of fat and glycogen.

The giant cells apparently attain their maximum size in the outer regions of the uterine tissues (Pl. XXVIII, fig. 15), where one occasionally finds isolated cells measuring as much as ·3 mm. in length, quite close to the muscularis. It is, however, around the embryonal formation that the giant cells are most abundant (Pls. XXVIII, XXIX and XXXII, figs. 16, 17 and 27). Here they constitute a vascular network, the meshes of which contain maternal blood. This network makes its appearance quite early. In the stage represented by Pl. XXV, fig. 3 the blastocyst is already surrounded by a belt of tissue which consists almost entirely of giant cells united by strands enclosing maternal blood. These large blood lacunae are therefore not extravasations, as they are commonly called, since their containing walls are of purely endothelial origin. As no injections were carried out I am unable to determine whether the blood, during life, circulates through the meshes of this network, but there is no reason to suppose that it does not. The maximum development of this vascular network is shown in Pl. XXVIII, fig. 16, and Pl. XXXII, fig. 27. Its innermost layer comes into contact with Reichert's membrane and the cytoplasmic filaments of its individual cells come into actual organic continuity therewith. The outer layer of giant cells is in contact with the maternal decidual cells which, under the influence of these phagocytic cells, flow together to form irregular, deeply-staining, symplasma masses. Pl. XXIX, figs. 17 and 18 show the formation of such symplasma from decidual cells in proximity to the megalokaryocytes. Ultimately these symplasma masses are ingulfed and absorbed by the giant cells, as shown in Pl. XXIX, figs. 19 and 20, with the result that, all the decidual tissue around the lateral walls and antimesometrial end of the embryonal formation, is replaced by giant cells. As the embryo increases in size, this giant cell network becomes stretched and its constituent cells become very attenuated, so that in later stages, such as that represented by Pl. XXXI, fig. 25, the yolk-sac splanchnopleur is only separated from the regenerated uterine epithelium by a thin layer composed of Reichert's membrane and the flattened giant cells. Around the margin of the placental disc, however, this stretching process is strictly limited, with the result that the giant cell network persists in this region and its cells increase in size; hence in later stages the giant cells are most conspicuous in the placental margin (Pl. XXXI, fig. 25 and Pl. XXXII, fig. 27).

The function of these giant cells would appear to be twofold. In the first place they serve, by their destruction and absorbtion of the maternal tissues, and by their resulting growth in size, to surround the implantation cavity with an exceedingly vascular spongy tissue, which permits and facilitates expansion of the embryo and which, constituting as it does the maternal portion of the yolk-sac placenta, also facilitates the nutrition of the embryo. In the second place, these cells serve as purely destructive agents which ingulf maternal tissues. As the embryo increases in size, a very considerable amount of maternal tissue must be removed from the lateral and antimesometrial portions of the decidua and there is probably a decided advantage in employing, for this phagocytic purpose, the same agents as are employed for increasing the vascularity of the implantation cavity wall, and agents, the life of which is moreover strictly limited.

With regard to those giant cells which are sometimes found close to the muscularis, and which attain a diameter of ·3 mm. (Pl. XXVIII, fig. 15), it is not clear what useful purpose they can serve, but their position may be more or less accidental, as we have no knowledge of those processes which condition the conversion of normal endothelial cells into megalokaryocytes. An isolated endothelial cell of some superficial blood vessel, if it once started its metamorphosis into a giant cell, might be expected to grow more rapidly than one surrounded by other giant cells, for in the latter case the food supply would of necessity be more limited. There is, as I have already stated, no evidence that these giant cells are migratory and I regard the presence of these isolated cells as an indication that migration does not take place, for if it did, these cells would probably make their way to the wall of the implantation cavity. The presence of giant cells in the placental labyrinth itself also points to the fact that they are not migratory. The advance of the foetal trophoblast into the maternal tissues is aided by the presence of giant cells which destroy the decidual cells and increase the vascularity of the tissues. These giant cells are surrounded by the trophoblast and apparently remain at their places of origin even when the allanto-chorionic villi penetrate the latter.

Although Disse studied *Arvicola arvalis* it is of interest to note that many of the figures which accompany his paper might have been drawn from my own preparations. His figs. 7 and 17 which, according to him, represent giant cells destroying by phagocytosis the walls of maternal blood lacunae prior to entering the blood stream, can be interpreted as large isolated endothelial cells. The fact that the endothelial lining is absent where in contact with the Riesenzellen indicates that the latter are derived from constituent cells of that endothelium.

Although Hubrecht later maintained that giant cells were of trophoblastic origin, yet his observations on Erinaceus support my view, for he remarked on the thickened endothelium of the maternal vessels and stated that it gave origin to a layer of bulky cells, with conspicuous nuclei, surrounding the blastocyst and enclosing spacious blood lacunae. The large individual units of this layer he called Deciduofracts. Finally, he suggested a possible homology between the Deciduofracts of Erinaceus and the giant cells of Rodents.

If this explanation which I have put forward of the origin of placental giant cells is applicable to other types such as the Field Vole, Rat and Mouse, it is remarkable that the earlier workers did not consider its possibility. Duval, in his account of the Rodent placenta, noticed that many sinuses containing maternal blood were lined by large cells, which he interpreted as trophoblastic.

According to him the trophoblast creeps up the walls of the maternal vessels destroying the endothelial lining and forming a pseudo-endothelium of trophoblastic origin which he termed the "couche plasmodiale endovasculaire." Jenkinson, in his more recent account of the Mouse placenta, criticised this statement as follows: "It seems to me obvious that his (Duval's) 'endovascular plasmodium' is nothing else but the lining of a trophoblastic sinus in the upper, glycogenic, portion of the placenta. In other words he is absolutely correct in attributing an embryonic origin to the cells which form the lining of these cavities, totally incorrect in regarding the cavities themselves as maternal." Jenkinson himself, apparently, had no doubt that these cells were trophoblastic, for he states: "The glycogenic tissue is traversed by sinuses leading into the sinuses which pass directly through the placenta, and, like these, lined by a pseudo-endothelium of flattened trophoblastic cells. These cells are always larger than the endothelial cells of the maternal tissues (figs. 35 and 39); they frequently project boldly into the lumen of the sinus and in fact may become almost large enough to deserve the name of megalokaryocytes."

Maximow, on the other hand, does not agree with this view for he states that the "couche plasmodiale endovasculaire" of Duval is simply an hypertrophied condition of the endothelial cells, which, according to him, later become infiltrated with leucocytes and destroyed.

It is of interest to note that in certain pathological conditions analogous changes, in the character of endothelial cells, occur.

Dr J. A. Murray has drawn my attention to the Report of the Tuberculosis Commission for 1911, in which Eastwood describes and figures certain changes in endothelial cells under the influence of tubercle bacilli. The report, which is exceedingly lengthy, contains the following passages:

> "In early infections it is constantly found that the endothelial cells of the affected area become swollen. This change must be attributed to some diffusible irritant associated with the presence of bacilli; it is not confined to the endothelial cells with which bacilli are actually in contact. Swollen endothelial cells often become detached and pass into the fluid contained within the endothelial lining. They then present the appearance of what are sometimes called 'macrophages'" (p. 279).
>
> "Associated with the swelling up of those endothelial cells which are in direct contact with bacilli, there are changes in the nucleus. The nucleus generally stains more darkly than the normal, and the material taking this stain often stains diffusely and tends to escape into the surrounding protoplasm" (p. 279).
>
> "Whilst these nuclear changes are going on there is also to be observed a dissolution of continuity in the protoplasmic outline and a tendency of the endothelial protoplasm to fuse with the protoplasm of contiguous parenchymatous or other cells" (p. 280).
>
> "A further stage in the process which is frequently observed is that these groups of nuclei continue, for a time, to multiply; they then form large groups which, taken in conjunction with their protoplasmic environment, are termed giant cells" (p. 163, sect. (3)).

In connection with the above it is perhaps significant that the cytoplasm of the placental giant cells stains diffusely with basic dyes, e.g. haematoxylin, and tends to fuse with the cytoplasm of decidual cells in contiguity with it. Pl. XXVII, figs. 9, 10, 11, and 12.

It appears therefore that some stimulus derived from the fertilised egg causes the endothelial cells of the capillaries, in the embryonal regions of the uterus, to grow into phagocytic giant cells. It is probably correct to attribute this stimulus to the embryo and not to the corpus luteum, since the endothelial cells in the inter-embryonal areas retain their normal character.

There remains for discussion the question of the significance of the large cells which are present at the antimesometrial end of the early blastocyst, referred to on page 342. The interpretation of these cells is by no means easy.

Sobotta described these cells at the antimesometrial end of the 6 days blastocyst of the Mouse and held that they were giant cells derived from the parietal trophoblast and that they served for the attachment of the blastocyst to the uterine tissues and, by their phagocytic activity, brought about extravasations of blood for the nourishment of the embryo.

Melissinos, on the other hand, maintained that the cells in question owed their apparent size to the fact that, through the shrinkage of the blastocyst during preservation, they are seen in sections in surface view and not in profile. Widakowich also noted these cells and accepted the explanation of their appearance put forward by Melissinos. Huber, in his more recent description of the development of the Albino Rat, supported this interpretation.

In *Arvicola amphibius* I am unable to accept the view that the size of these cells is apparent and not real, for the following reasons:

(*a*) The nuclei are considerably larger in all dimensions than those of the trophoblastic cells in other regions, measuring ·015 × ·02 × ·02 mm., as compared with ·01 × ·008 × ·01 mm.

(*b*) The cells in this region of the blastocyst remain the apparent largest throughout the whole series of sections, whereas if their apparent size were due merely to superficial cutting, they might well be expected to appear of normal dimensions in other sections.

(*c*) In horizontal sections through the implantation cavity, they still appear larger than the remainder.

Hitherto all workers are agreed that these large antimesometrial cells are trophoblastic; their identity does not appear to have been questioned. I venture to suggest, however, that they are maternal in origin, and that they are true giant cells, derived from endothelial cells in precisely the same way as the large megalokaryocytes of the placenta.

The question of the derivation of these cells is intimately bound up with a second one, namely, the mode of origin and growth of Reichert's membrane, and it must be admitted at the outset that it is almost impossible to demonstrate clearly, either by drawings or photomicrographs of sections of early blastocysts, that these cells are of maternal origin, since they frequently appear to be actually constituent cells of the vesicle wall. But this structureless membrane, whether it be regarded as a product of the parietal trophoblast of the early vesicle, or as a basement membrane laid down by the cells of the parietal entoderm, in later stages comes into most intimate connection with the giant cells and is then, undoubtedly, no longer a purely embryonal structure, for it increases enormously in thickness in that region where the giant cell network persists, i.e. around the margin of the placental disc, and processes of the giant cells fuse with it and are identical in appearance with it (Pl. XXX, fig. 23).

Moreover maternal leucocytes collect in large numbers outside this membrane, which undoubtedly serves to prevent the passage of leucocytes into the yolk-sac cavity, yet a certain number are actually embedded in its substance. This is strong evidence that the increase in thickness of this membrane is brought about through the agency of giant cells, for it is difficult to conceive how leucocytes, which are initially outside the membrane, can become encapsuled in it, if the latter is being added to on its inner surface. If, therefore, we admit that this membrane is partly the product of giant cells, it is not unreasonable to suggest that cells found in structural continuity with it in early stages, are actually maternal giant cells, and further that they are phagocytic endothelial cells.

If one examines the decidual tissue close around the antimesometrial end of the early blastocyst, one finds numerous capillaries, many of the endothelial cells of which are undergoing the initial changes which ultimately lead to the formation of giant cells. This change is probably due, as suggested above, to some stimulus derived from the egg, therefore one would expect to find it most evident in those endothelial cells which come into actual contact with the wall of the blastocyst. It seems exceedingly probable therefore, that these large cells, which form part of the outer wall of the early blastocyst and which have given rise to the view that some at least of the placental giant cells are of trophoblastic origin, are themselves of maternal origin.

With regard to the origin of the giant cells in the placenta of the Mouse.

I am of opinion that the giant cells arise in the same manner as in Microtus, and that the suggested homology between these cells and the Deciduofracts of Erinaceus is a true one. Although Hubrecht's description of the placentation of the Hedgehog, in which he makes this suggestion, was published 33 years ago, no worker seems to have confirmed it. This is remarkable because the work of Disse in 1906 and of Pujiula in 1908 established the fact that giant cells were derived from maternal tissues, whereas up till then most authorities were of opinion that the Deciduofracts of Erinaceus were trophoblastic in origin.

I have had no opportunity of examining the placenta of Erinaceus, but judging from Hubrecht's very detailed description and excellent figures, it seems clear that a change in the character of the endothelial cells occurs similar to that which has been described herein for Microtus. It should be noted that, in the Mouse, the change in character of the endothelial cells in early stages, corresponding to text-figs. 4 and 5, is far less marked than in Microtus; this is probably in correlation with the fact that the placental giant cells are far less numerous in the Mouse. In the Field Vole however, they are at least as marked as in the Water Vole. I hope at some future date to describe the origin of the giant cells in the Field Vole.

DEVELOPMENT OF THE PLACENTA

Placentation is initiated on the foetal side by the outgrowth and active proliferation of the trophoblast covering the upper pole of the blastocyst, the ectoplacental cone or Träger, and on the maternal side by the conversion of the uterine epithelium mesometrially to the egg, into a symplasma layer which rapidly disappears, with the result that the trophoblast is brought into contact with the sub-epithelial tissue. The latter is exceedingly rich in capillaries, the endothelial cells of which, in the neighbourhood of the implantation cavity, undergo those preliminary changes which lead ultimately to the formation of phagocytic giant cells. These endothelial cells often lose continuity with one another, with the result that blood extravasations take place into the uterine lumen mesometrially to the embryo. The foetal trophoblast grows rapidly upwards into this extravasation, losing, as it does so, its original compact pyramidal form and assuming the character of a coarse cellular network, enclosing in its meshes maternal blood.

At the same time a rapid metamorphosis of endothelial cells into giant cells takes place around the lateral walls and antimesometrial end of the implantation cavity. The giant cells thus formed ingulf the neighbouring decidual cells and enlarge the implantation cavity which in this way comes to be surrounded by a network of giant cells, the strands of which are of endothelial origin, and the meshes of which are filled with maternal blood. This belt of highly vascular tissue comes into intimate contact with the outer wall of the blastocyst, which consists of a fine structureless membrane derived from the original trophoblastic wall of the vesicle. Strands from the giant cells fuse with this membrane and are indistinguishable from it. The Träger, which is at first cone shaped in vertical section, extends rapidly in the lateral direction; thus increasing the area of attachment to the maternal tissues. Its penetration is greatly assisted by the activity of the giant cells, which not only ingulf and resorb the decidual cells but which also increase the vascularity of the tissue into which the trophoblast will extend. The development has now reached the stage represented by Pl. XXV, fig. 3, in which it will be seen that the blastocyst is surrounded by extensive blood lacunae the limiting walls of which are formed by the endothelial giant cells. The section shown in this figure does not pass through the Träger.

In the meantime the primordium of the allantois makes its appearance as an almost solid outgrowth of mesodermal cells at the level of the junction of the amnionic fold with the medullary plate (Pl. XXV, fig. 3). As development proceeds the allantois increases in size and grows upwards through the extra-embryonal coelom as a pear-shaped structure, the distal half of which is vesicular in character, i.e. it contains a fluid filled cavity, whilst the proximal portion consists of loosely packed stellate mesenchymatous cells. *Pari passu* with this growth of the allantois, the extra-embryonal coelom increases markedly in size, apparently under the influence of internal pressure, with the result that the chorionic roof is forced upwards until it comes into contact with the overlying trophoblast of the Träger (Pl. XXV, fig. 4).

This contact between the "chorion" and trophoblast is first initiated over the middle region as the result of which the ectoplacental or false amniotic cavity becomes restricted to an annular space, the external diameter of which corresponds roughly with the diameter of the Träger at its base. The "chorion" consists of a single layer of more or less cubical trophoblastic cells invested on its lower surface by an exceedingly attenuated mesodermal membrane in which the nuclei are widely separated and filiform in character. The trophoblastic cells of the "chorion" are apparently identical in character with and, after fusion has taken place, indistinguishable from, those of the Träger.

At the stage of development represented by Pl. XXV, fig. 3 the trophoblast is purely cellular, there is no differentiation into a cytotrophoblast and syncytiotrophoblast; moreover, it does not appear to be actively phagocytic; owing to the activity of the endothelial giant cells, the decidual tissue mesometrially to the Träger is largely resorbed with the result that the advancing edge of the trophoblast is preceded by a belt of giant cells and maternal blood. It should be noted, however, that this belt of giant cells, which probably corresponds to the "zone of ingrowth" or "Umlagerungszone" of the Rat, is not itself migratory. It is formed *de novo* in successive regions, always slightly in advance of the ingrowing trophoblast, which latter therefore comes to enclose in its meshes, not only maternal blood, but also endothelial giant cells. In these early stages many of the trophoblastic lacunae possess an endothelial lining, which soon, however, degenerates, though deeply-staining masses which represent the giant cell nuclei are recognisable for a considerable time. In the lateral regions and around the antimesometrial side of the embryonal formation similar changes in the maternal tissues are in progress. Immediately outside Reichert's membrane there is established a vascular giant cell network containing maternal blood. The decidual tissues adjacent to this zone become converted into multinucleate symplasma masses (Pl. XXIX, fig. 17) which are ingulfed and resorbed by the giant cells (Pl. XXIX, fig. 20). Similar symplasma masses are formed from the decidual cells mesometrially to the "zone of ingrowth."

An embryo at this stage possesses five pairs of mesodermal somites. The allantois measures 1·5 mm. in length and ·45 mm. in diameter at its distal vesicular end. The vesicular portion is at present quite devoid of blood vessels, but the presence of foetal vessels in the embryonal mesenchyme, adjacent to the attachment of the allantoic stalk, indicates that vascularisation will shortly take place.

Unfortunately no stages were obtained in which the first union of the allantois with the "chorion" was taking place, but it seems probable that by the time the vesicular portion has reached the trophoblast its vascularisation is completed. In the next developmental stage available it is seen that the area of allanto-chorionic union is almost as wide as the area of the decidua into which the trophoblast has penetrated. This wide area of union is doubtless correlated with, if not actually conditioned by, the vesicular character of the allantois, for it is clear that a more rapid flattening can take place in the case of a vesicle than in that of a solid sphere.

Immediately this layer of vascular allantoic mesenchyme has come into contact with the chorionic mesenchyme, the formation of foetal villi sets in. It appears, as Jenkinson has pointed out for the Mouse, that the overlying chorionic trophoblast is not merely invaginated into the trophoblast of the Träger by the upgrowth of the allantoic mesenchyme, but that it takes an active part in the process of ingrowth. In the case of the Mouse, however, the trophoblast of the Träger is already syncytial, constituting the "plasmoditrophoblast," whereas in Microtus the trophoblast retains its cellular character until the penetration of the allantoic villi has set in. In these early stages of placental formation it is therefore possible to distinguish three regions in the foetal portion of the placenta. Firstly an irregular zone of actively proliferating cellular trophoblast beyond the region of penetration of the allantois. Secondly a zone of syncytial trophoblast into which the foetal villi have penetrated. Thirdly a zone of cellular trophoblast, which Jenkinson calls the "cytotrophoblast," which is simply the floor of the original ectoplacental cavity. This cellular trophoblast very soon becomes perforated by the allantoic villi, with the result that the latter come into direct contact with the syncytial layer. The ingrowth of the allantoic villi results in the formation of a series of thin trophoblastic syncytial lamellae, containing maternal blood, separated by mesenchymatous villi carrying foetal capillaries. In this way the definitive allantoic placenta is established (Pl. XXXII, fig. 27).

From now onwards throughout the gestation period the changes in the placenta are purely of the nature of an elaboration of pre-existing structure.

In vertical sections through the placental disc of stages similar to, and more advanced than, that represented by figs. 25 and 27 three well defined zones are recognisable. The zone nearest the mesometrium consists of typical decidual tissue penetrated by wide blood lacunae, the endothelial lining cells of which are in various stages of conversion into giant cells, those nearest the ingrowing trophoblast being usually considerably more advanced in their metamorphosis, with the result that the decidual tissue in this region becomes converted into a syncytium which is resorbed by the giant cells. The middle zone of the placental disc consists of the actively proliferating cellular trophoblast, in which are embedded numerous giant cells and masses of maternal blood.

The third zone is constituted by the placental labyrinth consisting of trophoblastic syncytial lamellae honeycombed with channels, in which the maternal blood circulates, alternating with mesenchymatous villi carrying allantoic capillaries. Attached to the syncytial walls of the lamellae are numerous small giant cells, which have apparently remained at their places of origin on the vessel walls and become surrounded by the trophoblastic syncytium.

It seems clear that the "Umlagerungszone" of Grosser, which according to him is formed by the conversion of the superficial layer of the trophoblast into giant cells, is, in Microtus, represented by the irregular layer of giant cells formed from the endothelial cells lining the maternal blood sinuses in proximity to the ingrowing trophoblast.

According to Duval, the trophoblast creeps up the walls of these maternal sinuses, destroys the endothelial lining and forms a pseudo-endothelium of syncytial trophoblast which he termed the "couche plasmodiale endovasculaire." Jenkinson's interpretation of Duval's figures representing this endovascular plasmodium, differs somewhat. He agrees with Duval that the cavities are lined by trophoblast, but maintains that they are not maternal sinuses. He considers that they are simply spaces in the foetal trophoblast containing extravasated maternal blood.

There is little doubt that in Microtus these sinuses are maternal and that their containing walls are modified endothelial cells.

As development proceeds the proliferation of the cellular trophoblast fails to keep pace with the ingrowth of the foetal villi, with the result that the placental labyrinth increases in thickness at the expense of the middle layer. In the nearly ripe placenta the cellular trophoblast, which formerly constituted the middle zone, is only represented by comparatively small islands of tissue surrounded by giant cells, blood lacunae and decidual cells.

THE YOLK-SAC PLACENTA

The yolk-sac placenta in Microtus, as in other rodents with inversion of the germ layers, plays a subsidiary rôle in the nutrition of the embryo. Owing to the character of development, the yolk-sac cavity early comes into open continuity with the cavity of the blastocyst (text-fig. 4). At this time the entoderm cells constituting its persistent visceral wall are ovoid and simple in character, but by the time the blastocyst has reached the "egg-cylinder" stage they exhibit a differentiation which indicates that they are engaged in resorbtive activity (text-fig. 5).

The entodermal cells around the embryonal ectoderm first become columnar, their cytoplasm exhibits vacuolation, their free surfaces being granular and apparently engaged in absorbing nutrient fluid from the yolk-sac cavity. As already stated, there is no evidence in the case of Microtus that these cells contain haemoglobin. No maternal blood can reach the yolk-sac cavity, which remains throughout gestation shut off from the maternal tissues by Reichert's membrane, and any substance absorbed by the entodermal cells of the yolk-sac splanchnopleur must have passed by osmosis through this membrane.

It is of interest to note that these entodermal cells attain their maximum size and activity, below the embryonal ectoderm, quite early in development (text-fig. 5), whereas at a rather later stage, such as is represented in Pl. XXV, fig. 3, they have become reduced in size in this region and form a layer of cubical or flattened cells, which do not appear to be absorbtive at all, whilst on the other hand the cells covering the extra-embryonal coelom and ectoplacental cavity have become tall and columnar.

At a time when the embryo possesses about five somites, vascularisation of the yolk-sac splanchnopleur sets in, and concurrently therewith there are developed folds and villi, in that portion of the splanchnopleur which is adjacent to the placenta (Pl. XXV, fig. 4).

As development proceeds these entodermal folds increase in size and complexity and omphalopleural vessels penetrate into them (Pl. XXX, fig. 22).

These villous folds attain their maximum size over the margins of the placental disc, whereas on the antimesometrial side the entoderm has the form of a simple layer of columnar cells in close contact with Reichert's membrane. Apparently, this villous portion of the yolk-sac splanchnopleur is concerned with the absorbtion of nutritive material, which has diffused into the yolk-sac cavity from the annular zone of vascular giant cell tissue, which encircles the placenta proper.

At a stage corresponding to that shown in Pl. XXXI, fig. 25, the uterine lumen has been reformed on the antimesometrial side of the capsularis, and the yolk-sac splanchnopleur is only separated from the uterine cavity by a comparatively thin layer, consisting of Reichert's membrane, the network of attenuated and degenerating giant cells, and a thin layer of circular muscle fibres. As the embryo increases in size the capsularis becomes stretched still further, until, in very late stages, it is represented by a thin membrane composed of the now flattened cells of the yolk-sac splanchnopleur closely applied to Reichert's membrane.

According to Jenkinson and Grosser, this layer ruptures a considerable time before birth, with the result that the yolk-sac splanchnopleur becomes exposed to the uterine lumen. In *Arvicola amphibius* this does not occur, for in the latest stage which I possess, where the uterine swellings measure 16 mm. in diameter and the placenta 13 mm. × 3·5 mm., the splanchnopleur and Reichert's membrane are still intact.

Owing to the fact that the Water Vole material was collected in the wild state, it is not possible to ascertain the age of this foetus, but it is clear from its size and condition that it is close on full time.

It is worthy of note, therefore, that Reichert's membrane persists throughout the gestation period, or at all events, until parturition is imminent.

SUMMARY

1. The development of *Microtus amphibius* is of the excentric type. It agrees in general outlines with that of the Mouse and Rat.

2. The implantation cavity early becomes surrounded by a belt of maternal capillaries, the endothelial cells of which exhibit characteristic changes.

3. These endothelial cells become phagocytic giant cells. The decidual tissue adjacent to them breaks down with the formation of symplasma masses, which are resorbed by these giant cells.

4. All the placental giant cells are of maternal endothelial origin. The trophoblast does not contribute to their formation, as has been described in the Mouse and Rat.

5. The ectoplacental trophoblast does not appear to be actively phagocytic. Its penetration is assisted by the giant cells, which destroy the decidual tissue in its line of advance.

6. Around the antimesometrial end, and lateral walls, of the implantation cavity, the giant cells form a vascular network in contact with Reichert's membrane. This network serves to facilitate the rapid stretching of the capsularis which results from growth of the embryo.

7. The trophoblast of the Träger retains its cellular character until the penetration of the allanto-chorionic mesenchyme has set in, and even then the formation of syncytio-trophoblast is limited to that portion in contact with, or adjacent to, the allantoic villi.

8. The ripe placenta is of the discoidal, haemo-chorialis type, the maternal blood circulating in syncytial trophoblastic lamellae, subdivided by foetal mesenchymatous villi, carrying allantoic capillaries.

9. The yolk-sac splanchnopleur does not come into contact with maternal tissues until parturition, or very shortly prior thereto. It is always separated therefrom by the persistent Reichert's membrane.

REFERENCES TO LITERATURE

ASSHETON, R. (1905). "On the foetus and placenta of the Spring Mouse." *Proc. Zool. Soc. London.* vol. II.

—— (1895). "The attachment of the mammalian embryo to the walls of the uterus." *Quarterly Journ. Micros. Sci.* vol. XXXVII.

BERNARD (1859). "Sur une nouvelle fonction du placenta." *Comp. Rend. Acad. Sci.* Paris.

BIEHRINGER, J. (1888). "Ueber die Umkehrung der Keimblätter bei der Scheermaus." *Archiv f. Anat. und Phys.*

BISCHOFF, T. "Entwicklungsgeschichte des Meerschweinchens." *Abhand. der math. naturwiss. Classe der König. bayrisch. Akad. der Wissenschaften.*

BURCKHARD, G. "Die Implantation des Eies der Maus in die Uterus-schleimhaut und die Umbildung derselben zur Decidua." *Archiv f. mikr. Anat.* Bd. LVII.

DISSE, J. (1906). "Die Vergrösserung der Eikammer bei der Feldmaus." *Archiv f. mikr. Anat.* Bd. LXVIII.

DUVAL, M. (1889–1892). "Le placenta des Rongeurs." *Journ. de l'Anat. et de la Phys.*

Fraser, A. (1882). "On the Inversion of the blastodermic layers in the Rat and Mouse." *Proc. Roy. Soc.* No. 223.

Frommel (1888). *Über die Entwicklung des Placenta von Myotus murinus.* Wiesbaden.

Grosser, O. (1909). *Die Eihäute und der Placenta.* Wien.

Huber, G. C. (1915). "The Development of the Albino Rat, *Mus norvegicus albinus.*" Memoirs of the Wistar Institute of Anatomy and Biology. *Journ. Morphol.* vol. xxvi. No. 2.

Hubrecht (1889). "Studies in mammalian embryology. (I) The Placentation of Erinaceus." *Quart. Journ. Micros. Sci.* vol. xxx.

—— (1908–9). "Early Ontogenetic phenomena in mammals." *Quart. Journ. Micros. Sci.* vol. liii.

Jenkinson, J. W. "Observations on the histology and physiology of the placenta of the Mouse." *Tijd. Neder. Dierk. Ver.* ii, dl. vii.

Kupffer, C. (1882). "Das Ei von *Arvicola arvalis* und die vermeintliche Umkehr der Keimblätter an demselben." *Sitz. Ber. Akad. d. Wiss.* II. Kl.

Melissinos, K. (1907). "Die Entwicklung des Eies der Mäuse." *Arch. f. Mikr. Anat.* Bd. lxx.

Ochs, A. (1908). "Die intrauterine Embryonalentwicklung des Hamsters bis zum Beginn der Herzbildung." *Zeitsch. f. wiss. Zool.* Bd. lxxxix.

Pujiula, D. (1908). "Die Frage der Riesenzellen bei der Entwicklung der Maus." *Actas y memorias del Primer Congreso de Naturalistas Españoles.*

Reichert (1861). "Beiträge zur Entwicklungsgeschichte des Meerschweinchens." *Abhand. d. Akad. d. Wiss.* Berlin.

Robinson, A. (1892). "Observations upon the development of the segmentation cavity, the archenteron, the germinal layers, and the amnion in mammals." *Quart. Journ. Micros. Sci.* vol. xxxiii.

Salenka, E. (1883–4). *Studien über die Entwickelungsgeschichte der Thiere.* Wiesbaden.

Sobotta, J. (1903). "Die Entwicklung des Eies der Maus vom Schlusse der Furchungsperiode bis zum Auftreten der Amniosfalten." *Arch. f. Mikr. Anat.* Bd. lxi.

—— (1903). "Die Entwicklung des Eies der Maus vom ersten Auftreten des Mesoderms an bis zur Ausbildung der Embryonalanlage und dem Auftreten des Allantois." *Arch. f. Mikr. Anat.* Bd. lxxviii.

Von Spee (1901). "Die Implantation des Meerschweineis in die Uteruswand." *Zeitschr. Morph. Anthrop.* Bd. iii.

Widakowich, V. (1909). *Über die erste Bildung der Körperform bei Entypie des Keimes.* Leipzig.

DESCRIPTION OF PLATES XXV—XXXII

Fig. 1. Transverse section through a uterus containing an unattached egg. The characteristic change in the character of the uterine epithelial cells is clearly visible. × 200.

Fig. 2. An early stage similar to the above. Localised changes in the epithelial cells of the uterine lumen at the antimesometrial end are visible. × 200.

Fig. 3. Longitudinal vertical section through a uterus containing an early blastocyst. The section does not pass through the Träger. × 15.

Fig. 4. Transverse section through a uterus containing an embryo with about five somites. The ectoplacental cavity is obliterated, except around its margins, by the union of the "chorion" with the trophoblast. The vesicular character of the allantois is well shown. × 15.

Fig. 5. Section through the maternal tissue near the implantation cavity, in a stage corresponding to text-fig. 5 or fig. 21. The deeply stained strands are endothelial cells lining narrow maternal capillaries. × 150.

Fig. 6. A higher power view of the same tissue traversed by a fine capillary, the endothelial cells of which are beginning their metamorphosis into giant cells. × 360.

Fig. 7. Section through the placenta, showing a large maternal blood vessel. The endothelial cells are greatly enlarged. × 360.

Fig. 8. Section through the decidual tissue in which may be seen a maternal capillary, the lining of which has undergone hypertrophy. × 360.

Fig. 9. Section through the decidua showing a maternal vessel. Three endothelial cells have become giant cells. Their outer surfaces, which abut against the decidual cells, have fused therewith. × 360.

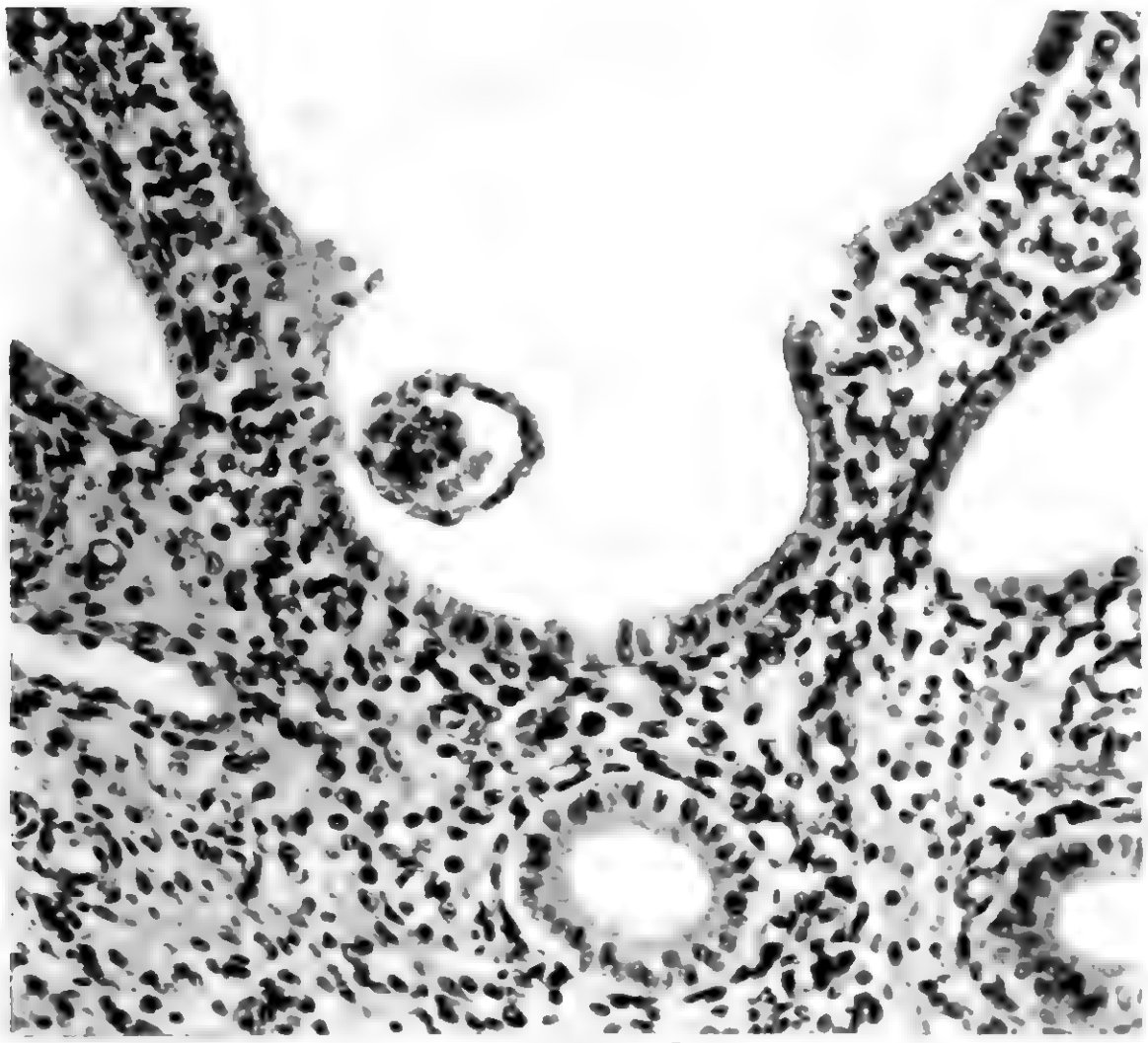

Fig. 1.

Fig. 2.

Fig. 3.

Fig. 4.

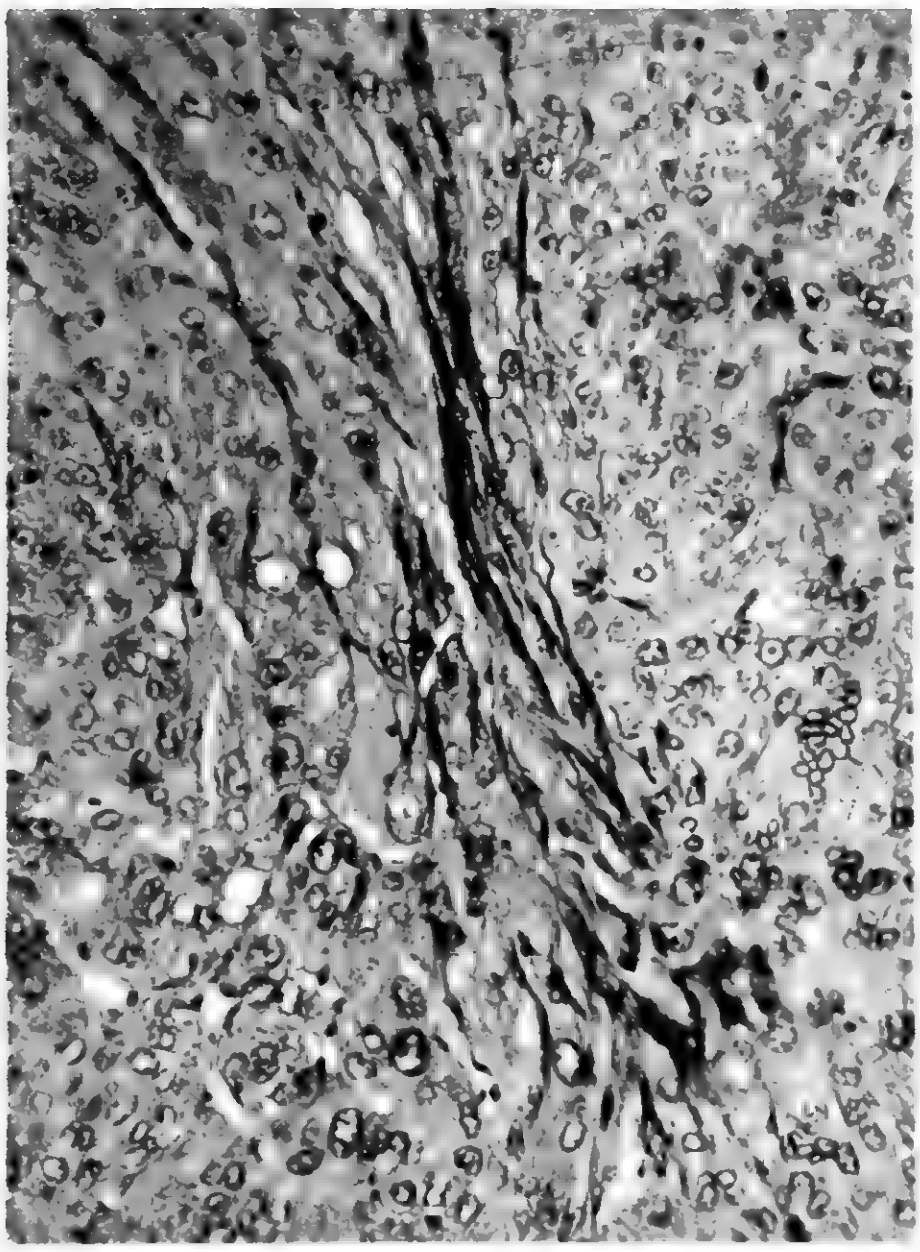

Fig. 5.

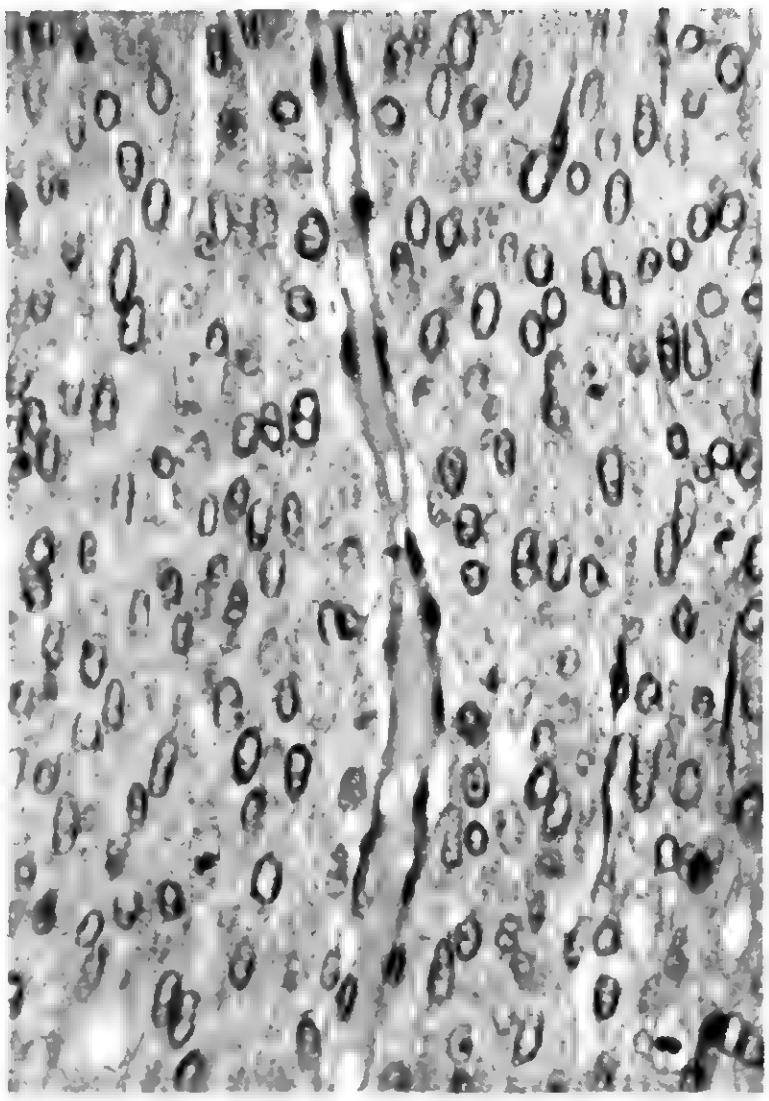

Fig. 6.

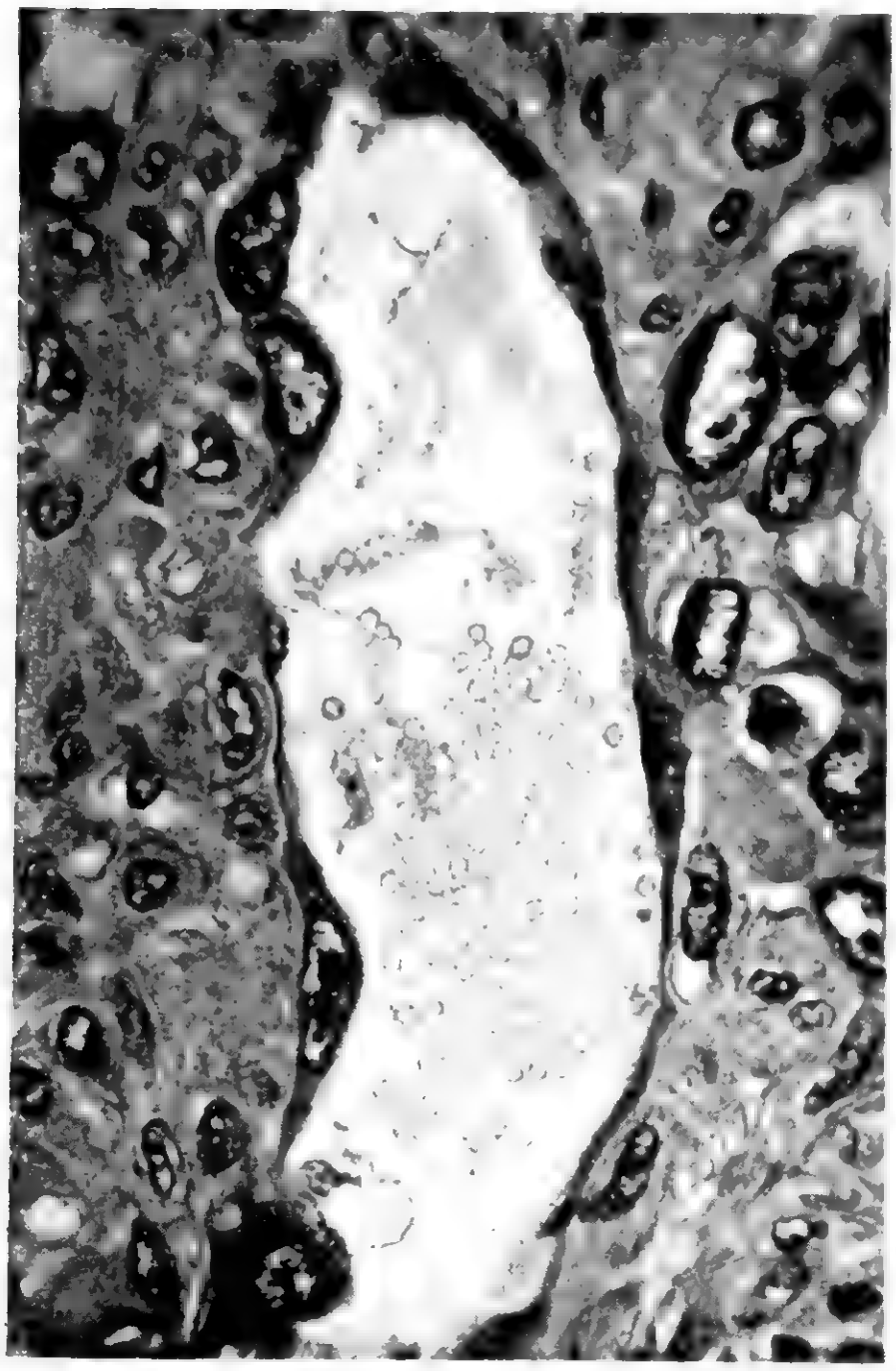

Fig. 7.

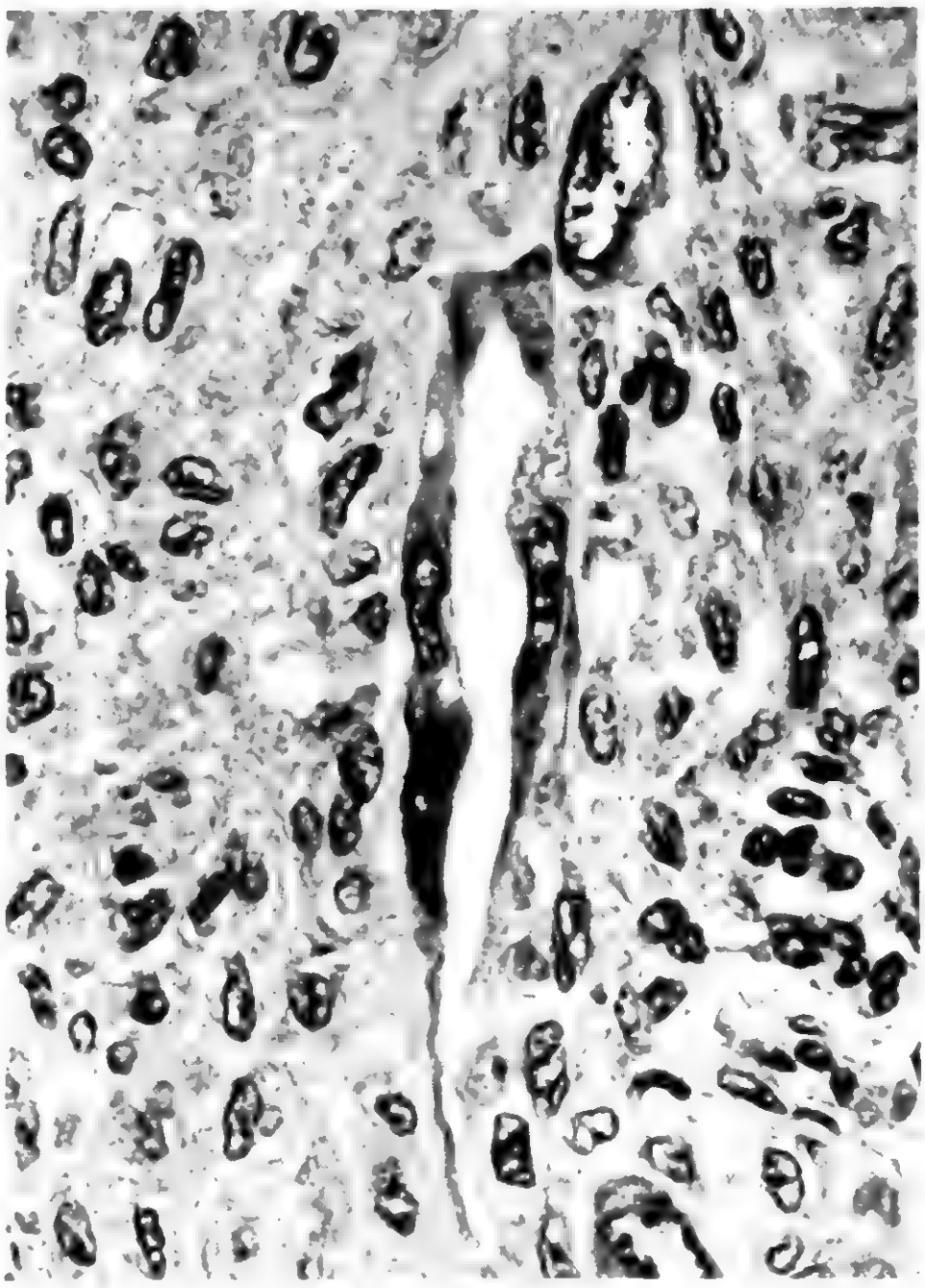

Fig. 8.

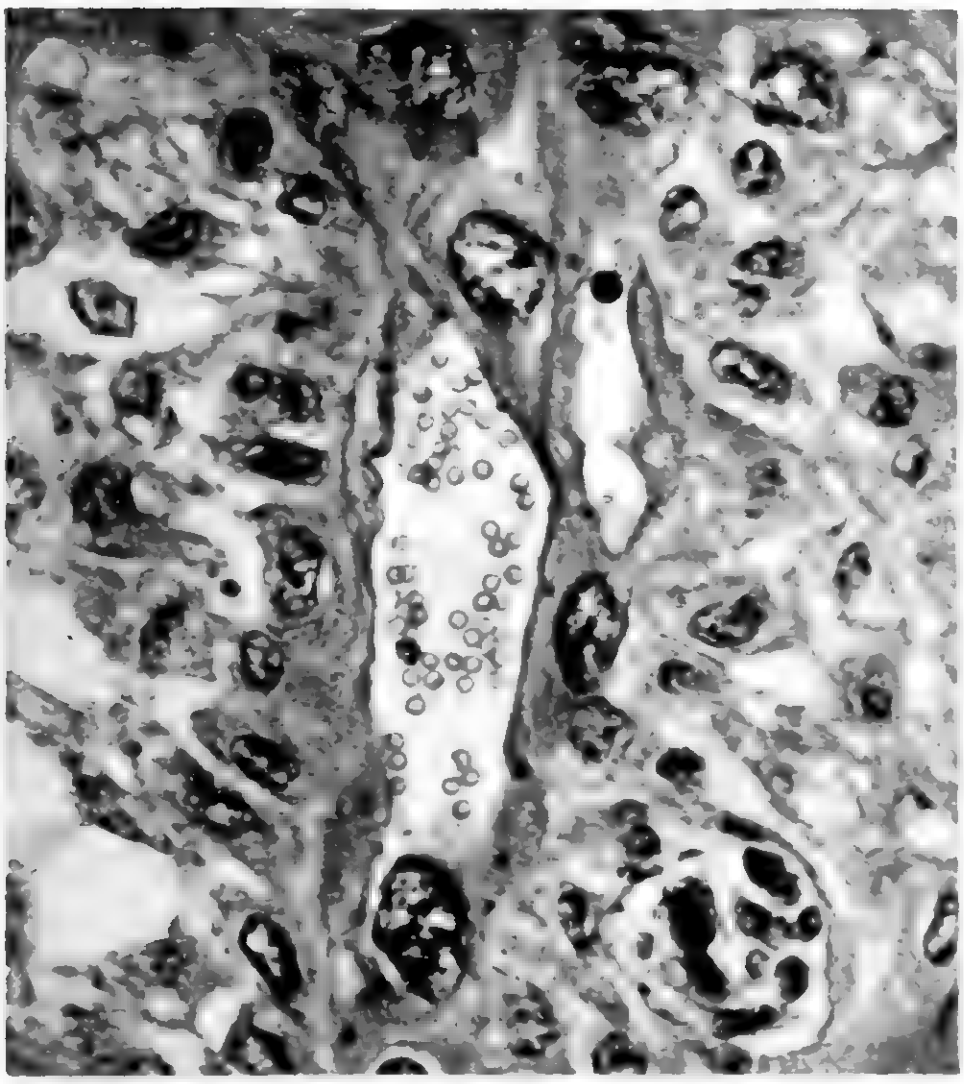

Fig. 9.

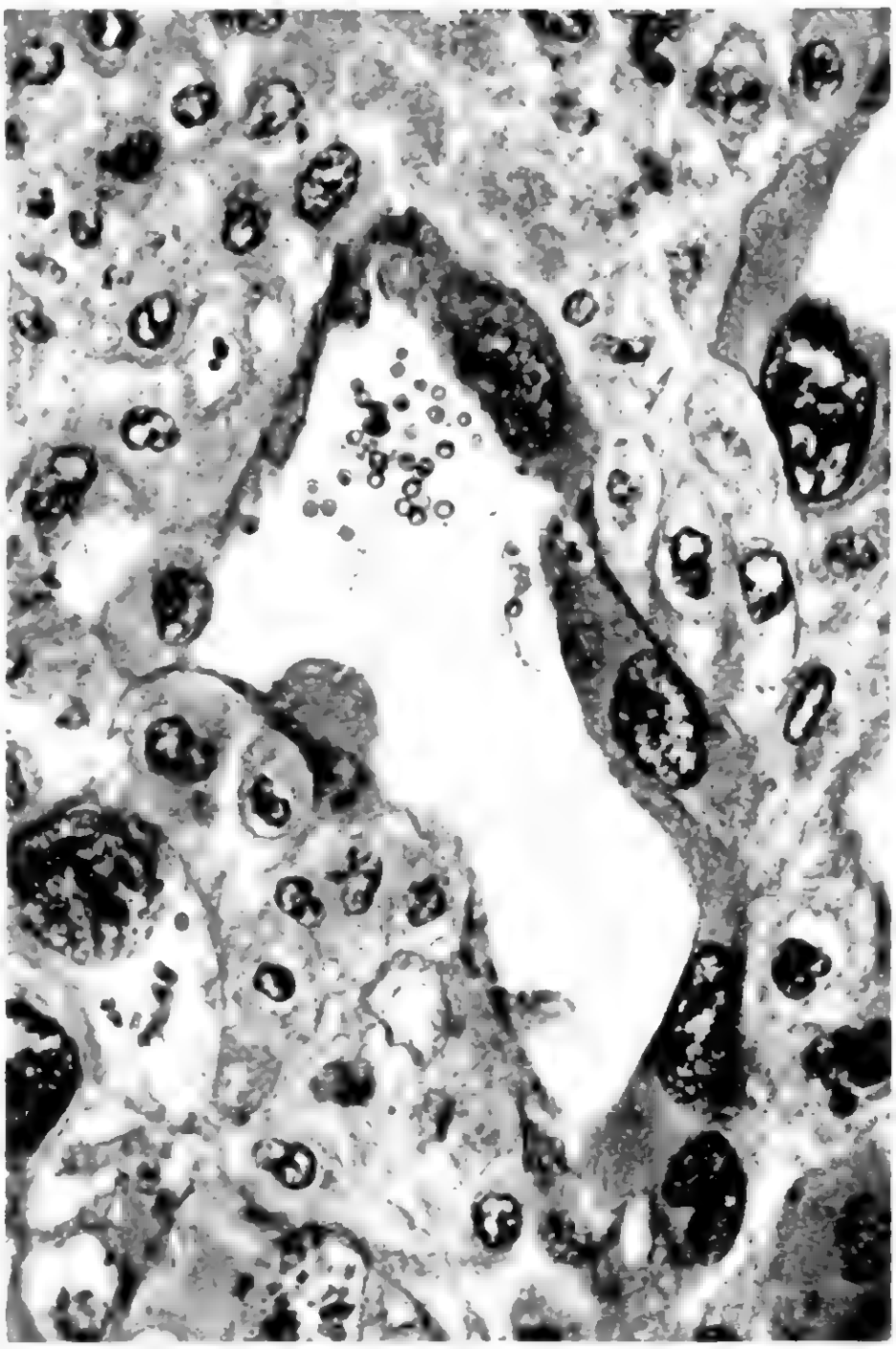

Fig. 10.

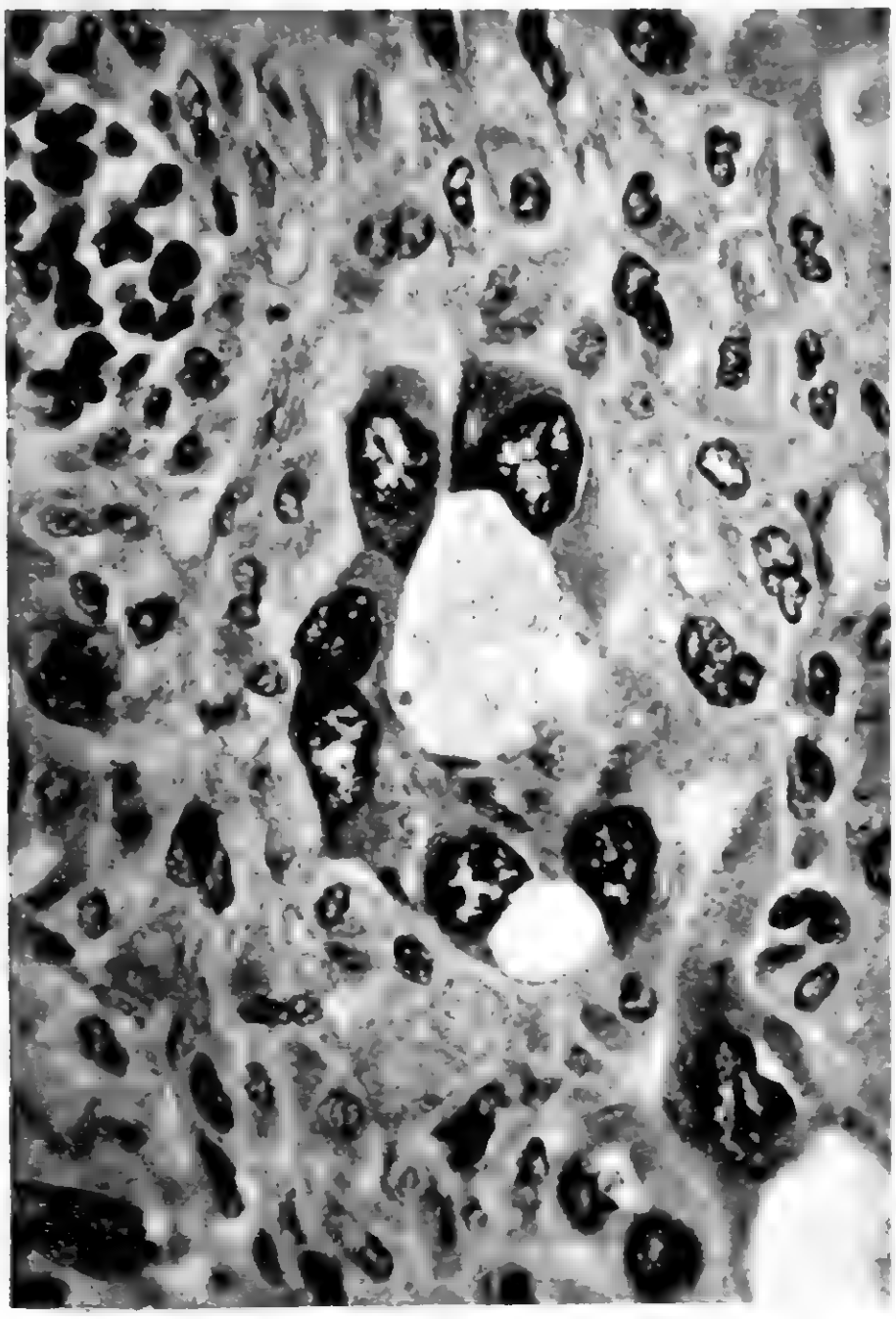

Fig. 11

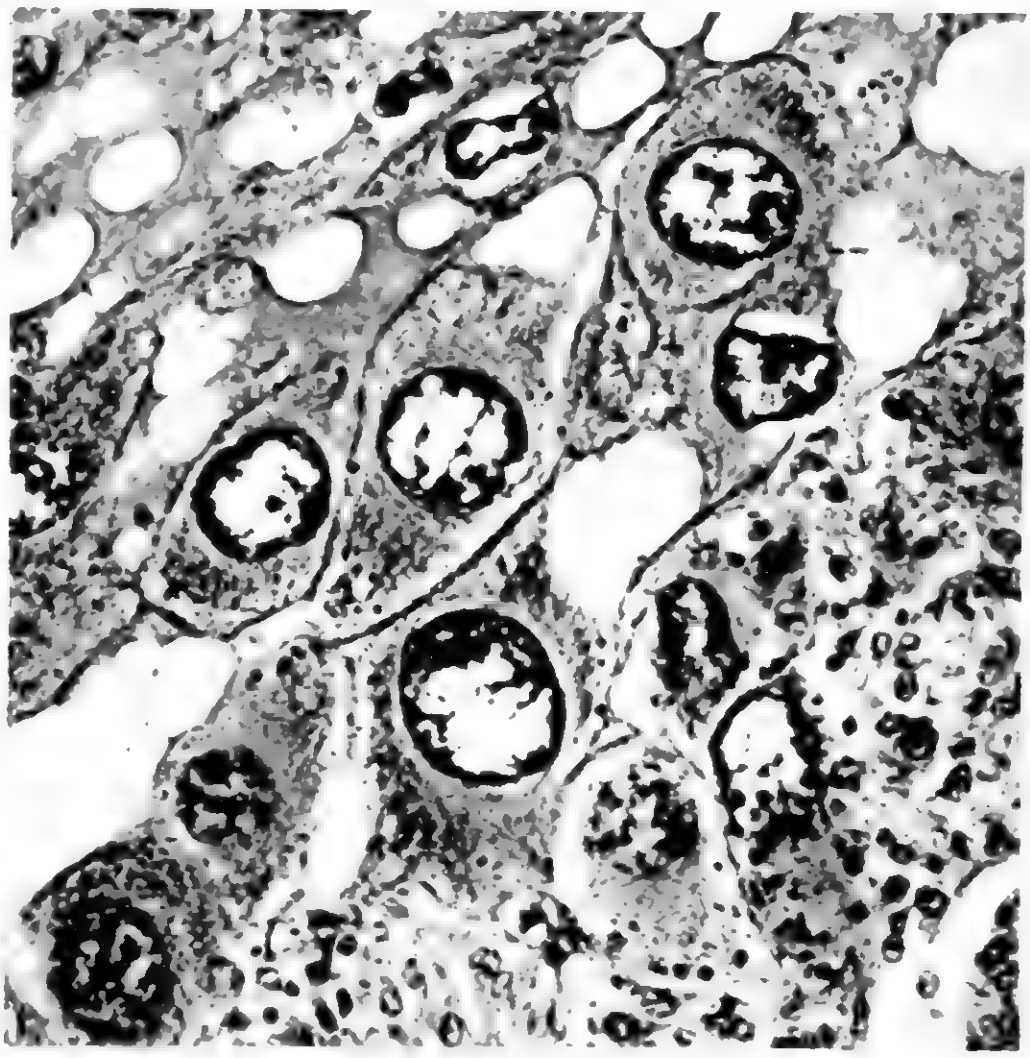

Fig. 12.

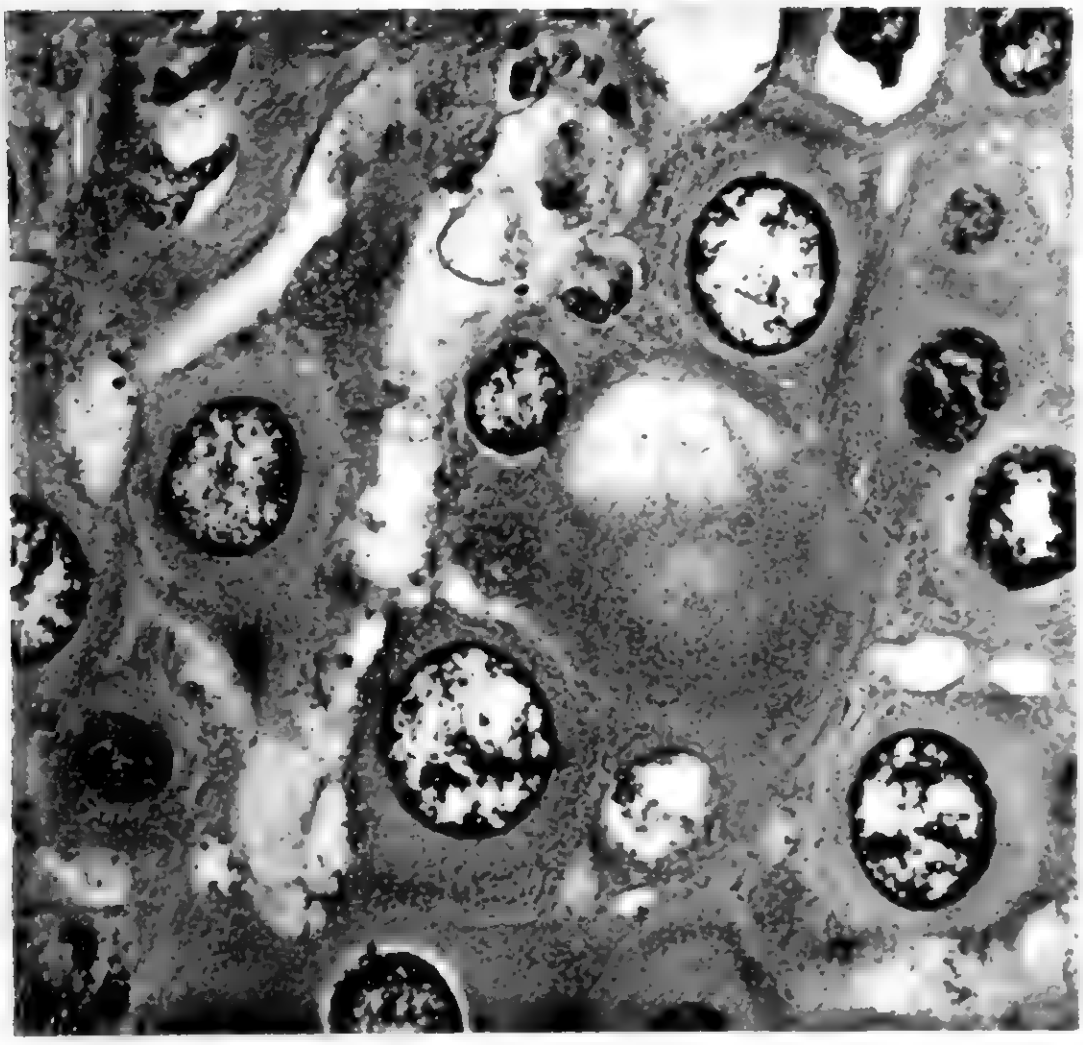

Fig. 13.

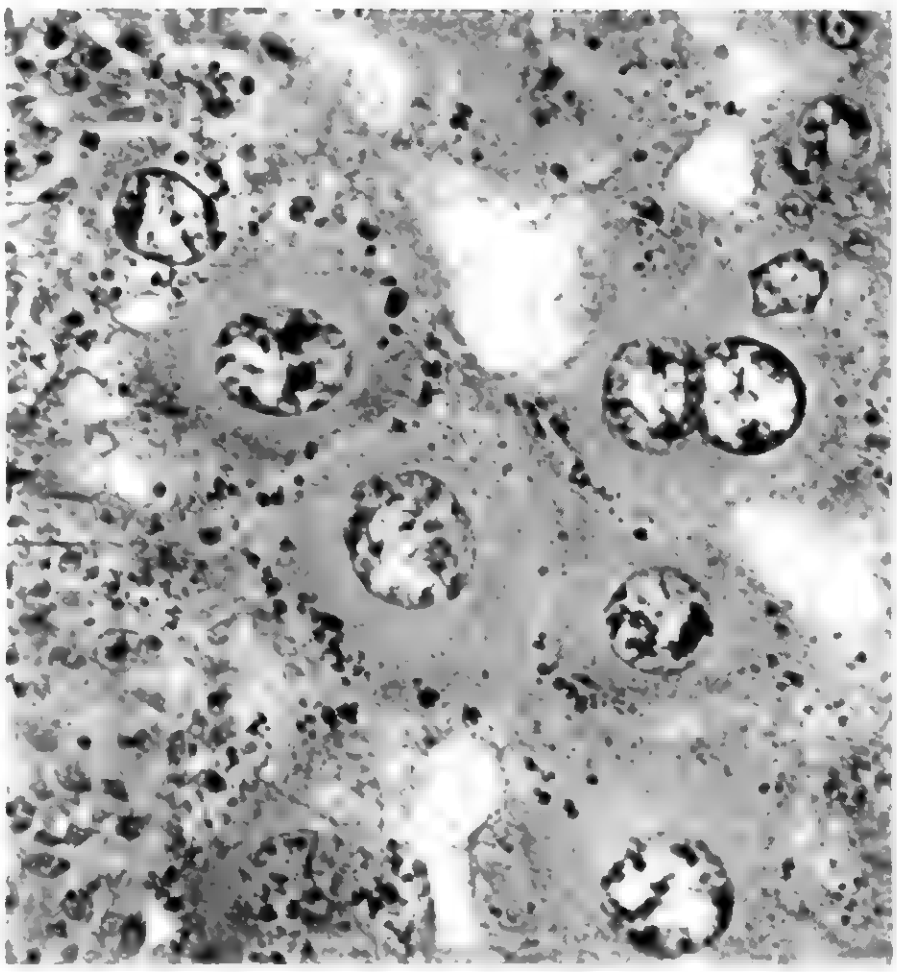

Fig. 14.

Fig. 15

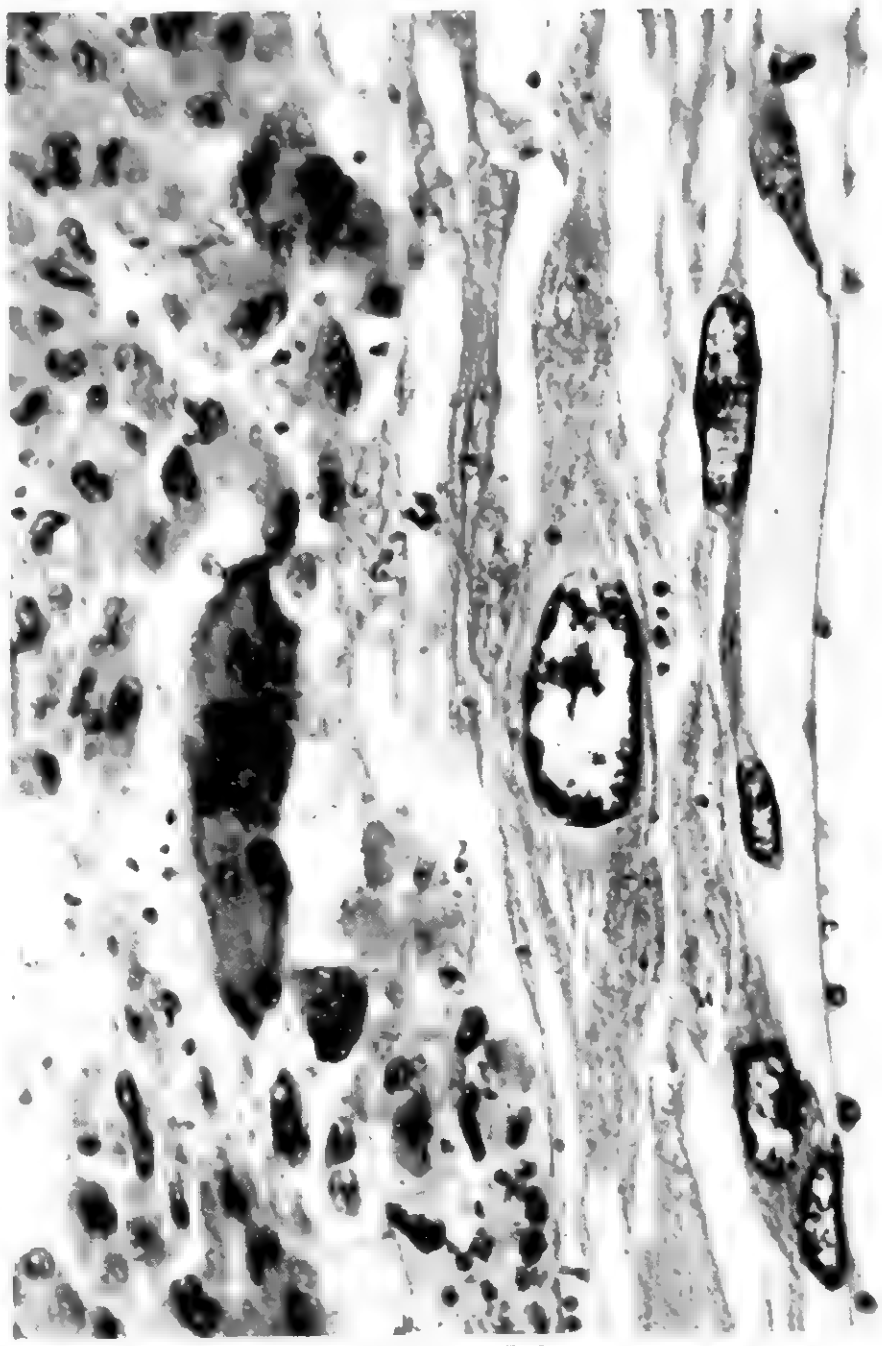

Fig. 16.

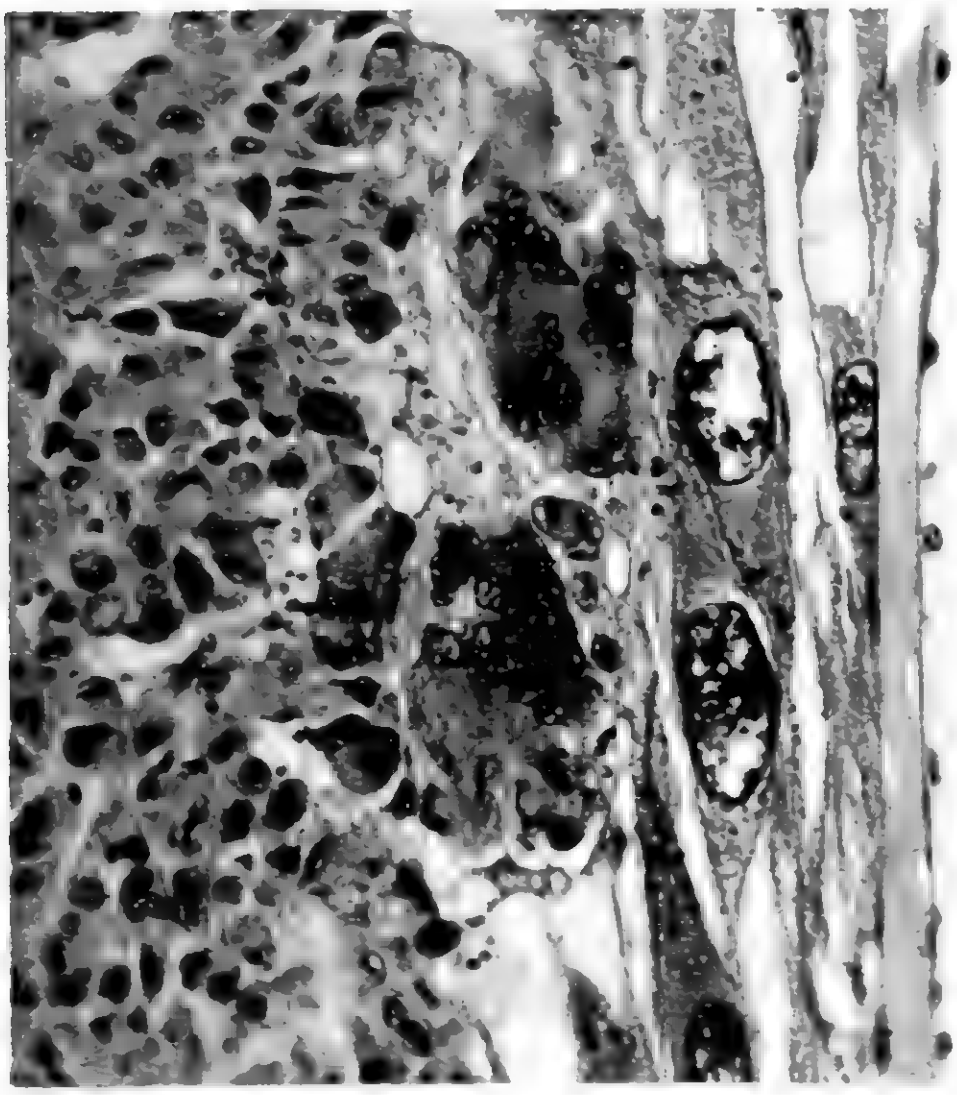

Fig. 17.

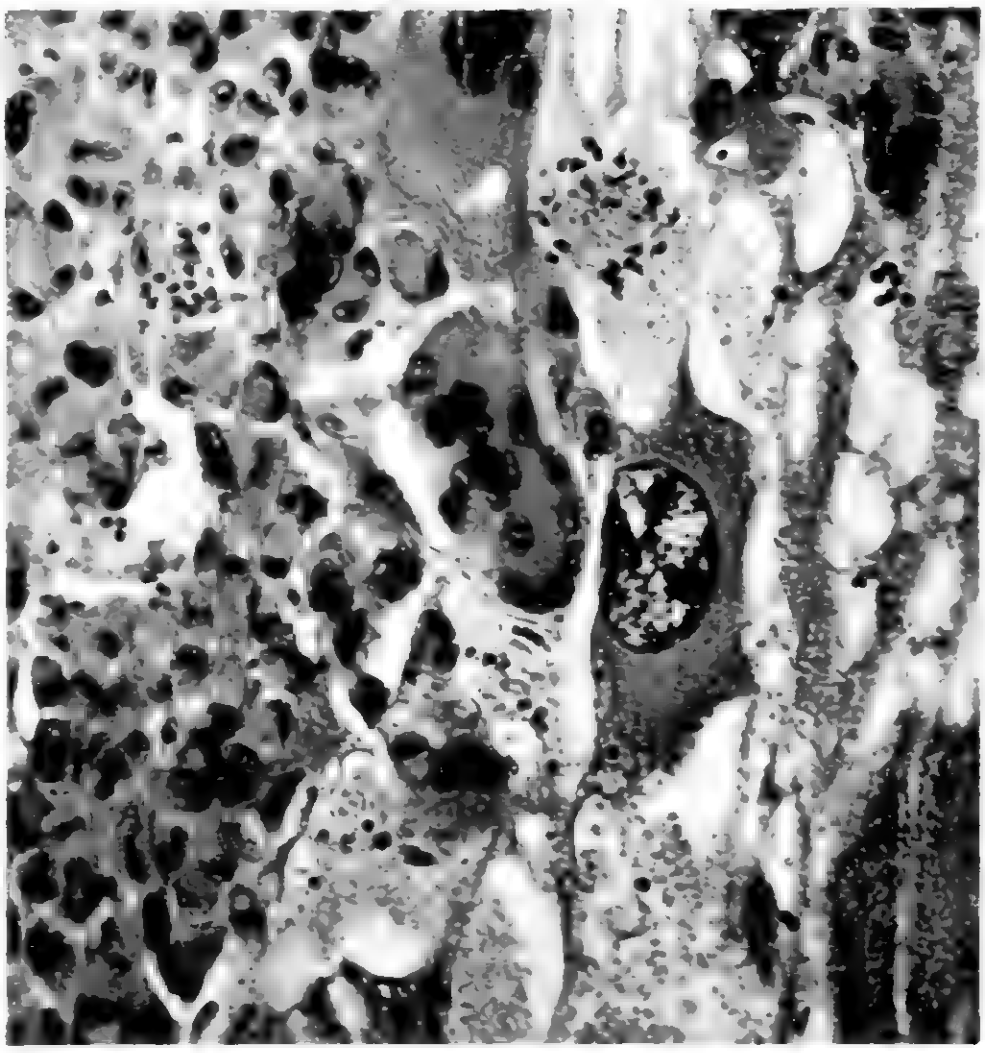

Fig. 18.

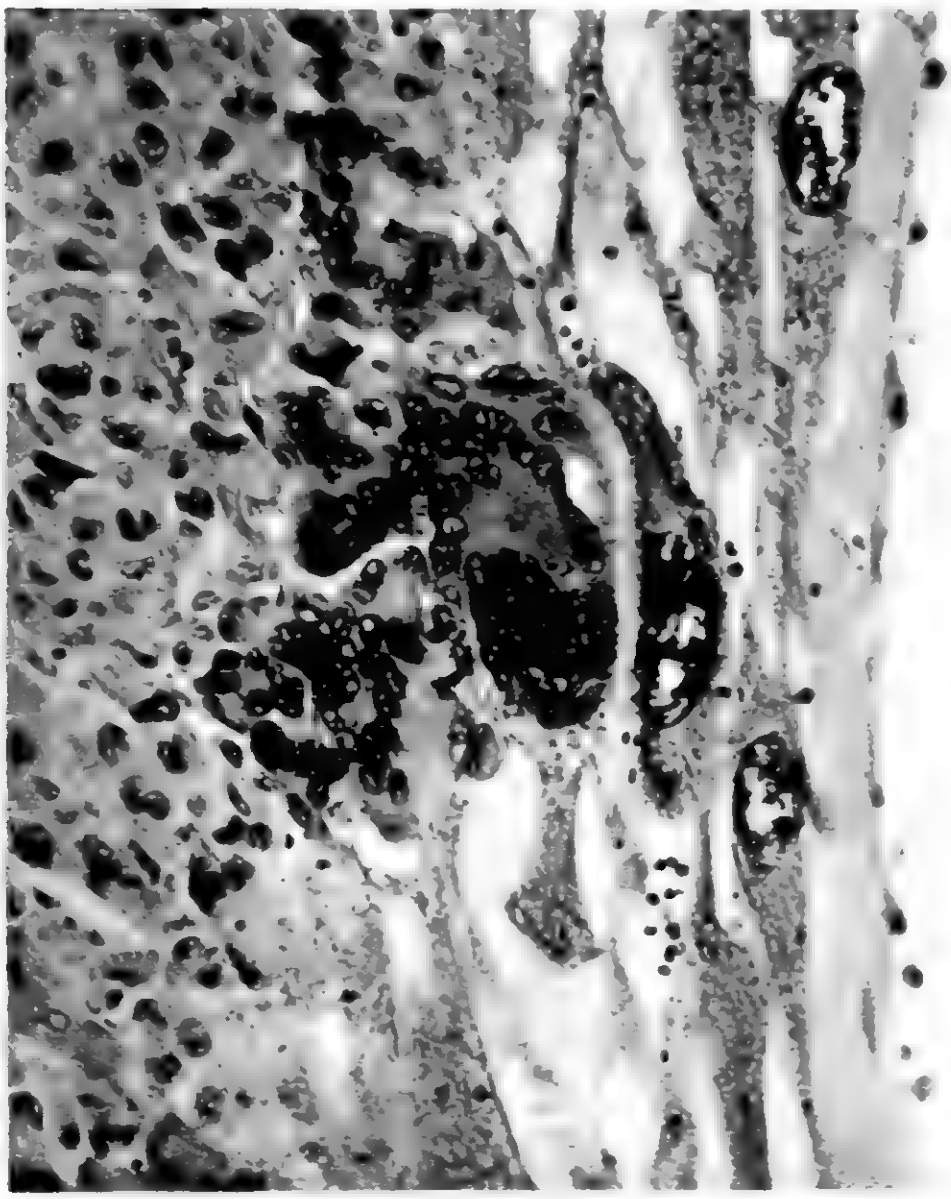

Fig. 19.

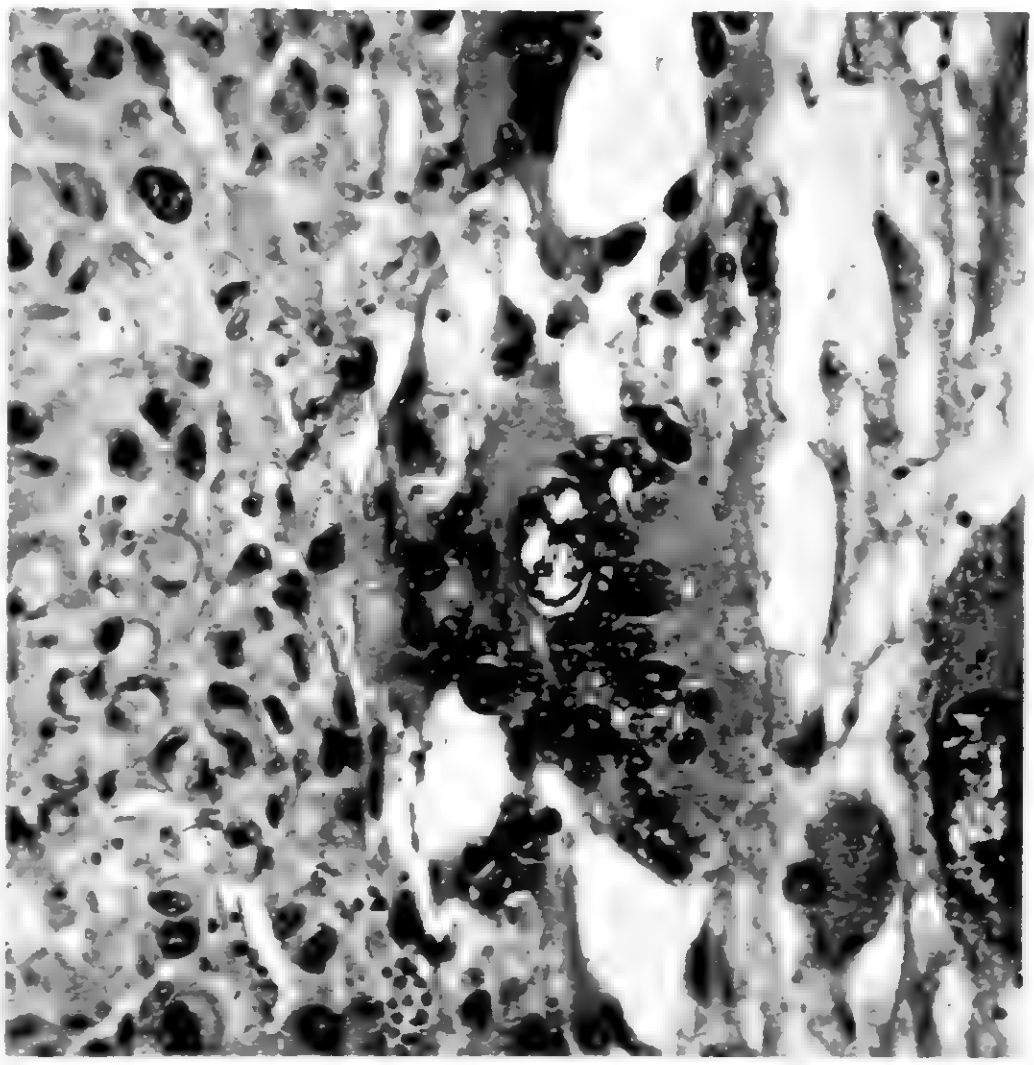

Fig. 20.

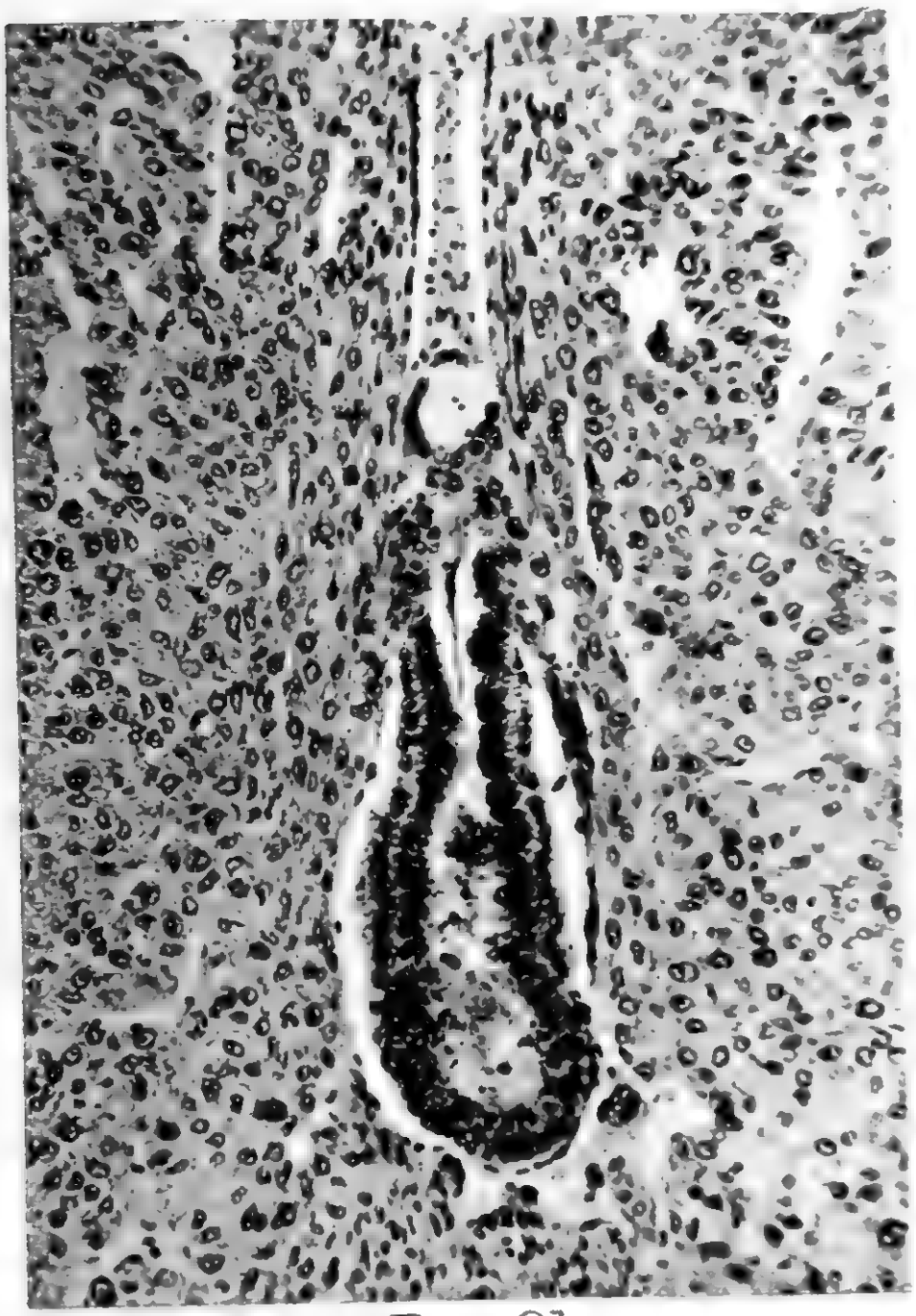

Fig. 21.

Fig. 22.

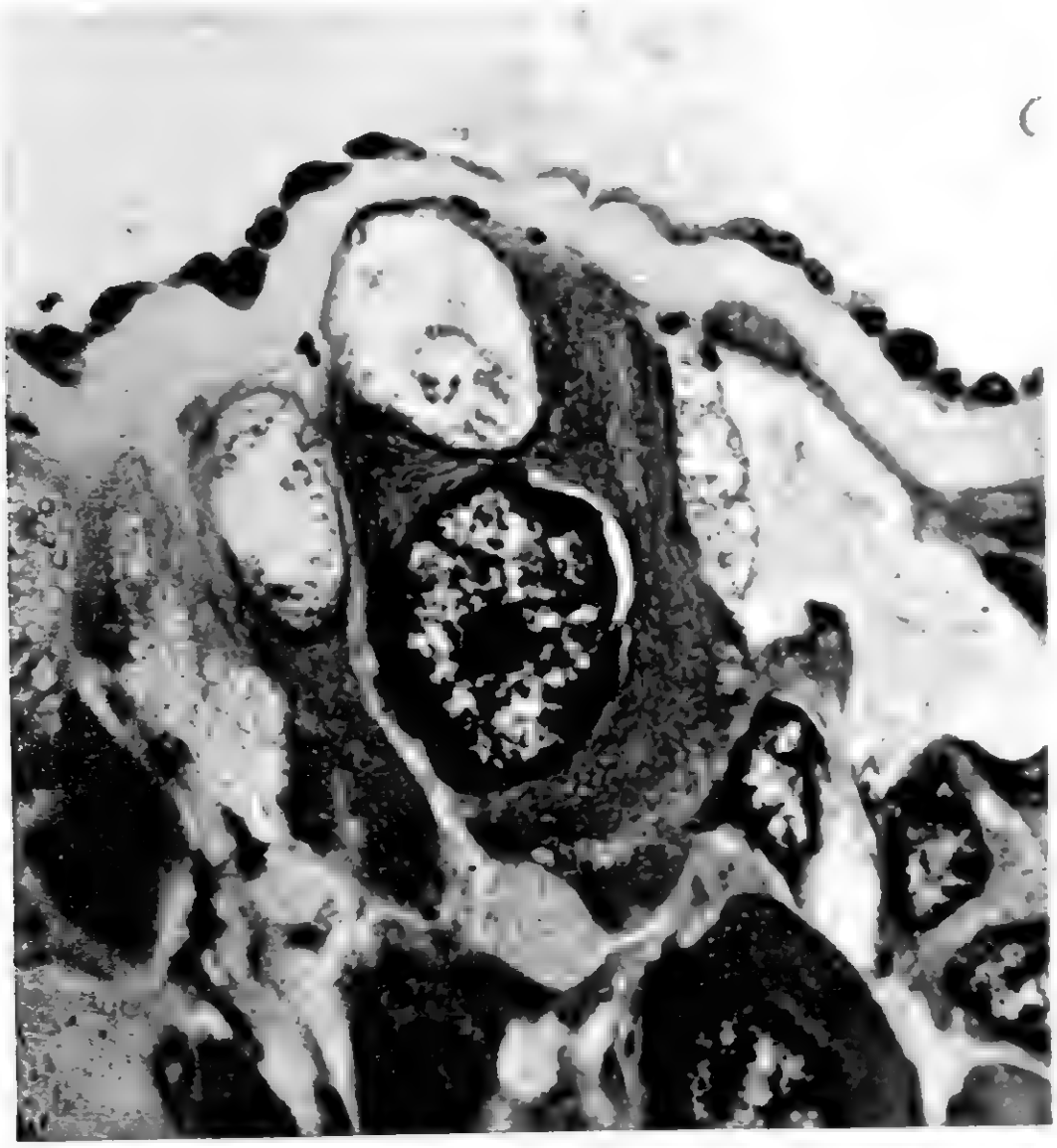

Fig. 23.

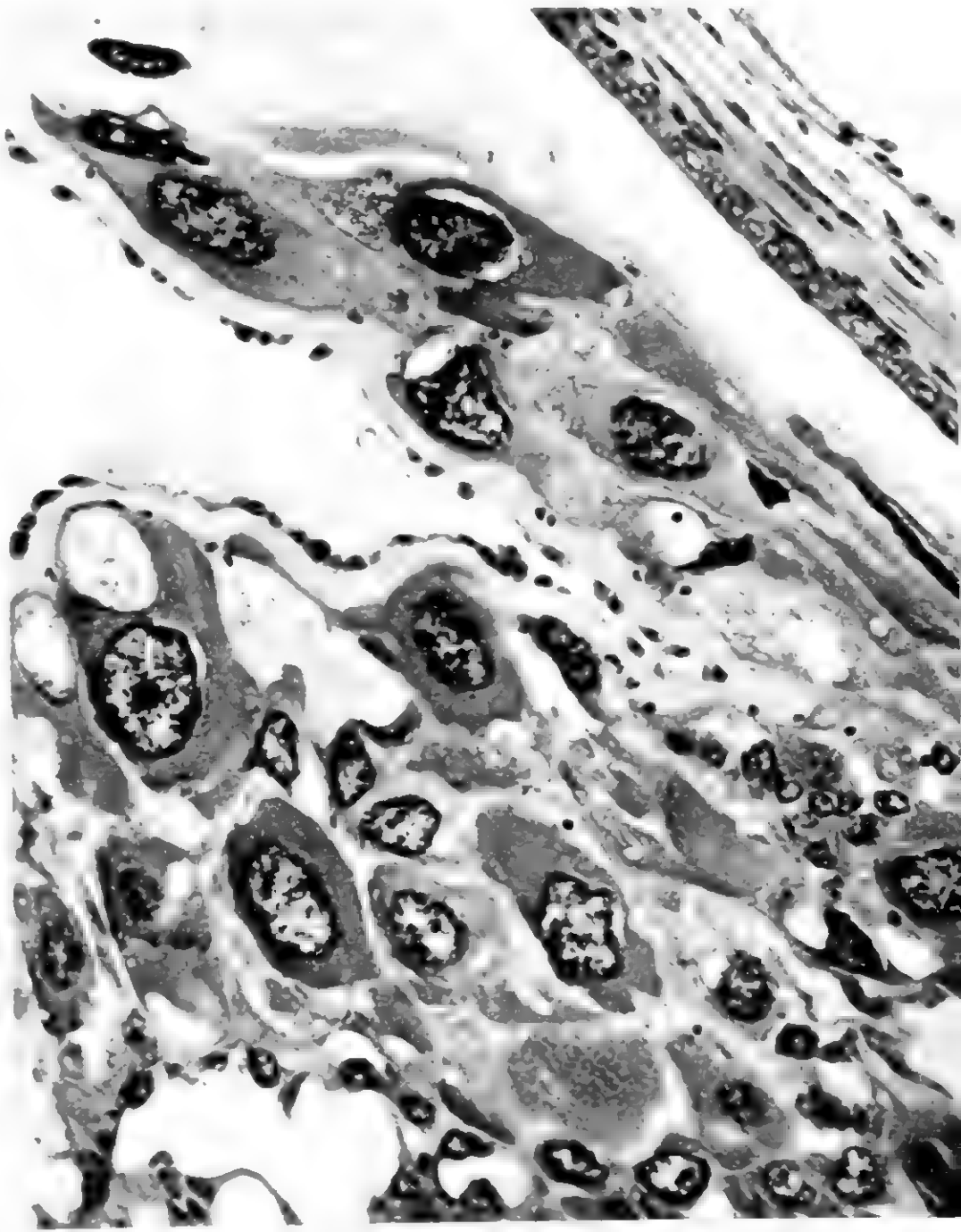

Fig. 24

Fig. 25.

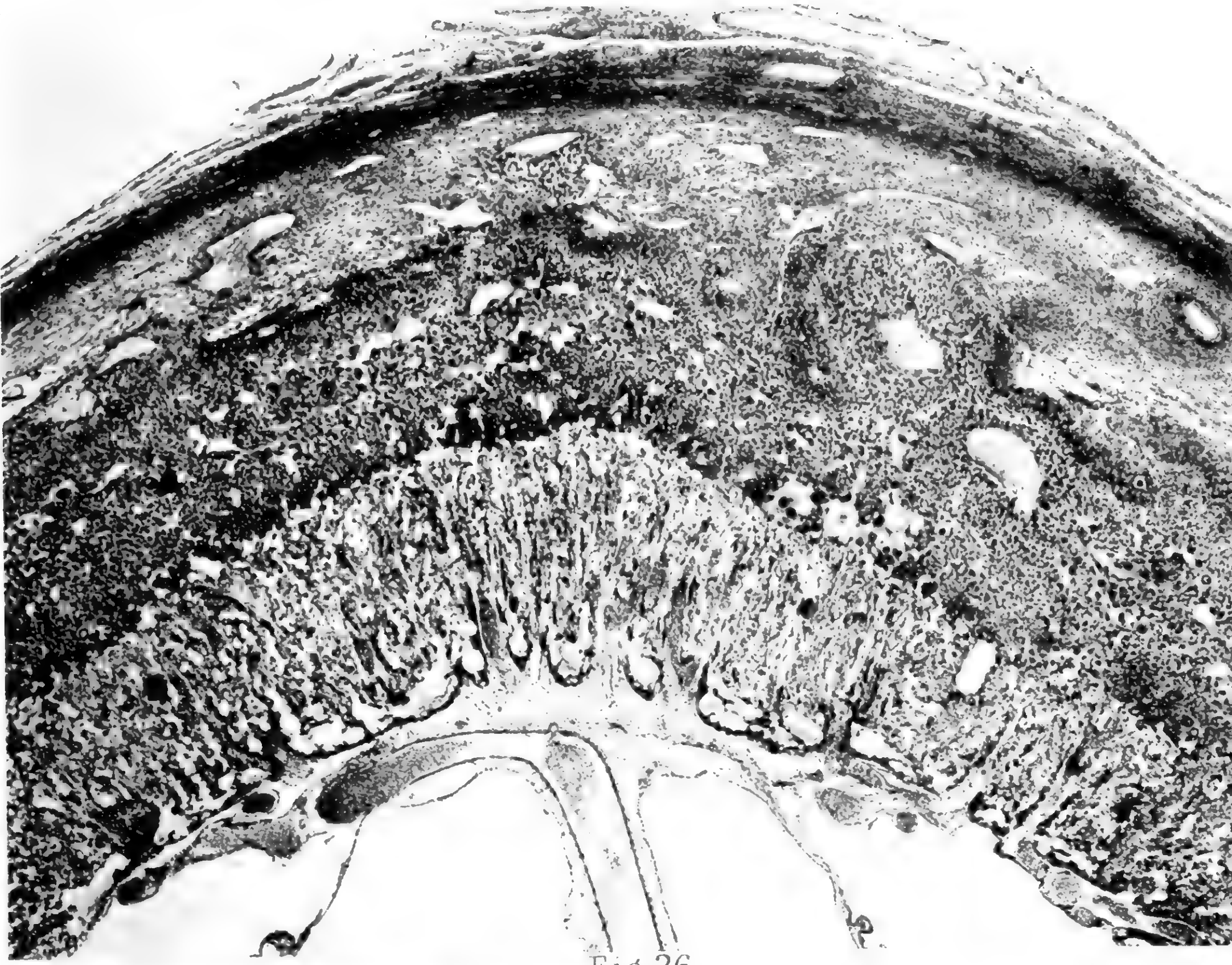

Fig. 26.

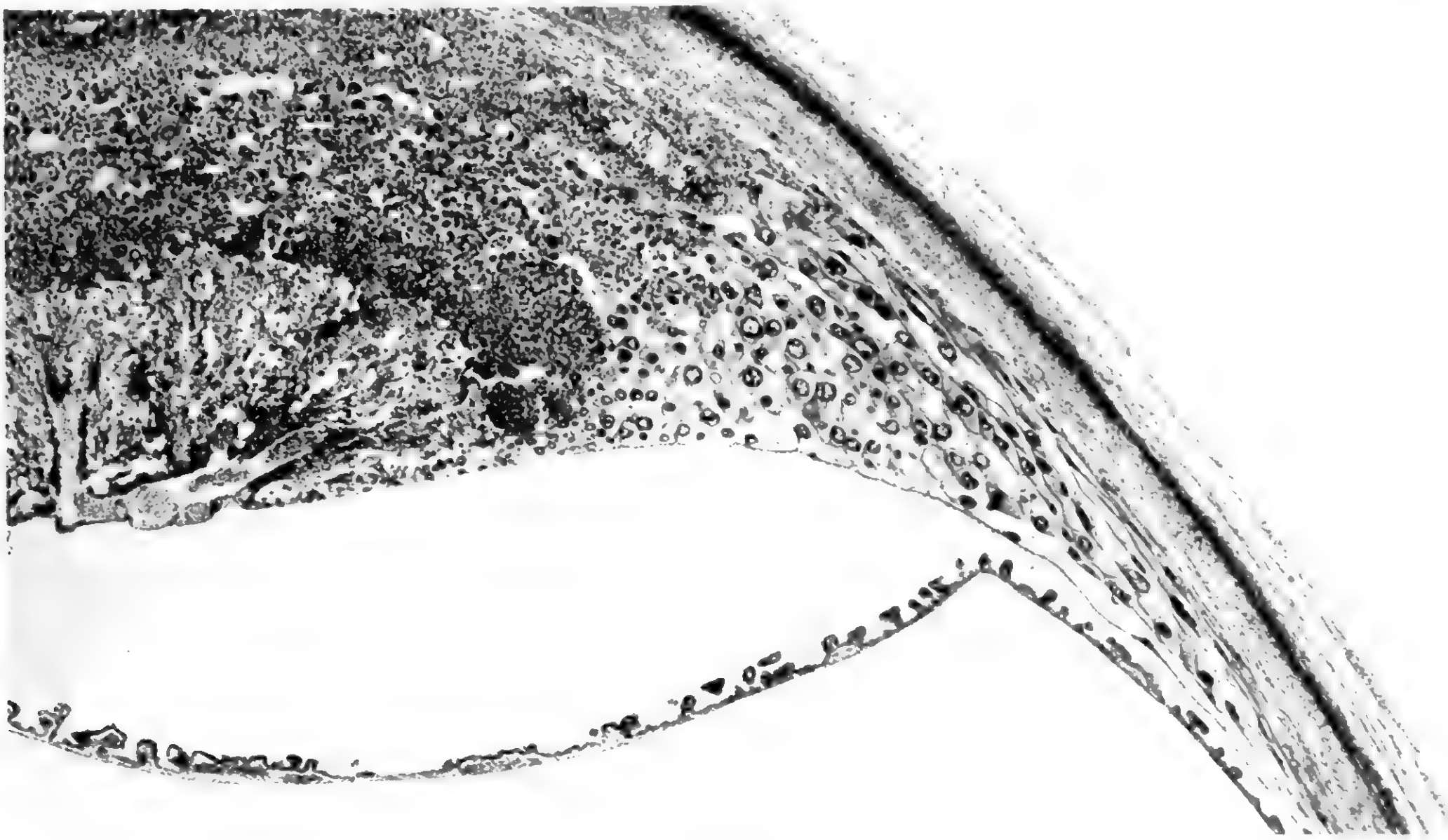

Fig. 27.

Fig. 10. Section through the decidual tissue, showing a large maternal blood sinus, the endothelial cells of which are typical giant cells yet retain their endothelial character. × 360.

Fig. 11. Section through the decidual tissue, showing a small maternal blood vessel, the endothelial cells of which have become typical giant cells. × 360.

Fig. 12. Section through the placenta at a stage rather earlier than that shown in fig. 25. The character of the giant cell network near the margin of the placenta is clearly indicated. The spaces between the cells are occupied by maternal blood. × 230.

Fig. 13. Section through the fairly late placenta near its margin. The giant cell network has attained its maximum development. × 220.

Fig. 14. Section through a similar region to the preceding one, showing the brown granules around the periphery of the giant cells. × 220.

Fig. 15. Section through the antimesometrial side of the decidual swelling close to the muscularis mucosae. An isolated giant cell measuring ·3 mm. in length is lying amongst the cells of the mucosa. × 150.

Fig. 16. Section through the wall of the implantation cavity, showing the structure of the giant cell network and its intimate connection with Reichert's membrane, on the right. To the left may be seen maternal symplasma formed from the decidual cells under the influence of the giant cells. × 220.

Fig. 17. Section through the wall of the implantation cavity. On the right is Reichert's membrane attached to the inner (right) surface of which are the isolated cells of the parietal yolk-sac entoderm. On the left of the giant cells is the decidual tissue, the portions of which nearest the giant cells are forming a symplasma. × 220.

Fig. 18. Section through the wall of the implantation cavity. On the right is the giant cell network, containing maternal blood, on the left the decidual tissue, which is becoming converted into a symplasma. × 220.

Fig. 19. Section through the wall of the implantation cavity, showing a large giant cell in process of ingulfing maternal symplasma. × 220.

Fig. 20. Section through the implantation cavity wall showing a large giant cell in the cytoplasm of which are masses of maternal symplasma. × 200.

Fig. 21. Longitudinal section through the egg-cylinder of the Field Vole—*Arvicola agrestis.* × 100.

Fig. 22. Section through the yolk-sac splanchnopleur of the late embryo, near its attachment to the placenta. Compare figs. 25 and 27. × 230.

Fig. 23. Section through the placental margin showing the growth in thickness of Reichert's membrane and its intimate connection with the placental giant cells. Embedded in the membrane are maternal leucocytes, while adherent to its inner (upper) surface are the cells of the parietal yolk-sac wall. The spaces between the giant cells are filled with maternal blood. × 380.

Fig. 24. Section through the margin of the late placenta. At the right hand top corner is the outer wall of the uterus with the regenerated uterine epithelium. To the left of the latter is the newly formed uterine lumen, bounded on the inside by the capsularis, which consists of a layer of giant cells in contact with Reichert's membrane, which attains its maximum thickness in this region. Adherent to its inner surface are the cells of the parietal entoderm, while embedded in it are maternal leucocytes. The large cavity shown in the figure is the yolk-sac cavity. × 200.

Fig. 25. Transverse section of the uterus containing a fairly late embryo. The section passes through the allantoic stalk and yolk stalk. The reformed uterine lumen is visible at the antimesometrial end. The capsularis is now comparatively thin. × 12.

Fig. 26. The centre of the placental disc of the same specimen. The general character of the placental labyrinth, and its relations to the cellular trophoblast immediately above it, are well shown. × 36.

Fig. 27. The margin of the placental disc of the same specimen, showing the structure of the giant cell network in this region. The membrane limiting the placenta on its lower surface is Reichert's membrane. Attached to the latter are the entodermal cells of the parietal yolk-sac wall. In the lower portion of the figure is the yolk-sac splanchnopleur. The cavity above it is the yolk-sac cavity, that below it is the extra-embryonal coelom. × 36.

ANATOMICAL NOTES ON THE ACCESSORY ORGANS OF THE EYE OF THE HORSE

By Maj.-Gen. Sir FREDERICK SMITH, K.C.M.G., C.B.,
Fellow and Hon. Associate, Royal College of Veterinary Surgeons

	PAGE
Periorbita	366
Muscles of the Eyeball	369
The Fascia of the Globe	375
Capsule of Tenon	377
Nerve Supply to the Muscles of the Eyeball	378
Fat Deposits	382
Membrana Nictitans	385
Lachrymal Apparatus	386
The Eyelids	387

THE PERIORBITA

The orbit of the horse is not a bony cavity; it is little more than a rim of bone, open behind. In this rim the eyeball is lodged, but the muscles are accommodated in the temporal fossa from which they are cut off by being enclosed within a membranous sac known as the *ocular sheath* or *periorbita.*

The periorbita is a cone-shaped fibro-elastic bag extending from the optic hiatus to the margin of the orbit; on its temporal side the sheath is protected by the temporalis muscle, fat, the coronoid process of the lower jaw, and the zygoma; on its nasal side is the thin bony wall of the temporal fossa.

The periorbita arises at the optic hiatus of the sphenoid bone, and passing forward is closely adherent throughout its length to the thin bony wall just mentioned, but its most powerful attachment is to that edge of the orbital process of the frontal bone which looks towards the temporal fossa. To this the whole of the temporal surface of the sheath is secured. After this attachment it continues forward, lines the bony orbit, and reaching the anterior margin splits into two layers; one unites with the periosteum of the face, the other runs into the eyelids and forms the basis of their structure.

Two short ligaments on the temporal surface of the sheath attach it above and below in the neighbourhood of the orbital process, while in the vicinity of the optic hiatus ligamentous material derived from the external pterygoid muscle and a band of fibrous tissue from the sheath of the maxillary division of the fifth nerve form part of its structure.

In general appearance the periorbita is fibrous, the fibres running in several directions, but the majority sweeping backwards from the orbital process. In the region of the process it is distinctly tendinous, and large glistening fibres are present which appear to be intimately connected with the masseter muscle.

Along the middle of the temporal surface is a long broad white strip of tissue which resembles a muscular band of the intestine and runs nearly its whole length. It is not elevated above the surface of the periorbita and is not composed of muscular tissue.

The normal colour of the periorbita is that of fibro-elastic tissue, but a large vein enters its base which discolours this part, especially in the region of the optic hiatus. Further it is difficult to secure specimens entirely free from haemorrhage into the ocular muscles, and this gives a pink colour to the membrane, especially in formalin preparations.

The periorbita consists primarily of an internal and an external layer. The internal is a thin white, and in parts semi-transparent membrane which encloses every part of the eyeball and its appendages. The external membrane, on the contrary, is thick, opaque, and does not cover the whole structure, but mainly its temporal surface. The external layer is composed of tendinous and fibro-elastic material, together with unstriped muscle fibres.

Various statements have been made as to the amount of plain muscle fibre found in the periorbita of animals; in the horse there appears to be but little, but the matter is at present under investigation.

Within the bony orbit, namely that part actually containing the eyeball, the periorbita functions as periosteum. Here it is yellowish in tint. On the inner wall there is a periosteal layer which is quite distinct from the inner thin layer of the periorbita.

The origin of the periorbita is from the dura mater surrounding the structures which enter the orbital hiatus through the various foramina. All the nerves are enveloped in a layer of dura mater which at the foramina opens out and forms the inner layer of the periorbita which extends forwards to the orbital rim. If the various canals leading to the optic hiatus be opened up it is possible to remove the contents and dural sheath intact, and gradually strip the periorbita completely forward to the orbital process. At this point a knife must be employed to divide the attachment of the external layer, which can be done without opening the periorbita by working close to the bone. The whole may now be stripped forward to the orbital rim, where it is again attached but can be separated by the handle of the scalpel when it is found to run into the periosteum of the face. It is possible by the exercise of patience to remove the periorbita entire from hiatus to orbital rim, and thence onwards to the periosteum of the face, in such a way that a complete fibrous cast of the orbit remains, which retains the shape of the bony original. In such a preparation it is impossible, excepting by the presence of the fibrous rim of the orbit, to determine where the periorbita ends and the periosteum of the face begins.

The periorbita on its temporal surface is of great strength and thickness, especially in the region of the orbital process; the nasal wall and a portion of the floor are thin, for here the external tunic is absent. Though cone-shaped in its length, it is flat on its nasal face, and partly concave on its temporal, in the region of the orbital process, where it has the appearance of being pulled inwards under great tension. This concavity is retained in hardened preparations, but in the fresh periorbita it disappears when the membrane is excised. The most concave area is opposite to the external rectus muscle.

The periorbita is perforated at several points to afford entry to certain structures and exit to others, but the most remarkable perforation is that due to a large vein, known as the alveolar or reflex, entering it from the face. This vein shortly before it penetrates the ocular sheath is a large venous cistern big enough to admit a finger; just before it enters the periorbita it contracts to the size of a lead pencil; this immense vessel boldly enters near the floor close to the optic hiatus where it loses its external coat which is plastered over the surface of the periorbita. It is the blood in this vein which so deeply stains the ocular sheath in the neighbourhood of the hiatus. The vein, however, does not penetrate into the interior of the sheath; it runs between its coats and, receiving the ophthalmic veins in its course, enters the foramen rotundum and so gains the cavernous sinus of the brain. There are no valves in the vessel outside the periorbita, but in the foramen rotundum valves exist and indicate the direction of the stream which is from without inwards, a remarkable anatomical arrangement the necessity for which is by no means clear.

Anticipating what has yet to be said about the origin of the muscles of the eyeball, it is evident, if the above description is clear, that these arise from the inner layer of the periorbita, namely from that layer provided by the dura mater, for when the membrane is stripped from the orbital hiatus and temporal fossa, as described above, all the muscles come away with it. Further, as the entire contents of the orbit may with equal readiness be stripped, leaving within them the loop formed for the passage of the superior oblique muscle, it is evident that this loop is also attached to the periorbita. Finally, in the stripping process the origin of the inferior oblique muscle comes away within the periorbita, so that this muscle likewise obtains its origin from the ocular sheath. We know of no other muscles or tendinous loops in the body of the horse which arise from membrane rather than directly from adjacent bone.

It is obvious that the periorbita forms a membranous socket for the eyeball, but more especially for its accessory organs. The great depth at which it lies is sufficient to ensure its safety; nevertheless there is always a large pad of fat covering the whole of its temporal surface which extends upwards and completely fills the temporal fossa where not otherwise occupied. This pad of fat is of considerable length and thickness, and is so completely moulded into and over the structure that all the surrounding tissues, the great branches of the fifth nerve, the blood vessels, and every crevice and cranny created by the periorbita itself, are filled with fat.

MUSCLES OF THE EYEBALL

All the muscles of the eyeball, including those of the eyelid, arise within the periorbita; even the inferior oblique muscle, the origin of which is so distant from the others, arises within this membrane. The seat of origin is within the optic hiatus, a relatively deep recess formed by the sphenoid bone, bounded on the temporal side by the sharp bony pterygoid crest and on the nasal side by the inner bony wall of the orbit. In this recess there are four foramina, superiorly the ethmoid, giving passage to the ethmoid nerves and vessels, next the optic, giving passage to the optic nerve, below this the foramen lacerum orbitale affording passage to the third, sometimes the fourth, ophthalmic division of the fifth nerve and to the sixth nerve together with certain blood-vessels, and the inferior—the rotundum—through which passes the maxillary division of the fifth nerve and its vessels. The area of the recess which gives origin to the muscles of the eyeball is about 20 mm. in length and 10 mm. in width. Within this small space numerous structures of extraordinary importance are located, including the origin of seven muscles; it is no wonder that the dissection is one of extreme difficulty.

With one exception all the muscles arise from the inner or nasal wall of the optic hiatus; they do not arise from the pterygoid crest. The muscle superiorly situated in the optic hiatus is the superior oblique, immediately below is the levator of the upper lid, then the superior rectus and the internal rectus, next the retractor, finally the external rectus and the inferior rectus. The muscle origins are not in all cases sharply defined, for the reason that some are linked together; for instance the retractor gives origin to the external rectus and is joined to the superior and inferior recti. Most of the muscles have tendinous material in their origins; this is especially true of the retractor and external rectus. Though bony origins have been assigned to the muscles, in reality they do not arise from bone but from periorbita. This may be stripped off the bone as described above, in which case it carries the muscles with it.

At their attachment to the globe all the recti and the superior oblique have a tendinous insertion, but the inferior oblique and the retractor have a wholly muscular insertion.

The longest of the recti muscles is the superior, the shortest are the external and internal; but in the group the longest muscle is the superior oblique, the shortest the inferior oblique, the retractor coming next. Excluding the retractor, the external and internal recti are the thickest and most powerful muscles, while the widest muscle is the external rectus. The retractor at its origin has the most numerous connections with other muscles, viz. the external rectus and the superior and inferior recti.

The *superior rectus* muscle arises below the ridge which separates the optic from the foramen lacerum orbitale and close to the latter, the optic nerve being on its nasal side. It is also attached to the retractor. The muscle, like all the recti, swells out from its origin so that its body is of some substance. As it approaches the globe it detaches from its surface a fascial covering and immediately afterwards a second and inner fascial sheet which envelopes the muscle and forms a bursa through which it passes. The external fascial covering is a firm moderately thick layer of yellow fascia, which on reaching the globe joins up with similar fascial coverings from the neighbouring muscles. The fusion of the fascial coverings forms a "belt" around the equator of the globe, the arrangement and subsequent distribution of which has to be studied in the section devoted to the fascia of the eye. The inner layer of fascia which forms a bursa through which the muscle moves is described in the section on fascia. Its importance here is its function in keeping the recti muscles in position on a globular surface. On opening the bursa it is found to be moist and shining; the muscle lies in a distinct furrow formed in the underlying fat; though the bursa in front is open it is cut off behind. The muscle cannot be lifted out of the groove until a delicate connective tissue attachment is divided, which shows the amount of play to be very limited, as indeed would be expected. Having passed under the lachrymal gland the superior rectus ends in a flat, wide and thin tendon which spreads itself out in order to obtain a wide area of attachment to the sclerotic. The width of the tendon is about 25 mm. but the area of attachment is larger than this by the tendon fusing with the deep layer of fascia. The tendon is inserted into the sclerotic somewhat obliquely so that on its temporal edge it is 5 mm. from the corneo-scleral junction, while on the nasal edge it is 7 mm.

The branch of the third nerve supplying this muscle enters on the temporal surface close to its origin and, breaking up into four or five fibres, spreads out in its interior.

The *inferior rectus* muscle arises from the nasal wall of the orbital hiatus in front of the foramen lacerum orbitale; it is also attached to the inferior part of the retractor. It at once separates from this muscle and in its passage towards the globe travels the whole distance in contact with the external rectus, being in this respect exceptional, as the recti muscles mostly diverge. On the floor of the orbit it runs side by side with the lower border of the cartilago nictitans and, passing between the inferior oblique muscle and the globe, terminates in a tendon which is inserted into the sclerotic. The tendon is the smallest of the recti group, measuring only 17 mm. in width; it is set on somewhat obliquely, so that its temporal edge is 8 mm. and its nasal edge 10 mm. from the corneo-scleral rim.

The inferior rectus on approaching the globe gives off the usual two layers of fascia, an outer and an inner. The former runs to the "belt"; the inner forms a bursa for the muscle. The bursa is located in a pad of fat and lies at some depth, the fat being channelled for the passage of the muscle. The inner layer also embraces the inferior oblique muscle where the inferior rectus passes between it and the globe, and this enables the inferior oblique to be kept in its place on the globe of the eye. The fascia is also inserted into a crescent-shaped membrane, composed of periorbita and periosteum, on which the lower eyelid is built.

On the upper surface of this muscle, close to its origin, is the ophthalmic ganglion, in the region of which a nest of nerves is found in the substance of the muscle. Coursing its way obliquely over the body of the muscle is a long branch of nerve which passes its outer edge and eventually turns under its lower surface. This nerve supplies the inferior oblique muscle[1].

The origin of the *external rectus* muscle is peculiar; it arises from the temporal surface of the retractor, a little below its highest point and above the inferior rectus. It immediately leaves the retractor and pursues its way to the globe, the lower edge of the muscle being for the whole distance in contact with the inferior rectus. The muscle is wide and powerful, being in fact the widest of the recti group. On approaching the globe it gives off first an outer, and then an inner, layer of fascia, the outer as usual forming a part of the "belt." This outer sheath is very large owing to the width of the muscle; the inner, or bursal sheath, is present but the groove through which the muscle passes is shallow. This muscle is inserted into the sclerotic by a wide tendon which is attached to the globe above the insertion of the inferior oblique muscle, close to the outer canthus of the eye. The end of the tendon is vertically placed, its superior border being 14 mm. from the corneo-scleral junction, and its inferior border 3 mm. distant. So close indeed is this tendon to the cornea that a portion may be found under the pigmented conjunctiva found at the outer canthus.

The *internal rectus* arises from the nasal side of the orbital hiatus, below and in front of the ethmoid foramen. This muscle prior to insertion furnishes the usual double layer of fascia and provides itself with a bursa deeply buried in a fat deposit. Its insertion into the sclerotic occurs far back from the corneo-scleral junction, the explanation being that it has to make way for the cartilago nictitans; there is no tendon of the recti group inserted so far back. The upper edge of the tendon may measure 20 mm. from the corneal rim, the lower edge 15 mm.

The fascial bands from this muscle are important[2]; the outer sheath is distributed to the nasal aspect of the levator of the lid, and keeps the nasal side of the lid applied to the globe; it also runs to the upper edge and nasal surface of the invisible or deep-seated portion of the cartilago nictitans, and keeps the cartilage bound down to the eyeball. A portion runs forward to the conjunctiva covering the visible part of the cartilago in the conjunctival sac, to the upper edge of which it is attached, and this keeps it applied to the eyeball. There is also a firm attachment of this sheath to the rim of the orbit, in front of and above the lachrymal sac where the upper and lower eyelids meet in the lachrymal pool. This attachment assists to keep the tissues of the "corner of the eye," including the caruncula, in place. The inner fascial sheath also furnishes a band to the deep-seated portion of the cartilago, both

---

[1] No name has been assigned it by anatomists.

[2] Owing to their importance they are dealt with here in detail, and referred to generally in the section dealing with the fascia.

to its upper edge and temporal surface, namely the surface applied to the eyeball; it is further connected through the conjunctiva with the visible portion of the cartilago, and terminates beneath the conjunctiva at the corneo-scleral junction.

The *superior oblique* muscle is the longest in the orbit; it is also very narrow. It arises close to and behind the ethmoid foramen. It is the most superiorly placed muscle in the optic hiatus, being above the level of the optic nerve and on the nasal side of it. In its course towards the eyeball the superior rectus is on its temporal margin, and on its nasal side and below is the internal rectus.

Having reached the globe the muscle enters a fibrous canal, formed of periorbita, which curves upwards; this directs the muscle away from the internal rectus. At the end of the canal is a loop, also formed of periorbita. As the muscle passes through the loop its direction is profoundly altered, for it now travels almost at right angles to its original course and in this way, by passing beneath the superior rectus, it travels across the globe and reaches the temporal side of the eyeball. The superior oblique is the only muscle of the eyeball to which the periorbita is connected, and the only part of the globe of the eye to which the periorbita is attached is the fibrous canal above described. The extraordinary change in direction taken by the superior oblique must be considered more closely.

The periorbita sends a reflection under the superior oblique and so isolates this muscle in a canal; this canal is secured throughout its length above to the frontal bone, while below it is attached to the "belt" of the eyeball and neighbouring fat by means of fascia; this occurs in the region lying between the rectus superior and the rectus internus. Within and towards the end of the canal is a loop attached in two places to the frontal bone; the loop is composed of periorbita, and its lumen looks obliquely to the front, namely, towards the orbital opening. The posterior arm of the loop has lying on it a disc of cartilage concave inferiorly; this disc has a gutter on its superior face in which the muscle rests, while on its inferior face is a bursa between it and the posterior limb of the loop. Where the muscle rests on the disc it is narrow, very smooth, and comes to an edge in order to fit into the gutter of the disc. One would expect on slitting up the canal to be able to lift up the muscle out of its bed, but this is not so; though the canal is smooth and glistening the muscle is tacked down to it throughout its length by connective tissue. The muscle terminates in a tendon the insertion of which looks towards the temple and not towards the cornea. The anterior edge of the tendon is 10 mm. from the cornea, the posterior edge 20 mm. from it. As usual the tendon is much wider than the muscle.

The loop is described above as attached to the frontal bone. Strictly speaking this is not correct, for the periorbita of the eyeball encloses the loop which may be pulled away from the bone without much effort; when the periorbita is stripped off, the loop is found intact within. In other words the loop is attached to the periorbita in the same way that the ocular muscles are attached to it in the orbital hiatus. One is struck with the resemblance of the loop and canal of the superior oblique to the fascial bands and bursa of the recti muscles.

The fourth nerve which supplies this muscle is very small and runs for a short distance along its upper border. When about half way to the eyeball it suddenly bends, its fibres separate and dip into the substance of the muscle.

The *inferior oblique* muscle is the shortest of the series, and it is further distinguished by being muscular throughout, both at its origin and insertion. It arises from a depression close to the edge of the orbit immediately posterior to the lachrymal sac, but its origin is from the periorbita, for if this be detached from the bone the muscle comes away with it. It has the largest area of origin of any of the muscles of the eyeball; this area is somewhat oval or triangular, measuring 12 mm. at its widest part. Its insertion measures 23 mm. or more across. This short, thick and powerful muscle increases in width from origin to insertion; its fibres are curved, the direction of the muscle being from the nasal to the temporal side of the orbit. In its passage from one side to the other it covers the tendon of the inferior rectus. It never loses contact with the globe, and is attached to the sclerotic below the insertion of the external rectus. Some of the fibres of this muscle are continued up the globe and may be found beneath the tendon of the external rectus. Its anterior fibres are placed so far forward as almost to touch the corneo-scleral junction at the outer canthus. At its origin the inferior oblique obtains from the internal rectus a layer of fascia which completely embraces it and so tends to keep the muscle well back in its place. At this point also it is closely applied to the nasal surface of the cartilago nictitans and so keeps this in contact with the globe. The nerve supplying this muscle takes, as previously indicated, a very roundabout course. It is a relatively large flat nerve in which the strands can distinctly be seen; it enters the muscle close to its origin and at once breaks up into a nest of fibres.

The *retractor* muscle has a singular origin. Within the canal of the foramen lacerum orbitale may be found[1] two small muscles with fine tendons; one is 25 mm. in length, the other 6 mm. These two tendons arise from the sheath surrounding the nerves, and the delicate muscles on gaining the periorbita at once join the retractor into which they are incorporated. The retractor has its chief origin from the nasal wall of the hiatus just below the small bony ridge which separates the optic from the foramen lacerum, and in front of the latter. It gives origin to the rectus externus and is attached to the recti superior and inferior. Into the origin of the retractor a considerable amount of tendinous material enters. The optic nerve is above the retractor in the hiatus but a few millimetres further forward the muscle is in contact with the nerve, embracing its temporal and inferior surface, and a little later the whole nerve is enveloped, lying practically in the centre of the muscle. The general shape of the muscle is that of a cone, the base of which is applied to

---

[1] Their absence has been observed.

the eyeball and contains a core of fat; the fibres of the muscle are loosely connected so that the bundles of muscle tissue are readily seen, and fibres, some as delicate as sewing cotton, can be obtained without difficulty. The capsule of Tenon envelopes the general structure and also sends in septa, the larger of which have the effect of grouping the muscle into four quarters corresponding to the recti series. The retractor is inserted into the sclerotic over a wide area, but the insertion on the temporal side of the globe is wider than on the nasal; some of these fibres run so far forward as to be inserted above the inferior oblique muscle. Speaking generally the muscle is inserted into the posterior half of the globe, and it is perhaps the sinuous outline of the insertion more than anything else which indicates that it is roughly arranged in four groups. On its nasal and lower surface the retractor muscle is concave in hardened preparations to accommodate a large pad of fat located there; on its temporal side the muscle is also concave in order to accommodate the external rectus. The superior group of fibres is convex, and over these is moulded the superior rectus muscle. The retractor is completely hidden from view until the recti and superior oblique muscles have been removed.

The relationship of the origin of the retractor muscle to the optic nerve has been mentioned above: 10 mm. in front of the hiatus it completely surrounds the nerve which lies in its centre. The nerve is not in direct contact with the muscle, as it is contained in a large, white, loose fibrous sheath. This sheath is derived from the dura mater and from its surface minute threads of muscle may be seen arising and joining the general body of the retractor[1]. The nerve does not penetrate the central part of the sclerotic but dips down and enters the eyeball near to the floor. When the retractor muscle reaches the globe it spreads out to obtain attachment to the sclerotic, and the large space thus created in the middle of the muscle is filled up with fat.

There is no branch of the third nerve to the retractor; it is supplied by the sixth, which enters it by a relatively small branch close to the head of the muscle. Speaking generally the retractor is singularly free from nerve fibres; in this respect owing to its size it presents a marked contrast to the other muscles of the eyeball.

The remaining muscle from the optic hiatus is the *levator* of the upper lid. It arises by a somewhat tendinous attachment immediately above the optic foramen. This small muscle in its passage forwards lies adjacent to and on the nasal side of the superior rectus. When it reaches the lachrymal gland it passes beneath it, becoming wide and fan-shaped, the fibres swerving towards the temporal side of the lid. Through the medium of the outer layer of fascia the tendon is spread over the eyeball from the inner to the outer canthus.

Though the muscles moving the globe of the eye originate in a bunch, as it were, they rapidly diverge in order to reach their destinations. The inferior and external recti, however, lie side by side until they reach the globe; the

---

[1] The reason of this is not clear; the fibres are mere threads though of remarkable length, and each is furnished with a minute glistening tendon.

superior rectus and superior oblique are also close together; while the inferior and internal recti lie widely apart. When the contents of the orbital cavity, i.e. the globe and its muscles with their periorbital cover, are viewed in position from above and behind, they resemble a pear in shape.

Relative to the corneo-scleral margin the external rectus occupies the largest space and is the nearest to the cornea; furthest away is the internal rectus; the superior and inferior recti occupy a midway position. Of the oblique muscles the insertion of the anterior fibres of the inferior is as close to the cornea as that of those of the external rectus, but the superior oblique is placed some distance back, its anterior fibres lying just behind the superior rectus. In connection with the insertion of the recti tendons their fascial connections cause their attachment to the globe to be much wider than is actually represented by the tendons themselves. Nor are the insertions of any of the muscles truly vertical or horizontal; they are all more or less on the curve, the inferior rectus being somewhat obliquely placed as its tendon lies between the inferior oblique muscle and the globe. Both oblique muscles have an oblique insertion.

THE FASCIA OF THE GLOBE

The fascia of the globe is complex in its arrangement. Roughly speaking there are two layers of fascia, an outer and an inner, and both of these are derived from the recti muscles. As previously pointed out, all four recti, just as they approach the globe, give off a fascial sheath, and if this be opened a second fascial sheath, also given off by the muscles, may be seen within. The outer sheaths of the four recti coalesce and thereby form a sheet of fascia over the globe, especially well marked by its colour and thickness at the equator, where it constitutes a "band" or "belt"; similarly all the inner sheaths coalesce and form a fascial sheet distributed to many parts of the eye anterior to the equator. These features must be dealt with in detail.

The outer fascial sheath comes off from the muscles as a thin transparent membrane which, by the time it reaches the globe, is yellow, elastic, thick and strong. Around the equator of the globe it forms a "belt" due to the fact that the sheath provided by each rectus, very shortly after its formation, fuses with that of its neighbour, producing a uniform membrane. The sheath when formed is not adherent, excepting for some very delicate connective tissue, to the muscles within, and it may readily be picked up with forceps from their surface. The "belt" is formed as explained above. Running forward past the equator the membrane of the "belt" changes in character, becoming fine, thin and semi-transparent, and in this form it runs from all meridians to the corneo-scleral junction for insertion.

The inner fascial layer—also from the recti muscles—arises at a point nearer to the globe than the outer layer; it is elastic, much finer in quality than the outer, and more translucent. It comports itself differently from the outer layer, as it forms a separate sheath for each rectus at the equator;

the sheath is shining, showing that some fluid exists to prevent friction. Having formed the sheath it coalesces with its neighbours and spreads out as a vast sheet which encircles the globe anterior to the equator. This sheet is external to the insertion of the recti tendons, is loosely tacked down to the sclerotic by a fine connective tissue, and finally ends at the corneo-scleral junction.

The inner and outer layers of fascia thus form two vast spaces, one between the outer and inner layers and one between the inner layer and the sclerotic (but external to the recti tendons). The retractor muscle possesses no fascial sheath, that of the inferior oblique is derived from the internal rectus and external fascial layer of the globe, but the superior oblique possesses a very extensive sheath. It, however, is provided not by the muscle itself, as in the case of the recti, but by the periorbita, and forms the fibrous channel and loop already described, through which this muscle passes, while at the same time it plasters it down to the globe.

One important use of the inner fascial layer is to provide a bursa through which each of the recti plays, not that the movement is considerable, for the muscle is lightly tacked down in its channel by means of connective tissue; in addition it keeps each muscle in position on the globe, as is evident from the depth of the furrow through which the muscle passes. This depth is obtained by a mound or eminence of fat flanking either side of the bursa; this is especially well marked in the case of the superior rectus where the structure, when laid open, strikingly resembles the flexor tendons where they pass over the sesamoids at the fetlock joint. The external rectus, being a very wide muscle and therefore suited to keep in its place on the convex eyeball, has only a shallow furrow, though the bursa and sheath are well marked. The rectus inferior and rectus internus have very deep furrows, these being provided by the pad of fat through which each muscle passes to reach the eyeball. While the bursal arrangement for the muscles is formed by the inner fascial layer, the outer fascial layer plays the same part as the annular ligament of a joint and keeps the muscles in their furrows.

In addition to these important functions, the two layers of fascia, when they subsequently spread out as independent annular membranes towards the cornea, have other anatomical functions to perform.

The external layer joins the tendon of the levator of the upper lid and thereby renders it much wider so that it is able to operate from the inner to the outer canthus. It furnishes bands of ligamentous material to the deep portion of the cartilago nictitans and so keeps the cartilage closely applied to the globe; it provides a layer which runs into the substance of both upper and lower lids; it furnishes attachment to the deep portion of the conjunctiva of the eyeball and also to the special fold of conjunctiva which envelopes the visible cartilago nictitans; it supplies a band which helps to secure the junction of the upper and lower lids at the inner canthus to the rim of the orbit and so keeps the lachrymal pool in position; on the floor of the eyeball it forms a complete sheath for the inferior oblique muscle, in fact envelopes it and so keeps it back in its place on the globe; and finally, unlike the layer in the upper eyelid, it obtains attachment to the crescent of periorbita on which the lower lid is moulded.

The internal layer of fascia is attached at its origin to the outer layer of fascia and also to the fat prominences and pads between the recti muscles; it is concerned in keeping the cartilago in position on the globe, and by its connection with the tendons of the recti muscles it increases the area of their attachment; it is also attached to the conjunctiva, especially that part of it connected with the visible portion of the cartilago; a portion of it runs into the lower lid, while the main sheet terminates in the same way as the external layer by attachment to the entire corneo-scleral margin.

The fascial connections furnished by the internal rectus are more elaborate than those of the other recti and have been specially dealt with in the description of this muscle.

Between the origin and insertion of the inner and outer layers of fascia there are structures intimately related to them other than those already mentioned; especially is this true of the masses of fat which envelope the globe. These receive a cover from both layers which is specially intended not only to invest but also to penetrate the mass or deposit in all directions, so that the fat of the eyeball is rendered quite fibrous, a point which is insisted upon in the section devoted to fat deposits.

CAPSULE OF TENON

A thin diaphanous membrane is found within the orbital sheath. It resembles the mesentery in fineness and transparency, and the resemblance is increased by the presence of streaks of fat in its substance. This membrane extends from the optic hiatus to the eyeball. It is reflected inwards in such a way that every muscle receives a sheath of this substance which can be readily picked up by forceps from its surface; between the muscles the septa enclose such fat, vessels, or nerves as may be in their vicinity. From this it is evident that a complicated arrangement exists whereby every muscle is enclosed in a capsule, the capsules of neighbouring muscles meeting at the septa. The structure is known as the capsule of Tenon. So thin is this capsule that its presence in places is difficult to determine unless it be lifted up or punctured, when air bubbles run beneath it and prove its presence. The precise method by which the capsule terminates on the globe of the eye is not clear. It is generally accepted that the capsule of Tenon is connected with the lymphatic system, but we have no information as the result of our dissections. The capsule of Tenon is quite distinct from the fascial sheaths of the recti muscles.

NERVE SUPPLY TO THE MUSCLES OF THE EYEBALL

The nerves to the muscles of the eyeball are supplied by the third, fourth, fifth and sixth cranial nerves, the arrangement being complex. Two distinct branches of the fifth are engaged, namely the ophthalmic and superior maxillary divisions; the former enters the periorbita direct; the latter has to penetrate it from without. The nerve supply is sensory, motor and secretory; both branches of the fifth nerve are sensory, the third, fourth and sixth are motor. The secretory nerves are contained in the fifth and sympathetic.

The sensory nerves, with one exception, lie on the surface of the muscles and are at once seen on slitting up the periorbita. They are large flat branches entangled in fat and capsule of Tenon, and may readily be divided into three groups. The superiorly placed nerve is the *frontal.* It is derived from the ophthalmic division of the fifth and enters the periorbita at the optic hiatus immediately on the temporal side of the superior rectus muscle close to its origin. It at once turns upwards, crossing obliquely the superior rectus and levator muscle as it travels from the temporal to the nasal side; when on the levator muscle and following its direction, it suddenly penetrates the inner layer of the periorbita. It then runs in a membranous canal, formed by two layers of periorbita, for a distance of about 40 mm. and finally emerges outside the ocular sheath in the region of the orbital process, and so reaches the supra-orbital foramen through which it passes and is distributed to the tissues of the forehead and upper eyelid. The group of nerves below the frontal is the *lachrymal.* These are also derived from the ophthalmic branch of the fifth. The main trunk emerges from the temporal side of the optic hiatus over the junction of the superior and external recti. As it pursues its way over the surface of the muscles to the lachrymal gland it forms two or three branches; the upper one or two as the case may be enter the lachrymal gland at its posterior border and break up into several branches which are lost in its substance. Quite large branches may be traced forward for some distance in the gland. The lowermost nerve of this group has no connection with the lachrymal gland. Having reached a point corresponding to the zygoma, it turns upward, penetrates the periorbita and so reaches the orbital fossa; keeping close to the zygoma it is eventually distributed to the temporal region. It ought to be designated the *temporal* nerve. This nerve, while still within the periorbita, may receive, midway between the optic hiatus and the globe, a branch from the inferior maxillary division of the fifth. The lowermost group of nerves, designated the *zygomatic,* is derived from the maxillary division of the fifth, which is outside the periorbita. They run forward to this structure and penetrate the outer tunic, running between the coats as far forward as where the alveolar or reflex vein enters; at this point they complete their penetration of the periorbita and are found lying just above the fissure between the external and inferior recti; on approaching the globe they divide into two or more branches which eventually supply the tissues at the outer canthus; some fibres then pass through the fascia of the inferior rectus muscle and thence through that portion of the periorbita on which the lower lid is built and are finally distributed to the lower lid.

There is a connecting nerve between the middle and inferior groups; sometimes, and perhaps more generally, it runs from the maxillary to the ophthalmic division, but the converse has been observed. In this case the connecting branch, a fine thread of nerve, took an unusual course. Running in the fissure between the superior and external recti, it got beneath the external rectus, then running on the upper surface of the retractor in the direction of the temporal side of the eyeball, it finally pierced the external rectus and joined the inferior group close to the eyeball.

All the above branches of the fifth are remarkable for their size, which they retain up to the tissues they supply; they are all flat nerves in which the bundles are distinctly seen; they all run on the surface of the muscles, and all the branches described are seen from the temporal side of the orbit. There are only two branches of the fifth on the nasal side, and these are contained in the next group of nerves to be described.

When the superficial group of nerves has been removed, the deep-seated are brought into view, though it is necessary first to clear away some capsule of Tenon and fat. It will be observed that with one exception all the nerves now to be described appear to be very short, the explanation being that they have scarcely shown themselves at the optic hiatus before they dip into and between the various muscles of the eyeball and are consequently lost to view. Viewed as they lie in position they present the following general arrangement:

The uppermost nerve is the fourth. It is also the finest and can readily be traced some distance upwards before it disappears over the levator muscle in order to gain the superior oblique. The nerve below the fourth is the third; it will be found lying on the temporal surface of the superior rectus muscle and is almost at once lost to view. Immediately below the third is the fifth (ophthalmic division) which will be found lying between the origins of the superior and external recti. In the same furrow is a small branch of nerve, the sixth, which is covered by some connective tissue and a blood-vessel; it almost immediately dips between the muscles and disappears. All these nerves enter the periorbita by the canal leading to the foramen lacerum orbitale, though sometimes, and in the writer's experience more commonly, the fourth enters by a separate canal. On laying open the foramen lacerum orbitale the remarkable thickness of the sheath investing these nerves is very evident. Until the mass is lifted from the canal only one nerve can be seen. This is the ophthalmic branch of the fifth within which is contained the third and sixth, the fifth either being rolled around them, or fitting into an angle formed by the third and sixth nerves. The ophthalmic branch is the largest; its bundles of nerve fibres are quite evident, and the nerve is moreover flat; the third, fourth and sixth nerves are round.

On entering the optic hiatus the strong investing sheath of the nerves, which is also the membrane lining the canal, at once leaves the nerves and spreads out to form the periorbita. In this process it fuses with the sheath investing the optic nerve, for both sheaths take part in the formation of the periorbita.

Fifth nerve, ophthalmic division (inter-muscular branches). The distribution of the frontal, lachrymal and zygomatic branches of the fifth nerve has already been traced; it will be remembered that they are all extra-muscular. The remaining portion of the fifth which has to be dealt with is the inter-muscular branch.

The nerve on issuing from the optic hiatus lies in the fissure between the superior and external recti. Some fibres of the latter muscle may be split to allow of its passage to its position beneath the superior rectus. Here it is resting on the retractor, crossing this muscle obliquely towards the nasal side, but it has only proceeded a few millimetres when it divides into two branches, one continuing forwards to the nasal side, the other and posterior branch running to the nasal side only as far as the superior oblique muscle and then turning backwards. The branch of nerve running forward is the inferior trochlear, the one running backwards is the ethmoidal. There is a great difference in the appearance of these two nerves. The ethmoidal maintains the flattened character and well-marked bundles of fibres seen in the parent trunk; the inferior trochlear is round and does not exhibit any bundles to ordinary observation. Throughout its course up to the point of division the main trunk is accompanied by the ophthalmic artery which at first lies in front of and then behind the nerve. In order to show the above features the superior rectus must be divided and turned back.

The *ethmoidal nerve.* Shortly after the bifurcation of the main branch this nerve makes a sharp bend backwards and inwards, so as to lie under the superior oblique muscle; from here it travels backwards on the top of the internal rectus into the optic hiatus lying on the nasal side of the optic nerve; it then bends sharply at right angles and passes out of the orbit through a small foramen and re-enters the cranial cavity in the vicinity of the olfactory bulb; it at once sharply bends forward, keeping close to the bone, and enters the ethmoid cells. Before escaping by the foramen into the olfactory region it gives off a long fine branch of nerve which travels on the nasal side of the internal rectus and terminates in the lateral fat pad on the inner side of the globe. This branch has no name. It is by no means clear why the ethmoid nerve requires so confusing an arrangement; as we have seen, it is a nerve intended for the organ of smell and not that of sight, yet it enters the periorbita, dives between the muscles of the eyeball, makes two sharp bends and escapes from the periorbita into the cranium, then leaves the cranium and enters the ethmoid cells.

The *infra-trochlear* branch runs obliquely forward on the retractor muscle towards its nasal edge, and passes between the superior oblique and the internal rectus; remaining in contact with the last named muscle, and hidden from view, the nerve passes under the bend of the superior oblique through the lateral fat pad which plasters over the terminal portion of the internal rectus, and so gains the nasal side of this muscle; running straight forward it pierces the periorbita in the region of the internal canthus and escapes from the orbit by means of one or two foramina in the orbital rim just above the lachrymal sac. During its course it furnishes sensation to the cartilago nictitans, lachrymal sac and neighbouring structures, and finally to the tissues situated at the inner canthus. It is difficult to understand why this nerve was not placed with the other sensory nerves on the surface of the muscles instead of being deep-seated between them. It corresponds to the long nerve on the temporal side, the zygomatic, which supplies the external canthus and lower lid.

The following nerves are purely motor:

The *third nerve* in contrast to the fifth is round and its bundles of fibres cannot be distinguished by the naked eye. While in the canal before reaching the foramen lacerum orbitale it divides into two branches, a long and a short, which remain side by side, the short being superiorly placed. On leaving the optic hiatus the nerve lies between the superior and external recti, and the short branch at once enters the origin of the superior rectus, penetrating the muscle on its temporal side and breaking up into fibrils. The long branch cannot be seen from the surface as it lies immediately beneath the short, but it turns down and, passing between a few fibres of the superior rectus, reaches the retractor a few millimetres behind the point where the fifth nerve bifurcates. The nerve now runs still more deeply, piercing the retractor close to the optic nerve on its temporal side and being attached to its sheath. It then gets below the optic nerve in order to form the *ciliary* or *ophthalmic ganglion.* The ganglion lies on the inferior rectus muscle or alternatively on the fissure between the inferior and internal recti, and is situated immediately beneath the optic nerve. The ganglion is small and occurs on the nerve about 12 mm. from the optic hiatus. Issuing from it are several short stumpy branches of nerve resembling fingers on a hand, which almost at once enter the inferior rectus muscle and break up within its substance into a veritable network of fibres which can be traced forward in the muscle for a considerable distance. From the front of the ganglion is also given off a somewhat longer, though still thick and stumpy branch, which, crossing to the nasal side, almost at once penetrates the neighbouring internal rectus muscle, where it breaks up in its substance into a nest of fibres. No muscles of the eyeball are so richly furnished with nerves as the inferior and internal recti. Another branch runs from the ganglion into the loose outer sheath of the optic nerve. It is very difficult to trace owing to fat, but several fine threads may be seen running within the sheath to the eyeball, where they penetrate the sclerotic and eventually reach the iris and the ciliary body. These are the ciliary nerves.

Inferior oblique nerve. From the anterior part of the ciliary ganglion is given off a fourth nerve, a long well-marked branch which crosses the inferior rectus obliquely towards its temporal side; it now appears on the external surface of this muscle by passing beneath the external rectus. It runs forward towards the eyeball, lying on the temporal side of the inferior rectus, but gradually gets beneath the muscle, and when opposite to the body of the inferior oblique it bends towards the nasal side and running parallel to the inferior oblique for about 15 or 17 mm. bends sharply to the front, pierces the fascia of the inferior oblique and enters this muscle at its posterior border about 12 mm. from its origin. Just as the nerve enters the muscle it flattens out, thus showing its fibres distinctly, nests of which are formed in the substance of the muscle. No name has been assigned by anatomists to this nerve, so I have called it the *inferior oblique.* Its erratic course is necessitated by the distance the inferior oblique muscle lies from the optic hiatus; this nerve is consequently one of the longest in the orbit.

The *fourth nerve* is very simple; it is a small round nerve contained either in the canal of the foramen lacerum orbitale and so enveloped by the ophthalmic division of the fifth, or else entering the periorbita by a foramen of its own. Within the periorbita it is located above the third, fifth and sixth nerves. Crossing the superior rectus and levator towards the nasal side, it reaches the superior oblique muscle; it runs forward along the upper border of this muscle for a distance of about 30 mm. from the hiatus, and then quite suddenly dips down and penetrates the muscle.

The *sixth nerve* is inferiorly placed in the periorbita, and also in the canal of the foramen lacerum orbitale, where, as already described, it is enveloped by the ophthalmic division of the fifth nerve. While still in the canal it divides into two short branches; on entering the periorbita these cross the external rectus obliquely and penetrate inwards between the origins of the superior and external recti; the small branch proceeds to the origin of the retractor and immediately enters it; the larger branch, which is inferiorly placed, at once enters the external rectus muscle on its inner face. Thus the sixth nerve supplies not only the abductor muscle of the eyeball but also the retractor. In view of its size it is very remarkable that the retractor has only one small motor nerve entering it; this is in great contrast to the inferior and internal recti, both much smaller muscles, which possess a nest of nerve ramifications.

No special branch of nerve has been traced to the levator of the lid.

FAT DEPOSITS

The deposits of fat both between and outside the muscles of the eyeball are complex in arrangement. Fat is found everywhere, both in deposits and layers; indeed, wherever there is a cleft, nook or cranny, whether outside the periorbita or within, there fat will be found. A superficial inspection suggests that the fat deposits are on the nasal side of the globe low down, and on the upper surface of the globe under the superior rectus muscle, with a further deposit on the rim of the orbit corresponding to the lower lid. Dissection, however, reveals that these are not separate fat deposits but one continuous layer, which by the way it enfolds, overlaps and underruns the structures, appears to have neither beginning nor end. In places the layer is enormously thick, forming veritable pads; this is especially the case where a large space has to be filled in, but the edges of this mass thin out, pass under or around neighbouring muscles, and, having got clear of them, again swell out when the next large space has to be filled in. Whether it is in the space enclosed by the retractor muscle, i.e. in the very heart of the muscles surrounding the globe, or whether it is a thin streak showing itself on the surface between two muscles or a deposit whose measurements are in centimetres, the fat all belongs to one piece or roll. The fat of the orbit is unlike ordinary fat in one essential. It is encapsuled and intersected by fascia so that it is quite fibrous and remarkably tough. In parts, especially around the "belt," the most diligent application of scalpel and forceps fails to clear the surface. In this respect the large masses are much more manageable. A lateral fat pad lies on the nasal side of the orbital contents; as viewed from the surface it is a prominent triangular shaped body, lying in the big space between the internal and inferior recti. The apex of the triangle, which is not sharp but rounded, looks towards the optic hiatus, and reaches within 20 mm. of it. The base extends as far forward as the lachrymal sac and origin of the inferior oblique muscle. This pad runs deeply under and within the inferior and internal recti and comes into contact with the retractor which is rendered concave for its reception; it is deeply grooved for the accommodation of the inferior and internal recti. While the internal rectus passes through the mass, further forward the inferior rectus, towards its insertion, passes outside of the pad. It is at this place, the two muscles being wide apart, that the lateral fat pad is attached to the nasal surface of the cartilago nictitans.

Tracing the course of the lateral fat pad up the globe, and starting at the point where it is penetrated by the internal rectus, we notice that the fat passes upwards under the bent portion of the superior oblique[1] and is here channelled for the passage of the frontal nerve; beneath the superior oblique it forms a prominence, on a part of which the cartilaginous disc of the loop of the superior oblique rests; the remaining portion shows as a pyramidal body of fat between the superior oblique and the superior rectus. This pyramidal mass runs between the levator muscle of the upper eyelid and the superior rectus; under the superior rectus it forms a thick pad of fat which rests partly on the retractor muscle and partly on the upper edge of the internal rectus. This thick mass is the superior pad, which, though given a specific designation, is merely an extension of the lateral pad described above. Like the lateral mass the superior pad is pyramidal, the apex reaching as far back as 30 mm. from the optic hiatus. The deep part of the base ends at the sclerotic under the insertion of the superior oblique, while the superficial part of it is a thin layer which runs over the superior oblique and is confounded with the fascia which ends in the conjunctiva of the globe. Continuing the wanderings of

---

[1] The expression "bent" indicates the shape of the superior oblique where it enters the fibrous canal, and does not refer to the right-angled turn it makes by passing through the loop.

the superior pad, it passes from beneath the superior rectus to beneath the external rectus, forming the fat prominence, so evident in the region of the "belt" which exists in the division between these two muscles. Some of the fat passes over the outer surface of the externus, though beneath its fascia, but the larger portion is under or within the externus, between it and the retractor muscle, and forms a big prominence at the "belt" between the external and inferior recti; within the inferior rectus this thins down and links up with the big lateral pad on the inner aspect. In this way we have followed the complete encirclement of the muscle of the globe with a continuous layer of fat, thin in some places, enormously developed in others. It has been seen that the large lateral mass is attached to the cartilago nictitans, of which an account will be given in connection with that structure, but nothing has yet been said of the connection of the enveloping mass with that found on the floor of the orbit in the region of the lower lid, nor of the deposit contained within the retractor.

The fat within the retractor is continuous with the superior fat pad through a division in the retractor that lies opposite to the external rectus. The pad within the retractor is pyramidal in shape, the base being applied to the sclerotic. The fat on the floor of the orbit is derived from that portion of the lateral pad which extends to the lachrymal sac. From here in an upward direction a layer of fat extends up the nasal side of the globe as far as the nasal side of the lachrymal gland. The portion which crosses the floor of the orbit from the lachrymal sac runs towards the temporal side where it lies beneath the fascia proceeding to the lower lid. It is a wedge-shaped piece of fat, being thin under the globe and thick towards the eyelid, especially thick, 5 or 6 mm., at that part corresponding to the central point of the lower lid. This fat is particularly fibrous towards the lid; fibrous material, derived from the periorbita and periosteal tissue (on which the lower lid is moulded), enters the fat and so keeps it in position. Moreover, the combined periorbita and periosteum meet the fascia proceeding to the lower lid and so enclose the fat in a fibrous case. The fat from the floor of the orbit then ascends the temporal side of the globe and terminates at the temporal end of the lachrymal gland. The nerves supplying the outer canthus and lower lid penetrate the fat and pierce the periorbita in order to reach the outside tissues. No fat covers the lachrymal gland.

The large venous plexuses of the eye and orbit are in intimate relation with the areas containing fat, especially the partial ring of fat just described as extending from the nasal side of the lachrymal gland beneath the eyeball to the temporal side of the gland.

The deposit of fat outside the periorbita consists of one long roll several centimetres in length extending from the maxillary tuberosity over the whole of the periorbita, and ascending in the temporal fossa until level with the upper edge of the orbital process. It is thick and permeated by a connective tissue which renders it very fibrous. It fills in every space or nook around the periorbita, and covers all the vast nerves and vessels in its neighbourhood.

MEMBRANA NICTITANS

The third eyelid is placed at the inner canthus of the eye; it consists of a deep-seated portion and a visible one. The latter can be seen from the front attached both above and below to the conjunctiva. On both temporal and nasal surfaces of the visible portion a cavity can be made by the introduction of the forefinger which will enter as far as the first joint; both surfaces are covered by conjunctiva. The living and post-mortem positions of the cartilago are not the same, for the contraction of the retractor muscle after death forces the membrane for a short distance across the cornea.

The larger and more important portion of the cartilago is out of sight and lies embedded in the anterior portion of the large pad of fat found on the inner and inferior aspect of the globe. The following observations refer entirely to the deep or embedded portion of the cartilago. On its temporal surface the cartilago is concave, in order that it may lie against the eyeball; on its nasal surface it is convex, and the most prominent portion of the convexity, which is anteriorly placed about opposite to the origin of the inferior oblique muscle, is covered by a thin layer of pinkish material known as the gland of Harder. This, however, is a very small and unimportant structure in the horse and is difficult to find; moreover, it is not always present. In the eyeball as removed from the socket it is impossible to locate the cartilago at sight; covered by fat it lies in the triangular space formed by the terminal portions of the internal and inferior recti. Even after the fat is removed from its surface it is still impossible to indicate the outline of the cartilago as it runs imperceptibly into the lateral fat pad in which it is lodged. The fat of this body is particularly fibrous and gains a strong attachment to the posterior edge and nasal surface of the cartilago; it is only by perception of the altered resistance offered to the point of the knife that it is possible to say where the cartilago ends and the fat begins. The superior border of the cartilago is accurately defined by the lower edge of the internal rectus muscle which just clears it in order to reach the globe; this muscle gives off stout fascial bands which firmly unite it to the cartilago. There is also a fascial connection, less important, with the inferior rectus muscle. The internal or temporal side of the cartilago is, as above noted, concave in shape for adjustment on the surface of the globe; if the fascial bands derived from the internal rectus muscle be divided, the cartilago can be lifted from the eyeball and its internal surface inspected; this is smooth and forms, with fascial bands from the internal and inferior recti, a bursa between these muscles and the globe, over which the cartilago freely moves; there is practically no fat on the internal surface of the cartilago. Though we have described the cartilago as moving freely in its bursa over the globe, it is actually over one of the insertions of the retractor muscle rather than over the sclerotic itself that the bursal arrangement is placed. The inferior oblique muscle arises about opposite the centre of the cartilago and crosses this structure in such a way as to keep it closely applied to the surface of the eyeball.

LACHRYMAL APPARATUS

The lachrymal gland is a large flat spleen-shaped body about 65 mm. in length and 35 mm. in width. It lies on the upper and temporal side of the eyeball, its tail being uppermost and corresponding in position to about the highest point of the cornea; its head lies low on the outside of the globe about opposite to the outer canthus. How closely this gland is applied to the inner surface of the orbital process will be readily recognised on removing that structure. It fills up the entire space between it and the eyeball, a small portion projecting in front of the orbital process; beneath it is the levator muscle, above it, between the gland and the orbital process, is the periorbita. Numerous nerves enter its posterior edge and large venous plexuses are connected with it both on the upper and the temporal sides of the eyeball. In appearance the gland is greyish-pink in colour and resembles the parotid. Its excretory ducts, which are extremely small, open into the conjunctival sac by minute openings at the outer canthus, but lie a long way back, as deep in fact as where the conjunctiva of the lid is reflected on to the eyeball. In considering this gland one is struck by the large and numerous branches of nerve, by the large venous plexuses present, by the large size of the gland, and by the minute openings of its excretory duct.

The lachrymal puncta in the lids are situated about 2 or 3 mm. above and below the caruncula and lead into the lachrymal ducts. The upper one turns inwards, then bends and runs forwards and downwards behind the caruncula to enter the lachrymal sac which is about 10 mm. below. The lower duct is shorter; it also turns inwards and takes a direct course into the lachrymal sac, lying in almost a horizontal line with it. The ducts and sac are rough internally, the walls being ribbed. The remarkable feature about both ducts and sac is their relatively large size; the ducts are several times larger in diameter than the puncta. The periorbita forms an almost cartilaginous capsule to the sac and a fibrous lining to the nasal canal, while a second layer invests the thick tissues surrounding the canal in its passage to the nasal chamber. The periorbital capsule of the sac is linked up with the caruncula and tissues at the inner canthus of the eye, an arrangement which keeps them firmly in position. The tissues at the inner canthus are accordingly very fibrous.

The lachrymal sac is concave posteriorly and the origin of the inferior oblique fits into the concavity; it is also concave on its temporal side where it is in contact with the fat covering the membrana nictitans. The duct leading from it to the nasal chamber has a remarkably thick corrugated inner wall. The thickness is out of all proportion to the function of the canal, while the actual size of the tear passage is relatively very small. Surrounding the walls of the nasal duct is a vascular plexus, so that the canal to the nasal chamber is much larger than the thick-walled duct it is carrying.

THE EYELIDS

The eyeball is smaller than the orbital cavity, but the presence of a large lachrymal gland above and on the temporal side, together with the existence of a pad of fat on the floor and nasal side, causes the orbit to be completely filled. The cornea projects between the two lids, but as it is placed below the centre of the globe the upper lid is deeper than the lower. The globe is placed so far forward in the orbital cavity that the cornea, iris, ciliary body, and a portion of the lens, are in advance of the bony orbital rim at the canthi. With the head in the normal position the tarsal margin of the upper lid may be 20 mm. and that of the lower lid 13 mm. in front of a vertical dropped from the rim of the orbit.

The skin of the eyelids is generally black, and the pigment extends to the tarsal margin in contact with the globe, where it abruptly ends. The hair on the upper lid is very short, but gradually lengthens in an upward direction and finally runs into the general hair of the face. On the lower lid there is a black shiny hairless surface just below where the scanty eyelashes exist; beneath this the hairs begin to appear in rows, at first very short but gradually increasing in length with each successive row, until the "feelers" are reached, by which time the full length of hair is obtained. The tarsal margin of the lids is relatively thick, the thickest part being midway between the canthi, where it measures about 2 mm. The margin is rounded, shiny, black and hairless; its conjunctival side is closely applied to the eyeball but towards the inner canthus, owing to the presence of the membrana nictitans, it is no longer in contact with the globe.

The eyelashes on the upper lid are large and well developed, excepting at the inner third, which is hairless, and are placed at a distance of about 2 mm. from the inner or conjunctival edge of the lid. There are two or three rows of eyelashes; each row takes a different direction, so that they cross lattice-wise. The longest lashes are centrally placed, and occupy the lowest row; they get progressively shorter in the upper rows. On the lower lid some fine hairs, corresponding to short eyelashes, may be seen, though they are frequently absent.

The upper lid is markedly wrinkled, the result of doing practically all the work, for the movement of the lower lid is very limited; the wrinkling takes a definite pattern, which is accentuated towards the inner third of the upper lid owing to the peculiar shape of the part. The line of the lid is "pulled up" as it were, and then descends by a sharp slope to the lachrymal pool. The lower lid has no such irregularity on its tarsal margin, but forms a semi-circle. Where the two lids meet at the inner canthus there is another hairless black surface also wrinkled which runs outwards towards the face.

The brow is formed by the tissues covering the orbital process; its most prominent point is on the nasal side where a large thick mass exists which is just clear of the eyelid and runs down almost to the inner canthus. The hair pattern on this prominence is distinctive; it runs upwards in a semi-circular sweep. There are no eyebrows, but large "feelers" exist on the brow which give warning of danger. Similar feelers are found on the lower lid and serve the same purpose. The "feelers" run completely through the skin and each is embedded in a capsule in the orbicularis muscle.

The basis of each eyelid is a layer of periorbita which in the upper lid enters directly, but is differently arranged in the lower. It will be remembered that the periorbita of the orbital process splits at the rim, one portion linking up with the periosteum, the other entering the eyelid. In the lower lid the periosteum and periorbita meet, fuse, and form a crescentic curtain across the orbital opening from one side to the other; it is on the upper edge of this curtain that the true lower lid is built. This crescentic curtain may be as much as 12 mm. in height at its central part and on this another 12 mm. of eyelid is superposed.

The structures found in the lids, detailed from within outwards, are as follows: conjunctiva, levator muscle, periorbita (or in the case of the lower lid a mixed layer of periorbita and periosteum), fascia, orbicularis muscle and skin. In each lid there is a well-marked, relatively thick tarsal cartilage and meibomian glands. The crescentic membrane on which the lower lid is constructed is closely applied to the external face of the fat which lies at the base of the eyeball; into this fat, in order to keep it in position, the membrane sends numerous fibres. The outer face of the elliptical membrane is covered by the orbicularis muscle. Above the layer of fat at the base of the eye, namely between it and the eyeball, is found the fascia which enters the lower lid; it is derived from the inferior rectus muscle.

The lachrymal lake at the inner canthus is constructed in very rigid tissue, composed of skin, muscle and an abundance of fibrous material. The whole of the "corner of the eye" is held firmly in position by the lachrymal ligament which runs from the orbital margin to the lachrymal lake.

The conjunctival sac is deepest in the vicinity of the upper lid, especially at its temporal side, where it extends beneath the orbital process for at least 20 mm. It is also deep on the nasal aspect. In the lower lid it is relatively shallow and limited to the depth of the true eyelid.

The *orbicularis oculi* muscle is a large, flat, oval-shaped structure surrounding the orbit. Over the orbital process and on its nasal side it links up with the *corrugator supercilii* and here the part is very thick and constitutes the marked prominence described in speaking of the brow. With this exception the orbicularis is a flat muscle arranged in layers and possesses an extensive fibrous base due to thickened periosteum or to layers of connective tissue outside the periosteum. It covers a wide area outside the orbital rim and plasters over both upper and lower lids. To the skin of these and the surrounding parts it is so intimately attached that it is impossible to separate the two structures cleanly.

The *corrugator supercilii* is a peculiar muscle arising from the frontal bone.

On contraction it wrinkles or "pinches up" the brow; it does not raise the upper lid.

The *caruncula lachrymalis,* a body the size of a small pea, is deeply pigmented and has a few hairs growing from its surface. On section it is found to be almost wholly glandular, the glands being of the sebaceous and mucous type.

I am greatly indebted to Captain F. C. MINETT, M.B.E., B.Sc., R.A.V.C., and the Authorities of the Royal Army Veterinary School, Aldershot, for the supply of anatomical material for this enquiry,

APPOINTMENT

The Council of the University of Birmingham has appointed Dr James Couper Brash to the chair of Anatomy in succession to the late Professor Peter Thompson. Professor Brash became a student demonstrator under Professor D. J. Cunningham in 1908 and later was appointed demonstrator in Pathology under Professor Greenfield. After acting for a short time as demonstrator of Anatomy under Professor Arthur Robinson at Edinburgh, he was appointed assistant to Prof. Kay Jamieson at Leeds in 1911. Holding a Commission in the Special Reserve of the R.A.M.C., he was mobilised, August, 1914, and remained on active service until April, 1919, when he again took up his demonstratorship at Leeds. In October, 1919, he was appointed assistant to Professor Peter Thompson in Birmingham. Here, owing to the state of the Professor's health, the work of the department fell to a great extent on Dr Brash—who carried on, during the two past years, the high traditions established in the University of Birmingham by Windle, Robinson and Thompson. Readers of this Journal are already acquainted with the finished nature of research work which Professor Brash has found time to do in the midst of military and other duties and will be glad to know that he has several investigations now in hand.

INDEX

Allis, Edward Phelps, Jr. The Myodome and the Trigemino-Facialis chamber in the Coelacanthidae, Rhizodontidae and Palaeoniscidae, 149
— The cranial anatomy of Polypterus, with special reference to *Polypterus bichir*, 189
Anencephalic Embryo, Report on, J. Ernest Frazer, F.R.C.S., 12
Appleton, A. B. On the hypotrochanteric fossa and accessory adductor groove of the primate femur, 295
Appointment. James Couper Brash to the Chair of Anatomy, University of Birmingham, 390
Arvicola (*Microtus*) *Amphibius*, early development and placentation in, with special reference to the origin of placental giant cells. By G. S. Sansom, B.Sc., 333
Aspermatic condition of the imperfectly descended Testis, suggestion as to the cause of. By F. A. E. Crew, M.D., D.Sc., 98

Blair, Duncan M., M.B., Ch.B. A Note on the Post-coronal Sulcus, with dissections of the Epicranial Aponeurosis in two cases of its occurrence, 44
Bolk, L., M.D. Odontological Essays, 107
Bones in the palate and upper jaw of the fishes, a new interpretation of. By H. Leighton Kesteven, D.Sc., M.D., Ch.M., 307
Brash, James Couper, appointed to Chair of Anatomy, University of Birmingham, 390
Braus, Hermann, Anatomie des Menschen: ein Lehrbuch für Studierende und Ärzte, Review, 161
Bresslau, Ernst. The Origin of Milk Glands: The Mammary Apparatus of the Mammalia, in the Light of Ontogenesis and Phylogenesis. Review, 55

Coelacanthidae, Rhizodontidae, and Palaeoniscidae, Myodome and the Trigemino-Facialis chamber in. By Edward Phelps Allis, Jr., 149
Colons, Iliac and Pelvic, abnormal position of. By Naguib Effendi Nicola, 53
Crew, F. A. E., M.D., D.Sc. A suggestion as to the cause of the aspermatic condition of the imperfectly descended Testis, 98
Cyriax, Edgar F., M.D. (Edin.). On certain normal irregularities in the Vertebral Column in its lower dorsal area, 147

Dart, Raymond A., M.Sc., M.B., Ch.M. and Joseph L. Shellshear, M.B., Ch.M. The Origin of the Motor Neuroblasts of the Anterior Cornu of the Neural Tube, 77
Dart, Raymond A., M.Sc., M.B., Ch.M. The misuse of the term "Visceral," 177
Das, Basanta Kumar, M.Sc. (Allahabad). On truncated umbilical arteries in some Indian mammals, 325
Dilworth, T. F. M., M.B., B.Ch. The Nerves of the human larynx, 48

Embryo, Anencephalic, Report on, J. Ernest Frazer, F.R.C.S., 12
— human, absence of the lens occurring in. By Ida C. Mann, M.B., B.S., 96
— of Lygosoma, skull and some related structures of. By Helga S. Pearson, B.Sc., 20
Epicranial Aponeurosis, Note on the Post-Coronal Sulcus, with dissections of. By Duncan M. Blair, M.B., Ch.B., 44
Eye of horse, anatomical notes of the accessory organs of. By Sir Frederick Smith, K.C.M.G., C.B., 366

Femur, mammalian, correlation between Habit and the Architecture of. By G. de M. Rudolf, M.R.C.S. (Eng.), L.R.C.P. (Lond.), D.P.H., 137
— of primate, hypotrochanteric fossa and accessory adductor groove of. By A. B. Appleton, 295
Fishes, a new interpretation of the bones in the palate and upper jaw of. By H. Leighton Kesteven, D.Sc., M.D., Ch.M., 307
Foetus, human, exhibiting Iniencephaly and other abnormalities. By William Ivon Hayes, M.B. (Melb.), 155
Frazer, J. Ernest, F.R.C.S., Report on an Anencephalic Embryo, 12

Habit and the Architecture of the mammalian femur, correlation between. By G. de M. Rudolf, M.R.C.S. (Eng.), L.R.C.P. (Lond.), D.P.H., 137
Hayes, William Ivon, M.B. (Melb.). A human Foetus exhibiting Iniencephaly and other abnormalities, 155
Herrick, C. Judson, What are viscera? 167
Horse, eye of, anatomical notes of the accessory organs of. By Sir Frederick Smith, K.C.M.G., C.B., 366
Hunter, John I., M.B., Ch.M. A case of early human Ovarian Pregnancy, 57
Hypotrochanteric fossa and accessory adductor groove of the primate femur. By A. B. Appleton, 295

Iliac and Pelvic colons, abnormal position of. By Naguib Effendi Nicola, 53
Indian mammals, truncated umbilical arteries in. By Basanta Kumar Das, M.Sc. (Allahabad), 325
Iniencephaly and other abnormalities, human Foetus exhibiting. By William Ivon Hayes, M.B. (Melb.), 155
Interphalangeal and Metacarpo-Phalangeal Joints, Nerve supply of. By John S. B. Stopford, M.D., 1

Jaw, upper, of fishes, a new interpretation of the bones in the palate and. By H. Leighton Kesteven, D.Sc., M.D., Ch.M., 307
Joints, Interphalangeal and Metacarpo-Phalangeal, Nerve supply of. By John S. B. Stopford, M.D., 1

Kesteven, H. Leighton, D.Sc., M.D., Ch.M. A new interpretation of the bones in the palate and upper jaw of the fishes, 307
Kidd, Walter, M.D., F.R.S.E. Initiative in Evolution, Review, 55

Larynx, human, Nerves of. By T. F. M. Dilworth, M.B., B.Ch., 48
Lens, absence of, occurring in the human embryo. By Ida C. Mann, M.B., B.S., 96
Lygosoma, Embryo of, Skull and some related structures of. By Helga S. Pearson, B.Sc., 20

Mann, Ida C., M.B., B.S. Absence of the lens occurring in the human Embryo, 96
Metacarpo-Phalangeal and Interphalangeal Joints, Nerve supply of. By John S. B. Stopford, M.D., 1
Myodome and the Trigemino-Facialis chamber in the Coelacanthidae, Rhizodontidae and Palaeoniscidae. By Edward Phelps Allis, Jr., 149

Nerve supply of the Interphalangeal and Metacarpo-Phalangeal Joints. By John S. B. Stopford, M.D., 1
Nerves of the human larynx. By T. F. M. Dilworth, M.B., B.Ch., 48
Neural Tube, origin of the Motor Neuroblasts of the Anterior Cornu of. By Raymond A. Dart, M.Sc., M.B., Ch.M. and Joseph L. Shellshear, M.B., Ch.M., 77
Neuroblasts, Motor, of the Anterior Cornu of the Neural Tube, Origin of. By Raymond A. Dart, M.Sc., M.B., Ch.M. and Joseph L. Shellshear, M.B., Ch.M., 77
Nicola, Naguib Effendi, Abnormal position of the Iliac and Pelvic colons, 53

Obituary notice of Dr Peter Thompson. By Arthur Robinson. Portrait, 164
Odontological Essays. By L. Bolk, 107

Palaeoniscidae, Coelacanthidae and Rhizodontidae, Myodome and the Trigemino-Facialis chamber in. By Edward Phelps Allis, Jr., 149
Palate and upper jaw of the fishes, a new interpretation of the bones of. By H. Leighton Kesteven, D.Sc., M.D., Ch.M., 307
Pearson, Helga S. The Skull and some related structures of a late Embryo of Lygosoma, 20
Pelvic and Iliac Colons, abnormal position of. By Naguib Effendi Nicola, 53
Placentation and development in *Arvicola* (*Microtus*) *Amphibius*, with special reference to the origin of placental giant cells. By G. S. Sansom, B.Sc., 333
Polypterus, cranial anatomy of, with special reference to *Polypterus bichir*. By Edward Phelps Allis, Jr., 189
Post-Coronal Sulcus, with dissections of the Epicranial Aponeurosis in two cases of its occurrence. By Duncan M. Blair, M.B., Ch.B., 44
Pregnancy, Ovarian, Case of early human. By John I. Hunter, M.B., Ch.M., 57

Reviews. Anatomie des Menschen: ein Lehrbuch für Studierende und Ärzte. By Hermann Braus, 161
— Hereditary disease. By Hermann W. Siemens, 162
— Initiative in Evolution. By Walter Kidd, M.D., F.R.S.E., 55
— Studies in the Palaeopathology of Egypt. By Sir Marc Armand Ruffer, C.M.G., M.D., 160
— The Origin of Milk Glands: The Mammary Apparatus of the Mammalia, in the light of Ontogenesis and Phylogenesis. By Ernst Bresslau, M.D., 55
Rhizodontidae, Coelacanthidae, and Palaeoniscidae, Myodome and the Trigemino-Facialis chamber in. By Edward Phelps Allis, Jr., 149
Robinson, Arthur. Obituary notice of Dr Peter Thompson. Portrait, 164
Rudolf, G. de M., M.R.C.S. (Eng.), L.R.C.P. (Lond.), D.P.H. Correlation between Habit and the Architecture of the Mammalian Femur, 137
Ruffer, Sir Marc Armand, C.M.G., M.D. Studies in the Palaeopathology of Egypt, Review, 160

Sansom, G. S., B.Sc. Early development and placentation in *Arvicola* (*Microtus*) *Amphibius*, with special reference to the origin of the placental giant cells, 333
Shellshear, Joseph L., M.B., Ch.M. and Raymond A. Dart, M.Sc., M.B., Ch.M. The Origin of the Motor Neuroblasts of the Anterior Cornu of the Neural Tube, 77
Siemens, Hermann W. Hereditary disease, Review, 162
Skull and some related structures of a late Embryo of Lygosoma. By Helga S. Pearson, B.Sc., 20
— Post-Coronal Sulcus of, with dissections of the Epicranial Aponeurosis in two cases of its occurrence. By Duncan M. Blair, M.B., Ch.B., 44
Smith, Sir Frederick, K.C.M.G., C.B. Anatomical notes on the accessory organs of the eye of the horse, 366
Stopford, John S. B., M.D. Nerve supply of the Interphalangeal and Metacarpo-Phalangeal Joints, 1
Sulcus, Post-Coronal, with dissections of the Epicranial Aponeurosis in two cases of its occurrence. By Duncan M. Blair, M.B., Ch.B., 44

Testis, imperfectly descended, suggestion as to the cause of the aspermatic condition of. By F. A. E. Crew, M.D., D.Sc., 98
Thompson, Dr Peter. Obituary notice of. By Arthur Robinson, Portrait, 164
Trigemino-Facialis Chamber and Myodome in the Coelacanthidae, Rhizodontidae and Palaeoniscidae. By Edward Phelps Allis, Jr., 149

Umbilical arteries, truncated, in some Indian mammals. By Basanta Kumar Das, M.Sc. (Allahabad), 325

Vertebral column in its lower dorsal area, certain normal irregularities in. By Edgar F. Cyriax, M.D. (Edin.), 147
Viscera, What are Viscera? By C. Judson Herrick, 167
"Visceral," misuse of term. By Raymond A. Dart, M.Sc., M.B., Ch.M., 177

PRINTED IN ENGLAND
AT THE CAMBRIDGE UNIVERSITY PRESS
BY J. B. PEACE, M.A.

Journal of anatomy

1920-22