




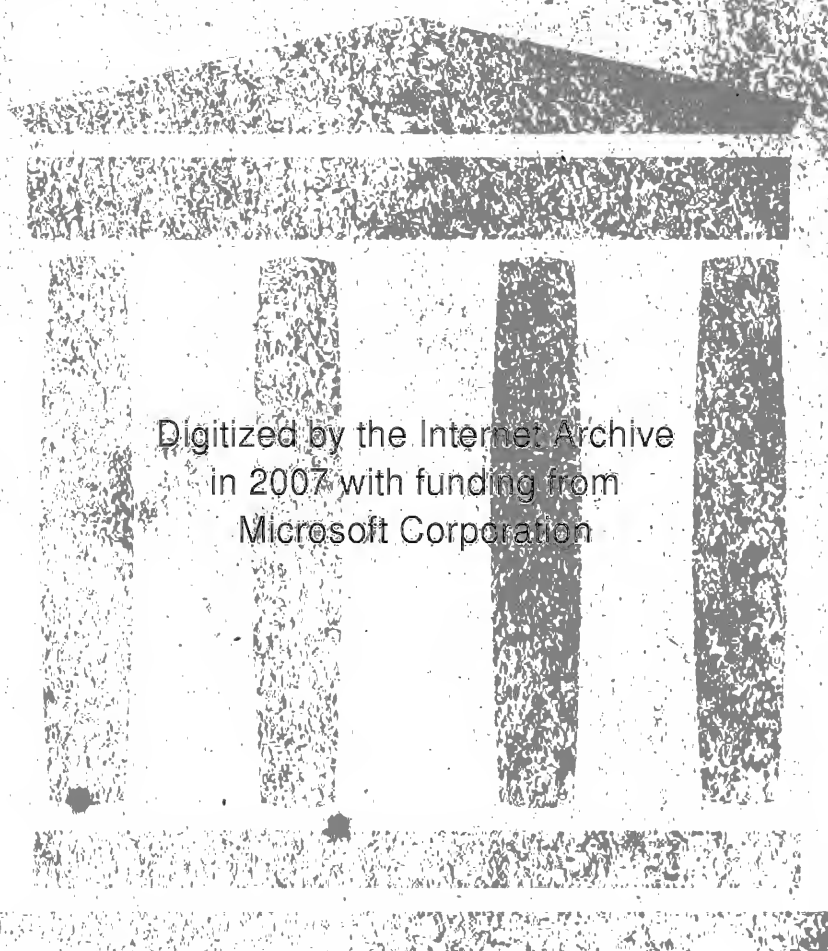
MEDICAL SCHOOL  
LIBRARY



EX LIBRIS

Dr. Monroe Sutter  
Memorial.

*M. Little*



Digitized by the Internet Archive  
in 2007 with funding from  
Microsoft Corporation







A LABORATORY MANUAL AND TEXT-BOOK

*of*

# EMBRYOLOGY

*By*

CHARLES WILLIAM PRENTISS, A.M., PH.D.

PROFESSOR OF MICROSCOPIC ANATOMY IN THE NORTHWESTERN UNIVERSITY MEDICAL SCHOOL, CHICAGO

*Northwestern  
Jan 1916  
U. of Cal.*

*copy 2*

WITH 368 ILLUSTRATIONS  
MANY OF THEM IN COLORS

PHILADELPHIA AND LONDON

W. B. SAUNDERS COMPANY

1915

UNIV OF CALIF  
MEDICAL SCHOOL

---

Copyright, 1915 by W. B. Saunders Company

---

---

PRINTED IN AMERICA

---

PRESS OF  
W. B. SAUNDERS COMPANY  
PHILADELPHIA

W. B. SAUNDERS  
PHILADELPHIA

1601  
91  
>15  
pp. 2

## PREFACE

THIS book represents an attempt to combine brief descriptions of the vertebrate embryos which are studied in the laboratory with an account of human embryology adapted especially to the medical student. Professor Charles Sedgwick Minot, in his laboratory textbook of embryology, has called attention to the value of dissections in studying mammalian embryos and asserts that "dissection should be more extensively practised than is at present usual in embryological work. . . . ." The writer has for several years experimented with methods of dissecting pig embryos, and his results form a part of this book. The value of pig embryos for laboratory study was first emphasized by Professor Minot, and the development of my dissecting methods was made possible through the reconstructions of his former students, Dr. F. T. Lewis and Dr. F. W. Thyng.

The chapters on human organogenesis were partly based on Keibel and Mall's *Human Embryology*. We wish to acknowledge the courtesy of the publishers of Kollmann's *Handatlas*, Marshall's *Embryology*, Lewis-Stöhr's *Histology* and McMurrich's *Development of the Human Body*, by whom permission was granted us to use cuts and figures from these texts. We are also indebted to Professor J. C. Heisler for permission to use cuts from his *Embryology*, and to Dr. J. B. De Lee for several figures taken from his "Principles and Practice of Obstetrics." The original figures of chick, pig and human embryos are from preparations in the collection of the anatomical laboratory of the Northwestern University Medical School. My thanks are due to Dr. H. C. Tracy for the loan of valuable human material, and also to Mr. K. L. Vehe for several reconstructions and drawings.

C. W. PRENTISS.

NORTHWESTERN UNIVERSITY MEDICAL SCHOOL,  
CHICAGO, ILL., *January*, 1915.



# CONTENTS

---

	PAGE
INTRODUCTION . . . . .	II
CHAPTER I.—THE GERM CELLS . . . . .	17
The Ovum . . . . .	17
Ovulation and Menstruation . . . . .	20
The Spermatozoön . . . . .	21
Mitosis and Amitosis . . . . .	22
Maturation . . . . .	24
Fertilization . . . . .	30
The Chromosomes in Heredity . . . . .	31
The Determination of Sex . . . . .	31
CHAPTER II.—SEGMENTATION AND FORMATION OF THE GERM LAYERS . . . . .	33
Segmentation in Amphioxus, Amphibian, Bird, and Reptile . . . . .	33
Segmentation of the Rabbit's Ovum . . . . .	36
Origin of the Ectoderm and Entoderm . . . . .	37
Origin of the Mesoderm, Notochord and Neural Tube . . . . .	42
Origin of the Mesoderm in Mammals . . . . .	45
The Notochord . . . . .	46
CHAPTER III.—THE STUDY OF CHICK EMBRYOS . . . . .	48
Chick Embryo of Twenty-five Hours . . . . .	48
Transverse Sections of Twenty-five-hour Chick Embryo . . . . .	50
Origin of the Primitive Heart . . . . .	52
Chick Embryo of Thirty-six Hours (18 segments) . . . . .	54
Central Nervous System . . . . .	54
Digestive Tube . . . . .	55
Heart and Vessels . . . . .	56
Mesodermal Segments . . . . .	61
Coelom . . . . .	63
Mesenchyma . . . . .	63
Derivatives of the Germ Layers . . . . .	64
Chick Embryo of Fifty Hours (27 segments) . . . . .	65
Nervous System . . . . .	66
Digestive Organs . . . . .	67
Blood System . . . . .	67
Study of Transverse Sections . . . . .	69
Amnion, Chorion . . . . .	74
Yolk-sac and Allantois . . . . .	75
CHAPTER IV.—THE FETAL MEMBRANES AND EARLY HUMAN EMBRYOS . . . . .	77
Early Human Embryos . . . . .	77
Fetal Membranes of Pig Embryos . . . . .	77
Umbilical Cord . . . . .	79
Fetal Membranes of Early Human Embryos . . . . .	80
Chorion . . . . .	81
Amnion . . . . .	83
Allantois . . . . .	84
Yolk-sac and Stalk . . . . .	86
Anatomy of a 4.2 mm. Human Embryo . . . . .	88
Central Nervous System . . . . .	89
Digestive Canal . . . . .	89
Urogenital and Circulatory Organs . . . . .	92
Age of Human Embryos . . . . .	95
CHAPTER V.—THE STUDY OF PIG EMBRYOS . . . . .	97
The Anatomy of a six mm. Pig Embryo . . . . .	97
External Form . . . . .	97
Internal Anatomy . . . . .	99
The Study of Transverse Sections . . . . .	III



	PAGE
The Anatomy of a 10 mm. Pig Embryo . . . . .	120
External Form . . . . .	120
Central Nervous System and Viscera . . . . .	122
Heart and Blood Vessels . . . . .	128
The Study of Transverse Sections . . . . .	132
<b>CHAPTER VI.—METHODS OF DISSECTING PIG EMBRYOS: DEVELOPMENT OF THE FACE, PALATE, TONGUE, TEETH AND SALIVARY GLANDS.</b> . . . .	145
Directions for Dissecting Pig Embryos . . . . .	145
Lateral Dissections of 6–35 mm. Embryos . . . . .	146
Median Sagittal Dissections . . . . .	148
Ventral Dissections . . . . .	153
Development of the Face in Pig and Human Embryos . . . . .	153
Development of the Hard Palate . . . . .	155
Development of the Tongue . . . . .	158
Development of the Salivary Glands . . . . .	161
Development of the Teeth . . . . .	162
<b>CHAPTER VII.—ENTODERMAL CANAL AND ITS DERIVATIVES</b> . . . . .	168
The Pharyngeal and Cloacal Membranes . . . . .	168
Pharyngeal Pouches and their Derivatives . . . . .	168
The Thymus Gland . . . . .	171
The Epithelial Bodies or Parathyroids . . . . .	172
The Thyroid Gland . . . . .	172
Larynx, Trachea and Lungs . . . . .	173
Digestive Canal . . . . .	177
Digestive Glands: Liver . . . . .	183
Pancreas . . . . .	186
Body Cavities, Diaphragm and Mesenteries . . . . .	188
Primitive Coelom and Mesenteries . . . . .	188
Septum Transversum . . . . .	191
Pleuro-pericardial and Pleuro-peritoneal Membranes . . . . .	192
Diaphragm and Pericardial Membrane . . . . .	195
Omental Bursa, or Lesser Peritoneal Sac . . . . .	197
The Mesenteries . . . . .	200
<b>CHAPTER VIII.—UROGENITAL SYSTEM.</b> . . . .	203
Pronephros . . . . .	203
Mesonephros . . . . .	205
Metanephros . . . . .	207
Nephrogenic Tissue . . . . .	210
Cloaca, Bladder, Urethra and Urogenital Sinus . . . . .	213
Genital Glands and Ducts . . . . .	216
Testis . . . . .	218
Ovary . . . . .	221
Union of Genital Glands and Mesonephric Tubules . . . . .	225
Uterine Tubes, Uterus and Vagina . . . . .	226
Ligaments of the Internal Genitalia . . . . .	228
Descent of Testis and Ovary . . . . .	230
External Genitalia . . . . .	232
Male and Female Genitalia Homologized . . . . .	235
The Uterus during Menstruation and Pregnancy . . . . .	238
The Decidual Membranes . . . . .	239
Chorion Læve and Frondosum . . . . .	243
Decidua Vera . . . . .	243
Decidua Capsularis . . . . .	244
The Placenta . . . . .	245
The Relation of Fetus to Placenta . . . . .	249
<b>CHAPTER IX.—VASCULAR SYSTEM.</b> . . . .	251
The Primitive Blood-vessels and Blood-cells . . . . .	251
Erythrocytes . . . . .	252
Leucocytes . . . . .	253
Blood plates . . . . .	254
The Development of the Heart . . . . .	255
Primitive Blood Vascular System . . . . .	267
Development and Transformation of the Aortic Arches . . . . .	270
Vertebral and Basilar Arteries . . . . .	272
Segmental Arteries . . . . .	274
Umbilical and Iliac Arteries . . . . .	275

	PAGE
Arteries of the Extremities.....	275
Vitelline and Umbilical Veins: Vena Porta.....	276
Anterior Cardinal Veins: Superior Vena Cava.....	279
Posterior Cardinal Veins: Inferior Vena Cava.....	280
The Veins of the Extremities.....	283
The Fetal Circulation.....	284
The Lymphatic System.....	286
Lymph Glands.....	287
Hæmolymp Glands and Spleen.....	288
<b>CHAPTER X.—HISTOGENESIS.....</b>	<b>290</b>
The Entodermal Derivatives.....	290
The Mesodermal Tissues.....	291
Sclerotomes and Mesenchyme.....	291
Supporting Tissues.....	292
Cartilage.....	294
Bone.....	295
Joints.....	298
Muscle.....	298
The Ectodermal Derivatives.....	303
Epidermis.....	304
Hair.....	305
Sweat Glands.....	307
Mammary Glands.....	307
Nails.....	308
The Nervous Tissues.....	309
The Differentiation of the Neural Tube.....	310
Neurones of the Ventral Roots.....	313
Spinal Ganglia and their Neurones.....	313
The Neurone Theory.....	315
The Supporting Tissue of the Nervous System.....	316
<b>CHAPTER XI.—MORPHOGENESIS OF THE CENTRAL NERVOUS SYSTEM.....</b>	<b>319</b>
The Spinal Cord.....	320
The Brain.....	325
The Differentiation of the Subdivisions of the Brain.....	330
Myelencephalon.....	330
Metencephalon.....	333
Cerebellum.....	334
Mesencephalon.....	335
Diencephalon.....	336
Hypophysis.....	337
Telencephalon.....	339
Chorioid Plexus of Lateral Ventricles.....	340
Cerebral Hemispheres.....	346
<b>CHAPTER XII.—THE PERIPHERAL NERVOUS SYSTEM.....</b>	<b>351</b>
The Spinal Nerves.....	351
Brachial and Lumbo-sacral Plexuses.....	353
Cerebral Nerves.....	355
Special Somatic Sensory Nerves.....	355
Somatic Motor Nerves.....	358
Visceral Mixed Nerves.....	359
The Sympathetic Nervous System.....	364
Chromaffin Bodies: Suprarenal Gland.....	366
The Sense Organs.....	368
General Sensory Organs.....	368
Taste Buds.....	368
Olfactory Organ.....	369
Eye.....	373
Ear.....	381
<b>INDEX.....</b>	<b>389</b>



# TEXT-BOOK OF EMBRYOLOGY

## INTRODUCTION

The study of human embryology deals with the development of the individual from the origin of the germ-cells to the adult condition. To the medical student human embryology is of primary importance because it affords a comprehensive understanding of gross anatomy. It is on this account that only recently a prominent surgeon has recommended a thorough study of embryology as one of the foundation stones of surgical training. Embryology not only throws light on the normal anatomy of the adult, but it also explains the occurrence of many anomalies, and the origin of certain pathological changes in the tissues. From the theoretical side, embryology is the key with which we may unlock the secrets of heredity, of the determination of sex and, in part, of organic evolution.

There is unfortunately a view current among graduates in medicine that the field of embryology has been fully reaped and gleaned of its harvest. On the contrary, much productive ground is as yet unworked, and all *well-preserved* human embryos are of value to the investigator. An institute of embryology for the purpose of collecting, preserving and studying human embryos has recently been established by Professor F. P. Mall of the Johns Hopkins Medical School. *Aborted embryos and those obtained by operation in case of either normal or ectopic pregnancies should always be saved and preserved by immersing them intact in 10 per cent. formalin or Zenker's fluid.*

The science of embryology is a comparatively new one, originating with the use of the compound microscope and developing with the improvement of microscopical technique. Chick embryos had been studied by Malpighi and Harvey previous to Leeuwenhoek's report of the discovery of the spermatozoön by Dr. Ham in 1677. At this period it was believed that the spermatozoa were both male and female and developed in the ovum of the mother; that the various parts of the adult body were *performed* in the sperm-cell. Dalenpatius (1699) believed that he had observed a minute human form in the spermatozoön. Previous to this period, many animals were believed to be spontaneously generated from slime and decaying matter as asserted by Aristotle. The *preformation theory* was first combated by Wolff (1759) who saw that the early chick embryo was differentiated

from unformed living substance. This theory, known as *epigenesis*, was proved correct when, in 1827, von Baer discovered the mammalian ovum and later demonstrated the germ-layers of the chick embryo. When, after the work of Schwann and Schleiden (1839), the cell was recognized as the structural unit of the organism, the ovum was regarded as a typical cell and, in 1843, Barry observed the fertilization of the rabbit's ovum by the spermatozoön. Henceforth all multicellular organisms were believed to develop each from a single fertilized ovum, which by continued cell-division eventually gives rise to the adult body. In the case of vertebrates, the segmenting ovum differentiates first *three primary germ-layers*. The cells of these layers are modified in turn to form *tissues*, such as muscle and nerve, of which the various *organs* are composed, and the organs together constitute the *organism*, or adult body.

**Primitive Segments—Metamerism.**—In studying vertebrate embryos we shall identify and constantly refer to the *primitive segments* or *metameres*. These segments are homologous to the serial divisions of an adult earth-worm's body, divisions which are identical in structure, each containing a *ganglion* of the nerve cord, a muscle segment, or *myotome* and pairs of blood-vessels and nerves. In vertebrate embryos the primitive segments are known as *mesodermal segments*, or *somites*. Each pair gives rise to a vertebra, to a pair of myotomes, or muscle segments, and to paired vessels; each pair of mesodermal segments is supplied by a pair of spinal nerves, consequently the adult vertebrate body is segmented like that of the earth-worm. As a worm grows by the formation of new segments at its tail-end, so the metameres of the vertebrate embryo begin to form in the head and are added tailwards. There is this difference between the segments of the worm and the vertebrate embryo. The segmentation of the worm is complete, while that of the vertebrate is incomplete ventrally.

#### GROWTH AND DIFFERENTIATION OF THE EMBRYO

A multicellular embryo develops by the division of the fertilized ovum to form daughter cells. These are at first similar in structure and, if separated, any one of them may develop into a complete embryo, as has been proved by the experiments of Driesch on the ova of the sea-urchin. The further development of the embryo depends (1) upon the multiplication of its cells by division; (2) upon the growth in size of the individual cells; (3) upon changes in their form and structure.

The first changes in the form and arrangement of the cells give rise to three

definite plates, or *germ-layers*, which are termed from their positions the *ectoderm* (outer skin), *mesoderm* (middle skin) and *entoderm* (inner skin). In function the *ectoderm*, as it covers the body, is primarily protective, and gives rise to the nervous system through which sensations are received from the outer world. The *entoderm*, on the other hand, lines the digestive canal and is from the first nutritive in function. The *mesoderm*, lying between the other two layers, naturally performs the functions of circulation, of muscular movement and of excretion; it gives rise also to the skeletal structures which support the body. While all three germ-layers form definite sheets of cells known as *epithelia*, the mesoderm takes also the form of a diffuse network of cells, the *mesenchyma*.

**The Anlage.**—This German word is the term applied to the first aggregation of cells which will form any distinct part or organ of the embryo. The various anlagen are differentiated from the germ-layers by a process of *unequal growth*. At points where multiplication of the cells is more rapid than in the circular area surrounding them, outgrowths or ingrowths of the germ-layer will take place. The outgrowths or *evaginations* are illustrated by the development of the finger-like villi from the entoderm of the intestine; ingrowths or *invaginations* by the formation of the glands at the bases of the villi. According to Minot, *the development of evaginations and invaginations, due to unequal rapidity of growth, is the essential factor in moulding the organs, and hence the body of the embryo.*

**Differentiation of Tissues.**—The cells of the germ-layers which form organic anlagen may be at first alike in structure. Thus the evagination which forms the anlage of the arm is composed of a single layer of like ectodermal cells, surrounding a central mass of diffuse mesenchyma (Fig. 131). Gradually the ectodermal cells multiply, change their form and structure and give rise to the layers of the epidermis. By more profound structural changes the mesenchymal cells also are transformed into the elements of connective tissue, tendon, cartilage, bone and muscle, aggregations of modified cells which are known as *tissues*. The development of modified tissue cells from the undifferentiated cells of the germ-layers is known as *histogenesis*. During histogenesis the structure and form of each tissue cell are adapted to the performance of some special function or functions. Cells which have once taken on the structure and functions of a given tissue can not give rise to cells of any other type. In tissues like the epidermis, certain cells retain their primitive embryonic characters throughout life and, by continued cell-division, produce new layers of cells which are later cornified. In other tissues all of the cells are differentiated into the adult type and, during life, no new cells are formed. This takes place in the case of the nervous elements of the central nervous system.

Throughout life, tissue cells are undergoing retrogressive changes. In this way the cells of certain organs like the thymus gland and mesonephros degenerate and largely disappear. The cells of the hairs and the surface layer of the epidermis become cornified and eventually are shed. Tissue cells may thus normally constantly be destroyed and replaced by new cells.

**The Law of Biogenesis.**—Of great theoretical interest is the fact, constantly observed in studying embryos, that the individual in its development recapitulates the evolution of the race. This *law of recapitulation* was asserted by Meckel in 1881 and was termed by Haeckel the *law of biogenesis*. According to this law, the fertilized ovum is compared to a unicellular organism like the amœba; the blastula embryo is supposed to represent an adult Volvox; the gastrula, a simple sponge; the segmented embryo a worm-like stage, and the embryo with gill-slits may be regarded as a fish-like stage. The blood of the human embryo in development passes through stages in which its corpuscles resemble in structure those of the fish and reptile; the heart is at first tubular, like that of the fish; the kidney of the embryo is like that of the amphibian, as are also the genital ducts. Many other examples of this law may readily be observed. A more complete account of the general conceptions of embryology is given in Minot's "Laboratory Textbook of Embryology."

**Methods of Study.**—Human embryos not being available for individual laboratory work, we employ instead the embryos of the lower animals which best illustrate certain points. Thus the ova of *Ascaris*, a parasitic round worm, are used to demonstrate the phenomena of mitosis; the larvæ of echinoderms, or of worms, are frequently used to demonstrate the segmentation of the ovum and the development of the blastula and gastrula larvæ; the chick embryo affords convenient material for the study of the early vertebrate embryo, of the formation of the *germ-layers* and of the *embryonic membranes*, while the structure of a mammalian embryo, similar to that of the human embryo, is best observed in the embryos of the pig, which are very readily obtained. An idea of the anatomy of the embryos is obtained first by examining the exterior of whole embryos and studying dissections and reconstructions of them. Finally, each embryo is studied in serial sections, the level of each section being determined by comparing it with figures of the whole embryo.

Along with his study of the embryos in the laboratory, the student should do a certain amount of supplementary reading. Only the gist of human organogenesis is contained in the following chapters. A very complete bibliography of the subject is given in Keibel and Mall's "Human Embryology," to which



the student is referred. Below are given the titles of some of the more important works on vertebrate and human embryology, to which the student is referred and in some of which supplementary reading is required.

## TITLES FOR REFERENCE

- Duval, M. *Atlas D'Embryologie*. Masson, Paris.
- His, W. *Anatomie menschlicher Embryonen*. Vogel, Leipzig, 1885.
- Keibel, F. *Normentafel zur Entwicklungsgeschichte der Wirbelthiere*. Bd. I. Fischer. Jena, 1897.
- Keibel and Elze. *Normentafel zur Entwicklungsgeschichte des Menschen*, Jena, 1908.
- Keibel and Mall. *Human Embryology*. Lippincott, 1910-1912.
- Kollmann, J. *Handatlas der Entwicklungsgeschichte des Menschen*. Fischer, Jena, 1907.
- Lee, A. B. *The Microtometist's Vade Mecum*. Blakiston, Philadelphia.
- Lewis, F. T. *Anatomy of a 12 mm. Pig Embryo*. *Amer. Jour. Anat.*, vol. 2.
- Minot, C. S. *A Laboratory Textbook of Embryology*.
- Thyng, F. W. *The Anatomy of a 7.8 mm. Pig Embryo*. *Anat. Record*, vol. 5.
- Wilson, E. B. *The Cell in Development and Inheritance*. Macmillan, New York.



## CHAPTER I

### THE GERM CELLS: MITOSIS, MATURATION AND FERTILIZATION

#### THE GERM CELLS

The human organism with its various tissues composed each of aggregations of similar cells is, like that of all other vertebrates, developed from the union of two germ cells, the ovum and spermatozoön.

**The Ovum.**—The female germ cell or ovum is a typical animal cell produced in the ovary [for structure of typical cell see histologic texts]. It is nearly spherical in form and possesses a *nucleus* with *nucleolus*, *chromatin network*, *chromatin knots*, and *nuclear membrane* (Fig. 1). The cytoplasm of the ovum is distinctly granular, containing more or less numerous yolk granules and a minute *centrosome*. The nucleus is essential to the life, growth, and reproduction of the cell. The function of the nucleolus is unknown; the chromatin probably bears the hereditary qualities of the cell. The yolk granules, containing a fatty substance termed *lecithin*, furnish nutrition for the early development of the embryo. A relatively small amount of lecithin is found in the ova of mammals, the embryo developing within, and being nourished by, the uterine wall of the mother. It is much larger in amount in the ova of fishes, amphibia, reptiles, birds, and the primitive mammalia, the eggs of which are laid and develop outside of the body. The so-called yolk of the hen's egg (Fig. 2) is the ovum proper and its yellow color is due to the large amount of lecithin which it contains. The albumen, egg-membrane, and shell of the hen's egg are secondary envelopes of the ovum.

The human ovum is of small size, measuring from 0.22 to 0.25 mm. in diameter (Fig. 1 A). The cytoplasm is surrounded by a relatively thick radially striated membrane, the *zona pellucida*. The striated appearance of the zona pellucida is said to be due to fine canals which penetrate it and through which nutriment is carried to the ovum by smaller follicle cells during its growth within the ovary. The origin and growth of the ovum within the ovary are known as oögenesis, and will be described in Chapter VIII. We may state here that each growing ovum is at first surrounded by small nutritive cells known as *follicle cells*. These increase

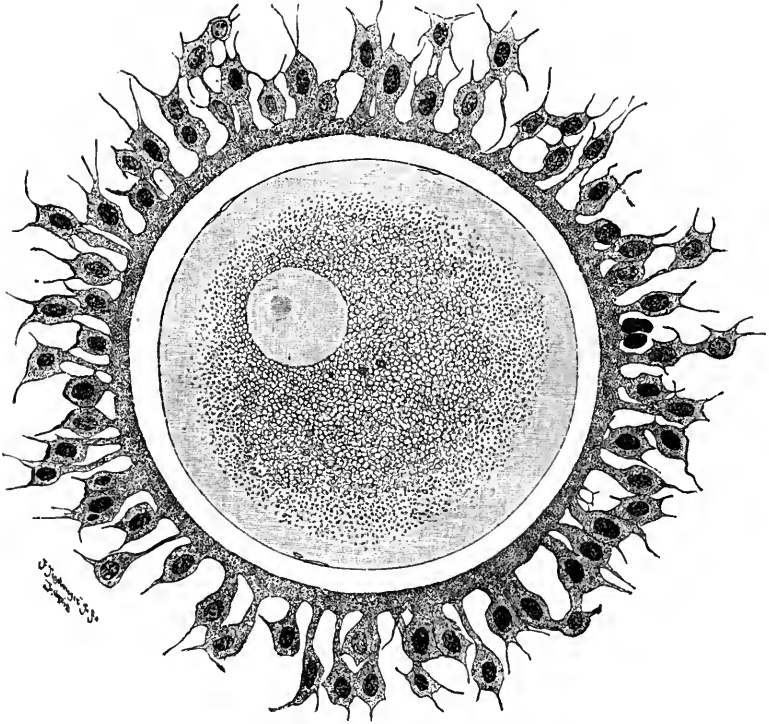


FIG. 1 A.

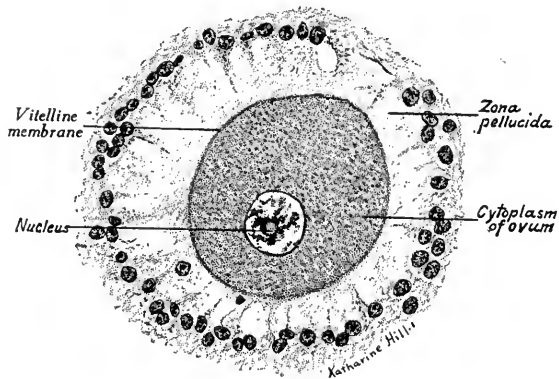


FIG. 1 B.

FIG. 1.—A, Human ovum examined fresh in the liquor folliculi (Waldeyer). The zona pellucida is seen as a thick, clear girdle surrounded by the cells of the corona radiata. The egg itself shows a central granular deutoplasmic area and a peripheral clear layer, and encloses the nucleus in which is seen the nucleolus; B, ovum of monkey.  $\times 430$ .

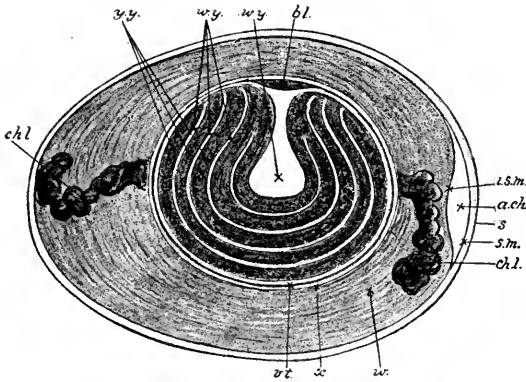


FIG. 2.—Diagrammatic longitudinal section of an unincubated hen's egg (after Allen Thomson, in Heisler). (Somewhat altered): *bl.*, germinal area; *w.y.*, white yolk, which consists of a central flask-shaped mass, and a number of concentric layers surrounding the yellow yolk (*y.y.*); *v.t.*, vitelline membrane; *x*, a somewhat fluid albuminous layer which immediately envelops the yolk; *w.*, albumen, composed of alternating layers of more and less fluid portions; *chl.*, chalazæ; *a.ch.*, air-chamber at the blunt end of the egg—simply a space between the two layers of the shell-membrane; *i.s.m.*, inner, *s.m.*, outer layer of the shell-membrane; *s.*, shell.

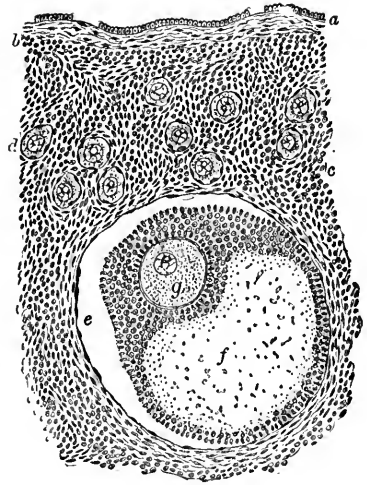


FIG. 3.—Section of human ovary, including cortex; *a*, germinal epithelium of free surface; *b*, tunica albuginea; *c*, peripheral stroma containing immature Graafian follicles (*d*); *e*, well-advanced follicle from whose wall membrana granulosa has partially separated; *f*, cavity of liquor folliculi; *g*, ovum surrounded by cell-mass constituting cumulus oöphorus (Pier-sol).




FIG. 4.—Section of well-developed Graafian follicle from human embryo (von Herff); the enclosed ovum contains two nuclei.

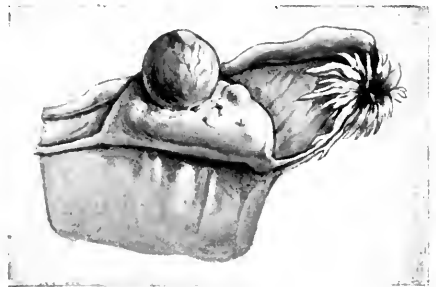

FIG. 5.—Ovary with mature Graafian follicle about ready to burst (Ribemont-Dessaigues).

in number during the growth of the ovum until several layers surround it (Fig. 3). A cavity appearing between these cells becomes filled with fluid and thus forms a sac, the *Graafian follicle*, within which the ovum is eccentrically located. The cells of the Graafian follicle immediately surrounding the ovum form the *corona radiata* (Fig. 1) when the ovum is set free.

**Ovulation and Menstruation.**—When the ovum is ripe, the Graafian follicle is large and contains fluid, probably under pressure. The ripe follicles form bud-like projections at the surface of the ovary (Fig. 5), and at these points

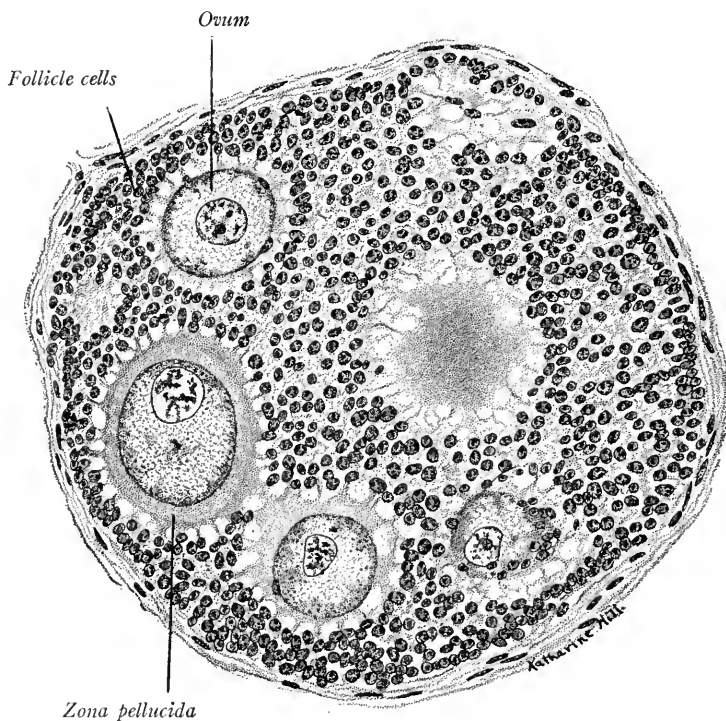


FIG. 6.—Immature follicle containing several ova. From the ovary of a young monkey.  $\times 430$ .

the ovarian wall has become very thin. It is probable that normally the bursting of the Graafian follicle and the discharge of the ovum are periodic and associated with the phenomena of menstruation. That ovulation or discharge of the ovum from the ovary may occur independent of the menstrual periods has been proven by the observations of Leopold. Also in young girls ovulation may precede the inception of menstruation and it may occur in women some time after the menopause.

At birth, or shortly after, all of the ova are formed in the ovary of the female

child. Hensen estimates that a normal human female may develop in each ovary 200 ripe ova. Most of the young ova, which may number 50,000, degenerate and never reach maturity. At ovulation but one ovum is normally ripened and discharged from the ovary. Several ova, however, may be produced in a single follicle in rare cases. Such multiple follicles have been observed in human ovaries and are of frequent occurrence in the ovary of the monkey. Fig. 6 shows such a follicle containing five immature ova.

**The Spermatozoön.**—The male cell or spermatozoön is a minute cell 0.05 mm. long, specialized for active movement. Because of their active movements, spermatozoa were, when first discovered, regarded as parasites living in the seminal fluid. The sperm cell is composed of a flattened *head*, indistinct *neck piece*, and *thread-like tail* (Fig. 7).

The *head* is about 5 micra in length. It appears oval in side view, pear-shaped in profile. When stained, the anterior two-thirds of the head may be seen to form a cap, and the sharp border of this cap is the *perforatorium* by means of which the spermatozoön penetrates the ovum. The head contains the nuclear elements of the sperm cell. The *neck* is said to be disc-shaped and to contain the centrosomes as the anterior and posterior centrosome bodies. The tail is divided into a short *connecting piece*, a *flagellum* which forms about four-fifths of the length of the sperm cell and a short *end-piece* (Fig. 7). The connecting piece is marked off from the *flagellum* by the *annulus*.

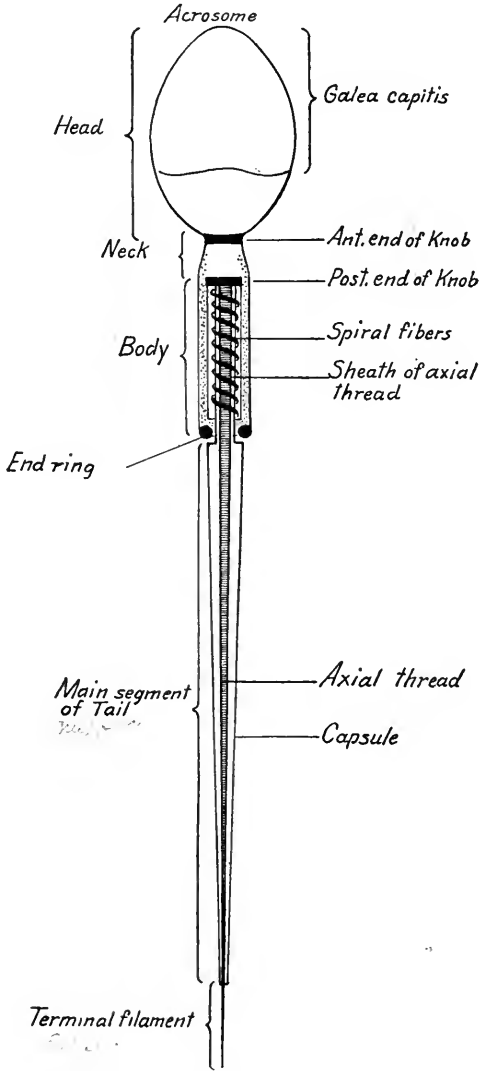


FIG. 7.—Diagram of a human spermatozoön, highly magnified, in side view (Meves, Bonnet).

The connecting piece is marked off from the *flagellum* by the *annulus*.



It is traversed by the axial filament (*filum principale*), and surrounded (1) by the sheath common to the *flagellum*; (2) by a sheath containing a *spiral filament*; and (3) by a *mitochondria sheath*. The flagellum is composed of an *axial filament* surrounded by a *cytoplasmic sheath* and the *end-piece* is the naked continuation of the axial filament.

The spermatozoa are motile, being propelled by the movements of the tail. They swim always against a current at the rate of about 25 micra per second, or 1 mm. every forty seconds. This is important, as the outwardly directed currents induced by the ciliary action of the uterine tubes and uterus direct the spermatozoa by the shortest route to the infundibulum. Keibel has found spermatozoa alive three days after the execution of the criminal from whom they were obtained. They have been found motile in the vagina twelve to seventeen days after coitus. They have been kept alive eight days outside the body by artificial means. It is not known for how long a period they may be capable of fertilizing ova but, according to Keibel, this period would be certainly more than a week.

#### MITOSIS AND AMITOSIS

Before the discharged ovum can be fertilized by the male germ cell, it must undergo a process of cell division and reduction of chromosomes known as *maturation*. As the student may not be familiar with the processes of cell division, a brief description may be necessary. (For details of mitosis see text-books of histology and E. B. Wilson's "The Cell".)

**Amitosis.**—Cells may divide directly by the simple fission of their nuclei and cytoplasm. This process is called *amitosis*. Amitosis is said to occur only in moribund cells. It is the type of cell division found in the epithelium of the bladder.

**Mitosis.**—In the reproduction of normally active cells, complicated changes take place in the nucleus. These changes give rise to thread-like structures, hence the process is termed *mitosis* (thread) in distinction to amitosis (no thread). Mitosis is divided for convenience into four phases (Fig. 8).

**Prophase** (Fig. 8, I-III).—1. The centrosome divides and the two minute bodies resulting from the division move apart, ultimately occupying positions at opposite poles of the nucleus.

2. Astral rays appear in the cytoplasm about each centreole. They radiate from it and the threads of the central or achromatic spindle are formed between the two asters, thus constituting the *amphiaster* (Fig. 8, II).

3. The nuclear membrane and nucleolus disappear, the nucleoplasm and cytoplasm becoming continuous.

4. During the above changes the chromatic network of the resting nucleus resolves itself into a skein or spireme, the thread of which soon breaks up into distinct, heavily-staining bodies, the chromosomes. A definite number of chromosomes is always found in the cells of a given species. The chromosomes may be block-shaped, rod-shaped, or bent in the form of a U.

5. The chromosomes arrange themselves in the equatorial plane of the central spindle. If U-shaped the base of each U is directed toward a common center. The *amphiaster* and the *chromosomes* together constitute a *mitotic figure* and at the end of the prophase this is called a *monaster*.

**Metaphase.**—The longitudinal splitting of the chromosomes into exactly similar halves constitutes the *metaphase* (Fig. 8, IV, V). The aim of mitosis is thus accomplished, an accurate division of the chromatin between the nuclei of the daughter cells.

**Anaphase.**—At this stage the two groups of daughter chromosomes separate and move *up* along the central spindle fibers, each toward one of the two asters. Hence this is called the *diaster* stage (Fig. 8, VI). At this stage, the centrioles may each divide in preparation for the next division of the daughter cells.

**Telophase** (Fig. 8, VII, VIII).—I. The daughter chromosomes resolve them-

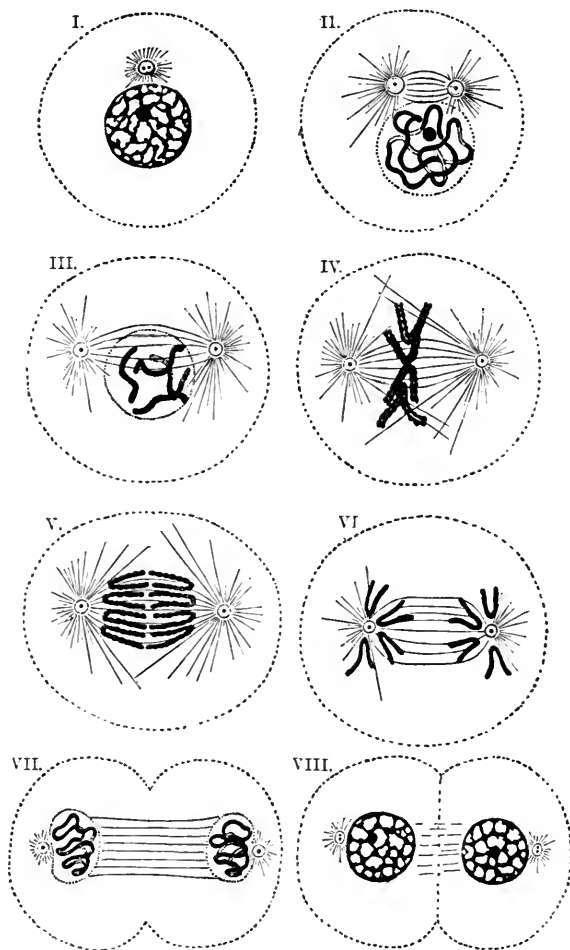


FIG. 8.—Diagram of the phases of mitosis (Schäfer).

selves into a reticulum and daughter nuclei are formed. 2. The cytoplasm divides in a plane perpendicular to the axis of the mitotic spindle. Two complete daughter cells have thus arisen from the mother cell.

The complicated processes of mitosis, by which cell division is brought about normally, seem to serve the purpose of accurately dividing the chromatic substance of the nucleus in such a way that the chromatin of each daughter cell may be the same qualitatively and quantitatively.

This is important if we assume that the chromatic particles of the chromosomes bear the hereditary qualities of the cell. The number of chromosomes is constant in the sexual cells of a given species. The number for the human cell is in doubt. It has been given as 16, 24, and 32. According to Winiwarter's recent work, the number of chromosomes in each immature ovum or oöcyte is 48, in each spermatogone 47. Wiemann (*Amer. Jour. Anat.*, vol. 14, p. 461) finds the number of chromosomes in various human somatic cells varies from 34 to 38. In species of *Ascaris megalcephala*, a parasitic worm, but two or four chromosomes are found and in their cells the processes of mitosis are most easily observed.

We have seen that reproduction in mammals is dependent upon the union of male and female germ cells. The union of two germinal nuclei (pronuclei) would necessarily double the number of chromosomes in the fertilized ovum and also the number of hereditary qualities which their particles are supposed to bear. This multiplication of hereditary qualities is prevented by the processes of *maturation* which take place in both the ovum and spermatozoön.

#### MATURATION

Maturation may be defined as a process of cell-division during which the number of chromosomes in the germ cells is reduced to one-half the number characteristic for the species.

The *spermatozoa* take their origin in the germinal epithelium of the testis. Their development, or *spermatogenesis*, may be studied in the testis of the rat; their maturation stages in the testis tubes of *Ascaris*. Two types of cells may be recognized in the germinal epithelium of the seminiferous tubules, the sustentacular cells (of Sertoli), and the male germ cells or *spermatogonia* (Fig. 9). The spermatogonia divide, one daughter cell forming what is known as a *primary spermatocyte*. The other daughter cell persists as a spermatogone and, by continued division during the sexual life of the individual, gives rise to other primary spermatocytes. The primary spermatocytes correspond to the ova before maturation. Each contains the number of chromosomes typical for the male of the species. The process of maturation consists in two cell divisions of the primary

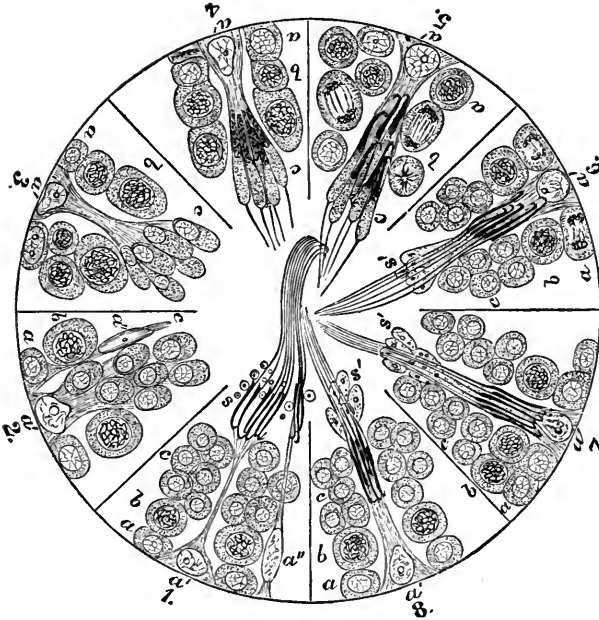


FIG. 9.—Diagram showing cycle of phases in the spermatogenesis of the rat (Schäfer, Brown). The numbered segments of the circle represent portions of different seminiferous tubules. *a*, spermatogonia; *a'*, sustentacular cells; *b*, spermatocytes actively dividing in 5; *c*, spermatids forming an irregular clump in 1, 6, 7 and 8 and connected to sustentacular cell *a'* in 2, 3, 4 and 5. In 6, 7 and 8 advanced spermatozoa of one generation are seen between spermatids of the next generation. *s'*, parts of spermatids which disappear when sperms are fully formed; *s*, seminal granules representing disintegration of *s'*; *a''*, in 1 and 2 are atrophied sustentacular cells.

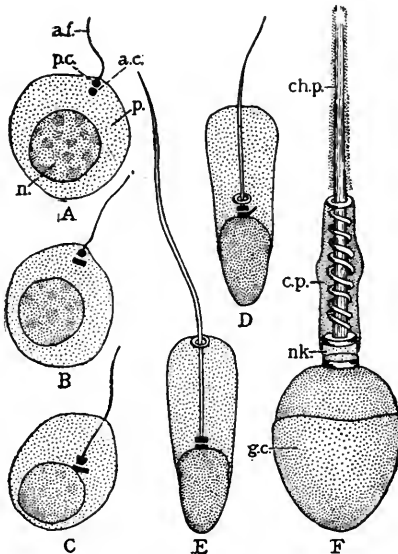


FIG. 10.—Diagrams of the development of spermatozoa (after Meves in Lewis-Stöhr); *a.c.*, anterior centrosome; *a.f.*, axial filament; *c.p.*, connecting piece; *ch.p.*, chief piece; *g.c.*, galea capitis; *n.*, nucleus; *nk.*, neck; *p.*, protoplasm; *p.c.*, posterior centrosome.

spermatocytes, each producing first, two secondary spermatocytes, and these in turn four cells known as *spermatids*. During these cell divisions the number of chromosomes is reduced to half the original number, the spermatids possessing just half as many chromosomes as the spermatogonia. Each spermatid now be-

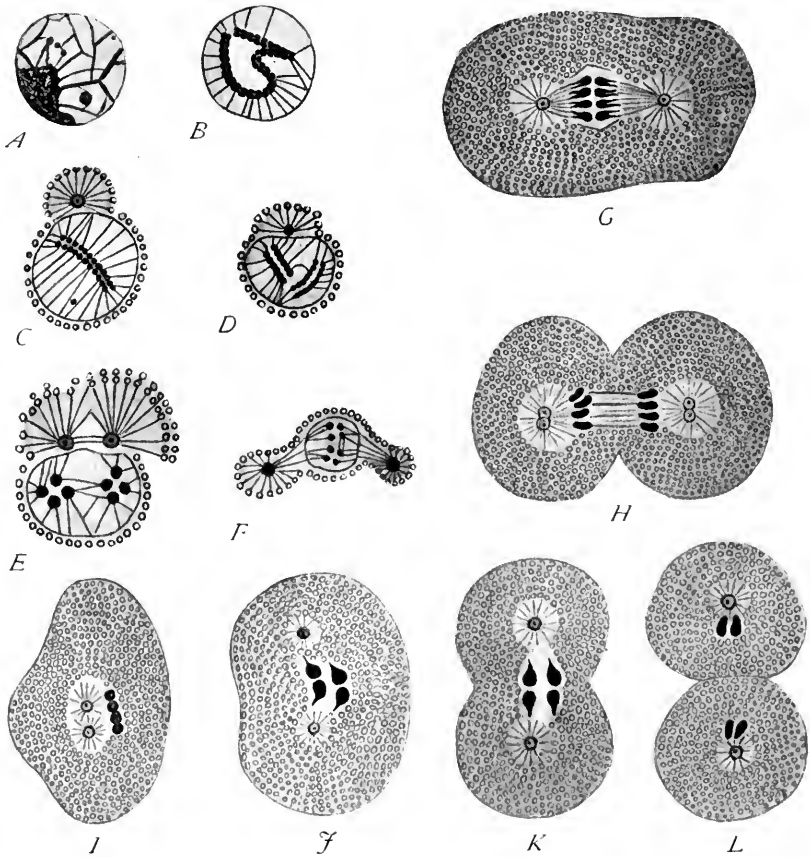


FIG. 11.—Reduction of chromosomes in spermatogenesis in *Ascaris megalocephala* (bivalens) (Brauer, Wilson). A-G, successive stages in the division of the primary spermatocyte. The original reticulum undergoes a very early division of the chromatin granules which then form a doubly split spireme (B). This becomes shorter (C) and then breaks in two to form two tetrads (D) in profile, (E, in end). F, G, H, first division to form two secondary spermatocytes, each receiving two dyads. I, secondary spermatocyte. J, K, the same dividing. L, two resulting spermatids, each containing two single chromosomes.

comes transformed into a mature spermatozoön (Fig. 10), the nucleus forming the larger part of the head, the centrosome dividing and lying in the *neck* or *middle piece*. The posterior centrosome is prolonged to form the axial filament, and the cytoplasm forms the sheaths of the middle piece and tail.

The way in which the number of chromosomes is reduced may be seen in the spermatogenesis of *Ascaris* (Fig. 11). Four chromosomes are typical for *Ascaris megalocephala bivalens* and each resting primary spermatocyte contains this number. When the first maturation spindle appears only two chromosomes are formed, but each of these is double, so four are really present. Each represents the union of two chromosomes, shows a quadruple structure, and is termed a *tetrad* (Fig. 11 E, F). At the metaphase (G) the two tetrads split each into two chromosomes which already show evidence of longitudinal fission and are termed *dyads*. One pair of dyads goes to each of the daughter cells, or secondary sper-

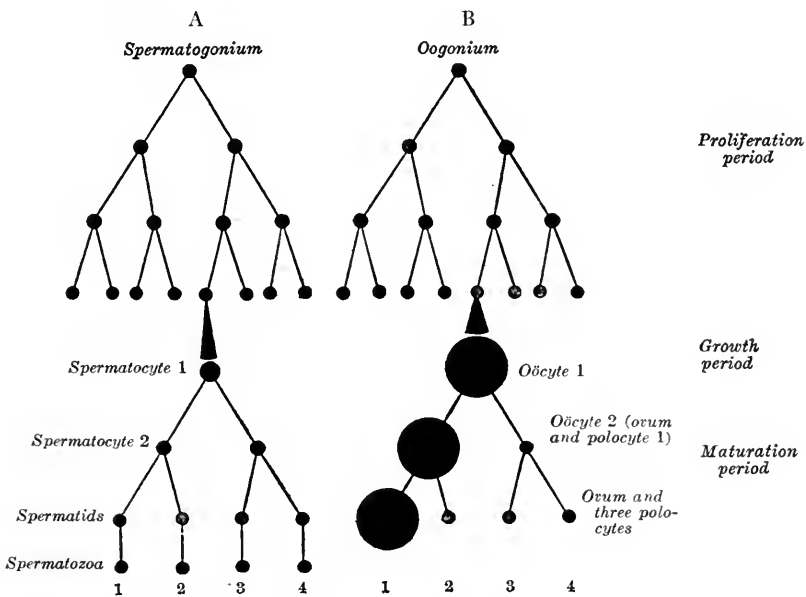


FIG. 12.—Diagrams of maturation, spermatogenesis and oögenesis (Boveri).

matocytes (Fig. 11 G, I). Before the formation of a nuclear membrane, the second maturation spindle appears at once, the two dyads split into four *monads*, and each daughter spermatid receives two single chromosomes, or one-half the number characteristic for the species. A diagram of maturation in the male *Ascaris* is shown in Fig. 12 A. The first maturation division is *reductional*, each daughter nucleus receiving *two complete chromosomes* of the original four, whereas in the second maturation division as in ordinary mitosis, each daughter nucleus receives a half of each of the two chromosomes, these being split lengthwise. In the latter case the division is equational, each daughter nucleus receiving chromosomes bearing similar hereditary qualities. In many insects and some ver-

tebrates it has been shown that the number of chromosomes in the oögonia is even, the number in the spermatogonia odd, and that all the mature ova and half the spermatids contain an extra or *accessory chromosome* (see p. 32).

Previous to fertilization, the *ova* undergo a similar process of maturation. Two cell divisions take place but with this difference, that the cleavage is *unequal* and, instead of four cells of equal size resulting, there are formed one large ripe ovum or *oöcyte* and three rudimentary or abortive ova known as polar bodies or *polocytes*. The number of chromosomes is reduced in the same manner as in the spermatocyte, so that the ripe ovum and each polar body contain one-half the number of chromosomes found in the immature ovum or primary oöcyte. The female germ cells, from which new ova are produced by cell division, are called *oögonia* and their daughter cells after a period of growth within the ovary are the *primary oöcytes*, comparable to the primary spermatocytes of the male. During maturation the ovum and first polocyte are termed secondary oöcytes (comparable to secondary spermatocytes), the mature ovum and second polocyte, with the daughter cells of the first polocyte, are comparable to the spermatids (see diagram B, Fig. 12). Each spermatid, however, may form a mature spermatozoön, but only one of the four daughter cells of the primary oöcyte becomes a mature ovum. The three polocytes are abortive and degenerate eventually, though it has been shown that in the ova of some insects the polar body may be fertilized and segment several times like a normal ovum. The maturation of human ova has not been observed, but such a process probably takes place. The reduction of the chromosomes may be best observed in the ova of *Ascaris* and of insects. The *mouse* offers a favorable opportunity for studying the maturation of a mammalian egg as the ova are easily obtained. Their maturation stages have recently been studied by Mark and Long (Carnegie Inst. Publ. No. 142).

**Maturation of the Mouse Ovum.**—The nucleus of the mature ovum is known as the *female pronucleus*. When the spermatozoön penetrates the mature ovum it loses its tail and its head becomes the *male pronucleus*. The aim and end of *fertilization* consists in the *union of the chromatic elements contained in the male and female pronuclei and the initiation of cell division*. In the mouse, the first polocyte is formed while the ovum is still in the Graafian follicle. In the formation of the maturation spindle no astral rays and no typical centrosomes have been observed. The chromosomes are V-shaped. The first polar body is segmented from the ovum and lies beneath the zona pellucida as a spherical mass about 25 micra in diameter (Fig. 13). Both ovum and polar body (secondary oöcytes) contain 10 or 12 chromosomes, or half the number normal for the mouse.



(According to Mark and Long, the chromosomes number 20.) The first maturation division is the reductional one and the chromosomes take the form of tetrads.

After ovulation has taken place, the ovum lies in the ampulla of the uterine tube. If fertilization takes place, a second polocyte is cut off, the nucleus of the

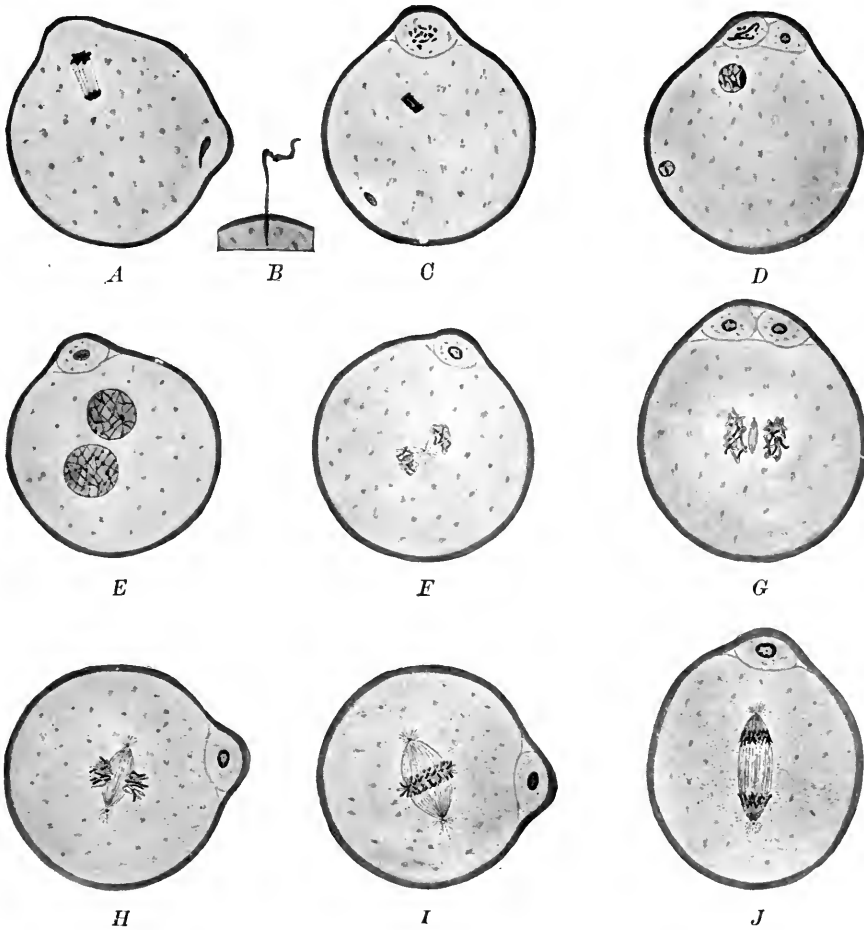


FIG. 13.—Maturation and fertilization of the ovum of the mouse. *A, C-J*,  $\times 500$ ; *B*  $\times 750$ . (after Sobotta). *A-C*, entrance of the spermatozoön and formation of the second polar body. *D-E*, development of the pronuclei. *F-J*, successive stages in the first division of the fertilized ovum.

ovum forming no membrane between the production of the first and second polar bodies (Fig. 13 *A-D*). The second maturation spindle and second polar body are smaller than the first. Immediately after the formation of the second polar body, the chromosomes resolve themselves into a reticulum and the *female pronucleus* is formed (Fig. 13 *D*).

**Fertilization of the Mouse Ovum.**—Normally, a single spermatozoön enters the ovum six to ten hours after coitus. While the second polar body is forming, the spermatozoön penetrates the ovum and loses its tail. Its head is converted into the male pronucleus (Fig. 13 D). The pronuclei, male and female, approach each other and resolve themselves into a spireme stage, then into two groups of 12 chromosomes. A centrosome, possibly that of the male cell, appears between them, divides into two, and soon the first segmentation spindle is formed. The 12 male and 12 female chromosomes arrange themselves in the equatorial plane of the spindle, thus making the original number of 24 (Fig. 13 I). Fertilization is now complete and the ovum divides in the ordinary way. The fundamental results of the process of fertilization are (1) the *union of the male and female chromosomes*, (2) the initiation of cell division or cleavage of the ovum.

These two factors are separate and independent phenomena. It has been shown by Boveri and others that fragments of sea-urchin's ova containing no part of the nucleus may be fertilized by spermatozoa, segment and develop into larvæ. The female chromosomes are thus not essential to the process of segmentation. Loeb, on the other hand, has shown that the ova of invertebrates may be made to segment by chemical and mechanical means without the coöperation of the spermatozoön. It is well known that the ova of certain invertebrates develop normally with or without fertilization (parthenogenesis). These facts show that the union of the male and female pronuclei is not the means of initiating the development of the ova. In all vertebrates it is, nevertheless, the end and aim of fertilization.

Lillie (*Science*, vols. 36 and 38, pp. 527-530 and 524-528) has recently shown that the cortex of sea-urchin's ova produces a substance which he terms *fertilizin*. This substance he regards as an *amboceptor* essential to fertilization with one side chain which agglutinates and attracts the spermatozoa, another side chain which activates the cytoplasm and initiates the segmentation of the ovum.

Spermatozoa may enter the mammalian ovum at any point. If fertilization is delayed and too long a period elapses after ovulation, the ovum may be weakened and allow the entrance of several spermatozoa. This is known as polyspermy.

**The fertilization of the human ovum** has not been observed, but probably takes place in the uterine tube some hours after coitus. Ova may be fertilized and start developing before they enter the uterine tube. If they attach themselves to the peritoneum of the abdominal cavity, they give rise to *abdominal pregnancies*. If the ova develop within the uterine tube *tubular pregnancies* result. Normally, the embryo begins its development in the uterine tube, thence passes into the uterus and becomes embedded in the uterine mucosa. The time required for the passage of the ovum from the uterine tube to the uterus is unknown. It probably varies in different cases and may occupy a week or more. The ovum may in some cases be fertilized within the uterus. Fertilization is favored by the fact that the spermatozoa swim always against a current. As the cilia of the uterus and uterine tube beat downward and outward the sperms are directed upward and inward. They may reach the uterine tubes within two hours of a normal coitus.

Usually but one human ovum is produced and fertilized at coitus. The development of two or more embryos within the uterus may be due to the ripening and expulsion of an equal number of ova at ovulation, these being fertilized later. Identical twins are regarded as arising from the daughter cells of a fertilized ovum, these cells having separated, and each having developed like a normal ovum.

**The Significance of Mitosis, Maturation and Fertilization.**—It is assumed by students of heredity that the chromatic particles of the nucleus bear the hereditary qualities of the cell. During the course of development these particles are probably distributed to the various cells in a definite way by the process of mitosis. The process of fertilization would double the number of hereditary qualities and they would be multiplied indefinitely were it not for maturation. At maturation not only is the number of chromosomes halved, but it is assumed also that the number of hereditary qualities is reduced by half. In the case of the ovum, this takes place at the expense of three potential ova, the polocytes, which degenerate, but is to the advantage of the single mature ovum which retains more than its share of cytoplasm and nutritive yolk.

*Mendel's Law of Heredity.*—Experiments show that all hereditary characters fall into two opposing groups, which alternate with each other and are termed *allelomorphs*. As an example, we may take the hereditary tendencies for black and blue eyes. It is supposed that there are paired chromatic particles in the germ cells which bear these hereditary tendencies. Each pair may be composed of similar particles, both bearing black-eyed tendencies or both blue-eyed tendencies, or opposing particles may bear the one black, the other blue-eyed tendencies. It is assumed that at maturation these paired particles are separated, and that one only of each pair is retained in each germ cell, in order that new and favorable combinations may be formed at fertilization. In our example, either a blue-eyed or a black-eyed tendency bearing particle would be retained. At fertilization the segregated tendency-bearing particles of one sex may enter into new combinations with the *allelomorphs* of the other sex, combinations which may be favorable to the offspring. Three combinations may be possible. If the color of the eyes is taken as the hereditary character, (1) two "black" germ cells may unite; (2) two "blue" germ cells may unite; (3) a "black" germ cell may unite with a "blue" germ cell. The resulting individual will be in (1) black-eyed; in (2) blue-eyed; in (3) either black-eyed or blue-eyed, according to whether one or the other tendency predominated. Were the black-eyed tendency in (3) predominant and the resulting individual black-eyed, there would still be blue-eyed bearing chromatin particles in his or her germ cells. In the next generation these recessive blue-eyed qualities may unite with similar qualities of another black-eyed individual. The offspring would be blue-eyed, though both the parents were black-eyed.

### DETERMINATION OF SEX

The assumption that the chromosomes are the carriers of hereditary tendencies is borne out by the observations of cytologists on the germ cells of insects and some vertebrates. It has been shown that in some forms the nucleus of the spermatogonia contain 23 chromosomes, while those of the oögonia contain 24. When maturation and reduction of the chromosomes take place, half of the spermatids contain 12 chromosomes, the other half only eleven, while all the oöcytes

and polocytes contain 12. There is thus one extra chromosome in each mature ovum and in each of half the spermatozoa. This chromosome is larger than the others in some insects, and is termed the *accessory chromosome*. McClung was the first to assume that the accessory chromosome was a sex determinant. It has since been shown by Wilson, Davis, and others that the accessory chromosome carries the female sexual characters. When the spermatozoan with 12 chromosomes fertilizes an ovum, the resulting embryo is a female, its somatic nuclei containing 24 chromosomes. An ovum fertilized by a sperm cell containing only 11 chromosomes (without the accessory chromosome) produces a male with somatic nuclei containing only 23 chromosomes. Winiwarther (*Arch. d. Biol. Bd.* 27) has recently made similar observations on the human germ cells but they have yet to be confirmed by other investigators. It is probable, however, that sex is transmitted by the human chromosomes in much the same way as in insects.

## CHAPTER II

### SEGMENTATION OF THE FERTILIZED OVUM AND ORIGIN OF THE GERM LAYERS

#### SEGMENTATION

The processes of segmentation, not having been observed in human ova, must be studied in other vertebrates. It is probable that the early development of all vertebrates is, in its essentials, the same. It is modified, however, by the presence in the ovum of large quantities of nutritive yolk. In many vertebrate ova the yolk collects at one end, the vegetal pole. Such ova are said to be *telolecithal*. Examples are the ova of *Amphioxus*, the frog and bird. When very little yolk is present, the ovum is said to be *alecithal* (no yolk). Examples are the ova of the higher mammals and man. The typical processes of cleavage may be studied most easily in the fertilized ova of invertebrates (Echinoderms, Annelids, and Mollusks). Among Chordates, the early processes in development are primitive in a fish-like form *Amphioxus*. The yolk modifies the development of the amphibian and bird's egg, while the early structure of the mammalian embryo can be explained only by assuming that the ova of the higher Mammalia at one time contained a considerable amount of yolk like the ovum of the bird and of the lower mammals.

**Amphioxus.**—The ovum is telolecithal, but contains little yolk (Fig. 14). About one hour after fertilization it divides vertically into two nearly equal daughter cells. The process is known as cell *cleavage*, or *segmentation* and takes place by mitosis. Within the same interval of time the daughter cells cleave in the same plane, forming four cells. Fifteen minutes later a third segmentation takes place in a horizontal plane. As the yolk is more abundant at the vegetal poles of the four cells the spindle lies nearer the animal pole. Consequently in the eight-celled stage the upper tier of four cells is smaller than the lower four. By successive cleavages, first in the vertical, then in the horizontal plane a 16- and 32-celled embryo is formed. The upper two tiers are now smaller and a cavity, the *blastocoel*, is enclosed by the cells. The embryo is called a *morula* (mulberry). In subsequent cleavages, as development proceeds, the size of the cells is diminished while the cavity enlarges (Fig. 14). The embryo is now a *blastula*,

nearly spherical in form and about four hours old. The cleavage of the *Amphioxus* ovum is thus *complete* and somewhat *unequal*.

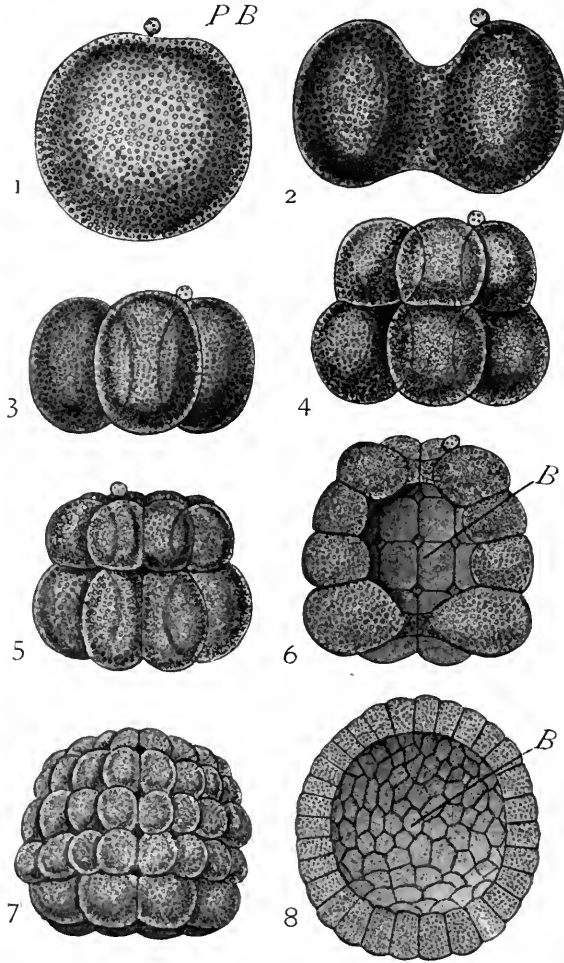


FIG. 14.—Segmentation of the egg of *Amphioxus*,  $\times 220$  (after Hatschek). 1. The egg before the commencement of development; only one polar body, *P.B.*, has been seen, but from analogy with other animals it is probable that there are really two present. 2. The ovum in the act of dividing, by a vertical cleft, into two equal blastomeres. 3. Stage with four equal blastomeres. 4. Stage with eight blastomeres; an upper tier of four slightly smaller ones and a lower tier of four slightly larger ones. 5. Stage with sixteen blastomeres in two tiers, each of eight. 6. Stage with thirty-two blastomeres, in four tiers, each of eight; the embryo is represented bisected to show the segmentation cavity or blastocoel, *B*. 7. Later stage: the blastomeres have increased in number by further division. 8. Blastula stage bisected to show the blastocoel, *B*.

**The Ovum of the Frog.**—The ovum contains so much yolk that the nucleus and most of the cytoplasm lies at the upper or animal pole. The first cleavage spindle lies in this cytoplasm. The first two cleavage planes are vertical and the four resulting cells are nearly equal

(Fig. 15). The spindles for the third cleavage are located near the animal pole and the cleavage takes place in a horizontal plane. As a result, the upper four cells are much smaller than the lower four. The large yolk-laden cells divide more slowly than the upper small cells. At the blastula stage, the cavity is small, and the cells of the vegetal pole are each many times larger than those at the animal pole. The cleavage of the frog's ovum is thus *complete* but *unequal*.

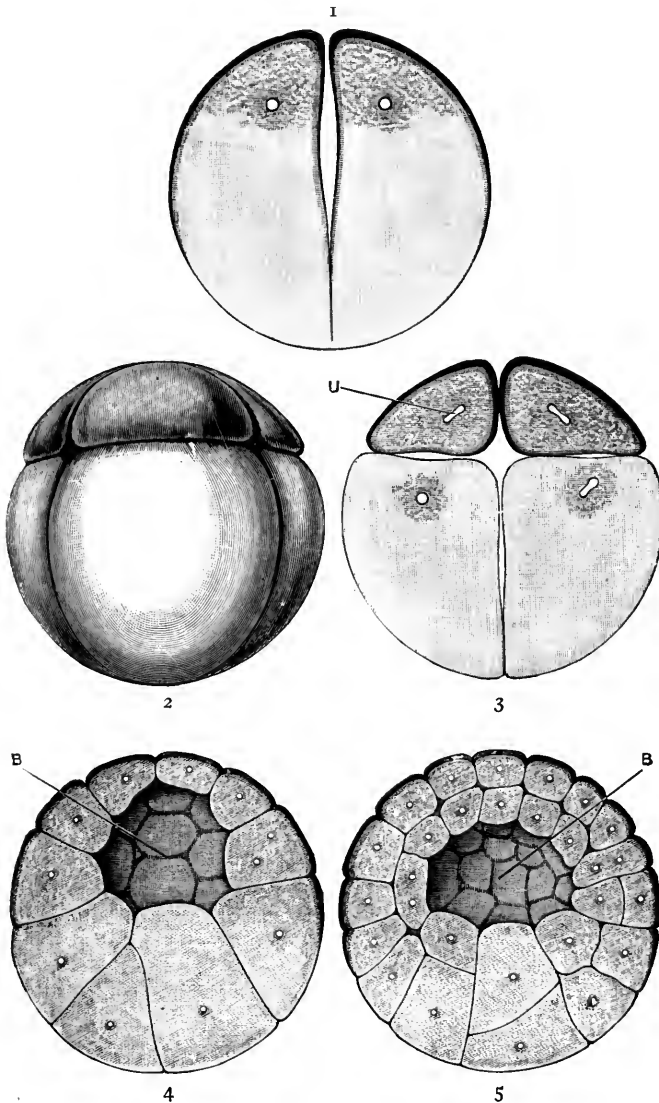


FIG. 15.—Segmentation of the frog's ovum (Hatschek in Marshall). *B*, segmentation cavity; *U*, nucleus.

**Ova of Reptiles and Birds.**—The ova of these vertebrates contain a large amount of yolk. There is very little pure cytoplasm except at the animal pole

and here the nucleus is located (Fig. 2). When segmentation begins, the first cleavage plane is vertical but the yolk, being lifeless matter, does not cleave. The segmentation is thus *incomplete* or *meroblastic*. In the hen's ovum the cytoplasm is divided by successive vertical furrows into a mosaic of cells which, as it increases in size, forms a cap-like structure upon the surface of the yolk. These cells are separated from the yolk beneath by horizontal cleavage furrows, and successive horizontal cleavages give rise to several layers of cells. The space between cells and yolk mass may be compared to the blastula cavity of *Amphioxus* and the frog (Fig. 17). The cellular disc or cap is termed the *germinal area* or disc. The yolk mass which forms the floor of the blastula cavity and the greater part of the ovum may be compared to the large yolk-laden cells at the vegetal pole of the frog's blastula. The yolk mass never divides, but is gradually used up in supplying nutriment to the embryo which is developed from the cells of the germinal area. Round the periphery of the germinal area new cells constantly form until they surround the yolk.

**The Ovum of the Rabbit.**—The ovum of all the higher mammals, like that of man, is microscopic in size and nearly alecithal (no yolk). Its segmentation has been studied in several mammals but we shall take the rabbit's ovum as an example. The cleavage is complete and nearly equal (Fig. 16), a cluster of nearly equal cells being formed within the zona pellucida. This corresponds to the morula stage of *Amphioxus*. Next an *inner mass of cells* is formed which corresponds to the *germinal area*, or *blastoderm*, of the chick embryo (Fig. 16). The inner cell mass is overgrown by an outer layer which we term the *troph-ectoderm* because, in mammals, it supplies nutriment to the embryo from the uterine wall. Between the outer layer and the inner cell mass fluid next appears, separating them except at the animal pole. As the fluid increases in amount, a hollow vesicle results, its wall composed of the single-layered troph-ectoderm except where this is in contact with the inner cell mass. This stage is known as the *germinal* or *blastodermic vesicle*. It is usually spherical or ovoid in form, as in the rabbit, and probably this is the form of the human ovum at this stage. In the rabbit it is of macroscopic size before it becomes embedded. Among Ungulates (hoofed animals) the vesicle is greatly elongated and attains a length of several centimeters, as in the pig.

If we compare the mammalian blastodermic vesicle with the blastula stages of *Amphioxus*, the frog and the bird, it will be seen that it is to be homologized with the bird's blastula, not with that of *Amphioxus* (Fig. 17). In each case there is an inner cell mass of the germinal area. The troph-ectoderm of the



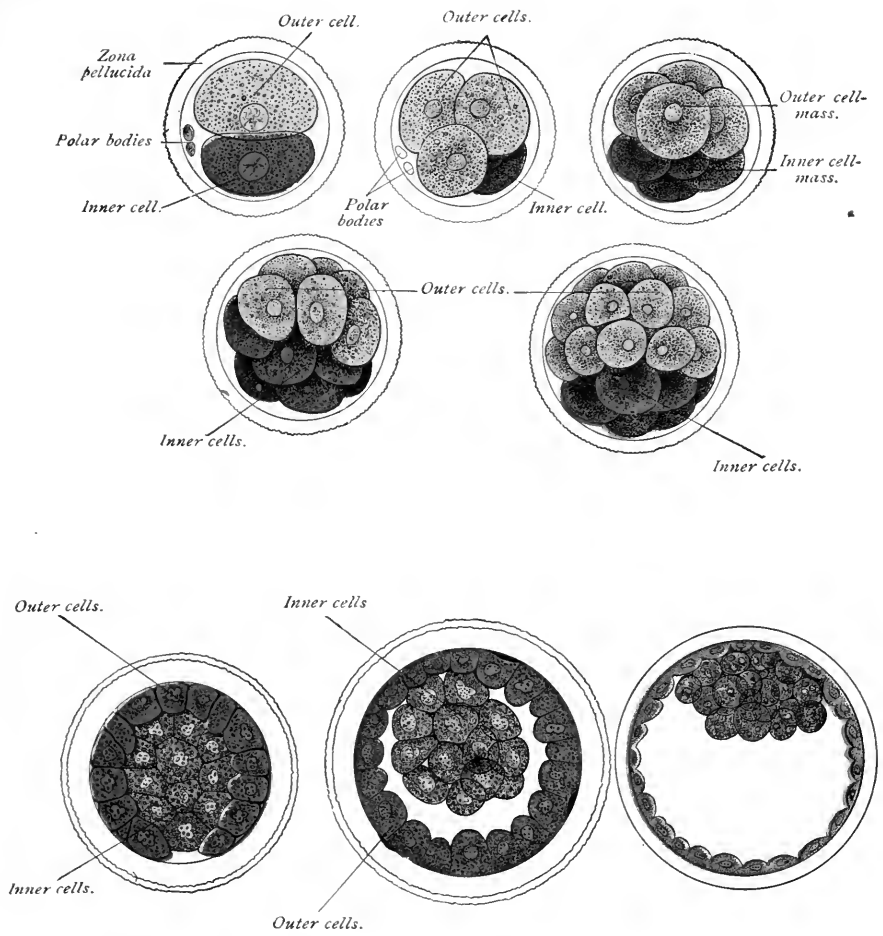


FIG. 16.—Diagrams showing the segmentation of the mammalian ovum and the formation of the blastodermic vesicle (Allan Thomson, after van Beneden).



mammal represents a precocious development of cells which, in the bird, later envelop the yolk. The cavity of the vesicle is to be compared, not with the blastula cavity of *Amphioxus* and the frog but with the *yolk mass plus the rudimentary blastocoel of the bird's ovum*. The mammalian ovum, although almost devoid of yolk, thus develops much like the yolk-laden ova of reptiles and birds. Its segmentation, however, is complete and the early stages in its development are abbreviated.

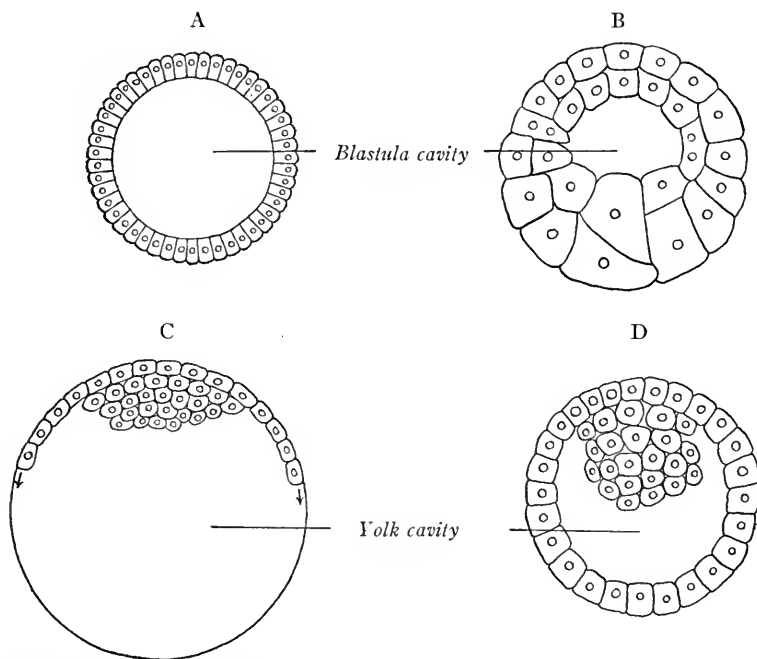


FIG. 17.—Diagrams showing the blastula: *A*, of *Amphioxus*; *B*, of frog, and *C* of chick; *D*, blastodermic vesicle of mammal.

In Primates, but one stage in segmentation has been observed. This, a four-celled ovum of *Macacus nemestrinus* figured by Selenka, shows the cells nearly equal and oval in form. This ovum was found in the oviduct of the monkey and shows that, in Primates and probably in man, segmentation as in other mammals takes place normally in the oviducts.

#### THE FORMATION OF THE ECTODERM AND ENTODERM

The blastula and early blastodermic vesicle show no differentiation into layers. Such differentiation takes place later in all vertebrate embryos and the three *primary germ layers*, *ectoderm*, *entoderm* and *mesoderm*, are formed. From these three layers all of the body tissues and organs are derived.

**Gastrulation.**—In the case of *Amphioxus* and amphibia the entoderm is

formed by a process termed *gastrulation*. The larger cells at the vegetal pole of the blastula either fold inward (invaginate) or are overgrown by the more rapidly dividing micromeres. Eventually the invaginating cells obliterate the blastula cavity and come into contact with the outer layer of cells (Fig. 18). The new cavity formed is the primitive gut, or *archenteron*. The mouth of this cavity is the *blastopore*. The outer layer of cells is the ectoderm, the inner, newly formed layer is the entoderm. The entodermal cells are henceforth concerned in the nutrition and metabolism of the body. The embryo is now termed a *Gastrula* (little stomach).

**The Origin of the Entoderm in Reptilia, Birds and Mammals.**—Here the entoderm arises in quite a different manner. Instead of a process of gastrulation by invagination of cells we have first a process of *delamination*. Cells are split off or delaminated from the under side of the germinal area, arrange themselves in a definite inner layer, and thus the *yolk entoderm* is formed. This layer is already apparent in a longitudinal section through the germinal area of a chick (Fig. 19). In mammals like the

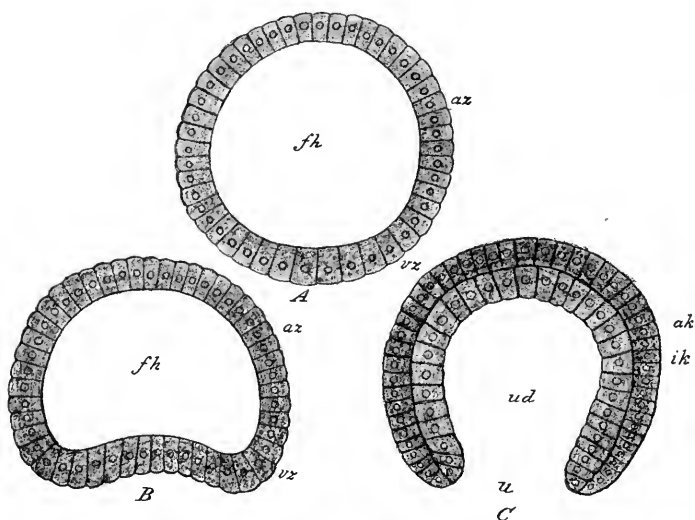


FIG. 18.—Gastrulation of amphioxus (modified from Hatschek). *A*, Blastula; *az*, animal cells; *vx*, vegetative cells; *fh*, cleavage-cavity. *B*, Beginning invagination of vegetative pole. *C*, Gastrula stage, the invagination of the vegetative cells being complete; *ak*, outer germ-layer; *ik*, inner germ-layer; *ud*, archenteron; *u*, blastopore (Heisler).

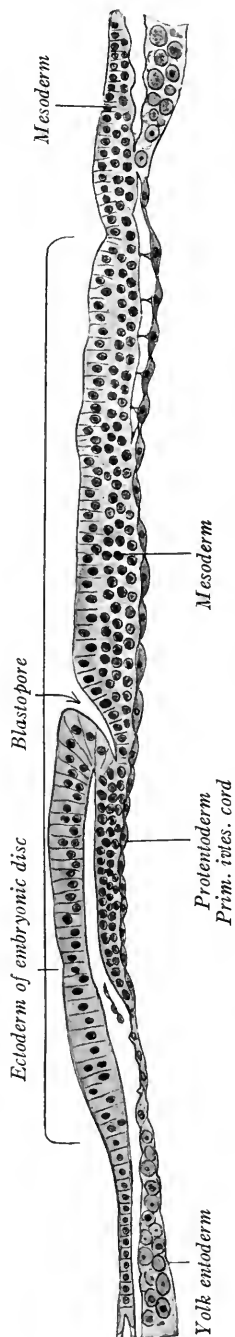


FIG. 19.—Formation of the primary entoderm in the chick embryo (after Bonnet).

rabbit, the entoderm is split from the under side of the germinal area and the cells soon grow around the inside of the blastodermic vesicle, and form an inner entodermal sac (Fig. 16). In *Tarsius*, a creature classed by Hubrecht

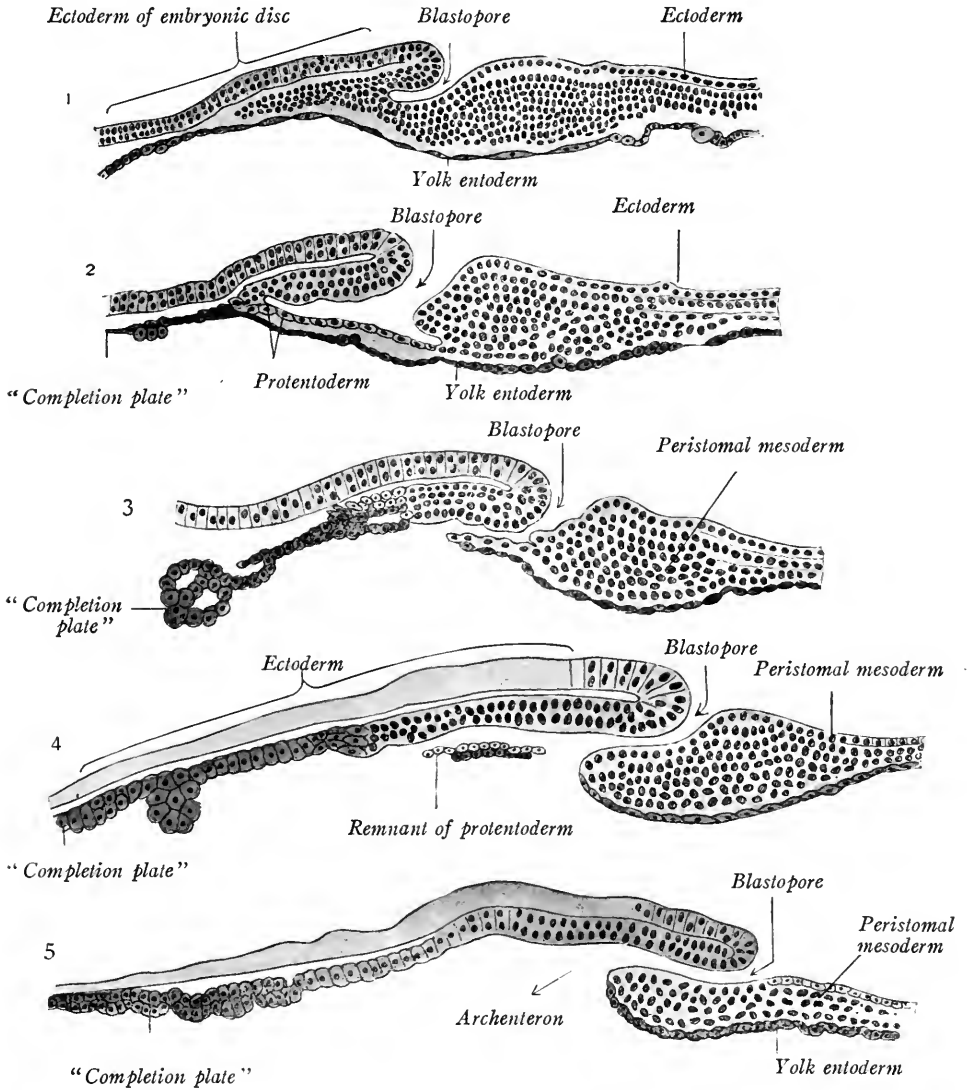


FIG. 20.—From medial vertical sections through embryonic disk of lizard, showing five successive stages in gastrulation (Wenckebach, Bonnet).

with the Primates, the entoderm cells, after splitting off, do not grow around the wall of the vesicle as in the rabbit, but soon form an entodermal sac separated by a space from the troph-ectoderm layer. Just how the vesicle is

formed is not known. It is attached only to the cells of the germinal area. Although this stage has not been observed in the human embryo it is probable from the structure of the youngest known human embryo that an entodermal

vesicle is formed in much the same way as in *Tarsius*.

**Gastrulation in Reptiles and Birds.**—After the formation of the *primary* or *yolk* entoderm in reptiles and birds, a process of invagination takes place which has been compared to gastrulation in *Amphioxus* and *Amphibia*. In the lizard after the primary entoderm has developed by delamination a curved depression is

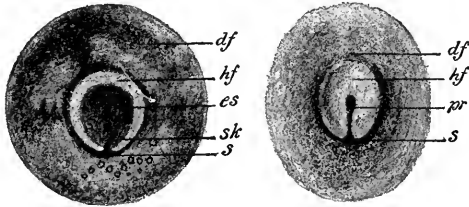


FIG. 21.—Two germ-discs of hen's egg in the first hours of incubation (after Koller in Heisler): *df*, area opaca; *hf*, area pellucida; *s*, crescent; *sk*, crescent-knob; *es*, embryonic shield; *pr*, primitive groove.

formed at the posterior border of the germinal area. There is a true invagination of cells at this point (Fig. 20). The cells grow cephalad and contain an invagination cavity. Later the floor of the cavity fuses with the yolk entoderm and disappears. The cells of the roof persist as the *dorsal or notochordal plate*. The *crescentic depression*, at which point invagination occurs, may be compared to the blastopore of *Amphioxus*. The invagination cavity is the gastrula cavity or archenteron and the dorsal plate represents the entodermal roof of the gastrula cavity.

In the bird, invagination takes place at a *crescentic groove* (Fig. 21), but the ingrowing cells form a solid plate, at first without an invagination cavity. The result is the same, however, the formation of a notochordal plate which lies beneath the ectoderm. The crescentic groove is interpreted as representing the blastopore (Fig. 19).

**Formation of the Primitive Streak in Birds.**—The germinal area increases in size by growth about its periphery, new cells constantly being formed here until eventually the germinal area surrounds the yolk. According to the interpretation of Duval and Hertwig, as the periphery of the germinal area extends itself, a middle point in the cranial lip of the crescentic groove remains fixed while the

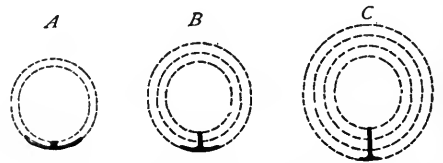


FIG. 22.—Diagram elucidating the formation of the primitive groove (after Duval). The increasing size of the germ-disc in the course of the development is indicated by dotted circular lines. The heavy lines represent the crescentic groove and the primitive groove which arises from it by the fusion of the edges of the crescent (Heisler).

edges of the lip on each side are carried caudad and brought together. Thus the crescent is transformed into a longitudinal slit, as in Fig. 26. The lips of the slit fuse, and the line of fusion is marked by the longitudinal *primitive groove*. This interpretation of the primitive groove and streak, shown in Fig. 22, is known as the *convergence theory*. According to the theory, the crescentic groove of reptiles and birds is homologous with the blastopore of Amphioxus. As it is transformed into the primitive streak and groove, these represent a modified blastopore. According to this view, a large part of the entoderm of birds, reptiles, and mammals is formed by gastrulation, as in Amphioxus.

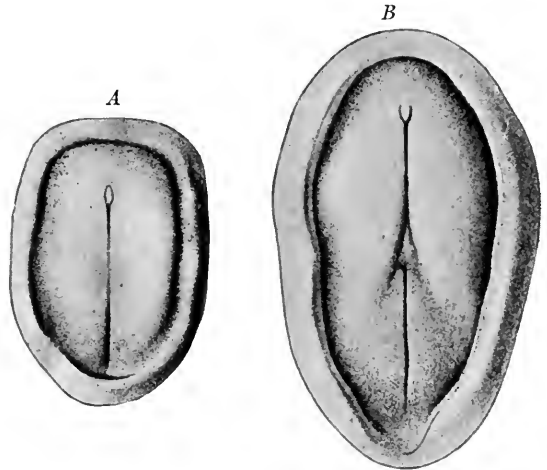


FIG. 23.—The primitive streak of pig embryos (Keibel). *A*, embryo with primitive streak and primitive node; *B*, a later embryo in which the medullary groove is also present, cephalad in position.

**Gastrulation in Mammals.**—As in reptiles and birds so also in mammals, a process resembling gastrulation takes place *but after the formation of the yolk entoderm*. A primitive streak appears at the posterior border of the germinal

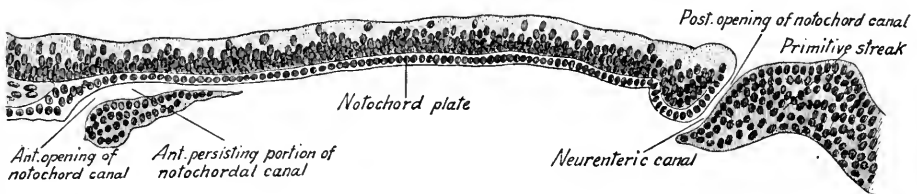


FIG. 24.—Median longitudinal section through the blastoderm of a bat (*Vespertilio murinus*) (after Van Beneden).

area (Fig. 23), with a crescentic opacity corresponding to the crescentic groove of birds. Longitudinal sections (Fig. 24) of the germinal area of the bat show the formation of a dorsal or notochordal plate which has replaced, and is fused laterally with, the yolk entoderm. A blastopore or notochordal canal is present lead-

ing from the dorsal surface of the germinal area into the space beneath the entoderm, the archenteron. No gastrulation stage for the human embryo has yet been observed but the primitive streak may be recognized in later stages (Fig. 73 A). There is also evidence of an opening, the notochordal or *neurenteric canal*, leading from the exterior into the cavity of the primitive gut (archenteron).

According to the view of Keibel and Hubrecht, the invagination of cells to form the notochordal plate in reptiles, birds and mammals is a secondary process not to be compared with formation of the entoderm by gastrulation, as in *Amphioxus*. The notochordal plate is not entodermal but ectodermal, and the primitive streak cannot be compared in its entirety to the blastopore of *Amphioxus*.

### THE ORIGIN OF THE MIDDLE GERM LAYER (Mesoderm), NOTOCHORD, AND NEURAL TUBE

**Amphioxus.**—The dorsal plate of entoderm, which forms the roof of the archenteron, gives rise to paired lateral diverticula or cœlomic pouches (Fig. 25). These separate both from the plate of cells in the mid-dorsal line (which form the *notochord*), and from the entoderm of the gut, and become the *primary mesoderm*.

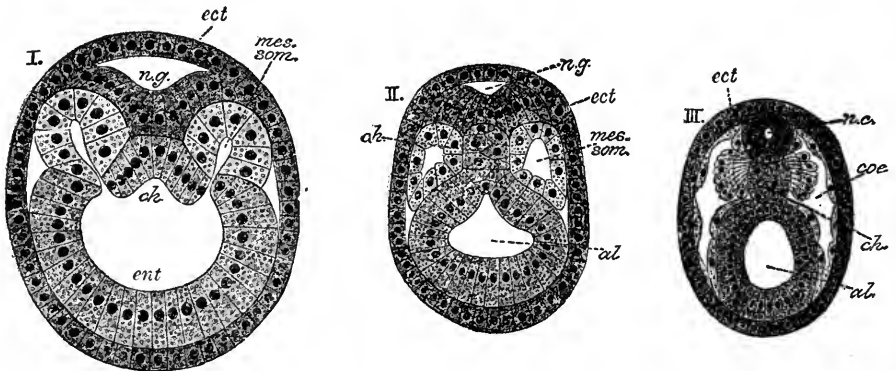


FIG. 25.—Origin of the mesoderm in *Amphioxus* (after Hatschek). *n.g.*, neural groove; *n.c.*, neural canal; *ch.*, anlage of notochord; *mes. som.*, mesodermal segment; *ect.*, ectoderm; *ent.*, entoderm; *al.*, cavity of gut; *coe.*, cœlom or body cavity.

The mesodermal pouches grow ventrad and their cavities form the cœlom or body cavity. Their outer walls, with the ectoderm, form the body wall or *somatopleure*; their inner walls with the gut entoderm, form the intestinal wall (*splanchnopleure*). In the meantime, a dorsal plate of cells cut off from the ectoderm has formed the neural tube (anlage of central nervous system), and the notochordal plate has become a cord or cylinder of cells extending the length of the embryo (axial skeleton). In this simple fashion the ground plan of the



chordate body is developed. In *Amphibia* from the dorsal plate of entoderm the mesodermal diverticula grow out as solid plates between ectoderm and entoderm. Later, these plates split into two layers and the cavity so formed gives rise to the coelom.

**Origin of the Mesoderm in Chick Embryos.—**

If we examine a chick embryo of twenty hours' incubation (Fig. 26), it will be seen that the primitive streak is formed as a linear opacity near the posterior border of the germinal area.

Over a somewhat pear-shaped clear area the yolk has been dissolved away from the overlying entoderm. This area, from its appearance, is termed the *area pellucida*.

It is surrounded by the darker and more granular *area opaca*. Whether or not the primitive streak represents the fused lips of the blastopore, it is certain that it represents the point of origin for the middle germ layer. It also indicates the future longitudinal axis of the embryo. Proliferation of cells takes place here between ectoderm and entoderm and there grows out laterally and caudally between these layers a solid plate of mesoderm, as in amphibia. The shaded area in Fig. 26 shows the extent of the mesoderm. It extends at first more rapidly caudad to the primitive streak, at the cranial end of which

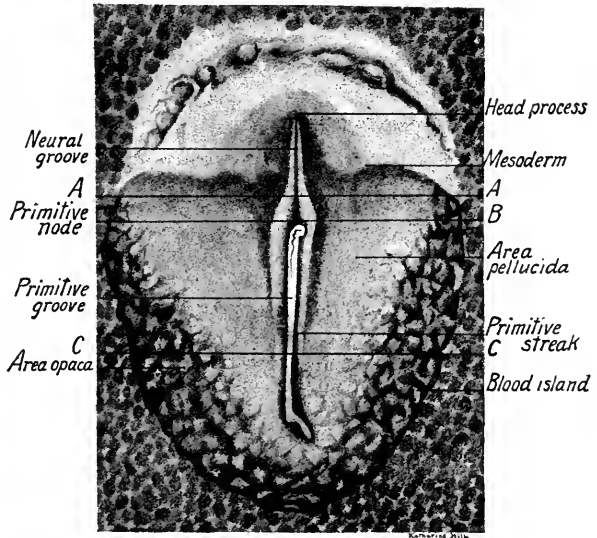


FIG. 26.—Dorsal surface view of a twenty-hour chick embryo showing primitive streak and extent of mesoderm (after Duval). The lines A, B, and C indicate the levels of the corresponding sections shown in Fig. 28.

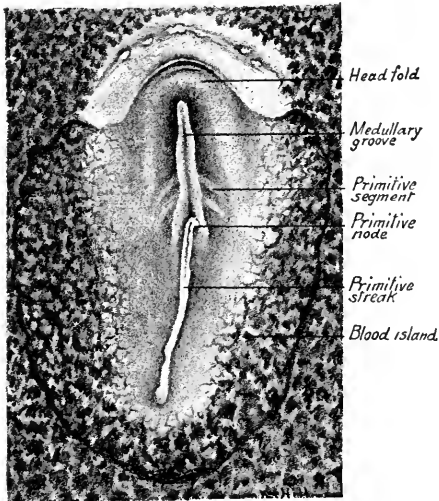


FIG. 27.—Surface view of a twenty-one-hour chick embryo, in which the head-fold and first pair of primitive mesodermal segments are present (after Duval).

appears a shaded thickening, the *primitive knot or node* (Hensen's). From this point it grows cranially, forming along the midline a thicker layer of tissue, the *notochordal plate or head process* (Fig. 26). At twenty-five hours (Fig. 31), the mesoderm forms lateral wings which extend cephalad beyond the limits of the *area pellucida*. The space between these wings is the *proamniotic area*. A transverse section through the primitive streak at twenty hours (see guide line C, Fig. 26) shows the three germ layers distinct

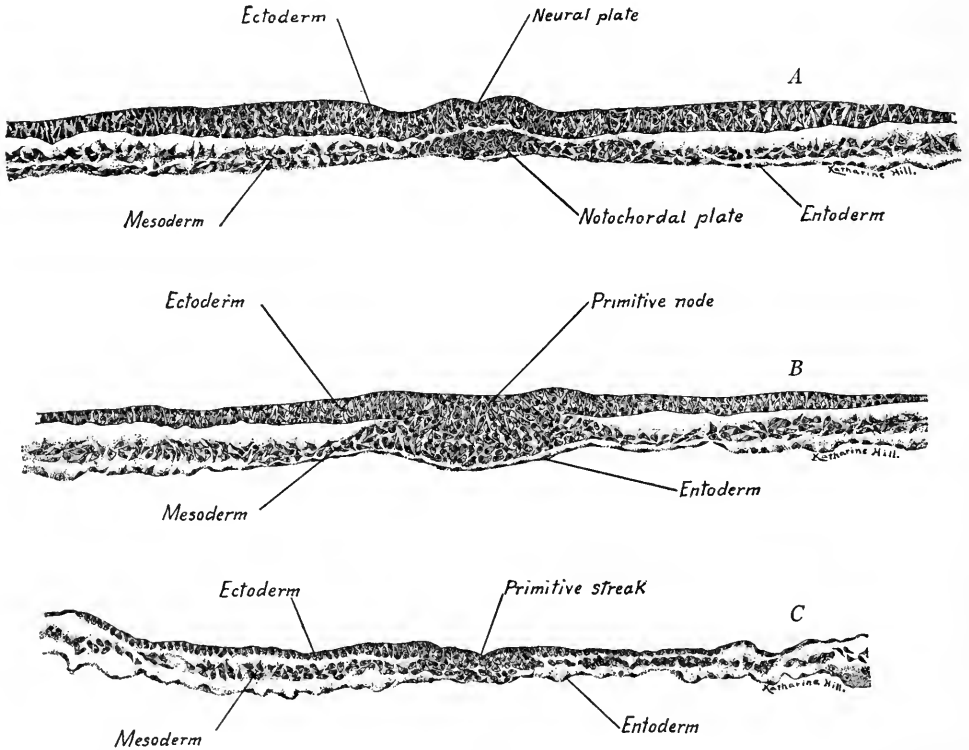


FIG. 28.—Transverse sections through the embryonic area of a twenty-hour chick. A, through the head process; B, through the primitive node; C, through the primitive streak.  $\times 165$ .

laterally (Fig. 28 C). In the midline, a depression in the ectoderm is the *primitive groove*. In this region there is no line of demarcation between ectoderm and mesoderm. A transverse section through the primitive node (Fig. 28 B, guide line B, Fig. 26) shows in this region the marked proliferation of cells, which are growing cephalad to form the *notochordal plate* (head process).

A transverse section through the *notochordal plate* just beginning to form at this stage (Fig. 28 A, guide line A, Fig. 26) shows the thickening near the midline which will separate from the lateral mesoderm and form the *notochord*.

After the notochordal plate becomes prominent at twenty hours the differentiation of the germinal area is rapid. A curved fold, involving the three layers of the germinal area, is formed cephalad to the notochordal process. This is the head-fold and is the anlage of the head of the embryo (Fig. 27). The ectoderm has thickened on each side of the mid-dorsal line, forming the *neural folds*. The groove between these is the *neural groove*. The closure of this groove will form the *neural tube*, the anlage of the central nervous system. The notochord is now differentiated from the mesoderm and may be seen in the mid-dorsal line through the ectoderm. In the mesoderm lateral to the notochord and cephalad to the primitive node, transverse furrows have differentiated a pair of *mesodermal segments*. As development proceeds these increase in number, successive pairs being developed caudally. They will be described in detail later.

To sum up, in the chick the mesoderm appears with the formation of the primitive streak. It originates from the primitive streak and node and spreads in all directions between the other germ layers as an undivided plate of cells. It grows cephalad in the midline as the notochordal process or plate from which the notochord is developed.

As the mesoderm is derived from the entoderm in *Amphioxus*, its origin is generally regarded as entodermal in birds and mammals. This would certainly be the case if we interpret the notochordal process and entoderm as formed by a process of gastrulation. Keibel (in Keibel and Mall, vol. I), however, holds that the mesoderm and notochordal plate are derived from the ectoderm, and that any relation which they bear to the entoderm is of secondary origin.

**The Origin of the Mesoderm in Mammals.**—As we have seen, the primitive streak is formed on the surface of the germinal area in mammalian embryos as in the chick. It has been described as due to a keel-like thickening of the ectoderm, and the knob-like mass of cells at its cephalic end, the primitive node, is the first to appear. The mesoderm is formed precisely as in the chick, growing out in all directions from the primitive streak and node between the other two layers. Its extent in rabbit embryos is shown in Fig. 29 A and B. Cranial to the primitive node the notochord is differentiated in the midline, the mesoderm being divided into two wings. The mesoderm rapidly grows round the wall of the blastodermic vesicle until it finally surrounds it and the two wings fuse ventrally (Fig. 30 A and B). The single sheet of mesoderm soon splits into two, the cavity between being the *calom* or *body cavity*. The outer mesodermal layer (somatic), with the ectoderm, forms the somatopleure or body wall, the inner splanchnic layer, with the entoderm, forms the intestinal wall or *splanchnopleure*. The neural tube having in the meantime been formed from the neural folds of the

ectoderm, we have the ground plan of the vertebrate body, the same in man as in *Amphioxus*.

The origin of the mesoderm in the human embryo is unknown, but in *Tarsius* it has two sources. (1) The primary mesoderm derived by delamination from the

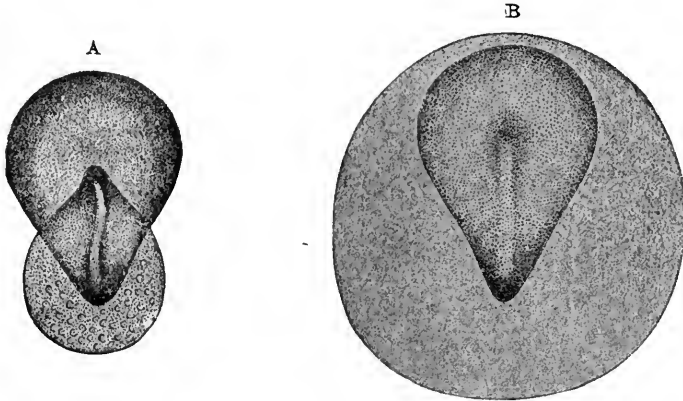


FIG. 29.—Diagrams showing the extent of the mesoderm in rabbit embryos (Kölliker). In *A* the mesoderm is represented by the pear-shaped area at the caudal end of the embryonic area; in *B* by the circular area which surrounds the embryonic area.

ectoderm at the caudal edge of the germinal area. This forms the *extra-embryonic* mesoderm and takes no part in forming the body of the embryo. (2) The secondary or *intraembryonic mesoderm*, which gives rise to body tissues, takes

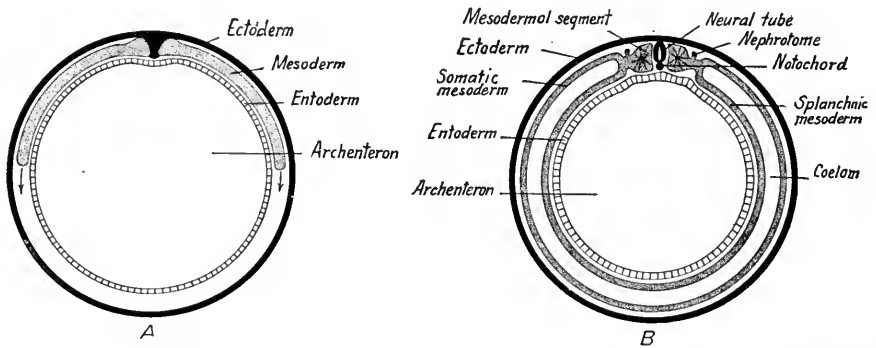


FIG. 30.—Diagrams showing the origin of the germ layers of mammals as seen in transverse section (modified from Bryce).

its origin from the primitive streak and node as in the chick and lower mammals. The origin of the mesoderm in human embryos is probably much the same as in *Tarsius*.

**The Notochord.**—In mammals and in man the notochordal plate is described

as taking its origin directly from the entoderm. Keibel points out that this connection of the notochord is only secondary. The notochordal process grows cephalad from the primitive node and the tissue from which it is derived is of ectodermal origin, according to Keibel's view. In later stages, the notochord extends in the midline beneath the neural tube from the tail to a dorsal out-pocketing of the oval entoderm known as Seessel's pocket. It becomes enclosed in the centra of the vertebræ and in the base of the cranium, and eventually degenerates. In *Amphioxus*, it forms the only axial skeleton and it is persistent in the axial skeleton of fishes and Amphibia. In man, traces of it are found as pulpy masses in the intervertebral discs.

## CHAPTER III

### THE STUDY OF CHICK EMBRYOS

In the following descriptions we shall use the terms *dorsad* and *ventrad* to indicate "towards the back" or "towards the belly"; *cephalad* and *cranially* to denote "headwards," *caudad* to denote "tailwards," and *laterad* when the location is at the side. As there is no single word in English to express the primitive cellular germ of a structure, the German word *anlage* has been adopted by embryologists and will be used here.

Chick embryos may be studied whole and most of the structures identified up to the end of the second day. The eggs should be opened in normal saline solution at 40° C. With scissors, cut around the germinal area, float the embryo off the yolk and remove the vitelline membrane. Then float the embryo dorsal side up on a glass slide, remove enough of the saline solution to straighten wrinkles, and carefully place over the embryo a circle of tissue paper with opening large enough to leave the germinal area exposed. Add a few drops of fixative (5 per cent. nitric acid gives good fixation) and float embryo into a covered dish. After fixing and hardening, stain in acid Hæmatoxylin (Conklin) or in acid Carmine. Extract surplus stain, clear, and mount on slide supporting cover-slip to prevent crushing the embryo. Acid Hæmatoxylin gives the best results for embryos of the first two days. For a detailed account of embryological technique see Lee's "Microtomist's Vade Mecum."

#### EMBRYO OF SEVEN SEGMENTS (TWENTY-FIVE HOURS' INCUBATION)

In this embryo (Fig. 31) there is a prominent network of blood-vessels and blood-cells in the caudal portion of the *area opaca*. In its cranial portion isolated groups of blood and blood-vessel forming cells are seen as *blood-islands*. Together, they constitute the *angioblast* from which arises the blood vascular system. The *area pellucida* has the form of the sole of a shoe with broad toe directed forward. The head-fold has become cylindrical and the head of the embryo is free for a short distance from the germinal area. The mesoderm extends on each side beyond the head leaving a median clear space, the *proamniotic area*. The entoderm is carried forward in the head-fold as the fore-gut, from which later arise the pharynx, esophagus, stomach and a portion of the small intestine. The opening into the fore-gut faces caudad and is the *fovea cardiaca*. The way in which the entoderm is folded up from the germinal disc and forward into the head is seen well in a longitudinal section of an older embryo (Fig. 32). The

tubular heart lies ventral to the fore-gut and cranial to the fovea cardiaca. In later stages it is bent to the right. Converging forward to the heart on each side of the fovea are the vitelline veins just making their appearance at this stage. The lips of the neural folds have met throughout the cranial two-thirds of the embryo but have not fused. The *neural tube* formed thus by the closing of the ectodermal folds is open at either end. Cephalad, the neural tube has begun to

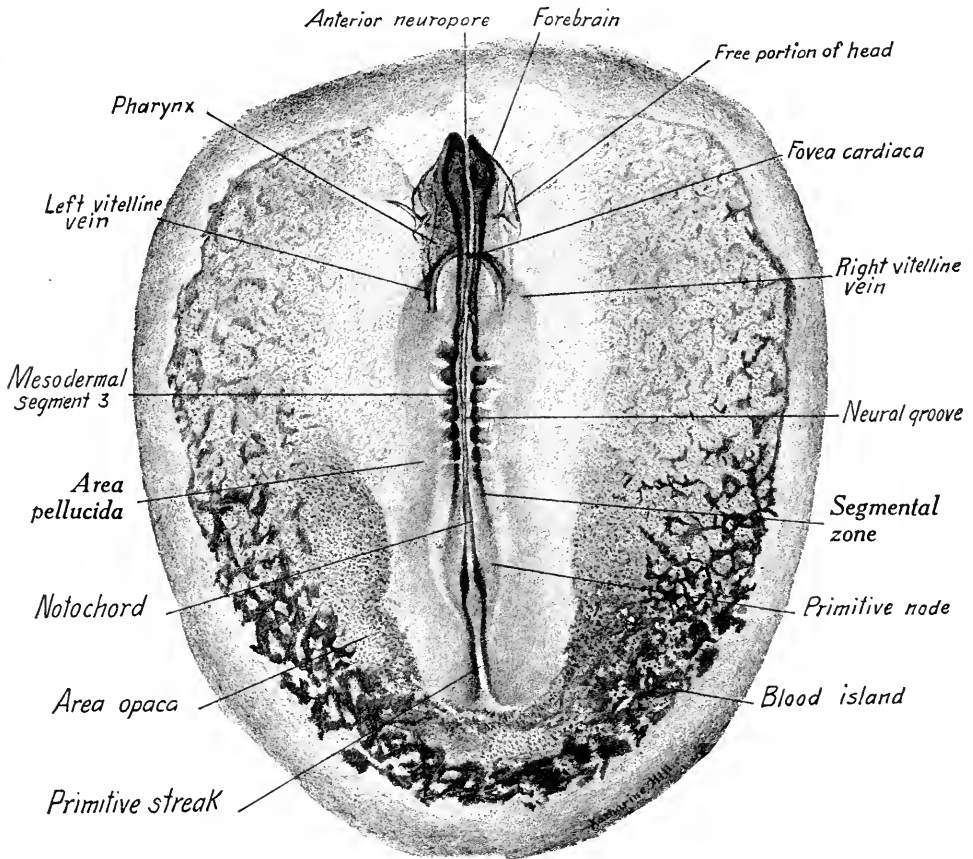


FIG. 31.—Dorsal view of a twenty-five-hour chick embryo with seven primitive segments.  $\times 20$ .

expand to form the brain vesicles. Of these only the fore-brain is prominent, and from it laterally the optic vesicles are budding out. The paraxial mesoderm is divided by transverse furrows into seven pairs of primitive segments. Caudally between the segments and the primitive streak there is undifferentiated mesoderm, but new pairs of segments will develop in this region. Looking through the open neural tube (rhomboidal sinus), one may see in the midline the chorda dorsalis extending from the primitive node cephalad until it is lost beneath the

neural tube in the region of the primitive segments. The primitive streak is still prominent at the posterior end of the area pellucida, forming about one-fourth the length of the embryo. Transverse sections through the primitive streak and open neural groove show approximately the same conditions as in the twenty-hour embryo (Figs. 26 and 28).

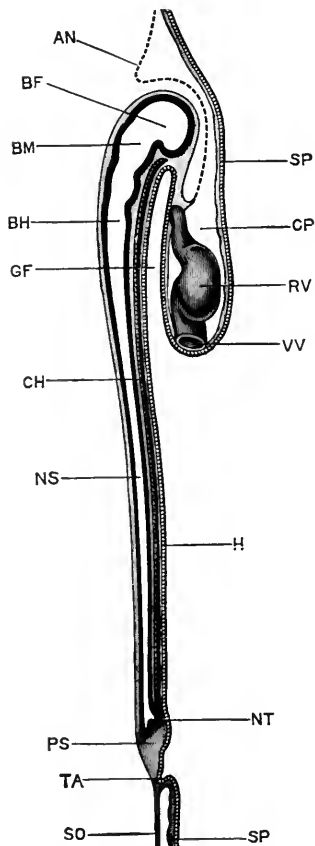


FIG. 32.—Median longitudinal section of a thirty-six-hour chick embryo (Marshall). *AN*, amnion fold; *BF*, fore-brain; *BH*, hind-brain; *BM*, mid-brain; *CH*, notochord; *CP*, pericardial cavity; *GF*, fore-gut; *H*, entoderm; *NS*, spinal cord; *NT*, neurenteric canal; *PS*, primitive streak; *RV*, ventricle of heart; *SO*, somatopleure; *SP*, splanchnopleure; *TA*, allantois.

A Transverse Section through the Fifth Primitive Segment (Fig. 33) is characterized by the differentiation of the mesoderm, the approximation of the neural folds and the presence of two vessels, the descending aortæ on each side between the mesodermal segments and the entoderm. The neural folds are thick and the ectoderm is thickened over the embryo. The notochord is a sharply defined oval mass of cells. The *mesodermal segments* are somewhat triangular in outline and connected by the *intermediate cell mass* with the lateral mesoderm. This is partially divided by irregular flattened spaces into two layers, the dorsal of which is the somatic, the ventral the splanchnic layer of mesoderm. Later, the spaces unite on either side to form the *cœlom* or *primitive body cavity*.

Transverse Section Caudal to the Fovea Cardiaca (Fig. 34).—The section is characterized (1) by the closing together of the neural folds to form the *neural tube*; (2) by the dorsad and laterad folding of the entoderm which, a few sections nearer the head end, forms the fore-gut or pharynx; (3) by the presence of the vitelline veins laterally between the entoderm and mesothelium; (4) by the wide separation of the somatic and splanchnic mesoderm and the consequent increase in the size of the cœlom. In this region, it later surrounds the heart and forms the *pleuro-pericardial cavity*.

The neural tube in this region forms the third brain vesicle or hind-brain. The neural folds have not yet fused. Mesodermal segments do not develop in



this region, instead a diffuse network of mesoderm partly fills the space between ectoderm, entoderm and mesothelium. This is termed *mesenchyma* and will be described later.

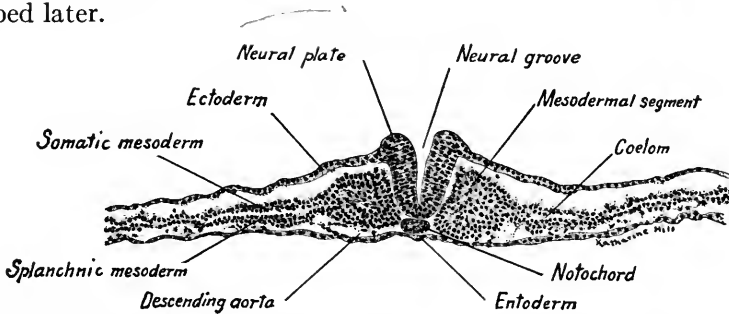


FIG. 33.—Transverse section through the fifth pair of mesodermal segments of a twenty-five-hour chick embryo.  $\times 90$ .

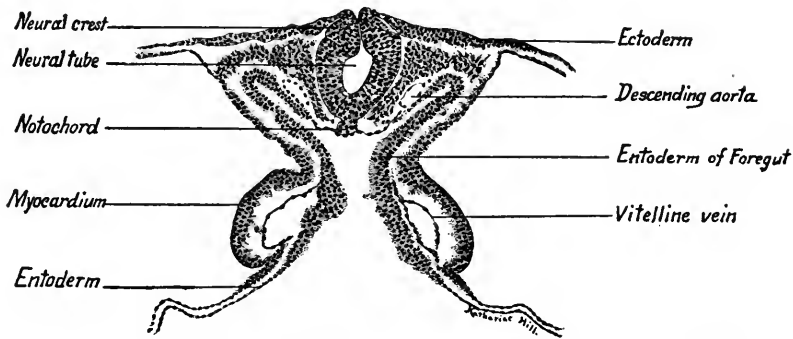


FIG. 34.—Transverse section caudal to the fovea cardiaca of a twenty-five-hour chick embryo.  $\times 90$ .

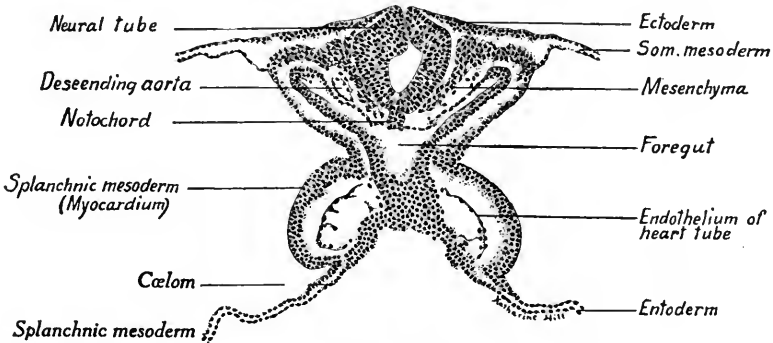


FIG. 35.—Transverse section through the fovea cardiaca of a twenty-five-hour chick embryo.  $\times 90$ .

**Transverse Section through the Fovea Cardiaca (Fig. 35).—**This section is marked by a vertical layer of the entoderm at the point where it is folded into the head as the fore-gut. The entoderm is thickened laterally and forms a continuous mass of tissue between the vitelline veins. The splanchnic mesoderm

is differentiated into a thick walled pouch on each side lateral to the endothelial layer of the veins.

**Transverse Section through the Heart (Fig. 36).**—As we pass cephalad in the series of sections the vitelline veins open into the heart just in front of the *fovea cardiaca*. The entoderm in the head-fold now forms the crescentic *pharynx* or *fore-gut* separated by the heart and splanchnic mesothelium from the entoderm of the germinal disc. The descending aortæ are larger, forming conspicuous spaces between the neural tube (hind-brain) and the pharynx. The heart, as will be seen, is formed by the union of *two endothelial tubes*, similar to those which form the walls of the vitelline veins in the preceding sections. The median walls of these tubes disappear at a slightly later stage to form a single tube. Thick-

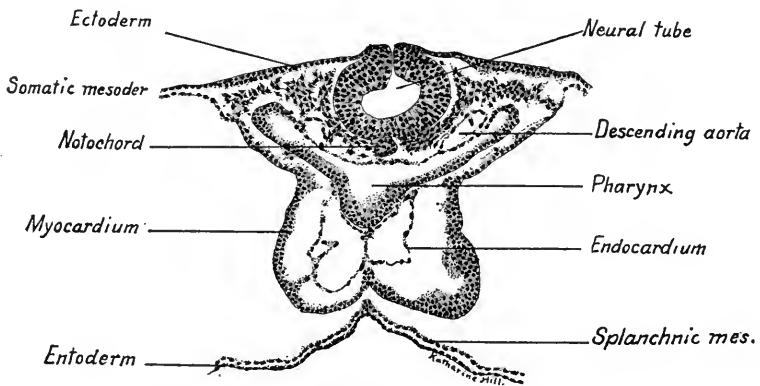


FIG. 36.—Transverse section through the heart of a twenty-five-hour chick embryo.  $\times 90$ .

ened layers of splanchnic mesoderm which, in the preceding section, invested the vitelline veins laterally, now form the mesothelial wall of the heart. In the median ventral line, the layers of splanchnic mesoderm of each side have fused, separated from the splanchnic mesothelium of the germinal disc and thus the two pleuro-pericardial cavities are in communication. The mesothelial wall of the heart forms the *myocardium* and *epicardium* of the adult. Dorsally, the splanchnic mesoderm is continuous with the somatic mesoderm and forms the dorsal mesocardium.

**Origin of Primitive Heart.**—From the two sections just described, it is seen that the heart arises as a pair of endothelial tubes lying in the pockets of the splanchnic mesoderm. Later, the endothelial tubes fuse to form a single tube. The heart then consists of an endothelial tube within a thick-walled tube of mesoderm. The origin of the endothelial cells of the heart is not surely known. They may be split from the entoderm, or arise from the mesoderm. According to another view, the endothelium arises in the vascular area and grows into the body

of the embryo. The vascular system is primitively a paired system, the heart arising as a double tube with two veins entering and two arteries leaving it.

**Origin of the Blood-vessels and Blood.**—We have seen that in the area opaca a network of blood-vessels and blood-islands are differentiated as the *angioblast*. This tissue gives rise to all of the primitive blood-vessels and blood-cells and probably is derived from the splanchnic mesoderm. The vessels arise first as reticular masses of cells, the so-called *blood-islands*. These cellular thickenings undergo differentiation into two cell types, the innermost becoming *blood-cells*, the outermost forming a flattened *endothelial* layer which encloses the blood-cells. All the primitive blood-vessels of the embryo are composed of an *endothelial* layer only. The endothelial cells continue to divide, forming vascular sprouts and in this way new vessels are produced. The first vessels arising in the vascular area of a chick embryo form a close network, some of the branches of which enlarge to form vascular trunks. One pair of such trunks, the vitelline veins, is differentiated opposite, and later connects with, the posterior end of the heart. Another pair, the vitelline arteries, are developed in connection with the aortæ of the embryo. The vessels of the vascular area thus appear before those of the embryo have developed, probably arise from the splanchnic mesoderm, and, both arteries and veins, are composed of a simple endothelial wall. As the cœlom develops in the region of the vascular area of the embryo soon after the differentiation of the angioblast the anlagen of the blood-vessels are formed only in the splanchnic layer. (For the development of the heart and blood-vessels see Chapter IX.)

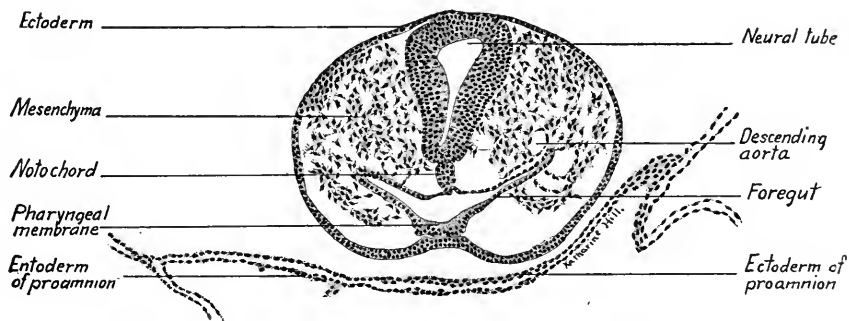


FIG. 37.—Transverse section through the pharyngeal membrane of a twenty-five-hour chick embryo.  $\times 90$ .

**Transverse Section through the Pharyngeal Membrane (Fig. 37).**—This section passes through the head-fold and shows the head free from the underlying germinal area. The ectoderm surrounds the head and near the mid-ventral line is bent dorsad, somewhat thickened, and in contact with the thick entoderm of the pharynx. The area of contact between ectoderm and pharyngeal entoderm forms the *pharyngeal plate* or *membrane*. Later, this membrane breaks through and thus the oral cavity arises. The expanded neural tube is closed in this region and forms the middle brain vesicle or mid-brain. The dorsal aortæ appear as small vessels dorsal to the lateral folds of the pharynx. The germinal area in the region beneath the head is composed of ectoderm and entoderm only. This is the proamniotic area. Laterad may be seen the layers of the mesoderm.

**Transverse Section through the Fore-brain and Optic Vesicle (Fig. 38).—**The neural tube is open here and constitutes the first brain vesicle or fore-brain. The opening is the anterior neuropore. The ectoderm is composed of two or three layers of nuclei and is continuous with the much thicker wall of the fore-brain. The lateral expansions of the fore-brain are the *optic vesicles*, which eventually give rise to the retina of the eye. The two ectodermal layers are in contact

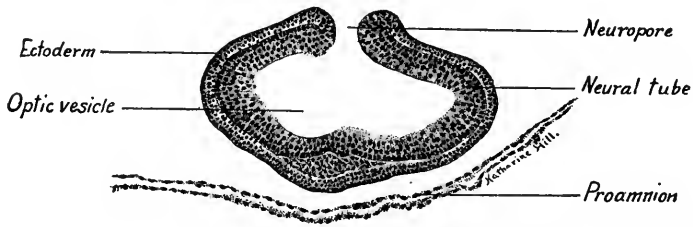


FIG. 38.—Transverse section through the fore-brain and optic vesicles of a twenty-five-hour chick.  $\times 90$ .

with each other except in the mid-ventral region, where the mesenchyma is beginning to penetrate between and separate them. The proamnion consists of a layer of ectoderm and of entoderm.

#### CHICK EMBRYO OF EIGHTEEN PRIMITIVE SEGMENTS (THIRTY-SIX HOURS)

The long axis of this embryo is nearly straight (Fig. 39), the area pellucida is dumb-bell shaped and the vascular network is well differentiated throughout the area opaca. The tubular heart is bent to the right, and opposite its posterior end the vascular network converges and becomes continuous with the trunks of the vitelline veins. Connections have also been formed between the descending aortæ and the vascular area, but as yet the vitelline arteries have not appeared as distinct trunks. The proamniotic area is reduced to a small region in front of the head, which latter is now larger and more prominent. In the posterior third of the vascular area blood-islands are still prominent.

**Central Nervous System and Sense Organs.**—The neural tube is closed save at the caudal end where the open neural folds form the *rhomboidal sinus*. In the head the neural tube is differentiated into the three brain vesicles marked off from each other by constrictions. The *fore-brain* (prosencephalon) is characterized by the outgrowing optic vesicles. The *mid-brain* (mesencephalon) is undifferentiated. The *hind-brain* (rhombencephalon) is elongated and gradually merges caudally with the spinal cord. It shows a number of secondary constrictions, the *neuromeres*. The ectoderm is thickened laterally over the optic ves-

icles to form the *lens placode* of the eye (Fig. 41). The optic vesicle is flattened at this point and will soon invaginate to produce the inner, nervous layer of the retina. In the hind-brain region, dorso-laterally the ectoderm is thickened and invaginated as the *auditory placode* (Fig. 43). This placode later forms the *otocyst* or *otic vesicle* from which is differentiated the epithelium of the *internal ear* (membranous labyrinth).

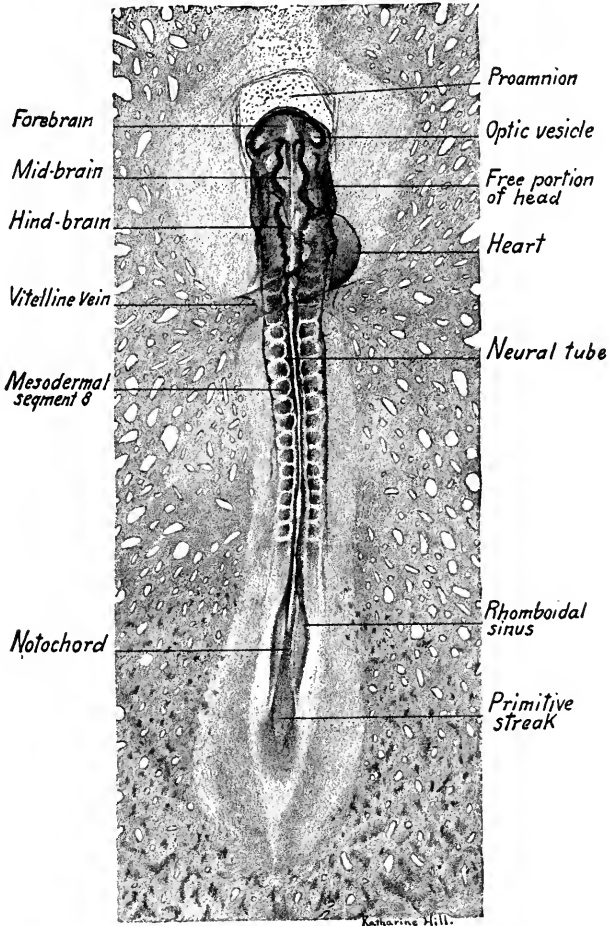


FIG. 39.—View of the dorsal surface of a thirty-six-hour chick embryo.  $\times 20$ .

**Digestive Tube.**—The entoderm is still flattened out over the surface of the yolk caudal to the fovea cardiaca. In Fig. 40 the greater part of the entoderm is cut away. The flattened fore-gut, folded inward at the fovea, shows indications of three lateral diverticula, the pharyngeal pouches. Cephalad the pharynx is closed ventrally by the pharyngeal membrane.

**Heart and Blood-vessels.**—As seen in the dorsal view of the embryo, the heart tube is bent to the right. Viewed from the ventral side, the bend is to the left (right of embryo) (Fig. 40). After receiving the vitelline veins cephalad to the *fovea cardiaca* the double-walled tube of the heart dilates and bends ventrad

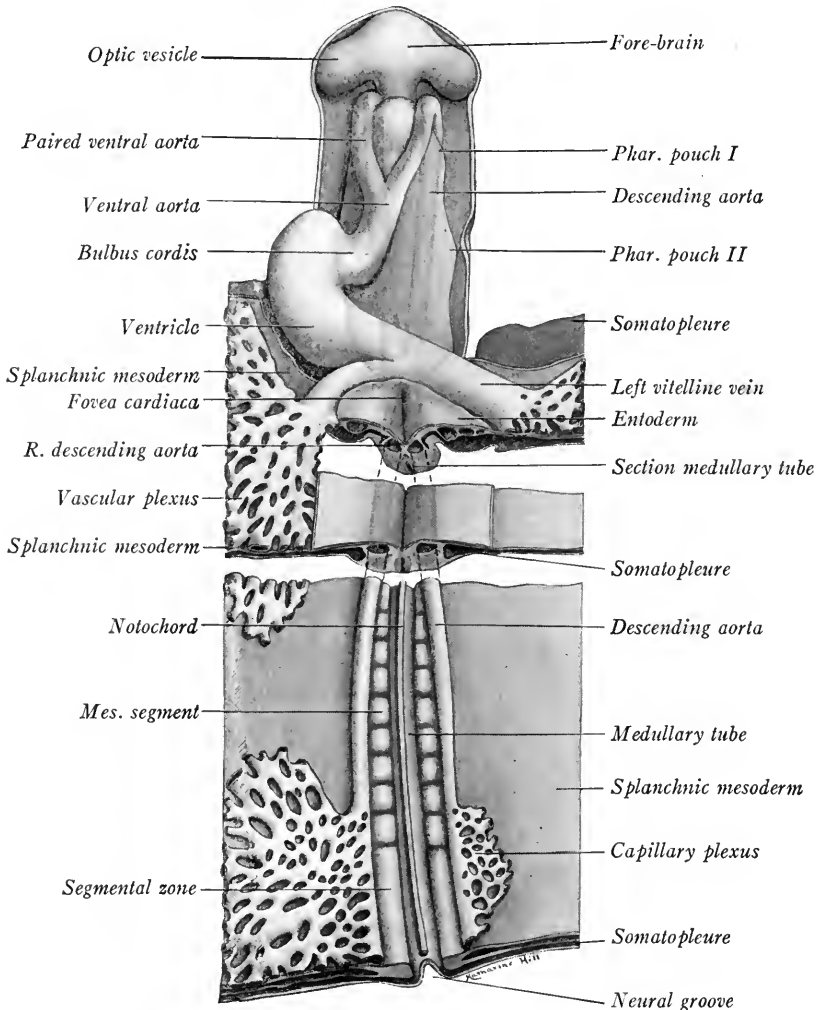


FIG. 40.—Ventral reconstruction of a thirty-six-hour chick embryo. The entoderm has been removed save about and caudal to the fovea cardiaca.  $\times 38$ .

and to the right (left of Fig. 43). It then is flexed dorsad and to the median line, and narrows to form the *ventral aorta*. The aorta lies ventrad to the pharynx and divides at the boundary line between the mid- and hind-brain into two *ventral aortæ*. These diverge and course dorsad around the pharynx. Before

reaching the optic vesicles they bend caudad, and as the paired descending aortæ may be traced to a point opposite the last primitive segments. In the region of the fovea cardiaca they lie close together and have fused to form a single vessel, the *dorsal aorta*. They soon separate and opposite the last primitive segments they are connected by numerous capillaries with the vascular network. In this region at a later stage the trunks of the paired *vitelline arteries* will be differentiated. The heart beats at this stage, the blood flows from the vascular area by way of the vitelline veins to the heart, thence by the aortæ and vitelline arteries back again. This constitutes the *vitelline circulation* and through it the embryo receives nutriment from the yolk for its future development.

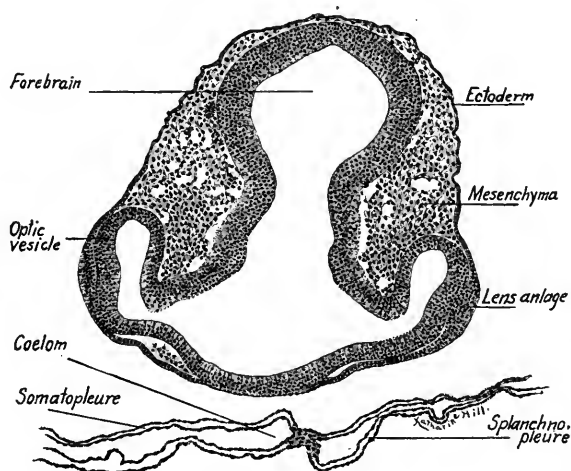


FIG. 41.—Transverse section through the fore-brain of a thirty-six-hour chick embryo.  $\times 75$ .

In studying transverse sections of the embryo the student should not only identify the structures seen, but should locate the level of each section by comparing with Figs. 39 and 40, and trace the organs from section to section in the series.

**Transverse Section through the Fore-brain and Optic Vesicles.** (Fig. 41).—The *optic stalks* connect the *optic vesicles* laterally with the ventral portion of the *fore-brain*. Dorsally the section passes through the *mid-brain*. We have alluded to the thickening of the *lens placode*. Note that there is now a considerable amount of mesenchyma between the ectoderm and the neural tube. In the germinal area the layers of mesoderm are present.

**Transverse Section through the Pharyngeal Membrane and Mid-brain** (Fig. 42).—In the mid-ventral line the thickened ectoderm bends up into contact with the entoderm of the rounded *pharynx*. At this point the *oral opening* will break through. On either side of the pharynx a pair of large vessels are seen; the ventral pair are the *ventral aortæ*. Two sections cephalad their cavities open into those of the dorsal pair, the *descending aortæ*. The section is thus just caudad to the point where the ventral aortæ bend dorsad and caudad to form the descending aortæ. The section passes through the caudal end of the *mesencephalon* which is here thick walled with an oval cavity. Note the large amount of undifferentiated

mesenchyma in the section. The structure of the germinal area is complicated by the presence of collapsed blood-vessels.

**Transverse Section through the Hind-brain and Auditory Placodes (Fig. 43).**—Besides the *auditory placodes* already described as the anlagen of the internal ear, this section is characterized (1) by the large *hind-brain*, somewhat flattened dorsad; (2) by the broad dorso-ventrally flattened *pharynx*, above which on each side lie the *dorsal aortæ*; (3) by the

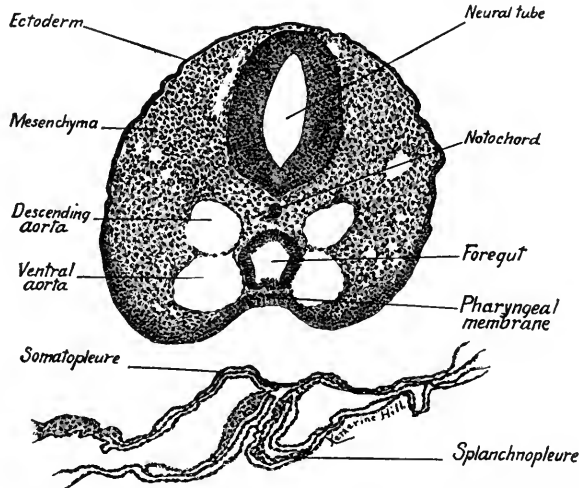


FIG. 42.—Transverse section through the pharyngeal membrane of a thirty-six-hour chick embryo.  $\times 75$ .

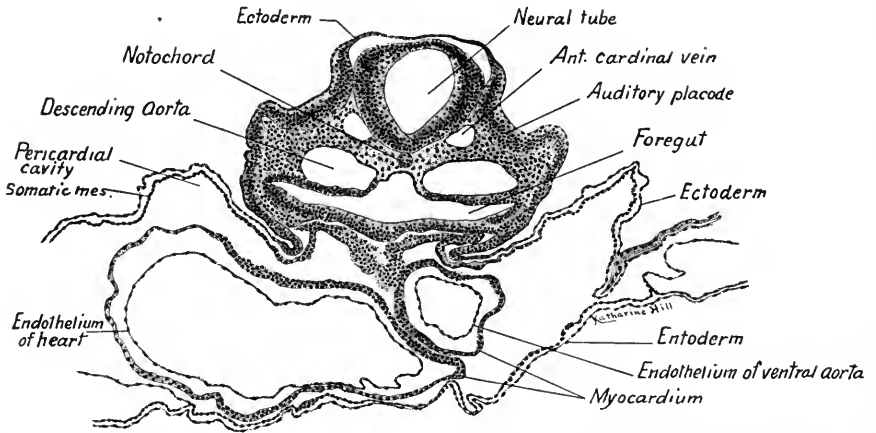


FIG. 43.—Transverse section through the hind-brain and auditory placodes of a thirty-six-hour chick embryo.  $\times 75$ .

presence of the *ventral aorta* and bulbar portion of the heart. The descending aortæ are located on each side dorsal to the pharynx. The ventral aorta is suspended dorsally by the mesoderm, which here forms the dorsal mesocardium. The bulbus of the heart lies to the left in the figure (right of embryo) and a few sections caudad in the series is continuous with the ventral aorta (see Fig. 40). Between the *somatic* and *splanchnic mesoderm* is the large *pericardial cavity*. It surrounds the heart in this section.



**Transverse Section through the Caudal End of the Heart (Fig. 44).**—The section passes through the *hind-brain*. The descending aortæ are separated only by a thin septum which is ruptured in this section. The mesothelial wall of the heart is continuous with the somatic mesoderm. On the right side of the section there is apparent fusion between the *myocardium* of the heart and the *somatic mesoderm*. Lateral to the aortæ are the *anterior cardinal*

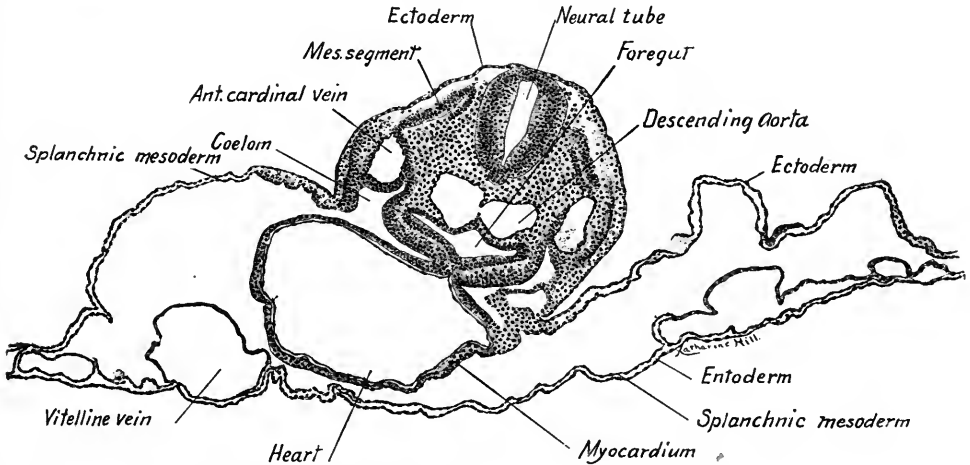


FIG. 44.—Transverse section through the caudal end of the heart of a thirty-six-hour chick embryo.  $\times 75$ .

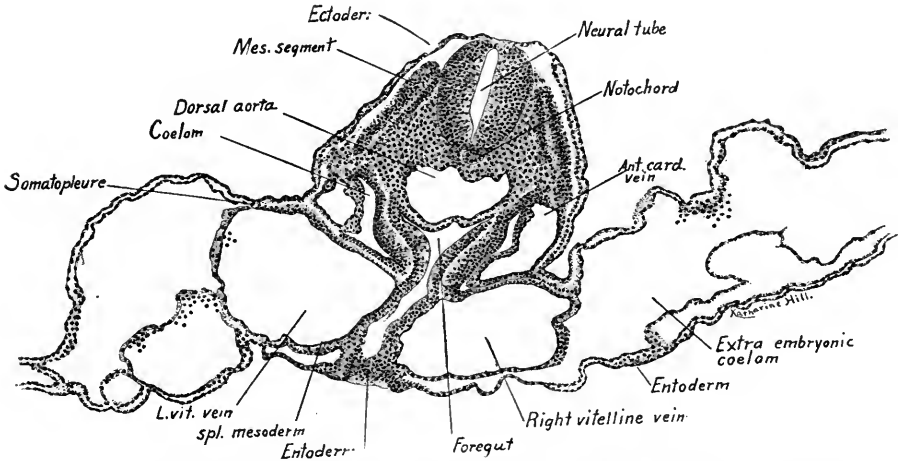


FIG. 45.—Transverse section through the fovea cardiaca of a thirty-six-hour chick embryo. *Ant. card. vein*, anterior cardinal vein; *L. vit. vein*, left vitelline vein; *Mes. segment*, mesodermal segment; *Spl. mesoderm*, splanchnic mesoderm.  $\times 90$ .

*veins*. A pair of primitive *mesodermal segments* may be seen in this section lateral to the hind-brain. It may be noted here that the primitive segments were not present in the sections of the head previously studied.

**Transverse Section through the Fovea Cardiaca (Fig. 45).**—The *descending aortæ* now form a single vessel, the *dorsal aorta*, the medium septum having disappeared. The section passes through the entoderm at the point where it is folded dorsad and cephalad into the

head as the *fore-gut*. The cavity is the *fovea cardiaca* and two sections caudad it communicates with the flattened space between the entoderm and the yolk. On each side of the fore-gut are the large *vitelline veins*, sectioned obliquely. As the splanchnic mesoderm overlies these veins dorsad, it is pressed by them on each side against the somatic mesoderm and the cavity of the coelom is thus interrupted.

**Transverse Section Caudal to the Fovea Cardiaca (Fig. 46).**—This section resembles the preceding save that the primitive gut is without a ventral wall. The *vitelline vein* on the left is still large.

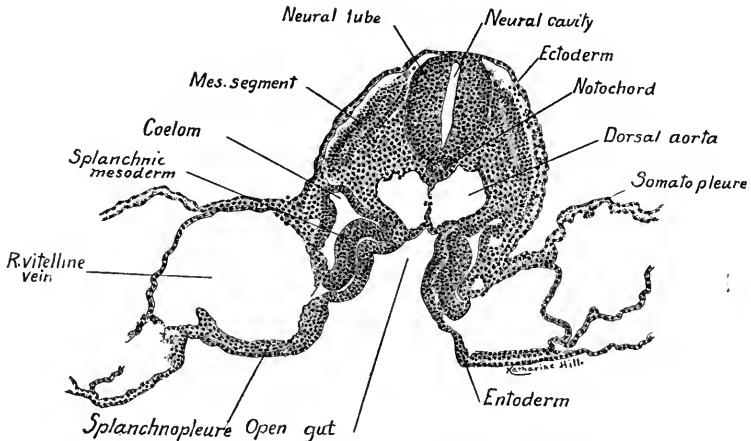


FIG. 46.—Transverse section caudal to the fovea cardiaca of a thirty-six-hour chick embryo.  $\times 90$ .

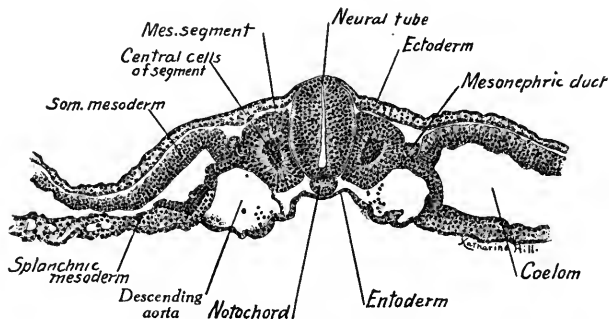


FIG. 47.—Transverse section through the fourteenth pair of mesodermal segments of a thirty-six-hour chick embryo.  $\times 90$ .

**Section through the Fourteenth Pair of Primitive Segments (Fig. 47).**—The body of the embryo is now flattened on the surface of the yolk. The dorsal aortæ have separated and occupy the depressions lateral to the primitive segments. The section is characterized by the differentiated mesoderm which forms the primitive segments, nephrotomes, somatic and splanchnic mesoderm, structures soon to be described.

**Transverse Section through the Rhomboidal Sinus (Fig. 48).**—The *neural groove* is open, the *notochord* is oval in form. The *ectoderm* is characterized by the columnar form of its cells. At the point where the ectoderm joins the neural fold a crest of cells projects ventrally on either side. These projecting cells form the *neural crests*, and from them the *spinal ganglia* are formed. The mesodermal plates have split laterally into layers, but the coelomic cavities are mere slits. Between the splanchnic mesoderm and the entoderm blood-vessels may be seen.

**Transverse Section through the Primitive (Hensen's) Node or Knot (Fig. 49).**—The section shows the three germ layers bound together at the "knot" or node into a mass of undifferentiated tissue. The mesoderm is split laterally into the somatic and splanchnic layers.

**Transverse Section through the Primitive Streak (Fig. 50).**—In the mid-dorsal line is the primitive groove. The germ layers may be seen taking their origin from the undiffer-

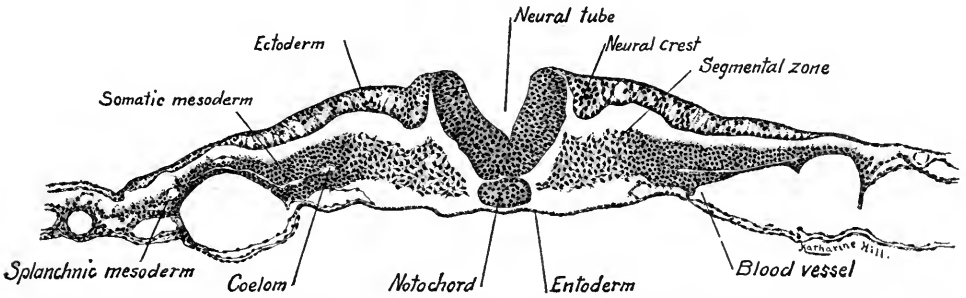


FIG. 48.—Transverse section through the rhomboidal sinus of a thirty-six-hour chick embryo.  $\times 90$ .

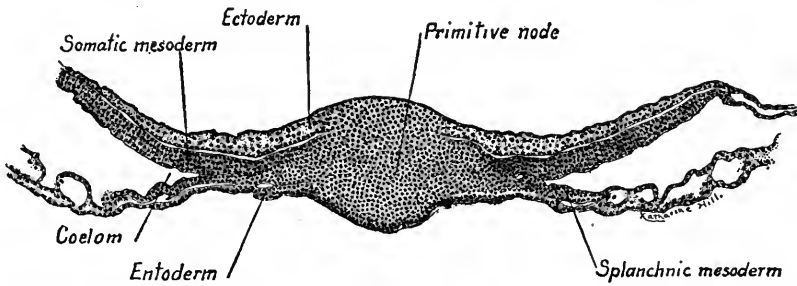


FIG. 49.—Transverse section through the primitive (Hensen's) node of a thirty-six-hour chick embryo.  $\times 90$ .

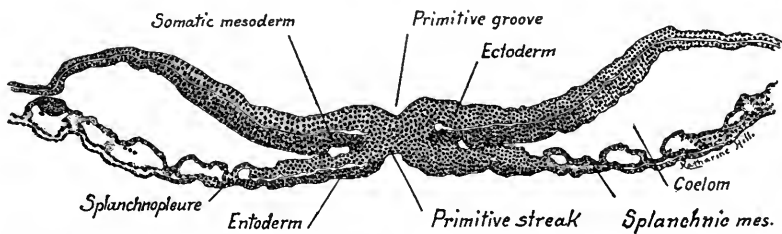


FIG. 50.—Transverse section through the primitive streak of a thirty-six-hour chick embryo.  $\times 90$ .

entiated tissue of the *primitive streak* beneath the *primitive groove*. Between the splanchnic mesoderm and entoderm blood-vessels are present laterad as in the preceding sections.

**Mesodermal Segments.**—We have seen that these are developed by the appearance of transverse furrows in the mesoderm (Fig. 51). Later a longitudinal furrow partially separates the paired segments from the lateral unsegmented mesoderm. The segments are block-like with rounded angles when viewed

dorsally, triangular in transverse section (Figs. 47 and 51). They are formed cranio-caudally, the most cephalad being the first to appear. The first three lie in the head region. The segments contain no cavity but a potential cavity representing a portion of the cœlom is filled with cells, and the other cells of the segments form a thick mesothelial layer about them. The ventral wall and a portion of the median wall of each primitive segment become transformed into *mesenchyma* which surrounds the neural tube and notochord (Fig. 282). The remaining portion of the segments persist as the *dermo-muscular plates* or *myotomes*. The cells of the myotomes elongate and give rise to the *voluntary muscle* of the body. The voluntary or skeletal muscles are thus at first all segmented

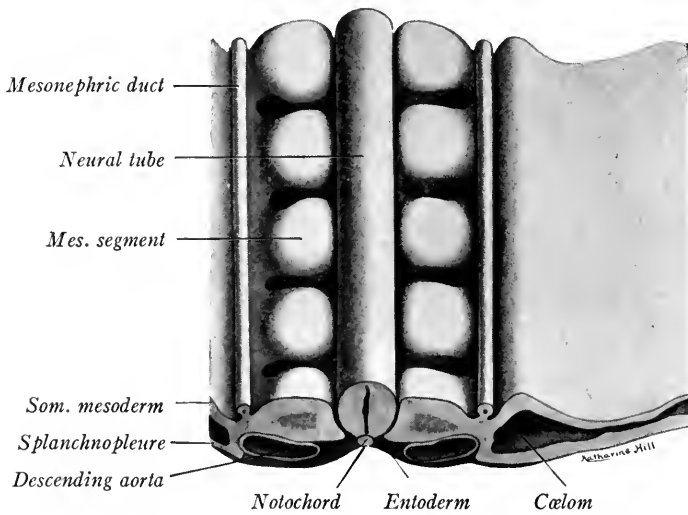


FIG. 51.—Semi-diagrammatic reconstruction of five mesodermal segments of a forty-eight-hour chick embryo. The ectoderm is removed from the dorsal surface of the embryo.

but later many of the segments fuse. In the trunk muscles of the adult fish the primitive segmented condition is retained.

**The Intermediate Cell Masses or Nephrotomes.**—The bridge of cells connecting the primitive segments with the lateral mesodermal layers constitutes the nephrotome (Figs. 47 and 51). The nephrotomes give rise dorsad to pairs of small cell masses segmentally arranged in the furrow lateral to the primitive segments. By the union of these cell masses solid cords are formed which run lengthwise in the furrow. These cords hollow out, grow caudad, and become the *primary excretory (mesonephric) ducts* (Fig. 51). The rest of the intermediate cell mass becomes the embryonic kidney or *mesonephros*, the tubules of which open into the primary excretory duct. As the genital glands develop in connection

with the mesonephros, and as the kidney of the adult (metanephros) is partly developed as an outgrowth of the primary excretory duct, we may regard the intermediate cell mass as the *anlage of the urogenital glands and their ducts*. They are thus of mesodermal origin.

**Somatopleure and Splanchnopleure.**—In the embryo of seven primitive segments we saw that the mesoderm split laterally into two layers, the *somatic* (dorsal) and the *splanchnic* (ventral) *mesoderm*. These layers persist in the adult, the somatic mesoderm giving rise to the pericardium of the heart, to the parietal pleura of the thorax and to the peritoneum of the abdomen, while the splanchnic layer forms the epicardium and myocardium of the heart, visceral pleura of the lungs, the mesenteries and mesodermal layer of the gut. The somatic mesoderm and the ectoderm with the tissue developed between them constitute the body wall, which is termed the *somatopleure*. In the same way the splanchnic mesoderm and the entoderm with the mesenchymal tissue between them constitute the wall of the gut, termed the *splanchnopleure*.

**Cœlom.**—The cavity between the somatopleure and splanchnopleure is the cœlom (body cavity). With the splitting of the mesoderm, isolated cavities are produced. These unite on each side and eventually form one cavity—the cœlom. With the extension of the mesoderm, the cœlom surrounds the heart and gut ventrally (Fig. 52). Later, it is subdivided into the *pericardial cavity* of the heart, the *pleural cavity* of the thorax and the *peritoneal cavity* of the abdominal region. In the stages we have studied, the embryo is flattened on the surface of the yolk and the somatopleure and splanchnopleure do not meet ventrad. If this were the case we should have the structural relations as in Fig. 52 which is essentially the ground plan of the vertebrate body.

**Mesenchyma.**—In the sections through the head of this embryo and through that of the preceding stage, we have found but three primitive segments present. The greater part of the mesoderm in the head appears in the form of an undif-

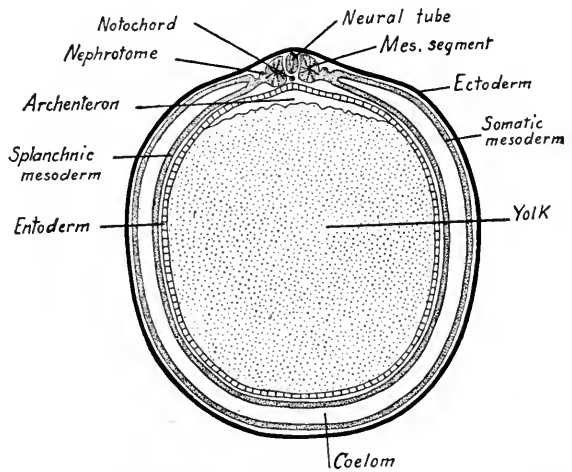


FIG. 52.—Diagrammatic transverse section of a vertebrate embryo (adapted from Minot).

ferentiated network of cells which fill in the spaces between the definite layers (epithelia). This tissue is *mesenchyma* (Fig. 53). The mesoderm may be largely converted into mesenchyma as in the head, or any of the mesodermal layers may contribute to its formation. Thus it may be derived from the primitive segments and from the somatic and splanchnic mesoderm. The cells of the mesenchyma form a syncytium or network, and are at first packed closely together. Later, they may form a more open network with cytoplasmic processes extending from cell to cell (Fig. 53). The mesenchyma is an important tissue of the embryo, as from it are differentiated the blood and lymphatic systems, together with most of the smooth muscle, connective tissue, and skeletal tissue of the body.

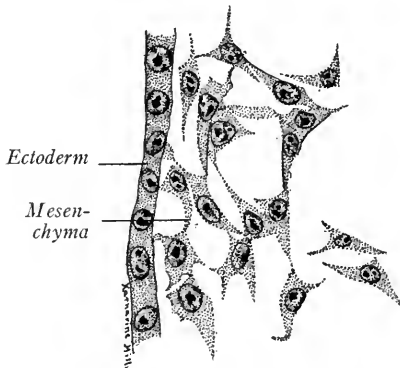


FIG. 53.—Mesenchyma from the head of a thirty-six-hour chick embryo.  $\times 495$ .

The body of the embryo is now composed (1) of cells arranged in layers—*epithelia*, and (2) of diffuse *mesenchyma*. The term “epithelium” may be used in a general sense or restricted to layers covering the surface of the body or lining the digestive canal and its derivatives. Layers lining the body cavities are termed *mesothelia*, while those lining the blood-vessels and heart are called *endothelia*.

**Derivatives of the Germ Layers.**—The tissues of the adult are derived from the epithelia and mesenchyma of the three germ layers as follows:

<i>Ectoderm</i>	<i>Mesoderm</i>	<i>Entoderm</i>
<ol style="list-style-type: none"> <li>1. Epidermis and its derivatives (hair, nails, glands).</li> <li>2. Conjunctiva and lens of eye.</li> <li>3. Sensory epithelia of organs of special sense.</li> <li>4. Epithelium of mouth, enamel of teeth, oral glands. Pituitary body.</li> <li>5. Epithelium of anus.</li> <li>6. Epithelium of amnion and chorion.</li> <li>7. Nervous, neuroglia and chromaffin cells of nervous system. Retina and optic nerve.</li> <li>8. Notochord (?)</li> <li>9. Smooth muscle of sweat glands and of iris.</li> </ol>	<ol style="list-style-type: none"> <li>A. Mesothelium.               <ol style="list-style-type: none"> <li>1. Pericardium.</li> <li>2. Pleura.</li> <li>3. Peritoneum.</li> <li>4. Serous layer of intestine.</li> <li>5. Epithelium of uro-genital organs.</li> <li>6. Striated muscle.                   <ol style="list-style-type: none"> <li>1. Skeletal.</li> <li>2. Cardiac.</li> </ol> </li> </ol> </li> <li>B. Mesenchyma.               <ol style="list-style-type: none"> <li>1. Blood-cells.</li> <li>2. Bone marrow.</li> <li>3. Endothelium of blood-vessels.</li> <li>4. Endothelium of lymphatics and spleen.</li> <li>5. Supporting tissues. (Connecting tissue, cartilage and bone.)</li> <li>6. Smooth muscle.</li> </ol> </li> </ol>	<ol style="list-style-type: none"> <li>1. Epithelium of digestive tract.</li> <li>2. Liver.</li> <li>3. Pancreas.</li> <li>4. Epithelium of pharynx.               <ul style="list-style-type: none"> <li>Eustachian tube.</li> <li>Tonsils.</li> <li>Thymus.</li> <li>Thyroids.</li> <li>Epithelial bodies.</li> </ul> </li> <li>5. Epithelium of respiratory tract.               <ul style="list-style-type: none"> <li>Larynx.</li> <li>Trachea.</li> <li>Lungs.</li> </ul> </li> <li>6. Notochord (?)</li> </ol>

For the histological development (histogenesis) of the various tissues from the primary germ layers see Chapter X.

#### CHICK EMBRYO OF TWENTY-SEVEN SEGMENTS (FIFTY HOURS)

This embryo, which is taken as a type of the forty-eight to fifty-two-hour stage, lies in the center of the vascular area and is peculiar in that the head is twisted  $90^\circ$  to the right. We therefore see the right side of the head but the dorsal side of the body. In the region of the mid-brain is the very marked head-bend

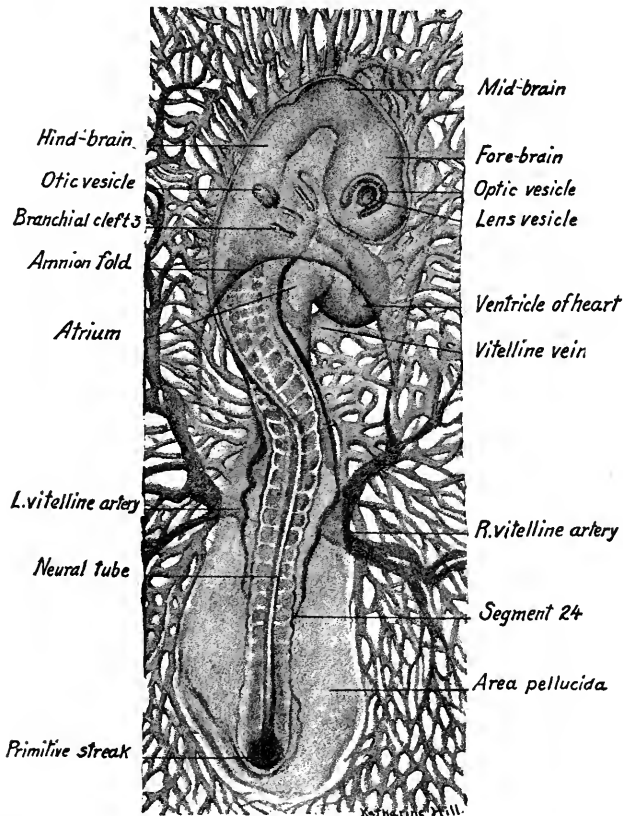


FIG. 54.—Dorsal view of a fifty-hour chick embryo, stained and mounted in balsam.  $\times 14$ .

or *cephalic flexure*. Below the head and ventral in position lies the tubular heart, now bent in the form of a letter S. Dorsal to the heart in the region of the pharynx, three transverse grooves or slits may be seen. These are the *branchial clefts* or *gill slits*. The head of the embryo is now covered by a double fold of the somatopleure, the head-fold of the *amnion*. It envelops the head like a veil.

Caudally a fold and opacity mark the position of the *tail-fold* from which develops the caudal end of the body. The curved fold embracing this is the *tail-fold of the amnion* which will eventually meet the head-fold and completely enclose the embryo.

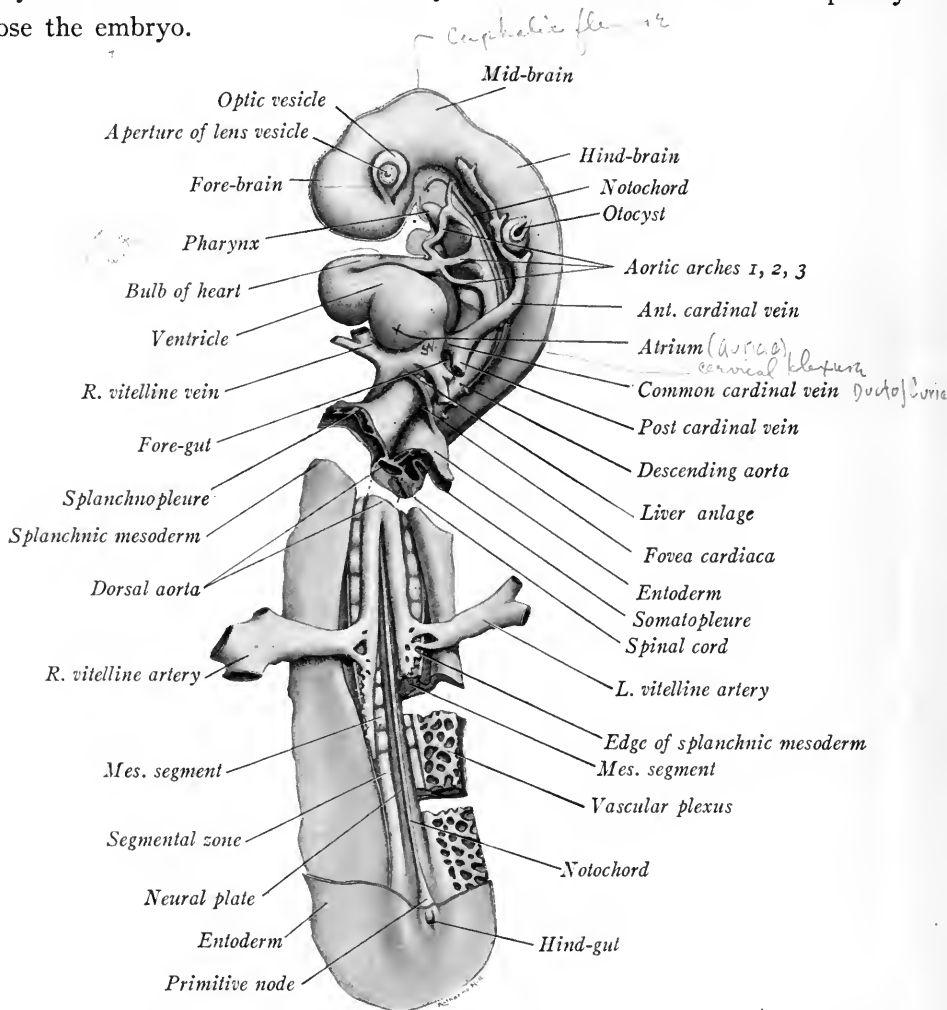


FIG. 55.—Semi-diagrammatic reconstruction of a fifty-hour chick embryo, ventral view.  $\times 22$ . The entoderm has been removed save in the region of the fovea cardiaca and of the hind-gut. The cranial third of the embryo is seen from the left side, the caudal two-thirds in ventral view owing to the torsion of the embryo.

**Central Nervous System and Sense Organs (Fig. 55).**—The neural tube is divided by constrictions cephalad into four vesicles. The fore-brain of the previous stage is now subdivided into two regions, the *telencephalon* and *diencephalon*. The *cephalic flexure* has been established in the region of the mesencephalon. The hind-brain is as yet undivided and is as long as the other three



vesicles. The lens of the eye has invaginated, pushing in the wall of the optic vesicle and thus forming a double-walled structure, the *optic cup*. The auditory placode has become a sac, the *otocyst*, which overlies the hind-brain opposite the second branchial groove and is still connected with the outer ectoderm, cut away in Fig. 55. The rhomboidal sinus is still open at the caudal end of the neural tube (Fig. 54).

**Digestive Canal.**—In a reconstruction from the ventral side the digestive canal shows differentiation into three regions. Of these, the *fore-gut* we have seen in earlier stages; the mid-gut is without ventral wall and overlies the yolk. A greater part of the *mid-gut* has been cut away to show the underlying structures. Caudad, a small fovea leads into the *hind-gut* which is just beginning to evaginate into the tail-fold. The pharyngeal membrane now lies in a considerable cavity, the *stomodæum*, formed by the invaginated ectoderm. The median ectodermal pouch next the brain-wall is known as *Rathke's pocket* and is the anlage of the anterior lobe of the *hypophysis*. The pharynx shows laterally three out pocketings, of which the first is wing like and is the largest. These pharyngeal pouches occur opposite the three branchial grooves and at these points entoderm and ectoderm are in contact. Between them are developed the *branchial arches*, in which course the paired *aortic arches*. Towards the fovea cardiaca the fore-gut is flattened laterally and before it opens out into the mid-gut there is budded off ventrally a bilobed structure, the anlage of the *liver* (Fig. 60). It lies between the vitelline veins and in its later development the veins are broken up into the *sinusoids* or blood spaces of the liver.

Just as the entoderm grows out into the head-fold to form the fore-gut so it grows into the tail-fold and forms the hind-gut. This at once gives rise to a tubular outgrowth which becomes the *allantois*, one of the fetal membranes to be described later.

**Blood Vascular System.**—The tubular heart is flexed in the form of a letter **S** when seen from the ventral side. Four regions may be distinguished: (1) The *sinus venosus*, into which open the veins; (2) a dilated dorsal chamber, the *atrium*; (3) a tubular ventral portion flexed in the form of a **U**, of which the left limb is the *ventricle*, the right limb (4) the *bulbus cordis*. From the *bulbus* is given off the ventral aorta. There are now developed three pairs of *aortic arches* which open into the paired descending aortæ. The first aortic arch passes cranial to the first pharyngeal pouch and is the primitive arch seen in the thirty-six-hour embryo. The second and third arches course on either side of the second pharyngeal pouch. They are developed by the enlargement

of channels in primitive capillary networks between ventral and descending aortæ. Opposite the sinus venosus the paired aortic trunks fuse to form the single dorsal aorta which extends as far back as the fifteenth pair of primitive segments. At this point the aortæ again separate and opposite the twentieth segments each connects with the trunk of a vitelline artery which was developed in, and conveys the blood to, the vascular area (Fig. 55). Caudal to the vitelline arteries the dorsal aortæ rapidly decrease in size and soon end.

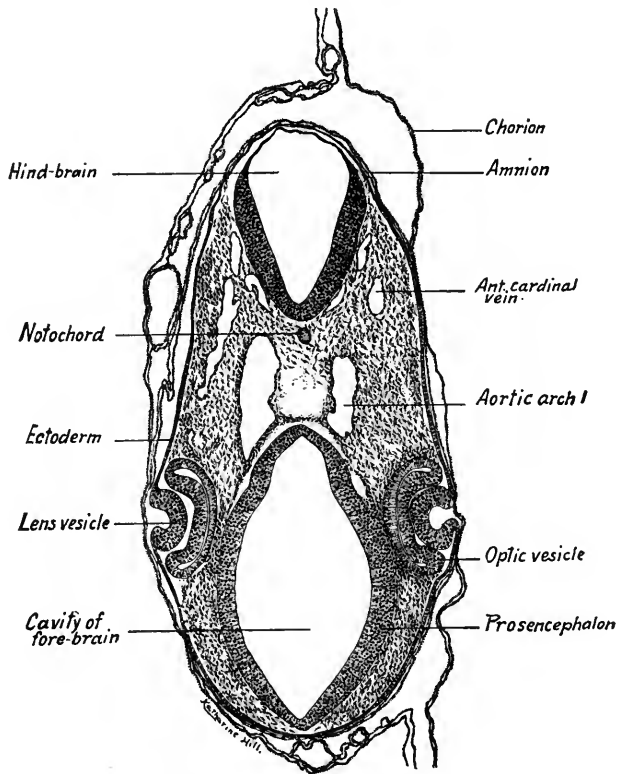


FIG. 56.—Transverse section through the fore-brain and eyes of a fifty-hour chick embryo.  $\times 50$ .

As in the previous stage, the blood is conveyed from the vascular area to the heart by the vitelline veins, now two large trunks. In the body of the embryo there have developed two pairs of veins. In the head have appeared the *anterior cardinal veins*, already of large size and lying lateral to the ventral region of the brain vesicles (Fig. 58). Caudal to the atrium of the heart, two smaller *posterior cardinal veins* are developed. They lie in the mesenchyma of the somatopleure laterad in position (Fig. 60). Opposite the sinus venosus the anterior and posterior cardinal veins of each side unite and form the *common cardinal veins* (ducts

of Cuvier) which open into the dorsal wall of the sinus venosus. The primitive veins are thus paired like the arteries, and like them develop by the enlargement of channels in a network of capillaries.

The following series of transverse sections from an embryo of this stage shows the more important structures. The approximate plane and level of each section may be seen by referring to Figs. 54 and 55.

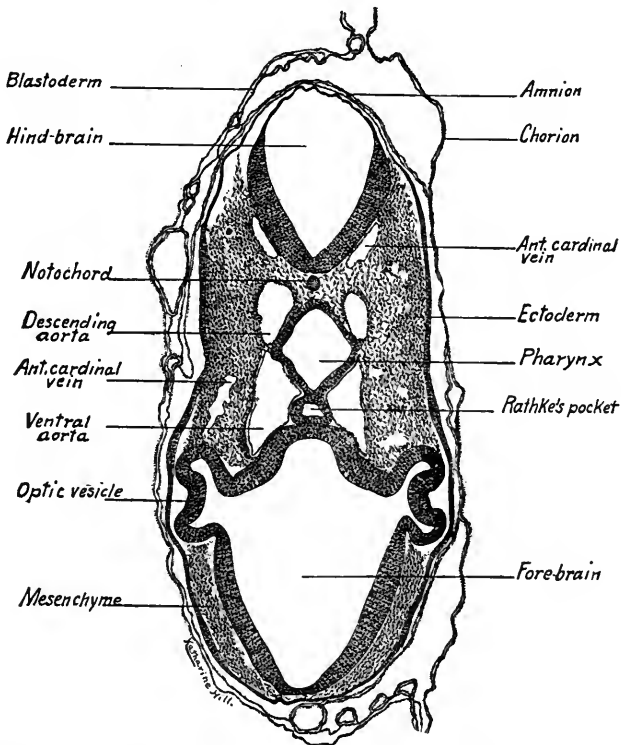


FIG. 57.—Transverse section through the optic stalks and hypophysis of a fifty-hour chick embryo.  $\times 50$ .

**Section through the Fore-brain and Eyes (Fig. 56).**—The section passes cranial to the optic stalks, consequently the optic vesicles appear unconnected with the fore-brain. The thickened ectoderm is invaginated to form the anlagen of the *lens vesicles*. The thicker wall of the *optic vesicles* next the lens anlage will give rise to the nervous layer of the retina, the thinner outer wall becomes the pigment layer of the retina. Ventrad in the section are the wall and cavity of the *fore-brain*, dorsad the *hind-brain* with its thin dorsal *ependymal layer*. Between the brain vesicles on either side are sections of the *first aortic arches* and lateral to the hind-brain are the smaller paired *anterior cardinal veins*, which convey the blood from the head to the heart.

**Section through the Optic Stalks and Hypophysis (Fig. 57).**—The section passes just caudal to the lens which does not show. The *optic vesicles* are connected with the wall of the *fore-brain* by the *optic stalks* which later form the path by which the fibers of the optic nerve pass from the retina to the brain. Both the *ventral* and the *descending aorte* are seen in section

about the cephalad end of the pharynx. Between the ventral wall of the fore-brain and the pharynx is an invagination of the ectoderm, *Rathke's pocket*.

**Section through the Otocysts and Second Aortic Arch** (Fig. 58).—The *otic vesicles* are sectioned caudal to their apertures and appear as closed sacs lateral to the wall of the hind-brain. The cavity of the *pharynx* is somewhat triangular and its dorsad wall is thin. The *anterior cardinal veins* pass between the otocysts and the wall of the hind-brain. Ventral to the pharynx the *bulbus cordis* is sectioned obliquely where it leaves the heart, and at this level gives off laterad the *second pair of aortic arches* which connect dorsad with the descending aorta. Surrounding the bulbus cordis is the large *pericardial cavity*. Between the first and second aortic arches (Fig. 58) is the *first pair of pharyngeal pouches*, lateral diverticula of the entoderm. The student should note that in the sections of this stage so far studied, the *mesen-*

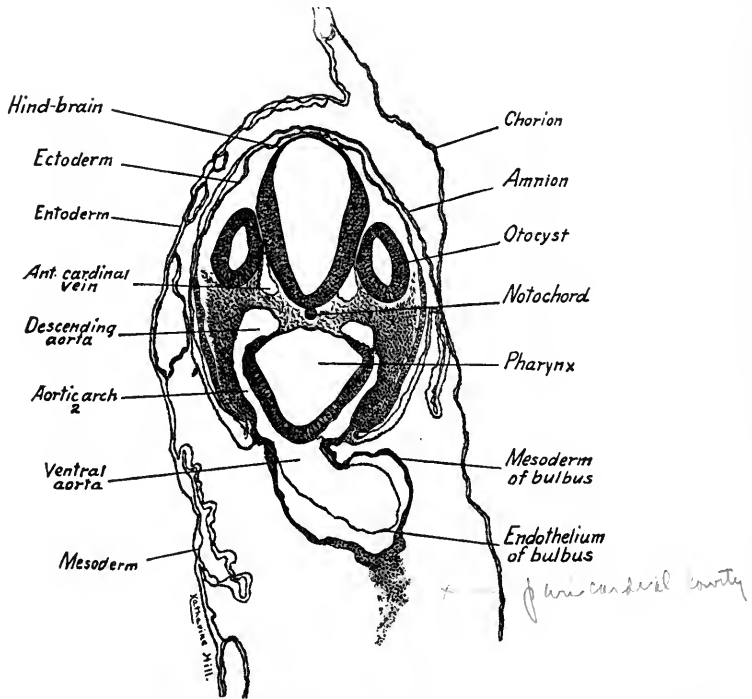


FIG. 58.—Transverse section through the otic vesicles and second aortic arches of a fifty-hour chick embryo.  $\times 50$ .

*chyma* of the head is undifferentiated, the tissues peculiar to the adult not yet having been formed.

**Section through the Sinus Venosus and Common Cardinal Veins** (Fig. 59).—At this level, the common trunk formed by the anterior and posterior cardinal veins opens into the thin-walled *sinus venosus*. The sinus receives all of the blood passing to the heart and is separated only by a slight constriction from the larger *atrium*. The *muscle plates* of the first mesodermal segments are seen, and the *descending aorta* have united to form a single dorsal vessel. On either side of the pharynx are seen subdivisions of the coelom which will form the *pleural cavities*. These cavities are separated from the pericardial cavity by the *septum transversum* in which the common cardinal veins cross to the sinus venosus.

The folds of the amnion envelop the right side of the embryo and the ectoderm of these

folds now forms the outer layer of the *chorion* and the inner layer of the *amnion*. The mesodermal folds of the amnion have not united.

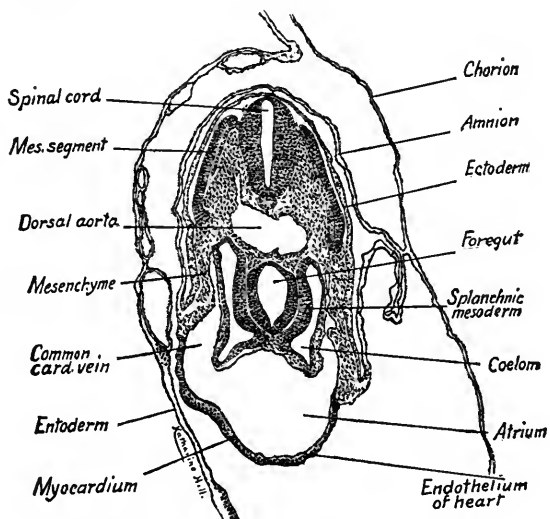


FIG. 59.—Transverse section through the sinus venosus and common cardinal veins of a fifty-hour chick embryo.  $\times 50$ .

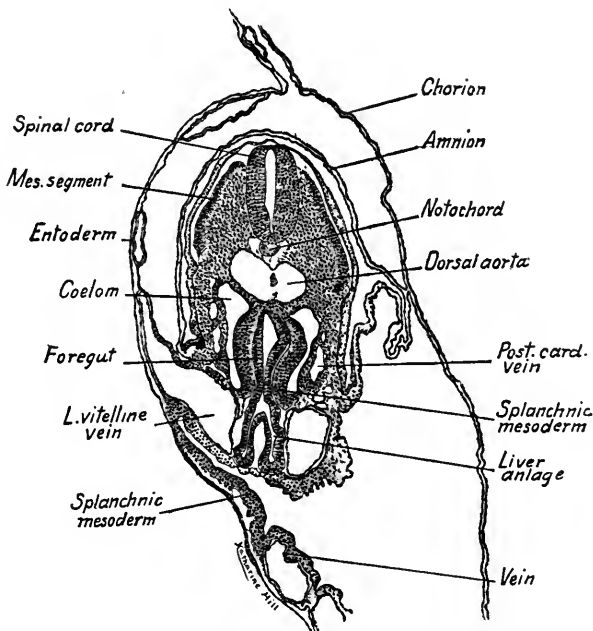


FIG. 60.—Transverse section through the anlage of the liver of a thirty-six-hour chick embryo.  $\times 50$ .

**Section through the Anlage of the Liver (Fig. 60).**—In this section the cavity of the fore-gut is narrow, the gut being flattened from side to side. Ventrad there are evaginated from the entoderm two elongate diverticula which form the anlagen of the *liver*. On either side

of the anlagen of the liver are sections of the *vitelline veins* on their way to the sinus venosus at a higher level in the series. Note the intimate relation between the entodermal epithelium of the liver and the endothelium of the vitelline veins. In later stages, as the liver anlagen branch, there is, as Minot aptly expresses it, "an intercrease of the entodermal cells constituting the liver and of the vascular endothelium" of the vitelline veins. Thus are formed the hepatic *sinusoids* of the portal system, which surround the cords of hepatic cells.

The *septum transversum* is still present at this level and lateral to the fore-gut are small body cavities. Lateral to the body cavities appear branches of the *posterior cardinal veins*.

**Section through the Cranial Portion of the Open Intestine** (Fig. 61).—The intestine is now open ventrad, its splanchnopleure passing directly over to that of the vascular area. The folds of the *amnion* do not join, leaving the amniotic cavity open. The dorsal aorta

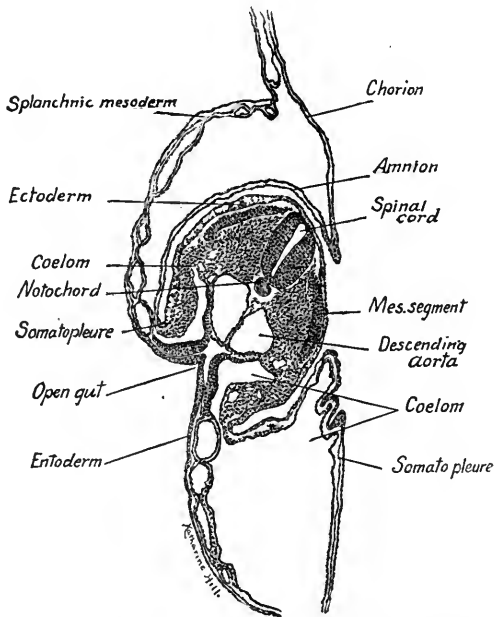


FIG. 61.—Transverse section through the cranial portion of the open intestine of a fifty-hour chick embryo.  $\times 50$ .

is divided by a septum into its primitive components, the *right and left aorta*. The cœlom is in communication with the extra-embryonic body cavity.

**Section through the Seventeenth Pair of Mesodermal Segments** (Fig. 62).—The body of the embryo is now no longer flexed to the right. On the left side of the figure the mesodermal segment shows a dorso-lateral *muscle plate*. The median and ventral portion of the segment is being converted into mesenchyme. On the left side appears a section of the *primary excretory or mesonephric duct*. The embryonic *somatopleure* is arched and will form the future ventro-lateral body wall of the embryo. The fold lateral to the arch of the somatopleure gives indication of the later approximation of the ventral body walls, by which the embryo is separated from the underlying layers of the blastoderm.

**Section through the Origin of the Vitelline Arteries** (Fig. 63).—At this level the embryo is more flattened and simpler in structure, the section resembling one through the mid-gut region of a thirty-six-hour chick (Fig. 47). The amniotic folds have not appeared. On the left side of the figure the *vitelline artery* leaves the aorta. On the right side the con-

nection of the vitelline artery with the aorta does not show, as the section is cut somewhat obliquely. The other structures were described in connection with Fig. 47.

**Section Caudal to the Mesodermal Segments (Fig. 64).**—The mesodermal segments are replaced by the *segmental zone*, a somewhat triangular mass of undifferentiated mesoderm from which later are formed the *segments* and *nephrotomes*. The *notochord* is larger,

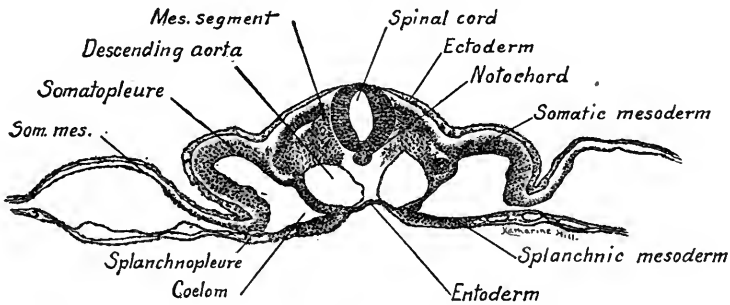


FIG. 62.—Transverse section through the seventeenth pair of mesodermal segments of a fifty-hour chick embryo.  $\times 50$ .

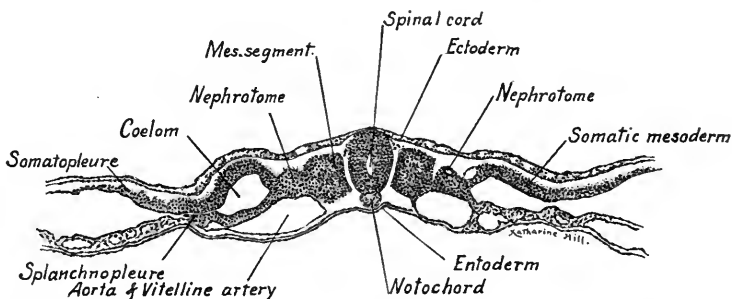


FIG. 63.—Transverse section of a fifty-hour chick embryo at the level of the origin of the vitelline arteries.  $\times 50$ .

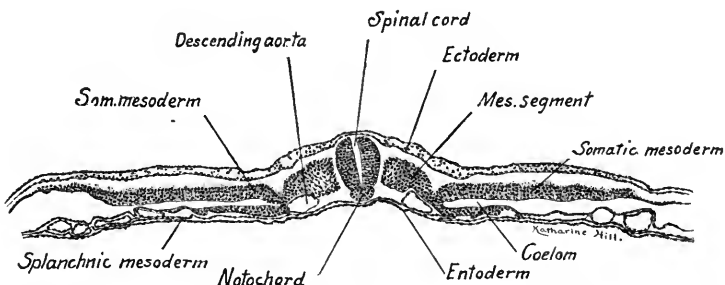


FIG. 64.—Transverse section of a fifty-hour chick embryo through the last pair of mesodermal segments.  $\times 50$ .

the aortæ smaller, and a few sections caudad they disappear. Laterally the *somatopleure* and *splanchnopleure* are straight and separated by the slit-like coelom.

**Section through the Primitive Node Cranial to the Hind-gut (Fig. 65).**—With the exception of the ectoderm, the structures near the median line are merged into an undifferentiated mass of tissue. The cavity of the neural tube and its dorsal outline may still be seen,

but its ventral portion, the *notochord*, *mesoderm* and *entoderm*, blend in a dense mass of tissue which is characteristic of the primitive node. Laterally the segmental zone and the various layers are differentiated.

**Section Passing through the Hind-gut (Fig. 66).**—In this embryo the caudal evagination to form the *hind-gut* has just begun. The section shows the small cavity of the hind-gut in the mid-line. Its wall is composed of columnar entodermal cells and it is an out-growth of the entodermal layer. Dorsal to the hind-gut may be seen undifferentiated cells of the *primitive streak* continuous dorsad with the *ectoderm*, ventrad with the *entoderm* of the hind-gut and laterally with the *mesoderm*.

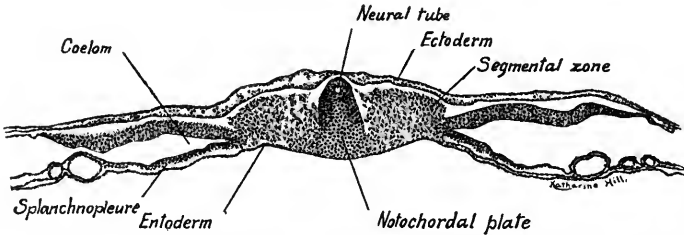


FIG. 65.—Transverse section of a fifty-hour chick embryo through the primitive node cranial to the hind-gut.  $\times 50$ .

In the chick embryos which we have studied there are large areas developed which are extra-embryonic, that is, lie outside the embryo. The splanchnopleure of the area vasculosa, for instance, forms the wall of the *yolk-sac*, incomplete in the early stages. The *amnion*, *chorion* and *allantois* are extra-embryonic membranes which make their appearance at the fifty-hour stage. These structures are important in mammalian and human embryos and a description of their further development in the chick, where their structure and mode of develop-

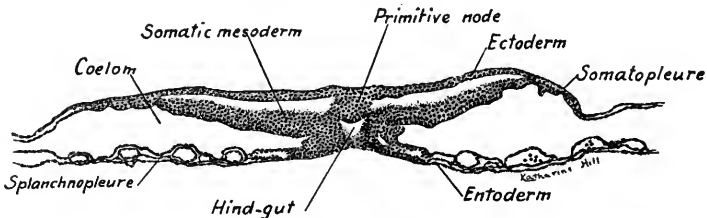


FIG. 66.—Transverse section passing through the hind-gut of a fifty-hour chick embryo.  $\times 50$ .

ment is primitive, will lead up to the study of mammalian embryos in which the amnion and chorion are precociously developed.

**Amnion and Chorion.**—These two membranes are developed in all Amniote Vertebrates (Reptiles, Birds and Mammals). They are derived from the extra-embryonic somatopleure. The amnion is purely a protective structure, but the chorion of mammals has a trophic function, as through it the embryo derives its nourishment from the uterine wall. Fig. 67 A shows the amnion and chorion



developing. The head-fold of the somatopleure forms first and envelops the head, the tail-fold makes its appearance later. The two folds extend laterad, meet and fuse (Fig. 67 B). The inner leaf of the folds forms the *amnion*, the remainder of the extra-embryonic somatopleure becomes the *chorion*. The actual appearance of these structures and their relation to the embryo we have seen in Figs. 60 and 61. The amnion, with its ectodermal layer inside, completely surrounds the embryo by the fourth day, enclosing a cavity filled with amniotic fluid (Fig. 68). In this the embryo floats and is thus protected from injury. The chorion is of little importance to the chick. It is at first incomplete but eventually entirely surrounds the embryo and its other appendages.

**Yolk-sac and Yolk-stalk.**—While the amnion and chorion are developing during the second and third day, the embryo grows rapidly. The head- and tail-folds elongate and the trunk expands laterally until only a relatively narrow stalk of the splanchnopleure connects the embryo with the yolk. This portion of the splanchnopleure has grown more slowly than the body of the embryo and is termed the *yolk-stalk*. It is continuous with the splanchnopleure which envelops the yolk and forms the *yolk-sac*. The process of unequal growth by which the embryo becomes separated from the yolk has been described as a

process of constriction. This, as Minot points out, is an error. The splanchnopleure at first forms only an oval plate on the surface of the yolk but eventually encloses it. In Fig. 67, C and D, the relation of the embryo to the yolk-sac is seen at the end of the first week of incubation. The vitelline vessels ramify on the surface of the yolk-sac and through them all the food material of the yolk is conveyed to the chick during the incubation period (about twenty-one days).

**Allantois.**—We have seen that in the fifty-hour chick a ventral evagination, the hind-gut, develops near its caudal end (Fig. 66). From it develops the anlage

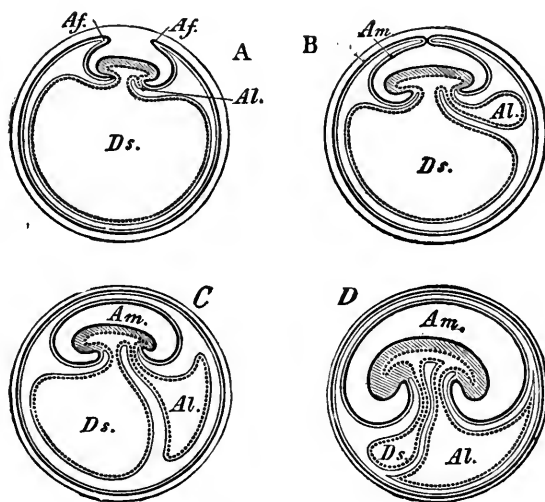


FIG. 67.—Diagrams showing the development of the amnion, chorion and allantois (Gegenbaur in McMurrich's "Human Body"). *Af.*, amnion folds; *Al.*, allantois; *Am.*, amniotic cavity; *Ds.*, yolk-sac.

of the allantois, and, as it is an outgrowth of the splanchnopleure, it is lined with entoderm and covered with splanchnic mesoderm (Fig. 67). It develops rapidly into a vesicle connected to the hind-gut by a narrow stalk, the allantoic stalk. At the fifth day it is nearly as large as the embryo (Fig. 68). Its wall flattens out beneath the chorion and finally it lies close to the secondary egg membrane (shell) but is attached only to the embryo. The functions of respiration and excretion are ascribed to it. In its wall ramify the *allantoic vessels*, which have been compared to the *umbilical arteries* and *veins* of mammalian embryos.

The chick embryo is thus protected by the *amnion* which develops from the

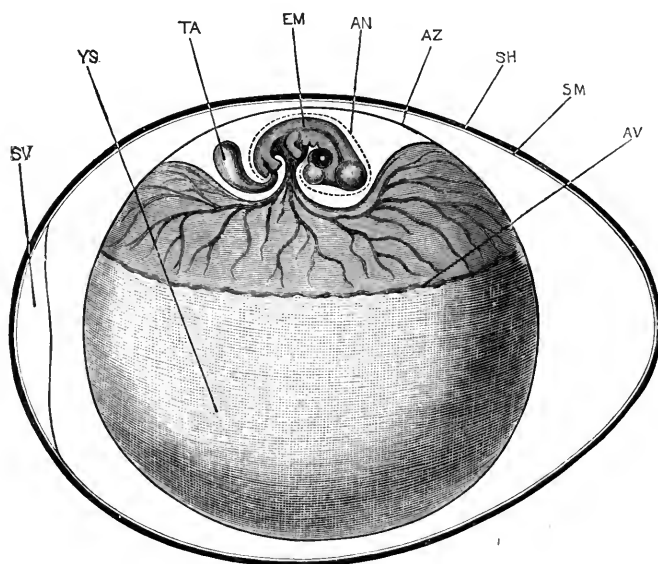


FIG. 68.—Diagram of a chick embryo of the fifth day showing amnion, chorion and allantois (Marshall). *AN*, inner or true amnion; *AV*, outer margin of the area vasculosa; *AZ*, outer or false amnion (chorion); *EM*, embryo; *SH*, shell of egg; *SM*, shell membrane; *SV*, air chamber; *TA*, allantois; *YS*, yolk-sac.

inner leaf of the folded somatopleure and is composed of an inner ectodermal and an outer mesodermal layer. Nutrient for the growth of the embryo is supplied by the *yolk-sac* and carried to the embryo by the vitelline veins. The allantois, which takes its origin from the splanchnopleure of the hind-gut and is composed of an inner layer of entoderm and an outer layer of splanchnic mesoderm, functions as an organ of respiration and serves as a reservoir for the excreta of the embryonic kidneys. As we shall see, the allantois becomes more important, the yolk-sac less important in some mammals, while in human embryos both yolk-sac and allantois are unimportant when compared to the *chorion*.

## CHAPTER IV

### THE FETAL MEMBRANES AND EARLY HUMAN EMBRYOS

The fetal membranes of mammals include the *amnion*, *chorion*, *yolk-sac* and *allantois*, structures which we have seen are present in chick embryos. Most important in mammals is the manner in which the embryo becomes attached to the uterine wall of the mother and in this regard mammalian embryos fall into two groups. Among the *Ungulates* or hoofed mammals (example the pig) the fetal membranes are of a primitive type, resembling those of the chick. Among *Unguiculates* (clawed animals like the bat and rabbit) and *Primates* (example Man) the fetal membranes of the embryo show marked changes in development and structure.

#### FETAL MEMBRANES OF THE PIG EMBRYO

The *amnion* and *chorion* develop very much as in the chick embryo (Fig. 67 A, B). A fold of the somatopleure forms very early about the whole embryo. The amnion is closed in embryos with but a few pairs of segments, but for some time remains attached to the chorion by a strand of tissue (Keibel). The *yolk-sac* develops early as in all mammals. In the pig it is small and the greater part of it soon degenerates. It is important only in the early growth of the embryo, its functions then being transferred to the allantois. Branches of the vitelline vessels ramify in its wall, as in that of chick embryos, but soon degenerate. The trunks of the vitelline vessels, however, persist within the body of the embryo. The *allantois*, developing as in the chick from the ventral wall of the hindgut (Fig. 67 A-D), appears when the embryo is still flattened out on the germinal area. In an embryo 3.5 mm. long it is crescent shaped and as large as the embryo. It soon becomes larger and its convex outer surface is applied to the inner surface of the chorion. As these surface layers are composed of splanchnic mesoderm they fuse more or less completely. A pair of allantoic veins and arteries branch in the splanchnic layer of the allantois. These branches are brought into contact with and invade the mesodermal layer of the chorion. The outer ectodermal layer of the chorion in the meantime has closely applied itself to the uterine epithelium, the ends of the uterine cells fitting into depressions in the

chorionic cells (Fig. 69). When the allantoic circulation is established, waste products given off from the blood of the embryo must pass through the epithelia of

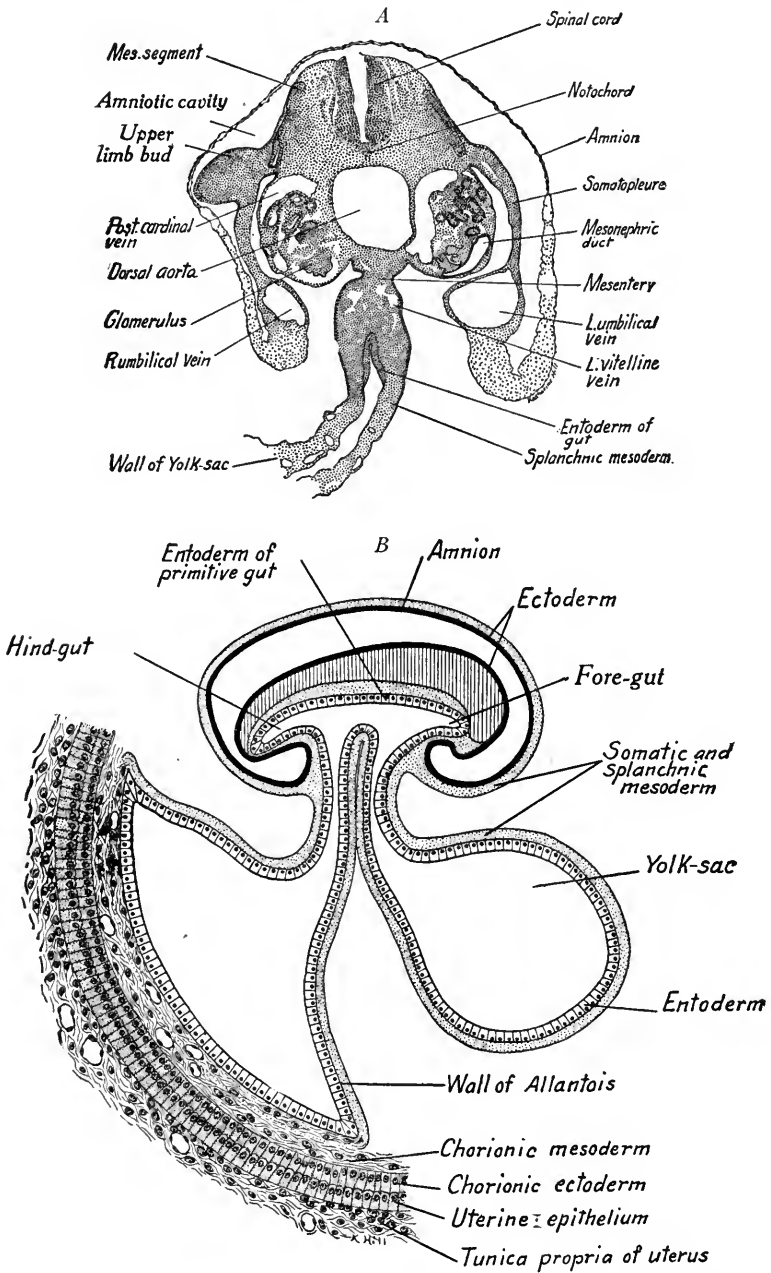


FIG. 69.—*A*, Transverse section through the yolk-sac and stalk of a 5 mm. pig embryo showing attachment of amnion. *B*, Diagram of the fetal membranes and allantoic placenta of a pig embryo in median sagittal section (based on figures of Heisler and Minot).

both chorion and uterus to be taken up by the blood of the mother. In the same way nutritive substances and oxygen must pass from the maternal blood through these layers to enter the allantoic vessels. This exchange does take place, however, and thus in Ungulates the allantois has become important not only as an organ of respiration and excretion but as an organ of *nutrition*. Through its vessels it has taken on a function belonging to the yolk-sac in birds, and we now see why the yolk-sac becomes a rudimentary structure in the higher mammals. Excreta from the embryonic kidneys are passed into the cavity of the allantois which is relatively large. The name is derived from a Greek word meaning sausage-like, from its form in some animals. The *chorion* is important only as it brings the allantois into close relation to the uterine wall, but in man we shall see that it plays a more important rôle.

#### UMBILICAL CORD

In their early development the relation of the amnion, allantois and yolk-sac to each other and to the embryo is much the same as in the chick of five days (Fig. 68). With the increase in size of the embryo, however, the somatopleure in the region of the attachment of the amnion grows ventrad. As a result, it is carried downward with the cœlom about the yolk-sac and allantois, forming the umbilical cord. Thus in a pig embryo 10 to 12 mm. long the amnion is attached at a circular line about these structures some distance from the body of the embryo. The cœlom at first extends ventrad into the cord, but later the mesodermal layers of amnion, yolk-stalk and allantois fuse and form a solid cord of tissue. This is the *umbilical* cord of fetal life and its point of attachment to the body is the *umbilicus* or navel. The cord is covered by a layer of ectoderm continuous with that of the amnion and of the embryo and contains, embedded in a mesenchymal (mucous) tissue (1) the yolk-stalk and (in early stages) its vitelline vessels; (2) the allantoic stalk; (3) the allantoic vessels. These, two arteries and a single large vein, are termed from their position the umbilical vessels. At certain stages (Figs. 117 and 118) the gut normally extends into the cœlom of the cord, forming an umbilical hernia. Later, it returns to the cœlom of the embryo and the cavity of the cord disappears. The umbilical cord of the pig is very short.

**Human Umbilical Cord.**—This develops like that of the pig and may attain a length of more than 50 cm. It becomes spirally twisted, just how is not known. In embryos from 10 mm. to 40 mm. long the gut extends into the cœlom of the

cord (Fig. 172). At the 42 mm. stage, according to Lewis and Mall, the gut returns to the coelom of the body. The mucous tissue peculiar to the cord arises from mesenchyme. It contains no capillaries and no nerves, but embedded in it are the large umbilical vein, the two arteries, the allantois and the yolk-stalk. The umbilical cord may become wound about the neck of the fetus, causing its death and abortion, or by coiling about the extremities it may lead to their atrophy or amputation.

#### EARLY HUMAN EMBRYOS AND THEIR MEMBRANES

Referring to the blastodermic vesicle of the mammal (Figs. 16 and 17), we find it consists of an outer layer, which we have called the *trophectoderm*, and the *inner cell mass*. The trophectoderm forms the primitive ectodermal layer of the chorion in the higher mammals and probably in man. From the inner cell mass are derived the primary ectoderm, entoderm and mesoderm. In the earliest known human embryos described by Teacher, Bryce, and Peters, the germ layers and amnion are present, indicating that they are formed very early. We can only guess at their early origin by what we know from other mammals. The diagrams (Fig. 70 A and B) show two hypothetical stages seen in median longitudinal section. In the first stage (A) the blastodermic vesicle is surrounded by the trophectoderm layer. The inner cell mass is differentiated into a dorsal mass of ectoderm and a ventral mass of entoderm. Mesoderm more or less completely fills the space between entoderm and trophoderm. It is assumed that as the embryo grows (Fig. 70 B) a split occurs in the mass of ectoderm cells, giving rise to the amniotic cavity and dividing these cells into the ectodermal layer of the embryo and into the extra-embryonic ectoderm of the amnion. At the same time, a cavity may be assumed to form in the entoderm, giving rise to the primitive gut. About this stage the embryo embeds itself in the uterine mucosa. In the third stage, based on Peter's embryo (Fig. 70 C), the extra-embryonic mesoderm has extended between the trophectoderm and the ectoderm of the amnion and the extra-embryonic coelom appears. The amniotic cavity has increased in size and the embryo is attached to the trophectoderm by the unsplit layer of mesoderm between the ectoderm of the amnion and the trophectoderm of the chorion. The latter shows thickenings which are the anlagen of the chorionic villi surrounded by trophoderm cells. In the fourth stage, based on Graf Spee's embryo (D), the chorionic villi are longer and branched. The mesoderm now remains unsplit only at the posterior end of the embryo, where it forms the *body-stalk* peculiar

to Ungulates and Primates. It connects the mesoderm of the embryo with the mesoderm of the chorion. Into it there has grown from the gut of the embryo the entodermal diverticulum of the allantois.

**The Chorion.**—The human chorion is derived directly from the outer trophoderm layer of the blastodermic vesicle and from the extra-embryonic somatic mesoderm. Its early structure resembles that of the pig's chorion. The troph-

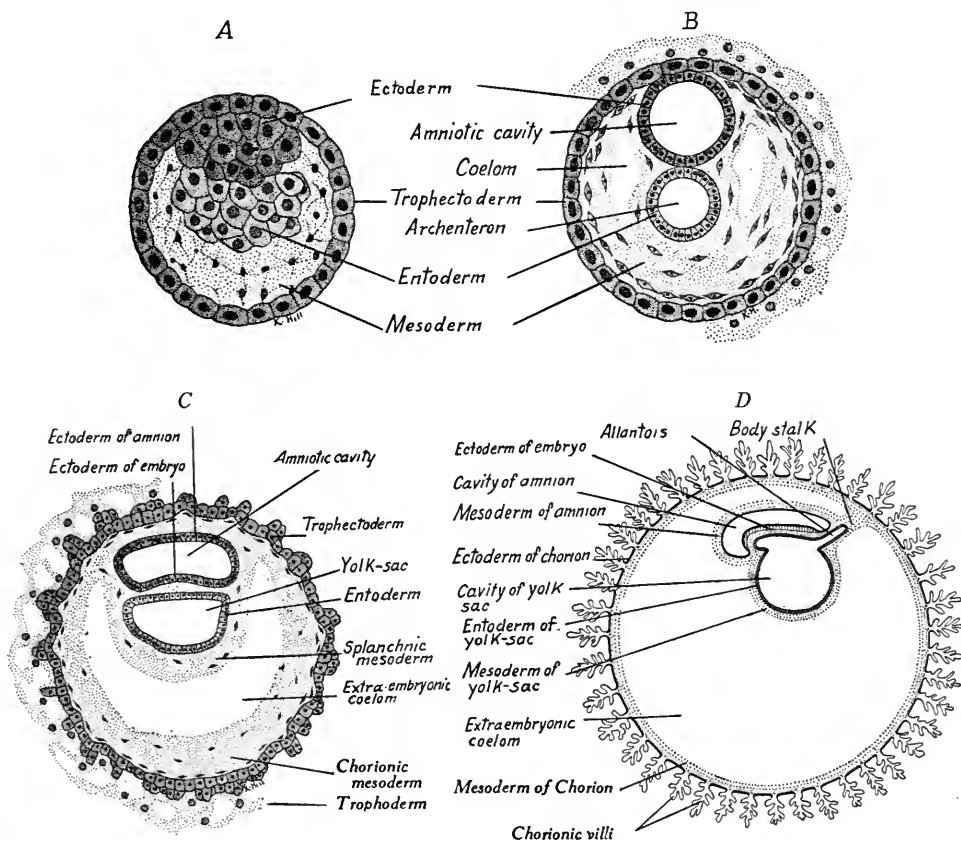


FIG. 70.—Four diagrams showing hypothetical stages of early human embryos (based on figures of Robinson and Minot).

ectoderm of the human embryo early gives rise to a thickened outer layer, the *trophoderm* (syncytial and nutrient layer). When the developing embryo comes into contact with the uterine wall the trophoderm destroys the maternal tissues. The destruction of the uterine mucosa serves two purposes: (1) the embedding and attachment of the embryo, it being grafted, so to speak, to the uterine wall; and (2) it supplies the embryo with a new source of nutrition. To obtain nutri-

ment to better advantage, there grow out from the chorion into the uterine mucosa branched processes or *villi*. The villi are bathed in maternal blood, and in them blood-vessels are developed, the trunks of which pass to and from the embryo as the umbilical vessels. The embryo receives its nutriment and oxygen,

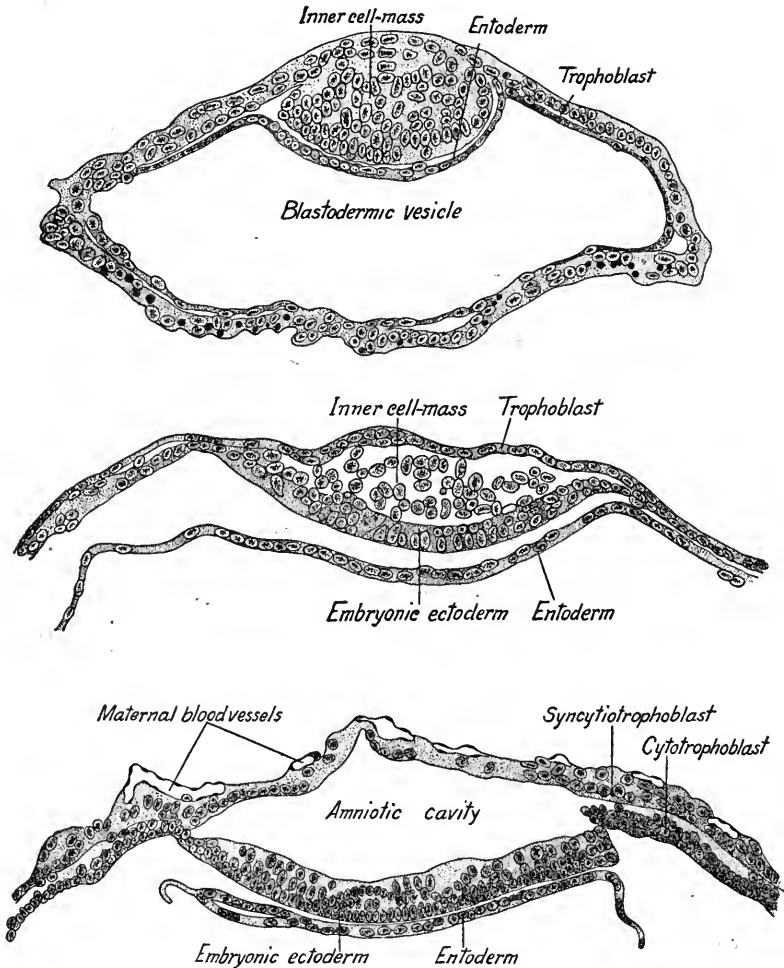


FIG. 71.—Section showing three stages in the formation of the amnion of bat embryo (after Van Beneden).

and gets rid of waste products through the walls of the villi. The region where the attachment of the chorionic villi to the uterine wall persists during fetal life is known as the *placenta*. It will be described later with the decidual membranes of the uterus. We saw how the allantois of Ungulates had assumed the nutritive



functions performed by the yolk-sac in birds, with a consequent degeneration of the ungulate yolk-sac. In man and Unguulates, the functions of the allantois are transferred to the chorion and the allantois in turn becomes a rudimentary structure.

**The Amnion.**—This is formed precociously in Unguulates and in a manner quite different from its mode of origin in Ungulates and birds. It is assumed that its cavity arises as a split in the primitive ectoderm of human embryos, as in bat embryos (Fig. 71). Later, a somatic layer of mesoderm envelops its ectodermal layer, its component parts then being the same as in birds and Ungulates, an inner layer of ectoderm and an outer layer of mesoderm (Fig. 70 D). It becomes

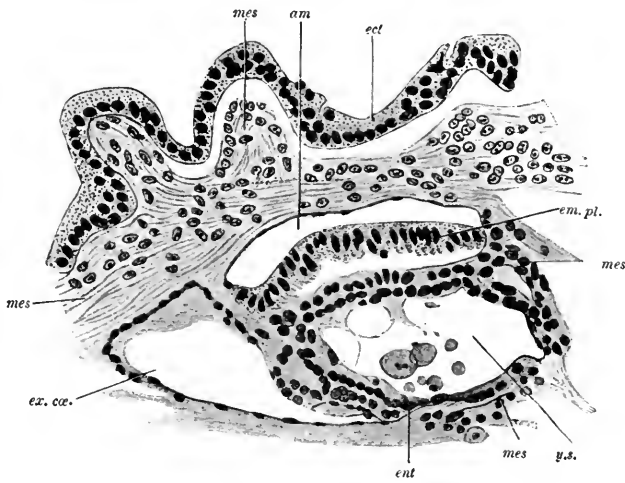


FIG. 72.—Section of embryonic rudiment in Peters' ovum (first week) (after Peters). *ect*, ectoderm of chorion; *mes*, mesoderm; *am*, amnion; *em. pl.*, embryonic plate; *y.s.*, yolk-sac; *ent*, entoderm; *ex. ca.*, portion of extra-embryonic coelom limited by a strand of the magma reticulare.

a thin, pellucid, non-vascular membrane and about a month before birth is in contact with the chorion. It then contains from one-half to three-fourths of a liter of amniotic fluid, the origin of which is unknown. During the early months of pregnancy the embryo, suspended by the umbilical cord, floats in the amniotic fluid. The embryo is protected from maceration by a white fatty secretion, the *vernix caseosa*.

At birth the amnion is ruptured either normally or artificially. If not ruptured, the child may be born enveloped in the amnion popularly known as a *veil* or "*caul*." The amniotic fluid may be present in excessive amount, the condition being known as *hydramnios*. If less than the normal amount of fluid is present, the amnion may adhere to the embryo and produce malformations. It has been found, too, that fibrous bands or cords of tissue may extend across the amniotic cavity and, pressing upon parts of the embryo

during its growth, may cause scars and splitting of eyelids or lips. Such amniotic threads may even amputate a limb or cause the bifurcation of a digit producing a type of polydactylism.

**The Allantois.**—The allantois appears very early in the human embryo be-

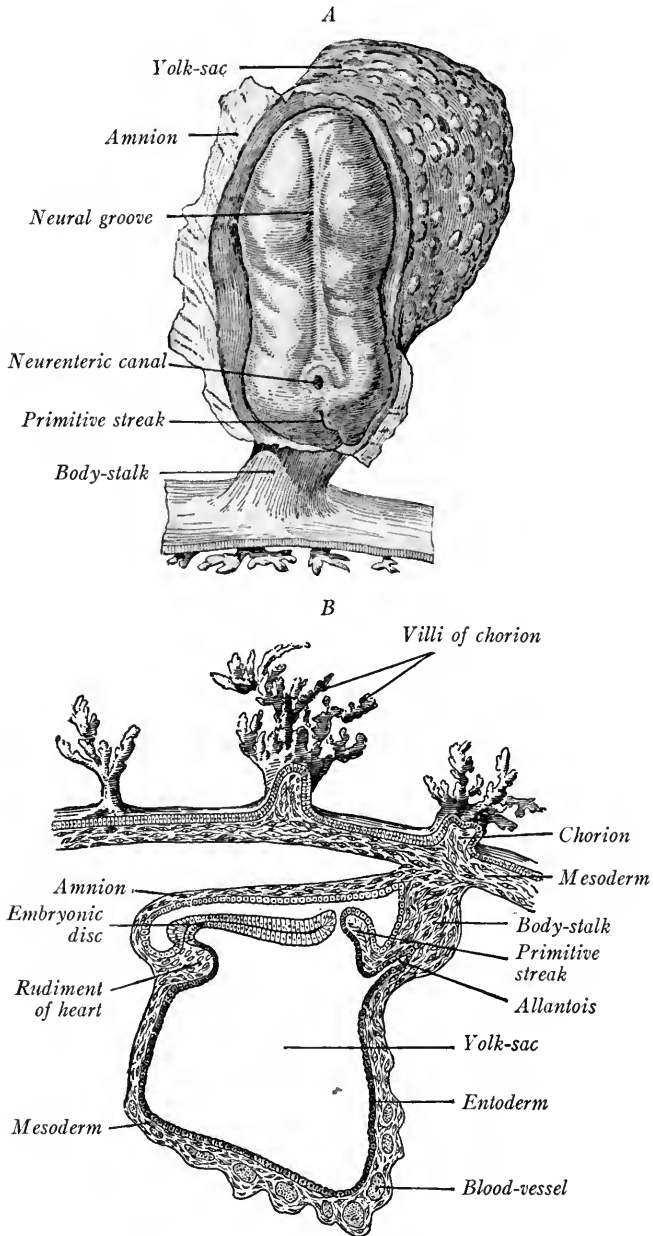


FIG. 73.—Views of a human embryo 1.54 mm. long. *A*, dorsal surface; *B*, median sagittal section (Graf Spee).

fore the development of the fore-gut or hind-gut. In Peter's embryo the amnion, chorion and yolk-sac are present but not the allantois (Fig. 72). In an embryo 1.54 mm. long, described by Von Spee (Fig. 73 A, B), there is no hind-gut, but the allantoic diverticulum of the entoderm has invaded the mesoderm of the body-stalk. This embryo, seen from the dorsal side with the amnion cut away, shows a marked neural groove and primitive streak. In front of the primitive knot a pore is figured leading from the neural groove into the primitive intestinal cavity, hence called the *neurenteric canal*. The fore-gut and head-fold have formed at this stage and there are branched chorionic villi.

A reconstruction by Dandy of Mall's embryo, about 2 mm. long with seven pairs of segments, shows well the embryonic appendages (Fig. 74). The fore- and hind-gut are well developed, the amniotic cavity is large, and the yolk-sac still communicates with the gut through a wide opening. The allantois is present as a long curved tube somewhat dilated near its blind end and embedded in the mesoderm of the body-stalk. As the hind-gut develops, the allantois comes to open into its ventral wall. A large umbilical artery and vein are present in the body-stalk.

In an embryo of 23 somites 2.5 mm. long, described by Thompson, the allantois has elongated and shows three irregular dilatations (Fig. 75). A large cavity never appears distally in the human allantois as in Ungulates. When it becomes included in the umbilical cord its distal portion is tubular and it eventually atrophies. That part of the allantois extending from the umbilicus to the cloaca of the hind-gut takes part in forming the *urogenital sinus*, the *bladder* and the *urachus*, a rudiment extending as a solid cord from the fundus of the bladder to the umbilicus. According to Felix, the allantois forms only the urachus and a portion of the bladder.

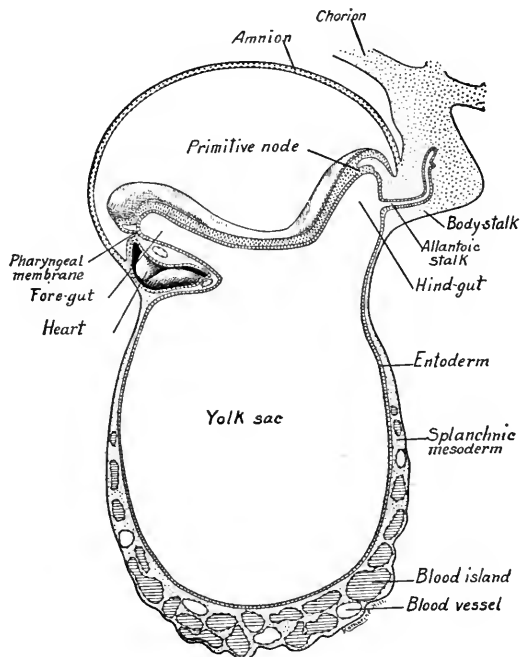


FIG. 74.—A human embryo of 2 mm. in median sagittal section (adapted from reconstructions of Mall's embryo by F. T. Lewis and Dandy).

The human allantois is thus small and rudimentary as compared with that of birds and Ungulates. As we have seen, the cavity is very large in the pig, and Haller found an allantoic sac two feet long connected with a goat embryo of two inches. In human embryos it appears very early and is not free but embedded in the body-stalk. Its functions, so important in birds and Ungulates, are in man performed by the chorion.

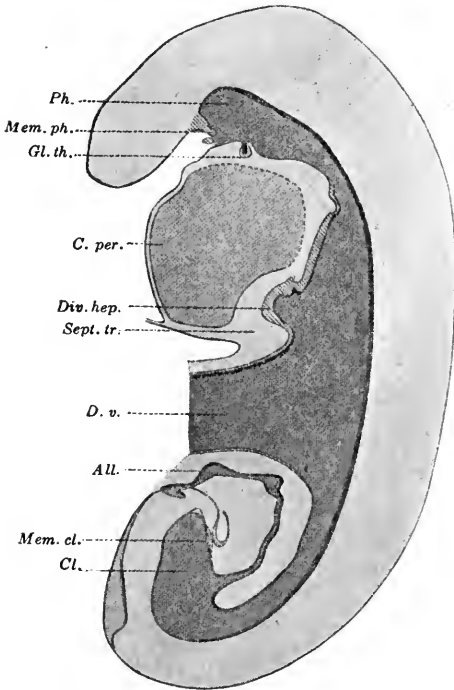


FIG. 75.—Median sagittal section of a 2.5 mm. human embryo showing digestive tract (after Thompson).  $\times 40$ . *All.*, allantois; *Cl.*, cloaca; *C. per.*, pericardial cavity; *Div. hep.*, hepatic diverticulum; *D. v.*, ductus vitellinus (yolk-stalk); *gl. th.*, thyroid gland; *Mem. cl.*, cloacal membrane; *Ph.*, pharynx; *Sept. tr.*, septum transversum.

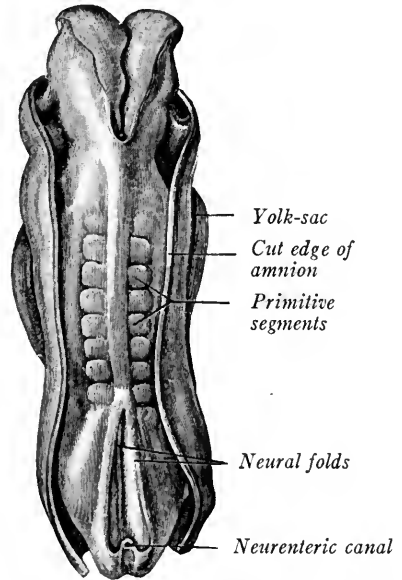


FIG. 76.—Human embryo of 2.11 mm. (Eternod).

**Yolk-Sac and Yolk-Stalk.**—In the youngest human embryos described (Peters) the entoderm forms a somewhat elongated vesicle. With the development of the fore-gut and hind-gut in embryos of 1.54 and 2 mm. (Figs. 73 and 74), the entodermal vesicle is divided into the dorsal intestine and ventral *yolk-sac*, the two being connected by a somewhat narrower region. This condition persists in an embryo of 2.5 mm. long (Fig. 75). In the figure most of the yolk-sac has been cut away. An embryo with 9 pairs of segments, with three brain vesicles and with the amnion cut away is seen in Fig. 76. The relation of the fetal appendages to the embryo shows well in the embryo of Coste (Fig.

77). The dorsal convexity is probably abnormal. A robust body-stalk attaches the embryo to the inner wall of the chorion. With the growth of the head- and tail-folds of the embryo, there is an apparent constriction of the yolk-sac where it joins the embryo. This will become more marked in later stages and form the *yolk-stalk*. His's embryo, 2.6 mm. long, shows the relative size of yolk-sac and embryo and the yolk-stalk (Fig. 78). The relations of the fetal membranes to the embryo are much the same as in the chick embryo of five days, save that the allantois of the human embryo is embedded in the body-stalk. The embryo shows a regular convex dorsal curvature, there is a marked cephalic bend in the region of the mid-brain and there are three gill clefts. The head is twisted to the right, the tail to the

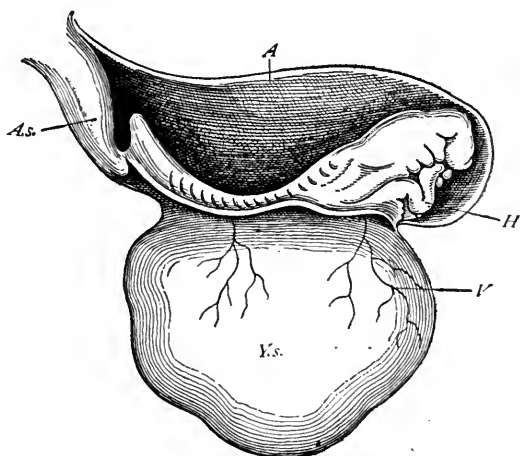


FIG. 77.—Human embryo at the commencement of the third week (from His, after Coste).  $\times 15$ . *A*, inner or true amnion; *A.s.*, body-stalk; *H*, heart; *V*, blood-vessel on yolk-sac; *Y.s.*, yolk-sac.

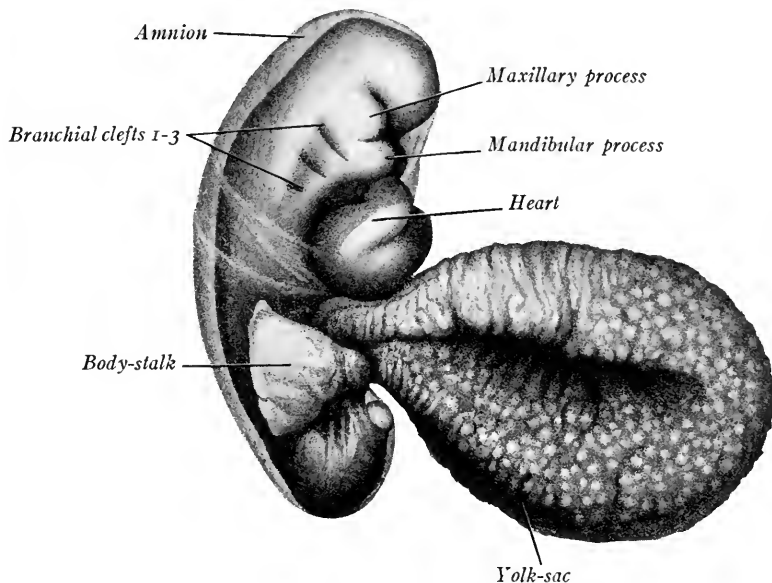


FIG. 78.—Human embryo 2.6 mm. long showing amnion, yolk-stalk and body-stalk (His).

left. At the side of the oral sinus are two large processes; the dorsal of these is the *maxillary*, the ventral the *mandibular process*. The heart is large and flexed in much the same way as the heart of the fifty-hour chick embryo.



FIG. 79.—Yolk-sac and-stalk of a 20 mm. human embryo.  $\times 11$ .

In later stages, with the development of the umbilical cord, the yolk-stalk becomes a slender thread extending from the dividing line between the fore- and hind-guts to the yolk-sac or umbilical vesicle (Fig. 114). It loses its attachment to the gut in 7 mm. embryos. A blind pocket may persist at its point of

union with the intestine and is known as Meckel's diverticulum, a structure of clinical importance because it may telescope and cause the occlusion of the intestinal lumen. The yolk-stalk may remain embedded in the umbilical cord and extend some distance to the yolk-sac which is found between the amnion and chorion (Fig. 79). The yolk-sac may be persistent at birth.

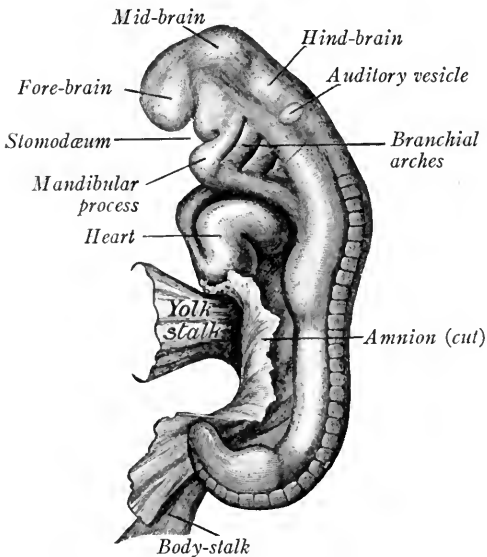


FIG. 80.—Left side of a human embryo of 4.2 mm. (His).

#### THE ANATOMY OF A 4.2 MM. HUMAN EMBRYO

This embryo, studied and described by His, is probably not quite normal. It shows a concave dorsal flexure which Keibel regards as due to distortion. Viewed from the left side (Fig. 80), with the amnion cut away close to its line of attachment, there may be seen the yolk-stalk, and a portion of the yolk-sac and of the

body-stalk. There is an indication of the primitive segments along the dorso-lateral line of the trunk. The head is bent ventrad almost at right angles in the mid-brain region (cephalic flexure). There are also marked cervical and caudal flexures, the trunk ending in a short blunt tail. The heart is large and flexed as in the earlier stage. Three gill clefts separate the four branchial arches. The first has developed two ventral processes. Of these the *maxillary process* is small and may be seen dorsal to the stomodæum. The *mandibular process* is large and has met its fellow of the right side to form the mandible or lower jaw. Dorsal to the second gill cleft may be seen the position of the oval *otocyst*, now a closed sac. Opposite the atrial portion of the heart and in the region of the caudal flexure bud-like outgrowths indicate the anlagen of the upper and lower extremities.

**Central Nervous System and Sense Organs.**—The neural tube is closed throughout its extent and is differentiated into brain and spinal cord. The brain tube or *encephalon* is divided by constrictions into four regions or vesicles as in the fifty-hour chick (Fig. 55). Of these, the most cephalad is the *telencephalon*. It is a paired outgrowth from the fore-brain, the persisting portion of which is the *diencephalon*. The mid-brain or *mesencephalon* located at the cephalic flexure is not subdivided. The hind-brain, or rhombencephalon, which is long and continuous with the spinal cord, later is subdivided into the *metencephalon* (region of the cerebellum and pons) and *myelencephalon* (medulla oblongata). The spinal cord forms a closed tube extending from the brain to the tail and containing the neural cavity, flattened from side to side.

The *eye* is represented by the optic vesicles and the thickened ectodermal anlage of the lens. Its stage of development is between that of the thirty-six and fifty-hour chick embryos.

The *otocyst* is a closed sac, no longer connected with the outer ectoderm as in the fifty-hour chick.

**Digestive Canal.**—In a reconstruction of the viscera viewed from the right side (Fig. 81), the entire extent of the digestive canal may be seen. The *pharyngeal membrane* which we saw developed in the chick between the stomodæum and the pharynx has broken through so that these cavities are now in communication. The *fore-gut*, which extends from the oral cavity to the yolk-stalk is differentiated into *pharynx*, *trachea* and *lungs*, *esophagus* and *stomach*, *small intestine* and *digestive glands* (pancreas and liver). The gut is suspended from the dorsal body wall by the *dorsal mesentery*.

The ectodermal limits of the oral cavity are indicated dorsad by the diverti-

culum of the hypophysis (Rathke's pocket). The fore-gut proper begins with a shallow out-pocketing known as Seessel's pocket. As the pharyngeal membrane disappears between these two pockets, it would seem that Seessel's pocket represents the persistence of the blind anterior end of the fore-gut. No other significance has been assigned to it.

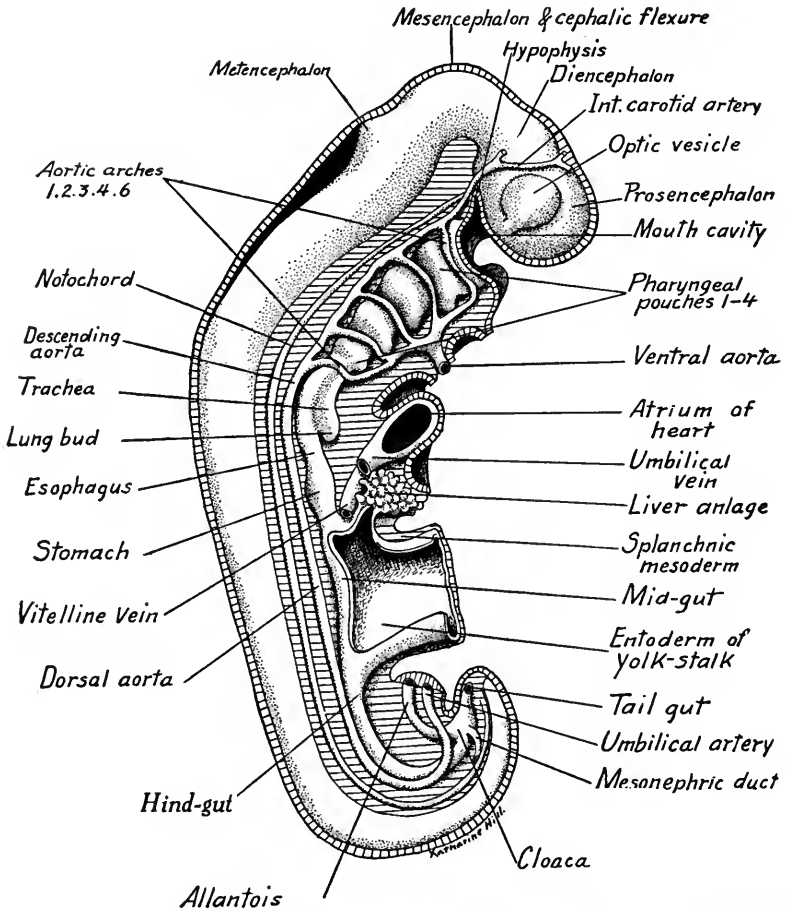


FIG. 81.—Diagrammatic reconstruction of a 4.2 mm. human embryo, viewed from the right side (adapted from a model by His).

The *pharynx* is widened laterally and at this stage shows four pharyngeal pouches. Later a fifth pair of pouches is developed (Fig. 82). The four pairs of pharyngeal pouches are important as they form respectively the following adult structures: (1) the *Eustachian tubes*; (2) the *palatine tonsils*; (3) the *thymus anlages*; (4) the *parathyroids* or *epithelial bodies*. Between the pharyngeal pouches are the five branchial arches in which are developed five pairs of aortic arches. Between the bases of the first and second branchial arches, on



the floor of the pharynx, is developed the *tuberculum impar* which may form a portion of the anterior part of the tongue. Posterior to this unpaired anlage of the tongue there grows out ventrally the anlage of the *thyroid gland*. From the caudal end of the trachea have appeared ventrally the lung buds. The trachea is still largely a groove in the ventral wall of the pharynx and esophagus. Caudal to the lungs a slight dilation of the digestive tube indicates the position

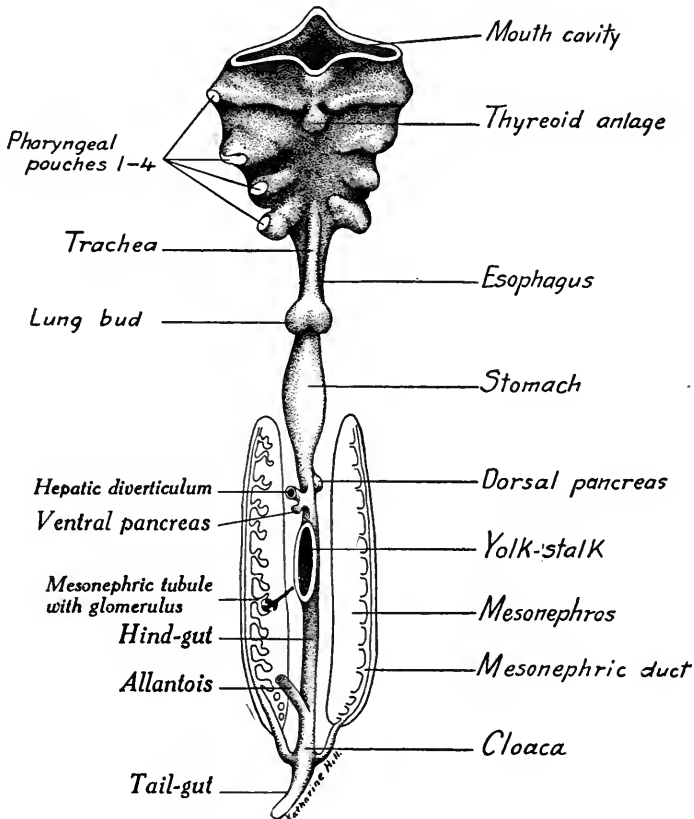


FIG. 82.—Diagrammatic ventral view of pharynx, digestive tube and mesonephroi of a 4-5 mm. embryo (based on reconstructions by Grosser and His). The liver and yolk-sac are cut away. The tubules of the right mesonephros are shown diagrammatically.

of the stomach. The liver diverticulum has grown out from the fore-gut into the ventral mesentery cranial to the wall of the yolk-stalk. It is much larger than in the fifty-hour chick, where we saw its paired anlage cranial to the *fovea cardiaca*, and is separated from the heart by the *septum transversum*. The small intestine between the liver and yolk-stalk is short and broad. In later stages it becomes enormously elongated as compared with the rest of the digestive tube. The yolk-stalk is still broad and wide. The region of its attachment

to the gut corresponds to the open mid-gut of the chick embryo. The *hind-gut* and tail-fold of this embryo are greatly elongated as compared with the chick embryo of fifty hours. The hind-gut terminates blindly in the tail. Near its caudal end it is dilated to form the *cloaca*. Into the ventral side of the cloaca opens the stalk of the *allantois*. Dorso-laterally the primary excretory (Wolffian) ducts which we saw developed in the fifty-hour chick have connected with and open into the cloaca. Caudal to the cloaca on the ventral side is the cloacal membrane, which later divides and breaks through to form the genital aperture and anus. That part of the hind-gut between the cloaca and the yolk-stalk forms the rectum, colon, cæcum, and appendix, with a portion of the small intestine (ileum).

**Urogenital Organs.**—We have seen that the primary excretory (Wolffian) ducts open into the cloaca. These are the ducts of the mid-kidney or *mesonephros*. At this stage the nephrotomes, which in the chick embryos formed the anlagen of these ducts, are also forming the kidney tubules of the mesonephros which open into the ducts (Fig. 82). The mid-kidneys project into the peritoneal cavity as ridges on each side. A thickening of the mesothelium along the median halves of the mesonephroi forms the anlage of the genital glands or *gonads* (Fig. 213).

**Circulatory System.**—The *heart* is an S-shaped double tube as in the fifty-hour chick. The outer myocardium is confined to the heart, while the inner endothelial layer is continuous, at one end with the veins, at the other end with the arteries. The disposition of the heart tube is well seen in a ventral view of a younger embryo (Fig. 83). The veins enter the sinus venosus just cranial to the yolk-sac. Next in front is the *atrium* with the convexity of its flexure directed cephalad. The ventricular portion of the heart is U-shaped and is flexed to the right of the embryo. To the left is the ventricular limb, to the right is the bulbus. The *arteries* begin with the ventral aorta which bends back to the midline and divides into five branches on each side of the pharynx (Figs. 83 and 84). These are the *aortic arches* and they unite dorsally to form two trunks, the *descending aortæ*. The aortic arches pass around the pharynx between the gill clefts in the branchial arches. The arrangement is like that of the adult fish which has its gill slits, branchial arches and aortic arches to supply the gills. The descending aortæ run caudad and opposite the lung buds unite to form a single median dorsal aorta. This in the region of the posterior limb buds divides into the two umbilical arteries, which, curving cephalad and ventrad, enter the body-stalk on each side of the allantois and eventually ramify in the villi of the chorion. The vitelline arteries, large and paired in the chick, are

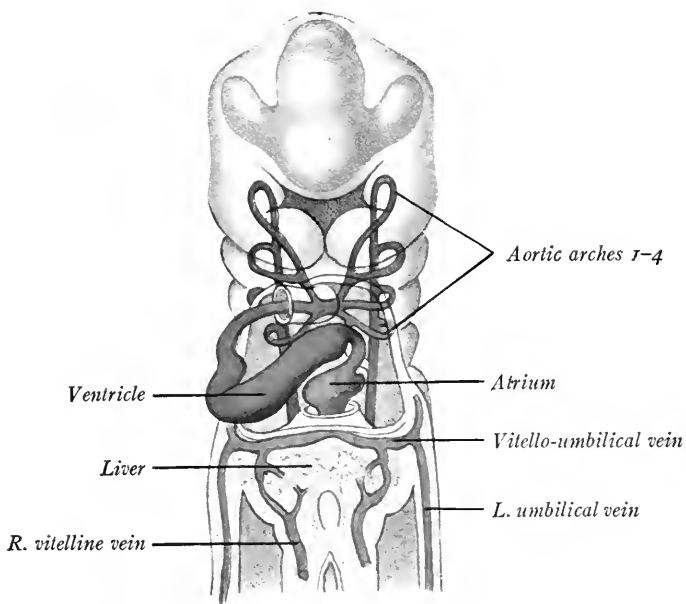


FIG. 83.—Ventral reconstruction of a 3.2 mm. embryo, showing vessels (His).

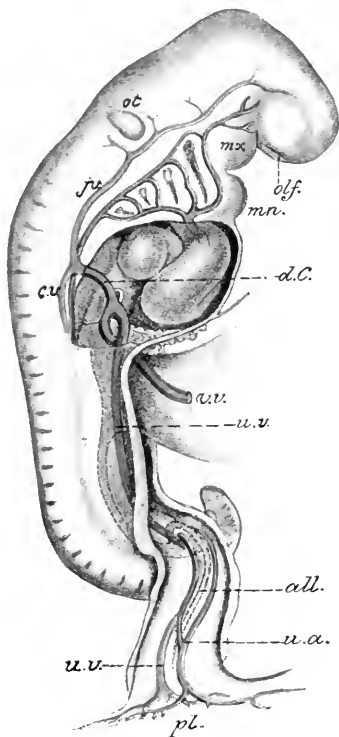



FIG. 84.—Lateral view of human embryo of 4.2 mm., showing aortic arches and venous trunks (His).  
*mx*, Maxillary process; *mm*, mandibular arch; *d.C.*, common cardinal vein; *j.v.*, anterior cardinal vein; *c.v.*, posterior cardinal vein; *v.v.*, vitelline vein; *u.a.*, umbilical artery; *u.v.*, umbilical vein; *all.*, allantois; *pl.*, placental attachment of body-stalk; *olf.*, olfactory pit; *ot*, otocyst.



represented by a single small trunk which branches on the surface of the yolk-sac (Fig. 84). Compared with the arterial circulation of the chick of fifty hours the important differences are (1) the development of the fourth and the fifth pairs of aortic arches, and (2) the presence of the chorionic circulation by way of the umbilical arteries in addition to the vitelline circulation found in the fifty-hour chick.

The *veins* are all paired and symmetrically arranged (Figs. 83 and 84). There are three sets of them: (1) The blood from the body of the embryo is drained, from the head end by the *anterior cardinal veins*; from the tail end of the body by the *posterior cardinal veins*. These veins on each side unite dorsal to the heart and form a single *common cardinal vein* which joins the umbilical vein of the same side. (2) Paired *vitelline veins* in the early stages of the embryo drain from the yolk-sac the blood carried to it by the vitelline arteries. The trunks of these veins pass back into the body on each side of the yolk-stalk and liver and with the paired umbilical veins form a trunk which empties into the sinus venosus of the heart. As the liver develops it may be seen (Fig. 83) that the vitelline veins break up into blood spaces called by Minot *sinusoids*. When the liver becomes large and the yolk-sac rudimentary the vitelline veins receive blood chiefly from the liver and intestine. (3) A pair of large *umbilical veins* which drain the blood from the villi of the chorion and are the first veins to appear. These unite in the body-stalk and, again separating, enter the somatopleure on each side. They run cephalad to the septum transversum where they unite with the vitelline veins to form a common vitello-umbilical trunk which empties into the sinus venosus.

The veins of this embryo are thus like those of the fifty-hour chick save that *the umbilical vessels are now present and take the place of the allantoic veins of later chick embryos*. The veins, like the heart and arteries, are primitively paired and symmetrically arranged. As development proceeds their symmetry is largely lost and the asymmetrical venous system of the adult results.

The later stages of the human embryo can not be described in detail here. The student is referred to the texts of Minot, Keibel, and Mall. Two embryos will be compared with the pig embryos described in Chapter V. Figs. 85 and 86 show the human embryos described by His, the age of which was estimated by him at from two weeks to two months. The figures show as well as could any description the changes which lead to the adult form when the embryo may be called a *fetus*. The external metamorphosis is due principally: (1) to changes in the flexures of the embryo; (2) to the development of the face; (3) to the development of the external structure of the sense organs (nose, eye and ear);

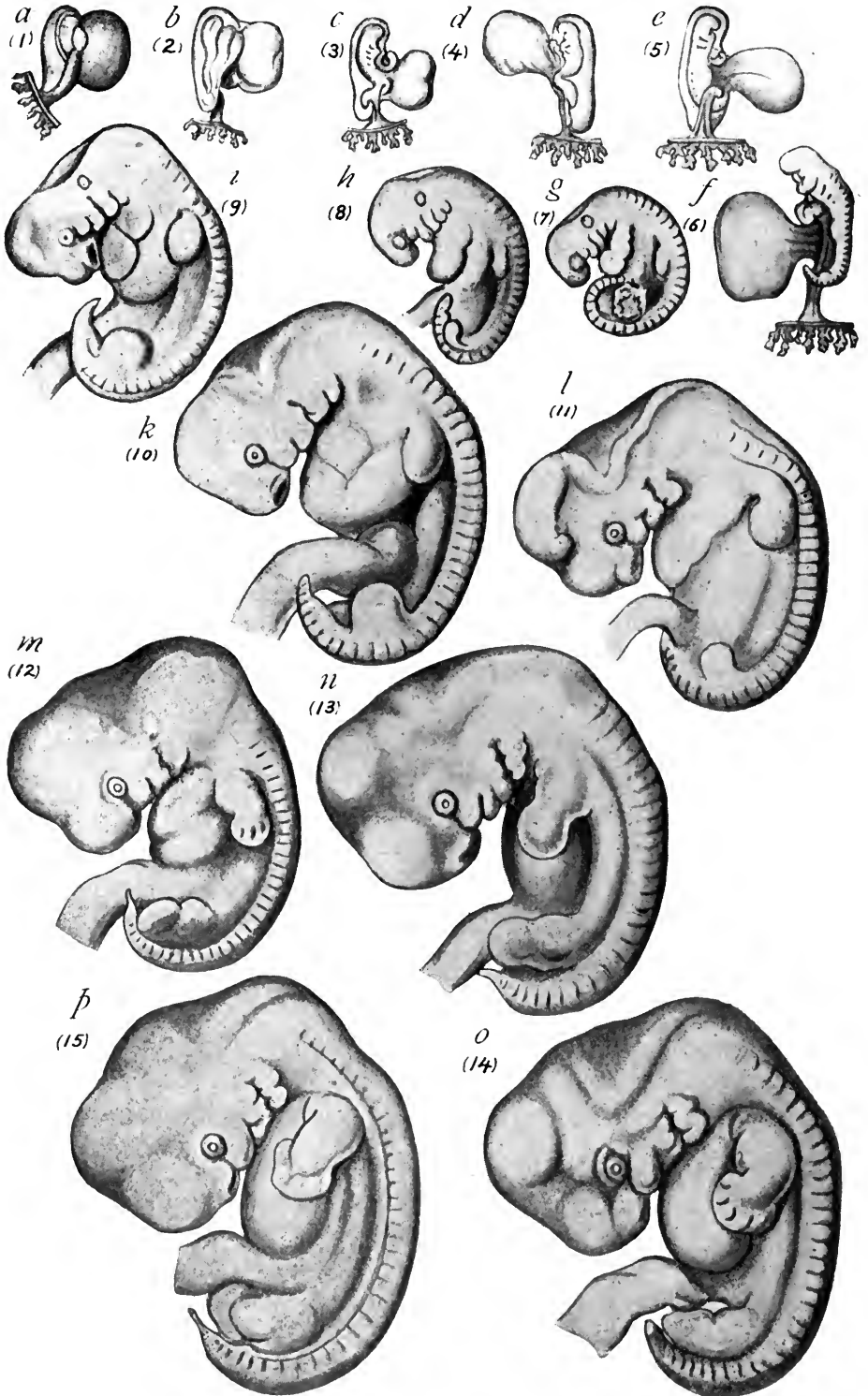


FIG. 85.—Embryos of His' Normentafel. The embryos figured are of the first month (Keibel and Elze).  
 × 5.

(4) to the development of the extremities and disappearance of the tail. The more important of these changes will be dealt with in later chapters.

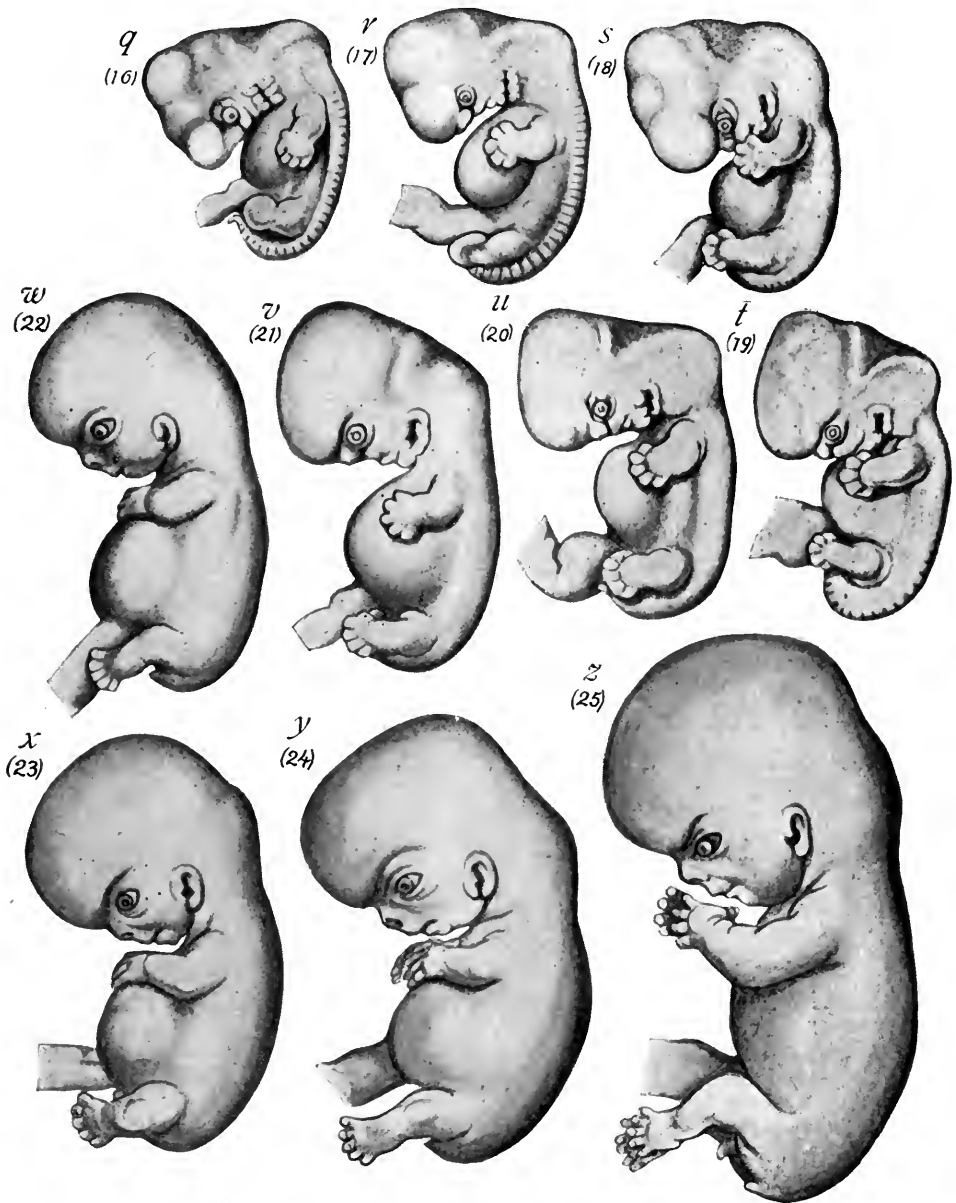


FIG. 86.—Embryos of the second month from His' Normentafel (Keibel and Elze).

**Age of Human Embryos.**—The ages of the human embryos which have been obtained and described can not be determined with certainty, because fertilization does not necessarily follow directly after coitus. It has been shown

also that ovulation does not always coincide with menstruation so that the menstrual period cannot be taken as the starting point of pregnancy. In 1868, Reichert, from studying the corpus luteum in ovaries obtained during menstruation, concluded that ovulation takes place as a rule just before menstruation and that if the ovum is fertilized the next menstruation does not occur. Reichert then decided that a human embryo of 5.5 mm., which he had obtained from a woman two weeks after menstruation failed to occur, must be two weeks, not six weeks, old. His accepted Reichert's views and since then the ages of embryos have been estimated on this basis. According to this view, Peter's ovum, obtained thirty days after the last period, is only three or four days old. This does not agree at all with what is known of the age of other mammalian embryos.

From the observations of Mall and obstetricians of the present day, we must conclude that ovulation does not immediately precede menstruation but that most pregnancies take place during the first or second week after the menstrual period. It is therefore more correct to compute the age of the embryo from the end of the last menstruation or, according to Grosser, from the tenth to the twelfth day before the first missed menstrual period. Peter's embryo then would be about fifteen days old. To compare an embryo with one of known age, the length from vertex to breech is usually taken. Embryos of the same age vary greatly in size so that their structure must be taken into account. At the present time, the exact relation of ovulation to menstruation is not known nor the exact time required for the fertilized ovum to reach the uterus. The computed age of the embryo can be thus only approximate.

The period of gestation of the human fetus is usually computed from the beginning of the last menstrual period. Forty weeks or two hundred and eighty days is the time usually allowed. As some women menstruate once or more often after becoming pregnant this is not a certain basis for computation.

The following are the estimated ages, lengths, and weights of human embryos according to Mall, Schroeder, and Fehling:

AGE	LENGTH IN MILLIMETERS	WEIGHT IN GRAMS
Eighteen to twenty-one days.....	0.5	..
Twenty-four to thirty days.....	2.5	..
Thirty-one to thirty-five days.....	5.5	..
Thirty-eight to forty-two days.....	11.0	..
Fifty days.....	20.0	..
Second lunar month.....	30.0	..
Third lunar month.....	70.0-100.0	20
Fourth lunar month.....	180.0	120
Fifth lunar month.....	250.0	285
Sixth lunar month.....	315.0	635
Seventh lunar month.....	370.0	1220
Eighth lunar month.....	425.0	1700
Ninth lunar month.....	470.0	2240
Tenth lunar month.....	500.0	3250



## CHAPTER V

### THE STUDY OF SIX AND TEN MILLIMETER PIG EMBRYOS

#### A. THE ANATOMY OF A 6 MM. PIG EMBRYO

In its early stages the pig embryo is flattened out on the surface of the yolk-sac like a chick embryo (Fig. 87), but as the head- and tail-folds elongate the body becomes flexed and twisted spirally, making it difficult to study. In embryos 5 to 7 mm. long the twist of the body begins to disappear and its structure may be seen to better advantage.

**External Form of 6 mm. Embryo.**—When compared with the form of the 4 mm. human embryo, its marked difference is the convex dorsal flexure which brings the head and tail regions close together (Fig. 88). The flexure at the mesencephalon forms an acute angle and there is a marked neck or cervical flexure. As a result, the head is somewhat triangular in form. The body is bent dorsad in an even convex curve and the tail is flexed sharply dorsad and to the right side. Lateral to the dorsal line may be seen the segments, which become larger and more differentiated as we go from tail to head. At the tip of the head a shallow depression marks the anlage of the *olfactory pit*. The *lens vesicle* of the eye is open to the exterior. Caudal to the eyes at the sides of the head are four *branchial arches* separated by three grooves, the *branchial clefts*. The fourth arch is partly concealed in a triangular depression, the *cervical sinus* (see Fig. 92). The first, or

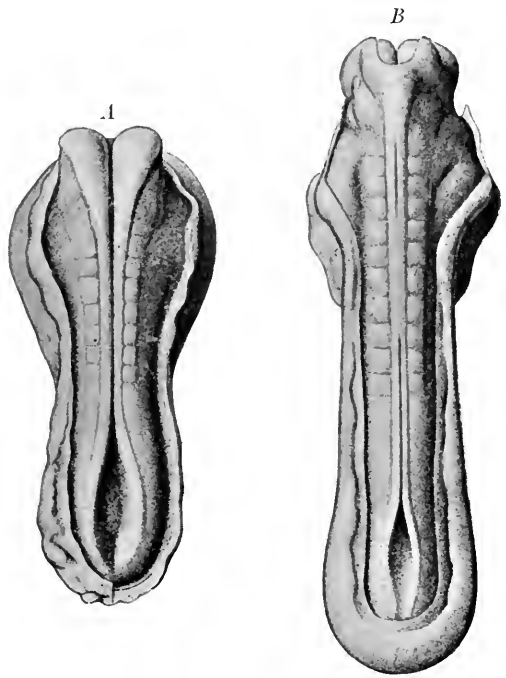


FIG. 87.—Pig embryos (A) of seven and (B) of eleven primitive segments, dorsal view, with amnion cut away (Keibel, Normentafel).  $\times 20$ .

*mandibular arch*, forks ventrally into two processes, a smaller *maxillary* and a larger *mandibular process*, and the latter with its fellow forms the mandible or lower jaw. The position of the mouth is indicated by the cleft between these processes. The groove between the eye and the mouth is the *lacrymal groove*.

The second or *hyoid arch* is separated from the mandibular arch by a *hyo-mandibular cleft* which persists as the *external auditory meatus*. About the dorsal end of the cleft develops the external ear.

The heart is large and through the transparent body wall may be seen the dorsal *atrium* and ventral *ventricle*. Caudal to the heart, a convexity indicates

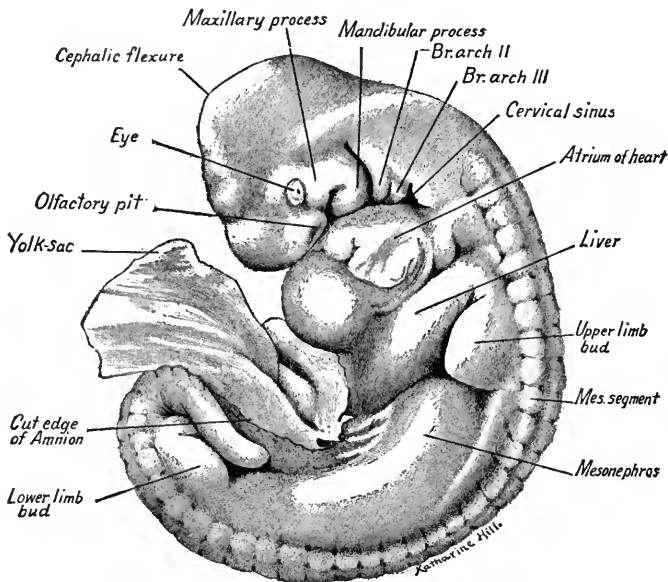


FIG. 88.—Pig embryo of 6 mm., viewed from the left side. The amnion has been removed and its cut edge is shown in the figure.  $\times 12$ .

the position of the *liver*. Dorsal to the liver is the bud of the *anterior extremity*, now larger than in the 4 mm. human embryo. Extending caudal to the anlage of the upper extremity, a curved convexity indicates the position of the right *mesonephros*. At its caudal end is the bud of the *lower limb*. The amnion has been dissected away along the line of its attachment ventral to the mesonephros. There is as yet no distinct umbilical cord and a portion of the body-stalk is attached to the embryo.

As the term of its development is shorter, a young pig embryo is somewhat precocious in its development as compared with a human embryo of the same size (Fig. 89). In a human embryo 7 mm. long the head is larger, the tail shorter.

The cervical flexure is more marked, the olfactory pits larger and deeper. The liver is more prominent, the mesonephros and segments less so than in the 6 mm. pig.

## LATERAL DISSECTION OF THE VISCERA

To understand the sectional anatomy of an embryo, a study of dissections and reconstructions is essential. For methods of dissection see p. 146, Chapter

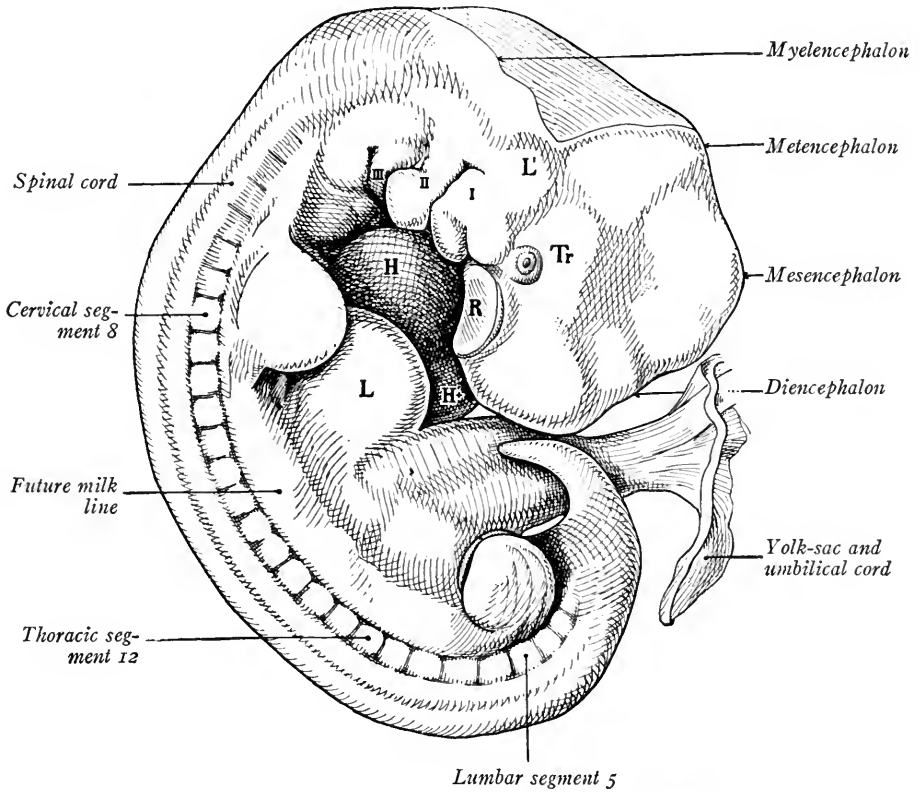


FIG. 89.—A human embryo 7 mm. long, viewed from the right side (Mall in Kollmann's Hand-atlas). *I, II, III*, branchial arches 1, 2 and 3; *H, Ht*, heart; *L*, liver; *L'*, otic vesicle; *R*, olfactory placode; *Tr*, semi-lunar ganglion of trigeminal nerve.

VI. Before studying sections, the student should become as well acquainted as possible with the anatomy of the embryo and compare each section with the figures of reconstructions and dissections.

**Nervous System.**—Fig. 90 shows the central nervous system and viscera exposed on the right side of a 5.5 mm. embryo. The ventro-lateral wall of the head has been left intact with the lens cavity, olfactory pit, and portions of the maxillary and mandibular processes, second and third branchial arches and

cervical sinus (see Fig. 88). The brain is differentiated into the five regions, *telencephalon*, *diencephalon*, *mesencephalon*, *metencephalon* and *myelencephalon*. The spinal cord is cylindrical and gradually tapers off to the tail. The anlagen of the cerebral and spinal ganglia and the main nerve trunks are shown. The *oculomotor nerve* begins to appear from the ventral wall of the mesencephalon. Ventro-lateral to the metencephalon and myelencephalon occur in order the

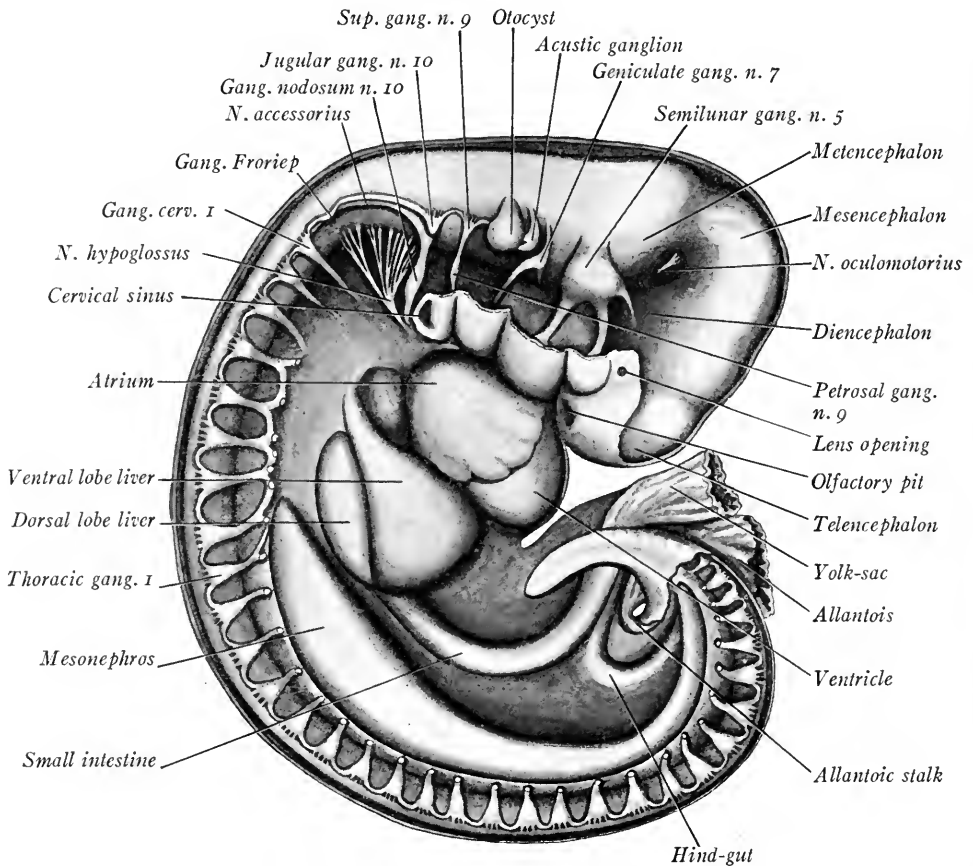


FIG. 90.—Dissection of a 5.5 mm. pig embryo, showing the nervous system and viscera from the right side.  $\times 18$ .

*semilunar ganglion* and three branches of the *trigeminal nerve*, the *geniculate ganglion* and nerve trunk of the *n. facialis*, the ganglionic anlage of the *n. acusticus* and the *otocyst*. It will be observed that the nerve trunks are arranged with reference to the branchial arches and clefts. Caudal to the otocyst a continuous chain of cells extends lateral to the neural tube into the tail region. Cellular enlargements along this *neural crest* represent developing cerebral and spinal

ganglia. They are in order the *superior* or *root ganglion* of the *glossopharyngeal* nerve with its distal *petrosal ganglion*; the ganglion *jugulare* and distal *ganglion nodosum* of the *vagus nerve*; the ganglionic crest and proximal portion of the *spinal accessory nerve*; and the anlage of *Froriep's ganglion*, an enlargement on the neural crest just cranial to the first cervical ganglion. Between the vagus and Froriep's ganglion may be seen the numerous root fascicles of the *hypoglossal nerve*, which take their origin along the ventro-lateral wall of the myelencephalon and unite to form a single trunk. The posterior roots of the spinal ganglia are very short; their anterior or ventral roots are not shown.

The position of the heart with its *ventricle*, *atrium* and *sinus venosus* are shown. The liver is divided into a small dorsal and a large ventral lobe. The *fore-gut* emerges from between the liver lobes and curves ventrad to the yolk-stalk and sac. The *hind-gut* is partly hidden by the fore-gut; it makes a U-shaped bend from the yolk-stalk to the caudal region. The gut is attached to the dorsal body wall by a double layer of splanchnic mesoderm which forms the *mesentery*. The long slender *mesonephros* lies ventral to the spinal cord and curves caudad from a point opposite the eighth cervical ganglion to the tail region. The cranial third of the mesonephros is widest and its size diminishes tailwards. Between the yolk-sac and the tail the allantois is seen, its stalk curving around from the ventral side of the tail region.

**Digestive Canal.**—The arrangement of the viscera may be seen in median sagittal and ventral dissections (Figs. 91 and 92), also in the reconstruction shown in Fig. 100. The *mouth* lies between the mandible, the median nasal process of the head, and the maxillary processes at the sides. The diverticulum of the *hypophysis*, flattened cephalo-caudad and expanded laterad, extends along the ventral wall of the fore-brain (Fig. 99). Near its distal end, the wall of the brain is thickened and later the posterior lobe of the hypophysis will develop from the brain wall at this point.

The **pharynx** is flattened dorso-ventrally and is widest near the mouth. Its lateral dimension narrows caudad, and opposite the third branchial arch it makes an abrupt bend, a bend which corresponds to the cervical flexure of the embryo's body (Figs. 99 and 100). In the roof of the pharynx just caudal to Rathke's pocket is the somewhat cone-shaped pouch known as *Seessel's pocket*, which may be interpreted as the blind cephalic end of the fore-gut. The lateral and ventral walls of the pharynx and oral cavity are shown in Fig. 93. Of the four arches the mandibular is the largest and a groove partly separates the processes of the two sides. Posterior to this groove and extending in the median line to the

hyoid arch is a triangular rounded elevation, the *tuberculum impar*, which later forms a part of the tongue. At an earlier stage the *median thyreoid* anlage grows out from the mid-ventral wall of the pharynx just caudal to the *tuberculum impar*. The ventral ends of the second arch fuse in the mid-ventral line and form a prominence, the *copula*. This connects the *tuberculum impar* with a

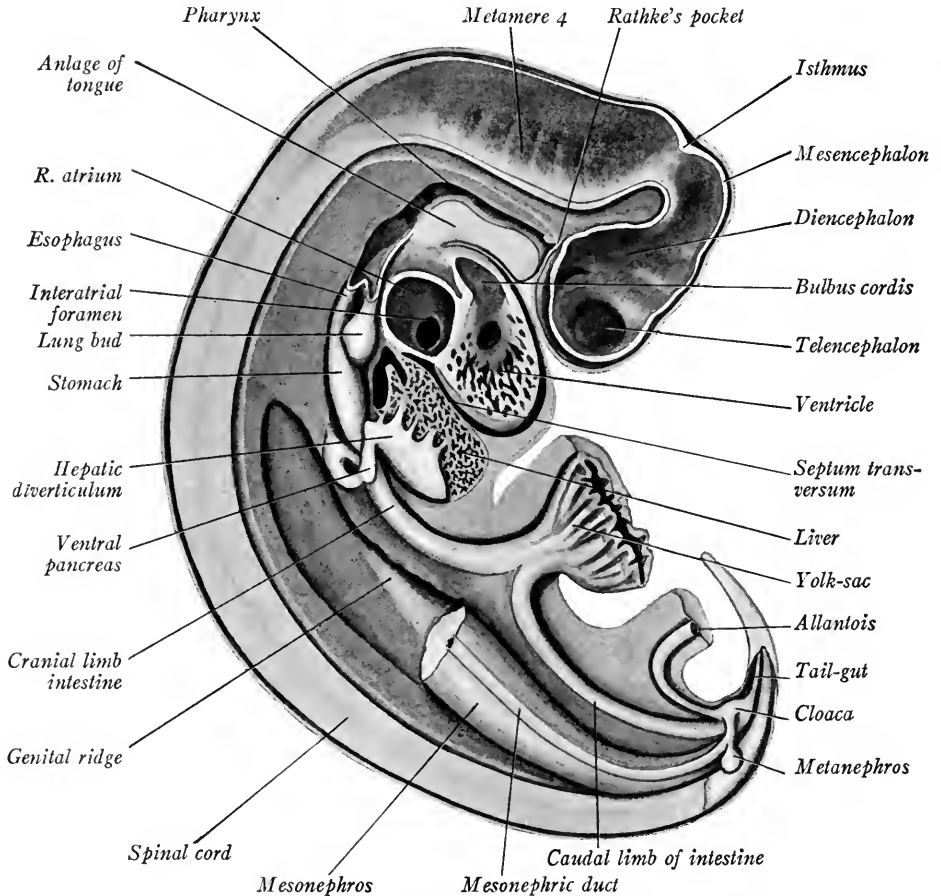


FIG. 91.—Median sagittal dissection of a pig embryo of 6 mm., to show viscera and neural tube.  $\times 18$ .

rounded tubercle derived from the third and fourth pairs of arches, the anlage of the *epiglottis*. Its cephalic portion forms the root of the tongue (compare Fig. 151 A and B). Caudal to the epiglottis are the *arytenoid ridges* and a slit between them, the *glottis*, leads into the trachea.

The *branchial arches* converge caudad and the pharynx narrows rapidly before it is differentiated into the *trachea* and *esophagus* (Figs. 99 and 100). Laterally and ventrally between the arches are the four paired outpocketings of

the pharyngeal pouches. The pouches have each a dorsal and ventral *diverticulum* (Fox, Thyng). The dorsal diverticula are large and wing-like (Fig. 99), meet the ectoderm of the gill clefts, fuse with it and form the *closing plates*. Between the ventral diverticula of the third pouch lies the *median thyroid anlage*. The fourth pouch is much smaller than the others. Its dorsal diverticu-

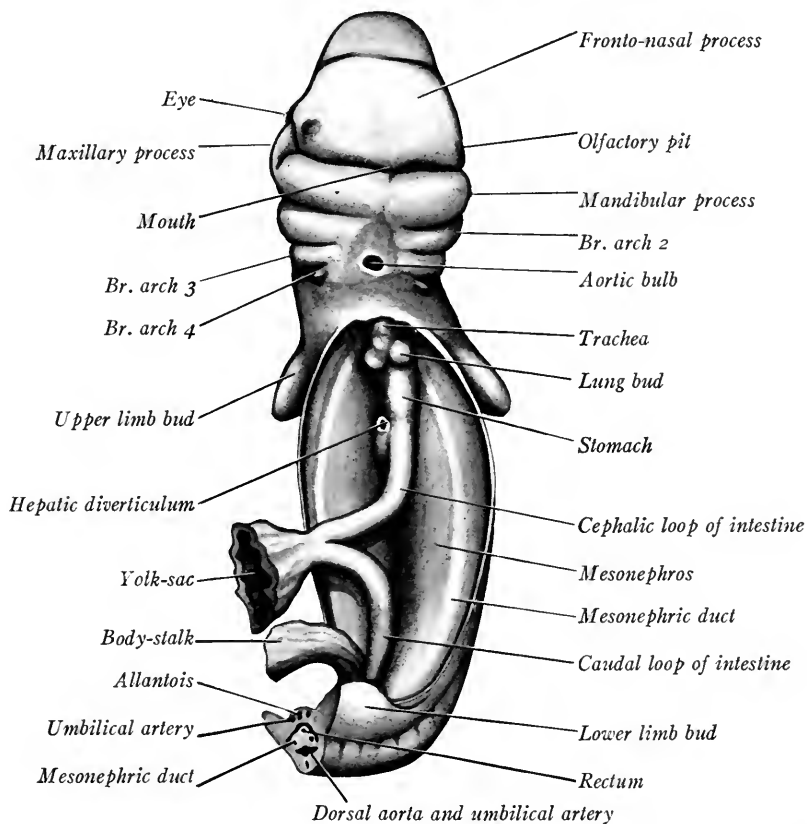


FIG. 92.—A ventral dissection of a 6 mm. pig embryo. The head has been bent dorsally. *Br. arch 2, 3 and 4*, branchial arches, 2, 3 and 4.

lum just meets the ectoderm, its ventral portion is small, tubular in form and is directed parallel to the esophagus (Fig. 99).

The groove on the floor of the pharynx caudal to the epiglottis is continuous with the tracheal groove. More caudally opposite the atrium of the heart the *trachea* has separated from the *esophagus*. The trachea at once bifurcates to form the *primary bronchi*, and the anlagen of the *lungs*. The lungs consist merely of the dilated ends of the bronchi surrounded by a layer of splanchnic mesoderm. They bud out laterally on each side of the esophagus near the cardiac end of the

stomach, and project into the *pleural calom*. The esophagus is short and widens dorso-ventrally to form the *stomach*. The long axis of the stomach is nearly straight, but its entodermal walls are flattened together and it has revolved on its long axis so that its dorsal border lies to the left, its ventral border to the right, as seen in transverse section (Fig. 106).

Caudal to the pyloric end of the stomach, and to its right is given off from the duodenum the *hepatic diverticulum*. Its opening into the gut is seen in the ventral dissection (Fig. 92). The hepatic diverticulum is a sac of elongated oval form which later gives rise to the gall bladder, cystic duct and common bile duct. It is connected by several cords of cells with the trabeculæ of the liver.

The *liver* is divided incompletely into four lobes, a small dorsal and a large ventral lobe on each side (Figs. 90 and 107). The lobation does not show in a median sagittal section. The *pancreas* is represented by two outgrowths. The

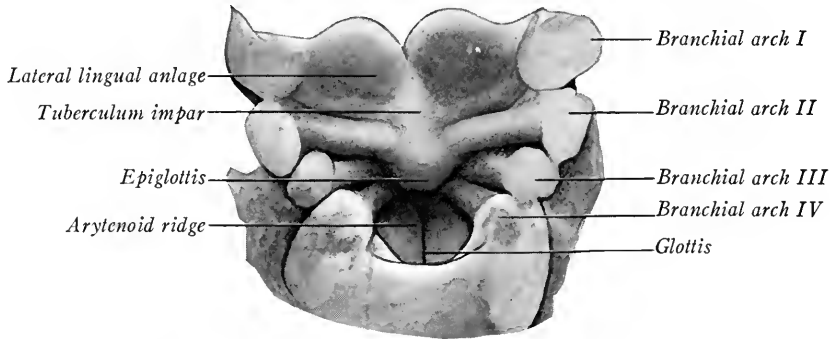


FIG. 93.—Dissection of the tongue and branchial arches of a 7 mm. pig embryo, seen in dorsal view.

*ventral pancreas* takes origin from the hepatic diverticulum near its attachment to the duodenum. It grows to the right of the duodenum and ventrad to the portal vein. The *dorsal pancreas* takes origin from the dorsal side of the duodenum caudal to the hepatic diverticulum and grows dorsally into the substance of the gastric mesentery (Figs. 100 and 108). It is larger than the ventral pancreas, and its posterior lobules grow to the right and dorsal to the portal vein and in later stages anastomose with the lobules of the ventral pancreas.

The *intestine* of both fore-gut and hind-gut has elongated and curves ventrally into the short umbilical cord where the yolk-stalk has narrowed at its point of attachment to the gut. As the intestinal tube grows ventrally, the layers of splanchnic mesoderm which attach it to the dorsal body wall grow at an equal rate and persist as the *mesentery*.

The *cloaca*, a dorso-ventrally expanded portion of the hind-gut gives off



cephalad and ventrad the allantoic stalk. This is at first a narrow tube but soon expands into a vesicle of large size, a portion of which is seen in Fig. 90. Dorso-laterad the cloaca receives the *primary excretory* (*Wolffian ducts*). The hind-gut is continued into the tail as the *tail-gut* (post-anal gut) which dilates at its extremity as in the 7.8 mm. pig described by Thyng. The mid-ventral wall of the cloaca is fused to the adjacent ectoderm to form the cloacal membrane. In this region later the *anus* arises (Fig. 100). The post-anal gut soon disappears.

The **urogenital organs** consist of the *mesonephroi*, the *mesonephric ducts*, the anlagen of the *metanephroi*, the *cloaca* and the *allantois*. The form of the mesonephroi is seen in Figs. 90 and 92. Each consists of large vascular glomeruli associated with coiled tubules lined with cuboidal epithelium and opening into the mesonephric duct (Figs. 107 and 109). The Wolffian ducts beginning at the anterior end of the mesonephros curve at first along its ventral, then along its lateral surface. At its caudal end each duct bends ventrad and to the midline, where it opens into a lateral expansion of the cloaca. Before this junction takes place, an evagination into the mesenchyme from the dorsal wall of each mesonephric duct gives rise to the anlagen of the *metanephroi*, or permanent kidneys. A slight thickening of the mesothelium along the median and ventral surface of each mesonephros forms a light-colored area, the *genital fold* (Fig. 91). This area is pointed at either end and confined to the middle third of the kidney. It is the anlage of the *genital gland* from which either testis or ovary is developed.

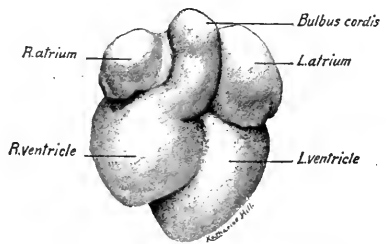


FIG. 94.—Ventral and cranial surface of the heart from a 6 mm. pig embryo.  $\times 14$ .

**Blood Vascular System.**—The *heart* lies in the pericardial cavity as seen in Fig. 91. The atrial region (Fig. 94), as in the 4.2 mm. human embryo, has given rise to two lateral sacs, the right and left atria. The bulbo-ventricular loop has become differentiated into right and left ventricles much thicker walled than the atria. The right ventricle is the smaller and from it the bulbus passes between the atria and is continued as the ventral aorta. Viewed from the caudal and dorsal aspect (Fig. 95), the *sinus venosus* is seen dorsal to the atria. It opens into the right atrium and receives from the right side the *right common cardinal vein*, from the left side the *left common cardinal*. These veins drain the blood from the body of the embryo. Caudally the sinus venosus receives the two

vitelline veins. Of these, the left is small in the liver and later disappears. The *right vitelline vein*, now the *common hepatic*, carries most of the blood to the heart from the umbilical veins, from the liver sinusoids, gut and from the yolk-sac.

Transverse sections of the embryo through the four chambers of the heart

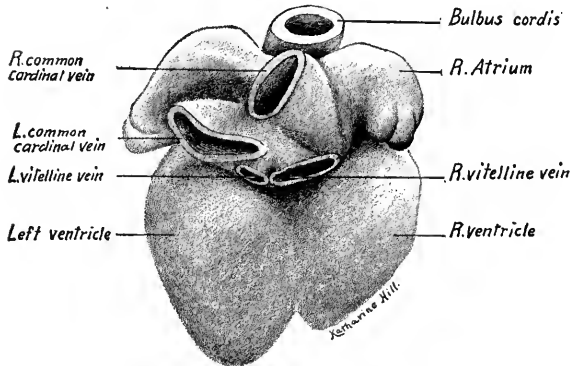


FIG. 95.—Dorsal and caudal view of the heart from a 6 mm. pig embryo.  $\times 21$ .

In Fig. 96, from a slightly smaller embryo, it is seen that the *septum primum* grows from the dorsal atrial wall of the heart and does not yet meet the endocardial cushions between the atrio-ventricular canals. This opening between the atria is known as the *interatrial foramen*. Before it closes, another opening appears in the septum, dorsal in position. This is the *foramen ovale* and persists during fetal life. In Fig. 96 these two openings may be seen, as may also the dorsal and ventral endocardial cushions. The outer mesothelial layer of the ventricles has become much thicker than that of the atria. It forms the *epicardium* and the *myocardium*, the sponge-like meshes of which are now being developed.

show the atria in communication with the ventricles through the *atrio-ventricular canals* (Fig. 104), and the sinus venosus opening into the right auricle. This opening is guarded by the right and left valves of the sinus venosus. Septa incompletely separate the two atria and the two ventricles. In Fig. 104 the atrial septum (*septum primum*) appears complete.

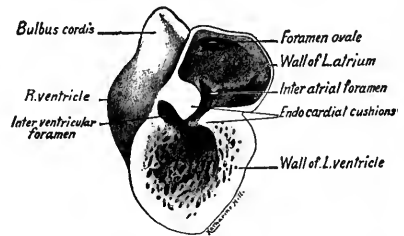


FIG. 96.—Dissection of a 5.5 mm. pig's heart from the left side, showing the septum primum and two interatrial foramina.  $\times 14$ .

The *arteries* begin with the *ventral aorta*, which takes origin from the bulbus cordis. From the ventral aorta are given off five pairs of aortic arches. These run dorsad in the five branchial arches (Figs. 99 and 100) and join the paired *dorsal or descending aortae*. The first and second pairs of aortic arches are very small and take origin from the small common trunks formed by the bifurcation

of the ventral aorta just caudal to the median thyreoid gland. The fourth aortic arch is the largest. From the fifth arch small *pulmonary arteries* are developing. Cranial to the first pair of aortic arches, the descending aortæ are continued forward into the maxillary processes as the *internal carotids*. Caudal to the aortic arches the descending aortæ converge, unite opposite the cardiac end of the stomach and form the *median dorsal aorta*. From this vessel and from the descending aortæ paired *dorsal intersegmental arteries* arise. From the seventh pair of these arteries (the first pair to arise from the median dorsal aorta), there are developed a pair of lateral branches to the upper limb buds. These vessels are the *subclavian arteries*. From the median dorsal aorta there are also given off *ventro-lateral arteries* to the glomeruli of the mesonephros, and *median ventral arteries*. Of the latter the *celiac artery* arises opposite the origin of the hepatic diverticulum. The *vitelline artery* takes origin by two or three trunks caudal to the dorsal pancreas. Of these trunks the posterior is the larger and persists as the superior mesenteric artery. Thyng (*Anat. Record*, vol. 5, 1911) has figured three trunks of origin in the 7.8 mm. pig. These unite and the single vitelline artery branches in the wall of the yolk-sac.

Opposite the lower limb buds the dorsal aorta is divided for a short distance. From each division arises laterad three short trunks which unite to form the single *umbilical artery* on each side. The middle trunk is the largest and apparently becomes the common iliac artery. A pair of short caudal arteries, much smaller in size, continue the descending aortæ into the tail region.

*The Veins.*—The *vitelline veins*, originally paired throughout, are now represented distally by a single vessel, which, arising in the wall of the yolk-sac, enters the embryo coursing cephalad to the intestinal loop (Figs. 97, 99 and 100). Crossing to the left side of the intestine and ventral to it, it is joined by the *superior mesenteric vein* which has developed in the mesentery of the intestinal loop. The trunk cranial to the union of these two vessels becomes the *portal vein*. It passes along the left side of the gut in the mesentery. Opposite the origin of the dorsal pancreas it gives off a small branch, a rudiment of the left vitelline vein, which courses cephalad and in earlier stages connects with the sinusoids of the liver. The portal vein then bends sharply to the right dorsal to the duodenum and as the *right vitelline vein*, passing between the dorsal and ventral pancreas to the right of the duodenum, it soon enters the liver and connects with the liver sinusoids. The portal trunk is thus formed by persisting portions of both vitelline veins, and receives a new vessel, the *superior mesenteric vein*. The middle portions of the vitelline veins are connected with the network of liver

sinusoids. Their proximal vitelline trunks drain the blood from the liver and open into the sinus venosus of the heart. The right vitelline trunk is much the larger and persists as the proximal portion of the *inferior vena cava* (for the development of the portal vein see Chapter IX).

The *umbilical veins*, taking their origin in the walls of the chorion and allantoic vesicle, lie caudal and lateral to the allantoic stalk and anastomose (Figs. 97 and 99). Before the allantoic stalk enters the body, the umbilical veins sepa-

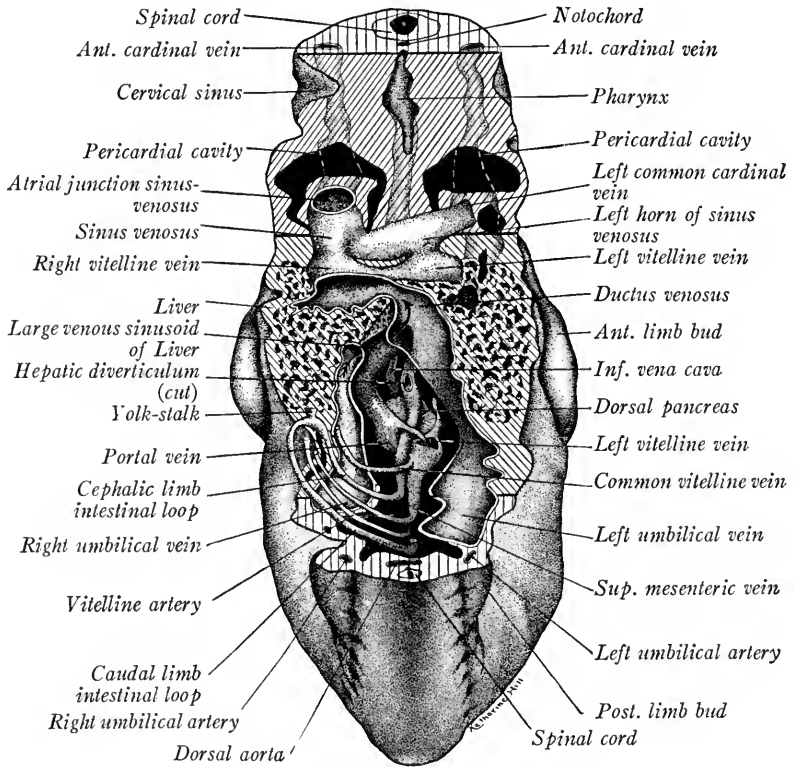


FIG. 97.—Reconstruction in ventral view of a 6 mm. pig embryo to show the vitelline and umbilical veins, the latter opened (original drawing by Mr. K. L. Vehe).

rate and run lateral to the umbilical arteries. The left vein is much the larger. Both, after receiving branches from the posterior limb buds and from the body wall, pass cephalad in the somatopleure at each side. Their course is first cephalad, then dorsad, until they enter the liver. The left vein enters a wide channel, the ductus venosus, which carries its blood through the liver, thence to the heart by way of the right vitelline trunk. The right vein joins a large sinusoidal continuation of the portal vein in the liver. This common trunk drains into the ductus venosus.

The *anterior cardinal veins* are formed by the plexus of veins on each side of the head which are drained by two trunks (Figs. 98 and 99). These extend caudad and lie lateral to the ventral portion of the myelencephalon. Each anterior cardinal vein receives branches from the sides of the myelencephalon, then curves ventrad, is joined by the *linguo-facial vein* from the branchial arches and at once unites with the posterior cardinal of the same side to form the *common cardinal vein*. This, as we have seen, opens into the sinus venosus.

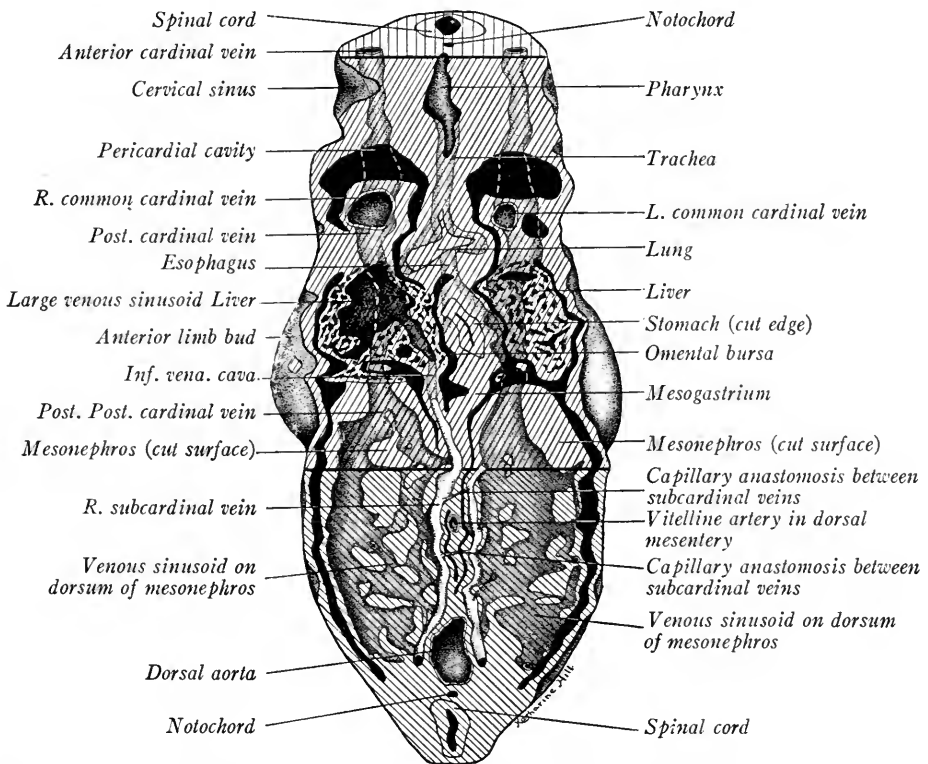


FIG. 98.—Reconstruction of the cardinal and subcardinal veins of a 6 mm. pig embryo showing the early development of the inferior vena cava (K. L. Vehe).

The *posterior cardinal veins* develop on each side in the mesonephric ridge, dorso-lateral to the mesonephros (Figs. 98 and 99). Running cephalad, they join the anterior cardinal veins. When the mesonephroi become prominent, as at this stage, the middle third of each posterior cardinal is broken up into sinusoids (Minot). Sinusoids extend from the posterior cardinal vein ventrally around both the lateral and medial surfaces of the mesonephros. The median sinusoids anastomose longitudinally and form the *subcardinal veins*, right and left. The

subcardinals lie along the median surfaces of the mesonephroi, more ventrad than the posterior cardinals with which they are connected at either end. There

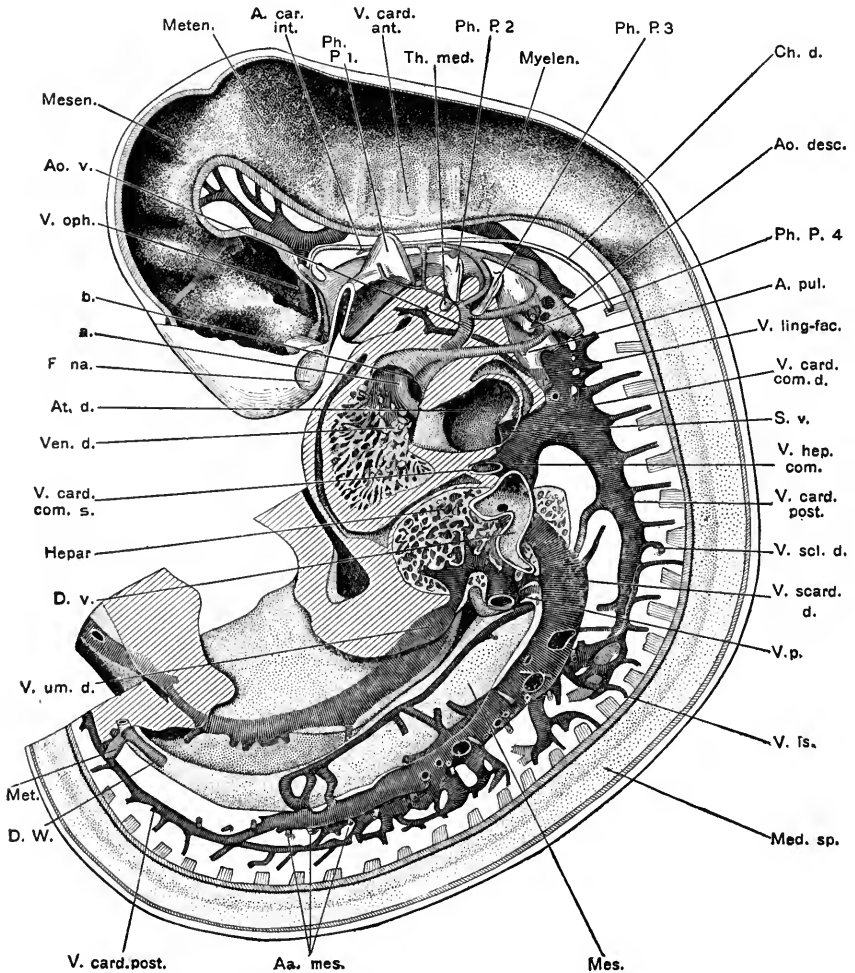


FIG. 99.—Reconstruction of 7.8 mm. pig embryo showing veins and aortic arches from the left side (Thyng).  $\times 15$ . *Ao. desc.*, descending aorta; *Ao. v.*, ventral aorta; *A. car. int.*, internal carotid artery; *Aa. mes.*, mesonephric arteries; *A. pul.*, pulmonary artery; *At. d.*, right atrium; *D. v.*, ductus venosus; *Ph. P. 1, 2, 3, 4*, pharyngeal pouches; *S. v.*, sinus venosus; *Th. med.*, thyræoid gland; *V. card. ant.*, anterior cardinal vein; *V. card. com. d.*, right common cardinal vein; *V. card. com. s.*, left common cardinal vein; *V. card. post.*, posterior cardinal vein; *V. hep. com.*, common hepatic vein; *V. is.*, intersegmental vein; *V. ling-fac.*, linguo-facial vein; *V. oph.*, ophthalmic vein; *V. p.*, portal vein; *V. scard. d.*, right subcardinal vein; *V. scl. d.*, right subclavian vein; *V. umb. d.*, right umbilical vein; *Ven. d.*, right ventricle.

is a transverse capillary anastomosis between them, cranial and caudal to the permanent trunk of the vitelline artery. The right subcardinal is connected with the liver sinusoids through a small vein which develops in the mesenchyme

of the plica venæ cavæ (caval mesentery) located to the right of the mesentery (Fig. 107). This vein now carries blood direct to the heart from the right posterior cardinal and right subcardinal, by way of the liver sinusoids and the right vitelline trunk (common hepatic vein). Eventually these four vessels form the unpaired *inferior vena cava*. (For the development of the inferior vena cava see Chapter IX).

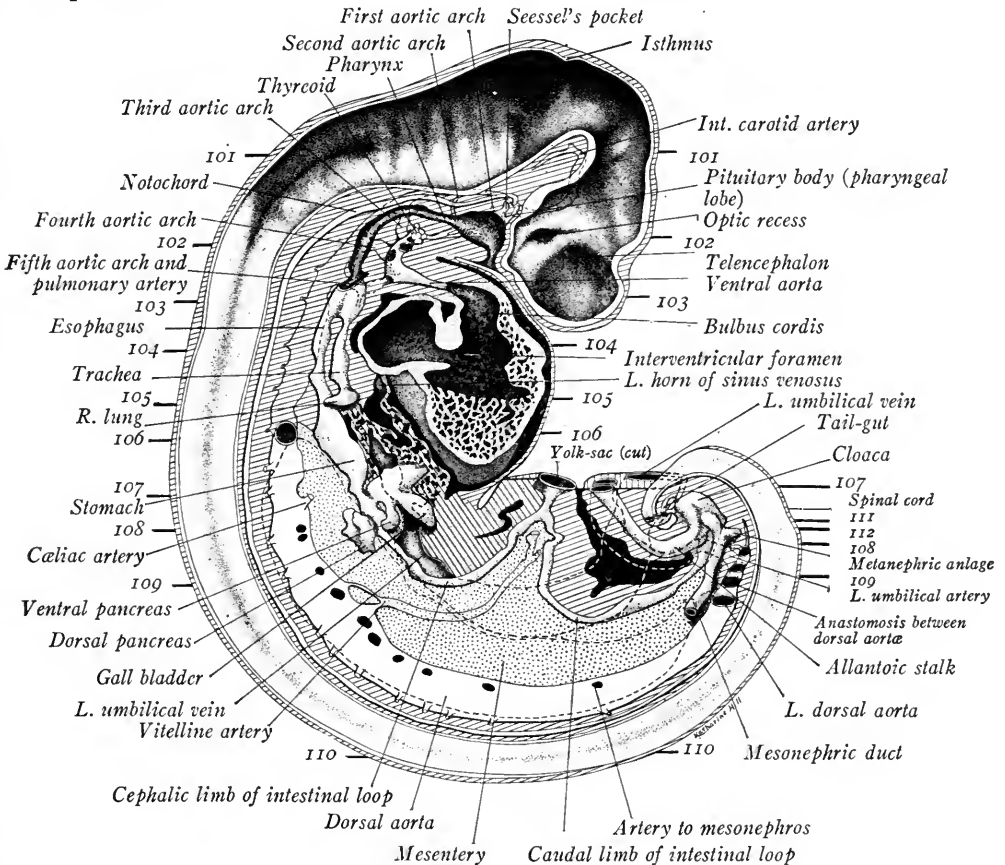


FIG. 100.—Reconstruction of a 6 mm. pig embryo in the median sagittal plane, viewed from the right side. The numbered heavy lines indicate the levels of the transverse sections shown in Figs. 101–112. The broken lines indicate the outline of the left mesonephros and the course of the left umbilical artery and vein. The latter may be traced from the umbilical cord to the liver where it is sectioned longitudinally. (Original drawing and reconstruction by Mr. K. L. Vehe).  $\times 16\frac{1}{2}$ .

TRANSVERSE SECTIONS

Having acquainted himself with the anatomy of the embryo from the study of dissections and reconstructions, the student should examine serial sections cut in the plane indicated by guide lines on Fig. 100. Refer back to the external structure of the embryo (Fig. 88), to the lateral dissection of the organs (Fig.

90), and note the plane of each section and the structures which would appear in Fig. 100. Sections typical of certain regions should be drawn. The various structures may be recognized by referring to the figures of sections in the text, and they should be traced through the series as carefully as time will allow.

**Transverse Section through the Myelencephalon and Otocysts of a 6 mm. Embryo** (Fig. 101).—As the head is bent nearly at right angles to the body, this section passes lengthwise through the myelencephalon. The *diencephalon* is cut transversely. The cellular walls of the myelencephalon show a series of six pairs of constrictions, the *neuromeres*. Lateral

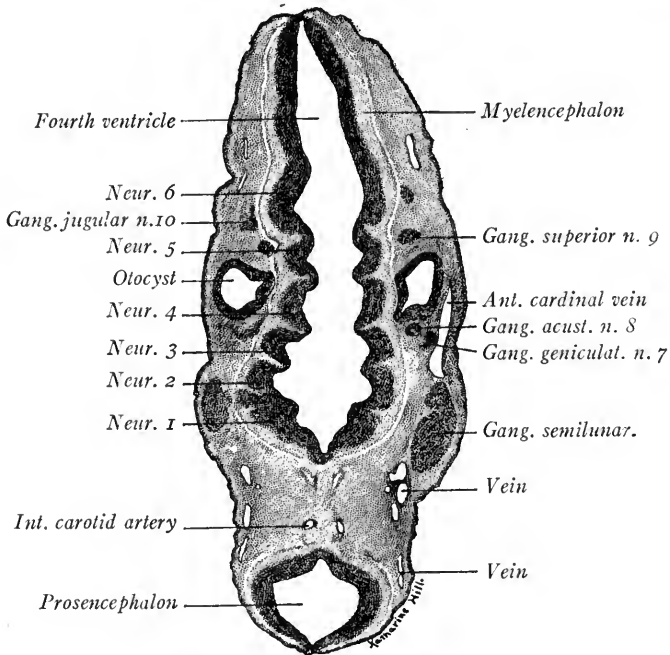


FIG. 101.—Transverse section through the myelencephalon and otocysts of a 6 mm. pig embryo.  $\times 26.5$ . *Ant. cardinal vein*, anterior cardinal vein; *Gang. acust. n. 8*, acoustic ganglion of acoustic nerve; *Gang. geniculat. n. 7*, geniculate ganglion of the facial nerve; *Int. carotid artery*, internal carotid artery; *Neur. 1, 2, 3, 4*, neuromeres 1, 2, 3, and 4.

to the fourth pair of neuromeres are the otocysts, which show a median outpocketing at the point of entrance of the endolymph duct. The ganglia of the nn. trigeminus, facialis, acusticus and the superior ganglion of the glossopharyngeal nerve occur in order on each side. Sections of the anterior cardinal vein and its branches show on the left side. Ventral to the diencephalon are sections of the *internal carotid arteries*.

Passing along down the series into the pharynx region, observe the first, second and third *pharyngeal pouches*. Their dorsal diverticula come into contact with the ectoderm of the branchial clefts and form the *closing plates*.

**Transverse Sections through the Branchial Arches and the Eyes** (Fig. 102).—The section passes lengthwise through the four branchial arches, the fourth sunken in the cervical sinus. Dorsad is the spinal cord with the first pair of cervical ganglia. The pharynx is cut across between the third and fourth branchial pouches. In its floor is a prominence,



the anlage of the *epiglottis*. Ventral to the pharynx the ventral aorta gives off two pairs of vessels. The larger pair are the *fourth aortic arches* which curve dorsad around the pharynx to enter the *descending aortæ*. The smaller *third aortic arches* enter the third branchial arches on each side. A few sections higher up in the series the ventral aorta bifurcates and the right and left trunks thus formed give off the first and second pair of aortic arches. Cranially in the angle between their common trunks lies the *median thyreoid anlage*. The *anterior cardinal veins* are located lateral and dorsal to the descending aortæ. The end of the head is cut through the *telencephalon* and the *optic vesicles*. On the left side of the figure the *lens vesicle* may be seen still connected with the ectoderm. The optic vesicle now shows a thick inner and a thin outer layer; these form the *nervous* and *pigment layers* of the retina respectively.

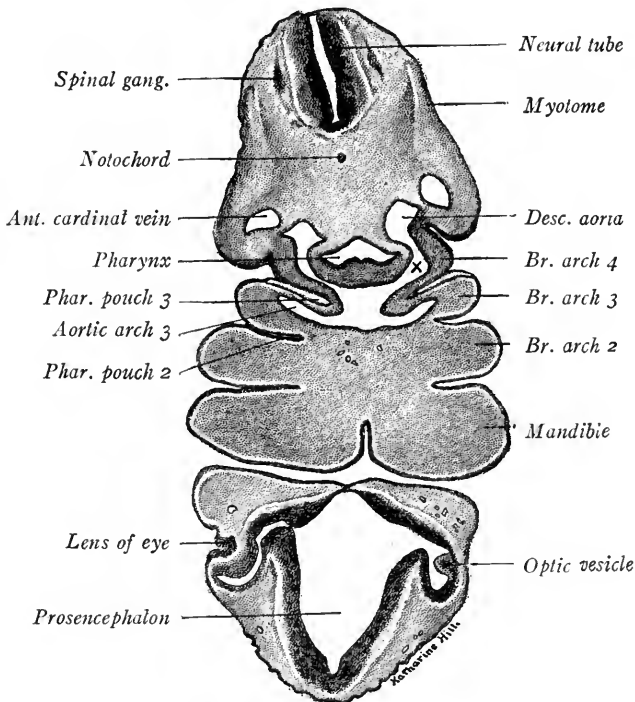


FIG. 102.—Transverse section through the branchial arches and eyes of a 6 mm. pig embryo.  $\times 26.5$ . *Desc. aorta*, descending aorta; *Br. arch 2, 3, 4*, branchial arch 2, 3 and 4; *Phar. pouch 2, 3*, pharyngeal pouches 2 and 3; *X*, aortic arch 4.

**Transverse Section through the Tracheal Groove, Bulbus Cordis and Olfactory Pits** (Fig. 103).—The ventral portion of the figure shows a section through the tip of the head. The *telencephalon* is not prominent. The ectoderm is thickened and slightly invaginated ventro-laterad to form the anlagen of the *olfactory pits*. These deepen in later stages and become the nasal cavities. In the dorsal portion of the section may be seen the cervical portion of the *spinal cord*, the *notochord* just ventral to it, the *descending aortæ*, and ventro-lateral to them the *anterior cardinal veins*. The pharynx now is small with a vertical groove in its floor. This is the tracheal groove and more caudad it will become the cavity of the *trachea*. The *bulbus cordis* lies in the large *pericardial cavity*. On either side the section cuts through the cephalic portions of the *atria*. These will become larger as we go caudad in the series.

**Transverse Section through the Heart (Fig. 104.)**—The section passes through the bases of the *upper limb buds*. Lateral to the descending aortæ are the *common cardinal veins*. The right common cardinal opens into the *sinus venosus* which in turn empties into the right atrium, its opening being guarded by the two *valves of the sinus venosus*. The *trachea* has now separated from the *esophagus* and lies ventral to it. Both trachea and esophagus are surrounded by a condensation of mesenchyme. The myocardium of the ventricles has formed a spongy layer much thicker than that of the atrial wall. An incomplete *interventricular septum* leaves the ventricles in communication dorsad. The *septum primum* is complete in this section but higher up in the series there is an *interatrial foramen* (see Fig. 96). The *foramen ovale* is not yet formed.

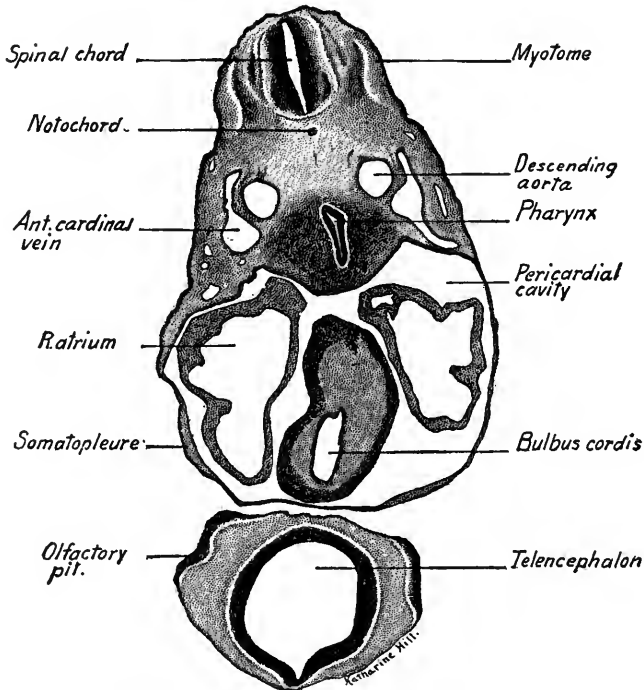


FIG. 103.—Transverse section through the bulbus cordis and olfactory pits of a 6 mm. pig embryo.  $\times 26.5$ .

**Transverse Section through the Lung Buds and Septum Transversum (Fig. 105.)**—The tips of the ventricles lying in the pericardial cavity still show in this section. Dorsally the pericardial cavity has given place to the *pleuro-peritoneal cavity*. Into this cavity project ventrad the *Wolffian ridges* in which the posterior cardinal veins partly lie. Into the floor of the pleuro-peritoneal cavities bulge the dorsal lobes of the liver, embedded in mesenchyme. This mesenchyme is continuous with that of the somatopleure, and forms a complete transverse septum ventrally between the liver and heart. This is the *septum transversum* which takes part in forming the ligaments of the liver and is the anlage of a portion of the *diaphragm*. Passing through the septum are the two proximal trunks of the *vitelline veins*. Projecting laterally into the pleuro-peritoneal cavities are ridges of mesenchyme covered by splanchnic mesoderm in which the lungs develop as lateral buds from the caudal end of the trachea. The *right lung bud* is shown in the figure. Between the esophagus and the lung is a crescent-shaped cavity, the end of the *lesser peritoneal sac*.

**Transverse Section through the Stomach (Fig. 106).**—The section passes through the upper limb buds and just caudal to the point at which the *descending aorta* unite to form the *median dorsal aorta*. As the liver develops in early stages, it comes into relation with the *plica venae cavae* along the dorsal body wall to the right side of the dorsal mesogastrium. The

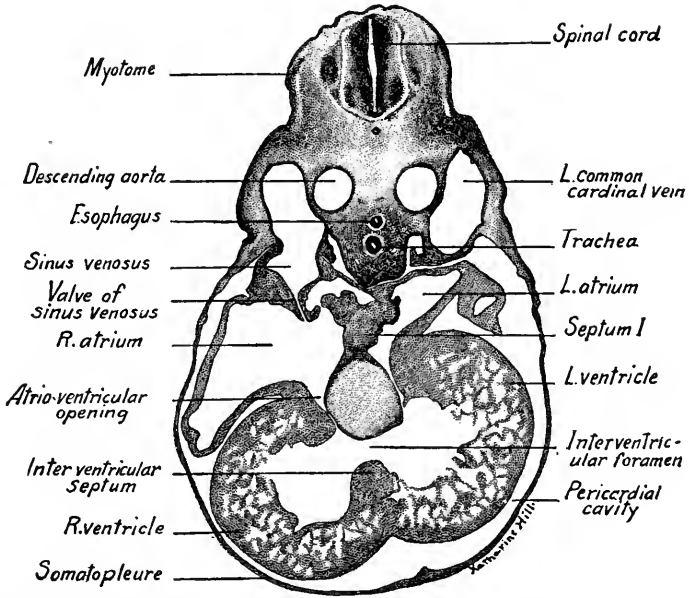


FIG. 104.—Transverse section through the four chambers of the heart of a 6 mm. pig embryo.  $\times 26.5$ .

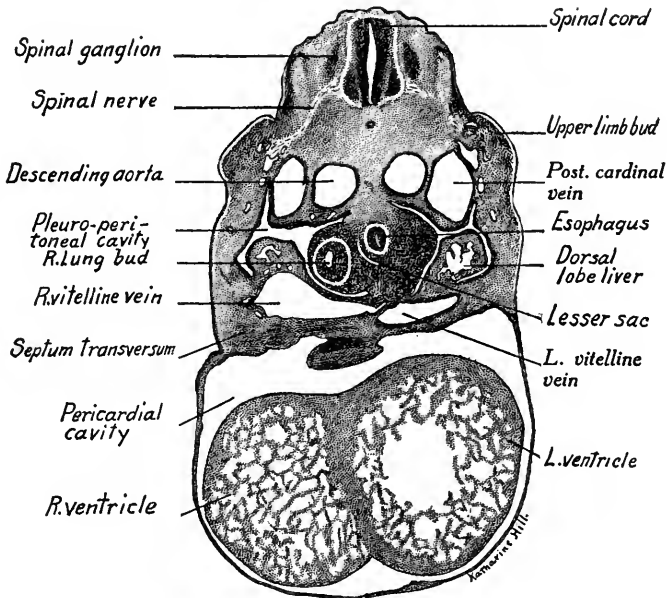


FIG. 105.—Transverse section through the right lung bud and septum transversum of a 6 mm. pig embryo.  $\times 26.5$ .

space between the liver and plica to the right, and the stomach and its omenta to the left, is a caudal continuation of the *lesser peritoneal sac*. The dorsal wall of the stomach is rotated to the left, its ventral wall to the right. The liver shows a pair of dorsal lobes and contains

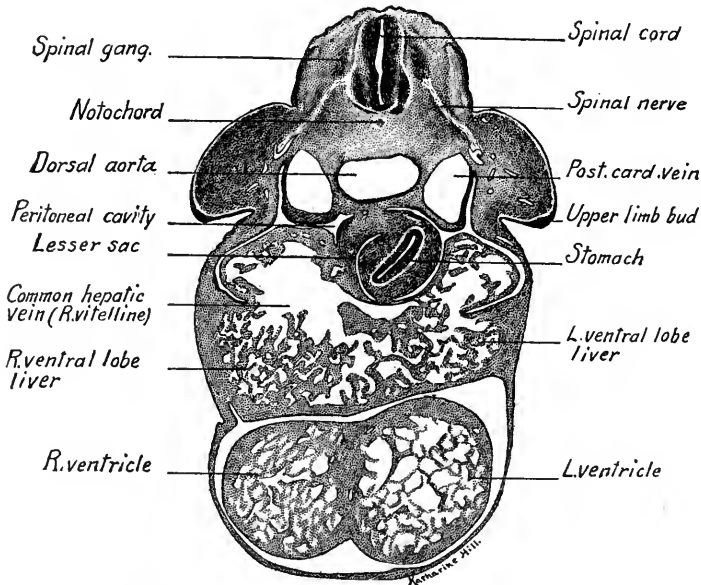


FIG. 106.—Transverse section through the stomach of a 6 mm. pig embryo.  $\times 26.5$ .

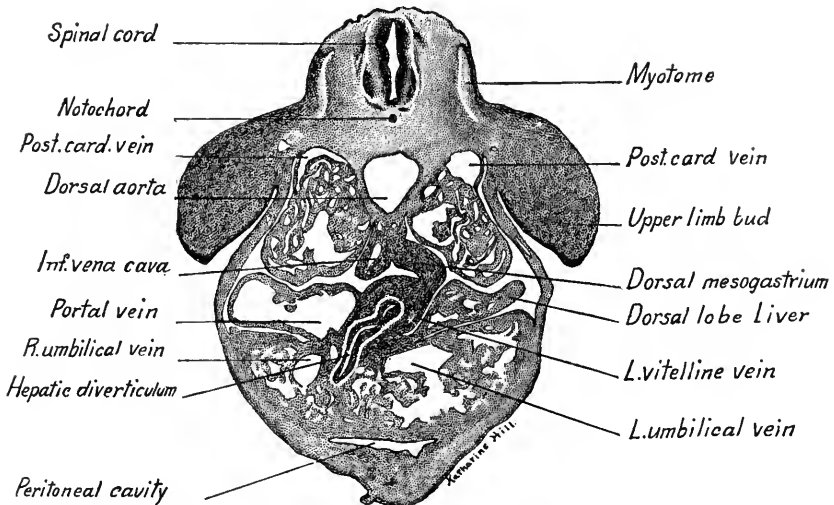


FIG. 107.—Transverse section through the hepatic diverticulum of a 6 mm. pig embryo.  $\times 26.5$ .

large blood spaces and networks of *sinusoids* lined with endothelium. Ventral to the liver, the tips of the ventricles are seen.

**Transverse Section through the Hepatic Diverticulum (Fig. 107).**—The upper limb buds are prominent in this section. The mesonephric folds show the tubules and glomeruli

of the mesonephroi and the *posterior cardinal veins* are connected with the mesonephric sinusoids. To the median side of the right mesonephros shows the *right subcardinal vein*. From the dorsal attachment of the liver there is continued down into this section a ridge on the dorsal body wall just to the right (left of figure) of the mesentery. In this ridge lies a small vein which connects cranially with the liver sinusoids, caudally with the right subcardinal vein. As it later forms a portion of the *inferior vena cava*, the ridge in which it lies is termed the *plica venæ cavæ* or *caval mesentery*. The right dorsal lobe of the liver contains a large blood space into which opens the *portal vein*. The duodenum has curved ventral to the position occupied by the stomach in the previous section. There is given off from it ventrad and to the right the *hepatic diverticulum*. In the sections higher up small ducts from the liver trabeculæ may be traced into connection with it. In the left ventral lobe of the liver, a large blood space indicates the position of the left umbilical vein on its way to the ductus venosus.

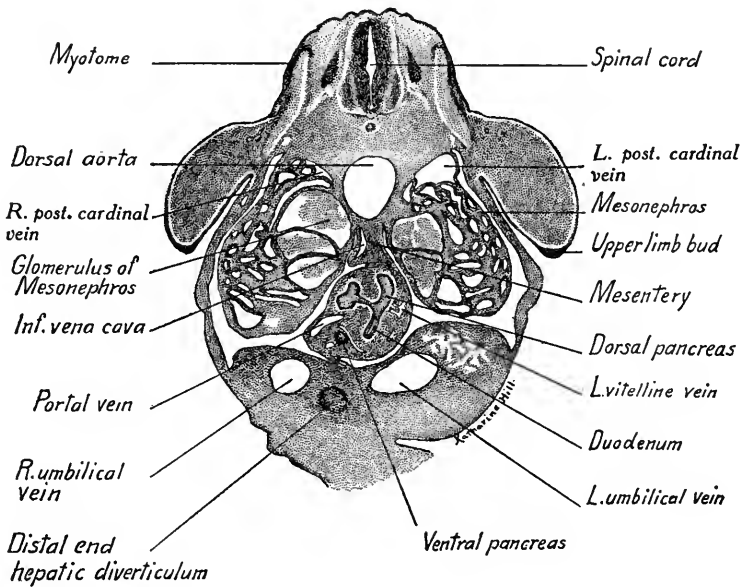


FIG. 108.—Transverse section through the dorsal pancreas of a 6 mm. pig embryo.  $\times 26.5$ .

**Transverse Section through the Dorsal Pancreas** (Fig. 108).—At this level the upper limb buds still show, the mesonephroi are larger and marked by their large glomeruli. The *right posterior cardinal vein* is broken up into mesonephric sinusoids. The vein in the *plica venæ cavæ* will, a few sections lower, connect with the *right subcardinal vein*. The anlage of the *dorsal pancreas* is seen extending from the duodenum dorsad into the mesenchyme of the mesentery. It soon bifurcates into a dorsal and right lobe, of which the latter is slightly lobulated. Ventro-lateral to the duodenum, the anlage of the *ventral pancreas* is seen cut across. It may be traced cephalad in the series to its origin from the hepatic diverticulum. To the right of the ventral pancreas (left of figure) lies the *portal vein* (portion of right vitelline). To the left of the dorsal pancreas is seen the remains of the *left vitelline vein*. The ventral lobes of the liver are just disappearing at this level. In the mesenchyme which connects the liver with the ventral body wall lie on each side the *umbilical veins*, the left being the larger. Between the veins is the extremity of the *hepatic diverticulum*. The body wall is continued ventrad to form a short *umbilical cord*.

**Transverse Section at Level of the Origin of the Vitelline Artery and Umbilical Arteries (Fig. 109).**—As the posterior half of the embryo is curved in the form of a half circle, sections caudal to the liver, like this one, pass through the lower end of the body at the level of the *posterior limb buds*. Two sections of the embryo are thus seen in one, their ventral aspects facing each other and connected by the lateral body wall. In the dorsal part of the section the *mesonephroi* are prominent with large *posterior cardinal veins* lying dorsal

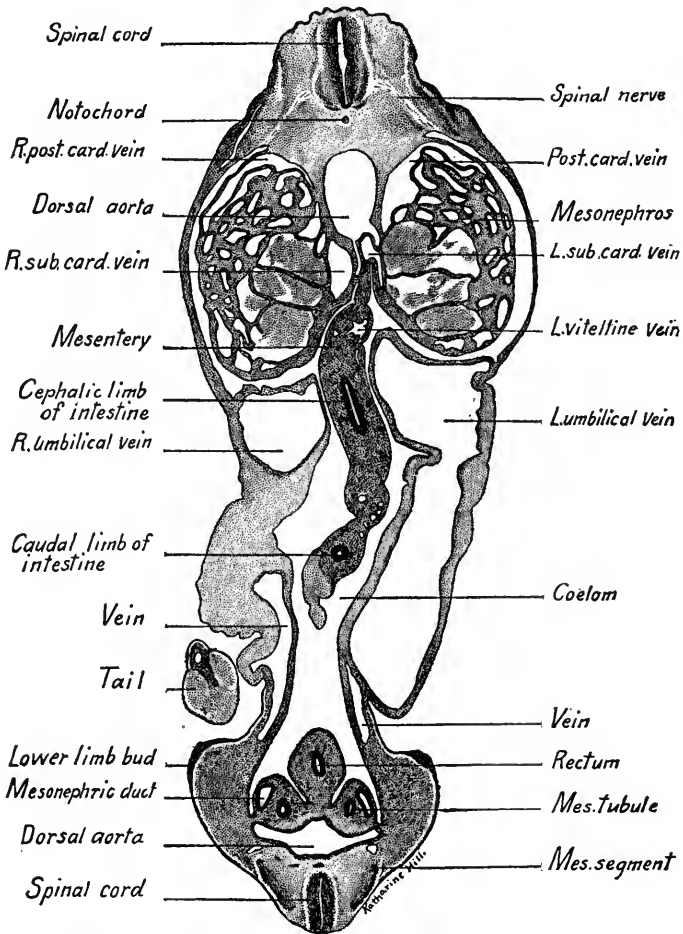


FIG. 109.—Transverse section of a 6 mm. pig embryo at the level of the origin of the vitelline artery. The lower end of the section passes through the posterior limb buds.  $\times 26.5$ . *Mes. tubule*, mesonephric tubule; *R. post. card. vein*, right posterior cardinal vein.

to them. The trunk of the *vitelline artery* takes origin ventrally from the aorta. It may be traced into the mesentery, and through it into the wall of the yolk-sac. On either side of the vitelline artery are the *subcardinal veins*, the right being the larger. In the mesentery may be seen two sections of the intestinal loop (the *small intestine* being cut lengthwise, the *large intestine* transversely), and also sections of the *vitelline artery and veins*. In the lateral body walls ventral to the mesonephros occur the *umbilical veins*. The left vein is large and cut lengthwise. The right vein is cut obliquely twice.

In the ventral portion of the section, the *lower limb buds* are prominent laterally. A large pair of arteries, the common iliacs, are given off from the aorta and may be traced into connection with the *umbilical arteries*. The *large intestine* supported by a short *mesentery* lies in the coelom near the midline. On each side are the *mesonephric folds*, here small and each showing a section of the *mesonephric duct* and a single vesicular anlage of the *mesonephric tubules*. The mesonephric ducts are sectioned as they curve around from their position in the dorsal portion of the section.

**Section through the Primitive Segments and Spinal Cord** (Fig. 110).—This section is near the end of the series and as the body is here curved it is really a longitudinal section. At the left side of the spinal cord the oval cellular masses are the *spinal ganglia* cut across. The ectoderm, arching over the segments, indicates their position. Each segment shows an outer dense layer, the *cutis plate*, lying just beneath the ectoderm. This plate curves lateral to the spindle shaped *muscle plate* which gives rise to the voluntary muscle. Next comes a diffuse mass of mesenchyma, the *sclerotome*, which, eventually, with its fellow of the opposite side, surrounds the spinal cord and forms the

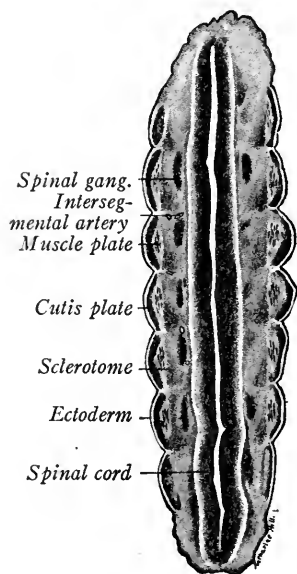


FIG. 110.—Transverse section through the primitive segments and spinal cord of a 6 mm. pig embryo.  $\times 45$ .

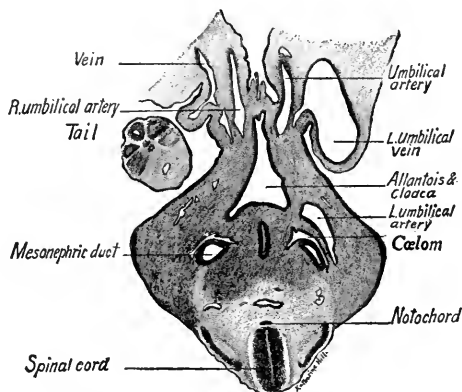


FIG. 111.—Transverse section through the umbilical vessels, allantois and cloaca of a 6 mm. pig embryo.  $\times 45$ .

anlage of a vertebra. From it is developed also connective tissue. A pair of spinal nerves and spinal ganglia are developed opposite each somite, and pairs of small vessels are seen between the segments. These are dorsal intersegmental arteries.

**Section through the Umbilical Vessels, Allantois and Cloaca** (Fig. 111).—We have now studied sections at various levels of the 6 mm. embryo to near the end of the series. We shall next examine sections through the caudal region and study the anlagen of the urogenital organs. Owing to the curvature of the embryo, we will now be going cephalad in our series. The first section passes through the bases of the limb buds at the level where the *allantoic stalk*, curving inward from the umbilical cord, opens into the *cloaca*. At either side of the allantoic stalk may be seen oblique sections of the *umbilical arteries* and lateral to these the large left and small right *umbilical vein*. The *mesonephric ducts* occupy the mesonephric ridges which project into small caudal prolongations of the coelom. Midway between the ducts lies the *hind-gut*, dorsal to the cloaca. The tip of the tail is seen in section to the left of the figure.

**Section through the Anlages of the Metonephroi, Cloaca and Hind-gut (Fig. 112).**—The *metonephroi* are seen as dorsal evaginations from the mesonephric (Wolffian) ducts just before their entrance into the cloaca. Each consists of an epithelial layer surrounded by a condensation of mesenchyme. Traced a few sections cephalad the *mesonephric ducts* open into the lateral diverticula of the *cloaca*, which, irregular in outline, because it is sectioned obliquely, lies ventral to them and receives dorsad the hind-gut. Caudal to the cloaca in this embryo, the tail bends abruptly cephalad and to the right. The blind prolongation of the hind-gut may be traced out into this portion of the tail until it ends in a sac-like dilatation.

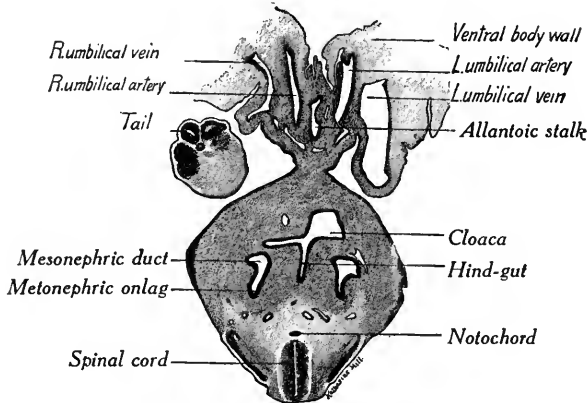


FIG. 112.—Transverse section through the anlagen of the metanephroi of a six mm. pig embryo.  $\times 45$ .

## B. THE ANATOMY OF TEN TO TWELVE MM. PIG EMBRYOS

The study of embryos at this stage is important as they possess the anlagen of most of the organs. The anatomy of a 12 mm. pig embryo has been carefully studied and described by Lewis (*Amer. Jour. Anat.*, vol. 2, pp. 211-225, 1903).

**External Form (Fig. 113).**—The head is now relatively large on account of the increased size of the brain. The *third branchial arch* is still visible in the embryo, but the *fourth arch* has sunken in the *cervical sinus*; usually both have disappeared at a slightly later stage. The *olfactory pits* form elongated grooves on the under surface of the head and the *lens* of the eye lies beneath the ectoderm surrounded by the *optic cup*. The *maxillary* and *mandibular* processes of the first branchial arch are larger and the former shows signs of fusing with the median nasal process to form the upper jaw. Small tubercles, the anlagen of the *external ear* have developed about the first branchial cleft which itself becomes the *external auditory meatus*.

At the cervical bend the head is flexed at right angles with the body bringing the ventral surface of the head close to that of the trunk and it is probably owing to this flexure that the third and fourth branchial arches buckle inward to form the cervical sinus. Dorsad the trunk forms a long curve more marked opposite



the posterior extremities. The reduction in the trunk flexures is due to the increased size of the heart, liver and mesonephroi. These organs may be seen

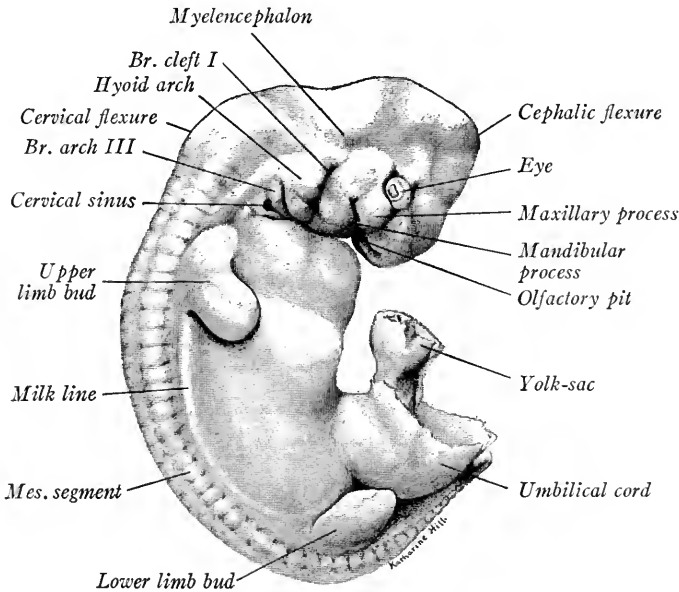


FIG. 113.—Exterior of a 10 mm. pig embryo viewed from the right side.  $\times 7$ . *Br. arch III*, branchial arch three; *Br. cleft I*, first branchial cleft; *mes. segment*, mesodermal segment.

through the translucent body wall and the position of the *septum transversum* may be noted between the heart and the diaphragm, as in Fig. 115. The limb buds are larger and the umbilical cord is prominent ventrad. Dorsally the mesodermal segments may be seen and extending in a curve between the bases of the limb buds is the *milk line*, a thickened ridge of ectoderm which forms the anlagen of the *mammary glands*. The tail is long and tapering. Between its base and the umbilical cord is the *genital eminence* (Fig. 115).

Human embryos of this stage or slightly older, vary considerably in size (Fig. 114). They differ from pig embryos in the greater size of

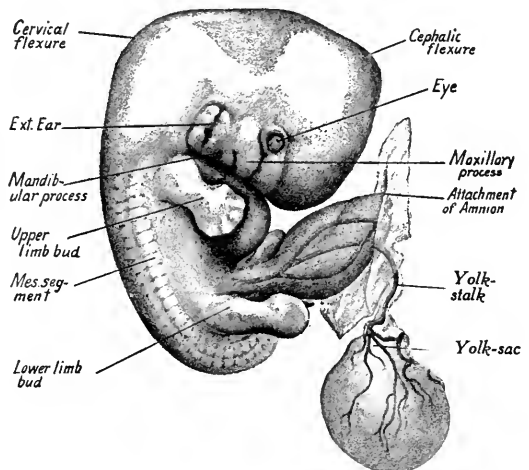


FIG. 114.—Exterior of a human embryo of 12 mm., viewed from the right side, showing attachment of amnion (cut away) and yolk-stalk and -sac.  $\times 5$ .

the head, the shorter tail, the much smaller mesonephric region, the longer umbilical cord and the less prominent segments. The *yolk-sac* is pear-shaped with long slender *yolk-stalk*.

**Central Nervous System and Viscera.**—Dissections show well the form and relations of the organs (Figs. 115, 116 and 117). Directions for preparing dissections are given in Chapter VI.

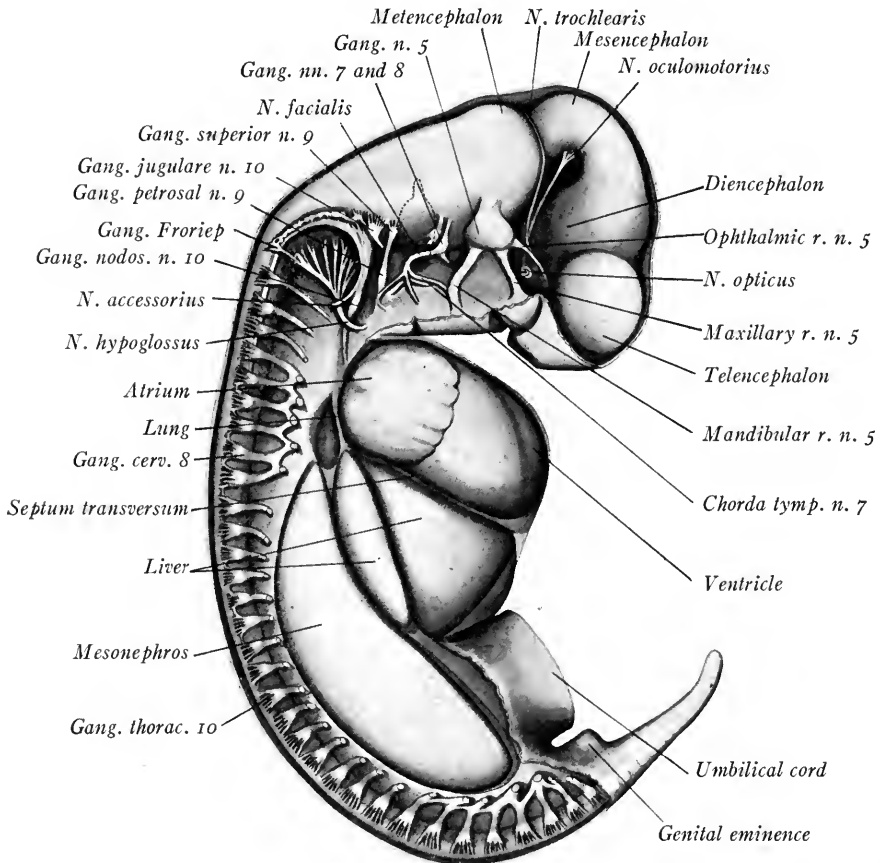


FIG. 115.—Lateral dissection of a 10 mm. pig embryo, showing the viscera and nervous system from the right side. The eye has been removed and the otic vesicle is represented by a broken line. The ventral roots of the spinal nerves are not indicated.  $\times 10.5$ . n., nerve; r., ramus.

**Brain.**—Five distinct regions may be distinguished (Figs. 115 and 117): (1) The *telencephalon* with its rounded lateral outgrowths, the *cerebral hemispheres*. Their cavities, the *lateral ventricles* communicate by the *interventricular foramen* with the third ventricle. (2) The *diencephalon* shows a laterally flattened cavity, the *third ventricle*. Ventro-laterally from the diencephalon pass off the optic stalks and an evagination of the mid-ventral wall is the anlage of the *posterior*

*hypophyseal lobe.* (3) The *mesencephalon* is undivided but its cavity becomes the *cerebral aqueduct* leading caudally into the *fourth ventricle*. (4) The *metencephalon* is separated from the mesencephalon by a constriction, the *isthmus*. Dorso-laterally it becomes the *cerebellum*, ventrally the *pons*. (5) The elongated *myelencephalon* is roofed over by a thin non-nervous ependymal layer. Its ventro-lateral wall is thickened and still gives internal indication of the *neuromeres*. The cavity of the metencephalon and myelencephalon is the *fourth ventricle*.

*Cerebral Nerves.* Of the twelve cerebral nerves all but the first (olfactory) and sixth (abducens) are represented in Fig. 115. For a detailed description

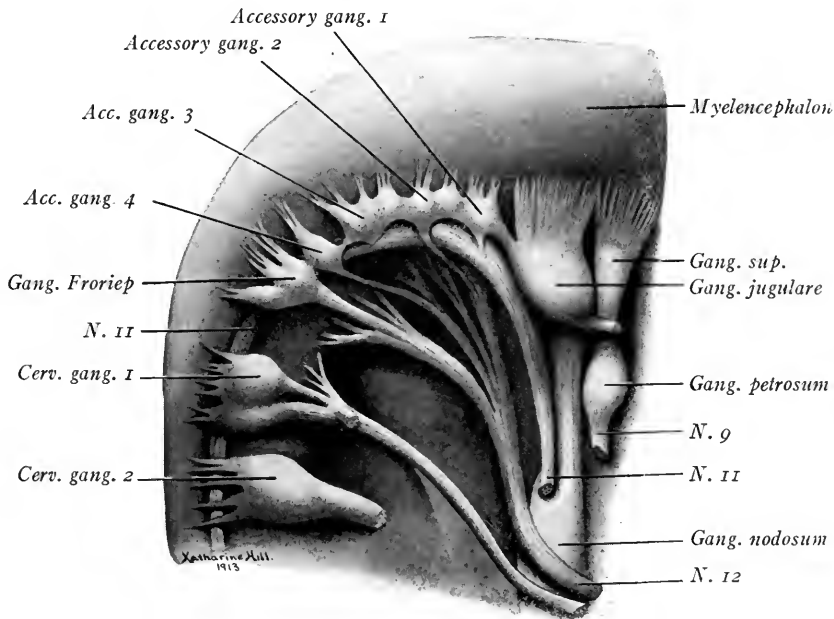


FIG. 116.—Dissection of the head of a 15 mm. pig embryo from the right side to show the accessory vagus ganglia with peripheral roots passing to the hypoglossal nerve.

of these nerves see Chapter XII. (2) The *optic nerve* is represented by the optic stalk cut through in Fig. 115. (3) The *oculomotor*, a motor nerve to the eye muscles, takes origin from the ventro-lateral wall of the mesencephalon. (4) The *trochlear nerve* fibers, motor, to the superior oblique muscle of the eye, arise from the ventral wall of the mesencephalon, turn dorsad and cross at the isthmus, thus emerging on the opposite side. From the myelencephalon arise in order (5) the *trigeminal nerve*, mixed, with its *semilunar ganglion* and three branches, the *ophthalmic*, *maxillary*, and *mandibular*; (6) the *n. abducens*, motor, from the ventral wall to the external rectus muscle of the eye; (7) the *n. facialis*, mixed,

with its *geniculate ganglion* and its *superficial petrosal, chorda tympani* and *facial branches*; (8) the *n. acusticus*, sensory, arising cranial to the otocyst, with its *acoustic ganglion* and sensory fibers to the internal ear; (9) caudal to the otocyst the *n. glossopharyngeus*, mixed, with its superior and petrosal ganglia; (10) *the vagus*, sensory, with its *jugular and nodose ganglia*; (11) accompanying the vagus the motor fibers of the *spinal accessory* which take origin between the *jugular and sixth cervical ganglia* from the lateral wall of the spinal cord and myelencephalon; the internal branch of the *n. accessorius* accompanies the vagus; the external branch leaves it between the jugular and nodose ganglia and supplies the sternocleidomastoid and trapezius muscles; (12) the *n. hypoglossus*, motor, arising by five or six fascicles from the ventral wall of the myelencephalon, its trunk passing lateral to the nodose ganglion and supplying the muscles of the tongue.

From the jugular ganglion of the vagus extends a nodular chain of ganglion cells. These have been interpreted as *accessory vagus ganglia*. They may, however, be continuous with *Froriep's ganglion* which sends sensory fibers to the *n. hypoglossus*. In pig embryos of 15 to 16 mm. this chain is frequently divided into four or five ganglionic masses, of which occasionally two or three (including Froriep's ganglion) may send fibers to the root fascicles of the hypoglossal nerve. Such a condition is shown in Fig. 116.

*Spinal Nerves.* These have each their *spinal ganglion*, from which the dorsal root fibers are developed (Figs. 115 and 131). The motor fibers take origin from the ventral cells of the neural tube and form the ventral roots which join the dorsal roots in the nerve trunk.

In Fig. 115 the *heart* with its right *atrium* and *ventricle*, the *dorsal and ventral lobes* of the *liver*, and the large *mesonephros* are prominent. Dorsal, and somewhat caudal to the atrium, is the anlage of the *right lung*. The *septum transversum* extends between the heart and the liver.

**Pharynx and Its Derivatives.**—Dorsally the anterior lobe of the hypophysis is long and forks at its end (Figs. 117 and 118). In the floor of the pharynx are the anlagen of the *tongue* and *epiglottis* (Fig. 151 A). From each mandibular arch arises an elongated thickening which extends caudal to the second arch. Between, and fused to these thickenings, is the triangular *tuberculum impar*. The opening of the *thyreoid duct* between the tuberculum impar and the second arch is early obliterated. A median ridge, or *copula*, between the second arches connects the tuberculum impar with the epiglottis, which seems to develop from the bases of the third and fourth branchial arches. On either side of the slit-like *glottis* are the *arytenoid folds* of the larynx. (For the development of the tongue,

see p. 158.) The *pharyngeal* pouches are now larger than in the 6 mm. pig (Fig. 118). The first pouch persists as the Eustachian tube and middle ear cavity, the closing plate between it and the first branchial cleft forming the *tympanic membrane*. The *second pouch* later largely disappears. About it, develops the *palatine tonsil*. The third pouch is tubular, directed at right angles to the pharynx

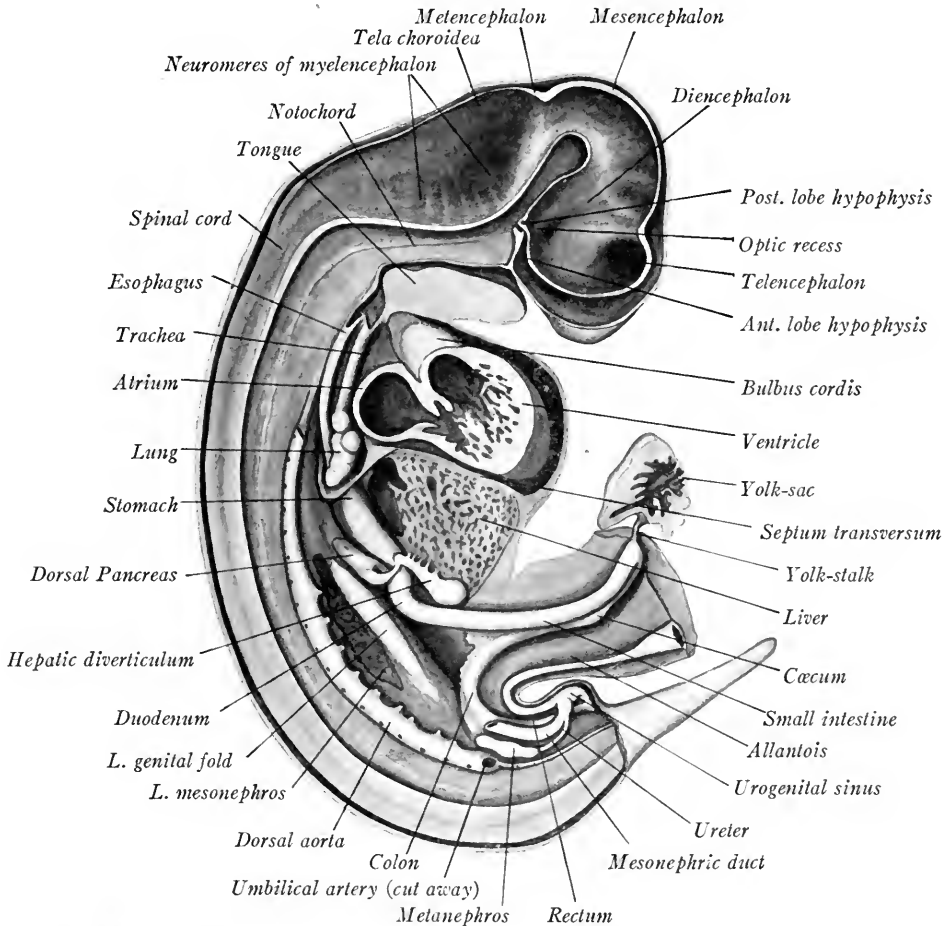


FIG. 117.—Median sagittal dissection of a 10 mm. pig embryo, showing the brain, spinal cord and viscera from the right side.  $\times 10.5$ .

and meets the ectoderm to form a "closing plate." Median to the plate, the ventral diverticulum of the third pouch is the anlage of the *thymus gland*. Its dorsal diverticulum forms an epithelial body, or *parathyreoid*. The *fourth pouch* is smaller and its dorsal diverticulum gives rise to a second parathyreoid body. Its ventral diverticulum is a rudimentary thymus anlage. A tubular

outgrowth, caudal to the fourth pouch, is regarded as a fifth pharyngeal pouch in human embryos and forms the *post-branchial body* on each side (see p. 172). The *thyroid gland*, composed of branched cellular cords, is located in the mid-line between the second and third branchial arches (Fig. 118).

**Trachea and Lungs.**—Caudal to the fourth pharyngeal pouches the es-

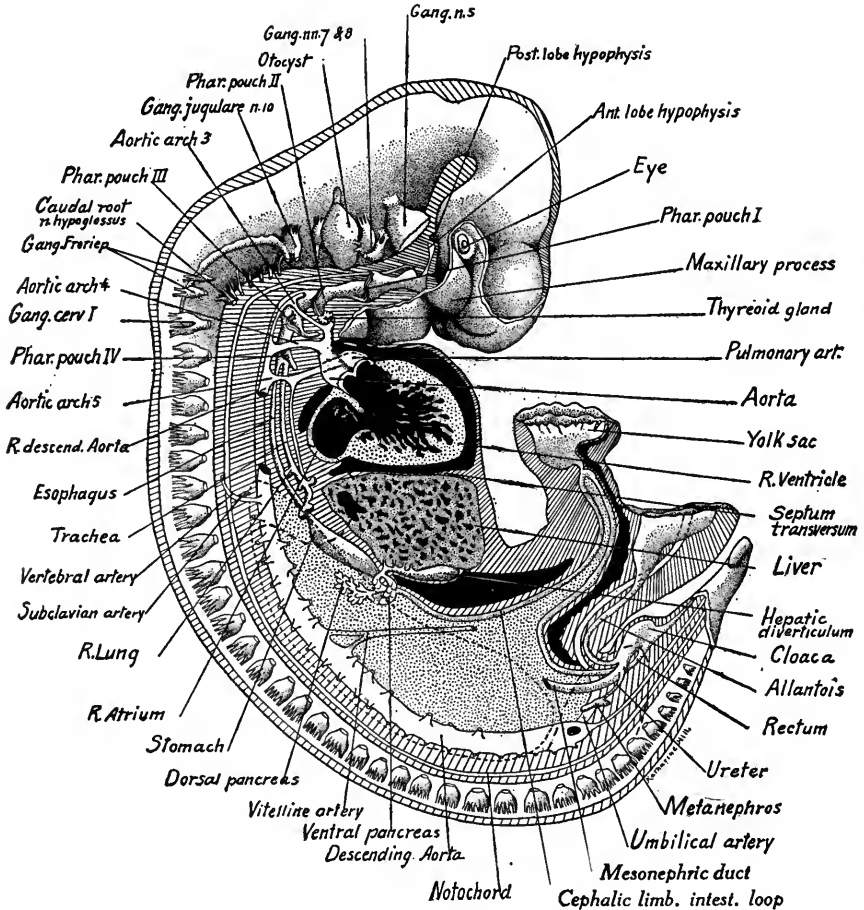


FIG. 118.—Reconstruction of a 10 mm. pig to show the position of the various organs from the right side. The veins are not indicated. Broken lines indicate the outline of the left mesonephros and the positions of the limb buds.  $\times 10$ .

phagus and trachea separate and form entodermal tubes (Figs. 117 and 118). Before the trachea bifurcates to form the primary bronchi there appears on its right side the tracheal bud of the upper lobe of the right lung. This bronchial bud is developed only on the right side and appears in embryos of 8 to 9 mm. Two *secondary bronchial buds* arise from the primary bronchus of each lung, and form the anlagen of the symmetrical lobes of each lung (Fig. 119).

**Esophagus and Stomach.**—The esophagus extends as a narrow tube caudal to the lungs, where it dilates into the stomach. The *stomach* is wide from its greater to its lesser curvature and shows a *cardiac diverticulum* (Lewis). The pyloric end of the stomach has rotated more to the right, where it opens into the *duodenum*, from which division of the intestine develop the liver and pancreas.

The **liver**, with its four lobes, fills in the space between the heart, stomach and duodenum (Fig. 117). Extending from the right side of the duodenum along

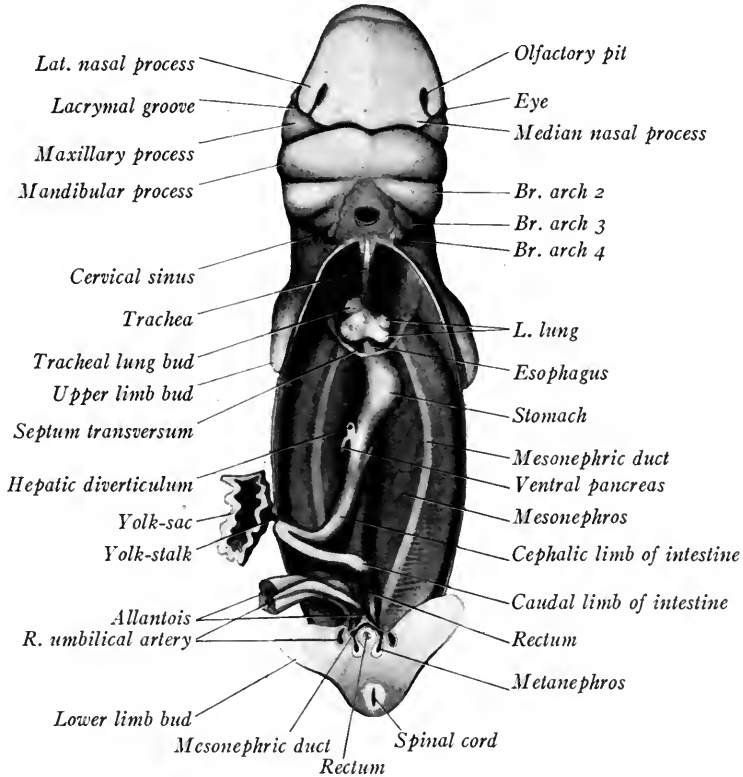


FIG. 119.—Ventral dissection of a 9 mm. pig embryo. The head is represented as bent dorsally.

the dorsal and caudal surface of the liver is the hepatic diverticulum. It lies to the right of the midline and its extremity is saccular. This saccular portion becomes the *gall bladder*. Several ducts connect the diverticulum with the liver cords. One of these persists as the *hepatic duct* which joins the *cystic duct* of the gall bladder. The proximal portion of the diverticulum becomes the common bile duct, or *ductus choledochus*. The *ventral pancreas* arises from the common bile duct near its point of origin (Fig. 118). It is directed dorsad and caudad to the right of the duodenum. The *dorsal pancreas* arises more caudally from the

dorsal wall of the duodenum and its larger, lobulated body grows dorsally and cranially (Figs. 118 and 135). Between the pancreatic anlagen courses the portal vein. In the pig, the duct of the dorsal pancreas persists as the functional duct.

**Intestine.**—Caudal to the duodenum, the intestinal loop extends well into the umbilical cord (Figs. 117 and 118). At the bend of the intestinal loop is the slender *yolk-stalk*. The cephalic limb of the intestine lies to the right, owing to the rotation of the loop. The small intestine extends as far as a slight enlargement of the caudal limb of the loop, the anlage of the *cæcum*, or *blind gut*. This anlage marks the beginning of the *large intestine* (colon and rectum). The intestinal loop is supported by the *mesentery* which is cut away in Fig. 117. The cloaca is now nearly separated into the *rectum* and *urogenital sinus*. The cavity of the rectum is almost occluded by epithelial cells (Lewis).

**Urogenital System.**—The *mesonephros* is much larger and more highly differentiated than in the 6 mm. embryo (Figs. 115 and 119). Along the middle of its ventro-median surface the *genital fold* is now more prominent (Fig. 117). In a ventral dissection (Fig. 119) the course of the *mesonephric ducts* may be traced. They open into the *urogenital sinus*, which also receives the *allantoic stalk*.

The *metanephros*, or permanent kidney anlage, lies just mesial to the umbilical arteries where they leave the aorta (Fig. 118). Its epithelial portion derived from the mesonephric duct is differentiated into a proximal slender duct, the *ureter*, and into a distal dilated *pelvis*. From this grow out later the *calyces* and *collecting tubules* of the kidney. Surrounding the pelvis is a layer of condensed mesenchyma, or *nephrogenic tissue*, which is the anlage of the remainder of the kidney.

**Blood Vascular System.**—*The Heart.*—In Fig. 120 the cardiac chambers of the right side are opened. The *septum primum* between the atria is perforated dorsad and cephalad by the *foramen ovale*. The *inferior vena cava* is seen opening into the *sinus venosus*, which in turn communicates with the right atrium through a sagittal slit guarded by the *right and left valves of the sinus venosus*. The right valve is the higher and its dorsal half is cut away. The valves were united cephalad as the *septum spurium*. The aortic bulb is divided distally into the aorta and the pulmonary artery, the latter connecting with the fifth pair of aortic arches. Proximally the bulb is undivided. The *interventricular septum* is complete except for the *interventricular foramen*, which leads from the left ventricle into the aortic side of the bulb. Of the *bulbar swellings* which divide the



bulb into aorta and pulmonary trunk, the *left* joins the interventricular septum, while the *right* extends to the endocardial cushion. These folds eventually fuse and the partition of the ventricular portion of the heart is completed. The endocardium at the atrio-ventricular openings is already undermined to form the anlagen of the *tricuspid* and *bicuspid* valves. From the caudal wall of the left atrium is given off a single *pulmonary vein*.

*The Arteries.*—As seen in Fig. 118, the first two aortic arches have disappeared. Cranial to the third arch, the ventral aortæ become the *external carotids*. The third aortic arches and the cephalic portions of the descending aortæ constitute the *internal carotid arteries*. The ventral aortæ between the third and fourth aortic arches persist as the *common carotid arteries*. The descending aortæ in the same region are slender and eventually atrophy. The fourth aortic arch is largest and on the left side will form the aortic arch of the adult. From the right *fourth arch* caudad, the right descending aorta is smaller than the left. Opposite the eighth segment, the two aortæ unite and continue caudally as the *median dorsal aorta*. The *fifth aortic arches* (the sixth of human embryos) are connected with the pulmonary trunk, and from them arise small pulmonary arteries to the lungs. *Dorsal intersegmental arteries* arise, six pairs from the descending aortæ, others from the dorsal aorta. From the seventh pair, which arise just where the descending aortæ fuse, the *subclavian arteries* pass off to the upper limb buds and the *vertebral arteries* to the head. The latter are formed by a longitudinal anastomosis between the *first seven pairs* of intersegmental arteries on each side, after which the stems of the first six pairs atrophy.

*Ventro-lateral arteries* from the dorsal aorta supply the mesonephros and genital ridge (Fig. 118). *Ventral arteries* form the *celiac artery* to the stomach region, the *vitelline* or *superior mesenteric artery* to the small intestine, and the *inferior mesenteric artery* to the large intestine.

*Ventro-lateral arteries* from the dorsal aorta supply the mesonephros and genital ridge (Fig. 118). *Ventral arteries* form the *celiac artery* to the stomach region, the *vitelline* or *superior mesenteric artery* to the small intestine, and the *inferior mesenteric artery* to the large intestine.

The umbilical arteries now arise laterally from secondary trunks which persist as the *common iliac arteries*.

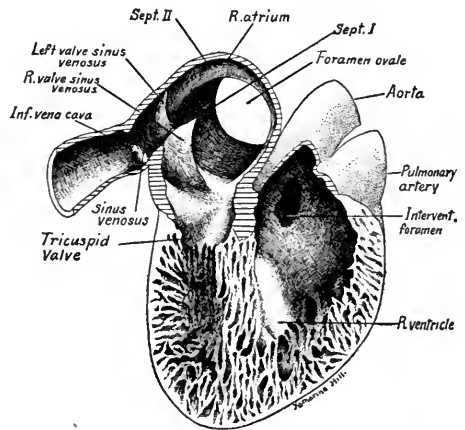


FIG. 120.—Heart of 12 mm. embryo dissected from the right side.

*The Veins.*—The *cardinal veins* have been reconstructed by Lewis in a 12 mm. pig (Fig. 121). The veins of the head drain into the *anterior cardinal vein*, which becomes the internal jugular vein of the adult. After receiving the *external jugular veins* and the *subclavian veins* from the upper limb buds the anterior cardinals open into the *common cardinal veins* (duct of Cuvier).

The *posterior cardinal veins* arise in the caudal region, course dorsal to the

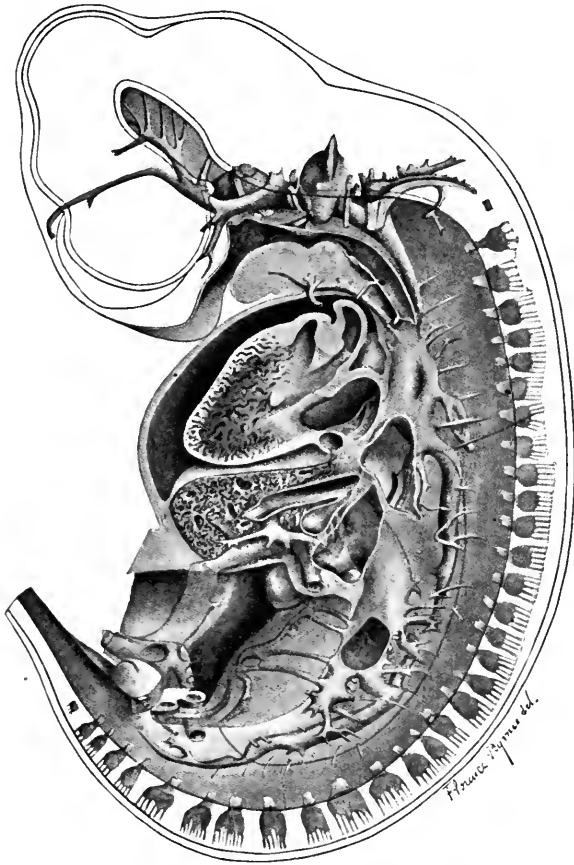


FIG. 121 A.—Reconstruction of a 12 mm. pig embryo to show the veins and heart from the left side. For names of parts see Fig. 121 B on opposite page (F. T. Lewis).  $\times 13.5$ .

mesonephroi, and drain the mesonephric sinusoids. The *subcardinal veins* anastomose just caudal to the origin of the superior mesenteric artery and the posterior cardinals are interrupted at this level. The caudal portion of the *right posterior* cardinal vein now anastomoses with the right subcardinal vein and with it forms a part of the *inferior vena cava*. The proximal portions of the posterior cardinals open into the common cardinal veins as in the 6 mm. embryo.

Of the two *subcardinal veins*, the right has become very large through its connection with the right posterior cardinal vein and the common hepatic vein, and now forms the middle portion of the *inferior vena cava*. For the development of this vein, see Chapter IX.

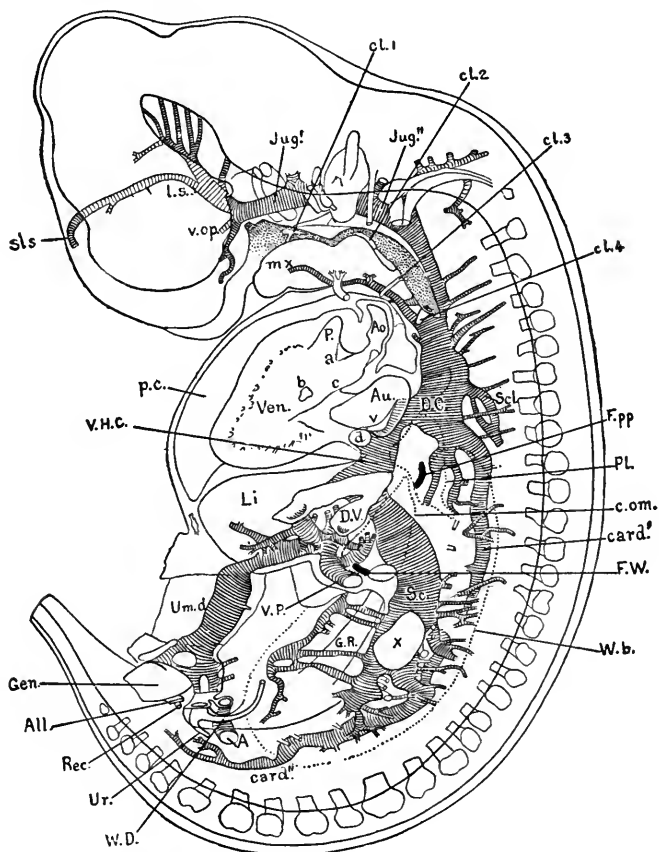


FIG. 121 B.—Reconstruction of a 12 mm. pig embryo to show the veins from the left side (Lewis).  $\times 13.5$ . A., umbilical artery; Ao., aorta; Au., right auricle (atrium); Card.', Card'', superior and inferior sections of posterior cardinal vein; d, left common cardinal vein; D.C., right common cardinal vein; D.V., ductus venosus; Jug', Jug'', jugular or ant. cardinal vein; L., liver; L.s., anlage of lateral sinus; mx, transverse vein; P., pulmonary artery; Sc., subcardinal vein; Scl., subclavian vein; Sls., anlage of sup. longitudinal sinus; Um. d., right umbilical vein; Ven., right ventricle; V.H.C., common hepatic vein; V.op., ophthalmic vein; V.P., portal vein; X, anastomosis between the right and left subcardinal veins:

The *Umbilical Veins* (Figs. 121 and 122) anastomose in the umbilical cord, separate on entering the embryo, and course in the ventro-lateral body wall of each side cranially to the ventral lobe of the liver. The left vein is much the larger and, after entering the liver, its course is to the right and dorsad. After connecting with the portal vein, it continues as the *ductus venosus* and joins the

proximal end of the inferior vena cava. The smaller *right umbilical vein* after entering the liver breaks up into sinusoids. It soon atrophies, while the left vein persists until after birth.

*The Vitelline Veins.*—Of these a distal portion of the left and a proximal portion of the right are persistent. The left vitelline vein, fused with the right, courses from the yolk-sac cephalad to the intestinal loop. Near its dorsal anastomosis with the right vein just caudal to the duct of the dorsal pancreas, it receives the *superior mesenteric vein*, a new vessel arising in the mesentery of the

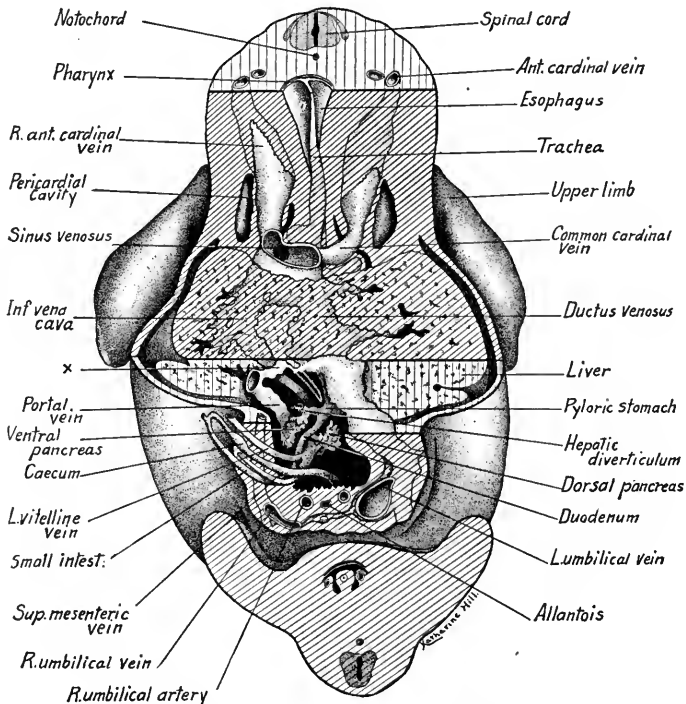


FIG. 122.—Reconstruction of a 10 mm. pig embryo to show the umbilical and vitelline veins from the ventral side. X indicates sinusoidal connection between left umbilical vein and portal vein.

intestinal loop. Cranial to its junction with the sup. mesenteric vein, the left vitelline with its dorsal anastomosis and the proximal portion of the right vitelline vein form the *portal vein*, which gives off branches to the hepatic sinusoids and connects with the *left umbilical vein*. For the development of the portal vein, see Chapter IX.

#### TRANSVERSE SECTIONS OF A 10 MM. PIG EMBRYO

Figures are shown of sections passing through the more important regions and should be used for the identification of the organs. The level and plane of

each section is indicated by guide lines on Fig. 123. The student should compare this with Figs. 113 and 118, and orient each section with reference to the embryo as a whole. Keep in mind the fact that the transverse sections are drawn from the cephalic surface so that the right side of the figure is the left side of the embryo.

**Transverse Section through the Eyes and Otocysts (Fig. 124).**—The brain is sectioned twice, lengthwise through the myelencephalon, transversely through the fore-brain. The brain wall shows differentiation into three layers: (1) an inner *ependymal layer* densely

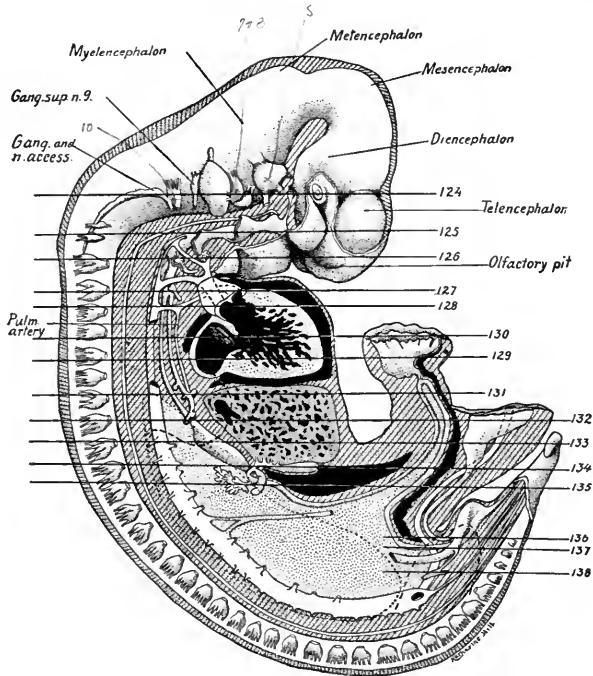


FIG. 123.—Reconstruction of a 10 mm. pig embryo, showing the chief organs of the left side. The numbered lines indicate the levels of transverse sections shown in the corresponding figures (124–138). For the names of the various structures not lettered see Fig. 118.  $\times 8$ . *Gang. and n. access.*, ganglion and n. accessorius; *Gang. sup. n. 9.*, superior ganglion of glossopharyngeal nerve; *Pulm. artery*, pulmonary artery.

cellular; (2) a middle *mantle layer* of nerve cells and fibers; (3) an outer *marginal layer* chiefly fibrous. These same three layers are developed in the spinal cord. A thin vascular layer differentiated from the mesenchyma surrounds the brain wall and is the anlage of the *pia mater*. The myelencephalon shows three neuromeres in this section. The *telencephalon* is represented by the paired *cerebral hemispheres*, their cavities, the lateral ventricles, connecting through the *interventricular foramina* with the *third ventricle* of the *diencephalon*. Close to the ventral wall of the *diencephalon* is a section of the *anterior lobe of the hypophysis* (Rathke's pocket). Lateral to the *diencephalon* is the *optic cup* and *lens vesicle* of the eye, which are sectioned caudal to the optic stalk. The outer layer of the optic cup forms the thin *pigment layer*; the inner thicker layer is the *nervous layer of the retina*. The *lens* is now a closed vesicle distinct from the overlying *corneal ectoderm*.

The large vascular spaces are the *cavernous sinuses*, which drain by way of the *vv. capituli*

lateralis into the *internal jugular veins*. Transverse sections may be seen of the *maxillary* and *mandibular branches* of the *n. trigeminus*; the *n. abducens* is sectioned longitudinally. Ventral to the otocyst are seen the *geniculate* and *acoustic ganglia* of the *nn. facialis* and *acusticus*. The wall of the *otocyst* forms a sharply defined epithelial layer. More cephalad in the series the *endolymphatic duct* lies median to the otocyst and connects with it. Dorsal to the otocyst the *n. glossopharyngeus* and the *jugular ganglion of the vagus* are cut transversely while the trunk of the *n. accessorius* is cut lengthwise.

**Section through the First and Second Pharyngeal Pouches** (Fig. 125).—The end of the head, with sections of the *telencephalon* and of the ends of the *olfactory pits*, is now

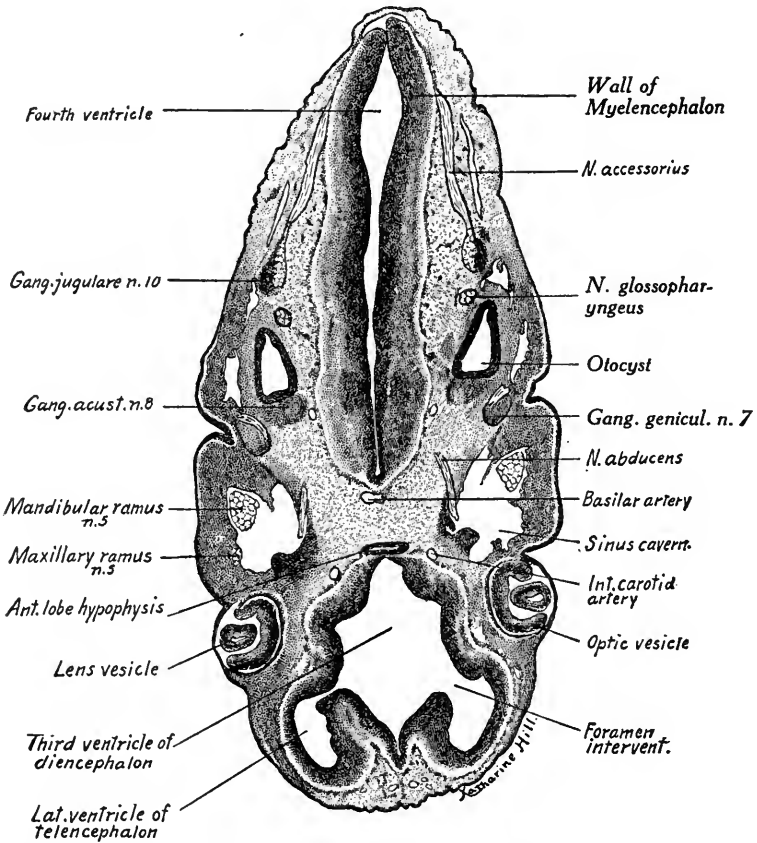


FIG. 124.—Transverse section passing through the eyes and otocysts of a 10 mm. embryo.  $\times 22.5$ .

distinct from the rest of the section. The *pharynx* shows portions of the *first* and *second pharyngeal pouches*. Opposite the first pouch externally is the *first branchial cleft*. A section of the *tuberculum impar* of the tongue shows near the midline in the pharyngeal cavity. The neural tube is sectioned dorsally at the level of *Froviép's ganglion*. Between the neural tube and the pharynx may be seen on each side the several root fascicles of the *n. hypoglossus*, the *fibers of the nn. vagus* and *accessorius* and the *petrosal ganglion* of the *n. glossopharyngeus*. Mesial to the ganglia are the *descending aortae* and lateral to the vagus is the *internal jugular vein*.

**Section through the Third Pharyngeal Pouches** (Fig. 126).—The tip of the head is now small and shows on either side the deep *olfactory pits* lined with thickened *olfactory epi-*

*thelium*. The first, second and third branchial arches show on either side of the section, the third being slightly sunken in the *cervical sinus*. The dorsal diverticula of the third pharyngeal pouches extend toward the ectoderm of the third branchial cleft. The ventral diverticula or thymic anlagen may be traced caudad in the series. The floor of the pharynx is sectioned through the epiglottis. Ventral to the pharynx are sections of the third aortic arches and the solid cords of the median thyroid gland. Dorsally the section passes through the spinal cord and first pair of cervical ganglia. Between the cord and pharynx, named in order, are the internal jugular veins, the hypoglossal nerve, and the nodose ganglion of the vagus. Lateral to the ganglion

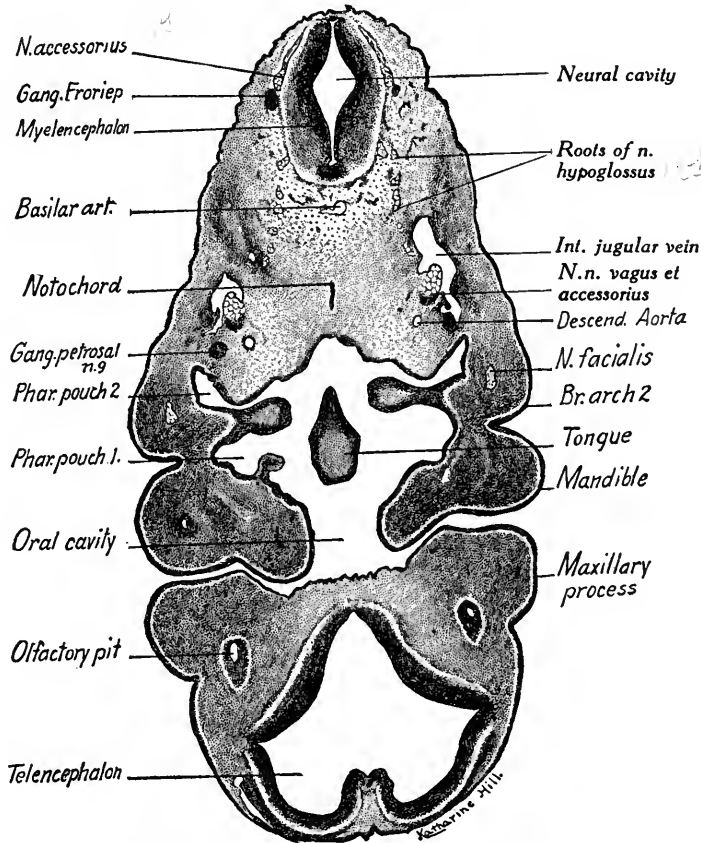


FIG. 125.—Transverse section passing through the first and second pharyngeal pouches of a 10 mm. pig embryo.  $\times 22.5$ .

is the external branch of the *n. accessorius*, and mesial to the ganglia are the small descending aorta.

**Section through the Fourth Pharyngeal Pouches** (Fig. 127).—This region is marked by the disappearance of the head and the appearance of the heart in the pericardial cavity. The tips of the atria are sectioned as they project on either side of the *bulbus cordis*. The bulbus is divided into the aorta and pulmonary artery, the latter connected with the right ventricle, which has spongy muscular walls. The pharynx is crescentic and continued laterally as the small fourth pharyngeal pouches. Into the mid-ventral wall of the pharynx opens the vertical slit of the trachea. A section of the vagus complex is located between the descending

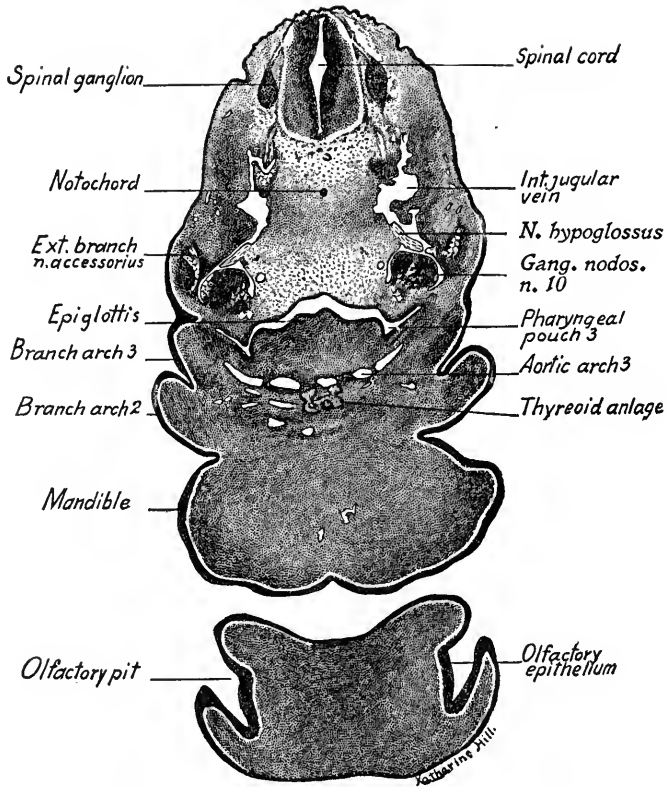


FIG. 126.—Transverse section through the third pharyngeal pouches of a 10 mm. pig embryo.  $\times 22.5$ .

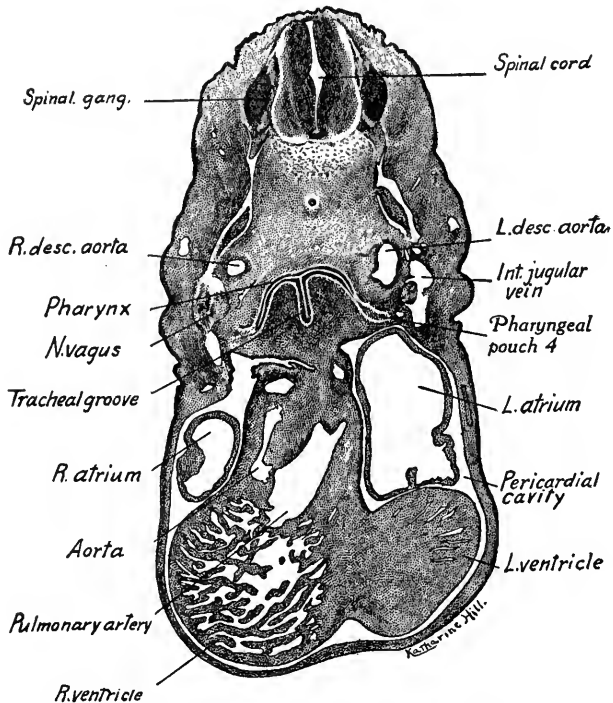


FIG. 127.—Transverse section through the fourth pharyngeal pouches of a 10 mm. pig embryo.  $\times 22.5$ .



aorta and the *internal jugular vein*. At this level the jugular vein receives the *linguo-facial vein*. The *left descending aorta* is larger than the right. The *ventral aorta* may be traced cranially in the series to the fourth aortic arches. The *pulmonary artery*, if followed caudad, connects with the *fifth aortic arches* as in Fig. 128.

**Section through the Fifth Aortic Arches** (Fig. 128).—The *fifth aortic arch* is complete on the left side. From these *pulmonary arches* small *pulmonary arteries* may be traced caudad in the series to the lung anlagen. The cavity of the pharynx forms a curved horizontal slit. All four chambers of the heart are represented, but the *aorta* and *pulmonary artery* are incompletely separated by the *right and left bulbar swellings or folds*.

**Section through the Sinus Venosus and the Heart** (Fig. 129).—The section is marked by the symmetrically placed *atria* and *ventricles* of the heart and by the presence of

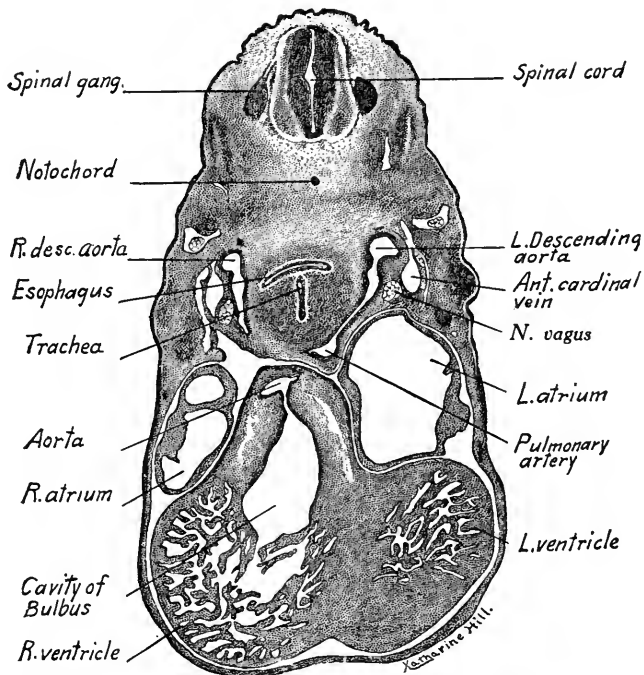


FIG. 128.—Transverse section through the fifth pair of aortic arches and bulbus cordis of a 10 mm. pig embryo.  $\times 22.5$ .

the *upper limb buds*. Dorsal to the atria are the *common cardinal veins*, the right vein forming part of the *sinus venosus*. The *sinus venosus* drains into the right atrium through a slit-like opening in the dorsal and caudal atrial wall. The opening is guarded by the *right and left valves* of the *sinus venosus*, which project into the atrium. The *septum primum* completely divides the right and left atria at this level, which is caudal to the foramen ovale and the atria-ventricular openings. The septum joins the fused endocardial cushions. Note that the esophagus and trachea are now tubular and that the *left descending aorta* is much larger than the right. Around the epithelium of both trachea and esophagus are condensations of mesenchyma, from which their outer layers are differentiated.

**Section through the Foramen Ovale of the Heart** (Fig. 130).—The level of this section is cranial to that of the previous figure and shows the *septum primum* interrupted dorsally to form the *foramen ovale*. Each atrium communicates with the ventricle of the same

side through the *atrio-ventricular foramen*. Between these openings is the *endocardial cushion*, which in part forms the anlagen of the *tricuspid* and *bicuspid* valves. The atria are marked off

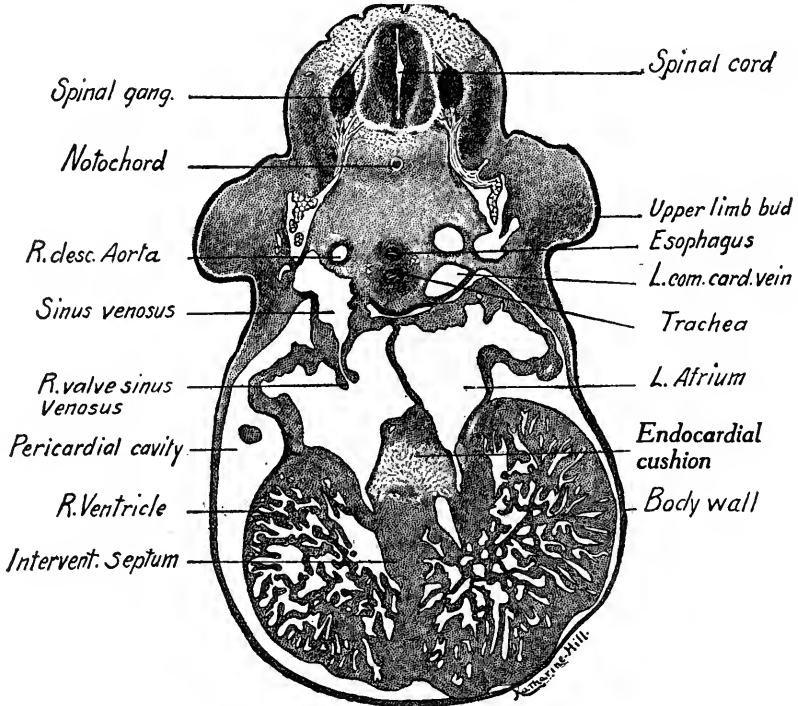


FIG. 129.—Transverse section through the sinus venosus of the heart in a 10 mm. pig embryo.  $\times 22.5$ .  
*L. com. card. vein*, left common cardinal vein; *R. desc. Aorta*, right descending aorta.

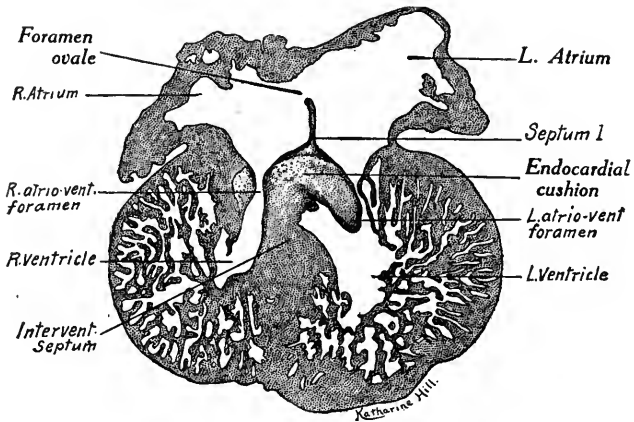


FIG. 130.—Transverse section through the foramen ovale of the heart in a 10 mm. pig embryo.  $\times 22.5$ . *L. atrio-vent. foramen*, *R. atrio-vent. foramen*, left and right atrio-ventricular foramen; *Intervent. septum*, interventricular septum.

externally from the ventricles by the *coronary sulcus*. Between the two ventricles is the *inter-ventricular septum*. The ventricular walls are thick and spongy, forming a network of muscular

*cords* or *trabeculae* surrounded by blood spaces or *sinusoids*. The trabeculae are composed of muscle cells, which later become striated and constitute the myocardium. They are surrounded by an endothelial layer, the *endocardium*. From the blood circulating in the sinusoids the mammalian heart receives all its nourishment until, later, the *coronary vessels* of the heart wall are developed. The heart is surrounded by a layer of mesothelium, the *epicardium*, which is continuous with the *pericardial* mesothelium lining the body wall.

**Section through the Liver and Upper Limb Buds** (Fig. 131).—The section is marked by the presence of the *upper limb buds*, the *liver* and the bifurcation of the trachea to form the *primary bronchi of the lungs*. The *limb buds* are composed of dense undifferentiated mesenchyme surrounded by the ectoderm which is thickened at their tips. The seventh pair

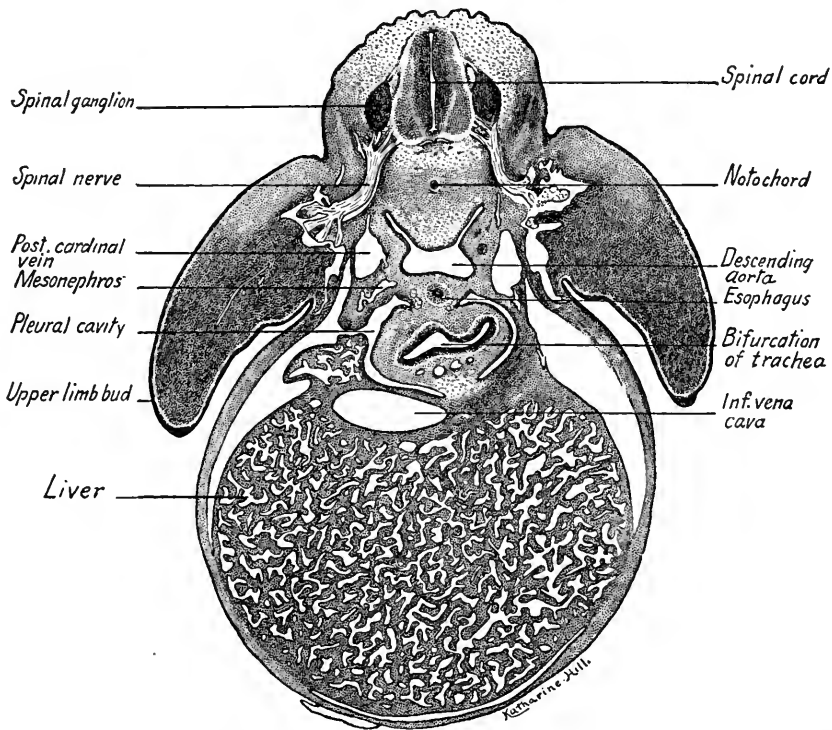


FIG. 131.—Transverse section through the liver and upper limb buds of a 10 mm. pig embryo at the level of the bifurcation of the trachea.  $\times 22.5$ . *Inf. vena cava*, inferior vena cava.

of cervical ganglia and nerves are cut lengthwise showing the spindle-shaped ganglia with the dorsal root fibers taking origin from their cells. The *ventral root fibers* arise from the ventral cells of the mantle layer and join the dorsal root to form the nerve trunk. On the right side, a short *dorsal ramus* supplies the anlage of the dorsal muscle mass. The much larger *ventral ramus* unites with those of other nerves to form the *brachial plexus*.

The *descending aortae* have now fused and the seventh pair of *dorsal intersegmental arteries* arise from the *dorsal aorta*. From these intersegmental arteries the *subclavian arteries* are given off two sections caudad in the series. Lateral to the aorta are the *posterior cardinal veins*. The esophagus, ventral to the aorta, shows a very small lumen, while that of the trachea is large and continued into the *bronchi* on either side. The *lung anlages* project laterally into the crescentic *pleural cavities*, of which the left is separated from the peritoneal cavity by the

*septum transversum*. The liver, with its fine network of trabeculae and sinusoids, is large and nearly fills the peritoneal or abdominal cavity. The liver cords are composed of liver cells surrounded by the endothelium of the sinusoids. Red blood-cells are developed in the liver

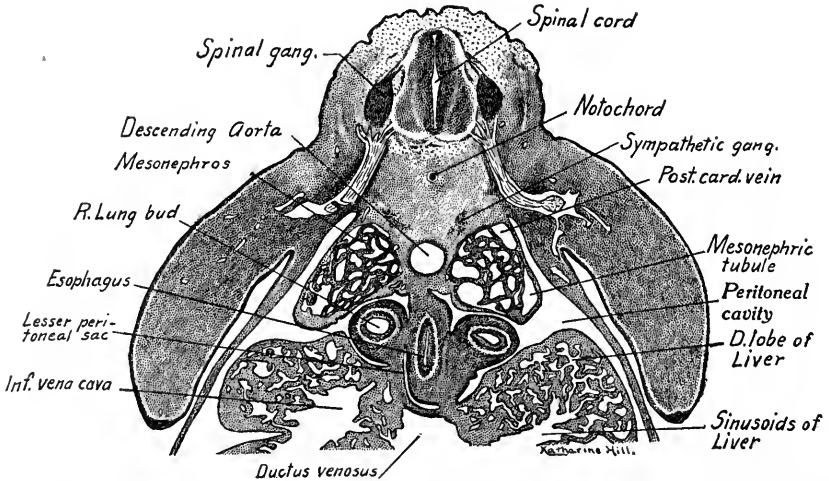


FIG. 132.—Dorsal half of a transverse section through the lung buds cranial to the stomach in a 10 mm. pig embryo.  $\times 22.5$ . *Post. card. vein*, posterior cardinal vein.

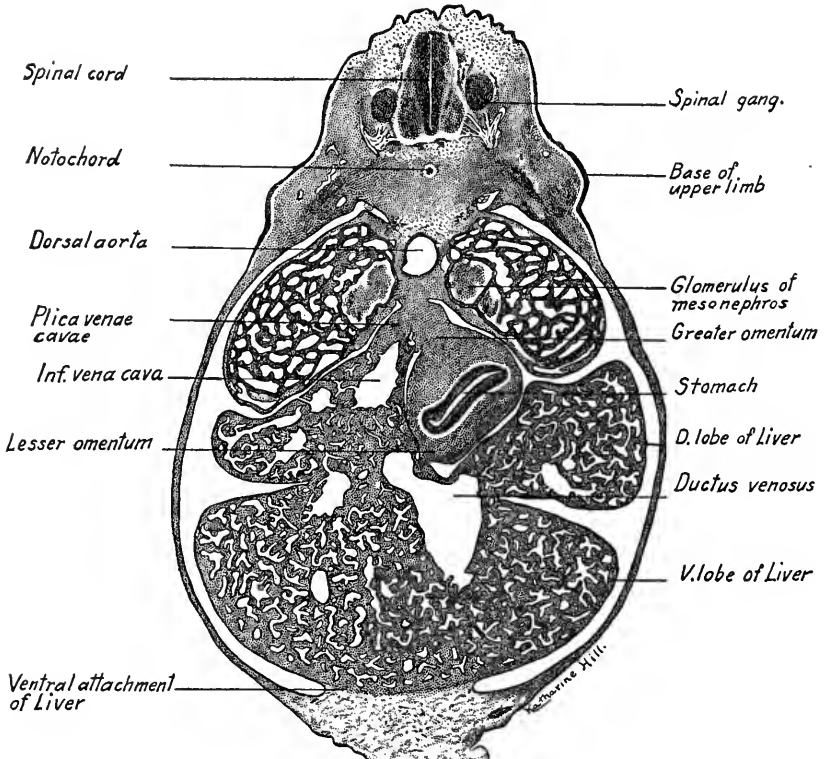


FIG. 133.—Transverse section through the stomach and liver of a 10 mm. pig embryo.  $\times 22.5$ .

at this stage. The large vein penetrating the septum transversum from the liver to the heart, is the proximal portion of the *inferior vena cava*, originally the *right vitelline vein*. Ventral to the bronchi may be seen sections of the *pulmonary veins*.

**Section through Lung Buds Cranial to Stomach** (Fig. 132).—The lungs are sectioned through their caudal ends and the esophagus is just beginning to dilate into the stomach. On either side of the circular dorsal aorta are the *mesonephroi*. The pleural cavities now communicate freely on both sides with the peritoneal cavity. A section of the *lesser peritoneal sac* appears as a crescent-shaped slit to the right of the esophagus. In the right dorsal lobe of the liver is located the *inferior vena cava*. Near the median line ventral to the lesser sac is the large *ductus venosus*.

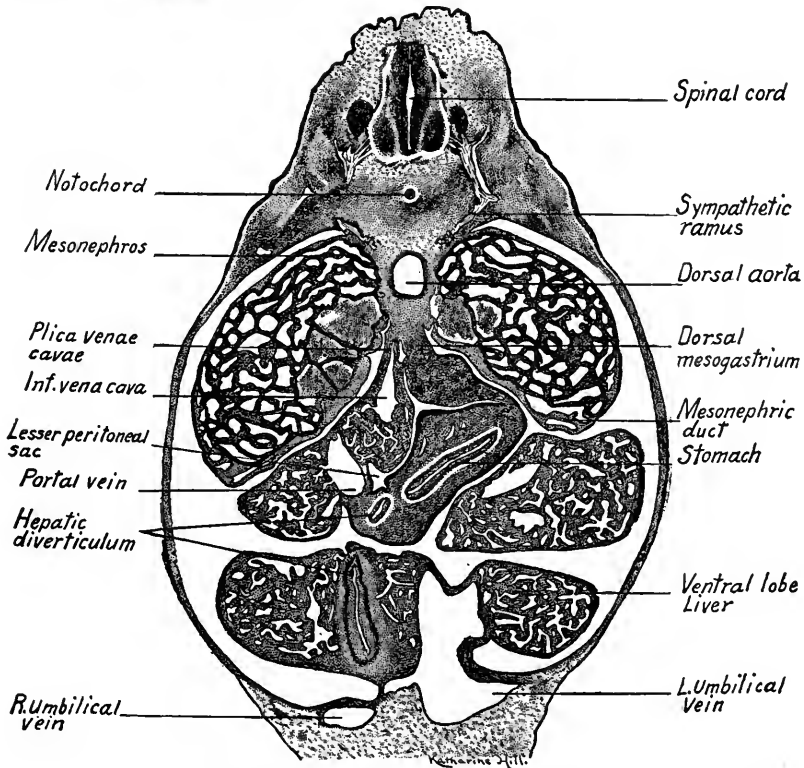


FIG. 134.—Transverse section through the hepatic diverticulum of a 10 mm. pig embryo.  $\times 22.5$ .

**Section through the Stomach and Liver** (Fig. 133).—Prominent in the body cavity are the *mesonephroi* and liver lobes. The mesonephroi show sections of coiled tubules lined with cuboidal epithelium. The *glomeruli*, or renal corpuscles, are median in position and develop as knots of small arteries which grow into the ends of the tubules. The thickened epithelium along the median and ventral surface of the mesonephros is the anlage of the *genital gland*. The body wall is thin and lined with mesothelium continuous with that which covers the mesenteries and organs. The mesothelial layer becomes the epithelium of the adult *peritoneum*, *mesenteries* and *serous layer* of the viscera. The stomach lies on the left side and is attached dorsally by the *greater omentum*, ventrally to the liver by the *lesser omentum*. The right dorsal lobe of the liver is attached dorsally to the right of the *great omentum*. In the liver ventral to this attachment courses the *inferior vena cava* and the attachment forms the *plica venae cavae*. Between the attachments of the stomach and liver, and to the right of the stomach,

is the *lesser peritoneal sac*. In the liver to the left of the midline is the *ductus venosus*, sectioned just at the point where it receives the *left umbilical vein* and a branch from the *portal vein*. The ventral attachment of the liver later becomes the *falciform ligament*.

**Section through the Hepatic Diverticulum** (Fig. 134).—The section passes through the pyloric end of the stomach and the duodenum near the attachment of the hepatic diverticulum. The great omentum of the stomach is larger than in the previous section and to its right, in the *plica venæ cavæ*, lies the *inferior vena cava*. Ventral to the inferior vena cava is a section of the portal vein. The ventral and dorsal lobes of the liver are now separate and in the right ventral lobe is embedded the saccular end of the *hepatic diverticulum*, which forms the *gall bladder*. To the right of the stomach, the diverticulum is sectioned again just as it enters the *duodenum*. Ventrally the *left umbilical vein* is entering the left ventral lobe of the liver. It is much larger than the right vein, which still courses in the body wall. On the left side of the embryo the *spinal nerve* shows in addition to its dorsal and ventral rami a *sympathetic ramus*, the fibers of which pass to a cluster of ganglion cells located dorso-lateral to the

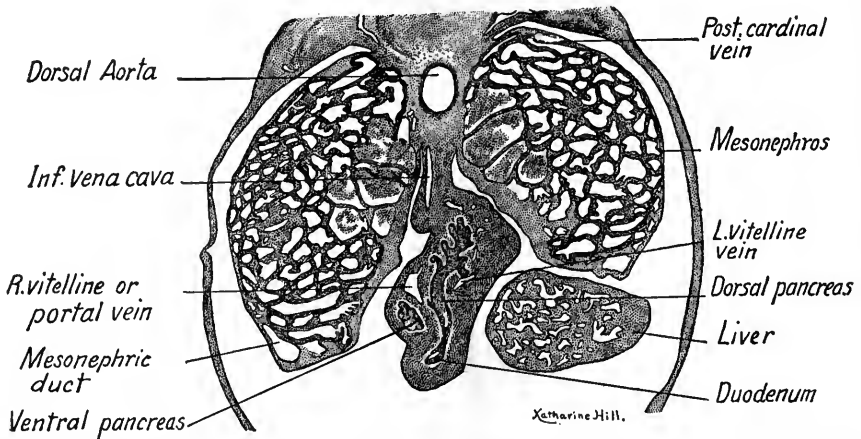


FIG. 135.—Portion of a transverse section through the pancreatic anlagen of a 10 mm. pig embryo.  $\times 22.5$ .

aorta. These cells form one of a pair of *sympathetic ganglia* and are derived from a spinal ganglion.

**Section through the Pancreatic Anlagen** (Fig. 135).—The lesser peritoneal sac just above the level of this section has opened into the peritoneal cavity through the *epiploic foramen* (of Winslow). The *mesonephric ducts* are now prominent ventrally in the mesonephroi. The duct of the *dorsal pancreas* is sectioned tangentially at the point where it takes origin from the duodenum. From the duct the lobulated gland may be traced dorsad in the mesentery. To the right of the dorsal pancreatic duct is a section of the *ventral pancreas*, which may be traced cephalad in the series to its origin from the *hepatic diverticulum*. Dorsal to the ventral pancreas is a section of the *portal vein*. The inferior vena cava appears as a vertical slit in the dorsal mesentery.

**Section through the Urogenital Sinus and the Lower Limb Buds** (Fig. 136).—The figure shows only the caudal end of a section, in the dorsal portion of which the mesonephroi were sectioned at the level of the *subcardinal anastomosis*. A portion of the *mesentery* is shown with a section of the *colon*. In the body wall are veins which drain into the umbilical veins, and on each side are the *umbilical arteries*, just entering the body from the umbilical cord. Between them, in sections cranial to this, the allantoic stalk is located. Here it has opened

into the crescentic *urogenital sinus*. Dorsal to the urogenital sinus (dorsal now being at the bottom of the figure owing to the curvature of the caudal region) is a section of the *rectum*, separated from the sinus by a curved prolongation of the coelom. From the ends of the uro-

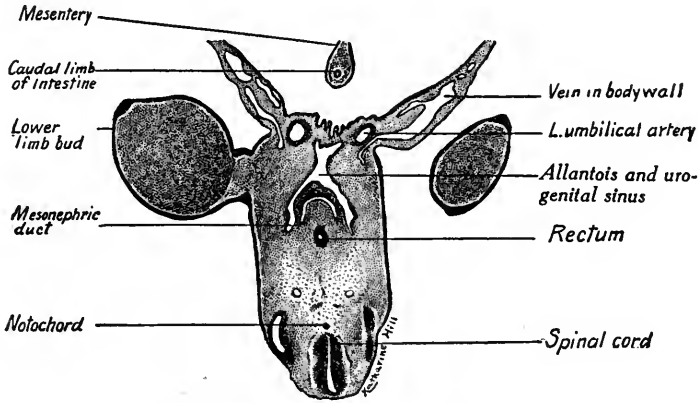


FIG. 136.—Transverse section through the urogenital sinus and rectum of a 10 mm. pig embryo.  $\times 22.5$ .

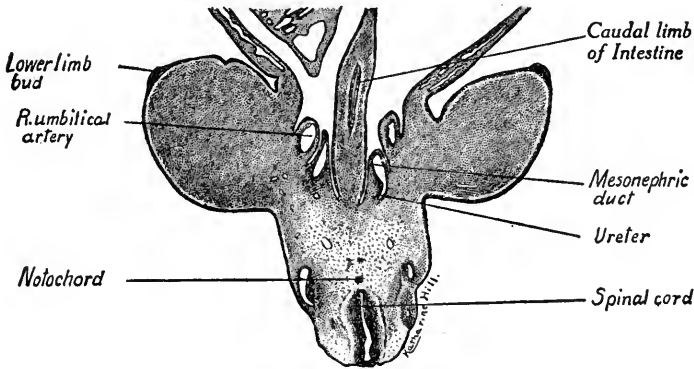


FIG. 137.—Transverse section of a 10 mm. embryo passing through the lower limb buds at the level of the openings of the ureters into the mesonephric ducts.  $\times 22.5$ .

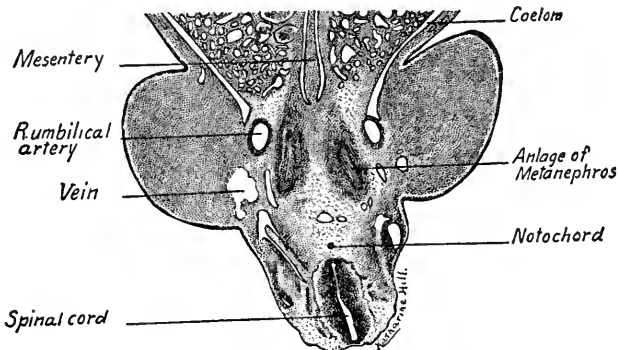


FIG. 138.—Transverse section through the anlagen of the metanephroi in a 10 mm. pig embryo.  $\times 22.5$ .

genital sinus, as we trace cephalad in the embryo (*downward* in the series), are given off the *mesonephric ducts*.

**Section through the Mesonephric Ducts at the Opening of the Ureter** (Fig. 137).—The section cuts near the middle through both lower limb buds. Mesial to their bases are the *umbilical arteries*, which lie lateral to the *mesonephric ducts*. From the dorsal wall of the left mesonephric duct is given off the *ureter* or duct of the *metanephros*. Tracing the sections down in the series, both ureters appear as minute tubes in transverse section. They soon dilate to form the *pelvis of the kidney* at the level of Fig. 138. Note the undifferentiated mesenchyme of the lower limb buds and their thickened ectodermal tips.

**Section through the Metanephroi and Umbilical Arteries** (Fig. 138).—The section passes caudal to the mesonephric ducts which curve along the ventral surfaces of the mesonephroi (Fig. 119). The umbilical arteries course lateral to the metanephroi which consist merely of the thickened epithelium of the pelvis surrounded by a layer of condensed mesenchyme, the *nephrogenic tissue*.



## CHAPTER VI

### THE DISSECTION OF PIG EMBRYOS FOR STUDY: DEVELOPMENT OF FACE, PALATE, TONGUE, SALIVARY GLANDS AND TEETH

As the average student will not have time to study series of embryos sectioned in different planes, dissections may be used for showing the form and relations of the organs. Cleared embryos mounted whole are instructive, but show the structures superimposed and are apt to confuse the student. Pig embryos 10 mm. or more in length may be easily dissected, mounted as opaque objects and used for several years. Success in dissecting such small embryos depends (1) on the *fixation and hardening* of the material employed; (2) on starting the dissection with a *clean cut in the right plane*; (3) on a knowledge of the anatomy of the parts to be dissected.

**Fixation and Hardening of Material.**—Embryos fixed in Zenker's fluid have given the best results. They should then be so hardened in 95 per cent. alcohol that the more diffuse mesenchyma will readily separate from the surfaces of the various organs, yet the organs must not be so brittle that they will crumble and break. Embryos well hardened and then kept for two weeks in 80 per cent. alcohol usually dissect well. Old material is usually too brittle, that just fixed and hardened may prove too soft. As a test, determine whether the mesenchyma separates readily from the cervical ganglia and their roots.

**Dissecting Instruments** include a binocular dissecting microscope, a sharp safety razor blade, large curved blunt-pointed dissecting needles, pairs of small sharp-pointed forceps and straight dissecting needles small and large.

**Methods of Dissection.**—In general, it is best to begin the dissection with a clean, smooth cut made by a single stroke with the safety razor blade, which should be flooded with 80 per cent. alcohol. The section is made free hand holding the embryo, protected by a fold of absorbent cotton, between the thumb and index finger. Having made preliminary cuts in this way, the embryo may be affixed with thin celloidin to a cover glass and immersed in a watch-glass containing alcohol. We prefer not to affix the embryo, as the celloidin used for this purpose may interfere with the dissection. Instead, a cut is made parallel to the plane of the dissection so that the embryo, resting in the watch-glass upon

this flat surface, will be in a fairly stable position. It may thus be held in any convenient position by resting the convex surface of a curved blunt dissecting needle upon some part not easily injured. The dissection is then carried on under the binocular microscope, using the fine pointed forceps, dissecting needles, and a small pipette to wash away fragments of tissue.

**Whole Embryos.**—For the study of the exterior, whole embryos may be affixed with celloidin to the bottoms of watch-glasses which may be stacked in wide-mouthed jars of 80 per cent. alcohol. The specimens may thus be used several years at a saving of both time and material. Preliminary treatment consists in immersion in 95 per cent. alcohol one hour, in ether and absolute alcohol at least thirty minutes, in thin celloidin one hour or more. Pour enough thin celloidin into a Syracuse watch-glass to cover its bottom, and immerse in this a circle of black mat paper, first wet with ether and absolute alcohol. Pour off any surplus celloidin, mount embryo in desired position and immerse watch-glass in 80 per cent. alcohol, in which the specimen may be kept indefinitely. Embryos may also be mounted in gelatine-formalin solution in small sealed glass jars.

**Lateral Dissections of the Viscera.**—Dissections like those shown in Figs. 139 and 140 may easily be prepared in less than an hour, and make valuable demonstration and laboratory specimens. Skill is required to demonstrate most of the cerebral nerves, but the central nervous system, cerebral and spinal ganglia and viscera may easily be exposed. Starting dorsally, make a sagittal section of the embryo slightly to one side of the median line and avoiding the umbilical cord ventrally. With the embryo resting on the flat sectioned surface, begin at the cervical flexure and with fine forceps grasp the ectoderm and dural anlage at its cut edge, separate it from the neural tube and pia-mater and strip it off ventralwards exposing the myelencephalon and cervical portion of the cord. As the mesenchyma is pulled away, the ganglia and roots of the cerebral nerves will be exposed. The mesenchyma between the ganglia and along the nerves may be removed with the end of a small blunt needle. Care must be exercised in working over the mesencephalon and telencephalon of the brain not to injure the brain wall, which may be brittle. By starting with a clean dissection dorsally and gradually working ventrad, the more important organs may be laid bare without injury. The beginner should compare his specimen with the dissections figured and also previously study the reconstructions of Thyng (1911) and Lewis (1902).

*Lateral dissections* of embryos 18 mm. and 35 mm. long show infinitely better than sections the form and relations of the organs, their relative growth and

their change of position (Figs. 139 and 140). Compare the organs of 6, 10, 18 and 35 mm. embryos and note the rapid growth of the viscera (see Figs. 90 and 115). Hand-in-hand with the increased size of the viscera goes the diminution of the *dorsal and cervical flexures*. In the brain, note the increased size of the

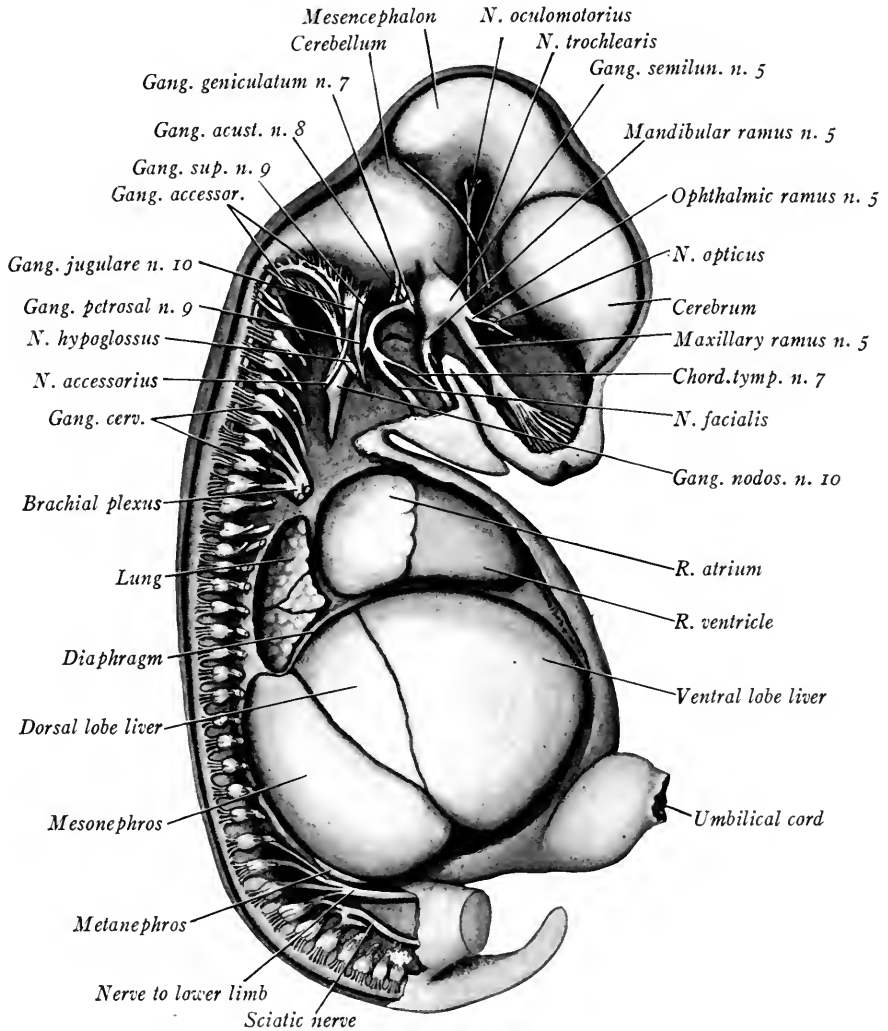


FIG. 139.—Lateral dissection of an 18 mm. pig embryo, showing the nervous system and viscera from the right side.  $\times 15$ .

*cerebral hemispheres* of the telencephalon and presence of the olfactory lobe of the *rhinencephalon*. The cerebellum also becomes prominent and a ventral flexure in the region of the *pons*, the *pontine flexure*, is more marked. The brain grows relatively faster than the spinal cord and, by the elongation of their dorsal

roots, the spinal ganglia are carried ventral to the cord. The body of the embryo also grows faster than the spinal cord, so that the spinal nerves at first directed at right angles to the cord course obliquely caudad in the lumbo-sacral region.

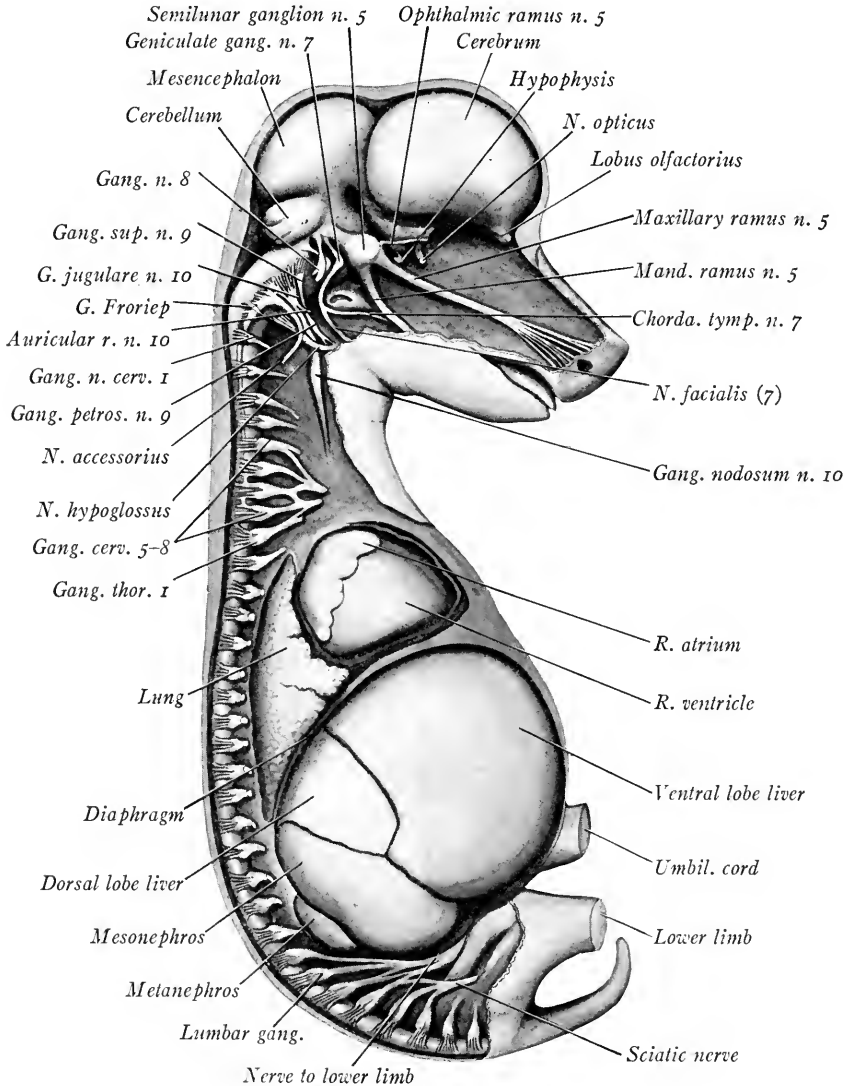


FIG. 140.—Lateral dissection of a 35 mm. pig embryo to show the nervous system and viscera from the right side.  $\times 7\frac{1}{2}$ .

**Median Sagittal Dissections** (Figs. 141 and 142).—Preliminary to the dissection, a cut is made dorsally as near as possible to the median sagittal plane. Beginning caudally at the mid-dorsal line an incision is started which extends in

depth through the neural tube and the anlagen of the vertebræ. This incision is carried to the cervical flexure, cranial to which point the head and brain are halved as accurately as possible. The blade is then carried ventrally and caudally, cutting through the heart and liver *to the right of the midline and of the umbilical cord* until the starting point is reached. A parasagittal section is next made well to the left of the median sagittal plane and the sectioned portion is removed, leaving on the left side of the embryo a plane surface. With the embryo resting upon this flat surface, the dissection is begun by removing with forceps the right half of the head. In pulling this away caudalwards, half of the dorsal body wall, the whole of the lateral body wall, and the parts of the heart and liver lying to the right of the midline will be removed, leaving the other structures intact. If the plane of section was accurate, the brain and spinal cord will be halved in the median sagittal plane. Wash out the cavities of the brain with a pipette and its internal structure may be seen. Dissect away the mesenchyma between the esophagus and trachea and expose the *lung*. Remove the right mesonephros, leaving the proximal part of its duct attached to the urogenital sinus. The right dorsal lobe of the liver will overlie the stomach and pancreas. Pick it away with forceps and expose these organs. Dissect away the caudal portion of the liver until the *hepatic diverticulum* is laid bare. It is whitish in color and may thus be distinguished from the brownish liver. Beginning at the base of the umbilical cord, carefully pull away its right wall with forceps, thus exposing the *intestinal loop* and its attachment to the yolk stalk. If in the caudal portion of the umbilical cord the umbilical artery is removed, the *allantoic stalk* may be dissected out. To see the anlage of the *genital gland*, break through and remove a part of the mesentery, exposing the mesial surface of the *left* mesonephros and the genital fold. The dissection of the metanephros and ureter is difficult in small embryos. In 10 to 12 mm. embryos, the umbilical artery, just after it leaves the aorta, passes lateral to the metanephros and thus locates it. By working carefully with fine needles the surface of the metanephros may be laid bare and the delicate *ureter* may be traced to the base of the mesonephric duct. The extent of the *dorsal aorta* may also be seen by removing the surrounding mesenchyma. With a few trials, such dissections may be made in a short time, and are invaluable in giving one an idea of the form, positions and relations of the different organs. By comparing the early (Figs. 91 and 117) with the later stages (Figs. 141 and 142) a number of interesting points may be noted:

In the brain, the *corpus striatum* develops in the floor of the cerebral hemispheres. The interventricular foramen is narrowed to a slit. In the roof of the

*diencephalon* appears the anlage of the *epiphysis* or *pineal gland*, and the *chorioid plexus* of the third ventricle. This extends into the lateral ventricles as the *lateral chorioid plexus*. The dorso-lateral wall of the *diencephalon* thickens to

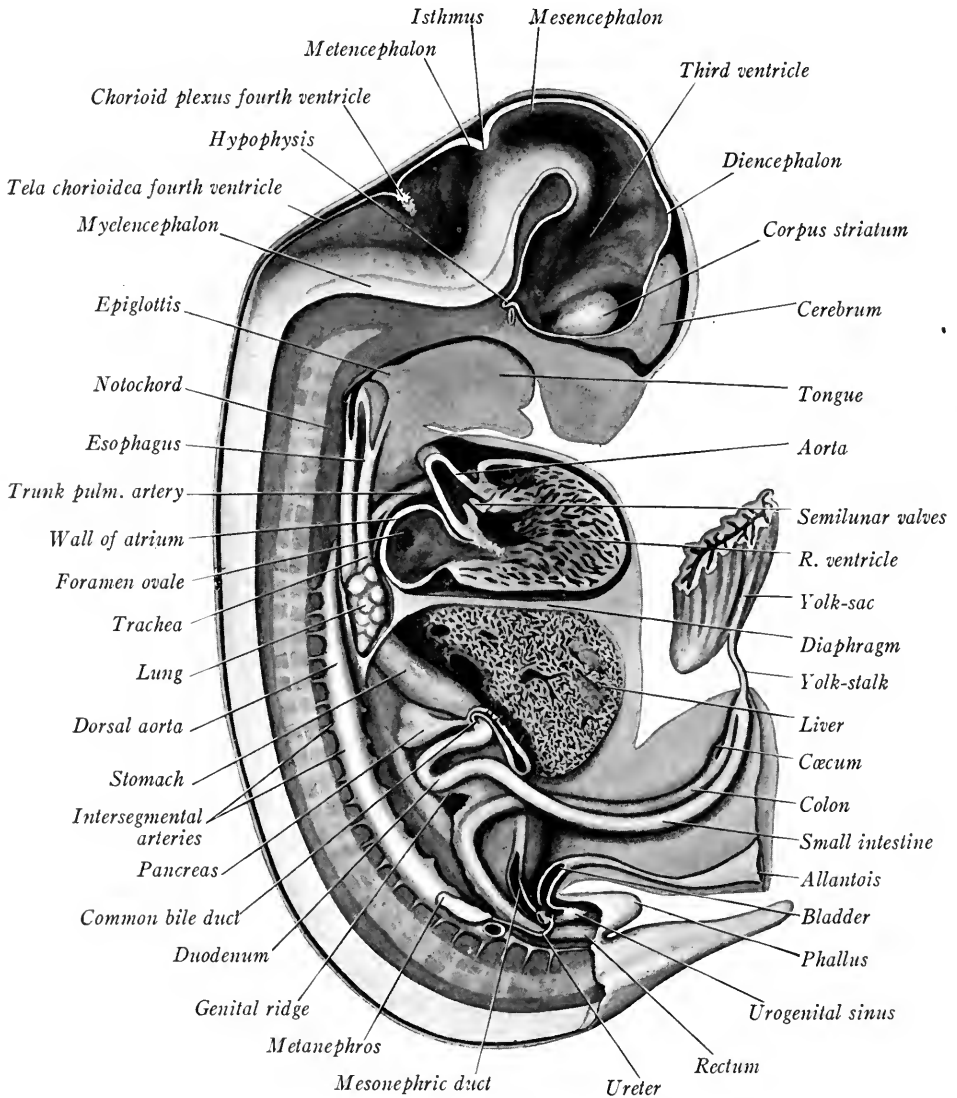


FIG. 141.—Median sagittal dissection of an 18 mm. pig embryo, showing central nervous system in section and the viscera in position.

form the *thalamus* and the third ventricle is narrowed to a vertical slit. The increased size of the *cerebellum* has been noted. Into the thin dorsal wall of the *myelencephalon* grows the network of vessels which form the *chorioid plexus* of

the *fourth ventricle*, which is now spread out laterally and flattened dorso-ventrally. About the notochord mesenchymal anlagen which form the *centra of the vertebræ* are prominent.

Turning to the alimentary tract, observe that the primitive mouth cavity

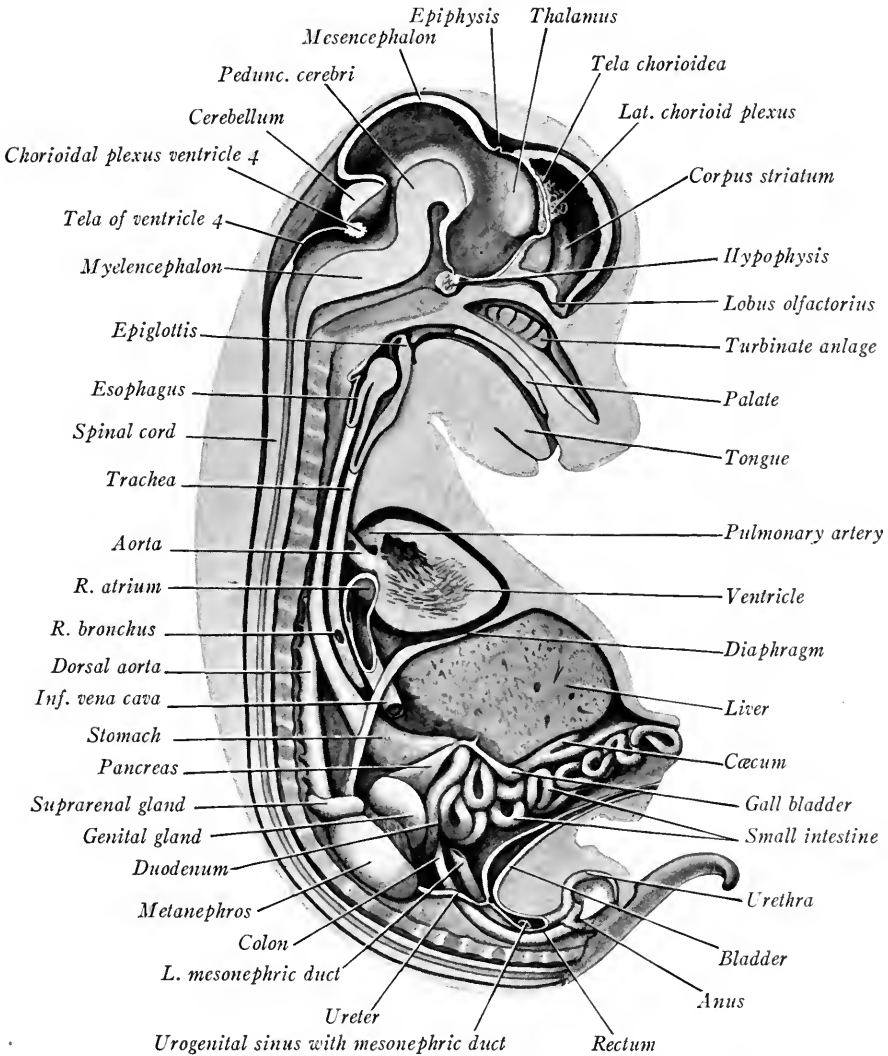


FIG. 142.—Median sagittal dissection of a 35 mm. embryo.

is now divided by the palatine folds into the upper *nasal passages* and lower *oral cavity*. In the lateral walls of the nasal passages develop the anlagen of the *turbinate bones*. On the floor of the mouth and pharynx, the *tongue* and *epiglottis* become more prominent. The *trachea* and *esophagus* elongate and the lungs lie

more and more caudad. The dorsal portion of the *septum transversum*, the anlage of a portion of the diaphragm, is thus carried caudad and although originally, when traced from the dorsal body wall, it was directed *caudad* and ventrad now it curves *cephalad* and ventrad, bulging cephalad into the thorax. The proximal limb of the *intestinal loop* elongates rapidly and, beginning with the duodenum, becomes flexed and coiled in a characteristic manner. The distal limb of the intestinal loop is not coiled, but its diverticulum, the *cæcum*, is more marked. Caudally the *rectum*, or straight gut, has completely separated from the urogenital sinus and opens to the exterior through the *anus*.

Of the *urogenital organs*, the *genital folds* have become the prominent *genital*

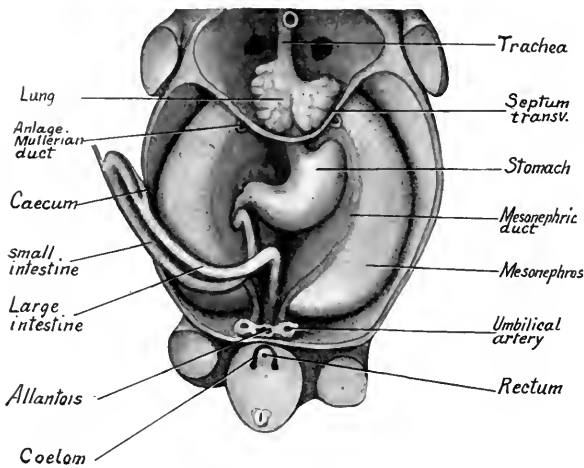


FIG. 143.—Ventral dissection of a 15 mm. embryo, showing lungs, digestive canal and mesonephroi. The ventral body wall, heart and liver have been removed and the limb buds cut across.  $\times 6$ .

*glands* attached to the median surfaces of the *mesonephroi*. The *metanephroi* have increased rapidly in size and have shifted cephalad. The proximal portion of the *allantoic stalk* has dilated and, with the adjacent part of the urogenital sinus, forms the *bladder*. As the urogenital sinus grows it takes up into its wall the proximal ends of the mesonephric ducts, so that these and the ureters have separate openings into the sinus.

Owing to the unequal growth of the sinus wall, the ureters open near the base of the bladder, the mesonephric ducts more caudally into the *urethra*. The *phallus* now forms the *penis* of the male or the *clitoris* of the female. Cranial to the metanephros a new organ, the *suprarenal gland*, has developed. These are ductless glands and are much larger in human embryos.

The *heart*, as may be seen by comparing Figs. 91 and 142, although at first pressed against the tip of the head, shifts caudally until in the 35 mm. embryo it lies in the thorax opposite the first five thoracic nerves. Later it shifts even further caudad. The same is true of the other internal organs, the metanephros excepted. As the chief blood-vessels are connected with the heart and viscera,



profound changes in the positions of the vessels are thus brought about, for the vessels must shift their positions with the organs which they supply.

**Ventral Dissections.**—Ventral dissections of the viscera are very easily made. With the safety razor blade, start a cut in a coronal plane through the caudal end of the embryo and the lower limb buds (Fig. 143). Extend this cut laterad and cephalad through the body wall and the upper limb bud. The head may be cut away in the same plane of section and the cut continued through the body wall and upper limb bud of the opposite side back caudally to the starting point. Section the embryo in a coronal plane, parallel with the first section and near the back, so that the embryo will rest upon the flattened surface. With forceps, now remove the ventral body wall. By tearing open the wall of the umbilical cord along one side it may be removed, leaving the intestinal loop intact. Pull away the heart, noting its external structure. The liver may also be removed, leaving the stomach and intestine uninjured. A portion of the septum transversum covering the lungs may be carefully stripped away and the lungs thus laid bare. Dissections made in this way show the trachea and lungs, the esophagus, stomach and dorsal attachment of the septum transversum, the course of the intestinal canal, and also the mesonephroi and their ducts. Favorable sections through the caudal end of the body may show the urogenital sinus, rectum and sections of the umbilical arteries and allantois (Figs. 92, 119 and 143). In late stages, by removing the digestive organs the *urogenital ducts* and *glands* are beautifully demonstrated (Figs. 216 and 217).

#### DEVELOPMENT OF THE FACE

The heads of pig embryos have long been used for the study of the development of the face. The heads should be removed by passing the razor blade between the heart and adjacent surface of the head, severing the neck. Next cut away the dorsal part of the head by a section parallel to the ventral surface, the razor blade passing dorsal to the branchial clefts and eyes. Mount ventral side up three stages from embryos 6, 12 and 14 mm. long as shown in Figs. 92 and 144 A and B.

In the early stages (Figs. 92 and 119) the four branchial arches and clefts are seen. The third and fourth arches soon sink into the cervical sinus, while the mandibular processes of the first arch are fused early to form the lower jaw. The frontal process of the head is early divided into *lateral* and *median nasal processes* by the development of the olfactory pits. The processes are distinct

and most prominent at 12 mm. (Fig. 144 A). Soon, in 13 to 14 mm. embryos, the median nasal processes fuse with the maxillary processes of the first arch and constitute the upper jaw (Fig. 144 B). The lateral nasal processes fuse with the maxillary processes and form the cheeks, the lateral part of the lips and the alæ of the nose. Later, the median nasal processes unite and become the median part of the upper lip and the *columna nasi*.

The early development of the face is practically the same in human embryos

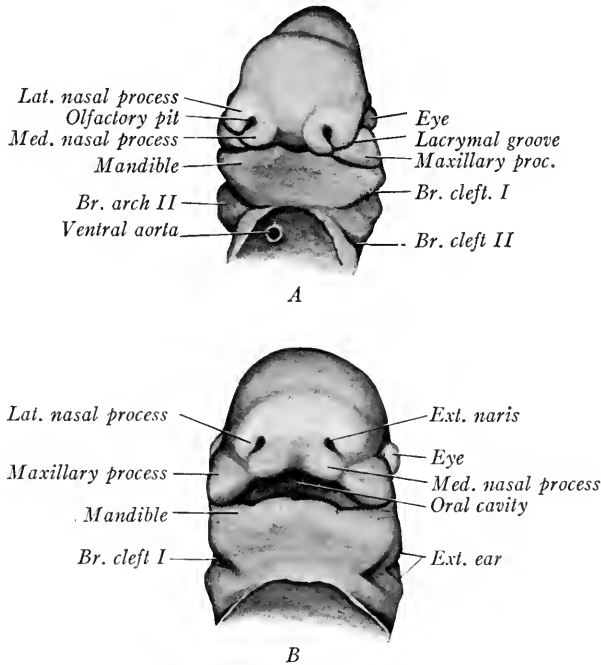


FIG. 144.—Two stages showing the development of the face in pig embryos. A, Ventral view of face of a 12 mm. embryo; B, of a 14 mm. embryo.

(Fig. 145). At the end of the fourth week, the lateral and median nasal processes have developed. During the sixth week, the maxillary processes fuse with the nasal processes, and at the end of the second month the median nasal processes have united. The mandibular processes fuse at the sixth week and from them a median projection is developed which forms the anlage of the *chin*.

The lips begin to appear as folds at the sixth week. As the median nasal processes and the maxillary processes take part in their development, the failure of these parts to fuse may produce *hare lip*. The lips of the new-born child are peculiar in that their proximal surfaces are covered with numerous villi, finger-like processes which may be a millimeter or more in length.

The *external ear* is developed around the first branchial cleft by the appearance of small tubercles which form the *auricle*. The cleft itself becomes the *external auditory meatus* and the concha of the ear. (For the development of the external ear see Chapter XII).

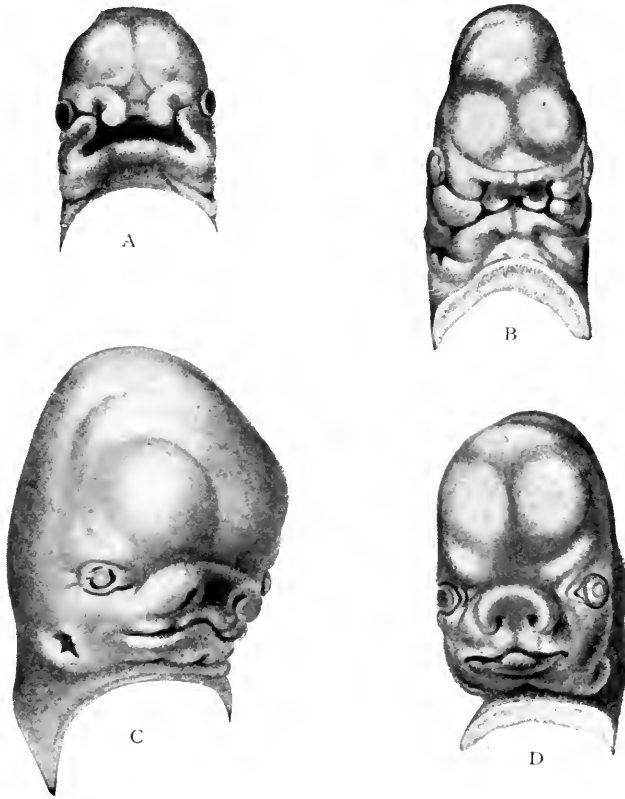


FIG. 145.—Development of the face of the human embryo (His). A, embryo of about twenty-nine days. The median frontal process differentiating into median nasal processes or processus globulares, toward which the maxillary processes of first visceral arch are extending. B, embryo of about thirty-four days: the globular, lateral nasal, and maxillary processes are in apposition; the primitive naris is now better defined. C, embryo of about the eighth week: immediate boundaries of mouth are more definite and the nasal orifices are partly formed, external ear appearing. D, embryo at end of second month.

#### DEVELOPMENT OF THE HARD PALATE

This may be studied advantageously in pig embryos of two stages: (a) 20 to 25 mm. long; (b) 28 to 35 mm. long. In the first stage, the jaws are close together and the mandible usually rests against the breast region. The palatine processes are separated by the tongue and are directed ventrad (Fig. 146 A). In embryos of 26 to 28 mm., the jaws open and the tongue lies ventral to the palatine processes which now approach each other in a horizontal plane (Fig. 146 B). Dissections may be made by carrying a shallow incision from the

angle of the mouth back to the external ear on each side. The incisions are then continued through the neck in a plane parallel to the hard palate. Before mounting the preparation, remove the top of the head by a section cutting through the eyes and nostrils parallel to the first plane of section. Transverse sections through the snout may also be prepared to show the positions of tongue and palatine folds before and after the fusion of the latter.

In the human embryo of two and a half months, three palatine anlages are

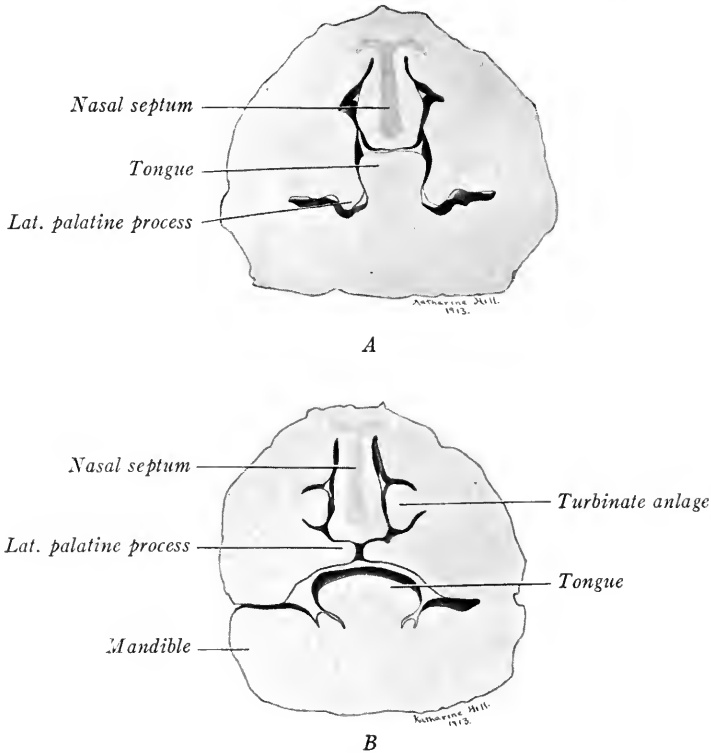


FIG. 146.—Sections through the jaws of pig embryos to show development of the hard palate. *A*, 22 mm; *B*, 34 mm.  $\times 8$ .

developed: a small median process developed from the fused median nasal processes, and paired lateral palatine processes developed from the maxillary processes, and extending from the line of fusion of the median nasal process and of the maxillary process caudally along the wall of the pharynx (Fig. 148). In pig embryos (Fig. 147 A and B), the median process forms a single heart-shaped structure. The lateral palatine processes lie at first lateral and ventral to the dorsum of the tongue and their edges are directed ventrad and mesially (Fig. 146 A). Before these processes can fuse, the tongue is withdrawn from between

them owing to a change in the position of the mandible due to the development of its arch (Fig. 146 B). With the withdrawal of the tongue the edges of the

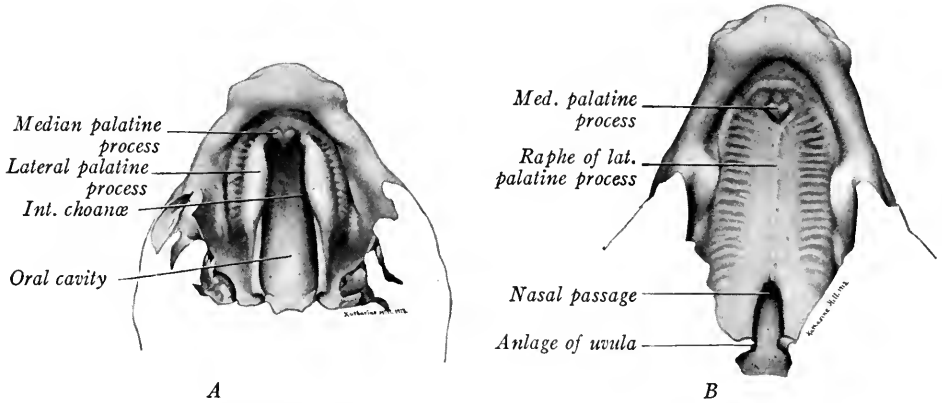


FIG. 147.—Dissections to show the development of the hard palate in pig embryos. *A*, ventral view of palatine processes of a 22 mm. pig embryo, the mandible having been removed; *B*, same of 35 mm. embryo showing fusion of palatine processes.

palatine folds are approximated and soon fuse, thus cutting off the nasal passages from the primitive oral cavity dorsad (Fig. 147 B). At the point in the median line where the lateral and median palatine processes meet, fusion is not complete, leaving the *incisive fossa*, and laterad between the two processes openings persist for some time, which are known as the *incisive canals* (of Stenson).

After the withdrawal of the tongue, the lateral palatine processes take up a horizontal position and their edges are approximated, because the cells on the ventral sides of the folds proliferate more rapidly than those of the dorsal side (Schorr, *Anat. Hefte*, Bd. 36, 1908). That the

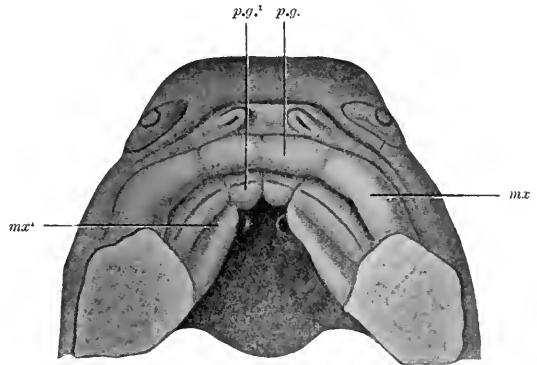


FIG. 148.—The roof of the mouth of a human embryo about two and a half months old, showing the development of the palate. *p.g.*, processus globularis; *p.g.'*, palatine process of processus globularis; *mx*, maxillary process; *mx'*, palatine fold of maxillary process. Close to the angle between this and the palatine process of the processus globularis on each side, the primitive choanae. (After His.)

change in position of the palatine folds is not mechanical, but due to unequal growth, may be seen in Fig. 149, a section through the palatine folds of a pig

embryo which shows the right palatine fold in a horizontal position, although the left fold projects ventral to the dorsum of the tongue. A region of cellular proliferation may be seen on the under side of each process.

At the end of the second month the *palatine bones* begin to develop in the lateral palatine folds and thus form the *hard palate*. Caudally the bones do not develop and this portion of the folds forms the *soft palate* and the *uvula*. The un-

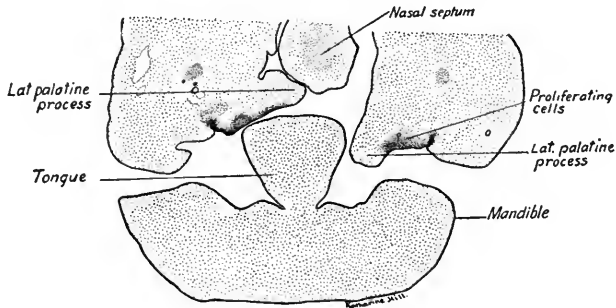


FIG. 149.—Section through the jaws of a 25 mm. pig embryo to show the change in the position of the palatine processes with reference to the tongue.

fused backward prolongations of the palatine folds give rise to the *arcus pharyngo-palatini*, which is taken as the boundary line between the oral cavity proper and the pharynx in adult anatomy.

The lateral palatine processes occasionally fail to unite in the middle line, producing a defect known as *cleft palate*. The extent of the defect varies considerably, in some cases involving only the soft palate, while in other cases both soft and hard palates are cleft.

#### THE DEVELOPMENT OF THE TONGUE

The tongue develops as two distinct portions, the *body* and the *root*, separated from each other by a V-shaped groove, the *sulcus terminalis*. Its development may be studied from dissections of pig embryos 6, 9 and 13 mm. long. As the pharynx is bent nearly at right angles, it is necessary to cut away its roof by two pairs of sections passing in different planes. The first plane of section cuts through the eye and first two branchial arches just above the cervical sinus (Fig. 150, I). From the surface, the razor blade should be directed obliquely dorsal in cutting toward the median line. Cuts in this plane should be made from either side. In the same way make sections on each side in a plane forming an obtuse angle with the first section and passing dorsal to the cervical sinus (Fig. 150, II). Now sever the remaining portion of the head from the body by a transverse sec-

tion in a plane parallel to the first (Fig. 150, III). Place the ventral portion of the head in a watch-glass of alcohol and, under the dissecting microscope, remove that part of the preparation cranial to the mandibular arches. Looking down upon the floor of the pharynx, remove any portions of the lateral pharyngeal wall which may still interfere with a clear view of the pharyngeal arches as seen in Fig. 151. Permanent mounts of the three stages mentioned above may be made and used for study by the student.

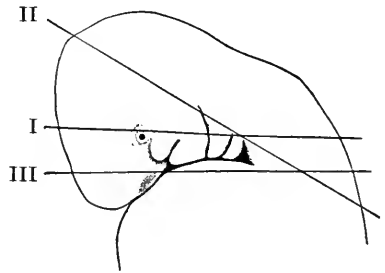


FIG. 150.—Lateral view of the head of a 7 mm. pig embryo. The three lines indicate the planes of sections to be made in dissecting the tongue as described in the text.

In both human and pig embryos, the body of the tongue is developed from three anlages which are formed in front of the second branchial arches. These are the median, somewhat triangular *tuberculum impar*, and the paired *lateral thickenings* of the mandibular arches, both of which are present in human embryos of 5 mm. (Fig. 152 A). At this stage, a median ventral elevation formed by

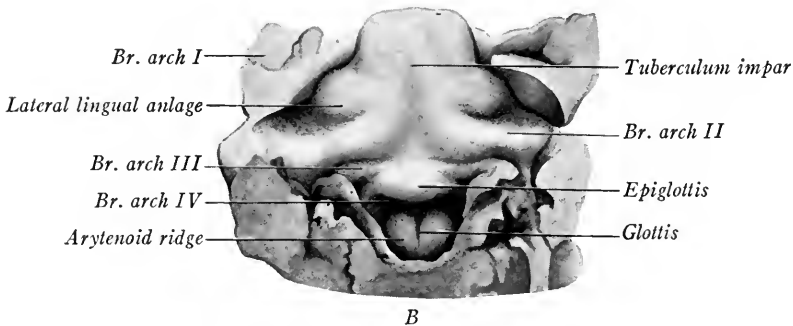
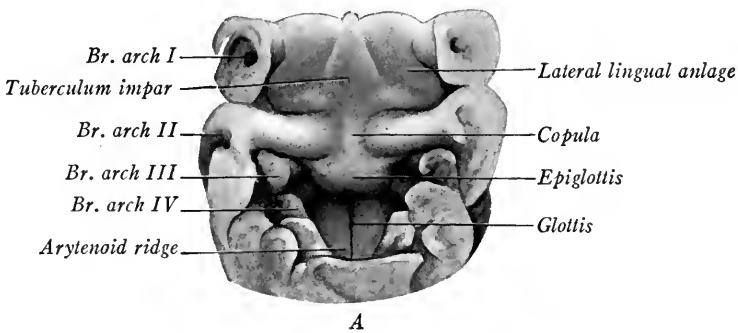


FIG. 151.—Dissections showing the development of the tongue in pig embryos. A, 9 mm. embryo; B, 13 mm. embryo.

the union of the second branchial arches forms the *copula*. This, with the portions of the second arches lateral to it, forms later the *base* or *root* of the tongue. Between it and the tuberculum impar is the point of evagination of the *median thyroid gland*. The copula also connects the tuberculum impar with a rounded prominence which is developed in the mid-ventral line from the bases of the third and fourth branchial arches. This is the anlage of the *epiglottis*. In later stages (Fig. 151 A and B) the lateral mandibular anlages increase rapidly in size, are bounded laterally by the linguo-alveolar grooves, and fuse with the tuberculum impar which lags behind in development and is said to form the median septum of the tongue. According to Hammar, it completely atrophies. The epiglottis becomes larger and concave on its ventral surface. Caudal to it, and in early

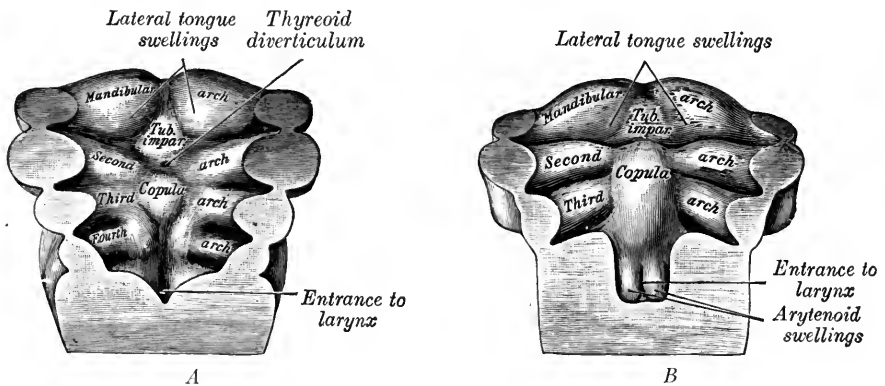


FIG. 152.—The development of the tongue in human embryos. A, 5 mm.; B, 7 mm. (modified from Peters).

stages continuous with it, are two thick rounded folds, the *arytenoid folds*. Between these is the slit-like *glottis* leading into the *larynx* (see p. 174).

The musculature of the tongue is supplied chiefly by the *hypoglossal nerve*, and both nerve and muscles develop caudal to the branchial region in which the tongue develops. The musculature migrates cephalad and gradually invades the branchial region beneath the mucous membrane. At the same time, the tongue may be said to extend caudad until its root is covered by the epithelium of the third and fourth branchial arches. This is shown by the fact that the sensory portions of the nn. *trigeminus* and *facialis*, the nerves of the first and second arches, supply the body of the tongue, while the nn. *glossopharyngeus* and *vagus*, the nerves of the third and fourth arches, supply the root and the caudal portion of the body of the tongue.

In embryos of 50 to 60 mm. the *fungiform* and *filiform* papillæ may be distinguished as elevations of the epithelium. *Taste buds* appear in the fungiform papillæ of 100 mm. embryos and are much more numerous in the fetus than in the adult. The *vallate papillæ* (Fig. 153 A) appear at 90 mm. as a V-shaped epi-





thelial ridge, the apex of the V corresponding to the site of the median thyreoid evagination. At intervals along the epithelial ridges circular epithelial downgrowths develop which take the form of inverted and hollow truncated cones (Fig. 153 B). During the fourth month circular clefts appear in the epithelial downgrowths, thus separating the walls of the vallate papillæ from the surrounding epithelium and forming the trench from which this type of papilla derives its name. At the same time, lateral outgrowths arise from the bases of the epithelial cones, hollow out and form the *ducts and glands of Ebner*. The taste buds of the vallate papillæ are also formed early, appearing in embryos of three months.

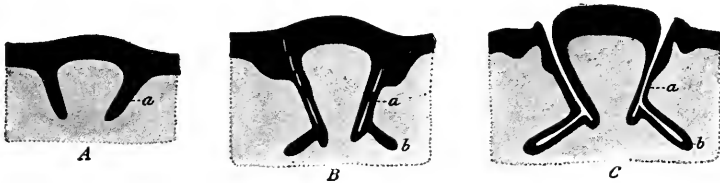


FIG. 153.—Diagrams showing the development of the vallate papillæ of the tongue (Graberg in McMurrich's "Human Body").

#### DEVELOPMENT OF THE SALIVARY GLANDS

The glands of the mouth are all regarded as derivatives of the ectodermal epithelium. Of the *salivary glands*, the *parotid* is the first to appear. Its anlage has been observed in 8 mm. embryos as a furrow in the floor of the *alveolo-buccal groove*. The furrow elongates and, in embryos of 17 mm., separates from the epithelial layer, forming a tubular structure which opens into the mouth cavity near the cephalic end of the original furrow. The tube grows back into the region of the external ear, branches and forms the gland in this region, while the unbranched portion of the tube becomes the parotid duct (Hammar, *Anat. Anzeiger*, Bd. 19, 1901).

The *submaxillary gland* arises as an epithelial ridge in the alveolo-lingual groove, its cephalic end located caudal to the frenulum of the tongue. The caudal end of the ridge soon begins to separate from the epithelium and extends caudad and ventrad into the submaxillary region where it enlarges and branches to form the gland proper, its cephalic unbranched portion persisting as the duct which soon hollows out.

The *sub-lingual* and *alveolo-lingual glands* develop as several solid evaginations of epithelium from the alveolo-lingual groove, appearing from the eighth to the twelfth week (Fig.

157). Of the alveolo-lingual glands nine or ten may develop on either side in embryos of 40 mm. (McMurrich in Keibel and Mall, vol. 2, p. 348-349.)

The branched anlagen of the salivary glands are at first solid and hollow out peripherally. The glands continue growing and enlarging until after birth. Mucin cells may be distinguished by the sixteenth week and acinus cells in the parotid glands at five months (McMurrich).

### THE DEVELOPMENT OF THE TEETH

The development of the teeth is described in all the standard textbooks of histology and only a brief account of their origin and structure will be given here. The *enamel organs*, which give rise to the enamel of the teeth and are the moulds, so to speak, of the future teeth, are of *ectodermal origin*. There first appears in embryos of 10 to 12 mm. an ectodermal downgrowth, *the dental ridge or lamina* on the future alveolar portions of the upper and lower jaws (Fig. 154). These

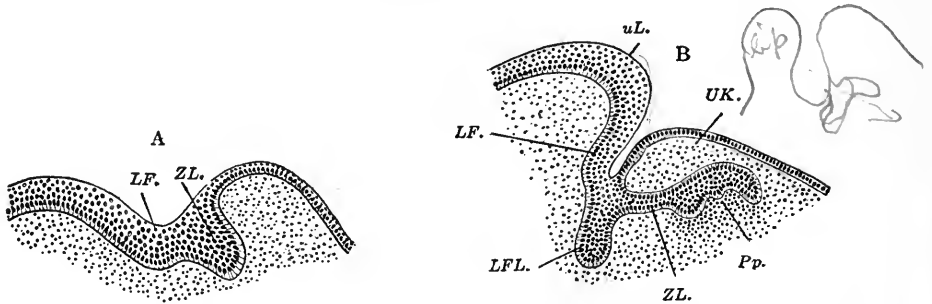


FIG. 154.—Early stages in the development of the teeth. A, 17 mm.; B, 41 mm. (Röse). LF., LFL., labial groove; Pp., dental papilla; UK., lower jaw; uL., lower lip; ZL., dental ridge.

laminae parallel and are mesial to the labial grooves, being directed obliquely toward the tongue. At intervals, on each curved dental ridge or *lamina* a series of thickenings develop, the anlagen of the *enamel organs* (Fig. 155). Soon the ventral side of each enamel organ becomes concave (embryos of 40 mm.) forming an inverted cup and the concavity is occupied by dense mesenchymal tissue, the *dental papilla* (Figs. 154 B and 156). An enamel organ with dental papilla forms the anlage of each decidual or milk tooth. Ten such anlagen are present in the upper jaw and ten in the lower jaw of a 40 mm. embryo. The connection of the dental anlagen with the dental ridge is eventually lost. The position of the tooth anlage between the tongue and lip is shown in Fig. 157.

The anlagen of those *permanent teeth* which correspond to the decidual, or milk teeth, are developed in the same way along the free edge of the dental lamina median to the decidual teeth. In addition, the anlagen of three permanent molars are developed on each side, both above and below from a backward or

aboral extension of the dental lamina, entirely free from the oral epithelium. The anlagen of the first permanent molars appear at seventeen weeks (180 mm.), those of the second molars at six months after birth, while the anlagen of the third permanent molars or wisdom teeth are not found until the fifth year. The permanent dentition of thirty-two teeth is then complete.

The internal cells of the enamel organs are at first compact, but later by the

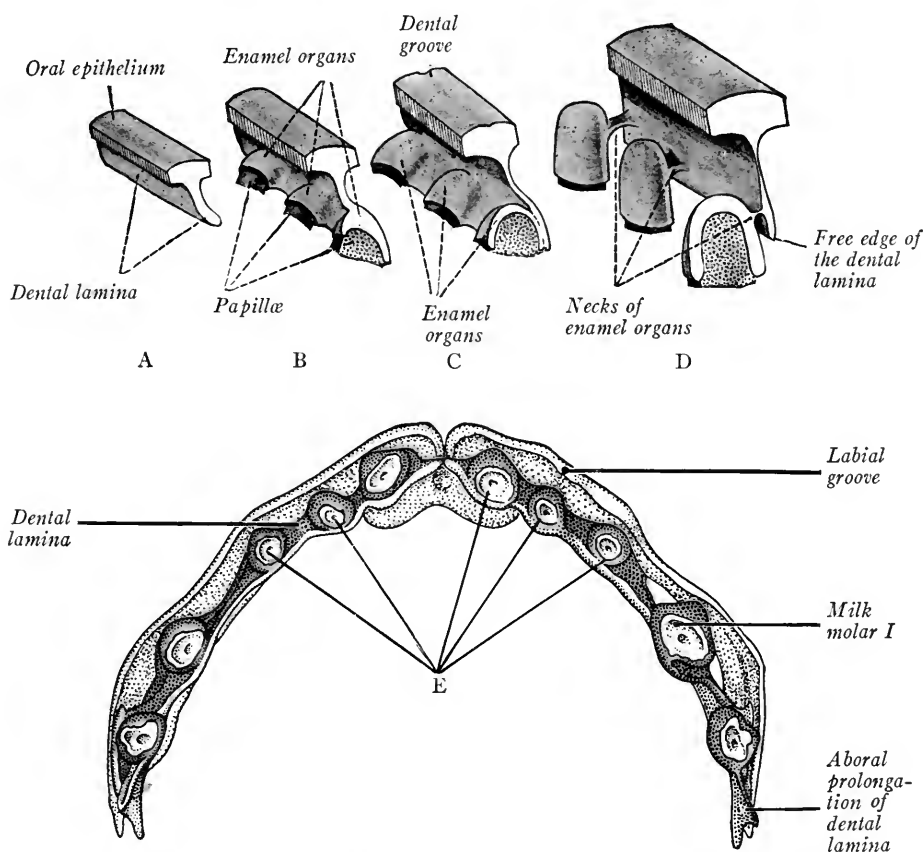


FIG. 155.—A, B, C, D, diagrams showing the early development of three teeth. One of the teeth is shown in vertical section (Lewis and Stöhr). E, dental lamina and anlagen of the milk teeth of the upper jaw from a fetus of 105 mm. (Röse in Kollmann's Handatlas).

development of an intercellular matrix the cells separate forming a reticulum resembling mesenchyma and termed the *enamel pulp* (Fig. 156). The *outer enamel cells*, at first cuboidal, flatten out and later form a fibrous layer. The *inner enamel cells* bound the cup-shaped concavity of the enamel organ. Over the crown of the tooth these cells, the *ameloblasts*, become slender and columnar in form, producing the *enamel layer* of the tooth along their basal ends (Fig. 158).

The *enamel* is laid down first as an uncalcified fibrillar layer which later becomes calcified in the form of enamel prisms. From the ends of the cells project cutic-

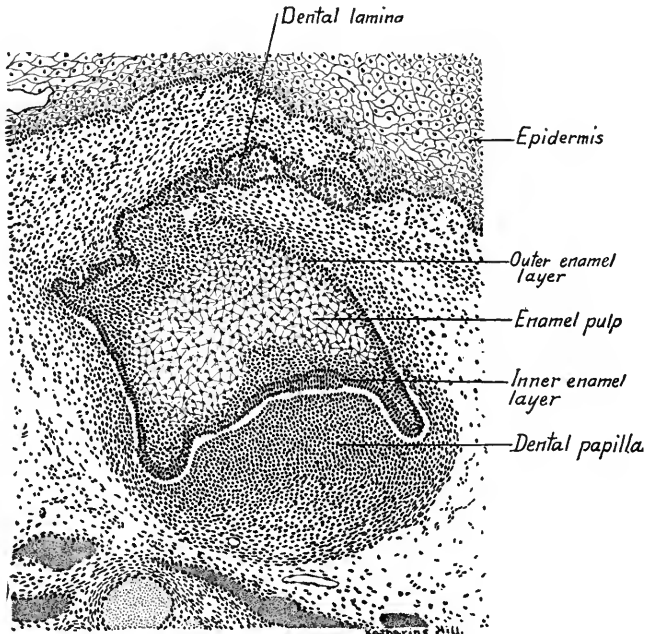


FIG. 156.—Section through the upper first deciduous incisor tooth from a 65 mm. human embryo.  $\times 70$ .

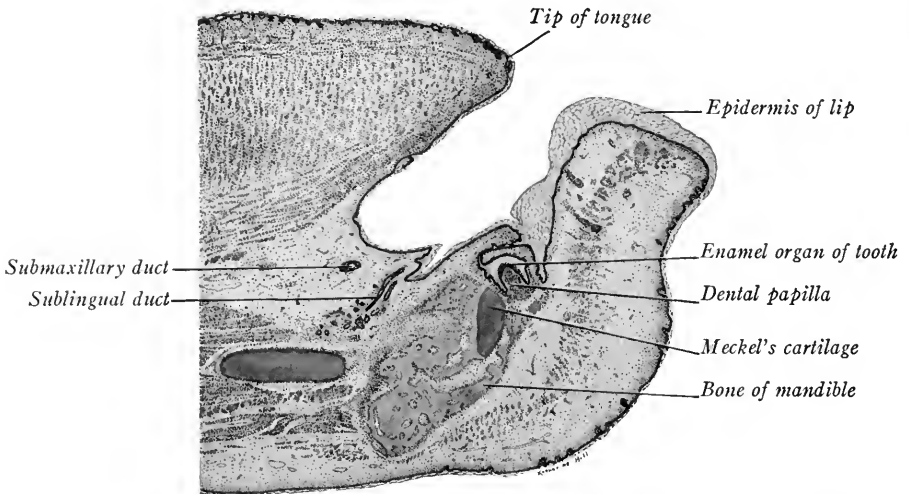


FIG. 157.—Parasagittal section through the mandible and tongue of a 65 mm. human embryo showing the position of the anlage of the first incisor tooth.  $\times 14$ .

ular fibers known as Tomes' processes (Fig. 158). The enamel is formed first at the top of the crown of the tooth and extends toward the root over the crown.

The enamel cells about the future root of the tooth remain cuboidal or low columnar in form, come into contact with the outer enamel cells and the two layers constitute the *epithelial sheath* of the root which does not produce enamel prisms.

**The Dental Papilla.**—The outermost cells of the dental papilla at the end of the fourth month arrange themselves as a definite layer of columnar epithelium. Since they produce the *dentine*, or *dental bone*, these cells are known as *odontoblasts*. When the dentine layer is developed, the odontoblast cells remain internal to it and branched processes from them (the dental fibers of Tomes) extend into the dentine and form the *dental canaliculi*. Internal to the odontoblast layer the mesenchymal cells differentiate into the *dental pulp*, popularly known

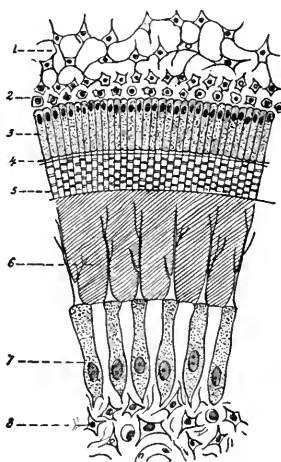


FIG. 158.—Section through a portion of the crown of a developing tooth showing the various layers (Tourneux in Heisler). 1, 2, cells of enamel pulp; 3, ameloblast layer of enamel-forming cells; 4, 5, enamel prisms; 6, layer of dentine containing processes of 7, odontoblast cells; 8, cells of dental pulp.

as the “nerve” of the tooth. This is composed of a framework of reticular tissue in which are found blood-vessels, lymphatics and nerve fibers. The odontoblast layer persists throughout life and continues to secrete dentine so that eventually the root canal may be obliterated.

**Dental Sac.**—The mesenchymal tissue surrounding the anlage of the tooth gives rise to a dense outer layer and a more open inner layer of fibrous connective tissue. These layers form the *dental sac* (Fig. 159). Over the root of the tooth a layer of *osteoblasts* or bone forming cells develops, and, the epithelial sheath formed by the enamel layers having disintegrated, these osteoblasts deposit about the dentine a layer of bone which is known as the *substantia ossea* or *cement*. The cement layer contains typical *bone cells* but no Haversian canals. As the

teeth grow and fill the alveoli the dental sac becomes a thin vascular layer continuous externally with the *alveolar periosteum*, internally with the periosteum of the cement layer of the tooth.

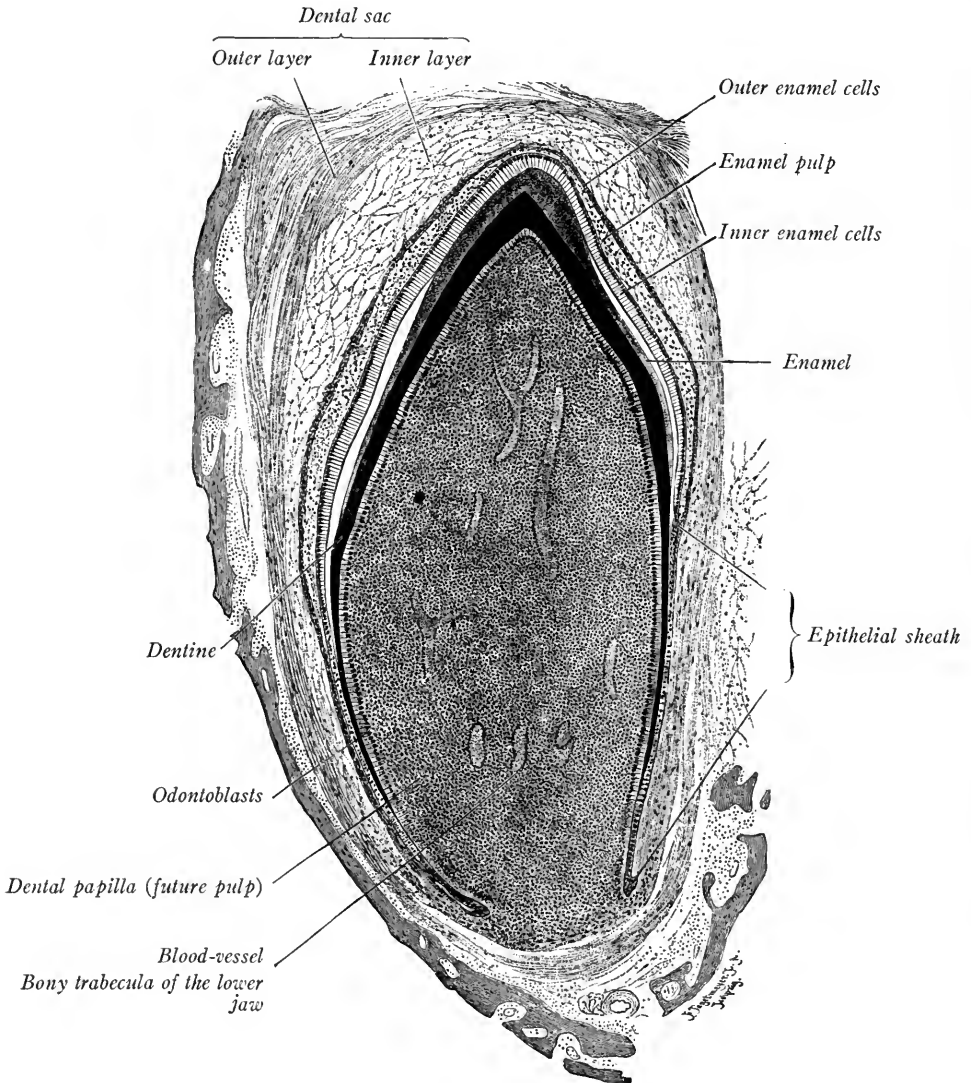


FIG. 159.—Longitudinal section of a deciduous tooth of a newborn dog.  $\times 42$ . The white spaces between the inner enamel cells and the enamel are artificial, and due to shrinkage (Lewis and Stöhr).

When the crown of the tooth is fully developed the enamel organ disintegrates, and as the roots of the teeth continue to grow their crowns approach the surface and break through the gums. The periods of eruption of the various

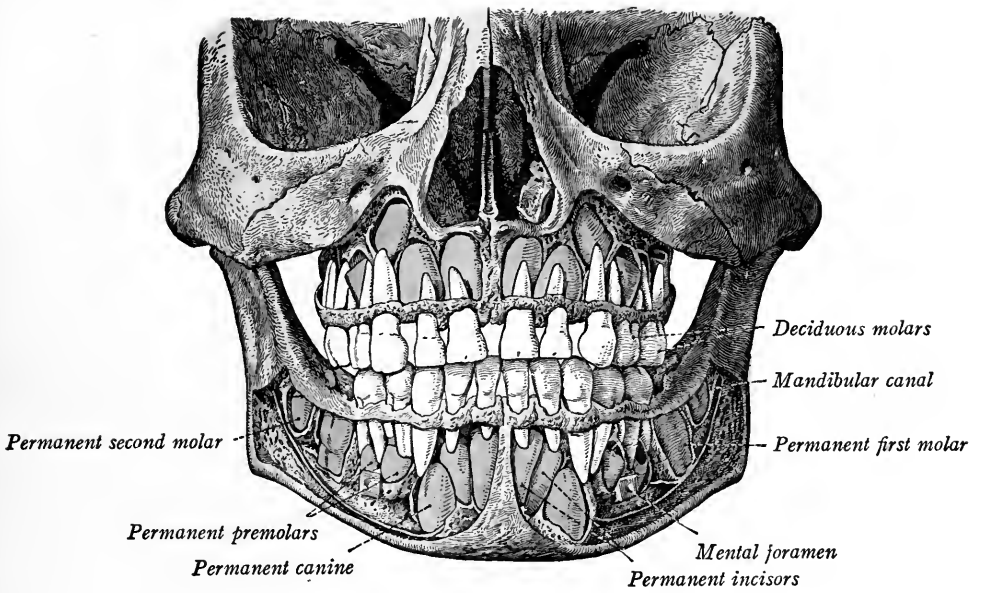


FIG. 160.—The skull of a five-year-old child showing positions of the decidual and permanent teeth (Sobotta-McMurrich, Atlas of Human Anatomy).





*milk* or *decidua* teeth vary with race, climate and nutritive conditions. Usually the teeth are cut in the following sequence:

## DECIDUAL OR MILK TEETH

Median Incisors . . . . .	sixth to eighth month.
Lateral Incisors . . . . .	eighth to twelfth month.
First Molars . . . . .	twelfth to sixteenth month.
Canines . . . . .	seventeenth to twentieth month.
Second Molars . . . . .	twentieth to twenty-fourth month.

The permanent teeth are all present at the fifth year. They are located mesial to the decidua teeth (Fig. 160), and, before the permanent teeth begin to erupt, the roots of the milk teeth undergo absorption, their dental pulp dies and they are eventually shed. The permanent teeth are "cut" as follows: (McMurrich in Keibel and Mall, vol. 2, p. 354).

First Molars . . . . .	seventh year
Median Incisors . . . . .	eighth year.
Lateral Incisors . . . . .	ninth year.
First Premolars . . . . .	tenth year.
Second Premolars . . . . .	eleventh year.
Canine Second Molars } . . . . .	thirteenth to fourteenth year.
Third Molars . . . . .	seventeenth to fortieth year.

Dental anomalies are frequent and may consist in the congenital absence of some or all of the teeth, or in the production of more than the normal number. Defective teeth are frequently associated with hare lip. Cases have been noted in which, owing to defect of the enamel organ, the enamel was entirely wanting. Many cases in which a third dentition occurred have been recorded and occasionally fourth molars may be developed behind the wisdom teeth.

The teeth of vertebrates are homologues of the placoid scales of elasmobranch fishes (sharks). The teeth of the shark resemble enlarged scales, and many generations of teeth are produced in the adult fish. In some mammalian embryos three or even four dentitions are present. The primitive teeth of mammals are of the canine type and, from this conical tooth, the incisors and molars have been differentiated.

## CHAPTER VII

### THE ENTODERMAL CANAL AND ITS DERIVATIVES: THE BODY CAVITIES

When the head- and tail-folds of the embryo develop, there are formed both cranially and caudally from the spherical vitelline sac blind entodermal tubes, the *fore-gut* and *hind-gut* respectively (Fig. 161 A). The region between these

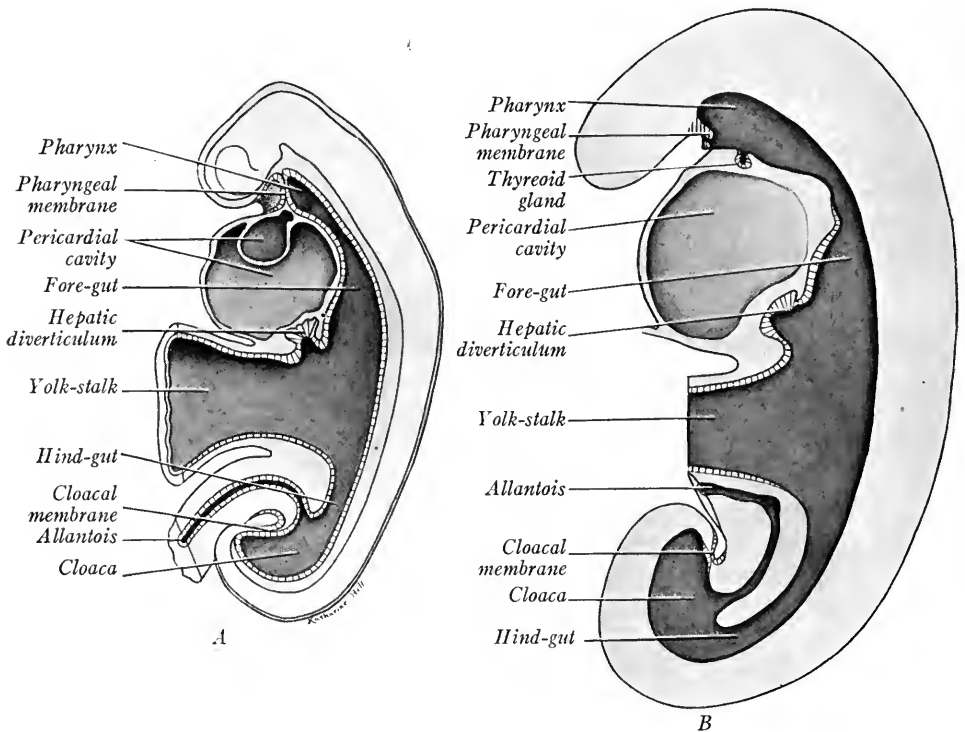


FIG. 161.—Diagrams showing in median sagittal section the alimentary canal, pharyngeal and cloacal membranes. *A*, 2 mm. embryo, modified after His; *B*, 2.5 mm. embryo, after Thompson.

intestinal tubes, open ventrally into the yolk-sac, is known as the *mid-gut*. As the embryo and the yolk-sac at first grow more rapidly than the connecting region between them, this region is apparently constricted and becomes the *yolk-stalk*, or *vitelline duct*. At either end the entoderm comes into contact ventrally with the ectoderm. Thus there are formed the *pharyngeal membrane* of the fore-

gut, the *cloacal membrane* of the hind-gut. In 2 mm. embryos the pharyngeal membrane separates the ventral ectodermal cavity, or *stomodæum*, from the pharyngeal cavity of the fore-gut. Cranial to the membrane is the ectodermal diverticulum, *Rathke's pocket*. In 2.5 to 3 mm. embryos (Fig. 161 B) the pharyngeal membrane is perforated and the stomodæum and pharynx are continuous. The blind termination of the fore-gut probably forms *Seessel's pocket*.

The fore-gut later forms part of the oral cavity and is further differentiated into the pharynx and its derivatives; into the esophagus, respiratory organs, stomach, duodenum, jejunum and a portion of the ileum. From the duodenum arise the liver and pancreas. The *hind-gut*, beginning at the attachment of the yolk-stalk extends caudally to the *cloaca*, into which opens the *allantois* in 2 mm. embryos. The hind-gut is differentiated into the ileum, cæcum, colon and rectum. The cloaca is subdivided into the *rectum* and *urogenital sinus* (for its development see Chapter VIII). At the same time, the cloacal membrane is separated into a *urogenital membrane* and into an *anal membrane*. The latter eventually ruptures and this opening is the *anus*. The yolk-stalk usually loses its connection with the entodermal tube in embryos of 7.5 mm. (Fig. 172).

We have seen how the palatine processes divide the primitive oral cavity into the nasal passages and mouth cavity of the adult, and have described the development of the tongue, teeth and salivary glands, organs derived wholly or in part from the ectoderm. It remains to trace the development of the pharynx and its derivatives.

### PHARYNGEAL POUCHES

There are developed early from the lateral wall of the pharynx paired outgrowths which are formed in succession cephalo-caudad. In 4 to 5 mm. embryos, five pairs of pharyngeal pouches are present, the fifth pair being rudimentary. At the same time there appears in the mid-ventral wall of the pharynx, between the first and second branchial arches, a small rounded prominence, the *thyreoid* anlage. This constricts off and forms a stalked vesicle (Fig. 82). Its stalk, the thyreo-glossal duct, opens near the aboral border of the tuberculum impar. Meantime, the pharynx has been flattened dorso-ventrally and broadened laterally and cephalad so that it is triangular in ventral view (Figs. 82 and 162).

From each pharyngeal pouch develop small dorsal and large ventral diverticula. The first four pouches come into contact with the ectoderm of the branchial clefts, fuse with it and form the *closing plates*. Only occasionally do the closing plates become perforate in human embryos. The first and second

pharyngeal pouches soon connect with the pharyngeal cavity through wide openings. The third and fourth pouches grow laterad and their diverticula communicate with the pharynx through narrow ducts in 10 to 12 mm. embryos (Fig. 162). When the cervical sinus is formed the ectoderm of the second, third and fourth branchial clefts is drawn out to produce *branchial and cervical ducts* and the *branchial vesicle*. These are fused at the closing plates with the entoderm of the second, third and fourth pharyngeal pouches.

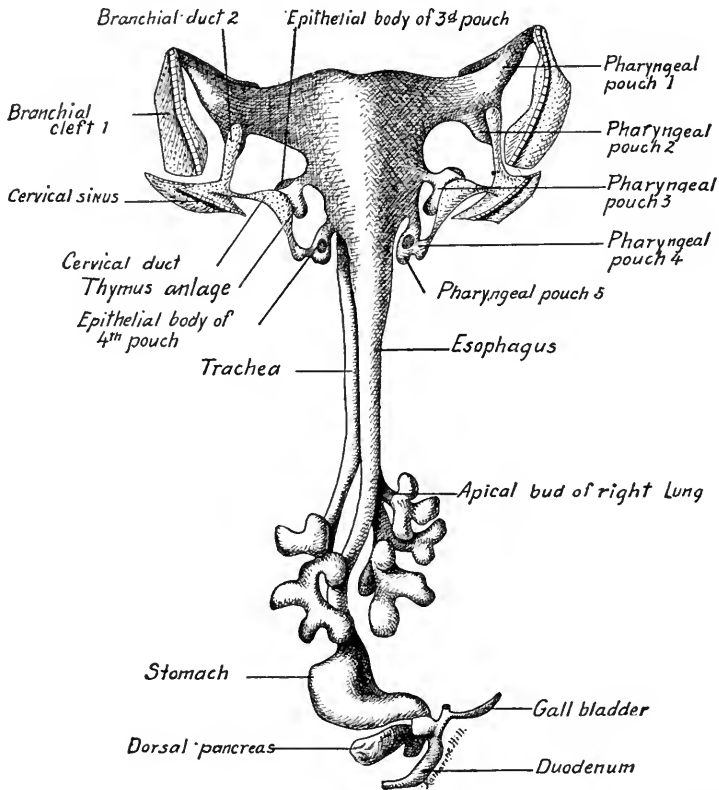


FIG. 162.—A reconstruction of the pharynx and fore-gut of an 11.8 mm. embryo seen in dorsal view (after Hammar). The ectodermal structures are stippled.

The *first and second pouches* soon differ from the others in form and give rise to an entirely different type of permanent structures. With the broadening of the pharynx the first two pouches acquire a common opening into it, the *primary tympanic cavity*. The first pouch later differentiates into the *tympanic cavity* of the middle ear and into the *Eustachian tube*. By the growth and lateral expansion of the pharynx the second pouch is taken up into the pharyngeal wall, its dorsal angle alone persisting to be later transformed into the *palatine tonsil*.

According to Hammar (*Arch. f. mikr. Anat.*, Bd. 61, 1903), the lateral pharyngeal recess (of Rosenmueller) is not a persistent portion of the second pouch as His asserted. Lymphocytes appear in the lymphoid tissue of the tonsils in embryos of 140 mm. They take their origin in the mesoderm (Hammar, Maximow).

THE THYMUS

The *third, fourth and fifth pharyngeal pouches* give rise to a series of ductless glands, of which the thymus is the most important. The *thymus anlage* appears in 10 mm. embryos as a ventral and medial prolongation of the third pair of pouches (Figs. 162 and 163). The ducts connecting the diverticula with the pharynx soon disappear so that the thymus anlagen are set free. At first hollow tubes, they soon lose their cavities, their lower ends enlarge and migrate caudally into the thorax passing usually ven-

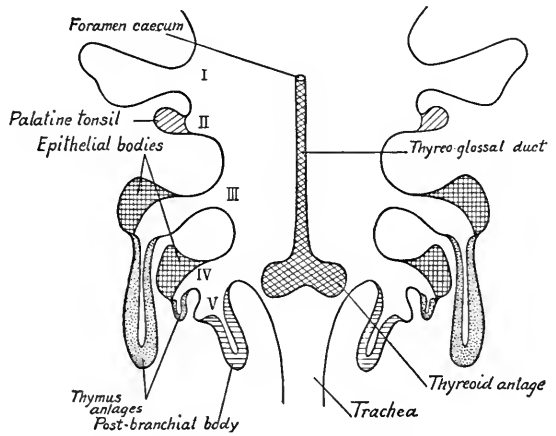


FIG. 163.—Diagram in ventral view of the pharynx and pharyngeal pouches, showing the origin of the thymus and thyroid glands and of the epithelial bodies (modified after Groschuff and Kohn). I, II, III, IV, and V, first, second, third, fourth and fifth pharyngeal pouches.

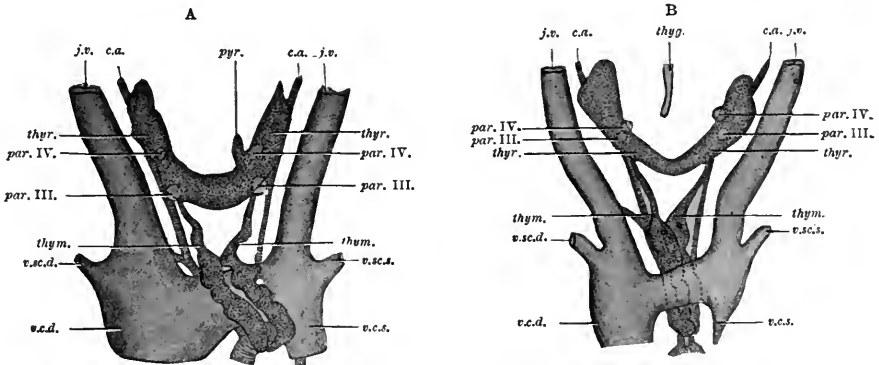


FIG. 164.—Two reconstructions of the thymus and thyroid glands. A, in a human embryo of 26 mm.; B, in one of 24 mm. (after Tourneux and Verdun). In A the thymus lies in front, in B, behind the left innominate vein. *thyr.*, thyroid; *thym.*, thymus; *par. IV.*, parathyroid of fourth pouch; *par. III.*, parathyroid of third pouch; *pyr.*, pyramidal lobe of thyroid; *thyg.*, thyroglossal duct; *c.a.*; carotid artery; *j.v.*, jugular vein.

tral to the left vena anonyma. Their upper ends become attenuate and atrophy or may persist as an accessory thymus lobe (Kohn). The enlarged lower ends of the anlagen form the body of the gland, which is thus a paired structure (Fig. 164).

At 50 mm. the thymus still contains solid cords and small closed vesicles of entodermal cells. From this stage on, in development, the gland becomes more and more lymphoid in character. Its final position is in the thorax dorsal to the cranial end of the sternum. It grows under normal conditions until puberty, after which its degeneration begins. This process proceeds slowly in healthy individuals, rapidly in case of disease. The thymus may function normally until after the fortieth year.

It is now generally believed that the entodermal epithelium of the thymus is converted into *reticular tissue* and *thymic corpuscles*. The "lymphoid" cells are regarded by Hammar and Maximow as immigrant lymphocytes derived from the mesoderm. According to Stöhr, they are not true lymphocytes but are derived from the thymic epithelium. Weill (Arch. f. mikr. Anat., Bd. 83, pp. 305-360) has observed the development of granular leucocytes in the human thymus gland.

### THE EPITHELIAL BODIES OR PARATHYREOIDS

The *dorsal diverticula* of the third and fourth pharyngeal pouches each give rise to a small mass of epithelial cells termed an *epithelial body* (Fig. 163). Two pairs of these bodies are thus formed and, with the atrophy of the ducts of the pharyngeal pouches, they are set free and migrate caudalward. They eventually lodge in the dorsal surface of the thyreoid gland, the pair from the third pouch lying one on each side at the caudal border of the thyreoid in line with the thymus anlage (Fig. 164). The pair of epithelial bodies derived from the fourth pouches are located on each side near the cranial border of the thyreoid. From their ultimate relation to the thyreoid tissue the epithelial bodies are often termed *parathyreoid* glands. The solid body is broken up into masses and cords of polygonal entodermal cells intermingled with blood-vessels. In post-fetal life, lumina may appear in the cell masses and fill with a colloid-like secretion.

The ventral diverticulum of the fourth pouch is a rudimentary thymic anlage. It soon atrophies.

The *ultimobranchial body* is the derivative of the fifth pharyngeal pouch (Fig. 163). With the atrophy of the duct of the fourth pouch it is set free and migrates caudad with the *parathyreoids*. It forms a hollow vesicle which has been termed the *lateral thyreoid*. According to Grosser (Keibel and Mall, vol. 2, p. 467) and Verdun, it takes no part in forming thyreoid tissue but atrophies. The term *lateral thyreoid* when applied to it is therefore a misnomer.

### THE THYREOID GLAND

The *thyreoid anlage* (Fig. 163) is bilobed before the thyreoglossal duct disappears. It soon loses its lumen and breaks up into irregular solid cords of tissue

as it migrates caudad. It takes up a transverse position with a lobe on each side of the trachea and larynx (Fig. 164). In embryos of 50 mm., lumina appear in the more peripheral cords which break up into hollow or solid groups of cells, the *primitive thyreoid follicles* (Grosser).

## LARYNX, TRACHEA AND LUNGS

In embryos of 23 segments, the anlage of the respiratory organs appears as a groove in the floor of the entodermal tube just caudal to the pharyngeal pouches. This groove produces an external ridge on the ventral wall of the tube, a ridge

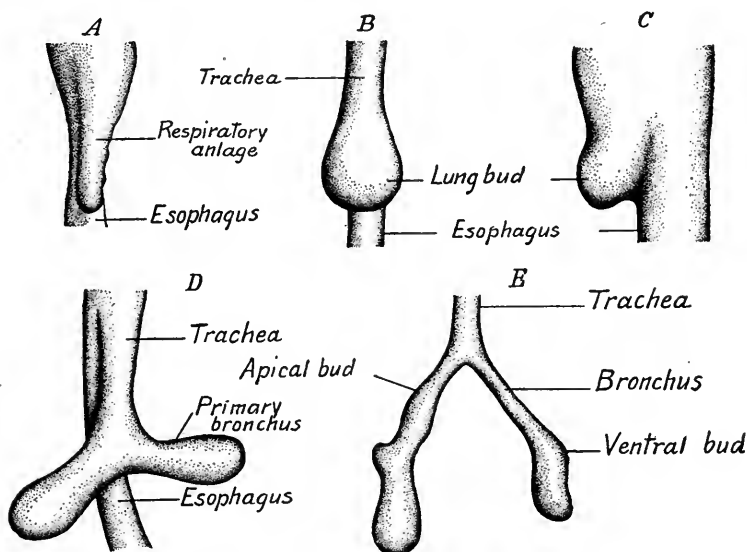


FIG. 165.—Diagrams of stages in the early development of the trachea and lungs of human embryos (based on reconstructions by Bremer, Broman, Grosser, and Naroht). A, 2.5 mm.; B, 4 mm.; C, B in side view; D, 5 mm.; E, 7 mm.

which becomes larger and rounded at its caudal end (Fig. 165). The *laryngo-tracheal* groove and the ridge are the anlages of the *larynx* and trachea. The rounded end of the ridge is the unpaired anlage of the *lungs*.

Externally two lateral longitudinal grooves mark off the dorsal esophagus from the ventral respiratory anlages. The lung anlage rapidly increases in size and becomes bilobed in embryos of 4 to 5 mm. The lateral furrows become deeper caudad and a septum is formed which grows cephalad, separating first the lung anlages and then the tracheal tube from the esophagus. At the same time the laryngeal portion of the groove and ridge is developed cranially until it lies between the third and fourth branchial arches (Fig. 82). At 5 mm. the respiratory

apparatus consists of the laryngeal groove and ridge, the tubular trachea and the two lung buds.

**The Larynx.**—In embryos of 5 to 6 mm. the oval end of the laryngeal groove is bounded on either side by two rounded prominences, the *arytenoid swellings* which, continuous orally with a transverse ridge, form the furcula of His (Fig. 152 B). The transverse ridge becomes the *epiglottis* and, as we saw in connection with the development of the tongue, it is derived from the third and fourth branchial arches. In embryos of 15 mm. the arytenoid swellings are bent near the middle toward the median line. Their caudal portions become parallel, while their cephalic portions diverge nearly at right angles (Fig. 166). The opening into the larynx thus becomes T-shaped and

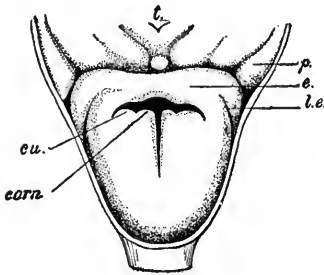


FIG. 166.—Entrance to larynx in a forty- to forty-two-day human embryo (from Kallius): *t.*, tuberculum impar; *p.*, pharyngo-epiglottic fold; *e.*, epiglottic fold; *l.e.*, lateral part of epiglottis; *cu.*, cuneiform tubercle; *corn.*, cornicular tubercle.

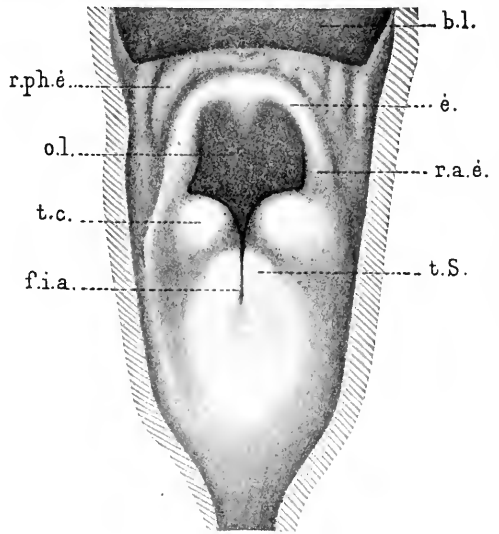


FIG. 167.—The larynx of 16 to 23 cm. human embryos (Soulié and Bardier). From a dissection. *b.l.*, base of tongue; *e.*, epiglottis; *f.i.a.*, interarytenoid fissure; *r.a.e.*, plica ary-epiglottica; *r.ph.e.*, plica pharyngo-epiglottica; *o.l.*, orifice of larynx; *t.c.*, tuberculum cuneiformis; *t.S.*, tuberculum corniculatum.

ends blindly, as the laryngeal epithelium has fused. In 40 mm. embryos this fusion is dissolved, the arytenoid swellings are withdrawn from contact with the epiglottis and the entrance to the larynx becomes oval in form (Fig. 167). At 27 mm. the *ventricles* of the larynx appear and at 37 mm. their margins indicate the position of the vocal cords. The epithelium of the vocal cords is without cilia. The elastic and muscle fibers of the cords are developed by the fifth month.

At the eighth week the cartilaginous skeleton of the larynx is indicated by a surrounding condensation of mesenchyme. The cartilage of the *epiglottis* appears relatively late. The



*thyreoid* cartilage is formed as two lateral plates, each of which has two centers of chondrification. These plates grow ventrad and fuse in the median line.

The anlagen of the *cricoid* and *arytenoid cartilages* are at first continuous. Later, separate cartilage centers develop for the arytenoids. The cricoid is at first incomplete dorsad but eventually forms a complete ring. The cricoid may therefore be regarded as a modified tracheal ring. The *corniculate cartilages* are portions of the arytenoid cartilages and separate from them. The *cuneiform cartilages* are derived from the cartilage of the epiglottis.

**The Tracheal Tube.**—This gradually elongates during development and its columnar epithelium becomes ciliated. Muscle fibers and the anlagen of the cartilaginous rings appear at 17 mm. The glands develop as ingrowths of the epithelium during the last five months of pregnancy.

**The Lungs.**—Soon after the lung anlagen or stem buds are formed (5 mm. embryos), the right bronchial bud becomes larger and is directed more caudally

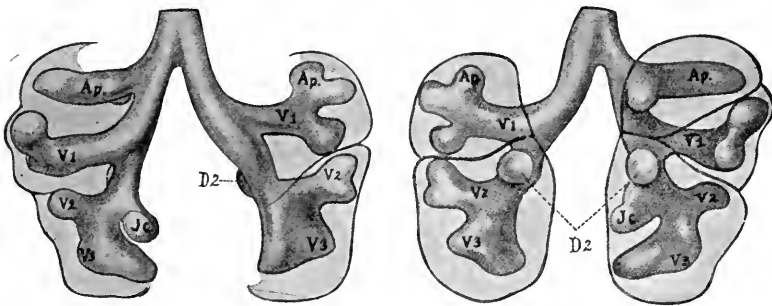


FIG. 168.—Dorsal and ventral views of the lungs from a human embryo of five weeks (Merkel). *Ap*, apical bronchus; *D1*, *D2*, etc., dorsal; *V1*, *V2*, etc., ventral bronchi; *Jc*, infracardial bronchus.

(Fig. 165). At 7 mm. the stem bronchi give rise to two bronchial buds on the right side, to one on the left. The smaller bronchial bud on the right side is the apical bud. The other buds, right and left, are known as *ventral bronchi*. There are thus formed three bronchial rami on the right side, two on the left, and these correspond to the primitive lobes of the lungs (Fig. 168).

On the left side, an apical bud is interpreted as being derived from the first ventral bronchus. It develops later and remains small so that a lobe corresponding to the upper lobe of the right lung is not developed in the left lung (Naroth). The upper lobe of the left lung thus would correspond to the upper and middle lobes of the right lung.

The bronchial anlagen continue to branch in such a way that the *stem bud* becomes the main bronchial stem (Fig. 168). That is, the branching is monopodial, not dichotomous, lateral buds being given off from the stem bud. Only in the later stages of development has dichotomous branching of the bronchi and

the formation of two equal buds been described. Such buds formed dichotomously do not remain of equal size (Flint, Amer. Jour. Anat., vol. 6, 1906-1907).

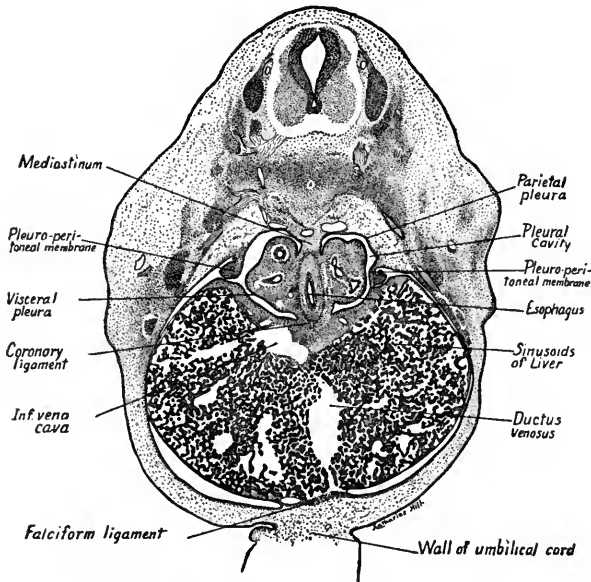


FIG. 169.—Transverse section through the lungs and pleural cavities of a 10 mm. human embryo.  $\times 23$ .

The entodermal anlagen of the lungs and trachea are developed in a median mass of mesenchyma dorsal and cranial to the peritoneal cavity. This tissue forms a broad mesentery termed the mediastinum (Fig. 169). The right and left stem buds of the lungs grow out laterad, carrying with them folds of the mesoderm. The branching of the bronchial buds takes place within this tissue which is covered by the mesothelium which lines the body cavity. The terminal branches of the bronchi are

lined with entodermal cells which flatten out and form the *respiratory epithelium* of the adult lungs. The surrounding mesenchyma differentiates into the muscle,

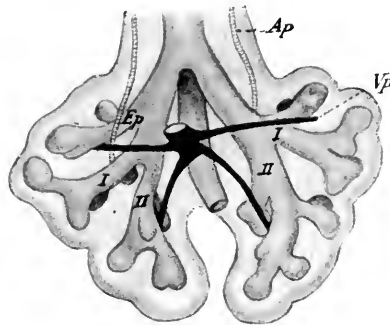


FIG. 170.—The lungs of a 10.5 mm. embryo showing the pulmonary arteries and veins (His from McMurrich's "Human Body"). *Ap.*, pulmonary artery; *Ep.*, apical bronchus; *Vp.*, pulmonary vein; *I, II.*, primary bronchi.

connective tissue and cartilage plates of the lungs, trachea and bronchial walls. Into it grow blood-vessels and nerve fibers. When the pleural cavities are

separated from the pericardial and peritoneal cavities, the mesothelium covering the lungs with the connective tissue underlying it becomes the *visceral pleura*. The corresponding layers lining the thoracic wall form the *parietal pleura*. These layers are derived respectively from the *visceral* (splanchnic) and *parietal* (somatic) *mesoderm* of the embryo.

In 11 mm. embryos the two *pulmonary arteries*, from the sixth pair of aortic arches, course lateral then dorsal to the stem bronchi (Fig. 170). The right pulmonary artery passes ventral to the apical bronchus of the right lung. The single pulmonary vein receives two branches from each lung, two larger veins from each lower lobe, two smaller veins from each upper lobe and the middle lobe of the right side. These four pulmonary branches course ventrad and drain into the pulmonary trunk. When this common stem is taken up into the wall of the left atrium, the four pulmonary veins open directly into the latter.

According to Kölliker, the air cells of the lungs begin to form at the sixth month and their development is completed during pregnancy. Elastic tissue may be recognized at the third month in the walls of the vessels and during the fourth month it appears in the largest bronchi. The abundant connective tissue found between the bronchial branches in early fetal life becomes reduced in its relative amount as the alveoli of the lungs are developed.

Before birth the lungs are relatively small, compact and possess sharp margins. They lie in the dorsal portion of the pleural cavities. After birth they normally fill with air, expanding and completely filling the pleural cavities. Their margins become rounded and the compact fetal lung tissue which resembles that of a gland in structure becomes light and spongy, owing to the enormous increase in the size of the alveoli and blood-vessels. Because of the greater amount of blood admitted to the lungs after birth their weight is suddenly increased.

In the most common anomaly involving the esophagus and trachea the former is divided transversely, the trachea opening into the lower portion of the esophagus, while the upper portion of the esophagus ends blindly. According to Lewis (in Keibel and Mall, vol. 2, p. 367), the anomaly may be produced by the abnormal development of lateral esophageal grooves which occlude the lumen of the esophagus. These grooves, though small, were found present in 4 mm. human embryos.

## ESOPHAGUS, STOMACH AND INTESTINE

**Esophagus.**—The esophagus in 4 to 5 mm. embryos is a short tube, flattened laterally, and extending from the pharynx to the stomach. Its *epithelium* is composed of two layers of columnar cells. The esophagus grows rapidly in length and in 7.5 mm. embryos its diameter decreases both relatively and absolutely (Forssner).

In embryos of from 8 to 16 mm. its laryngeal end is crescent-shaped and concave toward the trachea. Its middle portion is round or oval and opposite the bifurcation of the trachea it begins to enlarge and is flattened laterally. Its lumen is open throughout and shows from

two to four rows of nuclei. In 20 mm. embryos, vacuoles appearing in the epithelium give the esophagus the appearance of having several lumina. The result of vacuole formation is to increase the size of the lumen. In later stages the wall of the esophagus is folded and ciliated epithelial cells appear in 44 mm. embryos. The number of cell layers in the epithelium increases until at birth they number nine or ten. Glands are developed as ingrowths from the epithelium. The circular muscle layer is indicated at 10 mm. by a circular layer of myoblasts, but the longitudinal muscle layer does not form a definite layer until 55 mm. (F. T. Lewis in Keibel and Mall, vol. 2).

**Stomach.**—The stomach appears in embryos of 4 to 5 mm. as a laterally flattened fusiform enlargement of the fore-gut caudal to the lung anlagen (Fig. 171). Its epithelium is early thicker than that of the esophagus and is sur-

rounded by a thick layer of *splanchnic mesoderm*. It is attached dorsally to the body wall by its mesentery, the *greater omentum*, and ventrally to the liver by the *lesser omentum*. The dorsal border of the stomach enlarges to form the *fundus* and *greater curvature*. The dorsal wall grows more rapidly than the ventral wall and thus produces the convex *greater curvature*. The whole stomach becomes curved and its caudal end is carried ventrad and to the right (Fig. 162). This forms a ventral concavity, the *lesser*

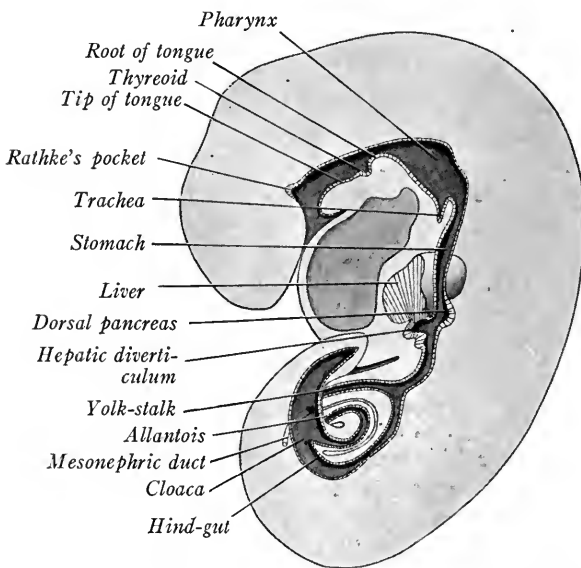


FIG. 171 A.—Median sagittal section of a 5 mm. embryo to show the digestive canal (modified after Ingalls).

*curvature*, and produces the first flexure of the duodenum. The rapid growth of the gastric wall along its greater curvature also causes the stomach to rotate upon its long axis until its greater curvature or primitive dorsal wall lies to the left, its ventral wall, the lesser curvature, to the right (Fig. 162). The original right side is now dorsal, the left side ventral in position, and the caudal or *pyloric* end of the stomach is ventral and to the right of its cardiac or cephalic end. The whole organ extends obliquely across the peritoneal cavity from left to right. The change in position progresses rapidly and is already completed in embryos of 12 to 15 mm. (beginning of the second month). The rotation of the stomach explains the asymmetrical position of the

vagus nerves of the adult organ, the left nerve supplying the ventral wall of the stomach, originally the left wall, while the right vagus supplies the dorsal wall, originally the right.

Gastric pits are indicated in 16 mm. embryos and at 100 mm. gland cells of the gastric glands are differentiated. These undoubtedly arise from the gastric epithelium, according to

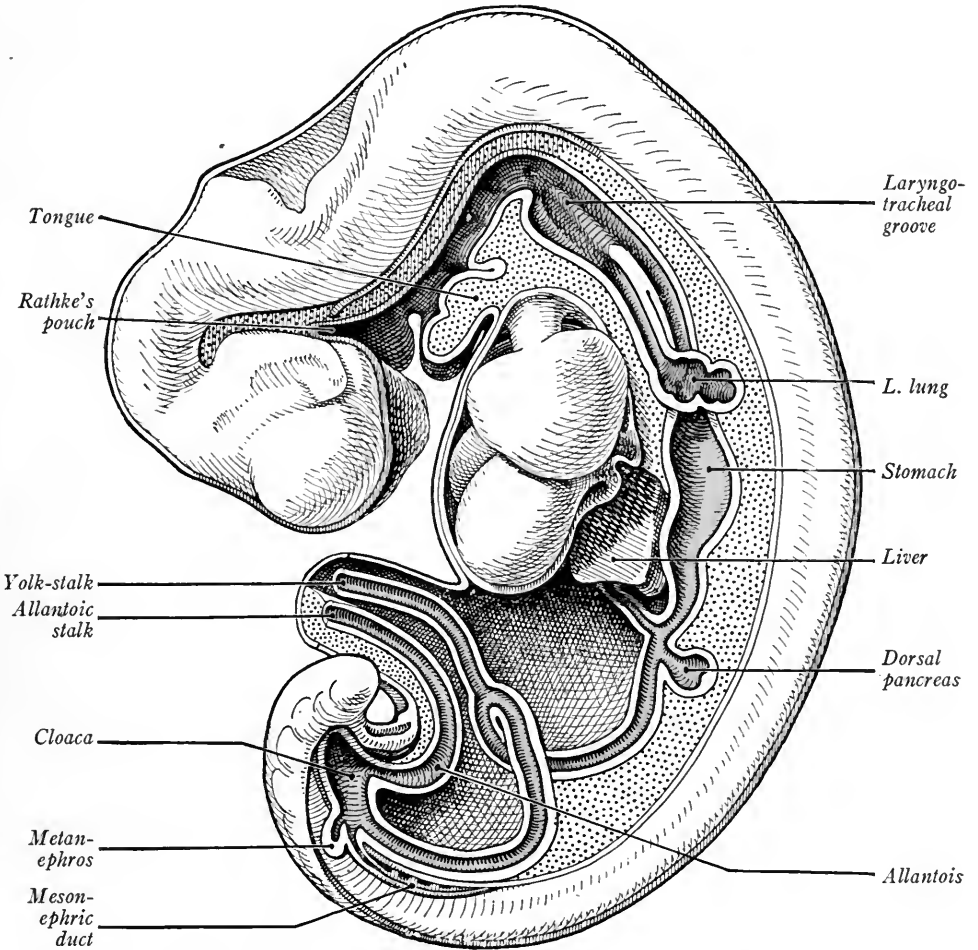


FIG. 171 B.—Reconstruction of a 5 mm. human embryo showing the entodermal canal and its derivatives (His in Kollmann's Handatlas).

Lewis. The cardiac glands are developed early (91 mm. embryos) and, according to Lewis, there is no "evidence in favor of Bensley's conclusion that the cardiac glands are decadent . . . fundus glands."

At 10 mm. the stomach wall is composed of three layers, *entodermal epithelium*, a thick *mesenchymal* layer and the peritoneal *mesothelium*. At 16 mm. the circular muscle layer is indicated by condensed mesenchyma. The *tunica propria* forms a dense layer at 55 mm.

At 91 mm. the cardiac region shows a few longitudinal muscle fibers, which become distinct in the pyloric region at 240 mm.

**The Intestine.**—In 5 mm. embryos (Fig. 171 A), the intestine, beginning at the stomach, consists of the *duodenum* (from which are given off the hepatic diverticulum and ventral pancreas), and the *cephalic* and *caudal limbs of the intestinal loop*, which bends ventrad and connects with the *yolk-stalk*. Caudally

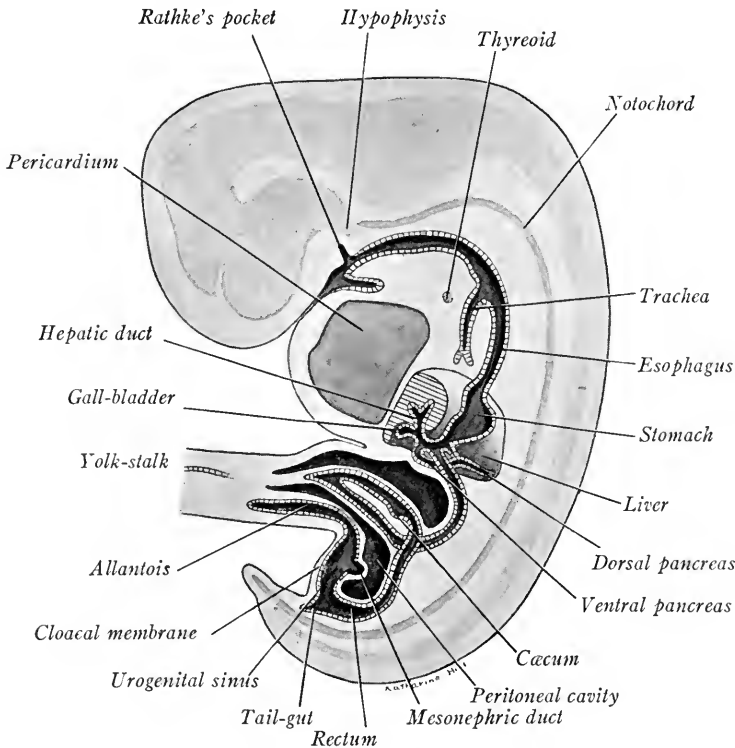


FIG. 172.—Diagram in median sagittal section showing the digestive canal of a 9 mm. human embryo (adapted from Mall).

the intestinal tube expands to form the *cloaca*. It is supported from the dorsal body wall by the *mesentery* (Fig. 171 B).

From 5 to 9 mm. the ventral bend of the intestinal loop becomes more marked and the attachment of the *yolk-stalk* to it normally disappears (Fig. 172).

The attachment of the *yolk-stalk* may persist in later stages (12 to 14 mm. embryos, according to Keibel, Elze and Thyng). Also in 20 per cent. of adult intestines a pouch 3 to 9 cm. long is found where the *yolk-stalk* was formerly attached. This pouch, the *diverticulum of the ileum* or *Meckel's diverticulum*, is of clinical importance as many cases of intestinal occlusion in infancy are due to its presence.

At the stage shown in Fig. 172, the dorsal pancreatic anlage has been developed from the duodenum and, in the caudal limb of the intestinal loop, there is formed an enlargement due to a ventral bulging of the gut wall which marks the anlage of the *cæcum* and the boundary line between the *large* and *small intestine*. The cæcal anlage later differentiates into the large *cæcum* and distal *vermiform process* of the adult.

Succeeding changes in the intestine consist (1) in its torsion and coiling due

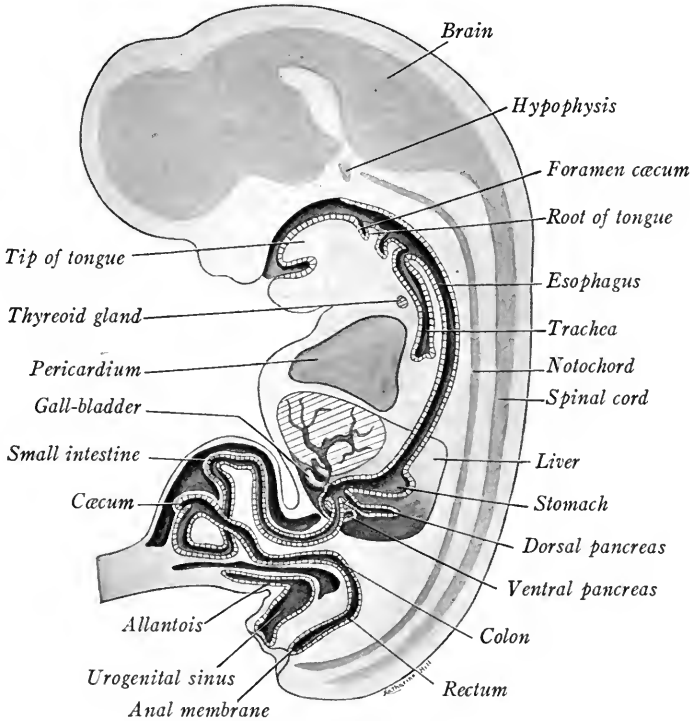


FIG. 173.—Diagrammatic median sagittal section of a 17 mm. human embryo showing the digestive canal (modified after Mall).

to its rapid elongation and (2) in the differentiation of its different regions. As the gut elongates in 9 to 10 mm. embryos the intestinal loop rotates. As a result, its caudal limb lies at the left and cranial to its cephalic limb (Fig. 172). At this stage the intestinal loop enters the cœlum of the umbilical cord.

The *small intestine* soon lengthens rapidly and at 17 mm. (Fig. 173) forms loops in the umbilical cord. *Six primary loops* occur and may be recognized in the arrangement of the adult intestine (Mall, Bull. Johns Hopkins Hosp., vol. 9, 1898). In embryos of 42 mm. the intestine has returned from the umbilical

cord into the abdominal cavity through a rather small aperture and the coelom of the cord is soon after obliterated.

In embryos between 10 and 30 mm. vacuoles appear in the wall of the *duodenum* and epithelial septa completely block the lumen. The remainder of the small intestine remains open, although vacuoles form in its epithelium. *Villi* appear as rounded elevations of the epithelium at 22.8 mm. (Johnson). They begin to form at the cephalic end of the jejunum, and at 130 mm. they are found throughout the small intestine (Berry). Intestinal glands appear as ingrowths of the epithelium about the bases of the villi. They develop first in the duodenum at 91 mm. and in the jejunum at 130 mm. The duodenal glands (of Brunner) are said to appear during the fourth month (Brand). From 10 to 12.5 mm. the circular muscle layer is formed. The longitudinal muscle layer is not distinct until 75 mm.

The impervious duodenum of the embryo may persist as a congenital anomaly, and we have already alluded to the persistence of the yolk-stalk as *Meckel's diverticulum*.

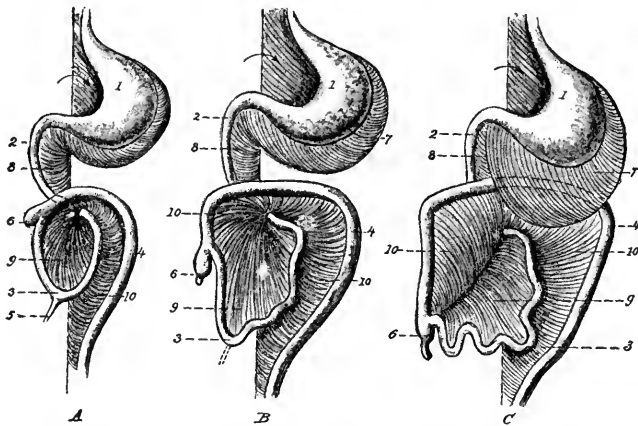


FIG. 174.—Three successive stages showing the development of the digestive tube and the mesenteries in the human fetus (modified from Tourneux): 1, stomach; 2, duodenum; 3, small intestine; 4, colon; 5, vitelline duct; 6, caecum; 7, great omentum; 8, mesoduodenum; 9, mesentery; 10, mesocolon. The arrow points to the orifice of the omental bursa. The ventral mesentery is not shown (Heisler).

The *large intestine*, as we have seen in 9 mm. embryos, forms a tube extending from the *caecum* to the cloaca. It does not lengthen so rapidly as the small intestine and, when the intestine is withdrawn from the umbilical cord (at 42 mm.), its cranial or caecal end lies on the right side and dorsal to the small intestine (Fig. 174). It extends transversely to the left side as the *transverse colon*, then bending abruptly caudad as the *descending colon*, returns by its *iliac flexure* to the median plane and forms the *rectum*.

The caecum (Fig. 175) is differentiated from the vermiform process at 65 mm. (Tarenetzky). The caecum and vermiform process make a U-shaped bend with the colon at 42 mm., and this flexure gives rise to the *ileo-caecal valve* (Toldt). In stages between 100 and 220 mm. the lengthening of the colon causes the caecum



and cephalic end of the colon to descend toward the pelvis (Fig. 174). The *ascending* colon is thus formed and the vermiform appendix takes the position which it occupies in the adult. The development of the mucous membrane of the intestinal tube has been described by Johnson (American Journal of Anatomy, vols. 10, 14 and 16, pp. 521-561; 187-233; 1-49).

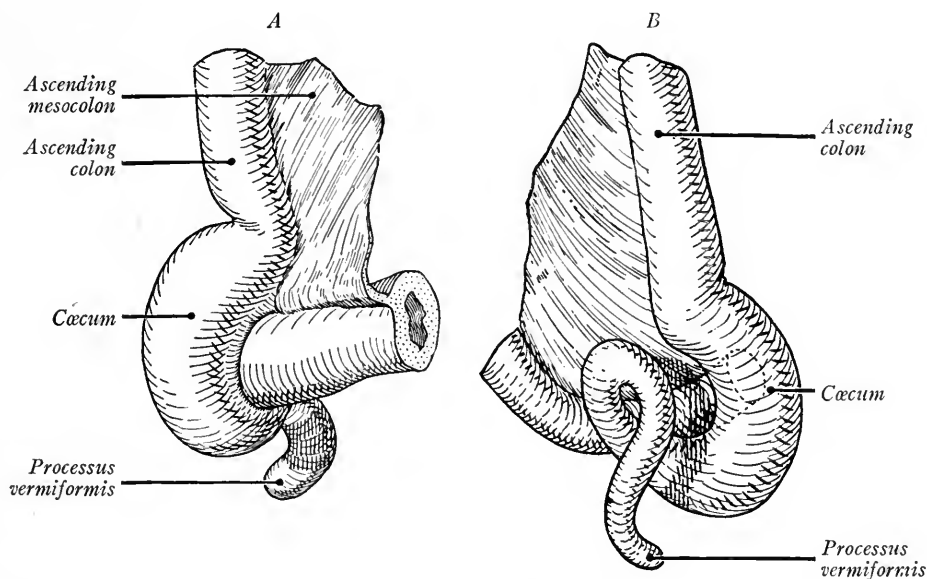


FIG. 175.—The cæcum of a human embryo of 5 cm. (Kollmann). *A*, from the ventral side; *B*, from the dorsal side.

## THE LIVER

In embryos of 2.5 mm. the liver anlage is present as a median ventral out-growth from the entoderm of the fore-gut just cranial to the yolk-stalk (Fig. 161 B). Its thick walls enclose a cavity which is continuous with that of the gut. The liver anlage is embedded in the ventral mesentery which lies in the median line between the fore-gut, the ventral body wall, and the septum transversum (Fig. 171 A). Thus, from the first the liver is in close relation to the septum transversum and later when the septum becomes a part of the diaphragm the liver remains attached to it.

In embryos 4 to 5 mm. long, solid cords of cells proliferate from the ventral and cranial portion of the liver anlage. These cords anastomose and form a crescentic mass with wings extending lateral and dorsal to the gut (Fig. 171 A).

This mass, a network of solid trabeculæ, is the glandular portion of the liver. The primitive, hollow, hepatic diverticulum later differentiates into the gall-bladder and the large biliary ducts.

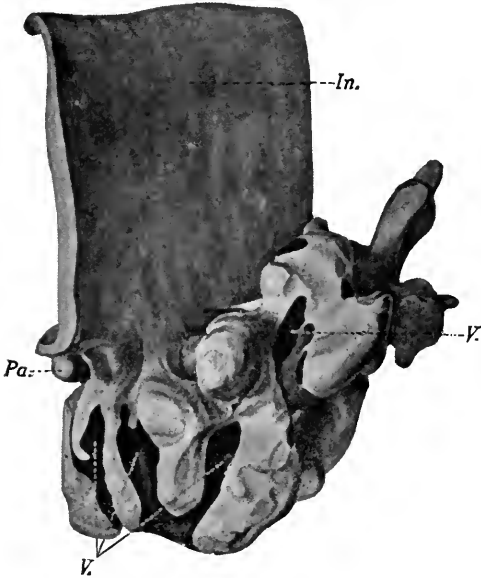


FIG. 176.—The liver anlage of a 4 mm. human embryo (Bremer). *In.*, intestine; *Pa.*, pancreas; *V.V.*, veins in contact with liver trabeculæ.

Referring to Figs. 83 and 176, it will be seen that the liver anlage lies between the vitelline veins and is in close proximity to them laterally. The veins send anastomosing branches into the ventral mesentery. The trabeculæ of the expanding liver grow between and about these venous plexuses, and the plexuses in turn make their way between and around the liver cords. The vitelline veins on their way to the heart are thus surrounded by the liver and largely subdivided into a network of vessels termed *sinusoids*.

The endothelium of the sinusoids is closely applied to the cords of liver cells which, in the early stages, contain no bile capillaries (Fig. 177). For the transformation of the vitelline veins into the portal vein and for the relations of the umbilical veins to the liver see Chapter IX.

The glandular portion of the liver grows rapidly and in embryos of 7 to 8 mm. is connected with the primitive hepatic diverticulum only by a single cord of cells, the *hepatic duct* (Fig. 178 A). That portion of

the hepatic diverticulum distal to the hepatic duct is now differentiated into the terminal solid *gall-bladder* and its *cystic duct*. Its proximal portion forms the

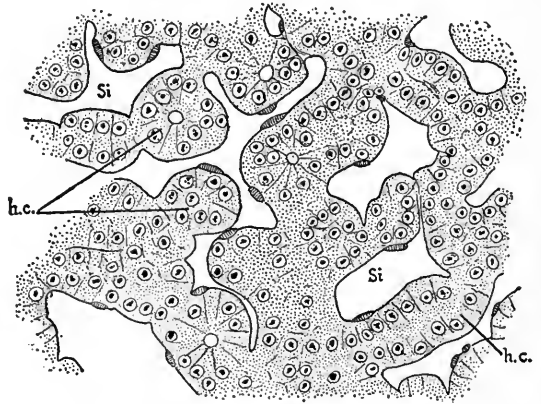


FIG. 177.—The trabeculæ and sinusoids of the liver in section. *h.c.*, trabeculæ of liver cells; *Si.*, sinusoids (after Minot).  $\times 300$ .

*ductus choledochus*. In embryos of 10 mm. (Fig. 178 B) the gall-bladder and ducts have become longer and more slender. The hepatic duct receives a right and left branch from the corresponding lobes of the liver. The gall-bladder is without a lumen up to the 15 mm. stage. Later its cavity appears surrounded by a wall of high columnar epithelium.

The glandular portion of the liver develops fast and is largest relatively at 31 mm. (Jackson, *Anat. Record*, vol. 3, pp. 361-396, 1909). The liver tissue degenerates, especially in the peripheral portion of the left lobe. In embryos of two months the liver weighs 2 gm.; at birth 75 gm.; in the adult 1500 gm.

During the development of the liver the endothelial cells of the sinusoids become stellate in outline, and thus form an incomplete layer. From the second month of fetal life to some

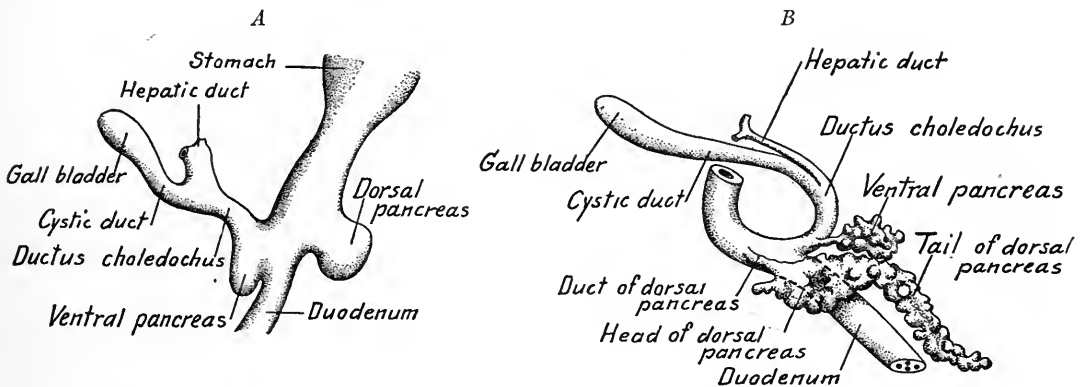


FIG. 178.—Reconstructions showing the development of the hepatic diverticulum and pancreatic anlagen. A, 7.5 mm. embryo,  $\times 36$  (after Thyng); B, 10 mm. embryo,  $\times 33$  (specimen loaned by Dr. H. C. Tracy).

time after birth, blood-cells are actively developed between the hepatic cells and the endothelium of the sinusoids. The hepatic trabeculae are mostly solid in 10 mm. embryos. At 22 mm. hollow *periportal ducts* develop, spreading inward from the hepatic duct along the larger branches of the portal vein. These ducts form a plexus, as has been proved by injections. Lumina bounded by five or six cells may be observed in some of the liver trabeculae of 10 mm. embryos (Lewis). In 44 mm. embryos, bile capillaries with cuticular borders are present, most numerous near the periportal ducts with which some of them connect. At birth, or shortly after, the number of liver cells surrounding a bile capillary is reduced to two, three or four.

The lobules, or vascular units of the liver, are formed, according to Mall, by the peculiar and regular manner in which the veins of the liver branch. The primary branches of the portal vein extend along the periphery of each primitive lobule, parallel to similar branches of the hepatic veins which drain the blood from the center of each lobule (Fig. 179). As development proceeds, each primary branch becomes a stem, giving off on either side secondary branches

which bear the same relation to each other and to new lobules as did the primary branches to the first lobule. This process is repeated until thousands of liver lobules are developed.

Until the 20 mm. stage the portal vein alone supplies the liver. The *hepatic artery* from the coeliac axis comes into relation first with the hepatic duct and gall-bladder. Later, it grows into the connective tissue about the larger bile ducts and branches of the portal vein, and also supplies the capsule of the liver.

The development of the ligaments of the liver is described on p. 200.

Anomalies of the liver occur chiefly in connection with the gall-bladder and ducts. The gall-bladder may be absent or two may be present. Duplications and absence of the hepatic duct has been observed, also duplication of the cystic duct. In some animals (horse, elephant) the gall-bladder is normally absent.

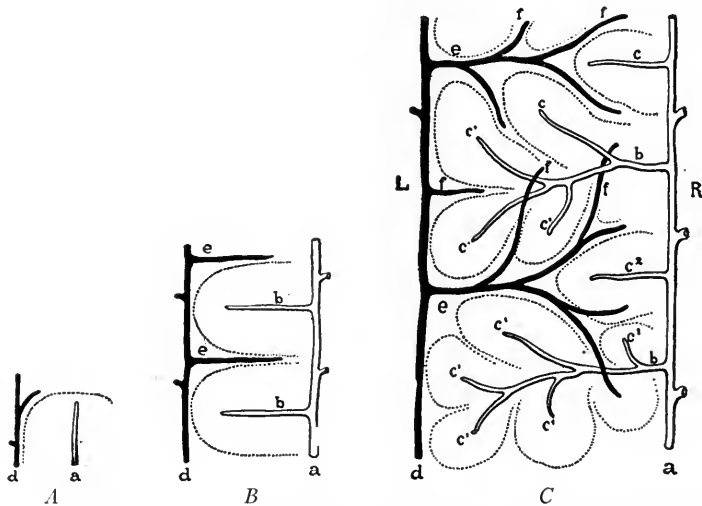


FIG. 179.—Diagrams of three successive stages of the portal and hepatic veins in a growing liver. *a*, Hepatic side; *d*, portal side; *b* and *c*, successive stage of the hepatic vein; *e* and *f*, successive stages of the portal vein (Mall).

### THE PANCREAS

Two pancreatic anlagen are developed almost simultaneously in embryos of 3 to 4 mm. The *dorsal pancreas* arises as a hollow outpocketing of the dorsal duodenal wall slightly cranial to the hepatic diverticulum. At 7.5 mm. it is separated from the duodenum by a slight constriction (Fig. 178 A). The *ventral pancreas* develops in the inferior angle between the hepatic diverticulum and the gut (Lewis) and its wall is continuous with both. With the elongation of the ductus choledochus it is gradually separated from the intestine.

The ventral pancreas may arise directly from the intestinal wall. In cases observed by Debeyre, Helly and Kollmann, the anlage was paired and in other embryos a paired structure is indicated.

Of the two pancreatic anlages, the dorsal grows more rapidly and in 10 mm. embryos forms an elongated structure with irregular nodules upon its surface. Its distal portion is constricted to form a short duct. It lies in the greater omentum between the duodenum and the stomach. The ventral pancreas is smaller and develops a short slender duct which opens into the ductus choledochus. As the latter elongates it bends dorsad and to the right of the intestine, while at the same time the stomach and intestine rotate to the right. This shifts the duct of the ventral pancreas so that it opens dorsally and somewhat to the left into the bile duct. At the same time, the ventral pancreas is brought into close proximity to the dorsal pancreas, and the duct of the latter is shifted to the left side of the intestine (Figs. 178 and 180). It is also carried further cephalad during the course

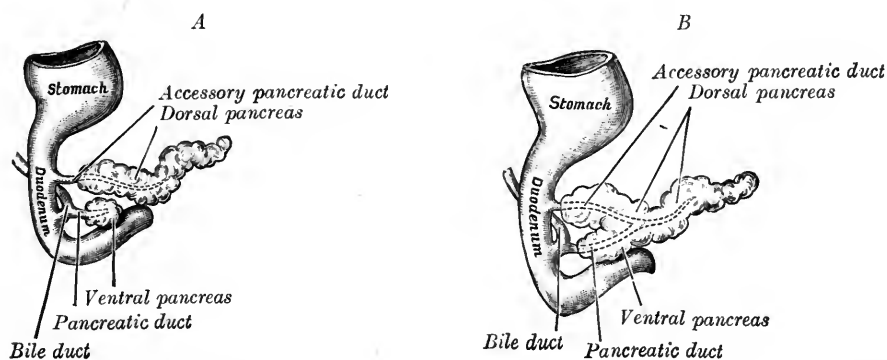


FIG. 180.—Two stages showing the development of the pancreas. *A*, at five weeks; *B*, at seven weeks (after Kollman).

of development so that in the adult the interval between the ducts is from 10 to 35 mm.

In embryos of 20 mm. the tubules of the dorsal and ventral pancreatic anlages interlock (Fig. 180 *B*). Eventually, anastomosis takes place between the two ducts and the duct of the ventral pancreas persists as the functional pancreatic duct of the adult. The proximal portion of the dorsal pancreatic duct forms the *accessory duct* which remains pervious, but becomes a tributary of the ventral pancreatic duct. The ventral pancreas forms part of the head and uncinuate process of the adult gland. The dorsal pancreas takes part in forming the head and uncinuate process and comprises the whole of the body and tail.

In 10 mm. embryos the portal vein separates the two pancreatic anlages and later they partially surround the vein. The chief branch of the portal in the adult, the superior mesenteric vein, thus passes through the pancreas, receiving the splenic vein which courses along and drains

the dorsal surface of the tail. The alveoli of the gland are developed as darkly staining cellular buds in embryos of 40 to 55 mm. The *islands* characteristic of the pancreas appear first in the tail at 55 mm.

Owing to the shift in the position of the stomach and duodenum during development the pancreas takes up a transverse position, its tail extending to the left. To its ventral surface is attached the transverse mesocolon.

### BODY CAVITIES, DIAPHRAGM AND MESENTERIES

**The Primitive Cœlom and Mesenteries.**—In the Peters embryo the primary mesoderm has already split to form the extra-embryonic cœlom (Fig. 232). When the intra-embryonic mesoderm differentiates, numerous clefts appear on

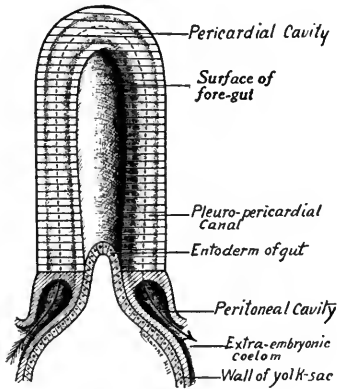


FIG. 181.—Diagrammatic dorsal view of the cœlom in an early human embryo (modified after Robinson).

either side between the somatic and splanchnic layers of mesoderm. These clefts coalesce in the cardiac region and form two elongated cavities lateral to the paired tubular heart. Similarly, right and left pleuro-peritoneal cavities are formed between the mesoderm layers caudal to the heart. The paired pericardial cavities extend toward the midline cranially and communicate with each other (Fig. 181). They also are prolonged caudally until they open into the pleuro-peritoneal cavities. These in turn communicate laterally with the extra-embryonic cœlom. In an embryo of 1.5 mm. the cœlom thus consists of a U-shaped pericardial cavity, the right and left limbs of which

are continued caudally into the paired pleuro-peritoneal cavities; these extend out into the extraembryonic cœlom.

When the head-fold and fore-gut of the embryo are developed, the layers of splanchnic mesoderm containing the heart tubes are folded together ventral to the fore-gut and form the *ventral mesentery* between the gut and the ventral body wall (Fig. 182). Owing to the position of the yolk-sac, the caudal extent of the ventral mesentery is limited. At the level on each side, where the vitello-umbilical trunk courses to the heart, the splanchnic mesoderm and the somatic mesoderm are united (Fig. 182). Thus is formed the *septum transversum*, which separates the ventral mesentery into a cranial and caudal portion. Cranial to the septum, the heart is suspended in the ventral mesentery which forms the *dorsal* and *ventral mesocardia* (Fig. 183 A). Into the ventral mesentery caudal

to the septum grows the liver. This portion of the ventral mesentery gives rise dorsally to the *lesser omentum* of the stomach and, with the septum transversum,

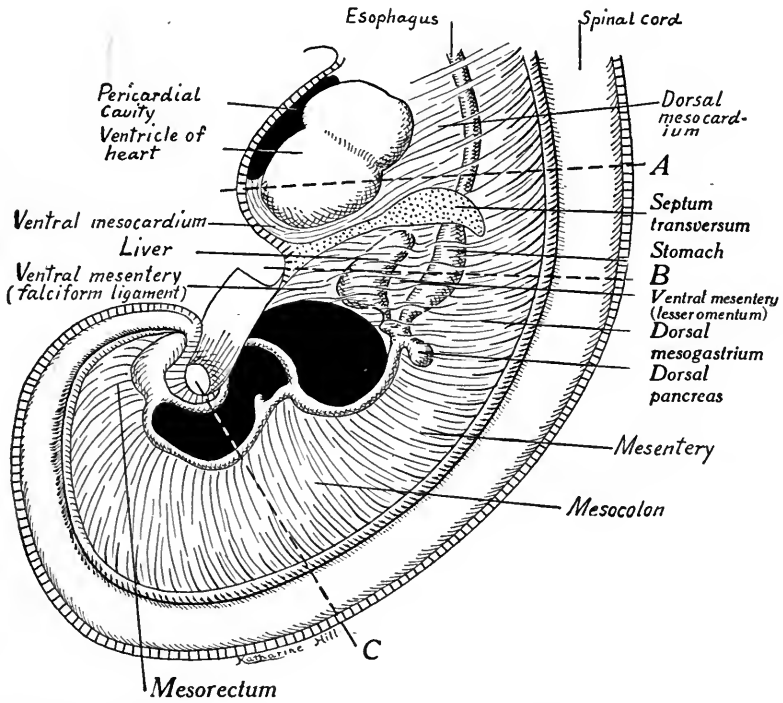


FIG. 182.—Diagram showing the primitive mesenteries of an early human embryo in median sagittal section. The broken lines A, B, and C indicate the level of sections A, B, and C in Fig. 183.

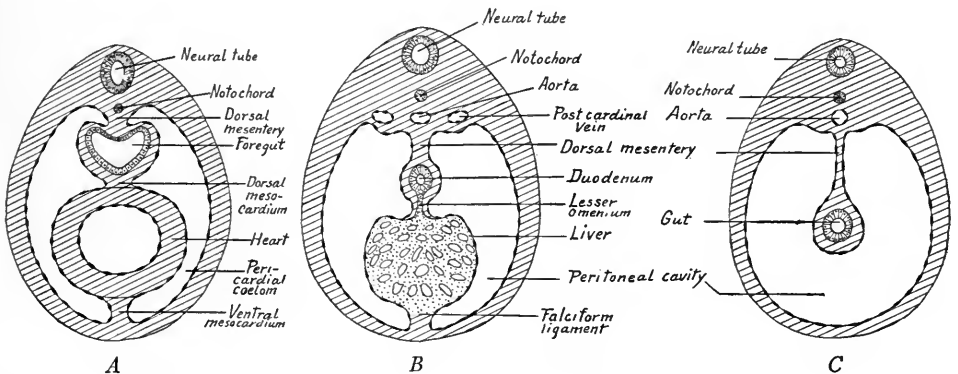


FIG. 183.—Diagrammatic transverse sections. A, through the heart and pericardial cavities of an early human embryo; B, through the stomach and liver; C, through the intestine and peritoneal cavity.

it forms the ligaments of the liver. Ventrally it persists as the falciform ligament (Fig. 183 B).

Dorsal to the gut the splanchnic mesoderm of each side is folded together in the median sagittal plane and constitutes the *dorsal mesentery* which extends to the caudal end of the digestive canal (Figs. 182 and 183 C). This suspends the stomach and intestine from the dorsal body wall and is divided into the *dorsal mesogastrium* or *greater omentum* of the stomach; the *mesoduodenum*, the *mesentery proper* of the small intestine, the *mesocolon* and the *mesorectum*.

The covering layers of the viscera, of the mesenteries and of the body wall, are continuous with each other and consist of a mesothelium overlying connective tissue. They are derived from the somatic and splanchnic layers of mesoderm.

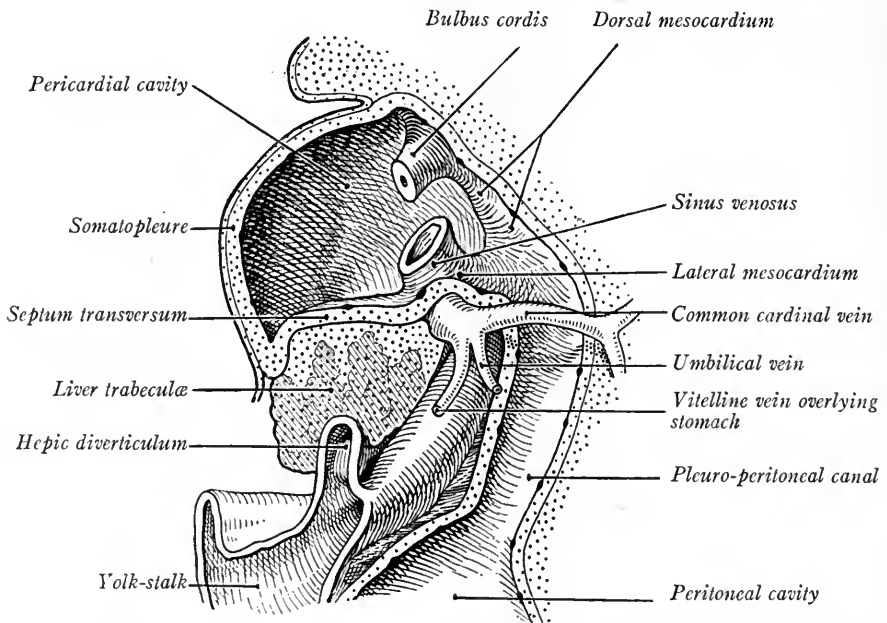


FIG. 184.—Reconstruction near median sagittal plane of a 3 mm. human embryo, showing the body cavities and septum transversum (Kollmann's Handatlas).

The primitive cœlom lies approximately in one plane, as in Fig. 181. With the development of the head-fold and the ventral flexion and fusion of the heart tubes, the pericardial cavity is bent ventrad and enlarged. The ventral mesocardium attaching the heart to the ventral body wall disappears and the right and left limbs of the U-shaped cavity become confluent ventral to the heart. The result is a single large pericardial chamber, the long axis of which now lies in a dorso-ventral plane nearly at right angles to the plane of the pleuro-peritoneal cavities, and connected with them dorsally by the right and left pleuro-peritoneal canals (Fig. 184).

The division of the *primitive cœlom* into separate cavities is accomplished by



the development of three membranes: (1) the *septum transversum*, which separates incompletely the pericardial and pleural cavities from the peritoneal cavities; (2) the *pleuro-pericardial membrane* which completes the division between pericardium and pleural cavity; (3) the *pleuro-peritoneal membrane* which completes the partition between each pleural cavity containing the lung and the peritoneal cavity which contains the abdominal viscera.

**The Septum Transversum.**—In embryos of 2 to 3 mm. (Fig. 184) the splanchnic mesoderm of the yolk-sac and that of the heart are continuous where the vitelline veins cross from one layer to the other; also where the umbilical veins course from the body wall to the heart the somatic and splanchnic layers of mesoderm are continuous. Thus, there is formed caudal to the heart a transverse partition filling the space between the sinus venosus of the heart, the gut and the ventral body wall and separating the pericardial and peritoneal cavities from each other ventral to the gut. This mesodermal partition was termed by His the *septum transversum*. It is the anlage of a large part of the diaphragm. At first it does not extend dorsal to the gut, but leaves on either side a *pleuro-peritoneal canal* through which the pericardial and pleuro-peritoneal cavities communicate (Fig. 183). In embryos of 4 to 5 mm. the lungs develop in the median walls of these canals and bulge laterally into them. Thus the canals become the *pleural cavities* and will be so termed hereafter.

On account of the more rapid growth of the embryo, there is an apparent constriction at the yolk-stalk and, with the development of the umbilical cord, the peritoneal cavity is finally separated from the extra-embryonic coelom.

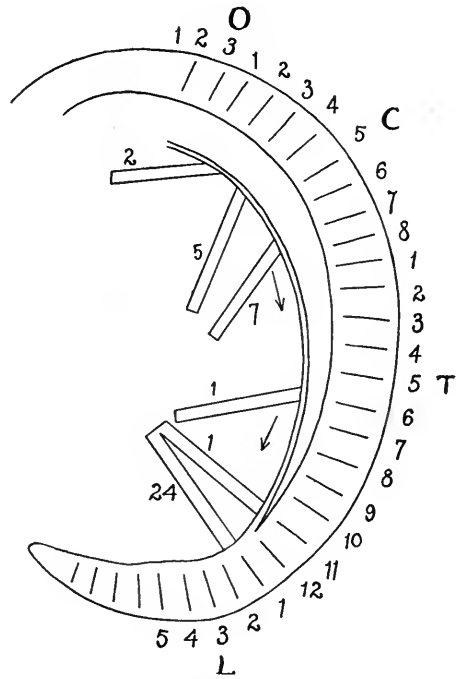


FIG. 185.—Diagram showing the change in position of the septum transversum in stages from 2 to 24 mm. (modified after Mall). The septum is indicated at different stages by the numerals to the left, the numbers corresponding to the length of the embryo at each stage. The letters and numbers at the right represent the segments of the occipital, cervical, thoracic and lumbar regions.

Dorsally the pleural and peritoneal cavities are permanently partitioned lengthwise by the dorsal mesentery.

The *septum transversum* in 2 mm. embryos occupies a transverse position in the middle cervical region (Fig. 185, 2). According to Mall, it migrates caudally, its ventral portion at first moving more rapidly so that its position becomes oblique. In 5 mm. embryos (Fig. 185, 5) it is opposite the fifth cervical segment, at which level it receives the phrenic nerve. In stages later than 7 mm. the sep-

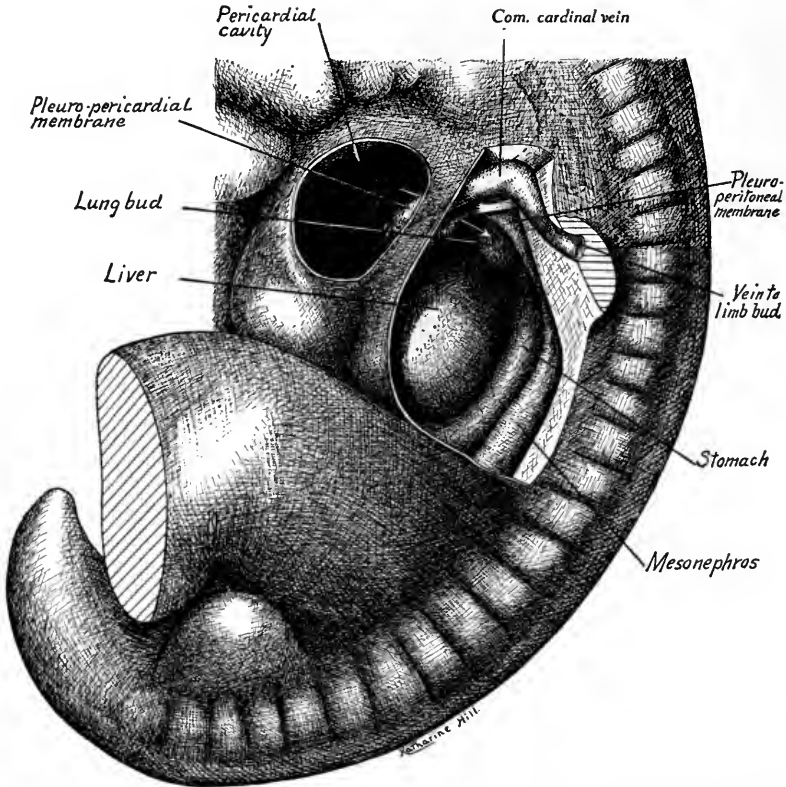


FIG. 186.—Reconstruction of a 7 mm. embryo showing from the left side the pleuro-pericardial membrane, the pleuro-peritoneal membrane and the septum transversum (after Mall).

tum migrates caudad, until at 24 mm. it is opposite the first lumbar segment. During this second period of migration its dorsal attachment travels faster than its ventral portion. Therefore, it rotates to a position nearly at right angles to its plane in 7 mm. embryos and its original dorsal surface becomes its ventral surface. In connection with the septum transversum two other membranes develop.

**The Pleuro-pericardial and Pleuro-peritoneal Membranes.**—The common

cardinal veins (ducts of Cuvier) on their way to the heart curve around the pleural cavities laterally in the body wall (Figs. 184 and 186). In embryos of 7 mm. each vein forms a ridge which projects from the body wall mesially into the pleural canals. This ridge, the *pulmonary ridge* of Mall, later broadens and thickens cranio-caudally (Fig. 186). Its cranial and caudal margins form two sides of a spherical triangle, the third side or base of which is the line of attachment of the dorsal mesentery to the body wall (Fig. 187). At its ventral angle the sides of

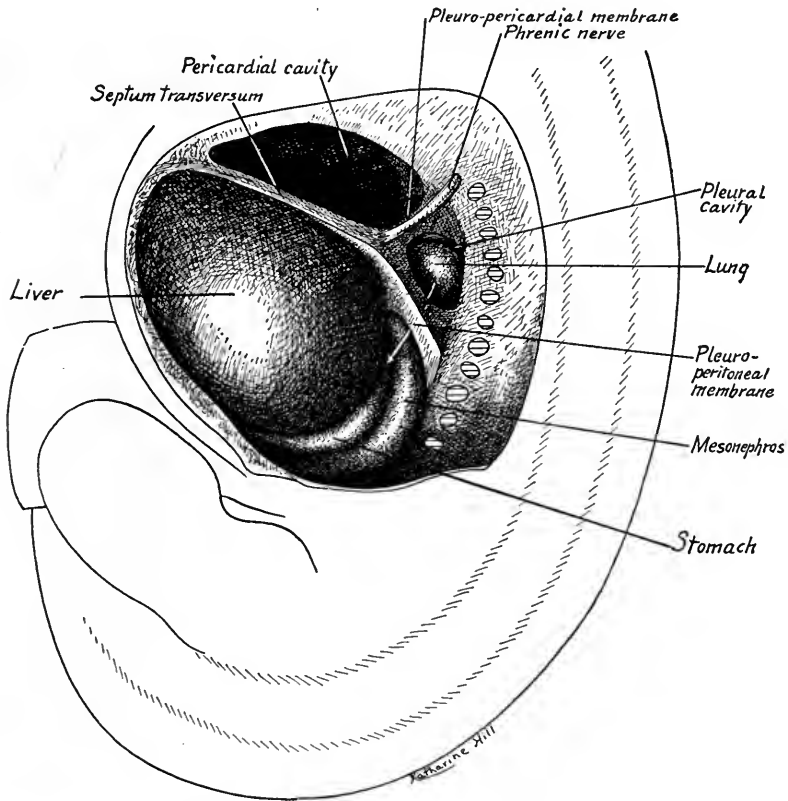


FIG. 187.—Reconstruction of an 11 mm. embryo to show the same structures as in Fig. 186 (after Mall).

this triangle are continuous with the septum transversum. Its cranial side forms the pleuro-pericardial membrane and in 9 to 10 mm. embryos reduces the opening between the pleural and pericardial cavities to a mere slit. Its caudal side becomes the pleuro-peritoneal membrane, which eventually separates dorsally the pleural from the peritoneal cavity. The membranes at first lie nearly in the sagittal plane and a portion of the lung is caudal to the pleuro-peritoneal membranes (Fig. 186). Between the stages of 7 and 11 mm. the dorsal attachment of the

septum transversum is carried caudally more rapidly than its ventral portion and its ventral surface becomes its dorsal side (Figs. 186 and 187). The pleuro-peritoneal membrane is carried caudad with the septum transversum until the lung lies in the angle between the pleuro-peritoneal and pleuro-pericardial membranes and is included within the spherical triangle which has been described above (Fig. 187). The dorsal end of the *pleuro-pericardial membrane* lags behind and so takes up a position in a coronal plane nearly at right angles to the septum transversum (Figs. 187 and 188). In 11 mm. embryos the pleuro-pericardial membranes have fused completely on each side with the median walls of the pleural

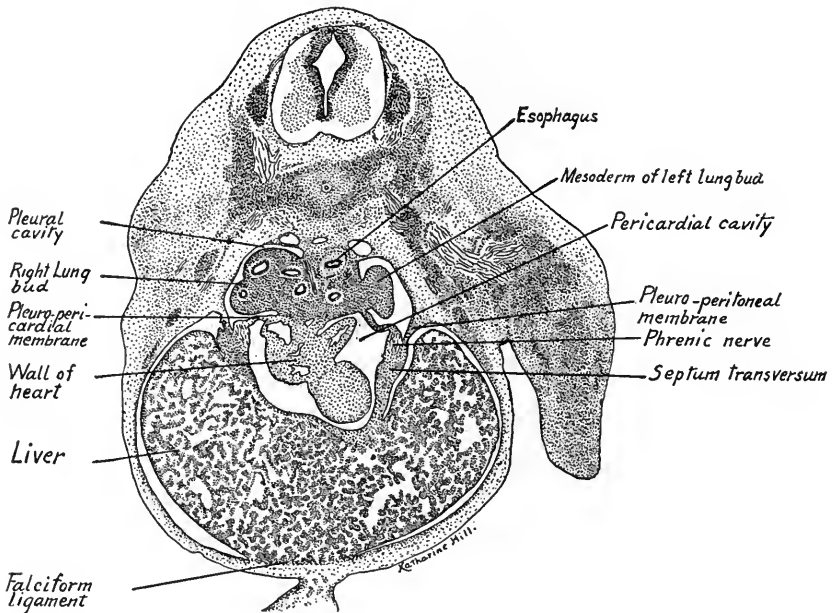


FIG. 188.—Transverse section through a 10 mm. human embryo showing the pleuro-pericardial membrane separating the pericardium from the pleural cavities.  $\times 33$ .

canals and thus separate the pericardium from the paired pleural cavities. By way of the pleuro-pericardial membranes the phrenic nerves course to the septum transversum (Fig. 187).

The *pleuro-peritoneal membranes* are continued dorsally and caudally along the mesonephric folds; ventrally and caudally they become on the liver the *dorsal pillars of the diaphragm* or *coronary appendages* (Lewis) (Fig. 189). Between the free margins of the membranes and the mesentery an opening is left on each side, through which the pleural and peritoneal cavities communicate (Figs. 187 and 193).

Owing to the caudal migration of the septum transversum and the growth of the lungs and liver, the pleuro-peritoneal membrane, at first lying in a nearly sagittal plane, is shifted to a horizontal position and gradually its free margin unites with the dorsal pillars of the diaphragm and with the dorsal mesentery. The opening between the pleural and peritoneal cavities is thus narrowed and finally closed in embryos of 19 to 20 mm.

**The Diaphragm and Pericardial Membrane.**—The lungs grow and expand, not only cranially and caudally, but also laterally and ventrally (Fig. 190 A, B). Room is made for them by the obliteration of the very loose, spongy mesenchyme

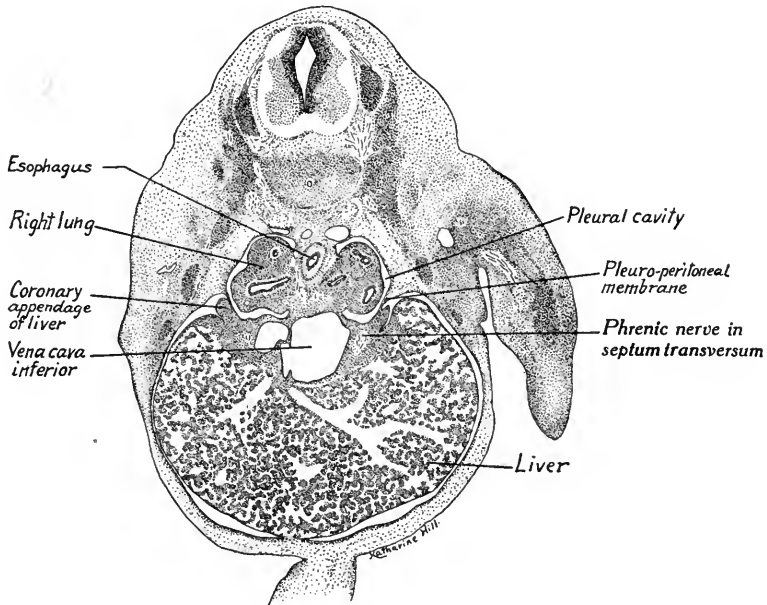


FIG. 189.—Transverse section through a 10 mm. embryo showing the pleuro-peritoneal membranes,  $\times 16$  (from an embryo loaned by Dr. H. C. Tracy).

of the body wall (Fig. 189). As the lungs grow laterally and ventrally in the body wall around the pericardial cavity, they split off from the body wall the *pericardial membrane* and more and more the heart comes to lie in a mesial position between the lungs (Fig. 190 B). The pleural cavities thus increase rapidly in size. At the same time, the liver grows enormously and on either side a portion of the body wall is taken up into the septum transversum and pleuro-peritoneal membranes. The diaphragm, according to Broman, is thus derived from four sources (Fig. 191): (1) its ventral pericardial portion from the septum transversum; its lateral portions from (2) the pleuro-peritoneal membranes plus (3) derivatives from the body wall; lastly, a median dorsal portion is formed

from (4) the dorsal mesentery. In addition to these, the striated muscle of the diaphragm, according to Bardeen, takes its origin from a pair of pre-muscle masses which in 9 mm. embryos lie one on each side opposite the fifth cervical segment. This is the level at which the phrenic nerve enters the septum trans-

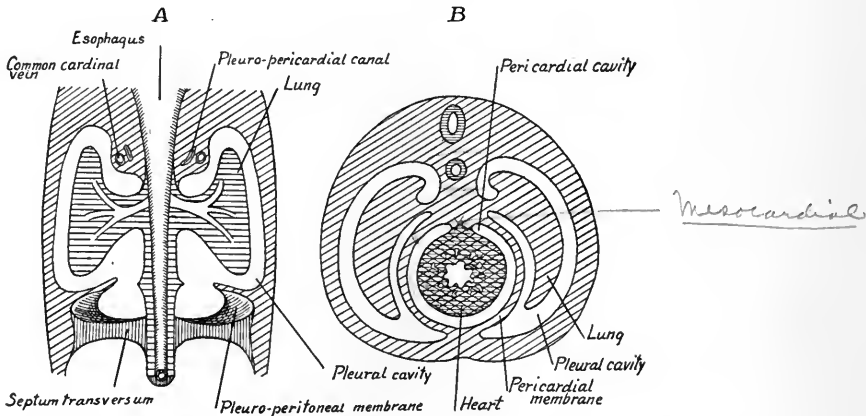


FIG. 190.—Diagrams showing the development of the lungs and the formation of the pericardial membrane (modified after Robinson). *A*, coronal section; *B*, transverse section.

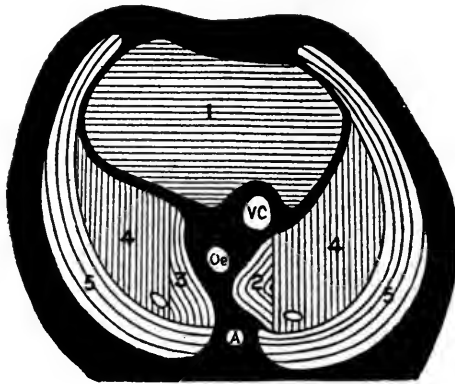


FIG. 191.—Diagram showing the origin of the diaphragm (after Broman). 1, septum transversum; 2, 3, derivatives of mesentery; 4, 4, derivatives of pleuro-peritoneal membrane; 5, 5, parts derived from the body walls.

versum. The exact origin of these muscle masses is in doubt but they probably represent portions of the cervical myotomes of this region. The muscle masses migrate caudally with the septum transversum and develop chiefly in the dorsal portion of the diaphragm, according to Bardeen.

Keith derives the muscle of the diaphragm also from the *rectus* and *transversalis* muscles of the abdominal wall.

The cavities of the mesodermic segments are regarded as portions of the coelom but in

man they disappear early. The development of the vaginal sacs which grow out from the inguinal region of the peritoneal cavity into the scrotum will be described in Chapter VIII.

**The Omental Bursa or Lesser Peritoneal Sac.**—According to Broman, the *lesser peritoneal sac* is represented in 3 mm. embryos by a peritoneal pocket which extends cranially into the dorsal mesentery to the right of the esophagus. A similar pocket present on the left side has disappeared in 4 mm. embryos. Lateral to the opening of the primitive peritoneal sac, a lip-like fold of the mesentery is continued caudally along the dorsal body wall into the mesonephric fold as the

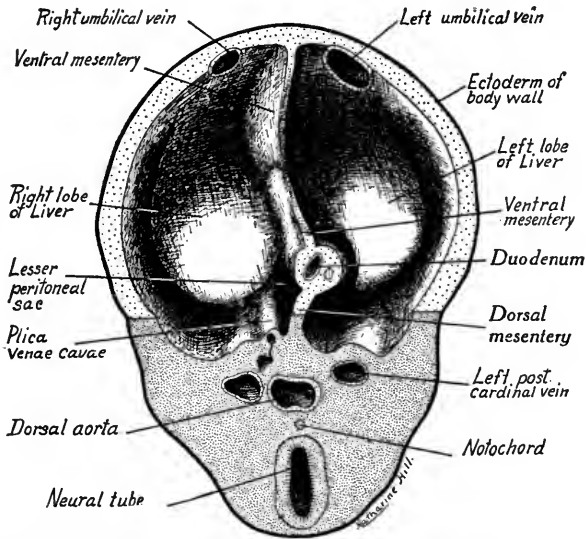


FIG. 192.—Diagrammatic view of an embryo of 7 to 9 mm. showing the position of the lesser peritoneal sac. The cranial portion of the embryo is represented as sectioned transversely, caudal to the liver, so that one looks at the caudal surface of the section and of the liver and cranially into the body cavities.

*plica venæ cavæ*, in which later the *inferior vena cava* develops (Fig. 192). The liver, it will be remembered, grows out into the ventral mesentery from the fore-gut and, expanding laterally and ventrally, takes the form of a crescent. Its right lobe comes into relation with the *plica venæ cavæ* and, growing rapidly caudad, forms with the *plica* a partition between the lesser sac and the peritoneal cavity. Thus the cavity of the lesser peritoneal sac is extended caudally from a point opposite the bifurcation of the lungs to the level of the pyloric end of the stomach. In 5 to 10 mm. embryos it is crescent-shaped in cross-section (Fig. 132) and is bounded mesially by the greater omentum (dorsal mesentery) and the right wall of the stomach, laterally by the liver and *plica venæ cavæ* and ven-

trally by the lesser omentum (ventral mesentery). It communicates to the right with the peritoneal cavity through an opening between the liver ventrally and the plica venæ cavæ dorsally (Fig. 194). This opening is the *epiploic foramen* (of Winslow). When the dorsal wall of the stomach rotates to the left the greater omentum is carried with it to the left of its dorsal attachment. Its tissue

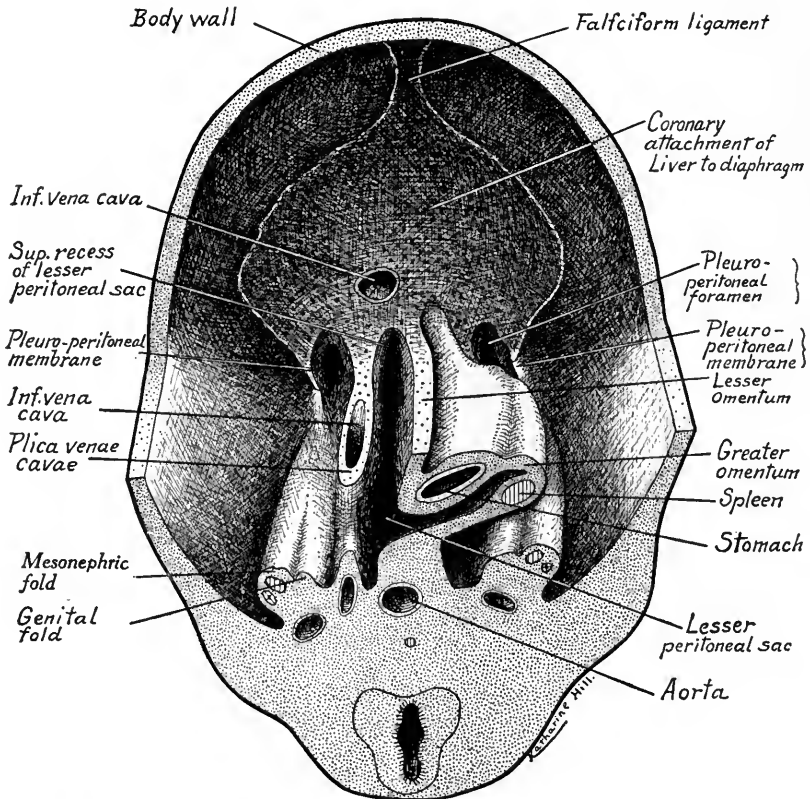


FIG. 193.—A diagrammatic ventral view of the middle third of an embryo 12 to 15 mm. long. The figure shows the caudal surface of a section through the stomach and spleen; a ventral view of the stomach, the liver having been cut away to leave the sectioned edges of the lesser omentum and plica venæ cavæ; and the caudal surface of the septum transversum and pleuro-peritoneal membrane. Upon the surface of the septum is indicated diagrammatically the attachment of the liver (based on figures of Mall and F. T. Lewis and model by H. C. Tracy).

grows actively to the left and caudally and gives the omentum an appearance of being folded on itself between the stomach and the dorsal body wall (Fig. 193). The cavity of the lesser peritoneal sac is carried out between the folds of the greater omentum as the *inferior recess of the omental bursa*.

From the cranial end of the sac there is constricted off a small closed cavity which is frequently persistent in the adult. This is the *bursa infracardiaca* and may be regarded as a



third pleural cavity. It lies to the right of the esophagus in the mediastinum and its average diameter in the adult is 10 mm.

When the stomach changes its position and form so that its mid-ventral line becomes the lesser curvature and lies to the right, the position of the lesser omentum is also shifted. From its primitive location in a median sagittal plane with its free edge directed caudally it is rotated through  $90^\circ$  until it lies in a coronal plane with its free margin facing to the right. The epiploic foramen now

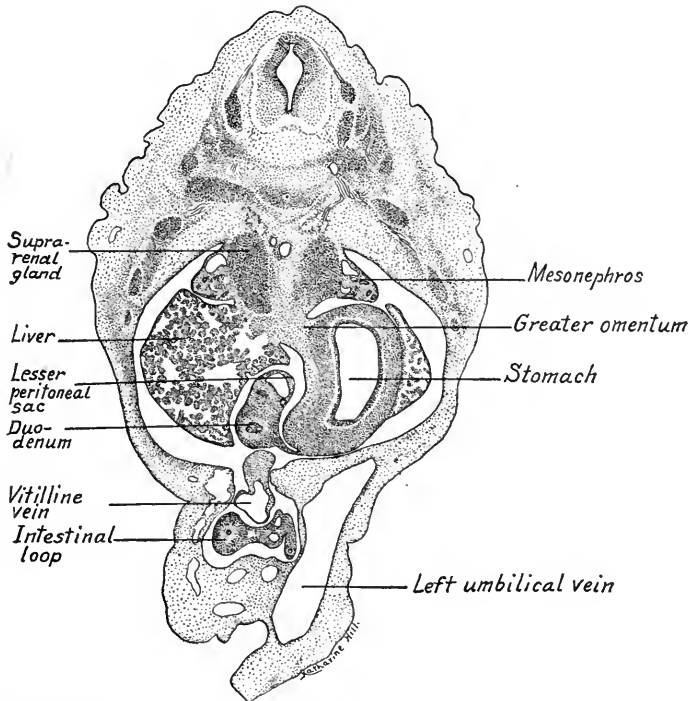


FIG. 194.—An obliquely transverse section through a 10 mm. embryo at the level of the epiploic foramen (of Winslow).  $\times 33$ .

forms a slit-like opening leading from the peritoneal cavity into the vestibule of the omental bursa. The foramen is bounded ventrally by the edge of the lesser omentum, dorsally by the inferior vena cava, cranially by the caudate process of the liver and caudally by the wall of the duodenum.

During fetal life the greater omentum grows rapidly to the left and caudad in the form of a sac flattened dorso-ventrally. It overlies the intestines ventrally and contains the inferior recess of the omental bursa (Fig. 195). The dorsal wall of the sac during the third and fourth months usually fuses with the transverse colon where it overlies the latter. Caudal to this attachment, the walls

of the greater omentum may be fused and its cavity is then obliterated. The inferior recess of the omental bursa thus may be limited in the adult chiefly to a space between the stomach and the dorsal fold of the greater omentum, which latter is largely fused to the peritoneum of the dorsal body wall. The *spleen* develops in the cranial portion of the greater omentum and that portion of the omentum which extends between the stomach and spleen is known as the *gastro-lienic ligament*. The dorsal wall of the omentum between the spleen and kidney is the *lieno-renal ligament*.

**Further Differentiation of the Mesenteries: Ligaments of the Liver.**—We have seen (p. 188) that the cranial portion of the ventral mesentery forms the mesocardium of the heart. In the ventral mesentery caudal to the septum trans-

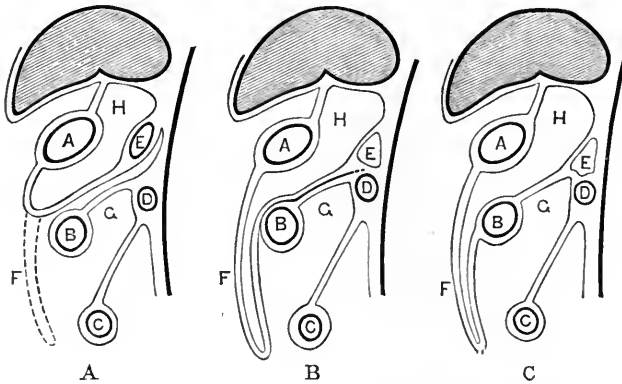


FIG. 195.—Diagrams showing the development of the mesenteries (Hertwig). *A*, illustrates the beginning of the great omentum and its independence of the transverse mesocolon; in *B* the two come into contact; in *C* they have fused; *A*, stomach; *B*, transverse colon; *C*, small intestine; *D*, duodenum; *E*, pancreas; *F*, greater omentum.

versum develops the liver. From the first, it is enveloped in folds of the splanchnic mesoderm which give rise to its *capsule* and *ligaments* as the liver increases in size (Fig. 183 *B*). Wherever the liver is unattached, the mesodermal layers of the ventral mesentery form its capsule (of Glisson), a fibrous layer covered by mesothelium continuous with that of the peritoneum (Fig. 183 *B*). Along its mid-dorsal and mid-ventral line the liver remains attached to the ventral mesentery. The dorsal attachment between the liver, stomach and duodenum is the *lesser omentum*. This in the adult is differentiated into the *duodeno-hepatic* and *gastro-hepatic* ligaments. The attachment of the liver to the ventral body wall extends caudally to the umbilicus and forms the *falciform ligament*.

In its early development the liver abuts upon the septum transversum, and in 4 to 5 mm. embryos is attached to it along its cephalic and ventral surfaces.

Soon dorsal prolongations of the lateral liver lobes, the *coronary appendages* come into relation with the septum dorsally and laterally. The attachment of the liver to the septum transversum now has the form of a crescent, the dorsal horns of which are the coronary appendages (Fig. 193). This attachment becomes the *coronary ligament* of the adult liver. The dorso-ventral extent of the coronary ligament is reduced during development and its lateral extensions upon the diaphragm give rise to the *triangular ligaments* of each side.

The right lobe of the liver, as we have seen, comes into relation along its dorsal surface with the *plica venæ cavæ* in 9 mm. embryos (Figs. 192 and 193). This attachment extends the coronary ligament caudally on the right side and makes possible the connection between the veins of the liver and mesonephros through which the inferior vena cava is in part developed. The portion of the liver included between the *plica venæ cavæ* and the lesser omentum is the caudate lobe (of Spigelius).

In a fetus of five months the triangular ligaments mark the position of the lateral coronary appendages. The umbilical vein courses in a deep groove along the ventral surface of the liver and with the vena porta and gall-bladder bounds the *quadrate lobe*.

*Changes in the Dorsal Mesentery.*—That part of the digestive canal which lies within the peritoneal cavity is suspended by the *dorsal mesentery* which at first forms a simple attachment extending in the median sagittal plane between body wall and primitive gut. That portion of it connected with the stomach forms the *greater omentum*, the differentiation of which has been described (p. 199). The mesentery of the intestine is carried out into the umbilical cord between the limbs of the intestinal loop. When the intestine elongates and its loop rotates, the cæcal end of the large intestine comes to lie cranially and to the left, the small intestine caudally and to the right, the future duodenum and colon crossing in close proximity to each other (Fig. 196 A). On the return of the intestinal loop into the abdomen from the umbilical cord the cæcal end of the colon lies to the right and the transverse colon crosses the duodenum ventrally and cranially. The primary loops of the small intestine lie caudal and to the left of the ascending colon (Fig. 196 B). There has thus been a torsion of the mesentery about the base of the superior mesenteric artery as an axis. From this focal point the mesentery of the small intestine and colon spreads out fan-like. The *mesoduodenum* is pressed against the dorsal body wall, fuses with its peritoneal layer and is obliterated (Fig. 195). Where the mesentery of the transverse colon crosses the duodenum it fuses at its base with the surface of the latter and of the pancreas. Its

fixed position now being transverse instead of sagittal, the mesentery is known as the *transverse mesocolon*. The mesentery of the ascending colon is flattened against the dorsal body wall on the right and fuses with the peritoneum. Similarly, the descending mesocolon fuses to the body wall of the left side (Fig. 196 A, B). There are thus left free (1) the transverse mesocolon; (2) the mesentery proper of the jejunum and ileum with numerous folds corresponding to the loops of the intestine; (3) the iliac mesocolon; (4) the mesorectum, which retains its primitive relations.

*Anomalies* of the diaphragm and mesenteries are not uncommon. The per-

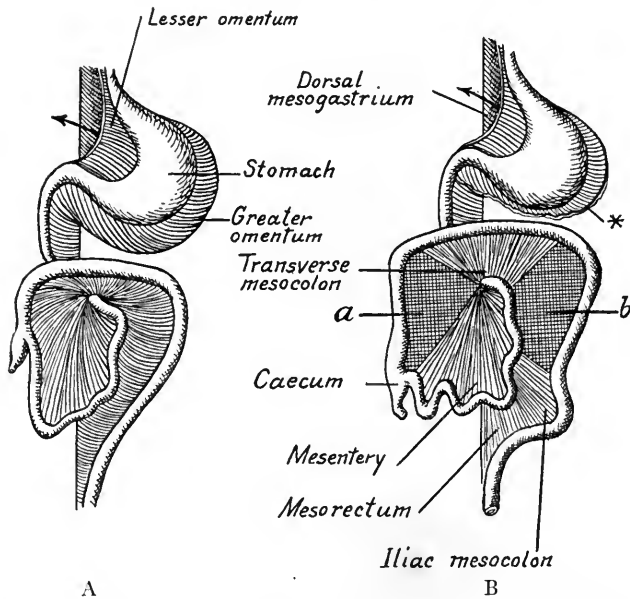


FIG. 196.—Diagrams showing the development of the mesenteries in ventral view (modified from Tourneux in Heisler). \* Cut edge of greater omentum; *a*, area of ascending mesocolon fused to dorsal body wall; *b*, area of descending mesocolon fused to dorsal body wall.

sistence of a dorsal opening in the diaphragm, more commonly on the left side, may be explained as due to the defective development of the pleuro-peritoneal membrane. Such a defect may lead to *diaphragmatic hernia*, the abdominal viscera projecting to a greater or less extent into the pleural cavity.

The mesenteries also may show malformations due to the persistence of the simpler embryonic conditions, usually correlated with the defective development of the intestinal canal. The ascending and descending mesocolon may be free, having failed to fuse with the dorsal peritoneum. The primary folds of the greater omentum may fail also to unite so that the inferior recess extends to the caudal end of the greater omentum.

## CHAPTER VIII

### UROGENITAL SYSTEM

The urogenital system is composed of distinct urinary and genital glands which, however, possess common ducts and have a common origin from the mesoderm. The excretory glands are the *pronephros*, *mesonephros*, and *metanephros*, organs which develop in this order. The first two named are the temporary kidneys of the mammalian embryo, but are functional in adult fishes and amphibia. The metanephros is the permanent kidney of reptiles, birds and mammals.

#### THE PRONEPHROS

The *pronephros*, when functional, consists of paired segmentally arranged tubules, one end of each tubule opening into the cœlom, the other into a longitu-

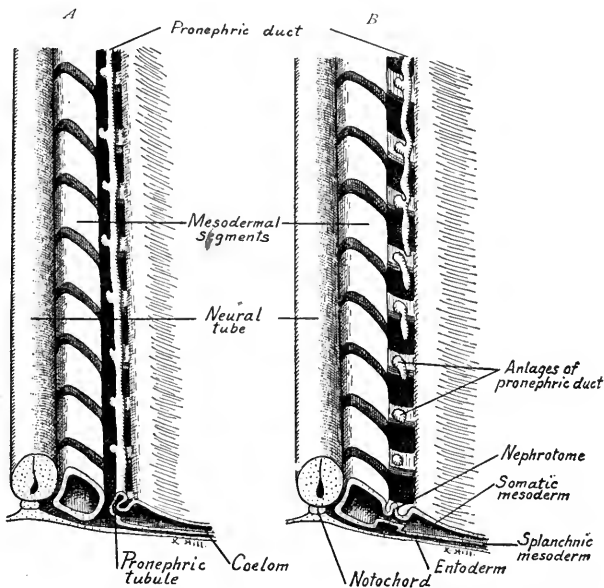


FIG. 197.—Diagrams showing the development of the pronephric duct and pronephric tubules (modified from Felix). *A* shows a later stage than *B*.

dinal pronephric duct which drains into the cloaca (Fig. 197 *A*). Near the *nephrostome*, the opening into the cœlom, knots of arteries project into the tubules,

forming *glomeruli*. Fluid from the *cœlom* and *glomeruli* and excreta from the cells of the tubules are carried by ciliary movement into the pronephric ducts.

The human *pronephros* is vestigial. It consists of seven pairs of rudimentary pronephric tubules derived from the mesoderm of the *nephrotomes* (Fig. 198), which are segmented portions of the cell mass intermediate between the primitive segments and the mesodermal layers (somatic and splanchnic). Anlages of pronephric tubules are formed as dorsal nodules in each segment from the seventh to the fourteenth. The nodules hollow out and open into the *cœlom*. Dorsally and laterally, the tubules of each side unite to form a longitudinal *collecting duct*.

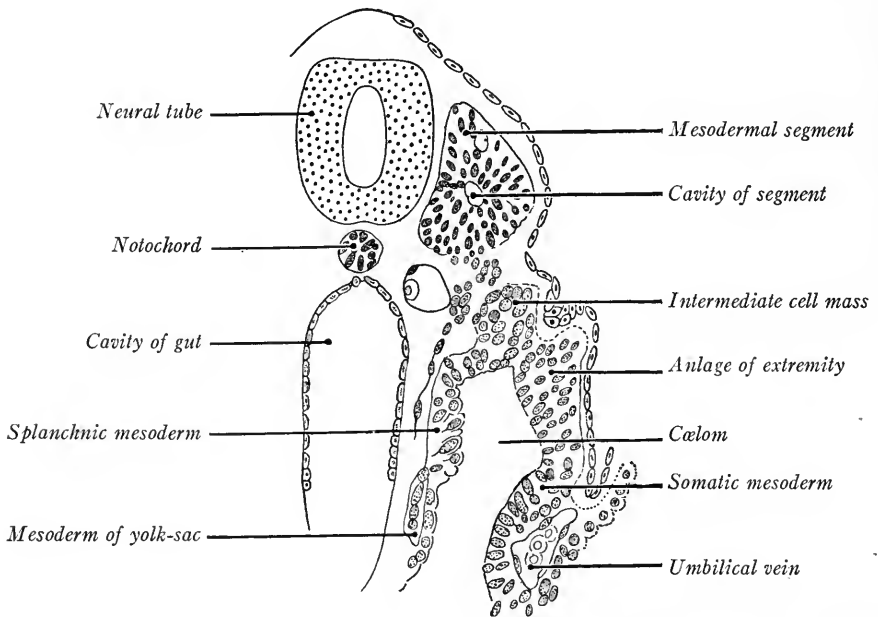


FIG. 198.—Transverse section of a 2.4 mm. human embryo showing the intermediate cell mass or nephrotome (Kollmann's Atlas).

The tubules first formed in the seventh segment begin to degenerate before those of the fourteenth segment have developed. Caudal to the fourteenth segment no pronephric tubules are developed, but the free end of the collecting duct apparently grows caudad, beneath the ectoderm and lateral to the nephrogenic cord, until it reaches, and opens through, the lateral wall of the cloaca. Thus are formed the paired *primary excretory (pronephric) ducts*. The pronephric tubules begin to appear in embryos of 1.7 mm. (Felix in Keibel and Mall, vol. 2); in 2.5 mm. embryos all the tubules have developed and the primary excretory duct is nearly complete. In 4.25 mm. embryos the duct has reached the wall of the

cloaca and soon after fuses with it. The pronephric tubules soon degenerate, but the primary excretory ducts persist and become the *ducts of the mesonephroi*, or mid-kidneys.

### THE MESONEPHROS

The mesonephros, like the pronephros, consists essentially of a series of tubules, each of which at one end is related to a knot of blood-vessels and forms a capsule surrounding a *glomerulus*, at the other end opens into the primary excretory duct. They differ from the pronephric tubules in that they do not open into the coelom, and as many as four may develop in a single segment. They arise from the mesoderm intermediate between the primitive segments and the lateral mesodermal layers, mesoderm which, in human embryos, is not segmented into nephrotomes caudal to the tenth pair of segments, but constitutes the unsegmented *nephrogenic cord* on either side. This may extend caudally as far as the twenty-eighth segment. The primary excretory ducts lie lateral to the nephrogenic cords. When the mesonephric tubules begin to develop and expand there is not room for them in the dorsal body wall and as a result this bulges ventrally into the coelom. Thus there is produced on either side of the dorsal mesentery a longitudinal *urogenital fold*, which may extend from the sixth cervical to the third lumbar segment (Fig. 213). Later, this ridge is divided into a lateral *mesonephric fold* and into a median *genital fold*, the anlage of the *genital gland*.

**Differentiation of the Tubules.**—The nephrogenic cord in 2.5 mm. embryos first divides into spherical masses of cells, the anlagen of the mesonephric tubules. Four of these may be formed in a single segment. Appearing first in the 13th, 14th and 15th segments, the anlagen of the tubules differentiate both cranially and caudally. In 5.3 mm. embryos the cephalic limit is reached in the sixth cervical segment, and thereafter degeneration begins at the cephalic end. In 7 mm. embryos the caudal limit is reached in the third lumbar segment and in later stages the caudal end of the mesonephros undergoes degeneration.

The spherical anlagen of the tubules differentiate in a cranio-caudal direction (Fig. 199). First, vesicles with lumina are formed (2.5 mm.). Next the vesicles elongate laterally, unite with the primary excretory ducts and become S-shaped (4.9 mm.). The free vesicular end of the tubule enlarges, becomes thin-walled and into this wall grows a knot of arteries to form the *glomerulus* (embryos of 5 to 7 mm.). The tubule, at first solid, hollows out and is lined with a low columnar epithelium. The outer wall of the vesicle about the *glomerulus* is *Bowman's*

capsule, the two constituting a *renal corpuscle* of the mesonephros (Fig. 199 D). In the human embryo, the tubules do not branch or coil as in pig embryos, consequently the mesonephros is relatively smaller. At 10 mm. 32 to 34 tubules are present in each mesonephros and the glomeruli are conspicuous (Fig. 200). Each tubule shows a distal excretory and a proximal collecting portion which connects with the duct (Fig. 201).

The glomeruli form a single median column, the tubules are dorsal and the

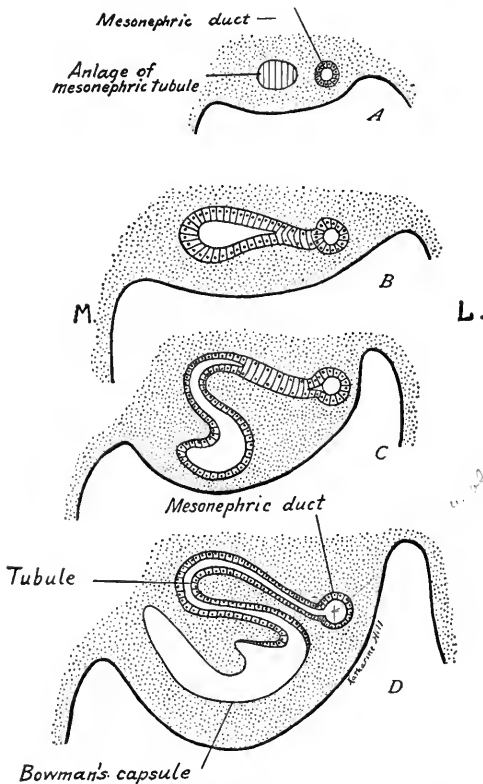


FIG. 199.—Diagrams showing the differentiation of the mesonephric tubules (modified after Felix). L, lateral; M, median.

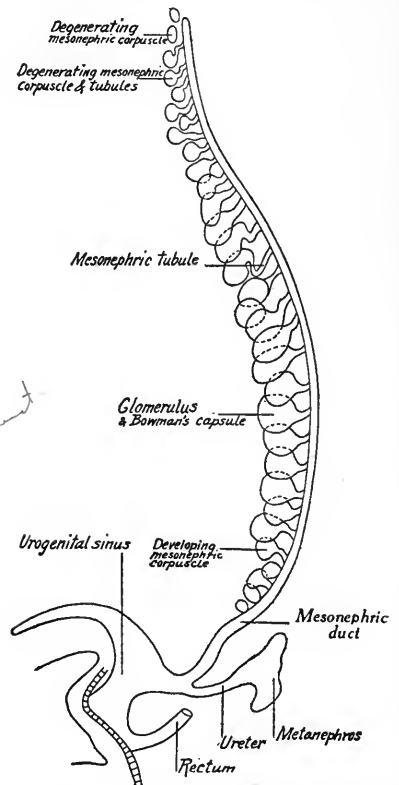


FIG. 200.—Diagram showing the anlagen of the urinary organs from the left side (based on reconstructions by Keibel and Felix).

duct is lateral in position. Ventro-lateral branches from the aorta supply the glomeruli, while the posterior cardinal veins, dorsal in position, break up into a network of sinusoids about the tubules (see Chapter IX).

The primary excretory duct or mesonephric duct is solid in 4.25 mm. embryos. A lumen is formed at 7 mm. wider opposite the openings of the tubules. The duct is important as from it grows out the ureteric anlage of the permanent kidney, while the duct itself is transformed into the genital duct of the male, and



its derivatives. The mesonephros is probably not a functional excretory organ in human embryos for its tubules degenerate before the metanephros becomes functional. It may have some other function and produce an internal secretion. Degeneration proceeds rapidly in embryos between 10 and 20 mm. long, beginning cranially. New tubules are formed at the same time caudally. In all, 83 pairs of tubules arise, of which only 26 pairs persist at 21 mm., and these are interrupted at the connecting points between the collecting and secretory regions. They are divided into an upper group and a lower group. The upper group, numbering 5 to 12, unites with the rete tubules of the testis or ovary. In the male they form the *efferent ductuli* of the epididymis. In the female they con-

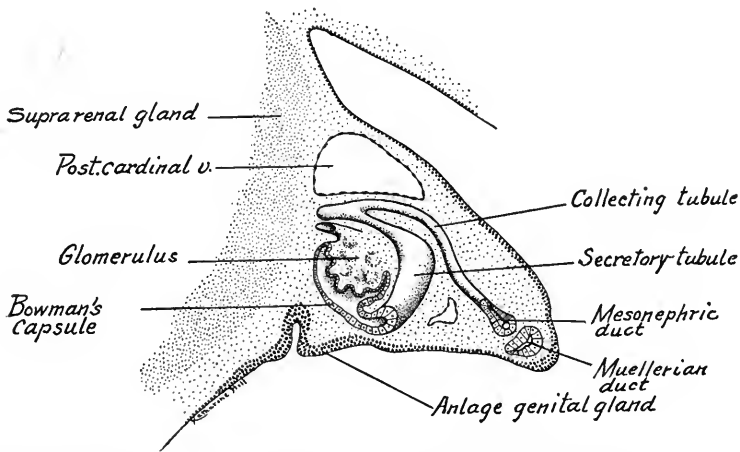


FIG. 201.—Reconstruction of a mesonephric tubule, glomerulus and mesonephric duct from a 12 mm. human embryo as seen in transverse section.  $\times 95$ . *Post. card. v.*, posterior cardinal vein.

stitute part of the *epoöphoron*. Of the lower group a few tubules persist in the male, as the *paradidymis* with its *canaliculus aberrans*. In the female they form the *paroöphoron*.

#### THE METANEPHROS

The essential parts of the permanent kidney are the *renal corpuscles* (glomerulus with Bowman's capsule), *secretory tubules* and *collecting tubules*. The collecting tubules open into expansions of the duct, the *pelvis* and *calyces*. The duct itself is the *ureter*, which opens into the *bladder*. Like the mesonephros, the metanephros is of double origin. The ureter, pelvis, calyces and collecting tubules are *outgrowths of the mesonephric duct*. The secretory tubules and the capsules of the renal corpuscles are differentiated from the caudal end of the *nephrogenic cord* and thus have the same origin as the mesonephric tubules.

In embryos of 4.5 to 5.5 mm. the mesonephric duct makes a sharp bend just before it joins the cloaca and it is at the angle of this bend that the ureteric anlage of the metanephros appears, dorsal and somewhat median in position (Fig. 209 B, C). The bud grows at first dorsally, then cranially. Its distal end expands and forms the *primitive pelvis*. Its proximal elongated portion is the ureter. The anlage grows into the lower end of the *nephrogenic cord* which, in 4.6 mm. embryos, is separated from the cranial end of the cord at the twenty-seventh segment. The nephrogenic tissue forms a cap about the primitive pelvis and, as the pelvis grows cranially, is carried along with it (Fig. 202). In embryos of 9 to 13 mm. the pelvis has reached a position in the retroperitoneal tissue dorsal to the

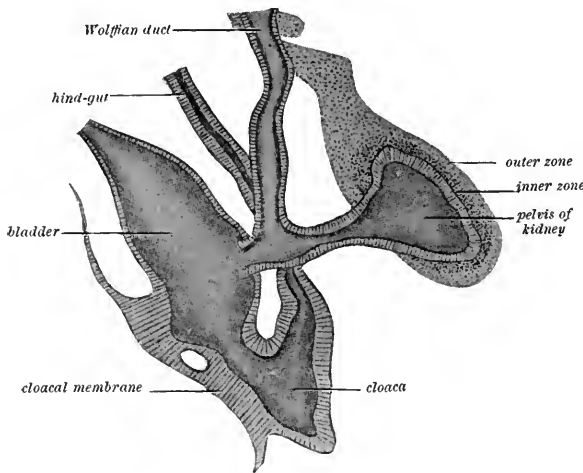


FIG. 202.—Reconstruction of the anlagen of the metanephros (after Schreiner). The layers lettered *inner* and *outer zones* constitute the nephrogenic tissue of the metanephros.

mesonephros and opposite the second lumbar segment. Thereafter, the kidney grows both cranially and caudally without shifting its position. The ureter lengthens as the embryo grows in length. The cranial growth of the kidney takes place dorsal to the suprarenal gland (Fig. 225).

*Primary renal tubules* grow out from the primitive pelvis in 10 mm. embryos. Of the first two, one is cranial, the other caudal in position, and between these are two to four others (Fig. 203 B, C).

From an enlargement, the ampulla, at the end of each primary tubule grow out two, three or four secondary tubules. These in turn give rise to tertiary tubules (Fig. 203 D) and the process is repeated until the fifth month of fetal life, when it is estimated that twelve generations of tubules have been developed. The pelvis and both primary and secondary tubules enlarge during development. The first two primary tubules become the major calyces, and the secondary tubules opening into them form the minor calyces (Fig. 204). The tubules of the third and fourth orders are taken up into the walls of the enlarged secondary tubules so that the tubules of the fifth order, 20 to 30 in number, open into the calyces minor as *papillary ducts*. The remaining orders of tubules

constitute the *collecting tubules* which form the greater part of the medulla of the adult kidney.

When the four to six primary tubules develop, the nephrogenic cap about the primitive pelvis is subdivided and its four to six parts cover the end of each pri-

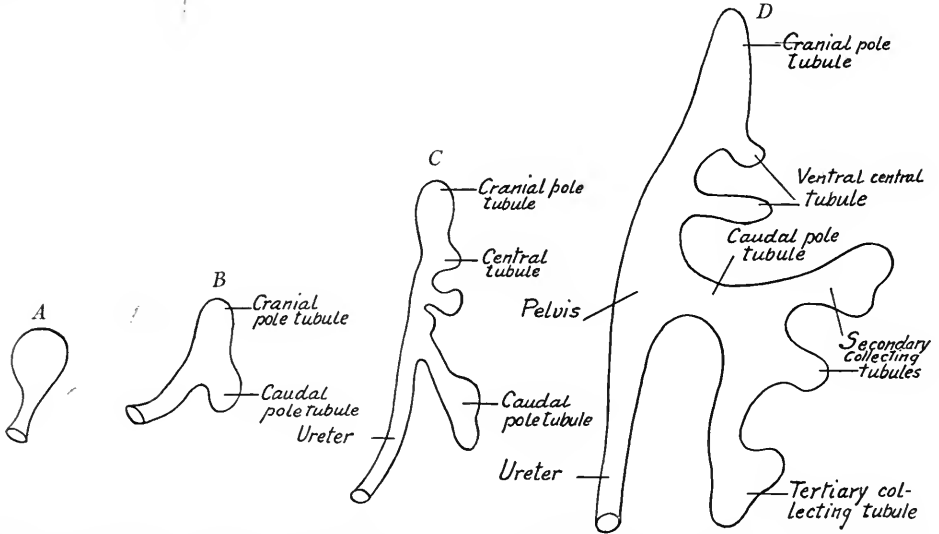


FIG. 203.—Diagrams showing the development of the primitive pelvis, calyces and collecting tubules of the metanephros (based on reconstructions by Schreiner and Felix).

mary tubule. As new orders of tubules arise, each mass of nephrogenic tissue increases in amount and is again subdivided until finally it forms a peripheral layer about the ends of the branches tributary to a primary tubule. The converging branches of such a tubular "tree" constitute a primary renal unit, or *pyramid*, with its base at the periphery of the kidney and its apex projecting into the pelvis. The apices of the pyramids are termed *renal papillæ* and through them the larger collecting ducts open. The nephrogenic tissue forms the *cortex* of the kidney, and each sub-division of it, covering the tubules of a pyramid peripherally, is marked off on the surface of the organ by grooves or depressions. The fetal kidney is thus distinctly lobated, the lobations persisting until after birth. The primary pyramids are subdivided into several secondary and tertiary pyramids. Between the pyramids the cortex of nephrogenic tissue dips down to the pelvis, forming the *renal columns* (of Bertini). The collect-

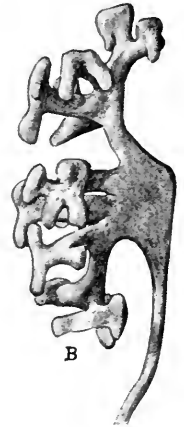


FIG. 204.—The pelvis, calyces, and their branches and a portion of the ureter, from the metanephros of a 16 mm. embryo (Huber).

ing tubules, on the other hand, extend out into the cortex as the cortical rays or *pars radiata* of the cortex. In these rays and in the medulla of the kidney the collecting tubules run parallel and converge to the papillæ.

#### DIFFERENTIATION OF THE NEPHROGENIC TISSUE

In stages from 13 to 19 mm. the nephrogenic tissue about the ends of the collecting tubules condenses into spherical masses which lie in the angles between the buds of new collecting tubules and their parent stems (Fig. 205). One such

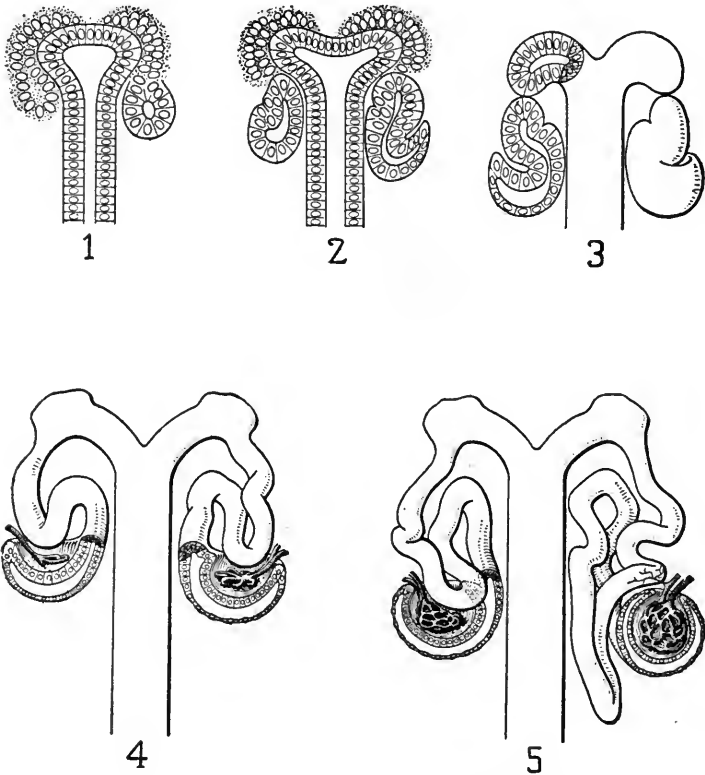


FIG. 205.—Semidiagrammatic figures of the anlage and differentiation of renal vesicles and early developmental stages of uriniferous tubules of mammals. 1 and 2, anlage and successive stages in the differentiation of renal vesicles, as seen in sagittal sections; 3, section and outer form of tubular anlage before union with collecting tubule at the beginning of S-shaped stage; 4 and 5, successive stages in the development of the tubules, Bowman's capsule and glomerulus beginning with a tubular anlage showing a well developed S-shape (Huber).

metanephric sphere is formed for each new tubule. The spheres are converted into vesicles with eccentrically placed lumina. The vesicle elongates, its thicker outer wall forming an S-shaped tubule which unites with a collecting tubule,

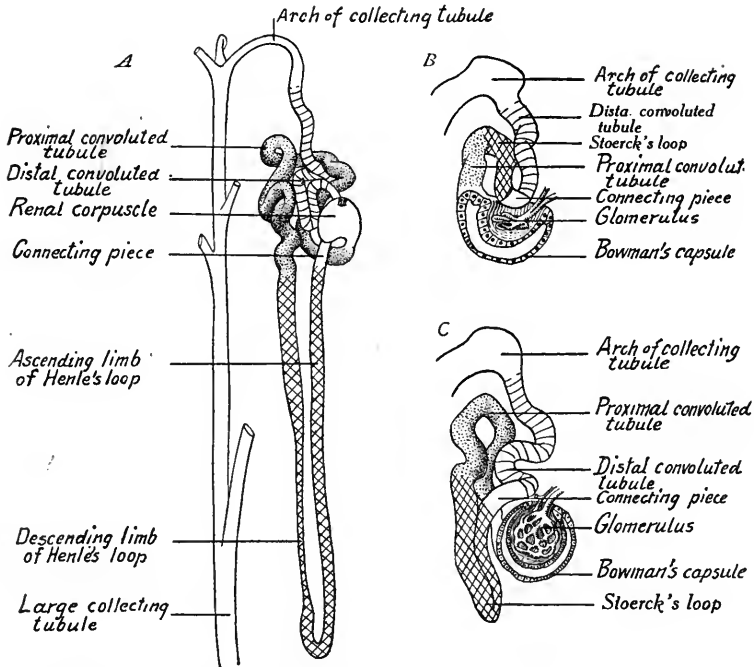


FIG. 206.—Diagrams showing the differentiation of the various parts of the uriniferous tubules of the metanephros (based on the reconstructions of Huber and Stoerck). *A*, from an adult human kidney; *B*, *C*, from human embryos.

its thin inner wall becoming the capsule (Bowman's) of a renal corpuscle. The uriniferous tubules of the adult kidney have a definite and peculiar structure and arrangement (Fig. 207 *A*). Beginning with a renal corpuscle, each tubule forms a *proximal convoluted portion*, a *U-shaped loop* (of Henle) with *descending* and *ascending limbs*, a *connecting piece*, which lies close to the renal corpuscle, and a *distal convoluted portion* continuous with the collecting tubule. These parts are derived from the S-shaped anlage, which is composed of a lower, middle and

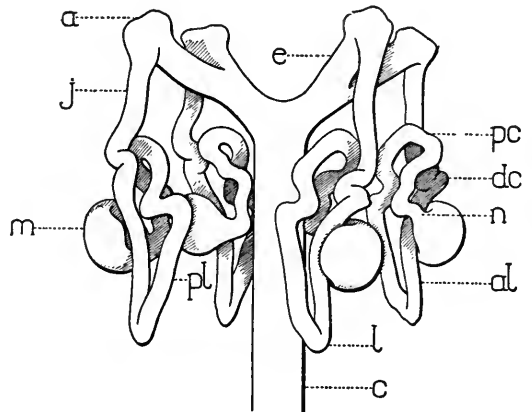


FIG. 207.—Diagram showing the relation of Bowman's capsule and the uriniferous tubules to the collecting tubules of the metanephros (Huber). *c*, collecting tubules; *e*, end branches of collecting tubules; *m*, renal corpuscles; *n*, neck; *pc*, proximal convoluted tubule; *pl*, descending limb of Henle's loop; *al*, ascending limb of Henle's loop; *dc*, distal convoluted tubule; *j*, junctional tubule.

upper limb. The middle limb, somewhat U-shaped, bulges into the concavity of Bowman's capsule (Fig. 206 B). By differentiation the lower portion of the lower limb becomes Bowman's capsule, ingrowing arteries forming the glomerulus. The upper part of the same limb by enlargement, elongation and coiling becomes

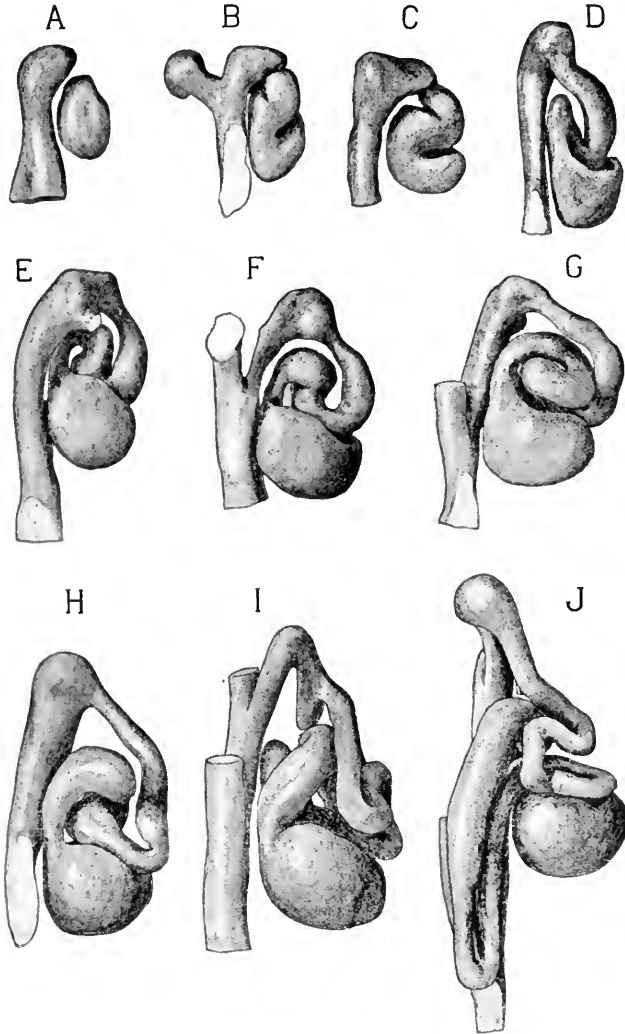


FIG. 208.—Several stages in the development of the uriniferous tubules and glomeruli of the human metanephros (reconstructions by Huber).

the proximal convoluted tubule. The neighboring portion of the middle limb forms the primitive loop (of Stoerck); the base of the middle limb gives rise to the connecting piece, and the rest of it, with the upper limb of the S, forms the distal convoluted tubule (intermediate piece of Felix). The primitive loop of Stoerck

includes both the ascending and descending limbs of Henle's loop and a portion of the proximal convoluted tubule. Henle's loop is differentiated during the fourth fetal month (Toldt) and extends from the pars radiata of the cortex into the medulla (Fig. 207). The concavity of Bowman's capsule, into which grow the arterial loops of the glomerulus, is at first shallow. Eventually the walls of the capsule grow about and enclose the vascular knot, except at the point where the arteries enter and emerge (Fig. 205, 4 and 5). Renal corpuscles are first fully formed in 28 to 30 mm. embryos. The new corpuscles are formed peripherally from persisting nephrogenic tissue, hence in the adult the oldest corpuscles are those next the medulla. Reconstructions of the various stages in the development of the uriniferous tubules are shown in Fig. 208.

**Renal Arteries.**—One or more of the mesonephric arteries is transformed into the renal artery of the metanephros. As any one of the mesonephric arteries may thus form the renal artery, and as they anastomose, the variation of the renal vessels both as to position and number is accounted for.

**Anomalies.**—If the uriniferous tubules fail to unite with the collecting tubules, cystic degeneration may take place. The cystic kidneys of pathology may thus be produced. The nephrogenic tissue of the paired kidney anlagen may fuse, resulting in the union of their cortex. Double or triple ureters are sometimes present.

#### ✓ DIFFERENTIATION OF CLOACA, BLADDER, URETHRA AND UROGENITAL SINUS

In embryos of 3 to 4 mm. the cloaca, a caudal expansion of the hind-gut, is in contact ventrally with the ectoderm, and ectoderm and entoderm together form the *cloacal membrane* (Fig. 209 A). Ventro-cranially the cloaca gives off the allantoic stalk. At a somewhat later stage, the cloaca receives laterally the mesonephric ducts and caudally is prolonged as the tail-gut (Fig. 209 B).

In embryos of 5 mm. the ureteric anlagen of the metanephroi are present as buds of the mesonephric ducts (Fig. 209 C, D). Next, the saddle-like partition wall between the intestine and allantois grows caudally, dividing the cloaca into a dorsal rectum and ventral primitive urogenital sinus. The division is complete in embryos of 11 to 15 mm. and at the same time the partition, fusing with the cloacal membrane, divides it into the *anal membrane* of the gut and the *urogenital membrane*.—At 11 mm., according to Felix, the primitive urogenital sinus by elongation and constriction is differentiated into two regions: (1) a dorsal vesico-urethral anlage which receives the allantois and mesonephric duct, and is connected by the constricted portion with (2) the phallic portion of the urogenital sinus (Figs. 210 and 211). The latter extends into the phallus of both sexes and forms a greater part of the urethra (Fig. 212). The vesico-

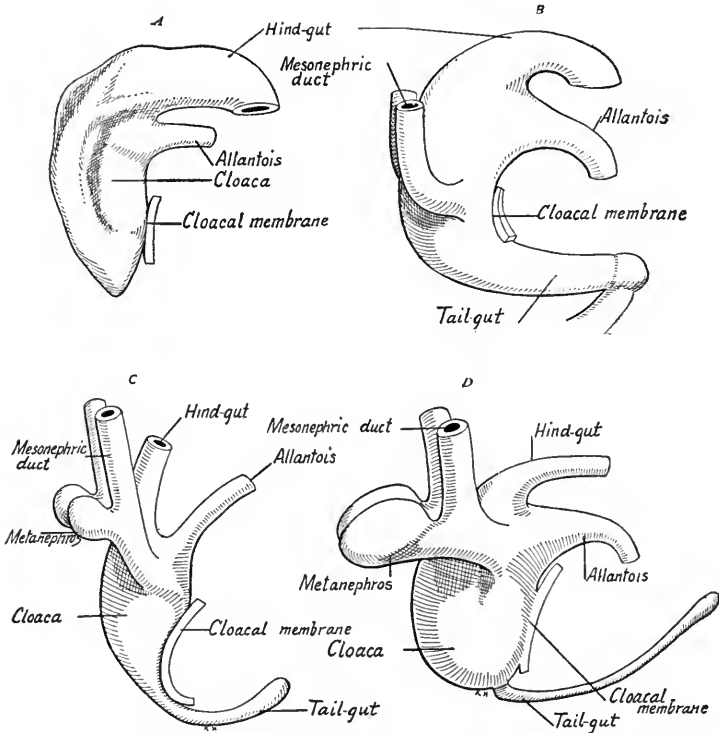


FIG. 209.—Four stages showing the differentiation of the cloaca into the rectum, urethra and bladder. *A*, from an embryo of 3.5 mm.; *B*, a somewhat later stage; *C*, from a 5 mm. embryo; *D*, from an embryo of 7 mm. (after reconstructions by Pohlman). About 100 diameters.

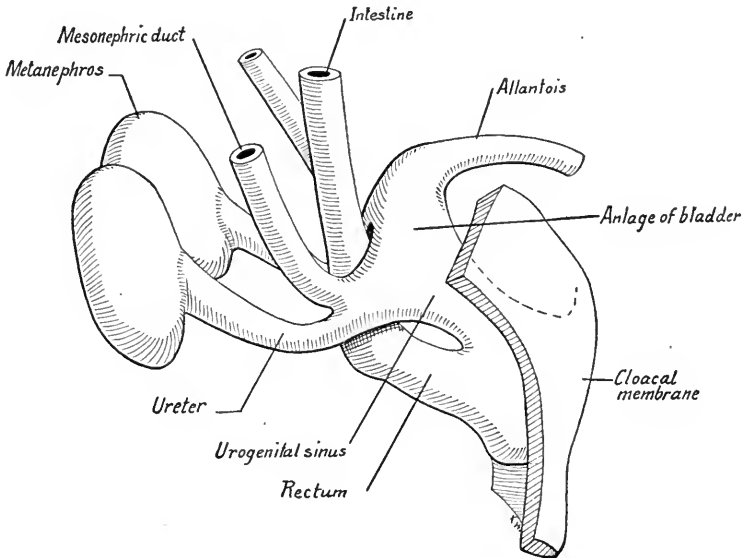


FIG. 210.—Reconstructions from a 12 mm. embryo showing the partial subdivision of the cloaca into rectum and urogenital sinus (after Pohlman).



urethral anlage enlarges and forms the *bladder* and a portion of the urethra. In 7 mm. embryos the proximal ends of the mesonephric ducts are funnel-shaped, and at 10 mm., with the enlargement of the bladder, these ends are taken up into

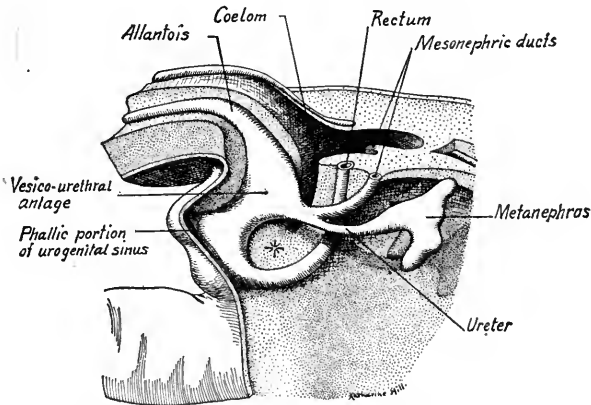


FIG. 211.—Reconstruction of the caudal portion of an 11.5 mm. embryo showing the differentiation of the rectum, bladder and urethra (Keibel).

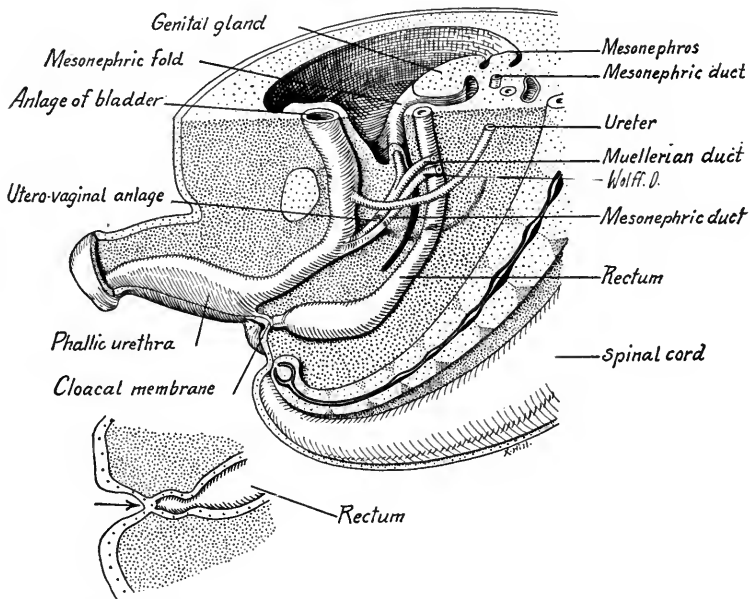


FIG. 212.—Reconstruction of the caudal end of a 25 mm. embryo showing the complete separation of the rectum and urogenital sinus and the relations of the urogenital ducts (after Keibel's model).

its wall until the ureters and mesonephric ducts acquire separate openings. The ureters, having previously shifted their openings into the mesonephric ducts from a dorsal to lateral position, now open into the vesico-urethral anlage lateral to the mesonephric ducts. The lateral walls of the bladder anlage grow more rap-

idly than its dorso-median urethral wall, hence the ureters are carried cranially and laterally upon the wall of the bladder, while the mesonephric ducts, now the male ducts, open close together into the dorsal wall of the urethra (Fig. 212). The fate of the phallic portion of the urogenital sinus is described on p. 234 in connection with the external genitalia.

The allantois between the bladder and the umbilicus is known as the *urachus*. Usually the epithelium of the urachus degenerates, but portions may persist and produce cysts. In some cases it forms after birth a patent tube opening at the umbilicus. Its connective tissue layers always persist as the fibrous lig. vesico-umbilicale medium.

The transitional epithelium of the bladder appears at 60 mm. The outer longitudinal layer of small muscle develops in 22 mm. embryos, and in 26 mm. embryos the circular muscle appears. The inner longitudinal muscle layer is found at 55 mm. and the sphincter vesicæ in embryos of 90 mm.

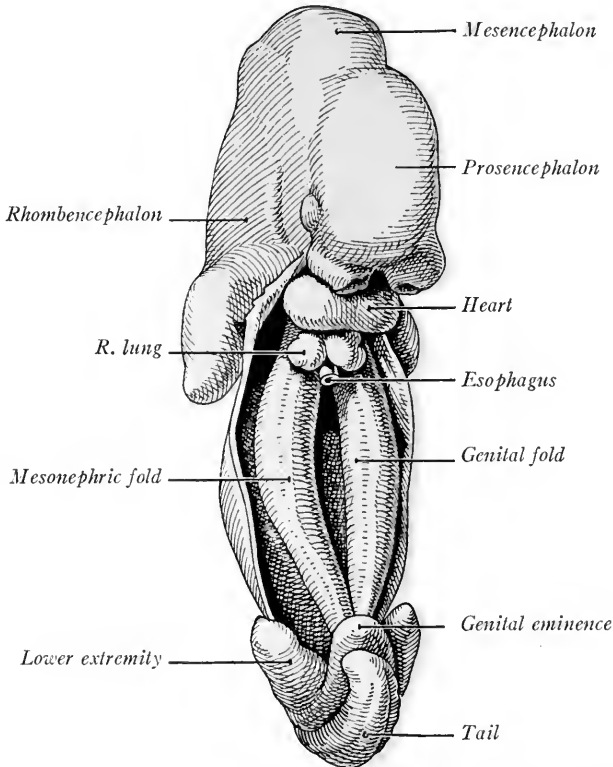


FIG. 213.—Ventral view of the urogenital folds in a human embryo of five weeks (Kollmann's Atlas).

#### THE GENITAL GLANDS AND DUCTS—INDIFFERENT STAGE

As to origin and early development, the ovary and testis are alike. The *urogenital fold* (see p. 205) is the anlage of both the mesonephros and the genital gland (Fig. 213). At first two-layered, its epithelium in embryos of 5 mm. thick-

ens over the ventro-median surface of the fold, becomes many-layered and bulges into the coelom ventrally, producing the longitudinal *genital fold*. The genital fold thus lies mesial and parallel to the mesonephric fold. At 10 to 12 mm. the genital epithelium shows no sexual differentiation (Fig. 214). There is a superficial *epithelial layer* and an *inner epithelial mass* of somewhat open structure.

Owing to the great development of the suprarenal glands and metanephroi, the cranial portions of the urogenital folds, at first parallel and close together, are separated. This produces a double bend in the fold and in 20 to 25 mm. embryos the fold shows a cranial *longitudinal portion*, a *transverse middle portion* between the bends, and a *longitudinal caudal portion*. In the last named, the mesonephric

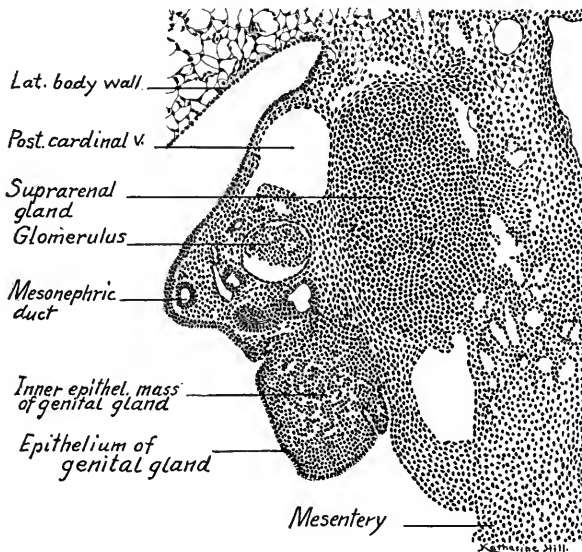


FIG. 214.—Transverse section through the mesonephros, genital gland and suprarenal gland of the right side; from a 12 mm. human embryo.  $\times 165$ .

ducts course to the cloaca and here the right and left folds fuse, producing the *genital cord* (Fig. 225). As the genital glands increase in size they become constricted from the mesonephric fold by lateral and ventral grooves until the originally broad base of the genital fold is converted into a stalk (Fig. 220). This stalk-like attachment extends lengthwise and forms in the male the *mesorchium*, in the female the *mesovarium*. The urogenital fold is, at the same time, constricted from the dorsal body wall until it is attached only by a narrow mesentery which eventually forms either the *lig. testis* or *lig. ovarii*.

**The Indifferent Stage of the Genital Ducts.**—The mesonephric ducts, with the degeneration of the mesonephroi, become the male genital ducts. In both

sexes there also develop a pair of female ducts (of Mueller). In embryos of 10 to 11 mm. the Muellerian ducts develop as ventro-lateral thickenings of the urogenital epithelium at the level of the third thoracic segment and near the cranial ends of the mesonephroi. Next, a ventro-lateral groove appears in the epithelium of the mesonephric fold (Fig. 215 A). Caudally, the dorsal and ventral lips of the groove close and form a tube which separates from and lies beneath the epithelium (Fig. 215 B). Cranially, the tube remains open as the funnel-shaped *ostium abdominale* of the Muellerian duct. The solid end of the tube grows caudalward beneath the epithelium, lateral to the mesonephric or male ducts

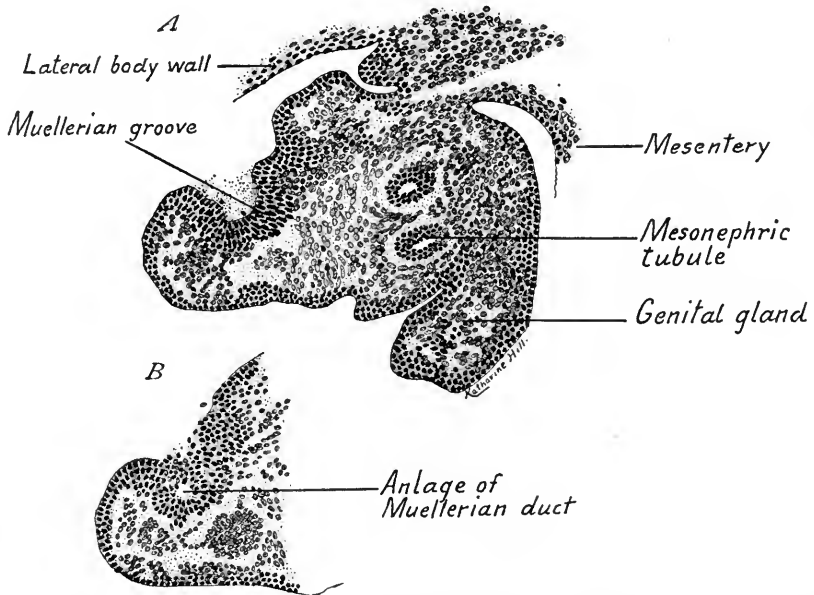


FIG. 215.—Transverse sections through the anlage of the right Muellerian duct from a 10 mm. embryo. A, showing the groove in the urogenital epithelium; B, three sections caudad showing the tubular anlage of the duct.  $\times 250$ .

(Figs. 216 and 218). Eventually, by way of the genital cord, the Muellerian ducts reach the median dorsal wall of the *urogenital sinus* and open into it. Their further development into uterine tubes, uterus and vagina is described on page 226. Embryos not longer than 12 mm. are thus characterized by the possession of indifferent genital glands, and of both male and female genital ducts. There is as yet no sexual differentiation. The development and position of the Muellerian ducts is well shown in ventral dissections of pig embryos (Figs. 216 and 217). Note the enormous size of the mesonephroi.

**Differentiation of the Testis.**—In male embryos of 13 to 15 mm. the genital

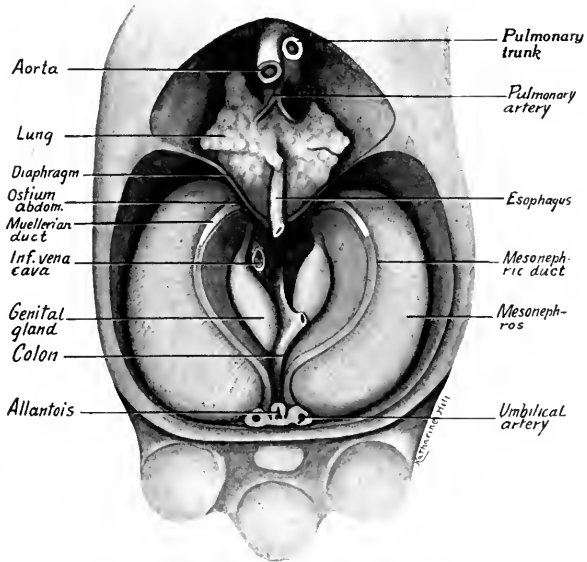


FIG. 216.—Ventral dissection of an 18 mm. pig embryo to show the anlagen of the Muellerian ducts.  $\times 7$ .

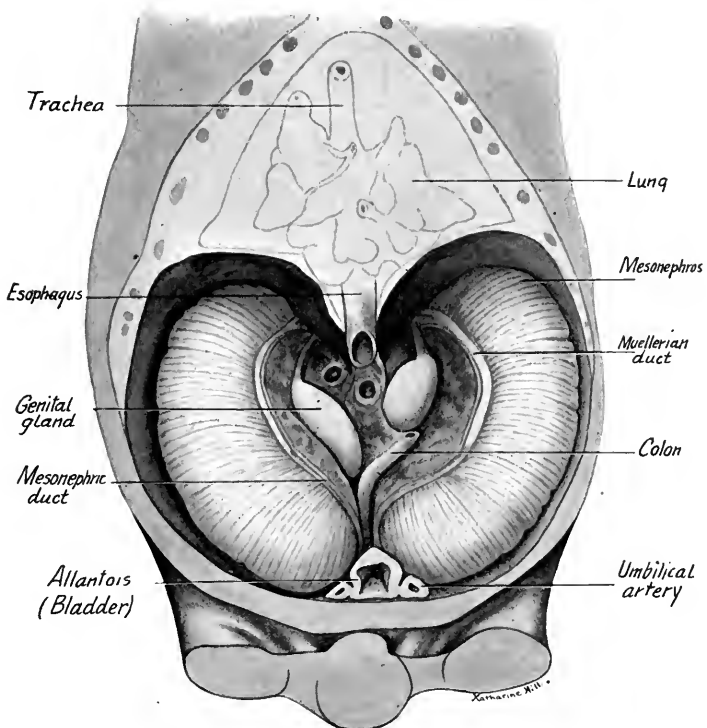


FIG. 217.—Ventral dissection of a 24 mm. embryo showing the anlagen of the Muellerian ducts at a later stage of development than in Fig. 216.  $\times 6$ .

glands show two characters which mark them as testes: (1) The occurrence of branched anastomosing cords of cells, the *testis cords*; (2) the occurrence between epithelium and testis cords of a layer of tissue, the anlage of the *tunica albuginea* (Fig. 218). According to Felix, the testis cords are developed suddenly from the loose inner epithelial mass by a condensation of its cells. The cords converge and grow smaller towards the mesorchium, where there is formed the undivided epithelial anlage of the *rete testis*. Two or three layers of loosely arranged cells between the testis cords and the epithelium constitute the anlage of the *tunica albuginea*. According to Allen (Amer. Jour. Anat., vol. 3, 1904), the testis cords are formed as active ingrowths of cords of cells from the epithelium.

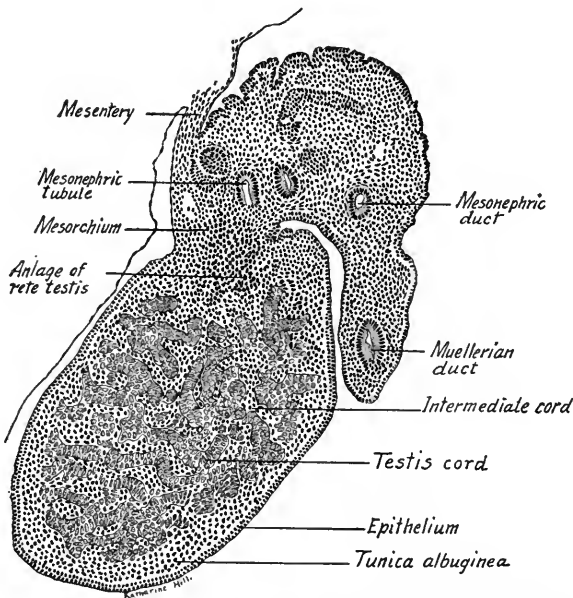


FIG. 218.—Transverse section through the left testis and mesonephros of a 20 mm. embryo.  $\times 250$ .

The testis cords soon become rounded and are marked off by connective tissue sheaths from the *intermediate cords*, columns of undifferentiated tissue which lie between them (Fig. 219). Toward the rete testis the sheaths of the testis cords unite to form the anlage of the *mediastinum testis*. The testis cords are composed chiefly of *indifferent cells* with a few larger *genital cells*. The cells gradually arrange themselves radially about the inside of the connective tissue sheath as a many-layered epithelium in which during the seventh month a lumen appears. The lumina appear in the peripheral ends of the testis cords and extending toward the rete testis meet lumina which have formed there. Thus the solid cords of both are converted into tubules. The distal portions of the testis

tubules anastomose and form the *tubuli contorti*. Their proximal portions remain straight as the *tubuli recti*. The rete testis becomes a network of small tubules which finally unite with the collecting tubules of the mesonephros (see p. 225).

The primitive genital cells of the testis cords form the *spermatogonia* of the spermatic tubules and from these at puberty are developed the spermatogonia (p. 24). The indifferent cells of the tubules become the sustentacular cells (of Sertoli) of the adult testis. Primitive genital cells of the intermediate cords are transformed into large pale cells which, after puberty, are numerous in the interstitial connective tissue and hence are called *interstitial cells*. The *intermediate cords* themselves are resorbed, but the connective tissue sheaths of the tubules unite to form *septula* which extend from the mediastinum testis to the *tunica*

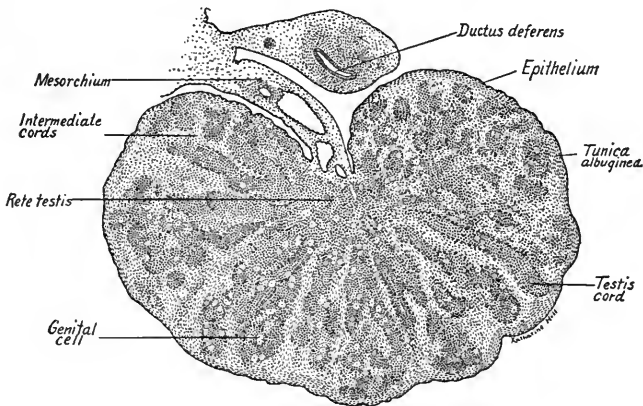


FIG. 219.—Section through the testis of a 100 mm. fetus.  $\times 44$ .

*albuginea*. The latter becomes a relatively thick layer in the adult testis and is so called because of its whitish appearance.

**Anomalies.**—The testis may be congenitally absent, the glands may be fused or they may fail to descend into the scrotum (cryptorchism). Duplications of the testis are of rare occurrence.

**The Differentiation of the Ovary.**—The primitive ovary, like the testis, consists of an *inner epithelial mass* and an outer epithelial layer. Much more slowly than in the testis the ovarian characters appear. In embryos of 50 to 80 mm. the inner epithelial mass composed of indifferent and primitive genital cells becomes less dense centrally and bulges into the mesovarian (Fig. 220). There may be distinguished a dense outer cortex beneath the epithelium, a clearer medullary zone containing large genital cells, and a dense cellular anlage in the mesovarium, the primitive *rete ovarii*, which is the homologue of the rete testis.

No epithelial cords and no tunica albuginea are developed at this stage, as in the testis. Later, three important changes take place: (1) There is an ingrowth of connective tissue and blood-vessels from the hilus, resulting in the formation of a *mediastinum* and of *septula*. (2) Most of the cells derived from the inner epithelial

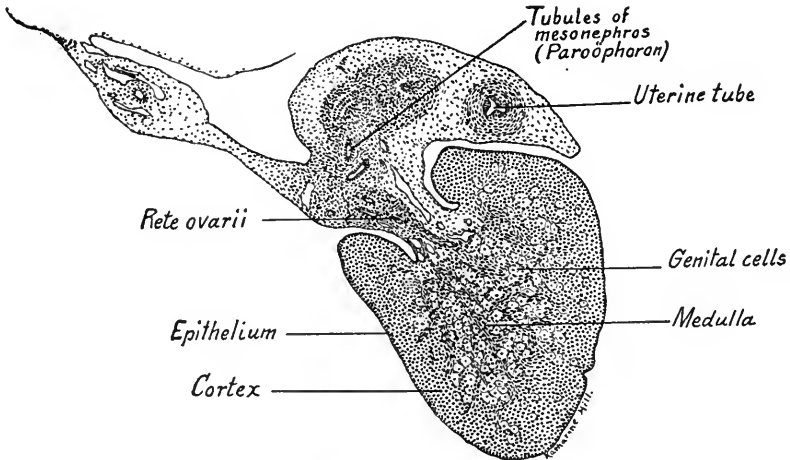


FIG. 220.—Section of an ovary from a 65 mm. embryo.  $\times 44$ .

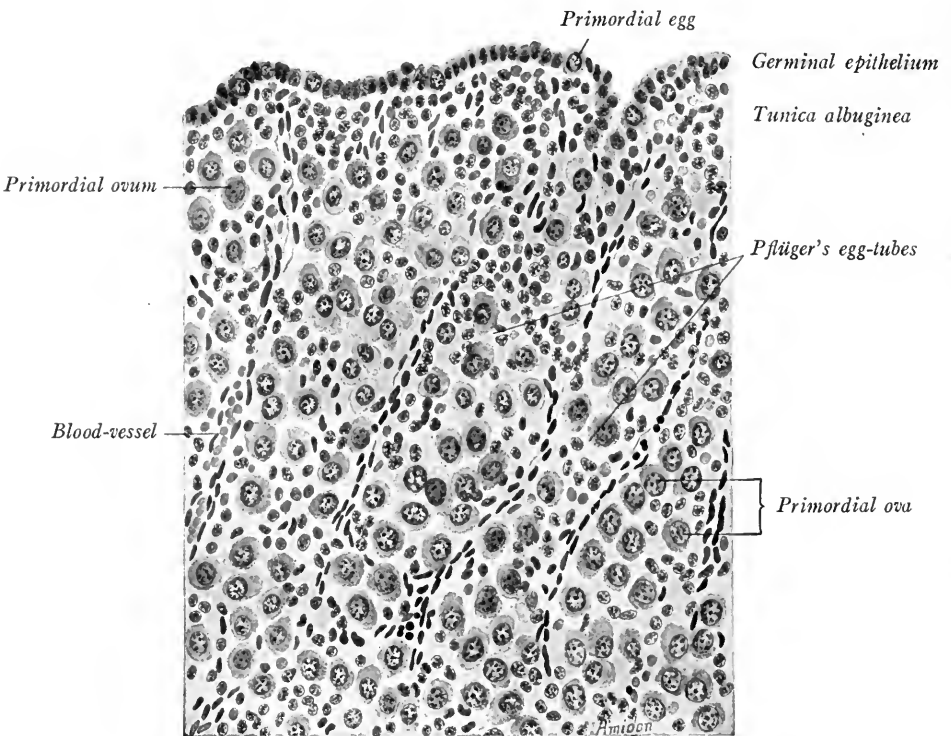


FIG. 221.—Ovary of five-months' fetus, showing egg-tubes and primordial follicles (De Lee).



mass are transformed into young ova, the process extending from the rete ovarii peripherally (Fig. 221). (3) In embryos of from 80 to 180 mm. length the ovary grows rapidly, owing to the formation of a new peripheral zone of cells, derived in part from the epithelium. At the end of this period the epithelial cells beneath the epithelium are gradually replaced by a fibrous *stroma*, the anlage of the *tunica albuginea*. Hereafter, although folds of the epithelium are formed, these do not penetrate beyond the tunica albuginea, and all cells derived from this source subsequently degenerate. In late fetal life, according to Felix, the so-called "germinal epithelium" does not give rise to primitive ova.

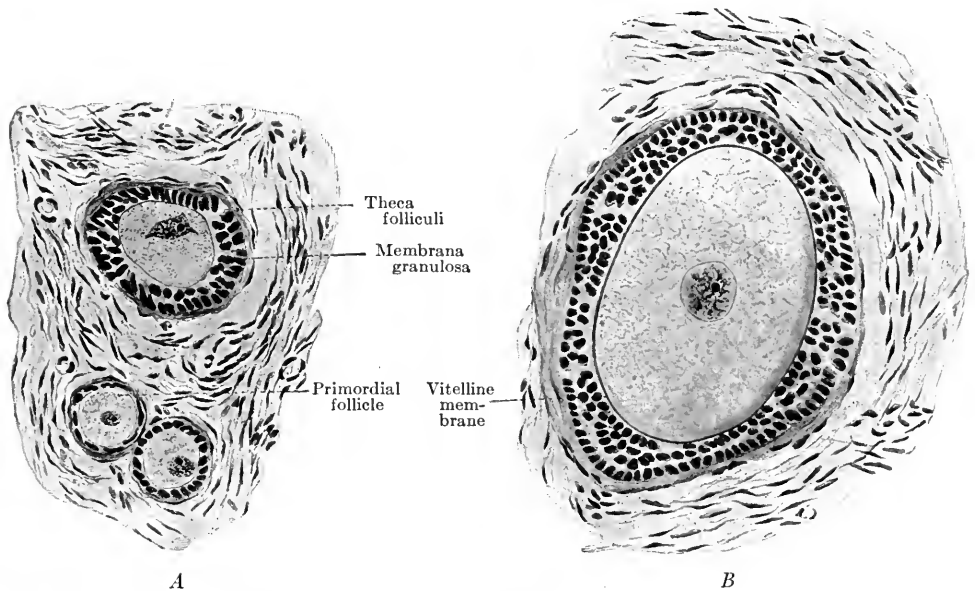


FIG. 222.—Primordial ova and early stages in the development of the Graafian follicle (De Lee's Obstetrics).

Coincident with the origin of a new zone of cells at the periphery of the ovary goes the degeneration of young ova in the medulla. By the ingrowth into this region of connective tissue septa, the ova are separated into clusters or cords, the genital cells of which all degenerate, leaving in the medulla only a *stroma* of connective tissue. Late in fetal life the indifferent cells, by surrounding young ova, produce primordial follicles (Fig. 222 A). During the first year after birth the primitive follicles are transformed into the vesicular Graafian follicles. By cell division the follicle cells form a zone many layers deep about the young ovum. (Fig. 222 B). Next a cavity appears in the sphere of follicle cells, enlarges and produces a vesicle filled with fluid (Fig. 223). The ovum is now eccentrically

located and the follicle cells directly surrounding it constitute the *cumulus oöphorus* (egg-bearing hillock). About the *stratum granulosum* formed by the original follicle cells there is differentiated from the stroma of the ovary the *theca folliculi*. This is composed of an inner vascular *tunica interna* and of an outer fibrous *tunica externa*.

Fully formed Graafian follicles are found in the ovaries during the second year and they may even be present before birth. Ovulation may occur at this time but usually these precociously formed follicles degenerate with their con-

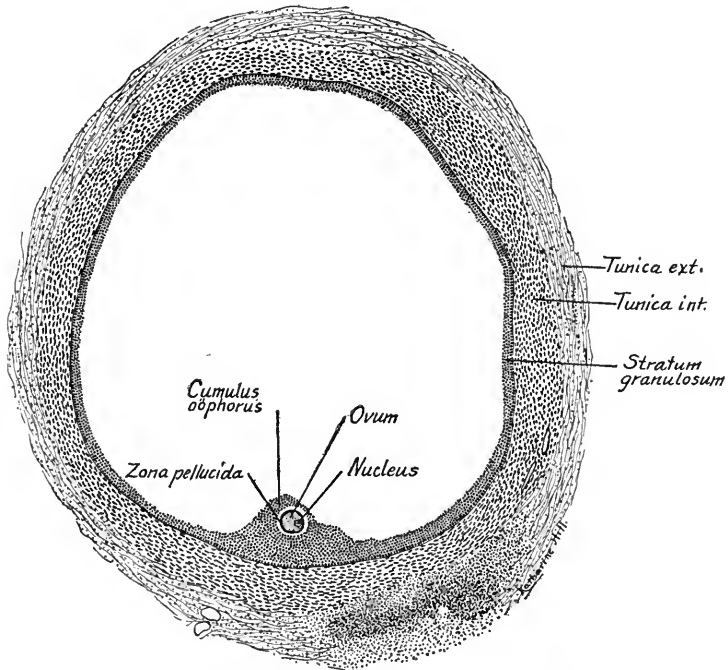


FIG. 223.—Graafian follicle and ovum from the ovary of a fifteen-year-old girl.  $\times 30$ .

tained ova. Thus, although thousands of ova are produced in the ovary, only a comparatively few are set free ready for fertilization during the sexually active life of the female, from puberty to the climacteric period or menopause. The relation of ovulation to menstruation has been discussed on p. 96.

*The Corpus Luteum.*—After ovulation a blood clot, the *corpus hemorrhagicum*, forms within the empty follicle. The follicle cells of the *stratum granulosum* proliferate, enlarge and produce a yellow pigment. The whole structure, composed of lutein cells and connective tissue strands, is termed the *corpus luteum* or yellow body. The blood clot is resorbed and replaced by fibrous scar tissue white in color and known as the *corpus albicans*. If pregnancy does not intervene the *corpus luteum spurium* reaches its greatest development within two weeks and then degenerates. In cases of pregnancy the *true corpus luteum* continues its growth until

at the fifth or sixth month it reaches a maximal diameter of 15 to 30 mm. At birth it is still a prominent structure in the ovary and it is believed to produce an internal secretion; for if the corpus luteum is removed the ovum fails to attach itself to the wall of the uterus.

*The Rete Ovarii.*—The cells of the rete ovarii remain compact, distinct and continuous only with the stroma of the medulla, the *medullary cords*. The anlage is differentiated into a network of solid cords in 60 mm. embryos (head-foot length) and these connect with the collecting tubules of the mesonephros. Some time before birth lumina appear in the cords transforming them into tubules homologous with those of the rete testis.

*Anomalies.*—The ovaries vary greatly in form and position. Congenital absence of one or both glands is rare. Cases of supernumerary and bilobed ovaries have been observed.

Comparing the testis and ovary in development, it is clear that the superficial epithelium *after forming the inner epithelial mass* takes no further part in the differentiation of the testis and only a small part in that of the ovary. (The testis cords, rete testis and tunica albuginea are formed early from the inner epithelial mass, which determines their form. The inner epithelial mass of the ovary develops slowly and its passive cells are separated and surrounded by actively ingrowing connective tissue. The primordial follicles when developed are not the homologues of the testis cords and the tunica albuginea appears late. The rete ovarii is the homologue of the rete testis but remains a rudimentary structure.)

**The Union of the Genital Glands and Mesonephric Tubules.**—In both male and female embryos of 21 mm. the mesonephros has degenerated until, according to Felix, only twenty-six tubules persist separated into a cranial and a caudal group. In the cranial group of 5 to 12 tubules the collecting portions have separated from the secretory portions. The free ends of these collecting tubules project against that part of the inner epithelial mass which gives rise to the rete tubules of either testis or ovary (Fig. 220). The cords of the rete develop in contact with the collecting tubules of the mesonephros and unite with them. In the *male* this union was observed by Felix in embryos of 60 mm. head-foot length. The lumina of rete and collecting tubules become continuous and the latter are transformed into the *ductuli efferentes* of the epididymis. They convey the sperms from the testis tubules into the mesonephric duct, which thus becomes the *male genital duct*. During the fifth month of pregnancy the ductuli efferentes coil at their proximal ends and when surrounded by connective tissue they are known as *coni vasculosi*. The cranial portion of the male genital duct also coils and forms the *canalis epididymis*. Its blind cranial end persists as the *appendix epididymis*.

The caudal portion of the male duct remains straight and as the *ductus deferens* extends from the epididymis to the urethra. Near its opening into the latter it dilates to form the *ampulla* and from its wall is evaginated the sacculated *seminal vesicle* in embryos of 60 mm.

The epithelium of the genital duct is at first a single layer of cubical cells. At 70 mm. the cells become columnar with non-motile cilia at their free ends. Quite late in development the surrounding mesenchyma gives rise to the muscular layers.

In the male, the rete testis, cranial group of mesonephric collecting tubules and mesonephric duct thus form functional structures (Fig. 231 C). The lower group of collecting tubules persist as the vestigial *paradidymis*. The Muellerian ducts of male embryos begin to retrograde at 30 mm. The middle portion of each degenerates but its cranial end persists as the *appendix testis*; its caudal end united with its fellow forms a pouch in the median dorsal wall of the urethra. This is the homologue of the vagina of the female and is called the *vagina masculina*.

In the female, the rete ovarii is always a rudimentary structure, yet some time before birth it unites with the cranially persisting group of mesonephric tubules and forms a rudimentary structure, the *epoöphoron* (Fig. 231 B). In its cords lumina appear, the epithelial cells become ciliated and smooth muscle tissue is developed corresponding to that of the *epididymis*. Usually the greater part of the male genital ducts atrophy in the female, the process beginning at 30 mm. Thus the tubules of the *epoöphoron* are without an outlet. The caudal portions of the male genital ducts persist as *Gartner's canals*.

These may extend as vestigial structures from the *epoöphoron* to the lateral walls of the vagina, passing through the broad ligament and the wall of the uterus. They open into the vagina close to the free border of the hymen (R. Meyer). The canals are rarely present throughout their entire length and are absent in two-thirds to three-quarters of the cases examined. It is an interesting fact that in male and female embryos the ducts of the opposite sex begin to degenerate at the same stage, 30 mm.

**The Uterine Tubes, Uterus and Vagina.**—The Muellerian, or female ducts, after taking their origin as described on p. 218, grow caudally, following the course of the mesonephric ducts (Fig. 217). At first lateral in position, the Muellerian ducts cross the mesonephric ducts and enter the genital cord median to them. In embryos of 20 to 30 mm. their caudal ends are dorsal to the urogenital sinus, extending as far as the Muellerian tubercle, a projection into the median dorsal wall of the vesico-urethral anlage (Fig. 212). This tubercle marks also the position of the future hymen. In embryos of 70 mm. the Muellerian ducts break through the wall of the urethra and open into its cavity. Before this takes place

the caudal ends of the Muellerian ducts, which are pressed close together between the mesonephric ducts in the genital cord, fuse, and in both male and female embryos of 20 to 30 mm. give rise to the unpaired anlage of the *uterus* and *vagina* (Fig. 224 A). The utero-vaginal anlage of the male remains rudimentary. The uterine portion of the anlage degenerates with the paired portions of the Muellerian ducts. The vaginal portion remains as the *vagina masculina*, and the extreme cranial end of each Muellerian duct persists as the *appendix testis*.

As pointed out by Felix, the term "uterus masculinus" as applied to the remains of the utero vaginal anlage is a misnomer, for the vaginal portion of the anlage persists and its uterine portion degenerates.

**Uterus and Vagina.**—Since the Muellerian ducts develop in the urogenital folds, they make two bends in their course corresponding to those of the folds

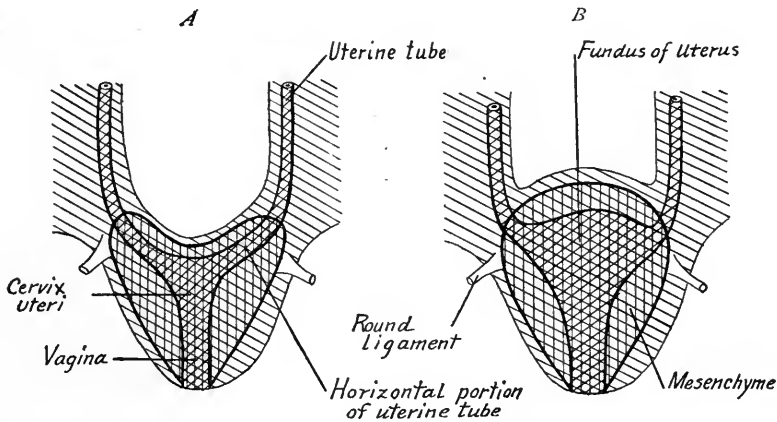


FIG. 224.—Diagrams showing the development of the uterus and vagina (modified after Felix).

(Fig. 224 A). Each consists of a cranial longitudinal portion, a middle transverse portion and a caudal longitudinal portion, which is fused with its fellow to form the utero-vaginal anlage. At the angle between the cranial and middle portions is attached the *inguinal fold*, the future *round ligament* of the uterus (Figs. 225 and 226). The mesenchyma condenses about the utero-vaginal anlage and the middle transverse portion of the Muellerian ducts, forming a thick, sharply defined layer, from which is differentiated the muscle and connective tissue of the uterus and vagina (Fig. 224 B). As development proceeds the cranial wall between the transverse portions of the Muellerian ducts bulges outward so that its original cranial concavity becomes convex (Fig. 224 B). The middle transverse portions of the ducts are thus taken up into the wall of the uterus forming its

*fundus*, while the narrow cervix of the uterus and the vagina arise from the utero-vaginal anlage. Through the differentiation of its mesenchymatous wall, the uterus is first brought into relation with the round ligament.

At 50 mm. the mesenchyma begins to differentiate a connective layer tissue. At 80 mm. the mucosa and muscularis may be distinguished. The first circular muscle fibers appear in 180 mm. embryos, the other muscle layers develop later. The epithelium of the uterine tubes and the tubular portion of the uterus (*fundus*) remains simple with cylindrical or cuboidal cells. The tubular fundus glands of the uterus may not appear until near puberty. At 38 mm. the epithelium of the cervix and vagina becomes stratified. The vagina is at first without a lumen. From the third to the sixth months of fetal life dorsal and ventral outgrowths of the epithelium form the *foreskins* of the vagina. The vaginal lumen appears in embryos of 150 to 200 mm., arising from the degeneration of the central epithelial cells. The foreskins hollow out and form the boundary line between the cervix uteri and the vagina. The epithelial cells of the former become stratified and cylindrical, those of the vagina are of the stratified squamous type. The paired cranial portions of the Muellerian ducts become the uterine tubes. The epithelial anlages of the Muellerian ducts form the epithelial layers of the uterine tubes uterus and vagina.

*The Hymen.*—At the point where the utero-vaginal anlage breaks through the wall of the urogenital sinus there is present the tubercle of Mueller, which marks the lower limits of the vagina. The tubercle is compressed into a disk lined internally by the vaginal epithelium, externally by the epithelium of the urogenital sinus. These layers with the mesenchyma between them constitute the *hymen*, which thus guards the opening into the vagina. A circular aperture in the hymen is for a time closed by a knob of epithelial cells, but later when the hymen becomes funnel-shaped the opening is compressed laterally to form a sagittal slit, the *ostium vaginae*.

*The Growth of the Uterus.*—The uterus grows but slowly until near puberty, being about the same length (27 mm.) at birth as in a girl of nine years. Just before and after puberty growth is more rapid, a length of 72 mm. being attained at 18 years. This is nearly the maximal length of the virginal uterus.

*Anomalies.*—Owing to the complicated processes leading to their formation, many cases of abnormal uterus and vagina occur. A complete classification of these cases is given by Felix (Keibel and Mall, vol. 2, p. 930). The more common anomalies are (1) complete duplication of the uterus and vagina due to the failure of the Muellerian ducts to fuse; (2) uterus bicornis, due to the incomplete fusion of the ducts. Combined with these defects the lumen of the uterus and vagina may fail, partly or completely, to develop and the vaginal canal may not open to the exterior. (3) The body of the uterus may remain flat (*uterus planifundis*) or may fail to grow to normal size (*uterus fetalis* and *infantilis*). (4) Congenital absence of one or both uterine tubes, uterus, and vagina rarely occurs, but may be associated with hermaphroditism of the external genitalia.

**The Ligaments of the Internal Genitalia.**—*Female.*—The loose mesenchyma of the genital cord gives rise laterally to the *broad ligaments of the uterus* in

females. In the genital fold, extending from the caudal end of the ovary to the genital cord, connective tissue and smooth muscle fibers developing form the *proper ligament of the ovary*. The uterus develops in the genital cord so the ligament of the ovary extends to the posterior surface of the uterine wall. In the male the homologue of the proper ligament of the ovary is the *ligament of the testis*.

In both sexes the *inguinal fold* extends from the urogenital fold to the *crista inguinalis*, located on the inside of the ventral abdominal wall, a point which marks the future entrance of the *inguinal canal*. The inguinal fold thus forms a bridge between the urogenital fold (in the middle portion of which the uterus develops in the female) and the abdominal wall at the entrance of the inguinal

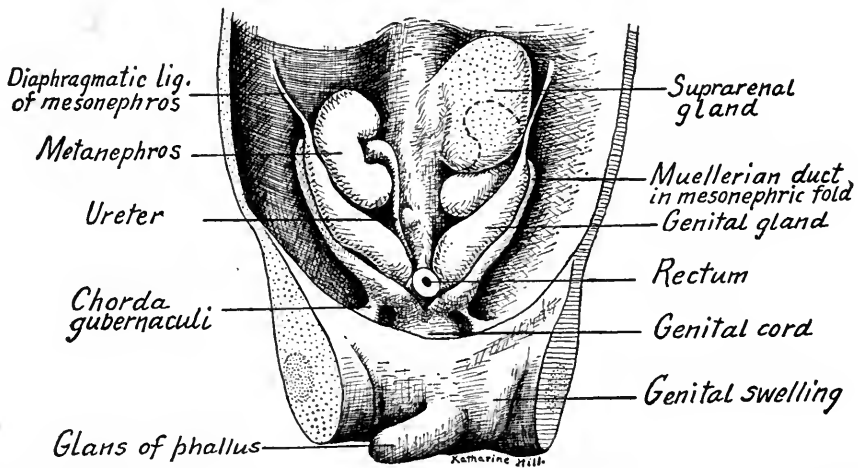


FIG. 225.—Ventral dissection of a human embryo of 23 mm. showing the urogenital organs. The right suprarenal gland has been removed to show the metanephros.

canal (Fig. 225). In the inguinal crest is differentiated the conical anlage of the *chorda gubernaculi*, which later becomes a fibrous cord. The abdominal muscles develop around it and the external oblique muscle leaves a foramen, through which it connects with a second cord termed in the male the *lig. scroti*, in the female the *lig. labiale* (Fig. 226). The *chorda gubernaculi* and the *lig. labiale* together constitute the *round ligament* of the uterus, as they form a continuous cord extending from the urogenital fold to the base of the genital tubercle. With the development of the uterus in the urogenital fold, the round ligament becomes attached to its ventral surface.

*Male.*—The *ligamentum testis*, like the *lig. ovarii*, develops in the genital fold and extends from the caudal end of the testis to the mesonephric fold at a

point opposite the attachment of the inguinal fold. The inguinal fold, as we have seen, is continuous with the inguinal crest and the chorda gubernaculi. A cord develops in the mesonephric fold and connects the ligamentum testis with the chorda gubernaculi, for in the male the uterus does not intervene between these two. The chorda gubernaculi is continued to the integument of the scrotum by way of the ligamentum scroti. Thus there is formed a continuous cord, the *gubernaculum testis*, extending from the caudal end of the testis through the inguinal canal to the scrotal integument. The gubernaculum is composed of the *ligamentum testis*, of a *mesonephric cord*, of the *chorda gubernaculi*, and of the *lig.*

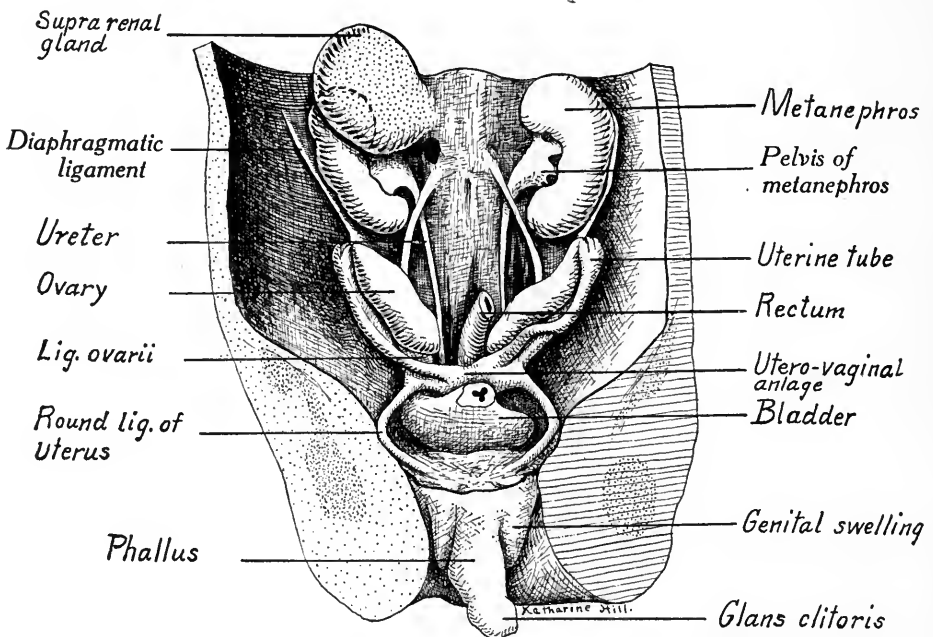


FIG. 226.—Ventral dissection of a female human embryo of 34 mm. The urogenital organs are dissected out and the left suprarenal gland has been removed.

*scroti*, and is the homologue of the *ovarian ligament* plus the *round ligament of the uterus*.

**The Descent of the Testis and Ovary.**—The original position of the testis and ovary is changed during the later stages of development. At first they are elongate structures, extending in the abdominal cavity from the diaphragm caudally towards the pelvis (Fig. 213). As development proceeds, their caudal ends enlarge and their cranial portions atrophy so that there is a progressive movement of the glands caudad. When the process of growth and degeneration is completed the caudal ends of the testis lie at the boundary line between the abdomen and



pelvis while the ovaries are located in the pelvis itself, a position which they retain. Owing to the rotation of the ovary about its middle point as an axis it takes up a transverse position. It also rotates nearly  $180^\circ$  about the Muellerian duct as an axis and thus comes to lie caudal to the uterine tube.

The testis normally leaves the abdominal cavity, descending into the scrotum. As described above, there is early developed between the testis and the integument of the scrotum a fibrous cord, the *gubernaculum testis*. Owing to changes in the position of the ventral abdominal wall and umbilical arteries, changes connected with the return of the intestinal coils into the cœlom, there are formed in each side of the abdominal wall sac-like pockets, the anlagen of the vaginal sacs. Close to each saccus vaginalis lies the caudal end of a testis, while extending into the scrotum beneath the peritoneum is the gubernaculum testis. The *saccus vaginalis* later invaginates into the scrotum over the pubic bone, carrying with it also representatives of the muscular layers of the abdominal wall. Whether due to the active shortening or to the unequal growth of the gubernaculum testis, the descent of the testis into the vaginal sac begins during the seventh month of fetal life and by the eighth month or at least before birth the testis is usually located in the scrotum (Fig. 227). It must be remembered that the testis and gubernaculum are covered by the peritoneum before the descent begins, consequently the testis follows the gubernaculum along the inguinal canal *dorsal to the peritoneum* and, when it reaches the scrotum, is invaginated into the saccus vaginalis. The gubernaculum is said to degenerate during the descent of the testis or immediately after. Abnormally, the testis may remain in the abdomen, a condition known as *cryptorchism* (concealed testis) and associated with sterility in man. In some mammals (bat and elephant) it is the normal condition.

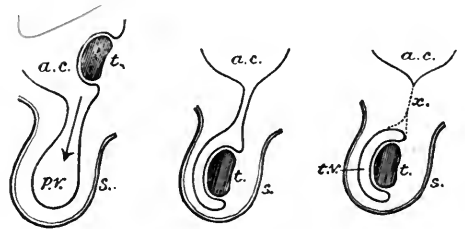


FIG. 227.—Descent of the testis (Cunningham). *ac*, abdominal cavity; *pv*, processus vaginalis; *t*, testis; *s*, scrotum; *tv*, tunica vaginalis; *x*, rudiment of processus vaginalis.

Shortly after birth the inguinal canal connecting the saccus vaginalis with the abdominal cavity becomes solid and its epithelium is resorbed. The now isolated vaginal sac becomes the *tunica vaginalis* of the testis. Its *visceral layer* is closely applied to the testis and its *parietal layer* forms the lining of the scrotal sac. The ductus deferens and spermatic vessels are of course carried down into the scrotum with the testis and epididymis. They are surrounded by connective

tissue and, with the spermatic vessels, constitute the *spermatic cord*. Owing to the descent of the testis, the ductus deferens is looped over the ureter in the abdomen (Fig. 231 C). In some cases the inguinal canals remain open so that the testis may slip back into the abdominal cavity. Such conditions may lead to *inguinal hernia* of the intestine. Open inguinal canals occur normally in the rabbit.

### THE EXTERNAL GENITALIA

**Indifferent Stage.**—In both sexes there develops early in the midline of the ventral body wall, between the tail and umbilical cord, the *cloacal tubercle* (Fig. 228). Upon this appears a knob-like structure, the *phallus*, and the two together

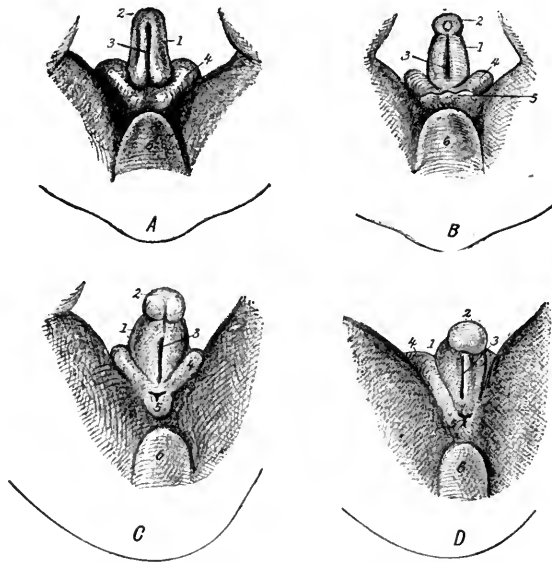


FIG. 228.—Four stages in the development of the external genitalia in embryos of 24 to 34 mm. Indifferent stage: 1, phallus; 2, glans; 3, primitive urogenital opening; 4, genital tubercle or swelling; 5, anus; 6, coccyx (Tourneux in Heisler's Embryology).

constitute the genital eminence. Cranially about the phallus the cloacal tubercle forms a crescent-shaped *genital tubercle*, which later gives rise to the right and left *genital swellings*. The phallus grows rapidly and into it extends the phallic portion of the urogenital sinus. At the end of the phallus the epithelium of the sinus forms a solid *urethral plate* (Fig. 212). Along the anal surface of the phallus in the midline, the wall of the urogenital sinus breaks through to the exterior and forms the slit-like primitive urogenital aperture. In embryos of 21 to 28 mm., at the end of the phallus, the glans is marked off from the base by a circular groove, the *coronary sulcus* (Figs. 225 and 228 B).

**Female.**—A deep groove appears about the base of the phallus separating it from the genital tubercle, which becomes a circular swelling (Fig. 229). From the swelling differentiates (1) cranially, the *mons veneris*; (2) laterally, the right and left *labia majora*; (3) caudally, the posterior commissure of the labia majora. The glans of the phallus forms the *glans clitoris* of the female. On the anal surface of the phallus beginning at the coronary sulcus the primitive urogenital opening closes distally, forming the *urethral groove*. Proximally it remains open, as

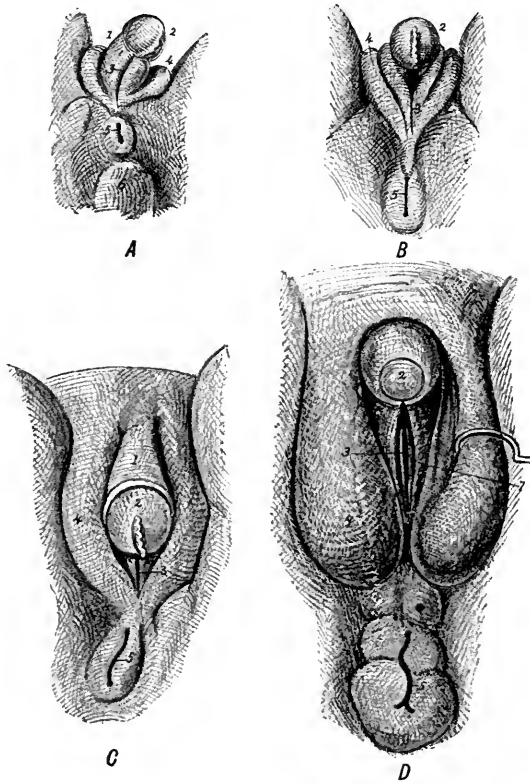


FIG. 229.—Four stages in the development of the female external genitalia (Tourneux in Heisler). 1, clitoris; 2, glans clitoris; 3, urogenital aperture on each side of which are the labia minora (7); 4, labia majora; 5, anus; 5, coccygeal eminence; 7, labia minora.

the definitive *urogenital opening* near the base of the phallus. The lips of this groove and opening enlarge and become the *labia minora*. The cranial surface of the phallus forms a fold, the *prepuceum*, which, however, is not the homologue of the male fore-skin. This in the female is represented by a ring-like rudiment at the base of the glans clitoris.

**Male.**—The phallus grows rapidly at its base so that the glans and primitive urogenital opening are carried some distance from the anus (Fig. 230). A cylin-

dricol fold of the epithelium, incomplete on the anal side, grows down into the end of the glans, which becomes the *glans penis*. By the disappearance of the central cells of the epithelial downgrowth an outer cylindrical mantle, the *prepuce* or *fore-skin*, is formed about the spherical glans. Where the epithelial downgrowth is incomplete the glans and foreskin remain connected, the persistent connection being the *frenulum prepucei*.

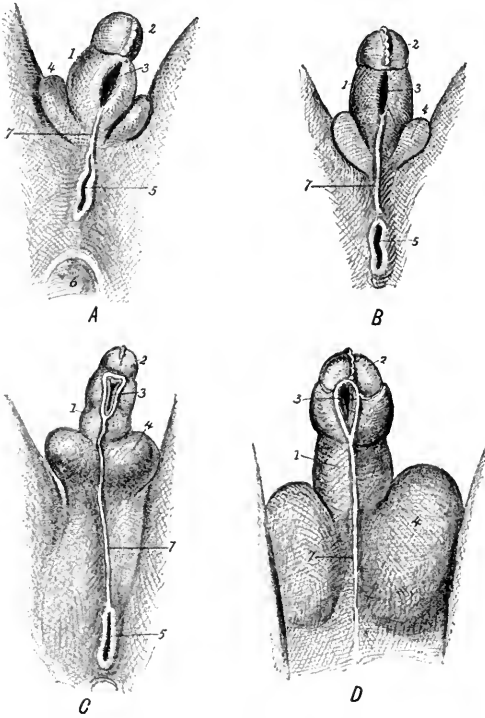


FIG. 230.—Four stages in the development of the male external genitals (Tourneux in Heisler). 1, penis; 2, glans; 3, urogenital groove; 4, urogenital swellings corresponding to labia majora of female; 5, anus; 6, coccygeal eminence; 7, scrotal area with perineo-scrotal raphe.

The urogenital sinus, as we have seen, extends out into the phallus and in the glans becomes the solid urethral plate. With the great elongation of the male phallus, the open portion of the urogenital sinus also is lengthened and forms the greater part of the penile *urethra*. In embryos of 70 mm. the groove-like primitive urogenital opening, located in the male near the glans and distant from the anus, closes and thus is formed a further portion of the urethra. The failure of this opening to close gives rise to an anomaly known as *hypospadias*. The lips of the urogenital opening, it will be remembered, correspond to the *labia minora* or *nymphae* of the female. Finally at 100 mm. the solid urethral plate of the glans splits, forms a groove to the

tip of the glans and this groove in turn is closed, continuing the urethra to the definitive opening at the tip of the glans. Owing to the rapid growth in length of the penis, there is formed between its base and the anus an unpaired area, termed by Felix the *scrotal area* as it is the anlage of the scrotum. At 60 mm. this forms a median scrotal swelling continuous with the paired genital swellings. When the scrotal sac develops in the scrotal area, the dense tissue in the median line is compressed and forms the *septum scroti*. The attachment of this septum forms an external median depression. The testes

descend into the vaginal sacs of the scrotum through the paired genital swellings, as described on p. 231, but the scrotum itself is an unpaired structure derived from the scrotal area. After the descent of the testes the genital swellings disappear.

Comparing the male and female external genitalia, it is plain that the glans penis and glans clitoris are homologous. The *labia minora* correspond to the phallic folds which close about the primitive urogenital opening and the anal surface of the penis. The greater part of the stem of the male phallus does not develop in the female. On the other hand, the genital swellings enlarge and become the *labia majora* of the female, while in the male they are only temporary structures. The scrotum does not develop in the female, being represented only by the posterior commissure of the *labia majora*.

**The Prostate Gland.**—This is developed in both sexes as several outgrowths above and below the entrance of the male ducts into the urogenital sinus. The tubules arise in five distinct groups and, according to Lowsley (*Amer. Jour. Anat.*, vol. 13, pp. 299–350), number from 53 to 74, the average being 63. In the male the surrounding mesenchyme differentiates both white fibrous connective tissue and smooth muscle fibers into which the anlagen of the prostate grow. In the female the tubules remain isolated. The prostatic anlagen appear in male embryos of 50 mm. (12th week), chiefly as dorsal and lateral outgrowths. Two-thirds of the tubules are caudal to the openings of the male ducts. In the female the gland is rudimentary, the maximal number of outgrowths being three.

The *bulbo-urethral glands* (of Cowper) arise in male embryos of 48 mm. as solid paired epithelial buds from the entoderm of the pelvic urogenital sinus. The glands grow into the mesenchyme which forms the *corpus cavernosum urethrae*, about which they enlarge. The glands branch and, at 120 mm., the epithelium becomes glandular. The *vestibular glands* (of Bartholin) are the homologues in the female of the bulbo-urethral glands. They appear in embryos of 36 mm., grow until after puberty, and degenerate after the climacterium.

**Male and Female Genitalia Homologized.**—From the standpoint of embryology the genital glands are homologous structures. In the indifferent stage (Fig. 231 A), there are in both male and female a pair of genital glands, a pair of mesonephric or male ducts, a pair of Muellerian or female ducts, and a genital tubercle bearing the phallus. The genital ducts open into the urogenital sinus, a part of which forms the bladder.

*Male* (Fig. 231 C).—In the male the Muellerian ducts degenerate except for small portions cranially and caudally, which persist respectively as the *appendix*

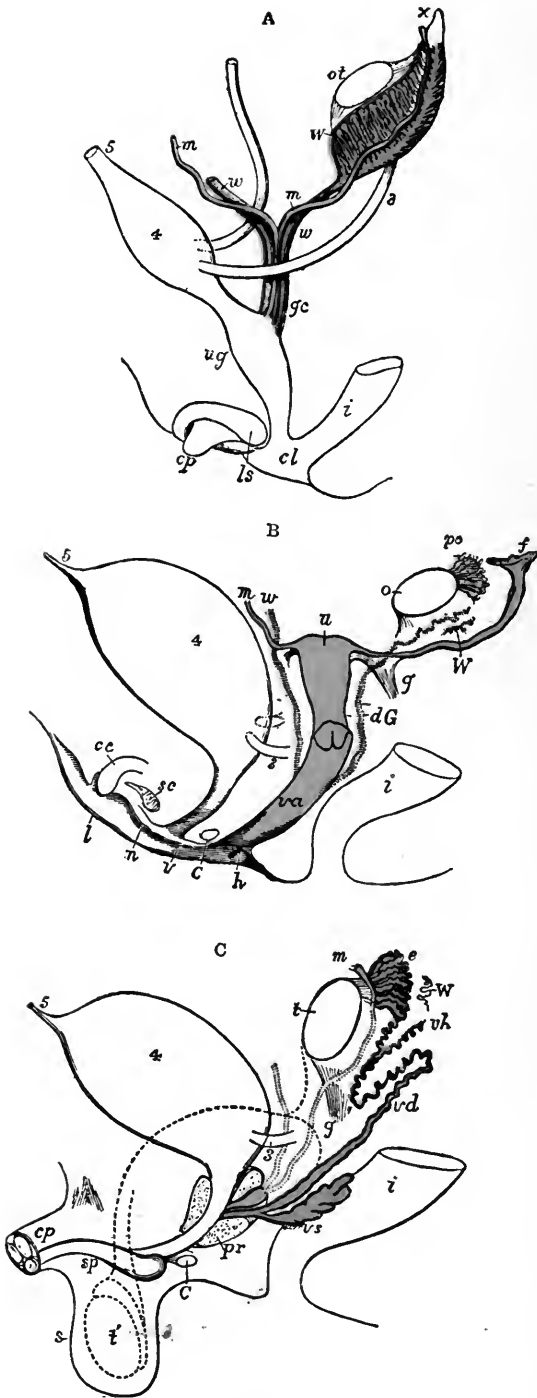


FIG. 231.

FIG. 231.—Diagrams to show the development of male and female generating organs from a common type (Allen Thomson).

A. Diagram of the primitive urogenital organs in the embryo previous to sexual distinction: 3, ureter; 4, urinary bladder; 5, urachus; *ot*, the genital ridge from which either the ovary or testicle is formed; *w*, left mesonephros; *w*, *w*, right and left mesonephric ducts; *m*, *m*, right and left Müllerian ducts uniting together and running with the mesonephric ducts in *g.c.*, the genital cord; *ug*, sinus urogenitalis; *i*, lower part of the intestine; *cl*, cloaca; *cp*, phallus which becomes clitoris or penis; *ls*, fold of integument from which the labia majora are formed.

B. Diagram of the female type of sexual organs: *o*, the left ovary; *po*, epoöphoron; *w*, scattered remains of mesonephric tubules near it (paroöphoron); *dG*, remains of the left mesonephric duct (canal of Gartner) represented by dotted lines; that of the right side is marked *w*; *f*, the abdominal opening of the left uterine tube; *u*, uterus; the uterine tube of the right side is marked *m*; *g*, round ligament, corresponding to gubernaculum; *i*, lower part of the intestine; *va*, vagina; *h*, situation of the hymen; *C*, gland of Bartholin (Cowper's gland), and immediately above it the urethra; *cc*, corpus cavernosum clitoridis; *sc*, vascular bulb or corpus spongiosum; *n*, nymphæ; *l*, labium; *v*, vulva.

C. Diagram of the male type of sexual organs: *t*, testicle in the place of its original formation; *e*, caput epididymis; *vd*, ductus deferens; *W*, scattered remains of the mesonephros, constituting the organ of Giralde's, or the paradidymis; *vh*, vas aberrans; *m*, Müllerian duct, the upper part of which remains as the appendix testis, the lower part, represented by a dotted line descending to the prostatic vesicle, constitutes the occasionally existing cornu and tube of the vagina masculina; *g*, the gubernaculum; *vs*, the vesicula seminalis; *pr*, the prostate gland; *c*, Bulbo-urethral gland of one side; *cp*, corpora cavernosa penis cut short; *sp*, corpus cavernosum urethræ; *s*, scrotum; *l'*, together with the dotted lines above, indicates the direction in which testicles and epididymis descend from the abdomen into the scrotum.

*testis* and the *vagina masculina*. The mesonephric duct is functional, its derivatives being the ductus epididymis, the ductus deferens, the ampulla and seminal vesicle. The collecting tubules of the mesonephros form the ductuli efferentia of the epididymis and the vestigial *paradidymis*. The *phallus* enlarges and becomes the *penis*, into which extends a portion of the urogenital sinus as the *urethra*. The genital tubercle disappears and the scrotum is developed as a new structure, into the vaginal sacs of which the testes descend.

*Female* (Fig. 231 B).—The genital gland becomes the ovary. The mesonephric duct degenerates except for the vestigial *Gartner's canal*. Two groups of mesonephric tubules persist, a cranial group united with the rete ovarii constituting the rudimentary *epoöphoron*, the homologue of the *epididymis*, a caudal group forming the *paroöphoron*, comparable to the *paradidymis*. The Muellerian ducts become the functional female ducts. Their lower ends fuse and with their middle portions form the vagina and uterus. Their upper portions persist as the paired uterine tubes. The phallus remains small and becomes the *clitoris*, the open lips of the urethral groove form the *labia minora*, and the genital tubercle constitutes the *mons veneris* and the paired *labia majora* of the vulva. The ovaries descend only into the true pelvis but the lig. ovarii and the round ligament of the uterus are the homologues of the gubernaculum testis.

**Hermaphroditism.**—*True hermaphroditism* consists in the development and persistence of both testes and ovaries in the same individual. It is of rare occurrence in man, is not uncommon in the lower vertebrates, and is the normal condition in some invertebrates (earth worms, snails, etc.). In cases of human hermaphroditism of this type the secondary sexual characters are usually intermediate between the male and female, tending now one way now the other. The external genitalia show a small penis with hypospadias, cryptorchism, or small vaginal opening.

*False hermaphroditism* is characterized by the presence of genital glands of one sex in an individual which exhibits more or less marked secondary characters and external genitalia of the opposite sex. In masculine hermaphroditism an individual possesses testicles, but the external genitals and secondary sexual characters are like those of the female. In feminine hermaphroditism ovaries are present, but the other sexual characters are male. The cause of hermaphroditism is unknown.

### THE UTERUS DURING MENSTRUATION AND PREGNANCY: PLACENTA AND DECIDUAL MEMBRANES

Two sets of important changes take place normally in the wall of the uterus. One of these is periodic and is the cause of *menstruation* (monthly flow). These periodic changes may also be regarded as preparatory to the second set of changes which take place if pregnancy occurs and give rise to the decidual membranes and placenta.

**Menstruation.**—The periodic changes which accompany the phenomenon of menstruation form a cycle which occupies 28 days. This period is divided into (1) a phase of uterine congestion lasting six or seven days; (2) a phase of hemorrhage and epithelial desquamation, duration three to five days; (3) a phase of regeneration of the uterine mucosa lasting four to six days; (4) finally an interval of rest or slight regeneration, varying from twelve to sixteen days duration.

During the first phase, the uterine mucosa is thickened to two or three times its normal condition, both because of vascular congestion and on account of the actual increase in amount of reticular tissue. The uterine glands become longer and their deeper portions especially are dilated and more convoluted because they are filled with secretion. From the enlarged veins and capillaries blood escapes into the reticular tissue beneath the epithelium and forms hæmatomata. At the end of this phase the uterine mucosa shows a deep spongy layer and a superficial compact layer, these corresponding to similar layers in the decidual membranes of pregnancy.

During the second phase, which is menstruation proper, blood escapes into the uterine cavity between the epithelial cells of the mucosa and there is an active discharge of secretion from the uterine glands. The surface epithelium and a portion of the underlying tissue may or may not be desquamated. In some normal cases the surface epithelium and most of the compact layer may be expelled, aided by painful contractions of the uterus.

In the third stage, the mucosa has become thin with straight narrow glands between which are fusiform, closely packed stroma cells. Any surface epithelium which has been desquamated is regenerated from the epithelium of the glands and gradually the mucosa returns to a resting condition during which, however, there is a slow process of cell proliferation.

The premenstrual changes of the first phase are regarded as the most important part of the whole process, the uterine mucosa being prepared for the reception of a fertilized ovum and for the development of the decidual membranes. Men-



struation proper, as seen in the second phase, is the result of an over-ripe condition of the mucosa and has been regarded as the abortion of an unfertilized ovum.

#### THE DECIDUAL MEMBRANES: PLACENTA

**The Implantation of the Ovum.**—Our knowledge concerning the implantation of the ovum is fragmentary, but certain facts have been deduced from observations on mammals (hedge-hog and guinea-pig), and from the careful study of early human embryos by Teacher, Bryce, Herzog and Peters. The embryo described by Teacher and Bryce, while it is the youngest yet observed, is perhaps not normal.

After ovulation, the ripe ovum is set free within the abdominal cavity, from whence by the beating cilia on the fimbriæ of the uterine tube it is carried into the ampulla of the latter. There it may be fertilized and is swept into the uterus by the cilia of the tubar epithelium. During this period of migration, which is estimated as occupying from five to eight days, the ovum loses its surrounding follicle cells and its membrane and begins its development. Thus when it reaches the uterus, and is ready for implantation, it is an embryo with trophoctoderm developed but still not more than 0.2 mm. in diameter (Graf Spee).

If ovulation precedes menstruation proper by ten or twelve days as *Ancel* and *Villemin* maintain, then the embryo would reach the uterus during the premenstrual period. The congestion and loosening of the uterine tissue at this time would favor the implantation of the embryo and the glandular secretion would afford nutriment for its growth until implantation occurs. The first phase of menstruation according to this view, that of *Grosser*, prepares the uterine mucosa for the reception of the embryo. If pregnancy supervenes, it soon inhibits any further premenstrual changes so that menstruation does not occur.

The embryo penetrates the uterine mucosa as would a parasite, the trophoctoderm supposedly producing a ferment which digests away the maternal tissues until the embryo is entirely embedded (Fig. 232). During implantation, the trophoctoderm also probably absorbs nutriment from the uterine mucosa for the use of the embryo. The process of implantation is supposed to occupy one day: At the point where the embryo enters the mucosa a fibrin clot soon appears and eventually the opening is completely closed.

**The Decidual Membranes** (Figs. 233 and 234).—With the increase in size of the embryo and chorionic vesicle, the superficial layers of the maternal mucosa bulge into the cavity of the uterus and form the *decidua capsularis* (old term, *decidua reflexa*). The deep layer of the mucosa on the side of the embryo away from the uterine cavity forms the anlage of the future maternal *placenta* and is the *decidua basalis* (d. *serotina*). The mucosa lining the rest of the uterus is differentiated into the *decidua vera* (*parietalis* of *Bonnet*).

**Differentiation of the Trophoctoderm.**—The chorion is at first composed of

an inner mesodermal layer and an outer epithelial layer, the trophoderm (Fig. 70). From the trophoderm there is developed an outer syncytial layer which we call the *trophoderm* (Fig. 232). This invades and destroys the maternal tissues. In it large vacuoles are formed either directly by the syncytial tissue (Teacher and Bryce) or by the blood escaping from the ruptured vessels under pressure (Peters), and thus *blood lacunæ* are produced. The trophoderm thickens at intervals and forms on the surface of the chorion solid cords of cells, the *primary villi* (Fig. 232). The chorionic mesoderm grows out into these cords, the cords branch

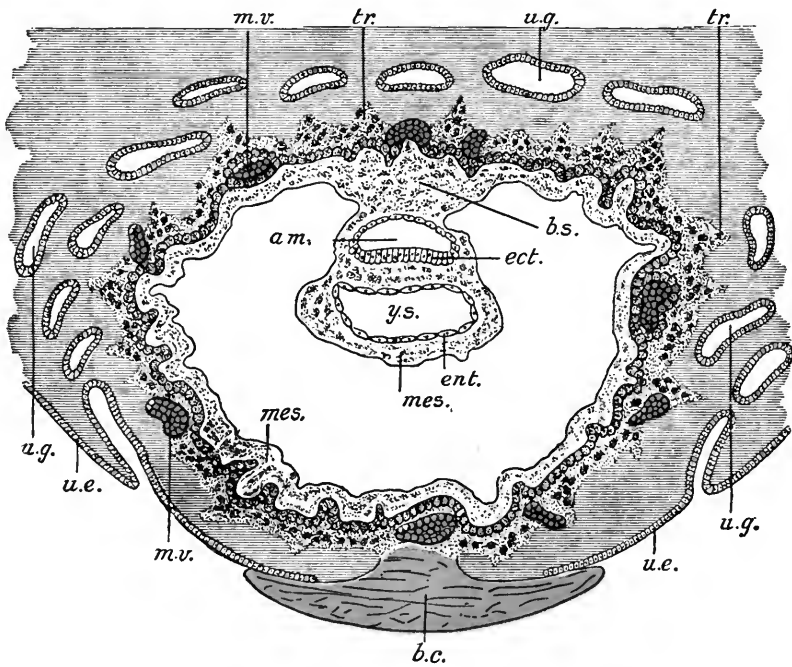


FIG. 232.—Section through an embryo of 1 mm. embedded in the uterine mucosa (semidiagrammatic after Peters). *Am.*, amniotic cavity; *b.c.*, blood-clot; *b.s.*, body-stalk; *ect.*, embryonic ectoderm; *ent.*, entoderm; *mes.*, mesoderm; *m.v.*, maternal vessels; *tr.*, trophoderm; *u.e.*, uterine epithelium; *u.g.*, uterine glands; *y.s.*, yolk-sac.

profusely and become *secondary, or true villi* (Fig. 235). During the development of the villi, the blood lacunæ in the trophoderm around the villi expand, run together, and produce *intervillous blood spaces* which surround the villi and bathe the epithelium with blood. The syncytial trophoderm, from being a spongy network, is now reduced to a continuous layer covering the outer surfaces of the villi and chorion. Branches of the umbilical vessels develop in the mesoderm of the chorion and villi. The mesodermal core of each villus and its branches is now covered by a two-layered epithelium, an inner ectodermal layer with distinctly

outlined cubical cells, and an outer syncytial trophoderm layer (Fig. 235). The epithelium also forms solid *columns* of cells which anchor the ends of certain villi to the maternal tissue. Islands, or nodes of epithelial cells, are attached to the

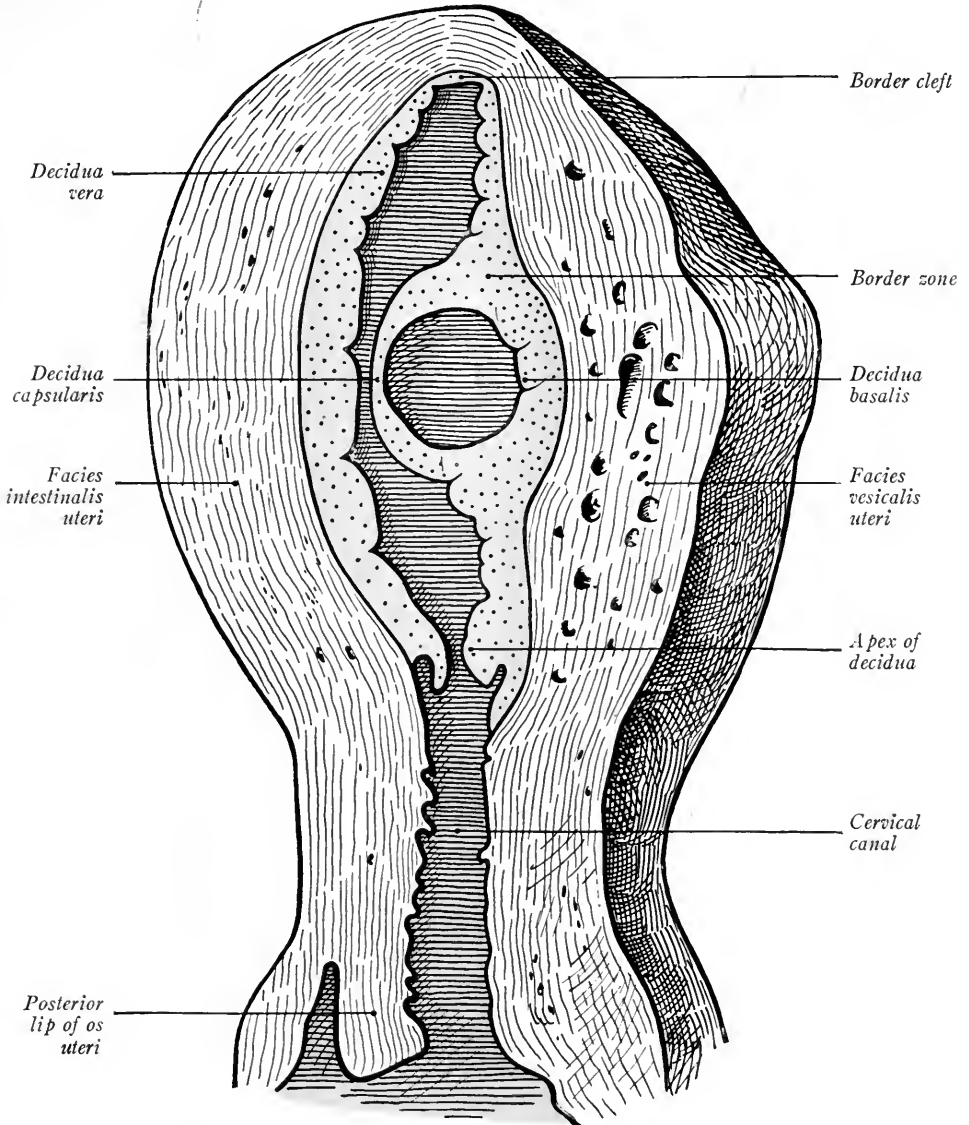


FIG. 233.—Section through a gravid uterus of twelve to fourteen days (Kollmann's Atlas).

villi or lie free in the decidua basalis and represent portions of the primitive trophoderm. In the vessels of the chorionic villi the chorionic circulation of the embryo is established. The blood-vessels of the uterus open into the intervillous

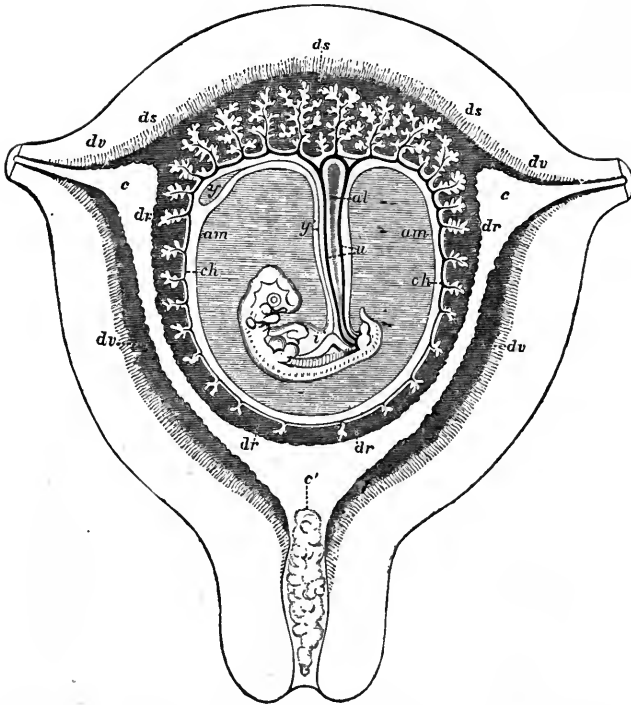


FIG. 234.—Diagrammatic section through a pregnant uterus at the seventh or eighth week (after Allen Thomson). *c, c*, openings of uterine tubes; *c'*, cervix with mucous plug; *dv*, decidua vera or parietalis; *dr*, decidua capsularis; *ds*, decidua basalis (serotina); *ch*, chorion with villi; the villi extending into the decidua basalis are from the chorion frondosum; *u*, umbilical cord; *al*, allantois.

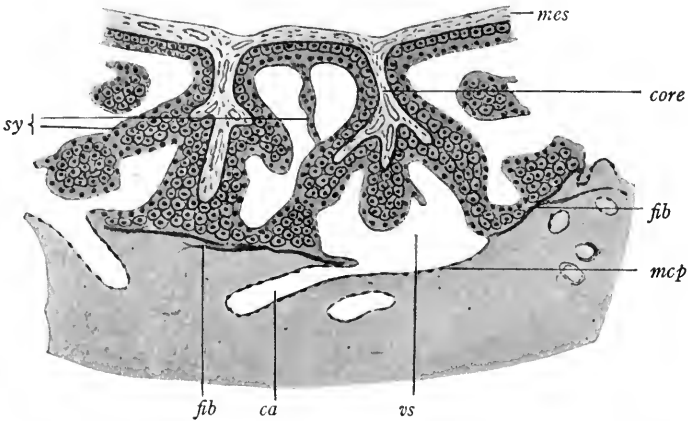


FIG. 235.—Diagram illustrating the second phase in the development of the chorionic villi and placenta (after Peters). *mes*, mesoderm; *core*, core of villus about which is the trophoblast layer; *sy*, syncytium of trophoblast; *mcp*, endothelium of maternal capillary; *vs*, intervillous space.

blood spaces and here the maternal blood circulates. The syncytial trophoderm covering the villi is bathed in the maternal blood. Its functions are three-fold: (1) like endothelium it prevents the coagulation of the maternal blood; (2) it allows of transfusion between the blood of fetus and mother; and (3) it assimilates substances from the maternal blood and transfers them to that of the embryo.

**Chorion Læve and Frondosum.**—The villi at first cover the entire surface of the chorion. As the embryo grows more and more out into the uterine cavity the decidua capsularis and that portion of the chorion attached to it are compressed, and the circulation in the intervillous spaces of these structures is cut off (Figs. 234 and 236). Thus, beginning at the pole of the decidua capsularis, the

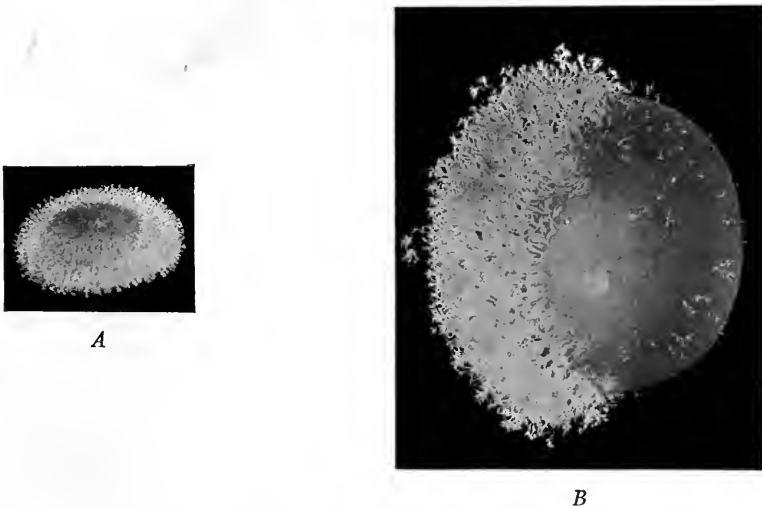


FIG. 236.—Human ova: *A*, of three weeks; *B*, of six weeks, showing formation of chorion læve by degeneration of the chorionic villi (De Lee's Obstetrics).

villi in this portion of the chorion degenerate during the fourth week and form the *chorion læve*. The villi on that part of the chorion which is attached to the decidua basalis continue their development and persisting form the *chorion frondosum*. This, with the decidua basalis of the uterus, constitutes the *placenta*. The embryo is attached first to the chorion frondosum by the body-stalk, later by the umbilical cord (Fig. 234). Through the umbilical vein and arteries in the latter the placental circulation of the embryo takes place.

**The Decidua Vera.**—During the first phase of menstruation the uterine mucosa begins to differentiate into a broad superficial *compact* layer and into a narrower deep *spongy* layer in which are found the dilated ends of the uterine glands. After pregnancy these two layers are still further differentiated in the

wall of the *decidua vera* and *d. basalis*. The *compact layer* is much thicker than the spongy layer and in it are found numerous stroma cells, enlarged blood-vessels and *decidual cells* (Fig. 237). The decidual cells are derived from the stroma cells of the mucosa. They are large, being  $50\ \mu$  in diameter, with clear cytoplasm and vesicular nuclei. Their function is in doubt. Glycogen has been found in them but during the later months of pregnancy many of them degenerate.

In the *spongy layer* of the mucosa occur the enlarged and tortuous uterine glands of pregnancy (Fig. 237). During the first two months of pregnancy the long axes of the glands are perpendicular to the surface of the mucosa. Later, as

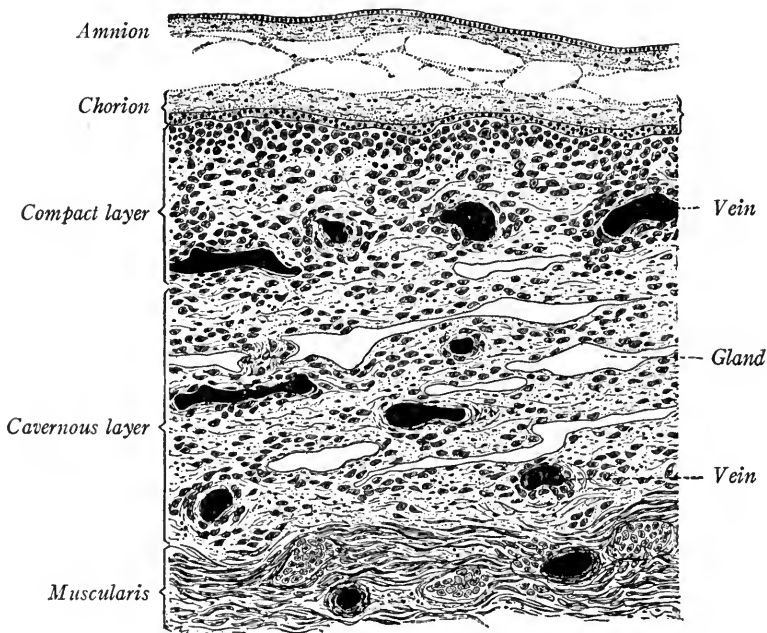


FIG. 237.—Vertical section through the wall of uterus about seven months pregnant with the membranes *in situ* (Schaper in Lewis-Stöhr).  $\times 30$ .

the decidua is stretched and compressed owing to the growth of the fetus, the glands are broadened and shortened and the cavities of the glands become elongated clefts parallel to each other and to the surface of the decidua. The gland cells become stretched and flattened until they resemble endothelial cells. At birth, or in case of late abortion, the plane of separation is in the spongy layer. Only the deep portions of the glands remain attached to the uterine wall and, by the division of their cells, regenerate the epithelium of the uterus.

**The Decidua Capsularis.**—The capsularis, as we have seen, becomes compressed as the embryo grows (Fig. 234). To it is attached the *chorion laeve*, the

villi of which degenerate. With the increased size of the fetus, the capsularis comes into contact with the decidua vera and fuses with it. Eventually it largely degenerates, completely so opposite the internal os uteri, where the chorionic villi are obliterated also. During pregnancy, the lumen of the cervix is closed by a plug formed by the secretion of the glands opening into the cervix uteri.

**The Placenta.**—The placenta is composed of the *decidua basalis*, constituting the maternal placenta, and of the *chorion frondosum*, the *placenta fetalis*. The area throughout which the villi of the chorion frondosum remain attached to the decidua basalis is somewhat circular in form, so that at term the placenta is disc-shaped, about seven inches in diameter and one inch thick (Fig. 238). Near

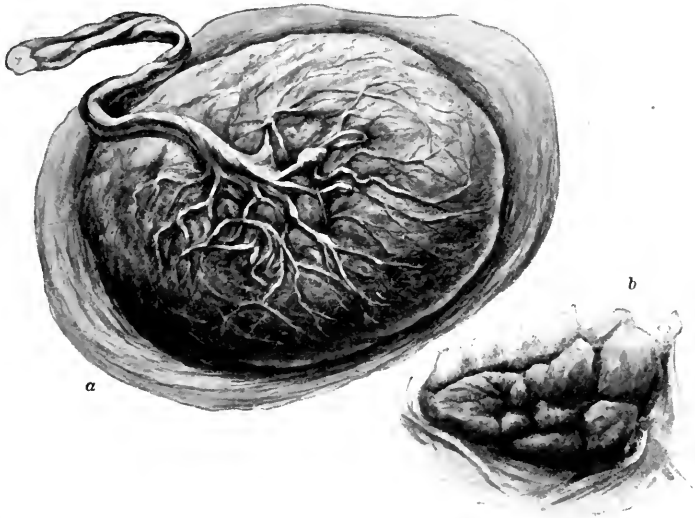


FIG. 238.—Mature placenta: *a*, entire organ, showing fetal surface with membranes attached to the periphery; *b*, a portion of attached surface (Heisler).

the middle of its fetal surface is attached the umbilical cord, and this surface is formed by the amnion, the mesoderm of which is closely applied to and fused with that of the chorion frondosum (Fig. 239).

**Chorion Frondosum.**—The villi of this portion of the chorion form profusely branched tree-like structures which lie in the intervillous spaces (Fig. 240). The ends of some of the villi are attached to the wall of the decidua basalis and are known as the anchoring villi. In the connective tissue core of each villus are usually two arteries and two veins, branches of the umbilical vessels, cells like lymphocytes and special cells of Hofbauer, the significance of which is not known. Lymphatics are also present. The epithelium of the villi, as we have seen, is at

first composed of a layer of trophoblast (of Langhans) with the outlines of its cuboidal cells sharply defined (Fig. 241 A). This layer forms and is covered by a syncytium, the trophoblast. In the later months of pregnancy as the villi

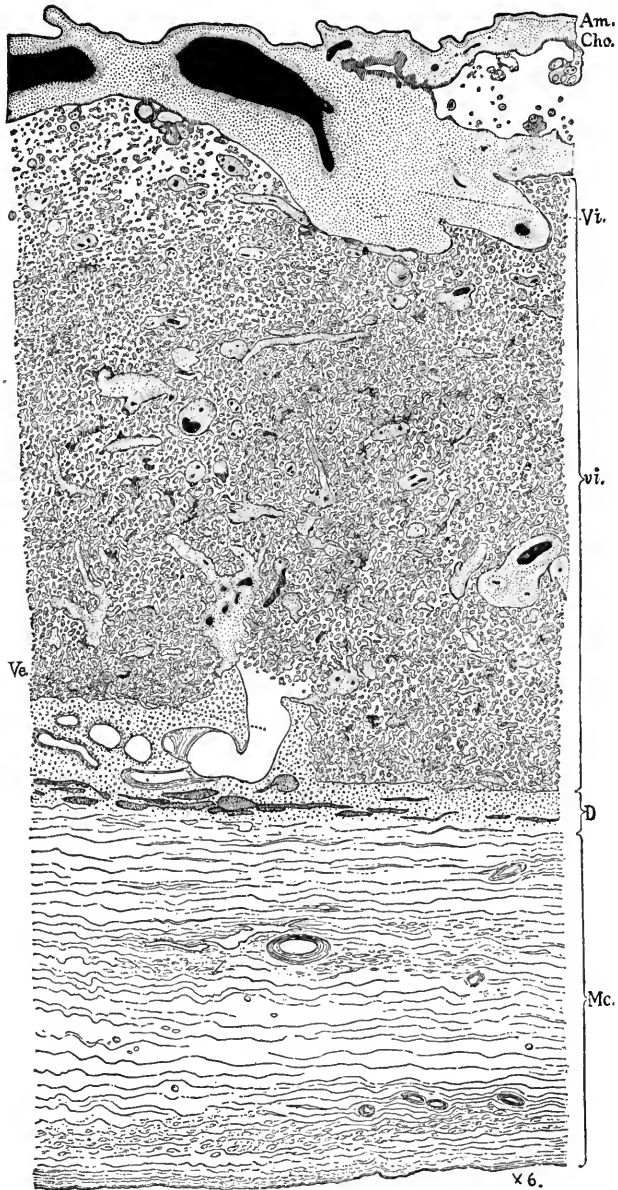


FIG. 239.—Section through a normal placenta of seven months *in situ* (Minot): *Am*, amnion; *Cho*, chorion; *Vi*, root of villus; *vi*, sections of small villi ramifying in the intervillous blood spaces; *D*, deep spongy layer showing remnants of large flattened glands; *Ve*, uterine vessel opening into intervillous spaces; *Mc*, muscular wall of uterus.



grow, the trophoblast is used up in forming the syncytium, so that at term the trophoblast is the only continuous epithelial layer of the villi (Fig. 241 B). About the margin of the placenta the trophoblast persists as the *closing ring*, which is continuous with the epithelium of the chorion laeve. Syncytial giant cells found in the decidua basalis are said to be derived from the trophoblast of the villi,

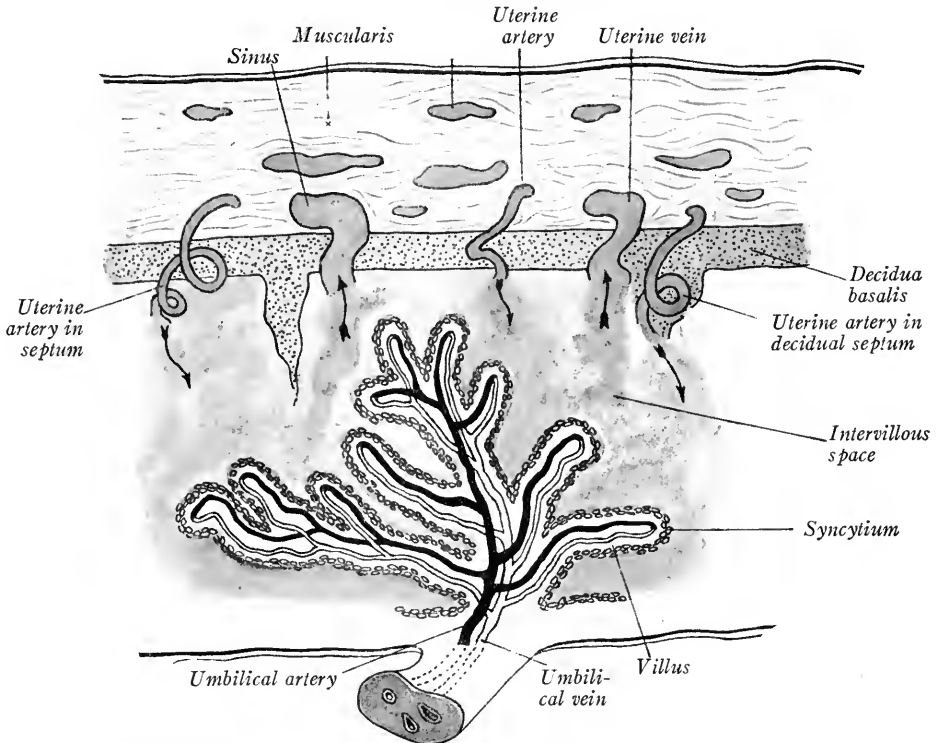


FIG. 240.—Scheme of placental circulation (Kollmann's Handatlas). Arrows indicate supply and exhaust of blood in the intervillous spaces.

also a portion of the *canalized fibrin* found in the decidua basalis of the placenta near term.

*Decidua Basalis.*—This, the maternal placenta, like the decidua vera is differentiated into a *compact layer* or *basal plate* which forms the floor of the intervillous spaces, and into a deep *spongy layer* (Figs. 239 and 240). The first is the remains of the *compact layer* of the uterine mucosa formed during the premenstrual phase and partially destroyed by the implantation of the ovum. The second is the modified *spongy layer* of the premenstrual period and, though thinner, shows the same differentiation as does this same layer in the decidua vera. The glandular spaces are less numerous in the spongy layer of the decidua basalis and between

the spaces occur the syncytial giant cells mentioned above. It is in the plane of this layer that the separation of the placenta takes place at birth.

The *basal plate*, or *compact layer* of the decidua basalis, is composed of a con-

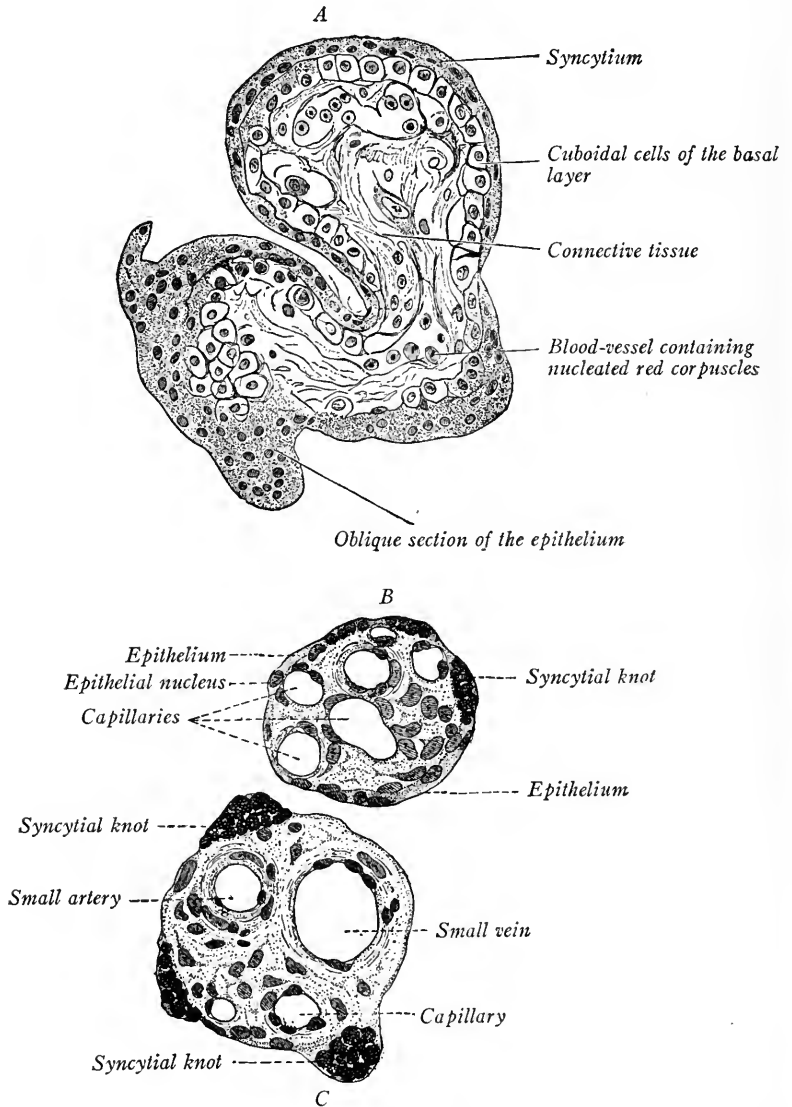


FIG. 241.—Transverse sections of chorionic villi; A, at the fourth week; B, C, at the end of pregnancy (Schaper in Stöhr-Lewis).

nective tissue stroma containing decidual cells, canalized fibrin and persisting portions of the epithelium of the villi. The canalized fibrin is believed to be formed both from the syncytial trophoderm of the villi and from the modified

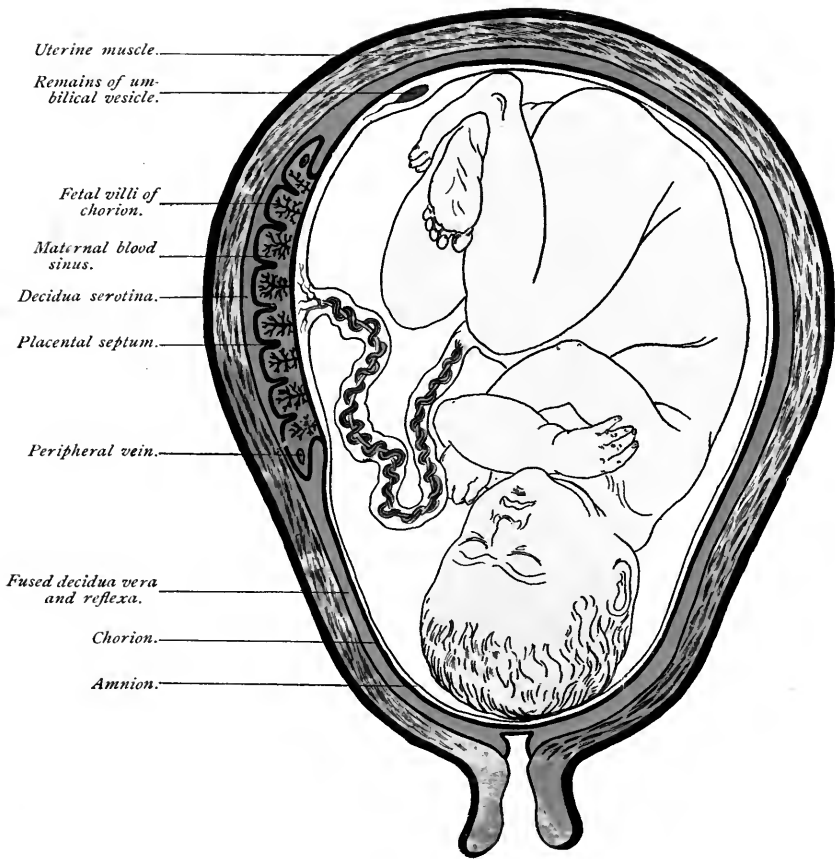


FIG. 242.—Semidiagrammatic section of uterus, showing relations of fetal and maternal placenta (Ahlfeld).  
*Decidua serotina*, decidua basalis; *d. reflexa*, old terminology for *d. capsularis*.



fibrin of the maternal blood. From the basal plate septa extend into the intervillous spaces but do not unite with the chorion frondosum (Grosser in Keibel and Mall, vol. 1, p. 162). Near term these constitute the *septa placentaë* which incompletely divide the placenta into lobules, or *cotyledons* (Fig. 240). The maternal arteries and veins pass through the basal plate, taking a sinuous course and opening into the intervillous spaces. Near their entrance they course obliquely and lose all but their endothelial layers. The original openings of the vessels into the intervillous spaces were formed during the implantation of the ovum, when their walls were eroded by the invading trophoderm of the villi. As the placenta increases in size the vessels grow larger. The ends of the villi are frequently sucked into the veins and interfere with the placental circulation. At the periphery of the placenta is an enlarged intervillous space, which varies in extent and never more than partly surrounds the placenta. This space is the *marginal sinus* through which blood is carried away from the placenta by the maternal veins (Fig. 240). The blood of the mother and fetus does not mix, but the epithelial cells of the villi are instrumental in transferring nutritive substances to the blood of the fetus, and in taking up excreta from the fetal circulation and passing them into the maternal blood stream of the intervillous spaces.

**The Relation of the Fetus to the Placenta and the Separation of the Decidual Membranes at Birth.**—The relation of the embryo to the fetal membranes has been described on p. 80. During the first months of pregnancy the embryo floats in the cavity of the amnion attached to the placenta by the umbilical cord (Fig. 234). Later, as we have seen, the amnion fuses more or less completely to the chorion frondosum and læve. The decidua capsularis largely disappears or is fused to the decidua vera. Before birth, the placenta is concave on its amniotic surface, its curvature corresponding to that of the uterus (Fig. 242). At term, the duration of which is taken as ten lunar months, the muscular contractions of the uterus, termed “pains,” bring about a dilation of the cervix uteri, the rupture of the amnion and chorion læve, and cause the extrusion of the child. With the rupture of the membranes the amniotic liquor is expelled, the fetal membranes remaining attached to the decidual membranes. The pains of labor begin the detachment of the decidual membranes, the plane of their separation lying in the spongy layer of the decidua basalis and decidua vera, where there are only thin-walled partitions between the enlarged glands. Following the birth of the child, the tension of the umbilical cord and the “after pains” which diminish the size of the uterus, normally complete the separation of the decidual membranes from the wall of the uterus. The uterine contractions serve also to diminish the size

of the ruptured placental vessels and prevent extensive hemorrhage. From the persisting portions of the spongy layer and from the epithelium of the glands the tunica propria, glands, and epithelium of the uterine mucosa are regenerated.

The decidual membranes and the structures attached to them when expelled constitute the "after-birth." The placenta usually is everted so that its amniotic surface is convex, its maternal surface concave. It is composed of the amnion, chorion frondosum, villi with intervillous spaces incompletely divided by the septa into cotyledons, and bounded on the maternal side by the basal plate and a portion of the spongy layer of the decidua basalis. The amnion is usually attached to the chorion but may be free and, failing to rupture, surround the child at birth as the "caul." Near the center of the placenta is attached the umbilical cord, and at its margins the placenta is continuous with the decidua vera and the remains of the chorion læve and decidua capsularis.

**The Position of the Placenta in Utero and its Variations.**—The position of the placenta is determined by the point at which embryo is implanted. In most cases it is situated on either the dorsal or ventral wall of the uterus. Occasionally it is lateral in position and very rarely (1 in 1600 cases) it is located near the cervix and covers the internal os uteri, constituting a *placenta prævia*. A partially or wholly duplicated placenta may be formed by the development of two groups of villi. Cases have been observed in which from three to seven subdivisions of the placenta occurred.

## CHAPTER IX

### THE DEVELOPMENT OF THE VASCULAR SYSTEM

#### I. PRIMITIVE BLOOD-VESSELS AND BLOOD-CELLS

The blood-cells and primitive blood-vessels arise from a tissue termed by His the *angioblast*. Its origin has been in doubt. According to Minot (in Keibel and Mall, vol. 2), it arises in the wall of the yolk-sac from the endoderm and from it endothelial sprouts grow into the body of the embryo. Another view as to its origin, more recently championed by Maximow, Felix, Schulte and Bremer, is that the angioblast arises from the mesoderm. The angioblast consists of a network of solid cords of cells which appear first in the splanchnic mesoderm of the chorion and yolk-sac. In human embryos with a medullary plate about 1 mm. in length, Bremer (Anat. Record, vol. 8, p. 97, 1914) finds a network of angioblast in the chorion, chorionic villi and body-stalk. This chorionic angioblast antedates in one case that developed in the yolk-sac and thus must develop independently from the splanchnic mesoderm. The solid cords of angioblast soon hollow out, the peripheral cells forming the *endothelium of the primitive vessels*, the inner cells persisting as the *primitive blood-cells* or *mesamœboids* of Minot. By the union of the isolated vascular spaces, the cellular network is soon converted into a vascular network. In the wall of the yolk-sac this network forms the *area vasculosa* (Fig. 74), in which aggregations of blood-cells form the *blood-islands*.

#### THE PRIMITIVE BLOOD-CELLS OR MESAMŒBOIDS (MINOT)

These show large vesicular nuclei surrounded by a small amount of finely granular cytoplasm (Fig. 243 a). They are without a cell membrane and are assumed to be amœboid. During embryonic life, the mesamœboid cells multiply rapidly by mitosis and develop successively in the wall of the yolk-sac, in the liver, in the lymphoid organs and in the red bone marrow.

Minot (in Keibel and Mall) and many embryologists hold at the present time that the blood-forming cells of the adult are derived directly from the mesamœboid cells of the embryo. Maximow (Archiv. f. mikr. Anat., vols. 67 and 73, pp. 680-757, and 444-561) maintains that blood-forming cells may take their origin from the mesodermal cells in embryos and also from mesenchymal cells of the adult connective tissue. From what is now known of the origin of the primitive blood-cells Maximow's view seems to be the more plausible of the two.

**Origin of the Erythrocytes (Red Blood Corpuscles).**—These take their origin from the mesamœboid cells of the embryo and from the *premyelocytes* of adult connective tissue and bone marrow as *erythroblasts*.

1. *Erythroblasts* (ichthyoid blood-cells of Minot, so-called because they are

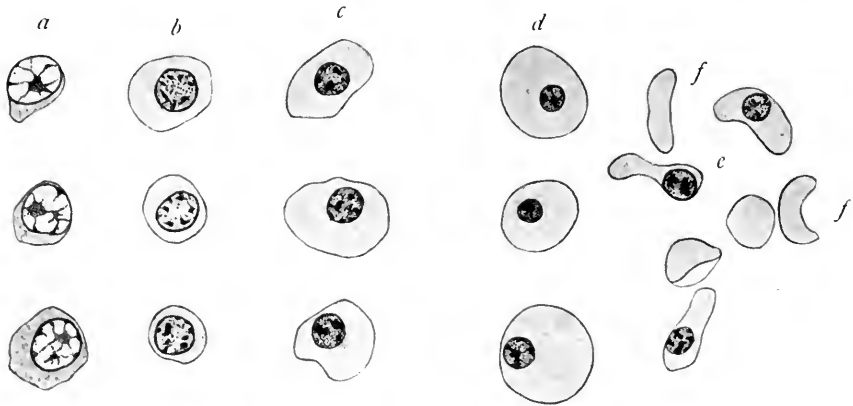


FIG. 243.—Blood-cells from embryos of 12 and 20 mm.  $\times 1160$ . *a*, primitive mesamœboid cells; *b*, ichthyoid cells or erythroblasts; *c*, sauroid cells; *d*, sauroid cells; *e*, cup-shaped nucleated cells; *f*, erythrocytes. *a*, *b* and *c* are from a 12 mm. human embryo; *d*, *e*, and *f*, from a 20 mm. embryo.

the typical red blood-cells of fishes), are characterized by the presence of hemoglobin in the homogeneous cytoplasm, which is thus colored red. The nuclei are vesicular with granular chromatin (Fig. 243 *b*). There is a definite cell membrane. The erythroblasts are the only red blood-cells of the first month of embryonic development, occurring in embryos of 10 mm.

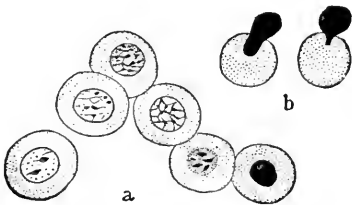


FIG. 244.—The development of red corpuscles in cat embryos (Howell). *a*, successive stages in the development of a normoblast; *b*, the extrusion of the nucleus.

2. *Normoblasts*, termed sauroid blood-cells because they are the red blood-cells of adult reptiles, are first formed in the liver from the erythroblasts in embryos of the second month, and are predominant at this stage. They are distinguished by their small round nuclei with dense chromatin which stains so

heavily that little or no structure can be seen (Fig. 243 *c*, *d*). The cytoplasm is larger in amount than in erythroblasts.

According to Maximow, the primitive erythroblasts in rabbit embryos all degenerate and the normoblasts are developed as a new generation of cells from primitive lymphocytes (mesamœboids of Minot).





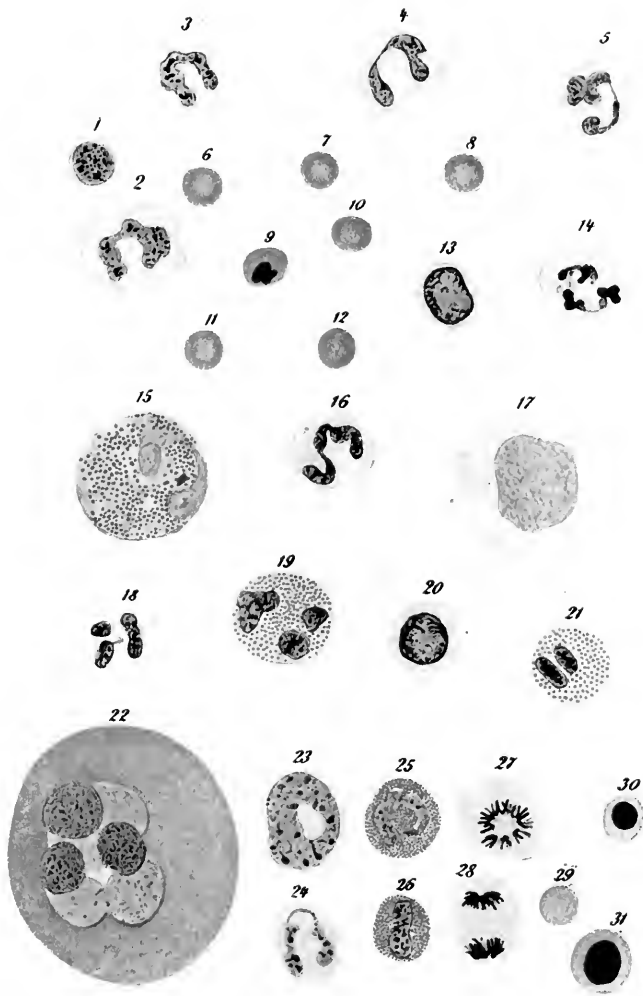


FIG. 245.—Human blood cells, 1-21; cells from the red bone marrow of the mouse, 22-31 (Sobotta). 6-12, erythrocytes, 9 showing a nucleus; 1, lymphocyte; 2, 3, 4, 5, 14, 16, 18, neutrophilic polymorphonuclear leucocytes; 15, 19, 21, eosinophiles; 13, 17, 20, mononuclear leucocytes; 22, giant marrow cell; 23, 24, neutrophiles of marrow; 25, 26, eosinophiles of marrow; 27, 28, cells in mitosis; 29, erythrocyte; 30, 31, erythroblasts ( $\times 700$ ).

3. *Erythrocytes* (red blood corpuscles, blood plastids) (Minot) are developed in mammals from normoblasts which lose their nuclei by extrusion (Fig. 243 F). The nucleus may be extruded as several small granules or as a whole (Fig. 244).

*Emmel* (*Amer. Jour. Anat.*, vol. 16) has studied cultures of blood-cells from pig embryos and has observed the formation of bodies resembling erythrocytes by the fission of the cytoplasm. He suggests that this may be their normal method of development in the embryo.

The first red blood corpuscles are spherical and are formed during the second month chiefly in the liver. During the third month the enucleated erythrocytes predominate and are disc-like or cup-shaped in form (Fig. 243 f). During the later months of fetal life, the red blood corpuscles are developed in the liver, in the red bone marrow and possibly in the spleen. According to the view of Minot, the cells from which they take their origin are mesamæboids which have lodged in the blood-forming organs and undergo cell division and differentiation there. In the bone-marrow these cells are known as *premyelocytes*. They differentiate into both *erythroblasts* and *myelocytes*; from the former normoblasts and erythrocytes arise; from the myelocytes the granular leucocytes are developed. Soon after birth the red bone marrow is the only source of new red blood corpuscles.

**Origin of the Leucocytes**, or white blood-cells (Fig. 245).—These are divided into non-granular and granular types. It is assumed that both types are derived from the primitive mesamæboid cells of the embryo.

#### I. *Non-granular Leucocytes*.

1. *Small lymphocytes* (22 to 25 per cent. of the leucocytes in adult blood) are regarded as young leucocytes. They vary from 4 to 7.5  $\mu$  in diameter and are developed in the lymphoid organs of the embryo and adult. The large nuclei containing several connected masses of chromatin stain darkly and are surrounded by a narrow zone of clear basic cytoplasm.

2. *Large mononuclear leucocytes* (1 to 3 per cent. of leucocytes) are developed from the endothelial cells lining the medullary sinuses of the lymph glands. This may be demonstrated by *intra vitam* staining with trypan blue (*Evans, Anat. Record*, vol. 8, p. 99, 1914).

#### II. *Granular or Polymorphonuclear Leucocytes*.

The blood-forming cells lodged in the red bone marrow are known as *premyelocytes*. They give rise to *myelocytes*, cells with round or crescentic nuclei and granular cytoplasm. Similar cells are developed in the lymphoid organs. By undergoing changes (1) in the form and structure of their nuclei, (2) in the size

and staining qualities of their cytoplasmic granules, the myelocytes give rise to three types of granular leucocytes:

1. *Neutrophiles*, or leucocytes with a finely granular cytoplasm which is neutral in its staining reactions, coloring slightly with both acid and basic stains. In development, their nuclei take up an eccentric position and become crescentic, horse-shoe shaped, or in the older stages moniliform (three or four pieces linked together). As it changes in form the nucleus undergoes pyknosis and stains intensely. Neutrophiles are produced in the bone marrow of the embryo during the fifth month. In the human adult they form 70 to 72 per cent. of the leucocytes in normal circulation.

2. *Eosinophiles*, or coarsely granular leucocytes, are characterized by their large cytoplasmic granules which stain intensely red with eosin. In development the nucleus becomes bilobed. Eosinophiles form 2 to 4 per cent. of the leucocytes in normal human blood.

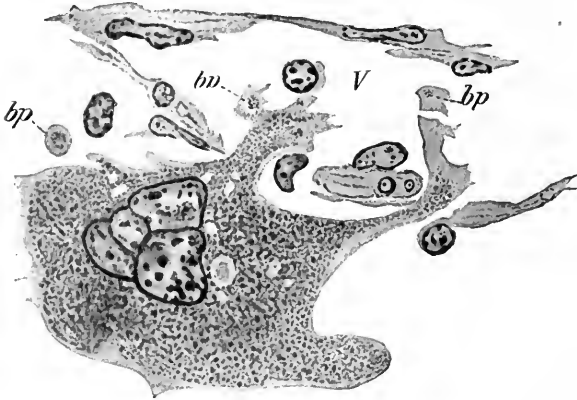


FIG. 246.—Giant cell from the bone marrow of a kitten, showing pseudopodia extending into a blood-vessel (*V*), and giving rise to blood-plates (*bp*) (J. H. Wright).

According to Weidenreich (*Arch. f. mikr. Anat.*, vol. 82, pp. 282–286), the eosinophilic granules are not endogenous but are fragments of red blood corpuscles which have been ingested by the leucocytes, or are formed from hemoglobin derivatives. Baderscher (*Amer. Jour. Anat.*, 1913,

vol. 15, pp. 69–86) finds in the vicinity of degenerating muscle fibers in salamanders numerous eosinophiles. Also during trichiniasis in man, when there is extensive degeneration of muscle fibers, the number of eosinophiles in the blood becomes greatly increased. Downey (*Anat. Record*, vol. 8, p. 135, 1914) finds that the granules of eosinophilic myelocytes differentiate from a non-granular cytoplasm. These basophilic granules become eosinophilic.

3. *Basophiles*, or *Mast Leucocytes* (Maximow), form only 0.5 per cent. of the leucocytes. Their nuclei are very irregular in form and may be broken down into several pieces which stain intensely. The granules are variable in number, size and form, and often stain so heavily as to obscure the nucleus. The cytoplasm is clear and vacuolated. Basophiles have been regarded as degenerating granular leucocytes but at present this view is not generally accepted.

**Origin of the Blood Plates.**—In the bone marrow and spleen pulp are *giant*

cells, the cytoplasm of which shows a darkly staining granular endoplasm and a clear hyaline exoplasm (Fig. 246). According to Wright (*Jour. Morphol.*, vol. 21, pp. 265-278), the blood plates arise by being pinched off from cytoplasmic processes of the giant cells. Wright has shown that genuine blood plates and giant cells occur only in mammals.

The granules of the plates are interpreted by Wright as derived from the endoplasm of the giant cells and stain in a similar manner. This view has been generally accepted by American embryologists who have seen Wright's preparations. Schäfer regards the blood plates as minute cells, and the granular endoplasm of Wright as a small nucleus.

#### EARLY DEVELOPMENT OF THE HEART AND PAIRED BLOOD-VESSELS

We have seen that the first blood-cells and blood-vessels take their origin in the angioblast, which develops in the wall of the yolk-sac and chorion probably from the splanchnic mesoderm. The first vessels derived from the angioblast (see p. 251) are small isolated blood spaces which unite and form capillary networks. From these endothelial sprouts grow out, meet and unite until complete networks are formed. In human embryos of 1 mm. or less these envelop the lower portion of the yolk-sac, the body-stalk and chorion. The origin of the heart and paired vascular trunks of human embryos is in doubt, but some facts are certain from our study of their development in birds and mammals.

According to His and Minot, all the blood-vessels of the embryonic body arise as endothelial ingrowths from the primitive vascular area of the yolk-sac. According to the investigations of Mollier (*Hertwig's Handb.*, vol. i, 1906), in all vertebrates the endothelial anlage of the heart is represented by cells which appear independent of the vascular area between the entoderm and the mesoderm in the distal portion of the head. These vascular cells occur as paired anlages. According to Mollier, vascular anlages arise *in situ* and give rise to the endothelium of the heart. Similarly other vascular anlages form the primitive aortic trunks.

Evans (*Amer. Jour. Anat.*, vol. ix, 1909) by injecting young chick embryos has shown conclusively that most of the descending aorta "is formed from the medial margin of the vitelline capillary plexus." In mammals, connection of the same plexus with the descending aorta has been demonstrated by Tursing. Bremer (*Amer. Jour. Anat.*, vol. 13, 1912, pp. 111-128) in summarizing his work on the development of the aorta and aortic arches in the rabbit says: "The dorsal aorta, the first aortic arch, the conus arteriosus, and the lateral heart are all parts of an original network of angioblast cords derived from the extra-embryonic plexus of blood-vessels."

Bremer points out that as the true vessels with cavities develop they are connected by intervening cords of the angioblast. This connection cannot be demonstrated by injection

methods. He believes that Mollier and Tursting have overlooked the angioblast cords between the capillary spaces and have thus described them as vascular anlagen independent of the extraembryonic plexus.

It thus seems probable that the endothelium of the primitive heart and vessels has a common origin from the endothelial cells of the area vasculosa. After the development of the endocardium and primitive aortæ it is certain that most

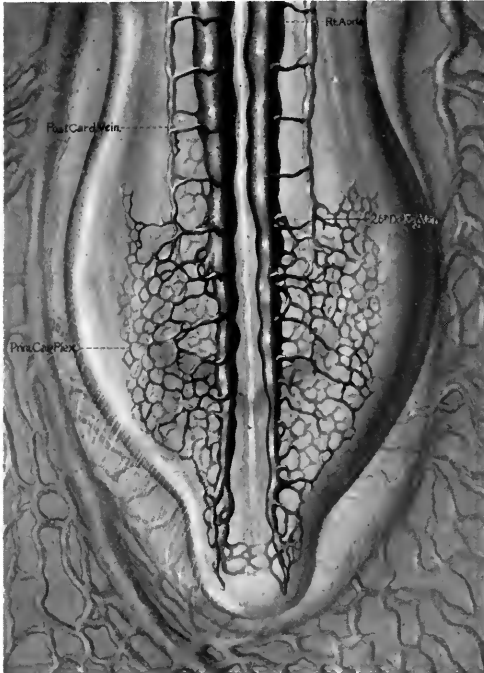


FIG. 247.—The caudal end of a chick embryo of 32 somites, showing the primary capillary plexus in the posterior limb buds. *26th Dor. Seg. Vein*, twenty-sixth dorsal segmental vein, *i. e.*, that in the twenty-seventh interspace (Evans).

other vascular trunks are formed first as capillary plexuses. By enlargement and differentiation of definite paths in such a capillary plexus the arterial and venous trunks are developed. By the injection methods of Mall and his students such capillary plexuses have been demonstrated in the limb buds, in the head and in many organs of chick and pig embryos (Fig. 247). Exceptions to the general rule are the intersegmental arteries which arise as single trunks from the aorta (Evans in Keibel and Mall, vol. 2).

#### Origin of the Tubular Heart.—

In chick and mammalian embryos it is known that paired endothelial anlagen of the heart bulge into a fold of the splanchnic mesoderm on each side when the embryo is still flattened on the surface of the yolk (Fig. 248, *A*). Paired endothelial anlagen are present in the Spee human embryo 1.54 mm. long. As the embryo grows away from the yolk, and the head-fold elongates, the entoderm is withdrawn from between the endothelial anlagen and these at once fuse (Fig. 248, *B, C*). The heart is now an unpaired endothelial tube lying in the folds of the splanchnic mesoderm. Soon the ventral attachment of the mesoderm disappears, leaving the heart suspended by the *dorsal mesocardium* in the single pericardial chamber (Fig. 248, *C*). The endothelial tube forms the *endocardium*, the splanchnic mesoderm later gives rise to the *epicardium*

and *myocardium* (muscle layer of heart). This type of heart occurs in human embryos of 2 mm. and 5 and 6 somites (Fig. 249) and shows three regions: (1) the *atrium*, which receives the blood from the primitive veins, (2) the *ventricle*, (3) the *bulb*, from which is given off the ventral aorta.

As the cardiac tube grows faster than the pericardial cavity in which it lies

it bends to the right, the bulbus and ventricle forming a U-shaped loop (Fig. 250, A, B). Four regions may now be distinguished: (1) the *sinus venosus*; (2) the *atrium*, also thin walled and lying cranial to the sinus; (3) the thick-walled *ventricular limb*, ventrad and caudad in position; (4) the *bulbar limb*, cranial

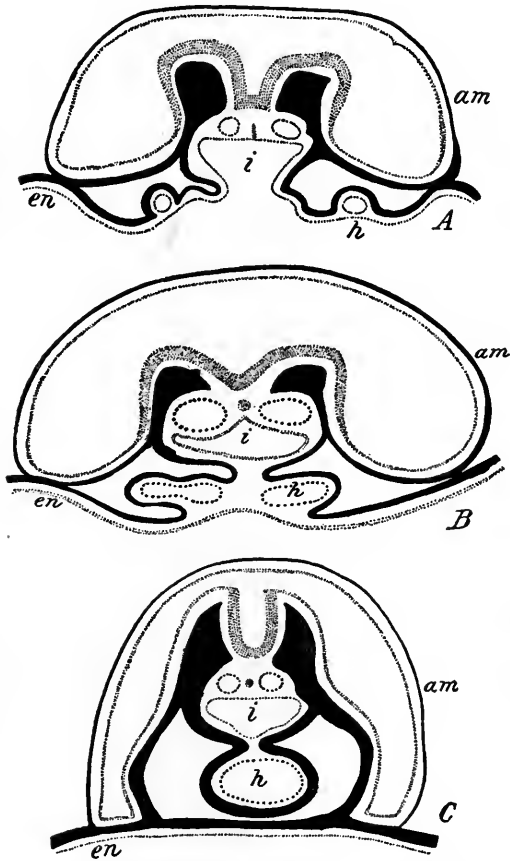


FIG. 248.—Diagrams to illustrate the origin of the tubular heart (Strahl and Carius, from McMurrich's "Development of Human Body"). *am*, amnion; *en*, entoderm; *h*, heart; *i*, digestive tract.

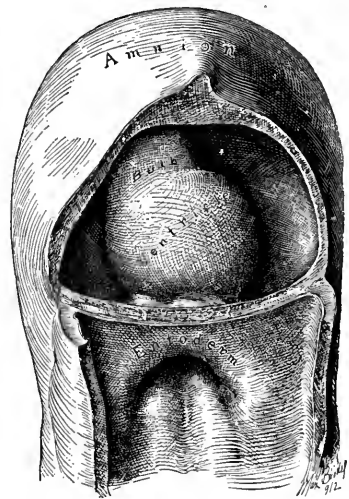


FIG. 249.—The heart of a 2 mm. human embryo in ventral view (Mall).

to the ventricular limb and separated from it by the bulbo-ventricular cleft. Next in embryos of 3 to 4 mm. the bulbo-ventricular loop shifts its position until its base is directed caudad and ventrad (Fig. 250, B). At the same time the sinus venosus is brought dorsal to the atrium, which in turn is cranial with relation to the bulbo-ventricular loop, and the bulbar limb is pressed against the ventral surface of the atrium and constricts it.

In embryos of 4 to 5 mm. the right portion of the sinus venosus grows more rapidly than the left, this being due to the fact that the blood flow of the left umbilical vein is shifted to the right side through the liver. As a result the enlarged right horn of the sinus opens into the right dorsal wall of the atrium through a longitudinally oval foramen, which is guarded on the right by a vertical fold.

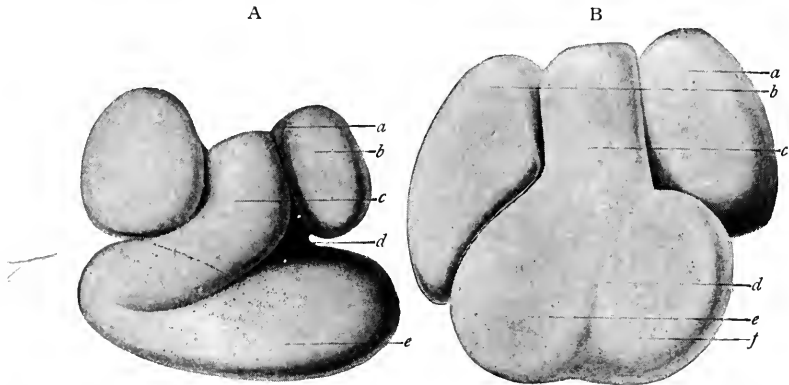


FIG. 250.—*A*, heart of human embryo of 2.15 mm. (His): *a*, bulbus cordis; *b*, primitive ventricle; *c*, atrial portion. *B*, heart of human embryo of about 3 mm. (His): *a*, bulbus cordis; *b*, atrial portion (behind); *c*, primitive ventricle (in front).

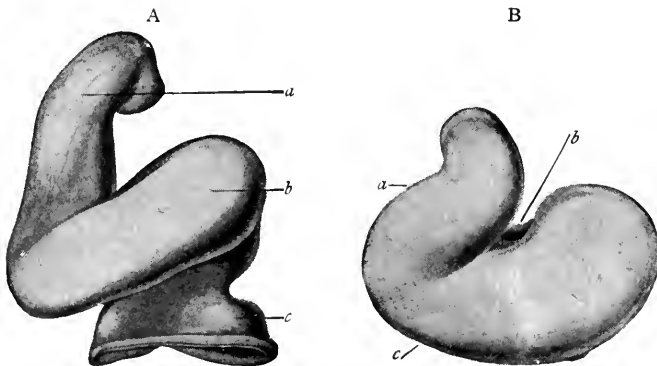


FIG. 251.—*A*, heart of human embryo of about 4.3 mm. (His): *a*, atrium; *b*, portion of atrium corresponding with auricular appendage; *c*, bulbus cordis; *d*, atrial canal; *e*, primitive ventricle. *B*, heart of human embryo of about the fifth week (His): *a*, left atrium; *b*, right atrium; *c*, bulbus cordis; *d*, interventricular groove; *e*, right ventricle; *f*, left ventricle.

This fold, which projects into the atrium, is the *right valve of the sinus venosus*. Later, a smaller fold forms the *left valve of the sinus venosus* (Fig. 253, *B*). The atrium is constricted dorsally by the gut, ventrad by the bulbus. It therefore must enlarge laterally and in so doing forms the *right and left atria* (Fig. 251, *A*, *B*) with the distal portion of the bulb between them. The deep external groove



between the atria and the bulbo-ventricular part of the heart is the *coronary sulcus*. As the bulbo-ventricular region increases in size, the duplication of the wall between the two limbs lags behind in development and finally disappears (Fig. 252 *a, b*), leaving the proximal portion of the bulb and the ventricular limb to form a single chamber, the *primitive ventricle*. In an embryo of 5 mm. the heart is thus composed of three undivided chambers: (1) the sinus venosus opening dorsad into the right dilation of the atrium; (2) the bilaterally dilated *atrium* opening by the single transverse *atrial canal* into (3) the primitive undivided ventricle. The three-chambered heart is persistent in adult fishes, but in birds and mammals a four-chambered heart is developed in which circulates venous blood on the right and arterial blood on the left.

The important changes leading to the formation of the four-chambered heart

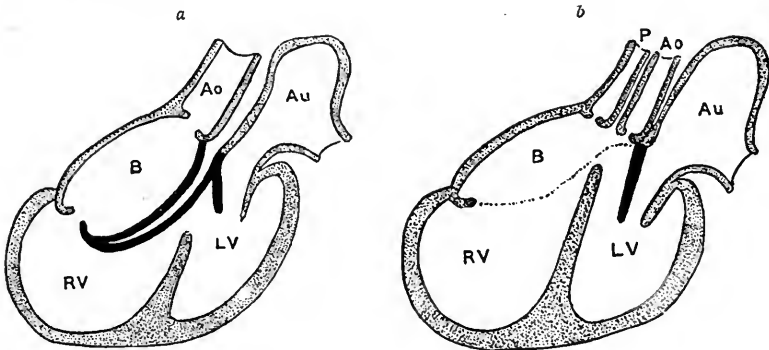


FIG. 252.—Reduction of the bulbo-ventricular fold of the heart (Keith). *Ao*, aortic bulb; *Au*, atrium; *B*, bulbus cordis; *RV*, right ventricle; *LV*, left ventricle; *P* (in *b*) pulmonary artery.

are: (1) the complete division of the atrium and ventricle, each into right and left chambers; (2) the division of the bulb and truncus arteriosus into the aorta and pulmonary artery; (3) the absorption of the sinus venosus into the wall of the right atrium; (4) the development of the semilunar and atrio-ventricular valves. The first of these changes is completed only after birth.

**Endocardial Cushions and Atrial Septa.**—In embryos of 5 to 7 mm. there develops a thin sickle-like membrane from the mid-dorsal wall of the atrium (Figs. 253 and 254). This is called the *atrial septum primum* (*I*). Simultaneously, endothelial thickenings appear in the dorsal and ventral walls of the atrial canal (Fig. 254, *A, B*). These are the *endocardial cushions* which later fuse, thus dividing the single atrial canal into *right* and *left atrio-ventricular canals*. The atrium is now partly divided into right and left atria which, however, communicate ven-

trad through the *interatrial foramen*. Next in embryos of 9 mm. the *septum I* thins out dorsad and cephalad and a second opening appears, the *foramen ovale* (Figs. 253 and 254, *B*). The atria are now connected by two openings, the *interatrial foramen* and the *foramen ovale*. Soon (embryos of 10 to 12 mm.) the ven-

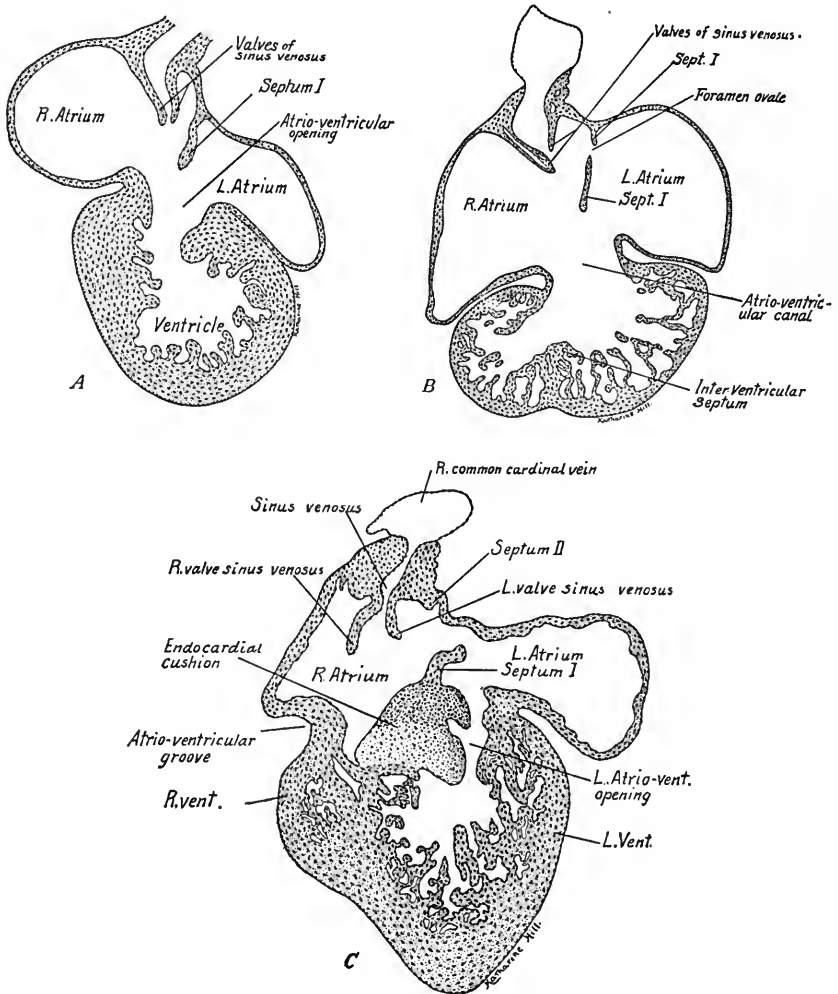


FIG. 253.—Oblique transverse sections of heart wall: *A*, 6 mm.; *B*, 9 mm.; *C*, 12 mm. (*A* and *B* are based on figures of Tandler).

tral and caudal edge of *septum I* fuses with the endocardial cushions, which have in turn united with each other (Figs. 253 and 254, *C*). The interatrial foramen is thus obliterated, but the foramen ovale persists until after birth. In embryos of 9 mm. the *septum secundum* is developed from the dorsal and cephalic wall of the atrium just to the right of the septum primum (Fig. 253, *C*). It is impor-

tant, as it later fuses with the left valve of the sinus venosus and with it forms a great part of the atrial septum of the late fetal and adult heart.

**Sinus Venosus and its Valves.**—The opening of the sinus venosus into the

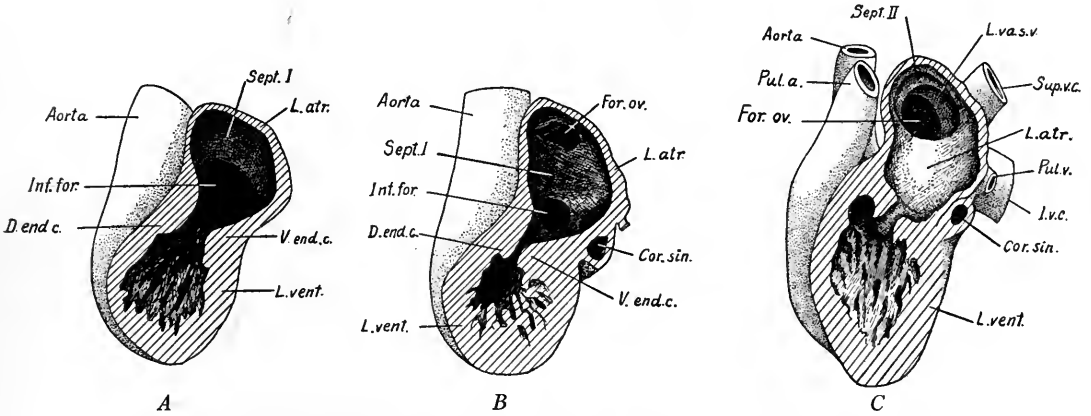


FIG. 254.—Lateral dissections of the heart from the left side. *A*, 6 mm.; *B*, 9 mm.; *C*, 12 mm. (*A* and *B* are based on reconstructions by Tandler). *Cor. sin.*, coronary sinus; *D. end. c.*, dorsal endocardial cushion; *For. ov.*, foramen ovale; *Inf. for.*, interatrial foramen; *I. v. c.*, inferior vena cava; *L. atr.*, left atrium; *L. va. s. v.*, left valve of sinus venosus; *L. vent.*, left ventricle; *Pul. a.*, pulmonary artery; *Pul. v.*, pulmonary vein; *Sept. I*, *Sept. II*, septum primum, septum secundum; *Sup. v. c.*, superior vena cava; *V. end. c.*, ventral endocardial cushion.

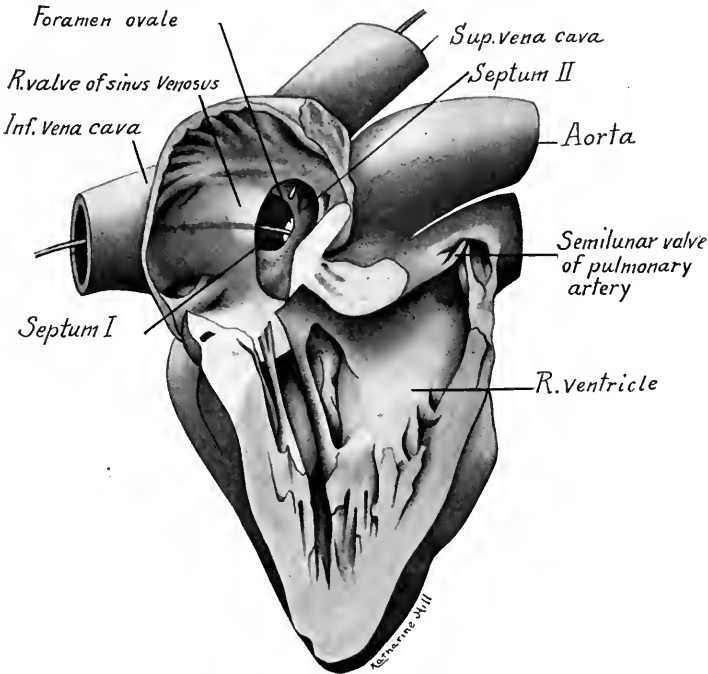


FIG. 255.—Dissection of the heart of a 65 mm. embryo from the right side.  $\times 12$ .

dorsal wall of the right atrium is guarded by two valves (Fig. 253). Along the dorsal and cephalic wall of the atrium these unite to form the *septum spurium*. Caudally the valves flatten out on the floor of the atrium, but the left valve later becomes continuous with the atrial septum II. In embryos of 10 to 20 mm. the atria increase rapidly in size and the right horn of the sinus venosus is taken up into the wall of the right atrium. The superior vena cava now opens directly into the cephalic wall of the atrium, the inferior vena cava into its caudal wall.

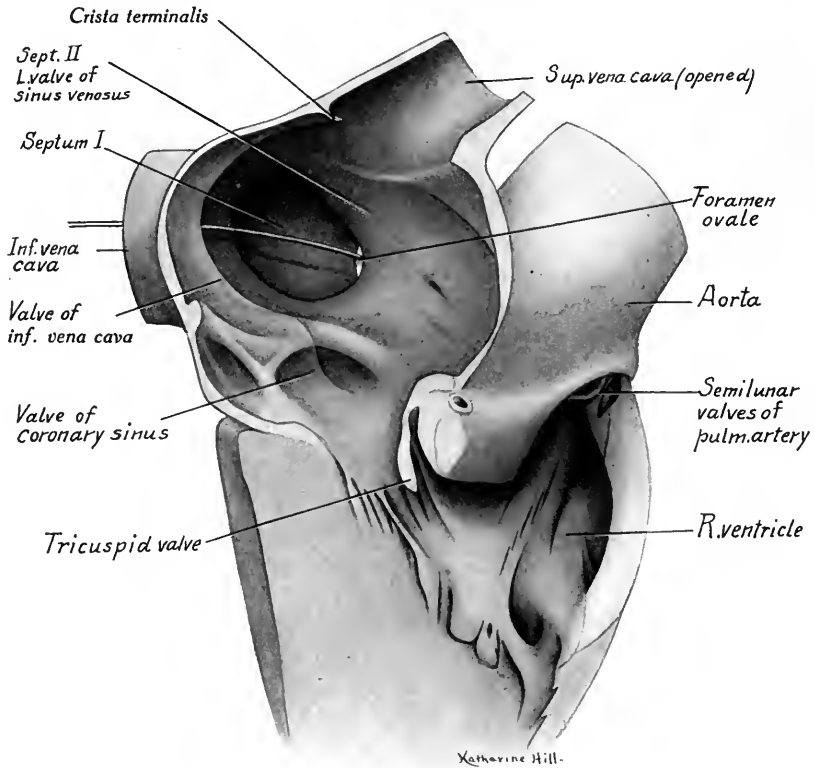


FIG. 256.—Dissection of the heart of a 105 mm. fetus from the right side.  $\times 7$ .

The transverse portion of the sinus venosus, as the persisting *coronary sinus*, opens into the posterior wall of the atrium.

The *right valve of the sinus venosus* is very high in 10 to 65 mm. embryos (first to third month) and nearly divides the atrium into two chambers (Fig. 255). It becomes relatively lower during the third and fourth months. Its cephalic portion becomes the rudimentary *crista terminalis* (Fig. 256); the remainder is divided by a ridge into two parts, of which the larger cephalic division persists as the *valve of the inferior vena cava* (Eustachian valve) located at the right of the

opening of the vein, and the smaller caudal portion becomes the *valve of the coronary sinus* (Thebesian valve).

The *left valve* of the sinus venosus becomes continuous with the septum secundum and in embryos of 20 to 22 mm. or larger the two bound an oval opening (Figs. 257 and 258). The bounding wall of the oval aperture is the *limbus ovalis*.

**Closure of the Foramen Ovale.**—The free edge of septum I is, in embryos of 10 to 15 mm., directed dorsad and cephalad (Fig. 254, C). Gradually in later stages (Figs. 257 and 258) its caudal and dorsal prolongation grows cephalad and

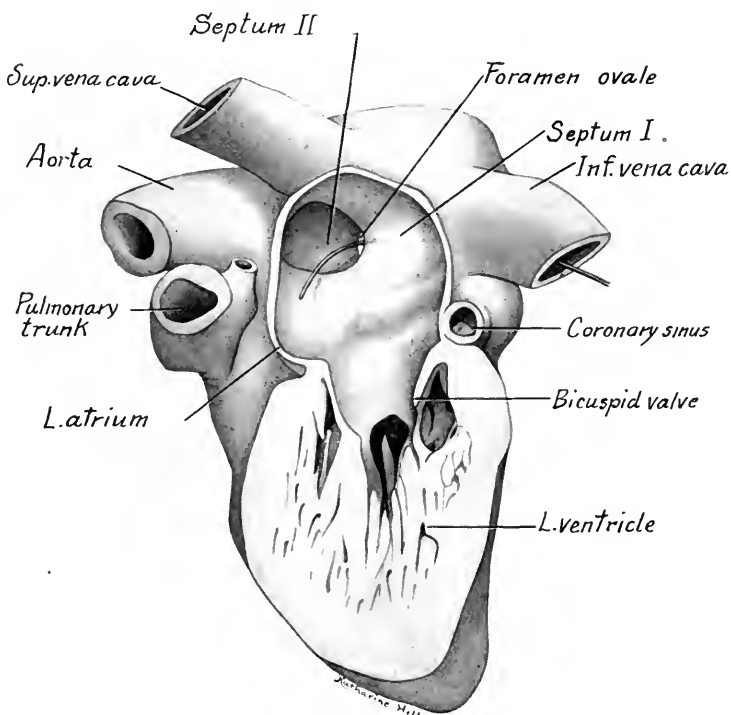


FIG. 257.—Dissection of the heart of a 65 mm. embryo, from the left side, showing the septa and the foramen ovale.  $\times 8$ .

ventrad until its free edge is so directed. *Pari passu* with this change the septum II with its free edge directed at first ventrad and caudad shifts until its free edge is directed dorsad and cephalad, and overlaps the septum I (Figs. 254, C, 257, 258). The opening between these septa persists until after birth as the foramen ovale.

During fetal life the left atrium receives little blood from the lungs, so that the pressure is much greater in the right atrium. As a result, the septum I is pushed to the left and the blood flows from the right into the left atrium through the foramen ovale. After birth the left atrium receives from the expanding lungs

as much blood as the right atrium, the septum I is pressed against the limbus of septum II, and soon fuses with it. The depression formed by the thinner walled septum I is the *fossa ovalis*.

The foramen ovale may fail to close soon after birth and the mixed blood produces a purplish hue in the child which is known popularly as a "blue baby." This condition may be persistent in adult life.

*Pulmonary Veins.*—In embryos of 6 to 7 mm. a single vein grows out from the caudal wall of the left atrium to the left of the septum I. This vein bifurcates

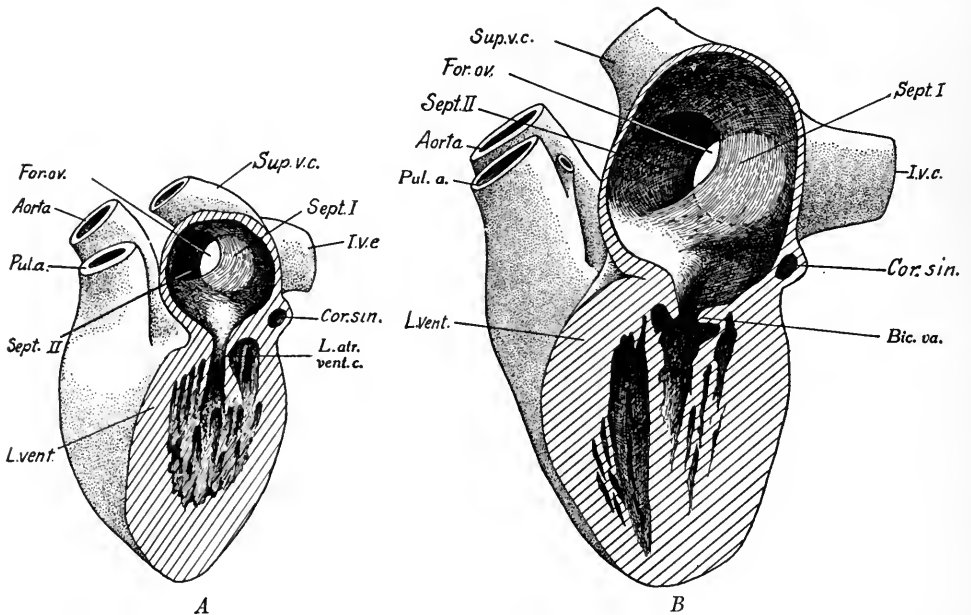


FIG. 258.—Dissections from the left side of human hearts: *A*, from a 22 mm. embryo; *B*, from a 105 mm. embryo. *Cor. sin.*, coronary sinus; *For. ov.*, foramen ovale; *I.v.c.*, inferior vena cava; *L. atr. vent. c.*, left atrio-ventricular canal; *L. vent.*, left ventricle; *Pul. a.*, pulmonary artery; *Sept. I*, *Sept. II*, septum primum and septum secundum; *Bic. va.*, bicuspid valve.

into right and left pulmonary veins which divide again before entering the lungs. As the atrium grows, the proximal portion of the pulmonary vein is taken up into the atrial wall. As a result, at first two, then four, pulmonary veins open into the left atrium.

**Origin of the Right and Left Ventricles.**—In embryos of 5 to 6 mm. there appears at the base of the primitive ventricular cavity a sagittally placed elevation, the *interventricular septum* (Fig. 253, *B*). It later grows cephalad and dorsad toward the endocardial cushions, and forms an incomplete partition between the right and left ventricles, which still communicate through the persisting *inter-*

*ventricular foramen*. Corresponding to the internal attachment of the septum there is formed externally the *interventricular sulcus* which marks the external line of separation between the large left ventricle and the smaller right ventricle.

**Origin of Aorta and Pulmonary Artery from Bulbus.**—Coincident with the

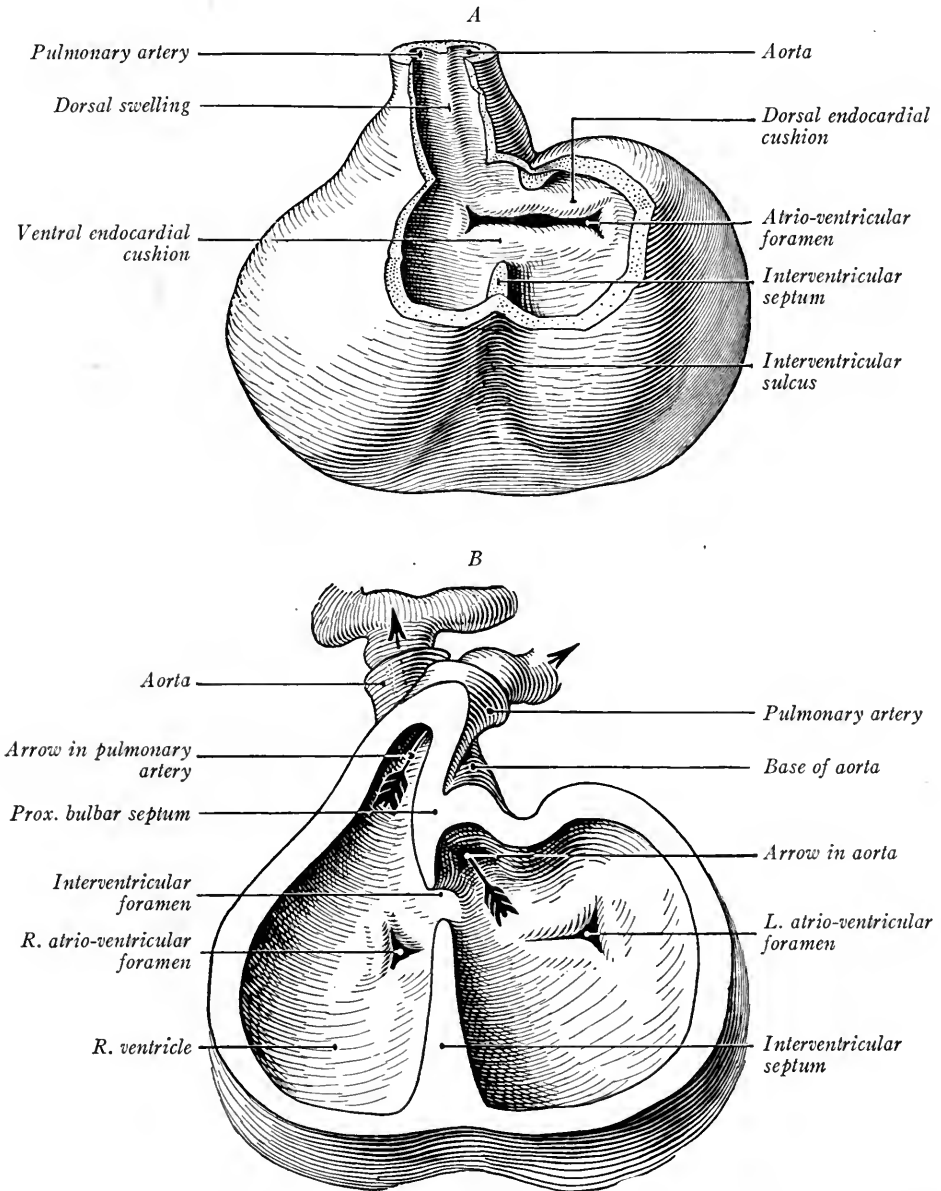


FIG. 259.—Two stages in the development of the heart to show the differentiation of the bulbus cordis into the aorta and pulmonary trunk: *A*, heart of a 5 mm. embryo; *B*, of a 7.5 mm. embryo (Kollmann's Handatlas).

formation of the interventricular septum there arise in the aortic bulb longitudinal thickenings, *four in the distal half, two in the proximal half of the bulb*. Of the four distal thickenings two, which we will number *a* and *c*, are larger than the other thickenings *b* and *d*. Thickenings *a* and *c*, which distally occupy right and left positions in the bulb, meet, fuse and divide the bulb into a dorsally placed aorta and ventrally placed pulmonary trunk (Fig. 259). Traced proximally they pursue a spiral course, *a* shifting from left to ventrad, and *c* from right to dorsad, and becoming continuous with the proximal swellings. Thickenings *b* and *d* are also prominent at one point proximally and when the bulb in this region is divided by ingrowing connective tissue into the aorta and pulmonary artery, the aorta contains the whole of thickenings *b* and half of *a* and *c*, while the pulmonary trunk contains the whole of *d* and half of *a* and *c* (Fig. 260). The three thickenings now present in each vessel hollow out on their distal surfaces and eventually form

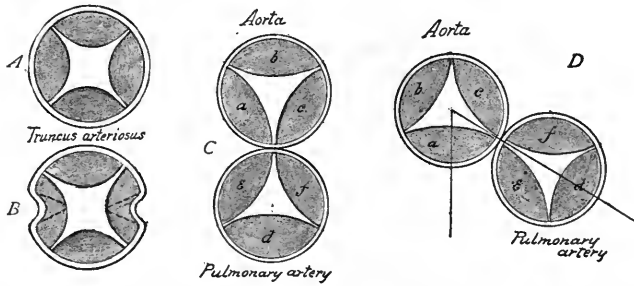
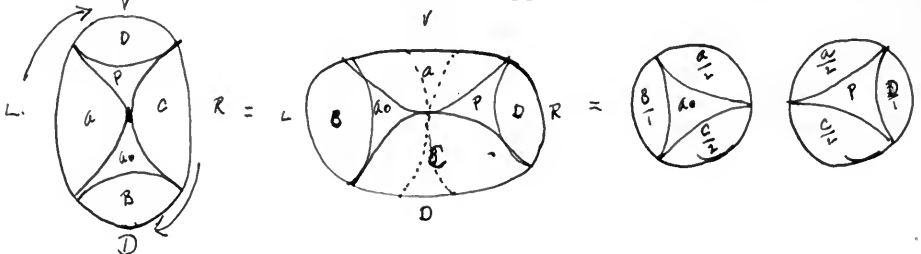


FIG. 260.—Scheme showing division of bulbus cordis and its thickenings into aorta and pulmonary artery with their valves. The division begins in *B*, the lateral thickenings dividing respectively into *a*, *e*, and *c*, *f*. Rotation from right to left shown in *D* (Heisler).

the thin-walled *semilunar valves* (Fig. 260). The anlagen of these valves are prominent in embryos of 10 to 15 mm. as thick plump swellings projecting into the lumina of the aorta and pulmonary artery.

The two proximal bulbar swellings fuse and continue the spiral division of the bulb toward the interventricular septum in such a way that the base of the pulmonary trunk, now ventrad and to the right, opens into the right ventricle, while the base of the aorta, now lying to the left and dorsad, opens into the left ventricle close to the interventricular foramen through which the two ventricles still communicate (Fig. 259, *B*).

**Closure of the Interventricular Foramen.**—The *interventricular foramen* in embryos of 15 to 16 mm. is bounded (1) by the interventricular septum; (2) by the proximal septum of the bulb; and (3) by the dorsal portion of the fused endocardial cushions. Soon these structures are approximated, fuse and by the de-





velopment of the *septum membranaceum* the interventricular foramen is closed. The *atrio-ventricular valves* arise as thickenings of the endocardium and endocardial cushions of the atrio-ventricular foramina. Three such thickenings are formed on the right, two on the left. The anlagen of the valves are at first thick and project into the ventricles. Later, as the ventricular wall differentiates, the valvular anlagen are undermined, leaving their edges attached to the ventricular walls by muscular trabeculæ or cords. The muscle tissue of both the valves and trabeculæ soon degenerates and is replaced by connective tissue, forming the *chordæ tendineæ* of the adult valves. Thus there are developed the three cusps of the *tricuspid valve* between the right chambers of the heart, and the two flaps of the *bicuspid* or mitral valve between the left atrium and left ventricle.

### PRIMITIVE BLOOD VASCULAR SYSTEM

It is assumed that the first paired vessels of human embryos are formed as longitudinal anastomoses of capillary networks which originate first in the angio-

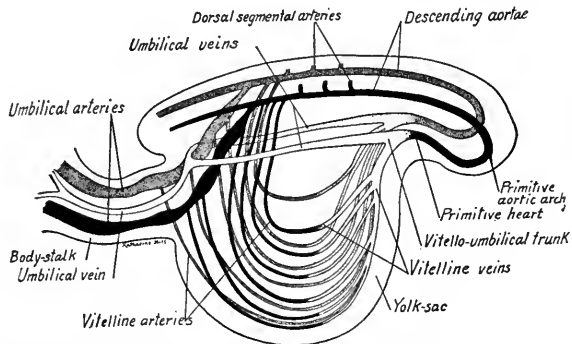


FIG. 261.—Diagram, lateral view, of the primitive blood-vessels in embryos of 1.5 to 2 mm. (adapted from Felix).

blast of the yolk-sac and chorion. In an embryo of 1.3 mm. in which the somites were not yet developed (Fig. 261) the paired vessels are already formed. They are the *umbilical veins* which emerge from the chorion, fuse in the body-stalk, then, separating, course in the somatopleure to the paired tubular heart. From the heart tube paired vessels as *ventral aortæ* extend cephalad, then bend dorsad as the first aortic arches and extend caudad as the dorsal or *descending aortæ*. These bend sharply ventrad into the belly stalk and branch in the wall of the chorion. The chorionic circulation is thus the first to be established.

In embryos 2 to 2.5 mm. long (5 to 8 somites) the heart has become a single tube (Fig. 262). From the yolk-sac numerous veins converge cephalad and form

a pair of *vitelline* veins. These join the umbilical veins and, as the *vitello-umbilical trunk*, traverse the septum transversum and open into the sinus venosus. The descending aortæ give off dorsally and cranially several pairs of dorsal *intersegmental arteries* and ventrad and caudad a series of non-segmental *vitelline arteries* to the yolk-sac. The umbilical arteries now take their origin from a plexus

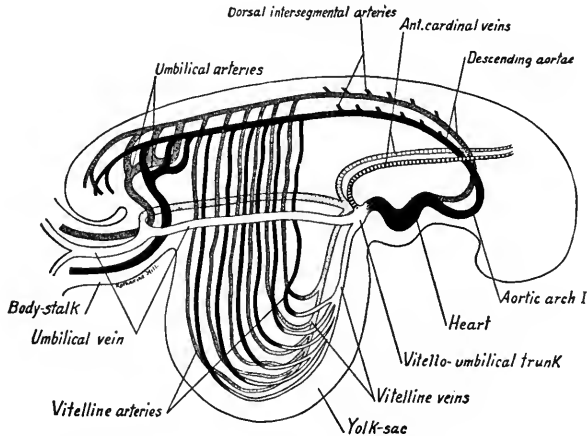


FIG. 262.—Diagram, lateral view, of the primitive blood-vessels in embryos of 2 to 2.5 mm. (adapted from Felix).

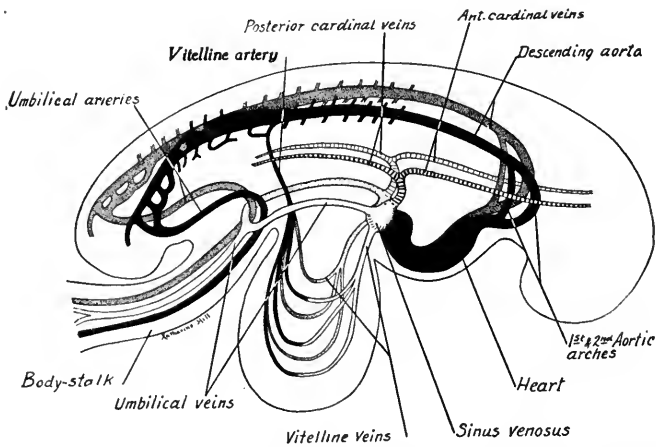


FIG. 263.—Diagram of the blood-vessels of embryos with 15 to 23 somites (modified from Felix).

of ventral vessels in series with the vitelline arteries. At this stage the vitelline circulation of the yolk-sac is established.

In embryos of 15 to 23 somites (Fig. 263) the veins of the embryo proper develop as longitudinal anastomoses of branches from the segmental arteries. The paired *anterior cardinal veins* of the head are developed first, and coursing back

on either side of the brain they join the vitello-umbilical trunk. In embryos of 23 somites the *posterior cardinals* are present. They lie dorsal to the nephrotomes and, running cranially, join the *anterior cardinal veins* to form the *common cardinal veins*. Owing to the later enlargement of the sinus venosus, the proximal portions of the venous trunks are taken up into its wall and thus three veins open into each horn of the sinus venosus: (1) the *umbilical veins* from the chorion; (2) the

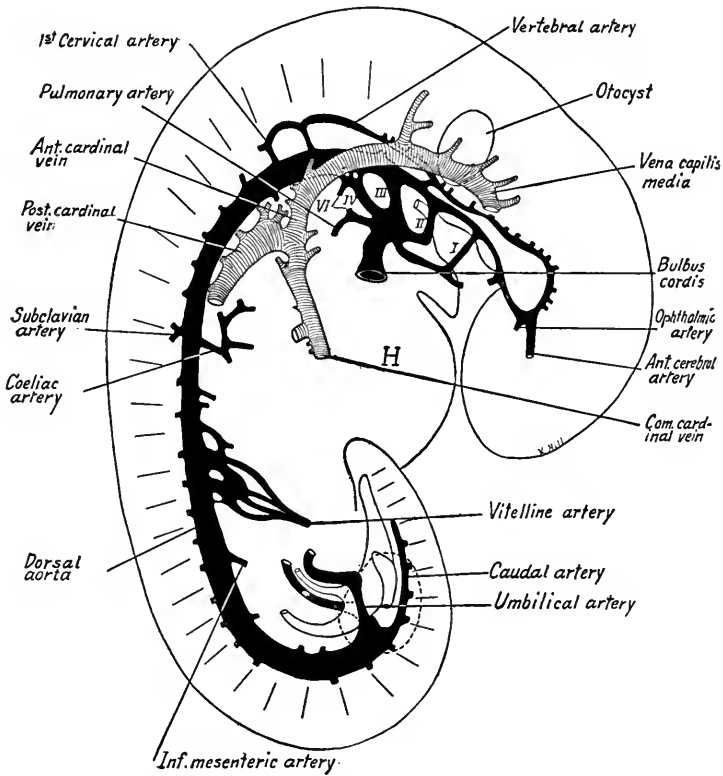


FIG. 264.—Arteries and cardinal veins of the right side in a 4.9 mm. human embryo (modified after Ingalls). II, heart; I, II, III, IV, and VI, first, second, third, fourth, and sixth aortic arches.

*vitelline veins* from the yolk-sac; (3) the *common cardinal veins* from the body of the embryo.

The *descending aortæ* have now fused caudal to the seventh intersegmental arteries and form the single dorsal aorta as far caudad as the origins of the umbilical arteries.

Of the numerous *vitelline arteries*, one pair are prominent and they fuse to form the single vessel which courses in the mesentery and later forms the *superior*

*mesenteric artery*. By the enlargement of capillaries connecting the ventral and dorsal aortæ a second pair of *aortic arches* is formed at this stage (Fig. 263).

**Development and Transformation of the Aortic Arches.**—In embryos 4 to 5 mm. in length five pairs of aortic arches are successively developed, the first, second, third, fourth and sixth (Fig. 264). An additional pair of transitory vessels which extend from the ventral aorta to the sixth arch appear later in embryos of

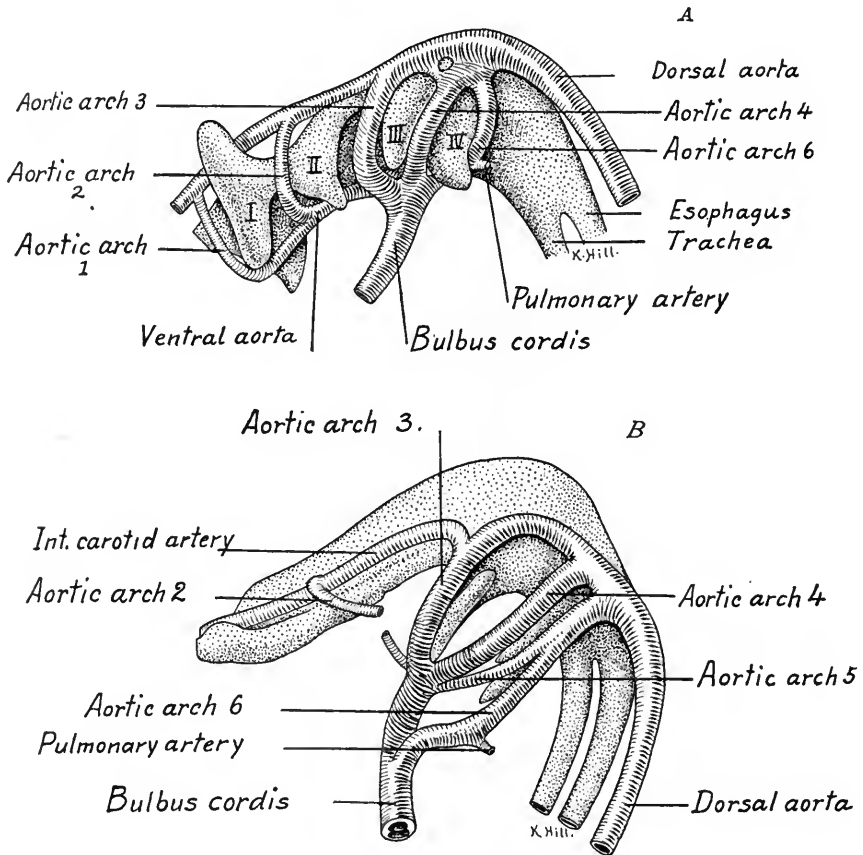


FIG. 265.—Aortic arches of human embryos: A, of 5 mm.; B, of 7 mm. (after Tandler). I, II, III, IV, pharyngeal pouches.

7 mm. but soon degenerate (Fig. 265, B). They are interpreted as being the *fifth* pair in the series. From each dorsal or descending aorta there develop cranially the *internal carotid arteries*. These extend toward the optic stalks where they bend dorsad and caudad, connecting finally with the first intersegmental arteries of each side. The descending aortæ are now fused to their extreme caudal ends and the umbilical arteries take their origin ventrally. Twenty-seven pairs of *dorsal intersegmental arteries* are present. From the seventh cervical pair of these

arteries arise the *subclavian arteries* of the upper limbs. Of the ventral vitelline vessels three are now prominent, the *coeliac artery* in the stomach-pancreas region, the *vitelline* or *superior mesenteric* in the small intestine region and the *inferior mesenteric* of the large intestine region.

Of the aortic arches the third pair is largest at 5 mm. From the sixth pair are given off the small *pulmonary arteries* to the lungs. At 7 mm. the first and second aortic arches are obliterated (Figs. 265, *B*, and 266), but the dorsal and ventral aortæ cranial to the third arch persist as parts of the internal and external arteries respectively. The third arches form the stems of the internal carotids, while the ventral aortæ between the third and fourth arches become the common

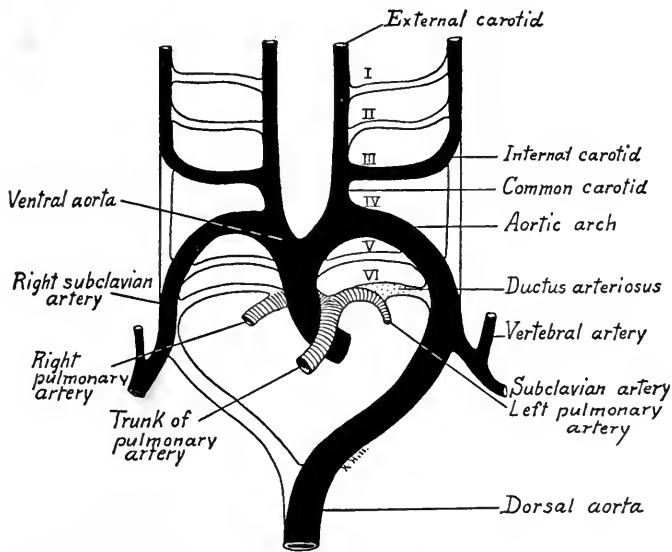


FIG. 266.—Diagram showing the aortic arches and their derivatives in human embryos.

carotids. In embryos of 15 mm. the bulbus cordis has been divided into the aortic and pulmonary trunks so that the aorta opens into the left ventricle and the pulmonary trunk into the right ventricle. The dorsal aortæ between the third and fourth arches disappear, but the fourth arch on the left side persists as the *aortic arch* of the adult. On the right side, the fourth aortic arch persists with the descending aorta as far as the *seventh intersegmental artery* and forms part of the *right subclavian artery*, which is thus longer than the left. On the right side, the sixth arch between the origin of the right pulmonary artery and descending aorta is early lost; on the left side, it persists as the *ductus arteriosus* and its lumen is only obliterated after birth. The proximal portion of the right sixth arch

forms the stem of the *right pulmonary artery*, but the proximal portion of the *left arch* is incorporated in the pulmonary trunk.

The aortic arches of the embryo are of especial importance comparatively, as five arches are formed in connection with the gills of adult fishes, three are represented on either side in adult amphibia and reptiles, while in birds the right, in mammals the left, fourth arch persists as the arch of the aorta.

From the primitive aortæ arise *dorsal, lateral and ventral branches* (Fig. 267). The *dorsal branches* are intersegmental and develop small dorsal and large ventral rami. From the dorsal rami are given off neural branches which bifurcate and form dorsal and ventral spinal arteries. Those of each side anastomose longitudinally in the median line and give rise to the dorsal and ventral *median*

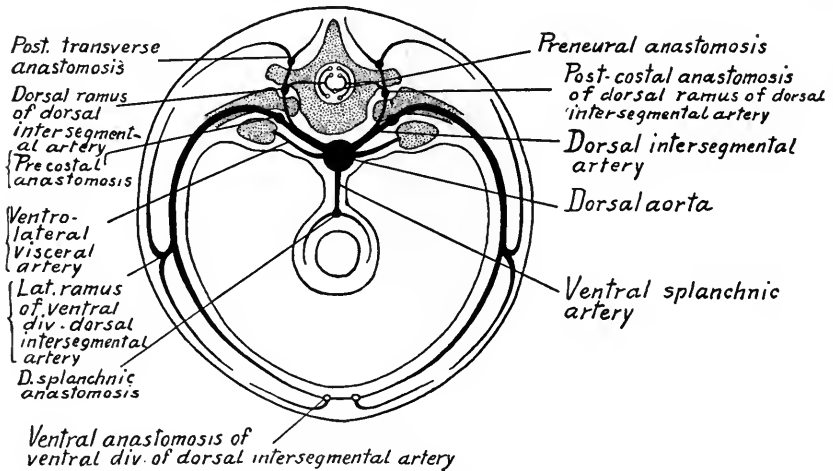


FIG. 267.—A diagram showing the arteries of the trunk in transverse section.

*spinal arteries*. The dorsal rami also form lateral anastomoses dorsal and ventral to the transverse processes of the vertebræ.

**Origin of the Vertebral Arteries and Basilar Artery.**—As we have seen (Fig. 264), the internal carotids are recurved cranially in the 5 mm. embryo and anastomose with the first two pairs of dorsal intersegmental arteries. The ventral longitudinal anastomosis of the dorsal rami of the first seven pairs of dorsal intersegmental arteries gives rise to the *vertebral arteries* (Fig. 268, *A*). The trunks of the first six pairs are lost so that the vertebrals take their origin with the subclavians from the *seventh pair of intersegmental arteries* (Fig. 268, *B*). In embryos of 9 mm. the vertebrals in the region of the metencephalon fuse to form a single median ventral vessel, the *basilar artery*, which thus is connected cranially with the internal carotids, caudad with the vertebral arteries.

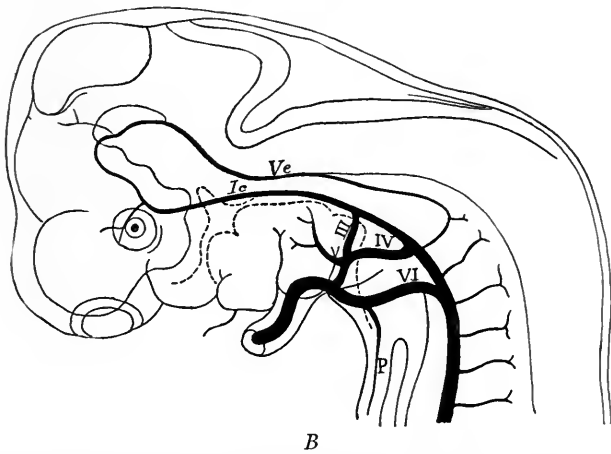
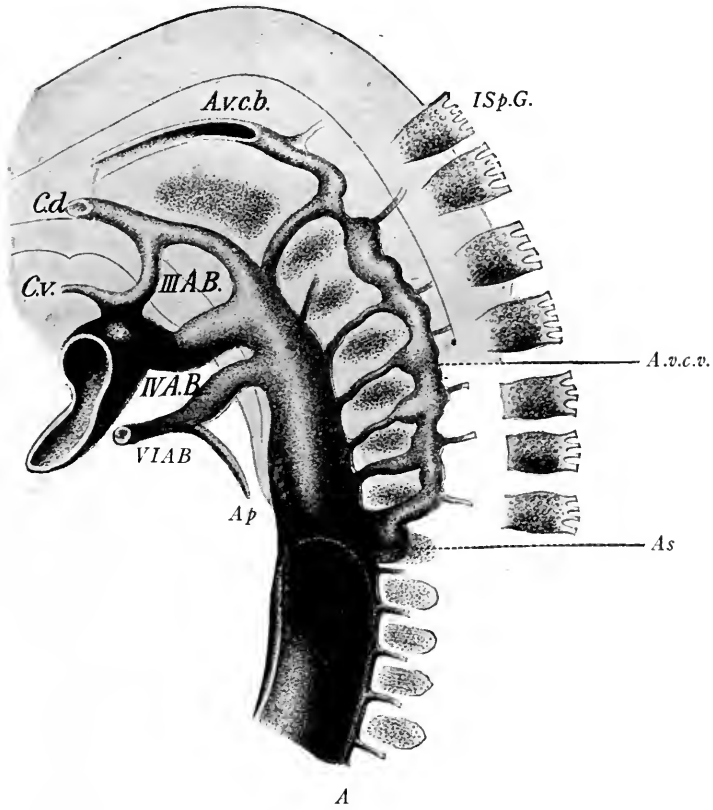


FIG. 268.—*A*, The development of the vertebral artery in a rabbit embryo of twelve days (Hochstetter from McMurrich). *III AB* to *VI AB*, branchial arch vessels; *Ap*, pulmonary artery; *Avcb.* and *Avcv.*, cephalic and cervical portions of vertebral artery; *As.*, subclavian artery; *Cd.* and *Cv.*, internal and external carotid arteries. *ISp.G.*, spinal ganglion. *B*, Arterial system of an embryo of 10 mm. (His). *Ic*, internal carotid; *P*, pulmonary artery; *Ve*, vertebral artery; *III* to *VI*, persistent aortic arches.

The internal carotids, after giving off the ophthalmic arteries, give rise cranially to the *anterior cerebral artery*, from which arise later the *middle cerebral artery* and the *anterior chorioidal artery*, all of which supply the brain. Caudalward many small branches to the brain wall are given off and quite late in development (48 mm. embryos) these form a true *posterior cerebral artery* (Mall).

The *ventral branches* of the *dorsal intersegmental* arteries become large in the thoracic and lumbar regions, and persist as the *intercostal* and *lumbar arteries*, segmentally arranged in the adult. The *subclavian* and a portion of the *internal mammary artery* are derived from the *ventral* ramus of the seventh cervical seg-

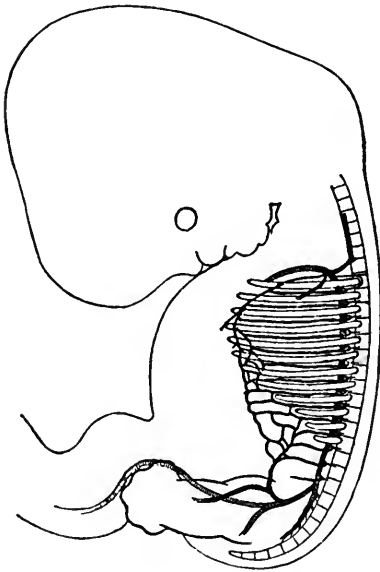


FIG. 269.—The development of the internal mammary and deep epigastric arteries in an embryo of 13 mm. (Mall from McMurrich's Human Body).

mental artery. The remainder of the *internal mammary* and the *superior and inferior epigastric arteries* are formed by longitudinal anastomoses between the extremities of the ventral rami from the thoracic and lumbar intersegmental arteries, beginning with the second or third thoracic (Fig. 269). The superior intercostal arteries arise from anastomoses which connect the lateral rami of these same branches on what will later be the inner surfaces of the dorsal portions of the ribs.

The *lateral branches* of the descending aortæ are not *segmentally* arranged. They supply structures arising from the nephrotome region (mesonephros, sexual glands, metanephros and suprarenal glands). From them later arise the *renal, suprarenal, inferior phrenic* and *internal spermatic or ovarian arteries*.

The *ventral arteries* are not definitely segmental or intersegmental. Primatively they form the paired vitelline arteries to the yolk-sac (Figs. 261 and 263). Coincident with the degeneration of the yolk-sac the prolongations of the ventral vessels to its walls disappear and the paired persisting arteries, passing in the mesentery to the gut, fuse to form unpaired vessels from which three large arteries are derived, the *cæliac artery*, the *superior mesenteric* and the *inferior mesenteric* (Fig. 264).

The primitive cæliac axis arises opposite the seventh intersegmental artery. Together with the mesenteric arteries, it migrates caudalward until eventually its origin is opposite the twelfth thoracic segment (Mall). This migration, according to Evans, is due to the unequal



growth of the dorsal and ventral walls of the aorta. The mesenteric arteries are displaced caudad only three segments, probably in the same way.

**The Umbilical and Iliac Arteries.**—As previously described, the umbilical arteries arise in young human embryos of 2 to 2.5 mm. from the primitive aortæ opposite the fourth cervical segment. They take origin from a plexus of ventral vessels of the vitelline series (Fig. 263), and are gradually shifted caudalward until they arise from the dorsal aorta opposite the twenty-third segment (fourth lumbar). In 5 mm. embryos the umbilical arteries develop secondary lateral connections with the aorta (Fig. 270, A). The new vessels pass lateral to the mes-

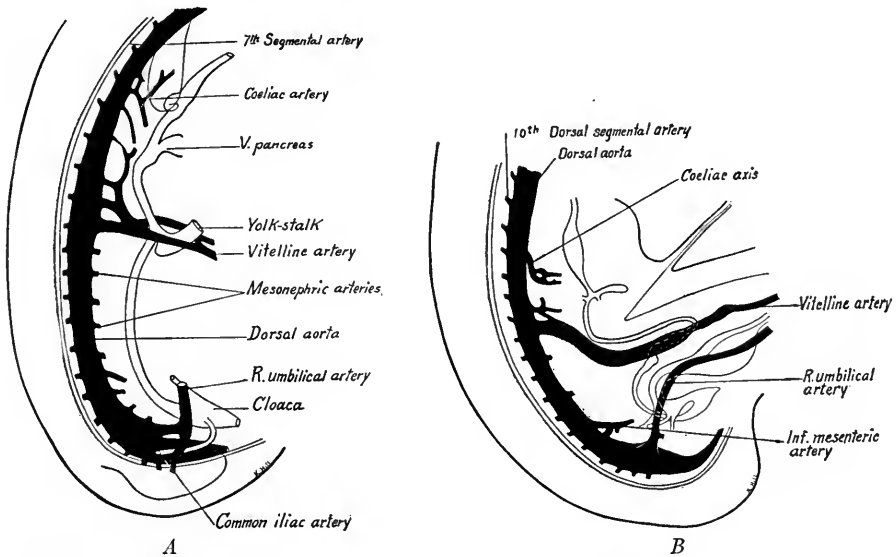


FIG. 270.—Reconstructions showing the development of the umbilical and iliac arteries: A, 5 mm. embryo; B, 9 mm. embryo (after Tandler).

onephric ducts, and in 9 mm. embryos the primitive ventral umbilical artery has disappeared. From the newly formed vessel an artery arises which becomes the *external iliac artery* of the adult. The new lateral umbilical trunk from the aorta to the origin of the external iliac now becomes the *common iliac* artery, and shifts its position to the ventral side of the aorta. The remainder of the umbilical trunk constitutes the *hypogastric artery*.

**Arteries of the Extremities.**—It is assumed that in man, as in mammals, the first vessels of the limb buds form a capillary plexus.

*Upper Extremity.*—The capillary plexus takes its origin by several lateral branches from the aorta. In human embryos of 5 mm. but one connecting vessel remains and this takes its origin secondarily from the seventh intersegmental artery, forming the ventral branch of this artery and its lateral ramus. The portion of this vessel in what will become the free arm is

plexiform at first, and later becomes a single stem which forms successively the *subclavian*, *axillary*, *brachial*, and *interosseous* arteries. Later, in the arm are formed the median, radial and ulnar arteries. For details as to their arrangement students are referred to textbooks of anatomy.

*Arteries of the Lower Extremity.*—In embryos of 7 mm. there is given off from the secondary lateral trunk of the umbilical artery a small branch which forms the chief stem of the vascular plexus in the lower extremity. This, the *arteria ischiadica*, is superseded in embryos of 15.5 mm. by the external iliac and femoral arteries. The *arteria ischiadica* persists as the inferior gluteal. We have already seen that the secondary lateral root of the umbilical artery becomes the common iliac.

#### DEVELOPMENT OF THE VEINS

We have seen that in embryos of 23 somites three systems of paired veins are present, the *umbilical veins* from the chorion, the *vitelline veins* from the yolk-sac, and the *cardinal veins*, *anterior* and *posterior*, which unite in the *common*

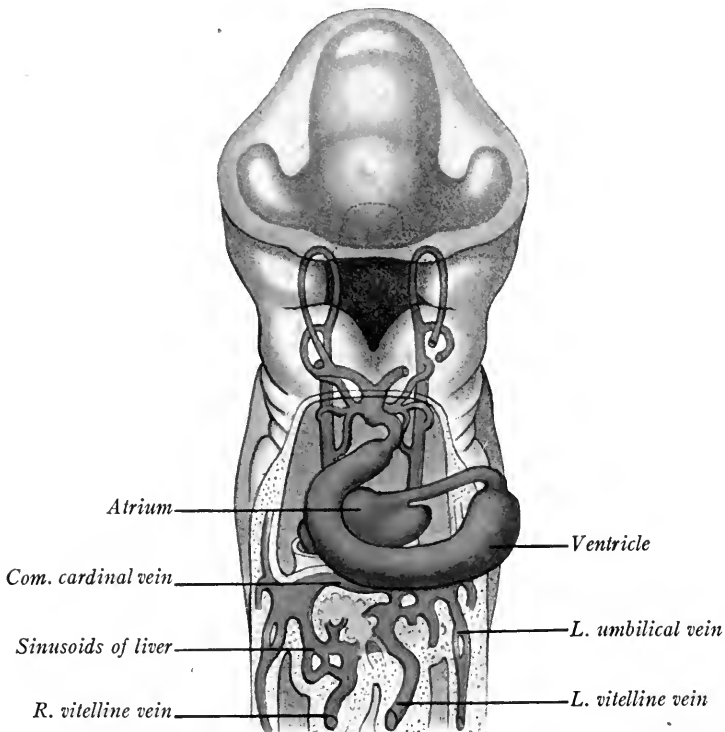


FIG. 271.—Reconstruction of the veins and arterial arches of a 4.2 mm. embryo in ventral view (His).

*cardinal veins*, from the body of the embryo. Thus three veins open into the right and three into the left horn of the sinus venosus (Fig. 263).

**Changes in the Vitelline and Umbilical Veins.**—*Vena porta.*—With the increase in size of the liver anlagen there is an intercrossing of the hepatic cords

and the endothelium of the vitelline veins. As a result, these veins form in the liver a network of sinusoids (Fig. 271), and each is divided into a *distal portion* which passes from the yolk-sac to the liver and into a *proximal portion* which carries blood from the liver sinusoids to the sinus venosus. The proximal portion of the left vitelline vein soon is largely absorbed into the sinusoids of the liver and shifts its blood flow into the right horn of the sinus venosus. In the meantime the liver tissue grows laterally, comes into contact with the umbilical veins and taps them so that their blood flows more directly to the heart through the sinusoids of the liver (Fig. 272). As the channel of the right proximal vitelline is larger, the blood from the left umbilical vein flows diagonally to the right horn of the sinus

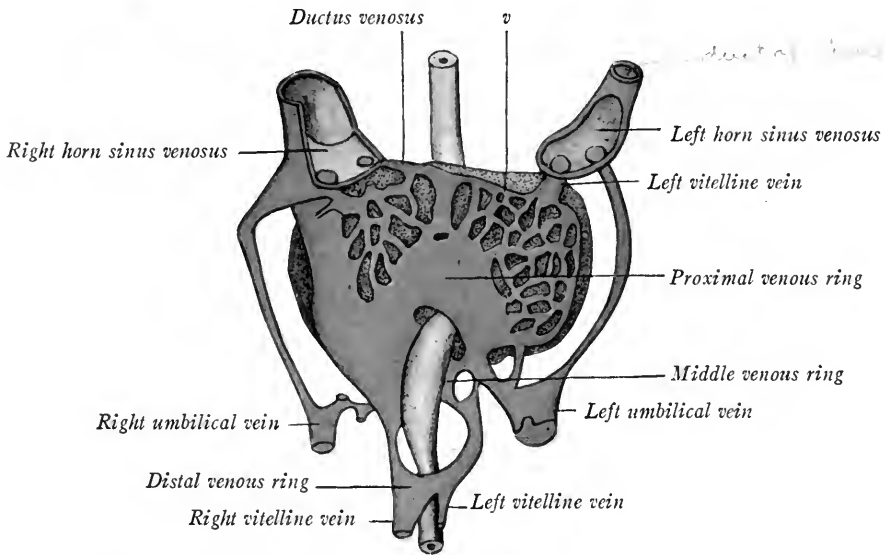


FIG. 272.—Reconstruction of the veins of the liver in a 4.9 mm. human embryo (after Ingalls).

venosus. When all the umbilical blood enters the liver, as in embryos of 5 to 6 mm., the proximal portions of the umbilical veins atrophy and disappear (Fig. 273). In 5 mm. embryos the vitelline veins have formed three cross anastomoses with each other: (1) a cranial transverse connection in the liver ventral to the duodenum; (2) a middle one dorsal to the duodenum; and (3) a caudal one ventral to it. There are thus formed about the gut a cranial and a caudal venous loop (Fig. 273). In embryos of 7 mm. the vitelline and umbilical blood flows chiefly to the left side. As a result, the left umbilical and vitelline veins have enlarged, while the corresponding right veins have degenerated. Of the right vitelline vein only the right limb of the cranial loop persists caudal to the liver.

The left vitelline vein is present except for the left limb of the cranial loop. A new vein, the *superior mesenteric*, develops in the mesentery of the intestinal loop and joins the left vitelline vein near the point of its dorsal middle connection with the right vitelline vein. Subsequently, with the atrophy of the yolk-sac the left vitelline vein degenerates caudal to its junction with the superior mesenteric vein. The persisting trunk from the superior mesenteric vein to the liver is the *vena*

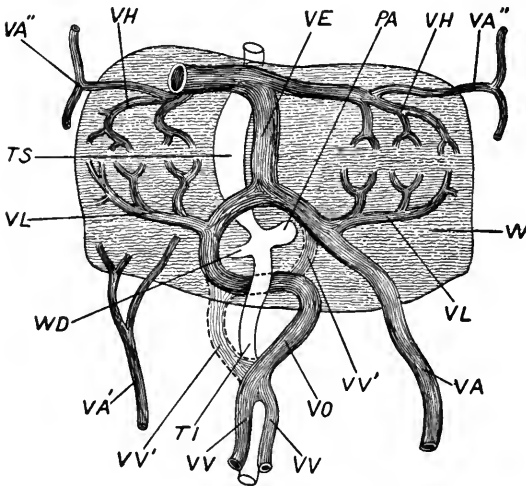


FIG. 273.—A diagram showing the development of the portal vein (His in Marshall's Embryology). PA, pancreas; TI, intestine; TS, stomach; VA, left umbilical vein; VA', right umbilical vein; VA'', cranial detached portions of umbilical veins; VE, ductus venosus; VH, efferent hepatic vein derived from right vitelline; VL, afferent hepatic vein; VO, trunk of portal vein derived from left vitelline; VV, right vitelline vein; VV', on right side of figure, superior mesenteric vein; VV'', VV'', portions of right and left vitelline veins which atrophy; W, liver; WD, bile duct.

*porta*, and thus represents (1) a portion of the left vitelline vein in the left limb of the caudal loop; (2) the middle transverse anastomosis between the vitelline veins; (3) the portion of the right vitelline vein which forms the right limb of the cranial loop.

In the liver the portal vein through its cranial and ventral anastomosis between the vitelline veins is connected with the left umbilical vein. As the right lobe of the liver grows, the course of the umbilical and portal blood through the intra-hepatic portion of the right vitelline vein becomes circuitous, and a new direct channel to the sinus venosus is formed through the hepatic sinusoids.

This is the *ductus venosus Arantii*, which is obliterated after birth and forms the *ligamentum venosum* of the post-natal liver.

According to Mall, the intra-hepatic portion of the right vitelline vein persists proximally as the *right ramus* of the hepatic vein and distally as the *ramus arcuatus* of the portal vein. The intra-hepatic portion of the left vitelline vein drains secondarily into the right horn of the sinus venosus and proximally forms later the *left hepatic ramus*. Distally, where it is connected with the left umbilical vein, it becomes the *ramus angularis* of the vena porta. In this way two primitive portal or supplying trunks and two hepatic or draining trunks originate. Later are differentiated first four, then six, such trunks within the liver and the six primary lobules supplied and drained by these trunks may be recognized in the adult liver.

Of the umbilical veins the right early disappears; the left persists during fetal life, shifts to the median line and courses in the free edge of the falciform ligament. After birth its lumen is closed and from the umbilicus to the liver it forms the *ligamentum teres*. In early stages veins from the body wall drain into the umbilical veins.

**The Anterior Cardinal Veins and the Origin of the Vena Cava Superior.**—The anterior cardinal veins consist each of two parts: (1) The true anterior cardinals located laterad in the segmented portion of the head and neck and draining into the common cardinal veins; (2) the *vena capitis medialis* extending into the unsegmented head proper and running ventro-lateral to the brain wall. In embryos of 20 mm. there has formed by anastomosis a large connection between the right and left anterior cardinals, which carries the blood from the left side of the head into the right vein (Fig. 274, C). Soon the left anterior cardinal loses its connection with the common cardinal on the left side (Fig. 274, D). The proximal portion of the left *common cardinal* with the transverse portion of the sinus venosus persists as the *coronary sinus*. The right common cardinal and the right anterior cardinal vein as far as its anastomosis with the left anterior cardinal become the *superior vena cava*. The anastomosis itself forms the *left vena anonyma*, while that portion of the right anterior cardinal between the left vena anonyma and the right subclavian vein is known as the *right vena anonyma*. The distal portions of the anterior cardinals become the internal jugular veins of the adult, while the external jugulars are new veins which develop much later.

The *vena capitis medialis* is the continuation of the anterior cardinal vein into the head of the embryo where at first it lies mesial to the cerebral nerves. Later it is partly shifted by anastomosis lateral to the cerebral nerves and forms the *vena capitis lateralis* (Figs. 275, 276). In 11 mm. embryos this emerges with the n. facialis and caudal to the n. hypoglossus becomes the *internal jugular*. Cranially the median vein of the head persists as the *sinus cavernosus* and receives the *ophthalmic vein* from the eye, and the *middle cerebral vein* from the fore- and mid-brain regions. Between the n. trigeminus and the facialis, the *middle cerebral vein* from the metencephalon (cerebellum) joins the v. capitis lateralis before it leaves the cranium. More caudally the *posterior cerebral vein* from the myelencephalon emerges through the jugular foramen and is drained with the others by the v. capitis lateralis into the internal jugular (Fig. 276, B). Soon the three cerebral veins reach the dorsal median line (Fig. 276, C), and longitudinal anastomoses are formed: (1) between the *anterior and middle cerebral veins*, giving rise to the *superior sagittal sinus*; and (2) between the *middle and posterior cerebral veins* forming the greater part of the lateral sinuses. In embryos of 33 mm. the v. capitis lateralis disappears and the blood from the brain passes through the superior sagittal and lateral sinuses and is drained by way of the jugular foramen into the internal jugular vein (Fig. 276, C, D). The middle cerebral vein becomes the *superior petrosal sinus*, but the *inferior petrosal sinus* is formed as a new channel median to the internal ear. For a more detailed account of the origin of the cephalic veins the student is referred to the original work of Mall (*Amer. Jour. Anat.*, vol. 4, 1905).

**The Posterior Cardinal Veins and the Origin of the Inferior Vena Cava.**—The posterior cardinal veins course cephalad along the dorsal side of the mesonephroi and open into the common cardinal veins (Fig. 274, A). Each receives an

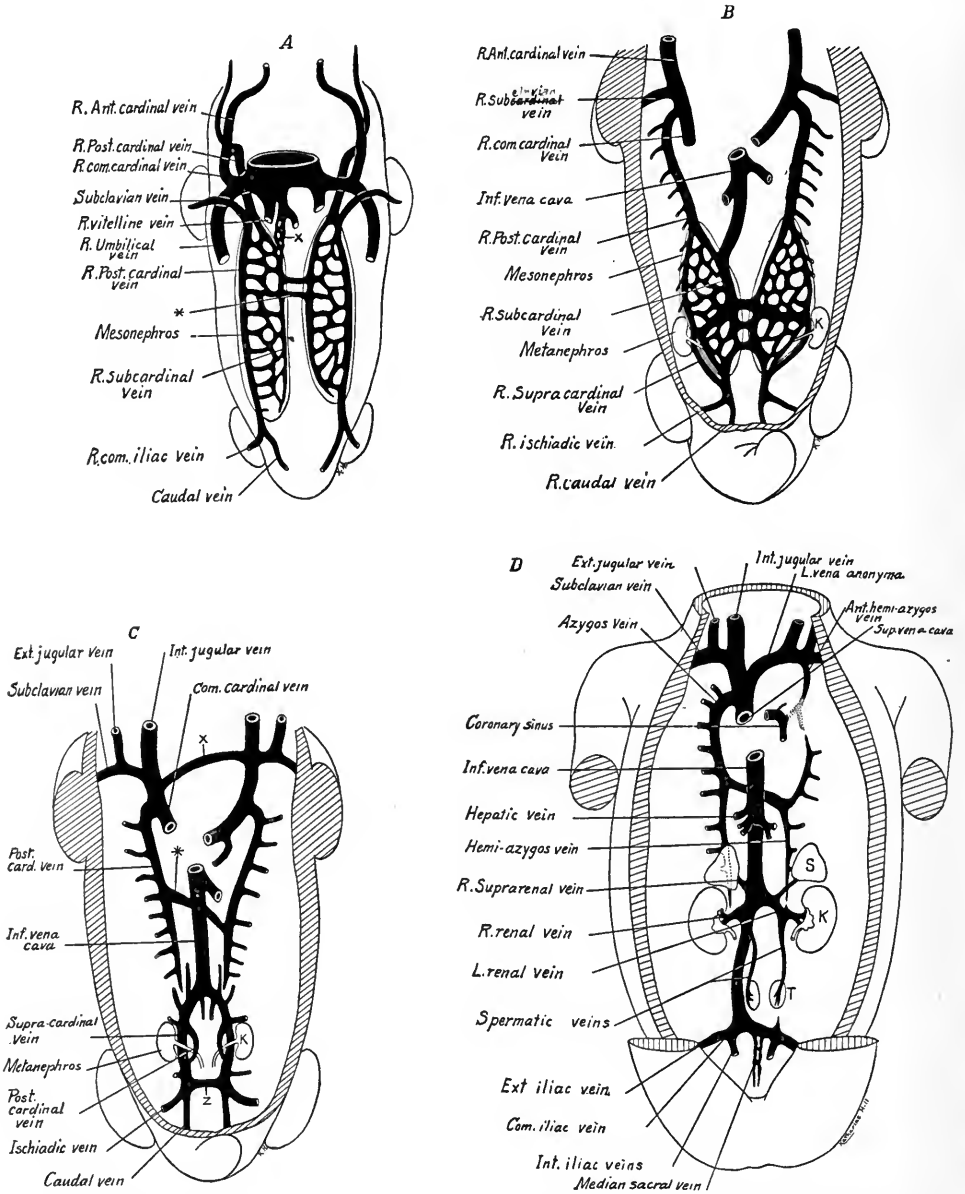


FIG. 274.—Four diagrams showing the development of the superior and inferior venæ cavæ and the fate of the cardinal veins (modified after Kollmann). × in A, anastomosis between hepatic and subcardinal vein; \*, anastomosis between subcardinal veins; × in C, anastomosis between anterior cardinal veins which forms the left vena anonyma; \* in C, cranial anastomosis between the posterior cardinal veins; z, caudal anastomosis between the same veins; K, kidney; S, suprarenal gland; T, testis.

*internal iliac vein* from the posterior extremities, *mesonephric branches* from the mid-kidney and dorsal segmental veins from the body wall (Fig. 274, *B*). Median

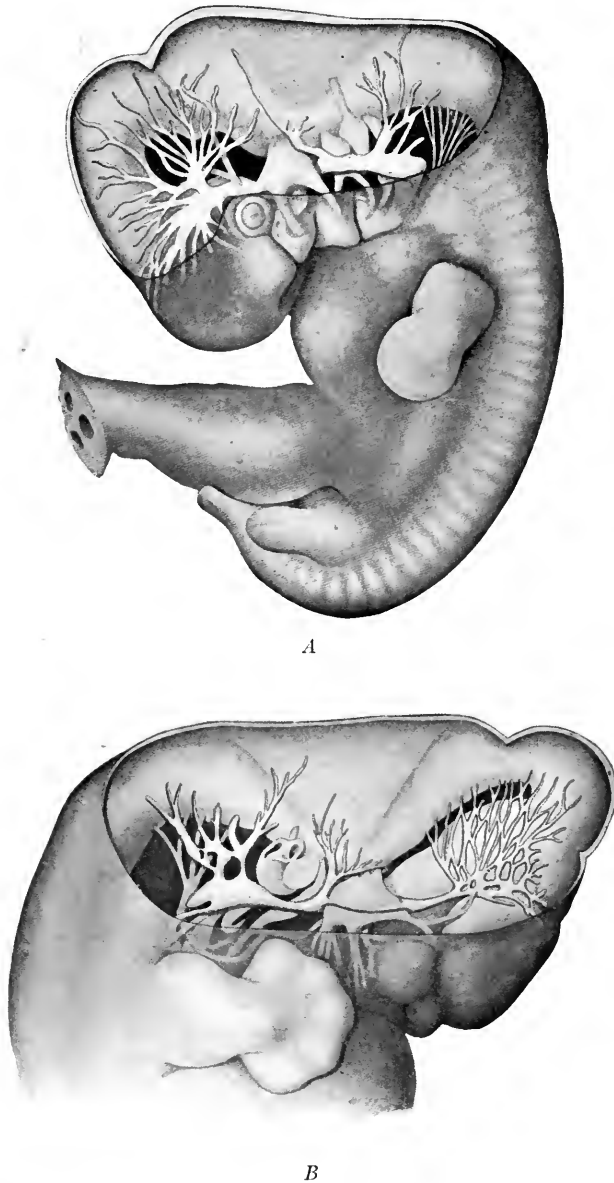


FIG. 275.—Veins of the head, *A*, in a 9 mm. human embryo; *B*, in an 11 mm. embryo (Mall).

and ventral to the mesonephros are developed the *subcardinal veins* which are connected at intervals with the posterior cardinal veins by sinusoids and with each other by anastomoses ventral to the aorta. Thus all the blood from the

mesonephroi, posterior extremities and dorsal body wall is in early stages drained by the posterior cardinal veins alone.

The development of the unpaired *vena cava inferior* begins when communication is established between the *right hepatic vein* of the liver and the *right subcardinal vein* of the mesonephros, primarily a tributary of the posterior cardinal vein (Lewis, 1902).

The liver on the right side becomes attached to the dorsal body wall and from its point of union a ridge, the *plica venæ cavæ* (Fig. 192), extends caudalward. According to Davis (1910), capillaries from the subcardinal vein invade the plica

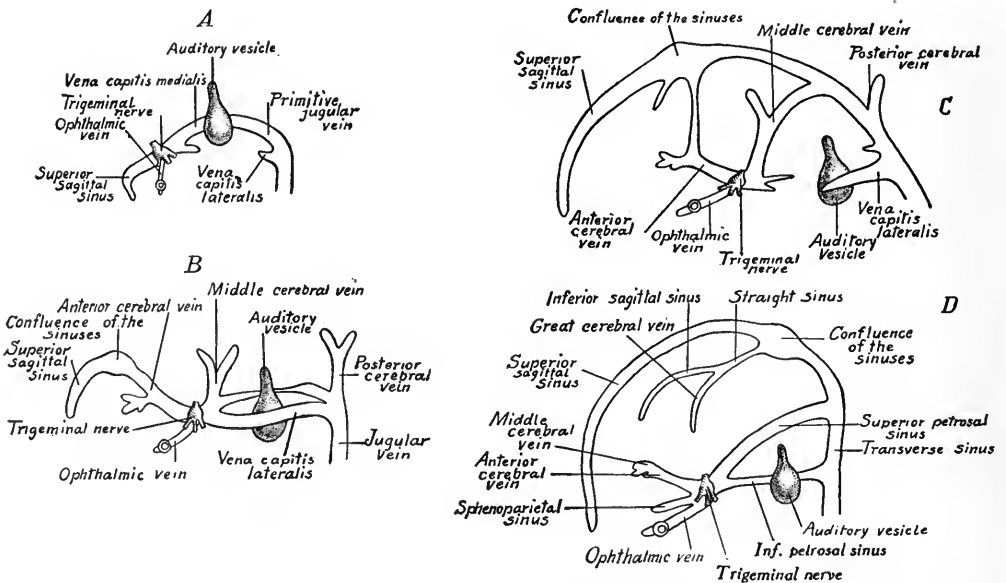


FIG. 276.—Four diagrams showing the development of the veins of the head (after Mall). *A*, at four weeks; *B*, at five weeks; *C*, at the beginning of the third month; *D*, from an older fetus.

*venæ cavæ* and, growing cranially, meet and fuse with capillaries extending caudal from the liver sinusoids.

Thus is formed the *vein of the plica venæ cavæ*, which is already present in human embryos of 2.6 mm. (Kollmann). This vein rapidly enlarges as also do the sinusoidal connections between the subcardinals and posterior cardinals at one point. Thus the blood from the lower posterior cardinals is soon carried to the heart, chiefly by way of the right subcardinal and right hepatic veins (Fig. B, 274). Soon the posterior cardinals just cranial to their enlarged anastomoses with the subcardinals become small and are interrupted. Cranial to their inter-



ruption these veins were formerly believed to persist as the vv. azygos and hemiazygos of the adult (Fig. 274, C).

Sabin (*Anat. Record*, vol. 8, p. 82, 1914) has confirmed the conclusions of Parker and Tozier (*Bull. Museum Comp. Zoöl.*, Harvard, 1908) that the vv. azygos and hemiazygos are new veins. They are formed in pig embryos as longitudinal anastomoses ventral to the vertebral and median to the posterior cardinal veins and open into the upper ends of the latter. Except for this short upper region the posterior cardinals in the thoracic region drain into the new veins and become tributary to them. The *right upper posterior cardinal vein* drains into the *v. azygos*, the left upper posterior cardinal vein into the *v. hemiazygos*.

The portions of the posterior cardinal veins caudal to their interruption remain for a while symmetrical and connected by anastomoses (Fig. 274, C). Soon the caudal anastomosis between them enlarges until the blood from both sides is drained into the right posterior cardinal vein (Fig. 274, D). A branch of the post-cardinal vein encircles the ureter of the metanephros. This vein is known as the *supracardinal*. Caudal to their transverse connection the right posterior cardinal becomes the *right common iliac vein*. The corresponding portion of the left posterior cardinal with the transverse anastomosis becomes the longer *left common iliac vein*. The blood from these veins is now drained by the unpaired *vena cava inferior* which is composed of the following veins: (1) the common hepatic and right hepatic veins (primitive right vitelline); (2) the vein of the plica venæ cavæ; (3) a portion of the right subcardinal vein; (4) the supracardinal vein of the right side; (5) a portion of the lower right posterior cardinal vein.

The permanent kidneys take up their positions opposite the great anastomosis between the posterior cardinals and the subcardinals and at this point the renal veins are developed. On the left side, the anastomosis connecting the right subcardinal with the left posterior cardinal persists as part of the *left renal vein*. A persisting portion of the lower left posterior cardinal, according to Hochstetter, forms the proximal part of the *left spermatic* or *ovarian veins*. The dorsal segmental veins of the lower posterior cardinals form the *lumbar veins*. Transverse anastomoses connect those of the left side with the right posterior cardinal after the atrophy of the left posterior cardinal. The cephalic portion of the left subcardinal vein persists as the *suprarenal vein*, which thus opens into the renal vein instead of joining the vena cava inferior as does the right suprarenal vein.

**The Veins of the Extremities.**—The primitive capillary plexus of the upper and lower limb buds gives rise to a *border vein* (Fig. 277), which courses about the periphery of the flattened limb buds (Hochstetter). In the upper extremity, the ulnar portion of the border vein persists, forming at different points the *subclavian*, *axillary*, *brachial* and *basilic veins*. The border vein at first opens into the dorsal wall of the posterior cardinal vein (embryos of 10 mm.), but, as the heart shifts its position caudalward it finally drains by a ventral connection into the anterior cardinal or internal jugular vein (F. T. Lewis). The *cephalic vein* develops secondarily in connection with the ulnar border vein, later in embryos of 23 mm. anastomoses with the external jugular and finally drains into the axillary vein as in the adult. With the development

of the digits, the *vv. cephalica et basilica* become distinct as in embryos of 35 mm. but later are again connected by a plexus on the dorsum mani, as in the adult (Evans in Keibel and Mall).

In the *lower extremity* the fibular border vein persists as the *v. saphena parva* which runs deep as the *v. glutea inferior* and drains into the hypogastric portion of the posterior vena cava. The *v. saphena magna* and the *v. femoralis* arise later and join the *v. ischiadica* which drains into the posterior cardinal vein. The veins to accompany the arteries are the last to develop.

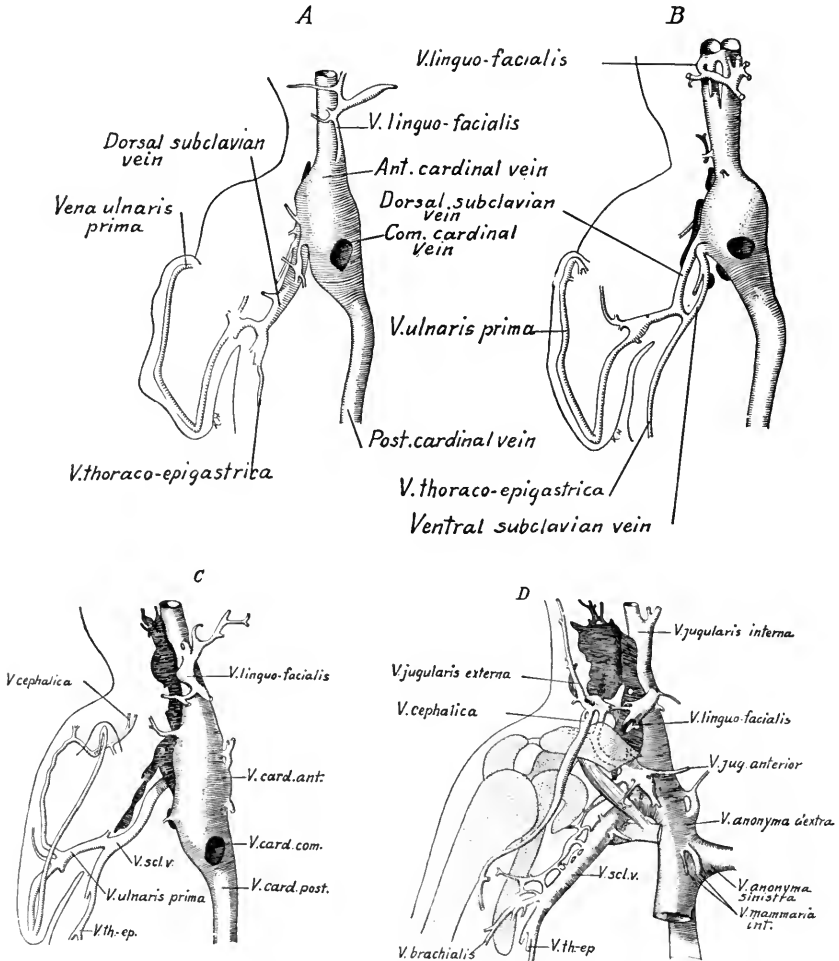


FIG. 277.—Four reconstructions of the veins of the right arm (after F. T. Lewis). A, 10 mm. embryo; B, 11.5 mm. embryo; C, 15 mm. embryo; D, 22.8 mm. embryo.

### FETAL CIRCULATION

During fetal life the placental blood enters the embryo by way of the large *umbilical vein* and is conveyed to the liver (Fig. 278). There it mingles with the small amount of venous blood brought to the liver by the *portal vein*. It is carried to the inferior vena cava either directly, through the *ductus venosus*, or indirectly

through the *liver sinusoids* and *hepatic vein*, and is again mixed with the venous blood. Entering the right atrium it mingles more or less with the venous blood which enters the atrium through the superior vena cava. From the right atrium the blood may take two paths. That from the inferior vena cava is said to be directed by the valve of this vein through the *foramen ovale* into the left atrium, which, before birth, receives little venous blood from the lungs. The venous blood of the superior vena cava, somewhat mixed, is supposed to pass from the right atrium into the right ventricle.

The purer blood of the left atrium enters the left ventricle, whence it is driven out through the aorta and distributed chiefly to the head and upper extremities. The mixed blood of the right ventricle passes out by the pulmonary artery. A small amount of this blood is conveyed to the lungs by the pulmonary arteries, but, as the fetal lungs do not function, most of it passes to the dorsal aorta by way of the *ductus arteriosus* and is distributed to the trunk, viscera and lower extremities. The placental circuit is completed by the *hypogastric* or *um-*

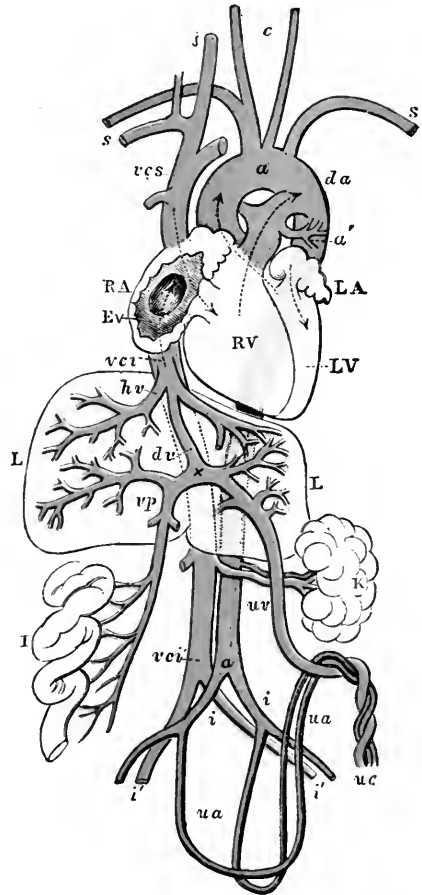


FIG. 278.—Diagrammatic outline of the organs of circulation in the fetus of six months (Allen Thomson).<sup>1</sup> RA, right atrium of the heart; RV, right ventricle; LA, left atrium;

Ev, valve of inf. vena cava; LV, left ventricle; L, liver; K, left kidney; I, portion of small intestine; a, arch of the aorta; a', its dorsal part; a'', lower end; vcs, superior vena cava; vci, inferior vena where it joins the right atrium; vci', its lower end; s, subclavian vessels; j, right jugular vein; c, common carotid arteries; four curved dotted arrow lines are carried through the aortic and pulmonary opening and the atrioventricular orifices; da, opposite to the one passing through the pulmonary artery, marks the place of the ductus arteriosus; a similar arrow line is shown passing from the vena cava inferior through the fossa ovalis of the right atrium and the foramen ovale into the left atrium; hv, the hepatic veins; vp, vena portæ; x to vci, the ductus venosus; uv, umbilical vein; ua, umbilical arteries; uc, umbilical cord cut short; i, i', iliac vessels.

<sup>1</sup> In this diagram the arteries are conventionally colored red and the veins blue, but these colors are not intended to indicate the nature of the blood conveyed by the respective vessels.

*bilical arteries*, which pass from the common iliac arteries by way of the umbilical cord to the placenta.

**Changes at Birth.**—At birth the umbilical vessels are ruptured and the lungs become functional. The *umbilical arteries and veins*, no longer used, contract and their lumina are obliterated by the thickening of the inner coat (*tunica intima*). The lumen of the umbilical arteries is occluded after four days, that of the umbilical vein within a week. The wall of the vein is persistent as the *ligamentum teres* of the liver.

The *ductus venosus* atrophies because after birth only the blood from the portal vein enters the liver, and this is all drained into the liver sinusoids, forming the *portal circulation*. The ductus venosus is persistent as the fibrous ligamentum venosum, embedded in the wall of the liver.

The *ductus arteriosus* ceases to function after birth, as all the blood from the pulmonary arterial trunk is conveyed to the expanded lungs. The ductus becomes impervious from ten to twenty days after birth and persists as a solid fibrous cord.

The *foramen ovale* does not function after birth, as the large amount of blood returned to the left atrium from the now functional lungs equalizes the pressure in the two atria. As a result, both during diastole and systole, the *septum primum*, or valve of the foramen ovale, is pressed against the *septum secundum*, closing the foramen ovale. Eventually the two septa fuse, though they may be incompletely united during the first year after birth, or even longer.

### THE LYMPHATIC SYSTEM

The development of the lymphatics is, according to Sabin (Keibel and Mall, vol. 2, p. 709), divided into two stages: (1) the development from the veins of isolated *lymph-sacs*, which become united with each other by the thoracic duct and acquire a secondary opening into the veins at the jugular valves; (2) the peripheral outgrowth of lymphatic vessels as endothelial sprouts from the lymph-sacs.

In 10 to 11 mm. embryos appear the *jugular sacs* lateral to the internal jugular veins and derived from them, first as a plexus of capillaries which becomes isolated, but later rejoins the vein, forming a valve at the opening. In 23 mm. embryos the *retro-peritoneal sac* (F. T. Lewis, 1901-2) appears at the root of the mesentery adjacent to the suprarenal bodies and caudal to the superior mesenteric artery. It is developed from a capillary plexus arising from the neighboring veins. Posterior lymph-sacs are developed from the v. ischiadica.

In embryos of 30 mm. the *thoracic duct* has developed, connecting the left jugular sac with the retroperitoneal sac and receptaculum chyli (Fig. 279). According to Lewis, the thoracic duct arises from the union of several detached lymphatics derived originally from the veins. The receptaculum chyli "is a secondary enlargement dorsal to the aorta." In later stages the lymph-sacs are replaced by plexuses of lymphatic vessels which grow to the head, neck, and arm from the jugular sacs; to the hip, back and leg from the posterior sacs, and to the mesentery from the retroperitoneal sac. Valves are developed in the lymphatic vessels from folds of their endothelium.

Huntington and McClure believe that the isolated lymphatic spaces are derived independently from the mesenchyma. Lewis (in *Amer. Jour. Anat.*, 1905, vol. 5, pp. 95-120) rejects this view for the following reasons:

"1. The lymphatic spaces do not resemble mesenchyma.

"2. After being formed the lymphatics increase like blood-vessels by means of blind endothelial sprouts and not by connecting with intercellular spaces.

"3. In early embryos detached blood-vessels may be seen without proving that blood-vessels are mesenchymal spaces.

"4. The endothelium of the lymphatics is sometimes seen to be continuous with that of the veins."

**The Lymph Glands.**—These are developed first as *plexuses of lymphatics* in connection with an artery and vein. The first pair are formed in the axillary

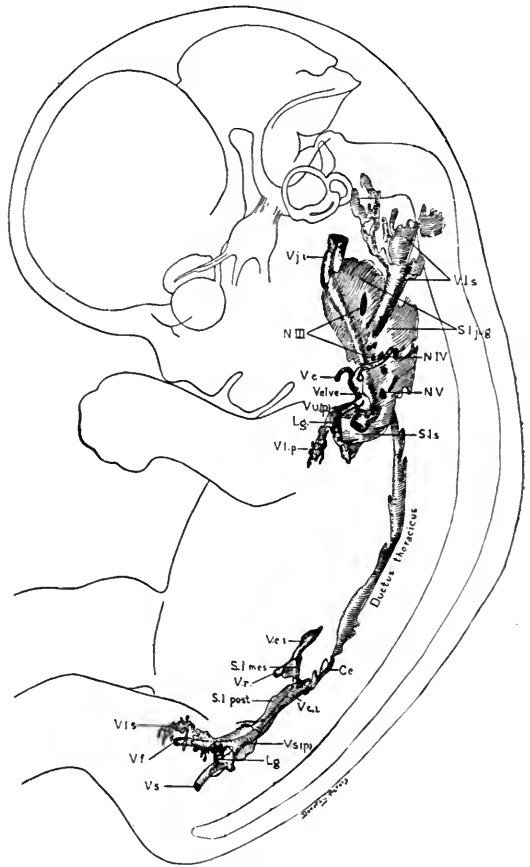


FIG. 279.—Flat reconstruction of the primitive lymphatic system in a human embryo 30 mm. long, Mall collection, No. 86,  $\times$  about 5.4. *Cc*, cisterna chyli; *Lg*, lymphoglandula; *N. III*, *N. IV*, and *N. V*, *Nn. cervicales*; *S.l.jug.*, saccus lymphaticus posterior; *S.l.s.*, saccus lymphaticus subclavius; *V.c.*, vena cephalica; *V.c.i.*, vena cava inferior; *V.f.*, vena femoralis; *V.j.i.*, vena jugularis inferior; *V.l.p.*, vasa lymphatica profunda; *V.l.s.*, vasa lymphatica superficialis; *V.r.*, vena renalis; *v.s.*, vena sciatica; *V.u. (p.)*, vena ulnaris (primitiva) (Sabin).

region from the jugular sacs. Connective-tissue septa occur between the vessels of the lymphatic network. Next *lymphocytes* collect in the connective tissue and a *capillary network* is formed connected with an artery and vein. The lymphocytes multiply and form *lymphoid tissue* (Fig. 280, *A*), and a peripheral *lymph sinus* is developed with *afferent* and *efferent lymphatics*. The blood-vessels enter the lymph gland at one point, the *hilus*. Soon the lymphatic vessels invade the lymphoid tissue and form anastomosing channels, so that the lymph enters at the periphery and is drained through the hilus. In the larger glands (Fig. 280, *B*) the connective tissue forms a definite *capsule* and extends through the gland as *cords* or *trabeculae*, in which course the larger blood-vessels. At the periphery of the gland the lymphocytes divide actively and form dense *lymph nodules* with

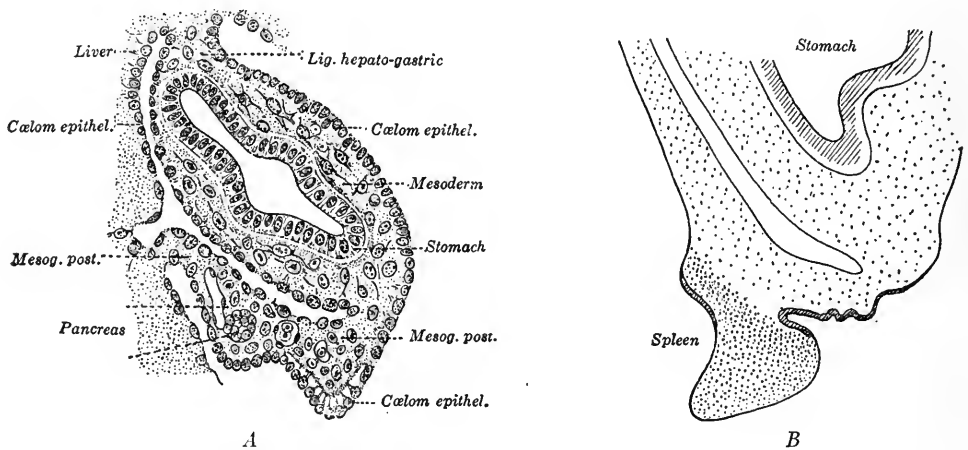


FIG. 281.—Two stages in the early development of the spleen: *A*, from an embryo of 10.5 mm. (Kollmann); *B*, from a 20 mm. embryo (Tonkoff).

*germinal centers* wherein the lymphocytes are actively dividing. The peripheral nodules constitute the *cortex* of the gland. At the center of the gland, and near the hilus, the network of lymph sinuses divides the lymphoid tissue into anastomosing *cords* and this region of the gland becomes the *medulla*.

**Hæmolymp glands**, according to Schumacher, begin their development like lymph glands, but soon after the formation of the peripheral sinus the lymphatic connections degenerate and the blood escapes from the blood capillaries into the sinuses.

**The Spleen.**—Little is known of the early development of the spleen in human embryos beyond the fact that it originates as a thickening of the dorsal mesogastrium due to the division of the cells of the peritoneal epithelium (Fig. 281). The spleen is a lymphoid organ in which blood sinuses, instead of lymph

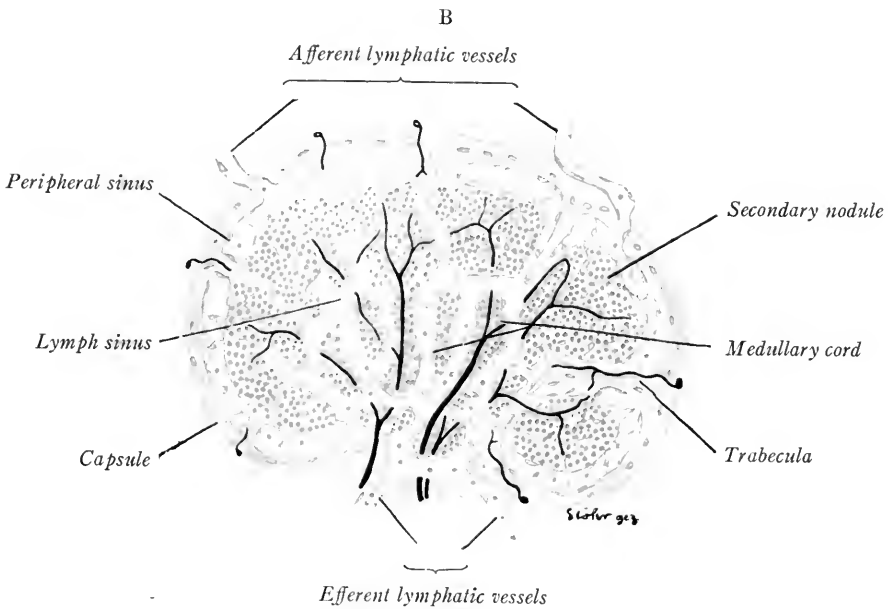
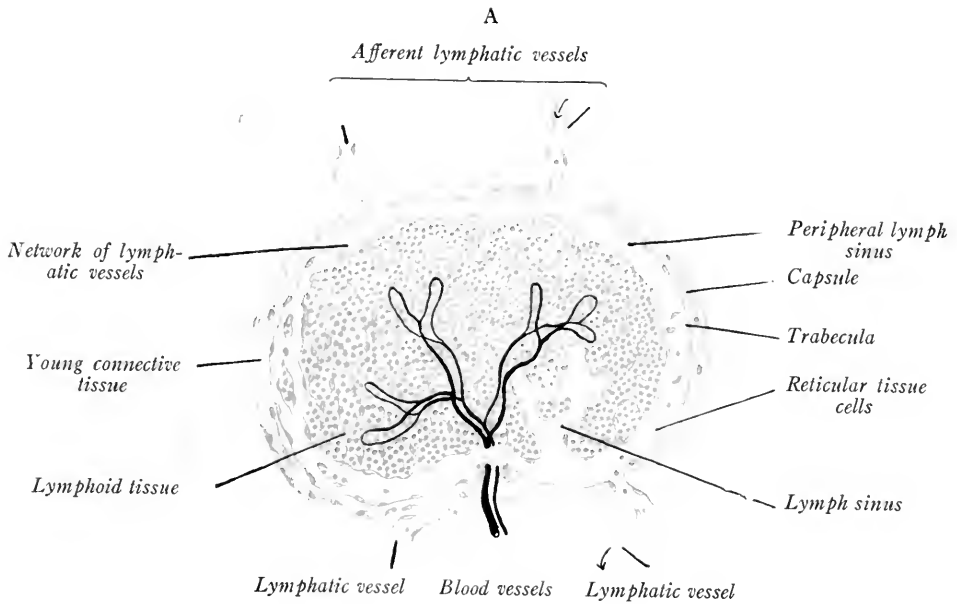



FIG. 280.—Diagrams representing four stages in the development of lymph glands. The earlier stages are shown on the left side of each figure (Lewis and Stöhr)





sinuses, are developed to form the spaces of the *splenic pulp*. Mall has shown by injecting pig embryos that in the younger fetuses the blood-vessels of the spleen form a closed system. In fetuses of 10 to 12 cm. the capillaries enlarge, giving rise to definite capillary units which drain into the veins through openings in their syncytial endothelium. The enlarged cavernous capillaries form the spaces in the splenic pulp.

Lifschitz has shown that, in human embryos between 15 and 30 cm. long, red blood-cells are actively formed in the splenic pulp around the giant cells. The *lymphoid tissue* of the spleen first appears as *ellipsoids* about the smallest arteries in fetuses of four months. At seven months the ovoid *splenic corpuscles* appear as lymphoid nodules about the larger arteries. The lymphoid tissue is not formed from tissue of the blood-vessels, but, like the lymph nodules of lymph glands, is developed around them from the mesenchyma.

## CHAPTER X

### HISTOGENESIS

The primitive cells of the embryo are alike in structure. The protoplasm of each exhibits the fundamental properties of irritability, contractility, conductivity and metabolism (the absorption, digestion, and assimilation of nutritive substances and the excretion of waste products, processes through which growth and reproduction are made possible). As development proceeds, there is a gradual differentiation of the cells into *tissues*, each tissue being composed of like cells, the structure of which has been adapted to the performance of a certain special function. In other words, there is division of labor and adaptation of cell structure to the function which each cell performs. The differentiation of tissue cells from the primitive cells of the embryo is known as *histogenesis*. On page 64 the derivatives of the germ layers are given. We shall take up briefly the histogenesis of the tissues derived from the *endoderm*, *mesoderm*, and *ectoderm* in the order named.

#### THE HISTOGENESIS OF THE ENTODERMAL EPITHELIUM

The cells of the entoderm are little modified from their primitive structure. From the first they are concerned with the processes of absorption, digestion, assimilation and excretion. They form always epithelial layers lining the digestive and respiratory canals and the glandular derivatives of these. In the pharynx, esophagus and trachea the cells are early of columnar form and ciliated. The epithelium of the pharynx and esophagus becomes stratified and the surface layers flatten to form squamous cells. The stratified epithelium is developed from a basal germinal layer like the epidermis of the integument (see p. 304). Throughout the rest of the digestive canal the simple columnar epithelium of the embryo persists. At the free ends of the majority of the cells is developed a cuticular plate. Other cells are converted into unicellular mucous glands or *goblet cells*. As outgrowths of the intestinal epithelium, are developed the simple tubular glands of the stomach and intestine and the liver and pancreas.

In the respiratory tract the entoderm forms at first a simple columnar epithelium. Later, in the trachea and bronchi this is differentiated into a pseudo-

stratified ciliated epithelium. The columnar epithelium of the alveoli and alveolar ducts of the lungs is converted into the flattened squamous respiratory epithelium. The development of the thymus and thyroid glands, liver and pancreas has been described in Chapter VII.

### HISTOGENESIS OF THE MESODERMAL TISSUES

The differentiation of the mesoderm has been described on p. 61, Fig. 51. It gives rise to the mesodermal segments, intermediate cell masses, somatic and splanchnic layers, all of which are epithelia, and to the diffuse *mesenchyme*. The

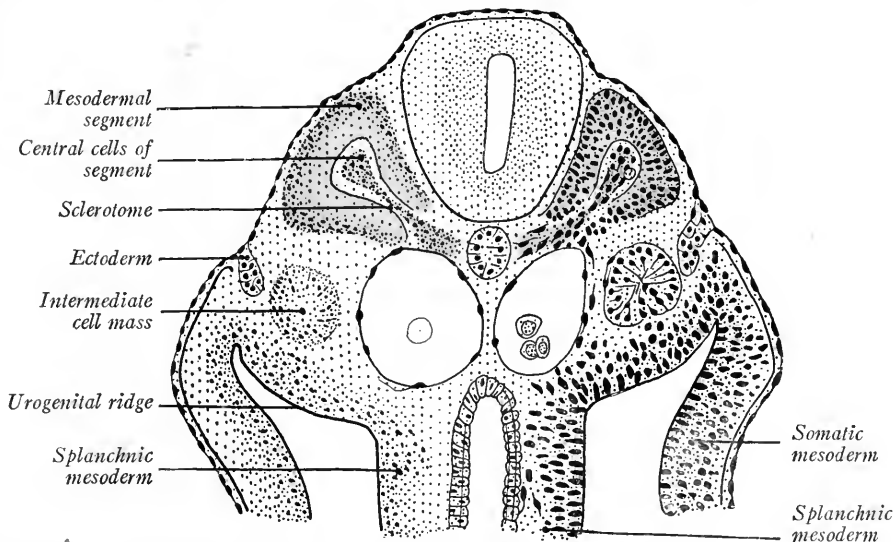


FIG. 282.—Transverse section of a 4.5 mm. embryo showing the development of the sclerotomes (Kollmann's Handatlas).

*somatic and splanchnic layers of the mesoderm* form on their cœlomic surfaces a single layer of squamous cells termed the *mesothelium*. This is the covering layer of the pericardium, pleura, peritoneum, mesenteries, serous layer of the viscera and lining of the vaginal sac in the scrotum. From this mesothelium is derived also the epithelium of the genital glands and that of the Muellerian ducts.

The *intermediate* cell masses or nephrotomes are the anlagen of the pronephros, mesonephros, metanephros, and their ducts (p. 203).

**The Sclerotomes and Mesenchyme.**—The cavities of the mesodermal segments become filled with diffuse spindle-shaped cells, then their median walls are converted into similar tissue which migrates mesially towards, and eventually surrounds, the neural tube and notochord (Fig. 282). This diffuse tissue is

*mesenchyme* (see p. 63), and that derived from a single mesodermal segment constitutes a *sclerotome*. The sclerotomes ultimately are converted into connective tissue, into the vertebræ, and into the basal portion of the cranium. The persisting lateral plate of the mesodermal segment becomes a *dermo-myotome*, from which the voluntary muscle is differentiated and probably the dermis of the integument.

In the head region cranial to the otocysts no mesodermal segments are formed, but the primitive mesoderm is converted directly into mesenchyme. Mesenchyme is derived also from the somatic and splanchnic mesoderm and from the primitive streak tissue. From the mesenchyme a number of tissues are developed (see p. 64). The origin of the blood and primitive blood-vessels and lymphatics has been described; it remains to trace the development of the supporting tissues (connective tissue, cartilage and bone) and of the smooth muscle fibers.

#### THE SUPPORTING TISSUES

The supporting tissues are peculiar in that during their development from the mesenchyme a fibrous, hyaline or calcified matrix is formed which becomes greater in amount than the persisting cellular elements of the tissue.

**Connective Tissue.**—Different views are held as to the differentiation of connective-tissue fibers. According to Laguess and Merkel, the fibers arise in an *intercellular matrix* derived from the cytoplasm of mesenchymal cells. Szily holds that fibers are first formed as processes of epithelial cells and that into this fibrous meshwork mesenchymal cells later migrate. The view generally accepted, that of Flemming, Mall, Spalteholz and Meves, is that the primitive connective-tissue fibers are developed as a part of the cell, *i. e.*, are *intracellular* in origin.

The mesenchyme is at first compact, the cell nuclei predominating. Soon a syncytium is developed, the cytoplasm increasing in amount and forming an open network. Next the cytoplasm is differentiated into a perinuclear granular *endoplasm* and an outer distinct hyaline layer of *ectoplasm* (Fig. 283, A). In the ectoplasm fibrils appear, derived from coarse filaments known as *chondrioconta* (Meves).

**Reticular Tissue.**—Single fibers of reticulin arise in the ectoplasm of the mesenchymal syncytium. The nuclei and endoplasm persist as reticular cells. According to Mall, reticular fibers differ chemically from white connective-tissue fibers

**White Fibrous Connective Tissue.**—The differentiation of this tissue may be

divided into two stages: (1) a prefibrous stage during which the ectoplasm is formed rapidly by the endoplasm of the cells, and fibrils resembling those of reticular tissue appear in the ectoplasm (Fig. 283, *A*). (2) The anastomosing fibers take the form of parallel bundles and are converted through a chemical change into typical white fibers. The spindle-shaped cells are transformed into the connective-tissue cells characteristic of the adult. In *tendons*, the bundles of white fibers are arranged in compact parallel fascicles, in areolar tissue they are interwoven to form a meshwork. The cells of the tendons are compressed be-

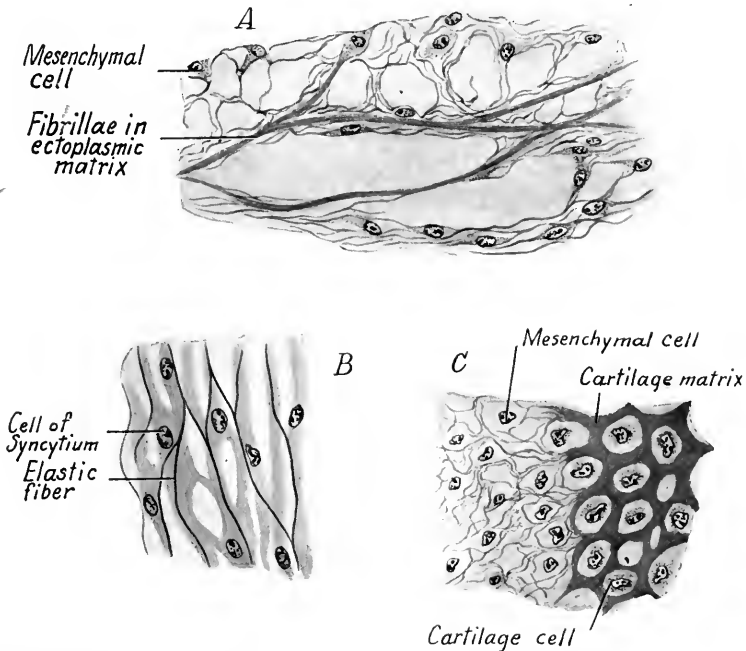


FIG. 283.—Figures showing the differentiation of the supporting tissues (after Mall). *A*, white fibers forming in the dermis of a 5 cm. pig embryo; *B*, elastic fibers forming in the syncytium of the umbilical cord from a 7 cm. embryo; *C*, developing cartilage from the occipital bone of a 20 mm. pig embryo.

tween the bundles of fibers and this accounts for their peculiar form and arrangement. In the *cornea* of the eye the cells retain their processes. The corneal tissue is thus embryonic in character and is without elastic fibers or blood-vessels.

**Elastic Tissue.**—With the exception of the cornea and tendon, yellow elastic fibers develop in connection with all white fibrous connective tissue. Like the white fibers they are produced in the ectoplasm of the mesenchymal syncytium (Fig. 283, *B*). They are developed as single fibers, but may coalesce to form the fenestrated membranes of the arteries. According to Ranvier, elastic fibers are

produced by the union of ectoplasmic granules, but this view is not supported by either Mall or Spalteholz.

**Adipose Tissue.**—Certain of the mesenchymal cells give rise not to fibroblasts but to fat-cells. They secrete within their cytoplasm droplets of fat which increase in size and become confluent (Fig. 284). Finally, a single fat globule fills the cell of which the nucleus and cytoplasm are pressed to the periphery. The fat-cells are most numerous along the course of the blood-vessels in areolar connective tissue and appear first during the fourth month.

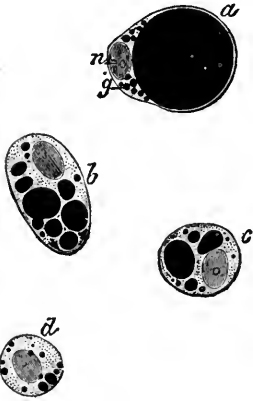


FIG. 284.—Developing fat-cells, the fat blackened with osmic acid (after Ranvier). *n*, nucleus; *g*, fat globules.

According to Mall, mesenchymal cells give rise first to an ectoplasm in which fibrillæ develop. Next, the cells increase in size and are gradually extruded until they lie in the spaces of the ectoplasmic matrix (Figs. 283C, 285, B). Simultaneously, the ectoplasm is converted into the hyaline matrix peculiar to cartilage, undergoing both a chemical and structural change. About the cartilage cells the endoplasm produces capsules of hyaline substance.

The interstitial growth of cartilage is due: (1) to the production of new hyaline matrix; (2) to the formation of capsules about the cells and their transformation into matrix; (3) to the proliferation of the cartilage cells, which may separate or occur in clusters within a single capsule.

*Perichondral* growth also takes place about the periphery of the cartilage and is due to the activity of persisting mesenchymal cells, which, with an outer sheath of connective tissue,

### CARTILAGE

Cartilage has been described as developing in two ways: (1) The mesenchymal cells increase in size and form a compact cellular precartilage. Later the hyaline matrix is developed between the cells from their cytoplasm (Fig. 285, A). The matrix may in this case be regarded as the ectoplasm of the cartilage cells. (2) Ac-

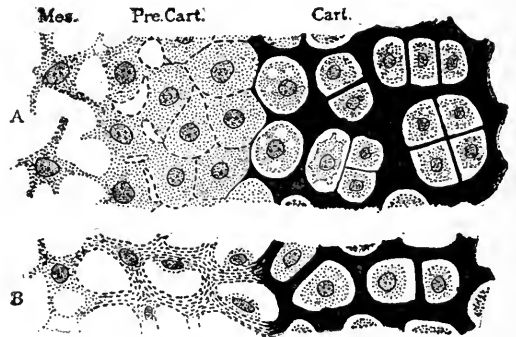


FIG. 285.—Diagrams of the development of cartilage from mesenchyma (Lewis and Stöhr). *A*, based upon Studnička's studies of fish; *B*, upon Mall's Study of Mammals. *Mes.*, mesenchyma; *Pre. cart.*, precartilage; *Cart.*, cartilage.

constitute the *perichondrium*. When cartilage is replaced by bone, the perichondrium becomes the *periosteum*.

In *hyaline cartilage* the matrix remains hyaline. In *fibro-cartilage* the fibrillations of the primitive ectoplasm are converted into white fibers. In *elastic cartilage* yellow elastic fibers are formed in the hyaline matrix, according to Mall; before the hyaline matrix is differentiated, according to Spalteholz. Most of the bones of the skeleton are laid down first in the form of cartilage. Later, this is gradually replaced by the development of bone tissue.

## BONE

Bone is a tissue appearing relatively late in the embryo. There are developed two types, the *membrane bones* of the face and cranium and the *cartilage bones* which replace the cartilaginous skeleton. Cartilage bones are not simply cartilage transformed into bone by the deposition of calcium salts, but represent a new tissue which is developed as the cartilage is destroyed.

**Membrane Bone.**—The bones of the face, the parietals, frontals and parts of the occipital, temporals and sphenoid are not preformed as cartilage; the mandible is developed around a pair of cartilages (of Meckel). The form of a membrane bone is determined by the development of a periosteal membrane from the mesenchyma. The bone matrix is differentiated within the periosteum from enlarged cells, the *osteoblasts* (bone-formers). Osteoblasts appear in clusters and from their cytoplasm is differentiated a fibrillated ectoplasmic matrix like that which precedes the formation of connective tissue and cartilage (Fig. 286 A). This fibrillated matrix, by a chemical change apparently, is converted into a homogeneous bone matrix, which first takes the form of spicules. The spicules coalesce, form a network of bony plates and constitute the bone matrix upon the surfaces of which osteoblasts are arranged in a single layer like the cells of an epithelium (Fig. 286 B). These cells may be cuboidal, columnar or flatten out as bone formation ceases. As the matrix of the bone is laid down, osteoblasts become enclosed and form *bone cells*. The bone cells are lodged in spaces termed *lacunæ*. These are connected by microscopic canals, the *canaliculi*, in which course delicate cell processes and anastomose with those of neighboring cells.

The plates of the spongy membrane bone are formed about blood-vessels as centers. As the bone grows at the periphery, the bone matrix is resorbed centrally. At this time large multinucleated cells (43 to 91  $\mu$  long) appear upon the surfaces of the bone matrix. These cells are known as *osteoclasts* (bone-destroyers). There is, however, no positive evidence that the osteoclasts are active in dissolving the bone. They may be interpreted also as degenerating osteoblasts. The cavities in which they are frequently lodged are known as

*Howship's lacunæ*. The bone lamellæ of the central portion of the membrane bone are gradually resorbed and this portion of the bone is of a spongy texture. Some time after birth, compact bone lamellæ are laid down by the inner osteoblast cells of the periosteum. In the case of flat bones, compact *inner and outer plates or tables* are thus developed with spongy bone between them. The spaces in the spongy bone are filled by derivatives of the mesenchyme: reticular tissue, blood-vessels, fat-cells and developing blood-cells. These together constitute

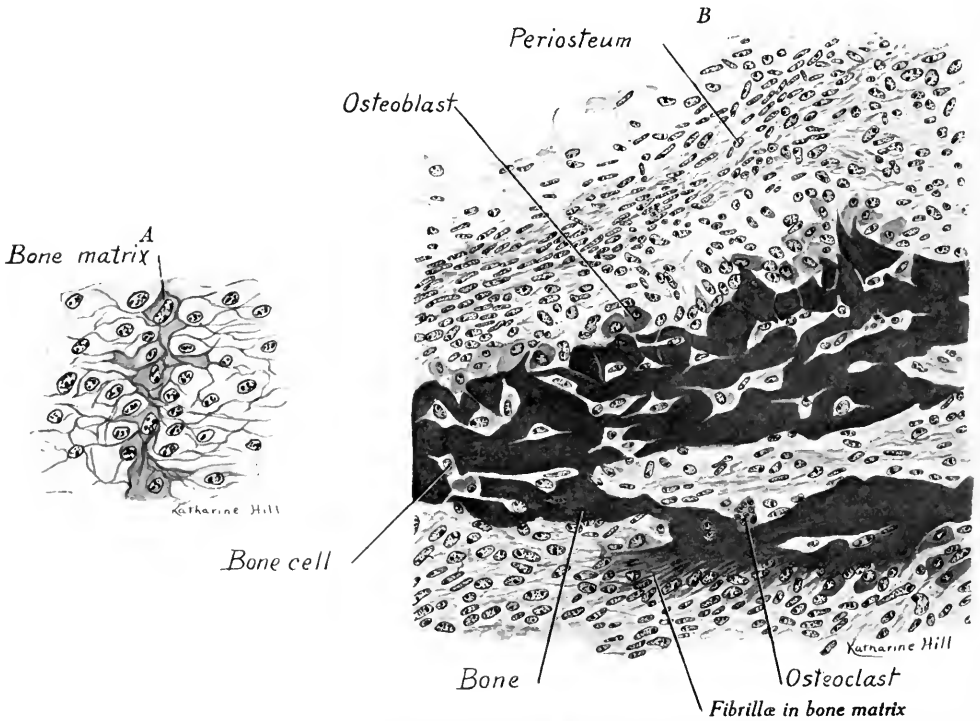


FIG. 286.—Two stages in the development of bone: *A*, section through the occipital cartilage of a 20 mm. pig embryo (Mall); *B*, section through the periosteum and bone lamellæ of the mandible from a 65 mm. human embryo.  $\times 325$ .

the *red bone marrow*. The ossification of membrane bones begins at the middle of the bone and proceeds in all directions from this primary center.

**Cartilage Bone.**—The form of the cartilage bone is determined by the pre-formed cartilage and its surrounding membrane, the perichondrium (Fig. 288). Bone tissue is developed as in membrane bones save that the cartilage is first destroyed and the new bone tissue develops (1) in and (2) about it. In the first case, the process is known as *endochondral* bone formation. In the second case, it is known as *perichondral* or *periosteal* bone formation.



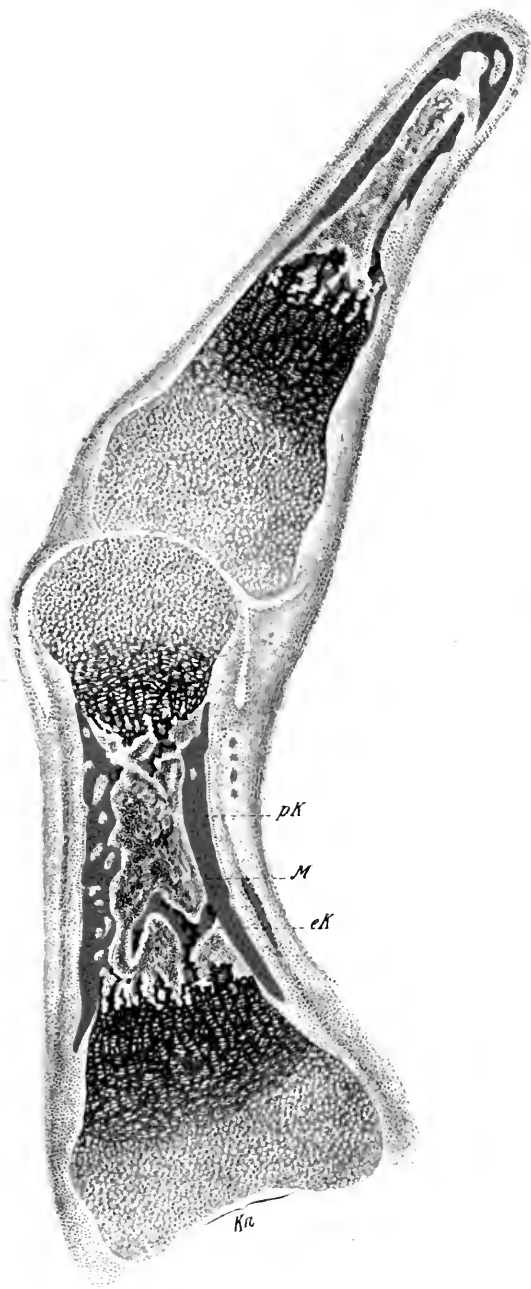


FIG. 287.—A longitudinal section of the two distal phalanges from the finger of a five-months' human fetus (Sobotta) ( $\times 15$ ). *Kn*, Cartilage showing calcification and resorption; *eK*, endochondral bone; *M*, marrow cavity; *pK*, periosteal bone.



**Endochondral Bone Formation.**—The cartilage cells enlarge, become arranged in characteristic rows and resorb the cartilage matrix (Fig. 287). The perichondrium becomes the periosteum. From its inner or osteogenic layer, which is densely cellular, ingrowths invade the cartilage as it is resorbed and fill the primary cavities. The invading osteogenic tissue gives rise to *osteoblasts* and *bone marrow*. By the osteoblasts bone is differentiated directly upon persisting portions of the cartilage. As new bone is developed peripherally, it is resorbed centrally to form large marrow spaces. Eventually, all of the cartilage matrix is destroyed. The fate of the cartilage cells is unknown.

### Perichondral Ossification.

—Compact bone is developed after birth by the osteogenic layer of the periosteum and thus are produced the *periosteal lamellæ*. In the ribs this is said to be the only method of ossification. The bone lamellæ deposited about a blood-vessel are concentrically arranged and form the *concentric lamellæ* of a *Haversian system*. The *Haversian canal* of adult bone is merely the space occupied by a blood-vessel.

### Growth of Cartilage Bones.

—In cartilage bones there is no interstitial growth as in cartilage. Most of the cartilage bones have more than one center of ossification and growth is due to the expansion of the intervening cartilage. Flat bones grow at the periphery, ring-like bones, such as the vertebræ, have three primary centers of ossification, between which the cartilage continues to grow (Fig. 288 A). In the case of the numerous long bones of the skeleton, the primitive ossification center forms the shaft or *diaphysis* (Fig. 288 C–F). The cartilage at either end of the diaphysis grows rapidly and thus the bone increases in length. Eventually, osteogenic tissue invades these cartilages and new ossification centers, the *epiphyses*, are formed, one at either end. When the growth of the bone in

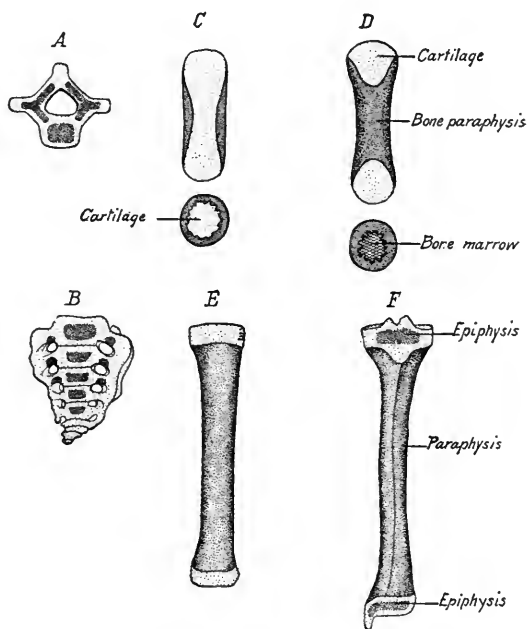


FIG. 288.—Diagrams to show the method of growth of A, a vertebra; B, of sacrum; C–F, of a long bone (the tibia).

length is completed, the epiphyses, by the ossification of the intervening cartilage, are united to the diaphysis.

The shaft of the long bones grows in diameter by the peripheral deposition of bone lamellæ and the central resorption of the bone. In the larger long bones spongy, or cancellated bone tissue persists at the ends, but in the middle portion a large *medullary*, or *marrow cavity*, is developed. This is filled chiefly with fat cells and constitutes the *yellow bone marrow*.

**Regeneration of Bone.**—If bone is injured or fractured, new bone is developed by osteoblasts derived either from the periosteum or from the bone marrow. The repair of a fracture is usually preceded by the formation of cartilage which unites the ends of the bones and is later changed to bone. In adults, the periosteum is especially important in the regeneration of bone tissue.

The special development of the various bones of the skeleton is beyond the scope of this book. The student is referred to the various text-books of anatomy, to Kollmann's *Handatlas of Embryology*, vol. i, and to Bardeen's chapter in Keibel and Mall (vol. I, p. 316 ff).

**Joints.**—In joints of the *synarthrosis* type in which little movement is allowed the mesenchyma between the ends of the bones differentiates into connective tissue or cartilage. This persists in the adult.

In joints of the *diarthrosis* type the bones are freely movable. The mesenchyma between the bones develops into an open connective tissue in which a cleft appears, the joint cavity. The cells lining this cavity flatten out and form a more or less continuous layer of epithelium, the synovial membrane. From the connective tissue surrounding the joint cavity are developed the various fibrous ligaments typical of the different joints.

### THE HISTOGENESIS OF MUSCLE

The muscular system is composed of muscle fibers which form a tissue in which contractility has become the predominating function. The fibers are of three types: (1) *smooth muscle cells* found principally in the walls of the viscera and blood-vessels; (2) *striated cardiac muscle*, forming the myocardium of the heart; (3) *striated voluntary muscle*, chiefly attached to the elements of the skeleton and producing voluntary movements. All three types are derived from the mesoderm. The only exceptions are the smooth muscle of the iris, and the smooth muscle of the sweat glands, which are derived from the ectoderm.

**Smooth Muscle** in general may be said to arise from the mesenchyme, or from embryonal connective tissue. Its development has been studied by McGill (*Internat. Monatschr. f. Anat. u. Physiol.*, vol. 24, pp. 209–245, 1907) in the esophagus of pig embryos. The stellate cells of the mesenchyma enlarge, elongate

and their cytoplasm becomes more abundant. The resulting spindle-shaped cells (Fig. 289 A) remain attached to each other by cytoplasmic bridges and develop in the superficial layer of their cytoplasm course myoglia fibers (Fig. 289 B) similar to the primitive fibrillæ of connective tissue. The myoglia fibers may extend from cell to cell, thus connecting them. These fibers are the products of coalesced granules found within the cytoplasm of the myoblasts. In embryos of 30 mm. fine myofibrillæ are differentiated in the cytoplasm of the myoblasts and give it a longitudinally striated appearance. The cytoplasmic processes of the muscle cells, the cytoplasmic bridges, later give rise to white connective tissue fibers which envelop the muscle fibers and bind them together. Smooth muscle increases in amount: (1) by the formation of new fibers from the mesenchyme of the embryo; (2) by the transformation into muscle fibers of interstitial cells; (3) by the multiplication of their nuclei by mitosis in the more advanced fetal stages.

**Striated Cardiac Muscle.**—This is developed from the splanchnic mesoderm which forms both the epicardium and the myocardium. The cells of the myocardium at first form a syncytium in which myofibrillæ develop from chondrioconta or cytoplasmic granules. The myofibrillæ are developed at the periphery of the syncytial strands of cytoplasm and extend long distances in the syncytium. They multiply rapidly in number and become differentiated each into alternating dark and light bands, due to a difference in density. The syncytial character of cardiac muscle persists in the adult and the nuclei remain central in position. The intercalated discs typical of adult cardiac muscle appear relatively late, just before birth in the guinea-pig, according to Jordan and Steele.

**Striated Voluntary Muscle.**—All striated voluntary muscle is derived from the mesoderm, either from the myotomes of the segments (muscles of the trunk) or from the mesenchyma (muscles of the head). According to Bardeen (in Keibel and Mall, vol. 1), after the formation of the sclerotome (Fig. 282 A), which gives rise to skeletal tissue, the remaining portion of the primitive segment constitutes the *myotome*. All the cells of the myotome give rise to myoblasts. Williams (Amer. Jour. Anat., vol. 88), working on the mesodermal segments of the chick, finds that only the dorsal and mesial cells are myoblasts. By multiplication they form a mesial myotome, while the lateral cells of the original mesodermal segment persist as a dermatome and give rise only to the connective tissue of the dermis (Fig. 291). The dermatome lies lateral to the myotome and the two together constitute the *dermo-myotome*, according to Williams (Fig. 45).

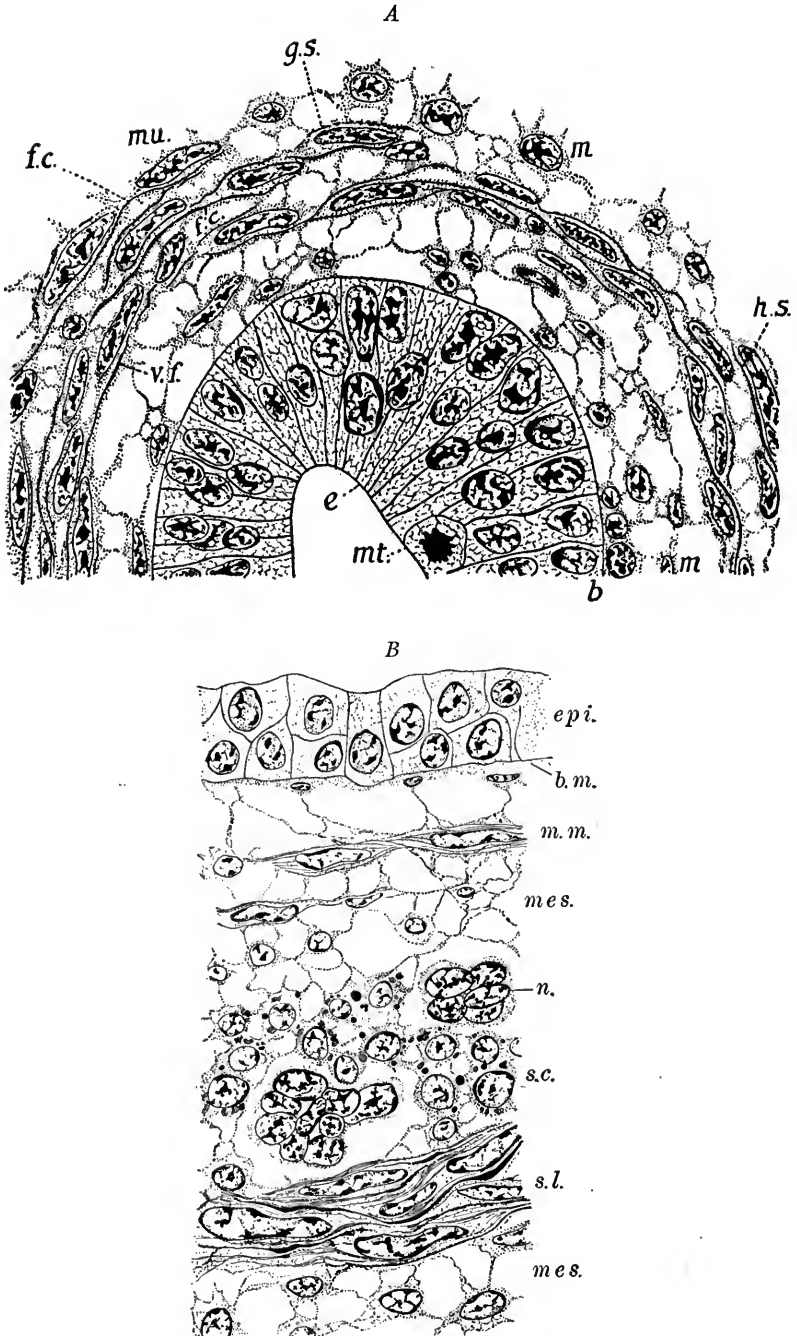


FIG. 289.—Two stages in the development of smooth muscle fibers; *A*, from the esophagus of a 13 mm. pig (McGill); *B*, a longitudinal section of the esophagus of a 27 mm. pig (after McGill in Lewis-Stöhr). *b*, *b.m.*, basement membrane; *e*, *epi.*, epithelium; *f.c.*, myoglia fibrils; *g.s.*, granules coalescing; *h.s.*, homogeneous fibers; *mes.*, mesenchyma; *mm.*, muscularis mucosæ; *mu.*, muscle cell; *n.*, nerve cells; *s.c.*, circular smooth muscle cut across; *s.l.*, longitudinal smooth muscle cut lengthwise.

As to the origin of the striated voluntary muscle fibers, there is also a difference of opinion. It is generally believed that the myoblasts elongate and, by the repeated mitotic division of their nuclei, become multinucleated. Godlewski holds that several myoblasts unite to form a single muscle fiber. The nuclei lie at first centrally, surrounded by the granular sarcoplasm in which myofibrils differentiate peripherally. The myofibrils become striated like those of cardiac muscle. During development the muscle fibers increase enormously in size, the nuclei migrate to the surface and the myofibrillæ are arranged in bundles or *muscle columns* (sarcostyles). This arrangement of the fibrillæ may, however, be due to shrinkage in the preparation of the sections observed.

According to Baldwin (*Zeitschr. f. allg. Physiol.*, vol. 14, 1912), the nucleus and perinuclear sarcoplasm is separated from the rest of the muscle fiber by the sarcolemma. With Apáthy, he would therefore regard the myofibrillæ as a differentiated product of the muscle cells and to be homologized with connective tissue fibers. The extrusion of the muscle cell from the muscle fiber may be compared to the extrusion of cartilage cells from the precartilage matrix, as described by Mall (see p. 294).

During the later stages in the development of striated voluntary muscle, there is, according to many observers, an active degeneration of the muscle fibers.

While smooth muscle fibers form a syncytium and the enveloping connective tissue is developed directly from the muscle cells, in the case of striated voluntary muscle each fiber is a multinucleated entity which is bound together with others by connective tissue of independent origin.

**Morphogenesis of the Muscles.**—The development of the individual muscles of the human body has been described in detail by W. Lewis (in Keibel and Mall, vol. 1, p. 473) and to this work the student is referred. We may state briefly here the origin of the muscles of the trunk, limbs and head.

**The muscles of the trunk.**—The deep muscles are derived from the myotomes which extend ventrally and fuse with one another (Fig. 290). This fusion is well advanced superficially in embryos of 9 to 10 mm. The deep portions of the myotomes do not fuse but give rise to the intervertebral muscles, which thus retain their primitive segmental arrangement. The various long muscles of the back arise by longitudinal and tangential splitting.

**The thoraco-abdominal muscles** arise as ventral extensions of the thoracic myotomes into the somatopleure, growing in along with the ribs.

**The musculature of the extremities.**—It has been generally believed that the muscles of the extremities were developed from buds of the myotomes which grew into the anlagen of the limbs. According to Lewis, "there are no observations of distinct myotome buds extending into the limbs." A diffuse migration of

cells from the ventral portion of the myotomes has been recorded by various observers, recently by Ingalls. These cells soon lose their epithelial character and blend with the undifferentiated mesenchyma of the limb buds (Fig. 291). From this diffuse tissue then the limb muscles are differentiated, the proximal muscles being the first to appear.

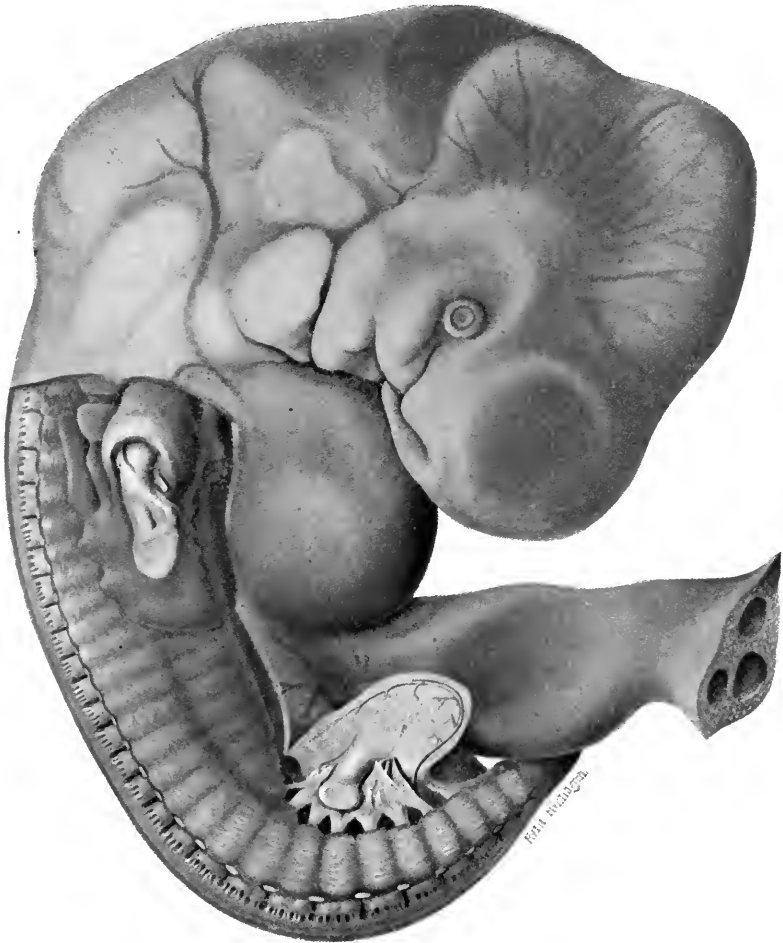


FIG. 290.—Reconstruction of a 9 mm. embryo to show the myotomes (Bardeen and Lewis).

**The musculature of the head** is derived from the pre-otic mesenchymal tissue which condenses to form premuscle masses. No myotomes are developed in this region.

**The pharyngeal muscles** probably arise from the mesenchymal tissue of the third branchial arch.



The intrinsic muscles of the *larynx* are differentiated from the mesenchyme at the ventral ends of the third and fourth branchial arches.

**The muscles of the tongue** are supplied by the n. hypoglossus and therefore

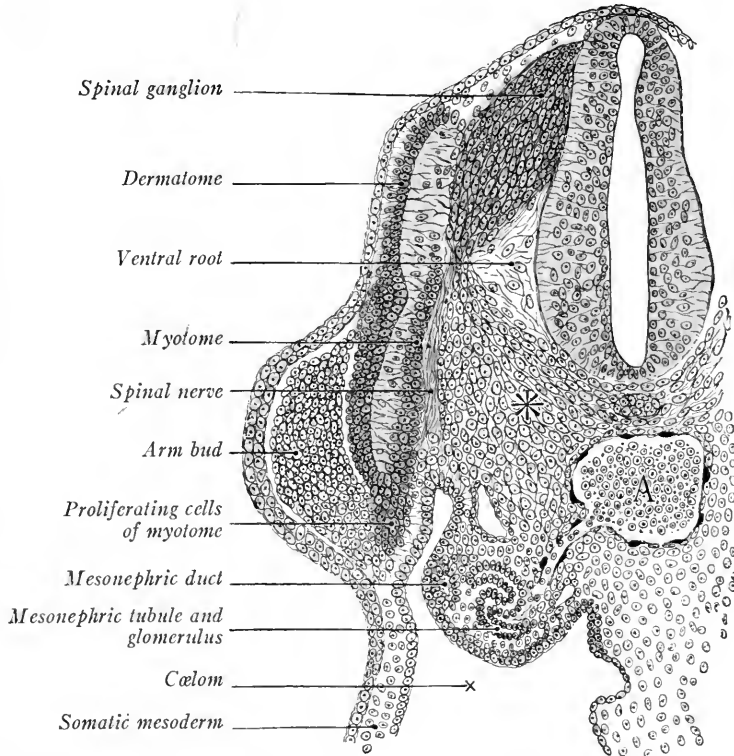


FIG. 291.—Transverse section of a 10.3 mm. monkey embryo showing the myotome and the mesenchyma of the arm bud (Kollmann's Handatlas). A, aorta; \*, sclerotome.

it has been assumed that they are derived from myotomes of the occipital region. According to W. Lewis, "there is no evidence whatever for this statement, and we are inclined to believe from our studies that the tongue musculature is derived from the mesoderm of the floor of the mouth."

### THE HISTOGENESIS OF THE ECTODERMAL DERIVATIVES

Besides forming the enamel of the teeth and salivary glands (see p. 161), the ectoderm gives rise: (1) to the epidermis and its derivatives (subcutaneous glands, nails, hair, and lens and cornea of the eye); (2) to the nervous system and sensory epithelia; (3) to parts of certain glands producing internal secretions such as the pituitary body, adrenal glands, and chromaffin bodies. We shall describe

here the histogenesis of the epidermis and the development of its derivatives and the histogenesis of the nervous tissues, reserving for final chapters the development of the nervous organs and the glands formed in part from them.

### THE EPIDERMIS

The single-layered ectoderm of the early embryo by the division of its cells becomes differentiated into a two-layered epidermis composed of an inner layer of cuboidal or columnar cells, the *stratum germinativum*, and an outer layer of flattened cells, the *epitrichium* or *periderm* (Fig. 292 A).

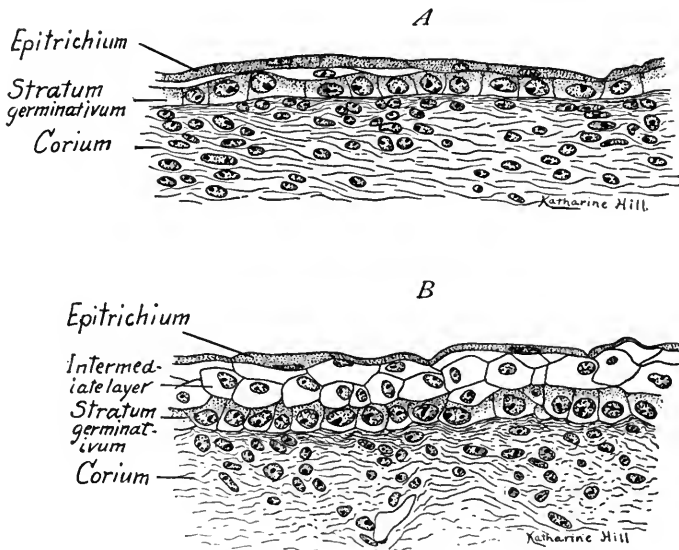


FIG. 292.—Sections of the integument from a 65 mm. embryo. A, section through the integument of the neck showing a two-layered epidermis and the beginning of a third intermediate layer; B, section from the integument of the chin in which three layers are well developed in the epidermis.  $\times 440$ .

The *stratum germinativum* is the reproducing layer of the epidermis. As development proceeds, its cells by division gradually give rise to new layers above it until the epidermis becomes a many layered or *stratified epithelium*. The periderm is always the outermost layer of the epidermis. In embryos of 30 to 88 mm. the epidermis is typically three-layered, the outer flattened layer forming the periderm, a middle layer of polygonal cells, the intermediate layer and the inner columnar layer being the stratum germinativum (Fig. 292 B). This condition may persist until the end of the fourth month. After the fourth month the epidermis becomes many layered. The inner layers of cells now form the *stratum germinativum* and are actively dividing cells united with each other by

cytoplasmic bridges. The outer layers of cells become cornified, the cornification of the cells proceeding from the stratum germinativum toward the surface. Thus, next the germinal layer are cells containing *keratohyalin*, which constitute the *stratum granulosum*, a single layer of cells. A thicker layer above the stratum granulosum shows cells in which drops of a substance called *eleidin* are formed. These droplets, which are supposed to represent softened keratohyalin, give these cells a clear appearance when examined unstained. Hence the layer is termed the *stratum lucidum*. In the outer layers of the epidermis the thickened walls of the cells become cornified and in the cells themselves a fatty substance collects. These layers of cells constitute the *stratum corneum*. The cells of this layer are also greatly flattened, especially at the surface.

When the hairs develop they do not penetrate the outer periderm layer of the epidermis but, as they grow out, lift it off. Hence this layer is known also as the *epitrichium* (layer upon the hair). Pigment granules appear soon after birth in the cells of the stratum granulosum. These granules are probably formed *in situ*. Negro children are quite light in color at birth but within six weeks their integument has reached the normal degree of pigmentation.

The *dermis* or *corium* of the integument is developed from mesenchyme or from the dermatomes of the mesodermal segments. For special points concerning its development see Keibel and Mall's "Human Embryology," vol. 1, p. 254.

### THE HAIR

Hairs are derived from thickenings of the epidermis and begin to develop at the end of the second month on the eyebrows, upper lip and chin. The hair of the general body integument appears at the beginning of the fourth month.

The first evidence of a hair anlage is the elongation of a cluster of epidermal cells in the inner germinal layer (Fig. 293 A). The bases of these cells project into the dermis and, above them, cells of the epidermis are arranged parallel to the surface. The elongated cells continue to grow downward until a cylindrical hair anlage is produced (Fig. 293 B, C). This consists of an outer wall formed of a single layer of columnar cells, continuous with the basal layer of the epidermis. This wall bounds a central mass of irregularly polygonal epidermal cells. About the hair anlage the mesenchyme forms a sheath, and at its base a condensation of mesenchyme produces the anlage of the *hair papilla*, which projects into the enlarged base of the hair anlage. As development proceeds, the hair anlage grows deeper into the corium and its base enlarges to form the *hair bulb* (Fig. 293 C).

The hair is differentiated from the basal epidermal cells surrounding the hair papilla. These cells elongate and grow centrally toward the surface distinct

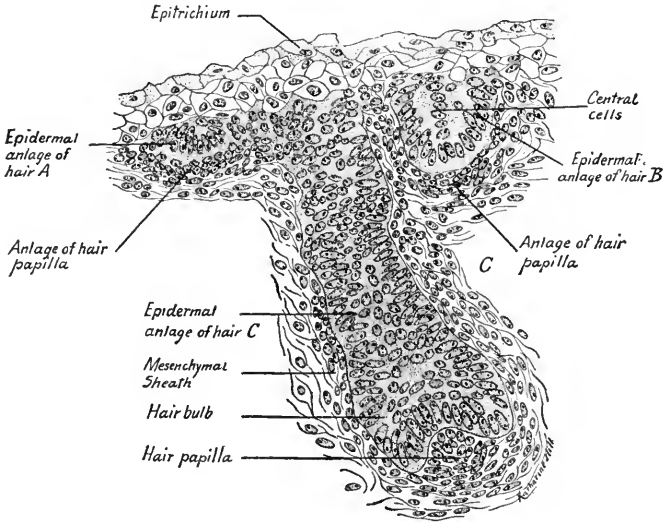


FIG. 293.—Section through the integument of the face of a 65 mm. embryo showing three stages in the early development of the hair.  $\times 330$ .

from the peripheral cells which form the *outer sheath* of the hair (Fig. 294). The central core of cells gives rise to the inner hair sheath and to the shaft of the hair.

At the sides of the outer hair sheath two swellings appear on the lower side of the obliquely directed hair anlage. The more superficial of these is the anlage of the *sebaceous gland* (Fig. 294). The deeper swelling is the "*epithelial bed*," a region where the cells by rapid division contribute to the growth of the hair follicle.

Superficial to the bulb, the cells of the hair shaft become cornified and differentiated into outer cuticle, middle cortex and central medulla. The inner hair sheath extends from the

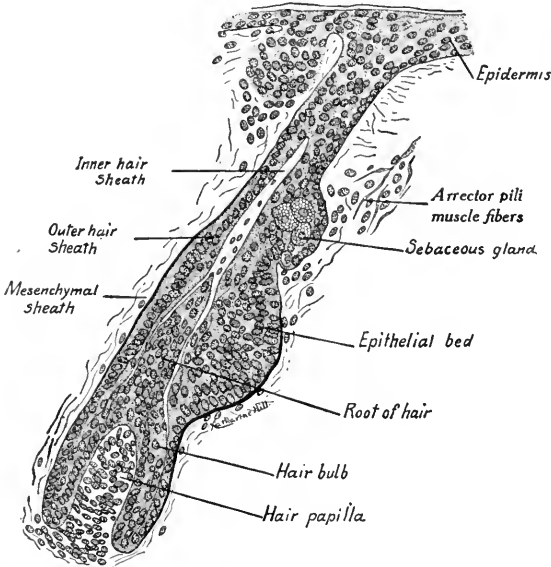


FIG. 294.—Longitudinal section through a developing hair from a five and one-half months' fetus (Stöhr).

bulb to the level of the sebaceous glands, where it disappears. The hair grows at the base and is pushed out through the central cavity of the anlage, the cells of which degenerate. When the hair projects above the surface of the epidermis it carries with it, and breaks up, the *epitrichial layer*. The mesenchymal tissue which surrounds the hair follicle in the neighborhood of the epithelial bed gives rise to the smooth fibers of the *arrector pili muscles*. Pigment granules develop in the basal cells of the hair and give it its characteristic color.

The first generation of hairs are short-lived and begin to degenerate before birth; usually the hair of the head is shed during the first and second years after birth, and new hairs develop as buds from the old hair follicles.

### SWEAT GLANDS

The sweat or sudoriparous glands begin to develop in the fourth month from the epidermis of the finger-tips, of the palms of the hands and soles of the feet: They are formed as solid downgrowths from the epidermis, but differ from hair anlagen in having no mesenchymal papillæ at their bases. During the sixth month the tubular anlagen of the gland begin to coil and in the seventh month their lumina appear. The inner layer of cells forms the *gland cells* while the outer cells become transformed into *smooth muscle fibers* which here arise from the ectoderm. In the axillary region sweat glands occur which are large and branched.

### MAMMARY GLANDS

The tubular mammary glands peculiar to mammals are regarded as modified sweat glands. In early embryos an ectodermal thickening extends ventrolaterally between the bases of the limb buds on either side. This linear epidermal thickening is the *milk line*. In the future pectoral region of this line by the thickening and downgrowth of the epidermis there is formed the papilla-like anlage of the mammary gland (Fig. 295 A). From this epithelial anlage buds appear (B) which elongate and form solid cords 15 to 20 in number, the anlagen of the *milk ducts* (Fig. 295 C). These branch in the mesenchymal tissue of the corium and eventually produce the alveolar end-pieces of the mammary glands. In the region where the milk ducts open on the surface the epidermis is evaginated to form the *nipple*. The glands enlarge at birth, at puberty and after parturition when they become functionally active.

The mammary glands are homologised with sweat glands because their development is similar, and because in the lower mammals their structure is the same. In many mammals

numerous pairs of mammary glands are developed along the milk line (pig, dog, etc.); in some a pair of glands is developed in the pectoral region (primates, elephants); in others only in the inguinal region (sheep, cow, horse). In man supernumerary mammary glands developed along the milk line are of not infrequent occurrence.

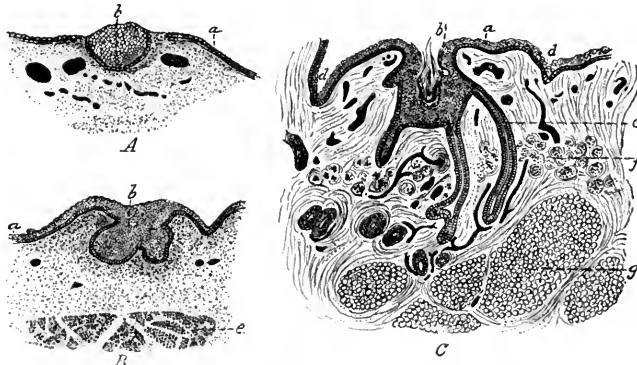


FIG. 295.—Sections representing three successive stages of development of the human mammary gland (Tourneux): *A*, fetus of 32.40 mm. (1.3 in.); *B*, of 10.16 cm. (4 in.); *C*, of 24.35 cm. (9.6 in.); *a*, epidermis; *b*, aggregation of epidermal cells forming anlage of gland; *c*, galactophorous ducts; *d*, groove limiting glandular area; *e*, great pectoral muscle; *f*, unstriated muscular tissue of areola; *g*, subcutaneous adipose tissue.

### THE NAILS

The anlagen of the nails proper are derived from the epidermis and may be recognized in embryos of 45 mm. A nail anlage forms on the dorsum of each digit extending from the tip of the digit almost to the articulation of the terminal phalanx. At the base of the anlage, that is, proximally, the epidermis is folded inward to form the proximal *nail fold* (posterior nail fold of the adult). This is curved, convex proximally, and extends transversely to the dorsum of the digit (Fig. 296 A, C). The nail fold also extends laterally on either side of the nail anlage and forms the *lateral nail fold* of the adult (A, B).

The matrix of the nail is developed in the proximal nail fold (C). In a layer of epidermal cells, lying parallel to the dorsum of the digit, there are developed keratin or horn fibrils during the fifth month of fetal life. These appear without the previous formation of keratohyalin granules as is the case in the cornification of the stratum corneum. The cells flatten and form the plate-like structure of which the solid substance of the nail is composed. Thus the nail substance is formed in the proximal nail fold. Over the area termed the *lunula* (the whitish crescent at the base of the adult nail) the nail is pushed toward the tip of the digit by the development of new nail substance in the region of the nail fold. The nail matrix, according to Bowen, represents a modified *stratum lucidum* of the epidermis. The stratum corneum of the epidermis for a time completely covers the nail

matrix and is termed the *eponychium* (Fig. 296 C). Later, this is thrown off but a portion persists during life as the curved fold of the epidermis which adheres to the lunula of the adult nail. During life the nail constantly grows at its base (proximally), is shifted distally over the bed of the corium, and projects at the tip of the digit. The corium distal to the lunula takes no part in the development

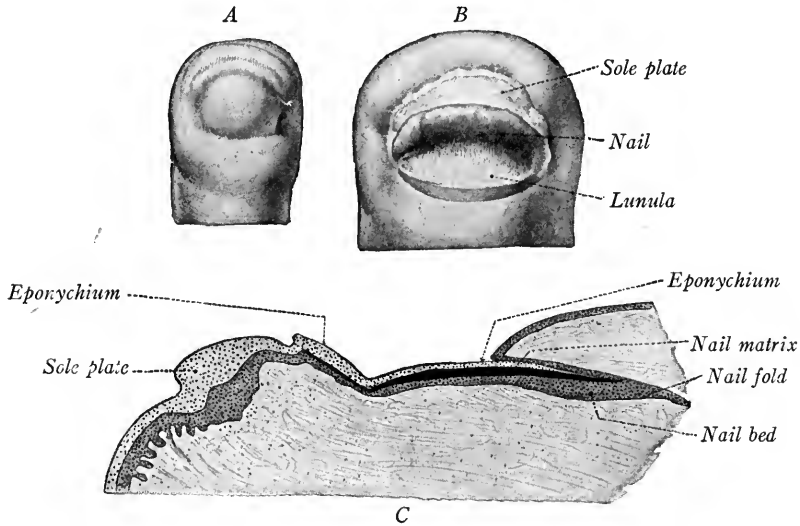


FIG. 296.—Figures showing the development of the nail. *A* and *B*, in surface view; *A* in a 4 cm., *B*, in a 10 cm. fetus; *C*, longitudinal section through the nail anlage of a 10 cm. fetus.  $\times 24$  (Kollmann's Handatlas).

of the nail substance and its surface of contact with the nail is thrown into parallel longitudinal folds. These folds produce the longitudinal ridges of the nails.

The nails of man are the homologues of the claws and hoofs of other mammals. During the third month thickenings of the integument over the distal ends of the metacarpals and metatarsals become prominent. These correspond to the *touch-pads* on the feet of clawed mammals. Similar pads are developed on the under sides of the distal phalanges.

### THE HISTOGENESIS OF THE NERVOUS TISSUES

The primitive anlage of the nervous system consists of the thickened layer of ectoderm along the mid-dorsal line of the embryo. This is the *neural plate* (Fig. 297 A, B) which is invaginated to form the neural groove. The edges of the *neural plate* come together and form the neural tube (Fig. 297 C, D). The cranial portion of this tube enlarges and is constricted into the three primary vesicles of the brain (Fig. 306). Its caudal portion remains tubular and constitutes the spinal cord. From the cells of this tube and the ganglion crest con-

nected with it are differentiated the nervous tissues, the single exception being the nerve cells and fibers of the *olfactory epithelium*.

**The Differentiation of the Neural Tube.**—The cells of the neural tube differentiate along two lines: There are formed: (1) *nerve cells and fibers*, in which irritability and conductivity have become the predominant functions; (2) *neuroglia cells* and fibers which form the supporting or skeletal tissue peculiar to the nervous system. The differentiation of these tissues has been studied by Hardesty in pig embryos (*Amer. Jour. Anat.*, vol. 3, 1904). The wall of the neural tube, consisting at first of a single layer of columnar cells, becomes many

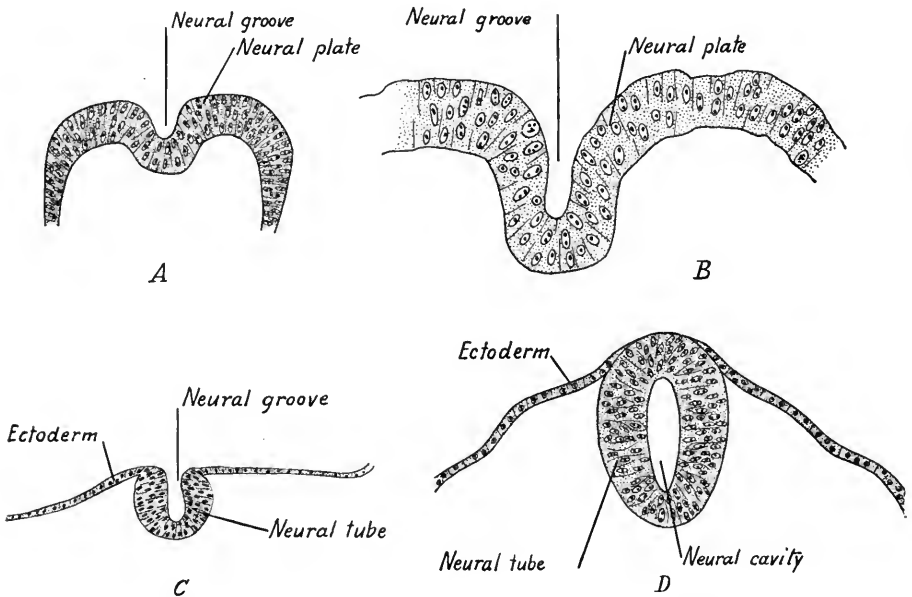


FIG. 297.—Four sections showing the development of the neural tube in human embryos: *A*, of an early embryo (Keibel); *B*, through head of a 2 mm. embryo (Graf Spee); *C*, neural tube of 2 mm. embryo (Mall); *D*, neural tube of 2.69 mm. embryo (Kollmann).

layered and finally three zones are differentiated (Fig. 298 A–D.) When the wall becomes many layered the cells lose their sharp outlines and form a compact cellular syncytium (Fig. 298 B). On its outer and inner surfaces there is differentiated from the cytoplasm an external and internal limiting membrane. In a 10 mm. embryo the cellular strands of the syncytium are radially arranged and directed nearly parallel to each other (Fig. 298 D). The nuclei are now so grouped that there may be distinguished three layers: (1) an *inner ependymal zone* with cells abutting on the internal limiting membrane, their processes extending peripherally; (2) a middle *mantle or nuclear zone*, and (3) an *outer or marginal*



zone, non-cellular, into which nerve fibers grow. The ependymal zone contributes cells for the development of the mantle layer (Fig. 298 D.) The cellular mantle layer forms the gray substance of the central nervous system, while the fibrous marginal layer constitutes the white substance of the spinal cord.

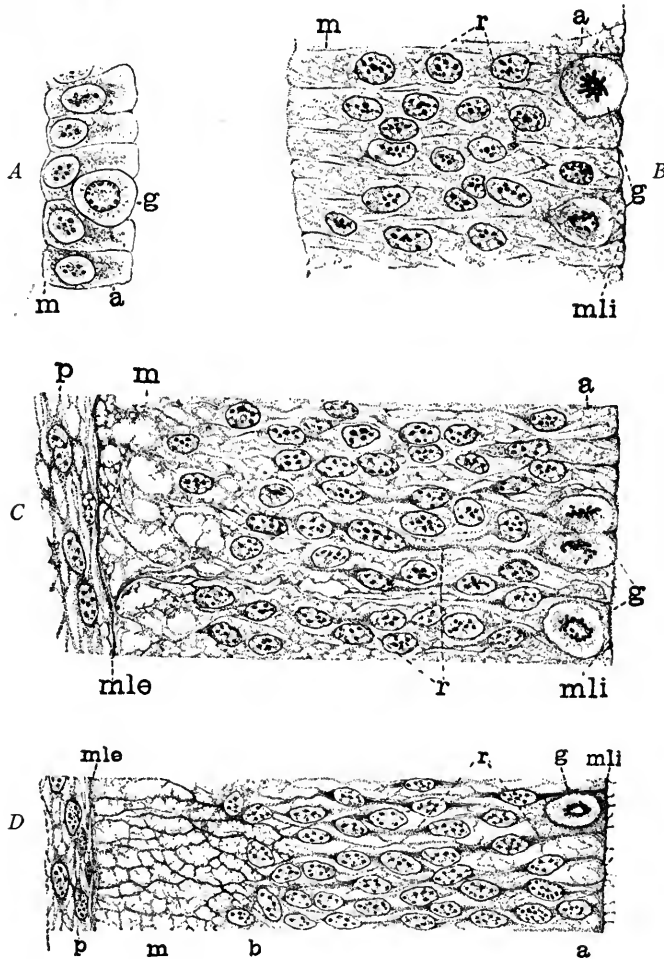


FIG. 298.—Three stages in the early development of the neural tube showing the origin of the syncytial framework: *A*, from rabbit before the closure of neural tube; *B*, from 5 mm. pig after closure of tube; *C*, from a 7 mm. embryo; *D*, from a 10 mm. pig embryo. *a*, ependymal layer; *b*, boundary between nuclear layer and marginal layer; *g*, germinal cell; *m*, marginal layer; *mle*, *mli*, external and internal limiting membranes; *r*, mantle or nuclear layer; *p*, mesoderm.

The primitive *germinal cells* of the neural tube divide by mitosis and give rise to the *ependymal* cells of the ependymal zone and to *indifferent cells* of the mantle layer. From these arise *spongioblasts* and *neuroblasts* (Fig. 299). The spongioblasts are transformed into *neuroglia cells* and fibers, which form the sup-

porting tissue of the central nervous system; the neuroblasts are primitive nerve cells and by developing cell processes are converted into *neurones*. The neurones are the structural units of the nervous tissue.

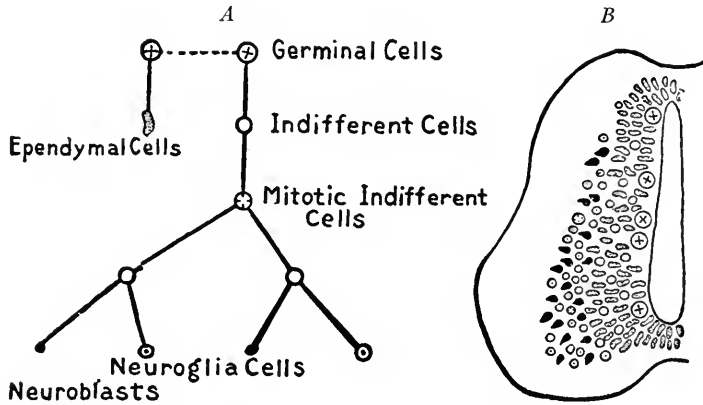


FIG. 299.—Diagrams showing the differentiation of the cells in the wall of the neural tube and the theoretical derivation of the ependymal cells, neuroglia cells and neuroblasts (after Schaper).

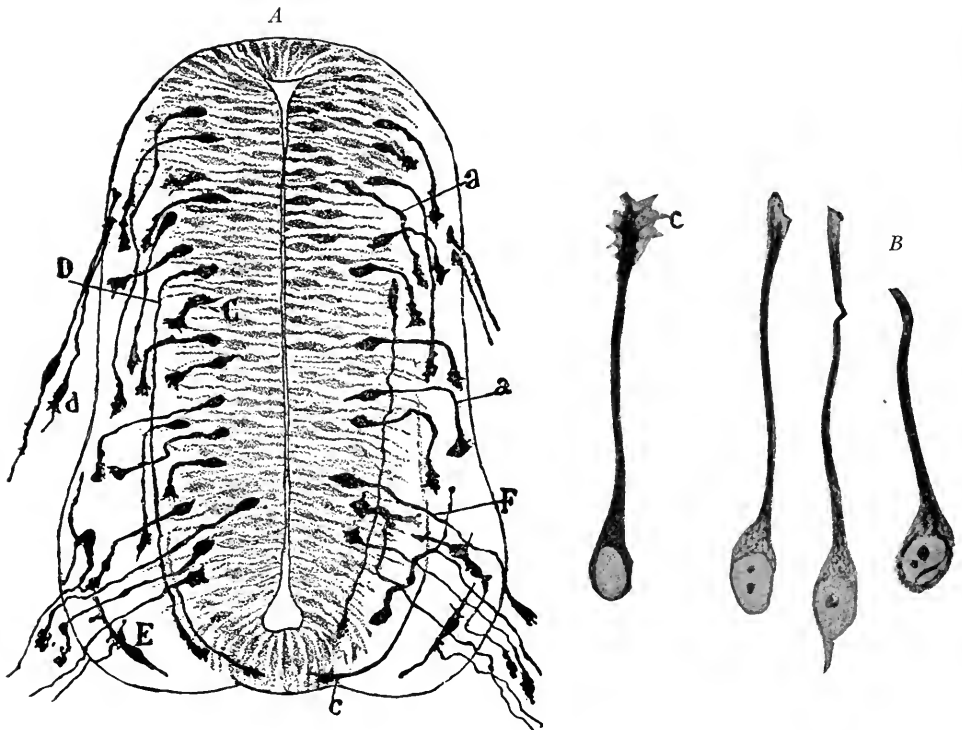


FIG. 300.—A, Transverse section through the spinal cord of a chick embryo of the third day showing neuraxons developing from neuroblasts of the neural tube *F* and from the bipolar ganglion cells, *d*. (Cajal); B, Neuroblasts from the spinal cord of a seventy-two-hour chick. The three to the right show neurofibrils; C, incremental cone.

**The Differentiation of the Neuroblasts into Neurones.**—The nerve fibers are developed as outgrowths from the neuroblasts, and a nerve cell with all its processes constitutes a *neurone* or cellular unit of the nervous system. The origin of the nerve fibers as processes of the neuroblasts is best seen in the development of the root fibers of the spinal nerves.

**The Efferent or Ventral Root Fibers of the Spinal Nerves.**—At the end of the first month clusters of neuroblasts separate themselves from the syncytium in the mantle layer of the neural tube. The outline of the neuroblasts becomes pyriform and from the small end of the cell a slender primary process grows out (Figs. 300 and 301). The process becomes the axis cylinder of a nerve fiber. The primary processes may course in the marginal layer of the neural tube, or, converging, may penetrate the marginal layer ventro-laterally and form the ventral roots of the spinal nerves. Similarly, the efferent fibers of the cerebral nerves grow out from neuroblasts of the brain wall. Within the cytoplasm of the nerve cells and their primary processes strands of fine fibrils early are differentiated. These are the *neurofibrillæ* and are the conducting elements of the neurones. The cell bodies of the efferent neurones soon become multipolar by the development of branched secondary processes, the *dendrites*.

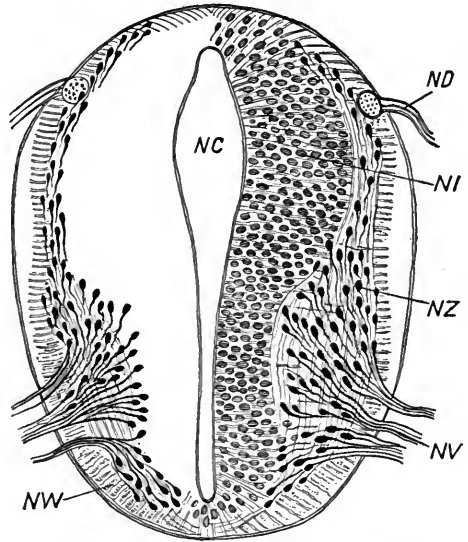


FIG. 301.—Transverse section of the spinal cord from an embryo of the fourth week showing pear-shaped neuroblasts giving rise to ventral root fibers (His in Marshall's Embryology). *NC*, central canal of spinal cord; *ND*, dorsal root of spinal nerve; *NI*, nuclei of spongioblasts; *NV*, ventral motor root fibers; *NW*, ventral funiculi; *NZ*, neuroblasts.

**The Development of the Spinal Ganglia and Afferent Neurones of the Spinal Cord.**—*The ganglion crest.*—After the formation of the neural plate and groove a longitudinal ridge of cells is differentiated on each side where the ectoderm and neural plate are continuous (Fig. 302 A). This ridge of ectodermal cells is the *neural* or *ganglion crest*. When the neural tube is formed and the ectoderm separates from it, the cells of the ganglion crest overlie the neural tube dorso-laterally (Fig. 302 C). As development continues they separate into right and left linear crests distinct from the neural tube, and migrate ventro-laterally

to a position between the neural tube and myotomes. In this position the ganglion crest forms a band of cells extending the whole length of the spinal cord and as far cranially as the otic vesicles. At regular intervals in its course along the spinal cord the proliferating cells of the crest give rise to enlargements, the *spinal ganglia* (Fig. 340). The spinal ganglia are segmentally arranged and connected at first by bridges of cells which later disappear. In the hind-brain region certain ganglia of the cerebral nerves develop from the crest but are not segmentally arranged.

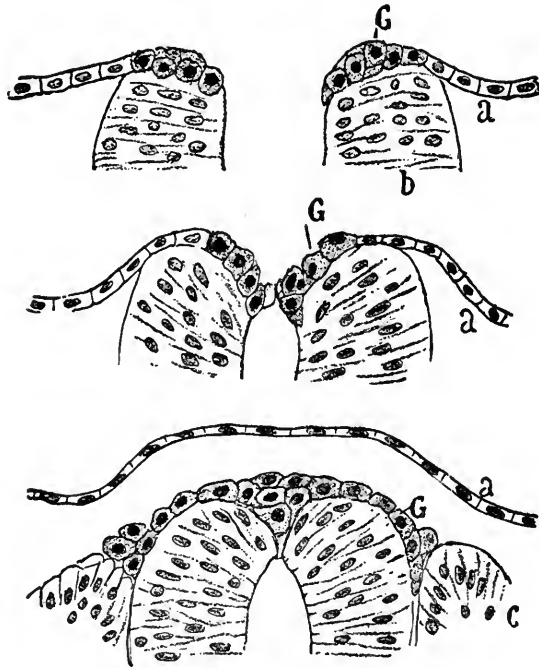


FIG. 302.—Three stages in the development of the ganglion crest in human embryos (after von Lenhossek in Cajal). *a*, ectoderm; *b*, neural tube; *c*, mesodermal segment; *G*, ganglioblasts.

**The Differentiation of the Afferent Neurones.**—The cells of the spinal ganglia differentiate into (1) *ganglion cells* and (2) *supporting cells*, groups which are comparable to the neuroblasts and spongioblasts of the neural tube. The neuroblasts of the ganglia become fusiform, develop a primary process at either pole and thus these neurones are of the bipolar type. The centrally directed processes of the ganglion cells converge and by elongation form the dorsal roots. They penetrate the dorso-lateral wall of the neural tube, bifurcate and course cranially and caudally in the marginal layer of the spinal cord (Fig. 300, *d*). By means of branched processes they anastomose with the neurones of the mantle layer. The peripheral processes of the ganglion cells as the *dorsal spinal roots* join the ventral

roots and, together with them, constitute the trunks of the spinal nerves (Fig. 307).

**The Differentiation of the Unipolar Ganglion Cells.**—At first bipolar, the majority of the ganglion cells become unipolar either by the unilateral growth of the cell body or by the bifurcation of a single primary process. In the first case, if the cytoplasm and nucleus take up an eccentric position, the two processes unite in a single slender connection with the cell body (Fig. 303). The ganglion cell, having one process, is now unipolar and its process is T-shaped. Many of the bipolar ganglion cells persist in the adult, and others develop several secondary processes and thus become multipolar in form. In addition to forming the spinal ganglion cells, neuroblasts of the ganglion crest are believed to migrate ventrally and form the sympathetic ganglia (Fig. 307).

*The Neurone Theory.*—The above account of the development of the nerve fibers is the one generally accepted at the present time. It assumes that the axis cylinders of all nerve fibers are formed as outgrowths, each from a single cell, an hypothesis first promulgated by His. The embryological evidence is supported by experiment. It has long been known from the work of Waller that if nerves are severed, the fibers distal to the point of section, and thus isolated from their nerve cells, will degenerate; also, that regeneration will take place from the central stumps of cut nerves, the fibers of which are still connected with their cells. More recently Harrison (*Amer. Jour. Anat.*,

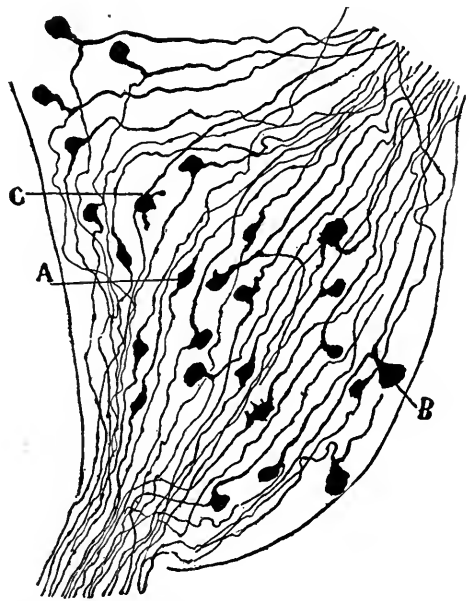


FIG. 303.—A portion of a spinal ganglion from a human embryo of 44 mm. Golgi method (Cajal).

vol. 5, 1906) experimenting on amphibian larvæ has shown (1) that no peripheral nerves develop if the neural tube and crest are removed; (2) that isolated ganglion cells growing in clotted lymph will give rise to long axis cylinder processes in the course of four or five hours.

A second theory, supported by Schwann, Balfour, Dohrn and Bethe, assumes that the nerve fibers are in part differentiated from a chain of cells, so that the neurone would represent a multicellular, not a unicellular structure. Apáthy and O. Schulze modified this *cell-chain theory* by assuming that the nerve fibers differentiate in a syncytium which intervenes between the neural tube and the peripheral end organs. Held further modified this theory by assuming that the proximal portions of the nerve fibers are derived from the neuroblasts and ganglion cells and that these grow into a syncytium which by differentiation gives rise to the peripheral portion of the fiber. This theory accords with the experiments of Bethe who found that in the peripheral portions of severed nerves, functional nerve fibers were regenerated in young animals.

**The Differentiation of the Supporting Cells of the Ganglia and Neural Tube.**

—The supporting cells of the spinal ganglia at first form a syncytium in the meshes of which are found the neuroblasts. They differentiate (1) into flattened *capsule cells* which form capsules about the ganglion cells and (2) into *sheath cells* which ensheath the axis cylinder processes and are continuous with the capsules of the ganglion. It is probable that many of the sheath cells migrate peripherally along with the developing nerve fibers (Harrison). They are at first spindle-shaped and, as primary sheaths, enclose bundles of nerve fibers. Later, by the proliferation of the sheath cells the bundles are separated into single fibers, each with its sheath (of Schwann), or *neurilemma*. Each sheath cell forms a segment of the neurilemma, the limits of adjacent sheath cells being indicated by constrictions, the *nodes of Ranvier*.

**The Myelin or Medullary Sheath.**—During the fourth month an inner *myelin sheath* appears about many nerve fibers. This consists of a spongy framework of *neurokeratin* in the interstices of which a fatty substance, *myelin*, is deposited. The origin of the myelin sheath is in doubt. By some it is believed to be a differentiation of the *neurilemma*, the myelin being deposited in the substance of the nucleated sheath cell. By others the myelin is regarded as a product of the axis cylinder. Its integrity is dependent at least upon the nerve cell and axis cylinder, for, when a nerve is cut, the myelin very soon shows degenerative changes.

In the central nervous system there is no distinct neurilemma sheath investing the fibers. Sheath cells are said to be present and most numerous during the period when myelin is developed. Hardesty derives the sheath cells in the central nervous system of the pig from a portion of the supporting cells, or *spongioblasts*, of the neural tube, and finds that these cells give rise to the myelin of the fibers.

Those fibers which are first functional receive their myelin sheaths first. The development of myelin is only completed between the fifteenth and twentieth year (Westphal). Many of the peripheral fibers, especially those of the sympathetic system, remain *non-medullated* and supplied only with a neurilemma sheath. The medullated fibers, those with a myelin sheath, have a glistening white appearance and give the characteristic color to the *white substance* of the central nervous system and to the peripheral nerves. Ranson (Amer. Jour. Anat., vol. 12, p. 67) has shown that large numbers of non-medullated fibers occur in the peripheral nerves and spinal cord of adult mammals and man. Those found in the spinal nerves arise from the small cells of the spinal ganglia.

**The Development of the Neuroglia Cells and Fibers.**—The spongioblasts of the neural tube (see p. 311) differentiate into the supporting tissue of the central nervous system. This includes the *ependymal cells*, which line the neural cavity, forming one of the primary layers of the neural tube, *neuroglia cells* and their fibers.

We have described how the strands of the syncytium formed by the spongioblasts become arranged radially in the neural tube of early embryos (Fig. 298 D). As the wall of the neural tube thickens, the strands elongate *pari passu* and form a

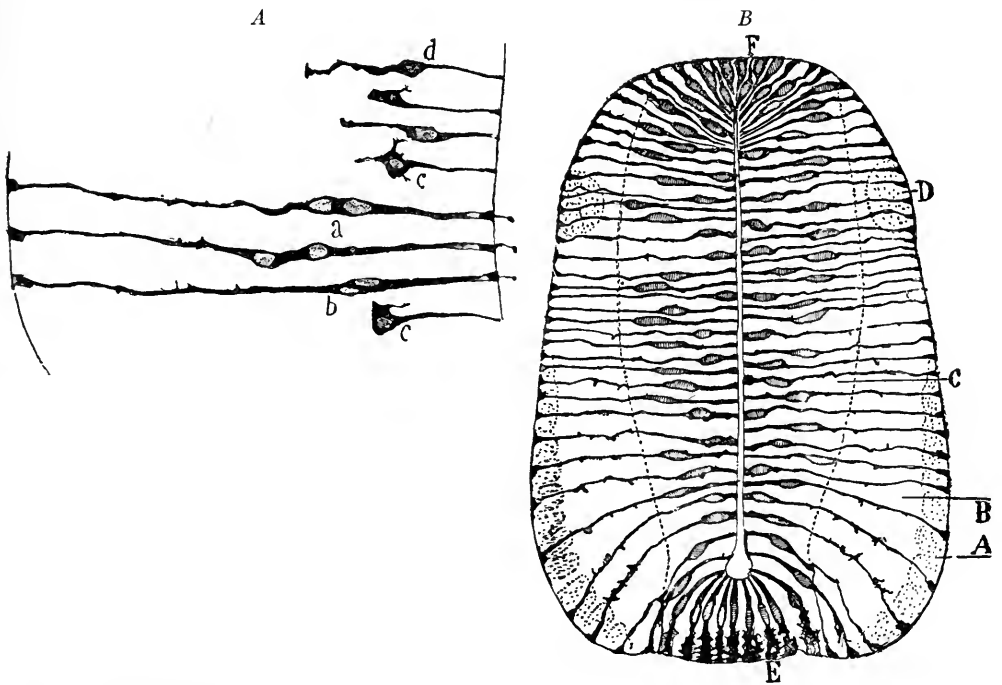


FIG. 304.—Ependymal cells from the neural tube of chick embryos: *A*, of first day; *B*, of third day. Golgi method (Cajal).

radiating branched framework (Fig. 304 *A*, *B*). The group of spongioblasts which line the neural cavity constitutes the *ependymal layer*. Processes from these cells radiate and extend through the whole thickness of the neural tube to its periphery. The cell bodies are columnar and persist as the lining of the central canal and ventricles of the spinal cord and brain (Fig. 305).

Near the median line of the spinal cord, both dorsally and ventrally, the supporting tissue retains its primitive ependymal structure in the adult. Elsewhere the supporting framework is differentiated into *neuroglia cells and fibers*. The *neuroglia* cells form part of the spongioblastic syncytium and are

scattered through the mantle and marginal layers of the neural tube. By proliferation they increase in numbers and their form depends upon the pressure of the nerve cells and fibers which develop around them.

**Neuroglia fibers** are differentiated from the cytoplasm and cytoplasmic

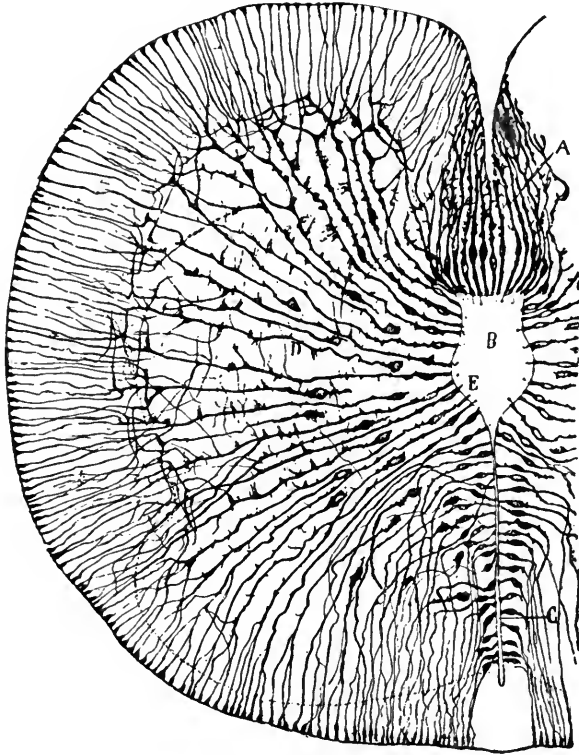


FIG. 305.—Ependymal cells of the lumbar cord from a human embryo of 44 mm. Golgi method (Cajal). *A*, floor plate; *B*, central canal; *C*, line of future fusion of walls of neural cavity; *D*, neuroglia cells and fibers.

processes of the neuroglia cells, and as the latter primarily form a syncytium, the neuroglia fibers may extend from cell to cell. The neuroglia fibers develop late in fetal life and undergo a chemical transformation into *neurokeratin*, the same substance which is found in the sheaths of medullated fibers.



## CHAPTER XI

### THE MORPHOGENESIS OF THE CENTRAL NERVOUS SYSTEM

In discussing the histogenesis of the nervous tissue we have described the early development of the neural tube, as an infolding of the neural plate and a closure of the neural groove (Fig. 297). The groove begins to close along the mid-dorsal line near the middle of the body in embryos of 2 mm. and the closure

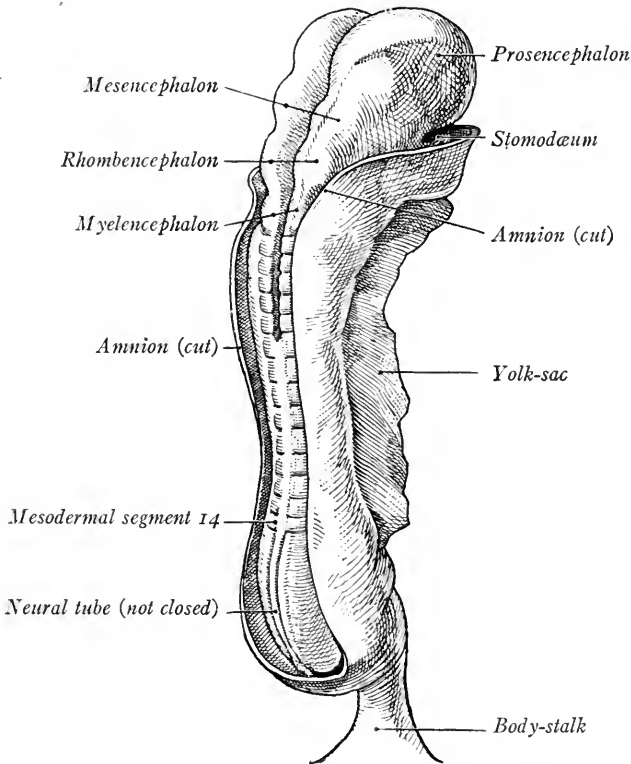


FIG. 306.—Human embryo of 2.4 mm. showing neural tube closing and the brain vesicles (after Kollmann).

extends both cranially and caudally (Fig. 306). Until the end of the third week there still persists an opening at either end of the neural tube, somewhat dorsad. These openings are the *neuropores*. Before the closure of the neuropores, in embryos of 2 to 2.5 mm. the cranial end of the neural tube has enlarged and is

constricted at two points to form the three *primary brain vesicles*. The caudal two-thirds of the neural tube, which remains of smaller diameter, constitutes the *anlage of the spinal cord*.

### THE SPINAL CORD

The spinal portion of the neural tube is at first nearly straight, but is bent with the flexure of the embryo into a curve which is convex dorsally. Its wall gradually thickens during the first month and the diameter of its cavity is di-

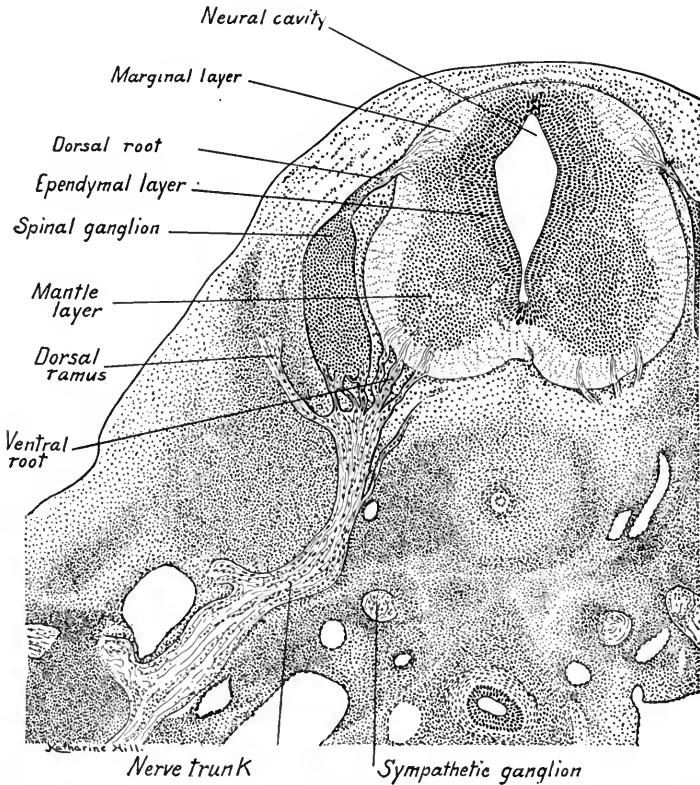


FIG. 307.—Transverse section through a 10 mm. embryo at the level of the arm buds showing the spinal cord and a spinal nerve of right side.  $\times 44$ .

minished from side to side. By the end of the first month three layers have been developed in its wall as described in Chapter X, p. 310 (Fig. 307). These layers are the *inner ependymal layer* which forms a narrow zone about the neural cavity; the *middle mantle layer*, cellular, and the *outer marginal layer*, fibrous.

**The Ependymal Layer** is differentiated into a dorsal *roof plate* and a ventral *floor plate* (Fig. 308). Laterally, its proliferating cells contribute neuroblasts and neuroglia cells to the mantle layer. The proliferation of cells ceases first in the

ventral portion of the layer, which is thus narrower than the dorsal portion in 10 to 20 mm. embryos (Figs. 307 and 308). Consequently, the ventral portion of the mantle layer is differentiated first. The neural cavity is at first somewhat rhomboidal in transverse section, wider dorsally than ventrally. Its lateral angle forms the *sulcus limitans* which marks the subdivision of the lateral walls of the neural tube into the dorsal *alar plate* and ventral *basal plate*. When the ependymal layer ceases to contribute new cells to the mantle layer its walls are approximated dorsally. As a result, in 20 mm. embryos the neural cavity is wider ventrally (Fig. 308). In the next stage, 34 mm., these walls fuse and the dorsal portion of the neural cavity is obliterated (Fig. 309). In a 65 mm. embryo the

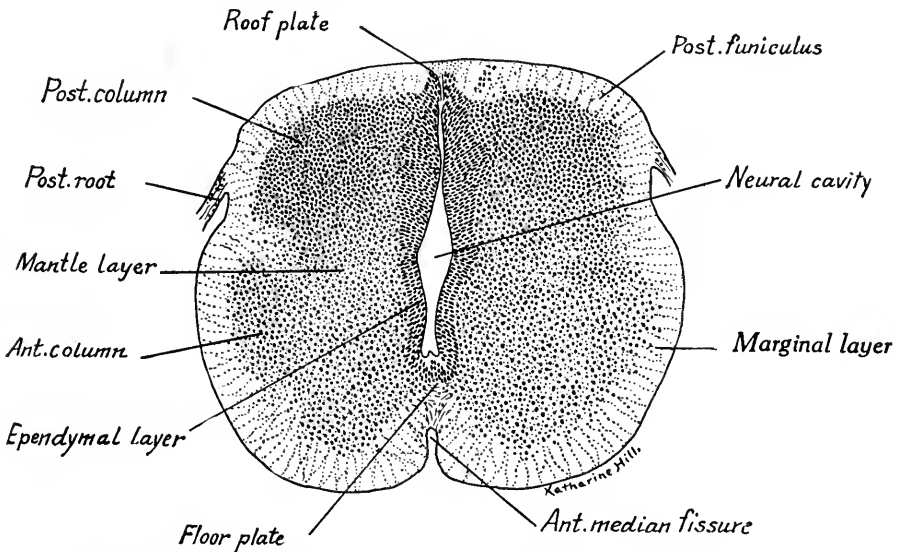


FIG. 308.—Transverse section of the spinal cord from a 20 mm. embryo.  $\times 44$ .

persisting cavity is becoming rounded (Fig. 310). It forms the *central canal* of the adult spinal cord. The cells lining the central canal are *ependymal cells* proper. Those in the floor of the canal form the persistent *floor plate*. Their fibers extend ventrally to the surface of the cord in the depression of the ventral median fissure.

When the right and left walls of the ependymal layer fuse, the ependymal cells of the roof plate no longer radiate, but form a median septum (Fig. 309). Later, as the marginal layers of either side thicken and are approximated the median septum is extended dorsally. Thus the roof plate is converted into part of the *dorsal median septum* of the adult spinal cord (Fig. 310).

**The Mantle Layer**, as we have seen, is contributed to by the proliferating

cells of the ependymal layer. A ventro-lateral thickening first becomes prominent in embryos of 10 to 15 mm. (Fig. 307). This is the *ventral gray column*, or *horn*, which in later stages is subdivided, forming also a *lateral gray column* (Fig.

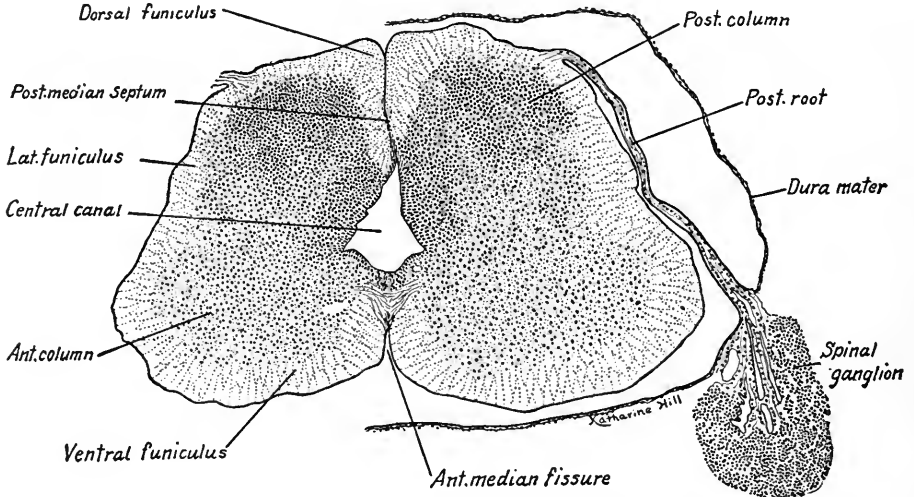


FIG. 309.—Transverse section of the spinal cord from a 34 mm. embryo, showing also the spinal ganglion and dura mater on the left side.  $\times 44$ .

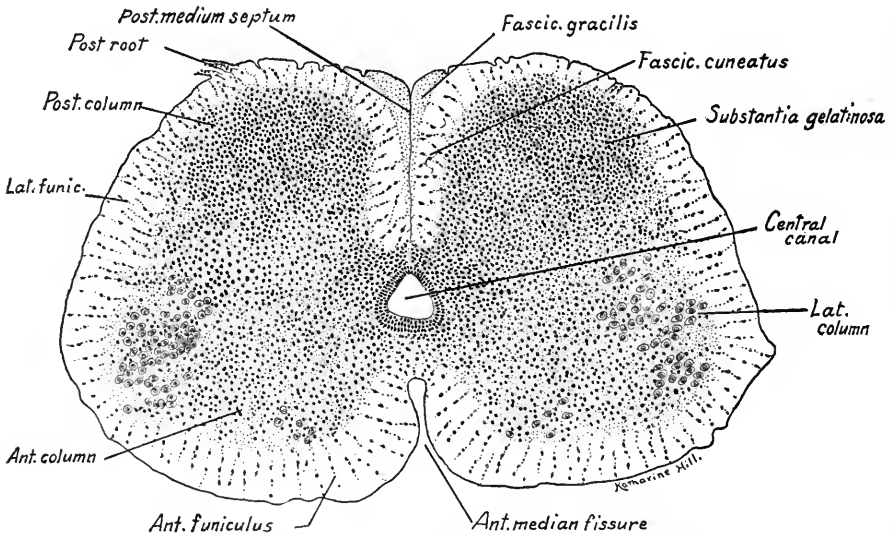


FIG. 310.—Transverse section of the spinal cord from a 65 mm. embryo.  $\times 44$ .

310). It is a derivative of the basal plate. In embryos of 20 mm. a dorso-lateral thickening of the mantle layer is seen, the cells of which constitute the *dorsal gray column* or *horn* (Figs. 208 and 209); about these cells end the collaterals of

the dorsal roof fibers. The cells of the dorsal gray column thus form terminal nuclei for the afferent spinal nerve fibers and they are derivatives of the *alar* plate of the cord. Dorsal and ventral to the central canal the marginal layer forms the *dorsal* and *ventral gray commissures*. In the ventral floor plate nerve fibers cross from both sides of the cord and form the *anterior white commissure*.

The **Marginal Layer** is composed primarily of a framework of neuroglia and ependymal cell processes. Into this framework grow the axis cylinder processes of nerve cells, so that the thickening of this layer is due to the increasing number of nerve fibers contributed to it by ganglion cells and neuroblasts located outside of it. When their myelin develops, these fibers form the white substance of the spinal cord. The fibers have three sources (Fig. 342): (1) they may arise from the spinal ganglion cells, entering as dorsal root fibers and coursing cranially and caudally in the marginal layer; (2) they may arise from neuroblasts in the mantle layer of the spinal cord (*a*) as fibers which connect adjacent nuclei of the cord (*fasciculi proprii* or ground bundles); (*b*) as fibers which extend cranially to the brain; (3) they may arise from neuroblasts of the brain (*a*) as long descending cerebrospinal tracts from the cortex of the cerebrum; (*b*) as descending tracts from the brain stem.

Of these fiber tracts (1) and (2 *a*) appear during the first month; (2 *b*) and (3 *b*) during the third month; (3 *a*) at the end of the fifth month.

The dorsal root fibers from the spinal ganglion cells entering the cord dorso-laterally subdivide the white substance of the marginal layer into a *dorsal funiculus* and *lateral funiculus*. The lateral funiculus is marked off by the ventral root fibers from the ventral funiculus (Fig. 309). The ventral root fibers, as we have seen, take their origin from the neuroblasts of the ventral gray column in the mantle layer. They are thus derivatives of the *basal plate*.

The *dorsal funiculus* is formed chiefly by the dorsal root fibers of the ganglion cells and is subdivided into two distinct bundles, the *fasciculus gracilis*, median, and the *fasciculus cuneatus*, lateral in position. The dorsal funiculi are separated only by the *dorsal median septum* (Fig. 310).

The lateral and ventral funiculi are composed of *fasciculi proprii* or *ground bundles*, originating in the spinal cord, of ascending tracts from the cord to the brain, and of the descending fiber tracts from the brain. The fibers of these fasciculi intermingle and the fasciculi are thus without sharp boundaries. The floor plate of ependymal cells lags behind in its development, and as it is interposed between the thickening right and left walls of the ventral funiculi, these do not meet and the ventral median fissure is produced (compare Figs. 307 and 310).

The development of myelin in the nerve fibers of the cord begins in the fifth month of fetal life and is completed between the fifteenth and twentieth years (Flechsig, Bechterew). Myelin appears first in the root fibers of the spinal nerves and in those of the ventral commissure, next in the ground bundles, and dorsal funiculi. The cerebrospinal (pyramidal) fasciculi are the last in which myelin is developed; they are myelinated during the first and second years. As myelin appears in the various fiber tracts at different periods, this fact has been utilized in tracing the extent and origin of the various fasciculi in the central nervous system.

**The Cervical and Lumbar Enlargements.**—At the levels of the two nerve plexuses supplying the upper and lower extremities the size of the spinal cord is

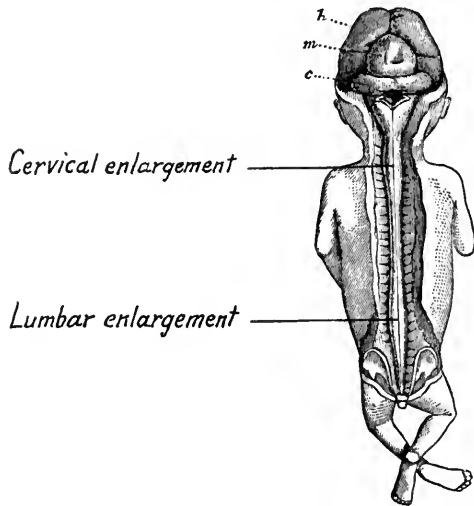


FIG. 311.—Dissection of the brain and cord of a three months' fetus, showing the cervical and lumbar enlargements (after Kölliker in Marshall). *c*, cerebellum; *h*, cerebrum; *m*, mid-brain. Natural size.

increased. As the fibers to the muscles of the extremities arise from nerve cells in the ventral gray column, the number of these cells and the mass of the gray substance is increased; also larger numbers of fibers enter the cord from the integument of the limbs, so that there are larger numbers of cells about which sensory fibers terminate. There is formed consequently at the level of the origin of the nerves of the brachial plexus the *cervical enlargement*, opposite the origins of the nerves of the lumbo-sacral plexus the *lumbar enlargement* (Fig. 311).

At the caudal end of the neural tube in an 11 cm. fetus an epithelial sac is formed which is adherent to the integument. Cranial to the sac the central canal is obliterated and this part of the neural tube forms the *filum terminale*. The caudal end of the central canal is irregularly expanded and is known as the *terminal ventricle*.

The vertebral column during and after the third month grows faster than the spinal cord. As the cord is fixed to the brain it is carried cranially with reference to the vertebræ, and with it shift the roots and ganglia of the spinal nerves. In the adult the origin of the coccygeal nerves is opposite the first lumbar vertebra and the nerves course obliquely downward nearly parallel to the spinal cord. As the neural tube is drawn cranially and its caudal tip is attached to the coccyx, its caudal portion is stretched into the slender solid cord known as the *filum terminale*.

The obliquely coursing spinal nerves with the filum terminale constitute the *cauda equina*.

## THE BRAIN

We have seen that in embryos of 2 to 2.5 mm. the neural tube is nearly straight, but that its cranial end is enlarged to form the anlage of the brain. The appearance of two constrictions in the wall of the anlage subdivides it into the three *primary brain vesicles*, the fore-brain or *prosencephalon*, mid-brain or *mesencephalon*, and hind-brain or *rhombencephalon* (Fig. 306).

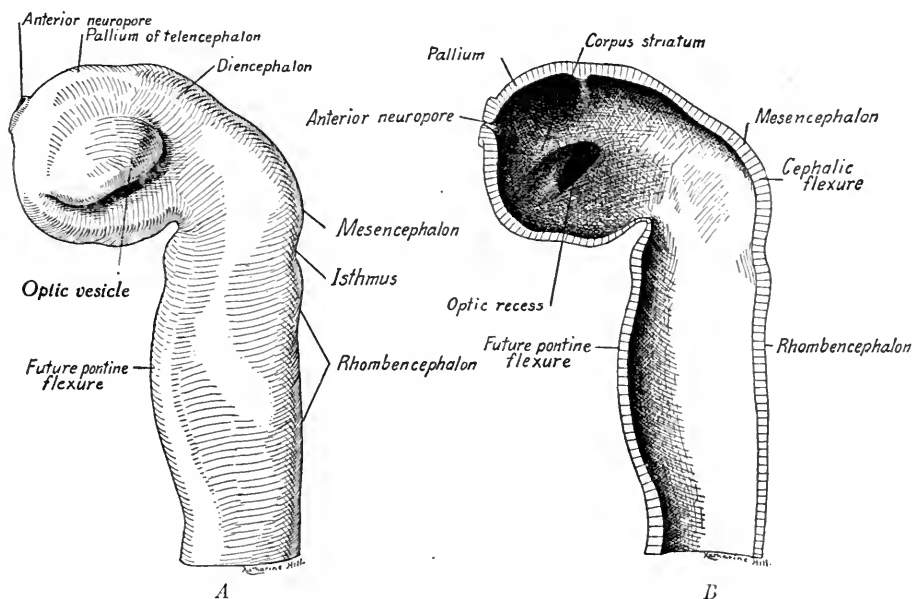


FIG. 312.—Reconstructions of the brain of a 3.2 mm. human embryo. A, lateral surface; B, sectioned in the median sagittal plane (after His).

In embryos of 3.2 mm., estimated age three weeks, three important changes have taken place (Fig. 312 A, B): (1) the end of the neural tube is bent sharply in the mid-brain region so that the axis of the fore-brain now forms a right angle with the axis of the hind-brain. This bend is the *cephalic flexure*; (2) the fore-brain shows indication dorsally of a fold the *margo thalamicus* which subdivides it into the *telencephalon* and the *diencephalon*; (3) the lateral wall of the fore-brain shows a distinct evagination, the *optic vesicle*, which projects laterally and caudad. A ventral bulging of the wall of the hind-brain indicates the position of the future *pontine flexure*.

In embryos of 7 mm. (four weeks) the neuropores have closed. The ceph-

alic flexure, now more marked, forms an acute angle and the pontine flexure, just indicated in the previous stage, is now a prominent ventral bend in the ventro-lateral walls of the hind-brain (Fig. 313 A, B). This flexure forms the boundary line which subdivides the rhombencephalon into a cranial portion, the *metencephalon*, and into a caudal portion, the *myelencephalon*. At a third bend the whole brain is flexed ventrally at an angle with the axis of the spinal cord. This bend is the *cervical flexure* and is the line of demarcation between the brain and spinal cord. The telencephalon and diencephalon are more distinctly subdivided, and the invaginated optic vesicle forms the optic cup attached to the brain wall by a hollow stalk, which later becomes the optic nerve. The walls of

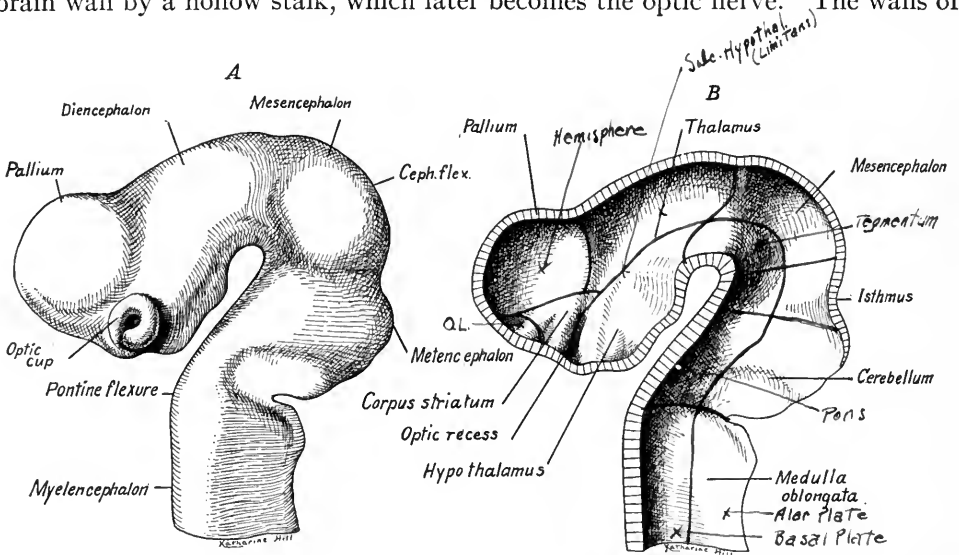


FIG. 313.—Reconstructions of the brain of a 7 mm. human embryo. A, lateral view; B, in median sagittal section (His). *Ceph. flex.*, cephalic flexure.

the brain show a distinct differentiation in certain regions. This is especially marked in the myelencephalon, which has a thicker ventro-lateral wall and thinner dorsal wall.

Embryos of 10.2 mm. show the structure of the brain at the beginning of the second month (Figs. 323 and 326). In Fig. 341 the external form of the brain is seen with the origins of the cerebral nerves. It will be noted that, with the exception of the first four (the olfactory, optic, oculomotor and trochlear), the cerebral nerves take their superficial origin from the myelencephalon. The five brain regions are now sharply differentiated externally but the boundary line between the telencephalon and diencephalon is still indistinct. The telencephalon



consists in paired lateral outgrowths, the anlagen of the cerebral hemispheres and rhinencephalon.

The cephalic flexure forms a very acute angle and, as a result, the long axis of the fore-brain is nearly parallel to that of the hind-brain. The oculomotor nerve takes its origin from the ventral wall of the mesencephalon. Dorsally there is a constriction, the isthmus, between the mesencephalon and metencephalon, and here the fibers of the trochlear nerve take their superficial origin. The dorsal wall of the myelencephalon is an exceedingly thin ependymal layer,

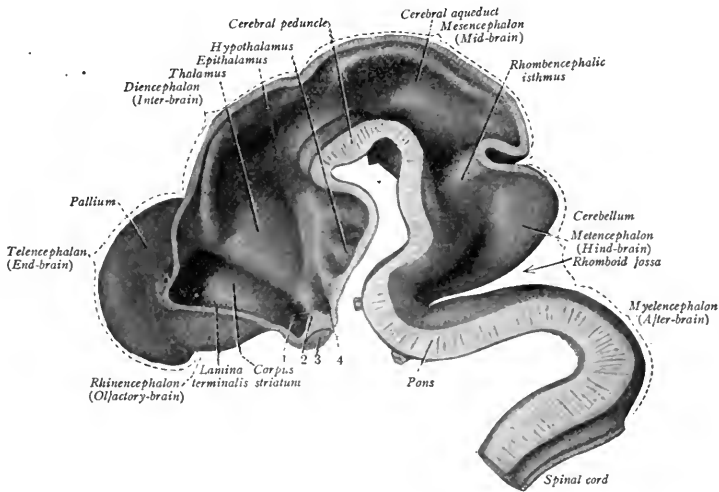


FIG. 314.—Brain of a 13.6 mm. human embryo in median sagittal section (after His from Sobotta's Atlas of Anatomy). 1, optic recess; 2, ridge formed by optic chiasma, 3; 4, infundibular recess.

the *tela chorioidea*. The ventro-lateral walls of this same region on the other hand are very thick.

A median sagittal section of a brain at a somewhat later stage shows the cervical, pontine and cephalic flexures well marked (Fig. 314). The thin dorso-lateral roof of the myelencephalon has been removed. The telencephalon is a paired structure. In the figure its right half projects cranial to the primitive median wall of the fore-brain which persists as the *lamina terminalis* (see Fig. 324). The floor of the telencephalon is greatly thickened caudally as the anlage of the *corpus striatum*. A slight evagination of the ventral wall of the telencephalon just cranial to the corpus striatum marks the anlage of the *rhinencephalon*. The remaining portion of the telencephalon forms the *pallium* or *cortex* of the *cerebral hemispheres*. The paired cavities of the telencephalon are the lateral (second)

ventricles and these communicate through the interventricular foramina (Monroi) with the cavity of the diencephalon, the third ventricle. The cavities of the olfactory lobes communicate during fetal life with the lateral ventricles and were formerly called the *first ventricles*.

The crossing of a portion of the optic nerve fibers in the floor of the brain forms the *optic chiasma* and this, with the transverse ridge produced by it internally, is taken as the ventral boundary line between the telencephalon and diencephalon (Fig. 314). A dorsal depression separates the latter from the *mesencephalon*. The lateral wall of the diencephalon is thickened to form the *thalamus*, the caudal and lateral portion of which constitutes the *metathalamus*. From the metathalamus are derived the *geniculate bodies*. In the median dorsal wall, near the caudal boundary line of the diencephalon, an outpocketing begins to appear in embryos of five weeks (Fig. 314). This is the *epithalamus* which later gives rise to the *pineal body*, or epiphysis.

The thalamus is marked off from the more ventral portion of the diencephalic wall, termed the *hypothalamus* by the obliquely directed *sulcus hypothalamicus*. Cranial to the optic chiasma is the optic recess, regarded as belonging to the telencephalon. Caudal to it is the pouch-like *infundibulum*, an extension from which during the fourth week forms the *posterior lobe of the hypophysis*. Caudal to the infundibulum the floor of the diencephalon forms the *tuber cinereum* and the *mammillary recess*; the walls of the latter thicken later and give rise to the *mammillary bodies*. An oblique transverse section through the telencephalon and hypothalamic portion of the diencephalon (Fig. 325), shows the relation of the optic recess to the optic stalk, the infundibulum and Rathke's pocket, and the extension of the third ventricle, the proper cavity of diencephalon, into the telencephalon between the corpora striata.

The *mesencephalon* in 13.6 mm. embryos (Fig. 314) is distinctly marked off from the metencephalon by the constriction which is termed the *isthmus*. Dorso-laterally thickenings form the *corpora quadrigemina*. Ventrally, the mesencephalic wall is thickened to form the *tegmentum* and *crura cerebri*. In the tegmentum are located the nuclei of origin for the *oculomotor* and *trochlear nerves*. The former, as we have seen, takes its superficial origin ventrally, while the trochlear nerve fibers bend dorsad, cross at the isthmus and emerge on the opposite side. As the walls of the mesencephalon thicken, its cavity later is narrowed to a canal, the cerebral aqueduct (of Sylvius).

The walls of the metencephalon are thickened dorsally and laterally to form

the anlage of the cerebellum. Its thickened ventral wall becomes the *pons* (Varolii). Its cavity constitutes the cranial portion of the *fourth ventricle*.

The caudal border of the pons is taken as the ventral boundary line between the metencephalon and *myelencephalon*. The myelencephalon forms the *medulla oblongata*. Its dorsal wall is a thin non-nervous *ependymal* layer, which later becomes the posterior medullary velum. From its thickened ventro-lateral

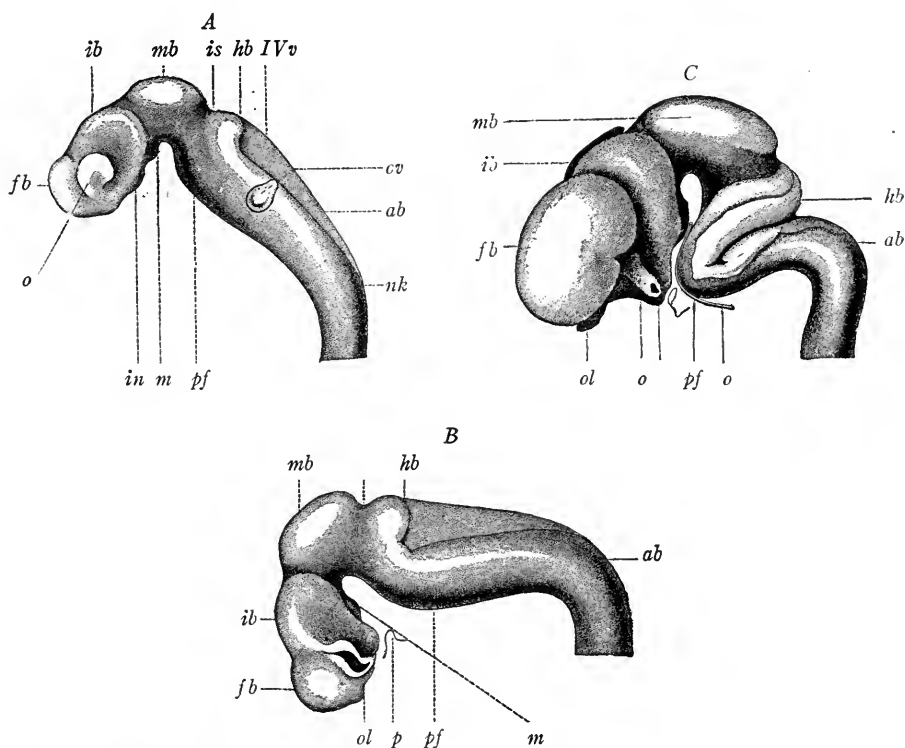


FIG. 315.—Brains of human embryos, from reconstructions by His: *A*, brain from fifteen-day embryo; *B*, from three-and-a-half-week embryo; *C*, from seven-and-a-half-week fetus; *fb*, *ib*, *mb*, *hb*, *ab*, fore-, inter-, mid-, hind-, and after-brain vesicles; *o*, optic vesicle; *ov*, otic vesicle; *in*, infundibulum; *m*, mammillary body; *pf*, pontine flexure; *IVv*, fourth ventricle; *nk*, cervical flexure; *ol*, olfactory lobe; *b*, basilar artery; *p*, pituitary recess (American Text-Book of Obstetrics).

walls the last eight cerebral nerves take their origin. Its cavity forms the greater part of the fourth ventricle which opens caudally into the *central canal* of the spinal cord, cranially into the cerebral aqueduct. The increase in the flexures of the brain and the relative growth of its different regions may be seen by comparing the brains of embryos of the third, fourth, and eighth weeks (Fig. 315).

In the following table are given the primitive subdivisions of the neural tube and the parts derived from them:

THE DERIVATIVES OF THE NEURAL TUBE

PRIMARY VESICLES	SUBDIVISIONS	DERIVATIVES	CAVITIES
Prosencephalon	Telencephalon	Cerebral cortex Corpora striata Rhinencephalon	Lateral ventricles Cranial portion of third ventricles
	Diencephalon	Epithalamus (pineal body) Thalamus & Hypophysis Optic tract Hypothalamus hypophysis tuber cinereum mammillare bodies	Third ventricle
Mesencephalon	Mesencephalon	Corpora quadrigemina Tegmentum Crura cerebri	Aqueductus cerebri (Sylvius)
Rhombencephalon	Metencephalon	Cerebellum Pons	Fourth ventricle
	Myelencephalon	Medulla oblongata	
Spinal cord		Spinal cord	Central canal

THE LATER DIFFERENTIATION OF THE SUBDIVISIONS OF THE BRAIN

**Myelencephalon.**—We have seen that the wall of the spinal cord differentiates dorsally and ventrally into *roof plate* and *floor plate*, laterally into the *basal plate* and *alar plate*. The boundary line between the basal and alar plates is the

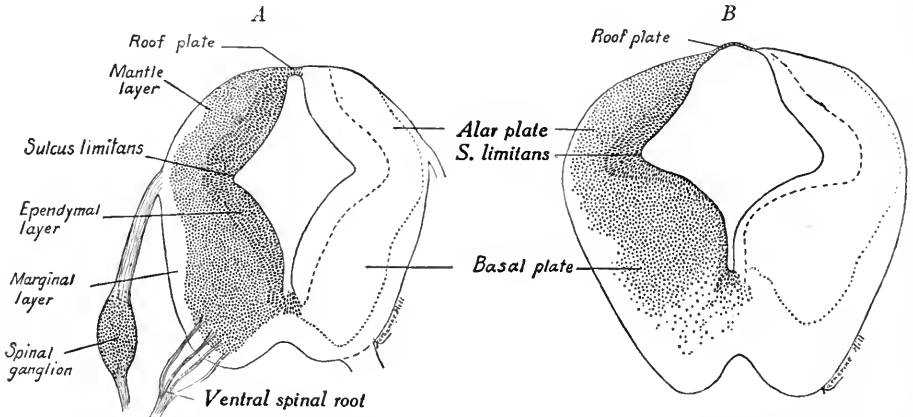


FIG. 316.—Transverse sections. *A*, through the upper cervical region of the spinal cord in a 10 mm. human embryo; *B*, through the caudal end of the myelencephalon of the same.  $\times 44$ .

*sulcus limitans* (Fig. 316 *A*). The same subdivisions may be recognized in the myelencephalon. It differs from the spinal cord, however, in that the roof plate is broad, thin and flattened to form the *ependymal layer* (Fig. 316 *B*). In the alar and basal plates of the myelencephalon the marginal, mantle and ependymal zones are differentiated as in the spinal cord (Fig. 317 *A, B*). Owing to the for-

mation of the pontine flexure at the beginning of the second month, the roof plate is broadened, especially in the cranial portion of the myelencephalon, and the alar plates bulge laterally (Figs. 318 and 319 A). The cavity of the myelen-

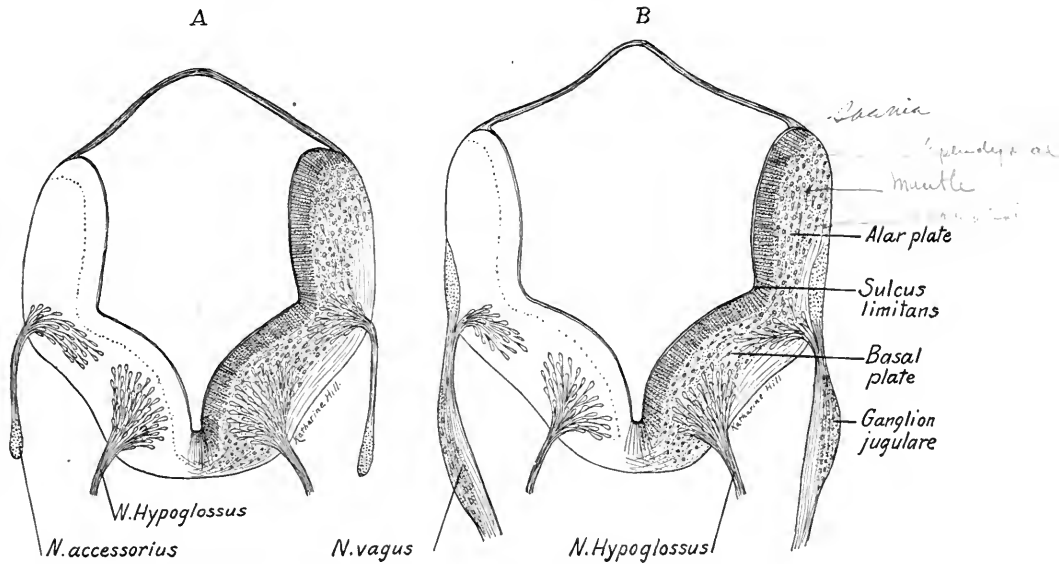


FIG. 317.—Transverse sections through the myelencephalon of a 10.6 mm. embryo (His). *A*, through the nuclei of origin of the spinal accessory and hypoglossal nerves; *B*, through the vagus and hypoglossal nerves (after His).

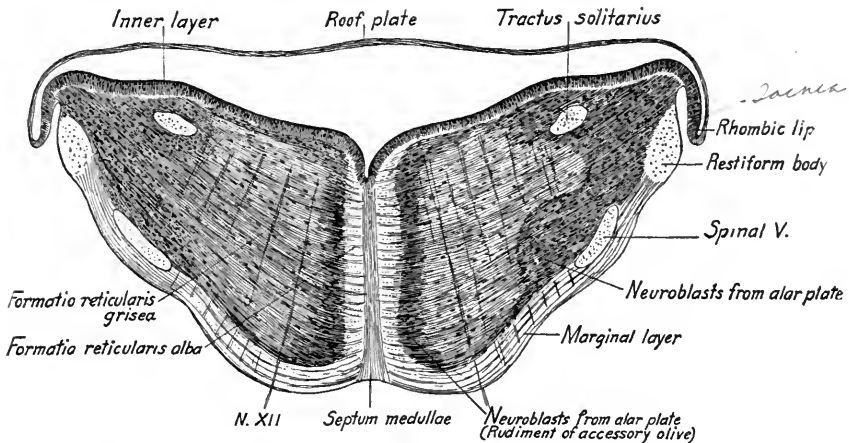


FIG. 318.—Transverse section through the myelencephalon of an eight weeks' human embryo (His).

cephalon is thus widened from side to side and flattened dorso-ventrally. This is most marked cranially where, between the alar plates of the myelencephalon and metencephalon, are formed the *lateral recesses* of the fourth ventricle (Fig.

319 A). Into the ependymal roof of the myelencephalon blood-vessels grow and, invading the lateral recesses, form there the *chorioid plexus* of the fourth ventricle. The plexus consists of small finger-like folds of the ependymal layer and its covering mesenchymal layer. The line of attachment of the ependymal layer to the alar plate is known as the *rhombic lip* and later becomes the *tania* and *obex* of the fourth ventricle (Fig. 319 B).

The further growth of the myelencephalon is due (1) to the rapid formation of neuroblasts, derived from the ependymal and mantle layers; (2) to the development of nerve fibers from these neuroblasts; (3) to the development and growth into it of fibers from neuroblasts in the spinal cord and in other parts of the brain.

The neuroblasts of the *basal plates* early give rise chiefly to the *efferent fibers* of the cerebral nerves (Fig. 317). They thus constitute motor nuclei of origin of the trigeminal, abducens, facial, glossopharyngeal, vagus complex and hypoglossal nerves, nuclei corresponding to the ventral and lateral gray columns of the spinal cord. The basal plate also produces part of the *reticular formation* which is derived in part also from the neuroblasts of the alar plate (Fig. 318). The axons partly cross as external and internal arcuate fibers and form a portion of the *median longitudinal bundle*, a fasciculus corresponding to the ventral ground bundles of the spinal cord. Other axons grow into the marginal zone of the same side and form *intersegmental fiber tracts*. The reticular formation is thus differentiated into a *gray portion* situated in the mantle zone and into a white portion located in the marginal zone (Fig. 318). The marginal zone is further added to by the ascending fiber tracts from the spinal cord and the descending pyramidal tracts from the brain. As in the cord, the marginal layers of each side remain distinct, being separated by the cells of the floor plate. The *alar plates* differentiate later than the basal plates. The afferent fibers of the cerebral nerves first enter the mantle layer of the alar plates and coursing upward and downward form definite tracts (tractus solitarius, descending tract of fifth nerve). To these are added tracts from the spinal cord so that an inner gray and an outer white substance is formed. Soon, however, the cells of the mantle layer proliferate, migrate into the marginal zone and surround the tracts. These neuroblasts of the alar plate form groups of cells along the terminal tracts of the afferent cerebral nerves (which correspond to the dorsal root fibers of the spinal nerves) and constitute the *receptive* or *terminal nuclei* of the fifth, seventh, eighth, ninth and tenth cerebral nerves. Caudally, the *nucleus gracilis* and *nucleus cuneatus* are developed from the alar plates as the terminal nuclei for the afferent fibers which ascend from

the dorsal funiculi of the spinal cord. The axons of the neuroblasts forming these receptive nuclei decussate through the reticular formation chiefly as *internal arcuate fibers* and ascend to the thalamus as the *median lemniscus*.

There are developed from neuroblasts of the alar plate other nuclei the axons of which connect the brain stem, cerebellum and fore-brain. Of these the most conspicuous is the *inferior olivary nucleus*.

The characteristic form of the adult myelencephalon is determined by the further growth of the above-mentioned structures. The nuclei of origin of the

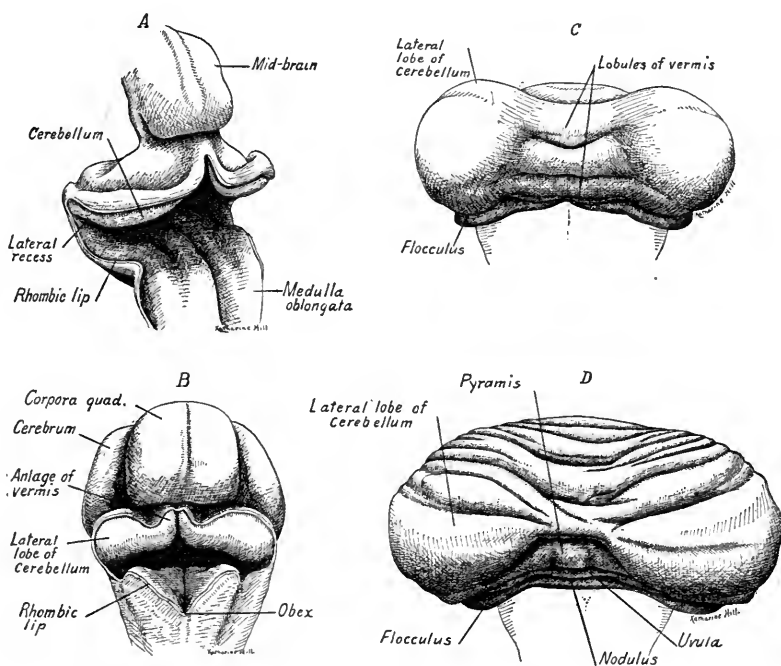


FIG. 319.—Dorsal views of four stages in the development of the cerebellum. A, of a 13.6 mm. embryo (His); B, of a 24 mm. embryo; C, of a 110 mm. embryo; D, of a 150 mm. embryo.

cerebral nerves, derived from the basal plate, produce swellings in the floor of the fourth ventricle which are bounded laterally by the sulcus limitans. The terminal nuclei of the mixed and sensory cerebral nerves lie lateral to this sulcus. The enlarged cuneate and gracile nuclei bound the ventricle caudally and laterally as the *cuneus* and *clava*. The inferior olivary nuclei produce lateral rounded prominences and ventral to these are the large cerebrospinal tracts or pyramids.

**The Metencephalon.**—Cranial to the lateral recesses of the fourth ventricle the cells of the alar plate proliferate ventrally and form the numerous and relatively large *nuclei of the pons*. The axons from the cells of these nuclei mostly

cross to the opposite side and form the *brachium pontis* of the cerebellum. Cerebral fibers from the cerebral peduncles end about the cells of the pontine nuclei. Others pass through the pons as fascicles of the pyramidal tracts.

**Cerebellum.**—When the alar plates of the cranial end of the myelencephalon are bent out laterally the caudal portions of their continuations into the metencephalic region are carried laterally also. As a result, the alar plate of the metencephalon

takes up a transverse position and forms the anlagen of the *cerebellum* (Fig. 319 A). During the second month the paired cerebellar plates thicken and bulge into the ventricle (Fig. 320 A). Near the mid-line a thickening indicates the anlage of the *vermis*, while the remainder of the alar plates form the anlagen of the lateral lobes or *cerebellar hemispheres*.

The cerebellar anlagen grow rapidly laterally and also in length so that their surfaces are folded transversely. During the third month their walls bulge outward and form on either side a convex *lateral lobe* connected with the pons by the *brachium pontis* (Fig. 319 C). In the meantime, the anlagen of the *vermis* have fused in the mid-line producing a single structure

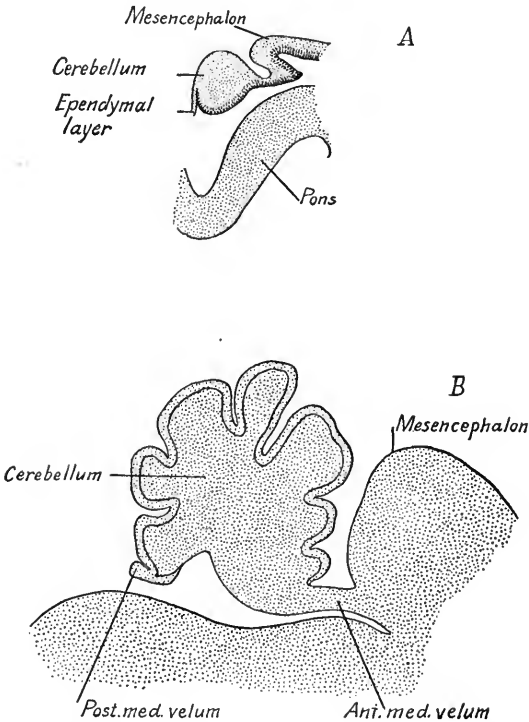


FIG. 320.—Median sagittal section of the cerebellum and part of mid-brain. A, from a 24 mm. embryo; B, from a 150 mm. embryo. *Ant. med. velum*, anterior medullary velum; *Post. med. velum*, posterior medullary velum.

marked by transverse fissures. The rhombic lip gives rise to the *flocculus* and *nodulus*. Between the third and fifth months the cortex cerebelli grows more rapidly than the deeper layers of the cerebellum and its principal lobes, folds and fissures are formed (Fig. 319 C, D). The hemispheres derived from the lateral lobes are the last to be differentiated. Their fissures do not appear until the fifth month.

Cranial to the cerebellum the wall of the neural tube remains thin dorsally



and constitutes the *anterior medullary velum* of the adult. Caudally, the ependymal roof of the fourth ventricle becomes the *posterior medullary velum*. The points of attachment of the vela remain approximately fixed, while the cerebellar cortex grows enormously. As a result, the vela are folded in under the expanding cerebellum (Fig. 320).

The anlagen of the cerebellum show at first differentiation into the same three layers which are typical for the neural tube. During the second and third months cells from the ependymal, and perhaps from the mantle layer, of the rhombic lip, migrate to the surface of the cerebellar cortex and give rise to the molecular and granular layers which are characteristic of the adult cerebellar cortex (Schäfer). The later differentiation of the cortex is only completed at or after birth. The cells of the granular layer become unipolar by a process of unilateral growth. The Purkinje cells differentiate later. Their axons and those of entering afferent fibers form the deep *medullary layer* of the cerebellum.

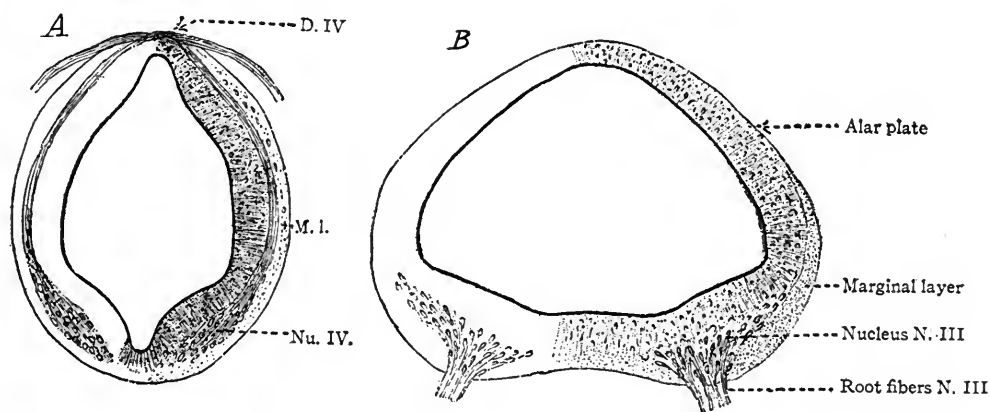


FIG. 321.—Transverse sections through the mesencephalon of a 10.6 mm. embryo. *A*, through the isthmus and origin of the trochlear nerve; *B*, through the nucleus of origin of the oculomotor nerve (His). *D. IV*, decussation of oculomotor nerve; *M. I.*, mantle layer; *Nu. IV*, nucleus of oculomotor nerve.

The cells of the mantle layer may take little part in the development of the cerebellar cortex, but give rise to neuroglia cells and fibers and to the internal nuclei. Of these the *dentate nucleus* may be seen at the end of the third month; later, its cellular layer becomes folded, producing its characteristic convolutions. The fibers arising from its cells form the greater part of the *brachium conjunctivum*. (For a detailed account of the development of the cerebellum see Streeter, in Keibel and Mall, vol. 2, p. 67.)

**Mesencephalon.**—The basal and alar plates can be recognized in this subdivision of the brain and each differentiates into the three primitive layers (Fig. 321). In the basal plate the neuroblasts give rise to the axons of motor nerves, the oculomotor cranial, the trochlear caudal in position (Fig. 321 B). In addition to these nuclei of origin, the *nucleus ruber* (red nucleus) is developed in

the basal plates ventral and somewhat cranial to the nucleus of the oculomotor nerve. The origin of the cells forming the red nucleus is not definitely known. The *alar plates* form the paired *superior* and *inferior colliculi* which together constitute the *corpora quadrigemina* (Fig. 331). The plates thicken and neuroblasts migrate to their surfaces, forming stratified ganglionic layers comparable to the cortical layers of the cerebellum and the cerebellar nuclei. With the development of the superior and inferior colliculi the cavity of the mesencephalic region decreases in size and becomes the *cerebral aqueduct*.

The mantle layer of the basal plate region is enclosed ventrally and laterally by the fiber tracts which develop in the marginal zone. Ventro-laterally appear the *median* and *lateral lemnisci* and ventrally develop later the descending tracts from the cerebral cortex, which together constitute the *peduncles of the cerebrum*.

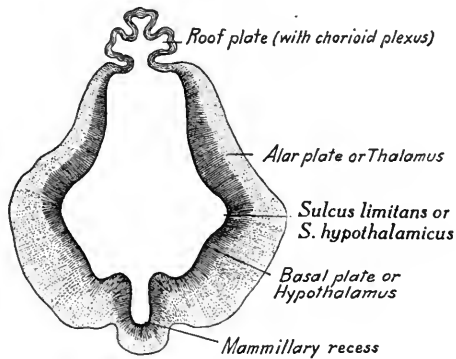


FIG. 322.—Transverse section through the diencephalon of a five weeks' human embryo (His).

**The Diencephalon.**—In the wall of the diencephalon we may recognize laterally the *alar* and *basal* plates, dorsally the roof plate and ventrally the floor plate (Fig. 322). The *roof plate* expands, folds as seen in the figure, and into the folds extend blood capillaries. The roof plate thus forms the ependymal lining of the *tela chorioidea* of the third ventricle. The vessels and ingrowing mesenchymal tissue form the chorioid plexus. Cranially, the tela chorioidea roofs over the median portion of the telencephalon and is folded laterally into the hemispheres as the *chorioid plexus of the lateral ventricles*. Laterally, the roof plate is attached to the alar plates and at their point of union are developed the *ganglia habenulae*. The *pineal body* or *epiphysis* is developed caudally as an evagination of the roof plate. It appears at the fifth week (Fig. 327) and is well developed by the third month (Fig. 324). Into the thickened wall of the anlage is incorporated a certain amount of mesenchymal tissue and thus the pineal body proper is formed. The

alar plate is greatly thickened and becomes the anlage of the thalamus and metathalamus. The latter, really a part of the thalamus, gives rise to the lateral and median geniculate bodies.

The *sulcus hypothalamicus* (Fig. 323) forms the boundary line between the thalamus (alar plate) and the hypothalamus (basal plate plus the floor plate). This sulcus thus corresponds to the *sulcus limitans* of the spinal cord and brain stem. The basal plate is comparatively unimportant in the dien-cephalic region as no nuclei of origin for motor nerves are developed here.

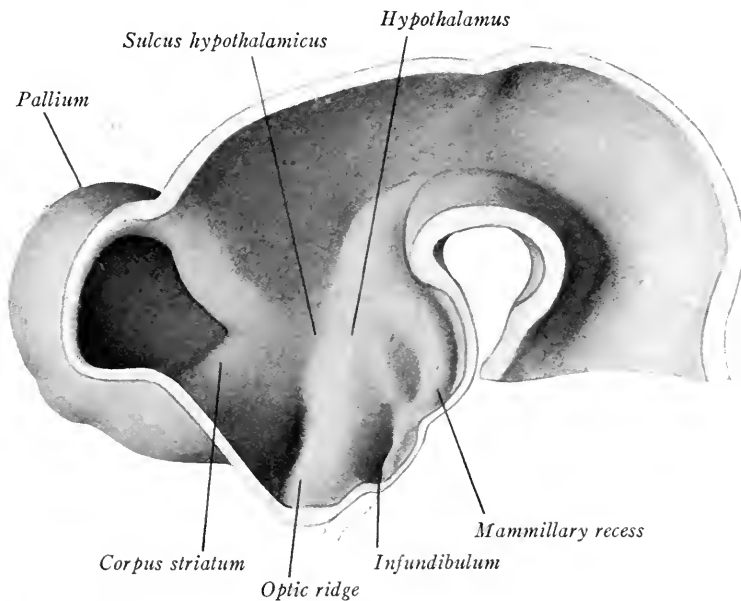


FIG. 323.—Median sagittal section of the fore- and mid-brain regions of a brain from a 10.2 mm. embryo (after His).

In the floor plate the ridge formed by the optic chiasma constitutes the *pars optica hypothalamica*.

**The Hypophysis.**—The *infundibulum* develops as a recess caudal to the *pars optica hypothalamica* (Figs. 324 and 325). At its extremity is the sac-like anlage of the posterior lobe of the *hypophysis* or *pituitary body*. During the fourth week the infundibular anlage comes into contact with Rathke's pouch, the epithelial anlage of the anterior lobe of the hypophysis (Fig. 325). The epithelial anlage is at first flattened and soon is detached from its epithelial stalk. Later, it grows laterally and caudally about the anlage of the posterior lobe and during the second month its wall is differentiated into convoluted tubules which obliterate its cavity. The tubules become closed glandular follicles surrounded by a rich

network of blood-vessels and produce an important internal secretion. *Pari passu* with the differentiation of the anterior lobe the infundibular anlage of the

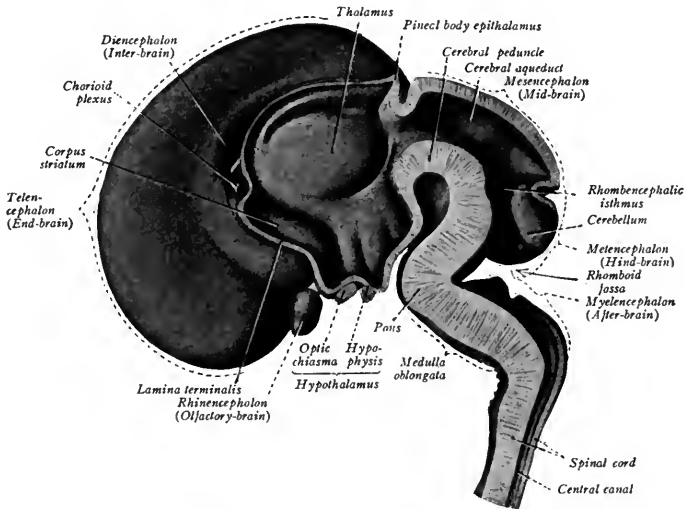


FIG. 324.—Median sagittal section of the brain from a fetus of the third month (His from Sobotta's Atlas).

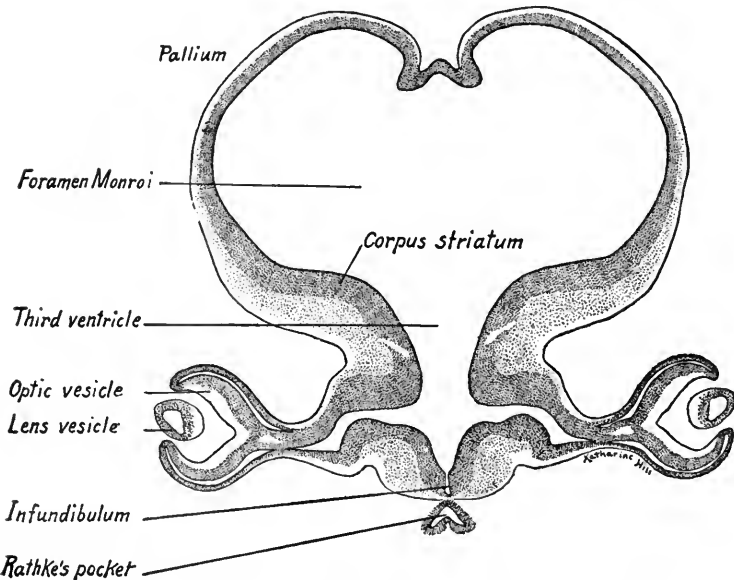


FIG. 325.—Oblique transverse section through the diencephalon and telencephalon of a 10 mm. embryo.  $\times 61$ .

posterior lobe loses its cavity, but the walls of the infundibulum persist as its solid permanent stalk. The lobe enlarges and its cells are differentiated into a

diffuse tissue resembling neuroglia. About the two lobes of the hypophysis the surrounding mesenchyme develops a connective tissue capsule.

Caudal to the infundibulum in the floor plate are developed in order the *tuber cinereum* and the mammillary recess (Figs. 323 and 324). The lateral walls of the latter thicken and give rise to the paired *mammillary* bodies.

The *third ventricle* lies largely in the diencephalon and is at first relatively broad. Owing to the thickening of its lateral walls it is compressed until it forms a narrow vertical cleft. In a majority of adults the thalami are approximated, fuse and form the *massa intermedia* or *commissura mollis*, which is encircled by the cavity of the ventricle.

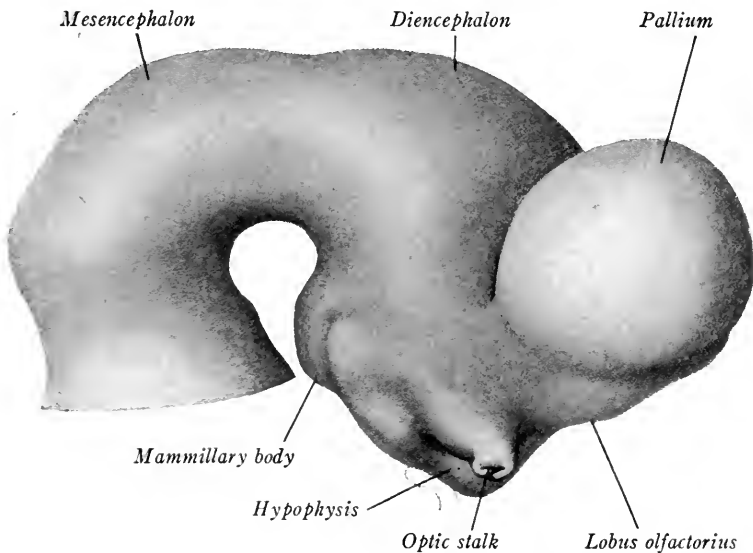


FIG. 326.—Lateral view of the fore- and mid-brains of a 10.2 mm. embryo (His).

**The Telencephalon.**—This is the most highly differentiated division of the brain (Fig. 326). The primitive structures of the neural tube can no longer be recognized but the telencephalon is regarded as representing greatly expanded alar plates and is therefore essentially a paired structure. Each of the paired out-growths expands cranially, dorsally, and caudally, and eventually overlies the rest of the brain (Figs. 326, 327 and 328). The telencephalon is differentiated into the *corpus striatum*, *rhinencephalon*, and *pallium* (primitive cortex of cerebral hemisphere). The median lamina between the hemispheres lags behind in its development and thus is formed the *great longitudinal fissure* between the hemispheres. The lamina is continuous caudally with the roof plate of the dien-

cephalon, cranially it becomes the *lamina terminalis*, the cranial boundary of the third ventricle.

**Chorioid Plexus of the Lateral Ventricles.**—It will be remembered that in the folds of the roof plate of the diencephalon develops the chorioid plexus of the third ventricle. Similarly the thin median wall of the pallium at its junction with the wall of the diencephalon is folded into the lateral ventricle. Into this fold grows a vascular plexus continuous with that of the third ventricle and projects into the lateral ventricle of either side (Figs. 327 and 329). The fold of the pallial wall forms the chorioidal fissure and the vascular plexus is the *chorioid*

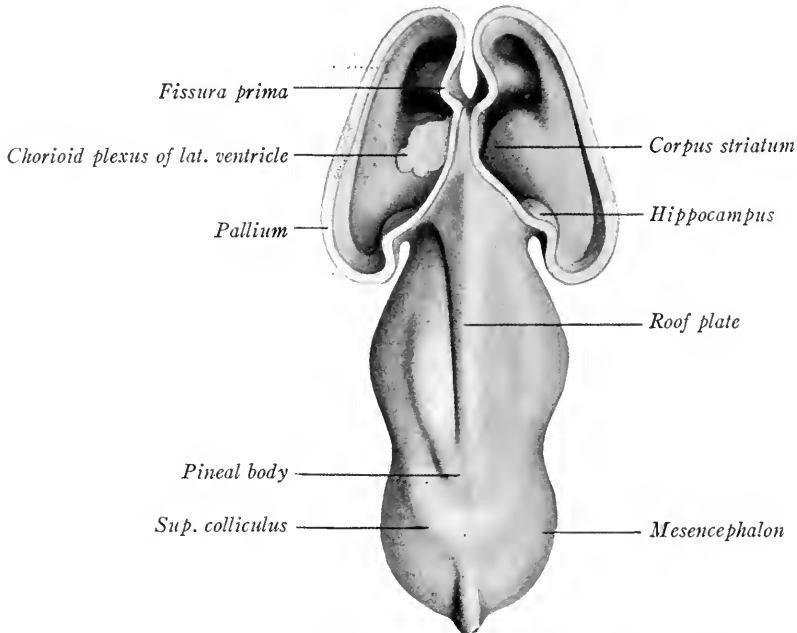


FIG. 327.—The fore-brain and mid-brain of an embryo 13.6 mm. long seen from the dorsal surface. The pallium of the telencephalon is cut away exposing the lateral ventricle (His).

*plexus* of the lateral ventricle. This is a paired structure and with the plexus of the third ventricle forms a T-shaped figure, the stem of the T overlying the third ventricle, its curved arms projecting into the lateral ventricles just caudal to the interventricular foramen. Later, as the pallium extends, the chorioid plexus of the lateral ventricles and the chorioidal fissures are extensively elongated into the temporal lobe and inferior horn of the lateral ventricle (Fig. 330).

The *interventricular foramen* (of Monro) is at first a wide opening (Fig. 325) but is later narrowed to a slit, not by constriction but because its boundaries grow more slowly than the rest of the telencephalon (Fig. 329).

The third ventricle extends some distance into the caudal end of the telencephalon and laterally in this region develop the optic vesicles. Into each optic stalk extends the *optic recess* (Fig. 325).

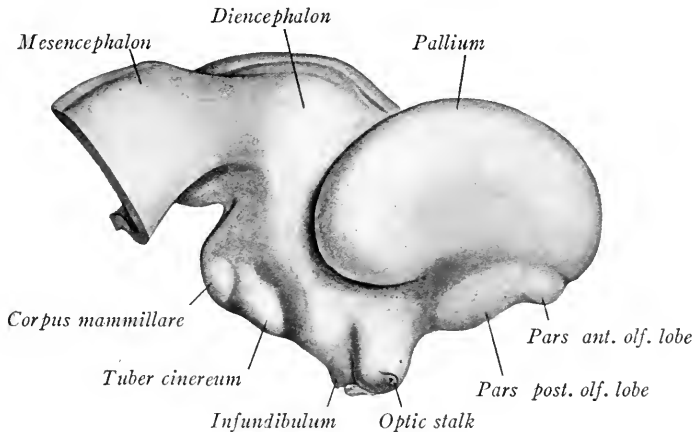


FIG. 328.—Lateral view of the fore-brain and mid-brain of a 13.6 mm. embryo (His).

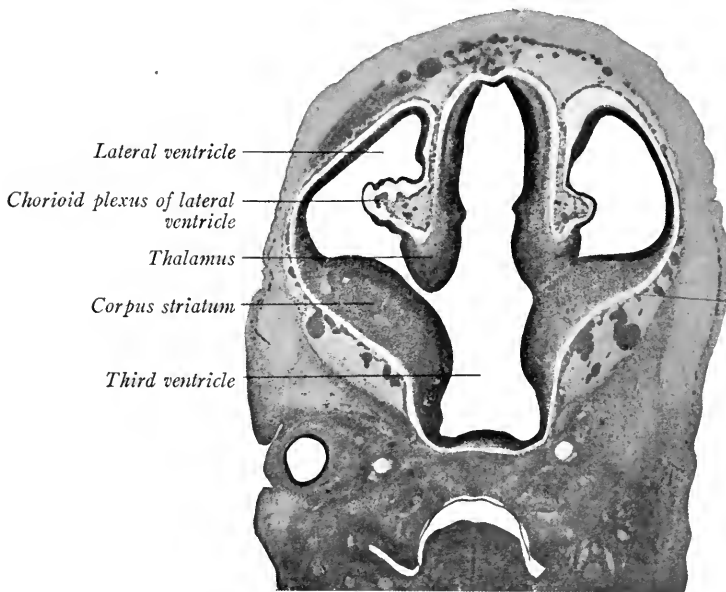


FIG. 329.—Transverse section through the fore-brain of a 16 mm. embryo showing the early development of the chorioid plexus and fissure (His).

*The corpus striatum* is developed as a thickening in the floor of each cerebral hemisphere. It is already prominent in embryos of five weeks (13.6 mm.) bulging into the lateral ventricle (Figs. 327 and 329). It is in line caudally with the

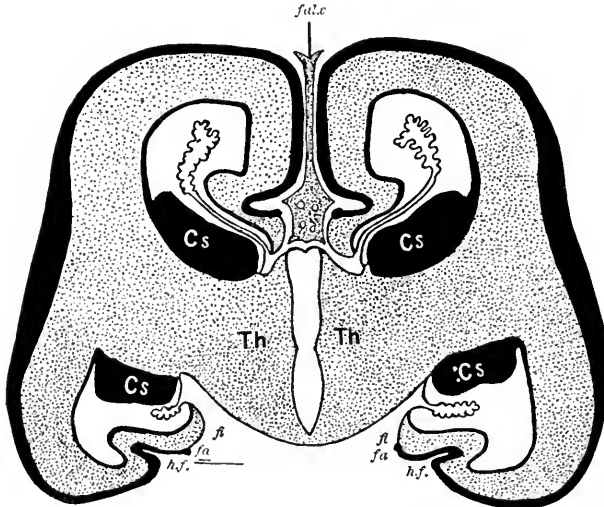


FIG. 330.—A transverse section through the telencephalon of an 83 mm. embryo (after His). *Th*, thalamus; *cs*, corpus striatum; *hf*, hippocampal fissure; *fa*, marginal gray seam; *fi*, edge of white substance.

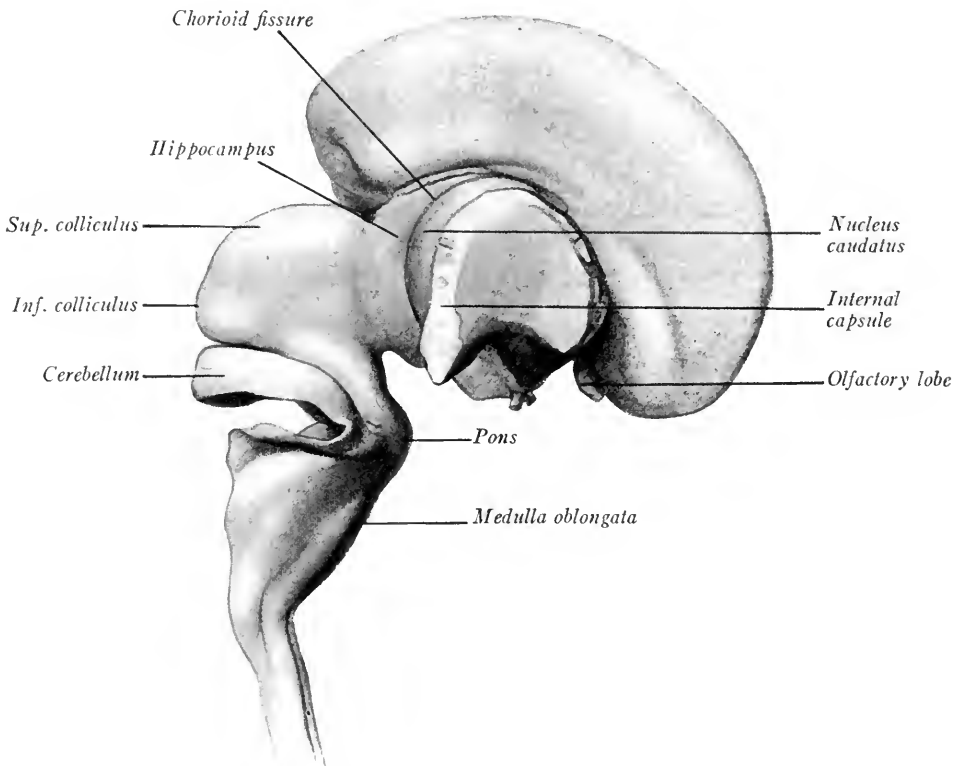


FIG. 331.—Lateral view of the brain of a 53 mm. fetus. The greater part of the pallium of the right cerebral hemisphere has been removed, leaving only that covering the lenticular nucleus, and exposing the internal capsule, caudate nucleus and hippocampus (His).



thalamus of the diencephalon and in development is closely connected with it, although the thalamus forms always a separate structure. The corpus striatum elongates as the cerebral hemisphere lengthens, its caudal portion curving around to the tip of the inferior horn of the lateral ventricle and forming the slender *tail of the caudate nucleus* (Fig. 331). The thickening of the corpus striatum is due to the active proliferation of cells in the ependymal layer which form a prominent mass of mantle layer cells. Nerve fibers to and from the thalamus to the cerebral cortex course through the corpus striatum as laminae which are arranged in

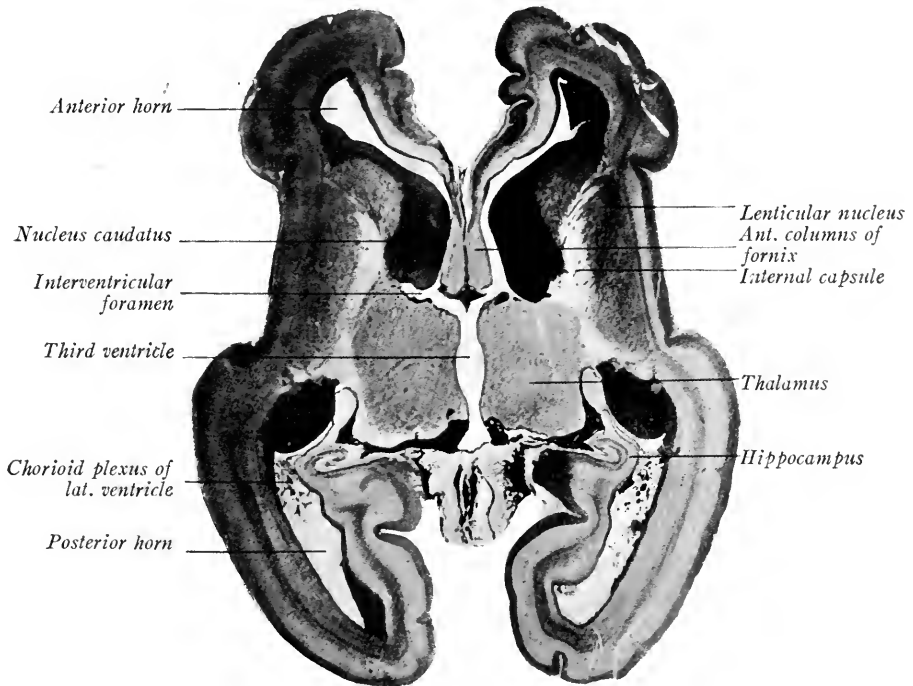


FIG. 332.—Horizontal (coronal) section through the fore-brain of a 16 cm. fetus (His).

the form of a wide V, open laterally, when seen in horizontal sections. This V-shaped tract of white fibers is the *internal capsule*, the cranial limb of which partly separates the corpus striatum into the *caudate* and *lenticular* nuclei (Fig. 332). The caudal limb of the capsule extends between the lenticular nucleus and the thalamus.

The thalamus and corpus striatum are separated by a deep groove until the end of the third month (Fig. 329). As the structures enlarge, the groove between them disappears and they form one continuous mass (Fig. 332). According to some investigators, there is direct fusion between the two.

**The Rhinencephalon or Olfactory Apparatus.**—This is divided into a basal portion and a pallial portion. The basal portion consists (1) in a ventral and cranial evagination (*pars anterior*) formed mesial to the corpus striatum, which is the anlage of the *olfactory lobe* and *stalk* (Fig. 328). This receives the olfactory fibers and its cells give rise to *olfactory tracts*. The tubular stalk connecting the olfactory lobe with the cerebrum loses its lumen. (2) Caudal to the anlage of the olfactory lobe a thickening of the brain wall develops (*pars posterior*) which extends mesially along the *lamina terminalis* and laterally becomes continuous with the tip of the temporal lobe (Figs. 323 and 328). This thickening constitutes the *anterior perforated space* and the *parolfactory area* of the adult brain.

The pallial portion of the rhinencephalon is termed the *archipallium* because it forms the primitive wall of the cerebrum. It forms a median strip of the pallial wall curving along the dorsal edge of the chorioidal fissure from the anterior perforated space around to the tip of the temporal lobe, where it is again connected with the basal portion of the rhinencephalon. The archipallium differentiates into the *hippocampus*, a portion of the *gyrus hippocampi* and into the *gyrus dentatus*. It resembles the rest of the cerebral cortex in the arrangement of its cells. The infolding of the hippocampus produces the *hippocampal fissure*.

**The Commissures of the Telencephalon.**—The important commissures are the *corpus callosum*, *fornix* and *anterior commissure*. The first is the great transverse commissure of the neopallium or cerebral cortex, while the fornix and anterior commissure are connected with the archipallium of the rhinencephalon. The commissures develop in relation to the lamina terminalis, crossing partly in its wall and partly in fused adjacent portions of the median pallial walls. Owing to the fusion of the pallial walls dorsal and cranial to it, the lamina terminalis thickens rapidly in stages between 80 and 150 mm. (Streeter in Keibel and Mall, vol. 2). "It [the lamina terminalis] is distended dorsalward and antero-lateralward through the growth of the corpus callosum, the shape of which is determined by the expanding pallium." Between the curve of the corpus callosum and the fornix a space is formed, the *fifth ventricle*, or *space of the septum pellucidum* (Fig. 333 A, B). This space is bounded laterally by a portion of the median pallial wall which remains thin and membranous, and constitutes the *septum pellucidum* of the adult.

The fornix takes its origin early, chiefly from cells in the hippocampus. The fibers course along the chorioidal side of the hippocampus cranially, passing dorsal to the foramen of Monro (Fig. 333 A). In the cranial portion of the lamina terminalis fibers are given off and received from the basal portion of the

rhinencephalon. In this region fibers crossing the midline form the *hippocampal commissure*. Other fibers, as the *anterior pillars* of the fornix, curve ventrally and end in the *mammillary body* of the hypothalamus. The commissure of the hippocampus, originally cranial in position, is carried caudalward with the caudal extension of the corpus callosum (Fig. 333 B).

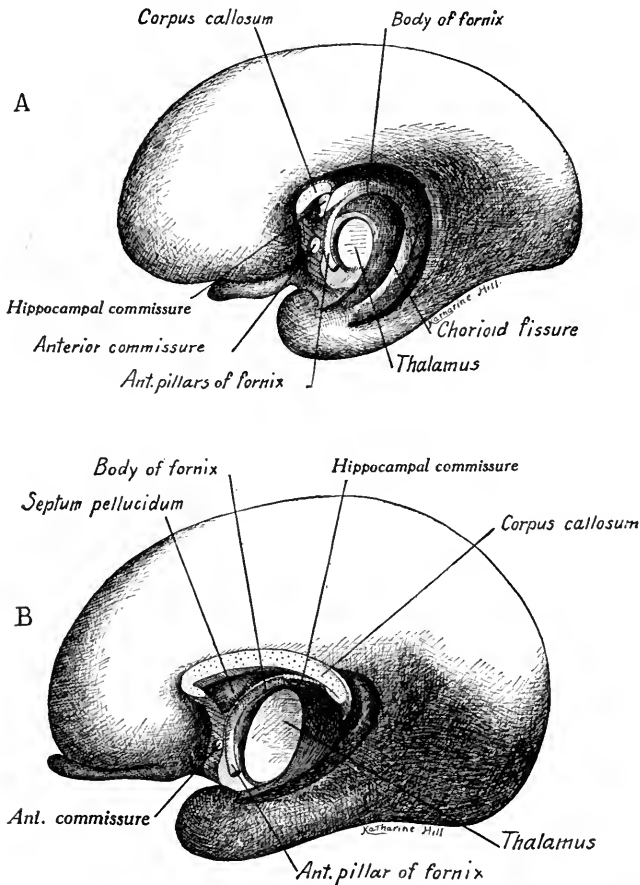


FIG. 333.—Two stages in the development of the cerebral commissure. A, Median view of the right hemisphere of an 83 mm. embryo; B, the same of a 120 mm. embryo. (Based on reconstructions by His and Streeter).

The fibers of the *anterior commissure* cross in the lamina terminalis ventral to the hippocampal commissure. They arise as a cranial and a caudal division. The fibers of the former take their origin from the olfactory stalk and the adjacent cortex. The fibers of the caudal division pass ventrally about the corpus striatum between it and the cortex, and may be derived from one or both of these regions.

The *corpus callosum* appears cranial and dorsal to the hippocampal com-

missure in the roof of the thickened lamina terminalis (Fig. 333 A). Its fibers arise from neuroblasts in the wall of the neopallium (cerebral cortex) and by them nearly all regions of one hemisphere are associated with corresponding regions of the other. With the expansion of the pallium the corpus callosum is extended cranially and caudally by the development of interstitial fibers. The fibers first found in the corpus callosum arise in the median wall of the hemispheres. In

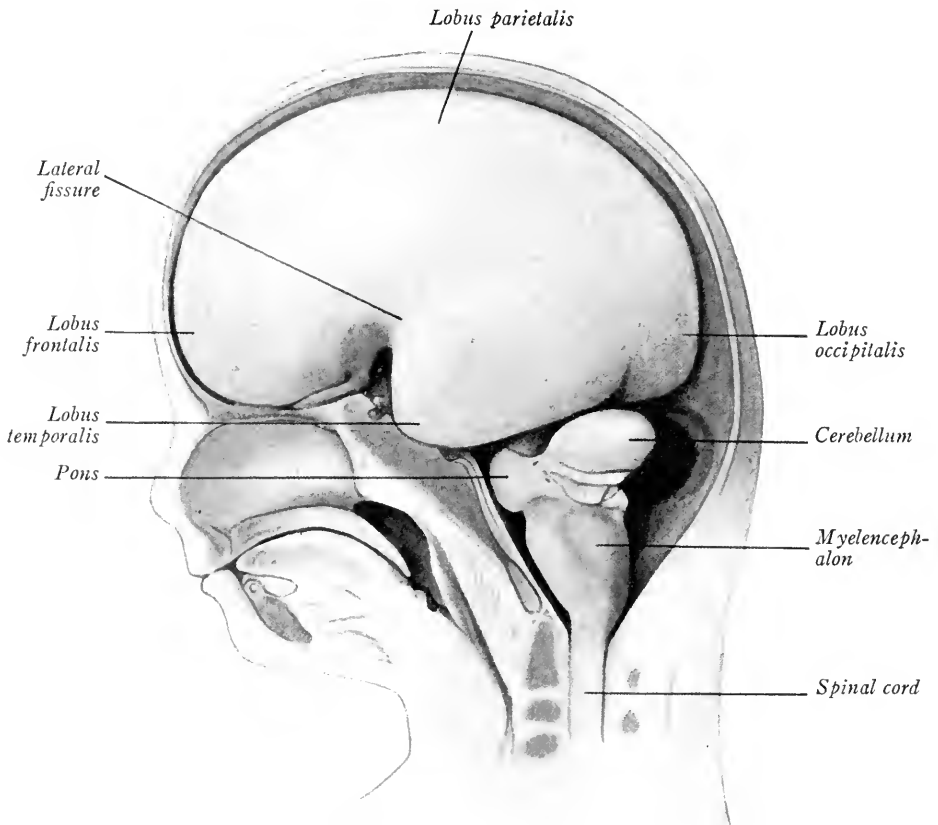


FIG. 334.—Lateral view of the brain of a 90 mm. embryo (His).

fetuses of 150 mm. (five months) this great commissure is a conspicuous structure and shows the form which is characteristic of the adult (Fig. 333 B).

**The Form of the Cerebral Hemispheres.**—When the telencephalon expands cranially, caudally and at the same time ventrally, four lobes may be distinguished (1) a cranial *frontal lobe*; (2) a dorsal *parietal lobe*; (3) a caudal *occipital lobe*, and (4) a ventro-lateral *temporal lobe* (Fig. 334). The ventricle extends into these regions and in each forms respectively the *anterior horn*, the *body*, the *posterior horn* and the *inferior horn* of the lateral ventricle. The surface extent

of the cerebral wall, the thin gray cortex, increases more rapidly than the underlying white medullary layer. As a result the cortex is folded, producing convolutions between which are depressions, the *sulci* and *fissures*. The chorioidal fissure is formed, as we have seen, by the ingrowth of the chorioid plexus. During the third month the *hippocampal fissure* develops as a curved infolding along the median wall of the temporal lobe. The infolded cortex forms the *hippocampus*. The *lateral fissure* (of Sylvius) makes its appearance also in the third month, but its development is not completed until after birth. The cortex overlying the corpus striatum laterally develops more slowly than the surrounding

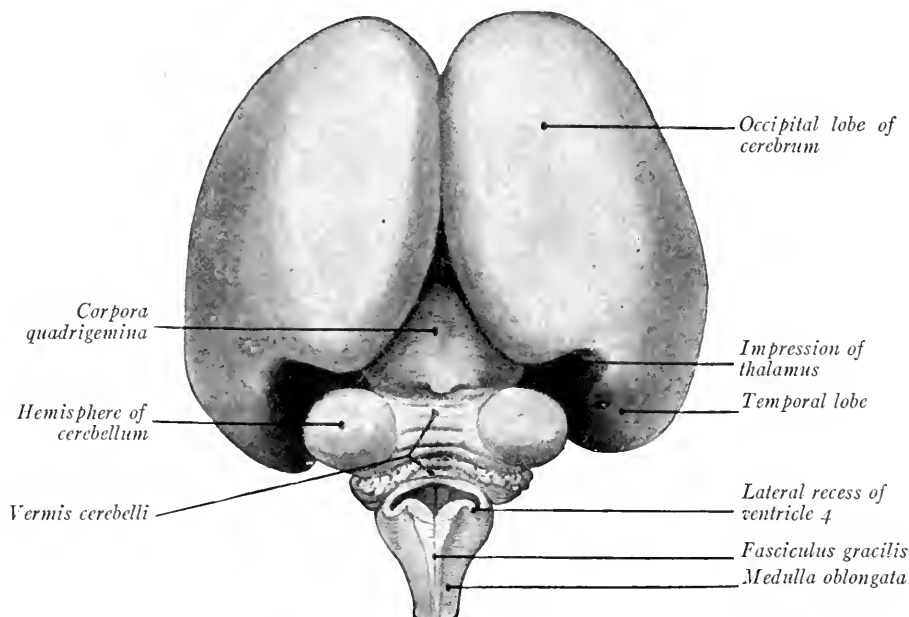


FIG. 335.—Posterior view of the brain from a 100 mm. embryo (Kollmann's Handatlas).

areas and is thus gradually overgrown by folds of the parietal and frontal lobes (fronto-parietal operculum) and of the temporal lobe (temporal operculum). The area thus overgrown is the *insula* (island of Reil) and the depression so formed is the *lateral fissure* (of Sylvius). Later, *frontal* and *orbital opercula* are developed ventro-laterally from the frontal lobe (Fig. 337). These are not approximated over the insula until after birth. The frontal operculum is included between the anterior limbs of the Sylvian fissure and the extent of its development, which is variable, determines the form of these limbs.

In fetuses of six to seven months four other depressions appear which later form important landmarks in the cerebral topography. These are: (1) the

*central sulcus*, or fissure of Rolando, which forms the dorso-lateral boundary line between the frontal and parietal lobes (Fig. 337); (2) the *parieto-occipital fissure*, which, on the median wall of the cerebrum, is the line of separation between the

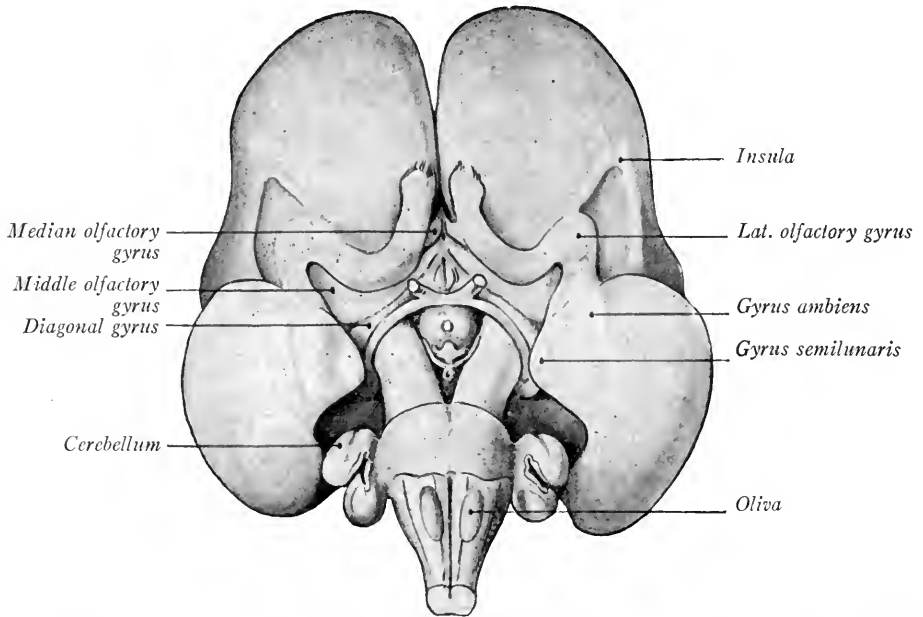


FIG. 336.—Ventral view of the brain of a 100 mm. embryo showing development of the rhinencephalon (Kollmann).

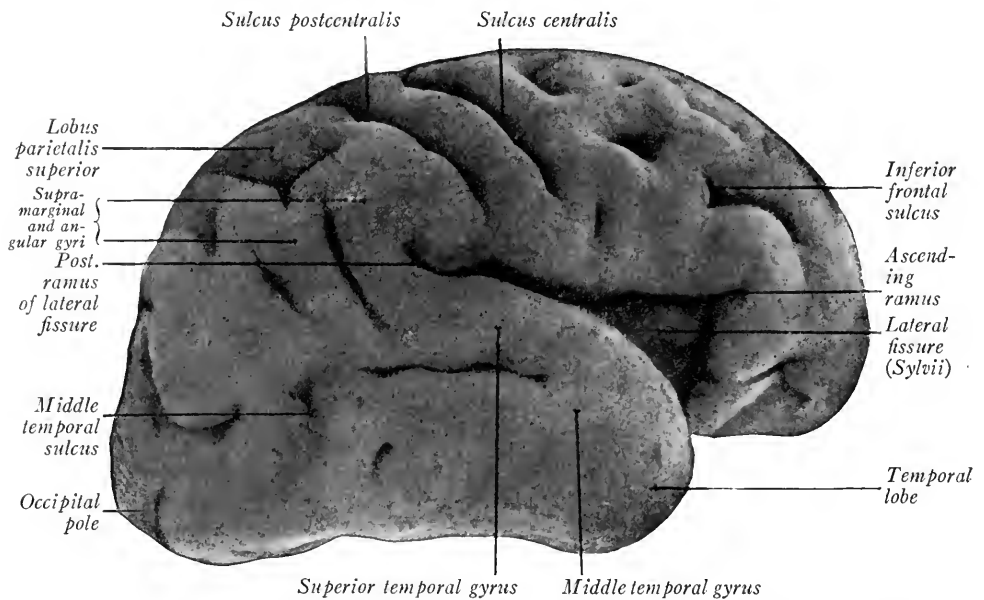


FIG. 337.—Lateral view of the right cerebral hemisphere, from a seven months' fetus (Kollmann).

occipital and parietal lobes (Fig. 338); (3) the *calcarine fissure* which includes between it and the parieto-occipital fissure the *cuneus* and marks the position of the visual area of the cerebrum; (4) the *collateral fissure* on the ventral surface of the temporal lobe, which produces the inward bulging on the floor of the posterior horn of the ventricle known as the *collateral eminence*. The calcarine fissure also affects the internal wall of the ventricle, causing the convexity termed the *calcar avis*.

Simultaneously with the development of the collateral fissure appear other shallower depressions known as *sulci*. These have a definite arrangement and

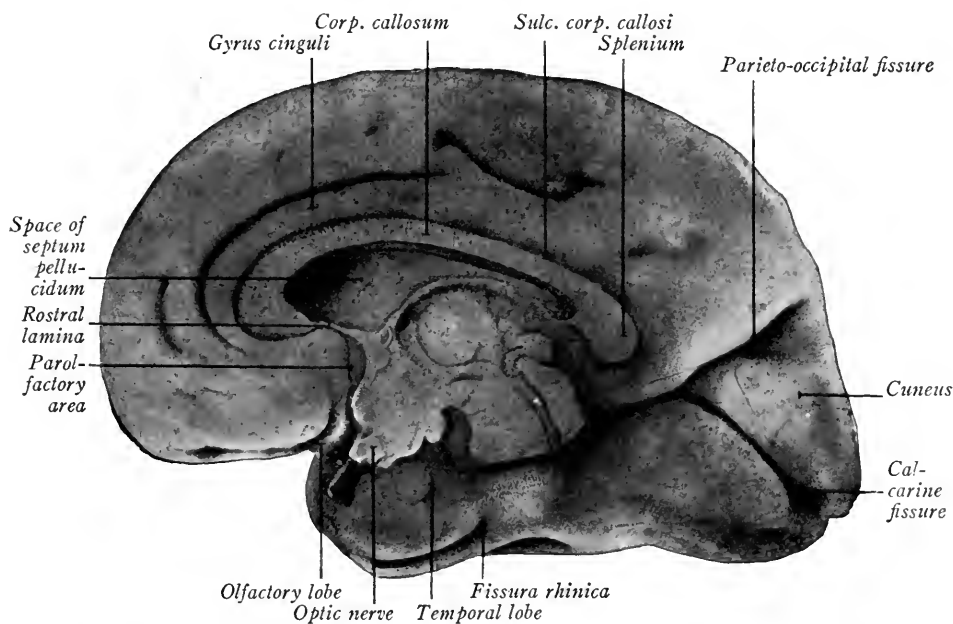


FIG. 338.—Median surface of the right cerebral hemisphere from a seven months' fetus (Kollmann).

with the fissures mark off from each other the various functional areas of the cerebrum. The surface convolutions between the depressions constitute the *gyri* and *lobules* of the adult cerebrum.

**Histogenesis of the Cerebral Cortex.**—The three primitive zones typical of the neural tube are differentiated in the wall of the pallium: the ependymal, mantle and marginal layers. During the first two months the cortex remains thin and differentiation is slow. At eight weeks neuroblasts migrate from the ependymal and mantle zones into the marginal zone and give rise to layers of *pyramidal* cells typical of the cerebrum. The differentiation of these layers is most active during the third and fourth months. From the fourth month on the

cerebral wall thickens rapidly owing to the development of (1) the fibers from the thalamus and corpus striatum; (2) of endogenous fibers from the neuroblasts of the cortex. The fibers form a white inner medullary layer surrounded by the gray cortex. As the cerebral wall increases in thickness the size of the lateral ventricle becomes relatively less, its lateral diameter especially being decreased. For the special differentiation of the cerebral cortex in different regions the student is referred to text-books on neurology.



## CHAPTER XII

### THE PERIPHERAL NERVOUS SYSTEM

The nerves, ganglia and sense organs constitute the peripheral nervous system. The peripheral nerves consist of bundles of medullated and non-medullated nerve fibers and aggregations of nerve cells, the *ganglia*. The fibers are of two types: *Afferent fibers* which carry sensory impulses to the central nervous system, and *efferent fibers*, which carry effective impulses away from the nervous centers. The peripheral *efferent fibers* of both brain and spinal cord take their origin from neuroblasts of the basal plate. Typically they emerge ventro-laterally from the neural tube. Those arising from the spinal cord take origin in the mantle layer, converge and form the *ventral roots* of the *spinal nerves*. The efferent fibers of the brain take origin from more definite nuclei and constitute the *motor* or *effector portions* of the *cerebral nerves*. The *peripheral afferent fibers* take origin from nerve cells which lie outside the neural tube. Those sensory nerve cells related to the spinal cord and to the brain stem caudal to the otic vesicle are derived from the *ganglion crest*, the origin of which has been described (Chapter X, p. 314).

#### A. SPINAL NERVES

The spinal nerves are segmentally arranged and each consists of dorsal and ventral roots, spinal ganglion and nerve trunks. In embryos of 4 mm. the ventral roots are already developing as outgrowths of neuroblasts in the mantle layer of the spinal cord (Fig. 339). The spinal ganglia are represented as enlargements along the ganglion crest and are connected by a bridge of cells.

In 7 mm. embryos (four weeks old) the cells of the spinal ganglia begin to develop centrally directed processes which enter the marginal zone of the cord as the *dorsal root fibers* (Fig. 340). These fibers course in, and eventually form the

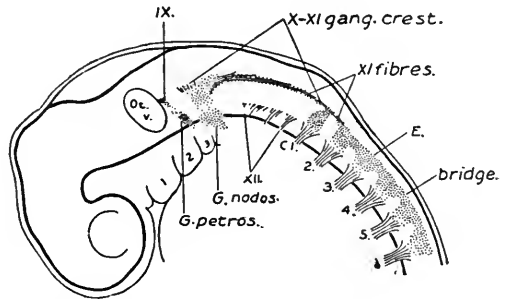


FIG. 339.—Reconstruction of an embryo of 4 mm. showing the development of the cerebrospinal nerves. C1., 2., etc., cervical spinal nerves (Streeter).

greater part of, the dorsal funiculi. Peripheral processes of the ganglion cells join the ventral root fibers in the trunk of the nerve (Fig. 342). At 10 mm. (Fig. 341) the dorsal root fibers have elongated and the cellular bridges of the ganglion crest between the spinal ganglion have begun to disappear. In transverse sections at this stage (Figs. 307 and 342) the different parts of a spinal nerve may be seen. The trunk of the nerve just ventral to the union of the dorsal and ventral

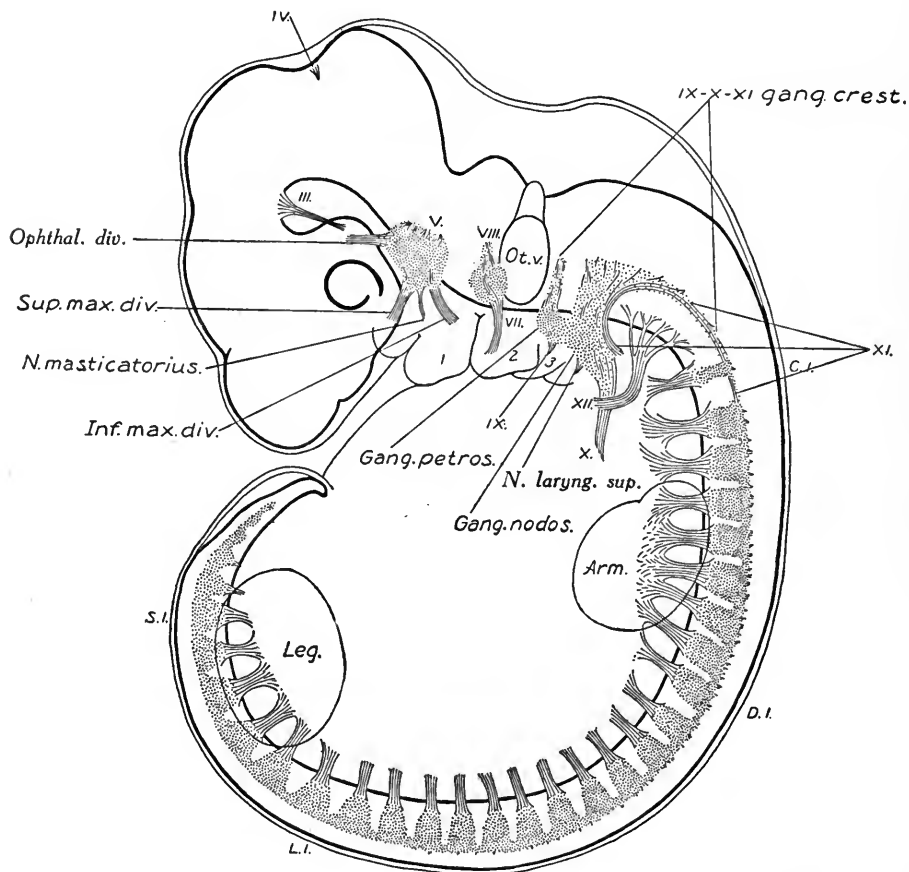


FIG. 340.—Reconstruction of a 6.9 mm. embryo showing the development of the dorsal root fibers from the spinal and cerebral ganglia (Streeter).  $\times 16.7$ .

roots gives off laterally the *dorsal*, or *posterior ramus*, the fibers of which supply the dorsal muscles. The ventral ramus continuing gives off mesially the *ramus communicans* to the sympathetic ganglion and divides into the *lateral and ventral* (anterior) *terminal rami*. The efferent fibers of these rami supply the muscles of the lateral and ventral body wall and the afferent fibers end in the integument of the same regions.

At the points where the anterior and lateral terminal rami arise, connecting loops may extend from one spinal nerve to another. Thus in the cervical region superficial and deep nerve plexuses are formed. The deep cervical plexus forms the *ansa hypoglossi* and the *phrenic nerve*.

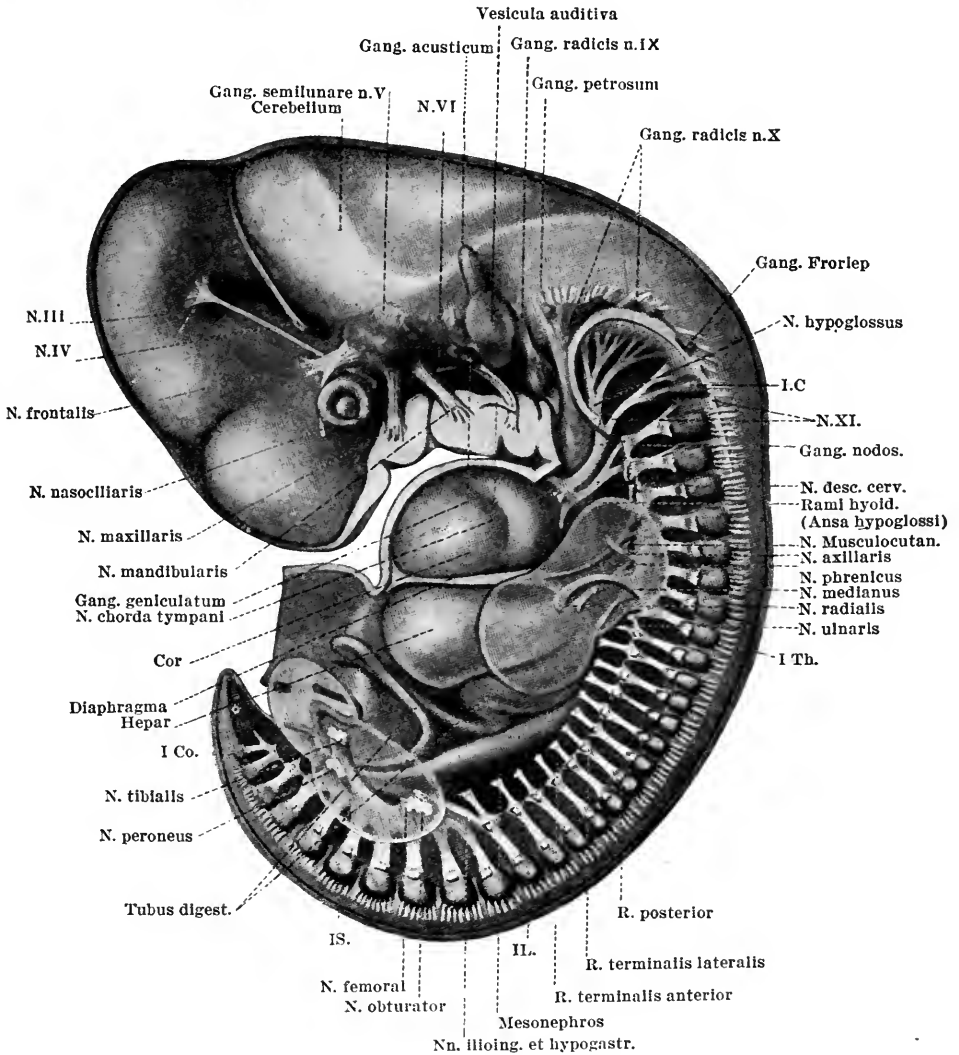


FIG. 341.—Reconstruction of the nervous system of a 10 mm. embryo (Streeter).  $\times 12$ .

**The Brachial and Lumbo-sacral Plexuses.**—The nerves supplying the arm and leg also unite to form plexuses. In embryos of 10 mm. (Fig. 341) the trunks of the last four cervical nerves and of the first thoracic are united to form a flattened plate, the anlage of the *brachial plexus*. From this plate nervous cords

extend into the intermuscular spaces and end in the pre-muscle masses. The developing skeleton of the shoulder splits the brachial plexus into dorsal and ventral laminae from which the various nerves to the arm and shoulder arise.

In 10 mm. embryos the lumbar and sacral nerves which supply the leg unite in a plate-like structure, the anlage of the *lumbo-sacral plexus* (Fig. 341). The plate is divided by the skeletal elements of the pelvis and femur into two lateral and two median trunks. Of the cranial pair the lateral becomes the *femoral nerve*; the median, the *obturator nerve*. The caudal pair constitute the sciatic nerve; the lateral trunk is the peroneal nerve, and the median trunk is the tibial.

Save for the neurones from the special sense organs (nose, eye and ear) which

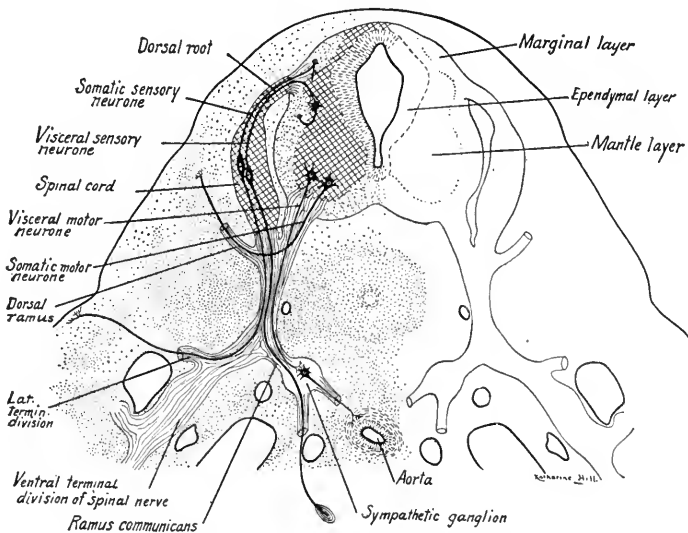


FIG. 342.—Transverse section of a 10 mm. embryo showing the spinal cord, spinal nerves and their function nervous components. Diagrammatic.

form a *special* sensory group, the neurones of the peripheral nerves, both spinal and cerebral, fall into four function groups (Fig. 342).

(1) *Somatic afferent*, or *general sensory*, with fibers ending in the integument of the body wall.

(2) *Visceral afferent*, or *sensory*, with fibers ending in the walls of the viscera.

(3) *Somatic efferent*, or *motor*, with fibers ending on voluntary muscle fibers.

(4) *Visceral efferent*, or *motor*, (a) with fibers ending about sympathetic ganglion cells, which in turn control the smooth muscle fibers of the viscera and blood-vessels (spinal nerves); or (b) with fibers ending directly on visceral muscle

fibers (mixed cerebral nerves). The relation of the sympathetic system to the central nervous system is described on page 364.

## B. THE CEREBRAL NERVES

The cerebral nerves of the human brain are twelve in number. They differ from the spinal nerves: (1) in that they are not segmentally arranged, and (2) in that they do not all contain the same types of nervous components. Classed according to the functions of their neurones they fall into three groups.

SPECIAL SOMATIC SENSORY	SOMATIC MOTOR OR EFFECTOR	VISCERAL SENSORY AND MOTOR
I. Olfactory.	III. Oculomotor.	V. Trigeminal.
II. Optic.	IV. Trochlear.	VII. Facial.
VIII. Acoustic.	VI. Abducens.	IX. Glossopharyngeal.
	XII. Hypoglossal.	X. Vagus complex including
		XI. Spinal Accessory.

It will be seen (1) that the nerves of the first group are purely sensory, corresponding to the general somatic afferent neurones of the spinal nerves; (2) that the nerves of the somatic motor group are purely motor and correspond to the somatic efferent or motor neurones of the spinal nerves; (3) that the nerves of the third group are of mixed function and correspond to the visceral components of the spinal nerves.

### I. THE SPECIAL SOMATIC SENSORY NERVES

1. The **Olfactory Nerve** though purely sensory has no ganglion. Its nerve cells lie at first in the olfactory epithelium of the nose and are of the bipolar type. From these cells peripheral processes develop and end directly at the surface of the olfactory epithelium. Central processes grow into contact with the olfactory lobe and form the strands of the olfactory nerve. They end in the olfactory bulb about the peculiar mitral cells. Some of the olfactory cells migrate from epithelium along with the developing nerve fibers, and may be found as bipolar cells along the course of the nerve. The olfactory nerve fibers are peculiar in that they remain non-medullated.

When the ethmoidal bone of the cranium is developed its cartilage is formed around the strands of the olfactory nerve, which thus in the adult penetrate the cribriform plate of the ethmoid.

Nerve fibers which pass from the epithelium of the organ of Jacobson also end in the olfactory bulb. The organ of Jacobson is a vestigial sense organ and its nerve is rudimentary. For the development of the olfactory organ see p. 369.

2. The **Optic Nerve** is formed by fibers which take their origin from neuroblasts in the nervous layer of the retina. The retina is differentiated from the wall of the fore-brain and remains attached to it by the optic stalk (Fig. 325). The neuroblasts from which the optic nerve fibers develop constitute the *ganglion cell layer* of the retina (Fig. 362). During the sixth and seventh weeks these cells give rise to central processes which form a *nerve fiber layer* on the inner side of the retina. The optic fibers converge to the optic stalk and grow through its wall back to the brain. The cells of the optic stalk are converted into a neuroglia framework and the cavity is obliterated. In the floor of the fore-brain at a point which forms the boundary line between telencephalon and diencephalon, the fibers from the median half of each retina cross to the opposite side (decussate), and this crossing constitutes the *optic chiasma* (from Greek letter X or "chi"). The decussation of the optic fibers takes place about the end of the second month. The crossed and uncrossed fibers constitute the *optic tract* which rounds the cerebral peduncles laterally and dorsally (Fig. 336). Eventually, the optic fibers end in the lateral geniculate body, thalamus and superior colliculus.

8. The **Auditory Nerve**, or **N. Acusticus**, is formed by fibers which originate from the cells of the acoustic ganglion. The origin of these cells is unknown, though they appear in 4 mm. embryos just cranial to the otic vesicle (Fig. 340). The cells become bipolar, central processes uniting the ganglion to the tuberculum acusticum of the myelencephalon and peripheral fibers connecting it with the wall of the otocyst. The acoustic ganglion is differentiated into the *vestibular* and *spiral ganglia* (Fig. 343). Its development has been studied by Streeter (Amer. Jour. Anat., vol. 6). The ganglion elongates and is subdivided into superior and inferior portions in 7 mm. embryos. The superior part supplies nerves to the utricle and to the anterior and lateral semicircular canals. It forms part of the *vestibular ganglion* of the adult. The inferior portion supplies nerves to the saccule and to the ampulla of the posterior semicircular canal and this portion of it with the pars superior constitutes the vestibular ganglion. The greater part of the pars inferior is, however, differentiated into the spiral ganglion, the peripheral fibers of which innervate the hair cells of the spiral organ (of Corti) in the cochlea. The spiral ganglion appears in 9 mm. embryos and conforms to the spiral turns of the cochlea, hence its name. Its central nerve fibers form the cochlear division of the acoustic nerve. This is distinctly separated from the central fibers of the vestibular ganglion which constitute the vestibular division of the acoustic nerve, the fibers of which are not auditory in function. The pars inferior of the vestibular ganglion becomes closely connected with the n. coch-

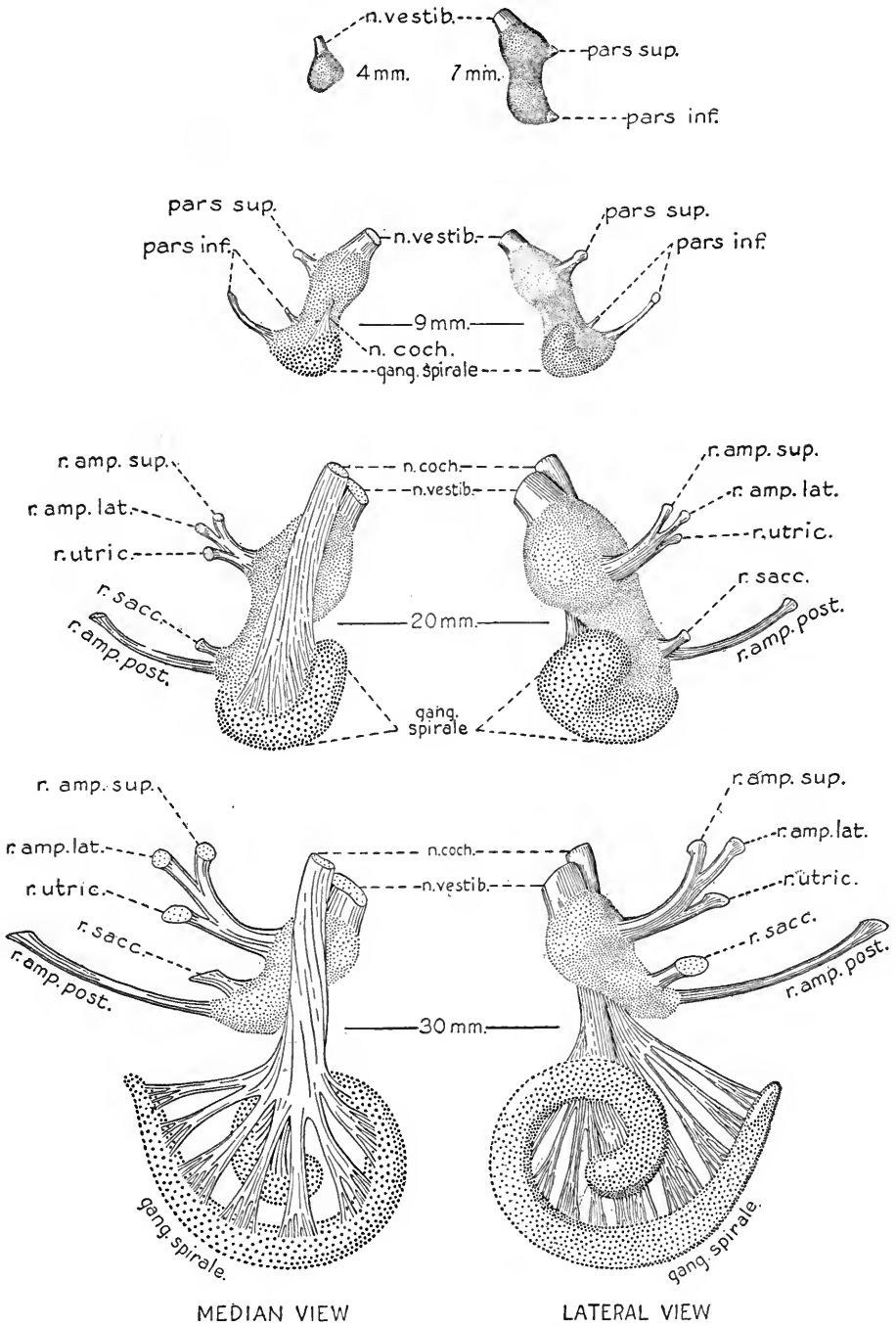


FIG. 343.—The development of the acoustic ganglia and nerves. The vestibular ganglion is finely stippled, the spiral ganglion coarsely stippled (Streeter in Amer. Jour. Anat.).

laris, and thus in the adult it appears as though the sacculus and posterior ampulla were supplied by the cochlear nerve. The cells of both the vestibular and spiral ganglia are of the bipolar type.

## II. THE SOMATIC MOTOR NERVES

The nerves of this group consisting of the three nerves to the eye muscles and the n. hypoglossus are purely motor nerves, the fibers of which take origin from the neuroblasts of the basal plate of the brain stem, near the midline. They are regarded as the homologues of the ventral motor roots of the spinal cord, but have lost their segmental arrangement and are otherwise modified. The nuclei of origin of these nerves are shown in Fig. 345.

12. **N. Hypoglossus.**—This nerve is formed by the fusion of the ventral root fibers of three to five precervical nerves. Its fibers take origin from neuroblasts of the basal plate and emerge from the ventral wall of the myelencephalon in several groups (Fig. 339). In embryos of the fourth week (7 mm.) the fibers have converged ventrally to form the trunk of the nerve (Fig. 340). Later they grow cranially lateral to the ganglion nodosum and eventually end in the muscle fibers of the tongue (Fig. 341). The nerve in its development unites with the cervical nerves to form the *ansa hypoglossi*. Its nucleus of origin is shown in Fig. 345.

That the hypoglossal is a composite nerve homologous with the ventral roots of the spinal nerves is shown: (1) by the segmental origin of its fibers; (2) from the fact that its nucleus of origin is a cranial continuation of the ventral gray column, or nucleus of origin for the ventral spinal roots; (3) from the fact that in mammalian embryos (pig, sheep, cat, etc.) rudimentary dorsal ganglia are developed, one of which at least (Froriep's ganglion) sends a dorsal root to the hypoglossal. In human embryos Froriep's ganglion may be present as a rudimentary structure (Figs. 341 and 344), or it may be absent and the ganglion of the first cervical nerve may also degenerate and disappear. In pig embryos the writer has found two and three accessory ganglia (including Froriep's) from which dorsal roots extended to the root fascicles of the hypoglossal nerve (Fig. 116).

3. The **Oculomotor Nerve**, as we have seen, takes origin from neuroblasts in the basal plate of the mesencephalon (Fig. 321 B). The fibers emerge as small fascicles on the ventral surface of the mid-brain in the concavity due to the cephalic flexure (Figs. 341 and 345). The fascicles converge, form the trunk of the nerve and end in the premuscle masses of the eye. The nerve eventually supplies all of the extrinsic muscles of the eye save the superior oblique and external rectus. A branch is also supplied to the ciliary ganglion. In the chick embryo bipolar cells migrate along the fibers of the oculomotor nerve to take part



in the development of the ganglion. The ciliary ganglion of human embryos is derived entirely from the semilunar ganglion of the trigeminal nerve.

4. The **Trochlear Nerve** fibers take origin from neuroblasts of the basal plate, located just caudal to the nucleus of origin of the oculomotor nerve. They are directed dorsally, curve around the cerebral aqueduct and, crossing in its roof, emerge at the isthmus (Fig. 321 A). From their superficial origin they are directed ventrally as a slender nerve which connects with the anlage of the superior oblique muscle of the eye (Fig. 341).

6. The **N. Abducens** takes origin from a nucleus of cells in the basal plate of the myelencephalon located directly beneath the fourth metamere of the floor of the fourth ventricle (Figs. 341 and 345). The converging fibers emerge ventrally at a point caudal to the future pons, and as a single trunk course cranially mesial to the semilunar ganglion, finally ending in the anlage of the external rectus muscle of the eye. Vestigial rootlets of the abducens and hypoglossal nerve tend to fill in the gap between these two nerves, according to Bremer and Elze.

### III. THE VISCERAL MIXED NERVES

The nerves of this group, the trigeminal, facial, glossopharyngeal and vagus complex (vagus plus the spinal accessory) are mixed in function. The trigeminal nerve, beside its visceral nerve components, contains also numerous somatic sensory neurones which supply the integument of the head and face.

5. The **Trigeminal Nerve** is largely sensory. Its *semilunar ganglion* is the largest of the whole nervous system and is a derivative of the ganglion crest, but very early is distinct from the other cerebral ganglia (Fig. 340). It arises laterally at the extreme cranial end of the hind-brain. Central processes from its cells form the large sensory root of the nerve which enters the wall of the hind-brain at the level of the pontine flexure (Fig. 341). The peripheral processes separate into three large divisions, the ophthalmic, maxillary and mandibular rami, and supply the integument of the head and face and the epithelium of the mouth and tongue. The central fibers fork and course cranially and caudally in the alar plate of the myelencephalon. The caudal fibers constitute the *descending spinal tract* of the trigeminal nerve, which extends as far caudalward as the spinal cord (Fig. 345).

The motor fibers of the trigeminal nerve arise chiefly from a dorsal motor nucleus which lies opposite the point at which the sensory fibers enter the brain wall (Fig. 345). In the embryo these fibers emerge as a separate motor root, course along the mesial side of the semilunar ganglion, and as a distinct trunk

supply the pre-muscle masses which later form the muscles of mastication. From the chief motor nucleus a line of cells extending cranially into the mesencephalon constitutes a second source of origin for motor fibers. In the adult, the motor fibers form a part of the mandibular division of the nerve.

The *facial, glossopharyngeal* and *vagus nerves* are essentially visceral in function. Their sensory fibers, chiefly of the visceral type, supply the sense organs of the visceral arches and viscera. These fibers originate in the ganglia of their respective nerves and, entering the alar plate of the myelencephalon, course caudally as the solitary tract (Fig. 345). A few somatic sensory fibers having

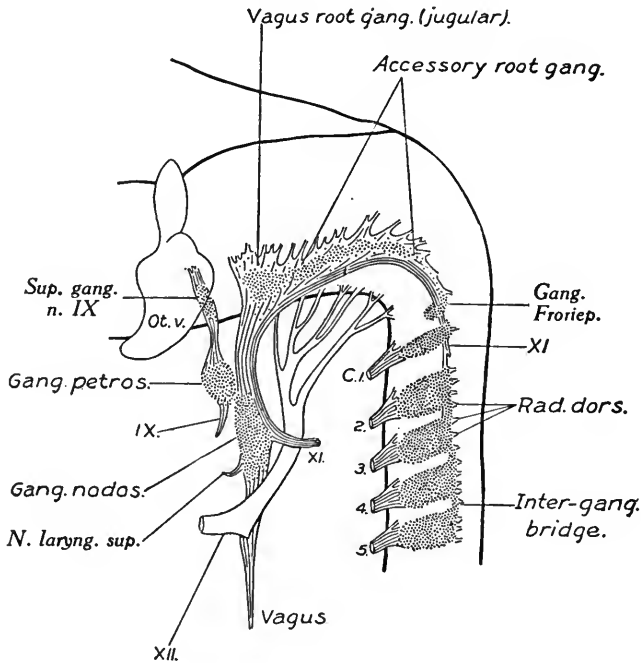


FIG. 344.—Reconstruction of the cerebrosplinal nerves of an embryo of 10.2 mm. (Streeter).  $\times 16.7$ .

the same origin and course in the myelencephalon supply the adjacent integument.

7. The **Facial Nerve** is largely composed of efferent motor fibers which supply the facial muscles of expression (Fig. 341). In 10 mm. embryos these fibers arise from a cluster of neuroblasts in the basal plate of the myelencephalon located beneath the third rhombic groove or neuromere (Fig. 345). The fibers from these cells course laterally, and emerge just mesial to the acoustic ganglion. The motor trunk then courses caudally and is lost in the tissue of the hyoid visceral arch, tissue which later gives rise to the muscles of expression. The sensory fibers of

the facial nerve arise from the cells of the geniculate ganglion, which are in turn derived from the ganglion crest (Streeter). This ganglion is present at the third week (Fig. 341), located cranial to the acoustic ganglion. The centrally directed processes of the geniculate ganglion enter the alar plate and form part of the solitary tract. The peripheral fibers in part course with motor fibers in the *chorda tympani*, join the mandibular branch of the trigeminal nerve and end in the sense organs of the tongue. Other sensory fibers form later the *great superficial petrosal nerve*, which extends to the sphenopalatine ganglion.

The motor fibers of the facialis at first course straight laterally passing

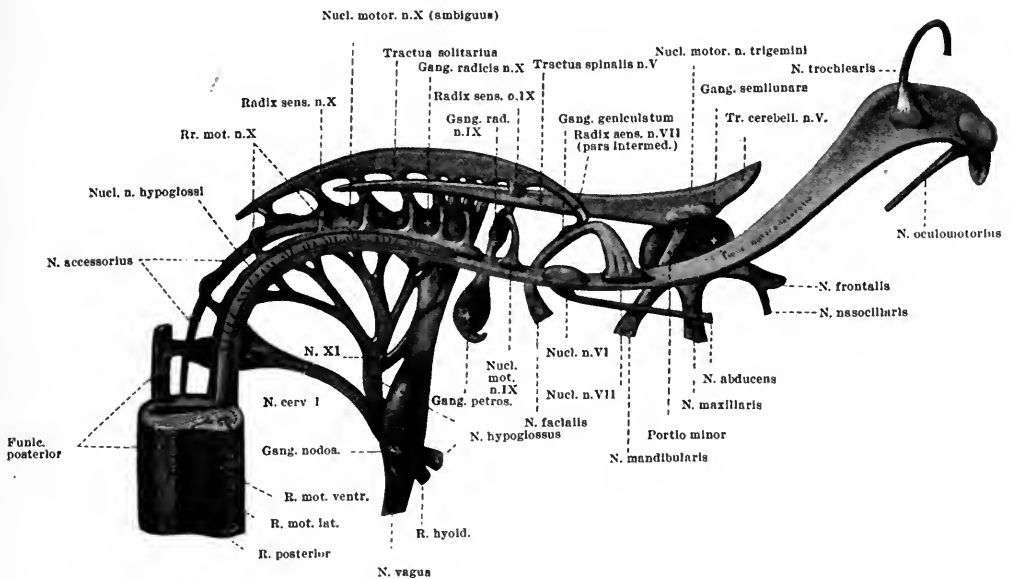


FIG. 345.—Reconstruction of the nuclei of origin and termination of the cerebral nerves in an embryo of 10 mm. The somatic motor nuclei are colored red (Streeter).  $\times 30$ .

cranial to the nucleus of the abducens. The nuclei of the two nerves later gradually shift their positions, that of the facial nerve moving caudally and lateralwards, while the nucleus of the abducens shifts cranialwards. As a result, the motor root of the facial nerve in the adult bends around the nucleus of the abducens producing the *genu* or *knee* of the former. The two together produce the rounded eminence in the floor of the fourth ventricle known as the *facial colliculus*.

9. The **Glossopharyngeal Nerve** takes its superficial origin just caudal to the otic vesicle (Figs. 340, 344 and 346). Its few motor fibers arise from neuroblasts in the basal plate beneath the fifth neuromeric groove. These neuroblasts form

part of the *nucleus ambiguus*, a nucleus of origin which the glossopharyngeal shares with the vagus (Fig. 345). The motor fibers course laterally beneath the spinal tract of the trigeminal nerve and emerge to form the trunk of the nerve. These fibers later supply the muscles of the pharynx.

The sensory fibers of the glossopharyngeal nerve arise from two ganglia, a superior or root ganglion and a petrosal or trunk ganglion (Figs. 341 and 346). These fibers constitute the greater part of the nerve and peripherally divide to form the tympanic and lingual rami. Centrally, these fibers enter the alar plate of the myelencephalon and join the sensory fibers of the facial nerve coursing caudally in the *solitary tract*.

10. 11. **The Vagus and Spinal Accessory.**—The vagus, like the hypoglossal, is composite, representing the union of several nerves which in aquatic animals supply the branchial arches (Figs. 341 and 346). The more caudal fascicles of motor fibers take their origin in the lateral gray column of the cervical cord as far back as the fourth cervical segment. The fibers emerge laterally and, as the *spinal accessory trunk* (in anatomy a distinct nerve), course cranialwards along the line of the neural crest (Figs. 340, 341 and 346). Other motor fibers take their origin from the neuroblasts of the *nucleus ambiguus* of the myelencephalon (Fig. 345). Still others arise from a dorsal motor nucleus which lies median in position. The fibers from these two sources emerge laterally as separate fascicles and join the fibers of the spinal accessory in the trunk of the vagus nerve. The *accessory fibers* soon leave the trunk of the vagus and are distributed laterally and caudally to the visceral premuscle masses which later form the *sterno-cleido-mastoideus* and *trapezius* muscles of the shoulder (Fig. 341). Other motor fibers of the vagus supply muscle fibers of the pharynx and larynx.

As the vagus is a composite nerve it has several root ganglia which arise as enlargements along the course of the ganglion crest (Figs. 341 and 346). The more cranial of these ganglia is the *ganglion jugulare*. The others are termed *accessory ganglia*, are vestigial structures and not segmentally arranged. In addition to the root ganglia of the vagus the *ganglion nodosum* forms a ganglion of the trunk (Fig. 346). The trunk ganglia of both the vagus and glossopharyngeal nerves are believed to be derivatives of the ganglion crest, their cells migrating ventrally in early stages.

The central processes from the neuroblasts of the vagus ganglia enter the wall of the myelencephalon, turn caudalward, and with the sensory fibers of the facial and glossopharyngeal nerves complete the formation of the solitary tract.

The peripheral processes of the ganglion cells form the greater part of the vagus trunks after the separation from it of the spinal accessory fibers.

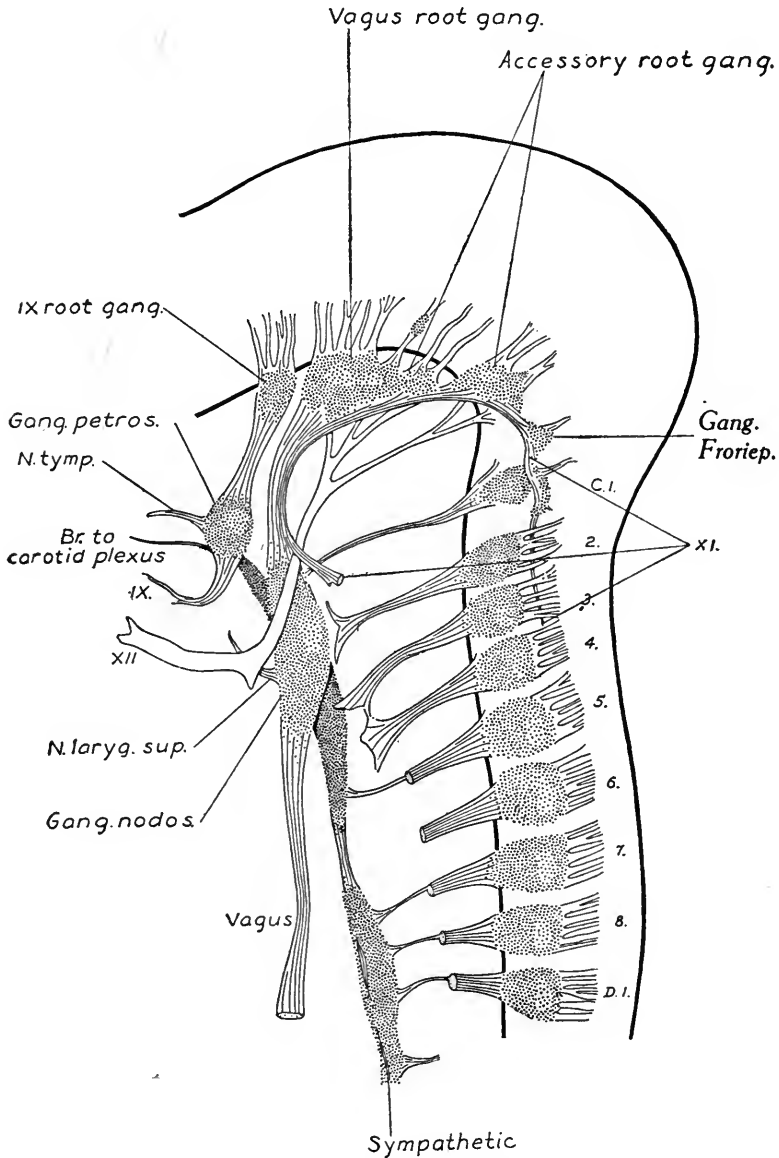


FIG. 346.—A reconstruction of the peripheral nerves in an embryo of 17.5 mm. (Streeter).  $\times 16.7$ .

In aquatic vertebrates special somatic sensory fibers from the lateral line organs join the facial, glossopharyngeal and vagus nerves, and their ganglion cells form part of the geniculate, petrosal and nodose ganglia. In human embryos the organs of the lateral line are represented by ectodermal thickenings or *placodes* which occur temporarily over the geniculate, petrosal

and nodose ganglia. The nervous elements supplying these vestigial organs have completely disappeared.

### C. THE SYMPATHETIC NERVOUS SYSTEM

The sympathetic nervous system is composed of a series of ganglia and peripheral nerves, the fibers of which supply gland cells and the smooth muscle fibers of the viscera and blood-vessels. It may function independently of the central nervous system and is hence known as the *autonomic* system.

The sympathetic ganglion cells are derived from the cells of the ganglion crest. At an early stage (6 to 7 mm.) certain cells of this crest migrate ventrally and give rise to a series of ganglia which, in the region of the trunk, are segmentally arranged (Fig. 342). The migration of the sympathetic cells is rapidly taking place in embryos of 6 to 7 mm. At 9 mm. the ganglionated cord is formed and fibers connecting the sympathetic ganglia with the spinal nerves constitute the *rami communicantes* (Streeter). The more peripheral ganglia (cardiac and cœliac) and the sympathetic ganglia of the head may be found in 16 mm. embryos (Fig. 347).

The cells which are to form the ganglia of the sympathetic chain migrate ventrally ahead of the efferent fibers and take up a position lateral to the aorta. The ganglionic anlagen are at first distinct but unite with each other from segment to segment, forming a longitudinal cord of cells. After the formation of the *rami communicantes* by the root fibers from the spinal nerves centripetal processes from the sympathetic cells grow back and join the trunks of the spinal nerves. The visceral spinal fibers later become medullated and constitute the *white rami*; the sympathetic centripetal fibers remain non-medullated and form the *gray rami* of each *ramus communicans* (Fig. 342). From neurones of the ganglionated cord nerve fibers extend from ganglion to ganglion and thus the cellular cord is in part converted into a fibrous longitudinal commissure. This commissure connects the persisting cellular masses which constitute the *sympathetic ganglia* of each segment. In the head region the sympathetic ganglia are not segmentally arranged but they are derived from cells of the cerebrospinal ganglia which migrate to a ventral position (Fig. 346). These cells likewise give rise to nerve fibers which constitute longitudinal commissures connecting the various ganglia of the head with the ganglionated cord of the trunk region. The small cranial sympathetic ganglia are probably all derived from the anlage of the semilunar ganglion (Fig. 347). The *ciliary ganglion* is related by a *ramus communicans* to the ophthalmic division of the trigeminal nerve and receives fibers from the

oculomotor nerve. Its cells are probably derived entirely from the semilunar ganglion.

The **sphenopalatine** and **submaxillary ganglia** probably take their origin from migrating cells of the semilunar ganglion, but as they are connected with the geniculate ganglion of the facial nerve some of their cells may be derived from this ganglion. The sphenopalatine ganglion is connected directly with the semilunar ganglion by two communicating rami. The submaxillary ganglion is intimately related to the mandibular division of the trigeminal and through it with the semilunar ganglion, while the *otic ganglion* is united to it by a plexus and is related to the glossopharyngeal nerve through its tympanic branch.

The **cervical ganglia** lose their segmental arrangement and represent the fusion of from two to five chain ganglia of the cervical and upper thoracic region. The more distally located *prevertebral* and *visceral ganglia* are derived from cells of the neural crest which migrate to a greater distance ventrally (Fig. 347). The *cardiac* and *coeliac plexuses* may be seen in 16 mm. embryos.

The sympathetic nerve cells give rise to axons and dendrites and are thus

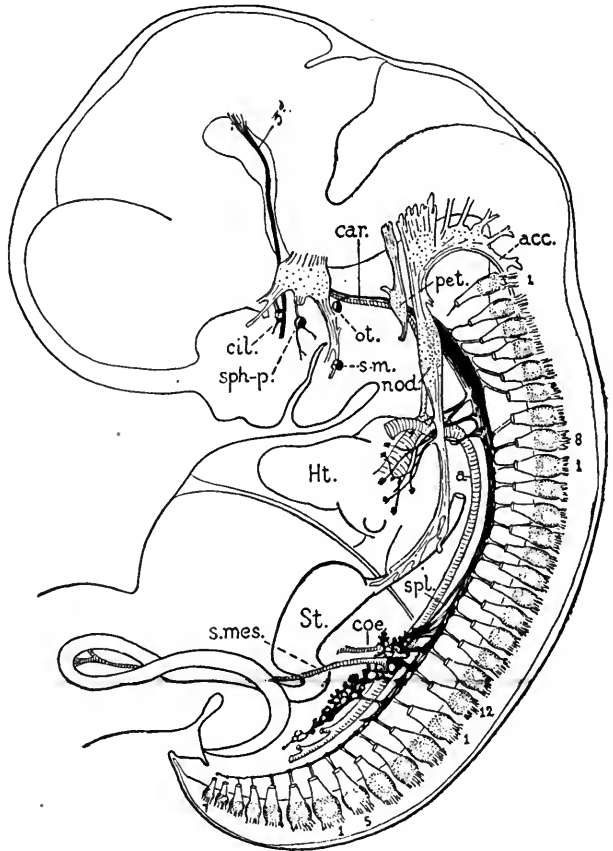


FIG. 347.—The sympathetic system in a 16 mm. human embryo (after Streeter). The ganglionated trunk is heavily shaded. The first and last cervical, thoracic, lumbar, sacral and coccygeal spinal ganglia are numbered. *a*, aorta; *acc*, accessory nerve; *car*, carotid artery; *cil*, ciliary ganglion; *coe*, coeliac artery; *Ht*, heart; *nod*, nodose ganglion; *ot*, otic ganglion; *pet*, petrosal ganglion; *s-m*, submaxillary ganglion; *s. mes.*, superior mesenteric artery; *sph.-p.*, sphenopalatine ganglion; *spl*, splanchnic nerve; *st.*, stomach. (Lewis-Stöhr.)

typically multipolar cells. Their axons possess a neurilemma sheath but remain non-medullated.

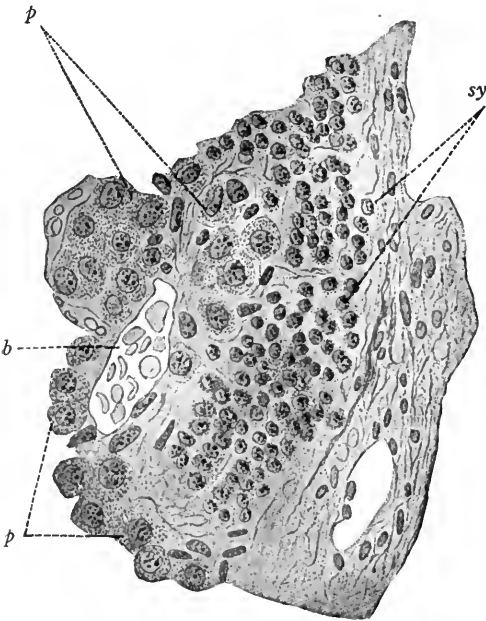
#### D. CHROMAFFIN BODIES: SUPRARENAL GLAND

Certain cells of the sympathetic ganglia do not form nerve cells but are transformed into peculiar gland cells which produce an internal secretion. The secretion formed by these cells causes them to stain brown when treated with chrome salts, hence they are called *chromaffin cells*. Cells of this type derived from the ganglionated cord of the sympathetic system give rise to structures known as *chromaffin bodies*. Chromaffin derivatives of the celiac plexus, together with mesenchymal tissue, form the anlage of the *suprarenal gland*, an organ which reaches a relatively large size in human embryos.

The **Chromaffin Bodies** of the ganglionated cord are rounded cellular masses partly embedded in the dorsal surfaces of the ganglia (Fig. 348). At birth they may attain a diameter of 1 to 1.5 mm. In number they vary from one to several for each ganglion.

FIG. 348.—Section through a chromaffin body in a 44 mm. human embryo (after Kohn). *p, p*, mother chromaffin cells; *sy*, sympathetic cells; *b*, blood-vessel.

Similar chromaffin bodies may occur in all the larger sympathetic plexuses. One of these, associated with the intercarotid plexus, is the *carotid gland*, which is thus regarded as a derivative of sympathetic chromaffin tissue. The anlage has been first observed in 20 mm. embryos. The largest of these structures found in the abdominal sympathetic plexuses are the *aortic chromaffin bodies*. These occur on either side of the inferior mesenteric artery ventral to the aorta and mesial to the metanephros. At birth they attain a length of 9 to 12 mm. and are composed of cords of chromaffin cells intermingled with strands of connective tissue, the whole being surrounded by a connective tissue capsule. After birth the chromaffin bodies degenerate but do not disappear entirely.





The **Suprarenal Gland** is developed from chromaffin tissue which becomes its medulla, and from mesodermal tissue which gives rise to its cortex. In an embryo of 6 mm. the anlage of the cortex is present, according to Soulié, and is derived from a thickening of the coelomic epithelium. At 8 mm. the glands are definite organs and at 9 mm. their vascular structure is evident. The cellular elements of the cortex are at first larger than the chromaffin cells which give rise

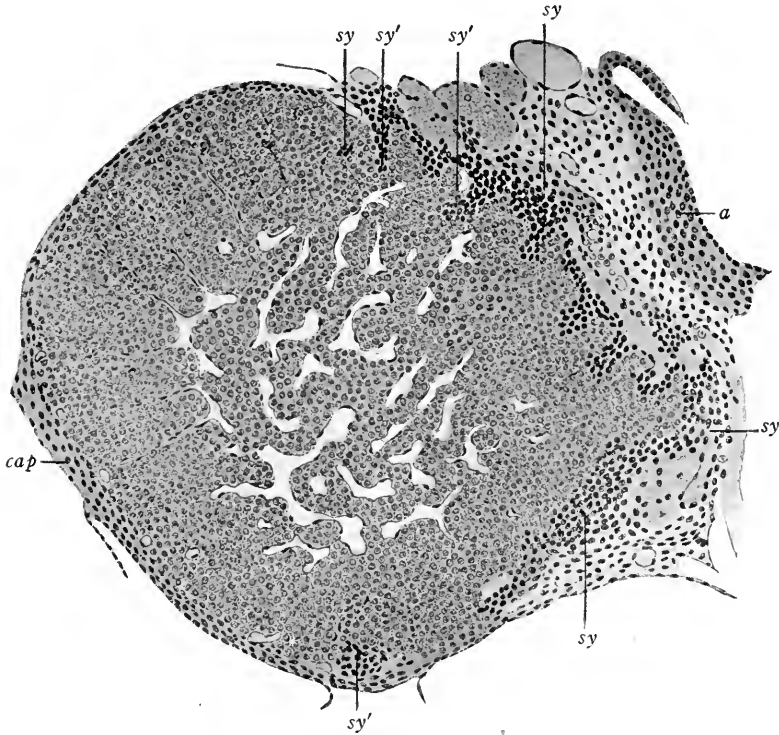


FIG. 349.—Transverse section through right suprarenal gland of a 15.5 mm. embryo (after T. H. Bryce). *sy*, sympathetic cells; *sy'*, groups of cells extending from the sympathetic into the suprarenal gland; *cap*, capsule of gland; *a*, aorta.

to the medulla. The anlages of the glands form projections in the dorsal wall of the coelom between the mesonephros and mesentery (Figs. 214 and 225).

The chromaffin cells of the medulla are derived from the coeliac plexus of the sympathetic system. In embryos of 15 to 19 mm. (Fig. 349) masses of these cells begin to migrate from the median side of the suprarenal anlage to a central position, and later surround the central vein which is present in embryos of 23 mm. The primitive chromaffin cells are small and stain intensely. They continue their immigration until after birth. The differentiation of the cortex into

its three characteristic layers is not completed until between the second and third years. The inner *reticular* zone is formed first, next the *fasciculate* zone and last the *glomerular* zone.

When the cells of the medulla begin to produce an internal secretion they give the chrome reaction. By using extract of the aortic bodies, which are entirely composed of chromaffin cells, Biedl and Wiesel have proved that its effect, like that of adrenalin, is to increase the blood pressure. The logical conclusion is that the effect of adrenalin, an extract of the suprarenal glands, is due to an internal secretion produced by the chromaffin cells of the suprarenal medulla.

Portions of the suprarenal anlage may be separated from the parent gland and form *accessory suprarenals*. As a rule, such accessory glands are composed only of cortical substance and may migrate some distance from their original position, accompanying the genital glands.

## E. DEVELOPMENT OF THE SENSE ORGANS

The nervous structures of the sense organs are derived from the ectoderm and consist of the general sense organs of the integument, muscles, tendons and viscera, and of the special sense organs which include the taste buds of the tongue, the olfactory epithelium, the retina, optic nerve and lens of the eye, and the epithelial lining of the ear labyrinth.

### I. GENERAL SENSORY ORGANS

*Free nerve terminations* form the great majority of all the general sensory organs. When no sensory corpuscle is developed, the neurofibrils of the sensory nerve fibers separate and end among the cells of the epidermis.

*Lamellated corpuscles* first arise during the fourth and fifth months as masses of mesodermal cells clustered around a nerve termination. These cells increase in number, flatten out and give rise to the concentric lamellæ of these peculiar structures. In the cat these corpuscles increase in number by budding.

The *tactile corpuscles*, according to Ranvier, are developed from mesenchymal cells and branching nerve fibrils during the first six months after birth.

### II. TASTE BUDS

The sense of taste resides chiefly in the taste buds of the tongue. The development of the tongue has been described (p. 158) and we may speak here only of the development and distribution of the taste buds.

In the fetus of five to seven months taste buds are more widely distributed than in the adult. They are found in the walls of the vallate, fungiform and foliate

papillæ of the tongue, on the under surface of the tongue, on both surfaces of the epiglottis, on the palatine tonsils and arches and on the soft palate. After birth many of the taste buds degenerate, persisting on the lateral walls of the vallate and foliate papillæ, on a few fungiform papillæ and on the laryngeal surface of the epiglottis.

The anlagen of the taste buds appear as thickenings of the lingual epithelium in 11 cm. fetuses (Keibel). The cells of the taste bud anlage lengthen and later extend to the surface of the epithelium. They are differentiated into the sensory *taste cells* with modified cuticular tips and into *supporting cells*. The taste buds are supplied by nerve fibers of the seventh, ninth and tenth cerebral nerves; the fibers branch and end in contact with the walls of the taste cells.

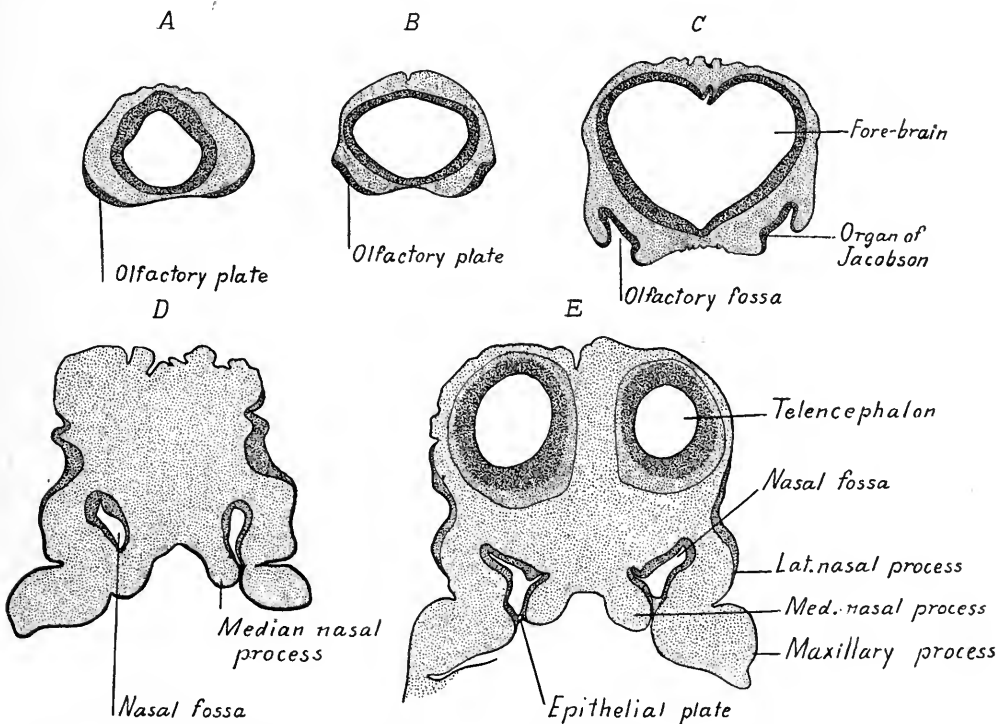


FIG. 350.—Sections through the olfactory anlagen of human embryos. A, 4.9 mm.; B, 6.5 mm.; C, 8.8 mm.; D and E, 10 mm. embryo. (A, B and C from Keibel and Elze.)

### III. THE OLFACTORY ORGAN

The olfactory epithelium arises as paired thickenings or *placodes* of the cranial ectoderm (Fig. 350 A). The placodes are bent inward to form the *nasal fossæ* about which the nose develops.

In embryos of 4 to 5 mm. the placodes are sharply marked off from the sur-

rounding ectoderm as ventro-lateral thickenings near the tip of the head. They are flattened and begin to invaginate in embryos of 6 to 7 mm. In 8 mm. embryos the invagination has produced a distinct pit or *fossa* surrounded everywhere save ventrally by a marginal swelling.

The later development of the olfactory organ is associated with that of the face. It will be remembered (see p. 153) that the first branchial arch forks into the maxillary and mandibular processes. Dorsal to the oral cavity is the frontal process of the head, lateral to it the maxillary processes, and ventral to it are the mandibular processes (Fig. 144). With the development of the nasal pits the

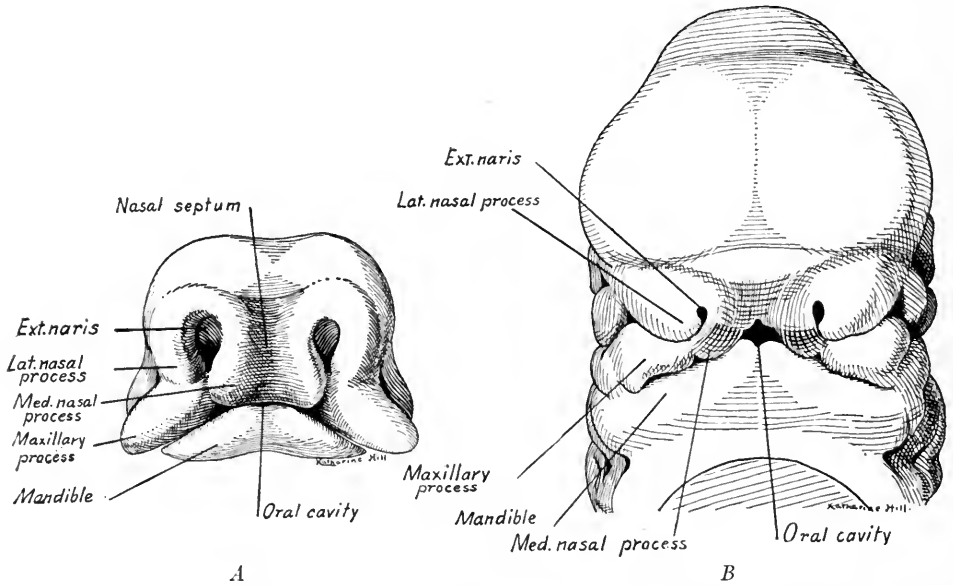


FIG. 351.—Two stages in the development of the jaws and nose. *A*, ventral view of the end of the head of a 10.5 mm. embryo (after Peter); *B*, of an 11.3 mm. embryo (after Rabl).

frontal process is divided into paired *lateral nasal processes* and a single *median frontal process*, from which later are differentiated the *median nasal processes*, or *processus globulares* (Fig. 351). The nasal pits are at first grooves, each bounded mesially by the median frontal process and laterally by the lateral nasal process and the maxillary process (Fig. 351 *A*). The fusion of the maxillary processes with the ventro-lateral ends of the median frontal process converts the nasal grooves into blind pits or fossæ, shutting them off from the mouth cavity (Fig. 351 *A, B*). Thus in embryos of 10 to 12 mm. the nasal fossa has but one opening, the external naris, and is separated from the mouth cavity by an ectodermal plate (Fig. 350 *D, E*).

The ventro-lateral ends of the median frontal process enlarge and become the *median nasal* processes which fuse with the lateral nasal processes and reduce the size of the external nares (Fig. 351 B). Externally, the nares are now bounded ventrally by the fused nasal processes. The epithelial plates which separate the nasal fossæ from the primitive mouth cavity become thin membranous structures caudally and, rupturing, produce two internal nasal openings, the *primitive choanæ* (Fig. 148). Cranially, the epithelial plate is destroyed by ingrowing mesoderm of the maxillary process and median nasal process which

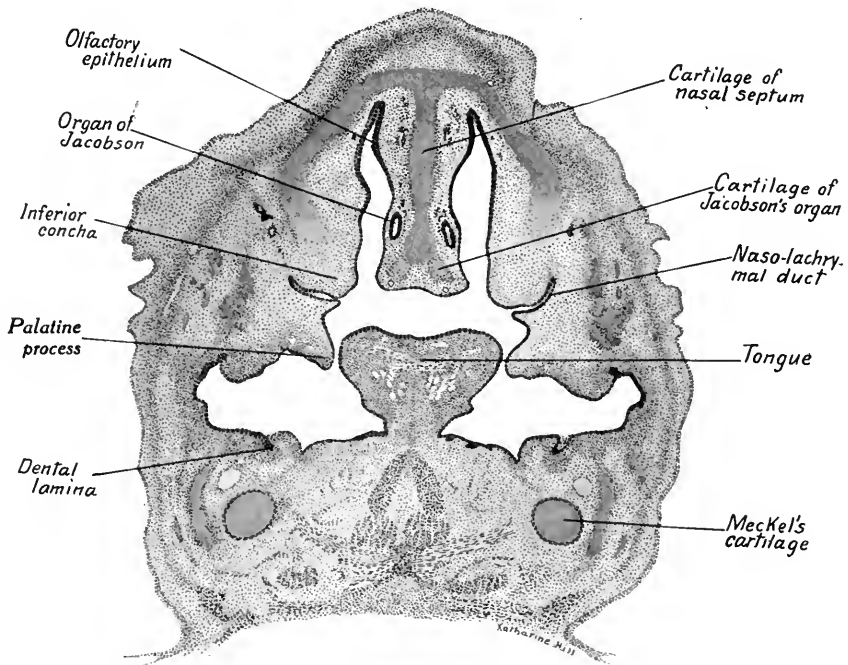


FIG. 352.—Transverse section through the nasal passages and palatine processes of a 20 mm. embryo. In the nasal septum is seen a section of the organ of Jacobson.  $\times 30$ .

replaces it and constitutes the *primitive palate* (Fig. 350 D). The primitive palate forms the *lip* and the *premaxillary palate*. The nasal fossæ now open externally through the external nares and internally into the roof of the mouth cavity through the *primitive choanæ*.

Coincident with these changes the median frontal process has become relatively smaller and that portion of it between the external nares and the nasal fossæ becomes the *nasal septum* (Fig. 351 A, B). As the facial region grows and elongates, the primitive choanæ become longer and form slit-like openings in the roof of the mouth cavity. By the development and fusion of the palatine pro-

cesses (described on p. 156) the dorsal portion of the mouth cavity is separated off and constitutes the nasal passages (compare Figs. 352 and 353). The nasal passages of the two sides for a time communicate through the space between the hard palate and the nasal septum. Later, the ventral border of the septum fuses with the hard palate and completely separates the nasal passages. The nasal passages of the adult thus consist of the primitive nasal fossæ plus a portion of the primitive mouth cavity which has been separated off secondarily by the development of the hard palate. The passages of the adult thus open caudally by secondary choanæ into the cavity of the pharynx.

The epithelium which lines the nasal fossæ is, a portion of it, transformed into

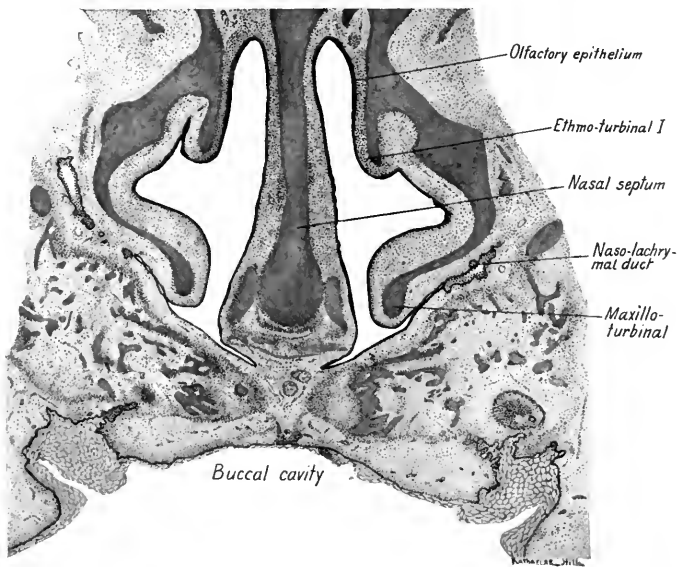


FIG. 353.—Transverse section through the nasal passages of a 65 mm. embryo.  $\times 14$ .

the sensory olfactory epithelium (Fig. 352). It is also differentiated by the development of the so-called organ of Jacobson, of the conchæ, of the *ethmoidal cells* and of the cranial *sinuses*.

The **Organ of Jacobson** is a rudimentary epithelial structure which first appears in 8.5 to 9 mm. embryos on the median wall of the nasal fossa (Fig. 350 C, E). The groove deepens and closes caudally to form a tubular structure in the cranial portion of the nasal septum (Fig. 352). At two and a half months it attains a length of 0.42 mm. It is supplied by nerve fibers which arise from cells in its epithelium and in part by the *n. terminalis*. In late fetal stages it often degenerates but may persist in the adult (Merkel, Mangakis). Special cartilages

are developed for its support (Fig. 352). The organ of Jacobson is not functional in man but in many animals constitutes a special olfactory organ.

The **Conchæ** are structures which are poorly developed in man. They appear on the lateral and median walls of the primitive nasal fossæ. The *inferior concha*, or *maxillo-turbinal*, is developed first in human embryos (Figs. 352 and 353). It forms a ridge along the caudal two-thirds of the lateral wall and is marked off by a ventral groove which becomes the *inferior nasal meatus*. The *naso-turbinal* is very rudimentary and appears after the fourth month as a slight elevation dorsal and cranial to the *inferior concha* (Fig. 354). Dorsal to the inferior concha arise five ethmo-turbinals, which grow smaller and are located more caudad as we pass from the first to the fifth (Fig. 354). According to Peter, the ethmo-tur-

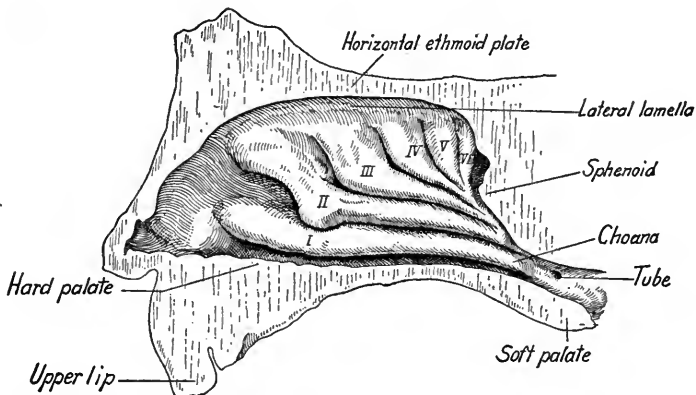


FIG. 354.—Right nasal passage of a fetus at term (Killian). I, maxillo-turbinal; II-IV, ethmo-turbinals.

binals arise on the median wall of the nasal fossa and, by a process of unequal growth, are transferred to the lateral wall (Fig. 353). Accessory conchæ are also developed, according to Killian.

In addition to the ridges formed by the conchæ, there are developed in the grooves between the ethmo-turbinals the *ethmoidal cells*. The frontal recess gives rise to the *frontal sinus*. At the middle of the third month the *maxillary sinus* grows out from the inferior recess of the first groove. The most caudal end of the nasal fossa becomes the *sphenoidal sinus*, which, as it increases in size, invades the sphenoid bone.

The cells of the olfactory epithelium become ciliated but only a small area, representing the primitive epithelial invagination, functions as an olfactory sense organ. The olfactory cells of this area give rise to the olfactory fibers which constitute the nerve. The development of this has been described on page 355.

#### IV. THE DEVELOPMENT OF THE EYE

The anlage of the human eye appears in embryos of 2.5 mm. as a thickening and evagination of the neural plate of the fore-brain. At this stage the neural

groove of the fore-brain has not closed (Fig. 312). At 4 mm. the optic vesicles are larger but still may be connected by a wide opening with the brain cavity (Fig. 355 A, B). In the section shown in Fig. 355 C, the optic vesicle is attached to the brain wall by a distinct *optic stalk*.

The thickening, flattening and invagination of the distal and ventral wall of the optic vesicle gives rise to the optic cup (Fig. 355 B, C, D). The area of invagination extends ventrally along the optic stalk and produces the *chorioid fissure* of the optic cup (Figs. 356 and 358).

At the same time that the optic vesicle is converted into the optic cup, the

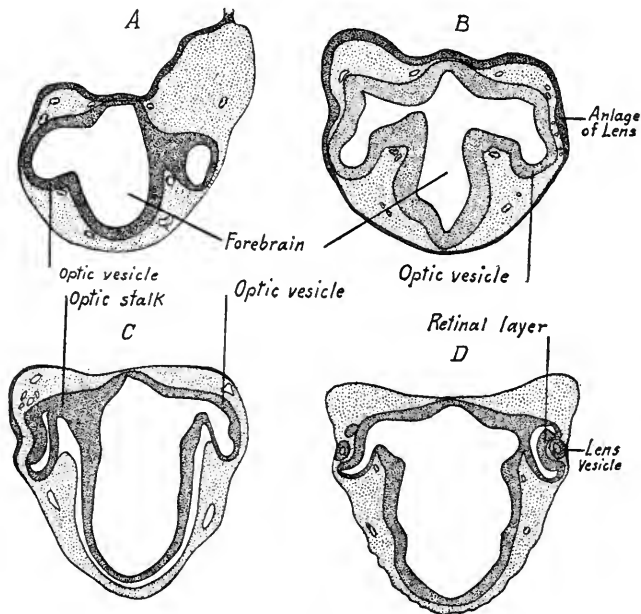


FIG. 355.—Stages in the early development of the eye. A, B, at 4 mm.; C, at 5 mm.; D, at 6.25 mm. (after Keibel and Elze).

ectoderm overlying the former thickens, as seen in Fig. 355 B, forming the *lens plate*, or *optic placode*. This plate invaginates to form the *lens pit*, the external opening of which closes in embryos of 6 to 7 mm. (Fig. 355 D), producing the *lens vesicle* which remains at first attached to the overlying ectoderm. In an embryo of 10 mm. (Fig. 357) the lens vesicle has separated from the ectoderm, which will form the epithelium of the cornea. The lens vesicle in earlier stages is closely applied to the inner wall of the optic cup, but now it has separated from it, leaving a space in which the vitreous body is developing. The inner *retinal layer* of the optic cup has become very thick and is applied to its outer layer, so



that the cavity of the primitive optic vesicle is nearly obliterated. Pigment granules have begun to appear in the outer cells which form the *pigment layer* of the retina. Mesenchymal tissue surrounds the optic cup and is beginning to make its way between the lens vesicle and the ectoderm. Here is later developed the *anterior chamber* of the eye as a cleft in the mesoderm. The distal mesenchymal tissue (next the ectoderm) forms the *substantia propria* of the *cornea* and its posterior epithelium, while the proximal mesenchyma (next the lens) differentiates into the *vascular capsule* of the lens. The mesenchyme surrounding the optic cup is continuous with that which forms the cornea and later

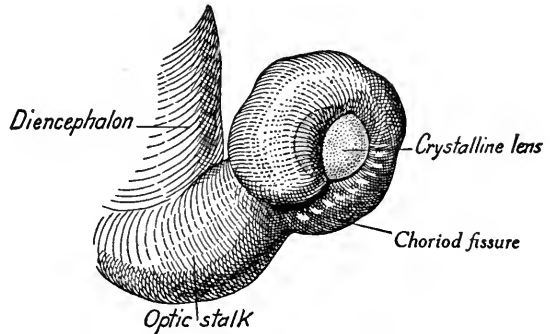


FIG. 356.—The optic stalk, cup and lens of an embryo of twenty-seven days. On the ventral surface of the optic cup is seen the chorioid fissure of the primitive eye (from Fuchs, after Hochstetter in Kollmann's Handatlas).

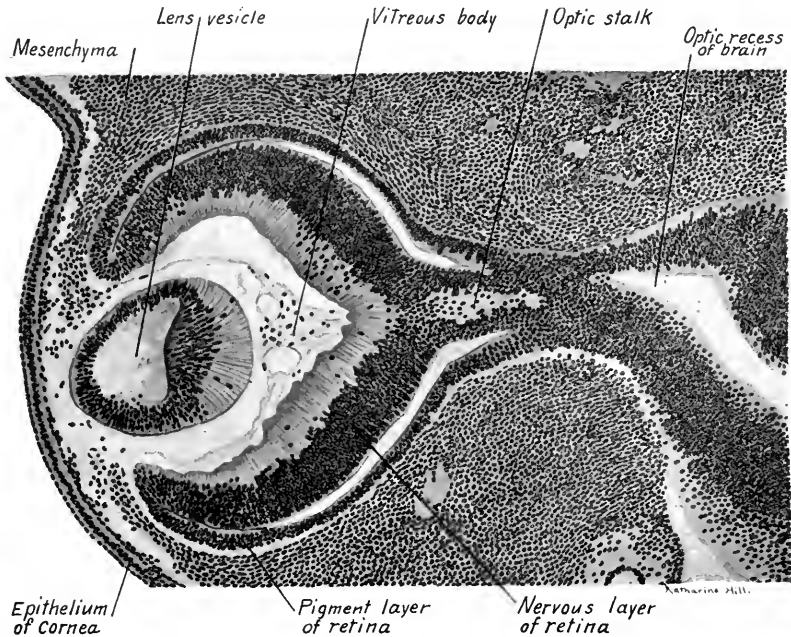


FIG. 357.—A transverse section through the optic cup, stalk and lens of a 10 mm. human embryo.  $\times 100$ .

gives rise to the sclerotic layer, to the chorioid layer and to the anterior layers of the ciliary body and iris.

Both the inner and outer layers of the optic cup are continued into the optic stalk, as seen in Fig. 357. This is due to the invagination of the ventral wall of the optic stalk and the formation in it of the *chorioid fissure* when the optic vesicle is transformed into the optic cup (Fig. 356). Into the chorioid fissure grows the central artery of the retina, and carries with it into the posterior cavity of the eye a small amount of mesenchyme, as seen in the eye of a 12 mm. embryo (Fig. 358). Branches from this vessel extend to the posterior surface of the lens and supply it with nutriment for its growth. At a later stage the chorioid fissure closes, so that the distal rim of the optic cup forms a complete circle.

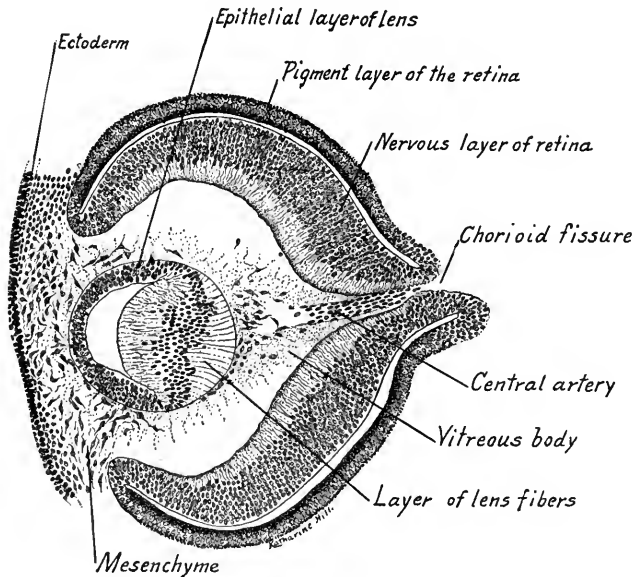


FIG. 358.—Transverse section passing through the optic cup at the level of the chorioid fissure. The central artery of the retina is seen entering the fissure and sending a branch to the proximal surface of the lens; from a 12.5 mm. embryo.  $\times 105$ .

If the chorioid fissure fails to close, the optic cup remains open at one point and this results in the defective development of the iris, ciliary body and chorioid layer. Such defects are known as *coloboma*.

It was formerly supposed that the development of the lens vesicle caused the formation of the optic cup by pushing in its distal wall. It has been shown by W. H. Lewis that this is not the case, for if an anlage of the optic vesicle from an amphibian embryo is transplanted to some other part of the embryo, it will not only develop into an optic cup, but the ectoderm over it will differentiate a lens vesicle.

The **lens vesicle** in its early development from the ectoderm has been described. Its proximal wall is much thickened in 10 mm. embryos and these cells form the *lens fibers* (Fig. 357). A few cells early separated off from the wall of

the lens pit are enclosed in the vesicle and have degenerated in 12.5 mm. embryos (Fig. 358). At this stage the lens fibers of the proximal wall are longer and this layer will soon obliterate the cavity of the vesicle, as in embryos of 15 to 17 mm. (Fig. 359). The cells of the distal layer remain of a low columnar type and constitute the epithelial layer of the lens. When the lens fibers attain a length of 0.18 mm. they cease forming new fibers by cell division. New fibers thereafter arise from the cells of the epithelial layer at its line of union with the lens fibers. The nuclei are arranged in a layer convex toward the outer surface of the eye and later degenerate, the degeneration beginning centrally. The structureless capsule of the lens is probably derived from the lens cells. Proximal and distal lens sutures are formed when the longer peripheral fibers overlap the ends of the shorter central fibers. These are later transformed into "lens-stars" (Fig. 360). The lens, at first somewhat triangular in cross section, becomes nearly spherical at three months (Fig. 360).

The origin of the **vitreous body** has been in doubt, one view deriving it from the mesenchyma which enters the optic

cup through the chorioid fissures and about the edge of lens, another view holding that it arises from cytoplasmic processes of cells in the retinal layer.

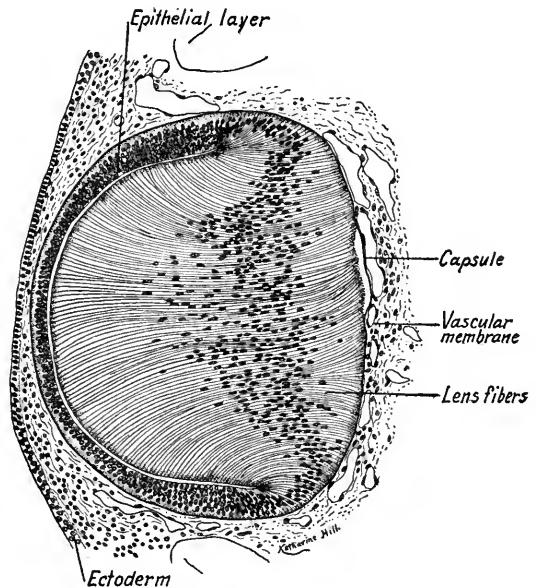


FIG. 359.—Section through the lens and corneal ectoderm of a 16 mm. pig embryo.  $\times 140$ .

It is certain that the vitreous tissue is formed before mesenchyma is present in the cavity of the optic cup. Szily regards this primitive vitreous body as a derivative of both retinal and lens cells, it forming a non-cellular network of cytoplasmic processes which are continuous with the cells of the lens and retina. With the ingrowth of the central artery of the retina, from which the artery of the lens passes to and branches on the proximal surface of the lens, a certain amount of mesenchymal tissue invades the optic cup and this tissue probably contributes to the development of the vitreous body (Fig. 358).

The vitreous body may therefore be regarded as a derivative both of the ectoderm and of the mesoderm.

The mesenchyma accompanying the vessels to the proximal surface of the

lens, and that on its distal surface, give rise to the *vascular capsule* of the lens (Fig. 358). On the distal surface of the lens this is supplied by branches of the anterior ciliary arteries and is known as the *pupillary membrane*. The vessels in this disappear and it degenerates just before birth. The artery of the lens also degenerates, its wall persisting as the transparent *hyaloid canal*. Fibrillæ extending in the vitreous humor from the pars ciliata of the retinal layer to the capsule of the lens persist as the *zonula ciliata* or *suspensory ligament* of the lens.

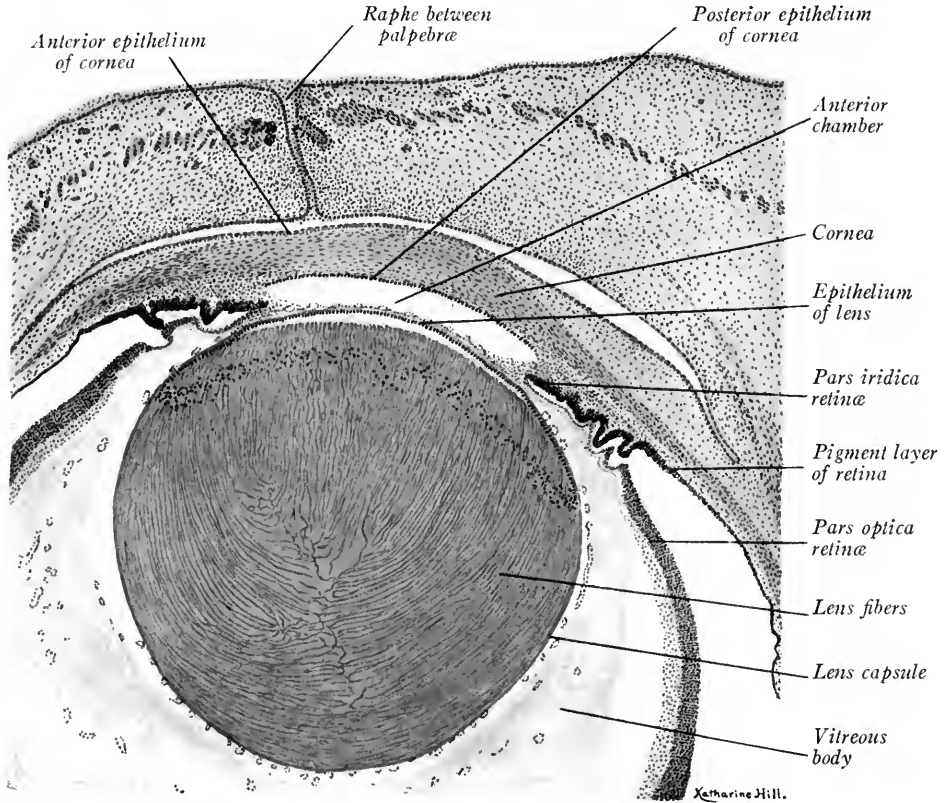


FIG. 360.—Section through the distal half of the eyeball and through the eyelids of a 65 mm. embryo.  
 × 35.

**Differentiation of the Optic Cup.**—We have seen that of the two layers of the optic cup the outer becomes the *pigment layer* of the *retina*. Pigment granules appear in its cells in embryos of 7 to 9 mm. and the pigmentation of this layer is marked in 12 mm. embryos (Fig. 358).

The inner layer of the optic cup is the retinal layer and is subdivided into a distal zone, the *pars cæca*, which is non-nervous, and into the *pars optica*, or the

nervous retina proper. The line of demarcation between the pars optica and the pars cæca is a serrated circle, the *ora serrata*. The blind portion of the retinal layer, the pars cæca, with the development of the ciliary bodies is differentiated into a *pars ciliaris* and *pars iridis retinae*. The former, with a corresponding zone of the pigment layer, covers the ciliary bodies. The *pars iridis* forms the proximal layer of the *iris* and blends intimately with the pigment layer in this region, its cells also becoming heavily pigmented (Fig. 360).

The *pars optica*, or *nervous portion of the retina*, begins to differentiate proximally, the differentiation extending distally. An outer *cellular layer* and an inner *fibrous layer* may be distinguished in 12 mm. embryos (Fig. 358). These correspond to the cellular layer (ependymal and mantle zones) and marginal




FIG. 361.—Section of the nervous layer of the retina from a 65 mm. embryo. The left portion of the figure shows diagrammatically the cellular elements of the retina according to Cajal.  $\times 440$ .

layer of the neural tube. In embryos of 65 mm. the retina shows three layers, large ganglion cells having migrated in from the outer cellular layer of rods and cones (Fig. 361). In a fetus of the seventh month all the layers of the adult retina may be recognized (Fig. 362). As in the wall of the neural tube, there are differentiated in the retina *supporting tissue* and nervous tissue. The supporting elements, or fibers of Mueller, resemble ependymal cells and are radially arranged (Figs. 361 and 362). Their terminations form internal and external limiting membranes.

The neuroblasts of the retina differentiate into an outer layer of *rod and cone cells*, the visual cells of the retina (Fig. 362). Internal to this layer are layers of bipolar and multipolar cells. The inner layer of multipolar cells constitutes the *ganglion cell layer*. Axons from these cells form the inner *nerve fiber layer*

of optic fibers. These converge to the optic stalk and grow back in its wall to the brain. The cells of the optic stalk are converted into neuroglia supporting tissue and the cavity of the stalk is gradually obliterated. The optic stalk is thus transformed into the *optic nerve* (see p. 356).

**The Sclerotic and Chorioid Layers, and their Derivatives.**—After the mesenchyme grows in between the ectoderm and the lens (Fig. 358) the lens and optic cup are surrounded by a condensed layer of mesenchymal tissue, which gives rise to the supporting and vascular layers of the eyeball. By condensation and

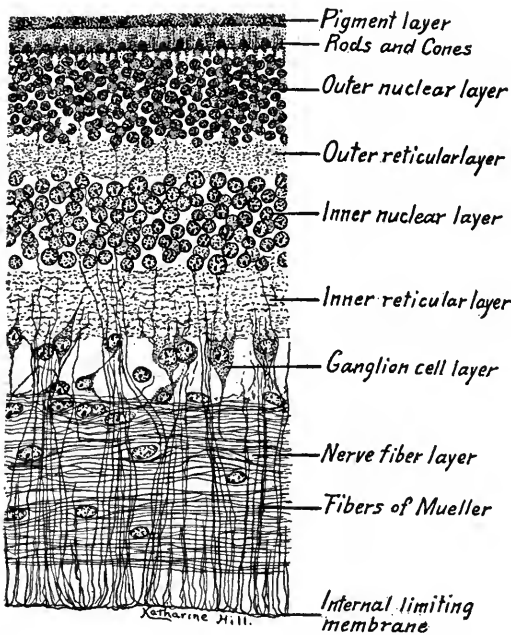


FIG. 362.—Section through the pars optica of the retina from a seven months' fetus.  $\times 440$ .

differentiation of its outer layers, a dense layer of white fibrous tissue is developed, which forms the *sclerotic layer*. This corresponds to the dura mater of the brain. In the mesenchyme of 25 mm. embryos a cavity appears distally, which separates the condensed layer of mesenchyme continuous with the sclerotic from the vascular capsule of the lens (Fig. 360). This cavity is the *anterior chamber* of the eye and separates the anlage of the *cornea* from the lens capsule. An inner layer of mesenchyme, between the anlage of the sclerotic and the pigment layer of the retina, becomes highly vascular during the sixth month. Its cells become stellate in form and pigmented so that the tissue is loose

and reticulate. This vascular tissue constitutes the *chorioid layer* in which course the chief vessels of the eye. The chorioid layer corresponds to the *pia mater* of the brain. Distal to the ora serrata of the retinal layer the chorioid is differentiated: (1) Into the vascular folds of the ciliary bodies; (2) into the smooth fibers of the ciliary muscle; (3) into the stroma of the *iris*. The proximal pigmented layers of the iris are derived from the pars iridis retinae and from a corresponding zone of the pigment layer. Of these the pigment layer cells give rise to the *sphincter* and *dilator muscles* of the iris. These smooth muscle fibers are thus of ectodermal origin.!

The **Eyelids** appear as folds of the integument in 20 mm. embryos. The lids come together and the epidermis at their edges is fused in 33 mm. embryos (Fig. 360). Later, when the epidermal cells are cornified separation of the eyelids takes place. The epidermis of the eyelids forms a continuous layer on their inner surfaces as the *conjunctiva*, which in turn is continuous with the anterior epithelium of the cornea.

The **Eyelashes**, or *cilia*, develop like ordinary hairs and are provided with small sebaceous glands. In the tarsus, or dense connective tissue layer of the eyelids, which lies close to the conjunctival epithelium, there are developed about 30 tarsal (Meibomian) glands. These arise as ingrowths of the epithelium at the edges of the eyelids, while the latter are still fused.

The **Lachrymal Glands** appear in embryos of 22 to 26 mm., according to Keibel and Elze. They arise as five or six ingrowths of the conjunctiva, dorsally and near the external angle of the eye. The anlagen are at first knob-like and rapidly lengthen into solid epithelial cords. They begin to branch in 30 mm. embryos. At stages between 40 and 60 mm. additional anlagen appear which also branch.

In 38 mm. embryos a septum begins to divide the gland into orbital and palpebral portions. This septum is complete at 60 mm., the five or six anlagen first developed constituting the orbital part. Lumina appear in the glandular cords in embryos of 50 mm. by the degeneration of the central cells. Accessory lachrymal glands appear in 30 cm. fetuses. The lachrymal gland is not fully developed at birth, being only one-third the size of the adult gland. In old age marked degeneration occurs.

The **Naso-lachrymal Duct** is formed as a solid epithelial outgrowth from the conjunctiva of the lachrymo-nasal groove at the internal angle of the eye. The anlage grows down through the mesenchyme to the nasal cavity. The *lachrymal canals* are budded out from the solid anlage of the lachrymal duct and become connected secondarily with the inner margins of the palpebræ. The primitive connection of the lachrymal duct with the conjunctiva is lost. The anlage of the duct appears in 10 mm. embryos and in 25 mm. embryos has not yet reached the nasal cavity. A lumen appears in the duct during the third month.

#### THE DEVELOPMENT OF THE EAR

The human ear consists of a sound-conducting apparatus and of a receptive organ. The conveyance of sound is the function of the *external* and *middle ears*. The end organ proper is the *inner ear* with the auditory apparatus residing in the *cochlear duct*. Besides this acoustic function the labyrinthine portion of the inner ear acts as an organ of equilibrium.

**The Inner Ear.**—The epithelium of the internal ear is derived from the ectoderm. Its first anlage appears in embryos of 2 mm. as thickened ectodermal plates, the *auditory placodes* (Fig. 363 A). These are developed dorsal to the second branchial grooves at the sides of the hind-brain opposite the fifth neuromeres (Fig. 364). The placodes are invaginated to form hollow vesicles which close

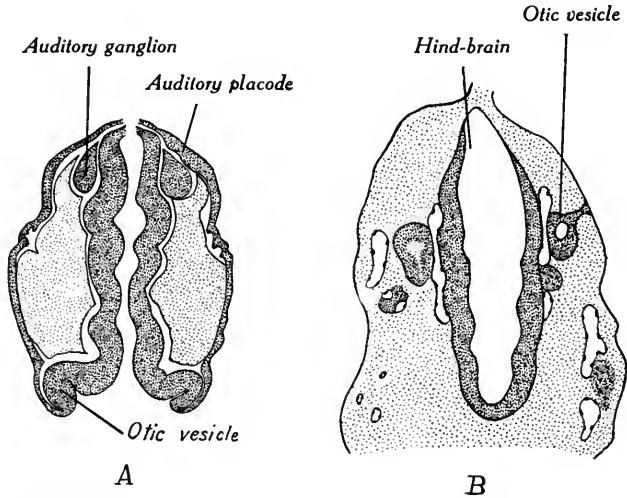


FIG. 363.—Two stages in the early development of the internal ear. *A*, section through the head of a 2 mm. embryo showing the auditory placode and otic vesicles; *B*, section through the hind-brain and otic vesicles of an early human embryo (Keibel and Elze).

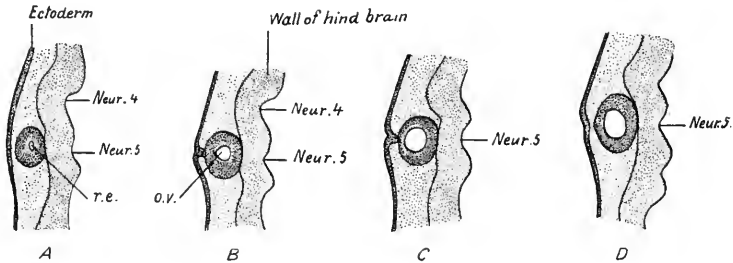


FIG. 364.—Four sections through the right otic vesicle of an early human embryo. *r. e.*, endolymphatic recess, the anlage of the endolymph duct and sac; *o. v.*, otic vesicle; *Neur. 4*, *Neur. 5*, neuromeres four and five of the myelencephalon (Keibel and Elze). About 30 diameter.

in embryos of 2.5 to 3 mm., but remain attached to the ectoderm for some time (Fig. 363 B).

The *auditory vesicle* or *otocyst* when closed and detached is nearly spherical, but at the point where it was attached to the ectoderm a recess is formed. The point of origin of this recess is shifted later from a dorsal to a mesial position and it constitutes the *ductus endolymphaticus* (Figs. 365 and 366 a). The endolymph



duct corresponds to that of selachian fishes, which remains open to the exterior. In man, its dorsal extremity is closed and dilated to form the *endolymphatic sac* (Fig. 366 *e*).

The differentiation of the auditory vesicle has been described by His, Jr. and more recently by Streeter (Amer. Jour. Anat., vol. 6, 1906). In an embryo of about 7 mm. the vesicle has elongated, its narrower ventral process constituting the anlage of the *cochlear duct* (Fig. 366 *a*). The wider dorsal portion of the otocyst is the *vestibular anlage* and it shows indications dorsally of the developing semicircular canals. These are formed in 11 mm. embryos as two

pouches, the anterior and posterior canals from a single pouch at the dorsal border of the otocyst, the external canal later from a lateral outpocketing (Fig. 366 *d*). The margins of these pouches are thickened, but elsewhere their walls are flattened together and fused to form an epithelial plate. Three such epithelial plates are produced and internally about the periphery of each plate canals are left communicating with the cavity of the vestibule. Soon the epithelial plates are resorbed, leaving spaces between the semicircular epithelial canals and the vestibule (Fig. 366 *c*). Dorsally a notch separates the anterior and posterior canals. Of these the anterior is completed first, next the posterior canal. The external canal is the last to develop.

In a 20 mm. embryo (Fig. 366 *e*) the three canals are present and the cochlear duct has begun to coil like a snail shell. It will be seen that the anterior and posterior canals have a common opening dorsally into the vestibule, while their opposite ends and the cranial end of the external canal are dilated to form *ampullae*. In each ampulla is located an end organ, the *crista acustica*, which will be referred to later. By a constriction of its wall the vestibule is differentiated into a dorsal portion, the *utricle*, to which are attached the semicircular canals, and a ventral portion, the *sacculus*, which is connected with the cochlear duct (Fig. 366 *e, f*). At 30 mm. the adult condition is more nearly attained. The

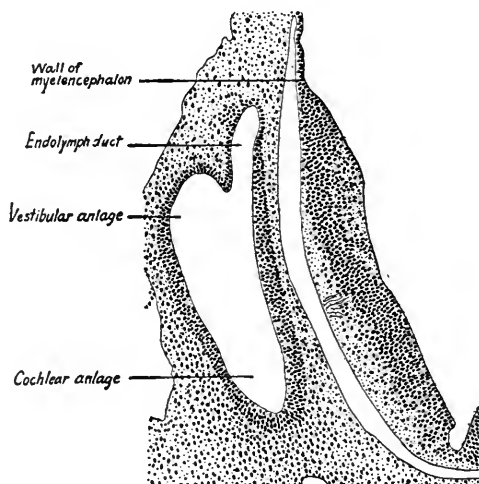


FIG. 365.—Transverse section through the right half of the hind-brain and through the right otic vesicle showing the position of the endolymphatic duct. From an embryo 6.9 mm. long (His).

sacculus and utriculus are more completely separated, the canals are relatively longer, their ampullæ more prominent and the cochlear duct is coiled about two and a half turns (Fig. 366 f). In the adult, the sacculus and utriculus become completely separated from each other, but each remains attached to the endolymph duct by a slender canal which represents the prolongation of their respective walls. Similarly, the cochlear duct is constricted from the sacculus, the basal end of the former becomes a blind process and a canal, the ductus reuniens, connects the cochlear duct with the sacculus.

The epithelium of the labyrinth at first is composed of a single layer of low columnar cells. At an early stage, fibers from the acoustic nerve grow between the epithelial cells in certain regions and it becomes modified to produce special sense organs. These end organs are the *cristæ acusticæ* in the ampullæ of the semicircular canals; the *maculæ acusticæ* in the utriculus and sacculus, and the *spiral organ* (of Corti) in the cochlear duct.

The *cristæ* and *maculæ* are *static* organs, or sense organs for equilibrium. In each ampulla transverse to the long axis of the canal the epithelium and underlying tissue form a curved ridge, the *crista*. The cells of the epithelium are differentiated: (1) Into *sense cells* with bristle-like hairs at their ends, and (2) into supporting cells. About the bases of the sensory cells branch nerve fibers from the vestibular division of the acoustic nerve. The *maculæ* resemble the *cristæ* in their development save that larger areas of the epithelium are differentiated into cushion-like end organs. Over the *maculæ* concretions of lime salts may form *otoconia* which remain attached to the sensory bristles. The true organ of hearing, the *spiral organ*, is developed in the *basal epithelium* of the cochlear duct, basal having reference here to the base of the cochlea. The development of the spiral organ has been studied carefully only in the lower mammals, in the pig by Shambaugh, Hardesty and Prentiss. In pig embryos of 5 cm. the basal epithelium is thickened, the cells becoming highly columnar and the nuclei forming several layers. In later stages, 7 to 9 cm., inner and outer epithelial thickenings are differentiated, the boundary line between them being the future spiral tunnel (Fig. 367 A). At the free ends of the cells of the epithelial swellings there is differentiated a cuticular structure, the *membrana tectoria*, which appears first in embryos of 4 to 5 cm. The cells of the inner (axial) thickening give rise to the *epithelium of the spiral limbus*, to the *cells lining the internal spiral sulcus* and to the *supporting cells and inner hair cells of the spiral organ* (Fig. 367 B, C). The outer epithelial thickening forms the *pillars of Corti*, the *outer hair cells* and *supporting cells of the spiral organ*. Differentiation begins in the basal turn of the

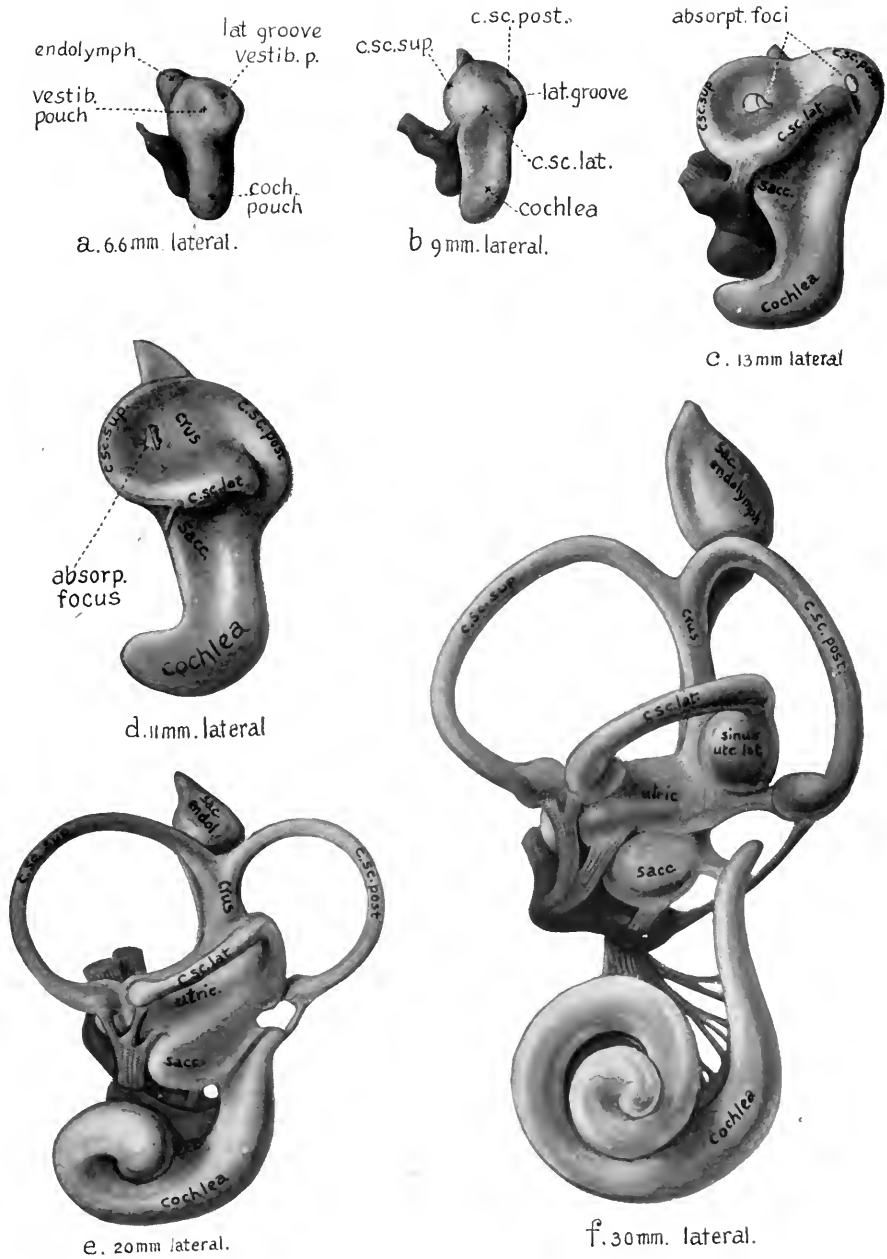



FIG. 366.—Six stages in the development of the internal ear. The figures show lateral views of models of the membranous labyrinth—a at 6.6 mm.; b, at 9 mm.; c at 13 mm.; d at 11 mm.; e at 20 mm., and f at 30 mm. (Streeter) (X 25). The colors yellow and red are used to indicate respectively the cochlear and vestibular divisions of the acoustic nerve and its ganglia. *absorp. focus*, area of wall where absorption is complete; *crus*, crus commune; *c.sc.lat.*, ductus semicircularis lateralis; *c. sc. post.*, ductus semicircularis posterior; *c.sc.sup.*, ductus semicircularis superior; *cochlea*, ductus cochlearis; *coch. pouch*, cochlear anlage; *endolymph.*, appendix endolymphaticus; *sacc.*, sacculus; *sac. endol.*, saccus endolymphaticus; *sinus utr. lat.*, sinus utriculi lateralis; *utric.*, utriculus.



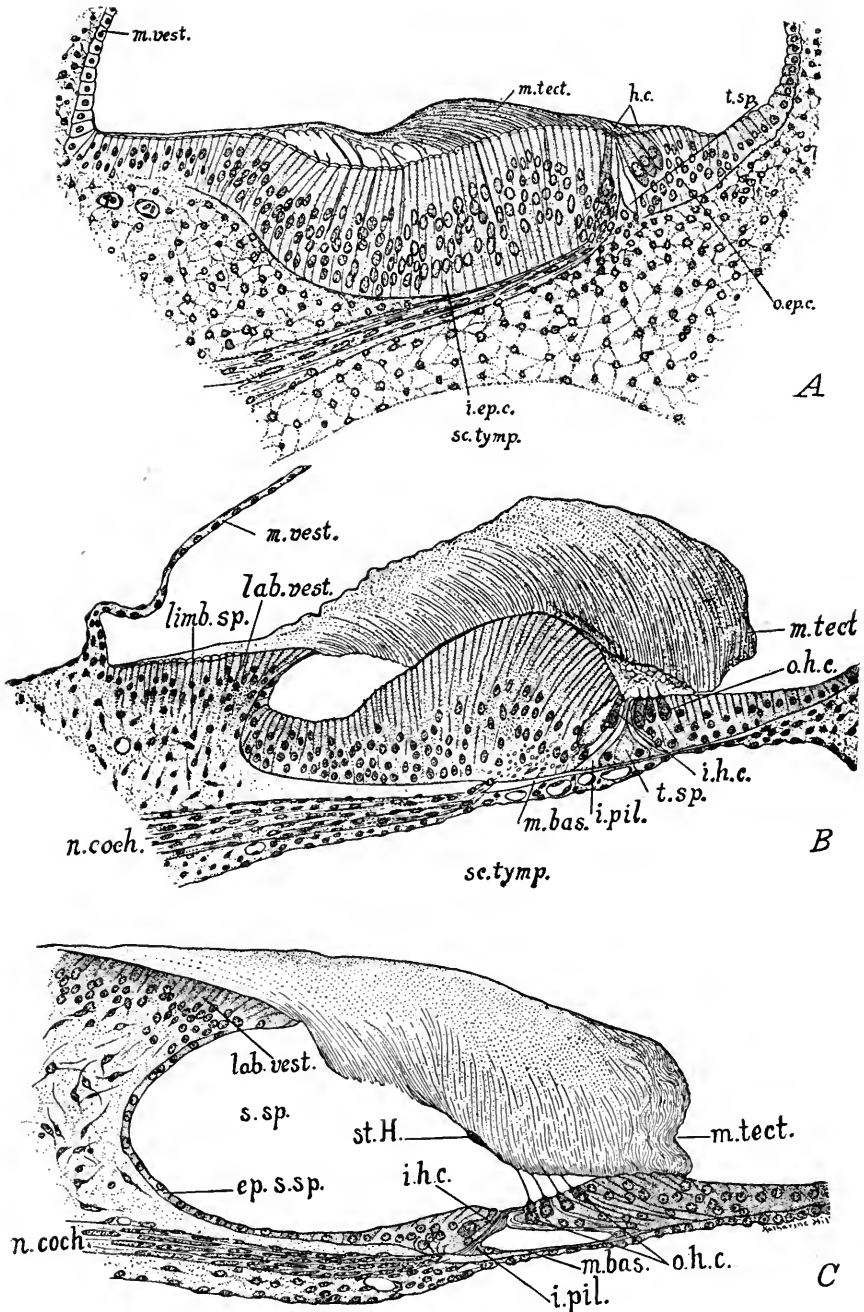


FIG. 367.—Three stages in the differentiation of the basal epithelium of the cochlear duct to form the spiral organ (of Corti), internal spiral sulcus and labium vestibulare. *A*, section through the cochlear duct of an 8.5 cm. pig fetus; *B*, the same from a 20 cm. fetus; *C*, from a 30 cm. fetus (near term). *ep. s. sp.*, epithelium of spiral sulcus; *h.c.*, hair cells; *i.ep.c.*, inner epithelial thickening; *i.h.c.*, inner hair cells; *i.pil.*, inner pillar of Corti; *lab. vest.*, labium vestibulare; *limb. sp.*, limbus spiralis; *m. bas.*, basilar membrane; *m. tect.*, membrana tectoria; *m. vest.*, vestibular membrane; *n. coch.*, cochlear division of acoustic nerve; *o.ep.c.*, outer epithelial thickening; *o.h.c.*, outer hair cells; *s.sp.*, sulcus spiralis; *sc.tymp.*, scala tympani; *st.H.*, stria of Hensen; *t.sp.*, spiral tunnel.

cochlea and proceeds toward the apex. The internal *spiral sulcus* is formed by the degeneration and metamorphosis of the cells of the inner epithelial thickening which lie between the labium vestibulare and the spiral organ (Fig. 367 B, C). These cells become cuboidal, or flat, and line the spiral sulcus, while the membrana tectoria loses its attachment to them. The membrana tectoria becomes thickest over the spiral organ and in full term fetuses is still attached to its outer cells (Fig. 367 C).

According to Hardesty (Amer. Jour. Anat., vol. 8) the membrana tectoria is not developed from the cells of the spiral organ and therefore is not attached to it at any time. From what is known of the development of the spiral organ in human embryos, it follows the same lines of development as described for the pig. It must develop relatively late, however, for in the cochlear duct of a new-born child figured by Krause the spiral sulcus and the spiral tunnel are not yet present.

The mesenchyme surrounding the labyrinth is differentiated into a fibrous membrane directly surrounding the epithelium, and into the perichondrium of the cartilage which develops about the whole internal ear. Between these two is a more open mucous tissue which largely disappears, leaving the *perilymph space*. The membranous labyrinth is thus suspended in the fluid of the perilymph space. The bony labyrinth is produced by the conversion of the cartilage capsule into bone. In the case of the cochlea, large perilymph spaces form above and below the cochlear duct. The duct becomes triangular in section as its lateral wall remains attached to the bony labyrinth, while its inner angle is adherent to the modiolus. The upper perilymph space is formed first and is the *scala vestibuli*, the lower space is the *scala tympani*. The thin wall separating the cavity of the cochlear duct from that of the scala vestibuli is the *vestibular membrane* (of Reissner). Beneath the basal epithelium of the cochlear duct a fibrous structure, the *basilar membrane*, is differentiated by the mesenchyme. The *modiolus* is not preformed as cartilage, but is developed directly from the mesenchyme as a membrane bone. The development of the acoustic nerve has been described on page 356 with the other cerebral nerves.

**The Middle Ear.**—The middle ear cavity is differentiated from the first pharyngeal pouch which appears in embryos of 3 mm. The pouch enlarges rapidly up to the seventh week, is flattened horizontally and is in contact with the ectoderm. During the latter part of the second month, in embryos of 24 mm., the wall of the tympanic cavity is constricted to form the tubo-tympanic (Eustachian) canal. This tube lengthens and its lumen becomes slit-like during the fourth month. The tympanic cavity is surrounded by loose areolar connec-

tive tissue in which the auditory ossicles are developed and for a time embedded. The pneumatic cells are formed at the close of fetal life.

The development of the *auditory ossicles* has been described by Broman (Verh. Anat. Gesellsch., Kiel, Anat. Anz. Suppl., vol. 14, 1898). According to his account, the condensed mesenchyma of the first and second branchial arches gives rise to the ear ossicles. This tissue is divided in the proximal part of the arches into lateral and median masses.

The *malleus* is formed from the distal portion of the median mesenchymal mass of the first arch, along with Meckel's cartilage of the mandible. The cartilaginous anlage of the malleus is continuous with Meckel's cartilage. Between it and the incus is an intermediate disk of tissue, which later forms an articulation. When the malleus begins to ossify it separates from Meckel's cartilage.

The *incus* is derived from the proximal portion of the lateral mesenchymal mass of the first branchial arch. The anlage of the incus unites with that of the capsule of the labyrinth and separates from it only when its cartilage develops. It is early connected with the anlage of the *stapes*, and the connected portion becomes the *crus longum*. Between this and the stapes an articulation develops.

The *stapes* and Reichert's cartilage are derived from the median mesenchymal mass of the *second branchial arch*. The mesenchymal anlage of the stapes is perforated by the *stapedial* artery, and its cartilaginous anlage is ring-shaped. This form persists until the middle of the third month when it assumes its adult structure and the stapedial artery disappears.

Fuchs, after studying the development of the ear ossicles in rabbit embryos, concludes: (1) that the stapes is derived from the capsule of the labyrinth; (2) that the malleus and incus arise independent of the first branchial arch.

**The External Ear.**—The external ear is developed from and about the first branchial groove. The *auricle* arises from six elevations which appear three on the mandibular and three on the hyoid arch (Fig. 368). These anlages were first described by His.

They are numbered ventro-dorsally on the mandible and in the reverse direction on the hyoid arch. Caudal to the hyoid anlages a fold of the integument is formed, the *hyoid helix* or auricular fold. A similar fold forms later dorsal to the first branchial groove and unites with the auricular fold, to form with it the free margin of the auricle. The point of fusion of these two folds marks the position of the *satyr tubercle*, according to Schwalbe. Schwalbe derives the *tragus* from mandibular hillock 1; the *helix* from mandibular hillocks 2 and 3; the *antihelix* from hyoid hillocks 4 and 5; the *antitragus* from hyoid hillock 6. *Darwin's tubercle* appears at

about the middle of the margin of the free auricular fold, and corresponds to the tip of the mammalian auricle.

The *external auditory meatus* is formed as an ingrowth of the first branchial groove. In embryos of 12 to 15 mm. the wall of this groove is in contact dorsally with the entoderm of the first pharyngeal pouch. Later, however, this contact is lost, and during the latter part of the second month, according to Hammar,

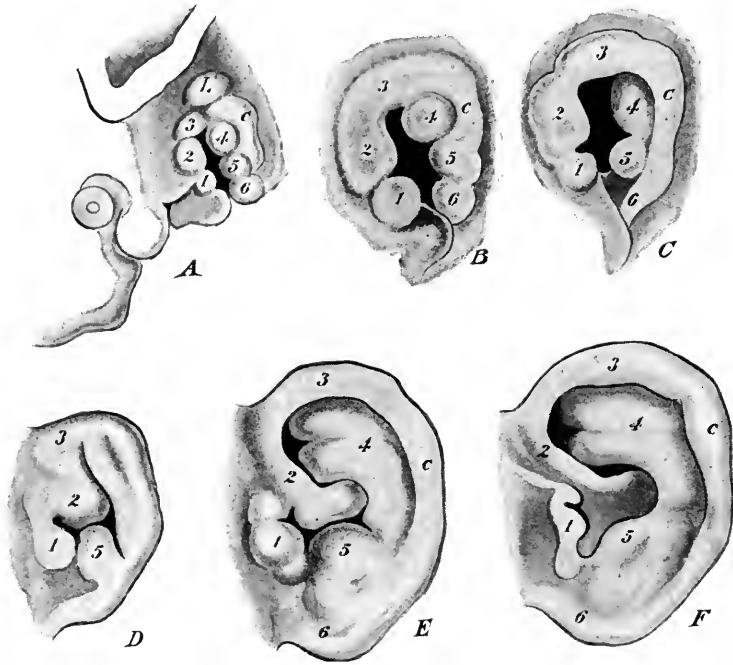


FIG. 368.—Six stages in the development of the external ear. 1, 2, 3, elevations on the mandibular arch; 4, 5, 6, elevations on the hyoid arch. 1, tragus; 2, 3, helix; 4, 5, antihelix; 6, antitragus. *c*, hyoid helix or auricular fold (His from McMurrich's "Human Body"). *A*, 11 mm.; *B*, 13.6 mm.; *C*, 15 mm.; *D*, beginning of third month; *E*, fetus of 85 mm.; *F*, fetus at term.

an ingrowth takes place from the ventral portion of the groove, to form a funnel-shaped canal.

The lumen of this tube is temporarily closed during the fourth and fifth months, but later re-opens. During the third month a plate of cells at the extremity of the primary auditory meatus grows in and reaches the lower wall of the tympanic cavity. During the seventh month a space is formed by the splitting of this plate, and the secondary portion of the meatus is thus developed.

The *tympanic membrane* is formed by a thinning out of the tissue in the region where the wall of the external auditory meatus abuts upon the wall of the tympanic cavity.



# INDEX

- ABDOMINAL pregnancy, 30  
Abortion, 80  
Acid carmine, 48  
    hæmatoxylin, 48  
Adipose tissue, 294  
Alæ nasi, 154  
Allantoic stalk, 76, 79, 152  
    vessels, 76, 77  
Allantois, 67, 76, 77, 83, 92, 105, 119  
    derivation of, 79, 83  
Amboceptor, 30  
Ameloblasts, 163  
Amitosis, 22  
Amnion, origin of, 74, 83  
    bat, 83  
    chick, 65, 75  
    human, 80, 83  
    pig, 77  
Amniota, 74  
Amphiaster, 22  
Amphioxus, 33  
Ampulla of ductus deferens, 226  
Anal membrane, 169  
Angioblast, 48  
    chick, 48  
    human, 251  
Anlage defined, 13, 48  
Annelids, 33  
Annulus, 22  
Anomalies, 167, 177, 182, 186, 202, 213, 225  
Ansa hypoglossi, 353, 358  
Anus, 105, 152, 169  
Aorta, origin of, 255  
    chick, 52  
    descending, 52, 92, 106, 137, 267  
    dorsal, 56, 106, 107  
    pig, 106, 107, 137  
    ventral, 56, 267  
Aortic arches, 92, 129, 137, 276  
    chick, 67  
    human, 92  
    pig, 107, 129, 137  
Appendix epididymis, 225  
    testis, 226, 236  
    vermiformis, 182  
Aqueduct, cerebral, 336  
Archenteron, 38  
Archipallium, 344  
Arcuate fibers, 333  
Arcus pharyngo-palatini, 158  
Area, germinal, 36  
    opaca, 43, 48  
    pellucida, 43, 54  
    vasculosa, 57  
Arteries, allantoic, 76, 77  
    basilar, 135, 272  
    carotid, 107, 129, 270  
    central, of retina, 376  
    changes at birth, 286  
    coeliac, 107, 129, 274  
    epigastric, 274  
    hepatic, 186  
    hypogastric, 275  
    iliac, 129, 275  
    intercostal, 274  
    internal mammary, 274  
    intersegmental, 107, 129, 268, 274  
    mesenteric, 129  
        inferior, 129, 269  
        superior, 129, 269, 274  
    of extremities, 275  
    of pig, 106, 129  
    ovarian, 274  
    phrenic, 274  
    pulmonary, 107, 129, 177, 265, 271  
    renal, 213, 274  
    spermatic, 274  
    subclavian, 107, 129, 270, 274  
    suprarenal, 274  
    umbilical, 92, 107, 118, 144  
    ventro-lateral, 107, 129  
    vertebral, 129, 272  
    vitelline, 57, 68, 92, 107, 118, 129, 268, 269  
Arytenoid swellings, 101, 124, 160, 174  
Ascaris megalcephala, 27  
Atrium, 67, 92, 258  
Auricle of ear, 387  
    of heart. See *Atrium*  
Autonomic system, 364  
Axial filament, 22

- BASOPHILE (mast leucocyte), 254  
 Biogenesis, law of, 14  
 Bladder, 85, 152, 213, 215  
 Blastocel, 33  
 Blastoderm, 36  
 Blastodermic vesicle, 36  
 Blastopore, 38  
 Blastula, 33, 37  
 Blood, 53  
   cells, 251  
   islands, 48, 251  
   plastids, 253  
   plates, 254  
 Blood-vessels, changes at birth, 286  
   chick, 53, 56, 67  
   human, 92, 251, 255  
   pig, 105, 128  
   primitive, 267  
 Body cavities, 188  
 Body-stalk, 80, 85  
 Bone, endochondral, 296  
   growth of, 297  
   histogenesis of, 295  
   membrane, 295  
   palatine, 158  
 Brachial plexus, 353  
 Brachium conjunctivum, 335  
   poutis, 334  
 Brain, human, 325  
   of pig, 123  
 Branchial arches, chick, 67  
   human, 89  
   pig, 97, 112  
   clefts, 65, 97  
   ducts, 170  
   vesicles, 170  
 Bulbar swelling, 128  
 Bulbo-urethral glands, 235  
 Bulbus cordis, 67, 92  
 Bursa infracardiaca, 199  
   omentalis, 197  
  
 CÆCUM, 152, 182  
 Calcar avis, 349  
 Canal, atrio-ventricular, 106, 259  
   Gartner's, 226, 237  
   hyaloid, 378  
   incisive (of Stenson), 157  
   inguinal, 231, 232  
   neurenteric, 41  
   notochordal, 41  
   pleuro-peritoneal, 191  
   semicircular, 383  
   tubo-tympanic, 387  
  
 Canalis epididymis, 225  
 Capsule of Bowman, 205  
   internal, 343  
   of liver, 200  
 Cartilage, arytenoid, 175  
   corniculate, 175  
   cricoid, 175  
   cuneiform, 175  
   histogenesis of, 294  
   Meckel's, 295  
   of epiglottis, 174  
 Cauda equina, 325  
 Caudal flexure, 89  
 Caudate lobe of liver, 201  
   nucleus, 343  
 Caul, 83  
 Cavity, body, 188  
   oral, 151  
   pericardial, 63, 188, 190  
   peritoneal, 63, 194, 195  
   pleural, 63, 194, 195  
   pleuro-pericardial, 50, 190  
   pleuro-peritoneal, 188, 190  
   tympanic, 170, 386  
 Cells, germ, 17  
   giant, 254  
   lutein, 224  
   sustentacular, 221  
   taste, 369  
 Centra of vertebræ, 151  
 Central nervous system, 319  
   chick, 49, 54, 66  
   human, 89, 319  
   pig, 122  
 Centriole, 22  
 Centrosome, 17  
 Cephalic flexure, 65, 87  
 Cerebellum, 150, 334  
 Cerebral cortex, 349  
   hemispheres, 147, 327, 346  
   nerves. See *Nerves*, 123  
 Chick embryos, 43, 48  
   preservation of, 48  
   study of, 48, 54, 65  
 Chin, 154  
 Choanæ, 371  
 Chorda dorsalis, 49. See *Notochord*  
   gubernaculi, 230  
 Chorioid plexus, 150, 332, 336, 340  
 Chorion, origin of, 74  
   chick, 74, 75  
   frondosum, 243  
   human, 81  
   læve, 243  
   pig, 77

- Chorion, villi of, 80, 240  
 Chromaffin bodies, 366  
     aortic, 366  
 Chromatin, 17, 24  
 Chromosomes, 23  
     accessory, 24, 32  
     number of, 24  
 Circulation, fetal, 284  
 Circulatory system, 92, 251  
 Clava, 333  
 Cleavage, 33  
 Clitoris, 152, 233, 237  
 Cloaca, 91, 104, 105, 119, 213  
 Cloacal membrane, 105, 169, 213  
     tubercle, 232  
 Closing plates, 103, 169  
 Cochlea, 384  
 Cœlom, 45, 50, 190  
     chick, 63  
     extraembryonic, 188  
     human, 188, 190  
     umbilical, 182  
 Collateral eminence, 349  
 Colliculus, facial, 361  
     inferior, 336  
     superior, 336  
 Coloboma, 376  
 Colon, 142, 182, 183  
 Column, gray, 322  
 Columna nasi, 154  
 Columns, renal, 209  
 Commissure, anterior, 344, 345  
     ganglionic, 364  
     gray, 322  
     hippocampal, 345  
     posterior, of labia majora, 233  
     white, 322  
 Conchæ, 373  
 Concrescence theory, 41  
 Coni vasculosi, 225  
 Conjunctiva, 381  
 Copula, 102, 124, 160  
 Cord, spinal, 320  
     nephrogenic, 205, 208  
     umbilical, 79  
 Cornea, 380  
 Corona radiata, 20  
 Coronary appendage, 194, 201  
     sinus of heart, 279  
     sulcus of phallus, 232  
 Corpora quadrigemina, 328, 336  
 Corpus albicans, 224  
     callosum, 344, 345  
     hæmorrhagicum, 224  
     luteum, 224  
 Corpus striatum, 327, 339, 341  
 Cortex cerebri, 339, 349  
 Crescentic groove, 40  
 Crista acustica, 383  
 Crura cerebri, 328  
 Cryptorchism, 221, 231  
 Cumulus oöphorus, 224  
 Cuneus, 333, 349  
 Cutis, 305  
     plate, 119  
 DECIDUA basalis (serotina), 239  
     capsularis (reflexa), 239, 244  
     vera (parietalis), 239, 243  
 Decidual cells, 244  
     membranes, 239  
     separation of, 249  
 Dentition, 167  
 Dermatome, 299  
 Dermis (corium), 305  
 Dermo-muscular plate, 62  
 Descending spinal tract of trigeminal nerve, 359  
 Diaphragm, 195  
     dorsal pillars of, 194  
     origin of, 195  
 Diaster, 23  
 Diencephalon, 66, 89, 100, 336  
 Differentiation of tissues, 13  
 Digestive canal, chick, 55, 67  
     human, 89  
     pig, 6 mm., 101  
     10 mm., 124  
     glands, 89  
 Dissecting instruments, 145  
 Dissections, face, 153  
     lateral, 99, 146  
     median, 148  
     palate, 155  
     pig embryos, 145  
     tongue, 158  
     ventral, 153  
 Diverticulum, cardiac, 127  
     hepatic, 104  
     Meckel's, 182  
     of pharyngeal pouches, 103  
 Ducts, bile, 127  
     branchial, 170  
     cervical, 170  
     cochlear, 383  
     cystic, 184  
     hepatic, 127, 184  
     mesonephric, 92  
     Muellerian, 218  
     naso-lachrymal, 381

- Ducts, papillary, 208  
   periportal, 185  
   pronephric, 204  
   thoracic, 287
- Ductuli efferentes, 207, 225
- Ductus arteriosus, 271, 286  
   choledochus, 127, 185  
   deferens, 226  
   endolymphaticus, 382  
   venosus, 108, 131, 278, 286
- Duodenum, 182
- Dyads, 27
- EAR, external, 155, 387  
   internal, 55, 382  
   middle, 386
- Ectoderm, 37  
   derivatives of, 34  
   formation of, 37
- Elastic tissue, 203
- Embryos, chick, 43, 48, 54, 65  
   human, 80. See *Human embryos*  
   pig, 6 mm., 97  
     10 mm., 120  
     dissection of, 145
- Enamel organ, 162
- Encephalon, 89
- Endocardial cushion, 138, 259
- Endocardium, 139, 256
- Endothelium, 64
- End-piece, 22
- Enlargement, cervical, 324  
   lumbar, 324
- Entoderm, 37  
   derivatives of, 64  
   histogenesis of, 290  
   origin of, 38
- Entodermal canal, 168
- Eosinophiles, 254
- Ependymal cells, 317  
   layer, 133, 317
- Epicardium, 52, 106, 139, 256
- Epidermis, 304
- Epididymis, 226
- Epigenesis, 12
- Epiglottis, 101, 124, 151, 160, 174
- Epiphysis (pineal body), 150, 336
- Epithalamus, 328
- Epithelial bodies, 90, 172
- Epithelium, 64
- Epitrichium, 305
- Eponychium, 309
- Epoöphoron, 226, 23
- Erythroblasts, 252
- Erythrocytes, 252, 253
- Esophagus, 89, 103, 127, 151, 177
- Ethmoidal cells, 373
- Eustachian tube, 90, 170
- External auditory meatus, 98, 120, 155
- Extraembryonic mesoderm, 46, 80
- Extremity, 89, 98, 121
- Eye, chick, 54, 66  
   human, 89, 373  
     anterior chamber of, 375  
   pig, 97, 122
- Eyelashes, 381
- Eyelids, 381
- FACE, development of, 153
- Facial colliculus, 361  
   nerve, 100, 123
- Falciform ligament, 142
- Fasciculi of spinal cord, 323
- Fasciculus, median longitudinal, 332
- Fertilization, 30
- Fetal membranes, human, 80  
   pig, 77
- Fetus, 93
- Fibrin, canalized, 248
- Filum terminale, 324
- Fissure, calcarine, 349  
   chorioid, of cerebrum, 340  
     of eye, 374, 376  
   collateral, 349  
   great longitudinal, 340  
   hippocampal, 347  
   lateral (Sylvian), 347  
   parieto-occipital, 348
- Fixation of pig embryos, 145
- Flagellum of spermatozoön, 21
- Flexures, caudal, 89  
   cephalic, 65, 89, 325  
   cervical, 147, 326  
   dorsal, 147  
   pontine, 147, 326
- Flocculus, 334
- Floor plate, 321, 330
- Foramen, epiploic (of Winslow), 142, 198, 199  
   interatrial, 106, 260  
   interventricular, of heart, 265, 266  
     Monroi, 328, 340  
   ovale, 106, 138, 260, 263, 286
- Fore-brain, chick, 49, 53  
   human, 319
- Fore-gut, chick, 51, 67  
   human, 168
- Fornix, 344
- Fossa, incisive, 157

- Fossa ovalis, 264  
 Fovea cardiaca, 48, 51  
 Frenulum of prepuce, 234  
 Funiculi of spinal cord, 232
- GALL bladder, 184**  
**Ganglion, accessory, 362**  
   cervical, 365  
   ciliary, 364  
   Frorier's, 101, 124, 134, 358  
   geniculate, 100, 124, 360  
   jugular, 101, 124, 362  
   nodosum, 101, 124, 362  
   otic, 365  
   petrosal, 101, 124, 362  
   prevertebral, 365  
   semilunar, 100, 123, 359  
   sphenopalatine, 365  
   spinal, 123, 313  
   spiral, 357  
   submaxillary, 365  
   superior, 101, 124, 362  
   sympathetic, 364  
   vestibular, 356  
   visceral, 365  
**Ganglion cells, 315**  
   crest, 100, 313  
**Gartner's canal, 226, 237**  
**Gastrula, 38**  
**Gastrulation, 38**  
   in mammals, 41  
**Geniculate bodies, 328**  
**Genital ducts, 216, 218**  
   folds, 105, 128, 152, 205, 217  
   glands, 105, 152, 216  
   swelling, 232  
   tubercle, 232  
**Genitalia, external, 232**  
**Germ cells, 17**  
   layers, 12, 13, 37, 64  
   derivatives of, 64  
**Germinal area, 36**  
**Glands, bulbo-urethral, 235**  
   cardiac, 179  
   carotid, 366  
   Ebner's, 161  
   gastric, 179  
   lachrymal, 381  
   lingual, 162  
   mammary, 307  
   of pregnancy, 244  
   parotid, 161  
   prostate, 235  
   salivary, 161
- Glands, sebaceous, 306**  
   sublingual, 161  
   submaxillary, 161  
   sudoriparous (sweat), 307  
   suprarenal, 152, 367  
   vestibular, 235  
**Glans clitoridis, 233**  
   penis, 234  
**Glomerulus, 141, 205**  
**Glottis, 124, 160**  
**Graafian follicle, 20, 224**  
**Gray column of spinal cord, 322**  
**Groove, laryngo-tracheal, 173**  
   neural, 309  
   primitive, 41  
   urethral, 233  
**Growth, law of, 13**  
**Gubernaculum testis, 230**  
**Gyrus dentatus, 344**  
   hippocampus, 344
- HÆMOLYMPH glands, 288**  
**Hair, 305**  
**Head-fold, 45**  
**Head-process, 44**  
**Heart, chick, 52, 56**  
   human, 92, 255, 256  
   pig, 105, 114, 128, 137, 152  
**Hemispheres, cerebellar, 334**  
   cerebral, 327, 346  
**Henle's loop, 211**  
**Hensen's node (knot), 44, 61**  
**Hepatic diverticulum, 104, 116, 142**  
**Heredity, theory of, 31**  
**Hermaphroditism, 237**  
**Hernia, diaphragmatic, 202**  
   inguinal, 232  
   umbilical, 79  
**Hind-brain, chick, 54**  
   human, 325  
**Hind-gut, 67, 91, 168**  
**Histogenesis, defined, 13**  
   of ectodermal derivatives, 303  
   of entodermal derivatives, 290  
   of mesodermal derivatives, 291  
**Human embryos, 80**  
   estimated age, 95  
   of Coste, 86  
   of Dandy, 85  
   of Eternod, 86  
   of His, 2.6 mm., 87  
   4.2 mm., 88  
   Normentafel, 94, 95  
   of Kollmann, 319

- Human embryos of Mall, 85, 98  
 of Peters, 85  
 of Spee, 85  
 of Thompson, 85
- Hydramnios, 83
- Hymen, 228
- Hyoid arch, 98
- Hyomandibular cleft, 98
- Hypophysis, 67, 89, 328, 337
- Hypospadias, 234
- Hypothalamus, 328, 330, 337
- ILEO-CÆCAL valve, 182
- Implantation of ovum, 239
- Incisive fossa, 157
- Incus, 387
- Infundibulum, 328, 337
- Inguinal canal, 229  
 fold, 227, 229
- Inner cell mass, 36, 80  
 epithelial mass, 217
- Insula, 347
- Intermediate cell mass, 50, 62
- Internal capsule, 343  
 ear, 55
- Interstitial cells of testis, 221
- Intestinal glands, 182  
 loop, 180
- Intestine, human, 89, 180  
 pig, 104, 128
- Introduction, 11
- Iris, muscles of, 380
- Isthmus, 327, 328
- JACOBSON'S organ, 355, 372
- Joints, 298
- KIDNEY, human, 207
- Knot, primitive, 44, 61
- LABIA majora, 233, 237  
 minora, 233, 234
- Lachrymal gland, 381  
 groove, 98
- Lamellated corpuscle, 368
- Lamina terminalis, 327, 340
- Laryngo-tracheal groove, 173
- Larynx, 173, 174
- Layer, choroid, of eye, 380  
 compact, 244  
 ependymal, 133, 330
- Layer, ganglion cell, 379  
 mantle, 133, 310, 321  
 marginal, 133, 310, 323  
 nerve-fiber, 379  
 sclerotic, of eye, 380  
 spongy, 244
- Lecithin, 17
- Lemniscus, 333, 336
- Lens of eye, chick, 55  
 human, 374  
 capsule of, 377  
 fibers of, 376  
 pupillary membrane of, 378  
 suspensory ligament of, 378  
 vascular capsule of, 375  
 pig, 97
- Lesser peritoneal sac, 141, 197  
 inferior recess of, 198  
 superior recess of, 198
- Leucocytes, 253
- Ligament, broad, 228  
 coronary, 201  
 duodeno-hepatic, 200  
 falciform, 200  
 gastro-hepatic, 200  
 gastro-lienic, 200  
 labial, 229  
 lieno-renal, 200  
 round, 227, 230  
 triangular, 201  
 vesico-umbilical, 216
- Ligamentum labiale, 229  
 ovarii, 229, 230  
 scroti, 230  
 teres, 286  
 testis, 229  
 venosum, 278
- Limbus ovalis, 263
- Lip, anlage of, 154  
 hare, 154
- Liver, anlage of, 67, 183  
 bile capillaries, 185  
 chick, 67  
 human, 183  
 lobules of, 186  
 pig, 104, 127, 139  
 quadrate lobe, 201  
 weight of, 185
- Lizard, germ layers of, 39, 40
- Lobes of cerebrum, 346  
 of liver, 201
- Lumbo-sacral plexus, 354
- Lungs, human, 89, 175  
 apical bud, 175  
 changes at birth, 177

- Lungs, human, stem bud, 175  
     pig, 126, 141  
 Lunula, 308  
 Lutein cells, 224  
 Lymph glands, 287  
     sacs, 286  
 Lymphocytes, 253
- MACULA acustica, 384  
 Malleus, 387  
 Mammary glands, 307  
 Mammillary body, 328, 339  
     recess, 328  
 Mandibular arch, 98  
     process, 87, 89, 98  
 Mantle layer, 133  
 Marginal layer, 133  
 Margo thalamicus, 325  
 Marrow of bone, 251  
 Massa intermedia, 339  
 Maturation, 24  
     of mouse ovum, 28  
 Maxillary process, 87, 89, 97  
 Maxillo-turbinal anlage, 373  
 Meatus, external auditory, 98, 120, 155, 388  
 Meckel's cartilage, 295  
     diverticulum, 88  
 Median thyreoid, 102  
 Mediastinum, 176  
 Medulla oblongata, 329  
     of kidney, 209  
 Medullary cords, 225  
     velum, 335  
 Membrana tectoria, 385  
 Membrane, anal, 169, 213  
     cloacal, 105, 169, 213  
     pericardial, 195  
     pharyngeal, 53, 168  
     pleuro-pericardial, 192  
     pleuro-peritoneal, 192  
     tympanic, 388  
     urogenital, 169, 213  
 Mendel's law, 31  
 Menstruation, 20, 238  
 Mesamœboid, 251  
 Mesencephalon, chick, 54  
     human, 89, 325, 328, 335  
     pig, 100  
 Mesenchyma, chick, 51, 63  
     human, 291  
 Mesentery, 104, 141, 188, 190, 201  
     dorsal, 89, 190, 201  
 Mesocardium, 52, 188, 256  
 Mesocolon, 190, 201, 202
- Mesoderm, amphibian, 43  
     Amphioxus, 42  
     bird, 43  
     mammal, 45, 46  
     somatic, 50, 63, 291  
     splanchnic, 50, 63, 291  
 Mesodermal segments, 45, 50, 61  
 Mesoduodenum, 190, 201  
 Mesogastrium, 190  
 Mesonephric duct, 92, 105  
     fold, 205, 206  
     pig, 105, 128, 141, 144  
     tubules, 205  
 Mesonephros, 62, 92, 128, 152, 205  
 Mesorchium, 217  
 Mesorectum, 190, 202  
 Mesothelium, 64, 291  
 Mesovarium, 217  
 Metamerism, 12  
 Metanephros, 105, 120, 128, 144, 152, 207, 208  
     calyces of, 207  
     collecting tubules, 128, 207  
     cortex, 209  
     medulla, 209  
     pelvis, 128, 207  
     tubules, 208  
     ureter, 128, 207  
 Metathalamus, 328  
 Metencephalon, 89, 100, 329, 333  
 Methods of dissection, 145  
     of study, 14  
 Mid-brain, 54, 325, 328, 335  
 Mid-gut, 67, 168  
 Milk line, 307  
 Mitochondria sheath, 22  
 Mitosis, 22  
     significance of, 31  
 Modiolus, 386  
 Monaster, 23  
 Monkey, ovum of, 20  
 Mons veneris, 233, 237  
 Morula, 33  
 Mouse, ovum of, 28, 30  
 Mucous tissue, 79  
 Muellerian ducts, 218  
     tubercle, 227  
 Muscle, cardiac, 299  
     histogenesis of, 298  
     plate, 119  
     smooth, 298  
     striated voluntary, 299  
 Muscles, morphogenesis of, 301  
     of diaphragm, 195  
 Myelencephalon, 89, 100, 112, 329, 330  
 Myelocytes, 253

- Myocardium, 52, 106  
 Myotome, chick, 62  
   human, 299  
   pig, 119
- NAIL, human, 308  
 Naris, 370  
 Nasal passages, 157  
   pits, human, 370  
   pig, 97, 120  
   processes, 153, 370  
 Naso-turbinal anlage, 373  
 Neck-bend, 147, 346. See *Cervical flexure*  
 Nephrogenic cord, 205, 208  
   tissue, 128, 210  
 Nephrostome, 203  
 Nephrotome, chick, 62  
   human, 204  
 Nerve fibers, histogenesis of, 310  
 Nerves, abducens, 123, 359  
   acoustic, 100, 124, 356  
   cerebral, 355  
   chorda tympani, 124, 361  
   facial, 100, 123, 360  
   femoral, 354  
   glossopharyngeal, 101, 124, 361  
   hypoglossal, 101, 124, 358  
   mandibular, 123, 359  
   maxillary, 123, 359  
   oculomotor, 100, 123, 358  
   olfactory, 123, 355  
   ophthalmic, 123, 359  
   optic, 123, 356  
   phrenic, 192, 353  
   sciatic, 354  
   spinal, 124, 351  
     accessory, 101, 124, 362  
   superficial petrosal, 361  
   sympathetic, 364  
   trigeminal, 100, 123, 359  
   trochlear, 123, 359  
   vagus, 101, 124, 362  
 Nervous system, 54, 99, 122  
 Neural crest, 100, 313  
   folds, 45, 309  
   groove, 45, 309  
   tube, 45, 330  
 Neurenteric canal, 41  
 Neuroblasts, 311, 313  
 Neuroglia, origin of, 310, 317  
 Neuromeres, 54, 112  
 Neurone theory, 315  
 Neurones, 312, 313  
 Neuropore, anterior, 54, 319  
 Neutrophiles, 254  
 Node of Ranvier, 316  
   primitive, 44, 61  
 Nodus cerebelli, 334  
 Normoblasts, 252  
 Notochord, origin of, 42, 46  
   chick, 49  
   human, 46  
 Notochordal canal, 41  
   plate, 40  
 Nuclei of origin, 332  
   terminal, 332  
 Nucleolus, 17  
 Nucleus ambiguus, 362  
   caudatus, 343  
   cuneatus, 332  
   dentatus, 335  
   gracilis, 332  
   lenticular, 343  
   of ovum, 17  
   of pons, 333  
   olivary, 333  
   ruber, 335
- OBEX, 332  
 Esophagus, 151, 177. See *Esophagus*  
 Olfactory bulb (lobe), 344  
   fossa, 369  
   nerves, 123, 335  
   organ, 369  
   placode, 369  
   tracts, 344  
 Olivary body, inferior, 333  
 Omental bursa, 197  
   inferior recess of, 198  
 Omentum, 141, 178, 199  
 Oöcyte, 28  
 Oögonia, 28  
 Operculum, 347  
 Optic chiasma, 328  
   cup, 67, 374  
   nerve, 123, 356  
   recess, 341  
   stalk, 374  
   vesicle, 49, 54, 328  
 Ora serrata, 379  
 Organ of Jacobson, 355, 372  
   spiral, 384  
 Ostium abdominale, 218  
   vaginae, 228  
 Otic vesicle, 55, 382  
 Otoconia, 384  
 Otocyst, 55, 67, 89, 100, 133, 382  
 Ova, primordial, 223



- Ovary, 221  
 compared with testis, 225  
 descent of, 230
- Ovulation, 20, 239
- Ovum, human, 17  
 implantation of, 239  
 maturation of, 28  
 structure of, amphibian, 17  
 bird, 17  
 frog, 35  
 monkey, 21  
 rabbit, 36
- PALATE, cleft, 158  
 hard, 155, 157  
 premaxillary, 371
- Pallium of cerebrum, 327
- Pancreas, human, 186  
 accessory duct of, 187  
 islands of, 188  
 pig, 104, 117, 127, 142
- Papillæ of tongue, 160  
 renal, 209  
 vallate, 161
- Paradidymis, 226, 237
- Parathyreoid gland, 90, 172
- Parolfactory area, 344
- Paroöphoron, 237
- Pars optica hypothalamica, 337
- Penis, 152, 237
- Perforated space, 344
- Perforatorium, 21
- Pericardial cavity, chick, 50  
 human, 188, 190
- Perichondrium, 294
- Periosteum, 297
- Peritoneum, 141, 291
- Phallus, 152, 232, 237
- Pharyngeal membrane, 53, 89  
 pouches, 90, 103, 125, 134, 169
- Pharynx, human, 89, 169  
 pig, 124
- Pia mater, 133
- Pig embryos, 41, 97, 120, 146, 148, 151  
 dissection of, 145  
 sections of 6 mm., 111  
 10 mm., 132
- Pigment layer of retina, 379
- Pillars of Corti, 384
- Pineal gland, 328
- Pituitary body, 337
- Placenta, human, 82, 245  
 cotyledons of, 249  
 intervillous spaces of, 249
- Placenta, human, position of, 250  
 relation of fetus to, 249  
 vessels of, 249  
 pig, 78
- Placodes, auditory, 55, 382  
 olfactory, 369  
 optic, 55, 374
- Plate, alar, 321, 330  
 basal, 321, 330  
 closing, 169  
 cutis, 119  
 floor, 321, 330  
 muscle, 119  
 neural, 309  
 notochordal, 40  
 roof, 321, 330  
 urethral, 232
- Pleura, 177
- Pleural cavity, 177
- Pleuro-pericardial cavity, 50, 190
- Pleuro-peritoneal cavity, 50, 188, 190
- Plexus, brachial, 353  
 cardiac, 365  
 chorioid, 150, 332, 336, 340  
 cœliac, 365  
 lumbo-sacral, 354
- Plica venæ cavæ, 142, 201, 282
- Polar bodies, 28
- Polocytes, 28
- Polydactylism, 84
- Polyspermy, 30
- Pons, 147, 329
- Pontine flexure, 147, 326
- Preformation theory, 11
- Pregnancy, abdominal, 30  
 tubular, 30
- Premyelocytes, 252
- Prepuce of clitoris, 233  
 of penis, 234
- Primary excretory ducts, 62, 204
- Primates, 77
- Primitive choanæ, 371  
 groove, 41, 61  
 knot, 44, 61  
 node, 44, 61  
 streak, 40, 61
- Proamniotic area, 44, 48
- Process, lateral nasal, 153, 370  
 mandibular, 87, 89, 98, 370  
 maxillary, 87, 89, 97, 370  
 median frontal, 370  
 nasal, 153, 370  
 palatine, 155, 373
- Pronephros, 203
- Pronuclei, union of, 30

- Pronucleus, 28, 29  
 Prosencephalon, 54, 325  
 Prostate gland, 235  
 Pyramidal cells, 349  
 Pyramids, 333  
   of kidney, 209
- QUADRATE lobe of liver, 201
- RAMUS communicans, 352, 364  
 Rathke's pocket, 67, 169  
 Receptaculum chyli, 287  
 Recess, lateral, 331  
 Rectum, 127, 143, 152  
 Reduction of chromosomes, 27  
 Reference, titles for, 15  
 Regression, 14  
 Renal anomalies, 213  
   arteries, 213  
   columns, 209  
   corpuscles, 206, 207  
   cortex, 209  
   papillæ, 209  
   pelvis, 207  
   pyramids, 209  
   tubules, 208  
 Respiratory epithelium, 291  
 Rete ovarii, 221, 225  
   testis, 220  
 Reticular formation, 332  
   tissue, 292  
 Retina, 378  
 Rhinencephalon, 147, 327, 339, 344  
 Rhombencephalon, 54, 89, 325  
 Rhombic lip, 332  
 Rhomboidal sinus, 49, 54, 67  
 Ridge, pulmonary, 193  
 Roots of spinal nerves, 139
- SACCULUS, 383  
 Saccus vaginalis, 231  
 Scalæ, 386  
 Sclerotome, 291  
 Scrotum, 234  
   ligament of, 230  
 Sections, chick, fifty-hours, 69  
   thirty-six-hours, 57  
   twenty-five-hours, 50  
   pig, 6 mm., 111  
   10 mm., 132  
 Seessel's pocket, 89, 101, 169  
 Segmental zone, 73  
 Segmentation of ovum, 33  
   Amphioxus, 33  
   frog, 34  
   mammals, 36  
   reptiles and birds, 35  
 Segments, primitive, 119. See *Mesodermal segments*  
 Seminal vesicle, 226  
 Sense organs, chick, 54, 66  
   human, 368  
   pig, 122  
 Septum, dorsal median, 321  
   interatrial, 259  
   interventricular, 264  
   membranaceum, 267  
   nasal, 372  
   pellucidum, 344  
   primum, 106, 260  
   secundum, 260  
   spurium, 128, 262  
   transversum, 91, 114, 140, 152, 188, 191  
 Sex, determination of, 31  
 Sheath, medullary, 316  
   mitochondria, 22  
   myelin, 316  
   neurilemma, 316  
 Sinus, cavernous, 133, 279  
   cervical, 97  
   coronary, 279  
   frontal, 373  
   lateral, 279  
   maxillary, 373  
   petrosal, 279  
   rhomboidal, 49, 55  
   sphenoidal, 373  
   superior sagittal, 279  
   urogenital, 85, 127, 142, 213, 218, 234  
   venous, 67, 137, 257, 261  
 Sinusoids of liver, 67, 184, 276  
 Somatopleure, 42, 63  
 Somites. See *Segments*  
 Spermatocord, 232  
 Spermatid, 26  
 Spermatocyte, 24  
 Spermatogenesis, 24  
 Spermatogonia, 24, 221  
 Spermatozoön, 21  
 Spinal cord, 320  
 Spireme, 23  
 Splanchnopleure, 42, 63  
 Spleen, 200, 288  
 Spongioblasts, 311  
 Stapes, 387  
 Stoerck's loop, 212  
 Stomodæum, 67

- Stomach, 89, 103, 115, 127, 141, 177  
 Stratum corneum, 305  
   germinativum, 304  
   granulosum, 224, 305  
   lucidum, 305  
 Streak, primitive, 40  
 Stroma of ovary, 223  
 Sulci of cerebrum, 349  
 Sulcus centrale, 348  
   coronary, 232  
   hypothalamicus, 328, 337  
   limitans, 321, 330, 337  
   spirale, 384  
   terminalis, 158  
 Suprarenal glands, 152  
 Sweat glands, 307  
 Sympathetic system, 364
- TACTILE corpuscles, 368  
 Tænia, 332  
 Tail-fold, 66  
 Tail-gut, 104  
 Tarsius, 39  
 Taste-buds, 368  
 Teeth, anlagen of, 162  
   cement of, 165  
   dental lamina of, 162  
     papilla, 162  
     pulp, 165  
     sac, 165  
   dentine, 165  
   enamel, 163  
   odontoblasts, 165  
 Tegmentum, 328  
 Tela chorioidea, 327  
 Telencephalon, chick, 66  
   human, 89, 339  
   pig, 100  
 Telolecithal ova, 33  
 Tendon, 293  
 Terminal nuclei, 332  
 Testis, 218  
   anomalies of, 221  
   cords, 220  
   descent of, 230  
   gubernaculum of, 230, 231  
   intermediate cords of, 220  
   interstitial cells of, 221  
   mediastinum, 220  
   rete, 220  
   tubuli contorti, 221  
     recti, 221  
     septula, 221  
 Tetrads, 27  
 Thalamus, 150, 328, 343  
 Theca folliculi, 224  
 Thomes' fibers, 165  
 Thymic corpuscles, 172  
 Thymus, 171  
 Thyreoglossal duct, 172  
 Thyreoid gland, 172  
   human, 91, 169, 172  
   pig, 102, 126  
 Tissue, adipose, 294  
   bone, 295  
   cartilage, 294  
   classification of, 64  
   connective, 292  
   differentiation of, 13  
   elastic, 293  
   muscle, 298  
   nervous, 309  
   origin of, 64  
   reticular, 292  
   supporting, 292  
   white fibrous, 292  
 Titles for reference, 15  
 Tongue of pig, 124, 151, 158  
 Tonsil, human, 159  
   origin of, 171  
   palatine, 90, 170  
 Trabeculae of liver, 184  
 Trachea, human, 173, 174  
   pig, 103, 126, 151  
 Tractus solitarius, 362  
 Triangular ligament of liver, 201  
 Trigeminal nerve, 100, 123, 359  
 Trophoctoderm, 36, 80, 239  
 Trophoderm, 81, 239, 243  
 Tuber cinereum, 328, 339  
 Tuberculum impar, 91, 102, 124, 159  
 Tubules of kidney, 211  
 Tubuli contorti, 221  
   recti, 22  
 Tunica albuginea, 220, 223  
   vaginalis, 231  
   vasculosa lentis, 375  
 Turbinal anlagen, 151  
 Tympanum, 386
- ULTIMOBRANCHIAL body, 172  
 Umbilical cord, human, 79  
   of pig, 79  
 Umbilicus, 79, 216  
 Unguiculates, 77  
 Ungulates, 36, 77, 82  
 Urachus, 85, 216  
 Ureter, 152, 207, 215  
 Urethra, 152, 213, 215, 234, 237  
 Urethral groove, 233  
 Uriniferous tubules, 211  
 Urogenital ducts, 153

- Urogeital folds, 216  
 organs, 92, 152, 203  
 sinus, 85, 127, 142, 213, 218, 234  
 system, 127, 203
- Uterine tube, 226
- Uterus, 226, 227, 238  
 anomalies of, 228  
 fundus of, 228  
 growth of, 228  
 ligaments of, 228, 229  
 masculinus, 227  
 menstrual changes of, 238
- Utriculus, 384
- Uvula, 158
- VAGINA, 226, 227  
 fornices of, 228  
 masculina, 226, 237
- Valves, bicuspid, 128, 267  
 Eustachian, 262  
 ileo-caecal, 182  
 of coronary sinus, 263  
 of sinus venosus, 128, 258, 261, 262  
 semilunar, 266  
 Thebesian, 263  
 tricuspid, 128, 267
- Veins, allantoic, of chick, 76, 77  
 anonymous, 171, 279  
 anterior cardinal, 68, 93, 109, 130, 268, 279  
 axillary, 283  
 azygos, 283  
 basilic, 283  
 brachial, 283  
 cephalic, 283  
 cerebral, 279  
 changes at birth, 286  
 common cardinal, 68, 93, 109, 269, 279  
 femoral, 284  
 gluteal, 284  
 hepatic, 278, 282  
 iliac, 281, 283  
 ischiadic, 284  
 jugular, 130, 279  
 linguo-facial, 109  
 lumbar, 283  
 mesenteric, superior, 278  
 of extremities, 283  
 of head, 279  
 of pig, 106, 107, 130  
 ophthalmic, 279  
 ovarian, 283  
 portal, 107, 132, 276  
 posterior cardinal, 68, 93, 109, 130, 269, 280  
 pulmonary, 177, 264  
 renal, 283  
 subcardinal, 109, 130, 281
- Veins, subclavian, 283  
 supracardinal, 283  
 suprarenal, 283  
 umbilical, human, 93, 276  
 pig, 107, 130  
 vitelline, 49, 93, 107, 132, 268, 276  
 vitello-umbilical, 93, 268
- Velum, medullary, 335
- Vena capitis lateralis, 279  
 medialis, 279  
 cava inferior, 111, 130, 282, 283  
 superior, 279  
 porta, 276, 278
- Venous system, 276
- Ventral roots, 313
- Ventricle, fifth, 344  
 first, 328  
 fourth, 329  
 lateral, 327  
 of heart, 67, 259, 264  
 terminal, 324  
 third, 328
- Vermiform process, 182
- Vermis cerebelli, 334
- Vernix caseosa, 83
- Vertebrae, human, 297  
 pig, 119, 149  
 centra of, 151
- Vesicle, brain, 320  
 branchial, 170  
 cerebral, 100  
 lens, 97  
 optic, 49, 54, 328  
 seminal, 226
- Vesico-urethral anlage, 213
- Vestibular glands, 235
- Vestibule, 383
- Villi, origin of, 82, 240  
 of chorion, 80, 240, 246  
 of intestine, 182  
 vessels of, 240
- Vitelline membrane, 48
- Vitreous body of eye, 377
- Vocal cords, 174
- WHOLE embryos for study, 146
- YOLK, 17  
 Yolk-cavity, 37  
 Yolk-sac, 75, 77, 85, 86  
 Yolk-stalk, 75, 79, 86, 87, 88, 168, 180
- ZONA pellucida, 17  
 Zone, segmental, 73  
 Zonula ciliata (of Zinn), 378





---

---

SAUNDERS' BOOKS

on

# Nervous and Mental Diseases, Children, Hygiene, Nursing, and Medical Jurisprudence

---

W. B. SAUNDERS COMPANY

WEST WASHINGTON SQUARE

PHILADELPHIA

9, HENRIETTA STREET

COVENT GARDEN, LONDON

---

---

## Dercum's Mental Diseases

**Clinical Manual of Mental Diseases.** By FRANCIS X. DERCUM, PH. D., M. D., Professor of Nervous and Mental Diseases at Jefferson Medical College, Philadelphia. Octavo of 425 pages. Cloth, \$3.00 net.

### TWO PRINTINGS IN FIVE MONTHS

This is a book *really useful to the family physician*—a book that tells you *definitely* how to diagnose, how to treat—either at home or in an institution—all classes of mental diseases. First, Dr. Dercum takes up the various primary forms of mental disease, giving emphasis to those you meet in your daily practice as general practitioner—delirium, confusion, stupor. Then melancholia, mania, the insanities of early life, paranoia, the neurasthenic-neuropathic disorders, and the dementias follow. The *mental disturbances of the infections* (syphilis, tuberculosis, malaria, pellagra, rheumatic fever, etc.), the various forms of intoxicational insanities, those due to metabolic disorders, visceral disease, diseases of the nervous system are all given you—and from *your* viewpoint. An important section is that devoted to the *insanities of pregnancy*. An entire part is devoted to the *psychologic interpretations of symptoms* as evolved by Freud and his disciples. You get a full discussion of the *rôle of dreams*.

### The Medical World

"This book gives just the information necessary, and gives it in a style studiously adapted to the needs of the general physician."

# Church and Peterson's Nervous *and* Mental Diseases

**Nervous and Mental Diseases.** By ARCHIBALD CHURCH, M. D., Professor of Nervous and Mental Diseases and Medical Jurisprudence, Northwestern University Medical School, Chicago; and FREDERICK PETERSON, M. D., formerly Professor of Psychiatry at the College of Physicians and Surgeons, N. Y. Handsome octavo, 944 pages; 350 illustrations. Cloth, \$5.00 net; Half Morocco, \$6.50 net.

## JUST OUT—THE NEW (8th) EDITION

For this *new (8th) edition* this standard work has undergone a thorough revision. Vertigo and its labyrinthine relations, as developed by Bárány, has received careful consideration; much new matter has been added to the section on Infantile Paralysis; syphilis of the nervous system has been brought into accord with recent epoch-making discoveries. Throughout, references to the new investigations of the spinal fluid, and the relation of spinal fluid changes to the various organic diseases of the brain and cord have been introduced. The bearing of internal secretion upon nervous disorders has been brought right down to date. Tetany has been given its place among nervous diseases associated with glandular disorder. Altogether over 300 interpolations and alterations have been made. It is more than ever *the standard*.

### American Journal of the Medical Sciences

"This edition has been revised, new illustrations added, and some new matter, and really is two books. . . . The descriptions of disease are clear, directions as to treatment definite, and disputed matters and theories are omitted. Altogether it is a most useful text-book."

# Kaplan's Serology of Nervous and Mental Diseases

**Serology of Nervous and Mental Diseases.** By D. M. KAPLAN, M. D., Director of Clinical and Research Laboratories, Neurological Institute, New York City. Octavo of 346 pages, illustrated. Cloth, \$3.50 net.

## JUST READY

This is an entirely new work, giving you the indications, contra-indications, preparation of patients, technic, after-phenomena, after-care, and disposal of the fluids obtained by lumbar puncture. You get a full discussion of the serology of all nervous and mental diseases of *non-luetic* etiology (including disorders of *internal secretion*), and of every type of *luetic* nervous and mental disease, giving the *Wassermann reaction in detail*, the use of *salvarsan* and *neosalvarsan*, etc.



---

# Brill's Psychanalysis

THE PRACTICAL APPLICATION OF ALL FREUD'S THEORIES

**Psychanalysis:** Its Theories and Practical Application. By A. A. BRILL, PH. B., M. D., Clinical Assistant in Neurology at Columbia University Medical School. Octavo of 392 pages. Cloth, \$3.00 net.

NEW (2d) EDITION

To the general practitioner, who first sees these "borderline" cases (the neuroses and the psychoses), as well as to those specially interested in neurologic work, Dr. Brill's work will prove most valuable. Dr. Brill has had wide clinical experience, both in America and in Europe. The results of this experience you get in this book. Here you get the practical application of all Freud's theories—and from the pen of a man thoroughly competent to write.

Unlike other forms of psychotherapy, psychanalysis deals with the neuroses as *entities*. It does not treat them as symptoms, as do hypnotism, suggestion, and persuasion. Such treatment is similar to treating the cough or fever regardless of the causal disease. Psychanalysis concerns itself with the individual as a personality. It gives you a real insight into the neuroses and the psychoses.

**Journal American Medical Association**

"A splendid summary of Freud's writings. We believe this book to be the best one-volume exposition of the Freudian doctrine that has been written for the non-specialist."

---

## Hunt's Diagnostic Symptoms of Nervous Diseases

**Diagnostic Symptoms of Nervous Diseases.** By EDWARD L. HUNT, M. D., formerly Instructor in Neurology and Assistant Chief of Clinic, College of Physicians and Surgeons, New York. 12mo of 229 pages, illustrated. Cloth, \$1.50 net.

## Stiles on the Nervous System

Just Out

**The Nervous System and its Conservation.** By PERCY G. STILES, Instructor in Physiology at Harvard University. 12mo of 230 pages, illustrated. Cloth, \$1.25 net.

# American Illustrated Dictionary

New (7th) Edition—5000 Sold in Two Months

**The American Illustrated Medical Dictionary.** A new and complete dictionary of the terms used in Medicine, Surgery, Dentistry, Pharmacy, Chemistry, Veterinary Science, Nursing, and kindred branches; with over 100 new and elaborate tables and many handsome illustrations. By W. A. NEWMAN DORLAND, M. D. Large octavo, 1107 pages, bound in full flexible leather, \$4.50 net; with thumb index, \$5.00 net.

The American Illustrated Medical Dictionary defines hundreds of terms not defined in any other dictionary—bar none. It gives the capitalization and pronunciation of all words. It makes a feature of the derivation or etymology of the words. Every word has a separate paragraph, thus making it easy to find a word quickly. The tables of arteries, muscles, nerves, veins, etc., are of the greatest help in assembling anatomic facts. Every word is given its definition—a definition that *defines* in the fewest possible words.

**Howard A. Kelly, M. D.,** *Johns Hopkins University, Baltimore.*

"The American Illustrated Dictionary is admirable. It is so well gotten up and of such convenient size. No errors have been found in my use of it."

---

## Goodnow's First-Year Nursing

**First-Year Nursing.** By MINNIE GOODNOW, R. N., formerly Superintendent of the Women's Hospital, Denver. 12mo of 328 pages, illustrated. Cloth, \$1.50 net.

Miss Goodnow's work deals *entirely* with the *practical* side of first-year nursing work. It is the *application* of text-book knowledge. It tells the nurse *how* to do those things she is called upon to do in her first year in the training school—the *actual ward work*.

## Roberts' Bacteriology and Pathology for Nurses

**Bacteriology and Pathology for Nurses.** By JAY G. ROBERTS, PH. G., M. D., Oskaloosa, Iowa. 12mo of 206 pages, illustrated. Cloth, \$1.25 net.

This new work is practical in the strictest sense. Written specially for nurses, it confines itself to information that the nurse should know. All unessential matter is excluded. The style is concise and to the point, yet clear and plain. The text is illustrated throughout.

---

# Kerr's Diagnostics of Diseases of Children

---

**Diagnostics of the Diseases of Children.** By LEGRAND KERR, M. D., Professor of Diseases of Children, Brooklyn Postgraduate Medical School, Brooklyn. Octavo of 542 pages, fully illustrated. Cloth, \$5.00 net; Half Morocco, \$6.50 net.

## FOR THE PRACTITIONER

Dr. Kerr's work differs from all others on the diagnosis of diseases of children in that the *objective symptoms* are particularly emphasized. The constant aim throughout has been to render a correct diagnosis as early in the course of the disease as possible, and for this reason differential diagnosis is presented from the very earliest symptoms. The many original illustrations will be found helpful.

### New York State Journal of Medicine

"The illustrations are excellent and numerous. It will meet the needs of the great mass of physicians who treat the diseases of infancy and childhood."

---

# Kerley's Pediatrics

---

**Practice of Pediatrics.** By CHARLES GILMORE KERLEY, M. D., Professor of Diseases of Children, New York Polyclinic Medical School and Hospital. Octavo of 878 pages, illustrated. Cloth, \$6.00 net; Half Morocco, \$7.50 net,

## THREE LARGE PRINTINGS IN EIGHT MONTHS

This work is not a cut-and-dried treatise—but the *practice* of pediatrics, giving fullest attention to *diagnosis* and *treatment*. The chapters on the newborn and its diseases, the feeding and growth of the baby, the care of the mother's breasts, artificial feeding, milk modification and sterilization, diet for older children—from a monograph of 125 pages. Then are discussed in detail every disease of childhood, *telling just what measures should be instituted*, what drugs given, *60 valuable prescriptions* being included. The chapter on *vaccine therapy* is right down to the minute, including every new method of proved value—with the exact technic. There is an excellent chapter on *Gymnastic Therapeutics*. Another feature consists of the *165 illustrative cases—case teaching* of the most practical sort.

**Dr. A. D. Blackader, McGill University, Montreal**

"Dr. Kerley is a pediatrician of large experience who thinks for himself and is never content to accept, without testing, the experiences or statements of previous writers. His book has a very definite value."

---

## Sanders' Nursing

**Modern Methods in Nursing.** By GEORGIANA J. SANDERS, formerly Superintendent of Nurses at the Massachusetts General Hospital. 12mo of 881 pages, with 227 illustrations. Cloth, \$2.50 net.

### THE BEST YET

Miss Sanders' book gives only *modern* methods. Then it gives the *details* of nursing *operation cases*, both in the hospital and in the home. The thorough way in which *ward work* is taken up makes her book indispensable for teaching purposes. In giving directions for mustard baths, poultices, etc., the *quantities* are given exactly. This is an important point often overlooked.

---

## Stoney's Nursing

**Practical Points in Nursing.** By EMILY A. M. STONEY. 12mo of 495 pages, illustrated. Cloth, \$1.75 net.

### THE NEW (4th) EDITION

In this volume the author explains the entire range of *private* nursing as distinguished from *hospital* nursing, and the nurse is instructed how best to meet the various emergencies of medical and surgical cases when distant from medical or surgical aid or when thrown on her own resources. An especially valuable feature will be found in the directions how to *improvise* everything ordinarily needed in the sick-room.

---

## Stoney's Technic for Nurses

**Bacteriology and Surgical Technic for Nurses.** By EMILY A. M. STONEY, formerly Superintendent at Carney Hospital, South Boston. Revised by FREDERIC R. GRIFFITH, M. D., Surgeon, of New York. 12mo, 311 pages, illustrated. Cloth, \$1.50 net.

### THE NEW (3d) EDITION

#### Trained Nurse and Hospital Review

"These subjects are treated most accurately and up to date, without the superfluous reading which is so often employed. . . . Nurses will find this book of the greatest value both during their hospital course and in private practice."

---

# Nursing in Diseases of the Eye, Ear, Nose, and Throat

**Nursing in Diseases of the Eye, Ear, Nose, and Throat.** By the Committee on Nurses of the Manhattan Eye, Ear, and Throat Hospital: J. EDWARD GILES, M. D., Surgeon in the Eye Department; ARTHUR B. DUEL, M. D. (Chairman), Surgeon in the Ear Department; HARMON SMITH, M. D., Surgeon in the Throat Department. Assisted by JOHN R. SHANNON, M. D., Assistant Surgeon in the Eye Department; and JOHN R. PAGE, M. D., Assistant Surgeon in the Ear Department. With chapters by HERBERT B. WILCOX, M. D., Attending Physician to the Hospital; and Miss EUGENIA D. AYERS, Superintendent of Nurses. 12mo of 260 pages, illustrated. Cloth, \$1.50 net.

## A VALUABLE BOOK

This is a practical book, prepared by surgeons who, from their experience in the operating amphitheater and at the bedside, have realized the shortcomings of present nursing books in regard to eye, ear, nose, and throat nursing. The scope of the work has been limited to what an intelligent nurse should know, and the style throughout is simple, plain, and definite.

**New York Medical Journal**

"Every side of the question has been fully taken into consideration."

---

# Stoney's Materia Medica for Nurses

**Practical Materia Medica for Nurses**, with an Appendix containing Poisons and their Antidotes, with Poison-Emergencies; Mineral Waters; Weights and Measures; Dose-List, and a Glossary of the Terms used in Materia Medica and Therapeutics. By EMILY A. M. STONEY, formerly of the Carney Hospital, South Boston. 12mo of 300 pages, Cloth, \$1.50 net.

## THE NEW (3d) EDITION

In making the revision for this new third edition, all the newer drugs have been introduced and fully discussed. The consideration of the drugs includes their sources and composition, their various preparations, physiologic actions, directions for administering, and the symptoms and treatment of poisoning.

**Journal of the American Medical Association**

"So far as we can see, it contains everything that a nurse ought to know in regard to drugs. As a reference-book for nurses it will without question be very useful."

## Hoxie and Laptad's Medicine for Nurses New (2d) Edition

**Medicine for Nurses and Housemothers.** By GEORGE HOWARD HOXIE, M. D., Physician to the German Hospital, Kansas City, Mo.; and PEARL L. LAPTAD, formerly Principal of the Training School for Nurses, University of Kansas. 12mo of 351 pages, illustrated. Cloth, \$1.50 net.

This work is truly a practice of medicine for the nurse, enabling her to recognize any signs and changes that may occur between visits of the physician, and, if necessary, to combat them until the physician's arrival. This information the author presents in a way most acceptable, particularly emphasizing the nurse's part.

### Crained Nurse and Hospital Review

"This book has our unqualified approval."

## McCombs' Diseases of Children for Nurses New (2d) Edition

**Diseases of Children for Nurses.** By ROBERT S. MCCOMBS, M. D., Instructor of Nurses at the Children's Hospital of Philadelphia. 12mo of 470 pages, illustrated. Cloth, \$2.00 net.

Dr. McCombs' experience in lecturing to nurses has enabled him to emphasize *just those points that nurses most need to know*. The nursing side has been written by head nurses, especially praiseworthy being the work of Miss Jennie Manly.

### National Hospital Record

"We have needed a good work on children's diseases adapted for nurses' use, and this volume admirably fills the want."

## Wilson's Obstetric Nursing The New (2d) Edition

**A Reference Hand-Book of Obstetric Nursing.** By W. REYNOLDS WILSON, M. D., Visiting Physician to the Philadelphia Lying-in Charity. 32mo of 256 pages, illustrated. Flexible leather, \$1.25 net.

Dr. Wilson's work discusses the subject of obstetrics entirely from the nurse's point of view, presenting in detail everything connected with pregnancy and labor and their management. The text is copiously illustrated.

### American Journal of Obstetrics

"Every page emphasizes the nurse's relation to the case."

## Frühwald and Westcott on Children

**Diseases of Children.** A Practical Reference Book for Students and Practitioners. By PROFESSOR DR. FERDINAND FRÜHWALD, of Vienna. Edited, with additions, by THOMPSON S. WESTCOTT, M. D., University of Pennsylvania. Octavo, 533 pages, 176 illustrations. Cloth, \$4.50 net.

## Boyd's State Registration for Nurses

**State Registration for Nurses.** By LOUIE CROFT BOYD, R. N., Graduate Colorado Training-school for Nurses. Octavo of 42 pages. 50 cents net.

**Aikens' Primary Studies for Nurses****New (2d) Edition**

PRIMARY STUDIES FOR NURSES: A Text-Book for First-year Pupil Nurses. By CHARLOTTE A. AIKENS, formerly Director of Sibley Memorial Hospital, Washington, D. C. 12mo of 437 pages, illus. Cloth, \$1.75 net.

This work brings together in concise form well-rounded courses of lessons in all subjects which, with practical nursing technic, constitute the primary studies in a nursing course.

**Trained Nurse and Hospital Review**

"It is safe to say that any pupil who has mastered even the major portion of this work would be one of the best prepared first-year pupils that ever stood for examination."

**Aikens' Clinical Studies for Nurses****New (2d) Edition**

CLINICAL STUDIES FOR NURSES. By CHARLOTTE A. AIKENS, formerly Director of Sibley Memorial Hospital, Washington, D. C. 12mo of 569 pages, illustrated. Cloth, \$2.00 net.

This new work is written along the same lines as Miss Aikens' former work on "Primary Studies," to which it is a companion volume. It takes up all subjects taught during the second and third years and takes them up in a concise, forceful way.

**Dietetic and Hygienic Gazette**

"There is a large amount of practical information in this book which the experienced nurse, as well as the undergraduate, will consult with profit. The illustrations are numerous and well selected."

**Aikens' Training-School Methods**

HOSPITAL TRAINING-SCHOOL METHODS AND THE HEAD NURSE. By CHARLOTTE A. AIKENS, formerly Director of Sibley Memorial Hospital, Washington, D. C. 12mo of 267 pages. Cloth, \$1.50 net.

**Trained Nurse and Hospital Review**

"There is not a chapter in the book that does not contain valuable suggestions."

**Aikens' Hospital Management****Extremely Practical**

HOSPITAL MANAGEMENT. By CHARLOTTE A. AIKENS, formerly Director of Sibley Memorial Hospital, Washington, D. C. 12mo of 488 pages, illustrated. Cloth, \$3.00 net.

**The Medical Record**

"Tells in concise form exactly what a hospital should do and how it should be run, from the scrubwoman up to its financing. A valuable addition to our literature on this subject."

## Bolduan and Grund's Bacteriology for Nurses

APPLIED BACTERIOLOGY FOR NURSES. By CHARLES F. BOLDUAN, M. D., Assistant to the General Medical Officer; and MARIE GRUND, M. D., Bacteriologist, Research Laboratory, Department of Health, New York City. 12mo of 155 pages, illustrated. Cloth, \$1.25 net.

We were fortunate in getting these practical physicians to write this work. It gives particular emphasis to the immediate *application* of bacteriology to nursing, only the really practical being included. A study of all the modes of infection transmission is presented. At the end of each chapter are suggestions for practical demonstration.

## Register's Fever Nursing

A TEXT-BOOK ON PRACTICAL FEVER NURSING. By EDWARD C. REGISTER, M. D., Professor of the Practice of Medicine in the North Carolina Medical College. 12mo of 352 pages. Cloth, \$2.50 net.

## Hecker, Trumpp, and Abt on Children

ATLAS AND EPITOME OF DISEASES OF CHILDREN. By Dr. R. HECKER and Dr. J. TRUMPP, of Munich. Edited, with additions, by ISAAC A. ABT, M. D., Assistant Professor of Diseases of Children, Rush Medical College, Chicago. With 48 colored plates, 144 text-cuts, and 453 pages of text. Cloth, \$5.00 net.

The many excellent lithographic plates represent cases seen in the authors' clinics, and have been selected with great care, keeping constantly in mind the practical needs of the general practitioner. These beautiful pictures are so true to nature that their study is equivalent to actual clinical observation. The editor, Dr. Isaac A. Abt, has added all new methods of treatment.

## Lewis' Anatomy and Physiology The New (3d) Edition

ANATOMY AND PHYSIOLOGY FOR NURSES. By LEROY LEWIS, M. D., Formerly Surgeon to and Lecturer on Anatomy and Physiology for Nurses at the Lewis Hospital, Bay City, Michigan. 12mo of 344 pages, with 161 illustrations. Cloth, \$1.75 net.

A demand for such a work as this, *treating the subjects from the nurses' point of view*, has long existed. Dr. Lewis has based the plan and scope of this work on the methods employed by him in teaching these branches, making the text unusually simple and clear.

### The Nurses Journal of the Pacific Coast

"It is not in any sense rudimentary, but comprehensive in its treatment of the subjects in hand. The application of the knowledge of anatomy in the care of the patient is emphasized."

## Friedenwald and Ruhrah's Dietetics New (3d) Edition

DIETETICS FOR NURSES. By JULIUS FRIEDENWALD, M. D., Professor of Diseases of the Stomach, and JOHN RUHRÄH, M. D., Professor of Diseases of Children, College of Physicians and Surgeons, Baltimore. 12mo volume of 431 pages. Cloth, \$1.50 net.

This work has been prepared to meet the needs of the nurse, both in the training school and after graduation. It aims to give the essentials of dietetics, considering briefly the physiology of digestion and the various classes of foods and the part they play in nutrition.

### American Journal of Nursing

"It is exactly the book for which nurses and others have long and vainly sought. A simple manual of dietetics, which does not turn into a cook-book at the end of the first or second chapter.



**Paul's Fever Nursing****New (2d) Edition**

NURSING IN THE ACUTE INFECTIOUS FEVERS. By GEORGE P. PAUL, M. D., formerly Assistant Visiting Physician to the Samaritan Hospital, Troy, N. Y. 12mo of 246 pages. Cloth, \$1.00 net.

Dr. Paul has taken great pains in the presentation of the care and management of each fever. The book treats of fevers in general, then each fever is discussed individually, and the latter part of the book deals with practical procedures and valuable information.

**The London Lancet**

"The book is an excellent one and will be of value to those for whom it is intended. It is well arranged, the text is clear and full, and the illustrations are good."

**Paul's Materia Medica for Nurses****New (2d) Edition**

MATERIA MEDICA FOR NURSES. By GEORGE P. PAUL, M. D., formerly Assistant Visiting Physician to the Samaritan Hospital, Troy. 12mo of 282 pages. Cloth, \$1.50 net.

Dr. Paul arranges the physiologic actions of the drugs according to the action of the drug and not the organ acted upon. An important section is that on pretoxic signs, giving the warnings of the full action or the beginning toxic effects of the drug, which, if heeded, may prevent many cases of drug poisoning.

**The Medical Record, New York**

"This volume will be of real help to nurses; the material is well selected and well arranged, and the book is as readable as it is useful."

**Pyle's Personal Hygiene****The New (5th) Edition**

A MANUAL OF PERSONAL HYGIENE: Proper Living upon a Physiologic Basis. By Eminent Specialists. Edited by WALTER L. PYLE, A. M., M. D., Assistant Surgeon to Wills Eye Hospital, Philadelphia. Octavo volume of 515 pages, fully illustrated. Cloth, \$1.50 net.

The book has been thoroughly revised for this new edition, and a new chapter on Food Adulteration by *Dr. Harvey W. Wiley* added. There are important chapters on Domestic Hygiene and Home Gymnastics, Hydrotherapy, Mechanotherapy, and First Aid Measures.

**Boston Medical and Surgical Journal**

"The work has been excellently done, there is no undue repetition, and the writers have succeeded unusually well in presenting facts of practical significance based on sound knowledge."

**Galbraith's Four Epochs of Woman's Life** **Second Edition**

THE FOUR EPOCHS OF WOMAN'S LIFE. By ANNA M. GALBRAITH, M. D. With an Introductory Note by JOHN H. MUSSER, M. D., University of Pennsylvania. 12mo of 247 pages. Cloth, \$1.50 net.

**Birmingham Medical Review**

"We do not as a rule care for medical books written for the instruction of the public; but we must admit that the advice in Dr. Galbraith's work is in the main wise and wholesome."

**Spratling on Epilepsy**

EPILEPSY AND ITS TREATMENT. By WILLIAM P. SPRATLING, M. D., Professor of Physiology and Nervous Diseases, College of Physicians and Surgeons, Baltimore. Octavo of 522 pages, fully illustrated. Cloth, \$4.00 net.

**The Lancet, London**

"Dr. Spratling's work is written throughout in a clear and readable style. . . . The work is a mine of information on the whole subject of epilepsy and its treatment."

## Macfarlane's Gynecology for Nurses New (2d) Edition

A REFERENCE HAND-BOOK OF GYNECOLOGY FOR NURSES. By CATHARINE MACFARLANE, M. D., Gynecologist to the Woman's Hospital of Philadelphia. 16mo of 150 pages, with 70 illustrations. Flexible leather, \$1.25 net.

**A. M. Seabrook, M. D.,** *Woman's Medical College of Philadelphia.*

"It is a most admirable little book, covering in a concise but attractive way the subject from the nurse's standpoint."

## Galbraith's Personal Hygiene for Women

PERSONAL HYGIENE AND PHYSICAL TRAINING FOR WOMEN. By ANNA M. GALBRAITH, M.D., Fellow New York Academy of Medicine, 12mo of 371 pages, with original illustrations. Cloth, \$2.00 net.

### Dietetic and Hygienic Gazette

"It contains just the sort of information which is very greatly needed by the weaker sex. Its illustrations are excellent."

## De Lee's Obstetrics for Nurses New (4th) Edition

OBSTETRICS FOR NURSES. By JOSEPH B. DE LEE, M. D., Professor of Obstetrics in the Northwestern University Medical School. 12mo volume of 508 pages, fully illustrated. Cloth, \$2.50 net.

**J. Clifton Edgar, M. D.,**

*Professor of Obstetrics and Clinical Midwifery, Cornell Medical School, N. Y.*

"It is far-and-away the best that has come to my notice, and I shall take great pleasure in recommending it to my nurses and students as well."

## Davis' Obstetric Nursing New (4th) Edition

OBSTETRIC AND GYNECOLOGIC NURSING. By EDWARD P. DAVIS, A. M., M. D., Professor of Obstetrics, Jefferson Medical College and Philadelphia Polyclinic. 12mo of 480 pages, illustrated. Buckram, \$1.75 net.

**The Lancet, London**

"Not only nurses, but even newly qualified medical men, would learn a great deal by a perusal of this book. It is written in a clear and pleasant style, and is a work we can recommend."

## Beck's Hand-Book for Nurses New (2d) Edition

A REFERENCE HAND-BOOK FOR NURSES. By AMANDA K. BECK, of Chicago, Ill. 32mo of 200 pages. Flexible leather, \$1.25 net.

## Aikens' Home Nurse's Hand-Book

HOME NURSE'S HAND-BOOK. By CHARLOTTE A. AIKENS. 12mo of 276 pages, illustrated. Cloth, \$1.50 net.

The point about this work is this: It tells you and *shows* you just how to do those little but important things often omitted from other nursing books. "Home Treatments" and "Points to be Remembered"—terse, crisp reminders—stand out as particularly practical. Just the book for those who have the *home-care* of the sick.

## Griffith's Care of the Baby

**The Care of the Baby.** By J. P. CROZER GRIFFITH, M. D., Clinical Professor of Diseases of Children, University of Penn.; Physician to the Children's Hospital, Phila. 12mo, 455 pp. Illustrated. Cloth, \$1.50 net.

### THE NEW (5th) EDITION

The author has endeavored to furnish a reliable guide for mothers. He has made his statements plain and easily understood, so that the volume will be of service to mothers and nurses.

#### New York Medical Journal

"We are confident if this little work could find its way into the hands of every trained nurse and of every mother, infant mortality would be lessened by at least fifty per cent."

## Grulee's Infant Feeding

**Infant Feeding.** By CLIFFORD G. GRULEE, M. D., Assistant Professor of Pediatrics at Rush Medical College. Octavo of 316 pages, illustrated, including 8 in colors. Cloth, \$3.00 net.

### NEW (2d) EDITION

Dr. Grulee tells you *how* to feed the infant. He tells you—and *shows* by clear illustrations—the *technic* of giving the child the breast. Then artificial feeding is thoughtfully presented, including a number of simple formulas. The colored illustrations showing the actual shapes and appearances of stools are extremely valuable.

## Ruhräh's Diseases of Children

**A Manual of Diseases of Children.** By JOHN RUHRÄH, M. D., Professor of Diseases of Children, College of Physicians and Surgeons, Baltimore. 12mo of 534 pages, fully illustrated. Flexible leather, \$2.50 net.

### THE NEW (3d) EDITION

In revising this work for the second edition Dr. Ruhräh has carefully incorporated all the latest knowledge on the subject. All the important facts are given concisely and explicitly, the therapeutics of infancy and childhood being outlined very carefully and clearly. There are also directions for dosage and prescribing, and many useful prescriptions are included.

#### American Journal of the Medical Sciences

"Treatment has been satisfactorily covered, being quite in accord with the best teaching, yet withal broadly general and free from stock prescriptions."

## Keefers' Military Hygiene

**Military Hygiene and Sanitation.** By LIEUT.-COL. FRANK R. KEEFER, Professor of Military Hygiene, United States Military Academy, West Point. 12mo of 305 pages, illustrated. Cloth, \$1.50 net.

### JUST READY

This is a concise, though complete text-book on this subject, containing chapters on the care of troops, recruits and recruiting, personal hygiene, physical training, preventable diseases, clothing, equipment, water-supply, foods and their preparation, hygiene and sanitation of posts and barracks, the troopship, hygiene and sanitation of marches, camps, and battlefields, disposal of wastes, tropical and arctic service, venereal diseases, alcohol and other narcotics, and a glossary.

## Bergey's Hygiene

**The Principles of Hygiene:** A Practical Manual for Students, Physicians, and Health Officers. By D. H. BERGEY, A. M., M. D., Assistant Professor of Bacteriology in the University of Pennsylvania. Octavo volume of 555 pages, illustrated. Cloth, \$3.00 net.

### JUST ISSUED—NEW (5th) EDITION

This book is intended to meet the needs of students of medicine in the acquirement of a knowledge of those principles upon which modern hygienic practises are based, and to aid physicians and health officers in familiarizing themselves with the advances made in hygiene and sanitation in recent years. This fifth edition has been very carefully revised, and much new matter added, so as to include the most recent advancements.

### Buffalo Medical Journal

"It will be found of value to the practitioner of medicine and the practical sanitarian; and students of architecture, who need to consider problems of heating, lighting, ventilation, water supply, and sewage disposal, may consult it with profit."

## Fiske's Human Body

**Structure and Functions of the Body.** By ANNETTE FISKE, A.M., Graduate of the Waltham Training School for Nurses. 12mo of 221 pages, illustrated. Cloth, \$1.25 net.

## Bohm and Painter's Massage

**Massage.** By MAX BÖHM, M. D., of Berlin, Germany. Edited, with an Introduction, by CHARLES F. PAINTER, M. D., Professor of Orthopedic Surgery at Tufts College Medical School, Boston. Octavo of 91 pages, with 70 *practical* illustrations. Cloth, \$1.75 net.

## Draper's Legal Medicine

**A Text-Book of Legal Medicine.** By FRANK WINTHROP DRAPER, A. M., M. D., Late Professor of Legal Medicine in Harvard University, Boston. Octavo of 573 pages, illustrated. Cloth, \$4.00 net; Half Morocco, \$5.50 net.

## Chapman's Medical Jurisprudence

Third Edition

**Medical Jurisprudence, Insanity, and Toxicology.** By HENRY C. CHAPMAN, M. D., late Professor of Institutes of Medicine and Medical Jurisprudence in Jefferson Medical College, Philadelphia. 12mo of 329 pages, illustrated. Cloth, \$1.75 net.

## Golebiewski and Bailey's Accident Diseases

**Atlas and Epitome of Diseases Caused by Accidents.** By DR. ED. GOLEBIEWSKI, of Berlin. Edited, with additions, by PEARCE BAILEY, M. D., Consulting Neurologist to St. Luke's Hospital, New York. With 71 colored illustrations on 40 plates, 143 text illustrations, and 549 pages of text. Cloth, \$4.00 net. *In Saunders' Hand-Atlas Series.*

## Hofmann and Peterson's Legal Medicine

In Saunders' Hand-Atlases

**Atlas of Legal Medicine.** By DR. E. VON HOFMANN, of Vienna. Edited by FREDERICK PETERSON, M. D., Professor of Psychiatry in the College of Physicians and Surgeons, New York. With 120 colored figures on 56 plates and 193 half-tone illustrations. Cloth, \$3.50 net.

## Jakob and Fisher's Nervous System

Saunders' Atlases

**Atlas and Epitome of the Nervous System and its Diseases.** By PROFESSOR DR. CHR. JAKOB, of Erlangen. Edited, with additions, by EDWARD D. FISHER, M. D., University and Bellevue Hospital Medical College. With 83 plates and copious text. Cloth, \$3.50 net.

## Crothers' Morphinism and Narcomania

**Morphinism and Narcomania.** By T. D. CROTHERS, M. D. 12mo of 351 pages. Cloth, \$2.00 net.

## Peterson and Haines' Legal Medicine and Toxicology

A thoroughly revised edition of this work is now in press. Every advance in these related subjects will be included, bringing the work right down to date.

**American Pocket Dictionary**

New (8th) Edition

AMERICAN POCKET MEDICAL DICTIONARY. Edited by W. A. NEWMAN DORLAND, M. D., Editor "American Illustrated Medical Dictionary." Containing the pronunciation and definition of the principal words used in medicine and kindred sciences, with 64 extensive tables. With 677 pages. Flexible leather, with gold edges, \$1.00 net; with patent thumb index, \$1.25 net.

"I can recommend it to our students without reserve."—J. H. HOLLAND, M. D., *Dean of the Jefferson Medical College, Philadelphia.*

**Morrow's Immediate Care of Injured**

New (2d) Edition

IMMEDIATE CARE OF THE INJURED. By ALBERT S. MORROW, M. D., Adjunct Professor of Surgery at the New York Polyclinic. Octavo of 360 pages, with 242 illustrations. Cloth, \$2.50 net.

Dr. Morrow's book on emergency procedures is written in a definite and decisive style, the reader being told just what to do in every emergency. It is a practical book for every day use, and the large number of excellent illustrations can not but make the treatment to be pursued in any case clear and intelligible. Physicians and nurses will find it indispensable.

**Powell's Diseases of Children**

Third Edition, Revised

ESSENTIALS OF THE DISEASES OF CHILDREN. By WILLIAM M. POWELL, M. D. Revised by ALFRED HAND, JR., A. B., M. D., Dispensary Physician and Pathologist to the Children's Hospital, Philadelphia. 12mo volume of 259 pages. Cloth, \$1.00 net. *In Saunders' Question-Compend Series.*

**Shaw on Nervous Diseases and Insanity**

Fifth Edition

ESSENTIALS OF NERVOUS DISEASES AND INSANITY: Their Symptoms and Treatment. A Manual for Students and Practitioners. By the late JOHN C. SHAW, M. D., Clinical Professor of Diseases of the Mind and Nervous System, Long Island College Hospital, New York. 12mo of 204 pages, illustrated. Cloth, \$1.00 net. *In Saunders' Question-Compend Series.*

"Clearly and intelligently written; we have noted few inaccuracies and several suggestive points. Some affections unmentioned in many of the large text-books are noted."—*Boston Medical and Surgical Journal.*

**Starr's Diets for Infants and Children**


DIETS FOR INFANTS AND CHILDREN IN HEALTH AND IN DISEASE. By LOUIS STARR, M. D., Consulting Pediatricist to the Maternity Hospital, Philadelphia. 230 blanks (pocket-book size). Bound in flexible leather, \$1.25 net.

**Grafstrom's Mechano-Therapy**


Second Revised Edition

A TEXT-BOOK OF MECHANO-THERAPY (Massage and Medical Gymnastics). By AXEL V. GRAFSTROM, B. Sc., M. D., Attending Physician to the Gustavus Adolphus Orphanage, Jamestown; New York. 12mo, 200 pages, illustrated. Cloth, \$1.25 net.









**DATE DUE SLIP**

UNIVERSITY OF CALIFORNIA MEDICAL SCHOOL LIBRARY

**THIS BOOK IS DUE ON THE LAST DATE  
STAMPED BELOW**

APR 4 1927

APR 15 1927

DEC 27 1929

NOV 22 1934

SEP 11 1944

APR 16 1945

NOV 11 1945

JUN 7 1948

Sep 30 48

Oct 8 48

Oct 15 48

Oct 25 48

This book may be kept

**7 Days**  
only

**It Cannot Be Renewed  
Because of special demand**

UNIVERSITY OF CALIFORNIA MEDICAL SCHOOL LIBRARY


18755

Library of the  
University of California Medical School  
and Hospitals

1m-9, '25

