




Digitized by the Internet Archive  
in 2007 with funding from  
Microsoft Corporation



ANATOMY

PRINTED BY  
SPOTTISWOODE AND CO., NEW-STREET SQUARE  
LONDON



A

# MANUAL OF ANATOMY

FOR SENIOR STUDENTS

BY

EDMUND LOWEN, M.B., F.R.C.S.

SURGEON TO ST MARY'S HOSPITAL, LONDON, AND CO-LECTURER ON SURGERY  
(LATE LECTURER ON ANATOMY) IN ITS MEDICAL SCHOOL

*'In a practical point of view Anatomy is of no use unless  
it can be realised on the living body'*—Francis Sibson

Qm31

097

1890

WITH NUMEROUS ILLUSTRATIONS

LONDON

LONGMANS, GREEN, AND CO.

AND NEW YORK : 15 EAST 16<sup>th</sup> STREET

1890

75816

All rights reserved

1110 10 1111  
10110 10111

TO THE MEMORY OF  
FRANCIS SIBSON,  
AND TO  
SAMUEL ARMSTRONG LANE,  
HIS EARLIEST TEACHERS  
IN  
MEDICAL AND SURGICAL ANATOMY,

THIS BOOK IS DEDICATED

BY

*THE AUTHOR.*

75816



## PREFACE

WHEN about to vacate the Chair of Anatomy which, for twelve years, I had occupied in the Medical School of St. Mary's Hospital, I desired to leave some permanent record of my work which might prove of interest and assistance to Senior Students.

Having always found it impracticable to draw a hard-and-fast line between facts which bear upon the Science of Medicine and those which chiefly concern the Practical Surgeon, I, a surgeon, have presumed in this MANUAL boldly to trespass upon the domains of the Physician, as well as of the Specialist.

Most of the ground has, I am aware, been already covered, especially as regards so-called Surgical Anatomy. But the entire range of Anatomy has not hitherto, I think, been treated from the point of view of the Senior Student, who, having quitted the dissecting-room, is in need of a volume which shall supply him with such anatomical information, free of wearying detail, as is essential for his successful and intelligent work in the Medical and Surgical Wards, and in the Special Departments of his Hospital.

The books to which I have chiefly referred in writing this MANUAL are those of Sibson, Tyler Smith, Ferrier, Gowers, and Ranney; Holmes, Ch. Heath, and Juler; Richet, Hilton, Holden, Quain, Gray, Tillaux, Treves, and Bellamy.

As regards the illustrations, Messrs. Longman have kindly arranged for my making use of many well-known blocks; others have been

obtained from private sources which are duly noted, and, lastly, some have been specially prepared for me.

Though the reader will not find his attention distracted by foot-notes, he will constantly meet with figures placed parenthetically in the text, thus : (p. 67). They direct him to pages whence side-lights are thrown upon the subject under consideration. It is by no means necessary that he should always use them ; but it is thought that their insertion may save him time in referring to the index, and induce him to make his knowledge of the part the more thorough.

For much kind help in seeing the proofs through the press, my warm thanks are due to Mr. J. Arthur Kempe, Demonstrator of Anatomy at Queen's College, Birmingham.

E. C.

LONDON : *February* 1890.

A

# MANUAL OF ANATOMY

---

*PART I*

## THE HEAD AND NECK

THE **platysma myoides** is a thin sheet of striated fibres between the two layers of the superficial fascia. It arises from the fasciæ of the deltoid and pectoral regions, and is inserted into the body of the lower jaw and with the muscles at the commissure of the lips. Thus its *action* is to depress the jaw and to draw down the corner of the mouth. Being a muscle of (unhappy) expression, its *nerve-supply* is from (the lower division of) the facial; it also receives twigs from the superficial cervical.

*Relations.*—Beneath it are the anterior and external jugular veins, the superficial branches of the cervical plexus, and the infra-maxillary nerve; the deep fasciæ; deltoid, clavicle, pectoralis major; sternomastoid; masseter; facial vessels, and buccinator.

Passing from the shoulder towards the jaw, the line of the fibres of the muscle is that of the external jugular vein, which is readily seen through the thin muscle. When bleeding from this vein, the surgeon must make his incision at right angles to the course of the vein and across the fibres of the platysma, so that the blood may freely escape through a widely open wound, and not become extravasated beneath the muscle.

### THE DEEP CERVICAL FASCIA

The deep fascia may be traced from the spinous process of the seventh cervical vertebra and the ligamentum nuchæ as a thin covering to the trapezius; having reached the anterior border of that muscle, it is slightly reinforced by a layer from beneath it. This thickened layer

then passes over the two posterior triangles, being attached to the occiput and the mastoid process, and, having reached the hinder border of the sterno-mastoid, splits to enclose it. At the front of that muscle the two layers again join, and, covering in the anterior triangle, the sheet blends in the middle line with that of the opposite side.

Over the posterior triangle the fascia is attached to the clavicle, being there perforated by the external jugular vein, which had hitherto lain between the deep fascia and the platysma.

In the anterior triangle it is attached to the lower jaw, and sends an offshoot to the zygoma to cover the masseter. Another sheet passes over the parotid gland, and an important slip from the angle of the jaw to the styloid process—the *stylo-maxillary ligament*—separates the parotid from the submaxillary gland.

In the front of the neck, where the deep fascia is attached to the hyoid bone, it is thin, but as it descends it becomes thicker, and splits into two layers, the more superficial of which is attached to the front of the manubrium, whilst the deeper incloses the sterno-hyoid and thyroid, and is connected with the back of the sternum. It also straps the tendon of the omo-hyoid to the first rib. One offset from the fascia beneath the sterno-mastoid joins with and strengthens the carotid sheath, another intervenes between the sterno-thyroid and the trachea (*see* 'Tracheotomy,' p. 131), which, descending in front of the trachea and of the carotid vessels, unites with the pericardium.

Deeper than all these, a layer, the *prævertebral fascia*, passes behind the pharynx and œsophagus, which, binding down the rectus anticus major, the longus colli, and the scaleni, descends with the brachial plexus and the subclavian vessels to blend with the sheath of the axillary vessels.

**Suppuration beneath the deep fascia** demands prompt drainage or it may become diffuse, causing great damage to such tissues as temporarily impede its course. At the front of the neck the pus may in time find its way to the surface, but it may be guided by the deep fascia into the anterior mediastinum, and then possibly set up an empyema. I once dissected a specimen in which the pus had found its way into the subclavian vein, causing fatal pyæmia. When beneath the deep fascia of the posterior triangle it may find its way into the œsophagus or chest, or may wander in the track of the subclavian vessels and set up an axillary abscess. The subject of post-pharyngeal abscess is alluded to on page 210.

The **trapezius** arises from the inner third of the superior curved line of the occiput, the ligamentum nuchæ, and all the dorsal spines and their supraspinous ligaments. The highest fibres descend, the median pass horizontally, and the lowest ascend to their insertion into the angle between the clavicle and the spine of the scapula. Thus the muscle is attached to the back of the flattened part of the clavicle and to the upper part of the spine of the scapula.



Acting with its fellow, it draws back and fixes the head and neck, and raises, or depresses, and fixes the shoulders. Its *nerve-supply* is from the spinal accessory, and also from the anterior divisions of the third and fourth cervical nerves. Either with or without the sterno-mastoid, the trapezius is apt to cause spasmodic wry-neck.

The *ligamentum nuchæ* ascends from the seventh cervical spine to the external occipital protuberance, and gives attachment to fasciæ and muscles.

The **sterno-cleido-mastoid** is attached, as its name suggests, to the sternum, clavicle (*κλεις, κλειδος, clavis*), and mastoid process. The sternal origin is by a tendon from the front of the manubrium; and the clavicular origin is by a wide mass of muscle and tendon from the upper border of the inner end of that bone. The two heads are separated by a narrow triangular interval, which corresponds with the common carotid artery, the vagus, and the last part of the internal jugular.

The muscle is enclosed in a definite sheath of the deep cervical fascia.

The two heads of origin slope upwards and backwards, and, having blended a little below the middle of the neck, are inserted into the mastoid process and into the superior curved line of the occiput. The *nerve supply* is from the spinal accessory and the anterior divisions of the second and third cervical nerves. The *arterial supply* is from the occipital, the superior thyroid, through the descending branch (p. 28), and the supra-scapular.

The anterior border of the muscle is the surgeon's guide in ligation of the common, external, or internal carotid artery, and in œsophagotomy; and the posterior border of its clavicular origin is the guide to the subclavian artery.

The chief *action* of the muscle is to draw the head down to the shoulder, and to turn the face to the opposite side. And this is necessarily the attitude of the head and face in that form of **wry-neck** which is secondary to contraction of the muscle. The common cause of congenital wry-neck is rupture of one or both heads of the sterno-mastoid during parturition, when the escaping head receives a vigorous and natural twist; the fibrous tissue by which the tear of the muscular fibres is mended undergoes subsequent contraction. The permanent drag upon that side of the face and head not only draws down the corner of the mouth, the outer commissure of the eyelids, and the side of the lower jaw, but also prevents the proper development of the bones of that side of the face. In due course other muscles and bands are shortened on the concave side of the neck, and the cervical vertebræ become deformed.

*Relations.*—The sterno-mastoid is covered by the platysma; the external jugular vein; lesser occipital, great auricular, and transverse cervical nerves, and the deep fascia.

Beneath it are another layer of the deep fascia, the sterno-hyoid,

sterno-thyroid, and omo-hyoid muscles; the posterior belly of the digastric; scaleni, levator anguli scapulæ, and splenius; the common, and perhaps the beginning of external and internal carotid arteries; the internal and anterior jugular veins; vagus; descendens and communicantes noni; spinal accessory; cervical nerves; occipital artery, lymphatic glands, and the deep part of the parotid. Beneath the muscle also, in contact with the scalenus anticus, are the subclavian vessels and the phrenic nerve.

Though contraction of the cicatrix left after congenital rupture of the muscle is the commonest cause of wry-neck, the deformity may also be determined by ulceration of the cervical vertebræ, in which case complaint will be made of peripheral neuralgias.

**Tenotomy of the sterno-mastoid.**—When the contraction of the muscle is such that the head cannot be brought straight, both slips of origin of the sterno-mastoid must be divided subcutaneously.

*Operation.*—The muscle having been put upon the stretch, a strong and slender blade is passed close beneath each band in turn, the section being made towards the skin. But the procedure is not devoid of risk, as the anterior jugular (p. 36) or some other large tributary of the subclavian or external jugular vein may be in the way of the knife. Should this happen, the wound in the vessel is held wide open, on account of the head being tightly dragged up, and thus air may pass by the subclavian vein into the heart, where, being churned up with the blood, it may cause a fatal arrest of the circulation.

As the anterior jugular and the subclavian are close behind the clavicle, the risk of wounding an important vessel is diminished if the tenotomy is done half an inch above that bone. The external jugular descends close by the posterior border of the clavicular head of the muscle.

Section of the clavicular part of the muscle may be conveniently and safely effected by a free and open wound above and parallel with the clavicle. In a case in which I recently operated by this method I found the internal jugular vein so close beneath the contracted band that, had I performed subcutaneous tenotomy, I could hardly have failed to wound it. Subcutaneous surgery has no doubt played a useful part, but at the present day it is an anachronism in many cases of wry-neck and in most cases of club-foot.

When spasmodic contraction is deemed to be due to irritation of the spinal accessory nerve, excision of half an inch of nerve as it is entering the muscle may be resorted to with some hope of success (p. 71).

The **levator anguli scapulæ** arises from the posterior tubercles of the four upper cervical vertebræ, and is inserted into the upper part of the vertebral border of the scapula. It is supplied by the anterior divisions of the middle cervical nerves.

## THE DEPRESSORS OF THE HYOID BONE

The **sterno-hyoid** arises from the back of the manubrium and the adjacent part of the clavicle, and, sloping towards the middle line, is inserted into the lower part of the body of the hyoid bone.

The **sterno-thyroid** arises from the manubrium, just below the sterno-hyoid, and, ascending under cover of that muscle, slopes slightly backwards to its insertion in the oblique line on the thyroid cartilage. This and the preceding muscle are often marked a little below their insertion by a tendinous intersection. The *nerve supply* of these two muscles is from the loop of the descendens and communicantes noni.

*Relations.*—These muscles ascend from the anterior mediastinum, and are under cover of the sterno-mastoid, the deep fascia, platysma, and the anterior jugular vein. The omo-hyoid joins company with them above on their outer side. They rest upon the trachea and the lower part of the larynx; the thyroid gland and its vessels; the innominate, subclavian, and common carotid arteries, and the internal jugular, subclavian, and innominate veins.

The **thyro-hyoid** continues the sterno-thyroid up to the body and great cornu of the hyoid bone. It hides the passage of the superior laryngeal vessels and nerve through the thyro-hyoid membrane, and is itself covered by the sterno-hyoid and omo-hyoid. Its motor nerve is a special branch of the hypoglossal.

The **omo-hyoid** ascends from the upper border of the shoulder-blade (*ωμος*) to the body of the hyoid bone, just external to the insertion of the sterno-hyoid. It is a double-bellied muscle, the median tendinous part being bound by a process of the deep cervical fascia, beneath the sterno-mastoid, to the first rib. As the posterior belly passes upwards and forwards to dip beneath the sterno-mastoid, it forms the base of the occipital and the upper border of the subclavian triangle; in a thin person this belly may be seen at work in its oblique position above the clavicle, especially when a deep inspiration is taken. And as the anterior belly emerges from beneath the sterno-mastoid and mounts to the hyoid bone it forms the upper boundary of the inferior and the base of the superior carotid triangle.

The *nerve-supply* is from the loop of the descendens and communicantes noni.

*Relations.*—Coming up from the shoulder-blade, the omo-hyoid is covered by the trapezius, clavicle and subclavius, the deep fascia, platysma, and integument, and it lies above the subclavian vessels, the lower cervical nerves, and the posterior and middle scalenes. It then passes beneath the sterno-mastoid and over the scalenus anticus and the phrenic nerve, and over the sheath of the common carotid with the internal jugular vein and the vagus. It subsequently rests

upon the sterno-thyroid and thyro-hyoid, being covered by the platysma and fasciæ.

The omo-hyoid crosses the carotid sheath at the level of the fifth cervical vertebra (*see* p. 23).

#### THE ELEVATORS OF THE HYOID BONE

The **digastric** arises posteriorly from the deep aspect of the mastoid process, and, therefore, under cover of the sterno-mastoid, splenius, and tracheo-mastoid, but upon the outer side of the occipital artery. And, as the parotid gland fills in the hollow in front of the sterno-mastoid, it also lies over the posterior belly of the digastric. This part of the muscle soon ends in a shining tendon, which, piercing the fleshy stylo-hyoid, joins with the tendon of the anterior belly, being bound down to the hyoid bone by the deep fascia.

*Relations.*—The posterior belly rests upon the stylo-glossus and stylo-pharyngeus, the internal jugular vein, pneumogastric nerve, and internal carotid artery; the occipital artery and hypoglossal nerve; the external carotid, and the lingual and facial arteries, and then upon the hyo-glossus (*see* p. 27). Its course is indicated by a line drawn from the mastoid process to the body of the hyoid bone.

The anterior belly arises from a depression close against the symphysis, and, passing downwards and backwards to the central tendon, rests upon the mylo-hyoid, being covered by skin, platysma, and fasciæ.

The posterior belly, with the stylo-hyoid, forms the upper limit of the superior carotid, and the hinder limit of the submaxillary triangle.

*Nerve-supply.*—The anterior belly helps the mylo-hyoid in raising and drawing forward the hyoid bone, and in depressing the jaw, and receives its supply from the mylo-hyoid nerve. The posterior belly acts with the stylo-hyoid in raising and drawing back the hyoid bone, and, like that muscle, is supplied by the facial nerve.

The **stylo-hyoid** arises from the outer side of the styloid process and is inserted into the body of the hyoid bone. It is pierced by the tendon of the posterior belly of the digastric. Its course, actions, and relations resemble those of the posterior belly of the digastric; and its nerve supply is identical.

The **mylo-hyoid** descends from the ridge at the back of the maxilla to the body of the hyoid bone, the posterior border being free, whilst the anterior is blended with its fellow in a median raphè.

*Relations.*—It is covered by the platysma and fasciæ; the anterior belly of the digastric; the mylo-hyoid nerve and artery; the submaxillary gland, and submental artery. Its deep surface helps to form the floor of the mouth, and is in contact with the genio-hyoid, genio-hyo-glossus; the hypoglossal and gustatory nerves; the deep part of the submaxillary gland and its duct, and the sublingual

gland. It is supplied by the mylo-hyoid branch of the inferior dental nerve.

The **genio-hyoid** lies upon the deep side of the mylo-hyoid, passing from the symphysis to the front of the body of the hyoid bone. Along its posterior border is the genio-hyo-glossus, in whose action and nerve supply (hypoglossal) it participates.

The **occipito-frontalis** may be taken as arising from the outer part of the superior curved lines and from the neighbouring part of the mastoid processes, and as inserted into the skin of the frontal region—not into frontal bone itself, or it could have no action. The two fleshy parts of the muscle are separated by a very thin intervening aponeurosis, which covers the vertex, and gives origin at the side of the head to the attollens and attrahens aurem. The tendon spreads out into loose connective tissue upon the temporal fascia (p. 8). The median fibres of the anterior part of the muscle blend with the pyramidalis nasi, and the others with the corrugator and with the orbicularis. The aponeurosis is very intimately blended with the skin—the student may remember that in his first dissection he could not avoid removing some of the aponeurosis with the skin, though he had no difficulty whatever in separating the aponeurosis from the skull.

When pus or blood is effused upon the top of the head its situation is certainly beneath the aponeurosis—not between it and the skin. A layer of loose connective tissue, the pericranium, intervenes between the aponeurosis and the skull-vault, and it is over this that the muscle and the scalp work. The scalp is readily torn down by accident, or as one sees effected in the mortuary; but when, during life, the calvaria is thus laid bare the occurrence of necrosis is by no means necessitated, as the nutrition of the outer table can be freely carried on by the vessels of the diploë. When cleaned and readjusted, the scalp promptly resumes its attachments and its office.

The *action* of the muscle is to raise the skin of the forehead in horizontal wrinkles, as in expressing surprise; the posterior fleshy part may be able to draw back the scalp, and so help the anterior part. Being a muscle of expression, it is supplied by the facial nerve, through its posterior auricular and temporal branches. When one facial nerve is paralysed the skin on that side of the forehead is destitute of wrinkles, and remains strangely expressionless when compared with the other half (p. 67).

The **masseter** arises from the zygomatic arch and is inserted into the angle and ramus of the jaw. It is supplied by the third division of the fifth nerve; its action is to raise the lower jaw.

*Relations.*—Between it and the integument are peripheral fibres of the orbicularis palpebrarum, the zygomatici, risorius, and platysma; the transverse facial artery; Stenson's duct, and an offshoot of the parotid gland (socia); and branches of both the divisions of the facial nerve, and the facial artery and vein. On its deep surface

are the buccinator and the lower jaw. The parotid gland is behind it.

The **temporal fascia** binds down, and gives origin to, the temporal muscle. It is attached above to the temporal ridge, and below, in two layers, to the zygomatic arch; between these layers, and running in a little fat, are the orbital branch of the temporal artery (p. 31) and a twig of the temporo-malar nerve.

Upon the fascia are fibres of the orbicularis palpebrarum; the aponeurosis of the occipito-frontalis; the attollens and attrahens aurem; and the superficial temporal vessels and nerves.

The **temporal muscle** arises from the temporal fossa and also from the temporal fascia, and, passing beneath the zygomatic arch, is inserted into the coronoid process—down to the last molar tooth. Its action is to raise the jaw and draw it backwards. Its nerve supply is from the third division of the fifth.

*Relations.*—It is covered by the temporal fascia and the structures lying thereon. Behind it are the masseteric vessels and nerves passing through the sigmoid notch, and beneath is the floor of the temporal fossa, with the deep temporal vessels and nerves.

The **external pterygoid**, pyramidal, arises from the outer side of the external pterygoid plate and the great wing of the sphenoid, and, running outwards and backwards, is inserted into the condyle of the jaw and into the inter-articular fibro-cartilage. When the jaw is dislocated the cartilage follows the condyle.

*Action.*—To advance and depress the jaw, and to carry it towards the opposite side.

*Relations.*—Below it are the internal pterygoid, the inferior dental vessels and nerve, and the gustatory nerve. The internal maxillary artery winds round the muscle to enter the pterygo-maxillary fossa between its heads.

The **internal pterygoid** arises from the inner surface of the external pterygoid plate, and passes downwards, outwards, and backwards to its insertion on the inner side of the angle of the jaw. Thus its action is to raise the jaw, to thrust it towards the opposite side, and to bring it forwards. Both pterygoid muscles are supplied by the third division of the fifth nerve.

*Relations.*—With the ramus of the jaw and the external pterygoid it roughly forms a triangular space through which pass the internal maxillary vessels, the inferior dental vessels and nerve, and the gustatory nerve.

Tetanus (*τέτανος, κρίνω, strain*), a continuous spasm of the muscles of the body, often begins in the maxillary region, so that the patient cannot separate the teeth or swallow without great effort or choking. This local tetanus is 'lock-jaw' or *trismus* (*τριζω, creak, gnash the teeth*).

## THE TRIANGLES OF THE NECK

The side of the neck may be represented as an oblong divided by the sterno-mastoid into a superior and inferior triangle. (The student will find it useful to practise drawing these triangles and their subdivisions in outline, and roughly filling in their chief contents.)

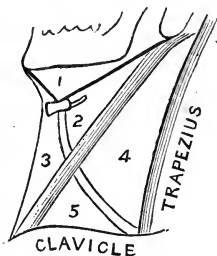
The **posterior triangle** has as its base that part of the clavicle which is between the posterior border of the sterno-mastoid and the anterior border of the trapezius—the muscles which form its sides—its apex being between the occipital attachments of those muscles. This triangle is divided by the posterior belly of the omo-hyoid into an occipital and a subclavian triangle.

The sides of the **occipital triangle** are formed by the borders of the trapezius and the sterno-mastoid, the posterior belly of the omo-hyoid being its base. In its floor, from above downwards, are the splenius capitis, levator anguli scapulæ, and the scalenus medius and posticus. It is covered by skin and fasciæ, and by the platysma inferiorly.

Superficial branches of the cervical plexus appear in the space, namely, the lesser occipital, great auricular, and the superficial or transverse cervical nerve (all of which wind round the posterior border of the sterno-mastoid) and the supra-clavicular branches, which leave the lower part of the triangle (*v. p. 145*). The spinal accessory nerve traverses the middle of the triangle in its course from the sterno-mastoid to the trapezius (*p. 70*), and the transverse cervical branch of the thyroid axis (*p. 233*) crosses its lower part. The glandulæ concatenatæ extend, deeply, along the posterior border of the sterno-mastoid.

The **subclavian triangle** is bounded below by the clavicle, in front by the posterior border of the sterno-mastoid, and above by the posterior belly of the omo-hyoid. It derives its name and its importance from the fact that the subclavian artery is usually tied in its depths.

The more muscular the subject, the smaller is the triangle. It is covered by the skin, fasciæ, and platysma, and is crossed by the supra-clavicular nerves. The external jugular vein (*p. 35*) pierces the deep fascia just behind the origin of the sterno-mastoid, to end in the subclavian vein, and it receives the suprascapular and transverse cervical veins as it passes through the triangle. The suprascapular and posterior scapular arteries also cross the space from beneath the sterno-mastoid. The third part of the subclavian artery and the subclavian vein



1, submaxillary triangle; 2, superior carotid; 3, inferior carotid; 4, occipital; 5, subclavian.

cross the floor of the triangle upon the first rib, and above the artery the trunks of the cervical nerves slant down for the brachial plexus. In front of the artery is the scalenus anticus, and behind the nerves is the scalenus medius. Some lymphatic glands lie in the space; they are apt to be enlarged in malignant disease of the mamma, œsophagus, and also of the stomach.

The **anterior triangle** is crossed obliquely by the anterior belly of the omo-hyoid and by the posterior belly of the digastric, and is thus divided into three triangles, which are named, from above downwards, the submaxillary, and the superior and the inferior carotid triangles.

The **submaxillary triangle** is bounded above by the lower border of the jaw, and by a line drawn from its angle to the mastoid process; below by the posterior belly of the digastric and the stylo-hyoid; and in front by the median line of the neck.

It is covered by a skin, superficial fascia, platysma, and deep fascia, together with branches of the infra-maxillary (p. 67) and superficial cervical nerves. Its floor is formed by the hyo-glossus, mylo-hyoid, and anterior belly of digastric.

The space contains the submaxillary gland, with the facial artery and vein (p. 29); the mylo-hyoid nerve and artery, and the submental branch of the facial artery. Behind the submaxillary gland is the stylo-maxillary ligament, immediately behind which is the parotid gland. (For the anatomy of the parotid region *see* page 117.)

The **superior carotid triangle** is bounded behind by the sterno-mastoid, above by the posterior belly of the digastric, and below by the anterior belly of the omo-hyoid. It is covered by skin, superficial fascia, platysma, and deep fascia, and is crossed by branches of the superficial cervical and infra-maxillary nerves. Its floor is formed by the thyro-hyoid and hyo-glossus, by the lower constrictors of the pharynx, and by the upper part of the thyroid cartilage. It takes its name from the fact that it contains the upper part of the common carotid and the beginning of the external and internal carotids. In the triangle the external carotid gives off the superior thyroid, lingual, facial, ascending pharyngeal, and occipital branches. Corresponding venous tributaries join the internal jugular, which, together with the vagus, is in the carotid sheath. Additional contents of the space are the hypo-glossal, descendens and communicantes noni, and the superior laryngeal nerve; and a small piece of the spinal accessory nerve may be seen in the highest angle, and of the recurrent laryngeal in the lowest angle, of the space. The sympathetic cord is behind the carotid sheath.

The **inferior carotid triangle** contains the lower cervical part of the common carotid. Its boundaries are the sterno-mastoid, the anterior belly of the omo-hyoid, and the median line of the neck. It is covered by skin, platysma, and fasciæ, together with branches of the superficial cervical nerve.

As a matter of fact, the carotid artery is shut out of this triangle by



the lower parts of the sterno-mastoid, sterno-hyoid, and sterno-thyroid, though, with the internal jugular vein and the pneumogastric nerve, it is popularly believed to be contained in it. Then, by only a very little more imagination, the inferior thyroid artery, the recurrent laryngeal nerve (p. 70), and the cord of the sympathetic are seen within the space—all of which are behind the carotid sheath. The trachea and the thyroid gland are similarly given in the triangle.

### THE BONES OF THE HEAD

The **frontal bone**.—The vertical part is marked by the frontal eminences, which correspond to the frontal lobes of the brain. Below them are the *superciliary ridges*, which are continuous internally with the root of the nose. They correspond with the frontal sinuses and give origin at their inner end to the corrugator supercilii and the orbicularis. In the case of fracture the external table may be driven into the sinus without the inner table being damaged, and on the man coughing, or blowing his nose, air may escape into the scalp and cause extensive emphysema.

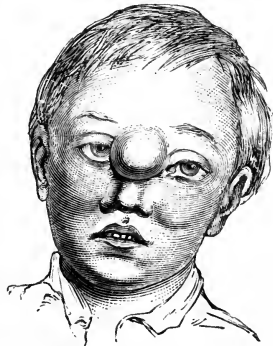The frontal sinuses are absent in childhood, and they are comparatively small in women. They communicate with the middle meatus by the infundibulum. A chronic abscess of the sinus which has opened externally must be drained into the nose.

Below the superciliary ridge comes the margin of the orbit, with the supra-orbital notch or foramen to the inner side of the middle. As the supra-orbital vein traverses this notch it receives a small diploic vein.

The supra-orbital arch ends at the strong *external angular process*, which articulates with the malar, and the temporal ridge ascends from it. This process overhangs the fossa for the lachrymal gland. The *internal angular process* articulates with the nasal process of the superior maxilla and the lachrymal; a hernial protrusion of the dura mater—a meningocele—sometimes occurs at that spot. Close behind the internal angular process is the fossa for the pulley of the superior oblique.

On the cerebral aspect, where the lateral halves join, is a ridge for the attachment of the falx cerebri, and the groove for the superior longitudinal sinus.

The horizontal part of the frontal consists of the thin plates for the roof of the orbit, the notch between them



Anterior Meningocele (BRYANT).

being filled by the cribriform plate of the ethmoid. There, also, a meningocele may protrude. At the line of articulation with the ethmoid are the ethmoidal foramina, by which the ethmoidal arteries and the nasal nerve enter the cranium. Fracture of this part of the skull may cause sub-conjunctival hæmorrhage from the ethmoidal arteries, and when this is associated with severe bleeding from the nose, and with escape of sub-arachnoid fluid (which must not be taken for the effect of a nasal catarrh), there is ample evidence of fracture having taken place. The upper surface of the plates is marked by the orbital convolutions of the frontal lobes.

The frontal bone is *developed* in lateral halves.

The **temporal**.—The **squamous** part lies in the temporal fossa, and its bevelled margin overlaps the parietal bone, whilst its lower and hinder part is bounded by the posterior root of the zygoma. The anterior root of the zygoma is the *eminentia articularis*, which is covered by cartilage, and receives the condyle of the jaw when the mouth is widely opened. Behind the eminentia is the glenoid fossa, cleft by the Glaserian fissure through which the chorda tympani leaves the middle ear; a branch of the internal maxillary artery also traverses it.

The front of the fossa, covered with cartilage, articulates with the condyle of the jaw, and the hinder part lodges some of the parotid gland; a thin lamina of bone partitions it from the tympanic cavity and the external auditory meatus. Thus it is that a parotid abscess may burst through the external ear. The inner surface of the squamous portion is deeply grooved by the middle meningeal artery.

The **mastoid portion** scarcely exists in childhood; it is developed with the petrous portion under the name of petro-mastoid bone. But as puberty comes on it is hollowed out into air-cells which open into the back of the middle ear, their mucous lining being covered with columnar ciliated epithelium. It is by way of these cells that tympanic suppuration sometimes reaches the surface as a post-auricular abscess, raising the skin and pushing the pinna forward; sometimes, however, the pus finds its way into the external meatus, thus the matter reaches the outer surface of the membrana tympani without traversing it.

Ossification of temporal bone. *b*, tympanic ring; *c*, petro-mastoid.



In the same way, in the case of fracture of the base of the skull, blood may escape from the external ear though the membrana, as shown by otoscopic examination, has not been damaged. In every case of suppuration in the mastoid process the surgeon should be prompt in securing evacuation by the gouge or trephine.

In certain cases in which the Eustachian tube has been blocked, the surgeon has endeavoured to ventilate the middle ear by making a permanent drill-opening into the mastoid cells, but the proceeding is dangerous, meningitis being apt to follow.

The *mastoid foramen* transmits a large vein into the lateral sinus, and a branch of the occipital artery for the dura mater; and in acute otitis, when every neighbouring vessel is engorged with blood, the application of a few leeches behind the ear affords direct and immediate relief.

If matter be long pent up in the mastoid cells it may find its escape into the cranial cavity and set up a purulent and fatal meningitis. Moreover, the lateral sinus, which is close upon the inner side of the cells, may become inflamed in the course of otitis media, and, septic coagulation of its contents taking place, pyæmia ensues.

On the inner aspect of the mastoid process is a fossa for the origin of the posterior belly of the digastric, and, more internally still, is the groove for the occipital artery.

On the cerebral surface of the mastoid portion is the wide and shallow groove for the lateral sinus (p. 39), into which the mastoid vein is opening. When the question arises of trephining in the region of the mastoid cells the surgeon must remember that the lateral sinus specially grooves the front of the cranial aspect of the mastoid process (Tillaux).

The **petrous portion**, hard as a stone (*πέτρος*), is wedged forwards and inwards into the floor of the skull. Its base is between the squamous and mastoid portions, and receives the external auditory meatus, which is surrounded by the outgrowth of the horse-shoe auditory process, to the surface of which the cartilage of the pinna is attached. Through the petrous portion winds the canal for the internal carotid artery (p. 33); by the articulation with the occipital the jugular foramen is enclosed.

The internal and middle ear are also contained within the petrous bone, and the facial nerve winds through it from the internal auditory meatus to its exit from the aqueductus Fallopii at the stylo-mastoid foramen.

*Fracture* across this brittle bone may be followed by rupture of the large vein and artery, and of the membrana tympani, and, further, by bleeding from the ear. The perilymph may also escape from the internal ear, diluting the blood, or staining the pillow long after bleeding has ceased. The facial nerve having been torn across, paralysis of the muscles of expression ensues.

On the anterior surface of the petrous bone is the upheaval which is caused by the superior semicircular canal of the internal ear; just outside this is the thin plate of bone roofing in the middle ear. Nearer to the middle line is the hiatus Fallopii, by which the petrosal branch of the facial escapes from the aqueduct to join the Vidian nerve.

The posterior surface shows the internal auditory meatus, down which pass the facial and auditory nerves in their arachnoid investment, and the auditory branch of the basilar artery. The facial nerve enters the aqueductus above the sieve-like part of the end of the canal through which the auditory filaments reach the internal ear.

The *styloid process* gives origin to small muscles for the pharynx, hyoid bone, and tongue; the piece of the deep cervical fascia which separates the parotid and submaxillary glands (p. 2) is also attached to it. The temporal bone is *developed* in four pieces: one for the squamous, one for the petrous and mastoid, one for the tympanic horse-shoe, and one for the styloid process.

The **sphenoid**.—The body is hollowed out into an air-chamber which opens into the back of the superior meatus of the nose, and on either side is a broad groove for the internal carotid artery and the cavernous sinus (p. 40). The posterior part is connected with the occipital bone by cartilage until the eighteenth year, after which the union is osseous and perfect. The upper surface of the *great wing* enters into the middle fossa, and is marked by the round and oval openings for the second and third divisions of the fifth nerve, and of the middle meningeal artery and vein. The outer surface enters into the temporal and pterygoid fossæ, and the anterior surface forms most of the outer wall of the orbit.

The *lesser wing* forms the back part of the roof of the orbit, and supports the frontal lobe. Its posterior border is lodged in the Sylvian fissure of the brain. Between the two wings is the *sphenoidal fissure*, which transmits the third, fourth, ophthalmic division of fifth, and the sixth nerves, the ophthalmic vein, and some sympathetic filaments. At the root of the process is the foramen by which the optic nerve and ophthalmic artery enter the orbit.

The *external pterygoid process* is a wide plate which gives origin to both the external and internal pterygoid muscles. The *internal process* descends parallel with the vomer, and forms the outer wall of the posterior nares. It ends below in the hamular process, round which the tendon of the tensor palati is reflected. This hook-like process is readily felt in the mouth (p. 107); to it are attached the superior constrictor and the pterygo-maxillary ligament. The tensor palati arises from the scaphoid fossa between the roots of the pterygoid processes.

The **ethmoid** consists of a vertical plate which enters into the septum of the nose, and of a horizontal, or cribriform, plate which forms part of the anterior fossa of the skull, and on the under surface of which are fixed the lateral masses. The front of the vertical plate extends into the crista galli, between which and the frontal bone is the foramen cæcum, transmitting a vein from the nose to the superior longitudinal sinus. At the side of the crista is the slit for the nasal nerve. Through the cribriform plate descend the olfactory filaments, and at

its outer border, where it articulates with the frontal, are the foramina for the anterior and posterior ethmoidal arteries, the nasal nerve accompanying the anterior vessel.

The lateral masses contain the anterior and posterior ethmoidal sinuses, which open respectively into the middle and superior meatuses. The *superior and middle turbinated bones* help to make up the mass. They are covered with mucous membrane in which the olfactory filaments are spread. The turbinated bones play the part of a respirator, warming and moistening the inspired air, and filtering it of solid particles. The outer wall of the lateral mass, the *os planum*, forms part of the inner wall of the orbit.

The **occipital** bone has its vertical part greatly strengthened by a protuberance (to which the *ligamentum nuchæ* is attached), by an internal and external median crest, and by two curved lines, or groins, which arch laterally from the external crest. The *trapezius* and *occipito-frontalis* arise from the superior curved line, and the *sternomastoid* and *splenius* are inserted into it. Between the lines the *complexus* and *superior oblique* are inserted; the 'straight' muscles of the back of the head are attached to the lower line.

The *condyles* have their long diameter sloping forwards and inwards, the movements at the *occipito-atloid* joints being only flexion and extension. Between the condyles is the *foramen magnum* for the transmission of the *medulla oblongata* and its membranes, the spinal accessory nerves, and the vertebral arteries. At the front and outer part of each condyle is the *anterior condylar foramen* for the transmission of the *hypoglossal nerve*, and perhaps of a twig from the *ascending pharyngeal artery*.

A vein may enter the lateral sinus through the posterior condylar foramen. In front of the *foramen magnum* is the *basilar process*, with a spine for the attachment of the *superior constrictor* of the pharynx.

The *cerebral surface* shows the cruciform markings of the superior longitudinal, the occipital, and the two lateral sinuses which meet at the internal protuberance over which the *torcular Herophili* is placed. The two superior fossæ thus marked out are for the occipital lobes of the cerebrum, the two inferior for the lobes of the cerebellum. The lateral sinus, having grooved the vertical part of the occipital bone, passes on to the posterior inferior angle of the parietal, the mastoid portion of the temporal, and then to the jugular process of the occipital, where it ends in the jugular fossa. The superior angle of the bone is received between the parietal bones, and corresponds to the site of the posterior fontanelle.

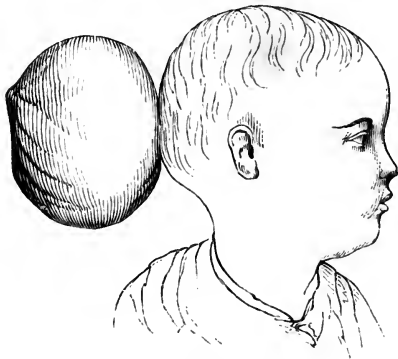
The upper surface of the *basilar process* supports the medulla and pons. Its border is grooved by the inferior petrosal sinus passing backwards to the jugular foramen, which also transmits the blood of the lateral sinus to the internal jugular vein, and the *glosso-pharyngeal*,

pneumogastric, and spinal accessory nerves. The under surface of the basilar process is in the roof of the pharynx, and may be explored by the finger in the case of suspected fracture of the base of the skull.

The bone is *developed* by seven centres : four for the vertical part, which blend at the occipital protuberance, one for each condylar part, and one for the basilar process.

The vertical part of the bone, as with those parts of the other bones which form the wall and roof of the skull, is developed from membrane, whilst the horizontal part, as is the case with those other pieces which form the base of the skull, is ossified from cartilage. This arrangement is to render the skull strong enough to protect the basal ganglia during its passage through the pelvis.

**Cranium bifidum** occurs when osseous union in the occipital region is incomplete, the membranes, and perhaps some of the encephalon, bulging backwards through the median cleft. (See Spina Bifida, p. 204.)



Occipital Meningocele.

The **parietal** (*paries*, wall).—The convex surface is marked by the curved temporal ridge, above which plays the aponeurosis of the occipito-frontalis, the temporal muscle arising below the ridge. Near the hinder part of the superior border is the *parietal foramen*, by which a vein for the scalp

passes into the longitudinal sinus, accompanied sometimes by a twig of the occipital artery.

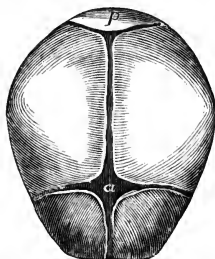
The internal surface is marked by cerebral convolutions, especially those of the motor area, and is deeply grooved by branches of the middle meningeal artery, which lead upwards from the anterior inferior angle. The posterior inferior angle is grooved for the lateral sinus, and along the superior border runs the shallow groove for the longitudinal sinus and the falx cerebri. Near this groove are depressions for the Pacchionian glands—villous processes of the arachnoid ; an uninformed man might take these irregular nodules for tubercular deposits. Some of them are deeply imbedded in the bone.

The posterior border articulates with the occipital in the lambdoid suture. In weakly infants who lie much in the supine position, the occipital bone may sink in between the parietals to such an extent as, according to some observers, to cause cerebral irritation. The articulation of the posterior inferior angle with the mastoid bone is often thinned (cranio-tabes) in syphilitic and rickety children, imparting:

to the finger and thumb the sensation of there being a parchment patch in the skull-wall.

There is a fontanelle at each angle of the parietal bone, as may be seen on p. 366, but those at the sphenoidal and mastoid angles are comparatively unimportant. In the case of tubercular inflammation attacking the membranes of the brain in a child before the fontanelle is closed, a bulging may be found at that region.

The **superior maxilla** is marked upon the anterior surface by the ridge caused by the fang of the canine tooth, which can be felt even through the lip. Just external to this is the canine fossa, from which the levator anguli oris arises. Above the origin to this muscle the infra-orbital nerve emerges under cover of the levator labii superioris and of the orbicularis oris.

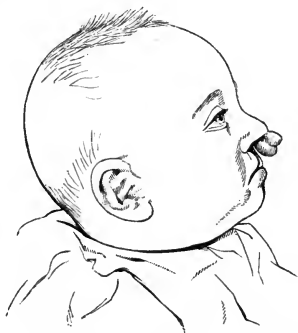

Fontanelles : α, anterior  
β, posterior.

The *orbital surface* articulates behind with the vertical part of the palate, internally with the lachrymal and ethmoid. It is separated from the great wing of the sphenoid by the spheno-maxillary fissure, which ends externally in the vertical, pterygo-maxillary fissure. Thus the hinder part of the jaw has no direct articulations.

In a bony canal beneath the floor of the orbit run the infra-orbital artery and the second division of the fifth nerve.

The under surface of the palate process is rough, and at the front it may be marked by a delicate articulation which runs outwards and forwards from behind the anterior palatine canals to the interval between the lateral incisor and canine teeth ; it shows the limit of the inter-maxillary bone. This segment has a separate centre of ossification, and is developed in connection with the vertical plate of the ethmoid and the vomer. In extreme cases of hare-lip the inter-maxillary bone adheres to the tip of the nose.



The *antrum* communicates with the middle meatus by a small round opening ; its inner wall is made up by the vertical plate of the palate, the lateral mass of the ethmoid, and the inferior turbinated. The cavity extends into the alveolar, malar, and zygomatic parts of the bone, and is shut out from the orbit only by a thin osseous plate. The roots of the first and second molar teeth cause projections upon its inner wall. Abscess in the antrum may be

tapped by raising the lip and cheek in the neighbourhood of the canine

fossa and drilling upwards and inwards ; but if the first or second molar be decayed it may be extracted, and the cavity opened by passing a gimlet up the emptied socket.

*Malignant disease* often attacks the superior maxilla, and, entering the antrum, grows at a great pace : advancing upwards, it raises, pushes forward, and disorganises the eyeball ; downwards, and it implicates the palate and loosens the teeth ; inwards, and it blocks the nostril, and, backwards, the pharynx. The only treatment likely to avail is **excision of the superior maxilla**. This operation is performed by making an incision from the inner corner of the orbit down the side of the nose, round the ala, traversing its cartilage, and through the middle of the upper lip, the coronary artery being promptly secured. From the top of the incision another is made horizontally outwards along the lower margin of the orbit, and through the periosteum, which is then easily raised from the floor of the orbit. The thick, irregular flap of the cheek is turned outwards. The malar bone is then sawn across, and the nasal process of the superior maxilla divided with bone nippers. The central incisor having been previously extracted, the palate processes of the palate and superior maxilla are nipped through, the soft palate having been detached, and the loosened bone is then caught with lion forceps and twisted out, the second division of the fifth nerve and branches of the internal maxillary artery being torn across during that procedure.

The soft palate remains behind. So also may the periosteum of the orbit, the latter structure playing a useful part in the subsequent support of the eyeball. Indeed, after some weeks, if all go well, the chasm is so filled up by contractions that there is little to indicate that so serious an operation has been performed, the eye-ball keeping its place.

During the operation the following *structures are divided* : the orbicularis oris, coronary artery, and labial mucous membrane ; lateral nasal branches of the facial artery and vein, and branches of the infra-orbital nerve passing to the nose ; the muscles which depress and dilate the nostril. In raising the upper part of the flap the orbicularis palpebrarum, levator labii superioris, and levator anguli oris would be cut, together with the infra-orbital nerve and artery, the angular branches of the facial vessels, and branches of the facial nerve supplying the muscles. The periosteum of the floor of the orbit and the origin of the inferior oblique would be detached and raised. The more distant structures detached are the buccinator ; the soft palate with the expansion from the tensor palati ; the superior maxillary nerve in front of the foramen rotundum, and posterior palatine and dental branches of the internal maxillary artery. The muco-periosteum of the hard palate is, of course, taken away with the bone. When the maxillæ are narrow, 'V-shaped,' the palatine arch is contracted and the teeth appear in great disorder. Not seldom, moreover, the deformity is associated with mental deficiency.



The **palate bone** consists of a vertical and a horizontal part. The former helps to close in the antrum and extends up into the floor of the orbit. The *horizontal part* forms the back of the hard palate and of the floor of the nose. Its under surface shows the ending of the posterior palatine canal, and is also marked by a ridge for the attachment of part of the tensor palati. To the posterior border is attached the palatine aponeurosis, and from the posterior nasal spine arises the azygos uvulæ.

The **lachrymal**, somewhat of the size and thickness of a fingernail, rests upon the inner border of the orbital plate of the maxilla, and helps to fill in the anterior ethmoidal cells. Its upper border articulates with the frontal, and its anterior with the nasal process of the maxilla. A vertical ridge upon the orbital aspect of the bone marks off a groove, which, with a groove upon the nasal process, lodges the lachrymal sac and the upper part of the nasal duct (p. 76). The tensor tarsi arises from the bone just behind the groove.

The lachrymal bone is easily broken through in a clumsy attempt to pass a style by the nasal duct, especially if the probe be held too much in the horizontal position.

The **inferior maxilla**.—The outer surface of the *body* is marked by an oblique line from which arise the muscles depressing the lower lip and the angle of the mouth; the platysma is inserted below this line. The mental foramen is about half-way down the outer surface, below the second bicuspid. The buccinator arises below the molar teeth.

The *outer surface of the ramus* is covered by the insertion of the masseter, and near the anterior inferior corner of this muscle the bone is grooved by the facial artery (p. 29). The levator menti arises in the incisive fossa.

An oblique ridge upon the inner surface of the body gives insertion to the mylo-hyoid, and below it, running from the inferior dental foramen, is the groove for the mylo-hyoid nerve and artery.

Below the ridge also are the fossæ for the sub-maxillary gland and for the origin of the digastric, the latter being just behind the symphysis. Separated from the digastric fossa by the anterior part of the mylo-hyoid ridge are the genial tubercles, and to the outer side of the genial tubercles, above the mylo-hyoid ridge, is a slight depression for the sublingual gland. The pterygo-maxillary ligament and the superior constrictor are attached to the inner side of the body just below and behind the last molar tooth.

To the inner side of the angle the internal pterygoid is inserted, and to the inner aspect of the coronoid process the temporal muscle. The external pterygoid is inserted into the neck of the condyle.

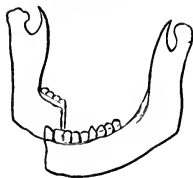
The lower jaw is *developed* in lateral halves, chiefly from the cartilage (Meckel's) of the first or the mandibular arch. The halves have a fibrous connection at the symphysis at birth, but this is ossified

by the end of the first year. At birth the jaw is a 'mere shell of bone,' with the sockets of the milk teeth, and until the teeth are cut there is hardly any ramus. For a long while the alveolar part is larger than the basilar, but in the adult these parts are of equal height, the mental foramen being midway between the upper and lower borders of the bone, the ramus passing up at a right angle. As old age advances the teeth fall out, the alveolar process dwindles into a sharp and useful cutting edge, covered with tough mucous membrane; the mental foramen, in consequence, comes close to the upper border of the bone, and the angle between the body and ramus widens out.

**Dislocation of the jaw** may result from over-action of the depressors in an attack of yawning, or from a blow upon the chin when the mouth is wide open. The condyle is carried forward upon the eminentia articularis, where it remains fixed, a wide hollow appearing in front of the mastoid process, and the mouth being wide open and fixed in that position. When the luxation is on one side only, the chin is thrust over to the opposite side. The coronoid process may be caught against the malar bone. The jaw is firmly fixed in the new position by the contraction of, and strain upon, its elevator muscles.

Reduction is effected by making a fulcrum of the thumbs, well protected, between the molar teeth; the symphysis being raised, the condyle is unhitched, and, with a snap, the jaw resumes its proper position. Simple pressure of the thumb downwards, backwards, upon the last molar tooth, however, generally suffices, and it has this merit, that it does not excite contraction of the temporal and internal pterygoid muscles. Both in the dislocation and in the reduction the fibro-cartilage follows the condyle.

**Fracture** may occur in any part; a common situation being a little in front of the insertion of the masseter, in which case the digastrics, mylo-hyoids, genio-hyo-glossi, genio-hyoids, and platysmas may draw the anterior part downwards and inwards, whilst the other piece may be drawn upwards and forwards by the temporal, internal pterygoid, and masseter. The line which the fracture has taken, however, may greatly influence the displacement



of the fragments. The treatment consists in maintaining the fragments in apposition until union is firm. This may be done by locking the lower jaw against the upper by a moulded splint and a four-tailed bandage; but sometimes it is necessary to fix and steady the fragments by a strong wire suture.

**Resection** may demand an incision along the lower border and half-way up the back of the ramus—not too far, lest the facial nerve be cut—the facial artery or arteries being promptly secured. The muscles are detached to a great extent by using the blunt raspatory. The genio-hyo-glossus, however, must be cut from the back of the

symphysis, and when this is done the tongue must be brought out by a strong loop, lest it fall back against the glottis. As the surgeon proceeds to denude the angle and ramus, he keeps his knife or raspatory close to the bone, lest he injure the internal maxillary artery; its inferior dental branch, with the vein and nerve, must be cut just as they enter the substance of the bone. The mucous membrane and the floor of the mouth (mylo-hyoid) and the sub-maxillary and sub-lingual glands are detached early in the operation, and the ramus is at last held merely by the ligaments of the joint and the insertions of the temporal and external pterygoid; these are easily severed, the coronoid process being perhaps snipped off with much of the temporal insertion.

*Necrosis* of more or less of the bone is generally the result of acute inflammation, which may be caused by a bad tooth, or may occur in the weakness left after measles or scarlet fever. The necrosis is due to the fact that the lower jaw abounds in compact tissue, inflammatory effusion quickly choking the vessels in the Haversian canals.

The **temporo-maxillary joint** belongs in man to the division arthrodia; in some animals, as the badger, it is a perfect hinge. Entering into its formation are that part of the glenoid cavity which is in front of the Glaserian fissure, the eminentia articularis, and the condyle. Each surface is covered with articular cartilage, but interposed between the upper and lower planes of the joint is a sinuous layer of *inter-articular fibro-cartilage*, which, receiving some of the insertion of the external pterygoid, closely follows all the movements of the condyle. The external lateral and the capsular ligaments are also attached to the fibro-cartilage. The *external lateral ligament*, a strong and short band, descends from the tubercle at the root of the zygoma to the neck of the condyle, being attached also to the inter-articular fibro-cartilage, as just noted. The *internal lateral ligament* is a long and unimportant band between the spine of the sphenoid and the inner edge of the inferior dental foramen. The internal maxillary artery and the inferior dental vessels and nerve pass between it and the jaw. As Tillaux remarks, the external lateral ligament of one side is the internal lateral ligament for the other. The *stylo-maxillary ligament* is but a piece of the deep cervical fascia; it separates the parotid and sub-maxillary glands. The *capsular ligament*, a loose and unimportant sac, is attached around the glenoid cavity and the neck of the condyle.

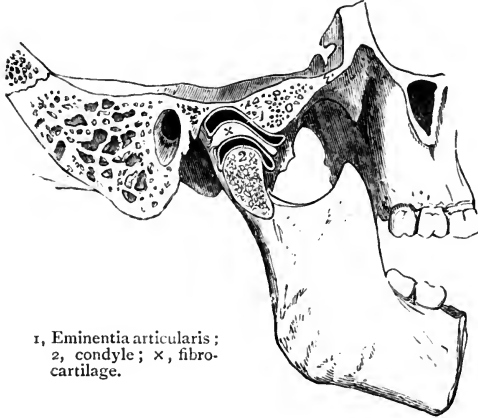
There are *two synovial membranes*, one between the temporal bone and the fibro-cartilage, and the other between it and the condyle. They may communicate by a gap in the middle of the cartilage.

*Supply*.—The arteries are branches of the masseteric, and of the vessels in the neighbouring parotid gland. The *nerves* come from the masseteric and the auriculo-temporal of the third division of the fifth.

*Movements*.—The jaw is depressed by the platysma, mylo-hyoid,

genio-hyoid, genio-hyo-glossus, and also by the external pterygoid. It is elevated by the masseter, temporal and internal pterygoid ;

advanced by the pterygoids and the superficial part of the masseter ; and retracted by the deep part of that muscle and the temporal. The pterygoids impart the lateral movements.



1, Eminentia articularis ;  
2, condyle ; X, fibro-  
cartilage.

*Relations* of the articulation externally are skin, fasciæ, and some of the parotid gland, but the movements of the condyle are readily followed from the exterior.

Behind are the external auditory meatus, some of the parotid gland, and the external carotid and its terminal divisions. Close above and behind are the tympanum and the internal ear.

*Permanent closure* of the jaws may demand **resection of the condyle** ; this is accomplished by making an incision along the lower border of the zygoma, beginning over and through the posterior border of the masseter, and continuing it back to the tragus. The raspatory then thrusts down the branches of the facial nerve, part of the parotid gland, and other tissues which hide the condyle ; the neck of the condyle is then cut with a fine saw and drawn out with some of the insertion of the external pterygoid, and perhaps with the inter-articular fibro-cartilage.

## THE ARTERIES OF THE HEAD AND NECK

The **common carotid artery** springs on the right side from the division of the innominate, but on the left side it ascends from the transverse part of the arch of the aorta.

Up to the level of the sterno-clavicular joint the left artery has exceptional relations, but from this point to the upper border of the thyroid cartilage, where the common carotids divide, the relations are similar on the two sides.

The **thoracic portion of the left carotid** springs from the transverse aorta, between the innominate artery and the left sub-

clavian, and ascends obliquely behind the manubrium to the clavicular joint.

*To mark out the root of the artery.*—As the transverse sternal ridge corresponds to the lower part of the transverse aorta (p. 179), a line drawn across the manubrium at about a thumb's breadth above that ridge marks the upper border of the arch. The innominate artery springs from the middle of that line; the left carotid, therefore, comes from a little to the left of the middle of the line, and mounts to the inner end of the clavicle.

*To mark the course of the common carotid artery in the neck,* the shoulders should be raised and the head thrown back, the face being slightly turned to the opposite side. A line is then drawn from the sterno-clavicular articulation to the interval between the condyle of the jaw and the mastoid process. This line, up to the level of the upper border of the thyroid cartilage, corresponds to the common, and above that to the external carotid.

The groove in the side of the neck running along the anterior border of the sterno-mastoid is the surgeon's guide to the artery. The higher that the vessel mounts in the neck, the more superficial it becomes, because the sterno-mastoid passes backwards from it, whilst the sterno-hyoid and thyroid have left it upon the inner side. Therefore the surgeon, who is free to choose, prefers to tie it in the upper part of its course, that is, above the omo-hyoid, which crosses at the level of the cricoid cartilage.

Remembering that all the large veins incline towards the right side of the median line—the right side of the heart being the venous side—the left internal jugular vein in its descent through the lower part of the neck gradually gets to the front of the common carotid, whilst the right vein slopes away from the outer side of its artery, to descend in front of the right subclavian artery.

*Rule.*—Above the level of the diaphragm the large veins are upon a plane anterior to the arteries; below that level they are on a posterior plane, with one exception (p. 356).

The *carotid artery may be compressed* with the employment of a slight force against the transverse process of the sixth cervical vertebra—the **carotid tubercle**. This may readily be made out a little below the level of the cricoid cartilage, in the situation of the carotid sheath, that is beneath the anterior border of the sterno-mastoid.

The **level of the fifth cervical vertebra** is an important station in the anatomy of the neck: it corresponds pretty nearly to the site at which the omo-hyoid crosses the carotid sheath, and to the position of the cricoid cartilage—thus marking the ending of the larynx and the beginning of the trachea, the ending of the pharynx and the beginning of the œsophagus. At that level also the inferior thyroid artery crosses inwards behind the sheath of the carotid, whilst the sympathetic cord,

descending in front of that branch, distinguishes the spot with its middle cervical or thyroid ganglion.

The **carotid sheath** contains, in addition to the common and the internal and carotid artery, the internal jugular vein and the pneumogastric nerve, the vein being to the outer side of the artery, and the nerve between and behind them. These three structures are separated from each other by delicate fibrous partitions. The sheath receives a considerable accession from the deep cervical fascia.

The surgeon in seeking the artery should open the sheath upon the inner, the arterial side, so as that the vein may not be in the way of his needle.

**Irregularities.**—The right common carotid artery may come from a high or low division of the innominate, or as a separate branch from the aortic arch. The two carotids may spring by a common trunk; or the left may come from *the* innominate, or from a left innominate artery. The common carotid may divide as low as the cricoid cartilage, or may be continued as far as the hyoid bone. Sometimes the common carotid gives off the superior thyroid branch.

**Relations of the common carotid in the neck.**—*In front* are the skin, platysma, and fasciæ; the sterno-mastoid, and the beginning of the sterno-hyoid and thyroid; the omo-hyoid, which crosses at the level of the fifth cervical vertebra; the sterno-mastoid branch of the superior thyroid artery, and the descendens noni lying upon the sheath, as shown on page 27; the anterior jugular vein, and the superior and middle thyroid veins running into the internal jugular.

*Behind* are the lower cervical vertebræ, covered by the longus colli and the rectus capitis anticus major. Additional posterior relations are the inferior thyroid artery, winding upwards and inwards (p. 233) from the subclavian; the sympathetic cord, and the recurrent laryngeal nerve.

*Internally* are the trachea and larynx, with a lobe of the thyroid body and the inferior thyroid artery passing to it; the œsophagus and pharynx, and the recurrent laryngeal nerve ascending between the trachea and œsophagus. *Externally* are the vagus and the internal jugular vein.

**In the thorax.**—As the second part of the arch passes more from before backwards than from right to left, and as the left carotid is given off after the innominate and before the left subclavian, it necessarily has the innominate a good deal in front of it and the subclavian behind.

Additional *anterior* relations are the origins of the sterno-hyoid and sterno-thyroid muscles; the left innominate vein, running obliquely across to join in the formation of the superior cava; and the remains of the thymus gland, which, in the child, is a very important relation so far as regards bulk (*v.* p. 155).

*Posteriorly* are the trachea, œsophagus, and thoracic duct.

*To the right* is the innominate artery, and, slightly, the trachea; and *to the left* is the left subclavian artery and the vagus, which in the neck descended along the outer side of the carotid.

**Aneurysm of the common carotid** is likely to occur just below its bifurcation. The pulsating tumour might be close by the side of, and be mistaken for, an enlarged lobe of the thyroid; but there is this manifest distinction between the two: a thyroid tumour moves with the larynx during deglutition, whereas the aneurysmal tumour does not. The pressure effects of the aneurysm may be: upon the internal jugular vein, causing headache, duskiness of the face, and œdema; upon the superior laryngeal nerve, causing cough; upon the recurrent laryngeal giving rise to hoarseness, laryngeal spasm, or to paralysis of a vocal cord; upon the sympathetic cord, with the production of dilatation, and, afterwards, of contraction of the pupil.

**Ligation of the common carotid.**—The subject lies supine, with a block beneath the shoulders, so that as the head is thrown back, and the face is turned to the opposite side, there may be more room, and also that the sterno-mastoid and the other tissues at the front of the neck may be made tense.

The surgeon then feels for the anterior border of the sterno-mastoid and for the thyroid and cricoid cartilages. With his finger on the cricoid he knows where the omo-hyoid crosses the sheath.

To tie the artery *above the omo-hyoid*, a 3-in., or in a fat subject a 4-in., incision is made along the front of the sterno-mastoid, from the level of the upper border of the thyroid cartilage, or even from just below the angle of the jaw, dividing skin, superficial fascia, platysma, and deep fascia. The head is then raised, so that the cord-like edge of the sterno-mastoid may be slackened and drawn outwards. In approaching the sheath a branch to the sterno-mastoid from the superior thyroid will be divided. The descendens noni may be seen and turned aside, and the omo-hyoid may be pulled downwards. The veins crossing the sheath are drawn upwards or downwards, and the sheath is opened on the inner side.

The aneurysm-needle is passed close to the artery, from without inwards, extreme care being taken not to wound the internal jugular vein, or to include the vagus in the ligation.

If ligation be required for aneurysm of the upper part of the common carotid, the surgeon must seek the vessel *below the omo-hyoid*, where, unfortunately, it is much more deeply placed. He makes an incision along the anterior border of the sterno-mastoid from the cricoid cartilage to the sterno-clavicular joint. The head having been brought forwards, the sterno-mastoid is drawn outwards and the omo-hyoid upwards, the sterno-hyoid and thyroid being drawn inwards. The anterior jugular vein may need attention. If the operation be performed upon the left side, and low down, the internal jugular vein may be found bulging over, or even lying upon the artery. If

there is much difficulty in reaching the vessel the sternal origin of the sterno-mastoid should be divided and turned outwards.

The *collateral circulation* would be carried on by the empty branches of the external and internal carotids. Of the external the following would prove useful: the superior thyroid with its fellow, and with the inferior thyroid; branches of the lingual, facial, superficial temporal, and occipital, with their fellows of the opposite side; and the occipital, with the profunda cervicis and the vertebral. The internal carotid would take in blood, by its anastomosis in the circle of Willis, from its fellow, and from the vertebral.

The **external carotid** is destined, as its name implies, for the external parts of the head; therefore, in its ascent, it lies superficial to the internal carotid, which is the direct continuation of the common trunk. For convenience, in giving off the superior thyroid, lingual, and facial branches, the external carotid bends forwards from its origin, and thus it is at first superficial and anterior to the internal carotid; but, inclining backwards again, it ultimately lies superficial to the internal trunk, and in the same line with it. Ascending into the parotid gland, it ends by dividing into the superficial temporal and internal maxillary.

Its *course is marked* by that part of the line, given on page 23 for the common carotid, which extends from the level of the upper border of the thyroid cartilage to the fossa behind the condyle of the jaw.

**Relations.**—*Superficial* to it are skin, platysma, and fasciæ; the digastric and stylo-hyoid muscles, and the hypoglossal nerve; and the lingual and facial tributaries of the internal jugular vein. In the parotid gland it is crossed by the facial nerve, and in a muscular subject its lower part is considerably overlapped by the sterno-mastoid. The beginning of the external jugular vein is also superficial.

*Beneath* it are the internal carotid and the intervening stylo-glossus and stylo-pharyngeus, and the glosso-pharyngeal nerve; and, lying more deeply than the internal carotid, the superior laryngeal nerve.

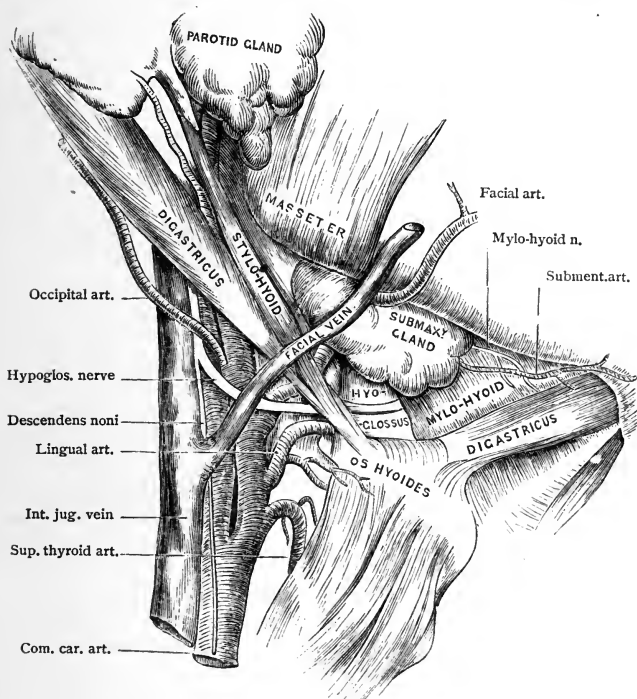
*Externally* are the anterior border of the sterno-mastoid and the commencement of the internal carotid; and *internally* are the pharynx and hyoid bone, and, just before its termination, the ramus of the jaw.

**Ligation of the external carotid.**—The patient is arranged as for ligation of the common carotid (p. 25), and an incision is made in the line of the artery, from just behind the angle of the jaw to the level of the cricoid cartilage. The superficial fascia and platysma having been traversed, the deep fascia is divided on a director; then the digastric, or the hypoglossal nerve, and some veins are seen crossing obliquely. The sterno-mastoid must be pulled outwards, the head having been raised, and the digastric must be drawn upwards.



The veins must be gently drawn upwards or downwards, but if any of them be absolutely in the way they must be tied in two places and cut. The artery is then denuded, and the needle is passed from without inwards, so that there may be no risk of wounding the sheath of the internal carotid and jugular vein.

If it be only the lowest part of the artery which is exposed, the surgeon must be careful not to tie the internal in mistake, for the two vessels lie side by side. If he can see them both, he remembers that



Digastric region. (HOLDEN.)

the external is anterior and becomes superficial to the internal; one of them gives off branches; it is, of course, the external. If the hypoglossal nerve be seen touching one of the trunks it must be the external carotid, for, at the level at which the nerve crosses, the internal is too deeply placed for the nerve to touch it. Lastly, the surgeon should see that compression of the artery, which he takes to be the external carotid, arrests the temporal pulse.

If he seek the artery above the crossing of the digastric, he must

begin his incision in front of the tragus, and keep away from the parotid gland, and avoid the branches of the facial nerve.

*Collateral circulation* is established by the empty branches bringing in arterial blood as follows: the superior thyroid, lingual, facial, superficial temporal, and occipital from their fellows of the opposite side; the superior thyroid from the inferior thyroid of its own side; the facial by its anastomosis with the ophthalmic at the inner corner of the orbit; the superficial temporal by its anastomosis with the supra-orbital of the ophthalmic; and the occipital with the profunda cervicis of the superior intercostal, and also with the vertebral.

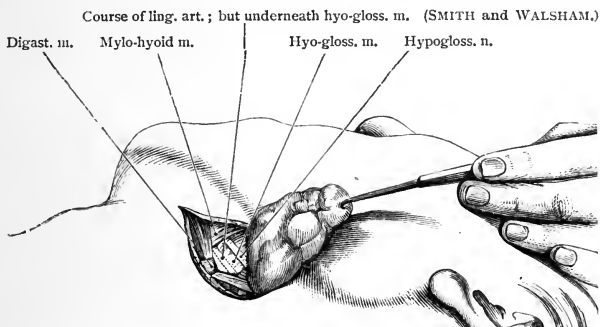
*Branches.*—The **superior thyroid** is given off in the superior carotid triangle (p. 10), being covered by skin, superficial fascia, platysma, and deep fascia. It runs upwards for a little, and then downwards and forwards, under the omo-hyoid, sterno-hyoid, and sterno-thyroid, to enter the thyroid body, where it anastomoses with its fellow and with the inferior thyroid. It sends a twig across the middle line below the hyoid bone, which anastomoses with its fellow, and a branch, which descends obliquely over the sheath of the common carotid, to supply the sterno-mastoid, which is probably severed in ligation of that artery. The *superior laryngeal* branch runs with the nerve of that name, through the thyro-hyoid membrane, for the interior of the larynx. The *crico-thyroid* branch runs across the crico-thyroid membrane to join its fellow. It is wounded in laryngotomy.

The **lingual** artery is given off opposite the great cornu of the hyoid bone, sometimes coming off in a common branch with the facial; it reaches the tip of the tongue as the *ranine*. In its course it not only ascends, but passes deeply, running out of the superior carotid triangle beneath the stylo-hyoid and digastric, and then under cover of the hyo-glossus, where it rests on the middle constrictor of the pharynx. It soon rests upon the genio-hyo-glossus, and ultimately upon the lingualis, being then beneath the mucous membrane of the tongue, by the side of the frænum. Its position there must be remembered in dividing the frænum, for if the scissors be clumsily directed upwards it may very easily be cut. The ranine vein may be seen through the mucous membrane on raising the tongue, but the artery, which is more deeply placed, cannot be made out.

The lingual sends inwards a *hyoid* twig which anastomoses with its fellow above the hyoid bone, and then a larger branch—the *dorsalis linguæ*—which ascends under the hinder part of the hyo-glossus to the tongue, soft palate, and tonsil. It anastomoses with its fellow in front of the epiglottis. The *sublingual* branch comes off just after the lingual has passed beyond the hyo-glossus. It supplies the sublingual gland and the floor of the mouth.

**Ligation of the lingual artery** may be performed in the superior

carotid triangle, but, as its course and position are there subject to variations, it is better to seek it at a spot where it is sure to lie, and in the depths of an area with very definite boundaries :—The head being thrown back, and the face turned to the opposite side, so as to get the angle of the jaw out of the way, a curved incision is made from behind the symphysis to just in front of the angle of the jaw, reaching the middle of the side of the hyoid bone, through skin, superficial fascia, and platysma. The deep fascia is then incised ; a large superficial vein or two may need to be tied and cut. The lower border of the sub-maxillary gland, which is then seen, must be detached with a director and turned up out of the way. Then a *very small triangle* is made out which is bounded above by the hypo-glossal nerve, behind by the pearly tendon of the digastric, and in front by the posterior border of the mylo-hyoid. The hyo-glossus forms the floor of this triangle. Possibly the digastric tendon may have to be drawn down, the better to expose the depths of the triangle. Then, with the director, the



hyo-glossus is scratched through close to the hyoid bone, and the artery is laid bare, resting upon the middle constrictor.

The **facial** artery, given off in the superior carotid triangle, has to turn over the maxilla in its course to the inner corner of the orbit, where, as the *angular* artery, it anastomoses with the nasal branch of the ophthalmic—itsself a branch of the internal carotid trunk. Winding out of the superior carotid triangle beneath the digastric and stylo-hyoid muscles, it enters the sub-maxillary triangle, embedding itself in the sub-maxillary gland. It then turns up over the maxilla, at the anterior inferior angle of the masseter. It courses beneath the platysma and the zygomatici, and rests upon the buccinator and the elevators of the upper lip. It is accompanied by the facial vein, which is thin-walled, and does not take the tortuous course of the artery. The vein is posterior to the artery and passes superficially to the salivary gland.

**Below the jaw** the facial artery gives off an *ascending palatine* and

a *tonsillar* branch, which, mounting by the internal pterygoid muscle, send twigs through the superior constrictor to the tonsil. The *submaxillary* branches of the facial supply the salivary gland, and the *submental* runs forward on the mylo-hyoid and supplies the chin and the lip, anastomosing with its fellow.

**Above the jaw** the branches are : *inferior labial* and *inferior coronary*, the latter lying between the mucous membrane and the orbicularis, as does also the *superior coronary*. These three branches anastomose with their fellows across the middle line, and the superior coronary gives a branch to the septum of the nose. The *lateral nasal* branches also anastomose with their fellows of the opposite side over the ridge of the nose, and the *angular*, as already mentioned, joins the nasal of the ophthalmic. The angular artery is upon the nasal side of the lachrymal sac. The facial may be readily compressed or tied as it passes over the lower jaw.

The **occipital artery** is a posterior branch of the external carotid in the superior carotid triangle, out of which it passes under the guidance of the digastric and stylo-hyoid to the interval between the transverse process of the atlas and the mastoid process. As the external carotid is anterior to the internal carotid, the occipital branch has to cross the internal carotid and jugular vein. The hypoglossal nerve hooks round the occipital artery. Arrived at the bony interspace just alluded to, the occipital artery necessarily lies under cover of the sterno-mastoid, splenius capitis, and trachelo-mastoid, in addition to the origin of the digastric. It grooves the temporal bone, and then lies on the superior oblique and complexus, and ultimately pierces the cranial origin of the trapezius. It ramifies in the scalp as high as the vertex, anastomosing with its fellow and with the posterior auricular and the superficial temporal arteries. At the back of the head it is accompanied by the great occipital nerve. As it mounts towards the vertex it crosses the middle of a line between the occipital protuberance and the external auditory meatus, at which spot it can readily be compressed.

*Branches.*—The occipital artery gives off *muscular* twigs ; an *auricular* branch to the concha ; meningeal twigs through the posterior lacerated foramen ; and the *princeps cervicis*, which descends between the complexus and semi-spinalis colli to anastomose with the vertebral and with the profunda cervicis of the superior intercostal artery. A more superficial branch of the princeps runs beneath the border of the trapezius, to communicate with the superficial branch of the transverse cervical.

The **posterior auricular** springs from the carotid above the crossing of the digastric, and, therefore, is not in the superior carotid triangle. It is crossed by the portio dura, and mounts under cover of the parotid gland to the crevice between the mastoid process and the concha, giving twigs to the scalp and to the pinna, which anasto-

mose with the occipital and the superficial temporal. Its **stylo-mastoid** branch enters the Fallopiian aqueduct as the portio dura is leaving it, and anastomoses with the petrosal branch of the middle meningeal. It supplies the tympanum, the mastoid cells, and the three semi-circular canals. In childhood a twig of this artery enters into an anastomotic circle with the tympanic branch of the internal maxillary upon the membrana.

The **ascending pharyngeal** is a slender and irregular branch which mounts from the beginning of the external carotid, between the internal carotid and the pharynx, to the base of the skull. It gives pharyngeal, tonsillar, and palatine branches, and some *meningeal* twigs which enter the skull through the middle, the posterior lacerated, or the anterior condylar foramen.

The **superficial temporal** comes from the bifurcation of the artery in the parotid gland; it ascends over the zygoma, and soon divides, upon the temporal fascia, into an anterior and a posterior trunk.

The *anterior division* anastomoses with the supra-orbital and frontal branches of the ophthalmic, the *posterior* joining with its fellow across the vertex, and with the posterior auricular and occipital arteries.

*Branches of the superficial temporal*:—The *transverse facial* emerges from the parotid gland and runs forwards over the masseter between the zygoma and the duct of the gland, and anastomoses with the infra-orbital branch of the internal maxillary, and with the facial.

The *middle temporal* dips through the temporal fascia to supply the muscle and to anastomose with deep temporal branches. It also sends forwards an orbital twig between the layers of the temporal fascia which may anastomose with the lachrymal and palpebral branches of the ophthalmic. *Auricular* branches anastomose with others upon the pinna.

**Arteriotomy**.—‘Bleeding’ is sometimes done from the anterior division of the artery, instead of from a vein, in the case of severe ophthalmia or meningitis. For arteriotomy the main trunk of the superficial temporal should not be selected, as it lies close to a large tributary of the external jugular vein and by divisions of the facial and auriculo-temporal nerves.

The anæsthetist conveniently feels the temporal pulse instead of the radial during an operation. When there is an obstruction to the flow of blood through the capillaries the anterior temporal artery becomes elongated and extremely tortuous, and its pulsations are apt to attract attention.

Hæmorrhage from the branches of the superficial temporal, and of other vessels in the scalp, is often extremely troublesome to arrest, as the vessels are incorporated with the surrounding fibrous tissue, and, therefore, unable to retract and contract. A deep suture is the most certain method of stopping the bleeding.

The **internal maxillary**, the larger terminal division of the external carotid, hurries inwards and forwards from the parotid gland, passing between the ramus of the jaw and the internal lateral ligament, beneath the insertion of the external pterygoid. This constitutes the *first part of its course*, and from it are given off the tympanic, middle and small meningeal, and the inferior dental branches.

The *tympanic* branch mounts behind the condyle of the jaw to the middle ear, which it enters by the Glaserian fissure. It forms an anastomotic circle upon the membrane with the stylo-mastoid branch of the posterior auricular. The **middle meningeal** enters the skull through the foramen spinosum, passing between the heads of the auriculo-temporal nerve (p. 63). It then divides. Its anterior trunk runs in a tunnel or groove in the anterior inferior angle of the parietal bone, and spreads in widely-reaching branches upon the convex surface of the dura mater, and in grooves upon the frontal and parietal bones. The posterior division winds backwards on the squamous and parietal bones, to end, like the other, in the supply of the dura mater and the cranium, and in anastomosis with its fellow of the opposite side and other meningeal arteries. The middle meningeal also gives a petrosal branch through the hiatus Fallopii, which anastomoses in the aqueduct with the stylo-mastoid artery, and sends branches through the great wing of the sphenoid into the orbit and the temporal fossa.

The *small meningeal* passes into the skull through the foramen ovale. The **inferior dental** enters the dental canal, and divides opposite the first bicuspid into a *mental* and an *incisive* branch. The former emerges by the mental foramen, and anastomoses with the inferior labial and submental branches of the facial, whilst the other continues in the lower jaw, supplying the canine and incisor teeth, and meeting its fellow across the middle line. Before entering the maxilla the inferior dental gives off the *mylo-hyoid* branch, which ramifies on the cutaneous surface of the mylo-hyoid muscle.

The *second part* of the artery lies in the triangle formed by the two pterygoids and the ramus of the jaw; it gives off deep temporal, pterygoid, masseteric, and buccal branches. The *anterior and posterior deep temporals* ascend beneath the temporal muscle, and anastomose with the superficial and middle temporal arteries, and with branches which enter the fossa from the middle meningeal and ophthalmic arteries. As the *masseteric* twig runs outwards through the sigmoid notch it supplies the maxillary joint. It anastomoses with the facial and the transverse facial arteries. The *buccal* branch anastomoses upon the cheek with the facial.

The *third part* of the artery enters the spheno-maxillary fossa. But just before doing so it gives off a trunk from which the alveolar and infra-orbital arteries arise. The *alveolar*, or *posterior dental*, distributes branches upon the tuberosity of the maxilla for the gums,

and others which enter the bone for the molar and bicuspid teeth, and for the antrum. The *infra-orbital* passes beneath the floor of the orbit, and emerges from the foramen, beneath the levator labii superioris, to supply the tissues in the neighbourhood and to anastomose with the facial. Whilst in the canal it sends branches up into the orbit, and others down the anterior wall of the antrum—the *anterior dental*—for the front teeth. The **posterior or descending palatine** branch leaves the sphenomaxillary fossa by a special osseous canal, and turns forwards on to the under surface of the hard palate through the posterior palatine foramen, which is on the inner side of the last molar tooth. It supplies the hard and soft palate and the tonsil.

A wound of this vessel may cause serious trouble in the operation for cleft palate, and if pressure fail to stop the bleeding the canal must be plugged by a sharp spigot of wood. The *Vidian* and the *pterygo-palatine* branches run back to the pharynx and the Eustachian tube; the former may also send a twig into the tympanum. The *nasal* or *spheno-palatine* branch enters the superior meatus, giving an offshoot to the septum of the nose, and twigs to the turbinated bones.

There is no venous trunk corresponding to the external carotid.

The **internal carotid artery** runs straight up from its origin at the level of the upper border of the thyroid cartilage to the base of the skull, which it traverses by the tortuous canal in the petrous bone. It then turns forwards in the cavernous sinus, in the groove upon the side of the body of the sphenoid, and upwards on the inner aspect of the anterior clinoid process. Then, having pierced the dura mater near the inner end of the Sylvian fissure, it divides into the anterior and middle cerebral arteries.

**Relations of the internal carotid in the neck.**—*Superficially* are the skin, platysma, and fasciæ, the anterior border of the sternomastoid, the posterior belly of the digastric and the stylohyoid, with the hypoglossal nerve and the occipital artery, and the lingual and facial tributaries of the internal jugular vein; the external carotid and the styloglossus, stylopharyngeus, and the glosso-pharyngeal nerve, and, as the artery approaches the petrous bone, the parotid gland.

The artery rests upon the transverse processes of three upper cervical vertebræ and the rectus capitis anticus major; the superior laryngeal branch of the vagus; and the superior cervical ganglion of the sympathetic.

*To its inner side* are the pharynx and tonsil, and the ascending pharyngeal artery. I have known of a case in which the stem of a clay pipe, driven through the tonsil and the pharynx, caused a fatal laceration of the internal carotid, and I have heard of another in which an aneurysm of the artery, which pushed the tonsil inwards, was incised under the belief that the swelling was a tonsillar abscess.

*To its outer side* are the internal jugular vein and the vagus.

Its *course* in the neck corresponds to that given for the external carotid (p. 23), but in that the external carotid is for the supply of the exterior of the head, whilst the internal carotid is for the brain and the orbit, the internal carotid lies deeper in its ascent.

The internal carotid takes its strange *tortuous course* through the petrous bone and through the cavernous sinus in order that the rush of blood from an energetic left ventricle into the delicate cerebral capillaries may be softened down. The same arrangement also obtains in the vertebral arteries in their sub-occipital ascent.

As the artery passes through the petrous bone it lies just in front of the middle ear, being separated from it by merely a thin osseous plate. It is accompanied by ascending filaments of the cervical sympathetic. In certain morbid conditions its pulsations are unpleasantly experienced by the auditory nerve.

As the artery winds along the inner wall of the cavernous sinus, the sixth nerve rests on its outer side. In the case, therefore, of aneurysm of that part of the artery the external rectus may be weakened or paralysed. Sympathetic filaments surround this part of the artery.

*Branches.*—A small *tympanic* twig comes off from the petrosal part of the artery, and anastomoses with the tympanic branches of the internal maxillary and posterior auricular.

The **ophthalmic, anterior, and posterior cerebral** divisions of the internal carotid are described on pages 81 and 42.

The internal jugular vein corresponds to the internal and common carotids.

## THE JUGULAR VEINS AND THEIR TRIBUTARIES

### VEINS OF HEAD AND NECK

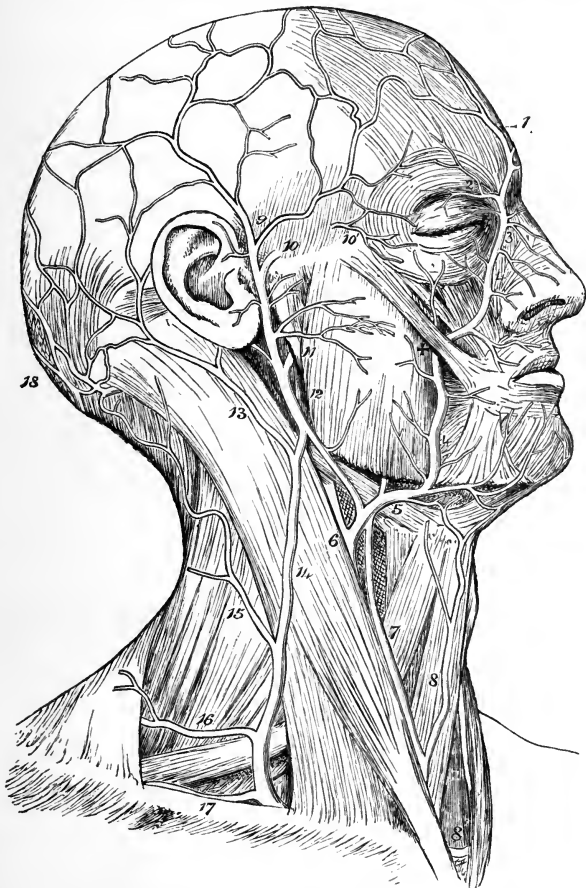The veins of the interior of the head and of the neck, like those of the lung, liver, kidney, uterus, and ovary, have no valves.

The *facial vein* begins as the angular at the inner corner of the orbit, where it has an important communication with the ophthalmic vein; it descends obliquely towards the anterior inferior angle of the masseter, lying behind the facial artery, and taking a straighter course. Below the jaw it is joined by a considerable trunk of the temporo-maxillary vein; it continues beneath the platysma and fasciæ, and, passing across the external and internal carotids, ends in the internal jugular. It brings down blood from the large median, *frontal*, and from the *supra-orbital* veins, and from many tributaries corresponding to the branches of the facial artery; its communications with the ophthalmic vein are of great importance.

The *temporal* is formed by the confluence of the superficial and



middle temporal veins, and, in the parotid region, is joined by the *internal maxillary vein*, which is bringing blood from the pterygoid, palatine, and deep temporal regions. The **temporo-maxillary vein** which is thus formed takes a short course in the parotid gland, and



1, Frontal; 3, angular; 4 and 5, facial; 8, anterior jugular; 9, temporal; 11, internal maxillary; 12, temporo-maxillary giving branches to facial and external jugular; 13, posterior auricular; 14, external jugular; 16, transverse cervical; 17, supra-scapular; 18, occipital.  
—PROF. THANE.

near the angle of the jaw gives off a tributary to the facial vein; being there joined by the *posterior auricular vein*, it forms the **external jugular**. The last-named vein descends almost vertically beneath the platysma and over the deep fascia, and, having passed obliquely

over the sterno-mastoid, turns down behind the clavicular origin of that muscle to empty into the subclavian vein. Near its termination it receives the *transverse cervical (posterior scapular)* and the *supra-scapular* veins, which form an important plexus over the front of the third part of the subclavian artery, and perhaps also the anterior jugular vein.

The *course of the external jugular vein* is marked by a line from the angle of the jaw to the back of the clavicular origin of the sterno-mastoid. Thus it runs almost parallel with the fibres of the platysma.

The **anterior jugular** begins by the confluence of some submental veins; descending in a superficial course near the middle line of the neck, it pierces the deep fascia just above the manubrium, and, passing outwards beneath the sterno-mastoid, ends in the external jugular or subclavian vein. In tenotomy of the clavicular part of the sterno-mastoid there is risk of wounding the anterior jugular (p. 4). Short transverse branches connect the two anterior jugular veins across the middle line.

The **internal jugular vein** begins just below the posterior lacerated foramen by the confluence of the inferior petrosal and lateral sinuses (p. 39). Thence it descends by the outer side of the internal and common carotid arteries to join the subclavian vein in the formation of the innominate vein. Its relations are very similar to those of the internal and common carotid arteries.

Lying in the carotid sheath, the vein is apt to overlap the common carotid artery, and especially so upon the left side (p. 25); on the right the end of the vein inclines somewhat to the outer side of the artery. The end of the vein passes in front of the subclavian artery in the first part of its course.

The *tributaries* of the internal jugular are the pharyngeal, facial, lingual, superior and middle thyroid, and the occipital.

The *occipital veins* begin in a plexus at the back of the head, and, running with the occipital artery, end in the internal jugular vein.

**Cut-throat.**—The man who draws a razor across his throat with suicidal intent, being probably right-handed, gashes the left side. If the brunt of the shock is received by the thyroid cartilage, as often happens, no serious harm may ensue. But if he happen to hit off the thyro-hyoid space there is little to hinder the progress of the blade. Thus, in addition to the skin, platysma, anterior jugular vein, cutaneous nerves, and the deep fascia, the anterior part of the sterno-mastoid may be traversed, and, more deeply, the external carotid, or its superior thyroid or lingual branch, and the corresponding vein. The sterno-hyoid, omo-hyoid, and the thyro-hyoid muscle and membrane and the superior laryngeal nerve, might also be cut, and possibly the incision might pass into the pharynx, wounding also the epiglottis.

To arrest the bleeding is the first treatment, and after that the man must be propped up in bed with his head brought forward. Sutures

must be used with discretion, and for the most part only at the ends of the gash, as to close the wound might be to lock discharges beneath the deep fascia and to have them guided into the chest. Still, in these days of antiseptic surgery, so much may be done to prevent suppuration that the edges of the wound may in appropriate cases be sutured, especially if tracheotomy have been resorted to. If there be a wound of the trachea there is great risk of emphysema being set up if the skin-wound is closely sutured. Death may result from entrance of air into the veins. As deglutition disturbs the muscles and tissues of the hyoid region, the man should be fed by a soft œsophageal tube.

**Lymphatic glands** are scattered in the *occipital* and *posterior auricular* regions. They are often enlarged in constitutional syphilis, in inflammation of the scalp, and in otorrhœa. Other glands are found in the *parotid*, *zygomatic*, *buccal*, and *submaxillary* regions.

The arrangement of the lymphatic vessels which enter the respective glands usually corresponds to that of the neighbouring veins.

The *superficial cervical glands* are grouped along the external jugular vein, and in the subclavian triangle they receive communications from axillary glands, and tributaries from the windpipe and gullet. They may be enlarged in malignant disease of the breast, and also of the œsophagus and stomach.

The *deep cervical glands* are grouped along the internal jugular vein; they receive supplies from the mouth, pharynx, tongue, and larynx, and from the tissues of the neck generally. They are in free communication with the axillary and thoracic glands.

The course taken by the lymphatic vessels is often erratic and peculiar; those coming from the occipital scalp, for instance, may enter glands beneath the anterior border of the sterno-mastoid, and those from the right side of the tongue may pass to the glands of the left side of the neck.

## MEMBRANES OF BRAIN AND VENOUS SINUSES

The **dura mater**, though forming the internal periosteum of the skull bones, is but loosely attached to them, except in the neighbourhood of the sutures and foramina: thus it is often separated from them in a considerable area by hæmorrhage from the middle meningeal artery, or by suppuration—the result of a blow on the head. It is firmly attached at the base of the skull and at the margin of the foramen magnum. From the foramen magnum it becomes continuous with the dura mater of the spinal cord. Its outer surface is rough, and from it small veins pass into the diploë. Its inner surface, paved with endothelium, is smooth, and bounds the subdural space.

Tubular sheaths of the dura mater emerge with the cranial nerves, and blend eventually with the external periosteum. In the

neighbourhood of the superior longitudinal sinus the dura is studded with granular elevations, *Pacchionian glands*, which are villous processes of the arachnoid. They have been mistaken for tubercular deposits.

The dura is continuous with the periosteum of the orbit through the sphenoidal fissure and the optic foramen, and with the pericranium through the sutures and foramina generally. And thus it happens in the case of inflammation in the orbit, or of erysipelas of the scalp, that secondary meningitis occasionally supervenes. If the meningitis implicate the venous sinuses, coagulation of their contents results, and pyæmia ensues.

The dura lines also the internal auditory meatus, and in the case of fracture of the base of the skull extending across the petrous bone, and rupturing the *membrana tympani*, subarachnoid fluid may escape from the external ear in such quantities as to saturate the pillow; the lesion is not necessarily fatal, however, for the fluid is very rapidly secreted.

The **arachnoid** forms a loose and delicate investment for the brain and is continued down over the cord. The interval between it and the pia mater constitutes the *subarachnoid space*, which is very roomy over the base of the brain between the optic nerves and the pons, and again between the cerebellum and the back of the medulla. By a small opening in the pia mater in the latter situation the subarachnoid space communicates with the interior of the fourth ventricle. This opening is the *foramen of Majendie*, and by it the serous fluid of the subarachnoid space maintains its tidal communication with that of the fourth, third, and of the lateral ventricles, constituting the so-called cerebro-spinal circulation. Tubercular inflammation at the base of the brain is apt to cause obstruction of this passage, and, as a result, dropsy of the ventricles. A small quantity of fluid exists between the dura and arachnoid—in the *subdural space*—but the chief amount of the cerebro-spinal fluid is in the subarachnoid interval. This fluid differs from ordinary serum in that it contains no albumen; it sometimes flows in very large quantities from the ear or from the nose after fracture of the base of the skull.

A doubled cuff of arachnoid accompanies the facial nerve into the auditory meatus, but, when after fracture of the petrous bone the cerebro-spinal fluid escapes, this sheath need not be lacerated, for the escape is not from the cavity of the arachnoid, but from the subarachnoid space.

The sheath around the optic nerve becomes distended when a tubercular deposit or a tumour is exerting pressure at the base of the brain, and in such cases congestion occurs in the veins of the optic disc—an evident and important sign.

The **pia mater** is a delicate fibrous network in which the vessels break up before entering the brain-substance. It dips into the sulci,

and turns in at the transverse fissure to form the velum interpositum and the choroid plexuses. It adheres closely to the cerebral cortex, whilst the arachnoid passes from convolution to convolution without dipping into the sulci.

**Falx and tentorium.**—Sickle-shaped processes of the dura dip between the hemispheres, down to the corpus callosum, and also between the lobes of the cerebellum; and a horizontal layer, the tentorium, forms a roofing to the cerebellum, and a support for the posterior lobes of the cerebrum. The attachment of the tentorium may be marked by a line from the external occipital protuberance to the external auditory meatus.

**Venous sinuses** are formed by a splitting of the dura; being part of the vascular system, they are of course completely lined with a flattened endothelium. They receive emissary veins from the skull, as well as from the cerebrum and cerebellum.

The *superior longitudinal sinus* begins at the crista galli by a vein which it receives from the nasal fossæ through the foramen cæcum. The sinus grooves the middle of the frontal bone and the adjacent edges of the parietals, and, descending on the occipital, communicates with the torcular Herophili and turns, for the most part, into one of the lateral sinuses. Trephining in the neighbourhood of the sinus may give rise to serious bleeding, and should generally be avoided. The vein which ascends to begin the sinus is in communication with the vessels of the nose; thus headache which is due to over-fulness of the cerebral vessels may be relieved by epistaxis or by leeching the nose. In its course the sinus receives the superior cerebral veins and a pericranial communication through the parietal foramen.

The *course of the sinus* may be marked by a line beginning at the root of the nose, passing up the middle of the forehead, backwards along the interparietal suture, and to the external occipital protuberance.

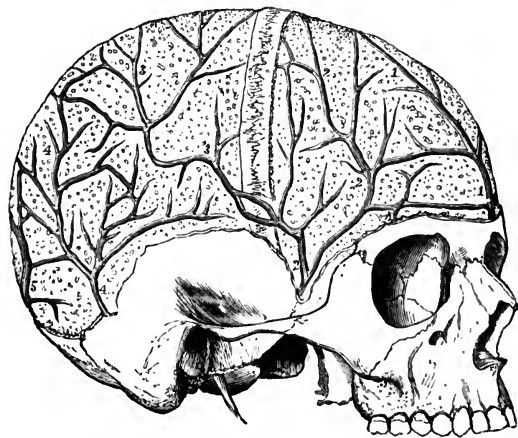
The **lateral sinuses** carry the blood from the region of the internal occipital protuberance to the posterior lacerated foramen, and so into the beginning of the internal jugular vein. After leaving the occipital bone the sinus grooves the posterior inferior angle of the parietal, and then the mastoid part of the temporal. As a rule, the right sinus carries away the contents of the superior longitudinal, whilst the left empties the straight sinus. In the case of injury, the surgeon will be loth to trephine near the mastoid process; but in the case of disease he may have no choice. In its course the lateral sinus receives the superior petrosal sinus, and at its termination in the jugular vein the inferior petrosal. It communicates with the veins of the pericranium by the *mastoid vein*, and by small vessels which enter through the posterior condylar foramen. The short mastoid vein runs from the posterior auricular vein through the mastoid bone. When, in the case of meningitis, leeches are applied behind the ear, it is by this vein that the intracranial circulation is relieved. The

nearness of the sinus to the middle ear explains how in abscess of that cavity septic thrombosis may occur.

The *position of the lateral sinus* is indicated by a line running horizontally outwards from the occipital protuberance to within about an inch of the external auditory meatus, and thence downwards to the mastoid process.

The **cavernous sinus**, at the side of the body of the sphenoid, receives the blood of the ophthalmic vein, which flows into it through the sphenoidal fissure. It also receives cerebral veins. It is emptied by the two petrosal sinuses. On the inner wall of the sinus winds the internal carotid artery, with the sixth nerve on its outer side, and in the outer wall of the sinus are the third and fourth nerves and the first division of the fifth. Tillaux alludes to some cases of aneurysmal communication between the internal carotid and the sinus; the signs of such lesion are dilatation of the ophthalmic vein and a pulsatory swelling behind the internal angular process of the frontal.

The *inferior longitudinal sinus* runs along the concave border of the falx, and ends in the *straight sinus*, which latter passes along the union of falx and tentorium to the torcular Herophili or into one of the lateral sinuses. The straight sinus also carries blood backwards, which the veins of Galen, emerging from beneath the corpus callosum, have brought from the interior of the brain. The straight sinus also receives veins from the upper surface of the cerebellum.



VEINS OF DIPLOË :

1, frontal; 2 and 3, ant. temporal; 4, post. temporal; 5, occipital.

from the frontal bone, to end in a deep temporal vein, and the *posterior temporal* emerges from the parietal bone to empty in the lateral sinus.

The *occipital* flows into an occipital vein or into the lateral sinus.

The **veins of the diploë** do not take their respective names precisely from the bone in which they ramify; they are not confined to any individual bone, but communicate across the sutures. The *frontal diploic vein* joins the supra-orbital as it passes through the supra-orbital foramen. The *anterior temporal* comes chiefly

All these veins have irregular communications with those of the pericranium and dura mater, and, being by their nature incapable of contraction, they are very prone to carry septic matter into the blood, in the case, for instance, of compound fracture of the skull. By means of the supra-orbital and neighbouring branches, the facial vein is in direct communication with the ophthalmic vein, and so with the cavernous sinus. Thus may be explained the thrombosis of the sinuses which sometimes follows facial erysipelas.

**Emissary veins** are the short, open vessels which establish a definite communication between the pericranial veins and the cerebral sinuses. The *mastoid* emissary is a large link between the posterior auricular or occipital vein and the lateral sinus, through the mastoid foramen. The application of leeches behind the ear, as already remarked, thus distinctly influences the intracranial circulation.

The *parietal* emissary passes through the parietal foramen, between a pericranial vein and the superior longitudinal sinus. A small *condylar* emissary runs from an occipital vein through the posterior condylar foramen into the lateral sinus, and a short vessel ascends from the pterygoid plexus to the cavernous sinus.

These emissary veins play an important part in septic wounds of the scalp, rapidly carrying septic material into the intracranial sinuses, and determining the onset of pyæmia.

The **cerebral veins**, which lie in the sulci, are thin-walled and valveless, and are in communication with each other across the middle line through the medium of the sinuses. The superior set of them open from behind forwards into the superior longitudinal sinus, the lower ones end in the cavernous, petrosal, and lateral sinuses.

The *veins of the corpus striatum* and of the choroid plexus emerge from the velum interpositum, and, under the name of *Galen's veins*, enter the straight sinus.

The **cerebellar veins** open into the straight, the lateral, and the petrosal sinuses.

The pressure of venous blood within the skull is equalised by the communication between the two cavernous sinuses by means of the small *circular sinus* around the pituitary body; by the *transverse sinus* which runs across the basilar process; by the communication between the lateral sinuses at the torcular, and by the thin-walled veins upon the surface of the brain which, destitute of valves, lie in the sulci and communicate freely in all directions.

The **arteries of the dura** are *anterior meningeal* from the ethmoidal of the ophthalmic, and others from the internal carotid; *middle meningeal* from the internal maxillary, entering by the foramen spinosum, the *small meningeal* entering by the foramen ovale; and a twig or two from the ascending pharyngeal, through the middle lacerated foramen. *Posterior meningeal* come from the vertebral and from the occipital through the posterior lacerated foramen, and perhaps

from the ascending pharyngeal, through the anterior condylar foramen.

The *veins*, with the exception of the pair of middle meningeals, which emerge by the foramen spinosum to join the internal maxillary vein, end in the adjacent sinuses.

The **middle meningeal artery** ascends for a short distance in the substance of the anterior inferior angle of the parietal, so that fracture of that part of the skull is apt to be followed by hæmorrhage between the bone and dura mater. For the most part, the vessel is wrapped in the dura, so that a rent of the membrane tears the vessel also, in which case bleeding is also external to the dura. The looseness of the attachment of the membrane to the vault of the skull allows the formation of an enormous blood-clot outside the dura, the brain being thereby gradually compressed. The nature of the compression is readily suspected: thus, it is over the motor area; the symptoms do not follow immediately on the accident, as they would if the compression were due to depression of bone: they come on gradually after a few days, and there is no rise of temperature such as would be associated with the compression due to suppuration.

Being thus enclosed in bone and in the dura, there is little chance of spontaneous cessation of bleeding when the artery is rent. The hæmorrhage being over the motor area, the progress of the clot can be precisely noted. Trephining will be indicated, and on opening the skull, if leakage from the vessel have not then ceased, there will be little difficulty in finding and securing the torn vessel. (Jacobson, 'Guy's Hospital Reports,' vol. xliii.)

The **arteries of the brain** are derived from the internal carotid and the vertebral, the former giving off the anterior and middle cerebral.

The **anterior cerebral** enters the front of the longitudinal fissure, where it is joined with its fellow by the short *anterior communicating* artery. It then winds on to the upper surface of the corpus callosum, where it anastomoses with the posterior cerebral. It gives off branches to the anterior perforated space (p. 53), to the anterior lobe, and to the median surface of the hemisphere.

The **middle cerebral**, 'the artery of cerebral hæmorrhage,' supplies the motor area (p. 48). Entering the Sylvian fissure, it gives branches to the island of Reil, through the anterior perforated space, to the corpus striatum, and to those parts of the frontal and parietal lobes adjacent to the fissure of Rolando. Thus, when the main artery of the left side (p. 49) is plugged, there is right hemiplegia and aphasia, and when the right vessel is plugged there is left hemiplegia. When a branch only is blocked the motor paralysis is partial, and, perhaps, temporary, as the anastomotic branches of the pia mater may in due time repair the lesion. The left middle cerebral is said to be more often plugged than the right, because, it is argued, a vegetation is more likely to pass with the blood-stream into it than into that of



the right side. This statement, however, is not apparently borne out by statistics; probably more 'left' cases are reported, because of the interesting clinical feature—aphasia—being present. Acute rheumatism, gout, atheroma, morbus cordis, granular disease of the kidney, syphilis, and injury are the chief causes of disturbance of arterial circulation in the motor area. And he who knows himself to be the subject of one or more of these conditions should try to avoid everything likely to put a strain upon his arterial system, such as running to catch a train, straining at stool, and so on.

The common seat of cerebral hæmorrhage is in the neighbourhood of the corpus striatum, and occurs from the good-sized branches which run straight up from the beginning of the middle cerebral artery into the lenticular and caudate nuclei; probably it is the directness of the course of these branches from the main trunk which causes them to burst under the shock of the ventricular contraction.

The *posterior communicating* artery passes from the back of the internal carotid to join the posterior cerebral. Just there, also, the carotid gives off the *anterior choroid* twigs, which, entering the descending cornu of the lateral ventricle, supply the hippocampus and the choroid plexus.

The **posterior cerebrals** come off at the bifurcation of the basilar, and wind round the crura to supply the occipital lobes, anastomosing there with the middle and anterior cerebrals. The posterior cerebral is joined by the posterior communicating from the internal carotid; it gives offsets to the optic thalamus, which enter by the posterior perforated space, and the *posterior choroid* twigs, which pass beneath the corpus callosum to the velum interpositum.

The **circle of Willis** is an arrangement for equalising the flow of blood between the internal carotid and the basilar, and between these trunks on the two sides of the middle line. Except for this arrangement, ligation of the common carotid would probably be followed by rapid degeneration of the brain. The vessels forming the circle are the anterior communicating, anterior cerebral, internal carotid, posterior communicating, posterior cerebral, and basilar. The circular arrangement does not always suffice for carrying on the supply across the middle line, for sometimes, as a direct result of ligation of the common carotid, apoplexy or softening occurs. The walls of the cerebral arteries are so thin that these vessels look like veins; they inosculate very freely in the pia mater, but their terminal branches do not anastomose. This last fact accounts for the complete loss of function of a part when its artery becomes plugged.

Within the circle are the lamina cinerea, optic commissure, infundibulum and tuber cinereum, corpora albicantia, and posterior perforated space.

The *cerebellum* derives its supply from the *posterior inferior cerebellar* of the vertebral, and from the *anterior inferior* and the *superior*

cerebellar of the basilar. The *pons* is supplied by small *transverse* branches of the basilar, and the *medulla* by the anterior and posterior spinal of the vertebrals, the anterior spinals becoming fused in their descent into a slender median artery.

#### THE ENCEPHALON

The brain, which weighs 49½ oz. in the male and 44 oz. in the female, is surrounded by a thin film of subarachnoid fluid, so that, floating on a water-bed as it were, it may not be seriously shaken when one is running or jumping. The violence may be so great as to fracture the base of the skull, yet the layer of water saves the brain from concussion, as is evinced by the man retaining perfect consciousness, though he may die shortly after from other effects of the fracture.

There are many other natural provisions against rough interference with the delicate structure of the brain, such as the 'give' in the joints of the foot, knee, hip, and pelvis; the curves of the tibia, femur, and spinal column; the fibro-cartilages of knee and spine; the arrangement of cancellated tissue of the bones, and so on. But sometimes, and especially when the subject is taken unawares, and so is unable to arrange his muscles and joints to break the shock, the brain is violently shaken in its bone-case, and, for a time, thrown out of working order. In common parlance, the man is 'stunned'; the surgical equivalent for the condition being '*concussion*'.

The shock which causes concussion is apt to lacerate a meningeal or cerebral vessel, the hæmorrhage occurring either outside or inside of the dura mater, the effect being *compression of the brain*, a much more serious condition than simple concussion. The larger the vessel torn, the more rapidly would the symptoms come on.

A deep **longitudinal fissure** separates the two cerebral hemispheres and lodges the falx cerebri; in its depths may be seen the fibres of the corpus callosum crossing the middle line.

The *lower limit of the cerebrum* is approximately shown by drawing a line from just above the supra-orbital ridge to the external auditory meatus, and thence up to the external occipital protuberance.

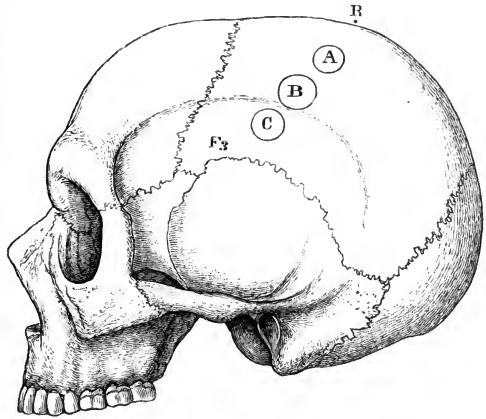
As the protuberance marks the level of the lateral sinus (p. 39), and, with it, the attachment of the tentorium, the cerebellum is necessarily below the hinder part of this line.

**The outer surface of the hemisphere** is deeply cut by the **fissure of Sylvius**, the beginning of which is at the front of the base of the brain; it lodges the lesser wing of the sphenoid, and the middle cerebral artery, 'the artery of cerebral hæmorrhage' (p. 42), winds into it. The fissure quickly divides, one part running upwards for an inch into the frontal lobe, the other extending backwards: these parts are respectively the *vertical* and *horizontal limbs* of the fissure. The horizontal limb cuts off the temporo-sphenoidal lobe below from the

frontal and parietal above. Within the beginning of the fissure is the island of Reil. The posterior border of the lesser wing of the sphenoid is lodged in the fissure.

The **fissure of Rolando** (*central fissure*) begins above near the middle of the longitudinal fissure, and runs downwards and forwards, almost to the spot where the Sylvian fissure bifurcates. It separates the frontal from the parietal lobe.

The **situation of the fissure of Rolando** on the vertex of the skull is  $\frac{1}{2}$  in. behind the middle of a line passing from the root of the nose to the occipital protuberance, from which it slopes downwards and a little forwards.



A, B, C, trephine-crowns over fissure of Rolando, R; F3, Broca's Region.—After ERICHSEN.

A simpler way of marking it on the shaven scalp is to draw a line with an aniline pencil, from that part of the vertex which is directly above the external auditory meatus, to the depression just in front of the piece of cartilage (tragus) anterior to the meatus; the fissure descends along this line almost to the level of the Sylvian fissure (*v.i.*). The line thus drawn runs almost parallel with the coronal suture, being about  $1\frac{3}{4}$  in. behind it above, and  $1\frac{1}{4}$  in. behind it below. But the knowledge of the relative position of suture and fissure is of no practical use to the surgeon, for the suture does not afford him a landmark when about to remove a tumour from the motor area; the aniline mark upon the scalp is, however, of the greatest service. Though, let it be remembered, the fissure of Rolando corresponds only to the upper part of that mark.

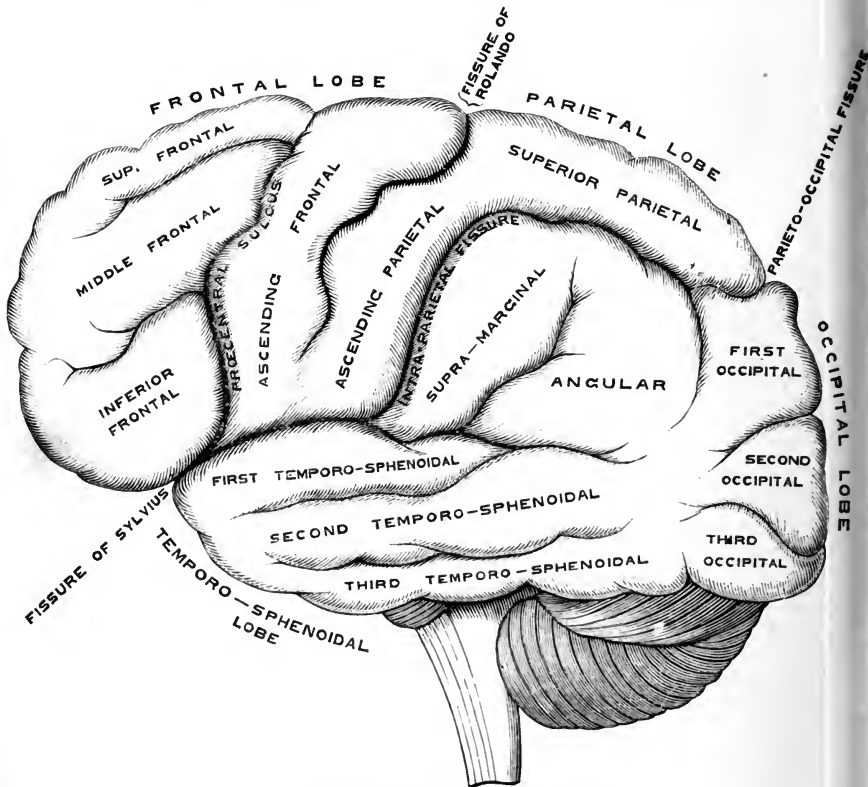
The *ascending frontal convolution* runs for the width of the finger in front of this line, and the *ascending parietal* mounts behind it. From the front of the former convolution it is easy to map out the three horizontal frontal convolutions.

The *temporo-sphenoidal* lobe is often the seat of abscess secondary to suppurative otitis. It may be reached by the trephine applied two inches above and behind the external auditory meatus. There are more complicated ways of indicating the situation of this spot, but I venture to say that they are not more precise.

In operating, the trephine must not be applied at a lower level, lest the lateral sinus be opened (p. 39).

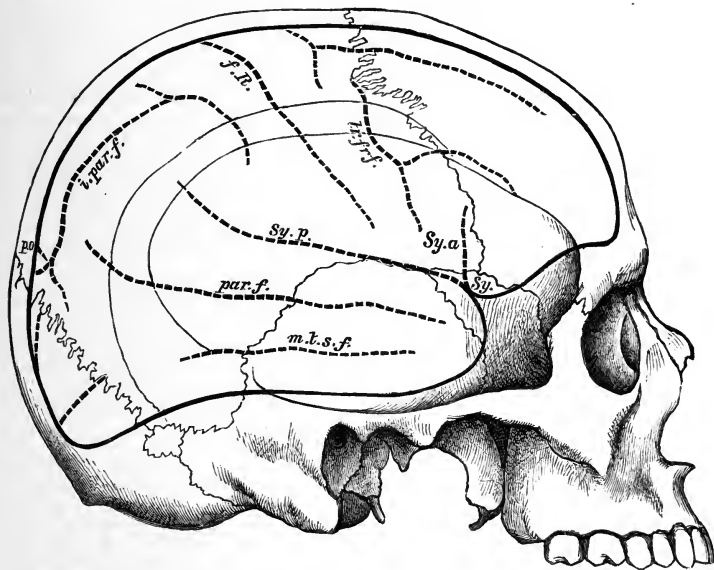
**The fissure of Sylvius** runs backwards and upwards between the frontal and the temporo-sphenoidal lobes. As the frontal lobe rests upon the roof of the orbit, the fissure must start from just below the level of the roof; it begins about  $1\frac{1}{4}$  in. behind the external angular process of the frontal bone, and runs to the parietal eminence—not quite to its centre, for that is occupied by the *supra-marginal gyrus*, which takes its name from being ‘above the end’ of the fissure. The main fissure runs for about  $\frac{3}{4}$  in. before it divides into its vertical and horizontal limbs; the former ascends for about 1 in., and the latter runs backwards and upwards through about the middle of the hemisphere.

The *parieto-occipital* fissure begins in the interior of the longi-



Outer Surface of Left Hemisphere. (GRAY.)

tudinal fissure, and runs a short distance on to the convex surface of the hemisphere between the parietal and occipital lobes.



This figure shows the relative position of the sutures of skull and the fissures of brain. (QUAIN.)

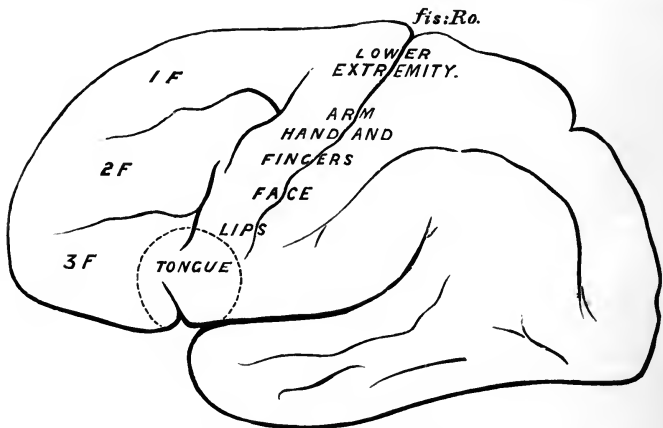
**Lobes.**—The *frontal lobe* reaches back to the fissure of Rolando ; that part of it which rests in the anterior fossa of the skull constitutes its *orbital surface*. The frontal lobe is marked by two horizontal sulci which map it into superior, middle, and inferior frontal convolutions, which, like the sulci, are directed from before backwards. Behind these horizontal lobes is a vertical furrow, the *transverse frontal fissure*, or, because it lies in front of the central (Rolando's) fissure, the *præ-central sulcus*. The vertical convolution which lies between this transverse frontal sulcus and the fissure of Rolando is the important **ascending frontal convolution**.

The *intra-parietal* fissure ascends for a while behind the fissure of Rolando and then turns backwards, perhaps to join the parieto-occipital fissure. The convolution between it and the fissure of Rolando is the **ascending parietal convolution**, and below the fissure of Rolando it becomes continuous with the ascending frontal convolution, the junction between their lower ends forming a thick flap which has to be lifted up in order to expose the island of Reil. Acting thus like a lid, the flap is called the *operculum* (*operio*, -ertum, cover, hide), the convolutions of the island being the *gyri operiti*.

Above, the ascending parietal convolution inclines backwards and ends in the *superior parietal lobule*, which is continuous on the mesial surface of the hemisphere with the *quadrate lobule*—which is just behind the para-central lobule (p. 53). That part of the parietal lobe which is above the end of the horizontal limb of the Sylvian fissure is the *supra-marginal lobule*, and that which is just behind the ending is the *angular lobule*. The former is covered by the parietal eminence.

The *occipital lobe* rests on the tentorium and is indistinctly mapped into three horizontal lobules, called *first*, *second*, and *third*. This lobe is continued into the parietal and temporo-sphenoidal lobes by four small *annectant convolutions*.

The **temporo-sphenoidal lobe** lies in the middle fossa of the base of the skull. It is limited above by the Sylvian fissure, and is mapped



The Motor Area, after GOWERS.

into first, second, and third convolutions (numbered from above downwards) by two antero-posterior fissures, the upper of which lies a little below, and parallel with the horizontal limb of the Sylvian fissure. Hence the upper furrow is called the *parallel fissure*.

The **motor area** comprises the hinder part of the three frontal convolutions, the convolutions bounding the fissure of Rolando, viz., ascending frontal and ascending parietal; the continuation of the latter into the superior parietal lobule; and that part of the marginal convolution which lies in front of the quadrate lobe—the *para-central lobe*. This last-named lobe is formed where the ascending frontal and parietal lobes blend above to prevent the fissure of Rolando entering the longitudinal fissure. The whole of this area is supplied by the middle cerebral artery (p. 42).

That part of the frontal lobe which lies in front of the coronal

suture, and which comprises the chief (anterior) part of the superior, middle, and inferior frontal convolutions, constitutes the *præ-frontal region*. It may be stimulated in experimental research, or destroyed by injury or disease, without the occurrence of motor or sensory disturbance.

Stimulation of various parts of the motor area causes definite movements, on the opposite side of the body, of leg, arm, hand, or face, whilst their complete destruction leaves the muscles paralysed. As already remarked, this area is supplied by the middle cerebral artery. This vessel, at its entrance to the Sylvian fissure, gives off branches through the anterior perforated space to the corpus striatum, so that this important ganglion may escape softening, when, on account of a plugging of the more distant part of the artery, the cortical area is degenerating.

The **island of Reil**, or the *central lobe*, lies deeply in the beginning of the Sylvian fissure, and is seen on gently raising the apex of the temporo-sphenoidal lobe. It is wedge-shaped, its apex corresponding to the anterior perforated space, and its base being hidden by the operculum. Its upper surface lies beneath the lenticular nucleus of the corpus striatum; its under surface is marked by some straight radiating grooves into the *gyri operati* (or hidden convolutions). Broca showed that the motor centres for speech are in the region of the left island of Reil. The *anterior perforated space* is a grey depression near the beginning of the Sylvian fissure, through which twigs of the middle cerebral artery enter the corpus striatum.

**Aphasia** (*a*, privative, *φάσις*, speech) means that a person has lost the faculty of speech—it may be because he has lost the memory for words, but then the disease is more properly called *amnesia* (*a*, priv., *μνησις*, remembrance); aphasia implies that he has the memory of words, but that he has lost the power of co-ordinating the muscles for articulating them. He knows the words, for he may be able to write them, provided that he has not right hemiplegia also; but he cannot say them as he would like to, though he may be able to pronounce certain words perfectly. This last fact proves that the dumbness is very different from that of bulbar paralysis (p. 71). Broca showed that in aphasia there is some serious disturbance with the third left frontal convolution, near the island of Reil. This is therefore, called **Broca's region**.

The defect may be due to a plugging of the middle cerebral artery, to cerebral softening, hæmorrhage, or to the pressure of some tumour or effusion. The speech-centre is not always on the left side, it has been shown clinically to be in the right third frontal convolution in the case of a left-handed subject, but we are, generally, left-brained just as we are right-handed. As regards the extremities, hemiplegia will be upon the right side because of the crossing of the motor filaments in the medulla.

Were the hemiplegia to be on the same side as the cerebral lesion, the explanation would be that, from an error of development, there was no crossing in the pyramids, but that all the motor fibres had descended uncrossed, like the fibres in the column of Türck (p. 215). This element in the calculation, however, may practically be disregarded.

In irritation of the motor area, as from meningitis or slight hæmorrhage, there is twitching of the muscles of the opposite side, but when the area is destroyed, as by abscess, injury, softening, or tumour, there is complete paralysis of motion only on the opposite side, with subsequent contracture of the muscles. The larger the area affected, the more extensive the hemiplegia. Thus, in the case of softening in the neighbourhood of the left fissure of Rolando, there will be right hemiplegia, right facial paralysis, and also aphasia. The softening is usually caused by plugging of the middle cerebral artery, and, the area of brain being suddenly deprived of its supply, the symptoms are much like those of apoplexy.

Disease in the motor area, as already remarked, causes loss of voluntary movements in the muscles of the opposite side; and, as the lateral columns of the cord become involved in a descending degeneration (p. 222), spasm and subsequent rigidity of these muscles are entailed. The degeneration may be traced by the microscope through the crus cerebri, anterior pyramid, and the antero-lateral column of the cord. There is no loss of sensation in these cases, unless, indeed, the degeneration extends deeply into the hemisphere. When hæmorrhage has occurred, and is continuing from a middle cerebral artery, the patient should be propped up in bed, so as to retard somewhat the leakage; and it is a question whether in some of these cases continuous compression, or even ligation, of the common carotid might not be resorted to with advantage.

**Varieties of paralysis.**—Paralysis of the arm with the leg constitutes *brachio-crural monoplegia*; the condition is a common one, for a tumour implicating the upper part of the arm-centre need spread but little to interfere with that of the leg. Perhaps the arm-centre might first be attacked, and then, as the growth extended upwards, leg-paralysis would follow, and as it extended downwards facial paralysis and aphasia would result.

The exact *situation of the leg-centre* is probably in the superior parietal lobule and in the para-central lobule (p. 53). Thus, briefly, the leg-centre is about the top of the fissure of Rolando.

*Crural monoplegia* means paralysis of the muscles of the lower extremity only (*μονος, alone*) that is, without any implication of the muscles of the upper extremity.

*Brachial.*—The centres for the *arm, hand, and fingers* are extensive, just as the movements of the limb are important and complicated; they are situated about the middle of the ascending frontal and ascend-



ing parietal convolutions. The wrist and fingers have their centres in the middle of the ascending parietal convolution, and the lowest of them is close against the centre for the mouth and face. Watch a man trying his very hardest to tie, or to untie a knotted cord, and note how the muscles of the corner of his mouth and of his face are at work. The vigorous motor impulse generated in the hand-centre is brimming over and stimulating the neighbouring oro-facial centre. Suppose that during this effort the branch of the middle cerebral artery which supplies the hand-centre were to burst, there would at first be a meaningless twitching of the hand and mouth, and, as the blood-clot grew, the centres would become disorganised, and the man might be left with brachio-facial paralysis—on the opposite side to the injury, of course (p. 49). And thus it comes about that brachio-facial paralysis is of more common occurrence than brachial monoplegia or facial monoplegia. There is no anatomical boundary between the arm-centre and the centres adjacent to it. In cerebral paralysis there will be neither loss of consciousness nor sensation if only the *motor* area be implicated.

Again, watch the demagogue upon the rostrum. The louder he speaks, the more he throws his arm about, because the energy in his speech-centre flows into the neighbouring hand-and-arm-centre. And, as the speech-centre is upon the left hemisphere, it is the *right* arm with which he gesticulates ; it is training only which makes the orator use his left arm to vary the monotony of the brachial movement. I do not know if the man whose speech-centre is upon his *right* side in his oratory neglects the use of his right hand, but I expect that he does, unless, indeed, he be a well-trained speaker.

Some untrained speakers, or ranters, throw out both arms in an emphatic manner ; this is because the centres of the two sides are held in association by certain commissural fibres. The need for such fibres is evident ; were there none of that sort, the facial muscles of one side, for instance, would be able to act without regard to those of the other, expression being reduced to an absurdity. In very many of our common acts, such as eating, talking, breathing, walking, it is essential that the muscles on the two sides of the body be in harmonious association, and the existence of commissural fibres by which this is effected must not be overlooked when problems in paralysis are being worked out.

*Facial monoplegia* is rare ; facial paralysis of cerebral origin usually being associated with brachial paraplegia when the lesion spreads upwards, or with aphasia when it implicates the base of the third *left* frontal convolution.

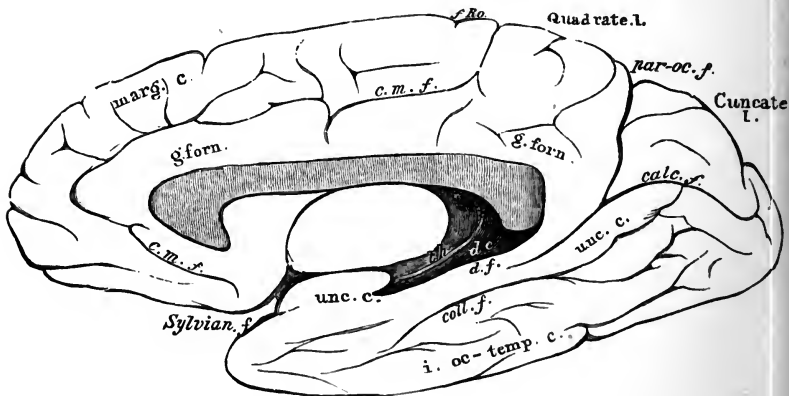
The *oro-lingual centres* (which are at the lower end of the fissure of Rolando) of one hemisphere are associated in their work with those of the other side by certain cross-fibres ; for, as already suggested, one does not use a lateral half of the tongue separately, nor does one

in eating or talking, for instance, confine the movements to one side of the face. When, therefore, these centres are damaged on the one hemisphere there is still some energy passing out to the opposite side of the tongue, so that, as Ferrier remarks, we then find *oro-lingual hemiparesis* (*παρεσις*, relaxation) instead of paralysis. When the lesion is in the left hemisphere the paresis of the right side of the tongue is generally associated with aphasia, because, the lesion being in Broca's region (p. 49), the centres for the muscles of speech—tongue, lips, palate, and vocal cords—are also damaged.

Sometimes, as already remarked, the oro-facial paresis is associated with brachial paralysis. The association of left hemiplegia with aphasia may happen in the case of a left-handed man, that is to say, in one whose right cerebral hemisphere has acquired the habit of performing the offices usually, by preference, localisation, carried out by the left.

It will simplify the problem of localisation if the student remembers that *the motor areas are inverted on the surface of the hemisphere*—like the landscape on the plate of the photographic camera. Thus the centres for the muscles of the lower extremity are grouped about the top of the fissure of Rolando, the arm-centres about the middle, and the centres for the face and mouth, and for the muscles of speech, at the bottom—near to the island of Reil. Thus it comes about in incomplete hemiplegias that the leg and arm may be affected together the face escaping; that in another case the arm and face may be affected without the leg; and that aphasia is much more likely to occur with paralysis of the right arm than of the right leg only, for the arm-centres intervene between those of the muscles of articulate speech and of the leg. (*See illustration on p. 48.*)

On the **mesial surface of the hemisphere** is the *gyrus fornicatus* (or arched convolution), which begins near the anterior perforated spot and arches round the corpus callosum to become continuous with



the uncinatè gyrus. Close above it is the convolution which lies along the margin of the longitudinal fissure—the *marginal convolution*. It begins at the anterior perforated space, and ends just in front of the quadrate lobe. Between the gyrus fornicatus, or callosal convolution, and the marginal convolution, is the *calloso-marginal fissure*.

The **para-central** lobe is chiefly formed by the top of the ascending frontal convolution, which looks into the marginal convolution.

The *quadrate lobe* is the mesial surface of the parietal lobe ; just behind it is the *cuneate lobe* of the occipital.

**Jacksonian epilepsy** is the convulsive attack, followed by temporary paralysis, of a group of muscles, which results from irritation of some part of the motor area. Chronic inflammation of the brain or its membranes is a common cause of it, the inflammation being very often the result of syphilis. Perhaps at first only one group of muscles is affected, but as the irritation extends the neighbouring parts of the cortex are implicated, and the convulsions become more widely distributed. From what has gone before (p. 52) it is evident that if the epilepsy begin as a facial spasm the muscles of hand and arm will be next involved, and lastly those of the leg. When the last group of muscles is first attacked those of the arm are likely to follow suit, and ultimately those of the face. If the disturbance begin in the arm-centres the muscles both of leg and of face are likely to be involved subsequently.

The fibres from the motor area subsequently pass through the corpus striatum and the internal capsule ; hæmorrhage, therefore, in either of these latter situations may cause extensive paralysis upon the opposite side of the body. Indeed, the corpus striatum has been called, on account of its associations, 'the motor ganglion,' the optic thalamus, on the other hand, being 'the sensory ganglion.'

The **sensory region of the cortex** is posterior to the motor, and in the case of a destructive lesion of the motor area, if there be hemi-anæsthesia as well, it is certain that the injury is widespread, and the chance of relief by trephining remote.

## THE BASAL GANGLIA

The **corpus striatum** is a grey ganglion which is streaked, or striated, by white fibres on their way down to the antero-lateral column of the cord, through the superficial, or motor, part of the crus—the *crusta*. These fibres reach the cortex through the fan-like corona radiata. The presence of the vesicular tissue in the ganglion detracts from its strength, and, being freely supplied with branches of the middle cerebral, which enter it through the anterior perforated space, it is often the seat of hæmorrhage. Motor paralysis of the opposite side results, just as if the lesion were in the motor area or in the crus.

Cerebral hæmorrhage is generally the result of kidney-disease, as

explained on p. 348. At the autopsy of such a case the arteries are found diseased, and therefore weakened, the left ventricle being hypertrophied and therefore strengthened.

Sometimes Nature hoists a danger-signal before the final apoplectic fit occurs : such signals are headaches, epistaxis, and retinal hæmorrhages which may be seen by ophthalmic examination.

The *internal capsule* consists of fibres from both the motor (*crusta*) and sensory (*tegmentum*) tracts of the crus, which hold the cortex in direct communication with the cord. Thus damage to the anterior part of the internal capsule causes motor paralysis, and to the posterior part loss of sensation, upon the opposite side of the body. The paralysis in the former case is diffuse, and not confined to a group of muscles as in the case of a cortical lesion.

The **optic thalami** lie behind the corpora striata, and nearer to the middle line, being separated from each other only by the narrow third ventricle. They receive fibres from the sensory tracts of the cord, which reach them through the cerebral aspect of the crura—the *tegmenta* ; each thalamus sends fibres into all parts of the cerebral cortex, and these constitute the *corona radiata*.

The **crura cerebri** consist of fibres ascending from the cord, those from its motor tracts being gathered in the superficial part, the *crusta*, and those from the sensory tracts in the deeper part, the *tegmentum*. The former set pass, for the most part, through the corpus striatum and internal capsule, to the motor area, by the corona radiata, whilst the tegmental set pass to the thalamus and through the corona radiata to the sensory area of the cerebral cortex. Between *crusta* and *tegmentum* is a mass of grey cells, *locus niger*, through which the fibres of the third nerve pass. Between the crura, as they diverge at the front of the pons Varolii, is the posterior perforated space, by which a group of vessels from the posterior cerebral artery reach the thalamus. The tegmental fibres descend in the cord, in the direct (Türck's) and in the crossed pyramidal tracts.

*Hæmorrhage into the crus cerebri* causes hemiplegia on the opposite side of the body, and of the third nerve upon the side of the lesion, provided that the inner fibres are involved.

**Pons Varolii.**—As the fibres descend from the crura to the medulla they pass under cover of the middle commissure of the cerebellar hemispheres, and, though the term 'pons' should only apply to the bridging cerebellar fibres, still the word is usually applied to the entire mass of the *tuber annulare*. As the fibres from both crura descend through the pons, cerebral hæmorrhage in its substance generally causes motor paralysis on both sides of the body, coma following immediately, and death not being long delayed. But when the hæmorrhage is limited to one side there is hemiplegia upon the opposite side of the body, but paralysis of fifth, sixth, and seventh nerves upon the same side.

Though the pons consists chiefly of white fibres, it contains also grey matter, and helps in co-ordinating muscular movements. There also decussation of the fifth and of the seventh nerves takes place. If a lesion, a small hæmorrhage, for instance, occur above the crossing of the facial fibres, there is paralysis of the opposite sides of face and of the body, whereas if it be below the crossing the facial paralysis is upon the same side as the lesion, whilst the hemiplegia is upon the opposite side, for the motor fibres of the cord cross in the medulla.

Hæmorrhage into the pons is usually accompanied by contraction of the pupils.

The **medulla oblongata** extends from the lower border of the pons to the ring of the atlas. Its anterior surface lies upon the basilar process of the occipital bone, and its posterior surface rests between the hemispheres of the cerebellum. Being an enlargement of the spinal cord, it consists of symmetrical lateral halves in which the various columns of the cord can be traced. In front is the median groove, which ends at the pons as the foramen cæcum, and the posterior median groove becomes widened out into the fourth ventricle, the grey commissure of the cord being exposed in its floor. The anterior columns of the cord are represented by the *anterior pyramids*; the bundles of fibres which decussate at the lower part of the groove between the pyramids actually belong to the lateral columns—they are called the *crossed pyramidal tracts*. The outermost fibres of the pyramids do not cross—they constitute the *direct pyramidal tracts*. (See SPINAL CORD, p. 213.)

The *olive* belongs to the lateral column. The **restiform bodies** (*restis*, rope) are cord-like bundles of fibres continuing the posterior column into the cerebellum; they bound the fourth ventricle. The posterior pyramid continues Goll's column along the median border of the restiform body, and its fibres gradually pass into the restiform body. In the exposed grey matter of the fourth ventricle descends a narrow median groove, which at the apex of the ventricle was originally continued into the central canal of the cord.

The medulla oblongata is described by Ranney as 'the true nerve-centre of animal life'; all the cranial nerves from the seventh to the twelfth arise directly from it, whilst others can also be traced thither, that is, to the floor of the fourth ventricle. It contains much grey matter: its action, therefore, is 'largely reflex.' Taking the nerves arising from it in numerical order, we find the seventh controlling the reflex movements of the facial muscles; the ninth (glosso-pharyngeal), of deglutition; the tenth (pneumogastric), of respiration; the eleventh (spinal accessory), of the larynx and heart; and the twelfth (hypoglossal), of the tongue.

The **spectral centres of the medulla** are *respiratory*, under the influence of the pneumogastric, trifacial, and other afferent fibres. 'This centre also presides over the acts of laughing, sighing, sobbing,

sneezing, and hiccough.' The efferent impulse leaves by the phrenic, intercostals, spinal accessory, certain cervical nerves, and facial. *Vaso-motor centre*, controlling the muscular coat of the large arteries of the thorax, abdomen, and pelvis, through efferent impulses carried down by the spinal cord, the dorsal nerves, and the splanchnics. Dilatation of these vessels follows section of the cord below the medulla. *Cardio-inhibitory*, through which the heart is held under control by afferent influences passing to the medulla, acceleration of the heart's action following section of the vagus. The medulla contains also a centre for *deglutition*, and one which, being stimulated, produces glycosuria—the *diabetic centre*—and a salivary centre. Sugar and albumen may be found in the urine in the case of lesion of the medulla.

**Bulbar paralysis** is the result of progressive degenerative changes in the nuclei of origin of the hypoglossal, spinal accessory, vagus, facial, and glosso-pharyngeal, which are near neighbours in the floor of the fourth ventricle. The co-ordination of muscles of articulate speech become gradually implicated, and the tongue and the muscles of the pharynx lose their power. The disease used to be called *labio-glosso-pharyngeal paralysis*; the term bulbar paralysis is shorter, and moreover indicates the seat of the primary lesion, in the 'bulbar' end of the spinal cord (*see p. 71*).

The *aqueduct of Sylvius* leads beneath the corpora quadrigemina and posterior commissure from the top of the fourth ventricle into the third. It is lined by a prolongation of the grey matter from the fourth ventricle, in which are the nuclei of origin of the motor oculi and patheticus.

When the basal ganglia are in physiological activity the vessels, which enter them in great abundance, are filled full, and the ganglia are increased in size. The corpora striata in their turgescence bulge into the lateral ventricles, displacing some of the intra-ventricular fluid which is secreted by the choroid plexuses, through the foramina of Monro, into the third ventricle; and the thalami, growing large, squeeze fluid out of that ventricle through the aqueduct and into the fourth ventricle, and so into the subarachnoid space. As an infant with spina bifida excites himself, and cries, the brain evidently increases in bulk, for the lumbar tumour becomes tense and swells up. And as the brain quiets down again the cerebro-spinal fluid re-enters the cranium, some of it, no doubt, passing into the third and lateral ventricles by the apertures of Sylvius and Monro. In cases of dilatation of the third lateral ventricles (*internal hydrocephalus*) Hilton<sup>1</sup> found that the communication between the ventricles and the subarachnoid space was permanently blocked, so that the intra-cerebral fluid could not escape. Sometimes the brain-tissue is represented by but a thin, smooth film enclosing the 'water,' which has sometimes measured, *post mortem*, twelve or twenty pints. In such cases the head may appear

<sup>1</sup> *Rest and Pain*, 2nd edit. p. 28.

translucent—like a hydrocele. ‘In Cardinal’s case this is said to have been observed when the sun was shining behind him.’—(Fagge.)

**Disease of the cerebellum** is often associated with pain at the lower and back part of the head, and with head-ache. There is also inco-ordination of movement, so that the patient staggers; he is often, moreover, attacked with vomiting.

### THE CRANIAL NERVES

No. 1.—The **olfactory** is shown by development to be a diverticulum from the cerebral hemisphere; in foetal life it is hollow and communicates with the lateral ventricle.

The external root of the nerve springs from the fissure of Sylvius, near the anterior perforated space. This area is close to Broca’s region (p. 49), and so it comes about that aphasia is often associated with an impaired sense of smell in the left nostril. The olfactory filaments descend through the cribriform plate in groups for the mucous membrane of the upper part of the septum and the roof, and of the superior and middle turbinated bones. Odorous particles best reach this area when the air in which they are suspended is ‘sniffed’ up. When, in nasal catarrh, swollen mucous membrane blocks the upper part of the passages, and the sense of smell is lost, the patient has to breathe by the floor of the nose or the open mouth.

The sense of smell may be entirely lost after a fracture extending across the anterior fossa of the skull, or as the result of malignant disease in the ethmoid region.

No. 2.—The filaments of the **optic nerve** pass out through the commissure into the optic tracts, by which they arise from the optic thalamus and the corpora quadrigemina. The tracts wind over the crura cerebri.

The nerve passes out through the optic foramen in a special sheath of dura mater, part of which blends with the orbital periosteum, whilst the rest runs on to the sclerotic. The fibres of the nerve pass through the lamina cribrosa of the sclerotic and spread out into the retina; those fibres which turn outwards, however, do not spread upon the surface until they have reached the vertical meridian of the eye-ball.

In the *optic commissure* the most anterior fibres are inter-retinal and the most posterior inter-cerebral; some fibres pass from the thalamus to the retina of the same side; and, lastly, others pass across from the thalamus of one side to the retina of the other. This decussation is needed because the outer half of one retina works in harmony with the inner half of the other. When we look to the right, for instance, the image falls upon the inner part of the right retina and the outer part of the left. (For the anatomy of the eye see p. 82.)

‘When, therefore, the *optic tract* of either side is pressed upon, so as to affect the entire thickness of the nerve, and thus to interfere with the action of all the fibres, the temporal side of the retina of that eye and the nasal side of the retina of the opposite eye will be rendered blind.’<sup>1</sup> (*Hemianopsia*.) When the *optic nerve* is pressed upon, in front of the commissure, as by sarcoma in the orbit, there is blindness of the one eye only, and it will probably be associated with paralysis of the third, fourth, or sixth nerves also, as they lie close together at the apex of the orbit. If the decussating fibres alone be implicated in the commissure, internal or nasal hemianopsia is found in each eye. ‘Double temporal hemianopsia indicates disease of each internal carotid artery, with symmetrical lateral pressure upon the commissure.’ Severe pressure upon the commissure might cause blindness in both eyes.

Optic neuritis, as determined by ophthalmoscopic examination, is usually followed by atrophy.

No. 3.—The **motor oculi** arises from the grey matter surrounding the Sylvian aqueduct (where the nerves of the two sides decussate), and emerges from the inner side of the crus; it then passes through the outer wall of the cavernous sinus, and divides into two branches which enter the orbit through the sphenoidal fissure, and between the two heads of the external rectus. Coming away from the crus, the third nerve traverses the narrow interval between the posterior cerebral and superior cerebellar arteries, so that if either of these arteries become dilated at that spot ptosis occurs.

The *upper division* supplies the levator palpebræ and the superior rectus; the *lower* supplies the internal and inferior recti, the inferior oblique, and, by the motor root to the lenticular ganglion, the ciliary muscle and the sphincter fibres of the iris.

(The superior oblique is supplied by the fourth nerve, and the external rectus by the sixth.)

**Contraction of the pupil** is effected through the third nerve: when a strong light falls upon the retina a sensation is transmitted by the optic nerve to the corpora quadrigemina, close to which, in the Sylvian aqueduct, the third nerve arises. By this nerve a motor impulse is carried to the lenticular ganglion, and so to the ciliary muscle and iris.

In **viewing near objects** both eye-balls are directed inwards, the right and left internal recti acting in unison; thus it becomes necessary that the third nerves be associated at their origin, which occurs, as already noted, in the grey matter around the Sylvian aqueduct.

As the axes converge upon the near object the pupil must contract so as to cut off peripheral rays; it is expedient, therefore, that the internal recti and the sphincter of the pupil be under the control of the

<sup>1</sup> *Applied Anatomy of the Nervous System*, Ambrose L. Ranney.



same (the third) nerve. Also, when a near object is viewed, the rays falling upon the eye are extremely divergent, and it is necessary that the lens be rendered more convex to focus them ; this is accomplished by the ciliary muscle, through the influence of the third nerve. Thus the third nerve has entire charge of the accommodation for near vision ; it converges the visual axes, contracts the pupil, and renders the front of the lens more convex.

**Dilatation of the pupil** is affected by radiating muscular fibres in the iris under the control of the sympathetic. The influence of the sympathetic upon the pupil, it may be remembered, is exactly the reverse of that upon a blood-vessel—when it is stimulated the pupil is dilated, whereas a blood-vessel would be contracted.

The '**Argyll Robertson pupil**,' as a symptom of posterior spinal sclerosis, is thus explained : when the eye of a healthy man is directed upon a distant object the pupil is dilated, and when he looks at a finger, in front of his nose, for instance, the pupil is contracted ; also when the eye is in shadow the pupil is dilated, but under the influence of a bright light it contracts. In the case of the light, contraction of the pupil is *reflex* ; but in the former case it is effected in *accommodation* (*vide supra*). Now, in sclerosis the *pupillary reflex*—the contraction under the stimulus of light—is abolished, whilst the accommodation-contraction remains. Many other reflexes in addition to those of the pupil are lost in locomotor ataxy as the result of degenerative changes in afferent fibres.

**When the third nerve is paralysed** the upper eye-lid drops, the levator palpebræ being unable to hold it up. The condition is called *ptosis* (*πτωσις*, a falling ; *πίπτω*), and, the internal rectus being thrown out of work, the external rectus holds the eye-ball in permanent abduction (*divergent squint*). The pupil is dilated and does not contract to light, and accommodation for near vision is impossible. Most of the muscles having relaxed their hold, the eyeball protrudes between the lids—*proptosis* (*προ*, forwards, *πτωσις*, falling). It cannot be tilted upwards, inwards, nor downwards.

Likely causes of the paralysis are syphilitic inflammation or deposit at the base of the brain, hæmorrhage, tumour, and diphtheria. When it is due to a lesion near the Sylvian aqueduct the paralysis may be bilateral, and the fourth and the sixth nerves may be implicated in due course. The roots of origin of the third nerve may also be caught in a widely-spreading degeneration which causes labio-glossopharyngeal paralysis (p. 56).

**Double vision** occurs when the recti act out of harmony, because the associated areas of the retina cannot be simultaneously directed upon the object.

No. 4.—The **patheticus**, a thread-like nerve, comes round the crus from its origin at the valve of Vieussens, and, passing along in the outer wall of the cavernous sinus, and through the sphenoidal fissure,

enters the upper surface of the superior oblique. Fibres of the nerve decussate in the grey matter around the Sylvian aqueduct, so that there may be harmony in the action of the two superior oblique muscles when the head is turned. When the nerve is paralysed and the head is moved sideways, the eye of the paralysed side moves with the head instead of being steadily fixed upon the object, and the subject sees double—*diplopia* (*διπλούς*, *double* ; *ωψ*, *ωπος*, *eye*).

No. 5.—The **trifacial** derives its name from its supplying the skin of the face in three situations, namely, in the supra-orbital, infra-orbital, and mental regions. It arises from the pons by two roots, of which the anterior, or motor, is quite small ; the deep origin being in the floor of the fourth ventricle.

The sensory part of the nerve expands on the apex of the petrous bone into the Gasserian ganglion, from the front of which come the ophthalmic and the superior and inferior maxillary nerves. The motor root takes an independent course beneath the ganglion, and eventually leaves by the foramen ovale to join the inferior maxillary trunk, the first and second divisions of the nerve being purely sensory.

*Tic douloureux*, or neuralgia of the fifth nerve or of one of its divisions, may be caused by pressure upon the main trunk, or upon its rootlets in the floor of the fourth ventricle, or by pressure upon a trunk as it leaves the skull—or elsewhere in its course. Sometimes the distress is due to peripheral irritation of a single filament, as in a carious tooth, and amongst more remote causes are cold, dyspepsia, and nervous exhaustion. The pain may shoot along the filaments of the supra-orbital or supra-trochlear nerve, along a division of the temporo-malar, or the branches of the superior maxillary nerve in the cheek, nose, or upper lip ; or along the twigs to the teeth, the temple, chin, lower lip, or side of tongue. On any branch of the nerve there may be a specially painful spot which the patient can precisely indicate. Sometimes the attack is associated with flushing or sweating of the surface, and sometimes it clears up with a profuse secretion of tears, nasal mucus, or saliva, showing, as Ranney remarks, the implication of the vasomotor filaments in the nerve. This association explains also the inflammatory changes which the skin of the affected region may undergo, and also the falling out or blanching of the hair which are sometimes associated with the neuralgia. When the 'tic' is spreading, and is associated with deep-seated headache and with paralysis of certain of the motor nerves, a cerebral lesion may be suspected. Because there is pain in the teeth it by no means follows that the teeth cause the pain, and their extraction should not be hurriedly resorted to.

*Clavus* is that variety of neuralgia in which the pain, though limited to a single spot, is so 'intense' that the patient (generally an hysterical young woman) feels as if a nail (*clavus*) were being hammered into her flesh and bone.

The **ophthalmic** division passes with the third and fourth nerves along the outer wall of the cavernous sinus, and breaks up into frontal, nasal, and lachrymal branches which enter the orbit through the sphenoidal fissure.

The *frontal* nerve lies under the middle of the roof of the orbit, and divides into *supra-orbital* and *supra-trochlear* branches. The former emerges by the supra-orbital notch, and, ascending beneath the orbicularis palpebrarum in two divisions, passes through the occipito-frontalis to supply the scalp, the outer set of filaments reaching back almost to the lambda suture.

In the case of an injury to the trunk of the supra-orbital nerve, I have seen a crop of vesicles on one side of the forehead and even amongst the roots of the hair, just as vesicles occur, after intercostal neuralgia, in the area of distribution of the affected nerve.

The *supra-trochlear nerve* escapes, as its name suggests, above the pulley of the superior oblique, and supplies the skin and mucous membrane of the inner end of the upper eye-lid, and the neighbouring part of the forehead.

The *nasal* nerve reaches the inner wall of the orbit by passing across the optic nerve, and enters the cranial cavity through the anterior ethmoidal foramen, leaving it again by the slit at the side of the crista galli. Descending in the nose, it gives branches to the front of the septum, to the roof, and to the upper spongy bones; it finally escapes between the bone and the cartilage to supply the skin near the nostril. In the orbit it gives off the sensory root to the lenticular ganglion, two long ciliary to the ciliary muscle and iris, and the infra-trochlear branch which supplies the skin and mucous membrane near the lachrymal sac.

The *lachrymal* nerve runs along the upper border of the external rectus and ends in the lachrymal gland and the upper eyelid.

The *lenticular ganglion* lies at the apex of the orbit on the outer side of the optic nerve. Its sensory root comes from the nasal, and its motor from the third nerve; its sympathetic twigs are from the cavernous plexus. It gives off eight or ten short ciliary nerves which pierce the back of the sclerotic to reach the ciliary muscle and iris.

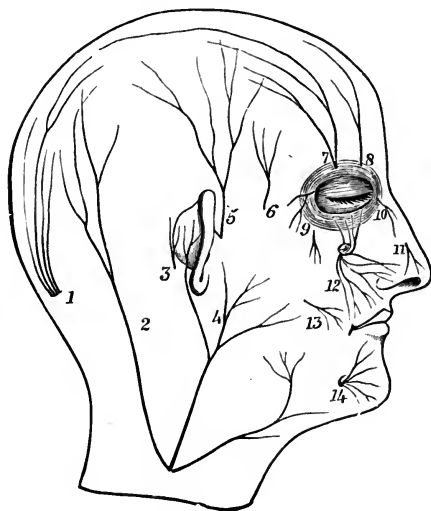Each division of the fifth nerve contains *trophic filaments* under whose influence the nutrition of the integuments to which the trunk is ultimately distributed is controlled. When the nerve is paralysed, not only is there insensibility in the forehead, eyelids, and in the conjunctiva and nose, in part, but these areas are apt to be the seat of ulcerations; conjunctivitis and corneitis may also occur, with escape of the aqueous humour and lens, total destruction of the eyeball resulting.

In cases of intractable neuralgia it may be deemed advisable to try the effect of stretching or of excising a portion of a nerve, but the treatment is somewhat speculative; if each division of the fifth nerve upon the face were affected the operation could hardly succeed, for the cause would then for certain be of central origin.

To reach the supra-orbital nerve a horizontal incision is made for about three-quarters of an inch, just above the border of the orbit—the skin, superficial fascia, orbicularis palpebrarum, and occipito-frontalis being traversed. The middle of the incision should be just above the supra-orbital notch, which can be made out by the finger. When instead of a notch there is a complete foramen in the bone the site of the nerve can be ascertained by pressure; it emerges at the junction of the inner middle thirds of the supra-orbital ridge.

When it is suspected that a person is shamming insensibility, steady pressure should be kept up with the finger on the nerve, just over the supra-orbital notch. No impostor could bear this for long, and he may thus be conveniently and promptly tested.

The **superior maxillary** division leaves by the foramen rotundum,



#### SENSORY NERVES.

- 1, Great Occipital.
- 2, Lesser Occipital.
- 3, Arnold's.
- 4, Great Auricular.
- 5, Auriculo-Temporal.
- 6 and 9, Temporo-Malar.
- 7, Supra-Orbital.
- 8, Supra-Trochlear.
- 10, Infra-Trochlear.
- 11, Nasal.
- 12, Infra-Orbital.
- 13, Buccal Branch of Inferior Maxillary.
- 14, Mental.

(HOLDEN.)

runs across the spheno-maxillary fossa, and, coursing beneath the floor of the orbit, emerges by the infra-orbital foramen under cover of the levator labii superioris. It then spreads out into branches for the nose, lower eyelid, and upper lip. It gives off an *orbital* branch which divides into a *temporal* and a *malar* twig, which pierce the outer wall of the orbit to supply the skin in the temporal and malar regions respectively. Other branches of the trunk are the sensory root to Meckel's ganglion; the *posterior dental*, which forms a loop in the bone and gives off twigs to the lining of the antrum, to the pulp-cavities of the molar teeth, and to the gums.

The *anterior dental* runs down in the front wall of the antrum to supply the incisors, the canine, and the bicuspid.

*Meckel's ganglion* lies in the spheno-maxillary fossa, being connected with the under part of the superior maxillary nerve by the twigs which constitute its sensory root. Its motor filament comes from the facial through the Vidian nerve, and this also brings a sympathetic communication from the carotid plexus. Branches from the ganglion supply the nasal fossa, gums, soft palate and uvula, roof of mouth, upper part of pharynx, Eustachian tube, tonsil, levator palati, azygos uvulæ, and palato-glossus and pharyngeus.

The infra-orbital nerve is found by dividing the orbicularis and the levator labii superioris above the second bicuspid tooth. If it is desired to remove the nerve, and also Meckel's ganglion, the course of the nerve may be followed backwards by trephining the front of the antrum and by breaking along the infra-orbital canal. The spheno-maxillary fossa is thus reached, and the nerve is found emerging through the foramen rotundum, near which it is to be cut with curved scissors.

The **inferior maxillary nerve** leaves by the foramen ovale, and divides into an anterior and a posterior trunk. Most of the motor root of the fifth nerve enters the anterior trunk, from which the following branches pass off: the *masseteric*, which, in its course through the sigmoid notch, supplies the temporo-maxillary joint; *deep temporal*, and *pterygoid*. It also gives a large *buccal* branch which traverses the external pterygoid: this is not, however, the motor nerve to the buccinator, for when the facial nerve is damaged that muscle is completely paralysed (p. 67). This buccal branch of the inferior maxillary is a sensory nerve, and ends in the supply of the skin and mucous membrane of the cheek. Thus, when the motor part of the fifth nerve is impaired there is paralysis of all the muscles of mastication on that side, with exception of the buccinator, which is supplied by the seventh. But, nevertheless, mastication does not appear to be much affected, as it is being efficiently carried on by the muscles of the opposite side.

The posterior trunk of the inferior maxillary nerve gives off the auriculo-temporal, gustatory, and inferior dental branches. The *auriculo-temporal* embraces the middle meningeal artery between its two heads of origin, it then turns up behind the condyle of the lower jaw and beneath the parotid gland, giving off auricular and temporal branches. The former supply the front part of the pinna and the meatus, whilst the latter end in the skin of the temple. The auriculo-temporal also gives twigs to the temporo-maxillary joint and the parotid gland, and supplies the sensory root to the otic ganglion.

The *gustatory nerve* descends between the two pterygoids, across the superior constrictor, along the side of the tongue and to its tip, lying just beneath the mucous membrane. It is a nerve of extremely delicate but common sensation. It is joined in the pterygoid region by the chorda tympani (p. 66), and upon the hyo-glossus by branches of the hypo-glossal; it gives branches to the anterior two-thirds of the

tongue, to the mucous membrane of the neighbouring part of the mouth, and to the sublingual gland.

When the fifth nerve is paralysed (as also in the case of facial paralysis, p. 68) the sense of taste on the tip of that side of the tongue may be lost or impaired.

*Division of the gustatory (or lingual) nerve* may be expedient in the case of intractable neuralgia in the anterior part of the tongue, as in lingual cancer. The nerve runs between the internal pterygoid and the ramus of the jaw, and then lies just beneath the mucous membrane of the mouth. Its exact position may readily be made out in one's own mouth by passing the tip of the index-finger downwards and backwards from the last molar tooth, and thrusting it outwards into the hollow beneath the prominent alveolar ridge; when the nerve is thus pressed against the bone the sensation is unmistakable. To make sure of dividing the nerve, it is best to take out about half an inch of it, which is easily done when the mouth is held wide open by a gag and the tongue is pressed down; the mucous membrane having been raised from over the hollow below the alveolar process, the nerve may be hooked up by an aneurysm-needle and deliberately dealt with.

The *inferior dental nerve* descends between the lateral ligament and the ramus of the jaw to the canal in the inferior maxilla. At its origin it contains some motor filaments which it sends off to the *mylohyoid and the anterior belly of the digastric*; then, in the substance of the maxilla, it supplies twigs to the teeth, and gives off the *mental* branch, which emerges by the foramen under cover of the depressor anguli oris. This branch is distributed to the mucous membrane and skin of the lower lip, and to the chin.

The mental foramen is below the second bicuspid, in the vertical line of the supra- and infra-orbital foramina.

Irritation of filaments of the nerve in the pulp of some carious tooth may give rise to disturbance in areas which are in anatomical association: as, for instance, upon the front of the pinna, or in the external auditory meatus; and thus it happens that the extraction of a carious tooth may at once put an end to 'ear-ache' and 'face-ache.'

The application of intense cold (produced by the ether-spray) in the region of the external auditory meatus has such a numbing effect upon the trunk of the nerve that under its influence a tooth may be extracted from the lower jaw without the usual pain.

*Stretching or resection* of part of the inferior dental nerve may be needed in certain cases of inveterate neuralgia of the lower teeth. The jaws being widely separated by a gag, a vertical incision is made through the mucous membrane of the mouth, above and in front of the insertion of the internal pterygoid (p. 8). Then, with a raspator, the mucous membrane is freely raised, and the nerve is found entering the dental foramen. Unless the nerve be separated from the accom-

panying artery, free hæmorrhage may occur if resection is being resorted to.

The mental nerve, emerging through the foramen in the body of the jaw in a line with the root of the second bicuspid, may be found by an incision through the integument (the exact position of the foramen having been first determined by means of a sharp probe) and through fibres of the depressor anguli oris and labii inferioris. Another way of reaching the nerve is by freely incising the mucous membrane as it is reflected from the lower jaw to the back of the lip, and working carefully down with a director in the region below the second bicuspid.

When the fifth nerve is paralysed, and the patient puts a cup to his lips, 'he feels only half of it; it seems to him exactly as though it were broken.' (Fagge.)

No. 6.—The **abducens** (because it supplies the external rectus) arises in the floor of the fourth ventricle, and emerges between the anterior pyramid and pons. It passes through the inner part of the cavernous sinus, lying on the outer side of the carotid artery, and, entering the orbit by the sphenoidal fissure, ends on the inner surface of the external rectus. At its origin this nerve does not decussate with its fellow across the median line, as the third does, because the two external recti have no experience of working in concert. When the nerve is paralysed the eye-ball is drawn inwards, and the patient sees a double image, because the yellow spots cannot both be placed in focus unless the head be turned and tilted to make up for the error (*see* p. 80). As he cannot abduct the eye-ball, he turns his head. And in this, as in every other case of ocular paralysis which is the result of cerebral lesion, the patient apologetically turns his head towards the side of the cerebral lesion—he keeps looking towards the cerebral damage, as it were.

No. 7.—The **facial nerve** arises, together with the sixth, from a nucleus in the floor of the fourth ventricle, and leaves the medulla just below the pons, through the groove between the olive and restiform. It enters the internal auditory meatus with, but above, the auditory nerve, and, passing into the aqueductus Fallopii, leaves the petrous bone by the stylo-mastoid foramen. It then passes through the parotid gland and divides into the temporo-facial and cervico-facial trunks, which, by secondary divisions, form the pes anserinus.

Some of the fibres of origin of the two facial nerves decussate across the middle line, and thus it happens that with a lateral pontine lesion there may be paralysis upon the corresponding or upon the opposite side of the face; hemiplegia, moreover, may exist with facial paralysis of the same or of the opposite side. The decussation takes place in the pons, at the level of the apparent origin of the fifth pair. A lesion anterior to this causes facial paralysis on the same side as the hemiplegia, that is, upon the opposite side to that of the lesion. But if the lesion be behind this level 'crossed paralysis' is produced—that

is to say, there is paralysis of the face muscles upon the side of the lesion, with hemiplegia upon the opposite side of the body.

When cerebral hæmorrhage, for instance, occurs within the anterior part of the pons, the decussating fibres of the facial nerve are damaged, together with fibres from the motor area which are passing down to the crossing of the pyramids, and so facial paralysis is, like the hemiplegia, upon the side of the body opposite to the lesion. But when the clot is formed in the lower part of the pons, the facial nerve upon the side of the lesion is paralysed, whilst hemiplegia still occurs upon the opposite side. 'Such clinical facts as these indicate that some of the deep fibres of the facial nerve pass upward into the cerebrum.' (Ranney.) Before the function of the portio dura was understood, Sir Charles Bell once divided it for facial neuralgia; its function was thus at once manifested; and, out of compliment to this experimental physiologist, the peripheral effect of lesion of this nerve is called **Bell's paralysis**.

In its course through the petrous bone the nerve gives off the great petrosal branch, which runs in the Vidian as the motor root to Meckel's ganglion, and so to the muscles of the soft palate. The facial also gives off the *chorda tympani*, which passes across the upper part of the membrana to leave the tympanic cavity by the Glaserian fissure. This slender branch supplies the transverse lingualis, which narrows and protrudes its own side of the tongue. When, therefore, the facial nerve is damaged in the aqueduct, that side of the tongue cannot be narrowed, and consequently, when, in protruding the tongue, the opposite lingualis contracts, the paralysed side cannot advance in due proportion, and so the tip of the tongue is pulled over to that side.

The chorda eventually joins the gustatory nerve (p. 63), and is closely concerned with the sense of taste, perhaps through its association with the submaxillary ganglion and gland.

Outside the stylo-mastoid foramen the facial nerve gives off the posterior auricular branch for the hindermost of the muscles of facial expression, namely the posterior belly of the occipito-frontalis and the retrahens aurem. The main trunk then supplies the posterior belly of the digastric and the stylo-hyoid.

The *temporo-facial division*, emerging from the parotid gland, crosses the external carotid artery and breaks up into temporal, malar, and infra-orbital branches. The *temporal* branches supply the attrahens and attollens aurem and the anterior belly of the occipito-frontalis, the upper part of the orbicularis palpebrarum, and the corrugator. The *malar* branches also send twigs to the orbicularis, and the *infra-orbital* supply the buccinator and orbicularis oris, and the neighbouring muscles of lips and nostrils.

The *cervico-facial division* breaks up into buccal and supra- and infra-maxillary branches. The *buccal* branches cross the masseter to supply the buccinator and orbicularis.



The *supra-maxillary* nerve takes its name from its position *upon* the lower jaw, and must not be confused with the superior maxillary nerve, the large sensory trunk which emerges from the infra-orbital foramen (p. 62). The supra-maxillary branches supply the platysma and the small muscles of expression connected with the lower lip and chin.

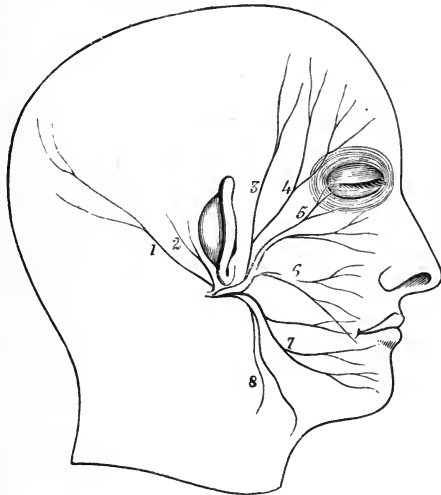
The *infra-maxillary* nerve is so called because it lies *below* the jaw; it supplies the platysma and joins with the superficial cervical nerve (v. p. 145). It must not be confused with the inferior maxillary nerve (p. 63).

When the **facial nerve is paralysed**, as in fracture of the petrous bone, all the muscles of expression on that side of the face are paralysed, and the wrinkles and furrows of the skin are smoothed out.

The forehead on that side can be thrown into neither horizontal (occipito-frontalis) nor transverse (corrugator supercilii) creases, and the patient cannot close his eye (orbicularis palpebrarum). Thus even during sleep the cornea remains exposed; and so, in such a case, to prevent inflammation, the lids had better be kept approximated by strips of adhesive plaster. But when the paralysis is of cerebral origin the orbicularis escapes, owing to the existence of certain commissural fibres.

The tensor tarsi—the muscle which holds the puncta lachrymalia against the eye-ball—being powerless, the tears fall over on to the cheek, and, as the orbicularis can no longer wash them inwards, the eye-ball becomes dry and irritable, though this may not occur if the patient keeps it clean and moist by dragging down the lid with his finger. The mouth, which is naturally balanced in the middle line, is now dragged by the unopposed muscles over to the sound side of the median line, as is particularly noticed when the patient laughs, for then the muscles contract with greater energy.

On account of paralysis of the orbicularis oris, the saliva dribbles



Branches of facial nerve:—1, to occip. front; 2, post-auricular; 3, temporal brs.; 4, malar brs.; 5, infra-orb. brs.; 6, buccal; 7, supra-maxillary; 8, infra-maxil. (HOLDEN.)

out of the flaccid corner of the mouth and he cannot arrange his lips for whistling (an excellent test); trying if he can spit is also a useful though less delicate test. Articulation is impaired, and the flabby cheek is puffed out with every deep expiration. Because the buccinator cannot contract, food lodges in the cheek, from which the patient has to clear it by his finger. He has no power to draw down that corner of the mouth by the action of the depressor anguli oris and platysma. Loud noises become distressing because of paralysis of the muscles of the middle ear.

The soft palate and uvula are dragged from the affected side when the nerve is damaged before it gives off the petrosal branches; and, the chorda tympani also being functionless, the tip of the tongue, as already noted (p. 66), is drawn to the paralysed side, though not to such an extent as may appear at first sight, the defect being exaggerated by the mouth being already drawn *from* the affected side. The exact amount of the deflection of the tip of the tongue towards the paralysed side is to be estimated by looking at the line between the central incisors. The effect of the paralysis upon the chorda tympani is often to pervert the taste. When the lesion is below the coming off of the great petrosal the muscles of the soft palate and uvula are not affected.

Partial facial paralysis is generally due to slight hæmorrhage at the origin of the nerve, and when associated with rigid arteries, hypertrophied left ventricle, and retinal degeneration, is sure evidence of a coming hæmorrhagic storm.

Facial paralysis is not always due to lesion at the root or of the trunk of the nerve; it may be the result of exposure near an open window in a railway journey, or to a cold wind.

*Stretching.*—The facial, being a motor nerve, cannot be concerned in facial neuralgia, but there are certain and obscure cases of facial spasm in which it may be expedient to give the main trunk a speculative jerk or two. In one such I saw my colleague Mr. Pye, operate by a two-inch incision along the front of the mastoid process and the topmost part of the sterno-mastoid, dividing skin, superficial fascia, platysma, and deep fascia, layer by layer. Then the sterno-mastoid was relaxed and drawn outwards, and, the parotid being drawn upwards, the posterior belly of the digastric came into view; along its anterior border, and hurrying to the parotid gland, was the nerve, which was then picked up and stretched by an aneurysm needle.

No. 8 is the **auditory** nerve; it arises in the floor of the fourth ventricle, and, emerging by the groove between the olive and restiform, passes down the internal auditory meatus beneath the facial. At the bottom of the meatus it breaks up into branches which are spread out in the cochlea, vestibule, and semi-circular canals.

No. 9, the **glosso-pharyngeal**, is distributed, as its name implies, to the tongue and pharynx. It is a sensory nerve, but those fibres of

it which supply the hinder part of the tongue are concerned in the special sense of taste.

Arising in the fourth ventricle, the nerve appears between the olive and restiform, and leaves the skull by the jugular foramen. It sends a branch (Jacobson's) to the tympanic plexus, and it enters into the formation of the pharyngeal plexus (p. 138) by passing downwards and forwards between the external and internal carotids. It gives branches also to the stylo-pharyngeus and the tonsil.

No. 10, the **pneumogastric**, or, as it might also be called, cardio-pneumogastric, takes a long and wandering (*vagus*) course, and holds the medulla in direct association with pharynx and œsophagus; the larynx, trachea, bronchi, and lungs; the heart; the cervical, thoracic, and abdominal sympathetics; and with the stomach, liver, and spleen.

It arises from the fourth ventricle and emerges between the olive and restiform, and, having left the skull by the jugular foramen, runs straight down, beneath and between the internal carotid artery and the jugular vein, and then between the vein and the common carotid artery (p. 24). Arrived at the root of the neck, it travels onward to the back of the root of the lung, passing on the right side over the beginning of the subclavian artery and behind the vein. On the left it descends between the common carotid and subclavian arteries, behind the left innominate vein, and over the transverse part of the aortic arch.

At the back of the root of the lung each nerve spreads out into the posterior pulmonary plexus, from which fibres pass into the lung, in company with sympathetic twigs.

From the back of the roots of the lungs the remnants of the vagi are gathered up into two cords which descend upon the œsophagus (*plexus gulæ*), those of the left side passing, for the most part, on to the front of the stomach, and those of the right on to the back of that viscus. The former branches communicate with the hepatic plexus, and the latter with the splenic and solar plexus.

As the vagus leaves the skull it gives off the *auricular*, or *Arnold's nerve*, which enters the petrous bone near the jugular fossa, and leaves it by the fissure between the external auditory meatus and the mastoid process; it supplies the skin behind the pinna, and the lining of the auditory meatus. It is generally supposed that the stimulation of this sensory filament by wetting the skin with cold water after a heavy dinner stimulates the pneumogastric to renewed efforts at digestion.

**Ear-cough.**—An important fact in connection with Arnold's nerve is that irritation of its branches, as by a plug of wax, or any foreign body in the meatus, may set up uncontrollable cough. The probable explanation is that there is a communication between this twig and the filaments of the superior laryngeal branch.

Outside the skull the pneumogastric nerve receives the accessory part of the spinal accessory. Some of the motor filaments which are thus obtained pass out for the pharyngeal plexus, and others

leave by the **superior laryngeal** nerve. This important branch runs downwards and forwards beneath the internal carotid, and then divides into an *external* and an *internal* laryngeal branch; the former supplies the crico-thyroid and the inferior constrictor, whilst the internal branch passes though the thyro-hyoid membrane to supply the arytenoideus and the mucous membrane of the larynx.

Irritation of the superior laryngeal nerve in weakly children sets up reflex spasm of the muscles of the glottis, and is thus concerned in *laryngeal asthma* or *laryngismus stridulus*.

The **recurrent laryngeal nerve** winds round the first part of the subclavian artery on the right side, and the transverse aorta on the left, and, ascending behind the common carotid and into the groove between the trachea and œsophagus, enters the lower and back part of the larynx. It gives off cardiac, œsophageal, and tracheal branches, and supplies all the muscles of the larynx except the crico-thyroid.

Pressure upon this nerve by an aortic, innominate, subclavian, or carotid aneurysm causes spasmodic contraction of the laryngeal muscles, and sets up a dry and suggestive cough. Sometimes the nerve is 'caught' in epithelioma of the œsophagus.

When one recurrent laryngeal nerve is paralysed the vocal cord of that side does not move; the voice is 'uncertain,' or it may be entirely lost, but the tidal air flows as usual. The abductor of the vocal cord is especially affected, and in due course 'contracture' occurs in the unopposed adductor, the cord being held in a useful position for phonation. Even when both nerves are paralysed there is no shortness of breath, but the voice is then completely lost.

In their course through the neck and through the thorax the vagi give off *cardiac branches*, which join with twigs of the left recurrent laryngeal to end in the aortic and cardiac plexuses.

No. 11.—The **spinal accessory** consists of an 'accessory' part (which arises like the vagus and eventually blends with that nerve) and of a 'spinal' part. The latter arises from the anterior grey cornu of the cord by several filaments, and, emerging from the lateral tract, ascends between the ligamentum denticulatum and the posterior roots of the five upper cervical nerves. It enters the skull by the foramen magnum, and leaves again with the vagus. It then passes downwards and backwards through the sterno-mastoid, which, with the help of the second and third cervical nerves, it supplies, and it ends in the trapezius. These two muscles derive a considerable supply from the cervical nerves. But probably their chief motor influence comes from the spinal part of the spinal accessory nerve, in order that there may be harmonious working between two important muscles of elevation and fixation of the sternum, clavicle, and scapula, and those of vocalisation.

That part of the nerve which is 'accessory' to the vagus conveys to it the motor filaments for the muscles of vocalisation: so actually

the spinal accessory is the nerve of phonation. As the spinal and the accessory parts of the eleventh nerve pass through the jugular foramen they interchange filaments, and thus it is that the sterno-mastoid and trapezius are in direct association with the muscles of the vocal cords.

Peripheral or central irritation of the spinal part of the nerve may cause spasmodic or tonic contraction of the sterno-mastoid and trapezius; rhythmic contraction and relaxation of those muscles of the two sides cause the nodding movement so often seen in old persons—nodding palsy.

*Stretching*, or *partial resection*, of the spinal accessory nerve may be needed in certain aggravated cases of spasmodic contraction of the sterno-mastoid. The nerve is sought as it runs beneath the anterior border of the muscle, previous to piercing it, about two inches below the mastoid process. The incision is made through skin, platysma, and fasciæ for about three inches along the front of the muscle, downward from the mastoid process. The muscle is then relaxed by raising the head, and, its anterior border having been drawn outwards, the nerve is seen entering it.

No. 12.—The **hypoglossal** is the motor nerve of the tongue; it arises in the floor of the fourth ventricle, and emerges from the groove between the anterior pyramid and olive, that is, in the line of the motor roots of the cervical nerves. It leaves the skull through the anterior condylar foramen, and descends with the vagus, between the internal jugular vein and the carotid artery, to the level of the angle of the jaw, when it passes forwards, over the internal and external carotids, and over the hyo-glossus; then, sloping upwards beneath the posterior tendon of the digastric, and under the mylo-hyoid, it ends in the genio-hyo-glossus. It supplies also the stylo- and hyo-glossus, the genio-hyoid, and, by a special branch, the thyro-hyoid.

It gives off the *descendens hypoglossi* (or *descendens noni*, when the motor linguæ is reckoned as the ninth nerve), which, joined by a communicating loop from the second and third cervical nerves, supplies the depressors of the hyoid bone. This nerve lies upon the sheath of the common carotid.

When one of the twelfth pair of nerves is paralysed the genio-hyo-glossus of that side cannot help in the protrusion of the tongue, which it should do by its posterior fibres; so that, on the patient trying to put out his tongue, the tip is carried over to the paralysed side (p. 68). And this paralysed side is weak, flabby, and greatly wasted.

**Duchenne's disease**, or *glosso-labio-laryngeal*, or *labio-glosso-pharyngeal paralysis*, is the result of disease of that part of the medulla from which the facial, glosso-pharyngeal, vagus, spinal accessory, and hypoglossal nerves arise. Another name for the disease is **bulbar paralysis**, because of the degeneration existing in the bulbar part of the cord.

The compound names so well express the clinical features of the disease that description is almost superfluous. The *lips* cannot seize the solid food, nor prevent the fluids from flowing away, and, as they are also helpless in vocalisation, speech is gravely affected.

The *tongue* is either protruded in a weak and trembling manner or else lies flaccid in the mouth. In the latter case the voice is still further altered; and, as neither the tongue within, nor the buccinator (p. 67) without, can keep solid food between the molar teeth, mastication is much impaired and the early stage of deglutition weakened. The facial expression is altered in a characteristic manner.

The *pharynx*, moreover, cannot grasp such food as is conveyed to it, and, in feeble attempts at swallowing, the food escapes again into the mouth and perhaps from between the lips. The *larynx* being thrown out of working order, the voice is still further altered and weakened.

In every case of Duchenne's disease all these nerves are not equally enfeebled; the features of the paralysis necessarily vary with the order in which the nuclei of the nerves are affected (*v.* p. 56).

### THE EYELIDS AND CONJUNCTIVA

The so-called *tarsal cartilages* are thin plates of fibrous tissue which form the foundation, or stiffening, of the eyelids. Their extremities are connected with the nasal process of the superior maxillæ and with the malar bones; one border is near the edge of the lid, and the other is attached to the margin of the orbit. The posterior surface of the upper lid may be examined by turning the lid inside out, over a probe laid on the outer surface of the lid, along the upper border of the cartilage, the patient looking down so as to slacken the oculo-palpebral fold of conjunctiva; the stiff cartilage then holds the lid in the everted position. The expanded tendon of the levator palpebræ is inserted over the front of the upper tarsal cartilage.

Superficial to each cartilage is the (striated) orbicularis palpebrarum, which is separated from the skin by a delicate fascia devoid of fat, and which, therefore, is readily infiltrated in Bright's disease.

The **orbicularis palpebrarum** is the sphincter of the lids. It arises from the inner corner of the orbit, and from the tendo oculi. From this the pale, but striated, fibres of its palpebral portion pass outwards between the skin and the tarsal cartilages. The fibres of the *orbital* part of the muscle are darker and coarser, and, like the others, blend at the outer part of the orbit, where, however, they have no important connection with bone. And thus it happens that when the muscle contracts the outer commissure of the lids is drawn inwards, so that the lachrymal secretion may be washed towards the inner corner of the orbit and to the puncta lachrymalia. (If you rest your

finger over the outer end of the lids and then cause the orbicularis to contract, the inward sweeping action of the muscle is manifest.)

It is supplied by the facial nerve.

The **tendo oculi** is for mooring the inner ends of the tarsal cartilages. It is attached to the nasal process of the superior maxilla anterior to the lachrymal groove, and passes outwards over the front of the lachrymal sac, giving accessory fibres to the sac. It can easily be felt when the lids are firmly drawn outwards; the sac should always be opened by incising just below the tendon.

**Blepharo-spasm** (*βλεφαρα, eyelids*) is spasmodic contraction of the orbicularis; it may be caused by a piece of grit lodged under the eyelid, in which case a sensory impulse is sent by a twig of the fifth nerve upon the conjunctiva, which returns from the brain as a reflex stimulus by palpebral twigs of the seventh; or it may be caused by conjunctivitis. When the spasm is inveterate, as it is apt to be in strumous ophthalmia, it may be expedient to sever the elliptical fibres at the outer commissure.

As a result of blepharo-spasm, the free borders of the lids may be 'turned inwards,' *entropion* (*εν, in; τροπη, turn*), against the front of the eye-ball, so that the eyelashes irritate the cornea. This complication is called *trichiasis* (*θριξ, τρικος, hair*), and may demand not only the removal of the eyelashes, but even some operation devised to everting the edge, for producing, in fact, an artificial *ectropium* (*εξ, outwards, and τροπη*) or eversion of the lids. It may be due to the contraction of a scar of the face, to paralysis of the orbicularis, or to the weakness of the muscle which is often found in old persons.

The **levator palpebræ superioris** arises just above the optic foramen, and runs forwards beneath the roof of the orbit and the frontal nerve, and above the superior rectus, to be inserted into the front of the cartilaginous foundation of the upper lid.

It is supplied by the third nerve. The muscle is, as its name implies, the opponent of the orbicularis palpebrarum, which is the sphincter of the lids. It is supplied by the third nerve, and the lid consequently droops, *ptosis* (*πτωσις, falling*), when that nerve is paralysed.

On the posterior surface of the lids is the delicate mucous membrane, the **conjunctiva**, which, reflected thence over the front of the eye-ball, 'joins together' the eyelids and the sclerotic. Like other mucous membranes, it consists of a basement membrane, with vessels, nerves, and connective tissue beneath it, and with epithelium on the free surface.

The *epithelium* is for the most part columnar, but it gradually becomes squamous as it approaches the free border of the lids. Over the front of the cornea the conjunctiva is represented only by the layers of epithelial cells, the most superficial of which are stratified.

Where it lines the lids it is thick and vascular, and is studded with papillæ, which, under the influence of chronic inflammation, become

enlarged, constituting the disease known as '*granular lids*.' So loosely is the conjunctiva attached over the sclerotic, however, that large extravasations of blood may occur beneath it. When this is observed after a fall upon the head the question arises as to the existence of a fracture extending across the anterior fossa of the base of the skull, with laceration of the ethmoidal arteries.

At the inner commissure the conjunctiva forms a mucous fold, the *plica semilunaris*, the homologue of the horizontal eye-lid of birds, the *membrana nictitans*. On the inner side of this is the *caruncula lachrymalis*—a collection of sebaceous glands beneath the conjunctiva.

*Chronic conjunctivitis* is sometimes spoken of as 'weakness of the eyes'; certainly it is often found when vision is imperfect, as the constant effort at accommodation is associated with increased flow of blood to the orbit, and with lachrymation.

In the case of unhealthy children, the chronic condition may sometimes be successfully dealt with by counter-irritation at the temple or behind the ear. Such beneficial effect has sometimes been inadvertently produced by piercing the lobe of the ear and inserting a ring, with the inartistic idea of personal adornment, and thus it has come about that 'ear-rings are good for weak eyes.' The late Mr. Critchett told the writer that some of his first success in practice was due to his having treated chronic conjunctivitis by a slender seton behind the ear, 'so that,' said he, 'friends remarked that my reputation hung on a thread!'

Sometimes a thick triangular growth of the conjunctiva extends from near one of the commissures towards the pupils; it is called a *pterygium* (*πτερυγιον*, a little wing), and, passing over the pupil, it ultimately obscures the vision. It may have to be removed by the operation of transplantation.

The *Meibomian glands* are arranged in pearly rows beneath the conjunctiva, imbedded in the tarsal cartilages; they can be seen on everting the lids, and their minute orifices detected near the eye-lashes. Their sebaceous secretion oozes upon the edges of the lids to lubricate the cornea and to render it waterproof.

Should secretion be retained in one of the Meibomian follicles, a small hard tumour is felt in the substance of the lid. It is called a *chalazion* (*χαλαζα*, hail) or *tarsal tumour*. It is treated by everting the lid and scooping out the contents of the cyst.

Supplementary sebaceous glands also open at the roots of the eye-lashes, and, should one of them become inflamed, the condition is known as *hordeolum* (*hordeum*, a barley-corn) or *stye*.

*Supply*.—The conjunctival *arteries* are derived from the palpebral, lachrymal, and other branches of the ophthalmic; the *nerves* come from the ophthalmic and infra-orbital parts of the fifth.

Hæmorrhages beneath the conjunctiva which occur in an oldish subject after an attack of coughing or vomiting are suggestive of atheroma, and sometimes come as warnings of an apoplectic storm.



## THE LACHRYMAL APPARATUS

The **lachrymal gland**, which is somewhat of the size and shape of an almond, is lodged in the hollow under the external angular process of the frontal bone. To reach the front of the globe, the tears have to pass through the conjunctiva, which they do through half a score of slender ducts, which open on the inner surface of the upper lid. Part of the gland descends behind the lid, and its lower border rests over the superior and external recti, and upon the eye-ball. Being thus poured upon the upper surface of the globe, the tears fall over the front of the eye-ball, washing it completely, whilst the contractions of the orbicularis (p. 72) sweep them constantly inwards, in their course to the puncta lachrymalia.

Its *structure* is like that of a salivary gland. It receives its supplies from special branches of the ophthalmic nerve (p. 61) and artery, and from the sympathetic.

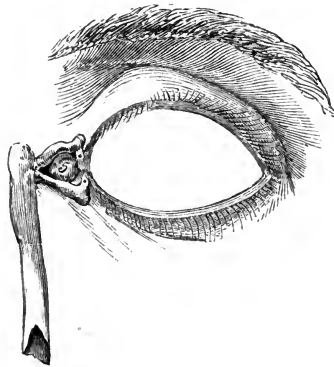
The **puncta lachrymalia** are the pin-point openings of the superior and inferior *lachrymal canals*, which lead from the inner sixth of the margin of the lids to the lachrymal sac. The punctum may be seen on a small papilla on everting the lid.

At first each canal runs for a slight distance vertically away from the border of the lid, then it alters its course and enters the lachrymal sac. The canal is composed of delicate fibrous tissue, and of mucous membrane lined with squamous epithelium.

The puncta are kept in position against the globe of the eye by the contractions of the small *tensor tarsi*, which is, really, a deep part of the orbicularis. It arises from the lachrymal bone, behind the lachrymal sac, and passes with the canals to the eye-lids. If the punctum is displaced it may be necessary to slit up the canal so that the tears may flow away along the gutter which is then formed.

The **lachrymal sac** is the upper, dilated end of the nasal duct, lying in the groove between the nasal process of the superior maxilla and the lachrymal bone. It has the strong *tendo oculi* in front and the *tensor tarsi* behind, whilst the lachrymal canals enter its external aspect.

**Lachrymal abscess** is the result of inflammation of the lining of the sac; it forms a swelling at the inner corner of the orbit which may



have a characteristic, hour-glass shape, on account of its bulging above and below the tendo oculi, while its middle is constricted by the unyielding tendon.

A *lachrymal fistula* may follow its evacuation; *stricture of the nasal duct*, the result of chronic inflammatory thickening, is generally associated with the fistula. The treatment of the stricture consists in slitting up the inferior lachrymal canal, and thus finding an entrance for a special probe into the sac. Before slitting up the canal, the lower lid should be drawn firmly outwards so that the canal may be made straight and direct. False passages may be made by the unscientific use of the probe, through the lachrymal bone and into the ethmoid, or between the cheek and the maxilla.

The **nasal duct**,  $\frac{3}{4}$  in. long, descends in the groove in the maxillary and the lachrymal bones, and against the inferior turbinated, to open into the inferior meatus. Its direction is downwards, with a slight inclination outwards and backwards; it is the unobliterated part of the orbital fissure (*v. p.* 123) which ran from the side of the fronto-nasal process through the mouth and into the orbit.

The sac and the duct are composed of fibrous tissue, and have a mucous lining which is carpeted with columnar ciliated epithelium, like that of the nose.

### THE ORBIT

The long axes of the orbits diverge considerably, so that the field of vision may be extended laterally. The inner wall is straight from before backwards, but the outer wall runs outwards as well as forwards; this slope is taken advantage of in enucleation of the eye-ball, the curved scissors being passed along the outer wall so as more easily to divide the optic nerve.

*Boundaries.*—The *floor* is formed of the superior maxilla and the malar and palate bones; the *roof* by the frontal and the lesser wing of the sphenoid.

The *inner wall* is composed of the nasal process of the maxilla, the internal angular process of the frontal, lachrymal, os planum of ethmoid, and body of sphenoid; and the *outer wall* of the malar, the external angular process of the frontal, and the great wing of the sphenoid.

The roof is extremely thin, and if a child fall with a pencil upright in his hand the point may be driven through into the anterior lobe of the brain. In chronic hydrocephalus (*p.* 56) the fluid within the lateral ventricles pushes down the frontal lobes and the roofs of the orbits until they bulge into the orbits and thrust forwards the eye-balls. The inner wall is also thin, and in roughly attempting to introduce a style into the nasal duct a clumsy manipulator may thrust it into the ethmoid

bone, and so into the nasal fossa. Below the floor of the orbit is the antrum, and tumours from that region readily bulge into the orbit. Immediately beneath the floor runs the superior maxillary division of the fifth nerve (p. 62).

Through the inner part of the floor descends the nasal duct, close to the outer side of which arises the inferior oblique. On the roof is a depression, at the outer part, for the lachrymal gland, and at the inner part is lodged the pulley of the superior oblique.

A large mass of yellow fat fills the back of the orbit, and forms a soft bed against which the eyeball rests. In phthisis and other wasting diseases this store of hydro-carbons is drawn upon and the eye becomes sunken.

A periostitis, an erysipelas, or other inflammatory condition of or about the orbit may spread by direct continuity of tissue through the optic foramen or the sphenoidal fissure into the interior of the skull, and there give rise to meningitis or to intracranial suppuration. In the case, moreover, of septic phlebitis in the ophthalmic vein the clot may extend into the cavernous sinus and set up fatal thrombosis.

The *periosteum of the orbit* is continuous through the optic foramen and the sphenoidal fissure with the dura mater; and anteriorly it turns round to spread into the pericranium. As the fibrous offshoot from the dura mater enters through the optic foramen to line the orbit it gives a tubular investment along the optic nerve, which, spreading out upon the sclerotic, is ultimately reflected from the antero-lateral part of the eye-ball, behind the conjunctiva, to the margin of the orbit, where it blends with the periosteum. By this arrangement of the fascia the eye-ball is completely shut off from the back of the orbit.

A point of great surgical interest in connection with these fibrous layers is that after removal of the superior maxilla (p. 18) the lower periosteum becomes thickened and strengthened, and forms so useful a floor to the orbit that there is but little permanent dropping of the eye-ball; the double vision which results from the first sinking of the globe soon passes away.

The **capsule of Ténon** is that part of the orbital fascia which surrounds the optic nerve and eventually spreads round the eye-ball. It has already been described as sending a post-conjunctival offshoot to the periosteum of the orbit, but, in addition, it sends back fibrous sheaths around the muscles of the eye-ball, which are intimately joined with their proper fascial investments.

The capsule of Ténon is connected with the sclerotic by delicate filamentous tissue, and forms a smooth bed in which the globe moves with absolute freedom. It is lined with endothelium, and is, in reality, the outer wall of a large lymph-space, like the pleura or peritoneum. The choroidal lymphatics enter the space around the venæ vorticosæ, and the space itself is in communication, under the fibrous sheath of the optic nerve, with the subdural and subarachnoid areas of the cranium.

## THE MUSCLES OF THE ORBIT

The levator palpebræ superioris, the four straight muscles, and the superior oblique one arise around the optic foramen; the straight muscles pass forwards, closely applied round the optic nerve, to their insertion into the sclerotic about a quarter of an inch behind the cornea. The third nerve supplies the superior, inferior, and internal recti, the external one being supplied by the sixth. Acting together, the straight muscles retract the eye-ball, whilst the oblique muscles draw it forwards.

The external rectus of one eye acts in concert with the internal rectus of the other.

If the long axis of the orbit were in the straight line with that of the eye-ball, the superior and inferior recti would simply turn the cornea upwards or downwards; but, because these muscles pass forwards obliquely to their insertion, that is, in the axis of the orbit, they turn the cornea slightly inwards as well. The inward inclination caused by the superior rectus is counteracted by the action of the inferior oblique, and that of the inferior rectus is checked by the superior oblique.

The **superior oblique** passes forwards to the upper and inner part of the orbit, where its slender tendon runs through a fibro-cartilaginous ring which is lubricated by a delicate synovial membrane. The tendon then passes downwards, outwards, and backwards, between the superior rectus and the sclerotic, to be inserted between the superior and external recti, in the hemisphere of the globe behind the transverse equator. The supply is from the fourth nerve, which has been called 'patheticus' on the supposition that it supplied the muscle which gave a 'pathetic' turn to the eye-ball. The pulley can be obscurely felt by thrusting the finger into the inner and upper part of the orbit.

Chronic serous effusion into the synovial membrane of the pulley causes a prominent cyst; it is often seen in those beyond middle life.

The **inferior oblique** arises from the superior maxilla just external to the nasal duct, and, passing obliquely upwards, between the inferior rectus and the floor of the orbit, and then between the sclerotic and the outer rectus, is inserted just below the superior oblique, behind the equator of the globe. It is supplied by the third nerve.

The **action of the oblique muscles**.—If an imaginary pin be driven vertically through the centre of the globe, movement becomes possible only in the horizontal plane, and the superior oblique, coming from the inner side, to be inserted on the outer side of the globe, behind the transverse axis, or equator, on contracting must draw the posterior hemisphere inwards and so turn the cornea outwards.

Similarly, the inferior oblique, passing outwards and backwards, also turns the pupil outwards.

If this imaginary pin be then thrust through the transverse axis of the globe, the superior oblique, which is inserted behind the pin, coming from above, turns the pupil downwards, whilst the other, coming from below, turns it upwards. Thus the oblique muscles work in harmony in turning the cornea outwards, but in antagonism in the upward and downward movements.

To turn the cornea downwards it would not do for the inferior rectus to act alone, or internal strabismus would result; so the superior oblique is called on to help the inferior rectus, abducting the eye-ball at the same time, so as to neutralise the adduction of the inferior rectus. Thus, the two muscles, acting together, merely turn the globe downwards.

Conversely, the inferior oblique acts with the superior rectus, the two muscles merely moving the eye to look upwards.

Thus even a simple movement of the front of the globe is not left under the control of a single muscle. *Inversion* is effected by the internal rectus, with the superior and inferior recti; *eversion* by the external rectus and the two obliques; *elevation* by the superior rectus and the inferior oblique; and *depression* by the inferior rectus, with the help of the superior oblique.

When the external rectus is paralysed, abduction of the eye-ball is limited. If the external rectus, say of the right eye, be paralysed, there may be no double vision as the man looks towards the left, but when he tries to look to the right, that is, to use his right external rectus, the right eye-ball remains almost stationary, though the left internal rectus directs the left eye-ball upon the object; the result is double vision. To save himself from this annoyance, the patient keeps his head constantly in such a position that the useless muscle may have no demand made upon it; that is, he keeps his head constantly turned towards the right, making, as it were, the left sternomastoid do the work of the right external rectus.

When the paralysis of the external rectus is only partial, the man expends an unusual amount of energy in inducing it to act; but a certain amount of this energy necessarily passes into the associate muscle, the opposite internal rectus, which then overacts its part and produces 'secondary deviation' of that eye inwards.

When the *right internal rectus is paralysed* the face is apologetically turned to the left, so that the visual defect may not occur. So also, due allowances being made, does it happen when a *superior or inferior rectus* fails to act.

When the *inferior oblique is paralysed* the cornea cannot readily be turned upwards and outwards; indeed, it falls somewhat downwards and inwards, and thus there is double vision. To correct the double vision, the subject makes up for the defect of the oblique muscle by

keeping the head in such a position that there is no work for the inferior oblique to do ; thus he keeps the head tilted upwards and outwards.

When the *superior oblique* is paralysed there is deficient abduction and depression of the cornea, so the head is turned to that side and is kept somewhat depressed.

**Rule.**—To enable the practitioner to detect the exact muscular paralysis by merely looking at the patient's face, Dr. Ranney has given this formula : 'The head is so deflected that the chin is carried in a direction corresponding to the action of the affected muscle.'

**Strabismus** (*squint*) is that condition in which the visual axes are not parallel. One eye or both eyes may be at fault. The commonest form is that in which the axes are directed towards the nose—*convergent squint*.

Upon the retina of the eye which deviates inwards the object falls to the inner side of the yellow spot, and double vision is produced, which, however, the person is able to educate himself to disregard.

To detect the *squinting eye*, the tip of the finger is held about eighteen inches in front of the eyes. One eye promptly fixes on to it ; the other wanders. Then a piece of ground glass is placed in front of the eye which watched the object, and the wandering eye after some hesitation becomes directed on the object. Then, on the observer looking through the dull glass, the original working eye is found adrift.

As a rule, the subject of convergent strabismus has that congenital defect—a shortness, it may be—of the eye-ball by which rays are not brought to a focus until they have passed beyond the yellow spot. Therefore his ciliary muscle has to struggle in a forced effort at accommodation, so that the rays may be duly focussed. But accommodation is closely associated with convergence (p. 58), and so the child in due course has his eye-balls adducted. Thus the frequent occurrence of convergent strabismus is fully accounted for.

With double convergent squint the object must fall to the inner side of the yellow spot in both eyes, but the child acquires the art of moving his head and arranging his eye-balls so that he can depend on the image falling correctly on one eye—which, in due time, becomes the 'working eye' ; moreover, he at last takes no notice of the image in the other eye. Thus, he is believed to squint with one eye only. If the 'working eye' be covered, and he focus the object with the 'wandering eye,' which he can quite well do, and the 'working eye' be then uncovered, it is found to squint ; but it promptly turns on to the object, as is its custom, and allows the other eye to get adrift again.

*The treatment of convergent squint.*—If the deviation be caused by hypermetropia (p. 86) it will yield in due course to convex glasses. But if the defect be permanent, subconjunctival tenotomy of the internal rectus or recti is demanded.

*The operation.*—The lids having been fixed apart by the speculum,

a fold of conjunctiva is pinched up, midway between the cornea and the caruncle, and is divided with the scissors, the capsule of Ténon being also opened. The tendon is then caught up by a blunt hook and divided. Unless the capsule of Ténon be opened, the rectus cannot be effectually dealt with. If after the operation the external rectus overact its part, its tendon will also require division.

The **ophthalmic artery** is given off from the internal carotid, and enters the orbit through the optic foramen, to the outer side of the optic nerve. It then crosses the optic nerve, beneath the superior rectus, to reach the inner wall of the orbit, and it eventually divides into the nasal and frontal arteries near the lachrymal bone.

*Branches.*—The *lachrymal* runs above the external rectus, and ends in twigs for the lachrymal gland and for the eyelids (the latter branches anastomose with the palpebrals). From it some emissary branches pass through the malar bone into the temporal fossa.

The *arteria centralis retinae* imbeds itself in the optic nerve and enters the eye-ball at the 'blind spot.'

The *supra-orbital* emerges through the foramen of that name, supplying the eyelid and the forehead, and anastomoses with the superficial temporal artery.

The *posterior ciliary* branches pierce the sclerotic around the optic nerve, and pass to the choroid; but on either side of the nerve one of them (*long ciliary*) runs on to pass between the sclerotic and choroid to the ciliary muscle and iris.

The *anterior ciliary* are derived irregularly from the *muscular* branches; 'they form a vascular ring beneath the conjunctiva at the fore-part of the eye-ball, and then pierce the sclerotic within a line or two of the margin of the cornea,' having formed an interesting and important anastomosis with the subconjunctival vessels.

The *anterior ethmoidal* artery passes with the nasal nerve through the anterior ethmoidal foramen, into the anterior fossa of the skull, where it gives off *anterior meningeal* branches to the dura mater, and twigs through to the ethmoid cells and to the nasal fossa. The *posterior ethmoidal* artery is smaller, and ends in the posterior ethmoidal cells and in the nose. The ethmoidal arteries may be torn across in fracture of the anterior fossa of the skull, and may cause suggestive bleeding from the nose, or beneath the conjunctiva.

Two small *palpebral branches* are given off near the front of the orbit. They supply the conjunctiva and the lachrymal sac, and then run outwards beneath the orbicularis to anastomose with the lachrymal.

The *nasal* artery ramifies at the root of the nose, anastomosing with the angular branch of the facial, and so completes a link between the internal and external carotids.

The *frontal* artery turns on to the forehead near the root of the nose where it anastomoses with its fellow of the opposite side.

**Enucleation of the eye-ball.**—The eye-lids are fixed asunder, and the conjunctiva is opened near the cornea, and it, together with the capsule of Ténon, is snipped with the scissors close to the cornea. The straight muscles are then caught up by the strabismus hook and severed, and the globe is pulled forwards. The scissors are then passed along the outer, the oblique, wall of the orbit, and the optic nerve is divided. Lastly, the attachments of the oblique muscles and the ciliary vessels and nerves, and some loose connective tissue, are divided.

Bleeding is checked by firmly bandaging into and over the orbit a wrung-out sponge. The hard walls of the orbit usually render the treatment of hæmorrhage by plugging efficient. But, if the disease for which the operation was performed were a tumour of extreme vascularity, pressure may absolutely fail to arrest the bleeding. In a case of this sort, in which I saw Mr. Richardson Cross, of Bristol, operate, he had no alternative but to tie the common carotid, and with an excellent result.

The **ophthalmic vein** begins in tributaries corresponding to the branches of the ophthalmic artery, and slowly pours its contents through the sphenoidal fissure into the cavernous sinus (p. 40). Pressure upon the vein or upon the cavernous sinus by an inflammatory deposit or a growth near the apex of the orbit delays the venous return and causes distension of the tributaries of the vessel, intra-ocular-injection, and a 'choking' of the optic disc. Thus the condition of the disc in the case of a supposed tumour of the base of the brain may afford valuable information. But, though the pressure upon the vein may be extreme, there may be no excessive injection if the condition have come on slowly, as the facial vein communicates very freely with the ophthalmic and relieves the intra-ocular pressure.

The *nerves of the orbit* are the optic; third; fourth; ophthalmic division of fifth; sixth; the temporo-malar branch of the second division of the fifth, and the sympathetic.

#### THE EYE-BALL.

Five-sixths of the vascular and nervous layers of the eye-ball are enclosed within a tough and opaque fibrous capsule, the **sclerotic** (*σκληρος*, *hard, tough*), which is directly continuous in front with the cornea. It is strongest posteriorly, and it is strong again in front after receiving the insertion of the straight muscles; the intermediate part is that which is most likely to yield to injury. It is covered in front by the conjunctiva, and in the rest of its extent by the flattened epithelium which lines the lymph-space in front of the capsule of Ténon. Its inner surface is stained by the lamina fusca (*fuscus, swarthy*), the delicate tissue which connects it with the choroid, across an intermediate lymph-space.



The strands of the optic nerve riddle the sclerotic  $\frac{1}{10}$  in. into the nasal side of the axis at the lamina cribrosa, at the centre of which is a conspicuous opening, the *porus opticus*, by which the arteria centralis reaches the retina.

Although the sclerotic is extremely strong, nevertheless, as the result of long-continued inflammation and intra-ocular pressure, the choroid stretches and bulges through it under the name of *staphyloma*, from the resemblance of the protrusion to a bunch of grapes (*σταφυλή*).

The **cornea**, the transparent part of the fibrous envelope of the eye-ball, stands out like the convex glass in the front of a watch-case. It is continuous peripherally with the sclerotic, by which it is somewhat overlapped. It is on account of this overlapping that in the operation for cataract the surgeon makes his incision through the sclerotic just beyond the cornea. As a matter of fact he divides the bevelled edges of both sclerotic and cornea. Some operators, however, make the incision entirely through the uncovered part of the cornea.

Sometimes a degenerative (fatty?) change occurs at the periphery of the cornea, rendering it white and opaque. As it is chiefly met with in old persons, it is termed *arcus senilis*.

*Structure.*—The cornea consists of a central, thick fibrous layer, which is covered in front by several layers of the epithelium of the conjunctiva, and behind by a homogeneous elastic lamella, at the back of which is the epithelium of the anterior chamber.

The fibrous foundation consists of about sixty lamellæ connected by a transparent cement; in this cement delicate lymph channels run, by which the nutrition of the cornea is carried on.

The *nerves*, represented only by the axis cylinders, come from the ciliary branches, and pass between the lamellæ. The cornea receives *no blood-vessels*, but just beyond its periphery is an important circle of conjunctival vessels which are engaged in *corneitis* or *keratitis* (cornu, *κερας*, *horn*, *lantern*; and *itis*). But, when keratitis advances to ulceration, a branch of a ciliary or conjunctival artery may pass boldly over the cornea to it. If the ulcer extend into the substance of the cornea it may ultimately traverse the elastic and the endothelial layer, and involve the escape of the aqueous humour. The pupillary border of the iris, escaping with the stream, may protrude upon the surface and there become glued by plastic effusion—*synechia anterior* (*συνεχης*, a *keeping together*). If the perforation be extensive, even the lens and the vitreous may escape.

The cicatricial patch which eventually makes the site of an ulcer may look like a little puff of smoke (*nebula*) upon the clear cornea; but if it be pearly white (*λευκος*) it is called *leucoma*. A central leucoma blinds a most important area of the retina, and compels the surgeon to let light through an artificial pupil (p. 88). After this operation the white patch may be tattooed with a fine needle and Indian ink, and so rendered unnoticeable.

In the treatment of corneal ulcer atropine should be used, so that, the pupil being dilated, the border of the iris may be unlikely to prolapse. Then, to diminish the risk of the aqueous bursting through the elastic layer, eserine must be used ; or *paracentesis of the anterior chamber* may even be expedient. This operation is performed by introducing a slender blade through the sclero-corneal margin, taking care that it does not pass between the layers of the cornea, and that, in withdrawing it, the iris do not escape with the aqueous.

In the case of a perforation of the central part of the cornea, atropine should be used, so that the pupillary border of the iris may be secured against collapse. But if the wound be near the periphery the pupil should be made to contract by eserene. If, however, a piece of the iris be already prolapsed, and it be found impossible to return it, it must be cut off flush with the cornea, the stump being tempted to return by the use of atropine, or eserene, as the case may be.

With *interstitial keratitis*, which is often the result of inherited syphilis, effusion takes place between the layers of the cornea, spoiling its transparency, and giving it the appearance of ground glass.

If inflammation run on to the formation of pus between the layers, and the corneal abscess be not promptly evacuated, it may cause perforation. Sometimes the inflammation is attended with separation of the lamellæ, so that the pus sinks to their lowest part, where it forms a collection, the form, size, and tint of which are like the little white crescent at the root of the nail (*ovvξ*), and is therefore called *onyx*.

Similarly pus in the anterior chamber forms a small, crescentic abscess, but this may be distinguished from onyx by its altering its position as the head is inclined to one side. The pus must be let out by paracentesis.

The cornea is the most important of the refracting media, refraction being the effect produced on rays of light passing from a rarer to a denser medium. Should it be too convex—a somewhat frequent congenital defect—it overacts its part, and rays are brought to a focus before they reach the retina. They have, therefore, to be somewhat scattered before they reach the cornea by biconcave lenses. (*Myopia*, p. 86.)

On the other hand, should the cornea be abnormally flat, the antero-posterior axis of the eye-ball is too short, and the rays have to be collected, somewhat before reaching the cornea, by the aid of convex glasses. (*Hypermetropia*, p. 86.)

If the curvature of the cornea be irregular, either in the vertical, horizontal, or oblique diameter, the rays come unevenly to a focus, some of them missing their mark, the error being called *astigmatism* ( $\alpha$ , priv., *στίγμα*, *mark*). Permanent unevenness with a resulting astigmatism is more apt to follow the extraction of a cataract when the incision is made through the cornea than when made through the corneo-scleral tissue.

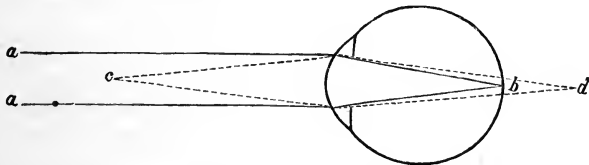
Sometimes the cornea grows thin and prominent, *conical*—it is not

known why ; it is not from intra-ocular pressure, for the signs of that affection are wanting. The earliest symptom is astigmatism.

The **choroid** is connected with the sclerotic by vessels and nerves, and by delicate fibres which pass across the intervening lymph-space. It is chiefly composed of blood-vessels, with pigment cells for absorbing the diffused rays of light. The external set of vessels are the ciliary arteries, and the venæ vorticosæ—tributaries of the ophthalmic vein ; the inner coat being composed of an extremely fine network of capillaries.

The **ciliary processes**, sixty or eighty in number, are continuous posteriorly with the choroid, and intervene as a vascular, erectile fringe between the ciliary muscle and the circumference of the lens. In front they blend with the periphery of the iris. Their blood supply is from the vessels of the choroid, and from the anterior ciliary arteries.

The **ciliary muscle** is a narrow circle of unstriped fibres which, arising from the line of junction of the sclerotic and cornea, pass backwards to be inserted into the neighbouring part of the choroid.



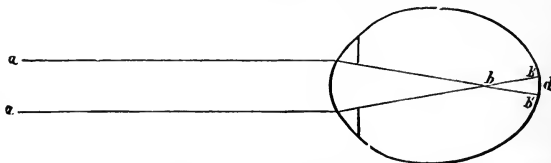
Emmetropic (sound) eye ; parallel rays, *a, a*, come to focus on retina at *b* ; divergent rays, *c*, would meet at focus, *d*, behind retina, but 'accommodation' brings them to a focus at *b*. (DIXON.)

Its *action* is to pull on the ciliary processes, and so to slacken the suspensory ligament and the capsule of the lens, in order that the elastic lens may again expand, and its convexity may be thus increased for viewing near objects. Together with the other muscles of accommodation, the internal, superior, and inferior recti, and the sphincter fibres of the pupil, the ciliary muscle is under the control of the third nerve.

The muscular act is known as 'accommodation' ; it is associated with contraction of the pupil, in order that the rays may pass through the most convex, refracting part of the lens only. As the individual can watch distant objects for a long while without tiring, his defect is spoken of as 'long-sightedness.' But when reading small print his eyes become bloodshot and tired, the fatigue of the ciliary muscle expressing itself, perhaps, as 'headache.'

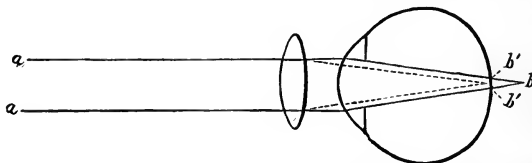
In the case of the person who is born with the antero-posterior axis too short, the life of the ciliary muscle is one constant struggle to collect and focus the divergent rays. It frequently breaks down in the task

after a long and enfeebling illness, such as scarlet fever, and then, for the first time, it may be discovered that the person is hypermetropic.



Myopic eye : axis too long ; parallel rays,  $a, a$ , brought to focus at  $b$  before reaching retina, and eventually giving blurred image at  $b', b'$  ; concave glass needed. (DIXON.)

With advancing age the power of accommodation naturally diminishes, whilst, at the same time, the lens grows flatter, so that the



Hypermetropic eye : axis too short ; parallel rays,  $a, a$ , tending to a focus at  $b$ , form circles of dispersion on retina at  $b', b'$ , but are brought to proper focus by the convex glass. (DIXON.)

old man (*πρεσβυς*) is almost sure to be hypermetropic. \*But, as the loss of accommodation in his case is the result of age, and not of a congenital defect, it is called *presbyopia*.

Reference is made elsewhere (p. 58) to the fact that contraction of the ciliary muscle is constantly associated with that of the internal rectus—both muscles being supplied by the third nerve—and so it comes about that the hypermetropic child who triumphs over the defective depth of his eye-ball by a course of ciliary athletics is apt to develop a convergent squint. It would, indeed, be a grave error to perform tenotomy in such a case ; the child should be treated by convex lenses.

In due course the myopic man finds such difficulty in securing binocular vision of near objects that he gets into the habit of using one eye at a time.

Mr. Juler<sup>1</sup> gives an excellent account of the anatomy of *near-sightedness*—*myopia* (*μυωπία*, *close*, *ωψ*, eye—from the habit which myopic people have of partly 'closing the eyes' for distant vision), the defect in which the eye-ball is too long, rays of light being brought to a focus before the proper time. The defect usually comes on in childhood, and is due to deficient strength in the ocular tunics, especially when the child is busied with fine work, and in a bad light; he attempts to obtain larger retinal images by keeping his head close down to

<sup>1</sup> *Ophthalmic Science and Practice*, 1884, p. 333.

the book ; then, that he may have binocular vision, the internal, the superior, and inferior recti must be in constant contraction. This causes the posterior, and unsupported, part of the feeble globe to bulge, so that its length becomes increased. The strained and stooping position of the head compresses the cervical veins, and hinders the return of blood from the eye-ball, which is already in a condition of too great physiological activity, and in which there is also excessive intra-ocular secretion.

That there is increased intra-ocular pressure is evidenced by the fact that the choroid becomes so much flattened and thinned in the neighbourhood of the optic nerve that a *myopic crescent* of the sclerotic can be detected by the ophthalmoscope.

The *treatment* is first preventive :—

‘ Not with blinded eyesight poring over miserable books.’

Subsequently it demands the careful adjustment of concave glasses, so that the rays of light may be rendered more divergent before they reach the cornea.

The **iris** is the coloured circular curtain which floats in the aqueous humour, in front of the lens, its central opening being the *pupil*. By its circumference it is attached to the junction of the sclerotic and cornea, and is continuous behind with the ciliary processes.

*Structure*.—The iris is composed of delicate connective tissue, the filaments being chiefly arranged in a radiating manner. Towards the anterior part are a group of coloured cells, and behind is a dark pigmentary layer, the *uvea* (*uva*, a bunch of grapes).

The posterior surface of the iris moves upon the front of the lens, the narrow space between it and the periphery constituting the *posterior chamber* of the aqueous. The anterior chamber is the interval in front of the iris, and, like the posterior chamber, is virtually a large lymph space.

The muscular tissue consists of a sphincter of plain fibres around the pupil, and of a radiating series which extend through the width of the iris. The sphincter set are governed by the third nerve, the dilator fibres being under the influence of the sympathetic.

Up to the seventh month of fetal life a *pupillary membrane* occupied the central opening of the iris. Its arteries were derived from the arteria centralis retinae and from those of the iris. In the eighth month the membrane begins to clear away from the centre, but occasionally it persists after birth.

The **vessels of the iris**.—The long ciliary—one running on either side of the optic nerve—eventually send an arterial circle around the attached border of the iris, where they anastomose with the short ciliary. Both sets then send twigs through the iris to make an anastomotic circle round the pupillary border.

The *nerves* come from the lenticular ganglion (p. 58), bringing motor influence from the third for the contraction of the pupil, and from the sympathetic for its dilatation (p. 59). Thus, irritation of the retina, the optic nerve, or the third nerve causes contraction of the pupil, and of the cervical sympathetic, dilatation.

**Iritis.**—When the iris is inflamed its vessels are so engorged, and its stroma is so infiltrated with effusion, that its bright colour is changed to a rusty hue, and it is hindered in its work. Thus the pupil but slowly contracts, even when a strong light is thrown upon the retina. A pink circle appears just beyond the border of the cornea, where the anterior ciliary arteries are bending inwards to the iris, and are also anastomosing with the conjunctival vessels. This interesting anastomosis is well shown in vol. ii. of ‘Quain’s Anatomy’ (9th edition, p. 403), by which it is easy to see that when the ciliary arteries are engorged a ring of subconjunctival congestion is almost inevitable.

So full are the vessels that serum escapes into the aqueous, and lymph oozes from the vessels and glues the iris to the capsule of the lens—*synechia posterior* (*συνεχής*, *holding together*). These adhesions may be complete and permanent; if, however, they be limited to certain spots, and if, under the influence of atropine, the free part of the pupillary border only be drawn away, the *pupil* becomes *irregular*. (The atropine probably acts by paralysing the third nerve, and so allowing the sympathetic filaments free play.)

The *treatment* of iritis demands the immediate application of atropine, so that the sticky border of the pupil may be kept from adhering to the capsule of the lens; or that, adhesions having formed, they may, if possible, be stretched and broken. Leeches should be applied to the temple to relieve the engorgement of the ophthalmic vessels. And, if the tension and pain persist, the distended anterior chamber may be treated as the inflamed pericardial lymph-space is treated in pericarditis, namely, by paracentesis.

When posterior synechia is permanent and universal, the aqueous humour which is behind the iris can no longer flow through the pupil, and, moreover, the iris itself is so disturbed by the attachment that secondary attacks of inflammation are apt to recur (*see* GLAUCOMA *infra*).

An **artificial pupil** is, therefore, needed:—An incision is made in the corneo-sclerotic margin (in the upper part, if possible, so that the unsightly vertical pupil may be under cover of the lid), and the pupillary border of the iris is gently dragged out of the wound by delicate forceps which have been introduced into the anterior chamber; the piece of iris is then snipped off.

The **lens**, biconvex, is suspended in the capsule, just in front of the vitreous, and behind the iris. Indeed, when the pupil is contracted a considerable extent of the iris is touching the lens, and even pushed forwards by it; but during dilatation of the pupil there is

no part of the iris in contact with the capsule. The posterior surface of the lens is more convex than the anterior.

*Structure.*—The lens is composed of transparent fibres which are connected by a clear cement. Diminution of the transparency constitutes **cataract** (the etymology of the word is uncertain).

If the opacity be central, the eye is almost blind in a strong light, as the contracted pupil admits light only over the opacity. Thus the subject sees best when the pupil is dilated, as towards evening, or in a fog or shade. In such circumstances the surgeon may content himself with making an artificial pupil.

The old operation for senile cataract was to dislocate the lens into the vitreous, where, however, it was apt to set up inflammatory disease.

In young people an opaque lens is soft, and the surgeon treats it by passing a needle through the cornea, tearing the capsule, and breaking the front of the lens, so that the aqueous humour may further soften it, and promote its complete absorption. In the adult, however, the hard and opaque lens (which has a strong resemblance to an 'acid drop') must be removed by extraction.

In the *operation of extraction* a preliminary iridectomy is sometimes done in order that the risk of iritis may be diminished, and also that there may be a more ready escape for the lens. The anterior part of the capsule is then lacerated with a 'cystitome,' and the lens is very gently squeezed out of the sclero-corneal wound by pressure delicately applied on the sclerotic, below the cornea. If the cystitome be used with too much force, the lens is apt to be dislocated into the vitreous; and if, after the use of the instrument, too much pressure be made upon the eye-ball the vitreous may be extruded.

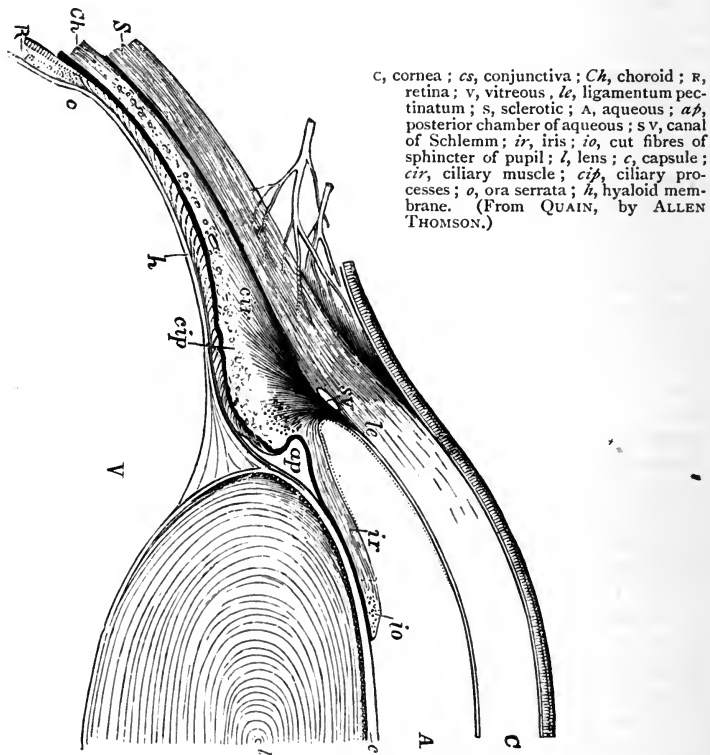
The lens being removed, the rays of light meet at a focus very far behind the retina, so that strong convex glasses are needed (p. 86).

The shape of the lens is regulated by the extremely elastic capsule which contains it. This elasticity is shown by the way in which, when it is scratched in the operation of extraction, the scratch becomes a tear, and the tear a rent, so that the cataractous lens is set free. But to ensure the ready escape of the lens the cataract should be fully 'ripe' before its extraction is attempted, otherwise its escape may be associated with that disagreeable phenomenon, the escape of the vitreous. Moreover, if some of the 'unripe' cortical part of the lens be left adhering to the capsule, it may in time become opaque, and entail further operation for its removal.

The **vitreous body** forms a transparent mould for the eye-ball, the retina being spread over the greater part of its circumference, and the lens being supported by it in front. Probably there is running throughout it a delicate reticular structure; it also contains corpuscular elements which usually float unobserved, but which, under certain conditions, can throw shadows upon the retina like gnats—

*muscæ volitantes*. In the foetus a slender canal through the vitreous transmits a branch of the arteria centralis retinae to the lens, iris, and pupillary membrane.

The **canal of Schlemm** is a narrow passage running all around the eye-ball in the substance of the sclerotic, close to the attachments of the cornea and iris. It is lined with endothelium, and, like the anterior chamber, with which it is continuous, is part of the lymphatic



C, cornea; cs, conjunctiva; Ch, choroid; R, retina; V, vitreous; l, ligamentum pectinatum; s, sclerotic; A, aqueous; sv, canal of Schlemm; ir, iris; io, cut fibres of sphincter of pupil; l, lens; c, capsule; cm, ciliary muscle; cip, ciliary processes; o, ora serrata; h, hyaloid membrane. (From QUAIN, by ALLEN THOMSON.)

system of the eye-ball. Its office is to drain away the nutrient fluid which the ciliary processes supply for the vitreous, and which enters the posterior chamber of the aqueous by permeating the suspensory ligament of the lens; and, in addition, to carry off the tide of the aqueous, which, coming also from the ciliary processes, leaks into the anterior chamber between the lens and the free border of the iris—that is, through the pupil.

These aqueous tides flow into the canal of Schlemm through the



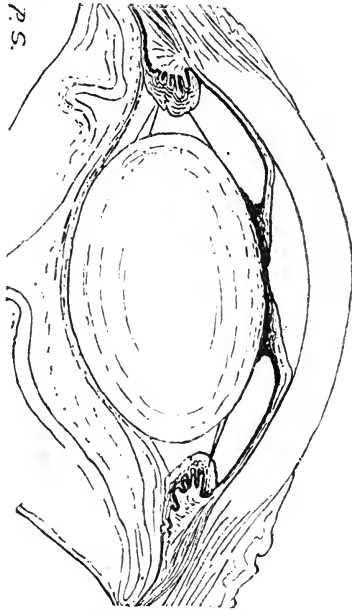
lattice-work, *ligamentum pectinatum* (*pectinatum*, adv., like the teeth of a comb), which occupies the narrow peripheral part of the anterior chamber, between the cornea and the root of the iris. This important crevice is, therefore, called **the filtration angle**. It becomes blocked when, as the result of an excessive secretion of the vitreous, the ciliary processes are thrust against the iris, and the iris is thrust against the cornea. And its connection with the posterior chamber is, of course, completely shut out when, as the result of iritis, the pupillary border of the iris is glued to the front of the capsule of the lens or to the posterior surface of the cornea.

Whenever the tideway from the vitreous and the posterior chamber into the anterior chamber is blocked, the fluids collect behind the iris and push it towards the cornea, increase of the ocular tension promptly taking place.

Thus, the tension may be increased in the case of excessive secretion from the ciliary processes into the vitreous, and also in that of a blockade of the filtration-angle. It is this increased tension of the eye-ball which is the essential feature of **glaucoma** (*γλαυκος*, bluish-green).

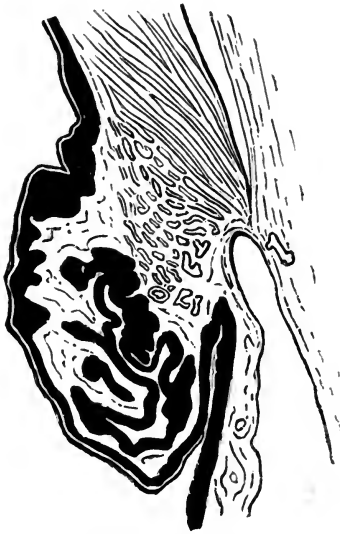*Symptoms of glaucoma*, in addition to that of hardness of the eye-ball:—Pain, on account of the compression of the ciliary nerves within the rigid sclerotic; advancement of the iris, as already explained, and errors of refraction, on account of the grave interference with accommodation.

Then, if the media are clear enough for the ophthalmoscope, the veins at the fundus are seen to be full and pulsating, because the tension of the sclerotic prevents their emptying themselves; and the arteria centralis is found throbbing in its endeavour to force its contents through the engorged capillaries. And the backward pressure of the vitreous causes a manifest depression or even a cupping of the optic disc, but in an acute case the general destruction of the tissues may render this invisible. Atropine must not be used, as this causes the iris still farther to encroach on the filtration-angle.

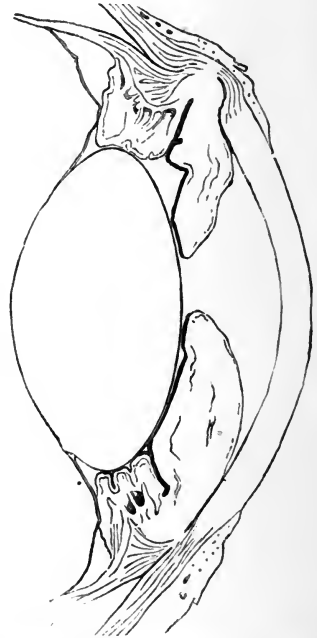

Iritis; annular posterior synechia, aqueous locked in behind iris, which, thus pushed forwards, blocks filtration-angle and determines glaucoma. (PRIESTLEY SMITH.)

*Treatment.*—Unless the tension be promptly relieved, the eye-ball will be ruined. Eserine (Calabar bean), constantly dropped between the lids, may help in this respect by contracting the pupil, and so drawing the iris out of the way of the filtration-angle. But, if the case be acute, iridectomy should be performed. This operation eases the tension by allowing some of the aqueous to escape, and, moreover, the section of the iris extending to its very root, the filtration-angle is inevitably once more opened up.



From an eye cured of acute glaucoma by iridectomy, filtration-angle being opened-out. (PRIESTLEY SMITH.)



Tumour of iris; filtration-angle blocked; secondary glaucoma. (PRIESTLEY SMITH.)

Looking back, one can now appreciate the peril which a complete anterior or posterior synechia entails (p. 88), and can also understand why some surgeons prefer to preface extraction of the lens by an iridectomy, lest iritis, synechia, and glaucoma should supervene. The preliminary iridectomy, however, is by no means necessary.

(For the anatomy of the optic nerve see CRANIAL NERVES, p. 57.)

The **retina** is the delicate expansion of the optic nerve. It is so thin that the hue of the subjacent choroidal blood is clearly diffused through it, and this, indeed, is all that can be made out in one's first

attempts at ophthalmoscopic examination. With a little practice, however, the *optic disc*, the entrance of the optic nerve, is discovered, whitish in appearance, on account of the absence of the choroid at the point of its perforation, there being nothing behind that part of the retina but the lamina cribrosa (p. 83). The ascending and descending divisions of the central artery and vein are then made out.

As the fibres of the nerve radiate on to the front of the choroid they leave a central depression in the disc, called the *cup*, and the margin of the lamina cribrosa—the *sclerotic ring*—may often be seen around the cup.

The optic disc is the '*blind spot*' of the retina ; and, for that reason, it is placed out of the way of the visual axis. The exact centre is the most delicate and useful part of the field, and is known as the *yellow spot*.

The nervous part of the retina extends to the ciliary processes, where it ends as the *ora serrata* (*ora*, *margin*), but the retina is continued a little farther forwards by delicate fibrous tissue, even to the capsule of the lens.

The retina depends entirely on the central artery for its *blood-supply*, and on a few twigs from the choroid which enter at the optic disc. If in disease of the aortic valve a small vegetation be detached, and carried into (embolus) and plug the arteria centralis, the eye, or part of it, becomes suddenly blind, for the retina is completely deprived of its nutrition. Examination then shows the arteries and veins of the fundus shrunken, whilst broken thrombi may be seen in the artery. In Bright's disease hæmorrhages are very apt to occur in the inflamed and swollen retina (albuminuric retinitis).

The delicacy of the connections of the retina renders it liable to detachment by injury and disease.

## THE EAR

The **external ear** consists of the expanded pinna, composed of yellow fibro-cartilage, and the auditory meatus.

The deepest part of the **pinna** is the *concha* (cockle-shell), at the front of which is a cartilaginous plate which acts as a shield to the meatus, on which grows a tuft of hair like the beard of a goat (*tragus*). Behind this shield is another plate, the *anti-tragus*, below which is the fibrous *lobule*. (A keloid tumour sometimes springs from the scar which necessarily results from piercing the lobule for an ear-ring.) The *tragus* and *anti-tragus* are separated by a deep *incisura*. The margin of the pinna is the *helix* (ἑλιξ, a spiral), and the groove beneath its incurved border is the *fossa of the helix*. Rather nearer to the meatus is a thicker ridge, the *anti-helix*, which bifurcates above to inclose the *fossa of the anti-helix*.

Beneath the skin are ligamentous and muscular slips, some of which connect the pinna with the side of the head. The skin of the pinna and of the meatus contains many sebaceous glands by which the wax is secreted for lubricating the canal and for preventing the entrance of insects. Sometimes it is secreted in excess, and forms at last a plug which blocks the canal and causes deafness.

As the result of violence, blood may be extravasated beneath the skin of the pinna, forming *hæmatoma auris*, or the cartilage of the ear may be crumpled up and permanently disfigured. Both these conditions may be found in vigorous and forward foot-ball players.

Passing down the meatus, the skin becomes gradually thinner, and is at last blended with the periosteum. It forms also the outer layer of the *membrana tympani*.

**Supply of the pinna.**—The *arteries* are derived from the posterior auricular and the superficial temporal. The *veins* take a corresponding course.

The *nerves*.—The great auricular, from the second and third cervical, supplies the lobule and the back of the pinna, the lesser occipital also gives twigs to the occipital aspect of the pinna, as does also the auricular branch of the pneumogastric. The auriculo-temporal branch of the fifth supplies the outer aspect of the pinna. The posterior auricular and temporal branches of the facial supply the intrinsic muscles of the pinna. (It is noted elsewhere (p. 64) that pains in the neighbourhood of the ear may be due to a lesion of the fifth nerve, and (p. 145) that pain at the back of the pinna may be the result of cervical caries.)

**Muscles of the external ear.**—The *attollens*, fan-shaped, arises from the aponeurosis of the occipito-frontalis, and is inserted into the front of the helix. The most anterior fibres of this muscle constitute the *attrahens*. The *retrahens* passes from the mastoid process forwards to the back of the concha.

Though the contemporary human anatomist hardly considers these as muscles of expression, the suggestive fact, nevertheless, remains that the facial nerve still supplies them: the *retrahens* by the posterior auricular, and the *attollens* and *attrahens* by filaments from the temporal division. The *attollens* may also receive a supply from the lesser occipital nerve.

The **external auditory meatus** is an osseo-cartilaginous canal about  $1\frac{1}{4}$  in. long, and is directed forwards and inwards. At the bottom of the concha its greatest diameter is vertical, but near the membrane it is transverse; the narrowest part is about the middle. It is developed by the outgrowth of the tympanic bone (p. 12).

To make a thorough inspection of the canal, the pinna should be drawn backwards, upwards, and a little outwards, the tragus being tilted forwards. In the young child the meatus is extremely short; the bony wall is a subsequent development.

A **foreign body in the ear** may be detected by the speculum, and perhaps extracted by appropriate forceps. If a stream of tepid water can be got behind it, but obviously not otherwise, it may be washed out by prolonged syringing, the stream being directed along the roof. A fine stream is better than a full one, as it is more likely to pass behind the foreign body. A large nozzle should not be used, lest, obstructing the outflow, it produce so much tension as even to burst the membrana. Rough syringing is always dangerous.

If the parts be much swollen the attempt at extraction should be delayed until they have quieted down; the foreign body may quietly lie at the bottom of the meatus for months or years and cause no harm. Possibly a hair-pin bent at the closed end, may happily bring it out, but no rough efforts should be made, lest the membrane be torn. If the case be urgent, the cartilaginous part of the meatus may be cut half across from behind the concha, flat with the surface of the head, when, the pinna being turned forwards, the body is found well within reach.

If insects have entered the meatus, warm oil should be poured in.

**Supplies.**—The *arteries* of the meatus come from the posterior auricular, internal maxillary, and superficial temporal. The veins run to the external jugular, and the lymphatics to the glands near the angle of the jaw.

The *nerves* come from the auriculo-temporal (p. 63), the great auricular, and from the auricular branch of the pneumogastric. It is owing to the presence of the last-named nerve that the introduction of a speculum, or the presence of a plug of wax, sometimes sets up a cough known as an '**ear-cough**' (see p. 69), which may be accounted for by the fact that the pneumogastric or the auriculo-temporal nerve conveys an impression to the grey matter of the medulla which is to the effect that some annoyance exists in the larynx—for which the usual remedy is a cough. It is a sort of physiological equivalent of a 'printer's error.' The information conveyed by nerves is not invariably true to the letter, and some have a worse character for veracity than others—notably the obturator (p. 359) and the vesical nerves (p. 411).

Sometimes irritation of the auricular branch of the pneumogastric, as by a plug of wax or by a foreign body, causes faintness, nausea, or reflex vomiting, which entirely ceases on the cause being removed.

The **tympanum** is a minute cavity situated between the external and the internal ear. Its outer limit are the membrana, and an osseous surface upon which are the apertures of entrance and exit of the chorda tympani (p. 66). Its inner wall is the bony partition which separates it from the internal ear. The roof is formed by a thin plate of bone separating it from the middle cranial fossa, and its floor is another thin plate which shuts it off from the jugular fossa. In front of it ascends the internal carotid artery, and at that aspect also enter two tubes, the upper one transmitting the tensor tympani, and

the lower the Eustachian tube ; they are separated by the cochleariform process of bone. Behind the tympanum are the mastoid cells.

On the inner wall of the tympanum is an oval foramen which is appropriately filled in by the oval plate of the stapes, but which otherwise would open directly into the vestibule. Below this foramen is a round one which leads towards the cochlea, but which is glazed with a threefold layer, like a miniature *membrana tympani* (p. 97), the innermost layer being the serous lining of the cochlea. Above the oval foramen is a slight ridge which marks the passage of the facial nerve in the subjacent aqueduct of Fallopius. The first turn of the cochlea, bulging outwards, forms a projection, the promontory, upon the inner wall ; and farther back is the pyramid, from the interior of which the stapedius arises.

After the loss of the membrane the inner wall of the tympanum is clearly shown by otoscopic examination, and Mr. McGill tells of a case in which a minute bubble of air under a film of mucus upon that part which is called the pyramid was for some time mistaken for the glistening head of a pin, which, according to one account, had been pushed into the ear.

The **ossicles**.—The head of the *malleus*, or hammer, articulates posteriorly with the incus. Its tapering handle descends vertically between the inner and middle layers of the *membrana*, the tensor *tympani* being inserted into its upper end.

The top of the *incus*, or anvil, articulates with the head of the hammer. Its short limb passes back to be lodged in the mastoid cells, and the long one runs parallel with the handle of the hammer to articulate, by the *os orbiculare*, with the head of the *stapes*, or stirrup, the plate of which blocks the *fenestra ovalis*. The joints between the ossicles are enclosed in delicate capsular ligaments, lined with synovial membranes, and are liable to attacks of disease. Thus chronic inflammation of the middle ear stiffens them, and so interferes with the oscillation that deafness steadily advances. The subjects of this troublesome complaint hear better when riding in a train or carriage, as the shaking of the vehicle imparts the needful vibration to the chain.

The *tensor tympani* arises from the walls of the bony canal by which it enters the tympanum, and is inserted near the root of the handle of the hammer. It is supplied by a branch from the otic ganglion. Its action is to draw inwards, and so to tighten the *membrana* ; at the same time it presses upon the perilymph and causes a disturbance of the auditory filaments. When the buzzing in the ear which is supposed to result from this pressure is constant, certain aural orthopædists have recommended a speculative tenotomy of the muscle. An artilleryman, who is awaiting the firing of a big gun, keeps his mouth open, so that the aerial concussion may rush along the Eustachian tube as well as down the auditory meatus, and that

the membrane may be evenly struck on each side ; at the same time also he sets the tensor tympani in action so as to steady the membrane ; otherwise the explosion may rend it.

The *stapedius* arises in a small pyramid of bone upon the inner wall of the tympanum, and is inserted into the neck of the stapes. It is supplied by a tympanic branch of the facial nerve. Its action is to drive the plate of the stirrup farther into the oval foramen, and so to compress the fluid in the vestibule.

The tympanum and the mastoid cells are lined by a delicate mucous membrane, which is continuous with that of the pharynx through the Eustachian tube. It covers the ossicles and the nerves, and forms the inner layers of the membrana tympani. Its epithelium is of the columnar ciliated variety.

**Supply of tympanum.**—*Arterial* twigs come from the internal carotid, stylo-mastoid, internal maxillary, and middle meningeal. The tympanic *veins* end in the petrosal and lateral sinuses, and in the internal jugular. The *nerve-supply* is from Jacobson's branch of the glosso-pharyngeal (p. 69) ; but Arnold's nerve also helps with a delicate twig. The chorda tympani wraps itself in mucous membrane as it hurries through the tympanum, passing between the handle of the hammer and the long process of the incus, but it gives no branch to the cavity. The lymphatics descend to glands behind the angle of the jaw, and massage over them, downwards from the mastoid process, may give much help in emptying mucus from the middle ear.

The **membrana tympani** is stretched obliquely at the bottom of the external auditory meatus. In the adult its border is fixed in a groove in the bone, but in the child to the tympanic ring. The ring being deficient above, the attachment there is less firm—only to the periosteum—and thus it may be unglued by a box-on-the-ear, or by blood or pus escaping from the tympanum. (Tillaux.)

The membrane is composed of circular and radiating fibres, which are covered on one side by a thin layer of skin from the external auditory meatus, and in the other by the mucous lining of the middle ear. Between this mucous membrane and the fibrous layer the handle of the malleus descends as far as the centre, to which part it is attached, drawing it slightly inwards at a sort of umbilicus. Its arteries are derived from the tympanic branch of the internal maxillary, and from the stylo-mastoid of the posterior auricular, which ramify respectively upon the lower and upper parts. The auriculo-temporal nerve endows it with sensibility.

**Paracentesis of the tympanum** may be required for the evacuation of abscess from the middle ear ; also for the transmission of waves of sound through a membrane which has become thickened and stiff by chronic inflammation—the auditory nerve being known to be healthy (p. 102). In this case it is often impossible to maintain the desirable patency of the opening, whereas after the opening of a tym-

panic abscess the wound in the membrane may obstinately refuse to close! Paracentesis should be performed through the lower part of the membrane, so as to avoid the risk of wounding the handle of the hammer and the chorda tympani, which are above the equator.

The instrument must be thrust through with great care, as the inner wall is but  $\frac{1}{10}$ -inch beyond the membrane. I once had a man under my care whose child had roughly practised the operation on him with a pair of scissors, and with such violence as to cut through the facial nerve as it ran in the substance of the inner wall. The man had complete facial paralysis (p. 67).

Polypi growing from the inner wall of the tympanum may cause great local disturbance, and in due time may make their way through the membrane and up the meatus; they are usually associated with much suppuration. Having been removed by snare or forceps, their base must be kept down by astringents.

When there is a hole in the membrane, and the Eustachian tube is clear, the subject can force air through it by blowing his nose hard. But the existence of an opening by no means implies deafness. Indeed, though the hammer and the anvil have escaped with the purulent discharge, hearing may persist, provided that the plate of the stirrup remains to close in the vestibular perilymph.

When the membrane has a large opening in it, and the Eustachian tube is clear, the tympanum may be washed out into the pharynx by sending a full stream of warm water down the auditory meatus, and in cases of chronic suppuration this treatment may be advantageously resorted to.

*Artificial membrana tympani.*—When the destruction of the membrane has been so great as to lay the meatus into the tympanic cavity, the hammer and the anvil having probably escaped, hearing may be improved by passing a delicate plug of cotton-wool against the inner wall of the tympanum, so that it presses against the head of the stirrup, and conveys the sound-waves to the perilymph of the vestibule.

**Acute inflammation of the middle ear** may be an independent disease, or may be secondary to a 'sore-throat.' As the muco-purulent fluid collects in the chamber with unyielding walls the effect of pressure becomes extremely serious: the first result may be noises in the ear, because the stapes is driven against the vestibular perilymph; then come intense headache and pains of a bursting character, which, increasing, may cause convulsions, delirium, and may be followed by death.

There is tenderness around the meatus and over the mastoid process. Swallowing causes pain by opening the inflamed Eustachian tube and causing air to enter the tympanum. Movements of the jaw also cause pain by disturbing the engorged tissues between the condyle and the tympanum.



The pus may be absorbed, or may happily escape along the inflamed Eustachian tube ; but, if it be allowed to remain uninterfered with in the tympanum, it may take its time in bursting through the membrane, and may, but not necessarily so, leave the ear permanently deaf.

**Complications.**—The abscess may burst through the roof of the tympanum and cause meningitis, and an intra-cranial abscess, in the neighbourhood of the petrous process and of the temporo-sphenoidal lobe. Sometimes the matter burrows into the mastoid cells, in which case its prompt escape may be helped by drilling behind the pinna, or by cutting through the inflamed and softened mastoid process with a gouge.

In the case of a boy who was recently under my care, the inflammation had extended from the tympanum throughout the entire petromastoid bone, which came away as a large sequestrum without implication of the internal carotid artery (which passes through it, p. 13), but with, of course, total destruction of the portio dura, permanent facial paralysis resulting.

Extension of ulceration from the tympanum may involve the carotid, or the jugular vein, fatal hæmorrhage occurring through the external meatus.

Suppuration from the petro-mastoid bone may reach the neck and cause cervical abscess. If the inflammation extend downwards, it may cause phlebitis in the internal jugular, and if downwards and backwards to the neighbouring lateral sinus it may there set up an inflammation; in both cases coagulation of the blood supervenes, and, pieces of the septic thrombi being carried into the circulation, pyæmia and metastatic abscesses result.

Cerebellar meningitis and abscess may follow extension of the inflammation from the back of the tympanum and the mastoid cells.

The *treatment of acute otitis* demands the free application of leeches behind the pinna and in front of the tragus, with subsequent fomentations. If the membrane be found congested and bulging, paracentesis must be promptly resorted to. If the mastoid cells be apparently involved they should be freely opened.

The **Eustachian tube**,  $1\frac{1}{2}$  inch long, leads into the pharynx from the middle ear, at the level of the inferior meatus ; its direction is forwards, inwards, and slightly downwards. Its posterior part is osseous, being at the junction of the squamous and petrous portions of the temporal bone. The anterior part is fibro-cartilaginous, and ends by a trumpet-shaped expansion, from the lower aspect of which the tensor and levator palati arise. Contraction of these muscles during deglutition opens the tube and allows air to enter the tympanum. A 'singing in the ear' may often be made to disappear by setting the tensor palati in action by swallowing, the inrush of air causing the membrane to yield with a slight crack.

The lining membrane of the tube contains mucous glands and is covered by columnar ciliated epithelium, except at the pharyngeal opening, where it is squamous. The osseous part of the tube receives its arterial supply from the vessels of the tympanum, and the cartilaginous part from those of the pharynx. The lymphatics end in glands about the angle of the jaw.

In the case of inflammation of the pharynx, the tube and the tympanum may be secondarily implicated, and when an acute inflammation has travelled back, abscess may be set up in the middle ear. Thus may be explained the destruction of the membrana tympani and the permanent deafness which sometimes follow scarlet fever, or which, in an unhealthy child, may result from acute tonsillitis.

On account of the tonsil being below the soft palate (p. 111), and the soft palate close below the opening of the tube, enlargement of the tonsil may, indirectly, cause obstruction of the tube and deafness, but more often the blockage is due to hypertrophy of the neighbouring adenoid tissue, which is affected at the same time as the tonsil.

**Obstruction of the Eustachian tube** is usually caused by inflammation. Air being then unable to enter the tympanum, the pressure on the exterior of the membrane is in excess of that within. The result is that the membrane and the malleus are thrust inwards, and, the incus being forced against the stapes, there is a constant pressure against the fluid of the vestibule; this causes irritation of the terminal filaments of the auditory nerve, which is recognised as a meaningless but annoying buzz or singing.

If the blocking of the tube be but slight, the singing may cease after the act of swallowing, as these movements pull down the lower end of the expanded opening of the Eustachian tube (p. 108) and allow air to pass along. If this fail, success may follow on the person holding the nose and blowing it hard, which effort may force the compressed air beyond the obstruction, thrusting out the membrana tympani, and drawing upon the plate of the stapes at the oval foramen. If this also fail, the surgeon may pump air up the nostrils by Politzer's apparatus at the instant that the patient swallows a mouthful of water, so that the compressed air may be locked above and behind the soft palate and the palato-pharyngei, and, instead of being dissipated down the œsophagus, may find its way into the middle ear.

As a last resource the *Eustachian catheter* must be used. This instrument, which is like a short and small silver catheter, is passed lightly along the floor of the nose, with the point downwards, until it touches the back of the pharynx. (It must not be allowed to enter the middle meatus.) It is then withdrawn a little, the point being turned outwards, and it should be felt to hitch against, and jump over, the posterior edge of the cartilaginous expansion of the tube; it is then gently pushed upwards and outwards into the tube, after which it should be felt to be in the firm grasp of the tube, otherwise the beak has not

been brought forward enough, but is lodged in the space between the posterior part of the opening and the back of the pharynx—the *fossa of Rosenmüller*.

The catheter being securely inserted into the tube, the surgeon connects his own ear with that of the patient by a flexible stethoscope and listens for the result of pumping air along the catheter. If the obstruction be absolute no air is heard rushing into the tympanum; if the tube be abnormally dry the sound is harsh, and if the tube and the tympanum contain mucus the air enters with a bubbling. But, if the obstruction be suddenly overcome, the air enters with a rush, driving the membrane outwards with a slight click. If the membrane be perforated the air escapes with a hissing sound.

If the catheter be so clumsily introduced as to tear the mucous membrane, and if air be then pumped up with considerable force, temporary emphysema of that neighbourhood may result.

The **internal ear** is a labyrinthine chamber hollowed out in the petrous bone, and consisting of three parts, the vestibule, semicircular canals, and the cochlea, which have a delicate lining for the secretion of perilymph. The bony labyrinth contains a membranous labyrinth of corresponding shape; it is hollow and floats in the perilymph; it, likewise, contains fluid, the endolymph. Thus, the auditory filaments, which are spread out upon it, are securely placed between the peri- and the endo-lymph. The membranous labyrinth is supplied by a small *auditory* branch of the basilar artery, which enters by the internal auditory meatus.

The *semicircular canals* occupy suggestive geometrical positions: the superior is in a vertical transverse plane; the posterior in a vertical antero-posterior plane; and the external one arches outwards in a horizontal plane. Their function is probably for maintaining the equilibrium of the head and of the body; when they are diseased the subject cannot keep upright.

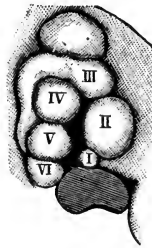
When the amount of fluid in the labyrinth is excessive the patient has sudden attacks of giddiness, headache, and sickness, and he promptly falls in a definite direction. He may at first think that the associated troubles, which are accompanied by deafness, are due to indigestion. The disease is named after M. Ménière, who first described it, and, because of its associations, it is often spoken of as 'ear vertigo.'

The **auditory nerve** passes down the internal auditory meatus and breaks up into branches which run through small holes to the vestibule, semicircular canals, and cochlea.

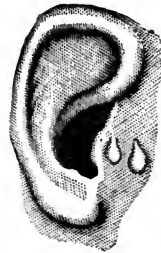The waves of sound reach these terminal filaments by the membrana tympani setting the ossicles in vibration, the oval plate of the stapes imparting a similar movement to the perilymph, by which the acoustic filaments are irritated. The nerve-filaments may also be set in vibration by the conduction of sound through the bones of the skull.

When a tuning-fork in vibration is placed on the vertex of the head of a person with healthy ears, and one external auditory meatus is then blocked, the sound is best heard on that side, as dissipation of the waves along the meatus is prevented, and they are, therefore, echoed again and again from the tympanic membrane to the perilymph. When the deaf ear of a patient cannot hear the tuning-fork so placed the auditory nerve must be at fault. When the 'deaf' ear hears the vibrations better than the other there is probably obstruction of either the external meatus or the Eustachian tube, and treatment may be hopefully undertaken, for the auditory nerve is evidently healthy.

**Development.**—The pinna is formed by the fusion of six small tubercles upon the integument at the end of the first visceral cleft, which is between the mandibular and hyoid arches. The fusion, how-



Development of pinna from six tubercles.  
(After HIS.)



Supernumerary and persistent auricular nodules. (BLAND SUTTON.)

ever, is never absolutely complete, for those tubercles from which the tragus, anti-tragus, and the lobule are developed assert their independence throughout life. Occasionally the fusion is extremely incomplete, *supernumerary auricles* and *pendulous growths near the meatus* resulting. (For a Note upon DEVELOPMENT *v.* p. 123.)

Sometimes the tragus-nodule is prevented from blending with the elongated nodule just above it (from which the helix is formed) by a recess of the epiblast which sinks between them and forms an *auricular fistula*. I saw such a case the other day, in which the involution caused a fistula which ran beneath the superficial temporal artery. From time to time it discharged a viscid secretion. It had to be laid open and scraped out. (*See also* Trans. Soc. Med. Chir. vol. lxi.) Occasionally a similar fistula exists between the lower part of the helix and the lobule, and sometimes the minute opening of one of these fistulæ becomes occluded, and the secretion collecting within distends it into a *dermoid cyst of pinna*.

Occasionally the tubercles are joined over the meatus in an elongated or confused mass which represents the pinna; this malforma-

tion is likely to be associated with imperfect development of the tympanic end of the first post-oral cleft. Sometimes the tubercles join over and hide the meatus; sometimes there is neither meatus nor pinna. On the other hand, by a sort of carelessness, or, possibly, over-zeal, on the part of Nature, a supplementary pinna, or an attempt at one, is sometimes developed at the end of one of the lower clefts.

The Eustachian tube and tympanum 'are developed in connection with the inner end of the first post-oral cleft, while the meatus externus and pinna are formed on the outside, the membrana tympani being interposed between them. (Quain.)



Rudimentary pinna developed at dorsal end of third branchial cleft. (BLAND SUTTON.)

## THE MOUTH

The **lips** consist of striated fibres of the orbicularis and other muscles covered on the outside by skin, and on the dental aspect by mucous membrane which is continuous with that of the gums and mouth. This entire mucous surface is covered with squamous epithelium. Where the membrane is reflected from the middle line of the upper and lower jaw to the lip, a prominent fold or *frænum* occurs, that of the upper lip being well-marked. Beneath the mucous membrane of the lips racemose labial glands are placed; and, should the orifice of one of them be occluded, a *labial cyst* occurs; sometimes the glands become the seat of suppuration.

The **orbicularis oris**, a sphincter of striated fibres, consists of a semi-elliptical portion in each lip; the fibres of each piece blend and cross at the corners of the mouth, where they join other muscles of expression; they become continuous externally with the anterior part of the buccinator.

The orbicularis arranges the lips in whistling, and when the facial nerve, which supplies it, is paralysed (p. 67) all efforts in that direction are attended with characteristic failure. Contraction of the separate halves of the muscle may spoil the plastic operation in hare-lip; it was to check this strain upon the wound that hare-lip pins were formerly so much used. The employment of abundant fine sutures

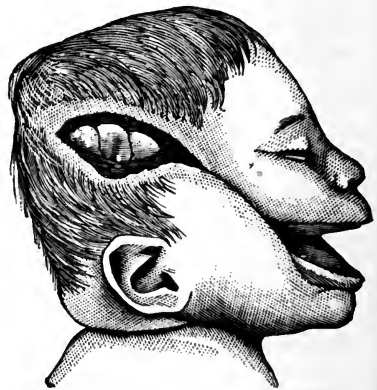at the front and back of the wound, and the judicious arrangement of strips of waterproof strapping are now taking the place of the pins, the use of which is apt to mark the lip with permanent scars.

**Supply.**—Below the region of the orbicularis the lower lip receives the submental and inferior labial branches of the facial artery. The coronary branches of the same artery pierce the orbicularis and form a circle close beneath the mucous membrane. In operating for hare-lip one suture should be passed beneath their cut ends. (There is no superior labial artery: an upper lip which is long enough to need one is an artistic defect.) The infra-orbital artery may help in the supply of the upper lip, and the mental branch of the inferior dental in that of the lower lip. The *lymphatics* pass to the submaxillary and to the cervical glands.

The *nerves* are derived from the terminations of the superior maxillary and inferior dental trunks; the mental branch of the inferior dental also helps in the supply of the lower lip.



Congenital Macrostoma and Supernumerary Auricular appendage. (FERGUSSON.)



Macrostoma in a child six weeks old. (BLAND SUTTON.)

**Development.**—The buccal cavity first appears as a depression in the epiblast between the fronto-nasal process above, the superior maxillary processes at the sides, and the mandibular plates (p. 105) below. The mouth is then separated from the pharynx, but the partition soon wears away at the region of the fauces. Sometimes the hinder part of the mandibular fissure (M.F., p. 124) fails to be obliterated; a large mouth, macrostoma, then results.

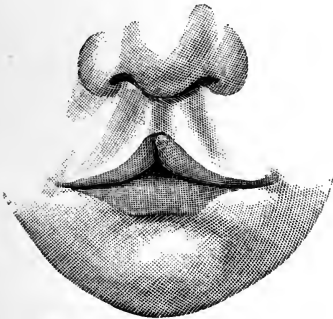**Hare-lip.**—The median part of the upper lip is formed by a flap which descends, in connection with the fronto-nasal plate, from the front of the cranium; the lateral parts are developed from the cover-

ings of the superior maxillary processes, which, extending inwards, are eventually fused with the descending flap at a short distance from the median line.

If a unilateral arrest of development take place, a single hare-lip results ; if the arrest be symmetrical, the cleft is double. The labial cleft is thus to the side of the median line, not *in* it, as it is in the hare. The cleft may extend into the nostril ; or may be represented by a mere notch or depression at the border of the lip. Sometimes a small triangular gap is found continuous by its apex with a vertical linear cicatrix, as if Nature herself had attempted a plastic operation with partial success. Hare-lip may be hereditary, several members of the same family being disfigured by it. Often it is associated with cleft palate, and the median piece of the lip may be attached with the inter-maxillary bone to the projecting nasal septum.<sup>1</sup> In double hare-lip the inter-maxillary bone should contain the four incisors, but more often it contains three, or two only.



Double hare-lip; præmaxilla attached to tip of nose.



Mr. Pitt's case of Median Hare-lip.



Notch in process descending to form median part of lip ; a deepening of this notch gives median hare-lip.

Fergusson taught that the lateral incisors were then lost in the cleft, but, from development (p. 17), this explanation does not suffice.

The median part of the lip descends as a bifid process, and if the gap between its lateral nodules be exaggerated, whilst their outer

<sup>1</sup> From *The Surgical Diseases of Children*, Cassell & Co.

borders are fused with the ingrowing maxillary parts, the fissure is exactly median. This condition, however, is extremely rare.<sup>1</sup>

The operation for hare-lip consists in freshing the sides of the cleft, freeing the maxillary attachments of the lip, and adjusting the cleft by stitches and strapping, arrangements being made that the muscles do not pull the edges asunder.

The **cheeks**, like the lips, with which they are continuous, consist of skin and mucous membrane, with intervening muscular tissue, namely, buccinator, zygomatici, platysma, and masseter. They contain, also, a good deal of fat; and beneath the mucous membrane are minute salivary glands resembling those of the lips.

On the mucous lining of the cheek, opposite the second molar tooth of the upper jaw, is a flat papilla upon which is the opening of the parotid duct, which has just traversed the buccinator. To save himself the annoyance caused by the flow of saliva during certain dental operations, the dentist sometimes stuffs a piece of cotton-wool between the upper jaw and the cheek so as to block the orifice of the duct.

The **buccinator** arises from the alveolar process above the molar teeth of the upper, and below those of the lower jaw; and, posteriorly, in the space between the jaws, from a fibrous seam connecting the muscle with the front of the superior constrictor—the pterygo-maxillary ligament. Thus the mouth is directly continuous with the pharynx.

*Action.*—The buccinator helps the man to ‘blow his own trumpet’; it is thus a muscle of expression, and is, therefore, under the control of the *facial nerve*. Its chief office is to gather up the half-chewed food which falls outwards from between the molar teeth, and to push it again into the mill. When the facial nerve is paralysed the food persistently collects in the cheek, whence the patient has to dislodge it with his finger. So useless is the muscle in facial paralysis that there can be no manner of doubt that the branches which the muscle gets from the inferior maxillary nerve (p. 63) are but sensory.

*Relations.*—The muscle is covered by skin, superficial fascia, and the muscles which draw the angle of the mouth downwards, backwards, and upwards; it is crossed by the facial artery and vein, and by branches of the facial and buccal nerves. Stenson’s duct passes through it opposite the second upper molar. A good deal of fat is packed in between it and the anterior border of the masseter; in phthisis this is gradually consumed and the cheeks sink in. Behind the muscle is the pharynx; in front is the orbicularis, and lining it is the mucous membrane of the mouth.

**Pterygo-maxillary ligament.**—The student is advised to pass the tip of his index-finger behind, and a little to the inner side of, the last molar tooth, where he will find a band beneath the mucous membrane. The more widely the mouth is opened, the tighter the

<sup>1</sup> See case reported by Bernard Pitts, *Lancet*, 1889.



band becomes ; it is the pterygo-maxillary ligament. If traced upwards it is felt to be attached to a somewhat springy piece of bone, the *hamular process* of the internal pterygoid plate ; and traced downwards it is evidently connected with the inner and back part of the lower jaw. From the front of this ligament the buccinator arises, and from the back the superior constrictor.

If the student will be good enough to continue the examination by bringing his finger upwards and forwards from the middle of the ligament, keeping his nail upon the *outer* surface of the last molar, he will feel the coronoid process of the jaw, separated from his finger, however, by the buccinator, the insertion of the temporal muscle, and the mucous membrane of the mouth. Then, lastly, if he will press firmly below the lower end of the ligament he will make out the gustatory nerve lying between the mucous membrane and the inner side of the jaw ; firm pressure upon it causes pain (p. 63).

#### THE PALATE

The **hard palate** consists of the horizontal plates of the two superior maxillæ and of the palate bones ; posteriorly it is continued into the soft palate by the palatine aponeurosis (*v.z.*). This surface of bone is roughened for the more firm attachment of the muco-periosteum. The muco-periosteum, which contains many glands, is covered with squamous epithelium. A median raphe (*ραφή, seam*) in the mucous membrane of the hard and soft palate indicates their development in lateral halves.

On the under surface of the palate bone is a ridge for the insertion of part of the tensor palati, and at the outer end of the ridge is the canal for the posterior palatine artery—that is, to the inner side of the last molar tooth. Bleeding from this artery may be arrested by finding the foramen with a sharp probe and then sticking a pointed spigot of wood into the canal.

The arteries of the hard palate are derived from the internal maxillary. The nerves come from the superior maxillary—Meckel's ganglion.

The **soft palate** is firmly attached in front to the posterior border of the hard palate, and from its sides pass off two folds of mucous membrane, the anterior of which descends to the tongue and the posterior to the pharynx, under the name of the *anterior and posterior pillars of the fauces*. Between the anterior and posterior pillars the tonsil is placed. The narrow passage between the two anterior folds is the *isthmus of the fauces*. The mucous membrane covering the pharyngeal aspect of the soft palate is thin, and, being continuous with that of the nares, is covered with columnar ciliated epithelium ; that upon the buccal surface is thick, and contains many mucous glands. Its epithelial covering is squamous. Forming a foundation

for the soft palate, and attached to the posterior border of the hard, is a strong *aponeurosis* which blends with the expanded tendon of the tensor palati.

The chief of the **muscles of the soft palate** is the *palato-pharyngeus*, which there consists of two layers, between which are the levator palati and the azygos uvulæ. Passing downwards and backwards in the posterior pillar of the fauces, it spreads out into the side of the pharynx and along the posterior border of the thyroid cartilage. As it descends from the outer border of the soft palate it is reinforced by fibres arising from the lower part of the Eustachian tube; these fibres constitute the *salpingo-pharyngeus* (*σαλπιγγίς*, *trumpet*), and, acting from below, they open the tube during deglutition (p. 99).

The *palato-glossus* blends above with its fellow of the opposite side on the under surface of the soft palate, and, passing down in the anterior pillar of the fauces, is inserted in the side of the tongue.

The *azygos uvulæ* arises from the posterior nasal spine and descends into the uvula.

The *levator palati* arises from the under surface of the petrous bone and from the lower border of the Eustachian tube, and, entering the pharynx above the upper border of the superior constrictor, is inserted between the slips of the palato-pharyngeus.

The *tensor palati* arises from the scaphoid fossa at the root of the internal pterygoid plate, and from the Eustachian tube; descending on the outer side of the inner plate, it ends on a tendon which is reflected round the hamular process to be inserted partly into the ridge on the under surface of the palate bone, and partly into the buccal aspect of the soft palate. The reason for part of it being inserted into the hard palate is that those fibres may be able to pull upon and open the Eustachian tube during deglutition. This, indeed, may, after all, be the chief use of the tensor palati.

*Nerves*.—The tensor is supplied by a branch from the otic ganglion. The facial, through the Vidian and Meckel's ganglion, supplies the levator and the azygos; and the pharyngeal plexus probably supplies the palato-glossus and palato-pharyngeus.

**Supply**.—The *vessels* of the soft palate are derived from the posterior palatine of the internal maxillary, the ascending palatine of the facial, and the ascending pharyngeal. The *veins* correspond. The *lymphatics* pass to the glands near the angle of the jaw. The *nerves* come from Meckel's ganglion and the glosso-pharyngeal.

**Cleft-palate** is the result of a want of union between the lateral halves of the soft and perhaps of the hard palate also; it generally passes back through the tip of the uvula. At the front of the palate the cleft leaves the middle line to pass through the articulation of the inter-maxillary with the rest of the upper jaw (p. 17), and then, probably, to finish off with a hare-lip (p. 105). When, as often happens, the median cleft diverges on either side of the inter-maxillary bones, the incisor

teeth may be found in an osseo-mucous tuft which is upon the tip of the nose, and when the inter-maxillary bones are attached to the tip of the nose (p. 17) the cleft is wide in the extreme, as is shown in the adjoining woodcut.

The palatine ingrowths from the maxilla are a comparatively late development of the bucco-pharyngeal cavity, and when their union fails to take place, on looking into the mouth, a view is obtained of the bright red membrane covering the turbinated bones. Many infants who are thus affected die of inanition, as they can



neither suck, nor satisfactorily swallow the milk which is poured into the mouth. For feeding they should be held upright, so that the milk may drop directly into the pharynx.

If, as the child grows up, the cleft be so wide that merely a trace of the maxillary plates exists, operative measures will be impossible, but the mechanical dentist may eventually be able to mould a serviceable obturator (*obturo, -avi, stop up*) to prevent the food entering the nostril, and to improve vocalisation.

The *plastic operation for cleft-palate* consists in freshening the edges of the cleft, detaching the muco-periosteum from the hard palate, and incising it close along the inner border of the alveolar process, so that the lateral flaps may be approximated, and secured by stitches. The flaps must be as wide as possible, so as to contain many branches of the posterior palatine artery, otherwise sloughing may occur. The aponeurosis of the soft palate must be detached from the hard palate, or the halves cannot be brought together. When the cleft in the soft palate has been stitched up, the halves would be drawn asunder again by the levator and tensor, and by the palato-pharyngeus of each side, if these muscles were not divided. Their division is best effected by a bold cut right through the outer part of the soft palate, in an antero-posterior direction. In my experience, the freer these cuts, the greater the prospect of the success of the operation.

In several cases lately I have operated with the child's head hanging back over the end of the table, so that the blood may escape by the nasal fossa and the anterior nares, rather than trickle into the larynx or œsophagus. This position serves well also in the removal of nasal polypi from the adult, especially if bleeding is likely to be free.

**Deglutition.**—In the first stage of the act the mouth is closed so as to give the tongue and the muscles attached to the lower jaw a fixed point; then the food is pressed backwards by the tongue along the roof of the mouth—the facial and the hypoglossal nerves being those which thus

far are concerned. If the student will try to swallow with the mouth open and the lower jaw unfixed, he will accomplish the act only with difficulty; but if he fixes the lower jaw by biting something, though the mouth remains widely open, the act is readily accomplished.

In the second stage of deglutition the soft palate is raised by the food being pushed against it by the tongue, and is fixed and tightened by the levator and tensor; the palato-pharyngei are also fixed, and, the posterior wall of the pharynx being drawn forwards by the superior constrictor, the back-way into the nares is completely shut off. (If the soft palate be cleft or perforated, it is at this stage that the food passes into the nose, to be ejected by the anterior nares.)

The larynx is now drawn forwards, and, the tongue being thrust backwards, the glottis is protected beneath its hinder part, the epiglottis also being shut down.

In diphtheritic paralysis of the soft palate food passes through the nostrils, or, at this stage of deglutition, if the muscles of the larynx and tongue be not working in harmony, some 'goes the wrong way' into the larynx and sets up coughing, or, perhaps, food-pneumonia. To avoid these risks, therefore, such patients must be fed by a soft catheter introduced into the pharynx through the inferior meatus of the nose.

In the third stage the constrictors take charge of the bolus, and, the larynx dropping, the food is carried from the posterior air-way, and hurried down the œsophagus.

The nerves concerned in *the reflex act of deglutition* are first those which convey the stimulus (afferent) to the medullary centre; they are palatine branches of the fifth, pharyngeal of glosso-pharyngeal, and œsophageal of vagus. The efferent or motor nerves are the hypoglossal (for first stage), mylo-hyoid of inferior maxillary, and pharyngeal branches of vagus which have come from spinal accessory.

The **uvula** consists of a double layer of mucous membrane with the azygos muscle included between them. Its office is not clearly known. Some compare it to a gargyle which guides the mucus from the nares to the back of the tongue and prevents its dripping into the glottis. Others deem it to be needful to fill in the interval between the posterior pillars of the fauces, and to block the naso-pharyngeal straits during deglutition. Nevertheless, many are benefited by its partial amputation.

In certain people it is greatly elongated; and, its blood-vessels being dilated after swallowing anything hot, or after smoking, it hangs against and tickles the back of the tongue to such an extent as to set up uncontrollable cough or retching. A medical friend of my own who possessed a long uvula, and a strange aversion from the performance of even a slight operation upon himself, was through five consecutive nights kept awake by a distressing uvula-cough. The ultimate removal, however, of half an inch of the œdematous mass brought him absolute and permanent relief.

## THE TONSIL

The tonsil is a lymphoid mass placed in the recess between the anterior and posterior pillars of the fauces (p. 107). Its situation corresponds to the angle of the jaw, and when the gland is enlarged it may cause a fulness in that neighbourhood. It is covered internally by the mucous membrane of the mouth, and upon its free surface are the openings of a dozen or fifteen crypts which extend into the substance of the tonsil. They have an epithelial lining, and upon the deep side of their basement membrane are nodules of lymphoid tissue.

**Relations.**—In front is the fold of membrane enclosing the palato-glossus, and behind is that enclosing the palato-pharyngeus; above is the soft palate, and below is the hinder part of the tongue. On the outer side is the superior constrictor of the pharynx, and more externally still are the internal carotid artery and the internal jugular vein; the vagus; the sympathetic ganglion, and the ascending pharyngeal artery. As the internal carotid is not only external to the tonsil, but also somewhat posterior to it, the jugular vein is still further away.

**Supply.**—The *arteries* are derived from the ascending pharyngeal; the ascending palatine and tonsillar of the facial; the *dorsalis linguae*, and the descending palatine of the internal maxillary. The *veins* form a plexus which empties into the pharyngeal veins and so into the internal jugular. The *lymphatics* pass to the glands below the angle of the jaw, and into those beneath the sterno-mastoid. The *nerves* are derived from the glosso-pharyngeal, and from descending branches of Meckel's ganglion.

**Hypertrophy.**—When the tonsils are enlarged they project from between pillars of the fauces, and may actually meet across the middle line. There is difficulty in swallowing, and as the masses obstruct the passage of air from the posterior nares the subject sleeps with his mouth open, so that air may enter also by the mouth. His respiration is always noisy, and at night he snores. Insufficient supplies of air entering, the chest is badly developed, and the excessive atmospheric pressure upon the exterior causes the child to become pigeon-breasted. Because the mouth is constantly open, the face becomes elongated, and because but little air passes through the nares the nose is small and flattened from side to side, and the nostrils are very narrow. Thus, the surgeon can often recognise the hypertrophy by the aspect of the patient. The voice is 'thick.'

Being below the soft palate, whilst the opening of the Eustachian tube is above it, the enlarged tonsil cannot actually occlude that opening, but deafness is often associated with the enlargement because the lymphoid tissue about the Eustachian orifice is simultaneously hypertrophied.

*Amputation of the tonsil* is best performed by dragging the mass

towards the middle line of the fauces by toothed forceps, and then slicing it off with a blunt-ended bistoury, the edge being kept in the vertical plane. Should the point of a knife be directed outwards, the whole depth of the tonsil and the superior constrictor might be traversed, and the internal carotid wounded; but such a disastrous accident is very unlikely to happen. Occasionally a malignant ulceration of the tonsil implicates the artery.

*Adenoid vegetations* are the result of hypertrophy of the lymphoid tissue, which, like scattered tonsillar elements, are placed in the mucous membrane of the upper and back part of the pharynx, and constitute a 'pharyngeal tonsil.'

**Quinsy** (acute tonsillitis) is associated with difficulty of swallowing and breathing; pain extends along the Eustachian tube; and because the inflamed mass is moved in deglutition that act is painful. If abscess have formed, or with the view of preventing its occurrence, the tonsil should be punctured, from before backwards, by a guarded bistoury; or, as the tissue is very soft, the swollen tissue may be painted with cocaine and the abscess opened by a backward thrust of the dressing-forceps. With ordinary care, however, there is no risk whatever of wounding the artery when operating upon the tonsil with a knife.

The **gums** consist of a layer of mucous membrane which is closely connected with the alveolar periosteum. The periosteum is continuous with the thin layer in the sockets of the teeth, and when caries attacks a tooth the inflammation may spread and give rise to a sub-periosteal alveolar abscess, or *gum-boil*. The pus being bound down by the dense membrane, there may be much pain until the gum-boil breaks or is lanced. Necrosis may follow this sub-periosteal suppuration.

For the *supply* of the gums the vessels and nerves of the jaws, teeth, palate, and lips contribute branches.

## THE TEETH

The *temporary* teeth are, in each half-jaw, two incisors, one canine, and two molars—giving a total of twenty. The *permanent* set number thirty-two: thus, two incisors, one canine, two bicuspids, and three molars.

The root of the third molar, or wisdom-tooth, shows but a trace of fangs. It often issues clumsily and painfully through the tender gum, and causes much swelling in the mouth and in the neighbouring lymphatic glands. Sometimes the process is accompanied by profuse suppuration.

**Structure.**—The chief part of a tooth is made of fine branching tubes of *dentine*, which imbibe nutriment from the pulp-cavity. The *pulp* consists of connective tissue, cells, and twigs of nerve and artery.

Hexagonal rods of *enamel* cover the working part of the tooth and protect the less durable dentine ; when they are worn away the dentine soon perishes.

The *crusta petrosa* is a thin layer of bone which covers the hidden surface of the tooth ; it contains rudimentary Haversian systems. In old people outgrowths from it are apt to form large exostoses.

**Development of the teeth.**—In the second month the margin of the rudimentary jaw is marked by a primitive dental groove ; the enamel is developed from the epithelial lining of this groove. The rest of the tooth grows up as a small papilla from the subjacent part of the groove and eventually becomes capped with the enamel. Each rudimentary and temporary tooth then becomes shut into a separate compartment of the dental groove, the small chamber constituting the *dentinal sac*. The permanent teeth are developed in secondary dentinal sacs which are budded off from the backs of the primary sacs.

**Eruption.**—It is impracticable to remember when each tooth of the two sets should be making its appearance, but every student should know that the first tooth of the milk-set is cut in the seventh month, and the first of the permanent set in the seventh year. The lower teeth appear before the upper, and the eruption of the lower central incisors should be taken as a hint that the child should be weaned. In the first set the lateral incisors appear after the central, and, at the end of the year, the first molars : then come the canines, and, in the second or third year, the back molars.

As regards the permanent set, in the seventh year the first lower molars appear. In the seventh and eighth years, respectively, the middle and lateral incisors emerge. In the ninth, tenth, eleventh, and twelfth years come the first and the second bicuspid, the canines, and the second molars ; just before the subject comes of age he is supposed to have cut his wisdom teeth.

It should be noticed that the temporary incisors, which are cut well within the first year, must needs be formed and calcified many months earlier, and that when hereditary syphilis attacks the mouth it is powerless to affect them. In the first year or two, however, when the congenital taint is exerting its prejudicial influence on nutrition, the teeth of the permanent set are being developed. They, therefore, and not those of the milk teeth, are defaced by the disease. Syphilitic teeth are unevenly arranged, and their narrowed cutting edge is marked by a crescentic notch. The 'test-teeth' of Hutchinson are the central, upper incisors of the permanent set.



If the teeth of the permanent set are very large, or the alveolar processes are too small to hold them, one or more of them may fail to reach the surface, and may migrate towards the antrum, or nasal fossa.

Its sac may then become distended into a so-called dentigerous cyst. In rare instances, as age advances and the jaw is less crowded, one of these belated teeth may make its appearance, which phenomenon may raise the vain anticipation of a third natural set of teeth.

When the teeth are irregularly crowded along the alveolus, a judicious weeding out of some of them may effect a great improvement. That there is considerable plasticity about the alveolar process in a child is evidenced by the fact that a constant and vigorous thumb-sucking causes repression of the lower incisors and an unsightly protrusion of the upper. Cases are not rare in which the alveolar process is drawn entirely out of the mouth by the contraction of an extensive cicatrix left after a burn of the front of the neck.

When it happens that the jaws cannot be separated, the surgeon must not propose the extraction of a tooth in order that the patient may be fed: as the patient lies in bed fluid food poured between the cheek and the back teeth readily finds its way into the mouth.

#### THE TONGUE

The tongue is a mass of intrinsic and extrinsic muscles covered with a mucous membrane. It is connected with the floor of the mouth, lower jaw, soft palate, epiglottis, and hyoid bone.

The *mucous membrane* consists of a basement membrane which is elevated into papillæ, depressed into glands, and covered with squamous epithelium. Down the middle of the dorsum is the raphé, which ends posteriorly in the foramen cæcum.

Fixing the tongue to the middle of the lower jaw is a fold of mucous membrane, the *frænum*. Sometimes, as a congenital defect, it is so short that the tip of the tongue is closely bound down behind the gum, and sucking is performed with difficulty; the infant is then said to be *tongue-tied*. It is best treated by raising the tongue by inserting the left index and middle finger, one on each side of the *frænum*, and then snipping the band below the fingers with blunt scissors. This being done, the band is torn through and the front of the tongue freed. As the ranine vessels run beneath the tongue, on either side of the *frænum*, there would be danger of cutting them should the scissors be



directed upwards. The old-fashioned steel director is still made with a flat, expanded, and cleft handle for raising the tongue and shielding the ranine vessels during division of the *frænum*, but it is rarely used for that purpose. That the ranine vessels are in danger of being wounded by a clumsy operator is evident: the vein is readily seen through the thin membrane at the side of the *frænum*. Some children have a dangerous trick of swallowing the tongue, and it may be necessary in such cases to shorten the *frænum* by a plastic operation.



An *ulcer* may form at the *frænum* of a little child whose tongue is constantly being scratched in a whooping-cough over the serrated edge of his lower incisors.

Of the *papilla*, the largest are the circumvallate, about ten in number, arranged in two oblique rows which slope back to the foramen cæcum. The *fungiform*, skittle-shaped, are chiefly scattered over the sides and apex of the tongue; they are deep-red, and in scarlet fever, when the tongue is coated with a yellow fur, they are conspicuous by their bright colour. The *filiform* are arranged as a protective layer over the anterior two-thirds of the dorsum.

At the back of the tongue there are many mucous glands and crypts like those in the tonsil.

The *fur* upon the tongue is the result of desquamation of the epithelium which is constantly taking place. When a person sleeps with the mouth open the fur becomes dried by the air passing over it, and the tongue gets hard and rough.

*Muscles.*—The **genio-hyo-glossus**, fan-shaped, arises from the upper of the genial tubercles, and is inserted in the middle line of the tongue from apex to base, into the pharynx, and into the hyoid bone.

*Action.*—Its anterior fibres retract the tongue, its posterior fibres raise its base and help in protrusion; they also increase the antero-posterior diameter of the pharynx, and draw upwards the hyoid bone and the pharynx.

When, during operation, the muscle is detached from the maxilla, the tongue is apt to fall back, and, the epiglottis sinking, suffocation may ensue.

*Its nerve* is the hypoglossal. When a patient under an anæsthetic is breathing with stertor, his lower jaw should be raised, so that the attachment of the genio-hyo-glossus may be pulled upon, and the base of the tongue thereby drawn out of the pharyngeal air-way.

*Relations.*—Its inner surface lies in contact with its fellow. Its outer surface touches the inferior lingualis, the hyo-glossus, the lingual artery and gustatory nerve, and the sublingual gland; the hypoglossal nerve enters its outer surface. Its inferior border rests against the genio-hyoid, and its superior border lies just behind the *frænum*.

The **hyo-glossus**, an oblong muscle, arises from the body and cornua of the hyoid bone, and is inserted into the side of the tongue. It is supplied by the hypoglossal nerve.

*Relations.*—Its deep surface rests against the lingualis, genio-hyo-glossus, and the middle constrictor of the pharynx. The glosso-pharyngeal nerve turns under its upper and posterior corner, and the lingual artery runs beneath it (p. 28). Superficially, it has the tendon of the posterior belly of the digastric, the stylo-hyoid, and the hypoglossal nerve; the gustatory nerve; the mylo-hyoid, and the deep part of the submaxillary gland and its duct.

The *stylo-glossus* arises from the tip of the styloid process and from the stylo-maxillary ligament, and runs with the stylo-pharyngeus, and the glosso-pharyngeal nerve, between the external and internal carotids, to blend with the upper part of the hyo-glossus and the lingualis. It is supplied by the hypoglossal nerve.

The **lingualis**, the intrinsic muscle, consists of four sets of striated fibres, namely, a superior and inferior longitudinal, a transverse, and a vertical. The inferior set, the more important, extend from the base of the tongue, and even from the hyoid bone, to the apex, lying between the hyo-glossus and the genio-hyo-glossus, the ranine vessels resting upon them. They help in retraction of the tongue. The transverse fibres pass from the median fibrous septum to the border; their action is to narrow, and thus help in protruding the tongue. The vertical fibres help to flatten and curl up the tongue.

**Supply of the tongue.**—The arteries are the lingual of the external carotid, and, perhaps, twigs of the ascending pharyngeal and ascending palatine. The *veins* run to the internal jugular. The *lymphatics* end in the deep cervical and submaxillary glands.

**Nerves.**—The gustatory branch of the inferior maxillary, a nerve of common sensation, is distributed to the mucous membrane at the side and tip. The extremely delicate sense of touch of this nerve is utilised by the dealer in precious stones when the eye alone cannot be trusted. Neuralgia of the nerve is sometimes so severe in cancer of the tongue as to demand its section (p. 64). The glosso-pharyngeal is the special nerve of taste behind the circumvallate papillæ. The hypoglossal supplies all the muscles, except the lingualis, which receives its stimulus from the chorda tympani (p. 66).

**Excision of the tongue.**—A strong-looped suture is first passed through each side of the tongue near the tip, the loops being dragged forward and slightly asunder; then the tongue is split with scissors down the median raphé, and each half is detached from the jaw, and from the floor of the mouth, by short snips with blunt-ended scissors. The loop of the *écraseur* is then passed far back, and fixed round one half by a firm pin, and as the wire is slowly tightened up the mass is cut through without loss of blood, the tough lingual artery being dragged out entire. The evulsed artery is then tied and divided; if necessary, the other half of the tongue is then similarly treated. Sometimes one of the lingual arteries is found quite small.

When the lymphatic glands and the jaw are implicated the operation is much more serious, and must be commenced by an incision from the front of the sterno-mastoid down to the hyoid bone and up to the symphysis, laryngotomy having first been performed. In one case in which I thus proceeded in the removal of advanced cancerous disease I had to tie the external carotid, and, before the operation was finished, I had removed the side of the pharynx and the tonsil.

The *structures divided* in an ordinary excision are the mucous

membrane passing to the jaw, the floor of the mouth, the soft palate, and the epiglottis; the genio-hyo-glossus, hyo-glossus, stylo-glossus, palato-glossus, and lingualis; the lingual artery and vein; the gustatory, hypoglossal, and glosso-pharyngeal nerves.

**Ranula** (? dimin. of *rana*, *frog*) is a collection of fluid in a mucous gland in the floor of the mouth, or in the duct of one of the salivary glands. The fluid, however, is not saliva; it is thick and glairy, and may be secreted again and again after incision and scraping of the cyst, and after swabbing out the interior with glacial carbolic acid. Simply to snip a piece out of the wall of the cyst rarely suffices for obliteration, for on the collapse of the cyst the edges of the wound fall together and unite, and the fluid begins again to collect.

### THE PAROTID GLAND

The parotid gland (*παρα*, *near*; *ovs*, *ωρος*, *ear*) is a compound racemose gland, enclosed in a tough capsule which is obtained from the deep fascia. It lies in the hollow which is bounded behind by the sterno-mastoid, the mastoid process, and the external meatus; in front by the ramus of the jaw; deeply, by the stylo-maxillary ligament, and above by the zygoma.

This limited space, however, is not sufficient; and some of the gland passes deeply behind the condyle into the glenoid fossa, and beneath the sterno-mastoid, against the digastric; a little of it extends over the sterno-mastoid, and a good deal of it spreads over the masseter. A portion of the gland also is tucked beneath the ramus of the jaw, and even between the pterygoid muscles. From this (anterior) part the duct emerges, and connected with it is an accessory piece of the gland, the *socia parotidis*. The gland is covered in by a process of the deep cervical fascia (p. 2), the lower part being also beneath the platysma.

Additional connections of the gland are as follows:—The external carotid artery, having entered it, sends off the superficial temporal and internal maxillary branches from its substance; the posterior auricular winds up between the gland and the mastoid process, and the transverse facial emerges from its anterior border. The external jugular begins in the gland by the confluence of the superficial temporal and internal maxillary veins, and sends a branch through the deep part of the gland to join with the internal jugular. The primary branches of the facial nerve come through the front of the gland, and the auriculo-temporal ascends beneath its upper end. Close beneath the gland are the internal carotid artery, the internal jugular vein, and the vagus.

**Supply.**—Branches for the gland come off from the various arteries in its substance, the blood being returned to the external jugular vein. The lymphatics pass to superficial glands near the parotid, and into

the glandulæ concatenatæ. The nerves are derived from the great auricular, auriculo-temporal, the facial, and the sympathetic.

The **duct, Stenson's**, comes off from the anterior part of the gland, and, crossing the masseter below the transverse facial artery, but above the chief part of the facial nerve, pierces the buccinator opposite the second upper molar. The duct consists of a strong fibrous coat with a mucous lining covered with columnar epithelium.

To mark out the course of the duct, a line must be drawn from the lower part of the concha to the middle of the upper lip. When the jaws are tightly closed the duct may be made out by running the finger up and down the front of the masseter.

In operations upon the cheek, care must be taken not to wound the duct, as a salivary fistula may occur, which is a most troublesome one to obliterate. Sometimes a small calculus blocks the duct, and a dilatation then occurs upon the parotid side of the obstruction, the cavity becoming distended at the smell or sight of food. It is often a very difficult matter to extract the calculus from the dilated part of the duct, as it may slip back towards the gland or into a pouch developed behind the angle of the jaw, or even beneath the ramus.

When malignant disease has invaded the parotid gland extirpation is impracticable, and an attempt to accomplish it is likely to entail profuse hæmorrhage, facial paralysis—and disappointment.

A *specific inflammation (mumps)* is apt to attack the gland; the swelling causes a bulging close below the jaw, and when it is symmetrical it renders the face very broad. The movements of mastication disturb the gland and cause pain. In rare cases facial paralysis is caused by pressure on the portio dura, and more rarely still deafness or abscess supervenes. In the latter case the pus might find its way into the external auditory meatus. Mumps is distinguished from cervical lymphatic enlargement by the fact that the chief swelling is above the angle of the jaw.

The **submaxillary gland** is placed in the submaxillary triangle (p. 9) resting upon the mylo-hyoid, and covered by skin, superficial fascia, platysma, and deep fascia, and by the overhanging border of the jaw. The deep part of the gland turns round the free border of the mylo-hyoid and rests on the hyo-glossus and stylo-glossus. Posteriorly, the gland is separated from the parotid by the stylo-maxillary ligament, and, anteriorly, from the sublingual by the mylo-hyoid. The hyo-glossus separates the gland from the lingual artery (*v.* p. 27). The facial artery runs through, and the vein over, the gland.

**Wharton's duct** comes up from the deep part of the gland, passing between the sublingual gland and the genio-hyo-glossus to open on a conspicuous papilla at the side of the frænum. The beginning of the duct rests upon the hyo-glossus, between the gustatory and hypoglossal nerves.

**Supply.**—The arteries and veins are branches of the facial trunks.

The lymphatics end in the glands beneath the jaw. The nerves come from the chorda tympani (p. 66) and from the branches of the submaxillary ganglion.

The **sublingual gland** lies in a slight depression behind the jaw, near the symphysis, and along the anterior border of the genio-hyo-glossus. It is at the side of the frænum, and, resting upon the mylo-hyoid, is covered only by mucous membrane. The hinder part is in relation with that piece of the submaxillary gland which is tucked beneath the mylo-hyoid. The *ducts* (*Rivianian*), a dozen or more, open separately by the side of the frænum, but some join Wharton's duct as it runs between the sublingual and the genio-hyo-glossus.

*Supply*.—Its arteries come from the sublingual and submental; the lymphatics pass to the submaxillary glands; the nerves come from the gustatory.

### THE NOSE

The *foundation of the nose* is made of the nasal processes of the superior maxillæ, the nasal bones, the nasal spine of frontal, and the vertical part of the ethmoid. But, with the view of obviating fracture, the rest of the organ is composed of small cartilaginous plates which are connected with each other, with the adjacent bones, and with the cartilage of the septum by fibrous tissue, as well as by skin and mucous membrane. These small cartilages can be acted on by muscles which raise, depress, dilate, or compress the nares under the guidance of the facial nerve.

**Supply**.—The *arteries* come from the lateral nasal of the facial, and from the superior coronary—the artery of the septum. The root of the nose also obtains blood from the nasal branch of the ophthalmic and from the infra-orbital of the superior maxillary. The *veins* enter the facial and the ophthalmic. The *lymphatics* pass to glands behind the ramus of the jaw. The *nerves* are branches of the facial (for the muscles), of the infra-orbital, of the nasal, and the infra-trochlear.

The **nasal fossa** opens in front by the nostrils, and into the pharynx by the posterior nares. The floor is formed by the superior maxilla and palate bones, and the roof by the nasal and frontal bones, the cribriform plate of the ethmoid bone, and the body of the sphenoid.

Syphilitic inflammation of the muco-periosteum of the nose in childhood is apt to cause necrosis of the nasal bones, involving a permanently sunken bridge.

As a result of imperfect ossification in the region of the anterior and median part of the frontal bone, the membranes of the brain may bulge forward and produce a **meningocele**. This defect is most often found at the root of the nose, but on rare occasions the protrusion has escaped by the cribriform plate of the ethmoid, and, having been

taken for and treated as a polypus, the base of the skull has been lacerated and fatal meningitis has supervened.

Building up the outer wall of the fossa are the nasal process and the body of the superior maxilla, the lachrymal, inferior turbinated, the vertical plate of the palate, and the internal pterygoid process. And entering into the formation of the septum, or inner wall, are the triangular cartilage, the vertical plate of the ethmoid, and the vomer. The septum often deviates so much to one side that that passage is useless for respiration. The bulging may be taken for a tumour or an abscess, but on introducing a probe or a finger into the free nostril the condition is at once recognised. The septum may sometimes be adjusted by force, but some cutting and trimming may be needed in addition.

The mucous membrane, which closely adheres to the periosteum, is continuous with that lining the pharynx, and, through the anterior nares, with the skin. In the last-named region its epithelium is squamous; in the middle—the respiratory part of the fossa—it is columnar ciliated, and in the region of distribution of the olfactory nerve it is columnar, but not ciliated. The membrane is thick, and is freely studded with mucous glands. Sometimes it is a good deal hypertrophied over the lowest spongy bone, where it may possibly be mistaken for a polypus.

The mucous membrane is easily stripped up from the septum, and, as it is strong, an abscess beneath it may raise it to a considerable extent before finding its discharge.

When, as the result of injury, the front cartilage is detached from the bone, great pain may ensue from bruising of the nasal nerve, which is escaping at the line of fracture (*v.* p. 62).

The nose has often a slight lateral inclination, and this may be noticed for the first time after the receipt of a blow. The person may then protest that it was previously quite straight. One of the greatest living sculptors affirms, indeed, that the two sides of the head and face are never symmetrical—unless in the case of professional beauties and of others of a like intellectual capacity.

The *inferior meatus* runs along the entire length of the floor of the nose, beneath the inferior turbinated bone. It receives towards the front the nasal duct. It is along this meatus that the Eustachian and the œsophageal catheters are passed.

The *middle meatus* occupies the posterior two-thirds of the fossa, being above the inferior and below the middle turbinated bone. It receives the opening of the antrum, and, through the infundibulum, the openings of the anterior ethmoidal and frontal sinuses.

The *superior meatus* occupies the posterior third of the cavity: it is above the middle spongy bone. Into it open the posterior ethmoidal, and, perhaps, the sphenoidal sinus.

**Supply.**—*Arteries* for the cavity come from the anterior and

posterior ethmoidal branches of the ophthalmic ; and, in the case of a fracture extending across the anterior fossa of the skull, these vessels may be lacerated, and severe bleeding may occur from the nose. The facial, and the spheno-palatine and the descending palatine of the internal maxillary, also afford branches, and the superior coronary sends a twig to the front of the septum. The *veins* correspond to the arteries.

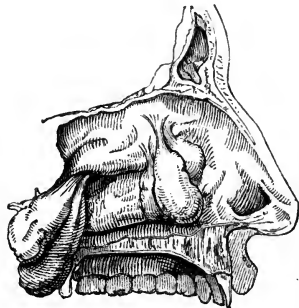
Of the *lymphatics*, some pass with the olfactory filaments into the subdural space, and others enter the glands near the angle of the jaw.

Of the *nerves*, olfactory filaments are distributed to the roof and to the inner and outer walls near the roof ; the nasal of the ophthalmic gives sensory branches to the anterior part of the fossa, and the anterior dental, Vidian, spheno-palatine, and descending palatine also send in branches.

Chronic purulent discharge from *one* nostril is very apt to be caused by necrosis or by the presence of a bead or a bean in the meatus. Discharge from both nostrils is more likely to be the result of constitutional disease. It may be treated by sending a gentle stream of tepid water from an irrigator up one nostril whilst the patient breathes through the open mouth ; the soft palate and the palato-pharyngei (p. 108) then keep the nasal part of the pharynx shut off from the buccal tract, so that the lotion, turning round the back of the vomer, flows out through the other nostril.

In two cases of necrosis high in the fossa I have successfully performed *Rouge's operation*, which consists in incising the superior labio-dental fold of membrane, and then detaching and everting the lip and the soft parts of the nose. In this way exploration of, and operation upon, the upper spongy bones can be most effectually carried out.

**Mucous polypi** generally hang from the superior and middle turbinated bones, and are usually covered with ciliated epithelium. They grow in crops, and, blocking the nostril, obstruct respiration. Pressing outwards, they may widen the nose, and, compressing the nasal duct, may cause the eye to 'water.' In inveterate cases, when crop succeeds crop of polypi, it may be expedient to draw out by the forceps the middle and superior spongy bones—taking care, of course, not to damage the cribriform plate.



**Bleeding from the nose**, if not the result of fracture of the base of the skull (p. 81), or of other injury, may be a general oozing from the en-

gorged capillaries, in which case it comes as a relief, but it is apt to be due to ulceration into an artery, in which case it is likely to occur from the cartilage of the septum ; if so, prolonged pressure between the finger and thumb may stop it at once. Pulmonary or cardiac disease, by delaying the venous return, may be the cause of the hæmorrhage. The subject should keep erect, so as to help the venous return, and he evidently should not blow his nose. Nor should he be allowed to hang his head over a basin, as this attitude compresses the jugular veins, and increases the venous engorgement (p. 36). The vaso-motor centre may be stimulated by cold applied to the back of the neck.

**Plugging the nares** may have to be resorted to if the bleeding become very serious. If no better apparatus be at hand, a piece of wire from a soda-water bottle may be bent into a suitable loop, and, having been armed with a doubled string, may be passed along the floor of the nose and down against the posterior wall of the pharynx. As soon as the string appears below the level of the palate the loop should be caught and brought out between the teeth, the wire being withdrawn from the nose. Another piece of string should be fixed in the loop for the subsequent drawing out of the plug, which should consist of a small roll of lint, a little larger than the last joint of the patient's thumb. This, having been secured in the loop, and having been helped round to the back of the soft palate by the finger in the mouth, should be drawn firmly into its place by pulling on the ends of the string which hang from the nostril. Then a plug is thrust into the nostril and tied in position by the two strings, the single string which hangs out of the mouth being also fixed to the anterior plug.

The posterior plug, being firmly jammed in the oblong, bony frame of the horizontal process of the palate bone, the internal pterygoid plate, the vomer, and the body of the sphenoid, may set up necrosis if it be too long retained.

**Development.**—The external nose is formed from a broad median lappet which comes down from the cranium. Its central part forms the tip of the nose, and, descending below the level of the nares, constitutes the septum between them (the *columella*) and, lower down, the lunula, or central part of the upper lip. The side of the nose is developed from the nasal process which comes down between the orbit and the maxillary process.

The depression for the eye is continuous with the mouth through an oblique cleft between the fronto-nasal and external nasal processes, internally and above, and the maxillary plate externally and below ; rarely does the entire fissure leading into the orbit remain uneffaced. As remarked on p. 76, the nasal duct is the unobliterated part of this cleft. (*See also* pp. 105 and 123.)

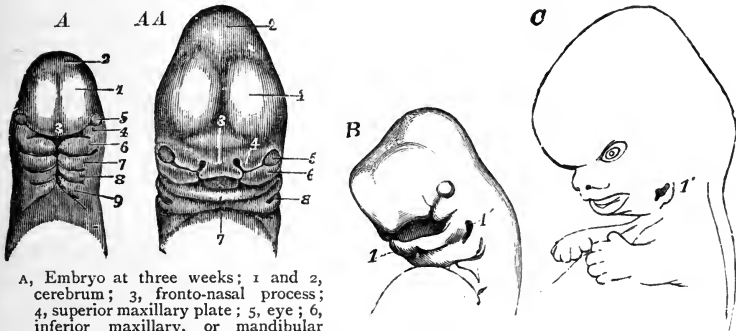


A NOTE UPON DEVELOPMENT GENERALLY

From the external layer of the blastoderm (*βλαστος, germ*; *δερμα, skin*)—the *epiblast*—the entire nervous system, central and peripheral, is developed, as are, also, the organs of sense, the cuticular covering of the body and the lining of the mouth, together with its accessory glands.

From the *hypoblast* are developed the epithelium of the alimentary canal and air-passages.

From the *mesoblast* come the bones, muscles, and vessels; the



A, Embryo at three weeks; 1 and 2, cerebrum; 3, fronto-nasal process; 4, superior maxillary plate; 5, eye; 6, inferior maxillary, or mandibular plate; 7, 8, and 9, second, third, and fourth plates, or branchial arches, and below each plate the corresponding pharyngeal cleft. AA, 1, 2, 3, and 5, same as in A; 4, lateral frontal or external nasal plate; 6, sup. max. plate; 7, mandibular; 8, first pharyngeal cleft, which becomes auditory passage; above and below 6 are seen the orbital and mandibular fissures respectively.

B, 1, Lower jaw; 1', first post-oral cleft widening out to form ext. auditory meatus; the second cleft is still visible, but the third and fourth clefts have become effaced. C, fœtus at nine weeks; first pharyngeal cleft is now obliterated, and the pinna, 1', is beginning to grow up around the unclosed dorsal end.

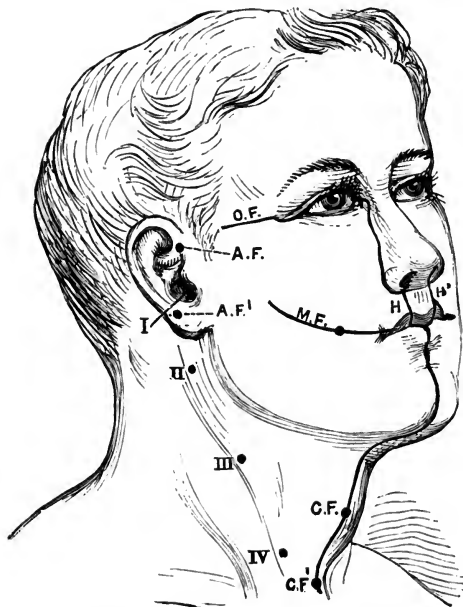
skin (not the epidermis); the alimentary canal (not the epithelium), and the genito-urinary apparatus.

The facial part of the head is developed from bar-like growths from the cranial base, some in front of, and some behind, the buccal cavity; the mouth, which is at first closed in, being a cleft between the facial plates. The *pre-oral plates* are the median fronto-nasal (p. 105) and the pairs of the lateral nasal and maxillary plates. The plates behind the mouth (*post-oral*) are in five lateral pairs: the mandibular, for the lower jaw; the hyoid, for the upper part of the hyoid bone; and three pairs down the neck. The post-oral plates are sometimes called branchial (*βραγχια, gills*) from their corresponding to the gill-plates of aquatic vertebrates.

The **branchial clefts** are the slits below the branchial plates, or the

arches through which the cervical epiblast blends with the pharyngeal hypoblast. From the first cleft the Eustachian tube and tympanum are developed, the meatus auditorius grows from its hinder end, and the pinna from the neighbouring integument (p. 102).

**Branchial fistulæ** may be found in the middle line of the neck, where the lateral arches have failed to meet, and down the side of the neck, by the anterior border of the sterno-mastoid, where the blending of the adjacent arches has been imperfect. Their most common situations are shown in the adjacent sketch, which has been kindly lent



A F, A F', situations of congenital auricular fistulæ; I, II, III, IV, external orifices of branchial fistulæ, I being the external auditory meatus; O F, orbital fissure; M F, mandibular fissure; H H, lines of hare-lip; C F, C F', show median cervical fistulæ.

clumsy representative of a needless raphé, by way of evidence of the fusion of the plates in the middle line.

**Dermoid cysts**, which are frequently found in the face, neck, and pinna, are due to pieces of the epiblast in some of the clefts having been closed in externally; their epidermal lining secreting a sebaceous material, the cysts become conspicuous, and may in due course demand removal. Sometimes the cysts contain hair and sebaceous glands.

by Mr. Bland Sutton, to whose *Lectures* in the 'Lancet' of 1888 the reader will do well to refer. These fistulæ lead by slender canals deeply into the neck, towards the pharynx, with which they were originally continuous. Sometimes they are in symmetrical pairs. Paget has noticed that their secretion is augmented during bronchial or nasal catarrh.

Occasionally a small pendulous nodule of skin, or of skin and cartilage, marks part of the line of closure of one of the clefts, just as nodules grow at the end of the first post-oral fissure to form the pinna, and sometimes a similar nodule persists in the middle line as a

## THE LARYNX

The larynx is hung from the hyoid bone and the styloid process. It is continuous with the trachea at the level of the lower border of the fifth cervical vertebra. Above and in front is the tongue; behind is the pharynx, into which it opens by the glottis.

Standing out in the middle line of the neck, between the two sternomastoids, it forms a groove in which lie the common carotid artery with the internal jugular vein and the vagus.

The **thyroid cartilage** consists of the *alæ* which unite in a prominent angle, the *pomum Adami*, separated from the fascia and skin by a small bursa.

On the outer surface of the *ala* a ridge runs downwards and forwards from the root of the superior cornu, for the insertion of the sterno-hyoid and the origin of the thyro-hyoid. The inferior constrictor of the pharynx arises from the surface behind the ridge. The inner surface of the *ala* is covered by mucous membrane, and, at the retiring angle, gives attachment to the vocal cords and the thyro-arytænoid muscles. To the upper border is attached the thyro-hyoid membrane. The crico-thyroid muscle and membrane are connected with the lower border.

The posterior borders of the cartilage are widely separated, the gap being filled in below by the cricoid and arytænoid cartilages, and they receive the insertion of the stylo-pharyngei. The width of the lower part of the pharynx is maintained by the attachment of the inferior constrictor to the posterior part of the *alæ*. The posterior borders lie close to the front of the middle cervical vertebræ, and in roughly pushing the cartilage across the front of the vertebræ a moist sort of crepitus is produced, which, being first noticed after an injury, might possibly suggest fracture.

*Fracture of the thyroid cartilage* may result from violence. There is difficulty and pain in coughing and swallowing, and there are swelling and tenderness about the larynx. The patient should be kept on his back and fed on enemata and liquid food; he should not be allowed to talk. Tracheotomy may be needed if the injury and swelling are great.

The **cricoid cartilage**, named from its resemblance to a signet-ring (*κρικος*), has its expanded part in the gap between the *alæ* of the thyroid, and its slender part in front, below the thyroid, with which it is connected by the crico-thyroid membrane. Its lower border is attached to the first ring of the trachea by a thin membrane. From the posterior part arise the crico-arytænoides postici and the longitudinal fibres of the œsophagus. The arytænoid cartilages articulate with the upper part of the expanded portion, and the inferior cornua of the

thyroid are hinged at the lower part of the side by capsular ligaments and synovial membranes.

When more room is needed in tracheotomy it may be expedient to divide the cricoid (*vid. inf.*).

The **arytænoid cartilages** are two small pyramids which articulate by their base with the upper and back part of the cricoid. Of their three surfaces, the inner looks towards its fellow, and is covered by mucous membrane; the posterior is connected with its fellow by the arytænoideus, and the anterior receives the insertion of the thyro-arytænoid muscle.

To the anterior angle is attached the true vocal cord; the external angle receives the insertion of muscular slips which arise on the cricoid, and the apex is connected with the corniculum laryngis, which is hidden in the arytæno-epiglottidean folds.

The **epiglottis**, shaped like an obovate leaf, is attached by its stalk to the back of the thyroid, just above the vocal cords; its anterior surface is connected with the back of the hyoid bone by the hyo-epiglottic ligament, and with the base of the tongue by three bands of mucous membrane—the glosso-epiglottidean folds. The posterior surface looks towards the back of the pharynx during respiration; but when the larynx is hidden beneath the base of the tongue during deglutition, and the glosso-epiglottidean folds are relaxed, the epiglottis falls over the laryngeal aperture, and its posterior surface is turned downwards.

*Structure.*—The epiglottis is composed of yellow fibro-cartilage, which does not ossify, but the thyroid, cricoid, and arytænoid cartilages are apt, like the costal cartilages, to ossify as age advances.

The **thyro-hyoid membrane** is attached to the upper border of the thyroid cartilage, and, ascending behind the hyoid bone, is connected with its upper border, a bursa intervening between the membrane and the back of the bone. On rare occasions this bursa becomes inflamed, or, being distended with fluid, forms a cyst. The bursa is placed there in order that the thyroid cartilage may ascend freely behind the hyoid bone during deglutition.

Through each side of the membrane run the superior laryngeal vessels and nerve.

The **crico-thyroid membrane** fills the interval between the cricoid and thyroid cartilages, and is firmly connected with them in front; laterally, however, it ascends free on the inner side of the thyroid, and becomes continuous above with the lower border of the true vocal cord. The anterior part of the membrane is subcutaneous, but its sides are covered by the crico-thyroid muscles. Upon it rests the anastomotic loop between the two crico-thyroid or external laryngeal arteries.

The membrane is traversed in the operation of laryngotomy, and sometimes the insertion of the tube fails to arrest bleeding from the divided artery.

The **superior aperture of the larynx** is triangular, the base being formed by the epiglottis, and the sides by the arytaeno-epiglottidean folds and the arytaenoid cartilages. In the folds the *cuneiform cartilages* may be recognised.

The **glottis** (*γλωσσα, γλωττα, tongue, throat*) or **rima glottidis** (*rima, chink*) is the narrow triangular opening between the true vocal cords and the bases of the arytaenoid cartilages. The apex of this space is forwards, corresponding to the thyroid attachment of the cords.

In ordinary respiration the glottis is wide open, the arytaenoid cartilages being far apart, but in vocalisation, and when respiration is forced, the space is narrowed.

The rima is the narrowest part of the larynx. In the adult male it measures about an inch from before backwards.

The **false vocal cords** are folds of mucous membrane lying parallel with and above the true cords; they are attached in front to the retiring angle of the thyroid, below the epiglottis, and behind to the front of the arytaenoid cartilages. The interval between them is wider than that between the true cords.

The **true vocal cords** are delicate elastic bands between the retiring angle of the thyroid and the anterior angle of the arytaenoid cartilage. They are covered with mucous membrane, continuous below with the upper border of the crico-thyroid membranes. The epithelium upon the true cords is squamous.

Between the true and false cords there is on each side a space, the *ventricle of the larynx*, which is continued upwards for nearly half an inch between the false vocal cord and the ala of the thyroid. It contains a large number of mucous glands for lubricating the vocal cords, for the membrane of the cords themselves is too delicate to contain glandular tissue.

*Muscles.*—The **crico-thyroid**, triangular, arises from the side of the cricoid cartilage and is inserted into the lower border of the thyroid. Its action is to tilt the thyroid down to the cricoid (or the front of the cricoid up to the thyroid), and so to tighten and elongate the cords. It is supplied by the external branch of the superior laryngeal nerve.

The **posterior crico-arytaenoid** arises from the back of the cricoid, and, passing upwards and outwards, is inserted into the outer angle of the arytaenoid cartilage. Drawing this angle backwards, the two muscles rotate the anterior angles outwards (abduction of cord) and widen the glottis. 'They come into action during deep inspiration. If paralysed, the lips of the glottis approach the middle line and come in contact with each inspiration, so that severe dyspnoea may be produced. Expiratory efforts, however, are not impeded, and vocalisation is unaffected.' (Quain.)

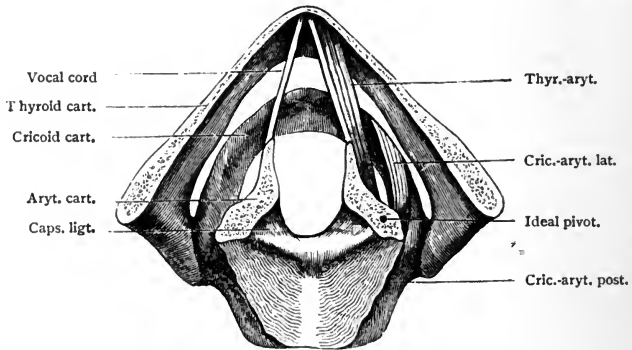
The **lateral crico-arytaenoid** arises from the upper border of the side of the cricoid, and, passing back, is inserted into the outer angle

of the arytaenoid. These muscles rotate the anterior angle of the arytaenoids inwards, and thus approximate the cords.

The **thyro-arytaenoid** runs along the outer side of the true vocal cord, being attached to the retiring angle of the thyroid, and to the anterior surface of the arytaenoid. Contracting, it shortens and slackens the cord; it is the antagonist of the crico-thyroid.

The **arytaenoideus** consists of bundles of striated fibres passing from the back of one arytaenoid cartilage to the other. Its action is to tilt the arytaenoid cartilages together and so to close the hinder part of the glottis. It derives its motor filaments both from the superior and the recurrent laryngeal branch of the vagus.

All the muscles of the interior of the larynx can act together as a sort of sphincter; and so it happens that when the epiglottis is destroyed by ulceration the patient can swallow without being choked. He is safest, however, when bending his head well down and sucking



Glottis dilated. (HOLDEN.)

up the food by a tube, when it is taken to the œsophagus in the zealous grasp of the constrictors.

**Laryngismus stridulus** (*λαρυγγίζω*, *shout*; *strideo*, *hiss*) is a spasmodic affection of the muscles of the cords in infancy; it is also called *laryngeal asthma*, and is often associated with spasmodic contractions in the hands and feet. It is the result of some central nervous irritation, and may be caused by indigestible food disturbing the pneumogastric filaments in the stomach. Spasmodic asthma in the adult may be caused by the pressure of aneurysmal or malignant tumours upon the recurrent laryngeal nerves. The spasm generally yields as carbonic acid poisoning comes on, but it may have to be treated with chloroform inhalations, or, in the adult, by opening the windpipe.

The **mucous membrane** of the larynx is continuous with that of the pharynx and of the trachea. It is covered with columnar ciliated

epithelium below the false vocal cords ; above that it is squamous, except in the lower half of the laryngeal aspect of the epiglottis, where it is columnar ciliated. It contains many mucous glands, in some of which the secretion may collect to form *cystic tumours*. About the upper aperture the mucous membrane contains much loose connective tissue, which becomes extensively infiltrated in œdema of the glottis.

**Œdema of the glottis** may be caused by boiling water having been swallowed, or by laryngitis ; the serous infiltration of the sub-mucous tissue resembles that of œdema of the prepuce or eyelid. The onset is marked by cough, hoarseness, and dyspnœa. Scarification of the swollen tissue may give relief, or a soft catheter may be passed along the floor of the nose, and through the glottis, by which respiration may be carried on ; but the surgeon must always be in readiness to open the windpipe below the obstruction.

In **acute laryngitis** the vocal cords swell, and, vibrating amiss, the voice becomes hoarse and the respirations noisy and difficult ; and there is a 'brassy' cough. On account of the close proximity of the pharynx, there is pain with deglutition. Unless relief be afforded, the patient may die of suffocation ; indeed, laryngotomy or tracheotomy may be early needed.

**Supply.**—The *arteries* are the superior and external laryngeal branches of the superior thyroid, and branches of the inferior thyroid, the blood being returned by the superior, middle, and inferior thyroid veins. The *lymphatics* pass to the deep cervical glands.

The *nerves* are the superior, and the recurrent laryngeal branches of the vagi, and filaments from the sympathetic. The superior laryngeals supply the mucous membrane, and give off the external laryngeal branches for the crico-thyroidei, and twigs to the arytaenoideus. The recurrent laryngeal supplies all the other muscles, and gives additional filaments to the arytaenoideus.

In making a **laryngoscopic examination** the observer should be seated at a rather lower level than the patient ; the mirror should be passed under the base of the uvula without having touched the tongue or the pillars of the fauces, but even then its gentle application may set up reflex vomiting (p. 70). The mirror being tilted, the epiglottis is seen in its upper part, and the arytaenoid cartilages are seen in the lower part ; but the vocal cord which is seen on the patient's right side is actually the right cord. The cords appear white, and above them are seen the false cords and the opening of the ventricle. The arytaeno-epiglottidean folds are conspicuous objects ; the front of the trachea is also seen, and possibly its division into the bronchi. Sometimes the wall of a thoracic aneurysm may be seen bulging into the trachea.

An **opening in the windpipe** is needed when the laryngeal air-way is seriously blocked. Among the chief signs of urgency are a sinking-in of the supra-clavicular, supra-sternal, and epigastric

regions ; a noisy passage of the air through the glottis ; and the distress which is associated with laboured and ineffectual attempts at respiration.

The simplest operation is that of passing a tube through the crico-thyroid space, but in the child this interval is far too narrow to serve, so that the trachea has to be opened instead—tracheotomy always in the child. Tracheotomy, moreover, is to be preferred in the adult when the tube has to be left in permanently, as it is further away from the vocal cords, and therefore less likely to set up inflammatory thickening in that important region. Tracheotomy is also resorted to in the adult when there is a foreign body below the cords.

In **laryngotomy** the shoulders are raised, and the head is thrown back and held perfectly square to the middle line. The surgeon feels for the thyroid cartilage, and, a little below its prominent inferior border, the arch of the cricoid. He then makes an inch incision down the middle line, beginning it  $\frac{1}{4}$  in. above the bottom of the thyroid, and traversing skin, superficial, and deep fasciæ. Thus the crico-thyroid membrane is readily exposed ; on it is the small arterial communication between the two superior thyroids, which is generally cut, but it rarely gives any troublesome bleeding. The membrane is incised across the middle line, so as to secure a more easy introduction for the tube.

**Thyrotomy.**—For the removal of a foreign body from the larynx, or for the clearing away of a crop of warty growths which impede respiration, or for the more efficient dealing with intra-laryngeal epithelioma, the thyroid cartilage may have to be split up the middle and the halves turned asunder.

Tracheotomy having been first performed, the skin and fasciæ are divided down the middle line of the *pomum Adami*, the wound being continued into that which is already made for the tracheotomy. The incision through the thyroid cartilage must be kept exactly in the middle line, as it has to hit the narrow interval between the anterior ends of the vocal cords. To make more room, the thyro-hyoid and crico-thyroid membranes should also be cut.

**Removal of the entire larynx**, a dangerous and unsatisfactory operation, may be undertaken after a preliminary tracheotomy, due provision having been made against the entrance of blood into the trachea.

A median incision through skin and fasciæ is made from the hyoid bone to the top of the trachea, and, at the top of this, a transverse one. Then, with the blunt end of a pair of scissors, the sterno-thyroid and thyro-hyoid and other soft tissues are torn through, raised from the larynx, and turned back with the skin, fasciæ, and the sterno-hyoid and omo-hyoid. The trachea is cut across just above the wound made for the silver tube, and the cricoid end of the larynx is drawn forward, and cleared by division of the recurrent laryngeal nerve and branches



of the inferior thyroid artery; the œsophagus and the inferior constrictor of the pharynx and the lobes of the thyroid gland are also detached.

The constrictor is then separated from the thyroid cartilage, and the superior laryngeal vessels and nerve are divided.

#### THE TRACHEA AND BRONCHI

The **trachea** begins at the lower border of the fifth cervical vertebra, and divides opposite the lower border of the fifth dorsal—that is, a little below the transverse sternal ridge (p. 149). It is about 4 in. long and  $\frac{3}{4}$  in. wide, and consists of about sixteen horse-shoe cartilages connected by elastic fibres, whilst in the tissue which fills the deficiency in the cartilages at the back of the trachea is a transverse layer of non-striated muscular fibres. Probably the trachea is flattened behind so that it may not encroach upon the œsophagus and impede deglutition; a foreign body impacted in the œsophagus, or malignant disease, may cause fatal dyspnœa. (For MUCOUS MEMBRANE, *v.* p. 195.)

*Relations.*—The most constant relation of the trachea is the œsophagus, which is close behind it both in the neck and in the thorax. In the lateral grooves between these tubes ascend the recurrent laryngeal nerves. The common carotid arteries, the lobes of the thyroid body, and the inferior thyroid arteries are also to the sides. In the superior mediastinum (p. 154) the trachea descends between the pleuræ, a pneumogastric passing on either side of it to form the œsophageal and the posterior pulmonary plexuses. The innominate artery is somewhat to the right, and the beginning of the left carotid to the left of the trachea.

In front are the skin and fasciæ, the isthmus of the thyroid, and the lowest thyroid artery and thyroid veins; the sterno-hyoid and sterno-thyroid, and some more deep fascia. Lower down the anterior relations are the manubrium, the remains of the thymus, the left innominate vein; the second part of the aortic arch with the origins of the innominate and left common carotid arteries, and the deep cardiac plexus.

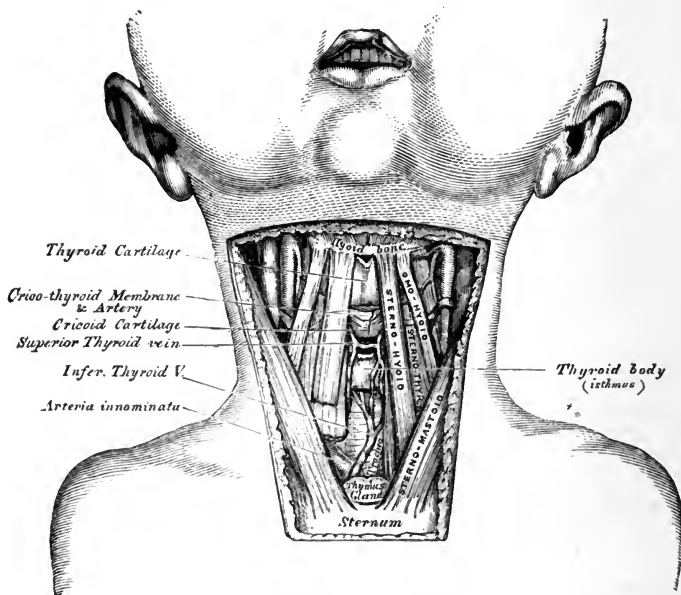
**Supply.**—The trachea derives its blood from the inferior thyroid artery, and returns it by the lower thyroid veins. The lymphatics pass to the deep cervical and the mediastinal glands.

The nerves are branches of the vagi, the recurrent laryngeals, and the sympathetic.

**Tracheotomy.**—The patient's shoulders are raised on a firm pillow, and the head is thrown straight back so as to draw up and steady the trachea, and to give more room to the operator. The thyroid and cricoid cartilages and the upper part of the trachea are then made out by the tip of the index-finger.

The incision even in a child had better be free, from  $1\frac{1}{2}$  to 2 in.

long ; it must be kept absolutely in the middle line and high up. The lower down the neck that it is made, the deeper lies the trachea ; it should, therefore, be begun over the lower border of the thyroid cartilage, and the surgeon should make it his object to open the very highest rings of the trachea, and, if need be, the cricoid also. This laryngo-tracheal operation does well in children, and, resorting to it, the surgeon is certain to escape the dangers and difficulties which are inseparable from the low operation.



Front of child's neck. (GRAY.)

The skin, superficial fascia, some tributaries of the anterior jugular vein, and the deep fascia are divided. The narrow interval between the sterno-hyoids is traversed with a director and forceps, and a second layer of the deep fascia is then torn through.

The trachea, having thus been denuded, is caught and fixed by a sharp hook, and a knife is plunged through the second or third ring, and, the edge being directed forwards, a sufficient opening is made in the upward direction for the tube. In old people the tracheal rings may be ossified.

Though the surgeon prefers not to open the trachea until all bleeding has been checked, he need not dread even free venous oozing ; for as soon as air enters the lungs the right side of the heart empties itself

again, and the engorgement of the tributaries of the innominate veins subsides.

In the high operation the surgeon opens the trachea above the isthmus of the thyroid gland. A great deal is discussed about the misfortune of wounding the isthmus; for my own part, I never give it a thought, but clear all the tissues from the front of the top rings of the trachea by using a director and pair of dissecting-forceps. If the isthmus happen to be across this track, and not easily displaced; it must be sacrificed. But, if the surgeon proceed to open the trachea below the isthmus, not only will he find it deeply placed, but he will also be traversing the region of the important inferior thyroid veins which descend from the isthmus to the innominate veins. Moreover, should the left common carotid come from the innominate, should there be a thyroidea ima, or should the left innominate vein cross above the level of the episternal notch, as sometimes happens, the complications might be extremely grave. He may even surprise himself by coming against the apex of the thymus, which in young children ascends well into the neck, as is shown by the figure on pp. 132 and 155.

The metal tube should not be too much curved, lest its sharp end impinge against the front of the trachea and set up an ulceration, which may eventually implicate the left innominate vein, or the innominate or common carotid artery, and entail a fatal hæmoptysis.

**Fallacies in the operation.**<sup>1</sup>—‘The skin wound may be too low and too short; the trachea may have been dragged aside, or not sufficiently incised, so that the tube . . . does not enter, but slips down in front of it. The trachea may be altogether missed if the dissection be not kept in the absolute middle line. If the wound in the trachea be made with a dull scalpel, and without the little plunge, the mucous lining may escape transfixion, the tube passing down between it and the tracheal wall. If air do not pass through the tube, either naturally or on compressing the chest, the chances are that the tube has not been passed into the trachea. . . . The tube may be blocked with mucus, or its aperture obstructed by false membrane. If the tracheal wound be open, search should be made for a membranous cast of the trachea, which might be drawn out by forceps. For thorough exploration, the tracheal wound should be enlarged slightly upwards, and a pair of forceps introduced. . . . Much more likely is it that the tube has been passed down amongst the ribbon muscles at the front of the trachea than that its end is blocked by a membranous cast of the trachea.

‘I know of a case in which, from the windpipe having been twisted from its position, the tube was found *post mortem* to have been introduced into the trachea through the œsophagus; and of another

<sup>1</sup> From *The Surgical Diseases of Children*, Cassell & Co., 1889.

in which the tube had been dashed right through the trachea and into the œsophagus!’

The **right bronchus** (*see also* p. 194), about an inch long, slopes downwards and outwards in the root of the lung, to enter opposite the fifth dorsal vertebra. As the right lung is larger than the left (which has to make room for the heart), the right bronchus is the larger, and, having a greater intake of air, is the more apt to receive a foreign body. Because the right bronchus is larger than the left, the tracheal septum must of necessity be rather to the left of the median line.

The vena azygos major arches over the right bronchus in its course to the superior cava.

The **left bronchus** has to run across the front of the third part of the arch of the aorta before it can divide in the root of its lung. It is two inches long; its diameter is less than that of the right. It enters the lung opposite the sixth dorsal vertebra, about an inch lower than the right. It passes in the root of the lung beneath the aortic arch, and in front of the œsophagus (p. 139), the third part of the arch, and the left auricle. This last relationship is of considerable clinical interest, for when, under the influence of mitral regurgitation, that auricle is greatly dilated, it may obstruct the flow of air along the left bronchus. (For the structure of the bronchi *see* p. 195.)

**A foreign body in the bronchus** may be extracted by appropriate forceps through a free opening made low in the trachea. For this purpose it will be well to stitch the edges of the tracheal wound to the skin as soon as bleeding has been arrested, so that the way into the bronchus may be made more direct and easy. If the foreign body were taken down at the end of an inspiration, the area of lung to which the bronchus led would be tideless but resonant, but after a while œdema and, perchance, suppuration would render it solid.

If attempts at extraction failed, the body might escape through the tracheal wound, which should be stitched wide open; or it might escape through a localised thoracic abscess; the pulmonary and costal pleuræ having become adherent, pneumothorax might not ensue.

#### THE THYROID GLAND

The thyroid gland consists of lateral lobes connected across the second and third rings of the trachea by the isthmus. The outer surface of the lateral lobes is convex; their inner aspect is fitted on to the side of the upper four or five rings of the trachea, the cricoid cartilage, and the lower part of the thyroid cartilage. Often the isthmus extends up to the level of the cricoid cartilage.

A slender *pyramidal lobe* sometimes mounts from the isthmus to the hyoid bone. Sometimes the isthmus is very wide and descends almost to the sternum—the tracheotomist should always endeavour to operate *above* the isthmus.

*Relations.*—The gland is covered by the deep fascia, the sterno-hyoid, sterno-thyroid, and omo-hyoid, and laterally by the sterno-mastoid. *Beneath* it is the sheath of the common carotid, and on the inner aspect are the trachea and larynx, the œsophagus (on the left side), and the pharynx.

The firm connection of the gland with the upper part of the wind-pipe is a fact of great clinical importance ; when there is dilatation of the vessels of one lobe a rounded tumour occurs in the groove between the larynx and sterno-mastoid, which, pulsating with thrill and expansion, strongly suggests aneurysm of the upper part of the common carotid. On making the patient swallow, however, the tumour glides up and down with the larynx : a carotid aneurysm is not influenced by the movements of deglutition. An accessory thyroid gland is not unknown.

**Supply.**—*Arteries* come from the superior, the inferior, and, sometimes, from the lowest thyroid branches. Of the *veins*, the superior and middle enter the internal jugular, whilst the inferior descend in front of the trachea as important tributaries of the innominate (p. 132). The *lymphatics* enter the deep cervical glands.

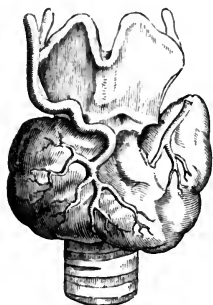
*Nerves.*—Sympathetic filaments come from the cervical ganglia along with the arteries, and other branches are derived from the external and the recurrent laryngeals.

**Structure.**—There is a fibrous coat which sends in processes dividing the gland into irregular lobules ; these consist of a gluey material containing seed-like vesicles. The vesicles contain corpuscular elements and more of the glue, and, when greatly distended, they cause cystic enlargement of the gland. Sometimes the cysts contain serum, sometimes blood.

The probable **function** of the gland is ‘the control of the mucinoid substances in the tissues of the body, and the manufacture of blood-corpuscles.’ (Horsley.) When the gland is atrophied, also when its bulk is increased at the expense of its proper elements, mucin is deposited in the connective tissues, as of the eye-lids, lips, and hands, so that they become puffy and permanently swollen. This disease is called *myxœdema*, and it is associated with the presence of an excess of colourless, and a diminution in the number of red, corpuscles of the blood. Horsley has produced the same association of symptoms in monkeys by removing the thyroid body. And in children who are born without a thyroid body the symptoms occur, begetting the disease known as *sporadic cretinism*, in which the subject is idiotic.

Enlargement of the thyroid gland, or **bronchocele** (*βρογχος*, *wind-pipe* ; *κηλη*, *tumour*), is called **goitre** in Switzerland, and, in England, *Derbyshire neck*. The enlargement may be solid or cystic, lateral or symmetrical. When the enlargement is due to dilatation of the blood-vessels of the gland it is often associated with prominence of the eye-balls and palpitation of the heart—*Graves’ disease*—the pro-

trusion being caused by dilatation of the blood-vessels in the back of the orbit, and it may be that this dilatation is caused by pressure upon the cervical ganglia of the sympathetic. As a secondary result, ophthalmia and even ulcerative corneitis may ensue.



Bronchocele or goitre with dilated superior thyroid artery. (FERGUSSON.)

The goitrous tumour may press upon the trachea and flatten it, causing dyspnœa and dysphasia; if only one lateral lobe be enlarged the windpipe and gullet may be pushed to the opposite side. Extending laterally, the tumour thrusts outwards the carotid artery and the internal jugular vein and the vagus, disturbing the cerebral circulation. The voice is altered, either from pressure upon the trachea or upon the recurrent laryngeal nerve. A large mass of the gland across the front of the neck impedes flexion.

As regards operative interference, cysts may be tapped, but the vascular thyroid enlargement which is associated with exophthalmos had best not be interfered with. In no case should the entire gland be removed, or myxœdema will be likely to supervene, unless perchance an accessory thyroid should be present.

Division of the isthmus or removal of one lateral lobe may determine atrophy of the rest of the enlarged gland; when the chief trouble is the dyspnœa the former operation should be resorted to. When relief of dyspnœa is sought by tracheotomy the surgeon should satisfy himself that the tube is long enough to reach below the collapsed part of the trachea, which may be very low down in the root of the neck.

The **operation** for removal of half of the gland is effected by a longitudinal incision through the skin, superficial and deep fascia, all bleeding vessels being secured; then, the less the knife is used the better: the surgeon should enucleate the mass with his finger and a blunt raspatory. The vessels entering are secured by double ligatures before being cut, and the greatest care must be taken not to pick up or damage the recurrent laryngeal nerve whilst the inferior thyroid branches are being dealt with.

#### PHARYNX AND ŒSOPHAGUS

The **pharynx** ( $\phi\alpha\rho\nu\gamma\xi = \textit{fauces}$ ), closed above by the base of the skull, opens at the level of the cricoid cartilage (fifth cervical vertebra) into the œsophagus; this is its narrowest part, its widest being near the hyoid bone.

There are *seven openings* into the pharynx: the two posterior nares, two Eustachian tubes, the mouth, larynx, and œsophagus.

When a mass of food is impacted in the pharynx it may cause suf-

focation by blocking the laryngeal opening, or by setting up a spasmodic contraction of the muscles which close it.

The finger, thrust directly backwards along the dorsum of the tongue, comes in contact with the body of the axis, and, when slanted slightly upwards, with the anterior ring of the atlas. On thrusting it somewhat downwards the body of the third vertebra is touched.

In the case of fracture or displacement of any one of these three vertebræ valuable information may be obtained by digital exploration through the mouth.

- **Relations of the pharynx.**—*Behind* are the vertebral column with the longus colli and rectus anticus major, and the layer of prævertebral fascia. Suppuration in this region constitutes post-pharyngeal abscess (p. 210).

*Laterally* are the sterno-mastoid, the lobe of the thyroid, the common, internal, and external carotids; the lingual artery; the internal jugular vein; and the vagus, glosso-pharyngeal and hypoglossal nerves.

*In front* are the nares, mouth, tongue, hyoid bone, and larynx.

The *muscular coat* consists of three constrictors, which are generally described from below upwards, because the lowest is the most external. They are of striated tissue.

The **inferior constrictor**, the thickest of the three, arises from the side of the cricoid cartilage, and from the thyroid cartilage behind the oblique line. Its lowest fibres are continuous with those of the œsophagus, and beneath them ascends the recurrent laryngeal nerve (p. 70); the other fibres pass upwards and inwards to the median raphé over the lower part of the middle constrictor.

The **middle constrictor** arises from the greater and lesser cornua of the hyoid bone, and is inserted into the median raphé. Its lowest fibres pass beneath the inferior constrictor, and its highest over those of the superior constrictor, from which it is separated by the stylo-pharyngeus. As the inferior constrictor arises from the thyroid cartilage, and the middle arises from the hyoid bone, the superior laryngeal nerve, which traverses the thyro-hyoid membrane, necessarily passes between their adjacent borders.

The **superior constrictor** arises from the internal pterygoid plate, and from the pterygo-maxillary ligament, which takes it to the mylo-hyoid ridge, from which also it arises, as well as from the side of the tongue. The fibres curve backwards to be inserted into the median raphé.

Just beneath the base of the skull, where muscular fibres could be of no use, the superior constrictor is deficient; thus, above the upper border of the muscle there is a gap, the *sinus of Morgagni*, through which the levator palati, the Eustachian tube, and branches of the ascending pharyngeal artery enter the pharynx.

The plan of the pharynx is like that of the canvas 'wind-sail' which is used on board ship to carry fresh air into the hold—it is closed at the top and sides, whilst its anterior part is held wide open by being

attached to fixed points. The fixed points by which the front of the pharynx is held wide open are the internal pterygoid plates and the halves of the lower jaw ; the cornua of the hyoid bone and the alæ of the thyroid ; and the sides of the cricoid cartilage.

The *pharyngeal aponeurosis* is a strong layer between the muscular and mucous coats, which fills in the vacancy at the sinus of Morgagni ; it is connected with the occipital and petrous bones, and blends posteriorly with the median raphé.

The **mucous membrane** is continuous with that of the nares, mouth, tympanum, and larynx. It contains many racemose glands, and a large amount of lymphoid tissue packed around follicular recesses. A mass of this tissue extending across the back of the pharynx, between the Eustachian tubes, constitutes the so-called *pharyngeal tonsil*.

The epithelium of the respiratory part of the pharynx, that is, down to the level of the floor of the nares, is columnar ciliated, but in the rest of its extent it is squamous.

The *pharyngeal bursa* is a recess in the posterior part of the mucous membrane which may reach up to the pharyngeal tubercle. Constantly present in infancy, it generally disappears with growth.

**Supply.**—The *arteries* are derived from the ascending pharyngeal of the external carotid, and the ascending palatine and tonsillar of the facial. The internal maxillary and lingual arteries may also supply small branches. The *veins* are tributaries of the internal jugular. The *lymphatics* pass to the glandulæ concatenatæ, and, quickly conveying septic matter from the surface of the pharynx, are a constant source of anxiety to the cervical glands. Some of the lymphatics of the pharynx also end in glands in front of the cervical vertebræ, which, becoming enlarged, may even be felt through the back of the pharynx, and which may be the starting-point of post-pharyngeal abscess, especially in young children.

The **pharyngeal plexus of nerves**, from which the muscular and mucous coats and the blood-vessels are supplied, is formed by branches of the pneumogastric, superior laryngeal, glosso-pharyngeal, and sympathetic. It is placed chiefly upon the middle constrictor.

A *pharyngeal polypus* may spring from the base of the skull, and, dragging upon its stalk, may hang like a pear behind the soft palate, pushing it forwards and obstructing deglutition as well as respiration. It may be removed by a wire snare passed along the floor of the nares, and guided by the finger in the mouth beneath and around the pedunculated mass.

The *stylo-pharyngeus* arises from the base of the styloid process and runs downwards and forwards between the external and internal carotids, with the stylo-glossus and the glosso-pharyngeal nerve, and, passing between the superior and middle constrictors, is inserted into the sides of the wall of the pharynx and into the posterior border of



the thyroid cartilage. It is supplied by the glosso-pharyngeal nerve. With its fellow it raises and widens the pharynx in deglutition.

The **œsophagus** (οἶσω, οἶσω, *carry*; φαγεῖν, *eat*), beginning at the fifth cervical vertebra, runs almost straight through the lower cervical region and the posterior mediastinum, and, passing through the muscular opening in the diaphragm, ends at the level of the tenth dorsal vertebra in the cardiac end of the stomach. It is ten inches long. Both in the neck and in the chest it lies a little to the left of the median line.

Its narrowest part is at the cricoid cartilage, and in that region, therefore, a plate of artificial teeth or a mass of food is most likely to be impacted; the plate may generally be felt on grasping the gullet between the finger and thumb.

*Relations.*—*In the neck* it has in front the flattened, membranous wall of the trachea; and, deviating somewhat to the left side, it has also in front the left lobe of the thyroid body. In front also are the left recurrent laryngeal nerve and the inferior thyroid artery, and the sterno-mastoid. Sometimes the recurrent laryngeal nerve becomes implicated in cancer of the œsophagus, the result being cough and aphonia. Behind are the lowest cervical vertebræ, the longus colli and the prævertebral fascia (p. 2); and at each side are the thyroid lobe, the common carotid sheath and its contents, and the recurrent laryngeal nerves.

*In the thorax* it has in front the trachea and the left bronchus; the left common carotid and subclavian arteries, the transverse aorta, and the heart and pericardium. Indeed, the transverse part of the aorta pushes the œsophagus a little towards the right, and, like the left bronchus, may slightly indent it.

The relationship of the heart and pericardium is important, for when the heart is greatly enlarged, or the pericardium dropsical, the patient may not be able to swallow with comfort as he lies on his back.

The crossing of the left bronchus is a favourite seat of epithelioma; should the malignant ulceration open into the bronchus, the contents of the gullet would enter the air-way and cause septic pneumonia.

Posteriorly are the dorsal vertebræ and the longus colli, the right intercostal arteries, the vena azygos, and the thoracic duct. And, just before traversing the diaphragm, the thoracic aorta is also behind.

Laterally, on the left, are the aorta and the pleura; and on the right are the pleura, the vena azygos, and, close by the diaphragm, the aorta.

The vagi form the *plexus gulæ* upon the œsophagus, and from its lower part the fibres of the left vagus descend chiefly in front, and those of the right vagus behind to their distribution on to the stomach.

Thus the œsophagus, running almost straight through the thorax, has the aorta winding round it: for the second part of the arch is in

front of the œsophagus, and the thoracic aorta is to its left, but as the large artery passes through the back of the diaphragm it is behind the gullet, and slightly to its right side.

*In the abdomen* the œsophagus runs a short and unimportant course, being covered in front and behind by peritoneum; in front also is the left lobe of the liver.

**Structure.**—The muscular coat consists of external longitudinal and internal circular fibres, which, being continuous with the fibres of the inferior constrictor above, are striated. Lower down, the muscle is a mixture of striated and pale fibres, and in the lower half of the œsophagus the fibres are entirely non-striated.

From the lower end of the œsophagus the longitudinal fibres pass on as the longitudinal fibres of the stomach, the circular fibres of the œsophagus becoming the oblique upon the cardiac end of the stomach.

The *mucous membrane* is extremely movable over the submucous coat, and it is usually thrown into temporary longitudinal folds or rugæ. The epithelium is thick and stratified.

**Supply.**—Œsophageal *arteries* come from the inferior thyroid, the thoracic aorta, the intercostals, and, possibly, from the internal mammary, also from the phrenic and gastric arteries. The *veins* take a somewhat similar course.

The *lymphatics* enter the cervical and posterior mediastinal glands. When cancer of the œsophagus, or even of the stomach, is suspected, the glands at the root of the neck should be examined.

The *nerves* come from the two vagi and from the sympathetic ganglia in the thorax.

*Stricture of the œsophagus* may be caused by the contraction of a scar left after swallowing corrosive liquids, and by malignant disease. In either case the probang must be used with the greatest care, for the walls of the dilatation which always exists upon the buccal side of the obstruction are necessarily thin, and, being easily traversed, the instrument may then wander into the posterior mediastinum, the pericardium, or the pleura, and so determine a fatal inflammation. Malignant ulceration of the gullet may open into the pleura and determine the occurrence of pneumothorax and empyema.

Sometimes œsophageal obstruction is due to the pressure of an aortic aneurysm, in which case rough instrumentation might cause an immediate and fatal hæmorrhage.

In malignant stricture gastrostomy (p. 223) has not proved a highly satisfactory procedure. Probably it will eventually be considered better surgery to pass a tube through the contraction before closure is complete, and to allow it to remain there, so that the patient may be fed with fluid nutriment, as recommended by Symonds.

**Œsophagotomy** may be needed for the extraction of a foreign body. The patient's shoulders are raised, his head is thrown back, and his face is turned to the right side. A three- or four-inch incision

is then made through the skin, platysma, and fasciæ along the anterior border of the left sterno-mastoid, the middle of the incision being over the foreign body. The head is then raised, as in ligation of the common carotid (p. 25), and the sterno-mastoid is drawn outwards. The omo-hyoid is then seen crossing the carotid sheath, and the sterno-hyoid and thyroid are passing inwards and upwards over the trachea.

As the œsophagus is imbedded between the trachea and the carotid sheath, the latter must be gently drawn outwards, and the sterno-hyoid and thyroid and the trachea inwards, the omo-hyoid being divided if necessary. The superior and middle thyroid veins must be tied and divided if they are in the way, but care must be taken not to injure the thyroid body, the inferior thyroid artery, or the recurrent laryngeal nerve.

The position of the œsophagus may be definitely shown, if necessary, by the introduction of a bougie or of curved forceps from the mouth. Bleeding having been entirely arrested, the gullet is opened and the foreign body extracted.

If the foreign body be impacted in the lower part of the œsophagus—and it is apt to be lodged just before the diaphragm is traversed—it may be extracted by gastrotomy, as demonstrated by Dr. Maurice Richardson, of Boston, U.S.A.

In *passing an œsophageal bougie* a gag may be needed between the teeth. Then the tube, being warmed and lubricated, is passed to the back of the pharynx, and, guided by the left forefinger, is pushed safely beyond the laryngeal orifice and down towards the stomach. As it passes by the soft palate and fauces the patient chokes, but as soon as the œsophagus is entered the choking ceases. It has happened that a physician, administering beef-tea by the stomach-pump, injected the trachea, and unfortunately set up a fatal pneumonia.

In diphtheritic paralysis of the palate the patient may conveniently be fed by a soft catheter passed across the floor of the nose and into the œsophagus.

#### THE PRÆVERTEBRAL MUSCLES

The **scalenus anticus** (*σκαληνος*, uneven) arises by a flat tendon from the tubercle upon the inner border and upper surface of the first rib, and, passing upwards and inwards, is inserted into the anterior tubercles of the transverse processes of the third, fourth, fifth, and sixth cervical vertebræ.

*Relations.*—In front are the clavicle, and the subclavius, sterno-mastoid, and omo-hyoid; the subclavian vein; the supra-scapular and transversalis colli arteries and the phrenic nerve. Behind it are the subclavian artery, the pleura, and the cords of the brachial plexus. On its inner side, between it and the longus colli, is the vertebral

artery, and between its insertion and the origin of the rectus anticus major is the ascending cervical artery.

The **scalenus medius**, the largest of the scaleni, arises from the upper surface of the first rib behind the groove for the subclavian artery, and at once begins to be inserted into the posterior tubercles of the transverse processes, beginning at the seventh and mounting to the axis.

*Relations.*—It lies behind the scalenus anticus, from which it is separated below by the subclavian artery and the dome of the pleura, and above by the cervical nerves. Behind it are the scalenus posticus and the levator anguli scapulæ. The nerve of Bell (p. 251), which is formed in the muscle, emerges from its outer surface.

The *scalenus posticus* arises from the outer surface of the second rib, and, ascending a little way behind the last muscle, is inserted into the posterior tubercles of the two lowest cervical transverse processes.

The scalene muscles incline the head and neck downwards and to the side, or, acting from above, help in inspiration. They are supplied by the anterior divisions of the lower cervical nerves.

The *rectus capitis anticus major* arises from the same points of bone as those into which the scalenus anticus is inserted; it is attached above to the basilar process of the occiput. It is supplied by the upper cervical nerves. In front of it are the pharynx, the sheath of the internal carotid with its contents, and the sympathetic cord.

*Appreciation.*—The upper surface of the transverse processes of the cervical vertebræ are grooved for the comfortable transmission of the cervical nerves; the borders of the grooves end externally in the anterior and posterior tubercles. The scalenus anticus is attached to the anterior tubercles, and the middle and posterior scaleni are attached to the posterior tubercles: therefore the cervical nerves emerge behind the anterior scalenus, and in front of the other scaleni.

The origin of the anterior scalene is between two grooves upon the first rib, and, as, according to the rule, the veins above the diaphragm lie in a plane anterior to the arteries, the subclavian vein is in front of, and the artery behind, the origin of the muscle. The phrenic nerve arises from the third, fourth, and fifth cervical nerves, that is, upon the outer side of the scalenus anticus, and it must pass inwards to enter the thorax, and this it does in front of the muscle; and, as the second part of the subclavian artery is behind the scalenus anticus, and the nerve descends upon the inner border of the muscle, it passes in front of the first part of the artery, but, to make its course as short as possible, behind the vein.

The thyroid axis is given off in the first part of the subclavian artery, and its supra- and posterior scapular branches must needs pass outwards to their destination—they run in front of the anterior scalene and the phrenic nerve.

The inferior thyroid, coming off also from the thyroid axis, lies to the inner side of the muscle till it turns inwards; and the vertebral artery, running up from the first part of the subclavian to the hole in the sixth transverse process, is to the inner side of the scalenus anticus, which, as already remarked, is inserted into the outer end of the transverse processes.

#### THE CERVICAL NERVES

Though there are but seven cervical vertebræ, there are eight cervical nerves, the first of which appears above the atlas, and the last below the vertebra prominens. The anterior divisions of the first four make up the cervical plexus, and those of the lower four join with part of the first dorsal to form the brachial plexus.

The **posterior primary divisions** of the cervical nerves divide, for the most part, into an inner and an outer branch. But the *posterior division of the first, or sub-occipital* nerve, does not divide; it emerges between the vertebral artery and the posterior arch of the atlas, and supplies the obliqui, recti postici, and complexus. Sometimes it sends up a cutaneous branch to the back of the head, which may be in great distress in the case of suboccipital disease.

The *posterior trunk of the second* is much larger than the anterior. Its *internal division* is the **great occipital**, which, as its name implies, is a large branch for the back of the scalp. Passing through the insertions of complexus and the trapezius, it accompanies the occipital artery, and communicates with the lesser occipital nerve. The *external division* is distributed solely to the erector spinæ.

The *internal division of the third* sometimes sends up an occipital twig in addition to a branch for the skin of the nape of the neck. The *internal divisions of the fourth and fifth* nerves give branches to the erector spinæ, as well as to the skin over the trapezius, whilst those of the three lowest usually give off no cutaneous twigs.

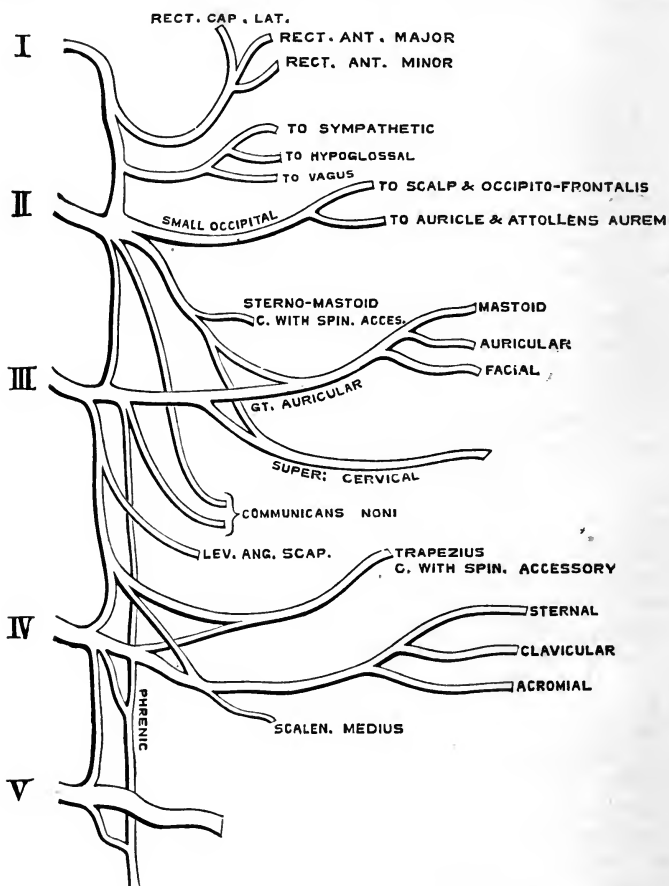
The *external divisions* of the posterior cervical nerves are for the muscles only.

The **cervical plexus** is formed by interlacements of the anterior divisions of the first four cervical nerves. The *anterior part of the first, or sub-occipital* nerve, is a slender branch, which winds forwards from beneath the vertebral artery on the posterior arch of atlas, and at the front of the first transverse process joins with a branch from the second nerve. It ends in the supply of the recti laterales and antici.

The *anterior part of the second* winds round the vertebral artery in its course from beneath the posterior ring of the atlas, and gives a division to the first nerve and one to the third.

The *anterior part of the third* divides to join the second and the fourth; and the *anterior part of the fourth*, having received the last-named branch, sends down a communicating twig to the fifth nerve, which belongs to the brachial plexus.

The communications between the upper four cervical nerves take place between the scalenus medius and levator anguli scapulæ behind, and rectus anticus major in front. They are under cover of the sternomastoid, so that all their superficial branches emerge by the border of of

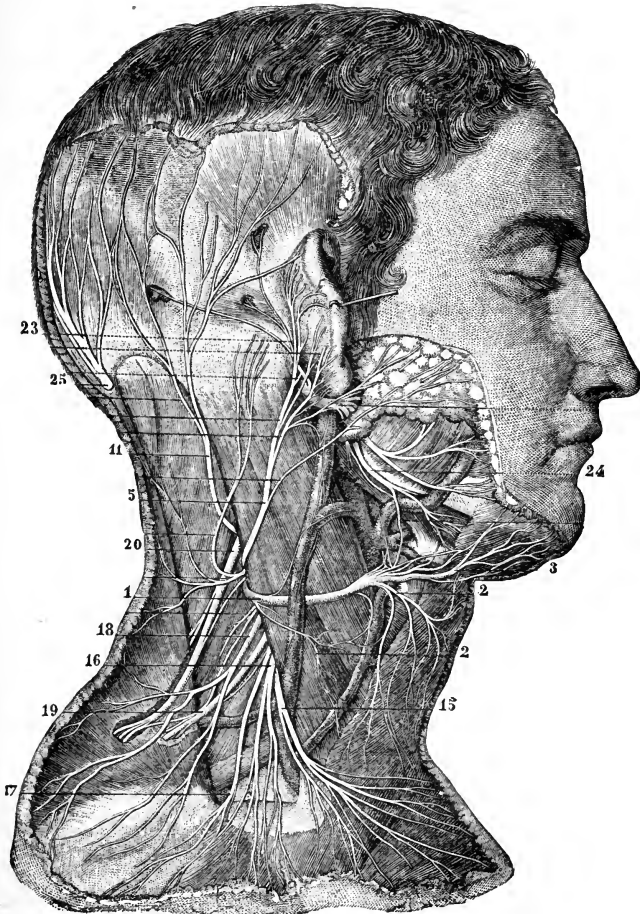


this muscle, and those which have an ascending or forward course pass over that muscle.

The **branches of the plexus** are *superficial* and *deep*.

**Superficial branches.**—The *lesser occipital*, from the second cervical nerve, winds upwards behind the sternomastoid, and, piercing the deep fascia, supplies the skin between the areas of distribution of

the great auricular and great occipital. Thus, be it noted, both the occipital nerves come from the second cervical—the lesser from its anterior, and the greater from the posterior division. The lesser occipital gives a branch to the back of the pinna.



1, Transverse or superficial cervical nerve with its descending (2) and ascending (3) branches ; 5, great auricular ; 11, lesser occipital ; 15 to 18, supra-clavicular ; 19, br. to trapezius ; 20, spinal accessory ; 23, post. auricular of facial ; 24, infra-maxillary of facial ; 25, great occipital.

The *great auricular* and the *transverse* or *superficial cervical* arise from the second and third. The *great auricular* emerges on a lower

level than the lesser occipital behind the sterno-mastoid, and, winding up over that muscle, reaches the parotid gland, giving branches to the skin of the masseteric and the mastoid regions, to the *back* of the pinna, and to the lobule.

The *superficial cervical* winds across the middle of the sterno-mastoid, under the external jugular vein and the deep fascia, and, piercing the fascia at the front of the neck, divides beneath the platysma into an *ascending branch*, which supplies the skin over the sub-maxillary region, joining there with the infra-maxillary branch of the facial, and a *descending branch*, which supplies the skin along the front and lower part of the neck.

The *supra-clavicular* are the lowest and last of the superficial branches; they come from the third and fourth trunks, and emerge from behind the sterno-mastoid. They descend in *sternal*, *median*, and *acromial* branches to supply the skin of the pectoral and deltoid regions. Sometimes one of the median set courses through the substance of the clavicle. In the case of fracture of the collar-bone branches of these nerves may be bruised between the fragments, great pain resulting.

The supra-clavicular nerves take the place of lateral cutaneous branches of the first and second dorsal nerves.

When, as the result of caries, for instance, there is pressure upon the posterior roots of the third and fourth nerves, peripheral pain usually occurs in the area of distribution of these nerves: symmetrical pains about the shoulders of a child should always direct attention to the neck.

*Peripheral neuralgias of the scalp, neck, pectoral region, or shoulder*, are often caused by inflammatory pressure upon the sensory roots of the nerve-trunks, and are often met with in disease of the occipito-atloid joint, and in caries of the upper cervical vertebrae. These pains are generally, but not always, in symmetrical areas, whilst neuralgia which is due to pressure of a tumour outside the spinal canal would be confined to one side, unless, indeed, it reached across the middle line. A little girl who was brought to me with mid-cervical caries suffered from darting pains across the front of the neck, which she quaintly called 'belly-ache in the neck.' When there is pressure upon the second nerve the pains in the area of the lesser and greater occipitals are often called 'head-ache,' and when those filaments of the second and third nerves which belong to the great auricular are in distress the neuralgia may be called 'ear-ache,' or 'face-ache.' It is, then, of the greatest importance to know the exact distribution of these nerves (*see* PINNA, p. 94).

Of the *deep branches*, some communicate with the sympathetic, vagus, and hypoglossal; the second and third send down also *communicantes hypoglossi* (or noni) over the internal jugular vein to join the descendens noni. Other branches pass to neighbouring muscles,



the most important of which are from the second and third for the sterno-mastoid ; the influence of these nerves may render futile section of the spinal accessory (p. 71) nerve in the case of spasmodic contraction of that muscle. The trapezius also receives branches from the third and fourth, which, like the sterno-mastoid branch, communicate with the spinal accessory.

The **phrenic** comes from the third and fourth, and receives a twig also from the fifth nerve, that is, from the upper part of the brachial plexus. It descends into the chest over the scalenus anticus and the subclavian artery, and behind the vein. It then runs in front of the root of the lung, between the pleura and pericardium, and supplies the diaphragm on its under-surface, giving off pleural and pericardial twigs in its course.

The left nerve is the longer, because it is pushed out of its course by the pericardium ; it bears an important relation to the front of the transverse aortic arch, whilst the right nerve descends on the outer side of the innominate artery and the superior cava.

Filaments of the right phrenic pass under the coronary and falciform ligament, into the substance of the liver ; and it is probably through their influence that, in disease of the liver, pain is referred to the point of the right shoulder (p. 339). The phrenic chiefly comes from the fourth cervical nerve, which also gives off acromial filaments in the supra-clavicular nerves, as already noted.

In paralysis of the diaphragm, as after diphtheria, the *phrenic nerve may be galvanised* on dragging the lower end of the sterno-mastoid slightly inwards (so that the rheophore may be placed over the scalenus anticus, the outer border of which muscle corresponds to the outer border of the sterno-mastoid), the other rheophore being placed over the costal attachment of the diaphragm.



## PART II

## THE THORAX

THE thorax (*θωραξ*, breast-plate) is enclosed by the dorsal vertebræ, the ribs, costal cartilages, and sternum; its apex is bifid and extends an inch and a-half above the first rib. The floor, formed by the diaphragm, is convex, and is higher on the right side than on the left by the depth of a rib, being pushed up by the liver; the centre is the lowest part, being on the level of base of the xiphoid. On the right side, after an ordinary expiration, the floor reaches the level of the fifth rib in front, and, after a forced expiration, to the level of the fourth. The lowest part of the floor extends from the base of the xiphoid to the eleventh or twelfth rib (p. 196).

The **sternum** consists of the manubrium, gladiolus, and xiphoid; to the last piece the linea alba is attached. At the top of the manubrium is a notch between the clavicles which receives the trachea in flexion of the neck. Below and to the outside of this notch the cartilages of the first ribs blend with the manubrium.

The downward slope of the first ribs brings the top of the manubrium opposite the second dorsal vertebra, from which it is separated by the space of two inches.

Down each lateral half of the sternum the pectoralis major arises, and from the upper part of the front of the manubrium arises the pointed tendinous head of the sterno-mastoid. At the back of the manubrium arise the sterno-hyoid and sterno-thyroid, and from the lower end of the gladiolus the triangularis sterni. The diaphragm is attached to the back of the xiphoid cartilage, and the linea alba to the tip.

The sternum is developed in lateral halves, together with the ribs, in the mesoblastic layer, in curved plates extending from the vertebral column. When these plates fail to meet along the middle line the thorax is open in front, the condition being called *cleft sternum*. For an extreme case of this defect, with ectopia cordis, see p. 318. Ectopia differs from cleft sternum in that not only is the sternum cleft, but the want of fusion in the middle line implicates the soft tissues as well as the bone, the heart being out of place.

Where the manubrium joins the gladiolus there is a *transverse ridge* which is easily felt on running the finger down the middle line. The cartilages at the ends of the ridge are those of the second ribs. In counting the ribs in a fat subject it is convenient to remember this. The ridge corresponds also with the lower border of the second part of the aortic arch.

*Fracture of the sternum* generally results from the chin being forcibly doubled into the chest, as in a fall on the head, the springiness of the ribs saving it from fracture from direct violence. Occasionally the manubrium is dislocated forwards over the gladiolus.

**Of the ribs**, seven articulate with sternum, but the lower five do not ; the eleventh and twelfth, being free anteriorly, are rarely broken. The first rib is rarely broken, unless the clavicle, which protects it, have first yielded. The ribs most often broken are the middle ones, and the seat of fracture is generally in front of their angle. A rib may be broken by direct violence, as by a blow with the fist, in which case the salient angle is more apt to damage the pleura and lung, than when the fracture is from indirect violence, as when a man is crushed against a wall, in which case damage to the pleura and lung occurs only when several ribs have been broken. When a man with fractured ribs spits bright and frothy, bloody sputa, there is evidently a wound of the lung ; possibly also pneumothorax exists.

The *groove* along the lower part of the inner surface of the rib contains the intercostal artery, with the vein above it and the nerve below, passing between the inner and outer intercostal muscles ; to avoid these, in puncturing the chest, the trocar should neither be introduced through the upper part of the intercostal space nor through the lower, where the collateral branch is coursing. *In medio tutissimus ibis.*

The *intercostal arteries* come from the superior intercostal of the subclavian, from the aorta, and from the internal mammary ; they anastomose freely with branches of the axillary and send emissaries through the spaces to supply the mamma ; a wounded intercostal artery may bleed into the pleural cavity (*hæmothorax*). If the skin be also wounded the artery may be compressed by the finger passed in under the rib.

The costal cartilage fits in a depression at the end of the rib ; the other end articulates with the sternum, and, with the exception of the first cartilage, which fuses with the manubrium, each chondro-sternal joint has a synovial membrane. Indeed, the joints of the second and third cartilages usually have each two membranes. As the result of injury either end of a costal cartilage may be detached. Comparative anatomy shows that the cartilages are anterior epiphyses.

The cartilages from the sixth to the ninth are connected with each other by capsular ligaments lined by synovial membranes.

Most of the ribs articulate by their head with the bodies of two vertebræ and with the intervertebral disc, being connected by the

*stellate* and *interarticular ligaments*, and by a capsule with two synovial membranes.

The neck of the rib is connected with the front of the transverse process by a strong *interosseous ligament*, and also with the transverse process next above it by the *anterior costo-transverse* band, which is continuous externally with the intercostal aponeurosis. The tubercle is connected with the tip of the process by a *capsule* and synovial membrane, and by the *posterior costo-transverse* ligament.

**Pigeon-breast** is produced in rickety, soft-boned children when inspiration is obstructed, as by enlarged tonsils—the contraction of the diaphragm causes a partial vacuum in the chest which the pressure of the external air helps to efface by thrusting inwards the weak costal ends of the ribs, with the effect of making the sternum project. Strengthening the child, removing the obstruction, and instituting respiratory gymnastics, gradually diminish the defect; no compression of the prominent sternum should be used.

The Prussian army surgeons have been ordered to measure narrow-chested recruits every four weeks. All are to be regarded as narrow-chested the circumference of whose chest is less than half the length of their bodies. Narrow-chested men whose chests are not widened by drill are regarded as predisposed to tuberculosis.

The **dorsal nerves**, twelve on each side (the twelfth emerging below the last dorsal vertebra), divide into an anterior and a posterior trunk; the former becomes the *intercostal nerve*, with the exception of the first, the chief part of which passes up for the brachial plexus, only a small intercostal branch being sent forward from it.

As the *anterior divisions of the upper dorsal nerves* run between the intercostal muscles, and are half-way in their course, they give off *lateral cutaneous* branches which pierce the outer intercostals and the serratus magnus in the axillary line, and then divide; the posterior division supplies the skin over the region of the latissimus dorsi and the scapula, and the anterior winds round the pectoralis major for the mamma and the neighbouring integument, or, in the case of the lower nerves, for the skin over the front of the abdomen.

The continuation of the intercostal nerve runs on and leaves the space by the side of the sternum, piercing the origin of the pectoralis major, and ending in the *anterior cutaneous* twigs.

The small, first intercostal nerve gives no lateral cutaneous branch, but from the second a large undivided offshoot runs across the arm-pit to end in the skin of the inner and back part of the arm. This is the **intercosto-humeral nerve**, and it is often joined by the lesser internal cutaneous. When the intercosto-humeral nerve is stretched by supuration in the arm-pit, or is caught in the enlargement of axillary glands which follows mammary scirrhus, neuralgia occurs in the area of its distribution, down to the internal condyle.

In their course the intercostal nerves supply the parietal pleura;

and thus it comes about that in inflammation of the upper part of that membrane pain is sometimes felt along the inner side of the arm.

The *lower intercostal nerves*, having reached the limit of the space, pass onwards between the internal oblique and transversalis to the sheath of the rectus, and, having pierced it and the rectus, appear as anterior cutaneous nerves near the linea alba. The lower intercostal nerves supply the oblique, the transverse, and the straight muscles of the abdomen.

Thus, pain over the upper part of the abdomen may be due to pleurisy, to pressure of thoracic tumours or of pleural collections of fluid, to caries of the lower dorsal vertebræ, or to disease of the cord above the lumbar enlargement.

The *anterior division of the last dorsal nerve* runs below the last rib, in company with the first lumbar artery, in front of the quadratus lumborum, and gains eventually the space between the transversalis and the obliquus internus. Its peripheral branches (anterior cutaneous) end about half-way between the umbilicus and pubes. The region of the 'pit of the stomach' is supplied by the endings of the sixth and seventh nerves. The nerve-supply of any part of the side or front of the thoracic or thoracico-abdominal region is indicated by continuing forward the lines of the intercostal spaces, and seeing which of them runs into that particular area.

When a patient complains of *pains over the upper part of the front of the chest*, the surgeon must not satisfy himself with tracing his finger along the upper intercostal spaces and with examining the higher dorsal vertebræ, but must carry his investigations also into the middle of the neck, as the third and fourth cervical nerves (p. 145) furnish cutaneous branches to that neighbourhood as well as the dorsal nerves.

The *lateral cutaneous branch of the last dorsal* comes over the iliac crest, through the internal and external obliques, and supplies the skin of the fore part of the buttock, as far as the great trochanter.

*Neuralgia in an intercostal nerve* may be due to inflammation in its fibrous elements, and may then be followed by a crop of vesicles in the area of skin supplied by it. The disease is called herpes zoster (*ζωστηρ*, *belt*) or shingles (*cingulum*, *girdle*), names which well describe the arrangement of the eruption.

The *posterior divisions of the dorsal nerves* give off internal and external branches. The *internal branches* of the upper six nerves supply the erector spinæ, and then send cutaneous twigs through the trapezius; all the *external branches* also give muscular twigs, but, in addition, the lower six send twigs through to the skin of the infra-scapular region.

According to Professor Griffith, the posterior branches descend obliquely for the depth of several vertebræ before ending in the skin, and so it comes about that the line of herpes zoster is transverse and

not oblique, and that the zone of anæsthesia in fracture of the spine is horizontal.

The **diaphragm**, an important muscle of inspiration, arises from the back of the xiphoid, the inner surfaces of the lower six ribs (where it interdigitates with the transversalis), and, posteriorly, from the arcuate ligaments. It also arises by two pointed crura, of which the right descends rather lower than the left, namely, to the fourth lumbar vertebra.

Roughly, the attachment of the phrenic plane may be marked by a line extending obliquely round the trunk from base of the xiphoid cartilage to the last rib.

According to Sibson, the central tendon descends about an inch during inspiration, and with it descend the superjacent, and attached, pericardium, the heart, and the base of the lungs. Sometimes, in an anæmic subject, with the descent of the heart and the ascent of the chest-wall during inspiration, the subclavian artery becomes so stretched over the edge of the first rib that a *bruit* is heard there, the radial pulse being lost at the very end of inspiration. That the *bruit* is not the result of subclavian aneurysm is proved by causing the patient to cease breathing after expiration, when the murmur disappears and the radial pulse returns.

The *openings in the diaphragm* are the osseo-aponeurotic notch in front of the twelfth dorsal vertebra for the aorta, vena azygos major, thoracic duct, and left sympathetic; a tendinous one between the right and central leaflets for the vena cava; and a third, an oval one, for the œsophagus and the vagi: this is muscular, being formed by the decussation of the inner fibres of the crura.

Just on the outer side of the xiphoid there is an irregular gap in the diaphragmatic fibres through which the superior epigastric artery descends and some hepatic lymphatics mount to the mediastinal glands. By this space also a *diaphragmatic hernia* may escape, and through it the subperitoneal connective tissue joins that of the anterior mediastinum. Along this loose tissue an anterior mediastinal abscess may find its way into the epigastric region.

Because of the upward extension of the abdominal cavity within the circle of the ribs, the liver, stomach, spleen, and kidneys might almost be counted as thoracic viscera. In fracture of the lower ribs the pleura and lung, as well as the peritoneum, liver, spleen, and kidney, may be lacerated by broken bone.

**Paralysis of the diaphragm** embarrasses all the expulsive efforts, and leaves respiration and vocalisation to be carried on almost entirely by the intercostals.

In healthy inspiration the ribs ascend and the diaphragm is depressed, the abdominal viscera being pushed downwards and forwards; but, the diaphragm being paralysed, when the patient takes a breath the ribs ascend as usual, but the abdominal muscles, taking advantage

of the flaccid thoracic floor, push the viscera upwards, so that there is an actual sinking in of the epigastric region.

The abdominal viscera press the diaphragm upwards as one lies in bed: therefore the bronchitic patient often breathes better when propped in the sitting posture.

**Pleurodynia** (*πλευρα*, side; *οδυνη*, pain) is pain in the chest-wall which is not the result of pleurisy; the chief merit of the term is in its vagueness. Does it mean costal periostitis, muscular rheumatism, intercostal neuralgia, or hepatitis? Or is it the result of pressure upon the posterior roots of some of the dorsal nerves of one side, or upon nerves leaving the spine or entering the intercostal spaces? For, after all, pain is but a symptom of a disease, and sometimes a very misleading one.

**Pains between the shoulders** are often complained of in dyspepsia, that is whenever the stomach is out of working order. They are probably caused by the association of filaments of the great splanchnic (*σπλαγχνα*, *viscera*, p. 224) with the solar plexus below, and with the higher dorsal nerves above, these latter nerves giving dorsal branches to the skin in that region. Similarly the pains about the right shoulder in liver disease were formerly explained, but a better reason for their occurrence is given on p. 147.

### THE CAVITY OF THE THORAX

The **upper opening of the thorax transmits** the apex of each lung, which extends for  $1\frac{1}{2}$  in. into the roof of the neck. In the middle line pass the sterno-hyoid and sterno-thyroid muscles, the inferior thyroid veins (p. 155), remains of thymus, the trachea and œsophagus with left recurrent laryngeal nerve, and also, on the left side, the thoracic duct.

A little removed from the middle line are the innominate artery, the right vagus, and the left common carotid and subclavian arteries, with the left vagus between them; the two innominate veins; the two phrenic nerves; cardiac filaments from sympathetic and from the vagi; the internal mammary and superior intercostal arteries descending into thorax; part of the anterior division of the first dorsal nerve mounting to the brachial plexus; the longus colli and the cords of the sympathetic.

### THE MEDIASTINA

The mediastina are the spaces which 'stand in the middle' (*medio*, *sto*) of the chest, between the sternum and the spine, with the lung and pleura on either side. The connective tissue which they contain is liable to be the seat of suppuration.

The **anterior mediastinum** is the space between the pleuræ in

front of the pericardium. It inclines, therefore, to the left. In front of it are the sternum and the adjoining parts of the fifth, sixth, and seventh cartilages. The *triangularis sterni* covers the anterior boundary of the space and shuts out the internal mammary vessels. It contains lymphatics ascending from the liver, and some small lymphatic glands which are associated with the inner part of the *mamma* (p. 203).

Abscess in the root of the neck readily finds its way into the anterior mediastinum by following the trachea or the sterno-hyoid and thyroid muscles.

The **middle mediastinum** contains the heart and pericardium, and the arterial and venous trunks which the pericardium encloses; the roots of the lungs, and the various structures associated therewith; the *vena azygos* turning over the root of the right lung, and the phrenic nerves.

The **posterior mediastinum** is limited by that part of the spine which is behind the pericardium and the roots of the lungs. In it are the third part of the arch and the thoracic aorta; the *œsophagus* with the *vagi*; the *azygos* veins, the thoracic duct, and some lymphatic glands, and the sympathetic chains with their splanchnic offshoots.

The **superior mediastinum** is defined by drawing an imaginary horizontal plane from the transverse sternal ridge (p. 149) to the lower border of the fourth dorsal vertebra. It contains the origin of the sterno-hyoid and thyroid muscles, the remains of the thymus gland, trachea, *œsophagus*, left recurrent laryngeal nerve, thoracic duct; the transverse part of the aortic arch with the origin of the innominate, left carotid, and left subclavian arteries; the innominate veins and the beginning of the superior cava; the phrenic, pneumogastric, and cardiac nerves, and lymphatic glands.

The **thymus** (*θυμος*, soul, life) is a ductless gland lying between the manubrium and the aortic arch; in early life it ascends into the root of the neck, in front of the trachea; below it reaches to the pericardium. It increases in bulk to the end of the second year, at which time, as regards size, it is an important anatomical structure. (See wood-cut on next page.)

Its *arteries* are derived from the internal mammary, and the inferior and superior thyroid. The *veins* end in the internal mammary and left innominate. The nerves come from the sympathetic.

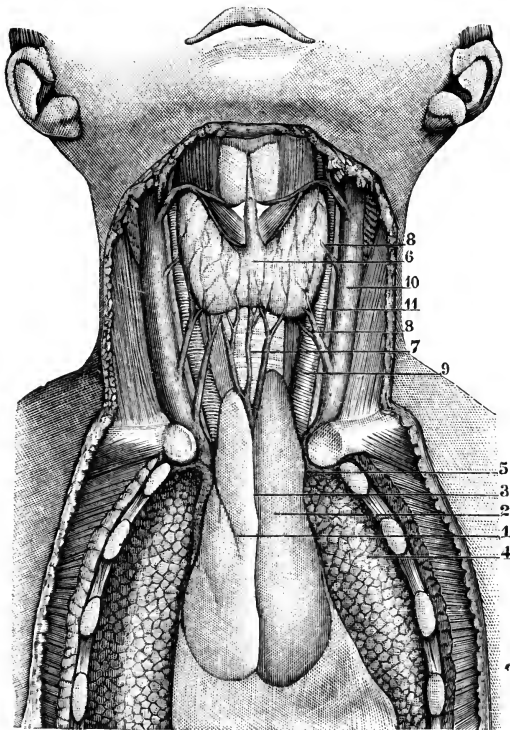
The **vena azygos major** is the great link between the *venæ cavæ*. Further, it receives the venous blood from the retro-cardiac region, where, of course, no *vena cava* exists.

It begins by tributaries from the right lumbar and renal veins, or from the inferior cava itself, and, passing through the aortic opening of the diaphragm, ascends upon the right side of the spine to the fourth dorsal vertebra, whence it turns forward over the root of the right lung to enter the *vena cava superior* just as it is about to



pierce the pericardium. It receives most of the right intercostal veins, and, from the left side, the smaller azygos (*v. p.* 185).

When the inferior cava is blocked, as by an hepatic cancer, venous blood from the lower part of the body finds a free collateral return to the heart through the vena azygos major, which may thus become as large as the thumb.



Thymus gland in a child of six months. (SAPPEY.)

1 and 2, Right and left lobes; 4, lung; 6, thyroid; 7 and 8, inf. thyroid veins; 9, com. car. art.; 10, int. jug. vein; 11, vagus.

The **internal mammary artery**, from the first part of the subclavian (*p.* 228), enters the thorax behind the first costal cartilage, and, descending behind the intercostal spaces, about  $\frac{1}{2}$ -inch from the border of the sternum, divides behind the seventh cartilage into the musculophrenic and superior epigastric. At first the artery lies behind the subclavian vein and in front of the pleura, being crossed obliquely by the phrenic nerve; but, lower down, the triangularis sterni separates it from the pleura.

*Its branches are:* the comes nervi phrenici, to the diaphragm; mediastinal; pericardial; sternal; *anterior intercostal*, two to each of the six upper spaces, to anastomose with the aortic intercostals, and many *perforating* branches which pass through the pectoralis major for the breast and the integument.

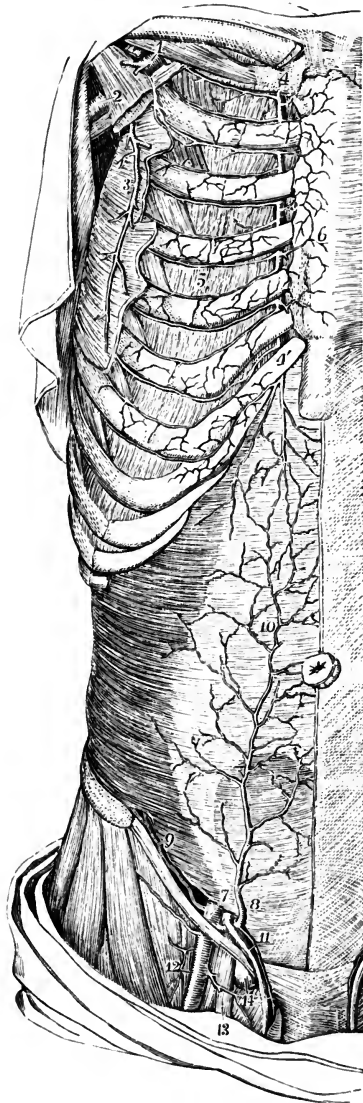The *musculo-phrenic*, the outer of the terminal divisions, slopes behind the sternal ends of the lower spaces, under cover of the diaphragm (which it supplies), and gives off anterior intercostals, like those described above.

The inner division, the *superior epigastric*, passes through the xiphoid gap in the diaphragm (p. 152) to enter the rectus abdominis, in which it descends to anastomose with the deep epigastric of the external iliac. A twig or two from it enter the falciform ligament to anastomose with branches of the hepatic artery.

The *internal mammary veins* end in the innominate veins.

**Ligation of the internal mammary** in its continuity may be required when an oblique wound, such as a stab, implicates the trunk behind a costal cartilage, so that the surgeon cannot secure it at the bleeding spot. It may be reached by making a two-inch incision from the side of the sternum through the middle of one of the higher spaces. The skin, fasciæ, and pectoralis major having been traversed, the aponeurosis is seen which continues the external

intercostal muscle to the sternum. Then comes the internal inter-



costal, and, in loose connective tissue, a little deeper, but in front of the triangularis sterni, or pleura, is seen the artery with a vein on either side. If the artery be tied in the second space, where the triangularis sterni is not behind it, extra care must be given not to damage the pleura in passing the aneurysm-needle.

The **superior intercostal artery** descends from the second part of the subclavian in front of the neck of the first and second ribs to supply the topmost spaces, which the aortic intercostals cannot conveniently reach. The artery lies behind the apex of the pleura and against the anterior division of the first dorsal nerve as it ascends to the brachial plexus. Its intercostal branches anastomose with the internal mammary and with thoracic branches of the axillary.

It gives off the *profunda cervicis*, which resembles the dorsal branch of an aortic intercostal artery. Passing backwards between the seventh cervical transverse process and the neck of the first rib, it eventually ascends beneath the complexus, and anastomoses with branches of the vertebral and with the princeps cervicis of the occipital (p. 30).

Of the *superior intercostal veins* the right turns down into the great azygos, whilst the left passes across the second part of the aortic arch to end in the left innominate vein.

The **thoracic duct** brings the chyle and lymph into the venous circulation, with the exception of the lymph from the right side of head, neck, and thorax, the right upper extremity, the right heart and lung, and the phrenic surface of the liver. It is eighteen inches long, extending from the abdomen, through the thorax, and into the neck, to the confluence of the left internal jugular and subclavian veins.

It begins on the front of the second lumbar vertebra in the *receptaculum chyli*, a dilatation into which is poured the contents of the lymphatics of the lower extremities, pelvis and abdomen, and of the lacteals.

*Relations.*—The duct is placed behind the abdominal aorta, and between it and the right crus. It enters the posterior mediastinum through the aortic opening, and ascends on the bodies of the dorsal vertebræ, between the thoracic aorta and the great azygos. As it is reaching the back of the transverse aorta it inclines towards the left, and, passing behind the œsophagus, ascends between it and the left subclavian artery. Having thus reached the root of the neck, it arches downwards and forwards in the gap between the carotid and subclavian arteries, to end in the confluence of the internal jugular and subclavian veins, on a plane anterior to the arteries.

At a *post-mortem examination* the duct is easily found, when the pleura has been opened, by drawing the right lung towards the left, and tearing through the parietal pleura along the right side of the dorsal vertebræ. The duct is there lying in some loose connective tissue between the great azygos and the œsophagus, whence it may be traced upwards or downwards.

As it traverses the thorax it receives the lymphatics from the œsophagus, trachea, left heart and lung, and from the left thoracic wall.

The *right lymphatic duct*, one inch long, brings the lymph from the right side of the head, neck, thorax and heart, and from the right upper extremity and lung; it enters the confluence of the right internal jugular and subclavian veins.

### THE PERICARDIUM

The *serous layer* of the pericardium covers the heart and the first  $1\frac{1}{2}$  in. of the large vessels, and is thence reflected on to the interior of the fibrous sac. It sends seven more or less complete tubular sheaths round the vessels—a common one for the aorta and the pulmonary artery, four for the pulmonary veins, one for the superior cava, and a scanty one for the inferior cava, which last vessel enters the auricle directly after coming through the diaphragm.

Laterally the pericardium is covered by the pleuræ and lungs, the phrenic nerves intervening between them. The anterior borders of the lungs and the pleuræ are also in front above, but, below, the pericardium approaches the thoracic wall in an important triangular area (p. 165) without the intervention of lung.

The close proximity of the pericardium and pleura explains the frequency with which inflammation of one membrane follows that of the other.

The *external layer* of the pericardium is of strong interlacing fibres, and is firmly connected with the central tendon of the diaphragm. Above, the fibrous sheath passes off in tubular prolongations which blend with the outer coats of the transverse aorta and of the right and left pulmonary arteries and veins, and of the superior cava. The lining is of pavement endothelium.

The close association between heart, lungs, and diaphragm not only causes a descent of the thoracic viscera during inspiration, but even of the trachea, as may be easily recognised by laying the finger on the larynx whilst a deep breath is taken.

When the pericardium is opened from the front the following structures are seen: the front of the right ventricle and the apex of the left; the right auricle and its appendix, and the appendix of left auricle; the root of the pulmonary artery, and a little of the aorta and of the cavæ.

**Supply.**—Pericardial twigs are derived from the aorta and from the internal mammary, bronchial, œsophageal, and phrenic arteries. Nerve-filaments come from the phrenic, the sympathetic, and the right vagus.

At the beginning of an attack of **pericarditis** the lining membrane is dry, and roughened from fibrinous deposit, and the heart no longer moves noiselessly against the parietal layer, but rubs against it, pro-

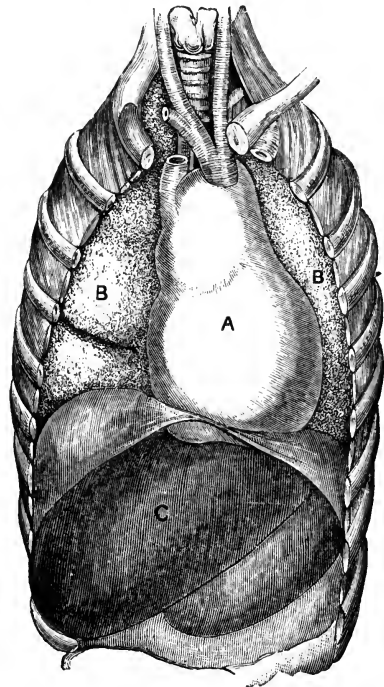
ducing a *friction-sound*. This sound may in time disappear from one of three causes : from the deposit clearing up and leaving the surfaces once more smooth and moist ; from adhesion occurring between heart and pericardium ; or from effusion of serum collecting between and separating them. In the last case the normal heart-sounds are, of course, masked.

A pericardial friction-sound does not cease, as does a pleural rub, when the patient holds his breath, but in either case the sound may be exaggerated by pressure made by the end of the stethoscope ; against such a fallacy the listener must be on his guard. On account of the pain associated with pericarditis, the diaphragm and the lower intercostals keep quiet in respiration, the work being done in the upper thoracic region.

When the visceral and parietal layers of the pericardium are inflamed and sticky with lymph they may closely adhere. But often the movements of the heart prevent such adherence ; and the constant unglueing of the opposed surfaces renders each of them rough or even shaggy.

In **pericardial effusion** the area of absolute dulness is pear-shaped, with the small end upwards ; whereas in hypertrophy and dilatation of the heart (p. 175) the shape of the dull area and the direction of its greater diameter are transverse. In pericardial effusion, also, the left end of the dulness reaches beyond the apex-beat—a most important diagnostic sign—but when the distending fluid is abundant the heart is insulated within it, and the apex can no longer beat against the chest-wall ; the cardiac sounds are then practically drowned in the fluid, and the apex-beat may be altogether indistinguishable.

When the distension of the sac is only partial, the area of dulness may be made to shift its site with the altered position of the patient (much as described in abdominal ascites, p. 316). The lungs being thrust from the

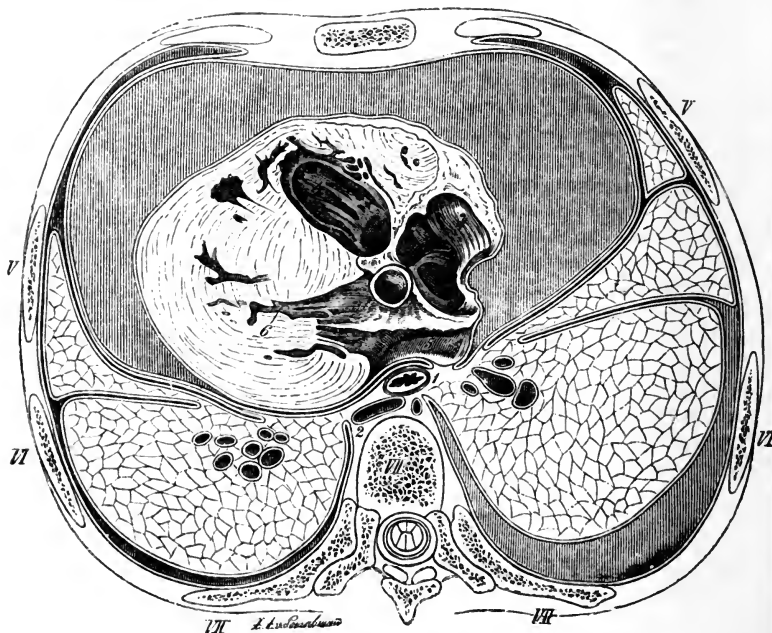


Effusion into pericardium, A ; lungs, B, B, pushed aside, and liver, C, depressed. (SIBSON.)

middle line and compressed, respiration is embarrassed, and the patient is hardly able to move himself in his bed.

When the effusion is excessive the lower two-thirds of the sternum, and the left cartilages, from the second to the seventh, are prominent, the intercostal spaces are widened, and the area of cardiac dulness is increased. In the young subject, with pliant chest-walls, the bulging is more marked than in the adult.

As the patient lies in bed the effusion does not at first increase the area of dulness, because it gravitates to the back of the sac—collecting behind the heart; but as the distension increases the lungs are pushed aside, and the ascitic pericardium bulges against the chest-wall, giving rise to a dull percussion-note as high, perhaps, as the first space, and extending widely behind the right and left cartilages, and the xiphoid.



Effusion into pericardium; lungs pushed aside; slight effusion into right pleura. v, vi, vii, ribs in section. (BRAUNE.)

The diaphragm, liver, and stomach are, at the same time, thrust downwards. In acute inflammation the sac may contain from twelve to eighteen ounces of serum, but when the disease is chronic the fluid may amount to three pints. In the latter case the left lung would be pushed far out, and the tumour would bulge so much towards the abdomen

that there might be pain on pressing the epigastrium ; there would be also a prominence of the sternum and of the left costal cartilages, especially in young subjects. If, as the patient lies in bed, the water-tumour press against the trachea, the dyspnœa may be relieved by letting him sit up, so that the fluid may be brought forwards. Pressure on the œsophagus may cause dysphagia, especially when the patient is lying down ; and by bulging against the right auricle and superior vena cava it may produce fulness of the veins of face and neck, with, possibly, œdema.

In the treatment of acute pericarditis venæsection and purgation may be of great service by relieving the heart of some of its work.

**Paracentesis pericardii** may be necessary when the pressure of the fluid seriously interferes with the heart's action.

The puncture may be performed in any part of the area of absolute cardiac dulness, but the course of the internal mammary vessels at half an inch from the border of the sternum must be remembered (p. 156). The sternal end of the fourth or fifth space serves well. It has been customary to operate on the left side, but I would urge that the sternal end of the fourth *right* space is preferable, as the pericardium is sure to be bulging there and the needle is less likely to injure the heart.

In *suppurative pericarditis* the abscess must be thoroughly evacuated and the cavity washed out and drained, the incision being made, layer by layer through the fourth or fifth intercostal space, to the outer side of the line of the left internal mammary artery. When the pericardium is reached it should be drawn well forwards so that the pus and the irrigation-fluid may not escape into the anterior mediastinum.

There is no definite sign by which *adherence of the heart and pericardium* may be absolutely recognised, but in such cases the contracting ventricles may be seen pulling-in the neighbouring intercostal spaces, and even the lower end of the sternum and the adjacent cartilages.

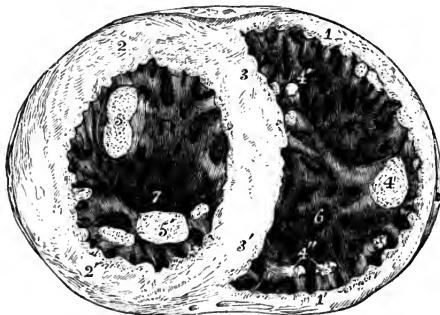
### THE HEART

The heart is, roughly, of the size of the closed fist of the individual ; its weight averages 10 oz. It rests by its flat surface upon the diaphragm ; its base is directed upwards, backwards, and to the right, *opposite the four middle dorsal vertebræ*, and its apex points downwards and to the left, beating against the fifth space. It lies behind the lower two-thirds of the sternum, encroaching on the left side of the thoracic cavity, and filling the space between the spine and the breast-bone.

The heart is free within the pericardium, and between the latter and the chest-wall the pleuræ and lungs intervene, only a small triangular part of the heart being uncovered by lung during inspiration.

The heart is lowered in the cases of pulmonary emphysema, left hydrothorax, large mediastinal tumours, and aneurysm of the aortic arch; also when the stomach and intestines are collapsed, as in œsophageal stricture. It is raised in ascites, tympanites, and in the case of ovarian, hydatid, or of other large abdominal tumours. It is pushed to the left in the case of effusion into the right pleura, and when the left pleura is water-logged the apex-beat may be found even to the right of the sternum (p. 189). It may be dragged to either side by a contracting lung or by pleural adhesions.

The *anterior part of the heart* is chiefly the right ventricle, the left ventricle being posterior.



1, Wall of right vent., and 2, 3, wall of left.

The left ventricle has much more work to do than the right; indeed, its wall is of treble thickness, and bulges into the right ventricle; thus, when the heart is removed from the body the ventricles may be distinguished by gently pinching each between the finger and thumb. Having comparatively little to do, the free border of

the right ventricle is thin and sharp (*margo acutus*), whilst that of the left ventricle is thick and rounded (*margo obtusus*). The left ventricle extends beyond the right and forms the apex of the heart.

The **apex-beat** appears, 'two inches below the left nipple and one inch to the sternal side,' as a gentle upheaval of the tissues of the fifth space. In children the impulse is sometimes in the fourth space; and in the aged, on account of the stiffness of the large arteries, it may be found in the sixth space.

The distinctness of the manifestation of the heart's impulse is due to the great strength of the left ventricle (which forms the apex), to the tilting of the heart forwards during systole, to the lengthening of the aorta as the blood is impelled into it (causing the heart to descend somewhat), and to the fact that there is no lung between the apex and the chest-wall.

The impulse of the apex-beat is felt as the ventricle discharges its contents into the large vessel, and resembles the 'kick' of the rifle. The impulse which is felt over the base is due to the energetic contraction of the thick ventricular mass. When the apex is covered with lung, as in emphysema, the apex cannot reach the chest-wall, and the cardiac impulse which is felt by the hand is then due to the contraction of the right ventricle. And, as remarked above, the apex-beat;



and even the basic impulse, are drowned in the case of abundant pericardial effusion. When, as the result of old adhesions, the apex clings to the hinder part of the pericardium, there may be no upheaval of the fifth space during systole, but, with each contraction of the heart, the space may actually recede, to thrill again or throb with ventricular relaxation. Thus the apex-beat is synchronous with diastole—a somewhat rare phenomenon.

**Displacement of apex-beat.**—The apex-beat is raised when the diaphragm is thrust up, as in ascites, tympanites, or abdominal tumour; it is depressed when the diaphragm is thrust down by emphysema, or by fluid in the left pleura: in these circumstances also it is displaced to the right, but the heart becomes more vertical as it sinks from the left side. When the right pleura is full the displacement is to the left. When the left lung is contracted the diaphragm is raised, and with it of course, the apex-beat, which is manifested more to the left.

Even in the healthy subject there is a considerable amount of fat about the grooves between the auricles and ventricles. When its deposit is greatly increased it is spoken of as a *fatty encroachment*, a much less serious condition than that in which muscular elements have passed into *fatty degeneration*.

**To mark out the heart upon the chest**, first make a dot corresponding with the apex, two inches below the left nipple and one inch to the sternal side; it is over the fifth space. Then draw a line to it from the right side of the xipho-sternal joint; this defines the flat side of the right ventricle, which rests on the diaphragm; it should be slightly convex downwards, as the margin of the heart bulges a little, as shown on p. 166.

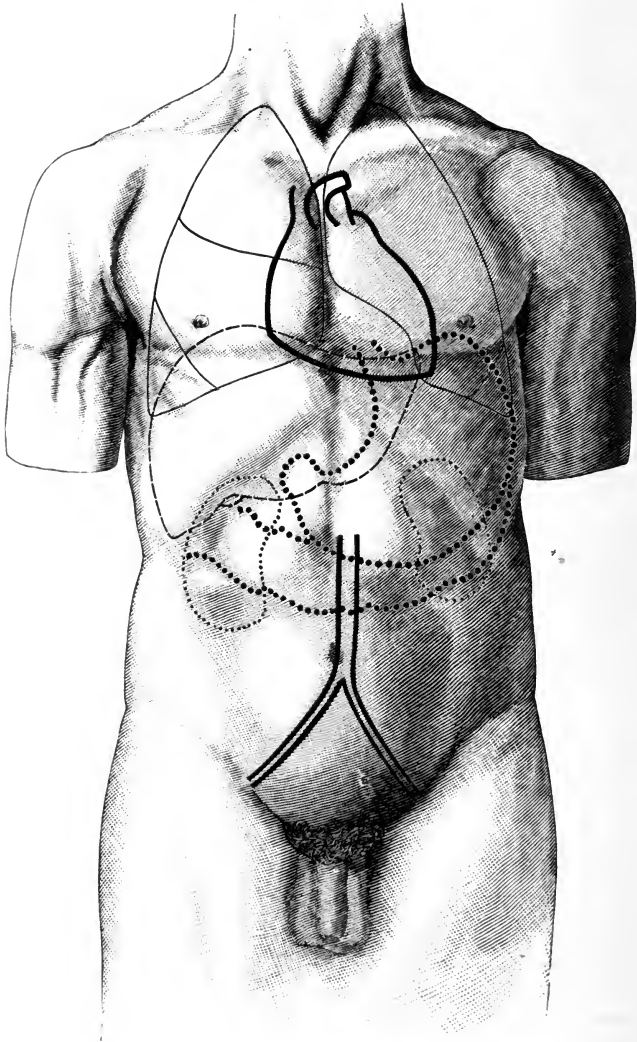
From the right end of this draw another line, bowing outwards half an inch from the right side of the gladiolus, to the top of the third chondro-sternal joint. This shows the bulge of the right auricle.

From the top of the last line draw another horizontally across the sternum and extending an inch to the left of the sternum; this marks the top of the auricles and the beginning of the great vessels.

It now remains to make a fourth mark from the left end of the superior horizontal line to the dot which is over the apex; this mark must be bowed so as to indicate the left convex border of the heart. The left and the flat borders must not meet at a point, but should be well rounded off, like the apex itself, which their junction represents.

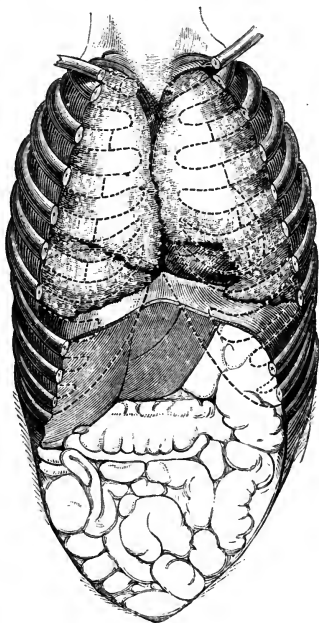
The situation of the heart varies only slightly with change of position of the subject, but when the diaphragm descends with inspiration the heart must, of course, descend also, though, resting on the central tendon of the diaphragm—which moves less than do the muscular domes—the change of position is not very great. The elevation with inspiration is not so extensive as it seems to be, because in that act the thoracic cage is raised in front of the heart.

The actual descent with inspiration is about one inch, whilst the apparent descent is nearer two inches. (Sibson.)



Chief viscera of thorax and abdomen outlined on front of body. (GODLEE and THANE.) For the back view see p. 333. See also figure on p. 295.

The **superficial cardiac area** is that part of the front of the heart which is not separated from the chest-wall by lung. The larger the lungs, the smaller that area: thus in emphysema the heart may be entirely covered by lung, but in phthisis, where the lung-tissue is wasted, the superficial cardiac area is extensive. It is triangular—one side of the space being formed by the straight margin of the right lung; the base corresponds with the flat border of the heart, resting on the diaphragm; and the third side by the sloping margin of left lung, behind the fourth left cartilage. During systole the apex of the heart displaces the little tongue of lung shown in the wood-cut, and impinges against the fifth space.



To mark out the *superficial cardiac area*, draw the line, as given above, from the xipho-sternal joint to the apex—this gives the base of the space; draw a second down the mid-sternum from the level of the fourth cartilage to the xipho-sternal joint, to define the margin of the right lung, and a third from the top of this line to the apex. This border of the space usually slopes down with the fourth cartilage or with the fourth space of the left side.

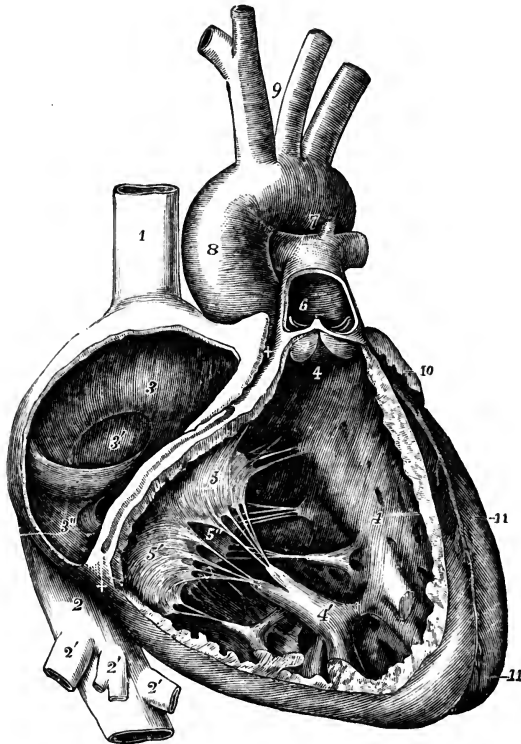
The tongue of lung which laps the apex of the heart is the lowest part of the upper pulmonary lobe, and it easily slips aside for the convenience of the movements of the apex of the heart.

#### THE INTERIOR OF THE HEART

The **endocardium** is a serous layer which lines the cavities of the heart, and is continued from them along the arteries and veins. Its reduplication, with some fibrous tissue intervening, forms the valves. It consists of pavement cells upon a stratum of connective tissue. Inflammation of the endocardium (as in acute rheumatism) may cause the growth of warts upon the cardiac valves. Endocarditis generally occurs on the left, the hard-worked side, of the heart, and it is often secondary to pericarditis, the inflammation having traversed the muscular wall of the heart to reach the endocardium.

The **right auricle** has a capacity of about two ounces. It consists

of a sinus and an appendix. Into the upper part of the sinus, behind and to the right side, the superior cava pours its contents in such a manner that the blood, descending from it, falls against the opening into the right ventricle. In the fœtus this stream passes in front of, and does not blend with, the wave of pure blood which is entering the auricle by the inferior cava and leaving it by the foramen ovale.



Interior of right heart :

- 1, Sup. cava.
- 2, Inf. cava, with hepatic veins.
- 3, Septum and fossa.
- 4, Pulmonary valve.
- 5, Tricuspid valve.
- 6, Pulmonary art.
- 7, Ductus art.
- 10, Left appendix.
- 11, Left ventricle.

The inferior vena cava opens into the lowest part of the auricle, sending its blood upwards and inwards against the inter-auricular wall, for this was the direction which it took in fœtal life, passing through the foramen ovale under the protection of the Eustachian valve. This valve is a reduplication of the auricular lining, and is attached by its convex border at the front of the inferior cava and just behind the auriculo-ventricular opening.

The *fossa ovalis* is on the inter-auricular septum, and marks the position of the foramen ovale by which, in the fœtus, the pure blood

from the inferior cava passed into the left auricle; the ridge around the fossa is the annulus ovalis.

The *coronary sinus* collects the blood from the two coronary veins, and returns it into the back of the right auricle; its orifice, which is guarded by an imperfect valve (Thebesian), is between the inferior caval and the ventricular orifices. Some small cardiac veins open independently by *foramina Thebesii* into the right auricle.

The auricular appendix has its wall strengthened by muscular bands which are arrayed like the teeth of a comb—the *musculi pectinati*.

The **right ventricle** has its flat side resting upon the diaphragm; its convex surface forms the chief part of the front of the heart, but it does not quite reach to the apex. The auriculo-ventricular opening is to the right side of its base, and is guarded by the tricuspid valve, which lies behind the sternum between the third intercostal spaces. The most important flap of the tricuspid valve is, of course, towards the left, so that as blood is being driven into the pulmonary artery there may be no risk of it flowing back into the auricle. Of the other segments one is anterior, the other posterior.

The bases of the flaps are attached to a fibrous ring around the orifice, and blend with each other laterally. To the free borders of the valve segments, and also to their ventricular surfaces, *chordæ tendineæ* are attached, so that they may not be swept up into the auricle with the stream of blood when the ventricle contracts. If the tendinous cords were connected by their other end with the ventricular wall they would become slack during systole—as the walls closed in upon their contents—and the tension of the valves would cease. They, therefore, lose themselves below on fleshy columns (*musculi papillares*), which contract simultaneously with the ventricular wall, and thus they hold the valves taut.

The *pulmonary artery* leads up from the conus arteriosus, and is near to the interventricular septum—that is, on the left side of the roof of the ventricle. Its mouth is guarded by semilunar valves, which are placed behind the third left chondro-sternal joint.

The **left auricle** has an appendix like that of the right; and it overlaps the root of the pulmonary artery on the left side. In front of the auricle are the aorta and the pulmonary artery. The four pulmonary veins enter the back of the sinus, two to the right and two to the left; they have no valve. Behind the auricle passes the left bronchus. On the inner wall is a depression marking the situation of the *foetal foramen ovale*.

The **left ventricle** makes the chief part of the back of the heart, only a small part of it being seen near to the apex on the anterior view, but it reaches beyond the right ventricle and forms the apex. Its opening into the left auricle is guarded by a valve of two flaps—like a bishop's mitre—which is behind the sternum at the level of the third

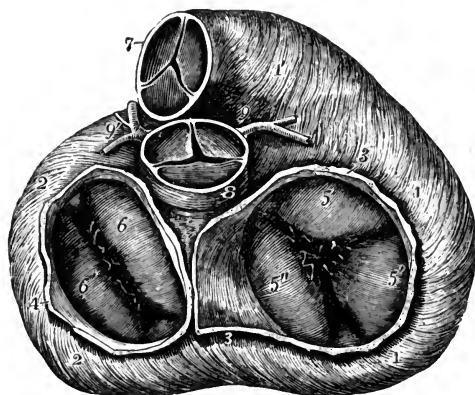
intercostal spaces, being behind, and a little to the left of the tricuspid valve. The two flaps of the *mitral valve* are unequal, the larger and stronger being placed to the right and in front, between the auriculo-ventricular and the aortic openings. The segments are connected with *musculi papillares* as in the right ventricle.

The *aortic orifice* is to the front of the ventricle and to the right of the opening into the auricle. It is behind the sternal end of the third left space, and is guarded by semilunar valves, like those at the root of the pulmonary artery, than which, however, they are larger and stronger. It is behind, and a little to the left of, the pulmonary orifice.

The *semilunar valves* are folds of the lining membrane of the heart over a foundation of fibrous tissue ; at the middle of the free border of each is a fibrous nodule, the *corpus Arantii*. These nodules block the centre of the aperture during diastole, when the valves fall together. The closed valve does not form a horizontal plane across the root of the artery ; the convex surfaces of its segments bulge against each other, and, the greater the strain, the greater the surfaces of contact and the less the chance of regurgitation.

The *sinus of Valsalva* is the dilated part of the artery behind the segments of the valve. When the ventricle ceases contracting, the elasticity of the artery drives the blood into the three sinuses and forces the valves together.

**The coronary arteries** are given off from the sinuses of Valsalva. The *right* comes forward on the right side of the pulmonary artery, and winds round the right auriculo-ventricular sulcus, sending one branch down the posterior inter-ventricular groove to the apex, and another



- 1, Right ventricle.
- 2, Left ventricle.
- 3 and 4, Parts of right and left auricles.
- 5, Tricuspid valve.
- 6, Mitral valve.
- 7, Pulmonary artery.
- 8, Aorta.
- 9, Coronary artery.

between the back of the left auricle and ventricle. The *left* coronary artery passes on the other side of the pulmonary artery, down the anterior

inter-ventricular groove, giving a transverse branch round the left auriculo-ventricular groove.

The coronary arteries give twigs to the large vessels as well as to the auricles and ventricles. When they are diseased (atheroma) they carry an insufficient amount of blood to the cardiac tissue, so that fatty degeneration, together with faintness and pain (angina pectoris), result. Should an embolus be carried into one of them, death may immediately occur from paralysis of cardiac muscle.

The **relative position of the chief cardiac orifices**.—The pulmonary artery and the aorta are developed together: they, therefore, lie close together; but the aortic opening is behind the pulmonary because the left ventricle is behind the right. Being close together, the pulmonary orifice must be on the left side of the right ventricle, and the aortic orifice must be on the right side of the left ventricle. The right auriculo-ventricular opening, then, must be to the right of the pulmonary aperture, and the left auriculo-ventricular opening must be to the left of the aortic aperture. (*See fig. on p. 168.*)

The **situation of the valves**.—The *aortic* valves are behind the sternal end of the fourth left space. The *pulmonary* are a little higher—at the junction of the third left cartilage with the sternum. The *auriculo-ventricular* orifices are behind the sternum at about the level of the third intercostal spaces.

‘Thus these valves are so situated that the mouth of an ordinary-sized stethoscope will cover a portion of them all if placed over the junction of the third intercostal space on the left side with the sternum. All are covered by a thin layer of lung; therefore we hear their action better when the breathing is for a moment suspended.’ (Holden.)

Occasionally a valve suddenly gives way during violent physical exercise, or as the result of a blow over the front of the chest; the lesion causes enfeeblement of the circulation and shortness of breath.

## THE SOUNDS OF THE HEART

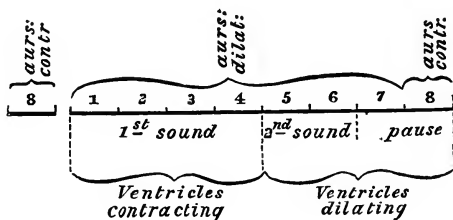
The **healthy heart-sounds** are a long and a short one: lūb dūp. Then comes a pause which is as long as the short, second sound; and then lūb dūp again. We may represent the rhythm by a series of dactyls thus:—lūb dūp pause | lūb dūp pause.

And, if we divide the dactyl into eight equal parts, four parts will be taken up by the first sound, two by the second, and two by the pause. Thus:—

$\underline{1, 2, 3, 4},$	$\underline{5, 6},$	$\underline{7, 8}$		$\underline{1, 2, 3, 4},$	$\underline{5, 6},$	$\underline{7, 8}$
1st sound,	2nd,	pause;		1st sound,	2nd,	pause.

The two ventricles dilate together and contract together, and the auricles dilate together and contract together. Having divided the

dactyl into eight parts (though, for the scheme of the sounds and the pause, four would have served equally well), the eight divisions are now needed for the demonstration of the workings of the auricles and ventricles ; thus :—



Thus, the auricles are filling during seven-eighths of the dactyl, and are emptying their contents into the ventricles in the eighth part, and, immediately after this emptying, the ventricles, which are now full to the utmost, contract, and the auricles begin to fill again. As regards the ventricles, they are contracting during the first four parts of the dactyl and dilating during the remainder.

The **first sound** takes place with contraction of the ventricles and is synchronous with the arterial pulse. It is due chiefly to the slamming of the auriculo-ventricular valves, and partly, perhaps, to the rush of blood out of the ventricles ; to the impulse of the apex against the chest-wall, and to the rumble of the contracting ventricular walls. With the first sound, then, the auriculo-ventricular gateways are shut, and the aortic and pulmonary are open.

The short **second sound** is due to the sharp closure of the semilunar valves, which takes place when the ventricles have finished their contraction, and the elastic coats of the pulmonary artery and aorta are trying to drive the blood back into the flaccid ventricles. It is like the noise which is caused by the vibration in a long, vertical, leaden pipe when the tap, through which water is quickly flowing, is suddenly turned off.

Take the hem of your handkerchief between the finger and thumb of your left hand, and about 3 in. along in the straight line take it also between the finger and thumb of the right hand. Now, by suddenly separating the two hands after having slightly approximated them, jerk the hem tight, and you get a long vibration or sound, something like that due to the sudden tension of the flaps of the auriculo-ventricular valves. That represents the long first sound. Now, in a similar way, snap the hem with the thumbs about an inch apart, and you will imitate the short, vibrating, second sound.

The fuller the large arteries, and the greater the pressure of the blood down upon the semilunar valves, the louder, sharper, and more



ringing is their slamming, and thus is explained the *accentuation of the second sound*.

When an abnormal sound is heard over the heart, the first point is to find if it is synchronous with ventricular contraction or not ; this is settled by listening to the sound whilst the finger is laid on the radial pulse. If the murmur be occurring with the ventricular contraction it must be due either to obstruction to the outflow of blood into the pulmonary artery or aorta, or to a reflux through an auriculo-ventricular valve ; and if it be heard during diastole it must be caused by regurgitation from the pulmonary artery or aorta, or by a difficult passage from an auricle into a ventricle ; almost for certain it is due to regurgitation, and, almost certainly, the regurgitation is from the aorta.

The aortic and pulmonary valves slam at the same time, making the second sound, which should be heard over the carotids, being propagated along the aorta in the blood-stream. If it cannot be heard in the neck the listener concludes that the aortic valves are unable to slam together, and this *loss of the second sound* makes him suspect aortic regurgitation (p. 173).

When the segments of the auriculo-ventricular valves do not slam exactly together the *first sound* is spoken of as '*reduplicated*.' A similar occurrence may be noticed as the lateral halves of a door-way are pushed asunder ; if they swing back into the middle line at the same instant a clear sound is heard, but if one of them lingers the noise of the closure is blurred or reduplicated. When there is a want of harmony in the closure of the aortic or pulmonary valves the *second sound is reduplicated*.

**Cardiac murmurs.**—When the aortic or pulmonary orifice is narrowed by chronic inflammation (endocarditis) or the presence of warty excrescences (vegetations), the blood passes through it with a scraping or whistling sound, called a *bruit*. Such *bruit* occurs, of course, when the ventricle is contracting, and is, therefore, systolic. (*Systolé*, contraction ; *συστελλω*, contract, *συν* with, *στελλω*, send. *Diastolé*, dilatation ; *δια*, asunder, *στελλω*.)

A river flowing peacefully in its wide bed becomes excited as it approaches the artificially narrowed passage under a bridge, and rushes from between its piers with an audible sound. So it is with the blood-stream which traversed a valve which has been made narrow and rigid by disease, and then dashes into a roomy space. The murmur is probably produced just after the blood has passed through the straits. In the same way, when a stethoscope is placed over and made to compress the common femoral artery, the bruit does not occur in the compressed part of the vessel, but in the roomy part just beyond the obstruction, where the blood-stream is opening out again.

The perfect working of a valve depends on the integrity of each individual segment, and if the valve be so defective as to hinder the passage of the blood its segments will probably fail completely to close

the opening after the blood has passed through ; thus, some of it slips back again (regurgitates) when the *vis a tergo* has ceased to act. There are various ways of expressing this doubly imperfect condition : the valve is 'stenosed' (*στενός*, narrow), and is also 'inadequate' ; there is 'obstruction' with 'insufficiency' also, and, therefore, regurgitation. Thus there are systolic and diastolic murmurs. An aortic obstruction-murmur occurs during systole, and a regurgitant murmur during diastole. But aortic obstructive and mitral regurgitant murmurs occur at the same time ; so also is it with pulmonary obstructive and tricuspid regurgitant.

When the aortic or pulmonary aperture is both narrow and incompetent there is a double murmur of obstruction during systole and of regurgitation during diastole ; in the case of the aortic valve the murmur of regurgitation accompanies or even takes the place of the second sound, for the valve-segments have ceased to slam tightly together. So also it would be with the pulmonary valve.

An auricle and ventricle both being dilated, the fibrous ring to which the bases of the valves are attached is stretched, and, as the valves do not at the same time grow larger, they are necessarily incompetent to prevent regurgitation.

*Disease of the tricuspid valve* is so rare that we need not consider the resulting murmur separately ; indeed, valvular disease of the right side of the heart is quite uncommon ; but tricuspid regurgitation may exist without valvular disease (*v. i.*). In nineteen cases out of twenty, valvular murmurs belong to the hard-worked left side of the heart—to the mitral or aortic orifice, the inlet and the outlet of the left ventricle. The natural inlet has become an outlet also : or the natural outlet is obstructed. (Watson.)

A cardiac murmur, therefore, most likely exists in the left side of the heart, and, as mitral obstruction is rare, it is either due to mitral insufficiency or to aortic derangement. If the former, it occurs during systole, and if it be due to aortic obstruction it will also be systolic, and heard along the aorta (p. 173) ; if diastolic it will be due to aortic insufficiency and will be heard over a more limited area.

A *tricuspid regurgitant murmur* when associated with aortic or mitral disease is a 'friendly' sound, for it means that the right ventricle is pumping some of its belated contents back into the right auricle, and so is lessening the risk of pulmonary apoplexy. It obviously occurs with ventricular systole—with the radial pulse ; it is best heard near the xiphoid, but it is of rare occurrence. The murmur of tricuspid obstruction is still more rare, and may be left out of consideration.

Notwithstanding the '*safety-valve arrangement*' at the *right auriculo-ventricular opening*, the energetic action of the right ventricle sometimes throws more strain upon the pulmonary capillaries than they could bear. Thus I have known of an athlete who, though apparently in perfect health and strength, was liable to hæmoptysis after any

unusual strain. Hæmorrhage even in such circumstances should be regarded with anxiety, though it may be merely of physiological import. It is probable that the safety arrangement not only insures the right side of the heart against strain, but also against disease. A similar arrangement, desirable though it might seem, could not exist at the left auriculo-ventricular opening, as the lungs would inevitably suffer by it.

Murmurs from *disease of the pulmonary valve* are best heard over the third left cartilage, that is over the valve; they grow fainter towards the apex. They are distinguished from aortic murmurs by their occupying a limited area; they certainly do not ascend into the neck (p. 171). They are usually the result of congenital malformation.

When the *left auriculo-ventricular valve* (mitral) is *narrowed* an obstruction-murmur may be heard immediately preceding the ventricular contraction. It is the *presystolic murmur*, and is of comparatively rare occurrence. When listening for it a finger should be kept on the radial pulse, so that the observer may know exactly when to expect it. The murmur runs with the blood-stream, and is heard over the apex.

**Mitral regurgitation**, a very common defect, occurs when the left ventricle is pumping blood backwards through the incompetent auriculo-ventricular valve—the murmur, of course, takes place with systole. It does not ascend into the large vessels at the root of the neck, as does a systolic aortic murmur, but is loudest heard in those regions where the ear can be approached to the left ventricle without the intervention of the right ventricle, as in the neighbourhood of the apex; also below the left shoulder-blade, and behind the lower middle dorsal vertebræ, the seventh and eighth (p. 166), for there the left ventricle is at the back of the heart, and in that direction the blood is rushing. As the left ventricle lies close over the stomach, a mitral murmur may often be heard in the gastric region, with that peculiar metallic thrill which is due to the vibrations passing across the stomach full of gas (*v.* p. 164).

The murmur of **aortic obstruction** is not best heard over the midsternum, that is over the situation of the aortic orifice (p. 169), for at this level the valve is deeply hidden behind the right ventricle and the root of the pulmonary artery; but the sound, being carried by the blood-stream, is heard where the aorta comes near the surface, as at the second right costal cartilage, behind the manubrium, in the large vessels at the root of the neck, and along the dorsal spine. It occurs with ventricular contraction, and is, therefore, synchronous with the radial pulse.

The murmur of **aortic regurgitation** is not well heard in the neck, for the regurgitant blood is actually rushing away from that region, back into the left ventricle. The carotids, however, which are half-emptied before the ventricle contracts again, fill and throb visibly with systole, especially when the patient sits or stands, as gravity in-

creases the amount of the reflux blood. The regurgitation murmur occurs immediately after the radial pulse, that is during ventricular diastole, and is heard at the second right cartilage, over the valve, along the left sternum, and down to the apex, replacing, possibly, the second sound, or all of it but that which is due to the slamming of the pulmonary valves. Now, for some obscure reason the regurgitating blood does not always carry this murmur down to the apex, but, throwing the sternum into vibration, it is well heard over that bone, for the sternum is a good conductor of sound. When the regurgitation continues until the ventricle is actually ready to contract again the murmur lasts until the first sound. This means that a little blood is squeezing its way back during the whole time that the aortic valves are shut. When the regurgitant murmur is a short one the valve must be desperately out of order, allowing the arterial tension to send plunging back as much blood as it likes, and all in a lump, as it were. Thus the short-lived aortic regurgitant murmur is of much graver import than that which persists up to the next ventricular contraction. When the aortic valve permits regurgitation the arteries cannot be kept full, and so it is that the radial pulse collapses during diastole. Then when the ventricle contracts again blood is injected into the half-empty vessel, and the *water-hammer*, or whipping pulse, is produced—a sign of great clinical value.

When an aortic murmur lasts only through the first half of the diastole, and the radial pulse is seen to expand and collapse rapidly, regurgitation is extreme. But when it lasts through the whole diastole, and the collapsing pulse is not very visible, even on raising the wrist, the valvular insufficiency is but slight. Aortic obstruction very often co-exists with aortic insufficiency; then a 'see-saw' murmur is produced.

*Engorgement of the superficial cervical veins* occurs when the right ventricle is much embarrassed, as in pulmonary emphysema; in mitral insufficiency; in tricuspid insufficiency; or when an aneurysmal or other thoracic tumour presses upon the superior vena cava or the innominate veins. The engorgement is less noticeable when the head and neck are raised, as then gravity helps to empty the veins. Inspiration relieves the cervical congestion; but with each expiratory act, and markedly in coughing, the intra-thoracic pressure is increased, and the veins stand out fuller than ever along the neck, showing a *respiratory undulation* imparted to their contents.

A definite *venous pulse in the neck* occurs when the right ventricle is unable to drive its contents through the lungs (p. 172) and some of the blood escapes by the tricuspid valve into the right auricle, and thence into the superior cava, the innominate and the jugular veins. Regurgitation may occur through even a healthy tricuspid valve. As already remarked, the right auriculo-ventricular orifice has a third flap to provide for this safety-action; through a healthy two-flap valve it

could hardly take place, so that, had the right auriculo-ventricular valve been on the pattern of the mitral, an overloaded right ventricle could have found relief only by pulmonary hæmorrhage. In the case of the venous pulse the jugular veins can be seen filling from below upwards.

The reflux blood passes straight into the right innominate vein, so that the venous pulse is more perceptible on the right side of the neck. The venous pulse is, of course, most marked in a case of tricuspid dilatation, when the external jugular may be widely distended, throbbing as high as the angle of the jaw. Occasionally the pulsations extend along the subclavian tributary of the innominate vein, and pass down the superficial veins of the arm. Sometimes the *tidal flow passes backwards in the inferior cava*, and through the hepatic veins, so that if the liver happen to be at the same time congested and large pulsations in it may be felt. Pulsation from tricuspid insufficiency has also been found as low as the femoral vein.

Just before the systolic venous pulsation occurs, a much slighter throb may be sometimes detected; it occurs as the overloaded auricle is struggling to empty itself into the ventricle, a portion of its contents being forced up into the superior cava.

A *respiratory pulse in the superficial veins* of the neck is often observable even in health, for during expiration the intra-thoracic pressure is increased, and the veins are unable to empty themselves. Then, with inspiration, their contents hurry into the right auricle, sucked, as it were, into the expanded chest, and their track is no longer visible.

**Hypertrophy.**—As the biceps of the blacksmith grows by constant exercise, so does the wall of the heart by the continual effort to overcome obstruction in the arterial circulation. When the obstruction first occurs, the ventricle, unprepared for it, is unable to empty itself of blood, and its cavity becomes dilated. Afterwards its wall begins to thicken. Aortic obstruction (p. 173) becomes of comparatively little importance when it is accompanied by hypertrophy of the left ventricle. Thus, hypertrophy, which is always preceded by dilatation, is compensatory for the dilatation, and for the thinning of the muscular wall. With hypertrophy the impulse is excessive and ‘heaving,’ and the cardiac region of the chest-wall may bulge, especially in a young adult.

The larger the heart, the more boisterous its action, and the more extensive its impulse. Thus, hypertrophy may be recognised at a glance, or by placing the hand over the front of the chest.

A greatly hypertrophied ‘bovine’ heart may weigh twenty, thirty, or even forty ounces, and, by pressing against the œsophagus (p. 139), may impede deglutition. Even in the ordinary way the heart would compress the gullet when the man is lying on his back, were it not swung in, and held by the pericardium. If the heart be greatly enlarged, the left cartilages and ribs from the fourth to the seventh bulge, and, the lungs being pushed aside, the dull area is increased, and the spaces are widened.

**Hypertrophy of the right ventricle** occurs when there is diffi-

culty in pumping blood through the lungs, as when the capillary area is diminished by dilatation of the air-cells, as in emphysema and in chronic phthisis, or by the compression of a pleuritic effusion. Obstruction at the pulmonary valve causes dilatation and hypertrophy of the right ventricle, and so especially does incompetence of the mitral valve, for the left ventricle then pumps blood back into the left auricle, and the pulmonary veins cannot empty themselves; the pulmonary capillaries being overloaded, the right ventricle struggles in vain to pass its blood onwards.

In these circumstances, the right ventricle may grow so large as entirely to cover the left ventricle and to hide the apex-beat. The impulse is felt over a large area, even up to the third left cartilage, and down in the epigastrium. But when the heart is working with a tremendous bustle, and the radial pulse is, nevertheless, poor, it is evident that the right ventricle, not the left, is hypertrophied.

**The left ventricle is dilated and hypertrophied** when, Sisyphus-like, it is struggling to force upwards its contents which are ever rolling backwards though an incompetent aortic valve; but these conditions sometimes occur independently of valvular disease, as in the case of athletes and others who are suddenly called upon for violent exertion.

In the case of severe aortic disease the left auricle remains overfull, the pulmonary circulation is delayed, and the right ventricle becomes hypertrophied as well as the left. The grave lung-complication does not occur so long as the left ventricle remains strong enough for its extra work, but it comes on as soon as the walls begin to yield.

Delayed pulmonary circulation eventually causes hypertrophy of the left ventricle as well as the right, as in emphysema; the lungs being full, the right heart is full, as are also the venous capillaries throughout the body, and thus the left ventricle is obstructed in its work.

*Hypertrophy of the left ventricle without dilatation* occurs in the case of simple narrowness of the aortic opening, and also in Bright's disease, when there is an increasing difficulty in forcing blood through the narrowed and rigid capillaries. In such circumstances hypertrophy must not be regarded as disease. It is, rather, Nature's remedy for disease. It is 'compensatory,' and of excellent omen. How perilous, on the other hand, is the state of the feeble individual who, with aortic obstruction, has a dilating ventricle with walls so thin as scarce to supply a perceptible apex-beat! So long as the ventricle is equal to its extra work all goes well; but when it begins to fail the left auricle becomes distended and the case becomes as serious as one of mitral regurgitation, venous congestion occurring, as already described.

With aortic regurgitation (p. 173), dilatation precedes hypertrophy and is inevitable; in aortic narrowness there need be no dilatation of the slowly thickening ventricle.

When the left ventricle alone is hypertrophied the impulse may be found in the sixth, seventh, or eighth space, and outwards towards the

left axillary line : when the right ventricle is enlarged the impulse extends to the right of the sternum. Displacement of the apex-beat downwards and outwards at once suggests hypertrophy of the left ventricle ; but an extensive impulse within the normal site does not necessarily imply enlargement, it may be due to recession of the lung—as in phthisis.

The extent of the hypertrophy cannot always be made out by percussion, as the heart, instead of pushing the lung aside, may hide beneath it.

Though the hypertrophied left ventricle labours and hurries to force the blood onwards, it never gets complete mastery over the situation. The result is that when any extra demand is made it becomes embarrassed, and the pulmonary veins, and the vessels of the lungs generally, are over-filled, and aëration is retarded. Thus, shortness of breath is a prominent sign of hypertrophy.

When the mitral valve is narrowed, also when it is incompetent, the left ventricle has but a small quantity of blood to force into the aorta ; thus, in mitral disease the left ventricle is the only part of the heart which is not hypertrophied.

*In valvular disease of the heart the prejudicial effects pass always in the direction opposite to that of the normal blood-stream.*

The *auricles* are *dilated and their walls thickened* when their labour is increased by a narrowing of the gateway into the ventricle, or when, from incompetence of that valve, the ventricle is able to pump some of its blood the wrong way. In mitral regurgitation the left auricle first enlarges, then the right auricle, on account of the obstruction in the lungs, and then the right ventricle.

The dilatation of the left auricle may cause so much pressure upon the left bronchus (which is close behind it, p. 194) as to obstruct the flow of air through it.

With mitral insufficiency the hypertrophied and embarrassed heart beats with such vigour against the chest-wall that recognition of the exact murmur may be difficult. A thin layer of lung, however, acts as a cushion and does away with the local excitement, and thus it is that in these cases the murmur is often most distinct towards the axilla. Sibson used to demonstrate this effect of the layer of lung on the heart-sound by placing a piece of blotting-paper between the chest and the stethoscope, and so diminishing the impulse-noise and bringing out the murmur. 'A mitral murmur is a proof of mitral regurgitation, but not of disease of the mitral valve ; it having been noticed in cases in which *post mortem* examination revealed a healthy mitral valve.'

The **effects of mitral disease**.—Catarrhal bronchitis, and, later on, œdema of the lung, hæmoptysis, and pulmonary apoplexy, may be caused by valvular disease of the heart, the pulmonary veins, and the bronchial veins which open into them, being engorged, and the lung 'splenified.' This condition occurs both when the mitral valve is

narrowed, for then the left auricle is always over-full, and when it allows regurgitation from the ventricle. Cough also is a sign of valvular disease, because the irregular passage of blood through the lungs worries the pneumogastric filaments.

The lungs and the right auricle being distended, the inferior vena cava is over-full and dilated, the liver becomes large and tender, and 'nutmeg' engorgement (p. 337) is produced. Later on, albuminuria, and dropsy of the peritoneum, pleura, and pericardium, and œdema of the legs, occur. The superior cava is also overloaded, and thus œdema of eyelids, headache, and apoplexy are accounted for, as is also the capillary congestion which gives rise to clubbing of the fingers. The kidneys and spleen are also engorged and the urine is albuminous. The albuminuria is the result of nephritis, for heart-disease causes nephritis just as it does bronchitis; but, the kidney being so much more distant from the heart than the lungs, the student is apt to overlook this pathological sequence.

The **structure of an artery**.—The innermost coat consists of a layer of flat endothelium upon a bed of elastic fibres and connective tissue (*intima*). Next come alternating layers of circular elastic and non-striated muscular fibres (*media*), and outside these more elastic and connective-tissue fibres (*adventitia*). The internal and middle coats break clean through and retract when a ligature is tightly applied, the external, tough coat being puckered up. Inflammation is set up by the operation, and the clot which forms becomes glued to the wall, and in time nourished by the vasa vasorum and duly organised. The narrow zone of artery which is girt by the ligature necroses, and is set free by linear ulceration in the adjoining tissue, the fibrinous plug being a safeguard against hæmorrhage.

An artery is usually enclosed in a fibrous sheath, often with a vein or with venæ comites; this sheath has to be opened up before the ligature is applied. If the artery be too freely denuded in the operation, the vasa vasorum are needlessly destroyed and the vessel runs a risk of sloughing.

A large artery, and especially so the *aorta*, has the middle coat greatly thickened by elastic fibres, so that it may yield as the blood is pumped into it, and then, when the semilunar valve is closed, may exert continuous pressure upon the blood, forcing it onwards.

#### THE ARCH OF THE AORTA

The arch of the aorta springs from base of the left ventricle at the level of the sternal end of the third left intercostal space.

The **first part** of the arch ascends obliquely forwards to the second right costal cartilage.

*Relations*.—It is within the pericardium, and has *in front* the pulmonary artery, which comes from the anterior ventricle, and the



right auricular appendix. *Behind* is the root of the right lung. *To the right* are the superior vena cava and the right auricle, and *to the left* is the pulmonary artery (*v. p.* 185).

The **second part** inclines backwards, and to the left, from the second right cartilage, gently bending over the trachea, till it reaches the left side of the fourth dorsal vertebra.

*Relations.*—*In front* are the left pleura and lung, and the left pneumogastric, phrenic, and cardiac nerves. The left innominate vein may overlap it above, and the left superior intercostal vein ascends obliquely in front to join the left innominate. *Behind* are the trachea, œsophagus, thoracic duct; the left recurrent laryngeal, and the deep cardiac nerves. *Above* are given off the innominate, the left carotid, and the left subclavian arteries; the left innominate vein runs across the roots of those arteries. *Below* are the bifurcation of the pulmonary artery, the ductus arteriosus, and the left recurrent laryngeal nerve.

This part of the arch is badly named 'transverse,' as it runs almost directly backwards from the second right cartilage.

Its upper border is about an inch below the episternal notch, and corresponds with the tip of the third dorsal spine, and its lower border is on the level of the transverse sternal ridge. But in feeble and small-chested persons the transverse aorta may lie on the level of the top of the manubrium; in big-chested men it is placed much deeper—behind the top of the gladiolus, for instance. Its concavity is, of course, downwards, but there is a second concavity directed backwards and to the right which is due to the vessel being bent round the trachea.

The **third part** of the arch is very short, extending only down the left side of the fifth dorsal vertebra, which thus forms its *posterior relation*. *In front* is the root of the left lung, and *on the right side* are the fifth vertebra, and the œsophagus and thoracic duct; *on the left* are the lung and pleura.

**To mark out the large vessels.**—The aorta begins opposite the sternal end of the third left space. Roughly, it is about as wide as the thumb. It slopes upwards to the second right cartilage. Thence it turns backwards, and slightly to the left, behind the manubrium, its lower border corresponding with the ridge between the manubrium and the gladiolus. The third part descends by the fifth dorsal vertebra, rather to the left of the middle line.

From immediately behind the middle of the manubrium the innominate artery and the left common carotid mount to their respective sterno-clavicular joints. The left subclavian ascends a little to the outer side of the left carotid.

The pulmonary artery, two inches long, ascends in the pericardium from the right ventricle to the concavity of the aortic arch, where it bifurcates; that is, it reaches from the third left chondro-sternal joint (the situation of the pulmonary valve) to the second left chondro-sternal joint.

**Irregularities of the aortic arch.**—Sometimes the heart and aorta, and the arterial and venous trunks associated with them, are transposed, so that the apex beats on the right of the sternum, the superior cava being on the left of the middle line, and the aorta arching to the right. But the aorta may, by the development of the right fourth branchial arch instead of the left, bend over to the right side, without there being any other transposition of thoracic viscera.

The right subclavian artery may come from the back of the left end of the arch, and reach the left scapuli by passing behind the trachea and œsophagus.

There may be two innominate arteries; the left carotid may come from the (right side) innominate; the two carotids may come off together, the subclavians arising on either side of the common trunk; the left vertebral may come off as a fourth trunk between the left carotid and subclavian; both vertebrales may thus arise, making five trunks. All four large trunks may arise separately, there being no innominate artery. Further, the vertebrales may arise separately, whilst the innominate may be divided, making six. The left carotid coming from the innominate may cross the windpipe dangerously near the knife of the tracheotomist (p. 133).

On account of the enormous strain which is thrown on the beginning of the aorta its wall is apt to yield, especially when weakened by disease—arteritis. **Aneurysm** is thus produced. The very root of the aorta being dilated, the valves fail to prevent regurgitation, and a diastolic murmur occurs. The first part of the arch is more likely to yield than the second, for the former is enclosed within the pericardium; whilst the latter has its walls strengthened by the fibrous part of the pericardium being blended with it. A fatal leakage of an aneurysm of the first part may take place into or through the pericardium, but before this happens certain pressure effects may be noticed; these, however, are not so varied and suggestive as they are in aneurysm of the transverse arch, for the tumour bulges forwards and usually bursts before it gets large. When it reaches the chest-wall a pulsating swelling occurs near the second or third right cartilage.

Tight-lacing, or tight clothing, especially about the neck and upper part of chest, is apt to check the emptying of the large vessels and to produce thoracic aneurysm.

The **general effects of thoracic aneurysm** are disturbance of the action of the heart by the pressure upon cardiac and pneumogastric filaments. Through the pneumogastric interference 'indigestion' may be complained of. The growth of the tumour displaces the lung and makes percussion dull. Later, there may be pain in the chest and back, especially when the swelling impinges against the spine. Pressure upon the root of the lung may cause dyspnoea, with strange breath sounds and cough. The patient may be unable to lie down in comfort, as the tumour then weighs the more heavily against the trachea. The

arch is lengthened and the heart lowered, and the struggling left ventricle is considerably enlarged. Circulation is delayed, and, an imperfect supply of blood passing to the lungs, shortness of breath is usually a prominent sign.

If the tumour happen to press upon and irritate a sympathetic chain there may be dilatation of the pupil of that side (p. 88); contraction of the pupil suggests that the pressure is severe enough to paralyse the sympathetic. In any case, the aneurysm is apt to cause inequality of the pupils.

In aneurysm of the aortic arch the pulsation is exactly synchronous with ventricular contraction; and there may be a quiet space between the region of the cardiac impulse and the abnormal pulsation. In examining the tumour one hand should be placed flat over the pulsating area in front, whilst the other is laid between the shoulders during expiration; in this way the characteristic expansion may be best detected. The sac may burst externally, or into the pericardium, pleura, lung, trachea, œsophagus, mediastinum, spinal canal, or even into the pulmonary artery itself.

Sometimes the chief and most characteristic symptom of the disease is pain down the left arm, or at the left shoulder—an important clinical fact which anatomy fails at present efficiently to explain.

*Aneurysm of the first part* is of the most frequent occurrence—perhaps, as already remarked, because the second and third portions are strengthened by the fibrous element of the pericardium. Another explanation is that the blood from the left ventricle is, on account of the obliquity of the heart, pumped forcibly against the outer side of the first part, which it gradually stretches and weakens. The aneurysm begins as a pulsating tumour in the *second right space*, close to the sternum; the apex-beat being displaced towards the left side. The dilatation is apt to start in a sinus of Valsalva, the right for choice, and it is, therefore, usually sacculated.

Aneurysm of the first part of the arch may press upon the superior vena cava, and cause venous congestion of both sides of the head and neck, and of both upper extremities; indeed, a case is recorded by Watson in which almost the whole of the blood coming from the head and arms was returned by dilated epigastric veins into the external iliacs, to reach the heart by the inferior cava. The obstructed return of blood from the brain causes dizziness and headache.

Bulging backwards against the root of the right lung, the tumour may obstruct the bronchus; and, pressing against the pulmonary artery, it may cause a systolic bruit. Sometimes it produces absorption of the ribs and sternum, and bursts at last into the pericardium, pulmonary artery, or pleura, or through the thinning integument.

*Aneurysm of the transverse aorta* forms a pulsating tumour behind the manubrium which may even extend to the left of that bone. It may press upon the trachea and cause dyspnoea, cough, and harsh breathing;

upon the recurrent laryngeal nerve, altering the voice and paralysing the muscles of the left cord (p. 70); upon the œsophagus, causing dysphagia and suggesting stricture of the gullet (p. 139); upon the thoracic duct, causing inanition; upon the left innominate vein, producing duskiness, venous congestion, and œdema of the left side of the head and neck and of the left arm, and possibly causing at last absorption of the manubrium. When the sac bulges into the episternal region the case may be taken for one of aneurysm of one of the aortic trunks; and the tumour may cause compression and even obliteration of the left carotid or subclavian artery, thereby increasing the risk of error in diagnosis. Should it bulge into the neck the resemblance to an aneurysm of the innominate or common carotid may lead to error of diagnosis.

More than once it has happened, unfortunately, that tracheotomy has been resorted to for the relief of dyspnœa which happened to be caused by pressure of an aortic aneurysm upon the trachea. When, however, it can be made out that the dyspnœa is due to pressure upon the left recurrent laryngeal nerve, the windpipe may be opened with advantage.

*Aneurysm of the third part* of the arch pulsates against, and may bulge through, the vertebral ends of the middle ribs of the left side, causing at first intercostal neuralgia and obscure dorsal pains suggestive of caries; then, reaching the spinal canal, it may determine paraplegia; and by pressing on the left pulmonary plexus, which is just in front of it, may cause spasmodic attacks like those of asthma, so that eventually air may entirely fail to enter the lung. It may press against, and eventually burst into, the œsophagus, trachea, left bronchus, pericardium, or pleura.

**The innominate artery**,  $1\frac{1}{2}$  in., arises at the beginning of the transverse aorta, behind the middle of the manubrium; passing upwards and to the right, it divides at the upper border of the right sterno-clavicular joint, between the heads of the sterno-mastoid muscle.

*Relations.*—Separating it from the manubrium are the origins of the sterno-hyoid and thyroid and the remains of the thymus gland; it is crossed by the left innominate vein and the right inferior thyroid veins. *Behind* is the trachea. *To the left* are the trachea and the left carotid; and *to the right* are the pleura and lung, with the right innominate vein and pneumogastric nerve.

*Varieties.*—The innominate artery may bifurcate in the thorax, or it may pass into the root of the neck before dividing. Sometimes it gives off the *thyroidea ima*, an irregular branch, to the lower part of the thyroid body, which, however, is occasionally derived from the left carotid, or from the transverse aorta itself. This little artery ascends to the thyroid body on the front of the trachea, and may be wounded in tracheotomy below the isthmus.

**Ligation of the innominate artery** is a desperate operation, as

the trunk may happen to be altogether intra-thoracic—dividing low down. In reaching it there may be alarming hæmorrhage from an accidental or inevitable wound of the right inferior thyroid vein, or of the left innominate vein; or the right vein, or even the vena cava itself, may be pierced by the aneurysm-needle working in the depths of the wound—and in the dark. The pleura may be damaged and become inflamed, or fatal secondary hæmorrhage may occur on account of imperfect plugging of the artery after the application of the ligature. After tying the innominate, a ligature should also be placed upon the common carotid artery so as to prevent the collateral circulation interfering with the formation of firm clots.

*Operation.*—The shoulders are raised so that the head may be thrown back with the view of pulling upon the carotid and raising the innominate to the utmost, the right arm being drawn well down. The root of the sterno-mastoid is to be raised by an L-shaped incision, one limb of which runs down the anterior border, whilst the other detaches at least the sternal head, each limb of the L being at least two inches long. The skin, superficial fascia, platysma, and deep fascia are divided, layer by layer, until the sterno-mastoid is reached. After reflection of the large muscle the sterno-hyoid and thyroid are divided on a director, and the right inferior thyroid veins are seen and carefully hooked aside, or, if necessary, tied and severed.

The root of the carotid is then sought and followed down until the innominate trunk is reached. The left innominate vein is then depressed, the right being drawn downwards and to the right, and the aneurysm-needle is gently passed from the venous, the pneumogastric and pleural side—the outer side—upwards and inwards.

To find the channels by which *collateral circulation* may be established, the best plan is to follow the empty trunk and to see what branches from it, or from its divisions, are likely to meet with well-filled vessels. Such branches quickly imbibe blood and bring it in the opposite direction to that in which they were accustomed to convey it—towards the occluded part. Thus the right common carotid divides into the external and internal carotids; the external gives off the superior thyroid, lingual, facial, occipital, temporal, and internal maxillary, which would bring in blood from their fellows of the opposite side.

The internal carotid would bring blood by the anterior communicating from the opposite side. The anastomosis through the posterior communicating would not serve, as the posterior cerebral which it joins has, because of the ligature, no blood to render; it might, however, obtain a little blood from the left vertebral through the basilar.

The subclavian trunk would be very serviceable: by the internal mammary it would bring up blood from the aortic intercostals, the deep epigastric of the external iliac, and the phrenics. The vertebral would bring blood direct from the basilar and from branches of its fellow of the opposite side. The inferior thyroid would bring in blood

from its fellow, but the supra- and posterior scapular arteries would be useless. The superior intercostal helps by its anastomosis with the first aortic intercostal, but its anastomosis with the occipital could not serve; by its thoracic branches, namely, the short, the acromial, the axillary, the alar, and the long; and by the ending of the subscapular on the chest, all of which anastomose with aortic branches.

**Aneurysm of the innominate artery** causes a bulging to the right of the manubrium, especially into the first right space. Eventually it may cause absorption of the upper ribs of right side, and of the manubrium, and appear as a pulsating tumour on the front of the chest. It is often impossible to diagnose it from aneurysm of the ascending aorta; indeed, both of those trunks are often dilated at the same time.

The dilatation interferes with the due filling of the trunks coming from the innominate, so that the carotid and radial pulse of the right side are altered. The left innominate vein (p. 186), and perhaps the right also, is compressed; the trachea is pushed towards the left side, the voice is feeble, and respiration may be spasmodic and difficult.

The frequency of the occurrence of aneurysm of the innominate artery may be due to the fact that the root of that vessel, together with the right side of the first part of the arch, receives the shock of the ventricular stroke.

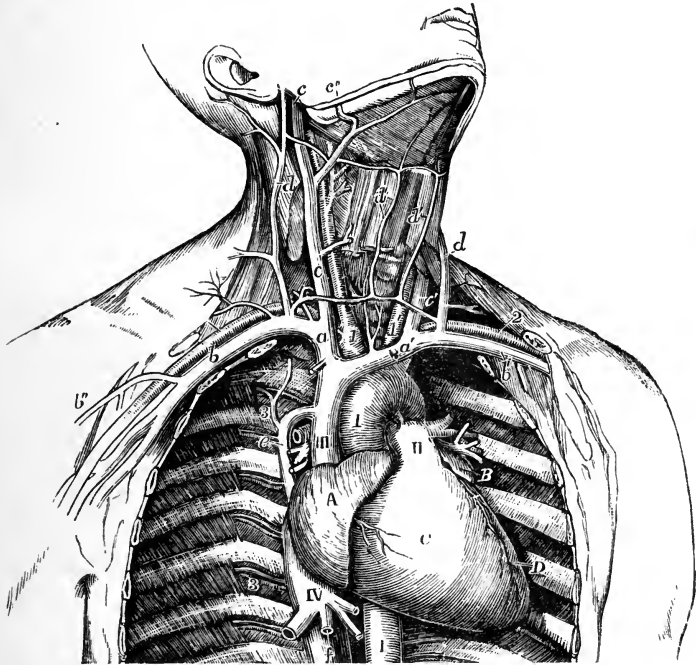
**Relations of the pulmonary artery.**—A coronary artery comes forward from the aorta on either side of its root. Springing from the right ventricle, the pulmonary artery is at first in front of the aorta, but as the first part of the arch ascends to the right the pulmonary artery is soon found to its left side. As these two large trunks were developed together, they lie in the same serous tube of pericardium. The bifurcation of the pulmonary artery is connected with the left side of the concavity of the aortic arch by the ductus arteriosus. (For Root of Lung *v.* p. 194.)

The **thoracic aorta** continues the third part of the aortic arch from the lower border of the fifth (p. 179) to the twelfth dorsal vertebra, where, passing through the diaphragm, it becomes the abdominal aorta. At first towards the left side of the dorsal column, it gradually inclines towards the middle line; and, lying upon the spine, it has also a curve with the concavity forwards.

*Relations.*—It rests upon the vertebral column and the left intercostal veins, and has *in front* some of the root of the left lung, the pericardium and heart, and the œsophagus. *To the left* are the pleura and lung; and just above the diaphragm the œsophagus also is to the left. *To the right* are the œsophagus above; the thoracic duct and vena azygos major, and the spinal column.

**Aneurysm of the thoracic aorta** may extend backwards, causing erosion of the vertebrae and ribs, producing spinal curvature; irritating the intercostal nerves, and causing ‘pleurodynia,’ or neuralgia in the

front of the chest and in the epigastric region. The peripheral pains due to aneurysm are most likely on one side, whilst those due to spinal caries are usually bilateral and symmetrical. Further, the aneurysm of the thoracic aorta may appear as a pulsating tumour by the costal angles. If it bulge forwards it presses upon the œsophagus, causing dysphagia, or upon the lung, giving rise to shortness of breath, and to the presence of a dull percussion-note. If it compress the thoracic duct rapid wasting occurs. Pushing the heart forwards, it causes palpitation and faintness, and an embarrassed circulation.



1, Aorta; II, pulmonary artery; *d d'*, anterior jugular veins; *c c'*, internal jugulars; *d d'*, external jugulars; *a a'*, innominate veins; III, superior cava; *e*, great azygos; IV, hepatics. N.B.—All the veins are anterior to the arteries. (A. THOMSON.)

It may at last leak through an ulcerated patch upon the skin, or may discharge itself into the œsophagus, pleura, or pericardium, or into a bronchus; or its contents may be extravasated along the posterior mediastinum.

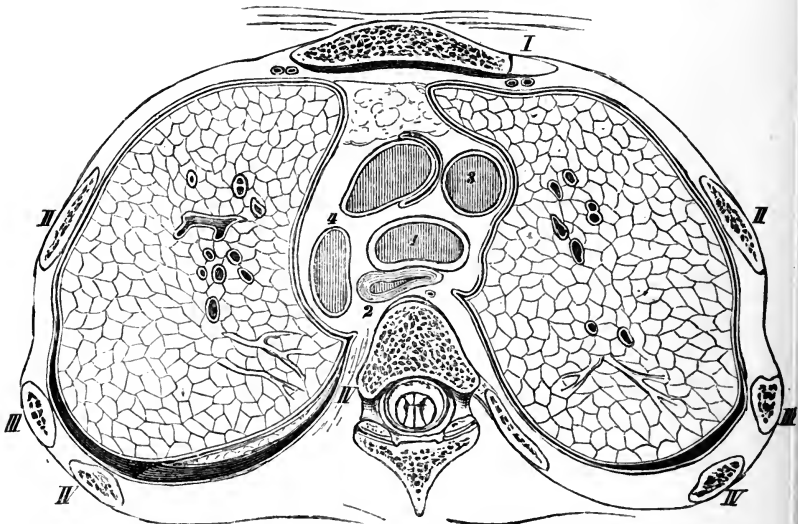
The *branches of the thoracic aorta* are bronchial, pericardial, œsophageal, intercostal, and posterior mediastinal.

The *intercostal arteries* are nine on each side, the first and second spaces being supplied by the superior intercostal of the subclavian

(p. 157). They pass out horizontally over the front of the external intercostal muscle, and behind the pleura. As the ribs slope downwards the arteries soon reach the upper part of the space, where they run between the intercostal muscles in the costal groove, the nerve being below, and the vein above, the artery.

Each intercostal artery gives off a *collateral branch*, which courses along the lower border of the space. In front the arteries anastomose with the internal mammary (p. 156). They also anastomose with the superior intercostal and with branches of the axillary, and with the epigastric and lumbar arteries, and, at the back of the space, with the bronchial arteries.

Each intercostal artery gives off a *dorsal branch*, and, in the female, the third, fourth, and fifth send out branches to the mamma.



Section through bottom of fourth dorsal vertebra. I, II, III, IV, V, ribs; 1, trachea; 2, oesophagus; 3, superior vena cava; 4 is placed between first and third parts of aortic arch. (BRAUNE.)

The **left innominate vein**, 3 in., is formed behind the inner end of the clavicle, in front of the beginning of the left carotid, by the confluence of the subclavian and internal jugular veins; lying on a rather higher level than the transverse aorta, but sometimes overlapping it, it is very near to the upper border of the manubrium, from which it is separated by the sterno-hyoid and sterno-thyroid muscles and the remains of the thymus gland.

The **right innominate vein**, 1 in., begins behind the end of the right clavicle, and descends by the outer side of the innominate artery; on its right side are pleura and lung.



The *tributaries* of the innominate veins are the vertebral, internal mammary, and inferior thyroid ; in addition, the left vein receives the left superior intercostal, which passes obliquely to it over the front of the transverse aorta.

The *inferior thyroid veins* descend in front of the trachea, on either side of the middle line ; the left ends in the left innominate, but the right slopes over the front of the arteria innominata, to end at the confluence of the innominate veins. These thyroid veins are important in tracheotomy below the isthmus, and in ligation of the innominate artery (p. 182).

The **superior vena cava**, 3 in., is formed by the junction of the innominate veins, behind the first right chondro-sternal joint.

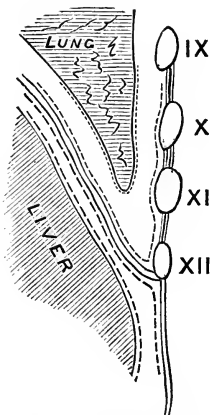
*Course and relations.*—It descends by the right side of the ascending aorta, behind the inner end of the first and second intercostal spaces, to the right auricle. Just at its beginning it lies on the right side of the innominate artery. To its outer side and in front are pleura and lung. Behind it is the root of the right lung, over which the vena azygos major is hooking to enter the vena cava (*v.* p. 185).

### THE PLEURA

The pleura consists of an external fibrous and an internal serous layer. It is a large lymph-space, and communicates by stomata with the adjacent lymph-vessels. By its outer surface it adheres to the chest-wall, diaphragm, and pericardium ; it surrounds the lung, passing in between the lobes. The interval between right and left pleuræ is divided into the mediastina (p. 154).

There is actually no cavity between the parietal and visceral layers, but, with a penetrating wound of the chest, or with rupture of the lung, or with a fistulous opening from a bronchus or cavity, air enters the pleural sac ; the lung then collapses on account of the elasticity of its wall, and that side of the chest becomes tympanitic, and ceases to move in respiration. This condition often follows compound fracture of a rib.

The lower border of the pleura is marked by a line passing obliquely from the costoxiphoid articulation to the vertebral end of the twelfth rib, but the border of the lung does not descend quite so far, not even in deep inspiration, nor does the pleura quite fill in the



Showing crevice between costal and phrenic pleura ; pulmonary pleura ; phrenic and hepatic peritoneum ; ribs, IX to XII.

crevice between the chest-wall and the diaphragm. A sharp instrument may pass through two layers of pleura in the costo-phrenic crevice, and penetrate the diaphragm and liver without wounding lung, and through such a wound a piece of omentum may even protrude.

The twelfth rib is covered by pleura, and in seeking the kidney from the loin the surgeon, keeping his incision too near to the rib, may open the pleura.

The apex of each pleura mounts  $1\frac{1}{2}$  to 2 inches into the neck (p. 164); and over the pleural dome the subclavian artery passes, in a slight groove.

A *peripleuritic abscess* is one which forms between the chest-wall and pleura; it is of limited extent, and is obviously very different from an empyema (p. 190).

Inflammation of the pleura, or **pleurisy**, causes a 'stitch' in the side, and produces a short cough. As the opposed surfaces become dry, and roughened by fibrinous deposits, they rub against each other during the movements of respiration, and produce a *friction-sound* or a vibration which may be appreciated even by the touch. The sound is lost as the surfaces again grow moist and smooth, also when they become glued together by plastic lymph, or when they are widely separated by intra-pleural effusion. It is lost also whilst the patient holds his breath, and this distinguishes it from a pericardial friction-sound, which is, of course, uninfluenced by respiration (p. 158). The friction-sound is like that which is often heard with a new saddle. The slower and deeper the inspiration, the more jerky and prolonged the sound, and it may usually be intensified by pressing the parietal pleura nearer to the visceral by thrusting the finger between the ribs. When a class of students are listening for the sound the first comers hear it best, for the deep respiratory movements temporarily smooth down the rough surfaces.

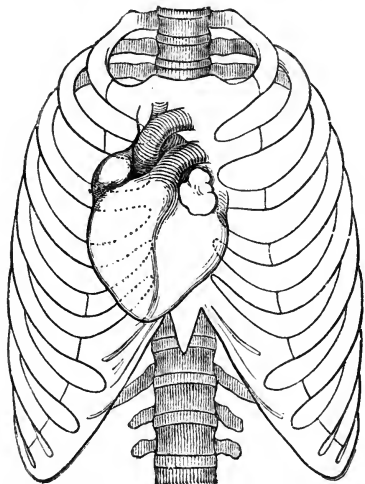
Movement causes pain, so the affected side of the chest hardly stirs in respiration; the fellow lung, therefore, does nearly all the respiratory work, hurrying to accomplish it. The respiratory movements are, therefore, quick, shallow, and almost unilateral; they are best noted by placing the hands flat on the ribs; sometimes one side lags or hardly moves at all.

The intercostal nerves supply not only the costal pleura, but also the levatores costarum, the intercostals, and the flat muscles of the abdomen. When, therefore, the parietal pleura is inflamed the nerve-trunks are in distress, the patient is neither willing nor able to draw a deep breath, and the utmost rest and comfort are required. The pleuritic patient should not be allowed to converse, as this entails considerable respiratory effort. Questions should be arranged so that 'yes' or 'no' are the only answers needed.

Sometimes the pleuritic patient has pain and tenderness in the epigastric region, on account of the trunks of the lower intercostal

nerves being implicated. Such peripheral pains are like those met with in lower dorsal caries, but they are not usually bilateral. If pain extend into the armpit or down the inner side of the arm, the explanation is to be sought in the distribution of the lateral cutaneous branches of the intercostal nerves, and especially of the intercosto-humeral.

**Hydrothorax.**—As the result of pleurisy, serum oozes from the capillaries of the pleura into the cavity, filling, perhaps, one side of the chest, but hydrothorax is apt to occur in disease of heart (p. 178) and of kidney. The fact of the pleura being a large lymph-space accounts for the rapid absorption which ‘water in the chest’ sometimes undergoes. If there be only a small amount of fluid in the chest there is a dull percussion note behind as the man lies supine, but as he is



Heart displaced vertically and to the right by effusion into left pleura. (BRAUNE.)

turned on to his face the dullness may shift its position. As he sits up the dull area is just above the diaphragm, front and back, the lung being floated up. When the pleura is choke-full the intercostal furrows of that side are effaced, the lung is driven into the costo-vertebral groove, and the heart, as shown by the position of the apex-beat (p. 162), is displaced right or left, as the case may be. The lung being compressed, that area is absolutely dull on percussion; the gentle breath-sounds are lost, and the water-logged side of the chest scarcely moves with respiration; the air may be heard at the back, however, entering and leaving the rigid tubes (*bronchial respiration*, p. 200). There is a general bulging of that side of the chest. The patient obviously prefers to be upon the heavy side; and, as he speaks, the hand placed on the chest detects *absence of vocal vibration*, for the fluid cuts off all the sound-waves. The lung does not float on the fluid.

Some of the above signs equally apply to a solid thoracic tumour, but a solid growth does not cut off the vibrations—a wooden carriage-seat transmits vibrations, a water-cushion dissipates them.

In the case of effusion the liver and spleen are driven from the shelter of the ribs and may be brought within reach of the fingers. The full pleura may also bulge below the clavicle or in root of neck.

In left hydrothorax, as the diaphragm and phrenic pleura are lowered, the pericardium, which is attached to the central tendon, also

descends, and, with it, the apex of the heart. At the same time the pericardium and heart are displaced towards the right, so that the apex-beat is felt in the epigastrium. If the heart be pushed still further to the right it has to glide up over the liver, and thus the apex-beat may be found in the fifth space, or even higher.

When the effusion is into the right pleura the apex-beat is necessarily displaced towards the left.

Pressure upon the venæ cavæ keeps them constantly full, but as soon as some of the fluid is withdrawn from the chest by paracentesis the superficial veins empty themselves, the aspect of the patient improves, and respiration is eased.

Sometimes the chest is found full of fluid without there having been a pleurisy or any other disease to account for it; it is then probably caused by the pressure of a malignant tumour upon the veins and lymphatics.

When the fluid is purulent the disease is called **empyema** (*εμ*, within; *πυον*, pus), and the pleural abscess, for such it is, may discharge itself by a bronchus, into the peritoneum, or through the chest-wall about the fourth or fifth space, outside the nipple-line and below the border of the pectoralis major—a situation in which the chest-wall is apparently weak; or it may work its way to the sternum between the planes of the intercostal muscles.

**Tapping the chest** is best done just in front of the angle of the scapula when the arm is by the side—through the middle of the fifth space. If the contents be purulent, and the space narrow, it may sooner or later be necessary to excise a piece of a rib, so as to ensure more room for drainage, the periosteum being raised by a raspatory, and the intercostal vessels being also turned out of the groove before the rib is cut with the nippers. If the opening were made through a low space—and especially if on the right side—there would be a risk of the diaphragm rising so high as to block the tube. Indeed, it has even happened that when an empyema has been incised too low down the diaphragm has also been traversed, and that omentum has escaped through the wound.

When the pleura has been evacuated, the lung, if not permanently crippled, and bound down by adhesions, expands again. If it fail to recover, and a pleural fistula persist, the ribs may have to be divided in front of their angle, so that the side of the chest may collapse and the suppurating pleura may be obliterated. But if this be not done the obliteration may ultimately be effected by the rising of the diaphragm, by displacement of the heart and sound lung, by a falling in of the chest, and by lateral curvature of the spine; the ribs become crowded together on that side, whilst they are expanded like a fan upon the sound side, the shoulder on the crippled side being depressed. The effacement of the former pleural space is effected by the formation of new fibrous tissue which has been developed out of the granulations sealing the space.

**Pneumothorax.**—When the pleura is full of air (p. 187) the percussion note is tympanitic, but as more air is pumped in at each expiratory movement the tension becomes so great that the air can no longer vibrate and the sound becomes *metallic*. These sounds may be imitated by slightly blowing out the cheeks and sharply striking one of them with the finger-nail, and then again striking when they are distended to the utmost ; in the latter case the note is more metallic.

The most likely cause of pneumothorax is the opening up of a vomica, but this is often provided against by the concomitant pleurisy having glued together the visceral and parietal layers. Malignant ulceration of the œsophagus sometimes lets air into the pleura, and the same condition has followed a mediastinal emphysema which was secondary to tracheotomy. (Fagge.)

In pneumothorax there is, as a rule, a certain amount of fluid in the cavity as well as air (*hydro-pneumothorax*), and in either of these conditions, the pleura being distended, the apex-beat may be displaced right or left, as described in hydrothorax (p. 189).

### THE LUNGS

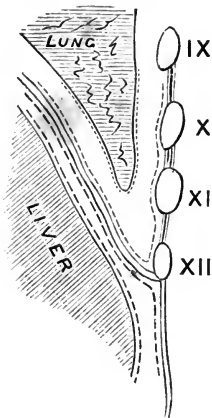
In infancy the colour of the lungs is pinkish ; in adult life grey, from the presence of particles of carbon ; and in those who have worked in coal-mines it may be quite black (*anthracosis*).

The lung-tissue of the fœtus, and of the newly-born child, unless breathing has been instituted, is solid and sinks in water, but after respiration it has become buoyant ; in this way it is determined whether an infant found dead was still-born or not. Pieces of the lung from which air has been dispelled by pneumonic exudation also sink in water.

The *apex of the lung* mounts in the robust an inch and a-half above the first rib, or an inch above the clavicle, into the region corresponding to the triangular interval between the posterior border of the sterno-mastoid and the anterior border of the trapezius. The subclavian artery grooves the front about  $\frac{1}{2}$  in. below the very apex, being separated from the lung by the parietal pleura. (See fig. on p. 164)

The *bases of the lungs* reach much lower behind than in front, for in front the diaphragm is level with the sterno-xiphoid joint. They are concave, corresponding with the surface of diaphragm, and are delimited by an oblique line passing over the chest from the sterno-xiphoid joint over the costal cartilages and above the last rib, and to the spine. The base of the right lung is immediately above the liver, the limit of its resonance and of hepatic dulness being clear and definite. The base of the left is above the stomach, and it is generally easy to define the area of the pulmonary resonance from the metallic note of the stomach. Still, the student must guard against mis-

taking the metallic note of the distended and elevated stomach for that of a pulmonary cavity or of a pneumothorax.



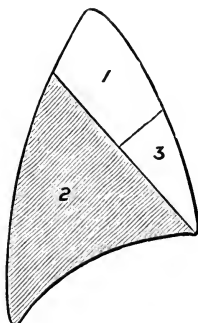
Right costo-phrenic crevice seen from behind. A stab of the liver through the 9th space would traverse four layers of pleura and two of peritoneum; if through the 11th space the lung would escape injury.

The lower border of the lung descends about an inch during inspiration, but in emphysema, when the air-vesicles are permanently dilated and inelastic, there is no movement in the costo-phrenic crevice.

The thick, posterior border lies in the costo-vertebral groove; the sharp, anterior border overlaps the pericardium. The inner surface of the lung is concave, the root entering it nearer to the back than the front. The thickness of the posterior border is well shown on p. 186.

The *left lung* (20 oz.) has two lobes; it is narrower than the right, so as to leave a hollow for the heart. The fissure between the lobes extends from the spine of the scapula (that is from the third rib behind) to the base of the lung in front. The upper is the anterior lobe.

The *right lung* (22 oz.) is the larger, because it does not have to make room for the heart; but it is shorter on account of the presence of the liver beneath it; it has three lobes, the third being sliced off the bottom of the upper lobe by a fissure running upwards and forwards. The middle lobe lies under cover of the fourth, fifth, and sixth ribs, at the side of the chest, and in front it reaches to the diaphragm.



Pneumonia of lower lobe (2) of right lung; dulness below spine of scapula, front resonant.

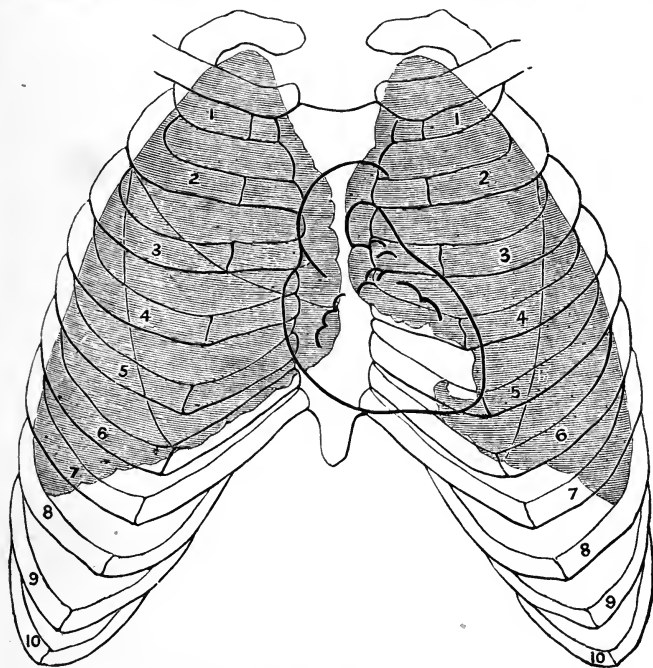
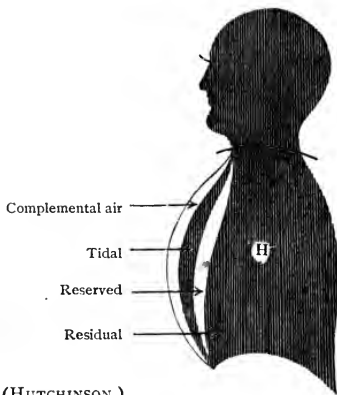
It is important to remember that the *fissure* between the upper and lower lobes extends from the third rib behind (spine of scapula) to the base of the lung in front. Thus, in pneumonia of the lower lobe the dulness is found ending abruptly at that oblique line, together with the bronchial breathing and increased vocal vibration; above that line all is healthy. And conversely, in phthisis, which has a preference for the upper lobe, the dull percussion sound posteriorly is above the spine of the scapula only, whilst in front it extends down to the diaphragm. The lower lobe is almost altogether behind the upper lobe.

The lower dorsal vertebrae advance into the interior of the chest, the ribs all the while receding, so that if a line be drawn across the

chest, just in front of the vertebral column, as much lung is found behind as in front of it. It is this thick posterior part which becomes sodden when a feeble person is kept long in bed in the supine position—*hypostatic pneumonia*.

Even after the deepest expiration about 200 cubic inches of 'residual' air, H, remain in the lungs; for convenience, another 100 cubic inches are 'reserved' in ordinary respiration, the 'tidal' air amounts to about 50 cubic inches more, and when an additional 100 cubic inches of 'complemental' air are inspired the lungs are full to the utmost.

**To mark the anterior border of the lung.**—From the apices (p. 164) the anterior borders of the lungs



Area of lungs shaded; heart in outline. (HOLDEN.)

gradually incline inwards behind the sterno-clavicular articulation, and the manubrium, to the middle of the transverse ridge on the sternum; they then descend together as far as the fourth cartilage. From this level the border of the right lung descends straight to the end of the gladiolus, whilst the other slopes outwards in a line from the fourth left cartilage to a spot two inches below and one inch internal to the left nipple—that is, to the apex of the heart—thus leaving a triangular surface of the right ventricle uncovered by lung; the size of this superficial cardiac region (p. 165) is, of course, in the inverse ratio of the size of the lung, being large in phthisis, small or effaced in emphysema. There is scarcely any lung-tissue behind the manubrium, the narrow space between it and the spine being occupied by the trachea and œsophagus and the large blood-vessels; but, as the aorta is fixed to the back of the chest by its intercostal branches, when the sternum advances in inspiration the edges of the lungs must then glide inwards towards the middle line.

The **root of the lung** consists of the pulmonary veins, the pulmonary artery, and the bronchus—in that order from before backwards. From above downwards the order is: on the left side, artery, bronchus, veins, but on the right side the bronchus is higher than the artery, the veins being still below and in front. The left bronchus descends to a lower level than the right in its course beneath the aortic arch. The root of the lung has pleura in front and behind, constituting the broad ligament, between the folds of which are the bronchial vessels, sympathetic and pneumogastric filaments, and lymphatics and lymphatic glands.

**Relations of the root of the lung.**—On the right side, in front, are the ascending aorta and the descending cava, the vena azygos major (*v.* p. 185) arching over the root to end in the vena cava.

On the left side the root lies in front of the œsophagus and the third part of the aorta, and slopes beneath the aortic bend. Malignant stricture of the œsophagus often occurs at the spot where it is crossed by the left bronchus—perhaps as the result of pressure. In front of the left bronchus is the left auricle (*v.* p. 177). The phrenic nerve and the anterior pulmonary plexus are in front of each root, and the vagus and the posterior pulmonary plexus are behind.

**Infarction.**—The branches of the pulmonary artery pass in with the bronchi and continue to divide until the ultimate capillaries enter their respective lobules; if a clot be dislodged from one of the systemic veins—say from an iliac vein, as after ‘white leg’—and be carried into the right heart and into a pulmonary artery, by acting as a plug it throws out of work all that area of lung which the artery supplied. This area will be wedge-shaped, with the apex at the site of the plug, and the base at the surface of the lung; in conformity to the arborescent distribution of the vessels, the base must reach the surface, for there the capillaries end. The larger the embolic clot (*ev*,



into ; βαλλειν, cast), the larger the vessel plugged and the more important the resulting asphyxia. An embolus caught at the forking of an artery does not completely block it, but allows a small quantity of blood to pass beyond it ; this additional fluid coagulates in the capillaries and eventually involves them in a *hæmorrhagic infarction* (*infarcio*, stuff-into, in allusion to the engorgement of the tissue with blood). The anatomy of infarction is the same whether it be in the lung, spleen, liver, kidney, heart, coronary artery, or the brain ; but only in the lung can the plug come from a systemic vein, for such, unless it be a very minute one, must lodge in the lung. An embolus in any other viscus may come from a pulmonary vein, from a vegetation detached from a mitral or aortic valve, or from a fragment which has scaled from a diseased artery—but not from one of the systemic veins. A patch of liver-tissue may also be damaged by an embolus brought through the portal vein. The infarcted area may slough, or become the seat of abscess, or may quietly undergo decolouration and organisation. Pulmonary infarctions are often associated with hæmoptysis.

Sometimes, on the occurrence of an extensive pulmonary infarct, a murmur which was previously heard on the right side of the heart disappears, the vegetation which caused the murmur having been washed off into a branch of the pulmonary artery.

The **pulmonary veins**, two from each lung, return the arterial blood by separate openings into the left auricle ; they have no valves. A vein comes from each lobe, and, as the third lobe of the right lung belongs to the upper lobe, so the median pulmonary vein joins the right upper vein.

In the root of the lung the veins are in front of the pulmonary arteries and of the bronchi. The right veins pass behind the right auricle and the ascending aorta, and the left pass in the root of the lung, in front of the third part of the aortic arch.

**Blood brought up from the lungs** is necessarily mixed with air, and is therefore bright-red and frothy ; it is alkaline, and is coughed up (*hæmoptysis*, αίμα, blood ; πτω, spit). That issuing from the stomach comes up with retching—it is dark, and often is mixed with food and gastric juice ; it is, therefore, acid (*hæmatemesis*—εμεω, vomit).

When blood which has been coughed up is small in quantity it usually comes from the bronchial capillaries, whilst severe bleeding is usually due to a large artery in the lung having been eroded. But even copious hæmorrhages can occur from the bronchial capillaries, just as fierce bleeding may occur from the capillaries of the nose.

The **trachea** consists of about sixteen horse-shoe cartilages. (For the anatomy of the trachea see p. 131.) The *mucous membrane* is covered with columnar ciliated epithelium, and contains in its depths mucous glands and lymphoid tissue.

The **bronchi** resemble the trachea in structure, but the smaller ones are not flat behind, the horse-shoe cartilages becoming complete circles.

The muscular tissue, which in the trachea lay only behind, in the small bronchi completely encircles them, and may be traced even into the divisions of the air-tube which are too small to possess any cartilage. The columnar epithelium which lines the tubes is rarely expectorated, even when bronchial catarrh is severe.

Ultimately the small bronchial tubes lose both cartilage and muscle and expand into *air-cells*, which are lined with flattened epithelium. Between these cells are crevices (stomata) which open into an alveolar lymph-space; through them germs, particles of soot or grit, may reach the lymphatic vessels. The group of air-cells into which an ultimate bronchial tube expands is cone-shaped and is called a *lobule*. The lobules are distinct, and are separated by a delicate fibrous tissue which is connected with the sub-pleural coat.

**Emphysema** (*ev*, in; *φυσσᾶω*, blow) is just that condition which would be induced by inserting the nozzle of bellows into the trachea and vigorously 'blowing into' the lungs. Some of the air-cells burst, and allow air to escape into the connective tissue of the lungs (*extra-vesicular* or *interlobular emphysema*), whilst others are over-stretched, and in some places many cells are blended into one large cell (*vesicular emphysema*). Interlobular emphysema is especially apt to occur in the delicate chest of a child with severe whooping-cough. When emphysema is imitated on the *cadaver* the anterior edges of the lungs glide over the heart, and their bases depress the diaphragm, liver, stomach, and spleen; the ribs are raised, the upper ones notably so, the chest becoming high and barrel-shaped, and the neck being shortened by the elevation of the sternum, the first rib, and the clavicle. And, if only the bones were soft enough, the expanding lungs would make the spine bow forwards, rendering the subject round-shouldered.

The chest of the emphysematous man is hyper-resonant, even to the twelfth rib, and on opening it *post mortem* the lungs do not collapse, for much of their elasticity has been destroyed in the vesicular dilatation, and the tubes are plugged with bronchitic mucus. The border of the lung generally has, moreover, a bubbly fringe, and if during life some of the bubbles had burst pneumothorax would have resulted.

The trombone-player, by his forcible blasts, over-stretches the air-cells and becomes emphysematous. So does the man with chronic cough, for emphysema is developed during expiration. But there is an additional reason for the subject of chronic bronchitis being emphysematous, for many of his small bronchial tubes become permanently plugged, the lobules associated with them collapsing; but at each inspiratory act the chest must still be filled, so the adjacent lobules undergo double expansion, for when a part of the lung is permanently thrown out of working order the air-cells in the healthy neighbourhood struggle to fill its place, and suffer in the act. The emphysema thus produced is called *vicarious*; it is likewise a constant accompaniment of chronic pneumonia.

As contiguous cells coalesce, the intervening capillaries perforce disappear, and the oxygenating area is diminished—thus, the large-chested man is actually short of breath. The right side of the heart is engorged, its ventricle is hypertrophied (p. 175), tricuspid regurgitation occurs (p. 172), and with it a systolic, venous pulse occurs in the neck. The venæ cavæ are overloaded, the face being dusky and livid ; piles may occur, and later on dropsy ; the liver becomes nutmeggy, and the urine may be albuminous. But, though the right ventricle is much hypertrophied, the impulse is imperceptible, and its sounds are not increased, for the heart is ‘smothered’ by the expanded lungs.

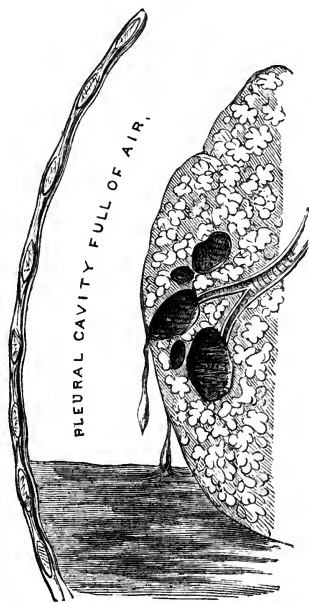
Though the liver is depressed, it may not be conspicuous below the ribs, for, the chest having been greatly enlarged from before backwards, plenty of room is thus provided for it.

Occasionally the enlargement of the lungs is such that their inflated borders overlap each other behind the sternum. Such lungs when removed from the thorax are sure to retain the prints of the ribs.

In extra-vesicular emphysema air may leak from the emphysematous lung into the connective tissue of the chest and so find its way into the subcutaneous tissue of neck and trunk (*general emphysema*). On rare occasions the parturient woman has, in her violent straining, ruptured certain air-cells, and air having escaped through the interlobular tissue has found its way to the face and eyelids, inability to see from between the lids having suddenly supervened.

Both in emphysema and pneumothorax there is a deficiency of breath-sounds, and there is also a hyper-resonance on percussion ; there is, however, no difficulty in distinguishing the conditions, as emphysema affects both sides of the chest, pneumothorax only one—bilateral pneumothorax being incompatible with life. Indeed, when both lungs are crippled by phthisis, and ulceration of the wall of a vomica allows air to escape into one pleura, death may suddenly occur, the remains of the other lung not sufficing for respiration.

Contraction of the muscular tissue of the bronchi, from irritation of the vagi, as in indigestion, causes *spasmodic asthma*, which may also be produced by direct irritation, as in the uræmia of Bright’s disease. The nerve-irritation may also be



Pyo-pneumothorax. (DR. FENWICK.)

secondary to uterine disease. In the case of dyspepsia there is irritation of the gastric filaments of the vagi, which, passing to the pulmonary plexus, is reflected along the sympathetic filaments. An asthmatic attack usually comes on suddenly, air being locked up in the pulmonary vesicles, and the percussion-note becoming hyper-resonant. Under the influence of an emetic, or of some special antispasmodic, the muscular contraction yields, and air once more freely passes to and fro.

Though there is but little connective tissue in the healthy lung, as the result of *chronic interstitial pneumonia*, or *fibroid phthisis*, large quantities are formed, which ultimately undergo condensation and atrophy (*see* cirrhosis of liver, p. 336). The disease may follow chronic bronchitis, or may be due to the irritation caused by particles of coal or grit (saw-grinder's phthisis). As the fibroid lung contracts, the walls of the bronchi are dragged asunder and the tubes are dilated into enormous cavities, under the atmospheric pressure (*bronchiectasis* : βρογχος, windpipe, εκ-τασσω, draw out), the diaphragm rises, and the chest-walls fall in. When the fluid which collects in these cavities is decomposed it may be necessary to tap and drain them through the chest-wall.

In extensive bronchiectases the right ventricle is hypertrophied (p. 175), and the veins are full even to the tips of the fingers, which are usually clubbed.

Thus, in fibroid phthisis and in hepatic cirrhosis atrophy of the new connective tissue ruins the histological structure of, and obstructs the flow of blood through, the viscus, but, whereas the cirrhotic liver dwindles to insignificant proportions, the lung is unable to do so, because, in obedience to the laws of atmospheric pressure, its exterior must lie close to the parietal pleura. So great is the contracting force, however, that, though the periphery of the lung cannot be pulled inwards, the bronchi, as just described, are widely stretched. The 'pull' continues in each case, but it is easier for contracting elements in the lung to drag the walls of the bronchi towards the surface of the lung than the surface of the lung towards the interior of the bronchi : so the tubes are opened out into large cavities.

In *phthisis* (φθω, waste away) the lungs are small ; the chest assumes the expiratory type, being low and flat ; the neck is long, because the clavicle, the first rib, and the sternum have dropped ; and the abdominal viscera hide in the phrenic dome. The shoulders are narrowed and sloping, and the supra- and infra-clavicular regions are flat, on account of the contracting fibrosis in the apices, and the percussion note there is dull.

In phthisis, as in emphysema, the capillary area of the lungs is diminished, and the right ventricle grows large in its constant struggle to get its contents passed through the degenerate pulmonary area. But the lungs, though poor, remain honest, and decline to send forth blood which is of inferior quality.

**Branches of the pulmonary artery** pass behind the bronchi to

end in fine capillaries between the air-cells. Indeed, the capillaries bulge on each side into the cells, being covered only by their thin epithelial pavement.

The **bronchial vessels** supply the machinery of the lungs, the pulmonary vessels being occupied with aëration of the blood. The bronchial *arteries*, two or three to each lung, come from the thoracic aorta or the intercostals; the *veins* empty into the azygos trunks. The *lymphatics* end in the **bronchial glands**, in the root of the lung. These glands are often loaded with particles of carbon which have been brought from the air-cells by the lymphatics. Often they are found calcareous *post mortem*; this is when they have been inflamed and enlarged, the salts having remained whilst the softer elements were absorbed.

The anterior and posterior pulmonary plexus supply *pneumogastric* and *sympathetic* filaments.

#### EXAMINATION OF THE CHEST

**Percussion** is most conveniently carried out by striking the middle finger of the left hand by tips of the partly flexed fingers of the right. The character of the sound thus obtained reveals the comparative density of the tissue beneath. Thus, over healthy lung the note is clear, over œdematous lung it is comparatively dull, and over solid lung, or over liver (with no lung intervening), it is absolutely dull. With a good ear and a clever touch the exact area of heart, of a hepatised patch of lung, of an aneurysm or a vomica, can generally be clearly defined. But in the case of serious disease examination should be discreetly carried out, lest the patient suffer from exposure, and lest his chest be so shaken as to set up cough or bring on hæmoptysis.

Percussion is resonant in the root of the neck, but the note is not so clear as it is below the clavicles, because the apex of the lung is small. Resonance should be good also along the middle of the clavicle.

On the right side the note begins to get dull from below the fifth rib, because of the decreasing volume of the lung over the liver. Below the liver-dulness the tympanitic resonance of the intestines begins.

The note is clear over the manubrium, though there is no lung behind that bone (p. 193); the resonance being due to vibration in adjacent lung-tissue. But it is clearer along the gladiolus, though from the fourth cartilage downwards, and to the left, comes the comparative dulness of the cardiac area (p. 165). The resonance is greater on inspiration, as the border of the lung glides further over the heart. Below the base of the left lung the tympanitic note of the stomach begins.

For the sake of comparison, the two sides of the chest must be percussed symmetrically from the supra-clavicular regions downwards, due allowance being made for the area of cardiac dulness. For per-

cussing the back, the patient should, if possible, sit up in bed, fold his arms across the thighs, and bend forwards.

A strange, chinking, *crack-pot sound* may sometimes be heard on percussing over a pulmonary cavity; it is due to some of the air being driven with each stroke into the opening of a bronchial tube. This may be imitated by keeping the palms of the hands loosely closed across each other, and then striking the back of one hand on the knee. If the hollow between the hands be made air-tight, the crack-pot sound is lost; similarly the pulmonary cavity must have a clear bronchial tube opening out of it, or it becomes an air-tight chamber and the sound is lost.

**Vocal fremitus** is the thrill of the vibrating vocal cords which is conveyed by the air in trachea, bronchi, and vesicles to the hands placed upon the chest. The nearer to the larynx, the larger the bronchus and the louder the fremitus. It is 'damped' by a thick layer of fat or muscle upon the chest, and by air in the pleura; whilst it is completely drowned by pleuritic effusion (p. 189). Its absence from the back of the lung, therefore, is a diagnostic sign between pleurisy with slight effusion and pneumonia; in the latter the vibrations are absolutely increased, for the solid lung is a good conductor of sound. Returning fremitus denotes absorption of fluid.

On listening at one end of a wooden beam whilst someone scratches the other end with a pin, the scratches are heard with extraordinary distinctness, for the solid material not only conveys the vibrations, but magnifies them. Similarly in exudation into the lung the vocal fremitus is exaggerated, provided always that the bronchial tubes are free to convey the vibrations from the trachea to the lung-tissue.

A pulmonary cavity may act as a reservoir, or a sounding-board for vocal vibrations (provided that it is not full of fluid), and thus vocal fremitus may be increased, especially if the surrounding lung-tissue be solid.

The healthy **respiratory sounds** vary with the site in which auscultation is made. Thus, if the stethoscope be placed over the episternal region, or over the spines of the lower cervical or upper dorsal vertebrae, and the patient draw a deep breath, the air is heard rushing through the trachea—this is *tracheal respiration*. It is a good deal like the blow of air through a keyhole. If the stethoscope be placed between the scapulæ, or over the sternum, the tidal blow is heard in a less degree, termed *bronchial*, or *tubular*. In other parts of the chest than over the trachea or bronchi the *respiratory*, or *vesicular murmur*, or *breath-sound* is heard as a soft blow, which has been poetically likened by Hughes to 'the song of a gentle gale in the thick summer foliage, or to the whisper of the retiring wave upon a sandy coast.'

When the pleura is full of air or liquid, and the lung lies collapsed against the spine, air still enters and leaves the larger bronchi, and so bronchial respiration is present in pneumothorax and empyema as

well as pneumonia. In collapse of the lung, however, the sound is heard only at the back, whereas in consolidation it is found also at the front of the chest, for solid lung is an excellent conductor. It is so clear in the healthy child that when it is somewhat exaggerated in the adult it is called 'puerile.'

When the lining of the small air-tubes is swollen, and the air does not enter the vesicles freely, the vesicular murmur becomes 'harsh,' and it is entirely lost when the lung is collapsed on account of the pleura being full of air, serum, blood, or pus; the space over which it is heard is diminished in partial collapse of the lung, and when a large tumour or a hypertrophied heart trespasses on the pulmonary area.

When pneumonic exudation has made the walls of the vesicles sticky, the air enters them with a *fine crepitation*, like that which is heard when a small bunch of hair near the ear is rolled backwards and forwards between the tips of the finger and thumb.

When the lining membrane of the bronchi is inflamed, as in bronchitis, viscid or watery mucus is poured into the tube, and the air passes through it in large bubbles, *rhonchi* (ῥογγος, snoring) or in smaller bubbles—râles.

The larger the tubes, the coarser the râles; and as death approaches, and the patient has not the strength to clear his larynx, trachea, and bronchi of the collecting mucus, the coarse bubbling of the air through the fluid is popularly known as the 'death-rattle.'

*Prolonged expiration* is due to obstruction in the bronchial tubes, as from inflammation of the mucous membrane; in the apex it is an early sign of catarrh, and if also pus be spat it is a grave sign of phthisis.

*Amphoric* (amphora, a flagon) breathing is that heard when the air enters a bronchiectatic or pulmonary cavity; it is something like the sound produced by blowing into an empty bottle.

*Metallic tinkling* is the sound produced by fluid vibrating in an air-cavity which contains some fluid; thus it is heard in large bronchiectatic and pulmonary vomicae; it is a kind of splash. It is probably due to the echo in the cavity of the bursting of an air-bubble. 'It nearly resembles the sound caused by shaking a pin in a decanter.' (Hughes.) A metallic splash is also heard when a pleura containing air and liquid (pyo-pneumothorax) is sharply shaken from beneath (*succussion*). The sound produced by air bubbling through the fluid in a pulmonary cavity is termed *cavernous*.

The **voice-sounds**.—If the stethoscope be placed over the larynx or trachea the voice is heard with extraordinary distinctness. This sound is called, when it is heard over other regions of the chest than that of the large air-tube, pectoriloquy (*pectus, pectoris*, breast; *loqui*, speak). It means that the voice comes so straight to the ear that it seems to be spoken in the chest itself, and not in the larynx; and, as healthy lung-tissue is a muffler of sound, pectoriloquism suggests

consolidation, for condensed lung-tissue is a good conductor (p. 189). *Bronchophony* is a lesser degree of pectoriloquy.

Sometimes the voice sounds cracked, or like the bleat of a goat (*αιξ*, *αιγος*, goat; *φωνη*, voice)—*xgophony*. It is due to a break-up of the sound-waves as they come splashing through a thin layer of fluid—probably of pleural effusion.

**Dyspnœa.**—When the free entry of air is prevented, as in laryngeal diphtheria, or œdema glottidis, the inspiratory muscles work with great energy, diminishing the intra-thoracic pressure; and, as the balance cannot be restored by air entering through the trachea, the equilibrium is partially restored by the jugular, intercostal, and epigastric regions falling in with each inspiratory effort.

### THE MAMMA

The **mamma** in the female reaches from about the third to the sixth rib. The nipple is over the fourth space, and points slightly outwards and upwards for the convenience of the infant in the mother's arms. As the ribs ascend in inspiration more than the breast, the nipple which lay over the fourth space on expiration will be over the fifth rib on inspiration. In emphysematous patients the nipple is considerably higher than in the phthisical, for in the latter the chest represents the type of expiration.

The developing breast at puberty is often tender and tingling. With old age the gland becomes wasted, and, when this retrogressive physiological change sets in, cancer is especially apt to invade the tissue.

The breast is placed within the superficial fascia, and is connected with the skin and with the deep fascia over the pectoralis major by slender ligamentous fibres.

The **nipple** may be absent in the virgin, its future site being surrounded by a pinkish zone, but in the second month of pregnancy it begins to grow, and the areola darkens and extends until it forms a deeply pigmented circle two inches in diameter. After parturition and weaning, the pigmentation does not entirely clear away, so that darkening of the areola is important as evidence of the first pregnancy only.

The skin of the nipple is somewhat leathery, on account of the fibrous tissue which it contains; it is, moreover, rich in sebaceous glands, which increase during pregnancy, to diminish the risk of cracking and tenderness during suckling. Along the centre of the nipple the milk-ducts (fifteen to twenty in number) ascend, and around them are pale muscular fibres, to the contraction of which under stimulation 'erection' of the nipple is due.

**Structure.**—The breast is surrounded by a fibrous capsule from



which processes pass off to blend with the skin, whilst others enter the gland, marking it out into separate lobes. Fat occupies the intervals between the lobes, and thus it happens that large fat breasts may be of less physiological value than those of a thin woman. A branch of a milk-duct enters each lobe, sending off ramifications which are connected with the small lobules. The ultimate lobule consists of terminal expansions of the ducts into alveoli lined with cubical epithelium, and surrounded with branches of blood-vessels, nerves, and lymph-sinuses. As the duct approaches the surface the epithelium becomes squamous. Chronic inflammation of the nipple and proliferation of its epithelial covering (*eczema of the nipple*) is often the starting point of cancer of the breast. Squamous epithelioma is the nature of the malignant growth in these cases, and it may eventually implicate the entire gland.

The ducts descending from the nipple radiate through the gland, and when an incision is made into the breast the scalpel should be directed straight from the centre towards the periphery, so that it may pass between and not across the ducts. During lactation a milk-duct may be so distended with milk as to form a large tumour, *galactocele*; the condition is like an encysted hydrocele of the testis.

*Supply.*—The mammary *arteries and veins* are branches of the long thoracic and other offsets of the axillary trunks, and of the internal mammary. The aortic intercostals also help in the supply.

Of the *lymphatics*, some few, from the inner side, pass between the costal cartilages to enter the mediastinal glands; the others pass along the border of the pectoralis major into the axillary glands.

The *nerves* come from the lateral cutaneous branches of the intercostals, and from the endings of the intercostal nerves themselves.

It has been suggested that the mammæ are but modifications of sebaceous glands, and sometimes during pregnancy enlargement of the sebaceous glands in the axilla may be discovered, representing supplementary mammæ. Occasionally additional mammæ and nipples exist, either in the pectoral region or down the front of the abdomen.

In *scirrhous mamma* a heterologous growth of fibres and cells forms a hard mass, generally upon the axillary side of the nipple. The malignant infiltration extends along the fibrous processes which attach the gland to the surrounding tissues, and so the mass becomes connected with the skin, the pectoral muscles, the chest, and even with the pleura. Subsequently the new fibrous tissue atrophies, so that the *skin is dimpled and the nipple retracted*.

Before the nipple is actually retracted it may show a slight but highly suspicious deviation from its normal inclination. Retraction of the nipple may also be due to atrophy of the new fibrous elements left after chronic inflammation, corresponding to the contractions described in cirrhosis of liver. The cut surface of the scirrhous mass becomes concave on account of the further contraction of the fibrous tissue.

Contraction of the new elements of the breast causes so much compression of the mammary tissues as to impede the return of blood from the skin of the pectoral region, so that the superficial veins are dilated and conspicuous, and the affected gland is even smaller than the other. The lymph-channels running from the breast to the axillary lymphatics are often invaded, and, like the glands themselves, should be cleared away. When the scirrhus is situated to the sternal side of the breast the axillary glands are involved later than when it is to the outer side. In the former case the glands in the anterior mediastinum are specially likely to be involved, and they may there form an enormous tumour against the heart or lung.

*Abscess* may occur in the breast or in the loose connective tissue superficial to or beneath it; from the rapidity with which the tension of the sensory nerves is produced, it is accompanied with much pain. A sub-mammary abscess, if left to itself, is likely to point near the anterior axillary fold. *Hypertrophy* is a multiplication of the normal elements throughout the breast, and *adenoma* (αδην, gland) is a 'chronic mammary tumour' of the normal cellular elements of the gland in a bed of fibrous tissue. *Cystic disease* (serous) is due to the dilatation of ducts or of lymph-spaces throughout the gland.

When a suckling woman has an abscess in one breast she ought at once to wean the child, as putting it to the sound breast inevitably causes physiological disturbance and irritation of the affected one.

In *amputating the breast* the arm should be abducted, so as to tighten the integument and the pectoralis major. A semi-elliptical incision is then made on either side of the nipple in a direction towards the armpit, so that the axillary glands can be extracted by a slight extension of the wound. It does not matter whether the upper or the lower incision is made first. It is important, in operating for cancer, that the whole of the gland and the nipple be taken away, even if only a part be involved. After operation the arm should be fixed to the side, and even when the wound is perfectly healed the arm should be worn in a sling, so as to ensure rest.

In the newly-born child, whether male or female, the mamma often contains a watery epithelial wreckage which looks like milk, and on rare occasions this pent-up secretion determines inflammation and suppuration.

### THE SPINAL COLUMN

**Spina bifida.**—A vertebra has three primary centres of ossification, two for laminae and one for body. The laminae are fused in the root of the spinous process. If development be arrested the spinal canal remains unenclosed posteriorly, the membranes with the cerebro-spinal fluid bulging as a soft tumour. The defect is found most often in the lumbar and sacral region, for there the laminae are last ossified.

It is possibly caused by an increase in the amount of cerebro-spinal, subarachnoid fluid in the early development, whereby the coalescence is prevented. The tumour is in the exact median line and has a firm attachment. It is often associated with imperfect innervation of the pelvic viscera, and with arrested development of the lower extremities.

When the child screams, some of the cerebral fluid is displaced from the interior of the skull and into the spinal canal, the tumour becoming more tense; and by gentle compression of the tumour some of the fluid can be squeezed into the cerebro-spinal canal, with the effect of causing irregular muscular movements or even convulsions.

Sometimes the sac contains no nerve cords or branches; sometimes the nerves are spread over its inner surface. The sac may be lined by the substance of the cord itself, the serous fluid being contained in the immensely dilated central canal of the cord. This is likely to be associated with internal hydrocephalus (p. 56). If the cord or the large nerves of the cauda equina be in the sac, they occupy the median part.

Operative treatment is directed towards obliterating the communication with the interior of the spinal canal, and the more slender the communication the greater the prospect of cure.

To put a ligature round the base of the tumour may be to set up a meningitis spreading from the cord to the brain; to tap and empty the sac is to leave the brain high and dry, with no counterpoise to the cerebral circulation; and freely to inject a stimulating fluid may be to excite meningitis and encephalitis, the child dying in convulsions.

The *spinous processes* of the upper cervical vertebrae can just be made out at the nape of the neck, especially that of the axis; the spines of the sixth and seventh are long, horizontal, and conspicuous. Indeed, the spine of the seventh (*vertebra prominens*) sometimes juts out so conspicuously as to suggest the appearance of angular curvature.

The dorsal spines are long, and overlap one another so as to prevent extension in the chest region, otherwise the heart and lungs might be interfered with in their work. The tip of a dorsal spinous process descends well over the body of the vertebra below. The lumbar spines are large and horizontal, and well hidden between the large masses of the erector spinae.

In counting the *spinous processes* the seventh cervical is at once recognised, with the sixth close above it, and the first dorsal just below. The third dorsal spine corresponds with the root of the spine of the scapula, and the fourth lumbar spine is on the level of the top of the iliac crests.

In the cervical region the spinal cord may be readily injured by a stab, but in the dorsal and lumbar regions it is well protected by the imbricated laminae.

The *transverse process of the atlas* stands well out in the side of

the neck ; it may be dimly felt below, and just in front of the tip of the mastoid process.

The *transverse process of the sixth cervical vertebra* is easily made out at the root of the neck—the carotid tubercle (p. 23).

**Ligaments.**—The bodies of the vertebræ are connected by the strong *anterior and posterior common ligaments*, the posterior being lodged within the spinal canal and separated from the central part of the body of each vertebra by the *vena basis vertebræ*.

Between the bodies are *discs of fibro-cartilage*, the peripheral parts of which are fibrous, whilst the central parts are pulpy and elastic. The discs form about a fourth of the flexible part of the spine ; they are flattened by prolonged standing. Thus, when a man rises from the bed of sickness he is actually taller, perhaps by a third of an inch, than he was when he took to it. The height is also increased by the night's rest.

The articular processes are connected by *capsular ligaments and synovial membranes*, the laminae by the elastic *ligamenta subflava*, the spinous processes by *inter- and supra-spinous ligaments*, and the transverse processes by less important fibres.

The *atlas is connected with the axis* by two *capsular ligaments and synovial membranes*.

The *transverse ligament* stretches behind the odontoid process from one lateral mass to the other, sending a slip up to the basilar process of the occiput, and one down to the back of the body of the axis ; thus its shape is *cruciform*. There is a synovial membrane between the odontoid process and the anterior arch of the atlas, and another between the process and the transverse part of the cruciform ligament.

The transverse ligament is less likely to give way from violence than are the adjacent bones, but when it is softened by disease it may suddenly yield; the head then falling forwards, the medulla is compressed against the back of the odontoid process, and sudden death results. In cases of the high cervical vertebræ absolute rest in bed is the only safe treatment.

The two *anterior atlo-axoid ligaments* are really part of the anterior common ligament, and the *posterior atlo-axoid* is the representative of the ligamentum subflavum.

Rotation is the only movement allowed between the atlas and axis ; their joints are supplied by the vertebral arteries and the second cervical nerves.

The condyles of the *occiput articulate with the atlas* by capsular ligaments and synovial membranes, and in such a way as to permit of nodding movements only. (Thus, a dumb person expresses 'yes' at the occipito-atloid joint, and 'no' at the atlo-axoid.) The occipito-atloid joints are supplied by the suboccipital nerves (p. 143) and the vertebral arteries.

The two *anterior occipito-atloid ligaments* represent the anterior

common ligament, just as the posterior occipito-atloid ligament represents the ligamentum subflavum. The posterior ligament is attached above to the back of the foramen magnum, and is pierced by the vertebral arteries and the suboccipital nerves. In front it is intimately connected with the dura mater as it descends into the spinal canal.

The *lateral ligaments* pass between the transverse process of the atlas and jugular eminence of the occipital bone.

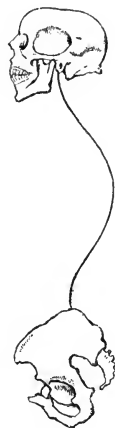The *occiput is connected with the axis* by an upward prolongation of the posterior common ligament, which blends at the front of the foramen magnum with the cranial dura mater.

Beneath it are two *cheek ligaments*, which pass from the tip of the odontoid process to the inner sides of the occipital condyles, and a third slip which runs up to the front of the foramen magnum.

When the weight of the head and the upper part of the body is greater than the spinal column is able to support it bends forwards in an exaggeration of the normal curve of the dorsal region, just as the stalk of corn yields when the ear of wheat is large and full. In the human subject the bending may be due to a deficiency of earthy matter in the bony segments, as happens in the rickety child, or to a settling down of the vertebræ and the intervening discs from long-continued pressure, as in the rheumatic or old and worn-out labourer. The curvature is dignified by the name of **kyphosis** (*κυφος*, *bowed forwards*).

**Lordosis**, or saddle-back (*λορδος*, *curved*), is the opposite condition, the trunk being thrown backwards by exaggeration of the normal lumbar curve, the concavity of which looks backwards. It is usually a compensatory curve which the subject instinctively acquires in order to keep the centre of gravity from being advanced too far, and unstable equilibrium being thereby produced. Thus, it is found in pregnant women, who are compelled to throw the shoulders backwards in walking; and, to a less degree, in the very fat man. It is still better marked when caries of the high dorsal vertebræ has allowed the head and shoulders to fall forward, and also when, from congenital displacement, the heads of the femora are behind their normal position, as figured on page 472.

**Lateral curvature.**—The commonest variety is that in which the right shoulder is raised, the convexity of the lateral dorsal curve being

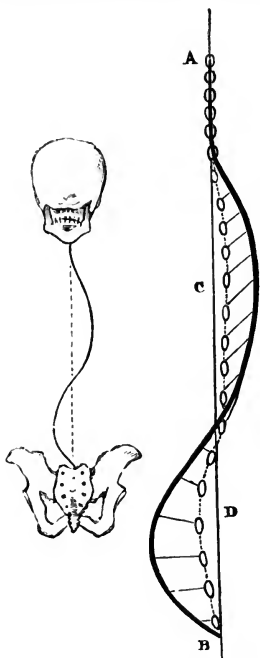


Kyphosis.

Lordosis.<sup>1</sup>

<sup>1</sup> These and similar figures are from Erichsen's *Surgery*.

towards the right. The chest on that side, therefore, is 'full,' but on the left the ribs are crowded together and the lung space is diminished ; such a diminution may happen after empyema, when the lung is permanently collapsed. But, as a rule, the curvature is caused by an uneven transmission of weight down the spine, especially in girls who are outgrowing their strength, and who sit or stand long at lessons or work. The muscles growing tired, the girl arranges her posture so that the ligaments, fasciæ, and articular processes, which are incapable of feeling fatigue, may bear the strain.



Lateral curvature; spinous processes rotated into concavities of curves, as at c and d. (SHAW.)

Often the curvature is caused by a difference in the length of the legs causing the pelvis to be tilted.

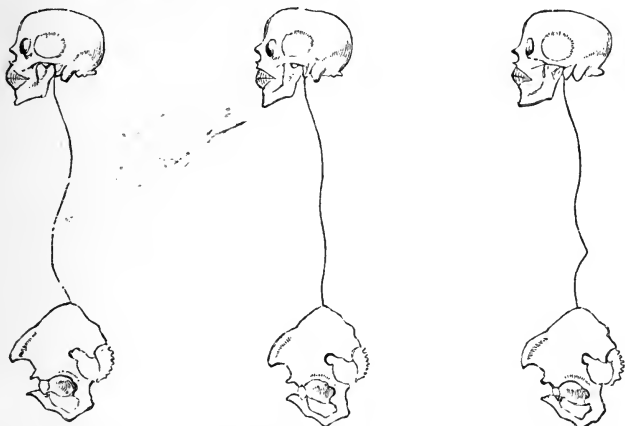
In addition to this lateral bending there is a strange rotation of the affected vertebræ, the spinous processes being tilted sideways into the concavity of the lateral curve.

The proper way of dealing with the ordinary case of lateral curvature is to keep the girl as much as possible in the fresh air, and to make her strengthen her flabby muscles by exercises such as her brothers delight in ; by not allowing her to resume the vicious lolling attitudes, and by employing massage and special gymnastics. The worst 'treatment' is to lock her up in a 'spinal support.' When

the lateral curvature is severe—that is when the bones have become misshapen and the girl's growth has ceased—the condition is past help.

**Spinal caries ; angular curvature.**—When the bodies of the vertebræ, destroyed by caries (ulceration), begin to fall together, the spinous processes are necessarily thrown backwards ; and if the disease be in the dorsal segment the processes, which in that region are already very prominent, stand out in a very conspicuous manner. But if the caries be in the cervical or lumbar region the falling together of the bodies is not at first accompanied by a corresponding projection of the spinous processes, because the neck-region and the loin-region of the spine are concave backwards. But instead of this the concavity is effaced. Thus, in the cervical and lumbar regions a straightness of the spine is as pathognomonic of vertebral caries as is the angular projection in the case of dorsal caries. In every case the disease is accompanied

with stiffness of the region affected. In trying to stoop the patient cannot bend his neck or back, and he stands with his hands on his thighs or resting against a table or chair.



Normal curves.

Early lumbar caries ; normal curves effaced.

Advanced dorsi-lumbar caries ; angular curvature.

If the advance of the angular curvature be slow, the cord adapts itself, and no pressure-effects are manifested. But if it come on rapidly, or, coming on slowly, be extreme, *motor paralysis* results, because of a projection taking place at the back of the bodies into the vertebral canal, and impinging against the front, the motor area, of the cord (p. 215). But, although a child may have complete muscular paralysis in his lower extremities for many months, he may at last completely recover movement ; the explanation being that much of the pressure has been of the nature of inflammatory deposits, rather than of the bony projection. In the paraplegic child with angular curvature there is no pressure upon the posterior aspect of the cord, so there is no loss of sensation, and, the skin being well supplied, there is no special likelihood of the occurrence of bed-sores, as obtains after fracture of the spine.

With pressure upon the front of the cord, the knee and ankle reflexes are exaggerated because the cerebral influence can no longer descend to control them (p. 220). But if the pressure be upon the lumbar enlargement, as may happen in caries of the lowest dorsal vertebræ, there may be so much disturbance within the cord that the afferent influence can no longer awaken the motor impulse, in which case the knee-jerk and ankle clonus may be lost.

In the progress of caries, inflammatory thickenings press upon the spinal nerves, causing characteristic **peripheral pains** in the area of their distribution. When the disease is in the *cervical* region there may

be pains, possibly called 'head-ache,' over the area of the occipital branches from the second cervical nerve; or in that of the great auricular from the second and third. A little girl suffered constant pain, darting over the region between the chin and the sternum, which she described as 'belly-ache in the neck'; it arose from pressure upon the trunk of certain nerves as they issued from the diseased region of the column. The third nerve joins in the formation of the transverse superficial cervical nerve, which supplies the skin over the front of the neck. Pains due to caries of the atlas are generally confined to one side because only one lateral mass, at any rate at first, is implicated.

If the disease be lower in the neck, symmetrical pains may be referred to the pectoral or deltoid regions, where the supraclavicular branches are distributed, as shown in the figure on p. 145.

If the lowest cervical vertebræ be inflamed the nerve-trunks of the brachial plexus are liable to compression, pain being referred to the shoulders, elbows, or even to the fingers.

When the *dorsal* vertebræ are diseased neuralgia may be felt in the intercostal nerves, or their peripheral branches. And when any part of the lower half of the dorsal column is affected pain may be referred to the epigastric or umbilical region, or even to the skin over the ilium, where the lateral cutaneous branch of the last dorsal nerve is distributed.

With *lumbar* disease the pains are referred to the ilio-hypogastric and ilio-inguinal nerves, or the genito-crural or external cutaneous.

Pains in the front of the thighs, that is, over the region of the anterior crural or obturator nerves, should direct attention to the neighbourhood of the third and fourth lumbar vertebræ. If it happen that the nerve-fibres destined for the long saphenous branch are irritated as they leave the column, pains will be referred to the inner side of the leg or foot, or to the ball of the great toe. Unfortunately obscure pains are too often ascribed to rheumatism and gout. *Symmetrical pains are the result of central mischief, and generally of spinal disease.*

**Spinal abscess.**—Spinal caries, like ulceration elsewhere, is usually accompanied by suppuration, and, unless the disease be very quiet, abscess forms in front of the vertebræ. Thus *cervical caries* gives rise to *post-pharyngeal abscess*, the bulging against the back of the pharynx causing difficulty in breathing and swallowing. The abscess has to be opened, the patient inclining the head forwards for that purpose; if the abscess were allowed to burst spontaneously, the pus might be drawn into the larynx, and the patient might die of suffocation or of septic pneumonia.

Sometimes the abscess from cervical caries points in front of or behind the sterno-mastoid, or follows the œsophagus into the posterior mediastinum.

In *dorsal caries* the pus collects in the posterior mediastinum, from which it may pass between the transverse processes to the back, there



to form a *dorsal abscess*. If it point forwards it may perchance open into the œsophagus, trachea or bronchus, pleura or pericardium. Or the pus may track forwards between the intercostal muscles, or between the inner intercostal muscle and the pleura, to point at the side of the sternum or of the rectus abdominis, or in some chosen part of the intercostal space. But more often it descends in the posterior mediastinum till it reaches the diaphragm, which it traverses under the inner or outer arcuate ligament: if under the former, to descend as a *psaos abscess*; if under the latter, to bulge as a *lumbar abscess*. When the psaos abscess has passed beneath Poupart's ligament it usually bulges on the outer side of the femoral vessels, and it not infrequently works thence, inwards and backwards, following the internal circumflex, to form a *gluteal abscess*.

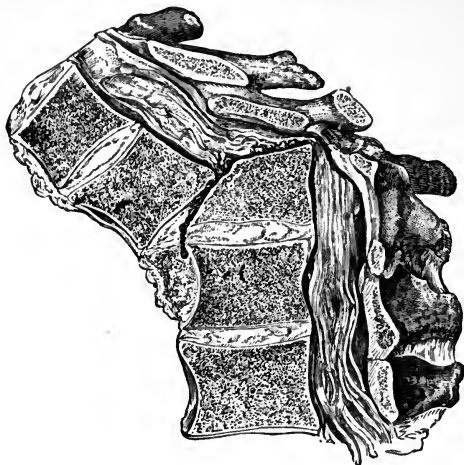
In *lumbar caries* the pus generally collects beneath the iliac fascia to form an *iliac* or *psaos abscess*. In the former case the tumour bulges in the iliac fossa, probably to point above Poupart's ligament; in the latter case it finds its way beneath the ligament, and points in Scarpa's triangle. In these cases, by pressing with one hand in the iliac fossa and the other in the triangle, one can get a 'see-saw' with the fluid under Poupart's ligament, especially when the thigh is slightly flexed.

But an iliac or a psaos abscess may push forwards and open into the peritoneal cavity, the alimentary canal, or ureter, or may descend into the bladder or ischio-rectal fossa, or, following the lumbo-sacral cord and the great sciatic, through the great sacro-sciatic notch, to form a *gluteal abscess*.

It frequently happens that pus which has descended beneath the outer arcuate ligament, or which, in lumbar caries, has been collecting anterior to or in the substance of the quadratus lumborum, escapes backwards in the gap between the twelfth rib and the iliac crest to form a *lumbar abscess*. In this course it passes through that weak part of the abdominal wall which is bounded in front by the posterior border of the external oblique, behind by the latissimus dorsi, and below by the iliac crest—the *triangle of Petit* (p. 305). I have operated for the cure of a reducible lumbar hernia in the case of a piece of bowel escaping by the track of an old lumbar abscess.

**Fractures and dislocations** are fairly common in the cervical region, where the vertebræ are small and the range of movement is free. Unless the lesion be associated with displacement of a vertebra, it may pass unrecognised; the most serious condition is that in which displacement causes pressure upon the cord. When the displacement is considerable the cord is torn across, or firmly compressed, and the symptoms are immediate. If the displacement be but slight, there may be no symptoms at first, but, as the local disturbance of the cord is followed by inflammation, its functions become impaired and the symptoms manifested. Thus, the patient is paraplegic (*παραπληξ*, struck badly), that is to say,

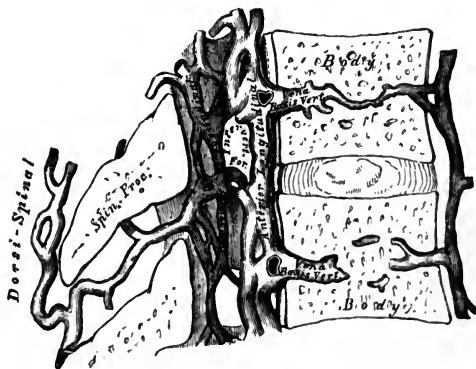
no messages can proceed from the brain to the muscles which are supplied by nerves coming off below the injured spot ; sensation also is lost (*see* p. 216). And the trophic influence for the skin being lost, bed-sores are very apt to appear. The patient, therefore, with a broken back, is placed upon a water-bed, so that the weight of his body may be distributed evenly, and not fall upon the prominent parts only. The bladder and the lower bowel do not work properly, because the reflex centre (p. 218) is cut off from cerebral control, and retention of urine and cystitis probably occur,



Fracture of spine; cord lacerated. (A. SHAW.)

possibly the man has priapism (p. 216), and the reflexes, as explained on page 219, are most likely exaggerated. The least touch upon the sole may cause violent contractions in the quadriceps extensor ; but if the displacement disorganise the lumbar enlargement these reflexes are then lost, for the chain is broken. They may be lost too for a while

when the grey matter has exhausted its energy by frequent discharges.



The *spinal veins* consist of a ladder-like network about the neural arches of the vertebræ ; of anterior longitudinal veins, which lie behind the bodies and receive the venæ basis vertebræ ; of posterior longitudinal veins, which are

also outside the dura mater, and which extend along the back of the cord ; and, lastly, of the veins of the cord itself, which pierce the dura mater,

to end in the surrounding spinal veins. The spinal veins empty into the vertebral, intercostal lumbar, and lateral sacral veins. *Hæmorrhage* from these veins, perhaps the result of injury, causes pressure upon the cord and sudden paraplegia. Suspension in the treatment of diseases of the spinal cord may possibly owe its value to the stimulus which is thereby imparted to the circulation in the veins of the cord (p. 214) and of the canal.

For *fracture through sacro-coccygeal joint*, v. p. 362.

### THE SPINAL CORD

The spinal cord is the continuation of the encephalon towards the trunk and extremities. It begins at the lower border of the medulla oblongata, at the level of the first cervical vertebra, and extends to the first lumbar, where it breaks up into the cauda equina. In early foetal life it reaches to the very end of the spinal canal, but its subsequent growth does not keep pace with that of the canal. Its average length in the adult is  $1\frac{1}{2}$  ft. and its weight  $1\frac{1}{2}$  oz.

It has *two enlargements*, one in the lowest cervical region, the other in the lowest dorsal. From the cervical enlargement the nerves issue for the brachial plexus, and from the lumbar enlargement emerge the nerves for the lumbar and sacral plexuses. The cord is enclosed in the pia mater, arachnoid, and dura mater, but even with these investments it does not nearly fill the canal, being separated from the bony wall by a plexus of veins and by loose connective tissue. Partly to this fact, and partly to its being suspended in cerebro-spinal fluid, does the cord owe its comparative freedom from injury.

The *dura mater* is continuous with that lining the cranium, but it does not act as periosteum, nor does it enclose venous channels. It is firmly attached to the border of the foramen magnum and to the back of the body of the axis. It forms a sheath to the cauda equina as far as the top of the sacrum, and gives an investment to each nerve as it passes out.

The *arachnoid* (*αραχνη, ειδος*, 'fine as a spider's web') intervenes between the dura and pia mater, being continuous with that of the brain. External to it is the sub-dural space, containing some cerebro-spinal fluid, and between it and the pia mater is the sub-arachnoidean space, the fluid of which is abundant, and which communicates with that in the cerebral ventricles through an opening in the floor of the fourth ventricle. In the case of a large spina bifida (p. 204) a distinct wave of fluctuation may sometimes be obtained by compressing the tumour with one hand whilst the other hand is over the anterior fontanelle; if, however, the pressure be made roughly, cerebral irritation results.

The fluid of the spinal canal, be it clearly understood, is in the

space between the arachnoid and pia mater—sub-arachnoidean ; in the cranium the fluid is partly in the sub-arachnoid space and partly in the cavity of the brain itself, the communication being through the Sylvian aqueduct. When the fluid escapes from a spina bifida the brain as well as the cord is drained, and, its support being lost, fatal convulsions usually occur. The track of the fluid is first through the foramen of Majendie and then through the aqueduct of Sylvius.

Inflammation of the membranes (*μενιγξ*) of the cord renders them more thick (*παχυσ*), the disease being called *fachy-meningitis*. The thickening causes pressure on the posterior roots of the spinal nerves and gives rise to peripheral pains (p. 209). This is common in caries and in fracture of the spine.

On account of the cord ending at the first lumbar vertebra, the lumbar and sacral nerves obviously cannot be given off at the level of their exit from the inter-vertebral foramina. The high cervical nerves have but slight obliquity, but from the dorsal enlargement the direction of the nerves is almost vertical, the sacral nerves descending through the entire length of the lumbar region.

**The situation of the nerves in the canal.**—The spine of the vertebra prominens corresponds to the origin of the first dorsal nerve from the spinal cord, the spine of the first dorsal to the origin of the third nerve, and the fifth spine to that of the seventh pair. In fact, all through the dorsal region the nerve emerges from the cord at the level of the spine of the vertebra two above. The nerves of the lumbar and sacral plexus arise in the interval between the eleventh dorsal and the first lumbar spines—that is from the lumbar enlargement (*v.* p. 216).

In the cervical region the nerves take the number of the vertebra above which they pass out, but in the other regions they pass out below the vertebra whose number they bear, the reason being that there are eight cervical nerves, but only seven cervical vertebræ, the first nerve emerging above the first vertebra.

In the brain the *grey matter* is for the most part on the exterior ; in the cord it occupies a central position, and in transverse section it is seen somewhat in the form of the letter **H**. A slender *central canal* runs in it, opening above in the floor of the fourth ventricle. It is the 'permanent remains of the ectodermal canal from which the spinal cord is developed.' Sometimes at birth it is enormously distended with fluid, causing that variety of spina bifida known as syringo-myelocoele (*συριγξ*, pipe ; *μυελος*, marrow ; *κηλη*, tumour).

The *arteries of the cord*, which first break up in a delicate network in the pia mater, are derived from the vertebral (anterior and posterior spinal), ascending cervical, intercostal, and lumbar. Of the *veins*, two are found in the grey commissure, one on either side of the central canal, and others in the anterior and posterior median fissures. They are tributaries of the spinal veins.

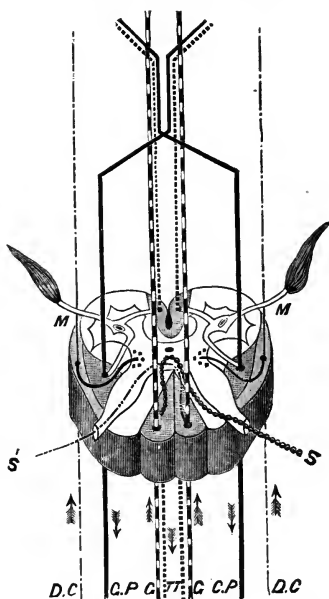
**Every spinal nerve arises by two roots**, an anterior and posterior,

the anterior containing motor, and the posterior sensory fibres. The posterior, the larger root, has a ganglion upon it—just as has the posterior or sensory division of the fifth cranial nerve. Just beyond the ganglion, which lies in the inter-vertebral foramen, the roots join. The mixed nerve then breaks into an anterior and a posterior primary division, each of which contains both motor and sensory fibres. The posterior primary divisions pass backwards to supply the erector spinæ and other muscles, and to carry sensory twigs to the back of the head, neck, and trunk, whilst the anterior divisions end, for the most part, in plexuses, except in the dorsal region, where they run forwards in the intercostal spaces.

*Nerve-roots.*—The filaments of the *anterior root* arise from the ganglionic cells in the anterior cornu of the grey crescent and pass out to the muscles. They are under the control of the motor strands descending from the brain in the direct columns of Türck and in the crossed pyramidal tracts.

In the *posterior root*, which is afferent, or sensory, are also filaments which preside over the nutrition of the skin—trophic filaments (*τροφεω*, nourish). Bed-sores are apt to occur when the function of the posterior roots is disturbed—as when disease or pressure interferes with the posterior columns. When the anterior roots or columns, however, are in distress, as in angular curvature of the spine, dermal trophic changes are conspicuous by their absence.

Of the fibres of the posterior root some straightway enter the tail of the grey crescent, but others pass into the postero-external column of Burdach, as shown in the adjacent diagram. All these sensory fibres pass over into the opposite half of the cord, and so up to the brain. If, therefore, the right *half of the cord* be destroyed, there is loss of sensation in the parts below on the *left* side of the body, the motor paralysis being on the right side, for the motor strands cross in the medulla oblongata (p. 55) and not in the cord. In the case of a lesion



D.C., direct cerebellar tracts; C.P., crossed pyramidal tracts; G, Goll's sensory columns; T, direct pyramidal (motor) tracts—Türck's columns; M, motor; S, S', sensory roots of spinal nerve; of these sensory filaments some pass through the posterior cornu of the grey crescent, and some through postero-external or Burdach's column. (After RANNEY.)

in the medulla above the level of the crossing in the pyramids, loss of motion as well as of sensation occurs upon the opposite side of the body.

**Total transverse lesions** involve, of course, complete loss of motion and sensation on both sides below, and, the sensory nerves in the proximal part of the cord, close to the lesion, being in distress, circumferential localised pains, 'girdle pains,' as they are called, result. The area of the girdle-pains indicates which nerves are crossing in the cord immediately above the damage, and points out the exact situation of the lesion. The girdle-pains which come on immediately after a fracture of the spine are due to the pressure of the displaced vertebra upon the nerves which run almost vertically along the side of the cord. The pains are referred by nerves which actually arise from the cord at the level of at least one vertebra higher than that which is displaced.

The region of the umbilicus is supplied by the tenth dorsal, and the ensiform area by the sixth and seventh.

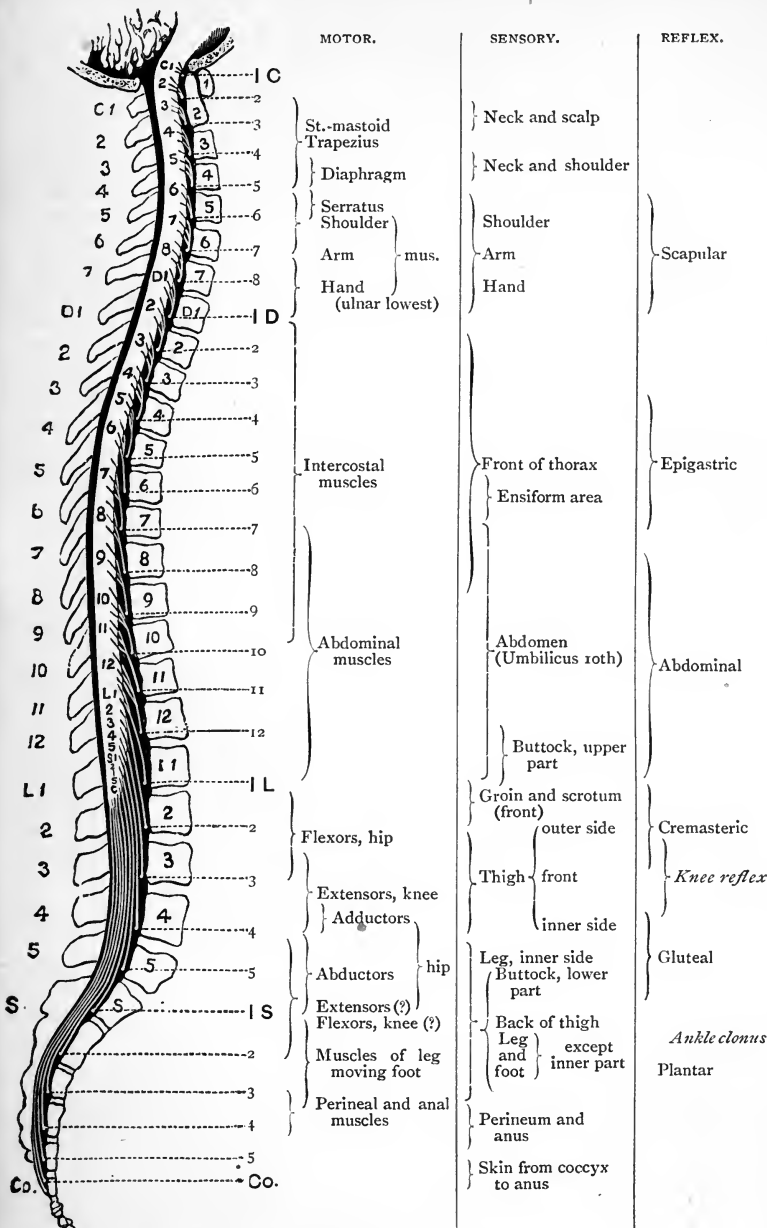
In complete transverse lesion of the middle of the lumbar enlargement the elements of the sacral plexus may be dissociated from central control, whilst those of the lumbar are not interfered with. Thus there may be anæsthesia along the outer side of the leg (from external popliteal nerve) with hyperæsthesia along the inner (internal saphenous of anterior crural). When the lower part of the cervical enlargement is traversed there is anæsthesia over the whole of the chest, and, on account of the implication of the fibres of the ulnar nerve, there is numbness along the little finger (p. 253). If the cord be seriously damaged by disease or injury at the level of the third and fourth lumbar nerves, the anterior crural, obturator, and great sciatic convey no stimulus, so that the quadriceps extensor, adductors, hamstrings, and muscles of leg and foot are paralysed, whilst there is loss of sensation in the thigh (except in area of distribution of the external cutaneous), leg, and foot. The sphincter ani also ceases to act.

The reflexes in all these cases are altered; most likely they are exaggerated, for no cerebral control can reach the affected segment.

*Priapism* often follows fracture above the lumbar enlargement, because, the cerebral control being lost, the reflex is exaggerated and is in constant action. If the bladder be paralysed, the urine is retained and undergoes decomposition, cystitis is the result, and, unless the greatest care and cleanliness be observed, bed-sores occur.

If the lesion be at the level of the *seventh dorsal*, there will, in addition, be paralysis of the abdominal and lower intercostal muscles, the area of insensibility reaching up to the level of the ensiform cartilage.

If at the level of the *first dorsal nerve* (seventh cervical vertebra) all the intercostals cease to move, and the muscles and skin supplied by that part of the first dorsal which enters the inner cord of the brachial plexus are paralysed, the skin over the whole of the thorax,



The approximate relation to the spinal nerves of the various motor, sensory, and reflex functions of the spinal cord. (GOWERS.)

except in the area of distribution of the supra-clavicular nerves (p. 146), becomes anæsthetic. (The *phrenic nerve* comes from the third, fourth, and fifth nerves, chiefly the fourth, which passes out above the fourth cervical vertebra.) When the lesion is in the *mid-cervical* region the diaphragm acts imperfectly and the whole of the brachial plexus is paralysed, as are, of course, all the nerves below. Death rapidly closes the scene. At the second, third, or fourth cervical vertebra the diaphragm, intercostals, and all other muscles of the trunk and extremities are paralysed; sensation may persist for a while in the upper part of the neck and in the face, but immediate death is the general result.

In the case of a man with a tumour of the dura mater, which pressed upon the back of the cervical cord, giving rise to agonising girdle-pains and paraplegia, Mr. Horsley removed the laminæ of the vertebræ, from the third to the sixth, opened the dura mater, and successfully removed the growth.

It has been remarked elsewhere (p. 411) that the *centre for micturition and defæcation* is in the lumbar enlargement. When the cerebral control is cut off, as in compression of the cord, the patient 'passes everything beneath him.' That is to say, he empties the bladder and rectum without intent or even knowledge. As soon as the viscus gets full the stimulus is conveyed to the grey matter of the cord and passes out as a motor influence to the muscular tissue of the viscus. Let it be remembered that these viscera, though containing non-striated muscular tissue, are under cerebro-spinal and not merely sympathetic control. (*See fourth sacral nerve*, p. 378.) When the centre for micturition is itself destroyed, as in extensive lesion of the lumbar enlargement, or in disease of any part of the circuit, reflex is lost, and the bladder quietly fills and overflows.

The **grey matter** in a cross section of the cord is seen as two crescents with their convex borders joined by a transverse band. This commissure is exposed at the bottom of the posterior median fissure by separating the lateral halves of the cord, but it is shut off from the bottom of the anterior fissure by a transverse band of white tissue.

The posterior horn of the grey crescent tapers to the surface at the postero-lateral fissure through which are issuing the sensory roots of the spinal nerves. The anterior cornu is thick and tuberculated, and does not reach the surface of the cord, the anterior roots of the spinal nerves passing into it through the anterior column. That part of the lateral half of the cord which the tapering posterior cornu cuts off constitutes the posterior column, that part of it which lies close along the median fissure being called the *posterior median column* or *Goll's column*. Disease of this column gives rise to no known symptoms.

Large, **multipolar, ganglionic cells** occupy the anterior cornu; they regulate the movements of the muscles, and preside over their nutrition as well as over that of the muscles and bones. The trophic



(*τροφος*, a nurse ; *τρεφω*, nourish) filaments from these cells run with the motor nerves. Inflammation of these cornua is called *anterior poliomyelitis* (*πολιος*, grey; *μυελος*, marrow); it sometimes follows in the wake of diphtheria, or, suddenly and obscurely occurring in a healthy child, causes **infantile paralysis**. This condition may also occur in the adult, however, as well as in the infant. When the cells are destroyed, not only are the muscles flabby and useless, but, together with the bones, their nutrition is affected and their development ceases, and they no longer respond to Faradism. The excito-motory circuit being broken, reflexes are lost, but, the posterior track of the cord being uninterfered with, sensation is not impaired.

It does not follow that the paralysis after poliomyelitis will be permanent. The cells which are placed in the centre of the storm-region are often completely wrecked, while many of the outlying cells receive only a passing shock. Sometimes after such a storm, in the cervical enlargement, for instance, all the muscles of an upper extremity are paralysed; but the power of movement may return again in all, with the exception, perhaps, of one small group of muscles. Sometimes only a single muscle is left permanently paralysed—the deltoid, for instance.

In the early days of infantile paralysis there is often a tenderness or a hyperæsthesia of the skin of the affected limb. The explanation of this is that the storm-wave happened also to disturb the posterior cornu, with which the posterior roots of the nerves are associated.

**Progressive muscular atrophy** differs from the paralysis just considered in that it is the result of a slow degenerative change—not a rapid inflammatory one—in the ganglionic cells. But, the motor and trophic cells only being diseased, there is no loss of sensation in the affected parts, though the muscles affected grow steadily smaller and weaker.

**Reflex action in cord.**—The sensory impulse conveyed through a spinal nerve passes by the posterior root into the grey crescent, and then, traversing the large bi-polar cells of the anterior cornu, is converted into a motor one, which is ‘reflected’ by the anterior root of the spinal nerve and causes certain muscles to ‘act.’

Thus, if the sole of the foot be tickled during sleep—when the brain has handed over general control to the reflex centres—the impulse is transmitted through the crescent in the lumbar enlargement to the motor filaments, certain muscles contract, and the foot is drawn away. But if the man be awake the sensory impulse passes at once across the grey commissure and up the opposite half of the cord to the brain, where it is duly appreciated, and whence it is reflected as a motor impulse by the pyramidal tracts, and then out by the anterior root to the muscles. Or ‘we can, if we wish, execute voluntarily a movement of the leg quite the same as the reflex act. Moreover, we can exercise some voluntary control over the reflex action and prevent the start of

the leg.' (Gowers.) If there be a serious flaw in any part of the chain the reflex does not work, and if there be a break in the fibres descending from the brain we cannot control it.

The reflexes are controlled by an *inhibitory impulse* descending by the antero-lateral columns of the cord (pyramidal tracts). When these columns are diseased the afferent impulse awakens in the grey matter a motor wave of disproportionate vigour. The *reflex* is then spoken of as '*exaggerated.*' Thus there is exaggerated knee-jerk when the pressure of angular curvature interferes with the antero-lateral columns of the cord.

Tetany, muscular spasms, limited and general convulsions—exaggerated spinal reflexes—are met with so frequently in young children because the control-fibres of the pyramidal tracts are late in acquiring due functional activity.

À *reflex being lost*, this question arises: 'Is there disease of the postero-external column with which the sensory roots are associated, as in locomotor ataxy; or in the grey matter, as in antero-polio-myelitis which had occurred in infantile or diphtheritic paralysis; or is there some degeneration affecting the anterior nerve-roots?' On account of the disturbance in the grey matter, exaggeration of a reflex often precedes its abolition.

**Special reflexes.**—When the skin in the pubic region of the thigh is stimulated, an impulse is conveyed by the ilio-inguinal nerve to the lumbar enlargement, and thence by the genital branch of the genito-crunal to the cremaster, which, contracting, draws up the testicle. This is the *cremaster reflex*; it is generally well marked in childhood. Its absence in the adult does not necessarily imply disease. The 'centre' for this reflex is in the lumbar enlargement.

Other superficial reflexes are the *plantar, gluteal, abdominal, epigastric, and scapular.*

It is unnecessary to describe each in detail, but one may say briefly that by irritating sensory nerve filaments in any one of these regions a gentle motor influence is duly passed out to the subjacent muscles provided that the reflex chain be in working order. In the case of the scapular reflex, irritation of the skin between the shoulder-blades sends a quiver through the *teres major*. The reflex centre for the scapular muscles is in the lower part of the cervical enlargement. When the cerebral control is lost, or the segment of the cord within an individual circle is excited by disease, the reflex is '*exaggerated.*'

By trying one reflex after the other on each side of the body, and duly comparing them, the condition of the cord in almost its entire length can be ascertained.

The **deep** or **tendon-reflexes** are obtained by irritating the sensory nerves of the muscles themselves. The muscle must first be placed in a condition of moderate tension and then smartly struck or over-stretched.

**Patellar tendon-reflex.**—The leg being crossed over the opposite knee, and the ligamentum patellæ being sharply struck with the inner border of the hand, an afferent impulse is conveyed by filaments of the anterior crural to the lumbar enlargement, and, being there converted into a motor wave, the quadriceps femoris is set in action and the leg is extended with a 'jerk.' Absence of the jerk is evidence of a flaw either in the sensory fibres of the nerve, in the posterior column of the cord, in the grey crescent, or in the motor filaments of the nerve. Thus, it is lost in locomotor ataxy when the posterior external column is sclerosed, and when in diphtheria or infantile paralysis there has been a serious disturbance in the anterior cornu of the crescent. Sometimes it will manifest itself only when the patient occupies his muscles and his attention by tightly linking his hands and trying to pull them asunder (*Jendrassik's method*).

The reflex is exaggerated in disease of the antero-lateral columns, and when the control is lost in cerebral disease, as, for instance, in hemiplegia.

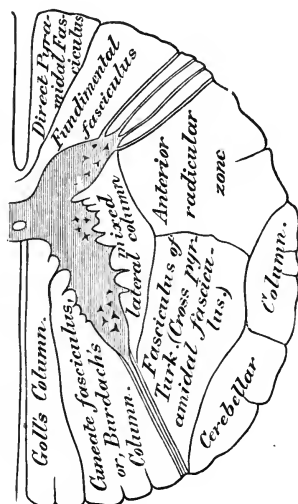
**Ankle-clonus** (*κλονος, any violent motion*).—When, the knee being slightly bent, the foot is flexed to a right angle, and is then kept in the over-flexed position by pressing the hand beneath the metatarsal bones, rhythmic contractions and relaxations of the calf-muscles ensue. Afferent and efferent branches (sural) of the internal popliteal, associated in the lumbar enlargement, constitute the reflex chain, and tension in the muscle irritates the nerve and stimulates immediate contraction. In the case of irritability of the cord, a series of rhythmical contractions are set up when the muscle is merely held in the strained position without any sudden flexion of the foot being required to start them.

The **tendo Achillis jerk** is shown by striking the tendon when the foot is placed in the flexed position, and the *peroneal reflex* is obtained in a similar way when the foot is inverted.

In the upper extremity deep reflexes may be searched in connection with the triceps, biceps, supinator longus, and wrist.

#### Transverse section of the cord.

—The *anterior median column* consists of those fibres which come straight from the anterior pyramid; it is therefore called the *direct pyramidal tract*. It is well to remember that it also bears the name of *Türk*.



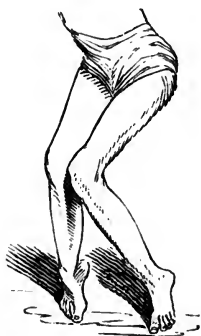Columns of the cord. (GRAY.)

That part of the anterior column which is to the outer side of Türck's column consists of fibres destined for the anterior roots of the spinal nerves ; its strands, therefore, are for *motor conduction*.

In the *lateral column* are two strands of fibres, one of which passes to the cerebellum, the *direct cerebellar tract*, the other being the *crossed pyramidal tract*. The latter is composed of fibres which have crossed in the decussation of the anterior pyramids of the medulla oblongata (those fibres of the pyramid which have not so decussated passing down in Türck's column). Thus, secondary to disease of the motor area of the cerebrum—say of the right side—degeneration occurs in the right direct (Türck's) tract and in the left crossed tract.

(The direct cerebellar tract is for the transmission of sensory impulses, as indicated in the diagram on p. 215.)

*Disease of the antero-lateral column* causes loss of voluntary action of the muscles below, and, control from the brain being lost, the reflexes are exaggerated and a spasmodic contraction results—*tetanoid paraplegia*. But the muscles implicated are not wasted unless the



Spastic paraplegia ; muscles contracted.

sclerosis extends into the anterior cornu, and there is no loss of sensation or of co-ordination, for the posterior columns are still sound. Children are specially subject to sclerosis of the lateral column, the disease being generally called *spastic paraplegia*. The child gradually loses the power of walking, and as he is being examined a storm of reflexes may arise ; his knees are thrown up in bed and his thighs are violently adducted. When he tries to walk a characteristic spasm of the muscles of locomotion prevents him, his heels being drawn up and his limbs stiffened. All the reflexes are in excess, and that of the ankle is so strong that rhythmic contractions are replaced by muscular rigidity. (The reflex loops are entire, but the cerebral control cannot travel down to them by the diseased motor paths.) Subsequently the muscles become *contractured*, the hands and feet are 'clawed,' and the patient is hopelessly bed-ridden.

As already remarked, the motor area of the brain is held in communication with the anterior roots of the spinal nerves by means of the pyramidal tracts—chiefly the crossed tract—with the intervention of the large multipolar cells of the anterior cornu. And thus, if a muscle of the arm, for instance, be paralysed, the fault may be in the motor area of the brain, in a pyramidal tract, in the ganglionic cells, or in the efferent filaments of the nerve.

**Descending degeneration.**—In the case of a lesion of the motor area of the brain (p. 48)—say of the right side—degeneration descends by the pyramidal tracts, those muscles being paralysed on the left side

which are supplied by the cross fibres, and those on the right which are supplied by the fibres of the direct tract, Türck's column. Thus it is that a lesion on one side of the brain may be followed by paralysis and contracture of muscles on both sides of the body. The degeneration descending in the pyramidal tracts (as after hæmorrhage in the motor area of the brain), the muscles associated with them are not only paralysed but also contracted, and if the disease extends into the anterior horn of the grey crescent they also begin to atrophy.

The *postero-external* or *Burdach's column* consists to a large extent of fibres of the posterior roots of the nerves and of fibres that convey tactile impressions to the brain. Under the guidance of the brain, these fibres co-ordinate muscular movements. Thus, when the postero-external columns are diseased the muscles are not paralysed, but they act tumultuously, without co-ordination. There are also the peripheral pains, impaired sensation, and the other characteristics of locomotor ataxy. Later, as the sclerosis extends to the anterior cornua, muscular weakness appears, with atrophy (p. 218). But when the anterior cornua remain sound, whilst the posterior and lateral columns are diseased, the nutrition of the muscles continues, though they become weak because of the implication of the crossed pyramidal tract. Thus **locomotor ataxy** (*ἀ*, without; *ταξίς*, order) is a want of harmony in the working of muscles of locomotion, and is due to fibroid degeneration (sclerosis: *σκληρός*, hard) beginning in the columns of Burdach and spreading into those of Goll. As the fibrosis is followed by atrophy in the spinal or dorsal cord, the disease also bears the name *tabes dorsalis* (*tabeo*, waste away). Burdach's column being very closely associated with the posterior roots of the spinal nerves—conveying sensory impulses and co-ordinating movements—the sclerosing irritation of the sensory nerve roots accounts for the characteristic peripheral 'lightning-pains' of locomotor ataxy; and as the strands are pressed upon by the inflammatory thickening their power of co-ordinating diminishes. Normal sensation is gradually lost, and the patient cannot tell when his feet touch the ground. As the disease advances the ataxic man can keep his muscles under nominal control only by watching every step; he stumbles and falls unless his path is light, and with his eyes shut he cannot keep his balance. As he walks his feet fly out in a meaningless manner, and in time the muscles of his hands and arms become affected. The patella reflex is entirely lost because the sensory impulse fails to reach or to traverse the grey crescent, and erection of the penis, another reflex act, becomes in due course impossible. (For the state of the *pupil*, *v.* p. 59.)

#### THE SYMPATHETIC SYSTEM

The sympathetic system consists of two knotted cords along the front of the vertebral column, which are joined together on the anterior communicating artery (p. 42), and, at the tip of the coccyx, in

the ganglion impar. From these knots, or ganglia, offshoots join the spinal nerves, and branches pass off, frequently in intricate plexuses along the neighbouring vessels. The chief office of the system is the control of the non-striated muscular tissue of the blood-vessels, lymphatics, and hollow viscera, and it is through them that the calibre of these vessels and viscera is regulated (asthma, p. 197).

In the *cervical region* the knots are represented by three ganglia which lie behind the carotid sheath, the *superior ganglion* being a long fusiform mass opposite the second and third vertebræ. The *middle ganglion* is at the level of the inferior thyroid artery, and the *lowest ganglion* is near the neck of the first rib, whence it sends filaments up with the vertebral artery.

From the superior cervical ganglion filaments ascend into the skull with the internal carotid artery, to form the cavernous and carotid plexuses, from which branches pass along the ophthalmic and the cerebral divisions of the artery. Other offshoots of the cervical ganglia accompany the branches of the external carotid, certain twigs join the pharyngeal plexus (p. 138), and some descend to the cardiac plexuses. Communications also pass to the spinal nerves.

**The cardiac plexuses.**—The superficial plexus is below the arch of the aorta, and receives branches from the cervical part of the left vagus and sympathetic, and from the deep plexus. The deep plexus receives a large number of branches from the gangliated cords, and also from the vagi in the neck. From these plexuses networks extend along the coronary arteries and into the pulmonary plexusés.

*In the thorax* the sympathetic ganglia, lying near the heads of the ribs, close behind the pleura, send branches to the dorsal nerves. The upper six ganglia also give filaments to the thoracic aorta and to the pulmonary plexus, and the lower six send down the splanchnic (*σπλάγχνα, viscera*) nerves to the viscera of the abdomen.

The *great splanchnic* is formed of offsets from the sixth to the tenth, and, descending through the crus of the diaphragm, ends in the semilunar ganglion and in the renal and supra-renal plexus.

The *lesser splanchnic*, from the tenth and eleventh, passes down to the cœliac plexus, and the *least splanchnic* to the renal plexus.

*In the abdomen* the four or five pairs of ganglia send branches on to the front of the aorta, and others over the common iliac arteries to form the *hypogastric plexus*. The *solar plexus*, part of the aortic network, is between the crura and behind the stomach, and sends filaments along the chief visceral branches of the abdominal aorta, under the names of supra-renal, renal, spermatic, cœliac, and superior mesenteric plexuses. The solar plexus contains several ganglia, of which the semilunar receive the ending of the great splanchnic nerves.

The *aortic plexus* is that part of the network which sends off the inferior mesenteric plexus; it ends in the hypogastric plexus.

## THE CLAVICLE AND SCAPULA

The **clavicle** articulates with the first costal cartilage, and, through the medium of a fibro-cartilaginous disc, with the sternum. Its inner two-thirds are almost cylindrical, and are concave on the posterior aspect, so that when the shoulder is lowered the subclavian vessels and the brachial plexus may not be pressed against the first rib.

The articulation between the clavicle and acromion forms the **shoulder**; the *shoulder-joint* is the articulation between the glenoid cavity and humerus.

The rounded end of the clavicle is so firmly held down to the first costal cartilage by the rhomboid ligament that *dislocation of the sternal end* is extremely rare. It may occur, however, on to the front of the manubrium, upwards, or backwards. In the last case the end of the bone might so press upon the trachea as to demand a partial excision of the bone. It might also press upon the end of the internal jugular or the beginning of the innominate vein, which are close behind it.

The **sterno-clavicular joint** belongs to the class Arthrodia, and its gliding movements are much increased by the presence of the *inter-articular fibro-cartilage* which intervenes between the sternal facet and the end of the clavicle. This disc effects, as part of its office, the breaking of shocks transmitted by a fall upon the hand. Each surface is covered by a synovial membrane, and these membranes may join by a hole in the disc. The larger membrane is that between the end of the clavicle and the disc, as it also lines the articulating surfaces of the clavicle and the first costal cartilage. The joint is enclosed by an anterior and a posterior ligament, and by superior fibres (the *inter-clavicular ligament*) which run from clavicle to clavicle with an intermediate connection with the supra-sternal notch.

In front of the joint is the sternal origin of the sterno-mastoid, and behind are the sterno-hyoid and thyroid.

The *rhomboid ligament* is a strong band connecting the inner end of the clavicle with the cartilage of the first rib; it prevents extreme elevation of the clavicle without a simultaneous effort at inspiration. In front of it is the origin of the subclavius, and close behind it runs the subclavian vein.

The outer third is flat, and articulates with the acromion by an oblique facet. Dislocation of this joint rarely occurs, because strong ligaments ascending from the coracoid to the clavicle (conoid and trapezoid) are a firm bond of union; the slope of the facets renders upward luxation of the clavicle the only one possible. As the bones are subcutaneous, the diagnosis is easily made out, but, though it may be

readily reduced, it is often impossible to keep the clavicle in position without obtaining, by a cutting operation, permanent ankylosis.

The joint has a synovial membrane and a capsule which is thickened by superior and inferior fibres. Sometimes the joint is divided by an inter-articular fibro-cartilage.

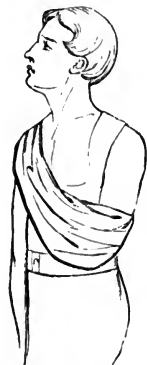The **conoid** and **trapezoid ligaments** bind the outer third of the clavicle to the coracoid process; the conoid is behind and to the inner side of the trapezoid, the base of the cone being upwards.

The chief *muscles attached to the clavicle* are the pectoralis major in the cylindrical and the deltoid in the flattened part, in front, and the trapezius behind the deltoid. The sterno-mastoid arises along the sternal third of the upper aspect, and the subclavius is inserted into the groove on the under surface.

**Fracture of the clavicle** usually occurs at about the middle of the convex part, the cause being a fall on to the hand or shoulder.

*Signs of the fracture.*—The shoulder at once drops, for there is now nothing but the trapezius and the levator anguli scapulæ to support the weight of the arm. The dragging is so painful that the man usually holds up the elbow in the other hand, and inclines his head to the injured side. The collar-bone is intended not only to hold the shoulder up, but to fend it from the chest. When, therefore, the bone is broken the pectoralis major and minor, latissimus dorsi, subclavius, trapezius, and rhomboids drag the scapula inwards, whilst the pectorals also drag it somewhat forwards.

The inner fragment does not stir: the costo-clavicular (rhomboid) and the adjacent ligaments hold it firm. As the finger is run along the broken bone the sternal fragment certainly does seem to be displaced, but it is not. It is the outer part that has fallen in beneath it.



Fracture of clavicle. (DRUITT.)

The *treatment* consists in raising the elbow—and with it the drooping scapula—and in bringing the elbow across the chest, a large pad being placed in the armpit. The pad acts as a fulcrum to the humerus—a lever of the first order: when the elbow is drawn inwards the scapular end of the bone is thrust outwards. The hand is laid flat over the opposite breast, and the arm, forearm, and hand are secured by a wide roller, or strapping, for about three weeks.

When the *clavicle* is broken *outside the conoid ligament* there is usually no displacement, for the shoulder-blade is still suspended by that ligament; there may be some drooping of the shoulder, however.

**Complications.**—The broken bone may, if the violence be great, wound the external jugular (p. 35), subclavian, or internal jugular vein, or even the subclavian artery. It may also lacerate the brachial plexus.



The *sternal end of the clavicle* has an *epiphysis* which begins to ossify about the eighteenth year and joins the shaft a few years later. Occasionally this epiphysis becomes detached, when careful measurement shows that the lesion is not a dislocation.



Epiphysis, 2, of clavicle at sternal end.

In *excision* of the bone the periosteum should be stripped off by the blunt raspatory, the knife being used only for the skin; thus there is but little risk of wounding the subclavian and supra-scapular vessels and the external jugular vein.

The **scapula** reaches from the second to the seventh rib. Its **spine** at the base corresponds to the third rib, and marks the posterior limit of the fissure between the upper and lower lobes of the lung (p. 192). The subscapularis and serratus magnus intervene between the scapula and the ribs. The bone is held in position by certain clavicular ligaments, and by the trapezius, levator anguli, rhomboids, and serratus magnus. The latissimus dorsi may be left out of the calculation, as its connection with the inferior angle is but slight and inconstant.

**Luxation of scapula** is that condition in which the inferior angle projects from the chest-wall. It is due, not to the angle having slipped over the border of the latissimus, but to paralysis of that part of the serratus which should hold the vertebral margin and the inferior angle against the chest. Frictions, and electrical stimulations along the nerve of Bell, usually efface the deformity.

The *acromion* and the *coracoid* processes have each two centres of ossification; they may become 'unglued,' especially so the latter, by direct violence or muscular action. The coracoid is ossified on to the rest of the scapula at puberty, the acromion at manhood.

After fracture of the coracoid the pectoralis minor, coraco-brachialis, and short head of biceps drag at the loosened process, but are unable to displace it materially, as the conoid and trapezoid ligaments still fix it to the clavicle. The fracture is treated by flexing the elbow (to slacken the biceps), and by drawing it across the chest (to take the strain from the pectoralis minor and coraco-brachialis), and by fixing the arm in that position for two or three weeks. The break may be repaired by a ligamentous union. Probably not a few of the specimens which are described as 'ununited fracture of the coracoid' are instances of imperfect ossification, fracture, especially from violence, being of rare occurrence. The only other fracture of the scapula which is of anatomical importance is that of the neck, when the coracoid process and the glenoid cavity are detached, and descend together with the head of the humerus into the axilla. The injury is excessively rare; it is distinguished from simple downward dislocation of the humerus by the fact that the contour of the shoulder is easily restored when the arm is raised, though it recurs directly the support is removed. In dislocation of the humerus the bone is firmly locked.

## THE SUBCLAVIAN ARTERY

On the left side the subclavian arises from the left end of the transverse part of the aortic arch, a little to the left of and behind the left common carotid. Thence it ascends through the superior mediastinum (p. 154), and, arching over the apex of the pleura, passes behind the scalenus anticus, just as it does on the right side.

**Relations of the first part of the left subclavian.**—It is much longer and more vertical than that of the right. It has *in front* the manubrium with the origin of the sterno-mastoid, and sterno-hyoid and thyroid, a little of the left lung and pleura intervening. As the artery ascends a little posterior to the left carotid the internal jugular vein and vagus, descending along the outer side of the thoracic part of the carotid, are on an anterior plane to the subclavian. The vertebral and the subclavian vein, the beginning of the left innominate vein, and the phrenic nerve, which has slipped down from the front of the anterior scalene, are also in front.

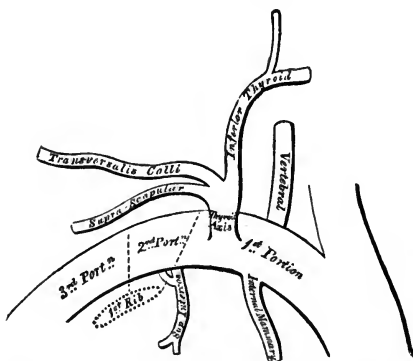
*Behind* are the œsophagus and thoracic duct, and the longus colli.

The left carotid and the trachea are *to the right side*; and as the subclavian ascends it has the œsophagus also to the right. Because the thoracic duct hooks forwards to the confluence of the jugular and subclavian veins it lies close on the inner side of the artery.

The lung and pleura are *to the outer side*.

As already remarked (p. 184), aneurysm of the innominate artery is of common occurrence, because that vessel receives much of the shock of the contraction of the left ventricle; on the other hand, dilatation of the first part of the subclavian is very rare.

The **right subclavian** artery springs from the innominate, behind the sterno-clavicular joint, and runs outwards and a little upwards to the inner border of the scalenus anticus, where the second part begins. It courses (first part) above the level of the clavicle, and, being somewhat horizontal, its relations are anterior, posterior, superior, and inferior.



Plan of branches of right subclavian artery. (GRAY.)

*In front* are the sterno-mastoid, sterno-hyoid, and sterno-thyroid; the internal jugular and vertebral veins, the pneumogastric and phrenic nerves, and cardiac branches of the sympathetic.

*Behind* are the recurrent laryngeal nerve, the sympathetic cord, the longus colli, and a little of the pleura.

*Below* are the pleura and the recurrent laryngeal; *above*, the vertebral branch is given off, and, below, the internal mammary.

The fact of the lung and pleura being somewhat behind the first part of the right subclavian, but in front of the left, is explained by the left artery not arising until the second part of the aortic arch had passed well back.

**Ligation of the first part** of the right subclavian is performed by raising a triangular flap, as in tying the innominate artery (p. 182). When the sterno-mastoid and sterno-hyoid and thyroid are divided and raised, the common carotid is to be followed down to the innominate, and the first part of the subclavian is then to be denuded.

The aneurysm-needle is passed from before backwards.

The operation is difficult and dangerous, not only on account of the depth at which the vessel is placed, but also on account of the important structures which risk being wounded, namely, the internal jugular and vertebral veins, the pleura and the apex of the lung, and the pneumogastric, recurrent laryngeal, and phrenic nerves. If the procedure be resorted to, the common carotid should also be tied, so as to cut off most of the collateral supply and to diminish the risk of recurrent hæmorrhage.

*Ligation of the first part of the left artery* is well-nigh impracticable; the vessel is closely surrounded by important veins and nerves, whilst the thoracic duct and the pleura are in the immediate neighbourhood.

The **second part of the subclavian artery** lies behind the scalenus anticus, additional anterior relations being the clavicular origin of the sterno-mastoid, the subclavian vein, and the phrenic nerve.

*Behind* are the apex of the pleura, and the scalenus medius.

*Above* are the cords of the brachial plexus, emerging between the origins of the anterior and middle scalenus, and *below* is the pleura.

The *second part* may be tied by cutting through the clavicular origin of the sterno-mastoid, turning inwards the phrenic nerve, and dividing the origin of the anterior scalene. There is, however, so great a risk of damaging the phrenic nerve, the internal jugular vein, and the pleura that the operation is very rarely resorted to.

The **third part of the subclavian artery** is comparatively superficial in the posterior inferior triangle (p. 9). It *rests upon* the first rib.

*Above it* are the omo-hyoid, and the cords of the brachial plexus.

*In front* are the platysma and the cervical fascia; the external jugular, supra-scapular, and transverse cervical veins; the subclavian vein, though on a lower plane; the clavicle and subclavius, and the supra-scapular artery. *Behind* are the scalenus medius and the lowest nerves of the brachial plexus.

**Ligation of the third part of the subclavian.**—The patient lies

supine, with the shoulders raised and the head thrown back, the arm being pulled down to the utmost, so as to lower the clavicle—the base of the posterior inferior triangle: when the clavicle is raised, as in axillary aneurysm, ligation is rendered much more difficult.

The *land-marks* are the clavicle, posterior border of sterno-mastoid, and, possibly, the anterior margin of the trapezius, but this is not generally defined. Perhaps the artery may be felt pulsating upon the first rib. In a muscular subject the interval between the sterno-mastoid and trapezius may be so small that much of the attachment of the muscles may need section.

The skin is well drawn down, and an incision is made through it, the superficial fascia, and the platysma for about  $2\frac{1}{2}$  to 3 in. along the middle of the clavicle, beginning at the posterior border of the sterno-mastoid. Then, when the skin is released, the incision is drawn up along the superior border of the clavicle. The external jugular vein is seen as it is about to pass through the deep fascia; if it be much in the way it must be tied in two places and divided. The deep fascia, which, being attached to the upper border of the clavicle, is not drawn down with the skin and platysma, is then divided above the clavicle, and the finger is passed through it into the connective tissue in the depths of the subclavian triangle.

The first rib is then felt, and the *scalene tubercle* with the attachment of the scalenus anticus—the outer border of that muscle lying behind that of the sterno-mastoid. As this tubercle is at the inner border of the rib, and as the subclavian artery passes behind the muscle, the finger must be directed outwards and a little backwards over the first rib, in order to feel the artery. The lowest cords of the brachial plexus are close behind the artery, and on a rather higher plane, resting upon the sloping rib; they are apt to be picked up in mistake for the artery. But even in the cadaver it is easy to make out the difference, for on rolling the artery with the tip of the finger upon the rib it is felt to be hollow and collapsing, the nerve being solid and cord-like.

The artery having been freed by the cautious use of the director, the aneurysm-needle is passed round it from behind, so that there may be no risk of any of the plexus being enclosed in the loop. The vein is well below the level of the artery, and behind the clavicle, and is in but slight danger of being wounded. The operator does not usually see the vein. Care must be taken that the point of the needle is not thrust too much downwards, lest the dome of the pleura be wounded.

On one occasion in which I was performing this operation a large and dusky lymphatic gland appeared in front of the artery, and at first sight looked like the swollen vein.

Some of the **irregularities** are mentioned on p. 180, the most interesting of them being that in which the right subclavian is given off

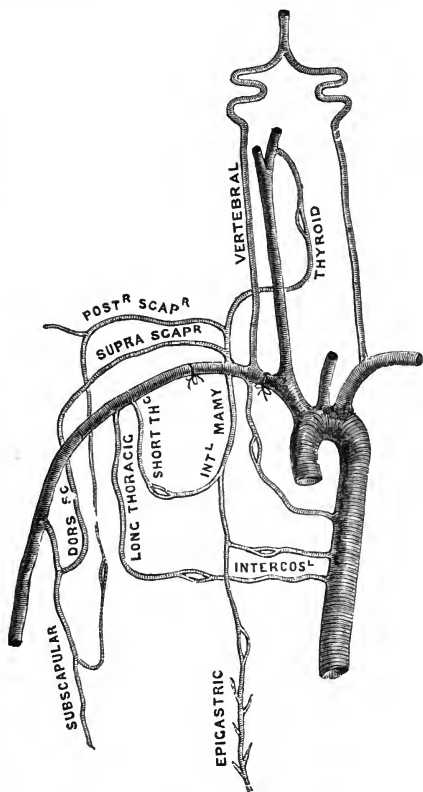
as the second or third trunk of the aorta, and reaches the scalenus by winding behind the trachea and œsophagus. Sometimes the artery passes in front of the scalenus anticus, and sometimes the vein passes behind the muscle.

**Compression of the subclavian** may be effected by the surgeon standing behind the patient, gripping the shoulder with his fingers, and thrusting the thumb towards the first rib, down the outer border of the sterno-mastoid, the shoulder and clavicle having been first drawn down. In certain cases it may be expedient to compress the artery by the aseptic finger introduced through an incision in the deep fascia.

**Collateral circulation** after ligation of the third part is carried on by the service of the empty branches of the axillary artery. Thus, the superior thoracic, acromial thoracic, the long and the alar thoracic branches, and the ending of the subscapular bring blood from the superior intercostals, and from intercostal branches of the aorta and internal mammary. The dorsalis scapulæ would help by its anastomosis with the supra- and posterior scapular arteries, and the acromial thoracic and the posterior circumflex by their communications with the supra-scapular in the acromial region.

The *branches* of the first part are the vertebral, internal mammary, and thyroid axis; from the second part comes the superior intercostal.

The **vertebral**, arising from the upper and back part of the first portion, makes a short ascent into the transverse process of the sixth cervical vertebra; it then passes through the transverse processes above this, and, taking a peculiarly twisted course near the posterior ring of the atlas, enters



Inosculation of subclavian artery. (HOLDEN.)

a peculiarly twisted course near the posterior ring of the atlas, enters

the skull through the foramen magnum, joining with its fellow to form the basilar.

**Relations of the root of the vertebral artery.**—As the vessel comes off at the very beginning of the subclavian, it can be but a little distance upon the outer side of the common carotid: as the internal jugular vein descends upon the outer side of the carotid, and in front of the subclavian artery, it lies just in front of the vertebral artery.

The scalenus anticus slopes upwards and inwards from the front of the second part of the subclavian to the anterior tubercle of the transverse process of the sixth cervical vertebra, and the longus colli is resting upon the front of the vertebræ: therefore the vertebral artery ascends in the interval between those muscles.

The thoracic duct, turning downwards and forwards to the confluence of the left internal jugular and subclavian veins, passes in front of the root of the vertebral, and the inferior thyroid also winds to the front. The vertebral vein, descending behind the end of the internal jugular, to open into the beginning of the innominate vein, is also to the front of the root of the vertebral artery.

As the artery courses with the vertebral vein through the transverse processes it passes across the emerging cervical nerves, the relative position of the structures being similar to the arrangement upon the first rib, that is, the vein is anterior and the nerves are posterior to the artery.

**Ligation of the vertebral artery.**—As the artery is ascending on the inner border of the narrow scalenus anticus, and as the outer border of that muscle corresponds to the outer border of the sternomastoid, a vertical incision of  $2\frac{1}{2}$  or 3 in. down that border of the sternomastoid must be only a little to the outer side of the vertebral artery. From the lower end of this incision a second is to be made inwards for about  $\frac{1}{2}$  in. through the clavicular origin of the muscle. Then, after the dexterous use of the end of the director, the artery is exposed. The structures in danger are the phrenic and pneumogastric nerves, the internal jugular vein, and the pleura and lung.

*Branches of the vertebral artery (spinal)* enter with the roots of the spinal nerves to the cord and its membranes; others pass out to the muscles and anastomose with the occipital, and with the deep and the ascending cervical arteries. *Posterior meningeal* branches ramify in the cerebellar dura mater, and *posterior* and *anterior spinal* descend along the medulla. The *inferior* (posterior) *cerebellar* is a good-sized artery. (The branches of the basilar are referred to on p. 43.)

The **vertebral vein** begins outside the back of the skull and passes down through the cervical transverse processes, in front of the vertebral artery. Having traversed the sixth process, it descends on a plane anterior to the first part of the subclavian artery, to end in the back of the innominate vein. It may receive a tributary through the posterior

condylar foramen, and it gathers many branches from the spinal cord and column, and from the muscles of the neck.

The **thyroid axis** comes from the front of the first part of the artery, and at once breaks into the inferior thyroid, and supra- and posterior scapular branches :—

The **inferior thyroid**, in order to reach the thyroid body, winds beneath the sheath of the common carotid and the middle sympathetic ganglion, at the level at which the omo-hyoid crosses the front of the sheath—opposite the fifth cervical vertebra.

*Ligation.*—Sometimes this artery is tied in the case of enlargement of the thyroid gland. An incision of 2 or 3 in. is made in front of the lower part of the sterno-mastoid, and the vessel is then sought opposite the cricoid cartilage.

*Branches.*—Unimportant twigs are given to the muscles in its neighbourhood.

The **ascending cervical** runs in the groove between the scalenus anticus and the rectus anticus major, giving twigs to those muscles, and others to anastomose with the vertebral in the spinal canal. *Tracheal, œsophageal, and laryngeal* branches also pass off.

The termination of the inferior thyroid anastomoses with its fellow of the opposite side, and with the superior thyroid artery in the lower part of the thyroid body.

The **supra-scapular artery** passes outwards in front of the scalenus anticus and phrenic nerve, and behind the clavicular origin of the sterno-mastoid. And, as the supra-scapular notch is below the level of the clavicle, the artery sinks behind the clavicle, where it lies in front of the third part of the subclavian artery, and gives twigs to the sterno-mastoid and subclavius. Then, winding on above the ligament, it ramifies beneath the supra- and infra-spinatus muscles, supplying the shoulder-joint, and anastomosing with the posterior and the dorsal scapular (*v. p. 231*) arteries.

It sends a twig through the trapezius, on to the acromion process, which anastomoses with the acromial thoracic.

The **posterior scapular**, in order to reach the vertebral border of the shoulder-blade, runs across the root of the neck ; this course gives it the alternative name of *transversalis colli*. The artery passes over the phrenic and the scalenus anticus, and lies in the subclavian triangle, but at a higher level than the supra-scapular artery. It leaves the triangle beneath the omo-hyoid, passing over the brachial plexus, and reaches the anterior border of the trapezius, where it gives off the *superficial cervical* branch, which anastomoses with the superficial part of the princeps cervicis of the occipital (*p. 30*).

The continuation of the artery then descends along the border of the shoulder-blade, beneath the levator anguli scapulæ and the rhomboids, anastomosing with the supra- and subscapular arteries, and, in the neighbourhood of the rhomboids, with the posterior intercostal.

The **internal mammary** is described on p. 155, and the **superior intercostal** on p. 157.

The **subclavian vein**, the continuation of the axillary, begins at the outer border of the first rib, and joins with the internal jugular behind the sterno-clavicular articulation to form the innominate; the two innominates eventually join to form the superior vena cava, as shown in the illustration on p. 185.

*Chief relations.*—The vein lies below and in front of the third part of the subclavian artery, and behind the subclavius muscle and the clavicle. It passes in front of the phrenic nerve and the scalenus anticus, and over the apex of the pleura.

Its *tributaries* are the external and anterior (p. 35) jugulars.

The wall of the vein adheres closely to the fascial sheath by which it is invested, and, indirectly, to the clavicle and costo-coracoid membrane, the vessel being expanded when the shoulder is brought forwards. ‘Hence care should be taken in operations about the root of the neck or the shoulder in order to avoid the danger of air being drawn into the circulation by movements of the limb.’ (Quain.) If this contingency should arise, the wound should be filled with water whilst the opening in the vein is being sought.





## PART III

## THE UPPER EXTREMITY

**Surface markings.**—The clavicle (p. 225) is convex forwards in its inner two-thirds and concave forwards in the outer third. Just where it articulates with the acromion process it has a considerable upward projection. The acromion process and the spine of the scapula are easily traced towards the vertebral column, the base of the spine corresponding to the third rib.

The meeting of clavicle and acromion constitute the **shoulder**. The **roundness of the shoulder** is due to the presence of the large head of the humerus and its tuberosities ; over this the deltoid is thinly spread. After amputation at, or excision of, the shoulder-joint, the prominent 'shoulder' remains, but the 'roundness of the shoulder' has vanished.

The lesser tuberosity is the inner ; between it and the outer, the bicipital groove may be felt : it is exactly at the front of the head of the bone when the arm is by the side and slightly rotated outwards.

The **coracoid process** is found on thrusting the fingers into the space between the pectoralis major and deltoid, at about an inch below the junction of the cylindrical and flattened parts of the clavicle. To make sure that the fingers have not gone too far outwards and are pressing against the lesser tuberosity of the humerus, the arm should be rotated.

The **course of the axillary artery** may be indicated by a line from the middle of the clavicle to the groove along the inner side of the coraco-brachialis and biceps, the arm being abducted and rotated outwards.

The prominent mass of the biceps in front of the arm suddenly tapers into the strong tendon, from the inner side of which the bicipital fascia may perhaps be made out as it expands over the muscles which are arising from the inner condyle of the humerus.

Along the inner side of the biceps is the groove which is continued down from between the axillary folds ; in it runs the brachial artery. The inner border of this muscle is the guide in tying that vessel. The muscle overhangs the artery.

For **compressing the brachial artery** the assistant should stand upon the outer side of the limb, and, passing the fingers round the biceps and just beyond the surface-groove, should drag and hook the artery with the tips of his fingers, and gently fix it against the bone. Very little force is needed, only it must be properly directed—outwards. At the back of the arm the triceps may be seen narrowing into its insertion into the olecranon process. The course of the musculo-spiral nerve may be shown by drawing the chalk from below the posterior fold of the axilla downwards, backwards, outwards, and then forwards to the front of the external condyle.

The **condylar ridges** descend from the middle of the shaft to the internal and external condyles ; the ulnar nerve may be felt as it passes along the back of the inner ridge to the space between the condyle and the olecranon. The inner ridge separates the biceps and brachialis at the front from the triceps behind. The outer ridge extends between the supinator longus and the long radial extensor, in front, and the triceps posteriorly.

In a thin subject the internal intermuscular septum may be clearly made out.

The **external condyle** is best examined on the forearm being fully extended, when it is found in a depression which is bounded on the inner side by the olecranon and the insertions of the triceps and anconeus, and on the outer side by the mass of the supinator longus and the extensors. In this depression, just below the condyle, is the prominent margin of the **head of the radius**, between which and the condyle is a transverse groove corresponding to the elbow-joint.

In *suspected fracture of the radius*, if there be no impaction of the fragments, the head of the bone does not rotate when the wrist is being pronated and supinated. The student should practise this method of examining the radius, the thumb or index-finger being pressed firmly against the radial head.

A little above the internal condyle a small spur of bone is occasionally met with ; it projects downwards, and beneath it the brachial artery and median nerve may take an irregular course—as in the carnivora. It may be felt beneath the skin, and should not be taken for an exostosis or any other morbid growth.

To **measure the length of the arm**, dot with ink the tip of each acromion process, and each external condyle of humerus, and then compare the two sides. To compare the forearms, dot the external condyles as before, and the tip of each radial styloid process, and then measure.

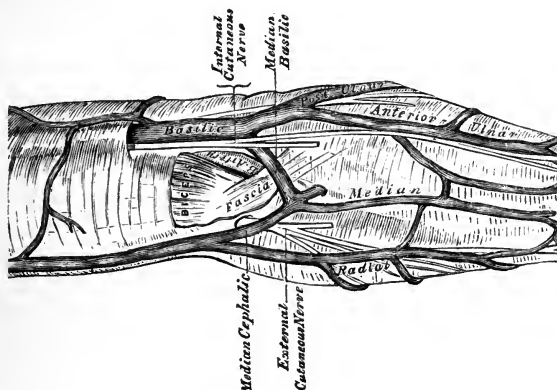
Between the chest and the arm is the depression corresponding to the *floor of the armpit* ; when the arm is raised the axillary fascia is tightened and the borders of the pectoralis major in front and the teres major and latissimus dorsi behind become prominent. When the arm is raised to the utmost, and the fingers are forcibly thrust towards

the apex of the space, the head of the humerus may be obscurely felt.

The **axillary line** is the plumb-line descending, from the middle of the first rib, between the axillary folds. In a deep inspiration the chest-wall in front of it moves forwards whilst that behind it moves backwards.

**Superficial veins.**—The *anterior ulnar vein* comes from the little finger and the palm of the hand, and, receiving tributaries in its course, is joined in the upper part of the forearm by the *posterior ulnar vein*, which begins on the back of the little finger as the *vena salvatella*. The *common ulnar vein* which is thus formed is soon joined by the inner division of the median vein to form the basilic.

The *radial vein* comes from the back of the hand (where it has large anastomotic arches with the posterior ulnar) and from the thumb ; at the elbow it is joined by the outer division of the median vein to form the cephalic.



Front of right elbow. (GRAY.)

The *median vein* ascends from the palm of the hand, and just before it reaches the bend of the elbow it receives the *communicating vein*, which brings blood from the *venæ comites* of the radial and ulnar arteries. It then divides into two short trunks, the outer of which joins the radial to form the cephalic, whilst the inner flows into the common ulnar vein to form the basilic. These short trunks are called from their connections *median-cephalic* and *median-basilic* respectively.

Thus, the veins at the bend of the elbow are arranged in the form of the letter **M**, with all the points prolonged.

The *median-basilic* is the vessel at the elbow which is generally chosen for **phlebotomy**, for the simple reason that it is usually larger than the median cephalic. It has this disadvantage, however, that just beneath it runs the brachial artery ; but, as the bicipital fascia

intervenes between these vessels, the artery is well protected from injury by the lancet. Branches of the internal cutaneous nerve cross in front of the vein.

Before using the lancet the surgeon should make out the exact situation of the brachial artery, and should satisfy himself that that irregularity does not exist in which the ulnar artery descends into the forearm superficial to the group of muscles arising from the internal condyle.

For **the operation of venesection** a tape should be tied round the arm above the elbow, just tight enough to prevent the venous return, but not to compress the artery, as I have known to happen. The patient should hold something in his hand on which he can keep exercising the flexors of his fingers, so as to hurry on the venous return. The staff which was formerly used for this purpose has been left in the keeping of the surgeon's old associate, the barber, who, having now no other use for it, has decorated it in spirals of clean and blood-stained tapes, and has fixed it over his shop-door as the sign of his present craft.

If during phlebotomy the lancet traverse the vein and wound the subjacent artery, and the lips of the adjacent wounds become glued together, blood is pumped with each ventricular contraction into the vein. Thus, not only the median basilic and the neighbouring veins become distended and varicose, but they pulsate after the manner of an aneurysm. The condition is called *aneurysmal varix*--it is a varix with an aneurysmal pulsation.

But when the edges of the wound in the vein do not become glued to those in the artery, and the blood collects in the intervening connective tissue before entering the vein, a pulsating tumour (aneurysm) exists in addition to the aneurysmal varix, the condition being called *varicose aneurysm*.

Both these lesions may be treated by forcible flexion of the limb, or, if that fail, by ligature of the artery above and below the wound.

The **basilic** vein is formed by the confluence of the median-basilic and common ulnar, and, lying along the inner side of the biceps, superficial to, but in a line with, the brachial artery, it pierces the deep fascia below the middle of the arm. It then lies alongside of the brachial artery, and joins its venæ comites at the lower border of the tendon of the teres major to form the axillary vein.

The **median-cephalic** vein ascends obliquely over the hollow between the biceps and supinator longus, the musculo-cutaneous nerve lying beneath it, but over the deep fascia. This vein when opened in 'bleeding' is said to be less easily compressed than the median-basilic because of its lying over the intermuscular hollow.

The **cephalic vein** ascends superficially on the outer side of the biceps, lying afterwards in the groove between the pectoralis major and deltoid. It pierces the deep fascia just below the clavicle, and then,

having traversed the costo-coracoid membrane (p. 240), runs over the first part of the axillary artery to end in the highest part of the axillary vein.

The **cutaneous nerves**.—In the pectoral region are supra-clavicular branches of the third and fourth cervical nerves, the endings of the intercostal nerves, and of their lateral branches. In the scapular region of the chest the cutaneous nerves come from the posterior divisions of the dorsal nerves, and from the lateral cutaneous branches of the intercostals. In the deltoid region are the acromial twigs of the supra-clavicular nerves, as shown on p. 145, and branches of the circumflex.

Down the arm the superficial nerves come (on the inner side) from the intercosto-humeral, the internal and the lesser internal cutaneous, and the musculo-spiral; and, on the outer aspect, from the circumflex and musculo-spiral. (See Brachial Plexus, p. 249.)

The **intercosto-humeral** nerve, the lateral cutaneous branch of the second intercostal, runs across the axilla to join the lesser internal cutaneous in the supply of the skin as far as the inner condyle. Implication of this nerve in cancerous invasion and in abscess of the axilla causes neuralgic pain along the inner side of the arm. The nerve is generally seen when the axilla is opened for the removal of cancerous lymphatics in scirrhus mammæ.

The **axillary fascia** is the deep and important layer which is continued from the front of the pectoralis major, across the floor of the space, and backwards over the latissimus dorsi. It is attached above to the clavicle, and in front to the sternum and chest. At the lower border of the pectoralis major it becomes continuous with the fascial investment of the pectoralis minor, and so, indirectly, with the costo-coracoid membrane and also with the sheath of the axillary vessels. Below the armpit it is continuous with the fascia around the arm. It is strong and well able to shut in an axillary abscess.

The **deep fascia of the arm** surrounds the limb, and is continuous above with that covering the deltoid and pectoralis major. It is strengthened by slips from the insertions of the deltoid, pectoralis major, and latissimus dorsi, and gives off strong *intermuscular septa* to the condylar ridges and condyles. - The inner of these septa is pierced by the inferior profunda and the anastomotica magna, the former vessel being accompanied by the ulnar nerve. The musculo-spiral nerve and superior profunda artery pass through the outer septum.

Below, the deep fascia of the arm is continuous with that of the forearm, and is attached to the olecranon process, but it is not attached to the head of the radius, or it would check its rotatory movements.

The **pectoralis major** arises from the inner half of the clavicle, the front of the sternum and the adjacent costal cartilages, and from the aponeurosis of the external oblique. It is inserted into the outer

lip of the bicipital groove, the clavicular part passing down in front of and below the thoracic part of the muscle.

*Relations.*—The mamma rests upon its anterior surface ; therefore, in the case of disease of that gland, the arm must be fixed to the side for the sake of perfect rest. Behind it are the ribs and the intercostal muscles ; the subclavius, the costo-coracoid membrane, the pectoralis minor, the axillary vessels, and the brachial plexus. Its outer border lies along the inner edge of the deltoid, an important interval separating them near the clavicle. The cephalic vein is lodged in this intermuscular groove.

The **pectoralis minor** ascends from the third, fourth, and fifth ribs and the intercostal fasciæ to its insertion along the thoracic aspect of the coracoid process. It lies beneath the larger muscle, and covers the second part of the axillary vessels, and the brachial plexus. The lowest border of the muscle is subcutaneous, and lies along the fifth rib.

Suppuration may occur between the two pectoral muscles or beneath them both. In the former case the pus is likely to descend to the lower border of the larger muscle and there to point. In the latter case it may eventually break through the floor of the axilla, or may ascend beneath the costo-coracoid membrane, and along the course of the vessels and nerves, into the neck ; the abscess may possibly find its way through the intercostal spaces unless promptly evacuated.

*Nerves.*—The two pectoral muscles are supplied by the anterior thoracic branches of the brachial plexus.

*Bursæ.*—There may be a small bursa over the acromion or over the outer end of the clavicle ; a large one between the deltoid and shoulder-joint ; and small ones between the tendons of the infraspinatus and teres minor and the capsule of the joint, which may communicate with the interior of the articulation. The bursa sheathing the tendon in the bicipital groove is a continuation of the synovial membrane of the shoulder-joint. A separate bursa intervenes between the tendons of the latissimus dorsi and teres major in the bicipital groove.

The **costo-coracoid membrane** is spread between the first rib, clavicle, and coracoid process ; below, it blends with the fascia of the lesser pectoral muscle, and with the sheath which the axillary vessels have brought down from the fascia about the scalene muscles. The membrane and the sheath of the vessels are pierced by the cephalic vein in its course to the axillary vein, and by the acromial thoracic artery.

The **subclavius** arises by a tendon from the cartilage of the first rib, and is inserted into the groove on the under surface of the clavicle. It is hidden by the origin of the pectoralis major, the costo-coracoid membrane intervening. Beneath it are the subclavian vessels and the brachial plexus, and when the shoulder is drawn down the muscle closely overhangs the highest part of the axillary vessels.

The **subclavian fossa** corresponds to the interval between the borders of the pectoralis major and deltoid at their clavicular origin ; the greater the muscular development, the narrower this crevice. In its depths may be felt the apex of the coracoid process, to the thoracic aspect of which the narrowest part of the pectoralis minor is passing. The second part of the axillary artery is beneath the lesser pectoral, the first part being between its upper border and the outer edge of the first rib. To the inner side of the artery is the vein, and to the outer are the two cords of brachial plexus.

The **serratus magnus** arises by nine digitations from the eight upper ribs, and, hugging the chest-wall, is inserted into the thoracic aspect of the vertebral border of the scapula. The muscles bounding the axilla anteriorly and posteriorly enclose it in front and behind, and the axillary vessels and the cords of the plexus, in their passage from the root of the neck, cross over the highest part of the muscle.

Its *nerve-supply* is from the nerve of Bell (p. 251), which descends upon its axillary surface.

The *action* of the muscle is to steady the shoulder-blade, to draw it forwards, and to keep its vertebral border and inferior angle close against the chest. In paralysis of the muscle the angle of the scapula projects like a rudimentary wing, and the fingers can be thrust up between it and the chest-wall almost to the glenoid cavity. This condition was formerly called '*luxation of the scapula.*' Over-action of the muscle is the usual cause of the paralysis—I have met with it in a nurse who spent most of her time in rubbing an old lady with chronic pleurisy, and in a girl who was skipping all day long. When the patient is told to raise the arm over the head the scapula is drawn upwards and inwards by the elevator and by the rhomboids, for there is nothing to keep it down to the side ; and, as the shoulder-blade cannot be rotated, the superior angle fails to be tilted upwards and the attempt at raising the arm fails.

The **deltoid** arises from the front of the clavicle, the acromion process, and the lower border of the spine of the scapula, and is inserted halfway down the outer surface of the humerus. It is supplied by the circumflex nerve and is sometimes paralysed after dislocation of the humerus ; the power of abduction being then lost.

*Relations.*—It is covered by the skin and fasciæ. Its inner border rests against the outer edge of the pectoralis major, and in the groove between these muscles lie the cephalic vein and the descending branch of the acromial thoracic artery. Beneath it is a large bursa which separates it from the shoulder-joint. The deltoid covers also the coracoid process and its muscles, namely the pectoralis minor, coraco-brachialis, and short head of biceps ; the coraco-acromial ligament ; the upper end of the humerus with the subscapularis inserted into the inner (lesser) tuberosity, and the supra- and infra-spinatus and the teres minor into the greater ; the bicipital groove,

with the long head of the biceps, and the insertions of the pectoralis major, latissimus dorsi, and teres major; the anterior and posterior circumflex vessels and circumflex nerve, and the outer and long heads of the triceps.

Abscess in the shoulder-joint in the sub-deltoid bursa may reach the surface by openings around the edges of the muscle, but the pus rarely finds its way through the substance of the muscle.

The *supra-spinatus* arises in the supra-spinous fossa and is inserted into the upper part of the greater tuberosity. It passes over the shoulder-joint, so, in sub-glenoid dislocation, it is tightly stretched, and holds and firmly hitches the head of the humerus against the lower rim of the socket. It is to relax this muscle that the arm is first abducted in the scientific method of reduction.

The *infra-spinatus* and *teres minor* arise from the infra-spinous fossa, and are inserted into the outer side of the greater tuberosity, the *teres minor* being the lower of the two. They are external rotators.

The supra- and infra-spinatus are supplied by the supra-scapular nerve; and the *teres minor* is supplied by the ganglionic branch of the circumflex.

The *subscapularis* arises from the vertebral two-thirds of the venter of the scapula, and by tendinous intersections from the ridges; it is inserted into the lesser tuberosity and into the bone just below it. Its tendon blends with the capsular ligament, but is separated from the neck of the shoulder-blade by a bursa. It forms part of the posterior wall of the axilla, and has resting upon it the origin of the coracobrachialis and biceps, and the axillary vessels and nerves. It is supplied by the upper and middle subscapular nerves, and its action is to roll the humerus inwards.

The *teres major* arises from the dorsal surface of the lower scapular angle, and, passing on the inner side of the shaft of the humerus, is inserted into the inner lip of the bicipital groove.

The *latissimus dorsi* arises from the back of the iliac crest, the lumbar, and the lower six dorsal spines, and the lowest ribs (interdigitating with the external oblique). Its tendon curls round, and is inserted in front of, that of the *teres major*, reaching the depths of the groove. (Sometimes a muscular slip of the *latissimus* crosses over the axillary vessels to be inserted with the *pectoralis major*.) These muscles draw the humerus downwards and backwards, and rotate it inwards; they are supplied by the middle and long subscapular nerves.

Though the *latissimus dorsi* is the lowest muscle in the posterior wall of the axilla, its tendon, which has curled round the *teres major*, does not descend so far along the humerus. Thus the muscles forming the back of the axilla are to be given in this order: *subscapularis*, *teres major*, and *latissimus dorsi*; but the artery lies on them in this order: *subscapularis*, *latissimus dorsi*, and *teres major*.

Occasionally a bursa exists between the upper border of the latis-



simus dorsi and the dorsal surface of the inferior angle of the scapula. Like other bursæ, it is liable to attacks of chronic inflammation, and to distension by accumulation of its fluid contents.

The **coraco-brachialis** arises from the tip of the coracoid process and is inserted halfway down the inner surface of the humerus, opposite to the deltoid. It is supplied by the musculo-cutaneous nerve, which runs through it.

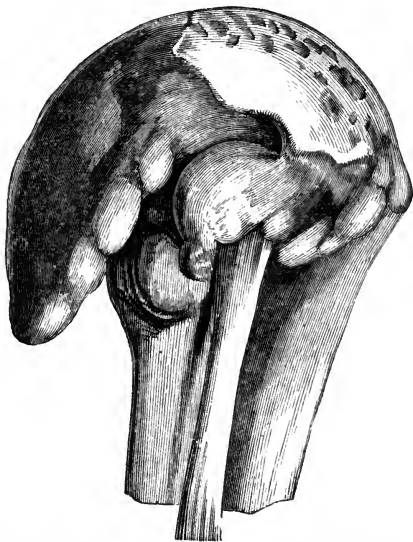
*Relations.*—It lies along the inner side of the biceps and the outer side of the axillary and brachial artery. It is covered by the deltoid and pectoralis major, and rests upon the muscles at the back of the axilla.

The **biceps** arises by its short head with the coraco-brachialis, and by its long head from the top of the glenoid cavity, the tendon spreading out into the glenoid ligament. This tendon then winds over the upper end of the humerus, strapping it in its place, and, passing between the tuberosities, escapes beneath the capsule. It carries with it a prolongation of the synovial membrane into the bicipital groove, along which an abscess in the joint may find its escape. The two heads of the muscle join below the middle of the arm. The insertion is into the back of the tuberosity of the radius, and a bursa, which is sometimes inflamed and filled with fluid, intervenes between the front of the tuberosity and the tendon. By this backward insertion the biceps becomes a powerful supinator. Its nerve-supply is from the musculo-cutaneous.

From the inner side of the tendon of the biceps a strong slip, the bicipital fascia, is given to join the deep fascia over the muscles arising from the inner condyle. This fascia lies beneath the branches of the internal cutaneous nerve, and the median-basilic vein, and separates them from the subjacent brachial artery, as shown on p. 237.

*Relations.*—Its upper end is covered by the deltoid and pectoralis major. It rests on the muscles

which form the floor of the axilla, and on the brachialis anticus and musculo-cutaneous nerve. Internally are the coraco-brachialis, median



Osteo-arthritis; biceps adhering to head of humerus.

nerve, and the brachial artery. Externally are the deltoid and supinator longus.

*Dislocation of the tendon of the long head of the biceps from the groove occurs in chronic osteo-arthritis, when osteophytes grow about the head of the humerus. When the articular disease is further advanced the tendon may be frayed out or thinned and ruptured, and adhering to one of the tuberosities. ('Med. Chirurg. Trans.,' vol. lviii.)*

The **brachialis anticus** arises from the front of the humerus and the intermuscular septa, and is inserted into the coronoid process of the ulna; its action is, therefore, solely to bend the elbow. Its nerve-supply comes from the musculo-cutaneous and sometimes also from the musculo-spiral. Contracting with great energy, it may detach the coronoid process, and if that process be broken off, as in dislocation of the ulna backwards, some of the fibres of insertion may drag it upwards.

*Relations.*—It is covered by the biceps, the brachial artery, and the median nerve. The musculo-cutaneous nerve lies between it and the biceps, and supplies them both. Its tendon lies close over the anterior ligament of the elbow.

The **triceps**.—The long or middle head descends from below the glenoid cavity; the inner head arises from the back of the humerus up to the level of the insertion of the teres major, and the outer head up to the level of the teres minor. The three heads leave a passage for the musculo-spiral nerve and superior profunda artery, and are inserted by a strong tendon into the top of the olecranon process, an important slip running on to join the deep fascia at the back of the forearm.

The scapular head of the muscle, descending between the teres minor and major, divides the area which is bounded above by the teres minor, below by the teres major, and externally by the humerus into a quadrilateral space through which wind the circumflex nerve and the posterior circumflex vessels, and a triangular one through which the dorsalis scapulae artery passes.

A piece of the triceps is continued from the back of the external condyle to the outer aspect of the olecranon under the name of *anconeus* (p. 281). Both muscles are supplied by the musculo-spiral nerve and are simple extensors of the elbow.

## THE AXILLA

The axilla is the pyramidal space between the chest and the arm; its apex reaches beneath the clavicle and into the neck. There is no barrier between the root of the neck and the axilla, and pus readily passes from one into the other unless escape be provided.

*Boundaries.*—The axilla is bounded in front by the pectoralis major and minor; behind by the subscapularis, teres major, and

latissimus dorsi; and on the inner side by the six upper ribs, the intercostal muscles, and the serratus magnus. The base is covered in by the deep fascia, which extends from over the pectoralis major to the latissimus dorsi, and on to the chest-wall.

The **space contains** the axillary vessels and their branches; the brachial plexus and most of its branches; the intercosto-humeral nerve; fat, and many lymphatic glands. The anterior and posterior folds meet at the bicipital groove, the coraco-brachialis and biceps filling this crevice.

The most important of the contents lie along the outer side of the space; against the inner wall there are merely the thoracic branches of the artery and vein, the intercosto-humeral nerve, the nerve of Bell, and lymphatics. Thus the surgeon may proceed with comparative freedom in the removal of malignant glands or other tumours from the thoracic side of the space, but along the humeral region he must act with much deliberation.

To **open an axillary abscess**, a small incision should be made with a scalpel through the deep fascia of the floor of the space, the opening being subsequently enlarged by the director and dressing-forceps, after the manner of Hilton. I have seen a paralysed serratus magnus in a man whose axillary abscess had been opened by a bold plunge of a surgeon's knife, the nerve of Bell having been severed. If the 'plunge' had been made into the outer part of the space instead of into the inner, the vessels would probably have been wounded.

The **axillary artery** continues the subclavian from the outer border of the first rib, through the apex and the outer part of the space, and down to the lower border of the tendon of the teres major, where the name changes to brachial. It lies to the inner side of the shoulder-joint and the humerus, being separated from the former by the insertion of the subscapularis. The narrow part of the pectoralis minor crosses it in the neighbourhood of the coracoid process, and divides it into *three parts*.

The first part of the artery extends from the first rib to the lesser pectoral—a very short distance. The second part is shorter still, being the mere width of the pectoralis minor just before its insertion. The third part is much longer, reaching from the lower border of the lesser pectoral to the lower border of the tendon of the teres major.

To **mark the course of the axillary artery**, the arm should be abducted and slightly rolled outwards, and a line drawn from the middle of the clavicle to the groove on the inner side of the biceps.

*Relations.*—The surgeon takes a more liberal view of the relations of an artery than is allowed to the student. The division of the artery into three parts concerns him only to this extent: that the second part, being under cover of both pectoral muscles, is inaccessible for a ligature; that the first part may be reached in the infra-clavicular

fossa (p. 241) ; and that the very end of the third part of the vessel is comparatively superficial. He does not consider the relations of the three parts separately, but regards the artery as a continuous trunk.

*In front* are the skin, superficial fascia and platysma, the deep fascia, and the pectoralis major and minor. Just below the clavicle the vessel is covered by the costo-coracoid membrane, and is crossed by the cephalic vein. The subclavius also overhangs the beginning of the artery, but in operations at that part the clavicle is raised, so that the muscle may be out of the way. The formation of the median nerve takes place over the third part of the artery.

*Behind*.—As the axillary artery is the continuation of the subclavian, which rests upon the first rib, its beginning must needs rest upon the first intercostal space and the top of the serratus magnus. The nerve of Bell descends behind the beginning of the artery to reach the chest-wall. The artery there rests upon the subscapularis, the posterior cord of the plexus and its derivatives—the musculo-spiral and circumflex—and on the tendons of the latissimus dorsi and teres major. And, as the shoulder-blade does not lie flat against the ribs, the artery crosses a gap in its course from the intercostal space to the subscapularis.

To the *inner side* is the axillary vein in the whole of the course of the artery, the inner cord of the plexus and its derivatives intervening between the two vessels in the second and third parts of their course.

To the *outer side* are the brachial plexus and the derivatives of the outer cord, namely, the musculo-cutaneous and the outer head of the median. At the lowest part of the artery the last-named nerve is to the outer side, as are also the coraco-brachialis and biceps.

*Branches*.—The first duty of the axillary artery is to give off branches to the side of the chest. The further that the artery descends, the wider is the gap between it and the chest, and the longer are its *thoracic* branches. The first is the *short* one. The second is the inner division of the *acromial-thoracic* ; the third is the *long* one ; the fourth is the *alar* ; the fifth is the *subscapular*, which is very largely concerned in the supply of the serratus magnus and chest-wall. All these arteries anastomose with vessels which are already between the ribs—the superior intercostal of the subclavian in the back of the highest spaces, and the aortic intercostals in the lower ; and the anterior intercostals of the internal mammary in the front of each space.

The *acromial* division of the acromial-thoracic runs through the costo-coracoid membrane, and anastomoses in the region from which it takes its name with branches of the supra-scapular and circumflex arteries. A *descending* branch runs in the inter-muscular groove with the cephalic vein. The *long thoracic* descends by the lower border of the pectoralis minor to the chest, giving branches through to the

mamma. The *alar* thoracic supplies lymphatic glands as well as the chest-wall, and its branches are useful in the collateral circulation.

The *subscapular* is a very large branch. It descends along the axillary border of the muscle which gives it its name, and at last reaches the chest-wall. It gives off a *dorsal* branch which passes on to the scapula under cover of the teres minor and the infra-spinatus to anastomose with the supra- and posterior scapular arteries of the thyroid axis.

The *circumflex* arteries are named from their being 'bent around' the surgical neck of the humerus. The *anterior*, the smaller, passes outwards beneath the coraco-brachialis and biceps, and as it runs across the bicipital groove it sends a branch up to the shoulder-joint. It ends by anastomosing with the *posterior* circumflex, which emerges from the axilla through the quadrilateral space bounded by the humerus and the long head of the triceps at the sides, and the teres minor and major above and below. It supplies the shoulder-joint and the deltoid, and anastomoses with the preceding vessel, and, on the acromion process, with the acromial-thoracic and the supra-scapular.

**Collateral circulation** after ligation of the first part of the axillary would be carried on as after ligation of the third part of the subclavian (p. 231); and after ligation of the lowest part of the axillary as after ligation of the brachial above the point of origin of the superior profunda (p. 265).

The *third part of the axillary artery may be reached and tied* by abducting the arm and rotating it outwards. The vessel lies in the upward continuation of the brachial groove, nearer to the anterior axillary fold than the posterior, and along the inner side of the coraco-brachialis.

A three-inch incision is made through the skin and superficial fascia from well up beneath the insertion of the pectoralis major down into the brachial groove. The deep fascia is divided on a director, the coraco-brachialis, which is the guide to the artery, being then looked for and followed down. Some more fibrous tissue is traversed by the director and forceps, and the median nerve is then turned outwards, and the axillary vein is gently separated from the inner side. The internal cutaneous nerve may, perhaps, have to be drawn inwards; the ulnar nerve will be hidden by the vein as it lies between the vein and artery, and it must be carefully excluded from the ligature, which is passed from the inner side. Sometimes a fleshy bundle passes from the latissimus dorsi over the artery, to be inserted with the pectoralis major; this might possibly be mistaken for the coraco-brachialis, especially if the incision-wound were small.

*Varieties.*—Occasionally the axillary gives off the radial or ulnar artery, or a slender *vas aberrans*, to join the radial or ulnar below the elbow. Sometimes a large branch runs by the side of the long

thoracic as an additional *external mammary* for the supply of the gland.

The artery may be accompanied by two venæ comites instead of by the single venous trunk.

The **axillary artery can be compressed** in the lowest part, where it is comparatively superficial, by thrusting the fingers under the pectoralis major and gently driving the vessel outwards against the humerus, under the coraco-brachialis and biceps.

It is not practicable to compress the beginning of the artery ; circulation is easily arrested, however, in the subclavian instead.

**Ligation of the axillary artery** may be performed *in the first part of its course* (but, as the vessel can be here reached only with danger and difficulty, the surgeon prefers to tie the subclavian, p. 229). The arm having been drawn from the side, so as to raise the clavicle and its muscle from the vessel, a slightly curved incision is made below the inner three-fourths of the clavicle, through the skin, superficial fascia and platysma, and the deep fascia, dividing a small superficial vein, perhaps, which links the cephalic and the external jugular. The cephalic vein is turned outwards from the pectoral muscle, which is to be divided at its clavicular origin, and the finger then feels for the pectoralis minor. The costo-coracoid membrane is torn through with the dissecting-forceps and director, care being taken not to wound the cephalic vein or the acromial thoracic artery as they traverse the membrane.

Then a loose sheath surrounding the vessels is torn through, and the artery is separated from the vein on its inner side and the brachial plexus on the outer. The needle is passed from the vein-side. The ligature is probably applied below the level at which the cephalic vein crosses the artery.

Of the **axillary lymphatic glands**, some are placed along the axillary vessels, and receive the lymph from the arm, whilst the thoracic set, which lie along the lower border of the pectoralis minor, receive their lymph from the mamma and the front of the chest. Other glands, which are deep in the arm-pit, are associated with the lymphatics of the back. A gland or two in the infra-clavicular fossa (p. 241) receive lymphatics passing up with the cephalic vein.

The superficial and deep lymphatic vessels for the most part follow the veins ; those running up the fore-arm join a small group of lymphatic glands which are situated near the brachial artery, above the inner condyle of the humerus.

In examining for enlarged lymphatic glands, as in suspected scirrhus of the breast, the front of the fingers should be laid flat upon the ribs, and the arm should be brought to the side so that the axillary floor may be rendered slack. I have known the inner border of the head of the humerus taken for an enlarged gland when the arm was

considerably abducted and the relaxed tissues allowed the fingers to be thrust high into the space.

In *enucleating glands* which have become implicated in scirrhus mammæ the surgeon employs his fingers, not his scalpel, lest he wound the large vessels; but in tearing them out he runs the risk of rooting a little alar thoracic artery from the main vessel. He must proceed with very great care when removing glands from the outer part of the space.

In the case of scirrhus mammæ the surgeon cannot be sure that there is no secondary implication of the glands until he has opened up the fascia of the floor of the axilla and introduced his finger. It is advisable, therefore, in every case of malignant disease to prolong the incision into the arm-pit in the search for implicated glands.

The axillary glands are associated beneath the clavicle with those at the root of the neck. When, therefore, the surgeon is considering the advisability of operating in mammary cancer he should carefully examine the supra-clavicular region as well as the arm-pit.

#### THE BRACHIAL PLEXUS

The brachial plexus is formed by the anterior divisions of the fifth, sixth, seventh, and eighth cervical nerves, and by the chief part of that of the first dorsal, which has come up in front of the neck of the first rib. Resting in the grooves on the transverse processes of the lower cervical vertebræ, the nerves emerge between the anterior and middle scalene muscles, which arise from the anterior and posterior tubercles of those processes, respectively. The subclavian artery also lies behind the anterior and in front of the middle scalene: the plexus is, thus, chiefly above the artery in the second and third portions of its course, but the lowest strand of the plexus is partly behind it. In this relative position the plexus and the artery descend beneath the clavicle and the subclavius muscle into the axilla.

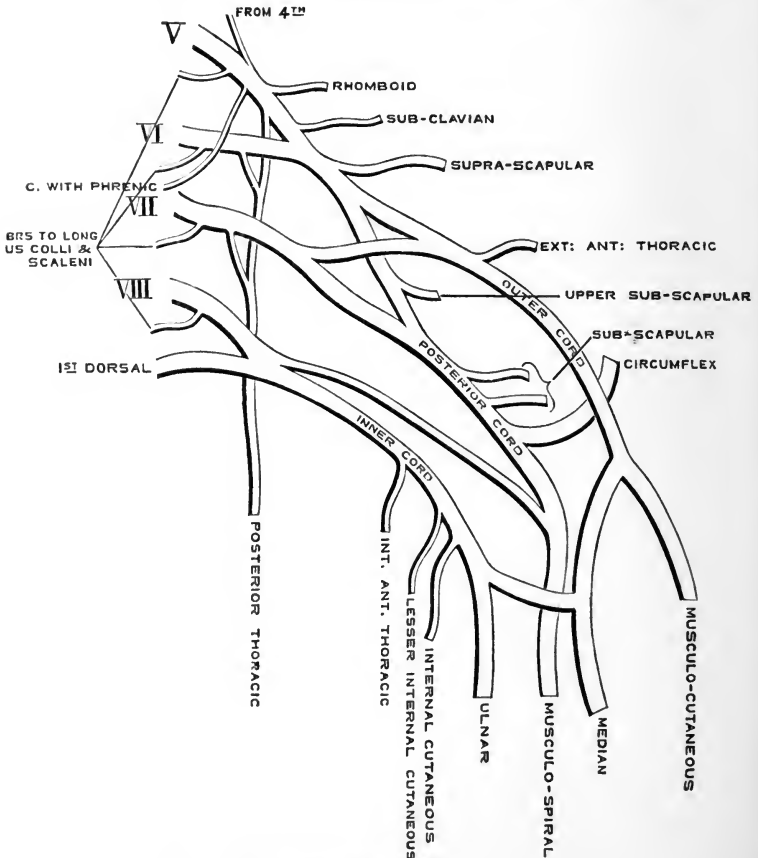
The anterior divisions of the fifth and sixth nerves join to form a single cord, as do also the divisions of the eighth cervical and the first dorsal, the division of the seventh passing on by itself.

On the outer side of the scalenus medius each of these three large bundles splits into an anterior and posterior trunk, of which the anterior trunks of the upper and middle unite to form the *outer cord of the plexus*. The lower anterior trunk runs on independently as the *inner cord*, whilst the *posterior cord* is formed, as might be anticipated, by the union of all three posterior trunks.

In the top of the arm-pit these cords lie above the axillary artery; behind the pectoralis minor they lie, as their names express, one to the outer side, one to the inner side of the vessel, and one behind it; and in the third part of the course of the artery they are breaking into their terminal branches.

The reason of there being a brachial plexus is probably this: Certain muscles habitually work together. Thus, for example, the biceps, brachialis anticus, and supinator longus bend the elbow. The motor fibres for them arise together in the cervical enlargement, but anatomically it may not be convenient for the fibres to reach all of them by the musculo-cutaneous nerve; some, therefore, are 'switched off' by the musculo-spiral. By adapting this theory to the different groups of muscles the need appears for a great primary interlacement at the root of the upper extremity.

The **branches given off above the clavicle** are twigs to the scaleni, the levator anguli scapulæ, rhomboids, longus colli, and sub-



Plan of brachial plexus. (GRAY.)



clavius, the branch to the last-named muscle descending in front of the third part of the subclavian artery. The fifth also gives a root to the phrenic, which thus comes from the fifth as well as from the third and fourth cervical nerves.

The **nerve of Bell** arises from the fifth and sixth nerves in the substance of the scalenus medius, and enters the apex of the axilla lying on the side of the chest. Coming out through the scalenus medius, it lies behind the trunks of the plexus, and posterior also to the first part of the axillary artery. It supplies the serratus magnus.

The **supra-scapular nerve** comes from the fifth and sixth after their junction, and descends beneath the trapezius, and through the supra-scapular notch, to supply the supra- and infra-spinatus, and the shoulder-joint.

**Below the clavicle** the nerves given off are: the *external* and *internal anterior thoracic* from the outer and inner cords, respectively, to the pectoralis major and minor.

Three **subscapular** branches come from the *posterior cord* (which is composed of fibres which are derived from the fifth, sixth, seventh, and eighth cervical nerves, and from the first dorsal nerve); of these three, the *short* subscapular supplies the subscapularis, the *middle* the subscapularis and the teres major, and the *long* the latissimus dorsi.

The **circumflex**, from the posterior cord (formed as above), winds with the posterior circumflex artery round the surgical neck of the humerus, through the quadrilateral space (p. 244), to supply the shoulder-joint and the deltoid. It gives off also a gangliform twig to the teres minor, and many branches to the skin over the lower part of the deltoid and the upper and back part of the arm.

The **musculo-spiral**, containing twigs of the fifth, sixth, seventh, eighth, and first, continues the posterior cord from behind the third part of the axillary artery, and winds in the spiral groove, with the superior profunda artery, between the inner and outer heads of the triceps, under cover of the long head. Piercing the external septum, it lies between the supinator longus and the extensor carpi radialis longior, on the outer side, and the brachialis anticus on the inner. In front of the external condyle it divides into the radial and posterior interosseous.

It gives off an *inner cutaneous* branch which descends to the interval between the inner condyle and olecranon, and *two outer cutaneous* branches which are distributed along the front and back of the fore-arm, almost to the ball of the thumb.

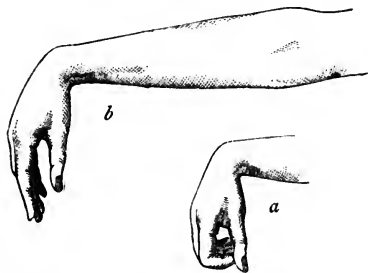
It also sends branches to the triceps and anconeus, the supinator longus and the extensor carpi radialis longior, and sometimes to the brachialis anticus.

The **radial nerve** descends from the musculo-spiral along the inner side of the supinator longus, and at about a third of the way down the fore-arm joins company with the radial artery; near the

outer side of this vessel it lies in the middle third of the fore-arm only, for it then turns backwards beneath the tendon of the supinator longus to become cutaneous a little above the wrist. It supplies the skin of the thumb, the index and middle fingers, and the inner side of the ring-finger as far as the first inter-phalangeal joint, the skin over the backs of the second and third phalanges being supplied by the digital branches of the median—except in the case of the back of the thumb, which the radial supplies entirely.

The **posterior interosseous** nerve, the other division of the musculo-spiral, gives a branch to the extensor carpi radialis brevis, and then winds round the radius in the substance of the supinator brevis, which it supplies; it then descends between the superficial and deep muscles at the back of the fore-arm, and ends in a gangliform enlargement on the back of the carpus. In its course it supplies also the extensors communis digitorum, minimi digiti, and carpi ulnaris in the superficial layer, and the extensors ossis metacarpi, primi et secundi internodii pollicis, and indicis in the deep layer.

**Musculo-spiral paralysis** may be caused by laceration of, or



Paralysis of musculo-spiral nerve after fracture of humerus; 'drop-wrist.' (ERICHSEN.) But when fingers have been flexed into palm, *a*, they can be extended at first inter-phalangeal joints by lumbricals and interossei, *b*, which are supplied by ulnar and median nerves.

injury to, the trunk as it winds round the humerus; or by severe pressure, as by a chair-back, by sleeping with the head pressing the arm against a hard pillow, or by a badly padded crutch (*crutch-paralysis*); often it is a symptom of lead-poisoning, when it is probably due to interference with the anterior cornu of the grey crescent of the spinal cord.

There may be complete loss of ability to extend the fore-arm, or, except for the action of the biceps, to supinate it; the extensors of the hand (*drop-wrist*) and fingers are also powerless, and the hand usually remains prone, with fingers flexed. Indeed, it is only by the lumbricals and interossei acting on the second and third phalanges that extension of the fingers can be in any way obtained, and even then the first phalanx must be held and fixed, or else those little muscles flex it to the palm. When the arm is raised above the head the triceps has no power to extend the fore-arm. There is loss of sensation in the region supplied by the radial nerve (*vide supra*).

There may be complete loss of ability to extend the fore-arm, or, except for the action of the biceps, to supinate it; the extensors of the hand (*drop-wrist*) and fingers are also powerless, and the hand usually remains prone, with fingers flexed. Indeed, it is only by the lumbricals and interossei acting on the second and third phalanges that extension of the fingers can be in any way obtained, and even then the first phalanx must be held and fixed, or else those little muscles flex it to the palm. When the arm is raised above the head the triceps has no power to extend the fore-arm. There is loss of sensation in the region supplied by the radial nerve (*vide supra*).

An interesting feature in the paralysis is that the grasp of the fingers is enfeebled; this is because the hand has fallen into the position of flexion, and there is too much 'slack' in the flexor tendons. (The best way to force a person to loose anything from the firmly

clenched hand is to forcibly flex the wrist ; by this trick the flexors are slackened, and, the extensors of the fingers being tightened, the grasp yields.)

The *inner cord*, which is composed of strands from the eighth cervical and first dorsal, supplies, in addition to an anterior thoracic nerve (*vide supra*), the ulnar, the inner head of the median, the internal cutaneous, and the lesser internal cutaneous.

The **internal cutaneous** (eighth and first) pierces the deep fascia at the middle of the arm, and gives off anterior branches which descend in front of the median-basilic vein to supply the front of the forearm nearly to the wrist, and posterior branches which wind behind the internal condyle for the back of the fore-arm. The nerve also sends twigs through to supply the skin on the inner side of the arm.

The *lesser internal cutaneous* (eighth and first) is joined by the intercosto-humeral, and, piercing the deep fascia halfway down the arm, is distributed to the skin over the inner head of the triceps.

The **ulnar nerve** (eighth and first) descends from the inner cord along the third part of the axillary and the beginning of the brachial artery ; but it gradually bears away towards the inner condylar ridge, resting on the brachialis anticus and the inner head of the triceps, in company with the inferior profunda artery. Having pierced the inner septum, it descends to the hollow between the internal condyle and the olecranon, entering the fore-arm there through the origin of the flexor carpi ulnaris, and giving branches to the elbow-joint.

It then lies upon the flexor profundus digitorum, under cover of the flexor carpi ulnaris, both of which it supplies, though the outer part of the latter muscle also receives branches from the anterior interosseous of the median.

Coming from behind the inner condyle, the nerve runs for some distance before it joins company with the ulnar artery ; it does not afterwards change its position, but runs close along the inner side of that vessel close external to the pisiform bone, under the shelter of which it passes over the annular ligament and into the palm. Like the median nerve, it gives off a *palmar cutaneous* branch. Its *dorsal cutaneous* branch passes, after the manner of the radial nerve, beneath a tendon (the flexor carpi ulnaris), and pierces the deep fascia to supply the dorsal surface of the little and of half the ring-finger. The ulnar nerve gives some twigs to the wrist-joint, and supplies the palmaris brevis and the palmar aspect of the little and of half the ring-finger.

The *deep palmar* branch dips between the abductor and flexor brevis minimi digiti, which, together with the opponens minimi digiti, it supplies. Passing with the deep palmar arch, it then gives branches to the two inner lumbricals and to all the interossei ; it ends in the adductor and the deep half of the flexor brevis pollicis.

In *paralysis of the ulnar nerve* adduction and flexion of the hand are imperfectly performed ; there is wasting of the muscles forming

the ball of the little finger and of the muscular web between the metacarpal bones of the thumb and index-finger (abductor indicis, adductor pollicis, and deep part of flexor brevis pollicis). All the metacarpal bones become extremely prominent on the back of the hand, on account of atrophy of the interosseous muscles. The patient is unable to wrinkle the skin on the inner side of the palm (palmaris brevis) to form the 'cup of Diogenes'; he cannot span (abductor minimi digiti); and he is able to bring the thumb towards the middle line of the hand only by the action of the flexor longus pollicis, the muscles of the first interosseous space being useless.

The two inner fingers are 'clawed,' or, as it is also called, *en griffe*—the two inner lumbricals and the interossei cannot flex the first phalanges nor extend the second and third (273); so the common extensor keeps the first phalanges extended whilst the second phalanges are kept slightly bent by the flexor sublimis. When this deformity is extreme the metacarpo-phalangeal knuckles become hollowed, for the extensor tendon is drawing back the first phalanx, and the interossei and lumbricals are powerless to hinder it.

The **median** is formed by two trunks, one from the inner, the other from the outer cord—fifth, sixth, seventh, eighth, and first—the two trunks join over the front of the third part of the axillary artery. The nerve then lies to the outer side of the axillary and the beginning of the brachial artery, and, crossing the latter in the middle of its course, is found, near the elbow, on its inner side, resting upon the brachialis anticus.

It enters the fore-arm between the two heads of the pronator radii teres, and, crossing the ulnar artery, descends between the superficial and deep flexors of the fingers. Above the wrist, where the muscles are ending in tendons, the nerve is exactly in the middle line—between the flexor carpi radialis and the outermost tendon of the flexor sublimis, under cover, but slightly to the inner side of the palmaris longus. It then passes beneath the annular ligament, and widens out preparatory to dividing into digital branches.

In its course it supplies the pronator radii teres, flexor carpi radialis, palmaris longus, and flexor sublimis digitorum. It gives off the *anterior interosseous* branch, which courses deeply, upon the membrane supplying the flexor longus pollicis, the outer part of the flexor profundus, and the pronator quadratus. A *palmar cutaneous* branch also comes from the median; it pierces the deep fascia, and descends over the annular ligament.



1, Palmar branch; 2, its filaments to pulp;  
3, its unguis twigs; 4 and 5, distribution  
on dorsal aspect.

In the *palm* the median nerve is flattened; it rests on the tendons of the superficial flexor, under the protection of the palmar fascia, and gives branches for the three and a-half outer digits, which, with the exception of those for the thumb,

send twigs over the back of the second and third phalanges and to the pulp of the nail.

The digital nerves lie beneath the superficial palmar arch, but in the fingers they are superficial to the digital arteries. The median also supplies the abductor, opponens, and the outer head of the flexor brevis pollicis, and the two outer lumbricals.

Thus, the ring drawn over the 'ring-finger' couples together digital branches of the median and ulnar upon the palmar aspect, and of the radial and ulnar on the dorsal.

In *paralysis of the median nerve* the front of the fore-arm is wasted, the supinator longus and flexor carpi ulnaris alone being unaffected. The pronators are useless, as are also the special flexors of the fingers, except the inner part of the profundus, which is supplied by the ulnar. The second phalanges (flexor sublimis) cannot be flexed, nor the ungual phalanges of the index- and middle fingers (outer part of profundus). The abductor pollicis being paralysed, the adductor (ulnar) keeps the thumb well up against the index-finger, and wasting of the muscles of the ball of the thumb becomes marked.

Flexion of the wrist has to be accomplished entirely by the ulnar flexor, and by the inner part of the deep flexor of the fingers, the hand, in consequence, being deflected to the ulnar side.

I have lately had a child under treatment whose median nerve was, as seen during a subsequent operation, completely severed, yet there was no loss of sensation of the skin of the hand or fingers. This probably was due to the presence of free communications between the median and the ulnar and radial nerves, an arrangement which may prove as valuable in an emergency as the anastomotic loops between veins or arteries. However, in paralysis of the median nerve in an adult, loss of sensation must be expected in the outer part of the palm (except over the ball of the thumb, where the radial is distributed), in the front of the three and a-half outer digits, and also over the backs of the last phalanges of those digits. The impaired nutrition (trophic fibres, p. 215) in these areas is apt to be associated with vesicles and sores, and with imperfect growth of the nails.

The **musculo-cutaneous** comes from the outer cord (fifth, sixth, and seventh), and, leaving the third part of the axillary artery on its inner side, passes obliquely through the coraco-brachialis to the space between the biceps and brachialis, in which it descends almost to the elbow. Piercing the deep fascia, it lies beneath the median cephalic vein, and divides into an anterior and a posterior branch, which supply the skin down to the ball of the thumb and over the back of the wrist. The musculo-cutaneous nerve supplies the coraco-brachialis, biceps, and brachialis anticus, the branch to the last-named muscle sending a twig to the elbow-joint.

## THE SHOULDER JOINT

The shoulder-joint is formed by the glenoid cavity and the humerus, the articular surfaces being enclosed in a loose *capsular ligament* which is attached just beyond the border of the glenoid cavity, and to the anatomical neck of the humerus. Its strongest part is superiorly, where it receives *accessory* fibres from the *coraco-humeral* ligament.

*In contact with the capsule* are the supra-spinatus above, the triceps below, the subscapularis in front, and the infra-spinatus and teres minor behind. Most of these muscles are blended with the capsule, and thus play the part of ligaments. The axillary vessels and nerves are to the inner side, separated from the capsule, however, by the subscapularis.

Above the joint are the acromion process and the coraco-acromial ligament; to the inner side are the coracoid process and its muscles, and covering all is the deltoid. A bursa underlies the deltoid, which in rheumatic subjects is often in communication with the interior of the joint through an opening in the upper part of the capsule. Other *openings in the capsule* are those by which the bursa beneath the subscapularis and that beneath the infra-spinatus communicate with the synovial membrane of the joint. There is also a gap between the tuberosities by which the tendon of the biceps and its synovial investment escape into the bicipital groove. When the subdeltoid bursa is in communication with the synovial membrane of the joint, the opening in the top of the capsule is occasionally so large that the head of the humerus comes into extensive contact with the under aspect of the acromion. In such cases a facet is produced, so that the appearance presented after death is of an upward partial dislocation of the humerus having existed. (See 'Trans. Soc. Med. Chirurg.,' 1875.)

The *glenoid* ligament is the fibro-cartilaginous rim which gives a pliable border to the glenoid cavity; just inside the capsule it is lined by synovial membrane. The origin of the long head of the biceps blends with it above.

The *synovial membrane* lines the capsule and the glenoid ligament, but, though reflected on to the joint-surfaces of the bones, it cannot after birth be traced over their articular cartilages. It often communicates with the subdeltoid bursa, and usually so with bursæ beneath the subscapularis and the teres minor. It sends a tubular process between the tuberosities to line the bicipital groove and to lubricate the tendon.

**Supply.**—The *arteries* supplying the joint come from the supra-scapular, the anterior and posterior circumflex, and the dorsalis scapulae; the *nerves* are derived from the supra-scapular and the circumflex.

**Movements.**—The humerus is raised by the supra-spinatus and

deltoid, and depressed by the subscapularis, infra-spinatus, and teres minor, and by the pectoralis major, teres major, and latissimus dorsi. It is drawn forwards by the pectoralis major, coraco-brachialis and biceps, and by the anterior part of the deltoid; backwards by the posterior part of the deltoid, the teres major, latissimus dorsi, and triceps.

The *external rotators* are the infra-spinatus and teres minor, and the *internal rotators* are the pectoralis major, teres major, latissimus dorsi, and subscapularis.

*Elevation of the arm above the head* is accomplished by the action chiefly of the trapezius and serratus magnus, and other muscles which rotate or fix the scapula; without rotation of the scapula the arm cannot be raised above the head.

In **synovitis of the shoulder-joint** there is impairment of movement, and when the patient is stripped and the arms are raised the scapula of the affected side moves with the humerus, its inferior angle travelling forwards as the arm is abducted. If effusion occur there is a deep-seated and elastic fulness beneath the deltoid.

If **abscess form in the joint**, the pus may escape by the offshoot of the synovial membrane which descends along the bicipital groove, and so the abscess becomes diffused in the subdeltoid tissue, whence it will work its way to the surface beneath the anterior or posterior border of the muscle, for it is not likely that the pus would approach the skin through the substance of the deltoid. Sometimes the articular suppuration escapes by the gaps which exist beneath the insertions of the subscapularis and infra-spinatus. The sinuses leading to the diseased joint may open through the infra-clavicular fossa at any spot along the anterior border of the deltoid, or even into the axilla, or along the posterior border of the muscle.

**Dislocations of the humerus.**—The great freedom of movement which the humerus enjoys renders it specially liable to dislocation, and when once the bone has slipped out of the shoulder-joint the luxation is apt to recur.

The commonest *cause of dislocation* is a fall upon the elbow or hand. When a man is falling he instinctively puts out his arm to 'break the fall.' This is done by the energetic contraction of the supra-spinatus and deltoid, the axillary muscles at the same instant contracting, so as to fix the arm. Then, partly by the shock transmitted to the socket, and partly by the downward muscular pull, the head of the bone tears through the lower part of the capsule. Sometimes the head of the humerus rests in the axilla as a **sub-glenoid** dislocation. But more often it is dragged by the muscles, or thrust by the shock, into the **sub-coracoid** or even into the **sub-clavicular** region.

If the elbow or hand happen to be advanced as well as raised when the humerus tears through the capsule, the head of the bone

may easily slip from the axilla, and be dragged and thrust beneath the origin of the infra-spinatus, to form a **sub-spinous** dislocation. But, as in the other instances, the capsule is rent in the lowest part.

As the roundness of the shoulder is due to the presence of the head of the humerus, *flatness of the shoulder is one of the characteristic signs of dislocation*; the end of the acromion stands out conspicuously, and the fingers may be thrust in beneath it towards the empty socket.

The humerus is hung, as it were, by the insertion of the over-stretched deltoid, and when its head is carried inwards, as in the sub-coracoid dislocation, the lower end is necessarily thrust outwards. So the man usually has his elbow abducted, and, the arm being thus fixed, *the hand cannot be laid upon the opposite shoulder whilst the elbow is touching the chest*. Lastly, the head of the bone may be detected in the infra-clavicular hollow, in the axilla, or bulging in the infra-spinous fossa.

*Reduction of the dislocation* is effected by first bending the elbow, to take tension off the long head of the biceps; the arm is then drawn from the side to relax the supra-spinatus, which is tightly stretched, and to 'unhitch' the margin of the humeral head from the border of the glenoid cavity. The arm is then forcibly adducted over a firm pad in the axilla, and thus, when the lower end of the humerus is forcibly brought forwards and inwards, the upper end is tilted backwards and outwards against and into the socket.

This can also be effected by putting the shoeless heel or the knee into the axilla, the patient in the latter case being in the sitting posture, and by then using the lower end of the humerus as a lever—the elbow being kept bent.

Sir Astley Cooper showed that the chief impediment to the reduction is the supra-spinatus locking the head beneath the glenoid cavity—hence the need of abduction in replacing the bone.

As the axillary vessels and the brachial plexus lie close on the inner side of the head of the humerus, they are apt to be pressed upon in subcoracoid or subglenoid dislocation; thus the limb becomes œdematous (from obstruction of the vein) and pulseless, or painful and numb (from pressure against the artery or nerves).

In the case of an *old-standing dislocation* violent attempts to reduce the luxation by the heel in the axilla are apt to rupture the artery, which by that time may have become adherent in its new bed, and indirectly affixed to the head of humerus. It has happened also that in such efforts to replace the bone fracture has occurred at the surgical neck, or even that the heel has been thrust through the skin and fasciæ into the space. In the case of an old dislocation, therefore, it is better to excise the head of the bone than subject the patient to such serious risks.



**Excision of the shoulder-joint**, or, rather, resection of the upper end of the humerus, is performed by thrusting the point of a short, strong scalpel through the deltoid in the space between the coracoid and acromion, the ligament between these processes being also traversed by it. The incision is continued three or four inches down the limb.

The arm is then rotated outwards, so that the subscapularis may be detached from the lesser tuberosity; the capsule is opened up in the bicipital groove, and the tendon of the biceps is raised from its bed and hitched inwards over the lesser tuberosity, and well to the inner side of the head. After this the arm is rotated inwards, and the insertions of the supra-spinatus, infra-spinatus, and teres minor are detached from the greater tuberosity. Some of the capsule has then to be divided before the end of the bone can be thrust through the wound and sawn off.

**Amputation at the shoulder-joint** is best performed by prolonging the incision, which was made in the last operation, a little further down the shaft of the bone. And, in those cases in which the surgeon does not know whether the disease will demand resection or amputation, he can begin by adopting the former method (short of sawing across the humerus), and then, if necessary, go on to amputate, clearing the humerus of the insertion of the muscles into the bicipital groove. The humerus having been brought out through the wound, an assistant thrusts his thumbs into the hollow whilst with his fingers on the outer side he compresses the blood-vessels; the soft parts are then cut. Compression of the subclavian artery in amputation at the joint is by no means satisfactory, though it is often advised; it is far better to grasp the vessel in the shell of the soft parts as just described. (Compare this operation with Furneaux Jordan's amputation at the hip-joint, p. 469.)

The *tissues divided in the vertical cut* are the skin, superficial and deep fasciæ; the deltoid, and part of the coraco-acromial ligament, and the capsule of the joint. Then, insertions of the subscapularis, supra-spinatus, infra-spinatus, and teres minor; the anterior circumflex; the pectoralis major; latissimus dorsi and teres major. The *transverse incision sweeps through* the skin, superficial fascia, cephalic vein, filaments of the internal and lesser internal cutaneous, intercosto-humeral, musculo-cutaneous, and circumflex nerves; the deep fascia; the coraco-brachialis and short head of biceps, the long head of biceps; the ending of the axillary vessels or the beginning of the brachial artery, venæ comites, and basilic vein; the ulnar, internal cutaneous, median, musculo-cutaneous and musculo-spiral nerves; also some part of the insertions of the pectoralis major, latissimus dorsi, and teres major, and the lower end of the deltoid. Branches of the posterior circumflex artery and of the circumflex nerve are cut in disarticulating, but the main trunks of the circumflex nerve and the posterior circumflex artery escape section.

## THE HUMERUS

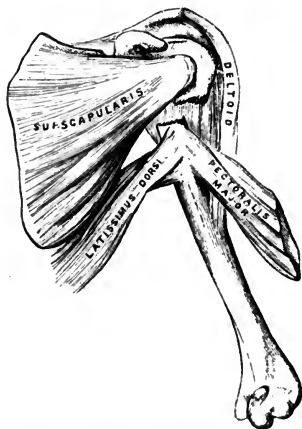
The humerus has seven centres of **ossification**, that for the shaft appearing very early in foetal life ; the head begins to ossify in the second year, and the tuberosities in the third. The lower end has four centres : for the radial head in the second year, the internal condyle in the fifth year, the trochlear surface in the twelfth, and the external condyle in the fourteenth year.



Ossification of humerus.

The nutrient artery, from the brachial, running towards the elbow, shows that the lower epiphysis joins the shaft (at puberty) before the upper (at manhood). But the prominent internal condyle, which begins to ossify early, does not become united until the eighteenth year.

**Fractures.**—The upper epiphysis may become ‘unglued’ at any time up to manhood, and that from comparatively slight violence at times. There is usually not much displacement, and if a small pad be placed in the axilla, to prevent the pectoralis major, latissimus dorsi, and teres major drawing the shaft inwards, and the arm be fixed to the side, union quickly occurs. The disturbance of the junction-cartilage, however, may interfere with subsequent growth of the bone.



Fracture of surgical neck. (GRAY.)

The **surgical neck** is slender and is often the seat of fracture ; then if the supra-spinatus be everting the upper fragment, and the muscles of the axillary fold be drawing the shaft inwards, and, with the help of the deltoid, biceps, coraco-brachialis, and triceps, upwards as well, there may be considerable overlapping of the fragments.

This is the classic form of the displacement, though I venture to doubt if, as is usually described, it is owing to the action of the supra-spinatus that the upper fragment is tilted outwards. Indeed, unless the subscapularis, infra-spinatus, and teres minor were in a conspiracy of silence, how could the supra-spinatus abduct the fragment ?

The displacement, if any there be after the fracture, is as follows : the shaft of the bone is drawn upwards and inwards, as already explained, and its upper end thus lies to the

inner side of the scapular end of the bone, which, perchance, is hitched outwards by the upper end of the shaft. The pectoralis major and deltoid may have something to do with the displacement. This fracture resembles somewhat a dislocation, but the presence of the head in the arm-pit at once negatives it.

For *treatment*, a pad must be placed in the axilla, to thrust out the lower fragment, and, as in the former case, the arm must be bandaged against the side, and the shoulder protected by a stiff leather or gutta-percha cap. An inside splint is of no possible value for steadying the fragments, for the seat of fracture is high up in the axilla and out of reach. When the upper end of the shaft-fragment is drawn inwards the displacement may be recognised by thrusting the fingers up into the arm-pit, and a biggish pad may be needed to keep the bone in position. As this shaft-fragment is apt to be drawn upwards on the inner side of the head-fragment, the elbow will require no support, for that might be to still further elevate the shaft-fragment. Indeed, when the overlapping is marked, it may be necessary to hang a shot-bag upon the elbow, the wrist only being supported in the sling, so as to bring down the end of the shaft-fragment.

In fracture of the upper end of the humerus the presence of the head of the bone beneath the acromion process contra-indicates dislocation, which the inward displacement of the shaft might at first sight suggest; and the fact of the head not moving when the elbow-end of the bone is rotated is clear evidence of fracture.

*Fractures of the lower end* are specially liable to occur up to puberty, a common form being that in which the epiphysis is carried backwards from the shaft together with the upper ends of the radius and ulna. The appearance is much like that of dislocation of the radius and ulna backwards, but in the latter injury the bones are rigidly fixed, whilst in separation of the epiphysis pronation and supination are still possible, and flexion and extension also, if, by a little gentle force, the epiphysis be brought into position. Such slight force could not bring the dislocated bones into position. As soon as the force is removed the elbow-end of the broken humerus slips back again. If the sound fore-arm be extended the top of the olecranon process is on a level with the condyles of the humerus; the relative position of these three pieces of bone is not disturbed in the case of the fracture, but it is in dislocation, for the upper ends of the radius and ulna are carried backwards and upwards behind the lower end of the humerus.

**A condyle may be detached** without the joint being implicated, but usually such a fracture extends obliquely into the articulation. The *internal condyle* may be detached by violent action of the group of pronators, or by a fall upon the elbow. The accident is most likely to happen before the eighteenth year, when ossification on to the shaft takes place; this fracture does not extend into the joint. It should be

treated by flexing and pronating the fore-arm, so as to take all strain from the loosened piece of bone.

The *external condyle* is not so likely to be detached as the internal, as it joins the shaft earlier, and is not so prominent nor so much exposed to injury. This fracture is likely to pass into the joint; and in such a case the elbow had better be put at a right angle and secured in a moulded splint, in case of ankylosis occurring.

*Non-union after fracture of the shaft of the humerus* is specially liable to occur unless the muscles which may move the fragments be preserved in absolute rest. For this purpose the fractured shaft should be fixed by an angular splint extending from shoulder to hand (so as to keep the fore-arm quiet), whilst short splints should be secured around the seat of fracture.

### THE BRACHIAL ARTERY

The brachial artery is the continuation of the axillary, and, beginning at the lower border of the tendon of the *teres major*, extends along the inner and anterior aspects of the humerus to end opposite the neck of the radius by dividing into radial and ulnar.

Its *course may be marked out* by a line drawn from beneath the anterior axillary fold along the furrow on the inner side of the biceps to the middle of the bend of the elbow.

**Compression.**—In its upper part the artery may be compressed by dragging it *outwards*, against the bone, near the insertion of the *coraco-brachialis*; in the lower part it must be thrust backwards towards the humerus, where the *brachialis anticus* is covering the bone.

Compression just above the elbow may be effected by forcibly flexing the fore-arm. The mass of the muscles of the upper part of the fore-arm then squeezes the vessel against the firm bed of the *brachialis anticus*. (See how your own radial pulse is stopped in energetic flexion of the elbow.) This is a useful method of treatment in aneurysm in that neighbourhood, as well as a temporary measure in the case of severe hæmorrhage from a wound in the palm.

*Relations.*—*Over the artery* are skin, superficial fascia, the basilic vein (which runs parallel with the artery), and, at the elbow, the median basilic vein; the deep fascia, and, between the artery and the median basilic vein, the bicipital fascia; the inner border of the biceps, which overhangs the artery, and the median nerve which crosses the middle of its course.

*Behind* are the insertion of the *coraco-brachialis*, the long and inner heads of triceps, and the *brachialis anticus*; and high up is the musculo-spiral nerve turning inwards and backwards away from the vessel. *To the outer side* are the shaft of the humerus, the *coraco-brachialis* and biceps, and the median nerve in the upper part. *To the inner side* are the internal cutaneous and ulnar nerves, and the median

in the lower part ; also to the inner side, but separated by the deep fascia and the bicipital fascia, are the basilic and the median-basilic veins. The artery has on either side a *vena comae*.

**Branches.**—The **superior profunda** springs from the very beginning of the brachial, and descends into the interval between the inner and outer heads of the triceps, under cover of the long head, and thus winds with the musculo-spiral nerve (p. 251) to the outer condylar ridge. It there passes through the external intermuscular septum and lies between the supinator longus and the brachialis anticus, where it anastomoses with the radial recurrent. It sends a branch to the back of the external condyle, which anastomoses with the interosseous recurrent, and another to the back of the internal condyle, which anastomoses with the posterior ulnar recurrent, and the posterior branches of the inferior profunda and anastomotica magna.

The **nutrient artery to the medulla** enters the bone near the insertion of the coraco-brachialis, and courses towards the elbow. In amputation just below the middle of the arm this vessel in the medullary canal may require a touch with the thermo-cautery.

The **inferior profunda** comes off below the middle of the arm, and runs with the ulnar nerve to the inner intermuscular septum, in front of which a branch may descend from it to communicate with the anastomotica magna and the anterior ulnar recurrent. The rest of the profunda passes through the septum, lying on the inner head of triceps, and anastomoses behind the condyle with the anastomotica magna, superior profunda, and posterior ulnar recurrent.

**Muscular** branches are given off to the coraco-brachialis, biceps, and brachialis anticus.

The **anastomotica magna** runs inwards on the brachialis anticus, about an inch above the condyle, anastomosing with the inferior profunda and the anterior ulnar recurrent ; some of it passes through the septum and anastomoses with the inferior and superior profunda and the posterior ulnar recurrent. Thus it anastomoses with every neighbouring branch except the radial recurrent, which it is obviously unable to reach without trespassing through the external intermuscular septum.

**Irregularities.**—The division into radial and ulnar may take place anywhere between the arm-pit and elbow, the two trunks descending side by side. If after ligature of an unusually small brachial artery pulsation continue in the radial or ulnar artery, search must be made a little to the inner or outer side for a '*second brachial*.'

At the **bend of elbow** there is a *triangular fossa* which is bounded on the outer side by the supinator longus, and on the inner by the pronator radii teres. The latter muscle slopes outwards, and the apex of the space is at the approximation of these muscles, and to the outer side of the fore-arm. The base is an imaginary transverse line drawn through the condyles of the humerus. Covering the fossa are skin and

superficial fascia, and the deep fascia with its reinforcement from the inner side of the biceps-tendon—the bicipital fascia. The floor of the space is formed by the brachialis anticus and by a little of the supinator brevis. In the superficial fascia are the M-like arrangement of the veins (p. 237) and many branches of the internal and musculo-cutaneous nerves.

*Contents.*—The most prominent object in the space is the tendon of the biceps; and, as the brachial artery has lain on the inner side of biceps all the way down the arm, it lies close to the inner side of its tendon in this fossa. On either side of the artery is a small companion vein, and well to the inner side is the median nerve.

In the fossa, at the level of the neck of the radius, the artery divides into the radial and ulnar, which, consequently, begin their course somewhat superficially. The radial artery leaves the space over the insertion of the pronator teres, but the ulnar artery quickly descends beneath the origin of that muscle and beneath the median nerve in its oblique course to the inner border of the fore-arm. The radial recurrent artery is seen ascending to the crevice between the brachialis anticus and the supinator longus. Under cover of the supinator longus, and, therefore, scarcely within the space, is the radial nerve. In a thin subject the posterior interosseous nerve may also be found coming from the division of the musculo-spiral, but to see so much the supinator longus will have to be pulled considerably outwards.

**Ligation of the brachial** is the proper treatment for recurrent hæmorrhage after a deep wound of the palm, for it is impracticable to search through the layers of nerves, tendons, and lumbricals to find the bleeding point. It is also resorted to for aneurysms high in the fore-arm.

*Operation.*—The patient is lying on his back with the arm abducted, rotated outwards, and resting on a firm pillow. An incision is then made for  $2\frac{1}{2}$  in. along the groove upon the inner side of the biceps. In dividing the superficial fascia, the basilic vein, if seen, must be drawn to one side. The deep fascia having been divided on a director, the inner border of the biceps is looked for and drawn outwards. The median nerve is probably lying over the arterial sheath, but if the operation be performed high in the course of the brachial the nerve will be to the outer side; if in the lower part, to the inner side. Heed must be given not to tie the nerve instead of artery, nor to include it with the artery in the ligature. A loose sheath is opened, and the needle passed round the artery (the venæ comites being avoided) from the side of the median nerve, whichever that may be.

If ligation be required at the bend of the elbow, the vessel is found by making a 2-inch incision along the inner side of the biceps tendon.

The lower limit of the incision reaches to the level of the internal condyle, and will probably be just above and to the outer side of the median-basilic vein. The bicipital fascia is divided on a director, and

the artery is found between its venæ comites, on the inner side of the biceps tendon and close to the outer side of the median nerve. The needle is passed from the inner, the nerve-side. Far to the inner side is the pronator radii teres.

**Collateral circulation.**—If the artery be tied above the origin of the superior profunda—that is, close below the ending of the axillary artery—the superior profunda brings in blood from the well-filled branches of the posterior circumflex, and thirsty muscular branches help by their anastomoses with unnamed muscular branches which are then given off in abundance directly or indirectly from the axillary.

If the ligature be applied below the origin of the superior profunda and above that of the inferior, the latter vessel will bring blood into the empty trunk by its anastomosis with the former in the neighbourhood of the internal condyle. Empty muscular branches will bring blood from unnamed and countless full ones; and the anastomotica magna, the posterior ulnar recurrent, and the radial and the interosseous recurrens will also return blood from the superior profunda.

If the ligature be below both profundæ, the collateral circulation will be maintained by muscular branches, as before, and by the empty anastomotica magna, the anterior and posterior ulnar recurrens, and the radial and interosseous recurrent returning blood from the well-filled branches of the profundæ near the elbow-joint.

## THE ELBOW JOINT

The elbow-joint is formed by the humerus, ulna, and radius, and the only movements there permitted are flexion and extension. It is a pure hinge-joint. The movements of pronation and supination take place at the superior radio-ulnar joint, and, though the head of the radius may then be touching the capitellum of the humerus, still these movements must not be considered as movements of the elbow-joint.

As over-flexion is checked by the soft part of the fore-arm and arm coming into mutual contact, and as over-extension is stopped by the olecranon process impinging against its fossa in the humerus, the *anterior and the posterior ligaments* are thin and mechanically unimportant. The former is attached to the humerus above the level of the coronoid fossa, and below to the coronoid process and the orbicular ligament. The posterior descends from above the olecranon fossa to the border of the olecranon process.

The *internal lateral ligament* is a strong triangular bundle, the apex of which is attached to the internal condyle of the humerus, whilst the base spreads into the borders of the coronoid and olecranon processes.

The *external lateral ligament* springs from just beneath the external condyle, and is blended below with the orbicular ligament.

Neither is the external lateral ligament nor any other part of the capsule of the joint, nor of the deep fascia, connected with the upper end of the radius, for there must be no check to its rotation.

The *capsule* of the elbow-joint consists of the anterior, posterior, and lateral ligaments in conjunction with all those intermediate fibres which connect them with each other.

The **synovial membrane** lines the capsule and is reflected over the articular surfaces of humerus, ulna, and radius ; it also lines the lesser sigmoid cavity of the ulna, and the orbicular ligament, and is wrapped around the neck of radius.

**Relations of the elbow-joint.**—*In front* is the brachialis anticus, and more anteriorly are the tendon of the biceps, the brachial artery, and the median nerve. *Behind* are the triceps and anconeus. *Internally* are the origin of the pronators and flexors, the ulnar nerve, and the inferior profunda artery. *Externally* are the supinator brevis and the origin of the extensors, and towards the front are the superior profunda artery and the musculo-spiral nerve dividing into the radial and posterior interosseous.

The *superior radio-ulnar joint* is formed by the head of the radius and the lesser sigmoid cavity of the ulna, the only movements allowed at that joint being pronation and supination. The orbicular binds the head and neck of the radius close against the ulna, and, forming the medium of attachment for the anterior and the external lateral ligaments of the elbow-joint, allows free pronation and supination. The synovial membrane is a prolongation from that of the elbow-joint.

**Supply.**—Branches of *artery* come from the superior and inferior profunda ; the anastomotica magna ; the anterior and posterior ulnar recurrents ; and from the radial and the interosseous recurrents. *Nerve-twigs* come from the ulnar and the musculo-cutaneous.

**Dislocations at the elbow-joint.**—In dislocation of both bones backwards the olecranon process stands out like a heel behind the elbow, and the button-head of the radius can be made out through the skin behind the external condyle. The coronoid process, if not broken off, sinks into the olecranon fossa ; the brachialis anticus and biceps are stretched round the lower end of the humerus, and the front of the fore-arm is strangely short. The bones of the fore-arm being so firmly fixed in their new position, flexion, extension, and rotation are impossible, and on attempting to flex the joint the appearance becomes still more characteristic.

*To reduce this dislocation*, the surgeon thrusts his knee into the front of the elbow, steadies the humerus with one hand, and pulls on the radius and ulna by grasping them above the wrist, and as he pulls he flexes the fore-arm round his knee, so as to unhitch the coronoid process. Thus the bones slip again into their position ; and there they securely remain unless the coronoid process happen to be broken off, in which case the luxation may recur. This recurrence suggests



separation of the lower humeral epiphysis, but this is excluded by the fact that when the lesion has recurred the top of the olecranon process is far above the horizontal line of the humeral condyles.

Other dislocations may take place, a not very uncommon variety being that in which the head of radius tears through the front of its orbicular ligament and the thin anterior ligament of the joint, and, slipping up above the capitellum, rests against the front of the lower end of the humerus. The characteristic features of the lesion are the absence of the head of the radius from the pit below the external condyle, and a mechanical impediment to full flexion of the joint, on account of the radial head impinging against the front of the humerus.

In children the head of the radius is apt to be dragged out of the orbicular ligament by a sudden pull upon the hand or fore-arm, the elbow at once becoming swollen and tender. To replace the bone, the elbow should be bent to a right angle, so that the head of the radius may be brought close to the empty collar, and then, by firmly and fully pronating, the bone is 'screwed' again into its place.

In **synovitis** there is a general fulness about the joint, with a bulging on either side of the olecranon and of the insertion of the biceps, and in the fossa below the external condyle, in which region the joint is comparatively superficial. The intra-articular effusion fixes the joint in a position midway between flexion and extension, the greatest use as well as the greatest comfort, moreover, being secured in this way; later on, the weight of the hand may carry the radius round to extreme pronation—a most undesirable condition. At the commencement of treatment, therefore, the elbow should be fixed at a right angle, and only halfway pronated.

**Abscess in the joint.**—If suppuration occur the pus will be likely to escape between one of the condylar ridges and the triceps, where the capsule is thin and comparatively near the surface of the limb.

**Excision of the joint** is performed by an incision of three or four inches through the triceps in the middle line, down to the bone, dividing the skin, superficial and deep fasciæ, the triceps, and the periosteum over the olecranon process and down the prominent posterior border of the ulna. By the aid of a raspatory the periosteum and the triceps are peeled from the humerus, and the insertion of the muscle is detached by a scalpel. In doing this the edge must be kept close to the bone, all those fibres which run to their insertion in the deep fascia being carefully preserved, so that the muscle may retain as much of its power of extension as possible. Chiefly by the raspatory, and slightly by the knife, the origins of the muscles from the condyles of the humerus are detached, but no transverse cuts are to be made, lest, by chance, the ulnar nerve be wounded and useful bundles of fibrous tissue be sacrificed. The ulnar nerve is raised from its bed between the condyle and the olecranon and turned inwards, but the operator ought not to expose it. If he do see it he has evidently

been dissecting dangerously near to it. The lower end of the humerus having been cleared of the attachment of the lateral and the anterior ligaments, and other indefinite fibres, is thrust out of the wound and sawn off. The olecranon process is cleared of the insertion of the anconeus, and of fibres of origin of the flexor carpi ulnaris. The lower part of the coronoid process is then cleared of the insertion of the brachialis anticus (and of fibres of origin of the flexor sublimis digitorum), but as much as possible of the process and of the insertion of the brachialis should be left; the ulna is then sawn across. The head of the radius is also removed. The arm had better not be fixed on a splint after the operation, as the surgeon desires to obtain a fibrous ankylosis, not a bony one as in the case of the knee, and, therefore, the sooner that he begins to move it, the better.

### *THE FORE-ARM, WRIST, AND HAND*

**Surface markings.**—From the olecranon process the posterior border of the ulna may be traced down to the styloid process, and the head of the bone may be made out between it and the inferior radio-ulnar joint. In the groove between the styloid process and the head of the ulna runs the tendon of the extensor carpi ulnaris, and in the gap corresponding to the radio-ulnar articulation passes the special extensor tendon of the little finger.

The tendon of the flexor carpi ulnaris may be traced along the front of the inner side of the fore-arm to the pisiform, and on flexing the wrist, so as to slacken that tendon, the sesamoid bone may be moved at its arthro-dial joint with the cuneiform. Along the radial side of the ulnar flexor tendon runs the ulnar artery, but its pulsations cannot be made out as readily as those of the radial artery, first, because the vessel is overlapped by the tendon, and, secondly, because the finger compresses the ulnar artery not against firm bone, as in the case of the radial, but against the less resisting mass of the flexor profundus digitorum.

On the radial side of the groove in which the artery descends are the tendons of the flexor sublimis, and in the middle line of the wrist, and quite superficially, is the tendon of the palmaris longus. Close to the outer side of the last tendon is that of the flexor carpi radialis, immediately on the ulnar side of which is the median nerve—under cover of the tendon of the palmaris longus. About  $\frac{1}{2}$  in. externally, in the groove on the ulnar side of the radial styloid process, is the radial artery, which here rests upon the pronator quadratus, and lower down on the radius itself. The tendon of the supinator longus can just be made out descending to the root of the styloid process.

Proceeding outwards and backwards, one encounters the prominent ridge of the tendons of the extensors ossis and primi, just beneath which the radial artery and its veins are winding. The fleshy bellies

of these muscles form a prominence on the back of the lower third of the radius. Then comes the 'anatomist's snuff-box,' in the depths of which are the tendons of the radial extensors, and on the inner side of which descends the oblique tendon of the extensor secundi. Still more internally pass the tendons of the extensor communis. The radial styloid process descends considerably lower than that of the ulna (p. 283).

At the *front of the wrist*, between the lower end of the radius and the root of the thumb, are the prominence of the scaphoid and the ridge of the trapezium, and on the inner side, behind the movable pisiform, is the cuneiform. (See fig. on p. 286.)

On the *back of the hand* are seen the venous arches from which the radial and posterior ulnar veins ascend. The spaces between the metacarpal bones are filled by the dorsal interosseous muscles; the chief of these is the abductor indicis, which, together with the adductor pollicis, makes the thick mass between the first and second metacarpal bones. When the ulnar nerve is paralysed these muscles waste and the bones become strangely prominent.

At the front of the first metacarpo-phalangeal joint can be felt the sesamoid bones in the heads of insertion of the flexor brevis pollicis.

In the *ball of the thumb* are the abductor, opponens, and the superficial head of the flexor brevis pollicis, and in the *ball of the little finger* are the abductor, flexor brevis, and opponens minimi digiti.

For the sake of strength and protection, the palm of the hand is continued a short distance beyond the bases of the first row of the phalanges.

The **transverse creases of the palm**.—If you gently flex the fingers to the palm you will see a thick ruck of integument stand out across the level of the metacarpo-phalangeal joints. This ruck is bounded below by the short transverse furrows at the roots of the fingers, and above by two well-marked creases which together stretch right across the palm. The inner of these creases stands across the heads of the fifth, fourth, and third metacarpal bones, the outer and superior across the head of the index metacarpal bone. This second crease would not be needed were all the metacarpal bones of the same length; but, the index metacarpal being shorter than the middle, a fresh crease has to be started in the outer part of the palm.

If the skin and the subjacent soft parts of the palm were but a thin layer, the transverse crease would correspond exactly to the line of the metacarpo-phalangeal joint; as it is, however, its thickness entails a double crease, in order that the fingers may be bent. This ruck of skin and fat plays a useful part in the hand of the oar's-man, cricketer, and labouring man, shielding the heads of the metacarpal bones from pressure; the firmer the grasp, the thicker becomes the transverse pad.

When one understands the reason of the appearance of the transverse fold of skin and fat, and appreciates its usefulness, one realises

the fact that the creases themselves are not landmarks to the joints, but that the line of the joints lies halfway between the palmar creases and the creases at the roots of the fingers, that is along the middle line of the transverse fold.

The **deep fascia** offers a strong investment to the superficial muscles of the fore-arm, and, dipping between them, supplies intermuscular septa from which they take additional origin. It receives important accessory fibres from the insertions of the biceps and triceps. It is attached along the posterior—the subcutaneous—border of the ulna, and above it is continuous with the deep fascia of the arm; below it passes to the front and back of the hand, being thickened to form the annular ligaments.

The **posterior annular ligament** is firmly connected by transverse fibres with the lower end of the radius, converting certain grooves into tunnels for the passage of the tendons; it slopes downwards, inwards, and forwards to the cuneiform and pisiform bones.

**The tendons at the back of the wrist.**—*Beneath the fascial band* are six canals for the extensor tendons, each being lined by a separate synovial sheath: the outermost is for the extensors ossis and primi; the second is for the extensors radialis longior and brevior; the third, narrow and oblique, for the extensor secundi internodii; the fourth, wide and shallow, is for the extensors communis digitorum and indicis; the fifth, between the radius and ulna, is for the tendon of the extensor minimi digiti; and the sixth, at the back of the ulna, is for that of the extensor carpi ulnaris.

*Superficial* to the posterior annular ligament are the radial and the posterior ulnar veins, and the radial and the dorsal ulnar nerves.

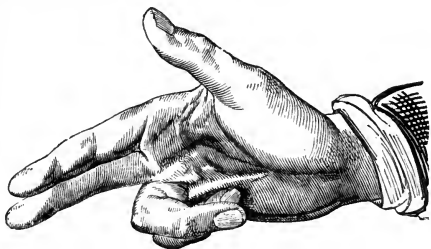
The **anterior annular ligament** is the thickened band attached to the prominences of the scaphoid and trapezium on the outer side, and to the pisiform and unciform on the inner. It strengthens the bony arch of the carpus, binds down the flexor tendons of the fingers, and affords origin to certain muscles of the thumb and little finger.

*Superficial to it* pass the tendon of the palmaris longus, the palmar cutaneous branches of the median and ulnar nerves, the superficialis volæ, and the ulnar artery and nerve.

*Beneath it* are the tendons of the flexors carpi radialis, sublimis and profundus digitorum, and of the longus pollicis; the median nerve and the comes nervi mediani.

The **palmar fascia**, continuous above with the anterior annular ligament and with the insertion of the palmaris longus, spreads more thinly over the muscles of the ball of the thumb and of the ball of the little finger. Its median piece is extremely thick, protecting the subjacent branches of the median and ulnar nerves and the superficial palmar arch. It sends slips to join the sheaths of the flexor tendons of the four inner digits, also to the webs of the fingers, and to the transverse ligament connecting the heads of the metacarpal bones.

**Dupuytren's contraction.**—Sometimes, as the result of pressure, and especially in gouty men, the bands of the palmar fascia descending to the ring and little fingers become permanently shortened, so that those fingers are rigidly bent into the palm, the flexor tendons and the joints being unaffected. Subcutaneous division of the contracted bands sets the fingers free, but relapse is apt to occur. The adjacent woodcut, from Fergusson, shows that the skin also may be implicated in the contraction.



The **supinator longus** arises from the upper two-thirds of the external condylar ridge of the humerus, and is inserted into the base of the styloid process of the radius. Its chief action is to flex the fore-arm ; as regards supination, all that it can do is to evert the pronated fore-arm until the thumb points upwards. Its *nerve-supply* is from the musculo-spiral.

*Relations.*—Just above its insertion it is overlaid by the tendons of the extensors ossis and primi. It overlaps the brachialis anticus ; the origin of the radial extensors of the wrist ; and the insertions of the supinator brevis and pronator teres. Along its inner aspect are the musculo-spiral and radial nerves, the anterior part of the superior profunda, and the radial artery and its recurrent branch. In the upper half of the fore-arm its fleshy, anterior border has to be everted in order to expose the radial artery.

The **pronator radii teres** arises from the region of the internal condyle of the humerus, and, by a small deep head, from the adjacent part of the coronoid process of the ulna ; between these heads the median nerve enters the fore-arm. The insertion is into the middle of the outer surface of the radius. It is supplied by the median nerve.

*Relations.*—Superficial to it at its insertion are the supinator longus and the radial nerve and artery. Its origin overlaps the brachialis anticus, the anterior ulnar recurrent artery intervening. It rests on the origin of the flexor sublimis digitorum. Along its ulnar border slopes the flexor carpi radialis ; its outer border limits the triangle at the bend of the elbow, and, therefore, is close to the inner side of the brachial artery and its division into the radial and ulnar. The ulnar artery passes beneath it, being separated there from the median nerve by the deep head of the muscle.

The **flexor carpi radialis** arises from the inner condyle ; it ends in a long tendon which passes through a separate compartment in the anterior annular ligament, and through the groove in the trapezium,

to be inserted in the base of index metacarpal bone. The median nerve supplies it.

*Relations.*—The fleshy part of the muscle is between the pronator teres and the palmaris longus, and rests upon the flexor sublimis digitorum. The tendon is just slightly to the outer side of the middle line of the fore-arm. Half an inch to its outer side, midway between it and the tendon of the supinator longus, is the radial artery with its companion veins; and close along the inner side of the tendon, between it and the outermost tendon of the flexor sublimis digitorum, and underneath that of the palmaris longus, is the median nerve.

The **palmaris longus** arises from the internal condyle, and its slender tendon passes over the annular ligament to be inserted into the palmar fascia. It is often absent. Like the next muscle, it is supplied by the median nerve.

The **flexor sublimis digitorum** arises from the internal condyle, coronoid process, and the oblique line of the radius; it is thin and wide and lies beneath the three preceding muscles. About halfway down the fore-arm it divides into four tendons, those for the middle and ring fingers lying, as they pass beneath the annular ligament, superficial to those for the index and little fingers. At the root of the first phalanges each tendon is pierced by one from the flexor profundus, and then sends a slip into either side of the middle phalanx.

*Relations.*—This flexor is mostly under cover of the foregoing muscles, but some of its tendons are superficial between those of the flexor carpi radialis, or palmaris longus, and the flexor carpi ulnaris. The deep fascia sends down a linear septum between this muscle and the adjoining flexor carpi ulnaris. It is by working through this septum that the surgeon seeks the ulnar artery in the upper part of its course; the septum is in the line extending from the internal condyle of the humerus to the pisiform bone. Beneath the flexor sublimis are the flexor profundus, flexor longus pollicis, the median nerve, and the ulnar nerve and artery.

*In the palm* the tendons lie beneath the superficial parts of the ulnar artery and median nerve, and, of course, beneath the deep fascia, whilst they rest on the tendons of the flexor profundus and the lumbricals.

The **flexor carpi ulnaris** arises from internal condyle, the inner border of the olecranon, and the posterior, the subcutaneous, border of the ulna. Passing along the inner side of the fore-arm, it is inserted into the pisiform and the fifth metacarpal bones, sending also a small slip outwards, across the ulnar nerve and artery, to the front of the annular ligament. Its nerve-supply is from the ulnar.

*Relations.*—Along its outer aspect are the flexors sublimis and profundus digitorum, and the ulnar nerve and artery; indeed, the outer aspect of the muscle is the ready guide to the ulnar artery in the lower two-thirds of the course of that vessel. Between its humeral and

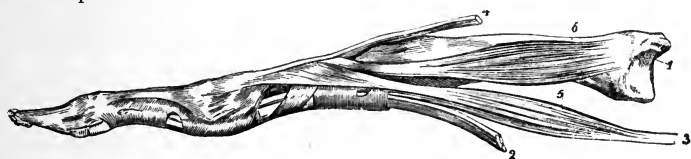
olecranon heads the ulnar nerve enters the fore-arm, and in that same interval is the anastomosis between the inferior profunda and posterior ulnar recurrent, over the internal lateral ligament of the elbow.

The **flexor profundus digitorum** is a bulky muscle arising from the upper two-thirds of the inner and anterior surfaces of the ulna, and from the adjacent part of the interosseous membrane. Its four tendons pass through those of the flexor sublimis, opposite the first phalanges, and are inserted into the bases of the unguis phalanges. The nerve-supply for its outer part is the anterior interosseous of the median, and, for the inner part, the ulnar.

*Relations.*—Superficial to it are the flexors sublimis digitorum and carpi ulnaris, the median and ulnar nerves, and the ulnar artery. The flexor longus pollicis lies along its outer side, and in the deep and narrow crevice between these muscles run the anterior interosseous nerve and artery. On its inner aspect is the flexor carpi ulnaris.

The **lumbricals** arise from the tendons of the deep flexor in the palm, and pass into the radial side of the common extensor tendons. These muscles are much used by the piano-forte player. They extend the first phalanx, and flex the second and third phalanges. The two outer are associated with the tendons of that part of the deep flexor which is supplied by the anterior interosseous nerve of the median, and consequently derive their nerve-supply from digital branches of the median, whilst the two inner are supplied by the ulnar nerve, which has already supplied the inner part of the deep flexor, from which come the tendons for the ring and little fingers.

When the lumbricals are paralysed the metacarpal phalanges are drawn backwards and the middle and terminal phalanges are flexed into the palm.



1, metacarpal bone; 2, tendons of flex. sublimis and, 3, profundus, bound down by fibrous sheath; 4, extensor communis; 5, lumbrical muscle; 6, interosseous muscle.

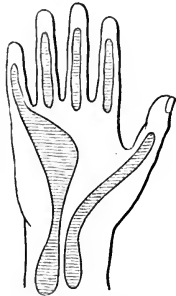
The **flexor longus pollicis** arises from the front of the radius between the flexor sublimis and the pronator quadratus, and from the adjoining part of the interosseous membrane. Its tendon passes over the square pronator, under the annular ligament, and between the heads of the flexor brevis pollicis, to be inserted into the base of the unguis phalanx of the thumb. Its nerve is the anterior interosseous.

Superficial to it are the flexors carpi radialis and sublimis digitorum, and the radial artery. Its ulnar border is separated from the flexor profundus by the anterior interosseous nerve and artery.

The **pronator quadratus** arises from the front of the lowest fourth of the ulna and is inserted into the corresponding surface of the radius. Its nerve is the anterior interosseous.

*Relations.*—It is covered by the tendons of the flexors profundus digitorum, longus pollicis, and carpi radialis, and by the radial artery and its venæ comites. The ulnar artery is widely separated from it by the mass of the flexor profundus—tendon and muscle.

Of the **synovial membranes beneath the anterior annular ligament**, one surrounds the tendons of the flexors sublimis and profundus together with the median nerve as they pass beneath the ligament. As



Usual arrangement of synovial sheaths in palm.

the tendons lie in the fibrous sheaths on the front of the first and second phalanges they are also invested by synovial bursæ, but these bursæ are distinct from the membrane beneath the annular ligament. In the case of the little finger, however, the synovial membrane from beneath the annular ligament is directly continuous with that which lines the digital sheath, as is shown in the adjoining wood-cut. The synovial sheath does not descend on to the ungual phalanx, for at the base of that bone the tendon of the deep flexor is inserted. The outer synovial membrane beneath the annular ligament accompanies the tendon of the flexor longus pollicis down into the fibrous sheath along the metacarpal bone and the first phalanx of the

thumb. The two large synovial bursæ beneath the annular ligament are separated from one another by the median nerve; they extend into the fore-arm about an inch above the annular ligament.

A reference to the wood-cut shows that a deep inflammation of the thumb or of the little finger is likely to lead to more serious complications than that of the second, third, or fourth fingers, as, the digital pouch of synovial membrane being implicated, suppuration may extend beneath the annular ligament and up into the fore-arm. Sometimes the inner and outer pouches communicate above the wrist by a tubular process across the median nerve, in which case a deep-seated suppuration in the thumb may eventually implicate the sheath of the flexor tendons of the little finger, the sheaths in the intermediate digits being unaffected.

In the case of acute suppuration in one or other of these bursæ it is expedient to lay it freely open, dividing the annular ligament at the same time. The purulent swelling bulges in the fore-arm and in the hand, and, being constricted beneath the ligament, is somewhat of hour-glass shape. When the sheath of one of the three middle digits only is affected, it is better to incise the thecal abscess over the head of the metacarpal bone than to slit open the sheath down the first and second phalanges, with the risk of producing a stiff and comparatively useless finger.



## THE ARTERIES OF THE FORE-ARM

The **radial artery** comes from the bifurcation of the brachial opposite the neck of the radius, and, though smaller than the ulnar, is, by its direction, the direct continuation of the parent trunk.

Its *course in the fore-arm may be marked* by a line from the middle of the bend of the elbow to the middle of the hollow between the styloid process of the radius and the tendon of the flexor carpi radialis. From this spot it winds round to the back of the wrist, and so into the palm of the hand, to form the deep palmar arch.

*Relations in the fore-arm.*—It is *covered* by skin, superficial and deep fasciæ, and is overlapped by the anterior border of the supinator longus. It *rests upon* the tendon of the biceps, the supinator brevis, the pronator teres, the radial origin of the flexor sublimis digitorum, the flexor longus pollicis, the pronator quadratus, and the radius.

*To its outer side* are the supinator longus, and, in the middle third, the radial nerve.

*Along its inner side* is the pronator teres, and, after that, the flexor carpi radialis. On either side runs a companion vein.

*Branches in the fore-arm.*—The **radial recurrent** ascends on the supinator brevis to the interval between the supinator longus and the brachialis anticus, where it lies against the musculo-spiral nerve, and anastomoses with the superior profunda. This is the only artery at the elbow which does not communicate with the anastomotica magna; the explanation being that these two branches are separated by the large mass of the brachialis anticus.

**Muscular** branches are given off freely and irregularly.

The **superficialis volæ** is given off close above the wrist, and runs over the anterior annular ligament, or through or over the root of the muscles of the ball of the thumb. Sometimes it joins in the formation of the superficial palmar arch, but it often ends in the muscles of the thumb. When this artery is large, the finger applied at the lower part of the front of the wrist detects a 'double pulse.'

The **anterior carpal** runs inwards beneath the flexor tendons to join a corresponding branch of the ulnar artery; it lies in front of the lower border of the pronator quadratus.

*Ligation in the upper part of the fore-arm.*—An incision of two and a-half inches is made in the line of the artery through the skin and the superficial and deep fasciæ, when the longitudinal muscular fibres of the supinator longus are exposed. The edge of this muscle may, perhaps, be a little to the inner side of the incision, but when the muscle is small the connective tissue over the vessel is at once exposed. The border of the muscle is gently drawn outwards, and, by working with the director through the bed of connective tissue, the artery, with a companion vein on either side, is found lying

on the insertion of the pronator radii teres. The radial nerve will probably not yet have joined company with the artery, or it may be approaching it from the outer side, deeply hidden beneath the supinator. The needle should be passed from the outer side, so as to make sure of not taking up the nerve.

*In the middle third of the fore-arm* an incision made in the course of the artery falls to the inner side of the supinator, and exposes the vessel in the interval between that muscle and the flexor carpi radialis. The artery is still between its venæ comites, with the nerve close on the outer side. From that side, therefore, the needle should be passed.

*Near the wrist* the artery is quite superficial, lying along the middle of the hollow between the tendons of the flexor carpi radialis and supinator longus; the latter, however, can hardly be made out as it is approaching its insertion into the styloid process. A two-inch incision being made through the thin skin and superficial fascia, the deep fascia is divided on a director, and the artery is at once exposed, together with its venæ comites. The nerve has long since left the artery to pass beneath the supinator longus towards the back of the hand and fingers.

**At the outer side of the wrist, the radial artery** winds beneath the extensor tendons of the thumb, over the external lateral ligament, and over the scaphoid and trapezium. It lies beneath the integument and fasciæ, and beneath branches of the radial vein and of the radial and musculo-cutaneous nerves in the hollow (often called the *anatomist's snuff-box*), which is bounded above by the styloid process, below by the root of the first metacarpal bone, externally by the prominent tendons of the extensors ossis and primi, and internally by the oblique tendon of the secundi. The course of the artery is shown by a line from the tip of the radial styloid process to the inner side of the base of the metacarpal bone of the thumb. The vessel is rather deeply placed.

The *branches* given off here are posterior carpal, the first dorsal interosseous, or metacarpal, the dorsales pollicis, and the dorsalis indicis. They are all small branches, and their courses are sufficiently indicated by their names. The first dorsal interosseous artery, like the others, is joined at the root of the space by a perforating branch of the deep palmar arch, and at the cleft it turns forward to communicate with the digital branch of the superficial arch.

*Ligation* may be performed by a  $1\frac{1}{2}$  in. incision downwards from the styloid process; branches of the radial vein and nerve are divided with the superficial fascia. The artery is found between its companion veins. The vessel is somewhat deep and inaccessible in this hollow, and the operation for its ligation there is not so desirable as at the front of the wrist.

**In the palm, the radial artery** crosses the roots of the metacarpal bones; it has entered between the heads of the first dorsal

interosseous muscle (abductor indicis), and lies, therefore, very deeply beneath the tendons of the flexor profundus and the lumbricals.

Its *position on the surface* may be marked by a transverse line an inch nearer to the wrist than that which shows the situation of the superficial palmar arch.

*Branches.*—The **princeps pollicis** descends between the abductor indicis and adductor pollicis, and at the base of the first phalanx divides to supply the sides of the thumb.

The **radialis indicis** descends between the same muscles to the radial side of the index-finger, at the tip of which it anastomoses with the outermost digital branch of the ulnar to complete the superficial palmar arch.

**Perforating** branches pass between the heads of the three inner dorsal interosseous muscles to join the dorsal interosseous arteries, and three **palmar interosseous** twigs descend to the clefts of the fingers to communicate with the digital branches of the ulnar.

The **ulnar artery** is the larger division of the brachial, and, beginning at the middle of the bend of the elbow, eventually reaches the palm under the protection of the pisiform bone, to the radial side of which it lies as it descends over the annular ligament.

To *mark the course of the artery in the fore-arm*, a slightly curved line, with the convexity inwards, is drawn from the inner side of the tendon of the biceps to a little above the middle of the fore-arm, and from that spot, straight down the radial border of the flexor carpi ulnaris, to the outer side of the pisiform.

In the curved part of its course the ulnar artery is burrowing deeply beneath the pronator radii teres and company, and is occupying a position of more interest to the anatomist than the surgeon. The surgeon does not attempt to reach the artery by cutting across those muscles, but prefers to wait for it until it is approaching the inner border of the upper part of the fore-arm.

*Relations.*—The *guide to the artery* is the flexor carpi ulnaris, but, as just remarked, in the beginning of its course the artery is separated from it by the group of muscles arising from the internal condyle, namely, the pronator teres, flexor radialis, palmaris longus, and flexor sublimis. To reach the flexor carpi ulnaris the artery does not pass over this group, or it would be dangerously superficial, and it cannot pass through it, so it passes beneath it. As it dips beneath the deep head of the pronator teres the median nerve is passing between the two heads of that muscle, therefore the median nerve is an additional superficial relation to the beginning of the artery.

The manner in which the median nerve crosses the ulnar artery is clear to the student when he traces on the surface of the fore-arm the boundaries of the triangle, and places in their proper position the tendon of the biceps, the brachial artery, and the median nerve. If the line of the median nerve be then prolonged to the inner side of

the tendon of the flexor carpi radialis, it is seen to cross that of the artery.

As the muscles narrow into their tendons the artery is found nearer to the surface, between the flexor carpi ulnaris and the innermost tendon of the flexor sublimis digitorum, being then covered only by the skin and the superficial and deep fasciæ, a branch or two of the anterior ulnar vein and of the internal cutaneous nerve.

The ulnar artery *rests upon*, first, the brachialis anticus, and, in the rest of its course, on the flexor profundus digitorum, a muscle which is bulky enough to prevent the artery coming into relationship with either the ulna or the square pronator.

The first definite *external relationship* is the innermost tendon of the flexor sublimis.

*On the inner side* of the artery are the ulnar nerve and the flexor carpi ulnaris, but these structures are not approached until the vessel has completed its inward bend, that is, not until it has reached nearly halfway to the wrist. The artery is accompanied by a small vein on either side.

*Branches.*—The **anterior ulnar recurrent** ascends deeply in the groove between the pronator teres and the brachialis anticus, to communicate with the anastomotica magna and the inferior profunda.

The **posterior ulnar recurrent** ascends behind the internal condyle, and communicates with the posterior branches of the anastomotica magna, and with the inferior and superior profundæ. It passes between the origins of the flexors sublimis and profundus, and between the heads of the flexor carpi ulnaris, lying against the ulnar nerve.

The **common interosseous** speedily divides into the **anterior** and **posterior interosseous**, the former of which descends upon the interosseous membrane in the crevice between the flexor profundus digitorum and the flexor longus pollicis. But, having reached the pronator quadratus, it passes through the membrane to the back of the fore-arm, where it anastomoses with the posterior interosseous and the posterior carpal arteries. It gives off *muscular twigs*, and the *nutrient* branches to the radius and ulna, the *comes nervi mediani*, and branches to anastomose with the anterior carpal arch. The branches to the radius and ulna run towards the elbow.

The **posterior interosseous** runs backwards between the oblique ligament and the interosseous membrane, and then between the adjacent borders of the supinator brevis and the extensor ossis. It afterwards descends between the superficial and deep layer of muscles, and ends in anastomosis with the anterior interosseous and the posterior carpal arch. It gives off the **interosseous recurrent** branch, which ascends between the external condyle and the olecranon process, and beneath the anconeus, to anastomose with the superior profunda, and perhaps with the posterior ulnar recurrent or the anastomotica magna.

The **anterior carpal** joins in the anterior carpal arch beneath the flexor tendons, and the **posterior carpal** winds beneath the flexor carpi ulnaris, and then beneath the tendons at the back of the wrist, to help form the posterior carpal arch. It gives off the *dorsal interosseous* branches to the two inner spaces.

**Ligation of the ulnar artery.**—*In the upper part of the fore-arm* the artery cannot be reached by an incision in its course (p. 277), as that would entail the division of the pronator teres and other muscles; it is sought, therefore, between the adjacent borders of the flexor sublimis digitorum and the flexor carpi ulnaris, by drawing a line from the internal condyle of the humerus to the pisiform, and by making an incision of  $2\frac{1}{2}$  to 3 in. in that line, beginning it  $1\frac{1}{2}$  in. below the condyle. Probably this incision implicates the posterior ulnar vein. The deep fascia is then exposed, and, *beginning in the lower end of the incision*, the surgeon opens up with a director, or the handle of the scalpel, the septum between those two muscles. This separation is easily effected if it be begun below; higher up the muscles are far more closely connected with each other. The ulnar nerve is seen lying on the flexor profundus digitorum, and after raising the flexor sublimis and searching beneath it the artery is seen with its *venæ comites*.

For *ligation of the ulnar artery in the middle of the fore-arm, or nearer the wrist*, a 2-in. incision is made close along the radial side of the tendon of the flexor carpi ulnaris. A thickish layer of fascia has to be divided, and the artery is found with its *venæ comites*. The nerve is between the vessels and the tendon; the needle must therefore be passed from the inner side.

**At the wrist** the ulnar artery continues over the annular ligament, close to the radial side of the ulnar nerve and the pisiform bone. It is covered by skin and superficial fascia with the transverse fibres of the palmaris brevis, and by the inner part of the palmar fascia, which is strengthened by a slip from the insertion of the flexor carpi ulnaris.

**In the palm** the artery curves downwards and outwards from the pisiform to make the *superficial palmar arch*, the convexity of which is directed towards the fingers. *The position of this arch is shown by* abducting the thumb and drawing a line across the palm at the level of the inferior, or distal, border of the web of the thumb. Sometimes the ulnar artery anastomoses at its outer end with the superficialis volæ, but the arterial anastomosis is more usually completed by the communication with the radialis indicis at the tip of the index-finger.

*Relations of the superficial palmar arch.*—It lies close beneath the integument and the strong palmar fascia, and rests upon the digital branches of the median nerve, and upon the tendons of the flexor sublimis digitorum.

*Branches in the hand.*—The **profunda ulnaris** dips between the abductor and flexor brevis minimi digiti to complete the deep palmar arch (p. 277) by joining with the radial.

Four **digital** branches come from the convexity of the superficial arch. The innermost runs along the ulnar border of the little finger, whilst the three others pass down to the clefts, where they divide to supply the adjacent sides of the four inner fingers. The outermost branch joins the radialis indicis in the pulp of the index-finger, and so completes the superficial arch. These digital arteries descend straight to the clefts, and thus lie in the lines of the interosseous spaces; the flexor tendons run in the lines of the fingers. In making exploratory incisions the lines of the clefts must be avoided.

In the palm the arteries are superficial to the nerves, but along the fingers the nerves are anterior.

At the clefts the digital arteries are joined by the palmar interosseous branches of the radial, and by the dorsal interosseous twigs of the posterior carpal arch.

**Irregularities.**—In the case of a high division of the brachial the ulnar artery may reach the inner border of the fore-arm by passing superficial to the group of muscles arising from the internal condyle, lying sometimes superficial even to the deep fascia.

The *comes nervi mediani* is occasionally almost as large as the radial or ulnar, and, accompanying the median nerve into the hand, may enter into the formation of one of the palmar arches. Sometimes it leaves its nerve and descends in front of the annular ligament.

As in the case of *recurrent or obstinate hæmorrhage from a wound of the palm*, it is quite possible that an irregular comes nervi may be involved, and, as in every case collateral circulation between the radial and ulnar arteries is extremely free, it is proper to tie the brachial at once, rather than the radial and ulnar arteries, or one of them singly.

#### THE BACK OF THE FORE-ARM

The **extensor carpi radialis longior** arises from the lower third of the external condylar ridge; it has a long tendon which is inserted into the base of the second metacarpal bone. *Nerve*, the musculospiral.

The **extensor carpi radialis brevior** arises from the external condyle by the common tendon, and is inserted into the base of the middle metacarpal bone. *Nerve*, the posterior interosseous.

These two muscles lie beneath the supinator longus, and their fleshy bellies project behind that muscle over the upper third of the radius. Their tendons run together under the annular ligament in the wide groove behind the radial styloid process, and are crossed by the tendons of the thumb-extensors.

The **extensor communis digitorum** lies along the ulnar side of the preceding muscle. Arising from the external condyle and from the fascia investing it, it divides into tendons for the four fingers. These pass in the shallow radial groove, together with the tendon of the extensor indicis, lubricated by the one synovial membrane. As they pass over the metacarpus the three inner tendons are connected with each other by short slips. The tendons spread out and form the posterior ligaments for the metacarpo-phalangeal joints; at the next joints they divide into three slips, of which the middle one is inserted into the base of the middle phalanx, while the lateral slips pass on to the base of the last phalanx; in each case they act as posterior ligaments. *Nerve*, the posterior interosseous.

The **extensor minimi digiti** arises like the last muscle, along the ulnar side of which it runs. Its slender tendon occupies a separate compartment beneath the annular ligament, in the groove between the radius and ulna, and is inserted in common with the innermost tendon of the extensor communis. *Nerve*, the posterior interosseous.

The **extensor carpi ulnaris** arises from the external condyle, between the extensor minimi digiti and anconeus, and passes along the edge of the latter muscle to the posterior border of the ulna, along which it also arises. Its tendon runs in the groove on the inner side of the head of the ulna, behind the styloid process, under the annular ligament, and is inserted into the base of the fifth metacarpal bone. Its *nerve-supply* is from the posterior interosseous.

The **anconeus** (*αγκων*, elbow) looks like a piece of the triceps which has been cut off by the external condyle, from the back of which it arises. It is inserted into the adjacent part of the olecranon process, and a little way down the back of the shaft of the ulna. Being in its origin, insertion, and action so like the triceps, it is naturally supplied by the same nerve as the triceps, the musculo-spiral.

The **muscles of the deep layer at back of fore-arm** are directed obliquely downwards and outwards, and intervene between the posterior interosseous vessels and nerve and the back of the interosseous membrane. The *supinator brevis* arises from the outer aspect of the ulna, and surrounds the upper third or more of the radius. The *extensor ossis metacarpi* arises from both bones, and the *extensor primi internodii pollicis* from the radius only; these two muscles form a projection at the back of the lower third of the radius as they descend over the radial extensors of the wrist to the groove on the outer side of the styloid process. The former of them is inserted into the base of the metacarpal bone, the latter into that of the first phalanx of the thumb; between the styloid process and the root of the thumb they cross the radial artery; serous effusion into their synovial sheath is not of infrequent occurrence.

The *extensor secundi* arises from the ulna, and so, to reach its insertion at the root of the ungual phalanx, it has to pass very

obliquely across the back of the wrist, where its tendon occupies a deep and solitary groove on the ulnar side of that for the radial extensors of the wrist. Its oblique tendon, which crosses the radial artery just as it is entering the root of the first interosseous space, is an important and conspicuous landmark. The *extensor indicis* arises from the ulna; its tendon passes with the tendons of the *extensor communis* and is inserted with the outermost of them (*v. p.* 287).

All the muscles of the deep layer are supplied by the posterior interosseous nerve.



Epiphyses of ulna.

The **ulna** begins to ossify at about the eighth week of foetal life, and at birth ossification has extended from the shaft through the coronoid and olecranon processes, with the exception of a shallow cap at the top of the olecranon, which is still cartilaginous, and which does not begin to ossify until the tenth year. This unimportant epiphysis joins the shaft at puberty, but the lower end of the bone, which begins to ossify in the fourth year, does not join until manhood.

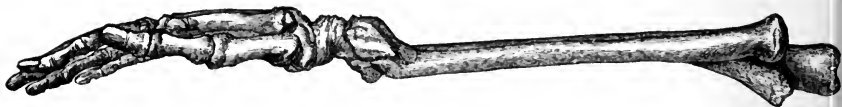Inflammation of the bursa which is placed between the skin and the olecranon process constitutes '*miner's elbow*'; I have seen it greatly enlarged in a bill-poster, as the result of constant friction against the walls and hoardings.



Epiphyses of radius.

The **radius** begins to ossify at about the eighth week, and at birth only its ends are cartilaginous. The lower epiphysis begins to ossify in the second year and joins at manhood; the upper epiphysis ossifies in the fifth year and joins at puberty.

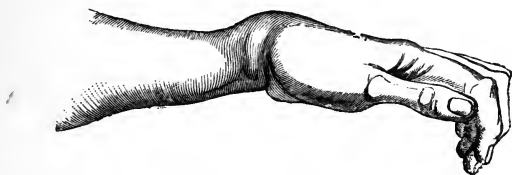
**Fracture** may occur in any part of the fore-arm, but the most



common site is at the lower end of the radius—**Colles's fracture**. At first view it seems unlikely that the stronger bone should oftenest break, and that the fracture should be through the strongest part of that bone. The explanation is simple: a man is falling and he puts out his hand to break the shock. The hand being in the position of pronation, the



shock is received by the scaphoid and the rest of the first row of the carpus, and by the front edge of the lower end of the radius. The result is that the carpal surface of the bone is cracked off, not straight, as happens when the *carpal epiphysis* is detached, but obliquely, the line of fracture being very near to the wrist-joint in front, but reaching  $\frac{3}{4}$  in., or more, above it posteriorly. The continuance of the shock which cracked off the end of the bone thrusts it, and the carpus with it, upwards on to the back of the radius. As the inner part of the carpus, and the ulna (which does not actually enter into the formation of the joint), receive little shock, there is, as a rule, no fracture or displacement on the ulnar side, further than that the head of the ulna may be left prominent and conspicuous when the outer part of the carpus is thrust upwards. Thus, the hand is found abducted



after the fracture and there is a considerable dorsal projection on the lower end of the radius, and its styloid process is raised. (The figure is after Erichsen.)

There is another explanation of the way in which the fracture occurs, that is by the sudden and powerful dragging upon the front of the the lower end of radius by the over-stretched anterior ligament of the joint and the flexor tendons when, in the fall, the hand is thrown back. The displacement of the carpal fragment is probably not in the least influenced by muscular action, but is all mechanical.

As regards *treatment* of Colles's fracture, the hand must be dragged forcibly downwards and adducted so as to replace the carpal fragment, a pistol-shaped splint being then applied to keep it in the adducted position, or some other form of splint which will keep the fragment in place.

*Fracture of the radius* between the insertions of the biceps and pronator teres is a rare injury. The fact of the bone being broken is detected by pressing with the thumb or the tip of the index-finger just below the external condyle, and finding that the head of the bone does not move in pronation and supination.

If the muscles exercised that important influence over the position of fractured bones which is so often ascribed to them (but which I am not prepared to admit), it is evident that the upper piece of the bone would be flexed by the biceps and supinated by that muscle and the supinator brevis, whilst the shaft of the bone would be rolled round by the pronators teres and quadratus, and at the same time drawn towards the ulna; but this arrangement does not necessarily obtain.

As the upper fragment cannot be influenced by pad or splint, the surgeon must direct his attention to the shaft-fragment, bringing it into the best position by flexing the fore-arm and supinating it, so as to relax the biceps.

**When both bones are broken**, say at about the middle of the fore-arm, the limb must not be put up with the hand either pronated or half-pronated, as in that position the radius closely overlies the ulna and there is risk of the four broken ends being solidly cemented together with new bone. When the fore-arm is supinated the bones are far apart; therefore, as a practical surgeon once remarked, 'you must arrange the limb so that the patient could spit into his hand.' That is, the elbow is flexed so as to relax the biceps, whilst the fore-arm is supinated and raised in a wide sling.

In dealing with a fracture in the fore-arm, the bandages must not be tight, lest the superficial veins be compressed—which easily happens—or lest the circulation through the arteries themselves becomes arrested, and pressure-sores or extensive gangrene supervene.

**Fracture of the ulna.**—As the result of direct violence or muscular action the *olecranon process* may be broken off. The separation does not take place through the epiphyseal cartilage, as this is a mere shell of bone at the top of the process, but through the narrow part halfway down the great sigmoid cavity. Sometimes the detached piece is dragged up by the triceps, but at other times, when the surrounding fibrous tissue is not much torn, there may be no displacement whatever. The fracture is, of course, into the joint, and is occasionally followed by arthritis and ankylosis. The union may be only of fibrous tissue, but, to secure the best chance of solid repair, the elbow must be kept on a straight splint for three weeks, so that there may be no dragging by the triceps.

*When a bone is broken in a synovial cavity*, as in the case of the olecranon process, the patella, and the neck of the femur, synovial fluid bathes the fractured surfaces and often prevents their osseous union. *Non-union of the olecranon* may leave the arm comparatively useless, the fragment being drawn up the arm by the triceps, and the power of extension being seriously interfered with. To remedy this defect the joint may be laid open from behind, the surfaces of bone freshened up, and the loose piece of the olecranon brought down and fixed by wire sutures.

The *coronoid process* may be broken off in backward dislocation of the bones of the fore-arm, or it may possibly be detached and drawn up by the energetic action of the brachialis anticus. Like the last injury, it is a fracture into the joint. The elbow has to be fixed by a rectangular splint for three weeks. In this way the brachialis anticus is kept in perfect rest, and the broken surfaces are approximated to the utmost degree attainable.

**Amputation in the fore-arm** may be performed in the upper,

middle, or lower third. What may be called the 'favourite situation' is just below the middle, so that the stump may be left under the government of the pronator radii teres as well as of the supinator brevis and its powerful ally, the biceps.

In *amputation at the wrist* the flap is dissected from the palm, and turned back over the lower end of the radius and the triangular fibro-cartilage. The head of the ulna and the membrana sacciformis are not exposed or interfered with.

Below the level of the superior radio-ulnar joint the bones of the fore-arm are connected by an *oblique ligament* which runs downwards from the coronoid process of the ulna to the radius, just below the tuberosity. Then begin the fibres of the **interosseous membrane**, which are oblique in the other sense, namely, downwards and inwards. Between the upper border of the interosseous membrane and the oblique ligament is a triangular gap through which the posterior interosseous vessels pass; the nerve, however, reaches the back of the fore-arm by passing round the outer side of the radius through the supinator brevis.

*Relations of the membrane.*—Upon the front lie the origins of the flexors profundus digitorum and longus pollicis, and deep in the interval between them run the anterior interosseous vessels and nerve. The pronator quadratus covers its lower third.

Upon the posterior surface rest the supinator brevis and the origins of the three extensors of the thumb and of the index-finger. Because of these oblique extensors covering the membrane, the posterior interosseous vessels do not reach it, but the anterior interosseous artery, which comes through above the pronator quadratus, and the ending of the posterior interosseous nerve, lie upon it just above the wrist.

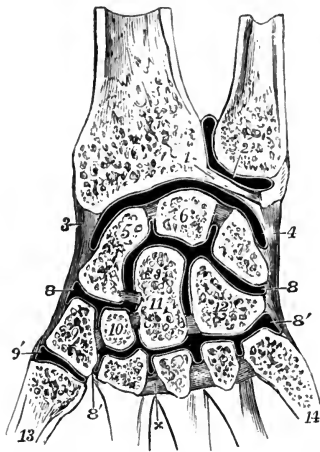
The *inferior radio-ulnar joint* consists of the lesser sigmoid cavity of the radius, and the head of the ulna. These surfaces are covered with cartilage and lubricated with a loose synovial membrane (*sacciformis*), and are connected in front and behind by short bands of fibres.

Extending from the root of the styloid process of the ulna to the lower border of the lesser sigmoid cavity of the radius is the *triangular fibro-cartilage*, which shuts the ulna out of the wrist-joint. The lower surface of this cartilage articulates with the cuneiform, and is lubricated by the synovial membrane of the wrist-joint. Sometimes the synovial membranes above and below the joint blend through a hole in the cartilage. (See next page.)

The joint is supplied by branches of the two interosseous arteries and nerves.

The **wrist-joint** is formed above by the radius and the triangular inter-articular fibro-cartilage, and below by the scaphoid, semilunar, and cuneiform bones, the last-named articulating with the fibro-carti-

lage. It is an arthrodioid joint, and is enclosed in a capsule consisting of anterior, posterior, and lateral ligaments. The articular surfaces are covered with hyaline cartilage and are lubricated by a synovial membrane which is special to this radio-carpal joint, though it is sometimes in communication with the membrane of the inferior radio-ulnar joint, as remarked above.



2, Membrana sacciformis; 3 and 4, lateral ligaments; 8, general synovial cavity of intercarpal and carpo-metacarpal joints; 8', synovial bursa between unciform and fourth and fifth metacarpal bones—is often separate; 9', synovial cavity of first carpo-metacarpal joint. (QUAIN.)

The *anterior ligament* is attached above to the anterior margin of the radius and ulna, and below to the front of the scaphoid, semilunar, and cuneiform bones. The *posterior* is a weaker band with attachments very similar to those just mentioned. The *external lateral ligament* extends from the tip of the styloid process of the radius to the scaphoid, whilst the *internal* passes from the tip of the styloid process of the ulna to the cuneiform and pisiform bones.

*Relations.*—In front of the joint are the flexor tendons, and behind are the extensor tendons. Over the external lateral ligament the radial artery winds, and close on the radial side of the flexor carpi ulnaris are the ulnar nerve and artery. The median nerve is separated from the anterior ligament by the flexor profundus.

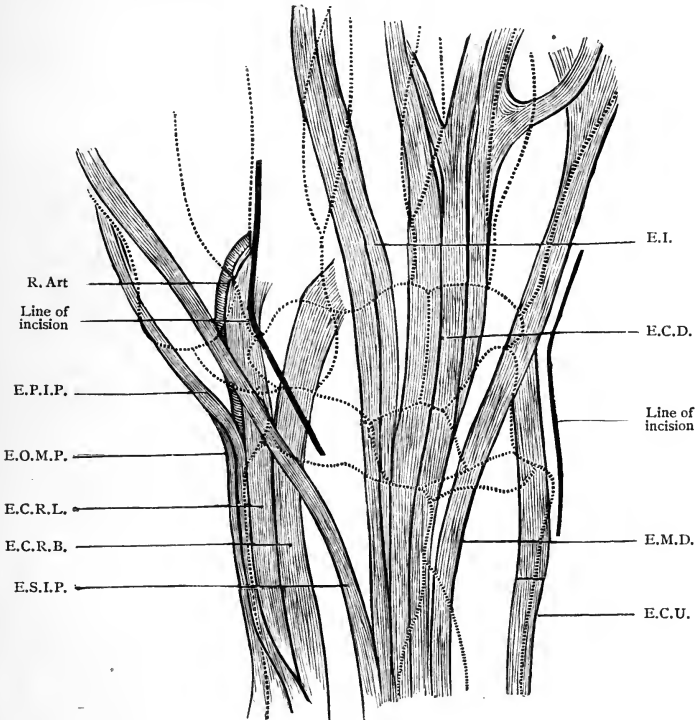
*Supply.*—Branches of artery come from the anterior and posterior carpal arches, the posterior interosseous, and the radial and ulnar. Its nerves are branches of the ulnar and of the anterior and posterior interosseous.

*Dislocations of the wrist* are very rare, although the articulation does not seem particularly secure; injury is far more likely to expend itself in fracturing the radius. In dislocation the first row of the carpal bones may be carried on to the back or front of the radius and ulna, beneath the extensor or flexor tendons. The luxation is easily recognised and reduced. The backward dislocation may look at first sight like a Colles's fracture (p. 282), but in the fracture the styloid process of the radius is displaced upwards and backwards with the carpus, whilst in the dislocation it remains in its proper place, and projects beneath the skin.

In opening a **palmar abscess** the scalpel must be used with great caution, especially in the regions of the superficial and deep palmar

arches, and, as shown elsewhere (p. 280), the lines of the clefts of the fingers must also be avoided. Pus lying deeply must be reached with the director ; but if an abscess have extended from the palm and along the flexor tendons it may be necessary to slit boldly through the anterior annular ligament.

In **synovitis of the wrist** there is a bulging all around the joint, so that the depressions are effaced and the position of the tendons is obscured. There is pain on moving the wrist, and also on pressing the carpus against the radial socket or drawing the articular surfaces asunder. I have recently had two patients under my care who had at the same time sub-acute inflammation of the wrist-joint and acute effusion into the synovial membrane of the extensor communis digitorum. Doubtless in these persons there was a gap in the posterior ligament through which the two synovial membranes were continuous. The fore-arm



Lister's excision of wrist.

and hand were secured in a moulded splint for some months, and the disease completely subsided.

**Excision of the wrist-joint** is very rarely needed ; it may be performed by straight lateral incisions, care being taken not to wound the radial artery.

In **Lister's method** the incision on the inner side of the joint is made in the ordinary way, from two inches above the ulnar styloid process down to the middle of the fifth metacarpal bone ; but the outer incision is made in the line of the second metacarpal bone, and then along the ulnar side of extensor secundi—the oblique tendon of thumb (p. 287). This tendon and the radial artery are carefully raised from the wrist, and the tendons of the carpi radialis longior and brevior are severed, as is also that of the carpi ulnaris. The flexor and extensor tendons of the fingers are raised, the pisiform and the hook of unciform being detached ; the trapezium requires a snip from the cutting pliers. The carpal bones, being cleared and separated, are taken out ; the carpal ends of the radius and ulna, and of the metacarpal bones, are laid bare and sawn off. It is evident that this latter part of the programme cannot be carried out unless the tendons of the special wrist-extensors had been previously divided, as they are inserted at the base of the metacarpus ; but, when extracting the trapezium, the tendon of the flexor carpi radialis is raised and saved. Personally, I should not attempt the complicated operation, which I have thus briefly sketched out, without carefully reading it up just before, and I deem it unfortunate that the same indulgence cannot always be extended to the student.

Much of the movement which apparently takes place at the radio-carpal joint actually occurs in the mid-carpal articulation, the flexor and extensors carpi radialis and extensor carpi ulnaris being inserted into the metacarpal bones so that they may influence the wrist and the transverse carpal joints at once.

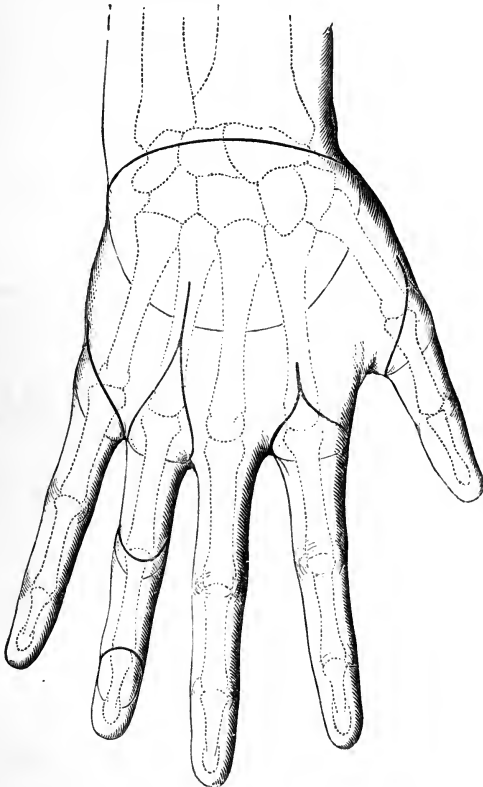
**The transverse carpal joint and the synovial membranes of the carpus.**—The lower surfaces of the scaphoid and semi-lunar bones form a socket for the head of the os magnum, which articulates on the outer side of the magnum with the trapezium and trapezoid, and on the inner side with the cuneiform and unciform, as shown in the fig. on p. 286. The two rows of carpal bones are connected by anterior, posterior, and lateral ligaments.

The transverse carpal joint is lubricated by a synovial membrane which is distinct from that of the radio-carpal articulation ; it sends processes between the bones of the second row which extend also into the articulations of the trapezoid and magnum with the middle metacarpal bones. A special synovial membrane is often found for the joint between the unciform and the fourth and fifth metacarpals. There are also separate membranes for the joints between the cuneiform and pisiform, and the trapezium and the first metacarpal bone. (The description here given differs somewhat from that figured on p. 286.)

*Supply.*—The joints about the wrist are supplied by the endings of the anterior and posterior interosseous arteries and by carpal branches of the radial and ulnar. The nerves come from the ulnar and the posterior interosseous.

The *pisiform reflex* is obtained by pressing the pisiform bone firmly with the thumb on to the cuneiform bone, when, if the reflex chain be entire, a motor impulse is promptly sent down to the palmaris brevis, and the skin along the inner border of the hand is puckered in.

The *metacarpo-phalangeal* and the *inter-phalangeal joints* are strengthened by lateral ligaments, and in front by a thick *glenoid*

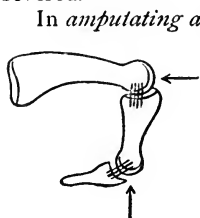


Lines of incisions. (After SMITH and WALSHAM.)

ligament containing much fibrous tissue. There is no posterior ligament, its place being taken by the extensor tendon. Each joint has a synovial membrane.

In *amputating a metacarpal bone* its base should, if possible, be left, as to remove it would be to open up a considerable extent of synovial membrane (p. 286). But this remark does not apply to the first metacarpal, which has an isolated joint with the trapezium. In amputating this bone, however, the utmost care must be taken lest, in attacking its base, the radial artery be wounded as it is passing to the root of the first space, as shown in the fig. on p. 287.

*Amputation of the thumb* at its joint with the trapezium may be performed by a racket-shaped incision, the 'handle part' of which runs from the root of the metacarpal bone and down the dorsum, whilst the 'loop part' encircles the head of the bone. The three extensor tendons are cut, and the abductor, opponens, flexors brevis and longus, and the adductor. The root of the first dorsal interosseous muscle is detached. The radial artery must be very carefully guarded, but its branches, the two *dorsales* and the *princeps*, must needs be severed.



In *amputating a finger or a phalanx* a difficulty may arise in hitting the articulation unless the finger be first bent. The knife should be passed so as to strike the middle of the head of the metacarpal bone, not its dorsal aspect. The joint being traversed from behind, a flap is cut from the flexor aspect. It is important to remember that the prominence of the knuckle is made by the head of the metacarpal bone or of the phalanx, and not by the base of the phalanx; unless this be understood, the operator may be expending his time in useless cuts against the head of the metacarpal bone or phalanx.

*Amputation through the first inter-phalangeal joint* is apt to leave the phalanx stiff and unmanageable, because it receives no insertion either from the flexor or the extensor tendons. It is preferable, therefore, to amputate through the middle of the second phalanx, as the stump then retains the slips of the superficial flexor and of the common extensor. But when only the first phalanx is left the tendons may still find a cicatricial insertion and render the stump extremely useful.

The *metacarpal bones* have a centre of *ossification* for the shaft which appears at the eighth week of foetal life, and one for the head which appears in the third year; they coalesce at manhood—20th year. The phalanges are developed on the same plan, except that in them the epiphysis is at the base instead of the head.

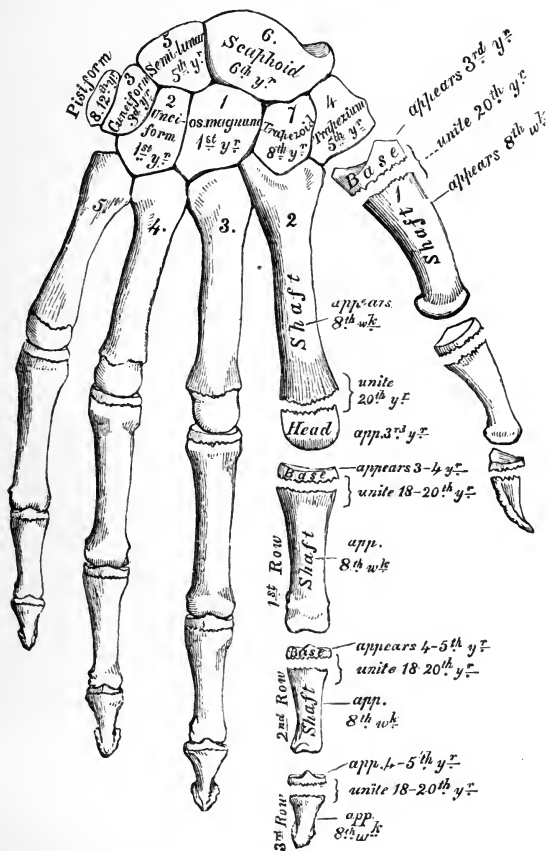
The first metacarpal bone, let it be noted, has its epiphysis at its base; thus, developmentally, it is a phalanx.

Occasionally the *first metacarpal* bone is *dislocated* at its saddle-shaped joint with the trapezium; sometimes *its epiphysis* is *detached*, in which case the appearance is a good deal like that of dislocation;



careful examination and measurement, however, quickly clear up any doubt.

The most important injury of the thumb is that in which the *first phalanx is dislocated* backwards, the end of the metacarpal bone slipping forwards between the heads of insertion of the flexor brevis pollicis with its allied muscles, the abductor pollicis with the outer



head, and the adductor with the inner. The result is that the more the surgeon pulls on the phalanges, the narrower the interval between the heads of the flexor brevis becomes, the more tense are those heads, and the firmer the grasp of the neck of the metacarpal bone. Before attempting reduction, therefore, the metacarpal bone should be thrust towards the palm, so as to slacken to the utmost the

abductor, flexor brevis, and adductor pollicis; if manipulations then fail it may be necessary to divide the abductor and the outer head of flexor brevis before the phalanx can be replaced. Sometimes the capsule of the joint or the intervention of the tendon of the long flexor is the impediment to reduction.

The *palmaris brevis* arises from the inner part of the anterior annular ligament, and is inserted into the skin along the inner border of the hand, which it raises to form the cup of Diogenes. Crossing over the ulnar vessels and nerve, it is supplied by the superficial part of the ulnar nerve.

In the **ball of the thumb** the most superficial muscle is the *abductor pollicis*, which arises from the annular ligament and is inserted with the flexor brevis into the outer part of the base of the first phalanx, through the medium of a sesamoid bone.

The *opponens* is so named because its action is to 'place the thumb opposite' the other digits; it is, therefore, inserted along the outer side of the metacarpal bone itself. It arises from the annular ligament and the trapezium, lying beneath the abductor.

The *flexor brevis* has a bulky origin from the annular ligament, the trapezium, os magnum, and the bases of the second and third metacarpal bones. Its outer head is inserted with the abductor, and its inner with the adductor pollicis, into the sides of the base of the first phalanx, through the medium of sesamoid bones. The tendon of the long flexor passes down between its heads of insertion.

The *adductor* arises from the middle metacarpal bone, and is inserted with the inner head of the short flexor.

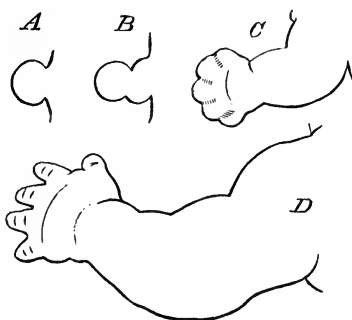
*Nerve-supply.*—The muscles of the ball of the thumb are supplied by the median, but the deep part of the flexor brevis, and the adductor pollicis are supplied by the deep part of the ulnar nerve.

The *muscles of the little finger* are the abductor, flexor brevis, and opponens. They arise from the pisiform region of the hand. Two of them are inserted into the base of the first phalanx, and the opponens is inserted into the metacarpal bone itself. They are supplied by the deep part of the ulnar nerve.

Of the *interossei*, four are dorsal and three palmar. The former are abductors, as is shown by looking at the outermost of them, which, lodged between the first and second metacarpal bones, constitutes the abductor indicis. The dorsal interosseous arise from two bones, and between the heads of origin of each passes an artery. In the case of the abductor indicis the artery is the radial, in the case of the others it is the perforating of the deep arch. The interossei are inserted partly into the bases of the first phalanges, helping to flex those phalanges, and partly into the extensor tendons, helping, therefore, to extend the second and third phalanges, as is shown on p. 273.

In the third month of foetal life the flattened distal end of the lappet or bud, A, B, from which the arm is developed, shows four notches, C

which, extending deeply, in a rough manner shape out the five digits, as at D. Should arrest of development occur in this process of cleavage, **web-fingers** result.



This condition is often hereditary, and when the fingers are webbed the toes are probably affected in the same manner. Further, it not unfrequently happens that the webbing is associated with imperfect mental development.



## PART IV

## THE ABDOMEN

THE transverse measurement of the abdomen (*abdo*, I conceal) is greater below than it is just beneath the diaphragm—and especially so in women ; but in children, on account of the imperfect development of the pelvis, the superior transverse diameter is the greater.

The **boundaries** are, laterally and anteriorly, the false ribs and diaphragm, and the oblique, transverse, and straight muscles ; posteriorly, the lumbar spine, the diaphragm, the lower ribs, quadratus lumborum, and the lamellæ of the transverse muscle. The expanded ilia also help to enclose the cavity and support the viscera.

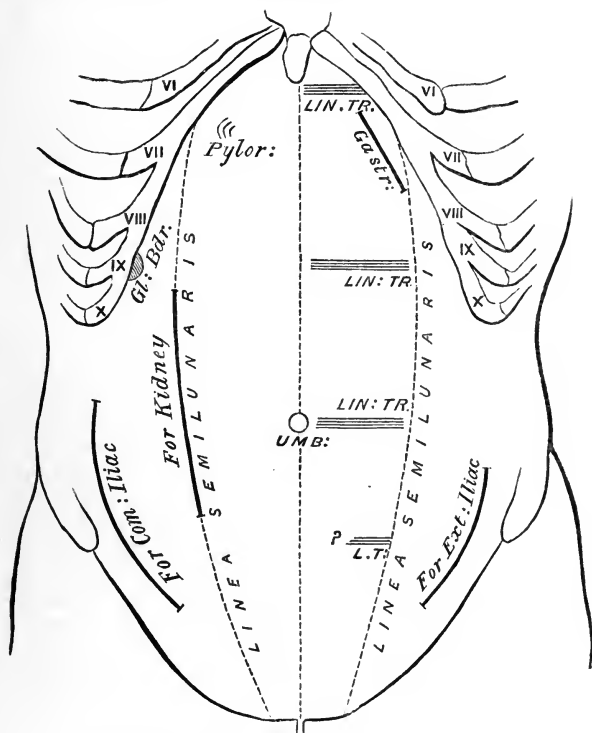
Though the diaphragm affords a definite limit above, the abdomen is separated from the pelvic cavity only by the shifting planes of peritoneum, which, under the name of false ligaments, slope to the bladder and rectum. Were the partition between the abdominal and pelvic cavities less movable, the ascent of the distended bladder and of the pregnant uterus would be impeded, and the descent of the coils of small intestine into the pelvis, when those viscera are empty, could not take place.

In cancer of the œsophagus or pylorus, on account of the emptiness of the alimentary canal, the front of the abdomen is flat ; and in tubercular meningitis, because of the irritability of the nervous system, the bowels being empty and contracted, the depressed surface of the abdomen is ‘boat-shaped.’

For *palpation of the abdomen*, the patient should be lying on his back, with the knees drawn up so that the abdominal wall may be relaxed to the utmost, and when a very thorough examination is to be made, precaution should be taken that the stomach, bowels, and bladder are empty. When a tumour descends with inspiration and rises with expiration its seat is in one of the abdominal viscera, and not in the abdominal wall.

A line drawn around the trunk from the base of the ensiform cartilage to the tenth dorsal spine suggests the **upper limit** of the abdominal cavity, which ascends a good deal beneath the dome of the diaphragm and under cover of the ribs and the base of the lungs.

**Surface markings** are made by the fleshy recti on either side of the **linea alba**—the line of junction of the aponeuroses of the oblique and transverse muscles. As the linea alba approaches the ensiform cartilage its position is marked by a shallow depression, the 'pit of the stomach.' Immediately behind this depression some of the liver and stomach are placed, and there, if slightly enlarged, the border of the liver may be felt. The linea alba contains no muscular fibres



Front of abdomen. (Modified from M'LACHLAN.)

or blood-vessels; the site serves well, therefore, for abdominal section, paracentesis, and supra-pubic operations on the bladder. Through this line is a strong fibrous seam; it gradually yields in extreme abdominal distension until it is frayed out into a thin membrane. Thus, in operating for ovarian dropsy the inner borders of the recti may be found several inches asunder. Similarly, when the 'pot-bellied,' rickety child raises himself from the horizontal to the sitting posture, the intestines are thrust forwards into a sausage-shaped protrusion along the

median line ; and, as the child lies supine, one's fingers may be thrust inwards through the chink.

The **viscera immediately behind the linea alba** are the *left* lobe of the liver, stomach, transverse colon, great omentum, small intestine and mesentery, and the distended bladder or pregnant uterus.

The **linea semilunaris** marks the splitting of the aponeurosis of the internal oblique along the outer border of the rectus ; it extends from the eighth costal cartilage to the outer end of the pubic crest. Like the 'white line,' it possesses neither muscular fibres nor blood-vessels ; it is the site of puncture when the ascitic patient is tapped lying upon his side ; in that position the fluid falls against the one flank, whilst the intestines float against the other and are thus out of the way of the trocar. Through the linea semilunaris also the kidney may be conveniently reached in the transperitoneal operation, or the stomach opened.

**Lineæ transversæ.**—Extending across the recti are several tendinous intersections which show on the surface of a well-developed man as slight depressions crossing from the white to the semilunar line ; quadrilateral segments of the muscle stand in relief between them. One of the lines is at the level of the umbilicus, one at the ensiform cartilage, and a third midway between them. Sometimes a fourth is found between the navel and the pubes. Occasionally a segment of muscle between two of the lines has been mistaken for abscess or tumour, and in hysterical subjects irregular contraction in them may produce a variety of '*phantom tumour.*'

In a fat subject two transverse creases intersect the linea alba : one at the umbilicus, the other a few inches above the pubes ; the bladder may be conveniently tapped at the spot where the lower furrow crosses the middle line. These furrows are the result of a folding of the front of the abdomen in leaning forward and stooping, a certain amount of the fat being absorbed by the constant pressure.

The **superficial fascia** consists of a fatty and of a deeper, membranous layer, between which the main tributaries of the superficial blood-vessels and the lymphatic glands are placed. The superficial layer has slight connection with the abdominal aponeurosis except at the umbilicus. In the female, just above the pubes, an extra deposit of fat in the subcutaneous tissue produces an elevation, the *mons veneris*.

The *deeper layer* of the superficial fascia is a firm, thin sheet, which, coming on either side from the thoracic and lumbar regions, is attached to the iliac crests, and along Poupart's ligament down to the pubic spines. Thence it passes in a loose investment around the spermatic cord, and helps in the formation of the scrotum. From the back of the scrotum the membrane runs on to the outer lip of the pubic and ischial rami (covering the crus and erector penis), and eventually joins the base of the triangular ligament. On the median side of

the spermatic cord the right and left sheets of the fascia are attached to the pubic crest nearer to the symphysis, blending with each other ; this layer also forms an investment for the penis ; on the scrotum and penis it joins with the more superficial layer of fascia, which there loses its fat and assumes non-striated muscular fibre instead. Some of its fibres pass into the suspensory ligament of the penis.

When air is pumped, by the movements of expiration, beneath the deep layer of the superficial fascia upon the chest, as after the fracture of a rib, emphysema cannot descend beyond Poupart's ligament ; but if the air pass superficial to this layer the emphysema might extend down the thighs. When pus descends beneath this fascia it is guided to the penis and scrotum, and not to Scarpa's triangle.

It is this deep layer of the superficial fascia which confines urine which is extravasated after the urethra has been ruptured in front of the triangular ligament. The urine cannot pass backwards into the ischio-rectal fossa, or on to the thighs, because of the attachment of the fascia to the base of the triangular ligament and the rami of the ischium and pubes. It passes, therefore, around the scrotum and penis, along the front of the spermatic cord, and up into the inguinal region. The firm connection of the fascia to Poupart's ligament and to the iliac crest prevents the fluid wandering down the front of the thigh or on to the buttock. (In making free incisions for the escape of the extravasating fluid, the surgeon must remember that a swelling along the cord may possibly be due to the presence of an inguinal hernia.)

The anterior wall of the abdomen is freely movable over the viscera, and offers so little resistance that, in a buffer-accident, liver, stomach, intestine, or arterial trunk may be ruptured without the surface of the body showing any bruise or discoloration. Moreover, a blow in the epigastric region may be followed by immediate death without the supervention of either external or internal ecchymosis ; this result is probably due to concussion of the subjacent solar plexus. It is asserted that hospital nurses used occasionally to adopt a rough and ready method of abdominal compression in dealing with their hysterical patients, by sitting upon them. In the female this is supposed to affect the ovaries alone, but it is evident that the large abdominal plexuses are all more or less influenced by it.

A house-surgeon should never refuse admission to the wards, at any rate for a time, to a person who has received injury to the abdomen ; it is impossible to say by outward inspection how serious it may be.

After the integument of the abdomen has been over-stretched, as by an ovarian tumour, or pregnancy, it does not return to its original smooth condition, but remains permanently flecked by whitish scars called *lineæ albicantes*. These marks are, therefore, evidence merely of antecedent distension of the abdomen, not necessarily of pregnancy.

The **umbilicus** (diminutive of *umbo*, boss of shield) is a fibrous cicatrix in the linea alba, opposite the *third* lumbar vertebra ; it is the

remnant of the gateway of the placental vessels. As the aorta bifurcates at the left of the *fourth* vertebra, the origin of the two common iliac arteries is represented by a spot about one and a-half inches below and slightly to the left of the umbilicus; thence to the middle of Poupart's ligament the line of the common and external iliac arteries can be chalked upon the surface; the first two inches of the line belong to the common, the rest to the external iliac artery.

In *compression of the aorta* the viscera should be empty and the trunk flexed, so as to slacken the abdominal wall; pressure is made immediately below and to the left of the umbilicus. Higher than this compression is less serviceable, as the ribs hold off the abdominal wall from the spine. Moreover, at the higher level important viscera lie in front of the aorta, and these might be damaged by the force needed to arrest the circulation.

**Umbilical hernia.**—In early development the abdomen is wide open in front, the lateral walls coming forward subsequently to join along the median line. The part last closed in is at the umbilicus, and this gap may persist after birth, the viscera being there covered only by integument and peritoneum. A piece of bowel escaping by the side of the hypogastric arteries may be accidentally tied or cut with the navel-string. A bulky cord should, therefore, be carefully dealt with, lest a loop of intestine be wounded and a faecal fistula result; it should be first emptied of bowel and then tied close to the abdominal wall.

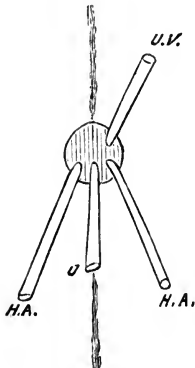
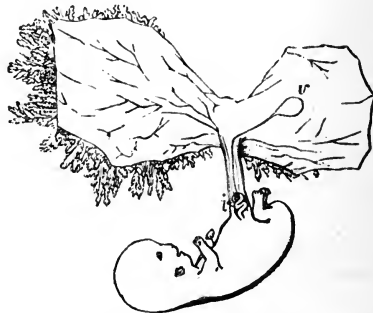

Diagram of back of umbilicus, showing linea alba, remains of urachus, U; obliterated hypogastric arts., H A, and umb. vein, U V.



Embryo at sixth week; *i*, coil of intestine in umb. cord; *v*, umb. vesicle. (A. THOMSON.)

Umbilical hernia in childhood is merely the result of an arrested development. In the adult the protrusion is not exactly at the navel-



scar—for that tissue is strong and resisting—but through the linea alba either above or below the navel—most likely above it, but possibly to one side of it. When a hernia takes place exactly at the navel itself, it is generally through the upper part—that is, above the level of the urachus and the obliterated hypogastric arteries—for this is the weakest part of the scar.

The coverings of an umbilical hernia are peritoneum, sub-peritoneal fat, transversalis fascia, and integuments ; but these tissues in time become fused together into a single, thin layer. Umbilical hernia occurs more frequently in women, and especially in those in whom the umbilical region has been stretched and weakened by pregnancy, and in those whose viscera are encumbered by the deposit of a large amount of fat.

The abdomen may be mapped out into nine regions, as follows :— A line is drawn around the body at the level of the two anterior superior iliac spines, and a second, parallel to it, over the ninth costal cartilages. These three zones are subdivided by two lines, parallel to the linea alba, from the middle of Poupart's ligament to one of the costal cartilages—probably the eighth.

These nine areas are, from above downwards, in the middle line, epigastric (*επι*, over ; *γαστηρ*, stomach), umbilical, and hypogastric (*ὑπο*, below) ; at the sides, hypochondriac (*ὑπο*, *χονδροι*, cartilages), lumbar (*lumbi*, loins), and inguinal (*inguen*, groin) or iliac (*ilia*, flanks).

The viscera contained in each region are liable to variation ; for instance, when the stomach is distended the colon is pushed far down, and when that piece of intestine is distended it may ascend high behind the ribs ; but, for the most part, the contents of each region are as follows :—

#### *Highest Zone.*

*Right hypochondriac.*—Liver and gall-bladder ; pyloric end of stomach (?) and duodenum. Hepatic flexure of colon and upper part of right kidney, supra-renal capsule, and, probably, pancreas. (The fundus of gall-bladder lies behind the ninth costal cartilage.)

*Epigastric.*—Part of liver and stomach ; transverse colon and great omentum. Pancreas ; the large abdominal vessels and some of their branches ; solar plexus.

*Left hypochondriac.*—Cardiac end of stomach, tail of pancreas, spleen ; splenic flexure of colon ; upper end of kidney, supra-renal capsule, and perhaps some of left lobe of liver.

#### *Median Zone.*

*Right lumbar.*—Ascending colon, descending duodenum, kidney ; coils of small intestine, ureter.

*Umbilical.*—Transverse colon and duodenum, great omentum ;

coils of small intestine. The bifurcation of aorta; and bladder, or stomach, when either viscus is greatly distended.

*Left lumbar.*—Descending colon, kidney, ureter, small intestine.

*Lowest Zone.*

*Right inguinal.*—Caput cæcum coli and vermiform appendix; small intestine, especially ileum; ovary, ureter, spermatic vessels.

*Hypogastric.*—End of omentum, rectum, small intestine and pregnant uterus; fundus of the child's bladder, and that of the adult when the viscus is full.

*Left inguinal.*—Sigmoid flexure of colon, small intestine, ovary, ureter, spermatic vessels.

In intestinal obstruction rolls of distended small intestine may cause prominent elevations across the anterior wall of the abdomen. These may be distinguished from the markings of the recti abdominis by their irregular situation, and also by their extending beyond the limit of the straight muscles; moreover, abdominal distension effaces the segmentation of the muscles.

Tight lacing greatly disturbs the relative position of viscera. It may even cause indentation of the convex surface of the liver by the ribs, and may thrust up the diaphragm until inspiration is imperfectly performed and the capillaries give evidence of imperfect aëration.

The outline of an enlarged liver or spleen, a distended gall-bladder or urinary bladder, may be traced upon the skin, and the upheaval caused by a distended stomach may be detected by smoothing the fingers gently over the abdomen.

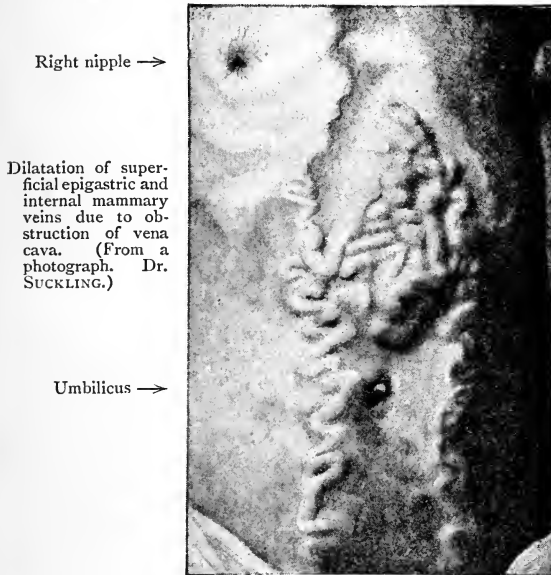
The better to explore a lumbar abscess or an abdominal tumour, the trunk must be flexed, and the knees drawn up, so that the abdominal walls may be relaxed by the ascent of Poupart's ligament. For when the thighs are flat upon the bed the fascia lata drags down Poupart's ligament and tightens up the abdominal aponeuroses which are attached to it, and so renders the depths of the abdomen inaccessible.

The *pancreas crosses the aorta* two or three inches above the umbilicus, at the second lumbar vertebra; pulsations may be transmitted by it from the aorta to the fingers placed between the umbilicus and the ensiform cartilage, especially in a thin subject. Pulsations thus transmitted in a thin, though healthy, subject may suggest aneurysmal or other tumour.

The *superficial arteries* of the abdomen come from the superior epigastric artery of the internal mammary, and from the deep epigastric of the external iliac. Twigs are also derived from the lower intercostal and the lumbar arteries, and from the superficial epigastric and circumflex iliac branches of the common femoral.

The *veins* are tributaries of the internal saphenous, and of the companion veins of the deep epigastric, lumbar, and intercostal arteries. Between these surface-veins there is a free anastomosis;

thus, when a tumour of the liver blocks the inferior vena cava, some of the blood from below finds its way into the intercostal, axillary, and subclavian veins. In hepatic congestion also, and especially in cirrhosis, the portal vein may be greatly relieved by the anastomosis of veins at the back of the liver with those of the abdominal wall. Occasionally in cirrhosis the superficial epigastric and mammary veins are enormously dilated.



Of the superficial *lymphatics*, those from above the level of the navel enter the glands of the armpit, and those from below it pass to the glands of the groin. Some of the lymphatics of the abdominal walls are in correspondence with the lumbar and pelvic series, and some pass to glands in the anterior mediastinum.

The *cutaneous nerves* are from the terminations of the lower intercostals, from the anterior divisions of the lower lateral cutaneous branches, and from the ilio-hypogastric of the first lumbar nerve. In the case of pressure upon the parent trunks of these nerves, pain is referred to their terminal filaments; thus pain along the front of the belly is a common symptom of spinal caries (p. 210). One or two of these nerves may be implicated in inflammation—perineuritis—when there is pain in the area supplied by them, and after a time a series of vesicles may appear in the course of the nerve, the result of impaired nutrition. This eruption, which may occupy the length

of one or two intercostal spaces, is *herpes zoster* (ζωστήρ, a girdle), or *shingles* (*cingulum*, a belt).

**Muscles.**—The **external oblique** arises from the eight lower ribs by as many digitations. The anterior part of this fleshy mass ends on a wide aponeurosis which passes over the rectus to join the aponeurosis of the opposite external oblique in the linea alba. The hindernmost part is muscular, and descends from the last rib, in a free border, to be inserted into the anterior half of the outer lip of the iliac crest. The shining aponeurosis is recognised during the operation of ligation of an iliac artery. The fleshy part of the muscle extends very slightly in front of a line running from the outer part of Poupart's ligament vertically to the eighth costal cartilage.

**Poupart's ligament** is that part of the aponeurosis which stretches over the iliacus and psoas, and over the femoral vessels, from the front of the iliac crest to the pubic spine, and to which the fascia lata of the thigh is fixed. It is imperfectly marked in women, but in man it forms an important seam between the deep layer of the superficial fasciæ of the abdomen and of the front of the thigh, and between the transversalis and iliac fasciæ (*see* crural sheath, p. 313) and the fascia lata. It also gives origin to the internal oblique and transversalis. The direction of the ligament shows, of course, the direction of the fibres of the muscle itself—downwards and outwards. Its inner end is firmly attached to the pectineal line through the medium of *Gimbernal's ligament*, which is a triangular septum extending, in the erect posture, almost horizontally between the pelvis and thigh. Its base is concave and free, and extends outwards as far as the crural sheath.

Femoral hernia passes below Poupart's ligament, inguinal comes out above it; the neck of a femoral hernia is placed below and to the outer side of the spine of the pubes, while an inguinal hernia is above it, and to its inner side. The **spine of the pubes** is an important landmark in the differentiation of the two herniæ, and is specially valuable in the case of a fat subject.

The structures **beneath Poupart's ligament** are the external cutaneous nerve, iliacus, anterior crural nerve, psoas; external iliac vessels in crural sheath; crural branch of genito-crural nerve, and lymphatics passing from the thigh towards the pelvic glands.

Between those fibres of the aponeurosis of the external oblique which are incorporated with the inner half of Poupart's ligament and those which blend with the linea alba there is a triangular or oval gap, the **external abdominal ring**. The base of the opening is at the pubic crest; the outer, and lower, side is formed by Poupart's ligament; and the inner boundary is made by those fibres which run downwards and inwards to the pubic symphysis. Certain transverse fibres which stretch as a kind of lacing across the opening constitute the *inter-columnar fascia*, a prolongation from which descends as a cover-

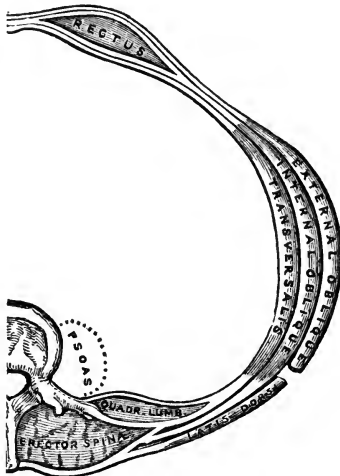
ing of the spermatic cord, and of an oblique inguinal hernia. The external abdominal ring, being the lower end of the inguinal canal, transmits the spermatic cord or the round ligament. And, as the spermatic cord is the more bulky of these two structures, the canal and the ring are more capacious in the male than in the female, and inguinal hernia, therefore, is more common among men than women.

Femoral hernia—a protrusion beneath Poupart's ligament—is more common in women, the great breadth of the pelvis necessitating a wide space below the ligament, which the iliacus and psoas, and the femoral vessels, but indifferently block up.

In the case of a tumour in the upper part of the scrotum, if the external ring contain nothing but the normal cord the swelling below it can have no association with the abdominal cavity—it is not a hernia. The tip of the finger need not be made actually to enter the ring by invaginating the scrotum and thrusting it up; but in every case of scrotal tumour the cord should be examined just below the ring.

On account of the fascia lata being closely attached to Poupart's ligament, tension of the fascia drags down the ligament and tightens the aponeurosis of the external oblique. Therefore, before attempting the reduction of an inguinal hernia, the thigh should be slightly flexed and inverted. The hernia is rarely strangulated at the external ring, because of the comparative slackness of its inner boundary; the constriction is almost invariably in the neck of the peritoneal sac.

The **internal oblique** has its fibres running upwards and inwards, almost at right angles to those of the external oblique, for the greater strength of the abdominal wall; the directions of the fibres in the two muscles are like those of the bars of a lattice-work. The internal oblique takes a fleshy origin from the outer half of Poupart's ligament, the anterior two-thirds of the iliac crest, and the fascia lumborum, and slopes upwards and forwards to be inserted into the four lower costal cartilages. As it approaches the outer border of the rectus it becomes aponeurotic, and then splits to enclose the rectus. The anterior sheet joins over the front of the rectus with the lamella of the external oblique, to reach the linea alba, while the deeper layer passes to the linea alba, along with the aponeurosis of the transversalis muscle



behind the rectus. Thus the **sheath of the rectus** is duly formed. The lower part of the rectus is naked on its posterior aspect; for in the hypogastric region the internal oblique does not split, but, fusing with the aponeurosis of the transversalis, passes over the rectus to the linea alba and pubic crest. This fusion constitutes the *conjoined tendon* of internal oblique and transversalis, which is attached just behind the external abdominal ring. Except for this tendon backing the ring, inguinal herniæ would be much more common.

In its course from the outer half of Poupart's ligament to the pubic crest the internal oblique does not arch clean over the cord; some of its lower border is carried down in front of the cord as looped muscular fibres and connective tissue; this is the *cremaster* or *cremasteric fascia* (*κρεμαστος*, hanging), and, like the inter-columnar fascia, beneath which it is placed, it gives a covering to the cord and to an inguinal hernia; over old herniæ the cremaster is thick and conspicuous. Under the stimulus of cold, the cremaster retracts the testicle; its nerve is derived from the genito-crural.

Posteriorly there is no free border to the internal oblique, as the muscle there arises from the lumbar fascia.

The **transversalis** is named from the direction of its fibres. It is the deepest of the flat muscles and arises from the inner surface of the lower six ribs (where it inter-digitates with the diaphragm), from the lumbar vertebræ, from the inner lip of the iliac crest, and from the outer third of Poupart's ligament. The lateral part of the muscle is fleshy, but as the fibres approach the linea semilunaris they are condensed into an aponeurosis which passes with the posterior lamella of the internal oblique behind the rectus, except in the lower part, where the transversalis ends in the conjoined tendon, as already pointed out.

The loin-part of the muscle arises in three aponeurotic layers, of which the most superficial is the strongest—the **fascia lumborum**—it comes from the tips of the spinous processes. The middle sheet passes between the erector spinæ and the quadratus lumborum to the tips of the transverse processes, and the anterior passes over the quadratus to the front of the transverse processes, as shown in the figure next above. The lowest border of the transversalis is free, arching high over the cord, and giving no covering to it or to a hernia.

The separation between the flat muscles of the abdomen is indicated by thin planes of connective tissue. In the neighbourhood of the iliac crest the deep epigastric vessels course between the internal oblique and transversalis, as shown on p. 156.

The **rectus** arises from the upper part of the pubes by a flat tendon which quickly becomes fleshy, and, widening as it ascends, is inserted into the front of the cartilages of the lowest *true* ribs. The segmentation of the muscle has been already alluded to (p. 296), and an account of the formation of its sheath is given above.

The lower part of the muscle is not inclosed in a sheath, its pos-

terior surface resting on the transversalis fascia. (For *lineæ transversæ*, see p. 296.)

When suppuration occurs in the substance of the rectus, the pus may be confined between two of the transverse intersections; but if the abscess be below the level of the inferior segment the pus finds its way down towards the pubes. Pus between the planes of the abdominal muscles is directed towards the linea semilunaris and may there reach the surface, but it may work its way down to the iliac crest, or along the inguinal canal, and into the scrotum. The starting point of such abscesses is, usually, caries of the spine.

The **quadratus lumborum** is placed between the anterior and middle layers of the lumbar aponeurosis of the transversalis muscle. Three of its sides are attached, namely, to the iliac crest, the lumbar transverse processes, and the last rib; its outer border is entirely free, and is a landmark in colotomy and in certain operations on the kidney.

In front of it are the diaphragm arising from the external arcuate ligament, the psoas, kidney, the ascending or descending colon (according to the side), the anterior trunk of the last dorsal nerve, the ilio-hypogastric and ilio-inguinal nerves. The anterior divisions of the lumbar arteries, and the erector spinæ, are behind it.

**Lumbar hernia** escapes on the outer side of the quadratus lumborum, taking, in addition to the covering from the peritoneum and sub-peritoneal fat, the transversalis fascia; it then causes a bulging of the transversalis and internal oblique muscles, or passes through their fibres, and escapes through the *triangle of Petit*, bounded below by the iliac crest, behind by the latissimus dorsi, and in front by the posterior border of the external oblique. I have just recently had under treatment a case of this sort, in which the hernia had emerged by the track of a lumbar (spinal) abscess. The tumour was resonant on percussion and reducible. Having returned it into the abdomen, I cut down to the aperture, approximating its edges by deep sutures, having thrust the sac within the abdomen. ('Brit. Med. Journal,' vol. i. 1888.)

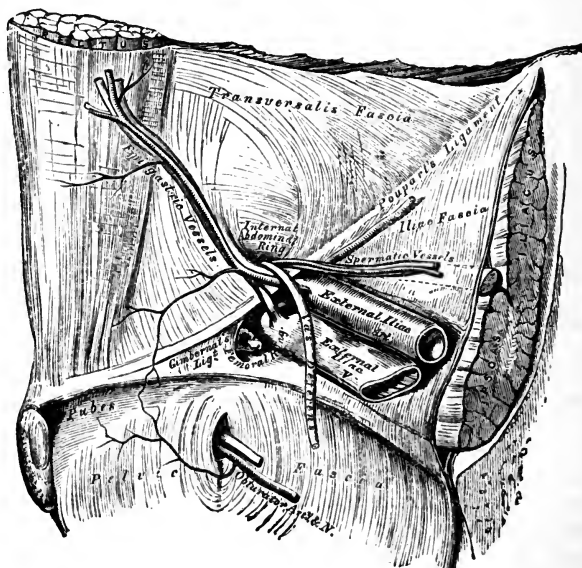
The **supply of the muscles** of the abdominal wall is from the anterior divisions of the lower intercostal and of the lumbar nerves, notably by ilio-hypogastric, ilio-inguinal, and genito-crural. These nerves run between the inner oblique and the transverse muscles to the outer border of the rectus.

The blood-vessels are branches of the intercostals and lumbar; of the epigastric and circumflex iliac branches of the external iliac, and of the internal mammary. The lymphatics are tributaries of lumbar, pelvic, and mediastinal glands.

The **transversalis fascia** covers the peritoneal surface of the abdominal wall; it is distinct from the transversalis aponeuroses (p. 304). Lining the transversalis muscle, it is attached along the

inner lip of the iliac crest, and along Poupart's ligament. Below, it is attached to the body of the pubes, covering the naked part of the rectus, and the posterior layer of the sheath of that muscle; it ascends as a thin sheet to lose itself in the phrenic vault. At the umbilicus it is firmly connected with the back of the linea alba. It is joined with the iliac fascia (p. 307) along the outer half of Poupart's ligament, but it descends free under the inner half of the ligament, in front of the external iliac vessels, forming the anterior layer of the crural sheath (p. 313). More internally, it is attached to Gimbernat's ligament, where it is again connected with the iliac fascia. Just before it passes beneath Poupart's ligament it is thickened and forms the so-called *deep crural arch*, a structure of no special interest.

The parts of the fascia which are of greatest surgical importance are the anterior layer of the crural sheath, and the process, like the finger of a glove, which the testis carries in front of it in its descent. This process is, at an early period of its development, much wider above than below, like a funnel, and is called the **infundibuliform fascia**. It entirely surrounds the spermatic cord, and the testicle lies at the bottom of it. In the adult who has no inguinal hernia the peritoneal aperture of the process is small and elliptical, constituting the **internal abdominal ring**. It is placed to the outer side of the



deep epigastric artery, about an inch above the middle of Poupart's ligament, as is shown in the adjoining figure from Gray.



As the transversalis fascia completely lines the antero-lateral aspect of the abdominal cavity, no hernia can escape thence without deriving a covering from it. The femoral variety takes an investment from it under the name of the anterior layer of the crural sheath; the oblique inguinal hernia is, like the cord, invested by the infundibuliform process, and direct inguinal and umbilical herniæ derive special investments from it.

The coverings of an oblique inguinal hernia are, then, skin, two layers of superficial fascia, intercolumnar fascia (of external oblique), cremasteric fascia (of internal oblique), infundibuliform fascia, sub-peritoneal fat, and the sac. In the female an oblique inguinal, **labial** hernia may enter the labium pudendi; it has the same coverings as a scrotal hernia, except that there may be no representative of cremasteric fascia.

The **iliac fascia** is a strong investment for the iliacus and psoas; it is beneath the iliac vessels, and is connected above with the internal arcuate ligament. Internally it is attached to the vertebral column and to the brim of the true pelvis; externally it meets the transversalis fascia at the iliac crest and along the outer half of Poupart's ligament. Passing down beneath the external iliac vessels, it forms the posterior layer of the crural sheath, and on the inner side of them it joins the transversalis fascia at Gimbernat's ligament. The branches of the lumbar plexus are beneath it. (For crural sheath *see* p. 313.)

The **iliacus** arises from the iliac fossa and ilio-lumbar ligament, and slightly from the capsule of the hip-joint, over which it passes to its insertion into the tendon of the psoas and into the femur below it. It flexes, adducts, and everts the thigh. It is closely covered in by the iliac fascia and has in front the external cutaneous nerve, peritoneum, cæcum or sigmoid flexure (according to side), and, more internally, the psoas and anterior crural nerve. It passes under Poupart's ligament, a bursa intervening between it and the hip-joint. Lower down, it is covered by the fascia lata, sartorius, and deep femoral vessels.

The **psoas** arises from the bodies and transverse processes of the last dorsal and the lumbar vertebræ, and from the intervening discs. Its upper end extends beneath the internal arcuate ligament; it descends below Poupart's ligament and is inserted into the lesser trochanter. Its action resembles that of the iliacus, but, in addition, it acts upon the lumbar spine.

It is invested by the iliac fascia, and in its substance is the lumbar plexus—the ilio-hypogastric, ilio-inguinal, and external cutaneous emerge along its outer side, the genito-crural pierces it in front, the obturator lies along its inner border, and the anterior crural is embedded between it and the iliacus, which is on its outer and posterior aspect. The vena cava, on the right, and the aorta, on the left, and, lower down, the common iliac vessels, lie along its inner border.

Additional anterior relations are the kidney, ureter, and renal and spermatic vessels, peritoneum and colon, and, lower down, the external iliac and common femoral artery. Behind it are the quadratus lumborum, the anterior division of last dorsal nerve, the anterior lumbar arteries, the brim of pelvis, capsule of hip-joint, and the bursa. Below Poupart's ligament the internal circumflex artery intervenes between its inner border and the pectineus.

The iliacus and psoas are supplied by the anterior crural nerve.

The **course taken by spinal abscess** is greatly controlled by the arrangements of fasciæ and muscles. Pus from caries of the lower dorsal vertebræ may find its way beneath the internal arcuate ligament into the substance of the psoas—beneath the vertebral part of the iliac fascia—and may descend beneath Poupart's ligament into the front of the thigh. Pus from lumbar caries may pass at once into that sheath, or, working behind the psoas, may enter the sheath of quadratus lumborum (*see* p. 305), and point on the outer side of the erector spinæ (lumbar abscess); or it may infiltrate itself between the large, flat muscles to point against the linea semilunaris, or it may wander into the inguinal canal and so reach the scrotum. From the lower lumbar vertebræ the matter may course under or through the psoas, to get beneath that piece of fascia which binds down the iliacus, and will then bulge in the inguinal region (iliac abscess), or, possibly, on the front of the thigh. Or, sinking in the pelvis, it may find exit by the great sacro-sciatic notch (gluteal abscess) or by the ischio-rectal fossa. When suppuration occurs between the transversalis muscle and the transversalis fascia, or between that fascia and the peritoneum, there is nothing to prevent the abscess extending across the middle line.

When the sheath of the psoas is filled by pus there is a fulness in the iliac fossa, the furrow over Poupart's ligament being partially effaced, and fluctuation being obtainable between the base of Scarpa's triangle and the inguinal region—that is, beneath Poupart's ligament. The thigh is kept flexed so as to diminish the pressure on the lumbar plexus. The presence of matter in the psoas gradually determines the absorption of the muscular tissue, and at last the sheath contains only the lumbar plexus bathed in pus. Psoas abscess is almost invariably the result of spinal caries.

The **sub-peritoneal fascia** is a loose layer of connective tissue and fat between the peritoneum and the transversalis and iliac fasciæ. It is thick in the loins, where it forms a soft bed for the kidneys. There is a good deal of it also in the iliac fossæ, where an unimportant horizontal fold of it, the **septum crurale**, blocks the innermost compartment of the crural sheath. A loose investment from it surrounds the cord, and gives an unimportant covering to inguinal hernia. (The coverings of the hernia are, therefore, skin, two layers of superficial fascia, intercolumnar cremasteric, and infundibuliform fasciæ and sub-peritoneal fat.)

Small lobulated offshoots from this subserous layer are apt to protrude through the linea alba, and sometimes they grow into mushroom-like masses which closely simulate omental herniæ. They differ from omental hernia in that they are enclosed in no peritoneal sac; but this cannot be recognised until they are exposed by an incision, as in an attempt to perform a radical operation for their obliteration. In puerperal cellulitis inflammation spreads rapidly through the subserous layer, and an abscess in it may open into the peritoneal cavity, into an abdominal or pelvic viscus, or, passing outwards, may find escape through the abdominal wall.

**Anastomosis between parietal and visceral blood-vessels.**—

In the sub-peritoneal tissue there is a delicate but general anastomosis between the blood-vessels of those viscera which are on any particular surface destitute of peritoneum, and those of the adjacent abdominal wall. Thus, the hepatic vessels communicate with phrenic and intercostals; renal and supra-renal with phrenic, intercostal, and lumbar; pancreatic and duodenal with phrenic and intercostal; colic with ilio-lumbar, circumflex iliac, lumbar and intercostal; ovarian with iliac; hæmorrhoidal with sacral, iliac, and pudic, and spermatic with cremasteric and perineal. These important anastomoses explain the value of cupping and leeching in hepatic and renal congestion, and in ovaritis, epididymitis, and orchitis.

The **inguinal canal** is the tunnel,  $1\frac{1}{2}$  in. long, through which the spermatic cord descends. It runs obliquely, so that there may be less chance of a piece of bowel entering it—in a similar manner the ureter passes through the strata of the vesical wall, so that in distension of the bladder the sides of the passage may be pressed against each other and regurgitation towards the kidney prevented.

The upper end of the inguinal canal is the internal abdominal ring, about an inch above the middle of Poupart's ligament; the lower end is the external ring, on the pubic crest. As the canal follows the downward course of Poupart's ligament, the internal ring is further from the middle line of the body than the external. Behind the canal the deep epigastric artery runs in a direction upwards and inwards. The artery lies, therefore, to the outer side of the external ring (but at a much deeper level), and to the inner side of the internal ring, as shown on p. 306.

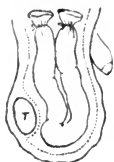
*Boundaries of the canal.*—The floor is formed by Poupart's ligament and the pubic crest. Posteriorly is the conjoined tendon. Above are the arched border of the transversalis muscle and the lower part of the internal oblique. In front are cremasteric and intercolumnar fasciæ. Loosely investing the cord is the funnel-shaped process of the transversalis fascia, which thus lines the canal.

## INGUINAL HERNIA

**Oblique** inguinal hernia follows the course of the spermatic cord through the internal abdominal ring and along the inguinal canal. Emerging on the outer side of the deep epigastric artery, it is also called *external* inguinal hernia. It passes in front of the spermatic cord, and may enter the scrotum or the labium.

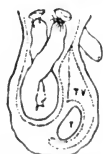If the protrusion be arrested in the inguinal canal, it is called **bubonocoele**, from its resemblance to a gland (*βουβων*, gland; *κηλη* tumour); its coverings then vary with the extent to which it has advanced.

On account of the recent descent of the testis, and the imperfect closure of the canal, oblique inguinal hernia is common in childhood; in the subsequent growth and development of the child it may be expected to disappear under the influence of a truss. This hernia passes down into the funicular process of peritoneum which accompanied the testis (*see* p. 429), and if it descend far enough it comes in contact with the testis, lying above and in front of it. Though this kind of hernia is frequently met with in adults, it bears the name **congenital**, as expressive of its anatomical peculiarity. In the female, congenital hernia descends in the canal of Nuck (p. 391).

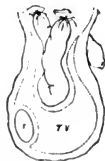

Congenital hernia; T, testis.

When the funicular process is closed only at the abdominal end, a hernia in a sac of its own may descend behind the tunica vaginalis, so that in front of the bowel there are three layers of peritoneum, the two layers of the tunica, and its own sac. This constitutes an **infantile** hernia. If the sac of an infantile hernia push its way into the top of the open tunica the variety is called **encysted**.



Hernia behind tunica vaginalis, T v.



Encysted hernia into tunica vaginalis, T v.

Occasionally an inguinal hernia in the adult, though emerging through the external abdominal ring, has not passed down with the cord, but has escaped from the abdominal cavity through that part of the anterior wall which is bounded externally by the deep epigastric artery, internally by the rectus, and below by the inner end of Poupart's ligament and the pubic crest. This space is **Hesselbach's triangle**, and the hernia which passes through it is designated, from the short and straight course which it takes to the surface of the body, **direct**, or, from the position of its egress as regards the epigastric artery, *internal*. The triangle is figured on p. 306.

The coverings of direct hernia vary according to the part of

Hesselbach's triangle through which it has escaped. If it have escaped close on the inner side of the artery, that is, between the artery and the outer border of the conjoined tendon, the coverings are just those of oblique hernia, only the fascia transversalis taken in front of it will not be the 'infundibuliform process,' as that is the piece of the fascia which specially surrounds the cord. A direct hernia emerges on the inner side of the cord, and its neck is close over the pubes, whilst the oblique runs as a pyriform mass from above the middle of Poupart's ligament. On reducing a direct hernia the external border of the rectus can be made out close on the inner side of the short straight passage by which the protrusion emerged.

If the direct hernia pass out nearer to the border of the rectus, it bursts through the conjoined tendon, or carries it in front; the coverings are then peritoneum (the sac), subperitoneal fat, transversalis fascia, conjoined tendon (unless it have passed through it), intercolumnar fascia, superficial fasciæ, and skin. This hernia pushes straight through the abdominal wall, and occupies but the lowest and innermost part of the inguinal canal. It cannot take a twofold investment from the internal oblique—it takes the internal oblique in the form of conjoined tendon, instead of the cremaster.

The **inguinal fossettes** are three depressions in the inguinal piece of the parietal peritoneum, caused by the ridge-like elevations over the obliterated hypogastric and the deep epigastric (p. 306) arteries. The innermost fossette is between the outer border of the rectus and the ridge of the hypogastric artery; the middle one is between that ridge and the elevation caused by the epigastric artery, and the outermost is external to the epigastric ridge—behind the internal abdominal ring. The *external direct* hernia passes through the middle fossette, and the *internal direct* through the innermost.

The **seat of stricture** in an oblique inguinal hernia may be at the external or internal abdominal ring, in which case the protrusion may be returnable after division of the external oblique aponeurosis, or the transversalis fascia, and without opening the peritoneal sac. But the strangulation is almost invariably in the narrow neck of the peritoneal sac itself, so that the operator generally has to open the sac; in doing this, discoloured serum escapes; he then sees the bowel, congested or plum-coloured, or black and gangrenous. Introducing a strong, narrow, probe-pointed knife, on the flat, and turning its edge against the constricting band, he makes a small incision directly *upwards*. Thus he is sure of avoiding the epigastric artery, which would be wounded if, in operating on a direct hernia, he were to cut outwards, or, in an oblique hernia, inwards. As he does not always know on which side of the artery the hernia has emerged, the rule to cut upwards is invariable. Generally he can recognise a direct hernia by its forming a rounded protrusion over the pubes. But an oblique

hernia of old standing may so drag down the epigastric artery as to lie close to the pubes ; he may then mistake it for a direct hernia. In every inguinal hernia, then, whether diagnosed as oblique or direct, the strangulation is to be eased by an upward incision in the neck of the sac.

A strangulated inguinal hernia does not necessarily require a cutting operation ; the surgeon may be able to return it by *taxis* (*ταξις*, an arrangement): he lays the patient supine, with the pelvis raised, and he flexes the thigh and inverts it, to relax Poupart's ligament and the abdominal wall ; then, taking the neck of the sac between the fingers and thumb of his left hand—making them into a sort of funnel—he endeavours to squeeze back the contents of the tumour. Years ago, the patient was prepared for taxis by emetics, hot baths, tobacco clysters, and even venæsection, with the view of diminishing general and local resistance ; ether has happily rendered this treatment obsolete. Before using taxis the patient should be kept on his back, with pelvis raised, in hopes that, the vessels of the bowel being emptied to the utmost, the mesentery may draw back the protruding knuckle.

**Réduction en masse** is the thrusting of the peritoneal sac and its contents bodily within the abdomen, the strangulation not being relieved. So symptoms persist ; and perhaps a tumour may be felt deep in the iliac fossa. Moreover, the scrotum is found empty of sac. In such a case the inguinal canal has to be opened up, the peritoneal cavity explored, the mass brought down, the strangulation relieved, and the bowel returned. Sometimes the sac and its contents get pushed up between the peritoneum and the abdominal wall.

If the constant wearing of a truss fail to prevent the descent of a hernia, the **radical treatment** may be contemplated. The old methods of performing the so-called radical 'cure' were as complicated in description as they were ingenious in execution ; they have now given place to straightforward and simple operations on the principle of occluding the neck of the peritoneal sac and partly closing the external abdominal ring : an incision is made down the axis of the tumour from the external ring, through skin and superficial fasciæ, intercolumnar, cremasteric, and infundibuliform fasciæ, till the sac is reached ; its contents are then returned, its neck, isolated from the elements of the subjacent cord, is tied as high up as possible, and the sac is cut away below the ligature. The wide mouth of the canal is then partially occluded by lace sutures securely passed through the pillars of the external ring.

The radical treatment is also usually performed after operating for the relief of a strangulated hernia.

#### FEMORAL HERNIA

The external iliac vessels are continued into Scarpa's triangle, beneath Poupart's ligament, between a prolongation of the transversalis

fascia in front and of the iliac fascia behind. These two prolongations join on either side of the vessels, and the funnel-shaped investment thus formed is the **crural sheath**; it blends with the connective-tissue sheath of the vessels about an inch below Poupart's ligament.

*Three compartments* are made in the crural sheath by two antero-posterior fibrous septa; the outermost compartment contains the common femoral artery, the middle the vein, and the innermost a lymphatic gland. The anterior crural nerve, being beneath the iliac fascia, cannot be within the sheath.

The innermost compartment is the femoral or **crural canal**; it extends less than an inch into the thigh: from the base of Gimbernat's ligament to the margin of the saphenous opening; its abdominal orifice, which is about large enough to admit the top of the little finger, is overlaid by the peritoneum; between it and the peritoneum is a (practically) unimportant layer of sub-peritoneal connective tissue, which, on account of its covering the aperture, is called the *septum crurale*. See illustration on p. 306.

**Relations of the crural canal.**—In front is Poupart's ligament; behind is the pubic part of fascia lata covering the ramus of pubes and the pectineus; internally is Gimbernat's ligament; and externally is the common femoral vein, and, possibly, the irregular obturator artery. Its apex reaches down to the top of the saphenous opening. The spermatic cord, which lies along Poupart's ligament, is just above and in front of the canal, and the deep epigastric artery, in its inward ascent, lies external and superior to it.

Femoral hernia descends through the crural ring and down the crural canal to the top of the saphenous opening. The bowel takes as its *coverings* a sac of peritoneum; then, probably, the sub-peritoneal fat—under the name of *septum crurale*; in the canal it derives an investment from the anterior wall of the crural sheath—that is from the prolongation of the fascia transversalis. Arrived at the lower limit of the crural canal, the hernia comes forward through the saphenous opening, taking the deep layer of the superficial or cribriform fascia, the fatty layer, and the skin. Thus, the coverings from above downwards are skin, two layers of superficial fascia, crural sheath, *septum crurale*, and peritoneum.

The *course of a femoral hernia* is downwards, into the canal; then forwards through the saphenous opening; and, lastly, upwards towards Poupart's ligament or the iliac crest.

The hernia is superficial to and above the saphenous vein.

Before employing *taxis* the thigh should be flexed and slightly inverted so as to relax the fascia lata, and especially its falciform border, against which the bowel would otherwise be bruised. The fingers and thumb of the left hand are arranged around the neck of the hernia—to steady it—and the tumour is gently but firmly squeezed

downwards, and backwards round the falciform process, and then upwards through the crural ring.

The *seat of the strangulation of a femoral hernia* is at the rigid margin of the crural ring, that is, outside the sac. Therefore, the operator may expect to effect reduction, after easing this constriction, with the hernia-knife, without opening the sac. He divides all the coverings down to the sac by a vertical incision, and then slips the probe-pointed bistouri through the crural ring, in front of the neck of the sac, easing the constriction by a slight incision upwards and inwards, but not too much upwards, lest he sever Poupart's ligament, and wound the spermatic cord which lies along it, or the epigastric artery which is above it. The fibres divided are those at the junction of Poupart's and Gimbernat's ligaments.

Allusion is made elsewhere (p. 371) to those rare instances in which the operator wounds an irregular obturator artery.

**Perineal and vaginal herniæ** are closely associated anatomically; they pass down in front of the rectum. The former descends in its peritoneal sac along the rami of the ischium and pubes to the perineum through the levator ani, deriving a covering from the rectovesical fascia; the latter simply bulges into the vagina.

**Obturator hernia** escapes through the upper part of the thyroid foramen, where it would compress the obturator nerve, causing peripheral neuralgia. (There is a good example of this hernia in the museum of St. Mary's Hospital, No. C. d. 19). To ease the strangulation of an obturator hernia, an incision would be made from the inner third of Poupart's ligament vertically down the thigh for three or four inches, dividing skin, superficial fascia, fascia lata—the common femoral and the long saphenous veins being carefully avoided. Then the pectineus would be exposed, and the interval between it and the adductor longus would be carefully traversed. The short adductor having been drawn downwards and inwards, the small protrusion would be recognised. If it were necessary to enlarge the shallow obturator canal, the obturator membrane might be incised by the hernia-knife.

Hernia through the great sacro-sciatic foramen, like the varieties just mentioned, is very rare.

#### THE CAVITY OF THE ABDOMEN

The **peritoneum** lines the abdominal cavity and is stretched around (*περι, τεινειν*) most of the viscera, its reflections constituting 'false ligaments.' The attachment to the abdominal walls is not very intimate except in the neighbourhood of the umbilicus; in the operation of ligation of an iliac artery the peritoneal pouch can be easily stripped up from the iliac fossa; whilst an abscess bursting through the back of the liver, between the layers of the coronary ligament,



may pass forwards between the peritoneum and transversalis fascia to the middle line or even across it.

Except in the female, where the Fallopian tubes pierce it, the peritoneum is a shut sac. It is lined by squamous endothelium, which secretes a serous exudation so as to allow the coils of intestine to roll freely over each other. In intestinal wounds and ulcerations plastic peritonitis often prevents leakage of the contents of the bowel into the general cavity. Thus, gall-stones may escape into the colon; spinal abscess may be discharged into small or large intestine, and pericæcal suppuration may be relieved through the groin with the occurrence of no more than a limited and conservative inflammation. By the theory of inflammatory adhesions encysted peritoneal collections are explained.

In **peritonitis**, on account of the swelling and tenderness, the patient lies supine with his shoulders raised and his knees drawn up, so as to relax the abdominal muscles and to ward off the weight of the bed-clothes. As the inflammation extends to the muscular wall of the intestine it paralyses it, and thus constipation sets in. Decomposition of the contents of the bowel occurs, gas being evolved, and tympanites resulting. To ensure complete rest for the inflamed bowel, opium is administered. As the descent of the diaphragm in respiration disturbs the inflamed membrane, respiration is carried on entirely by the ribs and the intercostal muscles. The arms are often thrown up and the hands placed behind the head, so as to give the pectoral muscles a greater command over the ribs.

Inflammation of the peritoneum is accompanied by the deposit of plastic material upon its surface, and when two areas of inflamed membrane lie in quiet apposition the effusion may glue them permanently together. But it often happens that before the effusion can be thus organised the movements of the bowel itself, or of the abdominal walls, gently drag the sticky surfaces apart, *false bands* and lengthened fibrous adhesions being thus spun out. These bands offer a dangerous snare to the neighbouring coils of bowel, and are a common cause of intestinal obstruction, especially in the neighbourhood of the uterus.

In the course of acute peritonitis the muscular coat becomes implicated in due course; the exudation into it and into the nerve plexuses throws them out of working order, and the symptoms of acute obstruction arise. It has happened to surgeons (besides myself) to open the abdomen for the relief of acute obstruction and to find no other cause for it than acute peritonitis.

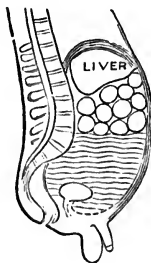
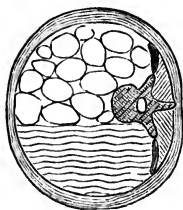
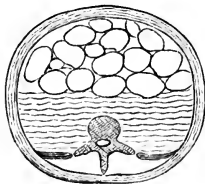
When a patient has intestinal muscular cramps—*colic*—it may be at first a question whether his distress is due to peritonitis or not. If the surgeon can move the flaccid abdominal wall freely over the bowel there is no peritonitis. The peritoneal cavity is like a joint—when the latter moves easily there is no synovitis.

On account of the close proximity of the peritoneum and pleura, pleurisy sometimes sets up peritonitis. The intestines being inflated, the diaphragm is so greatly raised that the heart and lungs work with difficulty, and the patient is thereby much distressed. Sibson advised that in such conditions a long flexible tube be passed into the stomach or colon, or that gas be removed by puncture of bowel.

The pains of colic may be relieved by pressure, but in peritonitis even the weight of the bed-clothes may be intolerable. In local peritonitis a roughened serous surface, of the liver, for instance, may rub against the parietal layer during respiration and so give rise to a friction-sound.

The convalescent from peritonitis walks about with a stoop; standing up straight causes pressure upon the still tender sac.

**Hernial sac.**—As, with certain exceptions, the whole of the intestinal canal (in addition to its proper serous coat) is enclosed within the general peritoneal cavity, no knuckle of bowel can escape from the abdomen without taking before it a pouch from the parietal layer; this constitutes the hernial sac.



The **great omentum**, attached above to the stomach and transverse colon, and descending as an apron in front of the small intestine, is apt to form part of the contents of a hernial sac; it escapes in front of the intestine through an abdominal wound. When, at a herniotomy, bowel and omentum are found in the sac, the bowel should be returned first. Omentum is almost certain to enter an umbilical hernia, and it may have to be torn through before the strangulated knuckle of bowel is reached. When the end of the omentum is fixed in a hernial orifice, or has, in some other way, formed an attachment to the abdominal wall, it may strangle a coil of intestine; a loop of bowel is sometimes caught in a hole in the omentum. Malignant tumours are apt to start from the pendulous folds.

**Ascites** (*ασκος*, a skin bottle) is effusion of serous fluid into the peritoneal cavity. When it is associated with dropsy of the body generally, it is probably due to obstructed flow of blood through heart, lungs, or kidneys. But when peritoneal dropsy is unassociated with œdema in other regions, obstruction is to be suspected

in the *liver*, the serous fluid oozing from the congested capillaries of the tributaries of the *vena portæ*. If the amount of effusion be

small, there is dulness in each flank, and resonance over the whole antero-lateral aspect of the abdomen as the patient lies on his back—the resonance being due to the inflated intestines floating on the fluid. But on turning the patient upon the side the area of dulness changes. Were the fluid enclosed in a cyst, as in ovarian disease, percussion would be but little affected by change of position. If the patient sit up or stand the area of dulness extends across the inguinal and hypo-gastric zone, the higher regions becoming resonant. When the effusion is excessive, resonance may be discoverable only behind the recti, as the patient lies supine. The diaphragm is then pushed far up, and respiration is short and thoracic. The patient may breathe more easily in the sitting posture, for in that way the compressible intestine, and not serum, lies against the diaphragm. (*See* figs. on p. 316.)

**Tapping the abdomen.**—An enormously distended bladder has sometimes been mistaken for ascites; the rule, therefore, is to empty the bladder before thrusting in the trocar. The puncture should be made in the median or semilunar line (p. 296); as the fluid escapes pressure is removed from the caval and other deep abdominal veins, which now become distended, so that the heart is robbed of its accustomed supply, and faintness comes on; the descent of the diaphragm also embarrasses the heart's action. Puncture through the semilunar line of the recumbent patient is a satisfactory operation; the patient should be rolled a little on to the side selected. But if there be so much distension that the rectus is flattened out and displaced, and the situation of the semilunar line cannot be determined, it were better to follow the usual English custom, and to operate in the exact median line. There, for certain, no vessel will be injured or muscular plane traversed. The patient sits over the edge of the bed, and the puncture is made a few inches below the umbilicus; as the fluid escapes, a jack-towel, which was previously arranged round the trunk, is tightened up, so that the risk of faintness may be lessened. Sometimes, when the serum is only partially drawn off, the flow is checked by the omentum or a piece of intestine being carried against the end of the tube; the obstruction is to be overcome by passing a probe down the cannula.

**Development of intestines.**—The early intestinal canal is a straight cylindrical tube in the internal blastodermic layer; it runs in the long axis of the germ, and its ends are closed. As the growth of the tube proceeds with great rapidity, it escapes in abundant coils through the front of the abdomen, which is as yet not closed in. But after the end of the second month energetic growth of the abdominal walls takes place, so that the truant viscera are soon surrounded and swept within the cavity. I have seen a new-born infant in whom there had not been this subsequent growth of the parietes, so that not only were the bowels protruding from sternum to pubes, but the liver and the urinary bladder were also prolapsed. These viscera

were covered only by a thin and transparent membrane. A congenital umbilical hernia is a slighter degree of the same arrest of development, but with the growth of the child it usually disappears.



Ectopia viscerum, the result of imperfect development of chest and abdomen. *a*, liver; *b*, heart; *c*, lung; *d*, stomach; *e*, spleen; *f*, bowel; *g*, kidney; *h*, chorion; *i*, amnion; *k*, umb. cord; *m*, placenta.

### THE ABDOMINAL VISCERA

**Stomach and intestine.**—The stomach extends across the epigastrium, between the two hypochondriac regions, but its position, like its shape and size, is liable to considerable variation. (See p. 164.)

Placed in the vault of the diaphragm, it has that muscle above and in front of it, the liver intervening between its anterior surface and the diaphragm towards the right side, whilst a wedge of lung descends between the ribs and diaphragm in front of the stomach on the left side. An additional anterior relation is the abdominal wall, close behind which it lies. Behind are the vertebral column, crura of diaphragm, aorta, vena cava, and pancreas. Below it are the transverse

colon and coils of small intestine. The left end fills in the hilum of the spleen and covers the kidney.

The heart is separated from the stomach only by the diaphragm, and their close proximity goes far towards justifying the advice—'If a patient complain of his "stomach" suspect heart-disease; if he complain of his "heart" suspect indigestion.' When the stomach is excessively distended it thrusts down the transverse colon and small intestine, and not only obliterates the depression below the ensiform cartilage, but causes it and the left ribs and their cartilages to bulge forwards; it also thrusts upwards the liver, diaphragm, and heart. Thus, flatulence may seriously interfere with the working of the heart as well as of the lungs. Sometimes after a heavy meal, on account of this elevation of the heart, the right side is so full of venous blood that the capillaries of the brain and of the head imperfectly empty themselves, the face becoming flushed and the cerebral circulation disturbed; respiration also is interfered with. The fuller the stomach, the farther the liver is pushed up under the right arch of the diaphragm; and when the stomach and the alimentary canal are empty, as in cancer of the œsophagus, the liver sinks towards the epigastrium, for it has lost much of its support; the diaphragm also descends and the heart is found on a very low level.

(The exact shape and size of the stomach may be made out by percussion, after the patient has swallowed first some tartaric acid and then some bicarbonate of soda. This method of examination must not be employed if there be a question of gastric ulcer; nor indeed, is it often needed.)

Into the *cardiac end of the stomach* the œsophagus opens without any other valvular arrangement than that afforded by the muscular fibres around the aperture by which the gullet passed through the diaphragm. The opening is at about the level of the tenth dorsal vertebra, a little to the left—behind the seventh costal cartilage. The right end is continuous with the duodenum, the junction being marked by a thickening of the circular fibres to form the *pyloric valve* (*πυλῆ*, gateway), which, when the stomach is empty, lies behind the liver, about a couple of inches below the gladiolus, and a little to the right of the linea alba, at the level of the first lumbar vertebra. When the stomach is distended the pylorus is thrust into the right hypochondriac region, where it lies behind the right lobe of the liver and the upper false ribs.

The upper border of the stomach is short and concave, and is fixed to the liver by the gastro-hepatic omentum, between the layers of which are the coronary artery and the vessels passing through the gateway of the liver. From the lower, convex, border the great omentum hangs. This border may descend even into the pelvis, as in the case of dilatation due to pyloric stricture.

When a person goes to bed with an undigested meal in his stomach

the hard masses fall against the lesser curvature and the cardiac end, and, irritating the pneumogastric, cause irregularity of the heart's action, palpitation, and faintness, or, perhaps, asthma. After an attack of vomiting the symptoms promptly subside.

*Structure.*—The stomach and intestine consist for the most part of serous, muscular, submucous, and mucous coats. The muscular coats consist of pale fibres arranged longitudinally, and, more deeply, in a circular manner, the circular fibres being aggregated to form the pyloric sphincter above and the internal sphincter ani below.

On the stomach the longitudinal fibres (continuous above and below with those of the œsophagus and duodenum) are chiefly along the two curvatures. The oblique fibres are deeply placed at the cardiac end and are continuous with the circular fibres of the œsophagus.

The stomach is invested front and back by peritoneum, which comes down in the gastro-hepatic omentum and is continued from the lower curvature as great omentum.

The mucous membrane from the cardiac orifice of the stomach to the anal part of the rectum is lined with columnar epithelium; columnar epithelioma is, therefore, the variety of malignant disease generally associated with the alimentary canal.

When a piece of intestine is wounded, as in a stab in the abdomen, the mucous membrane bulges through the wound in the serous and muscular coats and so plugs the opening.

The *arteries* of the stomach come from the gastric, splenic (vasa brevia and left epiploic), and hepatic (pyloric and right epiploic). The *veins* are tributaries of the portal vein and run chiefly along the greater curvature. They are often found much congested after death; such venous fulness is very different from the widely-spread congestion of the capillaries found after irritant poisoning, and may be recognised on opening the stomach and holding it up to the light. The *nerves* are the pneumogastrics, and branches of the solar plexus; the left pneumogastric passing chiefly to the anterior surface. The *lymphatics* end in glands along the curvatures, and are associated with the mediastinal glands, and indirectly also with those of the root of the neck (p. 140).

**Gastric catarrh** interferes with digestion and causes a feeling of fulness in the region of the stomach. The food undergoes decomposition in the stomach, gas being evolved, and the patient is worried with eructations, oppressed breathing, and cardiac disturbance, the diaphragm being raised by the distended stomach. The inflammation is chiefly along the greater curvature, so that discomfort occurs immediately food is taken into the stomach; whereas, in the case of gastric ulcer, the lesion is probably near the lesser curvature, so that pain does not come on so quickly after the meal. Though it is often difficult to differentiate between catarrh and ulcer, an important sign is that pain occurs only when food is in contact with the ulcer, so that

vomiting brings immediate comfort ; in catarrh the trouble is more constant. With ulcer there is pain in the back, over the lower dorsal spines, and, generally, blood is vomited.

**Gastric ulcer** is usually preceded by catarrh, the epithelial lining being detached over small areas ; the ulcer is most liable to attack the pyloric end of the posterior wall, near the lesser curvature. Should it implicate a large branch of artery, fatal hæmorrhage may result. In hæmatemesis (*ἔμεσις*, vomiting) the blood comes up in vomiting, not in coughing ; it is not frothy or bright-coloured, but it is acid from admixture with gastric juice ; blood from lung, pharynx, or nares may find its way into the stomach and be voided by vomiting, so that blood which is vomited is not necessarily the result of gastric hæmorrhage. If the ulcer cause perforation, the extravasated matter from the stomach may come directly in contact with the solar plexus, death occurring rapidly from shock or peritonitis, unless adhesions have glued the margin of the ulcer to liver, pancreas, duodenum, or colon. On the front of the stomach conservative adhesions are less likely to occur. Sometimes, however, the ulcer opens harmlessly into the duodenum or colon. If an ulceration be diagnosed upon the posterior wall, the patient must be kept lying prone.

When 'ulcer' has been diagnosed the diet should be of the lightest kind, and the patient should be kept lying down, so that if, as often happens, ulceration extend to the serous coat, local plastic peritonitis may glue the treacherous area to the liver, general peritonitis being thus averted. Grave collapse is the great sign of perforation, and of extravasation of food having occurred into the peritoneal cavity. To ensure absolute rest, no food whatever should be given by the mouth.

**Dyspepsia.**—In disease of the heart, as also in cirrhosis of the liver, there is impeded circulation, the vena portæ being overladen, and gastric catarrh and dyspepsia resulting. Thus it happens that 'indigestion' may be the most prominent symptom of morbus cordis. The nerves of the stomach grow over-sensitive, and, as soon as food comes in contact with them, there is discomfort, a feeling of fulness, or actual pain, which may be relieved only by vomiting. As the patient gets worse the food and glairy mucus which he vomits are streaked with blood which has escaped from the over-loaded capillaries, and as the disease still further advances the vomit consists of acid mucus and darkened blood. This is the 'black vomit' so often seen in the dying.

**Vomiting** is accomplished by the abdominal muscles compressing the stomach against the diaphragm and liver, the cardiac orifice being relaxed. First a deep inspiration is taken, so that the diaphragm may lie at its lowest level ; it is then fixed by the firm closure of the glottis ; a patient with an opening in the trachea cannot vomit, as the diaphragm cannot be fixed. The fuller the stomach, the easier is the

act, so that an emetic should be administered in plenty of warm water. Vomiting may be caused by irritation of the pneumogastric filaments in the pharynx as well as stomach, or even in the brain itself, as in cerebral disease, or in a sea-voyage. Free expectoration of bronchial mucus is excited by vomiting; thus in certain chronic pulmonary congestions an emetic is useful. In vomiting the tonsils are compressed by the superior constrictor, and in acute quinsy an emetic may thus effect the bursting of a tonsillar abscess, or, after amputation of tonsils, may check troublesome oozing.

The close association between the stomach and brain is exemplified by sea-sickness and by the vomiting which occurs on the return of consciousness after cerebral concussion. But irritation of the gastric filaments of the vagi is often misinterpreted by the brain as the result of pulmonary unrest; and so arises the 'stomach cough.' When vomiting is long-continued the bile-stained contents of the duodenum are voided, and, later, the lower part of the small intestine is emptied; the ejecta then have a stercoraceous odour; but in so-called 'fæcal vomiting' the large intestine is not being emptied: this is prevented by the ileo-cæcal valve.

*Eruclation* is that form of vomiting which is accomplished by the muscular coat of the stomach alone without the help of the diaphragm or of the abdominal walls.

*Post-mortem* digestion of the stomach affects its hinder wall, and chiefly in those parts which depend on either side of the vertebral column, that is where the gastric juice collects. The dissolution caused by an irritant poison would not affect these pouches only and avoid the rest of the lining of the stomach.

In **stricture of the pylorus** the stomach becomes much dilated, and, as nutrition fails, the patient becomes so thin that the hardened valve may be at last easily felt through the abdominal wall. If the growth happen to lie over the aorta the pulsations are apparent above the umbilicus, but the tumour feels solid and does not expand laterally as an aneurysm would. Sickness comes on much later after food has been taken in pyloric than in cardiac stricture, for in the former case the food may remain in the stomach until, in the ordinary course, it should be passing into the duodenum; as it tries to force its way through the pylorus pain may be intense. The stomach becomes enormously dilated in pyloric stenosis and may spread through the chief part of the abdominal cavity.

The condition of the stomach after death from pyloric stricture is like that of the bladder in the case of enlarged prostate, or of the left cardiac ventricle in aortic obstruction, the distended organ being not only dilated, but considerably thickened.

Food accumulating undergoes decomposition, and the patient is troubled with wind. If forcible dilatation of the contracted pylorus be not considered expedient—and in some cases it has answered well—



the treatment should consist in careful dieting, and in the frequent washing of the dilated viscus by means of a soft rubber-tube, a funnel, and hot water.

**Gastrostomy** is, literally, cutting a mouth ( $\sigma\tau\omega\mu\alpha$ ) in the stomach, and is resorted to in impassable stricture of the œsophagus, that the patient may be permanently fed thereby. Cutting into the stomach, as in the removal of a foreign body, is *gastrostomy*.

Gastrostomy may be done through the left linea semilunaris. The incision is begun close below the ribs and is continued downwards for 4 in. The peritoneum being opened, the left lobe of the liver is seen ; behind it is the front of the stomach, which is then drawn up and secured to the margin of the wound, where it soon becomes fixed by adhesion of the opposed surfaces of peritoneum. (The sacculated and movable transverse colon could best temporarily be mistaken for the smooth and fixed stomach.) In performing gastrostomy the viscus need not be opened straightway, but may be fixed to the abdominal wound for a few days by harelip pins to diminish the risk of fluid entering the peritoneal cavity.

Another method of operating, and one which gives more room, is by a three-inch incision which, beginning at about  $1\frac{1}{2}$  in. to the left of the linea alba, runs parallel to and about an inch below the cartilages of the left ribs. The outer part of the rectus and its sheath, and, of course, the oblique and the transverse muscle, are divided, the transversalis fascia and the peritoneum are opened, and the lower border of the stomach is brought to the wound and secured.

The stomach in all these operations is generally very small, and is hidden beneath the left lobe of the liver, or high in the phrenic dome, and the surgeon, seeing the transverse colon along his incision, is apt to take it at first sight for the stomach. The appendices epiploicæ and the longitudinal bands, however, soon show that he must look higher for the stomach, which he finds by passing his fingers round the liver, up to the transverse fissure, and down the lesser omentum. The great omentum descends from the lower border of the stomach.

**Digital dilatation of the pylorus** (Loreta) has been successfully employed in cases of fibrous contraction, which is usually diagnosed from the cancerous form by the lengthy and quiet course which the disease has run, and by the absence of a definite tumour in the right hypogastric or epigastric region. The stomach having been found through the oblique incision just given, and the pylorus having been drawn out of the wound, an opening is made on the anterior surface of the lesser end, away from all large vessels, and, the pylorus being steadied by the left hand, the right index and then the index and middle fingers are gradually worked through the orifice. The wound is then closed with Lembert's sutures and the stomach is dropped back.

The **small intestine** is about 20 feet long, hung from the spinal

column in coils contained within the mesentery, though the duodenum, which lies at the root of the transverse meso-colon, has no mesentery. The ileum is recognised by the comparative thinness of its wall, for it does not contain valvulæ conniventes, which abound in the jejunum to thicken its mucous coat and increase its physiological activity. There is no definite limit between jejunum and ileum, but, for convenience, the jejunum is considered as making about two-fifths of the entire length of small bowel (*jejunum*, empty; *ileum*,  $\epsilon\lambda\epsilon\upsilon\nu$ , twisted).

The *duodenum* is 10 in. long, and takes a horse-shoe bend around the head of pancreas.

The *first part* ascends from the pylorus to the neck of gall-bladder, and is 2 in. long; like the pyloric end of stomach, it is covered front and back by peritoneum, and is comparatively movable. In front of it are the liver and neck of gall-bladder; behind it are the vena portæ, and the hepatic artery and duct. Below it is the head of the pancreas.

The *second part* is 3 in. long, and descends on the anterior surface of the right kidney. In front of it is the ascending colon. To the left is the head of the pancreas, the pancreatico-duodenal artery lying in the crevice between them in front, and the common bile-duct behind. This part is firmly fixed.

The *third part* measures 5 in., and passes transversely across the spine at the level of the second lumbar vertebra to end in the jejunum. Behind it are the aorta, vena cava, thoracic duct, and crura of diaphragm. In front the superior mesenteric vessels descend to enter the mesentery; they come out from below the pancreas, which viscus lies along the upper border of the third part of the duodenum.

On account of the nearness of the gall-bladder, the duodenum is usually stained by bile, and by this, when the 20 ft. of small intestines are removed at a post-mortem examination, the upper end can be recognised at a glance.

Like the rectum, the first part of the duodenum is entirely surrounded by peritoneum, the second piece being covered only in front, and the third part being destitute of a serous coat.

The *jejunum* has a thick mucous coat, owing to the presence of the valvulæ conniventes. The *ileum* is thin-walled (on account of the comparative absence of the valvulæ), and is coiled chiefly in the right iliac fossa, where it is about to end in the cæcum.

*Peyer's patches* are oval collections of solitary glands in the ileum, arranged along the aspect which is opposite to the attachment of the mesentery.

On account of the presence of the ileum in the right iliac fossa, the physician gently presses his hand over that region to detect tenderness, and the gurgling of fluid, in enteric fever. When inflammation extends to ulceration, fatal collapse and bloody stools may follow the implication of a branch of artery, or perforation of the bowel may

determine peritonitis. The typhoid ulceration, like the Peyer's patch, has its long axis with that of the bowel, whilst tubercular ulceration generally extends across the long axis, that is, in the direction of the blood-vessels which encircle the bowel.

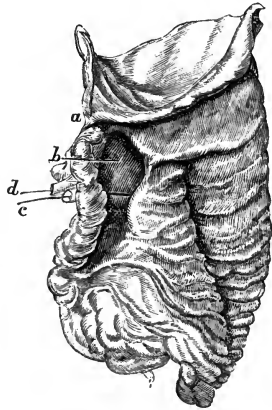
A special outgrowth, **Meckel's diverticulum**, is found about 2 ft. above the ileo-cæcal valve: it is the remnant of an early foetal canal, the vitelline duct, which extended from the interior of the ileum through the umbilicus; a loop of intestine is occasionally strangled around it or its remnant. Persistence of the duct may cause umbilical fistula, or may involve a fatal snaring of a coil of bowel.

The *arteries* of the small intestine are the superior and inferior pancreatico-duodenal (from the hepatic and superior mesenteric) and vasa intestini tenuis (superior mesenteric). The pancreatico-duodenal, or the gastro-duodenal (hepatic), is occasionally implicated in duodenal ulcer following a severe burn. The *veins* pass by the superior mesenteric vein into the vena portæ. The *lacteals* and *lymphatics* course between the layers of the mesentery to end in glands at its base. The *nerves* come from the aortic plexus of the sympathetic along the mesenteric artery, together with pneumogastric filaments.

On opening the abdomen in the case of intestinal obstruction absolute size of bowel is no guide to its recognition, for small intestine may be distended to the size of the forearm whilst the colon may be no larger than the thumb. Also when the colon is distended its three longitudinal bands of muscular fibres are temporarily effaced. But the large intestine may always be recognised by the presence of appendices epiploicæ, of which the small intestine is entirely destitute. The colon may also be recognised by its comparatively fixed position in the lateral and upper transverse parts of the abdomen.

The ileum occasionally shows offshoots, nearly as large as the bowel itself, called *diverticula*; structurally they resemble the parent bowel. They are generally hernial protrusions of the mucous membrane through the muscular coat.

The **mesentery** (*μεσος*, middle; *εντερα*, bowel) is the thin doubling of peritoneum by which the jejunum and ileum are surrounded, and are hung from the vertebral column; blood-vessels, lymphatics, and nerves course between its layers. Its attached end is from four to six inches wide, and slopes from the left side of the second lumbar vertebra



*b*, duodenal ulcer after burn; *a*, pylorus; *c* and *d*, bristles passed through ulcerations in pancreatico-duodenal artery and vein. (HOLMES.)

to the right sacro-iliac synchondrosis. It is spread out like a fan, and its intestinal border is about 20 ft. long. The measurement from the spinal to the intestinal border is 4 or 6 in., and the question still remains unanswered if, in a hernia, the mesentery was so deep as to let the bowel slip into the inguinal or femoral canal, or if the fold was pulled down and elongated by the emigrant bowel. The lymphatic glands at the root of the mesentery are prone to tubercular inflammation; the disease may spread and glue together adjacent coils of intestine, or may determine a suppurative peritonitis.

After resecting a piece of small intestine the edges of the triangular gap in the mesentery must be carefully adjusted by sutures.

The end of the ileum, especially in children, is apt to slip through the ileo-cæcal valve, and, with the invaginated cæcum, to be carried along the colon and possibly through the anus. In a few happy cases of this sort the invaginated bowel has sloughed off and the patient recovered.

Forcible inflation of the lower bowel occasionally succeeds in unsheathing the piece when the adjacent serous surfaces have not become too closely adherent by plastic effusion; abdominal section, too, has in rare instances availed ('Lancet,' August 4, 1888). Opium is the only drug to be prescribed: absolute quiet is essential.

The **colon**, about 5 ft., ascends from the right iliac fossa through the right lumbar into the hypochondriac region, passing in front of the quadratus lumborum, kidney, and descending piece of duodenum to the right lobe of the liver. Thence it turns across the top of the umbilical region below the stomach; reaching the spleen well behind the stomach, it descends in front of the left kidney and quadratus, and, at the end of the sigmoid flexure, is continued on as the rectum. As it passes across the abdomen it lies over the vertebral column and the large vessels; aortic abdominal aneurysm is apt to burst into the transverse colon. The transverse colon is often found in the sac of an umbilical hernia. Gall-stones may escape into the hepatic flexure, and renal or spinal abscess may be evacuated through the ascending or descending parts.

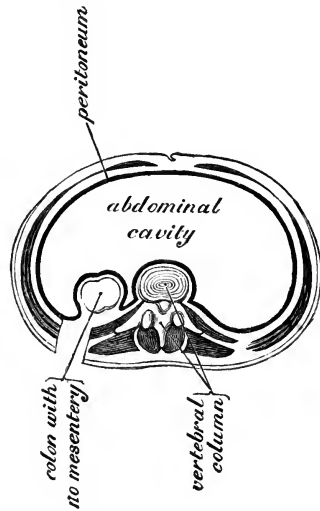
The sigmoid flexure is apt, in habitual constipation, to be so laden with fæces as to form a doughy tumour in the left iliac fossa. Sometimes a sigmoid loop swings over, producing that form of obstruction known as *volvulus*. With obstruction so low in the bowel the abdominal distension is extreme. In obstruction of the rectum the sigmoid flexure may become an enormous fecal reservoir which occupies the chief part of the abdominal cavity.

The ascending and descending colon are not generally entirely invested with peritoneum; the postero-internal strip is likely to be bare, and it is through that part that the bowel is opened in lumbar colotomy, as is shown on the next page.

The **cæcum**, which as a rule is entirely surrounded by peritoneum,

lies in the right iliac fossa, or rests upon the psoas ; it may even, like the sigmoid flexure, hang over into the true pelvis. Above it is carried on as the ascending colon, and on its inner side the ileum enters by the ileo-cæcal valve. It is about  $2\frac{1}{2}$  in. deep and the same across.

The **vermiform process**, 3 or 4 in. long, and, completely ensheathed by peritoneum, is curled up along the left aspect of the cæcum. Under its serous coat are muscular and mucous layers, as in the cæcum itself. A shot-corn, seed, or fæcal concretion lodged in the process may cause a localised peritonitis and inflammation of the neighbouring tissues generally ; the condition is named perityphlitis (*περι*, around ; *τυφλος*, blind). The tissues become matted together. In due course ulceration or gangrene of the process occurs, fæculent matter escaping, and suppuration advancing. The disease is characterised by hardness and tenderness deep in the right iliac fossa. The inflammation of the



Left lumbar colotomy. (HERBERT ALLINGHAM.)

muscular coat of the bowel entails paralysis of its fibres, constipation being the result. The constipation is beneficial in that it keeps the parts at rest and encourages the formation of adhesions which may shut the abscess out of the general peritoneal cavity ; opium, not purgatives, should be prescribed, and leeches may be applied. The abscess should be opened through the iliac fossa, or it may discharge into the colon, or may wander into the pelvis ; its bursting into the peritoneal cavity is always to be dreaded. Small hard masses are sometimes found in the vermiform process, which, though much resembling cherry-stones, are found on section to be formed of inspissated intestinal secretion.

In two cases of acute peritonitis in children which were under my care we found that the cause of the trouble was an ulceration over a concretion in the root of the process. I ligatured and amputated the process, and washed out the peritoneal cavity, but, unfortunately, the children sank shortly afterwards. In the case of recurrent typhlitis an exploratory laparotomy, and amputation of the vermiform process, may be indicated ; it must be remembered, however, that the ureter lies close in the neighbourhood and may possibly be implicated in the adhesions.

The surgery of the vermiform process is of far more interest than is its anatomy.

The *ileo-cæcal valve* is the chink by which the small intestine opens into the large. Its lips are so joined that, the fuller the blind end of the colon becomes, the tighter they are approximated and the less the chance of fluid passing back between them into the small intestine. In fæcal vomiting the contents of the large intestine do not regurgitate through the valve, and in the treatment of intestinal obstruction by inflation of the bowel the air does not pass through the valve.

**Serous coat of large intestine.**—The cæcum is entirely surrounded by peritoneum; <sup>1</sup> it is not, as it was formerly thought to be, attached to the iliac fossa by a meso-cæcum.

The ascending and the descending colon are completely invested except on that aspect which lies against the quadratus lumborum, whilst the transverse colon is covered on all aspects except where the arteries enter. The sigmoid flexure, like the transverse colon itself, is surrounded by a mesentery, and by this it hangs into the true pelvis. The peritoneum entirely covers the first part of the rectum except a strip on the sacral aspect; the beginning of the second part is covered only on the anterior and antero-lateral aspects, whilst the rest of the second part and the whole of the third part is destitute of serous covering. The fuller the colon becomes, the wider is the surface devoid of peritoneum, and, conversely, the more empty it is, the more complete is its mesentery.

I have operated in a case of strangulated cæcal hernia in which, though the bowel had a complete sac, I was unable to pass the finger round it, as one could have done, had an ordinary piece of bowel been down. The cæcum was attached to the back of the sac. It is said that the cæcum can descend along the inguinal canal behind the peritoneum, taking no peritoneum with it for its sac—such a hernia must, indeed, be rare.

The **appendices epiploicæ** are small tassels of peritoneum and fat which are attached to the large intestine; being only upon the intra-peritoneal surface of the bowel, they can give no help to the surgeon who is seeking for the colon through the loin, unless he be there performing a transperitoneal operation.

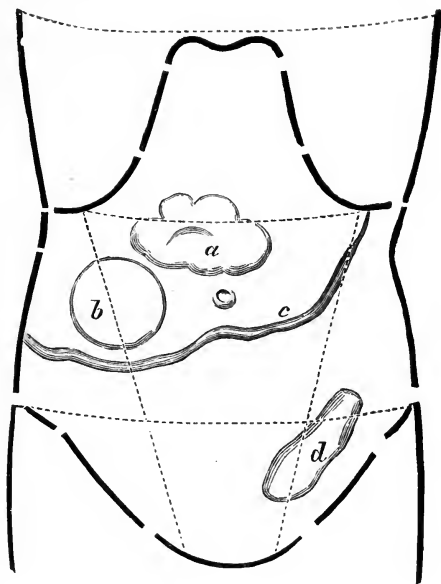
The longitudinal muscular fibres are chiefly collected in three conspicuous bands, commencing at the vermiform appendix, and ceasing at the end of the sigmoid flexure. When the large bowel is much distended the bands are less noticeable, but ordinarily they serve, as do the appendices epiploicæ, to distinguish the large from the small intestine when the peritoneum is opened. The sacculation of the colon is due to the comparative shortness of these bands. On account of the difference in size and shape the percussion-note of the transverse colon is of a higher pitch than that of the stomach.

The longitudinal bands are conspicuous only where the colon is covered by peritoneum; it is useless, therefore, to look for them as a

<sup>1</sup> See Treves, *Hunterian Lectures*, 1885.

guide to the bowel when Amussat's post-peritoneal operation is being performed.

Showing sites of fæcal accumulations: *a*, in transverse colon; *b*, in ascending colon; *c*, in transverse colon, between the double lines; *d*, in sigmoid flexure. (After BRIGHT.)



In fæcal accumulation a large and hard, or doughy, mass may be detected by careful examination; it is best removed by persistent massage and by enemata of soap and water. In the case of fæcal accumulation, as also of malignant tumour of the colon, pressure upon the anterior crural, obturator, or other branch of lumbar plexus may give rise to peripheral pains in loin, groin, or limb.

**Intestinal obstruction** is often caused by a piece of intestine being snared by a band of old peritoneal inflammatory tissue in the pelvis or abdomen, by a Meckel's diverticulum (p. 325), by a rent in the mesentery or omentum; by a twist, and in many other ways. The small intestine is more often strangulated than the large, and chiefly so because it is more movable; though, as regards a twist (*volvulus*), the slackened folds of the sigmoid flexure are more frequently concerned.

*Intussusception* is the passage of a piece of bowel into that next below it, the invaginated piece having the two peritoneal surfaces against each other; indeed, these surfaces becoming firmly glued together, the invaginated and inflamed piece of bowel may slough off, and pass *per anum*, the patient recovering. A common variety of this form of obstruction is that in which the ileum passes through the

ileo-cæcal valve ; ileum, valve, and cæcum may all slip into the colon and even hang into the rectum, so that in every case of obstruction the finger should be passed into the anus. In most of these cases bloody discharge occurs from the anus ; the piece of intussuscepted bowel stimulates the ensheathing piece, and painful straining to pass a motion (tenesmus) results. Where there is much fæculent or bloody discharge there is not much inflation of the bowel. The intussuscepted piece, like a ball of snow, grows larger as it travels onwards, and gives rise to a tumour which may be felt through the abdominal wall, in the course of the colon.

When obstruction is high in the small intestine the patient is sick each time he takes anything into the stomach ; thus the amount of urine must be greatly reduced ; moreover, he perspires profusely, the skin doing some of the work of the kidneys. The more constant the vomiting, the less must be the amount of gas in the alimentary canal ; in some cases of obstruction high in the jejunum the abdomen is flatter than normal. But as peritonitis sets in tympanites, of course, supervenes. When the small intestine is inflated and the abdominal walls are stretched the position of the transverse rolls may be felt and seen behind the recti. These elevations must not be mistaken for the natural segments in the muscles which occupy fixed and definite situations.

When obstruction is low in the large intestine, as in the case of a laden sigmoid flexure becoming twisted, or narrowed by malignant constriction, there may not be much vomiting, but the abdomen is greatly distended by flatus, and there is resonance in the flanks—in the course of the ascending and descending colon.

*Borborygni*, or ventral rumblings, are caused by the irregular passage of gas along the bowels, and are probably due to disturbance of peristaltic action through the influence of the sympathetic system. It is also by some irregular contraction of the circular fibres that a piece of small or large intestine is slipped into and strangulated by a piece of the bowel lower down (*see* also p. 329). The introduction of food into stomach or rectum increases peristaltic action, so that nothing but a little ice can be allowed in acute intestinal obstruction. Opium is given to check peristaltic action. Strychnia is used in chronic forms of constipation to excite peristalsis.

The *arteries of the large intestine* are ileo-colic, right colic, and middle colic from the superior mesenteric, and left colic, sigmoidean, and superior hæmorrhoidal from the inferior mesenteric. (For the supply of the rectum *see* p. 388.)

The *veins* are tributaries of the vena portæ, except those coming from the lower end of the rectum, which open into the internal pudic vein. The *nerves* come from the aortic plexus, and the lymphatics enter the lumbar glands.

**Littre's operation** is making an artificial anus in the sigmoid



flexure through the anterior abdominal wall, and through that part of the bowel which is covered with peritoneum. The operation is extremely simple, and, as the bowel is usually stitched to the skin wound, and is there allowed to become glued by adhesive inflammation before it is opened, the risk of peritonitis is very slight.

A curved incision of about 3 in. is made in the iliac region with the convexity towards the anterior superior iliac spine—much as for ligation of an iliac artery (p. 295). But after the two obliques, the transverse muscle, and the transversalis fascia have been divided the peritoneum is opened and the sigmoid loop brought up; it is easily recognised. Before it is stitched to the abdominal wound all its slack folds should be drawn down, so that the artificial anus may be made in the highest part and the risk of subsequent prolapse of bowel may be diminished.

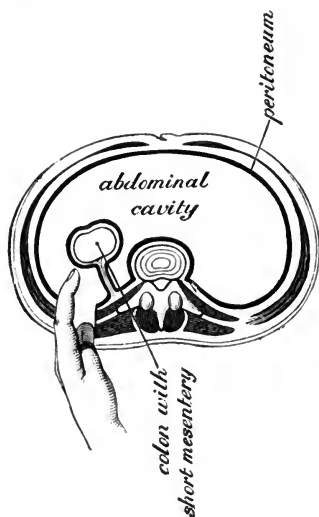
By drawing out a spur of the bowel evacuation can be completely and permanently secured by the artificial opening; unless this is done merely a fæcal fistula will be formed and much of the motions will escape again per anum.

**Amussat's operation** is best performed upon the left side, as obstruction in the large intestine is likely to be in the sigmoid flexure or rectum; thus the artificial anus is made much nearer the end of the canal than when the colon is opened on the right side, and fæcal accumulation is the more effectually obviated. Before operating, the surgeon inflates the bowel through the rectum, so as to steady it and to widen out the strip which is destitute of serous covering. He feels for the last rib and the iliac crest and makes his incision through the intervening space.

A line is drawn up from  $\frac{1}{2}$  in. behind the middle of the iliac crest to the last rib, and a 4-in. or 5-in. incision is made across that line.

The outer border of the erector spinæ is easily made out, and the incision is begun, or ended, just over it—say  $1\frac{1}{2}$  to 2 in. from the spine. (By the horizontal incision the lumbar arteries are avoided.) Skin and fascia are divided, and the fleshy borders of the latissimus dorsi and external oblique (figs. on pp. 303, 327) are notched; the posterior part of the fleshy internal oblique is freely incised on a director just as it arises from the lumbar fascia, and the transversalis muscle, chiefly a shining aponeurosis (fascia lumborum), though slightly fleshy at the front of the wound, is opened up. Then the outer border of the quadratus is bared, and, crossing from the front of it, the anterior division of the last dorsal, or an upper lumbar nerve is seen. Next comes a quantity of fat through which the surgeon carefully works with director and forceps; in front of this is the unimportant transversalis fascia, which is to be carefully torn through. Then the lower end of the kidney is felt, and the colon, which lies upon it, is traced down, and opened well on its posterior and internal aspect. Unless the surgeon keep quite to the back of the wound, he is apt to injure the peritoneum where it

passes from the colon to the lateral abdominal wall. Such an injury would be apt to prejudice the result of the operation. But if the surgeon, after prolonged search for the bowel, fail to discover it, it is better for him deliberately to incise the peritoneum and to bring up the colon with his hooked finger, rather than to blindly open some neighbouring coil of small intestine which he has encountered in the renal region, through a rent in the peritoneum. I have known this accident happen more than once, and, on the other hand, amongst the most successful cases of colotomy may be some of those in which the peritoneum has been accidentally or intentionally opened in the 'extra-peritoneal' operation.



Lumbar colotomy; peritoneum necessarily opened. (HERBERT ALLINGHAM.)

If the colon happen to have a short mesentery, or, practically, no mesentery at all, Amussat's operation is simple enough, but when the mesentery is long, as sometimes happens, it is absolutely impossible

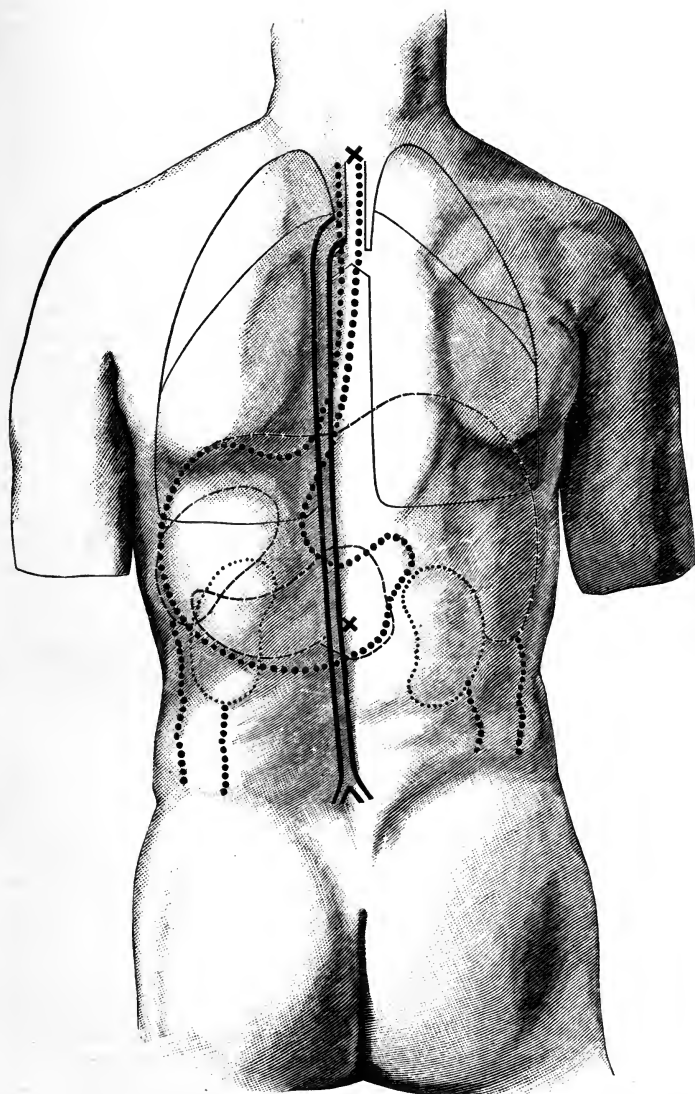
to perform an extra-peritoneal colotomy.

### THE LIVER

The liver (50 oz.) is situated in the right hypochondriac and epigastric regions; it often extends also into the left hypochondriac region. In the child (and in the adult when it is enlarged) it reaches to the left false ribs, in front of the cardiac end of the stomach and spleen.

At birth it is very large, reaching across to the spleen, the umbilical vein entering the longitudinal fissure in the median line of the body; but with the subsequent growth of the child the proportionate size of the liver diminishes, so that the left lobe lies behind the linea alba, the round ligament and the falciform ligament being dragged towards the right hypochondrium. In the adult, therefore, only the left lobe occupies the epigastric region, and its border slopes downwards and to the right, crossing the middle line about three inches below the base of the xiphoid cartilage. (See illustration on p. 163.)

Normally, the *highest level of the liver* corresponds with the right sixth or seventh rib; for draining an empyæma on the right side, therefore, the opening should not be lower than the fifth space. In the case of a large abdominal tumour, and of great inflation of the



Chief viscera of thorax and abdomen outlined on back. (GODLEE and THANE.) For the front view, *see* p. 164.

intestines, the liver is pushed up into and hidden in the dome of the diaphragm.

Ordinarily the **liver-dulness** extends to the eighth rib at the side of the chest, and, on account of the slope of the ribs, to the sixth rib near the sternum; near the spine, where the base of the lung comes well down, the tenth rib marks the upper border of liver-dulness. At the side of the chest the lower limit of dulness is the tenth or eleventh rib. In emphysema the dull area is much diminished because of the liver being shrouded by lung.

In the case of enlargement of liver, with ascites, Sibson used to teach us to find the liver through the fluid by what he called 'dipping,' that is, suddenly thrusting the tips of the fingers into the depths of the right infra-costal region—splashing the fingers through the fluid.

A liver, uniformly enlarged, grows downwards, dropping by its own weight, as it were; but when its upper surface is the seat of hydatid or malignant tumour, or abscess, it raises the diaphragm and the thoracic viscera, and pushes the heart towards the left.

**Relations.**—The upper surface, smooth and convex, is directed a good deal forwards, so as to lie against the six or seven lower ribs and the abdominal wall; its chief extent, however, occupies the phrenic vault. And thus it happens that hydatid cyst or abscess is apt to burst into pleura and lung. To the upper surface the base of the falciform ligament is attached; through the free border and the depths of that ligament the umbilical vein, or round ligament, reaches the transverse fissure.

Probably the liver is placed between the diaphragm and the abdominal walls so that the movements of respiration may stimulate its circulation. Certainly it often happens that when a free-living man is suddenly laid on his back—say on account of a broken thigh-bone—the portal circulation becomes congested, 'biliousness' resulting.

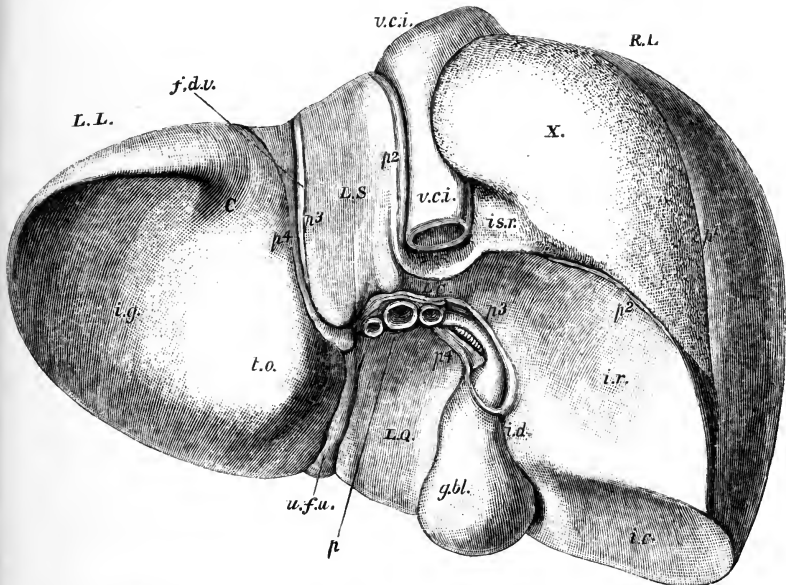
Though usually hidden behind the ribs, the *lower border* of the liver may descend within touch of the fingers on a deep inspiration being taken, and in the epigastric region, even after expiration, its border, overlapping the stomach and colon, may give a dull percussion-note. It is also thrust down in the case of emphysema, hydrothorax, and other conditions involving distension of the right side of the thorax; and from tight-lacing it may descend even to the iliac fossa. In hydatid or other tumour of the liver a more or less rounded mass descends with inspiration; the very weight of the liver, moreover, keeps the area of dulness depressed. But when the right lobe is implicated in abscess or hydatids the dull area ascends, the right lung is encroached upon, and the heart is pushed upwards and to the left. On the other hand, in phthisis and in collapse of lung the liver ascends, so that even the right hypochondriac region is resonant on account of the encroachment of inflated bowel.

When the peritoneal covering of the liver is roughened by inflam-

matory thickening, the respiratory movements give rise to a friction sound, just as in the case of pleurisy.

On account of the liver occupying the arch of the diaphragm, it is overlapped in front, laterally, and behind by the sharp border of the base of the lung. A horizontal stab may, therefore, pass through four layers of pleura and two of peritoneum before the liver is wounded. In a case of hydatid tumour of the upper surface of the liver, which I was recently treating with Dr. Broadbent,<sup>1</sup> we opened the pleura through the seventh intercostal space, traversing also the diaphragm; we then fixed the hydatid cyst to the edges of the skin-wound by hare-lip pins for a couple of days before incising and draining it, and with an excellent result. The lung collapsed on the pleural cavity being opened, but, the wound being sealed by adhesive inflammation, it soon expanded again. (See figure on p. 192.)

The lower surface of the liver is mapped out by five fissures, arranged in the shape of the letter H, into five lobes. In relation with this surface are the right kidney and supra-renal capsule posteriorly, and the ascending part of duodenum and colon more to the front; this surface also



R L, L L, right and left lobes; L S, Spigelian; L C, caudate; L Q, quadrate; p, portal fissure; u f, umbilical; f d v, for ductus venosus; g bl, gall-bladder; v c i, cava; i g, gastric impression; c, position of cardia; i c, impressio colica; i r, impressio renalis; i d, impressio duodenalis; X, surface destitute of peritoneum. (From QUAIN.)

<sup>1</sup> Transactions of the Clinical Society, 1888.

overlaps the stomach. Suppuration in it is apt to find escape by way of the stomach, duodenum, or colon.

The *posterior border*, thick and rounded, lies against the aorta and the crura of the diaphragm. The two layers of the coronary ligament which pass from the upper and lower surfaces on to the diaphragm leave this border destitute of peritoneum, and there, in a deep notch, ascends the vena cava.

The *hepatic tissue* is extremely friable, and may be ruptured by a blow which leaves no mark upon the surface of the body. As the result of the injury, fatal hæmorrhage may occur into the peritoneal cavity, especially from the tributaries of the hepatic veins, which rest wide open, on account of their intimate connection with the surrounding tissue. The portal and hepatic veins are destitute of valves.

On account of the intervention of the pouch of peritoneum between the liver and the abdominal parietes, leeches applied to the hypochondriac region do not abstract blood directly from the liver, but indirectly through the communication between the hepatic and phrenic veins.

From the front and back of the transverse fissure the peritoneum descends to the stomach as *the lesser omentum*, and between its layers pass the portal vein (posteriorly), the hepatic duct (to the right), and the hepatic artery (from the left); pneumogastric and sympathetic filaments, and lymphatics, also enter the liver through this fissure. These structures are loosely invested with fibrous tissue (Glisson's capsule) which, sending offshoots between the lobules, makes a lattice-work throughout the substance of the liver; the threads of this lattice-work eventually reach, and are connected with, the fibrous capsule of the liver itself, which lies just beneath the peritoneum.

**Cirrhosis.**—As the result of chronic alcoholic irritation the fibrous lattice throughout the liver becomes swollen, the liver itself growing large and hard, and perhaps tender (*hepatitis*). The patient is sick and dyspeptic, and, on account of the flow of the bile from the lobules being obstructed, the colouring matter is absorbed, and he becomes jaundiced. If the irritation be still continued, hypertrophy of the fibrous tissue results, and the subsequent contraction of this tissue entails compression of the lobules and a puckering of the hepatic capsule, rendering the surface nodular. Thus the liver becomes contracted, hard, and fibrous, its surface growing rough and irregular. This is the *gin-drinker's*, or *hob-nailed liver*; it is hard and fibrous, and its surface rough or tuberculated. (For the anatomy of the symptoms see p. 337.)

The substance of the liver consists of polygonal lobules—the size of millet-seeds—which are composed of closely-packed hepatic cells. The lobules are separated from one another chiefly by the interlobular plexus of the vena portæ, and by lattice offshoots from Glisson's capsule; in the contraction which follows the hypertrophy of the fibrous tissue, the peripheral cells of the lobule are the first to

atrophy on account of the compression. In the centre of the lobule is the tributary of the hepatic vein (intra-lobular); between the peripheral and the central part of the lobule is an intermediate zone, in which the hepatic artery breaks up.

In disease of heart or lungs the escape of blood from the hepatic veins into the vena cava is delayed, so that the central part of the lobule, which contains the radicle of the hepatic vein, is engorged; and, on section of the tissue being made, the dark centre and the paler periphery of the lobules give the appearance known as *nutmeg-liver*. The peripheral cells are pale because they have undergone fatty degeneration; and the cells of the intermediate zone are stained yellow by the stagnant bile.

In *albuminoid* disease the cells in the median zone of the lobule—that is, in the region of the chief distribution of the capillaries of the hepatic artery—are most infiltrated. In *fatty* degeneration the peripheral cells of the lobule are earliest affected, as the fresh products of digestion which are brought up by the vena portæ first come in contact with them.

As already remarked, the liver may become greatly enlarged in heart-disease (p. 178), reaching even to the umbilicus, and this enlargement is often, as Dr. Wilks remarks, a great help to diagnosis. ‘A medical man may be called to a patient for the first time, whom he finds dropsical, with albumen in the urine, and a state of heart which, from its weakness and the sounds of bronchitis, is not at once easy to make out.’ Is it a case of cardiac or of renal disease? The former: kidney disease does not cause hepatic enlargement, but morbus cordis entails both that and bronchitis.

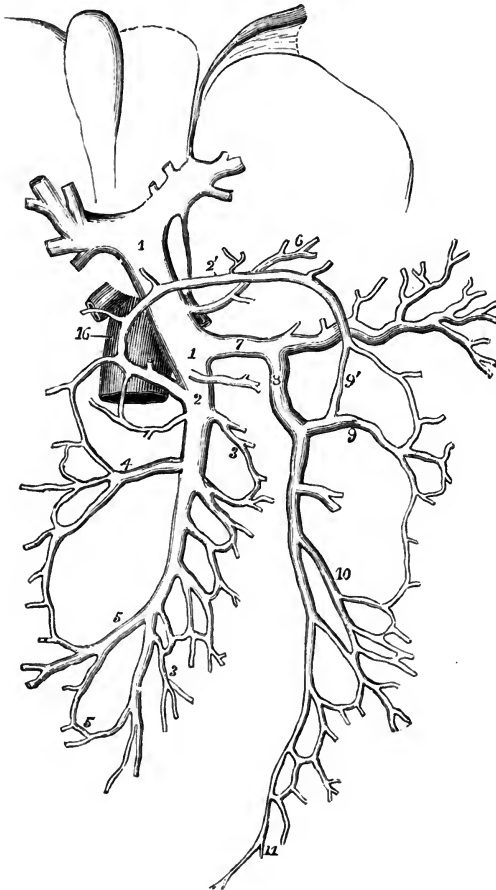
In albuminoid and fatty disease the liver may become enormously enlarged. It makes room for itself partly by pushing up the diaphragm, but chiefly by thrusting the abdominal viscera downwards and to the left, and by causing a bulging of the lower right ribs and their cartilages. When hepatic enlargement does not implicate the gland evenly throughout, as in abscess or hydatid cyst of right lobe, the encroachment is chiefly towards the thorax, as already noted.

The **portal vein** (3 or 4 in. long) is formed behind the pancreas by the confluence of the splenic and superior mesenteric veins; it also receives the venous blood from the stomach and pancreas. The inferior mesenteric opens into the splenic vein, and the vein from the gall-bladder into the portal vein. The inferior mesenteric vein communicates upon the rectum with the hæmorrhoidal plexus; thus hepatic congestion may be directly relieved by leeching the anal region.

In hepatic cirrhosis (*κίρρως*, yellowish) on section, the escape of blood from the vena portæ is retarded; the portal capillaries are engorged, and transudation of serum takes place. Thus, the lining of the stomach becomes sodden, and the patient loses appetite and becomes

dyspeptic. On getting out of bed in the morning he ejects from his irritable stomach the acid fluid which has been collecting during the night. As the disease advances he is frequently sick, and, owing to rupture of the engorged capillaries, the vomit is mixed with blood.

The destruction of the peripheral cells of the lobule is necessarily



- 1, Vena portæ, with tributaries.
- 2, Superior mesenteric.
- 3, Intestinal.
- 4, Right colic.
- 5, Ileo-colic.
- 6, Coronary.
- 7, Splenic.
- 8, Inferior mesenteric.
- 9, Left colic.
- 10, Sigmoid.
- 11, Superior hæmorrhoidal.
- 16, Inferior cava.

(From QUAIN.)

accompanied by diminution of the amount of bile, and, the muscular coat of the bowel being less stimulated, constipation results.

The effect of the engorgement of the splenic vein is that the spleen enlarges, and that the over-loaded veins of the rectum bleed and become prolapsed. The venous blood along the entire in-



testinal tract is stagnant, and water escapes into the bowel and causes diarrhœa, or into the peritoneal cavity, producing ascites (p. 316). A dropsy which begins in the peritoneal cavity is generally due to cirrhosis of liver. Hæmorrhage may occur along the alimentary canal, giving rise to black stools.

Because the blood cannot escape freely from the portal vein by the usual route, it learns to reach the general circulation by going through the veins of the abdominal wall, and through those upon the surface of the liver. In the former case a chain of dilated veins may be seen ascending from groin to chest; in the latter case the collateral route can be recognised only after death. (See the figure on p. 301.)

**Hepatitis.**—In acute inflammation of the fibrous tissue of the liver there is a tender and deep-seated fulness in the right hypochondriac region, and the patient lies upon that side, so that there may be no dragging upon the fibrous and peritoneal bands which keep the heavy gland in its place.

When the right lobe is the chief part involved, and this is usually the case, there is *pain in the top of the right shoulder*; and, the left lobe being implicated, there may be *pain at the left shoulder*. This, as shown on p. 147, is due to the fact that filaments of the phrenic nerves enter the substance of the liver; the phrenic nerve comes from the fourth, fifth, and sixth cervical nerves; the fourth gives off acromial twigs, and when the phrenic in the liver is implicated the pain is reflected by those supra-clavicular nerves.

The movements of the diaphragm distress the liver and set up a dry cough or a hiccough, and, by way of resting and protecting the inflamed gland, the abdominal muscles, and especially the right rectus, are rigid.

The figure on p. 192 shows how close the lung and the pleura are to the liver and peritoneum; and when there is pain in that neighbourhood, with a short cough and shallow breathing, it may be difficult to say promptly whether the base of the lung or the liver is inflamed. But 'the ear will tell us, if we employ auscultation and percussion, whether the contents of the chest or of the belly are suffering: and my own experience has taught me that sharp pain, with feverishness, occurring in the debatable ground of the right side, denotes pleuritic inflammation far more often than it denotes hepatic.' (Sir Thos. Watson.)

Acute hepatitis may end in **abscess**, and, the pus escaping, may set up fatal peritonitis. But more often the inflammation glues the liver to the stomach, bowel, or abdominal wall, a safe evacuation taking place. The pus may also be discharged through the diaphragm into the right pleura or into a bronchial tube, or even into the pericardium.

A frequent cause of hepatic abscess is dysenteric inflammation of the rectum, thrombi being carried through rootlets of the vena portæ,

which then lodge in the liver and become infecting foci. Sometimes it follows surgical operations upon the lower bowel, or simple ulcerations of the stomach or small intestine.

**Jaundice** is the result of the absorption of bile by the efferent vessels of the liver. The vena portæ carries up the elements of bile, and the liver prepares that fluid from them. Thus, if the bile cannot flow out into the intestine, as when a calculus blocks the hepatic or common bile-duct, or a tumour presses upon them, the intra-hepatic tension becomes so great that the blood-staining fluid has to be carried away by the branches of the hepatic veins. The student is apt to think that jaundice is always the prominent symptom of liver-diseases ; but when the bile-secreting cells are destroyed, as in certain cases of abscess and cancer, there is too little bile formed ; and if it be possible to imagine malignant disease destroying all the liver-cells, it is certain that no jaundice could occur, for no bile would be formed.

The hepatic circulation and the secretion of bile are under the influence of the pneumogastric and sympathetic filaments, and when the central nervous system is upset, not only may digestion be impaired or lost, but jaundice may occur. As an example of this, reference may be made to the brief clinical report of the lady in 'Twelfth Night,' who, concealing her too great love, pined in thought and was, in consequence, overcome by a 'green and yellow melancholy.'

The **arterial supply** is chiefly from the hepatic division of the cœliac axis, whose branches pass with ramifications of the portal vein, hepatic duct, and Glisson's capsule between the lobules. A small quantity of blood also comes from the right phrenic.

The blood brought by the vena portæ and by the hepatic artery is conveyed into the vena cava by the hepatic veins ; the descent of the diaphragm at each inspiration compresses the liver and helps to empty these capacious and valveless veins.

Of the *lymphatics*, some pass out by the transverse fissure to glands between the layers of lesser omentum, whilst the superficial ones join the anterior and posterior mediastinal glands.

The *nerves* are sympathetic filaments from the solar plexus, and twigs of the pneumogastric and phrenic nerves. The pain in the shoulder in hepatic congestion has been explained on p. 339.

The **gall-bladder** is pear-shaped ; its larger end reaches to the sharp edge of the right lobe of the liver, just behind the *ninth costal cartilage*. Its upper surface adheres to the liver ; the under surface is covered by peritoneum, and overhangs the pylorus or the beginning of the duodenum, and the hepatic flexure of colon. The stalk of the pear extends upwards and backwards to the transverse fissure, where it joins the common hepatic duct to form the common bile-duct, which opens with the pancreatic duct into the second piece of the duodenum. When a gall-stone blocks the cystic, or the common bile-duct, the gall-bladder becomes distended, and may form a

tumour in the right hypochondrium—near the ninth cartilage. It may readily be reached through the upper part of the left linea semilunaris, fixed to the abdominal wound, and drained, the obstruction being removed *secundum artem*.

A distended gall-bladder may open spontaneously into the stomach, duodenum, or colon, or through the abdominal wall.

By persistent kneading, Dr. Harley has successfully dislodged gall-stones which had blocked the duct. If by such artificial help the torpid gall-bladder could be made to empty itself every day, there would be little chance for the formation of concretions. When the duct is blocked the gall-bladder is full, and its contents may be made, by kneading, to play a useful part in dilating the duct and pushing the concretion onward.

#### THE SPLEEN

The spleen (8 oz.) lies between the cardiac end of the stomach and the ninth, tenth, and eleventh ribs, from which it is separated by the arch of the diaphragm, a wedge of lung intervening between the diaphragm and the ribs. It is placed in the interval between lines which continue the anterior and posterior folds of the left axilla, its long axis corresponding with the length of the ribs. The tip of the spleen lies beneath the apex of the eleventh rib; its anterior border is generally notched.

The external surface is convex. The inner surface is concave, and is secured to the stomach by the gastro-splenic omentum, between the layers of which the vessels pass to the hilum of the spleen, and the vasa brevia to the stomach. The hilum is one-third nearer to the posterior border than the anterior; the inner surface behind the hilum is in relation with the tail of the pancreas, the kidney and its capsule; that in front with the convex surface of the stomach. Behind and above is the diaphragm, and behind and below are the kidney and its capsule, and in front and below is the splenic flexure of the colon.

Placed thus between the base of the lung, the stomach, and the transverse and descending colon, the *area of normal dulness of the spleen* varies according to circumstances, and in pneumo-thorax or emphysema it may altogether disappear. When the left pleura is full of fluid the spleen may descend considerably below the ribs. On the other hand, when it is greatly enlarged it raises the heart and left lung, and causes palpitation, coughing, and shortness of breath; it may extend also to the linea alba, and to the pelvic brim. Its identity may be established by the characteristic notch in its front edge; its outline is not obscured by intestines floating in front of it, as is the case with the kidney. Moreover, a suppurating or enlarged kidney hides in the loin; it does not encroach anteriorly as the spleen does. Unless enlarged, the spleen cannot be felt by the fingers on the surface of the abdomen, but by hooking them round the lowest

ribs, and making the patient take a deep breath, it may be often felt in the child, especially if he be thin; in the adult the healthy spleen does not descend below the ribs, even on the deepest inspiration. The spleen is temporarily enlarged during digestion, and permanently so in cirrhosis of the liver (p. 337), in intermittent fevers, and in albuminoid disease; in ague it may form an enormous mass, 'ague-cake,' which may weigh as much as 20 lbs. The enlargement may be diagnosed from an ovarian tumour by its shape, and by the presence of the notch, which may generally be made out.

Beneath the peritoneum is the fibrous coat, which sends trabeculae into the interior to support the spleen-pulp.

The *splenic artery* is a large and tortuous trunk which reaches the hilum by passing along the upper border of the pancreas, giving branches to the pancreas and stomach in its course.

The *vein* runs close behind the pancreas to enter the vena portæ, receiving in its course gastric and pancreatic branches, and the inferior mesenteric vein. The lymphatics pass to glands in the hilum, and eventually to the thoracic duct.

The *nerves* are derived from the solar plexus, and from the right pneumogastric. The spleen is rich as regards its blood-vessels, but poor as regards nerves.

Occasionally the spleen breaks from its moorings, and, dragging its vessels and nerves, drifts towards the pelvis, causing so much discomfort as to demand extirpation. This may be effected through the left semilunar line. From buffer-accidents, and other injuries to the abdomen, the spleen may be ruptured and fatal hæmorrhage or peritonitis supervene, with, perhaps, no bruising of the surface of the body. When the lower ribs of the left side are heavily struck their broken ends may be driven through the diaphragm and into the spleen.

#### THE PANCREAS

The **pancreas** (3 or 4 oz.) (*παν κρεας*, *all flesh*) extends from the epigastric into the left hypochondriac region, crossing the aorta and the crura of the diaphragm at the level of the first and second lumbar vertebræ. The superior mesenteric vessels, splenic vein, and the beginning of the vena portæ are also posterior to it.

Lying behind the peritoneum, the pancreas may be reached by raising the great omentum and transverse colon and tearing through the lower layer of the transverse meso-colon, which descends to form the mesentery. Its head fits into the horse-shoe curve of the duodenum, the pancreatico-duodenal artery intervening between them in front, and the common bile-duct behind.

The body of the pancreas lies behind the stomach; its tail reaches the hilum of the spleen, and lies in front of the left kidney and capsule. Above are the celiac axis and the splenic artery.

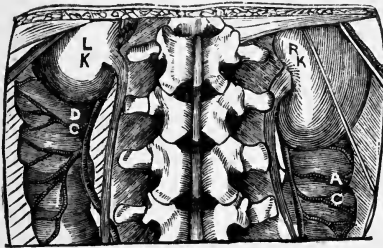
The duct leaves the substance of the gland at its head, and joins with the common bile-duct to open into the duodenum.

The *arteries* come from the splenic, and from the pancreatico-duodenal loop of the hepatic and superior mesenteric. Its *venous blood* enters the portal circulation. The *nerves* come from the cœliac plexus of the sympathetic.

In enlargement of the pancreas, especially if the patient be thin, the pulsations of the aorta are distinctly conveyed to the surface of the body in the epigastric region.

### THE KIDNEYS

The kidneys (each 5 oz.) are not quite on the same level, the right being depressed half an inch by the intervention of the liver between it and the diaphragm. On the under surface of the right lobe of the liver there is a depression for the kidney and supra-renal capsule. The kidneys lie against the outer border of the psoas, behind the peritoneum, in a bed of loose connective tissue and fat, and they rest upon the slope of the diaphragm, the twelfth rib, and the quadratus lumborum. Thus, they are about on a level with the last dorsal and the first and second lumbar vertebræ. (*See illustrations on pp. 164 and 333.*)



Kidneys, ureters, ascending and descending colon, from behind. (HOLDEN.)

In front of the right kidney are the descending piece of duodenum and ascending colon; the descending colon lying on the front of the left. The tail of the pancreas may also just touch the front of the left kidney above, whilst the great end of the stomach is in anterior relationship with it; the spleen is above and to the outer side.

A horizontal line through the umbilicus passes just below the normal kidneys, and a line drawn upwards from the middle of Poupart's ligament parallel to the linea alba runs nearly through the middle of each. On the posterior surface of the body their situation can be marked a little way from the spinous processes, from just above the last rib nearly to the iliac crest, the right being a little lower, and the notch of each being directed towards the spine. Renal abscess and calculi may escape through the loin.

Fissures and indentations of the surface of the kidney are often

found in young children, and occasionally in adults; they indicate the development of the gland in lobules, which remain through life distinct from each other, separated by fibrous tissue. Sometimes the kidneys are united by their lower ends across the aorta and vena cava, forming a *horse-shoe kidney*.

The *relative position of some of the chief abdominal viscera* may be remembered by such a system as this:—The stomach lies across the middle line and is prolonged into the right hypochondriac region, being continued on by the horse-shoe curve of the duodenum; the head of the pancreas fills in this duodenal curve, its body extending to the left, behind the stomach; its tail lies on the front of the upper part of the left kidney, and touches the concave surface of the spleen, into which the convex end of the stomach is fitting. As the tail of the pancreas passes in front of the top of the kidney to reach the spleen, the kidney must lie to the inner side of the spleen, and behind the stomach.

The peritoneum touches the front of the kidney, but does not give it an investment. A *movable kidney* is one which, on account of the looseness of its connection, can shift its position behind the peritoneum. A *floating kidney* has a complete serous investment, and swings about in the general peritoneal cavity at the end of a meso-nephron, tethered only by its blood-vessels. Its movements vary with the position of the subject, and also with respiration, and are often accompanied with unpleasant sensations and even pain. Tight-lacing, and the disturbance of the abdominal walls and viscera associated with pregnancy, render floating kidneys more common in women than men.

The removal of the kidney without wounding the peritoneum is, as far as concerns the anatomy of the parts, so like Amussat's operation (p. 331) that it is unnecessary here to describe it. The incision is made nearer to the last rib than in colotomy, but, as the pleura sometimes descends below the level of the twelfth rib, the knife must be used very carefully. When the kidney is loosened from its bed the vessels and ureter are ligated and divided, and the gland is taken out.

If the diseased kidney seemed to be too large to come readily through the space between the last rib and the iliac crest, it would be better to remove it through the corresponding *linea semilunaris*. In that case the peritoneal cavity would be opened and the intestines drawn aside, the peritoneum being traversed posteriorly on the *outer* side of the colon, so as not to risk interference with the vessels passing to and from the colon.

The fibrous capsule is a tough, thin layer which sends numberless filamentous processes throughout the interior of the gland; their peripheral attachment is noticed when the capsule is being stripped off.

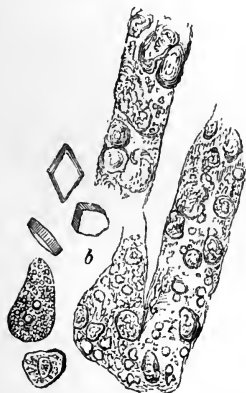The *hilum* leads into a cavity called the sinus of the kidney, into which the dilated end—*pelvis*—of the ureter opens. The *pelvis* of the ureter gives off three short primary divisions—*infundibula*—and these

quickly expand into calyces which, embracing the tops of the pyramids, collect the urine. (For *ureter*, see p. 349.)

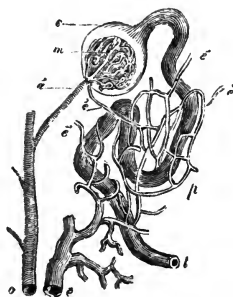
The function of the kidney is to get rid of the excess of water, with, of course, certain excrementitious substances in solution; it is thus closely associated with the skin, with the mucous membrane of the bowel, and to a certain extent with the lungs. When the diseased kidney demands rest the skin and the bowels should be set to work by diaphoretics and purgatives.

When a patient with acute intestinal obstruction is constantly vomiting there is little or no fluid for the kidney to drain off, and suppression of urine is noted; and when a man is perspiring profusely, or is racked with diarrhoea or cholera, he passes hardly any urine. That which comes away in such cases is laden with excrementitious materials and is consequently of high specific gravity.

**Structure.**—The *cortical part* consists of branching and coiled tubules, and of ramifications of blood-vessels, in which the bases of the twelve or twenty pyramids of the *medullary part* are received. These pyramids consist of parallel bundles of uriniferous tubules, and are partially separated from one another by offshoots of the cortical part, through which the blood-vessels pass outwards from the hilum.



Fibrinous mould of tube entangling epithelial and blood cells, with, *b*, three crystals of lithic acid in a case of acute desquamative nephritis. (JOHNSON.)



*a, a'*, br. of renal artery; *c*, Malpighian capsule; *e, e'*, efferent vessel ending in plexus, *f*, on tubule.

A *uriniferous tubule* begins in the cortex in a dilatation like a Florence flask (Malpighian capsule), in which a branch of artery and vein form a tuft (*glomerulus*), from which the watery part of the urine transudes, to escape at last by the apex of the pyramid (papilla) into the sinus of the ureter. The tubule has a continuous epithelial lining. Blood in the urine may be due to rupture of the engorged vascular

tufts. The vein, after emerging from the capsule, breaks up into a plexus upon the tubule, and under the influence of the epithelial lining of the tube rids itself of the solids of the urine in solution. In *desquamative nephritis* the epithelium is stripped off, leaving the interior of the tubes naked; then the urine is comparatively destitute of salts, and is of low specific gravity. If the glomeruli remain, however, there is still plenty of urine poured out, though of low specific gravity. In certain cases fibrinous moulds or *casts* are found in the urine with epithelial wreckage incorporated with them.

From those tubes whose epithelial lining has already been shed the casts are large and clear (as seen in microscopic examination of the urine), but in other casts epithelial cells and blood-corpuscles are imbedded. The large casts are of bad augury; they show that the tubes are stripped and valueless, and that the patient is in danger of non-elimination of the urine-salts.

**Congestion.**—It has been shown experimentally that ligation of the renal vein causes the escape of albuminous fluid from the congested renal vessels. Similarly, albumen or blood appears in the urine in inflammation of the kidneys, or in the more mechanical obstruction caused by the pressure of a gravid uterus, an aneurysm, or other tumour upon the vena cava or renal vein. Congestion may also be due to delayed circulation through the lung or the heart; and, as congestion is a preparatory stage to inflammation, so phthisis and emphysema, mitral and aortic disease, are common precursors of nephritis. Long continuance of congestion of the kidney begets thickening of the inter-tubular fibrous tissue, just as happens also in the case of liver-congestion; subsequently the tissue undergoes atrophy and the *cirrhotic* or *contracted kidney* is produced.

Congestion may be relieved by venesection or by cupping over the loins; in the latter case through the direct anastomosis between branches of the lumbar and renal vessels (p. 309).

In **Bright's disease** the kidney may be increased or diminished in size, the cortical part of the gland being chiefly affected. In one case the bases of the pyramids are thickly covered with cortex, in the other they approach very near to the surface of the gland. The large kidneys may together weigh twelve ounces, and the small ones but two; the former might in due course have contracted into small cirrhotic glands.

If the inflammation be acute, the renal capillaries, and especially the Malpighian tufts, are engorged, and in places even bursting, some of the tubules being choked with blood and abundant epithelial cells, whilst others are blocked with fibrinous moulds or 'casts.'

**Contracted kidney.**—As the result of inflammation of the kidney there is hypertrophy of the connective tissue pervading the gland; then atrophy supervenes (see cirrhosis of liver, p. 336) and, the tubules being compressed, disarranged, and strangled, the gland dwindles



into a small cicatricial mass. The fibrous capsule is so firmly incorporated with the thickened trabeculae of the interior of the gland that at the post-mortem examination it cannot be stripped off.

In the early days of cirrhosis the new fibrous element of the kidney is soft and vascular, but its subsequent contraction is only a matter of time; and during its progress, by pulling irregularly upon different parts of the kidney, it throws the histological arrangement into complete disorder, and, obliterating certain tubes, causes retention of their secretion and a wide-spread cystic degeneration.

**Renal dropsy.**—When the kidneys are or have been inflamed, their function, which is the excretion of urine, is necessarily impaired, and the vessels generally, and the capillaries in particular, are over-full. But from over-filled capillaries a certain amount of exudation is sure to occur, and the result is that in renal disease serous transudation takes place into the lymph-spaces and into the connective tissues generally. Thus, the eyelids and scrotum swell, the feet and ankles become 'puffy,' and the legs pit on pressure; the lungs become water-logged, and dropsical effusions fill the pleura, pericardium, or peritoneum. Pulmonary œdema is a very common and serious complication of kidney disease; so also is cerebral anasarca.

Because the feet are the lowest parts as the man walks or stands, the œdema first appears there. After the night's rest in bed the feet may resume their normal size, the fluid being absorbed and deposited, perhaps, in the face, which then becomes 'bloated.' But, after the patient has been up and about, the face improves again and the feet in turn are enlarged. The serum actually trickles down through the loose tissue, so that, as Watson remarks, a tight waistband may prevent the descent of the fluid and keep the upper part of the body alone œdematous, whilst if the patient lies constantly on one side that side only is infiltrated. Dropsy of the submucous tissue of the air-passages is frequently a cause of death.

Free purgation is often useful in the case of dropsy, as it diminishes the amount of fluid in the vessels and so encourages them to soak up and utilise the extravasated serum.

Dropsy from liver-disease appears first as abdominal ascites, whilst that from heart disease generally begins as anasarca in the legs. It is quite impossible to draw a hard-and-fast line, however, between these conditions. Indeed, kidney disease and heart disease often go hand in hand, as it were; for valvular disease of the heart begets venous congestion of the kidney, which is a common cause of nephritis. Thus the kidneys, being diseased, cannot work properly, so that impure blood is being circulated, and the capillaries throughout the body struggle to resist its passage through them, their muscular and fibrous walls becoming thickened. To overcome this resistance the left ventricle works with extra energy, and its walls increase in strength in consequence, just as a blacksmith's biceps grows by exercise. As a

part of this vascular change, the arteries lose their elasticity, and one day, as the vigorous ventricle is straining to force some unusually impure blood through the resisting capillaries, a vessel gives way, perhaps in the brain, and the patient is attacked with apoplexy.

The effect of the impure blood upon the lungs is to cause cough, bronchitis, and pneumonia; upon the stomach, to cause dyspepsia, loss of appetite, and vomiting; upon the bowel, to set up diarrhoea; and upon the brain, to give rise to headache, convulsions, and coma.

Occasionally the uriniferous tubules become distended in numberless spots by limpid urine, producing general *cystic degeneration* of the gland. As a tubule bulges, the vascular tissue and the neighbouring tubules disappear from pressure, the pyramids being first pressed upon and wasted.

There is much truth in the saying that a man is as old as his kidneys.

The practitioner should make it his rule to *examine the urine of every patient* with obscure illness; when it contains albumen or casts he may expect to find the pulse hard and resisting, the temporal arteries mobile and tortuous, the impulse of the heart increased, and its apex-beat displaced outside the normal line. The kidneys of such a patient should be rested to the utmost, by placing him upon a diet without alcohol and poor in nitrogenous foods; the bowels and skin should be encouraged to eliminate by purgings and sweatings, and he should be specially careful to avoid chills and violent exercise.

The kidney may be ruptured from a blow on the loin, blood escaping into the surrounding tissues, and also into the ureter, where it is well mixed with the urine. If a clot be carried into and plug the ureter, urine may collect above it. (For Surgical Kidney see p. 410.)

**Hydronephrosis.**—If from congenital malformation of ureter, bladder, or urethra, pressure of a tumour, clot, or stricture, there be serious impediment to the outflow of urine, the fluid collects in the interior of the kidney, and, by the mere effect of pressure, causes wasting of all the proper renal tissue and converts the gland into a mere water-bag.

A large and painless tumour, possibly yielding a sense of fluctuation, fills the entire lumbar region, and, on aspiration, limpid urine is withdrawn. For certain, the tumour is dull on percussion behind, but there will be resonance in front if the colon intervene between it and the anterior abdominal wall. The obstruction being overcome, an enormous quantity of pale urine is passed and the area of dulness subsides, the diaphragm descending and the coils of intestine passing outwards to resume their proper place.

The fluid of hydronephrosis does not change its position as the patient is turned; this distinguishes hydronephrosis from ascites, but not from ovarian dropsy. In ovarian disease, however, there may be some resonance in the loins, and the dulness is traceable into

the pelvis. Ovarian disease begins below, and hydro-nephrosis works downwards.

A large sarcomatous, cystic, or suppurating kidney may extend across the middle line as well as fill the flank.

(For *renal artery*, v. p. 354 ; for *renal vein*, v. p. 349.)

The *nerves* of the kidney come from the sympathetic system of the thorax (splanchnic) and of the abdomen (solar plexus). Filaments are also derived from the upper lumbar ganglia, and so the plexus becomes associated with the upper lumbar nerves. Offshoots from this network pass to the spermatic plexus.

The *lymphatics* enter the lumbar glands.

In **renal calculus** pains radiate widely on account of the extensive communications of the nerves of the kidney. Thus, they strike along the ureter to the bladder, causing frequent micturition ; and, descending in the spermatic offshoot of the renal plexus to the testis, they may so disturb its vaso-motor nerves as to set up orchitis. And, on account of the association between the renal plexus and the upper lumbar nerves through the higher lumbar ganglia, pains dart along the ilio-hypogastric and ilio-inguinal nerves (of the first lumbar nerve), and along the genito-crural (of the second) to the cremaster, so that retraction of the testis is to be looked for in renal calculus. Neuralgia may also extend along other branches of the lumbar nerves into the thigh ; and irritation through the neighbouring solar plexus may cause nausea and vomiting. The renal capillaries are bruised by the stone, and the urine becomes bloody. At the end of the ureter the stone may be for a while impacted, and by its presence it may cause obstruction of the ureter and disorganisation of the kidney. It may sometimes be felt fixed there, close to the bladder, by digital examination through the rectum. The pains which have been caused by the stone scraping along the ureter suddenly cease on its escape into the bladder.

In the case of disease of the second and third lumbar vertebræ, with inflammatory pressure upon the posterior root of the second lumbar nerve of one side, there would be dull pain in the back, which would be increased by exercise, and possibly some tenderness in the renal region, especially if abscess were forming. There would be pain referred to the testis, and, on account of the irritation of the genito-crural nerve, retraction of the testis. There might, moreover, be increased frequency of micturition. Thus it is quite possible that *lumbar caries* may be mistaken for *renal calculus*.

**Ureter.**—From the hilum the ureter emerges, sloping downwards and inwards ; it is behind the renal artery, the vein being in front of both. Though the anterior surface of the kidney is the more convex, and the upper end the larger, still the best way of *telling the right kidney from the left* is by the position of the ureter, which is posterior to the vessels and slopes downwards and inwards. It is about fifteen inches long, and, descending gently inwards, it rests upon the psoas and

genito-crural nerve, being crossed superficially by the spermatic vessels, which are inclining outwards, towards the internal abdominal ring. Coils of small intestine—especially of the ileum—lie in front of the right ureter, and the sigmoid flexure is anterior to the left. Entering the true pelvis, the ureter passes over the common iliac artery close to its division, or over the beginning of the trunks into which it divides, and, having passed into the posterior false ligament of the bladder, it enters that viscus by running obliquely through its base. The right ureter descends on the outer side of the vena cava, and, passing very near to the vermiform process, is sometimes glued to it in perityphlitis. In the male the vas deferens curls round between the side of the bladder and the ureter; in the female the ureter descends by the side of the neck of the uterus and the upper part of the vagina, and in epithelioma of the cervix uteri the ureter may be implicated and obstructed. Psoas abscess has been known to discharge through the ureter.

*Structure.*—Inside a fibrous coat are two layers of non-striated muscle, the outer of longitudinal, the inner of circular fibres; more deeply comes the mucous membrane lined with stratified epithelium.

The *blood supply* is from the vessels against which it is placed in its course, namely, renal, spermatic, internal iliac, middle and inferior vesical; so also with the veins.

The *nerves* come from the renal and the hypogastric plexus, and from the filaments about the kidney, spermatic cord and rectum, and indirectly, probably, from the lumbar plexus.

When a stone is passing down the ureter the pain may be intense, localised in part to the region of the ureter, and radiating, after the manner of renal colic, down to the bladder and penis, and even into the thigh.

The **supra-renal body** (2 drms.) is a ductless gland placed like a cocked-hat upon the top of the kidney. Above the right capsule is the liver; above the left, and external to it, is the spleen. Posterior to each is the beginning of the vault of the diaphragm. In front of the left are the tail of the pancreas and the stomach.

*Arteries* come to the capsule from the aorta (supra-renal) and from the renal, and twigs are derived also from the neighbouring diaphragmatic branches.

The right vein enters the vena cava; the other, like the spermatic, joins the left renal. The nerves come from the solar and renal plexuses; the lymphatics enter the lumbar glands.

Degeneration of the supra-renal bodies is associated with bronzing of the skin and with anæmia (Addison's disease).

#### THE ABDOMINAL AORTA

The abdominal aorta, the continuation of the thoracic, begins at the twelfth dorsal vertebra, and divides into the common iliacs at the left side of the fourth lumbar—that is, at a spot just below and to the left

of the umbilicus. Above the umbilicus the aorta may be felt pulsating, and may there be readily compressed in a thin subject

Sometimes the bifurcation is a little above, sometimes a little below, the fourth lumbar vertebra.

*Relations.*—It rests upon the four upper lumbar vertebræ, the left lumbar veins, and the beginning of the thoracic duct.

Anterior to it are the lesser omentum and stomach, pancreas and splenic vein, left renal vein, the third part of the duodenum, and the mesentery, and along its whole course is a dense interlacement of sympathetic nerves. (The left renal vein, crossing to the vena cava in front of the aorta, is the exception to the rule that above the diaphragm the large veins are in front of the large arteries, whilst below it they pass behind.)

To the right side is the vena cava; this is separated from the aorta above by the right crus, the beginning of the thoracic duct, and the large azygos vein. To the left are the left crus and the psoas, the tail of the pancreas, and the kidney.

*Aortic aneurysm.*—When injecting a subject for dissection through the aortic arch, the abdominal aorta often gives way just where the cœliac arises; there, also, aneurysm is apt to form during life. It is evidently a weak spot. When an aneurysm comes from the front of the aorta a pulsating tumour is noticed in the epigastric or in the upper part of the umbilical region; but a tumour of the pyloric end of the stomach, pancreas, or transverse colon may also give rise to this symptom, for the abdominal aorta advances far towards the anterior abdominal wall.

The aneurysm is best examined on flexing the trunk, so as to slacken the abdominal wall, and by getting the patient to expire fully so that the lower costal cartilages may sink. The bowels should previously be well opened.

Pain in the back is a sign of the aneurysm; for the sympathetic filaments along the aorta are associated with the lumbar nerves through the ganglia, and pain is reflected from these filaments to the spinal trunks, and along the posterior divisions of those nerves to the skin of the dorsi-lumbar region. A careless practitioner might satisfy himself with calling such pains 'lumbago.'

The aneurysm may, by disturbing the sympathetic plexus, produce indigestion and sickness; or, by constant pressure, may cause absorption of the bodies of the lumbar vertebræ, and may even bear upon the roots of the lumbar nerves. Pressure may also cause persistent neuralgia in the abdominal wall, testicle, groin, and thigh. The tumour may bulge against the diaphragm, œsophagus, and stomach, causing dyspnœa, dysphagia, and vomiting, and possibly a constant pain in the epigastrium. In some cases the pains are less when the patient lies upon his face, for then the tumour falls away from the nerves. The tumour may compress the transverse colon; it may thrust

forward the liver and suggest hepatic enlargement; should it impinge against the vena cava, œdema of the legs may occur; compression of a renal vein may be followed by albuminuria. Briefly, it may be said that if the tumour grow from the back of the aorta the pains are chiefly lumbar; if from the front the disturbance is chiefly visceral, and the pains are abdominal and epigastric. The aneurysm may leak into the peritoneal cavity, or behind it, forming an enormous, but pulseless, blood-tumour; or it may burst into the stomach, small intestine, or transverse colon, or, causing absorption of the diaphragm, may enter the chest.

**Ligation of the abdominal aorta** may be effected through the linea alba and the peritoneum, by separating the coils of intestine and then gently tearing through the root of the mesentery. Or the vessel may be reached without opening the peritoneum, as for ligation of the common iliac, the pouch being dragged rather further upwards. Should the patient survive, the collateral circulation would be freely established, as described on p. 369, with the additional help of the anastomosis of the lumbar arteries given off below the ligature with those above, and of the inferior mesenteric (should the ligature be placed above that vessel) with the superior mesenteric.

**Branches.**—The *phrenics* ascend obliquely over the front of the crura to the vault of the diaphragm, where they anastomose with the internal mammary and intercostal branches. The right phrenic also gives twigs to the liver.

The *celiac axis* arises opposite the top of the first lumbar vertebra, which would place it about four inches above the umbilicus, and just above the pancreas; it has a semilunar ganglion on either side. It divides into gastric, hepatic, and splenic trunks, of which, in the child, the hepatic is the largest, but, as the proportionate size of the liver decreases, the splenic becomes the largest.

The *gastric* (coronary) runs to the left end of the stomach, where it gives branches to the œsophagus, and then doubles on itself to descend in the lesser omentum to the pylorus, where it anastomoses with the hepatic; at the great end of the stomach it anastomoses with the splenic.

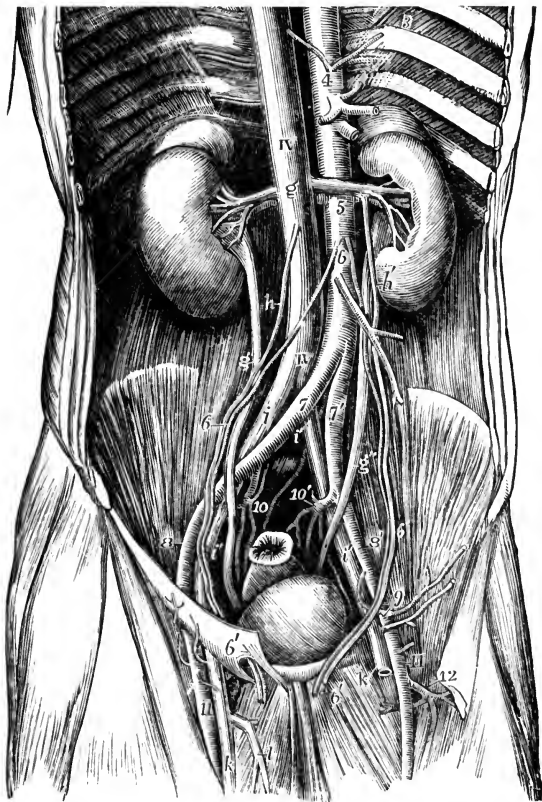
The *hepatic* hooks forwards and upwards to reach the portal fissure; in its ascent in the lesser omentum it has the bile-duct to the right and the vena portæ behind. It divides into a right and left trunk, the branches of which enter the lobes together with investments of Glisson's capsule. The right branch gives a twig to the gall-bladder. The branches of the hepatic are the pyloric to the lesser curvature of the stomach, to anastomose with the gastric; and the gastro-duodenal, which, descending behind the first part of the duodenum, divides into right gastro-epiploic (which joins on the great curvature with the branch from the splenic), and the superior pancreatico-duodenal, which winds round the head of the pancreas. This last-named

branch may be implicated in ulceration of the duodenum following severe burn (p. 325).

The *splenic* runs along the upper border of the pancreas, behind the stomach, and breaks up into several short trunks for the hilum of the spleen and the great end of the stomach (*vasa brevia*). In its course the splenic gives off the *pancreaticæ parvæ* and a *pancreatica magna*, and a large vessel, the *gastro-epiploica sinistra*, which runs in the root

- 4, Abdominal aorta.
  - IV, Inferior cava.
  - g, renal veins.
  - g', g'', ureters.
  - h, h', spermatic veins.
  - i, com. iliac vein.
  - k, com. fem. vein.
  - l, int. saphenous.
  - 5, renal arteries.
  - 6, 6' spermatics.
  - 7, 7' com. iliacs.
  - 8, ext. iliac.
  - 9, deep circumflexa ilii.
  - 10, internal iliacs.
  - 12, deep femoral.
- (A. THOMSON.)

N.B. — All the large veins—except the left renal—are posterior to the arteries.



of the great omentum, to meet the gastro-epiploic branch of the hepatic along the greater curvature of the stomach.

The *superior mesenteric* comes off close below the *cœliac axis*, just behind the pancreas and splenic vein, and emerges between the pancreas and transverse duodenum. It gives off from its right side the *inferior pancreatico-duodenal* branch; and, passing between the layers

of the mesentery, it reaches the right iliac fossa, where it gives a branch to the end of ileum and the beginning of colon, the ileo-colic. The superior mesenteric has a slight convexity to the left, and from this side are given off twelve or fifteen vasa intestini tenuis, which, by dividing and anastomosing, form a series of arches, three or four deep, from which twigs enter the wall of the jejunum and ileum. The highest of the vasa anastomoses with the pancreatico-duodenal loop, the lowest with the ileo-colic. The upper branch of the ileo-colic anastomoses with colica dextra, which comes from the right side of the superior mesenteric to supply the ascending colon. Higher up comes off the colica media, for the transverse colon; it anastomoses with the colica dextra, and with the colica sinistra on the descending colon. The colica dextra lies behind the peritoneum; the colica media runs between the two layers of the transverse meso-colon.

The *supra-renals* anastomose in the supra-renal capsule with branches of the phrenic and renal arteries.

The *renals* arise just below the superior mesenteric, the right being rather longer and higher than the left. Before entering the hilum they give off twigs to the supra-renal capsule and ureter, and to the bed of the kidney. The renal artery lies behind the vein, and in front of the ureter, the right renal passing behind the vena cava. The artery may be given off in several branches, and supplemental renals are sometimes derived from a mesenteric or iliac trunk.

As the testis or ovary was developed just below the kidney, so the *spermatic* or *ovarian* artery arises close below the renal. It is a slender vessel which descends behind the peritoneum obliquely over the psoas and ureter, the right lying also over the vena cava. In the female the artery passes inwards between the layers of the broad ligament to supply the ovary, and it gives off branches to the uterus, Fallopian tube, and round ligament. By the last-named structure some twigs of the ovarian artery may eventually reach the labium. In the male the artery emerges with the other constituents of the spermatic cord, and may anastomose with the artery of the vas and with the cremasteric branch of the deep epigastric.

The *inferior mesenteric* is given off within a couple of inches of the bifurcation of the aorta, that is, rather more than an inch above the umbilicus; it passes over the left common iliac vessels to the upper part of the rectum, down either side of which it sends a large branch, the *superior hæmorrhoidal*. Branches from these hæmorrhoidals pierce the muscular coat, and anastomose with the rectal twigs of the internal iliac and internal pudic arteries. The inferior mesenteric gives off the colica sinistra, which anastomoses on the descending colon with the colica media above, and with the arteria sigmoidea below. The colica sinistra lies behind the peritoneum, and in removing the kidney through the peritoneum the gland should be reached from the outer side of the descending colon, so that the colica sinistra



may be avoided. The arteria sigmoidea, from the inferior mesenteric, communicates with the colica sinistra above and with the superior hæmorrhoidal below.

The *lumbar* arteries, four on each side, run outwards, like the intercostal arteries. They pass beneath the psoas and behind the quadratus lumborum, and then between the inner oblique and the transverse muscles. They anastomose with branches of the internal mammary, deep epigastric, lower intercostal, ilio-lumbar, and deep circumflex iliac arteries. They also give branches (spinal) along the lumbar nerves, which supply the cauda equina, spinal cord, and the vertebral periosteum; and a branch (dorsal) which runs back between the transverse processes for the erector spinæ, and for the integument of the loin.

The *middle sacral* passes from the bifurcation of the aorta down the middle of the fifth lumbar vertebra, and the sacrum and coccyx; it gives branches to the anterior sacral foramina and to the rectum, which latter anastomose with other hæmorrhoidal arteries. On either side the sacra media anastomose with the lateral sacral branches, and at the tip of the coccyx it supplies Luschka's gland.

The coccygeal, or **Luschka's gland**, at the tip of the coccyx, is a pisiform tuft of small vessels derived from the ending of the sacra media. It is surrounded by granular cells, and by a fibrous coat which sends fine processes into the interior. Nerve-filaments enter it from the ends of the neighbouring sympathetic chains. The gland is of surgical importance in that it may be the starting point of certain coccygeal, sacral, and pelvic tumours of infant life.

#### THE INFERIOR VENA CAVA

The inferior vena cava begins at the right side of the fifth lumbar vertebra by the confluence of the common iliac veins. It ascends upon the right side of the aorta, being separated from it above by the right crus; it deeply notches the back of the liver (where it receives the hepatic veins), and, passing between the right and central leaflets of the phrenic tendon, opens at once into the right auricle. The right renal and lumbar arteries cross between it and the vertebræ. In front of it are coils of small intestine and mesentery; the right spermatic artery; transverse duodenum, pancreas, portal vein, and right lobe of liver. To the right side are the kidney, ureter, psoas, and ascending colon.

Its *tributaries* are the *lumbar*, which closely correspond in distribution with the lumbar arteries. The left lumbar veins are the longer, as they have to pass beneath the aorta. The upper lumbar veins communicate with a vena azygos.

The *right spermatic* and *supra-renal* and *lower phrenic veins* end

in the vena cava ; the corresponding vessels of the left side pass into the left renal vein.

The *ovarian* veins communicate freely with the uterine veins in the broad ligament ; they end like the spermatic veins.

The *renal* veins begin at the hilum of the kidney and pass inwards in front of the renal artery. The left vein is the longer ; it crosses in front of the aorta, and receives the inferior phrenic, supra-renal, and the spermatic or ovarian of the left side.

The *hepatic* veins return to the vena cava, by three or four large trunks, the blood which was brought to the liver by the portal vein and the hepatic artery. They enter the vena cava where it lies in the notch at the back of the liver, between the layers of the coronary ligament, and close below the diaphragm.

The descent of the diaphragm in inspiration, and especially so during active exercise, compresses the liver and gently squeezes the blood from its sluggish veins. (For portal system *see* p. 337.)

#### THE LUMBAR NERVES

The lumbar nerves break, like the other spinal nerves, into an anterior and a posterior division ; the posterior passes between the transverse processes and gives off an internal and an external branch. The *internal branch* is small, and ends in the erector spinæ ; the *external branch* also supplies the erector, but the three upper branches give, in addition, cutaneous twigs for the loin and buttock.

The **lumbar plexus** is formed by a descending (*dorsi-lumbar*) branch from the twelfth dorsal nerve, and by the anterior divisions of the first, second, and third lumbar nerves, and by most of that of the fourth. It is lodged in the hinder part of the psoas, and is thus anterior to the quadratus lumborum. The root-fibres for its nerves emerge from the lumbar enlargement of the cord.

In addition to a communicating twig to the second, the anterior division of the first lumbar nerve gives off the **ilio-hypogastric** and **ilio-inguinal** branches, both of which pass outwards below the anterior division of the last dorsal nerve, in front of the quadratus lumborum, and then through the transversalis and into the interval between that muscle and the internal oblique.

The ilio-hypogastric gives a branch through the oblique muscles which passes over the iliac crest, to the skin of the buttock, and another through the oblique muscles to the skin in the hypogastric region.

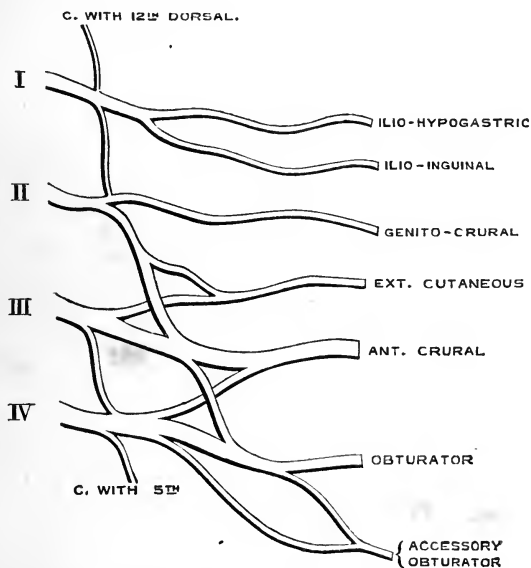
The ilio-inguinal escapes through the external abdominal ring and splits into a branch for scrotum or labium, and one for the skin over the upper and inner part of Scarpa's triangle. In their course the divisions of the first lumbar nerves supply the oblique muscles.

The first lumbar nerve lies below the first lumbar vertebra, and in

caries of that bone inflammatory pressure upon the posterior root of the nerve is manifested by definite peripheral neuralgias—the patient complaining of pains in the front of the belly, in each groin, or over the hips.

The second nerve sends down a branch to the third, and divides into the genito-crural and the external cutaneous, each of which, doubtless, derives a few filaments from the descending branch of the first.

The **genito-crural** descends on the front of the psoas, and breaks into a genital and a crural division. The *genital branch* passes down upon the external iliac artery, and eventually leaves the abdomen through the inguinal canal, ending in the supply of the cremaster, or over the round ligament. ‘Retraction of the testis’ (p. 349) is effected through the influence of this nerve. The *crural branch* passes beneath Poupart’s ligament and through the front of the crural sheath and the fascia lata, and supplies the skin over the outer part of Scarpa’s triangle.



The **external cutaneous** comes through the outer side of the psoas, creeps beneath the iliac fascia, and emerges from the pelvis below the outer end of Poupart’s ligament. Then, slowly piercing the fascia lata, it gives cutaneous branches to the buttock and to the outer aspect of the thigh as low as the knee.

The third and fourth nerves, with the twig from the second, combine to give off the anterior crural and the obturator,

The **anterior crural** nerve emerges from the outer side of the psoas, beneath the iliac fascia, and lies between the psoas and iliacus, both of which it supplies. Having passed beneath Poupart's ligament, and beneath the outer part of the crural sheath, it divides, in the upper part of Scarpa's triangle, into cutaneous and muscular branches.

The first-named *branches* are : the *middle cutaneous*, which pierce the sartorius to end in the front of the thigh ; the *internal cutaneous*, which cross the front of the superficial femoral artery for the inner side of the thigh and even the upper part of the leg. Filaments of the internal cutaneous nerve, beneath the fascia lata, join the middle cutaneous and the internal saphenous nerve in the formation of the patellar plexus.

The largest of the cutaneous branches of the anterior crural nerve is the *internal saphenous*, which crosses the artery obliquely from the outer side and lies in front of it in Hunter's canal, but, though in the canal, it is not within the proper sheath of the vessels. It leaves the canal with the superficial part of the anastomotica magna, and, coursing behind the sartorius to the knee, it pierces the fascia lata to lie by the internal saphenous vein ; it ends at the ball of the great toe. It gives branches to the obturator and patellar plexus and to the inner side of the leg and foot.

*Muscular branches.*—In addition to those given off in the false pelvis to the psoas and iliacus, the anterior crural sends a branch beneath the crural sheath to the pectineus ; to the rectus, which gives a twig to the hip-joint ; to the vastus externus, which reaches the interior of the knee-joint ; to the crureus and sub-crureus (which, also, may supply the knee-joint) ; and a large branch to the vastus internus, which journeys with, but to the outer side of, the long saphenous nerve. The sartorius may receive branches from the anterior crural as well as from the middle cutaneous.

*Neuralgia of the anterior crural* may be due to central disease of the cord, as in locomotor ataxy ; to pressure upon the posterior roots as they leave the spinal canal, as in the case of spinal tumour, meningitis, or lumbar caries ; to inflammation of, or abscess in, the psoas ; to the pressure of enlarged lumbar glands, or of iliac aneurysm ; to inflammatory thickening of the fibrous elements of the nerve, or to reflected irritation, as in the case of hip-joint disease.

The strange way in which the ultimate branches of a nerve may be distressed in the case of central pressure was well exemplified in a child with spinal caries, whose chief symptom seemed to be symmetrical darting pains at the ball of each great toe—at the endings of the internal saphenous nerves.

The **obturator** nerve descends along the inner border of the psoas, and through the fork of the external and internal iliac arteries, and out by the upper part of the thyroid foramen, above the obturator artery. It divides into a superficial and a deep branch.

The *superficial division* passes down in front of the adductor brevis

(behind the pectineus and adductor longus) and ends in the obturator plexus, though it sometimes wanders thence to the skin on the inner side of the upper part of the leg. In its course it gives a branch to the hip-joint, and branches to the adductors longus and brevis, the gracilis, and the pectineus. Its articular branch enters through the cotyloid notch and is chiefly distributed to the ligamentum teres.

At the lower border of the adductor longus, beneath the sartorius, the superficial part of the obturator nerve joins with branches of the internal cutaneous and of the internal saphenous to form the *obturator plexus*.

The *deep division* of the obturator nerve enters the thigh through the substance of the obturator externus, which it supplies, and descends behind the adductor brevis and in front of magnus, supplying both those muscles. It then passes through the large adductor into the upper part of the popliteal space, and, after resting upon the popliteal artery, enters the knee-joint, probably in company with the central articular artery.

Peripheral neuralgias are apt to disturb the obturator nerve in disease of the hip, sacro-iliac, and mid-lumbar joints. Pain in the knee, or the thigh over the region of the obturator plexus, is one of the most usual and early symptoms of hip-disease. I cannot explain the cause of this, but must content myself with calling attention to the fact that the superficial division sends a twig to the ligamentum teres, and that the deep division ends in the knee-joint. Analogous instances of the transference of neuralgia are : pain at the end of penis, symptomatic of vesical calculus, and at the point of the shoulder, of aortic disease or of hepatic disease. The fact of the obturator nerve supplying also the sacro-iliac joint (Hilton) accounts for the pain about the knee in disease of that synchondrosis. The weariness and aching of the thighs and knees in lumbar caries is readily explained by the effect of inflammatory pressure not only upon the obturator nerve but upon other branches of the plexus situated in the diseased region of the spine. The great feature in these pains is the symmetry of their arrangement. The child complains of both thighs or knees aching. When, after rest, the pains cease to be symmetrical, and are confined to or chiefly felt upon one side, the formation of abscess in the sheath of the psoas must be suspected.

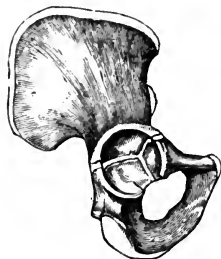The **accessory obturator**, an occasional branch of the third and fourth nerves, runs along the inner border of the psoas, and out of the pelvis over the horizontal ramus of the pubes and beneath the pectineus which it supplies. It also gives a twig to the hip-joint, and then merges its filaments with those of the superficial part of the obturator nerve.

The *anterior division of the fifth lumbar nerve* emerges below the fifth lumbar vertebra, and is at once joined by a branch from the fourth. The nerve thus formed is called the **lumbo-sacral cord** ; it descends from the inner border of the psoas beneath the common iliac vessels, and joins in the formation of the sacral plexus ; many of its strands, however, pass out into the superior gluteal nerve.

## PART V

## THE PELVIS

The **innominate bone** has *three primary centres* of ossification : for ilium at third month of foetal life, ischium at fourth, and pubes at fifth. During childhood these segments are joined in the acetabulum by a Y-shaped cartilage, which, becoming softened and disintegrated in hip-joint disease, readily allows pus to work through into the pelvis.



Five *secondary centres* appear at puberty : in the Y-shaped cartilage (so that the three parts of the bone are soon after fused together) ; in the iliac crest, which, as a cartilaginous rim, is sometimes detached by violence ; in the anterior inferior iliac spine, which may be torn off by energetic contraction of the rectus femoris, or by direct violence ; in the ischial tuberosity, and at the pubic symphysis. The bone is welded into a solid mass at about the twenty-fifth year.

**Weaver's bursa.**—The ischial tuberosity is separated from the gluteus maximus by a large bursa, and in those who sit much, as weavers, tailors, and coachmen, the sac may become inflamed, and may suppurate.

The **sacro-iliac joint** is formed by the auricular surfaces of the sacrum and ilium, each of which is covered with a layer of cartilage. The anterior sacro-iliac ligament is thin, the posterior is thick and strong, and, in addition, contains a large amount of interosseous fibres. The joint is supplied by branches of the gluteal and ilio-lumbar arteries, and by nerves from the superior gluteal, the sacral plexus, and perhaps from the obturator.

*Disease of the joint* may follow injury, or parturition, or may be secondary to spinal caries. The local tenderness may be detected by following the iliac crest round to the sacrum, and pressing below the posterior superior spine.

In addition to the constant pain at the bottom of the back, there

may be peripheral pains referred to the knee, on account of the obturator nerve sometimes giving a twig to the sacro-iliac joint, and to the thigh, on account of associations between the nerves of that joint and other branches of the sacral and lumbar plexuses. There is pain on pressing the fronts of the iliac crests together, and defæcation may cause distress. *Abscess* from the joint may open on to the back, or into the pelvis, or into the sheath of the psoas, or into the rectum.

**Ligaments.**—The fifth lumbar vertebra is connected with the sacrum by the ordinary ligaments of the vertebral column, but there is in addition a strong intertransverse ligament which spreads down into the lateral mass of the sacrum.

The *ilio-lumbar ligament* widens out from the tip of the last lumbar transverse process along the back of the iliac crest, giving origin to the quadratus lumborum.

The **great sacro-sciatic ligament** is attached by a broad base to the posterior inferior iliac spine and to the side of the sacrum and coccyx; as it passes downwards and outwards it gathers up its fibres into a thick band which afterwards spreads along the inner border of the ischial tuberosity, a *falciform process* being continued up the ischial ramus. A good deal of the ligament is continued into the origin of the hamstring muscles, especially the biceps. The ligament bounds posteriorly the pelvic outlet and the ischio-rectal fossa, giving origin to the gluteus maximus, and closing in the lesser sacro-sciatic foramen.

The **lesser sacro-sciatic ligament** spreads from the ischial spine into the side of the sacrum and coccyx, anterior to the attachment of the greater ligament; it closes in the great sacro-sciatic foramen, and the internal pudic vessels and nerve wind round it.

The **great sacro-sciatic foramen** transmits the pyriformis, and, above it, the gluteal vessels and the superior gluteal nerve; below it, the sciatic and internal pudic vessels and nerves, and small branches of the sacral plexus.

By the **smaller foramen** the obturator internus and its nerve leave the pelvis, and the internal pudic vessels and nerve re-enter on their way to the ischio-rectal fossa.

The **pubic symphysis** is enclosed by anterior, posterior, and superior, and the sub-pubic ligaments.

Each osseous surface is covered by an oval fibro-cartilaginous plate, and between these plates is an elastic pulp; as pregnancy approaches a synovial membrane may be developed in the joint.

Arterial twigs enter the joint from the obturator and deep epigastric; filaments of nerve come from the obturator.

The articulation of the fifth lumbar vertebra with the sacrum forms the **sacro-vertebral angle**, which may be felt by a long finger in the rectum. It must not be taken for a stricture of the bowel, nor for a pelvic tumour.

The *sacrum* is wedged between the haunch bones from above downwards and before backwards, the better to break shock and escape dislocation. Its lower end forms a slightly movable joint with the base of the coccyx, a fibro-cartilage being interposed; sometimes these bones are welded together; as the result of a fall on to the buttocks, or during parturition, fracture may occur and union fail to take place. Subsequently, during defæcation, and in every other movement of the coccyx, the last sacral nerve is subjected to painful contusions, and removal of the coccyx may be demanded. This distressing disease is called *coccydynia*. A subcutaneous section of the nerves irritated or of the muscles moving the coccyx is far less likely to afford relief than removal of the bone itself, which in these cases may be found necrosed. That the bone is loose or dislocated may be readily made out by taking the coccyx between the finger and thumb, the finger being in the rectum. In women who have spent much time on horseback the coccyx is especially incurved and likely to be broken in labour.

**Fracture of the pelvis** is often associated with injury to the pelvic viscera; information can often be obtained as to the nature of the fracture by digital examination through the rectum or vagina. The treatment consists of rest in bed, the thighs being flexed, so as to slacken the rectus femoris and the muscles of Scarpa's triangle, and a band being fixed around the pelvis, if expedient.

Fracture often traverses the slender pubic and ischial rami, in which case laceration of the urethra may occur. Blood in the urine is a grave symptom in fracture of the pelvis; a metal catheter should be carefully introduced, but if that cannot be done the perineal urethra, or the bladder itself, must be opened, lest extravasation of urine take place. The patient must not attempt to micturate.

From great violence the head of the femur may be driven through the acetabulum, or the pelvis crushed out of shape.

The *fetal pelvis* is small, so as not to interfere with parturition, and even after birth its development proceeds slowly up to puberty. During infancy there is not room in it for the bladder, which, together with the coils of small intestine and much of the rectum, are lodged in the abdomen. Thus it is that the young child's abdomen bulges so greatly; and that in perineal lithotomy difficulty may be experienced in introducing the finger into his bladder.

**Deformities of the pelvis** may be due to rickets or mollities ossium. In each case the bones are soft, and, in **rickets**, as the growing child walks, sits, and stands, the weight of the body thrusts the promontory of the sacrum towards the pubes at the expense of the conjugate diameter of the brim. If such a child have her weak and bending spine caged in an iron 'support,' the weight transmitted through the soft pelvis is much increased and the pelvis rendered all the narrower.

In **mollities ossium**, which comes on after puberty, the haunch-bones yield from the superimposed weight at their weakest part, that is

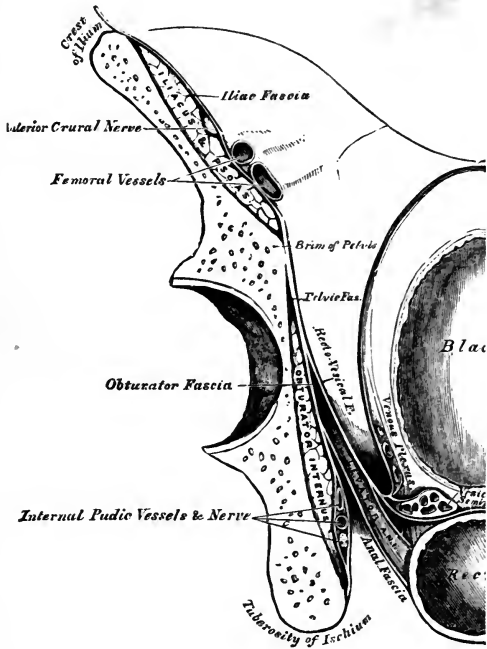


in the rami of the pubes and ischium, until the pelvis becomes 'beaked' or 'rostrated'; as the patient walks the acetabula are thrust inwards. Thus, in the rickety deformity the pelvis is flattened from before backwards, and in that of osteo-malacia from side to side, the aperture being tri-radiate.

The pelvis is also deformed when the bend of a lateral lumbar curvature is continued into the sacrum. The sacral vertebræ are rotated, and are diminished in the concavity of the lateral curve; and the sacro-iliac joint is apt to be synostosed, the pelvis being tilted and rendered *obliquely ovate*.

The **pelvic fascia** consists of various sheets which are all more or less continuous with each other, but, because its arrangement is usually studied in its various parts, the student often fails to understand it in its general design and arrangement. The design of the fascia is to steady and strengthen the pelvic viscera, and to shut the ischio-rectal fossa out from the general cavity.

The fascia lines the circumference of the pelvis, from the pubes in front to the sacrum behind, in one continuous layer, passing behind the internal iliac arteries, but in front of the sacral plexus. From the back of the pubes it descends to the prostate and neck of bladder, constituting the pubo-prostatic ligament; it also encloses the prostate and joins the back of the triangular ligament. Passing from the side of the pelvis, the fascia slopes down over the upper surface of the levator ani to form the true *lateral ligaments of the bladder*, continuous, of course, with the pubo-prostatic ligaments. Just behind the bladder it encloses the seminal vesicles and joins with the piece of the opposite side in front of the rectum. A little further back, but still over the levator ani, it loses itself upon

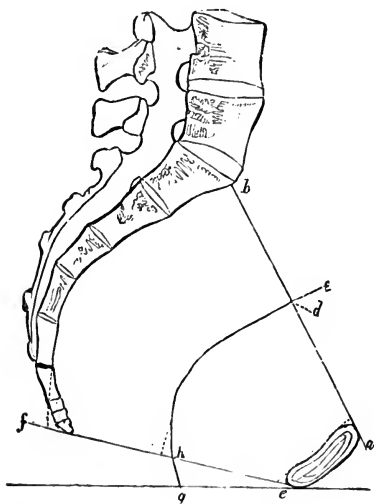


the side of the rectum, and, enclosing it, passes over the front of the pyriformis and sacrum. Thus the pelvis is completely shut off from the ischio-rectal fossæ by the fascia passing on to the sides of the rectum and bladder; this sheet is the *recto-vesical fascia*.

At the level of the upper border of the levator ani the pelvic fascia gives off two sheets, one of which is thin (*anal fascia*) and passes on the under surface of the muscle to the lower end of the rectum, whilst the other descends along the outer wall of the ischio-rectal fossa (*obturator fascia*) to cover the obturator internus, to be attached to the bony and ligamentous margin of the pelvic outlet, and to join the posterior layer of the triangular ligament. (The wood-cut is from Gray.)

### THE PLANES OF THE PELVIS

Obstetricians have divided the true pelvis into **three planes**, and have given each plane **three diameters**—*antero-posterior* or *conjugate*, *transverse*, and *oblique*.



*ab*, superior, and *cf*, inferior plane; *ed* and *hg*, axes of inlet and outlet.

In the *superior plane*—the brim of the true pelvis—the conjugate diameter extends between the sacro-vertebral angle and the crest of the pubes; it, *ab*, is the shortest diameter, 4 in., the transverse diameter, *tr*, being the greatest, 5 in.

In the *middle plane*—the pelvic cavity—the oblique diameter, *ob*, is the longest, 5 in.; it extends from the middle of the sacro-sciatic foramen to the obturator membrane. The antero-posterior diameter, between the middle of the sacrum and the symphysis, is  $4\frac{1}{2}$  in., the distance between the ischial tuberosities being  $4\frac{3}{4}$  in.

In the *inferior plane*—outlet—the diameter between the tip of the movable coccyx and the pubic arch, *cf*, is 5 in.; and, whilst the diameter extending obliquely from sciatic ligament to ischial ramus measures about 5 in., the interval between the tuberosities is but 4 in.

	Transverse	Oblique	Antero-posterior
Superior plane . . .	5 in.	$4\frac{3}{4}$ in.	4 in.
Middle plane . . .	$4\frac{3}{4}$ "	5 "	$4\frac{1}{2}$ "
Inferior plane . . .	4 "	5 "	5 "

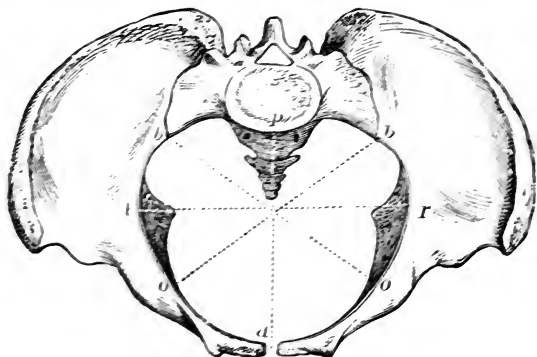
Thus, at the brim the longest diameter is the transverse, the shortest is the antero-posterior. In the middle plane the oblique diameter is the longest, and the shortest is the antero-posterior. At the outlet the antero-posterior is the longest and the transverse the shortest.

Diameters of pelvis :

*ap*, antero-posterior  
or conjugate.

*ob*, oblique.

*tr*, transverse.



**Axes.**—A line, *ed*, drawn at right angles to the middle of the superior plane shows the *axis of inlet* ; it extends between the navel and the tip of the coccyx ; the *axis of outlet* passes from the sacro-vertebral angle through the anus.

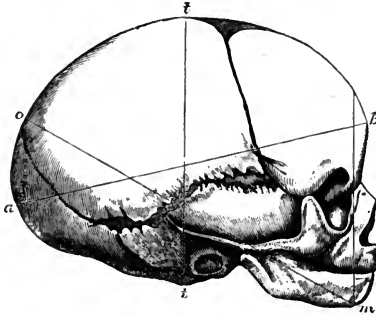
The spine of the ischium greatly influences the direction of the fœtal head during parturition.

**The fœtal head.**— Though the base of the fœtal skull is solidly developed, to protect important nerves and ganglia, the vault is extremely compressible, the edges of the bones being bevelled, and connected by membranous seams, so as to permit overlapping as the head passes through the pelvic straits.

Where three or more sutures meet, the membranous seams are wide and conspicuous, and the arterial pulsation which there exists gives those areas the name of **fontanelles**. There is a fontanelle at each angle of the parietal bone, those in the middle of the coronal and lambdoid sutures being extremely important ; by their shape and position the finger of the obstetrician recognises the kind of head presentation with which he is dealing. (*See fig. on p. 366.*)

The anterior fontanelle is like the ace of diamonds ; the posterior is triangular. The anterior is wide, but the posterior is encroached upon by the close proximity of the corners of the three bones which bound it. In the case of chronic hydrocephalus the anterior fontanelle may not be closed until after puberty. The lateral halves of the frontal bone are connected by a loose suture which extends downwards from the front of the anterior fontanelle ; it is the continuation of the sagittal suture.

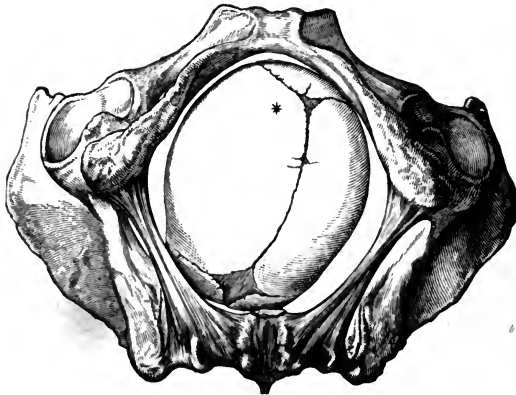
The *fœtal* head is measured by the obstetrician in the occipito-frontal diameter, *ab*, in the occipito-mental, *om*, in the cervico-bregmatic, *tt*, and in the fronto-mental diameter, *bm*. The fronto-mental measurement is small in the fœtus, because the jaw presents no teeth and the ramus hardly exists.



Skull at birth, showing lateral fontanelles:  
*ab*, occipito-frontal diameter.  
*om*, occipito-mental.  
*bm*, fronto-mental.  
*tt*, cervico-bregmatic.

The measurements of these diameters are thus given: *ab*,  $4\frac{1}{2}$  in., *om*, 5 in., *tt*,  $3\frac{3}{4}$  in., *bm*,  $3\frac{1}{4}$  in. of the male fœtal head. Bregma ( $\beta\rho\epsilon\gamma\mu\alpha$ ) means the 'top of the head'; in Latin the word is *sinciput* (*semi, caput*).

In parturition the long diameter of the head enters the superior plane in the transverse diameter; passing through the middle plane, it occupies the oblique diameter, and it emerges through the inferior



Fœtal head emerging in 'first position'; asterisk marks presenting portion.

plane antero-posteriorly, the occiput under the pubic arch and the face to the coccyx. Thus in its progress through each plane the long diameter of the head occupies the longest pelvic diameter. The adjacent sketch shows the head escaping through the outlet, its long

diameter taking advantage of the wide sweep between the sub-pubic arch and the movable coccyx. The head, as it were, screws itself through the pelvis.

The soft parts are dilated by the descent of the amniotic bag, which, under the contractions of the uterine and abdominal walls, plays an important preparatory part. Hasty rupture of the membranes may render the labour dry and tedious. When the os, the vagina, and vulva are fully dilated, the membranes burst, the 'waters' escape, and the uterine walls contract with renewed vigour. The muscular tissue of a feeble uterus may be stimulated by the administration of ergot; but this drug must not be used until the os is wide open, or, in a vain attempt to drive the fœtus through the unyielding os, the uterus may rupture itself. To aid the expulsion of the fœtus, the nurse may advise the woman to blow hard into a bottle; in this way the lungs are filled, the diaphragm is depressed and fixed, the abdominal cavity is diminished, and its muscles are set to work. By 'holding her breath,' or by hauling on a jack-towel fastened to the foot of the bed, the patient fixes the diaphragm and ribs, and thus gives the oblique, transverse, and straight muscles the greatest advantage. But the presence of the head in the vagina excites strong reflex contractions which fatigue the woman much less than voluntary acts would do. During the final expulsive act the escape of the contents of the rectum is almost inevitable.

When labour is threatening, the bladder and rectum should be thoroughly evacuated to clear the way for the fœtus, and to diminish the risk of the occurrence of a rent or gangrenous perforation.

During the detachment of the placenta the large veins which run obliquely into it through the muscular wall of the uterus are torn across, but the immediate and energetic contraction of the muscle closes their open mouths and prevents flooding. To check post-partum hæmorrhage the inert uterus must be stimulated to contract by cold, by bimanual pressure, by ergot, or by electricity. The lingering attachment of a piece of placenta checks contraction and is an incentive to bleeding; the uterus must at once be cleared.

**Pelvic abscess**, which may occur from cellulitis after parturition, and from other causes, is associated with deep-seated tenderness and fulness, and often with a bulging which may be made out through the rectum or vagina. The abscess may break through into either of these passages, or into the bladder or peritoneal cavity—or on to the surface of the abdomen or pubes. It may be dealt with after the manner of iliac abscess from spinal disease. In the case of the male the contents of a pelvic abscess may follow the spermatic cord towards the scrotum.

**Pelvic hæmatocele** (*αἷμα, blood; κηλη, tumour*) is a collection of blood in the retro-uterine pouch, or in the sub-peritoneal tissue around the uterus. The bleeding, which generally occurs at the time of menstruation, is from some congested vessels of the generative organs.

Unless the bleeding be furious and fatal, it trickles into Douglas's pouch (p. 390), where peritonitic adhesions may enclose it, coils of small intestine forming the roof of the cyst-wall. When the effusion is extra-peritoneal it is most likely between the layers of the broad ligament, and is due to the rupture of a varicose ovarian vein; or it may be diffused within the pelvis, in which case it may float the uterus out of the reach of the finger. In the case of sub-peritoneal extravasation, the hæmatocele is not encysted.

When the bleeding is into the peritoneal cavity there is sudden and great shock; the pressure upon the front of the rectum causes constant desire to defæcate, and the patient lies on her back with the knees drawn up. Suppuration may occur, the tumour discharging itself by the rectum or vagina, or into the general peritoneal cavity. The cavity may be evacuated by puncture through the vagina or rectum, as the bulging may indicate.

### THE COMMON ILIAC ARTERIES

The common iliac arteries come from the bifurcation of the aorta at the left side of the fourth lumbar vertebra; and as they divide opposite the *alæ* of the sacrum the right has to run the longer course. (For surface-marking *see* p. 164.) The artery begins about half an inch below and to the left of the umbilicus—in the line connecting the highest points of the iliac crests. Each is about 2 in. long, and the longer they are the shorter are their terminal trunks.

*Relations.*—The right artery *rests upon* both common iliac veins, upon their confluence to form the vena cava, and upon the fifth lumbar vertebra; the left similarly rests upon that vertebra, and upon the left common iliac vein. (*See fig.* on p. 353.)

*In front* of each common trunk are the peritoneum and coils of intestine, and close to the bifurcation is the ureter. Additional anterior relations on the left side are the beginning of the rectum, and the ending of the inferior mesenteric artery in the superior hæmorrhoidals.

Between the common iliac arteries are the rectum and the left common iliac vein. External to each trunk is the *psaos*, and, in addition, on the right side are the ending of the right vein and the beginning of the cava.

*Rule.*—Below the diaphragm the veins of the trunk are on a plane posterior to the arteries (except the renal), and inclining generally to the venous, the right, side.

**Irregularities.**—The common iliac artery may fall short of, or exceed the average length of two inches. Sometimes the trunk gives off the middle sacral or the ilio-lumbar artery.

**Ligation of the common iliac artery.**—A curved incision of  $4\frac{1}{2}$  or 5 in. is made through the skin and superficial fasciæ from the outer

side of the internal abdominal ring to the tip of the last rib, the convexity falling in front of the iliac crest. The external oblique (aponeurotic and fleshy) and the fleshy internal oblique and transversalis are divided to the extent of the skin-wound ; between the last two muscles a branch of the deep circumflex iliac artery, which runs in a little loose connective tissue, may require attention. The transversalis fascia is divided on a director and the peritoneum is gently dragged up by the out-spread fingers, and with it, probably, the ureter and the spermatic vessels. The external iliac artery is then made out, pulsating near the pubes, and is followed upwards until the internal trunk is felt descending into the pelvis ; the ligature is applied a little higher up. During the operation the finger would be brought in contact with the brim of the pelvis at the sacro-iliac articulation.

For the left artery the aneurysm-needle should be passed from within outwards, but on the right side it must be passed from without inwards. The veins are the important relations of the common iliac arteries, and the ligature is passed always from the chief venous (the right) side. As with the innominate artery (p. 185), the venous relations of the right common iliac are of paramount importance.

The curved incision affords more room for the surgeon's fingers ; it should not come further inwards than the middle of Poupart's ligament, or the deep epigastric artery might be wounded ; it should not run too close along the ligament and the iliac crest, or the deep circumflex artery may be cut ; and it should not be too high above the ligament and crest, or else the bag of the peritoneum is not so easily dragged up. A cleanly operator need not hesitate to tie the artery across the peritoneal cavity.

**Collateral circulation** would be established by those branches of the external and internal iliacs—all of them are empty—which ramify in the neighbourhood of well-filled vessels. Thus, of the external iliac, the deep epigastric would bring in blood from its fellow of the opposite side, from the lumbar, lower intercostals, and the internal mammary ; whilst the deep circumflex would help by its anastomosis with the lumbar arteries.

The serviceable anastomoses of the internal iliac are, from the anterior division, the middle hæmorrhoidal with those of the opposite side and with the inferior mesenteric ; vesical branches with those on the other side of the bladder ; the artery of the vas deferens with the spermatic ; vaginal with their fellows, uterine with their fellows and with branches of the aortic ovarian ; obturator with its fellow through the pubic branch (p. 306) ; internal pudic with its fellow through the inferior hæmorrhoidal, and perhaps with branches in the perineum and penis.

From the posterior division of the internal iliac there will be the lumbar branch of the ilio-lumbar anastomosing with the lumbar of the aorta, and the lateral sacral with their fellows of the opposite side and with the sacra media.

## THE EXTERNAL ILIAC ARTERY

The external iliac artery continues the direction of the common trunk, and extends from opposite the ala of the sacrum to the middle of Poupart's ligament, where the name changes to common femoral; it is about  $3\frac{1}{2}$  in. long. (For surface-marking *see* p. 164.)

**Relations.**—Its most important relation is its vein, which lies to its *inner side*, but which in the upper part of the artery is a good deal posterior. The vas deferens, descending from the internal abdominal ring towards the base of the bladder, is also an internal relation near the pubes, and when the bladder is empty the pouch of peritoneum and possibly some small intestine sink to the inner side. The beginning of the rectum overlaps the artery of the left side (*v.* p. 353).

*Externally* is the psoas in its sheath; but, as the artery descends, the psoas gets beneath it, and at the pubes the tendon is directly posterior. The anterior crural nerve is a good way on the outer side of the artery, being separated from it by the iliac fascia and the mass of the psoas.

*Anteriorly* are the bag of peritoneum with the intestines, and the spermatic vessels sloping to the internal abdominal ring. The deep circumflex vein coming from the iliac crest reaches the external iliac vein by running over the front of the trunk near the pubes, and the ureter may lie over the beginning of the artery; so also does a branch of the genito-crural nerve.

Above, *the artery rests upon* the vein, and, lower down, upon the psoas. The iliac fascia separates the artery from the psoas, and, descending behind it, forms the posterior layer of the crural sheath, the transversalis fascia descending on the front of the vessels.

**Branches.**—The **deep epigastric** is given off close above Poupart's ligament, and, running upwards and inwards to enter the sheath of the rectus, passes behind the inguinal canal. The internal abdominal ring is to its outer side, and the external ring is, of course, well to its inner aspect, and much nearer to the skin. (*See* fig. on p. 306.)

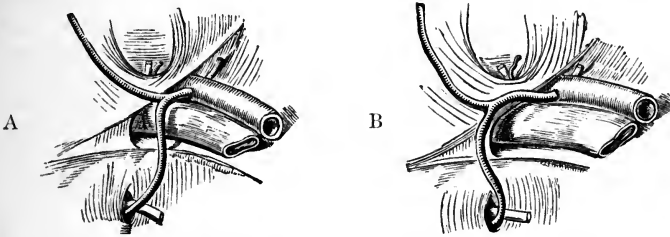
The *course of the deep epigastric may be marked on the surface* by a line from the middle of Poupart's ligament, that is, from the end of the external iliac artery, to the outer border of the rectus, about an inch below the umbilicus; and then straight up towards the ending of the internal mammary (*v.* p. 156).

At first the epigastric artery lies on the peritoneal side of the transversalis fascia where it is going to form the crural sheath, there being nothing behind it but the peritoneum. Then, piercing the transversalis fascia, it lies upon the back of the rectus, which there has no sheath; and a little higher it enters and ascends within the substance of the rectus. Above the level of the umbilicus it anastomoses with the ending of the internal mammary; earlier in its course it



may also anastomose with the lumbar and intercostal arteries. The vas deferens bends round the epigastric artery to reach the base of the bladder.

*Branches of the deep epigastric.*—The *pubic* descends to the back of the pubes, where it may anastomose with the branch of the opposite side and with the pubic branch of the obturator (p. 306). In every three or four subjects the latter anastomotic loop is of great size, and gives off the obturator artery itself. The branch thus coming from the epigastric



Irregular obturator from deep epigastric, taking, A, safe course, close to vein and on outer side of femoral ring, and, B, taking dangerous course on inner side of femoral ring. (GRAV.)

is called the *irregular obturator* artery, which generally dips down close on the inner side of the iliac vein, so that the neck of a femoral hernia would lie between it and Gimbernat's ligament, as shown herewith. But now and then the hernia slips down between the irregular artery and the external iliac vein, so that when the surgeon cuts upwards and inwards to ease the strangulation, hæmorrhage is unavoidable. Before making that incision he could rarely inform himself of the presence of the vessel, but on the occurrence of the bleeding he would quickly reduce the hernia, put his finger through the now empty crural ring, and try to seize the vessel with catch-forceps; or he might carefully dilate the opening and try to hook down the wounded artery. He could not enlarge the wound by cutting, because of the important surroundings.

The *cremasteric* branch supplies the coverings of the cord and may anastomose with twigs of the spermatic, with the artery of the vas, or with a branch of the common femoral.

The **deep circumflex iliac** arises near the deep epigastric and is similarly placed between peritoneum and transversalis fascia; running outwards, it lies in the crevice between the iliac and transversalis fasciæ as they are attached along the outer part of Poupart's ligament (p. 156). It then passes through the transversalis fascia and muscle to lie near the iliac crest in the connective tissue between the internal oblique and transversalis. It anastomoses with lumbar and lower intercostal arteries; with the iliac branch of the ilio-lumbar, and, over the iliac crest, with the gluteal; possibly also with the ascending branches of the external circumflex.

The accompanying vein has to cross over the external iliac artery to enter the main vein (*v. p.* 353).

**Ligation of the external iliac artery.**—A curved incision of 3 or 4 in., with the convexity downwards and outwards, is made from a little above and to the outer side of the middle of Poupart's ligament to just above the front of the iliac crest. Integuments, muscles, and fascia are divided, to the length of the skin wound, as detailed on p. 369. The peritoneum is then gently drawn up, and the artery is felt pulsating on the pubic ramus. The trunk is followed up for an inch, and is then freed of a little connective tissue which attaches it to its vein and to the sheath of the psoas. The aneurysm-needle is passed from the venous, the inner, side. (For line of incision *v. p.* 295.)

In aged persons, and in those with diseased capillaries, the external iliac artery is elongated and tortuous, and sometimes drops from the inner side of the psoas to form a considerable loop into the true pelvis.

**Collateral circulation.**—The deep epigastric would bring in blood from its fellow of the opposite side, and from the obturator, by the anastomosis behind the pubes; from the spermatic (aortic) through the cremasteric branch; from the lumbar and lower intercostals, and from the internal mammary (*p.* 156). The deep circumflexa would help by its communications with the iliac branch of the ilio-lumbar, and with the lower lumbar arteries.

Of the branches of the common femoral, the deep external pudic might join with the superficial of the internal pudic. Of the deep femoral, the anastomoses of the external circumflex with the gluteal and the sciatic, of the internal circumflex with the sciatic and obturator, and of the superior perforating with the sciatic would all help.

#### THE INTERNAL ILIAC ARTERY

The internal iliac artery descends from the bifurcation of the common trunk, for about  $1\frac{1}{2}$  in., to the great sacro-sciatic foramen, where it divides into an anterior and a posterior trunk.

**Relations.**—*In front* are the peritoneum and rectum, and the bladder and ureter. *Behind* are the internal iliac vein, the lumbo-sacral cord, and the side of the sacrum, the anterior division of the artery being continued over the sacral plexus and the pyriformis.

*To the outer side* is the brim of the pelvis, the obturator nerve, and the external iliac vessels. *Internally* is the rectum.

**Hypogastric arteries.**—In the infant the internal iliac arteries are so large that they seem to represent the divisions of the aorta itself, the external iliacs coming off as mere branches. They give off twigs into the pelvis, and run, but little reduced in size, along the brim of the pelvis and up the side of the bladder to leave the abdomen at the umbilicus, carrying impure blood to the placenta. Within the abdomen they are the *hypogastric arteries*, but outside they are the arteries of the umbilical cord (*v. p.* 298).

As already shown (p. 311), the hypogastric artery, in its ascent between the peritoneum and the abdominal wall, causes a ridge-like elevation of the peritoneum; at the sides of the ridge are slight depressions through either of which a direct inguinal hernia may pass.

After birth the hypogastric arteries dwindle into fibrous cords which, pervious nearly up to the top of the bladder, constitute the *superior vesical* arteries; the *middle vesical* branches are derived from the superior, whilst the *inferior vesical* comes as a special branch from the anterior division of the internal iliac, and supplies the base of the bladder, the prostate, and the seminal vesicle, and gives off the *artery of the vas deferens*. This last-named and thread-like vessel leaves the abdomen with the spermatic cord, and may eventually anastomose with the spermatic artery. The vesical arteries anastomose with each other and with their fellows of the opposite side, and with the lower rectal, vaginal, and perineal arteries.

The **uterine** artery ascends between the layers of the broad ligament, and anastomoses with the ovarian artery above, and with the uterine vessels across the middle line, and below with the vaginal arteries. The **vaginal** branch anastomoses with its fellow; with the uterine above; and in front and behind with vesical and rectal branches. The **middle hæmorrhoidal** anastomoses with the ending of the inferior mesenteric (p. 354); with its fellow of the opposite side; with the hæmorrhoidal branches of the internal pudic and perhaps lateral sacral, and with the vesical arteries.

The **obturator** artery runs forwards from the anterior trunk of the internal iliac to the upper part of the obturator foramen, through which it passes with, but below, the obturator nerve (p. 358). Before emerging it gives off a *pubic* branch which anastomoses with its fellow, and with the pubic branch of the epigastric (*v.* p. 306) behind the pubes. The obturator may also give off a vesical branch, and a twig to anastomose in the iliac fossa with the ilio-lumbar artery.

Outside the pelvis the obturator artery divides into a couple of branches which, diverging, form an arterial circle around the thyroid foramen; the branch which runs inwards supplies the origin of the adductor muscles, and anastomoses with ascending twigs of the internal circumflex. The outer division sends a branch to the hip-joint through the cotyloid notch, and, supplying the muscles about the ischial tuberosity, anastomoses with the sciatic.

The **irregular obturator artery** has been described on p. 371, and the **internal pudic** on p. 441.

The **sciatic** is one of the terminal branches of the anterior trunk of the internal iliac artery. It emerges below the pyriformis and passes over the small rotator muscles between the ischial tuberosity and the great trochanter to join in the upper part of the **cruciform anastomosis**; that is to say, it joins with the inner and the outer circumflex and the superior perforating arteries. The sciatic also

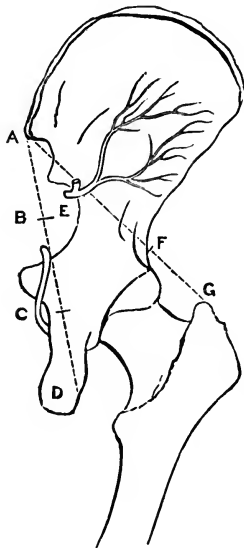
anastomoses with the obturator artery. It is covered by the gluteus maximus, which it freely supplies, anastomosing in it with the gluteal artery. Before leaving the pelvis the sciatic artery may give off some branches to the bladder and rectum; but its first-named branch is the *coccygeal*, which pierces the great sacro-sciatic ligament to supply the lower part of the origin of the gluteus maximus and the integument over it. The other named branch is the *comes nervi ischiatici*, which enters the great sciatic nerve and anastomoses with the perforating arteries and with superior muscular branches of the popliteal; it is an important branch in the collateral circulation.

To find upon the surface of the buttock the spot, at which the sciatic artery is leaving the pelvis, see below.

The other terminal branch of the anterior division of the internal iliac is the internal pudic artery.

The posterior trunk of the internal iliac gives off the **gluteal** artery, which, passing through the upper part of the great sacro-sciatic notch, at once divides into a *superficial* and a deep branch. The former appears between the gluteus medius and pyriformis, and ends in the supply of the gluteus maximus, anastomosing with the sciatic. The

*deep part* of the gluteal artery remains under cover of the gluteus medius, and divides into a *superior* and an *inferior* branch, both of which run towards the interval between the front of iliac crest and the great trochanter, where they anastomose with ascending branches of the external circumflex. The upper branch runs close around the border of the gluteus minimus, and, sending branches through the medius, anastomoses with the deep circumflexa ilii. The lower branch may anastomose with the sciatic as well as with the external and internal circumflex.



**Surface-marking.**—The spot at which the *gluteal artery leaves the pelvis* may be marked on rotating the thigh inwards and drawing a line, A G, from the posterior superior iliac spine to the great trochanter. The junction of the inner, A E, with the middle third, E F, of this line gives the position of the artery.

The *pudic artery lies over the spine of the ischium*. To find it, draw a line, A D, from the posterior superior iliac spine to the outer side of the tuber ischii, and take the junction of the middle and lower thirds, C. The junction of middle and upper thirds, B, marks the point of *emergence of the sciatic*. (Holden.)

The following *rationale* may make this scheme more easily re-

membered :—The gluteal artery coming out of the pelvis above the pyriformis is at a higher level than the pudic, which emerges below that muscle. The line to cross its course must, therefore, be that running from the posterior superior spine to the higher of the two processes of bone, namely, to the great trochanter. The line for the lower artery (pudic) runs to the lower land-mark—the ischial tuberosity. Further, the higher artery is at the junction of the highest third with the middle third of the upper line, the lower artery, the pudic, being at the junction of the lower third with the middle third of the lower line.

**Ligation of the gluteal artery** might be performed by making a five-inch incision in the line just given, namely, from the posterior superior spine of the ilium to the great trochanter, the body being placed in the position which is adopted in the dissecting-room when the buttock is being worked at. The coarse bundles of the great gluteus having been reached and separated with a director, and the mass of the muscle being traversed, the vessel is seen emerging above the pyriformis. The limb is then raised to the level of the body, so as to slacken the gluteus, and the ligature is applied as deeply as possible.

The **ilio-lumbar** artery passes upwards and outwards from the posterior division of the internal iliac, and beneath the psoas, and, as its name implies, divides into an iliac and a lumbar branch. The *iliac* branch supplies the iliacus, and anastomoses with the circumflexa ilii and with one of the lower lumbar arteries, whilst the *lumbar* branch supplies the quadratus lumborum, and likewise communicates with the lower lumbar arteries, and, perhaps, even, with the intercostals. The lumbar branch sends a twig into the spinal canal. The anastomoses of the ilio-lumbar artery are of great importance when the common or internal iliac is tied.

The **lateral sacral** branch, or branches, run from the posterior trunk of the internal iliac to the lateral part of the anterior surface of the sacrum, whence anastomotic branches are sent to the sacra media, to the branches of the opposite side, and to the rectum. Spinal branches enter the anterior sacral foramina, and send out twigs on to the gluteal region.

**Ligation.**—The internal iliac artery may be reached by a procedure like that described (p. 368) in the case of the common iliac; the external iliac is followed up until the bifurcation of the common trunk is reached; from that spot the internal iliac may be traced towards the depths of the pelvis for about half-an-inch, and there tied. The ureter would be raised from the artery in raising the peritoneum. The vein is behind the artery.

**Collateral circulation** would be abundant, the following vessels anastomosing across the middle line with their fellows of the opposite side: from the anterior trunk, the middle hæmorrhoidal, three vesical, uterine, vaginal, obturator, and internal pudic; and from the posterior trunk, the lateral sacral.

In addition to these sources, the empty middle hæmorrhoidal

would receive blood from the inferior mesenteric; the uterine, from the ovarian branch of the aorta; the obturator, from the deep epigastric and the internal circumflex; the gluteal and the ilio-lumbar, from the lumbar of the aorta, the circumflexa ilii, and the external circumflex; and the lateral sacral, from the sacra media. The empty sciatic artery would probably bring blood from the cruciform anastomosis, and the artery of the vas deferens (of the inferior vesical) might possibly help by its anastomosis with the spermatic.

**Sympathetic nerves of the pelvis.**—The two knotted cords of the sympathetic system are continued from the front of the last lumbar vertebra upon the sacrum, internal to the foramina, till they meet at last in front of the coccyx, in the *ganglion impar*. Each cord has four or five ganglia which communicate with the sacral nerves; several branches pass on to the middle sacral artery, and others to the *hypo-gastric plexus*—a network placed between the two common iliac arteries in front of the sacral promontory. From this plexus numberless branches descend on each side to form the *pelvic plexus*, where communications take place with the third and fourth sacral (spinal) nerves. Filaments also pass with every branch of the internal iliac artery; thus, the pelvic viscera and the penis (but not the testes, p. 432) are supplied.

The **sacra media** comes off from the bifurcation of the aorta, and descends between the two common iliac arteries over the last lumbar vertebra, and down the sacrum; it anastomoses with the lateral sacrals of either side, and it ends in Luschka's gland. In its course it gives twigs to the back of the rectum, which anastomose with other hæmorrhoidal branches.

#### THE LYMPHATIC GLANDS OF THE ABDOMEN AND PELVIS

are chiefly arranged along the abdominal aorta (*lumbar glands*) and the trunks of the iliac arteries (*pelvic glands*), those along the external iliac being in association with the inguinal glands; there are *sacral glands* also, which quickly enlarge in cancer of the rectum. The pelvic viscera are specially associated with the lymphatics which are grouped along the internal iliac artery. The lumbar and pelvic lymphatic vessels gradually reach the thoracic duct.

With malignant disease of the testicle, the lumbar lymphatic glands may be so much enlarged as to form a palpable abdominal tumour, which may, by compressing the vena cava, cause œdema in the lower extremities.

#### THE ILIAC VEINS

The **external iliac vein** is the continuation of the common femoral. The name changes at Poupart's ligament, where the vein, occupying the middle compartment of the crural sheath, lies to the inner side

of its artery. The external iliac vein joins the internal opposite the ala of the sacrum to form the common iliac.

Because of the general inclination of the veins towards the right, the right external iliac vein in its ascent gradually sinks beneath the corresponding artery; whereas, on the left side, the vein keeps always along the inner side.

The external iliac vein receives two tributaries just above Poupart's ligament, corresponding to the branches of the artery, namely, the *deep epigastric* and the *deep circumflex iliac veins*. The latter branch, having come from the region of the iliac crest, reaches the iliac vein by passing over the external iliac artery.

The **internal iliac vein** is formed by the confluence of the venæ comites of the branches of the internal iliac artery; though, of course, the single umbilical vein, which corresponds to the two hypogastric arteries, has no concern therewith. These venæ comites form a free anastomosis about the vagina, uterus, rectum, bladder, and prostate; and the hæmorrhoidal branches have an important communication with the inferior mesenteric vein, that is, with the beginning of the vena portæ.

The *prostatic plexus* of veins is placed between the capsule of the gland and the investment of the recto-vesical fascia. It is in free communication with the vesical and the lower hæmorrhoidal veins, and receives anteriorly the **dorsal vein** of the penis, which enters it through the triangular ligament (p. 413). The vesico-prostatic veins are often much dilated; they are liable to inflammation after lithotomy, and they sometimes contain calcareous concretions—*phleboliths*.

The **common iliac veins** are formed opposite the ala of the sacrum, by the confluence of the external and internal iliac veins; and, passing upwards and to the right, they unite at the right side of the fifth lumbar vertebra to form the inferior vena cava.

The common iliac veins lie, at their commencement, to the inner, the median, side of their respective arteries, and, to reach the right side of the fifth lumbar vertebra, each must pass beneath the right common iliac artery. Thus, in its ascent, the left vein is always on the inner (right) side of the left artery, and it ultimately crosses the right artery—on a posterior plane, of course. (See Rule, p. 368.) The beginning of the right vein is slightly to the inner side of the right common iliac artery, and, to reach the right side of the fifth lumbar vertebra, it has to cross the right common iliac artery—on a posterior plane. In its ascent, the right vein lies, for the most part, behind, and, ultimately, as it swells out into the beginning of the vena cava, a little to the outer side of its artery.

The student will best understand the arrangement of the iliac arteries and veins by making an outline sketch of the aorta, the common, external, and internal iliac arteries, placing a figure 4 at the division of the aorta—representing the fourth lumbar vertebra—and a

5 to the outer side of the right common iliac artery, to mark the point of origin of the cava. Then, with a blue pencil, let him place the external, and internal, and the beginning of the common iliac veins to the inner side of their respective arteries. Having done that, let him draw in the commencement of the cava. To continue the common veins into the cava, he must bring the left vein away from its artery and beneath the right artery, and send the right vein more quickly beneath the right artery and even to its outer side.

*Tributaries.*—The *sacra media vein* conveniently falls into the left common iliac vein as it crosses below the division of the aorta; the *ilio-lumbar vein* enters the corresponding common iliac vein.

### THE SACRAL PLEXUS

The sacral nerves descend from the lowest part of the lumbar enlargement, which is at the level of the last dorsal vertebra, in the cauda equina, and divide into an anterior and a posterior branch.

The *posterior sacral nerves* emerge by the posterior sacral foramina and give *internal branches* to the origin of the erector spinæ, and *external branches* which form loops about the great sacro-sciatic ligament, from which twigs pass through the origin of the gluteus maximus to supply the skin of the hinder part of the buttock.

The **sacral plexus** is formed by the junction of the lumbo-sacral cord with the anterior divisions of the first three sacral nerves and with part of that of the fourth. The *fourth sacral nerve* also sends branches to the rectum, bladder, vagina; to the coccygeus, levator ani, and external sphincter, and to the skin near the side of the coccyx.

The anterior division of the *fifth sacral* is an unimportant twig which passes out between the sacrum and coccyx, for the skin near the coccyx, together with a still smaller nerve, the *coccygeal*.

**Relations of the sacral plexus.**—The plexus lies upon the sacrum and pyriformis, and is separated from the rectum and bladder, and from the divisions of the internal iliac artery, by the pelvic fascia.

The upper part of the plexus consists of the lumbo-sacral cord and of the anterior divisions of the first and second and part of the third sacrals, and forms chiefly the great sciatic nerve; the rest of the third and the part of the fourth forming the internal pudic. But, in addition to these trunks, the plexus gives off the superior gluteal (from the lumbo-sacral cord), the lesser sciatic, and the inferior gluteal, and muscular branches to the pyriformis, obturator internus, gemelli, and quadratus femoris. The nerve to the obturator internus runs round the ischial spine, with the internal pudic nerve; and the nerve to the quadratus passes beneath the tendon of the obturator internus and the gemelli, and gives a twig through the back of the capsule of the hip-joint.

The **superior gluteal** nerve comes from the lumbo-sacral cord,



and emerges above the pyriformis; it courses between the gluteus medius and minimus, supplying them and the tensor fasciæ femoris. Thus it is the motor nerve of the internal rotators of the thigh.

The **inferior gluteal** comes partly from the back of the plexus, and partly from the lesser sciatic; it supplies the gluteus maximus. The two gluteal nerves are named from their situation as regards the pyriformis, one leaving the pelvis above and the other below that muscle.

The **small sciatic** nerve passes out below the pyriformis, under cover of the gluteus maximus, which it helps to supply. Its remaining branches are cutaneous; some of them curl round the lower border of the gluteus maximus, to supply the skin over the buttock, whilst others, *descending*, pierce the fascia lata at various points to supply the skin over the back of the thigh and the upper part of the calf. Another branch, the *long pudendal*, winds round the outer side of the ischial tuberosity to the outer part of the scrotum or to the labium. Pain in that region may be due to pressure upon the trunk of the long pudendal, or the lesser sciatic, or upon that part of the plexus, or of the spinal cord, from which the nerve-filaments arise.

The **internal pudic** nerve emerges below the pyriformis from the lower part of the plexus, and, winding round the ischial spine, enters the ischio-rectal fossa, where it divides into the *inferior hæmorrhoidal* (which supplies the external sphincter and the neighbouring integument), the *perineal*, and the *dorsal* nerve of the penis or clitoris. The *perineal* nerve runs superficial to the pudic artery, in the outer wall of the fossa, and gives off two superficial branches to the scrotum and the penis, and motor twigs to the anterior part of the levator and sphincter ani, to the transverse muscle, and to the accelerator urinæ and erector penis. (See fig. on p. 440.)

The *dorsal nerve of the penis* ascends between the two layers of the triangular ligament, where it supplies the compressor urethræ, and then passes through the anterior layer of the triangular ligament and the suspensory ligament, and along the dorsum, to end in the glans penis or clitoridis, and the prepuce.

Peripheral annoyance of the internal pudic nerve by a long or adherent prepuce may set up reflex irritation of so general and serious a nature as to entail want of co-ordination of the muscles of the extremity, paralysis, or other obscure nervous affections. Amongst the commonest of the reflex results of phimosis are priapism, incontinence of urine, and nocturnal emissions of semen.

The **great sciatic** nerve comes from the upper part of the plexus, and, passing out below the pyriformis, and under cover of the gluteus maximus, descends, shielded from pressure, in the hollow between the ischial tuberosity and the great trochanter, over the small external rotators, and on to the adductor magnus. It supplies the posterior surface of the great adductor, and, just below the middle of the thigh, divides into the two popliteal nerves.

*Its course may be chalked* by a line which connects the middle of the hollow between the tuberosity and the trochanter with the top of the popliteal space. It is crossed obliquely by the long head of the biceps. The nerve supplies the biceps, semi-tendinosus, and semi-membranosus. Its companion artery, the *comes nervi ischiatici*, is a branch of the sciatic artery.

*Sciatica* is a painful condition of the large nerve, and may be due to spinal disease, to intra- or extra-pelvic pressure, or to a chronic inflammatory condition of the connective tissue in and around the nerve-trunk. In due course it may cause wasting of the muscles and stiffening of the joints. The neuralgia may sometimes be relieved by massage along the back of the thigh, or by acupuncture.

*Bloodless stretching* of the nerve may be accomplished by flexing the foot to a right angle, extending the leg on the thigh, and then forcibly flexing the thigh upon the abdomen. A more efficient way of stretching the nerve is through an incision of five or six inches down the back of the thigh, extending downwards from the gluteal fold at a point midway between the tuberosity and the great trochanter. The incision passes through the superficial fascia (fat) and the fascia lata, down to the upper part of the hamstring muscles. These muscles are then drawn inwards, and the nerve is isolated from its bed of fat and connective tissue and *steadily* hauled upon for some minutes, first downwards, then upwards.

The **internal popliteal** nerve is much larger than the outer division of the great sciatic, and it continues the original course of the great nerve. In the upper part of the ham it lies superficial and external to the popliteal vessels; in the inter-condylar notch it is placed directly over them, and at the lower border of the popliteus it is to their inner side. Thence it is continued on as the posterior tibial.

The internal popliteal nerve gives off *three branches to the knee-joint* which accompany the superior and inferior internal articular, and the azygos articular arteries. *Muscular* branches supply the gastrocnemius, soleus, plantaris, and popliteus. The *external saphenous* branch descends between the bellies of the gastrocnemius, and, piercing the deep fascia below the calf, is joined by a branch of the external popliteal. It passes below the outer malleolus with the short saphenous vein, and ends on the dorsal aspect of the outer side of the foot and of the little toe.

The **posterior tibial** continues the internal popliteal nerve from the lower border of the popliteus to the inner ankle, where it divides into the two plantars. For the first inch it is placed to the inner side of the posterior tibial artery; it then passes over the artery and lies for the rest of its extent to the outer side. It is covered by the gastrocnemius and soleus, and by a second layer of the deep fascia, which separates it from the soleus. It rests upon the tibialis posticus, the flexor longus digitorum, the tibia and the ankle-joint. Behind the

malleolus it has the artery and its venæ comites close upon the inner side, and the tendon of the flexor longus hallucis a little to its outer side.

It supplies the tibialis posticus, flexor longus digitorum and flexor longus hallucis, and gives an additional branch to the soleus. It also gives off a *plantar cutaneous* branch for the inner border of the foot (which pierces the internal annular ligament), and *articular* twigs to the ankle-joint.

The **internal plantar** nerve is larger than the external, and comes from the division of the posterior tibial midway between the inner malleolus and the tuberosity of the os calcis, from under cover of the abductor hallucis. It supplies the plantar surface of the inner three and a-half digits (corresponding thus to the median nerve); the branch for the inner side of the great toe pierces the deep fascia near the middle of the inner side of the foot. The bed of the nail is supplied by the plantar nerves. *Muscular* branches are given to the abductor hallucis, flexor brevis digitorum, flexor brevis hallucis, and to the two inner lumbricals.

The **external plantar**, like the ulnar nerve, gives off few *digital* branches (to the little toe and the adjoining side of the fourth only), and many *muscular* branches, namely, to the flexor accessorius (over which it passes), to the abductor and flexor brevis minimi digiti, the two outer lumbricals, all the interossei, the transversus pedis, and the adductor hallucis.

The **external popliteal** or **peroneal nerve** descends close along the inner side of the tendon of the biceps, and, winding below the head of the fibula into the peroneus longus, divides into the musculo-cutaneous and anterior tibial. It gives three *branches to the knee-joint*, two of which accompany the outer articular arteries, and a *recurrent* branch which ascends to the joint through the tibialis anticus; some *cutaneous* branches to the outer side of the leg, and the *communicans peronei* to join the external saphenous.

The **musculo-cutaneous** nerve descends between the peronei longus and brevis and the extensor longus digitorum, and divides into two branches which pierce the fascia lata in the lower third of the leg; the inner of them supplies the inner side of the great toe and the cleft between the second and third toes (leaving the first cleft for the anterior tibial nerve), whilst the other division supplies the two outer clefts (leaving the outer side of the little toe for the short saphenous). *Muscular* branches pass into the peroneus longus and brevis.

The **anterior tibial** nerve gains the outer side of the corresponding artery by passing through the origin of the extensor longus digitorum; afterwards it holds relations very similar to those of the artery. Though the nerve may lie over the artery in some part of its course, it is again to its outer side beneath the annular ligament, where it divides into an inner and an outer branch, of which the former passes along

the outer side of the dorsalis pedis artery, to the cleft between the great toe and the next, whilst the outer branch ends in a ganglionic thickening beneath the short extensor of the toes, which muscle it supplies. Its other muscular branches are to the tibialis anticus, extensor proprius hallucis, extensor longus digitorum, and to the continuation of the last muscle, the peroneus tertius.

When there is *paralysis of the external popliteal nerve* the patient cannot flex or evert the foot, nor extend the toes. The foot remains in the position of inversion and extension, the toes being curled towards the sole; as the patient walks the toes catch against the ground, and progression is rendered difficult and dangerous. When there has been complete section of the nerve, as may happen after careless tenotomy of the biceps, sensation is impaired on the outer aspect of the leg and the dorsum of the foot; and, on account of the implication of the trophic filaments, sores may occur in the skin of those neighbourhoods.

### THE RECTUM

This last part of the large intestine is by no means 'straight.' It begins opposite the left sacro-iliac joint, and inclines to the middle of the sacrum (first piece); then it follows the curvature of the sacrum and coccyx (second piece), and afterwards it bends backwards for  $1\frac{1}{2}$  in. between the levatores ani, to end at the level of the external sphincter (third piece). It measures about 8 or 9 in., and is capable of enormous distension.

The curves taken by the rectum must be specially remembered in the introduction of an enema-tube or bougie. An ignorant and clumsy operator pushing an enema syringe directly upwards might injure the prostate or the recto-vaginal septum, and entirely fail to irrigate the bowel. And in the case of imperforate rectum, when the bowel is being sought through the perineum, the dissection must be carried well back along the sacro-coccygeal curve. In the young child, however, the rectum runs a comparatively straight course.

Though not properly a reservoir for fæces, the rectum is in some cases accustomed to contain a large amount of accumulation, as is often made out during digital exploration. In the healthy condition of the bowel the presence of fæces is a stimulus to the muscular wall to contract. But in the subject of habitual constipation the nerves and muscle become degenerate, and cease to act. The sensitiveness of the lining of the rectum is very slight at a little distance above the inner sphincter, and thus it happens that the bowel may be overloaded with fæces without the patient being in discomfort. In such a case a doughy tumour may be found in the left lumbar and iliac regions. The pressure thus exerted upon the iliac veins may cause œdema of the left thigh and leg. The more dilated the bowel, the

more stretched and thinned is its wall; the surgeon must proceed, therefore, with the utmost gentleness in using the enema or scoop when endeavouring to empty it. The muscular coat being greatly stretched and enfeebled, there is no chance of a natural evacuation taking place.

**Development.**—The blind end of the large intestine descending into the pelvis is separated by a thick septum from the surface of the perineum. Then a depression at the site of the future anus deepens upwards to form a short, shut sac; at last the septum is absorbed, and the pelvic and anal pieces of the rectum become continuous. Thus, the pelvic portion of the rectum is developed from the hypoblast, whilst the anal portion is the result of an involution of the epiblast.

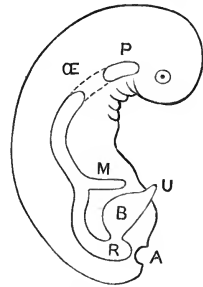
**Imperforate rectum** results from persistence of the septum; it may exist with a perfectly formed anus. Should absorption of the septum be incomplete, an annular constriction will be detected an inch or so within the anus.

The close association of the rectum and urinary bladder during development suggests how, from arrest of development, the bowel may open into the vagina or urethra, or on to the perineum.

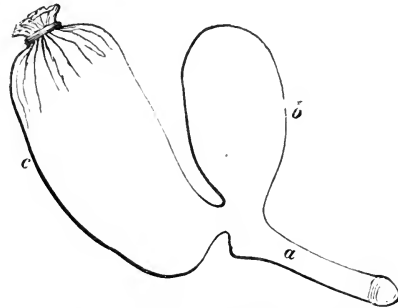
In obstinate constipation in infants digital exploration of the rectum must not be neglected, for, although the anus is well formed, the pelvic portion of the large intestine may not be developed, or may be represented only by a cord descending towards the perineum.

**Imperforate anus.**—Though the pelvic and anal portions may be perfectly developed, the orifice may be occluded by a membrane which may be easily broken through.

**Relations.**—The upper part of the rectum rests upon the sacrum, the sacral plexus, and the pyriformis. Coils of small intestine dropping down into the recto-vesical pouch intervene between it and the distended bladder. The uterus and vagina would also be in front of it (*v. p.* 389). The ureters and various branches of the internal iliac artery lie against its side. (There is no definite limit between the first and second parts of



A, depression for anal piece of rectum; R; B, bladder; M, Meckel's diverticulum; œ, future œsophagus; P, pharynx; U, urachus.



c, rectum, opening into bladder; b; a, penis.

the bowel—the first part ends at the middle of the third vertebra of the sacrum.)

The middle piece lies in the lower part of the sacro-coccygeal hollow, with some of the pyriformis and sacral plexus behind it. In its anterior bend rest the base of the bladder, the vesiculæ seminales and vasa deferentia, and the prostate gland, or the vagina and the cervix uteri. This part of the bowel is securely fixed, and is very capacious. It ends at the tip of the coccyx.

The third part, about  $1\frac{1}{2}$  in., turns back from the prostate or the vagina to the anus. It is surrounded by the (striated) external sphincter ani, and has supporting and fixing it on either side the levator ani with its two layers of pelvic fascia (p. 363). The urethra is separated from it by the perineum or by the vagina. This is by far the narrowest piece of the large intestine, but it is very dilatable, nevertheless.

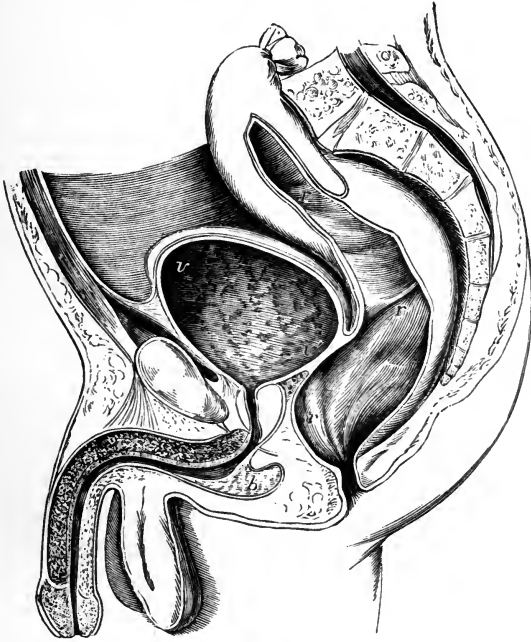
On introducing the finger about  $1\frac{1}{2}$  in. into the rectum the apex of the prostate gland can be felt, and just in front of and below this one can detect the beak of the catheter in the membranous urethra; and should the instrument wander thence into a false passage its beak can be felt just in front of the thin rectal wall. The finger can also explore the lobes of the prostate, detecting chronic hypertrophy, acute inflammation, or the boggy nature of a prostatic abscess. The vesiculæ seminales and the vasa deferentia can also be searched for tubercular or simple inflammatory enlargement; and even a small stone may be occasionally made out in the bladder or impacted at the orifice of the ureter. Also the degree of distension of the full bladder may thus be estimated. Information can also be obtained regarding fracture of the coccyx, and of the connections of a sacral or pelvic tumour. In the case of a tumour in the anterior wall of the rectum information must be sought by thorough digital examination when a sound is in the bladder, and the index-finger is in the vagina.

In supra-pubic operations upon the bladder that viscus is rendered much more accessible by gradually distending an india-rubber bag previously inserted in the rectum. Thus the anterior wall of the bowel and the base of the bladder are lifted up.

As remarked elsewhere (p. 386), a patulous condition of the anus is a strong suggestion of the existence of stricture, and Mr. Bryant has recently shown that a cavernous condition of the rectum—*ballooning* he calls it—is of like clinical import. Having no work to do, the muscular coat below the level of the stricture (which is then found high in the rectum, or which exists in the sigmoid flexure) becomes relaxed, and the wall widely yields all around the bowel.

**Serous coat.**—The arrangement of peritoneum is like that obtaining in the duodenum—the first piece being almost completely invested, the second part being covered in front, whilst the third piece has no serous coat. In the rectum, however, it is only the

beginning of the second piece that is covered in front, for the peritoneum soon passes on to the back of the bladder, at the level of the top of the vesiculæ seminales, to form the recto-vesical pouch and the posterior false ligaments of the bladder. The bladder is readily punctured through the anterior wall of the rectum, between the vesiculæ seminales, without damage to the peritoneum.



A considerable extent of the rectum—perhaps some 3 or 4 in.—may be removed for malignant disease, especially on the posterior and postero-lateral aspect, without great risk of wounding the peritoneum. At the front the peritoneum reaches to within about 3 or 4 in. of the anus, posteriorly it does not descend so low. In excising the end of the bowel the levator ani is divided on each side, and, for obtaining more room during the operation, the wound should be prolonged to the tip of the coccyx. The rectum is then dragged down by the vulsella.

The **muscular coat** consists of an outer layer of non-striated fibres arranged longitudinally, and of an inner one of circular fibres. The longitudinal fibres, which in the colon are found chiefly in three bands, spread evenly around the rectum in a thickish coat. Just within the anus the circular fibres are aggregated in a thick band

nearly an inch deep, the *internal sphincter*; its upper border forms a definite ridge beneath the mucous membrane, and just above it an ulcer or the opening of a fistula is often found.

The **external sphincter** (striated) is attached to the coccyx, and, passing around the sides of the anus, its fibres join again to reach the central tendon. It is under control of the will. It is supplied by branches of the inferior hæmorrhoidal vessels and nerves, and by twigs from the fourth sacral. It is advisable to forcibly dilate the sphincter after operating for internal piles, as the temporary paralysis which follows ensures perfect rest and freedom from spasm.

**Fissure of the anus** is a linear ulcer or crack which extends from just within the anus to the exterior. On account of its passing across the fibres of the external sphincter the sensory filaments in its depths are disturbed after every act of defæcation by the spasmodic contraction of the sphincter, whilst the anus itself is kept tightly occluded. Hence the pain is intense, and it often lasts for hours after stool. Before the ulcer can heal, temporary paralysis of the sphincter must be obtained, either by forcible dilatation, or by section of the superficial fibres. Spasmodic contraction of the sphincter may be due to the presence of a fissure which is so small as to escape detection. By obtaining the temporary paralysis of the muscle in an obscure case relief may generally be secured.

*Spasmodic contraction of the sphincter* is very characteristic of ulceration at or near the anus. Irritation of sensory filaments of the internal pudic nerve involves a message of unrest to the grey matter of the lumbar enlargement of the cord, which is there converted into a motor stimulus leaving by those fibres of the nerve which supply the muscle guarding the mucous orifice. Sometimes the pain is so severe, and the sensory impulse is so energetic, that the adjacent cells in the posterior part of the grey crescent are thrown into sympathetic vibration, and the patient complains of pains in the regions near those from which the afferent nerves are coming; thus he may have neuralgia in the back (lumbago?), down the thigh (sciatica?), or along the scrotum. And sometimes the efferent (motor) impulse is so severe that the testicles may be drawn up, or the bladder spasmodically evacuated; vaginismus also may be set up, or contraction of the sphincter vesicæ, retention of urine being the result.

By *inspection of the anus* information may sometimes be obtained as to the nature of rectal disease; thus in the case of fissure it is tightly closed, and only with difficulty can a search be made amongst the muco-cutaneous folds and furrows. But when obstruction exists, as in the case of simple or malignant stricture, or of a greatly enlarged prostate, the sphincter becomes atrophied and weak from want of use, and the anus flaccid and patulous. This is very characteristic. Even in the case of annular constriction of the sigmoid flexure I have found the anus flabby and patulous. (See also p. 384.)



In making a *digital examination of the rectum* the firm os uteri (felt through the anterior wall) must not be mistaken for 'tumour.' If there be any doubt as to the nature of the mass one finger should be passed into the vagina whilst the other remains in the bowel. Nor must the sacro-vertebral angle be taken for a cartilaginous or malignant tumour, or for some kind of rectal obstruction. A malignant mass in the rectum, which is just beyond the reach of the finger as the patient lies in bed, may sometimes be detected when the patient is examined in the erect position and 'bears down.'

The dilatability of the anus, and the capacity of the rectum, have occasionally tempted the surgeon to introduce his whole hand into the lower bowel for exploration. The practice is dangerous, even when the hand is small, as the bowel or its peritoneal covering may be torn, whilst the practical result obtained is extremely problematical. Moreover, permanent paralysis may follow such rough dilatation of the sphincter.

By the introduction of the hand after death—when permission cannot be obtained for a *sectio cadaveris*—abdominal and even thoracic viscera may be extracted for inspection.

When *hæmorrhage* takes place *into the rectum* no blood may escape by the anus until the pressure within becomes so urgent that evacuation can no longer be prevented by the external sphincter. Then an enormous quantity of fluid and clot may come away. Faintness, with a feeling of heat and fulness in the lower bowel after operation, suggest hæmorrhage, and demand the introduction of the finger.

The *mucous membrane* is but loosely attached by the sub-mucous coat. It is thick and vascular, and when the bowel is empty is thrown into folds. On account of the looseness of its connections it is apt to prolapse, especially in the child who strains at stool on account of vesical calculus, chronic constipation, or diarrhœa. Permanent transverse folds have been described as existing where the bowel changes its directions. They might possibly obstruct the introduction of a tube; their office is to allow free distension.

The mucous membrane of the large intestine is liable to dysenteric inflammation and ulceration, and cicatrization of these ulcers produces stricture. The nearer the anus, the greater the liability to ulceration. The disease probably begins in the solitary glands.

The *epithelium* is simple columnar; a rectal epithelioma is, therefore, of the nature of columnar epithelioma; sometimes the disease appears as a cord-like constriction. The epithelium at the anus being stratified, the malignant development from it is the squamous epithelioma. In an epithelioma occupying both the rectal and anal mucous membrane the elements might be of both varieties.

There is not always pain with cancer of the rectum, especially when the disease is high up; but even in this case distress comes on later when the primary disease, or the lymphatic invasion, has involved the

sacral nerves. Then there may be great pain in the back and along the peripheral branches of the sacral plexus. In most cases there is a sense of fulness of the lower bowel, on account of pressure upon its sensory nerves, and, therefore, a frequent desire for evacuation. The motions are often small and liquid, the solid part remaining behind as a hardening mass. The sphincter is usually dilated. If the disease is too far advanced for excision to be undertaken, comfort may be obtained and life prolonged by diverting the fæces through an artificial anus in the groin or loin.

**Arteries.**—The inferior mesenteric of the abdominal aorta lies behind the upper part of the rectum (*superior hæmorrhoidal*), and then divides into a trunk for either side of the bowel. Branches are thence given off which pierce the muscular coat and run in the submucous layer almost to the anus, anastomosing with those next described. The *middle hæmorrhoidals* are derived from the internal iliacs; branches also come from the lower vesical and sacral, and from the internal pudics within the pelvis; they communicate with each other and with the superior and inferior hæmorrhoidals. The *inferior* or external *hæmorrhoidal* arteries come from the internal pudics in the ischio-rectal fossa (p. 442). They anastomose with each other and with the higher hæmorrhoidal arteries. Their branches are divided in lateral lithotomy, and also in the operation for anal fistula.

**Veins.**—The hæmorrhoidal plexus is found in the lower part of the rectum, in the mucous and submucous coats. It communicates with the veins of the neck of the bladder and prostate. The branches are destitute of valves, and the chief of them enter into the inferior mesenteric vein which ends in the splenic, itself an important tributary of the vena portæ (p. 338); others flow into the internal iliac and internal pudic veins. Thus a noticeable communication is effected between the portal and systemic circulation.

**Piles** are varicose hæmorrhoidal veins; when prolapsed from the interior of the bowel they are covered with mucous membrane and are apt to bleed; external piles are tumours of the inferior hæmorrhoidal veins, and, possessing a thick (dermal) coating, they do not bleed. A branch of a hæmorrhoidal artery descends into the base of the internal pile; the pendulous tumour must therefore not be cut off unless this vessel is first secured, either by a clamp or ligature. In freeing the base of the pile for ligation the blades of the scissors must be passed up parallel to the wall of the rectum, and between it and the pile. Any condition which obstructs the return of the venous blood predisposes to dilatation of these veins. Piles may, therefore, be symptomatic of disease of the heart, lungs, or liver; of stricture of the rectum; of habitual constipation, pregnancy, ovarian disease or abdominal tumour; of prostatic enlargement, or of vesical calculus.

The *nerves* of the rectum are derived chiefly from the inferior mesenteric derivatives of the aortic plexus, and from the hypogastric

plexus, but important branches come from the fourth sacral nerve. Paralysis of this nerve after injury to the lumbar spine may help to explain the sluggishness of the bowel in such cases. On account of the close association of the nerves of the bladder and rectum, irritability of the latter set may cause constant desire to micturate, whilst operations upon the rectum are apt to give rise to retention of urine.

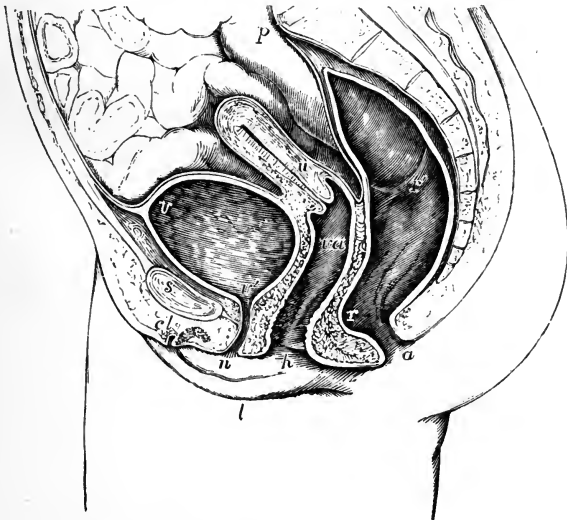
The anus is supplied by branches of the internal pudic nerve.

The *lymphatics* end in the pelvic and lumbar glands; those from the anus enter the glands arranged along the course of Poupart's ligament. Enlargement of the lymphatic glands may be caused by dysenteric or other non-malignant ulcerations of the rectum; therefore, when exploring the bowel in a case of ulceration, and feeling enlarged glands against the sacrum, one must not jump to the conclusion that the disease is malignant.

In the case of epithelioma of the anus the inguinal glands are first enlarged, and subsequently the pelvic glands.

### THE UTERUS

The uterus is about the size and shape of a small green fig; the large end is directed upwards and forwards, and the small end looks



*a*, anus; *c*, clitoris; *h*, hymen; *l*, labium; *n*, nympha; *r*, rectum; *u*, uterus; *va*, vagina.

downwards and backwards, to open into the vagina. Its anterior and posterior surfaces are flattened. Its long axis corresponds with a line

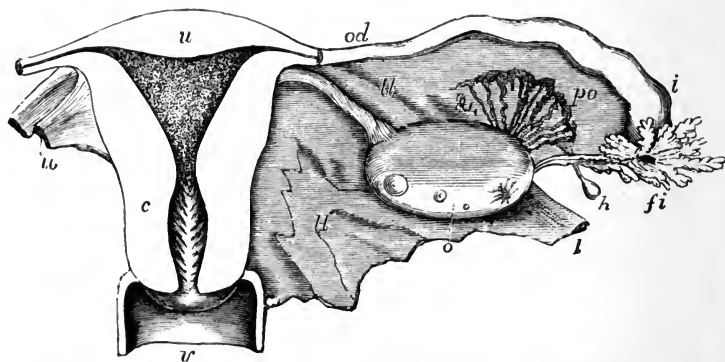
passing from the navel to the coccyx—that is with the axis of inlet of the pelvis (p. 364). In the normal state it is suspended within the true pelvis ; thus it cannot be felt above the pubes ; during pregnancy it ascends towards the anterior abdominal wall.

*Relations.*—The large end is surrounded by coils of small intestine. Posteriorly is the rectum ; and into the recto-vesical pouch of peritoneum loops of jejunum and ileum descend. In front is the bladder, and laterally are the ovaries and Fallopian tubes, between the layers of the broad ligament. Inferiorly is the vagina, and lower still is the perineum ; after rupture of the perineum the uterus sinks until the cervix and some of the body hang permanently outside the vulva ; this is *prolapse of the uterus*.

The presence of the uterus between the bladder and rectum divides the recto-vesical cavity into the antero-uterine and the retro-uterine pouches, each of which contains coils of small intestine ; the retro-uterine *cul-de-sac* is commonly called **Douglas's pouch**, which may be reached by the finger through the upper part of the back of the vagina.

When the bladder is distended the uterus is thrust backwards and upwards ; when the rectum is loaded it is pushed forwards.

The **peritoneal covering** of the body of the uterus is complete on the posterior surface ; indeed, the retro-uterine pouch descends considerably below the level of the body covering the posterior part of the cervix, which extends above the vagina, and the upper part of the back of the vagina itself. Laterally, the recto-uterine pouch is bounded by the ureters and the obliterated hypogastric arteries. Anteriorly the peritoneum does not descend so far, but, leaving a small part of the uterus bare below, passes forwards to the back of the bladder.



*u*, uterus ; *c*, cervix ; *od*, oviduct, and *i* and *fi*, fimbriated exty. ; *l*, round ligament ; *o*, ovary, and *lo*, its ligament ; *p*, *o*, parovarium, with small cyst, *h*.

The layers of peritoneum from the front and back extend laterally to the side of the pelvis under the name of **broad ligaments**. The

upper borders of these folds with the included uterus form a vertical septum in the pelvis, whilst the lateral margins of the pouches constitute the *two anterior ligaments*—vesico-uterine, and the *two posterior ligaments*—recto-uterine. The blood-vessels, lymphatics, and nerves of the uterus are placed between the folds of the broad ligament in a good deal of loose connective tissue; so are the ovary and its ligament, the Fallopian tube, and the *round ligament*. The last-named is a fibrous cord, five inches long, which is attached to the corner of the uterus just below the Fallopian tube, and which passes through the inguinal canal to spread out on to the tissues of the labium. In its descent it carries a follicular process of the peritoneum, the canal of Nuck, into which a piece of bowel, or even the ovary itself, may stray (inguinal hernia, p. 310), and down which serous fluid may gravitate (congenital hydrocele, p. 429). I have also seen an enormous encysted hydrocele in this funicular process. Operations have been designed for shortening these ligaments in the case of a backward tilting of the uterus. It has likewise been thought that a forward tilting might be due to a preternatural shortness of the ligaments.

The broad ligament, the vessels and nerves of the uterus and ovary which are within the broad ligament, the Fallopian tube, and the round ligament constitute the *pedicle of an ovarian tumour*. Unilocular cystic tumours—not ovarian—are often found in the broad ligament.

The delicate sub-peritoneal tissue which connects the serous and muscular coats of the uterus is liable to inflammation—*peri-metritis*—but it may be impossible to distinguish this disease from inflammation of the peritoneal coat itself.

**Structure.**—Beneath the sub-peritoneal coat is the thick wall of non-striated muscular tissue, the fibres of which pass longitudinally, obliquely, and transversely—the longitudinal fibres being chiefly external. Numerous blood-vessels run through this coat to the mucous membrane. Hypertrophic outgrowths from the muscular tissue, with a mixture of fibrous tissue, constitute the *uterine fibromata* or *myomata*; they may extend towards the cavity of the uterus, or appear as upheavals beneath the serous coat; the latter may grow harmlessly into the peritoneal cavity. According to their size and situation these tumours may prevent conception, arrest gestation, and complicate parturition. The intra-uterine growths cause frequent bleedings and constant distress, and should, if possible, be enucleated. These tumours sometimes shrivel up, or detach themselves under a long course of ergot; and sometimes, after parturition, they undergo involution with the rest of the uterine wall. Their presence may be determined, and size estimated, by the bimanual method of examination, and by the uterine sound. With one index-finger in the vagina and the other in the rectum, further information as to the size and position of a tumour may often be obtained. Sometimes a submucous tumour growing into the cavity stretches its base into a slender pedicle and

hangs against or through the os uteri as a *polypus*. It is a source of constant irritation, and the muscular wall of the uterus, in its attempts to expel it, undergoes hypertrophy, like the left ventricle in aortic obstruction or the bladder in prostatic disease.

The **cervix** is nearly an inch long, and ends in a transverse aperture, something like the mouth of a tench, *os tinca*. On account of the backward slope of the cervix, the anterior lip is also inferior; it is also the larger, and is the first seen through the vaginal speculum. The upper part of the cervix has a slight serous covering behind, but none in front, as shown on p. 389.

The **cavity of the cervix** is fusiform, opening above by the os internum, and into the vagina by the os externum or os tinca. The mucous membrane in the cavity of the cervix is arranged in a longitudinal and transverse pleat to allow for dilatation during pregnancy.

The *epithelium* of the interior of the cervix is columnar ciliated, but that upon the outside is, like the epithelium of the rest of the vaginal cavity, squamous.

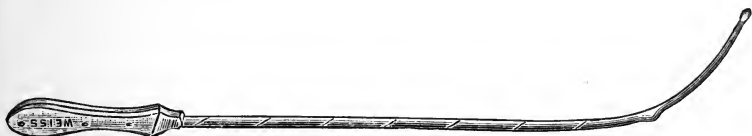
Sometimes the squamous epithelium on the cervix ends quite abruptly, being replaced by crops of projecting and close-set filiform papillæ. To the touch these patches are soft and velvety, and through the speculum they appear florid and pathological. They may be called **phantom ulcers**, and they deserve not that amount of personal attention and treatment which are at times so assiduously bestowed upon them. They are not the result of disease; but when the surface is persistently rubbed with lunar caustic a genuine ulceration is easily made.

During pregnancy the cervix grows broad and soft, and is drawn up from the cavity of the vagina, the os tinca being blocked by a plug of mucus. From chronic disease it is at times enormously hypertrophied. Stricture of the neck may cause dysmenorrhœa and sterility; it may be dilated by graduated sounds. Dilatation may also be so thoroughly effected as to allow complete introspection of the uterus, and the enucleation of large tumours. The cervix is often the seat of epithelioma which may extend to the body of the uterus, the vagina, bladder, or rectum, so that fæces and urine escape by the vulva. It is of the columnar variety. In the early stage the cervix may be conveniently amputated by the *écraseur*, but, later on, if operation be still justifiable, the entire uterus and its appendages should be taken away, either with or without abdominal section.

The presence of cancer of the cervix does not necessarily prevent conception, but if the disease be advanced natural delivery at the full time is almost impossible. In such circumstances the abdomen is opened through the *linea alba*, and the supra-vaginal part of the uterus, with the fœtus, ovaries, and tubes, are removed; this is *Porro's operation*.

The **cavity of the uterus** is small and triangular, the apex being continuous with the cavity of the cervix through the os internum, whilst the superior angles receive the Fallopian tubes, or oviducts; through the oviducts the mucous membrane is directly continuous with the peritoneum; hence, uterine injections escaping above may set up peritonitis.

A *uterine sound* passes for about two and a half inches into the normal uterus; it is marked in inches and fractions of an inch. The elbow in



the sound is to render introduction more easy along the axes of outlet and inlet of the pelvis. Its reckless use may cause abortion or inflammation.

The **mucous lining of the uterus** consists of a basement membrane covered with a single layer of columnar ciliated epithelium. It is continuous with the lining of the Fallopian tubes, and, through the cervix, with that of the vagina. Its deeper layer is very vascular, and rests upon the muscular layer without the intervention of a submucous stratum. The surface of the membrane is smooth and closely studded with the openings of tubular, glandular inflexions of the basement membrane. The membrane swells during menstruation, being then partially cast off; in certain cases of dysmenorrhœa nearly the whole of the lining comes away in pieces, with loss of blood. Much of the discharge in leucorrhœa comes from the tubular glands.

Vascular outgrowths of the mucous membrane may start into the cavity and, growing downwards, become pedunculated. Such polypi are a common source of hæmorrhage and dysmenorrhœa.

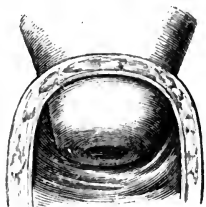
**Supplies.**—The *arteries* come from the tortuous ovarian branches of the aorta, and from the internal iliacs. They reach the uterus between the layers of the broad ligament, and anastomose freely with each other and across the median line. They form a close and delicate plexus in the mucous membrane, which eventually empties into venous sinuses in the muscular wall. The uterine *veins* and ovarian veins form a plexus in the broad ligament and enter respectively the internal iliac and the vena cava (right), or (left) the renal vein—like the spermatic veins. They communicate freely below with the vaginal veins also. The dense plexus of ovarian and uterine veins is liable to dilatation.

The *lymphatics* pass from the mucous and muscular coats into a delicate network beneath the peritoneum, and eventually enter the pelvic and lumbar glands.


The *nerves* are derived from the hypogastric plexus, and from

branches coming with the ovarian and uterine arteries (aortic and iliac plexuses); important twigs also come from the third and fourth sacral nerves.

When an examination is made *per vaginam* but a few days after conception the uterus is found hot and turgid as if formed of erectile tissue. The finger may also feel the enlarged body of the uterus through the front of the vagina, and the os is 'soft and cushiony.' The surface of the abdomen becomes flatter and the navel is deepened; hence the proverb, '*En ventre plat, enfant il-y-a.*'



Os and cervix at third month of pregnancy.



Os and cervix at eighth month.

In the third month the abdomen shows enlargement; in the fifth month the uterus can be felt above the pubes, perhaps halfway to the navel. There is no confirmation of the supposition that 'quickenings' is the result of a sudden ascent of the uterus. With advancing pregnancy souffles and pulsations are heard, and the movements of the foetus may be felt and seen through the abdominal wall.

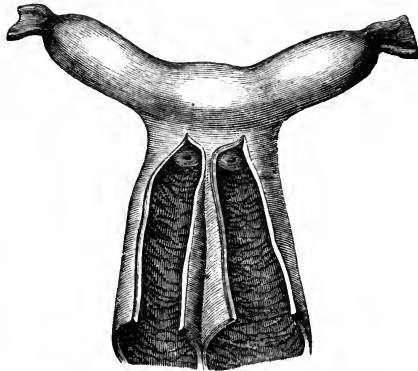
A few days before parturition the foetus sinks towards the pelvis, preparatory to delivery.

The pregnant uterus may press against the renal veins, or may indirectly irritate the kidneys, so that albuminuria occurs; the legs, vulva, hands, and face become œdematous, and uræmic poisoning may be obviated only by producing miscarriage. By pressure on the iliac veins the hæmorrhoidal plexus becomes congested and piles appear, and the saphenous veins become varicose. On account of irritation of the lumbar and sacral nerves, neuralgias and cramps occur. These conditions may be relieved by recumbency. The bladder is apt to be irritated and the rectum obstructed.

**Development.**—Early in foetal life an efferent duct descends from the ovary (which is then near the kidney); the outer part of the duct becomes the Fallopian tube, whilst the part nearer the middle line fuses with its fellow of the opposite to become the uterus. In some of the lower animals the fusion of the tubes is less perfect than in the human subject, so that the uterus remains bifurcated at the fundus—*uterus bicornis*. The cavity of the normal human uterus (p. 390) shows



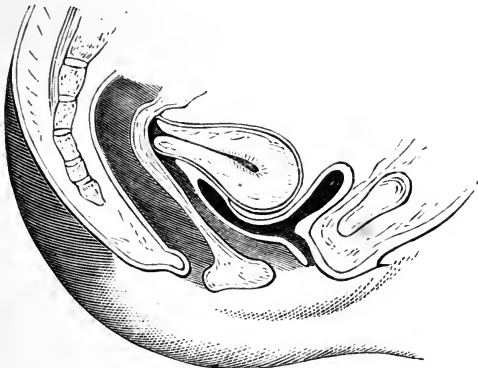
this inclination towards the lower type, and in some instances, from arrest of development, a double uterus results. The bicorned uterus may be associated with the halves of a vagina which is divided down the middle. Menstrual flow may be pent up in one of these chambers, the condition being called *unilateral hæmatokolpos* (*κολπος, womb*).



Uterus bicornis ; os uteri and vagina double.

**Flexions and versions**

are apt to occur in the flaccid uterus on account of the inefficiency of its ligamentous connections. In 'flexion' the body of the uterus is 'bent,' the neck remaining in its proper place. In 'version' the organ swings bodily; either condition may be caused by the weight of a fibrous tumour, or as a result of chronic inflammatory thickenings and adhesions. On account of the strain which is thus thrown on various pelvic nerves, versions and flexions cause neuralgia and pains in the back. The introduction of the uterine sound at once differentiates a version or flexion from a hæmatocele or a uterine tumour.



Anteversion. (G. HEWITT.)

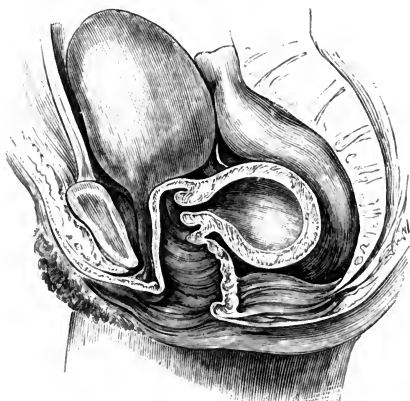
Excessive attention is occasionally bestowed upon a womb which is considered to occupy an incorrect position or plane : practice in uterine orthopædics has run a risk of being developed into too special an art.

The spinal column bent this way or that does not necessarily want a support, nor does the womb.

In **anteversion** the finger in the vagina fails to find the cervix at first, but eventually makes it out high up, and directed so much backwards that the os lies against the posterior vaginal wall. Through the anterior wall the finger detects the body of the uterus running forwards as a firm ridge towards the pubes, the fundus pressing against and irritating the bladder. The patient lying on her back, the uterus may be pushed up by the finger through the front of the vagina, and by the other hand working over the pubes. To keep it then in position, the patient must lie constantly supine; the bladder may be kept full and a binder applied. If necessary, a uterine support (a pessary) may be worn. It should not be left too long in position, or it may cause ulceration. A pessary has been known quietly to work its passage into the rectum, bladder, or uterus.

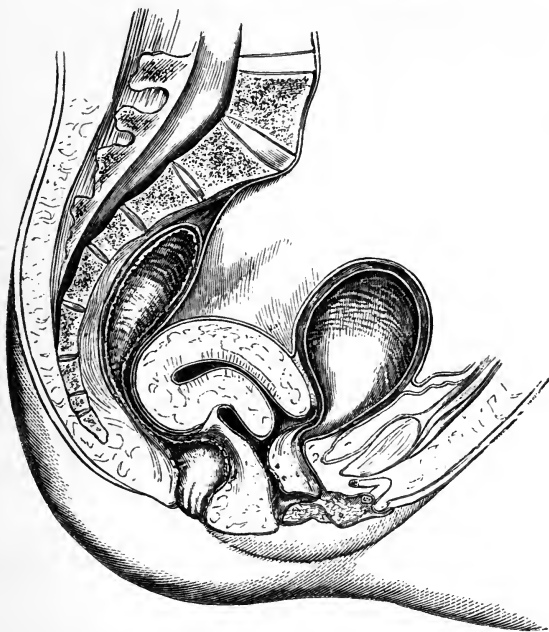
In **anteflexion** the fundus is bent forwards, with the result, if the flexion be extreme, of irritating the bladder; otherwise the symptoms may be only those due to the impeded escape of the uterine fluids—dysmenorrhœa. The displacement is apt to follow extensive rupture of the perineum, for the bladder, having thus lost much of its support, sinks, dragging with it the roof of the vagina and the uterus. It is said that the displacement sometimes occurs when a woman jumps from a height, carries too heavy a weight, or in some other way overtaxes the attachments of the womb.

In **retroversion** the fundus impinges against the rectum, impeding defæcation and causing tenesmus. Retroversion is apt to be found in women who have borne children, and especially so if, after labour, they have been too highly and persistently bandaged and kept too long lying supine. The condition is detected both by vaginal and rectal examination. In one case the pressure against the rectum was diagnosed as a 'malignant obstruction,' for the relief of which colotomy was most unfortunately performed.

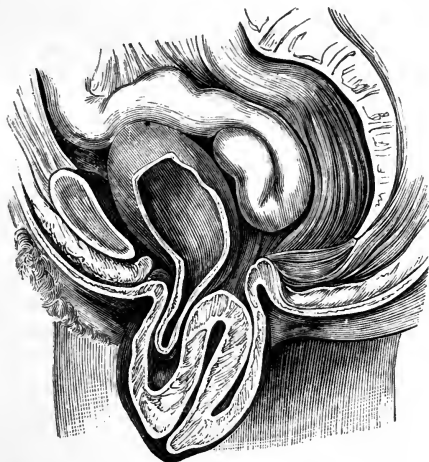


Retroversion. (FARRE.)

In **retroflexion** the body is bent towards the sacrum, the fundus falling into Douglas' pouch, where it may be felt by the finger in the rectum or vagina; the introduction of the sound shows that the mass is not a uterine tumour or a hæmatocele.



Retroflexion. (G. HEWITT.)



Extreme prolapse, or procidentia of uterus. (FARRE.)

In **proidentia**, after rupture of the perineum, or as the result of a yielding of attachments, the uterus sinks between the thighs, and in due time its mucous covering, which is the everted vaginal lining, becomes dry and tough like skin.

**Hæmatocele.**—The escape of the ovum from the ovary is associated with slight bleeding, but when this is unusually severe the blood trickles down into the retro-uterine pouch (*v.* p. 389). A hæmatocele may also result from a leakage from the veins of the Fallopian tube or from the uterus. Eventually the blood may undergo coagulation. By vaginal and rectal examination a doughy tumour is made out which may compress the rectum and thrust the fundus uteri forwards; if the effusion be sufficient, a hypogastric tumour may be detected. The collection may burst through the vagina or rectum, or it may be absorbed or become inert. Frequently such collections have been successfully tapped through the rectum.

Rupture of the pregnant uterus may be caused by violence, or by muscular energy during labour, especially if the passage of the fœtus be impeded. The rent is generally near the junction of the neck and body, but it may be so extensive as to allow the escape of the fœtus into the peritoneal cavity.

Flagging contractions of the uterus may be stimulated by the administration of ergot, but this drug should not be given until the os is so fully dilated as to offer no impediment to the passage of the fœtus, or rupture of the uterus might occur.

**Reflexes.**—The uterus has a strange and wide influence over the person; the word ‘hysterical,’ as applied to certain nervous phenomena, is derived straight from *ὑστέρα*, the womb. Hilton went so far as to ascribe the frequency of ‘hysterical’ affections of the hip and knee-joints to an association, through the sympathetic filaments, of the ovarian and uterine nerves with the sciatic and obturator!

## THE OVARY

The ovary has the shape of an almond, and weighs about  $\frac{1}{4}$  oz. It is placed between the layers of the broad ligament, being attached to the corner of the uterus by a short, slender ligament just behind the Fallopian tube; externally it is joined to a fringe of that tube (*v.* p. 390). It floats freely in the pelvis, but is apt to wander in childhood down the inguinal canal; I once had occasion to operate for a strangulation of the ovary through the crural canal. It may also be prolapsed into the antero- or retro-uterine pouch, where it can be felt through the vagina, movable and, perhaps, very tender.

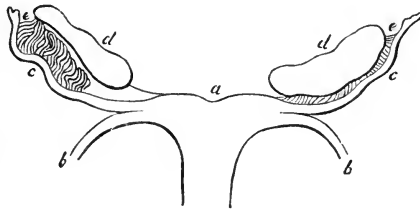
It consists of a fibrous coat, *tunica albuginea*, which sends delicate processes into the interior to support the blood-vessels and the Graafian follicles. The broad ligament invests it with a serous coat, *tunica vaginalis*, which is covered with columnar epithelial cells.

The **Graafian follicles** are lined by the cellular *membrana granulosa* and contain fluid and an ovum ; as they ripen and approach the surface of the ovary the fluid increases. During menstruation a follicle bursts, the ovum escaping through the peritoneal coat and into the Fallopian tube, through which it reaches the uterus. The burst follicle is then filled with a yellowish substance, the *corpus luteum*, which quickly shrivels up if conception have not taken place, but which grows into an important mass if pregnancy have occurred ; the latter mass is a *true corpus luteum*, the former a *false* one.

Abscess in a follicle (*suppurative ovaritis*) may burst into the peritoneum and involve it in a fatal inflammation.

Cysts of material 'like skin' (dermoid cysts) are often found in the ovary, containing hair, fat, epithelium, teeth, and such like ; their origin is congenital, and is probably due to an island of the external blastodermic layer having become entangled in the middle layer, from which the ovary is produced.

From a fœtus of three months:  
*a*, uterus.  
*b*, round ligaments.  
*c*, Fallopian tubes.  
*d*, ovaries.  
*e*, remains of Wolffian bodies. (See p. 390.)



The **parovarium**, or organ of Rosenmüller, may be seen between the ovary and the Fallopian tube by holding a fresh broad ligament up to the light. It is about an inch wide and consists of a series of tortuous tubes opening by one end into a slender canal, the duct of Gaertner, whilst the other end is connected with the ovary. Doran has counted as many as twenty-four of these tubes in the parovarium. They are lined with cylindrical epithelium and contain a small amount of fluid, which, increasing in amount, may form a 'cyst of the broad ligament.'

The parovarium is a remnant of the Wolffian body. The tubes of the parovarium correspond to the vasa efferentia and coni vasculosi, whilst the ovary represents the body of the testis.

**Supply.**—The *ovarian arteries* come from the aorta (spermatic) ; in the broad ligament they anastomose freely with the uterine of the internal iliac. As in the case of the testis, the *veins* form a pampiniform plexus, which ends in the caval or left renal vein.

The *nerves* come from the aortic plexus with the ovarian artery, whilst others are derived from the pelvic plexus, and accompany branches of the uterine artery.

Though malignant disease may attack the ovary, the common form of **ovarian tumour** is due to a collection of fluid in dilated Graafian follicles ; thus an enormous dropsy may be produced which

has to be **distinguished from abdominal ascites**. When several follicles are dropsical, *multilocular cystic tumours* occur.

Both in ovarian and abdominal dropsy there is a rounded swelling giving a wave of fluctuation on palpation. But as the patient lies supine the ovarian tumour bulges more on one side, the area of dulness on percussion varying little with change of position (*v. p.* 316). If the tumour extend across the middle line, it pushes away the intestine and renders the area absolutely dull; whereas, in ascites, there is generally some inflated bowel floating up under the umbilicus, rendering percussion resonant. The finger in the vagina makes out the semi-elastic tumour, and probably finds the cervix uteri swung over to that side by the body of the uterus having been pushed over to the opposite side by the tumour; the uterine sound also shows lateral deflection of the uterus; but let it be remembered that miscarriage is apt to follow the careless use of the sound. It should not be introduced if there be the least chance of pregnancy existing—I know of an instance in which a physician was spared the operation of ovariotomy itself by the patient giving birth to twins very early on the morning of the proposed operation.

When the diagnosis is between ovarian disease and pregnancy bimanual examination should be resorted to, the os uteri and the breasts should be examined, and the foetal heart-sounds should be listened for. If still there were doubt, time would certainly clear it up.

A large ovarian tumour presses upon the bladder and irritates it; upon the rectum and obstructs it, producing hæmorrhoids; upon the iliac veins, causing œdema of *one* lower limb. It may also irritate the stomach, and, by pushing up the diaphragm, impede the action of the heart and lungs. If it compress the ureter there will be renal pains and albuminuria. The legs may be painful and greatly swollen. At first the tumour occupies only one side of the false pelvis, but as it ascends into the abdomen it passes to the middle line and evenly occupies the cavity. By pressing upon the bladder it may entirely efface that cavity, so that the urine runs away by the urethra as quickly as it flows from the ureters.

**Ovaritis**, acute or chronic, may follow sexual and other irritations of the vagina and uterus, just as epididymitis is caused by irritation of the prostatic urethra. It is especially apt to follow specific (gonorrhœal) inflammation which has extended up the Fallopian tube. There is pain in the back and down the inner side of the thigh, as in orchitis, and tenderness deep in the iliac region.

**Ovariotomy**.—The bowels should be empty, and a catheter should be introduced into the bladder just before operating. The incision, which need not measure more than a few inches, should be made in the median line from an inch or so below the umbilicus. The parietal peritoneum is then opened, and the cyst is seen and tapped; and when

it is sufficiently empty and flaccid, it is drawn out of the wound. The pedicle is then transfixed, and, its spermatic vessels being securely tied with the broad ligament, the cyst is then cut off. The other ovary must be inspected; if enlarged, it also should be removed. The sponges and forceps are then carefully counted, and the wound is closed by sutures which enclose the parietal peritoneum as well as skin.

### THE FALLOPIAN TUBE

The Fallopian tube, 4 in., lies in the highest part of the free border of the broad ligament; it leads from the serous coat of the ovary into the cornu of the uterus, with which it communicates by a minute orifice. The ovarian end is trumpet-shaped and fringed, one of the fringes serving to connect it with the ovary, as shown on p. 390.

**Structure.**—Its external coat is of peritoneum, and is derived from the broad ligament. Then comes a muscular layer of longitudinal and circular fibres; and lastly the mucous lining, which is continuous with the peritoneum at one end, and with the lining of the uterus at the other. The *epithelium* is columnar ciliated. Through the tube micro-organisms, septic matter, and vaginal douches may find their way from the uterus into the peritoneal cavity.

The Fallopian tube depends for its *supplies* upon the vessels and nerves of the ovary and uterus.

The functions of the ciliated epithelium are to sweep the ovum into the uterus and to hinder the ascent of spermatozoa. When inflammation, possibly of gonorrhœal origin, has stripped the tube of the epithelium, the descent of the ovum is retarded and the ascent of spermatozoa little hindered, extra-uterine pregnancy being then specially apt to occur. As a result of the original infection, on examination of patients who have died from the effects of tubal pregnancy, old peritoneal adhesions are often met with. Such women have commonly been sterile, because 'their procreative machinery was out of gear.' (Lawson Tait.)

Rupture of the pregnant tube may occur into the peritoneal cavity—a dangerous casualty—or between the layers of the broad ligament.

Though the tube has normally a lumen only the size of a bristle, it may become greatly dilated and may be converted into a mucous or purulent cyst—hydro-salpinx or pyo-salpinx (*σαλπινγξ*, tube). The elongated tumour of a dilated tube may be recognised by the finger in the vagina. If allowed to remain, pain continues and great risk of suppurative peritonitis, from the bursting of the tumour, is incurred. The symptoms and treatment of pyo-salpinx have been clearly described by Lawson Tait.

## THE GENITO-URINARY APPARATUS OF THE FEMALE

(An outline of the **development** of the parts is given on pp. 329 and 420.)

The **labia majora** are two large muco-cutaneous folds containing fat, connected above the pubes in the **mons Veneris**, and tapering inferiorly towards the posterior commissure of the vulva, about an inch in front of the anus. They represent the lateral halves of the scrotum, and occasionally the ovaries, after the manner of the testes, pass into them from the inguinal canal. Inguinal hernia also may descend into the labium, but ordinarily nothing enters the labial mass but the **round ligament** of the uterus, the end of which then spreads out into its fibrous tissue. *Abscess* frequently occurs in the labium, and, on account of the looseness of the tissue of that part, œdema extends rapidly and widely. If the pus be in the superficial layer of the fascia (the fatty layer) it may be diffused towards the anus, thigh, or abdomen; but if it be beneath the deeper, or membranous layer, it can pass only towards the abdomen.

The blood-vessels, lymphatics, and nerves of the labia correspond to those of the scrotum (p. 426).

The **labia minora**, or **nymphæ**, are mucous folds which join above around the clitoris, and blend below with the inner surface of the labia majora; they contain much vascular tissue. They are apt to be redundant, and to project outside the vulva, especially in children. In certain adults, as among the Hottentots, they are often enormously hypertrophied.

At the junction of the nymphæ, and firmly attached to the pubic and ischial rami by two crura, is the **clitoris**. It corresponds to the corpus cavernosum of the penis, and is composed of erectile tissue. Amputation of the clitoris may be required for malignant disease.

In some hysterical women this organ is in a state of chronic erection; micturition is then difficult, and there may be complete (hysterical) retention of urine. (*See also* p. 406.)

The urethra has no connection with the clitoris, but opens into the vestibule about an inch lower down; its aperture, the *meatus urinarius*, is somewhat raised, and, to the finger, feels as a depression in the centre of a flat, round papilla. The urethra can be felt like a round cord between the anterior wall of the vagina and the pubes (*v.* p. 389.)

Further down is the opening of the vagina, which, in the virgin state, is partially occluded by the **hymen**. When the hymen has been ruptured its situation is marked by papillary elevations, **carunculæ myrtiformes**.

The hymen may form a complete diaphragm to the vagina, and cause retention of menstrual discharge. The presence of a hymen is not proof of the virginity of the subject, nor, on the other hand, can



its absence be regarded as evidence of intercourse having occurred ; sometimes, indeed, the hymen has to be incised in the parturient woman.

A *vulvo-vaginal gland* is placed on each side of the entrance to the vagina ; it corresponds to Cowper's gland, and discharges its secretion by a small duct opening in front of the hymen. The duct is liable to inflammation and suppuration, often the result of sexual or gonorrhœal irritation. The resulting abscess is hard, round, and painful, and the muco-cutaneous covering is bright-red.

Masses of erectile tissue, *bulbi vestibuli*, are placed beneath the mucous lining of the entrance of the vagina. They correspond to the lateral halves of the bulb of the male urethra. From injury or other cause, rupture of this tissue may occur, with the formation of a large, dusky, blood-tumour—a *pudendal hæmatocele*—which is more often met with in pregnant women. The external abdominal ring being clear shows that the pudendal swelling is not a hernia.

The **blood-vessels** and **lymphatics** of the labia correspond with those of the scrotum and penis ; separate description of them is not needed. The vein from the dorsum of the clitoris, however, joins in a plexus around the urethra, which communicates with the vaginal, vesical, and hæmorrhoidal branches of the anterior division of the internal iliac vein. The **nerves** are derived from the lumbar plexus, the internal pudic, and the lesser sciatic, as in the male.

The **urethra** is about  $1\frac{1}{2}$  in. long. It runs downwards and forwards, parallel with, and imbedded in, the anterior wall of the vagina. The narrowest part is the meatus urinarius. In the child the meatus is, on account of the slight development of the pelvis and its viscera, far within the opening of the vulva. The urethra is lined with mucous membrane arranged in longitudinal folds and covered with scaly epithelium. Next comes a submucous layer of white and elastic fibres, and then a layer of erectile tissue and pale muscular fibres continuous with those of the bladder. Around all, as the urethra passes through the rudimentary triangular ligament, is the striated compressor urethræ. Small vascular tumours grow from the mucous membrane of the meatus urinarius ; their effect upon the patient is like that which follows preputial irritation in the male ; they must be carefully searched for and cut off.

The female urethra is extremely dilatable, and after the introduction of the finger in exploration of the bladder the paralysis quickly passes away.

Even in the child the little finger of the surgeon may be gradually introduced, or a large lithotrite used, and fragments of calculus extracted, with merely a temporary incontinence of urine.

The **vagina** is the musculo-membranous passage which leads from the vulva to the uterus. It follows the axis of the pelvic outlet, lying close behind the bladder and the urethra, in front of the rectum, and

between the levatores ani. Its curve must be remembered at the time of introducing the speculum.

The prolonged pressure of the fœtal head during a tedious labour may cause a sloughing of the vaginal walls, opening the vagina into the bladder or rectum, the result being vesico-vaginal and recto-vaginal fistula respectively. Urine or flatus would not escape directly after parturition, as in the case of a laceration, but would be delayed until the slough had separated. The condition may eventually be remedied by dilating the vagina with a speculum, vivifying the edges of the fistula, and closing it by sutures.

In the case of a tumour implicating the anterior wall of the rectum, its size and connections should be examined by one index-finger in the bowel and the other in the vagina.

**Structure of vagina.**—With the exception of the slight peritoneal connection (p. 389), the vagina has no serous coat, the most external layer being of fibrous tissue, derived from the recto-vesical fascia. Next comes a coat of non-striated muscular tissue, arranged for the most part in a longitudinal and a deeper, circular layer. More internally is a thin coat of erectile tissue; and, lastly, a lining of mucous membrane covered with squamous epithelium. On the anterior and posterior walls the mucous membrane is raised in a longitudinal ridge with short transverse ridges passing from it. This arrangement is chiefly for preparing the canal for the severe dilatation to which it is submitted during parturition.

The orifice of the vagina is embraced by the striated **sphincter vaginæ**, which corresponds to the accelerator urinæ in the male; its spasmodic contraction produces the condition known as *vaginismus*; it might possibly demand a speculum in the vagina for an increasing length of time each day, the sphincter being thus tired out. Sometimes, however, the spasmodic contraction is due to small sensitive growths upon the mucous membrane; a careful inspection of the parts should be made under ether in every case before the adoption of empirical treatment. The state of the ovaries and of the uterus should also be enquired into.

After rupture of the perineum much of the support of the pelvic organs is lost, and during defæcation and micturition the anterior wall of the rectum or the posterior wall of the bladder is thrust down as a flaccid tumour through the vulva, the condition being a *rectocele* or *vesicocèle*, as the case may be. The uterus itself may descend until its neck and part of its body habitually remain outside the vulva. The perineal rupture may extend right through the sphincter ani, making of the vagina and rectum a vast cloaca.

Sometimes the vagina is divided in its length by a vertical septum, the lateral halves of the cavity being associated with the halves of a bifid uterus, as shown on p. 395.

The **blood-vessels of the vagina** are derived from the anterior

divisions of the internal iliac trunks, and from the uterine branches. The front and back of the vagina also derive twigs from the vesical and hæmorrhoidal vessels respectively ; and the entrance receives twigs from the internal pudic. The **lymphatics** pass to the pelvic glands. The **nerves** come from the vesical, hæmorrhoidal, and uterine ramifications, and from the hypogastric plexus itself.

As shown on p. 389, the upper part of the vagina is separated from the rectum by the retro-uterine pouch of peritoneum, which thus gives a partial serous covering to the vagina ; there is no peritoneum upon the front wall. I have known the peritoneal cavity opened in paring the edges of a fistulous communication between the upper part of the vagina and the rectum, some shreds of omentum appearing in the vagina. When epithelioma attacks the upper part of the posterior wall of the vagina the peritoneal cavity is quickly invaded, fatal peritonitis being entailed. A loop of small intestine may be driven in this pouch to bulge into the upper part of the vagina, constituting a *vaginal hernia*.

The **female bladder** is placed behind the pubes and the triangular ligament, and in front of the vagina ; and, when distended, it ascends in front of the uterus, being separated from it by a pouch of peritoneum. As there is no prostate gland, and as the base of the bladder is separated from the concavity of the rectum by the vagina, there is no pouch behind the vesical outlet in which urine can collect. The base of the bladder can be thoroughly explored by the sound when the index-finger is in the vagina, and in this way the presence of even small papillomatous growths may be detected. But, as remarked above, the finger may be conveniently passed into the bladder for the purpose of examination.

On account of the size of the urethra, cystitis and vesical calculus are rarely met with, and urethritis is uncommon. In crushing a stone, the lithotrite should be placed to one side of the elevation which the neck of the uterus may form at the back of the bladder.

The base of the bladder is closely adherent to the front of the vagina, without, of course, the intervention of any peritoneum ; and in amputation of the cervix uteri by the *écraseur* it has happened that part of the anterior vaginal wall and of the floor of the bladder have been accidentally included in the noose and taken away. By the intervention of the vagina and uterus between the bladder and rectum the female bladder has less of a peritoneal coat than that of the male. As in the male, there is no peritoneum on the anterior or antero-lateral aspect.

For chronic and intractable cystitis free dilatation of the urethra and irrigation of the bladder may be unhesitatingly performed, but vaginal cystotomy can rarely be necessary.

*Retention of urine in the female*, except from hysteria, or after parturition, or after an operation upon the rectum, is rare, because of the

shortness and capacity of the urethra and of its immunity from gleet. The signs of retention are inability to pass urine ; dribbling from overflow ; the presence of a rounded tumour—which may be made out by palpation and percussion above the pubes and by examination *per vaginam*. In a lady with every one of these signs it was discovered that an ovarian tumour growing centrally had compressed the bladder until it could contain no urine, the 'overflow' being the constant escaping of the urine directly after its exit from the ureters.

**Development.**—Early in fœtal life a hollow growth, like the finger of a glove, starting from the hinder end of the rudimentary intestinal canal, extends through a wide gap in the front wall of the abdomen. On the closing in of the abdomen, the part of the diverticulum between the intestine and the umbilicus persists as the bladder ; a small portion only (just behind the umbilicus) becomes obliterated, and constitutes the superior ligament—the remains of the *urachus*. Then a partition grows downwards and forwards, and converts the existing cloaca into two passages—the rectum and the urethra. Thus, at birth the fusiform bladder is found in the abdomen rather than in the pelvis ; it becomes rounded, and settles down, as the pelvis grows capable of receiving it. In perineal lithotomy in young children the knife must be thrust well upwards in order to open the bladder.

(For scheme of development *see* p. 383.)

In rare instances the obliteration of the urachus is delayed, so that, after birth, urine, or even vesical calculi, may escape through the opening at the umbilicus. Owing to an arrest of development the abdominal walls may fail to meet in front, and, there being at the same time an absence of the anterior wall of the bladder, the posterior wall and base of that viscus bulge out as a bright vascular tumour. On it may be seen the openings of the ureters and the trickling urine. The term **congenital hiatus** better describes the deformity than does the one more generally applied to it—*extroversion of the bladder*. It is associated with absence of the pubic symphysis, the urethra being represented by an open channel on the dorsum of an ill-developed penis (epispadias). The front of the bladder being deficient, its posterior wall and base are thrust forwards as a convex tumour by the subjacent viscera.

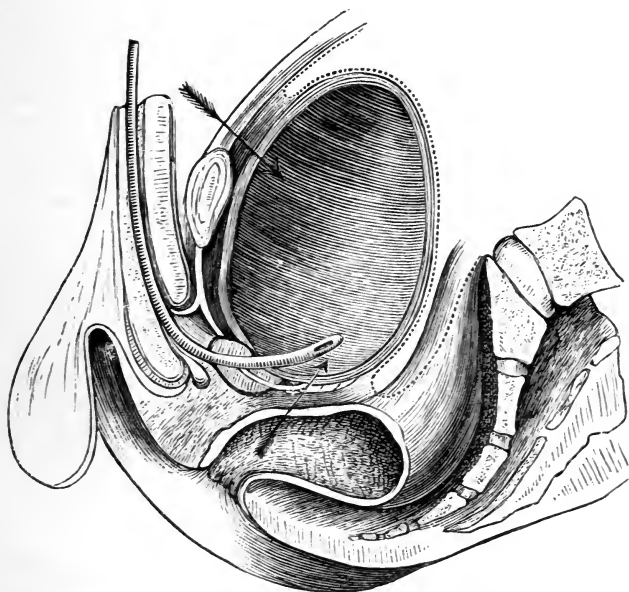
#### THE MALE BLADDER

**Relations.**—When empty, the bladder lies deeply behind the prostate, triangular ligament, and body of pubes. When distended, it mounts behind the recti abdominis and even to the umbilicus. Posteriorly are the rectum and recto-vesical pouch ; into the pouch coils of small intestine are falling ; lower down are the vesiculæ seminales and vasa differentia. Laterally are the pelvic walls, and around its

sides and summit are intestinal coils. The base of the bladder is fixed, and is close in front of the rectum. For further remarks upon the relative position of the bladder and rectum reference may be made to p. 385.

The bladder may be *emptied by manual compression* in those cases in which retention is due to paralysis, provided there is no inflammation or other disease of the bladder, and no urethral obstruction.

**Structure.**—A *partial serous coat*.—The *peritoneum* passes from the middle of the front of the rectum on to the back of the bladder, just above the vesiculæ seminales and the entrance of the ureters;



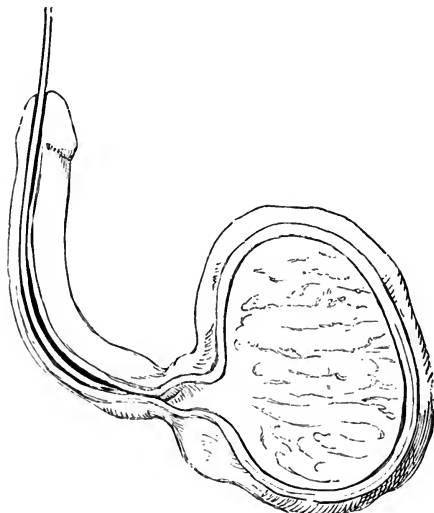
Arrows showing rectal and supra-pubic puncture of distended bladder. (HOLDEN.)

thence it ascends over the postero-lateral surface, and, reaching the hypogastric arteries and the urachus, is reflected on to the abdominal wall. When the bladder is empty the recto-vesical pouch may come within two inches of the anus, but when it is distended the pouch stands at about four inches from the perineum. Thus, the base of the bladder, the antero-lateral aspects, and the whole front surface are destitute of serous investment, and puncture for the relief of retention may be practised through the rectum (between the vesiculæ seminales) and above the pubes without risk of setting up peritonitis. At the latter situation the instrument should be thrust boldly back-

wards, lest, as I have seen happen, it descend in the cellular interval behind the pubes, and fail to enter the bladder.

In a fat subject the trocar may be introduced where the linea alba is crossed, a few inches above the pubes, by the transverse crease.

The *muscular coat* consists of non-striated longitudinal fibres chiefly at the front and back; some of them are connected with the prostate and also with the true ligaments; chiefly towards the neck of the bladder circular bands exist; they are associated with the prostate and form a kind of sphincter. When long-continued and extra work is



Stricture at bulb; membranous urethra dilated; bladder thickened, and mucous membrane roughened.

thrown upon the muscular coat, as in the case of old stricture, hypertrophy results; and sometimes a pouch of the mucous lining is forced through a gap between the thick muscular bands and forms a herniated sac in which a stone may be lodged. Should a calculus fall into such a sac, there would be a sudden cessation of symptoms, and the surgeon might thenceforth fail to strike it. In such cases examination by the rectum should give valuable assistance; and the stone might be successfully removed by a supra-pubic operation.

A definite band of muscular fibres extends between the two ureters—the *inter-uretal band*—and in cases of old-standing urinary obstruction it is recognised after death as a prominent ridge bounding the front of a deep depression of the mucous membrane.

The *mucous coat*, which is attached to the muscular by a layer of connective tissue, is thrown into rugæ which are effaced as the bladder fills. But in the triangular part of the floor which intervenes between the openings of the ureters and the beginning of the urethra there are no rugæ, the mucous coat being smoothly spread. This area is called the *trigone*; against it the stone is forcibly and painfully driven during micturition. In certain conditions the mucous coat is thrown into firm, permanent ridges, which, when the urine is alkaline, may become encrusted with phosphates. The epithelium is of a modified squamous type.

The *uvula* is a small sensitive elevation at the apex of the trigone ; it is situated above the 'middle lobe' of the prostate.

**Ligaments.**—The base of the bladder is firmly fixed by four sheets of the recto-vesical fascia, two of which pass on to its side along the upper surface of the levatores ani (p. 363), and two run on to it more (p. 413) anteriorly from the pubes and prostate—the lateral and pubo-prostatic ligaments, respectively. The urachus is reckoned as the fifth true ligament. The five *false ligaments* are the various sheets of the peritoneum which pass to or from the bladder. Thus the sides of the recto-vesical pouch make two of them ; the lateral reflections of the peritoneum from the side of the pelvis make two more, and the fifth is that piece of the peritoneum which runs up behind the obliterated hypogastric arteries and the urachus. The reflections of the peritoneum around the bladder steady it without absolutely fixing it ; they also prevent coils of the intestine falling between the bladder and the pubes.

**Supply.**—Blood is derived from the internal iliac, and especially from that portion of it which, under the name of the hypogastric artery, passed into the umbilical cord. The part which remains pervious after birth constitutes the *superior vesical artery* ; the *middle vesical* is a branch of it. The *inferior vesical* branches come independently from the internal iliac, and from other neighbouring vessels, such as the middle hæmorrhoidal, sciatic, obturator, pudic, uterine, and vaginal. The *veins* form an intricate plexus at the base of the bladder with those of the lower part of the rectum, the prostate, and seminal vesicles ; other branches pass at once into the internal iliac trunk. The vesico-prostatic plexus of veins is enclosed within the recto-vesical fascia.

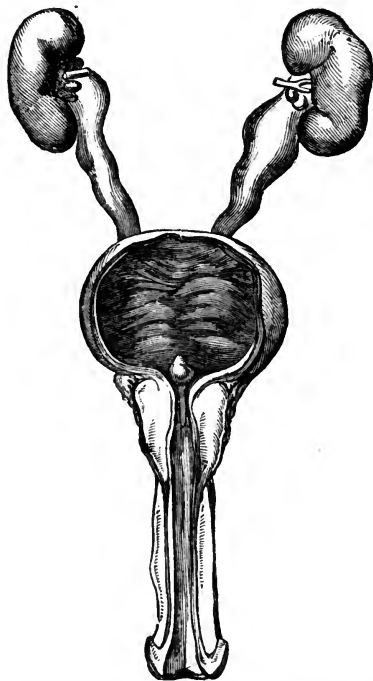
The *lymphatics* communicate with the glands by the side of the internal iliac artery.

The *nerves* are derived from the hypogastric plexus of the sympathetic, and also from the sacral nerves, especially the fourth ; thus, in the case of compression of the spinal cord, the patient may lose not only the power of micturating, but also the consciousness of the bladder being distended. The fact of the non-striated muscular tissue of the bladder receiving filaments from a spinal nerve (fourth sacral) is interesting and suggestive.

The subject of enlarged prostate sometimes finds that he can pass water better when sitting on a cold seat, as in that way he is able to stimulate the vesical nerves.

**Retention of urine.**—As the bladder becomes distended it expands laterally and also mounts behind the recti abdominis, lifting the coils of intestine. Bowel cannot intervene between the bladder and the abdominal wall, because of the reflection of the peritoneum behind the urachus (*v.* p. 385) ; thus, the hypogastric and lower umbilical region is full and rounded and dull on percussion. The

base of the bladder is thrust down against the rectum, and, by digital exploration, a semi-elastic and rounded bulging may be detected against its anterior wall; and, on gently striking the hypogastric region, fluctuation may be detected by the finger in the bowel. When the bladder is distended to the utmost, urine begins to leak out by the urethra; this overflow may continue for days or even months, the patient believing that the viscus is efficiently emptying itself. *Incontinence of urine* in the adult thus generally means a bladder full and overflowing; but in the child it suggests irritation. The more distended the bladder the more thinly are the coats spread out, and the greater the risk of rupture from injury. Over-distension may so stretch the muscular coat as to produce temporary paralysis. Thus, when a catheter is introduced the urine flows without force, and under the



Dilatation of ureters and disease of kidneys, the result of enlargement of middle lobe of prostate. (ERICHSEN.)

influence of the diaphragmatic contraction rather than of the vesical wall. But when stricture has long impeded micturition the muscular coat of the bladder is found thickened from exercise. In the same way the left ventricle of the heart grows thick and strong in the effort to force blood through the arterial system in Bright's disease.

In **cystitis** the mucous membrane swells, and perhaps to such an extent as to block the openings of the ureters and prevent the descent of urine. A malignant growth may have the same effect, and the ureters may in time be dilated to the size of a piece of small intestine. If this change be slowly and quietly brought about, the glandular structure may almost entirely disappear under pressure, the kidney being represented by a multilocular cyst into which its fibrous framework is expanded. But more commonly the result of obstructed outflow is the sequence of pathological events

associated with the so-called **surgical kidney**, which are as follows:—

The bladder being distended, decomposition of the urine occurs, and the inflammation of the mucous membrane extends along the



ureters to the pelvis of the kidney, where suppuration also takes place and where more of the decomposing urine is pent up. Inflammation extends thence through the gland, the tissue of which becomes riddled with foul and scattered abscesses. Sometimes one of these abscesses bursts through the capsule and sets up perinephritic suppuration. The decomposing urine is taken up by the blood, and the patient's breath has a strong ammoniacal odour. On tearing off the capsule at the post-mortem examination close adhesions are found in many places and small cortical abscesses are opened up.

**Vesical calculus.**—The pressure of the stone against the nervous filaments on the floor of the bladder gives rise to the sensation of the bladder containing an uncomfortable amount of urine, and thus frequency of micturition is an early sign. By night the boy wets the bed, and even during the day he may be unable to hold his water. The sacral plexus supplies the sensory filaments, and by the internal pudic nerve it also gives twigs to the end of the penis, to which spot pain is often referred. (Similarly pain is referred to the knee in disease of the hip, the obturator nerve supplying each articulation, p. 358.) During micturition the stone is driven against the sensitive trigone, and the effort at once becomes urgent and distressing; so violent is it that the boy runs to the closet lest in voiding the urine he also evacuate the rectum. Prolapse of the lining of the rectum occurs; and blood, and, later on, pus, may be mixed with the urine. Should the stone be driven against the urethral opening of the bladder, and so suddenly check the outflow of urine, the boy may scream with agony, but in time he finds that this distress does not occur when he micturates in the kneeling or horizontal posture, as the stone then falls away from the neck of the bladder.

The vesical sound should be formed of one piece of metal and must possess a short and almost rectangular beak, so that the base of the bladder, which may lie below the level of the prostate, may, with every other mucous area, be thoroughly explored. (For *lithotomy*, see p. 443.) The floor of the bladder may be rendered more accessible to the sound by raising it by the finger in the rectum, or by turning the patient on to his side.

Probably there is a *centre for micturition and defæcation* in the lumbar enlargement:—

From the bladder and rectum sensory filaments carry upwards the messages of unrest, but the reflex circle is not necessarily at once put in motion, for education and habit have placed the centre under the control of the will. But when the brain has lost the control, as in fracture of the dorsal spine, and in cerebral or medullary disease, the patient unconsciously 'passes everything under him.' The afferent impulse from the mucous membrane is converted into a motor impulse, which passes to the muscular coat, urging its contraction, the sphincters being at the same time relaxed. When the nerve-lesion is so great that the

centre is thrown out of working order, not only is the patient unaware when the bladder is full, but no motor impulse is transmitted to the muscular coat, and the bladder 'brims over.'

Extreme retention of urine may exist without causing distress when the patient has become gradually accustomed to it, but sudden accumulation from tension of sensory nerves, causes great agony. Chronic retention may be mistaken for abdominal ascites. Before tapping for the latter condition it is, therefore, the rule to pass a catheter. The over-loaded bladder may also be mistaken for ovarian disease or pregnancy. The distended bladder may be ruptured from violence. If the rent implicate the postero-lateral aspect, peritonitis is very likely to follow. If the rent be at the front or base of the bladder the escape will be extra-peritoneal, cellulitis and abscess probably occurring. As a rule the urethra gives way rather than the bladder, perineal abscess being the result.

The chief signs of the intra-peritoneal rupture are inability to micturate from the time of the injury; onset of collapse on account of the extravasation into the peritoneal cavity; the bladder containing only a little blood-stained urine whilst a long metal catheter may, perhaps, pass through the rent until its beak is found behind the linea alba. Lastly, warm water quietly injected into a ruptured bladder quickly disappears. Abdominal section, suture of the wound, and flushings of the peritoneum with a warm antiseptic solution, would be needed.

When ascites has been mistaken for retention of urine, the catheter being introduced and the bladder being found empty, the practitioner has sometimes imagined that the instrument was not thrust in far enough, and has thereupon driven the beak of the instrument through the posterior wall of the bladder, which would in such circumstances fall near to the trigone, and has thus evacuated the peritoneal cavity of serum.

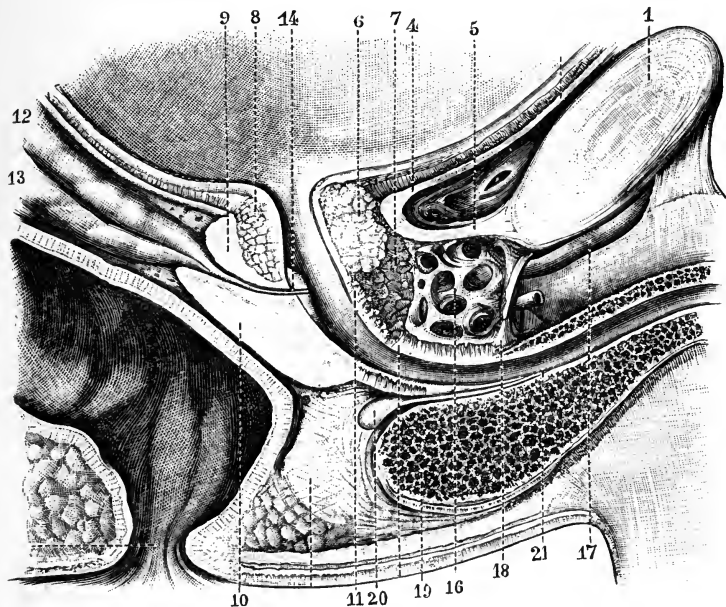
In the case of an enormous calculus, or of villous disease, the bladder may be opened above the pubes through an incision in the linea alba; but before performing this operation the bladder should be carefully washed out and distended, and thrust bodily forwards and upwards by the gentle inflation of an india-rubber bag in the rectum. Thus the peritoneum is pushed high up and the bladder opened without difficulty and without much danger. In the case of urgent cystitis from prostatic enlargement a tube might be permanently worn above the pubes.

Through an incision in the perineum the finger can usually be made to explore the whole of the interior of the bladder, its summit and anterior wall being pushed downwards by the hand upon the abdominal wall.

#### THE PROSTATE GLAND

The prostate is a mixture of fibrous tissue, non-striated muscle, and of follicular gland-tissue. It is placed in front of the bladder (*πρὸ*,

ἰσθημι), surrounding its neck. It is shaped like the ace of hearts, the apex pointing against the triangular ligament. It is about the size of a horse-chestnut, and consists of two lateral lobes and an intermediate portion. The urethra runs through it, but nearer to the upper surface. *Additional relations* are these :—The pubic symphysis lies above and in front. Behind, in addition to the bladder, are the vesiculæ seminales and the vasa deferentia. Close below and behind is the rectum, through which the index finger can define much of its outline. Below it is the thick mass of the perineum. (See fig. on p. 385.)



1, pubes; 5, pubo-prostatic ligament; 9, middle lobe of, 10, prostate; 12, left vas; 13, left vesicula; 14, com. ejaculatory duct; 16, prostatic plexus receiving 17, dorsal vein of penis; 19, bulb; 20, Cowper's gland.

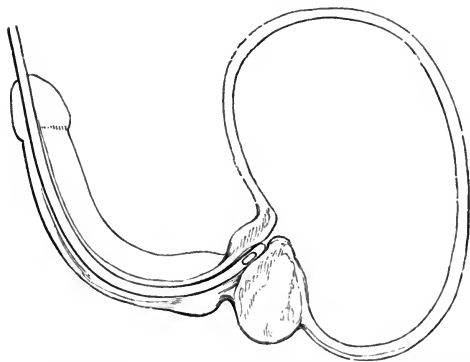
*Investments.*—A fibrous capsule immediately surrounds the prostatic tissue, and sends processes into its substance, being, indeed, part of the gland. On the outside of this is a plexus of veins, which is in communication with the veins of the bladder and rectum (vesico-prostatic plexus); and at the front the plexus receives the dorsal vein of the penis. This large venous plexus separates the fascial investment of the prostate from the fibrous coat of the gland. The veins are often dilated, and occasionally contain calcareous matter; they are divided in lateral lithotomy, and then, in the adult, may be the source of serious bleeding.

The prostatic plexus of veins empties on either side into the internal iliac vein.

The *arteries* of the prostate come from the internal iliac, inferior vesical, internal pudic, and inferior hæmorrhoidal. An irregular internal pudic artery may run by the side of the prostate (p. 442). The *nerves* are derived from the hypogastric plexus. The *lymphatics* enter the chain of glands along the internal iliac artery.

**Middle lobe.**—At the upper and back part of the prostate, between the lateral lobes, may be found a small, rounded lobe, 'intimately connected with the other two, and fitting in between them and the bladder and the adjacent part of the urethra. When prominent it corresponds to the elevation in the urinary bladder, called the uvula' (Quain). A slight enlargement of the 'middle lobe' upwards may cause serious obstruction at the neck of the bladder, and will give increased length to the urethra; nevertheless, if the rest of the prostate be not hypertrophied, a digital exploration by the rectum may give no information of the condition, the growth being into the bladder rather than towards the rectum. In most cases, however, hypertrophy of the prostatic

tissue is general, and can readily be estimated *per anum.* If the enlargement be extreme, the bladder is pushed upwards and forwards, the neck being increased in length. To draw off the retained urine, a long catheter with a sudden curve is needed. In enlargement of the middle lobe, a soft, elbowed (*coudé*) catheter answers well, the beak



Hypertrophy of median and of lateral lobes of prostate; bladder dilated and thickened; 'prostatic' catheter.

readily surmounting the obstruction. Enlargement of the prostate



obstructs micturition, and necessitates the subject of it learning the art of drawing off the residual urine by a catheter. Sometimes the patient stimulates the bladder to contract by sitting upon a cold seat. Some-

times he finds that he can more completely empty it by getting on to his hands and knees. The pressure of the tumour against the lower bowel gives rise to the sensation that defæcation is not complete, and may cause the patient to go to the closet to void the urine. On account of the straining at micturition and at stool, the enlargement is apt to cause piles. Pressure against the rectum may even obstruct defæcation, and render the sphincter flaccid and the anus patulous. The subject of enlarged prostate usually avoids a soft-seated chair, because the yielding cushion, forced up against the perineum, presses on the hypertrophied masses. Pieces of enlarged prostate have often been removed through a median perineal incision, and McGill has successfully excised with scissors and forceps, by a suprapubic operation, portions of enlarged prostates which prevented micturition. Probably in most cases in which a vesical calculus is associated with enlarged prostate, suprapubic lithotomy should be resorted to in order that, at the same time, the projecting middle lobe may be nipped off, as advised by McGill.

**Acute prostatitis** is caused by extension of gonorrhœal inflammation. The gland rapidly enlarges, and, blocking up the urethra, causes retention. The patient is in dire distress, and neither hot bath nor opium may afford relief. Examination by the rectum proves the gland to be swollen and tender. With the utmost gentleness a soft catheter should be passed and the water drawn off. Leeches may be applied in front of the anus. Should suppuration follow, the **prostatic abscess** will be likely to find its discharge into the urethra, bladder, or rectum, or even through the perineum. The strong fascial covering of the upper aspect of the prostate usually prevents the matter escaping into the pelvis. Should the abscess break into the urethra, recovery is apt to be tedious, pus escaping during micturition, especially towards the end of the act, when the gland is brought under the influence of the levatores ani. At other times by firm pressure in the perineum and by appropriate manipulation, pus may be made to escape from the meatus urinarius.

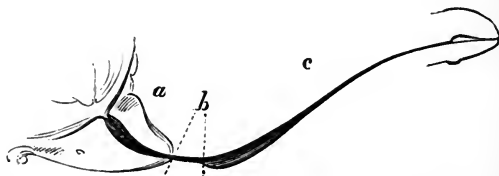
In *chronic prostatitis* enlargement may be detected per rectum; there may be irritability of the bladder, and a feeling of weight in the perineum. From the follicular glands of the prostate filamentous casts are shed, which float in the urine like vermicelli.

#### THE MALE URETHRA

From the neck of the adult male bladder to the meatus urinarius is about nine inches. The prostate contains the first inch and a-half; the next half-inch is between the two layers of the triangular ligament (membranous portion, p. 413), and the remainder is surrounded by the erectile tissue of the corpus spongiosum (p. 385). That piece of the urethra which is inclosed in the enlarged portion of the corpus

spongiosum—upon the front of the triangular ligament—is the bulbous portion.

Though usually represented in diagrams as a hollow cylinder, the urethra has its roof and floor closely approximated; it thus forms a long valve to the bladder. It possesses, when the penis is flaccid, two curves, of which the concavity of the posterior is turned upwards and of the anterior downward. The hinder of the curves is permanent; the other is obliterated when the penis is raised, the urethral curve being then like that of an ordinary metal catheter. The fixed part of the urethra is the more likely to be ruptured by injury.



Wax cast of normal urethra: *a*, prostatic; *b*, membranous; *c*, spongy. (THOMPSON.)

The **prostatic portion** of the urethra lies nearer the upper surface of the gland. It is wide and dilatible, especially in the middle, and readily admits the passage of the finger during lithotomy. Extending along the floor is the *veru montanum*, beneath which a tunnel, the *sinus pocularis*, runs from before backwards for nearly half an inch. This sinus is the homologue of the uterus, and the common ejaculatory ducts open within it, or upon its margins. On each side of the veru the floor is grooved by a *prostatic sinus*, which receives the secretion of about a dozen follicular glands. These glands are the chief source of that fluid which escapes from the urethra during strained defæcation, or under the expulsive efforts of the levatores ani at the end of micturition. The hypochondriac imagines it to be semen, but microscopic examination shows it to be destitute of seminal filaments. On the theory that involuntary seminal emissions may be the result of irritation about the veru montanum, close to the opening of the common ejaculatory ducts, it has been recommended that the small mucous area be touched with a strong solution of nitrate of silver. This speculative treatment has, in the practice of some surgeons, been believed to produce satisfactory results.

From the extension backwards of urethritis to the opening of the common ejaculatory duct, or from its being bruised by the passage of a catheter, or by an escaping fragment after lithotrity, inflammation may extend along the vas deferens to the epididymis. That the trouble is not 'metastatic orchitis' is shown by the fact that the vas deferens is tender and enlarged, whilst the body of the testicle is soft. Thus the vas deferens may be enlarged to the size of a pen-holder. The mild injection prescribed for a gleet should not be held accountable for

the occurrence of the so-called swelled testicle, which generally comes in a natural sequence of events.

The **membranous portion** is between the two layers of the triangular ligament, at about an inch below the symphysis. Because of the backward projection of the bulb, the floor is rather shorter than the roof. Around the mucous lining is a thin erectile layer, continuous behind with the tissue of the veru montanum and in front with that of the corpus spongiosum. More externally are pale muscular fibres, and around all is the compressor urethræ.

The **compressor urethræ** is an arrangement of striated fibres which sling up and encircle the urethra between the two layers of the triangular ligament. It has a slender origin from the upper part of each descending pubic ramus. It acts as a sphincter to the urethra, and assists in erection by compressing the efferent veins of the corpus spongiosum. Its nerve-supply is from the internal pudic.

*Spasmodic stricture* may be the result of energetic contraction of the compressor urethræ, but such spasm must be of short duration. 'I will tell you what spasmodic stricture often is. It is an exceedingly useful excuse for the failure of instruments. It is "a refuge for incompetence."' (Sir H. Thompson.)

*Cowper's glands* lie below the urethra, between the two layers of the triangular ligament. Their slender ducts pass forward—through the anterior layer of the ligament—to open upon the floor of the bulbous portion of the urethra.

The **spongy portion** measures about seven inches, the posterior part being enclosed within the bulbous enlargement, the anterior within the glans.

The bulbous part of the urethra is very capacious; externally it is covered by the accelerator urinæ. There is also a considerable dilatation, the *fossa navicularis* just behind the meatus urinarius. The meatus is the narrowest part of the canal; often it has to be incised to admit an instrument which readily passes along the rest of the urethra. Such incision should be made towards the frænum—not upwards into the tissue of the glans.

The junction of the membranous and bulbous portions of the urethra is also narrow. A slender catheter is apt to leave the canal in a false passage through the floor, and to pass up below the prostate and bladder. By the left index finger in the rectum the error is immediately recognised; it is less likely to happen if the beak of the catheter be kept along the roof of the canal; and if this rule be observed the instrument is less likely to hitch against the front of the triangular ligament, or to be caught in the sinus pularis. A full-sized instrument is less likely to be intercepted than a fine one.

Chronic inflammation (gleet) is apt to linger about the bulbous part of the urethra, with the result that *stricture* is of frequent occurrence just in front of the triangular ligament.

The association between gleet and stricture is briefly this : chronic urethritis determines the deposit of plastic material in the submucous coat ; this new tissue undergoes atrophy, the result being a constriction around the tube—a stricture. The stricture keeps up the irritation and discharge, so that the only way of curing a gleet may be by the gradual dilatation of the canal to its proper size. It may be necessary to increase the size of the bougie up to No. 13 or 14 of the English scale. The remarkable capacity of the normal urethra is shown by the ease and safety with which Bigelow's enormous lithotrites may be passed.

The *follicular glands of Littre* are more freely scattered along the floor of the spongy urethra ; but the largest of them, the *lacuna magna*, is yawning upon the roof of the fossa navicularis.

In an attack of urethritis, abscess may form in one of these follicles and cause troublesome gleet. Sometimes the abscess breaks on the under surface of the penis.

When the urethra is at rest its *mucous membrane* lies in longitudinal rugæ. It consists of a basement membrane covered by columnar epithelium ; in the prostatic portion, and in the fossa navicularis, the epithelium is laminated.

A calculus escaping from the bladder may be impacted in the urethra, plugging the canal, it prevents micturition ; calculus in the urethra is the most common cause of retention of urine in children. But if the stone be too small to completely block the canal, it will probably give rise to irritation and to incontinence of urine.

In **passing a catheter** the handle must not be depressed before the beak has entered the depths of the perineum ; but if the handle be not depressed soon enough, the beak will catch against the front of the triangular ligament. The rule is to keep the beak of the catheter along the roof of the urethra, thus the hitch may be avoided. On partially withdrawing the catheter, and then depressing the handle, the end glides over the obstructing ridge. But in the operation no force should be used, lest the end of the instrument pass out of the urethra and enter a *false passage* :—The instrument having been passed to the very hilt, no water flows, only blood escaping ; moreover, the instrument cannot be made to roll on its long axis, the point being still tightly held, and, further, perhaps, the handle has swerved from the middle line.

The error may be detected by introducing the finger into the rectum, when the catheter will be found alarmingly near the bowel, and it may be corrected by withdrawing the instrument—the finger being still within the bowel—and re-introducing it at a higher level. The accident may be followed by escape of urine on to the front of the triangular ligament, and by perineal abscess.

If the handle of the instrument be too suddenly and too forcibly depressed, a false passage is sometimes, though rarely, made through



the roof of the urethra, just behind the triangular ligament, the beak passing into the cellular interval between the front of the bladder and the pubes. Blood might escape but no water, and the beak might be clearly felt behind the abdominal wall. Digital exploration by the rectum would not distinguish the catheter in the bladder.

**Rules for catheterisation.**—Be very gentle. Keep the beak of the catheter along the roof of the urethra. When you can no longer feel the beak in the perineum introduce your finger into the rectum, as a guide and guard. Keep the handle in the exact median line, and in depressing it mind that the beak does not catch against the front of the triangular ligament. Learn, and remember against a future occasion, the geographical peculiarities of that urethra. Should spasmodic contraction of the compressor urethræ obstruct the passage of the instrument, pause until the muscle has yielded, and then gently proceed with the operation.

**Cock's operation.**—When retention of urine results from stricture of the urethra, that part of the canal which intervenes between the prostate and the stricture is (*see fig. on p. 408*) distended; if the end of a scalpel be boldly introduced into it the bladder empties itself, and, rest being secured, the stricture ultimately gives way. For the operation the patient must be placed in the lithotomy position, and the finger having been introduced into the rectum, and resting against the apex of the prostate, the scalpel is thrust up to it, with the back towards the rectum. The urethra is then opened from behind forwards. Urine at once escapes; if need be, a tube is easily passed into the bladder.

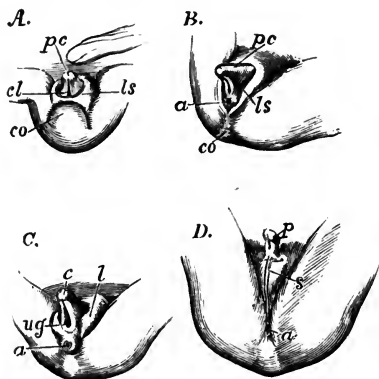
#### THE FEMALE URETHRA

The female urethra opens into the vulva about an inch below the clitoris. It is an inch and a-half in length, and descends close in front of the anterior wall of the vagina. Its coats consist of vascular and elastic tissue, and of an abundant lining of mucous membrane, which is thrown into longitudinal folds. The epithelium is transitional and squamous. Passing through the somewhat indefinite triangular ligament, the urethra is surrounded with the representative of a compressor urethræ. It is extremely dilatable, and may, by careful management, admit the index-finger for exploration of the bladder. Even in the child a lithotrite may be safely passed along it, or a good-sized stone removed through it, without more serious consequence than a temporary paralysis (*v. p. 389*.)

**To pass the female catheter** without exposure of the parts, cannot be done without practice; the operation should be learnt upon the cadaver. Descending from the anterior fourchette, the tip of the left index-finger just touches the clitoris; at about an inch further down is a flat papillary enlargement, in the centre of which is the urethral opening. The catheter is then run along the pulp of the

finger, which thus guides it to the meatus urinarius. In childhood the meatus is, proportionately, very far back, and the sound is apt to enter the vagina instead of the bladder. In case of doubt, a second sound may be introduced into the vagina, or the finger into the rectum.

**Development.**—For a considerable period of its existence the fœtus remains sexless; there is



a rudimentary penis or clitoris (A, *pc*), as the case may be; immediately below which is the uro-genital orifice (C, *ug*). On either side of this is a tegumental fold (A, *ls*); should the sex prove female, these folds remain separate—the labia majora; but, should a male be developed, they fuse in front of the anus (D, *s*), to form the scrotum. The median ridge upon the scrotum—the raphé—shows where the folds have joined. The lips of the urogenital sinus remain as the

nymphæ and enclose the clitoris above. The clitoris enlarges but slightly. 'In the male the penis continues to enlarge, and the margins of a longitudinal groove on its under surface gradually unite from the primitive urethral orifice behind, as far forwards as the glans, so as to complete the long canal of the male urethra, which is, therefore, a prolongation of the uro-genital sinus.' The corpora cavernosa, which are at first separate, become fused together in the chief part of the penis, but remain distinct against the pubes. In cases where the fusion of the lateral halves of the body has been imperfectly accomplished, a deepish dimple may persist in the skin of the middle line of the sacral or coccygeal region. Such a dimple is often associated with spina bifida. Should the depression extend still more deeply, it might in time become separated from the skin and remain as a closed sac beneath it; then, collecting epithelial elements in its interior, it would constitute a *dermoid cyst*. Dermoid cysts are often met with in the sacro-coccygeal neighbourhood.

Amongst the commonest of the twenty-four **malformations** which arise from arrest of development of these parts are the following:—

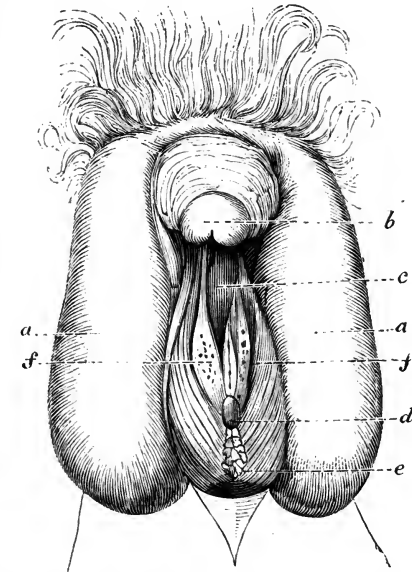
*Hypospadias* (*ὑπό*, beneath; *σπάω*, tear), from the floor of the urethra having been apparently 'torn' away. As the distal part of the canal is the last to be closed in, the deficiency is of more frequent occurrence towards the glans than along to the root of the penis. Sometimes the entire length of the floor is undeveloped. The urethral fissure

may extend deeply into the perineum, the halves of the scrotum remaining separate. Occasionally, the urethra opens on to the surface of the perineum at the site of the uro-genital (C, *ug*) aperture. In the case of doubt arising as to the sex of an imperfectly formed subject, the probability is that the subject is a male, in whom the process of development has been arrested. (Epispadias, p. 406.) Occasionally, during the fusion of the halves of the scrotum, and the closing in of the urethra, the penis becomes drawn down into and blended with the scrotum, so that the imperfectly developed subject is taken for a female.

A glance at the adjacent woodcut shows its close resemblance to fig. C above. It represents the parts of an imperfectly developed male, who had 'lived in a state of wedlock with three different men.' (See Todd's *Cyclo-*

*pædia*, vol. ii. p. 693.) The illustration closely represents also the external genitals of a person whom I recently saw in consultation, who, having been brought up as a female, was not aware of his true sex until near twenty years of age.

In a case of doubtful sex the testes may often be pressed down from the higher part of the inguinal canal; their discovery at once shows the child to be a male.



Hermaphroditism, the result of arrested development :  
*a, a*, halves of scrotum; *b*, penis; *c*, perineal  
 fissure; *d*, urethral aperture; *f, f*, mucous glands.

#### THE PENIS

The skin of the penis is thin; its loose subcutaneous tissue is destitute of fat, and is quickly infiltrated and distended by serous or urinary effusion. In case of a bulky hernia, or a large hydrocele, the lax penile coverings are requisitioned to such an extent that the penis is scarcely distinguishable in the full scrotal mass, its situation being marked by a mere depression whence the urine escapes. The skin is extremely movable, and in amputation of the penis it must not be drawn too far forward, lest the body and root of the organ be denuded.

In anasarca the prepuce is specially enlarged, so that to find the entrance to the urethra it may be necessary to slit up the swollen foreskin along the dorsal aspect. Œdema may be due to the root of the penis having been constricted by an elastic band or a string.

The *prepuce* of the new-born child is usually extremely long, but in the course of subsequent development a proper proportion between the parts is generally established.

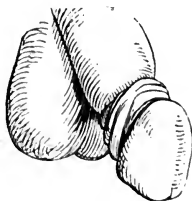
**Phimosis** (*φιμόω*, to close with a muzzle) implies that the prepuce is so tight, or redundant, as to be incapable of easy retraction. When the glans becomes inflamed (*balanitis*, *βάλανος*, *acorn*), or a sore occurs beneath the tight prepuce, circumcision is indispensable. Hardened crusts of smegma and calculi, which have escaped from the bladder, may be lodged beneath a tight foreskin. Phimosis is very apt to cause incontinence of urine (p. 379), especially in childhood.

I have seen the glans penis of an adult small and wrinkled from compression of a foreskin which had been tight from birth. In later life the effects of a chronic irritation of the glans from phimosis, and want of cleanliness, are likely to be hypertrophy of the papillæ in the form of large and branching warts, which are not necessarily of venereal origin, and a long continuance of the irritation may cause intractable eczema and eventually epithelioma. I have recently cured a young athlete of intractable and depressing seminal incontinence by removing his long prepuce.

Phimosis may so obstruct the outflow of urine as to cause the disease known as Surgical Kidney (p. 410).

For slight phimosis dilatation of the preputial orifice by a pair of dressing forceps may suffice, but, if the measure prove inefficient, circumcision should be performed forthwith. At the time of operation the furrow behind the corona should be completely exposed by breaking down adhesions, and all smegma should be cleared away.

When a prepuce with a small orifice has been retracted behind the glans, it may remain caught in the corona, the condition being called **para-phimosis** (*παρά*, beyond). The glans becomes greatly swollen from the constriction, as does also the lining of the prepuce, which has been thus everted. The constricting band, which is the preputial margin, is on the hindermost depression. By gently but firmly compressing the swollen tissues with the finger and thumb of the left hand, they may be emptied



of blood, so that with the finger and thumb of the other hand the glans may be pushed back again through the constriction. At some

time subsequently circumcision should be performed or para-phimosis will recur.

A long prepuce is apt to give rise to 'irritation of the bladder'; it is the converse of the proposition of stone in the bladder giving rise to an itching at the end of the penis. By day, the boy endeavours to allay the symptoms by pinching the prepuce; but by night, when the brain is dormant, the voluntary movements suspended, and the supervision of the genito-urinary tract given over to the cells of the grey matter of the cord, physiological mismanagement is apt to occur. The sensory filaments which are distributed to the muco-cutaneous tissue at the end of the penis are derived from the internal pudic trunk, itself a branch of the sacral plexus (p. 379). The nerves of the plexus lose themselves in the grey matter of a certain part of the spinal cord, from which are passing out, through that same interlacement, the efferent fibres, which are destined for the supply of the muscular walls of the bladder. But more than this, the same colony of cells receives the filaments which carry up sensations from the mucous membrane which lines that viscus. It may be on account of the exceeding instability of the protoplasmic substance of those cells, or that by education and design they are occupied with the care of the bladder rather than of the end of the penis; but in one way or another they are induced to interpret the irritation of the filaments coming from the latter and less important area as evidence of distress from the bladder itself. For this disquieting condition they have only one means of affording relief, and, putting it in force, the boy is punished in the morning, perhaps, for wetting his bed.

**Circumcision** may be rendered a bloodless operation by gently emptying the penis of blood, by compression, and then slipping an india-rubber ring over its root. The prepuce being cut off, the mucous membrane is torn back by two pairs of dressing-forceps and secured by fine catgut sutures. Sutures are not absolutely necessary, but they diminish the risk of secondary hæmorrhage and promote rapid healing. One suture should be passed deeply through the frænum, for thence hæmorrhage is most likely to occur. The operation should not be performed by passing a director under the dorsal aspect of the foreskin and then incising; for it has happened that the director has been run along the urethra, and that the dorsal part of the glans itself has been thus divided.

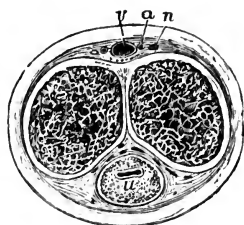
The *frænum* contains an artery of good size, and if the band be torn through during coitus, or if the artery be implicated in a venereal ulceration, serious hæmorrhage may result. A short frænum may cause discomfort, and may require division.

The *suspensory ligament* of the penis is attached above to the pubic symphysis, and descends in a fan-shaped manner to surround the penis in a thin aponeurotic layer, which, under the name of *fascia penis*, invests the vessels and nerves (p. 385). Pus forming beneath this fascia

may be guided to the pubes and there point ; the abscess should not be opened by incision along the median line, as the dorsal vessels might so be wounded.

The **corpus cavernosum** acts as a support for the corpus spongiosum, which lies in a shallow groove on its under surface. It divides behind into two strong masses, the crura, which are firmly attached to the inner surface of the pubic and ischial rami. The anterior extremity of the crus is capped by the glans penis, which is the enlarged end of the corpus spongiosum. The other end of the corpus spongiosum forms an enlargement in the perineum, the *bulb* ; it rests upon the front of the triangular ligament, where it encloses the first part of the spongy urethra and is invested by the accelerator urinae. (See fig. on p. 440.)

The corpus cavernosum is bounded by strong fibro-elastic tissue which contracts as the mass empties itself of blood, and which prevents distension beyond a definite limit. The interior is partitioned off into numberless small spaces by trabeculae, which interlace between the fibrous coat and the pectiniform septum. Pale, muscular tissue also exists in the framework. The spaces freely communicate with one another, and are occupied with venous dilatations, which are supplied by branches of the dorsal artery and of the artery of the corpora cavernosa. The blood is returned chiefly by veins, which emerge



*v*, urethra ; *v*, dorsal vein (single) ; *a*, *u*, dorsal artery and nerve.

near the corpus spongiosum and turn round the side of the penis to end in the dorsal vein. The other veins leave the root of the penis as tributaries of the internal pudic vein.

Bisecting the interior of the corpus cavernosum longitudinally is a vertical fibrous partition, which is connected with the fibrous coat near the dorsal and urethral grooves. The partition, which, viewed in profile, looks like a comb, is called the **pectiniform septum** (*pecten*, a comb). This septum is incomplete towards the fore-end, in order that the erectile tissue of one-half of the corpus cavernosum may be in free communication with that of the other, so that, if by chance one iliac or pudic artery be obstructed, distressing unilateral erection of the penis may not occur. The corpus cavernosum, in rare instances, yields to the blood-pressure within, and undergoes a kind of aneurismal dilatation.

The urethra tunnels through the corpus spongiosum. Coming through the triangular ligament, it enters the bulb, where it is somewhat dilated, and it ends in a vertical slit in the glans, the meatus urinarius (*v. p.* 385.)

The structure of the corpus spongiosum resembles that of the corpus

cavernosum, but the fibrous trabeculæ are connected with the urethral wall instead of with a median septum. The special arteries of the spongy body—the arteries of the bulb—are derived from the internal pudic trunk, and some branches of the dorsalis penis.

The **dorsal vein** begins in small branches, which emerge from the prepuce and glans; the trunk thus formed lies between the two arteries in the shallow dorsal groove. It receives in its course tributaries from the cavernous and spongy bodies, and, passing beneath the suspensory ligament and through both layers of the triangular ligament, ends in the prostatic plexus. Let this fact be well noted (*v.* p. 413.)

Most of the **lymphatics** end in efferent vessels, which course along the dorsum to end in the inguinal glands; a deeper set, however, pass beneath the pubic arch to the pelvic glands. A lymphatic gland is occasionally found near the suspensory ligament, where bubo and abscess may occur as a result of a preputial or urethral irritation.

The **nerves** are derived from the superficial perineal and the dorsales penis of the internal pudics; the erectile tissue receiving additional branches from the hypogastric plexus of the sympathetic.

**Priapism.**—Under the influence of nervous impressions descending from the brain or spinal cord, or arising in the nerves of the penis itself, or in some offshoot of the recto-vesical network of nerve-tissue, much more blood is brought into the venous sinuses of the trabecular tissue than is able to escape from them; thus erection of the penis is produced. The efflux is hindered by the expansion from the accelerator urinæ extending over the dorsal vein, and by the erectors of the penis, which compress the crura penis against the side of the pubic arch. Erection may be caused by any local irritation, or by mental stimulation acting through the erection centre in the grey matter of the lumbar enlargement of the cord. This, as part of our moral training, should be under cerebral control. When this control is cut off, as in lesions above the lumbar enlargement, from fracture or disease, chronic priapism is apt to occur.

When suppuration occurs in the body of the penis, the erectile tissue is disorganised and the fibrous cavity distended with pus, which readily makes its way across the pectiniform septum. Similarly, persistent priapism may be due to extravasation of blood taking place during coitus. When suppuration is the cause of priapism, the power of erection may subsequently be lost on account of the destruction of the erectile tissue.

Forcible flexion of the erect organ may give rise to a species of fracture, effusion of blood stiffening the penis and rendering it deformed.

When the urethra is inflamed, and serous effusion has taken place into the tissue of the corpus spongiosum, a diminution of its elasticity occurs, so that when the penis becomes erect the corpus cavernosum is bent downwards by the sodden and rigid spongy body. The painful condition thus produced is termed *chordee* (χορδή, bow-string).

In *amputation of the penis* the skin should not be drawn too far forward lest the stump of the organ be left raw. The corpus spongiosum should be cut longer than the corpus cavernosum. The arteries divided are the two upon the dorsum and the two of the crura; they may require ligatures.

When the penis is extensively implicated in epithelioma, and the condition of the inguinal glands shows that the disease is at present localised, removal of the entire organ is advisable. A sound having been passed, the scrotum is split into lateral halves, the crura of the corpus cavernosum are dissected from the pubic arch; and the posterior inch of the corpus spongiosum having been detached, the penis is removed bodily, and the truncated urethra is diverted through the posterior part of the scrotal wound.

### THE SCROTUM

The scrotum (*scortum*, skin) consists of the skin and the two layers of the superficial fascia. Above, the scrotum is continuous with the integuments of the abdomen and penis, and behind with those of the perineum, the two layers of the superficial fascia being blended into a single layer, which is destitute of fat. This fascia is thin, and contains amongst its loose meshes bundles of unstriped muscular fibre, which constitute the *dartos* (*δέρω*, *δaprós*, *flayed*, from the skin-like appearance of the muscular fascia). The skin and dartos are closely connected. Each testicle has its own fascial investment, but the two pouches are connected along the middle line to form the septum scroti. In the operation of castration, therefore, the opposite testis is not seen. (See fig. on p. 385.)

Along the under part of the scrotum is a dark cutaneous seam or ridge—the *raphé* which shows the line of fusion of the lateral halves of the scrotum. The root of the scrotum covers the perineal part of the urethra.

The superficial fascia of the scrotum, like that of the penis and eyelid, is devoid of fat, and is readily infiltrated with serous effusion. In this water-logged condition the scrotum may increase to an enormous size; in cellulitis, also, the parts rapidly swell, and gangrene of the scrotum from erysipelas, or from extravasation of urine, is not uncommon. The precise connections of the deep layer of the superficial fascia, and the importance of that fascia in urinary extravasation, are set forth on p. 439.

The *arteries of the scrotum* are derived from the superficial pudic branches of the common femoral and from the superficial perineal of the internal pudic. The *veins* are large, superficial, and tortuous, and empty into the termination of the long saphenous and into the internal pudic. They should be avoided in tapping a hydrocele. The scrotal veins communicate with the spermatic veins.



The *lymphatics* pass to the upper set of the inguinal glands. In malignant disease of the testis the inguinal glands are implicated, usually only when the disease has invaded the scrotum. In hot countries the lymphatics of the scrotum are often dilated and varicose. The disease is probably due to the irritation of micro-organisms circulating in the vessels. The effect of the disease is an enormous thickening of the integument, known as *elephantiasis*. Such tumours may attain enormous size, weighing more than the patient himself. The late Mr. Wordsworth assured the author that he saw one in the West Indies which was computed to weigh 200 lbs. ; the patient had been 'anchored' to it for many years and declined separation by surgical operation.

The *nerves* are derived from the ilio-inguinal (of the first lumbar), the genital branch of the genito-crural (second lumbar) lying in the cremaster ; the superficial perineal branches of the internal pudic, and the long pudendal branch of the small sciatic.

In caries of the highest lumbar vertebræ, with inflammatory pressure upon the afferent nerves, the patient may refer pain to the scrotal region of one or both sides ; and, from an association between these trunks and the renal and spermatic filaments of the sympathetic, there may be similar complaints when calculi are passing down the ureter. But, in the latter case, the neuralgic distress usually affects only one side ; there might also be retraction of the testicle from stimulation of the cremaster muscle.

The **coverings of the cord** and the testis beneath the skin and superficial fascia (which together constitute the scrotum) are considered elsewhere (p. 307) ; they are the intercolumnar, the cremasteric, and the infundibuliform fasciæ, and, as regards the testis itself, the peritoneum, or tunica vaginalis. The intercolumnar, cremasteric and transversalis fasciæ form a thin and close, but a comparatively unimportant, investment of the testis and cord, quite distinct from the scrotum, on the one side, and the tunica vaginalis on the other.

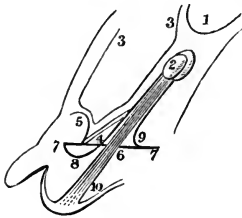
#### THE TESTIS

Early in foetal development, two important tubular organs are found in the abdomen by the side of the spinal column—the Wolffian bodies. They probably play the part of rudimentary and temporary kidneys. Before they are many weeks old they dwindle and make way for the permanent kidneys, which appear from behind them, and for certain organs of generation which appear in front of them. At this period the foetus is sexless ; there is nothing in the structure of the generative organ to show whether it would be evolved into ovary or testis (*v.* p. 399).

Then, just above the generative organ, a slender duct commences, which descends in front of the temporary kidney to open into that

part of the allantois which is to become the urinary bladder. This duct will be either the vas deferens or the Fallopian tube.

**The descent of the testis** soon begins. This 'descent' is partly



1, kidney; 2, testis; 3, peritoneum; 4, vas; 5, bladder; 6, abd. ring; 7, Poupart's lig.; 8, pubic part of cremaster, and, 9, outer part; 10, gubernaculum in scrotum.

due to the growth of the upper part of the body being out of proportion to that of the lower part, and partly to the influence of the *gubernaculum testis*, a soft, conical structure which lies between the peritoneum and the psoas. Its apex is connected to the testis, whilst its base passes through the inguinal region to a threefold attachment. Each division is said to contain striated muscular tissue. The inner piece runs to the pubic crest, the middle piece loses itself in the depths of the scrotum, whilst the outermost is attached to Poupart's ligament near the inguinal

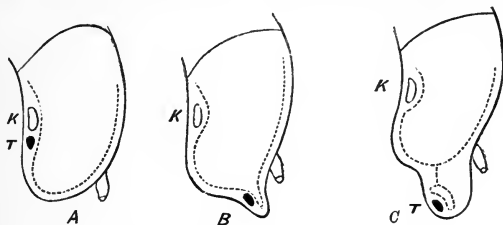
canal. Thus, the connections of the gubernaculum are those of the adult cremaster (p. 304); indeed, Curling believed that this foetal structure eventually becomes the cremaster. The piece of the gubernaculum which is attached to Poupart's ligament is supposed to guide the testis into the canal, the pubic piece to draw it through the external abdominal ring, and the scrotal piece to complete the descent.

The testis reaches the internal abdominal ring at about the seventh month of foetal life; during the eighth month it is working its way along the inguinal canal, and at birth it has generally reached the depths of the scrotum.

**Abnormalities.**—One or both testes may fail to reach the scrotum, remaining within the abdomen or the inguinal canal, or wandering into the groin or perineum. Beyond the limits of the deep layers of the superficial fascia, beneath which they are placed, they cannot stray. An inflamed testes in an unusual situation may be mistaken for abscess. An undescended gland is likely to be of no physiological value; moreover, it is somewhat apt to be attacked with malignant disease.

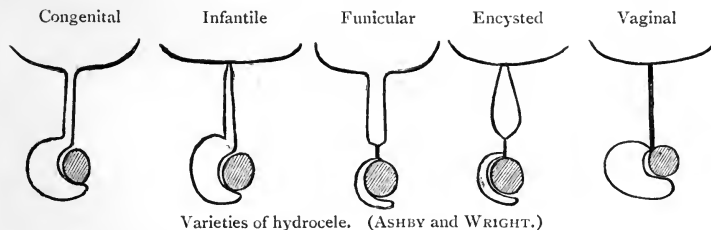
Whilst within the abdomen the testis is covered in front by peritoneum, and the accompanying diagrams show how the gland takes a serous covering in front of it down into the scrotum. The lower end of the funicular process eventually becomes detached from the rest of the peritoneal sac, and persists as the **tunica vaginalis**. The rest of the funicular process dwindles into a slender fibrous cord. The closure of the abdominal end of the serous process should occur about birth. The tunica vaginalis covers the front and sides of the testes, and is reflected from the epididymis to the scrotum; the laminated epithelium lining it ensures a moist and glistening surface, which allows the sensitive gland to escape injury in forcible abduction of the

thighs. The testis is not, like the heart, completely surrounded by the serous tunic; the posterior aspect is covered only by the



epididymis. Through the uncovered part of the testis the vessels enter and leave, and through it an incision could be made into the gland without wounding the serous sac. Occasionally the testis is found with the tunica vaginalis at the back and the epididymis in front, but this variation rarely occurs.

If, from arrest in the progress of development, obliteration of the funicular process of peritoneum fail to take place, the serous fluid which moistens the general peritoneal cavity may gravitate into the tunica vaginalis, and give rise to a scrotal water-tumour (*ὑδωρ*, water; *κίλη*, tumour), a **hydrocele**. And, as this variety of hydrocele is usually found at, or soon after, birth, it is distinguished by the adjective **congenital**; sometimes, however, it first appears in adult life. The contents of this variety of hydrocele can be emptied into the abdominal cavity by placing the patient on his back and raising the scrotum:



but, as soon as he is put once more upright, the fluid comes trickling down into the tunica vaginalis. Injecting such a hydrocele for radical treatment might set up an extensive and uncontrollable peritonitis. Treatment can only be expectant; the obliteration of the funicular process being aided by the constant pressure of a well-fitting truss. It is not in itself a serious condition, but, by maintaining the patency of the funicular process, it invites the descent of a piece of intestine. (Congenital hernia, p. 310.)

If the funicular process be closed at its abdominal end but open below, a collection of serum in the tunica vaginalis will distend the

process up to the external ring; the swelling being conical or hour-glass-shaped. It will differ from the variety just described, in that the fluid cannot be squeezed up into the peritoneal cavity. This is the **infantile hydrocele**.

If the funicular process be obliterated both at its abdominal and testicular end, but, remaining pervious between these spots, become filled with accumulating serum, a firm oval or round swelling appears in the course of the cord. This is **encysted hydrocele of the cord**. Sometimes the swelling is, from extreme distension, as hard as is the testicle which hangs below it; and it is often just about the size of that gland. It is then apt to be mistaken for a third testicle; a puncture by a grooved needle at once explodes the fallacy and removes the swelling. The cyst does not contain spermatozoa, for it has no association with the testis, being a derivative from the peritoneum. If the cyst be as large as a pigeon's egg, diagnostic aid may be obtained by the light-test.

As the funicular process descends in front of the cord, a congenital hydrocele or hernia has the cord behind it. The finger shows the external abdominal ring to be clear, and thus distinguishes the encysted hydrocele of the cord from a hernia; but if the cyst be situated within the inguinal canal, the diagnosis may be difficult. The history of the case shows that the swelling is not a strangulated hernia; and, as in the other case, puncture with a fine grooved needle solves the question. *Encysted hydrocele in the canal of Nuck* (p. 391) is met with every now and then.

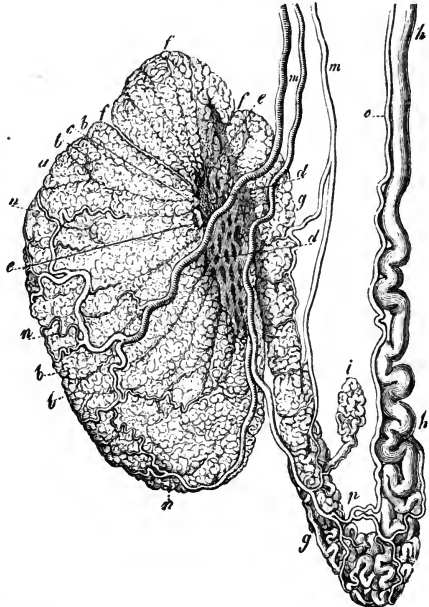
The commonest variety of hydrocele is that in which fluid collects in, and distends, the isolated tunica vaginalis. The swelling is pear-shaped, the stalk growing towards the external abdominal ring. The testicle is, of course, towards the back of the cyst; but, in tapping, it is more important to know where it is not, than where it is.

**Hæmatocele.**—Sometimes in tapping a hydrocele a branch of vein (spermatic?) is wounded, and blood oozes into the serous cavity and quickly refills the sac; but this time the cyst is opaque.

**Structure.**—The testis is composed of tubular gland tissue packed in a tough, fibrous envelope, the *tunica albuginea*. Outside this is the visceral layer of the tunica vaginalis, whilst upon its inner side, and also supported upon the trabeculæ which pass from its interior to the fibrous septum at the back of the gland, is a close interlacement of blood-vessels, which constitute the *tunica vasculosa*. A fibrous partition—the corpus Highmorianum—separates a small piece at the back from the rest of the gland. The somewhat conical spaces are occupied by masses of coiled tubes, the lobuli testis, from which straight vessels (vasa recta) convey the secretion to the network of tubes behind the partition, the rete testis. From the rete the vasa efferentia convey the semen through the upper part of the gland-capsule into conical masses of tubes, the coni vasculosi, which make

up the globus major of the epididymis (*ἐπί*, over; *δίδυμος*, twin). From the lower part of the globus major the body of the epididymis tapers downwards, but it thickens below into the globus minor, from which the vas deferens conveys the semen to the common ejaculatory duct, at the base of the bladder.

**Encysted hydrocele of the testis** results from accumulation of fluid in one of the coiled tubes of the gland or of the epididymis. The dilatation may be extreme; the fluid differs from that of an encysted hydrocele of the cord (p. 430) in that it contains seminal filaments. Multiple cystic disease of the testis is similarly produced, but, the proper secreting tissue having been destroyed, the fluid may be destitute of spermatozoa.



The **vas deferens** lies at the back of the cord, and, picked up between the finger and thumb, feels like a piece of whipcord. It is nearly two feet long. Having reached the upper opening of the inguinal canal, it bends downwards and inwards around the deep epigastric artery; and, lying close beneath the peritoneum, courses over the side of the bladder, lying to the vesical aspect of the ureter and to the median side of the vesicula seminalis, the duct of which it joins at the base of the prostate to enter the prostatic urethra at the sinus pocularis (p. 413). In its course from the internal abdominal ring it lies above the external iliac artery. From the ring it descends alone, the spermatic vessels passing up to the renal region. It consists of a mucous lining, a dense fibrous wall, and a thick and firm intermediate coat of non-striated muscular fibres; the mucous coat is covered with columnar epithelium. The artery of the vas is derived from one of the vesical branches, and, running towards the testis, it anastomoses with the spermatic artery, as shown in the adjacent figure.

b, lobules; c, vasa recta; d, rete; e, vasa efferentia; f, coni vasculosi; g, epididymis; h, vas deferens; i, vas aberrans; m, n, spermatic artery; o, artery of vas, and p, its anastomosis with spermatic.

A urethritis extending backwards may invade the openings of the common ejaculatory ducts, and, spreading along their lining membrane, may reach the epididymis and the body of the testis. That the inflammation travels by continuity of tissue is evinced by the swollen and tender condition of the vas, which thus becomes as large as an ordinary cedar pencil. The term 'gonorrhœal orchitis' is incorrect; the condition is almost invariably 'epididymitis' to begin with; and for some time the soft and unaffected gland may be found in front of, but obscured by, the enlarged epididymis. Epididymitis may come on in the course of a gonorrhœa or gleet when no injection or instrumentation has been employed; the use of an injection has, as a rule, nothing to do with its occurrence. Epididymitis is sometimes caused by a slight damage to the mucous membrane of the urethra by the passage of a lithotrite or by the removal of a fragment of stone. At times, too, it follows the passage of a catheter or sound when, in all probability, not the least abrasion of the mucous lining has occurred.

In acute orchitis and epididymitis the pain is intense, on account of the unyielding nature of the tunica albuginea. A few punctures of the inflamed gland allow the escape of effusion into the tunica vaginalis and afford almost immediate relief. Atrophy of the testis is apt to follow acute inflammation, on account of the disturbance of nutrition which was thereby caused.

At an early period of fetal life there is no connection between the vas deferens and the testicle, but, like the Fallopian tube, the vas begins by an open and disconnected extremity; so, through an arrest of development, the vas deferens may end blindly in the spermatic cord, without association with the testis; each organ may, however, be in itself thoroughly developed. The developmental distinction between the vas deferens and the testis proper explains the frequency with which an inflammation of the vas deferens and epididymis may extend itself in those structures without implicating the immediately adjoining testicular tissue, as in the case of gonorrhœal epididymitis.

**Vessels and nerves** of the testis. As the testis was originally formed in the neighbourhood of the kidney, the vessels and nerves which supply it are all derived from, and kept in permanent communication with, the corresponding systems of that neighbourhood (*v.* p. 353).

Thus, the spermatic artery comes from the abdominal aorta close to the renal artery, whilst the right and left spermatic veins empty into the vena cava and the left renal vein respectively. As the testis descends, the artery becomes elongated, and by the time that the gland has reached the scrotum the blood-vessel has become so long and slender that the student who does not understand the development wonders why the blood was not supplied by one of the iliac trunks or by some artery which was still nearer to the scrotum.

In its downward course the **spermatic artery** lies behind the peri-

toneum and rests upon the psoas and crosses very obliquely the ureter and the external iliac artery. The right artery lies over the inferior vena cava. Passing into the inguinal canal, the spermatic artery joins in the formation of the spermatic cord, and communicates with the cremasteric branch of the deep epigastric, and, when piercing the back of the fibrous capsule of the gland, with twigs of the artery of the vas deferens. Having entered the body of the testis through the posterior part of the fibrous capsule of the testicle, the branches of the spermatic artery spread out upon its inner surface, and upon the fibrous septa in the interior. Sir Astley Cooper compared the vascular layer to the pia mater, and called it the tunica vasculosa.

As the spermatic artery lies in the back of the cord near the vas deferens, the probability is that it will have been separated from the veins before the latter are ligated in the radical treatment of varicocele. If it be included in the ligature, atrophy of the testis is likely to follow (*vide infra*). But as the spermatic artery anastomoses with the artery of the vas deferens, and with the cremasteric branch of the deep epigastric, the testis does not depend entirely on the aortic branch for its supply.

The **spermatic veins** return the blood from the tunica vasculosa, and, leaving the gland through the back of the tunica albuginea, receive branches from the epididymis. They are much twisted together and communicate freely, and, though possessing valves, they may be injected in either direction. They are called the **pampiniform plexus**, from their resemblance to the tendrils (*pampinus*) of a vine. They become fewer as they ascend along the inguinal canal, and by the time that the renal region has been reached there is usually but a single vein; this on the right side enters the inferior vena cava, on the left the renal vein. In the development of the left testicle it would have been impracticable for its spermatic vein to pass over into the vena cava.

Within the abdomen the spermatic veins are behind the peritoneum, and those of the left side take their course beneath the sigmoid flexure of colon. When this piece of the bowel is habitually overloaded the return by these veins is impeded, and the dilated veins form a tumour—*varicocele* (*varix*, κηλη, tumour). A varicose vein is apt to burst into the cavity of the tunica vaginalis, and so form an opaque blood-tumour, *hæmatocele* (αἷμα, blood; κηλη, tumour). Rupture of a vein into the cord may give rise to 'diffuse hæmatocele of the cord,' and the extravasation may reach even to the renal region. Other reasons have been suggested for varicocele usually occurring on the left side: such as that the left spermatic vein is at times embarrassed in pouring its blood, at a right angle, into the renal vein; that, the left testicle hanging somewhat lower than the right, the vein is longer and consequently weaker.

In all probability there is some developmental explanation for the occurrence of the varix upon the left side. Certainly most of the

subjects of varicocele are not liable to constipation. It is probably a congenital defect, though its discovery is not made until puberty—that is until the rapid development of the generative apparatus is taking place.

The thickened and dilated veins feel just like ‘worms in a bag.’ They give rise to a sensation of fulness in the cord, and up to the loin-region. When they are much dilated before puberty they are likely to prevent the due development of the testicle.

In the palliative treatment of varicocele the bowels should be kept thoroughly open so as to remove pressure from the spermatic vein; the scrotum should be sponged daily with cold water to brace it up, and to stimulate the dilated veins a suspensory bandage should be used. A light truss may be worn over the external abdominal ring, to prevent the downward pressure of the long column of venous blood. If these gentler measures fail, it may be necessary to excise an inch of the veins, having tied them above and below; but, as the spermatic artery may possibly be entangled amongst the veins, the operation may be followed by atrophy of the testis, even if this have not already been determined by the defect in the venous return. The reason for excising a piece of the packet of veins is that after a mere ligation their continuity may not improbably be re-established.

In the case of **malignant disease of the testis** the heavy mass drags itself away from the external abdominal ring; in the case of fluid collecting in the tunica vaginalis the fulness ascends along the front of the cord towards the ring.

In all cases of disease of the testis the scrotum should be raised, so as to diminish the vascular supply. The patient should lie on his back when the epididymis or testis is acutely inflamed, with the scrotum supported over the pubes.

The **lymphatics** commence in and upon the gland, and on the surface of the tunica vaginalis; they ascend in the cord to end in the lumbar lymphatic glands. Unfortunately, when the surgeon is contemplating the removal of the testis for malignant disease, he is unable to inform himself whether the lymphatic glands are implicated or not, because of their deep situation at the back of the abdominal cavity. As a rule it is only when the cancer of the testis has invaded the scrotum that the *inguinal* lymphatic glands are invaded, but in rare instances it happens that they are implicated, and extensively so, whilst the scrotal tissues are remaining sound. This is explained by the lymphatic vessels of the testis having formed anastomotic communications with those of the inguinal integuments—a communication resembling that which exists between the spermatic artery and the cremasteric branch of the deep epigastric.

If there be much mechanical pressure upon the lymphatics or veins of the cord, from malignant disease of the lumbar glands, or from any other cause, the connective tissue of the cord may become infiltrated



with serum exuded from the congested vessels. This condition corresponds to the œdema of the arm associated with malignant invasion of the axillary glands; it is called **diffuse hydrocele of the cord**, and is more frequently described in books than observed in practice.

The **nerves** of the testis are derived from the aortic and renal plexus, and it is probable that a few filaments from the communication with the anterior trunks of the lumbar nerves pass down with the sympathetic fibres. The free association of the spermatic nerves with the great pre-vertebral system of the sympathetic system of the abdomen explains the sickness, faintness, or collapse which may accompany a blow upon the testis, symptoms which occur also on rupture of the stomach or kidneys. The pain extends into the loins, and the patient is 'doubled up'; that is, he slackens his abdominal muscles so as to take all pressure from the inguinal canal and from the abdominal plexus. The close association between the renal and spermatic plexuses is further shown by the neuralgia or the acute inflammation of the testis which may be caused by the passage of a renal calculus, and by the pain in the back which follows the injection of a hydrocele, or the dragging of a tumour of the testis.

**Leeching the front of the scrotum** in acute epididymitis affords relief through the anastomosis existing between the vessels of the gland, the cord, the tunica vaginalis, and the scrotum; the leeches should be chiefly placed along the course of the cord.

The supervention of orchitis on mumps has not yet been satisfactorily explained. All that is known is that there is a strange association between the parotid gland and the testis, or the ovary, and also with the inguinal and genito-urinary region generally. Parotitis sometimes follows operation on these parts—a parotitis which is not, apparently, septicæmic in origin.

In **castration** the testis is thrust well forwards by the grasp of the left hand, which is behind the scrotum, and an incision is made from the external abdominal ring down to the bottom of the scrotum. The cord is laid bare and raised, tightly ligated, and divided; the lower piece of the cord, the testicle, and the tunica vaginalis are then enucleated. The structures divided to lay bare the cord are the skin and the superficial fasciæ (which latter, in the scrotal part of the incision, constitute the dartos); the thin inter-columnar fascia derived from the aponeurosis of the external oblique; the cremasteric fascia from the internal oblique; the infundibuliform fascia from the fascia transversalis; and a little loose connective tissue. If the unobliterated funicular process of peritoneum be encountered it must be tied along with the cord. In reaching the cord, branches of the superficial epigastric and external pudic arteries, and the cremasteric twig of the deep epigastric artery, may be divided; also some twigs of the superficial perineal arteries. The ligature around the cord secures the following blood-vessels: the spermatic artery, from the abdominal

aorta; the artery to the vas deferens, from one of the vesica arteries; and the spermatic veins, which communicate above with the inferior vena cava, or (on the left side) with the renal vein. If the ligature be tightly tied in a business-like way, with a clove-hitch and a half-hitch over it, there will be no fear of the occurrence of bleeding within the abdomen when the cord is retracted.

The **vesiculæ seminales** are convoluted and sacculated tubes, about 2 in. long, placed, like the arms of the letter V, beneath the trigone of the bladder. They lie to the outer side of the vasa deferentia, and in front of the second piece of the rectum (*v. p. 413*), through which they may be made out by digital examination; they can best be examined when the bladder is full and is pressing them towards the bowel. They are enclosed in an offshoot of the recto-vesical fascia (*p. 363*), and their base is in contact with the recto-vesical pouch of peritoneum. During the passage of a bulky motion the pressure against the vesiculæ may cause the escape of some of their contents *per urethram*, and, the occurrence being noticed by a nervous man, he at once fancies that he is the subject of 'spermatorrhœa.' The anterior extremity of the vesicula seminalis joins the vas deferens to form the common ejaculatory duct, which tunnels through the back of the prostate to open in, or upon the margin of, the sinus pularis.

Placed between the bladder and rectum, the vesiculæ depend upon the inferior vesical and the middle hæmorrhoidal vessels for their supply; a twig is also derived from the artery of the vas deferens. Their *nerves*, which come from the hypogastric plexus, are in intimate association with those of the adjoining viscera. The *lymphatics* communicate with the pelvic glands.

#### THE ISCHIO-RECTAL FOSSA

The ischio-rectal fossa is the pyramidal space between the ischium and the rectum. Its base corresponds to the soft depression at the side of the anus, whilst its apex reaches upwards to the splitting of the pelvic fascia. It contains a considerable amount of fat, which is much drawn upon in wasting diseases, so that a deep hollow is then found on the surface. Its **boundaries** are internally the rectum, the sphincter, and the levator ani, covered by the anal fascia, as shown in the figure on *p. 363*, and, further back, a small piece of the coccygeus; externally are the ischial tuberosity, and the obturator internus, covered by the obturator fascia, and the body of the ischium. Behind are the tip of the coccyx and the great sacro-sciatic ligament, over which lies the lower border of the gluteus maximus. In front is the base of the triangular ligament (*v. p. 440*).

Even when the fat which occupies the fossa has been dissected out, the finger cannot be passed through the apex of the space into

the pelvis, on account of a sheet of fascia which, coming from the obturator fascia, slopes along the under surface of the levator ani to the anus. This is the *anal fascia*. A stronger and much more important layer of fascia also passes from the obturator fascia, over the upper surface of the levator ani and the coccygeus, to lose itself on the side of the rectum and bladder; it is the *recto-vesical fascia*. Behind the bowel the layers from the opposite sides of the pelvis meet and invest the pyriformis and the sacral plexus, and between the bladder and rectum the fascia invests the seminal vesicles. The opposite sheets also form the lateral and anterior true ligaments of the bladder, and also provide a special investment for the prostate and the prostatic plexus of veins. The most anterior part of this recto-vesical fascia constitutes the pubo-prostatic ligament (p. 413). The recto-vesical fascia helps the levator ani in preventing the abdominal viscera sinking towards the ischio-rectal fossa; it is at once a sloping floor to the abdomen and roof to the fossa. In lateral lithotomy the knife sometimes passes beyond the limit of the lobe of the prostate, and, the ischio-rectal fossa being opened up into the pelvic cavity, fatal cellulitis may occur.

The presence of abundant loose tissue in the fossa allows the descent and expansion of the rectum during defæcation; it is through the tissue at the front of the fossa that the surgeon cuts to reach the prostate and the neck of the bladder in lateral lithotomy (v. p. 443). As the return of venous blood from this tissue is aided neither by the influence of gravity nor by active pressure of surrounding muscles, the part is extremely liable to congestion and inflammation, and especially so in the subject of feeble circulation, embarrassed respiration (phthisis), or of advancing disease of the liver. Inflammation may also be set up by a wet seat, or by injury. If the inflammation be followed by suppuration, **ischio-rectal abscess** is the result. A common cause of ischio-rectal abscess is the escape of a foreign body, such as a fish-bone, or of some hard fæces, through the lateral wall of the bowel. Such perforation of the bowel may be preceded by an ulcer, especially in the case of stricture of the rectum or of tuberculosis.

When suppuration occurs the abscess bulges at the side of the anus, at the border of the gluteus maximus, or against the rectal wall. In the last case there is great pain on defæcation, and on introducing the finger into the bowel the fulness on its outer side is evident, and perhaps fluctuation may thus be detected. In sitting the patient bears all his weight on the opposite ischial tuberosity, resting upon the very edge of the seat of the chair.

If left to itself, the pus will find exit either into the rectum or through the skin at the side of the anus; the surgeon should open such an abscess through the base of the fossa, making his incision in a line radiating from the anus: that is, parallel with the hæmorrhoidal vessels. The sooner that he opens it, the less will be the resulting chasm.

As the pus drains away the cavity contracts, until it is represented only by a narrow, thick-walled passage—a *fistula*—which, if ‘complete,’ opens both into the bowel and on to the buttock. Such a fistula has small chance of healing without operation, as at and after defæcation its walls are constantly being dragged asunder towards the anus by the sphincter, and from the anus by the levator. Gas may be driven from the rectum into an internal or a complete fistula, rendering the tissues of that neighbourhood emphysematous.

The **structures divided in the operation for fistula** are the integument, the external sphincter ani, and the insertion of the levator ani (both muscles are striated); the longitudinal and circular fibres (internal sphincter) of the rectum (non-striated); the submucous and mucous coats, and branches of the inferior hæmorrhoidal vessels and nerves. (*See illustration on p. 440.*)

(Fistula near the anus may be due to caries of the spine, p. 211.)

The **internal pudic vessels and nerve** run in a tubular sheath of the obturator fascia at a little more than an inch above the ischial tuberosity, giving off the inferior hæmorrhoidal branches which cross the base of the fossa to reach the neighbourhood of the anus. The artery is accompanied by the dorsal nerve of the penis and the superficial perineal branches.

The **levator ani** arises from the back of the body of the pubes and from the inner surface of the ischial spine (below the origin of the coccygeus); and between these points it arises from the pelvic fascia where the oblique sheets are reflected downwards and inwards to the rectum and bladder, and to the anus (*v. p. 363*). Between the two levatores the rectum is suspended; the muscles helping to form the inner wall of the ischio-rectal fossæ and to close in the pelvic outlet. The muscle is inserted into the tip of the coccyx, and into the fibrous line leading from it to the anus; into the side of the third piece of the rectum, between the pale fibres of its longitudinal coat and the striated fibres of the external sphincter; into the central tendon, and still more anteriorly into the side of the prostate. The most anterior part of the muscle is the *levator prostate*. In the female the vagina passes between the levatores ani.

*Relations.*—The pelvic surface of the muscle is covered by the recto-vesical fascia, and lies against the rectum and prostate. Beneath it are the anal fascia, the external sphincter, and the fat of the fossa. Its posterior border lies along the lower edge of the coccygeus.

*Supply.*—Its vessels are derived from the inferior hæmorrhoidal; its nerves come from the internal pudic and the fourth sacral.

#### THE PERINEUM

The outlet of the pelvis is diamond-shaped, the long axis extending from the pubic symphysis to the tip of the coccyx. Its antero-posterior

diameter averages  $3\frac{1}{4}$  in., its transverse  $3\frac{1}{2}$  in. (*vide* Planes of Pelvis, p. 364). If a line be drawn between the ischial tuberosities the space is divided into the urethral and the anal triangles; superficial to the former are the tissues of the perineum; the posterior is occupied by the lower end of the rectum and the ischio-rectal fossæ. Thus the anterior triangle is subservient to genito-urinary functions, and the posterior to the alimentary canal. For the most part these two functions have separate and distinct sets of muscles, nerves, and vessels.

**Surface markings.**—In the middle line is a soft, antero-posterior elevation, caused by the hinder part of the corpus spongiosum and the bulb of the urethra; over it is the median *raphé*. The *raphé* is not a trustworthy indication to the middle line, it is easily displaced to one side or the other by inflammatory adhesions; it is the embryonic seam in which the integumental halves of the perineum were joined. At the side of the urethral projection the finger can be thrust into a shallow space beneath which the triangular ligament blocks the front of the pelvic outlet; more externally can be traced the rami of the pubes and ischium. Passing forwards, the corpus spongiosum loses itself within the base of the scrotum.

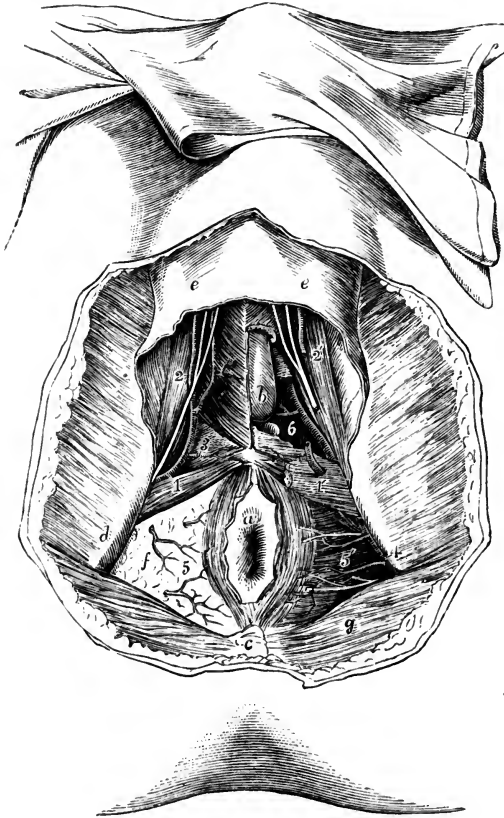
Beneath the skin is the superficial layer of the superficial fascia, which is continuous with the non-striated muscular tissue of the scrotum, laterally with the fat of the buttock, and behind with the fat in the ischio-rectal fossa. This layer of fascia consists of loose connective tissue with a little fat; it has no deep connections.

*The deep layer of the superficial fascia* is thin and membranous; it loosely covers in the corpus spongiosum, and, passing forwards, enters the tissue of the scrotum, becoming continuous with the dartos; it also invests the penis and passes up on to the abdomen, being attached below to Poupart's ligament and to the iliac crest. Laterally, in the perineum, this important fascia is attached to the pubic and ischial rami; posteriorly it loses itself on the base of the triangular ligament. An incomplete and unimportant septum attaches the deep surface of this fascia to the triangular ligament. (The student should demonstrate the arrangement of this fascia, with a sheet of muslin, upon a pelvis to which the ligaments are attached.)

When, in rupture of the urethra, urine is extravasated beneath this fascia, it cannot pass backwards into the fossæ, nor laterally on to the buttocks, but, coursing along by the penis and scrotum, it ascends by the spermatic cords to the iliac and hypogastric regions. In the dissecting-room air forced beneath the fascia takes the same course.

**Perineal abscess.**—Urine or pus locked in beneath this fascia causes a tense bulging behind the scrotum and beneath its root; as the fascia is too dense to allow of fluctuation, the tumour may feel as hard and solid as a cartilaginous growth. The pressure of the fluid beneath the urethra drives the floor against the roof, rendering micturition difficult, and the introduction of a catheter distressing and

dangerous. Sometimes the swelling is about the size of a filbert, and it may feel almost as hard as one. The surgeon waits neither for fluctuation nor redness, but deeply incises the perineum along the middle line. A *perineal fistula* results, but this gets well as the stricture, which was the original cause of the abscess, is dilated.



Right superficial, left  
deep dissection :

- a, anus.
- b, bulb.
- c, coccyx.
- d, ischium.
- e, superficial fascia.
- f, fat in ischio-rectal fossa.
- g, gluteus maximus.
- 1, transverse muscle.
- 2, erector penis.
- 3, trans. artery.
- 4, int. pudic artery, and 5, its hæmorrhoidal branches.
- 6, first layer of triang. ligament removed to show artery of bulb and Cowper's gland.

Beneath the deep layer of the superficial fascia, on either side, is a **muscular triangle**, the base of which is formed by the *transversus perinei*, which runs from the ischial tuberosity to the central tendon ; at the outer side is the *erector penis*, which passes from the tuberosity to the side of the corpus cavernosum, whilst in the middle line is the *accelerator urinæ*, surrounding the bulb, and sending its most posterior fibres into the triangular ligament ; its most anterior fibres encircle the corpus cavernosum, to blend with those of the opposite side over the

dorsal vein. Beneath these muscles the triangular ligament stretches across the sub-pubic arch. In lateral lithotomy, the surgeon, being right-handed, plunges his knife through the muscular triangle on the left side of the patient.

The superficial perineal vessels and nerves (from the internal pudics) pass forwards over the triangle, getting beneath the deep layer of the superficial fascia just where it is turning down to the base of the triangular ligament.

To expose the **triangular ligament** in the dissection of the perineum, the erector penis and the crus must be detached from the pubic arch, and the transverse muscle removed; and not only must the accelerator urinæ be dissected off, but the hinder end of the corpus spongiosum should be also cut away, and with it, of course, the bulbous part of the urethra. The chief use of the ligament is to steady and support the urethra as it curves below the pubic symphysis. The better to do this, it is composed of two aponeurotic sheets, which, separated from each other by an interval of about one-third of an inch, descend to blend with each other, and with the deep layer of the superficial fascia, at the base of the triangle. The deeper layer of the triangular ligament is joined also by the recto-vesical fascia.

The urethra pierces the two layers of the ligament about one inch below the symphysis; when running between them it is surrounded by a striated sphincter, the **compressor urethræ**. The beak of a catheter is apt to catch against the ligament unless the handle be well depressed. Closer beneath the symphysis the dorsal vein of the penis runs through the layers to join the prostatic plexus.

The endings of the internal pudic artery and nerve ascend between the two layers of the ligament towards the dorsum of the penis; they have entered the ligament near its base, and close against the ischial ramus. The short piece of the urethra enclosed in the triangular ligament is the **membranous** part, and close below it are Cowper's glands (*v. p.* 413). The triangular ligament is very strong, and prevents extravasated urine, and the contents of a perineal abscess, passing backwards to enter the pelvis. In addition to the parts already enumerated between its two layers are the sub-pubic ligament; a short branch of the internal pudic artery to the bulb of the urethra, and sometimes another transverse (deep) perineal muscle.

Cowper's glands are about the size of a pea; they are lobulated, and their ducts pass through the anterior layer of the triangular ligament to open on to the floor of the bulbous part of the urethra, as already noted, on p. 417.

The **internal pudic artery** is one of the terminal trunks of the anterior divisions of the internal iliac; leaving the pelvis below the pyriformis, it winds round the ischial spine into the ischio-rectal fossa, passing through the small sacro-sciatic foramen. In the fossa it lies in a tube of the obturator fascia, an inch or more above the tuber

ischii. Then, passing along the ischial ramus, it enters between the two layers at the base of the triangular ligament, and, ascending almost to the symphysis, runs through the anterior layer of the ligament, much diminished in size, as the dorsal artery of the penis.

*Branches.*—**Inferior hæmorrhoidal**, which are given off as the vessel lies under the obturator fascia: they pass inwards across the ischio-rectal fossa to supply the tissues about the anus, and to anastomose with their fellows of the opposite side and with the middle hæmorrhoidals (p. 388). They are wounded in lateral lithotomy and also in the division of an anal fistula. The **superficial perineal** runs in the muscular triangle, and under the deep layer of the superficial fascia, to supply the various tissues of the perineum and scrotum; it may anastomose with a pudic branch of the common femoral. The **transverse perineal** passes inwards upon the muscle of the same name, and anastomoses with its fellow; it is apt to be wounded in lateral lithotomy. The **artery of the bulb** is given off from the main trunk as it ascends between the layers of the triangular ligament; it is a short thick vessel, and passes inwards to supply the erectile tissue of the bulb and of the corpus spongiosum, giving, in its course, a *branch to Cowper's gland*, and twigs to the membranous urethra. The artery to the bulb should be well in front of the knife in lateral lithotomy, but if, as sometimes happens, it be given off earlier in the course of the internal pudic it would most likely be severed. Should this accident occur, the bleeding might be controlled by the self-holding forceps, by enlarging the wound and tying, by the petticoated tube, or by compressing the pudic with the finger through the wound against the ischial ramus.

The **artery to the corpus cavernosum** comes off, as one of the terminals of the internal pudic, between the layers of the triangular ligament. It is for the crus penis just what the artery to the bulb is for the corpus spongiosum, namely, for the supply of its erectile tissue. It courses in the cavernous body along the side of the pectiniform septum.

The **dorsal artery of the penis** is the other terminal branch, and, passing through the anterior layer of the triangular ligament, and through the suspensory ligament of the penis, it courses by the side of the vein, giving off branches to the corpus cavernosum, and ending in the glans, where it anastomoses with its fellow. It supplies the skin of the penis, even to the prepuce. Though there are two dorsal arteries of the penis, there is but one dorsal vein.

Sometimes the pudic is not large enough to give off all these branches; ending as the artery to the bulb, its terminal branches are then derived from an **accessory internal pudic**, which is either given off from the internal pudic itself, before it passes out of the great sacro-sciatic foramen, or else from the anterior division of the internal iliac. This irregular vessel hurries along the floor of the pelvis



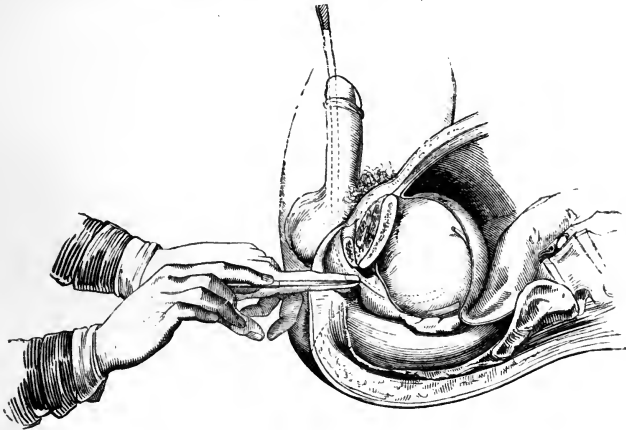
below the bladder and beneath the side of the prostate, to reach the penis by piercing the triangular ligament. In the operation of lateral lithotomy such a vessel could scarcely escape division when the incision is being made in the prostate.

*In the female the pudic artery* supplies the labia by its superficial perineal branches; the artery of the bulb enters the vaginal wall, and the terminal branches, which are very small, supply the clitoris.

To mark the position of the internal pudic artery on the surface of the buttock, *see* p. 374.

The **internal pudic vein** begins as the vein of the corpus cavernosum and receives branches corresponding to those of the artery, with the exception of the **dorsal vein of the penis**, which runs straight through the triangular ligament into the prostatic plexus, as shown on p. 413.

For **lateral lithotomy** the grooved staff is passed and the stone



Lithotomy on curved staff. (FERGUSSON.)

is struck, either by it or by the sound—the former for choice, for then the operator can be certain that the instrument is in the bladder; the patient is still lying supine. The assistant takes the staff, and the patient is then placed in the lithotomy position. The surgeon feels for the course of the pubic and ischial rami and the situation of the bulb—taking his landmarks, gauging the space. He then introduces his left index-finger into the anus, to feel that the staff has not wandered into a false passage; that the lower bowel is not loaded with fæces, and bulging over the line of incision; that the dilated part of the empty rectum is not in undue danger of being incised; to learn, perchance, the situation of the stone, and to see that the assistant is holding the staff according to his instructions. Then he

makes a little stab—in the middle line of the perineum, just behind the base of the scrotum and the bulb, and three-quarters of an inch, more or less, according to the size of the patient, in front of the anus. He cuts freely backwards and outwards, through the left ischio-rectal fossa, to halfway between anus and tuberosity. Thus far he has wounded skin, superficial layer of superficial fascia, and deep layer, a few branches of the superficial perineal vessels and nerves, and many twigs of the inferior hæmorrhoidals, and also the transverse vessels and nerve. After this he cuts towards the groove of the staff through the anterior part of the wound, dividing a few of the posterior fibres of the accelerator urinæ, the base of the triangular ligament, and within it the compressor urethræ and the urethra itself. The point of the knife being lodged in the groove, he slides the blade into the bladder, slicing part of the left lobe of the prostate and its investment of recto-vesical fascia, and dividing some of the prostatic fibres of the levator ani, some of the prostatic plexus of veins, and the neck of the bladder. Sometimes the common ejaculatory duct is also wounded.

The neck of the bladder being opened, urine escapes from the wound; so the surgeon lays down the knife, puts the index-finger on the naked staff in the membranous urethra, and artfully works it into the bladder, dilating the wound in the process. He touches the stone. Then he has the staff withdrawn, and, taking out the finger, he introduces the lithotomy forceps, and catches and withdraws the stone through the axis of outlet of the pelvis. He then re-introduces his finger to see that there is not a second stone, and, bleeding having well-nigh ceased, the patient's legs are brought down and he is taken back to bed.

**Cautions.**—First, the surgeon must not stab the perineum too far forwards or he will wound the vascular erectile tissue of the bulb; in tailing off the first incision he must not cut against the wall of the ischio-rectal fossa or he will wound the internal pudic vessels and nerve; and he must not bring the incision too far inwards or he will cut a hole in the wall of the rectum, which here is bulging over the fossa. His deep incision must not be too limited or the staff will not be sufficiently laid bare, and, in trying to introduce his finger into the bladder (itself unopened), he may tear the urethra across, and push the prostate and bladder bodily up into the pelvis. This is a frightful calamity, and a not infrequent cause of 'blank lithotomy.' On the other hand, he must not use the knife too freely, lest he cut through the whole length of the prostatic lobe, and, widely wounding its fascial investment, lay the ischio-rectal fossa, the neck of the bladder, and the interior of the pelvis into one large space. Thus urinary infiltration and a fatal cellulitis and peritonitis would probably be set up.

On account of the high pelvic position of the bladder in boyhood, lateral lithotomy is not an easy operation. To obtain confidence and

dexterity in operating, the student and young surgeon should lose no opportunity of rehearsing the operation on the cadaver, both of the child and of the adult.

**Median perineal cystotomy** is the operation of cutting into the bladder through the middle line of the perineum; should the incision be made for the extraction of a stone, the word 'lithotomy' takes the place of 'cystotomy.' Cystotomy is performed for exploration, and for intractable inflammation of the bladder. Median lithotomy is an excellent operation for the extraction of small stones or foreign bodies, as no blood-vessel of importance is wounded; it is an operation of dilatation rather than of cutting, and is thus performed:—A rectangular staff with a median groove is passed into the bladder; its elbow is lodged in the membranous urethra, where it is readily felt through the perineum when the patient is placed in the lithotomy position. The surgeon makes an inch-long button-hole in the median line, down to the elbow, and passes a steel director along the groove of the arm and into the bladder. The staff is then withdrawn and the finger is 'screwed' along through the membranous and prostatic urethra. The stone is felt, and then the director is withdrawn and the forceps are introduced.

The only **parts incised** are the skin and the superficial fasciæ for about an inch; the base of the triangular ligament and the compressor urethræ and the membranous urethra. The prostatic urethra is dilated, the prostate itself escaping the knife. The risk of hæmorrhage may be disregarded. As the opening is made high up under the pubes, where the arch is extremely narrow, this operation does not serve for the extraction of a large stone.

The **perineum of the female** is much shorter than that of the male, only about an inch intervening between the vulval and anal openings. In the female the longitudinal lateral folds (labia majora) fail to meet (in the male they are fused together to form the scrotum). Thus, the vulva is a cleft between the lateral halves of an undeveloped scrotum. The deep layer of the superficial fascia is continued along the labia majora and the rami of the pubes up into the inguinal region of the abdomen. The transversus perinei is but a rudimentary band; the erector clitoridis corresponds to the erector penis, and the sphincter vaginæ represents the accelerator urinæ; the 'artery of the bulb' supplies the vaginal wall. The triangular ligament supports the urethra, much as in the male, and contains the compressor urethræ, but the base of the ligament is defective owing to the passage through it of the vagina.

Tillaux cleverly demonstrates the closeness of the resemblance between the female and male perineum, by uncovering the muscular triangle, and then splitting the bulb down the middle line, and separating the lateral halves. The median cleft thus represents the vulva, and the halves of the bulb of the urethra represent the bulbs of the

vagina, Cowper's glands becoming the vulvo-vaginal glands, and the accelerator urinæ the sphincter vaginæ. The two lateral triangles now become insignificant by the half of the accelerator being displaced outwards towards the erector penis (clitoridis). (*See fig. on p. 440.*)

Sometimes the **perineum** is **ruptured** during labour, the vulva being torn through even into the rectum. If the woman be at once laid upon her side, the knees being tied together, immediate union may be secured. If, however, the repair be not thus established, the surgeon waits until she has regained health and strength, when he freshens up the torn surfaces and approximates them by sutures.



## PART V

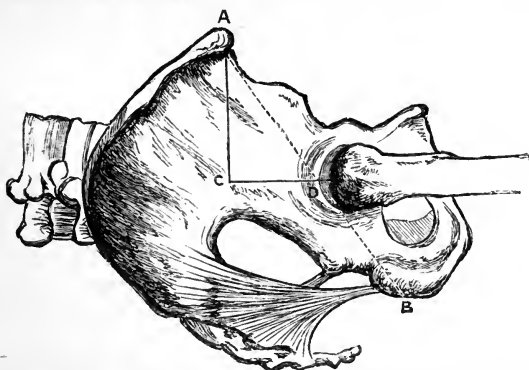
## THE LOWER EXTREMITY

**Surface markings.**—The furrow corresponding to *Poupart's ligament* extends from the front of the iliac crest to the pubic *spine*. From the spine the *pubic crest* may be traced inwards to the *symphysis*. From the sub-pubic arch the rami of the pubes and ischium may be followed to the ischial tuberosity.

When inquiring if a *hernia be inguinal or femoral*, the inner border of the hand should be laid along the line of *Poupart's ligament*; if the protrusion be chiefly above the hand it is inguinal, if below, femoral, for a femoral hernia comes up from the saphenous opening. The spine of the pubes is above and to the inner side of a femoral hernia.

Below *Poupart's ligament* is a triangular depression corresponding to *Scarpa's triangle*, and from its apex, which points downwards and inwards, runs a shallow groove in which the femoral vessels and the *sartorius descend*.

The **line of the artery** is drawn when the limb is slightly flexed



A B, *Nélaton's line*; C D, measurement from *Bryant's belt-line* to top of trochanter; the line A C should be continued round the body.

and everted, from the middle of the interval between the iliac spine and pubic *symphysis*, to the inner femoral condyle. Roughly, but not

with precision, it may be said that the artery begins 'under the middle of Poupart's ligament.' The artery is felt pulsating half an inch to the inner side of the middle of the ligament.

Unless the subject be fat, the head of the femur may be felt rotating in the middle of the base of Scarpa's triangle. It lies beneath the crease which runs from the scrotum to the ilium. When the capsule is distended this crease is partially effaced. The head of the femur has the same direction as the inner surface (tuberosity) of the internal condyle.

**Nélaton's line** is drawn over the buttock from the anterior superior iliac spine to the ischial tuberosity. In the sound limb it just touches the top of the great trochanter, but when injury or disease has seriously damaged the acetabulum or the joint, or the head or neck of the femur, the top of the trochanter may be above that line. It is useful in cases of doubtful dislocation, and of fracture of the neck of the femur.

**Bryant's measurement** is made when the patient is lying straight and flat on his back. A string is passed across the front of the abdomen at the level of the iliac spines, and another over the thighs at the tops of the trochanters. These strings ought to be parallel; but if, from injury or disease, one trochanter be raised, the vertical measurement, C D, between the lines is diminished on that side.

In **measuring a lower limb** it is not expedient to pay too much attention to a difference of one-fourth or one-third inch; often, indeed, the limbs are unequal in length from birth. In comparing lengths in a child, a good plan is to lay him on his back, and, keeping the pelvis flat and square, and the knees fully extended, to raise the soles of the feet towards the ceiling. A slight difference in the level of soles or of the inner malleoli is then at once manifested.

When *measuring by a tape*, the pelvis must first be arranged flat and square; a line is then taken from each anterior superior iliac spine to the tip of the inner or outer malleolus, the limbs being straight down, or, at any rate, in corresponding positions.

*For the thigh*, the measurement is made to the top of the patella, or from the pubic spine to the adductor tubercle (p. 449). *For the leg* alone, the tape is carried between the malleolus and the upper border of the tibial head.

Between the front of the iliac crest and the great trochanter is the thick mass of muscle consisting of the tensor fasciæ femoris, and of much of the gluteus medius and minimus—the **three internal rotators** of the thigh. They are supplied by the superior gluteal nerve (p. 378).

The **tensor fasciæ femoris** arises from the outer side of the anterior superior iliac spine, and, passing downwards and backwards, is inserted into the fascia lata about a quarter of the way down the thigh, from which level the thickened *ilio-tibial band* descends to the outer tuberosity of the tibia. This band receives two-thirds of the in-

sertion of the gluteus maximus, and may be traced upwards to the front of the iliac crest.

Below the spine of the pubes is the cord-like tendon of the adductor longus (p. 453); it is often extremely prominent in hip-joint disease, but it very rarely needs division. Sometimes this tendon is partially ossified (*rider's bone*). Along the inner side of the thigh is the rounded mass of the adductors longus, brevis, and magnus, covered on their inner surface by the broad, ribbon-like gracilis. This group of muscles is supplied by the obturator nerve. In a thin subject the rigid and slender tendon of the adductor magnus may be detected running to its insertion in the adductor tubercle on the upper part of the inner condyle. Sometimes in men who spend much time on horseback the insertion of this tendon is ossified into a *rider's bone*. The tendon of the gracilis, which lies near that of the adductor magnus is distinguished from it by the fact that it passes beyond the femur and on to the tibia.

The spur-like projection of bone which gives attachment to the tendon of the adductor magnus marks the level of the top of the epiphysis, and also that of the highest part of the trochlear surface. (Holden.)

Above the patella is a depression in which is the flat tendon of the rectus femoris, and, deeper still, much of the quadriceps extensor. Towards the outer side is the prominent ridge on the front of the external condyle, bounding the trochlear surface. This ridge, which should be carefully examined, is apparently quite subcutaneous, but, in addition to the skin, it is covered by fascia lata, and by the expansion from the vastus externus to the patella. An incision on to it opens the synovial membrane of the knee-joint. The outline of the articular margin of the external condyle may easily be made out below and behind the outer border of the patella. This definite ridge is irregularly covered by osteophytes in chronic osteo-arthritis, and in suspected cases of that disease is always to be inspected.

On the inner side is the inner condyle of the femur; it is larger than the outer, but it does not project so markedly beneath the skin, being covered by the fleshy mass of the vastus internus.

The **tuberosities of the femur** are the rounded projections upon the sides of the condyles. They are behind the vertical axis of the joint; the lateral ligaments are attached to them, so that in their descent they may be kept clear of the femur. Being behind the vertical axis, the lateral ligaments check over-extension of the joint. Below the joint are the tuberosities of the tibia. The level of the articulation may be recognised by keeping the finger firmly pressed below the tuberosity of the femur, and slightly bending or straightening the knee. In the crevice is the semilunar fibro-cartilage.

On either side of the patella is a depression which is quickly effaced when effusion occurs in the synovial membrane of the knee;

so also are the hollows at the sides of the *ligamentum patellæ*. This ligament is inserted into the lower part of the tubercle of the tibia. The prominent part of this tubercle corresponds with the level of the head of the fibula.

On the outer side of the knee, a little above the joint, are two thick fibrous bands, one anterior to the other: the larger and posterior is the tendon of the biceps, descending to the head of the fibula; the anterior is the ilio-tibial band of the fascia lata descending to the outer tuberosity of the tibia (p. 448). Between these bands is a shallow groove through which **abscess in popliteal space** is best attacked. The external popliteal nerve (p. 381) may often be made out close to the inner side of the biceps tendon; it pierces the peroneus longus, at the neck of the fibula, and ultimately divides into the musculo-cutaneous and anterior tibial trunks.

**Tenotomy of biceps** is often needed when a stiff knee is being straightened. The strong and narrow blade must be introduced close on the inner side of the tendon, feeling its way down, as it were, between the tendon and the external popliteal nerve. Section of the tendon is then accomplished by a sawing motion in the outward direction. If the tendon were divided from without inwards there would be considerable risk of the knife passing 'with a run' through the last bundles of fibres, and thus wounding the nerve.

When the joint is slightly bent, the fascia lata at the back of the thigh and knee is relaxed, and the fingers can explore the popliteal space, and also the slackened hamstring tendons. On the outer side is the biceps, and below and internal to it is a head of the gastrocnemius. On the inner side is the semi-membranosus, and a little to the fibular side of that tendon is the slender tendon of the semi-tendinosus. The tendon of the gracilis is more towards the front, and is not always very readily made out, especially in a fat subject. Still more to the inner side and to the front is the flat musculo-aponeurotic sartorius; its position is not marked by a tendon, but one can tell where it is by following its course from the groove between the vastus and the adductors, and noting, perhaps, a soft prominence caused by the muscle as it passes over the side of the inner condyle. On the fibular side of the inner hamstrings is the inner head of the gastrocnemius.

The **superficial fascia** consists of a fatty layer continuous with that of abdomen and buttock, and with the dartos, and of a deeper layer which is thin and membranous. The latter is beneath the saphenous vein and the lymphatic glands of the groin; it blocks up the saphenous opening; but at that situation it has so many perforations for blood-vessels and lymphatics that it is called *cribriform*. It is one of the coverings of femoral hernia.

The **internal saphenous vein** begins in an arch with the external or short saphenous on the dorsum of foot, and passes up in front



of the internal malleolus, by the inner and back part of the knee, and up the front of the thigh between the two layers of the superficial fascia. It pierces the cribriform fascia, and passes through the saphenous opening into the common femoral vein. Before doing so it receives the veins which correspond to the superficial branches of the common femoral artery from the iliac, epigastric, and pubic regions. A large tributary also joins it from the back of the thigh by winding round the inner side of the limb.

As a result of pressure upon the inferior vena cava or the common iliac vein—of ovarian tumour or in pregnancy—the saphenous becomes dilated and thickened—varicose (*varus*, crooked); the valves being rendered useless, a wound or ulceration of the vein may then cause fatal bleeding. I have seen a bunch of varicose branches of the vein form a very definite swelling at the base of Scarpa's triangle. The tumour could be emptied by placing the man supine, and it recurred only gradually when he got up again.

A femoral hernia by pressing against the common femoral vein may so hinder the venous return that dilatation of the surface veins and œdema of the limb may occur.

The **inguinal lymphatic glands** are placed between the two layers of the superficial fascia; they consist of two groups, one lying along Poupart's ligament, the other along the saphenous vein.

The *upper set* receive lymph from the abdominal wall below the level of the umbilicus; absorbents from the penis, scrotum, and anus also enter the innermost glands of this group, whilst those from the buttock and outer side of the thigh enter the outlying ones. Sometimes lymphatics from the genitals enter the lower glands as well as the upper.

The *lower group* receive the absorbents from the inner side of the foot and leg, and from the thigh. Lymphatic vessels generally run with the veins; those, therefore, from the outside of foot and leg pass with the external saphenous vein, and end in the popliteal glands.

The lymph from all these glands ascends through the iliac and abdominal glands towards the thoracic duct. Inflammation of a gland is commonly called *bubo* (*Βουβών*, gland). Practically it does not matter in which direction the suppurating gland is opened provided that the undermined and unhealthy skin be removed, and the gland-capsule be scraped out. Infections conveyed from one gland to another may involve the groin in sinuses which have to be opened up before healing can take place. If a sinus run with the lymphatics through the saphenous opening, and into crural canal, it must not be laid open by bold incision but scraped out to its depths, and drained by a short tube.

The **fascia lata** is attached to the iliac crest, Poupart's ligament, rami of pubes and ischium, to the great sacro-sciatic ligament, the sacrum and coccyx. It is especially thick on the outer side on account

of its receiving the insertion of the tensor fasciæ femoris and two-thirds of the gluteus maximus ; it passes as the *ilio-tibial band* (p. 450) from the iliac crest to the outer tuberosity of the tibia and head of fibula. At the back of the thigh the fascia is thinner, and as it ascends it gives one layer over gluteus maximus and one beneath. Investing the lower part of the thigh, it is attached to the condyles of the femur and sends intermuscular septa to the condylar ridges.

Covering in the popliteal space it is continued on as the deep fascia of the back of the leg ; but from the front of the thigh it does not reach below the knee, being gradually blended with the fibres of the quadriceps extensor, and with the periosteal covering of the articular ends of the bones. Guided by the fascia, abscess beneath the gluteus maximus may wander down the thigh and through the popliteal space into the calf.

The **saphenous opening** is about an inch below the inner end of Poupart's ligament, but its site is not usually marked upon the surface of the limb. It has a definite superior border formed by a sickle-shaped (*falciform*) process, which, coming from the pubic spine, sweeps outwards over the vessels to become continuous with that part of the fascia which covers the pectineus, and which slopes upwards and outwards beneath the vessels to join the sheath of the psoas. This latter part is the *pubic piece* of the fascia lata ; it is on a plane posterior to the outer piece, which, from its having come from the region of the iliac crest, is called the *iliac piece*. (Note well that the iliac piece of the fascia lata is not the iliac fascia, p. 307.) This arrangement of the fascia lata in two planes which, though continuous below, are separated by the thickness of the common femoral vessels above, is to permit the saphenous vein to continuously discharge its contents into the common femoral vein, even when the thigh is extended and everted.

As the falciform process arches over the vessels it is connected with the front of the crural sheath (p. 313).

When the thigh is extended and the fascia lata in the groin is tight, and is dragging down Poupart's ligament, the falciform process is rendered hard and sharp ; and when the thigh is flexed and rotated inwards the process is slackened. In attempting to reduce a femoral hernia without flexing the thigh, the bowel may be bruised against the sickle-shaped band.

Femoral hernia (p. 312) descends in the innermost compartment of the crural sheath, having the iliac part of the fascia lata in front of it, and the pubic part behind. At about an inch below the ligament the crural sheath ends by blending with the sheath of the vessels. As a femoral hernia can descend no farther along the vessels than where these sheaths blend, it bulges forwards through the saphenous opening, taking the anterior layer of the crural sheath and the cribriform fascia in front of it ; it then curls round the falciform process and on to the

front of the iliac piece of the fascia lata, along which it sometimes travels to the iliac crest.

The **sartorius** arises from the anterior superior iliac spine, and passes downwards and inwards over the iliacus and rectus, and the anterior crural nerve. It then descends vertically over and between the vastus internus and the adductor longus, covering the superficial femoral vessels, passing over the adductor magnus, gracilis, long saphenous nerve, and the internal lateral ligament of the knee. It is inserted below the inner tuberosity of the tibia, and into the deep fascia of the leg. It is supplied by the middle cutaneous and other branches of anterior crural nerve. Lying in the groove between the vastus and adductors it is the guide to ligation of the femoral artery, both at the apex of Scarpa's triangle and in Hunter's canal. The surgeon looks for its long parallel fibres as soon as he has incised the fascia lata.

The **rectus femoris** arises from the anterior inferior spine of the ilium, and from just above the acetabulum; these heads join in a tendon which soon spreads out into a bipenniform, fleshy mass, which, lying over the deeper part of the quadriceps extensor (crureus and vasti) is inserted with it into the patella.

*Relations.*—The origin of the muscle is deeply placed, lying upon the capsule of the hip-joint, beneath the gluteus minimus, iliacus and psoas, and the tensor fasciæ femoris; but in the rest of its extent it is beneath the fascia lata.

When the muscle contracts with excessive energy it may break off the anterior inferior iliac spine, or detach its epiphysis, or it may tear through the lower tendon. If it be acting with the rest of the quadriceps the patella may be broken across, or its ligament may be torn through.

The **adductor longus** arises by a slender tendon from the front of the angle of the pubes—just below the pubic spine—and passes downwards, outwards, and backwards to the middle third of the linea aspera. It separates the superficial from the deep femoral vessels; and, passing to its insertion behind the origin of the vastus internus, it forms the postero-internal boundary of Hunter's canal. Behind it descend the adductors brevis and magnus, and the anterior division of the obturator nerve. Along its outer and inner borders are the pectineus and the gracilis respectively.

The adductors longus and brevis and the pectineus are powerful external rotators as well as adductors of the thigh; they are supplied by the obturator nerve, but the gracilis is a pure adductor, and is supplied by the obturator nerve. The pectineus is as much a flexor as an adductor, and is supplied both by the anterior crural and the obturator; the psoas is simply a flexor, and is therefore supplied by the anterior crural only, or by twigs of the lumbar plexus.

## SCARPA'S TRIANGLE

Scarpa's triangle has its base at Poupart's ligament and its apex at the junction of the upper with the middle third of the thigh, where the sartorius passes over the inner border of the adductor longus. It is covered by skin, two layers of superficial fascia, and by the fascia lata. In the superficial fascia are the lymphatics and glands, branches of the ilio-inguinal, genito-crural, and middle cutaneous nerves, and the internal saphenous vein and its tributaries.

The floor of the triangle is formed by the iliacus, psoas, pectineus, perhaps by a little of the adductor brevis, and by the adductor longus.

The space contains the trunk of the common and superficial femoral artery, which bisects the triangle, and the corresponding veins, the deep femoral vessels and their branches, the anterior crural nerve breaking up into branches, and the external cutaneous nerve near the iliac crest.

**Hunter's canal** begins at the apex of Scarpa's triangle, and ends at the opening in the adductor magnus. Thus it occupies the middle third of the thigh. It is bounded on the outer side by the vastus internus, and behind and on the inner side by the adductors longus and magnus. It is roofed in by a fibrous expansion from the adductors to the vastus, and over the roof lies the sartorius.

*The canal contains* the superficial femoral vessels in their proper sheath, and the long saphenous nerve outside that sheath. The vein is behind the artery, and slightly external to it; and the nerve is crossing over the sheath from the outer side. The nerve eventually passes through the roof with the superficial part of the anastomotica magna, a branch given off from the femoral whilst in the canal.

*The femur winds round the main artery.*—The femoral and popliteal trunk of artery runs straight from the groin to the knee, lying first to the front of the head of the femur, then to inner side of shaft, and lastly behind it. In this changing position it is the femur that winds round the artery, and not the artery round the femur.

**The common femoral artery** is the continuation of the external iliac from beneath Poupart's ligament for about two inches into Scarpa's triangle, where it divides into the superficial and the deep trunk. As the **superficial femoral** is the direct continuation of the common, it is convenient to take the relations of the trunk in its continuity. (Its course upon the surface has been given on page 447.)

*Relations.*—The artery rests upon the psoas, which separates it from the capsule of the hip-joint; upon the pectineus, the adductor longus, (perhaps) brevis, and on the magnus. The deep femoral vein is behind it in the triangle, and the superficial femoral vein is behind it in Hunter's canal. Covering it are the skin and fasciæ, sartorius,

the overhanging vastus internus, and the roof of Hunter's canal; also the long saphenous nerve, which, like the sartorius, crosses it obliquely from the outer side.

To the outer side is the anterior crural nerve, and, lower down, are its saphenous branch and the sartorius, also the vastus internus, and, at the end of the canal, the superficial femoral vein. On the inner side are the common femoral vein and the pectineus, then the three adductors, and, further down, is the sartorius, which has crossed it.

**Note.**—To the surgeon the most important relations of the artery are the vein and the sartorius; and, fortunately, by remembering the position which the muscle occupies (which is sufficiently obvious) he remembers also the situation of the vein, which is upon just the opposite aspect of the artery. Thus, when the sartorius is entirely to the outer side, as at the base of Scarpa's triangle, the vein is entirely to the inner side. When the sartorius is gaining the front of the artery from the outer side the vein is getting behind it from the inner side, as towards the apex of the triangle. When the muscle is exactly over the artery, as at the apex of the triangle, the vein is exactly behind it; and when, as in Hunter's canal, the sartorius is lying above and to the inner side, the vein is beneath and to the outer side. Lastly, when the muscle is quite to the inner side, as at the lower end of the canal, the vein is quite to the outer side, in which relative position it is found at the top of the popliteal space.

The relationship of the long saphenous nerve to the artery is the same as that of the sartorius.

The *branches of the common femoral artery* are the three superficial twigs which, coming through the cribriform fascia, pass between the layers of the superficial fascia, towards, as their names respectively denote, the *epigastric* region, over Poupart's ligament, the *iliac* region (*circumflexa*), and the *external pudic* region. The former branches communicate with the deeper and larger vessels of the same name (p. 370). The third branch passes to the scrotum or labium, and, lying over the spermatic cord, is wounded in inguinal herniotomy and in castration. A fourth branch, the *deep external pudic*, pierces the fascia lata on the inner side of the thigh, and, ending like the last, anastomoses with the superficial perineal artery.

The superficial femoral artery gives off various *muscular branches*, and, in Hunter's canal, the **anastomotica magna**. This important branch divides into a *superficial part*, which leaves the canal through the roof, in company with the saphenous nerve; and a *deep part*, which passes obliquely across the lower end of the femur, under the quadriceps extensor, giving branches into the articulation, and anastomosing on the inner side with the superior articular of the popliteal, and on the outer side with the superior external articular, the recurrent tibial, and the descending branches of the external circumflex.

The **deep femoral artery** (*profunda femoris*) comes off from the back of the common trunk, an inch or two below Poupart's ligament, and, passing at first outwards, winds downwards and inwards to the adductor magnus.

*Relations.*—At first close beneath the superficial femoral vessels, it is afterwards separated from them by the adductor longus, and the deep femoral vein.

At its origin it touches the front of the iliacus; afterwards it rests upon the pectineus and the adductors brevis and magnus. On the outer side is the femur, covered by the vastus internus, and on the inner side are the adductors.

*The branches of the deep femoral artery* are the two circumflex and the three perforating, which, as their names imply, are either bent around the femur, or perforate the adductor magnus in their course to the back of the thigh.

The **external circumflex** passes outwards through the divisions of the anterior crural nerve, then under the sartorius and rectus, and over the crureus. It divides into *ascending branches* which pass under the tensor fasciæ femoris to the space between the iliac crest and the great trochanter, where they anastomose with the gluteal and the circumflexa ilii.

*Transverse branches* pass backwards through the vastus externus to anastomose with the sciatic, internal circumflex, and superior perforating, completing the cruciform anastomosis; and *descending branches* run in the vastus externus to anastomose with the superior external articular of the popliteal.

The **internal circumflex** leaves Scarpa's triangle between the psoas and pectineus, and, passing below the obturator externus, and above the adductor brevis, hits the interval between the quadratus femoris and the adductor magnus, by which it enters the cruciform anastomosis. When it is passing above the adductor brevis it gives a branch to anastomose with the obturator artery, and to help in the supply of the hip-joint. Another branch may pass by the tendon of the obturator externus to anastomose with the gluteal and sciatic.

Of the **perforating arteries**, the *first* runs through or above the adductor brevis to 'perforate' the magnus. It joins in the cruciform anastomosis, and communicates below with the *second*, which pierces both brevis and magnus, and anastomoses with the first and with the *third*. The third pierces the large adductor below the level of the short one, and anastomoses with the second and with the *termination of the profunda*, which comes through the magnus as a *fourth perforating*, and anastomoses freely with the superior muscular branches of the popliteal, and with the higher perforating branches.

The second perforating gives the special *nutrient branch* to the medulla of the femur, which enters by the linea aspera in an upward direction.

**Irregularities.**—The common femoral artery may divide close below Poupart's ligament, or as far down as the apex of Scarpa's triangle; in the latter case the circumflex branches come from the common trunk. There may be two superficial femoral arteries. Occasionally the femoral has been replaced by a giant sciatic artery which has eventually become the popliteal.

**The femoral veins.**—The *superficial femoral vein* continues the popliteal vein up through Hunter's canal, where it is lying external, and then posterior to its artery; through Scarpa's triangle where, in its ascent, it gradually passes from behind to the inner side, until it is joined, an inch and a half below Poupart's ligament, by the deep femoral vein to form the *common femoral*. This last lies altogether on the inner side of its artery, resting upon the pectineus. The relations and the tributaries are much like those of the corresponding arteries, with the exception that the veins corresponding to the branches of the common femoral artery enter the long saphenous vein, itself a tributary of the common femoral.

**Compression of the common femoral artery** against the iliopectineal eminence and over the head of the femur is easily accomplished by the thumb, the fingers grasping the great trochanter. If the circulation have to be controlled for a considerable time, the part should be first cleanly shaved, washed and dried, and then dusted with starch powder, a shot-bag being placed over the backs of the fingers, whilst the tips are laid along the artery. The necessary force, which is not great, should be directed a little upwards towards the pubic ramus.

The *india-rubber tourniquet* is applied by stretching it across the thigh below the ischial tuberosity, crossing the stretched ends over a pad in the groin, and taking them, spica-wise, front and back, to just below the opposite iliac crest, where they are secured.

If compression be made lower down the thigh, by a screw-tourniquet for instance, a pad (a rib-roller) should be laid over the artery, in the groove between the quadriceps and adductors; the pressure being directed outwards against the femur.

**Ligation of the common femoral** has not been a popular operation, because the surgeon cannot be sure that the trunk is not dividing high up, or that the circumflex trunks do not come from it. Then, close above the ligature, the deep epigastric and the circumflex iliac branches are given off, so that the risk of imperfect formation of the clot and of recurrent hæmorrhage is considerable. Ligation of the external iliac has usually been the alternative operation, but in spite of these objections ligation of the common femoral artery is often a very proper operation.

To secure the common femoral, the skin being shaved and cleansed, a two-inch incision is made from a spot midway between the iliac spine and pubic symphysis, through the skin and superficial fascia

and fascia lata. Then the crural sheath is sparingly opened and the artery is seen, to the outside of the vein. The needle is passed from the inner side. The anterior crural nerve is far out of sight (p. 358).

**Collateral circulation** is established by the anastomosis of the external circumflex with the gluteal, ilio-lumbar, and circumflexa ilii, and with the sciatic branches in the cruciform anastomosis; by the anastomosis of the internal circumflex with the obturator, gluteal, and sciatic; of the superior perforating with the sciatic; and of the perforating and superior muscular branches of the popliteal with the comes nervi ischiatici.

**Ligation of the superficial femoral in Scarpa's triangle** is performed at 'a hand's breath' (four inches) below Poupart's ligament—at a spot in which the artery is comparatively near the surface, and distant from the origin of any large branch. The line of the artery having been taken (p. 447), or traced by the pulsations, as the limb lies slightly flexed and everted upon a pillow, a three- or four-inch incision is made with its mid-point over the chosen spot. In incising the superficial fascia, the long saphenous vein, which is close on the inner side, must be avoided; the fascia lata is then divided on a director, when the inner border of the sartorius is looked for, exposed, and drawn outwards. The sheath of the vessels is thus brought into view and is opened for about half an inch, along the aspect most distant from the vein, which is, of course, upon the side of the sartorius—the outer side. Unless this point be attended to the thin-walled vein is in great danger of being wounded. The vein may not be seen, as it is behind the artery, though slightly to the inner side; the aneurysm-needle is passed from the inner side, close around the artery, threaded, and withdrawn.

**Ligation in Hunter's canal** is invariably performed in the case of a punctured wound in that situation, and sometimes in the case of aneurysm of the popliteal artery. A four-inch incision is made over the line of the artery in the middle of the thigh, care being taken to avoid the saphenous vein. The fascia lata having been divided, the fibres of the sartorius are seen running evenly in the length of the wound. Their direction distinguishes them from the oblique fibres of the vastus internus and of the adductor longus. The muscle is then drawn inwards, and the aponeurotic roof of the canal is exposed—perhaps with the saphenous nerve and the superficial part of the anastomotica magna passing through it. The roof is then divided on a director for an inch or so, when the saphenous nerve is found resting upon the sheath of the vessels. This sheath is cautiously opened for about a quarter of an inch, the artery is isolated, and the needle is passed from the outer side—the side of the vein.

In seeking the artery in Hunter's canal the *fallacy* is apt to be in making the incision too low down, so that the operator finds his wound deepening against the tendons of the gracilis and the adductor magnus



Practically, Scarpa's triangle occupies the upper third of the thigh, Hunter's canal the middle third, and the popliteal space the lowest third.

*After ligation of the superficial femoral* the circulation is carried on by the many unnamed, empty muscular branches of the femoral below the ligature bringing in blood from muscular branches above it; by the deep part of the anastomotica magna bringing in blood from the descending branches of the external circumflex; by the superior muscular branches of the popliteal anastomosing with the lower perforating arteries and with the comes nervi ischiatici (in a dissection which I once made this was the most important collateral route); and by superior external articular branches anastomosing with the external circumflex.

As an anatomical exercise the following question may be answered:—*What structures are divided in a transverse section across the middle of the thigh?* *Ans.:* Skin and superficial fascia, and, in the latter, branches of the internal, middle, and external cutaneous nerves, and of the lesser sciatic; also the long saphenous vein and lymphatics. The fascia lata, which is especially strong in the region of the ilio-tibial band. The sartorius, rectus femoris, vasti and crureus, and branches of the anterior crural nerve. The gracilis, adductors longus and magnus, and the obturator nerve. Hunter's canal, with the superficial femoral vessels and the saphenous nerve. Descending branches of the internal and external circumflex vessels; the termination of the profunda vessels, and of a perforating artery. The biceps semi-tendinosus and membranosus; the beginning of the internal and external popliteal nerves of the great sciatic; perhaps the comes nervi ischiatici, and ascending muscular branches of the popliteal artery; the femur and its periosteum.

**The gluteal region.**—Between the ischial tuberosity and the great trochanter a shallow space can be made out by thrusting the fingers into the gluteus maximus. In its depth are the small external rotators of the femur, and in the higher part of this space, under cover of the rotators, is the capsule of the hip-joint. In the case of acute effusion into the joint, a deep-seated fulness may be detected here, which may be aspirated through the muscle.

It is difficult to show by marking on the rounded buttock the position of parts which lie in the flat beneath it, and in attempting to do so the student must work at first with the dry bones beside him. He begins by tracing the iliac crest backwards to the posterior superior spine, which overhangs the side of the sacrum; descending an inch, his finger is over and upon the sacro-iliac articulation; in sacro-iliac disease there are a swelling and tenderness at that spot. A little below this is the posterior inferior spine. This spine, which is at the lower part of the sacro-iliac joint, and may be easily made out in a thin person, is to be the starting-point for a bold, sickle-shaped

line with its convexity towards the great trochanter, which marks the great sacro-sciatic notch, and ends on the ischial spine. From the ischial tuberosity arise the hamstring muscles, biceps, and semi-tendinosus and semi-membranosus.

The sciatic nerves (p. 379) leave the pelvis below the pyriformis; the greater then descends between the trochanter and the tuberosity, emerging in the mid-space from beneath the border of the gluteus maximus. It lies in this hollow so that it may be out of the way of pressure in the usual sitting posture. If, however, one sits sideways or on the edge of the chair, the nerve is compressed and numbness and discomfort result. For *nerve-stretching*, see p. 380; for the course of the gluteal artery, see p. 374.

The **gluteus maximus** arises from the back of the ilium, sacrum, coccyx, and sacro-sciatic ligament, and passes downwards and outwards; its thick and free lower border passes over the ischial tuberosity, and is inserted below the great trochanter. The upper two-thirds of the muscle glide as a strong, thin tendon over the trochanter, and are inserted with the tensor fasciæ femoris into the ilio-tibial band. The muscle is separated from the tuberosity and the trochanter by **two bursæ**, and in men who sit a great deal, such as coachmen, tailors, and weavers, the *ischial bursa* is apt to be greatly irritated, and even to suppurate. The inflamed bursa has a very unpoetic name. When the *trochanteric bursa* is inflamed the signs may at first suggest hip-joint disease; but there is no swelling of the joint itself, and the femur may be rotated in the acetabulum without causing distress.

The *fold of the nates* runs obliquely downwards and outwards in the direction of the lower border of the gluteus maximus, with which, however, it has no anatomical association. It is the result of the creasing of the skin when the thigh is extended. When it is flexed the crease and the fold disappear, which they would not do if their presence had depended upon the existence of the border of the muscle.

The *pyriformis* may be depicted as passing downwards and outwards from the notch already marked out, to the top of the great trochanter. It forms an elongated, triangular figure. Through the notch, above the muscle, emerge the gluteal artery and the superior gluteal nerve. As has already been shown (p. 374), the point of emergence of the artery is at the junction of the upper and middle thirds of a line running from the posterior superior spine to the top of the great trochanter.

#### THE FEMUR

The **femur generally changes its form** with age; in childhood the neck is short and in an almost vertical line with the shaft. In adult life it stands off at an obtuse angle, and often in old age, but by no

means always, it passes inwards at a right angle from the shaft, the head of the bone sinking even below the level of the top of the great trochanter. At this time the compact wall becomes thinned, and much of the cancellated tissue which it encases undergoes fatty degeneration and absorption. Fracture of the femoral neck is, in such circumstances, very apt to occur.

The **femur has five centres of ossification**; the centre for the diaphysis, or shaft, extends also into the neck. This is an important exception to the rule that only the epiphysis of a long bone enters into the formation of a joint; in the case of the hip some of the diaphysis is enclosed within the capsule.

The *knee-epiphysis* begins to ossify in the ninth month of foetal life: a fact of importance in medical jurisprudence. The *head* begins to ossify in the first year, the *great trochanter* in the fifth, and the *lesser* in the thirteenth year.

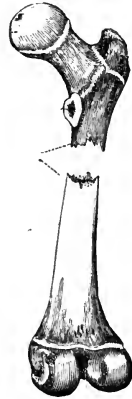
The epiphyses join the shaft, in the inverse order of their development, at the seventeenth, eighteenth, nineteenth, and twentieth years.

Increase in the girth of a bone depends upon deposit in the periosteum; increase in length by growth in the junction-cartilages. As the lower epiphysis of the femur is the last to join (twentieth year), its integrity is very essential to the growth of the limb; similarly, the scapular epiphysis of the humerus (p. 260) is the important one in the growth of the arm. In excision of the knee-joint, the surgeon guards the lower junction-cartilage, so as to diminish to the utmost the amount of the subsequent and inevitable shortening of the limb.

**Fracture of the femur** may occur in any part of the bone; reference will be made here to certain special varieties of fracture only. Before manhood the **lower epiphysis** may be 'unglued' from violence, and the bellies of the gastrocnemius, which arise from the condyles, may tilt the upper border of the epiphysis back into the popliteal space and against the artery. If there be difficulty in keeping the surfaces in apposition, as I have known to happen, the knee must be kept slightly bent, and, if necessary, the tendon of Achilles divided, so as to relax all muscular traction. Complete displacement of these wide surfaces rarely occurs.

*Fracture through the epiphysis* is apt to be followed by arrest of growth of the bone, and by stiffness of the knee.

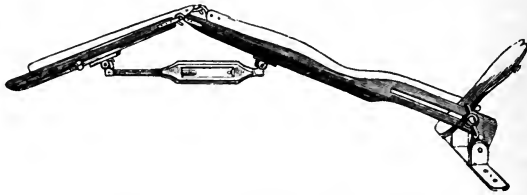
In **fracture above the condyles** of the fully ossified bone there is often no displacement whatever, especially if the plane be transverse; but if it be oblique, the lower fragment is most likely thrust backwards, the plane of fracture passing from behind, downwards and



Ossification of femur

forwards, the gastrocnemius helping materially in the displacement in the direction which the violence of the shock had first determined. But if the line of fracture be from before, downwards and backwards, there is neither gravity nor muscular action to unhitch the lower fragment, and there is, therefore, no displacement, though the heavy shaft of the femur may sink towards the mattress.

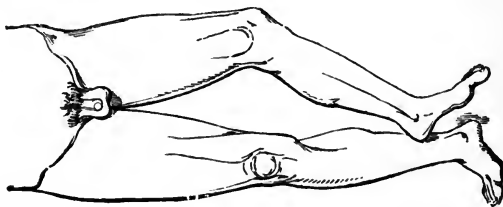
McIntyre's splint, which is a double inclined plane hollowed out for the thigh and leg, is very useful in the treatment of fracture above



the condyles, as, the knee being slightly bent, strain is taken from the gastrocnemius and popliteus.

**Signs of fracture of neck or shaft.**—As the lever is broken the limb cannot be raised, perhaps hardly moved, by the patient, and there is probably deep-seated swelling, the result of effusion from the torn vessels of the bone, medulla, periosteum, and adjacent muscles.

The weight, or natural inclination of the limb, carries it into the everted position. This **eversion** is not due to 'the numerous and strong external rotatory muscles' (Sir A. Cooper), for it is as characteristic of fracture of the middle of the shaft, that is below the chief mass of those rotators, as it is of fracture of the neck. Moreover, though the external rotators are superior in number to the internal rotators, they are not in strength.<sup>1</sup> The eversion persists, too, during anæsthesia, when muscular action is suspended, and I have seen a woman with old fracture of the neck roll the limb inwards at our request.



Fracture of left femur; limb shortened and everted. (ERICHSEN.)

More influence is ascribed to muscles in affecting the position of a limb after fracture than is their due. They are not constantly contending on opposite sides of a bone in a sort of 'tug of war,' ready to pull the fragment this side or that. If so, how is it that,

<sup>1</sup> *British Medical Journal*, Nov. 1, 1879.

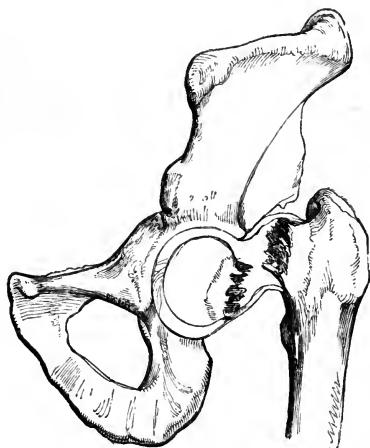
when the patella is broken across, the leg is not immediately and forcibly flexed, and that when the olecranon is separated the elbow is not rigidly flexed?

A sound limb does not rotate on the long axis of the femur, but on an imaginary axis which ascends through the mass of the adductors to the centre of the femoral head. The centre of gravity of the limb is far to the outer side of this axis, because the neck of the bone is fending the shaft from the pelvis and from the other thigh. It is this arrangement which makes eversion the natural position of the limb, as occurs when one is at rest in the supine position. When the femoral neck is broken, the impediment to further eversion is absent, and the limb rolls into the characteristic position. Sometimes, though very rarely, fracture of the femur is followed by inversion; this is due to the violence which effected the fracture having lifted the limb into, and temporarily left it in, that position.

Unless the line of a fracture in the shaft be transverse the lower fragment is apt to be 'unhitched' from the upper, and to be steadily drawn upwards by the elastic pull of muscles, nerves, vessels, fasciæ, and skin; thus **shortening** is a sign of fracture. In children, however, in whom the plane of fracture is generally square, there is no overlapping of the fragments, and therefore no shortening; and, as the neck of the femur is not directed much outwards, fracture of the shaft is not characterised by eversion.

That the shortening after fracture is not due entirely to muscular contraction is evinced by the fact that the amount of shortening is apt steadily to increase for some time; if it were due to muscular contraction the shortening should be immediate, and to the full. If the eversion were due to muscular contraction, how is it that it generally is to its full extent directly after the injury, while the shortening, which some attribute to the same cause, is but gradual?

When the shaft is broken, unless the surfaces are interlocked (impacted), when an assistant rotates the limb, the trochanter remains stationary. And, if the fracture be in the neck, the trochanter simply rotates in its long axis; it does not sweep in a semicircle as it does when the sound limb is rotated.



Intra-capsular fracture.

**Fracture of the neck** is a common injury in old subjects; the

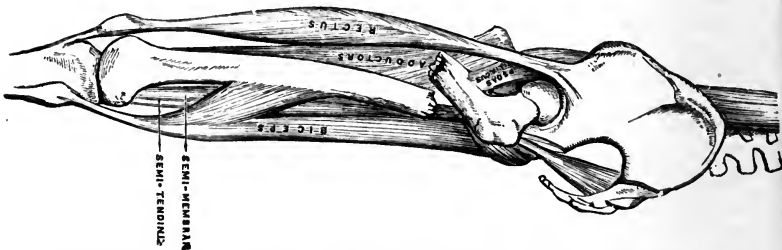
violence which causes it may be trifling, for the bone is weak and the shock of an unexpected step, or of a jarring, comes vertically across it. The limb is at once everted, shortened, and useless, and swelling and pain are at the hip. With such signs it is superfluous and unkind to try to elicit crepitus.

The **fracture** may be **within or outside of the capsule**. In the former case the shaft-fragment is tethered by the ligament, and the shortening may not amount to more than half an inch or so, but when the break is outside the capsule there is, practically, no limit to the amount of shortening, which may then amount to several inches.



Extra-capsular fracture.

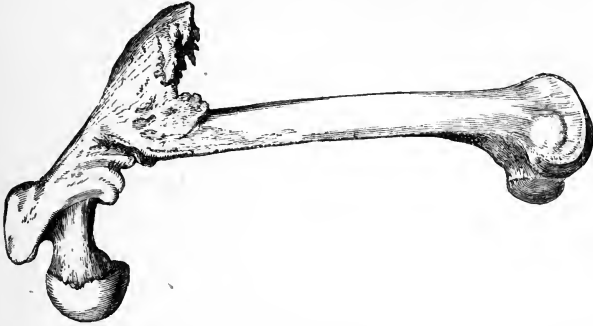**Union after intra-capsular fracture** very rarely occurs by bone, probably because, the fracture being in the joint, the surfaces are constantly bathed in sero-synovial fluid, instead of being wrapped in blood-clot, as happens in fracture in any other part of the body, with the exception of the patella, the olecranon, and the coronoid, which are all, be it noticed, instances of fracture into a synovial membrane. To explain the failure of bony union by reference to the age of the patient (upwards of fifty years) is incorrect, for if a man of one hundred years break the *shaft* of his femur firm union would be expected. To say, also, that the cause of non-union may be want of apposition of the surfaces is wrong; for months or years after the injury we may find the surfaces closely applied, polished by friction against each other, or closely connected by fibrous tissue. Neither is the theory of imperfect blood-supply to the parts valid.



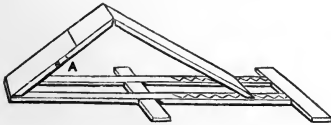
Fracture below lesser trochanter; upper fragment tilted forwards by psoas and iliacus. (After HIND.)

**In fracture below the lesser trochanter** the lower fragment—the chief part of the bone—drops by its own weight, and is pulled upwards, as explained above, and rolled outwards; the upper fragment is tilted forwards by the psoas, iliacus, pectineus, adductor brevis, and gluteus minimus; thus there is often considerable overlapping, deformity, and shortening. The injury cannot then be satisfactorily treated

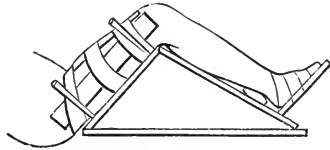
by the long splint, nor must any attempt be made to repress the upper fragment by pad or bandage, lest a sharp end work through the



muscles, fasciæ, and skin, and the fracture be rendered compound. It may be dealt with, however, by keeping the patient in a slightly sitting posture, so that, by flexing the trunk and pelvis on the femur, the psoas and allied muscles may be relaxed to the utmost; the knee



Double inclined plane; the thigh piece may be lengthened at A.



Fracture of upper end of femur; limb arranged on double inclined plane.

being flexed over a well-padded double inclined plane. Bending the knee takes the strain off the hamstring muscles, and raises the lower fragment of the femur to the level of the upper.

**Separation of the great trochanter** may occur from muscular or direct violence, but the fragment quickly becomes fixed again if the limb be kept in absolute rest, the loose piece being steadied by a bandage. The accident is apt to happen to the athlete whose femur is not yet ossified throughout.

### THE HIP-JOINT

The articular surfaces of the acetabulum and the head of the femur are encrusted with a layer of permanent cartilage, which disappears in chronic rheumatic arthritis. The dry surfaces of bone then become worn by friction, the acetabulum becomes loose and shallow, and the head of the femur flattened and worm-eaten. Or there may be a great deposit of new, hard bone, which takes a beautiful polish from the constant dry rubbing in the joint, so that it looks like porcelain.

The **capsule** is attached beyond the border of the acetabulum. In front it is extremely thick and descends to the intertrochanteric line, but behind, where it is thin and membranous, it does not reach to within a finger's breadth of the line. The anterior part is strengthened by the ilio-femoral, or **Bigelow's' ligament**, which descends like an inverted Y from the anterior inferior iliac spine to the upper and lower ends of the anterior intertrochanteric line. Fibres are reflected from the lower end of the capsule up around the neck, these fibres strengthen the periosteum; thus, sometimes it happens that the neck is cracked across without displacement occurring, the fragments being closely held together by the thick periosteal covering.

There is often a perforation in the front of the capsule, between the branches of the Y ligament, by which the synovial membrane of the joint communicates with the bursa beneath the psoas. Around the border of the acetabulum, just inside the capsule, is the fibro-cartilaginous *cotyloid* ligament, which acts as a 'sucker' around the head of the femur which it tightly embraces, securing its position by atmospheric pressure. It stretches across the cotyloid notch at the lower part of the acetabulum under the name of the *transverse* ligament, vessels and nerves entering the joint beneath it.

A *synovial membrane* lines the capsule and covers the neck of the femur, but its continuity cannot be traced over the opposed articular surfaces except in early foetal life, as, under the influence of pressure, it becomes absorbed.

The *ligamentum teres* is a hollow fibrous pyramid, which passes between the margin of a depression at the bottom of the acetabulum and the pit below and behind the centre of the head of the femur. It is surrounded by synovial membrane. It is not an important structure; sometimes it is represented by a mere shred. It is, of course, ruptured in dislocation. Possibly its chief function is to act as a cushion.

**Relations of the hip-joint.**—*In front* are the iliacus and psoas, the pectineus, the straight head of the rectus femoris and some of the gluteus minimus. *Behind* are the pyriformis, gemelli and obturator internus, obturator externus, and quadratus femoris. *Above* are the reflected head of the rectus and the gluteus minimus, and *below* are the obturator externus and the outer border of the pectineus.

The anterior crural nerve and the common femoral vessels are separated from the front of the capsule by the iliacus, psoas, and pectineus; and the sciatic vessels and nerves are separated from the posterior aspect by the pyriformis, the gemelli and the obturator internus, and the quadratus femoris.

**Supplies.**—*Arteries* come from the gluteal (above), the sciatic (behind), the obturator and internal circumflex (below). *Nerves* enter from the sacral plexus (*n.* to quadratus), the great sciatic, obturator, accessory obturator and anterior crural (*n.* to rectus).



**Disease of hip-joint** begins in the synovial membrane or bone, the first result often being an acute effusion into the synovial membrane. The joint is at once swollen, stiffened, deformed, and painful; it is swollen, because effusion distends the capsule, causing it even to bulge slightly into the buttock and into the base of Scarpa's triangle. Thus, the psoas and the common femoral artery are pushed forwards, the artery beating prominently beneath the skin; and the crease of the groin is obliterated by the general articular fulness. The stiffening and deformity are caused by the great intra-articular tension. Acute effusion into a joint always stiffens it. This is readily shown in the case of the hip-joint by injecting fluid into it from the pelvic side, when not only does the femur become rigidly fixed, but it passes first into the position of slight abduction, and then into that of flexion with inversion. Muscular action, as explained by Hilton, has probably no direct influence on the assumption of these positions, the limb taking them because, the joint being full, more room is found for the fluid when the femur is so arranged. In these positions, therefore, there is least tension of the sensory filaments of the joint. It is the unyielding anterior part of the capsule which determines the position of the limb.

The pain first complained of in hip-joint disease is on the inner side of the thigh, above the patella, in the popliteal space, or at the knee—that is, in the area of distribution of the terminal branches of the obturator nerve (p. 358). The reason of this is not clearly understood. The explanation usually given is that the obturator nerve supplies the hip-joint, thigh, and knee, and that when one set of peripheral fibres are irritated the trouble is referred to the area of distribution of those of the other division. In a similar manner we find that, when the bladder-branches of the sacral plexus are irritated by vesical calculus, the painful area is at the end of the penis, where the peripheral branches of the nerves supplying the bladder are distributed.

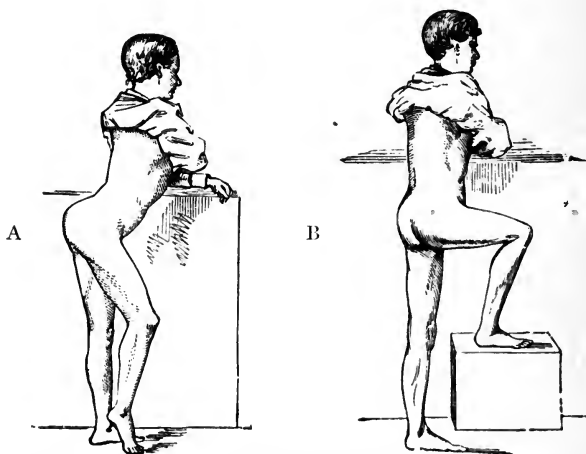
As the disease advances, the fulness of the groin and buttock increases, and an abscess forms which bursts through the thin, posterior part of the capsule.

The pus may then find its way under the gluteal muscles to below the great trochanter, round by the obturator externus to the inner part of Scarpa's triangle, beneath the great gluteus and into the upper and back part of the thigh, or through the floor of the acetabulum and into the pelvis. This last is by no means an uncommon event, and in examining an old case of hip disease the surgeon must not fail to pass his finger into the rectum so as to make a full exploration on the inner surface of the os innominatum. The pus is not in actual contact with the wall of the rectum, though it is felt by the finger (*v. p. 363*) close to it; it is separated by the periosteum of the os innominatum, the obturator internus and obturator fascia, and the levator ani and its fasciæ. It is quite possible, however, that the pus may by pressure effect a

thinning and an absorption of these tissues, and so escape through the ischio-rectal fossa, or by the rectum and anus.

Occasionally the matter escapes by the *perforation in the front of the capsule*, finding its way into the bursa beneath the psoas, in which case it may become extravasated upwards beneath the psoas and iliacus and so give rise to secondary pelvic abscess and to caries.

Often when disease has passed away, the hip-joint is synostosed, the femur being flexed and inverted. The limb can then be brought straight down only by tilting the pelvis forwards and arching the loins (lordosis). The exact amount of the deformity is calculated by correcting the lordosis, by raising the thigh, making the line which connects the anterior iliac spines pass at right angles to the middle line of the body ('*squaring the pelvis*,' as it is called), and noting the position which the limb thus assumes. If the ankylosis be in a very faulty position, the limb may be brought straight by dividing femur subcutaneously, below the great trochanter, with a keyhole saw.



Rectangular ankylosis following hip disease; A, lordosis, thigh being brought down; B, lordosis effaced by raising thigh. (ERICHSEN.)

As the joint-disease advances, and ulceration attacks the femur and acetabulum, the child finds that he can get greatest rest and quiet when the flexed knee is steadied over the other thigh, and protected from muscular startings and accidental movements by the other leg and foot, with which he lifts and arranges the damaged member. Thus the thigh becomes persistently flexed and inverted.

Dislocation of the femur, in the proper sense of the term, in hip-joint disease never occurs. It sometimes seems to have taken place when examination is made by Bryant's or Nélaton's (p. 447) method,

but this is due partly to further excavation of the acetabulum, partly to caries of the head and neck of the bone, and partly to the disease having arrested growth at the upper epiphysis (*v. p.* 461). Often in an advanced case of disease with apparent dislocation, as the surgeon proceeds to excise the head of the femur, he finds that it has already been carried away by molecular disintegration, the top of the great trochanter being high above the acetabulum. Thus there is no head to be dislocated, and no proper socket from which, or capsule through which, it could be dislocated were it present.

**Excision of head of femur** may be performed through a long incision over the great trochanter, or by one passing through the gluteus maximus. The latter site offers advantages for drainage. The knife should be used but little after the fascia lata has been traversed, the soft parts being thrust aside and the muscles detached by a strong raspator. The bone may be divided above or below the great trochanter, according to circumstances. If the bone be much diseased, and the trochanteric part of the shaft be taken away, the following muscles must be partially or entirely detached:—From the shaft the gluteus maximus, vastus externus, crureus, and pectineus; from the great trochanter, the gluteus medius and minimus, pyriformis, gemelli and obturators, and quadratus femoris; from the lesser trochanter, the psoas and iliacus.\*

When excision is being performed for disease in childhood, the great trochanter with the attachments of the gluteus medius and minimus is frequently detached, but unless it be diseased it need not be taken away.

*Resection by the anterior method* is performed by attacking the joint between the tensor fasciæ femoris and the glutei on the outer side, and the sartorius and rectus on the inner, the Y ligament and the front of the capsule being traversed.

**Amputation at the hip-joint** by transfixion is an operation of the past; Furneaux Jordan's method has superseded it. The latter operation consists in making a vertical incision on to the femur from above the great trochanter, and a third of the way down the thigh. Bleeding vessels in this longitudinal wound are secured one by one. The upper third of the femur is cleared of muscular attachments and disarticulated, the bared part being brought out of the wound by adducting the thigh. The assistant then grasps the hollow shell of the soft parts, firmly compressing all the vessels in them, and the surgeon cuts it with a circular sweep. The limb being thus amputated, the vessels are leisurely secured; the bleeding is very slight. In a case in which I enucleated a femur from the periosteum, the upper fourth of a new thigh-bone became developed in the long stump.<sup>1</sup>

**Dislocations of the femur** are rare, for the hip-joint is planned for

<sup>1</sup> Proceedings of Med. Soc. Lond. vol. ix. p. 205.

exceeding strength. The head of the bone presses most forcibly against the capsule during over-extension, but it is prevented bursting through it, not only by the great thickness of that part of the capsule, but also by the strap-like arrangement of the rectus femoris, psoas, iliacus, and gluteus minimus, which are then tightened to the utmost over the front of the joint.

Again, the strong, overhanging roof of the acetabulum is a sure check against the head of femur escaping through the upper part of the joint during forced adduction. I apprehend that the thigh-bone would sooner break than that this could occur.

In abduction, however, the head of the femur partially rolls out of the lower and unprotected part of the acetabulum; and when abduction is extreme, the bone escapes through the neighbouring and weak part of the capsule, tearing a ragged hole in its inner aspect. The ilio-femoral ligament remains entire, but the ligamentum teres is, of course, torn through. The head of the bone may then remain just below the acetabulum and form a *dislocation into the obturator foramen*, the limb being stiff, a little lengthened and abducted.

Obturator dislocation ought to be the commonest variety of displacement; but when the bone is in the act of escaping, or has actually escaped, either the direction of the violence, spasmodic muscular contraction, or a rotatory movement of the thigh or the trunk causes the bone to glide on to the dorsum ilii or into the great sacro-sciatic notch.

The **dislocation on to the dorsum ilii** is the commoner result, the smaller gluteal muscles being ploughed up, and the great trochanter being rolled towards the front of iliac crest. Let the student take the haunch-bone in one hand and the thigh-bone in the other and work out these luxations for himself; or, better still, let him use a moist preparation of the joint with ligaments prepared, and he will thoroughly understand them. He will find that in the dorsal dislocation the limb must be shortened because the head now occupies a higher level. That as the head has passed backwards the great trochanter is rolled forwards, and, being raised, that it lies near the anterior superior iliac spine. The upper end of the femur being thrust backwards, on to the flat bone, its lower end must needs be advanced. Thus, the limb is fixed, shortened (by two or three inches), and inverted. Fixation characterises every dislocation; a bone could hardly be as movable when its end is out of its socket as it is when in it. As the patient lies in bed, or attempts to stand, the flexed and inverted position of the thigh carries the knee across the lower part of the sound thigh, the ball of the great toe resting somewhere about the opposite ankle. But it should not be thought that a man who has just dislocated his femur stands up for inspection, as the sketches of some text-books might suggest!

When the head of the bone is **dislocated into the sciatic notch**

the shortening is evidently not much—an inch or less ; the inversion and flexion are also less, so that now the axis of the knee is only just above the opposite one, the ball of the great toe is scarcely raised, and the great trochanter is but little advanced towards the front of the iliac crest, though still it is above Nélaton's line.

The head of the femur lies above the tendon of the obturator internus in the high backward dislocation, but below it in the luxation into the notch. In either case, however, the muscle and tendon may be lacerated. If, as the bone travels upwards from the rent in the lower part of capsule, it do not rupture the obturator internus, the head may glide upon its pelvic or upon its gluteal surface. If by the latter route, it will rest in the notch, for the tendon over the front of the neck prevents its further ascent, but if it slip in front of the tendon it will reach the dorsum ilii.

**Dislocation on to the pubes** is rare. The head of femur is thrust up to the inner side and in front of the Y ligament, and under the iliacus and psoas, causing the common femoral vessels to be much advanced and perhaps arresting their circulation. The anterior crural nerve also is stretched. The head is raised about half an inch, and as it is advanced the great trochanter is rolled back and the limb is everted. Thus are presented two of the



Congenital displacement of femora. (BRODHURST.)

signs of fracture of the femur, shortening and eversion (p. 462), but the dislocated limb is rigidly fixed, the great trochanter is absent from its place, and the head of the femur is felt on the pubic ramus.

In each dislocation the ilio-femoral ligament remains entire, and impedes reduction—at any rate, when the attempt is made on the old system of extension by pulleys and counter-extension by a band around the perineum. But when the ligament has been first slackened, as occurs when the thigh is flexed, a small amount of movement, if in the right direction, suffices to get the head of the bone in its place again. ‘After flexion, and perhaps circumduction (to enlarge the rent in the capsule for the return of the femoral head), the reduction may be completed by rotation, or by extension of the thigh’ (Hamilton). This is the anatomical or scientific method of restoring the bone.

As a result of **congenital deformity** of the acetabulum, and of the hip-joint generally, the head of the femur rests upon the dorsum ilii, the great trochanter being above Nélaton’s line. On account of the backward displacement of the femora, the centre of gravity of the body is advanced, and, in order to ensure stable equilibrium, the shoulders have to be thrown back. Thus the defect is always associated with lordosis, and especially so when it happens to exist on both sides of the body. The buttocks are prominent and the lower limbs are small. (For illustration *see* last page.)

#### THE KNEE-JOINT

The bones forming the knee-joint are the femur, tibia, and patella; their articular surfaces are enclosed in a *capsule* which is greatly strengthened by fibrous expansions from the crureus and vasti, and from the hamstring tendons.

The *anterior ligament*, or the ligamentum patellæ, is the tendon of insertion of the quadriceps.

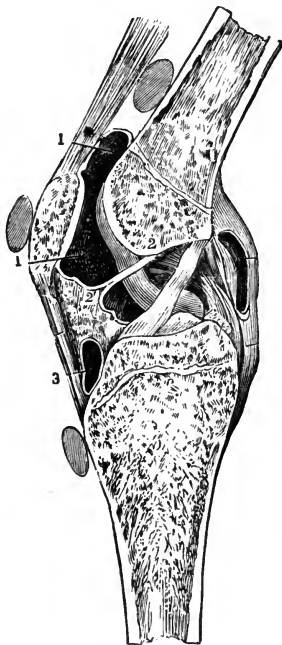
The *posterior ligament* descends from above the condyles of the femur to the back of the head of the tibia, and derives a strong accession from part of the insertion of the semi-membranosus. The popliteal vessels rest upon the posterior ligament.

The *lateral ligaments*, descending from the tuberosities of the condyles, are placed behind the vertical axis of the knee, so as to check over-extension. The inner band is wide, and descends several inches down the hinder border of the tibial shaft. The outer passes to the head of the fibula, over the tendon of the popliteus; its upper end may be felt beneath the skin, just in front of the tendon of the biceps, the knee being slightly bent.

The **crucial ligaments** cross each other obliquely, and, becoming locked together, specially check inward rotation of the leg. When, in an old case of knee-disease, the surgeon is able to rotate the extended leg inwards, he knows that these ligaments are deeply implicated, if not destroyed.

The **inter-articular fibro-cartilages** are attached by their cornua in front of, and behind the tibial spine, and their convex borders are connected with the margin of the tuberosities of the tibia by short, vertical fibres, which constitute the *coronary ligament*. The internal semilunar cartilage is firmly connected with the internal lateral ligament, but the outer disc is separated from the external lateral ligament by the tendon of origin of the popliteus which lies in a groove upon it. The inner cartilage is, therefore, far less movable than the outer; still, if one of the discs become loosened and interfere with the working of the joint, it is most likely the inner. I cannot explain this paradox, except on the theory that the outer one is so movable that it escapes injury from a wrench which loosens the inner. Both surfaces of the semilunar cartilages are covered with synovial membrane.

The **synovial membrane**, the largest in the body, lines the capsule, and, having ascended as a pouch for about the width of four fingers, beneath the quadriceps, turns down over the front of the femur. It forms also shallow pouches on either side of the patella and its ligament, and sends a collar round the tendon of the popliteus as it passes out of the joint. A cushion of fat intervenes between the ligamentum patellæ and the membrane which, in that region, sends a pouch on to the crucial ligaments (ligamentum mucosum); the free borders of this pouch are the ligamenta alaria. In the neighbourhood of the crucial ligaments the membrane has rudimentary fringes. When the knee is extended, the top of the synovial pouch is drawn up by the subcrureus working in harmony with the crureus. This part of the cavity is apt to communicate with a bursa higher up the shaft of femur under the quadriceps; that bursa may suppurate without the membrane of the knee being implicated.



Vertical section of knee of young subject. (After THOMSON, from QUAIN.)  
1, 1, synovial membrane; 2, lig. mucosum; 3, lig. patellæ with, 4, bursa behind it; 5 and 6, crucial ligts. Bursæ are also shown in front of tubercle of tibia, in front of patella, and beneath crureus (*v. p.* 478).

It is sometimes remarked that, because the synovial pouch ascends higher under the crureus when the knee is extended, one ought to keep the limb bent in operating upon the front of the femur near the joint.

As a matter of fact, however, the limb has to be straight ; for when it is flexed the patella is tightly dragged down below the condyles and the quadriceps is so tense that it is impossible to work beneath it. The cushion of fat behind the ligamentum patellæ is made very apparent when the knee is extended ; it is apt to be mistaken for abscess when attention is directed to it in the case of knee-disease, so soft and 'fluctuating' does it seem to be.

The **outline of the membrane may be traced** upon the skin by making a crescentic mark across the thigh, convex upwards, three inches above the patella, with its horns descending in front of the femoral tuberosities, and by then making a transverse line just above the apex of the patella. The latter mark shows the lower limit of the membrane, which does not cover the patella in its whole extent, but slopes from it down to the front of the tibial head. The line is then to be kept close along the top of the tibia and to skirt the femoral condyles below the tuberosities (to which the lateral ligaments are attached). Having crept through to the back of the articulation, the membrane ascends to line the posterior ligament, and to cover the back of the condyles.

**Synovitis** causes effusion into the joint, and if the effusion be rapid, the sensory nerves are suddenly stretched, great pain resulting. The tension of the capsule is then extreme. But if the effusion be gradual, as happens in chronic synovitis, there may be little pain, even though the joint contain several ounces of fluid, and bulge high above the patella, as the stretching of the nerves is slow and easy. At the sides, where the lateral ligaments strengthen the capsule and prevent it yielding, there is no bulging. Fluid collecting between the trochlear surface and the patella floats the patella off that surface, and the knee is slightly bent, as in that position there is more room for the fluid in the articulation.

In effusion into the joint the fluid is obviously behind the patella, whilst in effusion into the bursa patellæ the fluid is in front of the bone, obscuring, or even hiding, it.

When the **knee is distended with fluid** there is a bulging above and at the sides of the knee-cap, under the quadriceps, and on either side of the ligamentum patellæ. As the patella is actually in the substance of the capsule, when the latter becomes distended the knee-cap is carried forward or 'floated' from the trochlear surface, which it can be made to touch by being thrust back through the fluid. By grasping the front of the lower part of the thigh with the flat of the hand and laying the fingers and thumb along the sides of the knee-cap, the fluid may be made to bulge—even if only small in quantity—on either side of the ligament ; and from this region it may be driven by pressure with the other hand up again to the supra-patellar pouch, with a definite fluctuation beneath the patella.

To **open an abscess in the joint**, a bold incision on one side, or on both sides of the patella should be made ; if necessary, the incisions



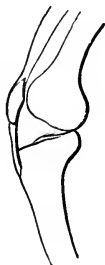may be connected by another which traverses the ligamentum patellæ. Thus the patella is thrown up and the interior of the joint thoroughly exposed. If further drainage yet be desired, an incision may be made through the ligamentum posticum, and a drainage-tube passed through the popliteal space between the popliteal vessels on the inner side, and the external popliteal nerve and the biceps on the outer side.

If the articular abscess be not attacked it may burst through the supra-patellar pouch, in which case the pus is extravasated not only beneath the deep fascia but also beneath the quadriceps extensor. Or, following the synovial sheath of the popliteus tendon, the pus may escape into the floor of the popliteal space, and, guided by the vessels, may find its way into the leg beneath the calf, or upwards amongst the hamstring muscles. A favourite place for articular abscess to point and break is (as the limb lies bent and resting upon its outer side) along the outer edge of the patella or its ligament. If it burst through the front of the lower part of the capsule the pus will be extravasated over the front of either tibial tuberosity, over the deep fascia, and between it and the superficial fascia of leg; thus the purulent extravasation is quite subcutaneous.

The **patella** is a sesamoid bone developed in the back of the tendon of the quadriceps. Many tough fibres descend over the front of the bone, whilst the posterior surface, covered by cartilage, articulates directly with the condyles of the femur, without the intervention of a synovial fold. The small bone does not touch the tibia, but it is connected with its spine (p. 473) by the *ligamentum patellæ*, a strong band which is, virtually, the tendon of insertion of the quadriceps; behind it there is a padding of fat. When the limb is loosely extended the patella is freely movable, but when the joint is flexed the quadriceps and its tendon are stretched, and the bone is firmly imbedded in the depths of the trochlear groove, where it acts as a shield to what would otherwise be an unprotected part of the articulation.

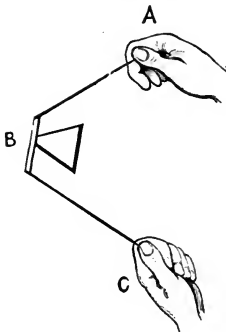
**Fracture of the patella**, which is almost invariably the result of muscular violence, occurs when the knee is partially bent, for then the bone is supported only across its equator, on the trochlear surface of the femur. The apex being firmly fixed by the strong ligament (as in walking upstairs), and the quadriceps contracting with great vigour, the bone is broken across, and necessarily into the joint.

When anyone wishes to break a tolerably thick stick, he puts it across his knee and suddenly pulls the ends backwards; transverse fracture of patella occurs in a very similar manner, except that the force acts at the upper end only, the other end being fixed. In the following scheme, from 'Lonsdale on Fractures,' B represents the patella supported at its



equator ; c, the ligament firmly holding it below, and A, the quadriceps acting on it from above.

The quadriceps, continuing its action, then draws the upper fragment of the bone from the lower ; the lower does not move, being firmly fixed by the ligament. The front of the capsule of the joint is often much torn, and then, of course, the separation of the fragments is wide. But sometimes the force is only just sufficient to break the bone, not to tear through the anterior expansion from the quadriceps, and then it is very easy to overlook the lesion and to diagnose merely a 'sprain.' In every case of obscure injury to the knee, the surgeon should catch hold of the upper and lower halves of the patella with his two hands, and try if he can move one inwards and the other outwards at the same time.



When the separation of the fragments is wide, the skin may be pushed in between them till the fingers make out clearly the articular part of the condyles of the femur. As the synovial membrane, the bone, and the periosteum are all torn, blood, serum, and synovia are quickly effused, and the knee is greatly swollen. This fluid has to be aspirated before the fragments can be brought into apposition. The knee is to be kept straight on a splint, so as to relax the quadriceps, and the limb is raised to remove all possible strain from the rectus femoris, which, coming from the pelvis, may possibly be dragging on the upper fragment. The upper fragment is then to be coaxed down towards the lower, and there steadied. Probably the fracture will be repaired by ligament only, not by bone, for the reasons given on page 464.

*Suturing the approximated fragments* with wire is a method of treatment introduced by Sir Joseph Lister, as suitable for old-standing and recent cases of transverse fracture. But though that eminent surgeon showed several patients who had been thus successfully treated, the operation, with its attendant risks, has not been generally adopted in the case of recent fracture. In old cases, however, with widely separated fragments, and a comparatively useless limb, the joint may be opened and the edges of the bone freshened and approximated with a good chance of obtaining bony union, and, due care being taken, the risks of the operation may well be run.

Even when the joint is opened, it may be necessary to divide the tendon of the rectus femoris before the upper fragment can be brought to the level of the lower fragment, which is immovably fixed by the ligamentum patellæ.

**Dislocation of the patella** is generally outwards, and the accident

is specially apt to occur in a knock-kneed subject, as the rectus femoris then inclines a good deal inwards in its descent to its insertion. And when it contracts with vigour it drags the patella a little outwards. An unusual amount of this outward movement lodges the bone on the front of the external condyle. Sudden flexion of the limb generally suffices to reduce the displacement; but, if not, the leg should be straightened to the utmost, the thigh being flexed so as to slacken the rectus, when the bone can usually be slipped into its place.

A characteristic **threefold displacement of head of tibia** occurs in cases of advanced and neglected knee-joint disease.—The limb rests on the outer side with the knee bent, this being the most comfortable position; and, as the ligaments become softened, the weight of the leg causes it to sink outwards, so the inner femoral condyle projects more and more, and the outer tibial tuberosity slides outwards from beneath its condyle. The flexion of the joint continuing, and the biceps, gastrocnemius, and the other posterior muscles contracting at times with a spasmodic start, the head of the tibia is steadily pulled into the popliteal space. Lastly, the weight of leg and foot in this flexed and everted position of the limb causes external rotation of the tibia. Thus the threefold displacement of the tibial head is outwards and backwards, with some external rotation. If the disease subside, the knee, even thus deformed, may be extremely serviceable. At any rate, forcible straightening will not improve the shape; to attempt it is to make the tibia slide still further back, or to detach the femoral or tibial epiphysis. If the deformity be extreme, excision may be needed before the limb can be made straight and useful.

A **foreign body in the joint** may be a piece chipped from a femoral condyle or a semilunar cartilage; a pendulous bud detached from the synovial membrane, or an organised blood-clot. The substance is apt to become suddenly caught between the femur and tibia, and to lock the joint. The sensory nerves are stretched and pained, and the injury is likely to set up an attack of synovitis. The joint must be opened at the side and the material extracted; but if the trouble be due to a loose fibro-cartilage (the inner most likely), the periphery of the crescentic disc must be firmly sutured to the capsule, so as to prevent further slipping.

**Supply.**—*Arteries* for the knee-joint come from the external circumflex, the anastomotica magna, the popliteal (five in number,



Fracture of patella; stretching of ligamentous union. (HOLTHOUSE.)

p. 482), and anterior tibial. The *nerves* are branches of the obturator, anterior crural, internal popliteal (three), and external popliteal (two).

**Pains about the knee** may be due to local troubles, such as disease of the synovial membrane, the bones, the epiphyses, or the bursæ (p. 473). But it may be due to some distant cause, such as disease of the spinal cord, or its membranes, or of the column (p. 210); to pressure upon the trunk of the anterior crural, obturator, or sciatic nerve; or to reflex irritation, caused by disease of the sacro-iliac or hip-joint.

**Bursæ in the neighbourhood of knee-joint.**—There is a large one between the patella and the skin, and a small one between the tubercle of the tibia and the skin. Either of these may become inflamed by continued pressure, the disease constituting *housemaid's knee*. When the bursal inflammation is acute, the surrounding parts are swollen, red, and hot, and the case looks like one of joint-disease. In the latter case the swelling is behind the patella and its ligament, whilst in bursal inflammation the effusion is in front of them. If suppuration occur the abscess should be promptly opened, lest the pus find its way into the articulation. (See illustration on p. 473.)

A third bursa intervenes between the ligamentum patellæ and the upper part of the tubercle of the tibia. When acutely inflamed, this bursa, bound down as it is, causes great pain, and bulges on either side of the ligament. There is a bursa beneath each head of the gastrocnemius; that beneath the inner head often communicates with the interior of the knee-joint, and also with another bursa which separates the tendon of the semi-membranosus from the head of the tibia. There are other bursæ between the internal lateral ligament and the tendons of the sartorius, gracilis, and semitendinosus, and between the external ligament and tendon of biceps. Lastly, there is the subcrureus bursa, to which reference has already been made.

The superior-tibio fibular membrane may communicate with that of the knee-joint.

The bursa under the inner head of the gastrocnemius and the insertion of the semi-membranosus is often full of fluid. When the knee is extended the tendons are tightened and the tumour is made hard and tense; when it is flexed the outline of the tumour becomes less definite. Sometimes fluctuation may be readily obtained between the contents of this tumour and the over-abundant synovial fluid in the joint. If the tumour be carelessly opened, septic inflammation spreading from it may involve the knee-joint in acute disease.

**The relative position of structures around the knee.**—In front the joint is almost subcutaneous. Behind are the popliteal vessels and the internal popliteal nerve; and on either side of them are the heads of the gastrocnemius (the plantaris being with the outer), the semitendinosus and membranousus, the biceps, and the external popliteal nerve. Internally are the gracilis and sartorius, the internal saphenous

nerve, the superficial part of the anastomotica magna, and the long saphenous vein. (The origin of the popliteus is within the joint.)

**Knock-knee.**—In the erect posture the tibiæ are vertical, with their heads close together; but the heads of the femora are separated by the width of the pelvis. The wider the pelvis the greater the separation of the femora above, and the greater the inward slant of the bones to the knee. All of us, then, are a little ‘in-kneed,’ and women particularly so. So that the lower surfaces of the condyles may be on the same level, the inner condyle must be the longer. Nevertheless, it is not so prominent anteriorly as is the outer (p. 449). In a weakly, rickety subject the internal lateral ligament is apt to stretch, over-growth of the internal condyle consequently taking place, for some of the pressure of the tibia against it is lost. Eventually the deformity becomes permanent.<sup>1</sup>

As the rectus femoris follows the axis of the femur, whilst the ligamentum patellæ follows that of the tibia, when the muscle contracts it is apt to drag the knee-cap over the external condyle; outward dislocation would happen still more often were it not for the presence of that prominent flange limiting the trochlear surface externally.

In **estimating the amount of knock-knee** the joint must be completely extended, so that the lateral ligaments may be tightened and the tibia firmly locked on the femur, for when these ligaments are at all slack a little lateral and rotatory movement is enough to efface the defect.

**Operation for knock-knee** has to be performed when gentler methods cannot avail. In a young child forcible straightening often succeeds without any cutting. In this operation the knee must be first extended to the utmost so as to prevent rotation of the tibia as the surgeon exerts his strength. It is not known exactly what occurs in this process: perhaps the external lateral ligament yields a little; perhaps the inner femoral condyle undergoes some condensation; perhaps the epiphysis is slightly separated from the diaphysis on the outer side. It is, however, a satisfactory procedure.

**Ogston** sliced off the inner condyle of the femur, and then, by bringing the leg straight, shifted the loosened condyle upwards until the lower surfaces of the condyles were on the same level. One great disadvantage of this original operation was that, the knee-joint being implicated, suppuration or stiffness was apt to ensue.

To obviate this risk, **MacEwen** partially divides the *shaft* of the femur above the internal condyle, and completes the operation by forcible fracture. He draws a transverse line a finger's breadth above the external condyle, and a vertical one half an inch in front of the tendon of the adductor magnus. At the meeting of these lines he makes a small vertical incision on to the femur and introduces his osteotome, which he then turns across the length of the femur, cutting the bone

<sup>1</sup> For ‘Anatomy of genu valgum’ see *Journal of Anat. and Phys.* 1879.

from the inner and back part. In this operation there is risk of wounding the *anastomotica magna*, the superior or internal articular, or even the popliteal artery itself. The articular artery, however, ought to be well below the track of the osteotome, and the *anastomotica*, running down close in front of tendon of the adductor magnus, should be hit.

The **popliteus** arises inside the capsule of the joint by a round tendon from the front of a groove on the outer condyle of the femur.

The tendon passes between the external semilunar cartilage, which it grooves, and the external lateral ligament. As it escapes beneath the outer part of the posterior ligament it is enclosed in a prolongation from the synovial membrane of the joint. It then spreads into a triangular fleshy layer, which is inserted above the oblique line of the tibia.

The insertion is covered by an expansion from the attachment of the semi-membranosus, and has resting on it the popliteal vessels, the internal popliteal nerve, and the heads of the gastrocnemius. Its nerve (from the internal popliteal) turns round its lower border to supply it on the anterior surface.

**Excision of the knee-joint** is performed by making a deep, crescentic cut—convex downwards—from one tuberosity of the femur, through the ligamentum patellæ to the other tuberosity, and turning up the flap of the quadriceps with the sesamoid bone in it; for, unless this bone is extensively diseased, it had better be left. The lateral and crucial ligaments being divided, and the end of the femur cleared, the knee is well bent, and the condyles are sawn off by directing the saw vertically to the head of tibia; thus the risk of wounding the popliteal artery is inconsiderable. As little as possible should be removed, so that the line of the junction-cartilage may not be approached, or at least implicated.

The head of the tibia is then thrust out of the wound and sliced off, and the sawn surface adjusted and fixed; but its sharp edge must not be allowed to fall back on to the popliteal artery, or secondary hæmorrhage may occur, amputation being then needed. Provision may be made for the free escape of discharges through the cornua of the incision, or by bringing a tube through the posterior ligament of the joint and out through the skin, passing it between the popliteal vessels and the external popliteal nerve.

#### THE POPLITEAL SPACE

The popliteal space is bounded above by the diverging hamstrings and below by the converging heads of the gastrocnemius. It is covered in by skin and superficial fascia, and by the fascia lata. The floor is formed by the lower fourth of the femur, the posterior ligament of the knee-joint, and the upper sixth of the tibia, with the popliteus.

In the superficial fascia ascends the **external saphenous vein**, which, beginning in an arch on the dorsum of the foot, in communication with the internal or long saphenous vein, passes behind the external malleolus, and between the bellies of the gastrocnemius, to pierce the fascia lata at the middle of the space. Like the long vein, it receives tributaries just before traversing the deep fascia; these are cutaneous branches descending from the back of the thigh. Sometimes when a tumour presses upon the popliteal or superficial femoral vein these descending branches are engorged and dilated. There is a communication between the venæ comites of the posterior tibial artery and the external saphenous vein near the ankle, and a branch on the thigh again links the two saphenous veins. The short saphenous nerve accompanies the external saphenous vein between the bellies of the gastrocnemius.

The *cutaneous nerves of the space* are branches of the small sciatic.

In the undissected limb the space is small, as the muscles which bound it closely overlap the artery. Thus, superficially, on the outer side, are the biceps, the outer head of the gastrocnemius, and the plantaris; and on the inner side are the semi-membranosus and the other head of the gastrocnemius.

The *deep fascia* is a continuation of the fascia lata, and it receives slips from the hamstring tendons. Its density prevents digital exploration of the depths of the space unless it be first slackened by bending the knee.

Close on the inner side of the tendon of the biceps runs the external popliteal nerve; the internal popliteal nerve descends in the middle line.

The **popliteal artery** enters the top of the space with the popliteal vein. The fact of these vessels coming through the opening in the adductor magnus, at the lower end of Hunter's canal, on the inner side of the shaft of the femur, suffices to place them well on the inner side at the top of the space. And, inasmuch as they are coming from the front of the thigh, they are very deeply placed on their entrance into the ham. Now, as the internal popliteal nerve is coming boldly down the back of the thigh into the middle of the space, it necessarily lies at first considerably external and superficial to the popliteal vessels.

The **relative position of the vein and artery** at the top of the space is the same as (p. 454) in Hunter's canal—which actually ends at the top of the space; the vein is on the outer side of the artery, and they are both resting upon the femur.

The passage from the crural to the sural (*sura*, calf) part of the ham is the notch between the condyles of the femur, and it is far too narrow to allow the nerve, the vein, and the artery to go through abreast; they are arranged, therefore, in single file, the vessels still being deeper than the nerve. In their preparation for the passage

the vein gradually mounts on to the artery ; and so, behind the plane of the joint, the nerve is nearest the skin, the artery is upon the posterior ligament, and the vein is between the two.

Having emerged from the intercondylar pass, the three structures spread out again, so that, as they rest upon the popliteus, the vein has dismounted from the artery on to its inner side, whilst the nerve is still more internal. At the lower border of the popliteus the artery divides into the anterior and posterior tibials, and the nerve changes its name to posterior tibial.

**Ligation of the popliteal artery** is rarely performed, first because of the extreme depth of the vessel in the space, and secondly because of an intimate fibrous adhesion which connects it with the vein. It is, therefore, resorted to only in the case of a wound of the artery, in every other case ligation of the superficial femoral being the preferable operation.

The popliteal artery can, however, be reached without much difficulty from the inner side, by a three-inch incision along the gap which can be made out by the fingers just in front of the semi-membranosus and gracilis, and behind the vastus internus and the tendon of the adductor magnus.

The internal saphenous vein must be avoided, and, the fascia lata having been divided on a director, and the sartorius having been recognised and drawn backwards with the tendon of the gracilis, the rigid tendon of the adductor magnus with the fleshy fibres of the vastus internus are seen. The long saphenous nerve may also be seen sloping backwards under the sartorius. The artery is looked for by working towards the back of the femur with the forceps and director. (The sartorius being to the inner side of the artery, the vein is, of course, to the outer side.)

*Branches of the popliteal artery.*—*Superior muscular*, to the hamstrings and the adductor magnus, which anastomose with the ending of the deep femoral, with other perforating branches, and with the comes nervi ischiatici. *Inferior muscular* (sural) to the muscles of the calf. Five *articular* branches, each of which runs under or through some important fibrous structure. The *superior internal* articular winds under the tendon of the adductor magnus, to join the *anastomotica magna*, the superior external, and also the *inferior internal* articular. The last-named branch passes under the internal lateral ligament, in the groove below the head of the tibia, and anastomoses with the *superior external* articular, which passes under the tendon of the biceps, and joins the descending branches of the external circumflex, the *anastomotica magna*, and the superior internal articular.

The *inferior external* articular passes above the head of the fibula, under the tendon of the biceps and the external lateral ligament. It anastomoses with the inferior internal, and the superior external



articular branches, and with the anterior tibial recurrent. Each inferior articular artery lies beneath a head of the gastrocnemius. The *central* articular, or *azygos*, pierces the ligamentum posticum.

As their names imply, all these five arteries are for the nutrition of the articulation.

The **popliteal vein** begins at the lower border of the popliteus, by the confluence of the venæ comites of the anterior and posterior tibial arteries, and possibly also of those of the peroneal artery. At its commencement it is to the inner side of the artery, but as it ascends between the heads of the gastrocnemius, and between the condyles of the femur, it lies superficial to, that is behind, the artery, and in the upper part of the space it is to its outer side. Its tributaries are the five articular, the external saphenous vein, and muscular branches—sural and crural.

The **popliteal lymphatic glands**, four or five in number, are lodged in the loose connective tissue in the depths of the space, one of them being generally placed upon the artery, which thus, when inflamed and enlarged, constitutes a pulsating tumour in the ham and may be mistaken for an aneurysm.

The popliteal glands receive their lymph from the back of the leg, the outer side of the foot, and from the lower part of the back of the thigh. (Superficial lymphatic vessels usually run with the neighbouring superficial veins.)

For the course and branches of the **internal** and **external popliteal nerves** see pp. 380 and 381, and for the **obturator nerve** in the space see p. 359.

**Aneurysm of the popliteal artery** is of common occurrence, for, as the artery is just behind the joint, it is constantly being bent and straightened; and, with arterial disease, a sudden and violent movement of the knee is apt to crack the inner coats. The outer coat is then dilated, and a pulsating tumour occurs in the ham; this is best examined when the patient is prone and the knee flexed, as the fascia lata is then slackened and the depths of the space are rendered accessible to the fingers. An enlarged lymphatic gland over the artery would also give rise to a pulsating tumour, which, like aneurysm, would be less prominent and would cease to pulsate, when the common femoral was compressed, but it would not give that lateral impulse which characterises aneurysm.

The aneurysm may compress the vein, and so cause congestion, varix, and œdema of foot and leg, or even gangrene. Pressing upon the internal popliteal nerve, it may set up peripheral pains and numbness, and local insensibility. Causing stiffness of the knee, it is apt to be taken at first for 'rheumatism.' Finally it may burst into the joint, distending it with blood; or its contents may be extravasated from the popliteal space into the back of the thigh and leg. When the artery bursts, pulsation ceases at the knee and in the popliteal

tibial and dorsalis pedis arteries. Coldness and gangrene quickly supervene, and amputation above the knee has to be resorted to.

The most certain method of *treatment* consists in ligation of the femoral artery at the apex of Scarpa's triangle ; compression of the common femoral and forcible flexion of the knee sometimes prove successful. But, when an aneurysm is large and its walls are likely to yield, the femoral must be tied at once.

**Popliteal abscess** may begin in one of the lymphatic glands, or in the connective tissue of the space, and the pus may eventually find its way into the joint, or amongst the muscles of the back of the thigh or leg. The strength of the fascia lata delays its spontaneous escape to the surface of the limb.

The **abscess should be evacuated** by incising the skin, superficial and deep fasciæ, in the groove between the ilio-tibial band and the bicipital tendon, the director and dressing-forceps being used for the deep part of the exploration. The lower end of the femur and the depths of the space are readily accessible in this way, and without risk of damaging important structures. The track being made in front of the external popliteal nerve, all that the surgeon has to guard against wounding is the superior external articular artery.

*Sinuses* left after the evacuation of an abscess may refuse to heal unless the limb is kept in absolute rest in a splint ; and it may be well to have the knee gently flexed.

In **amputation at the knee-joint** the long anterior flap, being but poorly supplied with blood, is apt to slough. The mass of condyles needs a very large flap. This flap is made by an incision extending from one tuberosity of the femur down over the tubercle of the tibia, and up to the other femoral tuberosity. The joint is opened through the ligamentum patellæ ; the lateral and crucial ligaments are divided, and the knife is passed through to the back of the joint, and, cutting downwards and backwards, severs the popliteus, the popliteal vessels and nerves, the hamstring tendons, gastrocnemius, and plantaris. As it descends behind the tibia and fibula, it detaches a short posterior flap.

**Carden** did a sort of 'Syme' (p. 499) at the joint, shaping the ordinary oval, anterior flap, removing the patella, and cutting straight back, making no posterior flap ; he removed the condyles just as Syme sliced off the malleoli in the case of amputation at the ankle.

**Gritti's** is on the principle of a 'Pirogoff' (500) ; it is much like Carden's, but instead of the patella being removed, a slice is taken from its articular cartilage, and the denuded surface is then turned under the sawn end of the femur.

An excellent amputation at the knee is by lateral flaps, the scar being eventually drawn up out of the way of pressure, behind and between the condyles.

In the case of *malignant disease in the leg* it is safer to amputate

in the lower third of the thigh than through the joint, as all the lymphatic glands, which may possibly be invaded, are thus taken away, and also the origins of the gastrocnemius, popliteus, and plantaris, and the bursæ about the joint, any of which may be the seat of a secondary and lurking malignancy.

**Amputation at the 'seat of election'** was the favourite operation years ago—before the days of Syme—in all cases demanding a sacrifice of the leg. The tibia was sawn just below the tubercle, and the patient went about subsequently upon a kneeling-crutch, the cicatrix being out of the way of all pressure. An improved and cheapened system of artificial legs, and a greater conservatism in practice, have now rendered the performance of this amputation of comparatively infrequent occurrence, and the quaint title almost obsolete. The surgeon now 'elects' the amputation which involves the least mutilation of the limb.

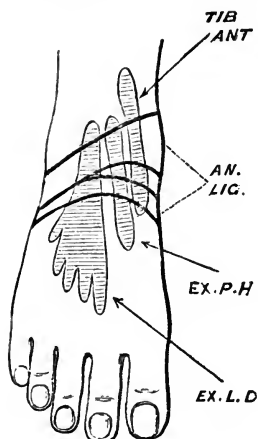
*Method of operation at the seat of election.*—With the left thumb and index-finger the operator marks two spots on the sides of the leg, two inches below the level of the tubercle, and from them he shapes out liberal convex flaps of skin in front and behind. The muscles are divided straight down to the bones; the fibula is sawn, and then the tibia, a piece being removed from the sharp crest of the latter bone. The arteries requiring ligation are the anterior and posterior tibial, and possibly the peroneal—and some large sural branches.

## THE LEG

The **deep fascia** on the front of the leg is thick, and gives origin to the tibialis anticus, extensor longus digitorum, and peroneus tertius. It is attached to the crest of the tibia, and follows the curve of the external tuberosity on to the head of the fibula. Down the latter bone it is attached indirectly by the septa which dip on either side of the peroneus longus and brevis. Below it is attached to the malleoli, forming the **anterior annular ligament**. The upper part of this ligament is a horizontal band which binds down the extensor tendons of the toes and the peroneus tertius. In addition, the tendon of the tibialis anticus passes beneath it, invested in a synovial sheath. Just below the bend of the ankle there is another, a vertical piece of the annular ligament, under which three synovial sheaths descend, namely, the one already mentioned, around the tibial tendon, a second investing the great toe extensor, and a third for the long extensor of the toes and the peroneus tertius. This lower part of the annular ligament is attached to the inner malleolus above, and to the front of the os calcis below.

Beneath these ligaments pass also the anterior tibial vessels and nerve, under cover of the extensor proprius hallucis, or, lower down,

between this tendon and that of the extensor longus digitorum, the nerve being to the outer side of the artery and its venæ comites.



Synovial sheaths at front of ankle.  
(After REEVES.)

When effusion—the result of a sprain or of gout, for instance—takes place into the synovial sheaths of the tendons about the ankle, the outline of the tendons is somewhat obscured, and flexion and extension of the foot are accompanied by painful and strange creakings or cracklings in the sheaths.

**At the back of the leg the deep fascia** is continuous with the fascia lata of the thigh, and receives some strengthening slips from the biceps, sartorius, gracilis, and semi-tendinosus. Over the ham, where it is very strong, it is pierced by the short saphenous vein. Lower down, it is continuous with the sheet which covers the peroneus longus and brevis, and it is attached between them, and the soleus and flexor longus hallucis, to the fibula. Internally it is attached to the posterior

border of the tibia. It binds down the calf muscles. **Another layer of deep fascia**, as remarked elsewhere (p. 490), passes across beneath the soleus, binding down the tibialis posticus and the flexors longus digitorum and proprius hallucis, covering also the posterior tibial vessels and nerve.

Towards the inner ankle these two layers of deep fascia blend to form the **internal annular ligament**, and are then lost in the deep plantar fascia. This annular ligament passes from the inner malleolus to the adjacent part of the os calcis, and binds down the **structures behind the inner ankle**. Most internally is the sheath for the tendon of the tibialis posticus, which, like that of the tibialis anticus, has a synovial investment of its own. Close to the outer side of this is another compartment for the tendon of the flexor longus digitorum, with its own synovial investment. Then comes a wide passage for the posterior tibial artery with a vena comes on either side, and, a little farther out, is the posterior tibial nerve. More externally still is the tunnel for the tendon of the flexor proprius hallucis, with its synovial sheath.

The **external annular ligament** passes from the tip of the external malleolus to the outer side of the os calcis, and binds down the tendons of the peroneus longus and brevis and their common synovial sheath, the shorter tendon being anterior. The longer tendon is apt to slip from its position and thereby to cause lameness and pain on walking; this accident may also happen to the tendon of the tibialis posticus as it winds behind the inner malleolus.

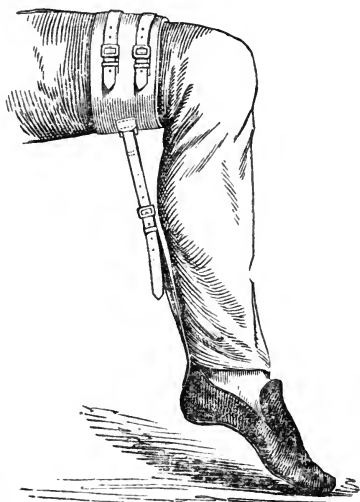The **gastrocnemius** arises from the condyles of the femur, and spreads out into two bellies, of which the inner is the larger; it is inserted with the subjacent soleus into the tendo Achillis. The short saphenous vein courses up between the bellies, separated from them by the deep fascia. (For *bursæ*, see p. 478.)

The **soleus** arises from the back of the head and the upper part of the fibula, and from a tendinous arch over the ending of the popliteal artery which carries it to the oblique line of the tibia, along which it also arises, and down the middle third of the posterior border of the tibia. The muscle lies beneath the gastrocnemius (the opposed surfaces being aponeurotic) and joins with it in the formation of the **tendo Achillis**. This tendon is inserted into the lower part of the posterior surface of the os calcis, a *bursa* intervening between it and the upper part of that surface. It is most slender at about an inch above the heel. The soleus covers the deep layer of muscles, the posterior tibial vessels and nerve, and the peroneal vessels, all of which are separated from the soleus by the second layer of deep fascia.

The gastrocnemius flexes the knee, and, acting with the soleus, extends the foot. The two muscles are supplied by the sural branches of the internal popliteal nerve.

**Achilles-tenotomy.**—The tendon may require section in talipes equinus, in fracture of the tibia when there is difficulty in adjusting the fractured surfaces, or in keeping them in apposition, and after subcutaneous osteotomy of a bowed leg. For the operation, the foot is flexed, so as to tighten the tendon, and the slender knife is introduced beneath its deep surface. If the knife be directed from the skin-surface of the tendon, there is a risk of dividing the posterior tibial artery, and especially so when the operation is being done for talipes, as in that case the tendon lies very close behind the artery.

**Rupture of the tendon** may occur with a sudden and painful snap from muscular action, the patient thinking that someone has hit him above the heel. It is treated by bending the knee and extending the foot, the limb being kept in that position by a strap which runs from a loop in the heel of a slipper to the back of a collar



which is fastened above the knee. In certain cases of paralytic talipes calcaneus a piece is cut out of the tendon, and the ends are spliced together.

The **flexor longus hallucis** is a large and very powerful muscle arising from the lower two-thirds of the back of the fibula. Its tendon passes over the tibia, to the outer side of the posterior tibial vessels and nerve, and behind the ankle-joint; it then grooves the back of the astragalus, and, passing under the sustentaculum tali, runs between the two heads of the flexor brevis hallucis to be inserted into the unguis phalanx. To the outer side of the muscle are the fibula and the soleus, to the inner side are the long flexor of the toes, the tibialis posticus, and the posterior tibial vessels and nerve; in its substance is the peroneal artery. In the sole the tendon is united with that of the flexor longus digitorum by a strong slip.

The **flexor longus digitorum** arises from the tibia below the soleus. Its tendon lies in the groove behind the inner malleolus, with that of the tibialis posticus, but in a separate synovial sheath; and, passing through the sole, where it receives a slip from the tendon of the long flexor of the great toe, it divides into four tendons which are inserted into the unguis phalanges of the four outer toes. These tendons perforate those of the flexor brevis digitorum. The posterior tibial vessels and nerves rest upon the long flexor.

*Tenotomy of the flexor longus* is sometimes required in extreme talipes equino-varus; the tendon is then divided, together with that of the tibialis posticus, by a wound made a little above the inner malleolus, or, preferably, by an open incision nearer the sole of the foot. In the former case, should the posterior tibial artery be accidentally punctured or divided, the bleeding may be arrested by bandaging a firm pad over the inner ankle, so as to compress the artery against the posterior surface of the tibia. It is rarely necessary to enlarge the wound and tie the vessel.

The **tibialis posticus** arises from the back of the interosseous membrane and from the adjacent surfaces of the tibia and fibula. The tendon passes inwards on the tibial aspect of that of the flexor longus digitorum, and rather to its inner side, and, running with that tendon beneath the head of the astragalus, is inserted into the scaphoid and internal cuneiform bones. It also sends back a slip to the sustentaculum tali, and other slips to the outer cuneiform bones, the cuboid, and the bases of the middle metatarsal bones. Thus it is an important structure in supporting the transverse as well as the antero-posterior arch of the foot.

The muscle is covered by the flexor longus digitorum on the inner, and by the flexor longus hallucis on the outer side; on it rest the beginnings of the posterior tibial and the peroneal arteries, and the posterior tibial nerve. At the ankle its tendon is the innermost, lying in the same groove with that of the flexor longus digitorum, but in a separate synovial sheath.

*Division of its tendon* may be performed above the malleolus by a puncture made close behind the posterior border of the tibia, which is exactly halfway between the anterior and posterior aspects of the limb; or in the hollow between the tip of the malleolus and the tuberosity of the scaphoid. The latter is the better site for its division, as there the tendon is quite subcutaneous, and out of the way of the posterior tibial artery. But it is equally convenient for the surgeon to divide it deep in the sole, by the same wound by which he cuts every other fibrous structure which hinders his straightening the deformed foot.

The three muscles of the deep layer of the back of the leg are supplied by the posterior tibial nerve. They all extend the foot; two of them also flex the toes, whilst the third inverts the foot.

The **posterior tibial artery** is one of the trunks coming from the bifurcation of the popliteal, at the lower border of the popliteus, the other being the anterior tibial (p. 492). It divides under cover of the abductor hallucis into the two plantars.

Its *course* may be marked by a line which begins about an inch below the lower part of the ham, and ends in the mid-space between the inner malleolus and the os calcis.

*Relations.*—At its origin, and for an inch or two down, *it rests on* the tibialis posticus, then on the flexor longus digitorum, and afterwards, as the muscles narrow into tendons, and the tibia expands, it lies upon the bone, and finally upon the posterior ligament of the ankle-joint.

*Posterior* to it are the skin, superficial and deep fascia, the gastrocnemius and soleus; the sub-soleus fascia (that is the second layer of deep fascia); and the posterior tibial nerve, which crosses the artery two or three inches below its origin.

*To the inner side* are the tibial origin of the soleus, the first few inches of the posterior tibial nerve, and, near the ankle, the tendons of the tibialis posticus and flexor longus digitorum.

*To the outer side* is the fibular origin of the soleus, the flexor longus hallucis, and, in the lower three-fourths of its course, the posterior tibial nerve.

Venæ comites, one on either side, join with each other by short branches across the artery, and they ultimately flow into the popliteal vein.

**Ligation of the posterior tibial artery** in the upper part of its course is performed by bending the knee and extending the foot, so as to slacken the deep fascia and the gastrocnemius, and by resting the limb upon the fibular side. An incision of four inches is made down the leg about a finger's breadth behind the posterior border of the tibia, care being taken not to wound the long saphenous vein. The deep fascia is then incised on a director, and the inner belly of the gastrocnemius, if encountered, is turned outwards. The tibial origin of

the soleus, and that important second layer of deep fascia beneath it, are divided in turn, and the artery is looked for at a considerable distance outwards, where it lies upon the tibialis posticus or flexor longus digitorum. The nerve is crossing it from the inner to the outer side, so the needle had better be passed from the inner side.

A good deal of fibrous tissue may be met with on the deep aspect of the soleus, which has to be traversed before that second layer of the deep fascia is seen. The division of the soleus should not be made too close to the border of the tibia, or the operator will be apt to lose himself amongst the fibres arising from the periosteum; thus he may possibly detach the flexor longus digitorum from the tibia and work outwards beneath it—even into the substance of the tibialis posticus.

**In the lower third of the leg the artery may be tied** by making the incision midway between the inner border of the tendo Achillis and the posterior border of the tibia, care being taken not to wound the internal saphenous vein, which is, or ought to be, a good deal to the front of the incision. Two layers of deep fascia again require division; the artery is found to the outer side of the tendons of the tibialis posticus and flexor longus digitorum, between its veins, the nerve being on its outer side, as before. Still farther out is the tendon of the flexor longus hallucis. The artery and its venæ comites, the nerve, and the tendons are here spread out flat on the surface of the tibia. The needle had better be passed from the outer side.

**At the ankle the artery may be reached** through a two-inch incision which curves round the inner malleolus, halfway between it and the inner tuberosity of the os calcis. There is no fear of damaging the internal saphenous vein. The layers of the deep fascia have here joined to form the internal annular ligament, which has to be divided on a director, when the artery is found laced in by fibres which form a sort of sheath. It lies between its venæ comites, with the large nerve external to it. The needle had better be passed from the outer side.

*Branches.*—The **peroneal** is given off an inch below the border of the popliteus; resting at first on the tibialis posticus, it descends along the inner border of the fibula, in the substance of the flexor longus hallucis. It is covered, in addition, by the gastrocnemius, soleus, and sub-soleus fascia. At about two inches above the ankle it divides into an anterior and a posterior branch. The *anterior peroneal* reaches the front of the leg through the interosseous membrane, and anastomoses with the external malleolar and tarsal arteries. The *posterior* division descends behind the outer ankle, and anastomoses with the branches just enumerated, and also with the external plantar. Other branches of the peroneal are *muscular*, *nutrient* to the fibula, and a *transverse communicating* branch to join a similar vessel from the posterior tibial, which crosses about two inches above the ankle, under the flexor longus hallucis.

*Irregularity.*—Sometimes the peroneal is as large as the posterior



tibial itself, and it may practically take its place ; sometimes this large artery passes through as the anterior peroneal to become the dorsalis pedis.

In addition to the peroneal, the posterior tibial also gives off a *nourishment* branch which runs downwards in the tibia ; *muscular* branches ; a *communicating* to join the corresponding branch from the peroneal, and some *internal calcanean* twigs which nourish the inner part of the flap in Syme's amputation.

**Collateral circulation** after ligation of the posterior tibial artery below the origin of the peroneal would be carried on by numberless muscular branches. Blood would also enter the empty trunk through the communicating artery, and the other anastomoses from the peroneal ; through the plantar arch, and through other communications with the anterior tibial and the dorsalis pedis.

*Ligation of the peroneal artery* is required in the case of a punctured wound, when the surgeon would have the track of the original wound to guide him. Should he be called upon, however, to tie the artery in its continuity, when there was no wound to guide him, he had better make a four-inch incision between the bellies of the gastrocnemius, and, having traversed that muscle, the soleus, and the second layer of deep fascia, secure the artery just previous to its entering the long flexor of the great toe.

The **internal plantar** division of the posterior tibial artery runs forward between the abductor hallucis and the flexor brevis digitorum, and, arriving at the ball of the great toe as a small twig, ends by anastomosing with the innermost digital branch. The internal plantar is an unimportant trunk ; it takes no part in the formation of the plantar arch.

The **external plantar artery** comes off from the bifurcation of the posterior tibial, under cover of the abductor hallucis. It is a large artery, and, having passed outwards between the flexors brevis and accessorius, runs forwards between the former muscle and the abductor minimi digiti to the base of the fifth metatarsal bone. From that situation it curves inwards across the metatarsal bones to the root of the first interosseous space, where it joins the branch from the dorsalis pedis to form the **plantar arch**. In this latter bend the artery lies deeply beneath the long flexor tendons and the lumbricals.

The *branches* are *calcanean*, *muscular*, and *cutaneous* ; also three *posterior perforating*, which mount through the roots of the three outer interosseous spaces to join the interosseous branches of the metatarsal artery, and four *digital* arteries, of which one runs along the outer side of the little toe, whilst the others pass in the interosseous spaces to divide at the three outer clefts, to supply the toes, and to insculate by short *anterior perforating* branches with the endings of the dorsal interosseous arteries. The innermost cleft, and the inner side of the great toe, are supplied by the dorsalis pedis.

The **tibialis anticus** arises from the outer aspect of the tibia, the deep fascia, and the interosseous membrane. It is inserted into the internal cuneiform and the scaphoid bones. Its tendon has a synovial sheath as it descends beneath the two bands of the annular ligament. Its action is to flex and invert the foot; its tendon often has to be divided in talipes varus. The *tenotomy* is best performed just below the front of the inner malleolus.

The **extensor longus digitorum** arises from the outer tuberosity of the tibia, the anterior surface of the fibula, and the deep fascia. Its tendons are inserted into the second and third phalanges of the four outer toes. The anterior tibial nerve comes through the upper end of its origin. The **peroneus tertius** is continued from the lowest part of this muscle, and is inserted into the dorsal surface of the base of the fifth metatarsal bone.

The **extensor proprius hallucis** (*pollicis*) arises from the middle two-fifths of the front of the fibula, and from the interosseous membrane; it is inserted into the unguis phalanx of the great toe.

*Course.*—At first it lies on the outer side of the anterior tibial artery, and to the inner side of the extensor longus digitorum between that muscle and the tibialis anticus, and overlapped by them. It then slowly crosses over the artery, and at the ankle its tendon lies to the inner side of the artery.

The foregoing muscles are flexors of the foot; they are supplied by the anterior tibial nerve.

The **peroneus longus and brevis** arise down the outer side of the fibula, the brevis being to the front of the longus and overlapped by it. They lie between the extensor longus digitorum and the peroneus tertius, to the front, and the soleus and flexor longus hallucis behind. Their tendons groove the back of the external malleolus and the outer side of the os calcis, the shorter tendon being above the peroneal tubercle, and the longer below it. The shorter tendon is then inserted into the outer side of the base of the fifth metatarsal bone, whilst the longer runs forwards and inwards in the tunnel under the cuboid bone, to be inserted into the tuberosity of the internal cuneiform and the outer side of the base of the first metatarsal bone.

These two muscles, which are supplied by the musculo-cutaneous nerve, extend and evert the foot, and in the case of extreme talipes valgus their tendons require division behind the malleolus. The external popliteal nerve divides in the substance of the longer muscle just below the head of the fibula. The tendons have a common synovial investment as they groove the malleolus.

The **anterior tibial artery** is one of the divisions of the popliteal. It comes through the top of the interosseous membrane, and runs down thereon until it rests upon the front of the expanded, lower end of the tibia. It afterwards lies upon the anterior ligament of the ankle-joint, where it changes its name to dorsalis pedis.

Its *course* is marked by a line from the inner side of the head of the fibula to the middle of the front of the ankle.

*Relations.*—The artery is *covered* by skin, superficial and deep fasciæ, by the muscles between which it passes, and especially by the extensor proprius hallucis, which, descending from the front of the fibula to the great toe, crosses the artery a little above the ankle. The anterior tibial nerve sometimes rests upon the artery.

*On the inner side* are the tibialis anticus, the tibia, and, near the ankle, the tendon of the extensor proprius hallucis. *On the outer side* are the extensor longus digitorum, the extensor proprius hallucis (in the middle third of the leg), and the anterior tibial nerve.

*Branches.*—*Recurrent*, which ascends through the tibialis anticus to the front of knee-joint, where it anastomoses with the lower articular branches of the popliteal, and perhaps with the anastomotica magna. *Muscular* twigs, which, in addition, supply the skin. The **internal malleolar** descends obliquely under the tendon of the tibialis anticus, to anastomose near the inner ankle with twigs of the posterior tibial (calcanean) and internal plantar. The **external malleolar** passes beneath the tendons of the extensor longus digitorum and peroneus tertius to anastomose with the anterior peroneal, and with tarsal branches of the dorsalis pedis. The supply of the ankle-joint is partly derived from these branches.

A **ligature** may be applied in the upper or in the lower part of the leg, but in the middle, where the great toe extensor is passing on to, or is crossing over, the artery, it is obviously inconvenient to attempt to secure the vessel.

**In the upper part of the leg** it is by no means easy to find the vessel, on account of the depth at which it lies between the tibialis anticus and the extensor longus digitorum. An incision having been made through the skin and superficial fascia from the inner side of the head of the fibula for three or four inches down the course of the artery, the strong, deep fascia is exposed. Search is made for the interval between the two muscles just mentioned. This is best accomplished by working with the director, or handle of the scalpel, in the lower part of the incision, where the space between the muscles is commencing. Thus the muscles are parted from below upwards, and are afterwards held asunder by spatulæ. The finger may then be passed upwards between the muscles, so as to make more room. The artery is found on the interosseous membrane, with a companion vein on either side. The anterior tibial nerve will probably be seen coming through the origin of the long extensor of the toes, and approaching the outer side of the artery. The ligature, therefore, may best be passed from the outer side.

**Just above the ankle the vessel is exposed** by an incision of two inches and a half through the skin, superficial fascia, and deep fascia. The deep fascia is here thickening into the anterior annular

ligament. The tibialis anticus tendon is well to the inner side, and that of the special extensor of the great toe, running along the artery from its outer side, must be drawn outwards. The nerve is most likely to the outer side, and from that side, therefore, the needle should be passed, the artery having been isolated from its companion veins. The great point in this operation is to keep close on the outer side of the tendon of the tibialis anticus, which is itself close to the tibial crest.

The **collateral circulation** after ligation of the anterior tibial would be carried on through muscular and periosteal branches; by inosculations of its empty branches with branches of the anterior peroneal and the posterior tibial arteries through the malleolar, tarsal, and metatarsal branches; and by the junction of the communicating branch of the dorsalis pedis with the external plantar in the plantar arch.

The **extensor brevis digitorum** appears as a firm elevation through the thin skin on the outer side of the dorsum of the foot. It arises from the front of the upper and outer part of the os calcis, and from the anterior annular ligament. The innermost of its four tendons is inserted independently into the base of the first phalanx of the great toe, but the three other slips join with the three inner tendons of the long extensor. Each of these conjoined tendons spreads out and divides into three slips, of which the middle piece is inserted into the base of the middle phalanx, whilst the lateral slips pass on to the last phalanx.

*Relations.*—The muscle is covered by a layer of deep fascia, by the peroneus tertius, and by the tendons of the extensor longus digitorum. It rests upon tarsal and metatarsal bones, the interosseous muscles, and the outer, ganglionic, branch of the anterior tibial nerve, which supplies the muscle as well as the tarsus. The dorsal artery lies along its inner side, and the inner border of the muscle may just overlap it. The innermost tendon crosses over the vessel in its course to the first phalanx of the great toe. The innermost border of the short extensor is the surgeon's guide to the artery.

The **dorsalis pedis artery** continues the anterior tibial from the middle of the front of the ankle in the line which passes thence to the cleft between, and the great and second toes. But, let it be well noted, the dorsal artery itself does not reach this cleft; a couple of inches behind this, at the root of the first interosseous space, it divides into the *dorsalis hallucis* and the *communicating*.

*Relations.*—The artery rests upon the astragalus, scaphoid, and internal cuneiform, and their dorsal ligaments. It is covered by the integument, superficial and deep fasciæ, and by the innermost slip of the extensor brevis digitorum. On the inner side is the special extensor of the great toe, and on the outer side are the long and short extensors of the toes, and the anterior tibial nerve. On either side is a companion vein.

**Ligation of the dor alis pedis.**—An incision of two inches is made over the artery in the line running from the middle of the ankle to the base of the first space, through the skin and the superficial and deep fasciæ. The tendon of the special extensor of the great toe is not the guide to the artery, which is running at some distance on its outer side; the guide is the inner belly and tendon of the short extensor of the toes. This latter closely overlaps the *dorsalis pedis*, and is beginning to cross it from the outer side. The artery is thus to be looked for close on the inner side of, or just beneath, that part of the *extensor brevis digitorum*, and a second layer of deep fascia, which binds the artery to the tarsus, has to be divided before the vessel is quite cleared. On either side is a vein, and to the outer is the anterior tibial nerve. The ligature is to be passed from the outer side.

*Branches.*—Various *tarsal* branches anastomose with the malleolar and plantar arteries, and the outermost of them may be also joined by twigs of the anterior peroneal. The *metatarsal* branch runs over the bases of the metatarsal bones, under the *extensor brevis digitorum*, and gives off *dorsal interosseous* branches, which run along the three outer spaces. These slender vessels divide at the clefts of the toes, and receive there the anterior perforating branches from the digitals of the external plantar. At the hinder end of the spaces the dorsal interosseous arteries are joined by the posterior perforating twigs of the external plantar. The outermost interosseous artery gives a branch along the outer side of the little toe.

The **dorsalis hallucis** comes from the bifurcation of the *dorsalis pedis*, and runs on the first dorsal interosseous muscle to the cleft, both sides of which it supplies. It also sends a branch under the tendon of the *extensor proprius hallucis* to the inner side of the great toe.

The **communicating** branch descends between the heads of origin of the first dorsal interosseous muscle to become continuous with the external plantar, and so to form the plantar arch. It supplies also the inner side of the great toe and the adjacent sides of the great and second toes on their plantar aspect, the internal plantar artery failing to reach so far forwards.

#### THE BONES OF THE LEG

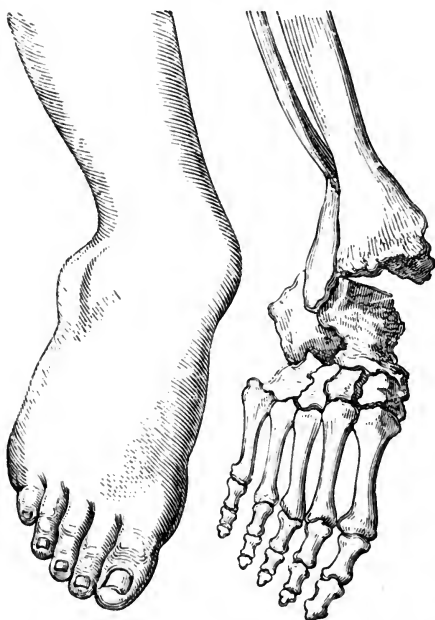The **tibia** has three centres of ossification, that for the shaft appearing early in foetal life. The upper epiphysis consists of the tuberosities and the tubercle, and begins to ossify at birth. The centre for the lower end appears in the second year and joins the shaft soon after puberty. The upper epiphysis joins at manhood, that is when the growth of the leg is perfected. The upper junction-cartilage, therefore, has more concern with the growth of the bone than the lower—for it is in active increase for several years longer—and must

be jealously protected in excision of the knee. The tibial epiphyses rarely become detached either by disease or injury.



The **fibula** also has three centres, the shaft beginning to ossify soon after the tibia. The lower epiphysis begins to ossify in the second year, as in the tibia. The upper epiphysis begins to ossify in the fourth year, and joins at manhood, as in the tibia. But the lower epiphysis, which was the first to ossify, joins a little earlier. This is the exception to the rule, that the epiphysis which ossifies first joins last. The head of the fibula lies far back beneath the outer tuberosity of the tibia, and is on a level with the tubercle of that bone. Tailors often develop a bursa over the external malleolus.

**Fracture** — From direct violence, as when a wheel passes over them, the two bones may be broken at the same level; but when the fracture is the result of indirect violence, as in a fall, they are likely to break in their weakest parts, the tibia in its lower third, the fibula near its neck.

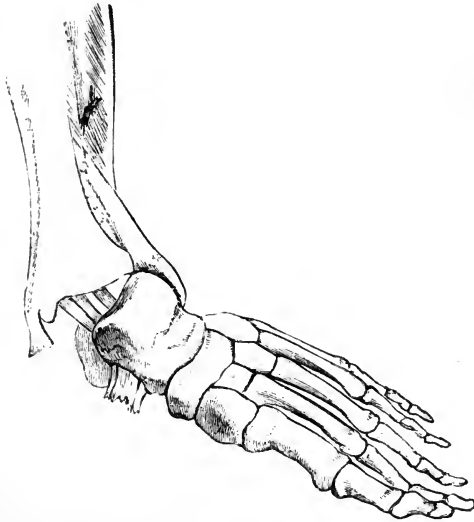


**Pott's fracture** results from a sudden twist of the foot, the internal malleolus or the lateral ligament giving way, and the fibula breaking a few inches above the ankle-joint. The condition was first described by Pott, from whose 'Chirurgical Works' the adjoining wood-cuts are adapted.

With a violent twist of the foot the lower end of the fibula becomes a lever of the first order: the fulcrum being at the lower tibio-fibular joint, the power the outward thrust against the external malleolus, and the resistance telling just where the bone yields. This spot is not the weakest part of the entire bone,

for that is in the upper third, and can hardly be influenced by a twist at the ankle.

There may be no displacement with this fracture, but generally the foot is everted, the astragalus being rolled outwards on its antero-posterior axis, or even dislocated. Often the foot is rigidly fixed in this everted position. Before trying to 'reduce' it the knee should be bent, so as to take all strain from the gastrocnemius. If it still prove immovable, an anæsthetic may be required before the soleus and the tibial muscles permit of its replacement. If, after this, the parts cannot be satisfactorily adjusted, it is advisable to divide the tendo Achillis, so as to insure absolute quiet of the calf-muscles. If this be not done, the leg should not be fixed on a back splint, as this keeps the knee straight and the gastrocnemius in a state of tension. Gypsum or wooden side-splints afford most convenient support, as then the knee can be kept flexed and the limb laid on the outer side.



Pott's fracture, showing rupture of internal lateral ligament.

In putting up the fracture it is very necessary to keep the foot flexed at a right angle, or else, when the man begins to get about again, the toes will be stiffly pointing downwards, and he will not be able to get his heel to the ground. He fancies that the leg is shortened by an inch or two, but with frictions and manipulations the ankle soon becomes flexed again. Sometimes, however, the surgeon is compelled to divide the tendo Achillis before the elevated heel can be brought down. Not infrequently his neglect to fix the foot, at the outset of treatment, with the toes pointing to the ceiling, is the cause of his lame patient ultimately resorting to a 'bone-setter,' who by rough and sudden flexion of the foot breaks down adhesions, and snatches a triumph from orthodox surgery.

It is quite possible to arrange the leg and foot in too straight a line in adjusting a fracture near the ankle. It must be remembered that the tibia is considerably bowed, and that the sole of the foot naturally inclines a little inwards.

It is not always easy to recognise fracture in the upper two-thirds of the fibula, for the bone is deeply shrouded by muscular attachments: the soleus and flexor longus pollicis behind, the peroneus longus and brevis on the outer side, and the extensors longus digitorum and proprius hallucis in front. The unbroken tibia steadies the fragments of the fibula, and prevents the surgeon obtaining crepitus.

The lower third of the fibula is subcutaneous in the interval between the peroneus longus and brevis, behind, and the tertius and extensor longus digitorum in front; a break in this part of the bone is, as a rule, easily detected.

### THE ANKLE-JOINT

The ankle-joint is formed by the lower end of the tibia, the two malleoli, and the astragalus. The fibular malleolus descends to a lower level than the tibial, therefore the outer articular surface of the astragalus is larger than the inner.

The *anterior and posterior ligaments* are unimportant; they descend from the front and back of the lower end of the tibia to the adjacent parts of the astragalus.

The **internal lateral ligament** is deltoid, spreading from the end of the malleolus to the scaphoid, the sustentaculum tali, and, behind, to the astragalus (*see* operation for club-foot, p. 503). There is a deep part of this ligament between the tip of the malleolus and the adjacent part of the astragalus. This deltoid ligament is crossed by the tendons of the tibialis posticus and the flexor longus digitorum. The **external lateral ligament** sends an anterior and a posterior band to the astragalus, and a vertical one to the os calcis; this last is crossed by the tendons of the peroneus longus and brevis.

The **synovial membrane of the ankle-joint** lines the anterior, posterior, and the lateral ligaments, and often sends up a slip into the lower tibio-fibular joint.

**Supply.**—The vessels come from the anterior and posterior tibials, the malleolar and the peroneals. The *nerves* are branches of the internal saphenous and of the anterior and posterior tibials.

**Structures around ankle.**—Beginning in front and passing from within outwards: the tibialis anticus, extensor proprius hallucis, the anterior tibial artery between its companion veins; the anterior tibial nerve; the extensor longus digitorum and the peroneus tertius. The peroneus brevis and longus; the flexor longus hallucis, the posterior tibial nerve, and the artery with its companion veins; the flexor longus digitorum and the tibialis posticus. Behind all is the tendo Achillis.

When **articular effusion** occurs, the capsule bulges under the tendons at the front of the ankle, obscuring their outline and obliterating the furrows between them. There is also a fulness around the malleoli,

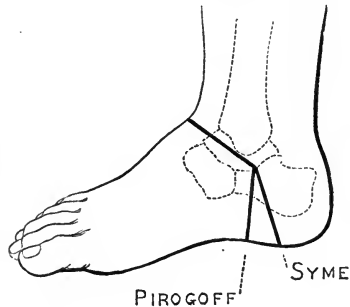


and at the back of the joint, on either side of the tendo Achillis. Such universal bulging is indicative of ankle-joint disease; when fulness in the neighbourhood is due to extra-articular causes it is limited to one aspect, or, at the most, to two aspects of the ankle.

**Excision of the ankle-joint** may be performed by lateral incisions which descend along the posterior borders of the malleoli, and by prolonging them a little forwards so as to obtain more room. The tendons are carefully turned back—the peroneus longus and brevis, and the tibialis posticus and flexor longus digitorum. The lateral ligaments are divided; the lower end of the fibula is sawn off, and the lower end of the tibia is scraped or sawn, as may be expedient, and the astragalus is thoroughly scraped over.

In **Syme's amputation** all the bones of the foot are removed, and a flap is shelled from the back of the os calcis which is flexed over the ends of the tibia and fibula, the malleoli having been removed.

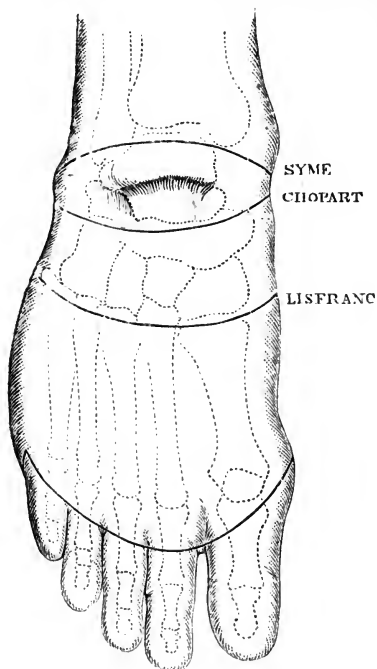
The **land-marks** for the operation are the tip of the external malleolus, and a spot on the inner side on exactly the same level, which is below and behind the tip of the inner malleolus. A large scalpel is used. The heel-flap is first cut by an incision connecting these points, and passing under the os calcis. It is sloped a little backwards, so that the flap is not made needlessly long and cup-shaped. This incision divides everything down to the bones: skin, superficial fascia, external saphenous vein and nerve; deep fascia (external and internal annular ligaments); the tendons of peroneus longus and brevis; the posterior tibial vessels and nerve; the flexor longus hallucis; the plantar fascia; the points of origin of the abductor hallucis, flexor brevis digitorum, and abductor minimi digiti. Then the end of the os calcis is uncovered by carefully peeling back the flap down to the bone, and round the point of the heel, care being taken to make no 'button-hole.'



The second incision is carried straight over the front of the ankle-joint, beginning and ending in the horns of the plantar incision. No attempt is made at shaping a dorsal flap; the knife is carried straight across, down to the bones and into the ankle-joint. This incision divides: skin, superficial fascia, internal saphenous vein and nerve, and the musculo-cutaneous nerve; the deep fascia (anterior, and part of internal annular ligament); the peroneus tertius and the extensor longus digitorum; the anterior tibial nerve and vessels; the extensor proprius hallucis, and the tibialis anticus; and, last or first, according

as the operation is on the right or left side, the tibialis posticus and flexor longus digitorum, for these two tendons just escaped division by the first incision.

The front of the foot being depressed, the articular ligaments are easily divided, and the joint traversed; and the knife, passing along the upper part of the os calcis, behind the tibia, reaches and divides the tendon of Achilles and the plantaris. The ends of the tibia and fibula are then sawn off.



Lines of incisions for amputations. (After SMITH and WALSHAM.)

The posterior tibial artery lies just where the two incisions meet, at the spot a little below and behind the tip of the inner malleolus.

When the operation is being done for disease of a child's ankle, the epiphysis, which represents the posterior part of the os calcis, may be detached. If so, it had better be dissected out, as it is likely to be unsound (*z.* p. 508).

The vitality of the flap depends on the calcanean branches of the posterior tibial, the malleolar of the anterior tibial, and the posterior branches of the peroneal.

In **Pirogoff's** modification of Syme's amputation, most of that part of the os calcis which is behind the astragalus is cut off and turned up, so that its sawn surface may become ossified on to the sawn surface of the tibia. The incision in the sole, therefore, may be sloped a trifle forwards, the plantar muscles, vessels, nerves, and tendons being cut right through to the bones. The heel-flap, of course, is not dissected up, but the back of the os calcis is sawn off after the ankle-joint has been opened from the front. To ensure rest and perfect apposition of the sawn surfaces, the tendon of Achilles should be divided.

#### THE FOOT

The **plantar fascia** is very thick and strong where it is attached to the tuberosities of the os calcis. Coming forwards, it spreads into

three pieces, of which the median is the strongest, and divides into five slips which join the sheath of the flexor tendons of each toe. These slips are strengthened by transverse fibres, under cover of which pass the digital vessels and nerves. The lateral pieces of the fascia blend with the middle piece, and with the deep fascia on the dorsum of the foot. The outer piece covers the abductor minimi digiti and extends to the base of the fifth metatarsal bone. The inner piece covers the abductor hallucis.

**Uses of the plantar fascia.**—It strengthens the transverse as well as the antero-posterior arches of the foot. It gives origin to the three muscles in the superficial layer, the middle one being the flexor brevis digitorum. It protects these muscles and the plantar vessels and nerves, as when the bather treads on a broken bottle or a jagged flint. (In company with other plantar structures, the fascia yields in the case of flat-foot.)

The three muscles in the superficial layer of the sole are the abductors hallucis and minimi digiti, with the flexor brevis digitorum between them. They all arise from the deep fascia, os calcis, and inter-muscular septa. The abductors are inserted into the base of the first phalanx of the great and little toes, and the flexor brevis digitorum is inserted, like the flexor sublimis in the hand (p. 272), into the sides of the penultimate phalanges of the four lesser toes, its tendons being pierced by those of the long flexor.

**Tarsal ligaments.**—The *long plantar* ligament passes from the under surface of the os calcis to the ridge on the under surface of the cuboid, converting the groove for the tendon of the peroneus longus into a tunnel. It then spreads into the bases of the second, third, and fourth metatarsal bones. The *short plantar* runs from the under and anterior part of the os calcis to the cuboid behind the groove.

The *internal calcaneo-cuboid* is a short, strong band between the inner and dorsal aspects of the bones. It forms the outer limb of the V-shaped union between the first and second rows of the tarsus, the inner limb being the *superior calcaneo-scaphoid* ligament, which passes on to the dorsal surface of the scaphoid.

The *inferior calcaneo-scaphoid* ligament is a broad, strong band between the sustentaculum tali and the tuberosity of the scaphoid. The tendon of the tibialis posticus passes like a strap beneath it. Its upper surface is lined by the synovial membrane from between the astragalus and os calcis, and supports the head of the astragalus. The front of the deltoid ligament blends with and supports it. It is sometimes called the 'spring ligament,' and it is one of the first structures to give way in flat-foot.

All these ligaments are necessarily divided in Chopart's amputation, which passes through the transverse tarsal joint.

**The bony arches of the foot.**—If the foot were a solid piece of bone it would be very liable to fracture; it would, moreover, possess

no elasticity, and man would walk heavily, ungracefully, and with discomfort.

When in the erect position, the weight of the body is received and transmitted by the inner tuberosity of the os calcis and by the heads of the first and of the fifth metatarsal bones ; the plantar vessels, nerves, muscles, and tendons occupy the intervening hollow, and are there kept from pressure by the strong plantar fascia.

The **antero-posterior arch** is best marked upon the inner side ; it is formed by the point of the os calcis, the astragalus, and the scaphoid, cuneiform, and the three inner metatarsal bones. Great elasticity is obtained by this arrangement. Along the outer side of the foot the antero-posterior arch has not so much spring, but it is extremely strong. It is composed of the os calcis, the cuboid, and the fourth and fifth metatarsal bones.

The **transverse arch** is built up of the scaphoid, the internal cuneiform, and the first metatarsal bones on the inner side, and of the cuboid and the fourth and fifth metatarsals on the outer.

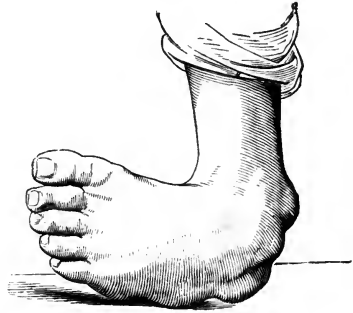The integrity of the antero-posterior and transverse arches is maintained by the keystone arrangement of the bones, by the dorsal, interosseous, and plantar ligaments, and by the tendons and fascia. The oblique tendon of the peroneus longus gives valuable support to both the antero-posterior and the transverse arch ; so also does the widespread insertion of the tibialis posticus.

**Flat-foot.**—Those who are not strong enough for the task and who carry about heavy burdens, who are wearied by too much walking or standing, complain of dull pains up the legs, and of aching feet. This is due to the stretching of sensory nerve filaments, and to the fatigue of muscles, which, like the tibials, are trying to support the sinking foot. Sometimes these aches are mistaken for rheumatic or for ‘growing’ pains. Even if the deformity be but slight, the subject is not fit for active work ; he tires after a long walk, and is, therefore, unfit for soldiering, and for hard physical work generally.

In flat-foot the inferior calcaneo-scaphoid, the long and short calcaneo-cuboid ligaments ; the plantar fascia ; the insertions of the tibialis posticus and anticus, and of the peroneus longus, have all yielded a little. The result is that the head of the astragalus rolls downwards and inwards, whilst the tuberosity of the scaphoid, the internal cuneiform, and the base of the first metatarsal bones sink to the inner side of the sole. The condition may be treated by rest, and by strengthening the tibial muscles, as by making the patient walk on tiptoe and on the outer side of the feet. An ingenious operation for flat-foot is that of opening the astragalo-scaphoid joint, scraping away all the articular lamellæ of cartilage and bone from its interior, and, having arched the foot, inducing the raw surfaces of astragalus and scaphoid to become ankylosed, in their tilted and improved position.

This operation should not be undertaken, however, until the gymnastic exercises have had a prolonged and patient trial.

**Talipes** (*talus*, ankle ; *pes*, foot), because, in the commonest variety of club-foot, the patient walks on the outer side of the ankle—this variety is **equino-varus**, the heel, or heels, being drawn up (as in *equus*), and the soles being turned inwards towards each other, *varus*.



Before birth the feet are normally in this position, in order that the embryo may be packed in the smallest space ; the compression of the uterine wall, in all probability, causes the arrangement. If, after birth, their position be not improved by development, the retaining bands become permanently shortened and the bones misshaped.

The structures which may require division in talipes equino-varus are the tendo Achillis (and in slight deformity this may suffice), the tibialis anticus, tibialis posticus, and flexor longus digitorum ; the anterior part of the deltoid ligament, which is holding back the tuberosity of the scaphoid bone ; the inner part of the plantar fascia, and possibly also the abductor hallucis. Indeed, every structure is to be divided until the foot can be placed in the proper position. After this it is fixed in a gypsum case till the wounds are soundly healed, then massage is employed. There need be no anxiety about the non-union of widely sundered tendon-ends, *so long as they are not divided in their synovial sheath*. At the present day the tendons are divided by a free incision in the sole, rather than above the malleoli, where they lie in synovial sheaths and in the neighbourhood of important vessels.

The tendon of Achilles is divided from before backwards an inch above its insertion ; the tibialis anticus is divided from the outer (the arterial side) just below and in front of the inner malleolus. The tibialis posticus is divided between the tip of the inner malleolus and the tuberosity of the scaphoid, and here also the anterior part of the deltoid ligament may be severed. The other bands are cut wherever they can be felt firm and resisting beneath the skin, and, as remarked above, by a free incision, so that the surgeon may see what he is doing ; subcutaneous tenotomy is often disappointing.

The flexor longus digitorum rarely needs section.

In the adult a wedge of bone has occasionally to be removed from the upper and inner part of the tarsus, before the man can become a plantigrade, or, better still, the astragalus is excised, as advised by Lund.

**Talipes valgus** is not the same as flat-foot; it is that condition in which the outer border of the foot is drawn up by contracted peroneal tendons. The condition is rare; and rarer still is that in which the peroneal tendons need division. Obviously it is wrong to divide the tendon of the peroneus longus in mere flat-foot, for, as remarked above, that tendon does much in supporting the arches of the foot.

Students often experience a difficulty in remembering which is talipes varus and which is valgus. They should think of the well-known condition of knock-knee, or genu valgum, for genu valgum is constantly associated with the flat-foot, the inner arch of the instep having sunk; flat-foot is also called spurious talipes valgus. *Talipes varus* is the opposite condition, in which the inner border of the foot is drawn up and the patient walks on its outer side. Often in talipes varus corns form over the external malleolus, the cuboid, and the base of the fifth metatarsal bone; in those places also bursæ may be developed and become inflamed.

Every new-born child has a little 'varus,' for this was the position of the foot *in utero*.

**Talipes calcaneus** is the reverse of **talipes equinus**. In the former condition the tibialis anticus and its associates may require division; in simple equinus Achilles-tenotomy may suffice. The latter operation is common enough, the former is rarely needed.

In paralysis of the calf-muscles the heel may drop from stretching of the tendon of Achilles, the patient becoming the subject of *paralytic calcaneus*. In this condition an oblique segment may be removed from the tendon, the cut surfaces being then spliced.

In equinus the first phalanx of the great toe, and the first phalanges of the other toes, to a certain extent, are drawn up towards the dorsum of the foot and even partially dislocated backwards. The reason of this is that when the heel is elevated the toes are pointed down, and, the distance between the origin and insertion of the long extensors of the toes being increased, whilst the muscles themselves are not lengthened, the toes are drawn into the position of extreme extension. The long flexor still holds down the unguis phalanx.

If the foot be forcibly flexed the position of the toes is at once improved, if not corrected.

**Pes cavus** is a rare congenital deformity, in which the heel is drawn up by a contracted tendo Achillis, whilst the plantar fascia shortens the foot and exaggerates the arch of the instep.

In pes cavus the tendon of Achilles and the plantar fascia may require division.

**Hammer-toe** is a congenital deformity in which the first phalanx of (generally) the second toe is drawn back, whilst the middle and unguis phalanges are flexed. Thus the angle of the first interphalangeal joint forms a prominent 'knee' which is constantly pressed

upon by the upper leather of the boot or shoe. Careful padding and strapping of the toe, or, in more extreme cases, division of the tendons, sometimes cures this deformity, but when the lateral ligaments have slipped behind the head of the metatarsal bone, nothing short of excision of the head of that bone, or amputation of the toe, will effect a cure. The deformity is often hereditary; it is doubtful if wearing tight boots is often accountable for it.

The inter-phalangeal articulations of the foot are like those of the hand (p. 289).

The great mobility which naturally exists between the astragalus and the scaphoid, and between the astragalus and os calcis, is necessarily at the expense of the strength of the union between the astragalus and those bones. So, as the result of great violence, the interosseous (astragalo-calcanean) ligament may be ruptured, and the os calcis, scaphoid, and the other bones of the foot shifted inwards, outwards, or even in the antero-posterior plane. The dislocation of the foot is called **subastragaloid**.

A modification of Syme's amputation is performed on this principle: the heel-flap being made as usual, but the ankle-joint not being opened. A short dorsal flap is made, the os calcis is removed with the rest of the foot, and the heel-flap is brought round the astragalus.

#### THE CUTANEOUS VESSELS AND NERVES OF THE FOOT

The venous arch on the dorsum receives tributaries from the backs of the toes, and empties itself by the internal and external saphenous veins. The direct communication between the saphenous veins enables one of them to do the work of both when inflammation and plugging have rendered its fellow impervious.

The arteries on the *dorsum* of the toes are smaller than the plantar digital branches. The three outer clefts, and the outside of the little toe are supplied by the dorsal interosseous branches of the metatarsal of the *dorsalis pedis*. The innermost cleft, and the inner side of the great toe, are supplied by the *dorsalis hallucis* (p. 494).

On the *under aspect* the three outer clefts and the outer side of the little toe are supplied by the digital branches of the external plantar artery; the innermost cleft and the inner side of the great toe get branches from the communicating branch of the *dorsalis pedis*.

*Nerves*.—The *dorsum* is chiefly supplied by branches of the musculo-cutaneous, but the cleft between the great and second toes receives the ending of the anterior tibial nerve, the inner side of the great toe getting its branch from the musculo-cutaneous. Along the outer side of the foot and little toe twigs are derived from the external saphenous.

The internal saphenous nerve supplies the inner border of the foot nearly to the *ball of the great toe*, but no farther (p. 358).

*In the sole* the plantar nerves are distributed, the inner to three toes and a half, and the external, like the ulnar nerve, to one and a half. An additional plantar cutaneous branch comes through the internal annular ligament from the posterior tibial nerve.

**In amputation of the great toe with its metatarsal bone** the ridge across the base of the first metatarsal is made out—the joint with the internal cuneiform is close behind. A longitudinal dorsal incision is made from half an inch behind this till the head of the metatarsal bone is approached. The incision then divides to make a racquet-shaped wound. The first metatarsal bone is then enucleated, disarticulated, and removed, together with its two phalanges.

During the operation *the following structures are divided*:—Skin and superficial fascia; plantar fascia; tributaries of the internal saphenous vein, and branches of the internal saphenous, musculo-cutaneous, anterior tibial, and internal plantar nerves; the dorsalis hallucis; branches of the communicating, and of the internal plantar arteries; the extensor proprius hallucis; the innermost tendon of the extensor brevis digitorum; the first dorsal interosseous muscle; the transverse ligament and muscle, the adductor, flexor brevis, and abductor hallucis; flexor longus hallucis; tibialis anticus and peroneus longus; and the ligaments connecting the first metatarsal with the internal cuneiform.

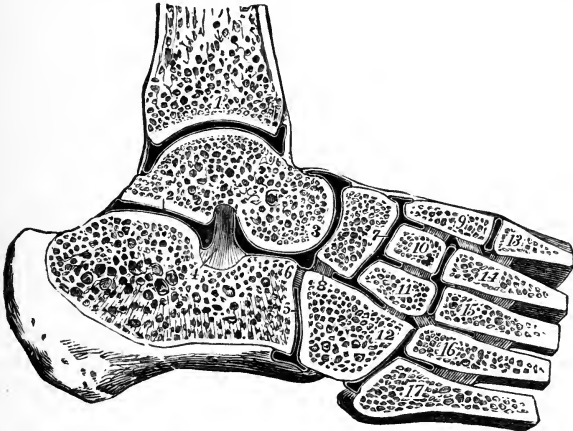Care must be taken not to wound the communicating artery as it dips through the root of the first dorsal interosseous muscle.

**Amputation of the little toe with its metatarsal bone** is performed on a similar plan, the dorsal incision being begun behind the articulation of the fifth metatarsal bone with the cuboid. *The structures divided* are tributaries of the external saphenous vein; branches of the external saphenous, musculo-cutaneous, and external plantar nerves, and of the dorsal interosseous, metatarsal, and external plantar arteries; the outer part of the plantar fascia; the outermost tendon of the extensor longus digitorum and of the flexor longus and brevis digitorum, and the fourth lumbrical; the transversus pedis muscle and ligament; a plantar and a dorsal interosseous muscle, and the insertions of the abductor and flexor brevis minimi digiti; the peroneus tertius and brevis, and the ligaments of the outermost tarso-metatarsal joint.

The web of the toes reaches about an inch beyond the head of the metatarsal bones. **In amputation of a toe** the web makes an excellent covering for the head of the metatarsal bone, but, in amputation of the great toe, the head of that metatarsal bone requires a large flap, which is best obtained from the under surface. The head of this metatarsal bone should, if possible, be preserved, on account of its importance in standing and walking.



**Bones of foot and synovial membranes.**—The astragalus articulates with the os calcis in two places, the interosseous ligament intervening between the facets. Its head fits into the fossa at the back of the scaphoid. The posterior of its two calcanean facets has a



Synovial membranes of ankle-joint and foot. (QUAIN.)

synovial membrane of its own, but the membrane which lubricates the anterior lines also the upper surface of the inferior calcaneo-scaphoid ligament, and follows the head of the astragalus into the astragalo-scaphoid joint.

*Excision of the astragalus* may be required in the case of caries, in intractable dislocation of the foot, and in infantile paralysis and inveterate talipes equino-varus (Lund), with the view of keeping the sole flat upon the ground. It is easily accomplished by a free incision across the front of the ankle-joint, the anterior tibial vessels and nerve, and as many of the neighbouring tendons as convenient, being placed aside. The anterior and lateral ligaments of the ankle-joint and the astragalo-scaphoid connection being severed, the bone is 'dug out,' the interosseous astragalo-calcanean ligament having been divided.

**Chopart's amputation.**—Much of the movement which apparently takes place at the ankle-joint actually occurs between the astragalus and scaphoid, on the inner side, and the os calcis and cuboid on the outer side of the foot. These articulations constitute the *transverse* or *mid-tarsal joint*; the partial removal of the foot, known as Chopart's amputation, is effected through it. In this amputation the flap is first shaped out in the sole, the limits of the flap being the borders of the sole laterally, and the roots of the toes in front. Thus all the soft parts are raised in a thick flap to cover the naked ends of the

astragalus and os calcis. A short dorsal flap is then made, the skin and subjacent tissues being reflected up to the line of the transverse tarsal joint. It is almost impossible to get the sole-flap too large.

The *land-marks*.—The tuberosity of the scaphoid on the inner side ; behind which the knife is introduced. On the outer side there is no prominence showing the line of the calcaneo-cuboid joint, but that articulation is surely opened by introducing the knife exactly midway between the tip of the external malleolus and the tuberosity on the base of the fifth metatarsal bone. The tendon of Achilles had better be divided, so that the heel may be brought well down ready for supporting the weight of the body.

*Fallacies*.—The mid-tarsal joint is not always easily found, the surgeon opening the joint between the scaphoid and cuneiforms ; or, on the outer side of the foot, plunging his knife into the hollow between the astragalus and os calcis, instead of into the calcaneo-cuboid joint. The flap is apt to be cut too short, so that it does not cover the articular surfaces ; this is especially apt to occur on the inner side, where the head of the astragalus stands forth so boldly.

The dorsal artery and the two plantars and their branches will require ligation.

The **os calcis** has an *epiphysis* into which the tendo Achillis is inserted ; this epiphysis is often detached in Syme's operation. The os calcis articulates in front with the cuboid ; this joint possesses a distinct synovial membrane, as shown in the illustration.



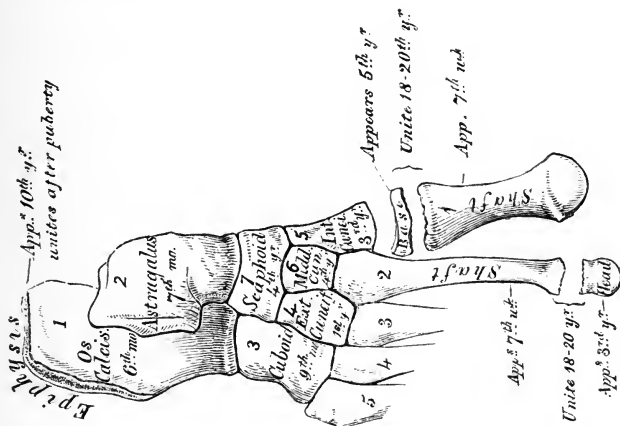
Os calcis and its epiphysis.

The **cuboid** is on the outer border of foot, between the os calcis and the fourth and fifth metatarsals. Its joint with the metatarsals has a separate membrane.

The **scaphoid** articulates with the rounded head of the astragalus, and in front with the three cuneiform bones. Its tuberosity bulges into the sole on the inner side, and is the landmark behind which the knife is kept in Chopart's, and also in the sub-astragaloid amputation.

The **cuneiform bones**.—The innermost has a large tuberosity dipping into the sole, corresponding with that of the scaphoid. The inner cuneiform articulates by a reniform facet with the base of the first metatarsal, and has there a special synovial membrane. A strong ligament holds the base of the second metatarsal bone against the internal cuneiform. The middle and external cuneiforms articulate with the second and third metatarsals ; the synovial membrane which lines those joints passing back between the cuneiforms to lubricate the joints between them and the scaphoid. It also sends a prolongation between the external cuneiform and the cuboid, and perhaps one between the scaphoid and cuboid. This arrangement is not shown in the wood-cut.

The **metatarsal bones** have a more or less rectangular base, for articulation with the cuneiforms and the cuboid, and a rounded head for the first phalanx. The first metatarsal, like a phalanx, has its epiphysis at the proximal end.



Scheme showing ossification of tarsal bones, and of first and second metatarsal bones. (GRAY.)

There is a vertical ridge on the inner side of the base of the first metatarsal which can be felt beneath the skin ; close behind this is the **joint with the innermost cuneiform**. This joint is exactly in the middle of the length of the foot, the arch of the foot being almost entirely behind it. In flat-foot (p. 502), therefore, when the arch has given way and spread out, the length of that part of the foot which is behind this joint greatly exceeds that which is in front of it.

The base of the second metatarsal bone is firmly mortised amongst the cuneiforms, and articulates with the middle cuneiform, its lateral surfaces lying against the internal and external cuneiforms, a strong interosseous ligament connecting it with the inner.

The third metatarsal articulates with the external cuneiform ; and the fourth and fifth articulate with the cuboid. The base of the fifth has a large tuberosity, which bulges behind the joint with the cuboid, so, to hit the joint, as in Hey's amputation, the knife must be slipped behind that tuberosity and then brought forwards and inwards.

The base of each of the three outer metatarsals articulates behind by an oblique facet ; these joints have the same slant—backwards and outwards—and the innermost of them is on the level of the joint between the first metatarsal and the internal cuneiform.

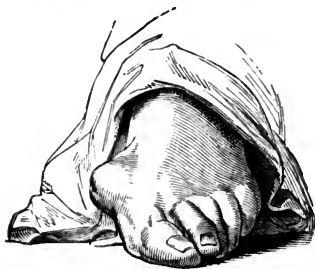**To draw the line of the tarso-metatarsal joints** upon the un-

dissected foot, a dot is made close behind the ridge on base of the first metatarsal bone; and another behind the tuberosity of the fifth, and these dots are provisionally connected by an oblique line. Then the shaft of the second bone is traced back into its expanded base amongst the cuneiforms, and there a squared, but a slightly oblique, notch is depicted. The latter part of this plan has to be made by estimation, as the mortise cannot be actually felt. It is about a quarter of an inch deep. It is shown on p. 507.

The tips of the index-finger and thumb are kept upon the inner and outer landmarks of this tarso-metatarsal joint in **Hey's** and in **Lisfranc's** operation. The latter amputation consists in disarticulating all the metatarsal bones; but in the amputation which bears the name of the English surgeon the base of the second bone is not disarticulated, but sawn across, or the internal cuneiform is divided.

In Hey's and Lisfranc's amputation a very short dorsal flap is raised, as in Chopart's operation (p. 500), whilst the sole of the foot is made to supply the covering for the naked surfaces of the cuboid and cuneiforms. This flap should be cut longer on the inner side, as the surface of the internal cuneiform which it has to cover is deeper than that of the cuboid. Branches of the two plantar arteries will require ligation; but the main trunk of the external, which crosses the roots of the metatarsal bones, may just escape the knife.

**Hallux valgus.**—As a result of wearing boots with narrow toes, the great toe is thrust outwards, until it may lie under or over the neighbouring toes. The partial outward dislocation of the base of the first phalanx leaves the inner surface of the head of the first metatarsal bone prominent beneath the skin, and unprotected from the pressure of the boot. It is, however, the strain upon the joint, not the pressure of the boot, which sets up the trouble and pain in the joint. The appearance presented by the great toe is something like knock-knee,




and is called hallux valgus. When the deformity is slight it may be treated by wide-toed boots, and by wearing a pad of cotton-wool in the first cleft. But, if it be severe, the shaft of the first metatarsal may be divided, the distal part of the bone being so arranged that the phalanges may lie in the direction of the inner border of the foot.

Unless the case be duly treated, the mucous bursa which is apt to be developed by friction on the inner side of the head of the metatarsal bone becomes inflamed. The large round and painful swelling then produced is called **bunion** (*ζουβος, mound*).

Gouty inflammation is specially apt to attack the first joint of the great toe : because it is a hard-worked joint, because it is far away from the centre of circulation, and because wearing a boot has caused the toe to be deflected so that the joint is not worked in the natural manner.

In certain flat-footed adolescents the first joint of the great toe becomes stiff and painful, or inconveniently flexed : the conditions are called **hallux rigidus** and **hallux flexus** ; the cause is unknown, and the treatment is unsatisfactory.



# INDEX

[Every dash (—) stands for a word in the line above it.]

## ABD

- abdomen, 294
  - cavity of, 314
  - dropsy of, 316
  - injuries of, 297
  - muscles of, 302
  - regions of, 299
  - superficial fascia of, 296
  - nerves of, 301
  - — vessels of, 300
  - tumours of, 300
  - viscera of, 318
  - — relative position, 344
  - wall of, 302
- abdominal aneurysm, 351
  - aorta, 350
  - ascites, 316
  - ring, external, 302
  - — internal, 306
  - wall, abscess of, 305, 308
- abducens, 65
- abnormality, *see* particular part
- abscess, abdominal, 305
  - axillary, 245
  - of buttock, 211, 308, 452, 467
  - cervical, 2, 210
  - of hip-joint, 467
  - iliac, 211, 308
  - in prostate, 415
  - in sheath of rectus, 305
  - ischio-rectal, 211, 308, 437, 468
  - lumbar, 211, 305, 308
  - mediastinal, 154
  - of liver, 339
  - of scalp, 7
  - palmar, 286
  - pelvic, 308, 367
  - perineal, 439
  - peripleuritic, 188
  - perityphlitic, 327
  - popliteal, 450, 485
  - post-pharyngeal, 210
  - prostatic, 415
  - psoas, 211, 308
  - renal, 410

## ANK

- abscess, retro-pharyngeal, 210
  - spinal, 210, 308
  - sub-peritoneal, 308
  - thecal, 274
- accelerator urinæ, 440
- accentuation of sound, 171
- accessory internal pudic, 442
- accommodation, 85
- acetabulum, 360, 465
- Achillis, tendo, 487
  - — reflex, 221
- acromion process, 227
  - ligaments of, 226
- Addison's disease, 350
- adductors of thigh, 453
- adenoid vegetations, 111
- adenoma mammae, 204
- adenoma of breast, 204
- ægophony, 202
- ague-cake, 342
- air in veins, 4, 234
- air-cells, 196
  - passages, foreign body in, 130, 134
- air, tidal, 193
- amphoric resonance, 201
- amputation, *see* special part
- Amussat's operation, 331
- anal fascia, 437
- anastomoses, parietal and visceral, 309
- anconeus, 244, 281
- aneurysm, *see* special artery
  - aortic, 180
- angina pectoris, 169
- angular curvature, 208
- ani atresia, 383
  - levator, 438
  - sphincter, 386
- ankle clonos, 221
- ankle-joint, 498
  - effusion into, 498
  - structures behind the, 486, 498
- ankylosis of hip, 468
  - of jaw, 22

## ANN

annular ligaments of ankle, 485  
 — — wrist, 270  
 annulus ovalis, 166  
 ano, fistula in, 438  
 anterior crural nerve, 358  
 — interosseous artery, 278  
 — — nerve, 254  
 — tibial artery, 492  
 — — nerve, 382  
 anthracosis, 191  
 antrum of Highmore, 17  
 anus, artificial, 330  
 — development of, 383  
 — epithelioma of, 387, 389  
 — fissure of, 386  
 — patulous, 386  
 aorta, abdominal, 298, 350  
 — arch of, 178  
 — ascending, 178  
 — thoracic, 184  
 — transverse, 179  
 — valves of, 168  
 — — disease of, 173  
 — — situation of, 169  
 aortic aneurysm, 180  
 apex-beat, 162  
 aphasia, 49  
 apoplexy, 50  
 appendices epiploicæ, 328  
 aqueduct of Fallopius, 13  
 aqueous humour, 84  
 arachnoid, 38  
 arch of aorta, 178  
 arches of foot, 501  
 arcus senilis, 83  
 Argyll-Robertson pupil, 59  
 arm, surface of, 237  
 Arnold's nerve, 69  
 arteria centralis, 81  
 arteriotomy, 31  
 artery, *see* special artery  
 — structure of, 178  
 articulation, *see* special joint  
 artificial anus, 330  
 arytenoid cartilage, 126  
 arytenoideus, 128  
 ascending cervical artery, 233  
 ascites, 316  
 asthma, 197  
 astigmatism, 84  
 astragalus, 507  
 atlas, 206  
 atlo-axoid joint, 206  
 atony of bladder, 410  
 atresia ani, 383  
 auditory meatus, external, 94  
 — — internal, 13  
 — nerve, 68

## BRA

auditory vertigo, 101  
 auricle, left, 167  
 — right, 165  
 — development of, 102  
 auricular nerve, 69  
 — — great, 145  
 — — posterior, 66  
 auriculo-temporal nerve, 63  
 auriculo-ventricular orifices, 167, 169  
 auscultation, 200  
 axilla, 244  
 axillary artery, 245  
 — — course of, 235  
 — fascia, 239  
 — glands, 248  
 — line, 237  
 — nerves, 249  
 — vein, 238, 246  
 axis, 206  
 azygos artery, 157, 185  
 — vein, 154  
  
 back, pain in the, 210, 349, 351, 386  
 balanitis, 422  
 'ballooning' of rectum, 384  
 band, ilio-tibial, 448, 452  
 basal ganglia, 53  
 base of skull, fracture of, 38, 74  
 basilic vein, 238  
 Bell, nerve of, 251  
 Bell's paralysis, 66  
 'belly-ache,' 210  
 bend of elbow, 263  
 biceps, of arm, 243  
 — of thigh, 450  
 — dislocation of, 224  
 bicipital fascia, 243  
 Bigelow's ligament, 466  
 bile-duct, 340  
 bladder, development of, 406  
 — extroversion of, 406  
 — female, 405  
 — hiatus of, 406  
 — inflammation of, 410  
 — irritation of, 423  
 — male, 406  
 — puncture of, 407  
 — rupture of, 412  
 — sacculation of, 408  
 — stone in, 411  
 bceding, 237  
 blepharo-spasm, 73  
 blind spot, 93  
 borborygmi, 330  
 brachial artery, 262  
 — — compression of, 236  
 — plexus, 249



## BRA

- brachialis anticus, 244  
 brachio-cephalic artery, 182  
 brain, 44  
 — arteries of, 42  
 — fissures, 47  
 — membranes of, 37  
 — topography of, 45  
 branchial clefts, 123  
 — fistulæ, 124  
 breast, 202  
 breath-sounds, 200  
 — thoracic, 315  
 bregma, 366  
 Bright's disease, 346  
 broad ligament, 390  
 Broca's region, 49  
 bronchi, 134, 195  
 bronchial breathing, 200  
 — glands, 199  
 — nerves, 199  
 — vessels, 199  
 bronchiectasis, 198  
 bronchitis, 198  
 bronchophony, 202  
 bronchocele, 135  
 brow-ague, 60  
 bruits, 171  
 Bryant's line, 448  
 bubo, 451  
 bubonocoele, 310  
 buccal nerve, 63  
 buccinator, 106  
 bulb of urethra, 417, 442  
 bulbar paralysis, 56, 71  
 bunion, 510  
 burn, ulcer after, 325  
 bursæ about ankle, 486  
 — buttock, 460  
 — elbow, 282  
 — hip, 468  
 — knee, 478  
 — shoulder, 240  
 — wrist, 270, 274  
 buttock, flattening of,
- cæcum, 326, 328  
 calcaneo-scapoid ligaments, 501  
 calcaneum, 508  
 canal, crural, 313  
 — Hunter's, 454, 458  
 — inguinal, 309  
 — of Nuck, 391  
 — of Schlemm, 90  
 canaliculi, 75  
 canals, semi-circular, 101  
 capsule, of Glisson, 336  
 — of Ténon, 77  
 — area, superficial, 165

## CIR

- Carden's amputation, 484  
 cardiac disease, 171  
 — murmurs, 171  
 — end of stomach, 319  
 — nerves, 224  
 caries of spine, 208, 210  
 carotid artery, common, 22  
 — — in thorax, 24  
 — — external, 26  
 — — internal, 33  
 — sheath, 24  
 — triangles, 10  
 — tubercle, 23  
 carpal arteries, 275  
 carpal joints, 288  
 carpus, 286  
 caruncula lachrymalis, 74  
 carunculæ myrtiformes, 402  
 castration, 435  
 cataract, 89  
 catheter, male, passing a, 418  
 — female, passing a, 419  
 — Eustachian, 100  
 catheterisation, rules for, 419  
 cauda equina, 213  
 cava inferior, 355  
 — superior, 187  
 cavernous sinus, 39  
 centres of medulla, 55  
 cephalhæmatoma, 7  
 cephalic vein, 238  
 cerebellar arteries, 43  
 cerebellum, 57  
 cerebral circulation, 42  
 — localisation, 48  
 — veins, 41  
 cerebro-spinal fluid, 38  
 cerebrum, 44  
 cervical cord, 218  
 — fascia, 1  
 — nerves, 143  
 — plexus, 143  
 — vertebræ, 205  
 cervicalis ascendens, 233  
 cervico-facial nerve, 66  
 cervix uteri, 392  
 cheek ligaments, 207  
 cheeks, 106  
 chest, 148  
 — tapping the, 190  
 Chopart's operation, 507  
 chorda tympani, 66  
 chordæ tendinæ, 16  
 chordee, 425  
 choroid, 85  
 ciliary arteries, 81  
 — muscle, 85  
 — nerves, 61  
 — processes, 85  
 circle of Willis, 43

## CIR

circumcision, 423  
 circumflex arteries of arm, 247  
 — — of thigh, 456  
 — iliac artery, 371  
 — nerve, 251  
 cirrhosis of liver, 336  
 clavicle, 225  
 clavus, 60  
 claw-fingers, 254  
 cleft palate, 108  
 clitoris, 402  
 club foot, 503  
 coccydynia, 362  
 coccygeal artery, 374  
 — gland, 355  
 coccygeus, 436  
 coccyx, 362  
 cochlea, 101  
 Cock's operation, 418  
 coeliac axis, 352  
 Colles's fracture, 282  
 colic, 315  
 colon, 325  
 colotomy in groin, 330  
 — — loin, 331  
 communicantes noni, 144  
 commissures, 54  
 concussion of brain, 44  
 condylar ridges, 236  
 condyles of femur, 449, 461  
 — — humerus, 236  
 congenital displacement of femur, 472  
 — hernia, 310  
 — hydrocele, 429  
 — sterno-mastoid tumour, 3  
 conjoined tendon, 304  
 conjunctiva, 73  
 constrictors of pharynx, 137  
 contracted muscles, 222  
 convolutions of brain, 45, 47  
 coracoid process, 235  
 — — ligaments of, 226  
 coraco-brachialis, 243  
 cord, spermatic, 433  
 — hydrocele of, 430  
 — spinal, 213  
 cornea, 83  
 corneitis, 84  
 coronal suture, 47  
 coronary arteries, 168  
 — sinus, 167  
 coronoid ligament, 226  
 — process, 284  
 corpus luteum, 399  
 — striatum, 53  
 costal cartilages, 149  
 costo-coracoid membrane, 240  
 cough, 95  
 Cowper's glands, 417  
 crack-pot sound, 200

## DIP

cranial nerves, 57  
 cranio-tabes, 16  
 cranium bifidum, 16  
 creases of palm, 269  
 cremaster, 304  
 cremasteric artery, 371  
 crepitation, 202  
 cribriform fascia, 313, 450  
 cricoid cartilage, 125  
 crico-thyroid membrane, 126  
 — muscle, 127  
 crista galli, 14  
 cruciform anastomosis, 373  
 crural arch, deep, 306  
 — canal, 313  
 — nerve, anterior, 358  
 — sheath, 313  
 crutch paralysis, 252  
 crus cerebri, 54  
 crusta, 54  
 cuboid bone, 508  
 cuneiform bones, 508  
 curves of spine, 207, 209  
 cut-throat, 36  
 cyphosis, 207  
 cystitis, 410  
 cystotomy, 445  
 cysts, dermoid, 102, 124  
 — of breast, 204  
 — of kidney, 348, 410  
 — of neck, 124  
 — of testicle, 431  
 dartos, 426  
 'death rattle,' 201  
 deep crural arch, 306  
 defecation, involuntary, 218  
 deglutition, 109  
 deltoid, 241  
 dental artery, inferior, 32  
 — — posterior, 32  
 — nerve, inferior, 63, 64  
 dentition, 113  
 dermoid cysts, 102, 124, 399, 420  
 descendens noni, 71  
 descent of testis, 428  
 development, general remarks upon,  
 123  
 diameters of pelvis, 364  
 diaphragm, 152  
 diastolic murmurs, 173  
 digastric muscle, 6  
 — region, 6, 27  
 dilatation of bronchus, 198  
 — — heart, 175  
 dimple near sacrum, 420  
 diploë, veins of, 40  
 diplopia, 59

## DIR

direct inguinal hernia, 310  
 diverticulum, 325  
 dorsal nerves, 150  
 — vein of penis, 425  
 dorsalis pedis, 494  
 — penis, 425, 442  
 — scapulæ, 247  
 Douglas, pouch of, 390  
 dropped wrist, 252  
 dropsy of abdomen, 316, 347  
 — — legs, 347  
 — — pleura, 189  
 — — scrotum, 426  
 Duchenne's disease, 71  
 duct, thoracic, 157  
 ductus arteriosus, 179  
 — venosus, 335  
 duodenum, 324  
 — ulcer of, 325  
 Dupuytren's contraction, 271  
 dura mater, arteries of, 41  
 — — of brain, 37  
 — — — cord, 213  
 — — venous sinuses of, 37  
 dysentery, 339, 387  
 dyspepsia, 319, 321  
 dyspnœa, 202

## ear, 93

— cough, 95  
 — development of, 102  
 — external, 93  
 — internal, 101  
 — middle, 95  
 — ring, 74  
 ear-ache, 94  
 ectopia, 318  
 ectropium, 73  
 ejaculatory ducts, 416  
 elbow joint, 265  
 — region of, 263  
 'election, seat of,' 485  
 embolism, 194  
 emissary veins of skull, 41  
 emmetropia, 85  
 emphysema, 196, 297  
 empyema, 190, 197  
 encephalon, 44  
 encysted hernia, 310  
 — hydrocele, 429, 430  
 endocardium, 165  
 entropium, 73  
 enuresis, 423  
 epiblast, 123  
 epicranial aponeurosis, 7  
 epididymis, 430  
 epididymitis, 432  
 epigastric artery, deep, 370  
 — — superficial, 455

## FILE

epiglottis, 126  
 epilepsy, 53  
 epispadias, 406  
 epistaxis, 121  
 eructation, 322  
 eruption of teeth, 113  
 ethmoid bone, 14  
 ethmoidal arteries, 81  
 Eustachian tube, 99  
 eversion of femur, 463  
 extensors of ankle, 488  
 — of wrist, 280  
 external abdominal ring, 302  
 — auditory meatus, 94  
 — carotid artery, 26  
 — iliac artery, 370  
 — mammary artery, 248  
 — thoracic nerves, 251  
 extravasation of urine, 439  
 eye-ball, excision of, 82  
 — lids, 72

## face, nerves of, 67, 145

facial artery, 29  
 — nerve, 65  
 — paralysis, 67  
 — vein, 34  
 fæcal fistula, 298  
 — impaction, 329  
 fæces, incontinence of, 218  
 Fallopian tube, 401  
 false passage, 417  
 falx, 39  
 fascia lata, 451  
 — lumborum, 304  
 fauces, 108  
 femoral artery, common, 454  
 — — deep, 456  
 — — ligation of, 458  
 — — superficial, 454  
 — hernia, 312  
 — veins, 457  
 femur, development of, 461  
 — dislocation of, 469  
 — fracture of, 461  
 fibula, 496, 498  
 fifth nerve, 60  
 filtration angle, 91  
 finger, amputation of, 290  
 fissure of anus, 386  
 — of Rolando, 45  
 — of Sylvius, 44, 46  
 fistula, branchial, 124  
 — fæcal, 298  
 — in ano, 438  
 — umbilical, 298  
 flat-foot, 502  
 flexors of ankle, 492  
 — — hand, 271

## FLE

- flexors of leg, 487  
 — thigh, 453  
 — toes, 488  
 foetal circulation, 166  
 — head, 365  
 fold of buttock, 460  
 fontanelles, 365  
 foot, 500  
 — amputations in, 507  
 — arteries of, 491, 494  
 — muscles of, 494, 501  
 — nerves of, 381, 382, 505  
 foramen of Majendie, 38  
 — — Monro, 56  
 forearm, arteries of, 275  
 — dislocation of, 266  
 — muscles of, 271  
 — nerves of, 252  
 — surface of, 268  
 foreign body in air-passage, 134  
 — — ear, 95  
 — — gullet, 140  
 fossa, ischio-rectal,  
 — subclavian, 9, 229  
 — of Rosenmüller, 101  
 fossettes, inguinal, 311  
 fourth nerve, 59  
 fracture, *see* special bone  
 — in a joint, 284  
 frænum linguæ, 114  
 friction-sound, 159  
 frontal artery, 81  
 — bone, 11  
 — sinus, 11  
 funicular process of peritoneum, 310,  
 428  
 — hydrocele, 429
- Gaertner, duct of, 399  
 galactoceles, 203  
 Galen, veins of, 40  
 gall-bladder, 340  
 ganglion, cervical, 224  
 — lenticular, 61  
 ganglionic cells, 218  
 Gasserian ganglion, 60  
 gastric catarrh, 320  
 — ulcer, 321  
 gastrocnemius, 487  
 gastrostomy, 323  
 gastrotomy, 323  
 generative organs, female, 389  
 — — male, 421  
 genito-crural nerve, 357  
 genu valgum, 479  
 Gimbernat's ligament, 302  
 glandulæ concatenatæ, 37  
 glans penis, 424  
 glaucoma, 91

## HUM

- glenoid cavity, 256  
 Glisson's capsule, 336  
 glosso-pharyngeal nerve, 68  
 glottis, 127  
 gluteal artery, 374  
 — bursæ, 460  
 — nerve, 379  
 — region, 374, 459  
 gluteus maximus, 460  
 goitre, 135  
 Graafian follicles, 399  
 great auricular nerve, 145  
 — occipital nerve, 143  
 — toe, 506  
 Gritti's amputation, 484  
 groin, 447  
 gubernaculum testis, 428  
 gums, 112  
 gustatory nerve, 63  
 gyri operati, 49
- hæmatemesis, 195, 321  
 hæmatocele, 367, 398, 430, 433  
 hæmatokolpos, 395  
 hæmoptysis, 195  
 hæmorrhoidal artery, 354, 373, 388,  
 442  
 hæmorrhoids, 388  
 hallux rigidus, 511  
 — valgus, 510  
 hammer-toe, 504  
 hamstring muscles, 450  
 hand, 269  
 hamular process, 107  
 hard palate, 107  
 hare-lip, 104  
 head, bones of, 11  
 heart, altered position of, 162, 163  
 — diseases of, 171  
 — marked on surface, 163  
 — situation of valves, 169  
 — sounds of, 169  
 heel, sore,  
 hemiplegia, 50  
 hepatic artery, 340, 352  
 — duct, 340  
 — cirrhosis, 336  
 — veins, 340, 356  
 hepatitis, 339  
 hermaphroditism, 421  
 hernia, *see* special variety  
 Herophili, torcular, 40  
 Hesselbach's triangle, 310  
 Hey's operation, 510  
 hip-joint, 465  
 — disease of, 467  
 — dislocation of, 469  
 housemaid's knee, 478  
 humerus, development of, 260

## HUM

humerus, dislocation of, 257  
 — fracture of, 260  
 — rotators of, 257  
 Hunter's canal, 454, 458  
 hydrocele, 429  
 — encysted, of testis, 431  
 — of neck, 124  
 hydrocephalus, 56  
 hydronephrosis, 348  
 hymen, 402  
 hyo-glossus, 115  
 hyoid bone, depressors of, 5  
 — — elevators of, 6  
 hypogastric artery, 372  
 — plexus, 224  
 hypoglossal nerve, 71  
 hypostatic pneumonia, 193  
 hypermetropia, 86  
 hypertrophy, 175  
 hypoblast, 123  
 hypospadias, 420

ileo-cæcal valve, 328  
 ileum, 324  
 iliac artery, common, 368  
 — — external, 370  
 — — internal, 372  
 — fascia, 307  
 — veins, 376  
 iliacus, 307  
 ilio-inguinal nerve, 356  
 ilio-lumbar artery, 375  
 ilio-tibial band, 448, 450, 452  
 imperforate rectum, 383  
 incontinence of fæces, 218  
 — — urine, 410  
 incus, 96  
 infantile hernia, 310  
 — hydrocele, 430  
 — paralysis, 219  
 infarction, 194  
 inferior dental artery, 32  
 — — nerve, 64  
 — maxilla, 19, 20  
 — profunda, 263  
 infra-clavicular region, 241  
 infra-maxillary nerve, 67  
 infra-orbital artery, 33  
 — nerve, 62  
 infundibuliform fascia, 306  
 inguinal canal, 309  
 — fossettes, 311  
 — hernia, 307, 310  
 — lymphatics, 451  
 — nerves, 356  
 inhibitory influence, 220  
 innominate artery, 182  
 — bone, 360  
 — veins, 186

## KNE

inter-articular fibro-cartilages, 473  
 intercolumnar fascia, 302  
 intercostal arteries, 156  
 — nerves, 151  
 intercosto-humeral nerve, 150, 239  
 intermaxillary bone, 17  
 internal abdominal ring, 306  
 — carotid artery, 33  
 — cutaneous nerve, 253  
 — iliac artery, 372  
 — jugular vein, 36  
 — mammary artery, 155  
 — maxillary artery, 32  
 — pudic artery, 438, 441  
 — — nerve, 379  
 — saphenous nerve, 358  
 — — vein, 450  
 interosseous arteries, 278  
 — membrane, 285  
 — nerves, 252, 254  
 irregular internal pudic, 442  
 intervertebral disc, 206  
 intestinal obstruction, 329  
 intestine, development of, 317  
 — large, 326  
 — small, 323  
 intracranial pressure, 50  
 intussusception, 329  
 iridectomy, 88  
 iris, 87  
 — structure of, 318  
 iritis, 88  
 ischio-rectal fossa, 363, 436  
 island of Reil, 49  
 isthmus of thyroid, 134

Jacksonian epilepsy, 53  
 Jacobson's nerve, 69  
 jaundice, 340  
 jaw, lower, 19  
 — upper, 17  
 jejunum, 324  
 joint, *see* special articulation  
 Jordan's amputation, 469  
 jugular vein, anterior, 36  
 — — external, 35  
 — — internal, 36

keratitis, 84  
 kidney, relations of, 343  
 — situation of, 333  
 — stone in, 349  
 — 'surgical,' 410  
 knee, bursæ about, 478  
 — region of, 449  
 — jerk, 221  
 knee-joint, 472  
 — — amputation at, 484

## KNE

knee-joint, excision of, 480  
 — pains at, 478  
 — structures around, 478  
 — synovial membrane of, 474  
 knock-knee, 479  
 kyphosis, 207

labia majora, 402  
 — minora, 402  
 labial arteries, 104  
 — hernia, 307  
 labio-glossal paralysis, 71  
 lachrymal apparatus, 75  
 — artery, 81  
 — bone, 19  
 — nerve, 61  
 large intestine, 326  
 — — arteries of, 330  
 laryngeal nerves, 70  
 laryngismus stridulus, 128  
 laryngoscopy, 129  
 laryngotomy, 130  
 larynx, 125  
 — removal of, 130  
 lateral curvature of spine, 207  
 — sacral artery, 375  
 — sinuses, 39  
 — ventricles, 56  
 latissimus dorsi, 242  
 left auricle, 167  
 — ventricle, 167  
 leg, back of,  
 — fascia of, 485  
 — front of,  
 lens, 88  
 lenticular ganglion, 61  
 lesser occipital nerve, 144  
 levator anguli scapulæ, 4  
 — ani, 438  
 — palati, 108  
 ligament, *see* special region  
 ligamentum nuchæ, 3  
 — patellæ, 450, 472  
 linea alba, 295  
 — semilunaris, 296  
 lineæ albicantes, 297  
 — transversæ, 206  
 lingual artery, 28  
 lingualis, 116  
 lips, 103  
 Lisfranc's amputation, 510  
 lithotomy, 443, 445  
 little finger, muscles of, 292  
 — toe, amputation of, 506  
 Littre's operation, 330  
 liver, 332  
 — pulsation in, 175  
 — stab of, 192, 335  
 lobes of brain, 45

## MEM

lobule of ear, 93  
 localisation, cerebral, 45  
 locomotor ataxy, 223  
 locus perforatus, 43, 49  
 longitudinal sinus, 39, 40  
 lordosis, 207, 468  
 lumbago, 210, 349, 351  
 lumbar aponeurosis, 304  
 — arteries, 355  
 — caries and renal calculus, 349  
 — fascia, 304  
 — glands, 376  
 — hernia, 211, 305  
 — nerves, 356  
 — plexus, 356  
 lumbo-sacral cord, 359  
 lumbricals, 273  
 lungs, outline of, 191, 193  
 — lobes of, 192  
 Luschka's gland, 355  
 lymphatics of abdomen, 376  
 — — groin, 451  
 — — neck, 37

macrostoma, 104  
 MacIntyre's splint, 462  
 Majendie, foramen of, 8  
 malar nerve, 62  
 malleoli, 496  
 malleus, 96  
 mammary gland, 202  
 margo acutus, 162  
 masseter, 7  
 mastoid cells, 12  
 — vein, 39  
 maxilla, inferior, 19  
 — superior, 17  
 — — excision of, 18  
 maxillary artery, 32  
 — nerve, inferior, 63  
 — — superior, 62  
 — — supra-, 67  
 measure, lower limb, 448  
 — upper limb, 236  
 meatus auditorius externus, 94  
 — — internus, 13  
 — of nose, 120  
 Meckel's diverticulum, 325  
 — ganglion, 63  
 median nerve, 253  
 — vein, 237  
 median basilic vein, 237  
 — cephalic vein, 238  
 — hare-lip, 105  
 — lithotomy, 445  
 mediastina, 153  
 medulla oblongata, 55  
 Meibomian glands, 74  
 membrana sacciformis, 285, 286

## MEM

- membrana tympani, 97  
 — — artificial, 98  
 membranes of brain, 37  
 — — spinal cord, 213  
 meningeal arteries, 32, 41, 42  
 meningocele, 12, 16, 119  
 mesenteric artery, inferior, 354  
 — — superior, 353  
 — veins, 337  
 mesentery, 325  
 mesial surface of hemisphere, 52  
 mesoblast, 123  
 metacarpal bones, 290  
 metallic tinkling, 201  
 metatarsal bones, 509  
 micturition centre, 411  
 middle meningeal artery, 32  
 — sacral artery, 355  
 miner's elbow, 282  
 mitral valve, 168  
 — — disease of, 173, 177  
 monoplegia, 50  
 Monro, foramen of, 56  
 mons Veneris, 296, 402  
 motor area of brain, 48, 52  
 — oculi, 58  
 mouth, 103  
 — development of, 104  
 mucous polypi, nasal, 121  
 mumps, 118  
 murmurs, cardiac, 171  
 muscæ, 90  
 muscular atrophy, 219  
 muscoli papillares, 167  
 — pectinati, 167  
 musculo-cutaneous nerve, 255, 381  
 musculo-spiral nerve, 251  
 — — paralysis, 252  
 mylo-hyoid artery, 32  
 — — muscle, 6  
 — — nerve, 64  
 myopia, 86  
  
 nares, plugging, 122  
 — posterior, 122  
 nasal artery, 81  
 — duct, 76  
 — fossa, 119  
 — nerve, 61  
 — polypi, 121  
 nates, fold of, 460  
 neck of child, 132  
 — triangles of, 9  
 — venous pulse in, 174  
 Nélaton's line, 447  
 nephritis, 346  
 ninth nerve, 71  
 nipple, 202  
 nose, 119  
 — bleeding, 121

## OVI

- nose, development of, 122  
 note on development generally, 123  
 Nuck, canal of, 391  
 nutmeg liver, 337  
 nymphæ, 402  
  
 oblique inguinal hernia, 307, 310  
 — muscles of abdomen, 302  
 — — — orbit, 78  
 obturator artery, 373  
 — — irregular, 371  
 — fascia, 364  
 — hernia, 314  
 — nerve, 358  
 — plexus, 359  
 occipital artery, 30  
 — bone, 15  
 — nerves, 14  
 — sinus, 15  
 — triangle, 10  
 occipito-frontalis, 7  
 oculi tendo, 73  
 œdema of ankles, 178  
 — — eyelids, 72  
 — — glottis, 129  
 œsophagotomy, 140  
 œsophagus, 136  
 olecranon, fracture of, 284  
 olfactory nerve, 57  
 omentum, 316  
 omo-hyoid, 5  
 onyx, 84  
 ophthalmic artery, 81  
 — ganglion, 61  
 — nerve, 61  
 — vein, 82  
 optic disc, 93  
 — nerve, 57  
 — thalamus, 54  
 orbicularis oris, 103  
 — palpebrarum, 72  
 orbit, 76  
 — fascia (cf. 77  
 — muscles of, 78  
 orbital fissure, 76, 124  
 orchitis, 416, 432, 435  
 os calcis, 508  
 os innominatum, 360  
 — uteri, 392  
 ossicles, 56  
 osteo-arthritis, 243, 465  
 otitis, 98  
 ovariectomy, 400  
 ovaritis, 400  
 ovary, 398  
 — artery of, 354  
 — tumour of, 399  
 — veins of, 356  
 oviduct, 401

## PAC

Pacchionian bodies, 38  
 pains over chest, 153  
 — peripheral, 209  
 palate, cleft, 108  
 — hard, 19, 107  
 — soft, 107  
 — — muscles of, 108  
 palatine artery, 33  
 palm, 269  
 palmar arch, deep, 277  
 — — superficial, 279  
 — fascia, 271  
 palmaris brèves, 292  
 palpebral artery, 81  
 pampiniform plexus, 433  
 pancreas, 300, 342  
 paracentesis abdominis, 317  
 — pericardii, 161  
 — thoracis, 190  
 — tympani, 97  
 paralysis, cerebral, 50  
 — infantile, 219  
 — spinal, 222  
 paraphimosis, 422  
 paraplegia, 222  
 parietal bone, 16  
 — and visceral anastomoses, 309  
 parotid gland, 117  
 parovarium, 399  
 parturition, 366  
 patella, 475  
 patellar reflex, 221  
 — plexus, 358  
 patheticus, 59  
 pectiniform septum, 424  
 pectoralis major, 239  
 — minor, 240  
 pectoriloquy, 201  
 pedicle, ovarian, 391  
 pelvic glands, 376  
 — fascia, 363  
 — viscera, 382  
 pelvis, 360  
 — fracture of, 362  
 penis, 421  
 — arteries of, 442  
 — muscles of, 440  
 — nerves of, 379, 425  
 — vein of, 377, 425  
 percussion of chest, 199  
 perforating arteries, 456  
 pericarditis, 158  
 pericardium, 158  
 pericranium, 7  
 perineal abscess, 439  
 — hernia, 314  
 perineum, female, 445  
 — male, 438  
 peripheral pains, 209  
 peritoneum, 314

## POS

peritonitis, 315  
 perityphlitis, 327  
 peroneal artery, 490, 491  
 — nerve, 381  
 — reflex, 221  
 peronei, 492  
 pes anserinus, 65  
 — cavus, 504  
 Petit's triangle, 305  
 petrosal nerve, 63  
 — sinus, 39  
 petrous bone, 13  
 Peyer's patches, 324  
 phantom tumour, 296  
 — ulcers, 392  
 pharyngeal artery, 31  
 — plexus, 138  
 pharynx, 136  
 phimosis, 422  
 phlebotomy, 237  
 phrenic artery, 352  
 — nerve, 147  
 phthisis, 198  
 pia mater, 38  
 pigeon-breast, 150  
 piles, 388  
 pinna, 93  
 Pirogoff's amputation, 500  
 planes of pelvis, 364  
 plantar arch, 491  
 — arteries, 491  
 — fascia, 500  
 — ligaments, 501  
 — nerves, 381  
 platysma myoides, 1  
 pleura, 187  
 pleurisy, 188  
 pleurodynia, 153, 184  
 plexus gulæ, 139  
 plica semilunaris, 74  
 pneumogastric nerve, 69  
 pneumonia, 192  
 — hypostatic, 193  
 pneumothorax, 191, 197  
 pons Varolii, 54  
 polio-myelitis, 219  
 popliteal artery, 481  
 — nerves, 380, 381  
 — — paralysis of, 382  
 — space, 480  
 — vein, 483  
 popliteus, 480  
 Porro's operation, 392  
 portal vein, 337  
 portio dura, 65  
 positions of cardiac valves, 169  
 post-pharyngeal abscess, 210  
 posterior auricular artery, 30  
 — — nerve, 66  
 — interosseous nerve, 252



## POS

- posterior scapular artery, 233  
 — tibial artery, 489  
 — — nerve, 381  
 Pott's fracture, 496  
 Poupart's ligament, 302, 447  
 pregnancy, 394  
 presbyopia, 86  
 presystolic murmur, 173  
 priapism, 425  
 profunda femoris, 456  
 prolapsus ani, 387  
 — uteri, 397  
 pronator radii teres, 271  
 — quadratus, 274  
 prostate, 412  
 — veins of, 377  
 psoas, abscess of, 308  
 — muscle, 307  
 pterygium, 74  
 pterygoid muscles, 8  
 pterigo-maxillary ligament, 106  
 pubic artery, 371  
 — spine, 302  
 pudendal hernia, 307  
 — nerve, 379  
 pudic artery, external, 455  
 — — internal, 441  
 — — irregular, 442  
 — nerve, 379  
 pulmonary apoplexy, 195  
 — artery, 167, 184, 198  
 — plexus, 199  
 — valve, 167  
 — veins, 195  
 puncta lachrymalia, 75  
 puncture of bladder, 407  
 pupil, contraction of, 58  
 — artificial, 88  
 pyloric artery, 352  
 pylorus, 319  
 — dilatation of, 323  
 — stricture of, 322  
 pyo-pneumo-thorax, 197

quadratus lumborum, 305  
 quadriceps extensor, 453  
 quinsy, 112

- radial artery, 275  
 — nerve, 251  
 — vein, 237  
 radical treatment of hernia, 306  
 radio-carpal joint, 285  
 — ulnar joint, 266  
 radius, 282  
 — head of, 236  
 ranine artery, 28  
 ranula, 117  
 rectocele, 404

## SCA

- recto-vesical fascia, 363, 437  
 — — pouch, 384  
 rectum, 382  
 rectus abdominis, 304  
 — femoris, 453  
 recurrent laryngeal nerve, 70  
 réduction en masse, 312  
 reduplication of sound, 171  
 reflexes exaggerated, 209  
 — of cord, 219, 220  
 — lost, 220  
 Reil, island of, 49  
 region of Broca, 49  
 renal calculus, 349  
 — vessels, 354, 356  
 respiration, 193  
 respiratory pulse in neck, 175  
 — sounds, 200  
 restiform bodies, 55  
 retention of urine, 409  
 retina, 92  
 retro-pharyngeal abscess, 210  
 rhomboid ligament, 225  
 ribs, 149  
 rider's bone, 449  
 right auricle, 165  
 — lymphatic duct, 158  
 — ventricle, 167  
 rima glottidis, 127  
 ring, abdominal, 302, 306  
 Rolando, fissure of, 45  
 root of lung, 194  
 round ligament, 402  
 Rosenmüller, fossa of, 101  
 — organ of, 399  
 rotators, internal, of thigh, 448
- sac of hernia, 316  
 sacra media, 376  
 sacral dimple, 420  
 — nerves, 378  
 — tumour, 204  
 sacro-iliac joint, 360  
 sacro-sciatic ligaments, 361  
 sacro-vertebral angle, 361  
 sacrum, 362  
 saphenous nerve, external, 380  
 — — internal, 358  
 — opening, 452  
 — vein, long, 450  
 — — short, 481  
 sartorius, 453  
 scaleni, 141  
 scalp, 7  
 — arteries of, 30, 31, 81  
 — lymphatics of, 37  
 — nerves of, 62, 67, 145  
 — veins of, 35  
 scapula, 227  
 — luxation of, 241

## SCA

Scarpa's triangle, 454  
 Schlemm, canal of, 90  
 sciatic artery, 373  
 — nerves, 379, 390  
 scirrhus mammae, 203  
 sclerotic, 82  
 scrotum, 426  
 — development of, 420  
 'seat of election,' 485  
 see-saw murmur, 174  
 semilunar cartilages, 473  
 — valves, 168  
 sensory area of cortex, 53  
 septum crurale, 308, 313  
 — pectiniforme, 424  
 serratus magnus, 241  
 seventh nerve, 65  
 sheath of rectus, 304  
 shingles, 151, 302  
 shoulder, 225, 235  
 — bursae at, 240  
 — dislocations, 258  
 — pains at, 339  
 — joint, 256  
 sigmoid flexure, 326  
 sinuses of dura, 39  
 — — Morgagni, 137  
 site of spinal nerves, 214  
 sixth nerve, 65  
 skull, fracture of, 13  
 — topography of, 45  
 small intestine, 324  
 snuffles, 121  
 soft palate, 107  
 solar plexus, 224  
 sole of foot, 500  
 soleus, 486  
 sounds of heart, 169  
 — morbid, 171  
 spasmodic stricture, 417  
 spastic rigidity, 222  
 spermatic artery, 354, 432  
 — cord, 431  
 — nerves, 435  
 — veins, 355, 433  
 spermatorrhœa, 416, 436  
 sphenoid bone, 14  
 sphincter ani veins, 212, 386  
 spina bifida, 204  
 spinal abscess, 210  
 — accessory nerve, 70  
 — arteries, 232  
 — cord, 213  
 — curvature, 207  
 — ligaments, 206  
 — nerves, 214  
 — reflexes, 219  
 — veins, 212  
 spine, 20  
 — caries of, 208

## SYL

spine, ligaments of, 206  
 — of pubes, 302, 447, 453  
 spinous processes, 205  
 splanchnics, 224  
 spleen, 341  
 splenic artery, 353  
 spongy part of urethra, 417  
 stapedius, 97  
 stapes, 96  
 Stenson's duct, 118  
 sterno-clavicular joint, 225  
 sterno-hyoid, 5  
 sterno-mastoid, 3  
 sternum, 148  
 stiff great-toe, 511  
 stomach, 318  
 stomach-cough, 322  
 stone in bladder, 411  
 — — kidney, 349  
 strabismus, 80  
 stricture, 417  
 styte, 74  
 styloid process, 14  
 stylo-maxillary ligament, 2  
 subarachnoid space, 38  
 sub-astragaloid amputation, 505.  
 subclavian artery, 228  
 — fossa, 241  
 — triangle, 9  
 — vein, 234  
 subclavius, 240  
 subdural space, 38  
 sublingual artery, 28  
 — gland, 119  
 submaxillary triangle, 10  
 — gland, 118  
 sub-peritoneal fat, 308  
 subscapular artery, 247  
 — nerves, 251  
 subscapularis, 242  
 succussar, 201  
 superficial cardiac area, 165  
 superior intercostal artery, 157  
 — laryngeal nerve, 70  
 — maxilla, 17  
 — maxillary nerve, 62  
 — thyroid artery, 28  
 — vena cava, 187  
 supinator longus, 271  
 — brevis, 281  
 supra-clavicular nerves, 146  
 supra-maxillary nerve, 67  
 supra-renal bodies, 350  
 supra-orbital artery, 81  
 — nerve, 61  
 supra-scapular artery, 233  
 supra-trochlear nerve, 61  
 'surgical kidney,' 410  
 suspension in spinal disease, 212.  
 Sylvius, aqueduct of, 56

## SYL

Sylvius, fissure of, 44, 46  
 Syme's amputation, 499  
 symmetrical pains, 210  
 sympathetic nerves, 223  
 — — of pelvis, 376  
 symphysis pubis, 447  
 synechia, 88  
 synovial sheaths at wrist, 274  
 synovitis of knee, 474

tailor's bursa, 360, 496  
 talipes, 503  
 tapping abdomen, 295, 296, 317  
 — pericardium, 161  
 — pleura, 190  
 tarsal cartilage, 72  
 tarso-metatarsus, 509  
 tarsotomy, 503  
 tarsus, 508  
 teeth, 112  
 tegmentum, 54  
 temporal artery, deep, 32  
 — — superficial, 31  
 — bone, 12  
 — fascia, 8  
 — muscle, 8  
 — nerves, 62, 67  
 — vein, 34  
 temporo-facial nerve, 66  
 temporo-maxillary joint, 20  
 — — vein, 34  
 temporo-sphenoidal lobe, 48  
 tendo oculi, 73  
 tendon of Achilles, 487  
 — reflex, 220  
 tendons of wrist, 270  
 Ténon, capsule of, 77  
 tensor palati, 108  
 — tympani, 96  
 tentorium, 39  
 teres muscles, 242  
 testis, 426  
 — vessels of, 432  
 tetanus, 8  
 thalami optici, 54  
 thigh, 447  
 third nerve, 58  
 thoracic aneurysm, 180, 184  
 — aorta, 184  
 — arteries, 156  
 — duct, 157  
 — nerves, 150  
 thorax, 148  
 — upper opening of, 153  
 thumb, amputation of, 290  
 — ball of, 269, 292  
 — dislocation of, 290  
 — extensors of, 281

## TUB

thymus gland, 154  
 thyro-hyoid membrane, 126  
 — — muscle, 5  
 thyroid artery, inferior, 233  
 — axis, 233  
 — — superior, 28  
 — body, 134  
 — cartilage, 125  
 — veins, 36, 185, 186  
 — — inferior, 187  
 thyroidea ima, 182  
 thyrotomy, 130  
 tibia, 495  
 — threefold displacement of, 477  
 tibial artery, anterior, 492  
 — — posterior, 488  
 — muscles, 492  
 — nerve, anterior, 381, 382  
 — — posterior, 381  
 tic, 60  
 tight lacing, 300  
 tinkling, metallic, 201  
 toe, great, amputation of, 505  
 toes, supplies of the, 505  
 tongue, 114  
 — excision of, 116  
 tongue-centres, 51  
 tonsils, 111  
 torcular Herophili, 39  
 torticollis, 3  
 trachea, 131  
 tracheotomy, 131  
 tragus, 93  
 transversalis muscle, 304  
 — fascia, 305  
 transverse cervical artery, 233  
 — — nerve, 145  
 — colon, 326  
 — section of cord, 221  
 trapezius, 2  
 trapezoid ligament, 226  
 triangle, at elbow, 263  
 — occipital, 9  
 — Scarpa's, 454  
 — subclavian, 9  
 triangles of neck, 9  
 triangular ligament, 441  
 — fibro-cartilage, 285  
 triangularis sterni, 148  
 triangle of Petit, 305  
 triceps, 244  
 tricuspid valve, 167  
 — — disease of, 172  
 trifacial nerve, 60  
 trigone, 408  
 trismus, 8  
 trochanter, bursa of, 460  
 — fracture of, 465  
 tube, Eustachian, 99  
 — Fallopian, 401

## TUB

- tuber annulare, 54  
 — ischii, 363  
 tunica vaginalis, 310, 428  
 tympani, membrana, 97  
 tympanum, 95
- ulcer of duodenum, 325  
 — — stomach, 321  
 ulna, 282  
 ulnar artery, 277  
 — nerve, 253  
 — veins, 237  
 umbilical hernia, 298  
 umbilicus, 297  
 upper extremity, 235  
 urachus, 298, 406  
 ureter, 344, 349  
 urethra, female, 403, 419  
 — male, 415  
 urethral triangle, 439  
 urine, incontinence of, 423  
 uterine artery, 373  
 uterus, 389  
 uvea, 87  
 uvula, 110  
 — of bladder, 409
- vagina, 403  
 vaginal artery, 373  
 — hernia, 314, 405  
 vaginismus, 404  
 vagus, 69  
 Valsalva, sinus of, 168  
 valve, ileo-cæcal, 328  
 valves of heart, 169  
 valvular disease, effects of, 177  
 varicocele, 433  
 varicose aneurysm, 238  
 Varolii, pons, 54  
 vas aberrans, 247  
 — deferens, 431  
 vasti, 453  
 veins at elbow, 237  
 — of Galen, 40  
 — — pelvis, 377  
 velum interpositum, 39  
 vena azygos, 154  
 — cava, inferior, 355  
 — — superior, 187  
 — portæ, 337

## ZYG

- vena salvatella, 237  
 venæ vorticossæ, 85  
 venæsection, 237  
 Veneris, mons, 402  
 venous pulse in neck, 174  
 — sinuses, 39  
 ventral hernia, 298  
 ventricles of brain, 38  
 — — heart, 167  
 verniform process, 327  
 vertebra, fifth cervical, 23  
 — prominens, 205  
 vertebræ, 205  
 vertebral artery, 231  
 — vein, 232  
 vertigo, aural, 101  
 veru montanum, 416  
 vesical arteries, 373  
 vesicocele, 404  
 vesicula seminalis, 436  
 vesicular breathing, 200  
 vestibule of ear, 101  
 Vidian artery, 33  
 — nerve, 63  
 vitreous, 89  
 vocal cords, 127  
 — fremitus, 200  
 voice-sounds, 201  
 volvulus, 326  
 vomiting, 321
- water-hammer pulse, 174  
 Wharton's duct, 118  
 Willis, circle of, 43  
 wind-pipe, opening the, 129  
 Wolfian body, 399  
 Wrisberg, nerve of, 253  
 wrist-drop, 252  
 — tendons of, 270  
 — joint, 285  
 — — excision of, 287  
 — — tendons around, 270, 287  
 wry-neck, 3
- yellow spot, 93
- zones, abdominal, 299  
 zoster, 302  
 zygomatici, 106


# MEDICAL AND SURGICAL WORKS.

---

---


- A DICTIONARY OF MEDICINE.** By Various Writers.  
Edited by R. QUAIN, M.D. F.R.S. &c. Fifteenth Thousand. With  
138 Woodcuts. Medium 8vo. 31s. 6d. cloth, or 40s. half-russia; to  
be had also in 2 vols. 34s. cloth.
- THE SCIENCE AND ART OF SURGERY :** being a Treatise  
on Surgical Injuries, Diseases, and Operations. By JOHN ERIC  
ERICHSEN, F.R.S. With 1,025 Illustrations. 2 vols. 8vo. 48s.
- QUAIN'S ELEMENTS OF ANATOMY.** The Ninth Edition.  
Re-edited by ALLEN THOMSON, M.D. LL.D. F.R.SS. L. & E.  
EDWARD SCHÄFER, F.R.S. and GEORGE DANCER THANE. With  
upwards of 1,000 Illustrations engraved on Wood, of which many are  
Coloured. 2 vols. 8vo. 18s. each.
- ANATOMY, DESCRIPTIVE AND SURGICAL.** By HENRY  
GRAY, F.R.S. late Lecturer on Anatomy at St. George's Hospital.  
With 569 Woodcut Illustrations, a large number of which are Coloured.  
Re-edited by T. PICKERING PICK. Royal 8vo. 36s.
- NOTES ON PHYSIOLOGY FOR THE USE OF STUDENTS  
PREPARING FOR EXAMINATION.** With 134 Woodcuts. By  
HENRY ASHBY, M.D. Lond. Fcp. 8vo. 5s.
- THE ESSENTIALS OF HISTOLOGY.** Descriptive and  
Practical. For the use of Students. By E. A. SCHÄFER, F.R.S.  
With 281 Illustrations. 8vo. 6s. or Interleaved with Drawing Paper,  
8s. 6d.
- THE HANDBOOK FOR MIDWIVES.** By HENRY FLY  
SMITH, M.B. Oxon. M.R.C.S. late Assistant-Surgeon to the Hospital  
for Sick Women, Soho Square. With 41 Woodcuts. Crown 8vo. 5s.
- CLINICAL LECTURES AND ESSAYS.** By Sir JAMES  
PAGET, Bart. F.R.S. D.C.L. &c. Edited by F. HOWARD MARSH,  
Assistant-Surgeon to St. Bartholomew's Hospital. 8vo. 15s.
- LECTURES ON SURGICAL PATHOLOGY.** By Sir JAMES  
PAGET, Bart. F.R.S. D.C.L. &c. Re-edited by the AUTHOR and  
W. TURNER, M.B. 8vo. with 131 Woodcuts, 21s.
- A MANUAL OF PATHOLOGY.** By JOSEPH COATS, M.D.  
Pathologist to the Western Infirmary and the Sick Children's Hospital,  
Glasgow. With 364 Illustrations engraved on Wood. 8vo. 31s. 6d.
- HANDBOOK ON DISEASES OF THE SKIN.** With espe-  
cial reference to Diagnosis and Treatment. By ROBERT LIVEING,  
M.A. and M.D. Cantab. Fifth Edition, revised and enlarged.  
Fcp. 8vo. 5s.

- A TREATISE ON GOUT AND RHEUMATIC GOUT (RHEUMATOID ARTHRITIS). By Sir ALFRED BARING GARROD, M.D. F.R.S. With 6 Plates, comprising 21 Figures (14 Coloured), and 27 Illustrations engraved on Wood. 8vo. 21s.
- THE ESSENTIALS OF MATERIA MEDICA AND THERAPEUTICS. By Sir ALFRED BARING GARROD, M.D. F.R.S. New Edition, revised and adapted to the New Edition of the British Pharmacopœia, by NESTOR TIRARD, M.D. Crown 8vo. 12s. 6d.
- A TREATISE ON THE CONTINUED FEVERS OF GREAT BRITAIN. By CHARLES MURCHISON, M.D. LL.D. &c. Revised by W. CAYLEY, M.D. Physician to the Middlesex Hospital. 8vo. with numerous Illustrations, 25s.
- CLINICAL LECTURES ON DISEASES OF THE LIVER, JAUNDICE, AND ABDOMINAL DROPSY. By CHARLES MURCHISON, M.D. LL.D. &c. Revised by T. LAUDER BRUNTON, M.D. and Sir JOSEPH FAYRER, M.D. 8vo. with 43 Illustrations, 24s.
- PULMONARY CONSUMPTION: its Etiology, Pathology, and Treatment. With an Analysis of 1,000 Cases to Exemplify its Duration and Modes of Arrest. By C. J. B. WILLIAMS, M.D. LL.D. F.R.S. F.R.C.P. and CHARLES THEODORE WILLIAMS, M.A. M.D. Oxon. F.R.C.P. Second Edition, enlarged and re-written by Dr. C. THEODORE WILLIAMS. With 4 Coloured Plates and 10 Woodcuts. 8vo. 16s.
- ON RENAL AND URINARY AFFECTIONS. By W. HOWSHIP DICKINSON, M.D. Cantab. F.R.C.P. &c. With 12 Plates and 122 Woodcuts. 4 vols. 8vo. £3. 4s. 6d.
- GUNSHOT INJURIES; their History, Characteristic Features, Complications, and General Treatment. By Surgeon-General Sir T. LONGMORE, C.B. F.R.C.S. With 58 Illustrations. 8vo. 31s. 6d.
- THE DIAGNOSIS AND TREATMENT OF DISEASES OF WOMEN, INCLUDING THE DIAGNOSIS OF PREGNANCY. By GRAILY HEWITT, M.D. New Edition, in great part re-written and much enlarged, with 211 Engravings on Wood. 8vo. 24s.
- LECTURES ON THE DISEASES OF INFANCY AND CHILDHOOD. By CHARLES WEST, M.D. &c. 8vo. 18s.
- THE DISEASES OF CHILDREN, MEDICAL AND SURGICAL. By HENRY ASHBY, M.D. Lond. Physician to the General Hospital for Sick Children, Manchester; and G. A. WRIGHT, B.A. M.B. Oxon. Assistant Surgeon to the Manchester Royal Infirmary. With 138 Illustrations. 8vo. 21s.
- A TEXT-BOOK OF ORGANIC MATERIA MEDICA. Comprising a Description of the Vegetable and Animal Drugs of the British Pharmacopœia, with other non-official Medicines, arranged systematically and especially designed for the use of Students. By ROBERT BENTLEY, M.R.C.S. Eng. F.L.S. With 62 Illustrations on Wood. Crown 8vo. 7s. 6d.









1872

1873

1874

1875

1876

1877

1878

1879

1880

1881

1882

1883

1884

1885

1886

1887

1888

1889

1890

1891

1892

1893

1894

1895

1896

1897

1898

1899

1900

1901

1902

1903

1904

1905

1906

1907

1908

1909

1910

1911

1912

1913

1914

1915

1916

1917

1918

1919

1920

1921

1922

1923

1924

1925

1926

1927

1928

1929

1930

1931

1932

1933

1934

1935

1936

1937

1938

1939

1940

1941

1942

1943

1944

1945

1946

1947

1948

1949

1950

1951

1952

1953

1954

1955

1956

1957

1958

1959

1960

1961

1962

1963

1964

1965

1966

1967

1968

1969

1970

1971

1972

1973

1974

1975

1976

1977

1978

1979

1980

1981

1982

1983

1984

1985

1986

1987

1988

1989

1990

1991

1992

1993

1994

1995

1996

1997

1998

1999

2000

2001

2002

2003

2004

2005

2006

2007

2008

2009

2010

2011

2012

2013

2014

2015

2016

2017

2018

2019

2020

2021

2022

2023

2024

2025

2026

2027

2028

2029

2030

2031

2032

2033

2034

2035

2036

2037

2038

2039

2040

2041

2042

2043

2044

2045

2046

2047

2048

2049

2050

2051

2052

2053

2054

2055

2056

2057

2058

2059

2060

2061

2062

2063

2064

2065

2066

2067

2068

2069

2070

2071

2072

2073

2074

2075

2076

2077

2078

2079

2080

2081

2082

2083

2084

2085

2086

2087

2088

2089

2090

2091

2092

2093

2094

2095

2096

2097

2098

2099

2100

2101

2102

2103

2104

2105

2106

2107

2108

2109

2110

2111

2112

2113

2114

2115

2116

2117

2118

2119

2120

2121

2122

2123

2124

2125

2126

2127

2128

2129

2130

2131

2132

2133

2134

2135

2136

2137

2138

2139

2140

2141

2142

2143

2144

2145

2146

2147

2148

2149

2150

2151

2152

2153

2154

2155

2156

2157

2158

2159

2160

2161

2162

2163

2164

2165

2166

2167

2168

2169

2170

2171

2172

2173

2174

2175

2176

2177

2178

2179

2180

2181

2182

2183

2184

2185

2186

2187

2188

2189

2190

2191

2192

2193

2194

2195

2196



