

COLUMBIA LIBRARIES OFFSITE
HEALTH SCIENCES STANDARD



HX00019828

RECAP


Columbia University
in the City of New York

College of Physicians and Surgeons
Library



Digitized by the Internet Archive
in 2010 with funding from
Open Knowledge Commons

MANUAL OF ANATOMY
SYSTEMATIC AND PRACTICAL, INCLUDING
EMBRYOLOGY



MANUAL OF ANATOMY

SYSTEMATIC AND PRACTICAL, INCLUDING
EMBRYOLOGY

BY

A. M. BUCHANAN, M.A., M.D., C.M., F.R.F.P.S. GLAS.

PROFESSOR OF ANATOMY IN ANDERSON'S COLLEGE, GLASGOW; EXAMINER IN ANATOMY FOR THE TRIPLE QUALIFICATION OF THE SCOTTISH LICENSING BODIES; EXAMINER IN ANATOMY FOR THE DENTAL DIPLOMA, AND EXAMINER IN ANATOMY (HUMAN AND COMPARATIVE) FOR THE FELLOWSHIP, OF THE ROYAL FACULTY OF PHYSICIANS AND SURGEONS OF GLASGOW; EX-EXAMINER IN ANATOMY TO THE UNIVERSITY OF GLASGOW; FORMERLY SENIOR DEMONSTRATOR OF ANATOMY IN THE UNIVERSITY OF GLASGOW.

SECOND EDITION

VOL. I.

WITH 266 ILLUSTRATIONS, MOSTLY ORIGINAL AND IN COLORS

ST. LOUIS
C. V. MOSBY COMPANY

1914

MAR 7 1946 GMK

DEDICATED BY PERMISSION


TO

THE RIGHT HONOURABLE LORD LISTER,

O.M., LL.D., D.C.L., F.R.S., Etc.,

IN GRATEFUL ACKNOWLEDGMENT OF THE
POWERFUL INFLUENCE WHICH HE EXERCISED OVER THE
INTELLECTUAL CULTURE OF HIS GLASGOW STUDENTS, OF WHOM
THE AUTHOR WAS ONE.

3/5/46
H. H. H. H. H.



PREFACE TO SECOND IMPRESSION

THE First Edition of this Manual has been so favourably received, and was published such a short time ago, that it has seemed unnecessary to make any very important alterations, or to effect a thorough and complete revisal in the meantime, in view of the early call for a Second Edition. In reprinting this Second Impression it has been considered advisable not to allow the Manual to remain out of print (as a revised edition throughout would necessitate), it being the only text-book of its kind which adheres to the old anatomical nomenclature.

The feeling among many teachers of anatomy seems to be setting against the adoption of the Basle nomenclature in its entirety. Moreover, among students there is a great deal of dissatisfaction at its use on account of its being so cumbrous, and occasionally not quite accurate. It has therefore been considered advisable to retain the old nomenclature, which is so simple and so correct for all practical purposes, until such time as a standard nomenclature has been fixed and generally accepted. The Appendix containing a large number of the terms of the Basle nomenclature has, however, been retained for the use of those who may desire to refer to it.

The errata and omissions, noted in the First Edition, have been put right, and certain critical remarks have received willing attention.

The subject of the ossification of bones, now so much modified, has been made more in conformity with the views of recent investigators, and in certain cases will be doubtless more acceptable to students than previous accounts.

ANDERSON'S COLLEGE, GLASGOW,
May, 1914.

PREFACE TO FIRST EDITION

IN the preparation of this work the object of the author has been to combine a manual of practical anatomy with a text-book of systematic anatomy, and so furnish students with a complete treatise on the subject, written entirely by himself.

The section on osteology is treated of in an exhaustive manner, and an account of the ossification of each bone follows its description.

The joints are described in the order in which they are met with in the course of dissection. Each of the sections of the upper limb, lower limb, abdomen, thorax, and head and neck has appended to it a complete guide to its dissection, giving full information as to the manner in which the dissections should be carried out, and detailing the structures which should be exposed.

The minute anatomy of the viscera and organs is fully described, and illustrated by drawings from microscopical preparations in the possession of the author.

Special sections are devoted to the nervous system, the eye, the ear, and the nose, and these are also fully illustrated.

The subject of embryology is dealt with by appending to the description of each viscus and organ a concise account of its development, in the hope that this method may enlist the attention of students in this very important subject.

The work is amply illustrated by drawings which have been executed by the well-known anatomical artist, Mr. James T. Murray, of Edinburgh, who has done his work with the greatest care and excellence, and whom the author desires to thank cordially. Most of the drawings are coloured (many of them in three tints), and the drawings of the bones have the origins and insertions of the muscles delineated in different colours, the origins being in red and the insertions in blue. The majority of the drawings have been specially executed for this work, and the sources from which the others have been taken are duly acknowledged. The author begs

to thank all who have generously and kindly granted permission to use their drawings.

Throughout the whole of the work the author, from his long experience, not only as a teacher but also as an examiner on various Boards, has kept constantly in view the examinational requirements of students, for whom this work is specially intended.

He has to acknowledge with deep gratitude the valuable assistance which he has received from Dr. J. Archibald Campbell, Senior Demonstrator of Anatomy in Anderson's College, and from Mr. Hugh F. Watson, Junior Demonstrator. He has also gratefully to thank the publishers for the immense amount of labour which they have kindly undertaken in various directions, for the very great care which they have bestowed upon the publication of this work, and for their uniform courtesy. Finally, he has gratefully to thank Mr. Alexander Duncan, B.A., LL.D., Librarian to the Faculty of Physicians and Surgeons of Glasgow, for many acts of kind and much appreciated aid.

ANDERSON'S COLLEGE, GLASGOW,


May, 1906.

ERRATA

- Page 40, line 29, *for* vertical *read* vertebral.
- „ 112, „ 22, *for* mesaticocephalic *read* mesaticcephalic.
- „ 134, „ 3, *for* zygomatic *read* external.
- „ 875, „ 14 from bottom, *for* thyroid *read* thymus.
- „ 918, „ 4 from bottom, *for* vestibuli *read* terminalis.
- „ 1033, „ 3 and 4 from bottom, transpose “prevertebral” and
“pretracheal.”
- „ 1303, „ 26, *for* cinerea *read* terminalis.
- „ 1318, „ 2 from bottom, *for* cinerea *read* terminalis.
- „ 1325, „ 18 and 20, *for* cinerea *read* terminalis.

CONTENTS

	PAGE
Osteology - - - - -	1
Arthrology - - - - -	260
Upper Limb - - - - -	386
Guide to dissection of the upper limb - - -	386
Lower Limb - - - - -	399
Guide to dissection of the lower limb - - -	556



A MANUAL OF ANATOMY

OSTEOLOGY

THE skeleton is the hard 'dry' osseous and cartilaginous framework of the body. It consists in the adult of 200 bones, exclusive of the small bones of the ear and sesamoid bones, most of which are held together by ligaments. The functions of the bones are as follows: (1) they impart shape to the body; (2) they support the soft parts; (3) they protect important organs; and (4) they afford attachment to the muscles. In the performance of this latter function the bones are to be regarded as passive organs of locomotion, the active organs being the muscles—that is to say, the bones act as levers to the muscles. There are two varieties of skeleton, namely, **endoskeleton** and **exoskeleton**. In the former, as in man, the bones are covered by soft parts. In the latter, as in crustacea, the bones are so disposed as to lie upon the surface, where they form a case which contains the soft parts of the animal. The human skeleton is arranged in two divisions, axial and appendicular. The *axial* skeleton comprises the head and trunk, and the *appendicular* represents the limbs. The head is composed of 23 bones, including the hyoid bone. The trunk is made up of the vertebral column, containing 26 separate bones in adult life; the sternum; and the ribs, with their costal cartilages, 24 in number, thus making 51 bones in all in the trunk. The appendicular skeleton comprises the two upper or pectoral limbs, each containing 32 bones, exclusive of sesamoid bones, and the two lower or pelvic limbs, each containing 31 bones, also exclusive of sesamoid bones.

Descriptive Terms.

Apophysis ('grow from'): this is any process or swelling on a bone.

Diaphysis ('grow between'): this term is applicable to long bones. It is the shaft of the bone, or the part which grows between the epiphyses.

Epiphysis ('grow upon'): this is a process of bone which has

a secondary centre of ossification, and which is attached for a time to the principal part of the bone by cartilage, but subsequently becomes consolidated.

Spine : this is a sharp-pointed process, and in certain bones is erroneously applied.

Tubercle (' swelling ') : a small rounded prominence on a bone.

Tuberosity : an exaggerated tubercle.

Trochanter (' running round ' or ' rolled ') : a prominence which has a rolled or wheel-like arrangement, and which runs round a portion of a bone.

Head : a rounded eminence, covered by cartilage, at the extremity of a bone.

Capitellum : a small head.

Neck : a constricted portion supporting a head.

Condyle (' knuckle ') : a small round eminence covered by cartilage—in reality a capitellum.

Foramen : an opening in the sense of a hole.

Hiatus : an opening in the sense of a gap.

Meatus (pl. *meatus*) : a passage or canal.

Fissure : a cleft or slit.

Fossa : a shallow depression.

Groove : a furrow or gutter.

Facet (Fr. *facette*, ' a little face ') : a small plane articular surface.

Sinus or *antrum* : a cavity in the interior of a bone.

Glenoid : like a shallow socket.

Cotyloid : cup-like.

Malleolus : a small hammer.

Neural : pertaining to the nervous system.

Medullary : pertaining to the medulla or marrow.

Clinoid : like a bed.

Trochlea : a pulley.

Styloid : pen-like.

Ventral : pertaining to the belly aspect of the body.

Dorsal : pertaining to the back aspect. In man ventral and dorsal are synonymous with anterior and posterior in the erect posture.

Cephalic : towards the head.

Caudal : towards the tail.

Ankylosis : bony union between two bones which are normally separate.

Mesial plane : this is the imaginary longitudinal plane which divides the body into two very nearly symmetrical halves, right and left. It extends from the mesial line on the ventral aspect to the mesial line on the dorsal aspect.

Sagittal : this means pertaining to the antero-posterior mesial plane with which it is parallel, and it practically means dorso-ventral or antero-posterior.

Coronal : this means intersecting the antero-posterior mesial plane at right angles in a vertical direction, and it is practically synonymous with transverse.

Internal or *mesial*: near to the mesial plane; and *external* or *lateral*: farther away from the mesial plane.

Preaxial and *postaxial*: these terms were originally used in connection with the embryo. Preaxial, proximal, or cephalic means towards the head (superior), and postaxial, distal, or caudal means towards the tail (inferior).

Morphology.—This is the science which investigates the form and structure of parts and organs in reference to the series of changes through which they pass during their development. In a morphological sense parts of man's body may be compared with one another, or parts of the body of one animal may be compared with apparently similar parts in the body of another animal, and in this way their actual identity may be established.

Homology.—Parts or organs which are represented in different animals are said to be homologous (homogenetic) when they are constructed on the same type and have the same embryonic origin, although they may differ in function. For example, the upper limb of man and the fore-limb of a quadruped are *homologous* (*homogenetic*). Parts in the body of man are said to be *serially homologous* (*homodynamic*) when they are repeated. For example, the humerus is serially homologous with the femur.

Analogy.—This is identity in function, but not necessarily in structure. The gills of a fish are analogous with the lungs of man, though differing in structure.

Segmental Type.—This consists in the repetition longitudinally of a series of segments similar to each other—*e.g.*, vertebræ, and ribs.

Chemical Composition of Bone.—Osseous tissue belongs to the connective tissues, and it consists of an organic matrix or ground substance, impregnated with mineral matter. The mineral matter is composed chiefly of calcium salts, and so it petrifies the ground substance. The organic matrix is usually spoken of as the animal matter, and it forms about 33 per cent. of the entire bone. The mineral matter is spoken of as the earthy matter, and it forms about 67 per cent. of the bone.

The **animal matter** imparts toughness and elasticity to the bone, and is composed of very delicate fibres, which are collected into bundles, held together by cement substance. The fibres consist of *collagen*, which is converted into gelatin by boiling. The animal matter can be separated from the earthy matter by steeping a bone for some time in dilute hydrochloric acid, the effect of the acid being to dissolve out the earthy matter. When bone is so treated it is said to be *decalcified*. There is left a tough, flexible, elastic substance, which can be bent and twisted in various directions, and even tied into a knot, but no amount of force applied to it, or pressure laid upon it, would cause it to break. A bone when so treated retains its original shape, but it loses weight to the extent of about two-thirds, and it also loses its property of hardness, so that it is incapable of bearing weight.

The **earthy matter** imparts hardness and rigidity to the bone, and is composed principally of calcium salts, of which the most abundant is *calcium phosphate*, there being about 57 per cent. of this salt present. Besides this there are *calcium carbonate* in the proportion of about 7 per cent., and *calcium fluoride* in the proportion of about 1 per cent. In addition to the calcium salts there are about 1 per cent. of *magnesium phosphate*, and about $\frac{1}{2}$ per cent. of *sodium chloride*. The earthy matter may be separated from the animal matter by burning a bone. The first effect of the heat is to char the animal matter, which is

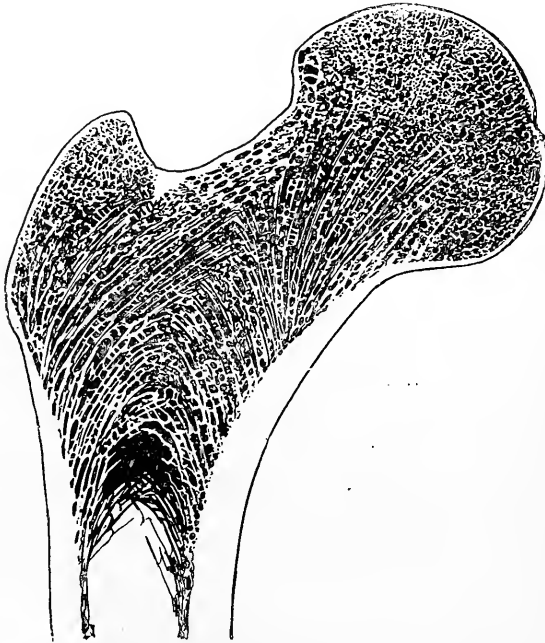


FIG. 1.—LONGITUDINAL SECTION THROUGH THE UPPER END OF THE FEMUR, SHOWING COMPACT AND CANCELLED OSSEOUS TISSUES.

subsequently consumed. When so treated a bone is said to be *calcined*, and the process is spoken of as combustion or *calcination*. There is left a white, chalk-like, very brittle substance, which, if of small size and carefully handled, retains its original shape. The slightest rough handling, however, will cause it to break, or crumble into a coarse powder. Calcined bone undergoes no change in shape, but it loses weight to the extent of about one-third. It also loses its toughness and elasticity. The only property it now possesses is hardness. As stated, it is also very brittle, and, by reason of this, it cannot be bent nor twisted in

the slightest degree. The animal and earthy matter, as they form bone, are intimately combined.

The proportion of about one-third of animal matter to about two-thirds of earthy matter applies to the healthy adult. In young children the relative amount of animal matter is much greater, so that in them the bones are very tough and elastic, but not very hard, and therefore not capable of bearing much weight. In old age there is a relatively large amount of earthy matter present. The bones of old persons, therefore, are very hard and brittle, but not very tough and elastic; hence the frequency of fractures in old persons from slight causes.

Structure of Bone.—There are two varieties of osseous tissue, namely, compact, and spongy or cancellated. Compact osseous tissue is so named because its constituents are so closely packed together that the bone appears to the naked eye (*macroscopic*)

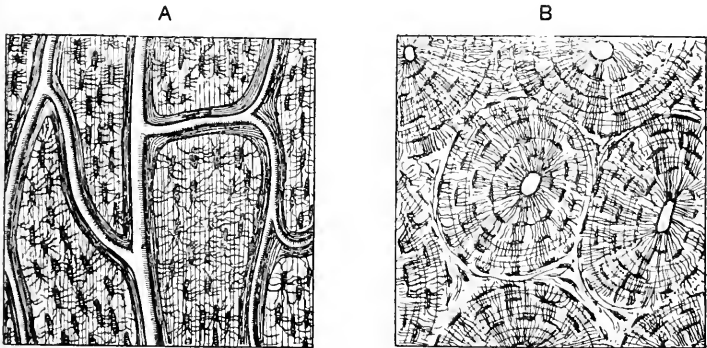


FIG. 2.—STRUCTURE OF COMPACT BONE.

A, Longitudinal section, showing Haversian canals; B, Transverse section, showing Haversian systems.

to be dense and close like ivory. Spongy or cancellated osseous tissue, on the other hand, presents an open porous appearance like a sponge. It is called cancellated because it resembles lattice-work. These two varieties of osseous tissue merge very gradually into one another.

When **compact bone** is viewed under the microscope in thin transverse section it presents a number of small round or oval openings, and when viewed in thin vertical section it presents short longitudinal tubes, called **Haversian canals**. These pervade every part of compact bone, and the innermost open into the marrow canal of long bones, whilst the outermost open by minute orifices on the external surface. They range in diameter from $\frac{1}{1000}$ to $\frac{1}{200}$ inch, the average being $\frac{1}{500}$ inch. The smallest lie nearest the external surface, and the largest are nearest the marrow canal. They are very short and longitudinal in direction, and they com-

municate freely with one another by connecting canals, some of which are oblique and others transverse. These connecting canals are very small, having a diameter of only $\frac{1}{20000}$ inch. The Haversian canals thus form a freely intercommunicating system of tubes throughout compact bone. The largest canals contain each an arteriole, a radicle vein, one or two lymphatics, and a small amount of marrow tissue. The smallest canals contain only one bloodvessel, which is of the nature of a capillary. Those nearest the external surface also contain very delicate thread-like processes of the periosteum. Nerve fibrils have been demonstrated in bone by Kölliker, Rémy, and Variot.

The bone around the Haversian canals is arranged in the form of concentric plates, called *Haversian* or *concentric bone lamellæ*. In transverse section these appear as concentric rings, and in longi-

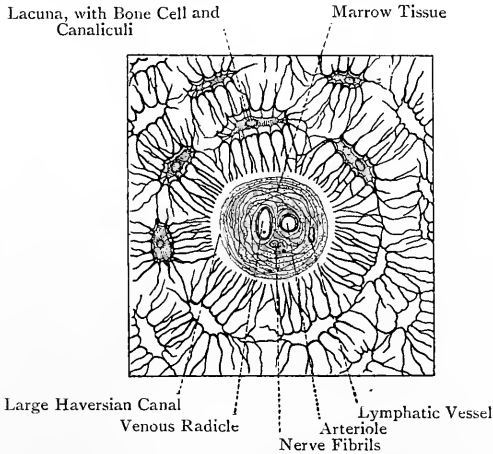


FIG. 3.—DIAGRAM OF A HAVERSIAN SYSTEM, MINUS THE CONCENTRIC BONE LAMELLÆ.

tudinal section as parallel lines. In the interspaces between the systems of Haversian or concentric lamellæ there are *intermediate*, *interstitial*, or *ground lamellæ*, and near the external surface there are *circumferential* or *peripheral lamellæ*, which are parallel with the surface. Some of the canals which pierce the circumferential lamellæ are devoid of concentric lamellæ, and are known as **Volkman's canals**. In the interspaces between the Haversian or concentric lamellæ there are small fusiform cavities, known as the *bone lacunæ*. These are about $\frac{1}{20000}$ inch in length, and, like the lamellæ, they are arranged concentrically round the Haversian canals. Radiating from these lacunæ there are minute channels, called *bone canalliculi*, which pass through perforations in the lamellæ, and so serve to connect the various lacunæ with one another. Some of those radiating from the innermost ring of lacunæ communicate

directly with the Haversian canal. The canaliculi thus constitute a system of intercommunicating channels which maintain a connection directly and indirectly between a given Haversian canal and the lacunæ arranged concentrically around it, and traverse the lamellæ in their course. Each lacuna contains a protoplasmic nucleated cell, called the *bone cell*, which almost completely fills it, and sends off processes into the canaliculi communicating with it. The canaliculi contain nutritive fluid derived from the arteriole. A given Haversian canal, with its concentric bone lamellæ, concentric bone lacunæ, and canaliculi, constitutes a **Haversian system**, and compact bone is simply an aggregation of such systems, with, in addition, the intermediate and circumferential lamellæ. Certain lamellæ are perforated perpendicularly by fibres which thus bind them together. These fibres are known as the *perforating fibres* of Sharpey. Some of them are composed of white fibrous tissue, and others of elastic tissue, and those nearest the periphery are connected with the periosteum from which they are derived. Others, however, more deeply placed, have no apparent direct connection with the periosteum. The perforating fibres are absent from the lamellæ of the Haversian systems.

Cancellated bone is composed of very slender trabeculæ, which are arranged in a reticular manner so as to enclose spaces, known as the *medullary spaces*. These spaces, in the recent state, are filled with marrow. The trabeculæ consist of superimposed lamellæ of compact bone. The strongest lamellæ are disposed in the direction in which the greatest pressure has to be borne, and these are known as *pressure lamellæ*. Other lamellæ which intersect these, are spoken of as *tension lamellæ*. The use of cancellated bone is to impart sufficient strength without adding unduly to weight.

Classification of Bones.—Bones are arranged in four classes, as follows: Long; short; tabular; and irregular.

A **long bone** consists of a shaft and two articular extremities. The shaft is more or less cylindrical, and contains a marrow canal, which is surrounded principally by compact bone. The articular extremities are composed of cancellated tissue, except at the surface where there is a thin shell of compact bone. Long bones are found in the appendicular skeleton.

A **short bone** consists mainly of cancellated tissue, except at the surface where there is a thin covering of compact bone. Short bones are more or less oblong in shape, and are found in the carpus and tarsus.

A **tabular bone** is composed of two plates or tables of compact bone, which enclose between them cancellated tissue. The scapula, ilium, and tegmental bones of the skull belong to this class. In the case of the latter the cancellated tissue is called *diploë*.

An **irregular bone** is one which is so irregular in form and in the relative distribution of the compact and cancellated tissues as to be

excluded from any of the preceding classes. The vertebræ belong to this class.

Ossification.—All bones are originally membranous. Some of them—for example, the tegmental bones of the cranium and most of the bones of the face—ossify in membrane, but the majority pass through a cartilaginous stage before becoming ossified. There are, therefore, two modes of ossification, namely **intramembranous** and **intracartilaginous**, and bones are consequently spoken of as *membrane-* and *cartilage-bones*.

Centres of Ossification.—These are primary and secondary. The *primary centre*, which as a rule appears early in intra-uterine life,




FIG. 4.—OSSIFICATION IN MEMBRANE.

is that from which the ossification of the principal part of the bone proceeds. This, in the case of a long bone, is the *shaft* or *diaphysis*. The *secondary centres*, which for the most part do not appear until after birth, are those from which the ossification of outgrowths of a bone proceeds, these forming what are known as the *epiphyses*.

Ossification in Membrane.—In this mode of ossification the bone is preceded by fibrous tissue. The fibres of this tissue are known as **osteogenetic fibres**, and they are arranged in small bundles. The tissue is very vascular, and contains many nucleated cells, called **osteoblasts**. At the centre of ossification the osteogenetic fibres, which have a covering of osteoblasts, become calcified, and bony spicula are thus formed, which radiate towards the circumference of the bone. These radiating spicula are connected at frequent intervals, and

so build up a bony reticulum. As the osteogenetic fibres grow and shoot out, they carry with them coatings of osteoblasts, and the process of calcareous incrustation goes on so that the bony spicula increase in length and gradually approach the periphery. During this process of spicular bony formation many of the osteoblasts are left behind, and become imprisoned in the lacunar spaces of the forming bone, where they represent the future bone cells. The ossification of a membrane bone is thus effected by means of osteogenetic fibres plus osteoblasts, the fibres acting as outrunners and becoming calcified.

Ossification in Cartilage.—The cartilage is covered by a membrane, called the *perichondrium*, which corresponds to the periosteum, and the process of ossification takes place in three stages.

First Stage.—In this stage the ossification is partly *endochondral*, and partly *ectochondral* or on the surface beneath the perichondrium. In the **endochondral form** the cartilage cells at the centre become enlarged, and the intervening matrix becomes calcified. Above and below the centre the cartilage cells are arranged in *long columns*, directed towards each extremity. The matrix between these columns becomes calcified by an extension of the calcareous matter at the centre, which now surrounds the cell-columns. The spaces in the calcified matrix, which contain these columns, are known as the *primary areolæ*. At the same time **ectochondral or subperichondral ossification** is proceeding in a manner similar to what takes place in membranous ossification, that is to say, by osteogenetic fibres, osteoblasts, and calcareous impregnation. In this way several layers of bone are laid down at the surface beneath the perichondrium, and these constitute the circumferential lamellæ. During this process some of the osteoblasts are detained in lacunar spaces, and form the *bone cells*.

Second Stage.—This is known as *the stage of irruption*. The inner or osteogenetic layer of the perichondrium bursts in through openings in the circumferential lamellæ, in the form of osteogenetic fibres, osteoblasts, and osteoclasts or bone destroyers. These incursions reach the calcified matrix, and the osteoclasts now commence their destructive work. The cartilage cells of the primary areolæ, as well as the walls of these areolæ, are absorbed, and larger spaces, called *secondary areolæ*, are formed in the original calcified matrix. These spaces contain osteogenetic fibres and osteoblasts, and the latter now build up lamellæ of bone.

Third Stage.—This is a repetition of the preceding two stages. The cartilage cells arrange themselves in rows; the intervening matrix becomes calcified, and invests them; the enclosed cartilage cells atrophy and give rise to primary areolæ; the osteoclasts produce partial absorption of the calcified cartilage, giving rise to medullary spaces; and the osteogenetic fibres and osteoblasts build up lamellæ of bone. Simultaneously with these processes, subperiosteal ossification is going on. The medullary canal is due to absorption by the osteoclasts of the osseous tissue in the centre of the shaft.

The ossification of the epiphyses of a bone is *endochondral*.

Periosteum.—The periosteum is a fibrous, vascular membrane, which closely invests bones, except where there is articular cartilage,




FIG. 5.—OSSIFICATION IN CARTILAGE.

at the margin of which it ceases. It consists of **two layers**—outer and inner. The fibres of the *outer layer* are arranged closely, and it is therefore dense. The *inner layer* consists chiefly of ramifying elastic fibres. Between the inner layer and the surface of the shaft of a long bone there is, especially during the development and growth of the bone, a layer of *subperiosteal areolar tissue*. Within its meshes cells, called **osteoblasts**, accumulate during the period of growth. These cells emerge from the outermost Haversian canals along the course of the entering arteries, and they represent the *bone cells* of the bone-lacunæ of compact bone which have migrated outwards. The osteoblasts take an important part in the formation of bone during its growth.

The periosteum is richly supplied with arteries which, after ramifying, enter the outermost Haversian canals, along with fine processes of the inner periosteal layer. The periosteum serves (1) as a bed in which the arteries subdivide before entering the bone, and (2) to give a firm hold to tendons and ligaments. It also takes part in ossification and regeneration of bone. When the periosteum is stripped from a bone the uncovered portion is liable to necrosis and exfoliation.

Marrow or Medulla.—The marrow fills the marrow canals of long bones and the medullary spaces of cancellated bone, and it also sends processes into the innermost Haversian canals. It is composed of a reticular fibrous matrix, which is pervaded by many blood-vessels and cells, the latter being called *myelocytes* (marrow cells). There are two kinds of marrow, yellow and red, which differ as to the character of the cells. In **yellow marrow** most of the cells have become transformed into fat cells, so that the marrow resembles adipose tissue. **Red marrow** contains very few fat cells. Many of its cells are colourless, protoplasmic, nucleated cells, which resemble the leucocytes of the blood, though of larger size, and like them are capable of amœboid movement. Other reddish cells, called *erythroblasts*, are present, which are the sources from which large numbers of red blood corpuscles are formed. In addition to these two sets of cells, there are large multinucleated, protoplasmic cells, called the *myeloplaxes of Robin*, which play an important part in the absorption of bone.

Yellow marrow is found in the marrow canals of long bones, whilst red marrow occurs in (1) articular ends of long bones; (2) medullary spaces of cancellated bone; (3) bodies of the vertebræ; (4) sternum; (5) ribs; and (6) the *diploë* of the cranial bones. Marrow serves the following uses: (1) it (red marrow) is an important *blood-forming organ* (red corpuscles); (2) it contributes to the nourishment of bone; and (3) it serves as a light packing material for all hollow spaces within bones, with the exception of the air-sinuses in the bones of the head.

The wall of the marrow canal of all long bones and that of the medullary spaces of all cancellated bone are lined with a very delicate layer of areolar tissue, which is richly provided

with bloodvessels. This is known as the *endosteum* or *medullary membrane*.

Osseous tissue is richly supplied with bloodvessels, which are derived from the periosteum and marrow.

I. THE BONES OF THE TRUNK.

A. The Vertebral Column.

The vertebral column is composed of thirty-three vertebræ in the young subject, and these in the adult are divided into two classes, namely, true or movable, and false, immovable, or fixed. The **true vertebræ** are those which, though connected by ligaments, are quite distinct from each other, so that a limited amount of movement is allowed between them. The **false vertebræ** are those

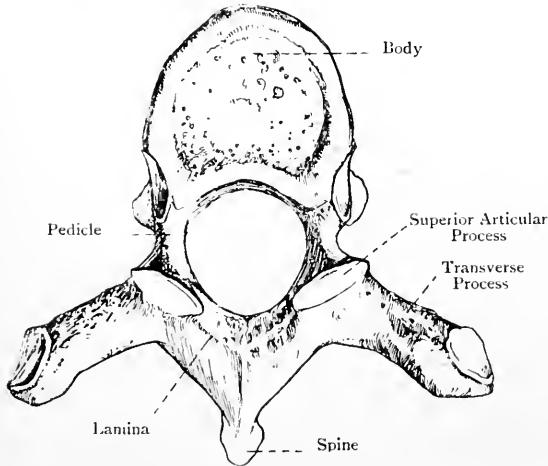


FIG. 6.—THE SIXTH THORACIC VERTEBRA (SUPERIOR VIEW).

which, though distinct up to a certain period of life, subsequently become ankylosed. The true vertebræ are subdivided into three groups—cervical, thoracic, and lumbar. The false vertebræ are subdivided into two groups—sacral, and coccygeal.

Component Parts of a Complete Vertebra.—A complete vertebra is composed of a body or centrum; a neural arch, consisting of two pedicles and two laminae (*neurapophyses*); a spinous process, or neural spine; two transverse processes; four articular processes (*zygapophyses*), two superior and two inferior; and a spinal or neural foramen. The *body* forms the anterior or ventral part of the bone, and is somewhat disc-shaped. The *neural arch* consists of two halves, the anterior portion of each being the *pedicle*, and the posterior portion the *lamina*. The pedicles

present, above and below, the *superior* and *inferior vertebral notches*. The *spinous process* is formed by the fusion of the two laminae in the median line posteriorly. The *transverse processes* project outwards, one at either side, from the neural arch at the junction of the pedicle and lamina. The *articular processes*, two superior and two inferior, project upwards and downwards from the junction of the pedicle and lamina at either side, and they are covered by cartilage. The *spinal* or *neural foramen* is enclosed by the body and neural arch. It is bounded in front by the posterior surface of the body, on either side by a pedicle and lamina, and behind by the fusion of the laminae to form the spinous process.

Structure of a Vertebra.—The body is composed of cancellated tissue, covered by a thin layer of compact bone. The chief lamellae are disposed in almost vertical curves, the convexities of which are directed towards the periphery. Crossing these there are horizontal lamellae, which are nearly parallel with the superior and inferior surfaces. The cancellated tissue is permeated by venous channels which converge to the two large foramina on the posterior surface of the body. The neural arch and its processes are chiefly composed of compact bone, the amount of cancellated tissue being for the most part small.

The Cervical Vertebrae.

The **cervical vertebrae** are seven in number, and they occupy the region of the cervix or neck. The distinctive character of all cervical vertebrae is the presence of an aperture at either side of the body, called the costo-transverse foramen. The **first** or **atlas**, the **second** or **axis**, and the **seventh** or **vertebra prominens** have such pronounced characters that they require a special description.

A Typical Cervical Vertebra.—The **body** is small and elongated from side to side. The *superior surface* presents at either side an antero-posterior lip, the inner surface of which is sloped towards the superior surface, and embraces the corresponding bevelled lateral border of the inferior surface of the body above. The whole surface is thus concave from side to side, and the posterior lip is on a slightly higher level than the anterior. The *inferior surface* is bevelled laterally, and its anterior lip is on a lower level than the posterior. The inferior surface is convex from side to side, and concave from before backwards. The superior and inferior surfaces give attachment to the intervertebral discs. The *anterior surface* is convex from side to side, and concave from above downwards. It is covered by the anterior common ligament, and it presents a number of nutrient foramina. The *posterior surface* is flat, and presents several nutrient foramina, two of which, one at either side of the middle line, are large, for the escape of the venae basis vertebrae. The *posterior surface* is related to the posterior common ligament. Each *lateral surface* forms the inner boundary of the costo-transverse foramen.

The **pedicles** spring at either side from the posterior part of the

lateral surface of the body, where each encroaches rather nearer the upper than the lower surface. They are smooth and almost cylindrical, and their direction is outwards and backwards. Above and below each pedicle there is a well-marked *vertebral notch*, the *superior* being narrower and slightly shallower than the *inferior*. The superior notch lodges a spinal nerve. When two vertebrae are in position the contiguous vertebral notches, at either side, form an intervertebral foramen.

The **laminae** spring each from a pedicle. They are compressed

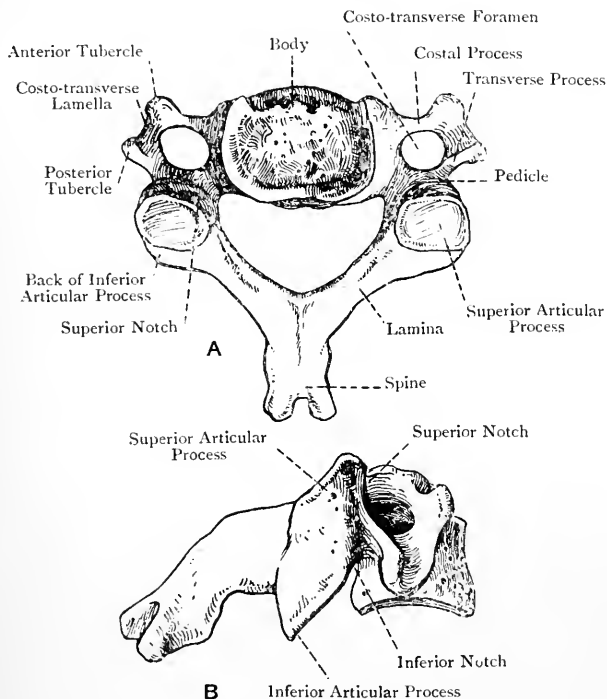


FIG. 7.—THE FIFTH CERVICAL VERTEBRA.
A, Superior view; B, Lateral view.

from before backwards, and their direction is backwards and inwards to the middle line, where they fuse, and so give rise to the spinous process. The upper border and adjacent portion of the posterior surface of each lamina give attachment to the ligamentum subflavum connecting it to the lamina above, whilst the lower part of the anterior surface near the lower border gives attachment to the ligamentum subflavum connecting it to the lamina below.

The **spinous process** is formed by the fusion of the two laminae.

It is triangular, and its direction is backwards and slightly downwards. Superiorly it presents an antero-posterior ridge for an interspinous ligament, and inferiorly a grooved surface, also for an interspinous ligament. It terminates behind in a bifid extremity, which, in the case of the third, fourth, and fifth vertebræ, presents a distinct triangular notch. The bifurcated extremity gives attachment to the deep fibres of the ligamentum nuchæ. The cervical spinous processes are very short, except those of the sixth and seventh, especially the latter, and in this way backward flexion or over-extension of the neck is not interfered with.

The **articular processes** spring from the junction of the pedicle and lamina at either side. Each is nearly circular, the plane being oblique, and the surface almost flat. The *superior pair* look backwards and upwards, and the *inferior pair* forwards and downwards.

The **transverse processes** (*diapophyses*) spring at either side from the junction between the pedicle and lamina, and are serially homologous with the transverse processes of a thoracic vertebra. Each terminates in a projection, known as the posterior tubercle.

The **costal processes** (*pleurapophyses*) project outwards from either side of the body anteriorly, and are serially homologous with the vertebral part of a rib. Each terminates in a projection, known as the anterior tubercle, which, with the posterior tubercle of the corresponding transverse process, gives attachment to the intertransversales muscles.

The transverse and costal processes are connected, at a short distance from the body, by a plate of bone, called the *costo-transverse lamella*, which is deeply grooved superiorly for a spinal nerve, this groove being continuous with the superior vertebral notch. There is thus formed, at either side, an aperture, called the **costo-transverse foramen**. This foramen is circular, vertical in direction (except in the case of the axis), and it transmits the following structures: the vertebral artery; the vertebral plexus of veins; and the vertebral sympathetic plexus of nerves. Though the foramen is present in each transverse process, it does not give passage to the foregoing structures in the case of the seventh. The vertebral vein, however, may pass through it. In many cases an additional foramen of small size is present on one or both sides, lying behind the main foramen, and, when this is so, it transmits a small vein. The costo-transverse foramina of either side, when in position, build up a canal, which is open in each intertransverse space.

The **neural foramen** is situated behind the body, and is triangular, with the angles rounded off. It is of larger size than in the thoracic or lumbar vertebræ, its direction is vertical, and it lodges the spinal cord with its membranes.

The Atlas.—The atlas is the first cervical vertebra, and is so named because it supports the head. Its distinctive characters are the absence of a body and spinous process. It has the form of a ring, narrow in front and wide behind, and its component parts

are as follows: an anterior arch: a posterior arch: two lateral masses; and a ring.

The **anterior arch** is a curved plate of bone which connects the antero-internal parts of the lateral masses. It is compressed from before backwards, convex in front, and concave behind. The *anterior surface* presents at its centre a conical prominence, called the *anterior tubercle*. This gives attachment at either side to a portion of the longus colli muscle, and its central part receives the accessory ligament. The *posterior surface* presents at its centre a circular concave facet, called the *odontoid facet*, for articulation with the anterior surface of the odontoid process of the axis. The upper border gives attachment to the anterior occipito-

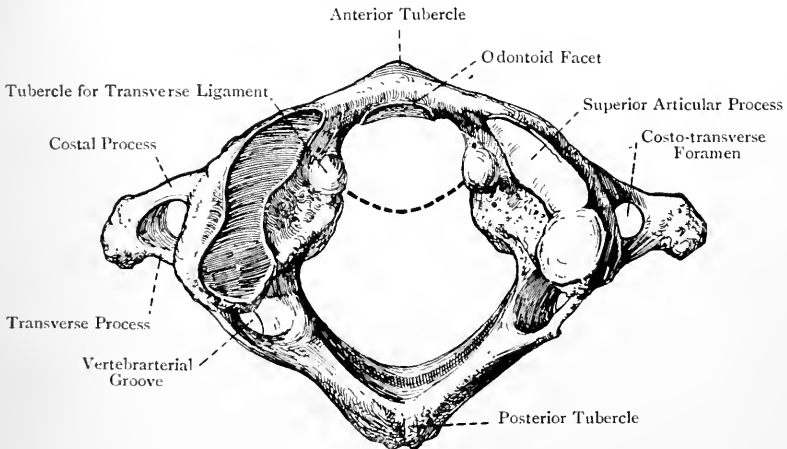


FIG. 8.—THE ATLAS (SUPERIOR VIEW).

(The Vertebrarterial Groove on this bone was converted into a Foramen on both sides.)

atlantal ligament, and the lower to the anterior atlanto-axial ligament.

The **posterior arch** is serially homologous with the laminae of other vertebrae. It springs at either side from the back part of a lateral mass, from which it sweeps backwards and inwards. The part close to the lateral mass at either side is flattened from above downwards. It presents on its upper surface a shallow depression, called the *vertebrarterial groove*, which lodges the vertebral artery and suboccipital nerve. This groove is sometimes converted into a foramen on one or both sides by a spiculum of bone extending from the back part of the superior articular process to the posterior arch behind the groove. The vertebrarterial groove is serially homologous with the superior vertebral notch of other vertebrae, but, unlike them, it lies *behind* the superior articular process. The inferior surface of the posterior arch, behind each lateral mass,

presents a shallow vertebral notch, which lies *behind* the inferior articular process. The centre of the posterior arch presents the *posterior tubercle*, which is the only representative of a spinous process. At either side of this tubercle the rectus capitis posticus minor arises. The upper aspect of the posterior arch gives attachment to the posterior occipito-atlantal ligament, and the lower aspect to the posterior atlanto-axial ligament.

The **lateral masses** support the superior and inferior articular processes, and laterally the transverse and costal processes spring from them. The anterior surface of each gives partial origin to the rectus capitis anticus minor. The internal surface of each presents anteriorly a tubercle for the transverse ligament. The *superior articular processes* are oval and deeply concave, to articulate with the condyles of the occipital bone. Their long axes are directed backwards

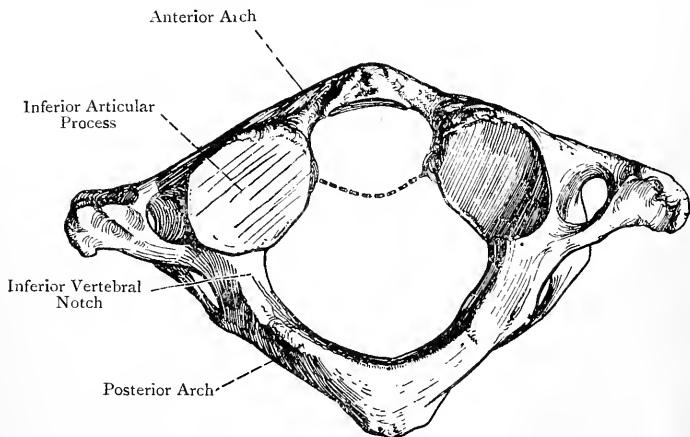


FIG. 9.—THE ATLAS (INFERIOR VIEW).

and outwards, so that they converge in front and diverge behind. Anteriorly they reach as far as the anterior arch, and posteriorly they overhang the vertebral arterial grooves on the posterior arch to a slight extent, but they do not extend farther back than about the centre of the ring. The plane of each is sloped downwards and inwards, and the direction of the surface is upwards and inwards. The movement between them and the occipital condyles is one of flexion and extension, or nodding. Sometimes one or both of them may be divided by a groove into two circular facets. The *inferior articular processes* are circular and slightly concave. The plane of each is sloped upwards and inwards, and the direction of the surface is downwards and inwards. They articulate with the superior articular processes of the axis, and the movement allowed is rotation. The articular processes of the atlas, being placed in front of the points of exit of the spina

nerves, do not correspond in position with the articular processes of succeeding vertebræ (with the exception of the superior pair of the axis). They occupy a position corresponding with the pedicular portions of the bodies of vertebræ, and in this way the superincumbent weight is transmitted to the vertebral bodies.

The **transverse and costal processes** spring from the side of each lateral mass, and, external to the costo-transverse foramen, the costo-transverse lamella and the anterior and posterior tubercles are more or less fused into one long irregular mass, though the posterior tubercle usually remains conspicuous. The upper surface of this mass at its front part gives origin to the rectus capitis lateralis, and at its back part to the obliquus capitis superior, whilst the lower surface at its back part gives insertion to the obliquus capitis inferior. The costo-transverse foramen is of large size in order to guard against the vertebral artery being compressed during the rotatory movements of the bone upon the axis.

The **ring** of the atlas, in the recent state, is divided into two compartments by the transverse ligament. The anterior small division is called the *odontoid compartment*, and it lodges the odontoid process of the axis. The posterior large division represents the neural foramen of other vertebræ, and it lodges the spinal cord with its membranes.

Varieties.—(1) The posterior arch may be incomplete at the centre, the deficiency being bridged over by fibrous tissue. (2) The costal process may be incomplete, the deficiency in the costo-transverse foramen being filled by fibrous tissue. (3) There is sometimes an additional small foramen on either side, a little behind the costo-transverse foramen, for the passage of the suboccipital radicles of the vertebral plexus of veins.

The Axis.—The axis is the second cervical vertebra, and is so named because its odontoid process, which is the distinctive character of the bone, forms a pivot on which the atlas, supporting the head, rotates. From the presence of this process the axis is sometimes called the *vertebra dentata*.

The **odontoid process** (*processus dentatus*) springs from the superior surface of the body, and represents the body of the atlas. It is constricted and somewhat circular close to the body, this part being called the *neck*. Above this it expands into a *head*, which tapers off at either side by two sloping surfaces, forming by their convergence an antero-posterior ridge, known as the *summit*. The anterior surface presents a circular convex facet, called the *atlantal facet*, for articulation with the odontoid facet on the posterior surface of the anterior arch of the atlas. The posterior surface presents a shallow transverse groove for the play of the transverse ligament of the atlas. The lateral sloping surfaces on either side of the summit give attachment to the lateral odontoid ligaments, whilst the summit itself gives attachment to the middle odontoid ligament.

The *superior surface* of the **body** is occupied by the odontoid process and portions of the superior articular processes. The *inferior surface* differs from that of other cervical vertebræ only in the greater downward projection of its anterior lip. The *anterior surface* presents a median vertical ridge which bifurcates inferiorly into diverging lips, enclosing a small triangular surface. On either side of the median ridge the surface is depressed, and gives attachment to a portion of the longus colli muscle. The other surfaces of the body present nothing peculiar.

The **pedicles** are concealed above by the superior articular processes. Each, on its inferior aspect, presents a wide and deep *inferior vertebral notch*, which is placed in front of an inferior articular process. The *superior vertebral notches*, which are very shallow, are situated on the upper borders of the laminae, and, like

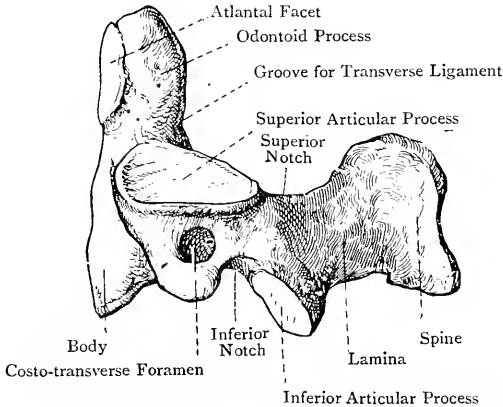


FIG. 10.—THE AXIS (LATERAL VIEW).

those of the atlas, are placed *behind* the superior articular processes.

The **laminae** are massive, and give attachment by their upper borders to the posterior atlanto-axial ligaments, whilst their anterior surfaces, near the lower borders, give attachment to ligamenta subflava, as in other vertebræ.

The **spinous process**, though short, is massive. Its direction is backwards, and it terminates in two strong tubercles, separated inferiorly by a triangular cleft. Each of these tubercles gives attachment to some of the deep fibres of the ligamentum nuchæ, and to the following muscles from above downwards: the rectus capitis posticus major; the obliquus capitis inferior; and the highest portion of the semispinalis colli.

The *superior articular processes* are situated on the upper surface of the pedicle at either side, the upper surface of the costal process, and a portion of the superior surface of the body, upon which

latter it encroaches very near to the odontoid process. The plane of each is sloped outwards and downwards. The surface is slightly convex from before backwards and circular, its direction being upwards and outwards. They articulate with the inferior articular processes of the atlas, and the movement allowed is rotation. The *inferior articular processes* differ from those of most vertebræ only in being situated principally upon the lower borders of the laminae. The superior pair, like all four articular processes of the atlas, being placed in front of the points of exit of the spinal nerves, do not correspond in position with the superior articular processes of succeeding vertebræ, but occupy a position corresponding with the pedicular portions of the bodies of vertebræ.

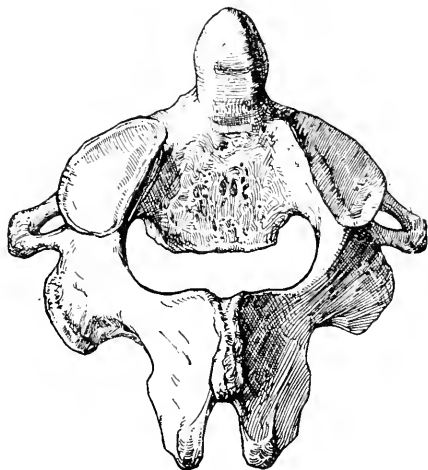


FIG. 11.—THE AXIS (SUPERIOR VIEW).

The **transverse processes** are very short, and are directed outwards and downwards. Each terminates in a single tubercle.

The **costal processes** do not terminate in tubercles, and the costo-transverse lamellæ are not grooved superiorly.

The costo-transverse foramen is directed upwards and outwards, the reason of this obliquity being as follows: when the atlas and axis are in position each costo-transverse foramen in the atlas lies farther out than that in the axis. In order, therefore, to obviate any sudden and undue bend in the vertebral artery, the foramen in the axis is directed obliquely upwards and outwards so as to guide the vertebral artery gradually to the foramen in the atlas.

There is nothing peculiar about the neural foramen.

Varieties.—(1) The summit of the odontoid process may present a facet, indicating an articulation with the anterior margin of the foramen magnum of the occipital bone, which in such cases presents a prominence known as the middle occipital condyle. (2) The odontoid process may, in very rare cases, remain separate from the body, thus forming the *os dentatum*. (3) An odontoid process in two halves has been recorded.

The seventh cervical vertebra.—The distinctive character of this vertebra is the great length of its spinous process, which is the only cervical spine that can readily be felt beneath the integument of the neck. On account of this outstanding prominence the seventh cervical is known as the **vertebra prominens**. The spinous process

is directed straight backwards, and terminates in a single large tubercular eminence. The other characters of this vertebra to be noted are as follows: the antero-posterior measurement of the body exceeds that of other cervical vertebræ; the transverse process is massive and comparatively long; the posterior tubercle is very distinct, but the anterior is rudimentary, or wanting; the costo-transverse foramen is of small size, and does not transmit the vertebral vessels and vertebral sympathetic plexus. The vertebral vein, however, may pass through it.

Varieties.—(1) The costal process may remain separate from the transverse process, thus giving rise to a cervical rib. (2) The costal process may be wanting on one or both sides, in which cases there is no costo-transverse foramen.

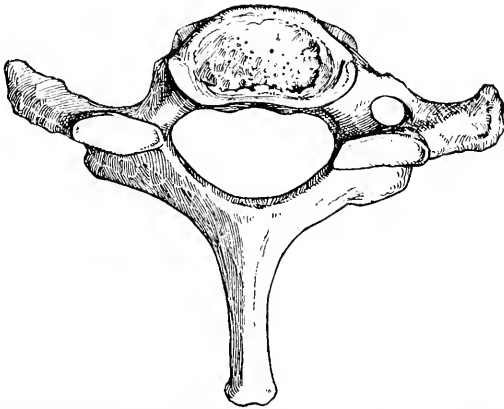


FIG. 12.—THE SEVENTH CERVICAL VERTEBRA (SUPERIOR VIEW).
(The Costal Process of the Left Side was undeveloped in this vertebra.)

It is to be noted that the **sixth cervical vertebra** is peculiar in the following respects: the spinous process, like that of the vertebra prominens, terminates in a single large tubercular eminence; and the tubercle of each costal process, known as the anterior tubercle, is of large size, and is called the **carotid tubercle of Chassignac**.

The cervical vertebræ receive their blood-supply from branches of the vertebral arteries.

The Thoracic Vertebræ.

The **thoracic vertebræ** are twelve in number, and their distinctive character is the presence of one or more facets on either side of the bodies for articulation with the heads of ribs. The **first**,

tenth, eleventh, and twelfth (sometimes also the ninth) are peculiar, and require separate descriptions.

A Typical Thoracic Vertebra.—The body is larger than that of a cervical vertebra, but smaller than that of a lumbar. When viewed from above or below it is cordate or heart-shaped, being broad and hollowed out behind, and narrow and rounded off in front. The posterior depth of the body exceeds the anterior, in adaptation to the backward curve of the vertebral column in the thoracic region. The *superior* and *inferior surfaces* present a raised rim round the circumference, due to the annular circumferential epiphysis, and this renders the whole of each surface slightly concave from the periphery towards the centre. The *anterior* and

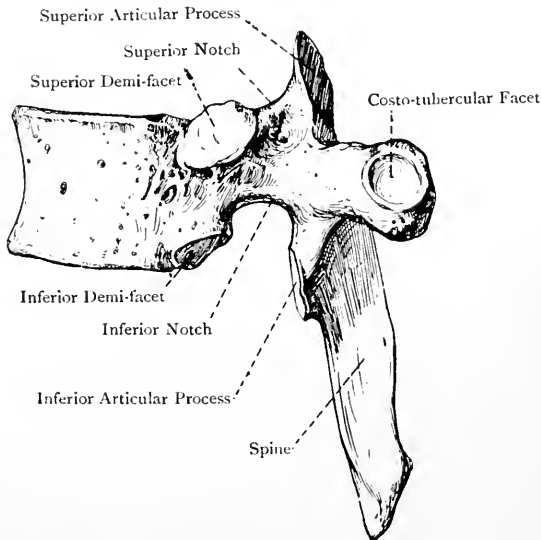


FIG. 13.—THE SIXTH THORACIC VERTEBRA (LATERAL VIEW).

lateral surfaces merge gradually into each other, and are concave from above downwards, the entire antero-lateral surface being convex from side to side and pierced by numerous nutrient foramina. Each lateral surface, close to the neural arch, presents two articular demi-facets, superior and inferior, of which the superior is the larger, and is situated upon the pedicular portion of the body, the inferior smaller one being just in front of the lower part of the inferior vertebral notch. These demi-facets are for articulation with the heads of the ribs, and are called the *costo-capitular facets*. When two vertebrae are in position the superior demi-facet of the lower vertebra and the inferior demi-facet of the upper form an articular cavity for the head of a rib. The *posterior surface* of the body is concave from side to side, and presents

nutrient foramina, as in the cervical vertebræ. The superior and inferior surfaces are related to the intervertebral discs, and the anterior and posterior surfaces are related to the anterior and posterior common ligaments.

The **pedicles** spring from either lateral extremity of the posterior surface of the body, and their upper borders are very nearly on a level with its superior surface. Each pedicle is laterally compressed, and is directed backwards and slightly outwards. The *superior vertebral notches* are shallow, and each is usually bounded in front by a transverse lip. The *inferior vertebral notches* are deep and wide.

The **laminae** are short, deep, and compressed from before backwards, their planes being sloped downwards and backwards. The

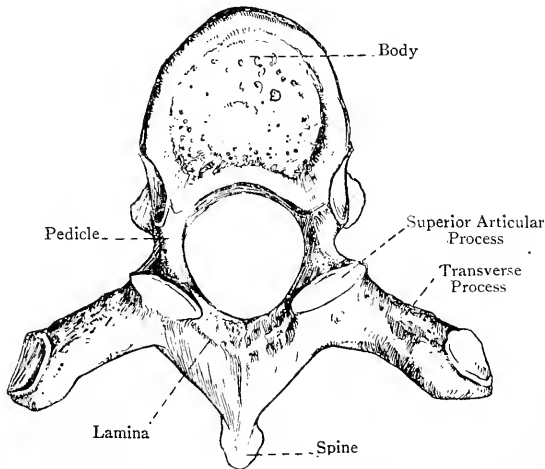


FIG. 14.—THE SIXTH THORACIC VERTEBRA (SUPERIOR VIEW).

markings for the ligamenta subflava are the same as in cervical vertebræ.

The **spinous process** is triangular or bayonet-shaped. Its direction is downwards and slightly backwards, and it terminates in a sloping border ending below in a sharp point. The spinous processes of the central thoracic vertebræ are imbricated or overlapping.

The **articular processes** are nearly circular, their surfaces are flat, and their planes are almost vertical. The *superior pair* project upwards from the junction between the pedicles and laminae, and they look backwards and slightly upwards and outwards. The *inferior pair* are placed on the anterior surfaces of the laminae, and they look forwards and slightly downwards and inwards.

The **transverse processes** spring from the junction of the pedicles and laminae, and each is directed outwards and backwards. They are long and club-shaped, being somewhat constricted at their bases, but expanding into knob-like enlargements at their extremities. The anterior surface of the extremity of each presents a circular concave facet, called the *costo-tubercular facet*, for articulation with the tubercle of a rib. The posterior surface of the extremity gives attachment to the posterior costo-transverse ligament. The anterior surface of the transverse process faces the posterior surface of the neck of a rib, and gives attachment to the middle costo-transverse or interosseous ligament. This region corresponds with the costo-transverse foramen in a cervical vertebra. The lower border of the transverse process gives attachment to the superior costo-transverse ligament, which connects it with the crest, or upper border of the neck, of the rib below. The transverse process is serially homologous with a cervical transverse process.

The **neural foramen** is almost circular, and is of smaller size than in the cervical or lumbar vertebrae.

Peculiar Thoracic Vertebrae.—These are the first, tenth, eleventh, and twelfth (sometimes also the ninth).

The First Thoracic Vertebra.—This vertebra closely resembles the seventh cervical, as, indeed, do one or two below it. Its distinctive character is the presence on each side of the body of one entire facet close to the upper part, and situated on the pedicular portion, for the head of the first rib, and one demi-facet close to the lower part for a portion of the head of the second rib. With the exception of the inferior articular and transverse processes, this vertebra in other respects closely corresponds with the seventh cervical, with this difference, that the antero-posterior lips of the superior surface of the body of the seventh cervical are replaced by transverse lips lying in front of the superior vertebral notches. The inferior articular and transverse processes are similar to those of a typical thoracic vertebra, each transverse process having the usual costo-tubercular facet on the anterior surface of its extremity.

The Tenth Thoracic Vertebra.—This vertebra has usually one entire facet on either side, mainly on the pedicle, for the head of the tenth rib. This facet, however, may only be a three-quarter facet, if the ninth thoracic vertebra is normal. It has, usually, a costo-tubercular facet on the anterior aspect of the extremity of each transverse process for the tubercle of the tenth rib, but this facet may be wanting. The body and spinous process of this vertebra show indications of the lumbar type, its other characters being thoracic.

The Eleventh Thoracic Vertebra.—This vertebra has an entire facet on the outer surface of each pedicle for the head of the eleventh rib, but there is no facet on the transverse process, which has become short and stunted, the tendency to the club shape being, however,

still perceptible. The lumbar type of the bone is more pronounced than in the case of the tenth.

The Twelfth Thoracic Vertebra.—This, like the eleventh, has an entire facet on the outer surface of each pedicle for the head of the

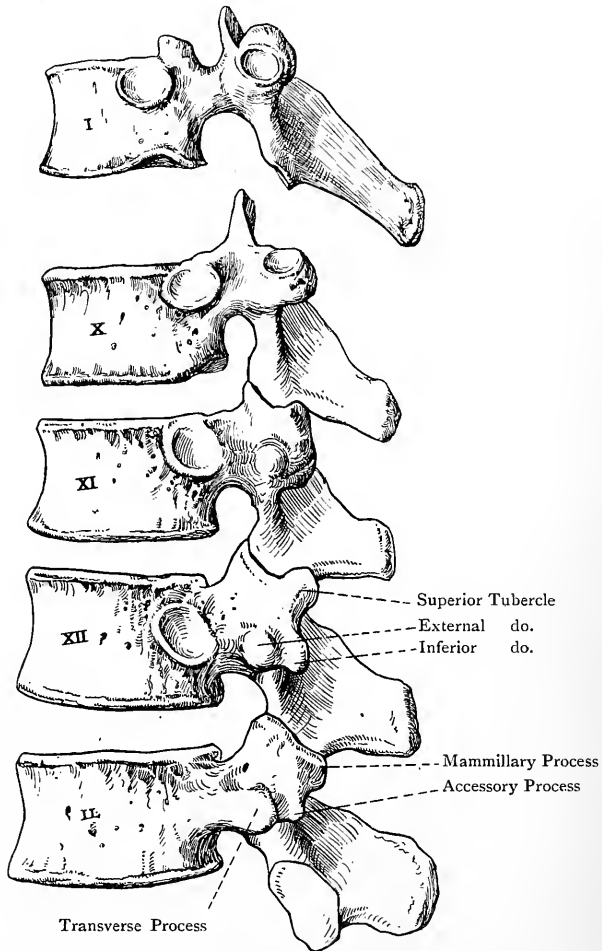


FIG. 15.—THE PECULIAR THORACIC VERTEBRÆ AND THE FIRST LUMBAR VERTEBRA.

twelfth rib, and no facet on the transverse process. The transverse processes are very stunted, and each presents three tubercles—external, superior, and inferior—a condition which also manifests itself, though not so conspicuously, in the transverse processes of the eleventh, and even the tenth. The external tubercle, along

with the twelfth rib, is serially homologous with a lumbar transverse process, the superior with a lumbar mammillary process, and the inferior with a lumbar accessory process. The superior articular processes are thoracic in type, whilst the inferior are like those of a lumbar vertebra, being convex and directed outwards and forwards, or away from each other. Sometimes the superior articular processes are also lumbar in type, being concave and looking inwards and backwards, or towards each other. When this is so, the inferior articular processes of the eleventh thoracic vertebra are also lumbar in type. The twelfth thoracic vertebra very closely resembles a lumbar vertebra, from which, however, it differs in having a facet on the outer surface of each pedicle. If the **Ninth Thoracic Vertebra** is peculiar this consists in the absence of the *lower* demi-facet on the side of the body.

The thoracic vertebræ receive their blood-supply from the intercostal arteries.

The Lumbar Vertebræ.

The **lumbar vertebræ** are five in number, and are so named because they occupy the region of the loins. They are the largest of the true vertebræ, and their negative characters are—the absence of a costo-transverse foramen in the transverse process; and the absence of any kind of costal facet on the side of the body. They increase in size from above downwards, the fifth being the largest, but, as this vertebra has certain distinctive characters, it will be separately described.

A Typical Lumbar Vertebra.—The **body**, when viewed from above or below, is reniform, being flattened from above downwards, convex transversely over its antero-lateral surface, and slightly concave transversely on its posterior surface. It is wider from side to side than from before backwards. The anterior depth is slightly greater than the posterior, in adaptation to the forward curve of the vertebral column in the lumbar region. The general characters correspond with those of the thoracic vertebræ.

The **pedicles** are short, strong, and directed backwards. The *superior vertebral notches* are shallow, the *inferior* being deep and wide.

The **laminae** are short, thick, and deep, and their planes are almost vertical.

The **spinous process** is axe-shaped, its direction being straight backwards, and it terminates in a round elongated border.

The **articular processes** are strong. The *superior pair* project upwards from the junction of the pedicles and laminae, and the *inferior pair* project downwards from the lower borders of the laminae. The *superior pair* are concave, their planes being vertical, and their direction being inwards and backwards, so that they almost face each other. They stand wide apart, so as to embrace the inferior articular processes of the vertebra above. On the posterior border of each there is a nipple-shaped projection, directed backwards and slightly upwards, called the *mammillary process* (*meta-*

pophysis), which corresponds with the superior tubercle of the lower thoracic transverse processes. The *inferior articular processes* are convex, their planes being vertical, and their direction being outwards and forwards, so that they look away from each other. They are nearer to each other than the superior pair, and are embraced between the superior pair of the vertebra below.

The **transverse processes** are comparatively slender, except in the case of the fifth; they are directed outwards and slightly backwards, and they increase in length from the first to the fourth. Each is spatula-shaped, being compressed from before

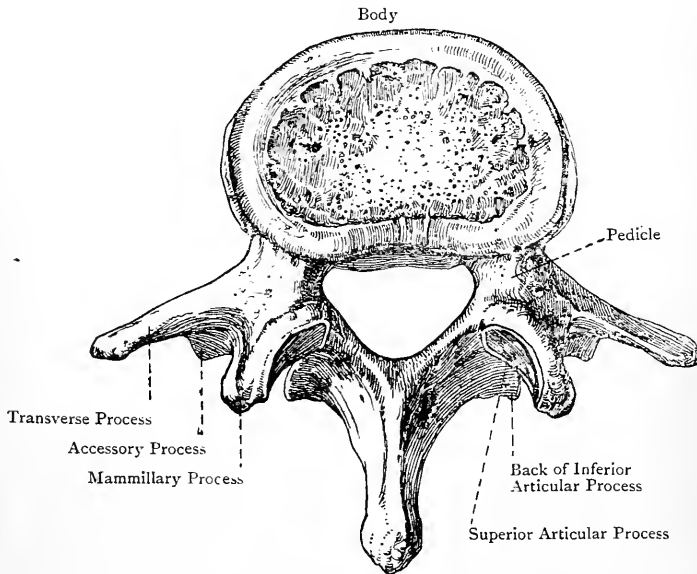


FIG. 16.—THE THIRD LUMBAR VERTEBRA (SUPERIOR VIEW).

backwards, and terminates in a short round border. It represents the vertebral portion of a rib, and therefore constitutes the *costal element* of the vertebra. Situated on the posterior aspect of the base of the transverse process, just external to and below the lower border of the superior articular process, there is a small sharp projection directed downwards, called the *accessory process (anapophysis)*, which is the rudiment of the true transverse process, and is serially homologous with the inferior tubercles of the lower thoracic vertebræ and the other thoracic transverse processes. In the case of the fourth and fifth lumbar vertebræ the transverse process becomes shifted on to the pedicle, and even slightly on to the body. Between the base of the transverse process and the accessory process posteriorly there are a few nutrient

foramina which correspond with the costo-transverse foramen in cervical vertebræ.

The lumbar transverse processes (costal elements) of man are serially homologous with the ribs, and also, in the case of the lower thoracic vertebræ, with the external tubercles of the transverse processes. In the lumbar region each transverse process (costal element) has fused with the accessory process (true transverse process), and so the costo-transverse foramen in the transverse process of a cervical vertebra is represented only by a few nutrient foramina.

The **neural foramen** is larger than in the thoracic vertebræ, but not so large as in the cervical, its shape being triangular with rounded angles.

The Fifth Lumbar Vertebra.—The distinctive characters of this

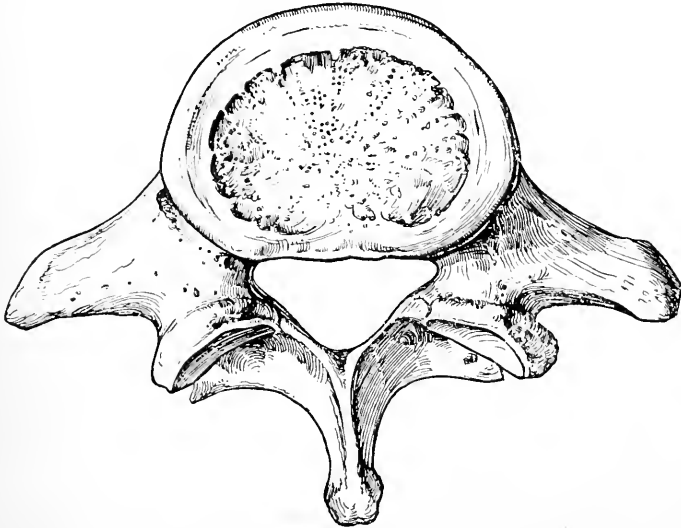


FIG. 17.—THE FIFTH LUMBAR VERTEBRA (SUPERIOR VIEW).

vertebra are as follows : (1) it is the most massive of all the lumbar vertebræ ; (2) the greater depth of the body in front is more conspicuous than in the others ; (3) the transverse processes are thick and conical ; and (4) the inferior articular processes are wide apart.

The lumbar vertebræ receive their blood-supply from the lumbar arteries.

Ossification of the True Vertebræ.

Each true vertebra ossifies in cartilage from **three primary**, and **five secondary**, centres. One primary centre is for the principal part of the body, and two are for the neural arch and its processes, including also a small portion of the body at either side adjacent to the pedicle. The centres for the neural arch appear

about the *seventh week* of intra-uterine life at the junction of the pedicles and laminae, and from these ossification invades the neural arch, with its processes, and the adjacent portions of the body. The centre for the principal part of the body appears about the *eighth week* in the portion of cartilage dorsal to

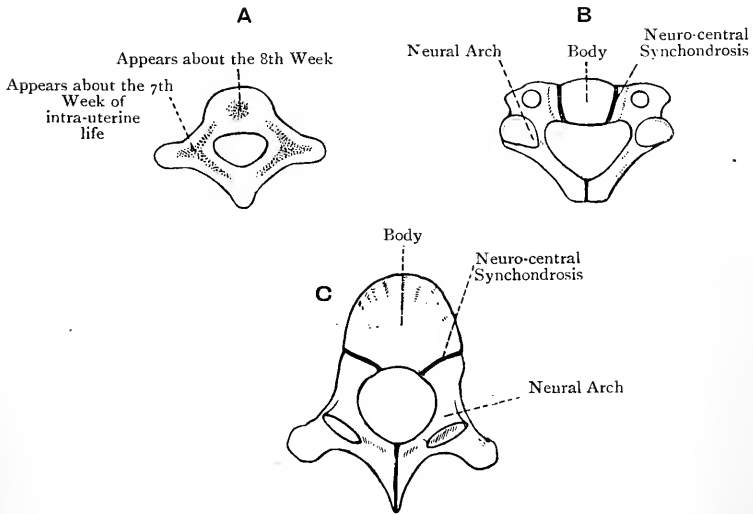


FIG. 18.—OSSIFICATION OF THE TRUE VERTEBRÆ.

A, Cervical Vertebra at the Third Month ; B, Cervical Vertebra at Birth ; C, Thoracic Vertebra at Birth.

the notochord. It is usually single at first, but it soon assumes a bilobed form, and so it comes to surround the notochord, which becomes constricted, and ultimately disappears. This nucleus may be double, and, if this character persists, the body ossifies in two separate parts, or, if one nucleus should be

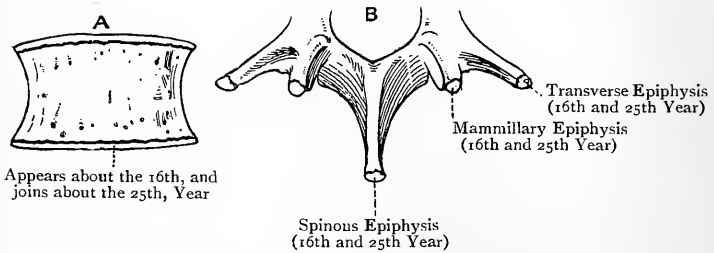


FIG. 19.—LUMBAR VERTEBRA, SHOWING THE EPIPHYSES.

A, The Body ; B, The Neural Arch.

arrested, only one-half of the body ossifies (Turner). At birth a vertebra is composed of three osseous parts, connected by cartilage, namely, the principal part of the body, and the two halves of the neural arch, each bearing a small portion of the body. The laminae unite behind in the *first year*, except in the

axis, where the union is delayed until the *fourth year*, and the neural arch joins the body in the *third year*. The cartilagenous union between the neural arch and the body at either side is called the *neuro-central synchondrosis*. In the thoracic vertebræ the superior demi-facets lie behind this, and so they are shown to be placed on the pedicular portion of the body. All vestiges of this synchondrosis have disappeared prior to the *sixth year*. The secondary centres, five in number, appear about the *sixteenth year*, and they are consolidated about the *twenty-fifth year*. One appears at the extremity of the spinous process, one at the extremity of each transverse process, and the other two take the form of epiphysial plates, one on the upper surface and the other on the under surface of the body. In the case of the **seventh cervical vertebra**, and sometimes one or two above it, the costal process has a special centre which appears *before birth*, and it may be developed into a cervical rib. The transverse process (costal element) of the first lumbar has occasionally a special centre, and in these cases it may be developed into a lumbar rib. The lumbar mammillary processes are ossified from special secondary centres. The **fifth lumbar** has sometimes four centres for the neural arch, two at either side, one of which is for the pedicle, transverse process, and superior articular process, and the other for the lamina, inferior articular process, and one-half of the spinous process. These parts may fail to unite, in which cases the neural arch presents a synchondrosis on either side, situated between the superior and inferior articular processes (Turner). Sometimes the laminae of the fifth lumbar fail to unite, and so a space is left, bridged over by fibrous tissue.

The Atlas.—The atlas has **three centres** of ossification, two for the lateral masses and posterior arch, appearing in the *seventh week* of intra-uterine life, and one (sometimes two) for the anterior arch, which does not appear until the

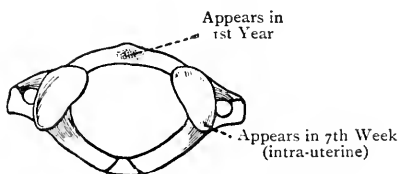


FIG. 20.—OSSIFICATION OF THE ATLAS.

first year. The two halves of the neural arch usually join towards the end of the *third year*, there being sometimes a special osseous deposit at the place of junction. The two halves, however, may remain separate throughout life, the interval being bridged over by fibrous tissue. The anterior arch joins the lateral masses in the *sixth year*. The anterior arch represents the hypochordal brace of the first vertebral bow.

The Axis.—Excluding the odontoid process, the axis has **three primary centres**, like an ordinary vertebra, two for the neural arch appearing about the *seventh week*, and one (sometimes two) appearing in the lower part of the common cartilage of the body and odontoid process in the *fourth month*. In the upper part of this common cartilage two centres, laterally disposed, appear in the *fifth month* for the **odontoid process**, and these unite into one centre about the *sixth month*. At birth the axis is composed of four osseous parts connected by cartilage, namely, a body, an odontoid process surmounted by cartilage, and two halves of the neural arch. The odontoid process joins the body about the *fourth year*. The two halves of the neural arch join each other, and the arch joins the body, in the *fourth year*. The **apical part** of the odontoid process has a special centre appearing in the *fourth year*, and it joins the rest of the process in the *twelfth year*. The body of the axis has the usual epiphysial plate on the under surface of the body, but there is no such plate

on the upper surface. The union between the odontoid process and the body is indicated by a small cartilaginous disc in the centre, which persists until advanced life. The odontoid process is to be regarded as the original *body of the atlas* for the following reasons: (1) in the embryo the notochord passes through its cartilage; (2) the notochord presents a swelling between

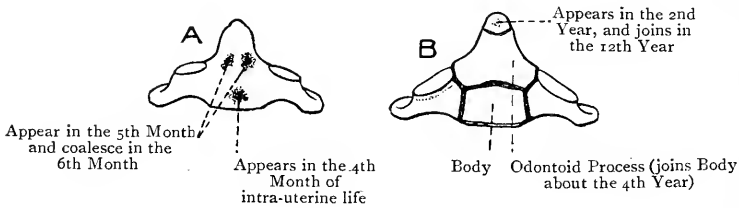


FIG. 21.—OSSIFICATION OF THE AXIS.

A, At the Fifth Month; B, at the Second Year.

the cartilage of the odontoid process and that of the body of the axis, as it does in the case of other vertebræ; (3) there is a cartilaginous disc concealed within the odontoid process, which is persistent until advanced life; (4) the odontoid process has two primary centres of ossification; (5) in chelonians it forms a separate ossicle; (6) a permanently separate odontoid process in man has been recorded.

The False Vertebræ.

The **false vertebræ** are usually nine in number, the upper five of which form the sacrum, and the lower four the coccyx.

The Sacrum.

The **sacrum** lies below the fifth lumbar vertebra, and is wedged in between the ossa innominata, where it forms the greater part of the posterior wall of the pelvis, its direction being downwards and backwards. The sacral vertebræ diminish in size from above downwards, which renders the bone triangular, the base being upwards.

The **ventral** or **pelvic surface**, which is directed downwards and forwards, is concave from above downwards, and from side to side. It presents along the centre a solid mass, representing the ankylosed bodies and ossified intervertebral discs, which is marked by four transverse ridges situated at the places of junction. Superiorly it presents a projecting lip, called the *promontory*. On either side there is a row of *anterior sacral foramina*, four in number, which diminish in size from above downwards, and are directed outwards and forwards from the intervertebral foramina, by means of which they communicate with the sacral canal. They transmit the anterior primary divisions of the first four sacral nerves.

The **lateral masses** are situated external to the anterior sacral

foramina at either side, and each is marked anteriorly by four transverse grooves, which prolong outwards the foramina and lodge the transmitted nerves. The pyriformis muscle arises from the front of each lateral mass by three slips, which are interposed between, and lie external to, the foramina. The lateral masses are formed by the fusion of the pedicles, transverse processes, and costal elements of the sacral vertebræ.

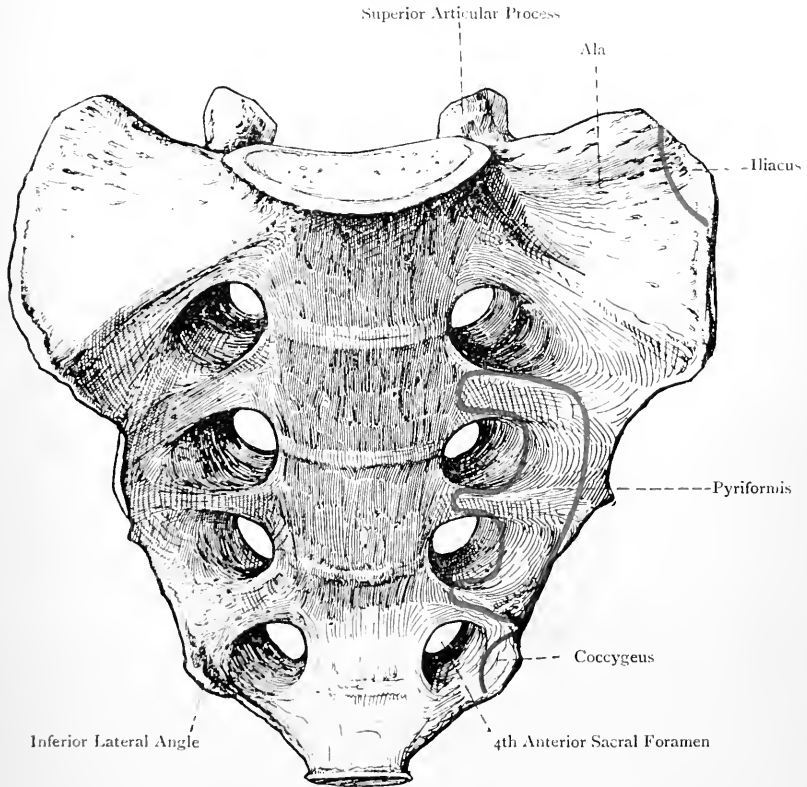


FIG. 22.—THE SACRUM (ANTERIOR VIEW.)

The **dorsal surface**, which is directed upwards and backwards, is irregularly convex and narrower than the ventral. In the middle line it presents four eminences, which may be distinct, or fused to form a ridge, representing the spinous processes of the upper four sacral vertebræ. The spinous process of the fifth vertebra is absent, the development of its laminae having been arrested, and there is thus left a triangular opening, which is the outlet of the sacral canal, to be presently described. On either side of the median

row of spines there is a solid mass formed by the ankylosed laminae, which forms the *sacral groove* for the origin of a portion of the multifidus spinae. External to this groove there is a row of foramina, four in number at either side, called the *posterior sacral foramina*, which are smaller than the anterior, and, like them, diminish in size from above downwards. These foramina open outwards and backwards from the intervertebral foramina (by which they communicate with the sacral canal), and transmit the

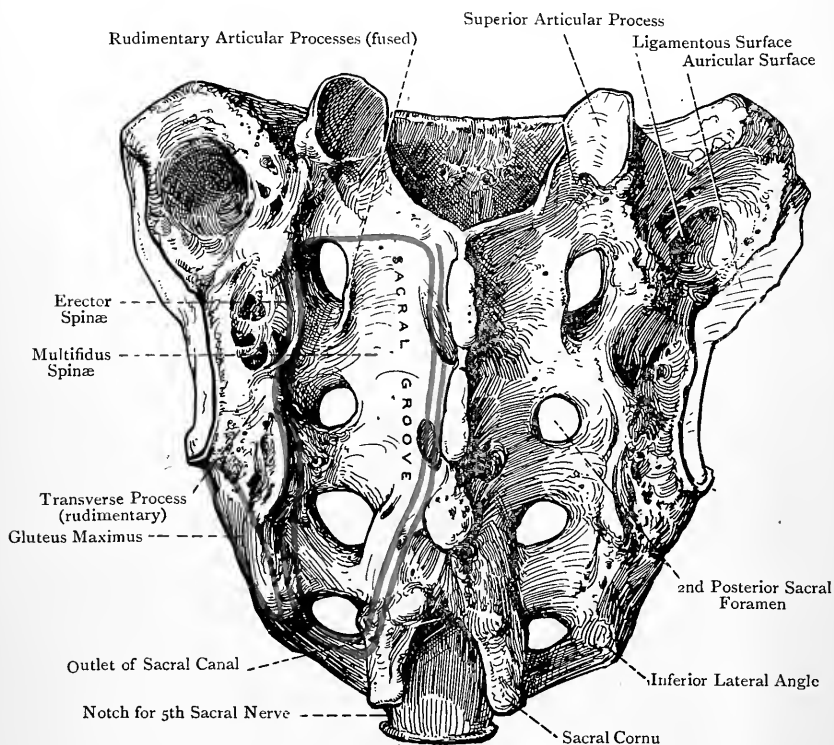


FIG. 23.—THE SACRUM (POSTERIOR VIEW).

posterior primary divisions of the first four sacral nerves. It is to be noted that they lie directly behind the anterior foramina. Internal to the posterior foramina, and encroaching upon them, there is a row of small projections which represent the articular processes of the sacral vertebrae. The lower pair, which belong to the fifth sacral vertebra, are prolonged downwards as two plates which end in enlargements. These are called the *sacral cornua*, and they are connected with the cornua of the first coccygeal vertebra, usually by ligaments, but sometimes by osseous union. The

interval thus bridged over at either side represents a fifth intervertebral foramen, through which the fifth sacral nerve passes. The solid portion external to the posterior foramina at either side is the lateral mass, and it presents a row of four tubercles, each of which is situated external to a posterior foramen. These represent the transverse processes of the lower four sacral vertebrae. The boundaries of the triangular outlet of the sacral canal are the spine of the fourth sacral vertebra above, and the imperfect laminae of the fifth sacral and the sacral cornua at either side. It

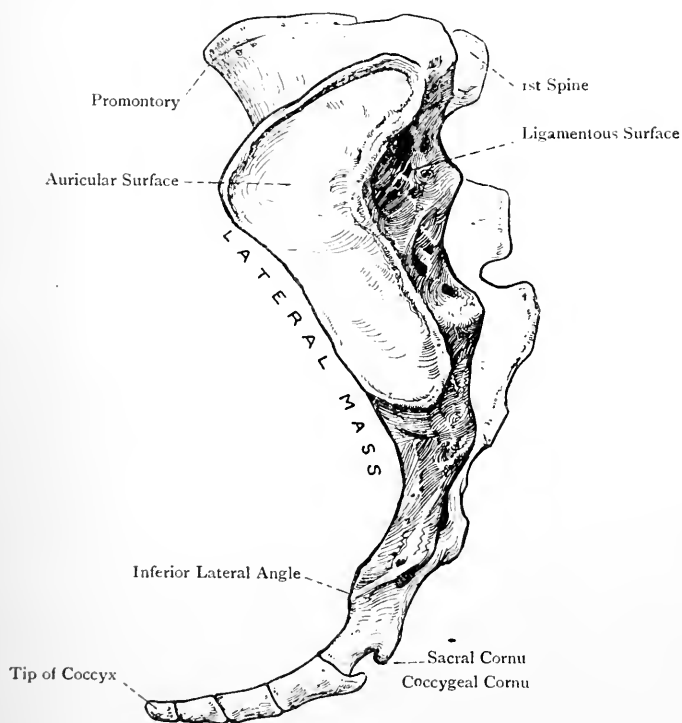


FIG. 24.—THE SACRUM (LEFT LATERAL VIEW).

transmits the fifth pair of sacral nerves and the two coccygeal nerves.

The **lateral surface** is broad above and narrow below. The upper part is divided into two portions—articular and non-articular. The articular division, anterior in position, is covered by cartilage, and is shaped like an ear, on which account it is called the *auricular surface*. It articulates with the iliac portion of the os innominatum, and extends over at least the first two sacral vertebrae. The non-articular division, posterior in position, is rough and irregular for

the attachment of the posterior sacro-iliac ligament, and it is known as the *ligamentous surface*. The lower part of the lateral surface corresponds with at least the lower two sacral vertebrae, and may include more or less of the third. It gives attachment to fibres of the great and small sacro-sciatic ligaments and a portion of the coccygeus muscle, whilst the adjacent portion of the posterior aspect gives origin to fibres of the gluteus maximus. Inferiorly the lower part is thinned away to a mere margin, and presents a process, called the *inferior lateral angle*. Below this is the transverse process of the first coccygeal vertebra when that is in position, a notch being thus formed on the side of the fifth sacral vertebra. The inferior lateral angle inclines towards the coccygeal transverse process, with which it is usually connected by a ligament, though in some cases the two processes become ankylosed. There is thus constructed a fifth anterior sacral foramen at either side for the

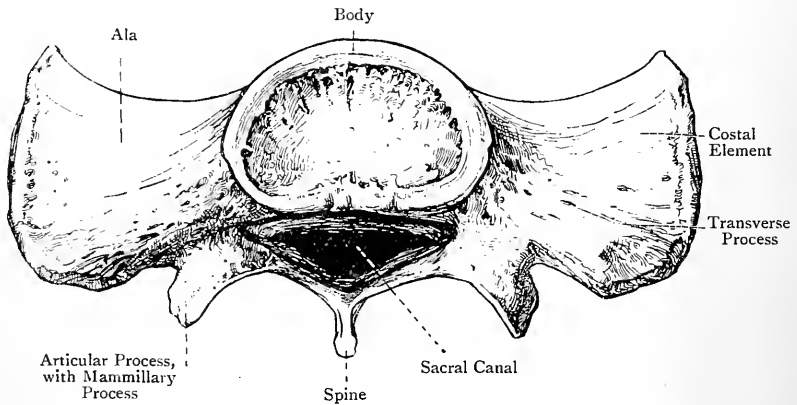


FIG. 25.—THE BASE OF THE SACRUM.

passage of the anterior primary division of the fifth sacral nerve.

The **base** presents a central and two lateral divisions. The central division corresponds in its characters with the superior surface of a lumbar vertebra. Each superior vertebral notch lodges a fifth lumbar spinal nerve, and the superior articular processes stand wide apart. The lateral divisions of the base are called the *alæ*. Each *ala* is triangular with the apex, which represents the transverse process, directed backwards. The alar surface is depressed, concave from side to side, and convex from behind forwards. It gives attachment to fibres of the iliacus, the lateral lumbo-sacral and anterior sacro-iliac ligaments, and it supports the lumbo-sacral nervous cord and the internal iliac vessels. The ala is formed by the fusion of the pedicle, transverse process, and costal element of the first sacral vertebra.

The **apex** is transversely oval, and articulates with the first

coccygeal vertebra, with the intervention of an intervertebral disc until advanced life, when ankylosis takes place.

The **sacral canal** is situated behind the bodies of the first four sacral vertebrae, as a rule. It is triangular in the upper part, but somewhat crescentic below. It is closed in front by the ankylosed bodies, and behind by the ankylosed laminae. Along each side it presents four intervertebral foramina for the passage of nerves. These are bounded externally by the lateral mass, but each opens on the ventral and dorsal surfaces by the anterior and posterior sacral foramina, which represent the limbs of a capital V, the apex

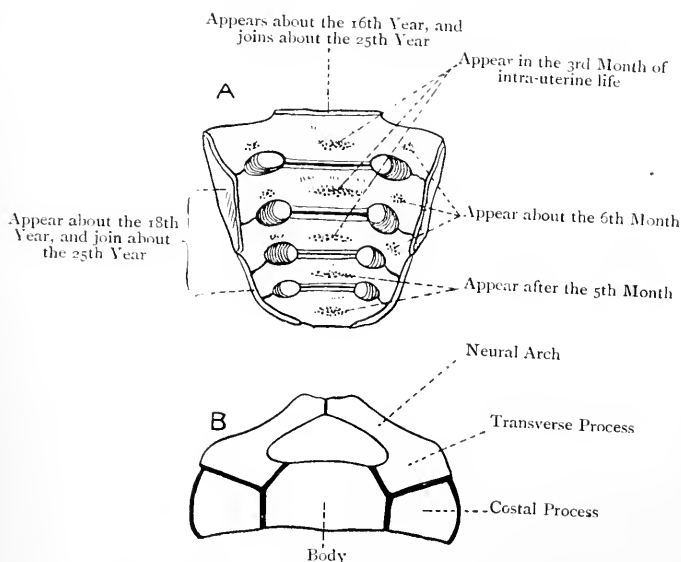


FIG. 26.—OSSIFICATION OF THE SACRUM.

A, Anterior View ; B, First Sacral Vertebra in early life (Superior View).

of which corresponds with an intervertebral foramen. The contents of the canal are the sacral and coccygeal nerves, and the filum terminale of the spinal cord.

The sacrum derives its blood-supply from the lateral sacral and middle sacral arteries.

Articulations.—*Superiorly* with the fifth lumbar vertebra, *inferiorly* with the coccyx, and *at either side* with the os innominatum.

Varieties.—(1) The number of sacral segments may be six, or more rarely four. Increase in the number is usually due to the incorporation of the first coccygeal vertebra, or sometimes the fifth lumbar. The decrease may be due to the fifth sacral vertebra forming a part of the coccyx, or to the first sacral forming a sixth lumbar. (2) The bodies of the first and second sacral vertebrae may remain permanently separate, though ankylosis has taken place in all their other parts. (3) The first sacral vertebra may be normal on one side,

but on the other side it may remain separate from the second, and present the characters of a fifth lumbar. (4) The number of sacral spines may be reduced from four to three, two, or one, or they may be entirely absent. As a consequence of this, the sacral canal, which usually opens on the back of the fifth sacral vertebra, may do so on the back of the fourth, third, second, or first, so that in some cases it may be entirely open posteriorly. (5) The sacrum is liable to much variety as regards the extent of its vertical curve.

Characters of the Female Sacrum.—In the female the sacrum is smoother, shorter, broader, less curved, and is set more backwards than in the male.

Ossification.—The sacrum ossifies in cartilage from **thirty-five centres**. Each segment has **three primary centres**, one for the body and two for the neural arch. The centre for the body appears in the *third month* of intra-uterine life in the case of the first three, and after the *fifth month* in the last two. The centres for the neural arches appear about the *sixth month*. The neural arches join the bodies, in order from below upwards, from the *second* to the *sixth year*. The union of the laminae takes place from the *eighth* to the *twelfth year*. It, however, fails in the lowest, and sometimes in those higher up. The anterior parts of the lateral masses of the first three vertebræ, which represent the costal elements, have separate centres, which appear about the *sixth month*. These join the neural arches before uniting with the bodies, the latter union taking place rather later than the union between the neural arches and the bodies. Each vertebra has two annular circumferential epiphysal plates, superior and inferior, which begin to ossify about the *sixteenth year*. On each side of the sacrum there are two epiphyses, an upper for the auricular surface, and a lower for the sharp edge below, which appear about the *eighteenth year*. Consolidation begins about the *eighteenth year*, and proceeds from below upwards, union taking place earlier between the segments of the lateral masses than between the bodies. In the latter case the ossification invades the intervertebral discs, but in the former it is direct union. The union is complete about the *twenty-fifth year*, at which period also the lateral epiphyses join the bone.

The Coccyx.

The **coccyx** is composed as a rule of four rudimentary vertebræ, and it lies below the apex of the sacrum, which constitutes its only articulation. The direction of the bone is downwards and forwards, and its elements diminish in size from above downwards. It is triangular.

The **first coccygeal vertebra** is compressed from before backwards, broad above, narrow below, concave in front, and convex behind. The superior and inferior surfaces are transversely oval, and the lateral borders are sloped downwards and inwards. Two processes project upwards from the dorsal surface at either side, called the *cornua*, which articulate with the sacral cornua, usually by ligaments, but sometimes directly. Each lateral border presents, superiorly, a projection, called the *transverse process*, which inclines towards the inferior lateral angle of the sacrum, and is usually connected to it by a ligament, which is sometimes ossified.

The **second coccygeal vertebra** presents traces of transverse processes and cornua, whilst the **third** and **fourth** are reduced to mere nodules.

The muscular attachments of the coccyx are as follows: the gluteus maximus to the back of the upper three segments close to the lateral border: the sphincter ani externus to the tip; the posterior fibres of the levator ani and a portion of the coccygeus to the lateral border. The great and small sacro-sciatic ligaments

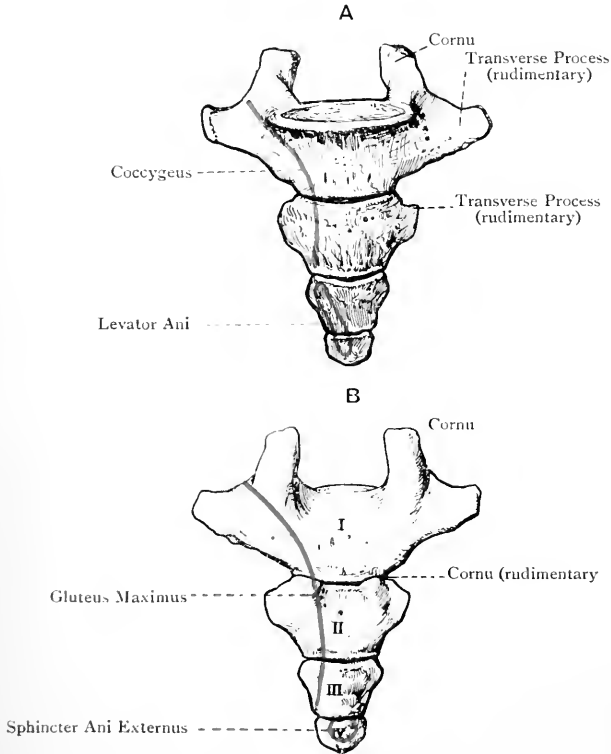


FIG. 27.—THE COCCYX.

A, Anterior View; B, Posterior View.

are partially attached to the lateral border of the first coccygeal vertebra.

The coccyx derives its blood-supply from the lower lateral sacral and middle sacral arteries.

Varieties.—The number of coccygeal segments may be increased to five, due either to the addition of an extra nodule, or to incorporation of the fifth sacral segment. The number may be reduced to three, due either to incorporation of the first coccygeal segment with the sacrum, or to suppression of one of the nodules.

Ossification.—The coccygeal vertebræ are cartilaginous at birth. Each has **one centre**, though the first may have two. The centre for the first appears

in the *first year*, that for the second some time between the *fifth* and *tenth year*, that for the third a little before puberty, and that for the fourth a little after that period. The union of the segments takes place from below upwards, the three lower having usually joined by middle life. At a later period the first segment joins the rest, and in advanced life (earlier in the male than in the female) the coccyx becomes ankylosed to the sacrum. Prior to middle life the segments are separated by intervertebral discs.

The Vertebral Column as a Whole.

The **vertebral column** supports the other parts of the skeleton, directly or indirectly. Its average length is about 28 inches in the male, and rather less in the female. When viewed from the front, it presents four pyramids. The *first* extends from the axis to the seventh cervical vertebra, its base being downwards. The *second* extends from the first to the fourth thoracic vertebra, its base being upwards. The *third* extends from the fifth thoracic to the fifth lumbar, its base being downwards. The *fourth* extends from the base of the sacrum to the tip of the coccyx. These pyramids are due to the differences in breadth of the bodies in different parts.

The column presents certain curves, which are arranged in two groups, antero-posterior and lateral. The antero-posterior group comprises four curves, named cervical, thoracic, lumbar, and pelvic. The cervical and lumbar curves have their convexities directed forwards, and the thoracic and pelvic curves have their convexities directed backwards. The lumbar and pelvic curves meet rather abruptly and form a projection, called the *sacro-vertebral angle*, which is estimated at 117 degrees in the male and 130 degrees in the female. The curves impart springiness or elasticity to the column, and so guard it against shock. The thoracic and pelvic curves are associated with the thoracic and pelvic cavities, the capacity of which they serve to increase. They appear in early foetal life, and are known as *primary curves*. The cervical and lumbar curves do not appear until after birth, and are known as *secondary* or *compensatory curves*. The primary curves are brought about by the greater depth posteriorly of the thoracic and sacral bodies, whilst the compensatory curves are largely due to the intervertebral discs, though in the lumbar region the greater depth of the bodies anteriorly, especially in the fifth lumbar, must also be taken into account.

The lateral group comprises two curves. One is situated in the upper thoracic region, with its convexity directed towards the right side in right-handed persons, and it is to be regarded as due to the greater use made of the right arm. To compensate for this curve there is another slight curve in the upper lumbar region, with the convexity to the left.

When viewed anteriorly, the column presents the bodies, which form the pyramids already described. When viewed laterally, it presents the sides of the bodies, pedicles, intervertebral foramina, and articular and transverse processes. The *intervertebral foramina*

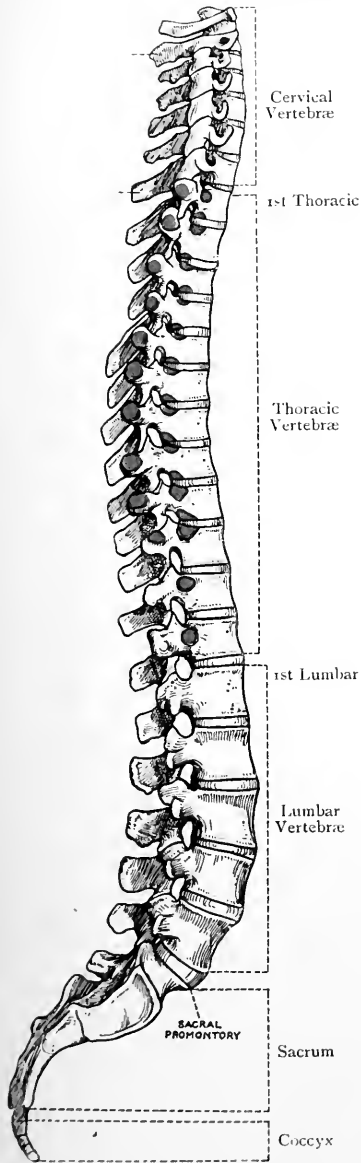


FIG. 28.—THE VERTEBRAL COLUMN (LATERAL VIEW).
(The Blue Markings represent the Facets on the Bodies and Transverse Processes.)

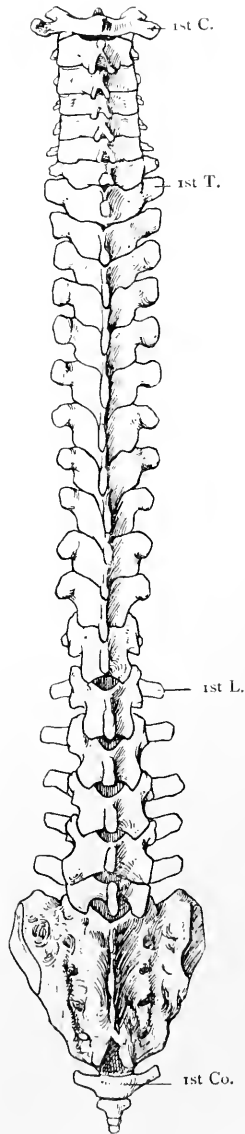


FIG. 29.—THE VERTEBRAL COLUMN (POSTERIOR VIEW).

are formed by the apposition of the superior and inferior vertebral notches of contiguous pedicles. They lead outwards from the spinal canal, and each transmits a spinal nerve. They increase in size from above downwards until the sacrum is reached, in which, though hidden at either side of the central mass, they diminish in size from above downwards. In this region each intervertebral foramen opens on the front and back of the sacrum by means of an anterior and posterior sacral foramen, the arrangement thus formed resembling a capital V, the apex being at an intervertebral foramen. On the lateral aspect of the thoracic portion of the column are seen the *costo-capitular facets*, which are twelve in number. The first is situated on the upper part of the side of the first thoracic body. The second to the tenth inclusive are situated on the contiguous margins of the bodies of the vertebræ, each being formed by the small inferior demi-facet of the upper body and the large superior demi-facet of the lower. The eleventh and twelfth are situated on the sides of the corresponding pedicles. The tenth facet may belong entirely to the tenth thoracic vertebra. The thoracic transverse processes, except the eleventh and twelfth (and sometimes the tenth), are faceted in front at their extremities for the tubercles of the ribs.

When the column is viewed from behind the following parts are seen: the spinous processes; the laminæ; the articular processes; the backs of the transverse processes; and the dorsum of the sacrum and coccyx. The cervical spines, except the sixth and seventh, are short, so as not to interfere with backward flexion or over-extension of the neck. The middle thoracic spines are imbricated, and the lumbar spines stand out horizontally. On either side of the spines there is the *vertical groove*, which is occupied by the deep muscles of the back, the deepest being the multifidus spinæ. This groove is bounded internally by the spines, and externally by the transverse processes in the cervical and thoracic regions, and by the mammillary tubercles in the lumbar region. The floor is formed by the laminæ, and its continuation over the back of the sacrum is known as the *sacral groove*.

The *spinal canal* is situated behind the bodies of the vertebræ, and is formed by the neural foramina of all the vertebræ except the fifth sacral and four coccygeal. It commences at the level of the atlas, and it terminates as a rule upon the back of the body of the fifth sacral vertebra. It adapts itself to the various curves of the column, and is large and triangular in the cervical and lumbar regions, small and circular in the thoracic, and triangular in the upper part, but crescentic in the lower part, of the sacral region. It contains the spinal cord and its membranes as low as about the level of the disc between the first and second lumbar bodies, and a copious plexus of vessels. Below the level just mentioned it contains the filum terminale of the spinal cord and the leash of nerves known as the cauda equina, with their coverings. The dura-matral covering or theca ceases by taking attachment to the back

of the second sacral body, and the *filum terminale* passes on to be attached to the back of the fifth sacral or first coccygeal vertebra.

B. The Ribs.

The **ribs** (*costæ*) are twelve in number at either side, and are arranged in two groups, true or sternal, and false or asternal. The **true ribs** are those which articulate directly with the sternum by their costal cartilages, and they represent as a rule the first seven at either side. The **false ribs** are those which have no direct articulation by their costal cartilages with the sternum, and they represent, as a rule, the last five at either side. The last two false ribs, eleventh and twelfth, are called the *free* or *floating ribs*, because their costal cartilages stand quite clear of each other and of the tenth. The ribs are elastic, and increase in length from the first to the seventh, whence they decrease to the twelfth. The first is the broadest, and the twelfth the narrowest. Their direction is at first downwards, outwards, and slightly backwards, then downwards and forwards, and finally inwards. The upper ribs are not so oblique as those lower down, the most oblique being the ninth. With the exception of the first rib, the surfaces of the others are vertically disposed posteriorly, but in front they are sloped downwards and forwards, and this circumstance renders most of them twisted.

A Typical Rib.—A typical rib presents for consideration a head, neck, tubercle, shaft, and sternal extremity.

The **head** (*capitulum*) forms the posterior or vertebral extremity, and is slightly expanded. It presents an irregularly flat surface and an anterior margin. The surface is marked by two oblique facets, upper and lower, which are separated by a horizontal ridge. The *lower* or *primary facet* is the larger of the two, and articulates with the large upper or primary demi-facet of the lower of the two thoracic bodies with which the head is connected. The *upper facet* articulates with the small lower demi-facet on the side of the upper thoracic body, and the intervening ridge gives attachment to the interarticular ligament. The anterior margin gives attachment to the anterior costo-central ligament.

The **neck** is about 1 inch long, and is compressed from before backwards. Its *anterior surface* is smooth and covered by the costal pleura. Its *posterior surface*, which is rough, faces the anterior surface of the lower thoracic transverse process, or that with which its tubercle articulates, and it gives attachment to the middle costo-transverse or interosseous ligament. Its superior border forms a sharp lip, called the *crest*, which gives attachment to the superior costo-transverse ligament. Its inferior border may show traces of the subcostal groove.

The **tubercle** is situated on the external surface of the rib at the outer extremity of the neck, and presents two divisions, articular and non-articular. The *articular division*, inferior and slightly

internal in position, presents a somewhat oval facet for articulation with that on the front of the extremity of the lower thoracic transverse process. The *non-articular division*, superior and slightly

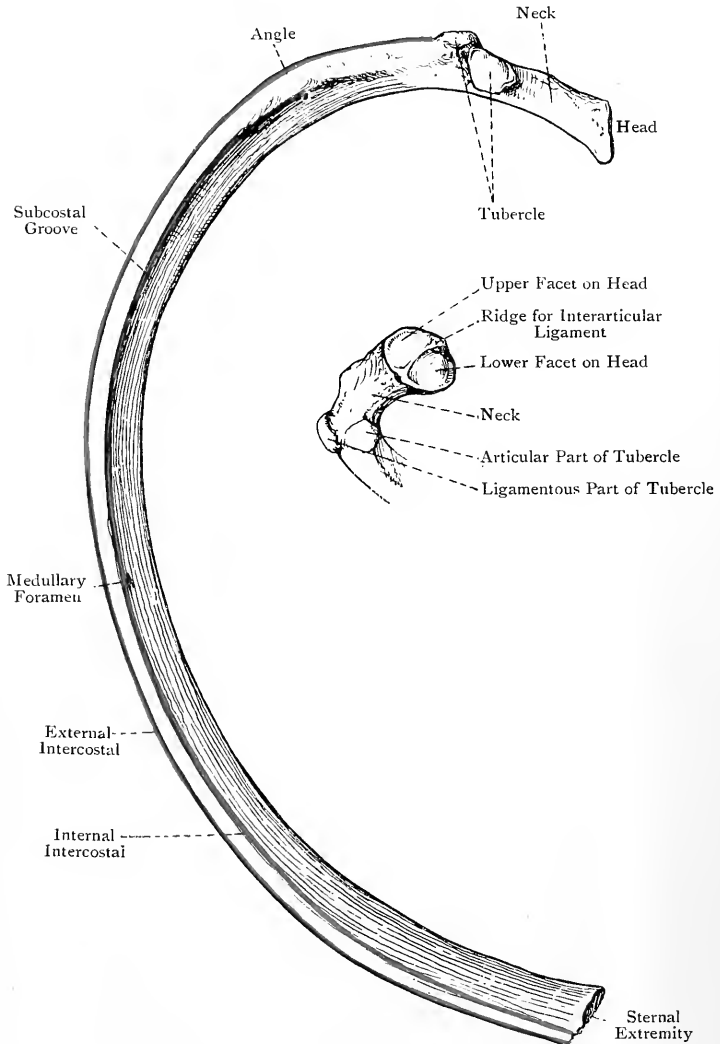


FIG. 30.—THE SIXTH LEFT RIB (INTERNAL VIEW).

external in position, gives attachment to the posterior costo-transverse ligament.

The **shaft** is curved and twisted. It presents two surfaces and

two borders. The *external surface* is convex, and its plane is vertical behind, but oblique in front, being here sloped downwards and forwards. Opposite the greatest bend of the rib it presents an oblique ridge, directed downwards and outwards, called *the angle*, for a tendinous slip of the erector spinæ. The surface between the tubercle and the angle gives attachment to the longissimus dorsi. Near to the anterior extremity (about 2 inches from it) the external surface presents another oblique ridge directed downwards and outwards, known as the *anterior angle*, where the rib describes a slight curve. The *internal surface*, which is concave, is covered by the costal pleura. At its lower part it presents the subcostal groove, to be presently described. The *superior border* is thick and round behind, but thin and sharp in front. Its outer lip gives attachment to an external intercostal muscle, and its inner lip to an internal intercostal, a collateral intercostal artery lying between the two muscles. The *inferior border* is for the most part sharp and wiry. Immediately within and above it there is the **subcostal groove**, which commences behind at the tubercle and disappears over the anterior fifth. Posteriorly the groove belongs to the inferior border. Its upper lip is rounded and gives attachment to an internal intercostal muscle, whilst the lower lip gives attachment to an external intercostal. The nutrient foramen is situated in the subcostal groove a little anterior to the centre of the bone, and the canal to which it leads is directed towards the head. It gives passage to a branch of the intercostal artery which lies in the groove. The contents of the groove from above downwards are an intercostal vein, artery, and nerve.

The **anterior or sternal extremity** presents an oval pit, which is almost vertical in direction, for the costal cartilage.

The Peculiar Ribs.—These are the first, second, tenth, eleventh, and twelfth.

The First Rib.—This is the shortest, broadest, and flattest of all the ribs, and its curve is very distinct, but there is no twist. The **head** is small, and presents a nearly circular facet for articulation with the entire facet on the body of the first thoracic vertebra. The **neck** is narrow, and compressed from above downwards. The **tubercle**, which is large, is situated on the external border at the junction of the neck with the shaft. Being placed opposite the greatest bend of the bone, it takes the place of the angle, and presents the usual articular and non-articular portions, the former being for the first thoracic transverse process.

The **shaft** is broad and compressed from above downwards, its surfaces being superior and inferior, whilst the borders are internal and external. The *superior surface* close to the anterior extremity gives attachment to the tendon of the subclavius and the costo-coracoid ligament. Farther back there are two oblique grooves, separated to a limited extent by a tubercle or spine for the scalenus anticus. The anterior groove is shallow, and lodges the subclavian vein, whilst the posterior deeper groove

is occupied by the third part of the subclavian artery and the trunks of the brachial plexus of nerves. Behind the posterior groove, and extending as far back as the tubercle, there is a rough impression for the insertion of the scalenus medius. The *inferior surface* is flat and covered by the costal pleura. Near the external border it gives attachment to the internal intercostal muscle of the first space. The *internal border*, which is thin and concave, gives attachment to Sibson's fascia. Fully 1 inch from

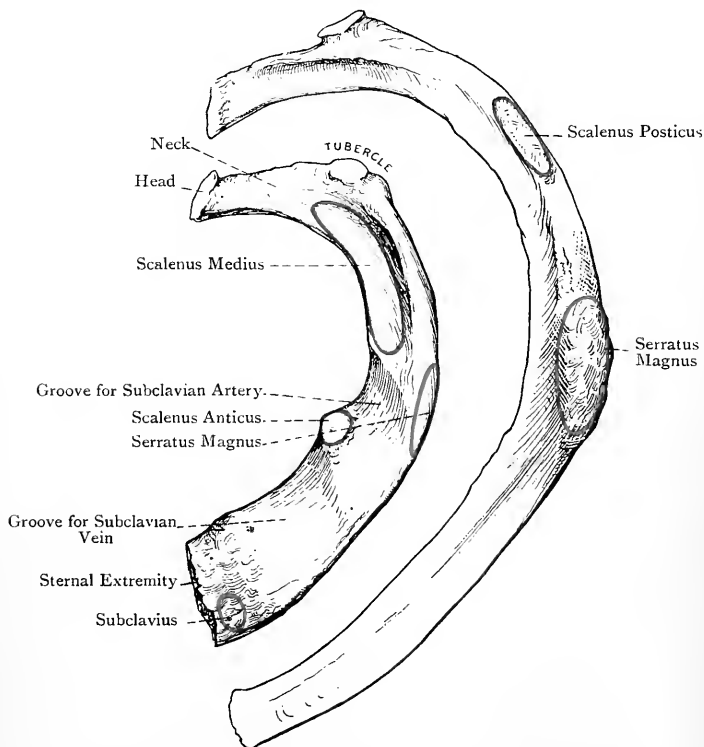


FIG. 31.—THE FIRST AND SECOND RIBS OF THE LEFT SIDE
(SUPERIOR VIEW).

the anterior extremity this border presents a projection, called the **scalene tubercle** or **spine** (*tubercle of Lisfranc*), for the insertion of the scalenus anticus. It encroaches slightly on the adjacent part of the superior surface, and is inclined backwards. The *external border* is convex. It gives attachment to the external intercostal muscle of the first space, and a portion of the first serration of the serratus magnus at a point opposite the groove for the subclavian artery, where the external border is often prominent. The

anterior extremity presents the usual oval pit for the first costal cartilage, its direction being horizontal from before backwards. The first rib has no subcostal groove.

The Second Rib.—The surfaces of the shaft of this rib occupy a transitional plane between that of the first and those of the succeeding ribs. It is practically destitute of a twist. The neck is compressed from above downwards, and from before backwards. The distinctive character of the bone is the presence on its supero-external surface, near the centre, of a rough oval eminence for a portion of the first and the second slips of the serratus magnus. Behind this impression the surface gives insertion to the scalenus posticus.

The Tenth Rib.—This bone may or may not be peculiar. If the body of the ninth thoracic vertebra has a lower demi-facet, there is nothing peculiar about the head of the tenth rib. If, however, the lower demi-facet is wanting on the ninth thoracic body, the head of the tenth rib has only one facet for that on the body and pedicle of the tenth thoracic vertebra. The tubercle has usually an articular facet for the tenth thoracic transverse process, but this may be wanting. The angle and subcostal groove are well marked.

The Eleventh Rib.—The head of this rib has one facet for that on the pedicle of the eleventh thoracic vertebra. There is a slight tubercle, destitute of an articular facet, a faint angle, and an equally faint subcostal groove. The anterior extremity is pointed, and only tipped with a costal cartilage, which is free.

The Twelfth Rib.—This is a very short bone. Its head has one facet for that on the pedicle of the twelfth thoracic vertebra. The tubercle, angle, and subcostal groove are wanting. The shaft is very narrow, and terminates anteriorly in a pointed extremity, which is merely tipped with a free costal cartilage. The lower border of the shaft has a rough, sharp outline, and gives attachment to a portion of the quadratus lumborum muscle, whilst the upper border, especially towards the back part, is smooth and round.

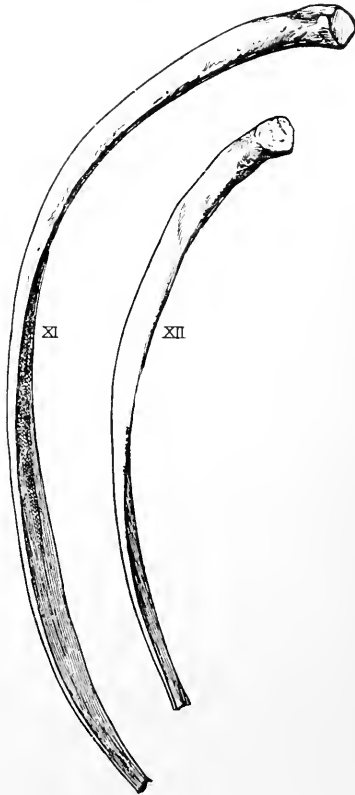


FIG. 32. — THE ELEVENTH AND TWELFTH RIBS OF THE LEFT SIDE (INFERIOR VIEW).

The ribs are supplied with blood by branches of the intercostal arteries.

Structure.—A rib is composed of loose cancellated tissue surrounded by compact bone.

Varieties.—(1) The number may be increased to thirteen on one or both sides, and the supernumerary rib may be cervical or lumbar. If cervical, it is developed in connection with the costal process of the seventh cervical vertebra. It may join the shaft of the first thoracic rib, or it may reach the sternum. If lumbar, it is developed in connection with the costal element of the first lumbar vertebra, is usually very short, and does not articulate with the body of that vertebra. (2) In rare cases the number may be decreased by one, at the expense of the twelfth rib. (3) The ribs are subject to variety in form as follows: (a) the vertebral end of the first thoracic rib may be joined by a cervical rib, or by the vertebral end of the second rib, in which cases the variety known as *bicipital rib* occurs; (b) the anterior extremity of a rib may be bifurcated; (c) adjacent ribs may be connected by small plates of bone.

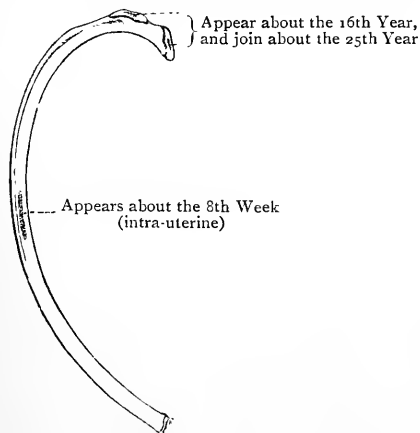


FIG. 33.—OSSIFICATION OF A RIB.

teenth year. One gives rise to the head, and of the other two one is for the *rough part* of the tubercle and the other for its *articular part*. The head and two parts of the tubercle join the shaft about the *twenty-fifth year*. The two secondary tubercular centres are absent in the eleventh and twelfth ribs.

The Costal Cartilages.

The **costal cartilages**, which are composed of hyaline cartilage, are twelve in number on either side. The outer extremity of each is received into the oval pit on the anterior extremity of a rib, and is there maintained in position by the continuity which takes place between the periosteum of the rib and the perichondrium of the cartilage. The inner extremities of the true ribs articulate with the side of the sternum by means of synovial joints, except in the case of the *first*, which is directly united to the presternum without the intervention of a synovial membrane. The eighth as a rule, ninth, and tenth do not reach the sternum, and they articulate with each other by synovial joints, each cartilage being widened at the place of articulation, where it sends downwards a process to the upper border of the cartilage below. In this way interchondral joints are formed between these cartilages, as well

as between the eighth, seventh, sixth, and sometimes the fifth. The eleventh and twelfth cartilages are mere nodules tipping the corresponding ribs, and they have no articulation with each other, nor has the eleventh with the tenth. The cartilages increase in length from the first to the seventh, beyond which they gradually diminish to the twelfth. They diminish in breadth from above downwards. The direction of the first cartilage is inwards and downwards, and that of the second horizontally inwards, whilst the succeeding ones, except the eleventh and twelfth, incline more and more upwards as they pass inwards. Prior to middle life the first costal cartilage undergoes superficial ossification underneath the perichondrium, and so a thin shell of bone is formed around it. In advanced life this condition may be met with in the other costal cartilages to a certain extent.

C. The Sternum.

The **sternum** or breast-bone is situated in the middle line of the anterior wall of the thorax, where it articulates on either side with the first seven costal cartilages, and superiorly with the clavicle. It occupies an oblique plane, which is directed downwards and forwards, forming an angle with the vertical of about 20 degrees. It is compressed from before backwards, of unequal width at different parts, and more or less curved from above downwards, the convexity being directed forwards, and being very pronounced in the condition known as 'pigeon-breast.' The bone is originally composed of six segments, called **sternebrae**. The first sternebra forms the manubrium ('handle') or presternum. The succeeding four sternebrae form the body, gladiolus, or meso-sternum, and the sixth sternebra forms the ensiform or xiphoid process (*xiphisternum*), otherwise known as the metasternum.

The **presternum** is irregularly four-sided, and broader above than below. It presents two surfaces and four borders. The *anterior surface* is convex from side to side, and concave from above downwards. It gives origin at either side to a portion of the pectoralis major, and at its upper and outer part to the sternal head of the sterno-cleido mastoid. Between the latter point and the clavicular depression on the upper border it gives attachment to the anterior sterno-clavicular ligament. The *posterior surface* is concave. At its upper and outer part it gives origin to portions of the sterno-hyoid and sterno-thyroid, the former being the higher of the two, and close to the clavicular depression it gives attachment to the posterior sterno-clavicular ligament. The *superior border* over its middle portion presents the *interclavicular* or *semi-lunar notch*, which gives attachment to fibres of the interclavicular ligament. At either side of this there is a large, oval, concavo-convex articular surface for the clavicle, which is directed upwards, outwards, and slightly backwards, an interarticular fibro-cartilage intervening between the bones. Close to the inner end of each

clavicular depression there may be found, on the anterior aspect, an ossicle, known as the *episternal bone*. The *inferior border*, which is short and straight, articulates with the mesosternum, a disc of fibro-cartilage intervening. In this situation there is a transverse

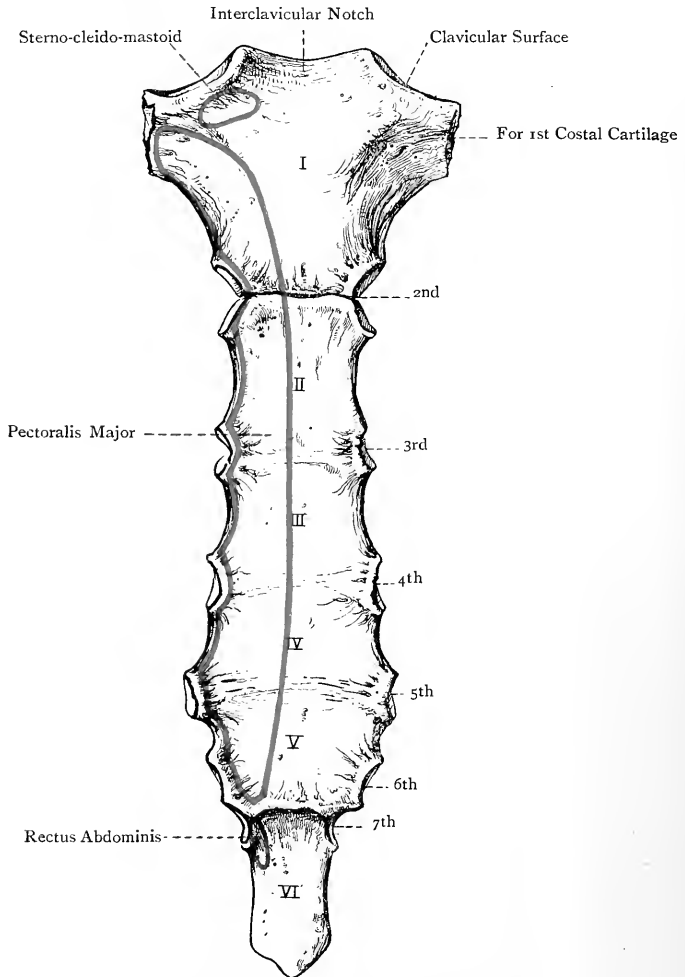


FIG. 34.—THE STERNUM (ANTERIOR SURFACE).

elevation, called the *sternal angle*, which serves as a guide to the second rib at either side. Each *lateral border* slopes downwards and inwards. The upper part presents a triangular depression for the first costal cartilage, and close to the lower part a demi-facet for a portion of the second costal cartilage.

The **mesosternum** presents two surfaces and four borders. The *anterior surface* is marked by three transverse lines, which indicate the places of junction of the original four sternobræ. At either side it gives origin to a large portion of the pectoralis major. The *posterior surface* presents traces of the highest transverse line, but the lower two have usually become effaced. Adjacent to each lateral border it gives origin to a portion of the triangularis sterni, as high as the level of the third costal facet. Each *lateral border* presents a series of costal facets, disposed as follows: close to the upper extremity there is a demi-facet for a portion of the second costal cartilage; opposite each of the three transverse lines there is an entire facet for the third, fourth, and fifth costal cartilages; and on the side of the fourth segment of the body there are usually one entire facet and one demi-facet lying close together, the former being for the sixth costal cartilage, and the latter for a portion of the seventh. Altogether there are usually four entire facets and two demi-facets on each lateral border, the demi-facets being situated one at either extremity. Sometimes, however, the inferior demi-facet is replaced by an entire facet for the whole of the seventh costal cartilage. Each of the upper three entire facets is made up of the contiguous demi-facets of two adjacent sternobræ, as in the bodies of most of the thoracic vertebræ. The *superior border* of the mesosternum articulates, as stated, with the presternum. The *inferior border*, which is very narrow, articulates with the metasternum, an intersternbral disc intervening until about the fortieth year, when osseous union usually takes place.

The **metasternum** is subject to much variety as regards condition,

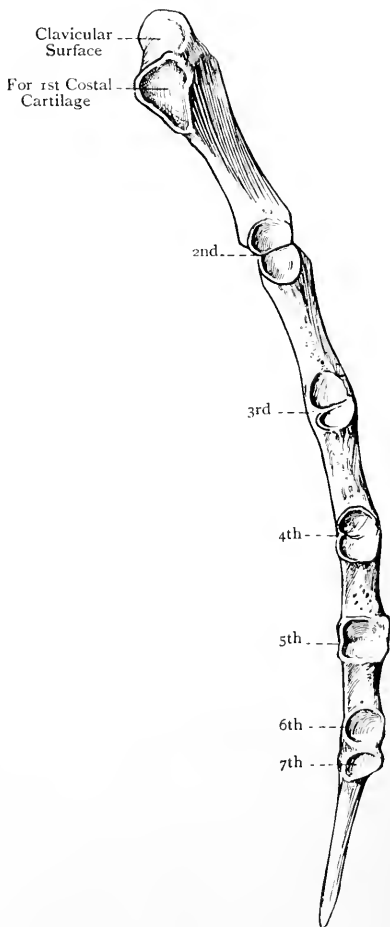


FIG. 35.—THE STERNUM
(LATERAL VIEW).

direction, and form. It may be entirely osseous, or osseous above and cartilaginous below. Its typical direction is downwards between the seventh pair of costal cartilages, but it may have an inclination forwards, backwards, or even to one side. It is narrow from side to side, and compressed from before backwards. It may terminate in a thin transverse border, in a sharp point, or in a bifurcated extremity. The *anterior surface* lies at the bottom of the infrasternal depression. The *posterior surface* gives origin at either side to a portion of the triangularis sterni, and inferiorly it gives origin to a portion of the diaphragm, usually in the form of two fleshy slips. The *superior border* articulates with the mesosternum, and the *inferior border* gives attachment to the linea alba. Each *lateral border* usually presents superiorly a demi-facet for a portion of the seventh costal cartilage, but this may be transferred to the fourth segment of the mesosternum. In rare cases there may be an entire facet for the eighth costal cartilage, this being constant in early life. The lateral border gives insertion at either side to some of the fibres of the internal oblique aponeurosis, and occasionally, at its upper part, to a portion of the rectus abdominis.

The sternum derives its blood-supply from branches of the internal mammary artery.

Articulations.—With the clavicle and first seven costal cartilages, at either side.

Structure.—The sternum is composed of cancellated tissue covered by a thin layer of compact bone.

Varieties.—(1) The sternum is sometimes characterized by its shortness, breadth, and great depression in its lower part. This condition is liable to be met with in cobblers. (2) A *sternal foramen* may be present in the mesosternum, usually in the third or fourth segment. (3) A sternal foramen may be present in the metasternum. (4) In very rare cases the sternum may be intersected from end to end by a *sternal fissure*, in which cases the heart and pericardium are left uncovered (ectopia cordis). (5) The costal cartilages may articulate with the sternum *asymmetrically*.

The Sternum of the Female.—The bone is usually shorter than in the male, the shortness affecting the mesosternum.

Ossification.—The sternum ossifies in cartilage from a variable number of centres. There is usually one centre for the presternum, which appears in the *sixth month* of intra-uterine life. Sometimes there are two, placed one above the other, and there may be as many as six, placed thus . . . The first segment of the mesosternum usually ossifies from one centre, appearing in the *seventh month*, though there may be two, disposed laterally. The second, third, and fourth segments of the mesosternum usually ossify from two centres each, which are disposed laterally and remain separate for some time, but subsequently unite as a rule. There may, however, be only one mesial centre for each of these segments. In the second segment they appear in the *eighth month*, in the third just before birth, and in the fourth during the *first year*. The metasternum ossifies from one centre, which appears in its upper part from the *third* to the *sixth year*, though it may be delayed to a later period. The lower three segments of the mesosternum unite in order from below upwards, the union commencing about puberty and being completed shortly afterwards. The first segment of the mesosternum joins the remainder about *twenty-five*. The metasternum unites with the mesosternum

about *forty*, but the presternum usually remains permanently separate unless in advanced life, when it may become ankylosed to the mesosternum.

The sternal cartilage from which the bone is developed consists originally of two elongated strips, each of which bears the cartilages of nine ribs. The strips are separated for some time by a median fissure, but fusion subsequently takes place, and so a single sternal cartilage is formed. The eighth costal cartilage usually loses its connection with the sternum, though it may articulate permanently with the metasternum. The ninth costal cartilage at either side is regarded as dividing into two parts, one of which

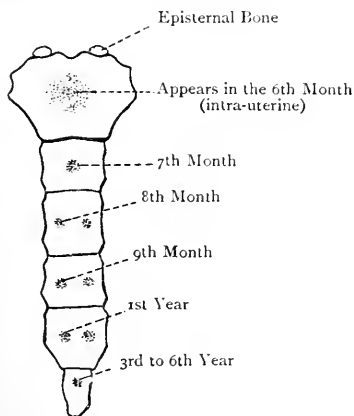


FIG. 36.—OSSIFICATION OF THE STERNUM.

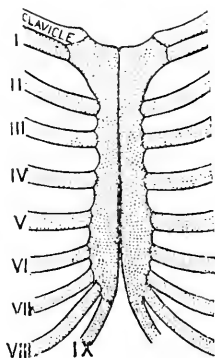


FIG. 37.—DEVELOPMENT OF THE STERNUM
(Modified from Ruge).

remains connected with the sternal cartilage and forms with its fellow the metasternum, whilst the other acquires a connection with the eighth costal cartilage. If the parts of the ninth costal cartilages, which remain connected with the sternal cartilage, do not unite with each other over their whole extent, a bifurcated metasternum is the result. They usually, however, unite wholly, or sometimes in such a manner as to leave a foramen at the centre. A sternal fissure is due to the permanent separation of the two original cartilaginous strips, which, as a rule, unite to form the sternal cartilage. A sternal foramen in the second, third, or fourth segment of the mesosternum is due to ossification from two collateral centres failing to meet at the median line.

Sometimes two ossicles, called the **episternal bones**, are met with at either side of the interclavicular notch of the sternum. These are developed in connection with the suprasternal ligaments, which extend between the inner end of each clavicle and the upper end of the sternum. These ligaments represent the inner extremities of the precoracoid cartilaginous bars.

The Thorax as a Whole.

The **thorax** constitutes an osseous and cartilaginous cage which lodges the heart and lungs, along with important bloodvessels and nerves, as well as the trachea and œsophagus. It is bounded *anteriorly* by the sternum, with the costal cartilages and anterior extremities of the first eight or nine ribs; *posteriorly* by the bodies of the thoracic vertebræ and the vertebral extremities of the ribs

from the heads to the angles; and *laterally* by the ribs beyond their angles. It is conical, the truncated apex being directed upwards, and it is somewhat flattened from before backwards.

The **superior aperture** is bounded *in front* by the upper border of the presternum and the first costal cartilages, *on either side* by

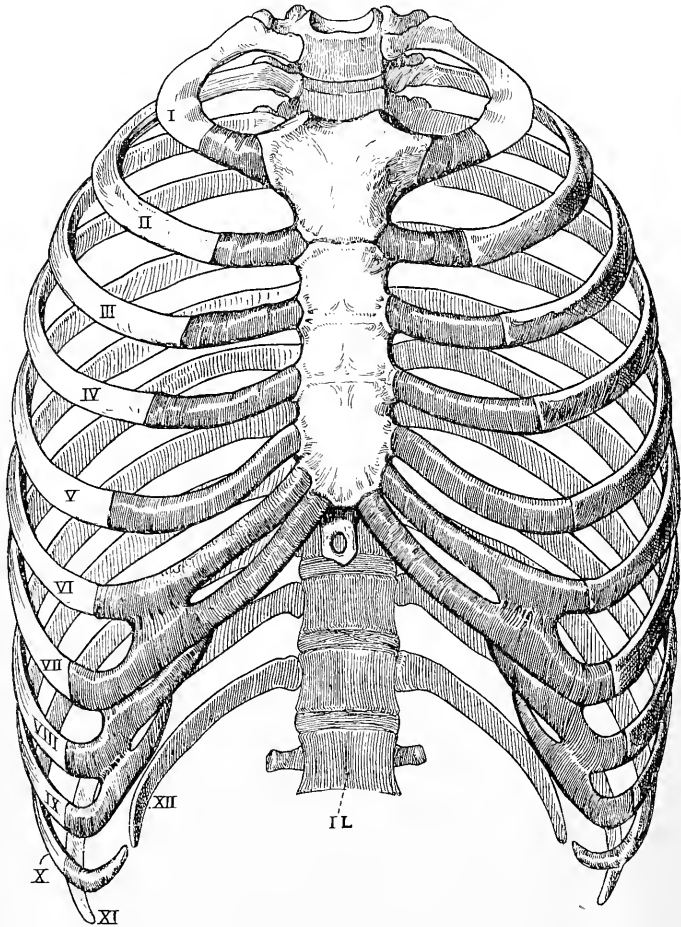


FIG. 38.—THE THORAX (ANTERIOR VIEW).

the first rib, and *behind* by the body of the first thoracic vertebra. Its transverse measurement exceeds the antero-posterior, and it is reniform, due to the forward projection of the first thoracic body. Its plane is oblique, being sloped downwards and forwards, so that the upper border of the presternum is on a level with the disc between the second and third thoracic bodies. The superior

aperture transmits the following structures: the apical parts of the lungs and pleuræ, the trachea and œsophagus, the pneumogastric, sympathetic, and phrenic nerves, the terminal part of the innominate artery, the left common carotid and left subclavian arteries, and the right and left innominate veins. In early life it also transmits the thymus body.

The **inferior aperture** is of large size, and is bounded *posteriorly* by the twelfth thoracic body, *laterally* by the twelfth rib on either side, and *anteriorly* by a line, on either side, connecting the costal cartilages from the twelfth to the seventh inclusive. These two lines constitute the *subcostal angle*, within which the metasternum is situated. The inferior aperture is occupied by the diaphragm, which presents certain openings for the passage of important structures.

The **cavity**, on either side of the thoracic bodies, presents an elongated groove, called the *pulmonary groove*, which lodges the thick posterior border of a lung. The cavity has the following diameters, namely, vertical, transverse, and antero-posterior. The *vertical diameter* extends from the superior aperture to the inferior. The *transverse diameter* extends from the centre of a given intercostal space to the centre of the corresponding space of the opposite side. The *antero-posterior diameter* extends from the anterior to the posterior wall, and is necessarily of less extent in the median line than on either side, on account of the projection formed by the thoracic bodies, its increase on each side being due to the presence of the pulmonary groove. The cavity is increased in all these diameters during inspiration, and diminished during expiration.

The **intercostal spaces** are eleven in number on either side. They increase in length from the first to the fifth, and are occupied for the greater part of their extent by the external and internal intercostal muscles.

The thorax of the female is rather shorter than that of the male, and is not so much flattened from before backwards.

In early life the thorax is flattened from side to side, and its height is relatively less than in the adult.

Development of the Vertebral Column, Ribs, and Sternum.

The **notochord** or **chorda dorsalis** is the primitive axis round which the vertebral column is developed. It is a cellular, rod-like structure of hypoblastic origin, which lies below the neural canal, where it is placed between the epiblast of that canal and the hypoblast of the visceral cavity, being connected with the mesoblast at either side. It becomes invested by a sheath formed of cells derived from the mesoblast. This sheath is known as the *skeletogenous sheath*, and it also invests the neural canal. This constitutes the **first stage** in the development of the vertebral column, namely, the **membranous stage**.

The mesoblast on each side of the notochord and neural canal becomes broken up into a number of segments, called protovertebræ or mesoblastic somites (body-segments). It is not, however, to be supposed that the so-called protovertebræ are the precursors of the future vertebræ. They have

specially to do with the development of the voluntary muscles from muscle-plates or myotomes. Each mesoblastic somite consists of cells arranged in three groups. From one of these groups the sheath of the notochord and that of the neural canal are derived, which form the membranous vertebral column. From another group are formed the muscle-plates or myotomes, which give rise to the voluntary muscles. The intervals between the mesoblastic somites are known as the *intersegmental septa*, and it is on a level with these septa that the bodies of the vertebræ are developed, the discs being opposite the somites. In the membranous stage of the vertebral column the *body* of the vertebra is represented by the *chordal part* of the skeletogenous sheath, and the *neural arch* by the *neural part* of that sheath. At this stage the vertebra is composed of a membranous body and a neural bow. The lateral limbs of the bow are placed on either side of the neural canal, and are continuous with each other below, or on the ventral aspect of, the membranous body, where they form the *hypochordal part* of the bow.

The **second or cartilaginous stage** consists in the chondrification of the membranous framework of the body and neural arch, with the exception of the hypochordal part of the bow, which becomes incorporated with an intervertebral disc. The two lateral limbs of the cartilaginous neural arch meet on the dorsal aspect of the neural canal, and so complete the arch. In the **atlas** the hypochordal part of the neural bow becomes chondrified also, and when ossified forms the *anterior arch*.

The cartilaginous body and neural arch now join, and the **stage of ossification** commences, which consists in the deposition of osseous centres in the body and neural arch. The osseous matter for the body is first deposited *behind* the notochord, and subsequently extends around it. The notochord thus becomes constricted, and ultimately disappears in the region of the vertebral bodies. The transverse and spinous processes are developed in cartilage which grows outwards into the intersegmental septa. The intervertebral discs are developed from the skeletogenous sheath of the notochord in the intervals between the vertebral bodies opposite the mesoblastic somites. The mesoblastic tissue becomes transformed into the fibro-cartilage and fibrous tissue of the discs, and in this situation the notochord forms the *central pulp* of each disc.

The **ribs** are developed in the septa between the thoracic mesoblastic somites from cartilage formed in extensions of their mesoblast. They are entirely supported by the neural arches of the vertebræ. At their ventral extremities the first nine cartilaginous ribs of each side form by their junction an elongated strip, and these two strips by their subsequent union give rise to the cartilage from which the **sternum** is developed.

II.—THE BONES OF THE HEAD.

The **head** or **skull** is supported on the upper end of the vertebral column, and is divisible into the cranium and face. The **cranium** or brain-case is composed of eight bones, namely, the occipital, two parietals, frontal, two temporals, sphenoid, and ethmoid. The **face**, which protects organs of special sense, such as the eyes, the olfactory mucous membrane, and the tongue, is composed of the following fourteen bones, the majority of which are arranged in pairs: the two superior maxillæ, two malars, two nasals, two lachrymals, two inferior turbinates, two palate bones, the vomer, and the inferior maxilla. All the bones of the skull, except the inferior maxilla, are immovably united by sutures.

The Occipital Bone.

The **occipital bone** is so named because it is situated against the posterior and inferior parts of the cranium. It is quadrilateral and curved, its long axis extending from above downwards and forwards. At its lower and anterior part there is a large opening, called the foramen magnum, by which the cranial cavity communicates with the spinal canal. The bone is divisible into four parts, which meet around this opening. The part behind is called the tabular portion, that in front the basilar process, and the part at either side the condylar portion.

The **tabular portion** presents two surfaces, three angles, and four borders. The *posterior* or *external surface* is convex and projected at its centre into the **external occipital protuberance**, from which a median ridge, called the **external occipital crest**, passes downwards and forwards to the foramen magnum. The protuberance and crest give attachment to the ligamentum nuchæ. Arching outwards on either side from the protuberance to the lateral angle there is the **superior curved line**, the convexity of which is directed upwards. The two lines with the protuberance divide this surface into an upper or interparietal and a lower or supra-occipital part. A little above each superior curved line there is the **highest curved line**, which has a bold curve with the convexity upwards, and gradually subsides in the superior curved line externally. Between these two lines there is a semilunar area, over which the bone is smooth and dense. The highest curved line gives attachment to the epicranial aponeurosis internally, and to fibres of the occipitalis externally. The superior curved line gives origin over about its inner third to the trapezius, and externally to fibres of the occipitalis, whilst over its outer half, or more, it gives insertion to the sterno-cleido-mastoid, immediately below which the splenius capitis is inserted over about the outer third. The portion of this surface above the highest curved lines is smooth, convex, and covered by the epicranial aponeurosis. The portion below the superior curved lines, which is rough and irregular, is divided into two equal lateral parts by the crest, and each of these is subdivided into an upper and lower portion by the **inferior curved line**, which extends from the centre of the crest to the extremity of the jugular process. The space between the superior and inferior curved lines gives insertion internally to the complexus, and externally, from above downwards, to the splenius capitis and obliquus capitis superior. The inferior curved line gives insertion over its outer part to the rectus capitis posticus major. The inner third of this line and the surface between that extent of it and the foramen magnum give insertion to the rectus capitis posticus minor.

The *anterior* or *internal surface* is irregularly concave and divided into four fossæ by two ridges—a longitudinal, extending from the superior angle to the foramen magnum, and a transverse, extending from one lateral angle to the other. At the point where these two

ridges intersect there is the **internal occipital protuberance**. The upper half of the longitudinal ridge gives attachment to a portion of the falx cerebri, and is marked by a groove for the superior longitudinal venous sinus, this groove being confined to one side of it, usually the right. The lower half is sharp and wiry, and is called the **internal occipital crest**. It gives attachment to the falx cerebelli,

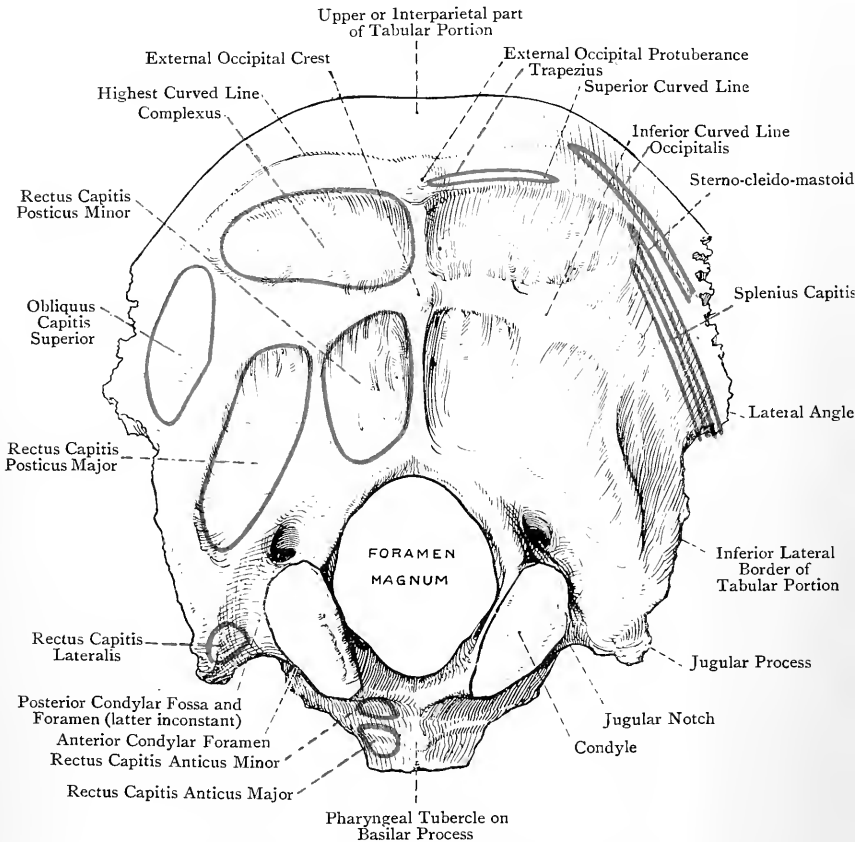


FIG. 39.—THE OCCIPITAL BONE (EXTERNAL VIEW).

and is occasionally grooved for the occipital venous sinus. Near the foramen magnum it divides into two parts, which diverge as they pass to that opening, and enclose between them the *vermiform fossa*, which receives a part of the vermiform process of the cerebellum. The transverse ridge gives attachment to the tentorium cerebelli, and is deeply grooved along each half for the lateral venous sinus. On one side of the internal occipital protuberance, usually

the right, there is a wide depression, at which point the longitudinal groove is continued into the corresponding lateral groove. This depression lodges the **torcular Herophili**, which is a dilatation formed where the superior longitudinal sinus bends sharply to become continuous with the right lateral sinus. The four fossæ are arranged in a superior pair, called superior occipital or cerebral, and an inferior pair, called inferior occipital or cerebellar. Each cerebral fossa presents a number of digitate impressions for the convolutions of the occipital lobe of the cerebrum, which is lodged in it. The cerebellar fossæ, which are separated by the internal occipital crest, are smooth, but may show transverse striations. They are much thinner than the cerebral, and lodge the hemispheres of the cerebellum.

The **angles** are superior and two lateral. The superior angle forms the highest part of the bone, and fits in between the postero-superior angles of the parietals. The lateral angles are situated at either end of the transverse ridge on the internal surface.

The **borders** are two superior and two inferior. Each superior border extends from the superior angle to the lateral angle, and is serrated for the posterior border of the corresponding parietal. Each inferior border extends from the lateral angle to the jugular process, and is faintly serrated for the mastoid portion of the temporal.

The **basilar process** (basi-occipital) is a compressed quadrilateral mass, which projects forwards and upwards in front of the foramen magnum. Its *superior surface* presents a broad median depression, called the **basilar groove**, which is sloped downwards and backwards to the foramen magnum, and lodges the medulla oblongata. At either side of this groove there is a narrow groove for the inferior petrosal venous sinus. The *inferior surface* presents at its centre the **pharyngeal tubercle** for the fibrous raphé of the pharynx. On either side of this tubercle there is a rough, oblique impression for the insertion of the rectus capitis anticus major, and between the outer part of this impression and the foramen magnum the surface gives insertion to the rectus capitis anticus minor. The *anterior border* is thick, rough, and truncated, and up to the twentieth year it articulates with the body of the sphenoid by synchondrosis, but thereafter ankylosis takes place. The *posterior border*, which is thin, smooth, and concave, bounds anteriorly the foramen magnum, and sometimes presents a third occipital condyle of small size for articulation with the tip of the odontoid process of the axis. This border gives attachment to the middle odontoid or suspensory ligament. Each *lateral border* is thick and rough for the petrous portion of the temporal.

The **condylar portions** (exoccipitals) are placed on either side of the foramen magnum, where they extend as far back as its posterior margin, and very nearly as far forwards as its anterior margin. Each bears on its under surface a condyle. The **condyles** are oval, convex, and covered by cartilage, and they articulate with the superior articular processes of the atlas. Their long axes are

directed forwards and inwards, and the direction of each surface is downwards and slightly outwards. They do not extend farther back on the lateral margins of the foramen magnum than the level of the centre, and the front part of each belongs to the basilar portion. The circumference of a condyle gives attachment to the capsular ligament of the corresponding occipito-atlantal joint, and on the inner aspect of each there is a tubercle for the lateral odontoid or check ligament. External to the front of each condyle is the

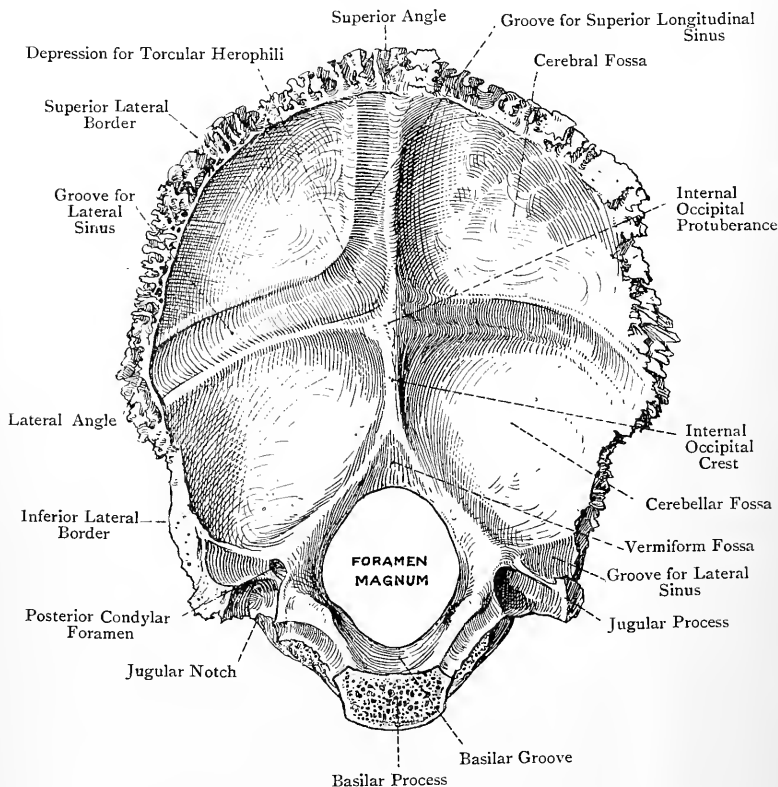


FIG. 40.—THE OCCIPITAL BONE (INTERNAL VIEW).

anterior condylar foramen, which opens forwards and outwards from the cranial cavity. It transmits the hypoglossal nerve and a meningeal branch of the ascending pharyngeal artery. Behind each condyle is the **posterior condylar fossa**, which may be pierced by a posterior condylar foramen, on one or both sides, for an emissary vein passing between the intracranial lateral sinus and the extracranial suboccipital venous plexus. The part external to the condyle is called the **jugular process**, which lies above the

transverse process of the atlas, and is homologous with it. Posteriorly it is continuous with the tabular portion, and anteriorly it presents the **jugular notch**, which, with the jugular fossa of the petrous portion of the temporal, forms the jugular foramen. Superiorly it presents a short, but deep and wide, groove for a portion of the lateral venous sinus just before it leaves by the jugular foramen. This groove may be pierced by a posterior condylar foramen. Inferiorly it gives attachment to the rectus capitis lateralis, and may send downwards a projection towards the transverse process of the atlas, which represents the *paramastoid process* of comparative anatomy. Externally the jugular process articulates with the jugular facet on the petrous portion of the temporal by synchondrosis up to the twenty-fifth year, after which ankylosis takes place.

The **foramen magnum** is situated at the lower and anterior part of the bone, and is oval, its long axis extending from before backwards. The inferior margin, in front of the condyles, gives attachment to the anterior occipito-atlantal ligament, and, behind them, to the posterior occipito-atlantal ligament. The foramen transmits the medulla oblongata and its membranes, the spinal accessory nerves, the vertebral arteries, and the anterior and posterior spinal arteries.

The chief blood-supply of the bone is derived from the occipital and posterior auricular arteries.

Articulations.—*Superiorly* with the parietals, *laterally* with the temporals (mastoid and petrous portions), *anteriorly* with the sphenoid, and *inferiorly* with the atlas, and in rare cases with the odontoid process of the axis.

Structure.—The occipital, being a tabular bone, is composed of two tables of compact bone, with cancellated tissue, called diploë, between them.

Varieties.—(1) There may be a minute foramen piercing the external occipital protuberance for an emissary vein, which passes between the intracranial torcular Herophili and one of the tributaries of the extracranial occipital vein. (2) The upper division of the tabular portion may be separate, representing the **interparietal bone** of comparative anatomy, and it may be in one piece, or in two or more. (3) The semilunar area between the highest and superior curved lines may be prominent, constituting the *torus occipitalis transversus*. (4) The anterior condylar foramen may be double on its cranial aspect. (5) There may be a third occipital condyle on the anterior margin of the foramen magnum. (6) There may be a paramastoid process on the under aspect of the jugular process. (7) The condyle may be divided into two parts, anterior and posterior. (8) There may be an intrajugular process on the front of the jugular notch, which may extend as far as the petrous portion of the temporal.

Ossification.—The bone is developed in **four parts**. The **tabular portion** usually ossifies from **four centres**, which appear around the internal occipital protuberance about the *eighth week* of intra-uterine life. Two are deposited in cartilage, one for each cerebellar fossa, which soon fuse and give rise to the lower or supra-occipital division. The other two are deposited in membrane, one in each cerebral fossa, which also soon fuse and give rise to the upper or interparietal division. Indeed, as a general rule, all four ultimately blend. There may, however, be two other centres for the interparietal portion, placed

on either side of the middle line not far from the future superior angle, which occasionally remain as separate ossicles, or they may fuse and give rise to the pre-interparietals. The interparietal portion may remain separate from the supra-occipital, with which it may be connected by a suture, or they may be separated by a partial fissure. Fissures, which persist for some time after birth, intersect the tabular part at the superior and lateral angles, and a membranous interval extends from the protuberance to the foramen magnum in early life, which remains for some weeks, after which it is replaced by bone.

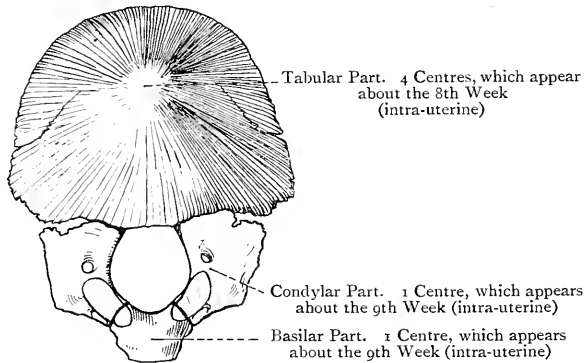


FIG. 41.—OSSIFICATION OF THE OCCIPITAL BONE.

(The figure shows the condition of the bone at birth.)

It is in this latter situation where an encephalocele may occur. The **basilar** and **condylar parts** have each **one centre** appearing in cartilage about the *ninth week*, the anterior part of each condylar portion deriving its ossification from the basilar centre. At birth the bone is in four parts, connected by cartilage. Union between the tabular and condylar portions is completed by the *fourth year*, and the condylar and basilar portions unite about the *sixth year*. After the *twentieth year* the basilar portion joins the sphenoid, and at the *twenty-fifth year* the jugular process becomes ankylosed to the petrous portion of the temporal.

The Parietal Bones.

The **parietal bones** are so named because they form a large part of the cranial wall. They lie between the frontal and occipital, and superiorly they articulate with each other by the sagittal or interparietal suture. Each bone is quadrilateral and curved, and presents two surfaces, four borders, and four angles. The *external surface* is convex, and near its centre is more elevated than elsewhere, this part, from which ossification originally proceeds, being called the **parietal eminence**. A little below this the surface is crossed from before backwards by two curved lines, called the **superior** and **inferior temporal ridges**, the narrow space between which is smoother and more glistening than the rest of the surface. The part above the superior ridge is covered by the epicranial aponeurosis, and the ridge itself gives attachment to the temporal fascia. The inferior temporal ridge limits the origin of the

temporal muscle, and the portion between it and the inferior border, which is vertically striated and called the *planum temporale*, forms a part of the temporal fossa, and gives origin to fibres of the temporal muscle. Near the superior border, about an inch in front of the postero-superior angle, is the **parietal foramen**, for an emissary vein which passes between the intracranial superior longitudinal sinus and one of the tributaries of the extracranial occipital vein.

The *internal surface* is concave, its deepest part, opposite the parietal eminence, being known as the parietal fossa. This surface presents a number of digitate impressions for the convolutions of

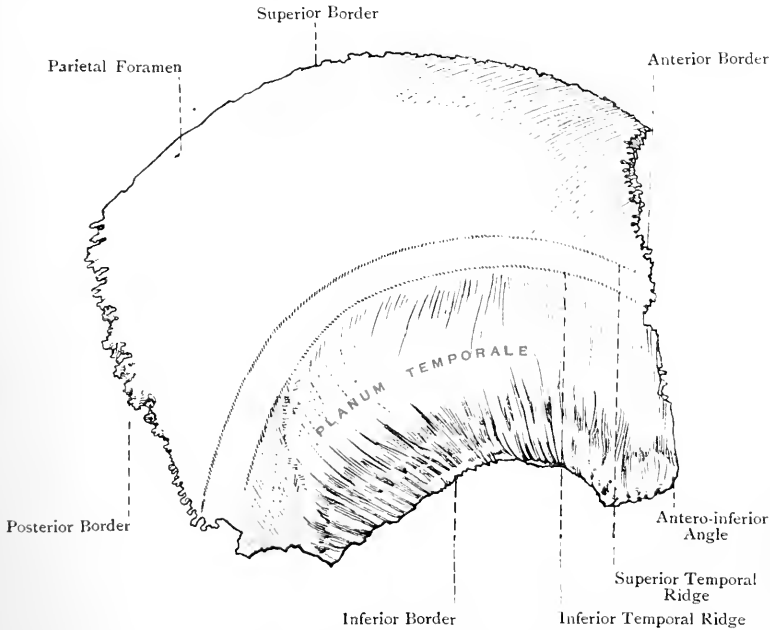


FIG. 42.—THE RIGHT PARIETAL BONE (EXTERNAL VIEW).

the parietal and part of the frontal lobes of the cerebrum, and a system of branching meningeal grooves for the divisions of the middle meningeal artery. These commence as two grooves, each of which soon becomes arborescent. The anterior, the larger of the two, commences on the inner surface of the antero-inferior angle, where it may be bridged over into a short canal, and the posterior starts from the centre of the inferior border. Superiorly, close to the superior border, there is a half groove which, with that of the opposite bone, lodges the superior longitudinal venous sinus. Along the course of this groove, but external to it, are several depressions, best marked in old persons, which lodge the

Pacchionian bodies. Close to the postero-inferior angle there is a short groove for part of the lateral venous sinus.

Borders.—The posterior, anterior, and superior borders are serrated. The *posterior* border articulates with the occipital; the *superior*, with its fellow; and the *anterior* with the frontal. The anterior border is bevelled below at the expense of the inner plate, where it overlaps the frontal, and it is slightly bevelled above at the expense of the outer plate, where it is overlapped by the frontal. The *inferior border*, which is the shortest, is for the most part concave and markedly bevelled at the expense of the outer plate,

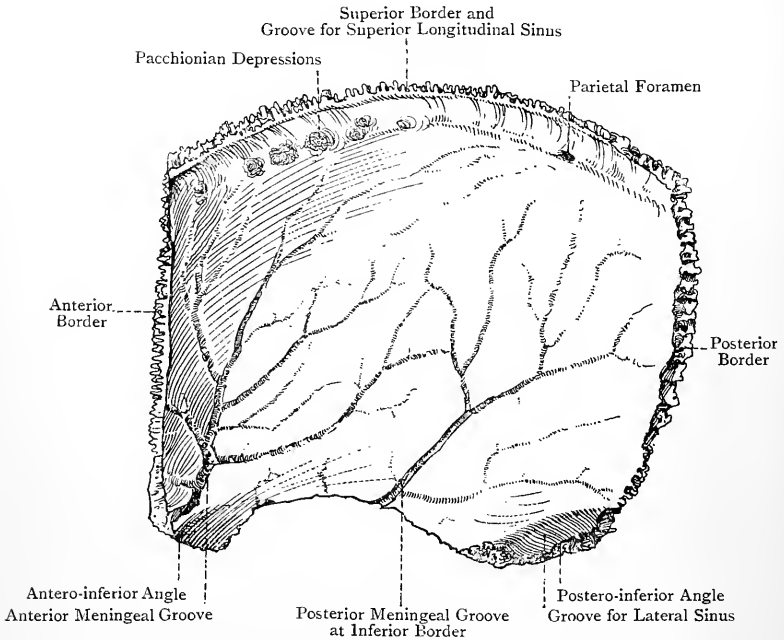


FIG. 43.—THE RIGHT PARIETAL BONE (INTERNAL VIEW).

where it is overlapped by the squamous portion of the temporal. Posteriorly, however, it is serrated for the superior border of the mastoid portion of the temporal.

Angles.—The *antero-superior* angle, with its fellow, lies in the situation of the original anterior fontanelle. The *postero-superior* angle, with its fellow, occupies the region of the original posterior fontanelle. The *postero-inferior* angle is truncated, and articulates with the mastoid portion of the temporal, being also recognised by the short groove for the lateral venous sinus on its inner aspect. The *antero-inferior* angle is prolonged and pointed, and articulates with the great wing of the sphenoid, being also

recognised by the large anterior meningeal groove on its inner surface.

The bone receives its chief blood-supply from the middle meningeal artery internally, and the occipital externally.

Articulations.—*Posteriorly* with the occipital, *superiorly* with its fellow, *anteriorly* with the frontal, *antero-inferiorly* with the sphenoid, and *inferiorly* with the temporal.

Structure.—It is a characteristic tabular bone.

Varieties.—(1) The bone may persist in two parts, upper and lower, connected by an antero-posterior suture. (2) The parietal foramen may be absent on one or both sides.

Ossification.—The parietal ossifies in membrane from **two centres**, which appear about the *seventh week* in the region of the future parietal eminence, one above and the other below it, and soon coalesce. The ossification radiates

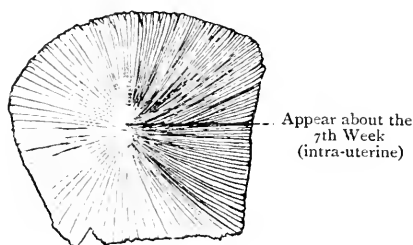


FIG. 44.—OSSIFICATION OF THE PARIETAL BONE.

from this point in such a manner as to leave a notch on the upper border a little in front of the postero-superior angle, which forms one-half of the sagittal fontanelle of the earlier half of foetal life.

The Frontal Bone.

The **frontal bone** forms the forehead and greater part of the roof of each orbit, and it lies in front of the parietals. It is divisible into a frontal portion and two orbital plates, the latter being situated inferiorly, where they are separated by the ethmoidal notch.

The **frontal portion** presents two surfaces, external and internal. The *external surface*, which is smooth and convex, presents a little below its centre, on either side, an elevation, called the **frontal eminence**. Below this, and separated from it by a shallow groove, there is the curved **superciliary ridge** which supports the eyebrow. This ridge is prominent internally, but it subsides externally. It supports the upper half of the orbicularis palpebrarum, and internally it gives origin to the corrugator supercilii, whilst the surface above each ridge supports the frontalis and part of the epicranial aponeurosis. Between the two superciliary ridges is an elevation, called the **nasal eminence** or **glabella**. Below each ridge is the curved **supra-orbital arch**, which is most prominent over its

outer two-thirds. At the junction of the inner third and outer two-thirds is the **supra-orbital notch**, sometimes a foramen, for the passage of the supra-orbital nerve and artery. Occasionally there is a frontal notch, inside the normal notch, for a branch of the supra-orbital nerve. The extremities of the supra-orbital arch form the **external** and **internal angular processes**. The external process is stout and serrated for articulation with the malar. The internal process is faintly marked, and lies by the side of the nasal

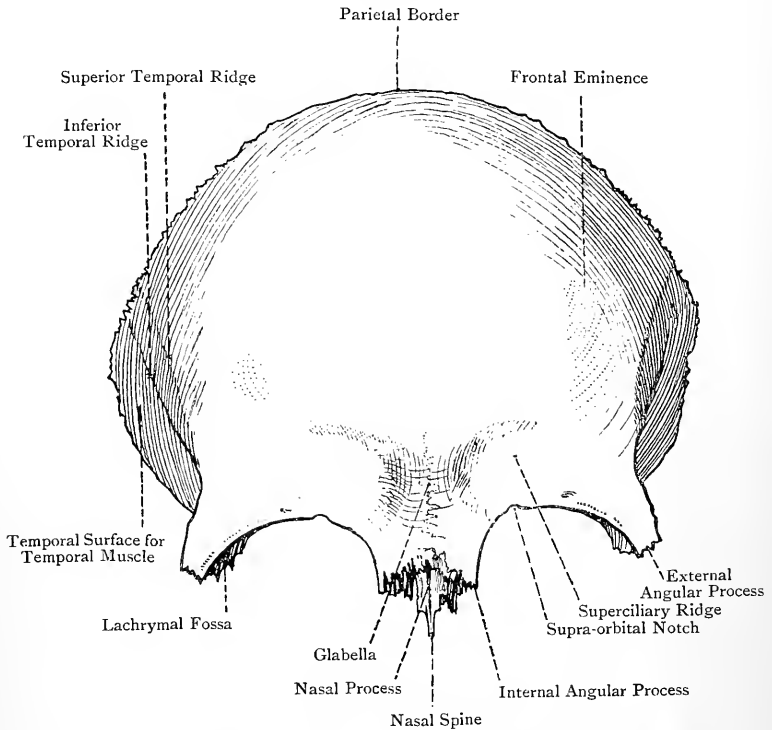


FIG. 45.—THE FRONTAL BONE (ANTERIOR VIEW).

notch, where it articulates with the lachrymal, and gives origin to some fibres of the orbicularis palpebrarum.

On the lateral aspect of the external surface there are two curved lines, called the **superior** and **inferior temporal ridges**, the superior being faint and the inferior bold. They spring from the external angular process, and arch upwards and backwards to become continuous with the corresponding ridges on the parietal. The superior gives attachment to the temporal fascia, and the inferior limits the temporal muscle, which arises from it and the surface below, this latter forming a part of the temporal fossa. Below the glabella

on the under aspect there is a rough, semilunar, serrated surface for articulation with the nasal bones and nasal processes of the superior maxillæ, and behind this is the **nasal notch**, bounded at either side by the internal angular process. Within the notch is the **nasal process**, which supports the nasal bones, and projecting downwards from it is the sharp **nasal spine**, which articulates in front with the upper part of the crest of the nasal bones, and behind with the vertical plate of the ethmoid. This spine enters into the nasal septum. On either side of the spine is the **ala**, which is grooved to take part in the roof of the corresponding nasal fossa.

The *internal* or *cerebral surface* of the frontal portion is concave, and in the middle line presents a groove, called the **frontal sulcus**, which lodges a part of the superior longitudinal venous sinus. On either side of the upper part of this groove there are a few depressions for the Pacchionian bodies. Inferiorly the groove is replaced by the **frontal crest**, which terminates at the **foramen cæcum**. This foramen is sometimes partly formed by the crista galli of the ethmoid, and it may be closed below, or it may transmit an emissary vein, which passes between the intracranial superior longitudinal sinus and the veins of the roof of the nose. The internal surface presents numerous digitate impressions for the convolutions of the frontal lobes of the cerebrum, and laterally there are a few meningeal grooves, transversely disposed, for branches of the middle meningeal arteries.

The *supero-lateral* or *parietal border* of the frontal portion is serrated for the parietal bones. Superiorly it is slightly bevelled near the middle line at the expense of the inner plate, where it overlaps the parietal, and at either lower extremity it is distinctly bevelled at the expense of the outer plate, where it is overlapped by the parietal. Internal to its lower termination at either side there is a rough triangular surface, which is serrated for the great wing of the sphenoid.

The **orbital plates**, thin and brittle, project backwards in a curved manner from the supra-orbital arches, and are widely separated by the **ethmoidal notch**, which is occupied by the cribriform plate of the ethmoid. Each is triangular, with the truncated apex directed backwards and inwards, and presents two surfaces and three borders. The *superior* or *cerebral surface* is irregularly convex, and marked by digitate impressions for the convolutions of the orbital surface of the frontal lobe, which rests upon it. The *inferior* or *orbital surface*, smooth and concave, forms the principal part of the roof of the orbit. Within the external angular process is the **lachrymal fossa**, which lodges the lachrymal gland, and near to the internal angular process is the small **trochlear fossa**, which gives attachment to the trochlea of the superior oblique muscle of the eyeball.

The **borders** are anterior, external, and internal. The *anterior border* represents the supra-orbital arch, and is free. The *external border* is sharp and irregular, and its direction is backwards and

inwards. It forms a right angle with its fellow of the opposite side, and abuts against the great wing of the sphenoid. The *internal border* is directed from before backwards, is parallel with its fellow of the opposite side, and forms the lateral boundary of the ethmoidal notch. It is bevelled at the expense of the lower plate, and the bevelled surface presents several excavations, which close in the ethmoidal cells on the upper border of the lateral mass of the ethmoid. This surface is crossed by two transverse grooves, anterior and posterior, which, with similar grooves on the contiguous part of the ethmoid, form the **anterior** and **posterior ethmoidal** (internal orbital) **canals**. These open on the inner wall

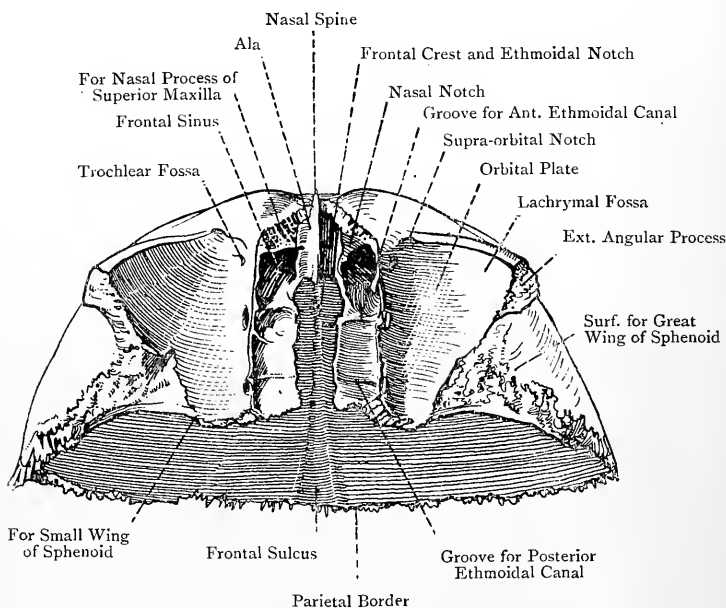


FIG. 46.—THE FRONTAL BONE (INFERIOR VIEW).

of the orbit, and the anterior gives passage to the nasal nerve and anterior ethmoidal vessels, whilst the posterior transmits the posterior ethmoidal vessels and speno-ethmoidal nerve. The truncated apex of the orbital plate articulates with the small wing of the sphenoid.

In front of the anterior ethmoidal groove on either side is the opening of the **frontal air sinus**. Each leads into a cavity within the bone, which extends outwards from near the middle line for a variable distance behind the superciliary ridge. The sinuses are separated by a median septum, and may be unilocular or multilocular. In the latter case the subdivisions may extend back-

wards for a variable distance within the roof of the orbit. Each sinus is lined by mucous membrane continuous with that of the corresponding nasal fossa, with which it communicates by a passage called the **infundibulum**.

The bone derives its blood-supply from the middle meningeal, meningeal branches of the internal carotid, and anterior and posterior ethmoidal arteries internally, and the supra-orbital and frontal arteries externally.

Articulations.—These are twelve in number, as follows: *posteriorly* with the two parietals above, and the sphenoid (great and small wings) below; by the *external angular processes* with the two malars; between the *orbits* with the two nasals, two superior maxillæ, and two lachrymals; and in the *middle line* with the lateral masses and vertical plate of the ethmoid.

Structure.—It is a tabular bone. The orbital plates, being destitute of diploë, are thin and translucent, except in those cases where extensions of the frontal air sinuses invade them.

Varieties.—(1) There may be a persistent frontal suture, called the metopic suture, this condition being known as metopism. (2) Wormian bones are sometimes met with at the centre of the supero-lateral border in the region of the anterior fontanelle, and, if these remain permanent, they give rise by their union to a bregmatic bone.

Ossification.—The frontal ossifies in membrane from **two centres**, one for each half, which appear about the *seventh week* of intra-uterine life in the situation of the future frontal eminences. At birth the bone consists of two halves united by membrane, and in the course of the *first year* they become united by a vertical frontal or metopic suture. This suture gradually becomes obliterated from below upwards, and usually disappears about the *sixth*

year, though slight traces may persist above and below, especially in the latter situation. Three pairs of secondary centres are described, two mesially placed for the nasal spine, one at either side in the region of the future trochlear fossa, and one for each external angular process. The frontal air sinuses begin to appear about the *seventh year*, but they do not attain any size till after puberty. They are rather larger in the male than in the female.

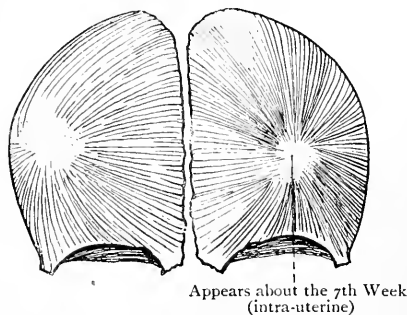


FIG. 47.—OSSIFICATION OF THE FRONTAL BONE.

The Temporal Bones.

The **temporal bones** (*ossa temporis*) are so named because the hair over the temple is the first to become gray, thus indicating advance in life. Each bone is situated on the lateral aspect of the head below the parietal. For convenience of description each is divided into three parts, namely: the **squamous portion**, which bears the

zygoma ; the **mastoid portion** ; and the **petrous portion**, which bears inferiorly the **styloid process**.

The **squamous portion (squamo-zygomatic)** lies almost vertically, and presents two surfaces, outer and inner, and a superior border. The *outer surface* is convex towards its centre, and forms a large part of the temporal fossa. It gives origin to fibres of the temporal muscle, and is marked by a groove for the middle temporal artery, which extends upwards and slightly forwards from a point just above the external auditory meatus to the superior border. The *inner surface*, which is concave, is related to the temporo-sphenoidal lobe of the cerebrum, and presents a few digitate impressions and meningeal grooves. The *superior border* is much arched, and describes about two-thirds of a circle. Except over the lower part of its anterior portion, it is markedly bevelled at the expense of the inner plate for the parietal, which it overlaps. Anteriorly over its lower part it is thick and serrated for the external border of the great wing of the sphenoid. The place of junction of the squamous and petrous portions is indicated at the lower part of the inner surface of the former by the narrow petro-squamous groove or suture.

The **zygoma (jugal process)** springs from the lower part of the outer surface of the squamous portion. Its base is compressed from above downwards, and directed outwards. It then undergoes a twist, and is directed forwards in a curved manner, being laterally compressed. This part of it presents two borders, two surfaces, and an extremity. The *superior border*, sharp and convex, extends farther forwards than the inferior, and gives attachment to the temporal fascia in two divisions. The *inferior border* gives origin to fibres of the masseter. The *outer surface* is convex and subcutaneous, whilst the *inner*, which is concave and looks towards the upper part of the zygomatic fossa, gives origin to fibres of the deep part of the masseter. The *extremity* is bevelled at the expense of the lower border, and serrated for the malar. The *base* of the zygoma presents two roots, anterior and posterior. The *anterior root*, which is continuous with the inferior border of the process, is directed inwards in front of the glenoid fossa. It is at first narrow, but subsequently thick and convex, where it is covered by cartilage. This portion is called the **eminentia articularis**, and in front of it there is a small triangular area which looks into the zygomatic fossa. The *posterior root*, which is continuous with the superior border of the process, passes backwards above the external auditory meatus, then between the squamous and mastoid portions, where it is known as the **supramastoid crest**, and finally it turns upwards, where it forms part of the posterior boundary of the temporal fossa. In front of the external auditory meatus it sends downwards a short offshoot, which lies between the external auditory meatus and the anterior part of the glenoid fossa. This is called the **postglenoid process**, and is sometimes referred to as the middle root of the zygoma.

On the outer surface of the zygoma, above the place where the anterior root becomes continuous with its lower border, there is a projection, called the **preglenoid tubercle**, which gives attachment to the external lateral ligament of the temporo-maxillary articulation.

Behind the anterior root is the **glenoid fossa**, which extends on to the tympanic plate. It is elongated from before backwards and inwards, and is divided into two parts by the fissure of Glaser. The anterior part, which belongs to the squamo-zygomatic portion

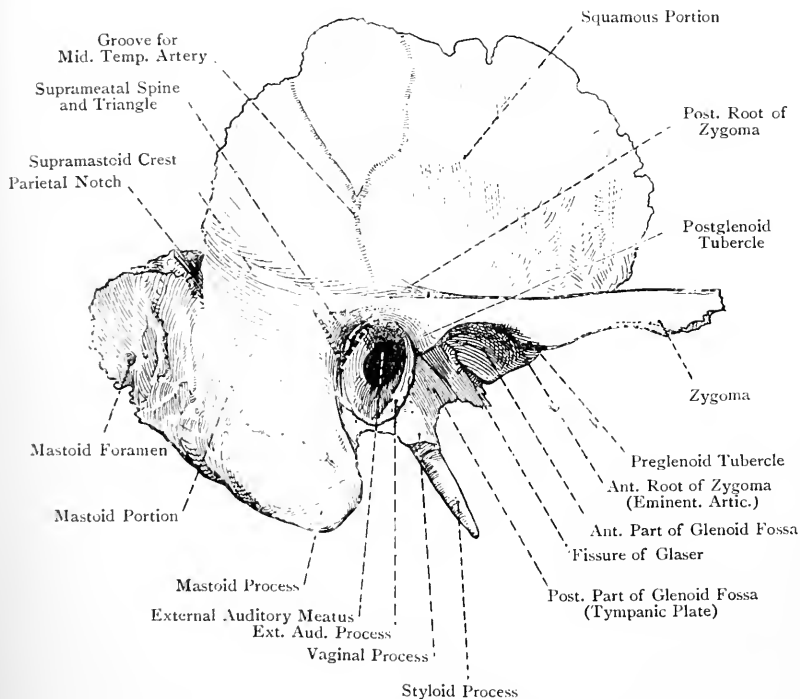


FIG. 48.—THE RIGHT TEMPORAL BONE (EXTERNAL VIEW).

of the bone, is covered by cartilage, and is triangular, with the apex at the preglenoid tubercle and the base at the Glaserian fissure. It is deeply concave, and is bounded anteriorly by the eminentia articularis, externally by the commencement of the posterior root of the zygoma, and posteriorly from without inwards by the postglenoid process and Glaserian fissure. It articulates with the condyle of the inferior maxilla when the mouth is closed, an interarticular fibro-cartilage intervening; but, when the mouth is open, the condyle with the fibro-cartilage moves forwards on to the eminentia articularis. The posterior part of the glenoid fossa is situated behind the

Glaserian fissure, and is formed by the tympanic plate, which separates it from the external auditory meatus. It is shallow, non-articular, and quadrilateral, and it lodges the deep part of the parotid gland.

The **fissure of Glaser**, which is the remains of the petro-tympanic fissure, is closed in its outer part, and is divided into two internally by means of a thin plate which descends from the *tegmen tympani*, and forms the chief part of the outer wall of the canals for the osseous part of the Eustachian tube and tensor tympani muscle. Between this plate and the tympanic plate the process gracilis of the malleus is located internally, and there is a small opening leading to the tympanic cavity for the passage of the tympanic branch of the internal maxillary artery and the anterior ligament of the malleus (so-called laxator tympani muscle) or band of Meckel. At the inner end of the Glaserian fissure is another minute opening leading from the tympanic cavity, called the **canal of Huguier**, or **iter chordæ anterioris**, which transmits the *chorda tympani* nerve.

The **mastoid portion** is so named from the mastoid process which it bears. It is limited above by the supramastoid crest and its own superior border, in front by the external auditory meatus and auricular or tympano-mastoid fissure, and behind by its posterior border. It presents two surfaces and two borders. The *external surface*, rough and convex, is prolonged downwards behind the external auditory meatus into the **mastoid process**, which presents on its inner surface two grooves. The outer, called the **digastric groove**, is deep, and gives origin to the posterior belly of the digastric; and the inner, called the **occipital groove**, is narrow, and lodges the occipital artery. The upper part of the outer surface of the mastoid process gives origin over its posterior half to the retrahens auriculam and part of the occipitalis, in this order from before backwards; and lower down, it gives insertion to the sternocleido-mastoid, splenius capitis, and trachelo-mastoid, in this order from above downwards. At the upper and back part of the mastoid portion, a little below the supramastoid crest, there may be the remains of the squamo-mastoid suture directed downwards and forwards, indicating the line of junction of the squamo-zygomatic and basal part of the petrous portions. Directly in front of the root of the mastoid process there is an important depressed area, called the **suprameatal triangle** (Macewen), which is bounded as follows: *above* by part of the posterior root of the zygoma, *below* by the postero-superior part of the external auditory meatus, and *behind* by a vertical line connecting the upper and lower boundaries, which line is continuous with the posterior part of the external auditory meatus. In the lower part of the suprameatal triangle is the **suprameatal spine**, a sharp, antero-posterior scale of bone, which gives attachment to a portion of the cartilage of the external ear. The outer surface of the mastoid portion presents several small nutrient foramina, and often there is a large opening, called

the **mastoid foramen**, usually placed near the posterior border, for a large emissary vein, which passes between the lateral sinus internally and the outermost tributary of the occipital vein, or the posterior auricular vein externally. In addition to these, there is the minute *arterial fissure* on the outer surface of the mastoid process below its centre for the mastoid branch of the occipital artery.

The *inner surface* presents the deep sinuous **sigmoid groove**, which lodges a part of the lateral venous sinus, and into which the mastoid foramen opens. The genu or bend of this groove and its descending limb lie behind the mastoid antrum.

The *superior border*, thick and serrated, articulates with the back part of the inferior border of the parietal. Near its anterior part it presents the **parietal notch**, which receives a portion of the parietal bone. The *posterior border*, also thick and serrated, articulates with the inferior border of the tabular portion of the occipital.

The interior of the mastoid portion contains a number of cavities lined with mucous membrane, called the mastoid air cells. These open into an irregular chamber, known as the **mastoid antrum**, which is situated at the upper part of the posterior wall of the tympanum, and is lined by mucous membrane continuous with that of the tympanum and mastoid cells. The upper part of the antrum communicates with the upper part or **attic** of the tympanum by an opening which faces that of the Eustachian tube, but the lower part is shut off from the tympanic cavity, and its floor is on a lower level than the floor of that cavity, which explains the difficulty in the drainage of fluid. The roof of the antrum, called *tegmen antri*, is continuous with the *tegmen tympani*, and both enter into the formation of the middle fossa of the base of the skull. The outer wall is formed by the squamo-mastoid junction in the region of the suprameatal triangle; the floor and inner wall are constructed by the petro-mastoid portion; and the posterior wall represents that part of the mastoid portion which bears the genu or bend and descending limb of the sigmoid groove. The **mastoid cells** extend from the antrum into the mastoid portion in a backward and downward direction, and are subject to variety as regards number and size. They are arranged in two groups—horizontal or superior, and vertical or inferior. The former are purely pneumatic or air cells, but the latter are of two kinds, the *upper* ones being pneumatic, and the *lower* ones, which extend to the tip of the mastoid process, being diploëtic and of large size. Superiorly the cells extend forwards over the roof of the external auditory meatus, upwards as high as the supramastoid crest, and inwards for a certain distance into the petrous portion. They may also extend into the jugular process of the occipital in old persons. At birth the mastoid cells are not developed, but the antrum is present.

The **petrous portion** is so named from its rocky consistence, and its direction is inwards and forwards into the base of the skull. It

has the shape of a four-sided pyramid, and presents four surfaces (one of which is concealed by the tympanic plate), four borders, an apex, and a base. The surfaces are superior, posterior, inferior, and anterior.

The *superior surface*, which has an inclination forwards, looks into the middle fossa of the base of the skull, and towards its outer part presents a few digitate impressions for convolutions of the temporo-sphenoidal lobe of the cerebrum. Near the apex is the **Gasserian depression** for the Gasserian ganglion, and below this is the outlet of

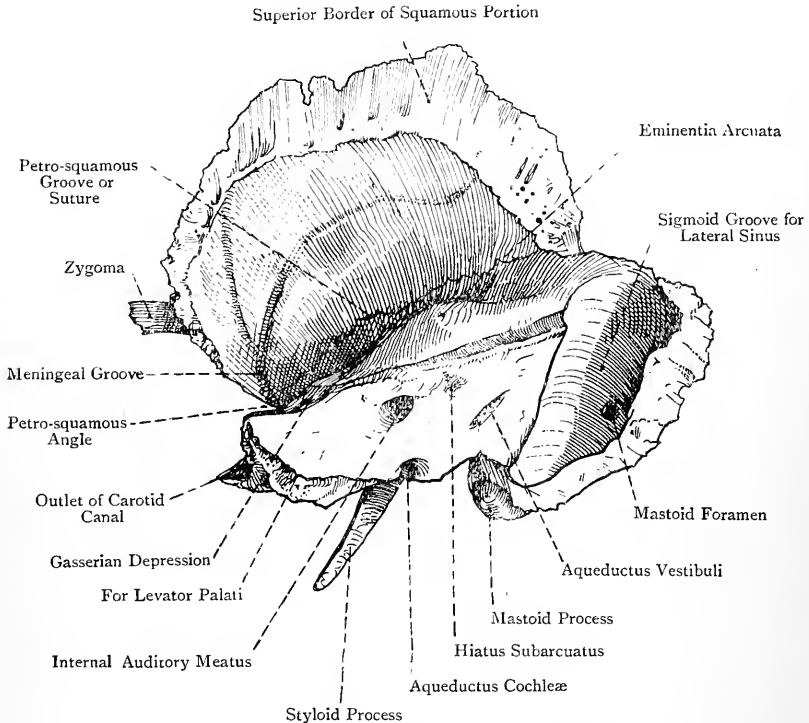


FIG. 49.—THE RIGHT TEMPORAL BONE (INTERNAL VIEW).

the **carotid canal** for the internal carotid artery. Proceeding backwards and outwards, there is a small groove leading to a foramen very nearly in line with the petro-squamous angle, called the **hiatus Fallopii**, within the thin margin of which there may be two openings. The inner and larger of these openings leads to the commencement of the aqueduct of Fallopius, and thence to the internal auditory meatus, and it transmits the great superficial petrosal nerve, along with the petrosal branch of the middle meningeal artery. The outer opening, of small size, also leads to the aqueduct of Fallopius,

and transmits the external superficial petrosal nerve. This latter, however, with the nerve, is inconstant. Another small groove marks the upper wall of the canal for the tensor tympani muscle at the petro-squamous angle, and leads backwards and outwards, parallel with the preceding groove, to a minute foramen, situated a little external to the hiatus Fallopii, called the **accessory hiatus**, which transmits the small superficial petrosal nerve. Behind and external to the hiatus Fallopii is an elevation, called the **eminentia arcuata**, which coincides with the position of the *superior* semicircular canal of the internal ear. Between this eminence and the hiatus Fallopii internally and the petro-squamous fissure externally there is a plate of bone, called the **tegmen tympani**, which forms the roof of the tympanic cavity and of the canal for the tensor tympani muscle.

The *posterior surface*, which looks backwards and inwards, forms part of the posterior cranial fossa. It presents about its centre a large opening, which leads into a short canal, called the **internal auditory meatus**, for the passage of the facial and auditory nerves, the *pars intermedia* of Wrisberg, and the auditory artery. At the deep end of this meatus there is a perforated plate of bone, known as the **lamina cribrosa**, which is divided into an upper and a lower fossa by a transverse ridge, called the **falciform crest**. The upper fossa presents at its anterior part a special foramen which leads into the aqueduct of Fallopius, and by this foramen the facial nerve leaves the meatus. The remainder of the upper fossa is known as the *superior vestibular area*, and it is pierced by the nerves and arteries destined for the utricle and the ampullæ of the superior and external semicircular canals. The lower fossa contains the *cochlear area*, which is pierced by the cochlear nerves and arteries, the *inferior vestibular area* for the nerves and arteries to the sacculæ, and the *foramen singulare* for the nerves and arteries to the ampulla of the posterior semicircular canal. The **aqueduct of Fallopius**, for the facial nerve, extends from the deep end of the internal auditory meatus to the stylo-mastoid foramen, between which points it takes a very circuitous course. It passes at first horizontally *outwards* between the cochlea and vestibule to the inner wall of the tympanum, then it bends sharply *backwards*, lying above the fenestra ovalis, and finally, making another abrupt bend, it *descends* in the angle between the inner and posterior walls of the tympanum to the stylo-mastoid foramen. The hiatus Fallopii leads from the commencement of the aqueduct to the superior surface of the petrous portion, and, as stated, transmits the great superficial petrosal nerve. The aqueduct, as it descends behind the tympanum, communicates with the canal of the **pyramid** by an opening through which the nerve to the stapedius reaches that muscle, and below the pyramid it presents another opening, called the **iter chordæ posterius**, by which the chorda tympani nerve passes into the tympanum.

About $\frac{1}{4}$ inch external to the opening of the internal auditory

meatus there is a narrow fissure, overhung by a thin scale of bone, called the **aqueductus vestibuli**, which contains a small artery and vein, and the *ductus endolymphaticus*. Close to the superior border, about midway between the opening of the internal auditory meatus and the aqueductus vestibuli, there is a depression containing a small opening, known as the **hiatus subarcuatus**, which represents the floccular fossa of early life.

The *inferior surface* appears on the exterior of the base of the skull. Near the apex there is a large rough surface which gives origin to fibres of the levator palati, and behind this a circular opening, called the **carotid foramen**, which is the inlet to the carotid

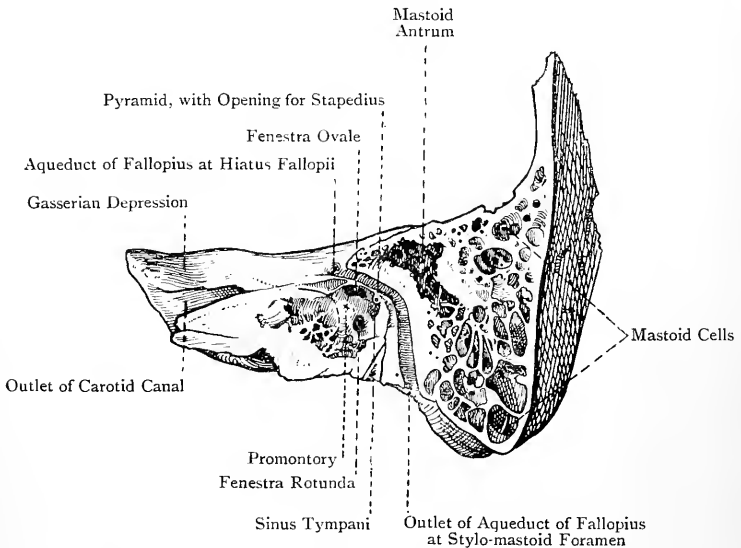


FIG. 50.—SECTION THROUGH THE PETROUS AND MASTOID PORTIONS OF THE TEMPORAL BONE, SHOWING THE TYMPANUM AND MASTOID CELLS.

canal. This canal, which transmits the internal carotid artery and the carotid sympathetic plexus, passes at first vertically *upwards*, and then, bending at a right angle, it passes horizontally *forwards* and *inwards*, to open at the apex, below the Gasserian depression, into the foramen lacerum medium. On the posterior wall of the vertical portion of the canal is a minute foramen for the tympanic branch of the carotid sympathetic plexus and tympanic branch of the internal carotid artery. Behind the carotid foramen is the **jugular fossa**, which, with the jugular notch of the occipital, forms the jugular foramen. On the outer wall of this fossa, near the root of the styloid process, there is the opening of the **auricular canaliculus** for the auricular branch (Arnold's nerve) of the pneumogastric. On the carotid ridge, between the carotid foramen and

the jugular fossa, is the opening of the **tympanic canaliculus** for the tympanic branch (Jacobson's nerve) of the glosso-pharyngeal and the tympanic branch of the ascending pharyngeal artery. Behind the jugular fossa, internal to the stylo-mastoid foramen, is the rough **jugular facet** for articulation with the extremity of the jugular process of the occipital, by synchondrosis up to the twenty-fifth year, after which ankylosis takes place. External to the jugular facet is the styloid process, immediately behind

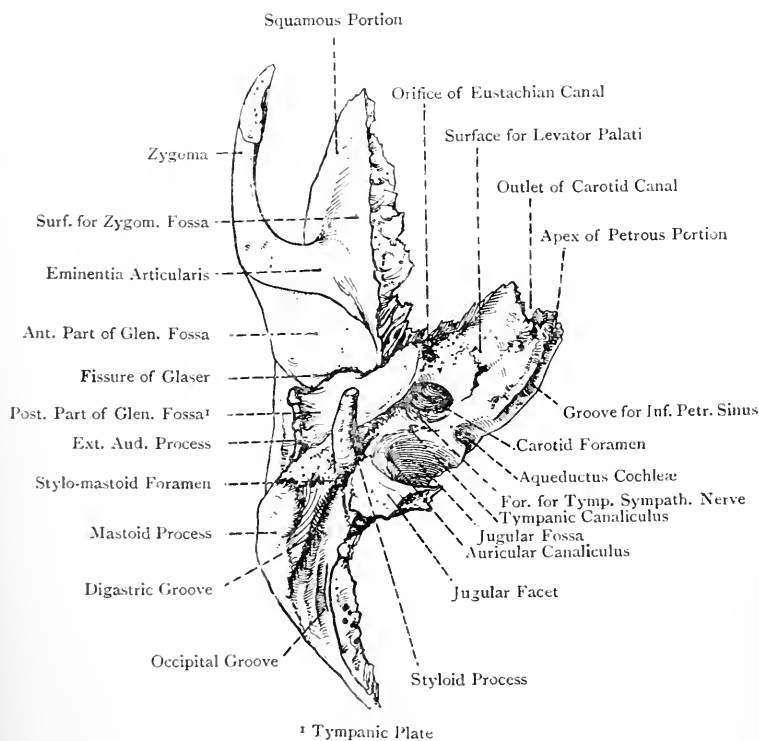


FIG. 51.—THE RIGHT TEMPORAL BONE (INFERIOR VIEW).

the root of which is the **stylo-mastoid foramen**. This foramen is the outlet of the aqueduct of Fallopius, and by it the facial nerve makes its exit, whilst the stylo-mastoid branch of the posterior auricular artery passes in. A little behind the stylo-mastoid foramen, between the mastoid process and tympanic plate, is the auricular or tympano-mastoid fissure for the exit of Arnold's nerve.

The *anterior* or *tympanic surface*, which is concealed by the tympanic plate, looks into the tympanic cavity, of which it

forms the posterior and inner walls, and it presents the mastoid antrum.

The **borders** are anterior, superior, posterior, and inferior. The *anterior border* separates the superior from the anterior or tympanic surface. It is very short, and forms an acute angle with the squamous portion, within which the posterior pointed extremity of the great wing of the sphenoid is received. This angle presents an opening, called the **Eustachian orifice**, and the canal to which it leads is divided into two compartments by a thin transverse shelf of bone, scooped out on its under surface, called the **processus cochleariformis**. The upper small compartment lodges the tensor tympani muscle, and the lower large one forms the osseous part of the Eustachian tube. Both of these canals lead upwards and backwards to the anterior part of the tympanic cavity. The *superior border*, which is the longest, separates the superior from the posterior surface. It gives attachment to the tentorium cerebelli, and is grooved for the superior petrosal venous sinus. The inner part of this border frequently presents a process, which projects over the upper end of the groove for the inferior petrosal venous sinus, and gives attachment to the *petro-sphenoidal ligament*. This ligament connects it with the lateral border of the dorsum sellæ of the sphenoid (which may present a superior petrosal process), and, if it ossifies, it bridges over a foramen through which the inferior petrosal sinus and sixth cranial nerve pass. The *posterior border* separates the posterior from the inferior surface. Its outer part, opposite the jugular fossa, enters into the formation of the jugular foramen, and its inner part presents a groove for the inferior petrosal sinus, and articulates with the side of the basilar portion of the occipital. In line with the opening of the internal auditory meatus it presents a triangular depression, which encroaches on the inferior surface and leads to a small canal, called the **aqueductus cochleæ**. This aqueduct transmits a small vein from the cochlea to the inferior petrosal sinus, and also a communication between the perilymph of the scala tympani and the subarachnoid space, sometimes called the *ductus perilymphaticus*. The *inferior border* separates the inferior from the anterior surface, and coincides with the line of contact of the tympanic plate with the petrous portion.

The **apex** of the petrous portion presents on its anterior aspect the Gasserian depression superiorly, and the outlet of the carotid canal inferiorly.

The **base** is the part of the petrous portion which appears on the external surface, and it presents a large opening leading into the **external auditory meatus**. This opening is oval, its long axis lying vertically, and it is bounded above by the posterior root of the zygoma, whilst the remainder of its circumference is formed mainly by the external auditory process of the tympanic plate. The external auditory meatus is formed chiefly by the tympanic and squamous portions, but also slightly by the mastoid portion. Its direction

is inwards, slightly forwards, and finally downwards, its length being rather more than $\frac{1}{2}$ inch (14 millimetres). It leads to the tympanum, and its deep end, which is nearly circular, is closed by the *membrana tympani*. This membrane is placed obliquely, and forms an acute angle with the lower wall and an obtuse angle with the upper, so that the floor of the meatus is longer than the roof, the anterior wall being also longer than the posterior. Its floor presents a slight elevation at the centre, where the passage is narrower than elsewhere, this portion being called the **isthmus**.

The **tympanic plate** is situated behind the fissure of Glaser, and is quadrilateral. It presents two surfaces and four borders. The *external surface* forms the posterior part of the glenoid fossa, and lodges the deep portion of the parotid gland. The *internal surface* forms the anterior, inferior, and part of the posterior, walls of the external auditory meatus, and the anterior and inferior walls of the tympanum, and at its inner or deep end it presents a groove, deficient above, for the *membrana tympani*, called the **sulcus tympanicus**. The *outer border* forms the **external auditory process**, and is curved and rough for the cartilage of the pinna. The *inner border* is situated immediately outside the bony part of the Eustachian tube, and is short and irregular. The *upper border* bounds the fissure of Glaser posteriorly, and the *lower border* forms at its back part the **vaginal process**, which ensheathes the base of the styloid process externally. The tympanic plate sometimes presents a small opening at its centre, called the **foramen of Huschke**.

The **styloid process**, which is cylindrical and tapering, starts from a point immediately in front of the stylo-mastoid foramen, and is directed downwards and inwards. The muscular and ligamentous relations of the process are as follows: The stylo-pharyngeus muscle arises from the inner aspect of the base; the stylo-hyoid muscle from the posterior and outer aspect of the process near its base; the stylo-glossus muscle from the front of the process near its tip; the stylo-mandibular ligament is attached to it just below the stylo-glossus; and the stylo-hyoid ligament is attached exactly to the tip.

The blood-supply of the bone is chiefly derived from the following sources: The squamous portion receives externally branches from the anterior and posterior deep temporal arteries of the internal maxillary, and internally branches of the middle meningeal. Other arterial twigs enter the bone at definite points, as follows: internal auditory from the basilar, through the internal auditory meatus; petrosal from the middle meningeal, through the hiatus Fallopii; stylo-mastoid from the posterior auricular, through the stylo-mastoid foramen; tympanic from the internal maxillary, through the Glaserian fissure; tympanic from the ascending pharyngeal, through the tympanic canaliculus; tympanic from the internal carotid, through the foramen on the posterior wall of the vertical portion of the carotid canal; the mastoid from the occipital, through the arterial fissure on the outer surface of the

mastoid process; and twigs from the mastoid division of the posterior auricular, through the foramina on the outer surface of the mastoid portion.

Articulations.—These are usually five in number, as follows: *posteriorly* and *internally* with the occipital, *superiorly* with the parietal, *anteriorly* with the sphenoid and malar, and *externally* with the condyle of the inferior maxilla, the latter being a movable articulation. Sometimes the temporal articulates with the frontal, giving rise to a fronto-squamosal suture.

Structure.—The **squamous portion** is thin, and is practically composed of two plates of compact bone. The **mastoid portion** is thick, and, as stated, contains the mastoid antrum and mastoid cells. The **petrous portion** is remarkable for its hardness, and it contains all the divisions of the organ of hearing, except the cartilaginous pinna on the outer side of the head. Thus it contains (1) the osseous external auditory meatus; (2) the tympanum or middle ear, with its three ossicles, malleus, incus, and stapes, etc.; and (3) the osseous labyrinth or internal ear, which contains the membranous labyrinth, consisting of the utricle, saccule, semicircular canals, and membranous cochlea. It also contains, for a certain distance, extensions of the mastoid cells.

Varieties.—(1) Foramen of Huschke in the centre of the tympanic plate, due to imperfect ossification. (2) Absence of petro-squamous suture. (3) Absence of the foramen within the hiatus Fallopii for the external superficial petrosal nerve.

Ossification.—The temporal bone is developed in three parts, namely, squamosal, tympanic, and petrosal. The squamosal and tympanic elements are formed *in membrane*, and the petrosal *in cartilage*. The **squamosal** gives rise to the squamo-zygomatic portion, and the upper and front part of the mastoid portion; the **tympanic** forms the tympanic annulus; and from the **petrosal** are developed the petrous portion and the greater part of the mastoid portion. It is to be noted that the mastoid portion is not an independent part developmentally, but belongs chiefly to the petrous and partly to the squamosal portions. The centre for the **squamosal** appears towards the end of the *second month* of intra-uterine life in the region of the root of the zygoma, and from this ossification extends upwards into the squamosal, forwards into the zygoma, and inwards into the glenoid fossa in front of the Glaserian fissure. From the posterior part of the squamosal a downward growth of bone takes place below the supramastoid crest, called the **postauditory process**, which forms the outer wall of the mastoid antrum, and gives rise to the upper and front part of the mastoid portion. The centre for the **tympanic element** appears towards the end of the *third month* of intra-uterine life in the lower part of the external membranous wall of the tympanum, and from this is developed the **tympanic annulus**. This ring forms about five-sixths of a circle, the deficiency being above, where it is closed by the squamosal, and within the circumference of the ring there is a groove for the membrana tympani. Previous to birth the extremities of the ring become ankylosed to the squamosal, and the **tympanic plate** is formed by an outward growth from it, so that it is ultimately located at the deep end of the external auditory meatus. The **petrosal element** or **periotic cartilaginous capsule** is developed from four centres, which appear towards the end of the *fifth month*, and from which ossification proceeds rapidly, union between the four centres being effected by the end of the *sixth month* of intra-uterine life. These centres are called opisthotic, pro-otic, pterotic, and epiotic, in the order of their appear-

ance. The **opisthotic centre** appears on the *promontory* on the inner wall of the tympanum, from which point ossification extends downwards around the fenestra rotunda, and forms (1) the floor of the vestibule, (2) the lower part of the fenestra ovalis, (3) the floor of the internal auditory meatus, (4) the greater part of the bony investment of the cochlea, (5) the carotid canal, and (6) the floor of the tympanum. The **pro-otic centre** appears near the inner limb of the *superior* semicircular canal in the region of the *eminencia arcuata*, and from it are formed (1) the bony investment of the superior semicircular

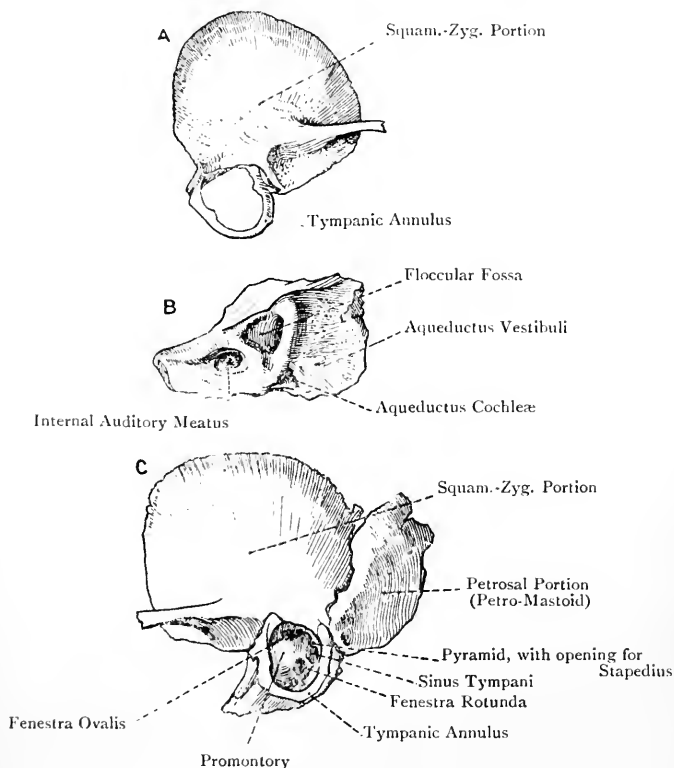


FIG. 52.—THE TEMPORAL BONE IN EARLY LIFE.

A, Squamo-Zygomatic Portion and Tympanic Annulus; B, Petrosal Portion; C, The Bone at Birth.

canal, (2) the roof of the vestibule, (3) the roof of the cochlea, (4) the roof of the internal auditory meatus, (5) the upper part of the fenestra ovalis, and (6) the upper and inner part of the mastoid portion. The **ptero-otic centre** (Bland-Sutton) appears over the outer limb of the external semicircular canal, and from it are formed (1) the covering of the external semicircular canal, and (2) the tegmen tympani. The **epi-otic centre**, sometimes double, appears in the region of the back part of the *posterior* semicircular canal, and from it the lower part of the mastoid is formed, as well as the investment of the posterior semicircular canal. At the period of birth (the tympanic having previously joined the squamosal) the temporal bone is composed of two parts—(1) a united

squamo-zygomatic and tympanic, and (2) a petrosal, a plate of cartilage intervening, and these unite in the course of the *first year*. At birth the bone is of loose consistence, the mastoid portion is flat, the external auditory meatus is undeveloped, the tympanic annulus and membrana tympani are on a level with the exterior of the bone, the glenoid and jugular fossæ are shallow, the floccular fossa is conspicuous, and the hiatus Fallopii is an open groove. The tympanic plate now becomes formed in fibrous tissue, by the extension of osseous matter outwards from two tubercles on the anterior and posterior parts of the outer aspect of the tympanic annulus superiorly. As these tubercles grow, they meet and enclose an opening in the floor of the external auditory meatus, which usually becomes closed before the period of puberty, but it may persist throughout life as the *foramen of Huschke*. The mastoid antrum is present at birth, and is of large proportionate size, its outer wall being very thin. The mastoid process becomes developed in the course of the *second year*, and the antrum becomes relatively smaller, its outer wall at the same time becoming thicker. The mastoid cells do not appear until the approach of the period of puberty.

Styloid Process.—This process is developed separately from the upper end of the cartilage of the *second visceral arch*. It has two centres of ossification, one for the **tympano-hyal** or basal part appearing before birth, which soon joins the rest of the bone, and the other for the **stylo-hyal** appearing in the *second year*. The latter portion does not attain marked development until after puberty, and its union with the tympano-hyal usually takes place in adult life, but it sometimes persists in an independent condition.

The Sphenoid Bone.

The **sphenoid bone** is so named from the wedge-like position which it occupies in the base of the skull, where it lies with its long axis placed transversely. It enters into the formation of the anterior, middle, and posterior, fossæ of the base, the temporal and nasal fossæ, and the orbits. It consists of a central portion or body, two great wings, two small wings, and two pterygoid processes.

The **body** presents six surfaces—superior, inferior, anterior, posterior, and two lateral, one at either side. Within the body are two large cavities, called the **sphenoidal air sinuses**, each of which opens on the anterior surface by a small circular aperture.

The *superior surface* presents at its centre a depression, called the **sella turcica** or **pituitary fossa**, for the pituitary body or *hypophysis cerebri*, and in the foetus it is pierced by the superior opening of the **cranio-pharyngeal canal**. In front of the sella turcica is the **oliviary eminence**, which indicates the place of junction of the presphenoid and postsphenoid portions, and anterior to this is a transverse furrow, called the **optic groove**, both of which support the optic commissure or chiasma. The groove leads at either side to the optic foramen, by which the optic nerve leaves the cranial cavity, and anteriorly it is limited by a transverse ridge, called the **limbus sphenoidalis**. In front of the limbus (border) is a smooth elevated platform, called the **jugum sphenoidale**, which is continuous laterally with the superior surface of the small wing, and presents at either side the **olfactory groove** for the olfactory bulb. The anterior border of the jugum is projected in the middle line into the **ethmoidal spine**, which articulates with the posterior

margin of the cribriform plate of the ethmoid. The sella turcica is bounded posteriorly by a prominent quadrilateral plate of bone, called the **dorsum sellæ** or **dorsum ephippii** (back of the saddle), which is directed forwards and upwards. The antero-inferior surface of this plate overhangs the sella turcica, and the postero-superior surface, called the **clivus** (slope), is inclined downwards and backwards to become continuous with the basilar groove of the occipital. The clivus lodges the upper part of the pons Varolii and the basilar artery. The antero-superior border of the dorsum sellæ presents at either side the **posterior clinoid process** for a portion

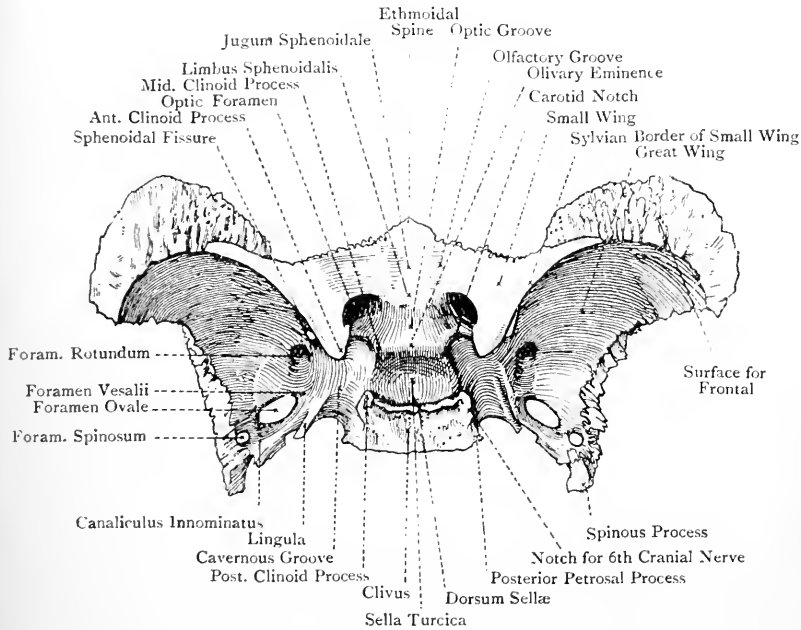


FIG. 53.—THE SPHENOID BONE (SUPERIOR VIEW).

of the tentorium cerebelli and the interclinoid ligament, which latter connects it with the anterior clinoid process, and is sometimes ossified. On each lateral border of the dorsum sellæ, a little below the posterior clinoid process, is a notch, which transmits the sixth cranial nerve. At the lower end of each lateral border there is a projection, called the **posterior petrosal process**, which articulates with the apex of the petrous portion of the temporal, and bounds internally the foramen lacerum medium.

The *inferior surface* of the body is limited at either side by the internal pterygoid plate of the pterygoid process. In the middle line it presents a vertical, antero-posterior ridge, called

the **rostrum**, which is continuous with the sphenoidal crest on the anterior surface, and is received into the cleft between the alæ of the vomer. At either side of the rostrum there is a thin scale of bone projecting inwards for a short distance from the root of the internal pterygoid plate, called the **vaginal process**, which articulates with the ala on the upper border of the vomer, and with it covers the greater part of the inferior surface of the body at either side of the middle line. On the inferior surface of this process there is a groove, which is converted by the sphenoidal process of the palate bone into a canal, called the **pterygo-palatine canal**, for the passage of the pharyngeal nerve and pterygo-palatine artery.

The *anterior surface* presents in the middle line a vertical ridge, continuous above with the ethmoidal spine and below with the rostrum, called the **sphenoidal crest**, which articulates with the perpendicular plate of the ethmoid and forms part of the nasal septum. On either side of this crest the surface is divided into two parts, outer and inner. The outer part is rough, and articulates with the back part of the lateral mass of the ethmoid and the orbital process of the palate bone. The inner part presents the opening of the sphenoidal air sinus of its own side, with the margins of which the sphenoidal turbinate or spongy bone articulates. When this bone is in position the opening of the sinus is small and circular, and is placed superiorly, but when the bone has been removed the opening is of large size and irregular outline. It communicates anteriorly with the speno-ethmoidal recess of the nasal fossa above and behind the superior meatus. The part of the anterior surface which presents the opening of the sphenoidal air sinus enters into the formation of the roof of the corresponding nasal fossa.

The *posterior surface* is rough and truncated. It articulates with the basilar process of the occipital by synchondrosis up to the twentieth year, after which ankylosis takes place.

The *lateral surface* gives attachment to the great wing and a portion of the small wing. Anteriorly, beneath the small wing, it forms the inner boundary of the sphenoidal fissure and the back part of the inner wall of the orbit. Above the attachment of the great wing it presents a winding groove, called the **cavernous or carotid groove**, which contains the cavernous venous sinus and the internal carotid artery. The direction of this groove is from behind forwards, and its deepest part is placed posteriorly, where it is bounded internally by the posterior petrosal process, and externally by the **lingula sphenoidalis** or **anterior petrosal process**. This latter process is a sharp scale of bone which projects backwards in the angle between the great wing and body.

The **small or orbital wings** (orbito-sphenoids) extend almost horizontally outwards on a level with the anterior part of the upper surface of the body. Each arises by two roots—an upper, which is expanded and compressed from above downwards,

and is on a level with the anterior part of the upper surface of the body; and a lower, slender and compressed from before backwards, which arises from the anterior part of the side of the body. The wing is triangular and flattened from above downwards. The *superior surface*, smooth and somewhat concave, forms the back part of the anterior cranial fossa. The *inferior surface* overhangs the sphenoidal fissure, and forms the back part of the roof of the orbit. Externally the wing ends in a slender, pointed extremity, which lies very near the great wing, but does not as a rule touch

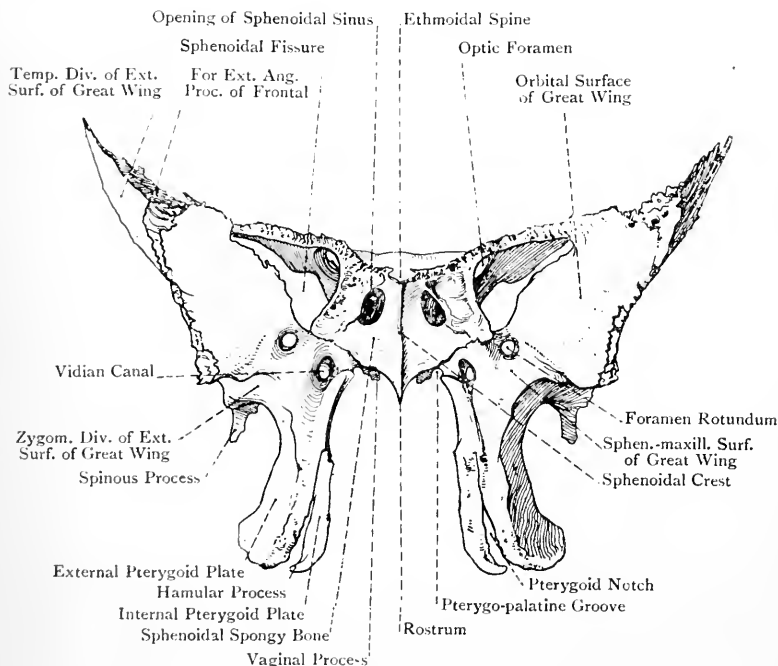


FIG. 54.—THE SPHENOID BONE (ANTERIOR VIEW).

it, though it may do so. The *anterior border* is thin and serrated for the orbital plate of the frontal. The *posterior border*, smooth, thick, and round, corresponds with the Sylvian fissure of the cerebrum, from which circumstance it is known as the Sylvian border. It forms at either side the line of demarcation between the anterior and middle cranial fossae, and terminates internally in the **anterior clinoid process** for a portion of the tentorium cerebelli and the interclinoid ligament.

Between the anterior clinoid process and the side of the olivary eminence is the semicircular **carotid notch**, which is the anterior

termination of the carotid groove, and lodges the internal carotid artery.

On either side of the body, close to the inner side of the anterior extremity of the carotid groove and posterior to the carotid notch, opposite the anterior clinoid process, there is usually a small tubercle, called the **middle clinoid process**. It is connected with the anterior clinoid process by the carotico-clinoid ligament, which bridges over the carotid notch. When this ligament undergoes ossification a **carotico-clinoid foramen** is formed, through which the internal carotid artery ascends after leaving the carotid groove.

In front of the carotid notch, between the upper and lower roots of the small wing, there is a circular aperture, called the **optic foramen**, which leads forwards and outwards into the orbit, and transmits the optic nerve and the ophthalmic artery.

The **great or temporal wings** (alisphenoids) extend outwards, upwards, and forwards from the sides of the body. The posterior part of each projects backwards, and ends in a pointed extremity, which is received within the petro-squamous angle of the temporal bone. From this extremity a sharp projection extends downwards for a short distance, called the **spinous process** or **alar spine**, which presents a groove on its inner aspect for the chorda tympani nerve. Anterior to this groove and encroaching on the posterior border of the great wing is another groove for the cartilaginous part of the Eustachian tube. The spinous process gives attachment to (1) the sphenomandibular ligament, (2) some fibres of the tensor palati, and (3) the anterior ligament of the malleus, or band of Meckel.

Each great wing presents three surfaces—superior, antero-internal, and external; and four borders—posterior, external, anterior, and internal.

The *superior or cerebral surface*, which at its front part rises almost vertically upwards, is concave, and enters into the formation of the lateral division of the middle cranial fossa. It supports the temporo-sphenoidal lobe of the cerebrum, and presents a few digitate impressions, whilst externally it is grooved for a branch of the middle meningeal artery. This surface presents several important foramina. At the anterior part of its attachment to the side of the body, just below the inner end of the sphenoidal fissure, is the **foramen rotundum**, which is directed from behind forwards and transmits the superior maxillary division of the fifth cranial nerve. A little behind and external to this foramen is the **foramen ovale**, of large size and opening vertically downwards, for the passage of the inferior maxillary division and the motor root of the fifth cranial nerve, the small meningeal artery, an emissary vein from the cavernous sinus, and sometimes the small superficial petrosal nerve. Internal and anterior to the foramen ovale, between it and the lingula sphenoidalis, there is sometimes a small opening, called the **foramen Vesalii**, which leads to the scaphoid fossa on the outer side of the root of

the internal pterygoid plate, or to the pterygoid fossa external to the scaphoid fossa. It transmits a small emissary vein from the cavernous sinus. Behind and external to the foramen ovale is the small circular **foramen spinosum**, close to the spinous process, which opens vertically downwards. It transmits the middle meningeal artery and a recurrent branch of the inferior maxillary nerve, and is sometimes incomplete posteriorly. Internal to this foramen, between it and the foramen ovale, there is sometimes a small opening, called the **canaliculus innominatus**, for the small superficial petrosal nerve.

The *antero internal surface* is divisible into a large orbital portion and a small sphenomaxillary portion. The *orbital division* is quadrilateral, smooth, and slightly concave, and it forms the greater part of the outer wall of the orbit. The *sphenomaxillary division* is situated at the lower and inner part above the root of the pterygoid process. It is pierced by the foramen rotundum, and lies in the posterior wall of the sphenomaxillary fossa.

The *external or temporozygomatic surface* is elongated from above downwards, and is continuous with the outer surface of the external pterygoid plate of the pterygoid process. Towards its lower part it is crossed by the **infratemporal crest**, which divides it into a large upper and a small lower portion. The *upper or temporal division*, which is directed outwards, forms part of the temporal fossa, and gives origin to fibres of the temporal muscle. The *lower or zygomatic division* looks downwards into the zygomatic fossa, and gives origin to the upper head of the external pterygoid muscle. At its lower and back part it presents the openings of the foramen ovale and foramen spinosum.

The *posterior border* extends from the spinous process to the body, passing in its course behind the foramen ovale. Over its inner two-thirds it bounds the foramen lacerum medium anteriorly, and over its outer third, where it becomes serrated, it articulates with the petrous portion of the temporal, the two forming a groove for the cartilaginous part of the Eustachian tube. The *external border* separates the superior or cerebral from the external or temporozygomatic surface. It is serrated behind, where it is bevelled at the expense of the upper or inner plate, but in front it is squamous and bevelled at the expense of the outer plate. The entire border articulates with the squamous portion of the temporal. The *anterior border* or **malar crest** separates the orbital and temporal surfaces. Its direction is downwards and inwards, and it is sharp and irregular for the malar. The *internal border* is situated between the orbital and cerebral surfaces. Its direction is backwards and inwards, and it forms the lower boundary of the sphenoidal fissure. About its centre it presents a small spine, which gives origin to fibres of the lower head of the external rectus muscle of the eye-ball. The great wing antero-superiorly becomes thick and expanded, and it here presents a rough, triangular, serrated surface for the frontal. At the outer end of this surface there is another small

triangular, serrated impression, for the antero-inferior angle of the parietal.

The **sphenoidal fissure**, also called the **foramen lacerum anterius** or **orbitale**, is situated between the great and small wings. It is triangular, and its direction is inwards and downwards. It is bounded above by the small wing, below by the internal border of the great wing, and internally by the anterior part of the side of the body, whilst externally it is closed by the frontal, or, it may be, the meeting between the two wings. It leads from the middle cranial fossa to the orbit, and transmits the following structures: the third cranial nerve, the fourth, the three branches of the ophthalmic division of the fifth (namely, frontal, lachrymal, and nasal), and the sixth cranial nerves, the sympathetic root of the ciliary ganglion,

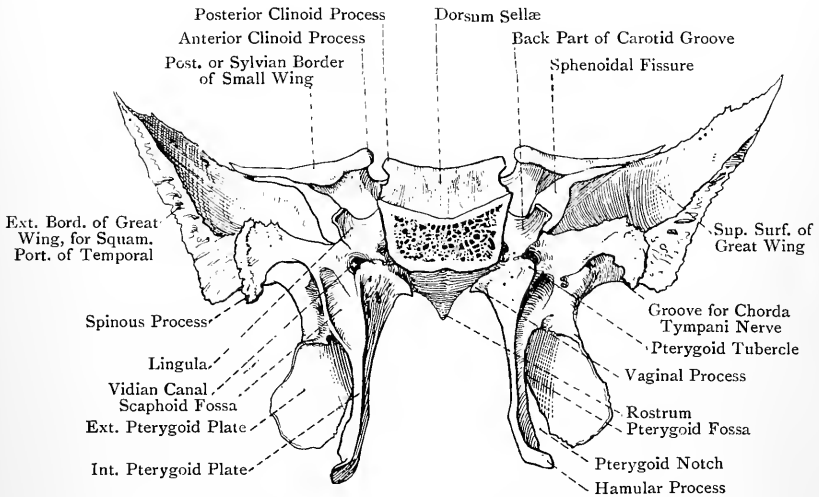


FIG. 55.—THE SPHENOID BONE (POSTERIOR VIEW).

the superior and inferior ophthalmic veins, the orbital branch of the middle meningeal artery, and a portion of the dura mater to form the orbital periosteum.

The **pterygoid processes** project downwards from the junction of the body and great wings. Each is composed of two plates, external and internal, united in front to form a thick round border, except inferiorly, where they are separated by the **pterygoid notch**, which receives the pyramidal process or tuberosity of the palate bone. At the upper end of the anterior border a triangular surface opens out, which lies in the posterior wall of the spheno-maxillary fossa, and presents the anterior orifice of the Vidian or pterygoid canal. Posteriorly the two plates diverge, and enclose between them the **pterygoid fossa**, which contains the internal pterygoid and tensor or circumflexus palati muscles.

The **external pterygoid plate** is broader and shorter than the internal, and is directed backwards and slightly outwards. Its outer surface looks into the zygomatic fossa, and gives origin to the lower head of the external pterygoid muscle. Its inner surface looks into the pterygoid fossa, and gives origin to the internal pterygoid muscle. The posterior border usually presents towards its upper part a sharp spine, from which the pterygo-spinous ligament extends backwards and outwards to the spinous process. This ligament sometimes becomes ossified, and a foramen is then formed, called the **pterygo-spinous foramen**, for the passage of muscular branches of the inferior maxillary nerve. Sometimes there is another spine towards the lower end of this border for another pterygo-spinous ligament.

The **internal pterygoid plate**, narrower and longer than the external, is prolonged inferiorly into the **hamular process**, which is inclined outwards, its outer and inferior aspects being smooth and grooved for the play of the tendon of the tensor or circumflexus palati. Superiorly this plate is inflected as the vaginal process, which articulates with the ala of the vomer, and presents on its under surface a groove forming part of the pterygo-palatine canal already referred to. The outer surface of the internal pterygoid plate looks into the pterygoid fossa, and is related to the tensor or circumflexus palati. The inner surface forms the back part of the outer wall of the nasal fossa. The posterior border at its upper end presents the **pterygoid tubercle**, which has the posterior end of the Vidian canal above and external to it. Between this tubercle and the Vidian canal on the one hand, and the pterygoid fossa on the other, is the **scaphoid fossa**, which gives origin to the tensor or circumflexus palati. On the posterior border of the internal pterygoid plate, below the lower pointed end of the scaphoid fossa, is the **Eustachian spine** or *processus tubarius*, which supports the cartilage of the Eustachian tube. The lower third of the posterior border and the hamular process give origin to fibres of the superior constrictor muscle of the pharynx, and the hamular process also gives attachment to the pterygo-mandibular ligament. The anterior border articulates with the posterior border of the perpendicular plate of the palate bone.

The **Vidian or pterygoid canal** pierces the bone from before backwards at the junction of the internal pterygoid plate and body on either side. Its anterior orifice appears on the posterior wall of the sphenomaxillary fossa, below and internal to the anterior orifice of the foramen rotundum, and posteriorly it opens on the anterior wall of the foramen lacerum medium, above and external to the pterygoid tubercle. It gives passage to the Vidian nerve and artery.

Summary of Openings in the Sphenoid Bone.—(1) Sphenoidal fissure, between small and great wings; (2) optic foramen, between the two roots of the small wing; and, in the great wing. (3) foramen rotundum; (4) foramen ovale; (5) foramen Vesalii (inconstant); (6) foramen spinosum; (7) canaliculus innominatus (inconstant);

and (8) Vidian or pterygoid canal, the last-named being between the internal pterygoid plate and the body. All these openings are common to each side.

The **sphenoidal air sinuses** are situated within the body, and are two in number, right and left. They are separated from each other by a septum, which is usually slightly bent to the left side. The sinuses are—at least, after adult life—usually multilocular, and they may extend backwards so as to invade the basilar process of the occipital, especially in old age. Each sinus may even extend slightly into the attached portion of the great wing. They are lined with mucous membrane, which is continuous with that of the nasal fossæ, and each opens anteriorly by a small circular aperture into the speno-ethmoidal recess above and behind the corresponding superior meatus.

The **sphenoidal turbinate** or **spongy bones** (sphenoidal turbinals or bones of Bertin) are situated on the anterior and inferior surfaces of the body of the sphenoid, of which they form a large part. In the adult they are blended with the sphenoid and adjacent parts of the ethmoid and palate bones, but in early life they are quite distinct. Each has the form of a three-sided, hollow pyramid, the apex of which is directed backwards and downwards to the front part of the vaginal process, whilst the base is in contact with the back part of the lateral mass of the ethmoid. The inferior surface looks into the posterior part of the roof of the nasal fossa, and it converts the speno-palatine notch on the upper border of the perpendicular plate of the palate bone into a foramen. The external surface appears on the inner wall of the speno-maxillary fossa, and a portion of it is sometimes seen on the inner wall of the orbit, behind the os planum of the ethmoid. The superior surface is in contact with the anterior and inferior surfaces of the front part of the body of the sphenoid. It is at the upper part of this surface, on either side of the middle line, where the openings of the sphenoidal air sinuses ultimately appear as small circular apertures. When the sphenoidal spongy bones are broken away these openings are of large size and irregular outline.

The blood-supply of the bone is derived from branches of the deep temporal arteries externally, the middle and small meningeal internally, and the Vidian, pterygo-palatine, and speno-palatine branches of the internal maxillary, as these traverse their respective passages.

Articulations.—The sphenoid articulates with fourteen bones, as follows: occipital, two temporals, two parietals, frontal, ethmoid, two sphenoidal turbinates, two malars, two palates, and vomer. It sometimes also articulates with the superior maxillæ.

Structure.—The body of the bone is excavated into two air sinuses.

Varieties.—(1) Middle clinoid process. (2) Carotico-clinoid foramen. (3) Ossification of interclinoid ligament between anterior and posterior clinoid processes. (4) The lateral margin of the dorsum sellæ may present a superior

petrosal process for the attachment of the petro-sphenoidal ligament, which connects it with a projection sometimes present on the inner part of the superior border of the petrous portion of the temporal. This ligament, which is sometimes ossified, bridges over a foramen through which the inferior petrosal venous sinus and sixth cranial nerve pass. (5) Pterygo-spinous foramen. (6) Foramen ovale and foramen spinosum are sometimes incomplete. (7) Foramen Vesalii. (8) Canaliculus innominatus. (9) The cranio-pharyngeal canal may remain persistent, opening into the pituitary fossa.

Ossification.—The sphenoid is developed in cartilage, with the exception of the internal pterygoid plates, which are developed in fibrous tissue.* The bone is originally divided into two parts—presphenoid, representing the part of the body in front of the olivary eminence, and the small wings; and post-sphenoid, including the part of the body behind the olivary eminence, the great wings, and the pterygoid processes. The **postsphenoid division** is developed from **four pairs of centres**. One pair appear in the *eighth week* of intra-uterine life, one at either side in the great wing between the foramen

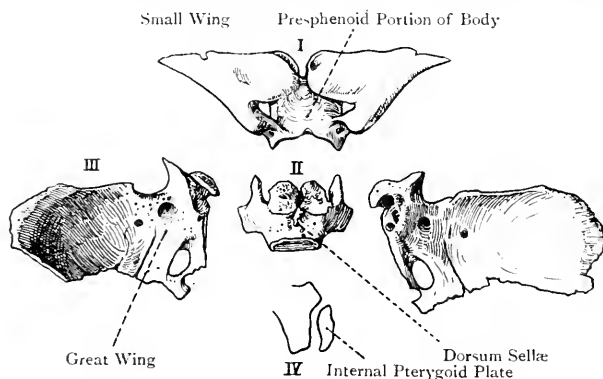


FIG. 56.—THE SPHENOID BONE IN EARLY LIFE.

I, Presphenoid Division; II, Postsphenoid Portion of Body; III, Great Wing and Pterygoid Process; IV, Elements of Pterygoid Process.

rotundum and foramen ovale, and from this ossification extends outwards into the great wing and downwards into the external pterygoid plate. Another pair appear about the same time in the sella turcica on either side of the cranio-pharyngeal canal, from which ossification extends around the canal, gradually constricting it, and finally leading to its closure. At this time another pair (sphenotics of Bland-Sutton) appear, one at either side, for the lingula. In the *fourth month* (ninth or tenth week, Fawcett) another pair of centres appear in fibrous tissue, one at either side, for the internal pterygoid plate, which unites with the external pterygoid plate before the *sixth month*. The **presphenoid division** is developed from **two pairs of centres**. Two appear in the *ninth week*, one at either side, external to the optic foramen, for the small wing. Another pair appear in the *eleventh week* internal to the optic foramina for the presphenoid portion of the body. The latter pair soon unite with each other, and also with those for the small wings. The presphenoid division, bearing the small wings, joins the postsphenoid division shortly before birth in the region of the olivary eminence. At birth the place of junction is indicated by a wide depression on the under

* According to recent observations made by Fawcett the external pterygoid plates are also developed in fibrous tissue.

aspect of that eminence, which may even extend through it and give rise to a small foramen on its upper surface.

At birth the bone is composed of three parts—a **central**, representing the presphenoid and postsphenoid portions of the body, the former bearing the small wings; and **two lateral**, each of which represents a great wing bearing a pterygoid process. In the *first year* the lingula joins the great wing, and the wing and body unite. About the same time the small wings come together and blend over the anterior part of the upper surface of the presphenoid portion of the body, where they give rise to a smooth, elevated, flat platform, called the **jugum sphenoidale**.

In foetal life a canal, called the **cranio-pharyngeal canal**, leads downwards from the sella turcica into the body, and contains a process of the dura mater. This canal is the remains of a cleft originally present in the base of the skull, through which a diverticulum of the buccal epiblast, known as the **pouch of Rathke**, originally passed upwards to form the anterior lobe of the pituitary body.

The sphenoidal air sinuses do not appear until after the *seventh year*.

In some animals the presphenoid and postsphenoid portions remain permanently separate, and the internal pterygoid plates form the pterygoid bones.

The sphenoidal turbinate bones commence to ossify in the *fifth month* of intra-uterine life. At birth each partially envelops a small extension of the nasal mucous membrane, and by the *third year* it has surrounded it in the form of a bony capsule, except anteriorly, where an opening, called the sphenoidal foramen, is left. Subsequently a portion of this capsule becomes absorbed, and its place is taken by the presphenoid, which latter, after the *seventh year*, is gradually invaded by the original extension of the nasal mucous membrane. The sphenoidal spongy bones become ankylosed to the ethmoid about the *fourth year*, and are sometimes regarded as belonging to that bone. By the *twelfth year* they have become united to the sphenoid, and also to the palate bones.

The Ethmoid Bone.

The **ethmoid bone** is situated at the anterior part of the base of the skull, where it lies in the middle line in front of the sphenoid. A portion of it occupies the ethmoidal notch between the orbital plates of the frontal, whence the greater part of the bone projects downwards to take part in the formation of the orbits and nasal fossæ. The only portions of the bone visible in the interior of the base are the cribriform plate and crista galli. It is irregularly cubical, its long axis being directed from before backwards, and it is remarkable for its lightness, which is due to the great number of enclosed air cells, these being surrounded by very thin plates of bone. It is composed of four parts, namely, a cribriform plate, a perpendicular plate, and two lateral masses.

The **cribriform plate** connects the upper borders of the lateral masses, and enters into the formation of the middle division of the anterior cranial fossa, where it occupies the ethmoidal notch of the frontal bone. In the middle line anteriorly it presents an upward extension of the perpendicular plate, called the **crista galli**. This is a stout, triangular, laterally-compressed process, which presents a smooth, sloping posterior border, for the falx cerebri. The anterior border, short and vertical, is somewhat narrow above, but soon expands into two **alar processes**, for the frontal bone,

and it here sometimes completes the foramen cæcum. The posterior border is prolonged backwards as a median ridge, and on either side of this ridge and the crista galli is the **olfactory groove**, which lodges the olfactory tract and bulb. Each half of the cribriform plate, which lies in the roof of the corresponding nasal fossa, is pierced by foramina for the filaments of the olfactory bulb. The foramina in each half are arranged in three sets, as follows—a middle set, which are simple perforations, and an internal and external set, which lead into small canals. These canals descend on the perpendicular plate and inner surface of the lateral mass respectively, branching and opening out as they descend. All the foramina lead to the upper part of the corresponding nasal fossa. At the anterior and inner part of each half of the cribriform plate, close to the side of the crista galli, near its anterior border,

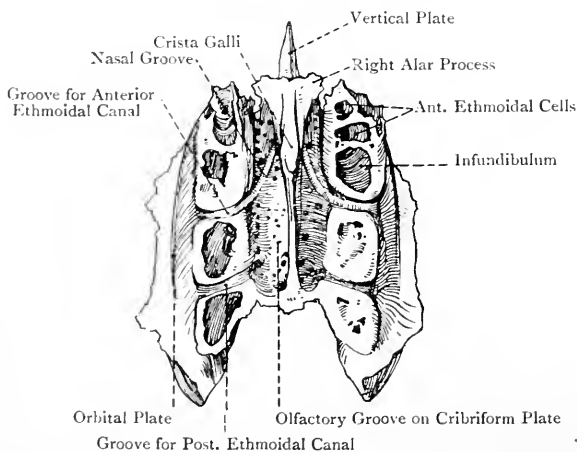


FIG. 57.—THE ETHMOID BONE (SUPERIOR VIEW).

there is an antero-posterior fissure, called the **nasal slit**, which transmits the nasal branch of the ophthalmic nerve and nasal branch of the anterior ethmoidal artery to the nasal fossa. Leading backwards and outwards from this slit to the anterior ethmoidal groove on the upper border of the lateral mass is the **nasal groove**, also for the nasal nerve. The posterior border of the cribriform plate articulates with the ethmoidal spine of the sphenoid.

The **perpendicular plate** (mesethmoid) extends downwards from the cribriform plate in the middle line. It lies between the lateral masses, where it forms about the upper third of the nasal septum, and it is usually inclined more to one side than the other. It is very thin and irregularly quadrilateral. The *superior border* projects above the cribriform plate and forms the crista galli. The *inferior border* articulates, in front, with the septal cartilage of the nose, and behind, with the alæ of the vomer in the intervening cleft,

with which alæ it is usually ankylosed in adult life. The *anterior border* articulates with the nasal spine of the frontal and the nasal crest of the nasal bones. The *posterior border* articulates with the crest of the sphenoid. Each *lateral surface* looks into the corresponding nasal fossa, and presents superiorly several small canals and grooves, which lead downwards from the internal set of foramina in each half of the cribriform plate, and transmit olfactory filaments.

The **lateral masses** or **lateral ethmoids** (ethmo-turbinals) form the principal part of the bone, and contain a number of air cells enclosed within very thin osseous plates. Each lateral mass or **labyrinth** is elongated from before backwards, and presents two surfaces and four borders.

The *external surface*, smooth and quadrilateral, with the long axis directed from before backwards, is called the **os planum** or **orbital**

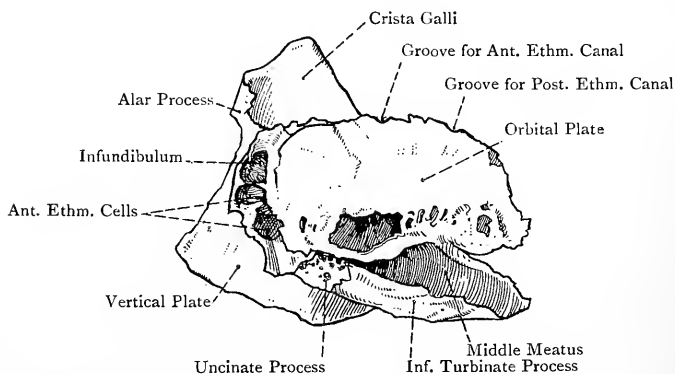


FIG. 58.—THE ETHMOID BONE (LATERAL VIEW).

plate, and forms the principal part of the inner wall of the orbit. It articulates *superiorly* with the inner border of the orbital plate of the frontal, *anteriorly* with the lachrymal, *inferiorly* with the inner margin of the orbital plate of the superior maxilla, and behind this with the orbital process of the palate bone, close to the postero-inferior angle, and *posteriorly* with the sphenoid, or, it may be, with a portion of the sphenoidal spongy bone. At the lower part of the external surface, below the os planum, there is a deep channel, elongated from before backwards, which forms the middle meatus of the nose, and is limited below by the inferior rolled border of the inferior turbinate process. This groove turns upwards in front, under cover of the anterior part of the inferior turbinate process, and is continued into the **infundibulum** which communicates with the frontal sinus of the same side. The anterior ethmoidal cells open into the ascending part of the middle meatus, whilst the middle ethmoidal cells and the antrum of Highmore

open into its horizontal part. Lying in the anterior part of this meatus is the uncinæ process.

The *internal surface* of the lateral mass forms a part of the outer wall of the nasal fossa. Superiorly it presents several small canals and grooves, which lead downwards from the external set of foramina in the cribriform plate and transmit olfactory filaments. This surface is doubly convoluted, and presents the **superior** and **inferior turbinate processes**, which are sometimes spoken of as the *superior* and *middle spongy bones*, or *conchæ*. These are continuous with each other in front, but posteriorly they are separated by the **superior meatus**, which is directed obliquely forwards and upwards, and communicates with the posterior ethmoidal cells. The **superior turbinate process** is short, and overhangs the superior meatus. The **inferior turbinate process** is longer and more convoluted than the superior. Its lower border, which is thick, is

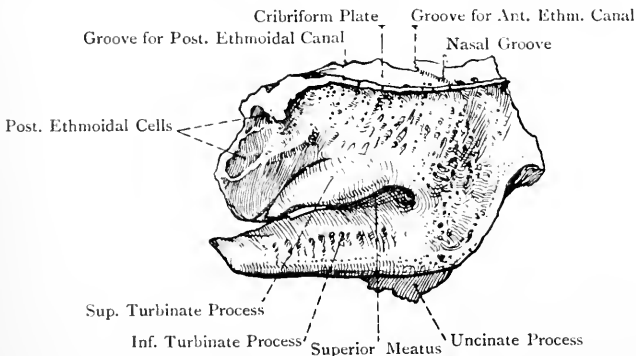


FIG. 59.—THE LEFT LATERAL MASS OF THE ETHMOID BONE (INTERNAL VIEW).

rolled outwards, and has been referred to in connection with the outer surface. It is free, as are also its thick anterior and pointed posterior extremities. This process overhangs the **middle meatus**. Both turbinate processes are pierced by nutrient foramina, and present grooves for olfactory filaments.

The *superior border* is covered by the bevelled inner margin of the orbital plate of the frontal, which closes in the depressions upon it, and converts them into air cells. Besides these depressions this border presents two transverse grooves about half an inch apart, which, with corresponding grooves on the orbital plate of the frontal, form the **anterior** and **posterior ethmoidal** or **internal orbital canals**. These open upon the inner wall of the orbit, and the *anterior* transmits the anterior ethmoidal vessels and the nasal nerve, whilst the *posterior* gives passage to the posterior ethmoidal vessels and the sphenothmoidal nerve. The *inferior border*, which is free on the outer wall of the nasal

fossa, is formed by the lower border of the inferior turbinate process. *Anteriorly* it articulates with the superior turbinate crest of the superior maxilla, and *posteriorly* with the ethmoidal or superior turbinate crest of the palate bone. The *anterior border*, like the superior, presents depressions, which form air cells when the lachrymal and nasal process of the superior maxilla are in position. This border projects slightly in advance of the front of the os planum, and from the lower part of this projecting portion there springs the **uncinate process**. This is a long, thin, curved plate which extends downwards, backwards, and slightly outwards into the anterior part of the middle meatus. In its course it crosses the opening of the antrum of Highmore in the superior maxilla, and thus forms part of the inner wall of that air sinus. The lower border of the process presents two spur-like projections, between which the border is markedly concave. The posterior terminal spur articulates with the ethmoidal process of the inferior turbinate bone. The *posterior border* of the lateral mass presents a few depressions, closed by the sphenoidal spongy bone and orbital process of the palate bone, which latter process becomes ankylosed with it about the fourth year.

The **ethmoidal cells** are contained within each lateral mass, and are lined with mucous membrane, which is continuous with that of the nose. They are arranged in three sets—*anterior, middle, and posterior*. The **anterior ethmoidal cells**, along with the frontal sinus of the same side, open by a common passage, already described as the infundibulum, into the ascending front part of the middle meatus; the **middle ethmoidal cells** open into the horizontal part of the middle meatus; and the **posterior ethmoidal cells** open into the superior meatus.

The bone receives its blood-supply from the anterior and posterior ethmoidal branches of the ophthalmic, and the sphenopalatine branch of the internal maxillary.

Articulations.—The ethmoid articulates with fifteen bones, as follows: (1) frontal (nasal spine and orbital plates); (2) sphenoid (ethmoidal spine and sphenoidal crest); (3) two sphenoidal spongy bones; (4) two nasal bones (nasal crest); (5) vomer (cleft between *alæ*); (6) two palate bones (ethmoidal or superior turbinate crests and orbital processes); (7) two lachrymals (upper part of internal surface); (8) two superior maxillæ (nasal processes, orbital plates, and opening of each antrum); and (9) two inferior turbinates (ethmoidal processes).

Structure.—The lateral masses are excavated into many thin-walled air cells, and the crista galli contains a small amount of cancellated tissue.

Ossification.—The ethmoid is developed in cartilage from **three centres**. Two of these appear in the *fifth month* of intra-uterine life, one in each os planum, from which ossification extends into the superior and inferior turbinate processes. At birth the lateral masses are ossified, but the perpendicular plate and crista galli are cartilaginous. In the *first year* a centre appears at the base of the crista galli, and from this ossification extends upwards into

that process, downwards into the perpendicular plate, and outwards into the cribriform plate, into which latter osseous matter also extends inwards from each lateral mass. The three original parts unite about the *fifth year*. The osseous ethmoidal cells usually make their appearance about the *third year*.

The Superior Maxillary Bones.

The **superior maxillary bone** forms, with its fellow, a large part of the face, and, besides supporting the upper teeth of its own side, it enters into the formation of the orbit, nasal fossa, and hard palate. It is composed of a central portion or body, and four processes—nasal, malar, alveolar, and palatal.

The **body** is excavated into a large cavity, called the antrum of Highmore or maxillary air sinus, and it presents four surfaces—antero-external, postero-external, superior, and internal.

The *antero-external* or *facial surface* is limited above by the infra-orbital border, below by the alveolar border, internally by the mesial border, presenting the nasal notch, and externally by the malar process and a ridge of bone extending downwards from it to the first molar alveolus. It presents inferiorly five ridges, coinciding with the roots of the incisor, canine, and bicuspid teeth, of which that of the canine is conspicuous, and is called the **canine ridge**. Internal to this ridge is the **incisor** or **myrtiform fossa** (like a myrtle-berry), which gives origin internally to the depressor alæ nasi, and externally to a deep slip of the orbicularis oris, whilst above, and external to, the latter the compressor naris arises. External to the canine ridge is the **canine fossa**, which, at its upper part, gives origin to the levator anguli oris, the bone being here thin and translucent in front of the antrum. Above the canine fossa, near the infra-orbital border, is the **infra-orbital foramen**, which is the outlet of the infra-orbital canal, and transmits the infra-orbital nerve and vessels. Immediately above this foramen the levator labii superioris arises. The mesial border of the facial surface presents the deep **nasal notch**, at the lower and inner part of which is a sharp projection, forming, with its fellow, the **anterior nasal spine**, below which the border is vertical.

The *postero-external* or *zygomatic surface* is situated behind the malar process and the ridge connecting that process with the first molar alveolus. Superiorly it is limited by the posterior border of the orbital surface, inferiorly by the molar portion of the alveolar border, and posteriorly by the posterior border of the bone. It looks into the zygomatic and speno-maxillary fossæ, and its outline is convex. Towards the centre it presents the openings of two or three **posterior dental canals**, which lead to the molar alveoli, and transmit branches of the posterior superior dental nerve and artery. At the lower and back part this surface gives rise to the **tuberosity**, which lies above and behind the last molar tooth. This tuberosity articulates with the pyramidal process of the palate bone, and gives origin to some fibres of the internal pterygoid muscle.

The *superior* or *orbital surface* is triangular, smooth, and slightly concave, and it forms the greater part of the floor of the orbit. This portion of the bone is known as the **orbital plate**. It presents the **infra-orbital groove**, which, commencing at the posterior border in a notch, ultimately becomes converted into the **infra-orbital canal**. This canal transmits the infra-orbital nerve and vessels. From its posterior part the **middle dental canal**, for the middle superior dental nerve and artery, passes downwards and forwards

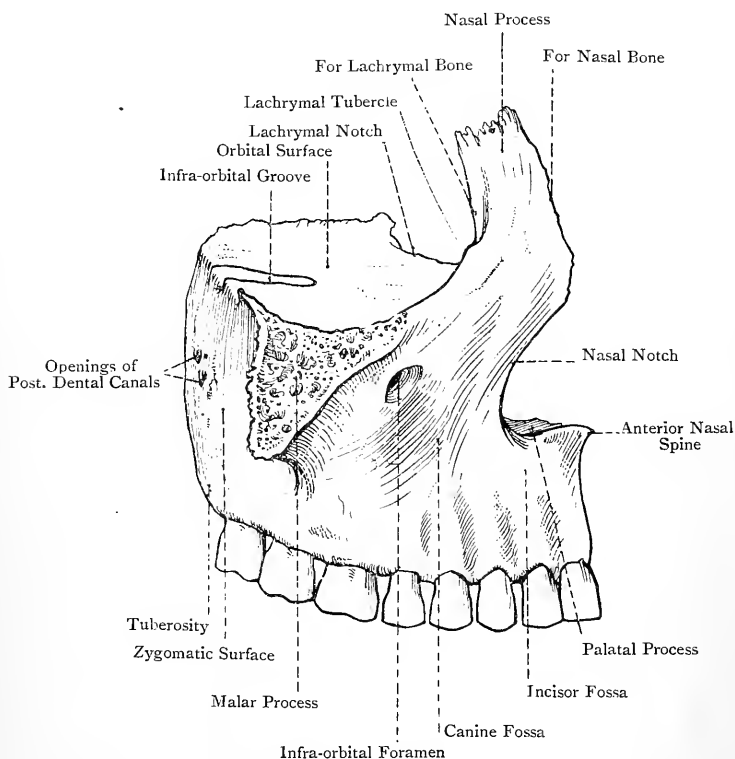


FIG. 60.—THE RIGHT SUPERIOR MAXILLARY BONE (EXTERNAL VIEW).

to the bicuspid alveoli, lying at first in the postero-external wall of the antrum, and subsequently in the antero-external wall. This canal is often for the most part a groove. The **anterior dental canal**, for the anterior superior dental nerve and artery, descends in a branching manner from the anterior part of the infra-orbital canal to the incisor and canine alveoli, lying in the antero-external wall of the antrum. At the anterior and inner part of the orbital plate, external to the lachrymal groove, there is a slight depression which gives origin to the inferior oblique muscle of the eyeball.

The borders of the orbital surface are anterior, posterior, and internal. The anterior border coincides with the infra-orbital border. The posterior border, which has an inclination outwards, forms the anterior boundary of the spheno-maxillary fissure, and presents a notch representing the commencement of the infra-orbital groove. The internal border, antero-posterior in direction, presents, behind the nasal process, the **lachrymal notch** for the lachrymal bone, and behind this it articulates, from before backwards, with the lower border of the os planum of the ethmoid and the orbital process of the palate bone. This border presents a few depressions which close in ethmoidal cells.

The *internal* or *nasal surface* forms part of the outer wall of the nasal fossa. It is limited in front by the mesial border of the bone, behind by the posterior border, above by the internal border of the orbital surface, and below for the most part by the palatal process. It presents the opening of the antrum of Highmore, in front of which is the deep **lachrymal groove**, directed downwards, outwards, and backwards, and, after a course of about $\frac{1}{2}$ inch, opening into the front part of the inferior meatus of the nose. This groove is converted posteriorly and internally into the lachrymal canal by the lachrymal and inferior turbinate bones, and it transmits the nasal duct. In front of the lachrymal groove is a slightly oblique ridge, called the **inferior turbinate crest**, for articulation with the inferior turbinate bone, and below this is a smooth concave surface which forms the anterior part of the inferior meatus. Above the crest is the commencement of another smooth surface, which extends upwards on to the inner aspect of the nasal process, and forms the outer wall of the atrium of the middle meatus. Behind the opening of the antrum the internal surface articulates with the perpendicular plate of the palate bone, and it presents, from the centre downwards, a groove, directed downwards and forwards, which, with the palate bone, forms the posterior palatine canal for the great or anterior palatine nerve, and the superior or descending palatine artery. Above the opening of the antrum are a few depressions on the internal border of the orbital surface, forming ethmoidal cells.

The **nasal** or **frontal process** ascends vertically from the mesial part of the facial surface above the nasal notch. It is somewhat triangular, and presents two surfaces and three borders. The *external surface* is continuous with the facial surface of the body, and gives attachment to the orbicularis palpebrarum, tendo oculi, and levator labii superioris aëque nasi. The *internal surface* forms part of the outer wall of the nasal fossa, and, at its back part superiorly, it presents one or two depressions, completing cells on the anterior border of the lateral mass of the ethmoid. The surface is crossed obliquely backwards and upwards by a ridge, called the **agger nasi** (mound) or **superior turbinate crest**, which represents the naso-turbinal of most mammals (Schwalbe). This crest bounds superiorly the atrium of the middle meatus, and

articulates posteriorly with the anterior extremity of the inferior turbinate process of the ethmoid. Above the agger nasi there is a groove, called the *sulcus olfactorius*. The superior border is short, thick, and serrated for the frontal. The anterior border is sharp and articulates with the nasal. The posterior border is thick, and in its lower part presents a continuation of the lachrymal groove, which here lodges the lachrymal sac. The lips of this part of the groove are sharp, the inner articulating with the lachrymal, and the outer, which is crescentic, being continuous

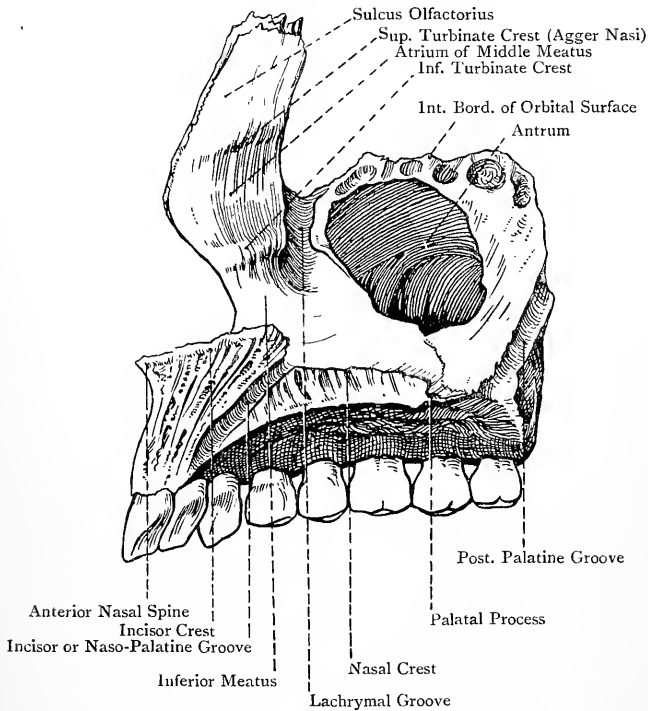


FIG. 61.—THE RIGHT SUPERIOR MAXILLARY BONE (INTERNAL VIEW).

with the infra-orbital margin, at which point there is a projection, called the **lachrymal tubercle**.

The **malar process** is stout and triangular. Its anterior surface is continuous with the facial surface of the body, and its posterior with the zygomatic surface, whilst the superior surface is rough and slightly serrated for the malar.

The **alveolar process** forms the dependent part of the bone, and is thick and curved, being convex externally and concave internally. The outer plate is known as the labial plate, and the inner as the lingual. The two plates are widely separated, and

the intervening space is partitioned off into **alveoli** or sockets by septa which pass between the two plates. The number of alveoli in the adult bone is as a rule eight, and they gradually narrow towards their upper or deep ends, where they are perforated by foramina for the nerves and arteries of the teeth. They lodge the roots of the teeth, which, in order from the middle line outwards and backwards, are as follows: central incisor, lateral incisor, canine, first bicuspid, second bicuspid, and first, second, and third molars. The alveoli correspond in shape with the roots of the teeth, the canine being the deepest. The outer surface of the alveolar border, over the extent of the three molar sockets, gives origin to fibres of the buccinator.

The **palatal process** is situated on the internal surface of the body, from which it projects horizontally inwards, and, with its fellow, it forms three-fourths of the hard palate. It is quadrilateral, and presents two surfaces and four borders. The *superior surface* forms three-fourths of the floor of the nasal fossa, and is smooth, concave, and covered in the recent state by the nasal mucous membrane. The *inferior surface* forms a part of the hard palate, and is rough, arched, and covered in the recent state by the buccal mucous membrane. It presents several depressions for the palatal mucous glands, and is perforated by several nutrient foramina. Laterally it is marked by a groove, directed from behind forwards, for the nerve and artery which reach the hard palate through the posterior palatine canal. The posterior border stops short of the back part of the alveolar border, and is short and serrated for the horizontal plate of the palate bone. The anterior border, superiorly, forms the lower part of the nasal notch. The external border is attached to the body. The internal or mesial border is faintly serrated, and articulates with its fellow. At the place of meeting it is elevated into a ridge, forming, with that of its fellow, the **nasal crest**, which is grooved to receive the lower border of the vomer. This mesial ridge becomes prominent in front, where it forms the **incisor crest**, which is projected to constitute, with its fellow, the **anterior nasal spine**. It supports the septal nasal cartilage, and the anterior extremity of the vomer lies behind it.

Close to the outer side of the incisor crest the palatal process is pierced by an opening leading into a canal, which is bounded internally by a thin plate of bone, and descends to the front part of the hard palate, being ultimately converted into a groove, due to its inner thin wall becoming deficient. This passage is variously known as the incisor or naso-palatine canal, or canal of Stensen (Steno), and the two canals, right and left, in the articulated condition form inferiorly a large orifice, called the **anterior palatine fossa**. This fossa, which is somewhat diamond-shaped, is situated in the middle line of the hard palate, behind the central incisor teeth. On looking into it from below four foramina are seen, two of which are placed in the middle line,

where they lie in the intermaxillary suture. These are known as the **foramina of Scarpa**, and they transmit the naso-palatine nerves, the *left nerve* passing through the *anterior*, which usually communicates with the left nasal fossa, and the *right* through the *posterior*, which usually communicates with the right nasal fossa. The other two foramina are situated one at either side, and are known as the **foramina of Stensen**, and the canal into which each leads opens superiorly on the floor of the corresponding nasal fossa, close to the outer side of the incisor crest. Each of Stensen's canals transmits a branch of the superior or descending palatine artery from the anterior palatine fossa to the nasal fossa. The inner wall of Stensen's canal, on each side, represents the mesial palatal process of the premaxilla or intermaxillary bone, and also a portion developed from the prepalatine centre. The canals of Stensen correspond to the incisor foramina of many animals—*e.g.*, the ruminantia, in which they are of large size, and each opens independently on the front part of the hard palate as a large aperture, there being no anterior palatine fossa. In such animals each incisor foramen leads up to the orifice of Jacobson's organ, which is a supplementary organ of smell. In man the canals of Stensen are the remains of a communication which existed in early foetal life between the nasal and buccal cavities.

Passing transversely outwards from the anterior palatine fossa at its back part to the interval between the lateral incisor and canine teeth a suture is always present in early life, and may persist in the adult, which indicates the line of junction of the maxillary portion proper and the premaxilla or intermaxillary bone, the latter representing the part which bears the central and lateral incisor teeth. This intermaxillary portion forms an independent bone in many animals.

The **antrum of Highmore** or **maxillary air sinus** is situated within the body of the bone, and is of large size, its capacity in health being equal to about 2 drachms. It has the shape of a four-sided pyramid, and is lined with mucous membrane continuous with that of the nasal fossa. The *apex* corresponds to the malar process, and the *base* represents the internal or nasal aspect. The *superior wall* or *roof* is formed by the orbital plate. The *inferior wall* or *floor* is formed by that portion of the alveolar border which contains the molar and second bicuspid alveoli, and, in some cases, the first bicuspid alveolus also. It is often very irregular, due to projections of the upper ends of the alveoli, and in some cases the root of the first molar, and, it may be, that of the second, projects into the antral cavity. The *antero-external wall* is formed by the facial surface, and is thin and translucent over the region of the canine fossa. It contains the anterior, and the lower part of the middle, dental canals. The *postero-external wall* is formed by the zygomatic surface, and it contains the upper part of the middle dental canal. The **opening** of the antrum, which is large and irregular, is situated on the base or nasal aspect. In the articu-

lated skull its size is considerably diminished by the perpendicular plate of the palate bone behind, the maxillary process of the inferior turbinate below, and above this by the uncinat process of the ethmoid. The opening is further curtailed by the adjacent mucous membrane. Under these circumstances it is reduced to a small aperture, situated near the upper part, which opens into the middle meatus of the nasal fossa. The antrum is usually unilocular, but it may be partially divided into compartments.

The bone derives its blood-supply from many sources, such as posterior dental, infra-orbital, middle and anterior dental, facial, frontal, superior or descending palatine, and naso-palatine arteries.

Articulations.—The superior maxilla articulates with nine bones, as follows: malar, nasal, frontal, lachrymal, ethmoid, inferior turbinate, palate, vomer, and its fellow of the opposite side. In addition to these it may articulate with the pterygoid process and great wing of the sphenoid.

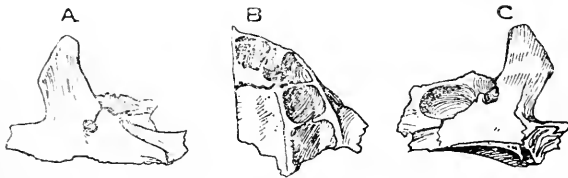


FIG. 62.—THE FETAL SUPERIOR MAXILLARY BONE.

A, External View, showing the Infra-orbital Groove and Foramen, with Fissure; B, Inferior View, showing the Incisor Fissure and Alveoli; C, Internal View, showing the Antrum and Incisor Fissure.

Structure.—The bone contains the maxillary air sinus. For the most part cancellated tissue is absent, except in the alveolar process around the alveoli.

Ossification.—The superior maxillary bone is ossified in membrane. According to Malland Fawcett it has **two centres**—maxillary proper and premaxillary, which appear about the *sixth week*, and join about the *third month*. The centre referred to as *maxillary proper* appears in the region of the future canine alveolus, and from it ossification proceeds backwards into the malar process, upwards into the *posterior half* of the nasal process, inwards into the *posterior three-quarters* of the palatal process, and downwards into the alveolar border, excluding the incisor portion.

The *premaxillary centre* gives rise to the premaxilla, which lies on the mesial side of the maxilla proper and bears the upper incisor teeth. It also gives rise to (1) the *anterior fourth* of the palatal plate, and (2), according to Fawcett, the *anterior half* of the nasal process. It is to be noted that, whilst the *anterior half* of the nasal process is ossified from the premaxillary centre, the *posterior half* of that process (bearing the lachrymal groove) is ossified from the maxillary proper centre.

Besides the premaxillary centre there is an *infravomerine centre*, according to Rambaud and Renault. This centre lies beneath the anterior part of the vomer, and it gives rise to the infravomerine part of the bone, which forms the mesial wall of Stensen's canal. The line of union between the premaxilla

and maxilla proper is indicated by the *premaxillary suture* on the palatal surface of young bones, which may, though somewhat rarely, persist in adult life. This suture extends outwards and forwards from a point directly behind the lower end of Stensen's canal to the alveolar border between the lateral incisor and canine alveoli.

The premaxilla of each side forms an independent bone in many animals. It may be developed in two parts from separate centres of ossification—an inner for the portion bearing the central incisor alveolus, and an outer for the portion containing the lateral incisor alveolus, and these two portions may remain separate. The inner portion is known as the *endognathion*, and the outer portion as the *mesognathion*, whilst the remainder and greater part of the bone is referred to as the *maxilla proper*.

The varieties of alveolar cleft palate are explained by a reference to these conditions of the bone. In **mesial cleft palate** the two premaxillæ (right and left) are separated by a mesial cleft. **Lateral cleft palate** may occur in two forms—the maxilla proper or *exognathion* and the entire premaxilla may fail to unite, and the cleft is situated between them, and invades the alveolar border between the lateral incisor and canine alveoli; or the premaxilla may exist in two parts, inner or *endognathion*, and outer or *mesognathion*, and the cleft may be between these two, in which case it invades the alveolar border between the central and lateral incisor alveoli. These conditions may occur on one or both sides.

In the earlier stages of intra-uterine life there is no trace of the antrum, and the alveolar border lies close to the infra-orbital border. In the course of the *fourth month*, however, the antrum makes its appearance as a shallow depression on the inner aspect of the bone, and, as this increases, it gradually separates the orbital, alveolar, and palatal portions. In the process of development the alveolar border first presents an elongated furrow, called the **dental groove**, on either side of which a plate grows downwards, forming the labial and lingual plates. The groove is thus converted into a trench with these ramparts on either side. Subsequently these plates are connected by a number of septa, which intersect the trench and break it up into alveoli. At this stage these are only five in number for each bone, and the canine alveolus is the first to be partitioned off. In early life the bone contains the temporary teeth, which are five in number on either side, but in the adult, as stated, it contains eight alveoli for the eight permanent teeth.

The Malar Bones.

The **malar** or **cheek-bone** is situated between the external angular process of the frontal and zygoma of the temporal on the one hand, and the malar process of the superior maxilla on the other, where it separates the orbit from the temporal fossa. It is quadrilateral, and presents two surfaces, four processes, and four borders. The *external surface* is convex, and near its centre there is the **malar tuberosity**. Above this is the **malar foramen** for the passage of the malar branch of the temporo-malar or orbital nerve, and a branch of the lachrymal artery. The portion of this surface close to the zygomatic process gives origin to the zygomaticus major, and the lower and anterior part to the zygomaticus minor. The *internal surface*, which is concave, looks into the temporal fossa above and zygomatic fossa below, and it is overhung superiorly by a curved plate of bone, called the orbital process. Anteriorly it presents a rough, slightly serrated, triangular area for the malar process of the superior maxilla. The **orbital process** projects backwards and inwards, in a curved manner, from the

upper part of the internal surface on a level with the orbital border. It is triangular, and its superior or orbital surface presents a sweeping concavity, which enables it to form the front part of the outer wall of the orbit, and a portion of the floor. This surface is pierced by one or, it may be, two openings. If there is one, it ultimately leads to two canals—**malar**, which opens on the external surface, and **temporal**, which opens on the temporal division of the internal surface, as a rule near the frontal process. These canals transmit the malar and temporal branches of the temporo-malar or orbital nerve. If there are two, each leads to its own canal. The inferior surface of the orbital process, which is convex, forms the anterior part of the temporal fossa. The rough margin of the process articulates by its superior part with the anterior border or malar crest of the

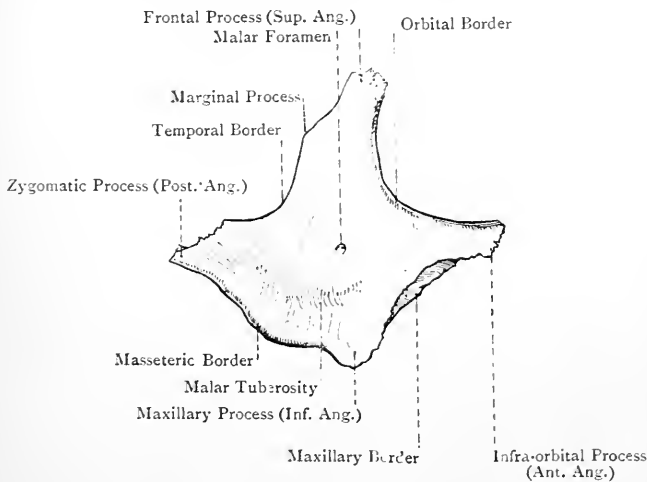


FIG. 63.—THE RIGHT MALAR BONE (EXTERNAL VIEW).

great wing of the sphenoid, and below with a part of the orbital plate of the superior maxilla. The part of this border between the sphenoidal and maxillary portions sometimes closes the anterior and outer extremity of the spheno-maxillary fissure, and thus intervenes between the great wing of the sphenoid and the superior maxilla.

The **processes** are four in number—superior, posterior, inferior, and anterior. The *superior* or **frontal process** is stout and prominent. Its direction is vertically upwards, and it terminates in a thick serrated extremity for the external angular process of the frontal. The *posterior* or **zygomatoc process** is short and usually blunt. Its direction is backwards, and it terminates in a serrated extremity for the zygoma of the temporal. The *inferior* or **maxillary process** is blunt and truncated. Its direction is downwards, and

it articulates with part of the malar process of the superior maxilla. The *anterior* or **infra-orbital process** is slender and pointed. Its direction is forwards, and it articulates with the superior maxilla near the infra-orbital foramen.

The **borders** are four in number—temporal, masseteric, maxillary, and orbital. The *temporal border* extends from the frontal process to the zygomatic, and is directed backwards. It is sinuous, and continuous with the upper border of the zygoma, and it gives attachment to the temporal fascia. Near the frontal process it usually presents a slight prominence, called the *marginal process*, to which a stout slip of the temporal fascia is attached. The masseteric border extends from the zygomatic process to the maxillary process, and looks downwards. It is thick, rough, and continuous with the lower border of the zygoma, and it gives origin

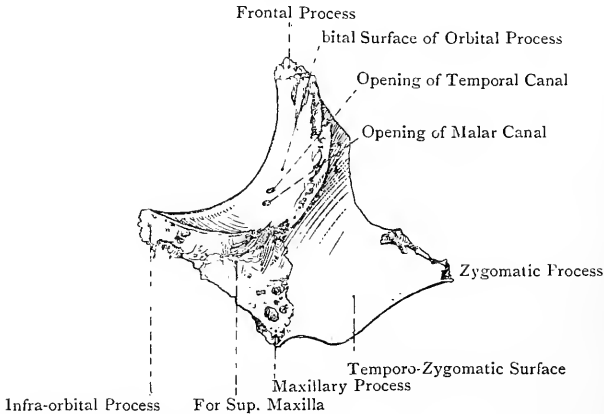


FIG. 64.—THE RIGHT MALAR BONE (INTERNAL VIEW).

to the anterior fibres of the superficial part of the masseter. The maxillary border extends from the maxillary process to the infra-orbital process, and it looks forwards and slightly downwards. It is rough and slightly concave, and, together with the rough, slightly serrated, triangular area on the internal surface adjacent to it, articulates with the malar process of the superior maxilla. The *orbital border* extends from the infra-orbital process to the frontal, and is smooth, round, and concave. Its direction is outwards and upwards, and it forms a large part of the circumference of the orbit.

The bone derives its blood-supply from the lachrymal, anterior deep temporal, and transverse facial arteries.

Articulations.—The malar articulates with four bones, as follows: *superiorly* with the frontal and sphenoid, *posteriorly* with the temporal, and *anteriorly* with the superior maxilla.

Structure.—The bone is mainly composed of compact tissue, the amount of cancellated tissue being small.

Varieties.—The bone may persist in two parts connected by a suture, which may be horizontal or vertical. It sometimes persists in three parts.

Ossification.—The malar is developed in membrane from **three centres**, which appear in the *eighth week* of intra-uterine life, and they unite at the end of the *fourth month*. These centres are called **premalar, postmalar, and hypomalar**. If all three centres should fail to unite, then a tripartite malar is the result. If the premalar and postmalar unite, and the hypomalar remains separate, a bipartite malar persists with a horizontal suture. If the postmalar and hypomalar unite, and the premalar remains separate, the suture is vertical. A bipartite malar occurs with great frequency amongst the Japanese, and from this circumstance the bone is known as the **os Japonicum**.

The Nasal Bones.

The **nasal bone**, which articulates with its fellow by its mesial border, forms with it the bridge of the nose. It lies in front of the nasal process of the superior maxilla, where it enters into the formation of the face and nasal fossa. The bone is elongated from above downwards, and presents two surfaces and four borders. The *anterior* or *facial surface* is smooth, concavo-convex from above downwards, and convex from side to side. Near its centre it usually presents a minute foramen for the passage of a small vein from the nose to the commencement of the facial vein. This surface supports the common aponeurosis of the pyramidalis nasi and compressor naris muscles. The *posterior* or *nasal surface* is rough superiorly, where it articulates with the nasal process of the frontal. Elsewhere it is smooth and concave from side to side, and in the recent state is covered by the nasal mucous membrane. It is traversed longitudinally near the centre by the **nasal groove** for the nasal nerve.

The *superior border* is short, thick, and serrated for the nasal notch of the frontal. The *inferior border* is thin and expanded for the upper lateral nasal cartilage. It usually presents the *nasal notch*, which is situated near its inner end. The *mesial border* articulates with its fellow. It is usually rather shorter and thicker than the external, and projecting backwards from it is a ledge of bone, which, with its fellow, forms the **nasal crest** for articulation with the nasal spine of the frontal and the anterior border of the perpendicular plate of the ethmoid. The *external border*, long and thin, is finely serrated for the nasal process of the superior maxilla.

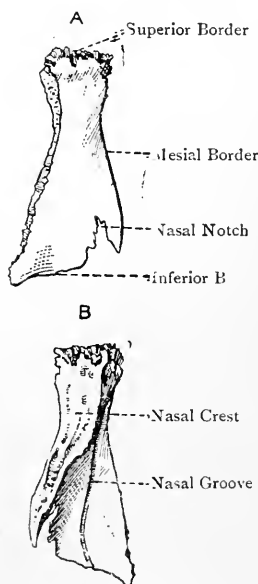


FIG. 65.—THE RIGHT NASAL BONE.

A, Anterior View; B, Posterior View.

The bone receives its blood-supply from the angular branch of the facial, and the nasal and anterior ethmoidal branches of the ophthalmic, arteries.

Articulations.—The nasal articulates with four bones, as follows: *superiorly* with the frontal, *externally* with the superior maxilla, *internally* with its fellow, and *posteriorly* with the ethmoid and again with the frontal.

Structure.—The bone is composed of compact tissue, and is therefore dense.

Ossification.—The nasal is developed in membrane from **one centre**, which appears about the *eighth week* of intra-uterine life.

The Lachrymal Bones.

The **lachrymal** or **tear-bone** is situated at the anterior part of the inner wall of the orbit, where it lies behind the nasal process of the superior maxilla, and in front of the os planum of the ethmoid. It is very thin and scale-like. From its resemblance in this sense to a finger-nail, it is known as the *os unguis*. It is quadrilateral and presents two surfaces and four borders, the inferior border being recognised by its presenting a hamular and a descending process. The *external* or *orbital surface* is traversed by the **lachrymal crest**, which is nearer the anterior than the posterior border, and divides the surface into two unequal parts. The *anterior division*, representing one-third, presents the **lachrymal groove**, which lodges the lachrymal sac and the commencement of the nasal duct. The lower end of this division is prolonged into the **descending process**, which takes part in the wall of the lachrymal canal, and articulates with the lachrymal process of the inferior turbinate. The *posterior division*, representing two-thirds, is smooth and forms part of the inner wall of the orbit. The

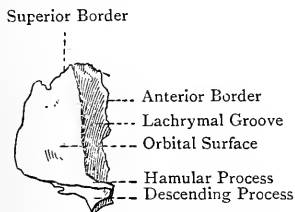


FIG. 66.—THE RIGHT LACHRYMAL BONE (EXTERNAL VIEW).

lachrymal crest gives origin to the tensor tarsi muscle, and inferiorly terminates in a hook-like projection, called the **hamular process**. This process is curved in a forward direction, and is received into the lachrymal notch at the front part of the internal border of the orbital plate of the superior maxilla, where it bounds externally the superior orifice of the lachrymal canal. It articulates with the lachrymal tubercle of the superior maxilla. The *internal surface* presents a vertical furrow corresponding with the position of the lachrymal crest on the external surface. Superiorly it articulates with the front part of the lateral mass of the ethmoid, where it helps to close ethmoidal cells, and forms part of the infundibulum. Inferiorly it forms part of the outer wall of the nasal fossa, and looks into the middle meatus.

The *superior border* is short, and articulates with the internal angular process of the frontal. The *inferior border*, behind the lachrymal crest, articulates with the internal border of the orbital surface of the superior maxilla, whilst in front of the crest it forms, as stated, the descending process, and articulates with the lachrymal process of the inferior turbinate. The *anterior border* articulates with the inner lip of the lachrymal groove on the posterior border of the nasal process of the superior maxilla. The *posterior border* articulates with the anterior border of the os planum of the ethmoid.

The bone derives its blood-supply from the nasal and anterior ethmoidal branches of the ophthalmic artery.

Articulations.—The lachrymal articulates with four bones, as follows: *superiorly* with the frontal, *anteriorly* with the superior maxilla, *inferiorly* with the inferior turbinate, and again with the superior maxilla, and *posteriorly* with the ethmoid.

Structure.—The bone consists of a thin translucent plate.

Ossification.—The lachrymal is developed in membrane usually from **one centre**, which appears during the *third month* of intra-uterine life. It may, however, have two or more centres.

The Inferior Turbinate Bones.

The **inferior turbinate** or **spongy bone** (maxillo-turbinal) sometimes called the *inferior concha*, is situated on the outer wall of the

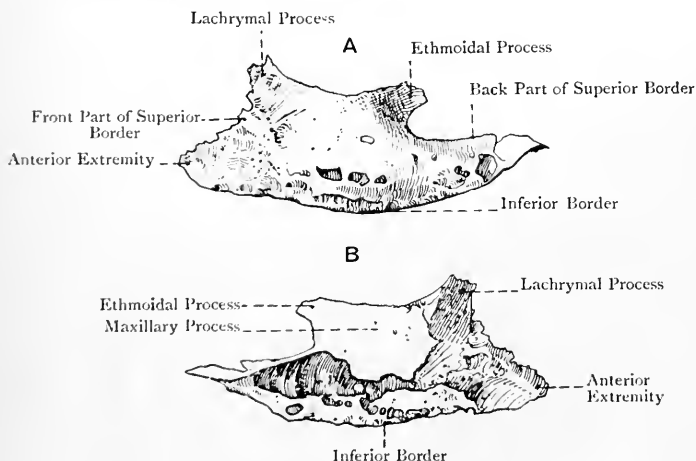


FIG. 67.—THE RIGHT INFERIOR TURBINATE BONE.

A, Internal View; B, External View.

nasal fossa, where it overhangs the inferior meatus, and is in series with the inferior turbinate process (middle spongy bone) of the ethmoid. It is elongated from before backwards, and presents

two surfaces, two borders, and two extremities. The *external surface* is concave, and is overhung above, over about its middle third, by the maxillary process. It looks towards the outer wall of the nasal fossa. The *internal surface* is irregularly convex, pitted, and marked by a few antero-posterior grooves. It bulges into the nasal fossa, and limits inferiorly the middle meatus.

The *superior border*, which is attached, slopes downwards and forwards in front, where it articulates with the inferior turbinate crest of the superior maxilla. Behind this it presents a slight concavity, limited in front by the **lachrymal process**, which articulates with the descending process of the lachrymal, and forms part of the lachrymal canal. Behind the concavity is the **ethmoidal process** for the uncinatè process of the ethmoid. The portion of the superior border between these two processes is folded downwards and outwards into a thin plate, called the **maxillary process**, which forms part of the inner wall of the antrum of Highmore below the opening of that cavity. Behind the ethmoidal process the superior border slopes downwards and backwards, and articulates with the inferior turbinate crest of the palate bone. The *inferior border* is convex, thick, pitted, and free. The *anterior extremity* is short and stunted, whilst the *posterior* is long, slender, and pointed.

The bone receives its blood-supply from the sphenopalatine branch of the internal maxillary, and anterior ethmoidal branch of the ophthalmic, arteries.

Articulations.—The inferior turbinate articulates with the following four bones: superior maxilla, lachrymal, ethmoid, and palate.

Structure.—The bone is light and porous.

Ossification.—The inferior turbinate is developed in *cartilage* from **one centre**, which appears in the *fifth month* of intra-uterine life.

The Palate Bones.

The **palate bone** enters into the formation of the hard palate, the outer wall of the nasal fossa, and the floor of the orbit. It consists of a horizontal and perpendicular plate, which meet at a right angle, and of three processes, namely, pyramidal process or tuberosity, situated at the meeting of the two plates posteriorly, and orbital and sphenoidal processes, situated at the upper extremity of the perpendicular plate, where they are separated by the sphenopalatine notch.

The **horizontal or palatal plate** is quadrate, and presents two surfaces and four borders. The *superior or nasal surface* is smooth and concave from side to side. It forms the posterior fourth of the floor of the nasal fossa, and is covered in the recent state by the nasal mucous membrane. The *inferior or palatal surface* forms the posterior fourth of one-half of the hard palate, and near its posterior border it presents a short transverse ridge, which gives insertion to a portion of the tendon of the tensor palati. The anterior border

is serrated for the posterior border of the palatal process of the superior maxilla. The posterior border is concave and sharp. It gives attachment to one-half of the soft palate, and at its inner extremity it forms a backward projection, which, with its fellow, constitutes the **palatal or posterior nasal spine**, for the attachment of the azygos uvulæ muscle. The external border is attached, and meets the perpendicular plate at a right angle. On its outer aspect posteriorly it is excavated by the lower part of the posterior palatine canal. The internal border is thick and serrated, and articulates with its fellow, forming an upward elevation, called the **nasal crest**. This crest is continuous with that of the palatal processes of the superior maxillæ, and, like it, is grooved superiorly for a portion of the inferior border of the vomer.

The **perpendicular plate** rises upwards from the outer border of the horizontal plate. It is long and thin, and presents two

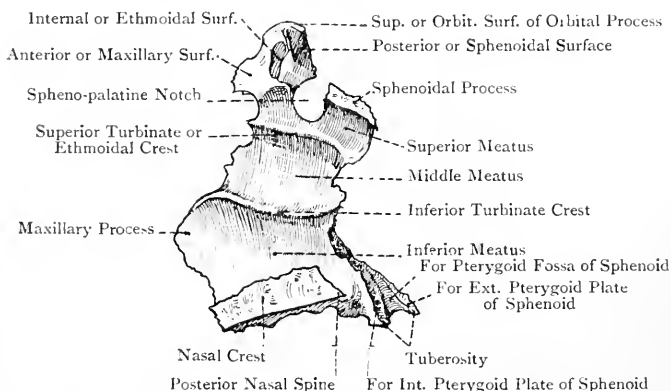


FIG. 68.—THE RIGHT PALATE BONE (INTERNAL VIEW).

surfaces and four borders. The *internal surface* forms part of the outer wall of the nasal fossa, and is crossed from before backwards by two ridges. The lower ridge is called the **inferior turbinate crest**, and articulates with the posterior sloping part of the superior border of the inferior turbinate bone. The upper ridge, which crosses the roots of the orbital and sphenoidal processes, is called the **ethmoidal or superior turbinate crest**, and it articulates with the inferior turbinate process of the ethmoid. Below the inferior turbinate crest is a smooth groove, which forms part of the inferior meatus of the nose; between the inferior and superior turbinate crests is another groove, which forms part of the middle meatus; and above the superior turbinate crest there is a third groove, which forms part of the superior meatus. The *external or maxillary surface*, towards its upper and posterior part, forms the inner boundary of the pterygo-maxillary fissure, and leading downwards from this part is a groove, which, with the superior maxilla, forms

the **posterior palatine** or **palato-maxillary canal** for the great or anterior descending palatine nerve and the superior or descending palatine artery. In front of this groove the external surface articulates with the inner surface of the superior maxilla behind the opening of the antrum. Behind the groove the external surface articulates inferiorly with the posterior border of the superior maxilla, and superiorly with the internal pterygoid plate of the sphenoid.

The anterior border of the perpendicular plate presents, just below the inferior turbinate crest, a leaf-like projection, called the **maxillary process**, which closes the lower and back part of the opening of the antrum of Highmore. Superiorly it articulates with the ethmoid, and inferiorly with the superior maxilla. The posterior border articulates superiorly with the anterior border of the internal pterygoid plate of the sphenoid, and inferiorly it

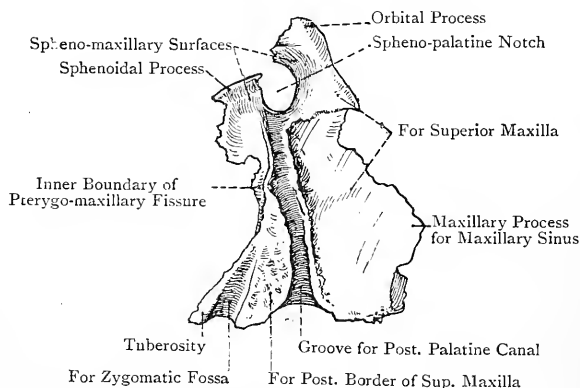


FIG. 69.—THE RIGHT PALATE BONE (EXTERNAL VIEW).

is prolonged into the tuberosity. The inferior border is attached, and meets the horizontal plate. The superior border presents the orbital and sphenoidal processes and the spheno-palatine notch, to be presently described.

The **pyramidal process** or **tuberosity** projects backwards, downwards, and outwards from the meeting of the horizontal and perpendicular plates, and is received into the pterygoid notch of the sphenoid. Posteriorly it presents three grooves. The central groove forms part of the pterygoid fossa, and gives origin to fibres of the internal pterygoid. The grooves on either side are rough, and articulate with the anterior borders of the corresponding pterygoid plates. The tuberosity on its inferior aspect, close to the horizontal plate, presents two small openings, which are the orifices of the **posterior** and **external accessory palatine canals**, the latter being the smaller of the two, and inconstant. These canals transmit the posterior and external descending palatine

nerves and arteries. Internally the tuberosity gives origin to a few fibres of the superior constrictor muscle of the pharynx. Externally there is a small free surface, which looks into the zygomatic fossa, between the pterygoid process of the sphenoid and the tuberosity of the superior maxilla.

The **orbital process** surmounts the anterior border of the perpendicular plate. It is of large size, and presents six surfaces, three of which are articular. The *superior* or *orbital surface* forms a small part of the floor of the orbit posteriorly. The *external* or *spheno-maxillary surface* looks into the spheno-maxillary fossa. The *anterior* or *maxillary surface* is continuous with the external surface of the perpendicular plate, and articulates with the back part of the internal border of the orbital surface of the superior maxilla. The *internal* or *ethmoidal surface*, which is excavated, articulates with the lower border of the os planum of the

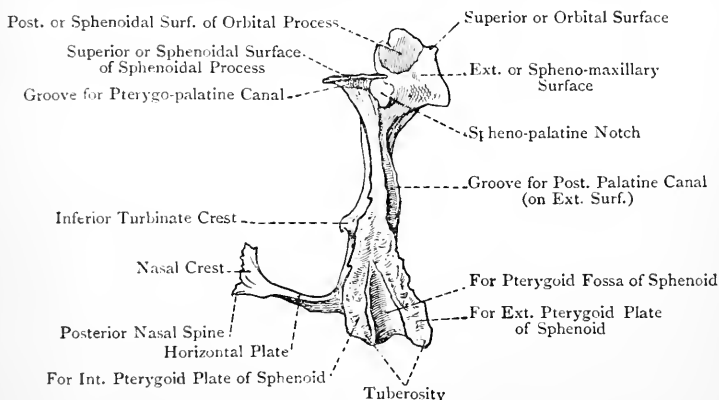


FIG. 70.—THE RIGHT PALATE BONE (POSTERIOR VIEW).

ethmoid at its back part, close to the postero-inferior angle. The *posterior* or *sphenoidal surface*, small and excavated, articulates with the front of the body of the sphenoid, and, as a rule, communicates with the sphenoidal air sinus. The *inferior* or *nasal surface* is continuous with the internal surface of the perpendicular plate, and forms part of the outer wall of the nasal fossa at its upper and back part, where it overhangs the groove for the superior meatus.

The **sphenoidal process** surmounts the posterior border of the perpendicular plate, and is slightly incurved. It presents three surfaces, and three borders. The *superior* or *sphenoidal surface*, which is grooved, articulates with the inferior surface of the body, and the vaginal process, of the sphenoid. The groove on this surface, with that on the under surface of the vaginal process, forms the **pterygo-palatine canal** for the pharyngeal nerve and pterygo-palatine artery. The *internal* or *nasal surface* is scooped out, and

has an inclination downwards as well as inwards. It forms part of the outer wall and roof of the nasal fossa. The *external* or *spheno-maxillary surface* forms part of the inner wall of the spheno-maxillary fossa. The anterior border bounds the spheno-palatine notch posteriorly, and may be projected over it to join the orbital process. The posterior border articulates with the internal pterygoid plate of the sphenoid. The internal border articulates with the ala of the vomer.

The **spheno-palatine notch** is situated between the orbital and sphenoidal processes, and is converted into a foramen usually by the inferior surface of the body of the sphenoid, representing the part formed by a sphenoidal spongy bone. It leads from the spheno-maxillary fossa into the superior meatus of the nose, and transmits the internal branches of the spheno-palatine or Meckel's ganglion, and spheno-palatine artery.

The bone derives its blood-supply from the spheno-palatine, descending palatine, and pterygo-palatine branches of the internal maxillary artery.

Articulations.—The palate bone articulates with six bones, as follows: the superior maxilla, inferior turbinate, ethmoid, vomer, sphenoid, and its fellow.

Structure.—The bone is very thin, especially over the upper part of the perpendicular plate.

Varieties.—(1) The groove for the posterior palatine canal may be bridged over. (2) The external accessory palatine canal may be absent. (3) The spheno-palatine notch may be converted into a foramen by a forward extension of the sphenoidal process.

Ossification.—The palate bone is ossified in membrane from **one primary centre**. The **primary centre** appears about the seventh week, at the angle of junction between the horizontal and vertical plates, or in the vertical plate (Fawcett). There may be a **secondary centre** for the orbital process.

The Vomer.

The vomer is situated in the median plane, and forms part of the septum of the nose. It presents two surfaces, four borders, and an anterior extremity. The surfaces are disposed laterally, and each looks into the corresponding nasal fossa. Traversing each there is a groove, directed forwards and downwards, for the naso-palatine nerve.

The *superior border* is characterized by two thick, everted alæ, separated by a groove, which receives the rostrum of the sphenoid. Each ala by its upper aspect fits against the inferior surface of the body of the sphenoid, and the lateral margin of each meets the vaginal process of that bone, and also articulates with the internal border of the sphenoidal process of the palate bone. The *inferior border* is irregular, and is received into the groove which marks the nasal crests of the palatal plates of the superior maxillæ and palate bones. The *anterior border* is sloped downwards and

forwards, and it may present two alæ, but these are very thin, and lie near each other, being separated by a narrow cleft. These characters are always more pronounced in earlier life. The cleft, in its lower part, receives the septal nasal cartilage, and superiorly the perpendicular plate of the ethmoid fits into it, being usually ankylosed with one or both alæ. In many cases, however, the anterior border is simply grooved. The *posterior border* is sharp, and almost vertical, and lies between the posterior nares. The *anterior extremity* forms a short irregular lip, which touches the back parts of the incisor crests of the superior maxillæ.

The bone receives its blood-supply from the sphenopalatine branch of the internal maxillary artery.

Articulations.—The vomer articulates with six bones, as follows: the sphenoid, two palate bones, ethmoid, and superior maxillæ. In addition to these it articulates with the septal nasal cartilage.

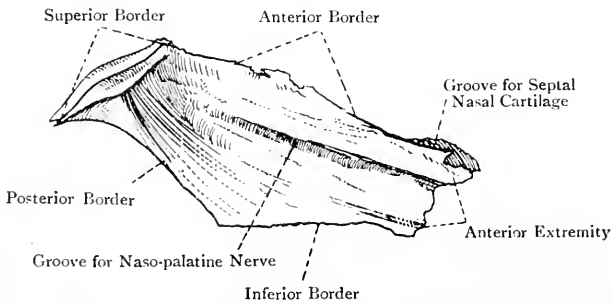


FIG. 71.—THE VOMER (LATERAL VIEW).

Structure.—The vomer is composed of two thin plates of compact bone, which are blended into one, except superiorly, and, it may be, to a certain extent anteriorly.

Varieties.—The bone is often much deflected to one or other side, more frequently the left, and so it may curtail the cavity of the nasal fossa to which it is deflected.

Ossification.—The vomer is developed in membrane from **two centres**, which appear about the *eighth week* of intra-uterine life. The centres unite below in the *third month*, and form a groove in which the septal nasal cartilage lies. The laminae forming the lips of the groove continue to grow upwards and forwards, and subsequently fuse, the enclosed cartilage becoming absorbed. Ultimately there are left the alæ on the superior border, and, it may be, on the anterior border, which are permanent indications of the original bilaminar condition of the bone.

The Inferior Maxillary Bone.

The **inferior maxillary bone** or **mandible** supports the lower teeth, and articulates at either side with the anterior part of the glenoid fossa of the temporal in a freely movable manner. It has the

shape of a horse-shoe, and consists of a central horizontal portion, called the **body**, and two upright portions, called the **rami**.

The **body** is arched, being convex in front and concave behind, and it presents two surfaces and two borders. The *external surface* presents a slight median vertical ridge over its upper two-thirds, which marks the **symphysis** or place of union of the two halves of which the bone is originally composed. This ridge bifurcates at the lower third, and its two divisions, diverging, pass to the lower border, where each terminates in the **mental tubercle**. Between these diverging divisions there is a triangular elevated surface,

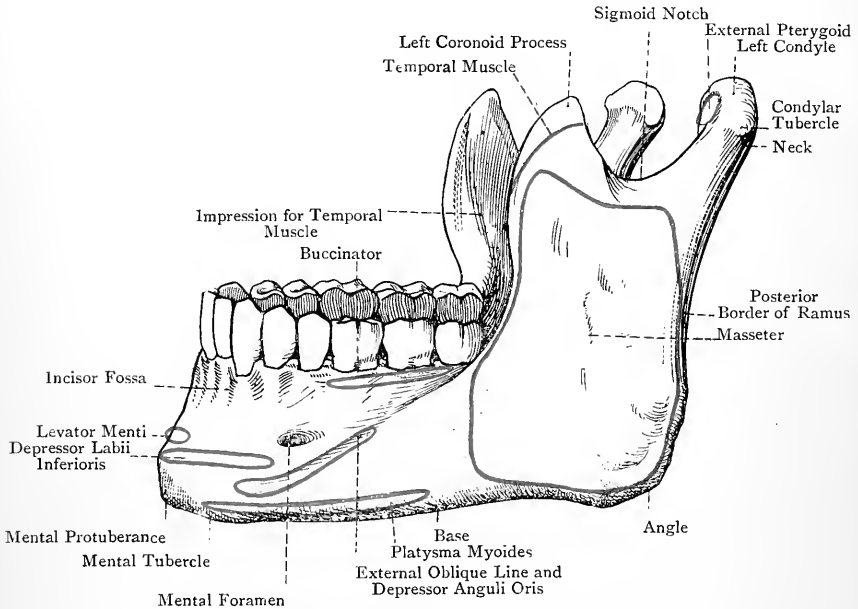


FIG. 72.—THE INFERIOR MAXILLARY BONE (EXTERNAL VIEW).

called the **mental protuberance** or chin. On either side of the symphysis is the **incisor fossa**, which gives origin to the levator menti and a deep slip of the orbicularis oris. A little external to this fossa is the **mental foramen**, which opens outwards from the inferior dental canal, and transmits the mental nerve and vessels. This foramen is in line with the septum between the two bicuspid alveoli, and in the adult it is midway between the superior and inferior borders. Below it is the **external oblique line**, which extends from the mental tubercle to the lower extremity of the anterior border of the ramus. This line gives origin to the depressor anguli oris. The lower part of the external surface, from near the symphysis to about the level of the mental foramen, gives origin to the depressor labii inferioris.

The *internal surface* presents a slight median groove over about its upper two-thirds, which coincides with the symphysis. Lower down there are four small projections, called collectively the **genial spines**, which are arranged in pairs on either side of the middle line. The *upper spine* gives origin, at either side, to the genio-hyo-glossus, and the *lower* to the genio-hyoid. Close to the lower border, at either side of the symphysis, is the oval **digastric impression**, which gives origin to the anterior belly of the digastric. Coinciding with the position of the external oblique line there is the

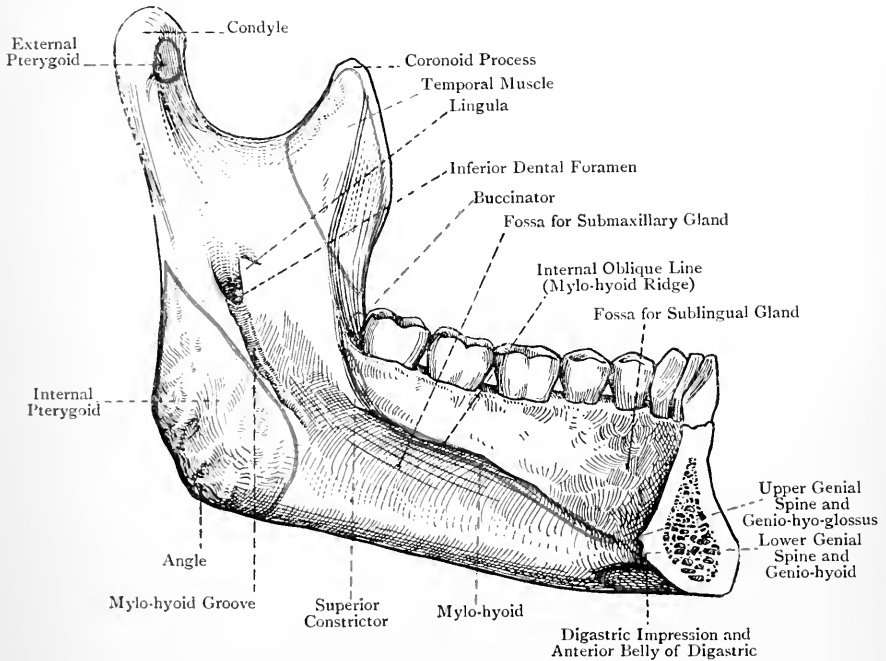


FIG. 73.—THE LEFT HALF OF THE INFERIOR MAXILLARY BONE (INTERNAL VIEW).

internal oblique line or mylo-hyoid ridge. This commences near the symphysis below the lower genial spine, and, passing obliquely backwards and upwards, it terminates a little behind the last molar alveolus. It gives origin to the mylo-hyoid muscle over its whole length, whilst at its upper and back part it gives attachment to some fibres of the superior constrictor muscle of the pharynx and the pterygo-mandibular ligament. Below the posterior part of this ridge is the **submaxillary fossa** for the submaxillary gland, and above its anterior part is the **sublingual fossa** for the sublingual gland.

The *superior or alveolar border* is excavated into sixteen alveoli

or sockets, eight in each half of the bone, which correspond with those in each superior maxilla. The outer surface of the alveolar border, over the extent of the three molar alveoli at either side, gives origin to some fibres of the buccinator. The *inferior border* or **base** terminates, at either side, on a level with the anterior border of the ramus. It projects more than the superior border, and gives insertion on its outer aspect to a portion of the platysma myoides. Near its termination it is marked by a short vertical groove for the facial artery.

The **ramus** rises, at either side, from the extremity of the body. It is compressed from without inwards, and presents two surfaces and four borders. The *external surface* gives insertion to the masseter, and, in the vicinity of the angle, it presents a few oblique ridges for the tendinous bands of that muscle. The *internal surface* presents, a little below its centre, the **inferior dental foramen**, which is on a level with the summit of the crown of the third molar tooth. This foramen leads to the **dental canal**, which traverses the bone to near the symphysis, and from which, near its anterior part, the mental foramen opens on the external surface. This canal lodges the inferior dental nerve and vessels, and communicates with the foramina which open on the extremities of the fangs of the teeth. The inferior dental foramen presents anteriorly and internally a thin, sharp plate of bone, called the **lingula**. Behind the lower end of the latter is a short crescentic margin on the inner aspect of the foramen, and proceeding downwards and forwards from this is the **mylo-hyoid groove**, which terminates a little below the posterior extremity of the mylo-hyoid ridge, and transmits the mylo-hyoid nerve and artery. The speno-mandibular ligament is attached to the lingula and to the crescentic margin behind it. Between the inferior dental foramen and the angle there is a rough impression, often strongly ridged, which gives insertion to the internal pterygoid.

The *anterior border* is continuous with the external oblique line opposite the third molar alveolus, and is shorter than the posterior. The *posterior border* meets the inferior border, thus forming the **angle**, which, in muscular subjects, is strongly marked and slightly everted. Externally and internally it presents rough impressions for portions of the masseter and internal pterygoid respectively, and between these muscles it gives attachment to the stylo-mandibular ligament. The angle is obtuse, and in the adult amounts on an average to 120 degrees. In early infancy it is as much as 150 degrees, and in old age it amounts to about 140 degrees. The *inferior border* is continuous with the inferior border or base of the body. The *superior border* presents the sigmoid notch, the coronoid process, and the condyle.

The **sigmoid notch** communicates with the zygomatic fossa, and transmits the masseteric nerve and artery to the deep surface of the masseter.

The **coronoid process** surmounts the anterior border of the ramus,

and is triangular and compressed from without inwards. Its external surface gives insertion to fibres of the masseter, and its internal surface, as well as the superior and anterior borders, to part of the temporal muscle. The internal surface is marked by a ridge which extends downwards on the internal surface of the ramus, not far from the anterior border, to a point on the inner side of the last molar alveolus, where it becomes continuous with the mylo-hyoid ridge. The temporal muscle continues to take insertion into this ridge, as well as into the elongated triangular depression between it and the anterior border of the ramus.

The **condyle** surmounts the posterior border of the ramus. It is oval and convex, and it articulates with the anterior part of the glenoid fossa of the temporal, an interarticular fibro-cartilage intervening. Its long axis is oblique, so that the axes of the two condyles, if sufficiently prolonged inwards and slightly backwards, would meet near the anterior margin of the foramen magnum. Externally the condyle presents a projection, called the **condylar tubercle**, for the external lateral ligament of the temporo-mandibular articulation. Below the condyle is the **neck**, which presents anteriorly a depression for the insertion of the greater part of the external pterygoid muscle.

The bone receives its chief blood-supply from the inferior dental branch of the internal maxillary artery. Other sources are the facial, and the sublingual branch of the lingual.

Articulations.—With the glenoid fossæ of the temporal bones.

Structure.—The inferior maxilla is composed of two dense plates of compact bone, which are particularly strong in the region of the base, but become thinner superiorly at the alveolar border. Between these plates there is cancellated tissue with wide meshes.

Ossification.—The mandible is a **mixed bone**, being chiefly a *membrane-bone*, but in part also a *cartilage bone*. It is ossified in connection with Meckel's cartilage and its fibrous investment. Each half of the bone has **one centre** (Low and Fawcett), which appears about the *sixth week* of intra-uterine life, being only preceded by the primary centres for the clavicle.

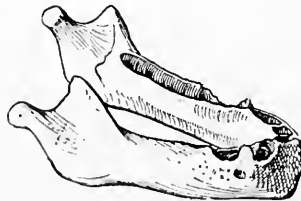


FIG. 74.—THE INFERIOR MAXILLARY BONE AT BIRTH.

It is deposited in the membrane which covers the *outer surface* of Meckel's cartilage in the region of the future mental foramen. From this centre one-half of the bone is ossified, chiefly in membrane, but also in cartilage, namely, the mesial end of Meckel's cartilage, and certain other *accessory cartilages*. The original centre gives membranous origin to (1) the walls of the alveoli and

dental canal, (2) the basilar border and angle, and (3) the ramus as high as the inferior dental foramen. The mesial part of Meckel's cartilage is invaded by osseous extension from the primordial membrane-bone formed from the single centre, the mesial part of Meckel's cartilage becoming incorporated with the bones so formed, and constituting the *incisor portion* of the mandible.

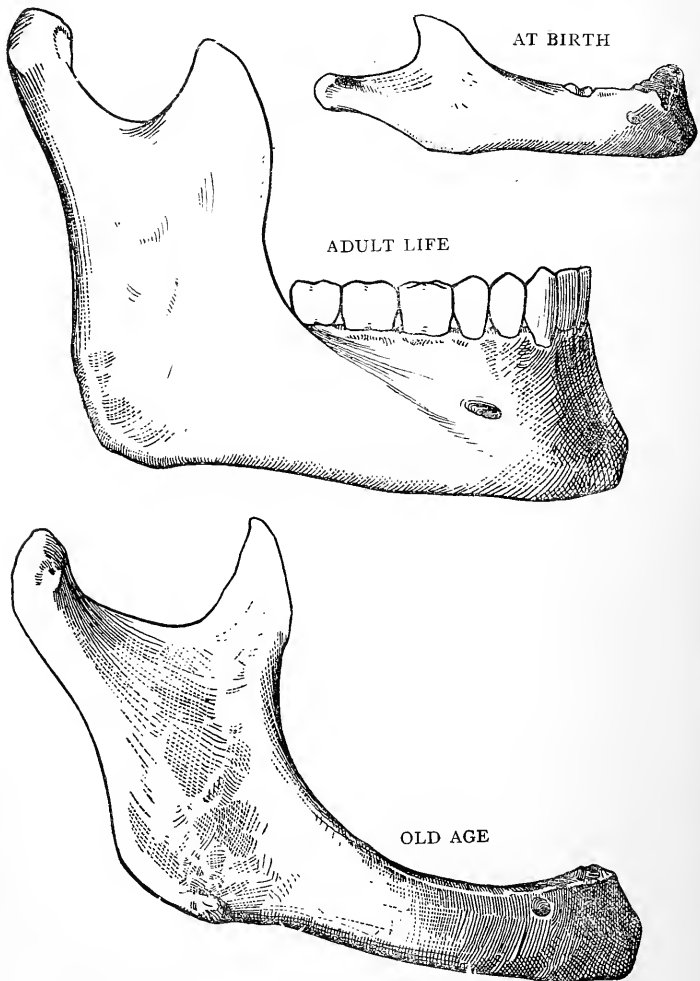


FIG. 75.—THE INFERIOR MAXILLARY BONE AT DIFFERENT PERIODS OF LIFE.

The *accessory cartilages*, which are distinct from Meckel's cartilage, are as follows: (1) Condylar, (2) coronoid, and (3) symphyseal. All these accessory cartilages become surrounded and invaded by osseous extension from the primordial membrane-bone formed from the single centre, and they become incorporated with the parts of the mandible so formed.

The **condylar cartilage** gives rise to (1) the condyle, and (2) the posterior

part of the ramus *as low as the inferior dental foramen*. The **coronoid cartilage** gives rise to (1) the coronoid process, and (2) the anterior part of the ramus *as low as the inferior dental foramen*. The **symphyseal cartilage** gives rise to the limited symphyseal part of the mandible.

At birth the mandible consists of *two halves*, connected at the symphysis by fibrous tissue. In the course of the *first year* osseous union takes place, which is completed towards the end of the first year or beginning of the second year.

Meckel's cartilage extends on either side downwards and forwards from the periotic cartilaginous capsule to the median line, where it meets its fellow. It is surrounded by a fibrous investment. The proximal end of the cartilage gives rise to the malleus and incus, two of the three ossicles of the tympanum. The part of the cartilage between the periotic cartilaginous capsule and the inferior dental foramen disappears, and the membranous investment of this part persists as the *spheno-mandibular ligament*. The part of the cartilage between the inferior dental foramen and the mental foramen also disappears, and its membranous investment undergoes ossification from a *single centre*, and gives rise to (1) the greater part of one-half of the body of the mandible (incisor and symphyseal parts excepted), and (2) the lower half of the ramus as high as the inferior dental foramen. The mesial part of Meckel's cartilage, when ossified, becomes the *incisor part* of the mandible.

At birth the inferior border is but little developed, and the body is consequently shallow. The rami are very short, so that each condyle is nearly on a level with the upper border of the symphysis, and the coronoid process is rather longer than the condyle. The mental foramen is nearer the inferior than the superior border, and the angle amounts to 150 degrees or more. Subsequently the body increases in depth, the rami lengthen, the angle decreases, and the mental foramen gradually assumes a position midway between the superior and inferior borders. In old age, after the bone becomes edentulous, the alveolar border undergoes absorption, the body consequently becomes shallower, the mental foramen lies near the superior border, the rami droop backwards, and each angle becomes increased to about 140 degrees. For the development of the alveolar border, and its relation to the milk-teeth, see the superior maxilla.

The Hyoid Bone.

The **hyoid bone** is situated in the median line of the neck, between the chin and the thyroid cartilage of the larynx, with which latter it is connected by means of the thyro-hyoid membrane and thyro-hyoid ligaments. It is closely connected with the base of the tongue, and is hence known as the *os linguae*. In its development it is associated with the skull, and it is suspended from the lower ends of the styloid processes of the temporal bones by two fibrous bands, called the stylo-hyoid ligaments (epi-hyals). It consists of a central portion or body and two pairs of cornua, great and small.

The **body** is elongated transversely, compressed from before backwards, and quadrilateral. Its surfaces, which are anterior and posterior, occupy an oblique plane, being sloped downwards and for

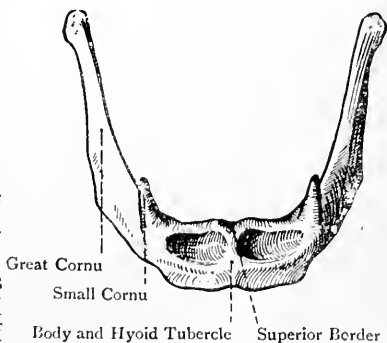


FIG. 76.—THE HYOID BONE
(ANTERIOR VIEW).

wards. The *anterior surface* is convex, and is crossed transversely by a ridge, which divides it into an upper and a lower part. At the middle line this is intersected at right angles by a vertical ridge, which, however, is often incomplete, being sometimes confined to the upper half, and sometimes to the lower. At the place of intersection of the two ridges there is a slight projection, called the **hyoid tubercle**. Each half of the anterior surface is thus mapped out into an upper and a lower irregular muscular division. The upper division, provided the upper border is not very thick, gives attachment to the genio-hyoid and genio-hyo-glossus, and the lower division to the digastric, stylo-hyoid, and mylo-hyoid. The *posterior surface* is concave, and is covered by the thyro-hyoid membrane as it ascends to be attached to the superior border, a synovial bursa intervening. This surface is related to the epiglottis.

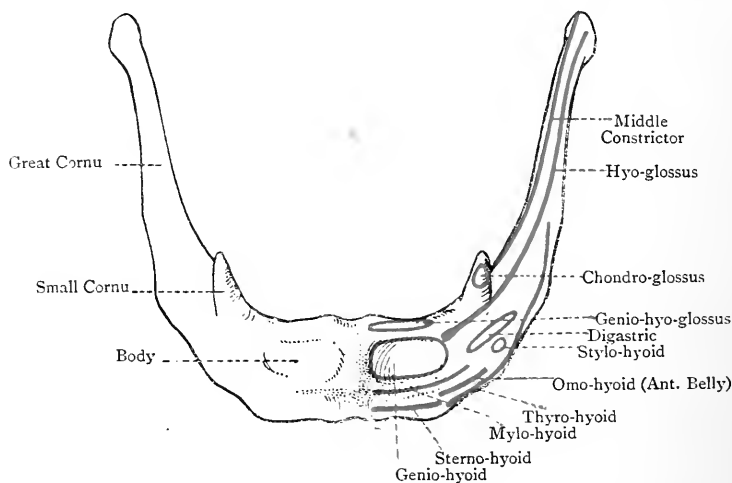


FIG. 77.—THE HYOID BONE, SHOWING ITS MUSCULAR ATTACHMENTS.

The *superior border* is somewhat thick, and occasionally is really a surface, in which cases it gives attachment to the genio-hyo-glossus, whilst its posterior lip gives attachment to the thyro-hyoid membrane. The *inferior border* is sharp, and gives insertion to the sterno-hyoid, anterior belly of the omo-hyoid, and thyro-hyoid muscles. Each *lateral border* is connected with a great cornu.

The **great cornua** project upwards and backwards from the lateral borders of the body. Each is compressed from above downwards, and gradually diminishes in size to its termination, where it ends in a small tubercle for the attachment of the thyro-hyoid ligament. It gives attachment to fibres of the thyro-hyoid, hyo-glossus, middle constrictor muscle of the pharynx, and the thyro-hyoid membrane. Each great cornu is connected with the body by synchondrosis up to middle life, after which ankylosis usually takes place.

The **small cornua** are short conical nodules, each of which projects upwards and backwards from the junction between the body and great cornu. Its tip gives attachment to the stylo-hyoid ligament, which is sometimes ossified, a possible condition to be borne in mind during digital examination of the upper part of the pharynx. Elsewhere it gives attachment to the middle constrictor muscle of the pharynx, and sometimes to the chondroglossus. The small cornua may be wholly or partially cartilaginous, and they articulate with the body by a synovial joint, unless in advanced life, when ankylosis usually takes place.

Ossification.—The hyoid bone is developed in connection with the second and third visceral arches. The cartilaginous bar of the second visceral arch is known as the hyoid bar, and is continuous with its fellow at the median line. The cartilaginous bar of the third visceral arch is known as the thyro-hyoid bar, and at the median line it blends with the junction of the hyoid bars. With the foregoing proviso, the hyoid bone is developed from **five**, or, it may be, **six centres**. One, or, it may be, two are deposited during the last month of intra-uterine life at the place of fusion of the two hyoid bars. If there are two centres they soon join, and give rise to the greater part of the body of the hyoid bone or **basi-hyal**. About the same time a centre appears at either side in the thyro-hyoid bar of the third visceral arch, and from these centres are developed the great cornua or **thyro-hyals**, and the adjacent portions of the body. In the course of the *first year* the two remaining centres appear, one at either side, in the lower or mesial part of each hyoid bar, and these centres give rise to the small cornua or **cerato-hyals**. The great cornua join the body in middle life, but the small cornua do not join until advanced life. The stylo-hyoid ligaments may become ossified more or less completely, and so represent the epi-hyal bones of many animals.

The Skull as a Whole.

The skull is spheroidal, the superior surface being convex, the lateral surfaces compressed, and the inferior surface flat and very irregular. It presents for consideration six regions—superior, inferior, anterior, posterior, and two lateral.

1. The Posterior Region.

The **posterior region** (*norma occipitalis*) is formed by the posterior parts of the parietal bones and the upper or interparietal division of the tabular part of the occipital. It is limited above by a line connecting the parietal eminences, and below by the superior curved lines of the occipital, whilst laterally it is limited by a line connecting the parietal eminence with the lateral angle of the tabular part of the occipital. A little above the centre it presents the **lambda**, which is the place where the sagittal meets the lambdoid suture in the situation of the posterior fontanelle of early life. Radiating from the lambda there are three sutures. One passes upwards and forms the posterior part of the sagittal or interparietal suture. The other two, diverging, pass outwards and downwards, and form together the lambdoid or occipito-parietal suture. About 1 inch above the lambda, at either side of the sagittal suture, is the

parietal foramen, and the point where the horizontal line connecting the parietal foramina intersects the sagittal suture is known as the **obelion**, which coincides with the situation of the sagittal fontanelle of early foetal life. This part of the sagittal suture is less serrated than elsewhere, and is the first to show signs of obliteration. At the lower part of the posterior region in the middle line is the external occipital protuberance, which is known as the **inion**. A little above this is the **occipital point**, which is the part in the median plane at the greatest distance from the glabella of the frontal. The tabular part of the occipital may present an occipital suture, if the interparietal division persists as a separate bone.

2. The Superior Region.

The **superior region** (*norma verticalis*) varies in shape. It may be oval with its long axis antero-posterior, and broader behind than in front. Such skulls are called **dolicocephalic**, and in them the zygomatic arches are usually visible at either side from above, a condition known as **phenozygous**. In other cases the superior region assumes a circular shape, due to the broadening of its anterior part. Such skulls are called **brachycephalic**, and in them the zygomatic arches are usually concealed from above, a condition known as **cryptozygous**. Some skulls are intermediate between the dolicocephalic and brachycephalic, and are known as **mesatiocephalic**. The bones which enter into the superior region are the upper part of the frontal and the anterior parts of the parietals. It is limited in front by a line connecting the frontal eminences, behind by a line connecting the parietal eminences, and on either side by the superior temporal ridges of the parietal and frontal bones. The highest point is situated in the course of the sagittal suture, and is called the **vertex**. The sutures in this region are usually two in number, coronal and sagittal, but there is sometimes a third, namely, the metopic or frontal. The coronal or fronto-parietal suture lies between the frontal and parietal bones. The anterior part of the sagittal or interparietal suture meets the coronal suture from behind, and the place of junction is known as the **bregma**, which coincides with the anterior fontanelle of early life. If there is a metopic or frontal suture present it connects the two halves of the frontal bone, and is a continuation of the sagittal suture as far as the fronto-nasal suture. The superior region, as viewed from above, reveals certain parts of the posterior region, namely, the posterior portions of the parietals, with the parietal foramina and obelion, the lambda, the interparietal portion of the occipital, and the lambdoid suture.

3. The Anterior Region.

The **anterior region** (*norma frontalis et facialis*) is limited above by a line connecting the frontal eminences, and below by the lower

border of the inferior maxilla. It is formed by a portion of the frontal, the nasals, superior maxillæ, malars, and inferior maxilla. It is subdivided into two portions, frontal and facial.

The **frontal division** is limited laterally by the superior temporal ridge, below by the supra-orbital border at either side of the median line, and by the fronto-nasal and fronto-maxillary sutures close to the median line. It presents the frontal eminences, superciliary ridges, external and internal angular processes, supra-orbital notches, or it may be foramina, all on either side of the median line, and the nasal eminence or **glabella** at the median line between the two superciliary ridges. The most prominent point of the glabella is known as the **antinion**. The meeting of the two fronto-nasal sutures is known as the **nasion** or **nasal point**. The centre of a line drawn from one temporal ridge to the other across the narrowest part of the frontal region is known as the **ophryon**.

The upper part of the **facial division** presents the openings of the orbits. These cavities are separated at the median line by the bridge of the nose, which is formed by the nasal bones and the nasal processes of the superior maxillæ, whilst externally each orbit is limited by the malar bone and the external angular process of the frontal. The point at the inner angle of the orbit where the horizontal fronto-maxillary suture meets the vertical lachrymo-maxillary suture is known as the **dacryon**, and the lower part of the internasal suture is known as the **rhinion**. Below the nasal bones is the anterior nasal aperture. It is bounded on either side by the nasal notch on the mesial border of the superior maxilla, and above by the inferior borders of the nasal bones, whilst inferiorly in the median line is the anterior nasal spine in two halves. The central point of the base of this spine is known as the **subnasal point**. The anterior nasal aperture is the common external opening of the two nasal fossæ, which are separated by a septum composed of bones and cartilage. An inspection of each nasal fossa will reveal two bulging prominences on its outer wall, the lower of which is formed by the inferior turbinate bone, and the upper by the inferior turbinate process of the ethmoid. Below the former is the inferior meatus, whilst between the two is the middle meatus. The outer wall, from its irregularity, thus presents a marked contrast to the floor, which is smooth and unbroken. The osseous septum is, as a rule, deflected to one side, most commonly the left, thus diminishing the capacity of the left fossa. Below the anterior nasal aperture are the alveolar borders of the superior maxillæ, which lodge the upper teeth. The point where the anterior margins of these two borders meet in the median line is known as the **alveolar point**. Below these borders is the entrance to the buccal cavity, and below this is the alveolar border of the inferior maxilla, which lodges the lower teeth. The middle point of the anterior lip of the lower border of the inferior maxilla is known as the **mental point** or **gnathion**.

The superior maxillæ having a wider range than the inferior

maxilla, the upper teeth slightly overlap the lower. According to the degree of projection of the maxillary bones, skulls are spoken of as **orthognathous**, **prognathous**, or **mesognathous**.

The chief small foramina of the anterior region are as follows, from above downwards at either side : **supra-orbital**, at the junction of the outer two-thirds and inner third of the supra-orbital arch of the frontal (which in most cases is a notch) ; **infra-orbital**, in the superior maxilla near the infra-orbital margin ; **mental**, in the inferior maxilla in line with the septum between the bicuspid alveoli ; and **malar**, situated above the malar tuberosity. The supra-orbital, infra-orbital, and mental foramina are in the same perpendicular line, and transmit the following important sensory nerves, in order from above downwards : supra-orbital, infra-orbital, and mental, which are branches of the ophthalmic, superior maxillary, and inferior maxillary divisions of the Gasserian ganglion on the sensory root of the fifth cranial nerve. The malar foramen transmits the malar branch of the temporo-malar or orbital nerve, from the superior maxillary division of the fifth.

The sutures in the anterior region are as follows : fronto-malar, fronto-maxillary, lachrymo-maxillary, fronto-nasal, internasal, nasomaxillary, malo-maxillary, and intermaxillary.

The Orbits.—The **orbits** have the shape of four-sided pyramids, their bases being directed forwards and outwards, and their apices backwards and inwards. The inner walls are nearly parallel, and occupy an antero-posterior plane, but the outer walls diverge, the plane of each being directed forwards and outwards, so that they almost form a right angle with each other. Each orbit is lined with periosteum, which is continuous with the dura mater through the sphenoidal fissure, and it contains the eyeball, with the ocular muscles, nerves, and bloodvessels, the lachrymal gland, and a large amount of fat. It presents an apex, a base, and four sides or walls. The **apex**, which is directed backwards and inwards, is formed by the inner end of the sphenoidal fissure, and just above and internal to this is the **optic foramen**. The **base** is free, and is directed forwards and outwards. Its circumference presents the fronto-malar suture externally, the malo-maxillary inferiorly, and the fronto-maxillary internally. The walls are superior, inferior, external, and internal.

The **superior wall** or **roof**, which is thin and brittle, is formed mainly by the orbital plate of the frontal, and behind this by the small wing of the sphenoid. It is smooth and concave. Within the external angular process it presents the **lachrymal fossa** for the lachrymal gland, and near the internal angular process the **trochlear fossa**, which gives attachment to the cartilaginous pulley of the superior oblique muscle of the eyeball.

The **inferior wall** or **floor** is formed by three bones, namely, the orbital surface (orbital plate) of the superior maxilla, external to which is a part of the orbital process of the malar, whilst posteriorly is the orbital process of the palate bone. The floor is thin, and sepa-

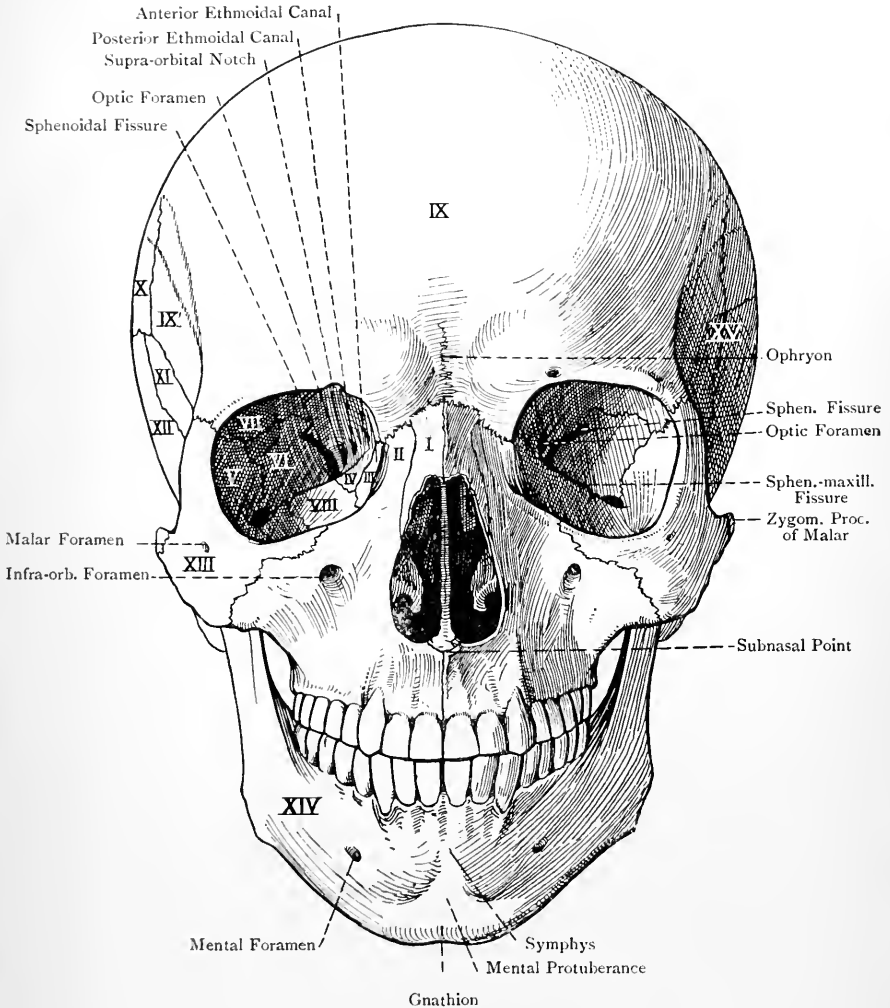


FIG. 78.—THE ANTERIOR REGION OF THE SKULL (NORMA FRONTALIS ET FACIALIS).

I, Nasal. II, Nas. Proc. of Sup. Maxilla. III, Lachrymal. IV, Ethmoid (Os Planum). V, Orbital Proc. of Malar. VI, Orb. Surf. of Great Wing of Sphenoid. VII, Orb. Plate of Frontal. VIII, Orb. Surf. of Sup. Maxilla. IX, Frontal. IX¹, Temp. Div. of Frontal. X, Parietal. XI, Great Wing of Sphenoid. XII, Squam. Port. of Temporal. XIII, Malar. XIV, Inf. Maxilla. XV, Temporal Fossa.

rates the orbit from the subjacent antrum of Highmore. It is traversed from behind forwards by the **infra-orbital canal**, which posteriorly is a groove. At its anterior and inner part is the upper orifice of the **lachrymal canal**, and external to this is a small depression which gives origin to the inferior oblique muscle of the eyeball.

The **outer wall** looks forwards and inwards, and is formed mainly by the orbital surface of the great wing of the sphenoid, and in front of this by a part of the orbital process of the malar. Between the outer wall and the floor is the **spheno-maxillary fissure**, the front part of which communicates with the zygomatic fossa, and the back part with the spheno-maxillary fossa. Between the outer wall and the roof, towards the posterior part is the outer portion of the **sphenoidal fissure**. The part of the orbital process of the malar which forms the front part of this wall presents two foramina (sometimes one) leading to the **malar** and **temporal canals**.

The **inner wall** is almost vertical, and looks directly outwards. It is formed by four (sometimes five) bones, in the following order from before backwards: (1) the nasal process of the superior maxilla; (2) the lachrymal; (3) the os planum or orbital plate of the ethmoid; and (4) the anterior part of the lateral surface of the body of the sphenoid. If there are five bones, the fifth is a portion of the sphenoidal spongy bone, which would lie behind the os planum of the ethmoid. Between the inner wall and roof, in the ethmo-frontal suture, are the openings of the **anterior** and **posterior ethmoidal** or **internal orbital canals**. At the anterior part of this wall is the **lachrymal groove**, which lodges the lachrymal sac, and behind this is the lachrymal crest, which gives origin to the tensor tarsi muscle.

The orbital sutures are as follows: superiorly, the orbito-sphenoidal; inferiorly, the malo-maxillary and palato-maxillary; externally, the spheno-malar; and internally, from before backwards, the lachrymo-maxillary, ethmo-lachrymal, and ethmo-sphenoidal, all of which three are disposed vertically, and ethmo-frontal, which is antero-posterior.

The orbit has ten (sometimes nine) openings communicating with it. (1) The **sphenoidal fissure** or **foramen lacerum anterius** or **orbitale**, the wide inner end of which forms the apex of the cavity, whilst the narrow outer part lies between the roof and the outer wall. This fissure transmits (*a*) the third nerve, the sympathetic filament to the lenticular ganglion, the fourth, the three branches (frontal, lachrymal, and nasal) of the ophthalmic division of the fifth, and the sixth, cranial nerves; (*b*) the superior and inferior ophthalmic veins; (*c*) the orbital branch of the middle meningeal artery; and (*d*) a portion of the dura mater. (2) The **optic foramen**, situated above and internal to the apex, for the optic nerve and the ophthalmic artery, along with a plexus of sympathetic nerve fibres. (3) The **supra-orbital notch** (or it may be foramen), on the supra-orbital border, for the supra-orbital nerve

and vessels. (4) The opening of the **infra-orbital canal**, on the floor, transmitting the infra-orbital nerve and vessels. (5) The opening of the **temporal canal**, and (6) the opening of the **malar canal**, both on the outer wall, for the branches of the temporo-malar or orbital nerve from the superior maxillary division of the fifth cranial nerve. (The temporal and malar openings may be combined into one.) (7) The **spheno-maxillary fissure**, at the junction of the outer wall and floor, which transmits the superior maxillary nerve to become the infra-orbital, and the infra-orbital vessels. (8) The **lachrymal canal**, at the anterior part of the inner wall, for the nasal duct. (9) The **anterior ethmoidal canal**, and (10) the **posterior ethmoidal canal**, both situated on the inner wall, the former transmitting the nasal nerve and anterior ethmoidal vessels, and the latter the posterior ethmoidal vessels and the spheno-ethmoidal nerve.

Eight muscles take their origin within each orbit. The four recti arise from a fibrous ring surrounding the optic foramen. The levator palpebræ superioris arises above and in front of the optic foramen, and the superior oblique arises internal to the last named. The inferior oblique arises from the depression at the anterior and inner part of the floor, external to the orifice of the lachrymal canal, and the tensor tarsi arises from the lachrymal crest behind the lachrymal groove.

The Nasal Fossæ.—The **nasal fossæ** are two in number, right and left, and they lie on either side of the median plane. They extend horizontally from before backwards, opening on the face as the anterior nares by means of the anterior nasal aperture, and communicating posteriorly with the naso-pharynx by the posterior nares. The vertical and antero-posterior dimensions of each fossa greatly exceed the transverse. The two fossæ are separated from each other by a partition, called the septum nasi, which is partly osseous and (in the recent state) partly cartilaginous. Each fossa presents a roof, floor, and two walls, inner and outer.

The **roof** over its central part is horizontal, but in front and behind it is inclined downwards. Six bones enter into its formation. The central portion is formed by one-half of the cribriform plate of the ethmoid. The sloping anterior part is formed by the grooved ala of the frontal bone, by the side of the nasal spine, and the posterior surface of the nasal bone. The sloping posterior part is formed by portions of the anterior and inferior surfaces of the body of the sphenoid, the ala of the vomer, and a part of the sphenoidal process of the palate bone. The central part of the roof is perforated by the foramina of one-half of the cribriform plate, including the nasal slit, and, at its back part, the aperture of the sphenoidal air sinus opens into the spheno-ethmoidal recess.

The **floor** is smooth and concave from side to side. Over its anterior three-fourths it is formed by the palatal process of the superior maxilla, and over its posterior fourth by the horizontal plate of the palate bone. Near its anterior extremity, close to

the incisor crest of the superior maxilla, is the upper opening of **Stensen's canal**.

The **inner wall** is known as the **septum nasi**. The osseous septum is formed by ten bones, in the following order, as nearly as possible, from the below upwards: the nasal crests of the palatal processes of the superior maxillæ and palatine bones; the vomer; the perpendicular plate of the ethmoid; the rostrum of the

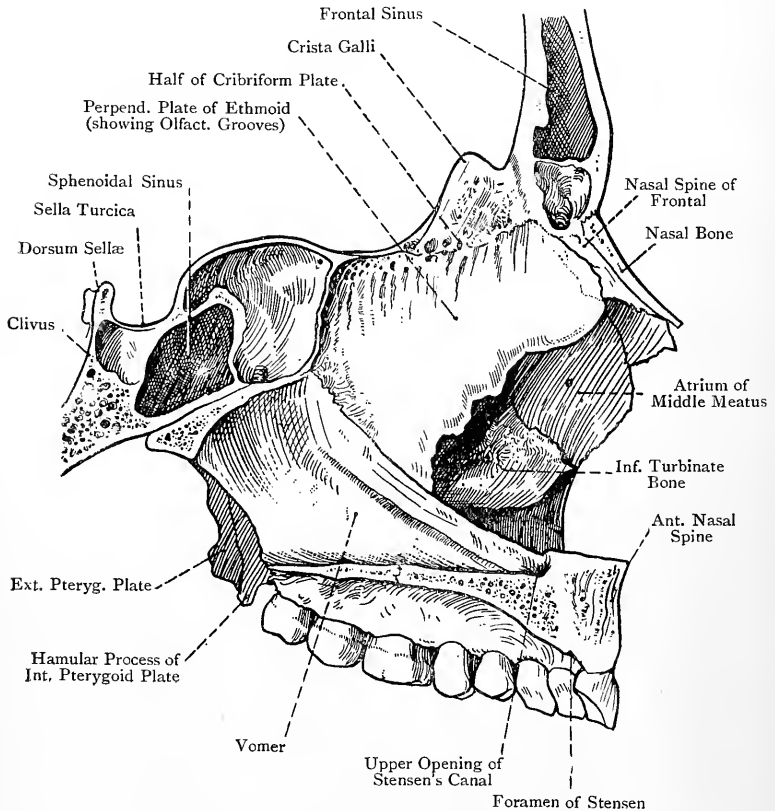


FIG. 79.—SAGITTAL SECTION OF THE ANTERIOR PART OF THE SKULL TO THE RIGHT OF THE NASAL SEPTUM.

sphenoid; the nasal crest of the nasal bones; and the nasal spine of the frontal. The anterior border of the osseous septum presents a triangular deficiency, which is occupied in the recent state by the septal cartilage. The posterior border is formed by the posterior border of the vomer, which lies between the posterior nares. As previously stated, the septum is usually deflected to one side, most commonly the left.

The **outer wall** is characterized by great irregularity, and is formed by seven bones, in the following order, as nearly as possible, from before backwards: (1) the nasal; (2) the nasal process of the superior maxilla; (3) the lachrymal; (4) the internal surface of the lateral mass of the ethmoid, presenting the superior and inferior turbinate processes (superior and middle spongy bones); (5) the inferior turbinate or spongy bone which lies below the last named; (6) the perpendicular plate of the palate bone, together with parts of its orbital and sphenoidal processes; and (7) the internal pterygoid plate of the pterygoid process of the sphenoid.

The bulging projections on this wall are produced by the superior and inferior turbinate processes of the ethmoid and the inferior turbinate bone, in this order from above downwards, and the deep channels thereby formed are known as the *meatus*. These are three in number—superior, middle, and inferior. The **superior meatus** is situated towards the back part of the outer wall, where it lies between the superior and inferior turbinate processes of the ethmoid. It is comparatively short, and is directed obliquely forwards and upwards. The posterior ethmoidal cells open into it anteriorly, and the sphenopalatine foramen posteriorly. The **middle meatus**, which is longer than the superior, lies between the inferior turbinate process of the ethmoid and the inferior turbinate bone. At its anterior part it turns upwards, and is continued into the passage known as the **infundibulum**, which communicates with the frontal air sinus of its own side. The ascending part also communicates with the anterior ethmoidal cells. The middle portion communicates with the middle ethmoidal cells, and presents the opening of the antrum of Highmore. The **inferior meatus**, which is the longest of the three, lies between the inferior turbinate bone and the floor of the nasal fossa. Near its anterior part is the lower orifice of the lachrymal canal, which lodges the nasal duct.

The Air Sinuses.—These are hollow cavities lined with mucous membrane, which are contained within the following bones: the frontal, sphenoid, ethmoid, superior maxillæ, and mastoid portions of the temporals. They communicate directly with the nasal fossæ, except the mastoid cells, which at either side are in communication with the tympanum, that in turn being connected by means of the Eustachian tube with the naso-pharynx, at a point external to the posterior naris. The maxillary air sinus or antrum of Highmore appears about the fourth month of intra-uterine life, but the other air sinuses do not appear until childhood, and they do not show much development until the period of puberty (see the individual bones). In old age they all tend to become enlarged.

The frontal sinus (through means of the infundibulum) and the anterior ethmoidal cells open into the ascending front part of the middle meatus. The middle ethmoidal cells and the maxillary sinus open into the central portion of the middle meatus. The

posterior ethmoidal cells open into the superior meatus, and the sphenoidal sinus opens into the sphenoidal recess.

The foramina which perforate the cribriform plate of the ethmoid transmit the filaments of the olfactory bulb, and are arranged in three sets, as follows: a middle set, which are simple perforations, and an external and internal set, which lead into small canals. These canals descend on the inner surface of the lateral mass and corresponding part of the perpendicular plate respectively, branching and opening out as they descend. The nasal slit transmits the nasal nerve and anterior ethmoidal artery. The sphenopalatine foramen leads from the sphenomaxillary fossa, and transmits the internal nerves of Meckel's ganglion and the sphenopalatine artery.

The **anterior nares** are the orifices by which the nasal fossæ open on the face through means of the anterior nasal aperture. Each naris is semipyriform, and is bounded above by the lower border of the nasal, externally by the nasal notch of the superior maxilla, and inferiorly by the premaxillary portion of that bone.

The **posterior nares** or **choanæ** are situated at the posterior extremities of the nasal fossæ, between the pterygoid processes of the sphenoid, and they communicate in the recent state with the naso-pharynx. They are oblong from above downwards, and their plane is oblique, being directed downwards and slightly forwards. Each naris is bounded externally by the internal pterygoid plate of the sphenoid, internally by the posterior border of the vomer, which separates the two nares, inferiorly by the posterior border of the horizontal plate of the palate bone, and superiorly by the vaginal process of the sphenoid, ala of the vomer, and sphenoidal process of the palate bone.

4. The Lateral Region.

The **lateral region** (*norma lateralis*) is formed by portions of the frontal, parietal, sphenoid, temporal, malar, superior maxilla, and inferior maxilla. It is somewhat triangular, with the base directed upwards. The base represents, for the most part, the superior temporal ridge, and corresponds with a curved line connecting the external angular process of the frontal with the lateral angle of the tabular part of the occipital. In front and behind it is limited by lines connecting the extremities of the base with the ramus of the inferior maxilla in the vicinity of the angle. This region presents the zygomatic arch, and, from behind forwards, are seen the mastoid process, opening of the external auditory meatus and suprameatal triangle, condyle of the inferior maxilla, lying in the anterior part of the glenoid fossa, eminentia articularis, and the sigmoid notch and coronoid process of the inferior maxilla, the latter lying within the front part of the zygomatic arch. The central point of the orifice of the external auditory meatus is known as the **auricular point**, and the outer side of the angle of the inferior maxilla is

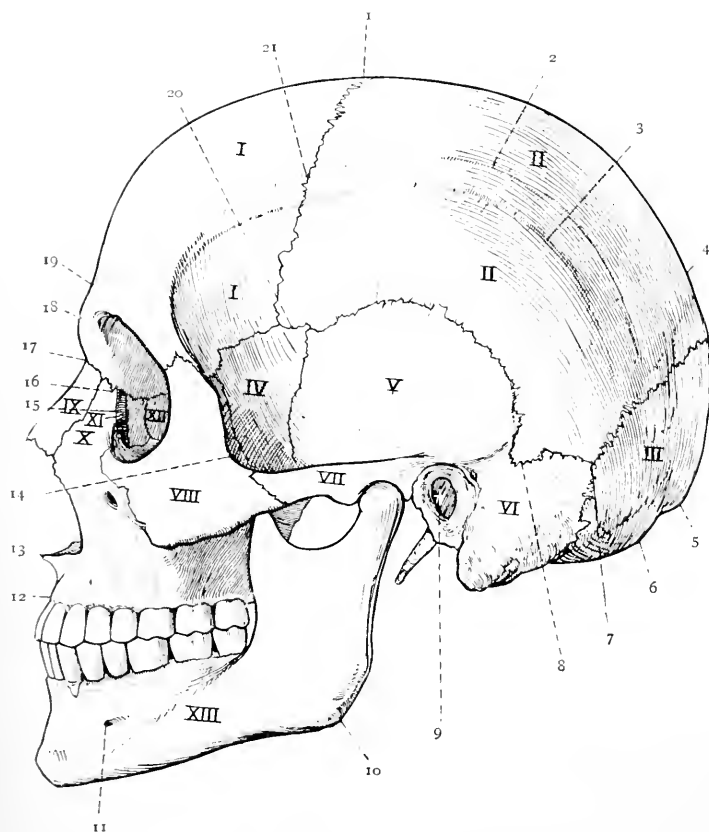


FIG. 80.—THE LATERAL REGION OF THE SKULL (NORMA LATERALIS).

1, I, Frontal; II, II, Parietal; III, Occipital; IV, Great Wing of Sphenoid; V, Squamous Portion of Temporal; VI, Mastoid Portion of Temporal; VII, Zygoma; VIII, Malar; IX, Nasal; X, Superior Maxilla (Nasal Process); XI, Lachrymal; XII, Ethmoid (Os Planum); XIII, Inferior Maxilla.

1, Bregma; 2, Superior Temporal Ridge; 3, Inferior Temporal Ridge; 4, Obelion; 5, Occipital Point; 6, Inion; 7, Asterion; 8, Entomion; 9, Auricular Point; 10, Gonion; 11, Mental Foramen; 12, Alveolar Point; 13, Subnasal Point; 14, Jugal Point; 15, Lachrymal Groove; 16, Dacryon; 17, Nasion; 18, Glabella; 19, Ophryon; 20, Pterion; 21, Stephanion.

known as the **gonion**. The point, situated at the angle which the posterior border of the frontal process of the malar makes with the superior border of its zygomatic process, is known as the **jugal point**.

The sutures in this region are the fronto-malar, spheno-malar, fronto-sphenoidal, spheno-parietal, squamo-sphenoidal, coronal, squamous or squamo-parietal, temporo-malar (zygomatic), parieto-mastoid, and a portion of the occipito-mastoid.

The point where the superior temporal ridge crosses the coronal suture is known as the **stephanion**, and the point where the parieto-mastoid, occipito-mastoid, and lambdoid sutures meet is known as the **asterion**. The latter coincides with the position of the postero-lateral fontanelle in early life. The point near the anterior part of the parieto-mastoid suture, where a process of the parietal is received into the parietal notch of the mastoid, is known as the **entomion**.

The lateral region is divided by the zygomatic arch into the temporal and zygomatic fossæ, the former being above the arch, and the latter within and below it.

The **temporal fossa** is bounded above by the superior temporal ridges of the frontal and parietal, and below by the upper border of the zygomatic arch externally, and the infratemporal crest of the great wing of the sphenoid internally. It is formed by five bones, as follows: in front by the orbital process of the malar, above by the lower portions of the frontal and parietal, and below by the temporal division of the outer surface of the great wing of the sphenoid and the squamous portion of the temporal. The place where the parietal, frontal, great wing of the sphenoid, and squamous portion of the temporal are related to one another, and more particularly the region of the spheno-parietal suture, is known as the **pterion**, which coincides with the position of the antero-lateral fontanelle of early life. In this situation a Wormian bone is sometimes present, called the **epipteric bone**. The temporal fossa gives origin to the temporal muscle as high as the inferior temporal ridge, and the temporal fascia, which covers that muscle, is attached to the superior temporal ridge.

The **zygomatic fossa** is situated below the level of the infratemporal crest of the sphenoid. It is bounded externally by the ramus of the inferior maxilla and the inner surface of the zygomatic arch, and, between the two, it communicates with the exterior by means of the sigmoid notch. Internally it is bounded by the external pterygoid plate of the sphenoid. Superiorly it is limited by the zygomatic surface of the great wing of the sphenoid below the infratemporal crest, where it presents the foramen ovale and foramen spinosum, and by a small part of the squamous portion of the temporal. Anteriorly its wall is formed by the lower portion of the internal surface of the malar and the zygomatic surface of the superior maxilla, which latter presents the openings of the posterior dental canals. Its superior limit is

the infratemporal crest of the sphenoid, the inferior limit being the molar portion of the alveolar border of the superior maxilla and the lower border of the external pterygoid plate.

The contents of the fossa are as follows: the coronoid process of the inferior maxilla with the insertion of the temporal muscle; the external and internal pterygoid muscles; the first and second parts of the internal maxillary artery, and the pterygoid plexus of veins; the inferior maxillary division of the fifth cranial nerve and

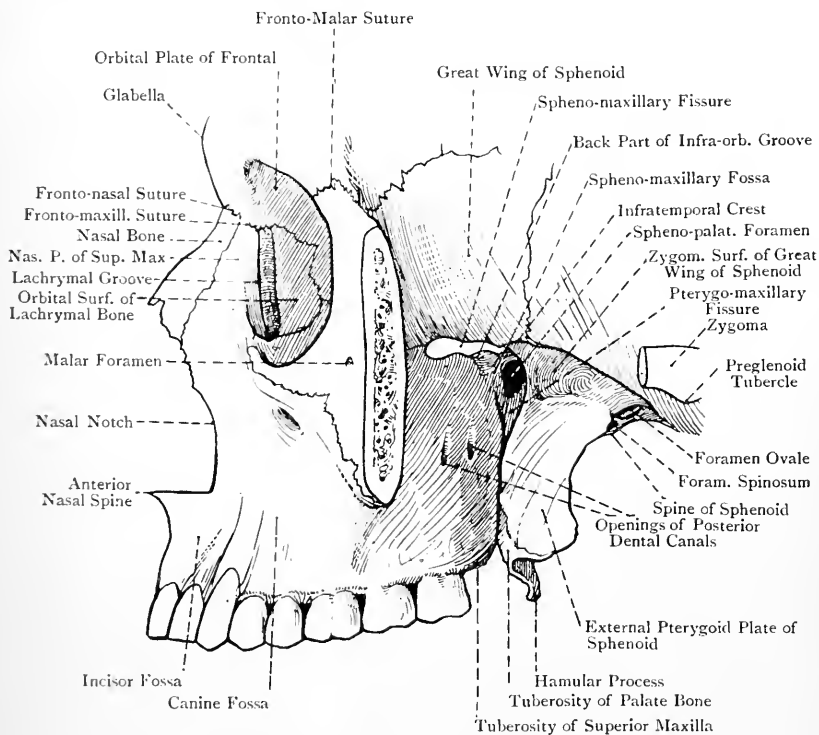


FIG. 81.—THE ZYGOMATIC AND SPENO-MAXILLARY FOSSÆ.

its branches, together with the otic (Arnold's) ganglion; the chorda tympani nerve; and the speno-mandibular ligament.

The foramina which communicate with the fossa are as follows: the **foramen ovale**; the **foramen spinosum**; the openings of the **posterior dental canals**; and the **inferior dental foramen**.

The fossa presents two fissures—spheno-maxillary and pterygo-maxillary.

The **spheno-maxillary** fissure lies horizontally between the great wing of the sphenoid and the superior maxilla. Externally it is

closed, as a rule, by the malar, but sometimes by the great wing of the sphenoid, which may here articulate with the superior maxilla. Internally it is bounded by the zygomatic surface of the orbital process of the palate bone. The fissure leads into the orbit, and transmits the superior maxillary nerve to become the infra-orbital, the infra-orbital vessels, the temporo-malar or orbital branch of the superior maxillary nerve, the orbital branches of Meckel's ganglion, and a communicating vein which passes between the inferior ophthalmic vein and the pterygoid plexus.

The **pterygo-maxillary** fissure lies vertically between the anterior border of the pterygoid process of the sphenoid and the posterior border of the superior maxilla, at their upper ends. Inferiorly the fissure is closed by the approximation of the bones forming its lips, a part of the tuberosity of the palate bone usually intervening between them, though direct articulation sometimes takes place between the pterygoid process and the superior maxilla. Internally the fissure is bounded by the perpendicular plate of the palate bone. It transmits the internal maxillary artery to the sphe-no-maxillary fossa. The pterygo-maxillary fissure meets the sphe-no-maxillary fissure at a right angle, and situated deeply within this angle is the sphe-no-maxillary fossa.

The boundaries of the **spheno-maxillary fossa** are as follows: *anteriorly*, the zygomatic surface of the superior maxilla at its inner and back part superiorly; *posteriorly*, the base of the pterygoid process of the sphenoid, and the lower and inner part of the anterior surface of its great wing; *internally*, the perpendicular plate of the palate bone, with its orbital and sphenoidal processes; and *superiorly*, the under surface of the body of the sphenoid. The contents of the fossa are the third part of the internal maxillary artery, the superior maxillary nerve, and the sphe-no-palatine or Meckel's ganglion, along with their branches. Two fissures communicate with this fossa, namely, the sphe-no-maxillary, leading into the orbit, and the pterygo-maxillary, opening into the zygomatic fossa. It also communicates with the superior meatus of the nose by means of the sphe-no-palatine foramen on its inner wall.

The foramina which open into the sphe-no-maxillary fossa are as follows: three on the *posterior wall*, in the following order from above downwards, and from without inwards: the **foramen rotundum** for the superior maxillary nerve, the **Vidian** or **pterygoid canal** for the Vidian nerve and vessels, and the **pterygo-palatine canal** for the pharyngeal nerve and pterygo-palatine vessels. On the *internal wall* is the **spheno-palatine foramen** for the internal branches of Meckel's ganglion and the sphe-no-palatine artery. *Inferiorly* is the opening of the **posterior palatine canal** for the great or anterior descending palatine nerve and the descending palatine artery. In this situation there may also be the openings of the **posterior** and **external accessory palatine canals** for the posterior and external descending palatine nerves, but these openings usually branch off

from the main canal. *Anteriorly* is the spheno-maxillary fissure. *Externally* the fossa communicates with the zygomatic fossa through the pterygo-maxillary fissure.

5. The Inferior Region.

The **inferior region** or **external base** (*norma basilaris*), from which the inferior maxilla is excluded, is limited in front by the central portions of the alveolar borders of the superior maxillæ, and behind by the superior curved lines of the occipital. At either side it is limited by the lateral portion of the alveolar border of the superior maxilla, and by a line connecting the tuberosity of that bone with the lateral angle of the tabular part of the occipital. It is very irregular, and presents three divisions—*anterior*, *middle*, and *posterior*.

The **anterior division** forms the hard palate, and resembles a horseshoe. It is bounded in front and laterally by the alveolar borders of the superior maxillæ, and behind by the posterior borders of the horizontal plates of the palate bones. The posterior border presents in the middle line the posterior nasal spine in two halves, from which the *azygos uvulæ* muscle arises. At either side of this it is sharp and concave for the attachment of the soft palate. The bones forming the hard palate are the palatal processes of the superior maxillæ over the anterior three-fourths, and the horizontal plates of the palate bones over the posterior fourth. The surface is vaulted, and is intersected by two sutures, *middle palatal* and *transverse palatal*. The middle palatal suture extends from the alveolar point to the posterior nasal spine, and indicates the meeting of the palatal plates of the superior maxillæ and palate bones of opposite sides. The transverse palatal suture crosses the middle one at right angles about $\frac{1}{2}$ inch in front of the posterior border, and externally it turns backwards to end at the posterior palatine foramen. It indicates the meeting of the palatal process of the superior maxilla and the horizontal plate of the palate bone of either side.

In young skulls two additional sutures are present, called *maxillo-premaxillary*, each of which extends from the posterior part of the anterior palatine fossa to the interval between the lateral incisor and canine teeth. Each of these sutures corresponds with the place of junction of the maxilla proper and the premaxilla.

The hard palate presents several openings. At the anterior extremity of the middle palatal suture is the diamond-shaped **anterior palatine fossa**. Within this are four openings, two being placed laterally, one at either side, called the **foramina of Stensen** (incisor foramina), and two in the median line in the intermaxillary suture, called the **foramina of Scarpa**, anterior and posterior respectively. Each of the former transmits a branch of the descending,

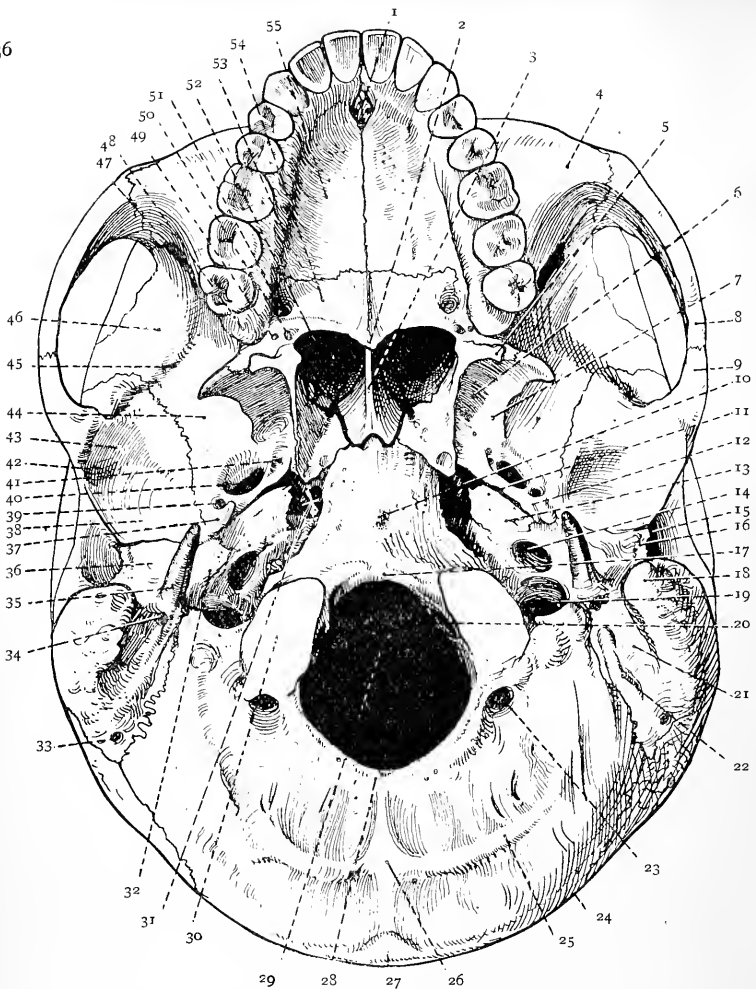


FIG. 82.—THE EXTERNAL BASE OF THE SKULL.

- | | | |
|---|--|---|
| 1. Ant. Palatine Fossa | 18. Mastoid Process | 37. Spinous Proc. of Sphenoid |
| 2. Post. Nasal Spine | 19. Jugular Foramen | 38. Ant. part of Glenoid Fossa |
| 3. Post. Border of Vomer | 20. Ant. Condylar Foramen | 39. Foramen Spinosum |
| 4. Facial Surf. of Sup. Maxilla | 21. Digastric Groove | 40. Foramen Ovale |
| 5. Hamular Process of Int. Pterygoid Plate of Sphenoid | 22. Occipital Groove | 41. Foramen Vesalii |
| 6. Pterygoid Fossa | 23. Post. Condylar Foramen | 42. Preglenoid Tubercle |
| 7. Ext. Pterygoid Plate | 24. Sup. Curved Line of Occipital | 43. Eminentia Articularis |
| 8. Zygomatic Process of Malar | 25. Inf. Curved Line | 44. Zygomatic Fossa |
| 9. Zygoma of Temporal | 26. Ext. Occipital Crest | 45. Infratemporal Crest |
| 10. Pharyngeal Tubercle (pointer crosses Foram. Lacerum Med.) | 27. Ext. Occipital Protuberance | 46. Temporal Division of Great Wing of Sphenoid |
| 11. Eustachian Groove | 28. Opisthion | 47. Spheno-Maxillary Fissure |
| 12. Groove for Chorda Tympani Nerve | 29. Foramen Magnum | 48. Tuberosity of Sup. Maxilla |
| 13. Petrous Portion of Temporal (Origin of Levator Palati) | 30. Right Occipital Condyle | 49. Ext. Access. Palat. Foramen |
| 14. Carotid Foramen | 31. Foram. Lacerum Medium at + | 50. Post. Access. Palat. Foramen |
| 15. Ext. Auditory Meatus | 32. Vaginal Proc. of Tymp. Plate | 51. Post. Palatine Foramen |
| 16. Ext. Auditory Process | 33. Mastoid Foramen | 52. Right Post. Naris (pointer crosses ridge for Tensor Palati) |
| 17. Basion | 34. Stylo-Mastoid Foramen | 53. Groove for Descend. Palat. Artery |
| | 35. Styloid Process | 54. Horiz. Plate of Palate Bone |
| | 36. Tympanic Plate (Post. part of Glenoid Fossa) | 55. Palat. Proc. of Sup. Maxilla |

palatine artery from the palate to the nasal fossa, whilst each of the latter transmits the naso-palatine nerve from the nasal fossa to the hard palate, the *anterior*, which usually opens from the *left* nasal fossa, containing the left nerve, and the *posterior*, which usually opens from the right nasal fossa, containing the right nerve. Internal to the last molar alveolus at either side is the **posterior palatine foramen**, which is the outlet of the posterior palatine or palato-maxillary canal, and through which the great or anterior descending palatine nerve and the descending palatine vessels pass. Leading forwards from this foramen there is a groove for the transmitted structures. A little behind the posterior palatine foramen is the **posterior accessory palatine foramen** for the posterior descending palatine nerve, and outside this is the **external accessory palatine foramen** for the external descending palatine nerve, but the last-named foramen is inconstant. Besides the foregoing openings, there are a number of nutrient foramina. Over its anterior three-fourths the hard palate presents several depressions for the palatal mucous glands, and extending inwards from the back part of the posterior palatine foramen at either side is a transverse ridge, which gives partial insertion to the tensor palati muscle.

The **middle division** extends from the posterior border of the hard palate to a transverse line on a level with the anterior margin of the foramen magnum. Laterally it is limited by a line extending from the tuberosity of the superior maxilla to the styloid process of the temporal. It is on a higher level than the anterior division, and its central or basilar part is known as the **guttural fossa**. The bones forming it at either side are the tuberosity of the palate bone, the pterygoid process, and a small part of the great wing, of the sphenoid, and the inferior surface of the petrous portion of the temporal. The central part is formed by the basilar process of the occipital, the body and vaginal processes of the sphenoid, the superior border and alæ of the vomer, and the sphenoidal processes of the palate bones.

Anteriorly it presents the posterior nares, already described, and at either side of these openings is the **pterygoid fossa**, which is bounded internally by the internal, and externally by the external, pterygoid plate of the sphenoid, the fossa being completed inferiorly by the tuberosity of the palate bone.

In a line extending backwards and outwards from the external pterygoid plate to the styloid process the following parts are seen, in order from before backwards: **foramen ovale**; **foramen spinosum**; **spinous process** of the sphenoid; internal border of the tympanic plate of the temporal, forming posteriorly the **vaginal process**; and **styloid process**. Inside the foregoing line anteriorly is the **Eustachian groove**, which lies obliquely between the great wing of the sphenoid and the apical part of the petrous portion of the temporal. This groove lodges the cartilaginous part of the Eustachian tube, and, when followed outwards and backwards,

it leads to the Eustachian canal in the angle between the squamous and petrous portions of the temporal.

On either side of the basilar process of the occipital is the **foramen lacerum medium**, also known as the sphenotic foramen from its relation to the sphenotic portion (lingula) of the sphenoid. It lies between the basilar process, the apex of the petrous portion of the temporal, and the great wing of the sphenoid near the root of the pterygoid process. In the recent state it is here closed by fibrous tissue, which is pierced by a meningeal branch of the ascending pharyngeal artery, and one or more emissary veins from the cavernous sinus.

In a line extending backwards and outwards from the foramen lacerum medium are the following markings on the inferior surface of the petrous portion of the temporal: the rough surface from which the levator palati arises: the **carotid foramen**, which transmits the internal carotid artery and the ascending branch of the superior cervical ganglion of the sympathetic: a minute foramen, on the posterior wall of the vertical portion of the carotid canal, for the tympanic branch of the carotid sympathetic plexus and tympanic branch of the internal carotid artery: the **jugular fossa**, which forms part of the jugular foramen: the **tympanic canaliculus**, on the ridge between the carotid foramen and jugular fossa, for the tympanic branch (Jacobson's nerve) of the glosso-pharyngeal and the tympanic branch of the ascending pharyngeal artery: and the **auricular canaliculus**, on the outer wall of the jugular fossa, for the auricular branch (Arnold's nerve) of the pneumogastric. Between the petrous portion of the temporal and the jugular process of the occipital is the **foramen lacerum posterius** or **jugular foramen**, which lodges the commencement of the internal jugular vein, and transmits the following structures: the glosso-pharyngeal, pneumogastric, and spinal accessory nerves: the inferior petrosal sinus; and meningeal branches of the ascending pharyngeal and occipital arteries.

External to the front of the occipital condyle is the **anterior condylar foramen** for the hypoglossal nerve and a meningeal branch of the ascending pharyngeal artery. The under surface of the basilar process of the occipital presents the **pharyngeal tubercle**.

The **posterior division** is limited in front by a transverse line on a level with the anterior margin of the foramen magnum, and behind by the external occipital protuberance and the superior curved line at either side. It is formed by the supra-occipital and condylar portions of the occipital and the mastoid portions of the temporal bones.

In the middle line is the **foramen magnum**, which transmits the medulla oblongata and its membranes, the spinal accessory nerves, the vertebral arteries, and the anterior and posterior spinal arteries. The centre of the anterior margin of the foramen magnum is known as the **basion**, and the centre of the posterior margin as the **opisthion**. Proceeding outwards

from this foramen are the **occipital condyle**, **jugular process**, **occipital groove** for the occipital artery, **digastric groove** for the posterior belly of the digastric, and the mastoid process. Behind the occipital condyle is the **posterior condylar fossa**, in which there may be a posterior condylar foramen for the passage of an emissary vein from the lateral sinus. Behind the foramen magnum is the supra-occipital portion of the occipital, which presents the **external occipital crest** in the median line, and the **inferior curved line** extending outwards on either side from its centre.

The Interior of the Cranium.

A sagittal or antero-posterior section of the skull a little to one side of the median plane shows the septum nasi already described. Along, and at either side of, the vault of the cranium is the groove for the superior longitudinal venous sinus, which extends from before backwards, and on either side of its parietal portion are the Pacchionian depressions. The internal openings of the parietal foramina may be seen, as well as the branching system of meningeal grooves, and digitate impressions. The basi-cranial, basi-facial, and basi-bregmatic axes are to be studied from this section. The **basi-cranial axis** represents a line drawn upwards and forwards from the basion to the sphenoid-ethmoidal suture. The **basi-facial axis** corresponds with a line drawn from the sphenoid-ethmoidal suture to the subnasal point. The angle formed by these two axes is known as the **cranio-facial angle**. The **basi-bregmatic axis** represents a line drawn vertically from the basion to the bregma.

The most instructive coronal or transverse section is one made in the plane of the basi-bregmatic axis. Such a section gives important views of the parts within the petrous portion of the temporal, such as the external auditory meatus, tympanum, and vestibule.

When a horizontal section has been made on a level with the occipital point and the most prominent part of the glabella, the vaulted roof of the cranium is removed. This is called the **calvaria**, or skull-cap, and it is formed by portions of the frontal, parietals, squamous portions of the temporals, and occipital. The outer plate is strong, except over the temporal region, but the inner is brittle and readily cracked, from which circumstance it is known as the vitreous (glassy) plate. Between the two plates there is cancellated tissue, here called **diploë**. The interior of the calvaria presents branching meningeal grooves, digitate impressions, and along the middle line the groove for the superior longitudinal venous sinus, with depressions at either side for the Pacchionian bodies. The openings of the parietal foramina may be noted.

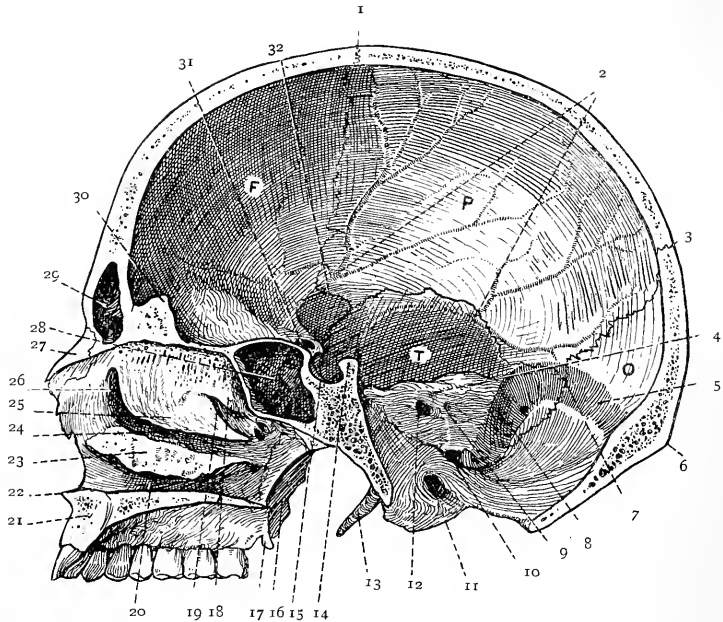


FIG. 83.—SAGITTAL SECTION OF THE SKULL TO THE RIGHT OF THE MEDIAN PLANE.

F, Frontal; P, Parietal; O, Occipital; T, Temporal.

- | | | |
|---|---|---|
| 1. Coronal Suture | 11. Anterior Condylar Foramen | 22. Anterior Nasal Spine |
| 2. Anterior and Posterior Meningeal Grooves | 12. Internal Auditory Meatus | 23. Inferior Turbinate Bone |
| 3. Lambdoid Suture | 13. Styloid Process | 24. Middle Meatus |
| 4. Hiatus Subarcuatus | 14. Dorsum Sellæ | 25. Inferior Turbinate Process of Ethmoid |
| 5. Sigmoid Groove | 15. Sella Turcica | 26. Infundibulum |
| 6. Inion (External Occipital Protuberance) | 16. External Pterygoid Plate | 27. Nasal Bone |
| 7. Asterion | 17. Hamular Process | 28. Right Sphenoidal Sinus |
| 8. Sigmoid Groove | 18. Superior Turbinate Process of Ethmoid | 29. Right Frontal Sinus |
| 9. Aqueductus Vestibuli | 19. Superior Meatus | 30. Crista Galli |
| 10. Jugular Foramen | 20. Inferior Meatus | 31. Optic Foramen |
| | 21. Right Superior Maxilla | 32. Pterion |

The Internal Base of the Skull.

The **internal base** forms the floor of the cranial cavity, and is of very irregular outline and thickness. The thickest and densest parts are the petrous portions of the temporals. The mastoid portion of the temporal and the basilar part of the occipital are also thick. The thinnest parts are the cribriform plate of the ethmoid and the orbital plates of the frontal, but the central portions of the cerebellar fossæ of the occipital are also thin, sometimes remarkably so. The interior of the base is divided into three fossæ—*anterior*, *middle*, and *posterior*.

Anterior Fossa.—The floor of this fossa is formed by the orbital

plates of the frontal, the cribriform plate of the ethmoid, and the small wings, jugum sphenoidale, and ethmoidal spine of the sphenoid. It is limited posteriorly by the posterior or Sylvian border of the small wing of the sphenoid at either side, and by the limbus sphenoidalis in the centre. It is subdivided into a central and two lateral parts.

The **central portion**, which is depressed, is formed by the cribriform plate of the ethmoid and the ethmoidal spine and jugum of the sphenoid. In the middle line it presents the **crista galli**, which gives attachment to the falx cerebri. In front of this is the **foramen cæcum**, which, when pervious, transmits an emissary vein passing between the intracranial superior longitudinal sinus and the veins of the roof of the nose. At each side of the crista galli are the **nasal slit** for the nasal nerve and anterior ethmoidal artery; the **cribriform foramina** for the filaments of the olfactory bulb; the cranial opening of the **anterior ethmoidal canal** for the anterior ethmoidal artery and nasal nerve; and the cranial opening of the **posterior ethmoidal canal** for the posterior ethmoidal artery and sphenothmoidal branch of the nasal nerve. The last two openings are situated at the outer side of the cribriform plate, external to the olfactory groove which marks it. Directly beneath each half of the cribriform plate is the corresponding nasal fossa.

Each **lateral portion** of the anterior fossa is irregularly convex, and forms the roof of the orbit. It is formed by the orbital plate of the frontal and the small wing of the sphenoid. It is very thin, and, except over the small wing of the sphenoid, it presents digitate impressions for the convolutions of the orbital surface of the frontal lobe of the cerebrum, which it supports. The sutures in the anterior fossa are the fronto-ethmoidal, fronto-sphenoidal, and sphenothmoidal.

Middle Fossa.—This fossa is on a lower level than the anterior. It is bounded in front by the posterior or Sylvian border of the small wing of the sphenoid at either side, and by the limbus sphenoidalis in the centre. Behind it is limited by the superior border of the petrous portion of the temporal at either side, and by the dorsum sellæ of the sphenoid in the centre. It presents a central and two lateral divisions. The central division is formed by the superior surface of the body of the sphenoid, posterior to the limbus sphenoidalis. Each lateral division, which is much depressed, is formed anteriorly by the superior surface of the great wing of the sphenoid, externally by part of the squamous portion of the temporal, and posteriorly by the superior surface of the petrous portion of that bone. It lodges the temporo-sphenoidal lobe of the cerebrum, and it presents the following sutures: the sphenoparietal; squamous or squamoparietal; squamosphenoidal; and petrosphenoidal.

The **central division** presents the following parts: the **optic groove** and **olivary eminence** for the optic commissure; the **optic foramen** of each side for the optic nerve and ophthalmic artery; the **anterior clinoid process** of each side; the **sella turcica** or

pituitary fossa for the pituitary body; the **cavernous** or **carotid groove**, at either side of the sella turcica, for the cavernous venous sinus and internal carotid artery, the latter being accompanied by the cavernous sympathetic plexus of nerves, and having the sixth cranial nerve on its outer side; the **middle clinoid process** of each side (sometimes connected with the anterior, which it faces); the **dorsum sellæ**; the **posterior clinoid process** of each side, at either lateral angle of the dorsum sellæ; and the **notch** for the sixth cranial nerve, on each side of the dorsum sellæ a little below the posterior clinoid process. The central division corresponds with the interpeduncular region at the base of the cerebrum.

Each **lateral division** is marked by meningeal grooves and digitate impressions, and presents the following openings: the **sphenoidal fissure**, or **foramen lacerum anterius** or **orbitale**, for the third cranial nerve, the fourth, the three branches of the ophthalmic division of the fifth (namely, frontal, lachrymal, and nasal), and the sixth cranial nerves, the sympathetic root of the ciliary ganglion, the superior and inferior ophthalmic veins, the orbital branch of the middle meningeal artery, and a portion of the dura mater to form the orbital periosteum; the **foramen rotundum**, leading to the speno-maxillary fossa, and transmitting the superior maxillary division of the fifth cranial nerve; the **foramen ovale**, leading to the zygomatic fossa, and transmitting the inferior maxillary division and the motor root of the fifth cranial nerve, the small meningeal artery, an emissary vein from the cavernous sinus, and occasionally the small superficial petrosal nerve; the **foramen Vesalii** (inconstant), leading to the scaphoid fossa at the root of the internal pterygoid plate, or to the pterygoid fossa external to the scaphoid fossa, and transmitting an emissary vein from the cavernous sinus; the **foramen spinosum**, leading to the zygomatic fossa, and transmitting the middle meningeal artery and a recurrent branch of the inferior maxillary nerve; and the **foramen lacerum medium** or **sphenotic foramen**, situated between the basilar process of the occipital, the apex of the petrous portion of the temporal, and the great wing of the sphenoid near the root of the pterygoid process. The posterior opening of the **Vidian canal**, which leads to the speno-maxillary fossa and transmits the Vidian nerve and artery, is to be found on its anterior wall, while the **carotid canal** for the internal carotid artery, with a plexus of sympathetic nerve fibres, opens on its external wall.

The superior surface of the petrous portion of the temporal presents the following markings: the **Gasserian depression**, near the apex, for the Gasserian ganglion; the **hiatus Fallopii**, to which a groove conducts for the great superficial petrosal nerve and the petrosal branch of the middle meningeal artery; (within this opening there may be a small one for the external superficial petrosal nerve); the **accessory hiatus**, to which a groove conducts, for the small superficial petrosal nerve; the **eminentia arcuata**,

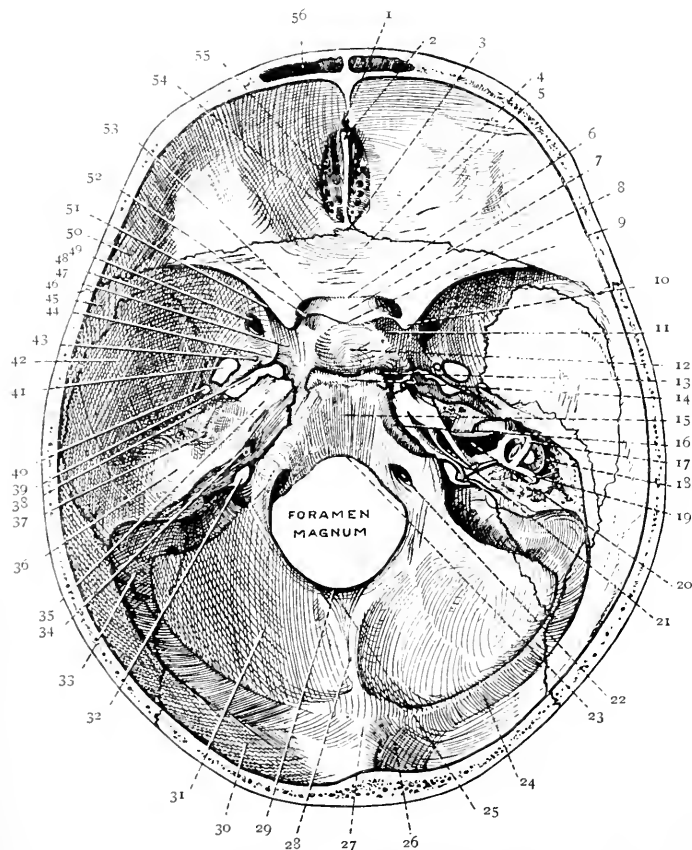


FIG. 84.—THE INTERNAL BASE OF THE SKULL.

(The Superior Surface of the Petrous Portion of the Right Temporal Bone has been removed to expose the Internal Auditory Meatus and Semicircular Canals.)

- | | | |
|---|--|-------------------------------|
| 1. Foramen Cæcum | 19. Posterior Semicircular Canal | 37. Hiatus Fallopii |
| 2. Crista Galli | 20. Internal Auditory Meatus (laid open) | 38. Accessory Hiatus |
| 3. Ethmoidal Spine of Sphenoid | 21. Opening of Internal Auditory Meatus | 39. Foramen Lacerum Medium |
| 4. Jugum Sphenoidale | 22. Anterior Condylar Foramen | 40. Foramen Spinosum |
| 5. Anterior Fossa | 23. Basion | 41. Foramen Ovale |
| 6. Limbus Sphenoidalis | 24. Groove for Lateral Sinus | 42. Middle Fossa |
| 7. Optic Groove | 25. Vermiform Fossa | 43. Foramen Vesalii |
| 8. Olivary Eminence | 26. Torcular Herophili | 44. Lingula of Sphenoid |
| 9. Sylvian Border of Small Wing of Sphenoid | 27. Int. Occipital Protuberance | 45. Parietal Bone |
| 10. Anterior Clinoid Process | 28. Internal Occipital Crest | 46. Coronal Suture |
| 11. Middle Clinoid Process | 29. Opisthion | 47. Cavernous Groove |
| 12. Sella Turcica | 30. Cerebral Fossa | 48. Pterion |
| 13. Posterior Clinoid Process | 31. Cerebellar Fossa | 49. Foramen Rotundum |
| 14. Dorsum Sellæ | 32. Jugular Foramen | 50. Orbital Plate of Frontal |
| 15. Basilar Groove | 33. Sigmoid Groove | 51. Sphenoidal Fissure |
| 16. Groove for Inf. Petrosal Sinus | 34. Internal Auditory Meatus | 52. Carotid Notch |
| 17. Superior Semicircular Canal | 35. Gasserian Depression | 53. Optic Foramen |
| 18. External Semicircular Canal | 36. Eminentia Arcuata | 54. Posterior Ethmoidal Canal |
| | | 55. Anterior Ethmoidal Canal |
| | | 56. Left Frontal Sinus |

which coincides with the position of the superior semicircular canal of the internal ear; and the **tegmen tympani**.

Posterior Fossa.—This fossa is on a lower level than the middle. It is limited in front by the dorsum sellæ of the sphenoid in the centre, and the superior border of the petrous portion of the temporal at either side. Behind, it is limited by the internal occipital protuberance and the groove at either side for the lateral venous sinus, which groove also marks its lateral extent. It lodges the pons Varolii, medulla oblongata, and cerebellum. The bones which form it are as follows: the dorsum sellæ of the sphenoid; the basilar, condylar, and supra-occipital portions of the occipital; the petrous and mastoid portions of the temporal; and the postero-inferior angle of the parietal. It presents the following sutures: the occipito-mastoid; parieto-mastoid; and petro-basilar. The following parts are to be noted: the **basilar groove**, the upper part of which lodges the pons Varolii and basilar artery, whilst the lower part contains the medulla oblongata; the **foramen magnum**, which transmits the medulla oblongata and its membranes, the spinal accessory nerves, and the vertebral, anterior spinal, and posterior spinal, arteries; the **anterior condylar foramen**, on either side of the foramen magnum, for the hypoglossal nerve and a meningeal branch of the ascending pharyngeal artery; the **internal occipital crest**, which gives attachment to the falx cerebelli, and is occasionally grooved for the occipital venous sinus; (near the foramen magnum this crest presents the **vermiform fossa**, which receives a part of the vermiform process of the cerebellum); the **cerebellar fossæ**, which lodge the hemispheres of the cerebellum; the opening of the **internal auditory meatus**, on the posterior surface of the petrous portion of the temporal, for the facial and auditory nerves, *pars intermedia* of Wrisberg, and auditory artery; the **aqueductus vestibuli**, about $\frac{1}{4}$ inch external to the preceding, for a small artery and vein, and the ductus endolymphaticus; the **hiatus subarcuatus**, representing the floccular fossa of early life, situated close to the superior border of the petrous portion, about midway between the opening of the internal auditory meatus and aqueductus vestibuli; and the **jugular foramen** or **foramen lacerum posterius**, between the jugular process of the occipital and petrous portion of the temporal.

The **jugular foramen** is divided into three compartments, which lie obliquely from behind forwards and inwards. The postero-external compartment transmits the lateral venous sinus to become the internal jugular vein, and a meningeal branch of the ascending pharyngeal artery; the middle compartment transmits the glosso-pharyngeal, pneumogastric, and spinal accessory nerves; and the antero-internal compartment gives passage to the inferior petrosal venous sinus. The antero-internal compartment may be more or less completely isolated by means of the intrajugular process, passing between the occipital and the petrous portion of the temporal.

The posterior fossa is grooved by the following venous sinuses: the lateral sinus, which extends from the internal occipital protuberance to the jugular foramen, grooving in its sinuous course the tabular part of the occipital, the postero-inferior angle of the parietal, the mastoid portion of the temporal, and the jugular process of the occipital, (opening from which there is usually the mastoid foramen, and occasionally the posterior condylar foramen); the superior petrosal sinus, which grooves the superior border of the petrous bone; the inferior petrosal sinus, along the course of the petro-basilar suture; and the occipital sinus, which sometimes grooves the internal occipital crest.

Wormian Bones.

The **Wormian bones** (so named after Wormius) are supernumerary bones which are frequently met with in the course of the cranial sutures, and occasionally in the face, as in the region of the lachrymal bones, and at the outer extremity of each sphenomaxillary fissure. From their position in the course of sutures they are known as *ossa suturarum*. They are for the most part of small size and triangular outline, and are hence sometimes spoken of as *ossa triquetra*. They are usually due to the appearance of special ossific centres. Their most common situation is along the course of the lambdoid suture, where they may form a regular chain. The superior angle of the occipital sometimes persists as a Wormian bone, called **pre-interparietal**, which may be double. One is often found between the antero-inferior angle of the parietal and great wing of the sphenoid in the region of the pterion, and it is known as the **epipteric bone**. If the metopic or frontal suture is persistent one or more Wormian bones may be present along its course, and, if at the upper part, they may give rise by their persistence and union to a **bregmatic bone**. In the condition known as chronic hydrocephalus Wormian bones of large size are present in great numbers along the cranial sutures.

The Skull at Birth.

The skull at birth is remarkable for its large size, and for the great development of the cranium as compared with the face. The face is equal to one-eighth of the cranium, whereas in the adult it is equal to one-half. The occipital, parietal, and frontal regions are well developed, the parietal and frontal eminences are very conspicuous, and the mastoid processes are absent. The bones are not united by sutures, but are connected by fibrous tissue, continuous with the periosteum externally and dura mater internally. Membranous intervals exist between the angles of certain bones, these being called **fontanelles** from the pulsation, or welling-up sensation, which can be felt there. They are six in number, two being placed in the median line, anterior and posterior, and two at either side, antero-lateral and postero-lateral. The **anterior fontanelle** is situated between the antero-superior angles of the

parietals and the superior angles of the two halves of the frontal. It is large and diamond-shaped, and it is not completely closed, as a rule, until towards the end of the second year. The **posterior fontanelle** is situated between the postero-superior angles of the parietals and the superior angle of the occipital. It is small and triangular, and is usually closed at, or shortly after, birth, but the surrounding bones are still movable. The antero-lateral and postero-lateral fontanelles correspond with these angles of the parietal. The **antero-lateral** is situated between the parietal,

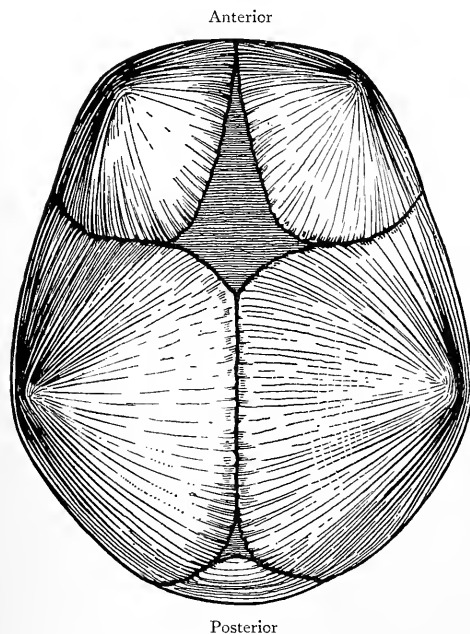


FIG. 85.—THE SKULL AT BIRTH, SHOWING THE ANTERIOR AND POSTERIOR FONTANELLES, AND THE PARIETAL EMINENCES.

are smaller and smoother than in the male. The mastoid processes, superciliary ridges, and glabella are less prominent. The frontal and occipital regions are not so well developed relatively to the parietal. The cranial capacity is rather less. The face as a rule is narrower, and bears a smaller proportion to the cranium.

Racial Peculiarities of the Skull.

In comparing the skulls of different races attention has to be directed to the following points: the capacity of the cranium, its circumference, its relative length, breadth, and height, the degree of forward elongation of the jaws, and the shape of the anterior nasal and orbital apertures. The **cranial capacity** may be ascertained by filling the skull with shot, or various kinds of seeds, and

sphenoid, frontal, and squamous portion of the temporal, whilst the **postero-lateral** is situated between the parietal, occipital, and mastoid portion of the temporal. For the **sagittal fontanelle** of the earlier part of foetal life, see p. 63.

The skull increases rapidly in size during the first six years, and a further marked increase commences on the approach of puberty, which is associated with the development of the air sinuses. The latter increase affects chiefly the frontal and facial regions. In old age the cranial bones become thinner, the air sinuses undergo enlargement, and the sutures show indications of obliteration.

Characters of the Female Skull.—

The bones

then measuring the contents in a graduated vessel. The capacity ranges from about 60 to 110 cubic inches, and, according to their capacity, skulls are divided into three groups, namely, **mesocephalic**, with a capacity of about 85 cubic inches, as in Chinese; **megacephalic**, with a capacity exceeding that, as in Europeans; and **microcephalic**, with a capacity under it, as in Australians.

In regard to craniometry the following craniometrical terms may here be summarized:

Alveolar point = the point of meeting of the anterior margins of the alveolar borders of the superior maxilla.

Antinion = the most prominent point of the glabella.

Asterion = the point where the parieto-mastoid, occipito-mastoid, and lambdoid sutures meet.

Auricular point = the centre of the opening of the external auditory meatus.

Basion = the centre of the anterior margin of the foramen magnum.

Bregma = the point of junction of the sagittal and coronal sutures.

Dacryon = the point where the horizontal fronto-maxillary suture meets the vertical lachrymo-maxillary suture.

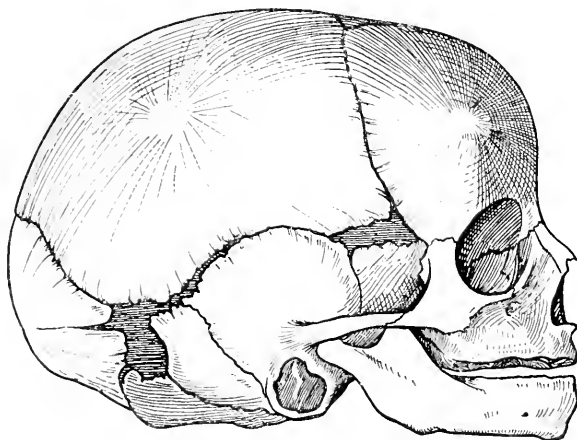


FIG. 86.—THE SKULL AT BIRTH, SHOWING THE ANTERO-LATERAL AND POSTERO-LATERAL FONTANELLES.

Entomion = the point near the anterior part of the parieto-mastoid suture where a process of the parietal is received into the parietal notch of the mastoid.

Glabella = a point midway between the superciliary ridges of the frontal.

Gnathion, or mental point = the middle point of the anterior lip of the lower border of the inferior maxilla.

Gonion = the outer side of the angle of the inferior maxilla.

Inion = the external occipital protuberance.

Jugal point = a point situated at the angle which the posterior border of the frontal process of the malar forms with the superior border of its zygomatic process.

Lambda = the meeting of the sagittal and lambdoid sutures.

Nasion, or nasal point = the meeting of the two fronto-nasal sutures.

Obelion = the point where the horizontal line connecting the parietal foramina intersects the sagittal suture.

Occipital point = the part of the occipital in the median plane at the greatest distance from the glabella.

Ophryon = the centre of a line drawn from one temporal ridge to the other across the narrowest part of the frontal region.

Opisthion = the centre of the posterior margin of the foramen magnum.

Pterion = the region of the speno-parietal suture.

Rhinion = the lower part of the internasal suture.

Stephanion = the point where the superior temporal ridge crosses the coronal suture.

Subnasal point = the centre of the base of the anterior nasal spine.

The **horizontal circumference** of the cranium represents the measurement at the level of a plane passing through the most prominent part of the glabella in front, the pterion laterally, and the occipital point behind.

The greatest **length** represents the measurement from the most prominent part of the glabella to the occipital point. The greatest **breadth** represents the transverse measurement at the level of the most prominent parts of the temporal fossæ above the supramastoid crests. The proportion of greatest breadth to greatest length is the index of breadth, or **cephalic index**. In civilized races about 7 inches represents an average length, and about 5½ inches an average breadth. According to their cephalic index, skulls are arranged in three classes, namely, **brachycephalic** (broad and short), with a cephalic index over 80, as in Malays, etc.; **mesaticephalic** (intermediate), with an index of 75 to 80, as in Europeans and Chinese; and **dolicocephalic** (long and narrow), with a cephalic index below 75, as in Kaffirs and Fijians.

The **height** of the skull represents the measurement from the basion to the bregma, and its proportion to the length is the index of height, or **vertical index**. Its average in civilized races corresponds with the breadth.

The **longitudinal arc** of the skull represents the measurement from the nasion to the opisthion carried over the roof, and the basi-nasal length represents the measurement from the basion to the nasion. These two measurements, plus the distance between the basion and the opisthion, represent the vertical circumference of the cranium in the median plane. The degree of projection of the jaws is ascertained from the **gnathic** or **alveolar index**. This index represents the proportion of the basi-alveolar length to the basi-nasal. According to the gnathic index, skulls are arranged in three classes, namely, **orthognathous** (straight and upright jaw), with a gnathic index below 98, as in Europeans; **mesognathous** (intermediate jaw), with an index of from 98 to 103, as in Chinese and Japanese; and **prognathous** (forward jaw), with an index over 103, as in Australians.

The form of the **anterior nasal aperture** is ascertained from the **nasal index**. This represents the proportion of the greatest transverse measurement of the aperture to the height, which latter is the measurement from the nasion to the subnasal point. According to their nasal index, skulls are arranged in three classes, namely, **leptorhine** (narrow nose), with a nasal index below 48, as in Europeans; **mesorhine** (intermediate nose), with an index of from 48 to 53, as in Chinese and Japanese; and **platyrhine** (broad nose), with an index above 53, as in Australians and Kaffirs.

The form of the **orbital aperture** is ascertained from the **orbital index**, which represents the proportion of the height to the width of the orbital aperture. There are three varieties of orbital index, namely, **megaseme** (great index), when it exceeds 89, as in the Chinese; **mesoseme** (intermediate index), when it is between 89 and 84, as in Europeans; and **microseme** (small index), when it is below 84, as in Australians.

Deformities of the Skull.

The most common cause of cranial deformities is premature synostosis or osseous union of bones which are normally separate, the result being closure or obliteration of certain sutures. When the sagittal suture becomes prematurely obliterated transverse growth is arrested, and, to compensate for this, increased growth takes place at the coronal and lambdoid sutures. The antero-posterior diameter of the cranium is greatly increased, and the vault assumes a boat-like shape. This variety is known as **scaphocephalus**. When the coronal suture becomes prematurely obliterated, increased growth takes place upwards, and the vertical diameter is greatly increased. This variety is known as **acrocephalus** (pointed head). When *one-half* of the coronal or lambdoid suture becomes prematurely obliterated, oblique deformity takes place, this

form being known as **plagiocephalus** (oblique or awry head). When the metopic or frontal suture becomes prematurely obliterated, growth is arrested in the frontal region, and the skull assumes a triangular shape. This variety is known as **trigonocephalus**. When premature obliteration of the sutures at the base of the skull takes place, the deformity known as **cretin skull** results. This is characterized by enlargement of the cranium (except in the occipital region), which becomes very heavy, and assumes an irregular, somewhat conical shape, with the apex at the sagittal suture. It is associated with mental dullness, idiocy, and stunted growth, and the general condition is known as **cretinism**.

Development of the Skull.

Development of the Cranium.—The **notochord** (see p. 53) extends beyond the region of the future vertebral column into the base of the skull, where it reaches as far forwards as the under aspect of the anterior end of the mid-brain. In the skull, as elsewhere, it is invested by mesoblast, which expands and forms a membranous capsule for the cerebral vesicles. This capsule

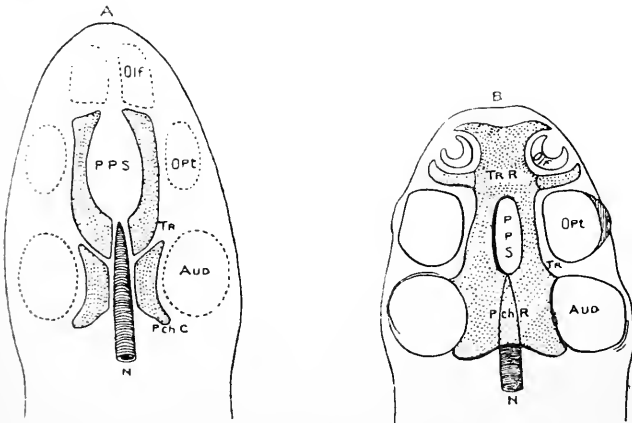


FIG. 87.—DIAGRAMS OF THE PRIMITIVE CARTILAGINOUS CRANIUM (WIEDERSHEIM).

- A. First Stage.—N, Notochord; PchC, Parachordal Cartilage; Tr, Prechordal Cartilage; PPS, Primitive Pituitary Space; Olf, Opt, Aud, positions of Organs of Smell, Sight, and Hearing.
 B. Second Stage.—N, Notochord; PchR, Parachordal Region (Basilar Plate); TrR, Fusion of Prechordal Cartilages; PPS, Primitive Pituitary Space; TrR, Prechordal Region; Olf, Opt, Aud, as in A.

represents the primitive membranous skull. Its basal part undergoes chondrification, whilst the remainder retains its membranous character.

The cartilage appears in the form of two pairs of rods, posterior and anterior. The posterior pair lie on either side of the notochord, and are called the **parachordal cartilages**. The anterior pair lie on either side of the 'primitive pituitary space,' and are called the **prechordal cartilages**. The parachordals unite to form a basilar plate, which ultimately invests the notochord on its dorsal and ventral aspects. Posteriorly the prechordals join the parachordals, whilst anteriorly they become fused in front of the primitive pituitary space. These changes give rise to one continuous basal cartilage, which is divisible into two regions—parachordal, posterior in position, and prechordal, situated anteriorly. The **parachordal region** gives rise to (1) the occipital bone, except its *interparietal portion*, and (2) the dorsum sellae, posterior part of the sella turcica, great wing, and *external pterygoid plate*, of the

sphenoid. The **prechordal region** posteriorly gives rise to the anterior part of the sella turcica, and, in front of this, it resolves itself into presphenoid and ethmoidal portions. The **presphenoid portion** gives rise to the presphenoid division of the sphenoid, and the **ethmoidal portion** is concerned in the development of the ethmoid and face.

External to each parachordal cartilage is the **membranous periotic capsule**, which becomes invested by cartilage, and these periotic cartilaginous capsules become connected with the parachordal plate. It is in this **periotic cartilaginous capsule**, at each side, that the centres of ossification for the petromastoid or periotic portion of the temporal appear. Anteriorly the periotic capsule of either side is separated from the cartilage of the great wing of the sphenoid by a membranous interval, and it is in this membrane that the squamous portion of the temporal is formed. The interparietal portion of the occipital, the parietals, and the frontal are developed in that part of the

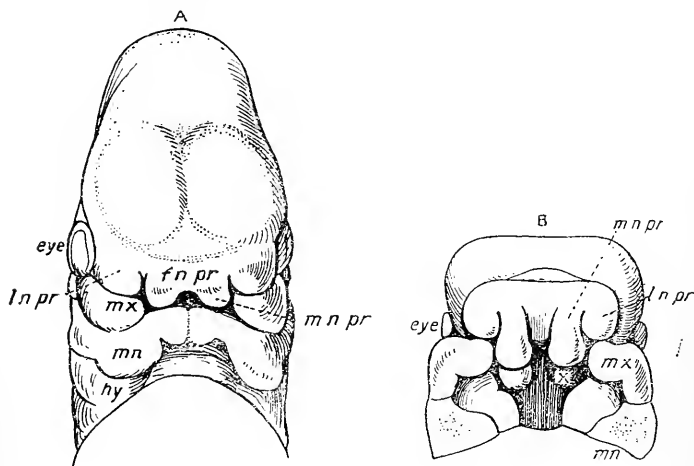


FIG. 88.—HEAD OF AN EMBRYO (HIS).

A, View from above.—B, View showing roof of mouth after removal of the Mandible. *fnpr*, Fronto-Nasal Process; *mnpr*, Mesial Nasal Process, terminating in Globular Process; *lnpr*, Lateral Nasal Process; *mx*, Maxillary Process; *mn*, Mandibular Arch; *hy*, Hyoid Arch. The \times in B indicates the Nasal Lamina.

membranous cerebral capsule which does not undergo chondrification. From the foregoing summary of the development of the cranium it will be observed that it is composed of *basal* or *cartilage* bones formed in the chondro-cranium, and of *tegmental* or *membrane* bones formed in the membranous cranium.

Development of the Face.—The bones of the face are developed from the fronto-nasal process, the two mandibular arches, and the two maxillary processes. The **fronto-nasal process** springs from the primitive cerebral capsule, and it contains a core derived from the ethmoidal division of the prechordal region. It consists of a central part and two symmetrical halves. Each half presents two processes, called mesial or internal, and lateral or external, nasal processes. The *mesial nasal process*, of each side, terminates inferiorly in an enlargement, which is known as the globular process. From each globular process a plate of cartilage grows backwards, these two plates being termed the *nasal laminæ*. They are at first separate, but they soon unite and form the greater part of the nasal septum. The septal cartilage gives rise to the perpendicular plate of the ethmoid, and the vomer is de-

veloped in the membrane which covers that cartilage. The *globular processes*, like the nasal laminae, are at first separate, but they soon unite. The depressed portion at the place of their fusion gives rise to the lower part of the nasal septum and the columella nasi. Each globular process forms the premaxillary part of the superior maxilla and the mesial portion of the upper lip. The *lateral nasal process* lies above the ventral part of the maxillary process, from which it is separated by the *lachrymal sulcus*. It has the *nasal pit* internal to it, and the *ocular depression* on its outer side. The lachrymal sulcus disappears as the lateral nasal process joins the maxillary process, but it indicates the deep position of the future lachrymal sac and nasal duct. The cartilage of the *lateral nasal process* gives rise to the lateral mass, and half of the cribriform plate, of the ethmoid, and the inferior turbinate bone; and the membrane which covers the cartilage gives rise to the nasal process of the superior maxilla, and the nasal and lachrymal bones.

Each **mandibular arch** contains a bar of cartilage, which is known as *Meckel's cartilage*. The upper end of this cartilage is connected with the periotic capsule, and the lower end meets its fellow. The upper end persists as the malleus and the incus, and the lower end gives rise to the incisor portion of the body of the mandible. The intervening portion of Meckel's cartilage disappears. The fibrous tissue which surrounds the lower part of this portion forms a large part of the mandible, whilst that which surrounds the upper part persists as the spheno-mandibular ligament.

Each **maxillary process** is an outgrowth from the dorsal end of the mandibular arch of its own side. It grows in a forward direction between the eye and the mouth, and abuts against the lateral nasal process, with which it blends. Under normal circumstances it also unites with the globular process, which belongs to the mesial nasal process. The maxillary process gives rise to the chief part of the superior maxilla, and to the malar bone. The process contains a small piece of cartilage, called the *pterygo-palatine bar*, and the membrane which invests this bar gives origin to the palate bone and the *internal pterygoid plate* of the sphenoid. The cartilaginous bar itself soon disappears.

Development of the Hyoid Bone.—This bone is developed from the cartilaginous bars of the second visceral or hyoid, and third visceral or thyro-hyoid, arches, of either side. The **hyoid bars** are continuous with one another at the median line through the *copula*, which gives rise to the *body* of the hyoid bone. The *small cornua* are developed from the ventral ends of the hyoid bars. The upper end of each gives rise to the styloid process of the temporal bone, and the intermediate part disappears, but its fibrous investment persists as the stylo-hyoid ligament. The **thyro-hyoid bar** of each side gives rise at its ventral end, which is connected with the copula, to the *great cornu* of the hyoid bone, whilst the remainder of the bar disappears.

THE TEETH.

The **teeth** are divided into two sets, namely, the temporary, milk, or deciduous, which belong to early infancy, and the permanent, which replace the temporary. The temporary teeth are twenty in number—ten upper, five in each superior maxilla, and ten lower, five in each half of the inferior maxilla. The number of permanent teeth is thirty-two—sixteen upper, and sixteen lower.

The Permanent Teeth.—Proceeding from the median line in a direction outwards and backwards, the permanent teeth are as follows: central incisor, lateral incisor, canine, first bicuspid, second bicuspid, and first, second, and third molars. The third molar is known as the *dens sapientiæ* or wisdom tooth. Each tooth is composed of the following parts: the **crown**, which is the part above the gum; the **root**, which is the part embedded

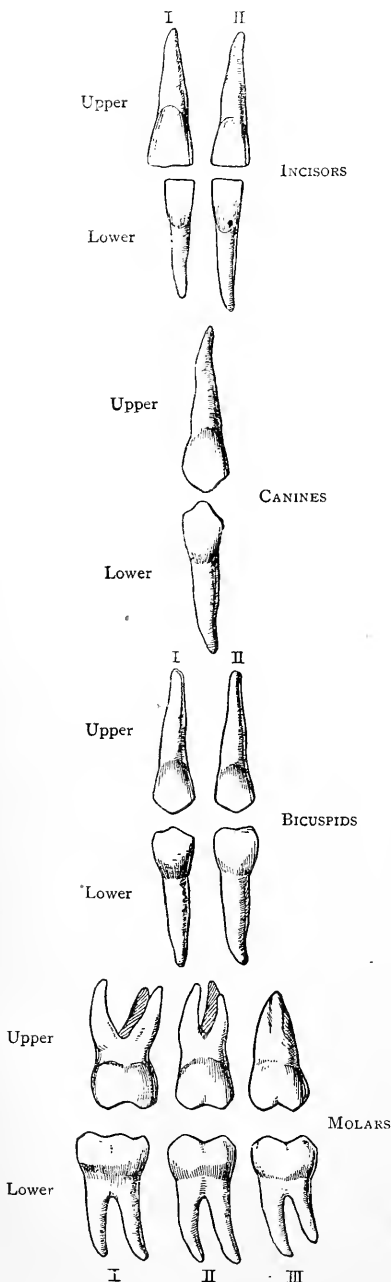


FIG. 89.—THE PERMANENT TEETH OF THE LEFT SIDE.

in the alveolus; and the **neck**, which lies between the crown and root. The surface of a tooth which looks towards the lip is called **labial**, and that looking towards the tongue **lingual**, whilst of the opposed surfaces one is called **mesial** or **proximal**, and the other **lateral** or **distal**.

The Incisors.—The crowns of the incisor teeth are chisel-shaped, the cutting edge of the *upper* being bevelled behind, and that of the *lower* in front.

The upper central incisor is larger than the lateral, and gradually tapers from the crown to the root. The length of the crown exceeds its breadth. The labial surface is convex, whilst the lingual is concave, and presents near the gum a prominence, called the *basal ridge* or *cingulum* (girdle). The root is long, tapering, conical, and flattened on either side. The upper lateral incisor is smaller than the central, which it for the most part resembles, the cingulum being more prominent.

The lower central incisor is smaller than the lateral, and narrower than the upper central incisor, and the root is much flattened laterally. The lower lateral incisor is larger than the central, which it for the most part resembles, but its root is longer, and on each flattened lateral surface there may be an indication of a longitudinal groove.

The Canines.—The crown of a canine tooth is larger than that of an incisor. It is conical, and terminates in a blunt cusp, from which it is known as the *cuspidate tooth*. The labial surface is convex, and the lingual concave. In each upper canine the lingual surface presents a median ridge,

which extends from the cusp to the cingulum. The root is long, thick, much compressed laterally, and marked on either side by a distinct longitudinal groove. The lower canines have no median ridge on the lingual surface, the cingulum is absent, and the root is shorter than in the upper.

The Bicuspid.—The bicuspid or premolar is smaller than the canine. The crown is quadrilateral, and its labial border is longer than the lingual. It is provided with two cusps, of which the labial is the larger and broader, and these are separated by a deep transverse fissure. The labial and lingual surfaces are convex, and there is no cingulum. The root is single, and is much flattened laterally. It usually presents on either side a longitudinal groove, which in many cases is so deep as to separate it into two fangs over the greater part of its length. The upper second bicuspid has its cusps nearly equal, and its root, if single, is more deeply grooved laterally than that of the first.

The lower bicuspid is smaller than the upper. The lingual cusp is small and narrow, a circumstance which renders the crown triangular, as seen from above. The cusps are connected by a ridge. The root is single, rounded, and tapering. The lower second bicuspid differs from the first in having a larger crown, of somewhat quadrilateral outline. The lingual cusp is more developed, and the crown approaches the molar type. The upper first bicuspid is the most predisposed of this group to have its root divided into two fangs.

The Molars.—The upper molar teeth have quadrate crowns with rounded angles. In the case of the *first* and *second*, the grinding surface is furnished with four cusps, situated at each angle of the square, two of them being labial and two lingual. The anterior lingual cusp is the largest, and it is connected with the posterior labial cusp by an oblique ridge. The root of each of the first and second molars has three fangs—two labial, and one palatal. The latter is the largest and most divergent, its direction being inwards towards the palate. The *third* upper molar is subject to much variety, and is usually of small size. The grinding surface of the crown is somewhat quadrate. The two lingual cusps are frequently confluent, and the fangs of the root are blended into one tapering cone.

The *first* lower molar is the largest. The crown is quadrate, and its grinding surface is provided with five cusps, four of which are placed at the angles of the square, being separated by a crucial fissure. The fifth cusp is situated at the posterior part of the crucial fissure, where it lies between the two distal cusps. The root has two fangs, anterior and posterior, both of which are much compressed from before backwards. Each fang is usually grooved along its centre, sometimes to such an extent as to give rise to four fangs. The *second* lower molar bears a general resemblance to the first. The fifth cusp, if present, is not so well marked, and it is regarded as being present in about 24 per cent. of cases. The two fangs of the root are frequently blended. The *third* lower molar is of larger size than the corresponding upper tooth. Its crown has usually five

cusps, and its root has two fangs, which may be separate, or confluent. In the latter case a groove indicates the two-fanged condition.

The Temporary Teeth.—Proceeding from the median line, these are as follows on either side: two incisors, central and lateral, one canine, and two molars, first and second. Their necks are more constricted than in the permanent set. The incisors and canines resemble, for the most part, those of the permanent set, but they are smaller. The molars, which are replaced by the permanent bicuspid, exceed them in size, the second molars being particularly large. The first upper molar has three cusps—two labial and one lingual, the second upper and first lower molars have each four, and the second lower molar has five.

Eruption of the Teeth.—The eruption of particular teeth of the lower jaw precedes that of the corresponding teeth of the upper jaw, and the periods are as follows:

Temporary Teeth.				
Incisors	6th to 12th month
First Molars	12th to 14th ..
Canines	14th to 20th ..
Second molars	20th to 24th ..

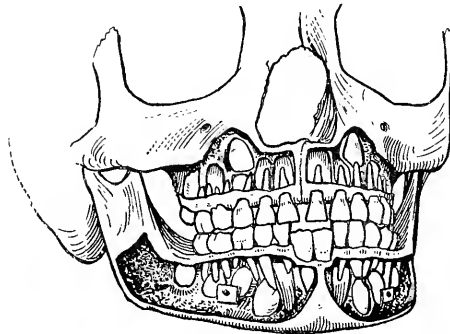


FIG. 90.—THE SUPERIOR AND INFERIOR MAXILLARY BONES AT THE SEVENTH YEAR, SHOWING MOST OF THE TEMPORARY TEETH, AND THE PERMANENT TEETH ABOUT TO REPLACE THEM.

The First Permanent Molars and the Permanent Lower Central Incisors are in position.

Permanent Teeth.				
First molars	6th year
Central incisors	7th ..
Lateral incisors	8th ..
First bicuspid	9th ..
Second bicuspid	10th ..
Canines	11th ..
Second molars	12th ..
Third molars	17th to 25th year

About the sixth year is the period at which most teeth are present in the jaws, there being the twenty temporary teeth, and all the

permanent, except the four wisdom teeth, (namely, twenty-eight), making in all forty-eight.

Structure of a Tooth.—The crown of a tooth contains a central cavity, called the **pulp cavity**, which is occupied by the **dental pulp**. The shape of the pulp cavity corresponds with that of the crown, and it extends into the root, and as many fangs as compose it, terminating in a small opening on the apex of the fang. The cavity also extends for a little into the cusps of the bicuspid and molars, and in the incisors it is continued into each angle of the crown. The wall of the cavity presents a number of openings, which lead into the dentinal tubules. The **dental pulp** is composed of a matrix of connective tissue, containing bloodvessels, nerves,

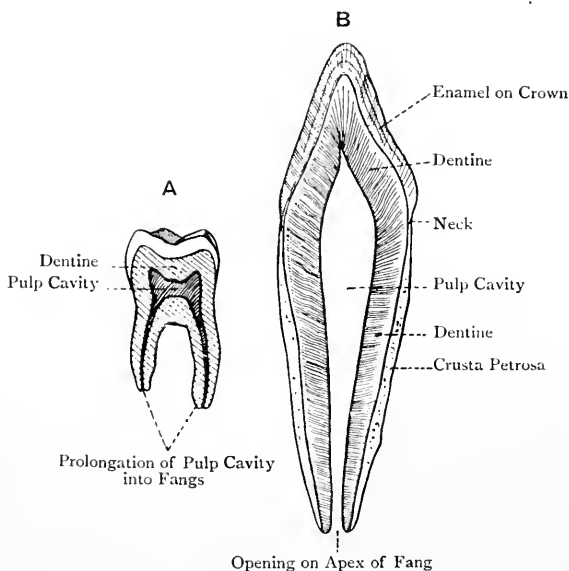


FIG. 91.—SECTIONS OF TEETH.

A, Lower Molar; B, Lower Incisor.

cells, and fibres, which latter seem to be processes of the cells. It is destitute of lymphatics. The cells are scattered throughout the matrix, and at the surface of the pulp they form a continuous layer, being there known as the **odontoblasts**. This layer is sometimes spoken of as the *membrana eboris*. The pulp is very vascular and sensitive, its vessels and nerves reaching it through the minute openings at the apices of the fangs.

The substance of the tooth is formed of three tissues, namely, ivory or dentine, enamel, and cement or crusta petrosa. The dentine forms the principal part of the tooth, surrounding the pulp cavity and its prolongations; the enamel covers the exposed part or crown; and the cement covers the root.

Dentine.—This bears a resemblance to bone, but contains rather less animal, and more earthy, matter, the proportion in 100 parts being about 28 of animal matter to 72 of earthy. The dentine has a striated appearance, due to the fact that it is traversed by a number of minute branched channels, called the **dentinal tubules**, which radiate in a curved manner outwards from the pulp cavity to the deep aspect of the enamel and cement. These tubules contain processes of the odontoblasts which form the *membrana eboris*, and are known as **Tomes' fibres**. The part of the dentine adjacent to the enamel and cement is known as the **granular layer**

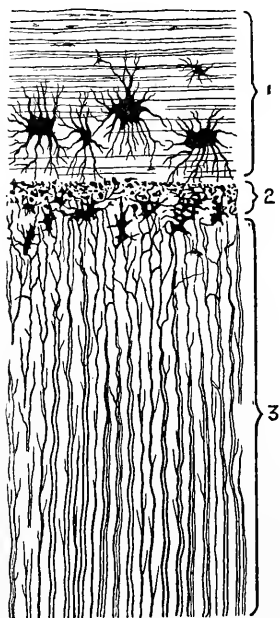


FIG. 92.—SECTION OF THE FANG OF
A TOOTH.

1, Cement ; 2, Granular Layer of Purkinje ; 3, Dentinal Tubules.

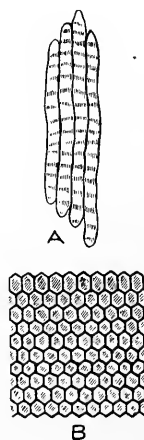


FIG. 93.—ENAMEL PRISMS.

A, Four prisms (Longitudinal View) ;
B, Surface of the Enamel.

of Purkinje. It presents a number of irregular spaces, known as the *interglobular spaces*, which are surrounded by minute globules of calcareous matter.

Enamel.—This caps and protects the dentine of the crown. It is exceedingly hard, which is due to the fact that it contains no animal matter—at least, to any appreciable extent. It consists of solid hexagonal prisms, which are marked by transverse striations. These are received by their deep extremities into depressions on the dentine, and are placed vertically on the summit of the crown, but horizontally on its sides. At the period of eruption

of a tooth, and for some little time thereafter, the enamel of the crown is covered by a thin membrane, called the **enamel cuticle** or **Nasmyth's membrane**.

Cement or Crusta Petrosa.—This covers the dentine which forms the root of the tooth. It is true bone, and contains lacunæ and canaliculi, but it is destitute of Haversian canals.

The root of a tooth is maintained in its alveolus by the **periodontal membrane** or dental periosteum, which covers the cement, and lines the wall of the alveolus, being continuous with the gum at the neck of the tooth. The articulation is called **gomphosis**.

Development of the Teeth.

The development of the milk teeth commences, about the sixth week of intra-uterine life, in a thickening of the deep layer of the stratified buccal epithelium along the course of the forming jaw. This epiblastic thickening is called the **common enamel** or **dental germ**, and it is received into a groove formed by the mesoblastic tissue of the forming jaw. A further development of the common enamel germ takes place in the form of special cell groups, known as the **special enamel germs**. A vascular **dental papilla**, in form like the crown of the future tooth, then grows from the mesoblast into the special enamel germ. The papilla is composed of a reticulum of cells, the outermost of which are called **odontoblasts**. Each special enamel germ, with its contained dental papilla, becomes separated from the buccal epithelium, and surrounded by an investment, called the **dental sac**, which is derived from the mucosa. The odontoblasts of the dental papilla give rise to the dentine, and the cellular reticulum of the papilla forms the tooth pulp. The dentine is laid down in successive layers, and, as the odontoblasts become shifted inwards, they leave behind them processes, which become invested by calcareous matter, and so the dentinal tubules are formed with processes of the odontoblasts within them. The portion of the special enamel germ which covers the dental papilla is known as the **enamel organ**, and it is composed of four parts, as follows: (1) a layer of columnar cells in direct contact with the dentine, called the **adamantoblasts** or **enamel cells**, which give rise to the enamel prisms by depositing matter ultimately becoming calcified; (2) the **stratum intermedium**, composed of two or three layers of polyhedral cells; (3) a reticulum of stellate cells; and (4) an outer layer of cubical epithelium. The enamel, like the dentine, is laid down in layers, the adamantoblasts gradually shifting their position outwards. During this process the other layers of the enamel organ are gradually disappearing, being wholly lost when the eruption of the tooth takes place. The last layer of matter deposited by the adamantoblasts does not undergo calcification, but forms the membrane, called the **enamel cuticle** or **Nasmyth's membrane**, which covers the crown of the tooth for some little time after its eruption.

The **cement** is developed from the inner part of the dental sac, which resembles the osteogenetic layer of periosteum, whilst the outer part of the dental sac gives rise to the dental periosteum.

Those permanent teeth which replace the temporary teeth, namely, incisors, canines, and bicuspid, are developed from enamel germs which are outgrowths from those of the temporary teeth. Each of these becomes provided with a papilla, and the various stages of development are as in the temporary teeth.

The twelve permanent molar teeth, six upper and six lower, do not take the place of any temporary teeth, and therefore arise in a different manner. They are developed from a backward extension of the original common enamel germ, and the formation from this of special enamel germs at somewhat long intervals. Thereafter the process of development proceeds as in the temporary teeth.

When the permanent teeth are fully formed the roots of the temporary teeth are absorbed by the osteoclasts of the dental periosteum, and, as they drop out, the permanent teeth take their place.

III. THE BONES OF THE UPPER LIMB.

The **upper limb** is arranged in four divisions, namely, the pectoral or shoulder-girdle, brachium or arm proper, antibrachium or forearm, and manus or hand. The **shoulder-girdle** consists of the clavicle and scapula, the **brachium** comprises the humerus, the **antibrachium** is composed of the radius and ulna, and the **hand** is subdivided into a *carpus*, comprising eight bones, a *metacarpus*, consisting of five bones, and *phalanges*, which number fourteen.

The Clavicle.

The **clavicle** or collar-bone is situated at the lower part of the neck anteriorly, where it lies above the first rib, and it extends outwards and backwards from the upper border of the presternum to the acromion process of the scapula. The bone presents two curves, an inner or sternal, occupying two-thirds, with its con-

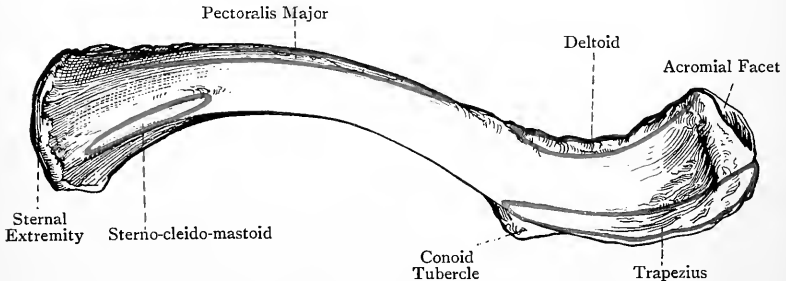


FIG. 94.—THE RIGHT CLAVICLE (SUPERIOR VIEW).

vexity directed forwards, and an outer or acromial, extending over the outer third, with its convexity directed backwards. These curves impart elasticity to the bone. The clavicle is divided into a shaft and two articular extremities.

The **shaft** is somewhat quadrilateral over its inner two-thirds, and compressed from above downwards over its outer third. The *superior surface* is for the most part narrow, but externally it becomes broad. At its inner end, near the postero-superior border, it presents a rough ridge, about $1\frac{1}{3}$ inches long, for the origin of the clavicular head of the sterno-cleido-mastoid. At its outer expanded part it is encroached upon by the tendinous fibres of the trapezius and deltoid. Elsewhere it is covered by the skin, fascia, and platysma myoides. The *anterior surface* is convex over its inner two-thirds, and concave over its outer third, where it is reduced to a mere rough border. Over the inner half it is rough for the origin of the clavicular portion of the pectoralis major, and over its outer marginal third it gives origin to the clavicular portion of the deltoid. At the inner end of the deltoid impression there is sometimes a pointed projection, known as the *deltoid spine*. The

posterior surface is concave over its inner two-thirds, and convex over its outer third, where it is narrowed into a rough border. The inner two-thirds overhang the subclavian vessels and trunks of the brachial plexus, whilst the outer marginal third gives insertion to the upper fibres of the trapezius. At the inner end of the impression for these fibres, opposite the deltoid spine, there is a conical projection which extends on to the inferior surface for a little, called the *conoid tubercle*, for the conoid ligament. About the centre of the posterior surface there is the **medullary foramen** for the medullary artery, which is a branch of the suprascapular. The canal to which the foramen leads is directed *outwards*. The foramen may be situated on the inferior surface in, or close to, the subclavian groove, or there may be two foramina, one on the posterior and one on the inferior surface, about an inch apart.

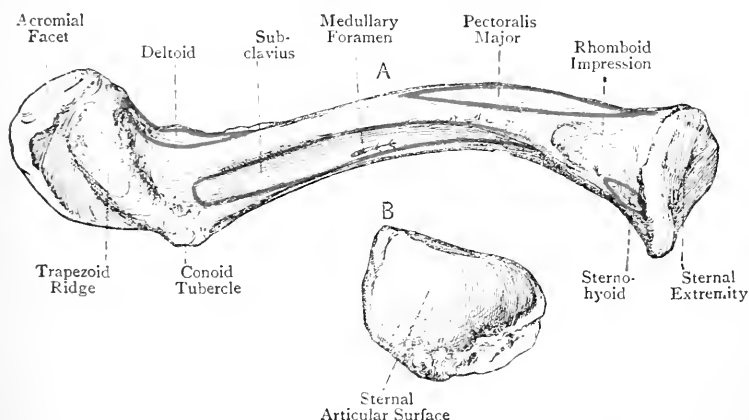


FIG. 95.—THE RIGHT CLAVICLE.
A. Inferior View; B. Sternal Extremity.

Close to the sternal end the posterior surface gives partial origin to the sterno-hyoid. The *inferior surface* presents near its sternal end the *rhomboid impression*, about an inch long, for the costo-clavicular or rhomboid ligament. External to this there is the *subclavian groove*, which extends from the rhomboid impression to near the conoid tubercle, and gives insertion to the subclavius. The groove is bounded by two lips, anterior and posterior, to which the costo-coracoid membrane is attached in two laminae. At the outer extremity of the inferior surface there is a rough oblique line, called the *trapezoid ridge*, which extends forwards and outwards from the conoid tubercle, and gives attachment to the trapezoid ligament. The conoid tubercle is more fully seen here than on the posterior border, and is situated at the postero-internal extremity of the trapezoid ridge.

The **borders** of the clavicle over its outer third are anterior and posterior. The *anterior border* bifurcates, over the inner two-thirds,

into an *antero-superior* and *antero-inferior* border, which enclose between them the anterior surface. The *posterior border* bifurcates, over the inner two-thirds, into a *postero-superior* and *postero-inferior* border, the latter forming the posterior lip of the sub-clavian groove. The antero-superior and postero-superior borders limit the superior surface, the postero-superior and postero-inferior limit the posterior surface, the postero-inferior and antero-inferior limit the inferior surface, and, as stated, the antero-inferior and antero-superior limit the anterior surface.

The **sternal extremity** is enlarged and covered by cartilage. As viewed on end, it is somewhat triangular, and presents a prominent posterior angle which is directed downwards, inwards, and backwards. The surface is concave from before backwards, and convex from above downwards, and it articulates with the clavicular impression on the upper border of the presternum, an inarticular fibro-cartilage intervening. The circumference of the sternal end is rough for the sterno-clavicular and interclavicular ligaments, except inferiorly, where there is a narrow strip for the first costal cartilage.

The **acromial extremity** presents an oval facet for the acromion process of the scapula.

The clavicle receives its blood-supply from the suprascapular artery and the thoracic axis.

Articulations.—*Internally* with the presternum and first costal cartilage, and *externally* with the acromion process of the scapula.

Structure.—The exterior is composed of compact bone which is thickest towards the centre, and the interior of coarse cancellated tissue, the principal lamellæ being disposed longitudinally. The clavicle has no medullary canal, but, towards the centre of the shaft, the medullary spaces of the cancellated tissue are of large size.

Varieties.—(1) There may be a deltoid spine. (2) The superior surface may present a small slit-like aperture, variously situated, for one of the descending branches of the cervical plexus of nerves.

The Clavicle of the Female.—The bone is smoother, more slender, straighter, and more cylindrical over its inner two-thirds, than that of the male.

Ossification.—The clavicle, which is the earliest bone to ossify, has **two primary centres** and **one secondary centre**. It is preceded by a rod of con-

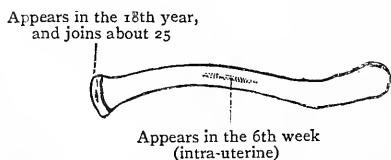


FIG. 96.—OSSIFICATION OF THE CLAVICLE.

nective tissue. Within the two halves of this rod collections of 'precartilaginous tissue' are formed, and within these at their contiguous ends the primary centres appear about the *6th week*. Subsequently the precartilag-

inous collections fuse, and thereafter the primary centres coalesce. Ossification from these two centres proceeds at first in the precartilaginous tissue, but subsequently in the cartilage to which this tissue gives place. The primary centres may fail to join, with the result that the clavicle may persist in two halves.

The **secondary centre** appears in the cartilage of the *sternal end* about the 20th year, and this epiphysis joins the shaft about the 25th year (Mall and Fawcett).

The **law of ossification** applicable to bones having a shaft and one epiphysis is as follows: *the medullary foramen and the canal to which it leads are directed towards that extremity which has no epiphysis*. This law is illustrated in the clavicle and the metacarpal, metatarsal, and phalangeal bones.

The Scapula.

The **scapula** or shoulder-blade is situated on the posterior aspect of the thorax, where it extends from the second to the seventh rib, being separated by muscles from the thoracic wall. It consists of a body and three processes, namely, a spine, an acromion and a coracoid process.

The **body** is a thin triangular plate, and it presents two surfaces, three borders, and three angles. The *anterior surface, venter*, or *subscapular fossa* is concave, and the bone forming it is for the most part thin, except near the external or axillary border, where there is a thick, round, elongated ridge. It gives origin to the subscapularis, except (1) along the anterior aspect of the base from the superior to the inferior angle, where the serratus magnus is inserted, and (2) over the front of the neck. The venter is crossed by three or four oblique ridges, which extend upwards and outwards from the base, and give attachment to tendinous septa intersecting the subscapularis muscle.

The *posterior surface* or *dorsum* is irregularly convex, and is divided into two unequal parts by the spine. The upper division, along with the superior surface of the spine, forms the *supraspinous fossa*. It represents about one-fourth of the dorsum, and gives origin over its inner two-thirds to the supraspinatus. In the region of the neck it presents a nutrient foramen for a branch of the suprascapular artery. The lower division, along with the inferior surface of the spine, forms the *infraspinous fossa*, and it represents about three-fourths of the dorsum. Towards the external or axillary border it presents an elongated concavity, external to which is an oblique line extending from its upper end downwards and inwards to the base near the inferior angle. The infraspinous fossa, as far out as this oblique line, gives origin to the infraspinatus, except at the upper and outer part, and it presents a nutrient foramen superiorly, close to the spine near the centre, for a branch of the dorsalis scapulae artery. The oblique line marks off impressions for the teres muscles and dorsalis scapulae artery, as follows: the teres minor arises from about the upper two-thirds, near the centre of which there is a groove for the dorsalis scapulae artery, and the

teres major arises from about the lower third. The impression for the latter muscle is oval; it extends on to the back of the inferior angle, and it is separated from the impression for the teres minor by a short rough line. This line gives attachment to an intermuscular septum which separates the teres muscles, and the oblique line to a septum which separates these muscles from the infraspinatus. The supra- and infraspinous fossæ communicate with each other by means of the *great scapular notch*, which lies outside

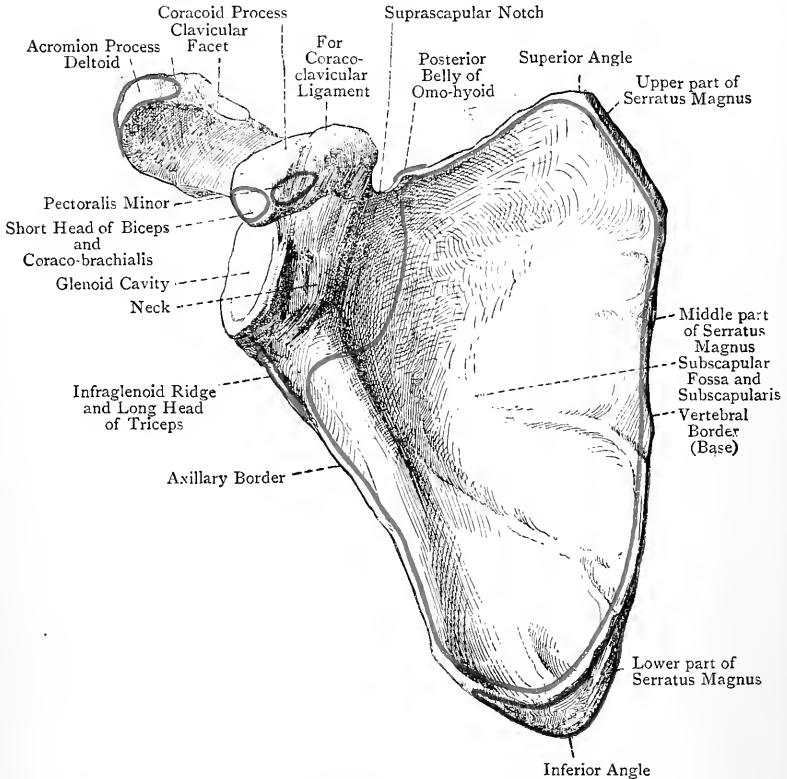


FIG. 97.—THE RIGHT SCAPULA (ANTERIOR VIEW).

the short external border of the spine, and transmits the suprascapular artery and nerve.

The **borders** are superior, internal or vertebral, and external or axillary. The *superior border*, which is the shortest and thinnest, extends from the superior angle to the coracoid process. Close to that process it presents the *suprascapular notch*. This is converted into a foramen by the suprascapular or transverse ligament, which sometimes undergoes ossification. The supra-

scapular nerve passes backwards beneath the ligament, and the suprascapular artery over it, whilst the posterior belly of the omohyoid arises from its inner part and from the adjacent portion of the superior border. The *internal* or *vertebral border* is known as the *base*. It is the longest, intermediate in thickness, and extends from the superior to the inferior angle. It is convex, and is divisible into three parts. One part represents the base of the small triangular surface by which the spine arises from the vertebral border, and it gives insertion to the rhomboideus minor; another extends from this to the superior angle, and gives insertion to the levator anguli scapulæ; and the third extends downwards to the inferior angle, and gives insertion to the rhomboideus major. On the ventral aspect close to this border there is a long narrow linear impression, which widens towards the superior and inferior angles, and gives insertion to the serratus magnus. The *external* or *axillary border*, which is the thickest and intermediate in length, extends from the inferior angle to the lower margin of the glenoid cavity. Below that cavity it presents a rough impression, an inch long, called the *infraglenoid ridge*, which gives origin to the long head of the triceps, and a little below this a groove for the dorsalis scapulæ artery, which also marks the dorsal aspect. The ventral aspect of the bone close to this border presents a groove over the upper two-thirds, which gives origin to many fibres of the subscapularis.

The **angles** are superior, inferior, and external. The *superior angle*, which is thin, is situated at the meeting of the superior and vertebral borders, and it forms the highest part of the body, being on a level with the second rib. Its ventral aspect gives insertion to a part of the serratus magnus, and its edge to a portion of the levator anguli scapulæ. The *inferior angle*, somewhat thick and round, is situated at the meeting of the vertebral and axillary borders, and it forms the lowest part of the bone, being on a level with the seventh rib. Its ventral aspect gives insertion to a part of the serratus magnus, and its dorsal aspect gives origin to a portion of the teres major. Below the impression for the latter muscle there is sometimes a rough semilunar marking for a slip of origin of the latissimus dorsi. The *external angle*, which is massive, is situated at the upper end of the axillary border. It forms the *head* of the bone, and supports the glenoid cavity, which articulates with the head of the humerus.

The **glenoid cavity**, so named from its shallowness, is pyriform, with the narrow end upwards, and its direction is outwards and forwards. Its margin is slightly elevated and rough for the glenoid ligament, and immediately outside the margin the capsular ligament of the shoulder-joint is attached. Superiorly it presents a small rough elevation, called the supraglenoid tubercle, which gives origin to the long head of the biceps. The *neck* is the constricted portion which extends from the suprascapular notch to a point immediately above the infraglenoid ridge, and it is most evident posteriorly,

where it forms, with the external border of the spine, the great scapular notch. In this latter situation there are numerous foramina for branches of the suprascapular artery.

The **spine** is situated on the dorsum of the bone, which it crosses in a direction outwards and slightly upwards. It commences at the vertebral border in a flat triangular surface, over which the tendon receiving the lower fibres of the trapezius glides, with the intervention of a bursa. It soon becomes very prominent, and at its outer

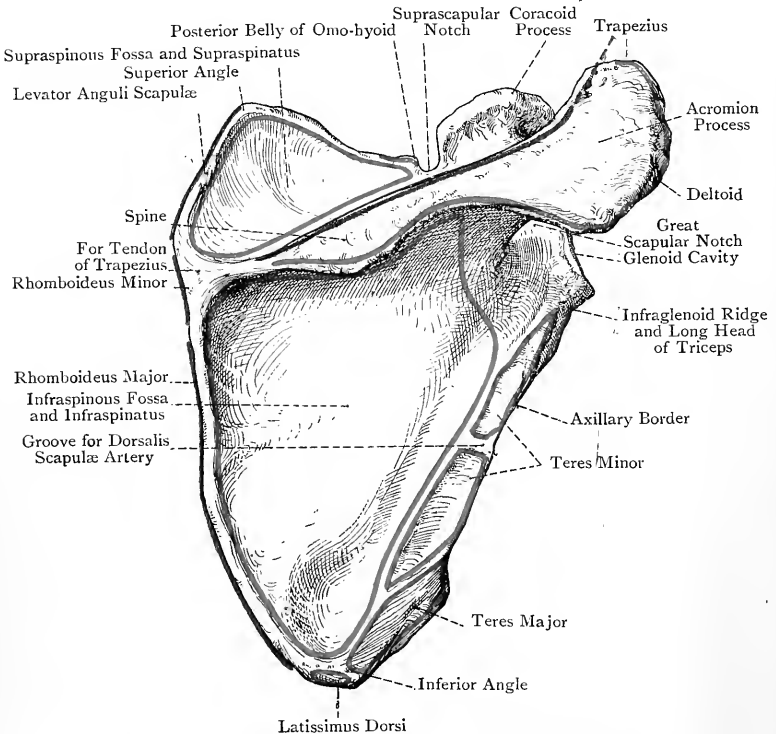


FIG. 98.—THE RIGHT SCAPULA (POSTERIOR VIEW).

extremity it undergoes a slight twist and forms the acromion process. It is triangular, and compressed from above downwards. The *superior surface* forms part of the supraspinous fossa, and gives origin to fibres of the supraspinatus, whilst the *inferior surface* forms part of the infraspinous fossa, and gives origin to fibres of the infraspinatus. The *external border*, which is short, bounds internally the great scapular notch. The *anterior border* is continuous with the body of the bone. The *posterior border* or *crest* presents an upper lip, which gives insertion to part of the trapezius, a lower lip, giving partial

origin to the deltoid, and an intervening rough surface which is encroached upon by the tendinous fibres of these two muscles. The upper lip is often very projecting at its inner end, where the tendon receiving the lower fibres of the trapezius is inserted.

The **acromion process** is situated at the outer extremity of the spine, and its direction is outwards, upwards, and forwards, so as to overhang the glenoid cavity. It is somewhat triangular, and is compressed from above and behind downwards and forwards. The *postero-superior surface*, which is rough, gives origin at its lower and inner part to some fibres of the deltoid, and elsewhere is subcutaneous. The *antero-inferior surface*, which is smooth and concave, overhangs the glenoid cavity, and is related to the subacromial bursa. The *outer border* is continuous with the lower lip of the posterior border of the spine, where there is a projection called the *acromial angle*, and this outer border gives origin to a portion of the deltoid. The *inner border* is continuous with the upper lip of the posterior border of the spine, near which it gives insertion to a part of the trapezius, whilst near the tip of the acromion it presents an oval facet for the outer extremity of the clavicle. The upper and lower margins of this facet are rough for the acromio-clavicular ligaments. The *tip* or *apex* of the process is situated at the meeting of the outer and inner borders. The acromion process is pierced by many arterial twigs derived from the acromial rete.

The **coracoid process**, which is strong and curved, springs from the upper aspect of the head, immediately external to the suprascapular notch. It is directed at first upwards and forwards for about $\frac{1}{2}$ inch, and then, bending sharply, it is directed forwards and outwards to terminate in a blunt tip. The *ascending portion* is compressed from before backwards. Its *anterior surface* is related to the subscapularis, and the *posterior* to the supraspinatus. Its *outer border* gives attachment to a portion of the coraco-humeral ligament, and the *inner border*, which bounds the suprascapular notch externally, gives attachment at its upper part to the suprascapular or transverse ligament. The *horizontal portion* of the process is compressed from above downwards. Its *antero-internal border*, which is long and convex, and the adjacent portion of the superior surface, give insertion anteriorly to the pectoralis minor, whilst posteriorly they give attachment to the costo-coracoid membrane and ligament. The *postero-external border*, which is short, receives the fibres of the coraco-acromial ligament, and gives attachment to a portion of the coraco-humeral ligament. At the back part of the antero-internal border there is the *conoid impression* for the conoid ligament. On the back part of the superior surface there is the *trapezoid ridge* for the trapezoid ligament, which ridge extends forwards and outwards from the conoid impression. The *inferior surface* of the horizontal portion is smooth and concave. The *tip* or *apex*, which is blunt, gives origin to the conjoined short head of the biceps and coraco-brachialis.

The coracoid process of man represents the *coracoid bone* of monotremata and lower vertebrates.

The scapula derives its blood-supply from the dorsalis scapulæ, suprascapular, and posterior scapular, arteries.

Articulations.—By its acromion process with the outer extremity of the clavicle, and by the glenoid cavity with the head of the humerus.

Structure.—The scapula is a flat or tabular bone, and is composed

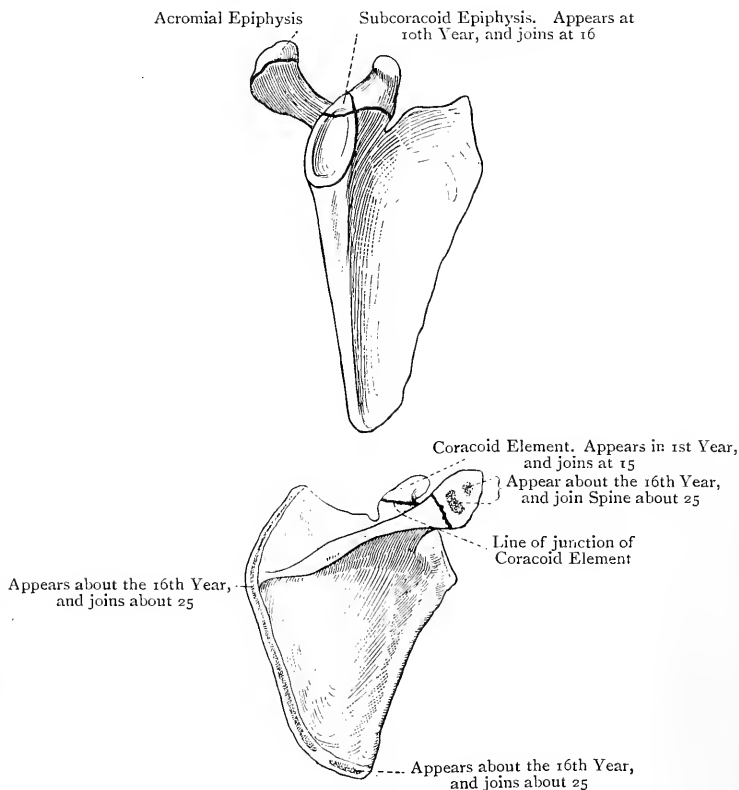


FIG. 99.—OSSIFICATION OF THE SCAPULA.

of two tables of compact bone. In the head, axillary border, inferior angle, and processes there is cancellated tissue between the two tables, but in the central portions of the supra- and infra-spinous fossæ there is none, and the two tables coalesce, so that the bone is very thin and transparent.

Varieties.—(1) Suprascapular foramen. (2) Fenestrated scapula, presenting one or more perforations in the subscapular fossa. (3) Separation of

the acromion process, which may be connected with the spine by a plate of cartilage, or by fibrous tissue. (4) Imperfect ankylosis of the coracoid process, which, however, is extremely rare.

Ossification.—The scapula has **one primary centre** and **eleven secondary centres**. The **primary centre** appears in the body near the neck about the *8th week*.

The **coracoid process**, cartilaginous at birth, has **four secondary centres**—coracoid, accessory coracoid, supracoracoid, and apical. The *coracoid centre* appears in the end of the *1st year*, and gives rise to the chief part of the process, which joins about the *15th year*. The *accessory coracoid centre* appears about *puberty*, and soon joins the main coracoid. It forms the triangular part of the process which enters slightly into the *extreme upper and inner part* of the glenoid cavity. The *supracoracoid centre* appears about the *18th year*, and forms a thin laminar epiphysis on the upper surface of the process. It gives about the *25th year*. The *apical centre* appears about the *18th year*, and forms an epiphysis which caps the tip of the process, and joins about the *25th year*.

Acromion Process.—The inner or basal portion is ossified from the spine, which in turn is ossified from the primary centre for the body. The greater portion constitutes an epiphysis, which has **two secondary centres**. These appear about the *16th year* and soon join. The acromial epiphysis usually joins the rest of the process about the *25th year* or earlier. Union, however, may not take place, and then the acromial epiphysis forms a separate *acromial bone*, connected with the rest of the process by cartilage or by fibrous tissue, and this condition may simulate a fracture.

Glenoid Cavity.—The fundus or bed of this cavity is ossified from the primary centre for the body, and its extreme upper and inner part is formed from the accessory coracoid centre. Besides these the cavity has two special secondary centres—superior and inferior. The superior glenoid or sub-coracoid centre appears about the *10th year*, and it joins the fundus or bed of the fossa about the *16th year*. The inferior glenoid centre appears about the *16th year*, and forms the glenoid epiphysial plate. It joins about the *20th year*, and gives rise to the slight concavity of the fossa.

The other secondary centres are allocated as follows: (1) Posterior border of spine; (2) inferior angle; (3) base. These centres appear about the *16th year*, and join about the *25th year*.

The Humerus.

The **humerus** extends from the shoulder to the elbow, its direction being downwards and slightly inwards. It is a long bone, and is divisible into a shaft and two extremities, upper and lower.

The **upper extremity** includes the head, anatomical neck, great and small tuberosities, commencement of the bicipital groove, and surgical neck. The **head**, which is almost hemispherical, is smooth, convex, and covered by cartilage. Its direction is upwards, inwards, and backwards, and it articulates with the glenoid cavity of the scapula. The *anatomical neck* is the constriction immediately beyond the cartilage of the head. It is best marked above, especially between the head and great tuberosity, and it gives attachment to the capsular ligament of the shoulder-joint. It is

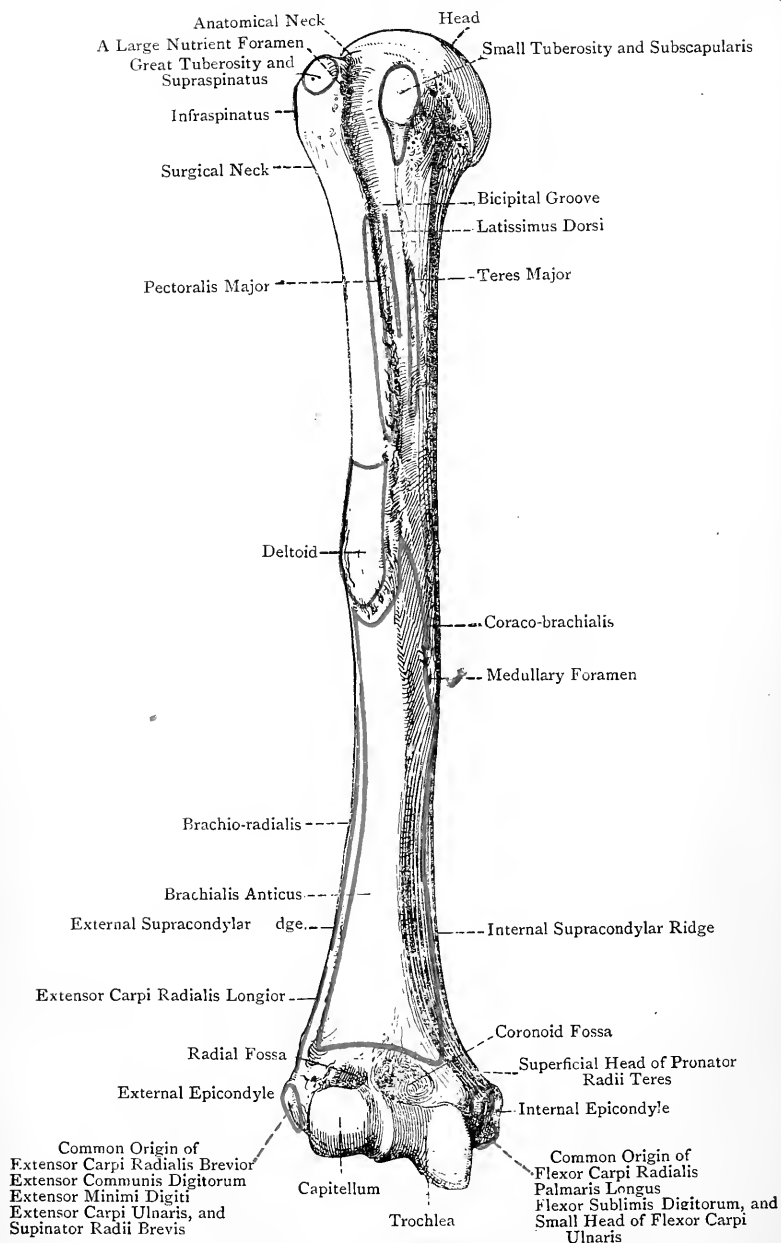


FIG. 100.—THE RIGHT HUMERUS (ANTERIOR VIEW).

pierced by numerous nutrient foramina. The **great tuberosity** is situated obliquely on the outer surface, immediately beyond the anatomical neck. It presents three flat muscular impressions—an *upper* for the insertion of the supraspinatus, a *middle* for the infraspinatus, and a *lower* for the teres minor, which latter muscle continues to take insertion into a rough marking on the shaft for at least $\frac{1}{2}$ inch below the lower impression. The **small tuberosity** is an oval prominence situated on the anterior aspect, immediately beyond the anatomical neck. It gives insertion to the subscapularis, which continues to take insertion into the adjacent part of the shaft for about $\frac{1}{2}$ inch. The commencement of the bicipital groove, which lodges the long tendon of the biceps, lies between the two tuberosities, where it is bridged over by the transverse humeral ligament. It presents a large nutrient foramen close to the great tuberosity for an offset of the ascending branch of the anterior circumflex artery. The *surgical neck* is the constriction below the tuberosities.

The upper extremity of the humerus receives its principal blood-supply from the anterior and posterior circumflex arteries.

The **shaft** is almost cylindrical in its upper half, but it is laterally expanded and triangular in its lower half. The *anterior aspect* presents superiorly the *bicipital groove*, which commences between the tuberosities, where it is deep, and passes downwards and slightly inwards, terminating about the junction of the upper and middle thirds. It is bounded by two rough ridges, outer and inner. The outer bicipital ridge, which is the more prominent, gives insertion over about its lower three-fourths to the pectoralis major, this portion being called the *pectoral ridge*. It is in line with the anterior border of the lower half of the shaft. The inner bicipital ridge gives insertion over about its lower two-thirds to the teres major, this portion being known as the *teres ridge*. It is in line with the internal border of the lower half of the shaft. The floor of the groove over about its middle third gives insertion to the latissimus dorsi. The groove is occupied by the long tendon of the biceps, invested by a tubular prolongation of the synovial membrane of the shoulder-joint; and the ascending branch of the anterior circumflex artery. The *outer aspect* of the shaft presents a rough V-shaped mark, called the *deltoid impression*, for the insertion of the deltoid. The point of the V, which is embraced by two slips of the brachialis anticus, is at the centre of the shaft, whence it extends upwards for about 2 inches. Its anterior margin is in line with the pectoral ridge, and its posterior margin bounds superiorly the lower part of the spiral groove. On the *inner aspect* of the shaft, about the centre, there is a rough line about $1\frac{1}{2}$ inches long, placed in the course of the internal border, for the insertion of the coraco-brachialis. Immediately below this line is the principal **medullary foramen** for the nutrient or medullary branch of the brachial artery, the canal to which it leads being directed *downwards*. The *posterior* and *external aspects* of the upper part of the shaft present a winding groove, called the

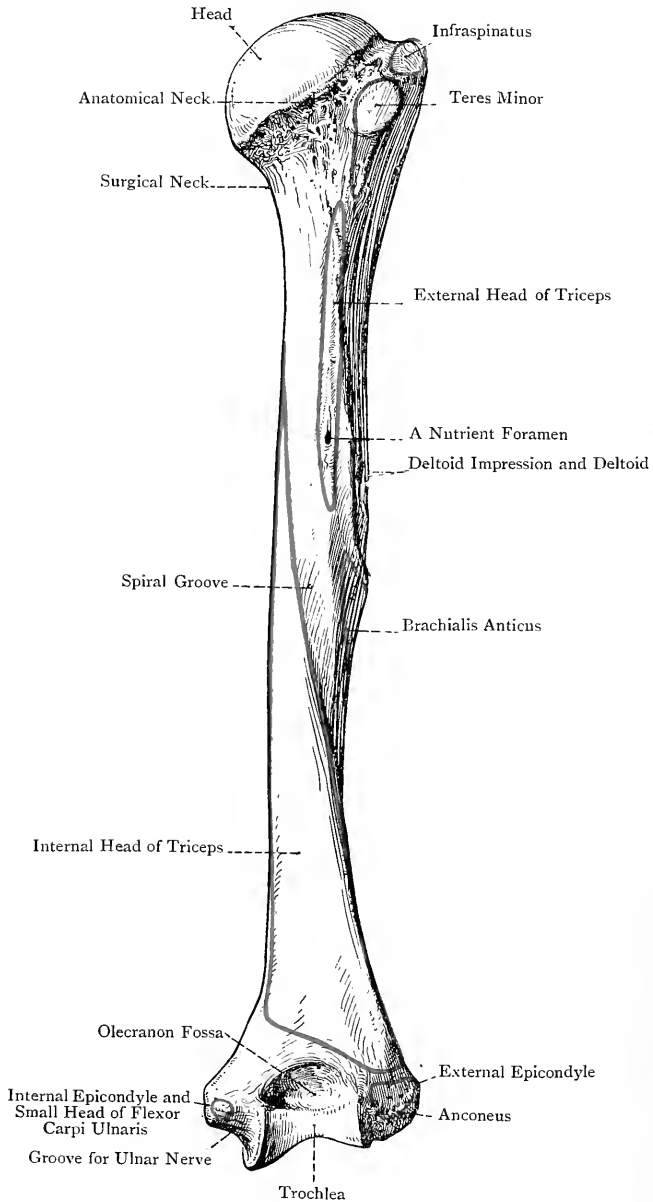


FIG. 101.—THE RIGHT HUMERUS (POSTERIOR VIEW).

spiral groove, for the musculo-spiral nerve and superior profunda vessels. It commences in the upper third posteriorly, and is directed downwards and forwards on to the external surface, where it terminates a little below and behind the apex of the deltoid impression. The lower part of this groove is occupied by a pointed slip of the brachialis anticus. In the upper part of the groove there is usually a nutrient foramen for a branch of the superior profunda artery. On the posterior aspect of the shaft, over about its upper third, external to the spiral groove, there is a rough marking which gives origin to the external head of the triceps, extending as high as the lower part of the insertion of the teres minor. The internal head of the triceps commences to arise in a pointed manner from the back of the shaft internal to the spiral groove, where it reaches a little above and behind the lower border of the tendon of the teres major.

The lower half of the shaft, being triangular, presents three surfaces and three borders. The *posterior surface*, which is flat, terminates at the olecranon fossa, and it gives origin to most of the fibres of the internal head of the triceps. The *external* and *internal surfaces*, as well as the anterior border which separates them, give origin to the brachialis anticus. The *anterior border*, which is round, separates the lateral surfaces, and is in line with the anterior margin of the deltoid impression, and, above this, with the outer bicipital ridge. The *external border* is called the *external supracondylar ridge*. It is sharp and prominent, and extends from the external epicondyle to the spiral groove. It gives attachment to the external intermuscular septum. Anteriorly its upper two-thirds give origin to the brachio-radialis (supinator radii longus), and the lower third to the extensor carpi radialis longior. Posteriorly it gives origin to the inner head of the triceps. The *internal border* forms the *internal supracondylar ridge*, and is not so prominent as the external. It commences at the internal epicondyle, and it can be followed up through the line for the insertion of the coracobrachialis into the inner bicipital ridge. It gives attachment to the internal intermuscular septum. Anteriorly it gives origin to the brachialis anticus, posteriorly to the inner head of the triceps, and in its lower part to some fibres of the superficial head of the pronator radii teres. The internal surface of the shaft, in front of the internal supracondylar ridge and about $2\frac{1}{2}$ inches above the internal epicondyle, sometimes presents a sharp spur-like projection directed downwards, called the *supracondylar process*. When present it gives attachment to a fibrous band which passes to the internal epicondyle, and gives origin to a third head of the pronator radii teres. In such cases the band forms an arch through which the median nerve passes, and frequently the brachial artery. The supracondylar process represents a portion of bone which forms a supracondylar foramen in many *carnivora*—e.g., the *felidæ*.

The **lower extremity** presents at either side the internal and external epicondyles, and inferiorly a transversely elongated articular

surface covered by cartilage, and divided by a vertical curved ridge into an external part, called the capitellum, and an internal, called the trochlea. Above the capitellum in front there is a rough transverse depression, called the radial fossa. Above the trochlea in front is the coronoid fossa, and above it posteriorly is the olecranon fossa.

The **internal epicondyle** (*epitrochlea*) is very prominent, and is directed inwards and slightly backwards. Its lower part and the adjacent portions of its anterior and posterior aspects give attachment to the internal lateral ligament of the elbow-joint. Its anterior aspect gives origin to the common tendon of the superficial head of the pronator radii teres, flexor carpi radialis, palmaris longus, part of the flexor sublimis digitorum, and one head of the flexor carpi ulnaris. Behind the internal epicondyle, close to the trochlea, is the *ulnar groove*, through which the ulnar nerve passes.

The **external epicondyle** is much less prominent than the internal. Anteriorly it gives origin to the common tendon of the extensor carpi radialis brevis, extensor communis digitorum, extensor minimi digiti, extensor carpi ulnaris, and supinator radii brevis. Posteriorly it presents an impression for the anconeus, and inferiorly a depression near the capitellum for the external lateral ligament of the elbow-joint.

The **capitellum** mainly takes the form of a rounded eminence. It is limited to the anterior and inferior aspects of the bone, and articulates with the cup-shaped depression on the head of the radius. Internal to the rounded portion there is a groove for the play of the inner convex part on the head of the radius. The *radial fossa* receives the anterior margin of the head of the radius in complete flexion of the elbow-joint.

The **trochlea** is pulley-shaped, and turns completely round from the front to the back of the bone, becoming rather broader posteriorly. It is concave from side to side, and convex from before backwards. The internal border is more prominent and thicker than the external, and extends lower down. As viewed from before, the borders are inclined downwards and slightly inwards, but posteriorly they incline upwards and slightly outwards, and so the trochlea is here brought into the centre of the bone. The trochlea articulates with the great sigmoid cavity of the ulna. The *coronoid fossa* receives the coronoid process of the ulna in flexion of the elbow-joint, and the anterior ligament is attached just above it. The *olecranon fossa*, much larger than the coronoid, receives the olecranon process of the ulna in extension of the joint, and its margins give attachment to the posterior ligament. The portion of bone which separates the two fossæ is thin, and is sometimes perforated by a foramen, called the *supratrochlear foramen*.

In the vicinity of the lower extremity there are numerous nutrient foramina for branches of the superior and inferior profundæ and anastomotica magna of the brachial, radial and ulnar recurrent, and interosseous recurrent, arteries.

Articulations.—*Superiorly* with the scapula, and *inferiorly* with the radius externally, and ulna internally.

Structure.—The shaft is composed of compact bone, which is thicker at the centre than at the extremities. It contains a medullary canal lined with a thin coating of cancellated tissue. The articular extremities are filled with cancellated tissue, except at the surface, where there is a thin layer of compact bone.

Varieties.—These are (1) a supracondylar process, and (2) a supratrochlear foramen.

Ossification.—The humerus ossifies in cartilage from **one primary**, and **six** (sometimes **seven**) **secondary, centres**. The primary centre appears at the middle of the shaft in the *eighth week* of intra-uterine life. At birth the

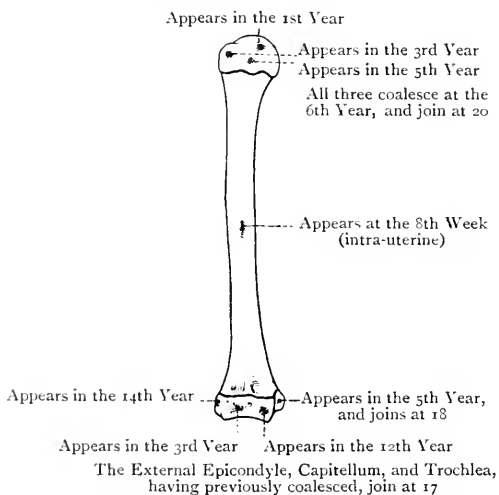


FIG. 102.—OSSIFICATION OF THE HUMERUS.

shaft is ossified, but the extremities are cartilaginous. The superior extremity is ossified from two or three secondary centres. The centre for the head appears in the *first year* (sometimes just before birth), and that for the great tuberosity in the *third year*. The small tuberosity may have a separate centre, and, if so, it appears in the *fifth year*, or it may be ossified from the centre for the great tuberosity. The upper epiphyses join to form one compound epiphysis in the *sixth year*, and this unites with the shaft in the *twentieth year*. The lower extremity is ossified from four secondary centres, as follows: one for the capitellum and outer half of the trochlea appearing in the *third year*; one for the internal epicondyle in the *fifth year*; one for the inner half of the trochlea in the *twelfth year*; and one for the external epicondyle in the *fourteenth year*. The trochlea, capitellum, and external epicondyle join to form one compound epiphysis, and this unites with the shaft in the *seventeenth year*. The internal epicondyle unites with the shaft, as an independent epiphysis, in the *eighteenth year*.

The **law of ossification** applicable to long bones with an epiphysis or epiphyses at either end is as follows: *the epiphysis or epiphyses,*

at the end towards which the medullary foramen and the canal to which it leads are directed, are the last to show signs of ossification, but they are the first to join the shaft. The only exception to this rule occurs in the *fibula*.

The Radius.

The **radius** is the external bone of the forearm (which is assumed to be in a position of supination). It is parallel with, and shorter than, the ulna, and extends from the elbow to the wrist. It is a long bone, and is divisible into a shaft and two extremities.

The **upper extremity**, which is small, presents a head and neck. The **head** is disc-shaped, and covered by cartilage, both on its upper surface and circumference. The *upper surface*, at its centre, presents a depression which articulates with the rounded portion of the capitellum of the humerus in flexion of the elbow-joint. Around this depression the surface is convex, especially on the inner side, and this portion glides on the inner grooved part of the capitellum. The circumferential cartilage is deeper on the inner aspect than elsewhere, and this portion articulates with the small sigmoid cavity of the ulna, whilst the remainder plays within the orbicular ligament. The constricted portion below the head is called the **neck**. It is cylindrical, and its upper part is embraced by the orbicular ligament, whilst beyond this on the outer aspect it gives insertion to a few fibres of the supinator radii brevis. The upper extremity presents several nutrient foramina for branches of the radial recurrent and interosseous recurrent arteries.

The **shaft** increases in size from above downwards, and is curved, the convexity being directed outwards and slightly backwards. This curve imparts elasticity to the bone, and guards it against the shocks to which it is so much exposed from the fact that it supports the hand. The shaft is triangular, and presents superiorly, on its antero-internal aspect just below the neck, an oval eminence, called the *bicipital tuberosity*. This is divided vertically into two parts, a rough posterior portion which gives insertion to the tendon of the biceps, and a smooth anterior part which is separated from that tendon by a bursa. Below the bicipital tuberosity the shaft presents three borders and three surfaces. The *anterior border* extends from the lower and anterior part of the bicipital tuberosity to the anterior border of the styloid process. In its upper third it crosses the shaft obliquely downwards and outwards, this portion of it being called the *anterior oblique line*. This line limits externally the insertion of the supinator radii brevis, and internally the origin of the flexor longus pollicis, whilst its prominent edge gives origin to the thin radial portion of the flexor sublimis digitorum. The *internal* or *interosseous border* commences at the lower and back part of the bicipital tuberosity, and near the lower extremity of the shaft it divides into two ridges, which pass to

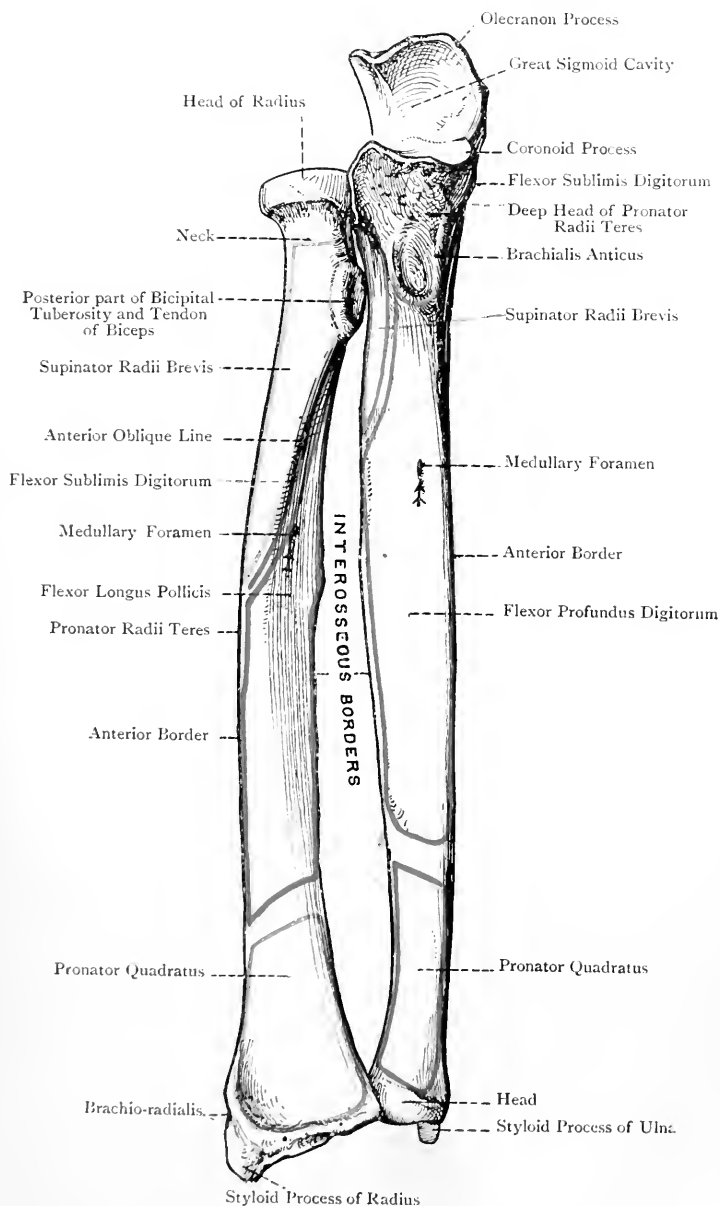


FIG. 103.—THE RIGHT RADIUS AND ULNA (ANTERIOR VIEW).

the anterior and posterior margins of the sigmoid cavity. At its commencement it is round and indistinct, and immediately below the bicipital tuberosity it gives attachment to the oblique ligament. Over the rest of its extent it is sharp and wiry for the attachment of the interosseous membrane, which is also connected with the posterior of the two lower divisions. The *posterior border* extends from the back of the bicipital tuberosity to the prominent radial tubercle about the centre of the posterior border of the lower extremity. In its upper third it crosses the shaft obliquely downwards and outwards, this portion of it, which is prominent, being called the *posterior oblique line*. This line limits the insertion of the supinator radii brevis above, and the origin of the extensor ossis metacarpi pollicis below.

The *anterior surface* is situated between the anterior and internal or interosseous borders. In the upper two-thirds it is concave, and gives origin to the flexor longus pollicis. In the lower third it is flat and expanded, and this portion gives insertion to the pronator quadratus, except close to the anterior border of the lower extremity, where it gives attachment to the anterior ligament of the wrist-joint. The anterior surface presents the **medullary foramen** about the junction of the upper and middle thirds. The direction of the canal to which it leads is *upwards*, and it gives passage to the medullary branch of the anterior interosseous artery. The portion of bone between the anterior oblique line, the lower part of the front of the neck, and the bicipital tuberosity gives insertion to a portion of the supinator radii brevis. The *external surface* is situated between the anterior and posterior borders. It is convex from above downwards, and from side to side. In its upper third it gives insertion to the supinator radii brevis; at its centre there is a rough impression, fully an inch long, for the insertion of the pronator radii teres; and below this it supports the tendons of the extensores carpi radialis longior et brevior, and is crossed obliquely by the tendons of the extensor ossis metacarpi pollicis and extensor brevis pollicis (primi internodii pollicis). The external surface also supports the brachio-radialis, which is inserted into its lower extremity close to the base of the styloid process. The *posterior surface* is situated between the posterior and internal or interosseous borders. Above the posterior oblique line it is covered by the supinator radii brevis, which takes insertion into its outer half. Below the posterior oblique line it is concave over about the middle third, where it gives origin from above downwards to the extensor ossis metacarpi pollicis and extensor brevis pollicis. The lower third is broad and convex, and it supports the tendons of the extensor longus pollicis, extensor communis digitorum, and extensor indicis.

The **lower extremity** is large and pentagonal, as viewed from below. Externally it presents the styloid process, internally the sigmoid cavity, and inferiorly the carpal articular surface, the latter two being covered by cartilage. The **styloid process** projects down-

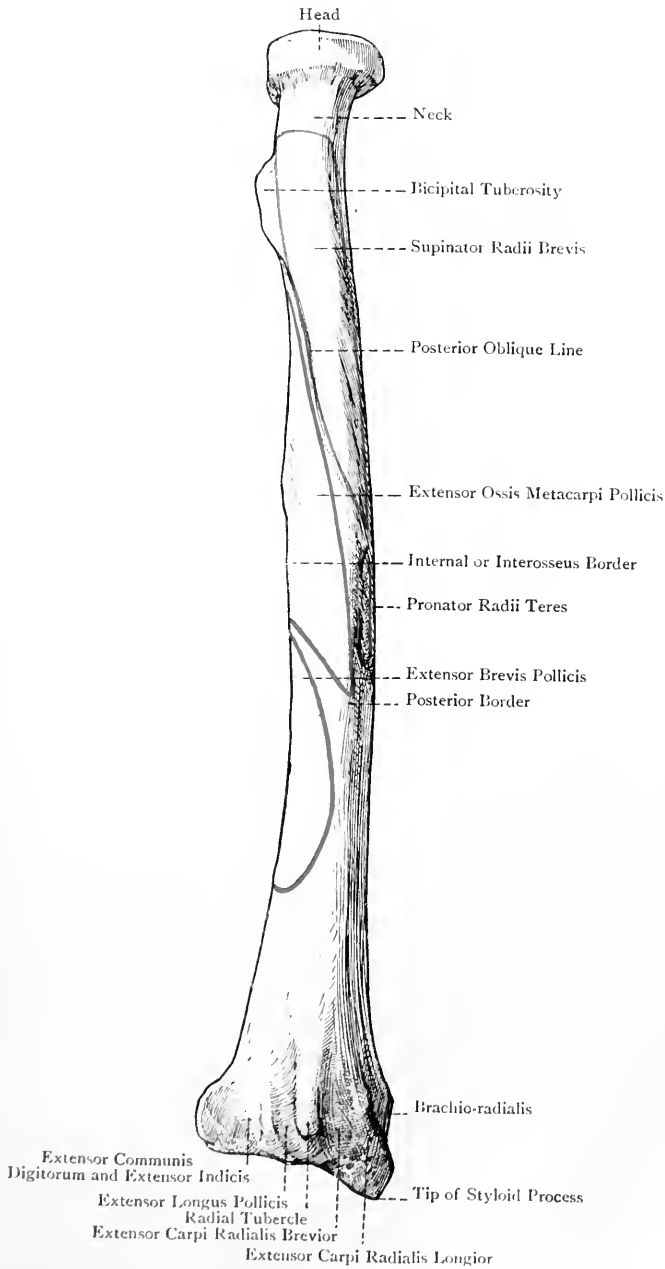


FIG. 104.—THE RIGHT RADIUS (POSTERIOR SURFACE).

wards as a stout conical process, terminating in a round tip which gives attachment to the external lateral ligament of the wrist-joint. The inner surface is covered by the cartilage of the carpal articular surface. The outer surface presents a groove directed downwards and slightly forwards, and subdivided into two compartments, the outer of which transmits the tendon of the extensor ossis metacarpi pollicis, and the inner that of the extensor brevis pollicis. This groove is separated from the pronator surface in front by a prominent ridge which gives attachment to the posterior annular ligament. The anterior surface supports a portion of the radial artery.

The **sigmoid cavity** is concave from before backwards, and articulates with the outer convex surface of the head of the ulna.

The **carpal articular surface** is of large size, and its plane is oblique, being sloped outwards and a little downwards. It is concave from before backwards, and from side to side, and is divided into two parts by an antero-posterior elevation. The outer division is triangular, its cartilage being prolonged on to the inner surface of the styloid process, and it articulates with the scaphoid bone. The inner division is quadrilateral, and articulates with the semilunar bone. It is separated from the sigmoid cavity by a sharp concave margin, which gives attachment to the base of the triangular interarticular fibro-cartilage. Immediately above the anterior border there is a rough surface for the attachment of the anterior ligament of the wrist-joint. The posterior border is on a slightly lower level than the anterior, and is irregularly convex. It presents about its centre a prominent elevation, called the *radial tubercle*, and is divided into three grooves—outer, middle, and inner. The *outer groove*, which is broad, is bounded externally by a ridge which separates it from the groove on the outer surface of the styloid process, and internally by the radial tubercle. It is usually subdivided by a faint line into two compartments, the outer of which transmits the tendon of the extensor carpi radialis longior, and the inner that of the extensor carpi radialis brevior. The *middle groove*, narrow and deep, is directed from above downwards and outwards, and is bounded externally by the radial tubercle, which slightly overhangs it, and internally by an oblique ridge separating it from the inner groove. It transmits the tendon of the extensor longus pollicis (*secundi internodii pollicis*). The inner groove is single, and transmits the tendons of the extensor communis digitorum and extensor indicis. It is separated from the sigmoid cavity by a sharp ridge which, with the ulna in position, bounds a groove for the tendon of the extensor minimi digiti. The ridges separating the grooves give attachment to deep expansions of the posterior annular ligament, which, with the ligament, convert the grooves into fibro-osseous canals.

The lower extremity presents several nutrient foramina for branches of the anterior and posterior interosseous arteries, and anterior and posterior carpal arches.

Articulations.—*Superiorly* with the capitellum of the humerus and small sigmoid cavity of the ulna, and *inferiorly* with the head of the ulna, scaphoid, and semilunar:

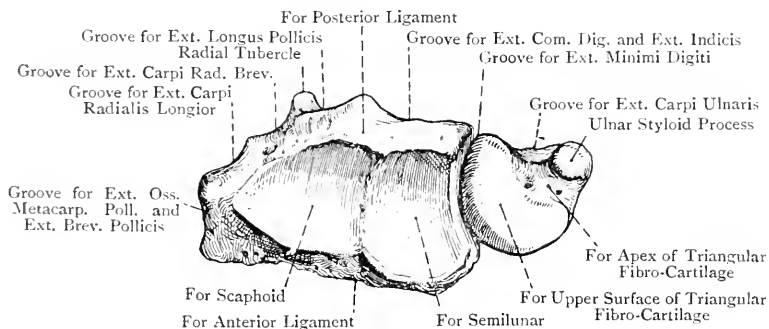


FIG. 105.—THE LOWER ENDS OF THE LEFT RADIUS AND ULNA AS SEEN FROM BELOW IN PRONATION.

(The Dorsal Aspect is upwards.)

Structure.—This is similar to that of long bones. At the lower extremity the cancellated tissue extends upwards for about $1\frac{1}{2}$ inches above the styloid process, this level being the site of Colles' fracture.

Ossification.—The radius ossifies in cartilage from **one primary**, and **two secondary**, centres. The primary centre appears at the middle of the shaft in the *eighth week* of intra-uterine life. At birth the shaft is ossified, but the extremities are cartilaginous. The secondary centre for the lower extremity appears in the *second year*, and that for the head in the *fifth year*. The

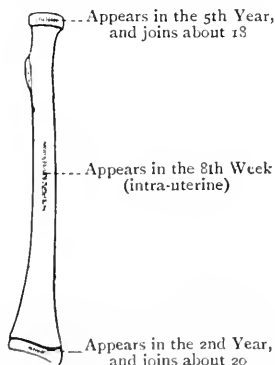


FIG. 106.—OSSIFICATION OF THE RADIUS.

upper epiphysis joins the shaft about the *eighteenth year*, and the lower epiphysis about the *twentieth year*. Sometimes the surface of the bicipital tuberosity forms an epiphysis, in which cases there is a special secondary centre for it, appearing about the *fourteenth year*, and joining the rest of the shaft very soon thereafter.

The Ulna.

The **ulna** is the internal bone of the forearm (which is assumed to be in a position of supination). It is parallel with, and longer than, the radius, and extends from the elbow to the wrist, being separated from the latter joint by the triangular interarticular fibro-cartilage. It is a long bone, and is divisible into a shaft and two extremities, the upper of which is of large size.

The **upper extremity** presents the olecranon and coronoid processes, and the great and small sigmoid cavities. The **olecranon process** forms the highest part of the bone, and is curved forwards at its upper part. It is largely subcutaneous. Superiorly it presents a broad, flat, quadrilateral surface, at the back part of which is a rough elevation for the insertion of the triceps. In front of this there is a smooth area where a bursa intervenes between that muscle and the bone. At its anterior part, near the anterior margin, there is a narrow transverse impression for part of the posterior ligament of the elbow-joint. The superior surface is limited anteriorly by a sharp convex border, projected at its centre into a process, called the *beak*, which overhangs the upper part of the great sigmoid cavity, and is received into the olecranon fossa of the humerus in extension of the joint. The anterior surface is directed downwards and forwards, and forms the upper part of the great sigmoid cavity. The posterior surface, smooth, flat, and triangular, is subcutaneous, and covered by a bursa. The inner surface presents a tubercle for the ulnar head of the flexor carpi ulnaris, and the inner border gives attachment to the posterior part of the internal lateral ligament of the elbow-joint. The outer surface gives insertion to a portion of the anconeus, and the outer border gives attachment to fibres of the posterior ligament of the joint.

The **coronoid process** is triangular, and projects forwards. The superior surface forms the lower and anterior part of the great sigmoid cavity. The inferior surface is rough and concave, and the roughness is prolonged upon the anterior surface of the shaft for about an inch, giving rise to a triangular impression, the inner half of which gives insertion to the brachialis anticus. The upper part of this surface, close to the anterior border of the process, affords attachment to the anterior ligament of the elbow-joint. The lower pointed portion presents externally a rough prominence, called the *tuberosity*, which gives insertion to fibres of the brachialis anticus, and attachment to the oblique ligament. The anterior margin is sharp, convex, and curved slightly upwards, and it is projected at its outer part into a process, called the *beak*, which is received into the coronoid fossa of the humerus in flexion of the elbow-joint. The inner border gives attachment to the anterior portion of the internal lateral ligament, and at its upper part it presents a tubercle for the ulnar head of the flexor sublimis digitorum. Leading downwards from this there is a short ridge for the origin of the deep head of the pronator radii teres, below which

a slip of the flexor longus pollicis sometimes arises. Behind the flexor sublimis tubercle there is a depressed surface which gives origin to the highest fibres of the flexor profundus digitorum. The outer surface presents the small sigmoid cavity.

The **great sigmoid cavity**, which articulates with the trochlea of the humerus, when viewed from the side, forms half a circle. The upper half of the cavity is formed by the anterior surface of the olecranon process, and the lower half by the upper surface of the coronoid process. It is constricted at the centre by a notch at either side, which marks the meeting of the olecranon and coronoid processes, the inner notch being bridged over by a fibrous band with which the middle part of the internal lateral ligament blends. The cartilage of the cavity is sometimes broken up at this part by a narrow, rough, transverse interval. Extending from the beak of the olecranon to the beak of the coronoid there is a longitudinal elevation, which divides the cavity into two lateral halves, the inner being concave from side to side, and the outer convex.

The **small sigmoid cavity**, which is situated on the outer surface of the coronoid process, is concave from before backwards, and articulates with the inner aspect of the head of the radius. Its anterior and posterior margins give attachment to the cornua of the orbicular ligament.

The upper extremity presents several nutrient foramina for branches of the anterior and posterior ulnar recurrent and interosseous recurrent arteries.

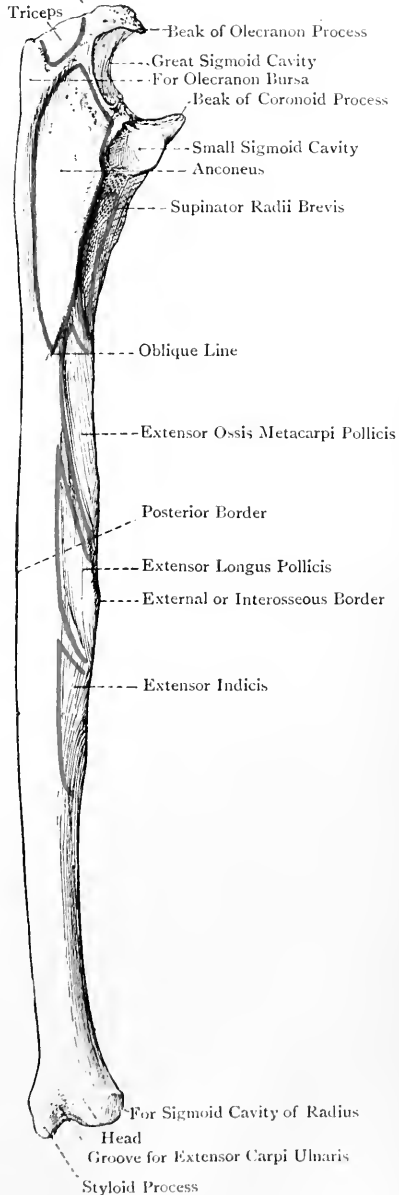


FIG. 107.—THE RIGHT ULNA
(POSTERIOR SURFACE).

The **shaft** diminishes in size from above downwards, and is triangular in its upper three-fourths, where it is slightly curved with the convexity directed backwards. In the lower fourth it is slender and subcylindrical, being flattened in front. It presents three borders and three surfaces. The *anterior border* extends from the flexor sublimis tubercle on the inner margin of the coronoid process to the front of the styloid process. Over its upper three-fourths it is round, and gives origin to fibres of the flexor profundus digitorum. Over its lower fourth it is sharp, and gives origin to the pronator quadratus. The *posterior border*, which is subcutaneous, extends from the apex of the triangular subcutaneous surface on the back of the olecranon to the back of the styloid process. Over its upper two-thirds it gives attachment to a strong aponeurosis, which gives common origin to the flexor, and extensor, carpi ulnaris, and flexor profundus digitorum. The *external* or *interosseous border* extends from the apex of the bicipital hollow, about two inches below the small sigmoid cavity, to the outer aspect of the head. Over the middle three-fifths of the shaft it is sharp and prominent, but over the lower fifth it is very faint. It gives attachment to the interosseous membrane.

The *anterior surface* is situated between the anterior and interosseous borders. It is concave over its upper three-fourths, and gives origin to part of the flexor profundus digitorum. The lower fourth is flat, and gives origin to the pronator quadratus. This surface presents the **medullary foramen** a little above the centre, the direction of the canal to which it leads being *upwards*. It gives passage to the medullary branch of the anterior interosseous artery. The *internal surface* is situated between the anterior and posterior borders. Over its upper two-thirds it gives origin to part of the flexor profundus digitorum, the lower portion being subcutaneous. The *posterior surface* is situated between the posterior and interosseous borders, and is directed backwards and outwards. It presents superiorly the *oblique line*, which extends from the supinator ridge on the posterior margin of the bicipital hollow to the posterior border at the junction of the upper and middle thirds. The triangular portion above this line is called the *anconeal surface*, which extends over the outer surface of the olecranon. It gives insertion to the anconeus. The posterior surface, below the oblique line, is divided into two lateral parts by a vertical ridge. The inner portion supports the extensor carpi ulnaris, and the outer gives origin, from above downwards, to the extensor ossis metacarpi pollicis, extensor longus pollicis, and extensor indicis. On the outer aspect of the shaft superiorly there is a triangular depression, called the *bicipital hollow*, which commences immediately below the small sigmoid cavity, and extends downwards for about 2 inches. It is bounded in front and behind by prominent lips, the anterior of which passes above into the outer margin of the coronoid process, and the posterior into the posterior margin of the small sigmoid cavity. The upper part of the posterior

lip, which is prominent, is called the *supinator ridge*, and it gives origin to a part of the supinator radii brevis. The two lips form by their meeting the commencement of the external or interosseous border. The anterior part of the bicipital hollow receives the bicipital tuberosity of the radius, with the tendon of insertion of the biceps, in pronation, whilst the posterior part gives origin to fibres of the supinator radii brevis.

The **lower extremity** is small, and presents a head and styloid process. These are separated behind by a groove for the tendon of the extensor carpi ulnaris, and below by a rough pit which gives attachment to the apex of the triangular interarticular fibro-cartilage. The outer aspect of the **head** is convex, and covered by cartilage for articulation with the sigmoid cavity of the radius, a portion of the synovial membrane, called *membrana sacciformis*, intervening. The inferior surface, also covered by cartilage, is flat, and is related to the upper surface of the triangular interarticular fibro-cartilage, with the intervention of another portion of the *membrana sacciformis*.

The **styloid process**, of small size and subcutaneous, projects downwards from the posterior and inner part of the head (mainly from the back part), and it terminates in a round tip which gives attachment to the internal lateral ligament of the wrist-joint.

The lower extremity presents several nutrient foramina for branches of the anterior and posterior interosseous arteries.

Articulations.—*Superiorly* with the trochlea of the humerus, and the inner aspect of the head of the radius; *inferiorly* with the sigmoid cavity of the radius, and the triangular interarticular fibro-cartilage, the latter structure separating it from the cuneiform or pyramidal bone.

Structure.—This is similar to that of long bones.

Ossification.—The ulna ossifies in cartilage from **one primary**, and **two secondary, centres**. The primary centre appears at the middle of the shaft in the *eighth week*, and from it the shaft, coronoid process, and greater part of the olecranon process are ossified. At birth the shaft and coronoid process are ossified, but the greater part of the olecranon and the lower extremity are cartilaginous. The secondary centre for the lower extremity appears in the *fourth year*, and from it the head and styloid process are ossified. The secondary centre for the upper extremity appears in the *tenth year*, and may involve only a thin scale on the summit of the olecranon process, or it may afford ossification to a third, or even a half, of that process. The upper epiphysis joins about the *sixteenth year*, and the lower about the *twentieth year*.

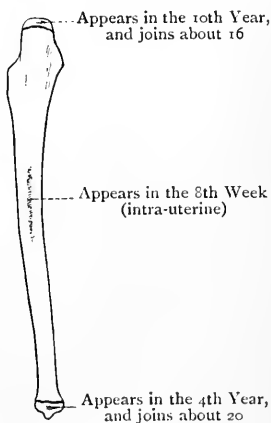


FIG. 108.—OSSIFICATION OF THE ULNA.

The Carpus.

The **carpus** or wrist is composed of eight short bones, which are arranged in two rows, there being four bones in each row. The rows are called *first* or *proximal*, and *second* or *distal*. The bones of the first row, from without inwards, are called scaphoid, semilunar, cuneiform, and pisiform, whilst those of the second row, in a similar order, are named trapezium, trapezoid, os magnum, and unciform.

The Scaphoid Bone.

The **scaphoid bone**, which is characterized by its boat-like shape, lies with its long axis oblique, the broad end being directed upwards and inwards, and the narrow end or prow downwards, outwards and forwards. *Superiorly* it presents a convex articular surface for the radius, which encroaches on the dorsal aspect. *Inferiorly* it also presents a convex articular surface directed downwards, out-

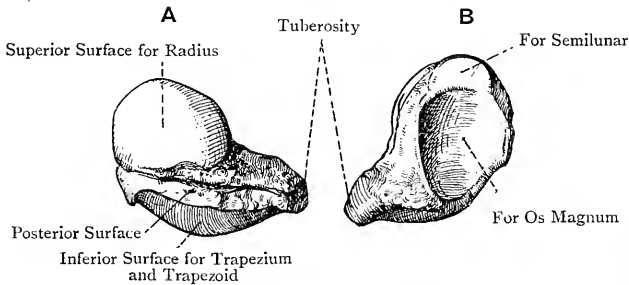


FIG. 109.—THE RIGHT SCAPHOID BONE.

A, Posterior View; B, Internal View.

wards, and backwards, which likewise encroaches on the dorsal aspect, and is divisible into two parts—an outer for the trapezium, and an inner for the trapezoid. The *internal surface* presents two articular facets—a superior, crescentic, narrow from above downwards, and looking inwards, for the semilunar, and an inferior, large, concave, and directed downwards as well as inwards, for the outer side of the head of the os magnum. The *external aspect* takes the form of a rough border, extending from the radial surface to the tuberosity, and giving attachment to the external lateral ligament of the wrist-joint. At its lower end there is a prominent *tuberosity*, directed forwards, which gives attachment to fibres of the anterior annular ligament and abductor pollicis. The *palmar surface* is rough and triangular. The *dorsal surface*, being encroached upon by the superior and inferior convex articular surfaces, is reduced to a rough oblique groove.

Articulations.—*Superiorly* with the radius, *inferiorly* with the trapezium and trapezoid, and *internally* with the semilunar and os magnum.

The Semilunar Bone.

The **semilunar** or **lunar bone** is characterized by the crescentic concavity on its inferior surface. *Superiorly* it presents a quadri-lateral, convex, articular surface for the radius, which encroaches on the dorsal aspect. The *inferior surface* is deeply concave from before backwards. The greater part of it articulates with the upper surface of the head of the os magnum, and the narrow inner strip with the upper border of the unciform. The *external surface*,

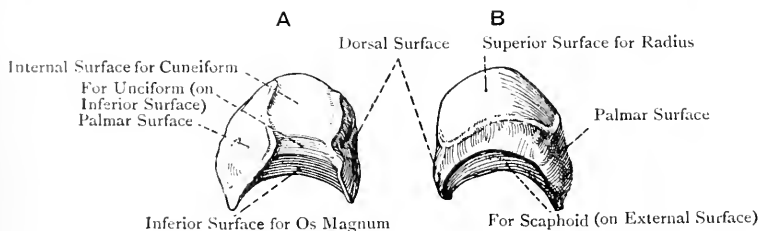


FIG. 110.—THE RIGHT SEMILUNAR BONE.

A, Internal View ; B, Supero-external View.

narrow from above downwards, presents a crescentic facet for the scaphoid. The *internal surface*, which is inclined downwards and outwards, is deep from above downwards, and presents a semi-oval facet for the cuneiform. The *palmar* and *dorsal surfaces* are rough, the former being large, convex, and quadri-lateral, and the latter small and flat.

Articulations.—*Superiorly* with the radius, *inferiorly* with the os magnum and unciform, *externally* with the scaphoid, and *internally* with the cuneiform.

The Cuneiform Bone.

The **cuneiform** or **pyramidal bone** is characterized by its resemblance to a wedge, or pyramid, and it lies obliquely with the base

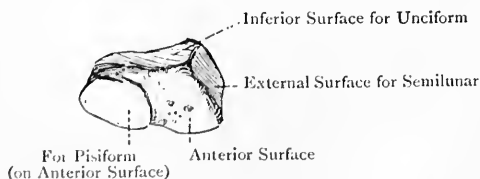


FIG. 111.—THE RIGHT CUNEIFORM OR PYRAMIDAL BONE (ANTERIOR, EXTERNAL, AND INFERIOR SURFACES).

directed outwards and upwards. The *external surface*, which corresponds with the base, presents a semi-oval facet for the semi-

lunar. The *internal surface*, which represents the rounded apex, is of limited extent, and rough for the internal lateral ligament of the wrist-joint. The *palmar surface* presents a circular, slightly convex facet, which occupies rather more than the inner and lower half, and articulates with the pisiform, the rest of the surface being rough. The *supero-posterior surface* is divisible into two parts, outer and inner. The outer portion, which is close to the base, presents a convex facet for the inferior surface of the triangular interarticular fibro-cartilage. The inner portion is marked by two rough oblique grooves, superior and posterior, separated by a ridge which is dorsally placed. The *inferior surface* presents a large triangular facet, concavo-convex from without inwards, for the unciform.

Articulations.—*Superiorly* with the triangular interarticular fibro-cartilage, *inferiorly* with the unciform, *externally* with the semi-lunar, and *anteriorly* with the pisiform.

The Pisiform Bone.

The **pisiform bone** is characterized by its resemblance to a pea, and is placed in front of the cuneiform, which constitutes its only articulation. It is irregularly round, except *posteriorly*, where it presents over its upper three-fourths a circular, slightly concave facet for the cuneiform, the lower fourth being non-articular. The

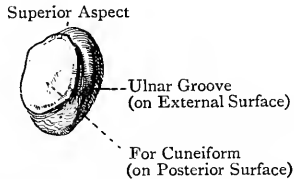


FIG. 112.—THE RIGHT PISIFORM BONE (POSTERO-EXTERNAL VIEW).

long axis of the bone is directed downwards and slightly outwards. The *palmar surface* gives attachment superiorly to the flexor carpi ulnaris, inferiorly to the pisi-uncinate and pisi-metacarpal ligaments, and abductor minimi digiti, and externally to a portion of the anterior annular ligament. The *internal surface* is irregularly convex, and the *external* presents the *ulnar groove*, which lodges the ulnar nerve and artery.

The Trapezium.

The **trapezium** is the external bone of the second row, and is characterized by a groove and ridge on its palmar surface, and a saddle-shaped facet on its inferior surface. It is polyhedral,

and its long axis is directed downwards and inwards. The *superior surface* presents a semi-oval, concave facet for the scaphoid. The *inferior surface* presents a saddle-shaped facet, concave from side to side, convex from before backwards, and directed outwards as well as downwards, for the base of the first metacarpal bone. The *internal surface* has two facets—an upper, which is large and concave, for the trapezoid, and a lower, which is small, for the base of the second metacarpal bone. The *external surface* is broad, pentagonal, and rough. The *palmar surface*, rough and elongated from above downwards and inwards, is broad above and narrow below. Superiorly it presents a deep groove, directed downwards and inwards, which transmits the tendon of the flexor carpi radialis, and external to this groove a prominent ridge, called the *tuberosity*, which gives attachment to the anterior annular ligament, abductor pollicis, and opponens pollicis. The

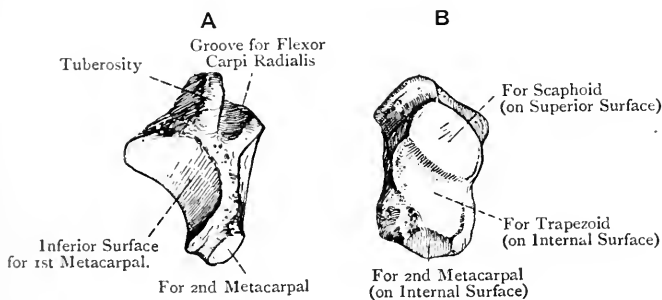


FIG. 113.—THE RIGHT TRAPEZIUM.

A, Antero-inferior View ; B, Supero-internal View.

dorsal surface is broader than the palmar, and its inferior and internal angle is much elongated towards the base of the second metacarpal bone, with which it articulates by the small facet on its inner aspect.

Articulations.—*Superiorly* with the scaphoid, *inferiorly* with the first metacarpal, and *internally* chiefly with the trapezoid, but also with the second metacarpal.

The Trapezoid Bone.

The **trapezoid bone** somewhat resembles the trapezium, but it is destitute of a groove and tuberosity. Its antero-posterior diameter is longer than the transverse. The *palmar surface* is small and pentagonal, and it gives origin to fibres of the adductor obliquus pollicis. The *dorsal surface* is large and has its internal and inferior angle elongated towards the styloid process of the third meta-

carpal bone. Both of these surfaces are rough for ligaments. The *superior surface* presents a quadrilateral, concave facet, elongated from before backwards, for the scaphoid. The *inferior surface* is characterized by a large saddle-shaped facet, convex from side to side and concave from before backwards, for the base of the second metacarpal bone. The *external surface* has a convex facet for the trapezium, below which there is a rough triangular surface with the base directed anteriorly. The *internal surface* is concave from before backwards, and its anterior portion presents a facet for the os magnum.

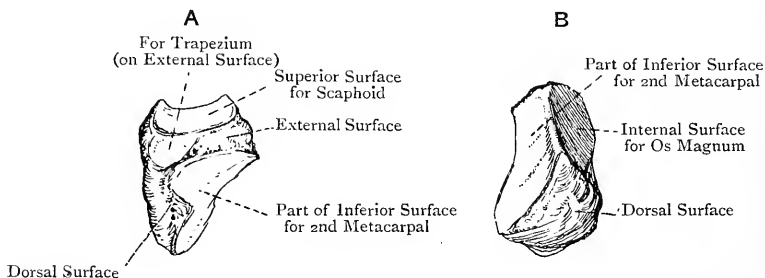


FIG. 114.—THE RIGHT TRAPEZOID BONE.

A, External View; B, Posterior View.

Articulations.—*Superiorly* with the scaphoid, *inferiorly* with the second metacarpal, *externally* with the trapezium, and *internally* with the os magnum.

The Os Magnum.

The **os magnum** is the largest bone of the carpus, its distinctive characters being that it is composed of a head, neck, and body. The superior and external aspects of the **head** are convex, and merge gradually into each other. The cartilage of the superior aspect is prolonged more behind than in front, and articulates with the semi-lunar. The external aspect of the head articulates with the scaphoid. The internal aspect of the head is flat, and presents the commencement of the facet for the unciform bone. The **neck** is mainly present in front and behind.

The **body** is quadrilateral, and narrower in front than behind. The *palmar* and *dorsal surfaces* are rough, the former giving origin to fibres of the adductor obliquus pollicis. The *external surface*, which is continuous with the outer convex aspect of the head, presents anteriorly a facet for the trapezoid. The *internal surface* presents at its back part the lower portion of the facet for the unciform, which is here narrow. The *inferior surface* is narrow in front, but broad behind, and the internal of the two posterior angles is elongated downwards and inwards. This surface presents

three facets. The middle one is the largest, and articulates with the third metacarpal bone. The external one is a narrow, concave strip for the second metacarpal bone. The internal one, small

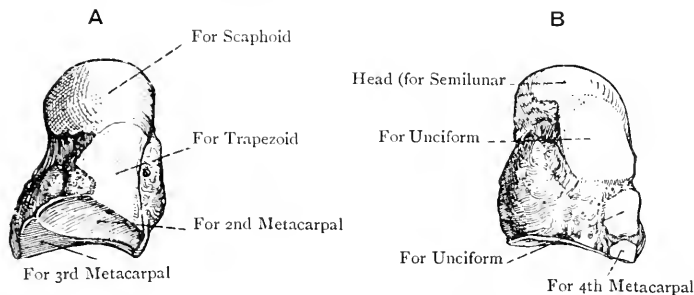


FIG. 115. — THE RIGHT OS MAGNUM.

A, External View; B, Internal View.

and circular, tips inferiorly the projecting postero-internal angle, and articulates with the fourth metacarpal bone.

Articulations.—*Superiorly* with the semilunar, *superiorly* and *externally* with the scaphoid, *inferiorly* with the second, third, and fourth metacarpal bones, *externally* with the trapezoid, and *internally* with the unciform.

The Unciform Bone.

The **unciform bone** is characterized by a hook-like process on its palmar surface. It is triangular, or wedge-shaped, and lies with its base downwards. The *superior extremity* presents a narrow facet for the semilunar. The *inferior surface* is divided by an antero-posterior ridge into two quadrilateral facets, the outer of which articulates with the fourth, and the inner with the fifth, metacarpal bone. The *palmar surface*, which is rough, presents at its lower and inner part a prominent curved projection, called the *unciform process*. This process is laterally compressed, the external surface being concave and the internal convex, so that the direction of the curve is outwards. Its borders are superior, inferior, and anterior. The internal surface gives origin to the flexor brevis, and opponens, minimi digiti, and close to the root it presents the *ulnar groove* for the deep branches of the ulnar artery and nerve. The anterior border gives attachment to the anterior annular and pisiform ligaments. The *dorsal surface* is extensive and rough. The *external surface* presents an elongated facet, broad above and narrow below, where it is confined to the back part, for articulation with the os magnum. The *supero-internal surface* is concavo-convex from below upwards, and articulates with the cuneiform. The internal border, situated at the meeting of the supero-internal and inferior surfaces, is narrow and rough, its direction being from before backwards.

Articulations.—*Superiorly* with the semilunar, *supero-internally* with the cuneiform, *inferiorly* with the fourth and fifth metacarpal bones, and *externally* with the os magnum.

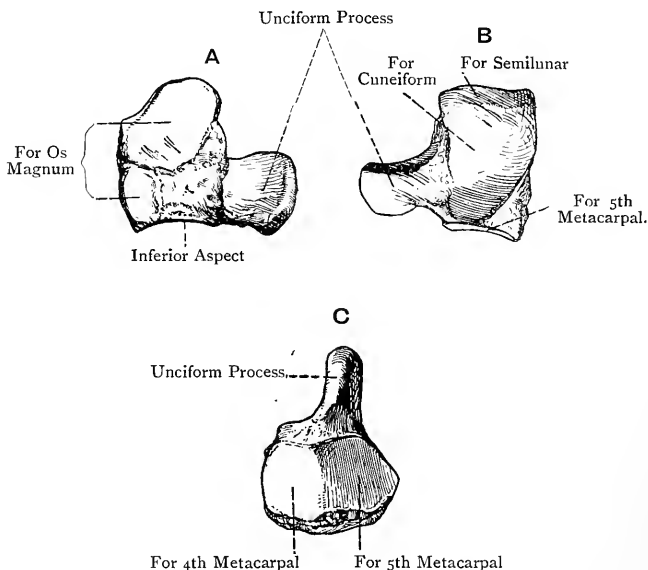


FIG. 116.—THE RIGHT UNCIFORM BONE.

A, External View; B, Supero-internal View; C, Inferior View.

The **carpus as a whole** is narrower above than below. The *dorsal aspect* is irregularly convex, and the dorsal surfaces of the bones of the first row (exclusive of the pisiform) are narrow, but in the second row they are broad, this being reversed on the palmar aspect. It is to be noted that the postero-internal angles of the trapezium, trapezoid, and os magnum are distinctly elongated. The *palmar aspect* is rendered concave by the tuberosities of the scaphoid and trapezium externally, and the pisiform bone and unciform process internally. These projections give attachment to the anterior annular ligament, which with the palmar concavity forms a fibro-osseous canal for the passage of the flexor tendons and median nerve. The *superior aspect*, which is directed backwards as well as upwards, is convex, and articulates with the radius and triangular interarticular fibro-cartilage. The *inferior or metacarpal aspect* is somewhat undulating. The *inferior surface* of the first row is for the most part deeply concave, but externally it is convex. The *superior surface* of the second row is concavo-convex from without inwards, the concavity being formed by the trapezium and trapezoid, into which the scaphoid convexity above is received, whilst the con-

vexity is formed by the os magnum and unciform, and is received into the concavity above.

Structure.—The carpal bones are each composed of cancellated tissue, covered by a thin shell of compact bone.

Varieties.—The number of carpal bones is sometimes increased to nine, which is brought about in one or other of the following ways : (a) the scaphoid, semilunar, trapezium, or os magnum may be divided into two parts ; (b) the styloid process at the base of the third metacarpal, or the hook-like process of the unciform, may remain an independent ossicle ; or (c) there may be a persistent *os centrale*, situated on the dorsal aspect between the scaphoid, trapezoid, and os magnum.

Ossification.—The carpal bones are all cartilaginous at birth. Each ossifies from **one centre**, in the following order, and at the following periods approximately :

Os magnum, 1st year.
Unciform, 2nd year.
Cuneiform, 3rd year.
Semilunar, 5th year.

Trapezium, 5th year.
Scaphoid, 6th year.
Trapezoid, 7th year.
Pisiform, 12th year.

The Os Centrale.—This appears as an independent cartilage in the *second month* of intra-uterine life on the dorsal aspect of the carpus between the cartilaginous scaphoid, trapezoid, and os magnum. As a general rule it joins the cartilage of the scaphoid in the *third month*, but it may ossify independently, and remain persistent, as in the water tortoises and many apes. It is the representative of the navicular or scaphoid bone of the tarsus.

The Metacarpus.

The **metacarpus** forms the palm of the hand, and is composed of five long bones, which are named numerically from without inwards, that of the thumb being the first. Each bone is divisible into a shaft and two extremities, proximal and distal. The **shaft** is triangular, except in the first, in which it is compressed from before backwards. It is longitudinally concave on the palmar aspect, and presents three surfaces, two lateral and a dorsal. The *lateral surfaces* give attachment to interosseous muscles, and are separated from each other by an anterior border. The *dorsal surface* over its proximal third presents a median ridge, which in the case of the fifth metacarpal is placed towards the inner side. Over the distal two-thirds the ridge bifurcates, its divisions passing each to the dorsal tubercle on the side of the head, and enclosing between them a flat triangular surface.

The **head** or **distal extremity**, which articulates with a first phalanx, is convex, and covered by cartilage, except laterally. The cartilage is prolonged farther on the palmar than on the dorsal surface, and terminates anteriorly in a concave border, the extremities of which form small *cornua*. Laterally the head is compressed, and presents at either side a dorsal tubercle and palmar depression for the lateral metacarpo-phalangeal ligament.

The **base** or **proximal extremity** is irregularly quadrilateral, being broader on its dorsal than palmar surface, and it articulates

superiorly with the carpus, and at either side with its fellows, except in the case of the first.

The First Metacarpal Bone.—This is shorter than any of the others, and its shaft is compressed from before backwards. The *palmar aspect*, which has an inclination inwards, has the anterior border placed nearer the inner than the outer side. The outer margin and adjacent part of the palmar aspect give insertion to the opponens pollicis, and the inner margin over its proximal half gives origin to the outer head of the first dorsal interosseous. The *dorsal surface* is slightly convex, and is destitute of the ridge which characterizes the others. The **head** is elongated transversely, and presents on its palmar surface two shallow depressions for the sesamoid bones. The **base** is transversely oval,

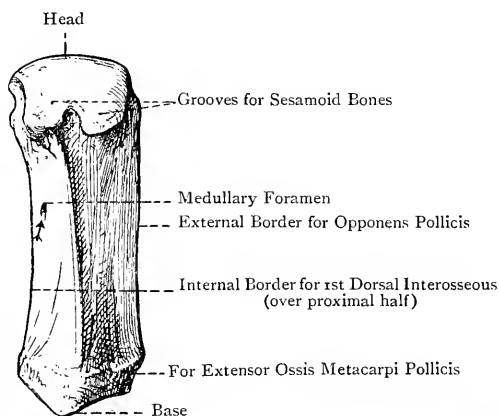


FIG. 117.—THE FIRST RIGHT METACARPAL BONE (PALMAR VIEW).

and has a saddle-shaped articular surface for the trapezium, which is concave from before backwards, and convex from side to side. Externally it presents a tubercle for the insertion of the extensor ossis metacarpi pollicis, and internally it gives origin to the deep head of the flexor brevis pollicis.

Articulations.—*Superiorly* with the trapezium, and *inferiorly* with the first phalanx of the thumb, and the two sesamoid bones.

The Second Metacarpal Bone.—This is the longest. Its **base**, which is the largest, is deeply excavated superiorly for the trapezoid, being concave from side to side. Internal to this, it rises into a prominent border, which presents a faceted strip for the os magnum, and externally at the back part there is a small facet for the trapezium. The inner side presents an antero-posterior facet, notched at the centre of its lower border, for the third metacarpal. The *palmar aspect* gives insertion to the principal part of the tendon of the flexor carpi radialis, and origin to a portion of the adductor obliquus

pollicis. The dorsal aspect at its outer part gives insertion to the extensor carpi radialis longior, and at its inner part to a small slip of the extensor carpi radialis brevior, there being a notch between the two impressions. The **shaft** gives origin to the first and second dorsal, and first palmar, interossei.

Articulations.—*Superiorly* with the trapezium, trapezoid, and os magnum, *internally* with the third metacarpal, and *inferiorly* with the first phalanx of the index finger.

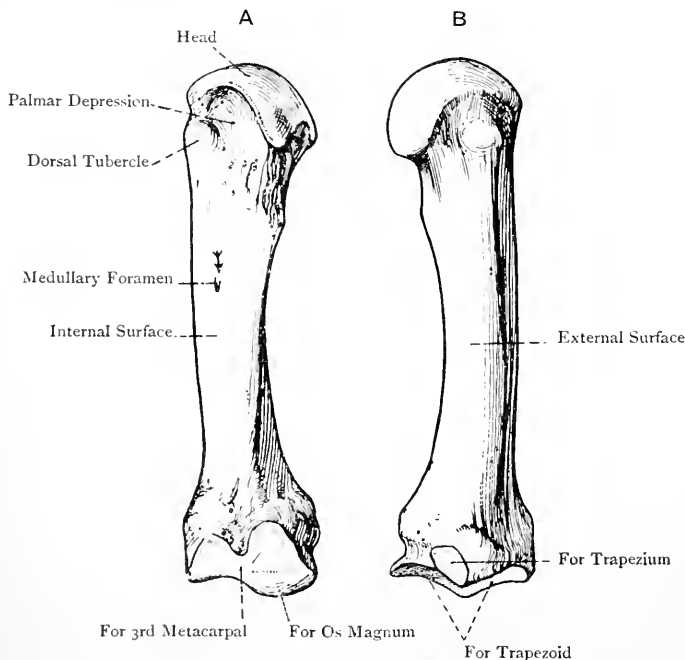


FIG. 118.—THE SECOND RIGHT METACARPAL BONE.

A, Internal View; B, External View.

The Third Metacarpal Bone.—This is next in length to the second. Its distinctive character is the styloid process at the base. The superior surface of the **base** articulates with the os magnum. The outer side presents an antero-posterior facet, notched at its lower border, for the second metacarpal. The inner side presents two circular facets, separated by a rough vertical groove, for the fourth metacarpal. The palmar aspect gives insertion to a slip of the flexor carpi radialis, and origin to a portion of the adductor obliquus pollicis. The dorsal aspect externally gives insertion to the principal part of the extensor carpi radialis brevior, and it is projected upwards at its outer angle into the **styloid process**. The anterior border of the **shaft**, over its distal two-thirds, gives origin to the

adductor transversus pollicis, and the shaft also affords origin to the second and third dorsal interossei.

Articulations.—*Superiorly* with the os magnum, and the second and fourth metacarpal bones, and *inferiorly* with the first phalanx of the middle finger.

The Fourth Metacarpal Bone.—This is shorter than the third, and its base is small. The outer side of the **base** presents two circular facets, separated by a rough vertical groove, for the third metacarpal. The inner side has a semi-oval facet for the fifth metacarpal. The superior surface presents two facets. One is large for the unci-

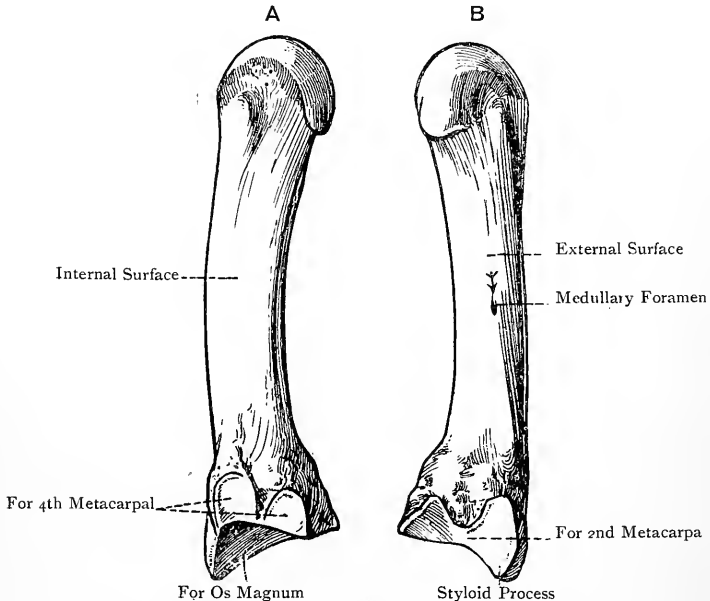


FIG. 119.—THE THIRD RIGHT METACARPAL BONE.

A, Internal View; B, External View.

form, whilst the other, situated at the outer and posterior part, is small for the os magnum. The **shaft** gives origin to the third and fourth dorsal, and second palmar, interossei.

Articulations.—*Superiorly* with the os magnum, unciform, and third and fifth metacarpals, and *inferiorly* with the first phalanx of the ring finger.

The Fifth Metacarpal Bone.—This is shorter than the fourth, but longer than the first. The superior surface of the **base** presents a quadrilateral facet for the unciform. The outer side has a semi-oval facet for the fourth metacarpal, and the inner side presents a rounded tubercle for the insertion of the extensor carpi ulnaris. The inner

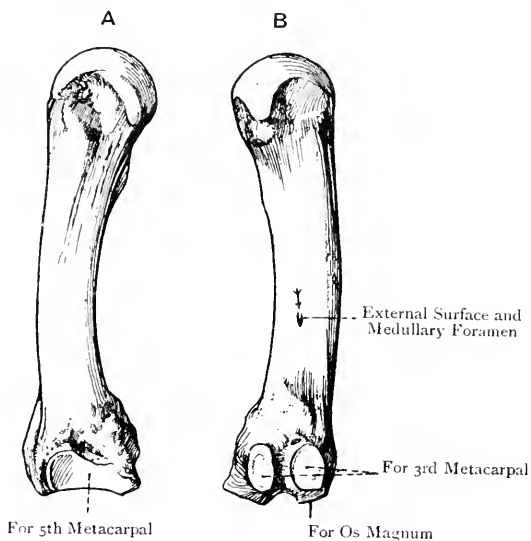


FIG. 120.—THE FOURTH RIGHT METACARPAL BONE.
A, Internal View; B, External View.

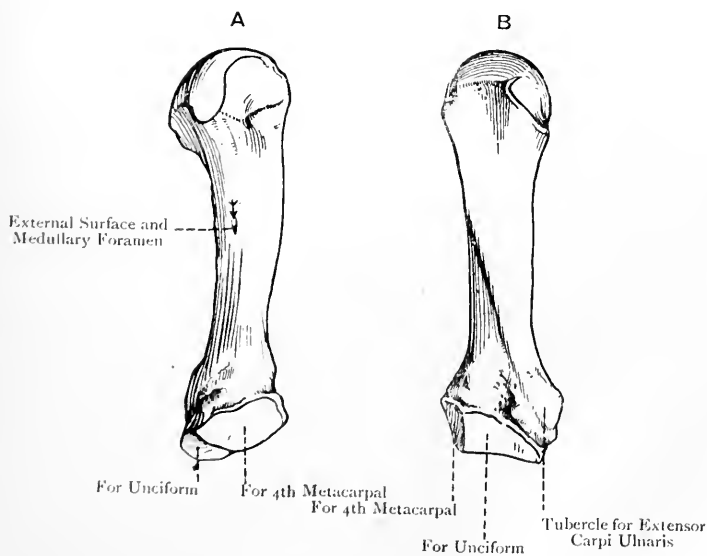


FIG. 121.—THE FIFTH RIGHT METACARPAL BONE.
A, External View; B, Dorsal View.

margin of the **shaft** gives insertion to the *opponens minimi digiti*, and the shaft also affords origin to the fourth dorsal, and third palmar, interossei.

Articulations.—*Superiorly* with the unciform, *externally* with the fourth metacarpal, and *inferiorly* with the first phalanx of the little finger.

Each metacarpal bone presents a **medullary foramen**, that of the first, and usually that of the second, being situated on the *inner* or *ulnar side* of each shaft, whilst those of the third, fourth, and fifth are situated on the *outer* or *radial side*.* The foramen of the first and the canal to which it leads are directed *downwards* towards the head, but those of the other four are directed *upwards* towards the base. The medullary artery of the *first* metacarpal is furnished by the *arteria princeps pollicis*, those of the *second* and *third* are branches of the first palmar interosseous, that of the *fourth* is furnished by the second palmar interosseous, and that of the *fifth* by the third palmar interosseous, arteries.

Structure.—The structure is that of a long bone.

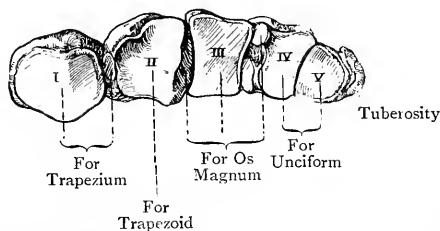


FIG. 122.—THE BASES OF THE RIGHT METACARPAL BONES (SUPERIOR VIEW).

The **metacarpus as a whole** is concave from side to side, and also longitudinally, on its palmar aspect, whilst the dorsal aspect is convex. The first metacarpal stands off at an angle from its fellows, and occupies a more anterior plane, thus fitting it for the important movement of *opposition* on the part of the thumb. The other four metacarpals lie very nearly parallel with each other. They articulate with one another by their bases, but diverge slightly towards their heads, where they are connected on their palmar aspects by the transverse metacarpal ligament. Between the five bones there are four intervals, called *interosseous spaces*, the first being that between the first and second bones.

The Phalanges.

The **phalanges** are also known as *ossa internodia*, from their position between the joints of the fingers. The fingers, of which they form the framework, are called pollex or thumb, index, middle,

* Of 100 second metacarpal bones examined, 59 had the medullary foramen on the inner side, and 41 on the outer.

ring, and little, respectively. The number of phalanges is fourteen, three for each of the four inner fingers, and two for the thumb. They are arranged in rows, both longitudinally and transversely, and they diminish in length from above downwards. They are distinguished as first or proximal, second or intermediate, and third, distal, or ungual, except in the case of the thumb, where the second is wanting.

The First Phalanx.—The **shaft** is compressed from before backwards, flat and concave longitudinally on the palmar aspect, and convex on the dorsal. The palmar surface presents at either side a rough border for the sheath of the flexor tendons. The **proximal end** or **base** is enlarged, and presents superiorly a concave articular surface, transversely oval, for the head of a metacarpal bone, and at either side a slight tubercular enlargement. The **distal end** is small, and presents a trochlear surface, grooved at the centre and elevated at either side of this into a small condyle, for articulation with the second phalanx, except in the case of the thumb, where it articulates with the ungual phalanx. The cartilage of the distal end is prolonged more on the palmar aspect than on the dorsal. At either side it presents a depression for the lateral interphalangeal ligament.

The Second Phalanx.—This is shorter and smaller than the first, from which it is distinguished by having on its **proximal end** or **base** two shallow articular depressions, separated by a median antero-posterior ridge, for the distal end of the first phalanx. The **distal end** resembles that of a first phalanx, except that it is smaller. The **shaft** resembles that of a first. Its palmar surface presents at the centre of the lateral borders two rough impressions, one at either side, which give insertion to the divisions of a superficial flexor tendon. The dorsal surface of the base is marked by a rough transverse ridge for the insertion of the middle division of a common extensor tendon.

The Third Phalanx.—This is of small size. The **proximal end** or **base** resembles that of a second phalanx, and has in front a rough transverse ridge for the insertion of a deep flexor tendon, whilst the dorsal surface gives insertion to the two lateral divisions of a common extensor tendon. The **distal end** presents a rough, tapering, convex

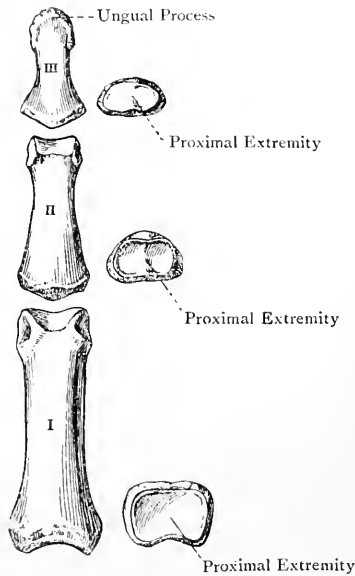


FIG. 123.—THE PHALANGES OF THE MIDDLE FINGER (DORSAL VIEW).

border, the roughness being continued for a little on the palmar aspect. This roughness, which is semilunar, is called the *ungual process*, and it supports the nail and the tissues forming the pulp of the finger.

The two phalanges of the thumb are of large size.

Special Muscular Attachments.—The base of the proximal phalanx of the thumb gives insertion externally to the abductor pollicis and superficial head of the flexor brevis pollicis, internally to the deep head of the flexor brevis pollicis, adductor obliquus pollicis, and adductor transversus pollicis, and posteriorly to the extensor brevis pollicis. The base of the distal phalanx gives insertion anteriorly to the flexor longus pollicis, and posteriorly to the extensor longus pollicis. The base of the proximal phalanx of the index finger gives partial insertion to the first dorsal interosseous externally, and the first palmar interosseous internally. The base of the proximal phalanx of the middle finger gives partial insertion to the second dorsal interosseous externally, and the third dorsal interosseous internally. The base of the proximal

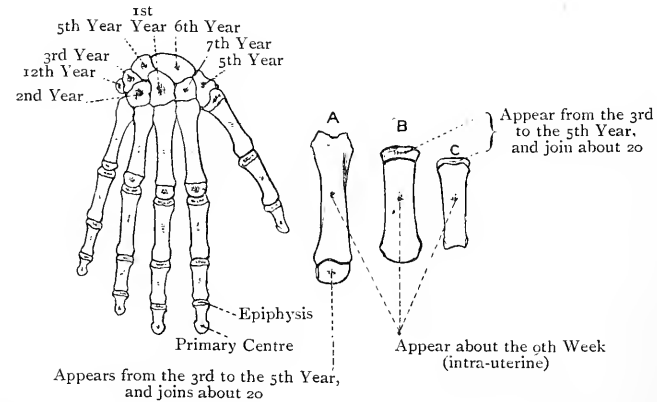


FIG. 124.—OSSIFICATION OF THE BONES OF THE HAND.

A, 2nd Metacarpal ; B, 1st Metacarpal ; C, 1st Phalanx.

phalanx of the ring finger gives partial insertion to the second palmar interosseous externally, and the fourth dorsal interosseous internally. The base of the proximal phalanx of the little finger gives partial insertion to the third palmar interosseous externally, and insertion to the abductor minimi digiti (partially) and flexor brevis minimi digiti internally.

The **medullary foramen** of each phalanx is situated on the palmar aspect of the shaft, not far from the distal end. It may be single, in which case it is mesially placed, or there may be two, one close to each lateral border. In all cases the direction of the foramen and the canal to which it leads is *downwards* towards the distal end. The medullary arteries are furnished by the corresponding palmar digital arteries.

Structure.—The structure is that of a long bone. In the terminal phalanges the medullary canal is replaced by cancellated tissue with wide meshes.

The Sesamoid Bones.—These are usually two in number, and are placed on the palmar aspect of the head of the first metacarpal bone. They are originally nodules of cartilage, one of which is developed in the tendon of insertion of the superficial head of the flexor brevis pollicis, and the other in that of the adductor obliquus pollicis. Similar ossicles are sometimes met with on the palmar aspects of the heads of the second and fifth metacarpal bones.

Ossification of the Metacarpal Bones and Phalanges.—Each of these bones ossifies in cartilage from **one primary, and one secondary, centre.** The primary centre appears about the *ninth week* of intra-uterine life at the middle of the shaft, except in the case of the unguis phalanges, in which it appears at the distal end. In the inner four metacarpal bones the epiphysis is placed at the distal end or head, but in the first metacarpal bone (that of the thumb), and in all the phalanges, it is placed at the proximal end or base. The secondary centre in each case appears from the *third* to the *fifth year*, and the epiphyses are united to their respective shafts about the *twentieth year.* The first metacarpal bone has sometimes a thin distal epiphysis, as well as a proximal, which begins to ossify about the *eighth year*, and joins soon thereafter; and the second metacarpal bone has sometimes a proximal epiphysis, as well as a distal. The first metacarpal bone, being a phalanx as regards its epiphysial ossification, is regarded by some as the proximal phalanx of the thumb, according to which view the bone wanting in the thumb is the metacarpal bone. The styloid process of the third metacarpal bone has sometimes a special centre, and, instead of joining the rest of the bone, it may remain persistent as a supernumerary bone of the carpus, or it may unite with the postero-internal angle of the trapezoid.

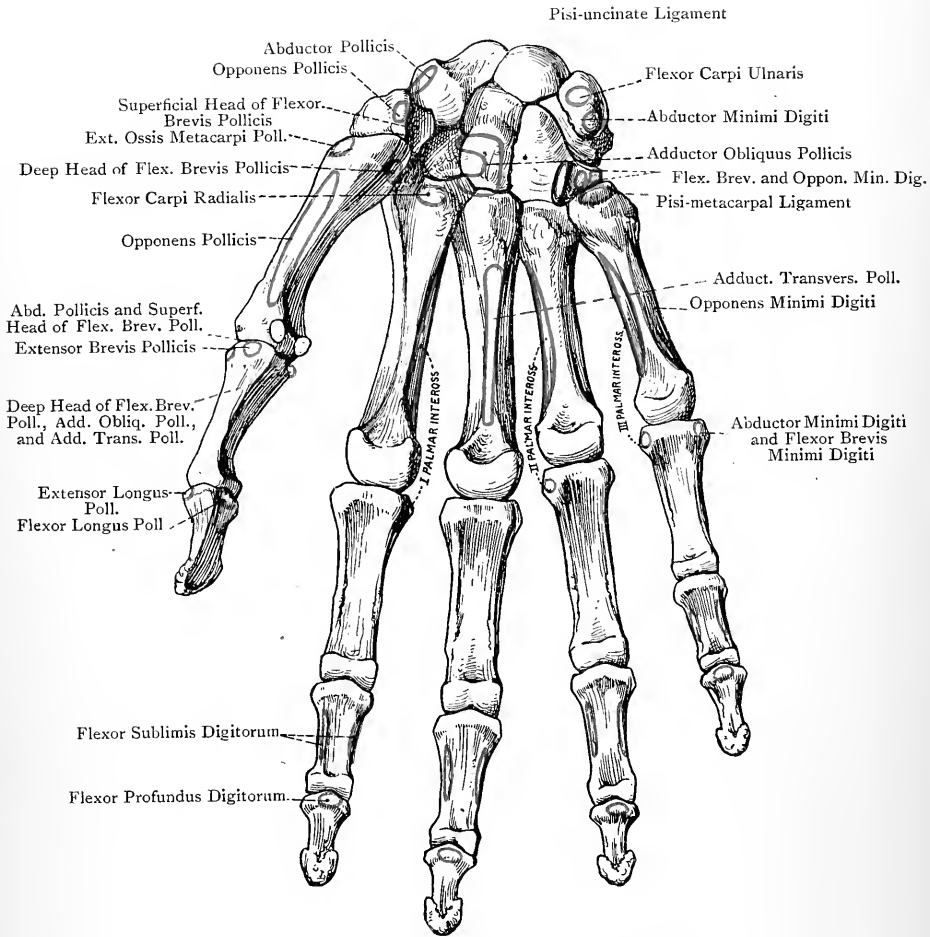


FIG. 125.—THE RIGHT HAND (PALMAR SURFACE).

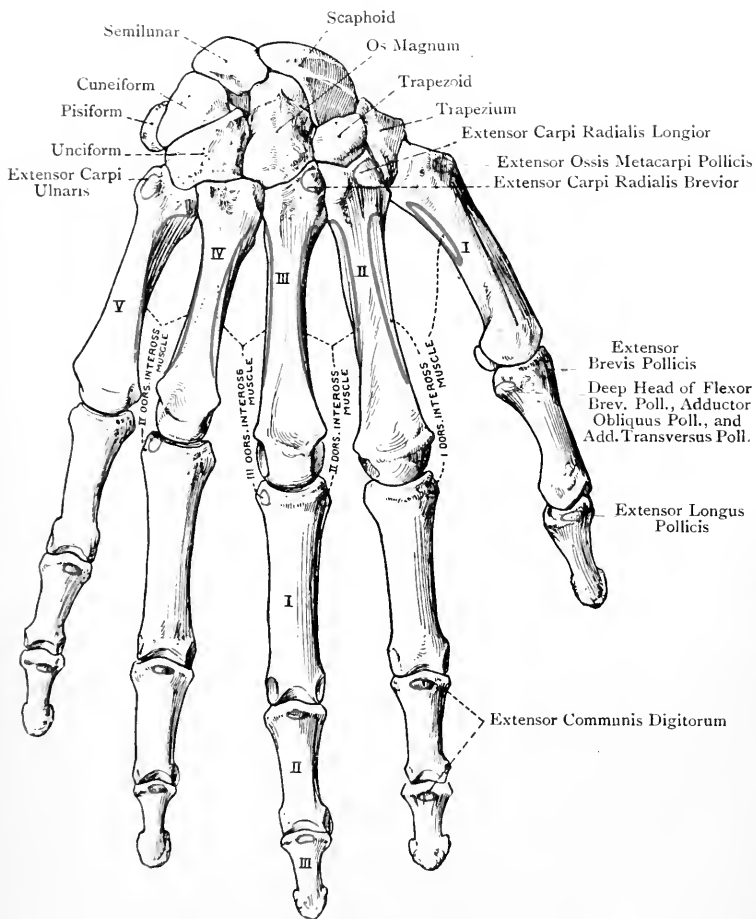


FIG. 126.—THE RIGHT HAND (DORSAL SURFACE).

IV. THE BONES OF THE LOWER LIMB.

The **lower limb** is arranged in four divisions, namely, hip, or pelvic girdle, thigh, leg, and foot. The **pelvic girdle** consists of the os innominatum; the **thigh** comprises the femur, with which is associated the patella; the **leg** is composed of the tibia and fibula; and the **foot** is subdivided into a *tarsus*, consisting of seven bones, a *metatarsus*, comprising five bones, and *phalanges*, which are fourteen in number.

The Os Innominatum.

The **os innominatum** (**os coxæ**) forms the lateral, and one half of the anterior, wall of the pelvis. It is much twisted, quadrilateral, and constricted about the centre. The external surface is characterized by the acetabulum, and below and internal to this is the obturator foramen. In early life the bone is composed of three parts—**ilium**, **ischium**, and **os pubis**—which unite in the acetabulum, and in the adult it is described under these three divisions.

The **ilium** is the expanded portion above the acetabulum, of which it forms rather less than the upper two-fifths. It presents three borders and two surfaces.

The **superior border** or **crest** is thick over its anterior and posterior thirds, but thin over the middle third. It presents two curves—**anterior** with the concavity directed inwards, and **posterior** with the concavity outwards. Anteriorly it terminates in the *anterior superior spine*, which gives attachment to Poupart's ligament and a portion of the sartorius. Posteriorly it ends in the *posterior superior spine*, which gives attachment to the oblique sacro-iliac ligament. The crest has two lips and an intervening space. The *outer lip* presents a tubercular prominence about 3 inches from the anterior superior spine. Over its whole extent this lip gives attachment to the iliac fascia lata; for $1\frac{1}{2}$ inches in front, to the tensor fasciæ femoris; over its anterior half, to the obliquus externus abdominis; and a little behind this, to the latis-simus dorsi. The *intervening space* over its anterior two-thirds gives origin to the obliquus internus abdominis, and over its posterior fifth, to the erector spinæ. The *inner lip* over its anterior two-thirds gives origin to the transversalis abdominis, and for about 2 inches posteriorly, to the ilio-lumbar ligament and quadratus lumborum. Immediately within the inner lip, over its anterior two-thirds, the fascia transversalis and fascia iliaca take attachment.

The **anterior border** extends from the anterior superior spine to the ilio-pectineal eminence. Superiorly it presents the anterior inter-spinous notch, the upper part of which gives partial origin to the sartorius. Below this notch is the *anterior inferior spine*, which gives origin anteriorly to the straight head of the rectus femoris, and inferiorly, to the ilio-femoral ligament. Internal to this spine

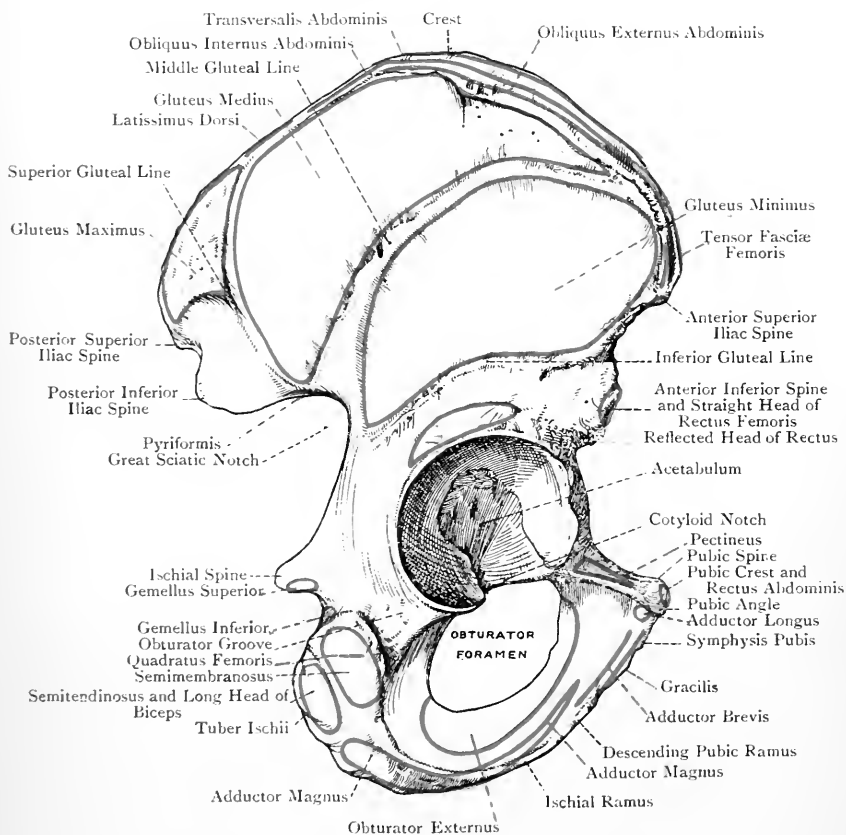


FIG. 127.—THE RIGHT OS INNOMINATUM (EXTERNAL VIEW).

there is a groove for the passage of the ilio-psoas, and internal to the groove is the *ilio-pectineal eminence*, which marks the junction of the ilium and superior pubic ramus. This eminence gives attachment to the ilio-pectineal intermuscular septum, and, it may be, partial insertion to the psoas parvus.

The **posterior border** extends from the posterior superior spine to a point a little below the deepest part of the great sciatic notch, where there is usually a faint transverse line on the external surface, indicating the place of junction of the ilium and ischium. Superiorly it presents the posterior interspinous notch, and below this the *posterior inferior spine*, which gives attachment to the great sacro-sciatic ligament, whilst immediately below this it gives origin to fibres of the pyriformis. Inferiorly the posterior border forms the upper part of the great sciatic notch, over which the pyriformis passes as it leaves the pelvis.

The **external surface** or **dorsum illi**, concavo-convex from behind forwards, is traversed by three ridges, called the superior, middle, and inferior gluteal, or curved, lines. The *superior gluteal line* commences at the outer lip of the crest about 2 inches in front of the posterior superior spine, and passes downwards and forwards to the upper part of the great sciatic notch. The surface which it cuts off is semilunar, and its upper part is rough for the origin of fibres of the gluteus maximus. The *middle gluteal line* commences at the outer lip of the crest $1\frac{1}{2}$ inches behind the anterior superior spine, and passes backwards and downwards to the upper part of the great sciatic notch, where it terminates close to the superior line. The surface included between the middle gluteal line, crest, and superior gluteal line, which is falciform, gives origin to the gluteus medius. The *inferior gluteal line* commences at the lower part of the anterior interspinous notch, whence it passes backwards to the deepest part of the great sciatic notch. The space between the inferior and middle gluteal lines gives origin to the gluteus minimus. Between the front part of the inferior gluteal line and the margin of the acetabulum there is a short transverse groove, which gives origin to the reflected head of the rectus femoris. The iliac portion of the bone is very thin and translucent toward the upper part of the middle third, where it is sometimes perforated, and it presents a strong rounded ridge, leading upwards from the margin of the acetabulum to the tubercular eminence on the outer lip of the crest. There is also a strong bar of bone extending from the upper margin of the acetabulum to the auricular surface on the internal aspect.

The **internal surface** is divisible into an anterior, and a posterior, portion. The *anterior division*, which represents two-thirds, is subdivided into a small lower, and large upper, part by the iliac portion of the ilio-pectineal line, the direction of which is forwards and downwards. The part below and behind the line enters into the lateral wall of the pelvis, and gives origin to a portion of the obturator internus. The part above the line is extensive and concave, and

forms the **iliac fossa**, which lodges the iliacus muscle. The iliac portion of the ilio-pectineal line gives attachment to the fascia iliaca, and for about an inch posteriorly to the parietal pelvic fascia. It may also give partial insertion to the psoas parvus near the ilio-pectineal eminence. The *posterior division* is subdivided into auricular, ligamentous, and muscular portions. The *auricular division*, antero-inferior in position, is broad in front and narrow behind, where it extends over the inner aspect of the posterior inferior spine. It is covered by cartilage in the recent state, and articulates with the auricular surface of the sacrum. The *ligamentous division*, situated above and behind the auricular, presents an elevation, called the tuberosity, for the posterior sacro-iliac ligament, its surface being marked by several pits. The *muscular division*, placed superiorly, gives origin to fibres of the multifidus spinæ.

The **ischium** forms the lower and back part of the bone, and is divisible into a body, tuberosity, and ramus. The **body** contributes rather more than two-fifths to the acetabulum, and forms the greater portion of its non-articular part. It is somewhat triangular, the truncated apex being directed downwards, and its surfaces are internal, external, and posterior. The *internal surface* extends from near the centre of the ilio-pectineal line to the ischial spine, and is narrow above, but widens inferiorly before reaching the spine. Its place of junction with the ilium is indicated by a line passing from the ilio-pectineal eminence backwards and downwards to a point a little below the deepest part of the great sciatic notch. Its junction with the superior pubic ramus is marked by a line passing from the ilio-pectineal eminence downwards to the posterior margin of the obturator foramen about $\frac{3}{4}$ inch below its upper end. This surface gives origin to part of the obturator internus. The *external surface* enters into the acetabulum, and between that cavity and the tuberosity it presents the obturator groove for the tendon of the obturator externus. The upper part of this groove gives attachment to the ischio-capsular ligament. The *posterior surface* is limited externally by the brim of the acetabulum, behind by the posterior border, and below by the upper border, of the tuberosity. At the lower part it presents a portion of the obturator groove, and it supports the pyriformis, and the sciatic nerves and vessels.

The **borders**, like the surfaces, are internal, external, and posterior. The *internal border* forms a portion of the posterior margin of the obturator foramen, and is sharp for the obturator membrane. It separates the internal from the external surface. The *external border* forms the posterior part of the margin of the acetabulum, and gives attachment to a part of the cotyloid ligament. The *posterior border* is continuous with that of the ilium. Superiorly it forms the lower part of the great sciatic notch, below which it presents a projection, called the *spine*, which has an inward curve towards the pelvis, and gives attachment to the

following structures: the small sacro-sciatic ligament at the tip, the levator ani, coccygeus, and white line of the pelvic fascia on the inner surface, and the gemellus superior along the lower border. The external surface (back) supports, from within outwards, the pudic nerve, internal pudic vessels, and nerve to the obturator internus.

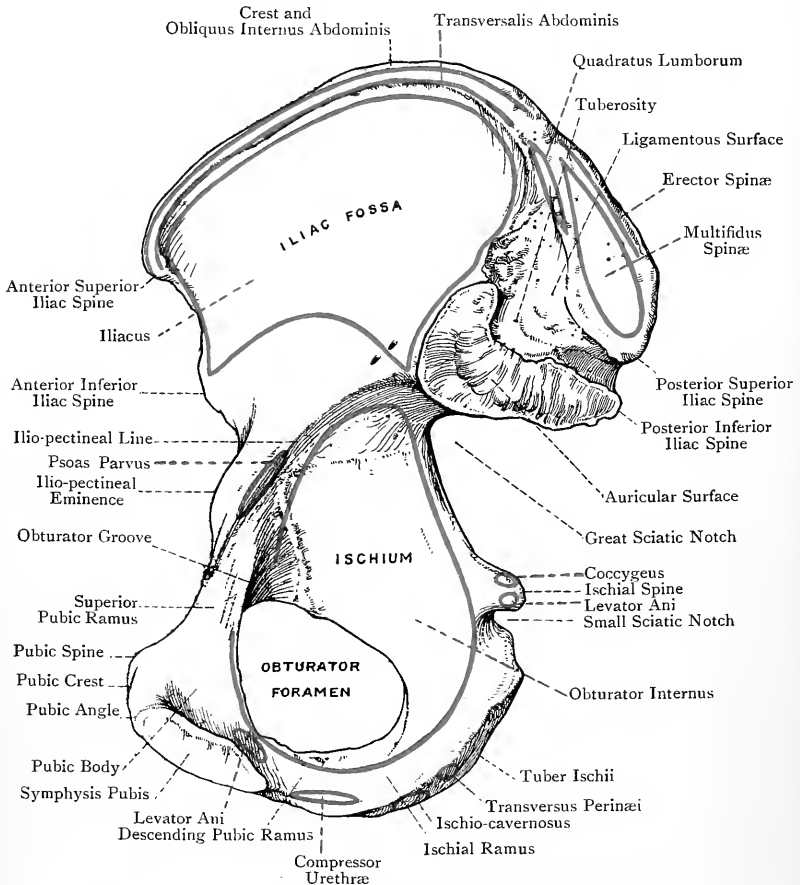


FIG. 128.—THE RIGHT OS INNOMINATUM (INTERNAL VIEW).

Below the spine is the small sciatic notch, which is covered by cartilage in the recent state for the play of the tendon of the obturator internus.

The **tuberosity (tuber ischii)** forms the thick dependent part, and supports the body in the sitting posture. The *upper border* limits inferiorly the obturator groove and small sciatic notch, and

in the latter situation it gives origin to the gemellus inferior. The *inner border* is prominent and sharp, and gives attachment to the great sacro-sciatic ligament. The *outer border* gives origin to the quadratus femoris. The *anterior border* is sharp and prominent, and forms the lower part of the posterior margin of the obturator foramen. The surfaces are postero-inferior, external, and internal. The *postero-inferior surface* lies between the outer and inner borders, and is divided into two parts. The *posterior portion* is somewhat quadrilateral, and is subdivided into two parts by a diagonal line directed downwards, forwards, and outwards. The upper and outer part gives origin to the semimembranosus, and the lower and inner, to the conjoined long head of the biceps and semitendinosus. The *inferior portion*, which is in line with the inner margin of the ramus, is rough and triangular, and gives origin to fibres of the adductor magnus. The *external surface* is situated between the outer and anterior borders, and supports the obturator externus. The *internal surface* is placed between the inner and anterior borders. It looks towards the ischio-rectal fossa, and gives origin to fibres of the obturator internus.

The **ramus** is the compressed portion which extends upwards and inwards, from the tuberosity, on the anterior aspect of the obturator foramen, where it joins the inferior pubic ramus, the place of meeting being indicated externally by a rough ridge. The *outer border* is sharp for a portion of the obturator membrane, and forms part of the anterior margin of the obturator foramen. The *inner border* is thick, and anteriorly it is rough and everted, more so in the male than in the female, for the attachment of the fascia of Colles, crus penis, and ischio-cavernosus muscle. In the female this part gives attachment to the crus clitoridis and erector clitoridis. Elsewhere the inner border gives attachment to the triangular ligament and compressor urethræ. The *outer surface* gives origin, from within outwards, to portions of the adductor magnus and obturator externus. The *inner or pelvic surface* gives attachment to part of the obturator internus and parietal pelvic fascia. At its lower part, near the inner border, there is a sharp ridge which gives attachment to the falciform process of the great sacro-sciatic ligament.

The **os pubis** lies in the anterior wall of the pelvis, and is composed of a body and two rami, superior and inferior. The **body** is compressed from before backwards, and occupies an oblique plane, which is directed downwards and backwards. It presents three surfaces—*anterior, posterior, and internal*. The *anterior or femoral surface* has an inclination downwards. At its upper and inner part, below and external to the pubic angle, it gives origin to the adductor longus, and, lower down, to the following muscles, in order from within outwards—gracilis, adductor brevis, a small portion of the adductor magnus, and obturator externus. The *posterior or pelvic surface* has an inclination upwards, and gives attachment from without inwards to the obturator internus,

parietal pelvic fascia, levator ani, and pubo-prostatic ligament. The *internal surface* is oval, and occupies an oblique plane, which is directed downwards and backwards. It is covered by cartilage, and articulates with its fellow to form the symphysis pubis, a plate of fibro-cartilage intervening.

The borders are external and superior. The *external border*, which is sharp, looks into the obturator foramen, and gives attachment to part of the obturator membrane. The *superior border* or *crest* is thick, and about an inch long. At its outer extremity is the *pubic spine*, which may be blunt or sharp, for the attachment of Poupart's ligament, and internally is the *pubic angle*, which surmounts the internal surface. The crest gives attachment to the conjoined tendon, pyramidalis, and outer head of the rectus abdominis.

The **inferior ramus** passes downwards and outwards, and corresponds in all respects with the ischial ramus, which it joins. Its *anterior surface* gives origin, from within outwards, to the gracilis, adductor brevis, adductor magnus, and obturator externus. The structures attached to the *posterior surface* are portions of the obturator internus and parietal pelvic fascia.

The **superior ramus** extends outwards and upwards from the body to the ilio-pectineal eminence and anterior part of the acetabulum, of which latter it forms one-fifth. It lies above the obturator foramen, and is triangular. Superiorly, at the back part, is a prominent ridge, representing the pectineal portion of the *ilio-pectineal line*, which leads to the pubic spine, and gives attachment to the following structures: the pubic lamina of the fascia lata, pectineus, Gimbernat's ligament, and conjoined tendon. In front of this line is the *superior* or *pectineal surface*, which is sloped downwards and forwards, and is triangular. It supports the pectineus, and is limited antero-inferiorly by the *obturator crest*, which extends from the pubic spine to the anterior margin of the cotyloid notch. The *inferior surface* presents the *obturator groove* for the obturator vessels and nerve, the direction of which is downwards, forwards, and inwards. The *posterior surface* gives partial origin to the obturator internus.

The **acetabulum** or **cotyloid cavity** is situated on the outer surface of the bone, and is directed downwards, outwards, and forwards. It is deep and circular, and articulates with the head of the femur. The ischium forms rather more than two-fifths of it, the ilium rather less, and the os pubis the remaining fifth. It is surmounted by a prominent brim, upon which the cotyloid ligament is set, except at the anterior and inferior part, where there is the *cotyloid notch*, this being bridged over by the cotyloid and transverse ligaments. The capsular ligament is attached to the bone just outside the brim. The interior is divided into two parts — articular and non-articular. The articular portion is covered by cartilage, which is arranged in the form of a horseshoe, and surrounds the circumference, except opposite the cotyloid notch. The non-articular part,

which is formed mainly by the ischium, is depressed, and lodges the Haversian gland of the hip-joint.

The **obturator** or **thyroid foramen** lies below, and internal to, the acetabulum, its boundaries being formed by the ischium and os pubis. Its long diameter is directed downwards and outwards, and it is oval in the male, but triangular, with rounded angles, in the female. Its circumference is sharp for the obturator membrane, which closes the opening, except opposite the obturator groove superiorly, where it converts that groove into a fibro-osseous canal.

The **great** and **small sciatic notches** are situated on the posterior border of the bone, and are separated from each other by the spine of the ischium. The *great* notch is formed partly by the ilium, and partly by the ischium; and the *small* notch lies between the ischial spine and tuber ischii.

In the recent state these notches are converted into foramina by the great and small sacro-sciatic ligaments. For the structures which pass through these foramina, see the description of the gluteal region.

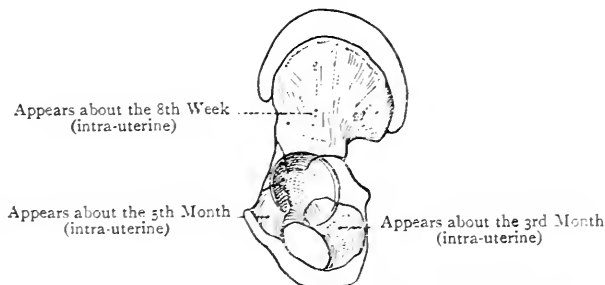


FIG. 129.—OSSIFICATION OF THE OS INNOMINATUM.

The os innominatum is pierced by a great number of nutrient foramina for arteries, the chief of which are situated as follows: along the inner aspect of the crest for branches of the deep circumflex iliac; in the iliac fossa near the auricular surface, where there are one or two for branches of the ilio-lumbar; on the external surface of the ilium, and around the margin of the acetabulum for branches of the gluteal; between the acetabulum and tuber ischii for branches of the obturator; on the ilio-pectineal eminence for branches of the deep circumflex iliac; and over the body of the os pubis for branches of the obturator, and of the pubic branches of the common femoral.

Articulations.—*Posteriorly* with the sacrum, *externally* with the femur, and *internally* with its fellow.

Ossification.—The os innominatum is ossified *in cartilage* from **3 primary** and **9 secondary centres**. The **primary centres** are iliac, ischial, and pubic. The **iliac centre** appears in the *8th week*; the **ischial centre** in the *3rd month*; and the **pubic centre** in the *5th month* in the superior pubic ramus.

The **ischial** and **inferior pubic rami** join about the *8th year*.

Acetabulum.—The **superior pubic ramus** is shut out from this cavity for some time by a triangular portion of cartilage, called the **pars acetabularis**. From its apex there is prolonged backwards a strip of cartilage (*ilio-ischial*). The entire cartilage resembles the letter Y, laid on its side. The open part of the Y is directed forwards, and forms the **pars acetabularis**. The Y cartilage has 3 *secondary centres*. One, called the *acetabular centre*, appears in the 12th year in the **pars acetabularis**, and ossification is completed by the 14th year. It then forms a distinct bone, called the **os acetabuli**, which joins the superior pubic ramus about the 16th year.

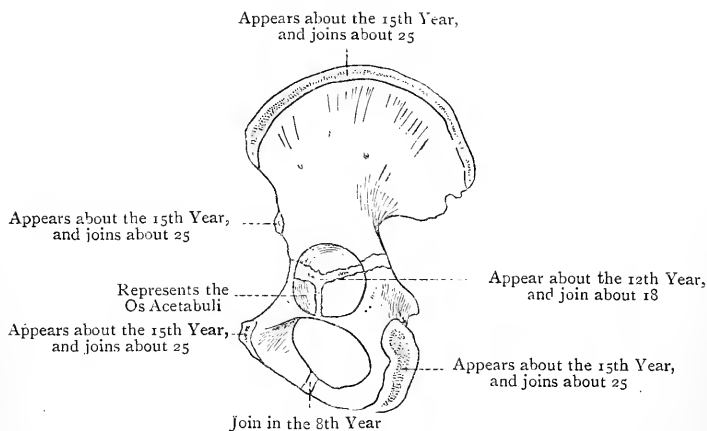


FIG. 130.—OSSIFICATION OF THE EPIPHYSES OF THE OS INNOMINATUM.

The *other two secondary centres* for the Y cartilage appear about the 14th year, one of them in the **ilio-ischial strip** or stem of the Y; and the other at the meeting of the two limbs and stem of the Y. The ossification of the bottom of the acetabulum is completed from the 16th to the 18th year.

Other Secondary Centres.—These are as follows: (1) One for the **crest**, one for the **anterior inferior iliac spine**, one (a thin scale) for the *surface* of the **tuber ischii**, and one for the **spine of the ischium**, each of these centres appearing about the 15th year; (2) one for the **pubic spine**, and one for the **pubic angle**, each of these two centres appearing about the 18th year. These epiphyses usually join about the 25th year.

The Pelvis.

The **pelvis** is formed by the ossa innominata, sacrum, and coccyx, the hip-bones constructing the anterior and lateral walls, whilst the sacrum and coccyx lie in the posterior wall. It is divided into two parts, called false pelvis and true pelvis, the division being effected by a plane passing through the upper border of the symphysis pubis, ilio-pectineal line, and sacral promontory.

The **false pelvis**, which lies above this plane, is formed by the iliac fossæ, and constitutes a part of the abdomen proper.

The **true pelvis** is situated below the plane referred to, and presents a brim or inlet, a cavity, and an outlet. The **brim** is formed in front by the upper border of the symphysis pubis, behind by the

sacral promontory, and between these two points by the following parts from before backwards—the angle, crest, and spine of the os pubis, the ilio-pectineal line, and the antero-inferior border of

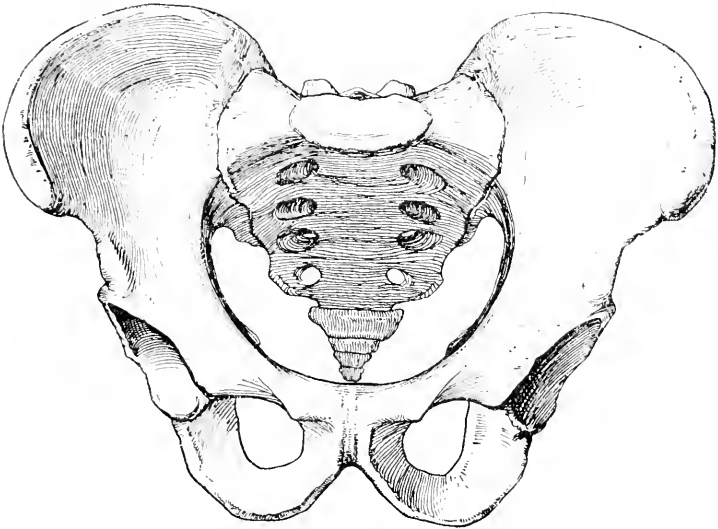


FIG. 131.—THE MALE PELVIS.

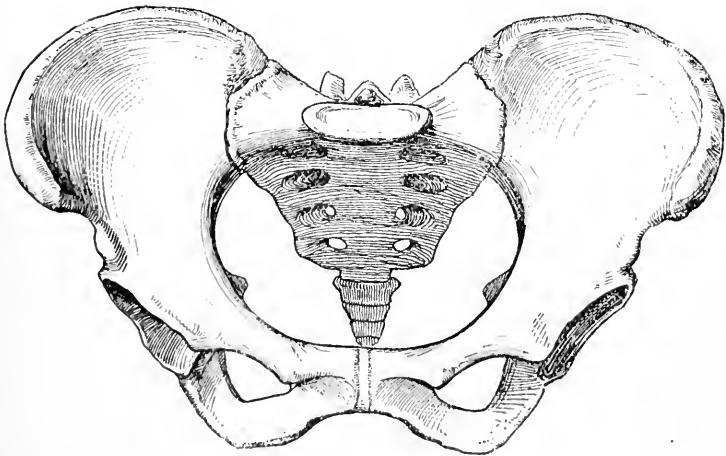


FIG. 132.—THE FEMALE PELVIS.

the ala of the sacrum. In the male it is cordate, the base of the heart, which is encroached upon by the sacral promontory, being directed backwards. In the female it is oval, the long diameter

being transverse. The **diameters** of the brim are *antero-posterior* or *conjugate*, *transverse*, *right oblique*, and *left oblique*. The antero-posterior or conjugate diameter extends from the upper border of the symphysis pubis to the sacral promontory; the transverse, from one ilio-pectineal line to the opposite, across the widest part of the brim; and the oblique, from one sacro-iliac articulation to the ilio-pectineal eminence of the opposite side. The oblique diameters are called right and left from the sacro-iliac articulations whence they extend.

The **cavity** is bounded in front by the bodies and rami of the pubic bones, behind by the sacrum and coccyx, and laterally by an extensive osseous plane, formed chiefly by the pelvic surface of the ischium, but also by that of the ilium, and terminating below in the incurved ischial spine. It is shallow in front, where its depth is from $1\frac{1}{2}$ to 2 inches, but deep behind, where it measures about $5\frac{1}{2}$ inches, following the curve of the sacrum. The plane of the anterior wall is oblique, being directed downwards and backwards. The posterior wall is curved, and at its upper part looks mainly downwards. The lateral wall is divided into two parts by an indistinct line extending downwards and backwards from the ilio-pectineal eminence to the spine of the ischium. These parts are spoken of as the anterior and posterior inclined planes of the ischium, the anterior looking slightly forwards and the posterior slightly backwards. The *conjugate diameter* of the cavity extends from the centre of the symphysis pubis to the upper margin of the third sacral segment; the *transverse*, from a point corresponding to the lower margin of the acetabulum on one side to the corresponding point on the other; and the *oblique*, from the centre of the great sacro-sciatic foramen on one side to the centre of the obturator membrane on the other.

The **outlet** presents three prominences, namely, the tuber ischii at either side, and the tip of the coccyx in the median line posteriorly. Its boundaries, at either side from before backwards, are as follows: the lower border of the symphysis pubis, inferior ramus of os pubis, ramus of ischium, tuber ischii, great sacro-sciatic ligament in the recent state, and tip of the coccyx. In front of an imaginary line connecting the ischial tuberosities is the *subpubic arch*, which is bounded at either side by the ischio-pubic ramus, and above by their meeting to form the *subpubic angle*. The arch is occupied by the triangular ligament of the urethra, and its plane is directed downwards and backwards. The *conjugate diameter* of the outlet extends from the lower border of the symphysis pubis to the tip of the coccyx, the *transverse* from one tuber ischii to the other, and the *oblique* from the middle of the lower border of the great sacro-sciatic ligament on one side to the place of union between the inferior pubic and ischial rami on the other.

The Inclination of the Pelvis.—In the erect posture the plane of the pelvic brim forms with the horizontal an angle of from 50 to 60 degrees, and the base of the sacrum is about $3\frac{3}{4}$ inches above the

upper border of the symphysis pubis. The brim is therefore directed upwards and forwards. An idea of this obliquity may be obtained by placing a pelvis against a wall in such a way that the anterior superior iliac spines and the upper border of the symphysis pubis will touch the wall so as to lie in the same vertical plane. A line connecting the tip of the coccyx with the lower border of the symphysis pubis forms with the horizontal an angle of about 11 degrees, and the tip of the coccyx is about $\frac{3}{4}$ inch above the subpubic angle. The direction of the outlet is downwards and backwards, principally downwards when the coccyx is extended. The plane of the symphysis pubis forms with the horizontal an angle of from 35 to 40 degrees. It is worthy of note that the sacro-vertebral angle is estimated at 117 degrees in the male, and as much as 130 in the female.

The Axes of the Pelvis.—The axes represent imaginary lines intersecting the planes of the brim, cavity, and outlet at right angles through their central points. The *axis of the brim* corresponds with a line drawn from the umbilicus to the sacro-coccygeal articulation, and its direction is downwards and distinctly backwards. The *axis of the outlet* represents a line drawn from the sacral promontory through the centre of the outlet, and its direction is downwards and very slightly backwards. The *axis of the cavity* intersects the planes having different inclinations, and is necessarily curved, the concavity being directed forwards. It is described as 'the perpendicular of a line drawn from the middle of the symphysis pubis to the centre of the sacro-coccygeal curve.' The average measurements of the axes of the female pelvis are as follows :

				Conjugate.	Transverse.	Oblique.
Brim	4 $\frac{1}{2}$	5 $\frac{1}{4}$	5
Cavity	5	5	5 $\frac{1}{4}$
Outlet	5	4 $\frac{3}{4}$	4 $\frac{1}{2}$

Sexual Differences.—The differences in the two sexes are as follows :

Female.

Bones smoother and more slender.
 Acetabula wide apart.
 True pelvis wider and shallower.
 Obturator foramen triangular.
 Ischial tuberosities wider apart and everted.
 Span of subpubic arch wide.
 Inner border of ischio-pubic ramus comparatively smooth.
 Brim transversely oval.
 Iliac more vertical.
 False pelvis narrower.
 Sacral promontory less projecting.
 Sacrum broader, shorter, and straighter.
 Coccyx more movably articulated with sacrum.
 Symphysis pubis shallower.

Male.

Bones rougher and more massive
 Acetabula not so wide apart.
 True pelvis narrower and deeper.
 Obturator foramen oval.
 Ischial tuberosities not so wide apart and inverted.
 Span of subpubic arch narrow.
 Inner border of ischio-pubic ramus strongly marked and everted.
 Brim cordate.
 Iliac less vertical.
 False pelvis wider.
 Sacral promontory more projecting.
 Sacrum narrower, longer, and more curved.
 Coccyx less movably articulated with sacrum.
 Symphysis pubis deeper.

The Pelvis of the Child.—The pelvis is of small size in the child. The iliac alæ are expanded, and the cavity is of small dimensions, so that a large part of the urinary bladder in both sexes lies in the hypogastric region of the abdomen. The sacro-vertebral angle is relatively greater, and the pelvis has consequently a greater inclination.

Varieties of Pelvis.—The proportion of the antero-posterior diameter to the transverse is the pelvic index. Pelves having an index above 95 are called *dolichopellic*, from 95 to 90 *mesatipellic*, and below 90 *platypellic*.

The Femur.

The **femur** extends from the hip to the knee, its direction being downwards, inwards, and slightly backwards. It is a long bone, and is divisible into a shaft and two extremities, upper and lower.

The **upper extremity** presents a head, neck, and two trochanters, great and small, together with anterior and posterior intertrochanteric lines. The **head** forms more than half a sphere, and its direction is upwards, inwards, and slightly forwards. Its surface is smooth and covered by cartilage, except at a point behind and below the centre, where it presents a rough depression. The *ligamentum teres* is attached to the upper part of this depression, which presents a small foramen for the passage of a nutrient artery. The head encroaches more upon the upper surface of the neck than on the under.

The **neck** forms with the shaft an angle of about 125 degrees on an average, the range being from 110 to 140. It is greater in the male than in the female. The direction of the neck is upwards, inwards, and slightly forwards. It is expanded at either extremity, especially towards the shaft, and it presents four aspects—*anterior*, *posterior*, *superior*, and *inferior*, of which the *posterior* and *inferior* are more extensive than the other two. The *anterior aspect* is on the same plane with the anterior surface of the shaft, from which it is separated by the *anterior intertrochanteric line*. This line passes downwards and inwards, and it presents at either extremity the *superior cervical*, and *inferior cervical*, tubercle. The anterior intertrochanteric line gives attachment along its cervical aspect to the anterior part of the capsular ligament of the hip-joint, including the ilio-femoral band. Its inferior relations are the vastus externus over about the upper third, and the crureus over about the lower two-thirds. The anterior aspect of the neck is entirely *intracapsular*, and is more or less ridged, being closely covered by the retinacula of the capsular ligament. The *posterior aspect* is of greater extent than the anterior, and is smooth and concave. It is separated from the shaft by the *posterior intertrochanteric line*, which presents at its junction with the posterior border of the great trochanter the *quadrate tubercle*, whence the *linea quadrati*, for the quadratus femoris muscle, descends. Only

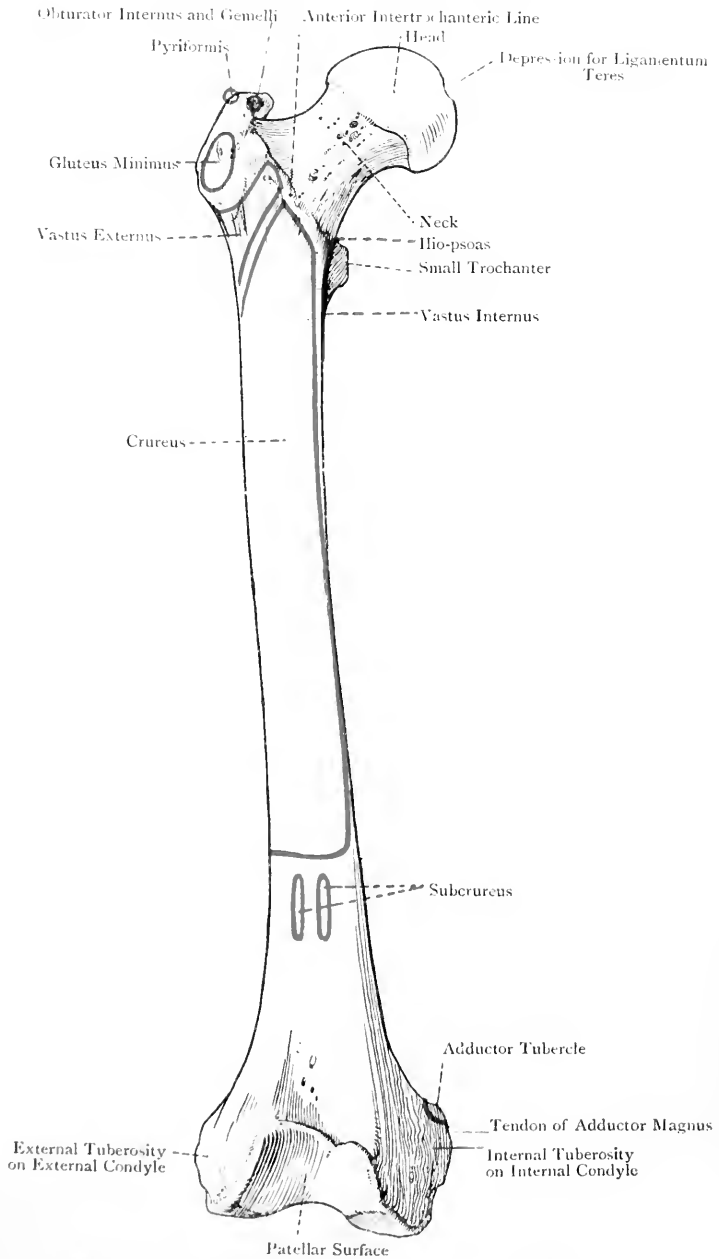


FIG. 133.—THE RIGHT FEMUR (ANTERIOR VIEW).

the upper two-thirds of this aspect are *intracapsular* and covered by retinacula, the capsular ligament being very loosely attached along the junction of the middle and lower thirds. The lower third is therefore *extracapsular*, and at its outer part it presents a horizontal groove which leads to the digital or trochanteric fossa, and lodges the tendon of the obturator externus. The *superior aspect* forms a short, almost horizontal border, which has a slight inclination downwards to the great trochanter. The *inferior aspect* forms a long, concave border, ending inferiorly at the small trochanter.

The neck is pierced by numerous nutrient foramina, which are more abundant and of larger size above and behind than elsewhere.

The head and neck receive their blood-supply from the obturator, sciatic, and external and internal circumflex, arteries.

The **great trochanter** is a quadrilateral eminence continuous with the outer surface of the shaft. It presents three surfaces and four borders. The external surface is marked by an oblique impression which extends from the postero-superior to the antero-inferior angle, and gives insertion to the gluteus medius. The anterior surface presents, towards its lower part, an impression for the insertion of the gluteus minimus. The internal surface at its lower part presents the *digital or trochanteric fossa* for the insertion of the obturator externus, whilst above and in front of this it affords insertion to the obturator internus and gemelli. The superior border, which is almost horizontal, meets the posterior border at a right angle, the pointed projection thus formed being called the postero-superior angle. Near the centre of this border there is an oval impression for the insertion of the pyriformis. The inferior border gives origin to fibres of the vastus externus. The anterior border skirts the front of the great trochanter, and ends above at the superior cervical tubercle. It also gives origin to fibres of the vastus externus. The posterior border is prominent and continuous with the posterior intertrochanteric line, the quadrate tubercle being situated at the junction of the two. The great trochanter is pierced by several nutrient foramina.

The **small trochanter** is a conical projection which springs from the posterior and inner aspects of the bone where the neck and shaft join. It gives insertion to the ilio-psoas, some of the fibres of the iliacus being inserted below and in front of it, where there is a depressed triangular surface lying between the prominence and the spiral line.

The trochanters receive their blood-supply from the circumflex arteries.

The **shaft** is longitudinally curved, the convexity being directed forwards. Its girth is least at the centre, and it expands at either end, more especially the lower. It is triangular in section in the middle third, the lateral angles being rounded off, and the posterior, formed by the *linea aspera*, prominent. Over its upper

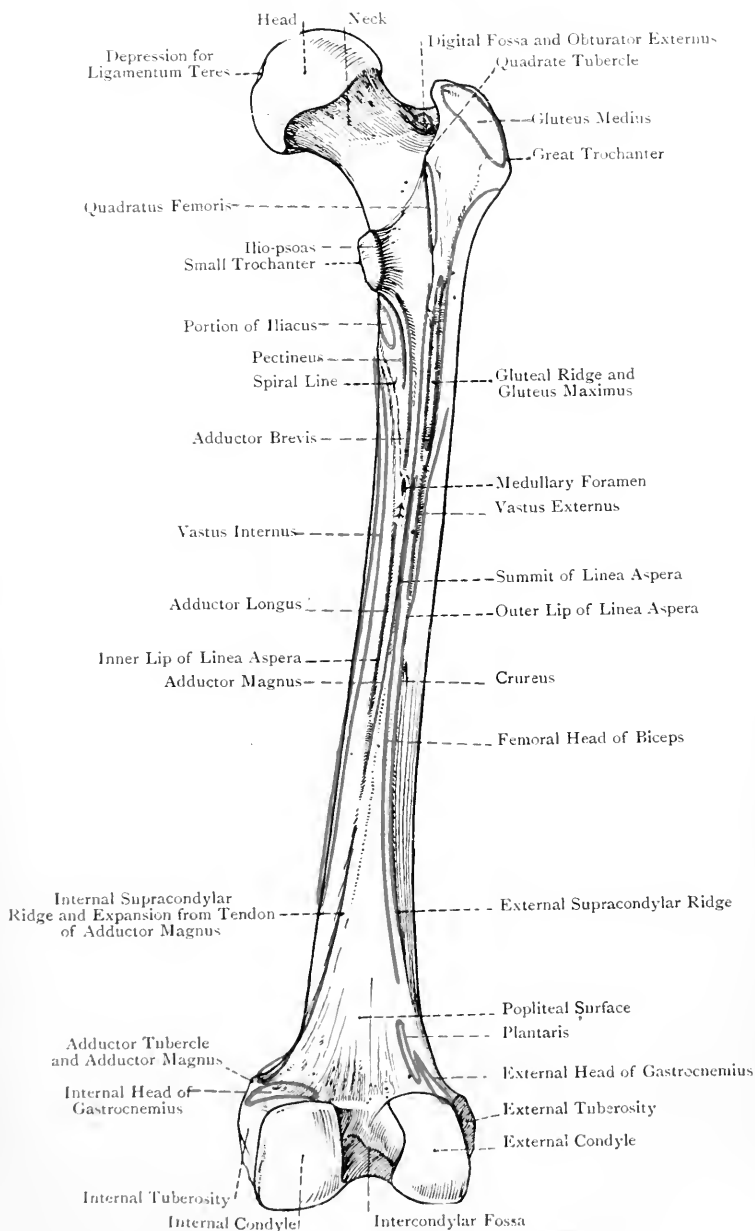


FIG. 134.—THE RIGHT FEMUR (POSTERIOR VIEW).

and lower thirds it is somewhat subcylindrical. The posterior aspect presents over its middle third a bold ridge, called the *linea aspera*, which has two lips, outer and inner, and a narrow intervening space. The *outer lip* gives attachment, from behind forwards, to the short head of the biceps, external intermuscular septum, vastus externus over its upper half, and crureus over its lower half. The *inner lip* gives attachment, from behind forwards, to the adductor magnus, adductor longus, internal intermuscular septum, and vastus internus. A little above the centre of the shaft, close to the inner lip, is the **medullary foramen** for a branch of the second, or third, perforating artery, the direction of the foramen and the canal to which it leads being *upwards* towards the head.

Over the upper third of the shaft the lips of the *linea aspera* diverge. The outer lip is prolonged to the base of the great trochanter posteriorly, and over about its lower 3 inches it is conspicuously rough, this portion being known as the *gluteal ridge*, which gives insertion to the lower part of the gluteus maximus. Close to the outer side of this ridge the vastus externus takes origin, and close to its inner side the upper fibres of the adductor magnus take insertion. The inner lip bifurcates. One division is prolonged in a winding manner round the inner aspect of the shaft, passing in front of the small trochanter and terminating at the inferior cervical tubercle, where it passes into the anterior intertrochanteric line. This winding division is called the *spiral line*, and it gives origin to the upper fibres of the vastus internus. The other division is prolonged to the back of the small trochanter, and it gives insertion over its upper third to the pectineus, and over its whole extent to the adductor brevis, the latter being behind the former. The relation of muscles at the back of the upper end of the shaft, from the small trochanter outwards to the outer margin of the gluteal ridge, is as follows: ilio-psoas; pectineus; adductor brevis; lower fibres of quadratus femoris; adductor magnus; gluteus maximus; and vastus externus. The narrow intervening space of the *linea aspera* between its two lips is in line with the *linea quadrati* above.

Over the lower third of the shaft the lips of the *linea aspera* diverge widely, and are prolonged to the condyles as the external and internal supracondylar ridges. These enclose between them a flat triangular area, called the *popliteal surface*, which is also known as the *trigonum femoris*. Over this region the periosteum is very thin, and this part of the bone is predisposed to necrotic changes. The popliteal surface forms the upper part of the floor of the popliteal space. The *external supracondylar ridge* gives attachment over its whole extent to the external intermuscular septum, and over about its upper two-thirds to the short head of the biceps and the crureus. For a short distance below, it gives origin to the plantaris, and immediately external to this, to fibres of the outer head of the gastrocnemius. The *internal supracondylar ridge* is interrupted about an inch below its commencement by a slight groove, which is produced by the femoral vessels, and at its lower extremity, close to the internal

condyle, there is a projection called the *adductor tubercle*, for the insertion of the tendon of the adductor magnus. Superiorly, for about an inch, this ridge gives insertion to a portion of the adductor magnus, and below the femoral groove to an expansion from its tendon.

The shaft presents three surfaces, anterior and two lateral, but these merge gradually into one another, except posteriorly in the situation of the *linea aspera* over the middle third. The *anterior* and *external surfaces* over about their upper three-fourths give origin to the crureus. The *internal surface* is non-muscular, and presents a characteristic elongated bare strip, which is merely covered by the vastus internus. The lower fourth of the anterior surface at its upper part gives origin to the subcrureus, and lower

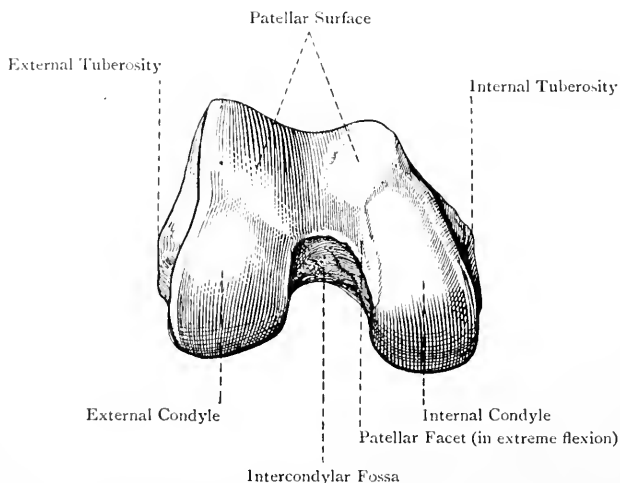


FIG. 135.—THE LOWER EXTREMITY OF THE RIGHT FEMUR.

down is covered by the suprapatellar bursa, and the pouch which the synovial membrane of the knee-joint sends upwards above the patellar surface of the bone.

The lower end of the shaft presents many nutrient foramina for the passage of branches of the anastomotic magna of the superficial femoral, and the articular branches of the popliteal, arteries.

The **lower extremity** presents an extensive articular surface, which is divided into three parts—*anterior* or *patellar*, and two *postero-inferior* or *condylar*. All three surfaces are continuous in front, but the condylar surfaces are widely separated behind by the intercondylar fossa. The *patellar surface* is trochlear, and presents a vertical groove with a convexity on either side. The groove is to the inner side of the centre, and the part external to it is broader, more prominent, and extends higher, than the internal part. The

upper border is therefore sloped inwards and slightly downwards. The greater forward prominence of the outer part of the surface explains why the patella is inclined inwards in extension of the knee-joint.

The **condyles** are convex from before backwards and from side to side. Posteriorly they become prominent, and on this aspect the external condyle extends a little higher than the internal. As viewed from below the external condyle is broad and short, the internal being long and narrow. When the femur is held vertically the internal condyle projects lower down than the external, and this brings the two condyles upon the same horizontal plane when the bone occupies its natural sloping position. The outer border of the external condyle is very nearly in the same line with the outer border of the patellar surface, and the outer border of the internal condyle is in the same line with the inner border of the patellar surface. The inner border of the internal condyle has a convex outline, and at its anterior part it turns outwards to the patellar surface. For the most part the condyles are parallel, the exception being the front part of the internal condyle, which inclines outwards to meet the patellar surface.

The demarcation between the condylar surfaces and the patellar surface is clearly marked at either side. The external condyle is separated from the patellar surface by a slightly elevated line and groove, extending outwards and slightly forwards from the front and outer part of the intercondylar fossa to the outer border of the cartilaginous surface, where there is a depression which receives the anterior part of the external semilunar fibro-cartilage during extension of the knee-joint. The internal condyle is separated from the patellar surface by a line and groove, extending from near the front and inner part of the intercondylar fossa forwards and slightly inwards to the inner border of the cartilaginous surface, at a point about 1 inch below the inner end of the upper border of the patellar surface. At this latter point there is a depression which receives the anterior part of the internal semilunar fibro-cartilage during extension of the knee-joint. The line and groove just referred to do not extend quite close to the intercondylar fossa. The groove subsides, but the line sweeps backwards in a curved manner along the outer part of the inner condylar surface, thus marking off a narrow semilunar zone from the general tibial surface. This zone lies close to the inner part of the intercondylar fossa, and is known as the *patellar facet*. In extreme flexion of the knee-joint, as in the position assumed by the miner when at work, the patella by its inner vertical zone articulates with this facet, which may be called the *miner's facet*.

The *outer surface* of the external condyle towards the back part presents the *external tuberosity*, which gives attachment to the long external lateral ligament of the knee-joint. Immediately above and behind the tuberosity is an impression for the outer head of the gastrocnemius, and behind and below it there is a groove, called the *popliteal groove*, which is directed downwards and forwards.

The tendon of the popliteus arises from the front part of the horizontal portion of the groove, and it is lodged in the groove only when the knee is flexed.

The *inner surface* of the internal condyle presents at its centre a large blunt eminence, called the *internal tuberosity*, for the attachment of the internal lateral ligament. Posteriorly, where the internal supracondylar ridge joins the internal condyle, the adductor tubercle is situated, and the line of origin of the inner head of the gastrocnemius extends almost transversely outwards from this tubercle above the internal condyle.

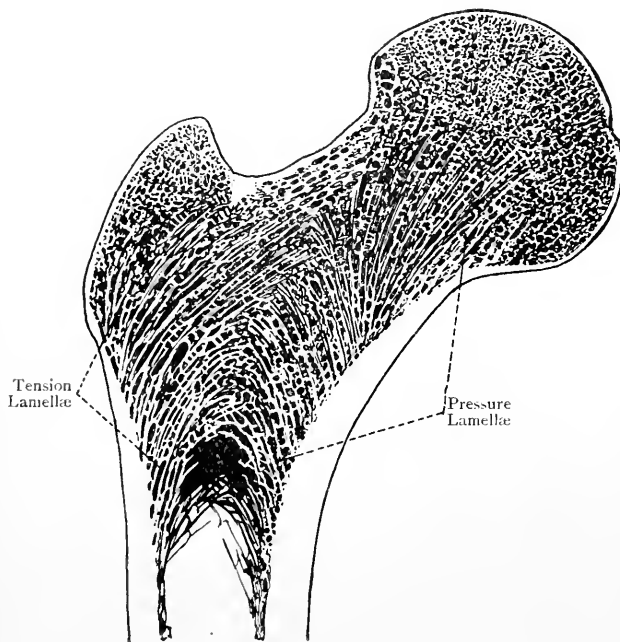


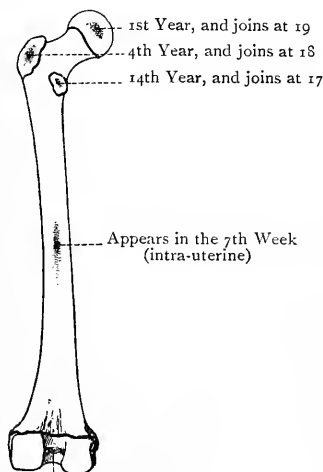
FIG. 136.—LONGITUDINAL SECTION THROUGH THE UPPER END OF THE FEMUR, SHOWING THE PRESSURE LAMELLÆ AND TENSION LAMELLÆ.

The markings in connection with the *intercondylar fossa* are for the crucial ligaments. The impression for the *anterior* crucial ligament is at the back part of the inner surface of the external condyle, whilst that for the *posterior* crucial ligament is at the front part of the outer surface of the internal condyle, and adjacent portion of the front of the intercondylar fossa. At the front of that fossa in the middle line the ligamentum mucosum is attached.

Articulations.—*Superiorly* with the acetabulum of the os innominatum, and *inferiorly* with the head of the tibia below, and the patella in front.

Structure.—The structure is that of a long bone. The marrow canal extends from a point just below the small trochanter to the level of the apex of the trigonum femoris. Above and below these points the bone is composed of cancellated tissue, except externally, where there is a shell of compact bone. The cancellated tissue at the upper extremity has its lamellæ arranged in a series of curves disposed in two systems, one of which represents the pressure lamellæ, and the other the tension lamellæ. The *pressure lamellæ* extend from the lower part of the neck and upper part of the shaft internally in a radiating manner, some, which are very strong, passing inwards to the head, whilst others pass outwards to the great trochanter. The *tension lamellæ* are disposed almost at right angles to the pressure lamellæ, and arch upwards and inwards from the outer aspect of the shaft, below the great trochanter, to the head and lower part of the neck. Additional strength is afforded by an almost vertically disposed plate of compact bone, called the *calcar femorale*, which runs upwards and downwards in front of, and above, the small trochanter, and lies in the line in which weight is transmitted. The cancellated tissue at the lower extremity has its lamellæ arranged in obliquely decussating lines which enclose somewhat rectangular meshes.

Varieties.—(1) The gluteal ridge may assume the form of a depression, called the *fossa hypotrochanterica*. (2) There may be a *third trochanter*, situated at the upper part of the gluteal ridge. (3) The *linea aspera* may be unduly prominent owing to muscular action, this condition being known as the *pilastered femur*.* (4) A *pressure facet* is sometimes met with, as in miners, at the upper end of the front of the neck, close to the cartilage of the head, with which it is continuous, this facet being due to prolonged maintenance of the flexed posture.



Appears just before birth,
and joins at 20.

FIG. 137.—OSSIFICATION OF THE FEMUR.

The Femur of the Female.—

(1) The bone is smoother than in the male. (2) The angle formed by the neck with the shaft is about 110 degrees. (3) The bones are farther apart above, more sloped inwards, and nearer to each other below, than in the male.

Ossification.—The femur ossifies in cartilage from **one primary**, and **four secondary, centres**. The primary centre appears at the middle of the shaft in the *seventh week* of intra-uterine life. The centre for the lower extremity appears *just before birth* in the bottom

* A pilaster (*pila*, a pile or column) is a square column set within a wall, and projecting for only a fourth of its breadth.

of the intercondylar fossa. At birth the shaft is ossified, and the lower epiphysis is showing signs of ossification, but the three upper epiphyses are cartilaginous. The centre for the head appears in the *first year*, that for the great trochanter in the *fourth year*, and that for the small trochanter in the *fourteenth year*. The small trochanter joins the shaft at *seventeen*, the great trochanter at *eighteen*, the head at *nineteen*, and the lower epiphysis at *twenty*. The neck is ossified from the centre for the shaft. The line indicating the junction of the lower epiphysis and shaft cuts the adductor tubercle into two, one portion belonging to the lower epiphysis, and the other to the shaft.

The Patella.

The **patella**, *rotula*, or knee-cap, is situated in front of the knee-joint, where it articulates with the patellar surface of the femur. It is originally a sesamoid cartilage developed in the tendon of the quadriceps extensor cruris. The bone is triangular with the apex downwards, and is compressed from before backwards. The

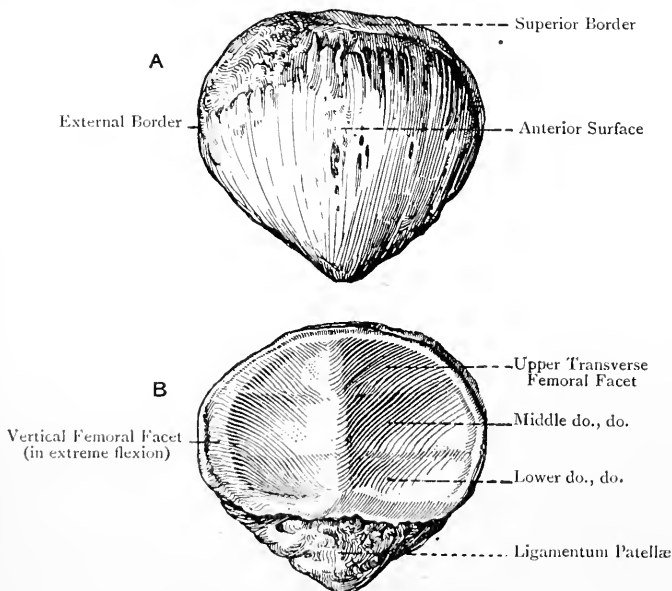


FIG. 138.—THE RIGHT PATELLA.

A, Anterior Surface; B, Posterior Surface.

superior border or *base* is broad, and its plane is inclined forwards and slightly downwards. It gives insertion anteriorly to the rectus femoris and crureus, in this order from before backwards, and posteriorly it is covered by a portion of the synovial membrane of the knee-joint. The *lateral borders* are sloped towards the apex, the outer being at first rather more prominent than the inner. The *outer border* over its upper third gives insertion to a portion of the vastus externus, and the *inner* over its upper half to a

portion of the vastus internus. The *apex* is blunt, and, together with the adjacent marginal parts, gives attachment to the ligamentum patellæ, by which the bone is connected with the tubercle of the tibia.

The *anterior surface*, which is slightly convex, is vertically striated and covered by a prolongation of the tendon of the quadriceps extensor cruris. It is perforated by numerous nutrient foramina, and is subcutaneous, being separated from the integument by the prepatellar bursa.

The *posterior surface* is divided into two parts—articular and non-articular. The *non-articular part* represents the lower fourth, and is rough and depressed. It lodges a collection of fat covered by synovial membrane. The *articular part* corresponds with the upper three-fourths, and is divided into two unequal parts by a round vertical ridge, which is received into the groove of the patellar surface of the femur. The *external division* is broad and concave from side to side, whilst the *internal* is narrow and convex in the transverse direction. Excluding a narrow vertical zone at the inner part of the inner division, each division is subdivided by two slight transverse ridges into three horizontal zones—upper, middle, and lower, of which the middle is the largest and broadest. These six horizontal facets articulate with the patellar surface of the femur, the lower facets being in contact with the upper part of the patellar surface in extension of the knee-joint, the middle patellar facets with the middle portion of the patellar surface of the femur in semiflexion, and the upper patellar facets with the lower parts of the patellar surface of the femur in flexion of the knee-joint. The vertical zone at the inner part of the inner division of the articular surface (close to the inner border of the bone) constitutes a seventh facet, which may be called the *miner's facet*. In extreme flexion of the knee-joint this facet articulates with the semilunar facet (miner's facet) on the outer part of the tibial surface of the internal condyle of the femur close to the intercondylar fossa, whilst the upper and outer horizontal facet is in contact with the front part of the external condyle.

The patella receives its arteries from the superficial branch of the anastomotica magna of the femoral, inferior articular branches of the popliteal, and anterior tibial recurrent.

Structure.—The patella, being a short bone, is composed principally of dense cancellated tissue with close meshes, surrounded by compact bone, which is much thicker in front than behind.

Ossification.—The original cartilage is deposited in the tendon of the quadriceps extensor cruris in the *third month* of intra-uterine life. In this cartilage a **single centre** appears in the *third year*, and ossification is completed about the age of puberty.

The Tibia.

The **tibia**, or shin-bone, is the inner and larger of the two bones of the leg, and alone transmits the weight of the body to the foot. The posterior surfaces of the shafts of the tibia and

fibula are on the same horizontal plane above and below, but over about the middle three-fifths the fibula projects slightly farther back on account of its curve. Anteriorly the tibia is on a more anterior plane than the fibula, a point to be borne in mind in making flaps by transfixion. The tibia is a long bone, and is divisible into a shaft and two extremities, upper and lower.

The **upper extremity**, known as the **head**, is broader from side to side than from before backwards. Antero-laterally it is convex, but posteriorly it is rendered concave by the *popliteal notch* at its centre. The enlargements of the bone on either side of the head are called the *tuberosities*, external and internal. The *external tuberosity* is rather smaller than the internal, and at its posterior and under aspect it presents a flat circular facet, directed downwards,

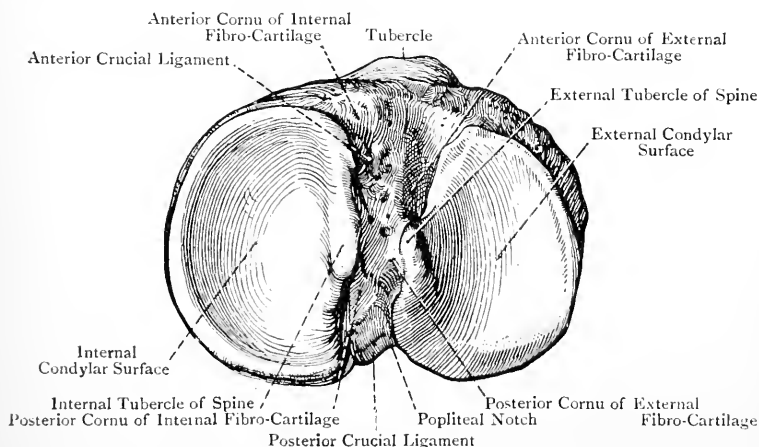


FIG. 139.—THE HEAD OF THE RIGHT TIBIA (SUPERIOR VIEW).

backwards, and outwards, which articulates with the head of the fibula. The cartilage of this facet is occasionally continuous with that of the external condylar surface. At the junction of its anterior and outer surfaces the external tuberosity presents an elevation, which usually assumes the form of a ridge, for the attachment of the ilio-tibial band of the fascia lata. The *internal tuberosity* is larger than the external, and has a distinct inclination backwards as well as inwards, a point to be noted in setting fractures of this bone. On its posterior aspect it presents a horizontal groove for the insertion of the chief portion of the tendon of the semimembranosus muscle. On the anterior aspect of the superior extremity, at the junction of the head and shaft, there is a well-marked projection, called the *tubercle* or *anterior tuberosity*. It is fully 1 inch in length, and its upper border is about $\frac{3}{4}$ inch

below the level of the upper surface of the head. It is divisible into two nearly equal parts, upper and lower. The lower division is rough, and is usually strongly ridged in the vertical direction for the attachment of the ligamentum patellæ. The upper division is smooth, and is separated from that ligament by a synovial bursa.

The *superior surface* of the head presents the two condylar articular surfaces, separated from each other by an irregular interval, which, amongst other markings, presents the bifid tibial spine. Each surface surmounts the corresponding lateral tuberosity. The *external condylar surface* is broad from side to side, and is almost circular. It is concave from side to side, and concavo-convex from before backwards. Its cartilage rises towards the middle line to coat the external surface of the outer tubercle of the tibial spine, and posteriorly it dips down for a little on the outer part of the back of the external tuberosity, where the tendon of the popliteus glides over it. It is in this situation where the cartilage is occasionally continuous with that of the fibular facet. The *internal condylar surface* is oval and concave, being elongated from before backwards, but narrow from side to side. The cartilage of this surface rises towards the middle line to coat the internal surface of the inner tubercle of the tibial spine. Each condylar surface is deepened by a semilunar fibro-cartilage, which is placed round its peripheral part.

The interspace between the condylar surfaces presents the spine, which is distant from the posterior border about one-third of the antero-posterior measurement. The *spine* is formed by an upward rising of the contiguous borders of the condylar surfaces, and is bifid, ending in two tubercles, of which the inner is the better marked and longer of the two. The interspace between these tubercles gives attachment to the posterior cornu of the external semilunar fibro-cartilage, which continues to be attached to a depression behind the outer tubercle. The surfaces of the tubercles which face each other are free from cartilage, but the other surfaces have each a cartilaginous covering.

In front of the spine there is a rough depression where important structures are attached as follows: in front of the outer tubercle of the spine the anterior cornu of the external semilunar fibro-cartilage is attached, and in front of the inner tubercle the anterior crucial ligament is attached to the bone. At the extreme anterior and inner part there is an impression for the anterior cornu of the internal semilunar fibro-cartilage. On the outer side of the impression for the anterior crucial ligament, and in front of that for the anterior cornu of the external semilunar fibro-cartilage, there is a depression which is partially occupied by a small collection of fat. At its outer part, however, there is a groove which receives a portion of the external semilunar fibro-cartilage in extension of the knee-joint. The immediately adjacent portion of the external condylar surface is specially faceted for the play of part of the

external condyle of the femur in extension of the joint. Behind the tibial spine there is a more limited rough depression, which leads backwards to the popliteal notch. The posterior cornu of the internal semilunar fibro-cartilage is attached to the inner part of this depression, and the posterior crucial ligament is attached to its back part, as well as to the popliteal notch.

Order of Structures attached to the Head.—The structures, enumerated as nearly as possible in order from before backwards, are as follows :

1. Anterior cornu of internal semilunar fibro-cartilage.
2. Anterior crucial ligament.
3. Anterior cornu of external semilunar fibro-cartilage.
4. Posterior cornu of external semilunar fibro-cartilage.
5. Posterior cornu of internal semilunar fibro-cartilage.
6. Posterior crucial ligament.

The head is pierced all round by many nutrient foramina for branches of the inferior articular arteries of the popliteal, and of the posterior and anterior tibial recurrents of the anterior tibial.

The **shaft** is massive and triangular. It diminishes in size from above downwards over its upper two-thirds, and then gradually enlarges towards its lower end. It presents three borders and three surfaces. The *anterior border* extends from the outer side of the anterior tuberosity above to the anterior margin of the internal malleolus below. Over the upper two-thirds, where it occupies the middle line, it is prominent, and is known as the *crest* or shin-ridge. This is doubly curved, the convexity of the upper curve being directed inwards, and that of the lower outwards. Over the lower third the anterior border inclines inwards, and the external surface of the shaft is thus allowed to come forwards. The crest is subcutaneous, and gives attachment to the deep fascia of the leg. The *internal border* extends from the inner and back part of the internal tuberosity to the posterior margin of the internal malleolus. For 3 or 4 inches superiorly it is rough, and gives attachment to the internal lateral ligament of the knee-joint. Over its middle third it is prominent, and it here gives origin to a portion of the soleus as low as the centre of the bone. The *external* or *interosseous border* extends from the front of the fibular facet above to a point about 2 inches from the lower end, where it bifurcates. The two divisions pass to the front and back of the sigmoid cavity, and enclose between them a rough triangular surface for the inferior interosseous ligament. This border is sharp and wiry, and gives attachment to the interosseous membrane.

The *internal surface* is situated between the crest and internal border. It is for the most part subcutaneous, and slightly convex. Superiorly, where it becomes expanded and flattened, it presents a vertical rough area, behind the tubercle, for the insertion of the sartorius, and behind this two vertical rough impressions in the same line with each other, the upper of which gives insertion

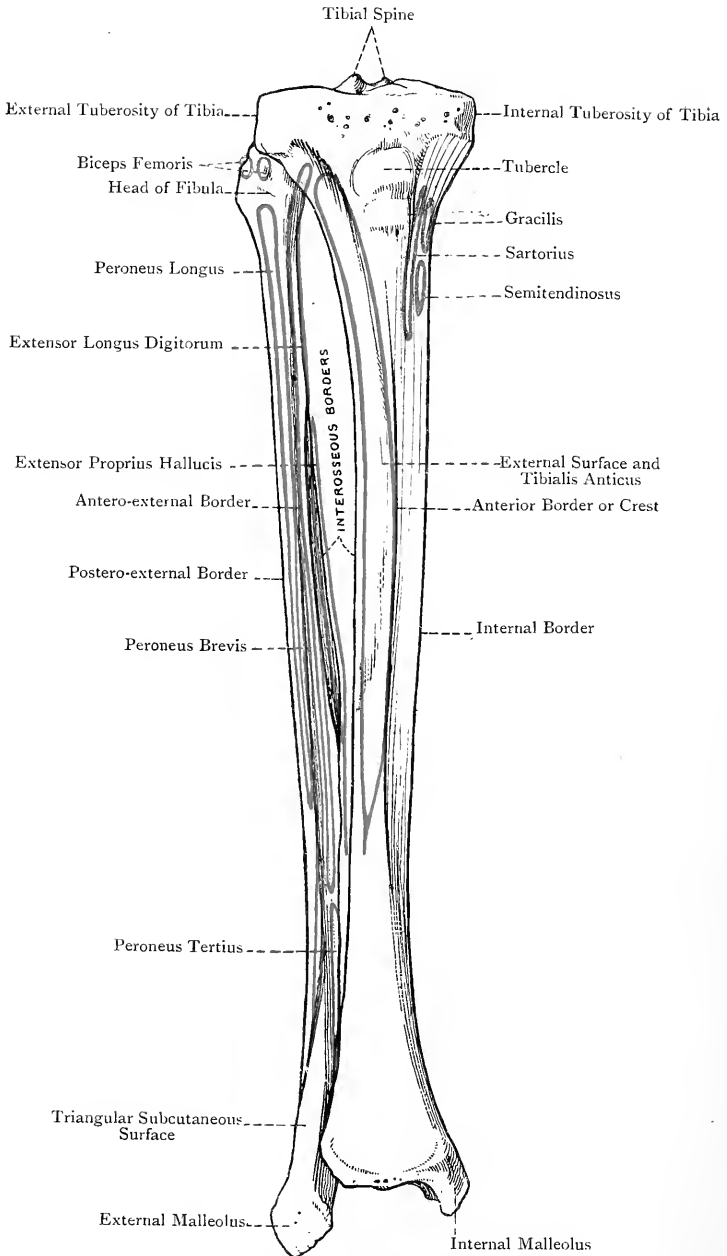


FIG. 140.—THE RIGHT TIBIA AND FIBULA (ANTERIOR VIEW).

to the gracilis, and the lower to the semitendinosus. The *external surface* is situated between the crest and interosseous border. It is concave over its upper two-thirds, where it gives origin to the tibialis anticus. Over the lower third, where it is convex, it turns to the front and supports the extensor tendons, and anterior tibial vessels and nerve. The *posterior surface* lies between the interosseous and internal borders. Superiorly it is crossed by the *popliteal* or *oblique line*, which is rough, and extends from the fibular facet downwards and inwards to the internal border at about the junction of the upper third and lower two-thirds. This line gives attachment to the popliteal fascia and part of the soleus, whilst the triangular popliteal surface above gives insertion to the popliteus muscle. The posterior surface below the oblique line presents over its middle third a vertical ridge which divides it into two parts. The outer portion is narrow, and gives origin to the tibialis posticus as low as a point just below the centre of the bone. The inner portion is broad, and gives origin to the flexor longus digitorum over the middle two-fourths of the bone. A little below the oblique line, close to the outer side of the vertical ridge, is the **medullary foramen** for a large branch of the posterior tibial artery. This foramen, which is the largest of its class, and the canal to which it leads are directed *downwards*. The posterior surface in its lower third supports the flexor tendons, and posterior tibial vessels and nerve.

The **lower extremity** presents a quadrilateral articular surface, concave from before backwards, and wider in this direction externally than internally. It is broader in front than behind, and articulates with the superior surface of the astragalus. The posterior border projects somewhat lower than the anterior. The anterior surface, immediately above the anterior border, is depressed and rough for the anterior ligament of the ankle-joint. The posterior border gives attachment to the posterior ligament of the ankle-joint as far inwards as the groove behind the internal malleolus. It presents the following grooves: one for the tendon of the flexor longus hallucis near the outer end; one (very faint) near the centre for the posterior tibial vessels and nerve; and one mainly situated on the back of the internal malleolus for the tendons of the tibialis posticus and flexor longus digitorum.

The inner aspect of the lower extremity presents the *internal malleolus*, which is a strong process having a downward direction. Its internal surface is rough, convex, and subcutaneous. The external surface is covered by cartilage, continuous with that which coats the lower extremity. The plane of this surface is vertical, and the cartilage coats it more deeply in front than behind. It articulates with the internal surface of the astragalus. The anterior border is rough and round for the attachment of the anterior and internal lateral ligaments of the ankle-joint. The lower border is indented by a notch, in front of which is the projection known as the *tip*, the internal lateral ligament being attached to both of these parts,

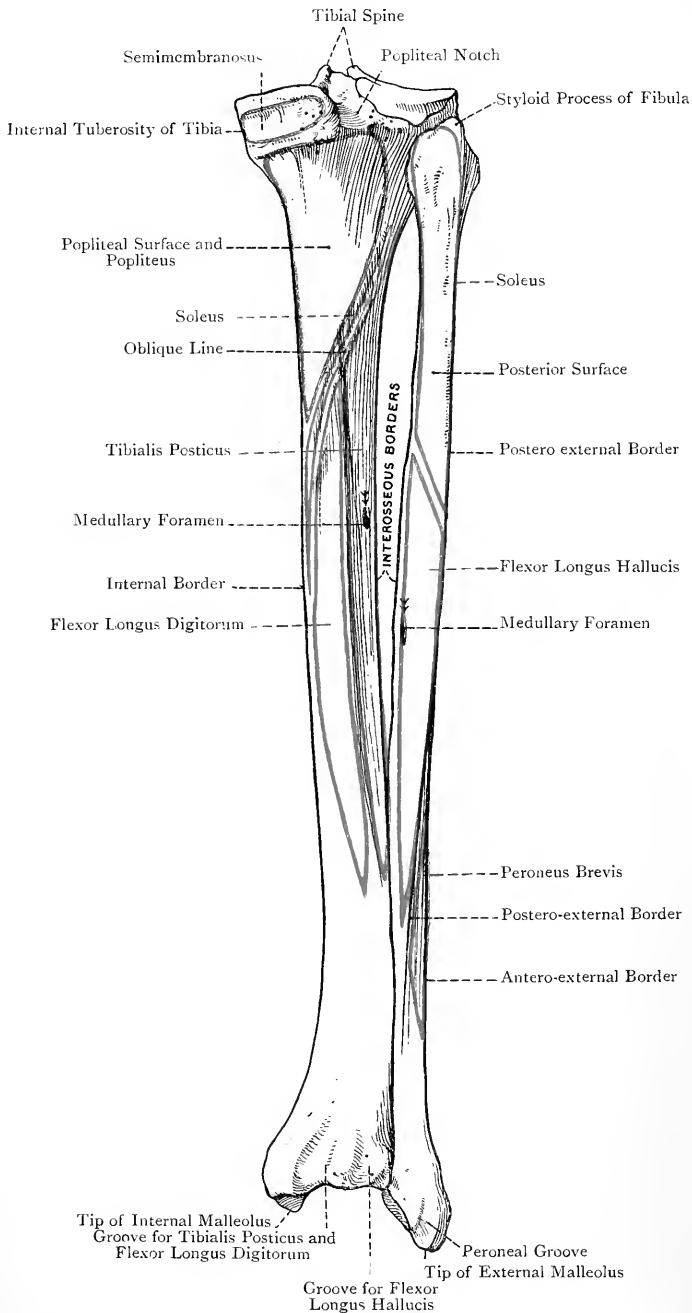


FIG. 141.—THE RIGHT TIBIA AND FIBULA (POSTERIOR VIEW).

Posteriorly is the groove for the tendons of the tibialis posticus and flexor longus digitorum. The outer aspect of the lower extremity presents a concave facet for the fibula, and above this a concave triangular rough surface about $1\frac{1}{2}$ inches long for the inferior interosseous ligament.

The inferior extremity of the tibia presents many nutrient foramina for branches of the anterior and posterior tibial, internal malleolar, and anterior peroneal, arteries.

Articulations.—*Superiorly* with the condyles of the femur above, and the head of the fibula postero-externally, and *inferiorly* with the fibula externally, and the superior and internal aspects of the astragalus below.

Structure.—The structure is that of a long bone. The medullary canal extends above to a point about $1\frac{1}{2}$ inches below the lower margin of the anterior tuberosity, and inferiorly to a point about 1 inch below the lower extremity of the crest. The cancellated tissue of the upper epiphysis has its lamellæ disposed somewhat vertically, whilst that of the upper end of the shaft has its lamellæ arranged in the form of arches. In the lower part of the shaft the cancellous lamellæ are disposed vertically, and the cancellated tissue of the lower epiphysis is closely meshed.

Varieties.—(1) The tibia is sometimes much compressed laterally, which leads to an increase in its antero-posterior diameter. In these cases the vertical ridge posteriorly becomes unduly prominent, a condition which is associated with a large development of the tibialis posticus muscle. Such a bone is spoken of as being *platynemic* (broad-legged), and the condition is known as *platynemism* (broadness of tibia). (2) The anterior aspect of the lower extremity of the bone sometimes presents a *pressure facet* at its outer part for articulation with the upper surface of the neck of the astragalus in extreme flexion of the ankle-joint.

Ossification.—The tibia is ossified *in cartilage* from 1 **primary** and 3 **secondary centres**.

The **primary centre** appears at the centre of the shaft about the *7th week*. The **3 secondary centres** are disposed as follows: 2 are *superior*, one for the **head**, and the other for the **tubercle**; and 1 is *inferior* for the *lower extremity and internal malleolus*. **Upper Extremity.**—The **centre for the head** appears *just before birth*, and from it the external and internal tuberosities are ossified, which constitute the **superior epiphysis**. The **centre for the tubercle** appears about the *12th year*. Soon afterwards it joins the **superior epiphysis**, which unites with the shaft about the *22nd year*. In some cases the **tubercle** is entirely ossified from the centre for the head. In other cases the upper smooth part of the tubercle is ossified from the centre for the head, and the lower rough part derives its ossification from the primary centre for the shaft.

Lower Extremity.—The **centre for the lower extremity and internal malleolus** appears towards the end of the *2nd year*, and this **lower epiphysis** joins about the *18th year*.

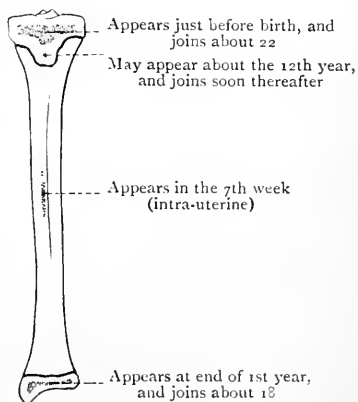


FIG. 142.—OSSIFICATION OF THE TIBIA.

The Fibula.

The **fibula**, or **peroneal bone**, is situated on the outer side of the tibia. It is very slender for its length, and is a rudimentary bone. It takes no part in transmitting the weight of the body, but serves chiefly to afford attachment to muscles, though it also forms part of the ankle-joint, and acts as a brace or support to the tibia. It is a long bone, and is divisible into a shaft and two extremities, upper and lower.

The **upper extremity**, or *head*, is enlarged and knob-like, its upper surface being somewhat flattened and sloping. It is situated about $\frac{3}{4}$ inch below the level of the head of the tibia. Posteriorly it is prolonged upwards into the *styloid process*, to the tip of which the *short* external lateral ligament of the knee-joint is attached. In front of this process the upper surface of the head is sloped downwards and forwards, and is divisible into an articular and a non-articular part. The articular division is internal in position, and takes the form of a flat circular facet, which is directed upwards, inwards, and forwards, to articulate with the facet on the posterior and under aspect of the external tuberosity of the tibia, by which latter it is overhung. The non-articular division is external in position, and takes the form of a rough depression, into which the tendon of the biceps femoris, previously divided into two parts by the long external lateral ligament, takes insertion. Posteriorly the head gives origin to the soleus. Externally it gives origin to the peroneus longus, and at a point nearly $\frac{1}{2}$ an inch anterior to the styloid process its outer margin gives attachment to the *long* external lateral ligament. Anteriorly it gives origin to the extensor longus digitorum. The constricted part below the head is called the *neck*.

The upper extremity presents several nutrient foramina for branches of the inferior external articular of the popliteal, and superior fibular of the anterior tibial, arteries.

The **lower extremity** is prolonged downwards into a massive projection, called the *external malleolus*, which is not only larger, but lower down and farther back, than the internal malleolus. It is triangular or pyramidal, the base being directed upwards. The external surface is rough, convex, and subcutaneous. The internal surface is divisible into two parts, articular and non-articular. The articular division is anterior in position, and occupies about two-thirds of the surface. It is triangular and convex, and it mainly articulates with the outer surface of the astragalus. Superiorly, however, for about $\frac{1}{4}$ inch, it assumes a somewhat semilunar outline, and this portion articulates with the outer aspect of the tibia. The non-articular division is posterior in position, and occupies about one-third of the surface. It is rough, depressed, and triangular, and is known as the *digital fossa*. Superiorly it gives attachment to the transverse ligament of the inferior tibio-fibular joint, and inferiorly to the posterior fasciculus

of the external lateral ligament of the ankle-joint. Above the external malleolus on the inner aspect there is a rough, convex, triangular surface about $1\frac{1}{2}$ inches long for the inferior interosseous ligament. The anterior border projects at first forwards, and then slopes downwards and backwards to the tip. The projecting part gives attachment to the anterior ligament, and the lower portion of the sloping part to the anterior fasciculus of the external lateral ligament of the ankle-joint. The posterior border is shorter than the anterior, and is vertical. It presents the *peroneal groove* for the tendons of the peroneus longus and peroneus brevis. The *tip* is the most dependent part, and is situated at the meeting of the posterior border and the lower sloping part of the anterior border. It gives attachment to the middle fasciculus of the external lateral ligament.

The lower extremity presents several nutrient foramina for branches of the anterior and posterior peroneal, and external malleolar, arteries.

The **shaft** is slightly curved, the convexity being directed backwards in the upper part, and inwards lower down. It is quadrilateral in its upper three-fourths, where it presents four borders and four surfaces, but it is somewhat triangular in the lower fourth. The *antero-external border*, which is the most prominent, commences in front of the head, and passes straight downwards until it reaches the lower fifth, where it bifurcates. One division passes to the anterior margin of the external malleolus, and the other to

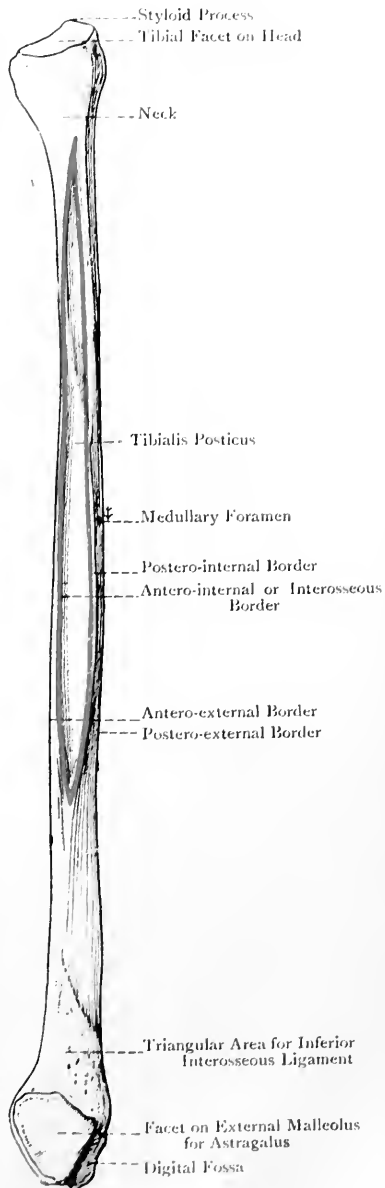


FIG. 143.—THE RIGHT FIBULA (INTERNAL VIEW).

the posterior margin, external to the peroneal groove. These two divisions enclose between them a triangular area which is continuous with the outer surface of the external malleolus. This border gives attachment to the antero-external intermuscular septum. The *antero-internal* or *interosseous border*, which gives attachment to the interosseous membrane, also commences in front of the head, where it is very near to the antero-external border. As it descends it keeps near to that border at first, but beyond the upper third it gradually diverges from it, and on reaching a point about 2 inches above the external malleolus it bifurcates. One division passes to the anterior margin of the malleolus, becoming incorporated with one of the divisions of the antero-external border, whilst the other passes to the posterior margin of the malleolus, internal to the upper end of the peroneal groove. The two divisions, as they diverge, enclose a rough triangular area, which is slightly convex and gives attachment to the inferior interosseous ligament. The *postero-internal border* commences on the inner side of the head, not far from the antero-internal. It descends in a backwardly-curved manner, gradually leaving the antero-internal border, but subsequently approaching it, until on reaching the junction of the upper two-thirds and lower third it ends by joining it. This border gives attachment to an intermuscular septum, which separates the tibialis posticus from the soleus and flexor longus hallucis. The *postero-external border* extends from the back of the head to the back of the external malleolus, internal to the peroneal groove, and in its lower part it turns inwards. It gives attachment to the postero-external intermuscular septum.

The *anterior surface* is situated between the antero-external and antero-internal or interosseous borders. It is very narrow over about its upper half, but becomes wider below. It gives origin over about its upper three-fourths to the extensor longus digitorum, over its lower fourth (except about 1 inch below) to the peroneus tertius, and over about its middle two-fourths to the extensor proprius hallucis, which is nearest to the antero-internal border. The *internal surface* is situated between the antero-internal and postero-internal borders. It is concave and fusiform, being narrow above and below, but wide at the centre, and it gives origin to the tibialis posticus. The *posterior surface* is limited by the postero-internal and postero-external borders, and in its lower fourth it undergoes a twist, and turns round to become internal. Over its upper third it gives origin to a part of the soleus, and over its lower two-thirds, except the last inch or more, to the flexor longus hallucis. The *external surface* lies between the antero-external and postero-external borders. It is the broadest, and in muscular subjects is deeply grooved over rather more than its upper half. Inferiorly it undergoes a twist, and turns round to become posterior, where it leads directly to the peroneal groove on the back of the external malleolus. In this manner the two peroneal tendons are guided to this groove. The upper two-thirds of this surface give origin to

the peroneus longus, and the lower two-thirds, except the last 2 inches, to the peroneus brevis, these two muscles overlapping towards the centre of the bone.

The **medullary foramen**, which is small, is usually situated on the posterior surface, but may be on the internal, a little above the centre, and there may be an additional one a little higher up. It is for a branch of the peroneal artery, and the direction of the foramen and the canal to which it leads is *downwards* towards the ankle.

Articulations.—*Superiorly* with the external tuberosity of the tibia, and *inferiorly* with the outer aspect of the tibia, and the external surface of the astragalus.

Structure.—The structure is that of a long bone, and the marrow canal is limited to about the middle three-fifths of the shaft.

Ossification.—The fibula ossifies in cartilage from **one primary, and two secondary, centres.** The primary centre for the shaft appears in the *eighth week* of intra-uterine life. At birth the shaft is ossified, but the extremities are cartilaginous. The centre for the lower extremity appears in the *second year*, and that for the upper extremity about the *fourth year.* The lower epiphysis joins the shaft about *twenty*, and the upper about *twenty-three.* The fibula forms an exception to the general law of ossification applicable to long bones with an epiphysis, or epiphyses, at either end, which may be here restated as follows: '*The epiphysis or epiphyses, at the end towards which the medullary foramen and the canal to which it leads are directed, are the last to show signs of ossification, but they are the first to join the shaft.*' In the fibula the *lower epiphysis not only joins the shaft first, but it is the first to show signs of ossification*—due to the fact that this extremity is the least rudimentary part of the bone.

The fibula in early life articulates with the femur. At about the seventh month of intra-uterine life the tibial and fibular malleoli are of nearly equal proportions, but by the second year, previous to the appearance of its centre of ossification, the fibular malleolus has attained the large relative size which characterizes it throughout life.

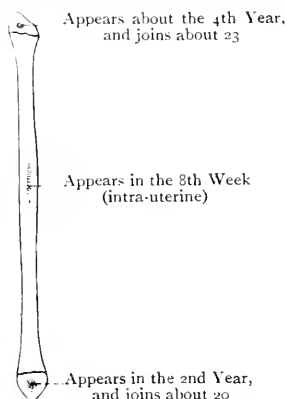


FIG. 144.—OSSIFICATION OF THE FIBULA.

The Tarsus.

The **tarsus** is composed of seven short bones, namely, the astragalus, os calcis, navicular or scaphoid, three cuneiforms, and cuboid.

The first two constitute the proximal row, the astragalus lying above the os calcis, and the last four comprise the distal row, the order from the inner or tibial to the outer or fibular side being internal, middle, and external cuneiform bones, and cuboid. The navicular occupies an intermediate position.

The Astragalus.

The **astragalus**, or **talus**, is characterized by having a head, neck, and body. It is situated between the tibia above and the os calcis below, is grasped laterally by the tibial and fibular malleoli, and has the navicular in front. It is the only tarsal bone which receives directly the weight of the body, and it lies with its long axis directed forwards and inwards. In point of size it comes next to the os calcis.

The **head** forms the anterior part of the bone, and presents an extensive convex articular surface, which looks forwards and also downwards. It is divided into three facets, called navicular, sustentacular, and 'spring.' The *navicular facet*, which is placed on the anterior surface, is pyriform, and its long axis is directed downwards and inwards. The *sustentacular facet*, continuous with the foregoing, is situated on the inferior surface. It is convex and elliptical, and its long axis is directed forwards and outwards. It is often crossed by an elevated ridge a little anterior to the centre, and it articulates with the sustentacular facet on the upper surface of the os calcis. The *spring facet* is situated on the inner aspect of the inferior surface, and is in contact with the superior surface of the inferior calcaneo-navicular or 'spring' ligament.

The **neck** is the constricted part behind the head. It is conspicuous superiorly, and passes inferiorly into the *interosseous groove*. This groove is directed forwards and outwards, its inner part being narrow and deep, and the outer wide and shallow. It gives attachment to the strong interosseous ligament which binds the astragalus to the os calcis. The neck is perforated all round with numerous nutrient foramina for offsets of the dorsalis pedis artery and its tarsal branch.

The **body** is quadrilateral, and presents four surfaces and a posterior border. The *superior surface* presents an extensive trochlear facet, which is concave from side to side, and convex from before backwards. Posteriorly it slopes downwards, and in this situation it usually presents a transverse groove for the play of the transverse ligament. The inner border is straight and slightly depressed, and as a rule it extends rather farther back than the outer, which latter is somewhat sinuous. The surface is broader in front than behind. The *external surface* is deep, and presents a large triangular facet for the external malleolus, the apex being downwards. It is concave from above downwards, and, immediately in front of it, the anterior fasciculus of the external lateral ligament of the ankle-joint takes attachment. The *internal surface* presents superiorly a falciform facet, broad in front and pointed behind, for the internal malleolus. This facet in the foetus encroaches on the inner side of the neck, a condition which is associated with the inversion of the foot at that period of life. This sometimes occurs in the adult, and, if it does so to any marked extent, it usually accompanies the condition known as talipes varus.

The *inferior surface* presents a large oval facet, concave from within forwards and outwards, for articulation with the os calcis. The *posterior border* is short, stout, and oblique, its direction being inwards and forwards. It presents a groove, which is directed down-

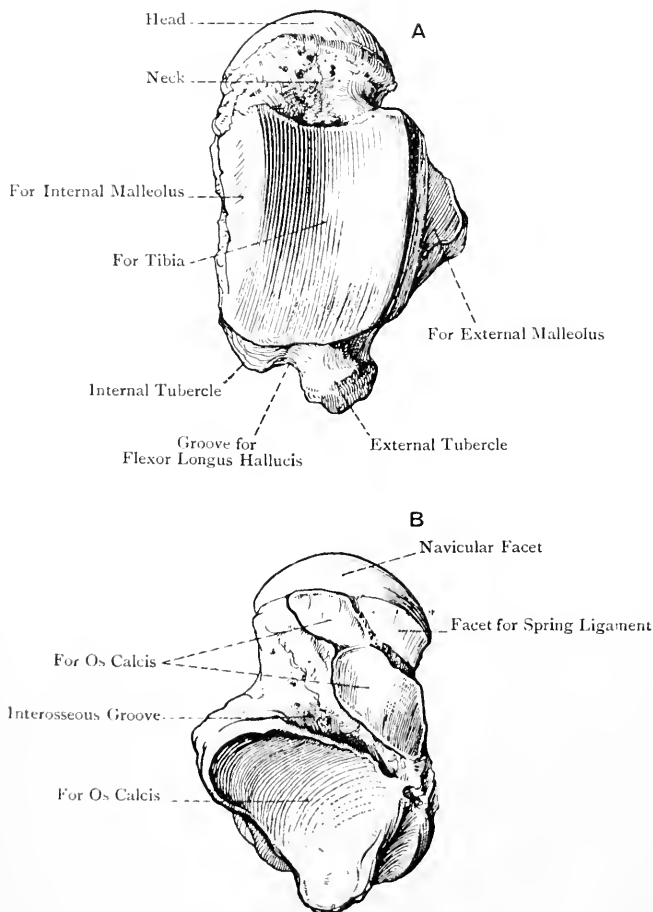


FIG. 145.—THE RIGHT ASTRAGALUS.
A, Superior View ; B, Inferior View.

wards and inwards, for the tendon of the flexor longus hallucis. On either side of this groove there is a tubercle, the internal being rudimentary, whilst the external is well developed and gives attachment superiorly to the posterior fasciculus of the external lateral ligament of the ankle-joint.

The astragalus derives its blood-supply from branches of the *dorsalis pedis* artery.

Articulations.—*Superiorly* with the shaft, and *internally* with the internal malleolus, of the tibia; *externally* with the external malleolus of the fibula; *inferiorly* with the os calcis; and *anteriorly* with the navicular, and occasionally with the lower and inner angle of the cuboid.

Structure.—The astragalus, being a short bone, is composed of cancellated tissue, surrounded by a thin shell of compact bone. The lamellæ of the cancellated tissue are arranged in a curved manner, and in two sets. Some pass downwards and backwards from the superior surface to the posterior calcaneal facet, whilst others arch downwards and forwards from the superior surface to the neck, these being the directions in which weight is transmitted.

Varieties.—(1) The external tubercle on the posterior border may form a separate ossicle, called the *os trigonum*. (2) There may be a pressure facet on the upper surface of the neck at its outer part, due to prolonged contact with the anterior margin of the lower end of the tibia.

The Os Calcis.

The **os calcis**, or **calcaneum**, is the largest bone of the tarsus, and is characterized by its elongation, lateral compression, and enlargement posteriorly into a tuberosity. It is situated below the astragalus, and behind the cuboid, where it lies with its long axis directed forwards and outwards. It presents two extremities and four surfaces.

The **posterior extremity**, which is enlarged, forms the *tuberosity* or *tuber calcis*, and constitutes the prominence of the heel. Posteriorly it is divided into three zones—an upper, which is smooth and separated from the tendo Achillis by a bursa; a middle, rough and vertically ridged, for the insertion of the tendo Achillis; and a lower, which is continuous with the tubercles on the plantar aspect, and supports the fat of the heel. In front of the tuber calcis there is a constriction, called the **neck**.

The **anterior extremity** presents a large, somewhat triangular facet, narrow towards the sole, which is concave from above downwards and outwards, and convex from side to side, for articulation with the cuboid.

The *superior surface* presents over its anterior part two facets for the astragalus, separated by an oblique groove, and posteriorly a non-articular surface. The antero-internal or sustentacular facet surmounts the sustentaculum tali. It is concave and somewhat elliptical, its long axis being directed forwards and outwards. It is constricted in front of the centre, and is sometimes broken up into two facets by a rough groove. The postero-external facet is large, oval, and convex from behind forwards and outwards. The intervening groove, which is directed forwards and outwards, becomes wide and shallow externally, and in front of the outer

part of the groove the upper surface gives origin to a portion of the extensor brevis digitorum, and the fundiform ligament of Retzius. When the astragalus is in position this groove is converted into a short tunnel, called the *sinus pedis*, which is occupied by the interosseous ligament. The superior surface behind the articular portion is rough, and supports a collection of fat.

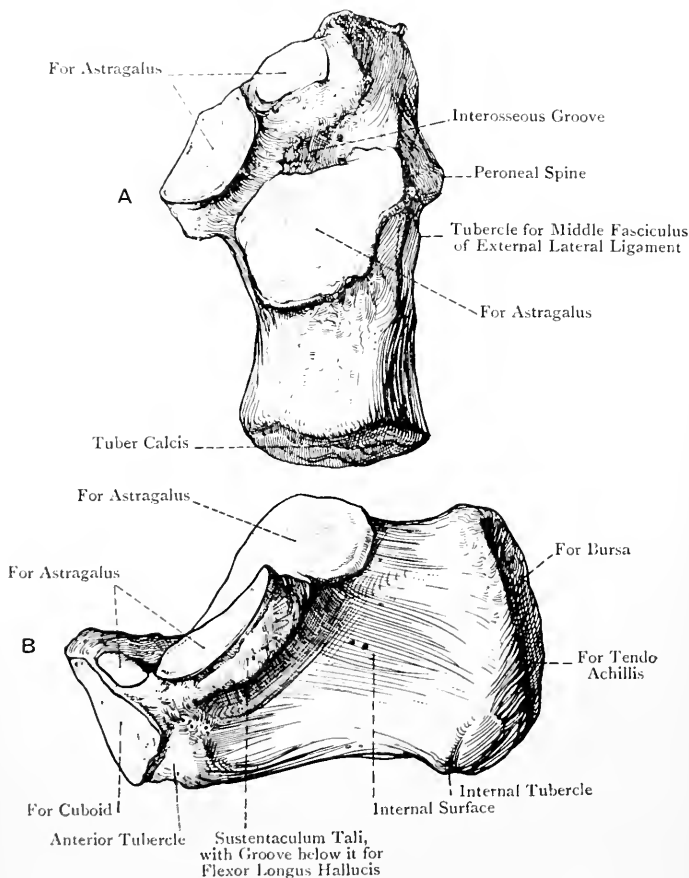


FIG. 146.—THE RIGHT OS CALCIS.

A, Superior View; B, Internal View.

The *inferior surface* is narrow and rough. Posteriorly it presents two tubercles, the *outer* of which is small but prominent, whilst the *inner* is large and blunt. The outer tubercle gives attachment to the external division of the plantar fascia, and a portion of the abductor minimi digiti, whilst the inner gives attachment to the central and internal divisions of the plantar fascia,

the outer head of the abductor hallucis, the flexor brevis digitorum, and a portion of the abductor minimi digiti. The greater part of the inferior surface gives attachment to the long plantar ligament, and anteriorly it presents a small round eminence, called the *anterior tubercle*, to which the short plantar ligament is attached.

The *internal surface* is concave, and is overhung at its antero-superior part by the *sustentaculum tali*. This latter is concave and articular above for the astragalus, and below it presents a groove for the flexor longus hallucis. Anteriorly it gives attachment to the inferior calcaneo-navicular or 'spring' ligament, below which a slip of the tibialis posticus takes insertion, and its inner margin gives attachment to fibres of the internal lateral ligament of the ankle-joint. The general concavity of the internal surface supports the tendon of the flexor longus digitorum and the plantar vessels and nerves, and anteriorly it affords origin to the inner head of the flexor accessorius.

The *external surface* is for the most part flat. Towards its anterior and lower part it presents a short oblique ridge, called the *peroneal spine* or *ridge*, which separates two grooves. The upper groove transmits the tendon of the peroneus brevis, and the lower that of the peroneus longus. Behind and a little above this spine there is a small tubercle, about the centre of the surface, for the middle fasciculus of the external lateral ligament of the ankle-joint.

The os calcis is pierced by many nutrient foramina for offsets of the calcaneal branches of the posterior tibial and external plantar, and the internal and external malleolar branches of the anterior tibial, arteries.

Articulations.—*Superiorly* with the astragalus, and *anteriorly* with the cuboid.

Structure.—The structure is that of a short bone. Some of the lamellæ of the cancellated tissue arch downwards and backwards from the large postero-external facet on the superior surface to the prominence of the heel. In addition to these, there are other lamellæ which pass in an antero-posterior direction just above the layer of compact bone which forms the plantar surface. In the region of the groove for the sinus pedis, especially towards the outer part, the upper compact layer is thicker than elsewhere.

Ossification.—The os calcis ossifies in cartilage from **one primary**, and **one secondary, centre**. The primary centre appears in the *sixth month* of intra-uterine life. The secondary centre appears in the *tenth year*, and forms a thin epiphysal scale over the posterior surface of the tuber calcis, which joins in the *sixteenth year*. This epiphysis includes the outer, and a large part of the inner, tubercle on the under surface, and it may include the whole of the posterior surface, or only the lower two-thirds.

The Navicular Bone.

The **navicular** or **scaphoid bone** is distinguished by its resemblance to a boat. It is situated on the inner side of the foot, where it is placed in front of the astragalus, and behind the three cuneiform

bones. It is compressed from before backwards, and its long axis is directed inwards and downwards. The *anterior surface* presents a large convex articular surface, divided into three facets by two ridges which converge inferiorly. The inner facet, for the internal cuneiform, is pyriform, with the narrow end upwards. The middle facet, for the middle cuneiform, is triangular, with the truncated apex downwards. The outer facet, for the external cuneiform, resembles the middle, except that it is rather shorter and has a rounder apex. The *posterior surface* is characterized by a large concave, pyriform facet for the front of the head of the astragalus, its narrow end being directed downwards and inwards. The

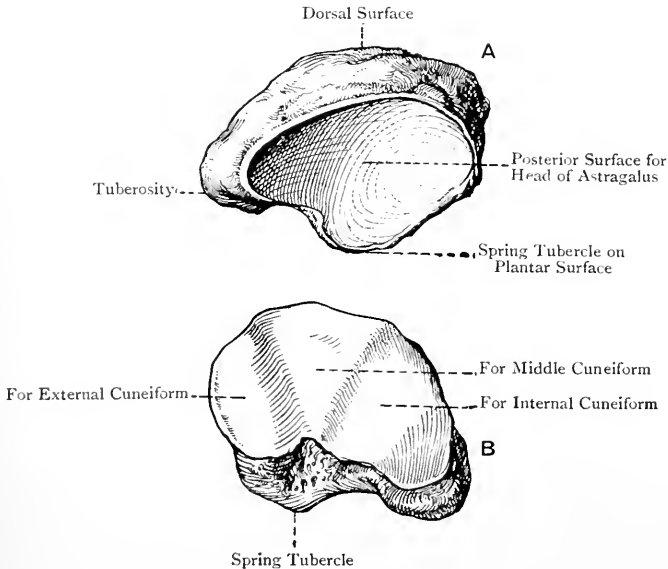


FIG. 147.—THE RIGHT NAVICULAR BONE.

A, Postero-superior View ; B, Antero-inferior View.

dorsal surface, extensive and rough, is sloped downwards and inwards. The *plantar surface*, narrow and rough, gives attachment to the inferior calcaneo-navicular or 'spring' ligament, and about its centre there is usually a knob-like projection, called the *spring tubercle*. The *external surface* is broad and rough, and it sometimes presents a small facet for the cuboid, contiguous to the outer facet on the anterior surface. The *inner extremity* (prow of the boat) is inclined downwards, and forms a stout, round projection on the inner side of the sole, called the *tuberosity*, which gives insertion to the principal portion of the tendon of the tibialis posticus.

Articulations.—*Posteriorly* with the astragalus, *anteriorly* with the three cuneiform bones, and sometimes with the cuboid *externally*.

Structure.—The structure is that of a short bone.

Variety.—The tuberosity sometimes forms a separate ossicle.

The Cuneiform Bones.

The **cuneiform bones** are three in number, namely, internal, middle, and external. They are situated between the navicular and the inner three metatarsal bones, and are characterized by their

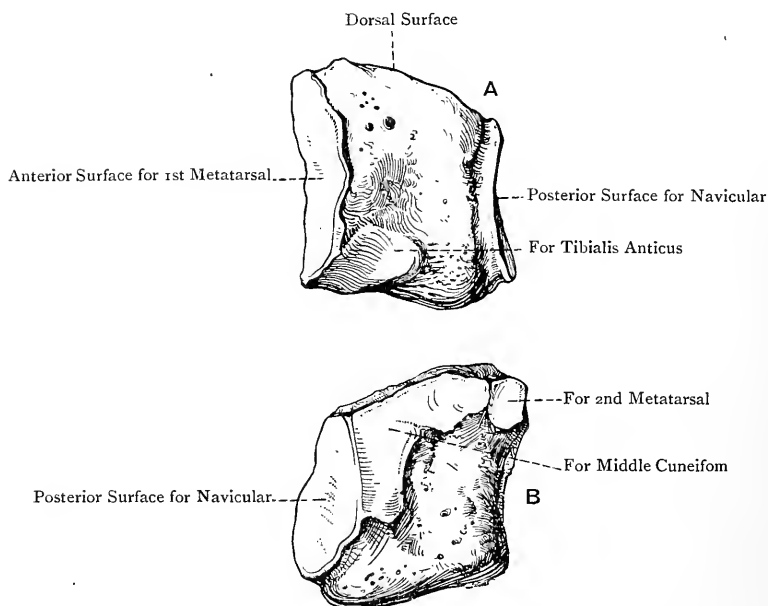


FIG. 148.—THE RIGHT INTERNAL CUNEIFORM BONE.

A, Internal View ; B, External View.

wedge shape. The internal cuneiform is the largest, and the middle is the smallest.

The **internal cuneiform bone** is situated on the inner side of the wedge upwards, and it supports the first metatarsal. The *dorsal surface* is narrow and rough. The *plantar surface* is thick and convex, and posteriorly it presents an eminence for a slip of the tendon of the tibialis posticus. The *internal surface* is traversed by an oblique groove, directed downwards and forwards, for the tendon of the tibialis

anticus, the principal portion of which is inserted into an impression situated at the lower part of the groove. The *external surface* presents, close to its superior and posterior borders, an L-shaped facet for the middle cuneiform, at the anterior extremity of which there is a small facet for the inner side of the base of the second metatarsal. When the bone is held in its proper position, the L is placed thus Γ in a right bone, and thus Υ in a left. The rest of the surface is concave and rough for strong ligaments, except at the lower and anterior part, where it gives insertion to a slip of the tendon of the peroneus longus. The *anterior surface* is deep, and presents a convex reniform facet for the first metatarsal, the concave border being directed outwards. The *posterior surface*, much smaller than the anterior, is characterized by a concave pyriform facet for the navicular, the narrow end being upwards.

Articulations.—*Posteriorly* with the navicular, *anteriorly* with the first metatarsal, and *externally* with the middle cuneiform and second metatarsal.

Variety.—The internal cuneiform may be divided into two parts, dorsal and plantar.

The **middle cuneiform bone** lies with the broad end of the wedge upwards, and it supports the second metatarsal. The *dorsal*

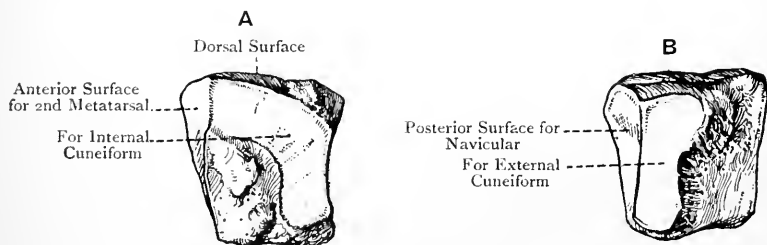


FIG. 149.—THE RIGHT MIDDLE CUNEIFORM BONE.

A, Internal View ; B, External View.

surface is rough and nearly square. The *plantar surface*, also rough, is narrow, and gives insertion to a slip of the tendon of the tibialis posticus. The *internal surface* presents, close to its superior and posterior borders, an L-shaped facet for the internal cuneiform, placed thus Υ for a right bone, and thus Γ for a left, the remainder of the surface being rough and ligamentous. The *external surface* has a vertical facet posteriorly for the external cuneiform, and elsewhere it is rough and ligamentous. The *anterior* and *posterior surfaces* are triangular and covered by cartilage, the former articulating with the second metatarsal, and the latter with the navicular. They are distinguished from each other in the following manner: the anterior surface is convex, whilst the posterior is concave; the apex of the anterior surface is more pointed than that of the pos-

terior ; and the posterior surface is rather broader than the anterior, and has one of the limbs of the **L** facet close to it.

Articulations.—*Posteriorly* with the navicular, *anteriorly* with the second metatarsal, *internally* with the internal cuneiform, and *externally* with the external cuneiform.

The **external cuneiform bone**, like the middle, lies with the broad end of the wedge upwards, and it supports the third metatarsal. The *dorsal surface* is rough, quadrilateral, and elongated from before backwards. The *plantar surface*, also rough, is narrow, and gives insertion to a slip of the tendon of the tibialis posticus. The *internal surface* presents a vertical facet posteriorly for the middle cuneiform, and two semi-oval facets anteriorly for articulation with the proximal pair of facets on the outer side of the base of the second metatarsal. The remainder of the surface is rough and ligamentous. The *external surface* has a large, almost circular, facet near the postero-superior angle for the cuboid, and there may be a

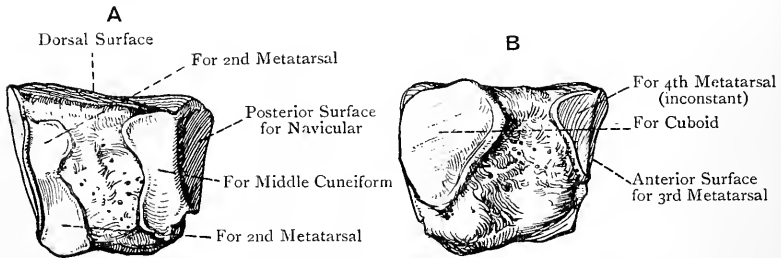


FIG. 150.—THE RIGHT EXTERNAL CUNEIFORM BONE.

A, Internal View ; B, External View.

small semi-oval facet at the antero-superior angle for the inner side of the base of the fourth metatarsal, but this facet is not constant. Elsewhere the surface is rough and ligamentous. The *anterior* and *posterior surfaces* are triangular, and covered by cartilage, the former articulating with the third metatarsal, and the latter with the navicular. They are distinguished from each other in the following manner: the anterior facet is deeper than the posterior, and its apex is more pointed ; the cartilage of the anterior surface extends over its entire length, but the lower part of the posterior surface is non-articular ; the anterior facet is slightly concavo-convex from below upwards, but the posterior is concave, and it has the large, almost circular, facet on the external surface contiguous to it.

Articulations.—*Posteriorly* with the navicular, *anteriorly* with the third metatarsal, *internally* with the middle cuneiform and outer side of the base of the second metatarsal, and *externally* with the cuboid, and, it may be, with the inner side of the base of the fourth metatarsal.

Structure of the Cuneiform Bones.—The structure of each is that of a short bone.

When the cuneiform bones are in position their posterior surfaces are on the same transverse plane, but the anterior surfaces of the

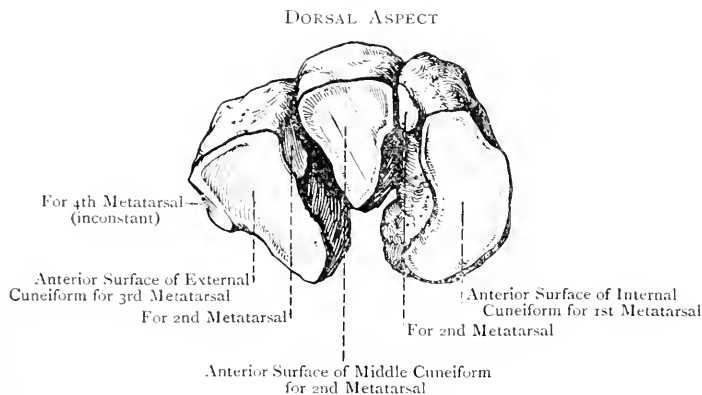


FIG. 151.—THE RIGHT CUNEIFORM BONES (ANTERO-SUPERIOR VIEW).

internal and external project farther forwards than that of the middle. In this manner a recess is formed, into which the base of the second metatarsal bone is received.

The Cuboid Bone.

The **cuboid bone** is characterized by its irregularly cubical shape, and by the groove and ridge on its plantar aspect. It is situated on the outer border of the foot, where it lies between the os calcis and the fourth and fifth metatarsal bones. The *anterior surface* has its cartilage divided by a vertical ridge into two facets—an inner quadrilateral for the fourth metatarsal, and an outer triangular for the fifth metatarsal. The *posterior surface* presents a large, somewhat triangular, facet, narrow towards the sole and deep internally, which is convex from above downwards and outwards, and concave from side to side. It articulates with the os calcis, and its internal and inferior angle, called the *calcaneal process*, projects backwards for a little beneath that bone. Below and inside the calcaneal process there may be a facet for the head of the astragalus. The *internal surface*, which is extensive and vertically disposed, presents a large, almost circular, facet for the external cuneiform, near the centre and extending to the dorsal surface. Behind this, and usually continuous with it, there may be a small facet for the navicular, the remainder of the surface being rough and ligamentous. The *external surface*, which is really a

border, is very short and narrow, and presents a notch leading to the peroneal groove on the plantar surface. The *dorsal surface* is rough, and is directed upwards and outwards. The *plantar surface* presents in front the deep *peroneal groove*, which is directed inwards and forwards, and lodges the tendon of the peroneus longus. Behind the groove is a stout, oblique ridge for the long plantar ligament. This ridge becomes enlarged externally into a tubercle, which is covered by cartilage on its anterior and outer aspects for the play of the sesamoid cartilage, or bone, usually present in the tendon of the peroneus longus. The surface behind the ridge gives attachment to the short plantar ligament, a slip of the tendon of the tibialis posticus, and some fibres of the flexor brevis hallucis, but the latter may spring from the internal surface.

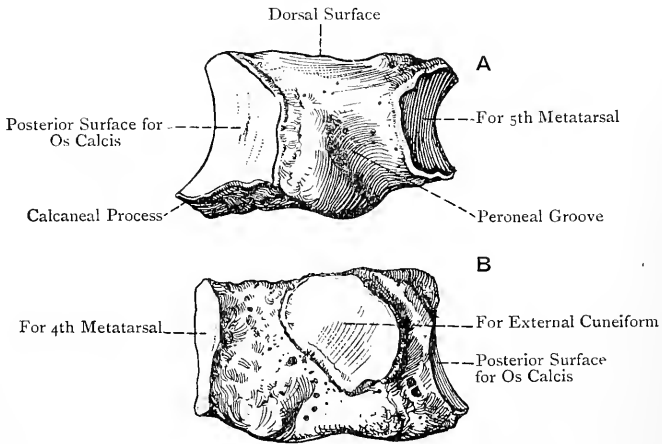


FIG. 152. — THE RIGHT CUBOID BONE.

A, External View ; B, Internal View.

Articulations.—*Posteriorly* with the os calcis, *anteriorly* with the fourth and fifth metatarsal bones, *internally* with the external cuneiform, and sometimes with the navicular, and at the lower and inner angle occasionally with the astragalus.

Structure.—The structure is that of a short bone.

The **tarsus as a whole** is convex superiorly, and concave inferiorly, from before backwards as well as from side to side. The part in front of the astragalus and os calcis constitutes the *instep*, and the entire tarsus forms two columns—an inner, comprising the astragalus, navicular, and three cuneiform bones, and an outer, representing the os calcis and cuboid.

Varieties.—The number of tarsal bones is sometimes increased to eight, which is brought about in one or other of the following ways : (1) the external tubercle on the posterior border of the astragalus may form a separate ossicle, called the *os trigonum* ; (2) the tuberosity of the navicular may form a

separate ossicle; (3) the internal cuneiform may be divided into two parts, dorsal and plantar; or (4) there may be an additional ossicle in the space at the antero-internal part of the os calcis, or between the internal cuneiform and the second metatarsal.

Ossification.—The tarsal bones ossify in cartilage, each from **one centre**, (except the os calcis, which has one primary, and one secondary, centre), and at the following periods approximately:

Os calcis, 6th month (intra-uterine).

Astragalus, 7th month (intra-uterine).

Cuboid, 9th month (intra-uterine).

External cuneiform, 1st year.

Internal cuneiform, 3rd year.

Middle cuneiform, 4th year.

Navicular, 4th year.

For the secondary centre of the os calcis, see page 240. The external tubercle on the posterior border of the astragalus has sometimes a secondary centre, and then it remains separate as the os trigonum.

The Metatarsus.

The **metatarsus** is composed of five long bones, which are named numerically from within outwards, that of the great toe being the first. Each bone is divisible into a shaft and two extremities, proximal and distal. The **shaft**, which is triangular, is massive in the first, slender and much compressed laterally in the second, third, and fourth, and compressed from above downwards in the fifth. Each shaft, except that of the first, is longitudinally convex on its dorsal aspect, and they are all longitudinally concave on their plantar aspects. The shaft presents three borders and three surfaces. In the outer four bones the borders are two lateral, and a plantar. The *lateral borders*, external and internal, extend from the sides of the proximal end or base, close to the dorsal aspect, to the dorsal tubercle on either side of the distal end or head, and their outline is sharp. The *plantar border*, round behind, but sharp in front, extends from the centre of the plantar aspect of the base forwards in the middle line to near the head, where it bifurcates, the divisions passing to the cornua on the plantar aspect of the head. The *dorsal surface* lies between the external and internal borders, and is narrow. Each *lateral surface* is situated between the lateral and plantar borders. The lateral surfaces, which are extensive and sloped, bound the interosseous spaces, and give attachment to the interosseous muscles. The shaft of the **first** metatarsal has its borders disposed as supero-external, infero-external, and internal. The *dorsal surface* is convex, and is directed upwards and inwards. The *plantar surface* is concave, and supports the tendon of the flexor longus, and the flexor brevis hallucis. The *external surface*, which is practically vertical, is narrow in front, but wide behind.

The **heads** of the **four outer** metatarsal bones are much compressed laterally. The cartilage is prolonged more on the plantar than on the dorsal aspect, and in the former situation it ends in a concave

border, surmounted at either side by a prominent *cornu*. On either side the head presents a dorsal tubercle and plantar depression for the lateral metatarso-phalangeal ligament. The head of the **first** metatarsal is of large size, and elongated transversely. On its plantar aspect it presents two well-marked grooves, separated by a median antero-posterior ridge, for the sesamoid bones in the heads of insertion of the flexor brevis hallucis.

The **bases** of the metatarsal bones articulate with the tarsus and with each other, except, as a rule, in the case of the first, and they present distinctive characters in each case.

First Metatarsal Bone.—This supports the great toe, and is the thickest and most massive of the series. The **base** is of large size, and presents a concave reniform surface, with the concavity out-

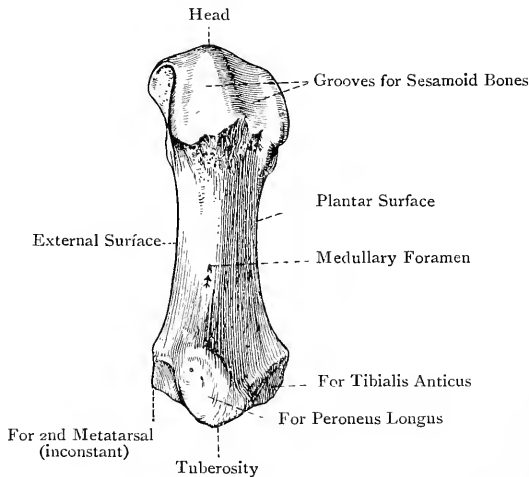


FIG. 153.—THE FIRST RIGHT METATARSAL BONE (PLANTAR VIEW).

wards, for the internal cuneiform. Inferiorly it presents a projection, called the tuberosity, which gives insertion, by its outer aspect, to the principal part of the tendon of the peroneus longus, and by its inner aspect to a slip of the tendon of the tibialis anticus. There is usually no facet on its outer surface, but sometimes it presents one for the second metatarsal, and it always gives origin to the inner head of the first dorsal interosseous.

Articulations.—*Posteriorly* with the internal cuneiform, and sometimes *externally* with the second metatarsal; *anteriorly* with the first phalanx of the great toe; and *inferiorly* with the two sesamoid bones.

Second Metatarsal Bone.—This supports the second toe. Its **base** is wedge-shaped, with the broad end upwards. It recedes between the internal and external cuneiform bones, and posteriorly

presents a concave triangular facet for the middle cuneiform. On the inner side, close to the dorsal aspect, there is a small facet for the internal cuneiform, and sometimes there is an additional facet, below and in front of this, for the first metatarsal. The outer side presents two facets, dorsal and plantar, separated by a rough antero-posterior groove, each of these being subdivided by a vertical ridge into two semi-oval facets. There are thus four facets in all—

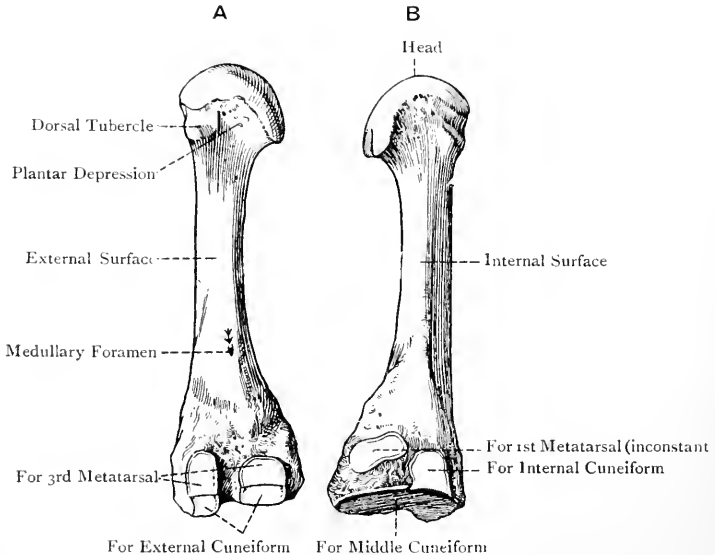


FIG. 154.—THE SECOND RIGHT METATARSAL BONE.

A, External View ; B, Internal View.

a posterior pair for the inner side of the external cuneiform, and an anterior pair for the inner side of the base of the third metatarsal. The plantar surface of the base gives insertion to a slip of the tendon of the tibialis posticus, and origin to a portion of the adductor obliquus hallucis. The shaft gives partial origin to the first and second dorsal interossei.

Articulations.—*Posteriorly* with the middle cuneiform, *internally* with the internal cuneiform, and sometimes with the first metatarsal, *externally* with the external cuneiform and third metatarsal, and *anteriorly* with the first phalanx of the second toe.

Third Metatarsal Bone.—This supports the third toe. The base resembles in shape that of the second, the broad end being upwards. Posteriorly it presents a triangular facet, concavo-convex from above downwards, for the external cuneiform. The inner side of

the base presents two semi-oval facets, dorsal and plantar, separated by a rough antero-posterior groove, for the anterior pair of facets on the outer side of the base of the second metatarsal. On the outer side there is a large semi-oval facet, dorsally placed, for the inner side of the base of the fourth metatarsal. The plantar surface of the base gives insertion to a slip of the tendon of the tibialis posticus, and origin to a portion of the adductor

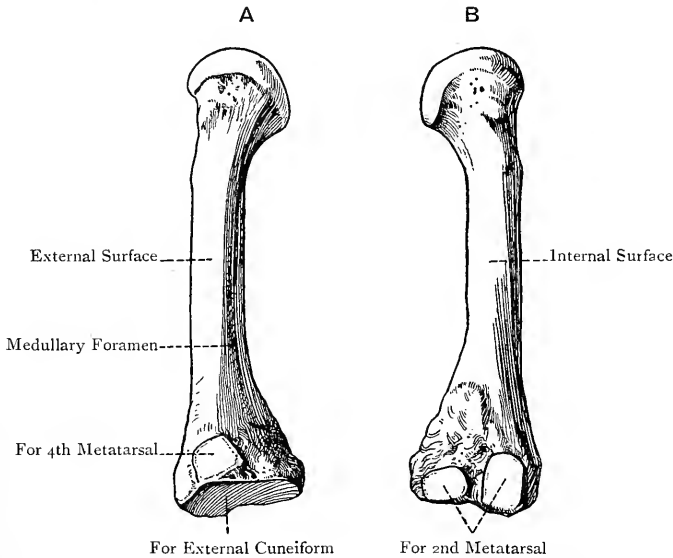


FIG. 155.—THE THIRD RIGHT METATARSAL BONE.

A, External View ; B, Internal View.

obliquus hallucis. The shaft gives origin to the first plantar interosseous, and partial origin to the second and third dorsal interossei.

Articulations.—*Posteriorly* with the external cuneiform, *internally* with the second metatarsal, *externally* with the fourth metatarsal, and *anteriorly* with the first phalanx of the third toe.

Fourth Metatarsal Bone.—This supports the fourth toe. The **base** is quadrilateral, and is somewhat broader above than below. Posteriorly it presents a quadrilateral facet for the cuboid. On the inner side there is a large semi-oval facet for the third metatarsal, and this is sometimes prolonged to the extremity of the base, thus forming an additional facet for the outer side of the external cuneiform. On the outer side there is a large semi-oval facet, dorsally placed, for the inner side of the base of the fifth metatarsal, and below this there is a deep rough groove. The plantar surface of the base gives insertion to a slip of the tendon

of the tibialis posticus, and origin to a portion of the adductor obliquus hallucis. The shaft gives origin to the second plantar

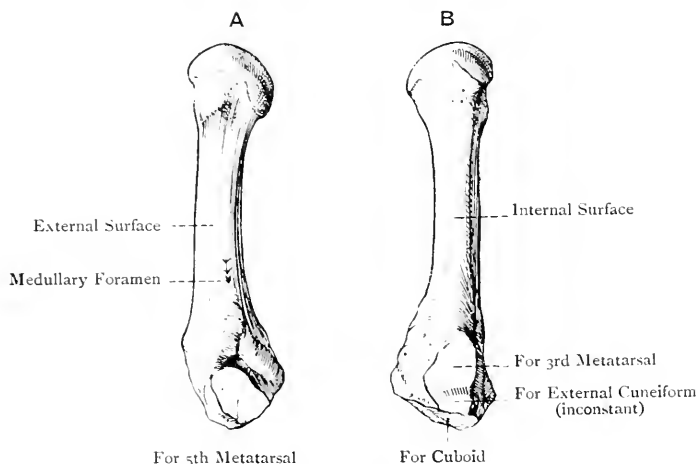


FIG. 156.—THE FOURTH RIGHT METATARSAL BONE.

A, External view; B, Internal view.

interosseous, and partial origin to the third and fourth dorsal interossei.

Articulations.—*Posteriorly* with the cuboid, *internally* with the third metatarsal, and sometimes with the external cuneiform, *externally* with the fifth metatarsal, and *anteriorly* with the first phalanx of the fourth toe.

Fifth Metatarsal Bone.—This supports the little toe. The **base** is elongated from side to side, and compressed from above downwards. Its leading characteristic is a stout, mammillary process, situated on its outer aspect, called the tuberosity, which is directed outwards and backwards, and gives insertion to the tendon of the peroneus brevis. The posterior surface presents a triangular facet for the cuboid, the plane of which is inclined inwards and forwards. This facet does not encroach upon the tuberosity. The inner surface presents a large semi-oval facet for the outer side of the base of the fourth metatarsal. The dorsal surface, which is rough and slightly convex, gives insertion, as a rule, to the tendon of the peroneus tertius. The plantar surface, which is rough and concave, gives origin to the flexor brevis minimi digiti. The shaft gives origin to the third plantar interosseous, and partial origin to the fourth dorsal interosseous.

Articulations.—*Posteriorly* with the cuboid, *internally* with the fourth metatarsal, and *anteriorly* with the first phalanx of the little toe.

Each metatarsal bone presents a **medullary foramen**, that of

the first and second, and usually that of the third and fourth, being situated on the outer side of each shaft, whilst that of

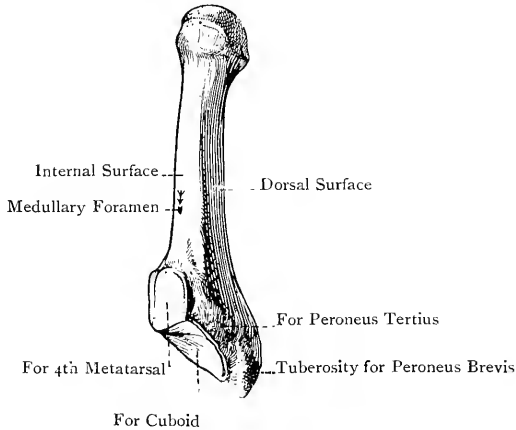


FIG. 157.—THE FIFTH RIGHT METATARSAL BONE (SUPERO-INTERNAL VIEW).

the fifth is situated on the inner side.* The foramen of the first and the canal to which it leads are directed *downwards* towards the head or distal end, but that of each of the other four is directed

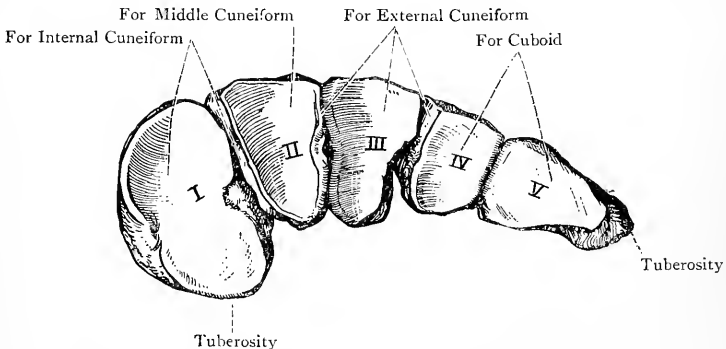


FIG. 158.—THE BASES OF THE RIGHT METATARSAL BONES (POSTERIOR VIEW).

upwards towards the base or proximal end. The first metatarsal receives its nutrient artery from the arteria magna or princeps hallucis, the second from the fourth digital artery, the third usually

* Of 100 third, and an equal number of fourth, metatarsal bones examined, 73 third metatarsals had the medullary foramen on the outer side, and 27 on the inner side; and 60 fourth metatarsals had it on the outer side, and 40 on the inner side.

from the third digital, and the fourth and fifth from the second digital artery.

Structure.—The structure is that of a long bone.

Varieties.—(1) The tuberosity on the outer side of the base of the fifth metatarsal, or the tuberosity on the plantar surface of the base of the first, may form a separate ossicle. (2) An additional ossicle is sometimes met with between the bases of the first and second metatarsals.

The **metatarsus as a whole** is convex on its dorsal aspect from side to side, and also longitudinally. The transverse convexity is due to the broad ends of the bases of the second, third, and fourth metatarsals being directed upwards. On its plantar aspect it is concave from side to side, and also longitudinally. All five bones are nearly parallel with each other, being slightly divergent in front. The interosseous spaces are as in the hand, the first being the innermost.

The Phalanges.

The **phalanges** are fourteen in number—three to each of the four outer toes, and two to the great toe. The toes, from within outwards, are called great toe or hallux, second, third, fourth, and fifth or little toe. In their general characters the phalanges so closely resemble those of the hand that a detailed description is unnecessary. The phalanges of the great toe, called proximal and distal, are characterized by their large size and great length, which, with the length of the first metatarsal bone, places the great toe on a level with those next it. The first phalanx of the four outer toes is characterized by being slender, and much compressed from side to side over its shaft, the proximal end being of large size, and almost triangular. The second phalanx is short, and compressed from above downwards. The unguis phalanx is very small.

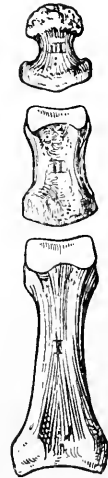

FIG. 159.

THE PHALANGES OF
THE SECOND TOE
(PLANTAR VIEW).

Special Muscular Attachments.—The base of the proximal phalanx of the great toe, which presents a tubercular enlargement at either side, gives insertion internally to the abductor hallucis and inner head of the flexor brevis hallucis; externally, to the outer head of the flexor brevis hallucis, adductor hallucis, and adductor transversus hallucis; and on its dorsal surface there is a rough transverse ridge for the innermost tendon of the extensor brevis digitorum. The base of the unguis phalanx of the great toe gives insertion, on its dorsal surface, to the extensor proprius hallucis, and, on its plantar surface, to the flexor longus hallucis. The base of the first phalanx of the second toe gives partial insertion internally to the first dorsal interosseous, and externally to the second dorsal interosseous. The base of the first phalanx of the third toe gives partial insertion internally to the first plantar interosseous, and externally to the third dorsal interosseous. The base of the first phalanx of

the fourth toe gives partial insertion internally to the second plantar interosseous, and externally to the fourth dorsal interosseous. The base of the first phalanx of the fifth toe gives partial insertion internally to the third plantar interosseous, and externally insertion to the abductor minimi digiti and flexor brevis minimi digiti. The second and unguinal phalanges of each of the four outer toes give insertion to extensor and flexor tendons, as in the case of the corresponding bones of the four inner fingers.

The **medullary foramen** and the canal to which it leads are, in each phalanx, directed towards the distal end. The nutrient arteries are derived from the corresponding plantar digital arteries.

Structure.—The structure of each phalanx resembles that of the corresponding bone in the hand.

Varieties.—Ankylosis of the unguinal and second phalanges of the fifth toe is of frequent occurrence, and may even involve those of other toes, up to and including the second.

Sesamoid Bones.—These are two in number, and are of large size. They are associated with the two heads of insertion of the flexor brevis hallucis, and lie on the plantar aspect of the head of the first metatarsal bone.

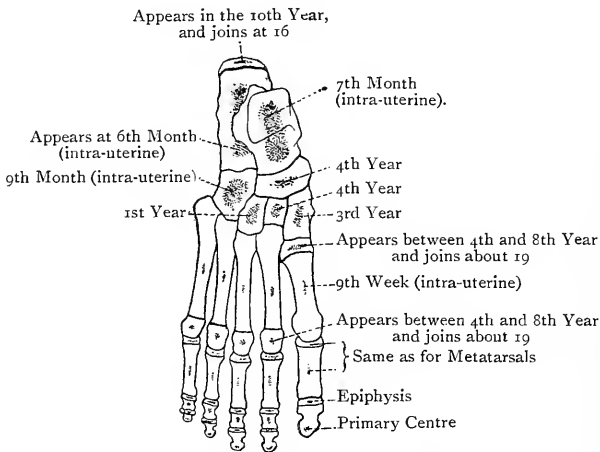


FIG. 160.—OSSIFICATION OF THE BONES OF THE FOOT.

Ossification of Metatarsal Bones and Phalanges.—Each bone ossifies in cartilage from **one primary**, and **one secondary**, centre, which closely agree with those of the corresponding bones of the hand in their disposition. The primary centres for the shafts appear about the *ninth week* of intra-uterine life, whilst the secondary centres appear between the *fourth* and *eighth year*. Each epiphysis joins its shaft about the *nineteenth year*.

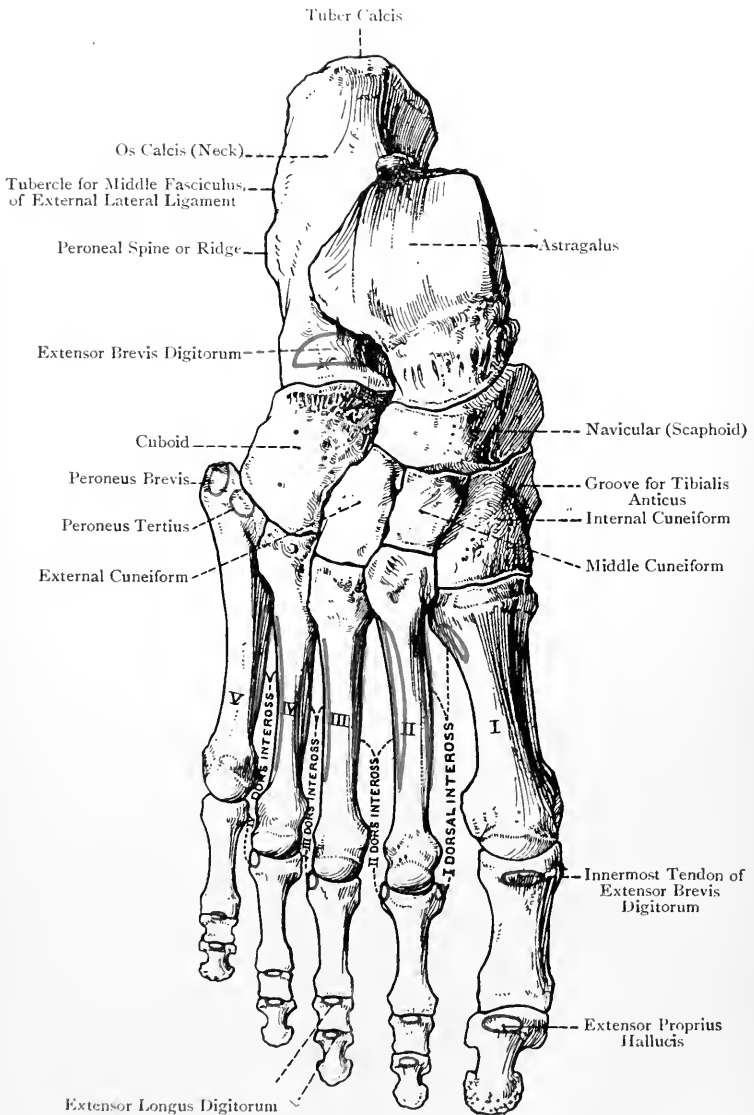


FIG. 161.—THE RIGHT FOOT (DORSAL SURFACE).

The Foot as a Whole.

The **foot** presents two arches, longitudinal and transverse. The posterior pier of the **longitudinal arch** is formed by the plantar aspect of the tuber calcis, and the anterior pier by the heads of the metatarsal bones. The arch is single behind, where it is formed by the posterior two-thirds of the os calcis, but it is divided into two pillars in front. The internal pillar is formed by the astragalus, navicular, three cuneiforms, and inner three metatarsal bones. It is more elevated from the ground than the external, and has to bear greater weight. The external pillar is formed by the anterior third of the os calcis, cuboid, and outer two metatarsal bones, and is nearer the ground than the internal.

The **transverse arch** is most conspicuous at the tarso-metatarsal articulations, and is due to the broad aspects of the middle and external cuneiforms, and the broad aspects of the wedge-shaped bases of the second, third, and fourth metatarsal bones being dorsally placed.

The arches serve the following purposes: they give strength and elasticity to the foot; they protect the structures contained in the sole; and they permit of the heel-to-toe movement in walking, which is characteristic of man.

The foot presents two surfaces, dorsal and plantar, and two borders, internal or tibial, corresponding with the great toe, and external or fibular, corresponding with the little toe. On its *plantar aspect* it presents the following projections: the inner and outer tubercles on the under surface of the tuber calcis; the anterior tubercle of the os calcis; the tuberosity of the navicular; the eminence on the plantar surface of the internal cuneiform bone; the tuberosity on the under surface of the base of the first metatarsal bone (the three last being along the inner aspect of the sole); and the tuberosity on the outer side of the base of the fifth metatarsal bone, which is on the outer border of the foot. All these projections, with their attachments, have been already described in connection with each individual bone.

APPROXIMATE HOMOLOGIES OF THE BONES OF THE LIMBS.

UPPER LIMB.

LOWER LIMB.

I. Shoulder Girdle and Pelvic Girdle.

Scapula - - -	=	Ilium.
Coracoid - - -	=	Ischium.
Precoracoid of mono- tremata and reptiles }	=	Os pubis.
Clavicle - - -	=	Absent.

(If, however, the clavicle is the morphological representative of the precoracoid of monotremata and reptiles, then it is homologous with the os pubis.)

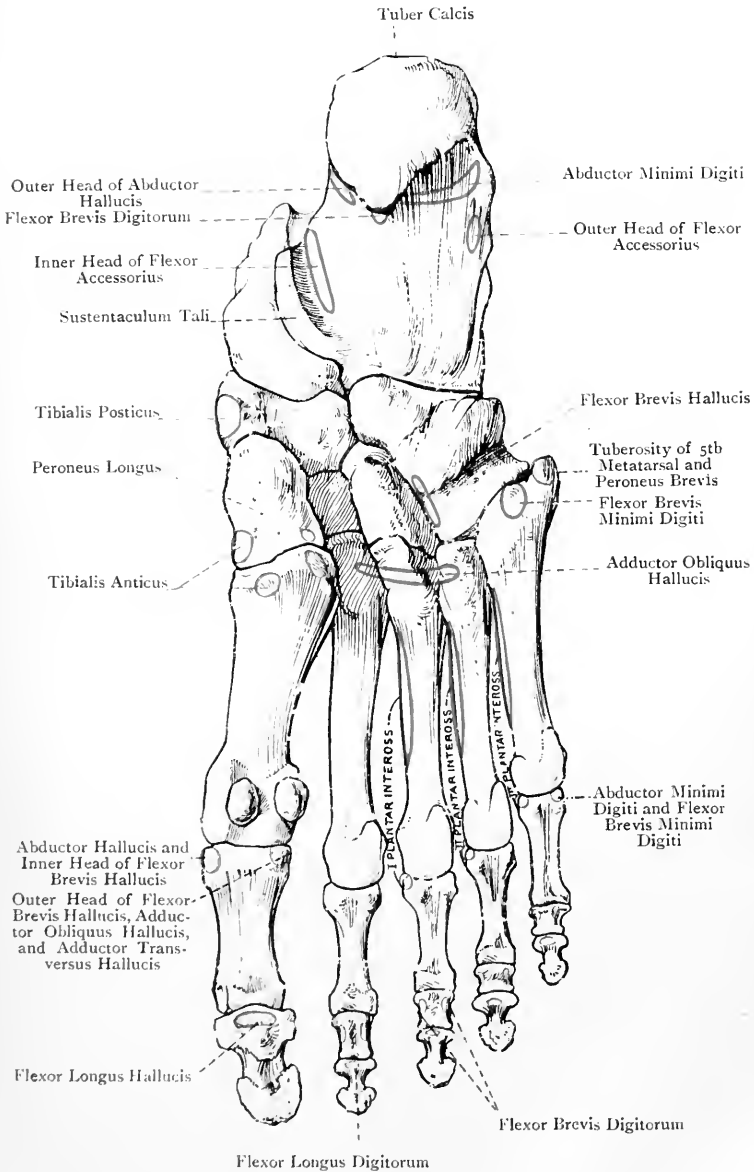


FIG. 162.—THE RIGHT FOOT (PLANTAR SURFACE).

UPPER LIMB.

LOWER LIMB.

Special Homologies of Scapula and Ilium (Flower).

<i>Scapula.</i>	<i>Ilium.</i>
Inferior angle - - =	Anterior superior spine.
Superior angle - - =	Posterior superior spine.
Base - - - =	Crest.
Axillary border - - =	Anterior border.
Superior border - - =	Posterior border.
Supraspinous fossa - =	Sacral surface.
Infraspinous fossa - =	Iliac fossa.
Spine and acromion - =	Ilio-pectineal line.
Subscapular fossa - =	Gluteal surface (dorsum ilii).
Glenoid cavity - - =	Cotyloid cavity.

II. Arm, Forearm, Thigh, and Leg.

Humerus - - =	Femur.
Absent - - =	Patella.
Radius - - =	Tibia.
Ulna - - =	Fibula.

Special Homologies of Humerus and Femur.

<i>Humerus.</i>	<i>Femur.</i>
Great tuberosity - - =	Small trochanter.
Small tuberosity - - =	Great trochanter.
External epicondyle and } =	Internal condyle.
capitellum - - - } =	
Internal epicondyle and } =	External condyle.
trochlea - - - } =	

III. Hand and Foot.

<i>Hand.</i>	<i>Foot.</i>
Carpus - - - =	Tarsus.
Metacarpus - - =	Metatarsus.
Digital phalanges - =	Digital phalanges.
Pollex - - - =	Hallux.

Homologies of Carpus and Tarsus.

<i>Carpus.</i>	<i>Tarsus.</i>
Scaphoid (except the part represented by the embryonic supernumerary cartilage), and semilunar - - - } =	Astragalus.
Cuneiform or pyramidal - - =	Os calcis.

(The pisiform is generally regarded as the rudiment of a suppressed digit.)

The part of the scaphoid formed by the embryonic supernumerary cartilage - } =	Navicular or scaphoid.
--	------------------------

(In apes and water-tortoises there is an additional carpal bone, called the *os centrale*, which represents the navicular of the tarsus.)

Trapezium	-	-	=	Internal cuneiform.
Trapezoid	-	-	-	Middle cuneiform.
Os magnum	-	-	-	External cuneiform.
Unciform	-	-	=	Cuboid.

Development of the Bones of the Limbs.

The pectoral and pelvic limbs appear about the fourth week as outgrowths or limb-buds, which spring at either side from a ridge of the mesoblast near the outer margins of the mesoblastic somites. These buds are covered by epiblast, and each receives prolongations from the muscle-plates of the contiguous somites, which prolongations give rise to the muscles, as well as processes from the spinal cord, which give rise to the nerves. In their development the limb bones pass through the same stages as the vertebræ, namely, **membranous, cartilaginous, and osseous**. The mesoblast in the centre of each limb-bud forms the membranous stage. About the fifth week chondrification takes place, and constitutes the cartilaginous stage. A little later osseous centres appear, and the process of ossification commences. The mesoblastic tissue between the cartilaginous frameworks of the bones assumes a hollow condition, and so the joint-cavities are formed, the synovial membranes and ligaments being developed from the surrounding mesoblast.

ARTHROLOGY

AN **articulation** or **joint** is the connection between two or more parts of the skeleton in the recent condition. In most joints the parts are osseous, but in certain cases cartilage forms the basis. The manner in which the parts are connected and the amount of movement allowed between them vary, and joints are accordingly divided into three classes, namely, synarthrosis, amphiarthrosis, and diarthrosis.

Synarthrosis.—This is direct union, there being only a small amount of intervening tissue without any joint cavity, and the joint is immovable. There are two varieties of this class—synchondrosis and suture.

1. **Synchondrosis.**—In this joint a thin plate of hyaline cartilage intervenes between the component parts, as, for example, between the diaphysis or shaft and epiphyses of a long bone. It is essentially a temporary joint.

2. **Suture.**—In this variety the bones are separated by a small amount of fibrous tissue, which is continuous with the periosteum. Such joints are only met with in the skull. There are three forms of suture, called true, false, and grooved. When the margins of the bones present a number of projections with intervening depressions, so that they become closely interlocked, the suture is called true. When the opposed margins are more or less flat, so that there is merely apposition without interlocking, the suture is spoken of as false. When one margin presents a ridge and the other a cleft into which the ridge is received, it is known as a grooved suture.

True sutures are of three kinds—serrated, dentated, and limbous. In the *serrated suture* the margins of the bones are saw-like, as in the frontal suture; in the *dentated suture* the margins present projections like teeth, as in the interparietal suture; and in the *limbous suture* the projections on the margins of the bones are bevelled so that they overlap, as in the fronto-parietal suture.

False sutures are of two kinds—squamous and harmonic. In the *squamous suture* the margins are bevelled so that one overlaps the other, as in the squamo-parietal suture. In the *harmonic suture* the surfaces, which are rough, are in direct apposition, as between

the superior maxilla. In the **grooved suture** a ridge on one bone is received into a cleft on another. Such a suture is known as *schindylesis*, and it is exemplified in the articulation between the rostrum of the sphenoid and the vomer.

Amphiarthrosis.—In this class the opposed surfaces are connected either by a disc of fibro-cartilage, or by an interosseous ligament, and the joint is partially movable. When the connecting medium is a disc of fibro-cartilage the name of *symphysis* is given to the joint, as between the bodies of the vertebræ, the bodies of the pubic bones, and between the presternum and mesosternum. When the connecting medium is an interosseous ligament the joint is called *syndesmosis*, as in the inferior tibio-fibular articulation. Union by means of an interosseous membrane is also a form of syndesmosis.

Diarthrosis.—While there is more or less continuity at a synarthrosis and an amphiarthrosis, there is none at a diarthrosis. The articular ends of the bones are free, and the joint is freely movable. The ends of the bones are smooth and polished, being covered by articular cartilage; they are connected by ligaments; and the interior of the joint is lined with a synovial membrane, except over the articular cartilages. This membrane secretes the synovia, which lubricates all parts of the interior. There are five varieties of diarthrosis.

1. **Enarthrosis or Ball-and-socket Joint.**—In this variety one articular end is spherical, and the other is hollowed into a socket for its reception, as in the shoulder- and hip-joints.

2. **Condylarthrosis or Condylar Joint.**—This is akin to enarthrosis. One articular end has the form of a condyle, and the other presents a shallow cavity, as in the metacarpo- and metatarso-phalangeal joints.

3. **Trochlearthrosis, Ginglymus, or Hinge Joint.**—In this variety one articular end has the form of a trochlea or pulley, and the other is so shaped as to adapt itself to it, as in the elbow- and ankle-joints.

4. **Arthrodia or Gliding Joint.**—In this joint the surfaces are almost plane, or in some cases concavo-convex, as in the joints between the articular processes of vertebræ, and the carpal and tarsal joints. Under this variety is to be included the *reciprocal* or *saddle joint*, where the articular surfaces are saddle-shaped and mutually adapt themselves to each other, as between the trapezium and the first metacarpal bone.

5. **Trochoides or Pivot Joint.**—In this joint one articular end forms a pivot, and the other is so arranged as to rotate around it, as between the atlas and the odontoid process of the axis.

Ligaments.—These are composed of white fibrous tissue, and, as their name implies, they bind the bones together. At a diarthrosis their chief use is to control movement, the bones being maintained in position by the muscles and atmospheric pressure. At their attachments they are intimately associated with the periosteum. When the fibrous tissue is arranged continuously round the joint the ligament is called a *capsular ligament*. In other cases the tissue is disposed as round cords, and in a third variety it forms flattened bands.

Synovial Membranes.—These membranes are so named because they secrete a fluid, viscid like white of egg, which is called *synovia*. They serve to diminish friction and so facilitate movement. Their situations are therefore associated with movable structures, such as joints, gliding tendons, and the integument over bony projections. Accordingly there are three kinds of synovial membrane—namely, articular, tendon or vaginal, and bursal.

The **articular synovial membranes** line the interior of diarthrodial joints, except where there is articular cartilage, and they stop at the margin of this cartilage. In some joints they give rise to folds, some of which contain adipose tissue. Such folds are known as *Haversian mucilaginous glands*.

The **tendon or vaginal synovial membranes**, also known as *synovial sheaths*, invest those tendons which have to glide within fibrous sheaths. They are met with around the ankle, particularly behind the external and internal malleoli, and upon the palmar aspect of the fingers.

The **bursal synovial membranes**, commonly called **synovial bursæ**, are synovial sacs which are situated between the integument or a muscle and some bony projection. They may be deep-seated or subcutaneous. The *deep-seated bursæ* are situated between a muscle, or its tendon, and the contiguous bone,—e.g., the tendon of the biceps brachii and the anterior part of the bicipital tuberosity of the radius. The *subcutaneous bursæ* are placed beneath the integument, which they separate from some bony projection—e.g., the prepatellar bursa.

Structure.—A synovial membrane consists of connective tissue, which is destitute of an endothelial lining properly so called. At intervals it may present scattered groups of branched cells, but these are not endothelial. There are many capillary bloodvessels, and lymphatic vessels are described as being present. The nerves are described as terminating in corpuscles of the nature of end-balls, in a plexiform manner, and in Pacinian corpuscles.

Development.—Synovial membranes are developed from the axial mesenchyme of the limb-buds, in the intervals between contiguous bones, which are being formed from that mesenchyme.

Interarticular Fibro-cartilages.—These are met with in certain joints either in the form of plates separating the articular ends, or as bands placed around cavities, which they serve to deepen, or around flat surfaces, which they render concave. They are known as *menisci*. When the fibro-cartilage takes the form of a plate it is spoken of as an *interarticular meniscus*. Such occur at the temporo-mandibular, sterno-clavicular, and radio-carpal joints. They act as buffers to break shock, and they compensate for irregularities of the opposed surfaces. When the fibro-cartilage is limited to the margin of a cavity, or the circumference of a surface, it is called a *marginal meniscus*, such as the glenoid ligament of the shoulder-joint, the cotyloid ligament of the hip-joint, and the semilunar fibro-cartilages of the knee-joint.

Movements.—The different kinds of movement at diarthrodial joints are angular, circumduction, rotation, and gliding.

Angular Movement.—This increases or diminishes the angle between two or more bones. When it takes place in a forward and backward direction, so as to bend or straighten a joint, it is spoken of as *flexion* and *extension*. When it takes place laterally, away from or towards the median plane of the body, it is called *abduction* and *adduction*. In the case of the hand the median line from or towards which abduction and adduction take place is a line passing through the centre of the *middle finger*, and in the case of the foot, through the centre of the *second toe*.

Circumduction.—This consists of the four forms of angular movement, occurring successively in such sequence as flexion, abduction, extension, and adduction. It occurs at ball-and-socket and condylar joints, and during the movement a part of the limb describes a cone, the apex of which is formed by the proximal end at the moving joint, whilst the base is described by the distal end.

Rotation.—This is movement of a bone round its axis without much disturbance of its position. It occurs at enarthrodial and trochoidal joints, and also at the knee-joint, which is a ginglymus.

Gliding Movement.—This consists of a simple to-and-fro or sliding movement of two articular surfaces, as between the articular surfaces of vertebræ, and at the carpal and tarsal joints. When the gliding is combined with a certain amount of turning or rolling, so as to bring different parts of the articular surfaces successively into contact in different positions of the joint, the movement is known as *coaptation*, as at the femoro-patellar joint.

A description of the different articulations will be found in connection with the regions to which they belong.

THE UPPER LIMB

THE BACK.

Landmarks.—The middle line of the neck presents a median furrow, called the **nuchal groove**, which lies over the line of the ligamentum nuchæ. It is due to the shortness of most of the cervical spinous processes and the prominence at either side, caused principally by the complexus muscle. At the upper end of this groove the strong bifid spine of the axis may be felt by sinking the finger deeply, but the spines of the third, fourth, and fifth cervical vertebrae cannot be detected, as these fall short of the surface so as to allow of dorsal flexion of the neck. At the lower end of the groove the spine of the seventh cervical or vertebra prominens can readily be felt, and usually also that of the sixth, and succeeding to these are the thoracic and lumbar spines. The spine of the first thoracic vertebra is, as a rule, the most conspicuous of the series. Along the middle line of the thoracic and lumbar regions there is an elongated furrow, called the **spinal groove**, which is produced by the prominence formed by the erector spinæ on either side. This groove is best marked in the lower thoracic and upper lumbar regions, and it subsides about the level of the third sacral spine. The outline of the scapula may be made out, unless in very muscular persons. It will be found to extend from the second to the seventh rib, and the spine and acromion process are usually readily felt. The root of the spine is on a level with the third thoracic spine, and the inferior angle coincides with the seventh rib. The crest of the ilium can be felt at the lower part of the back, its greatest prominence being on a level with the fourth lumbar spine.

Fascia.—The **superficial fascia** is thick, granular, and fatty, and in it the cutaneous nerves and vessels are met with. The **deep fascia** is thin and membranous, but firm. It contains no fat, and forms sheaths for the muscles.

Cutaneous Nerves.—These are most readily met with at the level of the deep part of the superficial fascia, and the cutaneous vessels serve as the best guide to them. They are derived from the posterior primary divisions of the spinal nerves, which, with a few exceptions, divide each into an *external* and *internal branch*.

In the *thoracic region* the internal branches of the upper six nerves become cutaneous near the spines of the vertebræ, and then turn outwards in the integument. The branch of the second is characterized by its great length, and it can be traced well outwards over the scapula. The external branches of the upper six thoracic nerves end in the muscles. The internal branches of the lower six thoracic nerves are muscular, and the external branches become

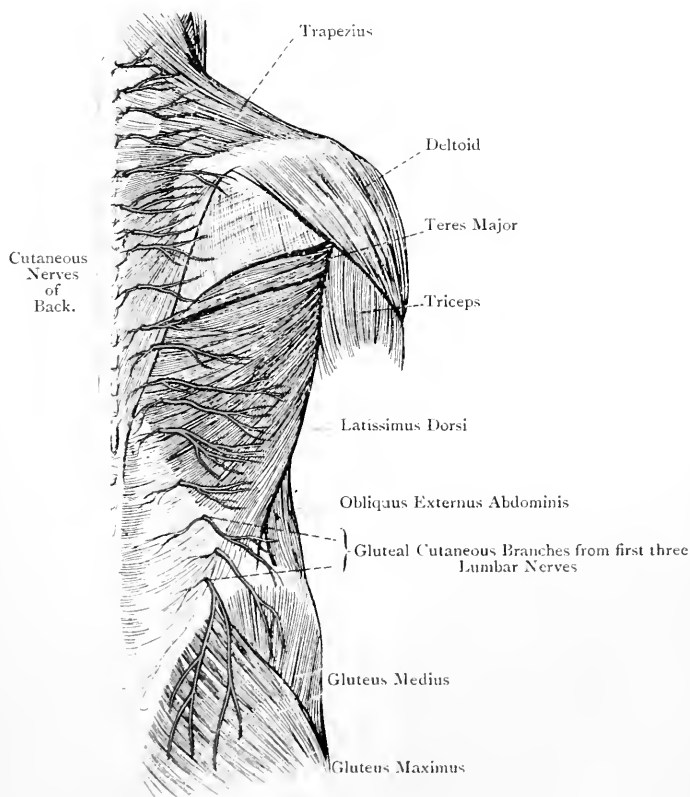


FIG. 163.—THE SUPERFICIAL DISSECTION OF THE BACK.

cutaneous along the course of the angles of the ribs. In the *lumbar region* the internal branches end in the muscles. The external branches of the first three nerves furnish cutaneous offsets which descend over the iliac crest in front of the outer border of the erector spinæ to the gluteal integument, supplying in their course the integument of the lumbar region. The external branches of the lower two nerves end in the deep muscles. In all cases the

tribution of the cutaneous nerves is at a lower level than their origin.

The **cutaneous arteries** which accompany the cutaneous nerves of the thoracic and lumbar regions are derived from the dorsal branches of the intercostal and lumbar arteries.

Muscles. Trapezius.—This muscle is so named because, along with its fellow, it presents a four-sided appearance like a table. The two muscles have also a resemblance to a monk's hood or cowl; hence the name *cucullaris*.

Origin.—(1) The inner third of the superior curved line of the occipital bone, and the external occipital protuberance; (2) the ligamentum nuchæ; and (3) the spinous processes and supraspinous ligaments of the last cervical, and, as a rule, all the thoracic vertebrae. The origins of the two muscles are markedly tendinous between the second cervical and third thoracic spines, where they give rise to an elliptical area, widest opposite the sixth cervical spine.

Insertion.—(1) The posterior border of the outer third of the clavicle; (2) the inner border of the acromion process, and upper lip of the posterior border of the spine, of the scapula; and (3) the tubercle which projects at the inner end of the upper lip of the spine near the root. The lower fibres end in a special tendon which glides over the triangular surface at the root of the spine, being separated from it by a synovial bursa.

Nerve-supply.—(1) The spinal accessory nerve (spinal portion), and (2) branches from the cervical plexus, which are derived from the anterior primary divisions of the third and fourth cervical nerves. The nerves enter the deep surface of the muscle after passing beneath its anterior border a little above the clavicle, and the spinal accessory, having become connected with the spinal nerves, can be traced over nearly the whole extent of its deep surface, where it lies about 2 inches from the spines of the vertebrae.

Blood-supply.—There is one specially-named artery, called the superficial cervical, which is a branch of the transverse cervical, and, like the nerves, enters the deep surface of the muscle.

The upper fibres of the muscle are directed downwards, outwards, and forwards; the middle fibres pass more or less horizontally outwards; and the lower fibres pass upwards and outwards.

Action.—The upper fibres, acting from their origin, elevate the outer end of the clavicle and the point of the shoulder. Acting from their insertion they extend the head and incline the neck towards the same side, the face being directed towards the opposite side. The middle fibres approximate the scapula to the spine, and the lower fibres draw it downwards and inwards, both of these sets of fibres also producing rotation of the bone, so as to elevate the point of the shoulder. The entire muscle draws the scapula to the spine, and produces a certain amount of rotation of the bone, the point of the shoulder being raised, as in the act of shrugging the shoulders.

Ligamentum Nuchæ.—This is a fibrous band, or intermuscular septum, which occupies the median line of the neck. Its superficial fibres are attached above to the external occipital protuberance, and below to the spine of the seventh cervical vertebra. Its deep fibres are attached to the external occipital crest, and to the spines of cervical vertebræ from the second to the sixth inclusive. They also extend into the interspinous intervals between the interspinales muscles, where they represent interspinous ligaments.

Latissimus Dorsi—*Origin.*—(1) The spinous processes and supra-spinous ligaments of the lower six thoracic vertebræ; (2) the posterior lamina of the lumbar aponeurosis, through means of which it is attached to the lumbar and sacral spines, and the posterior fourth of the outer lip of the iliac crest; (3) the outer lip of the iliac crest a little behind the centre for about 2 inches; (4) the outer surfaces of the last three or four ribs external to their angles by fleshy slips, which interdigitate with slips of the obliquus externus abdominis; and (5) the back of the inferior angle of the scapula, the last origin being inconstant.

Insertion.—The floor of the bicipital groove of the humerus about its middle third for about $1\frac{1}{2}$ inches.

Nerve-supply.—The middle or long subscapular nerve from the posterior cord of the brachial plexus, its fibres being derived chiefly from the seventh cervical nerve. The nerve is only seen during the dissection of the axillary space, and it enters the muscle on its deep aspect.

Blood-supply.—Branches of the subscapular artery.

The upper fibres of the muscle pass horizontally outwards, and cross the inferior angle of the scapula, which they bind to the chest wall; the succeeding fibres pass obliquely upwards and outwards; and those from the iliac crest and lower ribs pass almost vertically upwards.

Action.—The arm being raised, the muscle draws it downwards and backwards, producing at the same time internal rotation, as when the hands are crossed behind the back. When the muscle acts from its insertion, it raises the pelvis and trunk after the outstretched arms, as in the act of climbing a pole. It also elevates the last three or four ribs, as in forced inspiration.

At the inferior angle of the scapula the muscle is behind the teres major; it then winds round the lower border of that muscle; and eventually it is placed in front of it. The lower borders of the tendons of these muscles near their insertions are closely connected, but ultimately they become separated, a synovial bursa intervening between the two. Between the upper border of the latissimus dorsi, the lower border of the trapezius, and the base of the scapula, there is a triangular area in which are exposed a portion of the rhomboideus major, the sixth rib, and the sixth intercostal space.

Triangle of Petit.—The anterior border of the latissimus dorsi, between the iliac crest and last rib, may or may not overlap the

posterior border of the obliquus externus abdominis. If it does not do so, a small space is left, called the triangle of Petit, which is situated immediately above the centre of the iliac crest. It is bounded in front by the posterior border of the obliquus externus abdominis, behind by the anterior border of the latissimus dorsi, and below by the iliac crest near the centre. It is covered only by skin and fascia, and its floor is formed by a part of the obliquus internus abdominis. In this situation a lumbar hernia may occur, or a lumbar abscess may find its way to the surface.

Levator Anguli Scapulæ—*Origin*.—By four tendinous slips from the posterior tubercles of the transverse processes of the first four cervical vertebræ.

Insertion.—The base of the scapula from the superior angle to the triangular surface at the root of the spine.

Nerve-supply.—Branches of the cervical plexus, which are derived from the third and fourth cervical nerves, and a branch from the nerve to the rhomboids.

The muscle is directed downwards, backwards, and slightly outwards.

Action.—Acting from its origin the muscle elevates the superior angle of the scapula, thereby rotating the bone and causing the point of the shoulder to be depressed. Acting from its insertion it is a lateral flexor of the neck.

Rhomboideus Minor—*Origin*.—The lower part of the ligamentum nuchæ, and the spines and supraspinous ligament of the seventh cervical and first thoracic vertebræ.

Insertion.—The base of the scapula opposite the triangular surface at the root of the spine.

Rhomboideus Major—*Origin*.—The spines and supraspinous ligaments of thoracic vertebræ from the second to the fifth inclusive.

Insertion.—The base of the scapula from the triangular surface at the root of the spine to the inferior angle. The insertion takes place by means of a tendinous expansion, which is firmly attached near the inferior angle. Elsewhere the expansion is connected with the base of the bone by connective tissue, so that the muscle can be detached to a large extent without injury.

Nerve-supply of the Rhomboids.—The nerve to the rhomboids, which is a branch of the fifth cervical. This nerve, having pierced the scalenus medius, gives a branch to the levator anguli scapulæ, and passes beneath the upper border of the rhomboideus minor about 1 inch from the base of the scapula. Having given a branch to the deep surface of that muscle, it passes beneath the rhomboideus major and enters its upper part.

The direction of the rhomboid muscles is downwards and outwards.

Action.—The muscles draw the scapula backwards and upwards, and rotate the bone so as to depress the point of the shoulder.

Posterior Scapular Artery.—This vessel is usually a branch of the transverse cervical, but it may arise from the third part of the sub-

clavian. It passes backwards beneath the levator anguli scapulæ, and then downwards beneath the rhomboid muscles, lying close to the base of the scapula. It gives off branches to the adjacent muscles, and several offsets to the front and back of the scapula, which latter take part in the scapular anastomoses of arteries.

At the upper border of the scapula a limited view is obtained of the posterior belly of the omo-hyoid muscle, and the suprascapular artery and nerve. The former arises from the upper border of the bone inside the suprascapular notch, as well as from the suprascapular or transverse ligament. The suprascapular artery passes to the supraspinous fossa over the ligament, and the suprascapular nerve to the same region beneath it. The artery in this part of its course furnishes its supra-acromial branch to the upper surface of the acromion process. The transverse cervical artery is seen, at a higher level than the suprascapular, dividing into its superficial cervical and posterior scapular branches. The former passes superficial to the levator anguli scapulæ, and the latter beneath that muscle.

It will now be convenient to continue the description of the back to its termination, except the structures more immediately involved in the head and neck.

Serratus Posticus Superior—*Origin*.—The lower part of the ligamentum nuchæ, and the spines and supraspinous ligaments of the last cervical and first two thoracic vertebræ.

Insertion.—By fleshy and tendinous slips into the upper borders and outer surfaces of the second, third, fourth, and fifth ribs, external to their angles.

Nerve-supply.—The second, third, and fourth intercostal nerves.

The origin of the muscle is aponeurotic, and continues so over about half its length. The direction of the fibres is downwards and outwards.

Action.—The muscle elevates the ribs into which it is inserted, and is therefore a muscle of inspiration.

Serratus Posticus Inferior—*Origin*.—The posterior lamina of the lumbar aponeurosis, through means of which the muscle is attached to the spines and supraspinous ligaments of the lower two thoracic and upper two or three lumbar vertebræ, under cover of the latissimus dorsi.

Insertion.—By four fleshy slips into the lower borders of the last four ribs.

Nerve-supply.—The ninth, tenth, and eleventh intercostal nerves.

The serrations of insertion overlap each other from above downwards; the second is the broadest, and the third to a large extent conceals the fourth. The direction of the fibres is upwards and outwards.

Action.—(1) To draw backwards and slightly depress the lower four ribs, the effect of which is to increase the capacity of the lower part of the thoracic cavity; and (2) to steady the lower four ribs, and thus to act as an auxiliary to the diaphragm. In both cases it acts as a muscle of inspiration.

Posterior Lamina of the Lumbar Aponeurosis.—The lumbar aponeurosis is the posterior aponeurosis of the transversalis abdominis muscle, and is composed of three laminæ—*anterior, middle,* and *posterior*, the latter of which is alone fully exposed in this region. It is of considerable strength, and is attached to the spines of the lumbar and sacral vertebræ, and the posterior fourth of the outer lip of the iliac crest. It affords origin to a portion of the latissimus dorsi and to the serratus posticus inferior, and lies behind the erector spinæ, where it forms the posterior wall of its sheath. At the outer border of that muscle it blends with the middle lamina, which may be partially seen by raising the border. Superiorly it is joined by the vertebral aponeurosis.

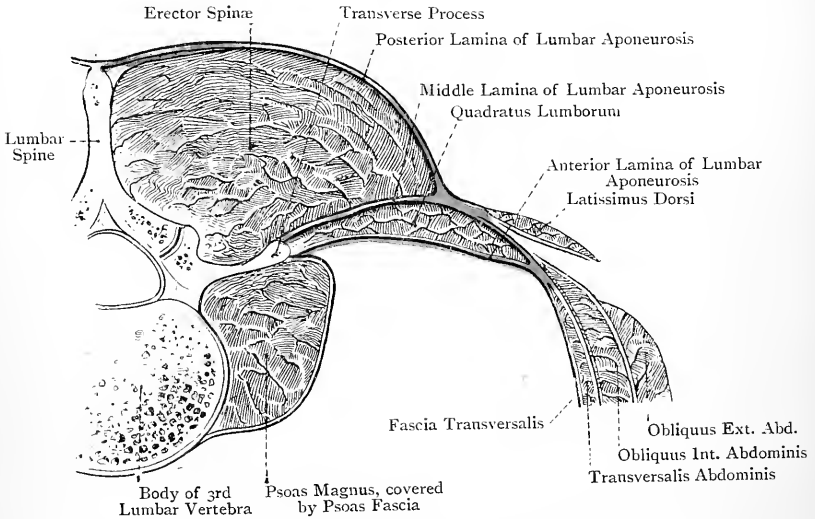


FIG. 164.—DIAGRAM OF THE LUMBAR APONEUROSIS.

Vertebral Aponeurosis.—This is a thin aponeurotic sheet which covers the erector spinæ. Its fibres are chiefly arranged transversely, being attached internally to the spines of the vertebræ, and externally to the angles of the ribs. Superadded to the transverse fibres there are a few which are longitudinal. Superiorly the aponeurosis passes beneath the serratus posticus superior, and becomes continuous with the deep cervical fascia as that ensheathes the splenius. Inferiorly it blends with the posterior lamina of the lumbar aponeurosis.

Splenius.—This muscle is so named because it straps or binds down the muscles beneath it. It is single at its origin, but at its insertion it is divided into two parts—**splenius capitis** and **splenius colli**.

Origin.—(1) The lower two-thirds of the ligamentum nuchæ, and (2) the spines of the last cervical and first six thoracic vertebræ.

Insertion—(a) **Splenius Capitis.**—(1) The lower part of the outer surface of the mastoid process of the temporal bone, and (2) the occipital bone below the outer third of the superior curved line, in each case under cover of the sterno-cleido-mastoid. (b) **Splenius Colli.**—The posterior tubercles of the transverse processes of the first two or three cervical vertebræ, internal to the levator anguli scapulæ, and in line with the cervicalis ascendens.

Nerve-supply.—The posterior primary divisions of the cervical nerves below the third, and of the upper five thoracic.

The direction of the fibres is upwards and outwards.

Action.—The muscle extends the head and flexes the neck to its own side, the face being turned to the same side.

Erector Spinæ.—This composite muscle is single below in the region between the last rib and iliac crest, where it is strongly tendinous internally, and fleshy externally. It subsequently, however, resolves itself into three columns—outer, middle, and inner, there being three muscles in each of the outer and middle columns, and one in the inner column, thus making seven muscles in all.

Origin.—(1) The spines of the last two thoracic, all the lumbar, and the upper four sacral vertebræ; (2) the back of the fourth sacral vertebra; (3) the posterior sacro-iliac ligament; and (4) the posterior fifth of the iliac crest. The *insertion* of the muscle is represented by the columns into which it divides. On approaching the last rib it presents a groove on its surface, which indicates its division at this stage into an outer and inner column, the latter representing the combined middle and inner columns.

Outer Column.—This column is composed of three muscles, which, from below upwards, are named ilio-costalis, musculus accessorius ad ilio-costalem, and cervicalis ascendens.

Ilio-costalis.—This is the direct continuation of the outer part of the erector spinæ, and it is *inserted* by fleshy and tendinous bundles into the angles of ribs from the seventh to the eleventh, and into the lower border of the twelfth rib.

Musculus Accessorius ad Ilio-costalem.—This muscle prolongs the ilio-costalis from the lower six to the upper six ribs. It *arises* by tendons, internal to the slips of insertion of the ilio-costalis, from the angles of ribs from the seventh to the eleventh, and from the outer surface of the twelfth rib, and it is *inserted* by tendons into the angles of the upper ribs from the second to the sixth, and into the outer border of the first rib external to the tubercle.

Cervicalis Ascendens.—This continues the musculus accessorius from the upper ribs to the neck. It *arises* by tendinous slips from the third, fourth, fifth, and sixth ribs, internal to the tendons of insertion of the musculus accessorius, and it is *inserted* into the posterior tubercles of the transverse processes of the fourth, fifth, and sixth cervical vertebræ, where it is in line with the splenius colli.

Action.—The muscles of the outer column act as extensors and lateral flexors of the vertebral column, and as depressors of the ribs, as in expiration.

Middle Column.—This column, like the outer, is composed of three muscles, which, from below upwards, are named longissimus

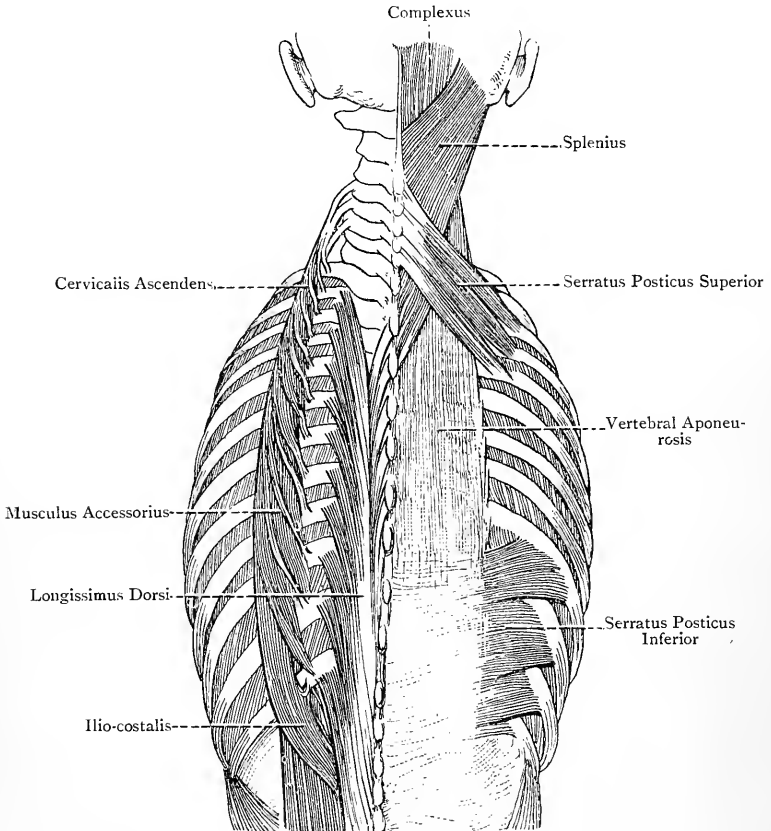


FIG. 165.—THE DEEP MUSCLES OF THE BACK.

dorsi, longissimus cervicis (transversalis cervicis), and trachelomastoid (longissimus capitis).

Longissimus Dorsi.—This is the direct continuation of the inner part of the erector spinæ, and it is inserted in a twofold manner. The *inner insertions* take the form of round, tapering tendons, which are attached to the accessory processes of the lumbar vertebræ and the extremities of the transverse processes of the thoracic vertebræ.

The *outer insertions* are fleshy, and are attached to the backs of the transverse processes of the lumbar vertebræ, and the outer surfaces of the lower ten ribs external to the tubercles.

Transversalis Cervicis (longissimus cervicis).—This continues the longissimus dorsi to the neck. It *arises* from the transverse processes of the upper five or six thoracic vertebræ, and is *inserted* into the posterior tubercles of the transverse processes of cervical vertebræ from the second to the sixth inclusive, where it is internal to the splenius colli and cervicalis ascendens.

Trachelo-mastoid (longissimus capitis).—This muscle has been so named because it extends from the neck to the mastoid process, and it continues the longissimus dorsi to the head. It *arises* from the transverse processes of the upper five or six thoracic vertebræ in close connection with the longissimus cervicis, and from the articular processes and capsular ligaments of the lower three cervical vertebræ. Its *insertion* is into the lower part of the outer surface of the mastoid process under cover of the splenius capitis. Towards its insertion this muscle is very narrow and ribbon-like, and it is marked by a tendinous intersection.

Action.—The muscles of the middle column act as extensors and lateral flexors of the vertebral column. They also extend the head and flex the neck to one side, the face being turned to the same side.

Inner Column.—This consists of the **spinalis dorsi**, which is intimately associated with the inner part of the longissimus dorsi. It *arises* from the lower two thoracic and upper two lumbar spines, and it is *inserted* by tendinous slips into the upper thoracic spines—sometimes the upper four, sometimes as many as the upper eight.

Action.—This muscle is an extensor of the thoracic portion of the vertebral column.

Nerve-supply.—The erector spinæ and its component muscles are supplied by the posterior primary divisions of the spinal nerves.

Between the iliac crest and the last rib the erector spinæ is enclosed in a sheath, the posterior wall of which is formed by the posterior lamina of the lumbar aponeurosis, affording origin to the latissimus dorsi and serratus posticus inferior, whilst the anterior wall is formed by the middle lamina of that aponeurosis. On the back of the sacrum its tendon gives origin deeply to fibres of the multifidus spinæ, whilst superficially, between the sacrum and the iliac crest, a few fibres of the gluteus maximus arise from it.

Complexus—Origin.—(1) The extremities of the transverse processes of the upper six thoracic and last cervical vertebræ; and (2) the backs of the articular processes and capsular ligaments of three or four cervical vertebræ above the seventh. The muscle may receive a fleshy slip from the spine of the seventh cervical.

Insertion.—The occipital bone between the superior and inferior curved lines, commencing at the crest and extending outwards for about 2 inches. The inner fibres of the muscle are interrupted about the level of the sixth cervical vertebra by an elongated tendinous intersection, having the appearance of a tendon, with a fleshy belly

at either extremity, from which circumstance this part is known as the **biventer cervicis**. About the level of the axis the muscle usually presents another faint transverse intersection.

Nerve-supply.—(1) The posterior primary division of the first cervical or suboccipital nerve; (2) the great occipital; and (3) the posterior primary divisions of cervical nerves below the second.

The innermost and longest fibres pass almost vertically upwards,

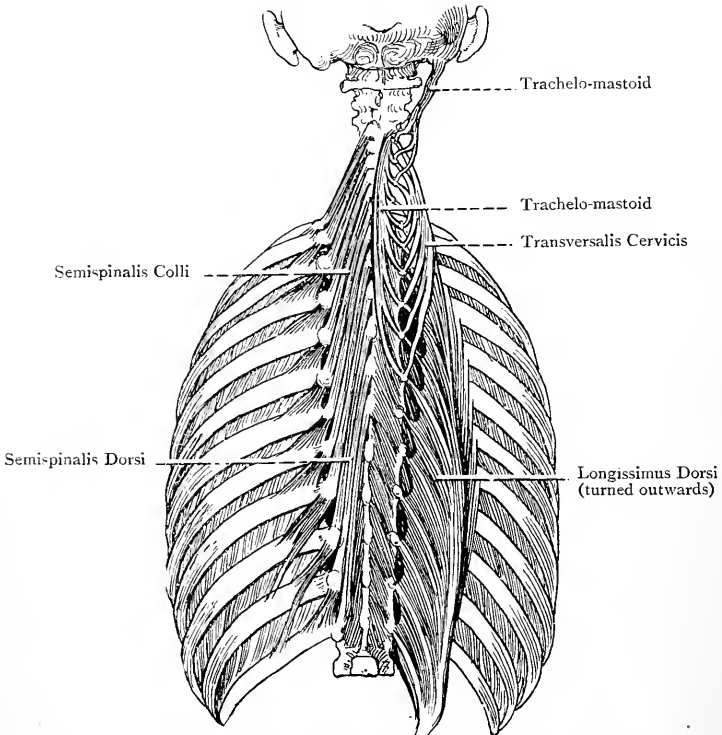


FIG. 166.—THE MIDDLE COLUMN OF THE ERECTOR SPINÆ, AND THE SEMISPINALES MUSCLES.

whilst the outer and upper fibres, which are short, pass upwards and inwards.

Action.—To extend the head and incline it to one side, the face being turned to the opposite side.

A small part of the complexus may appear superficially in the upper part of the posterior triangle of the neck, this portion being pierced by the great occipital nerve. As high as the axis spine the muscle rests upon the semispinalis colli, and in this situation an arterial anastomosis takes place between the deep cervical of the superior intercostal from the second part of the subclavian and the

deep branch of the ramus cervicalis princeps of the occipital from the external carotid. Above the level of the axis spine it covers the recti capitis postici and obliqui capitis muscles, and forms the roof of the suboccipital triangle.

Semispinalis Dorsi—*Origin*.—The extremities of the transverse processes of thoracic vertebræ from the sixth to the tenth inclusive.

Insertion.—The spines of the last two cervical and upper four thoracic vertebræ.

Semispinalis Colli—*Origin*.—The extremities of the transverse processes of the upper five thoracic vertebræ.

Insertion.—The spines of cervical vertebræ from the second to the fifth inclusive.

The bundle of fibres inserted into the axis spine is the largest, and the bundles overlap one another from above downwards.

Nerve-supply of the Semispinales.—The posterior primary divisions of the cervical and upper thoracic nerves.

The fibres of the two muscles are directed upwards and inwards.

Action.—The muscles are extensors and lateral flexors of the vertebral column. The semispinalis colli and the cervical portion of the semispinalis dorsi also rotate the cervical vertebræ towards the opposite side.

Multifidus Spinæ.—This muscle lies deeply in the groove by the sides of the spines of the vertebræ.

Origin.—(1) The sacral groove, and the deep surface of the tendon of the erector spinæ; (2) the posterior sacro-iliac ligament, and the inner lip of the iliac crest at its back part; (3) the mammillary tubercles of the lumbar vertebræ; (4) the transverse processes of the thoracic vertebræ; and (5) the articular processes of the lower four cervical vertebræ.

Insertion.—The spines of the vertebræ from root to tip.

The superficial fibres from any given origin pass over three or four vertebræ before taking insertion, the succeeding fibres pass over two or three, and the deeper fibres pass over one.

Nerve-supply.—The posterior primary divisions of the spinal nerves.

Action.—The muscle is an extensor and lateral flexor of the spinal column, producing at the same time rotation towards the opposite side in the cervical and thoracic regions.

Rotatores Spinæ.—These muscles are really the deepest fibres of the multifidus spinæ in the thoracic region. They are eleven in number.

Origin.—The upper and back part of a transverse process.

Insertion.—The lower border of the lamina of the vertebra immediately above.

Nerve-supply.—The posterior primary divisions of the spinal nerves.

Action.—To rotate the vertebræ towards the opposite side.

Interspinales.—These muscles are usually confined to the cervical and lumbar regions, where they are arranged in pairs between the spines, one on either side of the middle line. In the neck they are limited to the region of the apices of the spines, but in the

lumbar region they extend very nearly over their whole length. In the neck the muscles of each pair are separated by a deep process of the ligamentum nuchæ, representing an interspinous ligament, and in the lumbar region they are separated by the interspinous ligaments themselves.

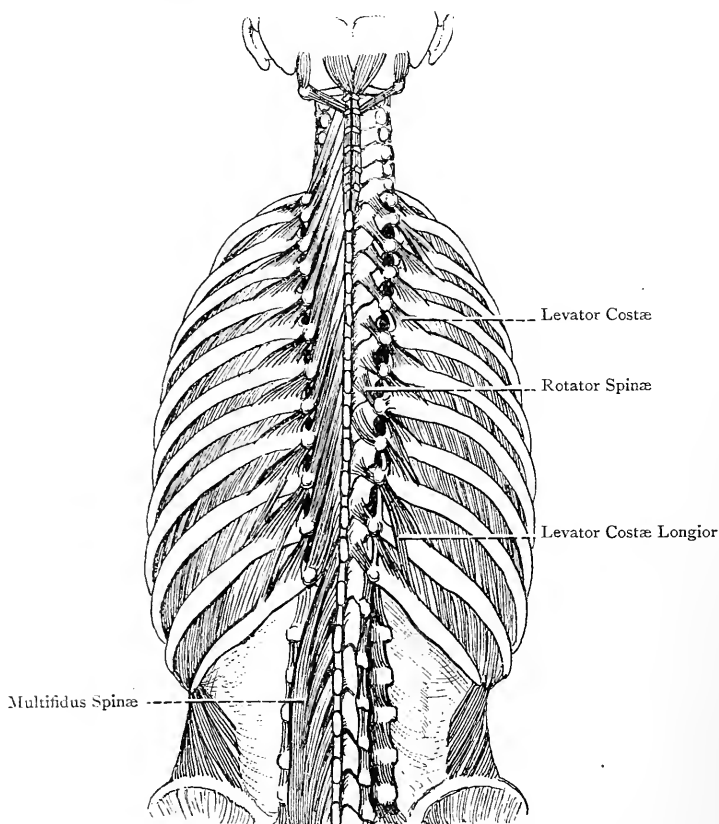


FIG. 167.—THE MULTIFIDUS SPINÆ AND LEVATORES COSTARUM MUSCLES.

Nerve-supply.—Posterior primary divisions of spinal nerves.

Action.—To extend the vertebræ.

Intertransversales.—These muscles occur chiefly in the cervical and lumbar regions, where they are arranged in pairs in each space. In the neck they extend between the anterior and posterior tubercles of adjacent vertebræ. In the lumbar region the muscles of each pair are arranged as lateral and mesial. The **intertransversales laterales** extend between two given transverse processes, and the

intertransversales mediales extend from the accessory process of one vertebra to the mammillary process of the vertebra below. Sometimes intertransversales muscles are met with in the lower thoracic region.

Nerve-supply.—Posterior primary divisions of spinal nerves.

Action.—The muscles act as lateral flexors of the vertebral column.

Levatores Costarum.—These are twelve in number on either side.

Origin.—The highest muscle arises from the tip of the transverse process of the seventh cervical vertebra, and the succeeding eleven arise from the tips of the transverse processes of the thoracic vertebræ from the first to the eleventh inclusive.

Insertion.—Each muscle is inserted into the outer surface of the rib below, from the tubercle to the angle. In the case of the lower two or three muscles the more superficial fibres pass over the first rib below and take insertion into the next rib, these fibres constituting the **levatores costarum longiores**.

Nerve-supply.—The intercostal nerves.

The muscles are directed downwards and outwards.

Action.—To elevate the ribs, as in inspiration.

Each muscle is somewhat fan-shaped, and contains an admixture of aponeurotic fibres. In direction the muscles coincide with the external intercostals, with which they are closely incorporated by their outer borders. They are covered by the erector spinæ, and by their deep surfaces they are related to the external intercostals.

Posterior Primary Divisions of Spinal Nerves.—These nerves in the thoracic region pass backwards, each through a four-sided space bounded below by the neck of a rib, above by the transverse process of the upper vertebra, externally by the superior costo-transverse ligament, and internally by the body of a vertebra. Between the transverse processes each divides into an internal and external branch. The **internal branches** incline inwards on the superficial surface of the multifidus spinæ, and the upper six become cutaneous near the spines of the vertebræ, whilst the lower six end in the deep muscles. The **external branches** pass outwards beneath the middle column of the erector spinæ, and, on reaching the interval between the middle and outer columns of that muscle, they end differently in the upper and lower parts of the back. The upper six end in the deep muscles, but the lower six become cutaneous along the line of the angles of the ribs. In the lumbar region the posterior primary divisions pass backwards, each through a space bounded externally by the quadratus lumborum muscle, internally by the intertransversalis lateralis muscle, and above and below by a transverse process. Their further disposition is as in the thoracic region, but the external branches of the first three only furnish cutaneous nerves, and, as already stated, these are principally gluteal in their distribution.

The **arteries** of the thoracic region are the dorsal branches of the intercostal arteries. Each **dorsal branch** passes backwards in company with the corresponding posterior primary division of a spinal nerve. Before passing through the quadrangular space it gives off a *spinal branch*, which enters the spinal canal through the intervertebral foramen. After passing backwards it divides into an internal and external branch, which have a distribution similar to those of the nerve.

The **veins** of the thoracic region terminate in the intercostal veins.

The **arteries** of the lumbar region are the dorsal branches of the lumbar arteries. Each accompanies the corresponding posterior primary division of a spinal nerve, and its distribution is as in the thoracic region.

The **veins** of the lumbar region terminate in the inferior vena cava.

THE PECTORAL REGION AND AXILLARY SPACE.

Landmarks.—The outline of the clavicle and acromion process of the scapula are readily made out, and, in connection with the acromion, it is to be borne in mind that the acromial epiphysis may remain permanently detached from the spine, and so simulate a fracture. The roundness of the shoulder is to be noted, this being due largely to the deltoid muscle, but also in part to the head of the humerus. Below the clavicle, at a point external to its centre, is a depression, called the **infraclavicular fossa**, which indicates the separation between the deltoid and pectoralis major. When the arm is abducted and the finger pressed into this hollow, the inner border of the coracoid process will be felt, and, if the finger be carried outwards under the deltoid, the tip of that process can be made out. In this region it is possible to compress the axillary artery against the second rib, but this requires deep pressure. The course of this artery may be indicated by a line drawn from the centre of the clavicle to the inner border of the coraco-brachialis, the arm having been raised to a right angle with the trunk, so as to define clearly the outline of that muscle. The anterior and posterior folds of the axilla are to be observed, the anterior being formed by the lower border of the pectoralis major, which practically coincides with the line of the fifth rib, and the posterior by the latissimus dorsi winding round the lower border of the teres major. The hollow between these folds indicates the position of the axillary space, and it will be seen to be narrow towards the arm, but wide towards the thoracic wall. In the female the prominence formed by the mammary gland is usually apparent on the surface of the pectoralis major. Its vertical extent is from the second to the sixth rib, and it reaches transversely from the side of the sternum to the anterior fold of the axilla, except at the lower and outer part, where it extends beyond this fold upon the serratus magnus. A little below and internal to the centre of the mammary prominence is the nipple, which is sur-

rounded by a coloured circle, called the areola. The exact position of the nipple is subject to variation. As a rule it may be said to lie over the fourth intercostal space about 4 inches from the mid-sternal line, but in corpulent persons, and in females with pendulous mammae, it is lower in position. Along the middle line the sternum can readily be made out, and about 2 inches below its upper border the transverse ridge, called the sternal angle, may be felt, which is the guide to the second costal cartilage at either side. Above the centre of the upper border of the sternum is a depression, known as the jugular fossa. Below the lower border of the mesosternum there is the infrasternal depression, which is situated between the seventh pair of costal cartilages, where it lies over the metasternum.

Cutaneous Nerves.—These nerves are arranged in three groups—descending, anterior, and lateral.

The descending nerves are branches of the cervical plexus, and are derived from the third and fourth cervical nerves. They are three in number—suprasternal or internal, supraclavicular or middle, and supra-acromial or external—and, as they descend, they lie beneath the platysma myoides. The **suprasternal nerve** crosses the inner end of the clavicle, and its branches are distributed to the subjacent integument, as well as to that over the upper part of the sternum. The **supraclavicular nerve** crosses the centre of the bone, and its branches have a fairly wide distribution to the pectoral integument. The **supra-acromial nerve** crosses the outer end of the clavicle, and its branches are distributed to the integument over the upper half of the deltoid.

The anterior cutaneous nerves are the terminal branches of the upper six intercostal nerves, and they pierce the pectoralis major close to the sternum. They furnish small twigs to the integument over that bone, but the principal part of each nerve takes an outward course and supplies the pectoral integument. The branch of the first nerve is sometimes absent.

The lateral cutaneous nerves are branches of the intercostal nerves from the third to the sixth inclusive. The first intercostal nerve gives no lateral cutaneous branch. The lateral cutaneous of the second intercostal nerve is undivided, and crosses the axillary space to the brachial region, under the name of intercosto-humeral. The succeeding lateral cutaneous nerves emerge from their intercostal spaces by piercing the external intercostal muscles not far from the lower border of the pectoralis major. Each then divides into an anterior and a posterior branch, which pass out between the digitations of the serratus magnus, being separated from each other by a slight interval. The *anterior branches* wind round the lower border of the pectoralis major to supply the pectoral integument, whilst the *posterior branches* pass backwards to supply the integument over the anterior border of the latissimus dorsi.

The anterior and lateral cutaneous nerves are accompanied by

corresponding arteries, the anterior being the perforating branches of the internal mammary, and the lateral being branches of the intercostal arteries.

Fascia.—The **superficial fascia** is continuous over the clavicle with the superficial fascia of the neck, and it is noteworthy in two respects.

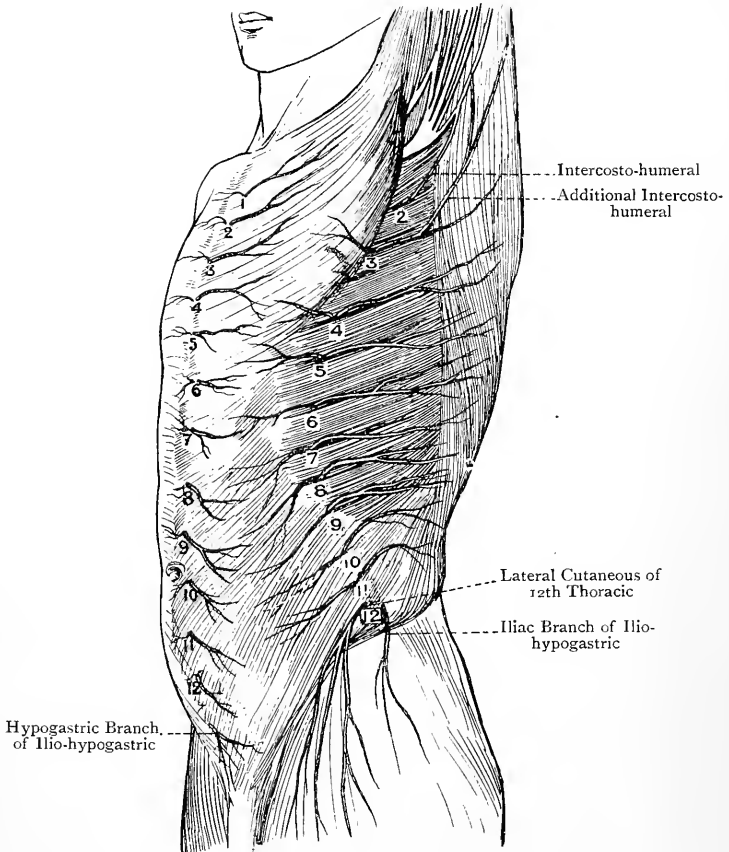


FIG. 168.—CUTANEOUS NERVES OF THE TRUNK (ANTERO-LATERAL VIEW) (AFTER HENLE).

1-12, Anterior Cutaneous ; 2-12, Lateral Cutaneous.

In the first place, just below the clavicle it has a faint reddish colour, due to the fact that over the clavicular portions of the pectoralis major and deltoid it gives origin to fibres of the platysma myoides, which can be seen on incising it. In the second place, in the region of the mammary gland it divides into two laminae, which ensheathe that gland. These laminae send processes into the sub-

stance of the gland which support its lobes, and from the anterior lamina fibrous bands pass to the integument, these being known as the **ligamenta suspensoria of Cooper**. Inferiorly the superficial fascia is continuous with that over the anterior abdominal wall, and externally it is prolonged over the floor of the axillary space to become continuous with the superficial fascia of the brachial region.

The **deep fascia** is thin and membranous, and it closely invests the pectoralis major. Superiorly it is attached to the front of the clavicle above the origin of that muscle, internally it is fixed to the front of the sternum, externally it is continuous with the deep fascia over the deltoid, and inferiorly it joins the axillary fascia at the lower border of the pectoralis major.

The **axillary fascia** is a firm membrane which stretches from the anterior to the posterior fold of the axilla, and forms the floor of that space. It is continuous in front with the deep pectoral fascia, and behind it blends with the deep fascia which ensheathes the latissimus dorsi. Externally it is continuous with the deep fascia of the brachial region, and internally with the fascia covering the serratus magnus. Its upper surface is convex, due to the fact that it receives, near the pectoralis major, the clavi-pectoral fascia, to be afterwards described. In this way the axillary fascia is drawn upwards into the space. It is of considerable strength, and is capable of affording much resistance to the pointing of an axillary abscess in this direction.

Mammary Gland.—This gland is situated on the surface of the pectoralis major. It is somewhat hemispherical, and extends vertically from the second to the sixth rib, and transversely from the side of the sternum to the anterior fold of the axilla, except below and externally, where it passes over that fold upon the serratus magnus. A little below, and internal to, the centre of the gland is the corrugated **nipple**, lying in the centre of a coloured circle, called the **areola**. There is no fat beneath the nipple and areola, and the skin of these parts is provided with plain muscular tissue disposed circularly, which, by its contraction, contributes to erection of the nipple by compressing its veins. The summit of the nipple is perforated by the openings of the lactiferous ducts. The skin of the areola presents a number of small projections due to sebaceous glands, which are known as the **glands of Montgomery**. The mamma is a compound racemose gland, which is composed of about twenty lobes, these in turn consisting of lobules, and all being connected by a fibrous stroma. The entire gland is ensheathed by the splitting of the superficial pectoral fascia into two laminae, and these send processes into its interior which support its component lobes. The posterior layer of the sheath is loosely connected to the deep pectoral fascia covering the pectoralis major, and sometimes deep processes of the gland penetrate into the substance of the muscle. The lobes are pyramidal, and their apices converge toward the nipple. Each of

them is distinct, and has its own duct. A lobe is made up of lobules, and each lobule is composed of a cluster of tubes, called **alveoli** or **acini**, which represent the secreting parts of the gland, and are lodged in spaces known as *loculi*. The alveolar tubes are lined with cubical epithelium, the cells of which contain fat globules during the period of the functional activity of the organ. The ducts of the lobes are about twenty in number, and are called the **lactiferous** or

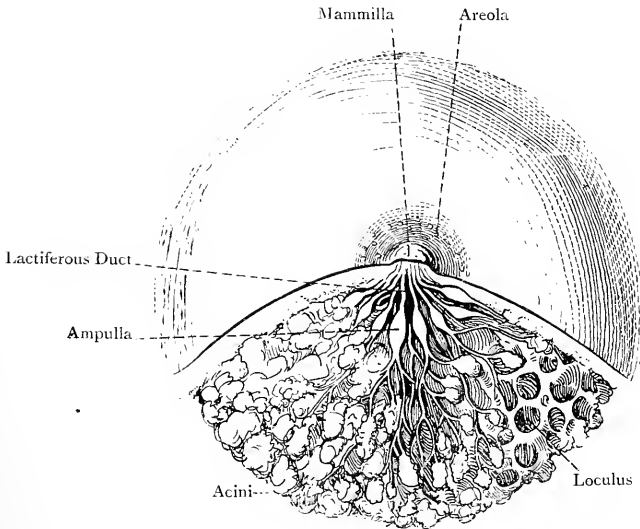


FIG. 169.—THE FEMALE MAMMA DURING LACTATION
(AFTER LUSCHKA).

galactophorous ducts. They are lined with columnar epithelium, and, as they approach the nipple, each presents a dilatation, called the **sinus** or **ampulla**. Thereafter each duct becomes narrow, and enters the nipple to terminate by a minute pore on its summit. The mammary glands are present in both sexes, but in the male their development, as a rule, is arrested, so that they are in a rudimentary condition.

Bloodvessels of the Mamma.—The **arteries** are as follows: long thoracic (external mammary) of the second part of the axillary; anterior cutaneous or perforating of the internal mammary; and branches from the intercostal arteries of the spaces over which the gland lies.

The **veins** pass to the axillary and internal mammary veins.

Lymphatics.—The most of the lymphatics pass to the pectoral group of axillary glands, but those from the inner portion of the organ pass to the internal mammary glands, which lie along the course of the artery of that name at the side of the sternum.

Nerves.—These are derived from the supraclavicular branch of the cervical plexus, and the anterior and lateral cutaneous branches of the upper intercostal nerves.

Accessory mammæ are sometimes met with on the upper, lower, and inner outskirts of the main gland, and more rarely in the axilla, or on the upper part of the anterior abdominal wall.

Structure.—The lactiferous ducts are lined with columnar epithelium, except near their orifices, where it is stratified. External to the epithelium there is a connective-tissue coat. The alveoli are lined, during the functional activity of the gland, with cubical epithelium, and the basement membrane consists of connective-tissue cells.

Development of the Mamma.—The mammary gland appears from the fifth to the sixth week of intra-uterine life as an annular ridge of the epiblast in the region of the future gland. This grows downwards at its centre into the mesoblast, which latter gives rise to the fibrous stroma. The cells of the depressed portion of the epiblast grow into the mesoblast in the form of solid processes, which, becoming hollow, give rise to the ducts of the gland, and these recesses, by their branching and subdivision, form the lobes, lobules, and alveoli. Subsequently the depressed area of epiblast becomes elevated, and gives rise to the nipple.

Pectoralis Major—*Origin.*—(1) The anterior surface of the clavicle over its inner half, and the anterior sterno-clavicular ligament; (2) one-half of the anterior surface of the sternum as low as the metasternum; (3) the anterior surfaces of the upper six costal cartilages, and slightly from the bony part of the sixth rib; and (4) the upper portion of the external oblique aponeurosis.

Insertion.—The outer bicipital ridge of the humerus over its lower three-fourths.

The muscle is divisible into two portions, *clavicular* and *sterno-costal*, which are separated by a slight interval extending downwards and outwards from the sterno-clavicular joint.

The tendon of insertion is folded upon itself so as to be composed of two layers, anterior and posterior, the former of which is the shorter, and both being continuous below. The *anterior layer* receives the sterno-costal fibres above the third costal cartilage, and it also receives superficially the clavicular fibres, which latter descend lowest at their insertion, where they are intimately connected with the tendon of the deltoid. The *posterior layer* receives all the fibres from the third costal cartilage downwards, and the lowest of these fibres, as they pass outwards and upwards, become successively folded underneath the fibres above. The result is that the fibres arising lowest reach the highest part of the posterior layer of the tendon, whilst the fibres above these reach its lowest part. The posterior layer ascends higher on the outer bicipital ridge than the anterior, and from its upper border a tendinous expansion passes to the great tuberosity of the humerus and the capsular ligament of the shoulder-joint, which conceals the long tendon of the biceps brachii. From the lower border of the tendon an expansion is given to the deep fascia of the arm.

Nerve-supply.—(1) The external anterior thoracic from the outer cord of the brachial plexus, (its fibres coming from the fifth, sixth, and seventh cervical nerves), the branches of which nerve enter

the deep surface of the clavicular and upper sterno-costal portions ; and (2) the internal anterior thoracic, the branches of which enter the deep surface of the sterno-costal portion, after having pierced the pectoralis minor.

Blood-supply.—Branches of the thoracic axis.

The upper fibres pass downwards and outwards, the middle transversely outwards, and the lower upwards and outwards.

Action.—Acting from its origin the muscle adducts the arm, draws it forwards—that is to say, flexes it at the shoulder-joint

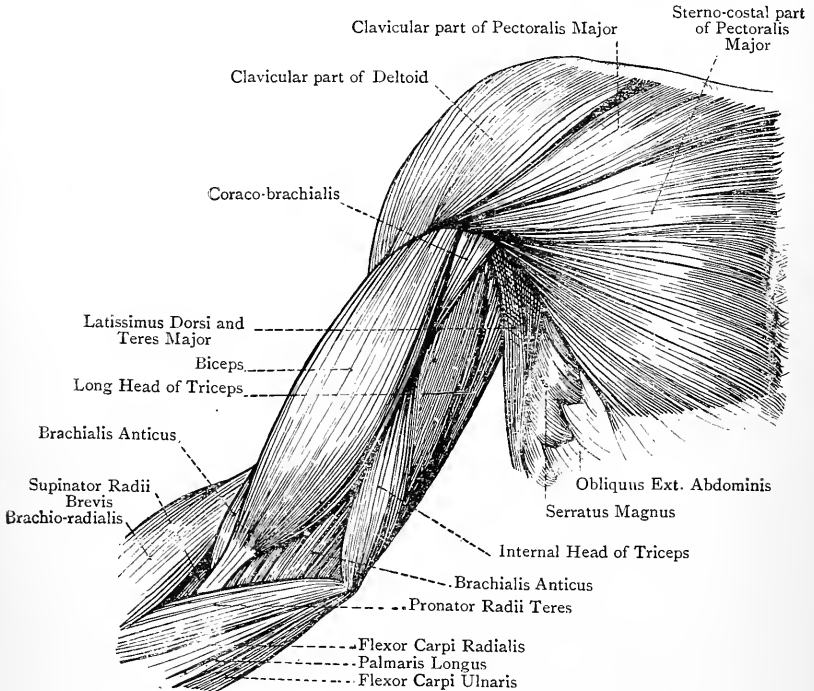


FIG. 170.—THE SUPERFICIAL MUSCLES OF THE FRONT AND INNER SIDE OF THE PECTORAL AND BRACHIAL REGIONS.

(by its clavicular portion), and rotates it inwards. Acting from its insertion it raises the trunk after the outstretched arm, as in climbing a pole, and it elevates the upper ribs in forced inspiration.

The upper border of the muscle is related to the deltoid, from which it is separated by a triangular interval for a short distance below the clavicle, and the cephalic vein and humeral artery intervene between the two. The lower border forms the anterior fold of the axilla. Sometimes there is a muscle, called the **sternalis**,

present, on one or both sides. It lies over the sternal fibres of the pectoralis major, and is connected below with the external oblique aponeurosis, whilst above it may terminate in the sternal head of the sterno-cleido-mastoid, or on the presternum.

Clavi-pectoral Fascia.—This is situated beneath the pectoralis major. Superiorly it is disposed in two laminae, which are attached to the anterior and posterior lips of the subclavian groove of the clavicle, and embrace the subclavius muscle. At the lower border of that muscle they unite to form the costo-coracoid membrane, which, on reaching the upper border of the pectoralis minor, divides to ensheath it. At the lower border of the muscle the two layers unite to form a single sheet, which joins the axillary fascia, and acts as a *suspensory ligament*.

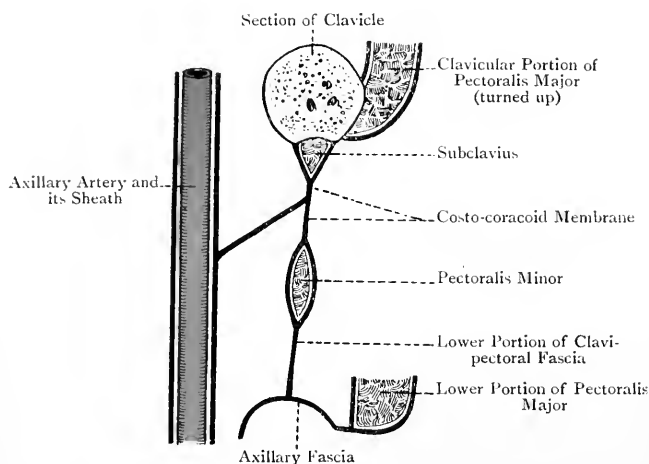


FIG. 171.—DIAGRAM OF THE CLAVI-PECTORAL FASCIA AND THE COSTO-CORACOID MEMBRANE.

Costo-coracoid Membrane.—This name is given to that portion of the clavi-pectoral fascia which extends from the lower border of the subclavius to the upper border of the pectoralis minor. The lower portion of the membrane is tense and cord-like, and is known as the **costo-coracoid ligament**. It is attached internally to the upper surface of the first rib at its sternal extremity in connection with the tendon of the subclavius, and externally it is attached to the posterior part of the antero-internal border and adjacent portion of the upper surface of the coracoid process. This membrane is connected by its deep surface with the axillary sheath; it is covered by the clavicular portion of the pectoralis major; and it is pierced by the cephalic vein, the thoracic axis, and the external anterior thoracic nerve.

The **costo-coracoid ligament** represents the ventral end of the coracoid bar of cartilage, the dorsal end of which forms the coracoid process.

Pectoralis Minor—*Origin*.—The upper borders and outer surfaces of the third, fourth, and fifth ribs near their anterior extremities, as well as from the fascia covering the adjacent external intercostal muscles.

Insertion.—The anterior half of the antero-internal border of the coracoid process of the scapula and the adjacent portion of its upper surface, where it is intimately connected with the common origin of the coraco-brachialis and short head of the biceps.

Nerve-supply.—The internal anterior thoracic nerve, which is a branch of the inner cord of the brachial plexus, its fibres being derived from the eighth cervical and first thoracic. The branches of the nerve enter the muscle on its deep surface, and a few of them pierce it to enter the deep surface of the pectoralis major.

Blood-supply.—The thoracic axis.

The direction of the fibres is upwards and outwards.

Action.—Acting from its origin the muscle draws the scapula downwards and forwards, the point of the shoulder being at the same time depressed. Acting from its insertion it elevates the ribs from which it arises, as in forced inspiration.

Subclavius—*Origin*.—By a rounded, tapering tendon from the upper surface of the first rib and its cartilage.

Insertion.—The subclavian groove on the under surface of the clavicle, extending from the rhomboid impression internally to the interval between the conoid tubercle and trapezoid ridge externally.

Nerve-supply.—The nerve to the subclavius, which arises from the front of the upper trunk of the brachial plexus, its fibres being derived from the fifth cervical. The nerve descends from the neck behind the clavicle, and enters the deep surface of the muscle.

Blood-supply.—The thoracic axis.

The direction of the fibres is upwards and outwards.

Action.—(1) To depress the clavicle and draw it slightly forwards, and (2) to support the sterno-clavicular joint by bracing the clavicle in an inward direction.

Axillary Space.—The axillary space is situated between the upper part of the arm and upper part of the thoracic wall. It has the form of a four-sided pyramid, and presents an apex, a base or floor, and four walls—anterior, posterior, inner, and outer. It is of much greater extent towards the thoracic wall than towards the arm, on account of the convergence in the latter direction of the structures forming the anterior and posterior walls. The **apex** is the narrowest part of the space, and is directed upwards towards the root of the neck. It is somewhat triangular, and lies between the clavicle, first rib, and upper border of the scapula. The **base or floor** is of considerable extent, and is formed directly by the axillary fascia, which, as stated, is drawn upwards into the space by the clavipectoral fascia. The **anterior wall** is formed over its whole extent by the pectoralis major, and, under cover of this, by the pectoralis

minor over about its middle third. Above the latter muscle the costo-coracoid membrane enters into the anterior wall. The lower border of the anterior wall, formed by the pectoralis major, constitutes the *anterior fold* of the axilla. The **posterior wall** is formed from above downwards by the subscapularis, teres major, and latissimus dorsi. Towards the arm the tendon of the latissimus dorsi lies in front of the teres major, the latter muscle extending a little lower down. The posterior wall is longer than the anterior, and its lower border, formed by the folding of the latissimus dorsi round the teres major to get in front of it, forms the *posterior fold* of the axilla. The **inner wall** is formed by the upper four or five ribs, with their intercostal muscles, and the corresponding serrations of the serratus

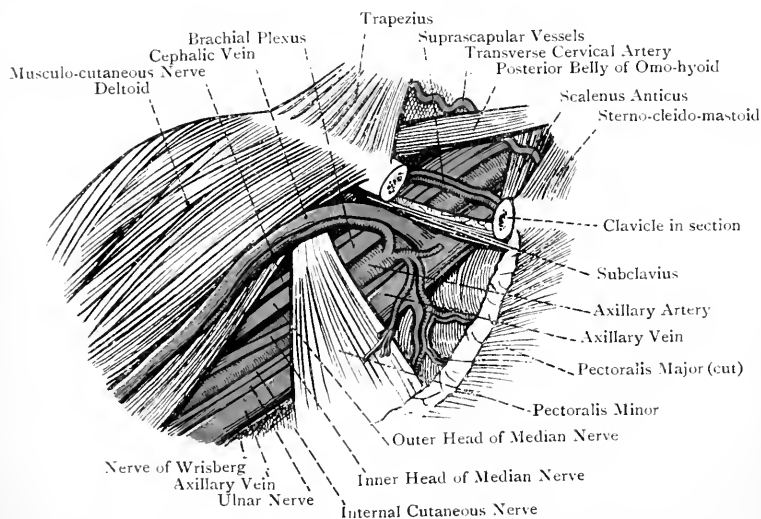


FIG. 172.—THE AXILLARY SPACE, AFTER REFLECTION OF THE PECTORALIS MAJOR, AND THE SUBCLAVIAN TRIANGLE.

magnus. The **outer wall**, which is very circumscribed, is formed by the upper part of the humerus and the common origin of the coracobrachialis and short head of the biceps.

Contents and their Position.—The axillary vessels and the nerves which arise from the brachial plexus lie for the most part along the outer wall. The thoracic axis and the long thoracic artery pass to the anterior wall, the former above the pectoralis minor, where it pierces the costo-coracoid membrane, the latter along the lower border of that muscle. The subscapular artery lies on the posterior wall, where it passes inwards on the lower border of the subscapularis. The posterior circumflex artery lies for a short distance on the posterior wall, but soon passes backwards between the subscapularis and teres major. The anterior circumflex artery passes outwards

in front of the humerus beneath the coraco-brachialis and biceps. The superior thoracic artery is above the thoracic axis, where it takes a course inwards to the thoracic wall.

The external anterior thoracic nerve pierces the costo-coracoid membrane to enter the deep surface of the pectoralis major. The internal anterior thoracic nerve enters the deep surface of the pectoralis minor, and sends branches through it to the major. The posterior thoracic nerve descends upon the inner wall, resting on the serratus magnus. The intercosto-humeral nerve pierces the second intercostal space, and crosses the axilla to the inner side of the arm. Below this nerve, on the thoracic wall, the succeeding lateral cutaneous branches of intercostal nerves pierce the intercostal spaces, and the posterior branch of the lateral cutaneous of the third intercostal gives a branch which crosses the axilla to the inner side of the arm, communicating in its course with the intercosto-humeral. The three subscapular nerves lie upon the posterior wall, and supply the muscles which form it. The circumflex nerve lies with the posterior circumflex artery, which it accompanies in its backward course. The musculo-spiral nerve descends behind the axillary artery, and eventually turns to the back of the humerus, but, before doing so, it gives off its internal cutaneous branch. The median nerve is upon the outer side of the main artery, and the ulnar nerve is internal to it, between it and the vein. The lesser internal cutaneous nerve is on the inner side of the vein, and the internal cutaneous nerve is usually met with partly over the line of the main artery and partly on its inner side.

The axillary lymphatic glands are arranged in three sets—an external, lying on the outer wall along the principal blood-vessels; an internal, lying along the course of the long thoracic artery within the anterior fold, some of them being scattered over the adjacent part of the inner wall; and a posterior, disposed along the course of the subscapular artery. Besides these glands there are two or three which lie upon the costo-coracoid membrane where that is pierced by the cephalic vein, these being known as the infraclavicular glands.

Axillary Artery.—The axillary artery is the continuation of the subclavian, and it extends from the outer border of the first rib to the lower border of the teres major, where it becomes the brachial. When the arm is by the side of the trunk the vessel describes a curve with the convexity upwards, but, when the limb is abducted to the position of a right angle to the trunk, its course is almost straight. In the latter position of the limb its course may be indicated by a line drawn from the centre of the clavicle to the inner border of the coraco-brachialis. The artery is crossed by the pectoralis minor, and is thus divided into three parts—first, second, and third.

First Part.—The first part extends from the outer border of the first rib to the upper border of the pectoralis minor, and it is about 1 inch long.

Relations.—*Anteriorly* it is covered by the skin, superficial fascia,

origin of the platysma myoides, deep fascia, clavicular part of the pectoralis major, costo-coracoid membrane, axillary sheath, and the lower border of the subclavius when the shoulder is depressed. It is also crossed by the cephalic and acromio-thoracic veins, and the communicating loop between the external and internal anterior thoracic nerves. *Posteriorly* it rests upon the first intercostal space, the first serration of the serratus magnus, and the upper portion of the second rib, with the intervention of

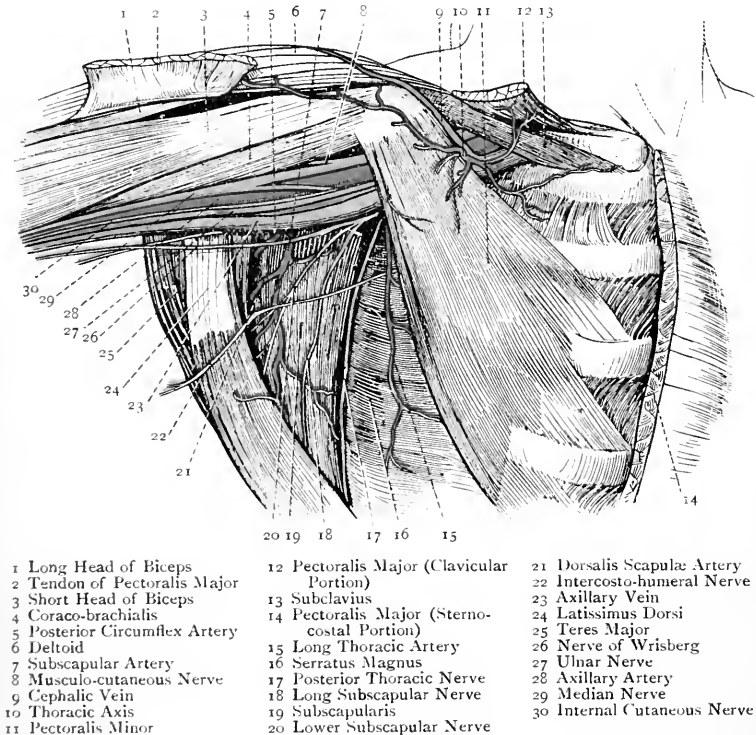


FIG. 173.—THE AXILLARY SPACE.

(The Pectoralis Major has been in great part removed.)

the axillary sheath, and the posterior thoracic and internal anterior thoracic nerves lie behind it. *Externally*, and above it, are the three cords of the brachial plexus. *Internally*, and slightly overlapping it, is the axillary vein.

Second Part.—The second part lies under cover of the pectoralis minor, and it is about $1\frac{1}{4}$ inches long.

Relations.—*Anteriorly* it is covered by the integument, and the pectoralis major and minor muscles. *Posteriorly* is the posterior cord

of the brachial plexus, behind which is a quantity of fat, separating the vessel from the subscapularis. *Externally* is the outer cord of the brachial plexus. *Internally* are the inner cord of the brachial plexus, the internal anterior thoracic nerve, and the axillary vein.

Third Part.—The third part extends from the lower border of the pectoralis minor to the lower border of the teres major, and its length is about 3 inches. The upper half of this part is under cover of the pectoralis major, but the lower half is free from muscular covering, which is due to the posterior wall of the axilla being longer than the anterior.

Relations.—*Anteriorly* over its upper half it is covered by the integument and pectoralis major, and over its lower half only by the integument of the arm. The inner root of the median nerve crosses it obliquely from within outwards, and the external vena comes of the brachial artery crosses it from without inwards. *Posteriorly* it rests, from above downwards, upon the subscapularis, tendon of the latissimus dorsi, and lower part of the teres major, and the circumflex and musculo-spiral nerves descend behind it. *Externally* is the coraco-brachialis, which sometimes slightly overlaps it. The outer root of the median nerve lies on its outer side, as does also the musculo-cutaneous. *Internally* is the axillary vein, and, for a short distance below, the internal vena comes of the brachial artery. Between the axillary vein and the artery are the inner root of the median nerve and the ulnar nerve; internal to the vein is the lesser internal cutaneous nerve; and the internal cutaneous nerve is partly on the artery and partly to its inner side.

Branches.—The **first part** gives off the superior or short thoracic, and the thoracic axis or acromio-thoracic artery. The **second part** furnishes the inferior or long thoracic, and the alar thoracic, which is very inconstant as a separate branch. The **third part** gives off the subscapular, the anterior circumflex, and the posterior circumflex.

Branches of the First Part.—The **superior or short thoracic artery** is a small branch which arises just below the subclavius. Its course is inwards and downwards behind the axillary vein to the first two intercostal spaces, where it anastomoses with branches of the first and second intercostal arteries. It supplies the adjacent intercostal muscles, upper part of the serratus magnus, and occasionally the pectoral muscles. The **thoracic axis or acromio-thoracic artery** is a short, but large, trunk which arises immediately above the upper border of the pectoralis minor. Passing straight forwards it pierces the costo-coracoid membrane, and then divides into radiating branches, called thoracic, acromial, humeral, and clavicular. The *thoracic branches* descend between the two pectoral muscles which they supply. The *acromial branches* pass outwards over the coracoid process to the deltoid, in which some of them end, whilst others pierce that muscle, and so reach the upper surface of the acromion process, where they anastomose with branches of the suprascapular and posterior circumflex. The *humeral (descending) branch* passes

downwards with the cephalic vein between the pectoralis major and deltoid, to the contiguous parts of which muscles it is distributed. The *clavicular branch* passes upwards to end in the subclavius.

Branches of the Second Part.—The **inferior or long thoracic artery**, also called the **external mammary**, is directed downwards and inwards along the lower border of the pectoralis minor to the thoracic wall. It is distributed to the pectoral muscles, serratus magnus, and intercostal muscles, and it sends branches round the lower border of the pectoralis major to the mammary gland. It also gives branches to the pectoral group of axillary glands, and it anastomoses with branches of the aortic intercostals and internal mammary. The **alar thoracic artery** is distributed to the axillary glands. It is seldom a special branch, its place being usually taken by branches of the long thoracic and subscapular.

Branches of the Third Part.—The **subscapular artery**, which is the largest of all the branches of the vessel, arises opposite the lower border of the subscapularis, along which it courses downwards and inwards to the lower angle of the scapula, in company with the long subscapular nerve, where it anastomoses with the posterior scapular and long thoracic. Besides giving branches to the muscles on the posterior wall, the serratus magnus, and the posterior group of axillary glands, it gives off near its origin a large branch, called the *dorsalis scapulæ*. This vessel at once passes backwards through the triangular space bounded *above* by the subscapularis, *below* by the teres major, and *externally* by the long head of the triceps. Thereafter it winds round the back of the axillary border of the scapula, piercing the origin of the teres minor and grooving the bone, and so it reaches the infraspinous fossa beneath the infraspinatus. Here it breaks up into numerous branches, which supply that muscle and the bone, and which anastomose with the suprascapular and dorsal branches of the posterior scapular. As it passes through the triangular space it furnishes a *ventral branch* (infrascapular), which ramifies in the venter of the scapula beneath the subscapularis, and anastomoses with the ventral branches of the suprascapular and posterior scapular. Before piercing the teres minor it gives off a *descending or teres branch*, which passes downwards between the teres major and minor as far as the lower angle of the scapula, where it anastomoses with the terminal part of the posterior scapular. The *dorsalis scapulæ* sometimes arises directly from the axillary.

The **anterior circumflex artery**, which is of small size, arises from the outer side of the vessel a little below the subscapular and opposite the posterior circumflex. It passes outwards in front of the surgical neck of the humerus, and beneath the coraco-brachialis and biceps. On reaching the bicipital groove it gives off an *ascending or bicipital branch*, which passes upwards in the groove with the long head of the biceps, to be distributed to the shoulder-joint and head of the humerus. Thereafter it continues its winding course to the outer side of the bone, where it anastomoses with the posterior circumflex.

The **posterior circumflex artery**, which is of large size, arises from the back of the vessel a little below the subscapular. Its course is backwards in company with the circumflex nerve through the quadrangular space, which is bounded *above* by the teres minor (subscapularis in front), *below* by the teres major, *internally* by the long head of the triceps, and *externally* by the surgical neck of the humerus. In its course it winds round the inner and posterior aspects of the neck of the bone, and it furnishes many branches, most of which enter the deep surface of the deltoid. A special *acromial branch* reaches the upper surface of the acromion process, and there anastomoses with the suprascapular and acromial branches of the thoracic axis. On the outer side of the neck of the bone the artery anastomoses with the anterior circumflex, and in this way an arterial circle is formed which closely embraces the surgical neck. Some of the branches supply the muscles bounding the quadrangular space, and one or two pass downwards between the long and outer heads of the triceps, where they anastomose with the superior profunda of the brachial. The posterior circumflex artery is subject to certain variations. (1) It may arise in common with the subscapular. (2) Its origin may be transferred to the superior profunda of the brachial, in which case it ascends behind the teres major. (3) It may give off the anterior circumflex, superior profunda, or dorsalis scapulæ.

Varieties of the Axillary Artery.—(1) The subscapular, circumflex, and profundæ of the brachial may arise by a common trunk. (2) The artery may give origin to a large branch, which may be the radial, ulnar, vas aberrans, or the interosseous trunk of the forearm.

The part of the axillary artery most accessible for surgical interference is the lower half of the third part, which is covered only by the integument of the arm.

Axillary Vein.—The axillary vein is the continuation of the basilic vein of the arm. It extends from the lower border of the teres major to the outer border of the first rib, where it becomes the subclavian vein. It is of large size, and throughout its entire course it lies to the inner side of the artery. Most of its tributaries correspond with the arterial branches, but the following two are specially noteworthy: (1) a little above its commencement it receives the trunk formed by the union of the venæ comites of the brachial artery, and (2) below the clavicle it is joined by the cephalic vein.

Axillary Sheath.—The axillary vessels and the brachial plexus of nerves are enclosed in a loose, infundibuliform sheath, which is called the axillary sheath. It is a downward prolongation of the deep cervical fascia, and it blends with the deep surface of the costo-coracoid membrane. It has been compared to the crural sheath of the femoral vessels, but it is in no sense such a defined structure.

Brachial Plexus.—The brachial plexus is situated in the lower part of the posterior triangle of the neck, behind the clavicle, and in the upper part of the axilla. Its complex formation is rendered simple

by arranging it into four stages, namely, (1) nerve roots, (2) nerve trunks, (3) divisions of nerve trunks, and (4) nerve cords.

First Stage.—The nerves which form the plexus are the anterior primary divisions of the fifth, sixth, seventh, and eighth cervical, and the greater part of that of the first thoracic. Superiorly the plexus is reinforced by a small descending branch from the fourth cervical, which joins the fifth, and inferiorly it is occasionally reinforced by a branch from the second thoracic, which joins the first. As regards the first thoracic nerve, the part of it which does not join the plexus, and which is of small size, enters the first intercostal space to become the first intercostal nerve. The nerves, as they emerge at the side of the neck, are placed between the scalenus anticus and scalenus medius.

Second Stage.—The fifth and sixth cervical nerves join at the outer border of the scalenus anticus to form the **upper trunk**; the seventh cervical remains meanwhile single, and forms the **middle trunk**; and the eighth cervical and greater part of the first thoracic unite between the scalene muscles to form the **lower trunk**. There are thus three trunks—upper, middle, and lower.

Third Stage.—A little above the clavicle each of the three trunks breaks up into an anterior and a posterior division.

Fourth Stage.—The anterior divisions of the upper and middle trunks unite to form the **outer cord** of the plexus; the anterior division of the lower trunk, which is of large size, forms the **inner cord**; and all three posterior divisions (that of the lower trunk being of small size) unite to form the **posterior cord**. As a variety, the anterior division of the middle trunk may subdivide into two branches, one entering the outer cord and the other the inner. There are thus three cords—outer, inner, and posterior.

Branches of the Plexus.—The branches are conveniently divided into two groups—supraclavicular, arising above the clavicle and coming from nerve roots and nerve trunks; and infraclavicular, arising below the clavicle and coming from nerve cords.

Supraclavicular Branches.—These are as follows: **Muscular branches** from the four cervical nerves to the scalene muscles and longus colli.

One root of the phrenic nerve (inconstant) from the front of the fifth cervical.

The Nerve to the Rhomboids.—This branch arises from the back of the fifth cervical close to, or along with, the highest root of the posterior thoracic, and it takes a backward course through the scalenus medius.

The Posterior Thoracic Nerve or External Respiratory Nerve of Bell.—This branch arises by three roots from the back of the fifth, sixth, and seventh cervical nerves. The upper two roots pierce the scalenus medius below the nerve to the rhomboids, either conjointly or separately, whilst the lowest root passes in front of the scalenus medius, and joins the trunk formed by the others near the first rib. The nerve then courses behind the first part of the axillary artery,

and subsequently descends upon the axillary surface of the serratus magnus, supplying branches to all its serrations.

The Nerve to the Subclavius.—This small branch arises from the front of the upper trunk, its fibres being derived from the fifth cervical. It descends over the third part of the subclavian artery, and, passing behind the clavicle, it enters the subclavius muscle on its deep aspect. This nerve sometimes communicates with the phrenic nerve.

The Suprascapular Nerve.—This is a large nerve which arises

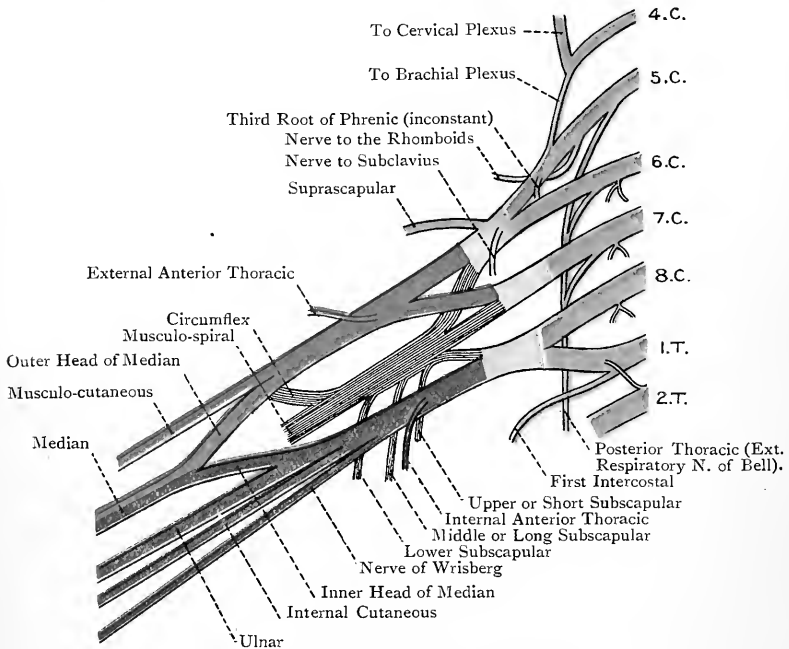


FIG. 174.—THE BRACHIAL PLEXUS.

Yellow = Spinal Nerves and their Branches; Blue = Trunks; Red = Outer Cord; Purple = Inner Cord; Grey = Posterior Cord.

from the back of the upper trunk, its fibres being derived from the fifth and sixth cervical. It is directed downwards, outwards, and backwards beneath the trapezius and posterior belly of the omohyoid to the upper border of the scapula, on approaching which it gets in company with the suprascapular artery. It is distributed to the supraspinatus, infraspinatus, and shoulder-joint.

Infraclavicular Branches.—*Outer Cord.*—The branches of this cord are the external anterior thoracic, musculo-cutaneous, and outer root of the median.

The **external anterior thoracic**, which derives its fibres from the

fifth, sixth, and seventh cervical, crosses over the first part of the axillary artery from without inwards, and gives a branch to the internal anterior thoracic. Thereafter it pierces the costo-coracoid membrane, and is distributed to the pectoralis major.

The **musculo-cutaneous** or **perforating nerve of Casserius**, which derives its fibres from the fifth, sixth, and seventh cervical, arises about the level of the pectoralis minor. For a short distance it lies on the outside of the axillary artery, but it soon leaves the vessel, and pierces the coraco-brachialis in a direction downwards and outwards. Before reaching the muscle it parts with a branch to it, which usually enters it in two divisions. The fibres of this branch are derived from the seventh cervical. The subsequent course of the musculo-cutaneous will be described later on.

The **outer root of the median** passes slightly on to the axillary artery, where it is joined by the inner root.

Inner Cord.—The branches of this cord are the internal anterior thoracic, the lesser internal cutaneous or nerve of Wrisberg, the internal cutaneous, inner root of the median, and ulnar.

The **internal anterior thoracic nerve**, which derives its fibres from the eighth cervical and first thoracic, passes behind the first part of the axillary artery, and then comes forwards between the artery and the axillary vein. Having received a branch from the external anterior thoracic nerve, which forms a loop over the first part of the artery, it breaks up into branches which enter the deep surface of the pectoralis minor, a few of them piercing that muscle to enter the deep surface of the pectoralis major.

The **lesser internal cutaneous** or **nerve of Wrisberg**, which derives its fibres from the first thoracic, is at first placed behind the axillary vein, but subsequently descends on its inner side, where it communicates with the intercosto-humeral nerve. This nerve is sometimes absent.

The **internal cutaneous**, which derives its fibres from the eighth cervical and first thoracic, descends partly on the axillary artery and partly to its inner side.

The **inner root of the median**, which is of smaller size than the outer, passes obliquely over the axillary artery, and joins the outer root a little below the lower border of the pectoralis minor. The trunk of the nerve, which derives its fibres from all the nerves of the plexus, then descends on the outer side of the third part of the artery.

The **ulnar nerve** is the largest branch of the inner cord, of which it is the continuation, and it derives its fibres from the eighth cervical and first thoracic. It appears at the lower border of the pectoralis minor, and then descends, lying deeply between the third part of the axillary artery and the vein.

Posterior Cord.—The branches of this cord are the three subscapular nerves, circumflex, and musculo-spiral.

The **subscapular nerves** are distinguished as upper or short, middle or long, and lower. The **upper** or **short** subscapular nerve,

which is of small size, derives its fibres from the fifth and sixth cervical. It is situated high up on the posterior wall of the axilla, and after a short course it enters the upper part of the subscapularis. The **middle** or **long** subscapular nerve derives its fibres chiefly from the seventh cervical, but to a certain extent also from the sixth and eighth. It descends along with the subscapular artery to the latissimus dorsi, which it supplies. The **lower** subscapular nerve derives its fibres from the fifth and sixth cervical. On approaching the lower border of the subscapularis it breaks up into branches, some of which enter the lower part of that muscle, whilst others pass to the teres major.

The **circumflex nerve** derives its fibres from the fifth and sixth cervical. For a short distance it lies behind the axillary artery, resting on the subscapularis, but, at the lower border of that muscle, it passes backwards through the quadrangular muscular space in company with the posterior circumflex artery. In doing so it furnishes an *articular branch* to the shoulder-joint, and then breaks up into an upper or anterior and a lower or posterior division. The *upper* or *anterior division* accompanies the posterior circumflex artery, and divides into a number of branches which enter the deep surface of the deltoid over its anterior part. Some of the branches, piercing the muscle, supply the integument over about its middle third. The *lower* or *posterior division* gives branches to the posterior part of the deltoid, a branch to the teres minor, and a cutaneous branch, which latter turns round the posterior border of the deltoid to be distributed to the integument over its lower third. The nerve to the teres minor presents a small reddish swelling, which has the appearance of a ganglion, but is really a fibrous thickening.

In connection with the distribution of the circumflex nerve **Hilton's law** may be here stated as follows: *a nerve trunk, supplying a given joint, also supplies the muscles moving that joint, and the integument covering their insertions.* For example, the circumflex nerve supplies the shoulder-joint, the deltoid, and the integument covering its insertion. This law, however, is not universally applicable.

The **musculo-spiral nerve** is the largest of all the branches of the plexus, and is the continuation of the posterior cord. It derives its fibres from the last four cervical nerves, and sometimes from the first thoracic. It descends behind the third part of the axillary artery, resting upon the subscapularis, latissimus dorsi, and teres major. Whilst in the axillary space it gives off muscular and cutaneous branches. The **muscular branches** are destined for the long and inner heads of the triceps, those for the long head entering it high up, whilst those for the inner head enter it at different levels. One of the latter, which is remarkable for its length, descends in company with the ulnar nerve to enter the inner head low down, this branch being known as the *ulnar collateral nerve* (Krause). The **internal cutaneous branch** usually arises in common

with one of the muscular branches, and it takes a backward course behind the intercosto-humeral nerve to be distributed to the integument of the back of the arm, reaching nearly as low as the elbow.

Intercosto-humeral Nerve.—The intercosto-humeral nerve is the undivided lateral cutaneous branch of the *second* intercostal, and it represents the posterior branch of the other lateral cutaneous nerves. Emerging from the second intercostal space it appears between two serrations of the serratus magnus, and then crosses the axillary space. In its course it usually communicates with a branch of the posterior division of the lateral cutaneous of the third intercostal, and towards the arm it also communicates with the nerve of Wrisberg and the internal cutaneous of the musculo-spiral. On reaching the arm it is distributed to the integument of the inner and back part over the upper half. Sometimes there is another intercosto-humeral nerve, which is the undivided lateral cutaneous branch of the first intercostal nerve. When this is so the nerve of Wrisberg is absent.

The **lateral cutaneous nerves** have been previously described in connection with the cutaneous nerves of the pectoral region on page 279. It may be stated, in addition, that the posterior branch of the lateral cutaneous of the third intercostal, as a rule, gives a branch across the axilla to the inner side of the arm, which communicates in its course with the intercosto-humeral, and may largely replace it, if it is small.

Axillary Glands.—The axillary glands are about twelve in number, and are arranged in three groups, which communicate freely with one another, as follows: (1) an *external group*, consisting of about five glands, lying upon the outer wall along the course of the axillary vessels, and receiving their afferent vessels from the limb; (2) an *antero-internal* or *pectoral group*, about five in number, lying within the anterior fold along the course of the long thoracic artery, one or two of them being placed internally on the serratus magnus, and receiving their afferent vessels from the greater part of the mammary gland and the front of the chest; and (3) a *posterior* or *subscapular group*, two or three in number, situated on the posterior wall along the course of the subscapular artery, and receiving their afferent vessels from the back of the trunk. Besides these three groups there is an *infraclavicular group*, two or three in number, which lie below the clavicle, in the interval between the pectoralis major and deltoid, and are in communication below with the axillary glands and above with the glands at the root of the neck. The glands of this group receive their afferent vessels from the shoulder and outer side of the arm. The efferent vessels of all the foregoing glands terminate on the *left* side in the thoracic duct, and on the *right* side in the right lymphatic duct, having followed the course of each subclavian vein. In some cases they are gathered up, on each side, into one vessel, called the *axillary lymphatic trunk*.

Serratus Magnus—*Origin*.—The outer surfaces of the first eight or nine ribs about midway between the angles and costal cartilages, by means of fleshy serrations which are curved with their convexities forwards. Each serration arises from one rib, except the first, which arises from the first and second ribs and a fibrous arch between them.

Insertion.—The anterior surface of the base of the scapula from the superior to the inferior angle.

Nerve-supply.—The posterior thoracic nerve, which arises by three roots from the fifth, sixth, and seventh cervical. The nerve descends on the axillary surface of the muscle.

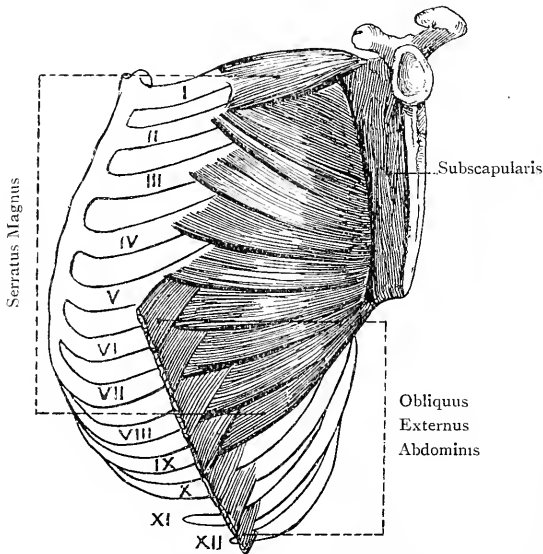


FIG. 175.—THE SERRATUS MAGNUS MUSCLE.

The muscle is arranged in three parts. The *upper part* is formed by the first serration, which is of large size, and it is inserted into the triangular area on the front of the superior angle of the scapula. The *middle part* forms a thin, expanded sheet, which is formed by the broad second and the third serrations, and it is inserted into the long, linear impression on the front of the base, reaching to near the superior angle and extending down to near the inferior angle. The *lower part*, which is formed by the lower five or six serrations, is fan-shaped, and towards the scapula is thick and stout, its insertion being into the expanded area in front of the inferior angle. The lower four or five serrations interdigitate with the obliquus externus abdominis.

Action.—The muscle draws the base of the scapula forwards, as in pushing, and the strong lower fibres, acting upon the lower angle, rotate the bone so as to elevate the point of the shoulder. In this latter action the muscle is auxiliary to the trapezius. An important use of the muscle is to steady the scapula, more particularly the glenoid cavity, this condition being necessary before the deltoid can elevate the humerus. The muscle by its contraction serves to keep the lower angle of the scapula in contact with the chest wall. When the shoulder is fixed the lower part of the muscle may elevate the ribs from which it arises.

THE SCAPULAR REGION.

Cutaneous Nerves.—The cutaneous nerves of the shoulder are derived from the supra-acromial of the cervical plexus and the circumflex. The **supra-acromial nerve**, having descended over the outer part of the clavicle and trapezius, divides into numerous branches, which supply the integument over the upper third of the deltoid. The **circumflex nerve** sends branches through the muscle which supply the integument over about its middle third. It also furnishes a special cutaneous branch which turns round the posterior border of the muscle a little below the centre, and supplies the integument over its lower third.

Deep Fascia.—The deep fascia is well marked over the infraspinatus, where it is strongly aponeurotic. It sends septa between that muscle and the teres muscles, and then passes forwards over them to the posterior border of the deltoid, where it splits into two layers which encase that muscle.

Deltoid—Origin.—(1) The anterior border of the outer third of the clavicle; (2) the outer border of the acromion process; and (3) the lower lip of the posterior border of the spine of the scapula.

Insertion.—The deltoid impression on the outer aspect of the humerus, commencing at the centre, and extending upwards for 2 inches or more.

Nerve-supply.—The circumflex nerve, which is a branch of the posterior cord of the brachial plexus, its fibres being derived from the fifth and sixth cervical.

Blood-supply.—The posterior circumflex and acromio-thoracic arteries.

The muscle, which has very coarse fasciculi, is triangular, the base being upwards. The clavicular portion passes downwards and outwards, the acromial downwards, and the spinal downwards and forwards.

Action.—The acromial portion abducts the arm to the position of a right angle with the trunk; the clavicular portion draws it forwards; and the spinal portion draws it backwards.

The acromial portion of the muscle, besides arising from the bone,

springs to a large extent from the sides of four fibrous septa, which descend into that part, and the fibres arising in this manner are inserted into the sides of three fibrous septa, which ascend from below.

The origin of the muscle corresponds with the insertion of the trapezius. The anterior border is related to the pectoralis major, the cephalic vein and humeral artery lying between the two. The posterior border is to a large extent bound down by the splitting of the deep fascia over the infraspinatus. The muscle covers the shoulder-joint, subacromial bursa, coracoid process, coraco-brachialis, biceps, tendons of insertion of the supraspinatus, infraspinatus, and teres minor, parts of the long and outer heads of the triceps, teres major, tendon of insertion of the pectoralis major, circumflex nerve, and posterior circumflex artery.

Subacromial Bursa.—This is a large bursa which intervenes between the acromion process and deltoid, on the one hand, and the upper part of the capsular ligament and the tendons inserted into the great tuberosity of the humerus, on the other.

Supraspinatus—*Origin.*—The inner two-thirds of the supraspinous fossa of the scapula, and the aponeurosis covering the muscle.

Insertion.—The upper impression on the great tuberosity of the humerus, its tendon being closely connected with the upper part of the capsular ligament, and with that of the infraspinatus.

Nerve-supply.—The suprascapular nerve, which arises from the back of the upper trunk of the brachial plexus, its fibres being derived from the fifth and sixth cervical.

The direction of the muscle is outwards and downwards.

Action.—To abduct the arm in association with the deltoid.

Posterior Belly of the Omo-hyoid—*Origin.*—The upper border of the scapula internal to the suprascapular notch, and, as a rule, the adjacent portion of the suprascapular or transverse ligament.

Infraspinatus—*Origin.*—(1) The infraspinous fossa of the scapula over about its inner two-thirds, the parts excepted being those for the teres muscles, and a portion at the upper and outer part of the fossa; and (2) the deep fascia covering the muscle.

Insertion.—The middle impression on the great tuberosity of the humerus, its tendon being closely connected with the back part of the capsular ligament, from which it is sometimes separated by a bursa. The tendon, which is fan-shaped, is at first concealed within the muscle.

Nerve-supply.—The suprascapular nerve.

The direction of the muscle is outwards.

Action.—When the arm is by the side of the trunk the muscle is an external rotator. When the arm is raised the muscle carries it backwards in association with the deltoid.

Suprascapular Artery.—The suprascapular artery (transversalis humeri) is a branch of the thyroid axis of the first part of the sub-

clavian. Having coursed transversely outwards behind the clavicle, it reaches the upper border of the scapula in company with the suprascapular nerve. The artery then passes backwards *over* the suprascapular ligament, whilst the nerve passes *beneath* it, and it descends into the supraspinous fossa beneath the supraspinatus, where it parts with several branches. Thereafter it passes behind the neck of the scapula through the great scapular notch, beneath the spino-glenoid ligament, into the upper and outer part of the infraspinous fossa under cover of the infraspinatus, where it anastomoses with the dorsalis scapulæ and posterior scapular.

Branches.—These are as follows: *muscular*, in the neck, to the sterno-cleido-mastoid and subclavius; *suprasternal*, over the inner end of the clavicle, to the integument over the presternum; *medullary* to the clavicle; *supra-acromial*, which pierces the trapezius to reach the upper surface of the acromion process, where it anastomoses with branches of the acromio-thoracic and posterior circumflex; *articular* to the acromio-clavicular and shoulder-joints; *ventral* to the belly of the scapula, given off as it passes backwards over the suprascapular ligament, this branch anastomosing with the ventral branches of the dorsalis scapulæ and posterior scapular; *supraspinous* to the fossa and its muscle; and *infraspinous* to the fossa and its muscle.

Suprascapular Nerve.—This nerve passes backwards beneath the suprascapular ligament into the supraspinous fossa, where it gives branches to the supraspinatus, and articular branches to the acromio-clavicular and shoulder-joints. It then accompanies the artery through the great scapular notch, beneath the spino-glenoid ligament, to the infraspinous fossa, where it ends in branches to the infraspinatus.

Teres Minor—*Origin.*—(1) The dorsum of the scapula close to the axillary border for its upper two-thirds, and (2) the septa between it and the infraspinatus and teres major.

Insertion.—The lower impression on the great tuberosity of the humerus, and the surgical neck of the bone for a short distance below, its tendon being closely connected with the back part of the capsular ligament.

Nerve-supply.—The circumflex nerve, the branch of which has a reddish enlargement presenting the appearance of a ganglion, but being in reality a fibrous thickening.

The direction of the muscle is outwards and slightly upwards.

Action.—The muscle is an external rotator of the arm when it is abducted, and it also helps in depressing the arm.

The muscle is pierced by the dorsalis scapulæ artery.

Teres Major—*Origin.*—(1) From an oval impression at the lower and outer part of the infraspinous fossa, which extends on to the lower angle, and reaches upwards on the axillary border for about its lower third; and (2) the septa between it and the teres minor, infraspinatus, and subscapularis.

Insertion.—The inner lip of the bicipital groove of the humerus for 2 inches over about its lower two-thirds.

Nerve-supply.—The lower subscapular nerve, which is a branch of the posterior cord of the brachial plexus, its fibres being derived from the fifth and sixth cervical.

The direction of the muscle is outwards.

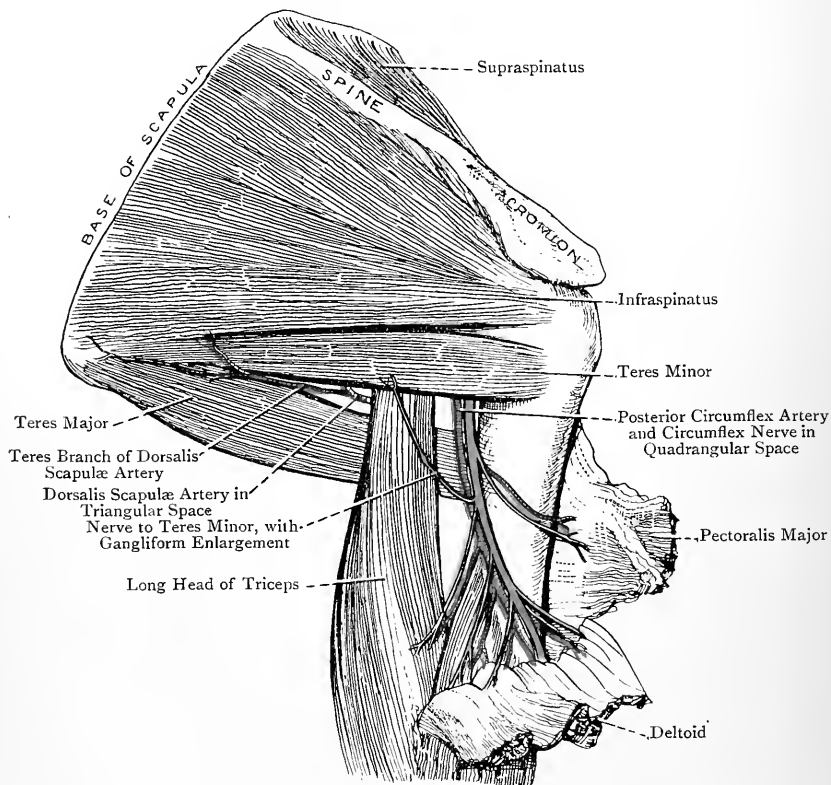


FIG. 176.—DISSECTION OF THE SCAPULAR AND UPPER BRACHIAL REGIONS FROM BEHIND.

(The Deltoid has been turned down, and the Triangular and Quadrangular Muscular Spaces, with their contents, are shown.)

Action.—The muscle adducts the arm. When the arm is abducted it acts as an internal rotator.

The latissimus dorsi winds round the lower border of the muscle, and is subsequently placed in front of it. The two tendons are at first closely connected by their lower borders, but are after-

wards separated by a bursa, and there is usually a bursa behind the teres major at its insertion.

Subscapularis.—*Origin*.—(1) The venter of the scapula, except near the neck, and along the front of the base where the serratus magnus is inserted; and (2) the sides of tendinous septa which intersect the muscle and are connected with the ridges on the venter.

Insertion.—The small tuberosity of the humerus, and the surgical neck of the bone for a short distance below.

Nerve-supply.—The upper or short, and part of the lower, subscapular nerves, which are branches of the posterior cord of the brachial plexus, their fibres being derived from the fifth and sixth cervical.

The direction of the muscle is outwards.

Action.—When the arm is by the side of the trunk the muscle is an internal rotator, and, when it is raised, it carries it forwards and downwards.

The muscle is closely connected with the front of the capsular ligament. Between its upper border and the coracoid process and neck of the scapula there is a bursa, which usually communicates with the synovial membrane of the shoulder-joint through an opening in the capsule.

Triangular and Quadrangular Spaces.—When the long head of the triceps is cut and displaced a large triangular space is seen, which, as viewed from behind, is bounded *above* by the teres minor, *below* by the teres major, and *externally* by the surgical neck of the humerus. As viewed from before, the subscapularis replaces the teres minor. When the long head of the triceps is in position it descends in front of the teres minor, and behind the teres major. It therefore passes through the triangular space and divides it into two, one triangular and the other quadrangular.

Triangular Space.—This, as viewed from behind, is bounded *above* by the teres minor, *below* by the teres major, and *externally* by the long head of the triceps. As viewed from before, the subscapularis replaces the teres minor. The dorsalis scapulæ artery passes backwards through this space, so long as the subscapularis forms one of its boundaries, but thereafter, and as seen from behind, it only lies in it preparatory to piercing the teres minor and winding round the axillary border.

Quadrangular Space.—This space, as viewed from behind, is bounded *above* by the teres minor, *below* by the teres major, *internally* by the long head of the triceps, and *externally* by the surgical neck of the humerus, the subscapularis replacing the teres minor in front. The structures which pass through it are the circumflex nerve and posterior circumflex vessels. It is covered by the deltoid.

Scapular Anastomoses of Arteries.—The anastomoses of arteries upon the scapula are divided into two sets—scapular proper, and acromial.

Scapular Anastomoses Proper.—The arteries which take part in these anastomoses are (1) the suprascapular and posterior scapular, representing the subclavian; and (2) the dorsalis scapulæ of the subscapular, representing the third part of the axillary. The suprascapular is a branch of the thyroid axis of the first part of the subclavian, and the posterior scapular arises from the transverse cervical, which is also a branch of the thyroid axis. The suprascapular is distributed to the supraspinous and infraspinous fossæ and venter, and so also is the posterior scapular. The subscapular is distributed by its dorsalis scapulæ branch to the infraspinous fossa and venter. In the supraspinous fossa the suprascapular anastomoses with the posterior scapular. In the infraspinous fossa the suprascapular anastomoses with the dorsalis scapulæ, as does also the posterior scapular. In the venter of the bone the ventral branches of the suprascapular and posterior scapular anastomose with the ventral branch of the dorsalis scapulæ. At the lower angle of the bone the posterior scapular anastomoses with the descending or teres branch of the dorsalis scapulæ.

Acromial Anastomosis.—The arteries which take part in the acromial anastomosis or rete on the upper surface of the acromion process are as follows: (1) the supra-acromial branch of the suprascapular; (2) branches of the acromio-thoracic artery of the first part of the axillary; and (3) a branch of the posterior circumflex of the third part of the axillary.

The importance of the scapular anastomoses comes into play after ligation of the subclavian artery in the third part of its course.

THE ARTICULATIONS OF THE CLAVICLE.

Sterno-clavicular Joint.—This joint belongs to the class **diarthrosis**, and to the subdivision **arthrodia**. The articular surfaces are the inner end of the clavicle and the clavicular impression on the upper border of the presternum. The articular surface of the clavicle is of larger size than that on the presternum, and the two are separated by an interarticular fibro-cartilage. The joint is surrounded by a complete capsule, which is weak above and below, but strong in front and behind, where it constitutes the anterior and posterior sterno-clavicular ligaments. Besides these there are the interclavicular and costo-clavicular or rhomboid ligaments.

The **anterior sterno-clavicular ligament** is broad, and its fibres extend obliquely downwards and inwards from the front of the clavicle to the front of the presternum. The sternal head of origin of the sterno-cleido-mastoid is in contact with it. The **posterior sterno-clavicular ligament** resembles the anterior, and is similarly disposed behind the joint. The sterno-hyoid muscle

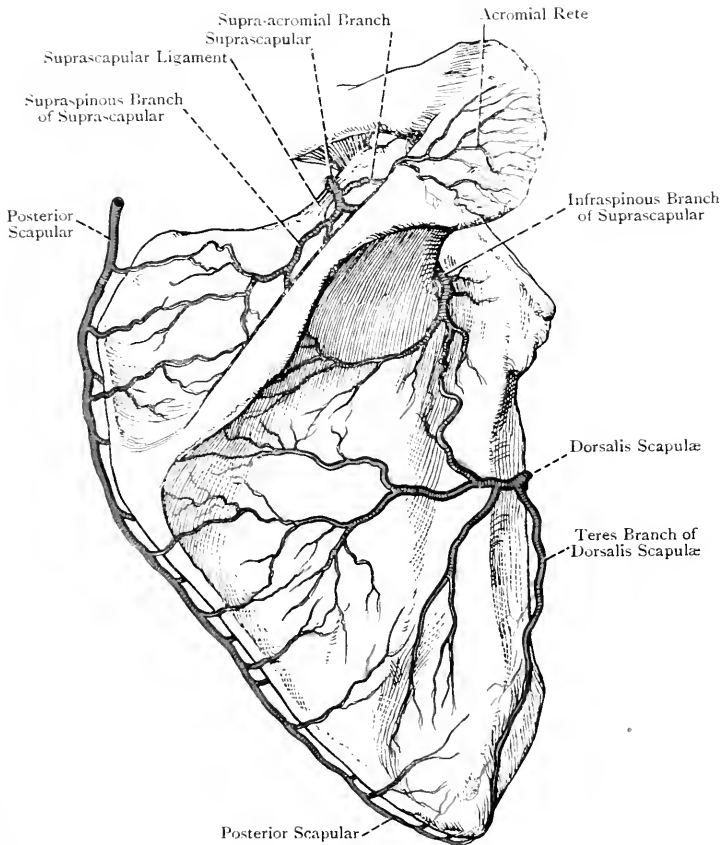


FIG. 176A.—THE ANASTOMOSES OF ARTERIES ON THE DORSUM AND ACROMION PROCESS OF THE SCAPULA.

arises in part from it. The **interclavicular ligament** is a well-marked, curved bundle of fibres, which is attached at either side to the upper and back part of the inner end of the clavicle. In crossing between the two bones it curves downwards to be attached to the interclavicular notch on the upper border of the presternum. The **costo-clavicular** or **rhomboid ligament** is a strong, quadrilateral band of fibres, which extends from the upper surface of the first costal cartilage to the rhomboid impression on the under surface of the clavicle, its direction being upwards, backwards, and outwards.

The **interarticular fibro-cartilage** is a nearly circular, flattened plate, which is thinner at the centre and lower part than elsewhere. It is attached superiorly to the upper and back part of the inner end of the clavicle, and inferiorly to the inner end of the first costal cartilage, where it inclines slightly outwards to form part of a socket

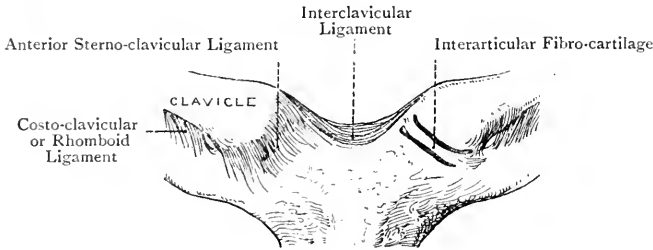


FIG. 177.—THE STERNO-CLAVICULAR JOINTS.

(The Left Anterior Sterno-clavicular Ligament has been removed.)

for the lower portion of the inner end of the clavicle. Its circumference is connected with the fibrous capsule of the joint. The plate sometimes presents a perforation at its centre.

There are two synovial membranes at this joint, one on either side of the interarticular fibro-cartilage. When the latter is perforated these are continuous with each other.

Arterial Supply.—The suprasternal branch of the suprascapular, and the internal mammary.

Nerve-supply.—The suprasternal branch of the cervical plexus.

Movements.—These take place in an upward, downward, forward, and backward direction. There is also circumduction. In the upward and downward movements the clavicle moves on the fibro-cartilage, and the forward and backward movements take place between the fibro-cartilage and the presternum. In the downward movement of the bone the interarticular ligament is put upon the stretch, and the upward movement is limited by the costo-clavicular ligament.

Acromio-clavicular Joint.—This belongs to the class **diarthrosis**, and to the subdivision **arthrodia**. The articular surfaces are the outer end of the clavicle and the facet on the acromion process.

These surfaces are sometimes partially separated by an inter-articular fibro-cartilage, and the joint is surrounded by a complete capsule, which forms the superior and inferior ligaments.

The **superior** and **inferior acromio-clavicular ligaments** extend between the contiguous margins of the bones on their upper and under surfaces, the former being strengthened by aponeurotic fibres from the trapezius and deltoid. The interarticular fibro-cartilage, when present, is limited to the upper part of the joint, where it is attached to the superior ligament. It may divide the joint into two synovial compartments, but there is usually only one.

The **coraco-clavicular ligament**, which is to be regarded as accessory to this joint, connects the clavicle with the coracoid process,

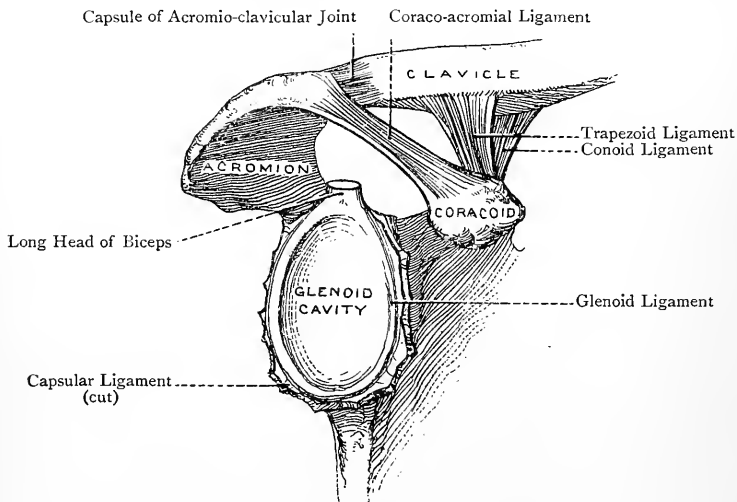


FIG. 187.—THE RIGHT GLENOID CAVITY, AND THE ADJACENT LIGAMENTS.

and is composed of two parts—conoid and trapezoid. The **conoid ligament**, internal and posterior in position, is attached below by its apex to an impression at the back part of the antero-internal border of the coracoid process, and above by its base to the conoid tubercle of the clavicle, its direction being upwards and backwards. The **trapezoid ligament**, external and anterior in position, is somewhat quadrilateral. It is attached below to the trapezoid ridge on the back part of the upper surface of the coracoid process, and above to the trapezoid ridge on the under surface of the clavicle, its direction being upwards, backwards, and outwards. Between the two ligaments there is a slight interval, in which there may be a bursa.

Arterial Supply.—The suprascapular and acromio-thoracic arteries.

Nerve-supply.—The suprascapular and circumflex nerves.

Movements.—The movements at this joint are limited, and are principally of a gliding nature in an upward and downward, and forward and backward, direction.

The Ligaments of the Scapula.

These are three in number—suprascapular, coraco-acromial, and spino-glenoid.

The **suprascapular** or **transverse ligament** extends from the upper border of the scapula, internal to the suprascapular notch, to the root of the coracoid process. It is thin and flat, and it bridges over the notch, which it converts into a foramen. It usually gives origin to some fibres of the posterior belly of the omo-hyoid, and the suprascapular nerve passes backwards *beneath* it and the suprascapular artery *over* it. This ligament sometimes undergoes ossification.

The **coraco-acromial ligament**, which is triangular, is attached by its apex to the tip of the acromion process, and by its base to the postero-external border of the coracoid process. Its superior surface is covered by the deltoid, and the inferior surface overhangs the shoulder-joint, the subacromial bursa intervening. The acromion process, coraco-acromial ligament, and coracoid process form the coraco-acromial arch, within which the head of the humerus fits when the arm is abducted. The arch therefore forms an auxiliary socket for the head of the bone.

The **spino-glenoid ligament** consists of a few fibres which extend from the outer border of the spine to the adjacent part of the margin of the glenoid cavity. It arches over the suprascapular artery and nerve as they pass through the great scapular notch on their way to the infrapinnous fossa.

THE ARM.

Landmarks.—The front of the brachial region presents a well-marked elongated prominence, due to the biceps, which reaches from the anterior fold of the axilla to near the elbow. Internal to this prominence, above, is another swelling caused by the coracobrachialis. On either side of the bicipital prominence is a groove, that on the outer side indicating the position of the cephalic vein, and that on the inner side the position of the basilic vein, brachial artery, and median nerve. External to the bicipital prominence, for a short distance above the elbow, is the prominence formed by the brachio-radialis and extensor carpi radialis longior. At the elbow the internal and external epicondyles of the humerus and the olecranon process of the ulna are to be noted. The internal epicondyle forms a very distinct projection, having an inclination backwards, and behind it, close to the olecranon, is the ulnar nerve. The external epicondyle, which is not well marked, may be felt in semiflexion of the joint. The olecranon process can easily be felt at the back. In extension of the joint the summit of the olecranon

is on the same line with the two epicondyles. When the arm and forearm are placed in the position of a right angle the summit of the olecranon falls below a line connecting the epicondyles. In extreme flexion of the elbow the summit of the olecranon is anterior to a line connecting the epicondyles. The posterior surface of the

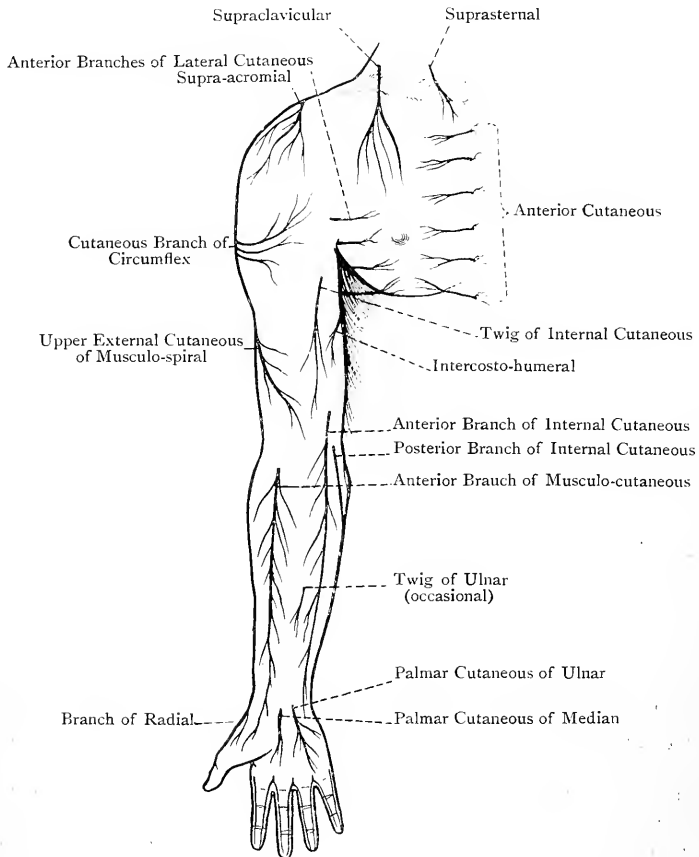


FIG. 179.—DIAGRAM OF THE CUTANEOUS NERVES OF THE UPPER LIMB (ANTERIOR ASPECT).

olecranon is covered by a subcutaneous bursa. The head of the radius can be felt, in extension of the joint, at the bottom of a depression situated at the outer and back part, where it lies just below the external epicondyle. It is most readily felt when the forearm is alternately pronated and supinated. In front of the elbow there is a slight hollow indicating the position of the anticubital fossa, and

in this region the outlines of the median basilic and median cephalic veins may be visible, especially the former. On the back of the forearm the posterior border of the ulna can readily be felt. It leads superiorly to the subcutaneous bursa on the back of the olecranon, and inferiorly it conducts to the styloid process of the bone, which is situated mainly on its posterior aspect. On the outer side of the lower end of the radius its styloid process can easily be felt, which projects lower down than that of the ulna, and in front of it is the radial artery. On the back of the radius, about its centre, is the radial tubercle, which bounds externally the groove for the tendon of the extensor longus pollicis.

Olecranon Bursa.—This bursa is situated subcutaneously over the posterior triangular surface of the olecranon process of the ulna.

Cutaneous Nerves.—The **intercosto-humeral nerve**, having crossed the axillary space, ramifies in the integument of the inner and back part of the arm over its upper half. It may be accompanied by an offset of the posterior branch of the lateral cutaneous of the third intercostal.

The **lesser internal cutaneous** or **nerve of Wrisberg** is distributed to the integument of the inner side of the arm, as low as the interval between the internal epicondyle and olecranon.

The **internal cutaneous nerve** furnishes one or more branches, which, piercing the deep fascia close to the axilla, are distributed to the integument over the biceps. The nerve itself pierces the deep fascia a little below the centre of the arm, and then divides into an anterior and a posterior branch. The *anterior branch* descends behind the median basilic vein, giving one or two twigs over it, and it is distributed to the integument of the anterior aspect of the inner side of the forearm. The *posterior branch* passes down-

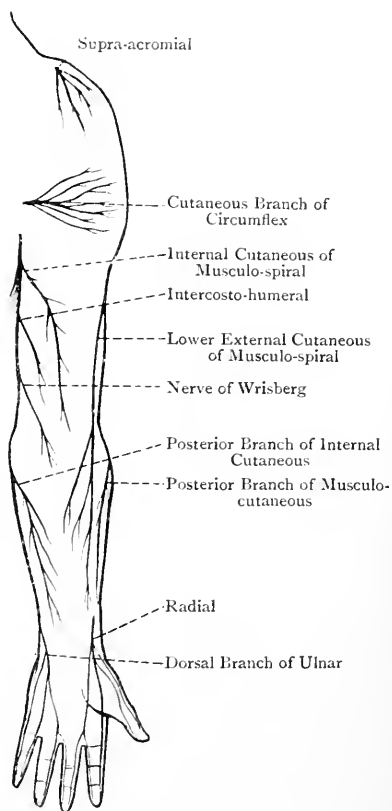


FIG. 180.—DIAGRAM OF THE CUTANEOUS NERVES OF THE UPPER LIMB (POSTERIOR ASPECT).

wards and inwards on the inner side of the basilic vein, and over the internal epicondyle, after which it turns backwards to supply the integument over the back of the inner side of the forearm.

The **internal cutaneous** of the **musculo-spiral** is distributed to the integument of the back of the arm, almost as low as the olecranon.

The **external cutaneous branches** of the **musculo-spiral** are two in number—upper and lower. They leave the main trunk towards the lower end of the spiral groove, just before the nerve passes through the external intermuscular septum, and the two branches pierce the deep fascia about $\frac{1}{2}$ inch apart. The *upper branch*, of small size, descends with the cephalic vein to the front of the elbow, giving branches to the integument of the outer and anterior aspects of the arm in its lower half. The *lower branch*, of larger size, descends behind the external epicondyle into the forearm, where it is distributed to the integument on the posterior aspect of the outer side as low as the wrist.

The **cutaneous branch** of the **musculo-cutaneous** pierces the deep fascia on the outer side of the biceps a little above the elbow. It descends behind the median cephalic vein, giving one or two twigs over it, and then it divides into two branches. One supplies the integument on the anterior aspect of the outer side of the forearm, and the other gives branches to the integument on the posterior aspect.

The **cutaneous branch** of the **ulnar**, which arises about the centre of the forearm, pierces the deep fascia, and has a limited distribution to the integument just below the centre, internal to the median line. This branch is inconstant.

Superficial Veins.—There are four principal superficial veins in the forearm, namely, the median, radial, anterior ulnar, and posterior ulnar.

The **median vein** is formed by the union of a few radicles which originate in the venous plexus in front of the wrist, and its course is upwards in front of the forearm. As it ascends it takes up several veins, and often receives a large tributary from the back of the limb. It is also in free communication with the radial and anterior ulnar veins. On arriving at the hollow in front of the elbow it receives a short but large branch, called the **deep median vein**, which establishes a communication between it and the deep venæ comites. Thereafter it divides into median cephalic and median basilic, which diverge from each other as they ascend, somewhat like the capital letter V. The **median cephalic vein**, the smaller of the two, passes upwards and outwards in the interval between the biceps and brachio-radialis, having the cutaneous part of the musculo-cutaneous nerve behind, and a few of its twigs over it. A little above the external epicondyle it receives the radial vein, the resulting trunk being called the **cephalic vein**. The **median basilic vein**, the larger of the two, passes inwards and

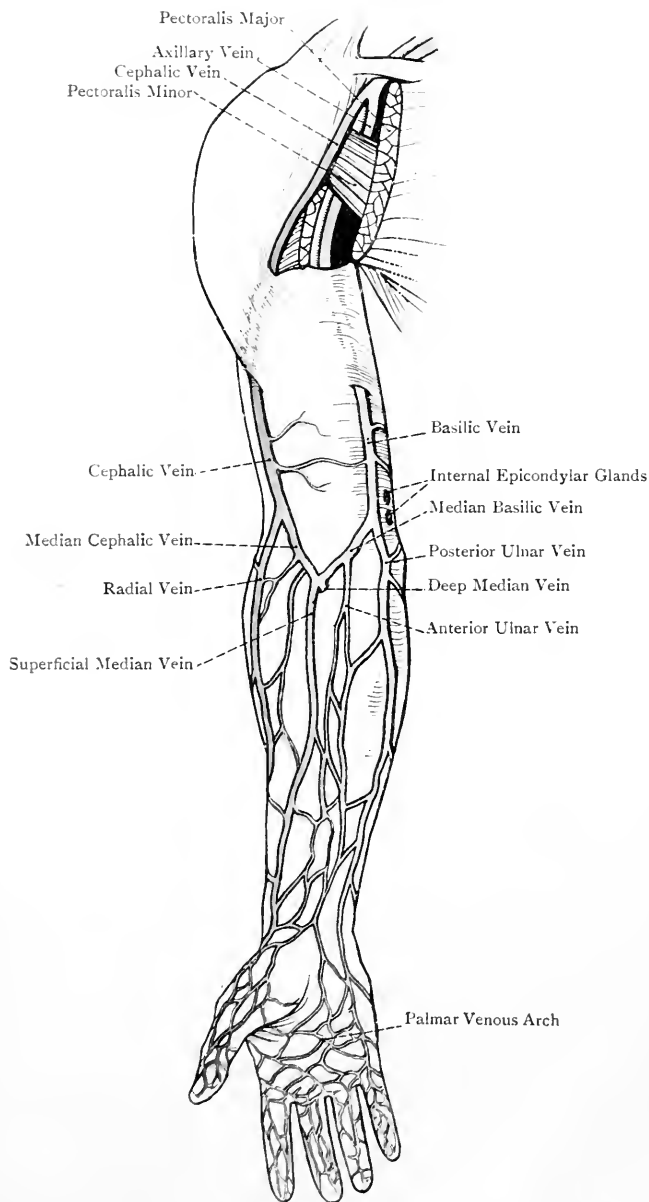


FIG. 181.—THE SUPERFICIAL VEINS OF THE UPPER LIMB (ANTERIOR VIEW).

upwards, crossing the bicipital fascia, which separates it from the brachial artery, and the anterior branch of the internal cutaneous nerve descends behind it, a few of its twigs passing over it. Just above the internal epicondyle it receives the anterior and posterior ulnar veins, either separately or as a common trunk, and the resulting vessel is called the **basilic vein**.

The **radial vein** commences in the outer part of the plexus on the back of the hand, and it ascends at first on the back of the outer side of the forearm, but gradually inclines to its outer aspect. A little above the external epicondyle it joins the median cephalic vein.

The **anterior ulnar vein** commences on the inner aspect of the front of the wrist, and it ascends in front of the inner side of the forearm, to end either in the median basilic or by joining the posterior ulnar vein.

The **posterior ulnar vein**, of large size, commences in the inner part of the plexus on the back of the hand, and it ascends along the back of the inner side of the forearm to join the median basilic, either separately or having previously taken up the anterior ulnar vein.

The principal superficial veins of the brachial region are the cephalic and the basilic.

The **cephalic vein** is formed by the union of the median cephalic and the radial a little above the external epicondyle. It then ascends, lying at first in the groove along the outer border of the biceps, and then between the pectoralis major and deltoid. Thereafter it crosses the first part of the axillary artery, and, piercing the costo-coracoid membrane and axillary sheath, opens into the axillary vein above the pectoralis minor.

The **basilic vein** is formed by the union of the median basilic, anterior ulnar, and posterior ulnar, just above the internal epicondyle. It then ascends in the groove along the inner border of the biceps, lying inside the line of the brachial artery. In the lower half of the arm it is superficial to the deep fascia, but about the centre it pierces it, and becomes the **axillary vein** at the lower border of the tendon of the teres major. In contact with the basilic vein, just above the internal epicondyle, there are one or two lymphatic glands.

Lymphatics.—The lymphatics of the upper limb are arranged in two sets—superficial and deep.

Superficial Lymphatics.—These commence in networks in the tissues around the nails, whence they pass along the sides of the fingers on their palmar and dorsal aspects, receiving vessels from the front and back of each finger. The palmar lymphatics end in a palmar network, and the dorsal in a dorsal network. The vessels proceeding from the palmar network pass over the wrist into the forearm, and ascend in three sets which accompany the radial, median, and ulnar veins. In this course the outer and inner lymphatics are reinforced at intervals by vessels which come round

from the back of the forearm, and which originate below in the dorsal network. The lymphatics of the inner set become the afferent vessels of the glands above the internal epicondyle, and the efferent vessels of these glands ascend along the inner border of the biceps, in company with the basilic vein, to become the afferent vessels of the external group of axillary glands. The lymphatics of the middle and outer sets pass upwards along the outer border of the biceps, and most of them gradually cross inwards over the muscle to end in the external axillary glands. Some of them, however, accompany the cephalic vein, and end in the infraclavicular group of glands. The superficial lymphatics from the integument over the deltoid also end in the infraclavicular glands.

Deep Lymphatics.—These accompany the bloodvessels. In the forearm there are four sets, accompanying the radial, ulnar, anterior interosseous, and posterior interosseous arteries. In the arm these four sets form one group, the vessels of which accompany the brachial artery and terminate in the external axillary glands.

The **lymphatic glands** are arranged in two sets—superficial and deep. There are no superficial glands in the hand or forearm. Sometimes there are one or two connected with the superficial lymphatics at the bend of the elbow, and there are always one or two just above the internal epicondyle, in contact with the basilic vein. A few deep lymphatic glands are sometimes met with along the course of the deep lymphatics which accompany the arteries of the forearm, and a few are placed along the brachial artery. The principal deep glands, however, are those in the axillary space, which have been already described.

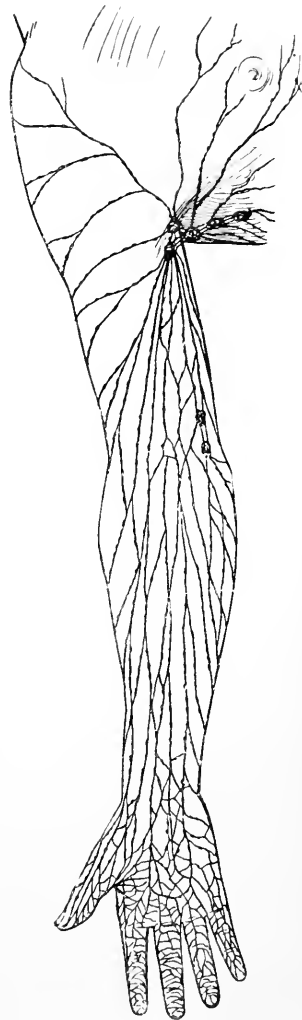


FIG. 182.—THE SUPERFICIAL LYMPHATICS OF THE UPPER LIMB (ANTERIOR VIEW).

FRONT OF THE BRACHIAL REGION.

Deep Fascia.—The deep fascia or aponeurosis forms a continuous investment to the arm, its fibres being principally disposed transversely, but others run more or less longitudinally. It is continuous above with the axillary fascia and the fascial investments of the pectoralis major and deltoid, the tendons of which give expansions to it. It is thin over the biceps, and somewhat thicker over the triceps, but it becomes specially strong in the region of the elbow, where it is attached to the epicondyles of the humerus and olecranon process of the ulna. In front of the elbow it receives a considerable accession of fibres from the bicipital or semilunar fascia. At about the centre of the arm, on its inner aspect, it presents an opening for the passage of the basilic vein. The deep fascia is connected with the lower part of the humerus on either side by two deep processes, called **intermuscular septa**. The *external* septum is attached to the external epicondyle, and external supracondylar ridge as high as a point posterior to the lower part of the tendon of insertion of the deltoid, with which it is connected. It gives origin posteriorly to fibres of the inner head of the triceps, below where it is pierced by the musculo-spiral nerve, and above that point to fibres of the external head. Anteriorly, from above downwards, it gives origin to a small part of the brachialis anticus, brachio-radialis, and extensor carpi radialis longior. It is pierced from behind forwards by the musculo-spiral nerve and the anterior terminal branch of the superior profunda artery, the posterior terminal branch descending behind it. The *internal* septum is stronger than the external, and is attached to the internal epicondyle, and internal supracondylar ridge as high as a point behind the insertion of the coraco-brachialis. It gives origin anteriorly to the brachialis anticus, and posteriorly to the inner head of the triceps. It is pierced, at its upper part, from before backwards by the ulnar nerve and inferior profunda artery, and, a little above the elbow, by the posterior branch of the anastomotica magna artery. Connected with the internal septum there is a fibrous band, known as the *internal brachial ligament* (Struthers), which extends from the humerus below the tendon of insertion of the teres major to the internal epicondyle. The two intermuscular septa divide the lower half of the arm into two compartments—*anterior* and *posterior*. The anterior compartment contains the biceps, brachialis anticus, brachio-radialis, extensor carpi radialis longior, basilic vein, brachial vessels, median nerve, ulnar nerve for a short distance above, internal cutaneous nerve, nerve of Wrisberg, and musculo-spiral nerve after it has pierced the external septum. The posterior compartment contains the triceps and a small part of the musculo-spiral nerve.

Coraco-brachialis—*Origin*.—(1) The tip of the coracoid process of the scapula; and (2) the inner aspect of the tendon of the short head of the biceps for 3 inches or more.

Insertion.—The inner side of the humerus at its centre for about an inch and a half. Some of the upper fibres are inserted into a fibrous band, which ascends in front of the tendons of the latissimus dorsi and teres major to be attached to the humerus below the small tuberosity.

Nerve-supply.—The musculo-cutaneous nerve, by a branch which derives its fibres from the seventh cervical.

The muscle is directed downwards, outwards, and slightly backwards.

Action.—To adduct and flex the humerus. It also braces the head of the bone against the glenoid cavity.

The muscle is pierced by the musculo-cutaneous nerve.

Biceps Flexor Cubiti—*Origin.*—(1) The **short head** arises from the tip of the coracoid process of the scapula in association with the coraco-brachialis: (2) the **long head** arises from the supraglenoid tubercle of the scapula by a rounded tendon, which lies within the capsular ligament of the shoulder-joint, and is continuous on either side with the glenoid ligament.

Insertion.—(1) The posterior rough portion of the bicipital tuberosity of the radius, being separated from the anterior smooth portion by a bursa; and (2) the deep fascia covering the muscles arising from the internal epicondyle of the humerus by means of the bicipital or semilunar fascia.

The short head arises by a short tendon, and the tendon of the long head is about 4 inches in length. This latter tendon arches over the head of the humerus, and leaves the interior of the joint by entering the bicipital groove, beneath the transverse humeral ligament. Within the joint it is invested by a tubular sheath formed by the synovial membrane, which accompanies it for a short distance in the bicipital groove, and is then reflected upwards to become continuous with the synovial lining of the capsular ligament. After leaving the bicipital groove the tendon is replaced by a conical bundle of fleshy fibres, and these join the fibres derived from the short head about the centre of the arm, giving rise to an elongated, oval, fleshy belly. At the level of the epicondyles of the humerus the belly gives place to the strong tendon of insertion, which sinks into the anti-cubital space, and undergoes a quarter of a turn before reaching its insertion. From the inner side of the tendon, towards its upper part, a strong band of fibres is given off, which passes to the deep fascia covering the muscles arising from the internal epicondyle. It is called the *bicipital* or *semilunar fascia*, and it passes over the brachial artery, whilst the median basilic vein lies upon it.

Nerve-supply.—The musculo-cutaneous nerve, which is a branch of the outer cord of the brachial plexus, its fibres being derived from the fifth, sixth, and seventh cervical.

Action.—(1) To flex the elbow-joint; (2) to supinate the forearm; (3) by its short head to adduct and flex the arm, and (4) by its long head to raise the arm.

Internal to the muscle in the upper half is the coraco-brachialis,

and in the lower half the brachial artery and median nerve. External to it is the cephalic vein. The biceps sometimes has a *third head*, which usually arises from the inner side of the humerus at or near the insertion of the coraco-brachialis. As a rule, it

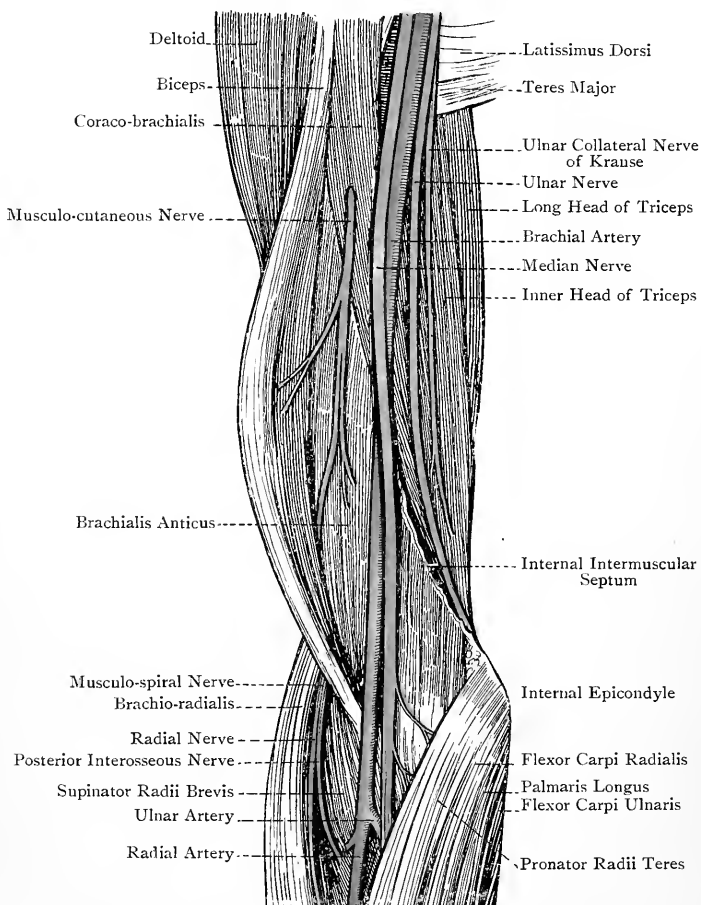


FIG. 183.—DISSECTION OF THE RIGHT BRACHIAL REGION, AND BEND OF THE ELBOW.

is external to the brachial artery, but sometimes it crosses the vessel.

Brachialis Anticus—*Origin*.—(1) The lower half of the front of the humerus ; (2) the front of the internal intermuscular septum over the whole of its extent ; and (3) the front of the external intermuscular septum for a short distance above.

Superiorly the muscle sends a pointed projection upwards on either side of the lower part of the insertion of the deltoid.

Insertion.—The inner part of the rough triangular surface on the front of the coronoid process of the ulna.

Nerve-supply.—(1) The musculo-cutaneous nerve, and (2) a twig from the musculo-spiral nerve.

Action.—The muscle is a direct flexor of the elbow-joint.

Brachial Artery.—The brachial artery is the continuation of the axillary, and it extends from the lower border of the *teres major* to a point just below the bend of the elbow, where it divides opposite the upper part of the neck of the radius into the radial and ulnar arteries. It is at first internal to the humerus, but gradually inclines to the front of the bone, and at the elbow it is equally distant from the two epicondyles. The course of the vessel is indicated by a line drawn from a point midway between the anterior and posterior folds of the axilla at the humerus to a point midway between the epicondyles of the bone. The artery is accompanied by two *venæ comites*, one on either side, which communicate with each other over the vessel at frequent intervals. It is for the most part superficial, being only slightly overlapped by the *coraco-brachialis* and *biceps*. At the bend of the elbow, however, it sinks deeply under cover of the semilunar fascia, and lies in the anti-cubital space.

Relations—*Superficial.*—Skin, superficial and deep fasciæ, median nerve about the centre of the arm, semilunar fascia of the *biceps*, and, superficial to this, the median basilic vein. *Deep.*—The long head of the *triceps*, with the intervention of the musculo-spiral nerve and superior profunda artery, inner head of the *triceps*, insertion of the *coraco-brachialis*, and *brachialis anticus*. *External.*—The *coraco-brachialis* and *biceps*, both of which slightly overlap the vessel, external vena comes, and the median nerve in the upper half of the arm. *Internal.*—The internal vena comes, internal cutaneous nerve (which may be slightly over the vessel) as low as the centre of the arm, ulnar nerve also as low as the centre, median nerve in the lower third, and basilic vein, which is superficial to the deep fascia in the lower half, but beneath it in the upper half. The nerve most intimately related to the artery is the median, which lies on its *outer side* in the upper half of the arm, *in front* of it for a little at the centre, and on its *inner side* in the lower third.

Branches.—The vessel gives off from its outer side a series of branches which are distributed to the muscles and integument of the front of the arm. The named branches arise from the inner and back part of the trunk. They are called superior profunda, inferior profunda, nutrient, and *anastomotica magna*.

The **superior profunda artery** is a large vessel which arises from the back of the brachial near its commencement. It passes downwards and backwards with the musculo-spiral nerve between the long and inner heads of the *triceps*, and it then winds round the back of the humerus, lying with the nerve in the spiral groove,

between the outer and inner heads of that muscle. Towards the lower end of the groove it divides into two terminal branches— anterior and posterior. The *anterior branch* accompanies the musculo-spiral nerve through the external intermuscular septum, and then descends between the brachio-radialis and brachialis anticus to anastomose with the radial recurrent artery. The *posterior branch* descends behind the external intermuscular septum, and anastomoses behind the external epicondyle with the posterior interosseous recurrent, and across the back of the humerus above the olecranon fossa with the *anastomotica magna*. Besides the two terminal branches the superior profunda gives off the following offsets: *muscular* to the triceps; an *ascending branch*, which passes upwards between the long and outer heads of the triceps to anastomose with a branch of the posterior circumflex; and a *nutrient branch*, which enters a foramen on the back of the humerus.

The superior profunda may arise from the third part of the axillary, and it may give off the posterior circumflex.

The **inferior profunda artery** arises from the brachial about the centre of the arm, or sometimes from the superior profunda. It accompanies the ulnar nerve through the internal intermuscular septum, and then descends with it on the inner head of the triceps to the back of the internal epicondyle, where it anastomoses with the *anastomotica magna* and posterior ulnar recurrent arteries. In its course it gives muscular offsets to the triceps.

The **nutrient or medullary artery** arises from the brachial opposite the lower border of the insertion of the coraco-brachialis, or it may come off from the inferior profunda. Its course is downwards, and it enters the medullary foramen of the bone to be distributed to its interior.

The **anastomotica magna artery** arises about 2 inches above the elbow. It passes inwards on the brachialis anticus, and divides into two branches—a small anterior and large posterior. The *anterior branch* descends beneath the pronator radii teres, and anastomoses with the anterior ulnar recurrent artery. The *posterior branch* pierces the internal intermuscular septum, and then passes outwards beneath the triceps, resting upon the back of the humerus above the olecranon fossa, where it forms an arch with the posterior branch of the superior profunda artery. It gives a branch to the back of the internal epicondyle, which anastomoses with the inferior profunda and posterior ulnar recurrent arteries.

Varieties.—1. The brachial artery may divide above the normal level. In most cases the vessel given off earlier than usual is the radial; more rarely it is the ulnar, and in these cases the interosseous trunk arises from the radial; still more rarely the premature branch is the interosseous trunk, or a large *vas aberrans*. The level at which a high division takes place is most frequently in the upper third of the arm, less so in the lower third, and it is of rarest occurrence in the middle third. When two arteries are present they usually lie side by side in the position of the normal vessel. When a *vas aberrans* is present it usually arises from the upper part of the brachial artery, and terminates below by joining, most commonly, the radial artery.

2. In rare cases the brachial artery divides high up into two vessels of equal size, which become reunited into one trunk a little above the elbow.

3. When a supracondylar process is present the brachial artery, along with the median nerve, may descend towards the internal epicondyle until it gets below the level of the process, round which it turns forward to the front of the elbow. This is the normal course taken by the artery in the *Felidæ*, in which there is a supracondylar foramen.

Collateral Circulation.—When the brachial artery has been ligatured above the centre of the arm, the collateral circulation is carried on by the superior profunda artery, which anastomoses below with (1) the radial recurrent, (2) the posterior interosseous recurrent, and (3) the anastomotica magna. When the artery has been ligatured in the vicinity of the elbow, the inferior profunda and anastomotica magna assist the superior profunda by anastomosing with the anterior and posterior ulnar recurrent.

Brachial Venæ Comites.—These are two in number, and they closely accompany the artery, one being placed on either side of it. Along the course of the vessel they communicate with each other across it at frequent intervals. Superiorly the external vena comes across inwards over the lower portion of the third part of the axillary artery to join the internal vena comes, and the resulting trunk opens into the axillary vein near the lower border of the subscapularis.

The **internal cutaneous nerve** and the **nerve of Wrisberg** are situated on the inner side of the brachial artery, the former slightly encroaching upon it. The **median nerve** lies on the outer side of the artery as low as the centre of the arm, where it passes over it, and then descends on its inner side in the lower third. Instead of crossing over the vessel it may pass behind it. It gives off no branch in the arm, but it sometimes receives a branch from the musculo-cutaneous. The **ulnar nerve** lies on the inner side of the artery as low as the insertion of the coraco-brachialis. Here it meets with the inferior profunda artery, and with it pierces the internal intermuscular septum from before backwards. It then descends on the inner head of the triceps to the interval between the olecranon and internal epicondyle. It gives off no branch in the arm. The **musculo-cutaneous nerve**, having pierced the coraco-brachialis, passes downwards and outwards between the biceps and brachialis anticus. A little above the elbow it appears at the outer border of the biceps, whence it descends to its cutaneous distribution, already described. Before piercing the coraco-brachialis, it gives off the branch to that muscle, and, as it courses between the biceps and brachialis anticus, it furnishes branches to them. It sometimes gives a communicating branch to the median nerve.

Anticubital Space.—This is the name given to the triangular hollow in front of the elbow-joint. The *roof* of the space is formed by the integument, median basilic and median cephalic veins, anterior division of the internal cutaneous nerve, cutaneous part of the musculo-cutaneous nerve, deep fascia, and semilunar fascia.

The *floor* is formed by the brachialis anticus and a small part of the supinator radii brevis. The *base* is represented by an imaginary line connecting the epicondyles of the humerus. The *outer boundary* is formed by the brachio-radialis, and the *inner* by the pronator radii teres, the *apex* being constructed by the former muscle overlapping

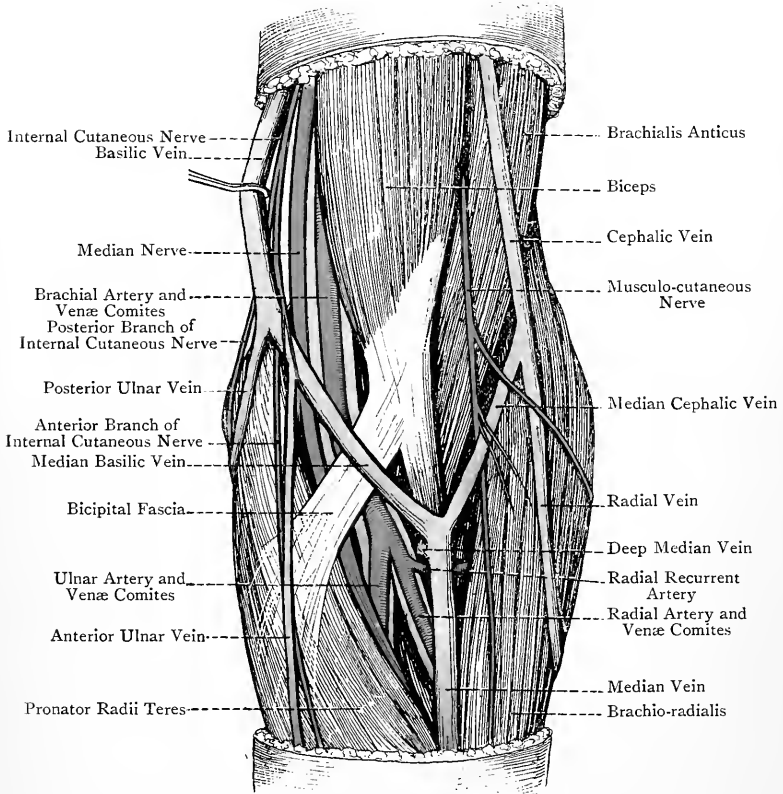


FIG. 184.—SUPERFICIAL DISSECTION OF THE FRONT OF THE LEFT ELBOW.

the latter. The space contains the terminal part of the brachial, and the commencement of the radial and ulnar, arteries, with their respective venæ comites. On the outer side of the brachial artery is the tendon of the biceps, and on its inner side is the median nerve. Under cover of the brachio-radialis are the radial and posterior interosseous branches of the musculo-spiral nerve.

BACK OF THE BRACHIAL REGION.

Triceps Extensor Cubiti—*Origin*.—(1) The **long head** arises from the infraglenoid ridge of the scapula, where it is superficially tendinous. (2) The **external head** arises from (*a*) the outer part of the posterior surface of the humerus, reaching as high as the insertion of the teres minor, and as low as the spiral groove; and (*b*) the back of the external intermuscular septum above the point where it is pierced by the musculo-spiral nerve. (3) The **internal head** arises from (*a*) the whole of the posterior surface of the humerus below the spiral groove, reaching upwards on the inner side of the groove, in a tapering manner, as high as a point about $\frac{1}{4}$ inch above, and posterior to, the lower border of the insertion of the teres major; (*b*) the back of the internal intermuscular septum over its whole extent; and (*c*) the back of the external intermuscular septum below where it is pierced by the musculo-spiral nerve.

Insertion.—(1) The back part of the upper surface of the olecranon process of the ulna; (2) the deep fascia covering the anconeus; and (3) slightly into the posterior ligament of the elbow-joint.

The long and external heads terminate in a broad flat tendon, which occupies about the lower half of the arm, the fibres of the long head ending on its inner side, and those of the external head on its upper and outer parts. Most of the fibres of the internal head terminate on the deep surface of the tendon, but some are inserted directly into the olecranon. The deepest and lowest fibres of this head are inserted into the posterior ligament of the elbow-joint, and form the so-called **subanconeus**. There is usually a bursa over the front part of the upper surface of the olecranon, separating the tendon of the muscle from the posterior ligament of the elbow-joint.

The long head is related to the lower part of the capsular ligament of the shoulder-joint.

Nerve-supply.—The musculo-spiral nerve, which is a branch of the posterior cord of the brachial plexus, its fibres being derived from the last four cervical, and sometimes from the first thoracic.

Action.—The external and internal heads are simple extensors of the elbow-joint. The long head also extends the elbow-joint, and from its relation to the shoulder-joint it depresses the arm upon the scapula.

Musculo-spiral Nerve.—This nerve at first lies behind the third part of the axillary artery, and then behind the upper part of the brachial. Thereafter it passes downwards and backwards, with the superior profunda artery, between the long and internal heads of the triceps. It next winds round the back of the humerus in the spiral groove, between the external and internal heads of the triceps. Having pierced the upper part of the external intermuscular septum, it descends in the groove between the brachio-radialis and brachialis anticus to a point a little above the external epi-

condyle, where it terminates by dividing into the radial and posterior interosseous nerves.

Branches—*Internal Branches*.—These, which arise on the inner

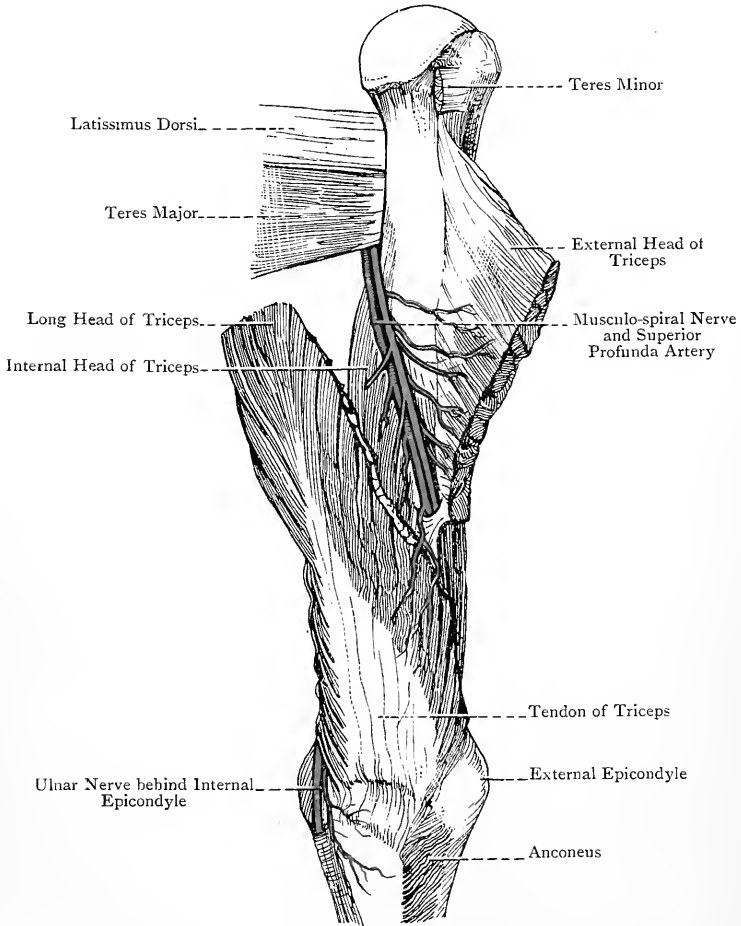


FIG. 185.—DISSECTION OF THE BACK OF THE BRACHIAL REGION.

(The External Head of the Triceps has been divided and reflected outwards to show the contents of the Spiral Groove.)

side of the humerus, are muscular and cutaneous. The **muscular branches** supply the long and internal heads of the triceps, those for the long head entering it high up, whilst those for the internal head enter it at different levels. One of the latter, which

is remarkable for its length, descends, along with the ulnar nerve, to enter the internal head low down, this branch being known as the *ulnar collateral nerve* (Krause). The **internal cutaneous branch** usually arises in common with one of the muscular branches, and is distributed to the integument of the back of the arm, reaching nearly as low as the back of the elbow.

Posterior Branches.—These arise behind the humerus, and are distributed to the external and internal heads of the muscle and to the anconeus, the nerve to the latter, which is long and slender, descending in the internal head.

External Branches.—These arise on the outer side of the humerus, and are cutaneous, muscular, and articular. The upper and lower external cutaneous nerves have been already described. The **muscular branches** are distributed to the brachio-radialis, extensor carpi radialis longior, and brachialis anticus, the latter branch being a small twig. The **articular branches**, one or two in number, are distributed to the elbow-joint.

THE SHOULDER-JOINT.

The shoulder-joint belongs to the class **diarthrosis**, and to the subdivision **enarthrosis** (ball-and-socket). The articular surfaces are the glenoid cavity of the scapula and the head of the humerus; and the ligaments are the capsular, coraco-humeral, gleno-humeral, and glenoid.

The **capsular ligament** is attached to the scapula around the margin of the glenoid cavity close to the glenoid ligament, with which many of its fibres are connected. Superiorly it extends to the root of the coracoid process, and inferiorly it is connected with the long head of the triceps. At the humerus it is attached to the anatomical neck, its fibres descending for a little on the inferior aspect. The ligament is very loose, so that, when the muscles in contact with it have been divided, the head of the humerus drops away from the glenoid cavity for over an inch. The ligament presents two openings. One, called the *foramen ovale*, is situated on its anterior aspect, behind the upper border of the subscapularis. Through this opening a protrusion of the synovial membrane of the joint takes place beneath the upper border of the subscapularis, where it forms the subscapular bursa. The other opening is placed between the great and small tuberosities of the humerus at the commencement of the bicipital groove, and it allows the long tendon of the biceps, with its synovial investment, to leave the interior of the joint, beneath the transverse humeral ligament. There is sometimes a third opening of small size on the posterior aspect of the capsule, which allows the synovial membrane to protrude and form a bursa beneath the infraspinatus.

The **coraco-humeral ligament** is a strong band which extends

from the outer border of the coracoid process, near the root, across the upper part of the capsule, with which it is closely connected, to the great tuberosity of the humerus.

The **gleno-humeral bands** are three in number, and are thickened parts of the capsule which project in an inward direction. The superior band is known as the **gleno-humeral ligament**, and is regarded as representing the ligamentum teres of the hip-joint. It extends from the apex of the glenoid cavity, and the root of the coracoid process, of the scapula to the small tuberosity of the humerus, where it lies on the inner side of the bicipital groove. The middle band, called **Flood's ligament**, extends from the anterior

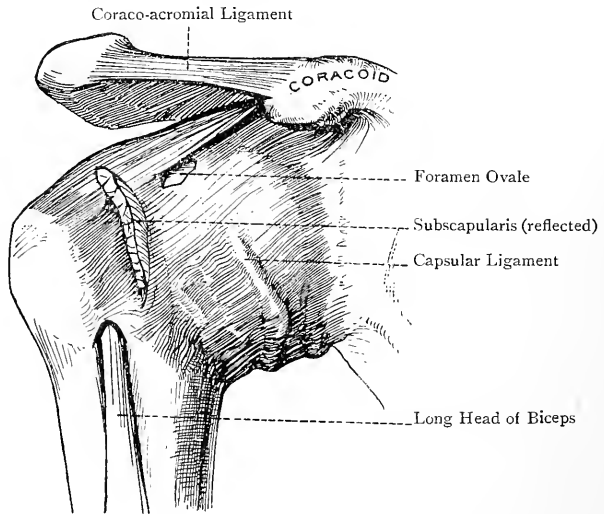


FIG. 186.—THE RIGHT SHOULDER-JOINT (ANTERIOR VIEW).

margin of the glenoid cavity to the lower part of the small tuberosity of the humerus. The inferior band, called **Schlemm's ligament**, extends from the lower part of the glenoid cavity to the lower part of the neck of the humerus. The gleno-humeral bands are best seen when the joint is opened from behind. Associated with the capsule there is also the **transverse humeral ligament**, which bridges over the upper end of the bicipital groove between the great and small tuberosities.

The **glenoid ligament** is a dense fibro-cartilaginous band which is implanted on the edge of the glenoid cavity, and so deepens it for the head of the humerus. Externally it is connected with the capsular ligament, and superiorly each lateral division blends with the long head of the biceps.

The **long head of the biceps** is to be regarded in the light of a

ligament, inasmuch as it arches over the head of the humerus, and tends to prevent upward displacement of the bone.

The **synovial membrane** lines the inner surface of the glenoid ligament, and is reflected from it over the inner surface of the capsule. From this it passes to the anatomical neck of the humerus, which it covers as far as the margin of the articular cartilage of the head. It protrudes through the opening in the front of the capsule to form the **subscapular bursa**, and it sometimes protrudes through an opening behind to form a bursa beneath the infraspinatus. The long head of the biceps, in passing from the supraglenoid tubercle to the bicipital groove, receives a tubular investment from it. This accompanies the tendon for a short distance in

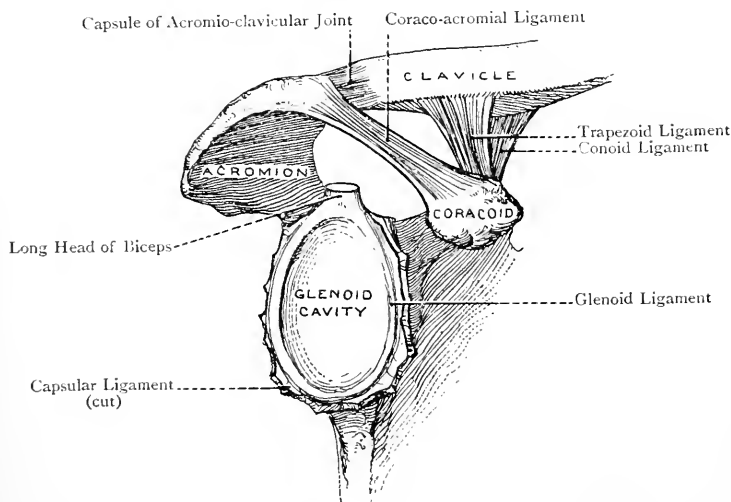


FIG. 187.—THE RIGHT GLENOID CAVITY, AND THE ADJACENT LIGAMENTS.

the bicipital groove, after which it is reflected upwards to become continuous with the synovial membrane lining the capsule.

Muscular Relations.—The capsular ligament is closely related to the following muscles: *superiorly*, the supraspinatus; *posteriorly*, from above downwards, infraspinatus and teres minor; *inferiorly*, long head of the triceps; and *anteriorly*, subscapularis.

Arterial Supply.—The suprascapular, and anterior and posterior circumflex, arteries.

Nerve-supply.—The suprascapular and circumflex nerves.

Movements.—Seven movements are allowed at the shoulder-joint, namely forward flexion, as in shaking hands, extension, backward flexion, abduction, adduction, rotation, and circumduction.

Muscles concerned in the Movements—Forward Flexion.—The clavicular parts of the pectoralis major and deltoid, short head of the biceps, and coracobrachialis. **Extension.**—The spinal portion of the deltoid, teres major, and

latissimus dorsi. **Backward Flexion.**—This movement being a continuation backwards of extension, the muscles concerned are the same as for that movement. **Abduction.**—The acromial portion of the deltoid and supraspinatus. **Adduction.**—The sterno-costal portion of the pectoralis major, short head of the biceps, coraco-brachialis, teres major, and latissimus dorsi.

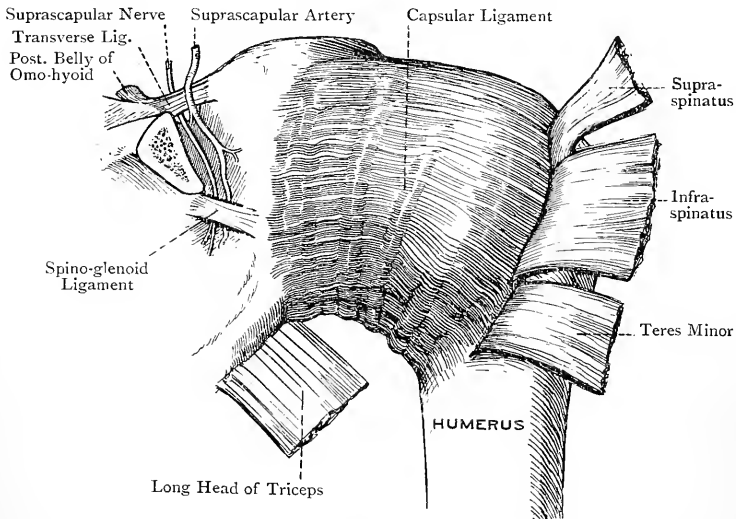


FIG. 188.—THE RIGHT SHOULDER-JOINT (POSTERIOR VIEW).

External Rotation.—Infraspinatus and teres minor. **Internal Rotation.**—Subscapularis, pectoralis major, teres major, and latissimus dorsi. **Circumduction.**—This movement, being a combination of flexion, abduction, extension, and adduction, is effected by the various muscles concerned in these movements.

THE FOREARM AND HAND.

Cutaneous Nerves.—Along the front of the outer side of the forearm is the anterior branch of the cutaneous part of the musculo-cutaneous, and along the back are its posterior branch and the lower external cutaneous branch of the musculo-spiral. Along the front and back of the inner side are the anterior and posterior divisions of the internal cutaneous. All these nerves have been already described. A small cutaneous branch of the ulnar nerve is given off from it about the centre of the forearm, which, after piercing the deep fascia and communicating with the anterior branch of the internal cutaneous, has a limited distribution to the integument just below the centre, internal to the median line. This branch is not constant.

The integument of the palm of the hand is supplied by the palmar cutaneous branches of the ulnar, median, and radial. The

palmar cutaneous branch of the **ulnar** arises in common with the branch to the integument of the forearm and descends on the ulnar artery, keeping beneath the deep fascia until it approaches the wrist, where it becomes cutaneous on the outer side of the tendon of the flexor carpi ulnaris. It then passes over the anterior annular ligament, and is distributed to the integument of the inner part of the palm. The **palmar cutaneous branch** of the **median** arises a little above the wrist, and pierces the deep fascia just above the anterior annular ligament, in the interval between the tendons of the flexor carpi radialis and palmaris longus. It then descends

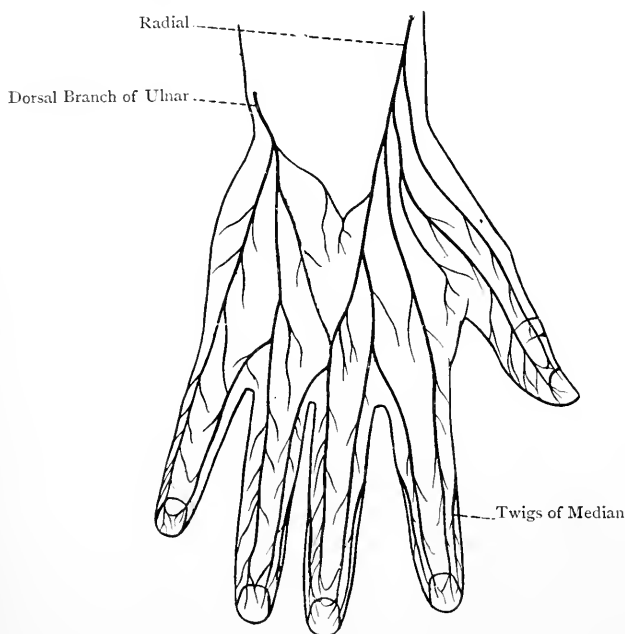


FIG. 189.—DIAGRAM OF THE NERVES OF THE HAND
(DORSAL ASPECT).

over the anterior annular ligament, and is distributed to the integument of the outer part of the palm, and slightly to that of the thenar eminence. It communicates internally with the palmar cutaneous of the ulnar, and externally with that of the radial. The **palmar cutaneous branch** of the **radial** arises from the external division of the nerve which passes to the outer side of the thumb. It is joined by a twig from the anterior branch of the musculocutaneous, and is distributed to the integument of the thenar eminence.

The integument of the dorsum of the hand and fingers is supplied

by the radial nerve and the dorsal branch of the ulnar. The **radial nerve** winds backwards beneath the tendon of the brachioradialis about 3 inches above the wrist, and then divides into two branches—external and internal. The *external branch* passes to supply the outer side of the thumb, giving off in its course the palmar cutaneous branch. The *internal branch*, having communicated with the posterior branch of the musculo-cutaneous, and having given a branch to the back of the wrist which communicates with the dorsal branch of the ulnar, divides into **four digital nerves**. The **first** supplies the inner side of the thumb, the **second** the outer side of the index finger, the **third** bifurcates at the cleft between the index and middle fingers into two collateral branches for the supply of their contiguous sides, and the **fourth** passes to the cleft between the middle and ring fingers. The latter in its course is reinforced by an offset from the dorsal branch of the ulnar, and then it divides into two collateral nerves for the supply of the contiguous sides of the middle and ring fingers.

The **dorsal branch** of the **ulnar nerve** arises about $2\frac{1}{2}$ inches above the wrist, and winds backwards beneath the tendon of the flexor carpi ulnaris. It then gives a branch to the back of the wrist, which communicates with a branch of the radial, and thereafter is distributed as follows: one branch supplies the inner side of the little finger; a second branch passes to the cleft between the little and ring fingers, giving an offset to the innermost digital branch of the radial, and it divides into two collateral branches for the supply of the contiguous sides of these fingers; whilst a third branch is distributed to the integument of the back of the hand.

The distribution of the dorsal digital nerves is as follows: on the thumb they extend as far as the nail, on the index finger to the distal end of the second phalanx, on the middle finger to near the distal end of the first phalanx, on the ring-finger to near the distal end of the second phalanx, and on the little finger as far as the nail. The portions of integument not supplied by the dorsal digital nerves derive their innervation from branches which pass backwards from the palmar digital branches of the median and ulnar nerves.

Veins.—The superficial veins of the forearm, already described, are the radial, median, anterior ulnar, and posterior ulnar. On the back of the hand is the dorsal venous plexus, and in front of the anterior annular ligament is the anterior plexus, of small size. The **dorsal venous plexus** receives the superficial digital veins, which commence in plexuses in the region of the nails. They are two in number to each finger, one being placed on each side towards the dorsal aspect. These veins form cross arches above and below the interphalangeal joints on the backs of the fingers. At the clefts the collateral veins unite to form in each case a single trunk, and these trunks end in the dorsal venous plexus. The superficial digital vein from the inner side of the little finger passes to the commence-

ment of the posterior ulnar vein, and is known as the *vena salvatella* or 'saving vein.' The blood is conveyed away from the outer side of the dorsal venous plexus by the radial vein, and from the inner side by the posterior ulnar vein. The radial vein receives a communicating branch from the *venæ comites* of the deep palmar arch at the proximal end of the first interosseous space. The posterior ulnar vein receives a communicating branch from the *venæ comites* of the profunda branch of the ulnar artery, which passes beneath the abductor minimi digiti muscle.

The **anterior venous plexus** receives its radicles from the palm, and the blood is conveyed away from it by the median vein. The anterior ulnar vein, as stated, commences on the inner aspect of the front of the wrist.

Deep Fascia of the Forearm.—The deep fascia is of considerable strength, its fibres being principally transverse, though some are disposed longitudinally and obliquely. Superiorly, below the internal epicondyle, it receives the semilunar fascia of the biceps, and behind it gets an accession of fibres from the tendon of the triceps. In front of the elbow it presents an opening for the passage of the deep median vein. In the region of the epicondyles it serves as a common tendon of origin to the muscles arising from these prominences, and it sends between them strong intermuscular septa which afford additional origin to them, and are readily recognised on the surface by white lines. It is attached above to the epicondyles of the humerus and the margins of the triangular surface on the back of the olecranon process of the ulna, and along the forearm to the posterior border of the latter bone. Anteriorly it sends an expansion between the superficial and deep muscles, and it acts in a similar manner on the posterior aspect, where the fascia is stronger than in front. At the wrist it blends with the anterior annular ligament, and posteriorly it forms the posterior annular ligament.

FRONT OF THE FOREARM.

Muscles.—The muscles of the front of the forearm are arranged in three layers—first or superficial, second or intermediate, and third or deep.

First Layer.—The muscles comprising this layer are, in order from without inwards, the pronator radii teres, flexor carpi radialis, palmaris longus (inconstant), and flexor carpi ulnaris.

1. **Pronator Radii Teres.**—This muscle arises by two heads—superficial or humeral, and deep or coronoid. The *superficial head*, which is of large size, *arises* from (1) the front and upper part of the internal epicondyle, and lower part of the internal supracondylar ridge, of the humerus; (2) the common tendon; and (3) the intermuscular septa between it and the flexor carpi radialis externally, and flexor sublimis digitorum deeply. The *deep head*, which is of small size, *arises* from the inner margin of the coronoid process of the

ulna, and, after a short course, it joins the deep surface of the superficial head at an acute angle.

Insertion.—By means of a flat tendon, about $1\frac{1}{2}$ inches broad, into the rough impression on the outer surface of the radius at its centre, where the curve of the bone is most prominent.

Nerve-supply.—The median nerve, which arises from the outer and inner cords of the brachial plexus, its fibres being derived from the last four cervical and first thoracic nerves. The branches are given off just before the median nerve passes between the two heads of origin of the muscle.

The muscle is directed downwards and outwards.

Action.—(1) To pronate the forearm, and (2) to assist in flexion of the elbow-joint.

The median nerve passes between the two heads of the muscle, and the ulnar vessels beneath its deep head.

The muscle may have a *third head*, arising from the internal intermuscular septum of the arm, or from a supracondylar process, and, when this is so, it bridges over the brachial artery and median nerve.

2. **Flexor Carpi Radialis**—*Origin.*—(1) The front of the internal epicondyle by means of the common tendon; (2) the deep fascia covering the muscle; and (3) the intermuscular septa separating it from the pronator radii teres externally, palmaris longus internally, and flexor sublimis digitorum deeply.

Insertion.—The front of the base of the second metacarpal bone, and by a small slip into the front of the base of the third.

The muscle presents a fusiform, fleshy belly in the upper half of the forearm, which is replaced in the lower half by a strong, flat tendon.

Nerve-supply.—The median nerve.

The direction of the muscle is downwards and outwards.

Action.—(1) To flex the wrist-joint, and (2) to assist in flexion of the elbow-joint.

The tendon of the muscle passes through a special compartment of the anterior annular ligament, where it traverses the groove on the palmar surface of the trapezium, and the radial vessels lie upon the outer side of the tendon in the lower half of the forearm.

3. **Palmaris Longus**—*Origin.*—(1) The front of the internal epicondyle by means of the common tendon; (2) the deep fascia covering the muscle; and (3) the intermuscular septa separating it from the flexor carpi radialis externally, flexor carpi ulnaris internally, and flexor sublimis digitorum deeply.

Insertion.—(1) The upper part of the central division of the palmar fascia, and (2) the front of the anterior annular ligament at its lower part.

Nerve-supply.—The median nerve.

Action.—(1) To render tense the central division of the palmar fascia; (2) to assist in flexing the wrist-joint; and (3) to assist feebly in flexing the elbow-joint.

The palmaris longus is the representative of an original superficial flexor of the fingers, the expanded portion of the tendon of which remains as the palmar fascia.

4. **Flexor Carpi Ulnaris.**—This muscle arises by two heads. One

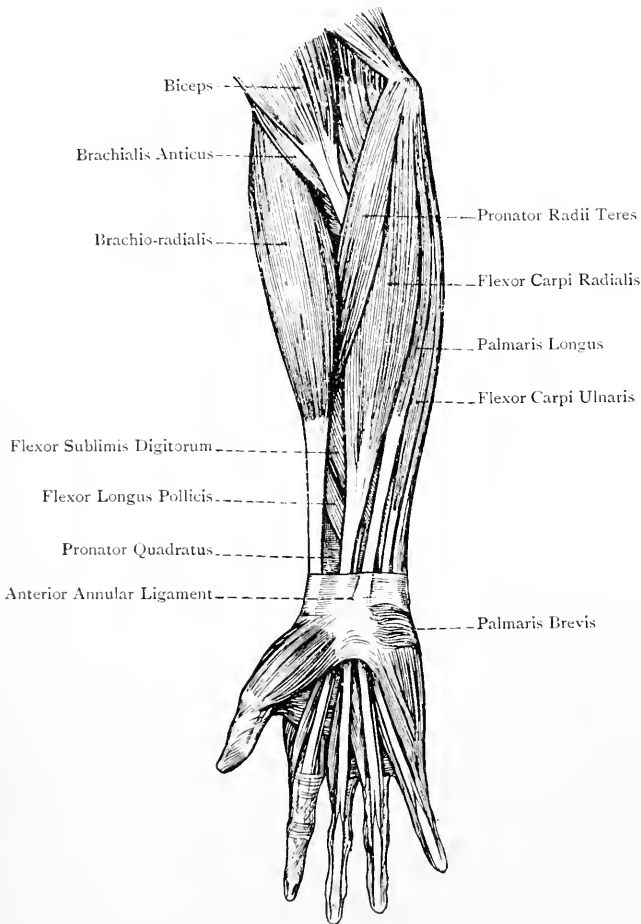


FIG. 190.—THE SUPERFICIAL MUSCLES OF THE FRONT OF THE FOREARM.

head *arises* from (1) the front of the internal epicondyle by means of the common tendon; (2) the deep fascia; and (3) the intermuscular septa between it and the palmaris longus and flexor sublimis digitorum. The other head *arises* from (1) the inner aspect of the olecranon process, and (2) the upper two-thirds of the posterior

border, of the ulna, by an aponeurosis common to it, the flexor profundus digitorum, and extensor carpi ulnaris.

Insertion.—The pisiform bone. From the tendon of insertion two prolongations are given off, known as the **psi-uncinate** and **psi-metacarpal ligaments**, the former being attached to the anterior border of the hook of the unciform bone, and the latter to the front of the base of the fifth metacarpal. The tendon also gives off laterally a band to the anterior annular ligament.

Nerve-supply.—The ulnar nerve, which is a branch of the inner cord of the brachial plexus, its fibres being derived from the eighth cervical and first thoracic.

The fibres are directed downwards and forwards, and terminate on the posterior aspect of the tendon which appears about the centre of the forearm.

Action.—(1) To flex and adduct the wrist-joint, and (2) to flex feebly the elbow-joint.

The ulnar nerve and posterior ulnar recurrent artery pass between the two heads of the muscle.

Second Layer.—**Flexor Sublimis Digitorum (flexor perforatus)**—*Origin.*—The *upper part* arises from (1) the internal epicondyle; (2) the intermuscular septum between it and the first layer; (3) the internal lateral ligament of the elbow-joint; and (4) the tubercle on the inner margin of the coronoid process of the ulna. The *lower part*, broad and thin, arises from the anterior oblique line of the radius.

Insertion.—By four tendons into the sides of the second phalanges of the four inner fingers, at their centre and on their anterior aspect.

The muscle in the lower part of the forearm is replaced by four tendons which pass beneath the anterior annular ligament in pairs. The tendons of the anterior pair are for the middle and ring fingers, whilst those of the posterior pair are for the index and little fingers. In this situation, as well as for a little above the wrist, and as low as about the centre of the palm, they are invested, along with the deep flexor tendons, by the great palmar bursa, to be afterwards described. In the palm the four tendons diverge, and each is accompanied by a tendon of the flexor profundus digitorum, which lies beneath it. At the commencements of the digits each pair of tendons enters the sheath on the palmar aspect of a finger, which binds them to the first and second phalanges. Towards the distal end of the first phalanx the flexor sublimis tendon splits into two parts to allow the flexor profundus tendon to pass through. The two divisions of the superficial tendon are folded round the deep tendon, and unite beneath it at the proximal end of the second phalanx. Beyond this point the superficial tendon is grooved to support the deep tendon, and then divides into its two parts of insertion. The sheath and its accessories will be afterwards described.

Nerve-supply.—The median nerve.

Action.—(1) To flex the second phalanges of the four inner fingers ;

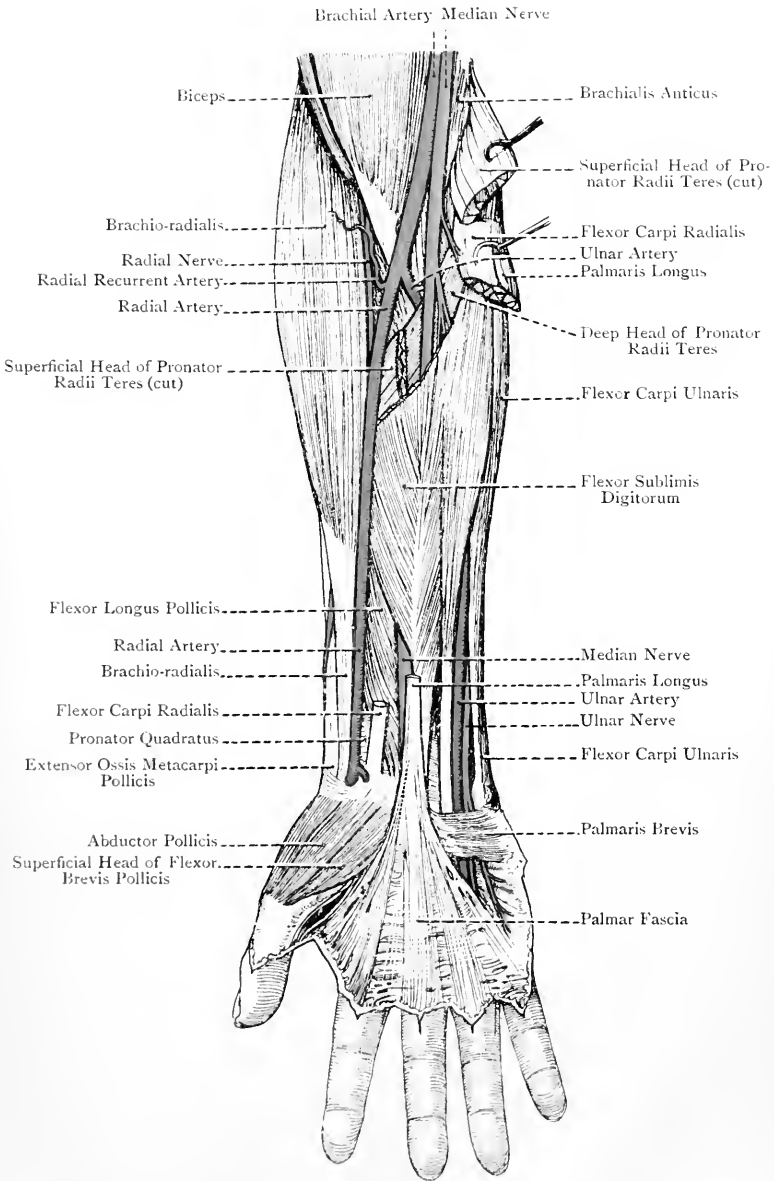


FIG. 191.—THE FRONT OF THE FOREARM, AND PALM OF THE HAND.

(2) to flex their metacarpo-phalangeal joints; (3) to flex the wrist-joint; and (4) to assist in flexion of the elbow-joint.

Radial Artery.—The radial artery is one of the terminal branches of the brachial, from which it arises in the anticubital space, opposite the upper part of the neck of the radius. It is smaller than the ulnar, which is the other terminal branch, and in point of direction the vessel is the continuation of the brachial. Its destination is the palm, to reach which it passes at first downwards and slightly outwards, as low as the styloid process of the radius. Here the vessel passes to the back of the wrist beneath the styloid process and upon the external lateral ligament, after which it sinks between the two heads of the abductor indicis muscle. In this way it reaches the palm, where it anastomoses with the profunda branch of the ulnar artery, and so forms the deep palmar arch. The vessel is divided into three parts. The first part lies in front of the forearm, the second on the back of the wrist, and the third in the palm.

First Part.—This part extends from the origin to the styloid process of the radius. Its direction is downwards and slightly outwards, and its course may be indicated by a line drawn from a point just below the bend of the elbow, midway between the epicondyles of the humerus, to a point about $\frac{1}{2}$ inch internal to the styloid process of the radius. In the upper third the vessel lies between the brachio-radialis externally and pronator radii teres internally, being overlapped by the fleshy belly of the former. Thereafter it is placed between the brachio-radialis externally and flexor carpi radialis internally, and in the lower half of the forearm, where these muscles are replaced by their tendons, the vessel is quite superficial.

Relations—Superficial.—The integument, and margin of the brachio-radialis in the upper third, or more. Branches of the musculo-cutaneous nerve are distributed over the line of the vessel. *Deep.*—From above downwards it lies upon (1) the tendon of insertion of the biceps; (2) the supinator radii brevis; (3) the tendon of insertion of the pronator radii teres; (4) the radial origin of the flexor sublimis digitorum; (5) the flexor longus pollicis; (6) the pronator quadratus; and (7) the lower end of the radius. *External.*—The brachio-radialis throughout the whole of the forearm, and the external vena comes. The radial nerve in the upper part lies a little to the outer side of the vessel; at the centre it is closer to it; and in the lower part the nerve leaves the artery by turning backwards beneath the tendon of the brachio-radialis. *Internal.*—The internal vena comes, pronator radii teres in the upper third, and thereafter the flexor carpi radialis.

Branches of the First Part.—The first part gives off the following branches, namely, radial recurrent, muscular, anterior radial carpal, and superficial volar.

The **radial recurrent artery**, usually of large size, arises from the outer side of the radial close to its commencement, and passes outwards beneath the brachio-radialis, where it rests on the supinator

radii brevis. Here it divides into branches which come into relation with the musculo-spiral nerve and its terminal divisions. Most of these are distributed to the muscles arising from the external epicondyle, and they anastomose with the posterior interosseous recurrent. One branch, however, ascends with the musculo-spiral nerve between the brachio-radialis and brachialis anticus, and anastomoses with the anterior terminal branch of the superior profunda of the brachial. The radial recurrent also gives articular twigs to the elbow-joint.

The **muscular branches** arise at frequent intervals along the forearm.

The **anterior radial carpal artery**, of small size, arises from the inner side of the radial at the level of the lower border of the pronator quadratus, along which it passes inwards, lying deeply beneath the flexor tendons. At the middle line it anastomoses with the anterior ulnar carpal artery to form the anterior carpal arch. This arch is reinforced from above by the anterior branch of the anterior interosseous artery, and from below by the recurrent branches of the deep palmar arch. In this manner the anterior carpal arch is converted into a rete, the branches of which are distributed to the wrist-joint, and the carpal articulations and bones.

The **superficial volar artery** arises either below the preceding, or sometimes above it. It passes downwards over, or through, the thenar muscles, in which, if of small size, it terminates. When large, it reaches the palm, and anastomoses with the ulnar artery to complete the superficial palmar arch.

Varieties of the First Part.—(1) The artery may arise high up from the brachial, or axillary. (2) When of high origin, it may descend superficial to the semilunar fascia of the biceps and deep fascia of the forearm. (3) The artery may turn backwards over the brachio-radialis just below the centre of the forearm. (4) It may be joined by a vas aberrans from the brachial, or axillary. (5) It may terminate at the lower part of the forearm, its distribution being taken up by the ulnar, median, or anterior interosseous.

The **second and third parts** of the radial artery will be afterwards described.

Radial Venæ Comites.—The radial artery is accompanied by two venæ comites, which are placed one on either side of the vessel, and they communicate at frequent intervals by transverse branches lying upon it. They terminate above by uniting to form the external brachial vena comes.

Radial Nerve.—The radial nerve is one of the terminal branches of the musculo-spiral, its fibres being derived from the sixth cervical, and sometimes from the fifth and seventh. It passes straight downwards under cover of the brachio-radialis, lying at first a little to the outer side of the radial artery, then getting closer to it at the centre of the forearm, and finally leaving the vessel in the lower part by turning backwards beneath the tendon of the brachio-radialis on its way to its cutaneous distribution, which has been already described. It is a *sensory* nerve, and gives off no branches until it reaches the back of the limb.

Posterior Interosseous Nerve.—This is the other and larger terminal branch of the musculo-spiral, its fibres being derived from the sixth, seventh, and sometimes the eighth, cervical. After a short downward course under cover of the brachio-radialis, it winds round the outer side of the radius, passing through the supinator radii brevis. Having reached the back of the limb near the lower border of that muscle, it descends, in company with the posterior interosseous artery, between the superficial and deep groups of muscles. At the upper border of the extensor longus pollicis it leaves the artery and passes beneath that muscle, where it meets the posterior branch of the anterior interosseous artery on the back of the interosseous membrane. Thereafter it passes through the groove on the back of the radius for the extensor communis digitorum and extensor indicis, lying beneath the tendons and the posterior annular ligament. It terminates on the back of the wrist in a gangliform enlargement, from which branches are given off to the wrist-joint and carpal articulations.

Branches.—The branches are muscular and articular.

Muscular Branches.—Before piercing the supinator radii brevis the nerve gives branches to that muscle and to the extensor carpi radialis brevior. After reaching the back of the forearm, it supplies the extensor communis digitorum, extensor minimi digiti, extensor carpi ulnaris, the three extensors of the thumb, and the extensor indicis.

Articular Branches.—These arise from the terminal gangliform enlargement, and are distributed to the wrist-joint and carpal articulations.

Ulnar Artery.—The ulnar artery is the larger of the two terminal branches of the brachial, and it arises in the anticubital space opposite the upper part of the neck of the radius. Its destination is the palm, which it reaches by passing over the anterior annular ligament, and there it forms the superficial palmar arch. It is at first directed downwards and inwards beneath both heads of the pronator radii teres, flexor carpi radialis, palmaris longus, and flexor sublimis digitorum, and it here describes a slight curve, the convexity of which is directed inwards. Having gained the front of the ulna it meets the ulnar nerve a little above the centre of the forearm, and it then descends on the outer side of the nerve, both structures resting on the flexor profundus digitorum, and being overlapped by the flexor carpi ulnaris. A little above the wrist the artery lies superficially on the outer side of the tendon of that muscle. It then crosses over the anterior annular ligament, lying close to the outer side of the pisiform bone, with the intervention of the ulnar nerve, and shortly thereafter it turns outwards in the palm towards the thenar muscles. The vessel is divided into three parts—first, second, and third.

First Part.—This part extends from the origin to the upper border of the anterior annular ligament. On account of the curve of the vessel at first no definite line can be given to indicate its

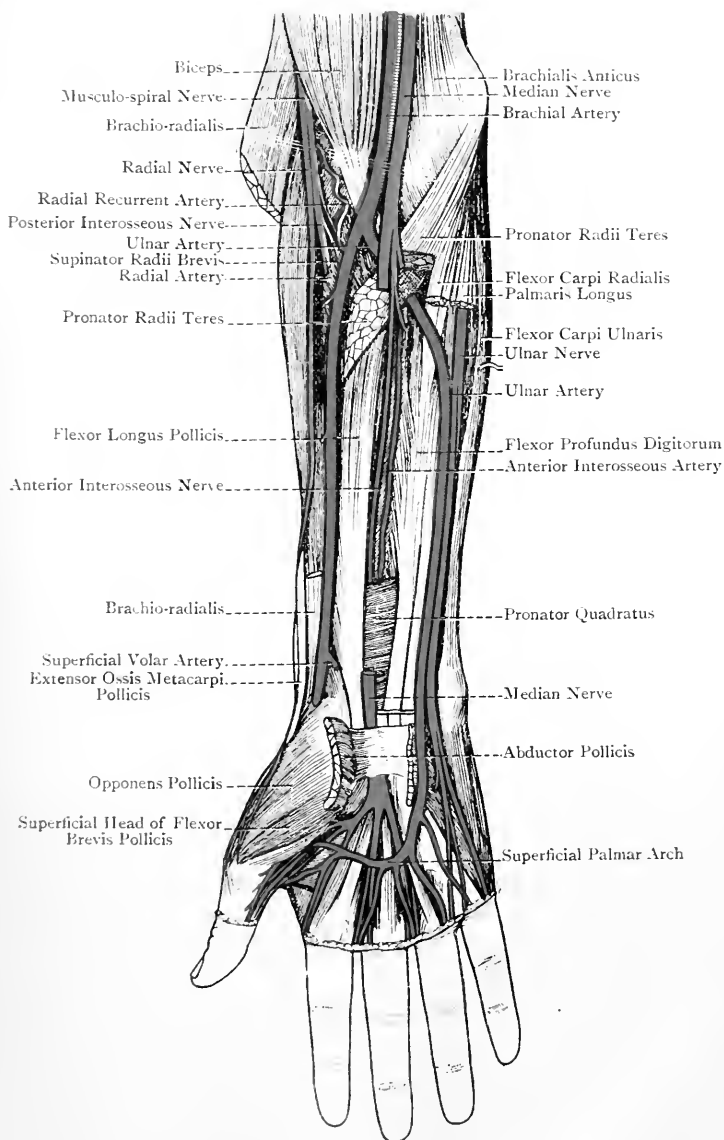


FIG. 192.—DEEP DISSECTION OF FRONT OF RIGHT FOREARM, AND SUPERFICIAL DISSECTION OF PALM.

entire course, but in the lower half of the forearm the border of the flexor carpi ulnaris is the guide.

Relations—Superficial.—In the upper half of the forearm the artery is deeply placed, being covered by both heads of the pronator radii teres, flexor carpi radialis, palmaris longus, and flexor sublimis digitorum. In the lower half it is overlapped by the tendon of the flexor carpi ulnaris, except for a little above the wrist, where it lies superficially on the outer side of that tendon. The palmar cutaneous branch of the ulnar nerve descends over the artery in the lower half. *Deep.*—Brachialis anticus for about 1 inch, and thereafter the flexor profundus digitorum. *External.*—The external vena comes, and, in the lower half, the flexor sublimis digitorum. *Internal.*—The internal vena comes, ulnar nerve for rather more than the lower half, and the tendon of the flexor carpi ulnaris for a little above the wrist. The nerves related to the first part of the artery are the median, ulnar, and palmar cutaneous branch of the ulnar. The median nerve lies for a little at first on the inner side of the vessel, but, at the point where the vessel passes beneath the deep head of the pronator radii teres, the nerve crosses it, being separated from it by the deep head of that muscle, and so gains its outer side. The ulnar nerve, having come from behind the internal epicondyle, is widely separated from the artery for rather more than the upper third of the forearm. A little above the centre the nerve and artery meet, and then descend in close contact, the nerve being on the inner side, with the intervention of the internal vena comes. The palmar cutaneous branch of the ulnar nerve, as stated, descends over the lower half of the vessel.

Branches of the First Part.—The first part gives off the following branches, namely, anterior ulnar recurrent, posterior ulnar recurrent, common interosseous (giving off anterior and posterior interosseous), muscular, posterior ulnar carpal, and anterior ulnar carpal.

The **anterior ulnar recurrent artery**, of small size, passes upwards and inwards on the brachialis anticus and beneath the superficial head of the pronator radii teres, to supply these muscles and anastomose with the anterior branch of the anastomotica magna of the brachial.

The **posterior ulnar recurrent artery**, of large size, arises just below the preceding, or sometimes in common with it. It passes inwards beneath the flexor sublimis digitorum, and then ascends with the ulnar nerve between the two heads of the flexor carpi ulnaris to the interval between the internal epicondyle and olecranon process. It supplies the adjacent muscles, ulnar nerve, and elbow-joint, and it anastomoses with the inferior profunda and posterior branch of the anastomotica magna. It also gives twigs over the back of the olecranon, which anastomose with the posterior interosseous recurrent, thus forming the olecranon rete.

The **common interosseous artery** is a short, thick trunk, which arises, below the preceding, about 1 inch from the commencement

of the ulnar. It is directed backwards to the upper border of the interosseous membrane, where it divides into the anterior and posterior interosseous arteries.

(1) The *anterior interosseous artery* descends on the front of the interosseous membrane, having a vena comes on either side of it, and the anterior interosseous nerve on its outer side. It lies between the flexor longus pollicis externally and the flexor profundus digitorum internally, both of which overlap it, and at the upper border of the pronator quadratus it divides into two terminal branches, anterior and posterior.

Branches.—These are as follows: the *median artery* (comes nervi mediani) is a long, slender branch which arises from the commencement of the vessel. It at once gets in contact with the median nerve, which it accompanies beneath the flexor sublimis digitorum, supplying the nerve and that muscle. If of large size, it passes beneath, or over, the anterior annular ligament into the palm, where it may join the superficial palmar arch, or if that should be abnormal, it furnishes certain digital arteries. Muscular branches are given off to the deep layer of muscles, and to the extensor muscles of the thumb on the back of the interosseous membrane. The branches to the latter muscles pierce the membrane. The nutrient or medullary arteries enter the radius and ulna. The anterior terminal branch descends beneath the pronator quadratus and joins the anterior carpal arch. The posterior terminal branch, which, passing backwards through the interosseous membrane, and having anastomosed with the posterior interosseous, descends beneath the extensor tendons and the posterior annular ligament to the back of the wrist, where it joins the posterior carpal arch.

(2) The *posterior interosseous artery* passes backwards between the upper border of the interosseous membrane and the oblique ligament. At the back of the forearm it appears between the supinator radii brevis and extensor ossis metacarpi pollicis, where it is joined by the posterior interosseous nerve. The artery, with the nerve, then descends between the superficial and deep group of muscles until it reaches the upper border of the extensor longus pollicis. Here the artery leaves the nerve, and passes over that muscle and the extensor indicis. At the lower border of the latter muscle it anastomoses with the posterior terminal branch of the anterior interosseous, and then ends in articular branches to the wrist-joint, though it may pass to join the posterior carpal arch.

Branches.—These are as follows: the posterior interosseous recurrent arises as soon as the vessel reaches the back of the forearm. It passes upwards beneath the anconeus to the back of the external epicondyle, where it anastomoses with the posterior branch of the superior profunda of the brachial. It also gives twigs over the back of the olecranon process which anastomose with branches of the posterior ulnar recurrent, and so form the olecranon rete.

In addition, it anastomoses with the muscular branches of the radial recurrent. Muscular branches supply the adjacent muscles. Articular branches are given off to the wrist-joint.

The **muscular branches** of the first part of the ulnar artery arise at frequent intervals along the forearm.

The **posterior ulnar carpal artery** arises a little above the pisiform bone, and passes backwards beneath the tendon of the flexor carpi ulnaris to the back of the wrist. Here it turns outwards beneath

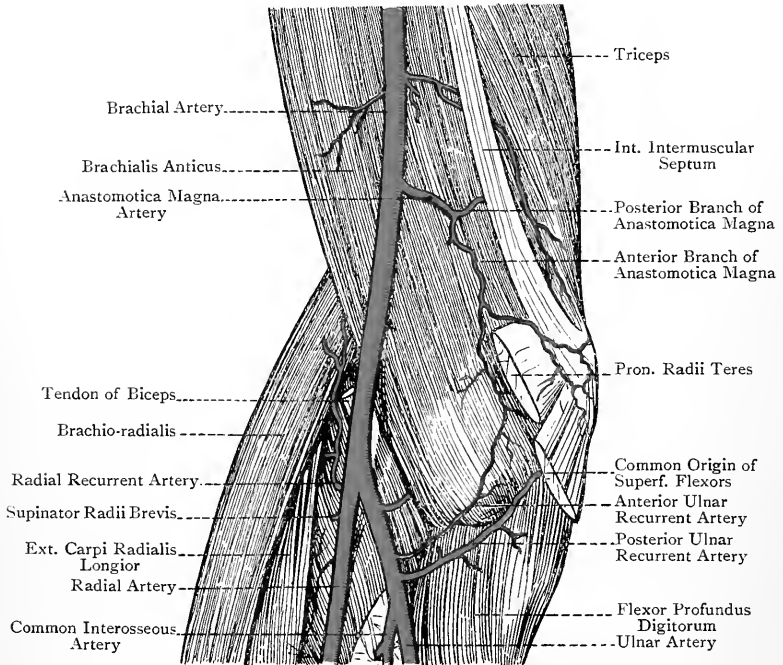


FIG. 193.—DEEP DISSECTION OF THE FRONT OF THE RIGHT ELBOW
(AFTER TIEDEMANN).

the extensor tendons, and anastomoses with the posterior radial carpal and posterior branch of the anterior interosseous to form the posterior carpal arch. It may give off the dorsal digital artery of the inner side of the little finger.

The **anterior ulnar carpal artery** arises opposite the lower border of the pronator quadratus. It passes outwards along the lower border of that muscle beneath the flexor profundus digitorum, and anastomoses with the anterior radial carpal, the anterior branch of the anterior interosseous, and the recurrent branches of the deep palmar arch, to form the anterior carpal arch or rete.

Anastomoses round the Elbow-Joint.—The anastomoses of

arteries round the elbow-joint are very free. In front of the internal epicondyle of the humerus the anterior branch of the anastomotica magna of the brachial anastomoses with the anterior ulnar recurrent. Behind the internal epicondyle the inferior profunda and the posterior branch of the anastomotica magna (both of the brachial) anastomose with the posterior ulnar recurrent. In front of the external epicondyle the anterior terminal branch of the superior profunda of the brachial anastomoses with the radial recurrent. Behind the external epicondyle the

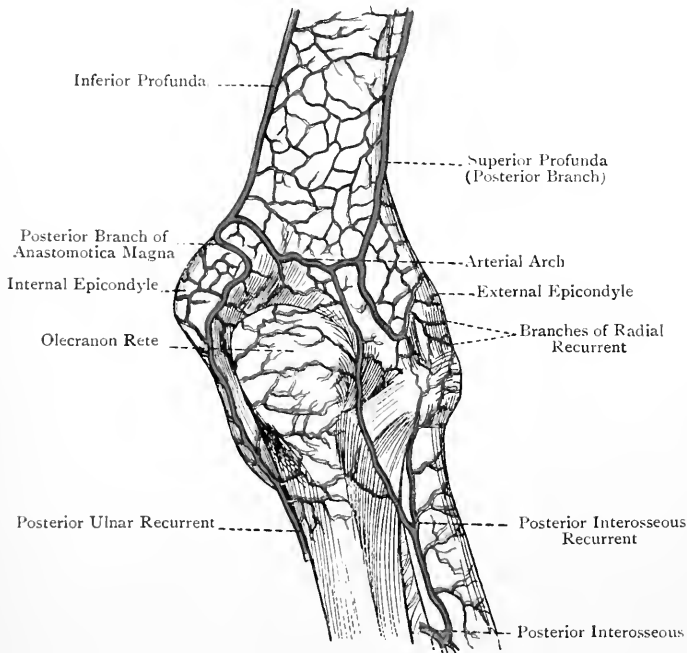


FIG. 194.—THE ANASTOMOSES ROUND THE RIGHT ELBOW-JOINT (POSTERIOR VIEW) (AFTER TIEDEMANN).

posterior terminal branch of the superior profunda anastomoses with the posterior interosseous recurrent. Upon the back of the shaft of the humerus, immediately above the olecranon fossa, a transverse anastomosis takes place between the posterior branches of the superior profunda and anastomotica magna, both of the brachial. Upon the back of the olecranon process is the olecranon arterial rete, which is formed by branches of the posterior interosseous recurrent and posterior ulnar recurrent.

Varieties.—(1) The ulnar artery may arise high up from the brachial, or axillary. In cases of high origin the vessel usually descends over the muscles

arising from the internal epicondyle of the humerus, and beneath the deep fascia, though it may be superficial to it. In such cases the common interosseous is a branch of the main trunk, and it furnishes the anterior and posterior ulnar recurrent arteries. (2) The artery, though normal in origin, may pass superficial to the muscles arising from the internal epicondyle.

Second Part of the Ulnar Artery.—The second part lies upon the anterior annular ligament, and extends from its upper to its lower border. It has a vena comes on either side of it, and the ulnar nerve on its inner side. It lies on the outer side of the pisiform bone, by which it is overhung, and on the inner side of the hook of the unciform bone, where it is under cover of the pisi-uncinate ligament.

Relations.—*Superficial.*—The integument, the expansion from the flexor carpi ulnaris tendon to the front of the anterior annular ligament, and the pisi-uncinate ligament. *Deep.*—The anterior annular ligament. *External.*—The external vena comes, and hook of the unciform bone. *Internal.*—The internal vena comes, ulnar nerve, and pisiform bone.

The branches of this part are unimportant.

The third part of the ulnar artery will be described in connection with the palm.

Ulnar Venæ Comites.—The ulnar artery in the first and second parts of its course is accompanied by two venæ comites, one being placed on either side of the vessel, and the two communicate at frequent intervals by transverse branches which lie upon it. They commence in the venæ comites of the inner parts of the superficial and deep palmar arches, and they terminate above by uniting to form the internal brachial vena comes.

Ulnar Nerve.—The ulnar nerve enters the forearm by passing through the interval between the internal epicondyle and olecranon process, where it lies between the two heads of the flexor carpi ulnaris. It then descends under cover of that muscle, lying upon the flexor profundus digitorum. A little above the centre of the forearm it meets with the ulnar artery, upon the inner side of which it subsequently lies. On approaching the wrist it escapes from beneath the flexor carpi ulnaris, and lies, with the artery, close to the outer side of its tendon. It then passes over the anterior annular ligament close to the outer side of the pisiform bone, by which it is overhung, and subsequently on the inner side of the hook of the unciform bone. Thereafter it enters the palm, where it divides into its two terminal branches, superficial and deep.

Branches.—These are articular, muscular, and cutaneous.

The **articular branches**, two or three in number, are given off to the elbow-joint as the nerve passes between the internal epicondyle and olecranon process.

The **muscular branches** arise in the upper part of the forearm, and are distributed to the flexor carpi ulnaris and the inner portion of the flexor profundus digitorum.

The **cutaneous branches** are three in number, and have been already described.

The ulnar nerve in the palm will be afterwards described.

Median Nerve.—The median nerve lies at first in the anticubital space, where it is placed on the inner side of the brachial and ulnar arteries. On leaving the space it passes between the two heads of the pronator radii teres, where it crosses the ulnar artery, the deep head of that muscle intervening between the two. It then passes beneath the radial origin of the flexor sublimis digitorum, and descends under cover of that muscle in the middle line, until it approaches the wrist. Here it escapes from beneath the muscle, and lies between its tendons and that of the flexor carpi radialis, where it parts with its palmar cutaneous branch. Thereafter it passes under the anterior annular ligament into the palm, where it will be afterwards described. The nerve is accompanied by the median artery, which is a branch of the anterior interosseous near its origin.

Branches.—The branches of the nerve in the forearm are articular, muscular, and cutaneous.

The **articular branches**, one or two in number, enter the elbow-joint on its anterior aspect.

The **muscular branches** supply all the muscles on the front of the forearm, except the flexor carpi ulnaris and the inner portion of the flexor profundus digitorum. The branch, or branches, to the pronator radii teres arise from the nerve before it passes between the two heads of that muscle. The branches for the flexor carpi radialis, palmaris longus, and flexor sublimis digitorum arise lower down. The flexor longus pollicis, outer portion of the flexor profundus digitorum, and pronator quadratus are supplied by the *anterior interosseous branch*. This long branch arises from the median just below the neck of the radius, and it descends on the front of the interosseous membrane, lying on the outer side of the anterior interosseous artery, both being overlapped by the contiguous borders of the flexor profundus digitorum and flexor longus pollicis. On reaching the upper border of the pronator quadratus the nerve passes beneath that muscle, and ends in two branches, one of which enters the deep surface of the muscle, whilst the other passes to supply the wrist-joint. The branch to the outer portion of the flexor profundus digitorum arises high up, and it communicates in the muscle with the branch of the ulnar nerve to its inner portion. The anterior interosseous nerve in its course furnishes an interosseous branch, which is distributed to the interosseous membrane, and gives off medullary filaments which accompany the medullary arteries of the radius and ulna.

Third Layer of Muscles.—The muscles comprising the third or deep layer are three in number, namely, the flexor profundus digitorum, flexor longus pollicis, and pronator quadratus.

1. Flexor Profundus Digitorum (flexor perforans)—*Origin.*—
(1) The upper three-fourths of the anterior surface of the ulna;

(2) the inner half of the front of the interosseous membrane; (3) the upper two-thirds of the inner surface of the ulna; and (4) the posterior border of the bone for a similar extent, by an aponeurosis common to it, the flexor carpi ulnaris, and extensor carpi ulnaris.

Insertion.—The front of the bases of the distal phalanges of the four inner fingers.

The tendinous part of the muscle makes its appearance about the centre of the forearm, and the index-finger tendon is usually separate from the rest of the tendinous mass over the greater part of its extent. The other three tendons become separate beneath the anterior annular ligament, so that in the palm there are four diverging tendons, connected with which are the lumbricales. Each deep flexor tendon accompanies a superficial flexor tendon, beneath which it lies, and both enter the sheath on the palmar aspect of a finger. Opposite the distal end of the first phalanx the deep tendon passes through the cleft in the superficial tendon, and so reaches its more distant point of insertion.

Nerve-supply.—(1) The anterior interosseous branch of the median supplies that portion of the muscle which acts upon the index finger, and in part the portion acting upon the middle and ring fingers; and (2) the ulnar nerve supplies that portion which acts upon the little finger, and in part the portion acting upon the ring and middle fingers. Sometimes the anterior interosseous nerve supplies the whole of the portion acting upon the middle finger.

Action.—(1) To flex the distal phalanges of the four inner fingers; (2) to assist in flexing the second phalanx and metacarpo-phalangeal joint; and (3) to assist in flexing the wrist-joint.

2. **Flexor Longus Pollicis**—*Origin.*—(1) The anterior surface of the radius, from the anterior oblique line above to the upper border of the pronator quadratus below; (2) the outer half of the front of the interosseous membrane; and (3) as a rule by a tendinous slip from the inner margin of the coronoid process of the ulna, or from the internal epicondyle of the humerus.

Insertion.—The front of the base of the distal phalanx of the thumb.

The tendon appears on the front of the muscle about the centre of the forearm, and receives fleshy fibres until it is near the wrist.

Nerve-supply.—The anterior interosseous nerve.

Action.—(1) To flex the distal phalanx of the thumb; (2) to assist in flexing its metacarpo-phalangeal joint; and (3) to act as an auxiliary flexor of the wrist-joint.

3. **Pronator Quadratus**—*Origin.*—The front of the ulna over its lower fourth.

Insertion.—The front of the radius for about 2 inches at its lower end, and the anterior part of the inner surface.

Nerve-supply.—The anterior interosseous nerve.

The fibres are disposed, for the most part, transversely, and the muscle is covered by a firm aponeurosis over about its inner third.

Action.—To pronate the radius upon the ulna.

FRONT OF THE WRIST AND PALM.

Landmarks.—Below, and internal to, the styloid process of the radius the tuberosity of the scaphoid can be felt, and below this the tuberosity of the trapezium. On the inner aspect of the front of the wrist the pisiform bone can easily be felt, and below, and external to, it, the hook of the unciform bone. The interval between these two projections indicates the position of the ulnar vessels and nerve. The centre of the palm presents a triangular hollow, the apex of which is directed upwards and inwards towards the wrist, and the base downwards towards the roots of the fingers, in which latter situation there is a transverse prominence, broken up by grooves leading to the four inner digits. The palmar hollow is bounded above and externally by the thenar eminence, and internally by the hypothenar eminence.

The integument of the palm presents four furrows, two being disposed transversely, and two more or less longitudinally. The lower transverse furrow is about 1 inch above the roots of the inner three digits, and is most conspicuous when the fingers are flexed. It commences at the inner border of the palm, and, passing outwards in a slightly arched manner, it terminates at the cleft between the index and middle fingers. It is produced by the flexion of the metacarpo-phalangeal joints of the inner three fingers. These joints are situated about midway between this line and the roots of the fingers when these are extended. The upper transverse furrow commences at the outer border of the palm about $\frac{3}{4}$ inch above the root of the index finger, and it passes inwards and slightly upwards to the inner border of the palm, lying about $\frac{1}{2}$ inch above the lower furrow. The outer part of this furrow is due to flexion of the metacarpo-phalangeal joint of the index finger, and the remainder to complete flexion of the metacarpo-phalangeal joints of the inner three fingers. One of the longitudinal furrows commences about the centre of the wrist, and curves downwards and outwards to meet the upper transverse furrow. It is produced by flexion of the joint between the trapezium and metacarpal bone of the thumb during the movement of opposition. The other longitudinal furrow runs downwards from the wrist internal to the preceding, and meets the lower transverse furrow. It is due to the movement of opposition of the little finger. The front of each of the four inner fingers presents three transverse furrows. The distal pair correspond with the interphalangeal joints, but the proximal furrow is about $\frac{1}{2}$ inch beyond the metacarpo-phalangeal joint. The front of the thumb presents only two transverse furrows.

The position of the superficial palmar arch corresponds with a line drawn across the palm from the web between the thumb and index finger (the thumb being abducted) to the outer side of the pisiform bone. This line is slightly arched, with the convexity towards the fingers. From the convexity of the arch the three compound

digital arteries pass forwards in line with the webs of the fingers, and they lie over the interosseous spaces. An incision, therefore, may be made with safety in the palm in the direction of the middle line of a finger, but it should not be carried nearer the wrist than the line indicating the position of the superficial palmar arch. The deep palmar arch lies about $\frac{1}{2}$ inch nearer the wrist than the superficial. The digital arteries are placed on the lateral aspects of the fingers.

On the back of the hand the radial tubercle may be felt about the centre of the lower end of the bone, and the heads of the metacarpal bones, which form the knuckles, are conspicuous when the fingers are flexed. Below and behind the styloid process of the radius there is a well-marked triangular hollow, the base of which is directed upwards, in which, by sinking the finger deeply, pulsation may be felt in the second part of the radial artery in the living subject. At the upper part the tendons of the radial extensors of the wrist may also be felt. The hollow is bounded *internally* by a prominence formed by the tendon of the extensor longus pollicis, *externally* by a prominence due to the tendons of the extensor ossis metacarpi pollicis and extensor brevis pollicis, and *above* by the lower end of the radius. The scaphoid and trapezium lie in its floor, and the radial vein and branches of the radial nerve are in its roof. This hollow is known as the *anatomical snuff-box* (Cloquet).

The middle line of the hand, from and towards which abduction and adduction take place, represents a longitudinal line drawn through the centre of the middle finger.

Superficial Fascia.—The superficial fascia, especially over the hollow of the palm, is lobulated, the lobules being separated by fibrous processes which pass between the skin and the central division of the palmar fascia.

Palmaris Brevis.—This is a thin, flat, subcutaneous muscle, of quadrilateral outline, and usually arranged in two or three bundles, separated by fat.

Origin.—(1) The front of the anterior annular ligament at its lower and inner part, and (2) the inner margin of the central division of the palmar fascia at its upper part.

Insertion.—The integument of the inner border of the hand at its inner part.

Nerve-supply.—The superficial division of the ulnar nerve.

Action.—To draw the integument into which it is inserted towards the middle line of the hand, thus giving rise to a wrinkled depression on the inner border at its upper part.

The muscle lies in the superficial fascia over the upper part of the hypothenar eminence, and covers the ulnar vessels and nerve, which it guards against pressure.

Superficial Transverse Ligament.—This ligament is composed of a bundle of transverse fibres, contained within the folds of skin which form the clefts of the four inner fingers.

Palmar Fascia.—The palmar fascia is arranged in three divisions—central and two lateral.

The **central division** is triangular, the apex being towards the wrist, where it is continuous with the tendon of the palmaris longus, and attached to the front of the anterior annular ligament close to its lower border. The superficial fibres of this division are longitudinal, and the deep fibres transverse, the latter being most conspicuous between the diverging digital processes. The base is directed towards the roots of the four inner fingers, on approaching which the fascia divides into *four* digital processes. These diverge and pass to join the sheaths of the flexor tendons on the fronts of the fingers. Each process gives fibres to the superficial transverse ligament and skin of the clefts of the fingers. Each also gives off a deep expansion at either side, which joins the transverse metacarpal ligament at either lateral margin of the head of a metacarpal bone. In this way short canals are formed for the superficial and deep flexor tendons on their way to the fronts of the fingers. Between the diverging digital processes three intervals are left, in which the digital arteries and nerves and lumbricales muscles make their appearance; and, as stated, the transverse fibres are here conspicuous, where they lie superficial to these structures. The central division is bound to the skin by fibrous processes which enclose spaces containing the lobules of the superficial fascia. Its deep surface is related to the great palmar bursa. At either side it gives off a deep septum which joins the interosseous fascia. The outer septum is placed between the thenar muscles and the centre of the palm, where the flexor tendons and digital vessels and nerves lie, and it is pierced by the digital nerves for the sides of the thumb and index finger. The inner septum is placed between the hypothenar muscles and the centre of the palm, and it is pierced by the digital branches of the ulnar nerve, and by a portion of the superficial palmar arch. In this way a large central fascial canal is formed, which contains the superficial palmar arch and its digital branches, the digital nerves, the superficial and deep flexor tendons, and the lumbricales. On either side of this central canal are the thenar and hypothenar canals, containing the short muscles of the thumb and of the little finger. The central division of the palmar fascia serves as an important protection to the superficial palmar arch and the digital arteries and nerves. From its great strength and capability of resistance it has an important bearing on the course taken by pus in a palmar abscess.

The central division represents the expanded portion of the tendon of an original superficial flexor muscle of the fingers.

The **external or thenar division** is thin, and covers the thenar muscles. Superiorly it is connected with the tendon of the palmaris longus and anterior annular ligament, and it receives an accession of fibres from the tendon of the extensor ossis metacarpi pollicis. Inferiorly it blends with the sheath of the tendon of the flexor longus pollicis on the front of the thumb.

The **internal** or **hypothenar division**, also thin, is connected above with the anterior annular ligament, and terminates below over the muscles inserted into the inner side of the base of the first phalanx of the little finger.

Third Part of the Ulnar Artery.—The third part of the vessel forms the superficial palmar arch. It descends for a little under cover of the palmaris brevis, and then turns outwards across the palm in an arched manner. About the middle of the thenar eminence it is joined by the superficial volar of the radial, or by a branch of the arteria radialis indicis, or, failing these, by a branch of the arteria princeps pollicis, and so the arch is completed externally. Its convexity is directed towards the fingers, and its course may be indicated by a line drawn across the palm from the web between the thumb and index finger (the thumb being abducted) to the outer side of the pisiform bone, the line being slightly arched, with the convexity towards the fingers.

Relations—*Superficial.*—The integument, the palmaris brevis for a short distance internally, and the central division of the palmar fascia. *Deep.*—From within outwards it rests upon the opponens minimi digiti, the digital branches of the ulnar nerve, the flexor tendons, and the digital branches of the median nerve. The arch lies within the great palmar bursa.

Branches.—The branches of the arch are cutaneous to the integument of the palm, muscular to the adjacent superficial muscles, the profunda branch, and the digital branches.

The **profunda artery** is given off from the commencement of the arch, opposite the lower border of the anterior annular ligament. It at once passes deeply, in company with the deep division of the ulnar nerve, between the abductor and flexor brevis minimi digiti, then through the opponens minimi digiti, and it terminates by anastomosing with the third part of the radial artery, thereby completing the deep palmar arch. In its short course it gives branches to the hypothenar muscles.

The **digital arteries** arise from the convexity of the arch, and are four in number. They are destined for the sides of the inner three and a half fingers, and are called first, second, third, and fourth, from within outwards. The first is a single artery, but the other three are compound, each ultimately dividing into two. The **first** digital artery, of small size, passes downwards and inwards over the hypothenar muscles, to which it gives twigs, and then it passes along the inner side of the little finger.

The **second, third, and fourth** digital arteries, which are compound, pass downwards over the fourth, third, and second interosseous spaces to near the clefts between the little and ring, ring and middle, and middle and index fingers, where each divides into two collateral digital arteries, which pass along the contiguous sides of these fingers. These four digital arteries account for the blood-supply of the sides of the inner three and a half fingers. The outer side of the index finger and both sides of the thumb are supplied by the arteria

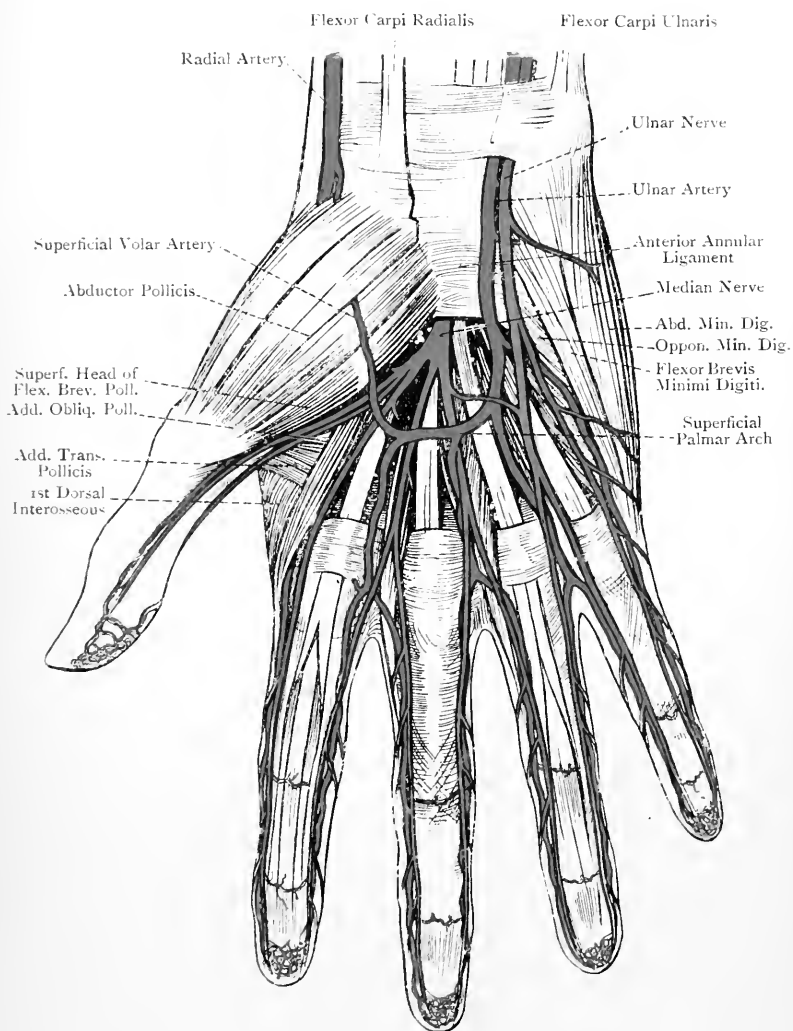


FIG. 195.—THE PALMAR ASPECT OF THE HAND.
(The Palmar Fascia has been removed.)

radialis indicis and arteria princeps pollicis of the radial. As the digital arteries pass towards the fingers they lie between the flexor tendons, and superficial to the digital nerves and lumbricales muscles. Along the sides of the fingers, however, the digital nerves are superficial to the arteries. Just before the outer three digital arteries divide into their collateral branches each is joined by a palmar interosseous artery from the deep palmar arch, and, it may be, by the inferior perforating branches of the dorsal interosseous arteries. The innermost digital artery receives its communicating branch from the innermost palmar interosseous about the centre of the hand. As the arteries pass along the sides of the fingers they anastomose with each other across the front of the phalanges to form arches, which are placed on the proximal side of the interphalangeal joints. Each also supplies the flexor tendons with their sheaths, and gives off a few dorsal branches. In front of each terminal phalanx the arteries of each finger unite to form an arch, from which many twigs are given off to supply the pulp of the finger and matrix of the nail.

The varieties of the superficial palmar arch will be afterwards described.

Veins.—The superficial palmar arch is accompanied by two venæ comites, and so are the digital arteries. The venæ comites of the digital arteries unite at the clefts of the fingers to form single vessels, and these end in the venæ comites of the superficial palmar arch. The venæ comites of the inner part of the arch unite, and so do those of the inner part of the deep palmar arch, and in this way the venæ comites of the ulnar artery are formed. Those from the outer side of the superficial arch go with the superficial volar artery, and, with those from the outer side of the deep arch which accompany the second part of the radial artery, form the radial venæ comites.

Median Nerve in the Hand.—The median nerve enters the palm by passing *beneath* the anterior annular ligament, where it lies within the great palmar bursa along with the superficial and deep flexor tendons, giving off articular twigs to the wrist-joint. Close to the lower border of the ligament it presents an enlargement, and breaks up into two divisions—external and internal. The **external division** gives off a muscular branch and three single digital nerves. The **muscular branch** passes outwards, and divides to supply the abductor pollicis, opponens pollicis, and superficial head of the flexor brevis pollicis. The **three single digital nerves** are distributed to the outer and inner sides of the thumb and the outer side of the index finger, and the latter nerve gives a branch to the first, or most external, lumbricalis. The **internal division** breaks up into **two compound digital nerves**. The **outer** of these passes to near the cleft between the index and middle fingers, where it divides into two collateral digital nerves for the supply of the contiguous sides of these fingers. In its course it gives a branch to the second lumbricalis. The **inner** passes to near the cleft

between the middle and ring fingers, where it also divides into two collateral digital nerves, which supply their contiguous sides. In its course it communicates with the outer digital branch of the ulnar nerve. In the palm the digital nerves lie beneath the superficial palmar arch and its digital branches, but along the sides of the fingers the nerves are superficial to the arteries. Occasionally a digital artery may pass through a digital nerve. On the sides of the fingers the nerves, which present small swellings, called Pacinian bodies, give branches to the integument of the palmar aspects of the fingers, and the metacarpo-phalangeal and inter-phalangeal joints. At the extremities of the fingers each nerve

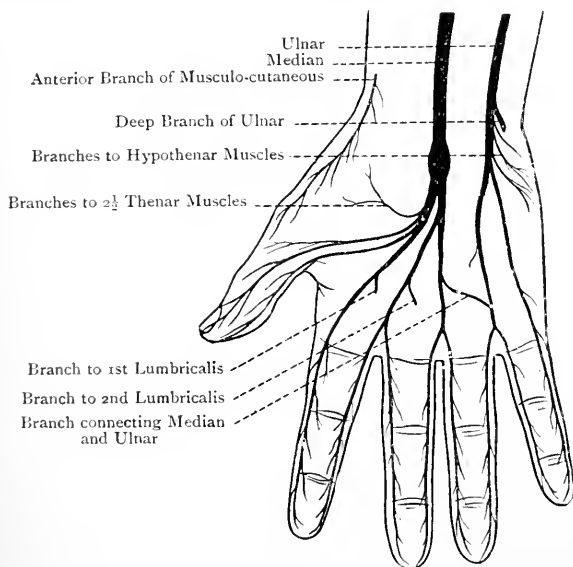


FIG. 196.—DIAGRAM OF THE NERVES OF THE PALM.

ends in branches for the pulp and matrix of the nail. The digital nerves also give branches which turn backwards to the dorsal aspects of the fingers. These, for the most part, supply the integument as follows: (1) the matrix of the thumb-nail; (2) the back of the terminal phalanx of the index finger; (3) the back of the second and terminal phalanges of the middle finger; and (4) the back of the terminal, and distal end of the second, phalanges of the ring finger.

Summary of the Median Nerve.—Muscular.—It supplies (1) all the muscles on the front of the forearm, except the flexor carpi ulnaris and inner portion of the flexor profundus digitorum; (2) two and a half muscles of the thenar eminence, namely, the abductor, opponens, and superficial head of the flexor brevis, pollicis; and (3) the outer two lumbricals. **Cutaneous.**—It supplies the outer part of the palm, and the outer three and a half digits. **Articular.**—It supplies branches to the elbow- and wrist-joints, as well as to several joints of the hand.

Ulnar Nerve in the Hand.—The ulnar nerve enters the hand by passing *over* the anterior annular ligament, where it lies on the inner side of the ulnar vessels, and is overhung by the pisiform bone. It then breaks up into two divisions—superficial and deep. The **superficial division** passes downwards beneath the palmaris brevis, which it supplies, and it ends in **two digital nerves**. The **inner** is a single nerve, and is distributed to the inner side of the little finger. The **outer**, which is compound, passes to near the cleft between the ring and little fingers, where it divides into two collateral digital nerves for the supply of their contiguous sides. This nerve communicates with the innermost digital branch of the median. The distribution of the nerves on the fingers corresponds with that of the median, and the branches which turn to the backs of the fingers are for the most part distributed as follows: (1) to the back of the terminal, and distal end of the second, phalanges of the ring finger, and (2) to the matrix of the nail of the little finger. The **deep division** of the ulnar nerve, along with the profunda branch of the ulnar artery, passes between the abductor and flexor brevis minimi digiti, and then through the opponens minimi digiti. Thereafter it accompanies the deep palmar arch, above which it lies, to the thenar region, and it has an extensive muscular distribution, as follows: it supplies the abductor, flexor brevis, and opponens, minimi digiti, the inner two lumbricales, the seven interossei, and two and a half muscles of the thenar eminence—namely, the deep head of the flexor brevis pollicis, adductor obliquus pollicis, and adductor transversus pollicis. It also gives articular twigs to the wrist-joint, and several of the joints of the hand.

Summary of the Ulnar Nerve.—**Muscular.**—In the forearm it supplies the flexor carpi ulnaris and inner portion of the flexor profundus digitorum; and in the hand it supplies (1) the palmaris brevis, (2) the three hypothenar muscles, (3) the inner two lumbricales, (4) the seven interossei, and (5) two and a half muscles of the thenar eminence, namely, the deep head of the flexor brevis, adductor obliquus, and adductor transversus, pollicis. **Cutaneous.**—It supplies the integument of (1) the front of the forearm for a little below the centre, and internal to the middle line; (2) the inner portion of the palm; and (3) the inner one and a half fingers. **Articular.**—It supplies branches to the elbow- and wrist-joints, and several of the joints of the hand.

Great Palmar Bursa.—This bursa has two compartments, inner and outer.

The *inner compartment*, which is large and loose, invests the superficial and deep flexor tendons and median nerve as they pass beneath the anterior annular ligament. It extends upwards into the forearm for rather more than an inch above the ligament, and downwards to about the centre of the palm. It is shut off from the synovial sheaths of the flexor tendons of the index, middle, and ring fingers, but internally it is prolonged downwards to be, as a rule, continuous with the synovial sheath of the flexor tendons of the little finger.

The *outer compartment*, which is long and narrow, invests the tendon of the flexor longus pollicis beneath the anterior annular

ligament, and reaches upwards to the same height as the inner compartment. Inferiorly it is prolonged uninterruptedly along the tendon to its insertion, so that it is continuous with its synovial sheath on the thumb. The disposition of the great palmar bursa in relation to the *thumb* and *little finger* is to be carefully noted in connection with whitlow of these fingers. It will be evident that pus could readily burrow upwards from the thumb and little finger into the lower part of the forearm, passing in its course beneath the anterior annular ligament.

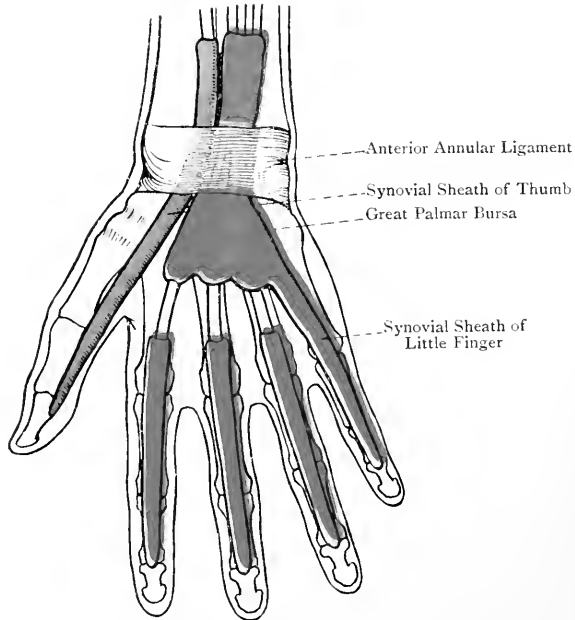


FIG. 197.—THE GREAT PALMAR BURSA, AND THE SYNOVIAL SHEATHS OF THE FLEXOR TENDONS.

Sheaths of the Flexor Tendons.—As the superficial and deep flexor tendons pass along the fronts of the four inner fingers each pair is contained in a fibro-osseous canal. The osseous wall is formed by the palmar aspects of the first and second phalanges, and the fibrous wall by a sheath. This sheath, over the greater parts of the first and second phalanges, is thick and strong, and these parts of it are known as the **vaginal ligaments**. The fibres of these ligaments run transversely, and are attached to the rough lateral margins of the palmar surfaces of the phalangeal shafts. Opposite the joints, in order not to interfere with flexion, the vaginal ligaments are replaced by thin membranes, superadded to which are obliquely

decussating fibres. Each fibro-osseous canal is lined by synovial membrane, which is reflected over the contained tendons in such a manner as to furnish a separate investment for each. The synovial sheaths of the index, middle, and ring fingers extend into the palm as far as the heads of the metacarpal bones, and they have no connection with the great palmar bursa. The synovial sheath of the little finger, however, is as a rule continuous with the large inner compartment of that bursa. The synovial membranes of the sheaths form certain bands, called **vincula accessoria tendinum**, which are of two kinds—ligamenta brevia and ligamenta longa. The *ligamenta brevia* are two in number—one for the superficial and one for the deep flexor tendon. They are broad, laterally compressed, triangular bands which connect each tendon, close to its insertion, with the distal end of the phalanx above that into which it is inserted. The *ligamenta longa*, few and inconstant, are narrow cords which pass between the tendons and the phalanges, or from one tendon to the other. The fibro-osseous canal for the tendon of the flexor longus pollicis is similar to those of the other flexor tendons, and its synovial membrane is continuous

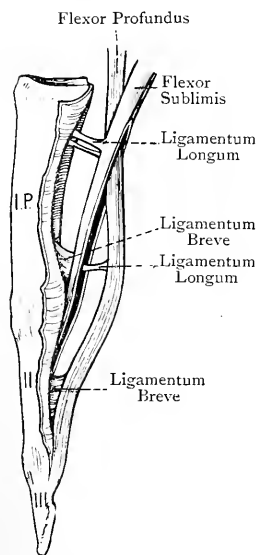


FIG. 198.—THE FLEXOR TENDONS OF A FINGER.

with the outer compartment of the great palmar bursa.

Lumbricales.—These are four tapering muscles which are connected with the deep flexor tendons in the palm, and they receive numerical names, the most external being the first. The first and second arise each from the outer side of the deep flexor tendon for the index and middle fingers, and the third and fourth arise from the adjacent sides of the two deep flexor tendons between which each lies, the tendons involved being those for the middle, ring, and little fingers. Each muscle tapers off, and ends in a tendon which, turning round the outer side of a metacarpo-phalangeal joint, expands, and is inserted into the outer side of the broad expansion of the extensor tendon on the back of the first phalanx.

Nerve-supply—*First.*—The digital branch of the median to the outer side of the index finger. *Second.*—The digital branch of the median, which divides to supply the contiguous sides of the index and middle fingers. *Third and Fourth.*—The deep division of the ulnar nerve.

Action.—(1) To flex the metacarpo-phalangeal joint, and (2) to extend the interphalangeal joints.

Anterior Annular Ligament.—This is a strong fibrous band which bridges over the concavity on the palmar aspect of the carpus,

and converts it into a fibro-osseous canal. Externally it is attached to the tuberosities of the scaphoid and trapezium, and internally to the pisiform and hook of the unciform. Its upper border is continuous with the deep fascia of the front of the forearm; its lower border is connected with the palmar fascia; at its upper and inner part it receives an expansion from the tendon of the flexor carpi ulnaris; and near its lower border it gives partial insertion to the tendon of the palmaris longus. The ligament is crossed by the last-mentioned tendon and the ulnar vessels and nerve, the latter structures lying close to the pisiform bone, where they are overhung by it, and overlapped by a slip from the flexor carpi ulnaris. At either side the ligament affords origin to muscles of the thenar and hypothenar groups. The fibro-osseous canal formed by the ligament and front of the carpus gives passage to the tendons of the flexor sublimis and flexor profundus digitorum, the tendon of the flexor longus pollicis, and the median nerve. The tendon of the flexor carpi radialis does not pass through this canal, but traverses a special compartment in the outer part of the ligament as it passes through the groove on the front of the trapezium, where it is invested by a special synovial sheath.

Thenar Muscles.—The short muscles of the thumb are five in number, namely, the abductor, opponens, and flexor brevis, pollicis, the adductor obliquus pollicis, and the adductor transversus pollicis.

1. Abductor Pollicis—*Origin.*—(1) The front of the anterior annular ligament; (2) the tuberosity of the scaphoid; and (3) the tuberosity of the trapezium.

Insertion.—(1) The outer side of the base of the first phalanx of the thumb, in association with the superficial head of the flexor brevis pollicis; and (2) the outer margin of the tendon of the extensor longus pollicis on the back of the first phalanx.

Nerve-supply.—The median nerve.

The muscle, which is triangular, is directed downwards and outwards.

Action.—(1) To abduct the thumb, and (2) to assist in flexing its first phalanx, the result being that the thumb is drawn forwards and a little inwards. It also assists in extending the distal phalanx.

The muscle rests upon the opponens pollicis, and the superficial head of the flexor brevis pollicis lies on its inner side.

2. Opponens Pollicis—*Origin.*—(1) The front of the anterior annular ligament, and (2) the tuberosity of the trapezium.

Insertion.—The outer border of the shaft of the metacarpal bone of the thumb, and the adjacent part of its palmar surface.

Nerve-supply.—The median nerve.

The muscle, which is triangular, is directed downwards and outwards.

Action.—To flex the first metacarpal bone, the result being that the thumb is drawn forwards and inwards across the palm, so as to oppose its tip to the tips of the four inner fingers.

The muscle supports the abductor pollicis, and has the superficial head of the flexor brevis pollicis along its inner border.

3. **Flexor Brevis Pollicis.**—This muscle arises by two heads—a large superficial or outer, and a small deep or inner. The *superficial head* arises from the outer two-thirds of the lower border of the anterior annular ligament, and the tuberosity of the trapezium. The *deep head* (**interosseus primus volaris**) arises from the proximal extremity of the first metacarpal bone on its inner aspect.

Insertion.—The *superficial head*, along with the abductor pollicis, is inserted into the outer side of the base of the first phalanx of the thumb, a sesamoid bone being contained within it. The *deep head* joins the adductor obliquus pollicis, and, along with it, is inserted into the inner side of the base of the first phalanx of the thumb.

Nerve-supply.—The superficial head is supplied by the median nerve, and the deep head by the deep division of the ulnar nerve.

Action.—To flex the metacarpo-phalangeal joint of the thumb, and so to assist in opposition.

4. **Adductor Obliquus Pollicis**—*Origin.*—By several bundles from (1) the fronts of the bases of the second and third metacarpal bones; (2) the fronts of the trapezoid and os magnum; and (3) the sheath of the tendon of the flexor carpi radialis.

Insertion.—The muscle, having received the small deep head of the flexor brevis pollicis, is inserted, along with the adductor transversus pollicis, into the inner side of the base of the first phalanx of the thumb, a sesamoid bone being contained within it.

In its course the muscle detaches, from its outer side, a large fleshy bundle, which passes outwards behind the tendon of the flexor longus pollicis and joins the superficial head of the flexor brevis pollicis.

Nerve-supply.—The deep division of the ulnar nerve.

The muscle is directed downwards and outwards.

Action.—To adduct the thumb and assist in opposition.

The muscle has the superficial head of the flexor brevis pollicis on its outer side, the tendon of the flexor longus pollicis lying between the two, and the adductor transversus pollicis along its inner and lower aspect, the radial artery passing between the two.

5. **Adductor Transversus Pollicis**—*Origin.*—The distal two-thirds of the anterior border of the shaft of the third metacarpal bone.

Insertion.—(1) The inner side of the base of the first phalanx of the thumb, along with the adductor obliquus pollicis and deep head of the flexor brevis pollicis; and (2) the inner margin of the tendon of the extensor longus pollicis on the back of that phalanx.

Nerve-supply.—The deep division of the ulnar nerve.

The muscle, which is triangular, is directed outwards.

Action.—To adduct the thumb and assist in opposition. It also assists in extending the distal phalanx.

The **tendon of the flexor longus pollicis** on its way to its insertion

has on its outer side the superficial head of the flexor brevis pollicis, and on its inner side the adductor obliquus pollicis.

Hypothenar Muscles.—The short muscles of the little finger are three in number, namely, the abductor, flexor brevis, and opponens, minimi digiti.

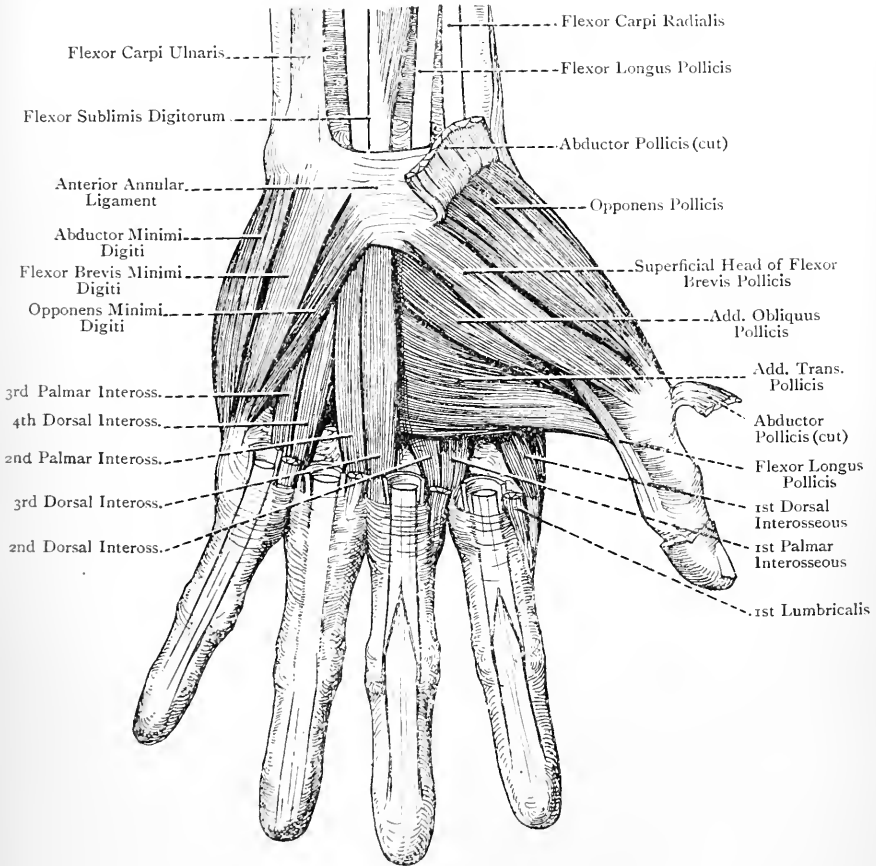


FIG. 199.—THE THENAR AND HYPOTHENAR MUSCLES.

1. **Abductor Minimi Digiti**—*Origin*.—The lower part of the pisiform bone.

Insertion.—(1) The inner side of the base of the first phalanx of the little finger, in common with the flexor brevis minimi digiti; and (2) the inner margin of the tendon of the extensor minimi digiti on the back of the phalanx.

Nerve-supply.—The deep division of the ulnar nerve.

Action.—(1) To abduct the little finger, and flex its metacarpophalangeal joint; and (2) to assist in extending the second and third phalanges.

2. **Flexor Brevis Minimi Digiti**—*Origin.*—(1) The inner surface of the hook of the unciform bone close to its tip, and (2) the front of the adjacent portion of the anterior annular ligament.

Insertion.—The inner side of the base of the first phalanx of the little finger, in common with the abductor minimi digiti.

Nerve-supply.—The deep division of the ulnar nerve.

Action.—To flex the metacarpophalangeal joint of the little finger.

This muscle is of small size, and lies on the outer side of the abductor minimi digiti, from which it is separated, close to its origin, by the profunda branch of the ulnar artery and deep division of the ulnar nerve.

3. **Opponens Minimi Digiti**—*Origin.*—(1) The inner surface of the hook of the unciform bone underneath the preceding muscle, and (2) the adjacent part of the anterior annular ligament.

Insertion.—The inner margin of the shaft of the fifth metacarpal bone.

Nerve-supply.—The deep division of the ulnar nerve.

Action.—To flex and adduct the fifth metacarpal bone.

The muscle supports the abductor and flexor brevis minimi digiti, and its deep surface is related to the interosseous muscles of the fourth space. The deep branches of the ulnar artery and nerve pass through it on their way to the deep part of the palm.

Third Part of the Radial Artery.—The third part, which forms the greater portion of the deep palmar arch, extends from the upper part of the first interosseous space to about the base of the fifth metacarpal bone, where it is joined by the profunda branch of the ulnar. It enters the palm by passing between the two heads of the abductor indicis, and then it crosses the palm, resting upon the bases of the second, third, and fourth metacarpal bones, and the adjacent interosseous muscles. In its course it describes a slight arch, the convexity of which is directed towards the fingers, and it is about $\frac{1}{2}$ inch nearer the wrist than the superficial palmar arch. The deep division of the ulnar nerve lies close above it. The third part of the vessel is at first under cover of the adductor obliquus pollicis; it then passes between that muscle and the adductor transversus pollicis; and thereafter it lies beneath the superficial and deep flexor tendons and lumbricales, where it forms the deep palmar arch.

Branches.—These are the arteria princeps pollicis, arteria radialis indicis, three palmar interosseous, recurrent, and superior perforating, the last three coming from the deep palmar arch.

The **arteria princeps pollicis** arises from the vessel immediately after it emerges from between the two heads of the abductor indicis, and it passes downwards along the first metacarpal bone, lying upon the abductor indicis and under cover of the adductor obliquus pollicis. On reaching the head of the bone it divides, under cover of the tendon

of the flexor longus pollicis, into two collateral digital arteries for the sides of the thumb, which appear on either side of the long flexor tendon, between the superficial head of the flexor brevis pollicis and adductor obliquus pollicis. Their distribution is similar to that of the other digital arteries. The arteria princeps pollicis may give a branch to complete the superficial palmar arch.

The **arteria radialis indicis** passes downwards along the outer side of the second metacarpal bone, lying upon the abductor indicis and under cover of the adductor obliquus, and adductor transversus,

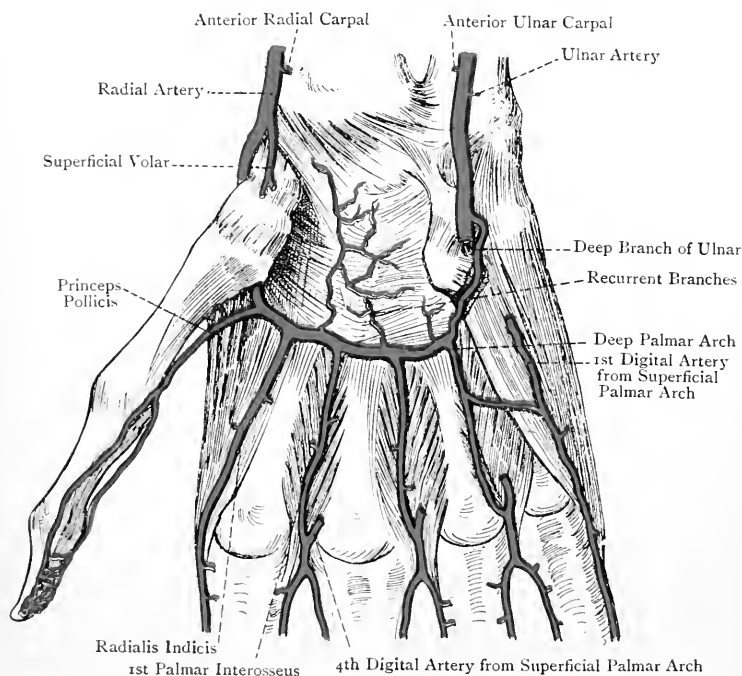


FIG. 200.—THE RADIAL ARTERY IN THE PALM (DEEP PALMAR ARCH)
(AFTER SPALTEHOLZ).

pollicis, and it becomes the digital artery of the outer side of the index finger. It may give a branch to complete the superficial palmar arch.

Branches of the Deep Palmar Arch.—The **palmar interosseous arteries**, three in number, arise from the convexity of the arch, and pass downwards over the second, third, and fourth interosseous spaces. Near the clefts of the corresponding fingers, they terminate by joining the three compound digital arteries of the superficial palmar arch. The innermost palmar interosseous, as a rule, gives off a communicating branch to join the single digital

artery from the superficial arch to the inner side of the little finger, the junction taking place about the centre of the palm. In those cases where the digital arteries from the superficial arch are wanting, the palmar interosseous arteries may take their place.

The **recurrent branches**, few and small in size, arise from the concavity of the arch, and pass upwards to take part in the anterior carpal rete.

The **superior perforating arteries**, three in number, pass through the upper ends of the inner three interosseous spaces between the two heads of the corresponding dorsal interosseous muscles, and on the back of the hand they join the dorsal interosseous arteries.

Varieties of the Ulnar and Radial Arteries in the Hand.—1. The **ulnar artery** may be deficient in the number of digital branches furnished by the superficial palmar arch, or the vessel may end as the profunda artery, in which latter case there would be no superficial arch. Under these circumstances the deficiencies are usually supplied by the palmar interosseous branches of the deep arch, but sometimes by a large median and large superficial volar artery.

2. The **radial artery** may be deficient in its normal branches, and the *arteria princeps pollicis* and *arteria radialis indicis* may arise from the superficial arch, from a median, or from a superficial volar, artery.

Veins.—The deep palmar arch is accompanied by two *venæ comites*, which receive tributaries corresponding to the branches of the arch. The destination of these *venæ comites* on either side has been already described in connection with the superficial palmar arch.

Summary of the Palmar Arches.—The **superficial palmar arch** is formed mainly by the ulnar artery, being completed by the superficial volar of the radial, or, if this fails, by a branch from the *arteria radialis indicis*, or *arteria princeps pollicis*. Its digital branches lie over the interosseous spaces, so that, to avoid them, incisions in the palm should be made in line with the centre of a finger, and should not be prolonged farther upwards than the line indicating the position of the superficial palmar arch. On the fingers the digital arteries are placed laterally, so that in cases of whitlow an incision should be made along the middle line of a finger. The superficial palmar arch is sometimes joined by a large **median artery**, which is a branch of the anterior interosseous high up in the forearm. In such cases, if the arch were to be punctured, and if the hæmorrhage could not be arrested by the graduated compress, it is evident that ligature neither of the ulnar nor radial artery would suffice. In order to arrest the circulation through a large median artery the ligature would require to be placed on the brachial artery.

The **deep palmar arch** is formed mainly by the radial artery, and is completed by the profunda branch of the ulnar. It lies about $\frac{1}{2}$ inch above the superficial arch.

BACK OF THE FOREARM AND HAND.

The cutaneous nerves, already described, are as follows: the posterior branch of the musculo-cutaneous and the lower external cutaneous branch of the musculo-spiral to the outer part, and the posterior division of the internal cutaneous to the inner part.

The deep fascia of the back of the forearm has been described in connection with the anterior aspect, and the posterior annular ligament will be presently referred to.

Muscles of the Outer Side of the Forearm.—These are three in number, namely, the brachio-radialis, extensor carpi radialis longior, and extensor carpi radialis brevior.

1. **Brachio-radialis** (supinator radii longus)—*Origin.*—(1) The upper two-thirds of the external supracondylar ridge of the humerus, and (2) the front of the external intermuscular septum over a corresponding extent.

Insertion.—The outer side of the radius close above the base of the styloid process.

Nerve-supply.—The musculo-spiral nerve.

Action.—Though called a supinator, the muscle is a flexor of the forearm, acting most directly when the limb is in a state of semi-pronation. An important use of the muscle is to maintain the forearm in the flexed position, as in holding a book. When the forearm is fully pronated the muscle is a feeble supinator, but only to the extent of semisupination. When the forearm is fully supinated it produces semipronation.

The muscle presents a fleshy belly to near the middle of the forearm. Thereafter it is replaced by a flat tendon, which first appears on the deep surface of the muscle. Superiorly the surfaces are directed outwards and inwards, but afterwards they look forwards and backwards.

2. **Extensor Carpi Radialis Longior**—*Origin.*—(1) The lower third of the external supracondylar ridge of the humerus, and (2) the front of the external intermuscular septum for a corresponding extent.

Insertion.—The back of the base of the second metacarpal bone over its outer half, a small bursa lying beneath the tendon.

Nerve-supply.—The musculo-spiral nerve.

Action.—(1) To extend the wrist-joint, and (2) to assist in external lateral flexion (abduction) of that joint.

The muscle presents a fleshy belly to near the middle of the forearm, and thereafter a tendon which descends at first upon, and then on the outer side of, the tendon of the extensor carpi radialis brevior. These two tendons pass beneath the posterior annular ligament, and occupy the outermost groove on the back of the lower end of the radius. The surfaces of the muscle are at first directed outwards and inwards, and then forwards and backwards.

3. **Extensor Carpi Radialis Brevior**—*Origin.*—(1) The external epicondyle of the humerus by the common tendon; (2) the external lateral ligament of the elbow-joint; and (3) the intermuscular septa between it and adjacent muscles.

Insertion.—The back of the base of the third metacarpal bone over its outer half, and often by a small slip into the back of the base of the second metacarpal over its inner part. A small bursa is placed beneath the tendon.

Nerve-supply.—The posterior interosseous nerve.

Action.—(1) To extend the wrist-joint, and (2) to assist in external lateral flexion (abduction) of that joint.

The tendon appears about the centre of the forearm, and becomes free from fleshy fibres in the lower third. It descends beneath the tendon of the long radial extensor, except near its insertion, where it lies internal to that tendon. It accompanies the long tendon beneath the posterior annular ligament, and passes with it through the outermost groove on the back of the lower end of the radius.

Muscles of the Back of the Forearm.—These are arranged in two layers—superficial and deep.

Superficial Layer.—The muscles of this layer, which are serially continuous with those of the outer side of the forearm, are four in number, namely, the extensor communis digitorum, extensor minimi digiti, extensor carpi ulnaris, and anconeus. The first three have a common tendon of origin, which they share with the extensor carpi radialis brevior.

1. **Extensor Communis Digitorum**—*Origin.*—(1) The external epicondyle of the humerus by the common tendon; (2) the deep fascia; and (3) the intermuscular septa between it and adjacent muscles.

Insertion.—The muscle ends in four tendons, which pass beneath the posterior annular ligament to the dorsum of the hand. Here they diverge and pass to the four inner fingers, that for the index finger being accompanied *internally* by the tendon of the extensor indicis. Having crossed the metacarpo-phalangeal joints, where they give fibres to their lateral ligaments, the tendons form broad expansions covering the backs of the first phalanges, which give insertion to the lumbricales and interossei. Towards the distal end of the first phalanx the expansion divides into three parts—central and two lateral. The central part is inserted into the back of the base of the second phalanx. The two lateral parts unite on the back of the second phalanx, and are inserted into the back of the base of the distal phalanx. The index and middle finger tendons are connected by a weak band of fibres. The ring-finger tendon is connected by a strong band of fibres with the tendon on either side of it, which explains the very limited amount of extension of which the ring-finger is capable, unless the middle and little fingers are extended along with it. The little finger tendon may divide into two parts, one joining the ring-finger tendon and the other the tendon of the extensor minimi digiti.

Nerve-supply.—The posterior interosseous nerve.

Action.—(1) To extend the first phalanges of the four inner fingers, and also the second and third phalanges slightly, these being extended principally by the interossei and lumbricales; and (2) to assist in extension of the wrist-joint.

The common extensor tendons, along with that of the extensor indicis, in passing beneath the posterior annular ligament, occupy the broad innermost groove on the back of the radius.

2. **Extensor Minimi Digiti**—*Origin.*—(1) The external epicondyle of the humerus by the common tendon; (2) the deep fascia; and (3) the intermuscular septum on either side.

Insertion.—Having passed beneath the posterior annular liga-

ment, where it occupies the groove between the radius and ulna, the tendon divides into two parts, the outer part being joined by the common extensor tendon to the little finger, or by its inner division. Both parts end in a broad expansion on the back of the first phalanx,

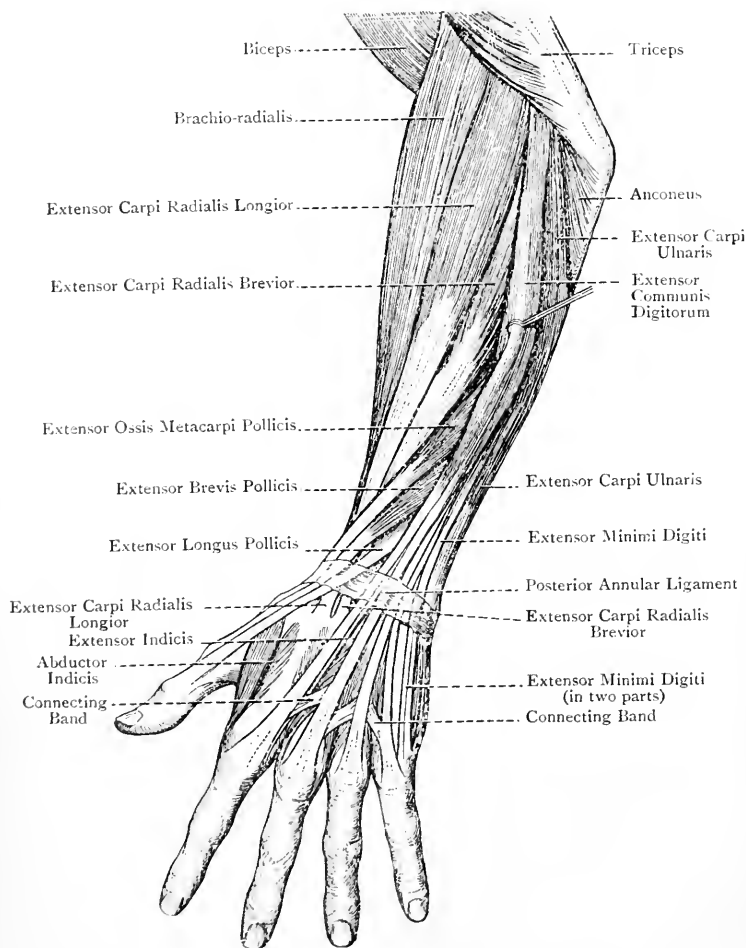


FIG. 201.—THE MUSCLES OF THE RADIAL SIDE AND BACK OF THE FOREARM.

and the ultimate insertion is as in the case of the common extensor tendons.

Nerve-supply.—The posterior interosseous nerve.

Action.—The muscle is the special extensor of the little finger,

as in inserting that finger into the ear canal. It also acts as a feeble auxiliary extensor of the wrist-joint.

3. **Extensor Carpi Ulnaris**—*Origin*.—(1) The external epicondyle of the humerus by the common tendon; (2) the deep fascia; (3) the intermuscular septum on either side; and (4) the upper two-thirds of the posterior border of the ulna by an aponeurosis which is common to it, the flexor carpi ulnaris, and the flexor profundus digitorum.

Insertion.—The tubercle on the inner side of the base of the fifth metacarpal bone.

Nerve-supply.—The posterior interosseous nerve.

Action.—(1) To extend the wrist-joint, and (2) to assist in internal lateral flexion (adduction) of that joint.

The muscle rests upon the inner half of the posterior surface of the shaft of the ulna, and its tendon, in passing beneath the posterior annular ligament, occupies the groove on the back of the ulna.

4. **Anconeus**—*Origin*.—The back of the external epicondyle of the humerus at its lower part.

Insertion.—The outer surface of the olecranon process, and the upper third of the posterior surface of the shaft, of the ulna.

The muscle, which is continuous with the internal head of the triceps, is triangular, the upper fibres being short and transverse, whilst the others pass obliquely downwards and inwards.

Nerve-supply.—The musculo-spiral nerve, by means of a long branch which descends in the internal head of the triceps, and enters the muscle on its deep surface near the upper border.

Action.—To assist the inner head of the triceps in extending the elbow.

The posterior interosseous recurrent artery ascends beneath the muscle to the back of the external epicondyle.

The **posterior interosseous nerve** will be found described on p. 336, and the corresponding **artery** on p. 339.

Deep Layer.—There are five muscles in this layer, namely, the supinator radii brevis, extensor ossis metacarpi pollicis, extensor brevis pollicis, extensor longus pollicis, and extensor indicis.

1. **Supinator Radii Brevis**—*Origin*.—(1) The external lateral ligament of the elbow-joint; (2) the orbicular ligament of the radius; (3) the back part of the bicipital hollow, and the supinator ridge, of the ulna; and (4) the aponeurosis covering the upper part of the muscle.

Insertion.—The shaft of the radius on its anterior, outer, and posterior aspects over about the upper third.

Anteriorly the muscle descends as low as the anterior oblique line, externally as low as the insertion of the pronator radii teres, and posteriorly as low as the posterior oblique line. It closely invests the radius over about its upper third, except on its inner aspect.

Nerve-supply.—The posterior interosseous nerve.

Action.—To supinate the radius upon the ulna.

The muscle is pierced by the posterior interosseous nerve, and,

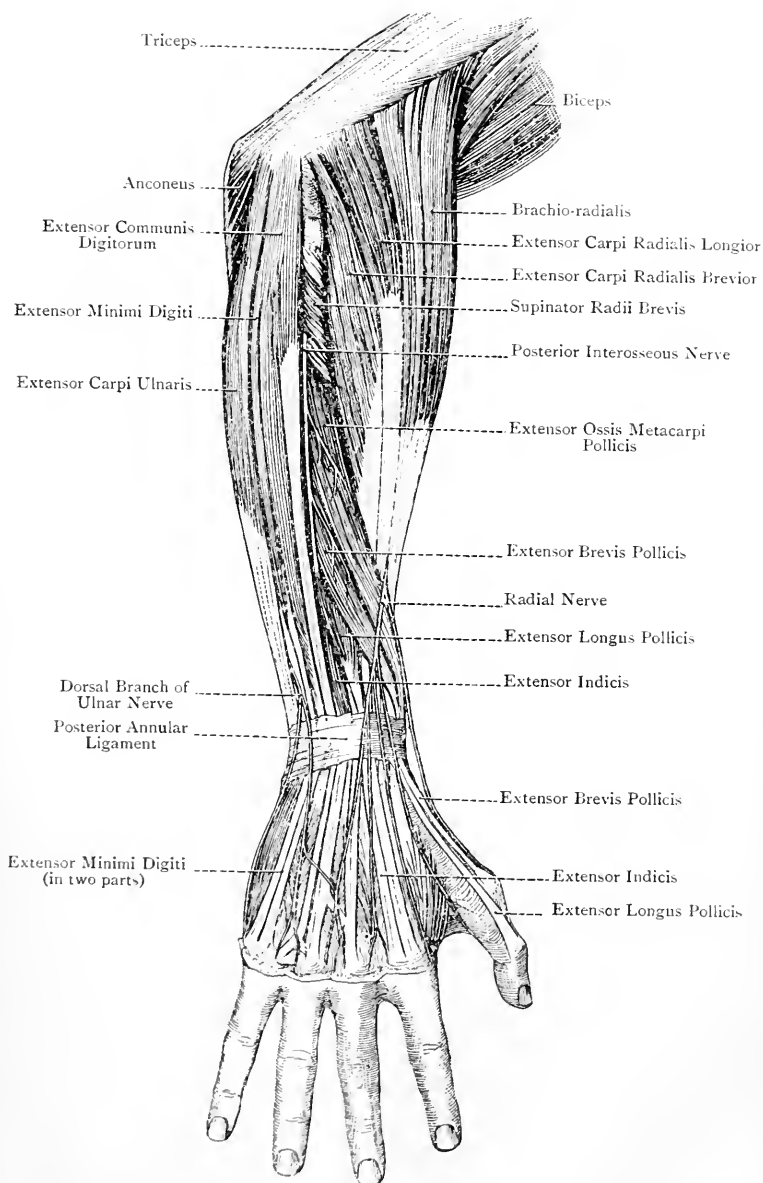


FIG. 202.—DEEP DISSECTION OF THE BACK OF THE FOREARM
(The Radial Nerve and the Dorsal Branch of the Ulnar Nerve are also shown).

in doing so, the nerve passes between the small superficial and large deep lamina, of which the muscle is composed.

2. **Extensor Osis Metacarpi Pollicis**—*Origin*.—(1) The posterior surface of the shaft of the radius for fully 2 inches below the posterior oblique line, where it meets the supinator radii brevis; (2) the adjacent portion of the interosseous membrane; and (3) the outer part of the posterior surface of the shaft of the ulna for a short distance below the oblique line, which limits the insertion of the anconeus.

Insertion.—The outer side of the base of the metacarpal bone of the thumb.

The muscle passes downwards and outwards, and its strong tendon is closely accompanied by that of the extensor brevis pollicis. Both of these tendons cross those of the radial extensors of the wrist, and traverse the groove on the outer side of the styloid process of the radius, where they occupy the outermost compartment of the posterior annular ligament. The tendon at its insertion gives a slip to the thenar portion of the palmar fascia, which gives it a double appearance.

Nerve-supply.—The posterior interosseous nerve.

Action.—(1) To extend and abduct the metacarpal bone of the thumb, and (2) to abduct the wrist-joint (external lateral flexion).

3. **Extensor Brevis Pollicis** (extensor primi internodii pollicis)—*Origin*.—The posterior surface of the shaft of the radius, and the interosseous membrane, for a short distance below the preceding muscle.

Insertion.—The back of the base of the first phalanx of the thumb.

The muscle closely accompanies the extensor ossis metacarpi pollicis.

Nerve-supply.—The posterior interosseous nerve.

Action.—(1) To extend the metacarpo-phalangeal joint of the thumb, and (2) to act as a feeble auxiliary to the extensor ossis metacarpi pollicis.

4. **Extensor Longus Pollicis** (extensor secundi internodii pollicis)—*Origin*.—(1) The outer part of the posterior surface of the shaft of the ulna over about its middle third, commencing immediately below the extensor ossis metacarpi pollicis; and (2) the adjacent portion of the interosseous membrane.

Insertion.—The back of the base of the distal phalanx of the thumb.

The muscle is directed downwards and outwards, and its tendon passes beneath the posterior annular ligament, where it occupies the narrow oblique groove on the radius, internal to the radial tubercle.

Nerve-supply.—The posterior interosseous nerve.

Action.—To extend the distal phalanx of the thumb. Thereafter the muscle, which acts strongly, assists in extending the first phalanx and metacarpal bone, the thumb being drawn backwards. It is also an auxiliary extensor of the wrist-joint.

5. **Extensor Indicis**—*Origin*.—(1) The outer part of the posterior surface of the shaft of the ulna, commencing just below the middle

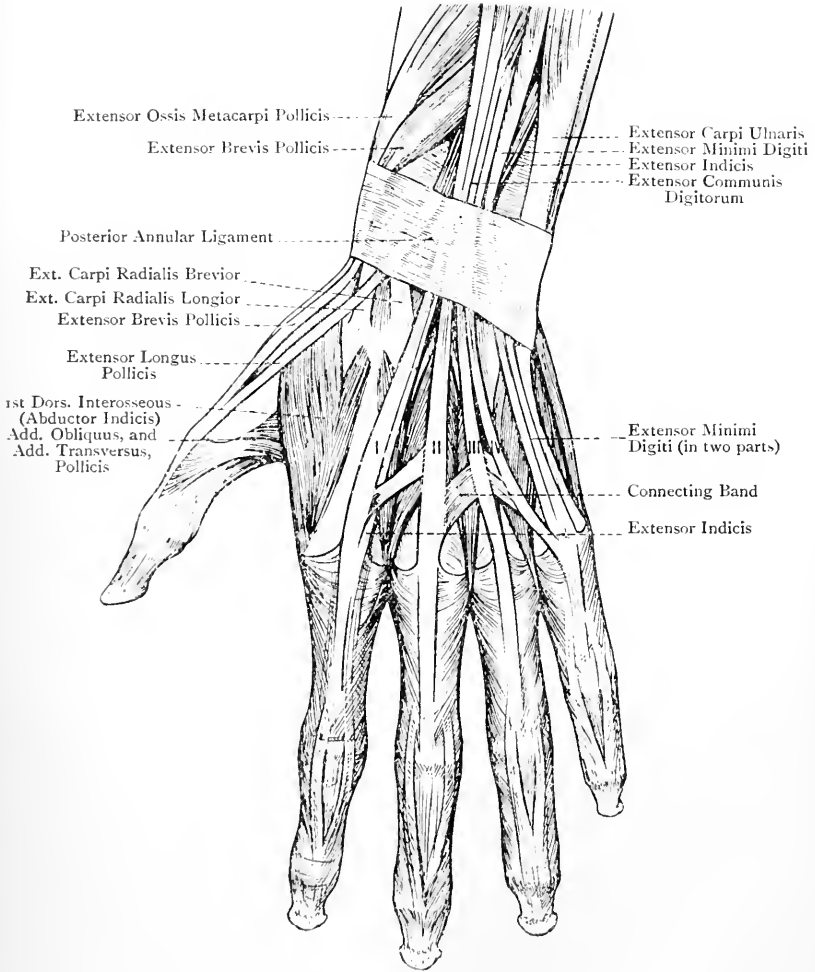


FIG. 203.—THE MUSCLES AND TENDONS OF THE BACK OF THE WRIST AND HAND.

I., II., III., IV., Tendons of Extensor Communis Digitorum.

third, and reaching to near the lower end of the bone; and (2) the lower part of the interosseous membrane.

Insertion.—The inner side of the common extensor tendon of the index finger, which it joins at the metacarpo-phalangeal joint.

The muscle is directed downwards and outwards, and its tendon passes beneath the posterior annular ligament, where it occupies the innermost groove on the back of the radius, in company with the common extensor tendons, beneath which it lies.

Nerve-supply.—The posterior interosseous nerve.

Action.—(1) The muscle is the special extensor of the index finger, as in pointing; and (2) it acts as a feeble auxiliary extensor of the wrist-joint.

The muscle is covered by the extensor communis digitorum, extensor minimi digiti, and extensor carpi ulnaris.

Posterior Annular Ligament.—This is a thickened portion of the deep fascia of the back of the forearm, and it lies obliquely on the back of the wrist. It is attached *externally* to the lower part of the anterior border of the radius, and *internally* to the inner and back part of the cuneiform and pisiform bones, as well as to the hypothenar portion of the palmar fascia. Its direction is inwards and downwards, and it bridges over the various grooves in this region, sending deep processes to be attached to the ridges which separate them. In this manner these grooves are converted into fibro-osseous canals for the passage of the extensor tendons. These canals are six in number, four being on the radius, one between that bone and the ulna, and one on the ulna. Proceeding from without inwards, the **first** canal corresponds with the groove on the outer surface of the styloid process of the radius, and it contains the tendons of the extensor ossis metacarpi pollicis and extensor brevis pollicis. The **second** canal corresponds with the outer broad groove on the back of the radius, and it contains the tendons of the extensor carpi radialis longior and extensor carpi radialis brevior. The **third** canal corresponds with the narrow, deep, oblique groove on the back of the radius, internal to the radial tubercle which overhangs it, and it contains the tendon of the extensor longus pollicis. The **fourth** canal corresponds with the broad, innermost groove on the back of the radius, and it transmits the tendons of the extensor communis digitorum and extensor indicis, together with the posterior interosseous nerve and posterior branch of the anterior interosseous artery. The **fifth** canal corresponds with the groove between the radius and ulna, and it contains the tendon of the extensor minimi digiti. The **sixth** canal corresponds with the groove on the back of the ulna, between the styloid process and head of the bone, and it transmits the tendon of the extensor carpi ulnaris. Each of the foregoing canals is lined by a separate synovial sheath, and these sheaths extend for a little above and below the posterior annular ligament.

Deep Fascia of the Back of the Hand.—The deep fascia in this region is continuous above with the posterior annular ligament, and

at either side with the thenar and hypothenar portions of the palmar fascia. It covers the extensor tendons, with which it is intimately connected. Besides this fascia there is another fascial investment, which is placed beneath the extensor tendons. This deeper layer covers the dorsal interosseous muscles, and, in the intervals between them, it is attached to the dorsal aspects of the shafts of the metacarpal bones.

Second Part of the Radial Artery.—The second part of the vessel winds backwards below the styloid process of the radius to the back of the wrist. It extends from a point on the front of the radius about $\frac{1}{2}$ inch internal to the styloid process to the upper end of the

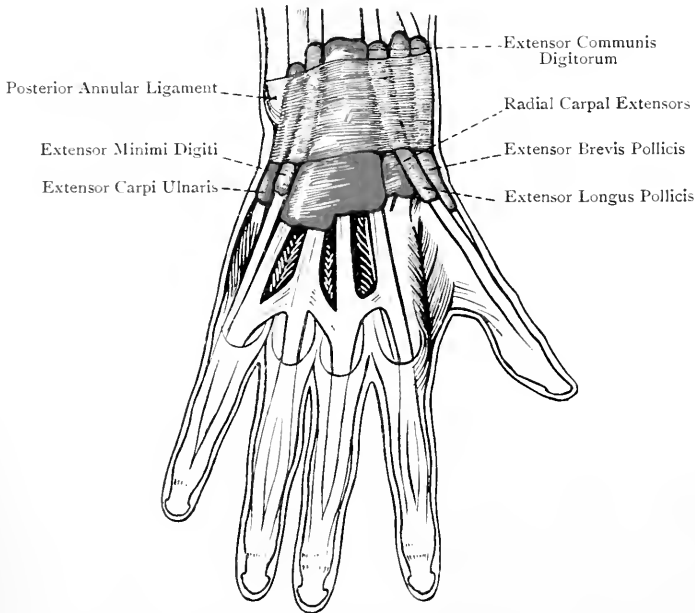


FIG. 204.—THE SYNOVIAL SHEATHS OF THE EXTENSOR TENDONS (AFTER L. TESTUT'S 'ANATOMIE HUMAINE').

first interosseous space on its posterior aspect, where it dips between the two heads of the abductor indicis muscle, and ends in the third part. Its course is at first backwards and then downwards.

Relations—Superficial.—The integument, radial vein, branches of the radial nerve, tendons of the extensor ossis metacarpi pollicis, extensor brevis pollicis, and extensor longus pollicis, the latter crossing the vessel just before it disappears between the two heads of the abductor indicis. At first it is deeply placed, but afterwards it is superficial, and, in the living subject, pulsation may be felt in it in the triangular hollow below and behind the radial styloid

process. *Deep*.—The external lateral ligament of the wrist-joint, and the scaphoid and semilunar bones. It is accompanied by two venæ comites.

Branches.—The branches are the posterior radial carpal, first dorsal interosseous, two arteriæ dorsales pollicis, and arteria dorsalis indicis.

The **posterior radial carpal artery**, of small size, arises from the radial as it lies upon the external lateral ligament. It passes in-

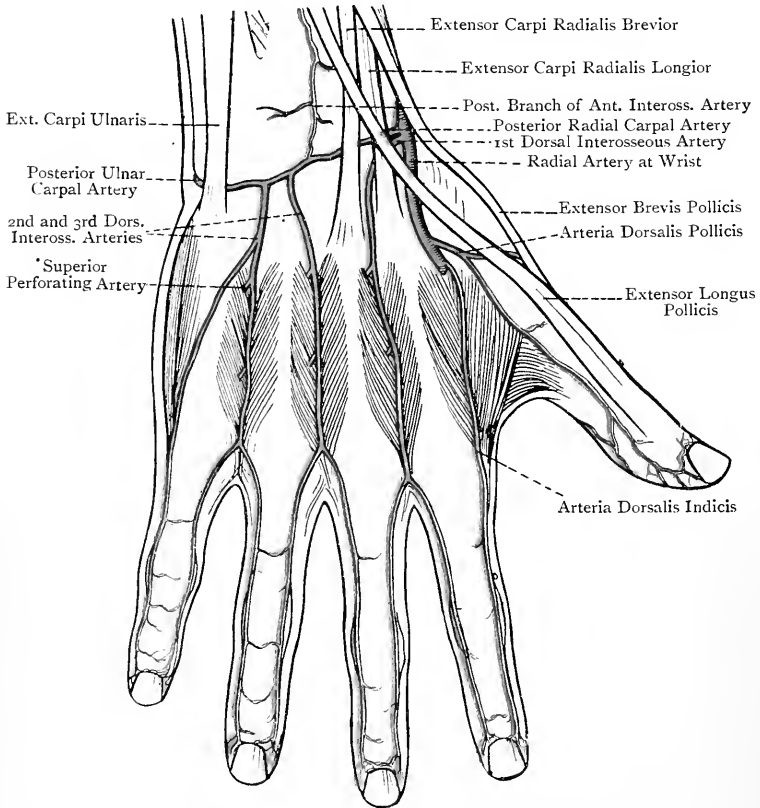


FIG. 205.—THE ARTERIES OF THE BACK OF THE WRIST AND HAND (AFTER L. TESTUT'S 'ANATOMIE HUMAINE').

wards on the back of the wrist beneath the extensor tendons, and anastomoses with the posterior ulnar carpal and posterior branch of the anterior interosseous to form the posterior carpal arch.

The **first dorsal interosseous artery** arises from the preceding, or from the radial a little lower down. It passes to the upper end of the second interosseous space, where it receives a superior

perforating branch from the deep palmar arch. It then descends over that space towards the cleft between the index and middle fingers, where it may send forward an inferior perforating branch to join the fourth or outermost digital artery from the superficial palmar arch. Thereafter it divides into two dorsal collateral digital arteries for the contiguous sides of the index and middle fingers.

The *second* and *third dorsal interosseous arteries* are branches of the posterior carpal arch. They descend over the backs of the third and fourth interosseous spaces, at the upper ends of which each receives a superior perforating branch from the deep palmar arch. Near the clefts between the middle and ring, and ring and little fingers, they may send forwards inferior perforating branches to join the second and third digital arteries from the superficial palmar arch, and thereafter each divides into two dorsal collateral digital arteries for the contiguous sides of the middle and ring, and ring and little fingers. The dorsal digital artery of the inner side of the little finger arises from the third (innermost) dorsal interosseous, or from the posterior ulnar carpal.

The **arteriæ dorsales pollicis**, two in number, arise separately or by a common trunk, from the radial opposite the base of the first metacarpal bone, and are distributed to the sides of the thumb.

The **arteria dorsalis indicis** arises below the preceding, just before the radial dips between the two heads of the abductor indicis. It descends on the outer side of the second metacarpal bone, and supplies the outer side of the index finger.

The distribution of the dorsal digital arteries ceases, as a rule, about the level of the first interphalangeal joint.

The Interosseous Muscles.

The interosseous muscles are seven in number, and are arranged in two groups—three palmar and four dorsal. The palmar interossei are seen only on the palmar aspect, but the dorsal interossei are seen on both aspects of the hand.

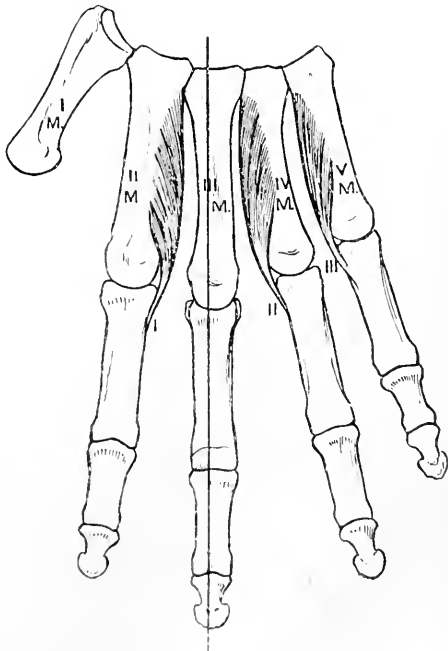


FIG. 206.—THE PALMAR INTEROSSEOUS MUSCLES OF THE RIGHT HAND.

The **palmar interossei** belong to the index, ring, and little fingers, and they are named from without inwards—first, second, and third. Each is connected only with one metacarpal bone. The *first* arises from the inner aspect of the shaft of the second metacarpal bone, and the *second* and *third* from the outer aspects of the shafts of the fourth and fifth metacarpals. The *first* is inserted partly into the inner side of the base of the first phalanx of the index finger, and partly into the expansion of the extensor tendon on the dorsal aspect of that phalanx. The *second* and *third* are inserted in a similar manner in the case of the ring and little fingers, except that each is inserted into the outer side of the base of the first phalanx.

The palmar interossei are covered by a thin fascia, called the **interosseous fascia**. At either side it joins the thenar and hypothenar portions of the palmar fascia, and inferiorly it is connected with the transverse metacarpal and anterior metacarpo-phalangeal ligaments. Two septa pass between it and the central portion of the palmar fascia.

The **dorsal interossei**, which are four in number, belong to the index, middle, and ring fingers, the middle finger having two. They are named from without inwards—first, second, third, and fourth, the first being specially called the abductor indicis. Each muscle arises by two heads from the contiguous sides of the shafts of the metacarpal bones between which it is placed, and always more extensively from the bone belonging to the finger upon which the muscle acts. The fibres of each muscle end upon a tendon which is placed in the centre, and this tendon is inserted partly into the side of the base of the first phalanx of a finger, and partly into the expansion of the extensor tendon on the back of that phalanx. The *first* or **abductor indicis**

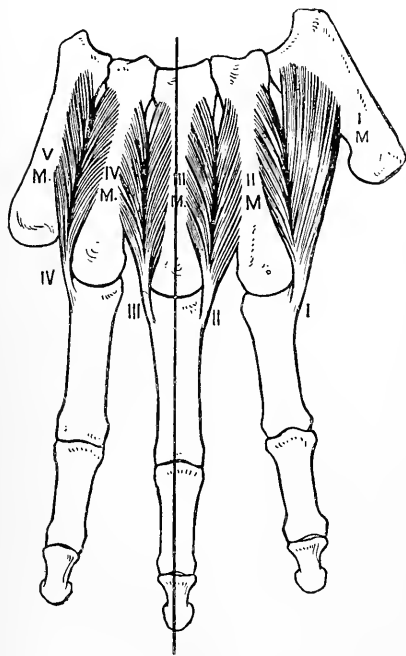


FIG. 207.—THE DORSAL INTEROSSEOUS MUSCLES OF THE RIGHT HAND.

is of large size. Its outer large head arises from the proximal half of the inner margin of the first metacarpal bone, and its inner small head from the whole length of the outer aspect of the shaft of the second metacarpal. It is inserted

into the outer side of the base of the first phalanx of the index finger, and the expansion of the extensor tendon on the back of that phalanx. The *second* is inserted into the outer side, and the *third* into the inner side, of the base of the first phalanx of the middle finger, and both into the expansion of the extensor tendon on the back of that phalanx. The *fourth* is inserted into the inner side of the base of the first phalanx of the ring-finger, and into the expansion of the extensor tendon on the back of that phalanx.

Nerve-supply.—All the interossei are supplied by the deep division of the ulnar nerve.

Action.—(1) The **palmar** interossei are *adductors*, the fingers which they adduct being the index, ring, and little. (2) The **dorsal** interossei are *abductors*, the fingers which they abduct being the index, middle, and ring, the middle finger having two abductors, inasmuch as it can be drawn to either side of the middle line which passes through its centre.

In speaking of adduction and abduction reference is made to an imaginary line passing through the centre of the middle finger, adduction being movement *towards* that line, and abduction *from* it. There is another very important action of all seven interossei, in the performance of which they are assisted by the lumbricales. This action is as follows: (1) to flex the metacarpo-phalangeal joints, in virtue of their insertion into the first phalanges of the four inner fingers, and (2) to extend their interphalangeal joints, in virtue of their insertion into the expansions of the extensor tendons. This action is well illustrated in making the hair- or up-stroke in writing.

Between the two heads of the abductor indicis superiorly is an interval for the passage of the radial vessels, and between the two heads of each of the other dorsal interossei superiorly there is an interval for the passage of a superior perforating artery from the deep palmar arch.

THE ELBOW-JOINT.

The elbow-joint belongs to the class **diarthrosis**, and to the subdivision **ginglymus**. The articular surfaces are the trochlea and capitellum of the humerus above, and the great sigmoid cavity of the ulna and the cup-shaped depression on the head of the radius below. The trochlea articulates with the great sigmoid cavity, and the humeral capitellum with the head of the radius. The joint is surrounded by a capsule, which is made up of four ligaments—*anterior, posterior, external lateral, and internal lateral*.

The **anterior ligament** is broad and thin, the central portion being the strongest. Its fibres are attached superiorly to the front of the humerus above the coronoid and radial fossæ, and inferiorly to (1) the front of the coronoid process of the ulna, and (2) the orbicular ligament of the radius. Some of its fibres run vertically and others

obliquely, the latter chiefly passing downwards and outwards superficial to the former. The ligament is closely covered by the brachialis anticus muscle.

The **posterior ligament** is thin and membranous. Superiorly it is attached to the upper part and sides of the olecranon fossa of the humerus, and inferiorly to (1) the front part of the summit of the olecranon process of the ulna, and (2) the orbicular ligament of the radius. The most of its fibres are disposed vertically, but a few pass transversely between the margins of the olecranon fossa.

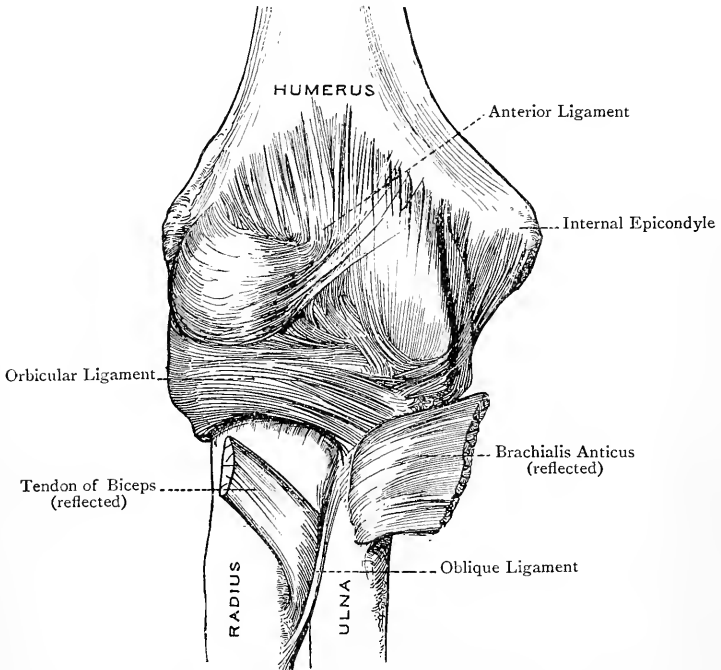


FIG. 208.—THE RIGHT ELBOW-JOINT (ANTERIOR VIEW).

The ligament is related to the tendon of insertion of the triceps, some of the fibres of the internal head being inserted into it, under the name of the subanconeus.

The **external lateral ligament** is a short, stout, flat band, which is attached superiorly to the lower part of the external epicondyle of the humerus, and inferiorly to the outer part of the orbicular ligament of the radius. A few of its posterior fibres pass over the orbicular ligament, and are attached to the outer margin of the ulna. It is intimately related to the origins of the extensor carpi radialis brevis and supinator radii brevis muscles.

The **internal lateral ligament** is triangular, with the apex up-

wards. It is attached superiorly to the anterior, inferior, and posterior parts of the internal epicondyle of the humerus, and inferiorly to the inner margin of the great sigmoid cavity of the ulna. It is divisible into three portions—*anterior*, *posterior*, and *middle*. The *anterior portion* is attached superiorly to the front and lower part of the internal epicondyle, and inferiorly to the inner margin of the coronoid process. The *posterior portion* is attached superiorly to the lower and back part of the internal epicondyle, and inferiorly to the inner margin of the olecranon process. The *middle portion* consists of fibres which pass transversely from the olecranon to the coronoid process, and blend with the fibrous band bridging over the notch on the inner margin of the great sigmoid cavity between these two processes. The ligament is intimately related to the origin of the flexor sublimis digitorum.

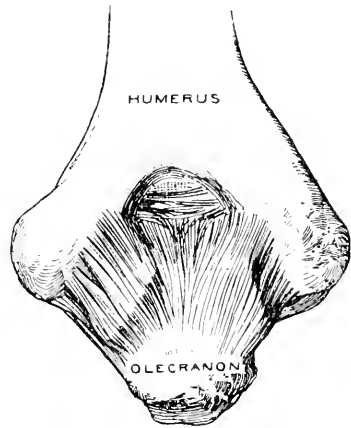


FIG. 209.—THE POSTERIOR LIGAMENT OF THE ELBOW-JOINT.

The **synovial membrane** lines the internal surface of the capsule,

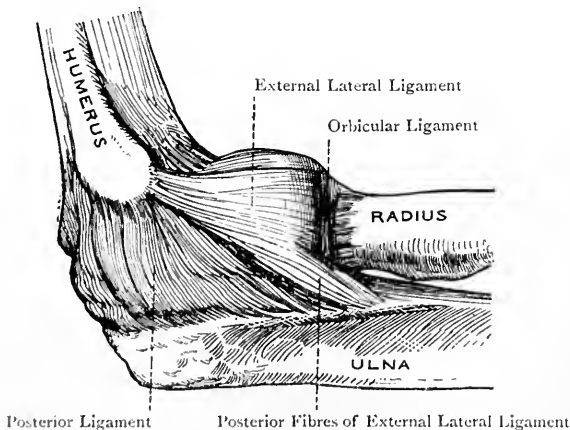


FIG. 210.—THE RIGHT ELBOW-JOINT (EXTERNAL VIEW).

and inferiorly is continued into the superior radio-ulnar joint, where it lines the internal surface of the orbicular ligament and upper part of the neck of the radius. It also lines the coronoid,

radial, and olecranon fossæ of the humerus, which contain small cushions of fat.

Muscular Relations.—The capsule is closely related to the following muscles: *anteriorly*, the brachialis anticus; *posteriorly*, the triceps; *externally*, the extensor carpi radialis brevis and supinator radii brevis; and *internally*, the flexor sublimis digitorum.

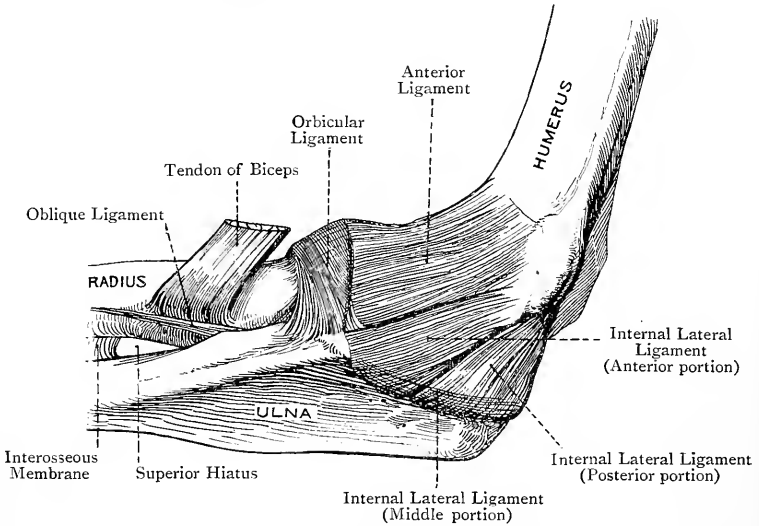


FIG. 211.—THE RIGHT ELBOW-JOINT (INTERNAL VIEW).

Arterial Supply.—The superior and inferior profundæ, anastomotica magna, anterior and posterior ulnar recurrent, radial recurrent, and posterior interosseous recurrent, arteries.

Nerve-supply.—The musculo-spiral, musculo-cutaneous, median, and ulnar nerves.

Movements.—Two movements are allowed, namely, flexion and extension, these being limited by the tension of the structures related to the joint, and flexion also by the coming into contact of the fleshy parts of the forearm and arm.

Muscles concerned in the Movements—Flexion.—This is produced by the biceps, brachialis anticus, brachio-radialis, and, as auxiliaries, the muscles arising from the internal epicondyle of the humerus. **Extension.**—This is produced by the triceps and anconeus, and, as auxiliaries, the muscles arising from the external epicondyle.

THE RADIO-CARPAL OR WRIST-JOINT.

The wrist-joint belongs to the class **diarthrosis**, and to the subdivision **condylarthrosis**. The articular surfaces are the carpal surface of the radius and the triangular fibro-cartilage above, and the superior facets of the scaphoid, semilunar, and cuneiform, as well as the interosseous ligaments on either side of the semilunar, below. The carpal surface of the radius, which presents an outer or scaphoid and an inner or semilunar division, and the triangular fibro-cartilage form a socket, which is concave from side to side

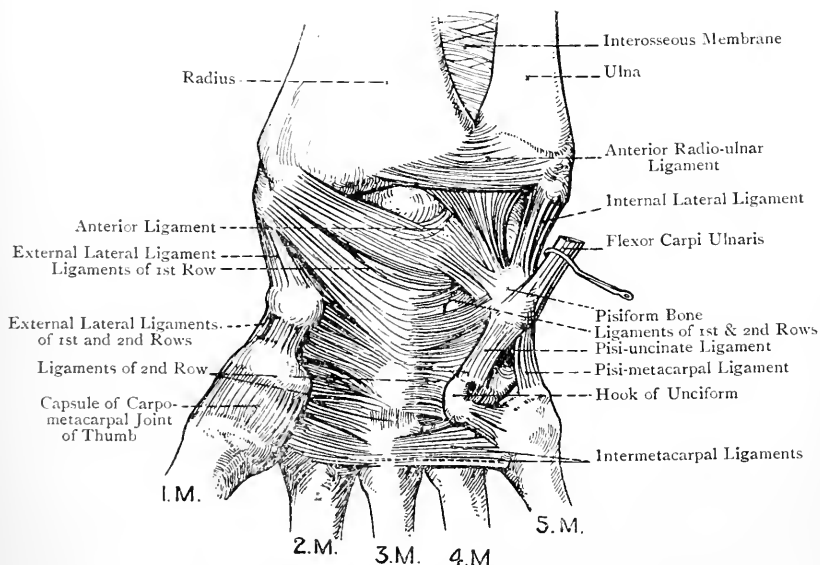


FIG. 212.—THE LIGAMENTS OF THE RADIO-CARPAL, CARPAL, CARPO-METACARPAL, AND INTERMETACARPAL JOINTS (ANTERIOR VIEW).

and from before backwards. The superior facets of the carpal bones extend more upon the dorsal than palmar aspects, and they present a convexity. The ulna is entirely excluded from this joint by the triangular fibro-cartilage. The joint is surrounded by a capsule, which is made up of four ligaments, namely, anterior, posterior, external, and internal.

The **anterior ligament** is a broad, strong membrane, the fibres of which are attached posteriorly to the front of the lower end of the radius, close above the anterior border, and to the anterior margin of the triangular fibro-cartilage. Inferiorly they are attached to the palmar surfaces of the scaphoid, semilunar, and cuneiform bones. The fibres for the most part are directed downwards and inwards.

The **posterior ligament** is a broad, weak membrane, the fibres of which are attached superiorly to the posterior border of the radius and triangular fibro-cartilage, and inferiorly to the dorsal surfaces of the scaphoid, semilunar, and cuneiform bones, especially the latter. Its fibres are directed downwards and inwards.

The **external lateral ligament** is a strong, flattened band, which extends from the tip of the styloid process of the radius to the outer aspects of the scaphoid and trapezium. It supports a portion of the second part of the radial artery.

The **internal lateral ligament** is a strong, round cord, which extends from the tip of the styloid process of the ulna to the cuneiform and pisiform bones.

The **synovial membrane** lines the internal surface of the capsule and the upper surfaces of the interosseous ligaments on either side of the semilunar. In cases where the triangular fibro-cartilage is perforated it is continuous with the synovial membrane of the inferior radio-ulnar joint, but it is distinct from that of the carpal articulations.

Muscular Relations.—*Anterior*.—From within outwards, the flexor carpi ulnaris, flexor profundus digitorum, flexor longus pollicis, and flexor carpi radialis. *Posterior*.—From within outwards, the extensor carpi ulnaris, extensor minimi digiti, extensor communis digitorum with the extensor indicis, extensor longus pollicis, extensor carpi radialis brevis, and extensor carpi radialis longior. *External*.—The extensor ossis metacarpi pollicis and extensor brevis pollicis.

Arterial Supply.—The anterior and posterior carpal retia.

Nerve-supply.—The median, ulnar, and posterior interosseous, nerves.

Movements.—Six movements are allowed, namely, palmar flexion, dorsal flexion, ulnar flexion or adduction, radial flexion or abduction, extension, and circumduction. In all forms of **flexion** an angle is produced between the hand and forearm. **Extension** is straightening, so as to efface the angle produced by flexion. **Circumduction** is a combination of all the foregoing movements occurring in alternate succession. Adduction is more extensive than abduction, the styloid process of the radius limiting the latter movement. When the hand is in line with the forearm, the scaphoid division of the carpal articular surface of the radius articulates with the scaphoid bone, and the semilunar division of the carpal articular surface of the radius, together with the triangular fibro-cartilage, articulates with the semilunar bone, the faceted part of the upper surface of the cuneiform being in contact with the inner portion of the capsule. When, however, the hand is adducted—that is to say, flexed in an inward direction—the faceted part of the upper surface of the cuneiform articulates with the triangular fibro-cartilage, the semilunar bone partially articulates with the scaphoid surface of the radius, and the scaphoid bone partially articulates with the outer portion of the capsule.

THE RADIO-ULNAR JOINTS.

The radius and ulna are united by a superior and an inferior radio-ulnar joint, and there is an intermediate connection between their shafts.

Superior Radio-ulnar Joint.—This joint belongs to the class **diarthrosis**, and to the subdivision **trochoides**. The articular surfaces are the deep inner part of the head of the radius, and the small sigmoid cavity of the ulna. There is one ligament at this joint, namely, the **orbicular** or **annular ligament**. This is a strong fibrous band, which forms about four-fifths of a circle, and surrounds the circumference of the head of the radius, which it retains in contact with the small sigmoid cavity. Its extremities are attached to the anterior and posterior margins of the small sigmoid cavity. The ligament is smaller below than above, and so it maintains the head of the radius in position. Its lower border is attached to the neck of the radius by loosely-disposed fibres. It gives attachment to (1) the external lateral ligament of the elbow-joint externally, (2) the outer fibres of the anterior ligament anteriorly, and (3) a portion of the posterior ligament posteriorly.

The **synovial membrane** is continuous with that of the elbow-joint, and lines the inner surface of the orbicular ligament and upper part of the neck of the radius.

Muscular Relations.—Extensor carpi radialis brevis and supinator radii brevis.

Arterial Supply.—The radial recurrent and posterior interosseous recurrent arteries.

Nerve-supply.—The musculo-cutaneous and musculo-spiral nerves.

Inferior Radio-ulnar Joint.—This joint belongs to the class **diarthrosis**, and to the subdivision **trochoides**. The articular surfaces are the sigmoid cavity of the radius, and the outer side of the head of the ulna. The ligaments are anterior and posterior, and the triangular fibro-cartilage.

The **anterior** and **posterior radio-ulnar ligaments** consist of scattered fibres in front of and behind the joint, which are attached to the adjacent portions of the radius and ulna. The bones, however,

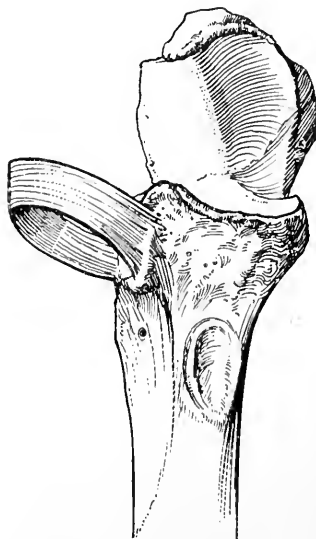


FIG. 213.—THE UPPER END OF THE ULNA, AND THE ORBICULAR LIGAMENT.

are chiefly connected by the **triangular fibro-cartilage**, which is a strong plate. It is attached by its base to the ridge on the radius which separates the sigmoid cavity from the carpal articular surface, and by its apex to the pit on the lower end of the ulna at the root of the styloid process. It is thicker at the circumference than at the centre, and its anterior and posterior borders are connected with the anterior and posterior ligaments of the wrist-joint. Its upper surface is related to the lower end of the ulna, and its lower surface enters into the wrist-joint, articulating with the semilunar bone when the hand is in line with the forearm, and with the faceted part of the upper surface of the cuneiform bone when the hand is adducted. It sometimes presents a perforation.

The **synovial membrane** is very loose, and is known as the *membrana sacciformis*. It consists of two parts, vertical and horizontal, which are continuous with each other. The vertical part extends upwards between the head of the ulna and the sigmoid cavity of the radius, and the horizontal part lies between the lower end of the ulna and the upper surface of the triangular fibro-cartilage. When the fibro-cartilage is perforated the *membrana sacciformis* is continuous with the radio-carpal synovial membrane.

Arterial Supply.—The anterior and posterior ulnar carpal arteries.

Nerve-supply.—The anterior and posterior interosseous nerves.

Intermediate Connection between the Radius and Ulna.—This is a variety of **syndesmosis**. The shafts of the two bones are connected by two ligaments, namely, the interosseous membrane and the oblique ligament.

The **interosseous membrane** is a strong expansion which extends between the interosseous borders of the shafts of the radius and ulna. Its fibres pass principally downwards and outwards from the radius to the ulna, but some pass in the opposite direction. Superiorly it reaches to a point about 1 inch below the bicipital tuberosity of the radius, and inferiorly to the upper part of the sigmoid cavity of that bone. The posterior interosseous artery passes backwards between the two bones over its upper border, and the posterior branch of the anterior interosseous artery pierces it a little above its lower end. The membrane, besides connecting the shafts of the two bones, serves to give origin to muscles of the front and back of the forearm.

Relations—*Anterior.*—The flexor profundus digitorum and flexor longus pollicis, with the anterior interosseous vessels and nerve lying between the two, as low as the lower fourth, where the pronator quadratus forms the anterior relation. *Posterior.*—From above downwards, the supinator radii brevis, extensor ossis metacarpi pollicis, extensor brevis pollicis, extensor longus pollicis, extensor indicis, and, for a short distance below, the posterior interosseous nerve and posterior branch of the anterior interosseous artery.

The **oblique ligament** is a narrow band which extends from the tuberosity of the ulna to the radius, close below the lower and back part of the bicipital tuberosity. Its fibres are directed downwards

and outwards. The interval between it and the upper border of the interosseous membrane gives passage to the posterior interosseous vessels.

Movements.—The movements allowed are **pronation** and **supination**, the latter being the stronger. In pronation the lower part of the radius, carrying with it the hand, crosses over the lower part of the ulna so as to lie on its inner side, the dorsum of the hand being directed upwards. In supination the radius and hand retrace their steps, so that the lower part of the radius lies on the outer side of the ulna, the palm of the hand being directed upwards. At the superior radio-ulnar joint the head of the radius rotates upon the capitellum of the humerus within the orbicular ligament, and comes into closest relation with the capitellum in semiflexion of the elbow-joint and semipronation of the forearm. At the inferior radio-ulnar joint the radius, carrying with it the triangular fibro-cartilage, rotates upon the head of the ulna, the movement being one of limited circumduction around an axis passing from the centre of the head of the radius to the styloid process of the ulna. There is also a limited amount of circumduction on the part of the ulna, the lower end of that bone moving outwards and backwards in pronation, and inwards and forwards in supination.

Muscles concerned in the Movements—(1) **Pronation.**—The principal pronator muscles are the pronator radii teres and pronator quadratus. (2) **Supination.**—The principal supinator muscles are the biceps and supinator radii brevis. The brachio-radialis is also a feeble supinator, but it only acts as such to the extent of semisupination. The biceps is enabled to act as a supinator in virtue of its insertion into the back part of the bicipital tuberosity of the radius.

THE ARTICULATIONS OF THE HAND.

Carpal Joints.—The carpal joints are divided into those of the first row, those of the second row, and the transverse carpal joint.

Joints of the First Row.—These belong to the class **diarthrosis**, and to the subdivision **arthrodia**. The bones of the first row, with the exception of the pisiform, are united by two dorsal, two palmar, and two interosseous ligaments. The dorsal and palmar ligaments extend transversely from the front and back of the semilunar to the corresponding surfaces of the scaphoid and cuneiform. The two interosseous ligaments are placed one on either side of the semilunar, and they connect it with the scaphoid and cuneiform. They are situated high up on the lateral surfaces of the bones, and their upper surfaces form part of the lower wall of the radio-carpal joint.

The synovial membrane is continuous with that of the transverse carpal joint.

Pisiform Joint.—The pisiform bone is united to the front of the cuneiform by a capsular ligament, which surrounds the joint and is attached to the bones at the circumference of their opposed articular surfaces. Superiorly the capsule is connected with the tendon of insertion of the flexor carpi ulnaris, and inferiorly with two prolongations of that tendon, called the *pisiform* and *pisiform* ligaments. The former is attached to the hook of the cuneiform bone, and the latter to the base of the fifth metacarpal. These ligaments

act by keeping the pisiform bone fixed during the action of the flexor carpi ulnaris.

The pisiform joint has a special synovial membrane.

Joints of the Second Row.—These belong to the class **diarthrosis**, and to the subdivision **arthrodia**. The four bones of the second row are connected by three dorsal, three palmar, and three interosseous ligaments, which are disposed similarly to those of the first row.

The synovial membrane is continuous with that of the transverse carpal joint.

Transverse Carpal Joint.—This is the joint between the first and second rows. It belongs to the class **diarthrosis**, and partly to

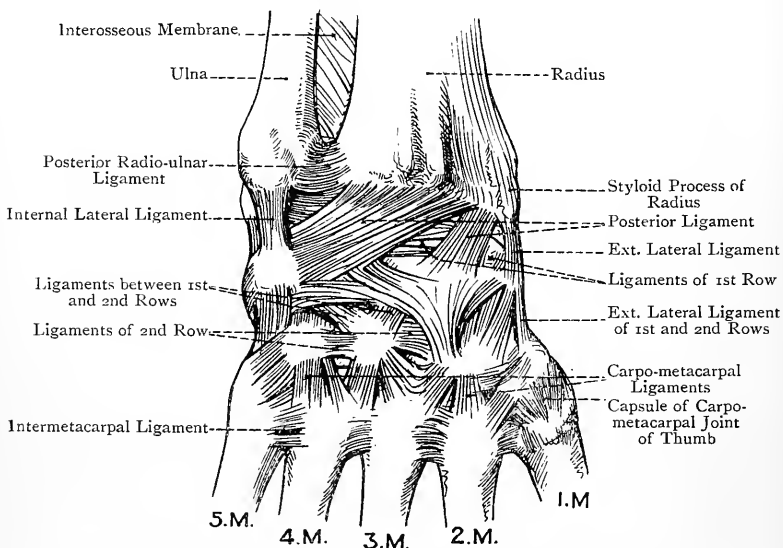


FIG. 214.—LIGAMENTS OF THE RADIO-CARPAL, CARPAL, CARPO-METACARPAL, AND INTERMETACARPAL JOINTS (POSTERIOR VIEW).

the subdivision **arthrodia** and partly to the subdivision **condylarthrosis**. The opposed surfaces of the two rows are each concavo-convex, the first in a direction from within outwards, and the second from without inwards. The convexity of the first row is formed by part of the scaphoid, and the concavity by part of the scaphoid, semilunar, and cuneiform. The concavity of the second row is formed by the trapezium and trapezoid, and the convexity by the head of the os magnum and part of the unciform. The two rows are connected by dorsal, palmar, and lateral ligaments. The dorsal ligaments are very indefinite and pass in different directions. The palmar ligaments for the most part radiate from the os magnum,

though a few pass from the other bones of the second row. The external lateral ligament connects the scaphoid with the trapezium, and the internal lateral connects the cuneiform with the unciform.

Carpal Synovial Membrane.—This membrane lines the transverse carpal joint, and gives off vertically-disposed processes. Two of these pass upwards, one on either side of the semilunar as far as its interosseous ligaments. Three pass downwards—one between the trapezium and trapezoid, another between the trapezoid and os magnum, and a third between the os magnum and unciform. Thereafter the synovial membrane is continued into the inner four carpo-metacarpal joints, and this latter portion of it sends processes into the joints between the bases of the inner four metacarpal bones.

Arterial Supply.—The anterior and posterior carpal retia.

Nerve-supply.—The median, ulnar, and posterior interosseous nerves.

Movements.—The movements between the bones of each row are extremely limited, and are of a **gliding** nature. The movements at the transverse carpal joint are more free, and take the form of flexion and extension in association with the corresponding movements at the radio-carpal joint. The number of the carpal articulations imparts to this part of the hand considerable strength and elasticity, and so enables it to disperse shock.

Carpo-metacarpal Joints.—*Inner Four Joints.*—These belong to class **diarthrosis**, and to the subdivision **arthrodia**. The bones concerned are the trapezium, trapezoid, os magnum, and unciform above, and the bases of the inner four metacarpal bones below. The ligaments are dorsal, palmar, and interosseous. The second, third, and fourth metacarpal bones receive each two dorsal ligaments as a rule, and the fifth receives one, namely, from the unciform. The palmar ligaments are usually one to each bone. There is only one interosseous ligament, which connects the adjacent parts of the os magnum and unciform with the inner aspect of the base of the third metacarpal bone towards its palmar aspect.

The synovial membrane is a continuation of that of the carpus.

These joints derive their arterial supply from the radial and ulnar arteries, and their nerve-supply from the deep division of the ulnar, and posterior interosseous, nerves.

Movements.—The movements are those of flexion and extension, the former being most free in the case of the fifth metacarpal, as in the formation of the 'palmar cup.'

Carpo-metacarpal Joint of the Thumb.—This belongs to the class **diarthrosis**, and to that variety of the subdivision **arthrodia** which is called the *reciprocal* or *saddle-joint*. The bones which enter into this important joint are the trapezium and the base of the first metacarpal. The articular surfaces are saddle-shaped, and are connected by a capsular ligament, which is attached round the margin of each articular surface, being strongest on the dorsal and outer aspects. This ligament is sufficiently loose to allow of considerable movement.

The synovial membrane is peculiar to the joint.

Arterial Supply.—The *arteria princeps pollicis* of the radial.

Nerve-supply.—The median nerve.

Movements.—The movements allowed are flexion, extension, abduction, adduction, and circumduction. It is at this joint where the important movement of **opposition** takes place, whereby the tip of the thumb can be opposed in succession to the tip of each of the four inner fingers.

Intermetacarpal Joints.—The basal intermetacarpal joints belong to the class **diarthrosis**, and to the subdivision **arthrodia**. The bones concerned are the inner four metacarpals, the first metacarpal bone standing off from the second, with which it has no articulation. The ligaments are dorsal, palmar, and interosseous. The dorsal ligaments are composed of stout fibres, which pass transversely between the contiguous aspects of the bases. The palmar ligaments are similarly disposed in front. The interosseous ligaments are strong bundles which pass between the opposed surfaces of the bases to which they are attached on the distal sides of the articular facets.

Nerve-supply.—The deep division of the ulnar nerve.

Arterial Supply.—The palmar and dorsal interosseous arteries.

The synovial membrane is a downward prolongation from that of the carpus.

The heads of the inner four metacarpal bones are connected by the **transverse metacarpal** (deep transverse) **ligament**. It extends transversely across the palmar aspects of the heads, and its fibres are attached to the fibrous plates on the palmar surfaces of the metacarpo-phalangeal joints. It receives the deep expansions of the digital processes of the central division of the palmar fascia, and the digital arteries and nerves pass in front of it, and the interosseous muscles behind it. It is to be noted that the transverse metacarpal ligament excludes the head of the first metacarpal bone, whereas the corresponding ligament of the foot includes the head of the first metatarsal.

The **synovial membranes** from the inferior radio-ulnar joint down to the intermetacarpal joints are five in number, as follows :

1. Inferior radio-ulnar or *membrana sacciformis*.

2. Radio-carpal.

3. Pisiform.

4. Carpal, composed of carpal proper, carpo-metacarpal, and intermetacarpal portions, all continuous with one another.

5. Carpo-metacarpal of the thumb.

Metacarpo-phalangeal Joints.—These belong to the class **diarthrosis**, and to the subdivision **condylarthrosis**, which is a modification of enarthrosis or ball-and-socket joint. In each joint the round head of a metacarpal bone articulates with the cup-shaped depression on the proximal end of a first phalanx.

Inner Four Metacarpo-phalangeal Joints.—Each of these joints has three ligaments—two lateral, and a palmar. The lateral

metacarpo-phalangeal ligaments are strong bands which are attached above to the dorsal tubercle and palmar depression on either side of the head of a metacarpal bone, and below to each side of the base of a first phalanx, and also to the lateral margin of the palmar fibrous plate. Each is connected with a deep expansion of a digital process of the central division of the palmar fascia. The palmar ligament takes the form of a *fibrous plate*. It is closely attached at either side to the lateral ligaments, inferiorly to the palmar aspect of the base of the first phalanx, and superiorly, where it is connected with the transverse metacarpal ligament, it is slightly attached to the palmar aspect of the head of a metacarpal bone, close above the articular cartilage. It increases the extent of the phalangeal socket for the head of a metacarpal bone, and it forms part of the tunnel for the passage of a pair of flexor tendons. Its deep surface is lined by the synovial membrane of the joint. There is no dorsal ligament, its place being taken by the extensor tendon.

Each joint is provided with a synovial membrane, which is looser in front than behind.

Arterial Supply.—The digital arteries from the superficial palmar arch, or the palmar interosseous from the deep palmar arch.

Nerve-supply.—The deep division of the ulnar nerve.

Movements.—The movements are flexion, extension, abduction, adduction, and circumduction. Flexion is particularly free, and is combined with adduction. Extension is associated with abduction, and dorsal flexion is prevented by the palmar fibrous plates and flexor tendons.

Metacarpo-phalangeal Joint of the Thumb.—The lateral ligaments of this joint are similar to those of the other joints, but there is no palmar fibrous plate, its place being taken by two sesamoid bones. Each of these bones resembles a split pea. The palmar surface is convex, whilst the deep surface is almost flat and covered by cartilage, to play upon a groove on the palmar surface of the head of the first metacarpal bone. The two bones are united by fibres which pass between their contiguous surfaces, and are related superficially to the tendon of the flexor longus pollicis. Inferiorly they are connected by fibres with the palmar aspect of the base of the first phalanx. At either side they are connected with the lateral ligaments, and posteriorly they are slightly connected with the head of the first metacarpal above the articular cartilage. The outer sesamoid bone is closely associated with the superficial head of the flexor brevis pollicis, and the inner with the adductor obliquus pollicis. The place of a dorsal ligament is taken by the tendons of the extensor brevis, and extensor longus, pollicis.

Arterial Supply.—The *arteria princeps pollicis* of the radial.

Nerve-supply.—The median nerve.

Movements.—Flexion, extension, and lateral movement, the latter only when the joint is partially flexed.

Interphalangeal Joints.—These belong to the class **diarthrosis**, and to the subdivision **ginglymus**. The ligaments are similar to

those of the inner four metacarpo-phalangeal joints, namely, two lateral, and an anterior fibrous plate, the extensor tendon taking the place of a dorsal ligament. Each joint is provided with a synovial membrane, and the arterial and nerve supply are derived from the digital arteries and nerves. Each of the inner four fingers has two interphalangeal joints, but the thumb, being destitute of a middle phalanx, has only one, and its dorsal ligament is represented by the tendon of the extensor longus pollicis, whilst its fibrous plate is grooved by the tendon of the flexor longus pollicis.

Movements.—The only movements allowed are flexion and extension, the former being very free.

Joints with Interarticular Fibro-cartilages.—The joints of the upper limb which have interarticular fibro-cartilages are as follows :

1. The sterno-clavicular joint.
2. The acromio-clavicular joint (inconstant).
3. The triangular fibro-cartilage of the inferior radio-ulnar articulation is to be regarded as an interarticular fibro-cartilage between the ulna and cuneiform bone at the radio-carpal joint.

The shoulder-joint has a circumferential fibro-cartilage, namely, the glenoid ligament.

GUIDE TO THE UPPER LIMB.

The Back.—To remove the skin, the following incisions may be made: one along the middle line from the seventh cervical spine to the second sacral spine; another from the upper end of this incision outwards to the acromion process, and thence downwards over the back of the shoulder in a curved manner to meet the posterior fold of the axilla; and a third from the lower end of the mesial incision outwards along the iliac crest. The cutaneous nerves will be found near the spines of the upper six thoracic vertebræ and near the angles of the lower six ribs. Three branches from the first three lumbar nerves are to be shown descending over the iliac crest to the gluteal region.

The trapezius muscle is to be cleaned, and, in doing so, as well as in the deep stages of this dissection, it is advisable that the dissector of the upper limb should work in concert with the dissector of the head. The spinal accessory nerve will be found passing beneath the anterior border of the trapezius. The latissimus dorsi is next to be cleaned, and turning backwards round its outer border will be found the posterior offsets of the lateral cutaneous branches of the intercostal nerves. Between the contiguous borders of the latissimus dorsi and obliquus externus abdominis, just above the centre of the iliac crest, the triangle of Petit is to be shown. The region between the trapezius, latissimus dorsi, and base of the scapula, and the parts contained therein, are to be studied. The trapezius is to be divided about 1 inch from the spines of the vertebræ, and the spinal accessory nerve, with branches of the third and fourth cervical nerves, and the superficial cervical artery, are to be dissected on its deep surface. The latissimus dorsi is to be divided by an incision carried downwards from its upper border about 3 inches from the spines of the vertebræ to the back part of the iliac crest internal to the iliac origin of the muscle, so as to leave undisturbed its slips of origin from the lower three or four ribs, as well as its iliac origin. In reflecting inwards the inner portion of the muscle care is to be taken not to injure the serratus posticus inferior, and, in turning outwards the outer portion, the serratus magnus is not to be interfered with.

The levator anguli scapulæ and rhomboid muscles are to be dissected, and the nerve to the rhomboids is to be looked for deeply between these two

muscles about 1 inch from the base of the scapula. The disposition of the rhomboideus major at its insertion is to be noted, and the fibrous band or arch shown. The levator anguli scapulae is to be divided about its centre, and the rhomboids about 1 inch from the spines of the vertebrae, which will bring into view the posterior scapular artery lying close to the base of the scapula. A branch to the levator anguli scapulae from the nerve to the rhomboids is to be looked for, and a very limited view will be obtained of the posterior belly of the omo-hyoid at the upper border of the scapula. In association with it the suprascapular nerve and artery may just be seen, but this dissection is not to be pushed.

The serratus posticus superior is next to be dissected, followed by that of the serratus posticus inferior, and before reflecting these muscles the vertebral aponeurosis is to be studied, and the posterior lamina of the lumbar aponeurosis, which gives origin to the latissimus dorsi and serratus posticus inferior. At this stage the internal or deep surface of the serratus magnus is to be examined. The serratus posticus superior is to be cut about 1 inch from the spines of the vertebrae, and each serration of the serratus posticus inferior is to be divided just below the rib into which it is inserted. The vertebral aponeurosis is also to be carefully removed. In this manner the erector spinae muscle is exposed. Before dissecting this muscle, however, the splenius is to be studied, in concert with the dissector of the head, and divided about 1 inch from its origin. Underneath the splenius will be found the complexus, the inner portion of which is known as the biventer cervicis, and external to the complexus is the narrow, ribbon-like trachelo-mastoid or transversalis capitis. The dissector should now replace over the lower part of the erector spinae the posterior lamina of the lumbar aponeurosis, having attached to it the latissimus dorsi and serratus posticus inferior. At the outer border of the erector spinae he should notice a portion of the middle lamina of the lumbar aponeurosis, of which more will come into view by raising the outer border of the muscle. He will thus see that the lower part of the erector spinae is enclosed in a sheath, the posterior wall of which is formed by the posterior lamina, and the anterior wall by the middle lamina, of the lumbar aponeurosis. The anterior lamina is not visible at this stage. The obliquus internus abdominis may be seen to arise from the lumbar aponeurosis between the iliac crest and the last rib.

The dissection of the erector spinae is now to be proceeded with. The separation between the outer and middle columns of the muscle will be apparent a little below the twelfth rib as a cellular interval, through which nerves emerge, and in line with which, higher up, nerves, accompanied by arteries and veins, also appear. Dealing first with the outer column, and dissecting it from below upwards, the slips of insertion of the ilio-costalis into the angles of the lower six ribs are to be shown. These are then to be turned outwards, and the slips of origin of the musculus accessorius lying internal to them are to be displayed, followed by the slips of insertion of that muscle into the upper ribs. The latter having been turned outwards, the slips of origin of the cervicalis ascendens will be found, and this muscle is to be followed up into the neck, where its three slips of insertion are to be brought out. In dealing with the middle column the dissector should first artificially separate from it the inner column, the connection between the two being very close, and he may at once dispose of the inner column or spinalis dorsi. Its four fleshy and tendinous origins below should be shown, and its tendons of insertion above, varying from four to eight in number. The series of arches formed by the tendons of this muscle should be noted. The middle column is next to be dissected, and the two series of insertions of the longissimus dorsi shown, the outer, fleshy, passing to the lumbar transverse processes and ribs, and the inner, round and tendinous, passing to the lumbar accessory processes and thoracic transverse processes. At the upper part of the back the dissector will find that the longissimus dorsi is prolonged into the neck by the transversalis cervicis, and to the head by the trachelo-mastoid. It is at this stage that the complexus is most advantageously studied. This muscle having been cut high up by the dissector of the head, the semispinalis dorsi and semispinalis colli are to be

dissected. The semispinales and longissimus dorsi having been removed, the multifidus spinæ is to be studied, and an effort made to show its deepest fibres, called the rotatores spinæ. The levatores costarum are to be carefully dissected, and the intertransversales and interspinales are to be looked to, chiefly in the cervical and lumbar regions.

Pectoral Region and Axillary Space.—To remove the skin, the following incisions should be made: a mesial incision along the sternum; another from the upper end of this along the clavicle to the acromion process, and thence downwards over the front of the shoulder to the inner side of the arm close to the anterior fold of the axilla; and a third transversely outwards from the lower end of the sternum. In the case of a female subject, a circular incision should be made around the margin of the areola. In removing the skin from over the mammary gland the fibrous processes, known as the ligamenta suspensoria of Cooper, which pass between the superficial fascia in front of the gland and the skin, are to be noted. The following cutaneous nerves are to be displayed: (1) the suprasternal, supraclavicular, and supra-acromial branches of the cervical plexus, which descend over the clavicle beneath the platysma myoides; (2) the anterior cutaneous branches of the intercostal nerves, which emerge through the upper six intercostal spaces close to the sternum; and (3) the anterior offsets of the lateral cutaneous branches of intercostal nerves below the second, which turn round the anterior fold of the axilla.

If the subject is a female, the mammary gland should now receive careful attention. Its relation to the superficial fascia, which ensheathes it, is to be studied, and also its relation to the deep fascia covering the pectoralis major. The thin skin of the areola is to be carefully raised towards the nipple, and the galactophorous ducts, each presenting a dilatation or ampulla, are to be shown. An endeavour should be made to display the glandular structure and loculi.

The pectoralis major and anterior portion of the deltoid are to be dissected, and in the groove between the two the cephalic vein and humeral branch of the acromio-thoracic artery are to be shown. Lying deeply in the upper part of this groove, just below the clavicle, the infraclavicular glands, two or three in number, are to be looked for. The clavicular part of the pectoralis major should now be divided and reflected. In doing so, the cephalic vein, external anterior thoracic nerve, and branches of the acromio-thoracic artery are to be preserved. The region now being dissected (infraclavicular) lies between the clavicle, pectoralis minor, and upper border of the sterno-costal portion of the pectoralis major. The costo-coracoid membrane, which is a part of the clavi-pectoral fascia, is to be shown, and the stout portion of it, called the costo-coracoid ligament, is to be noted.

Having studied the connections of the costo-coracoid membrane and the various structures piercing it, the membrane, along with the axillary sheath beneath it, is to be carefully removed, and the first part of the axillary artery, with its branches, the axillary vein, and the trunks of the brachial plexus are to be displayed. The internal anterior thoracic nerve will be found coming forwards between the artery and the vein, and a communication between it and the external anterior thoracic nerve is to be looked for over the artery. The posterior thoracic nerve, which lies behind the artery, is to be carefully preserved. The removal of the costo-coracoid membrane will also expose the subclavius muscle. Without further disturbing the pectoralis major meanwhile, the axillary space is now to be dissected from below. The axillary fascia forming the floor of the space, and its relations to the fascial investments of the pectoralis major and latissimus dorsi and fascia of the arm are to be noted. The fascia will be seen to be drawn up towards the space, this being due to the insertion of the clavi-pectoral fascia into its upper surface. The axillary fascia having been dissected, the adipose tissue in the space is to be removed with the greatest care. The lateral cutaneous branches of the intercostal nerves (except the first) will be found on the inner wall between the serrations of the serratus magnus. The lateral cutaneous branch of the second intercostal is to be followed as the intercosto-humeral nerve across the space

to the inner and back part of the arm. The lateral cutaneous branches of the succeeding intercostal nerves are to be shown in two divisions—anterior and posterior. The axillary glands are to be carefully looked for. They will be found in three groups, namely, pectoral, within the anterior fold and on the adjacent part of the inner wall; subscapular, on the posterior wall; and external, on the outer wall. The posterior thoracic nerve is to be followed out upon the serratus magnus, the long thoracic artery will be found along the lower border of the pectoralis minor, and the subscapular artery on the posterior wall. The dorsalis scapulæ branch of the subscapular artery is to be shown. The alar thoracic is seldom a special artery. The middle or long and lower subscapular nerves will be found on the posterior wall, the former, with the subscapular artery, going to the latissimus dorsi, the latter, farther out, supplying the teres major and adjacent part of the subscapularis. The upper or short subscapular nerve should not be looked for at present, as it lies too high up. The structures along the outer wall are next to be shown, namely, the axillary artery, giving off its subscapular, anterior circumflex, and posterior circumflex branches; the axillary vein; and the nerves arising from the cords of the brachial plexus. The internal cutaneous branch of the musculo-spiral nerve should be shown at this stage, and preserved. When the tributaries of the axillary vein have been noted in the course of the foregoing dissection they should be removed.

The sterno-costal portion of the pectoralis major is now to be divided and reflected, in doing which twigs of the internal anterior thoracic nerve will be seen entering its deep surface, after having pierced the pectoralis minor. The latter muscle is now to be dissected, the fascia, removed in preparing it, being continuous above with the costo-coracoid membrane, and being inserted below into the upper surface of the axillary fascia. The internal anterior thoracic nerve is to be shown entering the deep surface of the muscle. The pectoralis minor having been cut, the axillary space will be fully exposed. The second part of the axillary artery is to be dissected, and it will be found, as a rule, to give off the long thoracic, but the alar thoracic is very inconstant. The cords of the brachial plexus and their relation to the second part of the artery are to be noted, and the upper or short subscapular nerve may now be seen at the upper part of the posterior wall of the space, where it immediately enters the upper part of the subscapularis. The origins of the branches of the cords of the brachial plexus are to be shown as follows: external anterior thoracic, musculo-cutaneous, and outer root of the median from the outer cord; internal anterior thoracic, lesser internal cutaneous or nerve of Wrisberg, the internal cutaneous, inner root of the median, and ulnar from the inner cord; and the three subscapular nerves, circumflex, and musculo-spiral from the posterior cord.

The next duty of the dissector is to study the sterno-clavicular joint. Thereafter the clavicle is to be sawn through at its centre, and the subclavius muscle divided. At this stage the dissectors of the upper limb and head should work in concert. A full view will be obtained of the continuity between the subclavian and axillary arteries, and the nerve trunks and individual nerves of the brachial plexus, as well as the supra-clavicular branches of that plexus. The suprascapular artery and nerve, and the posterior belly of the omo-hyoid will also be seen. The vessels and nerves are then all to be included in two ligatures placed 1 inch apart, and divided between them, and the lower ligature is to be firmly secured to the outer cut end of the clavicle. The serratus magnus is to be studied, and it will be put upon the stretch if the shoulder is pressed outwards. The limb is then to be removed by dividing the serratus magnus, posterior belly of the omo-hyoid, and levator anguli scapulæ, if the latter has not been already cut.

Scapular Region.—After removal of the limb, the dissector is to trim the various scapular muscles already dissected, and the arrangement of the tendon of insertion of the pectoralis major is to be shown. The shoulder being supported on a block, the skin is to be removed from over the deltoid, and the cutaneous nerves shown, namely, the supra-acromial over the upper third, and a large cutaneous branch of the circumflex turning round the posterior

border of the muscle near its centre. In cleaning this border the relation to it of the deep fascia over the infraspinatus is to be observed. The deltoid having been fully dissected, and twigs of the circumflex nerve which pierce it having been noted, the muscle is to be divided about 1 inch below its origin. In turning it down the subacromial bursa and the circumflex nerve and posterior circumflex artery are to be shown, the latter two entering its deep surface.

The infraspinatus, teres minor, teres major, and long head of the triceps are then to be dissected, and the gangliform enlargement on the branch of the circumflex nerve to the teres minor is to be observed. The quadrangular and triangular muscular spaces, with their contents, are to be exposed, and the substitution of the subscapularis as a boundary in front for the teres minor behind is to be noted. The dorsalis scapulæ artery is to be shown winding round the axillary border of the scapula through the origin of the teres minor. The supraspinatus is next to be dissected, and, to follow the muscle to its insertion, the acromion process may be sawn through. At the upper border of the muscle will be found the posterior belly of the omo-hyoid and the suprascapular nerve and artery. The subscapularis is to be cleaned, and at this stage the upper or short subscapular nerve will be fully seen.

The supraspinatus, infraspinatus, and teres minor are to be stripped carefully from the bone and dissected up to their insertions, in doing which the intimate connection between their tendons and the upper and back parts of the capsule of the shoulder-joint will arrest attention. Between the infraspinatus tendon and the capsule a small bursa may be found. The careful removal of these muscles will allow the dissector to follow out the suprascapular artery and nerve, and the dorsalis scapulæ artery. The subscapularis is also to be stripped from the bone and dissected to its insertion, to do which the muscle must be raised from beneath the coraco-brachialis and short head of the biceps. The close connection between its tendon and the front of the capsule is to be noted, as well as the opening in the capsule through which the synovial membrane protrudes to form the subscapular bursa. The teres major and latissimus dorsi are to be followed to their insertions, the varying relations between the two are to be made clear, the intervening bursa shown, and in some cases a small bursa behind the tendon of the teres major close to the bone. Before leaving this region the dissector should carefully study the scapular anastomoses of arteries, the muscular relations of the capsule of the shoulder-joint, and the actions of the scapular muscles, with their nerve-supply.

Cutaneous Nerves and Veins of the Arm and Forearm.—The skin should be at once reflected as low as the wrist by a median incision down the front of the limb, and transverse incisions at the elbow and wrist. In reflecting it from over the back of the olecranon process the subcutaneous bursa, there situated, is to be attended to. The following cutaneous nerves are to be followed out to their distribution, care being taken to preserve the cutaneous veins: (1) the intercosto-humeral to the inner and back part of the arm in its upper half; (2) the internal cutaneous of the musculo-spiral to the back of the arm; (3) the nerve of Wrisberg to the lower half of the arm on its inner aspect; (4) twigs of the internal cutaneous to the front of the arm in its upper part; and (5) the upper external cutaneous branch of the musculo-spiral (which appears a little below the centre of the outer side of the arm) to the outer side and front of the arm over about its lower half. At the junction of the upper two-thirds and lower third of the arm on its inner side the internal cutaneous nerve will be found piercing the deep fascia in two divisions, separately or conjointly, and from this point the two divisions, anterior and posterior, are to be followed downwards along the inner part of the forearm, as low as the wrist in the case of the anterior. The lower external cutaneous branch of the musculo-spiral is to be followed from the outer side of the arm, a little below the centre, down the back of the outer side of the forearm as low as the wrist. The cutaneous part of the musculo-cutaneous will be found at the outer border of the biceps a little above the elbow, and it is to be traced down the outer side of the forearm as low as the wrist in two divisions, anterior and posterior.

In front of the forearm, just below the centre and internal to the middle line,

a cutaneous branch of the ulnar nerve may be met with, and towards the wrist the palmar cutaneous branches of the median and ulnar are to be shown. In the lower third of the forearm, posteriorly and on its outer aspect, the radial nerve is to be shown, as well as the dorsal branch of the ulnar nerve on its inner aspect. The cutaneous veins to be dissected are the radial, median, and anterior and posterior ulnar veins in the forearm; the median basilic and median cephalic at the bend of the elbow, with the deep median joining the superficial median close to its termination; and the basilic and cephalic in the arm, the basilic being superficial to the deep fascia in the lower half, but subsequently piercing it, and the cephalic being superficial throughout. In connection with the median basilic vein the semilunar fascia of the biceps is to be shown, and one or two supracondylar glands are to be carefully looked for a little above the internal epicondyle, close to the basilic vein.

Front and Inner Side of the Brachial Region.—The deep fascia of the arm is to be studied, and, as the dissection proceeds, the external and internal intermuscular septa, with the structures related to them, are to be noted. The biceps and coraco-brachialis are to be dissected, and, in connection with the tendon of insertion of the latter muscle, a fibrous band should be looked for passing upwards to the humerus below the small tuberosity, and forming an arch over the latissimus dorsi and teres major. The internal brachial ligament of Struthers is to be looked for, extending from the humerus near the insertion of the teres major to the internal epicondyle. The musculo-cutaneous nerve is to be shown piercing the coraco-brachialis, and, by raising the biceps, the nerve is to be followed between that muscle and the brachialis anticus to the outer border of the biceps, where it becomes cutaneous, and its muscular branches are to be shown. It may be found to give a communicating branch to the median. The semilunar fascia of the biceps is to be carefully dissected, and its relation to the brachial artery and median basilic vein is to be observed.

The brachial artery is next to be dissected, and the venæ comites on either side of it shown. These will be found to join above, and terminate in the lower part of the axillary vein. The median nerve is to be shown lying at first on the outer side of the artery, then crossing it just below the centre of the arm, and thereafter lying on its inner side. It gives off no branches in the arm, but it may receive one from the musculo-cutaneous. The branches of the brachial artery are to be shown as follows: (1) the superior profunda arises high up from the inner and back part of the vessel, and accompanies the musculo-spiral nerve to the back of the arm; (2) the inferior profunda arises from the inner side a little lower down than the preceding, and accompanies the ulnar nerve through the internal intermuscular septum to the interval between the internal epicondyle and the olecranon; (3) the nutrient or medullary artery arises from the inner side about the lower border of the tendon of insertion of the coraco-brachialis, and passes downwards to enter the medullary foramen of the humerus; (4) the anastomotica magna arises from the inner side about 2 inches above the elbow, and divides into two branches—*anterior*, passing downwards in front of the internal epicondyle beneath the pronator radii teres, and posterior, piercing the internal intermuscular septum to reach the interval between the internal epicondyle and the olecranon; and (5) several muscular branches arising from the outer side of the vessel.

The musculo-spiral nerve is to be shown lying, for a little, behind the upper part of the brachial artery, and the branches which it here gives off, namely, internal cutaneous to the back of the arm, and muscular to the long and internal heads of the triceps, are to be noted. One of the latter descends with the ulnar nerve, as the ulnar collateral nerve of Krause, to enter the internal head of the muscle low down. The ulnar nerve is to be dissected as low as the internal epicondyle and the olecranon, and it is to be shown piercing the internal intermuscular septum. It gives off no branches in the arm. The internal cutaneous nerve and the nerve of Wrisberg are also to be noted. The brachialis anticus is to be dissected by displacing the biceps outwards, and it is to be separated from the brachio-radialis. In this way a part of the musculo-spiral nerve will be exposed, and it is to be followed carefully downwards to near the external epicondyle, where its two terminal branches, radial and

posterior interosseous, are to be shown. In this part of its course the nerve will be found to furnish branches to the brachio-radialis and extensor carpi radialis longior, and a twig to the brachialis anticus, the latter arising high up in the spiral groove. Descending with the musculo-spiral nerve in this groove will be found the anterior terminal branch of the superior profunda artery, and coming up from below to anastomose with it a branch of the radial recurrent.

The anticubital space or triangular hollow in front of the elbow is next to be dissected, and its roof, floor, boundaries, and contents carefully studied. If the brachio-radialis is held aside, the posterior interosseous nerve will be seen piercing the supinator radii brevis; and, if the superficial head of the pronator radii teres is raised, the anterior ulnar recurrent artery, of small size, will be found ascending to the front of the internal epicondyle, where it anastomoses with the anterior branch of the anastomotica magna. The mode of insertion of the tendon of the biceps is to be carefully noted, and its action in this connection studied.

Back of the Brachial Region.—The triceps is to be dissected, and its three heads clearly shown. The long head is obvious, but the external and internal heads require careful dissection. The dissector should pull upon the musculo-spiral nerve to make evident its winding course round the back of the humerus, and he should then make an incision through the muscle over the course of the nerve, avoiding its long head. When the cut parts of the muscle are separated, the spiral groove of the humerus is laid bare, with the musculo-spiral nerve and superior profunda artery lying in it. The portion of the muscle above and external to the groove is the external head, and the small, peaked portion inside the groove and all the fibres arising from the back of the humerus below the groove represent the internal head.

The branches of the musculo-spiral nerve behind the humerus are to be shown, and one long branch to the anconeus, which descends in the internal head of the triceps, is to be followed out. The nerve, on leaving the spiral groove, will be seen to pierce the external intermuscular septum from behind forwards, along with the anterior branch of the superior profunda artery. This artery is also to be dissected, and its posterior terminal branch is to be shown descending behind the external intermuscular septum to the back of the external epicondyle, where it anastomoses with the posterior interosseous recurrent. The internal head of the triceps may now be cut into inferiorly, in order to show its deepest fibres, under the name of the subanconeus, taking insertion into the back part of the capsule of the elbow-joint.

Aeromio-clavicular Joint.—In connection with this joint the coraco-clavicular ligament is to be displayed in two parts—conoid and trapezoid—and between these will be found a little fat and a small bursa. The ligaments of the joint itself are next to be dissected, and, when the joint is opened, an incomplete interarticular fibro-cartilage may be found within it at the upper part.

Special Ligaments of the Scapula.—The suprascapular or transverse ligament is to be made evident, with the suprascapular nerve passing backwards beneath it, the suprascapular artery over it, and fibres of the posterior belly of the omohyoid arising from it. The coraco-acromial or deltoid ligament is next to be dissected, and its relation to the capsule of the shoulder-joint carefully noted. The spino-glenoid ligament is to be shown passing between the outer border of the spine and the adjacent part of the margin of the glenoid cavity. It will be seen to bridge over the suprascapular artery and nerve on their way to the infraspinous fossa.

Shoulder-Joint.—The dissector should first revise the subacromial bursa and the muscular relations of the capsule of this joint. The capsular ligament is then to be studied, and the coraco-humeral ligament is to be noted incorporated with its upper aspect. Two openings in the capsule are to be observed. One is situated in front, behind the upper border of the tendon of the subscapularis, and through this opening the synovial membrane will be found protruding to form the subscapular bursa. The other opening is situated between the tuberosities of the humerus, at the entrance to the bi-

capital groove, this being for the passage of the long tendon of the biceps. The transverse humeral ligament will be found bridging over this part of the bicipital groove. The joint should now be opened by removing the posterior part of the capsule, and the three gleno-humeral ligaments are to be looked for. They are situated on the inner and anterior aspect of the capsule. The front part of the capsule should now be removed and the glenoid ligament examined. The tendon of the long head of the biceps, as it arches over the head of the humerus, is to be noted, and its relation to the glenoid ligament at the apex of the glenoid cavity is to be shown. The synovial membrane and movements are then to be studied.

Front of the Forearm.—The deep fascia is to be examined and removed, except the part covering the muscles arising from the internal epicondyle. These muscles are to be dissected, from without inwards, in the following order: pronator radii teres, flexor carpi radialis, palmaris longus, flexor carpi ulnaris, and flexor sublimis digitorum. Having noted the common tendon of origin of these muscles, what is left of the deep fascia is to be removed, and the muscles carefully separated from each other up to their origins. In doing so, the strong intermuscular septa are to be noted. The small, deep head of the pronator radii teres is to be displayed, with the median nerve passing between the two heads of the muscle, and the ulnar artery beneath its deep head, and it should be noted that the median nerve, which is at first internal to the ulnar artery, crosses it to get to its outer side.

The muscular branches of the median nerve are to be caught high up, as well as its anterior interosseous branch, in connection with which latter care is to be taken to preserve the median branch of the anterior interosseous artery, which is usually of small size. The ulnar nerve is to be shown entering the forearm between the two heads of the flexor carpi ulnaris, where it lies between the internal epicondyle and olecranon, and gives off articular twigs to the elbow-joint. Thereafter its branches to the flexor carpi ulnaris and inner portion of the flexor profundus digitorum should be displayed high up.

The radial artery is next to be dissected as low as the wrist, its venæ comites being noted. The branches to be shown are the radial recurrent, close to the origin, muscular down the forearm, and anterior radial carpal and superficial volar near the wrist. The radial nerve is also to be dissected until it turns to the back of the forearm beneath the tendon of the brachioradialis. The ulnar artery is then to be dissected as low as the wrist, and, descending over its lower half, the palmar cutaneous branch of the ulnar nerve is to be preserved. The branches of the vessel to be shown are the anterior and posterior ulnar recurrences, the interosseous trunk, soon dividing into anterior and posterior interosseous, the former of which gives off the median artery (all of these branches arising high up), muscular down the forearm, and posterior and anterior ulnar carpals near the wrist. The posterior interosseous artery is to be shown passing backwards between the radius and ulna, and the median branch of the anterior interosseous artery is to be carefully studied, as it is sometimes of large size and may be continued into the palm to join the superficial palmar arch. The ulnar nerve is to be dissected as low as the wrist. Its occasional branch to the front of the forearm below the centre is to be looked for, and the palmar cutaneous and dorsal branches are to be shown, the former arising a little below the centre of the forearm and the latter about 2 inches above the wrist, after which it turns backwards beneath the tendon of the flexor carpi ulnaris.

The flexor sublimis digitorum is then to be raised and held aside, to show the median nerve, with the median artery, descending in close contact with its deep surface as far as a little above the wrist, where the nerve comes to lie on the outer side of the muscle, and gives off its palmar cutaneous branch. At this stage the dissector should carefully note that the great palmar bursa is prolonged upwards round the flexor tendons for fully an inch above the anterior annular ligament, and the arrangement of the superficial flexor tendons in pairs before they pass beneath that ligament is to be shown. By pulling upon the individual tendons, those of the anterior pair will be seen

to belong to the middle and ring fingers, and those of the posterior pair to the index and little fingers.

The deep muscles of the front of the forearm are next to be dissected, namely, the flexor profundus digitorum, flexor longus pollicis, and pronator quadratus. The anterior interosseous nerve and artery, the latter having two venae comites, are to be followed down the front of the interosseous membrane beneath the pronator quadratus. In this latter situation the nerve should be shown to supply the pronator quadratus, and give an articular branch to the wrist-joint. The artery should be here shown to divide into anterior and posterior branches, the former descending to take part in the anterior carpal rete, and the latter piercing the interosseous membrane to reach the posterior carpal rete.

Front of the Hand.—The various landmarks are to be carefully studied. Thereafter the skin is to be removed by a median incision from the centre of the wrist to the cleft between the middle and ring fingers, and a transverse incision across the roots of the fingers. Median incisions are also to be made down the centre of the thumb and each finger, and the skin removed from these parts. In removing the skin from the palm fibrous processes will come into view, which connect it with the central division of the palmar fascia. The lobulated condition of the superficial fascia of the palm is to be noted, and the superficial transverse ligament is to be looked for as a few scattered transverse fibres lying within the skin at the roots of the fingers. The palmar cutaneous branches of the median and ulnar nerves are to be followed out, and twigs of the radial nerve, reinforced by twigs from the musculo-cutaneous, are to be shown over the thenar eminence. The palmaris brevis muscle is to be carefully dissected, as it is subcutaneous and arranged in bundles. The expansion from the tendon of the flexor carpi ulnaris to the anterior annular ligament is to be noted, as well as the pisi-uncinate and pisi-metacarpal expansions, which are known as ligaments. The ulnar artery and nerve are then to be followed over the anterior annular ligament till they disappear beneath the palmaris brevis, and their relation to the pisiform bone and hook of the unciform are to be noted.

The palmar fascia should now receive careful attention. Its thenar and hypothenar divisions, which are thin, are to be noted, but attention is to be concentrated on the central division. Its triangular shape, great strength, and the longitudinal direction of most of its fibres are to be observed. Some of the fibres, however, will be seen to be disposed transversely, especially towards the roots of the fingers. In this latter situation it should be shown dividing into four digital processes, which pass to become incorporated with the sheaths of the flexor tendons of the inner four fingers. The thenar and hypothenar divisions of the fascia are removable with ordinary care in order to expose the muscles, and no important structure is in danger. The central division, however, must be removed with the greatest care. In doing so the dissector should particularly note its great strength, which will show him how it would resist the pointing of a palmar abscess, and the necessity of early incision to give vent to the pus. As this division is being removed a deep lateral expansion is to be looked for at either side of it, these expansions passing to join the more deeply placed interosseous fascia. The result is that a great central fibrous tunnel is formed in the palm, which contains the superficial palmar arch, digital arteries and nerves, and flexor tendons, all enclosed in the great palmar bursa. In reflecting the digital processes of the central division deep lateral expansions should be looked for, which, along with them and the anterior fibrous plates of the metacarpo-phalangeal joints, form short tunnels for each pair of flexor tendons.

On removal of the central division of the palmar fascia the great palmar bursa is to be thoroughly mastered. The superficial palmar arch is then to be dissected, and its position and branches are to be carefully studied. The profunda branch is to be shown coming off from the commencement (inner part) of the arch, and, along with the deep division of the ulnar nerve, it will be seen to disappear between the abductor, and flexor brevis, minimi digiti. Four digital arteries are to be followed from the convexity of the

arch, the inner one being single and the other three compound, for the supply of the inner three and a half fingers. It should be noted that the digital arteries, in passing to the fingers, lie over the interosseous spaces and superficial to the digital nerves. About the centre of the palm the inner artery will be found to be reinforced by a communicating branch from the deeply-placed innermost palmar interosseous, and the outer three arteries, close to their points of bifurcation, will be found to be joined each by a palmar interosseous artery. The possible presence of a large median artery joining the superficial palmar arch is to be borne in mind.

The median and ulnar nerves are next to be dissected in the palm as far as the roots of the fingers. The median nerve, after emerging from beneath the anterior annular ligament, will be found to present an enlargement, and then to break up into outer and inner divisions. The outer division is to be shown giving off a muscular branch which supplies the abductor pollicis, opponens pollicis, and superficial head of the flexor brevis pollicis, and then to arrange itself into three single digital nerves to both sides of the thumb and outer side of the index finger, the last branch giving a twig to the first or outermost lumbricalis muscle. The inner division furnishes two compound digital nerves, each of which divides near the clefts of the fingers into two branches for the supply of the contiguous sides of the index and middle, and middle and ring fingers. The compound digital nerve to the cleft between the index and middle fingers will be found to give a twig to the second lumbricalis, and that to the cleft between the middle and ring fingers communicates by a cross branch with the compound digital branch of the ulnar nerve to the cleft between the ring and little fingers.

The ulnar nerve is next to be dissected as far as the fingers. Its division into a superficial and deep branch is to be shown, the latter accompanying the profunda artery between the abductor, and flexor brevis, *minimi digiti*. The superficial division will be found to supply the palmaris brevis and then to divide into two digital nerves—an inner single to the inner side of the little finger, and an outer compound for the supply of the contiguous sides of the little and ring fingers. The digital arteries and nerves are now to be followed along the sides of the fingers, where the nerves will be seen to be superficial to the arteries, and to present minute swellings, called Pacinian bodies. In dissecting the digital nerves on the outer side of the index finger and both sides of the thumb the *arteria radialis indicis* and the two branches of the *arteria princeps pollicis* are to be shown.

The sheaths of the flexor tendons are now to be examined. The strong, almost cartilaginous, vaginal ligaments over the first and second phalanges are to be noted, and the weak membrane opposite the interphalangeal joints, with its obliquely-decussating fibres, is to be shown. The sheath being opened, the synovial lining is to be studied, and the insertions of the superficial and deep flexor tendons are to be examined. In connection with the synovial lining the *vincula accessoria tendinum* are to be displayed, namely, the *ligamenta longa* and *ligamenta brevia*. The sheath of the tendon of the flexor obliquus pollicis is to be examined in a similar manner. The relations of the synovial sheaths of the flexor tendons on the digits to the great palmar bursa are to be carefully studied.

The thenar muscles are now to be dissected. The most superficial is the abductor pollicis, and beneath this is the opponens pollicis. The superficial head of the flexor brevis pollicis lies internal to the opponens pollicis, and close to the outer side of the tendon of the flexor longus pollicis, and the adductor obliquus pollicis is close to the inner side of that tendon. The adductor transversus pollicis lies beyond the obliquus, from which it is separated by the radial artery. The deep head of the flexor brevis pollicis is difficult to show. It lies deeply, and arises from the inner side of the base of the first metacarpal bone, and it joins the adductor obliquus pollicis. A large bundle of fibres should be looked for passing from the adductor obliquus pollicis to the superficial head of the flexor brevis pollicis, and in each of these muscles at its insertion a small sesamoid bone will be met with. The median nerve will be found to supply the abductor, opponens, and superficial head of

the flexor brevis pollicis, the others being supplied by the deep division of the ulnar nerve. The three hypothenar muscles are then to be dissected. The profunda branch of the ulnar artery and deep division of the ulnar nerve pass between the abductor, and flexor brevis, minimi digiti, and then pierce the opponens minimi digiti, these three muscles being supplied by the deep division of the nerve.

The anterior annular ligament is now to be dissected, the structures related to it superficially are to be revised, and the ligament is then to be divided in order to examine the contents of the fibro-osseous canal which it forms with the front of the carpus. The great palmar bursa is to be carefully noted passing upwards beneath it, and descending will be found the superficial and deep flexor tendons, tendon of the flexor longus pollicis, and median nerve. Lying in a special compartment of the ligament, at its outer part, will be found the tendon of the flexor carpi radialis, as it traverses the groove on the palmar aspect of the trapezium. The superficial flexor tendons may then be divided in the palm, to enable the deep flexor tendons to be raised and placed over the handle of a scalpel. The lumbricales, arising from these deep tendons, are then to be dissected, and their nerve-supply noted, namely, the deep division of the ulnar for the inner two, and the median for the outer two. The deep flexor tendons are to be cut and turned downwards with the lumbricales, in order to expose the radial artery in the palm, where it forms the deep palmar arch, which is completed by the profunda branch of the ulnar. The arteria princeps pollicis and arteria radialis indicis are to be shown arising from the radial as it passes to the front of the hand, and the palmar interosseous, recurrent, and superior perforating branches of the deep palmar arch are to be dissected. The deep division of the ulnar nerve is next to be followed out, and its extensive muscular distribution is to be carefully studied.

Back of the Forearm and Hand.—The skin having been carefully removed, the dorsal venous arch, with its tributaries, is to be shown on the back of the hand, and the radial nerve and the dorsal branch of the ulnar nerve are to be followed to their digital distributions. In removing the deep fascia from the back of the forearm, care should be taken to leave intact the thickened portion of it on the back of the wrist which forms the posterior annular ligament. The muscles on the outer side of the forearm are to be dissected first, in the following order: brachio-radialis, extensor carpi radialis longior, and extensor carpi radialis brevior. The superficial layer of muscles on the back of the forearm are then to be dissected as follows: extensor communis digitorum, extensor minimi digiti, extensor carpi ulnaris, and anconeus. Without disturbing meanwhile the posterior annular ligament, the extensor tendons are to be followed over the back of the hand to their insertions. In doing this, the thin, deep fascia on the dorsum, continuous above with the posterior annular ligament, is to be noted, and care is to be taken to preserve the dorsal arteries. The dissector will find the tendon of the extensor indicis lying inside the common extensor tendon to the index finger, and the tendon of the extensor minimi digiti will usually be found to be double. The flat bands which connect the ring-finger tendon with that on either side of it are to be shown, as well as a band connecting the middle-finger tendon with the common extensor tendon to the index finger. The expansions of the common extensor tendons over the backs of the first phalanges are to be shown, and it will be seen that these receive the insertions of the lumbricales and interossei. The mode of insertion of the extensor tendons is then to be examined.

Returning to the back of the forearm, the superficial muscles are to be held well aside, and the posterior interosseous nerve and artery dissected. The nerve, having wound round the outer side of the radius in the supinator radii brevis, will be found emerging from that muscle behind near its lower border, and a little below this the artery meets it, after having passed backwards between the radius and ulna. The nerve is now to be followed downwards between the superficial and deep muscles, and then beneath the extensor longus pollicis, but no lower in the meantime, and its muscular distribution

is to be noted. The posterior interosseous artery will be found to give off its posterior interosseous recurrent branch as soon as it reaches the back of the forearm. This branch is to be followed upwards beneath the anconeus to the back of the external epicondyle, where it anastomoses with the posterior terminal branch of the superior profunda. If well injected, it will be found to give branches to the back of the olecranon process, which anastomose with branches of the posterior ulnar recurrent to form the olecranon rete. The posterior interosseous artery, as it descends with the nerve, gets very small, and usually ceases before reaching the wrist, where its place is taken by the posterior branch of the anterior interosseous, with which it anastomoses.

The muscles of the deep layer are then to be dissected in the following order : supinator radii brevis, extensor ossis metacarpi pollicis, extensor brevis pollicis, extensor longus pollicis, and extensor indicis. The posterior annular ligament is next to be carefully dissected, and, by opening it up, the fibro-osseous canals which it forms with the grooves on the lower ends of the radius and ulna are to be studied. The localization of the various tendons in these canals is to be mastered, and careful attention is to be given to their synovial sheaths. The mode of termination of the posterior interosseous nerve is also to be shown at this stage. It will be found to end beneath the tendons of the extensor communis digitorum in a gangliform enlargement, from which articular twigs are given off to the adjacent joints. The radial artery on the back of the wrist and its branches are next to be dissected, and the dissector is to note that the artery, just before it dips between the two heads of the abductor indicis, is crossed by the tendon of the extensor longus pollicis. In connection with the posterior radial carpal artery, the posterior ulnar carpal is to be shown, as well as the posterior carpal arch, beneath the extensor tendons. The inner two dorsal interosseous arteries are to be shown arising from this arch, and they are to be followed downwards over the inner two interosseous spaces to near the clefts between the middle and ring, and ring and little fingers, where each divides into two dorsal collateral digital branches. The inner of the two arteries may give a branch to the inner side of the little finger, or this may arise from the posterior ulnar carpal. The first dorsal interosseous artery is to be followed from the radial over the second interosseous space to near the cleft between the index and middle fingers, where it also divides into two dorsal collateral digital arteries. The superior perforating branches of the deep palmar arch are to be shown after they have pierced the upper ends of the inner three interosseous spaces between the two heads of the dorsal interosseous muscles, where each joins a dorsal interosseous artery. Each of these dorsal interosseous arteries may give off an inferior perforating branch, before it bifurcates, to join a digital artery from the superficial palmar arch. The *arteria dorsalis pollicis* is next to be shown, and it will be found to divide into two branches (which sometimes arise separately) for the sides of the thumb. Lastly, the *arteria dorsalis indicis*, which arises from the radial just before it leaves the back of the wrist, is to be followed along the outer side of the second metacarpal bone to the outer side of the index finger.

The interosseous muscles are next to be dissected. In cleaning the palmar interossei the interosseous fascia is to be noted, and its relation to the central division of the palmar fascia is to be revised. In cleaning the dorsal interossei a thin, deep dorsal fascia will be removed. It will also be necessary to dissect the transverse metacarpal (deep transverse) ligament, which stretches across the heads of the four inner metacarpal bones on their palmar aspects. This having been cut, the muscles are now to be fully dissected, and their nerve-supply and actions carefully studied.

Elbow-Joint.—The muscles related to this joint are to be replaced, and their relation to it noted. The adjacent nerves are also to be observed, and the anastomoses of arteries around the joint are to be thoroughly mastered. The ligaments which compose the capsule, namely, anterior, posterior, external lateral, and internal lateral, are to be dissected, and the joint is then to be opened. The articular surfaces are to be examined, the pads of fat noted, and the synovial membrane and movements studied.

Wrist-Joint.—This joint is to be studied in the same way as the elbow-joint.

Radio-ulnar Joints.—The superior radio-ulnar joint has only the orbicular or annular ligament, and its synovial membrane is continuous with that of the elbow-joint. The chief bond of union at the inferior radio-ulnar joint is the triangular fibro-cartilage, which is to be carefully examined, along with the synovial membrane, which is called the *membrana sacciformis*. As regards the intermediate connection between the radius and ulna, the interosseous membrane is to be dissected, and its anterior and posterior relations studied. The opening in it near its lower part for the posterior branch of the anterior interosseous artery is to be shown. The oblique ligament at the upper end is to be examined, and between it and the upper border of the interosseous membrane will be seen the interval for the passage of the posterior interosseous vessels. The movements of pronation and supination are to receive close attention, and the dissector is to make himself thoroughly familiar with the muscles concerned in these important movements.

Carpal Joints.—The transverse carpal joint is to be dissected first, and the ligaments and movements are to be studied. The pisiform joint is next to be examined, and its capsular ligament shown. The dorsal, palmar, and interosseous ligaments of the other three bones of the first row are next to be examined, followed by those of the second row. The carpo-metacarpal joints are to be studied, and special attention should be directed to the joint between the trapezium and first metacarpal bone. The intermetacarpal (basal) joints follow next. The deep transverse ligament which connects the palmar aspects of the heads of the four inner metacarpal bones has been already dissected. The metacarpo-phalangeal joints, followed by the interphalangeal, are next to be dissected. The strong anterior fibrous plate is to be noted, and the absence of a dorsal ligament, its place being taken by the extensor tendon. In the metacarpo-phalangeal joint of the thumb no anterior fibrous plate will be found, its place being taken by two sesamoid bones. Special attention is to be given to the arrangement of the synovial membranes, from the inferior radio-ulnar joint above, with its *membrana sacciformis*, to the intermetacarpal (basal) joints below. The number of these synovial membranes and the complexity of that of the carpus are to be noted.

THE LOWER LIMB

THE GLUTEAL REGION.

Landmarks.—The crest of the ilium is almost entirely obscured by the prominence of the abdominal muscles above it and the gluteus medius below it, so that as a rule its position is indicated by a groove. This groove conducts the finger to the posterior superior iliac spine, which is on a level with the second sacral spine and the centre of the sacro-iliac synchondrosis. The spinous processes of the sacral vertebræ, usually four in number, may be distinguished as separate projections, or they may be fused into one median ridge. The fifth sacral spine being undeveloped, no median projection can be felt, but at either side of the middle line the sacral cornua may be made out. The coccyx is felt in the **natal cleft** between the buttocks. The **tuber ischii** is obscured by the lower border of the gluteus maximus when the hip-joint is extended, but, when that joint is flexed, the prominence is easily made out. The **great trochanter** is felt at the lower and outer part of the gluteal region, and behind it there is a natural depression. The prominence of the natis or buttock is formed by the gluteus maximus, covered by a large amount of adipose tissue. The **fold of the natis** is produced by a fold of the skin and fascia, and is very perceptible when the hip-joint is extended. It takes the form of a transverse furrow, which commences internally a little below the lower border of the gluteus maximus, and terminates externally on the surface of that muscle, having crossed its lower border. The fold is horizontal in direction, whilst the lower border of the gluteus maximus is oblique. It is possible to feel the great sciatic nerve in this fold, but that nerve lies deeply at a point very nearly midway between the great trochanter and tuber ischii, being rather nearer the latter than the former.

Cutaneous Nerves.—These are met with in the following situations : (1) line of origin of gluteus maximus ; (2) iliac crest ; (3) outer and lower part of gluteus maximus ; and (4) lower border of gluteus maximus.

1. **Line of Origin of Gluteus Maximus.**—The cutaneous nerves met with in this situation are divisible into three sets.

(a) Two or three twigs from the external branches of the posterior primary divisions of the first three sacral nerves. These external branches form two sets of loops, one set being situated deeply on the back of the sacrum, and the other set more superficially on the posterior surface of the great sacro-sciatic ligament. It is from this latter set of loops that the two or three cutaneous twigs are derived, and their direction is chiefly outwards.

(b) One or two twigs from the undivided posterior primary divisions of the last two sacral nerves and the coccygeal nerve. These divisions form a loop on the back of the sacrum, from which the cutaneous twigs are derived, their distribution being confined to the coccygeal integument.

(c) Twigs from the so-called coccygeal plexus, which is situated on the pelvic surface of the coccygeus muscle. These twigs pierce that muscle and the small sacro-sciatic ligament, as well as the gluteus maximus, and are distributed to the coccygeal integument.

2. **Iliac Crest.**—The cutaneous nerves in this situation from behind forwards are also divisible into three sets.

(a) Three offsets from the external branches of the posterior primary divisions of the first three lumbar nerves, which descend over the iliac crest, in front of the outer border of the erector spinæ muscle.

(b) Iliac branch of the ilio-hypogastric nerve, which crosses the iliac crest at the junction of the middle and anterior thirds.

(c) Undivided lateral cutaneous or iliac branch of the anterior primary division of the twelfth thoracic (subcostal) nerve. This is a large and long nerve which descends over the anterior part of the iliac crest, 1 inch behind the anterior superior iliac spine, and is distributed to the integument of the anterior part of the gluteal region as low as the great trochanter.

3. **Outer and Lower Part of Gluteus Maximus.**—The cutaneous nerves appearing in this situation are branches of the posterior division of the external cutaneous nerve, which is derived from the lumbar plexus.

4. **Lower Border of Gluteus Maximus.**—The cutaneous nerves met with in this locality are as follows :

(a) Three or four recurrent branches from the small sciatic nerve, which supply the integument over the lower and outer part of the gluteus maximus.

(b) Perforating cutaneous branch of the sacral plexus, more particularly from the back of the second and third sacral nerves, which supplies the integument over the lower and inner part of the gluteus maximus.

Fasciæ.—The **superficial fasciæ** is very thick, and loaded with adipose tissue. It is continuous over the iliac crest with the superficial fasciæ of the back of the trunk, and it contributes to the prominence of the natal region. Between the iliac crest and the upper border of the gluteus maximus there is a considerable accession of adipose tissue to the deep surface of the superficial

fascia, and so the depression in that region is filled up. The **deep fascia** forms a part of the fascia lata. Over the fleshy part of the gluteus maximus it is thin, but, at the insertion of the muscle and over the anterior two-thirds of the gluteus medius, it is dense. In these latter situations it gives insertion to a considerable part of the gluteus maximus, and origin to the superficial fibres of the gluteus medius in its anterior two-thirds. In passing from the gluteus medius on to the gluteus maximus it straps down the upper border of the latter muscle.

Muscles. Gluteus Maximus—*Origin*.—(1) The posterior 2 inches of the outer lip of the iliac crest; (2) the upper part of the rough surface on the dorsum ilii between this part of the crest and the superior gluteal line; (3) the posterior lamina of the lumbar aponeurosis; (4) the lateral part of the back of the fourth and fifth sacral vertebræ; (5) the back of the upper three coccygeal vertebræ close to the lateral border; and (6) the superficial surface of the great sacro-sciatic ligament.

Insertion.—(1) Rather more than the upper half of the muscle is inserted between two laminae of the fascia lata on the upper and outer part of the thigh; (2) the superficial fibres of rather less than the lower half are also inserted into the fascia lata, but the deep fibres of this portion are inserted into the gluteal ridge of the femur. The part of the fascia lata which gives insertion to the gluteus maximus is known as the ilio-tibial band.

Nerve-supply.—The inferior gluteal nerve from the sacral plexus, which enters the muscle on its deep or anterior surface in its lower third.

The direction of the coarse fasciculi of the muscle is downwards and outwards.

Action.—Acting from its origin the muscle extends the thigh upon the pelvis, as in rising from the sitting posture, or ascending a stair. The upper part, acting alone, would abduct the thigh, and the lower part would adduct it and rotate it outwards. The muscle also takes part in the completion of extension of the knee-joint, and in the maintenance of extension, as in standing, through means of the ilio-tibial band of the fascia lata. Acting from its insertion the muscle extends the pelvis upon the thigh, as in raising the trunk from the stooping posture.

The gluteus maximus, which is quadrilateral, has a short upper border which is bound down to the gluteus medius by the fascia lata, and a long lower border which is free.

Deep Relations.—These, from above downwards, are as follows: the posterior fleshy third of gluteus medius; superficial division of gluteal artery; extrapelvic part of pyriformis; great and small sciatic nerves; inferior gluteal nerve; sciatic and internal pudic arteries; pudic nerve; nerve to obturator internus, supplying a branch to gemellus superior; common nerve to gemellus inferior and quadratus femoris; gemellus superior; extrapelvic part of obturator internus; gemellus inferior; quadratus femoris; crucial anastomosis

of arteries; upper horizontal part of adductor magnus; origins of hamstring muscles from tuber ischii; portion of vastus externus, just below the great trochanter; and great sacro-sciatic ligament,

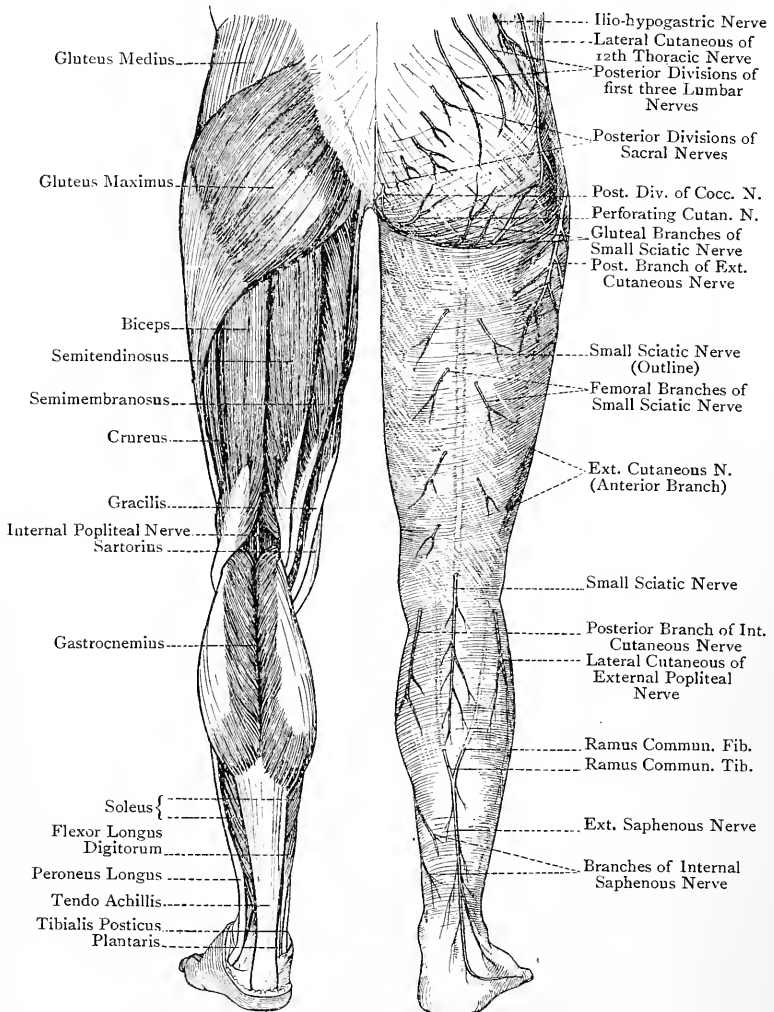


FIG 215.—MUSCLES AND CUTANEOUS NERVES OF THE LOWER LIMB (POSTERIOR ASPECT).

pierced by the coccygeal branch of the sciatic artery, the sacral branch of the internal pudic artery, and the perforating cutaneous branch of the sacral plexus.

Three synovial bursæ are found underneath the muscle. One, which is single, is situated between the lower border of the muscle and the tuber ischii. Its importance consists in the fact that it is concerned in the condition known as 'lighterman's bottom.' A second lies between the muscle and the great trochanter, this one being multilocular. The third is found between the muscle and the upper part of the vastus externus, just below the great trochanter.

Gluteus Medius—*Origin*.—(1) The dorsum ilii between the crest, superior gluteal line, and middle gluteal line; and (2) the fascia lata covering the anterior two-thirds of the muscle.

Insertion.—The oblique impression on the outer surface of the great trochanter, extending from the postero-superior angle downwards and forwards to the antero-inferior angle.

Nerve-supply.—The superior gluteal nerve.

The direction of the anterior fibres of the muscle is downwards and slightly backwards, and of the posterior fibres downwards and forwards. The fibres of the muscle converge from their origin to the fan-shaped tendon of insertion, and they correspond in direction with those of the gluteus minimus.

Action.—Acting from its origin the muscle abducts the thigh. The anterior fibres also act as an internal rotator, and the posterior fibres as an external rotator, of the thigh. Acting from its insertion it balances the pelvis upon the thigh, as in standing upon one leg, and it is also a lateral flexor of the pelvis.

The gluteus medius is triangular. The posterior fleshy third is covered by the gluteus maximus, and the anterior two-thirds by the fascia lata. The muscle covers the gluteus minimus except posteriorly, the deep division of gluteal artery, and the superior gluteal nerve, and a synovial bursa intervenes between it and the upper part of the great trochanter.

Gluteus Minimus—*Origin*.—The dorsum ilii between the middle and inferior gluteal lines.

Insertion.—The lower part of the anterior surface of the great trochanter.

Nerve-supply.—The lower division of the superior gluteal nerve.

The fibres of the muscle correspond in direction, for the most part, with those of the gluteus medius.

Action.—Acting from its origin the muscle is an abductor and internal rotator of the thigh. Acting from its insertion it balances the pelvis upon the thigh, and is a lateral flexor of the pelvis.

The gluteus minimus is fan-shaped, and the tendon of insertion spreads out into an aponeurotic expansion over its lower part. It is covered by the gluteus medius except at the posterior part, where the pyriformis rests upon it. Its deep surface is related to the capsular ligament of the hip-joint and the posterior or reflected head of the rectus femoris. The tendon of insertion of the muscle

is separated from the great trochanter by a synovial bursa, and is connected with the upper part of the capsular ligament of the hip-joint by a strong arched band of fibres.

The anterior portion of the *gluteus minimus* is sometimes detached from the rest of the muscle, and, when this occurs, the separated part represents the *gluteus quartus* or *musculus scansorius* (climbing muscle) of certain animals.

Pyramiformis—*Origin*.—(1) By three fleshy slips from the anterior surfaces of the second, third, and fourth sacral vertebræ, which are interposed between, and lie external to, the adjacent anterior sacral foramina; (2) the deep surface of the great sacro-sciatic ligament; and (3) the posterior border of the ilium immediately below the posterior inferior iliac spine.

Insertion.—The upper border of the great trochanter near its centre.

Nerve-supply.—Two branches from the sacral plexus, which enter the intrapelvic part of the muscle. The branches come from the dorsal divisions of the first and second sacral nerves.

Action.—External rotator of the thigh.

The *pyramiformis*, in emerging from the pelvis through the great sacro-sciatic foramen, divides that foramen into a small upper and a large lower compartment. Through the *upper compartment* the gluteal vessels and superior gluteal nerve pass. Through the *lower compartment* the following structures are transmitted: the sciatic and internal pudic vessels, great and small sciatic nerves, inferior gluteal nerve, pudic nerve, nerve to obturator internus, and common nerve to gemellus inferior and quadratus femoris. The extrapelvic part of the *pyramiformis* is sometimes pierced by the external popliteal nerve.

Gemellus Superior—*Origin*.—The lower border and adjacent portion of the external surface of the spine of the ischium.

Insertion.—The upper border of the tendon of the obturator internus.

Nerve-supply.—Branch from the nerve to the obturator internus, which enters the muscle on its anterior or deep surface near the upper border, close to the origin.

The *gemellus superior* is sometimes absent.

Obturator Internus—*Origin*.—(1) The internal surface of the obturator foramen; (2) the posterior surface of the body of the os pubis, descending pubic ramus, and ascending ramus of the ischium; (3) the inclined plane of the ischium, extending as far back as the great sacro-sciatic foramen, and nearly as high as the iliac portion of the ilio-pectineal line; and (4) the parietal pelvic fascia covering the muscle.

Insertion.—The inner surface of the great trochanter, above and in front of the digital fossa.

Nerve-supply.—The nerve to the obturator internus from the sacral plexus.

Action.—External rotator of the thigh.

The intrapelvic and extrapelvic parts of the muscle form very nearly a right angle with each other. It emerges from the pelvis through the small sacro-sciatic foramen, and the deep surface of its tendon is here broken up into from three to five columns, separated from each other by grooves. The small sciatic notch is covered by cartilage, which presents as many grooves as there are columns on the deep surface of the tendon, these grooves being separated by slight ridges. The grooves lodge the columns of the tendon, and the ridges are received into the grooves between the tendinous columns. A bursa intervenes between the tendon and the cartilage covering the notch.

Gemellus Inferior—*Origin*.—The upper part of the tuber ischii, and the lower margin of the small sciatic notch.

Insertion.—The lower border of the tendon of the obturator internus.

Nerve-supply.—Branch from the nerve to the quadratus femoris, which enters the muscle on its deep or anterior surface near the upper border, close to the origin.

The gemelli muscles are merely extrapelvic origins of the obturator internus, of which they form accessory parts. As they take insertion into the upper and lower borders of the obturator tendon they are folded over it, so as to overlap and partially conceal the tendon on its superficial aspect. They are auxiliary to the obturator internus in action.

Small Sacro-sciatic Foramen.—The structures which pass through this foramen are as follows: (1) obturator internus; (2) nerve to the obturator internus; (3) pudic nerve; and (4) internal pudic artery with its venæ comites.

Quadratus Femoris—*Origin*.—The outer border of the tuber ischii.

Insertion.—The linea quadrati of the femur, extending as low as the small trochanter.

Nerve-supply.—The nerve to the quadratus femoris from the sacral plexus, which enters the muscle on its deep or anterior surface near the upper border, close to the origin.

Action.—External rotator of the thigh.

The muscle conceals part of the obturator externus and the small trochanter of the femur, from which latter it is separated by a small bursa. When the gemellus inferior and quadratus femoris are separated, part of the obturator externus comes into view. Between the lower border of the muscle and the upper border of the adductor magnus the transverse branch of the internal circumflex artery appears, which here takes part in the crucial anastomosis. When the lower border of the muscle is raised, the small trochanter comes into view with the tendon of insertion of the ilio-psoas.

Arteries.—The chief arteries of the gluteal region are the gluteal, sciatic, and internal pudic.

Gluteal Artery.—This vessel arises from the posterior division of the internal iliac artery. Piercing the parietal pelvic fascia, it

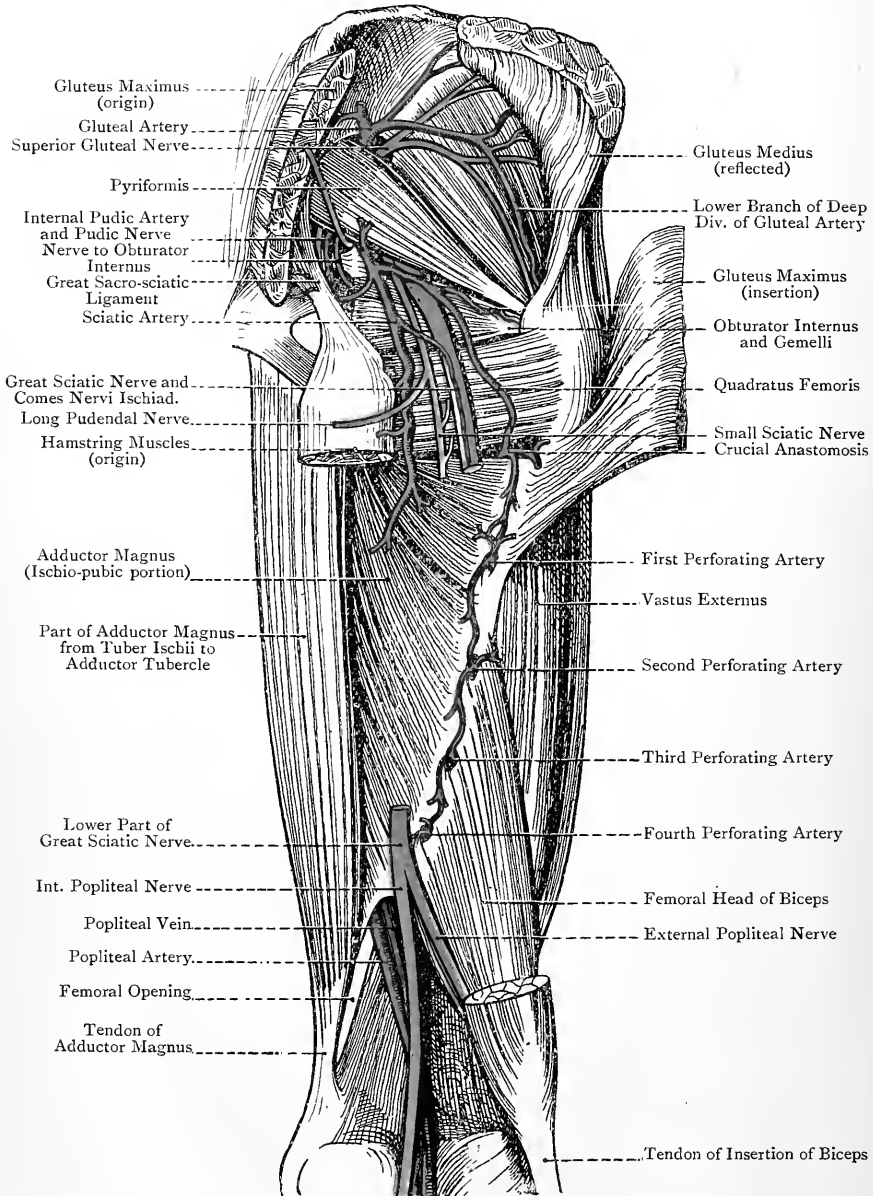


FIG. 216.—THE GLUTEAL REGION AND BACK OF THE THIGH (DEEP DISSECTION).

passes between the lumbo-sacral cord and the anterior primary division of the first sacral nerve, after which it emerges through the upper compartment of the great sacro-sciatic foramen above the piriformis, and breaks up into two divisions—superficial and deep. The **superficial division** passes backwards between the posterior border of the gluteus medius and the piriformis, and then enters the deep or anterior surface of the gluteus maximus near its origin. Some of its branches become cutaneous by piercing the muscle, and they anastomose with the posterior branches of the lateral sacral arteries from the posterior division of the internal iliac.

The **deep division** passes beneath the gluteus medius, where it subdivides into an upper and a lower branch. The *upper branch* courses along the upper border of the gluteus minimus, in company with the upper division of the superior gluteal nerve. It supplies the ilium and adjacent muscles, and anastomoses with the deep circumflex iliac of the external iliac and the ascending branch of the external circumflex of the arteria profunda femoris. The *lower branch* passes forwards over the centre of the gluteus minimus, in company with the lower division of the superior gluteal nerve. It supplies the gluteus medius and gluteus minimus muscles. It also gives an articular branch to the hip-joint, and a branch to the digital fossa which anastomoses with the sciatic, the ascending branch of the internal circumflex, and a branch of the first perforating of the arteria profunda femoris. The lower branch of the deep division also anastomoses with the ascending branch of the external circumflex.

The place of emergence of the gluteal artery from the pelvis is indicated as follows: the thigh being rotated inwards, draw a line from the top of the great trochanter to the posterior superior iliac spine, and take a point in this line at the junction of the inner third and outer two-thirds.

The **gluteal vein** terminates in the internal iliac vein.

Sciatic Artery.—This vessel arises from the anterior division of the internal iliac artery. It descends, usually behind the internal pudic, upon the piriformis and sacral nerves, and emerges through the lower compartment of the great sacro-sciatic foramen below the piriformis. It then passes between the great trochanter and tuber ischii, lying under cover of the gluteus maximus, on the inner side of the great sciatic nerve, and resting upon the gemelli, obturator internus, and quadratus femoris. On leaving this hollow, it descends upon the posterior surface of the upper part of the adductor magnus, where it terminates.

For the intrapelvic portion of the artery, see dissection of the pelvis.

Branches.—The extrapelvic branches are as follows: coccygeal, inferior gluteal, muscular, anastomotic, articular, gluteal cutaneous, and comes nervi ischiadici.

The **coccygeal branch** pierces the great sacro-sciatic ligament

and gluteus maximus, and is distributed over the back of the coccyx. The **inferior gluteal branch** enters the deep surface of the gluteus maximus with the inferior gluteal nerve, and it anastomoses in the muscle with the superficial division of the gluteal artery. The **muscular branches** are distributed to the adjacent external rotator muscles and the origins of the hamstrings. In the latter muscles an anastomosis takes place with the external terminal branch of the obturator artery.

The **anastomotic branches** are two in number. One passes to the digital fossa, where it anastomoses with the gluteal, ascending branch of the internal circumflex, and first perforating arteries. The other passes to the interval between the quadratus femoris and adductor magnus, where it anastomoses with the transverse branch of the internal circumflex, the transverse branch of the external circumflex, and the first perforating arteries. This fourfold anastomosis is called the *crucial anastomosis*.

The **articular branches** are two or three in number. They pass beneath the gemelli and obturator internus with the nerve to the quadratus femoris, and pierce the back part of the capsular ligament of the hip-joint.

The **gluteal cutaneous branches** pass round the lower border of the gluteus maximus with the gluteal cutaneous branches of the small sciatic nerve, and are distributed to the integument over the lower part of the muscle.

The **comes nervi ischiadici** is a long branch which descends for some distance with the great sciatic nerve, to which it is distributed, and in which it anastomoses with the perforating branches of the arteria profunda femoris. After ligation of the femoral artery in the upper third of the thigh this branch becomes much enlarged.

The place of emergence of the sciatic artery from the pelvis is indicated as follows: draw a line from the posterior superior iliac spine to the outer border of the tuber ischii, and take a point in this line at the junction of the middle with the lower third.

The **sciatic vein** terminates in the internal iliac vein.

The sciatic artery in the early embryo is the leading arterial trunk of the lower limb. As the femoral artery is developed it forms a junction with the sciatic in the neighbourhood of the knee, and so becomes the chief artery, and the part of the primitive sciatic between the knee and the gluteal region for the most part disappears.

Internal Pudic Artery.—This vessel arises from the anterior division of the internal iliac, and at first lies within the pelvic cavity. It is only the second part of the vessel which is seen in the gluteal region, and which will be described here. Having emerged from the pelvis through the lower compartment of the great sacro-sciatic foramen below the pyriformis, the artery passes downwards for a short distance, and crosses over the back of the spine of the ischium. It then courses through the small sacro-sciatic foramen, and is lost to view.

Relations—*Superficial or Posterior*.—Gluteus maximus. *Deep or Anterior*.—Posterior surface of spine of ischium.

On either side of the artery is a vena comes. The pudic nerve lies on the inner side, and the nerve to the obturator internus on the outer side.

Branches.—**Muscular**, to gluteus maximus, and **sacral**, which pierces the great sacro-sciatic ligament, and ramifies over the back of the lower end of the sacrum, where it anastomoses with the coccygeal branch of the sciatic artery.

The position of the second part of the internal pudic artery upon the back of the spine of the ischium, which spine is about 4 inches below the posterior superior iliac spine, is ascertained as follows: the thigh being rotated inwards, draw a line from the upper border of the great trochanter to the junction of the sacrum with the coccyx, and take a point in this line at the junction of the inner third and outer two-thirds.

Relation of Structures on Back of Spine of Ischium.—The relation from within outwards is as follows: (1) pudic nerve, (2) internal vena comes, (3) second part of internal pudic artery, (4) external vena comes, and (5) nerve to obturator internus muscle.

Deep Nerves. **Superior Gluteal Nerve**.—This nerve arises from the sacral plexus, more particularly from the dorsal divisions of the descending branch of the fourth lumbar, the fifth lumbar, and the first sacral nerves. It passes through the upper compartment of the great sacro-sciatic foramen, above the pyriformis, with the gluteal artery, and then beneath the gluteus medius, where it divides into a small upper and large lower branch. The **upper branch** accompanies the corresponding division of the deep part of the gluteal artery along the upper border of the gluteus minimus, and it supplies the gluteus medius. The **lower branch** passes outwards over the centre of the gluteus minimus with the lower division of the deep part of the gluteal artery. It supplies the gluteus medius and gluteus minimus, and terminates by supplying the tensor fasciæ femoris.

Inferior Gluteal Nerve.—This nerve arises from the sacral plexus, more particularly from the dorsal divisions of the fifth lumbar, and first and second sacral nerves. It passes through the lower compartment of the great sacro-sciatic foramen, below the pyriformis, in close contact with the small sciatic nerve. It then divides into several branches which enter the deep surface of the gluteus maximus in its lower third.

Nerve to Obturator Internus.—This nerve arises from the sacral plexus, more particularly from the ventral divisions of the fifth lumbar, and first and second sacral nerves. It passes through the lower compartment of the great sacro-sciatic foramen, below the pyriformis, internal to the great sciatic nerve; over the posterior surface of the spine of the ischium, where it lies to the outer side of the internal pudic vessels; and through the small sacro-sciatic foramen to the intrapelvic part of the obturator internus. At the lower

border of the pyriformis it gives a branch to the gemellus superior, which enters that muscle on its deep surface near the upper border, close to the origin.

Nerve to Quadratus Femoris.—This nerve arises from the sacral plexus, more particularly from the ventral divisions of the descending branch of the fourth lumbar, the fifth lumbar, and the first sacral nerves. It passes through the lower compartment of the great sacro-sciatic foramen, below the pyriformis, where it lies in close contact with the deep surface of the great sciatic nerve. It then passes, in succession, beneath the gemellus superior, obturator internus, gemellus inferior, and quadratus femoris, entering the last muscle on its anterior or deep surface near the upper border, close to the origin. As it passes beneath the gemellus inferior, it parts with its branch to that muscle, which enters its deep surface near the upper border, close to the origin.

The nerve to the quadratus femoris also supplies, as a rule, an articular branch to the back of the hip-joint.

Lymphatics.—The **superficial lymphatics** of the gluteal region terminate in the inguinal glands (superior or oblique superficial inguinal glands). The **deep lymphatics** enter the pelvis, and terminate in the internal iliac glands.

For the great and small sacro-sciatic ligaments see the description of the pelvis in Abdomen Section.

THE THIGH

Back of the Thigh and Popliteal Space.

Landmarks.—The hamstring muscles give rise to a prominence along the back of the thigh, but they cannot be individually recognised until they reach the popliteal space. The **great sciatic nerve** is deeply placed, being under cover of the long or ischial head of the biceps femoris, but its course may be indicated by drawing a line from the centre of the back of the knee-joint to a point between the great trochanter and the tuber ischii, rather nearer the latter than the former. The upper two-thirds of this line correspond with the great sciatic nerve, and the lower third with the internal popliteal nerve.

The situation of the **popliteal space** behind the knee-joint is indicated by a depression when the joint is flexed. The strong tendon of the biceps femoris can be felt on the outer side, as it descends to reach the head of the fibula, and in front of it the long external lateral ligament of the knee-joint can be distinguished by its tense, cord-like feel. Anterior to this ligament the lower part of the ilio-tibial band of the fascia lata may be felt. The **external popliteal nerve** is close to the inner side of the biceps tendon. Lower down it can be felt just below the head of the fibula. On the inner side of the popliteal space, over the back of the inner

condyle, three tendons may be felt. The most superficial one is that of the semitendinosus, which, though firm, is narrow, and is traceable for some distance above the knee-joint. Underneath it is the tendon of the semimembranosus, and, internal to this, is the slender tendon of the gracilis. The course of the **popliteal artery** practically coincides with the middle line of the popliteal space, but the vessel can only be felt when the joint is well flexed. During this manipulation the popliteal lymphatic glands, if enlarged, may be detected.

Back of the Thigh.—There is nothing noteworthy in the superficial fascia. The deep fascia will be described in connection with the fascia lata.

Small Sciatic Nerve.—This nerve arises from the sacral plexus, more particularly from the back of the first, second, and third sacral nerves. It emerges through the lower compartment of the great sacro-sciatic foramen, below the pyriformis. It then passes downwards between the great trochanter and tuber ischii, resting upon the superficial surface of the great sciatic nerve, and being under cover of the lower part of the gluteus maximus. After escaping from beneath this muscle, it descends in the middle line superficial to the hamstring muscles, and beneath the deep fascia covering them, and, passing over the popliteal space, it pierces the deep fascia at the back of the knee-joint. It then enters the back of the leg, and descends as low as about the centre of the calf, in company with the external or short saphenous vein. The nerve is entirely sensory.

Branches.—The branches are gluteal cutaneous, long pudendal nerve of Soemmering, femoral cutaneous, and sural cutaneous.

The **gluteal cutaneous branches** are three or four in number, and take a recurrent course, winding round the lower border of the gluteus maximus, and supplying the integument over its lower and outer part. The **long pudendal nerve of Soemmering** arises at the lower border of the gluteus maximus, and winds inwards towards the anterior part of the perineum, lying a little below the tuber ischii and crossing behind the origins of the hamstring muscles from that prominence. It then pierces the fascia lata fully 1 inch in front of the tuber ischii, and, passing over the ischio-pubic ramus and through Colles' fascia, it courses forwards and inwards, in company with the two superficial perineal nerves and the superficial perineal artery, to the scrotum in the male and the labium majus in the female. In the anterior part of the perineum it communicates with the two superficial perineal nerves, and with them forms the three long scrotal (or labial) nerves. Its branches are *femoral cutaneous*, to the upper and inner part of the thigh on its posterior aspect; and *scrotal* or *labial*, to the scrotum or labium majus, according to the sex. The **femoral cutaneous branches** of the small sciatic supply the integument of the back of the thigh as low as the knee-joint. The **sural cutaneous branches** are the terminal branches of the nerve.

They supply the integument of the back of the leg as low as about the centre of the calf, and communicate with branches of the *ramus communicans tibialis* from the internal popliteal.

Muscles.—The muscles of the back of the thigh are called the **hamstring** muscles, and are three in number, namely, *biceps femoris*, *semitendinosus*, and *semimembranosus*.

Biceps Femoris or Biceps Flexor Cruris—*Origin.*—The muscle arises by two heads—long or ischial, and short or femoral. (1) **Long or Ischial Head.**—This arises, in conjunction with the *semitendinosus*, from the lower and inner impression on the posterior surface of the *tuber ischii*. (2) **Short or Femoral Head.**—This arises from (1) the outer lip of the *linea aspera*, (2) the upper two-thirds of the external supracondylar ridge, and (3) the external intermuscular septum.

Insertion.—The upper surface of the head of the fibula in front of the styloid process, by means of a round tendon which sends an expansion downwards to the deep fascia covering the *peroneus longus*. A few fibres are also inserted into the external tuberosity of the tibia.

The long external lateral ligament of the knee-joint passes through the tendon of insertion, and divides it into two parts, from which the ligament is separated by the bursa wrapped around it. The two divisions of the tendon are anterior and posterior, the anterior, which is the stronger, being inserted into the external tuberosity of the tibia, as well as into the head of the fibula. The expansion to the deep fascia of the leg is derived from the posterior division of the tendon.

Nerve-supply.—Great sciatic nerve. The long or ischial head receives branches from the *internal* popliteal part of the nerve, and the short or femoral head from the *external* popliteal part.

Action.—Acting from its origin the muscle is an extensor of the hip-joint and a flexor of the leg upon the thigh, and, having flexed the knee-joint, it acts as an external rotator of the leg. The long or ischial head alone extends the hip-joint. Acting from its insertion the muscle, by means of its long or ischial head, is an extensor of the pelvis upon the thigh. In virtue of its double insertion into the head of the fibula and external tuberosity of the tibia, the *biceps femoris* contributes materially to the strength of the superior tibio-fibular joint by bracing the bones together.

In rare cases the *biceps femoris* has a third head of origin, which may arise from the *tuber ischii*, *linea aspera*, or internal supracondylar ridge.

Semitendinosus—*Origin.*—The lower and inner impression on the posterior surface of the *tuber ischii*, in conjunction with the long or ischial head of the *biceps femoris*.

Insertion.—The upper part of the internal surface of the shaft of the tibia, behind the *sartorius* and below the *gracilis*. From the tendon of insertion an expansion is given to the deep fascia of the leg.

Nerve-supply.—Great sciatic nerve. The branches come from the internal popliteal part of the nerve.

Action.—Acting from its origin the muscle is an extensor of the hip-joint and a flexor of the leg upon the thigh, and, having flexed the knee-joint, it acts as an internal rotator of the leg. Acting from its insertion it is an extensor of the pelvis upon the thigh. The semitendinosus is intimately connected with the long or ischial head of the biceps femoris in the upper fifth of the thigh, and its belly is crossed at its centre by an oblique tendinous intersection. In the lower third of the thigh the muscle has a long, narrow, round tendon, which broadens out at its insertion, and crosses the internal lateral ligament of the knee-joint. A bursa intervenes between it and that ligament, and also between it and the tendon of the sartorius.

Semimembranosus—*Origin*.—By means of a broad, flat tendon from the upper and outer impression on the posterior surface of the tuber ischii.

Insertion.—The insertion is threefold, as follows: (1) the chief insertion is by means of a strong tendon into the horizontal groove on the posterior surface of the internal tuberosity of the tibia; (2) by an expansion which passes upwards and outwards to the upper and back part of the external condyle of the femur, and which forms a large part of the posterior ligament of the knee-joint, known as the *ligamentum posticum Winslowii*; (3) by a broad expansion, which passes downwards and outwards to the oblique or popliteal line on the posterior surface of the shaft of the tibia. This expansion covers the popliteus muscle, and is called the **popliteal fascia**.

Nerve-supply.—Great sciatic nerve. The branches come from the internal popliteal part of the nerve.

Action.—Acting from its origin the muscle is an extensor of the hip-joint and a flexor of the leg upon the thigh, and, having flexed the knee-joint, it acts as an internal rotator of the leg. Acting from its insertion it is an extensor of the pelvis upon the thigh..

The strong tendon of origin is prolonged downwards for some distance upon the outer side of the muscle, and the chief tendon of insertion is prolonged upwards for some distance upon its inner side. The belly of the muscle is composed of short, oblique fasciculi, an arrangement which gives it great power of action, but a limited range of movement. The chief tendon of insertion is under cover of the posterior border of the internal lateral ligament of the knee-joint. Previous to this it is separated from the internal head of the gastrocnemius by the popliteal bursa, which frequently communicates with the synovial membrane of the knee-joint through an opening often present in the posterior ligament. The chief tendon of insertion is also separated by a bursa from the upper lip of the groove on the posterior surface of the internal tuberosity of the tibia.

The hamstring muscles descend in close contact through the upper three-fourths of the thigh, being held together by the fascia lata. When, however, they reach the lower fourth, they part

company, the biceps femoris passing downwards and outwards, and the semitendinosus and semimembranosus downwards and inwards; and so the popliteal space begins to open out.

Great Sciatic Nerve.—This nerve arises from the sacral plexus, more particularly from the descending branch of the fourth lumbar, the fifth lumbar, and the first, second, and upper branch of the third sacral nerves. It emerges from the pelvis through the lower compartment of the great sacro-sciatic foramen, below the pyriformis, and descends between the great trochanter and tuber ischii, being somewhat nearer the latter than the former. It then passes down the middle line of the back of the thigh, under cover of the long or ischial head of the biceps femoris, and, about the junction of the middle and lower thirds, it terminates by dividing into internal and external popliteal nerves.

The great sciatic nerve is about $\frac{3}{4}$ inch broad. Its course may be indicated as follows: draw a line from the centre of the back of the knee-joint to a point between the great trochanter and tuber ischii, rather nearer the latter than the former. The upper two-thirds of this line correspond with the great sciatic nerve, and the lower third with the internal popliteal nerve.

Chief Relations. *Superficial or Posterior.*—Gluteus maximus, small sciatic nerve, and long or ischial head of the biceps femoris. *Deep or Anterior.*—From above downwards the nerve is in contact with the following structures: the ischium, the nerve to the quadratus femoris, gemellus superior, obturator internus, gemellus inferior, quadratus femoris, and posterior surface of adductor magnus. *Internal.*—Semimembranosus.

Branches.—The branches are muscular and terminal.

The **muscular branches** arise in the upper part of the thigh, with the exception of the branch to the short head of the biceps femoris, which arises about the centre. They supply the hamstring muscles, and also that part of the adductor magnus which descends from the tuber ischii to the adductor tubercle of the femur. The branch to this part of the adductor magnus arises in common with the nerve to the semimembranosus. The branch to the short head of the biceps femoris is derived from the *external* popliteal part of the great sciatic nerve, but all the other muscular branches come from the *internal* popliteal part.

The **terminal branches** are the internal and external popliteal nerves. They arise about the junction of the middle and lower thirds of the thigh, and will be described in connection with the popliteal space.

The great sciatic nerve supplies an articular branch to the hip-joint in those cases where the nerve to the quadratus femoris fails to do so.

Blood-supply.—The nerve is supplied by the arteria comes nervi ischiadici from the sciatic, and the perforating branches of the arteria profunda femoris.

The great sciatic nerve is not infrequently replaced by the external

and internal popliteal nerves. Under these circumstances the external popliteal nerve often pierces the pyriformis.

Popliteal Space.—The popliteal space or *ham** is situated behind the knee-joint, whence it extends upwards to the junction of the upper three-fourths and lower fourth of the thigh, and downwards to the junction of the upper sixth and lower five-sixths of the leg. In shape the space resembles a diamond.

Boundaries. External—(a) *Above the Knee-joint.*—Biceps femoris. (b) *Below the Knee-joint.*—External head of the gastrocnemius, and plantaris.

Internal—(a) *Above the Knee-joint.*—Semitendinosus, semimembranosus, gracilis, sartorius, and tendon of the adductor magnus, in the order named from behind forwards. (b) *Below the Knee-joint.*—Internal head of the gastrocnemius.

The superior median angle of the space corresponds with the divergence of the hamstring muscles, the inferior median angle by the approximation of the external and internal heads of the gastrocnemius, the external angle by the meeting between the biceps femoris and external head of the gastrocnemius, and the internal angle by the meeting between the semimembranosus and internal head of the gastrocnemius.

The **roof** is formed by the integument. It contains the small sciatic nerve, and, in its lower part, the terminal portion of the external or short saphenous vein.

The **floor** is formed, from above downwards, by the popliteal surface or trigone of the femur, the posterior ligament of the knee-joint, and the popliteus muscle, covered by the popliteal fascia.

Contents.—The contents are the popliteal artery and its branches, the popliteal vein and its tributaries (including the termination of the external or short saphenous vein), the internal popliteal nerve and its branches, the external popliteal nerve and some of its branches, the geniculate branch of the obturator nerve (inconstant), lymphatic glands, and a large amount of fat.

Popliteal Artery.—This vessel is the continuation of the femoral artery. It extends from the posterior margin of the femoral opening, which is in connection with the adductor magnus, to the lower border of the popliteus muscle, where it divides into anterior and posterior tibial arteries. The division takes place on a level with the lower border of the tubercle of the tibia, and fully $1\frac{3}{4}$ inches below the level of the upper surface of the head of that bone. The vessel at first passes downwards and outwards until it reaches the middle line of the limb. It then takes a straight course downwards between the condyles of the femur, and finally it sinks

* The word *ham* is derived from a Teutonic verb signifying 'to be curved or crooked,' and it has been applied to the popliteal space because that space is situated behind the 'crook,' 'curve,' or bend of the knee. By a later extension of the word *ham* it came to be applied to the whole of the back of the thigh—hence the name *hamstring*, which is given to the muscles of that region.

beneath the approximation of the external and internal heads of the gastrocnemius.

General Relations. *Superficial or Posterior.*—Skin, superficial and deep fasciæ, small sciatic nerve, terminal part of the external or short saphenous vein, fat, semimembranosus for about 1 inch after the artery enters the space, approximation of the external and internal heads of the gastrocnemius, and the plantaris, which crosses the artery from without inwards. *Deep or Anterior.*—Fat, popliteal surface or trigone of the femur, posterior ligament of the knee-joint, and popliteus muscle, covered by the popliteal fascia.

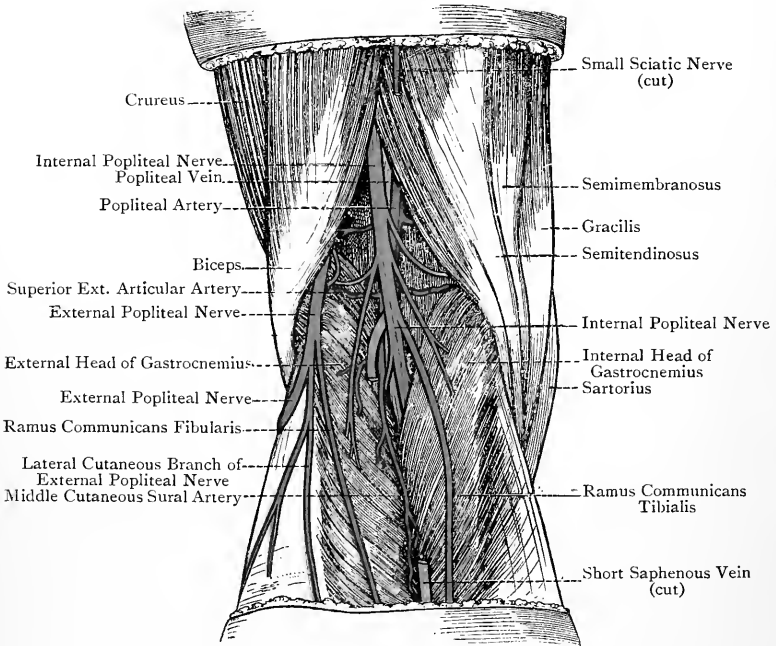


FIG. 217.—THE POPLITEAL SPACE (SUPERFICIAL DISSECTION).

Special Relations.—In the *upper part* of the space the popliteal vein is close behind, and on the outer side of, the artery, and the internal popliteal nerve is close behind, and on the outer side of, the vein, so that they overlap one another. In the *middle* of the space the popliteal vein is entirely behind the artery, and the internal popliteal nerve is directly behind the vein. In the *lower part* of the space the popliteal vein is close behind, and on the inner side of, the artery, and the internal popliteal nerve is close behind, and on the inner side of, the vein, a relation which is the reverse of that in the upper part of the space. The geniculate branch of the obturator nerve (when present), having pierced the adductor magnus

close above the femoral opening, descends at first upon the inner side of the popliteal artery, and then in front of it as low as the origin of the central or azygos artery, where the nerve leaves the main vessel and passes, with that branch, through the posterior ligament of the knee-joint to the interior of the articulation.

Branches.—The branches are (1) muscular and cutaneous, and (2) articular.

The **muscular and cutaneous branches** are divided into a superior and an inferior set.

The *superior set* are purely muscular, and are distributed to the lower parts of the hamstring muscles. They anastomose with the lower two perforating branches of the *arteria profunda femoris*.

The *inferior* or *sural set* are partly muscular and partly cutaneous. The muscular branches supply both heads of the *gastrocnemius* and the *plantaris*. The cutaneous branches are three in number, and supply the integument over the upper half of the calf. The middle cutaneous branch lies in the groove between the two heads of the *gastrocnemius* with the external or short saphenous vein. This branch is sometimes of large size, and in these cases, under the name of the *external saphenous artery*, it descends to the back of the external malleolus.

The **articular branches** are five in number—two superior, external and internal, one central or azygos, and two inferior, external and internal.

The **superior external articular artery** courses outwards close above the external condyle of the femur, passing beneath the biceps femoris and through the external intermuscular septum into the *crureus* muscle, where it breaks up into branches. These anastomose with the following arteries: (1) descending branch of the external circumflex; (2) inferior external articular; (3) deep branch of the *anastomotica magna*; (4) superior internal articular; and (5) fourth or lowest perforating branch of the *arteria profunda femoris*.

The **superior internal articular artery** courses inwards close above the internal condyle of the femur, and, having passed beneath the tendon of the *adductor magnus*, it enters the *vastus internus*, where it divides into branches. These anastomose with the following arteries: (1) inferior internal articular; (2) deep branch of the *anastomotica magna*; and (3) superior external articular.

The **central or azygos articular artery**, if a separate branch, arises from the front of the main artery, but it is often a branch of the superior external articular. It passes through the posterior ligament of the knee-joint to supply the synovial membrane and ligaments within the joint.

The **inferior external articular artery** courses horizontally outwards beneath the tendon of the biceps femoris and the long external lateral ligament of the knee-joint to the outer side of the

articulation, where it divides into branches. These anastomose with the following arteries: (1) superior external articular; (2) inferior internal articular; (3) anterior tibial recurrent; and (4) posterior tibial recurrent (inconstant).

The **inferior internal articular artery** courses at first obliquely downwards and inwards along the upper border of the popliteus muscle, and then passes inwards below the level of the internal tuberosity of the tibia, where it lies beneath the internal lateral ligament of the knee-joint. On reaching the inner side of the articulation, it divides into branches which anastomose with the following arteries: (1) superficial branch of the anastomotica magna; (2) superior internal articular; (3) inferior external articular; (4) anterior tibial recurrent; and (5) posterior tibial recurrent (inconstant).

Varieties of Popliteal Artery.—1. The vessel may divide into its anterior and posterior tibial branches at the upper border of the popliteus muscle.

2. The terminal branches may be three in number instead of two, the additional branch being the peroneal artery.

3. In very rare cases the popliteal artery divides high up into two branches of equal size, which subsequently unite prior to the normal termination of the vessel.

Popliteal Vein.—This vessel commences at the lower border of the popliteus muscle, where it is formed by the union of the venæ comites of the anterior and posterior tibial arteries, and it terminates at the posterior margin of the femoral opening, which is in connection with the adductor magnus, where it becomes the femoral vein. The relations of the vessel have already been described. Its tributaries correspond with the branches of the popliteal artery, with the addition of the external or short saphenous vein.

Internal Popliteal (Tibial) Nerve.—This nerve is one of the terminal branches of the great sciatic, and it derives its fibres from the ventral divisions of the descending branch of the fourth lumbar, the fifth lumbar, the first and second sacral, and the upper branch of the third sacral nerves. It extends from the superior angle of the popliteal space to the lower border of the popliteus muscle, where it becomes the posterior tibial nerve. The relations of this nerve have been given in connection with the popliteal artery.

Branches.—The branches are articular, cutaneous, and muscular.

The **articular branches** are three in number (sometimes two), as follows: *superior* (inconstant), accompanying the superior internal articular artery; *central* or *azygos*, going with the corresponding artery; and *inferior*, accompanying the inferior internal articular artery.

The **cutaneous branch** is called the **ramus communicans tibialis**. It descends in the middle line beneath the deep fascia as far as the centre of the calf. Here it pierces the deep fascia, and shortly afterwards it is joined by the ramus communicans fibularis from the external popliteal. In this manner the external or short saphenous nerve is formed.

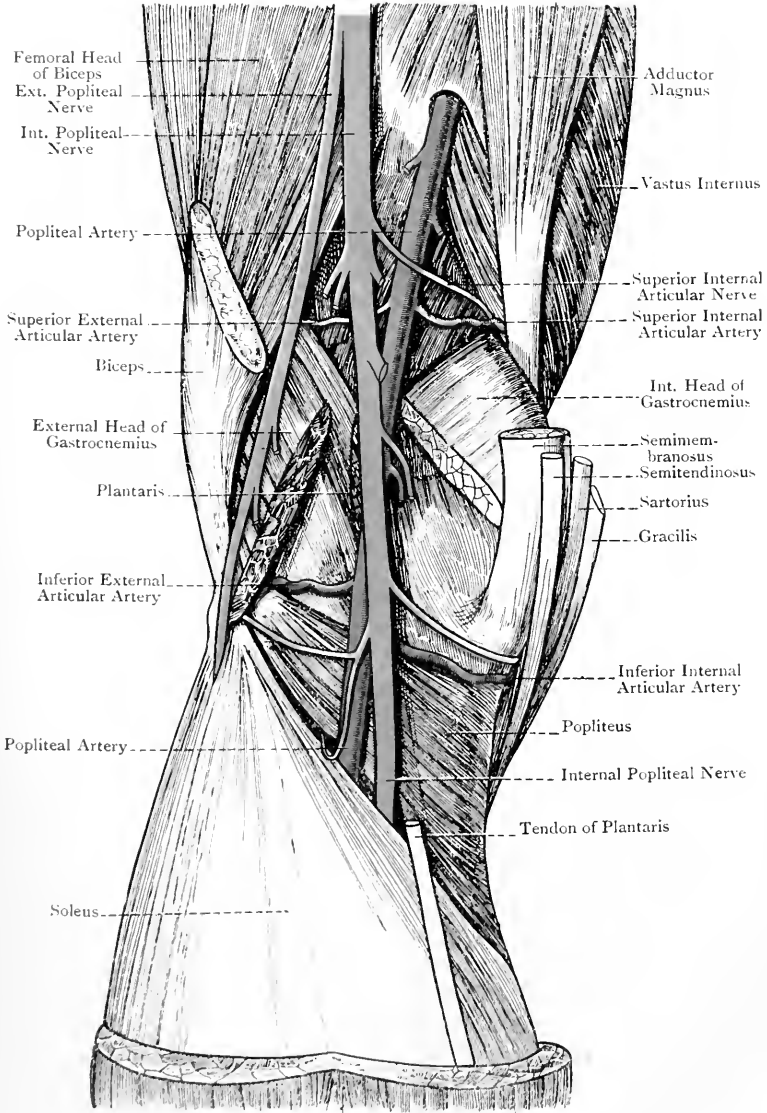


FIG. 218.—THE POPLITEAL SPACE (DEEP DISSECTION).

The **muscular (sural) branches** are usually five in number, which are distributed as follows: one to the external head of the gastrocnemius, one to the plantaris (which sometimes comes from the preceding), one to the internal head of the gastrocnemius, one to the soleus, and one to the popliteus. The **nerve to the popliteus** descends over the popliteal fascia, lying to the outer side of the popliteal vessels. On arriving at the lower border of the popliteus, it turns round that border and enters the deep surface of the muscle. This nerve, besides supplying the popliteus, furnishes the following branches: *articular* to the superior tibio-fibular joint; *medullary*, which enters the large nutrient or medullary foramen on the back of the tibia; *vascular* to the anterior and posterior tibial arteries; and *interosseous*. The interosseous branch is a long nerve which descends in the interosseous membrane to terminate in the inferior tibio-fibular joint.

External Popliteal or Peroneal (Fibular) Nerve.—This nerve is the other terminal branch of the great sciatic, and it derives its fibres from the dorsal divisions of the descending branch of the fourth lumbar, the fifth lumbar, and the first and second sacral nerves. It commences at the superior angle of the popliteal space, and descends obliquely downwards and outwards as low as the back of the neck of the fibula, where it passes forwards between the bone and the peroneus longus, to end on the outer side of the fibular neck in its terminal branches. The nerve lies at first close to the inner border of the biceps femoris, and then it rests upon the back of the external head of the gastrocnemius, between which and the biceps tendon it may be regarded as lying.

Branches.—The branches are articular, cutaneous, and terminal.

The **articular branches** are three in number, as follows: *superior*, accompanying the superior external articular artery; *inferior*, going with the inferior external articular artery, which it reaches as the vessel is about to pass beneath the biceps tendon; and *recurrent articular*, accompanying the anterior tibial recurrent artery.

The **cutaneous branches** are two in number, as follows: **lateral cutaneous branch**, which supplies the integument of the outer side of the leg over about its upper two-thirds, as well as the adjacent integument of the sural region; and **ramus communicans fibularis**, which passes downwards and inwards over the external head of the gastrocnemius and beneath the deep fascia to the centre of the calf, where it pierces the deep fascia and shortly afterwards joins the ramus communicans tibialis, to form the external or short saphenous nerve.

The **terminal branches** are three in number, as follows: **recurrent articular**, already referred to; **anterior tibial** (see p. 481); and **musculo-cutaneous** (see p. 475).

For the **geniculate branch** of the obturator nerve, see p. 447.

Popliteal Lymphatic Glands.—These are usually four in number, and lie in close contact with the popliteal artery, one being

superficial to the vessel, one beneath it, and the remaining two being disposed laterally. They receive their afferent lymphatics from the following sources: (1) sole of the foot; (2) deep part of the back of the leg; (3) some of the superficial lymphatics accompanying the external or short saphenous vein; and (4) the two efferent lymphatics which proceed from the anterior tibial lymphatic gland on the front of the interosseous membrane at its upper part. The course of these two efferent lymphatics is backwards above the interosseous membrane, or through the superior hiatus in it.

The efferent lymphatics of the popliteal glands ascend to become the afferent lymphatics of the deep femoral glands, which lie in contact with the femoral vein near Poupart's ligament.

Front and Inner Side of the Thigh.

Landmarks.—*Thigh.*—The **anterior superior spinous process of the ilium** is situated at the anterior extremity of the iliac crest, and can readily be felt. It is the point from which the measurement of the lower limb is taken. It is also a guide to the great trochanter of the femur, that prominence being situated about 4 inches below the spine, and about 4 inches behind a line let fall vertically from it. The crest of the ilium extends backwards in a curved manner from the anterior superior spinous process. **Poupart's ligament** passes between the anterior superior iliac spine and the pubic spine. It can be felt as a tense, firm band, especially when the thigh is extended, abducted, and rotated outwards. Immediately below it the inguinal lymphatic glands may be felt. Poupart's ligament, when traced inwards, conducts the finger to the **pubic spine**, which is situated at the lower and inner part of the anterior abdominal wall about $1\frac{1}{4}$ inches outside the upper part of the symphysis pubis. It is sometimes a sharp-pointed process, and then it can readily be felt beneath the integument. In most bodies, however, it takes the form of a more or less indistinct tubercle, and, especially in corpulent bodies, it cannot be felt. In such cases the scrotal integument may be invaginated with the finger so as to raise the adipose tissue from over the spine. If it cannot be felt in this way, the thigh should be well abducted to render prominent the adductor longus muscle, the tendon of origin of which will serve as a guide to the spine, which lies above and to the outer side of it. The pubic spine is the guide to the following openings: the **external abdominal ring**, which lies immediately above and to the outer side of it; the **crural or femoral ring**, which is situated fully 1 inch external to the spine in a line drawn outwards from it across the front of the thigh; and the **saphenous opening**, which is situated below, and a little external to, it.

The **pubic crest** extends inwards for about 1 inch from the pubic spine, and terminates in the **pubic angle** above the symphyseal surface of the os pubis. The crest may be felt if the scrotal integument is invaginated and the little finger passed into the ex-

ternal abdominal ring, of which the crest forms the base. The angle cannot usually be felt. The ischio-pubic ramus can be felt extending from the tuber ischii at the back of the limb to the lower part of the symphysis pubis. The saphenous opening is situated below and external to the pubic spine, and it extends downwards for about $1\frac{1}{2}$ inches below the inner third of Poupart's ligament. At the lower extremity of the opening the superficial femoral or saphenous lymphatic glands may be felt. The most prominent part of the head of the femur will be felt immediately below Poupart's ligament, at a point just external to its centre.

The **great trochanter** is situated about 4 inches below the anterior superior iliac spine, and about 4 inches behind a line let fall vertically from it. Its outline is more or less obscured by the muscles which cover it, but the following guides may serve to localize the prominence :

Holden's Guide.—The top of the great trochanter is pretty nearly on a level with the pubic spine in the recumbent posture.

Nélaton's Line.—This is a line drawn from the anterior superior iliac spine to the most prominent part of the tuber ischii. It coincides with the top of the great trochanter, and runs through the centre of the acetabulum.

Bryant's Test-Line.—The subject being in the horizontal position, a triangle (ilio-femoral) is constructed in the following manner: draw two lines from the anterior superior spine of the ilium, one being vertical and traversing the outside of the hip to the horizontal plane of the body, and the other impinging on the tip of the great trochanter. Then construct the base by drawing a line from, and at right angles to, the vertical line to the trochanter. The base represents Bryant's test-line for shortening of the neck of the femur. 'Any shortening of this line, on comparing it with the same taken on the uninjured side, indicates with precision a shortening of the neck of the thigh-bone.'

The position of **Scarpa's triangle** is indicated by a slight depression which exists below Poupart's ligament. The outline of the adductor longus muscle is easily seen when the limb is firmly abducted. If the prominence thereby produced is followed upwards, the narrow round tendon of origin of the muscle is readily felt at a point on the body of the os pubis below and internal to the pubic spine. The rectus femoris gives rise to a median vertical prominence on the front of the thigh. The well-marked prominence over the lower fourth of the thigh on its inner aspect is due to the vastus internus muscle. When the knee is flexed, the narrow round **tendon of the adductor magnus** can be felt as it descends, posterior to the vastus internus, to reach the adductor tubercle of the femur.

Knee.—The outline of the **patella** is readily felt along with that of the ligamentum patellæ, which passes from the lower pointed end of the patella to the tubercle of the tibia.

The internal condyle of the femur forms a large prominence looking inwards. On its inner surface the blunt internal tuberosity is easily felt. At its upper and back part the **adductor tubercle** can be felt, when the knee-joint is flexed, with the narrow round tendon of the adductor magnus taking insertion into it. The upper border of the

patellar surface of the femur may be felt when the knee-joint is flexed, but it is somewhat obscured by the tendon of the quadriceps extensor cruris. It is oblique in direction, and rises higher externally than internally. The adductor tubercle is on the same level as the outer part of the upper border of the patellar surface. A line connecting these two points, and at the same time cutting the adductor tubercle into two, indicates the line of junction of the lower epiphysis of the femur with the shaft at the twentieth year. The external condyle of the femur, though not very prominent, may be felt. The external tuberosity of the tibia forms a marked prominence at the outer and anterior part of the knee-joint, and it here presents a tubercle, or ridge, for the ilio-tibial band of the fascia lata. The head of the fibula is easily felt below and behind the external tuberosity of the tibia. The **tubercle of the tibia** is felt at the upper end of the sharp anterior border or crest of the bone. Its upper border is on the same level as the upper part of the head of the fibula. It is to be noted that the internal tuberosity of the tibia has a slight inclination backwards as well as inwards.

The lower limit of the **synovial membrane** of the knee-joint corresponds with the level of the tubercle, or ridge, on the anterior and outer part of the external tuberosity of the tibia for the attachment of the ilio-tibial band of the fascia lata. If this tubercle cannot be felt, a transverse line just above the head of the fibula indicates the lower limit of the membrane. In this direction the membrane clothes the deep or posterior surface of the ligamentum patellæ in its upper half. Behind the lower end of this ligament there is a bursa separating it from the upper smooth part of the tubercle of the tibia. Superiorly the synovial membrane extends upwards above the patella in the form of a large pouch upon the front of the femur for about 2 inches above the upper border of the patellar surface of the bone. This pouch lies beneath the tendon of the quadriceps extensor cruris, and communicates with a bursa which is situated immediately above it, and which extends upwards for about another inch beneath the tendon.

In extension of the knee-joint the patella is situated above the level of the condyles of the femur. In flexion it lies over the intercondylar fossa. In extreme flexion the patella articulates chiefly with the semilunar impression on the outer part of the tibial surface of the internal condyle of the femur, close to the intercondylar fossa. The particular part of the patella which so articulates is the inner vertical zone on its posterior surface, immediately adjoining its internal border. In flexion of the joint there is a depression on either side of the ligamentum patellæ, and also on either side of the patella itself, the latter depression being greater on the inner than on the outer side. In this position of the joint the anterior margin of each tibial tuberosity is readily felt, and, above each, there is a hollow which separates it from the corresponding femoral condyle. In extension of the joint the depression on either side of the patella is also manifest, being, as in flexion, greater on its inner side. The

depression on either side of the ligamentum patellæ, however, is not present, this being due to the lateral dispersion of the fat which normally lies underneath the ligamentum patellæ.

Cutaneous Nerves. Crural Branch of Genito-crural Nerve.—The genito-crural nerve is a branch of the lumbar plexus, its fibres being derived from the first lumbar and the ventral division of the second lumbar nerves. Its **crural branch** emerges beneath Poupart's ligament immediately to the outer side of the femoral artery, and within the crural sheath. Having supplied a twig to the coats of that vessel, it pierces the sheath and the fascia lata, to be distributed to the integument over Scarpa's triangle.

Inguinal Nerve (Ilio-inguinal).—This is a branch of the lumbar plexus, its fibres being derived from the first lumbar nerve. It emerges from the inguinal canal through the external abdominal ring, where it lies directly to the outer side of the spermatic cord, or round ligament of the uterus, according to the sex. It then pierces the intercolumnar fascia, and is distributed to the integument of the inner side of the thigh in the upper third, and to the adjacent integument of the scrotum in the male and the labium majus in the female.

External Cutaneous Nerve.—This is a branch of the lumbar plexus, its fibres being derived from the dorsal divisions of the second and third lumbar nerves. It emerges beneath the outer end of Poupart's ligament, and shortly afterwards divides into a small posterior and a large anterior division. The *posterior division* is distributed to the integument of the outer side of the thigh in the upper fourth, and also to the integument of the outer and lower part of the gluteal region. The *anterior division* is at first contained in a tube of the fascia lata for about 4 inches, and then it enters the integument of the outer side of the thigh which it supplies, reaching in some cases as low as the patella, and taking part in the patellar plexus.

Middle Cutaneous Nerve.—This is a branch of the anterior division of the anterior crural nerve. It pierces the fascia lata in two divisions, outer and inner, about 4 inches below Poupart's ligament. The outer division usually passes through the upper part of the sartorius, and then descends with the inner division to supply the integument of the front of the thigh in the lower two-thirds. The two divisions extend as low as the patella, where they take part in the patellar plexus.

Internal Cutaneous Nerve.—This is a branch of the anterior division of the anterior crural nerve. It crosses over the femoral artery from without inwards near the apex of Scarpa's triangle, either as one nerve, or in its two final divisions, anterior and posterior. These two divisions now descend on the inner side of the thigh beneath the fascia lata, and along the line of the long saphenous vein. At the junction of the middle and lower thirds of the thigh the *anterior division* pierces the fascia lata, and descends near the tendon of the adductor magnus to the inner side of the knee-joint,

supplying the integument of the inner side of the thigh in the lower third. It finally turns outwards over the patella, and enters into the patellar plexus. The *posterior division* descends along the posterior border of the sartorius, and keeps beneath the fascia lata until it reaches the level of the internal condyle of the femur. Here it pierces the fascia lata, and descends to the inner side of the leg, lying posterior to the long saphenous nerve, and supplying the integument as low as the centre. The internal cutaneous nerve, whilst in Scarpa's triangle, gives off two or three cutaneous branches, which, having pierced the fascia lata, cross the femoral artery and are distributed to the integument of the inner side of the thigh in the middle third, along the course of the long saphenous vein. The posterior division of the nerve gives off a branch to the subsartorial plexus about the centre of the thigh on its inner aspect.

Internal or Long Saphenous Nerve.—This is a branch of the posterior division of the anterior crural nerve, and is deeply placed as far as the knee-joint. In the lower two-thirds of Scarpa's triangle it lies close to the outer side of the femoral artery, and in Hunter's canal it gets in front of that vessel. It leaves Hunter's canal at its lower end by piercing the aponeurotic roof, in company with the superficial branch of the anastomotica magna artery, and then it descends beneath the sartorius to the inner side of the knee-joint. Here it pierces the fascia lata on a level with the lower border of the sartorius, and enters the inner side of the leg, along which it courses, usually in two divisions, in company with the long saphenous vein, the larger division being behind that vessel, and the smaller in front. At the ankle-joint the larger division passes in front of the internal malleolus, and then along the inner border of the foot as far as the centre. The long saphenous nerve, in passing through Hunter's canal, gives off a branch which pierces the aponeurotic roof, and enters into the subsartorial plexus. At the level of the internal femoral condyle it furnishes its *patellar branch*. This passes through the sartorius and fascia lata, and is distributed to the integument over the front of the knee, where it takes part in the patellar plexus.

In its further course beyond the knee-joint the nerve supplies branches to the integument of the inner side of the leg, back of the leg in its lower and inner part, internal malleolus, and inner side of the foot as far as the centre. In the upper part of the leg it communicates with the posterior division of the internal cutaneous nerve, and on the inner side of the foot it is connected with the musculo-cutaneous.

Obturator Nerve.—The anterior division of the obturator nerve usually furnishes a branch which pierces the fascia lata about the centre of the thigh, between the posterior border of the sartorius and the anterior border of the gracilis, to be distributed to the integument for a variable distance.

Patellar Plexus.—This free interlacement of nerves is so named because it is situated over the anterior surface of the patella.

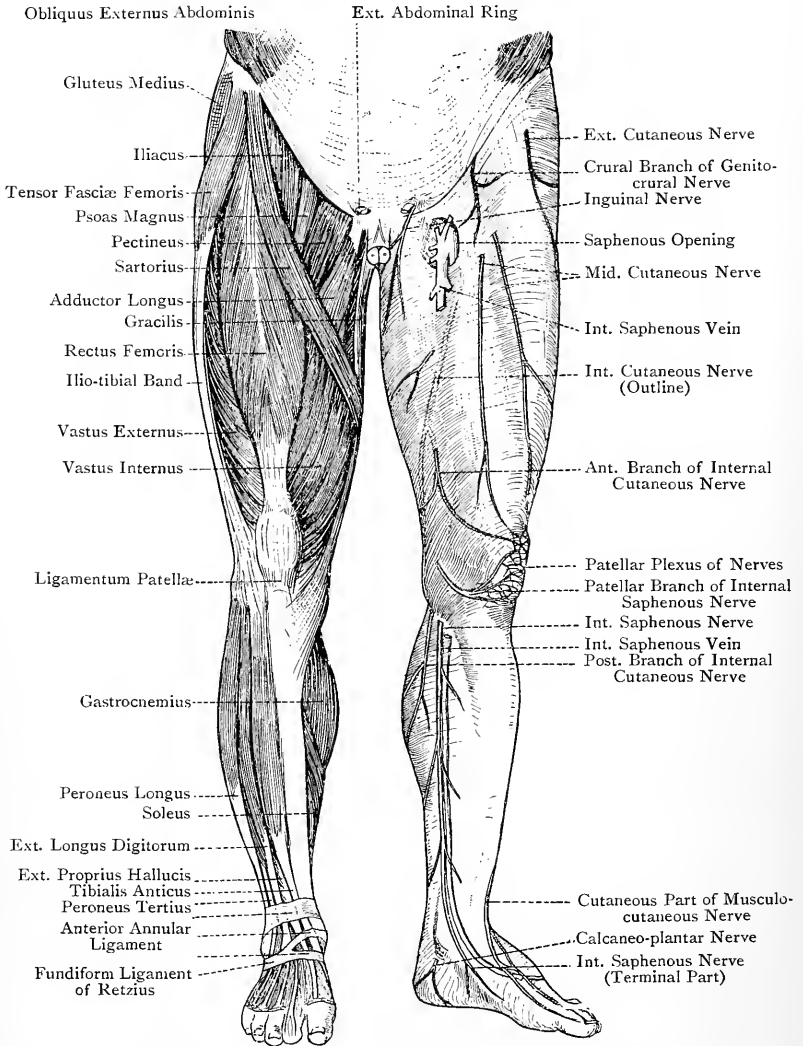


FIG. 219.—MUSCLES AND CUTANEOUS NERVES OF THE LOWER LIMB (ANTERIOR ASPECT).

The nerves which take part in it are as follows: the patellar branch of the long saphenous; both divisions of the middle cutaneous; the anterior division of the internal cutaneous; and the anterior division of the external cutaneous (which, however, is not constant).

Subsartorial Plexus.—This plexus is situated in the middle third of the thigh on its internal aspect, and lies beneath the sartorius upon the aponeurotic covering of Hunter's canal. The nerves which take part in its formation are as follows: the long saphenous; the posterior division of the internal cutaneous; and the superficial or anterior division of the obturator. The branches furnished by this plexus are distributed to the integument of the inner side of the thigh for about its middle third.

Superficial Fascia.—The only point to be noted in connection with the superficial fascia is that, for about 3 inches below Poupart's ligament, it is divisible into two layers—subcutaneous and deep. The subcutaneous layer is fatty, and, when traced upwards, becomes continuous with the fascia of Camper on the anterior abdominal wall. The deep layer is a very delicate membrane, which is best seen on the inner side of and beneath the long saphenous vein, as that vessel lies between it and the subcutaneous layer. It can be traced upwards to a line about $\frac{1}{4}$ inch below Poupart's ligament, where it blends with the fascia lata. In passing upwards it covers the saphenous opening, to the outer margin of which it is closely bound by fibrous bands, more especially over the middle third. The part of this layer which lies over the saphenous opening is called the *cribriform fascia*, because it presents numerous foramina for the passage of the following structures: (1) the long saphenous vein; (2) the efferent lymphatics of the inguinal and superficial femoral glands; (3) the superior external pudic artery; and (4) the superficial epigastric and superficial circumflex iliac arteries. The latter two vessels, however, sometimes pierce the fascia lata forming the outer margin of the saphenous opening.

Lymphatic Glands.—The glands of the upper part of the front of the thigh are arranged in two groups—superficial and deep.

Superficial Group.—The glands which comprise this group are arranged in two sets—inguinal and superficial femoral or saphenous.

The **inguinal glands** are otherwise called the *superior or oblique superficial inguinal glands*. They are situated immediately below Poupart's ligament, and lie underneath the subcutaneous layer of the superficial fascia, their long axes being oblique. They are usually from six to eight in number, and the innermost two or three, which lie internal to the upper part of the saphenous opening in the vicinity of the pubic spine, are spoken of as the *pubic glands*. The inguinal glands receive their **afferent** lymphatics from the following sources:

1. The superficial lymphatics of the anterior abdominal wall below the level of the umbilicus.
2. The superficial lymphatics of the gluteal region.

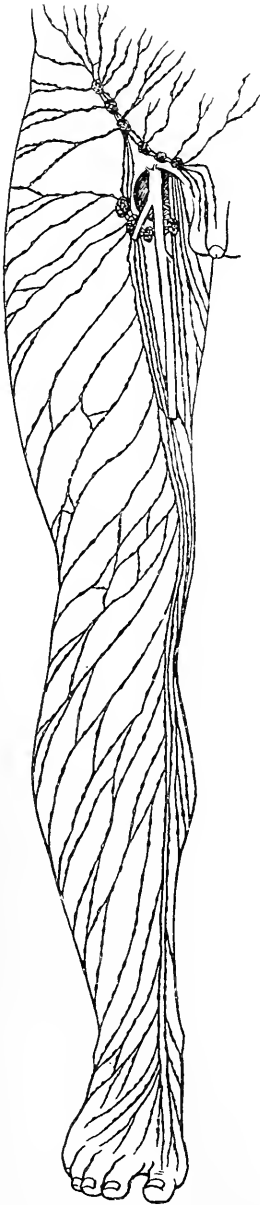


FIG. 220.—THE SUPERFICIAL LYMPHATICS OF THE LOWER LIMB.

3. The outer and back part of the thigh (superficial).

4. The upper and inner part of the thigh (superficial).

5. The scrotum in the male (except its back part), and the external genital organs in the female.

6. The superficial lymphatics of the penis, including those of the glans penis, some of those of the membranous portion, and all those of the spongy portion, of the urethra.

7. The superficial lymphatics of the perineum, the lower part of the anal canal, and the anus.

8. The lower third of the vagina, and the female urethra.

The **effluent** lymphatics of the inguinal glands pierce the cribriform fascia and anterior wall of the crural sheath, and terminate in two ways. Some of them become the afferent lymphatics of the deep femoral glands, whilst others enter the abdominal cavity, where they become the afferent lymphatics of the external iliac glands.

Blood-supply.—The inguinal glands derive their arterial supply from the superficial circumflex iliac, superficial epigastric, and superior or superficial external pudic branches of the common femoral artery.

The **superficial femoral** or **saphenous glands** are otherwise called the *inferior* or *vertical superficial inguinal glands*. They are situated at the lower end of the saphenous opening, where they lie, with their long axes vertical, on either side of the terminal part of the internal or long saphenous vein, underneath the subcutaneous layer of the superficial fascia. They are usually from four to six in number, and they receive their **afferent** lymphatics from the following sources :

1. The superficial lymphatics of the foot and leg, except a few of those which accompany the external or short saphenous vein, these latter terminating in the popliteal glands.

2. The superficial lymphatics of the thigh, except those from (a) the outer and back part, and (b) the upper and inner part, which terminate in the inguinal glands.

The **efferent** lymphatics of the superficial femoral or saphenous glands pierce the cribriform fascia, and terminate in a manner similar to those of the inguinal glands.

Blood-supply.—These glands derive their arterial supply from two or three saphenous branches of the superficial femoral artery.

Deep Group.—These are called the **deep femoral glands** (*deep inguinal glands*). They are from three to four in number, and are situated within the crural sheath. One of them lies in the crural canal at its upper end, being attached to the inferior convex surface of the septum crurale. The others are situated in the middle compartment of the crural sheath, where they lie on the inner side of the femoral vein. The deep femoral glands receive their **afferent** lymphatics from the following sources :

1. The inguinal glands.
2. The superficial femoral or saphenous glands.
3. The deep lymphatics of the knee and thigh.
4. The popliteal glands.

The **efferent** lymphatics of the deep femoral glands enter the abdominal cavity, where they become the afferent lymphatics of the external iliac glands.

Blood-supply.—The deep femoral glands derive their arterial supply from the superior or superficial external pudic branch of the common femoral artery.

Internal or Long Saphenous Vein.—This vessel arises from the inner end of the venous arch on the dorsum of the foot. It passes in front of the internal malleolus and along the inner side of the leg, where it lies about a finger's breadth from the internal border of the tibia. It then courses along the inner side of the knee-joint, being situated behind the most prominent part of the internal condyle of the femur, and so it enters the thigh. Thereafter it ascends along the inner side of the thigh superficial to the sartorius, until it reaches the upper third of that division of the limb. Here it turns to the front of the thigh, and in its subsequent course lies at the junction of the inner fourth and outer three-fourths. On reaching a point $1\frac{1}{2}$ inches below Poupart's ligament it pierces the cribriform fascia and anterior wall of the crural sheath, and terminates in the femoral vein. Throughout its whole course the vein is superficial to the deep fascia. It receives many tributaries from the front and back of the leg and thigh, and it communicates at frequent intervals with the venæ comites of the anterior and posterior tibial arteries, these communicating branches being intermuscular. Two tributaries in the upper part of the thigh are specially noteworthy from their size and constancy. One, collecting the blood from the front of the thigh, is called the *external femoral cutaneous*, or *anterior saphenous vein*. The other returns the blood from the inner and back parts of the thigh, and is called the *internal femoral cutaneous*, or *posterior saphenous vein*. These two tributaries terminate in the long saphenous vein near the

saphenous opening. It is to be noted that the external femoral cutaneous or anterior saphenous vein lies over the sartorius muscle at the apex of Scarpa's triangle, where it is liable to be cut in operating in this situation. Before piercing the cribriform fascia the internal or long saphenous vein receives as final tributaries the following veins: the superficial circumflex iliac; the superficial epigastric; the superior or superficial external pudic; and the inferior or deep external pudic. The long saphenous vein has usually about fifteen valves. One of these is found in the vein just before it pierces the cribriform fascia, and another at its opening into the femoral vein.

The guide to the vein in the femoral part of its course is a line drawn from a point immediately behind the most prominent part of the internal condyle of the femur to a point on the front of the thigh $1\frac{1}{2}$ inches below Poupert's ligament, at the junction of the inner fourth and outer three-fourths of the limb.

The vein is occasionally double in the femoral part of its course. This condition is brought about by the vein dividing into two branches shortly after it enters the thigh, which ascend close together and unite to form one trunk close to the saphenous opening.

Deep Fascia or Fascia Lata.—The fascia lata is a very strong fibrous membrane which forms a continuous tubular sheath swathing the powerful muscles in this region. *Superiorly* it is attached as follows: (1) to Poupert's ligament as far inwards as the pubic spine; (2) to the outer lip of the iliac crest, where it covers the anterior two-thirds of the gluteus medius; (3) to the posterior lamina of the lumbar aponeurosis; (4) to the back of the lower end of the sacrum and coccyx; (5) to the lower border of the great sacro-sciatic ligament; (6) to the tuber ischii; (7) to the ischio-pubic ramus; (8) to the anterior or femoral surface of the body of the os pubis close to the symphysis; and (9) to the anterior lip of the pubic crest as far outwards as the pubic spine. *Inferiorly*, in the region of the knee, the fascia lata is disposed as follows: (1) on the outer side it is attached to the head of the fibula and external tuberosity of the tibia; (2) anteriorly it is attached to the lateral borders of the patella, in which latter situations it forms the larger portions of the so-called lateral patellar ligaments; from its attachments to the lateral borders of the patella an expansion is sent over that bone and downwards to the head of the tibia, which confines the prepatellar bursa; (3) posteriorly it is continued uninterruptedly into the back of the leg, covering the popliteal space as it descends, and becoming continuous with the deep fascia; (4) internally it is continued into the inner side of the leg, taking a limited attachment to the internal tuberosity of the tibia, and becoming continuous with the deep fascia.

The fibres of the fascia lata interlace freely, some of them being circular and others longitudinal. It is pierced by a large

number of minute foramina for the passage of bloodvessels and nerves. The fascia is strongest upon the outer side of the thigh, where it gives insertion superiorly to a large part of the gluteus maximus, and lower down to the tensor fasciæ femoris. It is also strong over the popliteal space and prepatellar region, receiving in the former situation accessions of fibres from the hamstring tendons, and, in the latter, similar accessions from the tendons of the muscles which form the quadriceps extensor cruris. Upon the inner side of the thigh the fascia is very thin.

The portion upon the outer side of the thigh, between the fore part of the iliac crest and the anterior part of the external tuberosity of the tibia and outer border of the patella, is spoken of as the **ilio-tibial band**. At the insertion of the tensor fasciæ femoris it gives off a deep lamina which passes upwards on the deep surface of the muscle to be attached to the bottom of the groove on the dorsum of the ilium above the acetabulum, where the posterior or reflected head of the rectus femoris takes its origin. This deep lamina is intimately connected with the capsular ligament of the hip-joint and the tendon of the gluteus minimus.

The fascia lata on the front of the thigh divides at a point $1\frac{1}{2}$ inches below the inner third of Poupart's ligament into two laminae, iliac and pubic. The *iliac lamina* passes upwards to be attached to Poupart's ligament, lying superficial to the outer portion of the anterior wall of the crural sheath. The *pubic lamina* is on a deeper or more posterior plane than the iliac, and passes upwards upon the flat pectineus muscle to be attached to the pectineal portion of the ilio-pectineal line and anterior

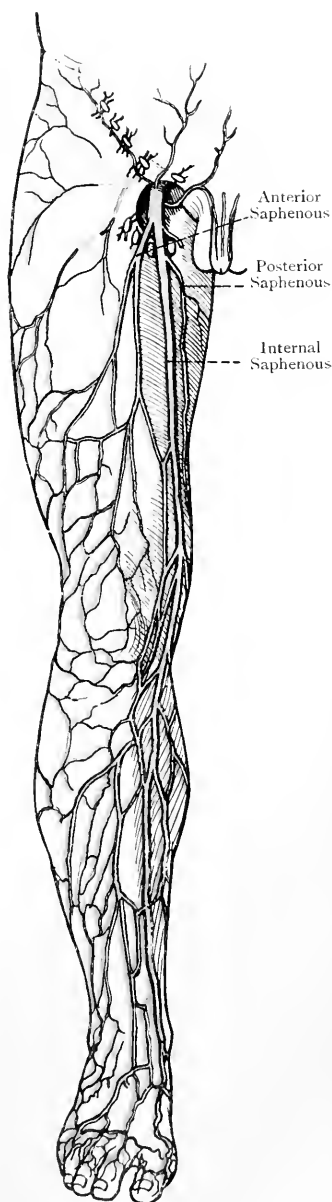


FIG. 221.—THE INTERNAL SAPHENOUS VEIN AND ITS TRIBUTARIES.

lip of the pubic crest. This pubic lamina, when followed outwards, passes behind the crural sheath and ends by blending with its posterior wall. It will thus be seen that the iliac lamina is superficial or anterior to the femoral vessels enclosed in the crural sheath, and that the pubic lamina is on a plane deeper than, or posterior to, the femoral vessels.

Processes of the Fascia Lata.—These processes, which for the most part are indicated on the surface by white lines, pass between the muscles, forming **intermuscular septa**, and taking part in the muscular sheaths. Three of them are specially noteworthy, and are called external, internal, and posterior. The *external* intermuscular septum is a deep expansion from the ilio-tibial band, and it is attached to the outer lip of the linea aspera and external supracondylar ridge of the femur in its whole extent. It separates the vastus externus and crureus in front from the femoral head of the biceps behind, and it gives partial origin to these muscles. The *internal* intermuscular septum is a delicate process, which is attached to the inner lip of the linea aspera, especially in its lower part. Over the internal supracondylar ridge its place is taken by an expansion from the tendon of the adductor magnus. This septum separates the vastus internus in front from the adductor longus and adductor magnus behind. The *posterior* intermuscular septum is a very delicate process which is attached to the summit of the linea aspera. It is situated behind the adductor magnus, which it separates from the femoral head of the biceps.

Saphenous Opening.—This is an opening in the fascia lata for the passage of the long saphenous vein, and it is of importance surgically inasmuch as a femoral hernia may protrude through it. It is situated on the front of the thigh below and outside the pubic spine, just below the inner third of Poupart's ligament. It is not so much an opening as an oval depression in the fascia lata, formed by the division of that fascia into its iliac and pubic laminæ, the iliac lamina passing upwards superficial to the outer part of the anterior wall of the crural sheath, and the pubic lamina passing upwards on a plane posterior to the posterior wall of the crural sheath, with which it becomes continuous. The average length of the opening is $1\frac{1}{2}$ inches, and its breadth is from $\frac{1}{2}$ to $\frac{3}{4}$ inch. The lower border of the opening is called the **inferior cornu**, and over this the long saphenous vein passes. It is firm, sharp, and crescentic, with the concavity directed upwards. The inner part, formed by the pubic lamina of the fascia lata, is for the most part flat, the fascia being here spread out upon the pectineus muscle, whence it passes outwards to blend with the posterior wall of the crural sheath. Over the lower fourth, however, the opening has a distinct inner border, which is continuous with the inferior cornu. The outer border, formed by the iliac lamina of the fascia lata, is on a plane superficial to the outer part of the anterior wall of the crural sheath, to which it is bound by fibrous bands. In-

teriorly this border is continuous with the inferior cornu. Superiorly it curves inwards over the anterior wall of the crural sheath. The whole border is concave or semilunar, the concavity being directed inwards and slightly downwards. The upper border is the portion in front of the anterior wall of the crural sheath, and it lies immediately below Poupart's ligament. It is called the **superior cornu**.

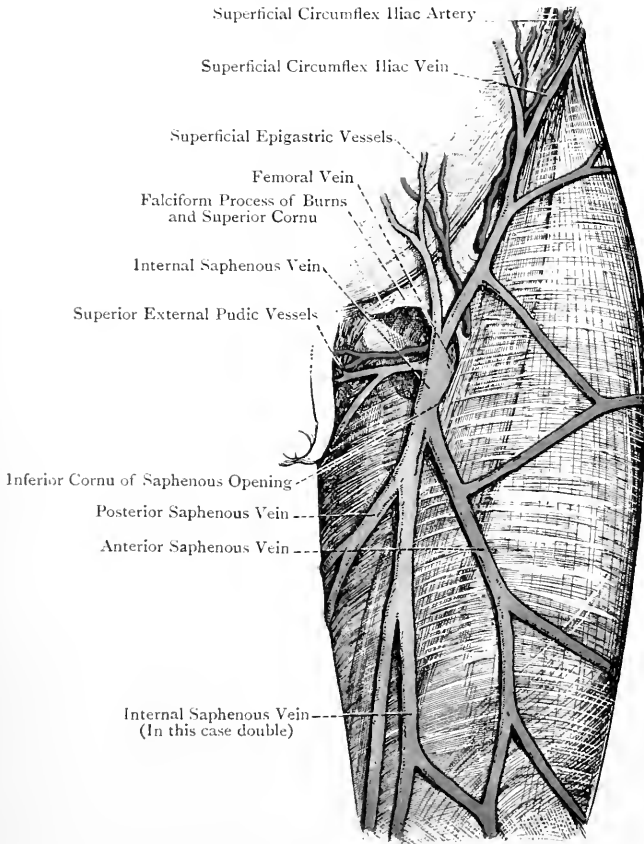


FIG. 222.—THE LEFT INTERNAL SAPHENOUS VEIN IN THE THIGH, WITH ITS TRIBUTARIES, AND THE SAPHENOUS OPENING.

It is triangular, and is continuous with the outer border. Superiorly it is attached to the inner part of Poupart's ligament, extending inwards as far as the pubic spine, and a few of its fibres join the antero-inferior or femoral surface of Gimbernat's ligament. The inner portion of the superior cornu is internal to the femoral vein, and lies in front of the crural canal. It is this portion, inside the

femoral vein, which has been called the **falciform process of Burns** (John),* or the **femoral ligament of Hey**. The importance of this process or ligament is that it impresses upon a femoral hernia its final change in direction, inasmuch as it causes the protrusion to turn upwards over Poupart's ligament upon the anterior abdominal wall, or upwards and outwards towards the anterior superior iliac spine.

The saphenous opening is covered by the cribriform fascia, which is more intimately attached to the outer border than elsewhere.

Parts concerned in Femoral Hernia.

Poupart's Ligament or the **Superficial Crural Arch**.—This is the thickened lower border of the aponeurosis of the external oblique muscle. It is folded upon itself in a backward direction, and is attached externally to the anterior superior iliac spine and internally to the pubic spine.

Gimbernat's Ligament.—This is the reflection of Poupart's ligament from the pubic spine along the ilio-pectineal line for $\frac{1}{2}$ inch. It is triangular, and presents a free base which is sharp, wiry, and concave, and is situated immediately to the inner side of the crural or femoral ring.

Deep Crural Arch.—This is a thickening of the fascia transversalis, due to an accession of fibres as it is prolonged downwards beneath Poupart's ligament. It extends from the centre of that ligament on its deep aspect to the pectineal portion of the ilio-pectineal line, where it is attached behind Gimbernat's ligament near its base.

Falciform Process of Burns.—This has just been described in connection with the superior cornu of the saphenous opening.

Crural or Femoral Sheath.—This sheath extends from Poupart's ligament to a point about $\frac{1}{2}$ inches below it, where it blends with the special sheath of the femoral vessels. The outer wall is straight, but the inner is oblique, being sloped downwards and outwards. In shape the sheath resembles a funnel, from which circumstance the term *infundibuliform* has been applied to it. The anterior wall is formed by the fascia transversalis, and the posterior wall by the fascia iliaca, both of which fasciæ are prolonged downwards beneath Poupart's ligament. The outer wall is formed by the union of these two fasciæ close to the outer side of the femoral artery. The inner wall is formed by their union at a point $\frac{1}{2}$ inch to the inner side of the femoral vein.

Within the sheath there are two septa, external and internal, both of which extend from the anterior to the posterior wall, the external septum being close to the outer side of the femoral vein, and the internal septum close to its inner side. By means of these two septa the interior of the sheath is divided into three distinct compart-

* *Edinburgh Medical and Surgical Journal*, July 1, 1806, p. 269.

ments—outer, middle, and inner. The *outer compartment* contains the common femoral artery and the crural branch of the genito-crural nerve for a short distance at its upper part, where the nerve lies immediately external to the artery. The *middle compartment* contains the femoral vein and three of the deep femoral glands. The *inner compartment* is called the crural or femoral canal, and it contains one of the deep femoral glands and a certain amount of adipose tissue, the gland lying at the upper end of the canal.

Crural or Femoral Canal.—This is the inner compartment of the crural sheath, and it is $\frac{1}{2}$ inch in length. Its upper end forms the crural or femoral ring, and is on a level with the base of Gimbernat's ligament. Its lower end is just below the superior cornu of the saphenous opening. The boundaries of the canal are as follows: the *anterior wall* is formed by the fascia transversalis; the *posterior wall* by the fascia iliaca; the *inner wall* by the junction of the fascia transversalis and fascia iliaca; and the *outer wall* by the internal septum within the sheath.

Crural or Femoral Ring.—This is by no means a patent opening, but is bridged over by the subperitoneal areolar tissue of the abdominal wall. The septum thus formed between the crural canal and abdominal cavity is called the **septum crurale** (fascia of Cloquet). It protrudes slightly into the canal, and the lymphatic gland which lies at the upper end of the canal is attached to its under convex surface. When the septum crurale has been removed from the crural ring, the aperture presents an oval shape, with the long measurement lying transversely, in which direction it measures $\frac{1}{2}$ inch. It readily admits the little finger, and it is somewhat larger in the female than in the male. The situation of the ring is close to the outer side of the base of Gimbernat's ligament, and its position may be ascertained in one of two ways.

(1) Draw a line from the pubic spine horizontally outwards across the front of the thigh, and take a point in this line fully 1 inch to the outer side of the pubic spine.

(2) Find the central point between the anterior superior iliac spine and the symphysis pubis; then take a point on Poupert's ligament rather more than $\frac{1}{2}$ inch to the inner side of this central point.

Boundaries—*Anterior.*—The inner part of Poupert's ligament, and the deep crural arch. *Posterior.*—The pubic lamina of the fascia lata, joined by Cooper's ligament;* the pectineus muscle; and the superior pubic ramus. *Internal.*—The base of Gimbernat's

* The **pubic ligament of Cooper** is a strong bundle of fibres extending between the ilio-pectineal eminence and the pubic spine, between which points it is attached to the pectineal portion of the ilio-pectineal line. It has the pectineal border of Gimbernat's ligament immediately behind it, and is closely incorporated with the pubic lamina of the fascia lata, where that is attached to the pectineal portion of the ilio-pectineal line.

ligament. *External.*—The upper extremity of the internal septum within the crural sheath.

Normal Relation of Bloodvessels to the Crural Ring—*Anterior.*—The pubic branch of the deep epigastric artery, as it courses inwards behind the inner half of Poupart's ligament. *Supero-anterior.*—The vessels of the spermatic cord in the male, or of the round ligament of the uterus in the female. *Supero-external.*—The deep epigastric vessels. *External.*—The femoral vein, becoming the external iliac vein, and separated from the ring by the upper extremity of the internal septum within the crural sheath.

There are normally no vessels behind the ring, nor internal to it. Under no circumstances are there ever any vessels behind it, but in certain cases there may be a vessel on its *inner side*, namely, an abnormal obturator artery.

Abnormal or Aberrant Obturator Artery.—The obturator artery normally arises from the anterior division of the internal iliac, and under these circumstances it has no relation to the crural ring. In about 30 per cent. of cases, however, the obturator arises from the deep epigastric artery near its commencement. This origin is more common in the female than in the male, and is rarely bilateral. In most of these cases the aberrant obturator passes backwards close to the inner side of the commencement of the external iliac vein, and therefore upon the *outer side* of the crural ring. In a few cases the aberrant vessel passes backwards across the centre of the crural ring. In very rare cases it passes inwards behind Poupart's ligament, and then arches backwards either close to the base of Gimbernat's ligament, or a line or two inwards from it, and therefore upon the *inner side* of the crural ring. If a femoral hernia should occur under these latter circumstances, the aberrant obturator artery would lie upon the inner side of the neck of the sac, and it would thus be endangered in the operation for the relief of the strangulation. This very rare position of an aberrant obturator artery is more frequent in the male than in the female, and, according to Lawrence, it occurred once in a hundred cases.

The origin of an aberrant obturator artery from the deep epigastric is due to a more or less complete obliteration of a normal obturator at its origin, and an enlargement of the normal anastomosis which takes place between the pubic branches of the deep epigastric and obturator arteries behind the body of the os pubis.

Femoral Hernia.—This is a protrusion of an abdominal viscus, or part of a viscus, through the crural or femoral ring. The course of the hernia is as follows: entering the crural ring by elongating the septum crurale, it descends through the crural canal, on reaching the lower end of which it is placed in the upper part of the saphenous opening, immediately below the falciform process of Burns or femoral ligament of Hey. This structure now impresses upon the hernia the following change in its course: the front part of the hernia being arrested in its downward course by that structure, the posterior part, which is free, comes down, and, passing forwards, turns upwards upon the anterior abdominal wall, or upwards and outwards along Poupart's ligament. The course of a femoral hernia, when complete, is thus at first downwards through the crural ring and crural canal, then forwards through the upper part of the saphenous opening, and finally either upwards or upwards and outwards.

Coverings of a Femoral Hernia.—The coverings, from within outwards, are as follows:

1. Peritoneum, which forms the sac.
2. Septum crurale.

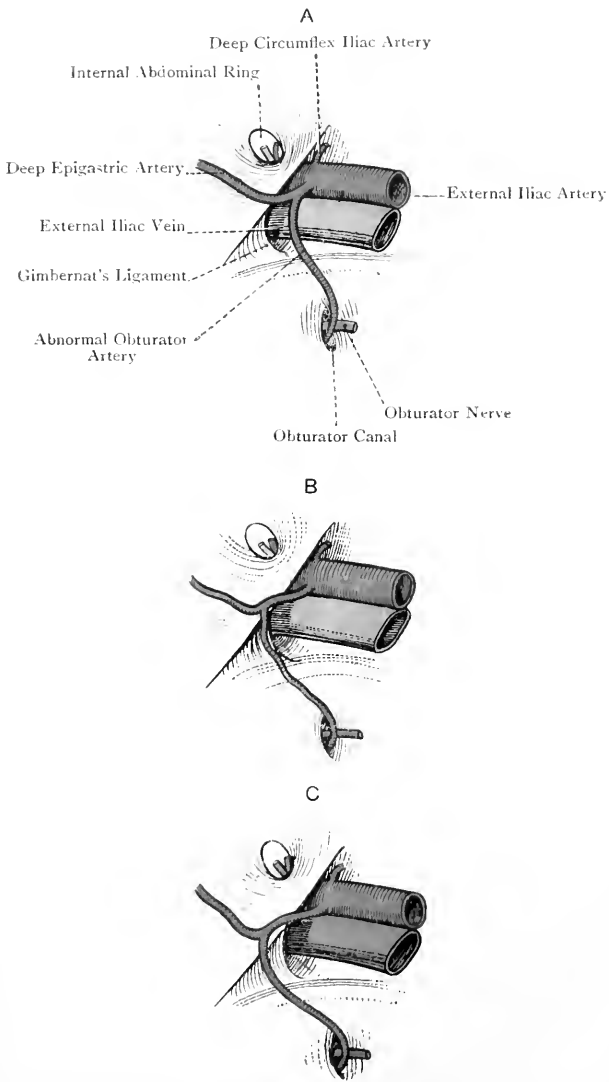


FIG. 222A.—DIAGRAMS OF ABNORMAL OBTURATOR ARTERY.
 (The red X indicates the position of the Crural or Femoral Ring).

[A and B after Gray].

A, Artery external to Crural Ring ; B, Artery internal to Ring, and close to Base of Gimbernat's Ligament ; C, Artery internal to Ring, and one or two lines from Base of Gimbernat's Ligament.

3. Anterior wall of the crural sheath, or fascia transversalis.
4. Cribriform fascia.
5. Subcutaneous layer of superficial fascia.
6. Skin.

The septum crurale is usually inseparably united with the anterior wall of the crural sheath, thus forming the **fascia propria of Cooper**. The neck of the sac is on a level with the base of Gimbernat's ligament, which is the most common cause of strangulation.

Prepatellar Bursa.—This bursa, which is of large size, is situated on the anterior surface of the patella, beneath a fascial expansion derived from the fascia lata along its attachments to the lateral borders of the bone. When it becomes inflamed the condition is known as *housemaid's knee*.

Anterior Femoral Muscles. Sartorius—*Origin.*—(1) The anterior superior iliac spine, and (2) the upper part of the anterior inter-spinous notch of the ilium.

Insertion.—The internal surface of the shaft of the tibia immediately behind the tubercle. From the tendon of insertion two expansions are given off—one from the upper border to the capsule of the knee-joint, and another from the lower border to the deep fascia of the leg.

Nerve-supply.—The anterior division of the anterior crural nerve, the branches from which, arising in common with the middle cutaneous nerve, enter the muscle near the apex of Scarpa's triangle.

Action.—Acting from its origin the muscle is (1) a flexor of the knee-joint, and an internal rotator of the leg; and (2) a flexor of the hip-joint, and an external rotator and abductor of the thigh. Acting from its insertion it is a flexor of the pelvis upon the thigh.

The sartorius is a long ribbon-like muscle, the fasciculi of which are the longest of any muscle in the body. The muscle, therefore, has a wide range of movement, but comparatively little power. It is at first directed downwards and inwards over the front of the thigh, where it forms, by its inner border, the outer boundary of Scarpa's triangle. Having crossed the superficial femoral artery at a point about $3\frac{1}{2}$ inches below Poupart's ligament, the muscle passes vertically downwards as far as the internal condyle of the femur. Beyond this point, it curves forwards to its insertion, where it covers the subjacent tendons of the gracilis and semitendinosus, from which it is separated by a bursa. This bursa is a prolongation of that which lies between the internal lateral ligament of the knee-joint and the more superficially placed tendons of the gracilis and semitendinosus. The muscle, in its lower part, is usually pierced by the patellar branch of the long saphenous nerve.

The two most important relations of the sartorius are as follows: (1) it crosses the superficial femoral artery from without inwards at a point about $3\frac{1}{2}$ inches below Poupart's ligament; and (2) it covers the superficial femoral artery in Hunter's canal.

Tensor Fasciæ Femoris.—Although this muscle is on the same plane as the gluteus maximus, it may be described in this place.

Origin.—(1) The outer lip of the crest of the ilium for $1\frac{1}{2}$ inches at its anterior part; (2) the dorsum ilii for $\frac{1}{4}$ inch close to the upper part of the anterior interspinous notch; and (3) the fascia lata covering the muscle.

Insertion.—The angle of division of the ilio-tibial band of the fascia lata into a superficial and deep lamina, at the junction of the upper fourth and lower three-fourths of the thigh.

Nerve-supply.—The lower division of the superior gluteal nerve from the sacral plexus, the branch of which enters the muscle on its deep surface.

Action.—(1) Abductor and internal rotator of the thigh; and (2) extensor of the knee-joint. The muscle, in association with the gluteus maximus, takes part in the completion of extension of the knee-joint, and in the maintenance of extension through means of the ilio-tibial band, as in standing.

The tensor fasciæ femoris is a flat, strap-like muscle, the direction of which is downwards, with a slight inclination outwards and backwards.

Ilio-Psoas.—The femoral portion of this muscle is alone described in this place. For a full description of the psoas magnus and iliacus, see Abdomen Section. The ilio-psoas is *inserted* into the small trochanter of the femur, the outer fibres of the iliacus taking insertion into the triangular surface which is situated below and in front of the small trochanter, between it and the spiral line.

The outer portion of the muscle, which is fleshy, represents the iliacus, and the inner portion, which is tendinous, represents the psoas magnus. Lying deeply between the two is the anterior crural nerve; the femoral artery, enclosed within the crural sheath, rests upon the psoas magnus; and the femoral vein, similarly enclosed, lies between the psoas magnus and pectineus. The ilio-psoas covers the front of the capsular ligament of the hip-joint, a bursa intervening between the psoas portion and the ligament.

Pectineus—*Origin.*—(1) The pectineal portion of the ilio-pectineal line of the os pubis; (2) the adjacent portion of the upper or pectineal surface of the superior pubic ramus; and (3) the pubic lamina of the fascia lata, as it covers the muscle in this situation.

Insertion.—The upper third of the line which leads from the back of the small trochanter of the femur to the inner lip of the linea aspera.

Nerve-supply.—The anterior division of the anterior crural nerve, the branch from which passes inwards behind the crural sheath, and enters the superficial surface of the muscle close to its outer border. The pectineus sometimes receives an additional nerve from the anterior division of the obturator, or from the accessory obturator (when present), which enters the deep surface of the muscle.

Action.—(1) Flexion of the hip-joint, and (2) adduction and external rotation of the thigh, as, for example, in crossing one leg over the other.

The pectineus is a flat, four-sided muscle, which is directed down-

wards, outwards, and backwards. The surfaces at first look forwards and backwards, but, towards its insertion, the muscle undergoes a slight twist, and its surfaces are then external and internal. Its deep surface is related to the capsular ligament of the hip-joint, the anterior division of the obturator nerve, and the adductor brevis.

Quadriceps Extensor Cruris.—This is a composite muscle, which consists of the rectus femoris, vastus externus, crureus, and vastus internus. The rectus femoris arises from the os innominatum,

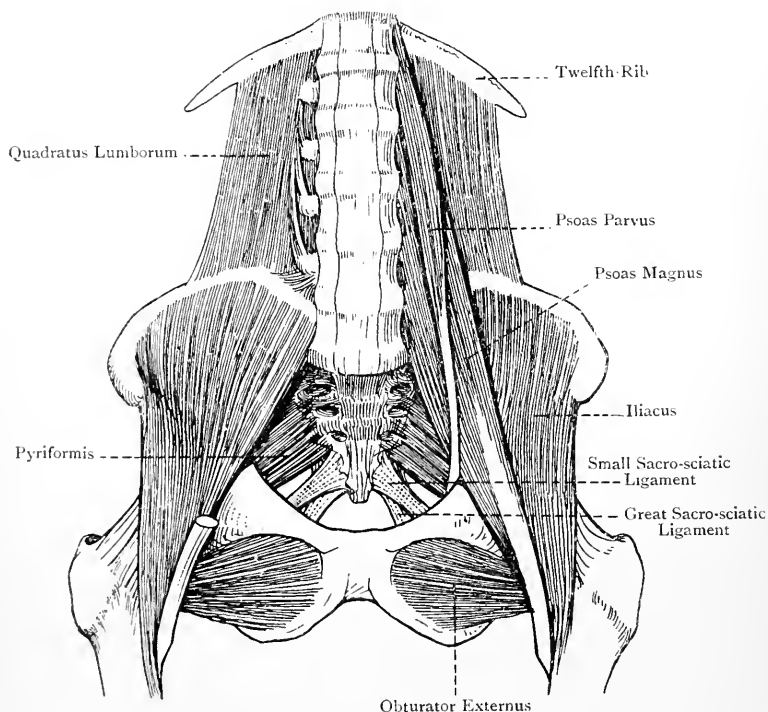


FIG. 223.—THE PSOAS, ILIACUS, AND QUADRATUS LUMBORUM MUSCLES.

whilst the other three muscles take origin from the femur, the crureus being situated between the vastus externus and vastus internus.

1. Rectus Femoris—Origin.—By two strong tendinous heads— anterior or straight, and posterior or reflected. The **anterior or straight head** arises from the anterior inferior iliac spine. The **posterior or reflected head** arises from the groove on the anterior part of the dorsum ili immediately above the brim of the acetabulum, where it is under cover of the gluteus minimus. The two heads unite at an angle of about 50 degrees.

Insertion.—The anterior part of the upper border of the patella by a flat tendon, which is free from fleshy fibres in its lower 3 inches.

Nerve-supply.—The posterior division of the anterior crural nerve, the branch from which furnishes an offset to the hip-joint.

Action.—(1) The muscle is a powerful extensor of the knee-joint ; and (2) it is a flexor of the hip-joint. In extending the knee-joint the rectus femoris acts entirely from its anterior or straight head when the hip-joint is *extended* ; but, when the hip-joint is *flexed*, the muscle in extending the knee-joint acts from its posterior or reflected head.

The fibres which form the fleshy belly are very short, and, springing in a bipenniform manner from the common tendon of origin, they pass obliquely to end upon the tendon of insertion as low as a point 3 inches above the patella. This arrangement gives the muscle great power of action, but limited range of movement. Superiorly the muscle is related to the capsular ligament of the hip-joint.

2. **Vastus Externus**—*Origin.*—(1) The upper third of the anterior intertrochanteric line of the femur ; (2) the anterior and inferior borders of the great trochanter ; (3) the outer side of the gluteal ridge ; (4) the outer lip of the linea aspera in its upper half ; (5) the adjacent portion of the shaft of the femur ; and (6) the upper part of the external intermuscular septum.

Insertion.—(1) The outer half of the upper border of the patella posterior to the rectus femoris ; (2) the upper third of the outer border of the patella ; and (3) very slightly into the outer border of the tendon of the rectus femoris.

Nerve-supply.—The posterior division of the anterior crural nerve, the branch from which furnishes an offset to the knee-joint.

The vastus externus at its origin is aponeurotic, and the aponeurosis spreads downwards upon the superficial surface of the muscle for a considerable distance. The fibres are directed downwards and forwards or inwards. The anterior border is free.

3. **Crureus**—*Origin.*—(1) The lower two-thirds of the anterior intertrochanteric line ; (2) the anterior and external surfaces of the shaft of the femur over about their upper three-fourths ; (3) the outer lip of the linea aspera in its lower half ; (4) the upper two-thirds of the external supracondylar ridge, as well as the immediately adjacent portion of the bone ; and (5) the contiguous part of the external intermuscular septum.

Insertion.—The inner half of the upper border of the patella behind the rectus femoris, where it has many of the fibres of the vastus internus associated with it.

Nerve-supply.—The posterior division of the anterior crural nerve, the branches from which are two or three in number. The most internal of these branches furnishes an offset to the knee-joint, which in its course supplies the subcrureus muscle.

The direction of the fibres of the crureus is chiefly downwards,

except in the lower and outer part of the muscle, where they pass forwards.

4. **Vastus Internus**—*Origin*.—(1) The part of the spiral line of the femur which extends from the inferior cervical tubercle to the inner

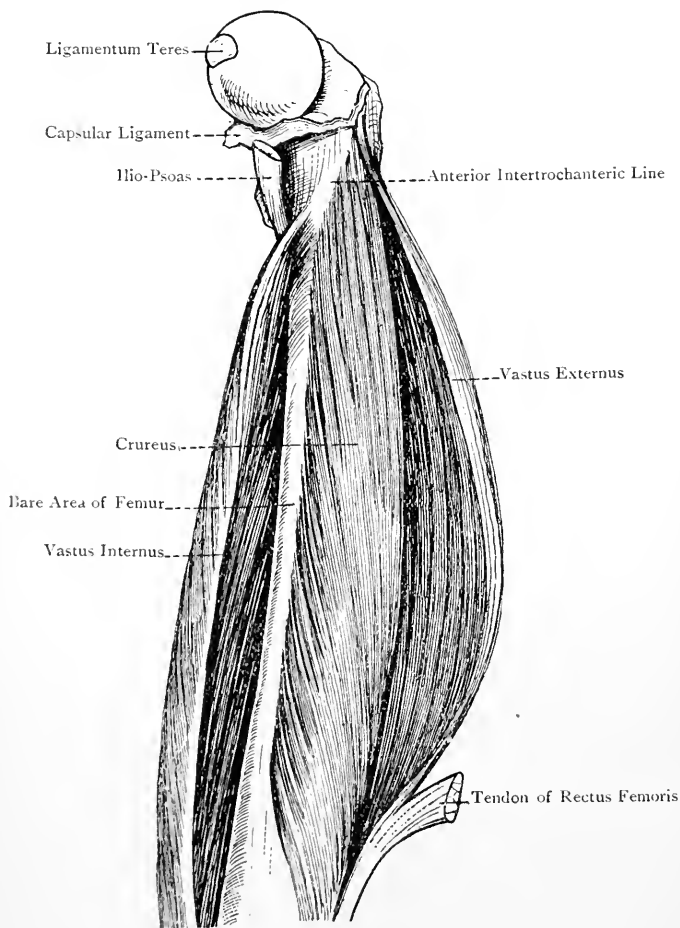


FIG. 224.—DISSECTION OF THE QUADRICEPS EXTENSOR CRURIS MUSCLE.

lip of the linea aspera; (2) the inner lip of the linea aspera in its whole extent; (3) the internal intermuscular septum; and (4) the front of the tendon of the adductor magnus almost as low as the adductor tubercle.

Insertion.—(1) The inner half of the upper border of the patella,

in close association with the crureus ; (2) the upper half of the inner border of the patella ; and (3) very slightly into the inner border of the tendon of the rectus femoris.

Nerve-supply.—The posterior division of the anterior crural nerve by a branch called the nerve to the vastus internus. This nerve descends in close contact with, and on the outer side of, the long saphenous nerve, and with that nerve it traverses the upper half of Hunter's canal. It furnishes a large offset to the knee-joint.

The direction of the fibres of the muscle is downwards and forwards or outwards.

Whilst the vastus externus is easily separable from the crureus, the vastus internus and crureus appear at first sight to be one muscle. A cellular interval, however, can be traced directly upwards from the inner border of the patella to the inferior cervical tubercle of the femur, along the course of which the two muscles can be distinctly separated. When this separation has been effected, a characteristic elongated strip of the femur is laid bare upon the inner side of the shaft, which is free from muscular fibres.

Suprapatellar Tendon.—This is the common tendon in which the four muscles constituting the quadriceps extensor cruris terminate. The part of it which belongs to the rectus femoris is inserted into the anterior part of the upper border of the patella, whence an expansion of fibres descends over the front of that bone to blend with the fibres of the ligamentum patellæ. The tendon of the crureus is behind that of the rectus femoris, where it has many of the fibres of the vastus internus associated with it, the rest of the last-named muscle terminating partly upon the upper half of the inner border of the patella, and partly upon the inner border of the tendon of the rectus femoris. The vastus externus is partly behind the rectus tendon, and in part it joins the outer border of that tendon, and terminates upon the upper third of the outer border of the patella. Beneath the suprapatellar tendon there is a bursa, called the suprapatellar bursa. It is continuous with the pouch which the synovial membrane of the knee-joint sends upwards above the patellar surface of the femur.

Action of the Vasti and Crureus.—These three muscles act as powerful extensors of the knee-joint, the lowest fibres of the vastus internus at the same time drawing the patella inwards.

Subcrureus.—This muscle is in reality the lowest and deepest portion of the crureus. Viewing it as an independent muscle, it *arises* in two bundles from the front of the femur about 4 inches above the patellar surface, and it is *inserted* into the suprapatellar bursa, which is continuous with the upward prolongation of the synovial membrane of the knee-joint above the patellar surface of the femur.

Nerve-supply.—The articular branch to the knee-joint which comes from the innermost muscular branch to the crureus.

Action.—The subcrureus is a tensor of the synovial membrane of the knee-joint.

Ligamentum Patellæ (infrapatellar tendon).—This ligament is really a continuation of the common tendon of the quadriceps extensor cruris, the patella being originally a sesamoid cartilage developed in that tendon. It is a very strong, flat, broad ligament, about 2 inches in length. It is attached superiorly to the blunt apex and adjacent margins of the lower part of the patella, and inferiorly to the lower rough half of the tubercle of the tibia, a bursa intervening between the tendon and the upper smooth half of that tubercle.

Anterior Crural Nerve.—This is the largest branch of the lumbar plexus, its fibres being derived from the dorsal divisions of the second, third, and fourth lumbar nerves. In the abdomen the nerve lies deeply between the psoas magnus and iliacus muscles, and in this position it passes into the thigh beneath Poupart's ligament. In the upper part of Scarpa's triangle it continues to lie deeply between these two muscles, being outside the crural sheath and about $\frac{1}{4}$ inch to the outer side of the common femoral artery. In this situation the nerve becomes broad and flat, and, at a point about $\frac{3}{4}$ inch below Poupart's ligament, it breaks up into two divisions. One of these is called the superficial or anterior division, and it is partly muscular and partly cutaneous; the other is called the deep or posterior division, and it is principally muscular and articular, only one cutaneous nerve, namely, the long saphenous, arising from it.

Branches.—These are conveniently divided into intra-abdominal and extra-abdominal or femoral.

The **intra-abdominal branches** arise from the trunk of the nerve, and are as follows: muscular, three or four in number, to the iliacus; and an arterial branch to the coats of the femoral artery.

The **extra-abdominal or femoral branches** arise from the two terminal divisions of the nerve in Scarpa's triangle.

The **branches of the superficial or anterior division** are muscular to the sartorius and pectineus, and cutaneous, namely, middle cutaneous and internal cutaneous, to the integument of the front and inner side of the thigh, and of the inner side of the leg in its upper half.

The **branches of the deep or posterior division** are muscular to the rectus femoris, vastus externus, vastus internus, crureus, and subcrureus; articular to the hip-joint and knee-joint (see nerve-supply of quadriceps extensor cruris); and the long saphenous nerve, already described.

Internal Femoral Muscles. Gracilis (adductor gracilis)—*Origin.*—(1) The anterior or femoral surface of the body of the os pubis in its lower half, close to the symphysis; and (2) the front of the descending pubic ramus close to its inner border.

Insertion.—The upper part of the inner surface of the shaft of the tibia, above the semitendinosus, and under cover of the sartorius.

Nerve-supply.—The anterior or superficial division of the obturator nerve.

Action.—The muscle is an adductor of the thigh, and a flexor of the knee-joint. Having flexed the knee-joint, it acts as an internal rotator of the leg.

The gracilis is flat and strap-like in the upper third of the thigh. In the middle third it becomes thick and narrow, and it gradually tapers into a long, narrow, round tendon which expands towards its insertion. The surfaces are directed inwards and outwards, the borders looking forwards and backwards. In the lower third of the thigh the tendon has the sartorius in front of it, and the semi-tendinosus behind it, and it is separated from the internal lateral ligament of the knee-joint by a bursa.

Adductor Longus—*Origin.*—The upper and inner part of the anterior or femoral surface of the body of the os pubis, immediately below and external to the pubic angle.

Insertion.—The inner lip of the linea aspera of the femur.

Nerve-supply.—The anterior or superficial division of the obturator nerve.

Action.—The muscle is an adductor and external rotator of the thigh, and a flexor of the hip-joint.

The adductor longus is a flat, triangular muscle, the direction of which is downwards, outwards, and backwards. It lies to the inner side of the pectineus, and rests upon the adductor brevis, the anterior or superficial division of the obturator nerve, and the adductor magnus. The superficial femoral artery is superficial to it, and the arteria profunda femoris beneath it.

Adductor Brevis—*Origin.*—(1) The anterior or femoral surface of the body of the os pubis for rather less than its lower half, immediately external to the gracilis; and (2) the front of the descending pubic ramus, where it is likewise external to the gracilis.

Insertion.—The line leading from the back of the small trochanter to the inner lip of the linea aspera.

Nerve-supply.—The anterior or superficial division of the obturator nerve (occasionally the posterior division).

Action.—The muscle is an adductor and external rotator of the thigh, and a flexor of the hip-joint.

The adductor brevis is quadrilateral, and is directed downwards, outwards, and backwards. It lies behind the pectineus and adductor longus, and upon the adductor magnus. The anterior or superficial division of the obturator nerve is in front of it, and the posterior or deep division behind it. It is pierced by the first two perforating branches of the arteria profunda femoris.

Adductor Magnus—*Origin.*—(1) The anterior or femoral surface of the body of the os pubis in its lower fourth, between the adductor brevis internally and the obturator externus externally; (2) the front of the ischio-pubic ramus; and (3) the inferior portion of the postero-inferior surface of the tuber ischii.

Insertion.—(1) The inner side of the gluteal ridge of the femur : (2) the inner lip of the linea aspera, and the upper part of the internal supracondylar ridge for fully 1 inch ; and (3) the adductor tubercle, by means of a narrow, round tendon which gives a fibrous expansion to the internal supracondylar ridge below the femoral groove.

Nerve-supply.—The posterior or deep division of the obturator nerve. The postero-inferior part of the muscle, representing the fibres which arise from the tuber ischii, is supplied by the branch of the great sciatic nerve to the semimembranosus.

Action.—The muscle is a powerful adductor of the thigh. The part inserted into the shaft of the femur also acts as an external rotator of the thigh, and the part extending from the tuber ischii to the adductor tubercle as an extensor of the hip-joint.

The adductor magnus is triangular or fan-shaped. The uppermost fibres are horizontal ; the succeeding fibres are oblique ; and those which arise from the tuber ischii are almost vertical. The part of the muscle which is inserted into the inner side of the gluteal ridge usually forms a distinct portion, which is triangular in shape, and is sometimes called the **adductor minimus**. The insertion of the muscle into the shaft of the femur is interrupted by four tendinous arches, which give passage to the perforating branches of the arteria profunda femoris. Between the tendon which descends to the adductor tubercle

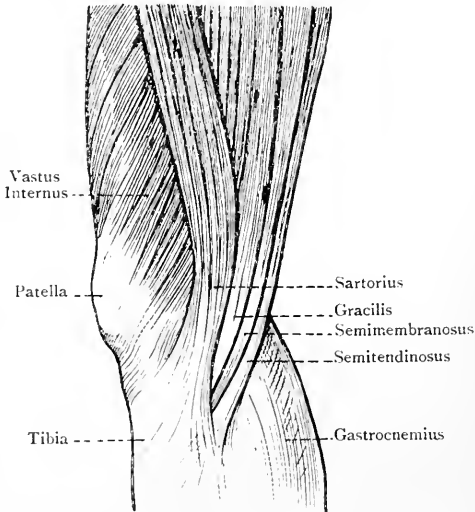


FIG. 225.—THE TENDONS OF THE INNER SIDE OF THE KNEE.

and the part of the muscle which is inserted into the upper end of the internal supracondylar ridge there is an aperture, called the *femoral opening*, for the passage of the superficial femoral vessels. It is triangular, with the apex rounded off, and is tendinous in front, but fleshy behind. It is of larger size than is necessary for the passage of the vessels, being so adapted that the vessels are not in any way interfered with during the action of the muscle. The muscle supports the adductor brevis, adductor longus, and posterior or deep division of the obturator nerve. Its posterior surface is related to the hamstring muscles and the great sciatic nerve.

The adductor muscles come into action in riding upon horseback, enabling the rider to grasp the saddle with his thighs, and they are hence called 'the rider's muscles.' In this act the adductor longus is specially subjected to strain, and its narrow round tendon of origin is occasionally ruptured. At the seat of rupture ossification sometimes takes place, thus giving rise to the so-called 'rider's bone.'

Obturator Externus—*Origin*.—(1) The external surface of the obturator membrane over its inner half; (2) the adjacent portion of

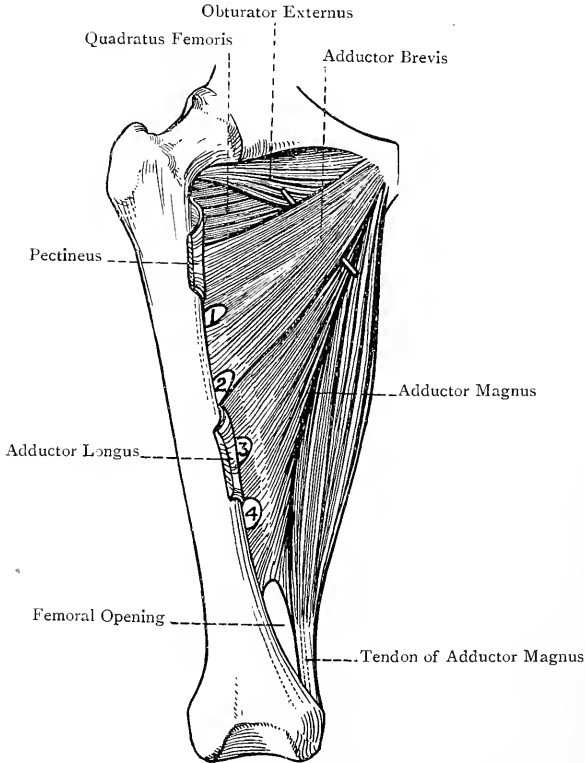


FIG. 226.—THE RIGHT INTERNAL FEMORAL MUSCLES (ANTERIOR VIEW).
1, 2, 3, 4, Openings for the Perforating Arteries.

the anterior or femoral surface of the body of the os pubis; and (3) the front of the ischio-pubic ramus close to the obturator foramen.

Insertion.—The digital or trochanteric fossa of the femur.

Nerve-supply.—The deep or posterior division of the obturator nerve as it passes through the upper part of the muscle.

Action.—The muscle is an external rotator and adductor of the thigh.

The obturator externus is somewhat triangular, and is directed at first outwards, and then backwards and upwards. Its round tendon of insertion is closely applied to the back of the neck of the femur, which it slightly grooves in its lower or extracapsular part. The superficial or anterior division of the obturator nerve passes over the upper border of the muscle, and the deep or posterior division pierces the upper part of it. The muscle is in close contact with the lower and back part of the capsular ligament of the hip-joint, a bursa being usually interposed.

Obturator Nerve.—This nerve is a branch of the lumbar plexus, and generally arises by three roots from the ventral divisions of the second, third, and fourth lumbar nerves, but the root from the second may be absent. For a description of the nerve within the abdomen and pelvis, see these sections. It escapes from the pelvic cavity by passing through the obturator canal, in which it breaks up into two divisions—superficial or anterior, and deep or posterior. The **superficial or anterior division** passes over the upper border of the obturator externus, and then descends in front of the adductor brevis, but behind the pectineus and adductor longus. This division communicates with the accessory obturator nerve (when present). The **deep or posterior division** pierces the upper part of the obturator externus, and then passes behind the adductor brevis and in front of the adductor magnus.

Branches—Superficial or Anterior Division.—The branches of this division are as follows: **articular** to the hip-joint, which arises in the obturator canal, and enters the joint through the cotyloid foramen; **muscular** to the gracilis, adductor longus, adductor brevis as a rule, and occasionally to the pectineus; **arterial** to the coats of the femoral artery; and **cutaneous**. This last branch commences at the lower border of the adductor longus, and, after a short course downwards, it pierces the fascia lata between the posterior border of the sartorius and the anterior border of the gracilis, to be distributed to the integument of the inner side of the thigh for a variable extent about the centre. Before this branch pierces the fascia lata it gives one or two twigs which communicate with branches of the long saphenous and the posterior division of the internal cutaneous beneath the sartorius, to form the subsartorial plexus.

Deep or Posterior Division.—This division furnishes the following branches: **muscular** to the obturator externus, adductor magnus, and adductor brevis (provided the latter is not supplied by the superficial or anterior division); and **articular** to the knee-joint, called the *geniculate branch*. This latter branch descends upon the adductor magnus, which it subsequently pierces close above the femoral opening, and so reaches the popliteal artery. It accompanies that artery, lying at first on its inner side and then in front of it, as low as the origin of the central or azygos branch. Here the nerve leaves the main artery, and passes with its central or azygos branch through the posterior ligament of the knee-joint to the

interior of the articulation. The geniculate nerve is frequently absent.

Accessory Obturator Nerve.—This nerve is present in about 30 per cent. of bodies. It is comparatively small in size, and arises by two roots from the anterior primary divisions of the third and fourth lumbar nerves, the roots being interposed between those of the anterior crural and obturator nerves. It descends along the inner border of the psoas magnus, close to the brim of the pelvis, underneath the external iliac vessels. It then passes over the superior pubic ramus, where it passes beneath the pectineus, and so emerges on to the thigh beneath Poupart's ligament. Under cover of the pectineus it divides into the following three branches: (1) *articular* to the hip-joint; (2) *muscular* to the deep surface of the pectineus; and (3) a *reinforcing branch* to join the superficial or anterior division of the main obturator nerve.

Scarpa's Triangle.—This triangle is situated on the front of the thigh below Poupart's ligament. The **base**, which is directed upwards, is formed by Poupart's ligament. The **outer boundary** is formed by the inner border of the sartorius in its upper fourth, and the **inner boundary** is constructed by the internal border of the adductor longus in its upper part. The **apex** is about $3\frac{1}{2}$ inches below Poupart's ligament, and is formed by the overlapping which there takes place between the superficially placed sartorius and the more deeply placed adductor longus. The **roof** is formed by the skin, two layers of the superficial fascia, and fascia lata. The following structures also lie in the roof: the crural branch of the genito-crural nerve; the inguinal and superficial femoral or saphenous glands; the cutaneous branches of the common femoral artery (except the inferior external pudic), with their corresponding veins; the saphenous opening; and the terminal part of the long saphenous vein, with the anterior and posterior saphenous veins joining it. The **floor** contains the following muscles, in order from within outwards: adductor longus; pectineus; psoas magnus; and iliacus (the latter two being here united to form one muscle, called the ilio-psoas). Occasionally a small part of the adductor brevis is seen between the adductor longus and pectineus, and, when this is so, the superficial or anterior division of the obturator nerve may be seen in part.

Contents.—The contents are as follows: the common femoral artery and its branches; the first part of the superficial femoral artery and its branches; the upper part of the femoral vein and its tributaries; and the anterior crural nerve, with its divisions and their branches.

Hunter's Canal.*—This is a somewhat triangular, musculo-aponeurotic canal, which occupies the middle two-fourths of the thigh on its inner aspect.

* The canal has received this complimentary name because John Hunter was the first surgeon who tied the superficial femoral artery in this part of its course for popliteal aneurism in the year 1785.

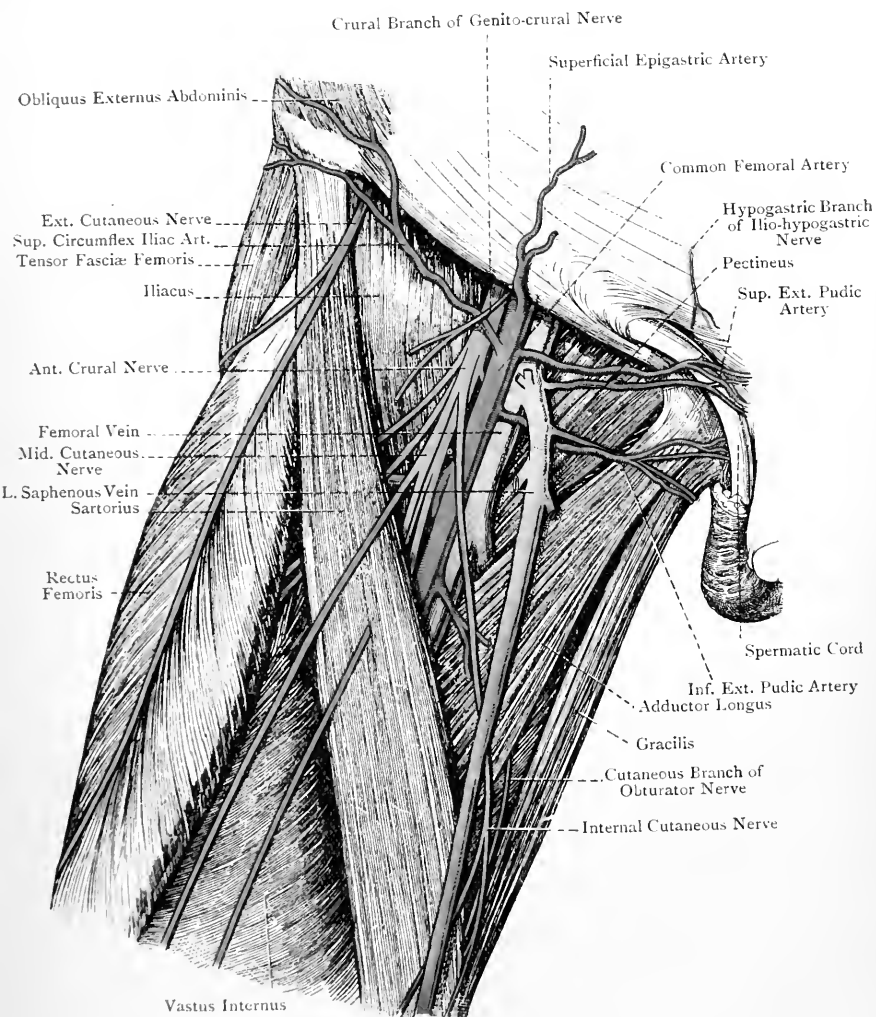


FIG. 227.—THE FRONT OF THE THIGH (SCARPA'S TRIANGLE).

Boundaries—*External*.—The vastus internus, closely covering the inner surface of the femur as far back as the inner lip of the linea aspera. *Internal and Posterior*.—The adductor longus and subsequently the adductor magnus, both of which extend back to the inner lip of the linea aspera, where they meet the vastus internus and so form the apex of the triangle. *Anterior or Superficial*.—This boundary is commonly called the **roof** of the canal. It represents the base of the triangle, and is formed by an aponeurotic expansion which extends from the adductor longus and adductor magnus on the inner side to the vastus internus on the outer side. Superficial to this expansion in its whole length is the middle portion of the sartorius, and the subsartorial plexus of nerves lies between the two in the middle third of the thigh. The aponeurosis is comparatively weak over the upper half of the canal, but over the lower half it is strong, and, below, it is continuous with the anterior margin of the femoral opening in connection with the adductor magnus.

Contents.—These are as follows: the superficial femoral artery in the second part of its course, and its branches; the first portion of the femoral vein, and its tributaries; the long saphenous nerve; and the nerve to the vastus internus muscle in the upper half of the canal.

Femoral Artery.—This vessel extends from the lower border of Poupart's ligament to the posterior margin of the femoral opening, which is in connection with the adductor magnus. It is the direct continuation of the external iliac artery, and at its termination becomes the popliteal. It occupies the upper three-fourths of the thigh, and its direction is downwards and inwards. The course of the vessel is indicated in the following manner: the thigh being partially flexed upon the abdomen, and at the same time slightly abducted and rotated outwards, draw a line from a point midway between the anterior superior iliac spine and the symphysis pubis to the adductor tubercle of the femur, or, if this tubercle cannot be felt, to the internal tuberosity on the inner surface of the internal condyle. This line over its upper three-fourths represents the course of the vessel.

At a point about $3\frac{1}{2}$ inches below Poupart's ligament the sartorius takes up a position over the artery, and from this point onwards that muscle continues to lie over the vessel. For at least the first $1\frac{1}{2}$ inches of its course the vessel corresponds in size with the external iliac artery. When, however, it reaches a point from $1\frac{1}{2}$ inches to 2 inches below Poupart's ligament it gives off a large branch, called the *arteria profunda femoris*, after which it undergoes a sudden diminution in size. The part of the vessel between Poupart's ligament and the origin of the *arteria profunda femoris* is known as the **common femoral**; the part beyond the origin of that large branch is called the **superficial femoral**; and the *arteria profunda femoris* is spoken of as the **deep femoral**; that is to say, the common femoral artery is regarded as dividing into superficial

femoral and deep femoral at a point from $1\frac{1}{2}$ inches to 2 inches below Poupart's ligament. For convenience of description, the femoral artery (meaning thereby the whole of the leading artery of the thigh) is divided into two parts—first and second—the first part lying in Scarpa's triangle, and the second part occupying Hunter's canal.

First Part.—The first part of the femoral artery extends from the lower border of Poupart's ligament to the apex of Scarpa's triangle, within which triangle it lies.

Relations—Superficial or Anterior.—The skin; superficial fascia in two layers; fascia lata; anterior wall of the crural sheath for the first $1\frac{1}{2}$ inches, and subsequently the anterior wall of the special sheath; internal cutaneous nerve crossing the vessel from without inwards, either as one nerve or in its two divisions, just above the apex of Scarpa's triangle and outside the special sheath; two or three cutaneous branches of the internal cutaneous nerve on their way to the inner side of the thigh; superficial circumflex iliac vein near Poupart's ligament; and external cutaneous femoral or anterior saphenous vein just above the apex of Scarpa's triangle.

Deep or Posterior.—The posterior wall of the crural sheath for the first $1\frac{1}{2}$ inches, and subsequently the femoral vein; branch of the anterior crural nerve passing inwards to the pectineus muscle, and lying close behind the crural sheath; psoas magnus in the upper part and pectineus in the lower part, the artery being separated from the latter muscle by the femoral vein and profunda femoris vessels, the femoral vein being nearest to the artery.

External.—The crural branch of the genito-crural nerve for a short distance below Poupart's ligament, where the nerve is within the crural sheath; anterior crural nerve for about $\frac{3}{4}$ inch below Poupart's ligament, and separated from the artery by an interval of about $\frac{1}{4}$ inch; long saphenous nerve and nerve to the vastus internus muscle, the former being nearest to the artery, and both being outside the special sheath; and the arteria profunda femoris for about $\frac{1}{2}$ inch at its commencement.

Internal.—For about 2 inches below Poupart's ligament the femoral vein lies to the inner side of the artery, with the intervention of the external septum of the crural sheath. Thereafter the vein gradually leaves the inner side of the artery to take up its position behind it, towards the apex of Scarpa's triangle.

The femoral artery immediately below Poupart's ligament is anterior to the inner part of the head of the femur, but in the rest of its course the vessel is situated on the inner side of that bone.

Second Part.—The second part of the artery (superficial femoral) extends from the apex of Scarpa's triangle to the posterior margin of the femoral opening in connection with the adductor magnus, where it becomes the popliteal. In this part of its course the superficial femoral lies in Hunter's canal, and passes over the adductor longus, whilst the deep femoral is behind that muscle.

Relations—*Superficial or Anterior*.—The skin ; superficial fascia ; long saphenous vein ; fascia lata ; sartorius ; subsartorial plexus of nerves ; the aponeurotic covering of Hunter's canal ; and the long saphenous nerve in the act of crossing the vessel from its outer to its inner side. *External*.—The vastus internus, covering the inner surface of the femur ; and the long saphenous nerve and the nerve to the vastus internus, both in the upper half of the canal. *Internal*.—At first the adductor longus, and lower down the adductor magnus, both of which muscles also lie behind the artery. In Hunter's canal the femoral vein still maintains its position close behind the artery until the lower end of the canal is reached, when the vein inclines a little to the outer side of the artery.

The superficial femoral artery in Scarpa's triangle, as well as in Hunter's canal, is surrounded by a sheath, which also contains the femoral vein.

Branches of the Femoral Artery.—The branches are as follows : superficial epigastric ; superficial circumflex iliac ; superior or superficial external pudic ; inferior or deep external pudic ; arteria profunda femoris or deep femoral (all from the common femoral) ; muscular (from the superficial femoral in Scarpa's triangle and in Hunter's canal) ; saphenous (from the superficial femoral in Scarpa's triangle) ; and anastomotica magna (from the superficial femoral in Hunter's canal).

The **superficial epigastric artery** arises from the common femoral about $\frac{1}{2}$ inch below Poupart's ligament. It then pierces the crural sheath and the cribriform fascia, or the outer border of the saphenous opening, after which it turns upwards over Poupart's ligament a little to the inner side of the centre, and ramifies in the integument of the anterior abdominal wall as high as the umbilicus. In its course it supplies branches to the inguinal glands, and anastomoses with branches of the deep epigastric of the external iliac.

The **superficial circumflex iliac artery** frequently arises in common with the superficial epigastric. Having pierced the crural sheath and the outer border of the saphenous opening, it passes outwards below the outer half of Poupart's ligament to the anterior part of the iliac crest, where it ramifies in the integument of that neighbourhood. In its course it supplies branches to the iliacus, sartorius, and outer inguinal glands, and anastomoses with the deep circumflex iliac of the external iliac, and the gluteal of the internal iliac.

The **superior or superficial external pudic artery** arises from the common femoral about $\frac{3}{4}$ inch below Poupart's ligament. Having pierced the crural sheath and cribriform fascia, it emerges through the saphenous opening, after which it passes inwards and upwards over the spermatic cord, or round ligament of the uterus, according to the sex, to be distributed to the integument of the suprapubic region, the adjacent portion of the scrotum in the male, and the labium majus in the female, and the dorsum of the

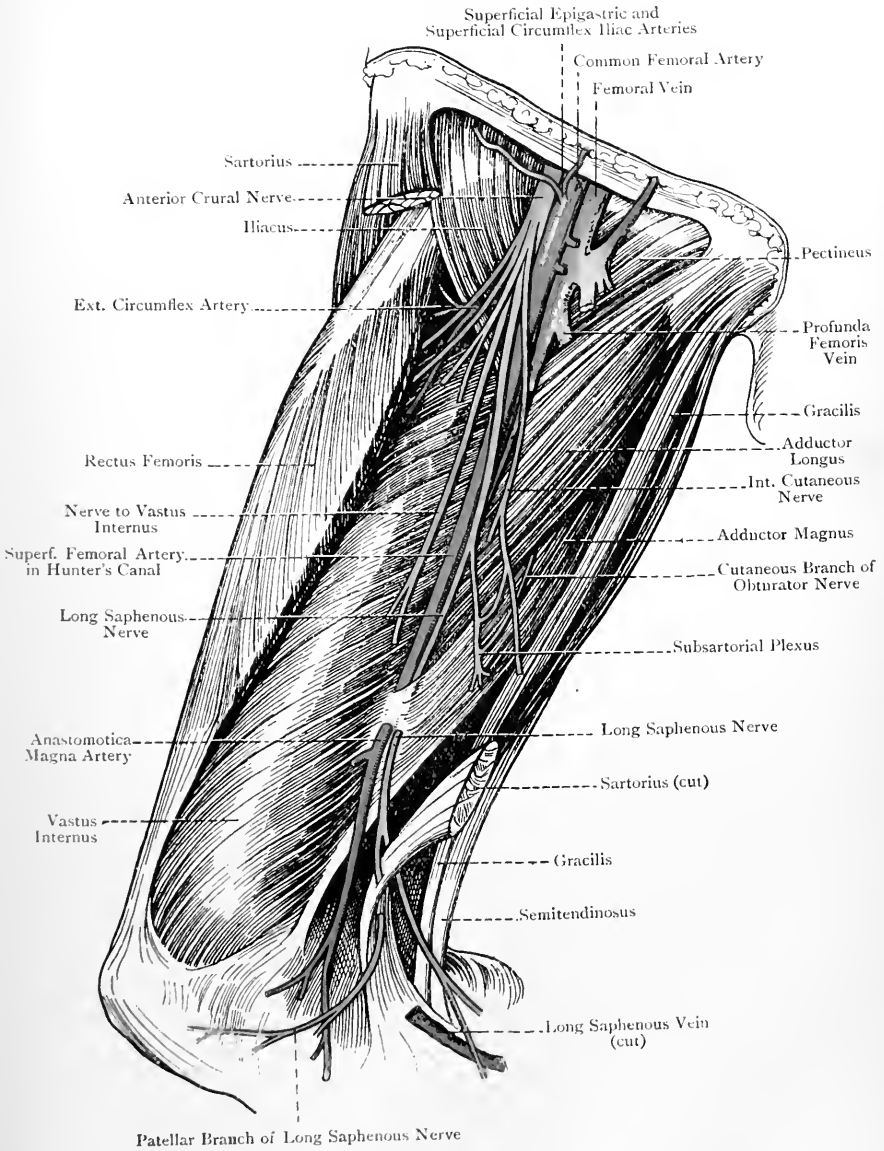


FIG. 228.—THE FRONT AND INNER SIDE OF THE THIGH (The Sartorius has been in great part removed).

penis by a branch which extends as far as the prepuce in the vicinity of the corona glandis, lying in its course external to the dorsalis penis artery. The vessel in its course gives branches to the inner inguinal or pubic glands, the deep femoral glands, and the coverings of the spermatic cord or of the round ligament of the uterus. It anastomoses with (1) the cremasteric branch of the deep epigastric, in crossing the spermatic cord, that branch being represented in the female by the artery of the round ligament of the uterus; (2) its fellow of the opposite side; (3) the inferior or deep external pudic; and (4) the dorsalis penis artery, which is a branch of the internal pudic from the internal iliac.

The **inferior or deep external pudic artery** arises from the common femoral a little lower down than the preceding. Unlike the superior branch, it does not pass through the saphenous opening, but, after piercing the crural sheath, it passes inwards on the pectineus and adductor longus, under cover of the fascia lata. Having reached the inner side of the thigh, it pierces the fascia lata to be distributed to the side of the scrotum in the male and the labium majus in the female. In its course it gives branches to the muscles upon which it rests, and anastomoses with (1) the superior or superficial external pudic, (2) the cremasteric, and (3) the superficial perineal, which is a branch of the internal pudic.

The four arteries just described are spoken of as the cutaneous arteries of the groin.

Arteria Profunda Femoris or Deep Femoral Artery.—This important vessel is one of the terminal branches of the common femoral, arising from the outer and back part of that artery at a point from $1\frac{1}{2}$ inches to 2 inches below Poupart's ligament. At first it lies for about $\frac{1}{2}$ inch on the outer side of the superficial femoral, where it rests upon the iliacus. It then bends sharply, and passes inwards over the pectineus, where it lies immediately behind the superficial femoral vessels and its own vein, the latter being nearest to it. Thereafter it descends behind the adductor longus, resting, in succession, upon the adductor brevis and adductor magnus, and, having become comparatively small, it terminates in the fourth or last perforating artery. As the profunda vessel passes behind the adductor longus, it is separated by that muscle from the superficial femoral artery.

Branches.—The branches are as follows: external circumflex; internal circumflex; and perforating, which are four in number.

The **external circumflex artery**, which is of large size, arises from the arteria profunda femoris close to its origin. Its direction is outwards beneath the sartorius and rectus femoris, and between the nerves arising from the posterior division of the anterior crural, supplying in this part of its course branches to the surrounding muscles, and resting upon the crureus. It terminates by dividing into three sets of branches—ascending, transverse, and descending.

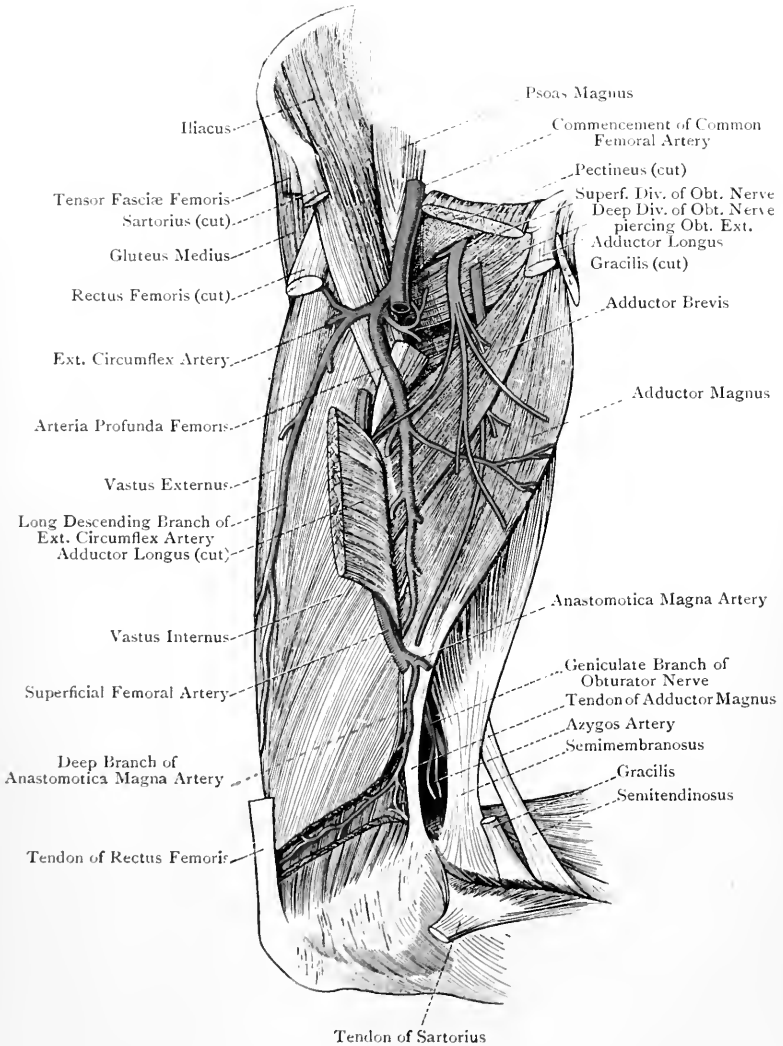


FIG. 229.—THE FRONT AND INNER SIDE OF THE THIGH (DEEP DISSECTION).

The *ascending branch* passes upwards beneath the tensor fasciæ femoris to the fore part of the gluteal region. Its branches supply the tensor fasciæ femoris and the anterior portions of the gluteus medius and gluteus minimus. It also supplies an articular branch to the hip-joint, which reaches the articulation under cover of the rectus femoris. The ascending branch anastomoses with the gluteal of the posterior division of the internal iliac, and the deep circumflex iliac of the external iliac.

The *transverse branches* are at least two in number. They enter the vastus externus, in which they wind round the outer part of the femur, supplying that muscle in their course. One of them, piercing the femoral insertion of the gluteus maximus, reaches the back of the thigh, where it anastomoses with the first perforating artery, the sciatic, and the transverse branch of the internal circumflex, thus forming the **crucial anastomosis**.

The *descending branches* are three or four in number. They pass downwards with the nerve to the vastus externus, lying along the anterior border of that muscle, and supplying in their course the rectus femoris, vastus externus, and crureus. One of them is long, and descends upon the vastus externus as low as the knee-joint, where, piercing that muscle, it anastomoses with the superior external articular of the popliteal, the fourth or lowest perforating of the arteria profunda femoris, the deep branch of the anastomotica magna of the superficial femoral, and the lowest muscular branch of the superficial femoral. The other descending branches anastomose in the crureus with the lower two perforating arteries.

The **internal circumflex artery** is of smaller size than the external. Arising from the inner and back part of the arteria profunda femoris, opposite the origin of the external circumflex, it passes backwards round the inner side of the femur towards the small trochanter. In this course it passes, in succession, between the pectineus and psoas magnus, and between the adductor brevis and obturator externus, giving off branches to the obturator externus and adductor muscles. On reaching the interval between the adductor brevis and obturator externus, it terminates in two branches—ascending or anterior, and transverse or posterior.

The *ascending or anterior branch* passes with the obturator externus to the digital fossa of the femur, where it anastomoses with the gluteal and sciatic of the internal iliac, and the first perforating, thus forming the **digital anastomosis**.

The *transverse or posterior branch* continues the course of the main artery backwards, passing between the upper border of the adductor magnus and lower border of the quadratus femoris, in which situation it anastomoses with one of the transverse branches of the external circumflex, the first perforating, and the sciatic of the internal iliac, thus forming the crucial anastomosis. The branches which the internal circumflex gives to the

obturator externus anastomose in that muscle with the obturator artery, which is a branch of the internal iliac.

The **perforating arteries** are four in number—first, second, third, and fourth. They pass backwards round the inner side of the femur, and under the tendinous arches of the adductor magnus. The first and second arteries pierce the adductor brevis and adductor magnus, whilst the third and fourth pierce the adductor magnus only. On reaching the back of the thigh, all four arteries give off the following branches: muscular, to the hamstring muscles; branches to the great sciatic nerve; and cutaneous, to the integument of the outer and back parts of the thigh. The first perforating also gives branches to the lower part of the gluteus maximus, and the second (or third) furnishes the chief nutrient or medullary artery of the femur. The perforating arteries, now much reduced in size, wind round the back and outer side of the femur. In this course the first pierces the femoral insertion of the gluteus maximus, and the second, third, and fourth pierce the femoral head of the biceps and the external intermuscular septum. The first and second terminate in the vastus externus, and the third and fourth in the crureus, all four anastomosing with branches of the external circumflex, the fourth also taking part in the deep geniculate arterial rete. At the back of the thigh the perforating arteries anastomose freely with one another. The first perforating also anastomoses with the gluteal, sciatic, and ascending branch of the internal circumflex in the digital fossa, thus forming the digital anastomosis, and with the sciatic and transverse branches of the internal and external circumflex between the adductor magnus and quadratus femoris to form the crucial anastomosis. The lower two perforating arteries anastomose at the back of the thigh with the superior muscular branches of the popliteal. The branches of the perforating arteries to the great sciatic nerve anastomose with the comes nervi ischiadici branch of the sciatic.

The **muscular branches** of the superficial femoral artery arise partly in Scarpa's triangle and partly in Hunter's canal. The lowest of these branches, which is somewhat large and very constant, is given off at the lower end of Hunter's canal. It passes outwards behind the femur, piercing the external intermuscular septum and the femoral head of the biceps, and it terminates in the crureus, in which it anastomoses with the long descending branch of the external circumflex, the fourth perforating, and the superior external articular of the popliteal.

The **saphenous branches** are two or three in number, and arise from the superficial femoral in Scarpa's triangle. They supply the superficial femoral or saphenous glands and the structures around the terminal part of the long saphenous vein.

The **arteria anastomotica magna** arises from the superficial femoral at the lower end of Hunter's canal, and at once divides into a superficial and deep branch. In many cases these branches arise independently from the main vessel. The *superficial branch*

pierces the aponeurotic covering of Hunter's canal, and descends in company with the long saphenous nerve between the sartorius and gracilis, where it lies beneath the fascia lata. It subsequently pierces that fascia, and enters the leg on its inner aspect, to be distributed to the integument over the upper third. This branch anastomoses with the inferior internal articular of the popliteal. The *deep branch* at once enters the vastus internus, in which it descends anterior to the tendon of the adductor magnus. It gives branches to the vastus internus and crureus, and anastomoses with the superior internal articular of the popliteal. It also furnishes a cross branch, which passes outwards in front of the femur above the patellar surface to form an arch with a branch of the superior external articular of the popliteal. Additional anastomoses are formed with the long descending branch of the external circumflex, and the lowest perforating branch of the arteria profunda femoris.

Varieties of the Femoral Artery.—I. The Trunk.—(1) In rare cases the femoral artery may be found on the back of the thigh in company with the great sciatic nerve. In such cases the vessel is derived from the internal iliac, and may be regarded as a large sciatic artery. Under these conditions the external iliac artery ends as the arteria profunda femoris.

(2) Occasionally the superficial femoral artery divides just below the origin of the arteria profunda femoris into two branches of equal size, which descend in close contact, and subsequently unite to form one trunk before reaching the femoral opening in connection with the adductor magnus.

II. The Branches.—(1) Arteria Profunda Femoris.—In normal cases this artery arises from the common femoral from $1\frac{1}{2}$ to 2 inches below Poupart's ligament. The common femoral artery, however, may divide into superficial femoral and deep femoral at any point between this and Poupart's ligament. The superficial and deep femoral arteries may even spring from the lower part of the external iliac a little above Poupart's ligament, in which case two large arteries would pass out beneath that ligament, instead of one. More rarely, the division of the common femoral into superficial and deep femoral may take place lower down than the normal level, even as low as 4 inches below Poupart's ligament.

(2) **External Circumflex Artery.**—This vessel is very liable to variation. It may arise from the common femoral instead of the deep femoral, as in cases of low origin of the latter vessel, or it may arise in two branches, one from the deep femoral and one from the common femoral, or both from the deep femoral, or both from the common femoral.

(3) **Internal Circumflex Artery.**—This vessel is not so liable to variation as the external circumflex. It may arise along with the external circumflex; it may spring from the common femoral; it may be a branch of the deep epigastric; or it may be derived from the external iliac.

In cases of low origin of the deep femoral, the external and the internal circumflex arteries usually spring from the common femoral.

(4) **Arteria Anastomotica Magna.**—In very rare cases the superficial branch of this artery assumes considerable length, and, under the name of the *internal saphenous artery*, accompanies the internal saphenous vein down the inner side of the leg as far as the internal malleolus.

Unusual Branches.—The deep epigastric, the deep circumflex iliac, or an abnormal obturator artery, may arise from the common femoral near Poupart's ligament.

Collateral Circulation after Occlusion of the Femoral Artery.—I. The Common Femoral Artery.—(a) The superficial perineal and dorsalis penis arteries, both from the internal pudic of the internal iliac, anastomose with the superior and inferior external pudics of the common femoral.

(b) The cremasteric from the deep epigastric of the external iliac anastomoses with the superior external pudic of the common femoral.

(c) The obturator of the internal iliac anastomoses with the internal circumflex of the arteria profunda femoris.

(d) The deep circumflex iliac from the external iliac and the gluteal from the internal iliac anastomose with the ascending branch of the external circumflex from the arteria profunda femoris.

(e) The sciatic of the internal iliac anastomoses with the transverse branch of the internal circumflex, the transverse branch of the external circumflex, and the first perforating artery, all branches of the arteria profunda femoris.

(f) The sciatic and gluteal, both branches of the internal iliac, anastomose in the digital fossa with the ascending branch of the internal circumflex of the arteria profunda femoris.

2. **The Superficial Femoral Artery below the Origin of the Arteria Profunda Femoris.**—(a) The descending branch of the external circumflex of the arteria profunda femoris takes part in the deep geniculate arterial rete.

(b) The third and fourth perforating branches of the arteria profunda femoris anastomose at the back of the thigh with the superior muscular branches of the popliteal.

(c) The fourth perforating artery and the descending branch of the external circumflex, both from the arteria profunda femoris, anastomose with the lowest muscular branch of the superficial femoral.

A continuous anastomotic chain of arteries extends from the gluteal region down the back of the thigh to the region of the knee, and it is formed in the following manner: the gluteal anastomoses with the sciatic, the sciatic with the external and internal circumflex, the gluteal, sciatic, external circumflex, and internal circumflex with the perforating branches of the arteria profunda femoris, and the perforating branches of the arteria profunda femoris with the upper muscular and articular branches of the popliteal. This chain is of special importance after occlusion of the common femoral artery, and the *comes nervi ischiadici* branch of the sciatic is particularly liable to enlargement.

Femoral Vein.—This vessel extends from the posterior margin of the femoral opening, which is in connection with the adductor magnus, to the lower border of Poupart's ligament, where it becomes the external iliac vein. In the lower part of Hunter's canal it lies close behind the superficial femoral artery, with a slight inclination to the outer side. In ascending, however, it soon takes up a position behind the artery, which it maintains until it has entered Scarpa's triangle. The vein now gradually inclines to the inner side of the artery, and for about 2 inches below Poupart's ligament it is quite to its inner side, but on the same plane, being separated from the artery by the external septum of the crural sheath, and lying here between the pectineus and *psaos magnus*.

Tributaries.—These are as follows: the *venæ comites* of the *anastomotica magna* artery at the lower end of Hunter's canal; the *venæ comites* of each of the muscular branches of the superficial femoral artery: the profunda femoris vein at a point about $1\frac{3}{4}$ inches below Poupart's ligament; and the long saphenous vein at a point about $1\frac{1}{2}$ inches below Poupart's ligament, and above the point where the profunda vein terminates. The long saphenous vein has been previously reinforced by the anterior saphenous or external cutaneous femoral, the posterior saphenous or internal cutaneous femoral, the superficial circumflex iliac, the

superficial epigastric, and the superior and inferior external pudic veins.

The **profunda femoris vein** is formed by the venæ comites which accompany each of the branches of the arteria profunda femoris. It is a large vessel, and is provided with several valves.

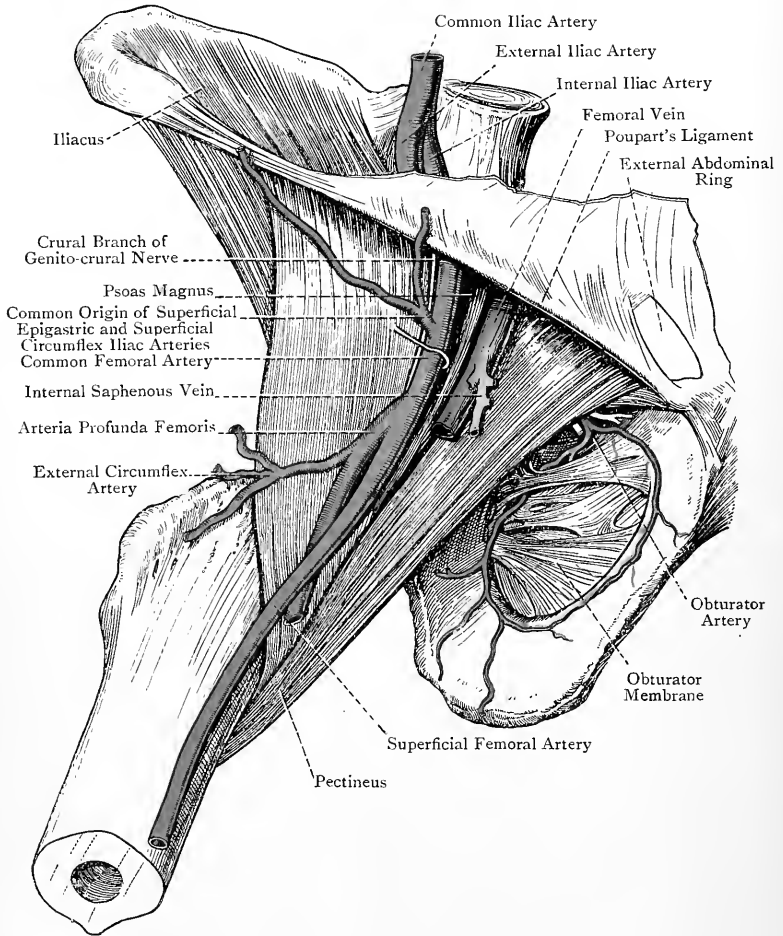


FIG. 230.—DEEP DISSECTION OF SCARPA'S TRIANGLE.

The femoral vein is provided with five pairs of valves. Three of these are situated in the part of the vessel below the point where it receives the profunda femoris vein. Of the other two, one is placed immediately above the termination of the profunda femoris vein, and the other at the point where the femoral vein ends in the

external iliac. This last valve is known as the ilio-femoral valve of Bennett.

Varieties of the Femoral Vein.—1. The vein is sometimes absent from Hunter's canal. In such cases, instead of passing through the femoral opening in connection with the adductor magnus, it ascends for some distance upon the posterior surface of that muscle, which it subsequently pierces, and so enters Scarpa's triangle.

2. The vein may be double, simulating the arrangement known as *venae comites*, in which case the femoral artery would have a vein on either side of it, with communicating branches passing between the two at frequent intervals over the vessel.

Obturator Artery.—This vessel normally arises from the anterior division of the internal iliac, and for the most part is placed on the outer wall of the pelvic cavity. The artery, having passed through the obturator canal, divides at once into its two terminal branches, internal and external. These descend upon the anterior surface of the obturator membrane under cover of the obturator externus, the internal branch coursing along the inner margin, and the external along the outer margin, of the membrane. The *internal branch* supplies the obturator externus and adjacent adductor muscles. The *external branch* divides into two at the lower part of the obturator membrane. One of these divisions passes inwards and anastomoses with the internal branch, thus completing an arterial loop at the circumference of the membrane. The other division takes an outward course below the acetabulum to the region of the tuber ischii, where it supplies the origins of the hamstring muscles and anastomoses with the sciatic artery. This latter division supplies an articular branch to the hip-joint, which passes beneath the transverse ligament. The external branch, in addition to the foregoing offsets, supplies the obturator externus, in which both terminal branches anastomose with the internal circumflex of the *arteria profunda femoris*.

The **obturator vein** terminates in the internal iliac vein.

THE HIP-JOINT.

The hip-joint belongs to the class **diarthrosis**, and to the subdivision **enarthrosis**. The articular surfaces are the head of the femur and the acetabulum of the os innominatum. The ligaments are the capsular ligament, with its accessory parts, the ligamentum teres, the cotyloid ligament, and the transverse ligament.

The **capsular ligament** is of great strength, and completely surrounds the joint. It is tight-fitting, and hardly admits of separation taking place between the articular surfaces. Its **superior attachments** are as follows: *above* and *behind* it is attached to the os innominatum immediately external to the cotyloid ligament and about three lines from the brim of the acetabulum. *In front* it is attached to the base of the anterior inferior iliac

spine; the outer surface of the cotyloid ligament; the iliopectineal eminence; the outer extremity of the obturator crest of the superior pubic ramus; and the adjacent portion of the obturator membrane. *Antero-inferiorly* (opposite the cotyloid notch) it is attached to the outer surface of the transverse ligament. *Inferiorly* it is attached to the upper part of the groove between the acetabulum and the tuber ischii. Its **inferior attachments** are as follows: *superiorly* it is attached to the anterior part of the upper border of the great trochanter of the femur and the superior cervical tubercle. *Anteriorly* it descends as low as the anterior intertrochanteric line, into which it is firmly implanted as low as the inferior cervical tubercle. *Inferiorly* and *internally* it is attached to the femur about $\frac{3}{4}$ inch in front of the small trochanter.

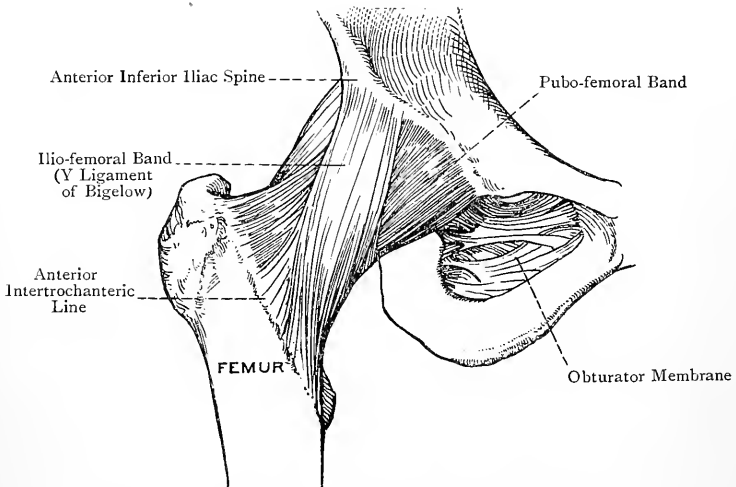


FIG. 231.—THE RIGHT HIP-JOINT (ANTERIOR VIEW).

Posteriorly it is attached very loosely to the neck of the femur at the junction of the middle and lower thirds.

The majority of the fibres of the ligament are disposed longitudinally, but some are circular. The circular fibres are best marked at the posterior and inferior parts of the capsule, where they form a band, nearly $\frac{1}{2}$ inch in depth, called the **zona orbicularis**. In certain situations the longitudinal fibres form thickened bands which constitute the accessory portions of the capsule. These **accessory bands**, usually designated as special ligaments, are as follows: ilio-femoral, ilio-trochanteric, ischio-capsular, and pubo-femoral.

The **ilio-femoral ligament** has been compared to an inverted Y, and is known as the **Y-shaped ligament of Bigelow**. It is situated on the anterior aspect of the capsule, and is attached superiorly

to the inferior aspect of the anterior inferior iliac spine below the origin of the straight head of the rectus femoris. The lateral fibres as they descend form two strong bands, outer and inner, which diverge very slightly from each other. The inner band passes almost vertically to be attached to the lower end of the anterior intertrochanteric line of the femur and the inferior cervical tubercle. The outer band, shorter than the inner, passes obliquely downwards and outwards to be attached to the upper end of the anterior intertrochanteric line and the superior cervical tubercle. The central fibres are attached to the middle portion of the anterior intertrochanteric line, and the part of the capsule covered by them is comparatively weak.

The **ilio-trochanteric ligament** is situated immediately external to the outer part of the ilio-femoral ligament. It is attached superiorly

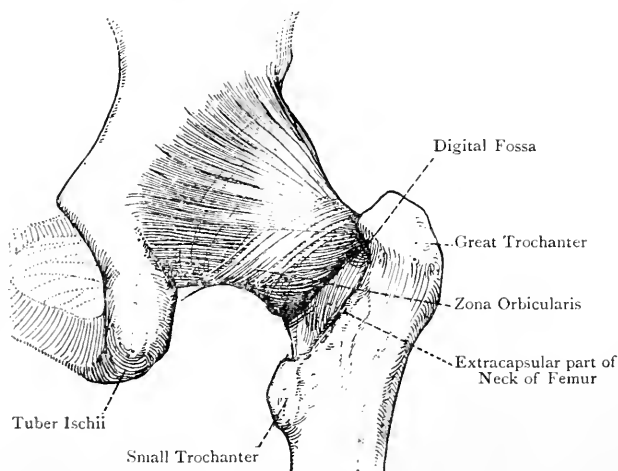


FIG. 232.—THE RIGHT HIP-JOINT (POSTERIOR VIEW).

to the lower and anterior part of the dorsum ilii immediately above the acetabulum, close to the upper attachment of the ilio-femoral ligament, and inferiorly to the great trochanter in the region of the superior cervical tubercle.

The **ischio-capsular ligament** is a thickened band which extends from the upper part of the obturator groove (just below the acetabulum) to the zona orbicularis.

The **pubo-femoral ligament** is the weakest of the three accessory ligaments. Its fibres are attached in a somewhat scattered manner to the ilio-pectineal eminence, the outer part of the obturator crest, and the adjacent portion of the obturator membrane. From these points the fibres converge to be attached to the anterior, inner, and lower parts of the capsular ligament, where they lie close to the inner band of the ilio-femoral ligament.

In addition to the accessory ligaments, the capsule receives expansions from the reflected head of the rectus femoris and gluteus minimus. When the hip-joint is opened the innermost fibres of the capsular ligament are seen to be reflected upwards from their femoral attachments upon the neck of the femur as far as the margin of the articular cartilage of the head. The longitudinal folds thereby produced are called *retinacula*. Three of these are specially well marked, two being situated anteriorly, and corresponding in position with the outer and inner bands of the ilio-femoral ligament, and the other being situated at the upper and back part of the neck.

The capsular ligament is strongest anteriorly and superiorly.

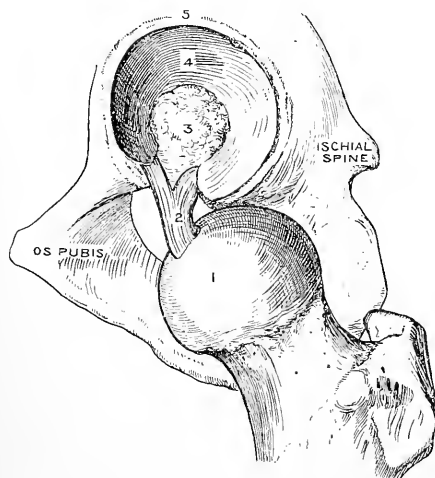


FIG. 233.—INTERIOR OF THE LEFT HIP-JOINT.

- 1, Head of Femur; 2, Ligamentum Teres;
3, Haversian Gland; 4, Cartilage of
Acetabulum; 5, Cotyloid Ligament.

The thinnest part is situated between the ilio-femoral and pubo-femoral ligaments. In this region there is sometimes an opening in the capsule which allows the bursa beneath the ilio-psoas to communicate with the synovial membrane of the joint. The capsule is also thin where it is attached to the posterior surface of the neck of the femur and to the transverse ligament. It is to be noted that, though the anterior surface of the neck of the femur is entirely covered by the capsular ligament, and is therefore *intracapsular*, the posterior surface of the neck is only intracapsular in its upper two-thirds, the lower third being wholly *extracapsular*.

The **ligamentum teres** is also called the *interarticular ligament*. Its femoral extremity, which is single and somewhat flattened, is attached to the upper part of the rough pit on the head of the femur behind and below its centre. On approaching the cotyloid notch, the ligament becomes expanded and divides into two bands, which are attached to the margins of the notch and to the under surface of the transverse ligament. The direction of the ligament is downwards from the femur to the cotyloid notch, and it rests upon the Haversian gland in the bottom of the acetabulum. It is invested by the synovial membrane of the hip-joint, which forms a tubular prolongation around it. A small nutrient artery is conducted by the ligament to the head of the femur.

Two views may be stated regarding the morphology of the ligamentum teres.

1. It may be regarded as a part of the capsule of the hip-joint which has been cut off by the outgrowth of the articular surface of the head of the femur (Keith).

2. It may be regarded as the separated tendon of the pectineus muscle (Bland-Sutton).

The **cotyloid ligament** is a firm annular band of fibro-cartilage which is implanted upon the brim of the acetabulum, thereby deepening that cavity and bridging over the cotyloid notch. Its fibres are oblique in direction, and are for the most part attached to the outer and inner surfaces of the brim, but opposite the cotyloid notch they are attached to the transverse ligament. The outer surface of the cotyloid ligament is convex, whilst the inner surface is concave and is closely applied to the head of the femur. Both surfaces are covered by the synovial membrane. The ligament is triangular, the base being implanted on the brim of the acetabulum, and the apex representing the free margin, which is incurved so as to grasp the head of the femur.

The **transverse ligament** bridges over the cotyloid notch. It is somewhat complex in structure, being composed of three bundles of fibres intimately blended with one another. The superficial bundle is formed by that part of the cotyloid ligament which stretches over the notch. The other two bundles are more deeply placed, and are arranged as two decussating bands extending between the margins of the notch, and blending closely with the superficial bundle. The transverse ligament does not completely fill up the cotyloid notch, a space being left between the ligament and the bottom of the notch for the passage of articular vessels and nerves.

The **synovial membrane** covers the anterior surface of the neck of the femur and the upper two-thirds of the posterior surface, passing over the retinacula and extending as high as the margin of the cartilage covering the head. From the neck it is reflected over the inner surface of the capsular ligament, which it completely invests. After leaving the capsular ligament at its acetabular attachments it passes over the cotyloid ligament, and covers both of its surfaces. Thereafter it is reflected over the Haversian gland in the bottom of the acetabulum, from which it is prolonged as a tubular sheath around the ligamentum teres as far as the pit on the head of the femur. In those cases where the capsular ligament presents an opening between the ilio-femoral and pubo-femoral ligaments, the synovial membrane is in communication through that opening with the bursa beneath the ilio-psoas. It is to be noted that the ligamentum teres, though intracapsular, is extrasynovial. Further, the synovial membrane is visible from the exterior of the joint at the lower part of its posterior aspect, on account of the very slight attachment of the capsular ligament to the back of the neck of the femur.

The so-called **synovial or Haversian gland** occupies the rough

pit in the bottom of the acetabulum, and is simply a collection of adipose tissue covered by the synovial membrane. The ligamentum teres rests upon it, and the synovial membrane which covers it is thicker and more vascular than elsewhere. It serves as a cushion for the head of the femur.

Muscular Relations.—Commencing at the inner aspect of the capsular ligament and passing over its anterior, outer, and posterior surfaces to its lower part, the muscles in contact with the ligament are as follows: (1) pectineus on the inner aspect and adjacent part of the anterior surface; (2) ilio-psoas in front; (3) the two heads of the rectus femoris, with the tendon formed by their union, and the gluteus minimus on the outer and upper aspects; (4) pyramidalis, gemellus superior, obturator internus, and gemellus inferior on the upper and posterior aspects; and (5) obturator externus on the posterior and inferior aspects. Between the ilio-psoas and the ligament there is a bursa, which sometimes communicates with the synovial membrane of the joint through an opening in the capsule.

Arterial Supply.—The hip-joint receives its arterial supply from the following sources:

1. The transverse branch of the internal circumflex.
2. The ascending branch of the external circumflex.
3. The external terminal branch of the obturator.
4. The inferior branch of the deep division of the gluteal.
5. The sciatic.

Nerve-supply.—The hip-joint receives its nerves from the following sources:

1. The nerve to the rectus femoris, which is a branch of the posterior division of the anterior crural.
2. The anterior or superficial division of the obturator nerve, or the accessory obturator when it is present.
3. The nerve to the quadratus femoris, or, if that nerve does not supply an articular branch, the great sciatic.

The first two nerves are branches of the lumbar plexus, and the others are derived from the sacral plexus.

Movements.—These are as follows: flexion, extension, abduction, adduction, rotation, and circumduction.

Flexion.—This is of two kinds—ventral and dorsal. In ventral flexion the thigh is drawn upwards towards the anterior abdominal wall. In dorsal flexion the thigh is carried backwards beyond the perpendicular. The extent of ventral flexion depends upon the condition of the knee-joint, being greater when that joint is flexed and more limited when it is kept extended. Assuming the knee-joint to be flexed, ventral flexion is limited by the coming into contact of the fleshy parts of the front of the thigh and anterior abdominal wall. When the knee-joint is kept extended, ventral flexion is checked earlier by the tension of the hamstring muscles. Dorsal flexion is in most persons soon checked by the tightening of the front part of the capsular ligament.

Extension.—In extending the hip-joint from the position of ventral flexion the movement is limited by the tightening of the front part of the capsular ligament. When a person stands at rest the hip-joint is in a state of extension. The vertical line passing through the centre of gravity then falls behind the centre of rotation at the hip-joint, and there is thus a tendency on the

part of the pelvis to fall backwards. This tendency, however, is counteracted by the tightening of the capsular ligament in front, and so the erect attitude is maintained without any muscular effort.

Abduction.—This movement is controlled by the tightening of the pubo-femoral ligament and the lower part of the capsule; the locking which takes place between the upper border of the neck of the femur and the adjacent margin of the acetabulum; and the tension of the adductor muscles.

Adduction.—This movement is controlled by the outer band of the ilio-femoral ligament and upper part of the capsule, and the locking which takes place between the inner part of the neck of the femur and the anterior margin of the acetabulum. If the hip-joint is flexed adduction is also controlled by the tightening of the ligamentum teres.

Rotation.—This consists in movement of the femur round its longitudinal axis without much change of position. The axis of rotation is represented by a line passing through the centre of the head of the femur to meet the vertical line of the centre of gravity of the lower limb at a point corresponding with the middle of the intercondylar notch when the knee-joint is extended.

Rotation may take place outwards or inwards. External rotation is controlled by the tightening of the outer band of the ilio-femoral ligament. Internal rotation is checked by the tightening of the ischio-capsular ligament; by the zona orbicularis; and by the muscles in contact with the back of the joint. The range of rotation is about 60 degrees.

Circumduction.—This is a composite movement, consisting of flexion, abduction, extension, and adduction, following each other in rapid succession, the result being that the femur describes a cone, the head of the bone forming the apex and the lower extremity describing the circumference of the base.

Ligamentum Teres.—This ligament is loose in the state of extension of the hip-joint, but becomes tightened in flexion and adduction.

Muscles concerned in the Movements—Flexion.—Ilio-psoas, rectus femoris, sartorius, pectineus, adductor longus, and adductor brevis, the ilio-psoas being the most powerful flexor. **Extension.**—Gluteus maximus, biceps femoris by its ischial head, semitendinosus, semimembranosus, and adductor magnus by the fibres which extend from the tuber ischii to the adductor tubercle.

Abduction.—Gluteus medius, gluteus minimus, gluteus maximus by its *upper* fibres, tensor fasciæ femoris, and sartorius. **Adduction.**—Adductores gracilis, longus, brevis, et magnus, pectineus, gluteus maximus by its *lower* fibres, and obturator externus. **Internal Rotation.**—Gluteus medius by its *anterior* fibres, gluteus minimus, tensor fasciæ femoris, and adductor magnus by the fibres which extend from the tuber ischii to the adductor tubercle. **External Rotation.**—Gluteus maximus by its *lower* fibres, gluteus medius by its *posterior* fibres, pyriformis, obturator internus and gemelli, quadratus femoris, pectineus, adductores longus, brevis, et magnus (the latter by the fibres which are inserted into the shaft of the femur), obturator externus, and sartorius.

Relation of Muscles on the Femoral Aspect of the Body of the Os Pubis.

Commencing at the symphysis pubis, and passing outwards as far as the inner margin of the obturator foramen, the relation of muscles is as follows: (1) gracilis, (2) adductor brevis, (3) a small portion of the adductor magnus, and (4) obturator externus.

The adductor longus does not take part in this relation, its origin being at the upper and inner part of the anterior or femoral surface of the body of the os pubis, from an impression which can be covered with the point of the little finger.

Relation of Muscles at the Back of the Upper End of the Shaft of the Femur.

Commencing at the small trochanter, and passing outwards over the back of the femur as far as the outer margin of the gluteal ridge, the relation of muscles is as follows: (1) ilio-psoas, (2) pectineus, (3) adductor brevis,

(4) lower fibres of the quadratus femoris, (5) adductor magnus, (6) gluteus maximus, and (7) vastus externus.

Relation of Muscles along the Linea Aspera of the Femur.—Commencing at the outer lip of the linea aspera, and passing inwards as far as the inner lip, the relation of muscles is as follows: (1) vastus externus and crureus in one line; (2) short head of biceps femoris; (3) adductor magnus; (4) adductor longus; and (5) vastus internus.

THE LEG.

Landmarks.—The sharp sinuous anterior border of the tibia, being entirely subcutaneous, can readily be felt, and will guide the finger to the **tubercle**, which is situated at its upper end, where it gives attachment to the ligamentum patellæ. The lower border of the tubercle corresponds with the division of the popliteal artery into anterior and posterior tibial vessels. The **head of the fibula** forms a prominent landmark on the outer side of the leg, and is situated about 1 inch below the level of the upper surface of the external tuberosity of the tibia. The shaft of the fibula is for the most part obscured by muscles. It can be felt, however, over its lower fourth. The bone occupies a more posterior plane than the tibia. The prominence along the front of the leg in its upper two-thirds is mainly due to the fleshy belly of the tibialis anticus.

The **internal** and **external malleoli** form bold projections at the lower end of the leg, the internal being formed by the tibia, and the external by the fibula. The malleoli are upon the same plane posteriorly, but the internal malleolus projects further forwards than, and does not descend so low as, the external malleolus; that is to say, the internal malleolus is a little higher up and further forwards than the external, but the two project equally far back. This has to be borne in mind in Syme's amputation at the ankle-joint. It should be carefully noted that, whilst the internal malleolus looks directly inwards, the internal tibial tuberosity has a slight inclination backwards as well as inwards. The tendons of the tibialis posticus and flexor longus digitorum may be felt behind the internal malleolus, the former being the larger and in close contact with the bone. If the inner border of the foot is raised so as to invert the sole, the tendon of the tibialis posticus will be more readily felt. The tendons of the peroneus longus and peroneus brevis are situated behind the external malleolus, where they lie one upon the other, the brevis tendon being in close contact with the bone. Several tendons can readily be felt in front of the ankle-joint. From within outwards they are as follows: tibialis anticus; extensor proprius hallucis; extensor longus digitorum; and peroneus tertius. All these tendons are best felt in the living subject when the foot is flexed upon the leg—that is to say, when the foot is raised.

The back of the leg is characterized by the prominence of the calf, which is produced by the gastrocnemius and soleus muscles. This prominence gives place inferiorly to the **tendo**

Achillis, which stands out boldly beneath the integument, and subsides at the tuber calcis. Upon either side of the projection formed by the tendo Achillis there is an elongated furrow. The furrow on the outer side indicates the situation of the short saphenous vein and nerve and the peroneal artery, whilst that on the inner side corresponds with the position of the posterior tibial vessels and nerve.

The course of the **anterior tibial artery** on the front of the leg is indicated by a line drawn from the superior tibio-fibular articulation to the centre of the front of the ankle-joint, midway between the two malleoli. This practically coincides with the outer border of the tibialis anticus. The course of the **posterior tibial artery** corresponds with a line drawn from the centre of the popliteal space to a point midway between the tip of the internal malleolus and the inner part of the point of the heel.

It is to be noted that another large artery is situated upon the back of the leg. This is the **peroneal branch** of the posterior tibial, and in operations it will be caught upon the back of the fibula, the posterior tibial being between the tibia and fibula, except in the lower part of the leg, where it lies on the back of the tibia.

The anterior and posterior tibial arteries can readily be compressed with one hand by placing the thumb in front of the ankle-joint midway between the two malleoli, and the middle finger midway between the tip of the internal malleolus and the inner part of the point of the heel.

The **long saphenous vein** may be visible in front of the internal malleolus, and from this point it may be traceable upwards along the internal subcutaneous surface of the tibia.

The short saphenous vein is rarely perceptible. It lies behind the external malleolus, then in the hollow upon the outer side of the tendo Achillis, after emerging from which it soon gains the middle line, where it lies in the groove between the two heads of the gastrocnemius.

Deep Fascia.—The deep fascia is in part a prolongation of the fascia lata of the thigh, the continuity being established at the inner and posterior aspects of the knee-joint. Elsewhere it is attached superiorly to the head of the fibula, external tuberosity of the tibia, lower part of the patella, ligamentum patellæ, and tubercle, and front of the internal tuberosity, of the tibia. In the leg it is attached to the crest of the tibia, from which it is prolonged backwards over the inner surface to be attached to the internal border. It is also attached to the antero-external and postero-external borders of the fibula. At the ankle the deep fascia is attached to the internal and external malleoli. Over the inner surface of the tibia and at its malleolar attachments it becomes closely incorporated with the periosteum. The chief direction of the fibres of the fascia is vertical. There are, however, superadded transverse fibres behind the knee-joint and in the vicinity of the ankle-joint, in which latter region important annular ligaments are formed.

The part of the fascia behind the knee-joint presents an opening for the passage of the short saphenous vein. In the region of the gastrocnemius and over the inner surface of the tibia the deep fascia is very thin. Over the front and outer parts of the leg, however, more especially in the upper half, it attains considerable strength and density, and there it gives origin by its deep surface to the superficial fibres of the muscles which it covers. In the region of the knee-joint it receives many strong accessions of fibres from the tendons of the quadriceps extensor cruris, biceps femoris, sartorius, gracilis, and semitendinosus.

Four expansions are given off from its deep surface, which are called **intermuscular septa**—anterior, antero-external, postero-external, and posterior or transverse. The *anterior* intermuscular septum is limited to the upper third of the leg, where it extends between the tibialis anticus and extensor longus digitorum, to both of which muscles it gives partial origin. The *antero-external* intermuscular septum is attached to the antero-external border of the fibula, and extends between the extensor longus digitorum and peroneus tertius on the anterior surface, and the peroneus longus and peroneus brevis on the external surface. The *postero-external* intermuscular septum is attached to the postero-external border of the fibula, where it extends between the peroneus longus and peroneus brevis on the external surface, and the soleus and flexor longus hallucis on the posterior surface. The peroneus longus and peroneus brevis are thus completely shut off from the adjacent muscles by the two external intermuscular septa. These septa, along with the deep fascia at the surface and the external surface of the shaft of the fibula, form a long fibro-osseous canal which contains the peroneus longus and peroneus brevis. The *posterior* or *transverse* intermuscular septum is a broad expansion which passes transversely between the postero-external border of the fibula and the internal border of the tibia. It lies beneath the soleus and upon the deep muscles of the back of the leg, as well as upon the posterior tibial vessels and nerve, binding down the structures which it covers.

Annular Ligaments.—These are situated in the region of the ankle-joint, and are thickened portions of the deep fascia. They serve to confine and maintain in position the strong tendons in that vicinity, and are three in number—external, internal, and anterior.

The **external annular ligament** extends between the posterior border of the external malleolus and the outer border of the tuber calcis and adjacent portion of its outer surface. Its direction is downwards and backwards over the peroneal groove behind the external malleolus. The tendons of the peroneus longus and peroneus brevis pass beneath it, and are thereby kept in position. The tendon of the peroneus brevis is close to the bone, and that of the peroneus longus is directly behind the brevis tendon, both being invested by one common synovial sheath. The external annular ligament at its anterior border is continued forwards to

form two distinct fibrous sheaths for the peroneal tendons, which are here lying one above the other (the peroneus brevis tendon being the upper one) as they traverse the outer surface of the os calcis. Each tendon has now its own synovial investment, the common synovial sheath beneath the external annular ligament having sent forward two prolongations.

The **internal annular ligament** is chiefly formed by a thickening of the posterior or transverse intermuscular septum, but superficial to it there is also the proper deep fascia, though that is here very thin. This annular ligament extends between the posterior border of the internal malleolus and the internal border of the tuber calcis, and is directed downwards and backwards. Its upper border is continuous principally with the posterior intermuscular

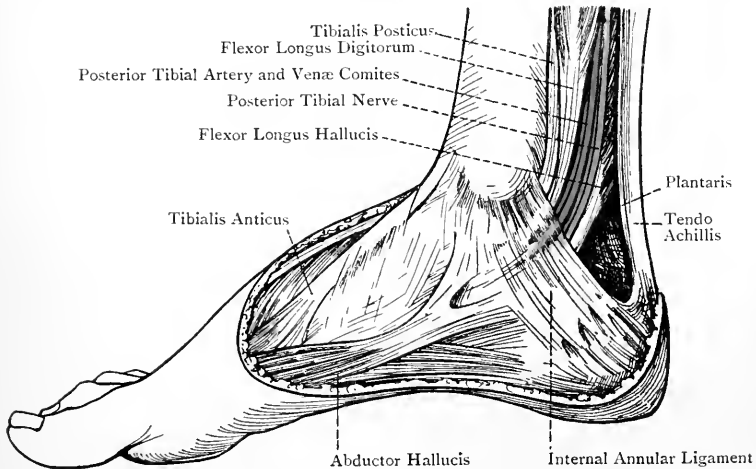


FIG. 234.—THE STRUCTURES BETWEEN THE INTERNAL MALLEOLUS AND THE HEEL.

septum. Its lower border gives origin on its deep aspect to the inner head of the abductor hallucis, and on its superficial aspect it is in part continuous with the lower limb of the Y division of the anterior annular ligament. The internal annular ligament passes over the grooves on the back of the lower end of the tibia, and converts these into canals for the flexor tendons and posterior tibial vessels and nerve. There are in all four canals, three of them being fibro-osseous and one fibrous. The relation of structures beneath this ligament, from the internal malleolus outwards to the tuber calcis, is as follows: (1) the tendon of the tibialis posticus, lying in the groove behind the internal malleolus close to the bone, and occupying one of the fibro-osseous canals; (2) the tendon of the flexor longus digitorum, lying behind, and slightly external to, that of the tibialis posticus, and occupying the

fibrous canal; (3) the internal vena comes, posterior tibial artery, external vena comes, and posterior tibial nerve, all occupying a second fibro-osseous canal; (in cases of an early division of the posterior tibial nerve into external and internal plantar nerves these two nerves are found in this canal, the internal on the inner side of the internal vena comes, and the external on the outer side of the external vena comes); (4) the tendon of the flexor longus hallucis, occupying the third fibro-osseous canal, and lying in the groove at the outer part of the posterior border of the lower end of the tibia. Each of the three tendons mentioned is invested by a special synovial sheath. The internal annular ligament is pierced by the calcaneo-plantar branch of the posterior tibial nerve and the internal calcaneal branch of the posterior tibial artery.

The **anterior annular ligament** is composed of two divisions. One division is situated on the front of the leg above the ankle-

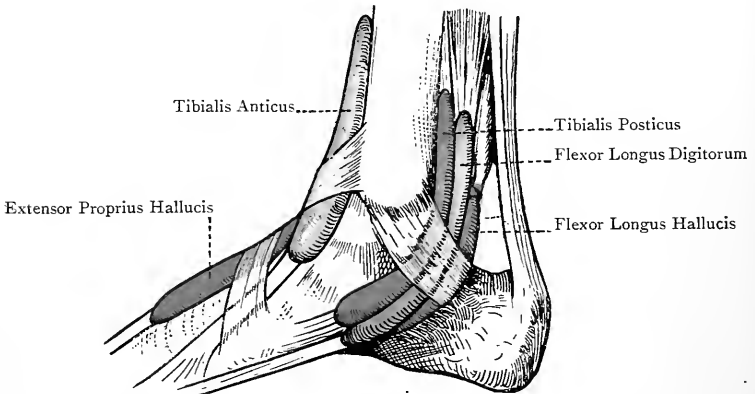


FIG. 235.—THE SYNOVIAL SHEATHS AT THE ANKLE (INTERNAL VIEW)
(AFTER L. TESTUT'S 'ANATOMIE HUMAINE').

joint, and is called the superior anterior annular ligament. The other division lies in front of the bend of the ankle, and is called the inferior anterior annular ligament, anterior annular ligament proper, or lambdoid ligament.

The *superior anterior annular ligament* is a broad band extending transversely between the anterior borders of the tibia and fibula, and measuring about 2 inches from above downwards. Immediately beyond it the deep fascia is exceedingly thin. The structures passing beneath it, in order from within outwards, are (1) tibialis anticus, (2) extensor proprius hallucis, (3) internal vena comes, (4) anterior tibial artery, (5) external vena comes, (6) anterior tibial nerve, (7) extensor longus digitorum, and (8) peroneus tertius. These structures occupy one common compartment, the tibialis anticus tendon alone being surrounded by a synovial sheath,

which is continuous with that investing it as it passes through the lambdoid ligament.

The *inferior anterior annular* or *lambdoid ligament* is a more defined structure than the superior. Being placed in front of the ankle-joint, it serves to strap down the extensor tendons as they are entering upon their horizontal course on the dorsum of the foot. It may be likened either to the capital letter \leftarrow placed upon its side as indicated, or to the Greek letter λ (lambda), also laid upon its side, as shown. From the former resemblance it may be called the *Y* annular ligament. The outer part, which is a single narrow band, is attached to a depression on the upper surface of the os calcis at its anterior and outer part, immediately in front of the interosseous groove. This part forms a loop through which the tendons of the extensor longus digitorum and peroneus tertius pass, invested by one synovial sheath. From the fact that it forms a loop it has been called by Retzius the *fundiform ligament*. It gives partial origin to the extensor brevis digitorum, and at its inner end it is continued into two diverging bands, upper and lower. The upper band is attached to the internal malleolus, and the tendon of the extensor proprius hallucis passes underneath it, being surrounded by a synovial sheath. The tendon of the tibialis anticus passes through it, the main portion of the band being underneath that tendon, and a small expansion from it passing superficial to the tendon. The tendon of the tibialis anticus has its own synovial sheath, which is prolonged upwards from this point along the tendon, to be continuous with the synovial sheath investing it as it passes behind the superior anterior

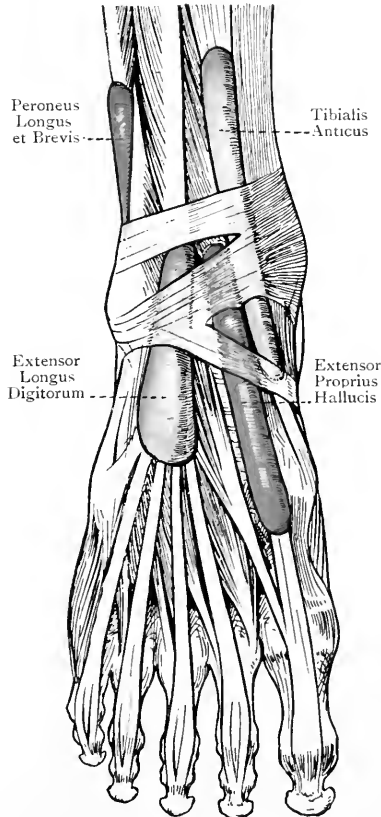


FIG. 236.—THE SYNOVIAL SHEATHS AT THE ANKLE (ANTERIOR VIEW) (AFTER L. TESTUT'S 'ANATOMIE HUMAINE').

annular ligament. The lower band of the lambdoid ligament is a comparatively weak structure which passes to the inner border of the foot, where it joins partly the plantar fascia and partly the lower border of the internal annular ligament. The tendons of the extensor proprius hallucis and tibialis anticus both pass underneath it. There are thus three distinct synovial sheaths in connection with the lambdoid ligament—one for the extensor longus digitorum and peroneus tertius, one for the extensor proprius hallucis, and one for the tibialis anticus, the latter being continuous with that which invests the tendon beneath the superior annular ligament. The dorsalis pedis artery, with its venæ comites, and the dorsalis pedis nerve pass underneath or behind both bands of the fundiform ligament.

Internal Aspect of the Leg.

The internal surface of the tibia, except at its upper end, is subcutaneous. The deep fascia is here very thin, and is intimately incorporated with the periosteum. The structures met with on this aspect are the long saphenous vein and nerve, the posterior division of the internal cutaneous nerve, and the superficial branch of the anastomotica magna artery. The long saphenous vein lies about a finger's breadth from the internal border of the tibia, and it receives many tributaries from the anterior and posterior aspects of the leg. The long saphenous nerve lies immediately behind it. The posterior division of the internal cutaneous nerve is confined to the upper half of the inner aspect of the leg, and the superficial branch of the anastomotica magna artery ramifies in the upper third. At the upper end of the internal surface of the tibia the tendons of insertion of the sartorius, gracilis, and semitendinosus are met with, as well as the internal lateral ligament of the knee-joint. Proceeding in a direction backwards from the tubercle of the tibia to the internal border of the bone, the relation of these structures is as follows: (1) tendon of the sartorius; (2) tendons of the gracilis and semitendinosus in the same vertical line, the gracilis being the higher of the two, and both being under cover of the sartorius; and (3) the internal lateral ligament of the knee-joint. The tendons of the gracilis and semitendinosus cross the internal lateral ligament in a forward direction, and are separated from it and the subjacent bone by a bursa, which furnishes an expansion to separate them from the more superficially placed sartorius. The portion of the internal lateral ligament met with in this region is a long, flat, expanded band, attached to the internal border, and adjacent portion of the internal surface, of the tibia, upon which it descends for fully 3 inches. The inferior internal articular artery passes transversely forwards underneath it, below the internal tuberosity of the tibia; and beneath the posterior border of the ligament the chief tendon of the semimembranosus passes to be inserted into the horizontal groove on the posterior surface of the internal tuberosity.

Anterior Aspect of the Leg and Dorsum of the Foot.

Musculo-cutaneous Nerve (Superficial Peroneal).—This nerve is one of the terminal branches of the external popliteal, arising from that nerve on the outer side of the neck of the fibula, where it lies between the bone and the peroneus longus. It then descends in the antero-external intermuscular septum, lying between the extensor longus digitorum in front, and the peroneus longus and peroneus brevis behind. When it reaches the junction of the upper two-thirds and lower third of the leg, it becomes cutaneous by piercing the deep fascia, and almost immediately afterwards it divides into its two terminal branches, internal and external.

Branches.—The branches of the nerve are as follows: **muscular** to the peroneus longus and peroneus brevis; and **cutaneous** to the integument of the front of the leg in its lower third, which arises as soon as the nerve pierces the deep fascia.

The **internal terminal branch** descends to the dorsum of the foot, lying superficial to both divisions of the anterior annular ligament. It then divides into two branches, inner and outer. The *inner branch* supplies twigs to the integument of the internal malleolus and inner side of the foot, which communicate with the terminal part of the long saphenous nerve, and it then becomes the dorsal digital nerve of the inner side of the great toe. It gives a communicating branch to the dorsalis pedis nerve as that lies upon the first dorsal interosseous muscle. The *outer branch* passes to the cleft between the second and third toes, where it divides into two dorsal collateral digital nerves for the supply of the contiguous sides of these toes.

The **external terminal branch**, like the internal, descends to the dorsum of the foot, and also lies superficial to both divisions of the anterior annular ligament. On the dorsum of the foot it divides into two branches, inner and outer. The *inner branch* passes to the cleft between the third and fourth toes, and the *outer* to the cleft between the fourth and fifth toes. At these clefts the inner and outer branches divide each into two dorsal collateral digital nerves for the supply of the contiguous sides of the third and fourth, and fourth and fifth toes. The outer branch in its course supplies twigs to the integument of the

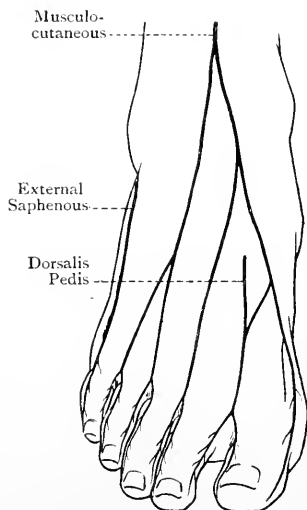


FIG. 237.—DIAGRAM OF THE NERVES OF THE FOOT (DORSAL ASPECT).

external malleolus and outer border of the foot which communicate with the terminal part of the short saphenous nerve.

Summary of the Distribution of the Musculo-cutaneous Nerve.—The nerve is distributed to the peroneus longus, peroneus brevis, integument over the front of the leg in its lower third, integument of the malleolar regions and outer and inner borders of the foot, and the integument of (1) the inner side of the great toe, and (2) the contiguous sides of the second and third, third and fourth, and fourth and fifth toes, all on their dorsal aspects. The dorsal digital nerve of the outer side of the fifth toe is the terminal part of the short saphenous nerve.

The dorsal collateral digital nerves for the supply of the contiguous sides of the great toe and second toe are derived from the dorsalis pedis nerve, which is the continuation of the anterior tibial nerve.

Muscles. Tibialis Anticus—*Origin.*—(1) The external tuberosity of the tibia at its lower part : (2) the upper two-thirds of the external surface of the shaft of the tibia and adjacent portion of the anterior surface of the interosseous membrane : and (3) the deep fascia, and the anterior intermuscular septum which lies between it and the extensor longus digitorum in the upper third of the leg.

Insertion.—The tendon, having traversed the groove on the inner surface of the internal cuneiform bone, divides into two slips. The posterior slip is inserted into an oval impression at the lower part of the inner surface of the internal cuneiform bone, and the anterior slip is inserted into the inner surface of the tuberosity on the plantar aspect of the base of the first metatarsal bone.

Nerve-supply.—The anterior tibial nerve.

Action.—(1) To flex the foot upon the leg, and (2) to raise the inner border of the foot, thereby inverting the sole.

Extensor Proprius or Longus Hallucis—*Origin.*—The middle two-fourths of the anterior surface of the shaft of the fibula, and the adjacent portion of the anterior surface of the interosseous membrane.

Insertion.—The dorsal surface of the base of the distal phalanx of the great toe.

Nerve-supply.—The anterior tibial nerve.

Action.—(1) To extend the distal phalanx of the great toe, and (2) to flex the foot upon the leg.

The extensor proprius hallucis is a very narrow muscle which lies deeply between the tibialis anticus and extensor longus digitorum, both of which conceal it until its tendon appears on the front of the lower part of the tibia.

Extensor Longus Digitorum.—*Origin.*—(1) The external tuberosity of the tibia : (2) the head and upper three-fourths of the anterior surface of the shaft of the fibula : (3) the anterior surface of the interosseous membrane in its upper fourth : (4) the intermuscular septa between it and adjacent muscles : and (5) the deep fascia.

Insertion.—The second and distal phalanges of the four outer toes. The four tendons pass to the dorsal aspects of the metatarsophalangeal joints of the four outer toes. At this point they broaden

out into expansions which receive the tendons of the lumbricales and interosseous muscles. In the case of the tendons destined for the second, third, and fourth toes, their expansions are also joined by the outer three tendons of the extensor brevis digitorum. Each tendinous expansion passes forwards over the dorsum of the first phalanx, and at its distal end divides into three bands. The middle band is inserted into the dorsal aspect of the base of the second phalanx. The two lateral bands, having united, are inserted into the dorsal aspect of the base of the distal phalanx.

Nerve-supply.—The anterior tibial nerve.

Action.—(1) To extend the second and distal phalanges of the four outer toes, and (2) to flex the foot upon the leg.

Peroneus Tertius—*Origin.*—(1) The anterior surface of the shaft of the fibula in its lower fourth, except for an inch or more below, and (2) the adjacent portion of the anterior surface of the interosseous membrane, and the antero-external intermuscular septum between the muscle and the peroneus brevis.

Insertion.—The dorsal surface of the base of the fifth metatarsal bone.

Nerve-supply.—The anterior tibial nerve.

Action.—(1) To flex the foot upon the leg, and (2) to raise the outer border of the foot slightly.

The peroneus tertius is to be regarded as a detached portion of the extensor longus digitorum.

Anterior Tibial Artery.—This vessel is one of the terminal branches of the popliteal artery. It commences at the lower border of the popliteus muscle on a level with the lower border of the tubercle of the tibia (fully $1\frac{3}{4}$ inches below the level of the upper surface of the head of that bone), and it terminates on the anterior ligament of the ankle-joint midway between the two malleoli by becoming the dorsalis pedis artery. Being placed at its commencement on the back of the leg, the vessel passes at first forwards between the two heads of the tibialis posticus, and over the upper border of the interosseous membrane, where it lies below the superior tibio-fibular articulation. (The artery sometimes passes through an aperture in the upper part of the interosseous membrane, called the superior hiatus.) Having reached the front of the leg, the vessel changes its course somewhat abruptly, and then descends in close contact with the anterior surface of the interosseous membrane, until it reaches the junction of the upper two-thirds and lower third of the leg. Beyond this point it gradually inclines towards the anterior aspect of the tibia, and in the lower fourth it lies upon that surface, and finally upon the anterior ligament of the ankle-joint. The course of the vessel on the anterior aspect of the leg corresponds with a line drawn from the superior tibio-fibular articulation to the centre of the front of the ankle-joint midway between the two malleoli.

Relations—*On the Back of the Leg.*—The artery lies here between the two heads of the tibialis posticus, having the lower border of the

popliteus muscle above it, and being under cover of the gastrocnemius.

On the Front of the Leg—Superficial.—In the upper three-fourths the artery is deeply placed, and is covered by the integument, and the meeting between the tibialis anticus on the inner side and

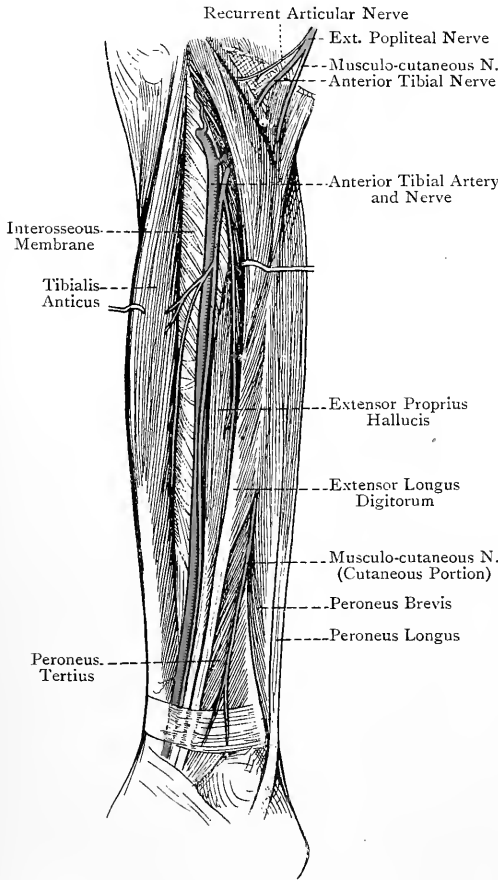


FIG. 238.—THE FRONT OF THE LEFT LEG (DEEP DISSECTION).

the extensor longus digitorum and extensor proprius hallucis on the outer side. In the lower fourth the vessel is comparatively superficial, the muscles having now ended in their tendons, and it is covered by the integument, upper division of the anterior annular ligament, and extensor proprius hallucis, the tendon of the latter muscle crossing it from without inwards about $3\frac{1}{2}$ inches above the ankle-joint. *Deep.*—Anterior surface of the interosseous membrane (to which it is bound by fibrous tissue), anterior surface of the tibia in lower fourth, and the anterior ligament of the ankle-joint. *External.*—Extensor longus digitorum in the upper fourth of the leg, extensor proprius hallucis in the middle two-fourths, and extensor longus digitorum again in the lower fourth. *In-*

ternal.—Tibialis anticus in the upper three-fourths, and extensor proprius hallucis in the lower fourth.

The artery is accompanied by two venæ comites, which closely embrace its sides and communicate with each other at frequent intervals by transverse branches, crossing superficial to the vessel. These venæ comites, having passed backwards over the upper

border of the interosseous membrane (or through a superior hiatus in it), join to form one trunk, which unites with the trunk formed by the junction of the venæ comites of the posterior tibial artery to form the popliteal vein.

The anterior tibial artery in the upper fourth of the leg is separated from the anterior tibial nerve by the fibula and the extensor longus digitorum, the artery having passed forwards between the tibia and fibula, and the nerve having wound obliquely round the outer side of the bone. At the junction of the upper fourth and lower three-fourths of the leg the nerve, having pierced the antero-external intermuscular septum and extensor longus digitorum, comes into contact with the artery, along the outer side of which it descends for a short distance. It then lies on the artery for a little, and finally it again takes up a position upon the outer side of the vessel in the lower fourth of the leg.

Branches.—The branches from above downwards are as follows: posterior tibial recurrent; superior fibular; anterior tibial recurrent; muscular; internal malleolar; and external malleolar.

The **posterior tibial recurrent artery** is an inconstant branch. When present it arises from the anterior tibial artery whilst on the back of the leg. Its course is upwards beneath the popliteus muscle, and it is distributed to that muscle, the posterior ligament of the knee-joint, and the superior tibio-fibular articulation. It anastomoses with the external and internal inferior articular arteries on the back of the leg.

The **superior fibular artery** also arises from the anterior tibial whilst on the back of the leg. Its course is outwards behind the neck of the fibula, where it pierces the soleus, and it is distributed to that muscle, the peroneus longus, and the adjacent integument.

The **anterior tibial recurrent artery** arises from the anterior tibial whenever it reaches the front of the leg. Entering the upper part of the tibialis anticus, to which, as well as to the superior tibio-fibular joint, it gives branches, it ascends to the external tuberosity of the tibia, in company with the recurrent articular branch of the external popliteal nerve. Its terminal branches anastomose with the external and internal inferior articular arteries.

The **muscular branches** are very numerous, and are distributed chiefly to the muscles on the anterior aspect of the leg. Some offsets, however, reach the integument, and others, piercing the interosseous membrane, terminate in the tibialis posticus, in which they anastomose with branches of the posterior tibial artery.

The **internal malleolar artery** is a small branch which arises from the inner side of the anterior tibial near the lower end of the tibia. Its course is inwards beneath the tendon of the tibialis anticus, and it is distributed over the internal malleolus, where it anastomoses with (1) the internal malleolar branches of the pos-

terior tibial, (2) the superior internal tarsal branch of the dorsalis pedis, and (3) branches of the internal plantar, thus forming the internal malleolar anastomosis.

The **external malleolar artery** arises from the outer side of the anterior tibial at a slightly lower level than the internal malleolar. Its course is outwards beneath the tendons of the extensor longus digitorum and peroneus tertius, and it is distributed over the external malleolus, where it anastomoses with (1) the anterior peroneal, (2) the posterior peroneal, and (3) the external tarsal branch of the dorsalis pedis, thus forming the external malleolar anastomosis.

The veins which accompany the branches of the anterior tibial artery are, in each case, arranged as venæ comites, and they terminate as tributaries of the anterior tibial venæ comites.

Varieties—1. **Origin**.—The vessel may arise from the popliteal at the upper border of the popliteus muscle. In these cases it may descend on the posterior surface of that muscle (this being the more frequent position), or it may pass deeply in front of it.

2. **Course**.—The vessel in the lower fourth of the leg may be found upon the fibula instead of the tibia, in which cases it makes a sudden bend at the ankle-joint to become the dorsalis pedis artery. In very rare cases the vessel may become superficial at the centre of the leg instead of in the lower fourth.

3. **Size**.—The vessel is occasionally very small, and, if the diminution in size is very pronounced, it may fail to furnish the dorsalis pedis artery, in which cases that vessel is supplied by the anterior peroneal.

Anastomoses round the Knee-Joint.—The arteries which take part in these anastomoses are as follows: (1) the two superior, and the two inferior, external and internal articular branches of the popliteal; (2) the long descending branch of the external circumflex of the profunda femoris; (3) the anastomotica magna of the superficial femoral; (4) the fourth perforating of the profunda femoris; and (5) the posterior tibial recurrent (inconstant), and the anterior tibial recurrent, both of which are branches of the anterior tibial artery. For the special anastomoses of the foregoing arteries see the descriptions of the individual vessels, and Fig. 251.

The anastomoses are divided into *superficial* and *deep*, the former being placed superficial to the patella, and the latter being in contact with the lower end of the femur and the head of the tibia.

Three transverse arches are to be noted anteriorly as follows: one lies in the substance of the crureus, just above the patellar surface of the femur, and is formed by branches of the superior external articular of the popliteal, and the deep branch of the anastomotica magna of the superficial femoral. A second arch lies in front of the head of the tibia, near the superior surface, and is formed by branches of the inferior external articular, and the superior internal articular. A third arch lies in front of the tibia just above the tubercle, and is formed by branches of the anterior tibial recurrent, and the inferior internal articular artery.

The terminal part of the **anterior peroneal artery**, having reached the front of the leg by passing through the inferior hiatus in the interosseous membrane, descends in front of the inferior tibio-fibular articulation under cover of the peroneus tertius, to both of which it furnishes branches. It finally takes part in the external malleolar anastomosis, along with (1) the external malleolar of the anterior tibial, (2) the external tarsal of the dorsalis pedis, and (3) the posterior peroneal.

Anterior Tibial Nerve (Deep Peroneal).—This nerve is one of the terminal branches of the external popliteal. It commences upon the outer side of the neck of the fibula, where it lies between the bone and the peroneus longus, and it terminates at the anterior ligament of the ankle-joint, where it becomes the dorsalis pedis nerve. At first it is directed downwards, forwards, and inwards through the antero-external intermuscular septum and extensor longus digitorum, and it comes into contact with the anterior tibial artery at the junction of the upper fourth and lower three-fourths of the leg. It then descends in close contact with that artery as far as its termination, lying at first external to the vessel, then in front of it, and finally again on its outer side. The general relations of the nerve closely correspond with those of the artery on the front of the leg.

Branches.—These are muscular and articular. The **muscular branches** supply the tibialis anticus, extensor longus digitorum, extensor proprius hallucis, and peroneus tertius. The **articular branches** arise from the lower part of the nerve, and are distributed to the ankle-joint and inferior tibio-fibular articulation.

Anterior Tibial Gland.—This lymphatic gland is situated in front of the interosseous membrane at its upper part in close proximity to the anterior tibial artery. Its afferent vessels take up lymph from the dorsum of the foot and anterior aspect of the leg in its more deeply-placed parts. The efferent vessels, which are usually two in number, pass backwards either above the interosseous membrane or through a superior hiatus in it, lying along the anterior tibial artery, and they become afferent vessels to the popliteal glands.

Dorsum of the Foot. Deep Fascia.—This is a delicate membrane which is prolonged forwards from the lambdoid ligament over the long extensor tendons. Two other thin layers of deep fascia are met with, one covering the extensor brevis digitorum, and the other covering the dorsal interosseous muscles and the dorsal surfaces of the metatarsal bones.

Extensor Brevis Digitorum—Origin.—(1) The anterior part of the upper surface, and adjacent part of the external surface, of the os calcis; and (2) the outer single portion of the lower division of the anterior annular ligament—that is to say, the fundiform ligament of Retzius.

Insertion.—Into the four inner toes, namely, the great toe, second, third, and fourth, by means of four tendons in the following

manner: the innermost tendon has a special insertion into the dorsal surface of the first phalanx of the great toe near its base. The other three tendons join the outer borders of the long extensor tendons which go to the second, third, and fourth toes, the union taking place at the metatarso-phalangeal joints.

Nerve-supply.—The external branch of the dorsalis pedis nerve.

Action.—(1) Innermost tendon.—This tendon extends the great toe at the metatarso-phalangeal joint, and it also acts as an adductor of that toe. (2) Second, third, and fourth tendons.—These extend the corresponding toes in conjunction with the long extensor tendons. In doing so they tend, by the obliquity of their direction, to draw the toes outwards, and in this way they counteract the opposite tendency of the long extensor tendons, which of themselves would incline the toes inwards.

The muscle lies obliquely upon the dorsum of the foot, and is directed forwards and inwards. The innermost fleshy bundle is always the largest, and separates from the parent muscle sooner than the others. It has accordingly been regarded as a separate muscle, and as such is called the *extensor brevis hallucis*.

Dorsalis Pedis Artery.—This vessel is the continuation of the anterior tibial artery. It commences at the anterior ligament of the ankle-joint, midway between the two malleoli, and terminates at the proximal end of the first interosseous space, where it divides into two branches, plantar or perforating, and arteria dorsalis hallucis or first dorsal interosseous artery. The course of the vessel is along the inner part of the dorsum of the foot, and is indicated by a line drawn from the centre of the front of the ankle-joint, midway between the two malleoli, to the proximal end of the first interosseous space.

Relations—*Superficial.*—The skin, superficial fascia, lower division of anterior annular ligament, deep fascia, and innermost tendon of the extensor brevis digitorum, which crosses it from without inwards near its termination. *Deep.*—Upper border of the head of the astragalus, navicular, middle cuneiform, base of second metatarsal, and the corresponding ligaments. *External.*—External vena comes, dorsalis pedis nerve, innermost tendon of the extensor longus digitorum, and, near its termination, the innermost tendon of the extensor brevis digitorum as it is about to cross the artery. *Internal.*—Internal vena comes, tendon of the extensor proprius hallucis, and, near its termination, the innermost tendon of the extensor brevis digitorum after it has crossed the vessel.

The artery is firmly bound down by connective tissue to the subjacent bones and ligaments. It is accompanied by two venæ comites, one on either side, which communicate with each other by transverse branches lying superficial to the vessel, and ultimately become the venæ comites of the anterior tibial artery.

Branches.—The branches are as follows: internal tarsal, external tarsal, metatarsal, arteria dorsalis hallucis or first dorsal

interosseous, and plantar or perforating, which latter divides in the sole of the foot into arteria magna or princeps hallucis, or first plantar interosseous, and plantar communicating, which latter completes the plantar arch.

The **internal tarsal arteries** are two or three in number, and supply the adjacent structures on the inner border of the foot, where they anastomose with branches of the internal plantar

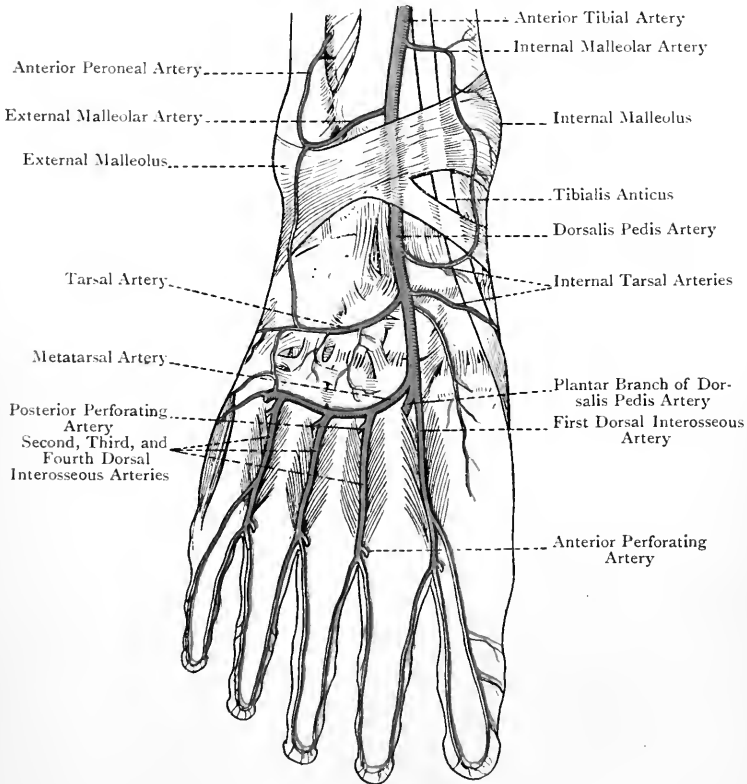


FIG. 239.—THE ARTERIES ON THE DORSUM OF THE RIGHT FOOT (AFTER L. TESTUT'S 'ANATOMIE HUMAINE').

artery. The highest of them also takes part in the internal malleolar anastomosis.

The **external tarsal artery** passes outwards beneath the extensor brevis digitorum. It supplies the adjacent structures, and at the outer border of the foot it anastomoses with the metatarsal and external plantar arteries. It also takes part in the external malleolar anastomosis.

The **metatarsal artery** arises on a level with the bases of the metatarsal bones, over which it passes on its way to the outer border of the foot, being under cover of the extensor brevis digitorum. At the outer border it anastomoses with the tarsal and external plantar arteries. The vessel forms a slight arch with the convexity directed forwards. From the concavity of the arch a few *recurrent branches* are given off to the tarsal articulations. From the convexity *three dorsal interosseous arteries* are given off, which pass forwards over the outer three interosseous spaces. At the level of the metatarso-phalangeal joints each divides into two dorsal collateral digital arteries, which supply the contiguous sides of the second and third, third and fourth, and fourth and fifth toes. The most external dorsal interosseous artery, before it divides into its two collateral branches, furnishes a single dorsal digital artery to the outer side of the fifth or little toe. At the proximal end of the second, third, and fourth interosseous spaces the three dorsal interosseous arteries (in themselves small) are reinforced each by a *posterior perforating artery*, the three posterior perforating arteries being branches of the plantar arch. At the distal end of these interosseous spaces the three dorsal interosseous arteries are usually further reinforced each by an *anterior perforating artery*, the three anterior perforating arteries being branches of the three compound plantar digital arteries from the plantar arch.

The **arteria dorsalis hallucis** is the first dorsal interosseous artery. Arising from the terminal part of the dorsalis pedis artery, it continues the direction of that vessel, and passes forwards over the first interosseous space. On reaching the cleft between the great toe and the second it divides into two dorsal collateral digital branches for the supply of the contiguous sides of these two toes, and it furnishes a small single dorsal digital artery for the supply of the inner side of the great toe. The dorsalis hallucis artery is not reinforced by any posterior perforating branch. Before, however, dividing into its digital branches it receives an *anterior perforating artery*, which is derived from the arteria magna or princeps hallucis in the sole.

The dorsal digital arteries as they pass along the sides of the toes communicate with each other across their dorsal aspects, and also with the corresponding plantar digital arteries.

The plantar or perforating artery will be described in connection with the sole of the foot.

Varieties of Dorsalis Pedis Artery—1. **Origin.**—The vessel may be the continuation of the anterior peroneal artery.

2. **Course.**—The vessel often describes a considerable curve outwards before it reaches the proximal end of the first interosseous space. In these cases the artery may terminate at the back of the second interosseous space instead of the first.

3. **Branches.**—There is considerable deviation from the normal in respect of branches. The branch most affected is the metatarsal artery. This may arise in common with the tarsal branch. The metatarsal arch is often very

indefinite. The metatarsal artery is sometimes absent, and when this occurs the dorsal interosseous arteries of the outer three interosseous spaces are usually furnished by the three posterior perforating arteries from the plantar arch, or, it may be, by the tarsal artery.

Dorsalis Pedis Nerve.—This nerve is the continuation of the anterior tibial. It commences at the anterior ligament of the ankle-joint, and terminates at the distal end of the first interosseous space by dividing into two dorsal collateral digital nerves

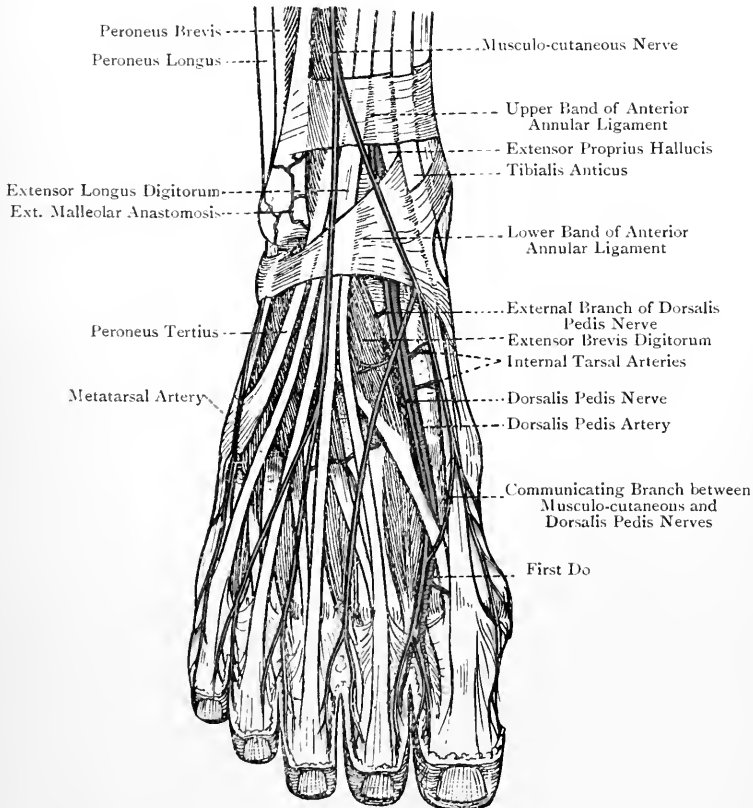


FIG. 240.—DISSECTION OF THE DORSUM OF THE RIGHT FOOT.

for the supply of the contiguous sides of the great toe and the second. Its relations correspond with those of the dorsalis pedis artery, on the outer side of which it lies, with the intervention of the external vena comes. As the nerve passes over the dorsal aspect of the first interosseous space it is reinforced by an offset from the inner branch of the internal division of the musculo-cutaneous nerve.

Branches.—The branches are as follows: external or tarsal, interosseous, and terminal.

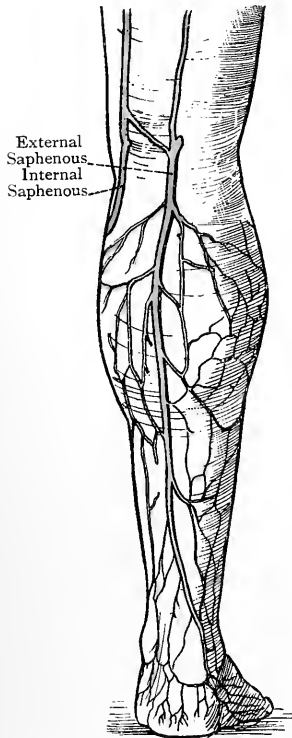
The **external or tarsal branch** arises from the dorsalis pedis nerve as soon as it emerges from beneath the lower division of the anterior annular ligament. It passes outwards beneath the extensor brevis digitorum, and in that situation it presents a gangliform enlargement from which branches are furnished to the extensor brevis digitorum and the tarsal articulations. Three interosseous branches also arise from it, which pass over the dorsal aspects of the three outer interosseous spaces, supplying the adjacent tarso-metatarsal and metatarso-phalangeal articulations. The interosseous branch, which lies over the second interosseous space, usually supplies a small twig to the dorsal interosseous muscle of that space.

The **interosseous branch** passes over the dorsal aspect of the first interosseous space, supplying the adjacent tarso-metatarsal and metatarso-phalangeal articulations. It also gives a twig to the first dorsal interosseous muscle.

The **terminal branches** are the dorsal collateral digital nerves for the contiguous sides of the great toe and the second.

Dorsal Venous Arch.—This arch is superficial to the deep fascia, and is situated well forward upon the dorsum of the foot, being about 2 inches from the webs of the toes. The convexity of the arch, which is but slight, is directed forwards. It receives (1) the dorsal digital veins, (2) small veins from the dorsum of the foot, and (3) the efferent interdigital veins which come from the plantar transverse venous arch situated near the clefts of the toes. The blood is carried away from the dorsal venous arch by the two saphenous veins. The internal or long saphenous vein arises from the inner end of the arch, and, having received branches from the superficial plantar venous plexus which turn round the inner border of the foot, it passes in front of the internal malleolus, and thus reaches the inner side of the leg. Its further course has been previously described.

FIG. 241.—THE EXTERNAL SAPHENOUS VEIN AND ITS TRIBUTARIES.



The **external or short saphenous vein** arises from the outer end of the arch, and, having received branches from the superficial

plantar venous plexus which turn round the outer border of the foot, it passes below and behind the external malleolus, and thus reaches the back of the leg. It then passes upwards and inwards, lying at first to the outer side of the tendo Achillis. On reaching the middle line of the calf, it ascends in the groove between the two heads of the gastrocnemius until it arrives at the interval between the condyles of the femur. Up to this point the vein is superficial to the deep fascia. It now, however, passes through an opening in that fascia, and terminates in the popliteal vein. As high as the centre of the calf the vein is accompanied by the short saphenous nerve, which lies on its outer side. From the centre of the calf up to where the vein pierces the deep fascia it is accompanied by the terminal part of the small sciatic nerve and the middle superficial or cutaneous sural artery. It receives many tributaries from the calcaneal region, and from the outer and back parts of the leg, and it communicates at intervals with the venæ comites of the posterior tibial and peroneal arteries. Just before it pierces the deep fascia a communicating branch passes upwards and inwards from it to join the long saphenous vein. The external or short saphenous vein is provided with about ten valves.

External Aspect of the Leg.

In this region the lateral cutaneous branch of the external popliteal nerve is met with. It supplies the integument of the outer side of the leg over about its upper two-thirds, as well as the adjacent integument of the sural region.

Muscles. Peroneus Longus—*Origin*.—(1) The external aspect of the head of the fibula; (2) the adjacent part of the external tuberosity of the tibia; (3) the upper two-thirds of the external surface of the shaft of the fibula; (4) the antero-external and postero-external intermuscular septa; and (5) the deep fascia.

Insertion.—The tendon of insertion divides into two parts. The main part is inserted into the outer side of the tuberosity on the plantar surface of the base of the first metatarsal bone, and the other into the lower and anterior part of the outer surface of the internal cuneiform bone.

Nerve-supply.—The musculo-cutaneous nerve.

Action.—(1) To extend the foot upon the leg; (2) to abduct or turn out the fore part of the foot; (3) to depress the inner border of the foot, the effect of which is to raise the outer border and produce eversion of the sole; and (4) to support and strengthen the transverse arch of the foot.

The tendon descends behind that of the peroneus brevis, and, along with it, passes through the groove behind the external malleolus and beneath the external annular ligament, the two tendons having one synovial sheath in common. After leaving the malleolar groove, the tendon passes forwards on the outer surface of the os

calcis, where it occupies the groove below the peroneal spine or ridge. In this part of its course the tendon is surrounded by a fibrous sheath, which is derived from the lower border of the external annular ligament, and it is here invested by a special synovial sheath, which is a prolongation of that beneath the external annular ligament. It then turns round the peroneal notch on the

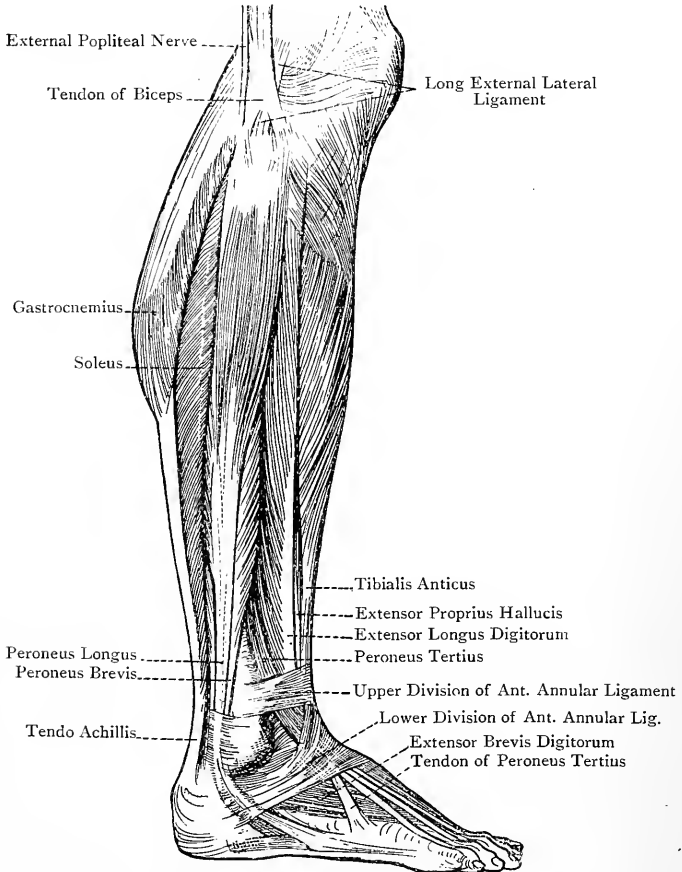


FIG. 242.—MUSCLES OF THE LEG (EXTERNAL VIEW).

outer border of the cuboid, and traverses the peroneal groove on the plantar surface of that bone, which is converted into a fibro-osseous canal by an expansion derived from the long plantar ligament. Finally, after leaving this fibro-osseous canal, in which it is invested by a special synovial sheath, the tendon crosses the sole of the foot to its twofold insertion, taking a direction forwards

and inwards. In that part of the tendon which turns round the outer border of the cuboid a sesamoid fibro-cartilage is found.

Peroneus Brevis—*Origin*.—(1) The lower two-thirds of the external surface of the shaft of the fibula, except the last 2 inches; (2) the antero-external and postero-external intermuscular septa; and (3) the deep fascia.

Insertion.—The tuberosity on the outer side of the base of the fifth metatarsal bone. From the tendon of insertion a slip is often given to the long extensor tendon of the little toe.

Nerve-supply.—The musculo-cutaneous nerve.

Action.—(1) To extend the foot upon the leg, but in a feeble manner; (2) to abduct or turn out the fore part of the foot; and (3) to raise directly the outer border of the foot, thus producing eversion of the sole.

The middle third of the external surface of the fibula is occupied by both peroneus longus and peroneus brevis, the former arising from the posterior half, and the latter from the anterior half, so that the two muscles overlap. The tendon of the peroneus brevis passes through the groove behind the external malleolus with the tendon of the peroneus longus, which is directly behind it. Both tendons lie beneath the external annular ligament, where they have one synovial sheath in common. After leaving the malleolar groove the tendon of the peroneus brevis passes forwards on the outer surface of the os calcis, where it occupies the groove above the peroneal spine or ridge. In this part of its course the tendon is surrounded by a fibrous sheath, which is derived from the lower border of the external annular ligament, and it is here invested by a special synovial sheath, which is a prolongation of that beneath the external annular ligament. After leaving the outer surface of the os calcis the tendon passes over the cuboid bone, and so reaches its insertion.

On the outer surface of the os calcis the two peroneal tendons are completely separated from each other, that of the brevis being above that of the longus. The separation is effected partly by a strong fibrous septum, and partly by the peroneal spine or ridge. The peroneus longus and peroneus brevis are contained in a fibro-osseous canal formed by the deep fascia, the intermuscular septum on each side, and the external surface of the shaft of the fibula.

Posterior Aspect of the Leg.

Superficial Structures.—The following superficial structures are met with in this region: the external or short saphenous vein, the cutaneous sural branches of the popliteal artery, the terminal part of the small sciatic nerve, the ramus communicans tibialis nerve, the ramus communicans fibularis nerve, and the external or short saphenous nerve. These, except the last named, have been already described.

External or Short Saphenous Nerve.—This nerve is formed by the union of the ramus communicans tibialis of the internal popliteal and the ramus communicans fibularis of the external popliteal. The union takes place at, or just below, the centre of the calf, and superficial to the deep fascia. The nerve descends on the outer side of the short saphenous vein, and external to the tendo Achillis. It then passes behind and below the external malleolus, and so reaches the outer border of the foot, along which it passes to the outer side of the little toe, of which it is the dorsal digital nerve. The nerve supplies the integument of the back of the leg in its lower half, the external malleolar region, the outer side of the calcaneum, and the outer border of the foot and outer side of the little toe. It also furnishes articular branches to the ankle-joint, and the astragalo-calcaneal articulation.

Muscles.—The muscles of the back of the leg are divided into two groups—superficial and deep.

Superficial Group.—This group comprises the gastrocnemius, soleus, and plantaris, which are collectively called the sural (calf) muscles.

Gastrocnemius.—This muscle is so named because it forms the ‘belly of the leg,’ that is to say, the fleshy enlargement at the back of the leg which is called the calf.

Origin.—The **external head** arises from (1) the outer surface of the external condyle of the femur immediately above the commencement of the popliteal groove, and close behind and above the external tuberosity; and (2) the adjacent part of the posterior surface of the femur, vertically, for at least an inch immediately external to the lower part of the external supracondylar ridge. The **internal head** arises from (1) an oblique impression on the posterior surface of the femur immediately above the internal condyle, and extending inwards for fully an inch as far as the adductor tubercle; and (2) the lower extremity of the internal supracondylar ridge for a short distance.

Insertion.—The fleshy part of the muscle gives place to a flat tendon, which joins the subjacent tendon of the soleus at the centre of the leg to form the tendo Achillis. Through this latter the gastrocnemius is inserted into the middle zone on the posterior surface of the tuber calcis, a bursa intervening between the tendon and the upper zone.

Nerve-supply.—The internal popliteal nerve, which furnishes two branches, one for each head.

Action.—Acting from its origin, the muscle is a powerful extensor of the foot upon the leg, thus raising the heel. Acting from its insertion, as when the ankle-joint is fixed by the muscles of the anterior aspect of the leg, the gastrocnemius is a flexor of the knee-joint.

The two heads come into contact at the junction of the upper sixth and lower five-sixths of the leg, and so they limit the lower part of the popliteal space. After coming together they are sepa-

rated superficially by a longitudinal groove, and when the lips of this groove are held apart a tendinous band or raphé is seen to lie between them. The fleshy fasciculi of both heads are short and oblique, and they terminate upon the lower tendon, which extends upwards upon the deep or anterior surface of the muscle in the form of an expanded aponeurosis. The shortness of the fleshy bundles gives the muscle great power of action, but the range of movement is limited.

The internal head is separated from the tendon of the semimembranosus by a large bursa, called the *popliteal bursa*, which frequently (one in five) communicates with the synovial membrane of the knee-joint. Another small bursa is situated a little higher, between the internal head and the posterior surface of the femur. In the external head a sesamoid fibro-cartilage is occasionally met with.

Soleus.—This flat muscle has been so named from its resemblance to a sole-fish.

Origin.—(1) The posterior surface of the head, and the upper third of the posterior surface of the shaft, of the fibula; (2) the postero-external intermuscular septum; (3) the fibrous arch thrown over the popliteal vessels and internal popliteal nerve; (4) the oblique or popliteal line of the tibia; and (5) the internal border of the tibia over its middle third.

Insertion.—The tendon joins that of the gastrocnemius at the centre of the leg to form the tendo Achillis, which is inserted into the middle zone on the posterior surface of the tuber calcis.

Nerve-supply.—(1) The internal popliteal nerve, the branch from which enters the muscle on its superficial or posterior surface near the upper border; and (2) the posterior tibial nerve, the branch from which enters the muscle on its deep or anterior surface near the centre of the leg.

Action.—Acting from its origin the muscle is a powerful extensor of the foot upon the leg, thus raising the heel. Acting from its insertion, as when the ankle-joint is fixed by the muscles of the anterior aspect of the leg, the soleus steadies the leg upon the foot.

The fasciculi of this muscle are short and oblique, like those of the gastrocnemius. It has therefore great power of action, but its range of movement is limited. Only a limited number of the fibres of the soleus spring directly from the bony surfaces. The majority arise from two aponeurotic laminae, which are almost entirely concealed within the muscle, and which descend, one from the fibula, and the other from the oblique line of the tibia and the fibrous arch over the popliteal vessels. The fibres which arise from the anterior surfaces of these two laminae terminate upon a median tendinous band or raphé, which is deeply placed, and those arising from their posterior surfaces end upon a broad expanded aponeurosis, which covers the superficial or posterior surface of the muscle, giving it an appearance similar to that of the deep or anterior surface of the gastrocnemius. This aponeurosis is

simply an upward expansion of the tendon of insertion of the muscle.

Tendo Achillis.*—This very strong tendon is formed by the union of the tendons of the gastrocnemius and soleus. It extends from the centre of the leg to the prominence of the heel, and is inserted into the middle zone on the posterior surface of the tuber calcis, a bursa intervening between it and the upper zone. The tendo Achillis is at first broad and comparatively thin. As it descends, it becomes narrower and thicker until it reaches a point about $1\frac{1}{2}$ inches above the tuber calcis, beyond which it again broadens to its insertion. The short saphenous vein and nerve lie on its outer side, the tendon of the plantaris and the posterior tibial vessels and nerve on the inner side, and a large quantity of fat beneath it.

Plantaris—Origin.—(1) The lower 2 inches of the external supracondylar ridge of the femur, internal to the external head of the gastrocnemius; and (2) the adjacent part of the posterior ligament of the knee-joint.

Insertion.—The middle zone on the posterior surface of the tuber calcis immediately to the inner side of the tendo Achillis, with which it is closely connected. It may, however, terminate upon the inner border of the tendo Achillis, in the deep fascia of the leg, upon the internal annular ligament, or in the plantar fascia.

Nerve-supply.—The internal popliteal nerve.

Action.—(1) The plantaris acts as a very weak auxiliary to the gastrocnemius. (2) From its connection with the posterior ligament of the knee-joint the muscle has a slight action as a retractor of that ligament during flexion of the joint, and thus it guards the ligament against being nipped or pressed upon by the articular surfaces of the femur and tibia.

The fleshy belly of the muscle is limited to the upper sixth. The tendon is very narrow and remarkably long, being the longest tendon in the body. It is also very extensible, so that when grasped by the fingers and stretched laterally it can be drawn out into a ribbon of about 2 inches in breadth.

The plantaris, which is sometimes absent, is a vestigial muscle, being the crural remains of a superficial flexor of the toes, the plantar portion of the tendon of which, having been divorced, remains persistent as the central division of the plantar fascia. The homologue of the plantaris in the upper limb is the palmaris longus.

Deep Group.—The muscles which comprise this group are four in number, namely, the popliteus, flexor longus digitorum, tibialis posticus, and flexor longus hallucis. The popliteus muscle is covered by the popliteal fascia, which is one of the modes of insertion of the semimembranosus. The other muscles, together with

* Being inserted into the heel, it has been called the tendo Achillis, because it was believed that the heel was the only part in which the Greek hero, Achilles, could be wounded.

the posterior tibial vessels and nerve, are covered by the posterior or transverse intermuscular septum.

Popliteus—*Origin*.—(1) By a narrow round tendon from the front part of the horizontal portion of the popliteal groove on the outer surface of the external condyle of the femur, and (2) slightly from the posterior ligament of the knee-joint.

Insertion.—(1) The popliteal surface of the tibia, and (2) the popliteal fascia which covers the muscle.

Nerve-supply.—The internal popliteal nerve. The branch from this nerve descends over the posterior surface of the muscle, and, turning round its lower border, enters the deep or anterior surface in its lower part.

Action.—The muscle is a feeble flexor of the leg upon the thigh, and, when the knee-joint has been flexed, it acts as an internal rotator of the leg.

The tendon of origin is within the capsular ligament, and beneath the long external lateral ligament, of the knee-joint. Whilst within the joint it is in contact with the posterior and outer aspect of the external semilunar fibro-cartilage, which it grooves. It then pierces the capsule, and the fleshy fibres spread out in the manner of a fan as they diverge downwards and inwards. The popliteal fascia, which covers the muscle, represents part of the insertion of the semimembranosus muscle, and it is attached to the oblique or popliteal line of the tibia.

Flexor Longus Digitorum (flexor perforans)—*Origin*.—(1) The inner division of the posterior surface of the shaft of the tibia, commencing at the oblique or popliteal line, and extending downwards over the middle two-fourths of the bone; (2) the posterior intermuscular septum which covers the muscle; and (3) the intermuscular septum between it and the tibialis posticus on its outer side.

Insertion.—By means of four tendons which go to the four outer toes, where each is inserted into the plantar surface of the base or proximal end of the distal phalanx.

Nerve-supply.—The posterior tibial nerve.

Action.—(1) The muscle acts as a flexor of the distal phalanges of the four outer toes, and (2) when these have been flexed, it acts as an extensor of the foot upon the leg.

The muscle crosses behind the tibialis posticus obliquely from within outwards in the lower third of the leg. The tendon passes behind the internal malleolus and beneath the internal annular ligament, lying behind and slightly external to the tendon of the tibialis posticus, and occupying a special, purely fibrous compartment, in which it is invested by a distinct synovial sheath. It then enters the sole of the foot, where it passes forwards and outwards to the middle line, crossing beneath the tendon of the flexor longus hallucis, from which it receives a slip. On reaching the middle line it gives insertion to the flexor or musculus accessorius, and immediately afterwards it divides about the centre into four

tendons which, after having given origin to the four lumbricales muscles, go to the four outer toes. Each tendon, as it passes along the plantar surface of a toe, has a tendon of the flexor brevis digitorum lying close beneath it as far as the second phalanx, the two tendons occupying a fibro-osseous canal lined by a synovial membrane, which furnishes a separate investment to each tendon. Opposite the first phalanx the brevis tendon divides into two parts, and the longus tendon passes through the cleft thus formed (hence the name flexor perforans) on its way to the distal phalanx. The fibro-osseous canals and their synovial membranes, with the vincula accessoria tendinum of the latter, namely, ligamenta brevia and ligamenta longa, correspond with those of the fingers.

In the leg the muscle occupies a fibro-osseous canal formed by intermuscular septa and the posterior surface of the shaft of the tibia.

Tibialis Posticus—*Origin*.—(1) The outer division of the posterior surface of the shaft of the tibia, extending as high as the commencement of the oblique or popliteal line, and ceasing just below the centre of the bone; (2) the posterior surface of the interosseous membrane, except the lower 2 inches; (3) the internal surface of the shaft of the fibula; (4) the posterior or transverse intermuscular septum, as it covers the muscle; and (5) the intermuscular septa on either side, separating it from the flexor longus digitorum internally and the flexor longus hallucis externally.

Insertion.—The tuberosity of the navicular or scaphoid bone. From this insertion eight expansions are given off. One passes backwards to the anterior part of the under surface of the sustentaculum tali of the os calcis. The other seven pass forwards, and are attached as follows: three to the internal, middle, and external cuneiform bones, one to the cuboid bone, and three to the bases of the second, third, and fourth metatarsal bones, all on their plantar aspects.

Nerve-supply.—The posterior tibial nerve.

Action.—(1) The muscle inverts the sole of the foot; (2) it is an extensor of the foot upon the leg; and (3) it contributes in a material degree to the support of the longitudinal arch of the foot, and so helps to guard against the condition known as *flat foot*, being in this respect auxiliary to the inferior or internal calcaneo-navicular or spring ligament.

In the lower third of the leg the muscle passes obliquely inwards in front of the flexor longus digitorum. The tendon passes through the groove behind the internal malleolus, where it is beneath the internal annular ligament, occupying one of the fibro-osseous canals, and having the tendon of the flexor longus digitorum (enclosed within its fibrous canal) lying behind and slightly external to it. In this part of its course the tendon has a special synovial investment, which is also prolonged forwards around it as far as the navicular bone. As it passes over the head of the astragalus and spring ligament it contains a sesamoid fibrocartilage.

The greater part of the muscle in the leg is contained in a fibro-osseous canal formed by the posterior or transverse intermuscular septum, the interosseous membrane, the intermuscular septa on either side, and the surfaces of the tibia and fibula from which it arises.

Flexor Longus Hallucis—*Origin*.—(1) The lower two-thirds of the posterior surface of the shaft of the fibula, except the last inch or more; (2) the postero-external intermuscular septum, which separates the muscle from the peroneus longus and peroneus brevis; (3) the intermuscular septum between it and the tibialis posticus; and (4) the posterior or transverse intermuscular septum, as it covers the muscle.

Insertion.—The plantar surface of the base of the distal phalanx of the great toe.

Nerve-supply.—The posterior tibial nerve.

Action.—(1) The muscle acts as a flexor of the distal phalanx of the great toe; (2) it is an extensor of the foot upon the leg; (3) it contributes to the support of the longitudinal arch of the foot; and (4) by means of the slip which it gives to the tendon of the flexor longus digitorum in the sole it is an auxiliary of that muscle, more especially in flexing the second and third toes.

The tendon passes through the groove on the back of the lower end of the tibia at its outer part, where it lies beneath the internal annular ligament, occupying one of the fibro-osseous canals, and having a special synovial investment. Beyond this point it passes in succession through the groove on the posterior border of the astragalus, and through that on the under surface of the sustentaculum tali of the os calcis. Each of these grooves is converted into a fibro-osseous canal by a fibrous expansion, and in each case the tendon has a synovial investment. In the sole the tendon is crossed superficially or inferiorly, and from within outwards, by that of the flexor longus digitorum, to which it gives a slip. In most cases this slip is incorporated with the long flexor tendons of the second and third toes (Turner). As it passes along the first phalanx it is contained in a fibro-osseous canal lined by synovial membrane, which also invests the tendon and gives rise to a ligamentum breve. In the leg the flexor longus hallucis is contained within a fibro-osseous canal formed by intermuscular septa and the posterior surface of the shaft of the fibula.

Posterior Tibial Artery.—This vessel is the larger of the two terminal branches of the popliteal, the other being the anterior tibial. It commences at the lower border of the popliteus muscle on a level with the lower border of the tubercle of the tibia, fully $1\frac{3}{4}$ inches below the upper surface of the head of that bone, and it terminates at the lower border of the internal annular ligament by dividing into the internal and external plantar arteries. The termination of the vessel is situated midway between the inner part of the point of the heel and the tip of the internal malleolus. In the upper two-thirds of the leg it is deeply

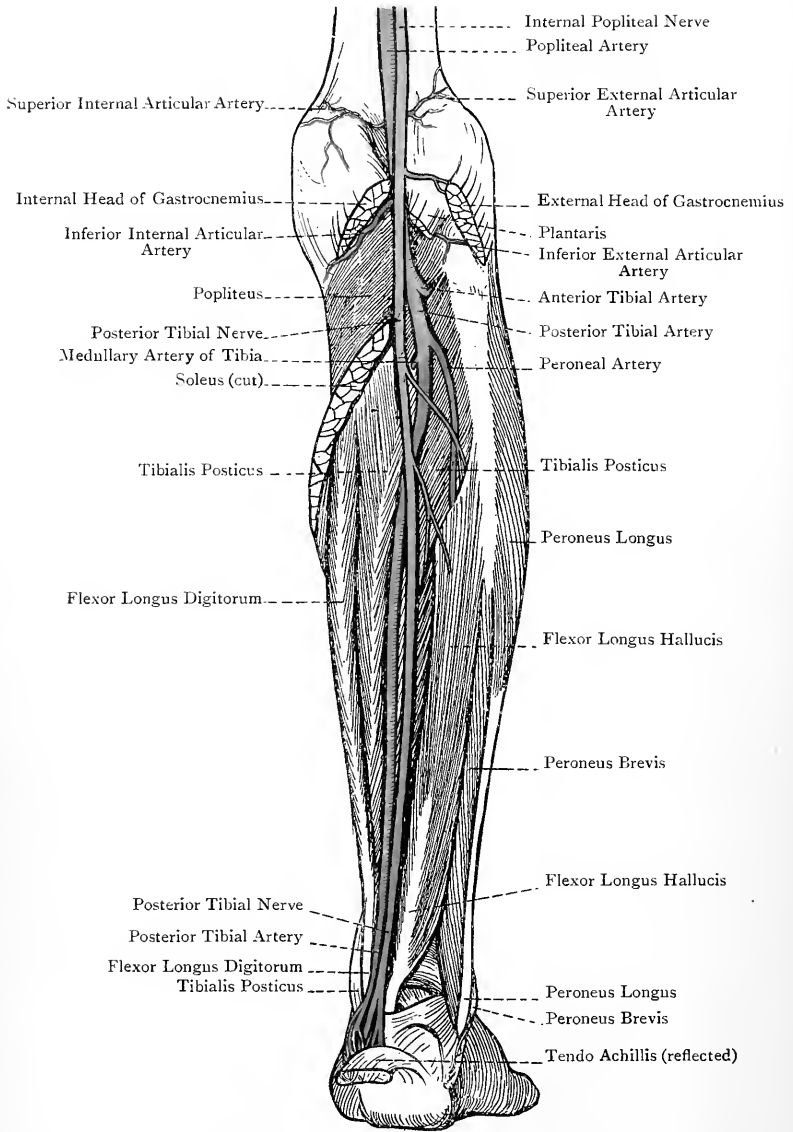


FIG. 243.—THE BACK OF THE RIGHT LEG (DEEP DISSECTION).

placed, being situated between the superficial and deep muscles, and over the interval between the tibia and fibula. It then inclines inwards, and in the lower third of the leg it lies over the back of the tibia and to the inner side of the tendo Achillis, where it is comparatively superficial. The course of the vessel may be indicated by drawing a line from the centre of the lower part of the popliteal space to a point midway between the inner part of the point of the heel and the tip of the internal malleolus.

Relations—*Superficial* or *Posterior*.—In the upper two-thirds the vessel lies beneath the gastrocnemius, soleus, and posterior or transverse intermuscular septum; and, in the lower third, it is covered by the skin, superficial fascia, deep fascia, and the internal annular ligament. *Anterior* or *Deep*.—The tibialis posticus (to which it is bound by the posterior or transverse intermuscular septum), flexor longus digitorum, posterior surface of the tibia, and internal lateral ligament of the ankle-joint (in this order from above downwards). *External*.—The tendo Achillis in the lower part of the leg. The artery in this part of its course lies about midway between the inner border of the tendo Achillis and the internal border of the tibia. As the vessel passes beneath the internal annular ligament it occupies a special fibro-osseous canal along with its venæ comites and the posterior tibial nerve, the latter being on the outer side. In this situation the tendons of the tibialis posticus and flexor longus digitorum lie on the inner side of these structures, and the tendon of the flexor longus hallucis on their outer side.

The artery is accompanied by two venæ comites, which closely embrace its sides, and communicate with each other at frequent intervals by transverse branches crossing superficial to the vessel. These venæ comites ultimately join to form one trunk, which unites with that formed by the junction of the venæ comites of the anterior tibial artery to form the popliteal vein, the union taking place at the lower border of the popliteus muscle. The posterior tibial nerve is at first internal to the artery for about $1\frac{1}{2}$ inches. It then crosses over the vessel just below the origin of the peroneal branch, and from this point onwards it lies on its outer side. Beneath the internal annular ligament the artery has frequently a nerve upon either side of it, an arrangement which is brought about by an early division of the posterior tibial nerve into its internal and external plantar branches.

Branches.—These are as follows: peroneal, muscular, medullary or nutrient, cutaneous, communicating, internal malleolar, internal calcaneal, and terminal.

The description of the peroneal artery, from its large size and numerous branches, will be deferred to the last.

The **muscular branches** are numerous, and are distributed to the deep group of muscles and to the soleus.

The **medullary** or **nutrient artery** is the largest of all the arteries bearing that name. Arising from the upper part of the posterior

tibial, it pierces the tibialis posticus and enters the medullary foramen of the tibia, accompanied by the medullary branch of the nerve to the popliteus.

The **cutaneous branches** are distributed to the integument of the inner and back part of the leg.

The **communicating branch** arises about an inch above the ankle-joint. It passes transversely outwards between the tibia and flexor longus hallucis, and anastomoses with the communicating branch of the peroneal artery.

The **internal malleolar branches** are usually two in number. Passing inwards beneath the tendons of the flexor longus digitorum and tibialis posticus, they reach the front of the internal malleolus, where they take part in the internal malleolar anastomosis.

The **internal calcaneal branch** arises beneath the internal annular ligament, which it pierces near the lower border to be distributed over the inner surface of the os calcis, where it anastomoses with the internal calcaneal branches of the external plantar artery.

The **terminal branches** are the internal and external plantar arteries, which will be afterwards described.

Peroneal Artery.—This vessel, which is of large size, arises from the posterior tibial fully 1 inch below its commencement. It is at first directed downwards and outwards over the tibialis posticus to the back of the fibula. Having reached that bone, it descends along its posterior surface close to the postero-internal border, lying between the bone and the flexor longus hallucis, or within that muscle, or in a fibrous canal between that muscle and the tibialis posticus. About 2 inches above the ankle-joint it escapes from beneath the flexor longus hallucis, and divides into anterior and posterior peroneal arteries.

Branches.—The branches are as follows: muscular, medullary or nutrient, cutaneous, communicating, and terminal.

The *muscular branches* are distributed to the adjacent muscles.

The *medullary or nutrient artery* enters the medullary foramen of the fibula.

The *cutaneous branches* are distributed to the integument on the outer and back part of the leg.

The *communicating branch* arises about 1 inch above the ankle-joint. It passes transversely inwards and anastomoses with the communicating branch of the posterior tibial artery.

The *terminal branches* are the anterior peroneal and posterior peroneal.

The *anterior peroneal artery* arises from the peroneal artery near the lower part of the interosseous membrane, and passes forwards through the inferior hiatus in it. Having reached the front of the leg, it descends under cover of the peroneus tertius, and takes part in the external malleolar anastomosis, along with the external malleolar of the anterior tibial, the external tarsal of the dorsalis pedis, and the posterior peroneal.

The *posterior peroneal artery* is the continuation of the peroneal artery. It passes behind the external malleolus, and along the outer border of the foot for a variable distance. Its branches are chiefly distributed over the outer surface of the os calcis, and these external calcaneal branches take part in the external malleolar anastomosis. Over the prominence of the heel they anastomose freely with the internal calcaneal branches of the external plantar, and on the outer border of the foot the posterior peroneal again anastomoses with branches of the external plantar.

The peroneal artery is accompanied by two *venæ comites*, which ultimately join the posterior tibial *venæ comites*.

Varieties of the Posterior Tibial Artery.—The vessel is sometimes very small, in which cases the peroneal artery is of large size, as well as the communicating branch normally given off about 1 inch above the ankle-joint, and so the small posterior tibial artery is reinforced. In rare cases the vessel does not reach the ankle, and it may even be entirely absent, in which cases there is always a large peroneal artery to make good the deficiency.

Varieties of the Peroneal Artery.—The level at which this vessel arises from the posterior tibial is subject to variety. Its normal origin is fully 1 inch below the commencement of the posterior tibial, but it may arise lower down or higher up, or it may even spring from the popliteal, or from the anterior tibial. In some cases it is of large size, in order to compensate for a small posterior tibial. In other cases the peroneal artery may stop short of the ankle, its place being taken by a branch of the posterior tibial. The anterior peroneal branch is sometimes of large size, in order that it may reinforce a small anterior tibial, or even furnish the *dorsalis pedis* artery.

Posterior Tibial Nerve.—This nerve is the continuation of the internal popliteal. It commences at the lower border of the popliteus muscle, and its normal termination corresponds with the lower border of the internal annular ligament, where it divides into internal and external plantar nerves. The division, however, frequently takes place at the upper border of the internal annular ligament, or as the nerve passes beneath it. The nerve closely accompanies the posterior tibial artery throughout the whole of its course. It lies at first on the inner side of the artery, with the intervention of the internal *vena comes*, but it only maintains this position for about $1\frac{1}{2}$ inches. It then crosses over the vessel, and descends upon its outer side, the external *vena comes* intervening. The general relations of the nerve are similar to those of the corresponding artery.

Branches.—These are muscular, fibular, calcaneo - plantar, articular, and terminal.

The **muscular branches** are given off from the upper part of the nerve, and supply the flexor longus digitorum, tibialis posticus, flexor longus hallucis, and soleus, the branch to the last muscle entering it on its deep or anterior surface near the centre of the leg.

The **fibular branch** is a long nerve which is usually associated at its origin with the branch to the flexor longus hallucis. It accompanies the peroneal artery, and furnishes (1) a medullary

branch, which goes with the medullary artery into the interior of the fibula; (2) periosteal branches to the fibular periosteum; and (3) twigs to the coats of the peroneal artery.

The **calcaneo-plantar branch** arises from the posterior tibial whilst it is beneath the internal annular ligament. Having pierced the ligament, it divides into internal calcaneal and plantar branches. The former supply the integument of the inner side of the heel, and the latter are the cutaneous nerves of the inner and posterior part of the sole.

The **articular branches**, two or three in number, arise from the posterior tibial close to its termination, and enter the ankle-joint on its inner aspect by piercing the internal lateral ligament.

The **terminal branches** are the internal plantar and external plantar nerves, which will be afterwards described.

THE KNEE-JOINT.

The knee-joint belongs to the class **diarthrosis**, and to the subdivision **ginglymus**. Though the chief movements are flexion and extension, there is also a certain amount of gliding or to and fro movement, as well as rotation. The joint, therefore, partakes of the nature of an **arthrodial joint**. It is really made up of three joints, namely, one into which the patella and the patellar surface of the femur enter (femoro-patellar), and other two into each of which a femoral condyle and a tibial condylar surface enter (femoro-tibial). These three joints in man communicate freely with one another.

The articular surfaces are (1) the condyles and patellar surface of the femur, (2) the upper three-fourths of the posterior surface of the patella, and (3) the condylar articular surfaces of the tibia.

The ligaments are divided into two groups, external and internal.

1. **External Ligaments.**—These are as follows: anterior or ligamentum patellæ, posterior, external lateral, internal lateral, and capsular.

The **anterior ligament** or **ligamentum patellæ** is attached superiorly to the apex and adjacent margins of the lower part of the patella, and inferiorly to the lower rough portion of the tubercle of the tibia, a bursa intervening between it and the upper smooth portion of the tubercle. It is a very strong, flat, broad ligament, the lateral margins of which are connected with the lateral patellar ligaments.

The **posterior ligament** is really a part of the capsular ligament. It covers the back parts of the femoral condyles, and extends between the external and internal lateral ligaments. Superiorly it is attached to the upper margin of the intercondylar

fossa, and at either side of this to the back of the femur immediately above each condyle. Inferiorly it is attached to the posterior border of the head of the tibia. It constitutes a broad membranous ligament, which in itself is thin, but it receives a considerable accession of fibres from the tendon of the semimembranosus. These fibres form a strong prominent bundle, which represents one mode of insertion of that muscle, and is known as the *ligamentum*

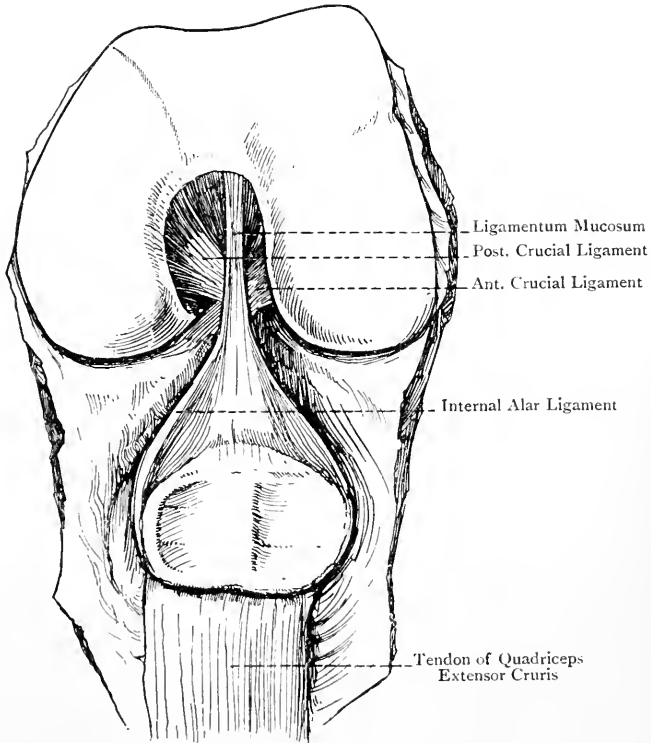


FIG. 244.—INTERIOR OF THE LEFT KNEE-JOINT
(ANTERIOR VIEW).

posticum Winslowii. It is directed upwards and outwards from the tendon of the semimembranosus towards the outer condyle of the femur and outer head of the gastrocnemius. Internally the posterior ligament blends with the internal lateral ligament, and externally (regarding it as a part of the capsular ligament) it sends an expansion over the long external lateral ligament. The posterior ligament presents a number of openings for the passage of nutrient vessels and nerves, the largest of these being at its centre for the

azygos artery, accompanied by a branch of the internal popliteal nerve and, it may be, the geniculate branch of the obturator nerve. At the outer part of the ligament there is a special opening for the tendon of the popliteus. Another opening is frequently present over the upper and back part of the inner condyle, and, when this is so, the popliteal bursa between the semimembranosus and the inner head of the gastrocnemius communicates with the synovial membrane of the joint. The upper and outer part of

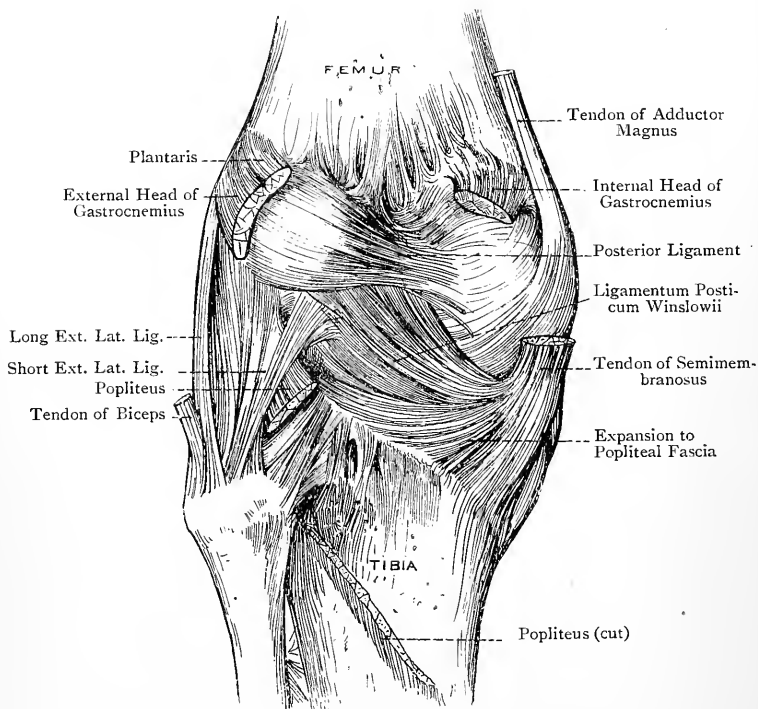


FIG. 245.—THE LEFT KNEE-JOINT (POSTERIOR VIEW).

the posterior ligament gives origin to some of the fibres of the plantaris.

The **external lateral ligament** consists of two divisions—*anterior* and *posterior*. The anterior division is the proper external lateral ligament, and is known as the *long external lateral ligament*. It is firm and cord-like, and passes vertically downwards, lying clear of the joint. It is attached superiorly to the external tuberosity of the femur, and inferiorly to the outer margin of the head of the fibula about $\frac{1}{2}$ inch anterior to the styloid process. The ligament crosses the tendon of the popliteus, and, near the head of the fibula,

it pierces the tendon of the biceps femoris, being there provided with a synovial investment. The inferior external articular vessels and nerve pass beneath it. The long external lateral ligament represents the original tendon of origin of the peroneus longus from the femur. The posterior division of the ligament, which is known as the *short external lateral ligament*, lies a little behind the long, and is not well defined. If distinct, it is attached above to the external condyle close to the outer head of the gastrocnemius, where it blends with the posterior ligament, its inferior attachment being to the styloid process of the fibula. Its direction is downwards and forwards, and it is to be regarded as an expansion in that direction of the posterior ligament.

The **internal lateral ligament** is a long, flat, strong band of unequal width, being broader at the centre than at either end. It is attached superiorly to the internal tuberosity of the femur, and inferiorly to the internal border and adjacent part of the internal surface of the shaft of the tibia, extending from the internal tuberosity downwards for fully 3 inches. Its posterior border covers the chief part of the tendon of the semimembranosus, and blends with the posterior ligament. As the ligament passes over the inner side of the knee-joint it is closely adherent to the internal semilunar fibro-cartilage, and, lower down, the inferior articular vessels and nerve pass beneath it. The internal lateral ligament represents the original insertion of the adductor magnus into the tibia.

The **capsular ligament** is formed to a large extent by expansions derived from the tendons of the vastus externus, vastus internus, sartorius, and semimembranosus, and from the fascia lata. It surrounds the joint except above the patella, where its place is taken by the suprapatellar tendon. The posterior part of the capsule, which forms the posterior ligament, is specially strong, being reinforced by the ligamentum posticum Winslowii. In other situations it is comparatively thin. It furnishes a thin expansion over the ligamentum patellæ, and on either side of the patella it forms the lateral patellar ligaments. Externally, where it is closely incorporated with the ilio-tibial band of the fascia lata, it covers the long external lateral ligament. Internally, where it receives accessions of fibres from the sartorius and semimembranosus, it blends with the internal lateral ligament.

The **lateral patellar ligaments** are two in number, external and internal, and they take the form of flat membranous bands, sometimes called the *retinacula*. The *external* extends between the outer border of the patella and the anterior margin of the outer tuberosity of the tibia. It is intimately connected with, and in part formed by, the ilio-tibial band of the fascia lata. The *internal* extends between the inner border of the patella and the anterior margin of the inner tuberosity of the tibia.

2. **Internal Ligaments.**—The internal ligaments, properly so called, are as follows: the two crucial ligaments; the two

semilunar fibro-cartilages, with their coronary ligaments; and the transverse ligament. There are other structures, within the joint, designated as ligaments, namely, the ligamentum mucosum and ligamenta alaria; but, as these are merely folds of the synovial membrane, they will be described in connection with it.

Crucial Ligaments. — These are two in number, anterior or external, and posterior or internal, and they bind the condyles of the femur to the head of the tibia. They are very powerful, somewhat round bundles situated in the centre of the joint, and so disposed as to form a cross.

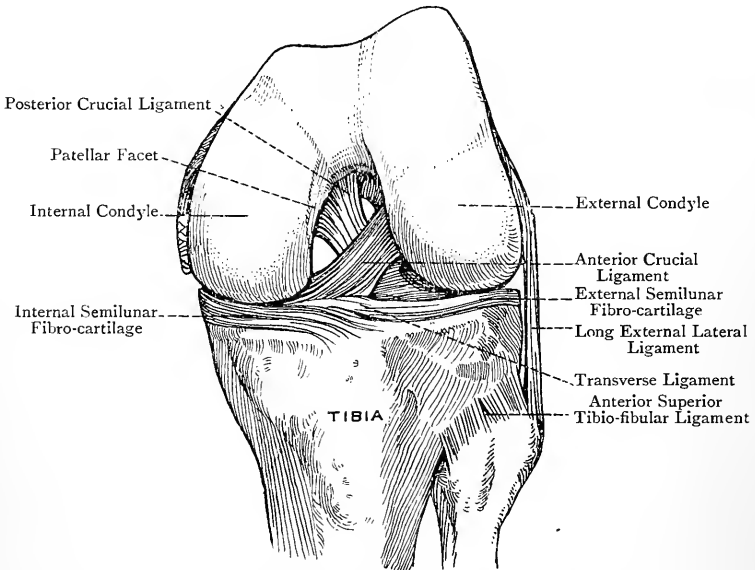


FIG. 246.—THE CRUCIAL LIGAMENTS OF THE LEFT KNEE-JOINT (ANTERIOR VIEW).

The *anterior* or *external crucial ligament* is attached inferiorly to the inner part of the rough depression on the upper surface of the head of the tibia in front of the inner tubercle of the spine. Superiorly it is attached to the depression on the posterior part of the internal surface of the external condyle of the femur. Its direction is upwards, backwards, and outwards. At its tibial attachment it has the anterior cornu of the internal semilunar fibro-cartilage in front of it, and the anterior cornu of the external semilunar fibro-cartilage behind and to its outer side. The anterior crucial ligament is tense in extension of the knee-joint, and prevents over-extension. It is also tense in internal rotation of the leg. The ligament is at one period the internal lateral ligament of the external femoro-tibial joint.

The *posterior* or *internal crucial ligament* is attached inferiorly to the back part of the rough depression on the head of the tibia behind the spine, and to the popliteal notch. Superiorly it is attached to the anterior part of the external surface of the internal condyle of the femur, close to the front part of the intercondylar fossa, upon which it slightly encroaches. Its direction is upwards, forwards, and slightly inwards. It is stronger, but shorter, than the anterior crucial ligament, and is not so oblique. At its tibial

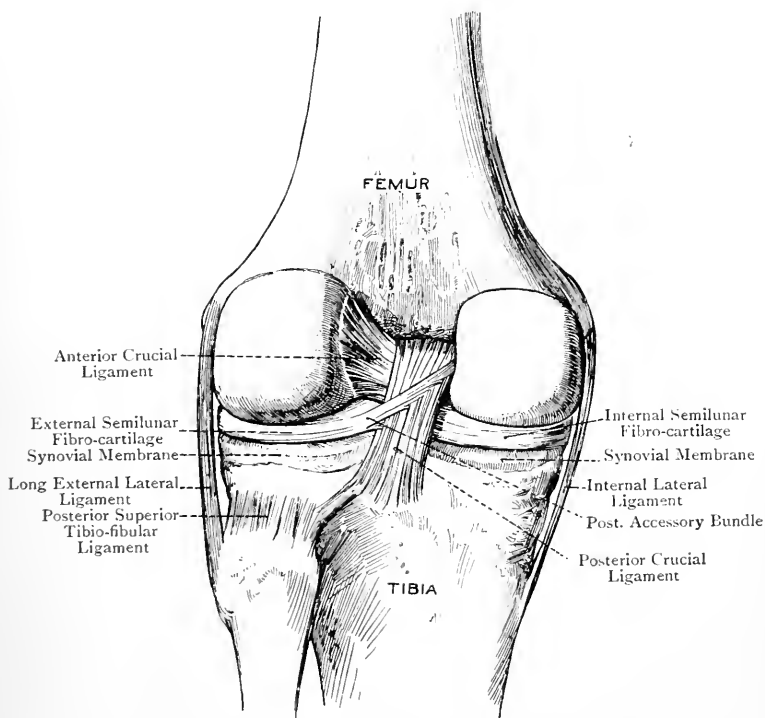


FIG. 247.—THE CRUCIAL LIGAMENTS OF THE LEFT KNEE-JOINT (POSTERIOR VIEW) (AFTER SPALTEHOLZ).

attachment it is behind the posterior cornua of both semilunar fibro-cartilages, the posterior cornu of the internal one being more immediately in front of it and to its inner side.

The posterior crucial ligament is tense in flexion of the knee-joint, and checks over-flexion. It is at one period the external lateral ligament of the internal femoro-tibial joint.

Two views may be stated as to the origin of the crucial ligaments. (1) According to Keith, they are originally parts of the capsule of the knee-joint, but have become separated from that structure as the result of the

outgrowth of the condyles of the femur. (2) According to Bland-Sutton, they are modifications of muscles, but there are no certain facts as to which muscles they originally belonged.

The **semilunar fibro-cartilages** are two in number—**internal** and **external**. They are lunated plates, of very firm consistence, which are placed upon the peripheral parts of the condylar articular surfaces of the tibia so as to deepen them for the reception of the condyles of the femur. They also serve as cushions, which mitigate pressure and diminish shock. Each presents two surfaces, superior and inferior; two borders, outer and inner; and two extremities or cornua, anterior and posterior. The superior surface is slightly concave to adapt itself to a femoral condyle, being sloped from the outer to the inner border. The inferior surface is flat, and rests upon a condylar surface of the tibia at its circumference. Both these surfaces are covered by the synovial membrane of the joint. The outer border is convex and thick, and it is attached to the margin of the corresponding tuberosity of the tibia by fibres which are really a part of the capsular ligament, but which have received the name of coronary ligament (one for each fibro-cartilage). The external semilunar fibro-cartilage is more loosely attached in this manner than the internal. Partly on this account, and partly by reason of the close proximity of its two cornua, the external fibro-cartilage is more movable than the internal. The inner border of each fibro-cartilage is very thin, sharp, and concave. It is quite free, and covered by the synovial membrane.

The extremities or **cornua** are thin fibrous bands, which have the following attachments: the anterior cornu of the *internal* semilunar fibro-cartilage is attached to the rough depression in front of the spine of the tibia at its anterior and inner part; or, to put it in another way, it is attached to the upper surface of the head of the tibia in front, and to the outer side, of the internal condylar surface. It has the anterior crucial ligament directly behind it. The posterior cornu is attached to the inner part of the rough depression behind the spine of the tibia, where it has the posterior crucial ligament behind it. The internal semilunar fibro-cartilage is semicircular, and may be likened to the capital letter **C**, its cornua being wide apart, and embracing between them the cornua of the external semilunar fibro-cartilage. It is intimately connected with the internal lateral ligament.

The anterior cornu of the *external* semilunar fibro-cartilage is attached to the head of the tibia immediately in front of the outer tubercle of the spine, where it is placed on the outer side of and behind the anterior crucial ligament. The posterior cornu is attached to the rough depression between the two tubercles of the spine, and also to a depression immediately behind the outer tubercle. The external semilunar fibro-cartilage is almost circular, thus **O**, its cornua being very close together, and being embraced by the cornua of the internal semilunar fibro-cartilage. The pos-

terior and outer aspect of the external semilunar fibro-cartilage is grooved by the tendon of the popliteus, and this tendon separates it from the long external lateral ligament, whilst posteriorly it is connected with the posterior ligament.

The semilunar fibro-cartilages move forwards when the knee-joint is extended, and backwards when it is flexed, the external more so than the internal.

The so-called **coronary ligaments** are really portions of the capsular ligament. They represent fibres which connect the outer convex borders of the semilunar fibro-cartilages to the margins of the tuberosities of the tibia, more loosely in the case of the external than the internal.

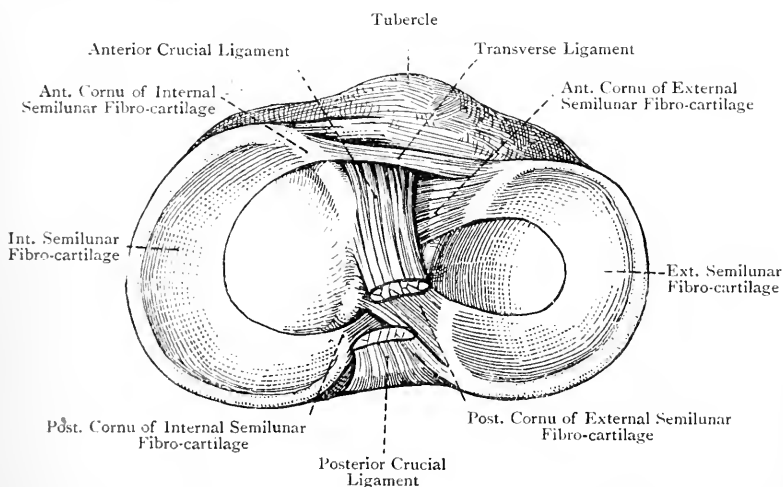


FIG. 248.—THE LIGAMENTS AND FIBRO-CARTILAGES ON THE HEAD OF THE RIGHT TIBIA.

In connection with the external semilunar fibro-cartilage there are two **accessory bundles**, anterior and posterior. The posterior bundle extends from the back part of the external semilunar fibro-cartilage to the external surface of the internal condyle of the femur, where it is attached close to the posterior crucial ligament. It is thick and strong, and may be double, in which case the two bundles are disposed one in front of, and the other behind, the posterior crucial ligament. If single it may be in front of that ligament, or behind it, and it may be closely connected with the tibial attachment of the ligament. It serves as a kind of anchor to the back part of the external semilunar fibro-cartilage, and so prevents too much displacement of it during rotation. The anterior bundle constitutes the transverse ligament.

The external semilunar fibro-cartilage is to be regarded as originating from the biceps femoris, and the internal from the semimembranosus, certain textural alterations having taken place in the course of the metamorphosis.

The **transverse ligament** is a narrow band which extends from the front of the external semilunar fibro-cartilage to the

front of the internal. It prevents the front part of the external semilunar fibro-cartilage from moving too far backwards during flexion of the joint.

The **synovial membrane** invests the inner surface of the capsular ligament. On reaching the semilunar fibro-cartilages it is reflected over their upper and under surfaces, and is then conducted by the coronary ligaments to the margins of the tuberosities of the tibia. Between the front of the head of the tibia and the patella the membrane covers a collection of fat, known as the **infrapatellar**

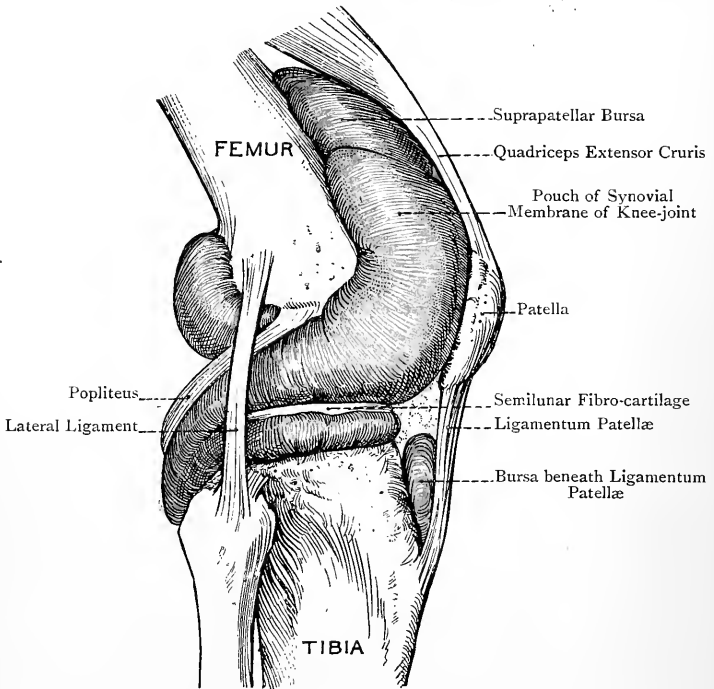


FIG. 249.—THE SYNOVIAL MEMBRANE OF THE RIGHT KNEE-JOINT (EXTERNAL VIEW) (AFTER SPALTEHOLZ).

pad, and in this situation it is raised into certain folds, called ligaments, namely, the **ligamentum mucosum** and **ligamenta alaria**, to be presently described. Above the patella the membrane extends upwards in the form of a large pouch upon the front of the shaft of the femur for about 2 inches above the upper border of the patellar surface of the bone. This pouch lies beneath the suprapatellar tendon of the quadriceps extensor cruris, and communicates with the suprapatellar bursa, which is situated immediately above it, and which extends upwards for about 1 inch beneath the suprapatellar tendon.

From the posterior ligament the synovial membrane is reflected forwards in the form of two laminae, one of which passes over the outer surface of the anterior crucial ligament, and the other over the inner surface of the posterior crucial ligament. After having done so, these two laminae become continuous with each other in front of the crucial ligaments. It will thus be evident that the following parts of these ligaments are destitute of synovial membrane: (1) the posterior surface of each ligament, and (2) that part of the anterior surface of the posterior ligament which is in contact with the anterior ligament.

In connection with the posterior ligament of the knee-joint it is to be noted that there is a narrow median vertical zone which is destitute of synovial membrane, on account of the forward reflection of that membrane in two laminae. This interlaminar zone is covered by a certain amount of fat.

The synovial membrane furnishes an investment to the tendon of the popliteus, which separates that tendon from the long external lateral ligament. This prolongation also extends in a downward direction between the posterior part of the external semilunar fibro-cartilage and the outer tuberosity of the tibia, so as to facilitate the movement of the tendon of the popliteus at that point. It may extend so far down as to become continuous with the synovial membrane of the superior tibio-fibular joint. At the back of the joint the synovial membrane frequently communicates with the popliteal bursa between the semimembranosus and inner head of the gastrocnemius.

The synovial membrane, as it covers the infrapatellar pad of fat, forms three folds—the *ligamentum mucosum* and *ligamenta alaria*. The **ligamentum mucosum**, which contains a little fat, extends backwards to be attached to the front part of the intercondylar fossa of the femur. It is narrow and pointed at its femoral attachment, but over the infrapatellar pad of fat it widens out and becomes triangular. The lateral borders of this latter part of the *ligamentum mucosum* constitute the so-called **ligamenta alaria**, which extend for a short distance in an upward direction along the lateral margins of the patella.

The *ligamentum mucosum*, which serves to adjust the infrapatellar pad of fat to the different positions of the joint, is the remains of the double synovial partition which originally separates the femoro-tibial articulations.

The **articular fat** forms two chief collections, called *infrapatellar* and *suprapatellar*, which represent the Haversian glands of the knee-joint. The *infrapatellar* pad is the larger of the two, and fills up the space between the lower end of the femur, the head of the tibia, and the patella with its ligament. It adapts itself to the different positions of the joint, and the *ligamentum mucosum* acts as its regulator. The *suprapatellar* pad is situated around the *suprapatellar* bursa and the pouch which the synovial membrane sends upwards above the patellar surface of the femur.

Muscular Relations.—The muscular relations are as follows :

Anterior.—The quadriceps extensor cruris.

External.—The biceps femoris.

Posterior.—The popliteus, plantaris, and outer head of the gastrocnemius externally, and the inner head of the gastrocnemius and semimembranosus internally.

Internal.—The sartorius, gracilis, semitendinosus, and semimembranosus.

Arterial Supply.—The joint receives its arterial supply from the following sources : (1) the long descending branch of the external circumflex of the arteria profunda femoris ; (2) the deep branch of

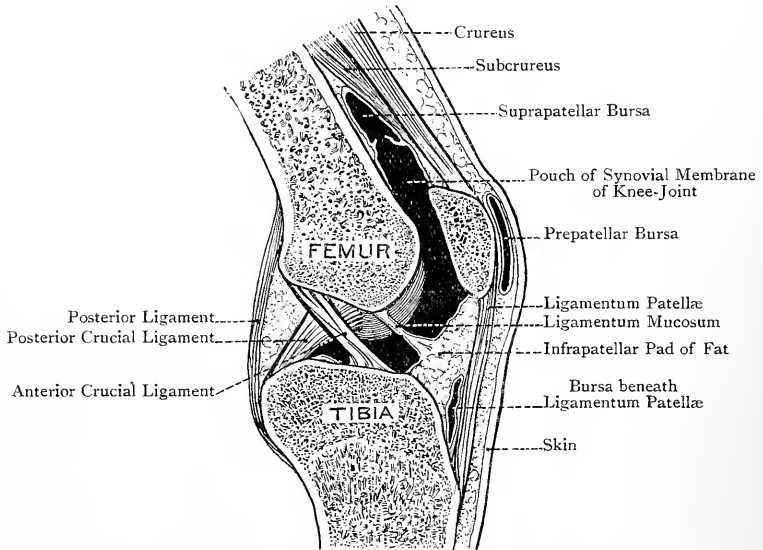


FIG. 250.—SAGITTAL SECTION OF THE RIGHT KNEE-JOINT, VIEWED FROM THE OUTER SIDE.

the anastomotica magna of the superficial femoral ; (3) the superior and inferior external and internal articular and the central or azygos articular branches of the popliteal ; and (4) the anterior tibial recurrent and posterior tibial recurrent (inconstant) branches of the anterior tibial.

Nerve-supply.—The joint receives its nerves from the following sources : (1) the external and internal popliteal, both from the great sciatic ; (2) the anterior crural ; and (3) the obturator.

The **external popliteal nerve** furnishes three articular branches, one with the superior external articular artery, one with the inferior external articular, and a recurrent branch with the anterior tibial recurrent. The **internal popliteal nerve** furnishes three (sometimes

two) articular branches, one with the superior internal articular artery (inconstant), one with the central or azygos articular, and one with the inferior internal articular.

The **anterior crural nerve** furnishes articular branches as follows: (1) the nerve to the vastus externus furnishes one articular branch; (2) the most internal of the branches to the crureus furnishes another articular branch, which in its course supplies the subcrureus; and (3) the nerve to the vastus internus furnishes a third articular branch, which is of large size, and ultimately accompanies the deep branch of the anastomotica magna artery.

The **obturator nerve**, by its deep or posterior division, furnishes an articular branch called the geniculate nerve. This branch, however, may be absent.

If the nerve-supply of the knee-joint is compared with that of the hip-joint, it will be evident that there is a nervous sympathy between these two articulations.

Movements—Femoro-tibial Joints.—The movements between the condyles of the femur and the condylar articular surfaces of the tibia are of two kinds, namely, flexion and extension, and rotation, the latter movement being only possible when the knee-joint is flexed.

Flexion and Extension.—These movements are complicated by the spiral outline of the femoral condyles, and they partake partly of gliding and partly of rolling. During extension the two condyles move parallel to each other up to a certain stage, namely, towards the end of extension. When this stage has been reached, the anterior part of the outer condyle is in contact with the outer tibial articular surface. The inner condyle, however, being longer than the outer, continues to glide backwards so as to bring its oblique anterior part into contact with the inner tibial articular surface. The result is that the femur is rotated inwards on the tibia. Hence, at the very com-

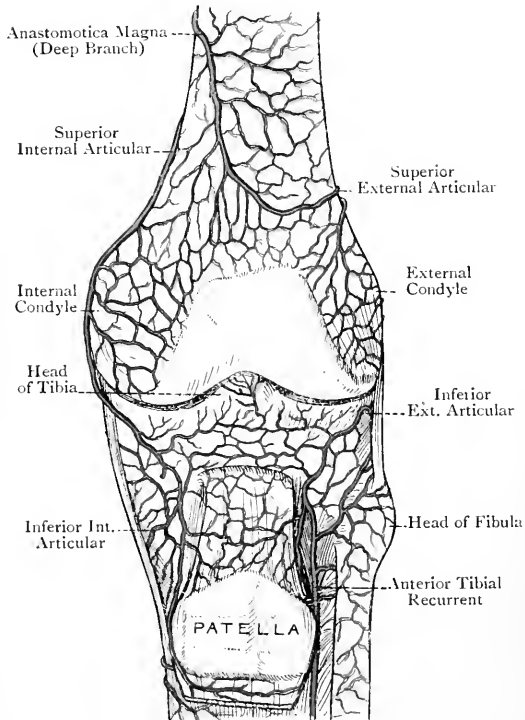


FIG. 251.—THE DEEP ANASTOMOSES ROUND THE KNEE-JOINT (ANTERIOR VIEW) (TIEDEMANN).

mencement of flexion, the femur is rotated outwards on the tibia. When the joint is completely extended, the following ligaments are rendered tense : (1) anterior crucial, (2) posterior ligament, and (3) long external lateral and internal lateral ligaments. Over-extension is checked (1) by the tightening of the anterior crucial, the posterior ligament, and the two lateral ligaments ; (2) by the anterior portions of the semilunar fibro-cartilages being pressed into the depressions of the femoral condyles ; (3) by the locking which takes place between the anterior crucial ligament and the front part of the intercondylar fossa ; and (4) by the locking which takes place between the inner depression of the outer femoral condyle and the front of the outer tubercle of the tibial spine (Bruce Young). At the end of extension the outer condyle pushes the anterior and inner part of the external semilunar fibro-cartilage over the anterior and inner border of the outer condylar surface of the tibia. When this has been done, the depression at the inner end of the groove on the outer condyle comes into contact with the front of the outer tubercle of the tibial spine, and with a special facet in front of that tubercle (at the anterior and inner part of the outer condylar surface of the tibia), and so the locking takes place.

In flexion of the knee-joint the external ligaments are relaxed, except the ligamentum patellæ. Over-flexion is checked by (1) the stretching of the quadriceps extensor cruris ; (2) the meeting of the fleshy parts of the calf and back of the thigh ; (3) the tightening of the posterior crucial ligament ; and (4) the extreme posterior and outer part of the inner condyle (which here presents a special facet) being pressed against the back part of the inner tubercle of the tibial spine (Cleland).

In extension of the joint the semilunar fibro-cartilages move forwards, and in flexion they move backwards.

Rotation.—This movement is impossible in extension of the knee-joint, owing to the tightening of the anterior crucial and the external ligaments, except the ligamentum patellæ. In semiflexion, however, a fair amount of rotation is allowed. Internal rotation is checked by the anterior crucial ligament, and external rotation by the internal lateral ligament.

The range of rotation is about 40 degrees. Assuming that all the muscles and external ligaments are cut, in which case the femur and tibia would be connected only by the crucial ligaments, if the femur is grasped firmly and the tibia rotated inwards the movement will be seen to be arrested by the tightening of the anterior crucial ligament. If, however, the tibia is rotated outwards neither crucial ligament interferes with the movement, so that the tibia can be made to describe half a circle, thus directing the front of the head of the bone backwards.

Muscles concerned in the Movements—Flexion.—The muscles which produce flexion are the biceps femoris, semitendinosus, semimembranosus, sartorius, gracilis, and popliteus. If the ankle-joint is fixed, the gastrocnemius, with the plantaris as a feeble auxiliary, acts as a flexor. **Extension.**—The chief extensor is the quadriceps extensor cruris. The gluteus maximus and tensor fasciæ femoris, however, take part in the completion of extension by means of the ilio-tibial band of the fascia lata. **Internal Rotation.**—This movement is produced by the popliteus, semitendinosus, semimembranosus, gracilis, and sartorius, in each case after flexion has been effected. **External Rotation.**—This movement is produced by the biceps femoris after it has flexed the joint.

Femoro-patellar Joint.—The movement at this joint is of a gliding or to-and-fro nature, associated with a certain amount of rolling of the patella, the result of which is to bring different parts of the opposed articular surfaces into contact in different positions of the joint. This combination of gliding and rolling constitutes the movement called **coaptation**. In extension of the knee, when the patella is drawn up by the quadriceps extensor cruris, the inferior pair of patellar facets are in contact with the upper part of the patellar surface of the femur. In semiflexion the middle pair of patellar facets are in contact with the middle part of the patellar surface of the femur. In ordinary flexion the upper pair of patellar facets are in contact with the

lower part of the patellar surface of the femur. In extreme flexion, as in the position assumed by the miner when at work, the patella is entirely off the patellar surface of the femur, and, being turned outwards by the internal condyle, the inner vertical facet of the patella articulates with the semilunar facet on the outer part of the tibial surface of the internal condyle close to the intercondylar fossa, and the upper and outer horizontal patellar facet is in contact with the front part of the external condyle of the femur. When the patella is turned inwards in extension of the joint, the outer lateral patellar ligament is put upon the stretch, and so prevents over-displacement inwards. When the patella is turned outwards in flexion by the internal condyle, the inner lateral patellar ligament is put upon the stretch, and so prevents over-displacement outwards.

When a person stands erect with both feet upon the ground, the vertical line of the centre of gravity falls in front of the axis of movement at the knee-joint. There is thus a tendency to over-extension, which, however, is resisted by the tension of the ligaments. In the erect attitude the knee-joint is, therefore, maintained in a state of extension to a large extent without muscular effort. This is proved by the fact that each patella is freely movable. When, however, one limb is raised from the ground, muscular effort now becomes necessary to maintain extension, and the patella of each limb becomes fixed. The *gluteus maximus* and *tensor fasciæ femoris* muscles, acting through the ilio-tibial band of the fascia lata, contribute to the maintenance of extension at the knee-joint, as in standing.

SOLE OF THE FOOT.

Landmarks.—Along the inner border of the foot there are several important bony landmarks which can be made out without much difficulty. The internal malleolus is a good starting-point. One inch below this projection the **sustentaculum tali** of the *os calcis* can be felt, and a little in front of it is the tuberosity of the navicular or scaphoid bone. The **navicular tuberosity** is situated about $1\frac{1}{2}$ inches in front of the internal malleolus, and on a lower level. The recess between the sustentaculum tali and the navicular tuberosity is bridged over by the spring ligament and the tendon of the *tibialis posticus*, the latter being the more superficial. Immediately in front of the navicular tuberosity the eminence on the plantar surface of the internal cuneiform bone may be felt, and anterior to it is the tuberosity on the plantar aspect of the proximal end of the first metatarsal bone. Along the outer border two projections can be felt, namely, the external malleolus and the tuberosity on the outer side of the proximal end of the fifth metatarsal bone.

The guide to the **astragalo-navicular joint** on the inner side of the foot is the tuberosity of the navicular bone, the joint being situated immediately behind that tuberosity. The guide to the **calcaneo-cuboid joint** on the outer side of the foot is a point midway between the external malleolus and the tuberosity on the outer side of the proximal end of the fifth metatarsal bone. The astragalo-navicular and calcaneo-cuboid joints lie in the same transverse plane, and are the joints at which disarticulation is performed in Chopart's operation. The guide to the joint between the internal

cuneiform and first metatarsal bones is a point $1\frac{1}{2}$ inches in front of the navicular tuberosity. This is to be remembered in connection with the tarso-metatarsal operations of Lisfranc and Hey. The joint between the cuboid and fifth metatarsal bones is situated immediately behind the tuberosity on the outer side of the proximal end of the fifth metatarsal bone.

The course of the **external plantar artery** is complicated by the fact that it first crosses the sole of the foot from within outwards, and afterwards from without inwards. The former course is indicated by a line drawn from a point midway between the inner part of the point of the heel and the tip of the internal malleolus to a point about 1 inch internal to the tuberosity on the outer side of the base of the fifth metatarsal bone. A line drawn from the latter point to the proximal part of the first interosseous space indicates the position of the artery as it recrosses the foot. To indicate the course of the **internal plantar artery** start from the same point as for the commencement of the external plantar vessel, and draw a line to the centre of the metatarso-phalangeal joint of the great toe.

The skin of the sole is characterized by great thickness over the bony prominences of the heel and balls of the toes, in which situations bursæ are frequently developed. The superficial fascia is coarse and granular. It forms a thick pad composed of lobules of fat, which lie between, and are supported by, processes of fibrous tissue passing between the skin and the plantar fascia.

Plantar Fascia or Aponeurosis.—The plantar fascia is connected to the skin by fibrous processes, which enclose and support the lobules of the superficial fascia, and it presents two longitudinal grooves, along the course of which intermuscular septa pass deeply into the sole. These grooves indicate the division of the plantar fascia into three portions—central and two lateral.

The **central division** covers the flexor brevis digitorum, and is of considerable strength. It is triangular, being somewhat pointed behind and expanded in front. Posteriorly, where it is narrow and thick, it is attached to the inner tubercle on the plantar aspect of the tuber calcis. From this point the fibres pass forwards towards the toes, the central division meanwhile widening out and becoming thinner. At the heads of the metatarsal bones it divides into five digital processes, one for each toe. The direction of its fibres is longitudinal—that is to say, they run from heel to toes, but towards the balls of the toes transverse fibres make their appearance. Moreover, in the webs of the toes there are other superadded transverse fibres, which constitute the *superficial transverse ligament*. This ligament arches over the digital vessels, nerves, lumbricales muscles, and digital processes. Each of the five digital processes forms an arch over the flexor tendons as these are about to pass to the plantar aspects of the toes. The final disposition of each process is as follows: (1) it is attached superficially to the skin; (2) it joins the vaginal ligament of the

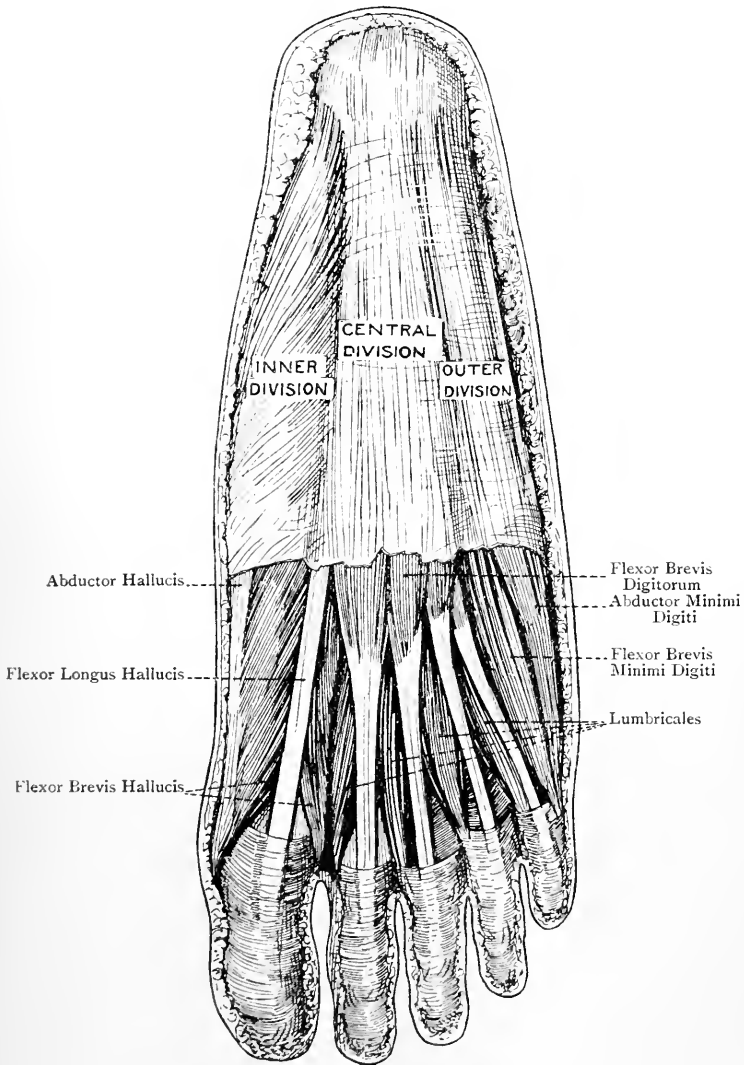


FIG. 252.—THE PLANTAR FASCIA, AND FIRST LAYER OF MUSCLES (IN PART).

flexor sheath anteriorly; and (3) at each side of the flexor tendons it sends a deep process upwards, which joins the transverse metatarsal (deep transverse) ligament connecting the heads of the metatarsal bones, and is also attached to the corresponding lateral metatarso-phalangeal ligament. There is thus formed a tunnel for the passage of the flexor tendons. The lumbricales muscles and the digital vessels and nerves make their appearance between the diverging digital processes. The central division contributes to the maintenance of the longitudinal arch of the foot by its tendency to approximate the toes to the heel. When it becomes contracted it gives rise to an exaggeration of the longitudinal arch, a condition known as pes cavus. Morphologically it represents the divorced plantar portion of the tendon of the plantaris.

The **external division** is weaker than the central. It is attached posteriorly to the outer tubercle on the plantar aspect of the tuber calcis, whence it passes forwards over the abductor minimi digiti muscle. Internally it is continuous with the central division along the line of attachment of the external intermuscular septum; externally it is continuous round the outer border of the foot with the deep fascia of the dorsum; and anteriorly, having become very thin, it is attached to the proximal end of the first phalanx of the little toe on its outer aspect. This division forms a specially strong band between the outer tubercle of the os calcis and the tuberosity on the outer side of the base of the fifth metatarsal bone, which is the remains of the *abductor ossis metatarsi quinti*, or Wood's muscle.

The **internal division** is the weakest of the three. It is attached posteriorly to the internal aspect of the inner tubercle on the plantar surface of the tuber calcis, and to the lower border of the internal annular ligament, whence it passes forwards over the abductor hallucis muscle. Externally it is continuous with the central division along the line of attachment of the internal intermuscular septum; internally it is continuous round the inner border of the foot with the deep fascia of the dorsum; and anteriorly, where it becomes very thin, it is attached to the proximal end of the first phalanx of the great toe on its inner aspect.

The **intermuscular septa** are two in number, external and internal, and they extend upwards into the sole at either side of the central division along the course of the longitudinal grooves. They are situated on either side of the flexor brevis digitorum, the *internal* septum lying between that muscle and the abductor hallucis, and the *external* septum intervening between it and the abductor minimi digiti. Each septum gives partial origin to the muscles between which it lies. The plantar fascia and the two intermuscular septa form three muscular compartments—inner, middle, and outer.

Cutaneous Nerves.—The cutaneous nerves are as follows:

calcaneo-plantar, branches of the internal plantar, and branches of the external plantar.

The **calcaneo-plantar nerve** is a branch of the posterior tibial whilst that nerve is beneath the internal annular ligament. Having pierced that ligament, the nerve divides into internal calcaneal and plantar branches. The former supplies the integument of the inner side of the heel, and the latter the inner and posterior part of the sole.

The plantar cutaneous branches of the internal plantar nerve appear along the groove between the abductor hallucis and flexor brevis digitorum, and, having pierced the plantar fascia, are distributed to the integument of the inner half of the sole.

The plantar cutaneous branches of the external plantar nerve appear along the groove between the flexor brevis digitorum and abductor minimi digiti, and, having pierced the plantar fascia, are distributed to the integument of the outer half of the sole.

It is to be noted that the integument of the outer side of the heel and outer border of the foot, including the outer side of the little toe, is supplied by the short saphenous nerve, the external branch of the musculo-cutaneous nerve also taking part in the supply of the outer border, whilst the integument of the inner border of the foot is supplied by the long saphenous, and by the internal branch of the musculo-cutaneous nerve.

The **cutaneous arteries** of the sole are branches of the internal and external plantar vessels, and in their course and distribution they accompany the corresponding cutaneous nerves. There is a very copious supply of arteries to the integument of the heel, represented by the internal calcaneal branches of the external plantar and posterior tibial arteries on the inner side, and the external calcaneal branches of the posterior peroneal artery on the outer side.

Superficial Veins.—The superficial veins are very numerous, and are for the most part arranged in the form of a plexus, which lies immediately beneath the skin. Besides this plexus, there is a transverse venous arch situated near the clefts of the toes. The destination of the venous blood of the plexus and transverse arch is the dorsum of the foot. The blood is conveyed away from the plantar subcutaneous plexus by anterior efferent and lateral efferent vessels. The anterior efferent vessels terminate in the transverse venous arch near the clefts of the toes. The lateral efferent vessels turn round the outer and inner borders of the foot, the external set terminating in the short saphenous vein, and the internal set in the long saphenous vein, just where these vessels are springing from the extremities of the dorsal venous arch. The transverse venous arch near the clefts of the toes receives the anterior efferent vessels of the plantar subcutaneous plexus, and the plantar digital veins. The blood is conveyed away from it by means of efferent veins, called *interdigital*, which pass upwards to the dorsum of the

foot, where they terminate in the dorsal venous arch. The superficial veins of the sole are all furnished with valves, which are so placed as to direct the flow of blood to the dorsum of the foot.

Muscles.—The muscles of the sole are divided into four layers—first, second, third, and fourth.

First Layer.—The first layer consists of the following three muscles, named in order from within outwards: abductor hallucis, flexor brevis digitorum, and abductor minimi digiti. All three lie immediately beneath the corresponding divisions of the plantar fascia, each muscle having a compartment to itself.

Abductor Hallucis—*Origin.*—The **outer head** arises from (1) the internal aspect of the inner tubercle on the plantar surface of the tuber calcis; (2) the deep surface of the internal division of the plantar fascia; and (3) the internal intermuscular septum, which separates it from the flexor brevis digitorum. The **inner head** arises from (1) the lower border of the internal annular ligament on its deep aspect; and (2) the fibrous structures along the adjacent part of the inner side of the sole, such as the tendon of the tibialis posticus and some of its expansions.

Insertion.—The tubercular enlargement on the inner side of the base of the first phalanx of the great toe.

Nerve-supply.—The internal plantar nerve.

Action.—(1) To abduct the great toe from the imaginary middle line of the foot, which passes through the centre of the second toe; and (2) to flex the metatarso-phalangeal joint of the great toe. The tendon of the muscle receives on its outer and deep aspect the fleshy inner head of the flexor brevis hallucis.

Flexor Brevis Digitorum (flexor perforatus)—*Origin.*—(1) The front of the inner tubercle on the plantar surface of the tuber calcis; (2) the deep surface of the central division of the plantar fascia; and (3) the intermuscular septum on either side.

Insertion.—By means of four tendons which go to the four outer toes, where each is inserted into the sides of the shaft of the second phalanx at its centre and on its plantar aspect.

Nerve-supply.—The internal plantar nerve.

Action.—(1) To flex the second phalanges of the four outer toes, and (2) to flex the metatarso-phalangeal joints.

Each tendon, as it passes along the plantar surface of a toe, has a tendon of the flexor longus digitorum above it as far as the second phalanx, the two tendons occupying a fibro-osseous canal lined by a synovial membrane which furnishes a separate investment for each tendon. Opposite the first phalanx the brevis tendon divides into two parts, and the longus tendon passes through the cleft thus formed; hence the name *flexor perforatus* for the brevis muscle. Thereafter the two divisions of the brevis tendon unite by their adjacent margins on the upper or deep surface of the longus tendon, but they soon separate and take insertion into the sides of the shaft of the second phalanx at its centre and on its plantar aspect. Each brevis tendon has a ligamentum breve

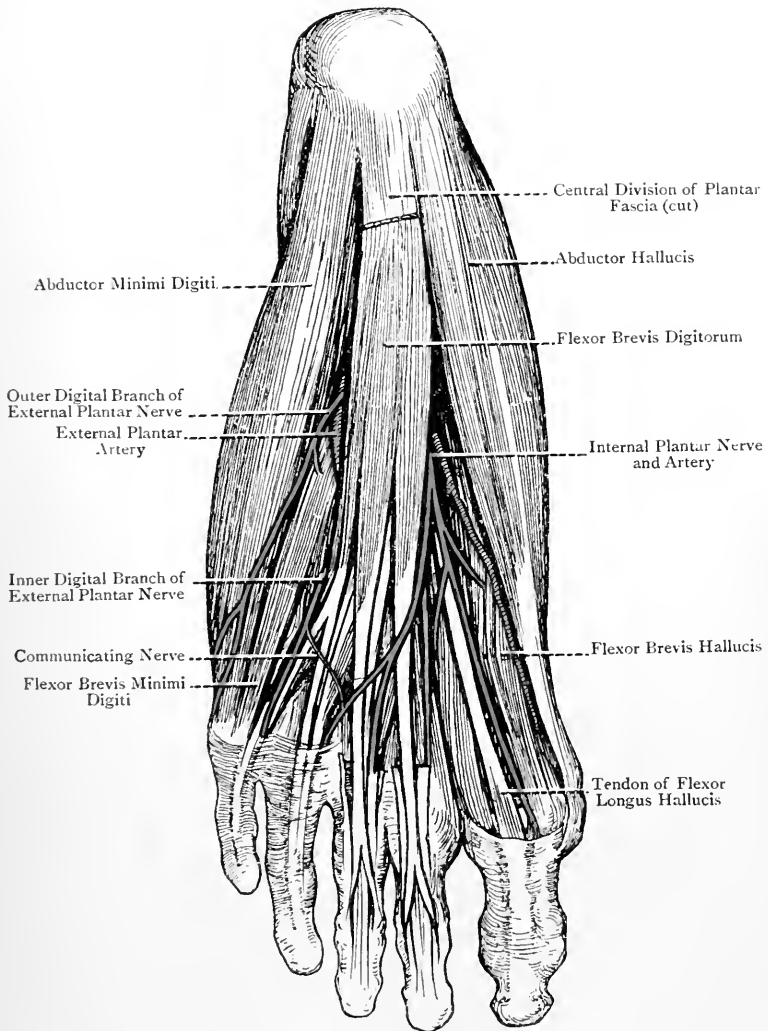


FIG. 253.—THE FIRST LAYER OF PLANTAR MUSCLES (LEFT FOOT).

which passes between its upper surface near its final division and the distal end of the first phalanx. The fibrous sheaths of the tendons, as they pass along the plantar aspects of the toes, as well as the accessories of these sheaths, correspond with those of the fingers. As the long and short flexor tendons are about to pass to the plantar aspects of the respective toes, and before entering the fibro-osseous canals, each pair of tendons passes through a short fibrous tunnel, corresponding in position with the balls of the toes, and constructed in the following manner: superiorly or deeply it is formed by a portion of the transverse metatarsal ligament; inferiorly or superficially by a digital process of the central division of the plantar fascia; and on either side by the deep expansion of the digital process which joins the transverse metatarsal ligament and lateral metatarso-phalangeal ligament.

Abductor Minimi Digiti—*Origin*.—(1) The outer side and front of the outer tubercle on the plantar aspect of the tuber calcis; (2) the front of the inner tubercle; (3) the external intermuscular septum; and (4) the external division of the plantar fascia, more particularly the strong band which extends between the outer tubercle of the os calcis and the tuberosity on the outer side of the base of the fifth metatarsal bone.

Insertion.—The outer side of the base of the first phalanx of the little toe, in conjunction with the flexor brevis minimi digiti. It often takes attachment also to the base of the fifth metatarsal bone on the outer aspect of its plantar surface.

Nerve-supply.—The external plantar nerve.

Action.—(1) To abduct the little toe, and (2) to flex its metatarso-phalangeal joint.

Occasionally a fourth muscle is met with in the first layer, called the **abductor ossis metatarsi quinti** or Wood's muscle. It *arises* from the outer tubercle on the plantar aspect of the tuber calcis, and from the adjacent portion of the plantar fascia, and it is *inserted* into the tuberosity on the outer side of the base of the fifth metatarsal bone. In most cases, however, this muscle has undergone degeneration, and is only represented by the strong band of the external division of the plantar fascia, which extends between the outer calcaneal tubercle and the tuberosity on the outer side of the base of the fifth metatarsal bone.

Second Layer.—This layer consists partly of tendons and partly of muscles. They are as follows: the tendon of the flexor longus hallucis; the tendon of the flexor longus digitorum; the flexor or musculus accessorius; and the lumbricales.

Tendons of Flexor Longus Hallucis and Flexor Longus Digitorum.—The tendon of the flexor longus hallucis, after leaving the groove on the under surface of the sustentaculum tali of the os calcis, is directed forwards and inwards, lying in its course between the two heads of the flexor brevis hallucis, and the tendon of the flexor longus digitorum is directed forwards and outwards towards the middle line of the sole. The two tendons,

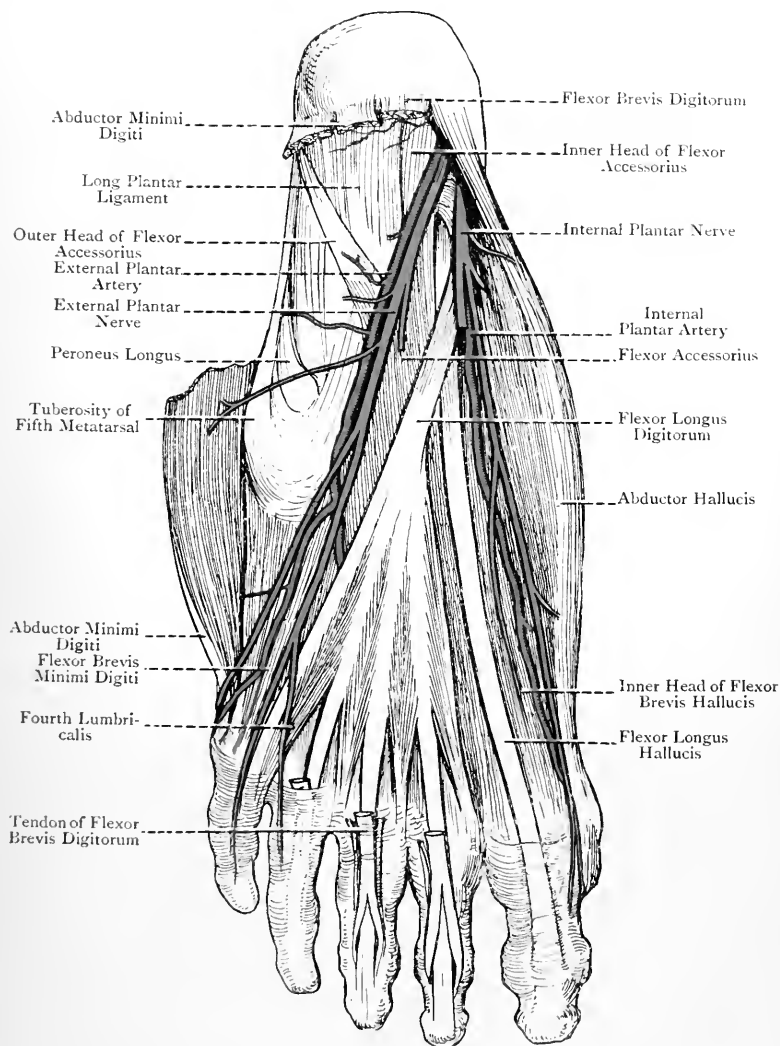


FIG. 254.—THE SECOND LAYER OF PLANTAR MUSCLES (LEFT FOOT).

therefore, cross each other, that of the flexor longus hallucis being above, or on the deep surface of, the other, and giving a slip to it. The tendon of the flexor longus digitorum, on reaching the middle line of the sole, receives the flexor or musculus accessorius, and thereafter terminates in four tendons for the four outer toes, with which tendons the lumbricales are associated.

Flexor or Musculus Accessorius.—This muscle is so named because it is accessory to the long flexor. It arises by two heads, inner and outer, which embrace between them the os calcis and the long plantar ligament.

Origin.—The **inner head** arises from the internal concave surface of the os calcis below the groove on the under surface of the sustentaculum tali. The **outer head** arises from (1) the junction of the external and plantar surfaces of the os calcis in front of the outer tubercle; and (2) the adjacent portion of the long plantar ligament.

Insertion.—The outer border and upper surface of the tendon of the flexor longus digitorum about the centre of the sole.

Nerve-supply.—The external plantar nerve.

Action.—(1) To flex the terminal phalanges of the four outer toes, and (2) to counteract the tendency of the long flexor tendons to draw the toes inwards during flexion. In performing this latter action, the muscle keeps the long flexor tendon in the middle line, so that its four divisions act in a straight line upon the toes.

The inner head of the muscle is broad and fleshy, whilst the outer head is narrow, pointed, and tendinous.

This muscle is to be regarded as a detached portion of the flexor longus digitorum, forming an additional tarsal origin for the purpose of counteracting the obliquity of its tendons.

Lumbricales.—These muscles are four in number.

Origin.—From the tendons of the flexor longus digitorum where these begin to diverge, the outer three taking origin each from the contiguous sides of the tendons between which it lies, and the most internal springing *only* from the inner side of the long flexor tendon destined for the second toe.

Insertion.—The tendons, having passed round the inner sides of the metatarso-phalangeal joints of the four outer toes, take insertion each into the expansion formed by the extensor tendon on the dorsal aspect of the first phalanx.

Nerve-supply.—The most internal or first lumbricalis is supplied by the internal plantar nerve, more particularly by its second digital branch on its way to the cleft between the great toe and the second. The outer three lumbricales, or the second, third, and fourth, are supplied by the deep division of the external plantar nerve.

Action.—(1) To flex the metatarso-phalangeal joint, and (2) to extend the interphalangeal joints.

The muscles are to be regarded as detached portions of the flexor longus digitorum.

Third Layer.—The third layer consists of the following four

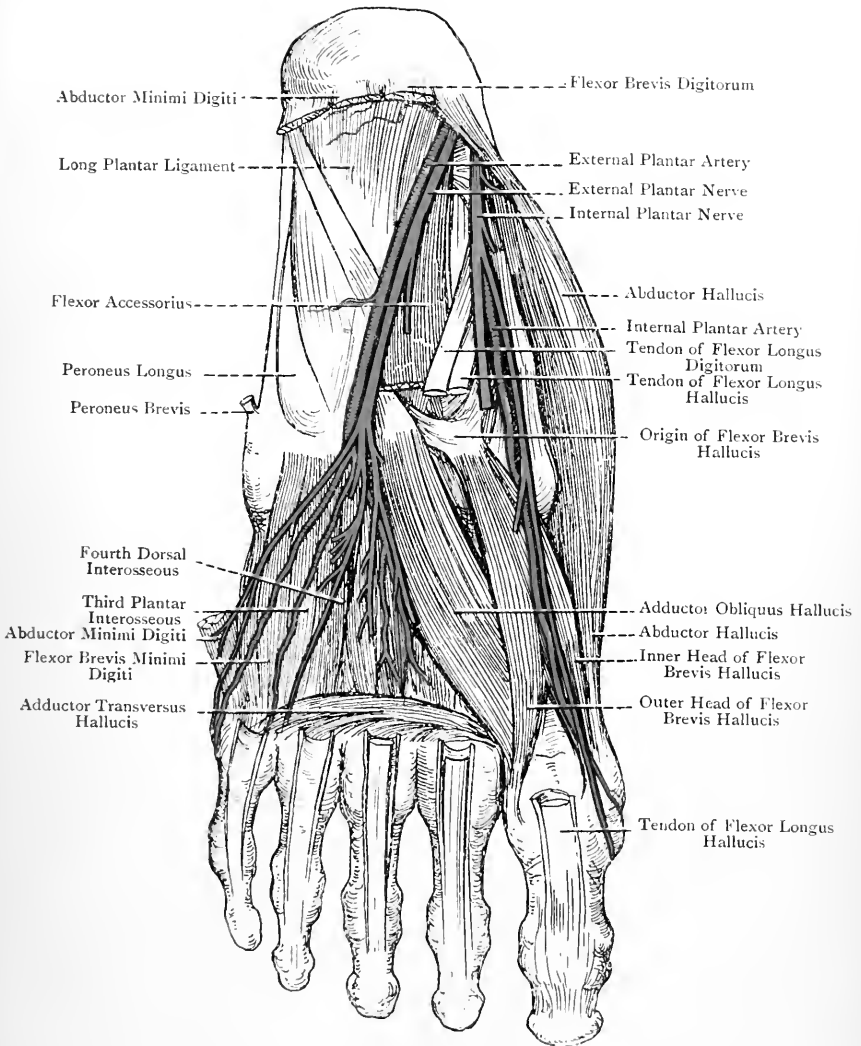


FIG. 255.—THE THIRD LAYER OF PLANTAR MUSCLES (LEFT FOOT).

muscles: flexor brevis hallucis; adductor obliquus hallucis; adductor transversus hallucis; and flexor brevis minimi digiti.

Flexor Brevis Hallucis—*Origin*.—(1) The inner part of the plantar surface of the cuboid bone (sometimes the internal surface), and (2) the expansions of the tibialis posticus tendon to the middle and external cuneiform bones.

Insertion.—By means of two heads, outer and inner. The **inner head** is inserted into the tubercular enlargement on the inner side of the base of the first phalanx of the great toe, in conjunction with the abductor hallucis. The **outer head** is inserted into the tubercular enlargement on the outer side of the base of the first phalanx of the great toe, in conjunction with the adductor obliquus hallucis and adductor transversus hallucis.

Nerve-supply.—The internal plantar nerve, more particularly its first or most internal digital branch.

Action.—To flex the metatarso-phalangeal joint of the great toe. It may at the same time act as a very slight adductor of that toe.

The flexor brevis hallucis lies along the outer side of the tendon of the abductor hallucis. It is tendinous and narrow behind, but soon becomes fleshy and divides into an inner and outer head of insertion, between which is the tendon of the flexor longus hallucis. In each head there is a sesamoid bone.

Adductor Obliquus Hallucis—*Origin*.—(1) The sheath of the tendon of the peroneus longus, and (2) the plantar surfaces of the bases of the second, third, and fourth metatarsal bones.

Insertion.—The tubercular enlargement on the outer side of the base of the first phalanx of the great toe, in conjunction with the outer head of the flexor brevis hallucis on the inner side and the adductor transversus hallucis on the outer side.

Nerve-supply.—The deep division of the external plantar nerve.

Action.—(1) To adduct the great toe, and (2) to flex the metatarso-phalangeal joint.

The muscle lies obliquely on the outer side of the flexor brevis hallucis.

Adductor Transversus Hallucis (transversalis pedis)—*Origin*.—(1) The inferior metatarso-phalangeal ligaments of the third, fourth, and fifth toes, and (2) the transverse metatarsal ligament.

Insertion.—The tubercular enlargement on the outer side of the base of the first phalanx of the great toe, in conjunction with the adductor obliquus hallucis.

Nerve-supply.—The deep division of the external plantar nerve.

Action.—(1) To adduct the great toe, and (2) to approximate the toes to each other.

The muscle consists of three fleshy bundles which join into one, and it lies transversely upon the heads of the four outer metatarsal bones. It is to be regarded as a detached portion of the adductor obliquus hallucis, which has become shifted forwards to the balls of the toes.

Flexor Brevis Minimi Digiti—*Origin*.—(1) The plantar surface of the base of the fifth metatarsal bone, and (2) the sheath of the tendon of the peroneus longus.

Insertion.—The outer side of the base of the first phalanx of the little toe, in conjunction with the abductor minimi digiti. A few of the fibres also take attachment to the plantar surface of the shaft of the fifth metatarsal bone over its anterior part. These fibres represent the muscle called *opponens minimi digiti*, the origin of which corresponds with those fibres of the flexor brevis minimi digiti which spring from the sheath of the tendon of the peroneus longus.

Nerve-supply.—The superficial division of the external plantar nerve, and usually the outer digital branch of that division to the outer side of the little toe.

Action.—To flex the metatarso-phalangeal joint of the little toe. The muscle is a small fleshy slip which lies upon the plantar surface of the fifth metatarsal bone, under cover of the abductor minimi digiti. It is liable to be taken for a plantar interosseous muscle, lying, as it does, in close contact with the most external plantar interosseous.

Plantar Triangle.—This is a muscular triangle in connection with the third layer of muscles, the boundaries of which are as follows: *Anterior* or *Base*.—Adductor transversus hallucis. *Internal*.—Adductor obliquus hallucis. *External*.—Flexor brevis minimi digiti. *Floor*.—Portions of the plantar and dorsal interosseous muscles, covered by the interosseous fascia. *Roof*.—The long flexor tendons and the lumbricales. *Contents*.—(1) A limited portion of the deep part of the external plantar artery; (2) some of the digital branches of the plantar arch, especially the second and third, and the corresponding veins; and (3) a limited portion of the deep division of the external plantar nerve.

Fourth Layer.—The fourth layer consists of the interosseous muscles; the tendon of the peroneus longus; and the tendon of the tibialis posticus.

Interosseous Muscles.—The interosseous muscles are seven in number, and are arranged in two groups—plantar, of which there are three, and dorsal, of which there are four. The plantar muscles are seen only in the sole, but the dorsal muscles are seen on the dorsum of the foot as well as in the sole. The plantar aspects of the muscles are covered by the thin interosseous fascia which joins anteriorly the transverse metatarsal ligament.

Plantar Interossei.—These belong to the three outer toes, and are named first, second, and third from within outwards.

Origin.—(1) The inner surfaces of the shafts of the third, fourth, and fifth metatarsal bones, and (2) the sheath of the tendon of the peroneus longus.

Insertion.—(1) The inner sides of the bases of the first phalanges of the third, fourth, and fifth toes, and (2) the expansions formed by the long and short extensor tendons (in the case of the fifth toe

long extensor only) on the dorsal aspects of the first phalanges of the same toes.

Dorsal Interossei.—These belong to the second, third, and fourth toes, the second toe having two. They are named first, second, third, and fourth, from within outwards.

Origin.—Each muscle arises by two heads from the adjacent lateral surfaces of the shafts of the metatarsal bones between which it is situated, but more extensively from the metatarsal bone of the toe upon which the muscle acts than from the other bone. In the case of the first (most internal) muscle its inner head is comparatively small, and arises from the outer side of the base of the first metatarsal bone, as well as from the adjacent portion of the internal cuneiform.

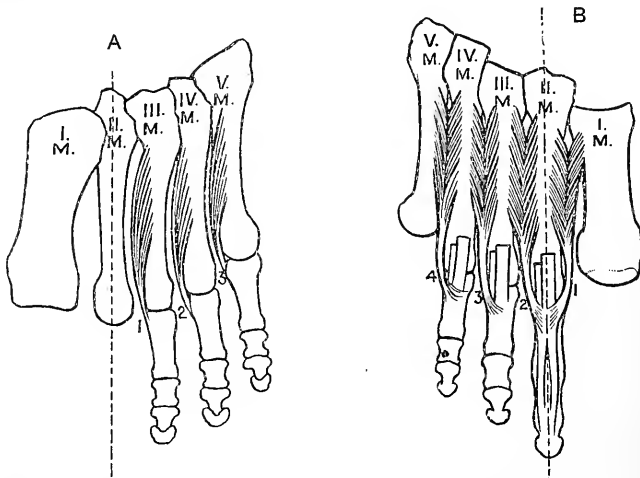


FIG. 256.—THE INTEROSSEOUS MUSCLES OF THE RIGHT FOOT.
A, Plantar; B, Dorsal.

Insertion.—The dorsal interossei are inserted in a manner precisely similar to the plantar interossei. The *first* and *second* dorsal interossei belong to the second toe, one on either side; the *third* belongs to the outer side of the third toe; and the *fourth* to the outer side of the fourth toe. In the case of all the interosseous muscles the insertion into a first phalanx is comparatively slight, the chief insertion being into the expansion of the extensor tendon on the dorsal aspect of the first phalanx.

Nerve-supply.—The external plantar nerve in the following manner: the deep division of the nerve usually supplies the interosseous muscles, with the exception of the two which occupy the fourth (most external) interosseous space, namely, the fourth dorsal and third plantar. These two are usually supplied by the outer digital branch of the superficial division of the external plantar

nerve to the outer side of the little toe. Sometimes, however, the deep division of the nerve supplies all seven interosseous muscles. In all cases the nerves enter the muscles on their plantar aspects.

Action—Plantar Interossei.—These are *adductors*, the toes which they adduct being the third, fourth, and fifth. **Dorsal Interossei.**—These are *abductors*, the toes which they abduct being the second, third, and fourth.

In speaking of adduction and abduction in the case of the foot, reference is made to an imaginary line passing through the centre of the second toe, adduction being movement *towards* that line, and abduction movement *from* it.

The first and second dorsal interossei, acting both upon the second toe, abduct it from the imaginary line passing through its centre, the first abducting it to the inner side and the second to the outer side. The third and fourth dorsal interossei abduct the third and fourth toes.

The interosseous muscles, aided by the lumbricales, also act as follows: (1) they flex the metatarso-phalangeal joints of the four outer toes, and (2) they extend the interphalangeal joints of these toes.

The tendons of the peroneus longus and tibialis posticus have been already described.

Plantar Nerves.—The plantar nerves are two in number, internal and external. They are the terminal branches into which the posterior tibial nerve divides on a level with the lower border of the internal annular ligament, though the division frequently takes place on a level with the upper border of that ligament, or at some point beneath it. The internal plantar is the larger of the two nerves, and it accompanies the internal plantar artery, which is the smaller of the two plantar arteries. The external plantar nerve accompanies the external plantar artery.

Internal Plantar Nerve.—This nerve has a wider cutaneous, but a more limited muscular, distribution than the external plantar. From its origin it passes forwards on the outer side of the internal plantar artery, being at first under cover of the abductor hallucis, and subsequently lying between that muscle and the flexor brevis digitorum. About the middle (in length) of the foot it divides into its terminal branches.

Branches.—These are muscular, articular, plantar cutaneous, and digital.

The **muscular branches** supply the abductor hallucis and flexor brevis digitorum.

The **articular branches** are distributed to the astragalo-navicular and naviculo-cuneiform articulations.

The **plantar cutaneous branches** are distributed to the integument of the inner half of the sole.

The **digital branches** are four in number, and are named first, second, third, and fourth from within outwards. The first is a single nerve, but the other three are compound. The **first digital**

nerve is distributed to the inner side of the great toe, and it furnishes a branch to the flexor brevis hallucis muscle. The **second** digital nerve gives off a twig to the first lumbricalis, and near the cleft between the great toe and the second it divides into two collateral plantar digital nerves, which supply the contiguous sides of these two toes. The **third** digital nerve divides near the cleft between the second and third toes into two collateral plantar digital nerves, which supply the contiguous sides of these two toes. The **fourth** digital nerve also divides near the cleft between the third and fourth toes into two collateral plantar digital nerves, which supply the contiguous sides of these two toes. Before dividing, it communicates by a twig with that digital branch of the superficial division of the external plantar which supplies the con-

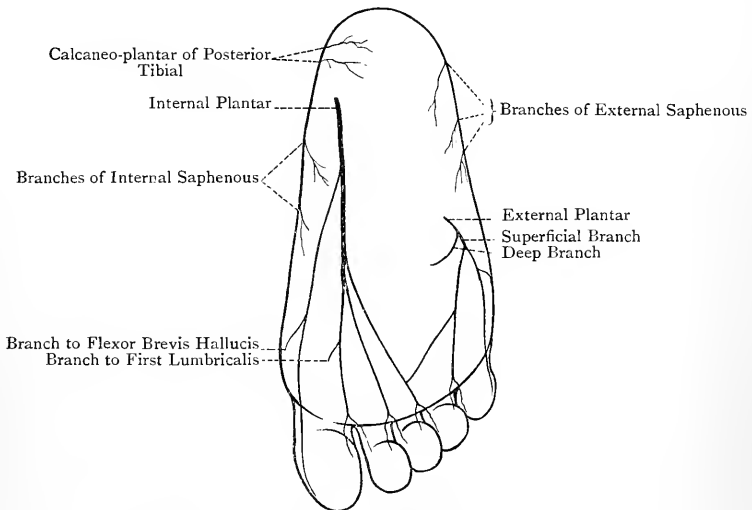


FIG. 257.—DIAGRAM OF THE NERVES OF THE FOOT (PLANTAR ASPECT).

tiguous sides of the fourth and fifth toes. The nerves on the sides of the toes are placed below the digital arteries. They furnish articular branches to the joints of the toes and cutaneous branches to the plantar and dorsal surfaces of the toes. Finally each terminates in two branches—one to the matrix of the nail, and the other to the pulp of the toe. The branches of the digital nerves are beset with numerous Pacinian bodies.

Summary of the Internal Plantar Nerve.—**Muscular** branches to abductor hallucis, flexor brevis digitorum, flexor brevis hallucis, and first lumbricalis. **Cutaneous** branches to the integument of the inner half of the sole and the inner three and a half toes. **Articular** branches to the astragalo-navicular, naviculo-cuneiform, and digital articulations.

The internal plantar nerve in its digital distribution corresponds closely

with the median nerve in the hand. There is this difference, however, between these two nerves : the internal plantar has one single digital nerve and three compound digital nerves, whereas the median has three single digital nerves and two which are compound.

External Plantar Nerve.—This nerve has a more limited cutaneous, but a wider muscular, distribution than the internal plantar. From its origin it is directed forwards and outwards to the base of the fifth metatarsal bone, where it breaks up into two divisions, superficial and deep. In this course it lies at first between the flexor brevis digitorum and flexor or musculus accessorius, and subsequently in the groove between the former muscle and the abductor minimi digiti. It is close to the inner side of the external plantar artery, and occupies the concavity of the curve described by that vessel. This part of the nerve is spoken of as the trunk.

Branches of the Trunk.—The branches are as follows : *muscular* to the flexor or musculus accessorius and abductor minimi digiti ; *articular* to the calcaneo-cuboid articulation ; *cutaneous* to the integument of the outer half of the sole ; and *terminal*.

The **terminal branches** are two in number, superficial and deep, and they spring from the trunk at the base of the fifth metatarsal bone.

The **superficial division** furnishes two digital nerves, outer and inner. The **outer digital nerve** is single, and is distributed to the outer side of the little toe, supplying branches to the flexor brevis minimi digiti and, as a general rule, to the interosseous muscles of the fourth interosseous space, namely, the fourth dorsal and the third plantar. It may, however, fail to supply these two interosseous muscles, in which case they derive their nerve-supply from the deep division of the external plantar nerve. The **inner digital nerve** is compound. In its forward course it communicates by a twig with the most external digital branch of the internal plantar nerve which supplies the contiguous sides of the third and fourth toes, and near the cleft between the fourth and fifth toes it divides into two collateral plantar digital nerves, which supply the contiguous sides of these two toes. The digital branches of the superficial division of the external plantar nerve resemble in all respects those of the internal plantar.

The **deep division** is muscular and articular in its distribution. It sinks deeply into the sole with the external plantar artery as that vessel forms the plantar arch. Its direction is inwards and forwards on the deep or superior surface of the musculus accessorius, long flexor tendons and lumbricales, and adductor obliquus hallucis, and lying upon the bases of the second, third, and fourth metatarsal bones.

Branches.—The branches of the deep division are muscular, articular, and perforating.

The **muscular branches** supply (1) the interosseous muscles, plantar and dorsal, with the exception, as a general rule, of the two which occupy the fourth interosseous space, namely, the

fourth dorsal and third plantar—though these two may be included; (2) the outer three lumbricales; (3) the adductor transversus hallucis; and (4) the adductor obliquus hallucis.

The **articular branches** supply the tarsal and tarso-metatarsal articulations. They sometimes also supply the metatarso-phalangeal articulations.

The **perforating branches** pass upwards through the proximal parts of the interosseous spaces, and join the interosseous branches of the dorsalis pedis nerve.

Summary of External Plantar Nerve.—**Muscular** branches to the flexor or musculus accessorius, abductor minimi digiti, flexor brevis minimi digiti, all seven interossei, outer three lumbricales, adductor transversus hallucis, and adductor obliquus hallucis. **Cutaneous** branches to the integument of the outer half of the sole and the outer one and a half toes. **Articular** branches to the tarsal, tarso-metatarsal, and, in some cases, metatarso-phalangeal articulations. **Perforating** branches to join the interosseous nerves on the dorsum of the foot.

The external plantar nerve corresponds with the ulnar nerve in the hand.

Plantar Arteries.—The arteries of the sole of the foot are three in number, namely, the internal plantar, the external plantar, and the plantar branch of the arteria dorsalis pedis. The internal and external plantar arteries are the terminal branches into which the posterior tibial divides on a level with the lower border of the internal annular ligament. The internal plantar is much smaller than the external, and each vessel is accompanied by the corresponding plantar nerve.

Internal Plantar Artery.—This vessel passes forwards along the inner side of the sole with the internal plantar nerve, which lies on its outer side, and it usually terminates on the inner aspect of the metatarso-phalangeal joint of the great toe by anastomosing with the digital branch of the arteria magna or princeps hallucis to the inner side of that toe. It is at first under cover of the abductor hallucis, and subsequently lies between that muscle and the flexor brevis digitorum. It is accompanied by two venæ comites.

Branches.—These are as follows :

Muscular to the muscles in its immediate vicinity.

Cutaneous to the integument of the inner half of the sole.

Articular to the articulations along the inner side of the foot.

The **internal tarsal branches** pass inwards beneath the abductor hallucis to the inner border of the foot, where they anastomose with the internal tarsal branches of the arteria dorsalis pedis.

The **superficial digital arteries** are three in number, and are usually very small. They accompany the three compound digital branches of the internal plantar nerve to the clefts where these nerves divide into their collateral branches, and there they terminate by joining the inner two digital arteries from the plantar arch and the arteria magna or princeps hallucis.

External Plantar Artery. — This vessel, which is much larger than the internal plantar, arises from the posterior tibial artery on a level with the lower border of the internal annular ligament,

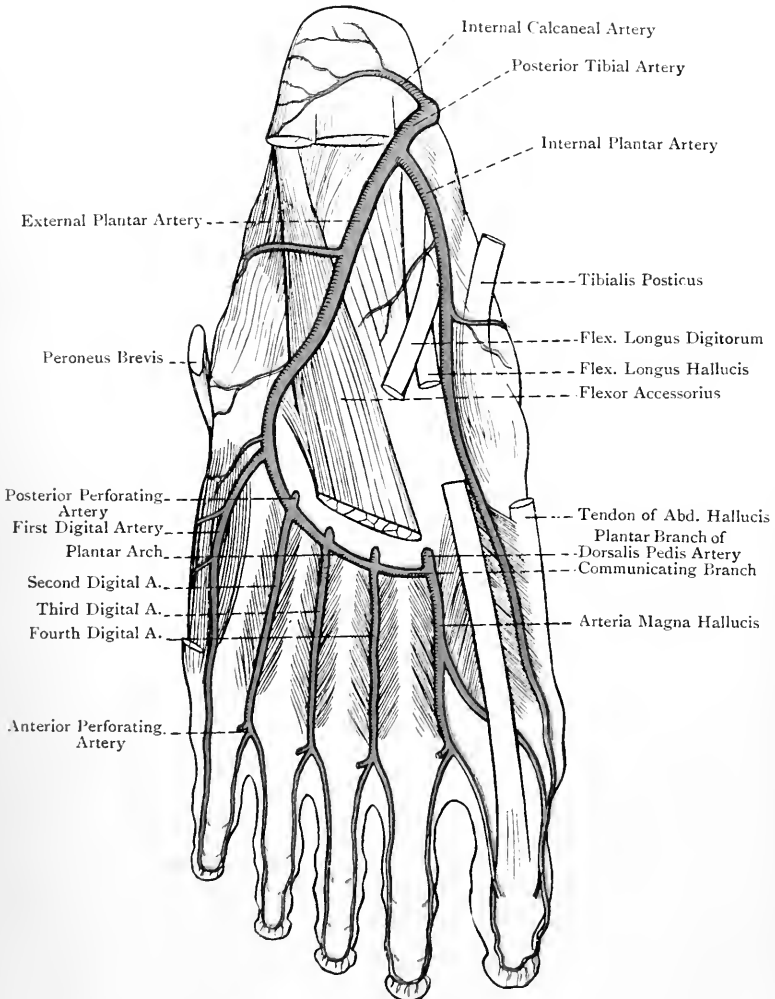


FIG. 258.—THE PLANTAR ARTERIES (LEFT FOOT) (AFTER L. TESTUT'S 'ANATOMIE HUMAINE').

and terminates at the proximal part of the first interosseous space by anastomosing with the communicating branch of the plantar division of the arteria dorsalis pedis.

The artery is accompanied by the external plantar nerve throughout its whole course, and by two venæ comites. At its origin it is situated on the inner surface of the os calcis, from which point it is directed outwards and forwards across the sole to the base of the fifth metatarsal bone. It here describes a sharp bend, and, sinking deeply, it recrosses the sole on its way to the proximal part of the first interosseous space. The vessel is divided into two parts, first and second. These two parts together describe one great curve, the concavity of which looks inwards and is occupied by the external plantar nerve.

The **first part** extends from the lower border of the internal annular ligament to the base of the fifth metatarsal bone. Its course may be indicated by drawing a line from a point midway between the tip of the internal malleolus and the inner tubercle on the plantar aspect of the tuber calcis to the base of the fifth metatarsal bone. The direction of this part is outwards and forwards.

Relations.—It is covered in succession by the abductor hallucis, flexor brevis digitorum, and finally only by the skin, superficial fascia, and plantar fascia. It rests upon the os calcis and the musculus accessorius.

It is to be noted that this part of the vessel is very superficial for a short distance close to the base of the fifth metatarsal bone, where it lies between the flexor brevis digitorum and abductor minimi digiti.

The **second part** extends from the base of the fifth metatarsal bone to the proximal part of the first interosseous space. Its course may be indicated by a line connecting the limits of this part of the vessel. It is directed inwards and forwards in a slightly curved manner, with the convexity of the curve forwards, and thus it forms the **plantar arch**, which is completed by the communicating branch of the plantar division of the arteria dorsalis pedis. The second part is accompanied by the deep division of the external plantar nerve, and is very deeply placed.

Relations.—It is covered by the skin, superficial fascia, central division of the plantar fascia, flexor brevis digitorum, flexor longus digitorum, lumbricales, and adductor obliquus hallucis. It rests upon the bases of the second, third, and fourth metatarsal bones and the corresponding interosseous muscles.

Branches of the First Part.—The branches are as follows :

Muscular to the muscles in its immediate vicinity.

The **internal calcaneal branches** are two or three in number. After piercing the origin of the abductor hallucis, they reach the inner surface of the os calcis, where they anastomose with the internal calcaneal branch of the posterior tibial artery. Over the prominence of the heel they also anastomose freely with the external calcaneal branches of the posterior peroneal artery.

Cutaneous to the integument of the outer half of the foot.

Branches also turn round the outer border of the foot, where they anastomose with the tarsal and metatarsal branches of the arteria dorsalis pedis and with the posterior peroneal artery.

Branches of the Second Part.—The branches of the second part, or **plantar arch**, are as follows: articular, posterior perforating, and digital.

The **articular branches** arise from the concavity of the arch, and pass backwards to supply the tarsal articulations.

The **posterior perforating arteries**, which are three in number, arise from the upper aspect of the arch. They pass upwards through the proximal parts of the three outer interosseous spaces, and between the two heads of the corresponding dorsal interosseous muscles. On reaching the dorsum of the foot they anastomose with the dorsal interosseous branches of the metatarsal artery, which is a branch of the *arteria dorsalis pedis*.

The **digital arteries** are four in number—first, second, third, and fourth, from without inwards. They arise from the front or convexity of the arch and pass forwards. The first, which is a single artery, lies over the fifth metatarsal bone and flexor brevis minimi digiti. The second, third, and fourth, which are compound arteries, are placed over the fourth, third, and second interosseous spaces respectively, where they lie upon the corresponding interosseous muscles. The **first** is distributed to the outer side of the little toe, of which it is the plantar digital artery. The **second, third, and fourth** pass over the deep surface of the adductor transversus hallucis, and bifurcate near the clefts between the four outer toes, each dividing into two collateral plantar digital arteries. Those of the second supply the contiguous sides of the fourth and fifth toes, those of the third the contiguous sides of the third and fourth toes, and those of the fourth the contiguous sides of the second and third toes. Each of the inner three digital arteries at its point of bifurcation gives off an *anterior perforating artery*. These anterior perforating arteries pass upwards through the distal ends of the outer three interosseous spaces, and, on reaching the dorsum of the foot, anastomose with the dorsal interosseous arteries. The inner two (third and fourth) digital arteries are joined near the clefts of the toes by the outer two superficial digital branches of the internal plantar artery.

On the sides of the toes the plantar digital arteries furnish branches to the flexor tendons and their sheaths, and anastomose freely with the dorsal digital arteries. Near the distal end of the first and second phalanx, and on the plantar aspect of each, the plantar digital arteries of opposite sides form arches from which articular twigs are given to the interphalangeal articulations, and on the plantar aspect of the terminal phalanx they end by forming another arch. From this latter arch branches are furnished to the pulp of the toe and matrix of the nail. Each digital artery is accompanied by two *venæ comites*. The external plantar artery corresponds with the deep branch of the ulnar artery in the palm.

It has been seen that the plantar arch, by means of its four digital branches, supplies the outer three and a half toes. There

thus remain one and a half to be accounted for, namely, both sides of the great toe and the inner side of the second toe.

Plantar or Perforating Branch of Arteria Dorsalis Pedis.—This artery is one of the terminal branches of the *arteria dorsalis pedis*. Having entered the sole through the proximal part of the first interosseous space, between the two heads of the first dorsal interosseous muscle, it immediately divides into two branches—communicating and *arteria magna* or *princeps hallucis*.

The **communicating branch** is a short vessel, which ends by joining the second part of the external plantar artery to complete the plantar arch.

The *arteria magna* or *princeps hallucis* is the **fifth plantar digital artery**. Commencing at the proximal end of the first interosseous space it passes forwards over the plantar aspect of that space and the corresponding dorsal interosseous muscle towards the cleft between the great toe and second toe. In this part of its course it furnishes a single plantar digital artery, which, having crossed the first metatarsal bone, beneath the tendon of the *flexor longus hallucis*, is distributed to the inner side of the great toe. Near the cleft between the great toe and second toe it receives the innermost superficial digital branch of the internal plantar artery, and then divides into two collateral plantar digital arteries for the supply of the contiguous sides of these two toes. Before dividing, it communicates with the *arteria dorsalis hallucis* by an anterior perforating branch, which passes through the distal end of the first interosseous space.

Varieties—1. **Internal Plantar Artery.**—This vessel is sometimes very small, and it may then terminate in the *flexor brevis hallucis*. In other cases it is of fairly large size, and then it may replace the *arteria magna* or *princeps hallucis*, and furnish the plantar digital branches for both sides of the great toe and the inner side of the second toe. In very rare cases the internal plantar artery communicates with the external plantar, and so forms a superficial plantar arch. In such cases the superficial digital arteries arise from this arch.

2. **External Plantar Artery.**—This artery is liable to be diminished in size, and this may occur to such an extent as to exclude it from any share in the plantar arch. Such deficiencies are compensated for by an enlargement of the *arteria dorsalis pedis* and its plantar branch.

The posterior perforating branches of the plantar arch are sometimes of comparatively large size, and then they furnish the dorsal interosseous arteries after they reach the dorsum of the foot.

* For the tendon of the *peroneus longus* in the sole see p. 488.

Tendons Involved in Club-foot.

The chief varieties of club-foot are as follows: *talipes equinus*, *talipes varus*, *talipes equino-varus*, *talipes valgus*, *talipes calcaneus*, and *talipes calcaneo-valgus*.

Talipes Equinus.—In this variety the foot is extended upon the leg, the heel being raised from the ground, so that the person walks upon the toes. The chief tendons involved are (1) the *tendo Achillis*, and (2) the *plantaris tendon*. The latter, however, is insignificant.

Talipes Varus.—In this variety the inner border of the foot is raised so as to invert the sole, and the foot is at the same time slightly extended upon

the leg, so that the person walks upon the outer border of the foot. The chief tendons involved are those of the *tibialis anticus* and *tibialis posticus*.

Talipes Equino-varus.—This is a combination of *talipes equinus* and *talipes varus*, the heel being raised as well as the inner border of the foot. The chief tendons involved are as follows: (1) *tibialis posticus*, (2) *tibialis anticus*, (3) *tendo Achillis*, and (4) *plantaris*. In addition to these tendons the *abductor hallucis* and the *plantar fascia* are usually implicated.

Talipes Valgus.—In this variety the outer border of the foot is raised so as to evert the sole, and the person walks upon the inner border of the foot. The tendons involved are those of the *peroneus longus* and *peroneus brevis*.

Talipes Calcaneus.—In this variety the foot is flexed upon the leg, the toes being raised, so that the person walks upon the heel. The tendons involved are as follows: (1) *extensor longus digitorum*, (2) *peroneus tertius*, (3) *extensor proprius hallucis*, and (4) *tibialis anticus*.

Talipes Calcaneo-valgus.—This is a combination of *talipes calcaneus* and *talipes valgus*, the foot being flexed and the outer border of the foot raised. The tendons involved are those which are implicated in *talipes calcaneus* and *talipes valgus*.

Summary of the Veins of the Lower Limb.

The veins of the lower limb are divided into two groups—superficial and deep.

Superficial Veins.—In the sole of the foot there are (1) a **plantar subcutaneous plexus**, and (2) a **transverse venous arch** situated near the clefts of the toes, which receives the *plantar digital veins*. The blood is carried away from the *plantar subcutaneous plexus* by *anterior* and *lateral efferent vessels*. The **anterior efferent vessels** terminate in the *transverse venous arch* near the clefts of the toes. The **lateral efferent vessels** turn round the outer and inner borders of the foot, the external set terminating in the *short saphenous vein*, and the internal set in the *long saphenous vein*, where these vessels spring from the *dorsal venous arch*. The blood is conveyed away from the *transverse venous arch* by means of *efferent veins*, called **interdigital**, which pass upwards to the *dorsum* of the foot, where they terminate in the *dorsal venous arch*.

The **dorsal venous arch** is situated well forward upon the *dorsum* of the foot, being about 2 inches from the webs of the toes. It receives (1) the *dorsal digital veins*, (2) small veins from the *dorsum* of the foot, and (3) the *efferent interdigital veins* from the *plantar transverse venous arch*. The blood is carried away from the *dorsal venous arch* by the *long* and *short saphenous veins*. The **long saphenous vein** arises from the inner end of the arch, and, having received branches from the *plantar subcutaneous venous plexus*, passes *in front* of the *internal malleolus*, and thus reaches the inner side of the leg. Its subsequent course is upwards along the inner side of the leg, knee, and thigh, and finally, having reached the front of the thigh, it passes through the *saphenous opening* $1\frac{1}{2}$ inches below *Poupart's ligament*, and terminates in the *femoral vein*. It receives many tributaries in its course; in the leg it communicates at frequent intervals with the *venæ comites* of the *anterior* and *posterior tibial arteries* by *intermuscular branches*; and near its termination it is reinforced by the *posterior saphenous*, *anterior saphenous*, *superficial circumflex iliac*, *superficial epigastric*, and *superior* and *inferior external pudic veins*. The **short saphenous vein** arises from the outer end of the *dorsal venous arch*, and, having received branches from the *plantar subcutaneous venous plexus*, it passes *below* and *behind* the *external malleolus*, and thus reaches the back of the leg. It then passes upwards and inwards, and subsequently straight upwards until it arrives at the interval between the *condyles* of the *femur*. Here it passes through an aperture in the *fascia lata*, and terminates in the *popliteal vein*. It receives many tributaries from the *calcaneal region* and the outer and back parts of the leg; it communicates at intervals with the *venæ comites* of the *posterior tibial*

and peroneal arteries; and near its termination it communicates with the long saphenous vein.

Deep Veins.—The deep veins accompany the various arteries and their branches. Below the level of the popliteus muscle they are arranged in pairs along the arteries which they accompany, this arrangement being known as *venæ comites*. Opposite the lower border of the popliteus muscle the posterior tibial *venæ comites*, having previously received the peroneal *venæ comites*, unite with the anterior tibial *venæ comites*, and so the popliteal vein is formed, which is continued into the femoral vein.

Lymphatic Vessels.—Lymphatic vessels pervade every part of the lower limb, and are divided into a superficial and deep group.

Superficial Group.—The superficial lymphatics form digital, plantar, and dorsal plexuses, and pass in two sets, inner and outer, from the respective parts of the foot. The **inner lymphatics** pass partly in front of, and partly behind, the internal malleolus, and, following the course of the long saphenous vein, terminate in the superficial femoral or saphenous glands. The **outer lymphatics** proceed from the outer part of the foot, and most of them pass in front of the external malleolus, though some pass behind it. Many of them then turn inwards over the front of the leg, and join the inner lymphatics. Others continue their course upwards along the outer and back parts of the leg and knee, and subsequently incline inwards to join the inner set. A few, which pass behind the external malleolus, accompany the short saphenous vein and terminate in the popliteal glands.

Deep Group.—The deep lymphatics accompany the bloodvessels. Below the level of the knee they form three sets—anterior tibial, posterior tibial, and peroneal, all of which terminate in the popliteal glands, the anterior tibial set having previously passed through the anterior tibial gland. The efferent vessels from the popliteal glands, together with the lymphatics accompanying the branches of the superficial and deep femoral arteries, form the deep lymphatics of the thigh, and terminate in the deep femoral glands.

Summary of the Lymphatic Glands.—The lymphatic glands of the lower limb form the following groups: (1) inguinal (superior or oblique superficial inguinal), (2) superficial femoral or saphenous (inferior or vertical superficial inguinal), (3) deep femoral (deep inguinal), (4) popliteal, and (5) anterior tibial.

THE ANKLE-JOINT.

The ankle-joint belongs to the class **diarthrosis**, and to the subdivision **ginglymus**. The articular surfaces are the lower extremity of the shaft and the outer surface of the internal malleolus of the tibia, the inner surface of the external malleolus of the fibula, and the superior and both lateral surfaces of the astragalus. The **ligaments** are anterior, posterior, internal lateral, and external lateral.

The **anterior ligament** is a thin membrane which covers the joint in front. Superiorly it is attached from within outwards

to the anterior border of the internal malleolus, anterior surface of the lower end of the tibia two or three lines above the anterior border, anterior inferior tibio-fibular ligament, and anterior border of the external malleolus. Inferiorly it is attached to a groove on the upper aspect of the head of the astragalus, immediately behind the cartilaginous surface and in front of the neck. The fibres of the ligament are chiefly disposed in a transverse direction.

In addition to the tendons which lie upon it, this ligament is related to the anterior tibial vessels and nerve. Its deep surface is covered by the synovial membrane of the joint, and inferiorly is in contact with a collection of fat which lies in the hollow on the upper surface of the neck of the astragalus.

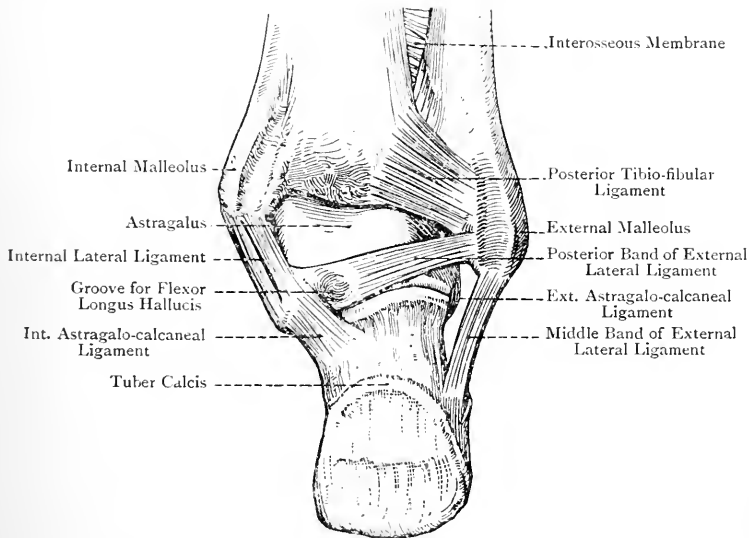


FIG. 259.—THE RIGHT ANKLE-JOINT (POSTERIOR VIEW).
(The Posterior Ligament has been removed.)

The **posterior ligament** is weaker and less defined than the anterior. Superiorly it is attached from without inwards to the posterior aspect of the external malleolus internal to the peroneal groove, posterior inferior tibio-fibular ligament, and posterior border of the tibia as far inwards as the groove behind the internal malleolus. Inferiorly it is attached to the upper aspect of the posterior border of the astragalus immediately behind the superior articular surface, where it extends between the posterior fasciculus of the external lateral ligament and the internal lateral ligament. Its fibres are disposed obliquely, and radiate in an inward direction from the external malleolus.

The **internal lateral ligament** is also known as the **deltoid ligament**. It is a strong, flat, triangular structure, which is attached superiorly to the lower border, tip, and anterior border of the internal malleolus, in which latter situation it is superficial to the fibres of the anterior ligament. A strong bundle of fibres springs from the notch which indents the lower border of the internal malleolus. From the superior attachment the fibres diverge in a radiating manner. The posterior fibres, strong and short, descend with an inclination backwards to be attached to the rough, depressed inner surface of the astragalus below the internal facet, where they extend as far back as the inner tubercle on the posterior border of the bone. The anterior part of the ligament, somewhat thinner and more radiating than the posterior, is attached to

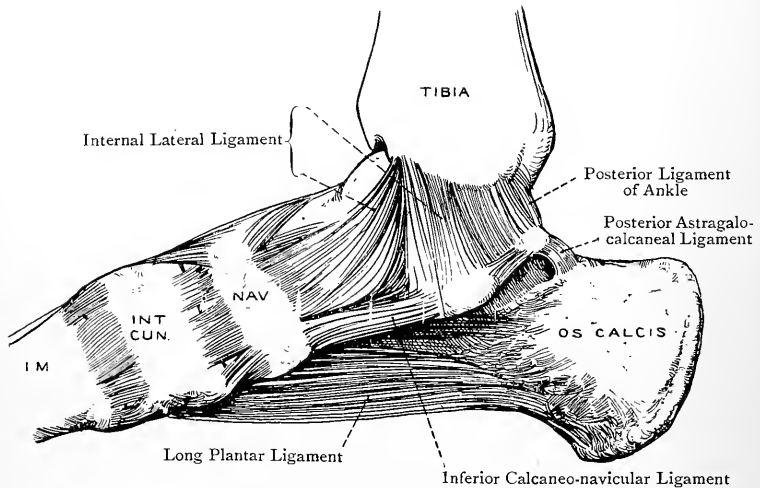


FIG. 260.—LIGAMENTS OF THE RIGHT FOOT (INTERNAL VIEW).

the inner border of the sustentaculum tali of the os calcis, inner border of the internal calcaneo-navicular or spring ligament, and inner part of the dorsal surface of the navicular bone.

The **external lateral ligament** is composed of three distinct fasciculi—*anterior*, *middle*, and *posterior*.

The *anterior fasciculus (astragalo-fibular)* is flat, and extends from the lower part of the anterior border of the external malleolus to the outer surface of the astragalus immediately in front of the external facet. Its direction is forwards and inwards, and it is the shortest of the three fasciculi.

The *middle fasciculus (calcaneo-fibular)*, which is round, is attached superiorly to the tip of the external malleolus, and inferiorly to a tubercle on the outer surface of the os calcis situated about the centre, behind and above the peroneal spine. Its direction is down-

wards and backwards, and it is related to the tendons of the peroneus longus and peroneus brevis.

The *posterior fasciculus (astragalo-fibular)* is the strongest bundle of the three. It is attached by one extremity to the lower part of the digital fossa on the inner surface of the external malleolus behind the articular facet. The other extremity is attached to the upper surface of the outer tubercle on the posterior border of the astragalus. Its direction is inwards and slightly backwards.

The **synovial membrane** lines the inner surfaces of the ligaments in a loose manner, and it covers collections of fat (Haversian glands) at the front and back of the joint, where it forms folds

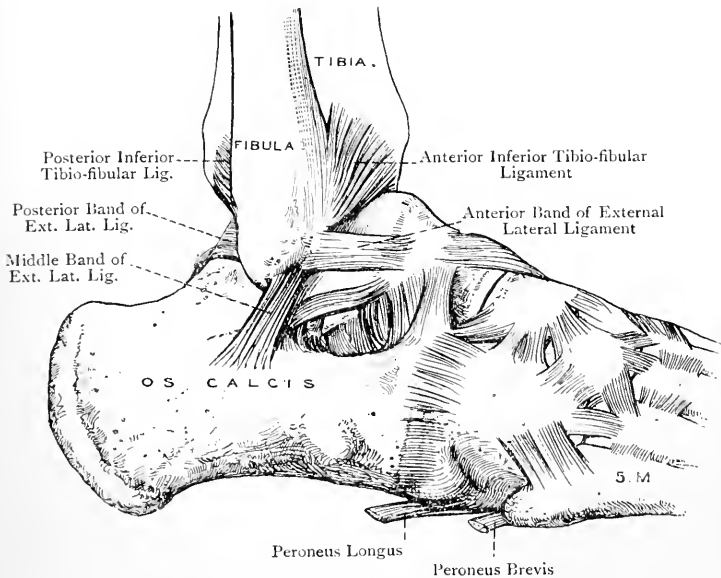


FIG. 261.—LIGAMENTS OF THE RIGHT INFERIOR TIBIO-FIBULAR, ANKLE, TARSAL, AND TARSO-METATARSAL JOINTS (EXTERNAL VIEW).

which project between the astragalus and the tibia. It is also prolonged into the inferior tibio-fibular articulation so as to line the anterior and posterior ligaments of that joint.

Tendinous Relations of the Ankle-Joint—*Anterior*.—From within outwards these are the tibialis anticus, extensor proprius hallucis, extensor longus digitorum, and peroneus tertius. *External*.—Peroneus longus and peroneus brevis. *Posterior*.—From without inwards these are the peroneus longus and peroneus brevis, tendo Achillis and plantaris, with the intervention of a large amount of fat, flexor longus hallucis, and flexor longus digitorum and tibialis posticus. *Internal*.—Tibialis posticus.

Arterial Supply.—The anterior tibial, external and internal malleolar, anterior peroneal, posterior tibial, and posterior peroneal arteries.

Nerve-supply.—The posterior tibial, short saphenous, and external division of the dorsalis pedis nerve, or the anterior tibial nerve itself.

Movements.—The chief movements at the ankle-joint are flexion and extension. When, however, the foot is extended a certain amount of lateral movement is allowed. The foot is said to be *flexed* when it is raised from the ground towards the front of the leg, as in standing upon the heels, and it is said to be *extended* when the heel is raised towards the back of the leg, as in standing upon the toes. In flexion of the foot the broad anterior part of the superior articular surface of the astragalus is carried backwards into the narrow posterior part of the tibial socket, and lateral movement is then impossible. Flexion is limited by (1) the tension of the posterior and middle portions of the internal lateral ligament; (2) the tension of the posterior and middle fasciculi of the external lateral ligament; and (3) the locking which takes place between the upper surface of the neck of the astragalus and the anterior border of the lower end of the tibia. In extension of the foot the narrow posterior part of the superior articular surface of the astragalus is carried forwards into contact with the broad anterior part of the tibial socket, and a certain amount of *lateral movement* can now take place. Extension is limited by (1) the tension of the anterior part of the internal lateral ligament; (2) the tension of the anterior and middle fasciculi of the external lateral ligament; (3) the tension of the anterior ligament, particularly of its inner part; and (4) the locking of the posterior part of the astragalus against the posterior border of the lower end of the tibia. The range of movement in the direction of flexion and extension is about 90 degrees, and it takes place round a transverse axis passing through the body of the astragalus in a direction forwards and outwards. At the end of extension there is a tendency to abduction or turning in of the foot, due to the following factors: (1) the greater length posteriorly of the inner border of the superior articular surface of the astragalus; (2) the greater depression of the corresponding part of the outer border of the astragalus; and (3) adduction at the astragalo-calcaneal joint.

The vertical line of the centre of gravity falls in front of the axis of movement at the ankle-joint. There is thus a tendency to over-flexion, which, however, is counteracted by a certain amount of muscular effort on the part of the sural muscles.

Muscles concerned in the Movements—Flexion.—This is produced by the tibialis anticus, peroneus tertius, extensor longus digitorum, and extensor proprius hallucis.

Extension.—This is produced by the gastrocnemius and soleus by means of the tendo Achillis, plantaris, tibialis posticus, flexor longus digitorum, flexor longus hallucis, peroneus longus, and peroneus brevis.

Abduction.—The foot is everted by the peroneus longus and peroneus brevis.

Adduction.—The foot is inverted by the tibialis anticus and tibialis posticus.

THE TIBIO-FIBULAR JOINTS.

The superior and inferior extremities of the tibia and fibula form direct articulations, and the shafts are connected by means of an interosseous membrane.

Superior Tibio-fibular Joint.—This joint belongs to the class *diarthrosis*, and to the subdivision *arthrodia*. The articular sur-

faces are the facets on the head of the fibula and on the external tuberosity of the tibia, and the ligaments are two in number, namely, **anterior** and **posterior**. Their fibres pass downwards and outwards from the outer tuberosity of the tibia to the head of the fibula, and they completely cover the joint in front and behind. Superiorly and inferiorly they meet, and thus construct a capsule for the joint. The anterior division of the tendon of the biceps femoris is closely related to the anterior ligament, and contributes materially to the strength of the joint, the more so because that division has an insertion into the outer tuberosity of the tibia as well as into the upper surface of the head of the fibula.

The **synovial membrane** is usually distinct from that of the knee-joint. Occasionally, however, it is in communication with it posteriorly by means of the synovial investment which surrounds the tendon of the popliteus.

Arterial Supply.—The arterial supply is derived from the inferior external articular, posterior tibial recurrent (inconstant), and anterior tibial recurrent arteries.

Nerve-supply.—The inferior external articular and recurrent articular, both branches of the external popliteal, and the nerve to the popliteus muscle, which is a branch of the internal popliteal.

Movements.—The movements are extremely limited, and are of a gliding or to-and-fro nature in an upward and downward direction. The knee being almost fully extended, if the fingers are placed over the head of the fibula whilst the foot is alternately flexed and extended, the head of the bone will be felt to glide upwards during flexion and downwards during extension of the foot.

Inferior Tibio-fibular Joint.—This joint belongs to the class **diarthrosis**, and to the subdivision **arthrodia**. The articular surfaces are the upper part of the facet on the inner surface of the external malleolus of the fibula and the facet on the outer aspect of the lower end of the tibia. The ligaments are anterior, posterior, inferior interosseous, and transverse.

The **anterior ligament** is a strong, flat band, the fibres of which pass obliquely downwards and outwards from the tibia to the fibula. It is related anteriorly to the peroneus tertius, and posteriorly is in contact with the inferior interosseous ligament.

The **posterior ligament**, which is disposed like the anterior, is in contact with the transverse ligament inferiorly, and with the inferior interosseous ligament anteriorly.

The **inferior interosseous ligament** is an important ligament, and is of considerable strength. It consists of short fibres which pass directly between the opposed rough triangular surfaces at the lower ends of the shafts of the tibia and fibula. It is continuous above with the interosseous membrane, and its extent is about $1\frac{1}{2}$ inches. Anteriorly and posteriorly it is in part related to the anterior and posterior inferior tibio-fibular ligaments. The part of the inferior tibio-fibular joint occupied by the inferior inter-

osseous ligament belongs to the class **amphiarthrosis**, and to the subdivision **syndesmosis**.

The **transverse ligament**, which is strong, narrow, and somewhat round, extends almost horizontally from the posterior border of the lower end of the tibia to the upper part of the digital fossa of the external malleolus. Externally it lies along the lower border of the posterior inferior tibio-fibular ligament, by which it is slightly overlapped. It fills up a slight hollow between the tibia and fibula, and it plays across the back part of the upper articular surface of the astragalus, where it usually gives rise to a transverse groove. The transverse ligament completes the back part of the tibial socket for the upper surface of the astragalus.

The **synovial membrane** is continuous with that of the ankle-joint.

Arterial Supply.—The posterior and anterior peroneal arteries, and the external malleolar of the anterior tibial.

Nerve-supply.—The interosseous branch of the nerve to the popliteus muscle, and the external division of the dorsalis pedis nerve.

Movements.—These are very limited, and are of a gliding nature, chiefly upwards and downwards, the fibula moving on the tibia. Though the bones are firmly bound together by the inferior interosseous ligament, there is yet a certain amount of lateral separation allowed during flexion of the foot.

Intermediate Connection between the Tibia and Fibula.—The union between the shafts of the tibia and fibula is effected by means of an interosseous membrane. This kind of union is a form of **syndesmosis** (union by an interosseous ligament). The **interosseous membrane** extends from the external border or interosseous ridge of the tibia to the antero-internal border or interosseous ridge of the fibula. The chief direction of the fibres is downwards and outwards from the tibia to the fibula, but a few pass in the opposite direction. Superiorly it terminates about 1 inch below the superior tibio-fibular joint in a sharp concave margin, the concavity of which is directed upwards. An interval is thus left above the membrane for the passage of the anterior tibial vessels and the efferent lymphatics of the anterior tibial gland. Sometimes these structures pass through a distinct aperture in the membrane, called the *superior hiatus*. Inferiorly it becomes continuous with the inferior interosseous ligament, and in this neighbourhood it presents a small opening or *inferior hiatus* for the passage of the anterior peroneal vessels. The interosseous membrane serves as a surface of origin to muscles.

Relations.—*Anterior.*—Tibialis anticus, over the upper two-thirds of the inner half; extensor longus digitorum, over the upper fourth of the outer half; extensor proprius hallucis, over the middle two-fourths of the outer half; peroneus tertius, over the lower fourth of the outer half; anterior tibial vessels, over the upper two-thirds in the middle line; and anterior tibial nerve, over the middle third.
Posterior.—Tibialis posticus.

Arterial Supply.—The anterior tibial and peroneal arteries.

Nerve-supply.—The interosseous branch of the nerve to the popliteus muscle, which descends within it to terminate in the inferior tibio-fibular joint.

THE ARCHES OF THE FOOT.

The foot presents two arches—antero-posterior or longitudinal and transverse.

Antero-posterior or Longitudinal Arch.—The posterior pier of this arch is formed by the plantar aspect of the tuber calcis, and the anterior pier by the heads of the metatarsal bones. The arch is single behind, where it is formed by the posterior two-thirds of the os calcis, but it is divided into two pillars in front. The internal pillar is formed by the astragalus, navicular, all three cuneiforms, and the inner three metatarsal bones. It is more raised from the ground, and has to bear more weight, than the external. The external pillar is formed by the anterior third of the os calcis, cuboid, and outer two metatarsal bones, and is nearer the ground than the internal. There is a natural tendency in the erect posture to flattening of the antero-posterior arch, but this is guarded against by (1) the inferior or internal calcaneo-navicular or spring ligament, (2) the calcaneo-cuboid ligaments (long and short plantar ligaments), (3) the central division of the plantar fascia, and (4) the tendon of the tibialis posticus, with its various expansions.

Transverse Arch.—This arch is best marked at the tarso-metatarsal articulations, and is due to the broad aspects of the middle and external cuneiform bones being dorsally placed, and the broad aspects of the wedge-shaped bases of the second, third, and fourth metatarsal bones being also dorsally placed. There is a tendency to flattening of the transverse arch when a person stands upon the toes, but the arch is maintained by the plantar and interosseous ligaments.

THE ARTICULATIONS OF THE FOOT.

The articulations of the foot are divided into tarsal, tarso-metatarsal, intermetatarsal, metatarso-phalangeal, and interphalangeal.

The Tarsal Articulations.

I. Astragalo-calcaneal Joints.—The astragalus is connected with the os calcis by two synovial joints, anterior and posterior, both of which belong to the class **diarthrosis**, and to the subdivision **arthrodia**.

Posterior Astragalo-calcaneal Joint.—The ligaments are interosseous, posterior, internal, and external.

The **interosseous ligament** passes between the oblique grooves separating the two articular surfaces of each bone, and forming

by their apposition the tunnel called the *sinus pedis*. It is very strong, and is to be regarded as the anterior ligament of the posterior astragalo-calcaneal joint.

The **posterior ligament** extends from the posterior aspect of the outer tubercle on the posterior border of the astragalus to the adjacent upper and inner surfaces of the os calcis. It is thin and membranous, and its fibres are arranged in a radiating manner.

The **internal ligament** is a narrow band which passes from the inner tubercle on the posterior border of the astragalus to the back of the sustentaculum tali of the os calcis. It is related to the tendon of the flexor longus hallucis.

The **external ligament** extends from the lower part of the outer surface of the astragalus, below the facet, to be attached to the adjacent part of the outer surface of the os calcis. It is under cover of, and parallel with, the middle fasciculus of the external lateral ligament, which, along with the internal lateral ligament of the ankle-joint, contributes to the strength of this articulation.

The **synovial membrane** of this joint is peculiar to it.

Arterial Supply.—The arterial supply is derived from the posterior tibial, external malleolar of the anterior tibial, posterior peroneal, and external tarsal of the dorsalis pedis artery.

Nerve-supply.—The short saphenous and the posterior tibial, or it may be the external plantar, nerves.

Anterior Astragalo-calcaneal Joint.—This joint has a lateral ligament at either side, and a posterior, but it is continuous anteriorly with the astragalo-navicular joint. The ligaments are interosseous or posterior, internal astragalo-calcaneal, and external or superior calcaneo-navicular.

The **interosseous** or **posterior ligament** has already been described in connection with the posterior astragalo-calcaneal joint.

The **internal astragalo-calcaneal ligament** extends from the inner surface of the neck of the astragalus to the upper margin of the inner border of the sustentaculum tali of the os calcis. It blends posteriorly with the inner end of the interosseous ligament, and anteriorly with the upper border of the internal calcaneo-navicular or spring ligament. It is strengthened by the internal lateral ligament of the ankle-joint. The internal or inferior calcaneo-navicular or spring ligament is also an internal ligament of this joint, but, inasmuch as it ranks as a ligament of the astragalo-navicular joint, it will be described in connection with that articulation.

The **external** or **superior calcaneo-navicular ligament** is placed on the outer side of the joint. It also ranks as an external lateral ligament of the astragalo-navicular joint. It is strong, and extends from the anterior part of the upper surface of the os calcis, external to the anterior facet, to a depression on the outer surface of the navicular bone near its posterior margin. Inferiorly it blends with the internal calcaneo-navicular ligament, and superiorly with the superior astragalo-navicular ligament.

The **synovial membrane**, though distinct from that of the posterior astragalo-calcaneal joint, is continuous in front with that of the astragalo-navicular articulation.

The **arterial supply** and **nerve-supply** are the same as for the astragalo-navicular articulation.

Movements between the Astragalus and Os Calcis.—The movements at the astragalo-calcaneal joints are abduction, adduction, and rotation. In abduction the foot and toes are turned outwards, and in adduction they are turned inwards, these movements being associated with a certain amount of rotation round an axis passing from the inner side of the neck of the astragalus downwards, backwards, and outwards to the lower and outer part of the tuber calcis. In adduction or inversion the posterior facet of the os calcis moves forwards and downwards upon the astragalus, and the front part of the os calcis is carried slightly inwards. During the movements the navicular bone rotates on the head of the astragalus, and the cuboid bone moves along with the os calcis.

II. Astragalo-navicular Joint.—This belongs to the class **diarthrosis**, and to the subdivision **enarthrosis**. It is in direct continuity behind with the anterior astragalo-calcaneal joint, with which it shares its synovial membrane, and the two articulations are sometimes described as one composite joint under the name of the astragalo-calcaneo-navicular joint. The ligaments are astragalo-navicular, external or superior calcaneo-navicular, and internal or inferior calcaneo-navicular, or spring, ligament.

The **astragalo-navicular ligament** is a thin membrane which covers the joint on its dorsal aspect. It is attached posteriorly to the upper margin of the head of the astragalus close behind the cartilage, and also to its outer and inner surfaces. Anteriorly it is attached to the dorsal surface of the navicular bone. Its fibres are arranged in a radiating manner, and converge towards the navicular bone. At the attachment to the astragalus they frequently form three bands, outer, dorsal, and inner, which, however, are continuous with one another.

The **external** or **superior calcaneo-navicular ligament** has been described in connection with the anterior astragalo-calcaneal joint, of which it ranks as the external ligament.

The **internal** or **inferior calcaneo-navicular ligament** is one of the most important ligaments of the foot, and is known as the **spring ligament**. It is a broad, thick, strong band of the consistence of fibro-cartilage, and is composed of fibrous and elastic tissues. Posteriorly it is attached to the front of the sustentaculum tali and the adjacent portion of the plantar surface of the os calcis. Anteriorly it is attached to (1) the plantar surface of the navicular bone, (2) the back of its tuberosity, and (3) the inner part of its dorsal surface. It is directed forwards and inwards, and covers the joint on its inner and lower aspects. Internally it blends with the anterior part of the internal lateral ligament of the ankle-joint and the astragalo-navicular ligament, and externally it blends with the external calcaneo-navicular ligament. The superior or deep surface of the ligament is in contact with a special

facet on the internal aspect of the inferior surface of the head of the astragalus. This surface of the ligament is covered by synovial membrane, and forms part of the articular socket for the head of the astragalus. It has a smooth, polished appearance, and presents no indication of its fibrous structure. The inferior or superficial surface, on the other hand, has the ordinary fibrous appearance of a ligament, and is in close contact with the tendon of the *tibialis posticus*, which is a powerful auxiliary to the ligament in supporting the antero-posterior arch of the foot. The spring ligament sometimes contains a sesamoid fibro-cartilage, which occasionally becomes ossified.

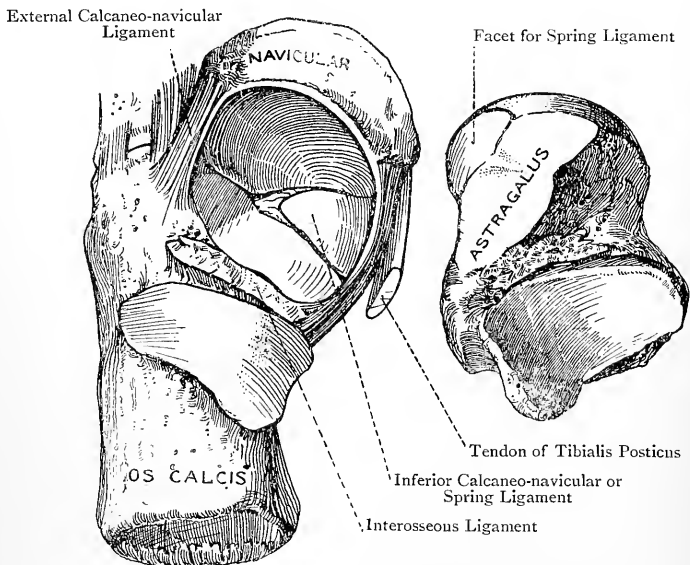


FIG. 262.—THE INFERIOR CALCaneo-NAVICULAR OR SPRING LIGAMENT OF THE LEFT FOOT (SUPERIOR VIEW).

The astragalo-navicular, external or superior calcaneo-navicular, and internal or inferior calcaneo-navicular ligaments form together a capsule for the astragalo-navicular joint.

The **synovial membrane** is continuous with the synovial membrane of the anterior astragalo-calcaneal joint.

Arterial Supply.—The anterior tibial, external tarsal branch of the *dorsalis pedis*, and internal plantar arteries.

Nerve-supply.—The internal plantar and the external division of the *dorsalis pedis* nerve.

The movements at this joint will be described with those at the calcaneo-cuboid joint.

III. Calcaneo-cuboid Joint.—This belongs to the class **diarthrosis**, and to the subdivision **reciprocal** or **saddle-joint**. The ligaments are dorsal, internal or interosseous, long plantar, and short plantar.

The **dorsal ligament** is a broad, flat band which passes between the superior surfaces of the os calcis and cuboid.

The **internal or interosseous ligament** is a strong band which lies deeply in the hollow between the fore parts of the astragalus and os calcis, where it is connected with the external calcaneo-navicular ligament. Its attachments are to the adjacent inner portions of the os calcis and cuboid.

The **long plantar (long inferior calcaneo-cuboid) ligament** is very strong, and is attached posteriorly to the plantar surface of the os calcis, upon which it extends from the inner and outer tubercles to the anterior tubercle. Anteriorly most of its fibres are attached to the ridge on the plantar surface of the cuboid bone behind the peroneal groove. Some of them, however, are continued forwards to be attached to the plantar aspects of the bases of the second, third, fourth, and fifth metatarsal bones. These latter fibres, as they pass over the peroneal groove, cover the tendon of the peroneus longus, and so complete its fibro-osseous canal.

The **short plantar (short inferior calcaneo-cuboid) ligament** is more deeply placed than the preceding. Posteriorly it is attached to the plantar surface of the os calcis in front of the anterior tubercle, as well as to the fore part of that tubercle, and anteriorly to the plantar surface of the cuboid bone behind the ridge.

The long and short plantar ligaments are in early life continuous with the tendo Achillis, but they become subsequently separated from it as the result of the backward growth of the heel.

The **synovial membrane** of this joint is peculiar to it.

Arterial Supply.—The external tarsal branch of the dorsalis pedis and the external plantar artery.

Nerve-supply.—The external plantar and the external division of the dorsalis pedis nerve.

Movements at the Astragalo-navicular and Calcaneo-cuboid Joints.—The movements at these joints are flexion and extension, combined with abduction, adduction, and rotation. Flexion occurs during extension of the ankle-joint, and extension during flexion of that joint. The axis of these movements passes from the inner side of the neck of the astragalus obliquely downwards, outwards, and backwards to the lower and outer part of the tuber calcis. During flexion and extension of the astragalo-navicular joint rotation of the navicular bone on the head of the astragalus takes place. The most free movement at this joint is downwards and inwards, or upwards and outwards. In adduction and abduction of the foot movement takes place at this joint as well as at the astragalo-calcaneal articulations. In adduction or inversion the navicular bone moves downwards and inwards, and so also does the cuboid at the calcaneo-cuboid joint, the result being that the antero-posterior arch of the foot is diminished. In abduction or eversion the navicular and cuboid bones move upwards and outwards, and the antero-posterior arch is increased.

In walking the head of the astragalus tends to sink upon the spring ligament,

and a certain amount of abduction or eversion of the foot takes place. When a person stands erect with both feet upon the ground, abduction or eversion is prevented by the astragalo-calcaneal ligaments. If, however, the spring ligament is in a weak condition, the tendon of the tibialis posticus is not of itself sufficient to prevent displacement of the head of the astragalus downwards and inwards. Displacement accordingly takes place in that direction, and so the condition known as **flat foot (pes planus)** is produced.

At the calcaneo-cuboid joint, besides the movements of flexion and extension combined with adduction and abduction, movement takes place downwards and inwards, or upwards and outwards. The astragalo-navicular and

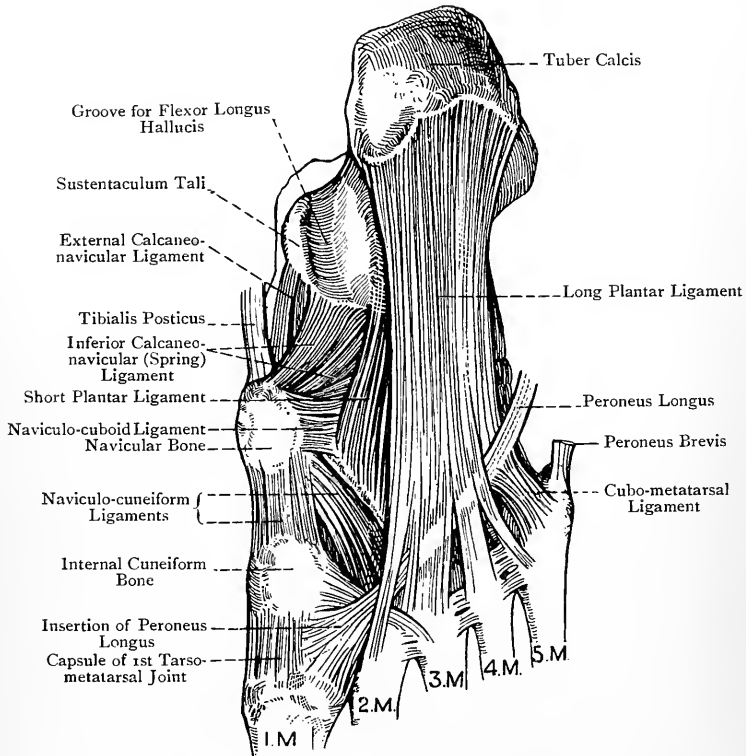


FIG. 263.—LIGAMENTS OF THE RIGHT FOOT (PLANTAR ASPECT).

calcaneo-cuboid joints together constitute the **transverse tarsal articulation**, the direction of which is in a straight line across the foot. It is at this transverse tarsal joint where disarticulation is performed in Chopart's operation.

IV. Naviculo-cuboid Joint.—This belongs to the class **diarthrosis**, and to the subdivision **arthrodia**, but only in those cases where the two bones articulate directly with each other by faceted surfaces. The ligaments are dorsal, plantar, and interosseous.

The **dorsal ligament** passes from the outer part of the dorsal

surface of the navicular bone to the middle third of the inner border of the dorsal surface of the cuboid.

The **plantar ligament** is a strong band which extends from the outer part of the plantar surface of the navicular bone to the internal part of the plantar surface of the cuboid. Its direction is forwards and outwards.

The **interosseous ligament** is also a strong band which extends between the contiguous surfaces of the two bones. The navicular and cuboid bones do not, as a rule, articulate directly with each other by cartilaginous surfaces, and under these circumstances there is no synovial membrane at this joint. Sometimes, however, the two bones come into actual contact, and then each has a special articular facet, that on the navicular bone being situated on its outer extremity, adjacent to the facet for the external cuneiform, and that on the cuboid being situated on its internal surface, behind the normal facet for the external cuneiform. When the two bones are thus in actual contact the joint is provided with a synovial membrane which is continuous with that of the naviculo-cuneiform articulation.

V. Naviculo-cuneiform Joint.—This belongs to the class **diarthrosis**, and to the subdivision **arthrodia**. The ligaments are dorsal, plantar, and internal.

The **dorsal ligament** is a strong, continuous sheet of fibres passing from the dorsal surface of the navicular bone to the dorsal surfaces of the three cuneiform bones.

The **plantar ligament** extends between the plantar surface of the navicular bone and the plantar surfaces of the three cuneiform bones. To a large extent it derives its fibres from the adjacent expansions of the tendon of the tibialis posticus.

The **internal ligament** passes between the tuberosity of the navicular bone and the inner surface of the internal cuneiform, and it blends with the dorsal and plantar ligaments.

VI. Intercuneiform Joints.—These belong to the class **diarthrosis**, and to the subdivision **arthrodia**. The ligaments are dorsal, interosseous, and plantar.

The **dorsal ligaments** are two in number, and their fibres pass transversely between the dorsal aspect of the middle cuneiform and the dorsal aspects of the internal and external cuneiform bones.

The **interosseous ligaments** are also two in number, and are very strong. They are deeply placed, and pass between the sides of the middle cuneiform and the contiguous sides of the internal and external cuneiform bones in front of the articular facets. They constitute the chief bond of union between the three bones.

The ligament between the middle and external cuneiform is attached to the entire vertical extent of the contiguous surfaces, whilst that between the middle and internal cuneiform is generally limited to the inferior and anterior portions of the contiguous surfaces.

The **plantar ligament** passes between the inner aspect of the eminence on the plantar surface of the internal cuneiform and the plantar aspect of the middle cuneiform.

VII. Cubo-cuneiform Joint.—This belongs to the class **diarthrosis**, and to the subdivision **arthrodia**. The ligaments are dorsal, plantar, and interosseous.

The **dorsal ligament** passes between the dorsal surface of the external cuneiform bone and the dorsal surface of the cuboid.

The **plantar ligament** passes from the plantar aspect of the external cuneiform bone to the internal surface of the cuboid over its anterior half, close to the plantar surface.

The **interosseous ligament**, which is strong and deeply placed, passes between the entire vertical extent of the contiguous surfaces of the two bones in front of the articular facets.

Synovial Membrane of the Naviculo-cuneiform, Intercuneiform, and Cubo-cuneiform Joints.—The naviculo-cuneiform synovial membrane is usually prolonged into the cubo-cuneiform joint, though

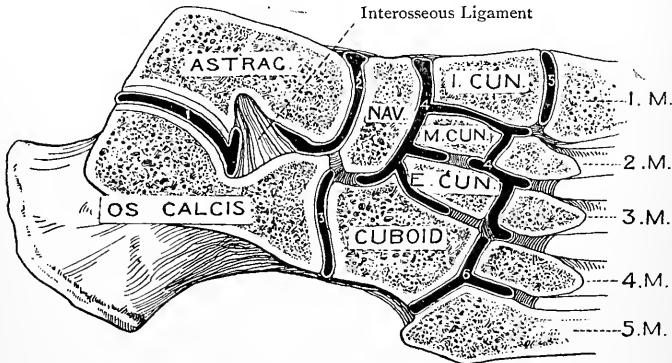


FIG. 264.—THE SYNOVIAL CAVITIES OF THE TARSAI AND TARSO-METATARSAL JOINTS.

occasionally the latter has a synovial sac peculiar to it. It is also continued into the naviculo-cuboid joint in those cases where these two bones articulate by facets. Further, it sends forwards two prolongations, one on either side of the middle cuneiform. The prolongation between the middle and external cuneiform and that between the external cuneiform and cuboid are entirely shut off from the synovial cavity of the middle tarso-metatarsal joint (the joint between the cuneiform bones and the second and third metatarsal bones). The explanation of this is that the interosseous ligaments between the middle and external cuneiform and between the external cuneiform and cuboid, which are placed in front of the articular surfaces, are attached over the entire vertical extent of the contiguous surfaces from the dorsal ligaments above to the plantar below. The prolongation, however, between the middle

and internal cuneiform is usually continuous in front with the synovial membrane of the middle tarso-metatarsal joint, because the interosseous ligament between these two bones is generally limited to the inferior and anterior portions of the contiguous surfaces. If this ligament should reach the dorsal surface, the naviculo-cuneiform synovial membrane would be entirely isolated from that of the middle tarso-metatarsal joint.

Arterial Supply.—The arterial supply of the naviculo-cuboid, naviculo-cuneiform, intercuneiform, and cubo-cuneiform joints is derived from the metatarsal branch of the dorsalis pedis and the internal and external plantar arteries.

Nerve-supply.—The dorsalis pedis, internal plantar, and external plantar nerves.

Movements at the Naviculo-cuneiform, Intercuneiform, and Cubo-cuneiform Joints.—The movements at these joints are very limited, and are of the gliding or to-and-fro variety. They do not affect the position of the foot as regards flexion and extension, or inversion and eversion, but they influence the transverse arch by increasing or diminishing its span. Downward gliding would increase the span, and upward gliding would diminish it.

The portion of the transverse arch which is formed by the three cuneiform and cuboid bones has the following muscles attached to its various parts—tibialis posticus, flexor brevis hallucis, adductor obliquus hallucis, peroneus longus, flexor brevis minimi digiti, and tibialis anticus. The first four muscles diminish the span, and so deepen the arch, whilst the tibialis anticus increases the span, and so renders the arch wider.

The Tarso-metatarsal Joints.

The tarso-metatarsal joints are divided into internal, middle, and external. They all belong to the class **diarthrosis**, and to the subdivision **arthrodia**.

I. Internal Tarso-metatarsal Joint.—This is the joint between the internal cuneiform and the first metatarsal bone. The dorsal and plantar ligaments of this joint are so disposed as to meet upon its inner and outer aspects, and thus a complete capsule is formed round the articulation, which capsule is stronger inferiorly and internally than elsewhere.

The **synovial membrane** of this joint is peculiar to it.

II. Middle Tarso-metatarsal Joint.—The bones which enter into this joint are the three cuneiforms and the bases of the second and third metatarsals (sometimes a part of the base of the fourth also). The ligaments are dorsal, plantar, and interosseous.

The **dorsal ligaments.**—The dorsal surface of the base of the second metatarsal bone receives three dorsal ligaments, one from each cuneiform. The dorsal surface of the base of the third metatarsal bone receives a dorsal ligament from the external cuneiform. Moreover, the external cuneiform is connected by a dorsal ligament with the dorsal surface of the base of the fourth metatarsal bone.

The **plantar ligaments** are three in number. One passes between the base of the internal cuneiform and the plantar aspects of the

bases of the second and third metatarsals, having the slips of the tendon of the tibialis posticus behind it; a second passes between the middle cuneiform and the base of the second metatarsal; and a third passes between the external cuneiform and the base of the third metatarsal, the latter two also having the slips of the tendon of the tibialis posticus behind them.

The **interosseous ligaments** are three in number—internal, middle, and external.

The *internal* interosseous ligament extends from the anterior and upper part of the outer surface of the internal cuneiform to the inner surface of the base of the second metatarsal. In each case it is attached below and in front of the articular facet, and it separates the internal from the middle tarso-metatarsal joint. It is a very strong ligament, and offers considerable resistance to the knife in the performance of Lisfranc's operation. The *middle* interosseous ligament extends from the anterior part of the inner surface of the external cuneiform, between the two semi-oval facets, to the groove on the outer surface of the base of the second metatarsal which separates the two facets. The *external* interosseous ligament extends from the anterior part of the outer surface of the external cuneiform, below the inconstant antero-superior facet, to the outer side of the base of the third metatarsal below the facet. It is also attached to the inner side of the base of the fourth metatarsal, and it ranks as the interosseous ligament of the cubo-metatarsal joint.

The **synovial membrane** of the middle tarso-metatarsal joint is usually continuous with that of the naviculo-cuneiform joint, the continuity taking place between the internal and middle cuneiform bones. Sometimes, however, they are quite distinct from each other. It sends prolongations forward between the bases of the second and third and third and fourth metatarsals.

III. External Tarso-metatarsal or Cubo-metatarsal Joint.—The bones which enter into this joint are the cuboid and the fourth and fifth metatarsals. The ligaments are dorsal, plantar, and interosseous.

The **dorsal ligament** passes from the dorsal surface of the cuboid to the dorsal surfaces of the bases of the fourth and fifth metatarsals.

The **plantar ligament** extends between the plantar surface of the cuboid in front of the peroneal groove and the plantar aspects of the bases of the fourth and fifth metatarsals. It is closely associated with the forward expansion of the long plantar ligament and with one of the slips of the tendon of the tibialis posticus.

The **interosseous ligament** is the same as the external interosseous ligament of the middle tarso-metatarsal joint.

The dorsal, plantar, and interosseous ligaments construct a capsule round the cubo-metatarsal joint.

The **synovial membrane** is peculiar to this joint, and sends a prolongation between the bases of the fourth and fifth metatarsals.

Arterial Supply.—The tarso-metatarsal joints derive their arterial

supply from the dorsalis pedis artery and its metatarsal branch, the internal plantar artery, and the plantar arch.

Nerve-supply.—The dorsalis pedis, internal plantar, and external plantar nerves.

Movements at the Tarso-metatarsal Joints.—The movements allowed are flexion and extension. At the internal tarso-metatarsal joint flexion is associated with a certain amount of abduction, whilst extension is accompanied by slight adduction. At the middle tarso-metatarsal joint flexion and extension are allowed, but no lateral movement. At the cubo-metatarsal joint flexion and extension, combined with abduction and adduction, are allowed, lateral movement being tolerably free in the case of the fifth metatarsal. A certain amount of gliding or to-and-fro movement is also permissible at the tarso-metatarsal joints in the following manner: the third metatarsal base can glide upwards, whilst the pair on either side of it can glide downwards, the effect being to diminish the span of the transverse arch of the foot. When the reverse movement takes place the span of the arch is increased.

The portion of the transverse arch which is formed by the bases of the metatarsal bones has the following muscles attached to its various parts: tibialis posticus, adductor obliquus hallucis, peroneus longus, flexor brevis minimi digiti, and tibialis anticus. The first three muscles diminish the span, and so deepen the arch, whilst the tibialis anticus increases the span, and so renders the arch wider.

Surgical Anatomy of the Tarso-metatarsal Joints.—It is in this situation where Lisfranc's and Hey's amputations are performed. The guide to the line of articulation on the outer border of the foot is the tuberosity on the outer side of the base of the fifth metatarsal, which can always be felt without difficulty. The joint between the cuboid and the fifth metatarsal is situated immediately *behind* this tuberosity. The guide to the line of articulation on the inner border of the foot is a point $1\frac{1}{2}$ inches in front of the tuberosity of the navicular bone. The line of articulation is in no sense transverse, its inner part being about 1 inch further forwards than the outer part. The tarso-metatarsal joints are remarkable for their irregularity, which is due to two causes. In the first place, the anterior surfaces of the three cuneiform bones do not present an even frontage. The internal and external cuneiform project further forwards than the middle cuneiform, and so a recess is formed which receives the base of the second metatarsal as that extends backwards to articulate with the middle cuneiform. The base of the second metatarsal thus becomes locked between the internal and external cuneiform. In the second place, the external cuneiform extends a little further forwards than the cuboid. The line of the tarso-metatarsal articulations, from the inner border of the foot to the outer border, is as follows: (1) *outwards*, between the internal cuneiform and first metatarsal; (2) *backwards*, for about $\frac{1}{2}$ inch (at this stage a very strong interosseous ligament has to be divided, as it passes between the internal cuneiform and the inner side of the base of the second metatarsal); (3) *outwards*, between the middle cuneiform and second metatarsal; (4) *forwards*, for about $\frac{1}{4}$ inch; (5) *outwards*, between the external cuneiform and third metatarsal; (6) *backwards*, for about $\frac{1}{4}$ inch; and (7) *outwards* and *backwards*, between the cuboid and the fourth and fifth metatarsals.

The Intermetatarsal Joints.

The basal intermetatarsal joints belong to the class **diarthrosis**, and to the subdivision **arthrodia**. The bones concerned are the outer four metatarsals. The first metatarsal bone does not usually articulate with the second, but sometimes it does. The ligaments are dorsal, plantar, and interosseous.

The **dorsal ligaments** are short transverse bands, three in number, which pass between the dorsal aspects of the bases of the second and third, third and fourth, and fourth and fifth metatarsals.

The **plantar ligaments** are disposed in a similar manner to the preceding on the plantar aspects of the bases of the four outer metatarsals.

The **interosseous ligaments**, which are three in number, are deeply placed and of considerable strength. They constitute a very firm bond of union between the contiguous sides of the bases of the outer four metatarsals, to the non-articular parts of which they are attached.

Synovial Membrane.—In the case of the joints between the bases of the second and third and third and fourth metatarsals the synovial membrane is a forward extension of that of the middle tarso-metatarsal joint, which sends forward two prolongations.

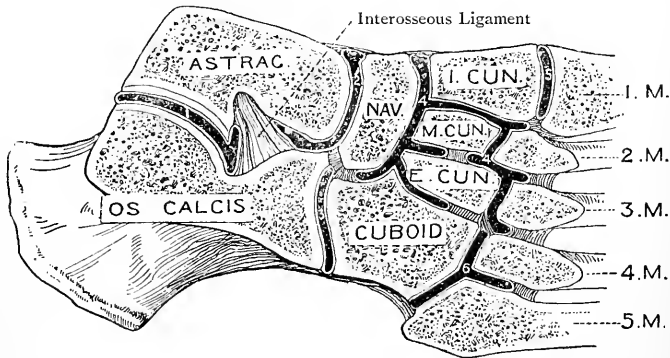


FIG. 265.—THE SYNOVIAL CAVITIES OF THE TARSAI AND TARSO-METATARSAL JOINTS.

In the case of the joint between the bases of the fourth and fifth metatarsals the synovial membrane is a forward prolongation of that of the cubo-metatarsal joint. As regards the contiguous sides of the bases of the first and second metatarsals, if they should articulate, a special synovial bursa is usually provided which sometimes communicates with the synovial membrane of the internal tarso-metatarsal joint.

The arterial supply and nerve-supply are derived from the same sources as in the case of the tarso-metatarsal joints.

Movements.—These are of a purely gliding or to-and-fro nature, so as to increase or diminish the span of the transverse arch of the foot.

The heads of *all* the metatarsal bones are connected by the **transverse metatarsal** (deep transverse) **ligament**, which extends across their plantar aspects. Its fibres are attached to the fibrous plates on the plantar surfaces of the metatarso-phalangeal joints,

and it receives the deep expansions of the digital processes of the central division of the plantar fascia. It is to be noted that the transverse metatarsal ligament includes the head of the first metatarsal bone, whereas the corresponding ligament in the hand (transverse metacarpal) excludes the head of the first metacarpal bone.

Summary of the Tarsal and Tarso-metatarsal Synovial Membranes.

—These are usually **six** in number.

1. Posterior astragalo-calcaneal.
2. Astragalo-calcaneo-navicular.
3. Calcaneo-cuboid.
4. Naviculo-cuneiform, cubo-cuneiform, cubo-navicular (inconstant), intercuneiform, and middle tarso-metatarsal.
5. Internal tarso-metatarsal.
6. External tarso-metatarsal or cubo-metatarsal.

Sometimes the middle tarso-metatarsal synovial membrane is distinct from the naviculo-cuneiform and intercuneiform synovial membrane, in which case the number would be increased to **seven**. Occasionally the cubo-cuneiform synovial membrane is distinct from the naviculo-cuneiform and intercuneiform, in which case there would be **eight** synovial membranes. In addition to these, there may be a synovial bursa between the contiguous sides of the bases of the first and second metatarsals if these articulate with each other, as they sometimes do.

The Metatarso-phalangeal Joints.

These joints belong to the class **diarthrosis**, and to the subdivision **condylarthrosis** or condyloid joint. They are formed by the heads of the metatarsal bones and the proximal ends of the first phalanges. The ligaments of the four outer joints are three in number, two lateral and an inferior or plantar fibrous plate. In the metatarso-phalangeal joint of the great toe the plantar fibrous plate of the other joints is replaced by two sesamoid bones, which are closely associated with the heads of insertion of the flexor brevis hallucis. In the case of each joint the expansion of an extensor tendon serves the purpose of a dorsal ligament. Each joint is provided with a synovial membrane. The ligaments, synovial membranes, and movements of these joints closely correspond with those of the metacarpo-phalangeal joints. Abduction, adduction, and circumduction, however, are much more limited.

Arterial Supply.—The plantar digital and dorsal interosseous arteries.

Nerve-supply.—The deep division of the external plantar nerve (either directly or through its branches to the interosseous muscles), or the adjacent digital nerves.

The Interphalangeal Joints.

These joints belong to the class **diarthrosis**, and to the subdivision **ginglymus**. They are formed by the distal end of one phalanx and the proximal end of the adjoining phalanx. The ligaments are three in number, two lateral and an inferior or plantar fibrous plate, the extensor tendon taking the place of a dorsal ligament. Each joint is provided with a synovial membrane. The ligaments,

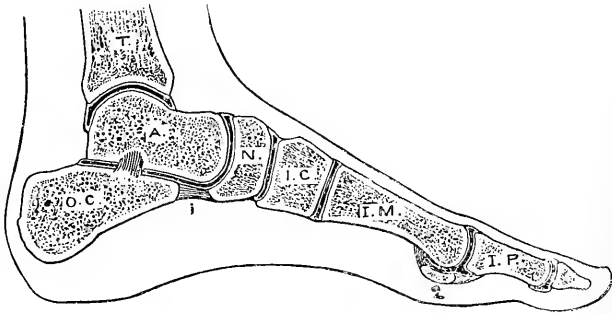


FIG. 266.—SAGITTAL SECTION OF ANKLE AND FOOT, PASSING THROUGH THE GREAT TOE.

1, Spring Ligament; 2, Inner Sesamoid Bone.

synovial membranes, and movements of these joints closely correspond with those of the interphalangeal joints of the hand.

The only joint in the lower limb which has **interarticular fibro-cartilages** is the knee-joint. The hip-joint has a circumferential fibro-cartilage, namely, the cotyloid ligament.

GUIDE TO THE LOWER LIMB.

Gluteal Region.—The landmarks having been studied, the skin is to be removed by making the following incisions: one extending from the level of the spine of the fifth lumbar vertebra outwards along the iliac crest as far as the position of the body will allow, and another extending from the fifth lumbar spine downwards in the middle line as low as the coccyx, after which it is prolonged outwards and downwards to the outer side of the thigh at a point about 5 inches below the great trochanter. The skin having been reflected, the gluteal cutaneous nerves are to be exposed in the following situations: (1) line of origin of gluteus maximus; (2) iliac crest; (3) outer and lower part of gluteus maximus; and (4) lower border of gluteus maximus. The superficial fascia should now be removed, and the deep fascia examined. It will be seen that, in passing from the gluteus medius to the gluteus maximus, it firmly straps down the upper border of the latter muscle to the former. When the gluteus maximus has been reflected, the fascia will be seen to divide into two laminae, which embrace and give insertion to rather more than the upper half of that muscle.

The gluteus maximus should be cleaned in the direction of its coarse fasciculi, and in connection with its lower border the bursa between it and the tuber ischii should be displayed. The muscle is to be divided about $1\frac{1}{2}$ inches from its origin. As the greater part of it is being reflected outwards, the following arteries should be exposed entering its deep surface: the superficial branch of the gluteal, the inferior gluteal branch of the sciatic, and branches of the first perforating of the arteria profunda femoris. The inferior gluteal nerve should also be shown entering the deep surface of the muscle in its lower third. Between the great trochanter and the insertion of the muscle into the fascia lata a large multilocular bursa will be found, and another single bursa should be noticed between its insertion and the vastus externus just below the great trochanter. The twofold insertion of the muscle should be noted. The origin of the muscle is now to be removed so as to expose the great sacro-sciatic ligament and the structures piercing it, namely, the coccygeal branch of the sciatic artery, the sacral branch of the internal pudic artery, and the perforating cutaneous branch of the sacral plexus of nerves. On the superficial surface of the ligament will be found the plexiform loops formed by the external branches of the posterior primary divisions of the first three sacral nerves.

The fascia lata should next be removed from the anterior part of the gluteus medius, and in doing so it should be noted that the superficial fibres of the muscle arise from the deep surface of the fascia. The various structures underneath the gluteus maximus are to be cleaned from above downwards, as follows: the posterior fleshy part of the gluteus medius, gluteal vessels, pyriformis, great and small sciatic nerves, sciatic vessels, pudic nerve and internal pudic vessels, nerve to the obturator internus, furnishing a branch to the gemellus superior, common nerve to the gemellus inferior and quadratus femoris, gemellus superior, tendon of the obturator internus, gemellus inferior, quadratus femoris, upper horizontal part of the adductor magnus, origins of the hamstring muscles from the tuber ischii, and the upper tendinous fibres of the vastus externus. The digital and crucial anastomoses should be looked for, the former in the digital or trochanteric fossa, and the latter between the quadratus femoris and adductor magnus.

The small sciatic nerve should be displayed so as to show its long pudendal branch, and the great sciatic nerve is to be exposed in the hollow between the tuber ischii and the great trochanter. The sciatic artery and its branches are to be followed out. The pudic nerve, the internal pudic vessels, and the nerve to the obturator internus (with its branch to the gemellus superior) are to be shown as they cross the back of the spine of the ischium. The tendon of the obturator internus should be divided to show the columns on its under surface, the synovial bursa between the tendon and the small sciatic notch, and the cartilage facing that notch, with its grooves and ridges for the columns of the tendon. The sacro-sciatic ligaments, great and small, should be studied. The mode of formation of the great and small sacro-sciatic foramina should be made out, and the various structures passing through each should be noted. The upper border of the quadratus femoris is to be displaced downwards so as to show the obturator externus and the ascending branch of the internal circumflex artery, both on their way to the digital fossa. The lower border of the quadratus femoris should be raised to show the small trochanter and the insertion of the ilio-psoas in part. The common nerve to the gemellus inferior and quadratus femoris will be found at first underneath the great sciatic nerve, and subsequently passing beneath the gemelli, obturator internus, and quadratus femoris. Its articular branch to the hip-joint should be looked for. If absent, its place will be taken by a branch from the great sciatic nerve.

The gluteus medius (except its anterior fibres) should now be stripped from the dorsum ilii, and the bone cleaned by scraping, so as to show the exact bony origin of the muscle. The pyriformis being also divided, the gluteus minimus is to be cleaned, along with the upper and lower branches of the deep divisions of the gluteal artery and superior gluteal nerve. One of each

of these structures will be found coursing along the upper border of the *gluteus minimus*, and crossing outwards over its centre. The latter branch (lower) of the artery should be shown to give a branch to the digital fossa to take part in the digital anastomosis, and the corresponding branch of the superior gluteal nerve should be followed outwards to the outer aspect of the thigh as far as possible on its way to the *tensor fasciæ femoris*, which it supplies. The *gluteus minimus* (except its anterior fibres) is to be stripped from the bone, after which the surface thereby exposed should be cleaned. The posterior or reflected head of the *rectus femoris* is to be shown arising from the *dorsum ilii* immediately above the brim of the *acetabulum*. The muscular relations of the capsular ligament of the hip-joint should be carefully attended to in so far as the position of the body will allow.

Popliteal Space.—This space should be dissected before the structures on the back of the thigh are disturbed. The landmarks having been studied, the skin is to be removed by the following incisions: (1) a median vertical incision extending from the junction of the upper two-thirds and lower third of the thigh to the junction of the upper fourth and lower three-fourths of the leg; and (2) two transverse incisions, one at either end of the median incision.

The small sciatic nerve is to be displayed after it pierces the *fascia lata* at the back of the knee-joint, and it should be followed to its terminal distribution over the upper part of the back of the leg. The upper part of the external or short saphenous vein is to be dissected, and in connection with it the following two veins should be noticed: (1) a fairly large tributary vessel, which descends from the lower part of the back of the thigh; and (2) a communicating branch, which passes upwards and inwards to join the long saphenous vein. Three cutaneous sural arteries (branches of the popliteal) may be looked for—an external, over the outer head of the *gastrocnemius*; an internal, over the inner head; and a middle, accompanying the short saphenous vein. The *fascia lata* should next be cleaned, and the accession of strength which it here receives from superadded transverse fibres should be observed. Above the level of the knee-joint the small sciatic nerve will be found in the middle line beneath the *fascia lata*. This *fascia* is now to be removed, and the boundaries of the popliteal space are to be cleaned.

The principal contents of the space are to be displayed by the removal of a large amount of fat. The great sciatic nerve should be exposed close to the upper median angle, and its external and internal popliteal branches cleaned downwards from that point. The external popliteal nerve is to be followed along the inner border of the *biceps femoris* as far as a point just below the head of the fibula. In cleaning this nerve, the dissector should look for the following branches, namely, (1) superior articular, to accompany the superior external articular artery; (2) inferior articular, to accompany the inferior external articular artery; (3) lateral cutaneous, to the integument of the outer side of the leg over about its upper two-thirds; and (4) *ramus communicans fibularis*, which passes downwards and inwards to the middle line of the calf on its way to join the *ramus communicans tibialis*, and so form the external or short saphenous nerve.

The internal popliteal nerve is to be followed through the centre of the space as low as the interval between the heads of the *gastrocnemius*. In cleaning it, the following branches should be looked for: (1) superior articular (inconstant), to accompany the superior internal articular artery; (2) central or *azygos articularis*, to accompany the corresponding artery; (3) inferior articular, to accompany the inferior internal articular artery; (4) *ramus communicans tibialis*, which takes a straight course downwards to the calf, where it forms the chief part of the external or short saphenous nerve; and (5) four or five muscular (sural) branches, as follows: (a) one to the outer head of the *gastrocnemius*; (b) one to the *plantaris* (which sometimes comes from the preceding branch); (c) one to the inner head of the *gastrocnemius*; (d) one to the *soleus*; and (e) one to the *popliteus*. The nerve to the *popliteus* should be preserved with great care.

The internal popliteal nerve should be hooked to one side, and the popliteal

vein exposed, its varying relation to the more deeply-placed popliteal artery being noted. The tributaries of the popliteal vein, when dissected, should be cut. These correspond with the branches of the popliteal artery, the short saphenous vein being a special tributary. The vein should next be hooked to one side, which will prepare the popliteal artery for dissection. In order to expose the vessel fully to its termination, the inner head of the gastrocnemius may be divided. In cleaning the artery, the geniculate branch of the obturator nerve should be looked for. If present, it will be found piercing the adductor magnus close above the femoral opening, after which it usually descends at first upon the inner side of the artery and then in front of it, until it comes into contact with the central or azygos branch, which it accompanies through the posterior ligament of the knee-joint to the interior of the articulation. During this dissection the popliteal lymphatic glands may come into view in the interval between the femoral condyles, one gland being superficial to the artery, one beneath it, and one on either side. The branches of the artery are to be carefully cleaned, as follows: (1) muscular, to the hamstring and sural muscles; (2) cutaneous, to the upper part of the back of the leg; and (3) the following five articular arteries: (a) two superior, external and internal, above the knee-joint, usually close above the femoral condyles and lying very deeply; (b) central or azygos, at the back of the joint, and coming either from the front (deep) surface of the main vessel, or in many cases from the superior external articular; and (c) two inferior, external and internal, below the level of the joint. The floor of the popliteal space should next be cleaned and examined, as follows: (1) the popliteal surface or trigone of the femur; (2) the posterior ligament of the knee-joint, with the ligamentum posticum Winslowii; and (3) the popliteal fascia covering the popliteus muscle.

Back of the Thigh.—The landmarks having been studied, the skin is to be removed by making a single vertical incision in the middle line. In the superficial fascia the femoral cutaneous branches of the small sciatic nerve are to be looked for, along the inner and outer aspects. At the upper and inner part of the back of the thigh twigs may be met with from the long pudendal branch of the small sciatic nerve.

The superficial fascia having been removed, the deep fascia or fascia lata should be studied. The deep fascia having been removed, the small sciatic nerve should be shown, and the hamstring muscles, namely, the biceps femoris, semitendinosus, and semimembranosus, should be cleaned and studied. The relation of the long head of the biceps to the great sacro-sciatic ligament should be noted.

The great sciatic nerve is also to be cleaned to its division into external and internal popliteal nerves, which latter nerves sometimes take the place of the great sciatic. The muscular branches of the great sciatic should be dissected, and it should be noted that, with one exception, they are derived from the internal popliteal part of the nerve. The exception is the branch to the femoral head of the biceps, which is derived from the external popliteal part of the nerve. It should also be noted that the nerve to the semimembranosus gives a branch to that part of the adductor magnus which extends from the tuber ischii to the adductor tubercle of the femur. The whole course and relations of the great sciatic nerve should be thoroughly mastered. The posterior surface of the adductor magnus should next be cleaned, showing the four arches with the four perforating arteries passing backwards under them, and the femoral opening where the femoral artery becomes the popliteal.

The distribution and anastomoses of the perforating arteries on the back of the thigh should be carefully studied, and it should be noted that they communicate above with the sciatic and gluteal, and below with the popliteal. It should further be noted that the perforating arteries do not terminate on the back of the thigh, and for this purpose an effort should be made to show all four passing outwards preparatory to their winding round the outer side of the femur to the outer side of the thigh, in which situation they end. The relation of muscles at the gluteal ridge of the femur should be studied, as well as the relation of muscles along the *linea aspera*.

Front of the Thigh.—The dissector should make himself thoroughly familiar with the landmarks of the front of the thigh and of the knee. The first dissection should be limited to the upper 4 inches in connection with the parts involved in femoral hernia. For this purpose three incisions are required for the removal of the skin, as follows: one along the line of the groin from the anterior superior iliac spine to the pubic angle, a second extending from the pubic angle vertically downwards along the inner side of the thigh for 4 inches, and a third extending from the lower end of the second incision transversely across the front of the thigh as far as its outer aspect.

It is to be desired that the subsequent dissection, which has to do with the superficial fascia and cutaneous vessels, should be undertaken in concert with the dissector of the abdomen. The superficial fascia in this region should be shown to be divisible into a subcutaneous fatty layer and a deep thin membranous layer, which correspond with Camper's and Scarpa's fasciæ of the lower part of the anterior abdominal wall. In order to reflect the subcutaneous layer, a transverse incision should be carefully made across the thigh, the depth of this incision coinciding internally with the long saphenous vein, which lies between the two layers of the superficial fascia. Another incision should be made vertically upwards on the inner side of the thigh, and extending only through the subcutaneous layer. Acting simultaneously with the dissector of the abdomen, the dissector of the thigh can now reflect outwards the subcutaneous layer, and both dissectors will see that it is continuous over Poupart's ligament with Camper's fascia of the anterior abdominal wall. Care should be taken not to disturb the lymphatic glands of this region. The inguinal glands (including the pubic glands) and the superficial femoral or saphenous glands are next to be dissected. The former will be found lying with their long axes oblique just below Poupart's ligament, and the latter with their long axes vertical along the terminal part of the long saphenous vein.

The cutaneous arteries of the groin, with their corresponding veins, are to be dissected, namely, the superficial epigastric, superficial circumflex iliac, and superior external pudic. The inferior external pudic, being beneath the fascia lata, is not to be dissected at present. The terminal part of the long saphenous vein should be shown, up to the level of the saphenous opening, and the following tributaries should be displayed joining it, namely, the external femoral cutaneous or anterior saphenous from the front of the thigh, the internal femoral cutaneous or posterior saphenous from the inner and back parts of the thigh, and the cutaneous veins of the groin, namely, the superficial epigastric, superficial circumflex iliac, and superior and inferior external pudic.

The deep layer of the superficial fascia is next to be raised towards Poupart's ligament. It lies immediately beneath the long saphenous vein, and upon the deep fascia or fascia lata. When raised towards the groin it will be seen to cover the saphenous opening, and thereafter to be firmly bound down to the fascia lata about $\frac{1}{4}$ inch below Poupart's ligament. The portion of it which covers the saphenous opening should be carefully studied. It is called the cribriform fascia, and it should be shown to be closely attached to the outer border of the saphenous opening, but only loosely to the inner part. It will be obvious that a hernia in passing through the saphenous opening must receive a covering from the cribriform fascia.

The following nerves should now be dissected, namely, (1) branches of the inguinal nerve (so-called ilio-inguinal), which will be found on the inner aspect of the thigh; (2) the crural branch of the genito-crural, appearing immediately external to the femoral artery just below Poupart's ligament, after having pierced the outer part of the crural sheath; and (3) the external cutaneous nerve, which will be found emerging beneath the outer end of Poupart's ligament.

The fascia lata is next to be cleaned, and the saphenous opening exposed, which should be carefully dissected. The best starting-point is the inferior cornu, which will readily come into view by raising the long saphenous vein. The cribriform fascia is to be carefully removed, and the various

parts of the opening displayed. Before disturbing the opening, the dissector should note that a part of the anterior wall of the crural sheath is seen lying within it. Having studied the saphenous opening, the dissector should now separate the outer border of the opening from the anterior wall of the crural sheath by dividing the fibrous processes which connect them. The superior cornu is next to be detached from Poupart's ligament, and turned downwards and outwards along with the outer border of the opening. This will bring fully into view the anterior wall of the crural sheath. The deep crural arch should be shown at this stage as a bundle of fibres extending from the centre of Poupart's ligament on its deep aspect inwards over the anterior wall of the crural sheath to the pectineal portion of the ilio-pectineal line, where it is attached behind Gimbernat's ligament.

Having studied the sheath as it now appears, and having observed that the crural branch of the genito-crural nerve pierces the outer part of the sheath just below Poupart's ligament, three vertical incisions are to be made in its anterior wall—one over the femoral artery, another over the femoral vein, and a third a line or two internal to the vein. The interior of the sheath should then be shown to be divided into three compartments by means of two septa, which pass backwards on either side of the femoral vein. The femoral artery and, for a very limited distance, the crural branch of the genito-crural nerve should be shown in the outer compartment, whilst the femoral vein, having on its inner side two or three of the deep femoral (deep inguinal) glands, will be found in the middle compartment. The inner compartment is called the crural canal. It is of considerable surgical importance, and should be studied with the closest attention. It will be seen to contain a little fat, and at its upper end one of the deep femoral glands will be found. The dissectors of the thigh and abdomen, who should be working in concert at this stage, should now thoroughly explore the canal. The little finger should be inserted into it, and carried upwards to a point beneath Poupart's ligament. At the upper end of the canal the finger will detect the septum crurale, which shuts off the canal from the abdominal cavity. By breaking down this septum, the point of the finger will lie in the crural or femoral ring, and the sharp wiry base of Gimbernat's ligament will readily be felt on the inner side of the ring, this being the usual cause of stricture in femoral hernia. Behind the finger as it lies in the crural ring is Cooper's ligament. This structure, however, can only be shown by making a deep dissection of the parts beneath Poupart's ligament, in conjunction with the dissector of the abdomen. The parts around the crural ring should be studied with the greatest care, as it is through this ring and the crural canal that femoral hernia may occur.

The remainder of the skin of the thigh is now to be removed by making a vertical incision down the inner side of the thigh to a point just below the level of the patella, and carrying this incision transversely across the front of the leg immediately below the patella on to the outer aspect of the limb. This will enable the dissector to reflect the skin from the patella as well as from the front of the thigh. The prepatellar bursa will be found lying in front of the bone, where it is confined by an expansion which the fascia lata sends over the bone from its lateral borders.

A complete dissection of the cutaneous nerves and the femoral part of the long saphenous vein is now to be made. The external cutaneous nerve, which has been already caught, should now be followed out. Its small posterior division and large anterior division should be shown, and it should be noted that the latter is contained in a tube of fascia lata for about 4 inches before it enters the integument. The middle cutaneous nerve will be found piercing the fascia lata (usually in two divisions) about 4 inches below Poupart's ligament, and both should be followed down to the patellar plexus. It has been seen that the inguinal nerve is distributed to the integument of the inner aspect of the thigh in its upper third. In dissecting the long saphenous vein in the middle third of the thigh, twigs of the internal cutaneous nerve will be met with along the course of that vein. There may also be found branches of the subsartorial plexus ramifying in this region (middle third). Another nerve which should be looked for at this level is the cutaneous

branch of the superficial or anterior division of the obturator nerve. When present it will usually be found piercing the fascia lata at about the centre of the inner side of the thigh, between the posterior border of the sartorius and the anterior border of the gracilis. The two divisions of the internal cutaneous nerve, anterior and posterior, should next be dissected. The anterior division will be found piercing the fascia lata at the junction of the middle and lower thirds of the thigh. It should then be followed to the inner side of the knee and patellar plexus. The posterior division will be found piercing the fascia lata at the level of the inner condyle, after which it descends to the inner side of the leg, where it will be afterwards dissected. The patellar branch of the internal or long saphenous nerve is to be shown. It pierces the sartorius and the fascia lata at the level of the inner condyle, and should be followed to the integument over the patella and patellar plexus. The patellar plexus itself is to be carefully dissected.

The fascia lata is now to be cleaned and examined. Its deep processes will only come into view as it is being removed to expose the muscles. The muscles of the front and inner side of the thigh are to be cleaned by removing the fascia lata. A strip of this fascia, the so-called ilio-tibial band, about 2 inches broad, and extending from the fore part of the iliac crest to the front of the external tuberosity of the tibia, should be preserved. In removing the fascia lata from the pectineus and adductor longus the inferior external pudic artery is to be dissected.

The boundaries of Scarpa's triangle should be defined. In the triangle the following muscles should be cleaned from without inwards, namely, the iliacus, psoas magnus, pectineus, and adductor longus. The contents of the triangle are now to be cleaned and studied, namely, (1) the anterior crural nerve; (2) the common femoral and superficial femoral arteries; (3) the origins of the superficial epigastric, superficial circumflex iliac, superior external pudic, and inferior external pudic arteries; (4) the origin of the arteria profunda femoris, and its external circumflex and internal circumflex branches, and (5) the femoral vein and its tributaries. In cleaning the anterior crural nerve its branch to the pectineus should be noted as it passes inwards behind the crural sheath.

Having completed the superficial dissection of Scarpa's triangle, the remainder of the sartorius should be cleaned. The following muscles should also be cleaned in the order named: tensor fasciæ femoris, rectus femoris, and gracilis. In cleaning the tensor fasciæ femoris the branch of the superior gluteal nerve entering its deep surface should be shown by dissecting between the muscle and the gluteus medius, the ilio-tibial band should be studied, and a strong lamina of the fascia lata should be shown passing upwards on the deep surface of the muscle to the dorsum of the ilium. The two heads of the rectus femoris should be exposed.

The sartorius should now be held aside in the middle two-fourths of the thigh, in order to study Hunter's canal and its contents. The aponeurotic covering or roof of the canal should be shown as an upward expansion from the tendinous anterior margin of the femoral opening in connection with the adductor magnus. It should be observed that this tendinous roof is strong over the lower part of the canal, where it is pierced by a branch of the long saphenous nerve to the subsartorial plexus, and by the arteria anastomotica magna. An endeavour should be made at this stage to expose the subsartorial plexus as it lies upon the aponeurotic covering of Hunter's canal. This covering should now be removed, and the contents and boundaries of the canal exposed. It should be observed that the nerve to the vastus internus is only contained in the upper half of the canal, and that the arteria anastomotica magna arises from the superficial femoral at the extreme lower end of the canal.

The deep dissection of Scarpa's triangle should now be undertaken. A slight interval may be noted between the lower part of the pectineus and adductor longus, in which a partial view may be obtained of the adductor brevis and the superficial or anterior division of the obturator nerve. The superficial femoral artery should be divided just below the origin of the arteria profunda femoris, as well as the femoral vein. The arteria profunda femoris

should now be studied as far as the upper border of the adductor longus, and this will be facilitated by dividing the corresponding vein. Its external circumflex branch should be followed out in its ascending, transverse, and descending branches, and the anastomoses of these branches should be carefully studied. An articular offset to the hip-joint from the ascending branch should be looked for. The long descending branch of this artery to the geniculate arterial rete should be noted.

The branches of the anterior or superficial and posterior or deep divisions of the anterior crural nerve should be dissected, and the following articular nerves should be looked for, namely, one to the hip-joint from the nerve to the rectus femoris, and three to the knee-joint, as follows: one from the nerve to the vastus externus; one from the most internal of the branches to the crureus, supplying in its course the subcrureus; and one from the nerve to the vastus internus, which ultimately accompanies the deep branch of the arteria anastomotica magna.

The vastus externus, crureus, and vastus internus are next to be dissected. The vastus internus and crureus are to be separated by dissecting along the course of a cellular interspace, which extends upwards in the direction of a line drawn from the inner border of the patella to the inferior cervical tubercle of the femur. When the vastus internus is reflected inwards, a bare strip along the inner aspect of the shaft of the femur, devoid of muscular fibres, is to be noted. The crureus should next be turned aside in two halves by making a vertical incision down the centre of the muscle. This will show the lower limit of origin of the muscle, and it will bring into view the subcrureus. The bursa beneath the suprapatellar tendon and the prolongation of the synovial membrane of the knee-joint, which is continuous with it, should be shown. In dissecting the lower part of the vastus internus the deep branch of the arteria anastomotica magna and an articular branch to the knee-joint from the nerve to the vastus internus should be followed out.

The pectineus and adductor longus should be divided and reflected. When the pectineus has been reflected it should be noted that a portion of the capsular ligament of the hip-joint (including the pubo-femoral ligament) is exposed. This will bring fully into view the adductor brevis, with the anterior or superficial division of the obturator nerve resting upon it, and the obturator externus lying above it. The continuation of the arteria profunda femoris is also exposed. The four perforating branches of this vessel should be shown, the first and second piercing the adductor brevis and adductor magnus, whilst the third and fourth pierce only the adductor magnus.

The internal circumflex artery should be studied at this stage. Replacing the pectineus, the artery should be traced backwards between that muscle and the psoas magnus, and then between the adductor brevis and obturator externus. In this latter situation the artery should be shown to divide into its two terminal branches, namely, (*a*) ascending, or anterior, passing with the obturator externus to the digital fossa; and (*b*) transverse or posterior, passing backwards between the quadratus femoris and upper border of the adductor magnus, and furnishing in its course an articular branch to the hip-joint which enters beneath the transverse ligament. It should be observed that the internal circumflex artery gives branches to the obturator externus, which anastomose in that muscle with branches of the obturator artery.

The adductor brevis should be divided without injuring the anterior division of the obturator nerve, and the obturator externus should be dissected. Its relation to the neck of the femur and the capsular ligament should be noted, as also its relation to the obturator nerve. This nerve is now to be dissected. An articular branch to the hip-joint from the anterior division should be looked for, and the termination of this division in cutaneous and vascular branches should be noted. The posterior division should be followed out in the expectation of finding it terminating in the inconstant geniculate branch. An accessory obturator nerve may be found emerging over the superior pubic ramus beneath the pectineus, after which it will be seen to end in three

branches, as follows: one to the hip-joint, one to the pectineus, and one to reinforce the anterior division of the normal obturator nerve.

The obturator externus is next to be cut and reflected, in order to expose the obturator membrane and obturator artery. The artery should be shown to divide into an internal and external branch (the latter furnishing an articular branch to the hip-joint), and the arterial loop formed by these two branches at the circumference of the obturator membrane should be made out. The anastomosis in the obturator externus between the obturator and internal circumflex arteries will now be readily understood. The adductor magnus is next to be fully studied. Its division into three parts is to be shown, as well as the four tendinous arches under which the four perforating arteries pass. The relation of the muscle to Hunter's canal is to be noted, and the femoral opening for the passage of the superficial femoral artery and corresponding vein is to be dissected. The dissector should now replace the adductor brevis, adductor longus, and pectineus, and the relative positions of these muscles should receive attention. The anterior portions of the gluteus medius and gluteus minimus should be cleaned by removing the fascia lata, and when they are reflected the bursæ between them and the great trochanter should be shown, as well as the strong arched band of fibres which connects the tendon of the gluteus minimus with the upper part of the capsule of the hip-joint.

Hip-Joint.—A careful study of the hip-joint should now be made, preparatory to the removal of the limb, and this should be done in the following order: (1) The muscular relations of the capsular ligament should be carefully noted, the muscles not yet cut should be divided, the bursa beneath the ilio-psoas should be observed, and the two heads of the rectus femoris should be again studied. The actions of the various muscles upon the joint should also be studied. (2) The capsular ligament should be cleaned, and an occasional opening in it should be looked for underneath the ilio-psoas bursa. The various accessory bands should be attended to, and their influence over the movements of the joint should be observed. The attachments of the capsule to the femur in front and behind are to be noted, and the difference in direction of the anterior and posterior fibres, as well as their relative strength, observed. The effect of different positions of the limb upon the head of the femur should be attended to. (3) The capsular ligament should be divided, and the ligaments within the joint studied, namely, (*a*) the cotyloid ligament, (*b*) the transverse ligament, and (*c*) the ligamentum teres. The synovial or Haversian gland is also to be noted. As regards the ligamentum teres, a good plan to adopt is as follows: the dissector of one limb should examine the hip-joint in the usual manner, namely, from the front, and the dissector of the other limb should avail himself of this examination. The dissector of the other limb should saw through the upper part of the shaft of the femur, and leave the hip-joint undisturbed in the meantime. Subsequently, when the pelvis has been sufficiently dissected, the dissectors of the abdomen, in conjunction with the dissectors of the lower limbs, should open into the hip-joint on the side on which it has been left undisturbed by operating upon the smooth inclined pelvic aspect of the ischial portion of the hip-bone. This dissection will enable the dissectors to study the action of the ligamentum teres with the capsular ligament left undisturbed. (4) The synovial membrane of the joint is to be studied. (5) The bony articular surfaces are to be examined. (6) The movements at the joint, and the muscles by which these are effected, are to be thoroughly mastered, and the arterial supply and nerve-supply are to be reviewed.

The relations of structures to the anterior intertrochanteric line should next receive attention, and the obturator canal and its contents should be examined. The relative position of the muscles from the symphysis pubis outwards to the obturator foramen should be noted. Finally, the relative positions of the tendons of insertion of the sartorius, gracilis, and semi-tendinosus, and the bursa in connection with them, should be examined.

The dissector is now prepared to remove the limb. Any muscles passing between the pelvis and the thigh are to be cut, and the ligamentum teres is

to be divided, after which the limb can be separated. The first duty of the dissector is to trim the femoral muscles, and revise their attachments and relations. On the inner side of the knee-joint, if not previously displayed, he should show the long saphenous vein and nerve, the posterior division of the internal cutaneous nerve, and the superficial branch of the *arteria anastomotica magna*. The deep branch of the last-named artery, if not previously dissected, should now be followed out. The relation of the long external lateral ligament of the knee-joint to the tendon of insertion of the biceps femoris, as well as the bursa in this situation, and the expansion from the tendon to the deep fascia of the leg, should be shown.

Front and Sides of the Leg and Dorsum of the Foot.—The dissector is to make himself thoroughly familiar with the landmarks of the leg and foot. The skin is then to be removed by making the following incisions: a vertical incision along the anterior border of the tibia, and along the dorsum of the foot as far as the web between the second and third toes; a transverse incision at the ankle-joint, and another at the webs of the toes; a median incision along the dorsum of each toe; and a transverse incision across the dorsum of each toe close to the nail. The skin is to be reflected to either side, and the following structures should be exposed on the inner aspect of the tibia: (1) the long saphenous vein, which should be shown passing in front of the internal malleolus, and traced as far as the inner end of the dorsal venous arch; (2) the long saphenous nerve, accompanying the foregoing vein as far as the centre of the inner border of the foot; (3) the posterior division of the internal cutaneous nerve, ramifying in the integument of the upper half of the leg; and (4) the superficial branch of the *arteria anastomotica magna*, ramifying in the upper third. Communications are to be sought for between the long and short saphenous veins, and also between the former and the deep-seated veins on the front of the leg.

The venous arch on the dorsum of the foot should next be displayed, care being taken to preserve the cutaneous nerves. The long saphenous vein will conduct to it, and the small tributary veins from the superficial plantar venous plexus may be shown turning round the inner border of the foot to join the long saphenous vein. The short saphenous vein should be traced from the outer end of the arch to a point below and then behind the external malleolus; the small tributary veins from the superficial plantar venous plexus may be shown turning round the outer border of the foot to join it; and an endeavour may be made to show the following tributaries of the dorsal venous arch, namely, (1) the dorsal digital veins; (2) small veins from the dorsum of the foot; and (3) the efferent or interdigital veins from the plantar transverse venous arch.

The dissector should now display the musculo-cutaneous nerve. He will find it piercing the deep fascia on the outer side of the leg about the junction of the upper two-thirds and lower third. Branches should be traced to the integument of the front of the leg in its lower third, and the main nerve should be followed on in two divisions, to be distributed to the inner side of the great toe and the contiguous sides of the second and third, third and fourth, and fourth and fifth toes, as well as to the integument of the malleoli and dorsum of the foot.

The external or short saphenous nerve should next be dissected along the outer border of the foot as far as the outer side of the little toe. Upon the outer side of the leg the dissector will find the lateral cutaneous branch of the external popliteal nerve, which ramifies in the integument of about the upper two-thirds. The deep fascia of the front and sides of the leg should next be studied. Three intermuscular septa are to be noted, namely, anterior, antero-external, and postero-external. In the region of the ankle-joint the following parts of the deep fascia are to be specially dissected, namely, (1) the external annular ligament, strapping down the tendons of the *peroneus longus* and *peroneus brevis*; and (2) the anterior annular ligament, which will be found in two divisions—one above the ankle-joint and the other in front of it. The following points are to be specially noted in connection with the two divisions of the anterior annular ligament, namely,

(1) the number of compartments in each division; (2) the tendons passing beneath each, and their relative position; and (3) the number of synovial sheaths.

The anterior tibial muscles are next to be dissected to their insertions in the following order, namely, the tibialis anticus, extensor longus digitorum, peroneus tertius, and extensor proprius hallucis. In connection with the expansions formed by the long extensor tendons on the dorsal aspects of the metatarso-phalangeal joints, the tendons of insertion of the lumbricales and interossei are to be carefully preserved. The anterior tibial nerve will be found coming into contact with the outer side of the anterior tibial artery about the junction of the upper fourth and lower three-fourths of the leg, and it should be followed from this point as far as the front of the ankle-joint. The anterior tibial artery is now to be shown lying deeply upon the interosseous membrane over about the upper two-thirds, but upon the anterior surface of the tibia in the lower fourth. In dissecting the upper part of the artery, the anterior tibial lymphatic gland should be looked for, and the venæ comites accompanying the artery should be noted. The following branches of the artery should be shown, namely, anterior tibial recurrent, muscular, internal malleolar, and external malleolar. In dissecting the anterior tibial recurrent artery, the recurrent articular branch of the external popliteal nerve should be looked for. The terminal part of the anterior peroneal artery should be exposed as it appears through the inferior hiatus in the interosseous membrane, and it should be followed downwards under cover of the peroneus tertius and in front of the inferior tibio-fibular articulation, to take part in the external malleolar anastomosis.

The dissector should now turn his attention to the dorsum of the foot. The deep fascia should be examined. The extensor brevis digitorum is to be dissected, and the insertion of its innermost tendon and its relation to the arteria dorsalis pedis are to be noted. The arteria dorsalis pedis and its venæ comites are to be dissected, and the following branches of the artery are to be followed out, namely, internal tarsal, external tarsal, metatarsal, and arteria dorsalis hallucis. The arch formed by the metatarsal branch is to be noted, and three dorsal interosseous arteries are to be dissected forwards from it. The dorsalis pedis nerve (the continuation of the anterior tibial nerve) is next to be dissected as far as the cleft between the great toe and second, where it will be found to divide into two collateral dorsal digital branches for the supply of the contiguous sides of these two toes. The offset which it receives from the branch of the musculo-cutaneous nerve to the inner side of the great toe is to be shown, and the external branch of the nerve is to be followed beneath the extensor brevis digitorum. In this situation its gangliiform enlargement is to be looked for, and the offsets arising therefrom may be followed out.

The four dorsal interosseous muscles should now be dissected. In connection with the first dorsal interosseous the plantar or perforating branch of the arteria dorsalis pedis is to be noted, and in connection with the second, third, and fourth, the posterior and anterior perforating arteries should be looked for.

The dissector should now turn his attention to the external aspect of the leg, where the peroneus longus and peroneus brevis are to be dissected. The latter muscle should be dissected throughout its entire course, but the former should only be followed meanwhile as far as the groove on the outer border of the cuboid bone. In dissecting these muscles, the fibro-osseous tunnel in which they lie is to be noted. The musculo-cutaneous and anterior tibial nerves are now to be traced upwards to their origin from the external popliteal at the level of the neck of the fibula. In doing so, in the case of the musculo-cutaneous nerve, both peroneal muscles are to be cut in so far as may be necessary, and in the case of the anterior tibial nerve the extensor longus digitorum and peroneus longus are to be cut. The mode of ending of the external popliteal nerve will now be made manifest, its terminal branches being the anterior tibial, musculo-cutaneous, and recurrent articular.

Back of the Leg.—A transverse incision having been made over the heel, the

skin is to be reflected from the back of the leg. The terminal distribution of the small sciatic nerve having been revised, the dissector should trace the ramus communicans tibialis and ramus communicans fibularis nerves to the centre of the calf, the former lying in the median groove of the gastrocnemius, and the latter descending obliquely inwards over the outer head of that muscle. At or about the centre of the calf these two nerves will usually be found to unite, and so form the external or short saphenous nerve. This nerve, along with the short saphenous vein, should be followed superficial to the deep fascia downwards and outwards along the outer side of the tendo Achillis (the nerve meanwhile giving branches to the integument of the lower half of the back of the leg), then behind and below the external malleolus (in which situation the nerve supplies calcaneal and malleolar branches), and subsequently along the outer border of the foot. Communications between the short saphenous vein and the long saphenous vein are to be sought for, as well as communications between the former and the deeply-seated veins which accompany the posterior tibial and peroneal arteries.

The deep fascia of the back of the leg is next to be dissected, and thereafter the gastrocnemius muscle is to be studied. The inner head of the muscle having been previously cut in connection with the dissection of the lower part of the popliteal space, the outer head is now to be divided, and both heads are to be reflected upwards in order to show the exact origin of each, that of the inner head lying obliquely, whilst that of the outer head lies vertically. The popliteal bursa, which separates the inner head from the semimembranosus, should be sought for, and its relation to the synovial membrane of the knee-joint examined. In the outer head of the muscle will be found a sesamoid fibro-cartilage (sometimes ossified). The belly of the gastrocnemius and its tendon is to be reflected downwards as far as the commencement of the tendo Achillis. The plantaris is then to be dissected, and its long, narrow tendon should be taken between the index-finger and thumb of each hand and stretched laterally to demonstrate its distensibility. The soleus is next to be dissected, and the fibrous arch over the posterior tibial vessels is to be shown, with fibres of the muscle springing from it. A branch from the internal popliteal nerve is to be found entering the superficial surface of the muscle near its upper border. The other nerve-supply from the posterior tibial will only come into view as the muscle is being reflected. The tendon of the soleus is to be shown joining that of the gastrocnemius to form the tendo Achillis. The aponeurotic appearance presented by the deep surface of the gastrocnemius and the superficial surface of the soleus is to be noted. The tendo Achillis is to receive careful attention.

Before the soleus is disturbed, the hollow on either side of the tendo Achillis is to be noted. In the outer hollow the short saphenous vein and nerve have been already dissected, their position being here superficial. Lying deeply in the hollow on the inner side of the tendon are the posterior tibial vessels and nerve. A limited opening should be made in the deep fascia to show the exact position and relations of these structures. The soleus is now to be stripped from its tibial and fibular origins and turned downwards. In the course of this dissection a branch from the posterior tibial nerve is to be shown entering the deep surface of the muscle about the centre of the leg. The tendo Achillis having been turned downwards, the large quantity of fat beneath it is to be observed, and the bursa between the tendon and the upper zone of the posterior surface of the tuber calcis is to be shown. By dissecting into the deep surface of the soleus, the arrangement of its very short fibres will be brought into view.

The lower part of the popliteal vessels and internal popliteal nerve, though previously dissected, should now be revised. The division of the artery into anterior tibial and posterior tibial at the lower border of the popliteus muscle should be noted. The commencement of the anterior tibial artery is to be dissected, showing the vessel passing forwards between the two heads of the tibialis posticus, and between the tibia and fibula. Its branches in this situation are to be shown, namely, posterior tibial recurrent (inconstant), and superior fibular. The nerve to the popliteus from the internal popliteal, if

not previously dissected, is to be followed out. The inferior external and inferior internal articular arteries are to be studied. The popliteal fascia covering the popliteus muscle is to be inspected, noting that it is one of the modes of insertion of the semimembranosus. The fascia is now to be removed, in doing which it should be noted that the superficial fibres of the popliteus muscle take insertion into its deep surface. In the meantime, the exact origin of that muscle cannot be shown, so that the dissector should content himself with showing the tendon after its escape from the interior of the knee-joint, when it is almost immediately replaced by fleshy fibres.

The sural muscles having been completely turned aside, the expansion of the deep fascia, called the posterior or transverse intermuscular septum, is to be studied. In connection with it the internal annular ligament is to be displayed (but not opened up as yet) between the internal malleolus and the tuber calcis. In doing so, care must be taken to preserve the calcaneo-plantar branch of the posterior tibial nerve and the internal calcaneal branch of the posterior tibial artery, both of which pierce the ligament. The deep muscles of the back of the leg are to be cleaned, and at the same time the posterior tibial vessels and nerve are to be dissected. The muscles from within outwards are the flexor longus digitorum, tibialis posticus, and flexor longus hallucis. It should be observed that the tibialis posticus is covered superficially by a strong aponeurotic expansion, which stretches across between the muscles on either side of it. In dissecting the lower portions of these muscles in the neighbourhood of the ankle-joint, the internal annular ligament is now to be opened, when it will be seen to contain four canals, three of which are fibro-osseous, and one (for the flexor longus digitorum) purely fibrous. The relation of the tendons, posterior tibial vessels, and posterior tibial nerve as they traverse these canals is to be studied, and the synovial sheaths are to be noted. The branches of the posterior tibial artery and nerve are to be displayed. As regards the branches of the artery, they should be dissected in the following order from above downwards, namely, (1) peroneal, of large size, and arising about 1 inch below the commencement of the posterior tibial; (2) medullary, for the tibia (of large size); (3) muscular; (4) communicating or transverse, near the ankle, and passing transversely outwards to join a similar branch of the peroneal; (5) internal malleolar, usually two in number, and passing beneath the tendons behind the internal malleolus to take part in the internal malleolar anastomosis; (6) internal calcaneal; and (7) the two terminal branches, internal and external plantar arteries. Two *venæ comites* are to be dissected with the posterior tibial artery, which communicate at frequent intervals by transverse branches placed superficial to the vessel. These *venæ comites* should be shown to join those of the anterior tibial artery at the lower border of the popliteus muscle, and so form the popliteal vein. The peroneal branch of the posterior tibial artery requires special dissection. After reaching the back of the fibula, it sinks deeply and disappears from view, its course being either between the fibula and the flexor longus hallucis, or in that muscle, or in a fibrous canal between that muscle and the tibialis posticus. It will next be found becoming superficial about 2 inches above the ankle, where it should be shown to end by dividing into an anterior and a posterior peroneal branch. Two *venæ comites* are to be dissected with the peroneal artery, which end by joining those of the posterior tibial. The following branches of the peroneal artery are to be dissected from above downwards, namely, (1) muscular; (2) medullary to fibula; (3) communicating or transverse; (4) anterior peroneal, disappearing through the inferior hiatus in the interosseous membrane; and (5) posterior peroneal. The last-named artery is to be shown passing behind the external malleolus on to the outer border of the foot for a variable distance. It will be seen to give off external calcaneal branches, which take part in the external malleolar anastomosis, and anastomose across the heel with the internal calcaneal branches of the external plantar. On the outer border of the foot it will be seen again to anastomose with branches of the external plantar.

Knee-Joint.—The knee-joint is to be dissected before proceeding with the sole of the foot. The muscular and tendinous relations of the joint are to be

studied, and the threefold insertion of the semimembranosus is to be displayed. The arteries entering into the geniculate arterial rete are to be studied as fully as possible. All the external ligaments of the joint are now to be dissected, namely, (1) the ligamentum patellæ; (2) the lateral patellar ligaments; (3) the internal lateral ligament, with the inferior internal articular artery passing beneath it, and the main division of the tendon of the semimembranosus overlapped by it posteriorly; (4) the long and short external lateral ligaments, with the inferior external articular artery passing beneath the long ligament; (5) the posterior ligament, with its thickened part, known as the ligamentum posticum Winslowii; and (6) the capsular ligament. In connection with the ligamentum patellæ, the bursa between it and the upper part of the tubercle of the tibia should be shown. The exact origin of the tendon of the popliteus is to be displayed, and its relation to the joint and the long external lateral ligament noted. The expansion of the synovial membrane of the joint upwards above the patella and beneath the suprapatellar tendon is to be again studied. The articulation is now to be opened from before by cutting transversely down through the synovial membrane just above the patella. This bone, along with the ligamentum patellæ, having been turned downwards, underneath them will be seen a collection of fat covered by the synovial membrane, and representing the Haversian gland of the joint. In connection with this portion of the synovial membrane, the following so-called ligaments are to be studied, namely, the ligamentum mucosum and the ligamenta alaria. The crucial ligaments are next to be examined *in situ*, as well as the semilunar fibro-cartilages.

The synovial membrane is to be examined, and thereafter the following external ligaments, are to be cut, namely, the capsular and the posterior, thus leaving only the two lateral ligaments intact. The joint is now to be placed in different positions—*e.g.*, flexion, extension, internal rotation, and external rotation—and the conditions of the crucial and lateral ligaments, as well as of the semilunar fibro-cartilages, are to be carefully attended to.

The lateral ligaments are then to be cut, when the femur will be bound to the tibia only by the crucial ligaments, which should be completely mastered. The femur should be firmly grasped and the tibia rotated inwards in order to see the effect of this upon the anterior crucial ligament. The tibia should next be rotated outwards, and it will then be made to describe half a circle, neither crucial ligament interfering with this movement. In connection with the posterior cornu of the external semilunar fibro-cartilage, the posterior accessory bundle is to be observed, and thereafter the crucial ligaments are to be divided. The upper surface of the head of the tibia being now fully exposed, the semilunar fibro-cartilages are to be studied, and in connection with their anterior aspects the transverse ligament is to be examined. Lastly, the bony articular surfaces are to be examined.

Sole of the Foot.—The skin is to be removed from the sole and plantar aspects of the toes by making the following incisions: a median incision from the heel to the roots of the toes, a transverse incision across the roots of the toes, a median incision along the plantar aspect of each toe, and a transverse incision across the tip of each toe. Within the skin of the webs of the toes a bundle of transverse fibres, called the superficial transverse ligament, is to be dissected. The superficial fascia should be examined, and the calcaneal and plantar divisions of the calcaneo-plantar branch of the posterior tibial nerve are to be followed out to their distribution.

The superficial fascia is now to be removed so as to expose the dense deep fascia, known as the plantar fascia. In dissecting the three divisions of this important fascia, care is to be taken to display the following structures: (1) cutaneous branches of the internal plantar artery and nerve, which appear in the groove between the inner and middle divisions; and (2) cutaneous branches of the external plantar artery and nerve, which appear in the groove between the middle and outer divisions. The three divisions of the fascia are then to be carefully studied, and the grooves between them, indicating intermuscular septa, are to be noted. In the outer groove, near the base of the fifth metatarsal bone, the external plantar artery should be exposed,

and its superficial position noted. Special attention is to be directed to the middle division of the fascia. On being followed towards the toes, it should be shown to divide into five digital processes, one for each toe. The longitudinal direction of the fibres (from heel to toes) should be observed, but towards the toes superadded transverse fibres are to be displayed. In the interval between the diverging digital processes the plantar digital vessels and nerves are to be sought for and followed along the sides of the toes. The manner in which the digital processes are disposed is to be studied, and the bearing of the middle division of the plantar fascia upon the deformity known as *pes cavus* is to be carefully noted. In connection with the outer division of the fascia attention should be paid to the strong band which passes between the outer tubercle of the *os calcis* and the tuberosity on the outer side of the base of the fifth metatarsal bone, and which may be represented by a muscle known as the *abductor ossis metatarsi quinti* or Wood's muscle.

The plantar fascia is now to be removed in the following manner : (1) the thin inner division is to be removed in the ordinary way so as to expose the *abductor hallucis* muscle, which it covers ; (2) the stronger outer division is also to be removed in the usual way so as to expose the *abductor minimi digiti*, which lies underneath it ; (3) the very strong middle division, which closely covers the *flexor brevis digitorum*, is to be carefully divided transversely about 1 inch in front of the heel, the posterior narrow part is to be dissected backwards, and the expanding anterior part is to be reflected forwards. This dissection will bring into view the *flexor brevis digitorum*, and it will show the extent to which the superficial fibres of that muscle take origin from the deep surface of the middle division of the fascia. In dissecting the tendon of insertion of the *abductor hallucis*, the inner head of the *flexor brevis hallucis* is to be shown joining it, and a branch from the internal plantar nerve is to be looked for entering the *abductor hallucis* on its deep aspect about the centre. In dissecting the *flexor brevis digitorum*, it should be shown to end in four tendons for the four outer toes. Each tendon will be found to lie superficial to a tendon of the long flexor of the toes, and the canal in which each pair of tendons lies before passing along the toes should be studied.

The sheaths which confine the flexor tendons as they pass along the plantar aspects of the toes are next to be dissected. Upon one or more toes the sheaths are to be laid open, the insertions of the tendons made out, and the *vincula accessoria tendinum* (*ligamenta longa* and *ligamenta brevia*) shown. A similar dissection is to be made in connection with the tendon of the *flexor longus hallucis*. The intermuscular septum on either side of the short flexor is to be noted, and twigs from the internal plantar nerve are to be looked for entering the muscle on its deep surface. In dissecting the *abductor minimi digiti*, twigs from the external plantar nerve are to be looked for entering the deep surface of the muscle at its back part.

The muscles of the first layer are to be divided near their origins and thrown forwards. The tendons of the *flexor longus digitorum* and *flexor longus hallucis* are now to be dissected, the former passing forwards and outwards, and the latter forwards and inwards. The crossing between these two tendons should be noted, that of the *flexor longus hallucis* being uppermost, and the slip which this tendon furnishes to that of the long flexor of the toes should be displayed. The tendon of the *flexor longus hallucis* is to be followed out to its insertion, and the *vincula accessoria tendinum* shown within its sheath on the great toe. The flexor or *musculus accessorius* is to be dissected in connection with the tendon of the long flexor of the toes previous to its division. In dissecting the *musculus accessorius* the external plantar vessels and nerve are to be carefully preserved as they cross the sole, and twigs of the nerve are to be looked for entering the inferior surface of the muscle at its back part. The four *lumbricales* muscles are to be dissected in connection with the four tendons of the long flexor of the toes. It should be noted that the innermost *lumbricalis* arises only from one tendon, whilst the other three arise each from the contiguous sides of two tendons. A branch from the second digital nerve of the internal plantar should be shown

entering the innermost lumbricalis, whilst the other three will be found to receive their nerve-supply from the deep part of the external plantar nerve.

The internal plantar nerve is now to be dissected, as well as the internal plantar artery. The small size of the artery and the large size of the nerve are to be noted, and each is to be followed out to its distribution. The external plantar artery and nerve are next to be dissected in the first part of their course as they cross the sole from within outwards. The large size of the artery is to be noted, and the nerve is to be shown supplying the *musculus accessorius* and *abductor minimi digiti*, besides giving off articular and cutaneous branches. The superficial terminal branch of the external plantar nerve is also to be followed out, showing its two digital nerves, the outermost of which supplies the *flexor brevis minimi digiti*, and, as a rule, the interosseous muscles of the fourth space. The tendons of the *flexor longus hallucis* and *flexor longus digitorum* and the *musculus accessorius* are now to be divided near the ankle and turned forwards, but the plantar vessels and nerves are to be left undisturbed.

The dissector is then to display the third layer of muscles in the following order from within outwards: *flexor brevis hallucis*, *adductor obliquus hallucis*, and *flexor brevis minimi digiti*. Lying across the heads of the four outer metatarsal bones will be found the *adductor transversus hallucis* (*transversalis pedis*). In dissecting the *flexor brevis hallucis* its single origin and double insertion are to be noted, and a sesamoid bone is to be looked for in each head of insertion. Its nerve is to be found coming from the first or most internal digital branch of the internal plantar. The nerve of the *adductor obliquus hallucis* is to be found coming from the deep part of the external plantar nerve. In dissecting the *flexor brevis minimi digiti* care must be taken to separate it from the most external plantar interosseous, close to which it lies, and with which it is apt to be confounded. Its nerve is usually to be found coming from the outer digital branch of the superficial part of the external plantar. In dissecting the *adductor transversus hallucis* it should be noted that the digital nerves on their way to the toes lie superficial to the muscle, whilst the digital vessels lie on its deep surface. The nerve-supply of this muscle is to be found coming from the deep part of the external plantar. The dissector should now show the relation of muscles which take insertion into the base of the first phalanx of the great toe, as follows: inner side—*abductor hallucis* and inner head of *flexor brevis hallucis*; outer side—outer head of *flexor brevis hallucis*, *adductor obliquus hallucis*, and *adductor transversus hallucis*. The plantar triangle and its contents should next be examined.

The further stage of the dissection of the sole consists in dividing the *flexor brevis hallucis* and *adductor obliquus hallucis*, in order to expose (1) the deep parts of the external plantar artery and nerve, (2) the plantar (and dorsal) interossei muscles, and (3) the plantar or perforating branch of the *arteria dorsalis pedis*. In the case of the deep part of the external plantar nerve, muscular, articular, and perforating branches are to be looked for. It is to be noted that the deep part of the external plantar nerve gives branches to the outer three lumbricales. In the case of the deep part of the external plantar artery the plantar arch and its branches are to be dissected. The plantar or perforating branch of the *arteria dorsalis pedis* is to be found appearing at the proximal part of the first interosseous space, and the following branches are to be dissected, namely, *arteria magna* or *princeps hallucis*, and communicating to the plantar arch.

The external plantar artery and nerve may now be cut to enable them to be laid fully aside, and the plantar interosseous muscles are to be dissected. Care must be taken not to confound the most external plantar interosseous with the *flexor brevis minimi digiti*. At this stage of the dissection the insertion of the lumbricales is to be studied. The innervation of the interossei will be found to come from the deep part of the external plantar nerve, except in the case of the interossei of the fourth space, which usually get their nerve-supply from the outer digital branch of the superficial part of the external plantar. The dissector should now revise the insertion of all the tendons connected with the foot, and, if any have not yet been followed out to their

insertions, this should now be done. The actions of the muscles to which these tendons give insertion should be mastered, with special reference to the different varieties of club-foot, and an articulated foot should be before the dissector to enable him to illustrate these varieties and the actions of the muscles involved in producing them.

Attention is now to be directed to the remaining articulations, namely, the tibio-fibular joints, the ankle-joint, and the joints of the foot. Before removing the muscles of the front of the leg and the deep muscles of the back, the anterior and posterior relations of the interosseous membrane should be studied, and the muscular relations of the ankle-joint mastered. Thereafter the muscles are to be removed, and attention is to be directed first to the superior tibio-fibular joint. The relation of the tendon of insertion of the biceps femoris to the joint is to be noted, as well as the relation of the tendon of the popliteus. More especially, the relation of the anterior division of the biceps tendon to the anterior ligament of the joint is to be studied. Having dissected the ligaments (anterior and posterior), the joint is to be opened and the synovial membrane examined. The bony articular surfaces are also to be inspected, and the movements of which the joint is capable are to be studied. The interosseous membrane is next to be dissected. The large deficiency left at its upper part for the passage of the anterior tibial vessels and lymphatics is to be noted, and the anterior tibial lymphatic gland, if not previously dissected, is now to be shown. In the lower part of the interosseous membrane a small opening is to be displayed for the passage of the anterior peroneal vessels. The inferior tibio-fibular joint is next to be examined, pursuing the same order as in the examination of the superior. The ligaments to be dissected are anterior, posterior, inferior interosseous, and transverse, special attention being directed to the inferior interosseous ligament. The joint having been opened, the synovial membrane (which is continuous with that of the ankle-joint) is to be examined. Attention should next be directed to the bony articular surfaces and the movements of which the joint is capable.

The ankle-joint should now be carefully examined. The dissector should first revise the muscular relations of the joint, and thereafter he should dissect the following ligaments: anterior, posterior, internal lateral or deltoïd, and external lateral in three fasciculi, anterior, middle, and posterior. The anterior and posterior ligaments are then to be cut and the synovial membrane examined. Its continuity with the synovial membrane of the inferior tibio-fibular joint is to be noted, and collections of fat covered by it (Haversian glands) are to be shown at the front and back of the joint. The bony articular surfaces are to be examined, and special attention is to be given to the movements of which the joint is capable, and the muscles by which these are effected.

The longitudinal and transverse arches of the foot should now receive careful attention, and a review of the different varieties of club-foot and the tendons involved will prove advantageous. Thereafter the articulations of the foot are to be dissected, and in doing so it is advisable that the dissector should have before him an articulated foot and the individual bones, all belonging to the same side as that which he is dissecting. The tarsal articulations are to be studied first, in the following order: (1) astragalo-calcaneal; (2) astragalo-navicular; (3) calcaneo-cuboid; (4) naviculo-cuboid; (5) naviculo-cuneiform; (6) intercuneiform; and (7) cubo-cuneiform. Before pursuing this order the dissector should make himself familiar with the transverse tarsal articulation—that is to say, the conjoined astragalo-navicular and calcaneo-cuboid joints, where disarticulation is performed in Chopart's operation. He should also study the expansions from the tendon of insertion of the tibialis posticus, and he should at this stage revise the tendon of the peroneus longus as it crosses the sole of the foot. In connection with the astragalo-calcaneal articulation two joints are to be recognised—posterior and anterior. The following ligaments are to be studied in connection with the posterior joint: interosseous, posterior, internal, and external. Only a lateral view of the interosseous ligament will be obtained at this stage, as it lies in the sinus pedis. It is to be noted that this joint has a synovial membrane peculiar to it. The anterior astragalo-calcaneal joint is next to

be dissected, and the following ligaments studied: interosseous, internal astragalo-calcaenal, and external or superior calcaneo-navicular. It is to be noted that the synovial membrane of this joint is continuous with that of the astragalo-navicular articulation. The bony articular surfaces of the astragalo-calcaenal joints cannot be studied until the astragalus is removed, which should presently be done. Meanwhile, by removing all the ligaments, except the interosseous, and dividing the synovial membranes, the movements between the astragalus and os calcis are to be studied.

The astragalo-navicular joint should now be examined. Inasmuch as this is one of the most important joints of the foot, it should receive careful study. The ligaments to be dissected are as follows: astragalo-navicular, dorsally placed; external or superior calcaneo-navicular; and internal or inferior calcaneo-navicular, a most important ligament, commonly spoken of as the **spring** ligament. The last-named ligament is to be studied from two points of view, namely, from below, by removing the tendon of the tibialis posticus, and from above, by removing the astragalus. In performing the latter dissection the interosseous astragalo-calcaenal ligament is to be studied, and it is to be observed that, whilst it is the anterior ligament of the posterior astragalo-calcaenal joint, it is the posterior ligament of the anterior astragalo-calcaenal joint. An excellent view is obtained from above of how the spring ligament supports and forms a part of the socket for the under aspect of the head of the astragalus, and from below it can be well seen how the tendon of the tibialis posticus serves as an important strengthening adjunct to the ligament. It is to be noted that the synovial membrane of the astragalo-navicular joint is continuous behind with that of the anterior astragalo-calcaenal. The movements at the astragalo-navicular articulation are to be carefully studied, and the manner in which pes planus may be brought about is to be observed. Attention should also be directed to the support which the spring ligament, aided by the tendon of the tibialis posticus, gives to the inner longitudinal arch of the foot. The bony articular surfaces are also to receive attention.

The calcaneo-cuboid joint is next to be studied. The ligaments to be dissected are dorsal, internal or interosseous, long plantar, and short plantar. On opening the joint the synovial membrane will be found to be peculiar to it, and the movements of which the articulation is capable are to be studied. Attention is also to be given to the bony articular surfaces. The naviculo-cuboid joint is next to be attended to, the ligaments being dorsal, plantar, and interosseous. The remaining tarsal articulations are to be studied in the following order: naviculo-cuneiform, intercuneiform, and cubo-cuneiform, and the complicated synovial membrane of these articulations should be examined. The bony articular surfaces and movements are also to be studied.

The dissector should next direct his attention to the tarso-metatarsal articulations, which should be studied in the following order: (1) internal tarso-metatarsal, (2) middle tarso-metatarsal, and (3) external tarso-metatarsal. Special notice should be taken of the internal interosseous ligament of the middle tarso-metatarsal joint. It will be found extending between the outer surface of the internal cuneiform and the inner surface of the base of the second metatarsal bone. The synovial membranes, bony articular surfaces, and movements of these articulations are to be attended to, and their surgery is to be carefully studied in connection with Lisfranc's operation.

The intermetatarsal articulations are to be studied next, attention being directed to the basal intermetatarsal joints, and the union between the heads of the metatarsal bones. The tarsal and tarso-metatarsal synovial membranes should be reviewed at this stage. The metatarso-phalangeal articulations are now to be dissected, the ligaments being two lateral and an inferior or plantar fibrous plate. The synovial membranes, bony articular surfaces, and movements are to be studied. Lastly, the interphalangeal articulations are to be dissected in a similar manner and to a like extent.





COLUMBIA UNIVERSITY LIBRARIES (hsl.stx)
QM 34 B85 1914- C.1 v. 1
Manual of anatomy systematic and practic



2002190125

QM34

Buchanan

B85

1914

v.1

Manual of anatomy.

NOV 6 1951

JAN 10 1952

Chas H. Mansalabis
P. Aump

QM34

B85

1914

v.1.

