

SF 995  
.G87  
Copy 1

THE DEVELOPMENT, MORPHOLOGY,  
AND ECONOMIC IMPORTANCE  
OF CHICKEN CESTODES

Morphology of Adult and Larval Cestodes from Poultry  
Studies on the Transmission and Prevention of Cestode  
Infection in Chickens

BY

JOHN EARL GUTBERLET

A. B. Bethany College, Kansas, 1909

A. M. University of Illinois, 1911

---

THESIS

Submitted in Partial Fulfillment of the Requirements for the

Degree of

DOCTOR OF PHILOSOPHY

IN

THE GRADUATE SCHOOL

OF THE

UNIVERSITY OF ILLINOIS

1914



ON THE DEVELOPMENT, MORPHOLOGY,  
AND ECONOMIC IMPORTANCE  
OF CHICKEN CESTODES

Morphology of Adult and Larval Cestodes from Poultry  
Studies on the Transmission and Prevention of Cestode  
Infection in Chickens

BY

JOHN EARL GUTBERLET

A. B. Bethany College, Kansas, 1909

A. M. University of Illinois, 1911

---

THESIS

Submitted in Partial Fulfillment of the Requirements for the

Degree of

DOCTOR OF PHILOSOPHY

IN

THE GRADUATE SCHOOL

OF THE

UNIVERSITY OF ILLINOIS

1914

[Urbana, 1916]

SF995  
.G87

1917  
52nd Cavalry  
21 1916



## MORPHOLOGY OF ADULT AND LARVAL CESTODES FROM POULTRY\*

JOHN E. GUTBERLET

During the course of experimental studies on the life history of certain chicken cestodes described in the succeeding section of this work (Gutberlet, 1916) it was necessary to determine exactly the morphological features of the species, which to be sure, had been studied by others but were only partially and imperfectly known. In the former paper I recorded experiments which demonstrated the intermediate stage of *Choanotænia infundibuliformis* to be in the common housefly, *Musca domestica*, and discussed the symptoms of infection and methods of control for tapeworm diseases in chickens.

In this paper are taken up the structure of the adult and cysticercus of *Choanotænia infundibuliformis* (Goeze), and also the adult form of four other species occurring in chickens of this country.

As described more fully in the preceding paper the worms were removed from the intestine under water. The use of normal salt solution was avoided since it was found to be injurious. The cestodes were killed in a corrosive-acetic solution and preserved in 70% alcohol and glycerine. Best results were secured by staining in Delafield's or Ehrlich's acid hæmatoxylin and destaining in acid alcohol.

The five species discussed here were collected at two widely separated points, a farm at Hardy, Nebraska, and the poultry farm at the University of Illinois. These morphological studies were carried on at the Zoological Laboratory of the University of Illinois. This work was taken up at the suggestion of Dr. Henry B. Ward, to whom I am greatly indebted.

---

\*Contributions from the Zoological Laboratory of the University of Illinois under the Direction of Henry B. Ward, No. 57.

## STRUCTURE OF ADULT AND LARVA (CYSTICERCUS)

## A. ADULT

*Choanotænia infundibuliformis* (Goeze 1782) Railliet 1896

1. Diagnosis: Length 50 to 200 mm. Scolex (Fig. 2) small, rounded, or conoidal, about 0.4 mm. wide. Rostellum (Fig. 2, 3, *r*) 60 to 70 $\mu$  in diameter, armed with a single row of 16 to 20 hooks (Fig. 8) 25 to 30 $\mu$  long, with long dorsal root and short ventral root. Suckers prominent, elongated antero-posteriorly, length 180 to 210 $\mu$ ; breadth 135 to 175 $\mu$  between the extreme outer edges. Neck short and unsegmented, somewhat narrower than broad. In specimens well extended neck much narrower than head. Anterior proglottids very short and as they become older funnel-shaped, much narrower at anterior than at posterior margins; posterior segments 1.5 to 2.5 mm. broad and 1.5 to 3 mm. long according to amount of contraction, with convex lateral borders, nearly as wide at anterior as at posterior margin. Genital pores irregularly alternating, situated one in each segment in the anterior third of the lateral margin, usually under cover of the backward projecting border of the preceding segment. Vas deferens (Fig. 14, *vd*) and vagina pass between excretory canals and dorsal to nerve trunk.

*Male Reproductive Organs:* Testicles (Fig. 14, *t*) 25 to 40 or more, 60 in some cases, in posterior half of proglottid, posterior and lateral to large yolk gland, within limits of excretory canals. Vas deferens passes forward and in anterior third of proglottid forms a mass of coils between ovary and excretory vessels from which it extends outward as a convoluted tube to base of cirrus pouch. Cirrus pouch (Fig. 14, 15, *cp*) ovoid in shape, 75 to 95 $\mu$  in long diameter. Portion of vas deferens in cirrus pouch is much coiled. Cirrus 50 to 65 $\mu$  long, armed with spines; outer surface of cirrus pouch forms base of deep genital cloaca.

*Female Reproductive Organs:* Vaginal opening in genital cloaca posterior to cirrus. Vagina posterior to cirrus pouch, after crossing ventral excretory canal dilated to form ovoid seminal receptacle, posterior and ventral to vas deferens, extending to well developed shell gland, 40 to 50 $\mu$  in diameter located in front of middle of proglottid. Transversely elongated ovary (Fig. 14, *o*)

occupies anterior portion of middle field of proglottid in front of shell gland. Large yolk gland posterior to ovary and shell gland, irregular in shape, elongated transversely, with convex ventral surface and concave dorsal surface. Uterus (Fig. 16, *u*) developed as tube between anterior and ventral lobes of ovary. Gravid uterus fills up most of proglottid, extending beyond excretory canals on each side. Eggs oval (Fig. 7), with very thin membrane next embryo, followed by thick, smooth membrane 40 by  $32\mu$  to 45 by  $36\mu$  in diameter, and one or two outer membranes, very thin and wrinkled in preserved material. Diameter of outer membrane 65 by  $40\mu$  to 60 by  $45\mu$ ; at each pole of outer membrane a delicate appendage. Embryonal hooks  $18\mu$  long. Embryo 32 by  $22\mu$  in diameter.

2. *Morphology*: The scolex of the living worm shows up very prominently and can be used as a distinguishing feature. When first removed from the intestinal wall the suckers appear distinct and the neck is much narrower than the scolex. Soon after the removal it often contracts and takes on the appearance of a flattened bulb which includes the neck and anterior segments (Fig. 1). This feature is characteristic of this species and is a factor which alone assists very materially in distinguishing it from others that occur in chickens.

The rostrum or crown of the scolex is somewhat pointed when the rostellum is enclosed within its sheath (Fig. 2). The rostellum is an ovoid structure with a bulbous expansion at its anterior end. It has a length of  $140\mu$  and a breadth of 60 to  $65\mu$  at its anterior end. A crown of 18 hooks is arranged in a single row around the bulbular anterior end. The structure of the wall is of a fibrous nature and presents a transversely striated appearance due to contraction. In the interior of the rostellum the structure is a connective tissue mass with few cells, some of which possess long processes. The hooks (Fig. 8) are  $30\mu$  in length with a long dorsal root and a short ventral root.

The rostellar sheath or sac (Fig. 3, *rs*) into which the rostellum is withdrawn is oval in shape and 230 to  $240\mu$  in length by 80 to  $90\mu$  in width at its broadest point. Histologically, the structure is that of a fibrous connective tissue type with spherical and spindle-shaped cells. The cells coming in contact with the rostellum, as

well as those on the outer edge of the sac, bear long processes. The outer layer of the rostellar sac is composed of longitudinal and oblique fibers of a muscular nature which probably have for their function the movement of the rostellum.

The four excretory canals, that have extended forward through the entire length of the body, unite in the scolex to form a ring (Fig. 3, *ex*), which lies in the tissue of the rostellar sac around the body of the rostellum.

The suckers are prominent. They are oval in shape and in preserved specimens measure 180 to 210 $\mu$  in length and from 135 to 175 $\mu$  in extreme breadth. In the center of each sucker there is a depression or an acetabulum, 30 to 40 $\mu$  in diameter. The entire inner surface of the suckers possesses minute hooklets or spines (Fig. 4) 1.5 to 2 $\mu$  long. These hooklets not only line the suckers but also extend over the entire surface of the scolex (Figs. 3, 5) and down onto the neck region; they disappear before reaching the first segment. They appear more distinctly on scolices that are somewhat contracted than on those that are well extended. These hooklets can be seen only in sections as they are too small to be distinguished readily in whole mounts.

*Musculature:* The longitudinal muscle fibers are arranged in bundles which are scattered, forming a loose irregular layer. The bundles are numerous and nearly of a uniform size. There are no transverse muscle fibers present except a few minute oblique fibers which connect some of the longitudinal fibers near the ends of the proglottids. Some dorso-ventral fibers are present, but they are not abundant.

*Nervous System:* The longitudinal nerve fibers are arranged in fiber tracts which approach the structure of a nerve cord. The individual fibers do not form a compact mass, but are more or less free in the tract. Nerve cells have no definite arrangement, but are situated irregularly along the fiber tract (Fig. 6). The nerve cells are somewhat spindle-shaped and quite large, being from 20 to 25 $\mu$  long by 6 to 8 $\mu$  wide with large nuclei. Transverse nerves are composed of individual cells with long processes extending transversely from the lateral fiber tracts. The transverse fibers are much scattered and have no definite arrangement except that they



are more numerous near the ends of the proglottids. Peripheral nerve cells are widely and irregularly distributed. They are more numerous at the anterior end of the proglottids, especially on the portion that is covered by the backward extension of the preceding segment.

*Excretory System:* The excretory system is fairly well developed in this form. The ventral canal (Fig. 14, *v ex*) is the larger, and has a diameter of 28 to 30 $\mu$ . A transverse canal unites the two longitudinal canals in each segment. The dorsal canals (Fig. 14, *d ex*) are much smaller, having a diameter of 6 to 8 $\mu$  and are not united by transverse connections. The four longitudinal canals extend anteriorly to the scolex where they unite to form a ring which lies in the rostellar sheath around the body of the rostellum. The vas deferens and vagina pass between the dorsal and ventral excretory canals.

*Male Reproductive Organs:* The testes vary in number, usually from 25 to 40, but in a few cases the number is much greater, being as high as 55 or 60. The testes are quite large, being from 40 to 55 $\mu$  in diameter, and are located in the posterior half of the proglottid (Fig. 14, *t*), posterior and lateral to the yolk gland. The testes are not arranged in layers, but are grouped in a more or less compact mass almost entirely within the limits of the excretory canals. The vas deferens (Fig. 14, *vd*) in the anterior third of the proglottid forms a coiled mass at the side of the ovary, from whence it passes laterad to the cirrus pouch as a convoluted tube. The portion of the vas deferens inside the cirrus pouch is coiled, varying in extent in different specimens (Figs. 14, 15). The vas deferens passes into the cirrus. There is no seminal vesicle formed by the vas deferens in the cirrus pouch nor are there any accumulations of sperm cells. The cirrus pouch (Fig. 15) is ovoid in shape and is from 75 to 90 $\mu$  in diameter. The wall is made up of layers of fibers which are both circular and oblique, forming a basket-like network which incloses the cirrus and a portion of the vas deferens. The outer wall of the cirrus pouch forms the inner wall of the deep genital cloaca. The cirrus is a compact structure from 50 to 65 $\mu$  long and lined with spines. It is a slightly curved structure passing from the cirrus pouch and curving posteriorly

toward the vagina which is directly posterior to it. The cirrus was not observed extending from the genital cloaca, but was noted in some specimens curving toward the vagina, though not passing into it. A few sperm cells were present in the vas deferens, also in the vagina and the seminal receptacle.

*Female Reproductive Organs:* The large ovary (Fig. 14, *o*) lies in the anterior third of the proglottid and extends transversely across the segment. It has a length of  $300\mu$  and a breadth of about  $75$  or  $80\mu$  at its broadest point. It is irregular in shape, being composed of a number of lobes. The end which is nearest the genital pore is smaller than the other, allowing room for the mass of coils of the vas deferens, the vagina, and the seminal receptacle. The ovary is concave on the dorsal surface and convex on the ventral. On the dorsal surface of the end nearest the genital pore is located the seminal receptacle and the vagina. The ova are large and very distinctly shown in the ovary (Fig. 16). Posterior to the ovary is the large yolk gland (Fig. 14, 16, *y*) which lies about the middle of the proglottid. It is irregularly elongate in shape and extends transversely across the segment, having a length of from  $120$  to  $130\mu$  and a breadth of from  $35$  to  $50\mu$ . Immediately in front of and dorsal to the yolk gland and posterior to the ovary is the shell gland (Fig. 14, *sg*) which is slightly ovoid in shape,  $40$  to  $50\mu$  in diameter. A small duct, the vitelline duct (Fig. 16, *v*), passes from the yolk gland through the shell gland from which it receives a duct. The combined ducts after passing through the shell gland unite with the oviduct (Fig. 16, *ov*) which appears as a curved tube leading from the ovary. These united tubes or ducts pass anteriorly and slightly ventrad into the uterus which develops as a blind tube in the region of the ventral lobes of the ovary. This blind tube (Fig. 16, *u*) grows in size and extends transversely across the segment. As it becomes larger the tube forms pockets which extend anteriorly and posteriorly and also dorsally, until it takes up the entire mass of the proglottid between the excretory canals. In gravid segments it even extends beyond the excretory canals. A small tube or duct, which is really the end of the vagina, connects the seminal receptacle with the yolk-shell gland duct and oviduct. This tube serves to carry the sperm to the eggs in the oviduct for fertilization. The

seminal receptacle (Fig. 16, *sr*) is a dilation of the vagina into an oval shaped structure which is about  $50\mu$  long and from 25 to  $30\mu$  in breadth at the widest part. From the seminal receptacle the vagina passes laterad, lying posterior to the cirrus pouch, and unites with the genital cloaca. The genital cloaca has its pore on the lateral margin near the anterior end of the proglottid. The pore is usually covered by the backward projection of the segment anterior to it. The vas deferens and vagina pass between the dorsal and ventral excretory canals and dorsal to the nerve tract. The vas deferens is dorsal and anterior to the vagina.

In the mature segments the uterus becomes filled with ova and it increases in size until it occupies the entire area between the excretory canals, even extending beyond the canals in the gravid proglottids. The uterus finally breaks up into compartments, each containing a single embryo. The embryos (Fig. 7) are about 32 by  $22\mu$  in diameter with onchospheric hooks  $18\mu$  long. Usually three membranes, but often four, enclose the embryo. The inner membrane is thin and closely surrounds the embryo; the next is heavy, being from 1.5 to  $2\mu$  thick, composed of fibrous layers with a few cells present. This layer is variable in thickness, depending considerably upon the amount of contraction of the segment, as it ranges in size from 40 to  $32\mu$  to 50 by  $36\mu$ , or it may be even slightly larger. Usually one (Fig. 7) and sometimes two thin membranes are found on the outside of the thick layer. These are often wrinkled and bear at each end an appendage formed from the outer membrane by which it is attached to the wall of the capsule or compartment of the uterus.

In this species the oldest proglottids drop off from the worm before they are fully mature. The embryos from the oldest segments on the worm do not show the characteristics of entirely mature ones, and there are distinct differences between them and those that have been separated from the worm for some time. Single proglottids that have separated from the worm are quite active and remain in the intestine for some time before passing out with the feces. Proof of this is furnished by the fact that a large number of the free proglottids are found in the intestine at any time. Even tho only a few worms are present in the intestine of a bird there is

usually a large number of free proglottids. If they did not remain in the intestine for a considerable length of time there would not be nearly as many. Further proof is furnished by the fact that the free proglottids have embryos which are mature, showing the oncospheric characteristics, while the oldest segments that are still attached to the worm have embryos that are not entirely mature. This same condition has been observed in *Davainea proglottina* as Blanchard (1891:435) states that the oldest proglottids separate from the others and remain in the intestine to become mature before passing out. The proglottids do not always separate from the worm singly, but may drop off in groups of three or four.

The fact that the proglottids separate from the worm before they are entirely mature is one of great importance in taking up experimental work for infection of intermediate hosts. If the embryos are fed to insects or other invertebrates before they are mature they will be digested, and thus infection cannot be produced.

#### B. CYSTICERCUS

The cysticercus of *Choanotenia infundibuliformis* was found in the abdominal region of the body cavity in the common house fly, *Musca domestica*. The flies had been fed on embryos from ripe proglottids of this species of worm, and at the end of twelve days were killed. The cysticerci appear to be nearly ripe or ready for transmission into the adult host. The time for the development of the cysticercoid varies with different species and under different conditions. Grassi and Rovelli (1892:85) found that *Davainea proglottina* developed from the oncosphere into a ripe cysticercus in less than twenty days. Schmidt (1894:9) found that the development of the cysticercoid of *Drepanidotenia anatina* (Krabbe) varied with the time of the year and the influence of the temperature. In the summer the embryo developed in an ostracod, *Cypris ovata*, into ripe cysticercoids in two weeks.

The cyst proper (Figs. 11, 12, *c*) containing the scolex is oval in shape,  $220\mu$  long and  $120\mu$  in diameter.

The bladder (Fig. 12, *b*) or tail, which is also oval in shape, is located against one side of the cyst and is somewhat flattened on that side. It is 220 to  $230\mu$  long and from 116 to  $120\mu$  in breadth.

The scolex is  $80\mu$  in breadth and  $120\mu$  in length; neck is  $40\mu$  in diameter and 30 to  $35\mu$  long; suckers are 55 to  $60\mu$  in diameter. The rostellum is  $60\mu$  long and  $20\mu$  in breadth, armed with a crown of 18 hooks arranged in a single row. These hooks (Fig. 9) are  $30\mu$  long with a long dorsal root and a short ventral root. The suckers are lined with numerous minute hooklets or spines 1.5 to  $2\mu$  long which extend over the edges of the suckers and also over the greater part of the surface of the scolex, including a part of the neck region. Schmidt (1894: 16) described cuticular hooklets on the suckers of *Drepanidotania anatina*.

The size of the scolex may be somewhat variable as shown by those in the cysticercoids of *Drepanidotania anatina* by Schmidt (1894: 10). In that species the intermediate host could be one of two or more species of crustaceans and the size of the cysticercoid varied with the size of the host in which it was parasitic.

The head of the rostellum is conical in shape, bearing a bluntly pointed apex anterior to the end of the dorsal roots of the hooks (Fig. 10, *r*). This part of the rostellum is composed of minute muscle fibers which are both circular and oblique. The rostellum is slightly broader below the circle of hooks as it is an oval shaped body.

The rostellar sac (Fig. 10, *rs*) is a deeply stained structure 10 to  $12\mu$  thick. It extends from  $10\mu$  below the hindermost part of the rostellum to the anterior extremity of the scolex, forming an oval shaped sac or sheath. It is composed of parenchymatous tissue with large heavily stained oval or spindle shaped cells which bear processes. The outer part of the sac is composed of a thin layer of fine fibers which help to give it a definite shape. At the lower edges of the sac the fibers are connected or associated to some extent with similar fibers that form the inner layer of the suckers. The anterior region of the rostellar sac, which forms the sheath for the free head portions of the rostellum, is constructed of an inner layer of fine fibers and an outer layer of large spindle-shaped cells, the most of which bear fibrous processes at one or both ends.

The suckers are composed of large spindle-shaped cells which are arranged perpendicular to the edge. These are heavily stained

and form a compact layer. The inner boundary of the suckers is composed of a layer of fibers which are both circular and oblique. Some of these at the upper edges are associated with similar fibers in connection with the rostellar sac.

The cyst is composed of two cell layers with an irregular cavity between them. The cells are large and irregular in shape with no special arrangement in the layer. Large intercellular spaces lie between the cells, thus forming a loose network structure, except at the base of the neck. At this point where the neck is attached to the inner layer of the cyst the cells are smaller and are in a compact mass. There is no definite boundary to the outer part of the inner layer as well as to the inner part of the outer layer of the cyst. Few cells with long connective processes extend across the cavity from one layer to the other. This then forms an irregular cavity (Fig. 11 *ca*) 2 to  $20\mu$  in width between the two layers of the cyst. This is the primitive cavity of Grassi and Rovelli (1889: 373). The two layers of the cyst are formed apparently by a fold which extends upward and inward from the base of the neck, forming the gastrula cavity of Grassi and Rovelli (1889: 402, *g*) and enclosing the scolex. This cavity varies in width from 3 to 10 or  $15\mu$ .

The bladder, an oval shaped structure, is located at one side of the cyst and is attached to it at the posterior end by a narrow connection (Fig. 12, *cn*). The posterior end of the cyst or the region caudad of the base of the neck is somewhat drawn out (Fig. 12). From this point is given off the attachment to the bladder or tail portion of the cysticeroid. The fact that this bladder is really a tail, even though it possesses a cavity, is shown by the presence of the onchospheric hooks, which are located at the end of the bladder opposite to that of the attachment of the cyst (Fig. 12, *oh*).

The order of arrangement of the onchospheric hooks is individual. In some specimens they are situated at the end of the bladder, while in others they are at the side. In some the arrangement is in a group, while in others they are in pairs. Some of my specimens show a pair of embryonic hooks in the layers of

the cyst between the base of the neck and the attachment of the bladder, while the other two pairs of hooks are located in the bladder.

The cavity of the bladder is formed apparently by a splitting or hollowing out of the cells of the tail, because the wall is continuous and of the same histological structure. The wall of the bladder is constructed of two layers, an inner cell layer and an outer cuticular layer. The outer cuticular layer is more or less striated on account of minute fibrils uniting it with the inner cell layer. Histologically, the structure of the inner layer is constructed of somewhat granular substance arranged in fibers forming a network which encloses clear spherical cells with large nuclei (Fig. 13). Outside of the cuticular layer is located the peritoneum of the host which lies upon the bladder and surrounds it as well as the cyst.

#### C. COMPARISON OF ADULT AND CYSTICERCUS

A comparative study of the adult and the cysticeroid shows the likeness which exists between them. The presence of the same number of hooks, having exactly the same size and shape as seen by comparing Figures 8 and 9. Minute hooklets of the same size are present in both cysticeroid and adult lining the suckers, the entire surface of the scolex and a part of the neck region. Rosseter (1891: 365) shows that the hooks on the rostellum and suckers of *Echinocotylus Rosseteri* undergo no changes during the act of transition from cysticeroid to adult stage. The rostellar sac is of the same general shape in both. The head of the rostellum is not expanded in the cysticeroid as in the adult because it has not functioned as yet. This corresponds to figures as shown by Schmidt (1894, Pl. VI, Fig. A) of the cysticeroid and Krabbe (1869, Pl. VI, Fig. 114) of the adult of *Drepanidotania anatina*, and by Grassi and Rovelli (1892, Pl. IV, Fig. 7, 8) of the cysticeroid and Blanchard (1891: 16) of the scolex of *Davainca proglottina*. No measurements are given for the rostellum of either the cysticeroid or the adult by the above authors.

There is a great deal of difference in the size of the scolex between the cysticeroid and the adult. In my specimens the

scolex of the adult is between four and five times as large as that of the cysticercoïd. The scolex of the cysticercoïd has as yet not functioned so that the musculature of the organs is not developed as in the adult, consequently is not nearly as massive. The cells also are smaller than those of the adult.

Schmidt (1894: 10, 44) shows that the adult scolex of *Drepanidotænia anatina* is about three times as large as that of the cysticercoïd. He also states that the size of the cysticercoïd may vary with the size of its host.

Different forms become modified in changing from the intermediate to the adult hosts as shown by Schmidt (1894) in *Drepanidotænia anatina*, Rosseter (1891) in *Echinocotylus Rosseteri*, and Grassi and Rovelli (1892) in *Davaïnea proglottina*.

Onchospheric hooks in the wall of the tail are the same size ( $18\mu$ ) and shape as those of the embryos found in the mature proglottids.

A consideration of these factors of morphological significance which demonstrate the resemblances between the cysticercoïd and adult, indicates clearly that this cysticercoïd is the intermediate stage of *Choanotænia infundibuliformis*.

#### OTHER CHICKEN CESTODES IN THE UNITED STATES

##### 1. *Davaïnea tetragona* (Molin 1858) Blanchard 1891

*Diagnosis:* Length 10 to 250 mm. by 1 to 2.5 mm. in breadth, varying with state of contraction. Scolex (Fig. 19) 175 to 215 $\mu$  in diameter, with retractile rostellum 25 to 50 $\mu$  in diameter, armed with single row of about 100 hooks. Rostellar hooks (Fig. 20) 6 to 9 $\mu$  long through longest axis, hammer-shaped, with long ventral root and short dorsal root, prong short and recurved. Suckers oval, 60 to 110 $\mu$  in diameter, armed with 8 to 10 rows of small hooks of various sizes. Acetabular hooks (Fig. 21) range in size from 4 to 8 $\mu$  through longest axis, having thorn-like prong, short dorsal root, and longer flattened ventral root, which is shorter than prong. Neck long and slender, but often as broad as head. Segments trapezoidal and imbricate, edges of strobila serrate. Oldest segments usually longer than broad, often bell-



shaped. Genital pores usually unilateral, situated one in each segment, at or in front of middle of lateral margin, frequently marked off by papilla. Male and female canals pass on dorsal side of nerve and excretory vessels.

*Male Reproductive Organs:* Testes 20 to 30 in median field surrounding female organs, most of them lying on aporse side of latter. Vas deferens situated in anterior third of segment, beginning near median line, and extending in much convoluted course laterally to base of cirrus pouch which it enters and, after a few coils in basal portion of latter, passes into cirrus. Cirrus pouch pyriform, 75 to 100 $\mu$  in length. Basal portion surrounded by prominent layer of longitudinal muscle fibers, neck with thick layer of transverse fibers. Cirrus without apparent spines.

*Female Reproductive Organs:* Ovary in middle of segment. Yolk gland posterior to ovary, irregularly reniform, slightly longer in its transverse axis, about 100 $\mu$  in diameter. Shell gland prominent, 50 $\mu$  in diameter, immediately in front of yolk gland. Vagina begins at genital pore, posterior to opening of cirrus pouch, at first very slender but at distance of 15 to 25 $\mu$  from genital pore swells out into thick-walled tube, functioning as seminal receptacle. This extends transversely across segment and joins oviduct on dorsal side of ovary near median line. Oviduct, after being joined in shell gland by vitelline duct, proceeds forward and ends on dorsal side of ovary. Definite and persistent uterus not developed. Eggs pass from distal end of oviduct, become imbedded in fibrous and granular or gelatinous mass which fills up most of segment. This mass divides into 50 to 100 portions to form egg capsules, each surrounded by membrane and containing 6 to 12 or more eggs. Egg is surrounded by three envelopes,—inner, close to onchosphere, often scarcely visible; middle layer or envelope much folded, giving appearance of network between inner and outer membranes; and smooth outer envelope. The onchosphere measures 10 to 15 $\mu$  in diameter; the outer envelope measures from 25 to 50 $\mu$  in diameter.

---

One point noted here that has not been mentioned before by other authors is that the genital pores are irregularly alternate.

They are usually unilateral. The existence of this irregularly alternate occurrence of the genital pores may be an anomaly, but it is rather frequent for such a condition.

2. *Davainea echinobothrida* (Megnin 1880) Blanchard 1891

*Diagnosis:* Length up to 250mm; width 1 to 4 mm. Head (Fig. 22) 0.25 to 0.45 mm. in diameter, with retractile rostellum 100 to 150 $\mu$  in diameter, armed with crown of about 200 hooks arranged in two rows. Suckers round or oval, 90 to 200 $\mu$  in diameter, armed with 8 to 10 rows of hooks. Rostellar hooks (Fig. 23) similar to those of *Davainea tetragona*, but larger, measuring 10 to 13 $\mu$  in length. Acetabular hooks (Fig. 24) likewise similar to those of *D. tetragona*, but also larger; size variable, smallest being 7 or 8 $\mu$  in length and largest measuring from 14 to 16 $\mu$ . Neck thicker and generally shorter than *D. tetragona*, nearly equal to width of head. Strobila resembling that of *D. tetragona*, but serrate border more pronounced. Oldest segments in preserved specimens also differ from those of *D. tetragona*, being less elongate and frequently marked by median constriction. Owing to this constriction adjacent borders of most posterior segments pull apart in median line and remain joined only at sides, giving rise to median series of openings through posterior portion of strobila. Genital pores irregularly alternate, or sometimes almost entirely unilateral, situated one in each segment posterior to middle of lateral margin. Male and female canals pass on dorsal side of nerve and excretory vessels.

*Male Reproductive Organs:* Testes 20 to 30, arranged in median field surrounding female glands as in *D. tetragona*. Vas deferens lies in anterior third of segment much as in *D. tetragona*. Cirrus pouch flask-shaped, 130 to 180 $\mu$  in length. Basal portion globular or ovoid, surrounded by layer, about 10 $\mu$  thick, of longitudinal muscle fibers inside of which is a layer about 12 $\mu$  thick of transverse fibers. Neck of pouch measures 50 $\mu$  to 75 $\mu$  in length by 15 to 20 $\mu$  in diameter, surrounded by layer of transverse fibers thickened at distal end to form sphincter. According to M $\acute{e}$ gnin, the cirrus is armed with minute spines.

*Female Reproductive Organs:* Female organs same as in *Davainea tetragona*, and onchospheres (Fig. 25) are also similar

in structure and size, 14 to 15 $\mu$  in diameter. Onchospheric hooks 6 to 7 $\mu$  long. Egg capsules in groups of 6 to 12 or more, embedded in a fibrous gelatinous mass.

In the living specimens very little difference can be noticed except in size of the species *D. tetragona* and *D. echinobothrida*. They are both quite transparent and appear much alike in every respect in external appearance, except that *D. tetragona* is slightly more transparent, while the oldest segments of *D. echinobothrida* have very distinct median constrictions between them, appearing almost as a series of openings.

The chief differences between *D. tetragona* and *D. echinobothrida* are that in the latter the animal is larger, the hooks are more numerous and larger, and the structure and size of the cirrus pouches show a very distinct difference. There is also a difference in the pathological effect of these spiny-suckered forms. *D. echinobothrida* produces large nodules or ulcers in the intestinal wall. The scolex bores through the mucosa of the intestine and in some cases nearly through the muscular coats. This disease in fowls is termed "nodular tæniasis", as described by Moore (1895: 1), and is often mistaken for other diseases.

### 3. *Davainea cesticillus* (Molin 1858) Blanchard 1891

*Diagnosis:* Length 10 to 125 mm. Maximum width 1.5 to 3 mm. Head cylindrical (Fig. 28), sometimes spheroidal, 0.3 to 0.6 mm. wide and 0.2 to 0.4 mm. long. Suckers unarmed, about 100 $\mu$  in diameter. Rostellum broad and flat or hemispherical, 0.25 to 0.35 mm. wide, armed with a crown of 200 to 300 hooks which are very unstable and easily lost, arranged in two ranks. Hooks (Fig. 29) 8 to 12 $\mu$  long with short dorsal root and long ventral root. Neck very short. Anterior segments three to five times as broad as long; the following increase in size until they become equal in length and breadth and finally even longer than broad; borders overlapping. Genital pores irregularly alternate, one in each segment, somewhat in front of middle of lateral margin in young segments and nearer the middle in older segments. Vagina and cirrus pouch pass dorsal of the two excretory canals and nerve.

*Male Reproductive Organs:* Testes (Fig. 17, *t*) 20 to 30 in number in posterior portion of segment. Vas deferens much coiled before entering base of cirrus pouch, also coiled within latter. Cirrus pouch ellipsoidal, 120 to 150 $\mu$  long by 55 to 70 $\mu$  wide. Cirrus when protracted 10 $\mu$  in diameter, armed with minute spines, and with bulbous enlargement 20 $\mu$  in diameter at its base, where it becomes continuous with cirrus pouch.

*Female Reproductive Organs:* Vagina enlarged before reaching median line into small seminal receptacle (Fig. 17, *sr*). Ovary occupies middle field in front of testes. Yolk gland and shell gland posterior to ovary, ventral and dorsal, respectively, in relative position. Uterus at first in front of ovary as cord of cells; gradually increasing in size, finally occupies most of segment and frequently extends laterally beyond excretory canals. In oldest proglottids it becomes divided into compartments, or capsules, each containing a single egg. Embryo (Fig. 30) 36 by 27 $\mu$  in diameter, with very thin membrane closely adherent to surface. Embryo further enveloped by thicker, smooth fibrous membrane, oval in shape, 45 to 40 $\mu$  in diameter, with filament at each pole attaching to thin outer wrinkled membrane about 35 by 50 $\mu$  in diameter: finally egg is surrounded by capsule composed of outer and inner membrane, latter closely adherent to or fused with outer egg membrane; and former more or less widely separated from latter and connected with it by number of septa.

---

One of the principal points noted here that is not mentioned by other authors is the size of the rostellar hooks. In my specimens they seem to be somewhat larger than those described by others. They have been described as being 8 to 10 $\mu$  long, while my forms show many of them to be distinctly 12 $\mu$  in length. A second point noted here is the method of the development of the uterus. The uterus develops in front of the ovary. It first appears as a solid cord of cells connected with the united ducts of the ovary, shell gland, and yolk gland. The solid cord of cells which later gives rise to the uterus becomes hollow and appears as a blind sac or tube. This then grows in size, forming pockets, and finally fills up the entire proglottid.

This form is one of the most common chicken tapeworms and is the most easily recognized. It can be identified by the head with its broad, flat rostellum which shows up very prominently; the width of the most anterior segments is usually equal to or greater than the width of the head, and the eggs are distributed in individual egg capsules in mature proglottids.

4. *Hymenolepis carioca* (Magalhaes 1898) Ransom 1902

*Diagnosis:* Length 30 to 80 mm. Breadth at neck 75 to 150 $\mu$ , at posterior end 0.5 to 0.7 mm. Segments three to five times or more broader than long throughout strobila. Head (Fig. 26) flattened dorso-ventrally, 140 to 160 $\mu$  long, 150 to 215 $\mu$  wide and 100 to 140 $\mu$  thick. Suckers shallow, 70 to 90 $\mu$  in diameter, unarmed. Rostellum unarmed; in retracted position 25 to 40 $\mu$  in diameter and 90 to 100 $\mu$  in length, with small pocket opening to exterior in anterior position. Unsegmented neck portion of strobila 0.6 to 1.5 mm. long. Genital pores almost entirely unilateral, a single pore being located in each segment slightly in front of middle of right-hand margin.

*Male Reproductive Organs:* Testicles three in number, normally two on left and one on right of median line. On dorsal side of inner end of cirrus pouch vas deferens is swollen into prominent seminal vesicle (Fig. 18, *sv*) which may attain a size of 70 by 50 $\mu$ . Cirrus pouch (Fig. 18, *cp*) in sexually mature segments 120 to 175 $\mu$  long by 15 to 18 $\mu$  in diameter; almost cylindrical, slightly curved toward ventral surface of segment; on outer surface about 20 longitudinal muscle bands, 2 to 3 $\mu$  in thickness, very prominent in cross section; vas deferens enlarged within cirrus pouch to form small seminal reservoir occupying proximal two-thirds of pouch; distal third of portion of vas deferens within pouch very slender, about 1 $\mu$  in diameter and functions as cirrus. Genital cloaca 12 to 36 $\mu$  deep.

*Female Reproductive Organs:* Opening of vagina in floor of genital cloaca, ventral and posterior to cirrus opening. First portion of vagina very narrow, 1 $\mu$  in diameter. Small vaginal sphincter 8 to 10 $\mu$  from vaginal opening. On inner side of sphincter vagina gradually increases in diameter, and in sexually mature

segments swollen into prominent seminal receptacle (Fig. 18, *sr*) which extends forward to anterior border of segment and inward considerable distance beyond proximal end of cirrus pouch. Ovary faintly bilobed or trilobed in posterior half of proglottid. Yolk gland spherical or ovoid, 30 to 40 $\mu$  in diameter, situated near median line of segment, posterior and dorsal of ovary. Uterus at first solid cord of cells extending transversely across segment along anterior border of ovary; becomes hollowed out and grows backward on dorsal side of ovary; in gravid segments occupies nearly entire segment and filled with eggs. Eggs (Fig. 27) in gravid uterus spherical or oval, with four thin membranes, the two middle membranes often approximate to form thick layer which shows somewhat of a cellular or coarse granular structure. Diameter of outer membrane 36 by 36 $\mu$  to 75 by 70 $\mu$ , of outer middle membrane 30 by 30 $\mu$  to 65 by 60 $\mu$ , of inner middle membrane 26 by 26 $\mu$  to 40 by 35 $\mu$ , of inner membrane 24 by 16 $\mu$  to 29 by 21 $\mu$ . This membrane often lies so close to onchosphere that it can scarcely be distinguished from edge of embryo. Onchosphere is 18 by 14 to 27 by 19 $\mu$  in diameter; length of embryonal hooks 10 to 12 $\mu$ .

This form is thread-like and usually occurs in great numbers. It is very delicate and fragile and can be recognized by that fact alone, as it is the most fragile of the chicken forms known.

#### SUMMARY

1. By morphological comparison of the cysticercoids produced experimentally in flies and adult of *Choanataenia infundibuliformis* they are shown to be identical.

2. Morphological points noted are the presence of minute hooklets on the suckers and entire surface of scolex in *Choanataenia infundibuliformis*. The manner of development of uterus in the same species is by means of a blind tube which grows in size, forming pockets, and later breaks up into small compartments. In *Davainea tetragona* the genital pores were found to occur irregularly alternate in the proglottids. The hooks on the rostellum of *Davainea cesticillus* were found to vary in length from 8 to 12 $\mu$ . The uterus in development first appears as a solid cord of cells which becomes hollow and in growing forms pockets, filling the entire proglottid.

## BIBLIOGRAPHY

BLANCHARD, R.

1891. Notices helminthologiques. Sur les téniaés a ventouses armées. Mem. soc. zool. France., 4: 420-489.

DAVAINE, C.

1877. Traité des entozoaires et des maladies vermineuses de l'homme et des animaux domestiques. Paris. Ed. 2, 1003 p.

GRASSI, B., and ROVELLI, G.

1888. Bandwürmer Entwicklung. I. Centralbl. Bakt. und Parasitenk., 3: 173.
1889. Embryologische Forschungen an Cestoden. Centralbl. Bakt. und Parasitenk., 5: 370-377; 401-410.
1892. Ricerche embriologiche sui Cestodi. Atti. Accad. Gioenia Sci. Nat. in Catania, 4: 1-108.

GUTBERLET, J. E.

1916. Studies on the Transmission and Prevention of Cestode Infection in Chickens. (In Press.)

HASSALL, A.

1896. Bibliography of Tapeworms of Poultry. Bull. Bur. An. Ind., 12: 81-88.

KRABBE, H.

1869. Bidrag til Kundskat om Fuglenes Baendelorme. Vid Selsk. Skr. v. Roekke. Nat. og Math., 8: 251-368.

MAGALHAES, P. S. DE

1898. Notes d'helminthologie Brésilienne. Arch. Parasit., 1: 442-451.

MOLIN, R.

1858. Prospectus helminthum, quae in prodromo faunae helminthologicae Venetiae continentur. Sitzber. k. Akad. Wiss. Wien, math. naturw. kl., 30: 127-158.

MOORE, V. A.

1895. A Nodular Taeniasis in Fowls. Bur. An. Ind. Cir. 3; 4 pp.

MRÁZEK, AL.

1907. Cestoden Studien. I. Cysticercoiden aus Lumbriculus variegatus. Zool. Jahrb., Syst., 24: 591-624.

PIANA, G. P.

1882. Di una nuova specie di Tenia del gallo domestico (Taenie bothrioplitis) e di un nuova cisticerco delle lumachelle terrestri (Cysticercus bothrioplitis). Mem. Accad. Sci. Inst. Bologna, 2: 387-394.

**RANSOM, B. H.**

1900. A new Avian Cestode-Metroliaesthes lucida. Trans. Amer. Micr. Soc., 21: 213-226.
1902. On Hymenolepis carioca (Magalhães) and H. megalope (Nitzsch) with Remarks on the Classification of the Group. Trans. Amer. Micr. Soc., 23: 151-172.
1904. The Tapeworms of American Chickens and Turkeys. Ann. Report Bur. An. Ind., 21: 268-285.
- 1904a. Manson's Eye-worm of Chickens (Oxyspirura Mansoni). Spiny-Suckered Tapeworms of Chickens. Bull. Bur. An. Ind., 60; 72 pp.
1909. The Taenoid Cestodes of North American Birds. Bull. U. S. Nat. Mus., 69: 1-141.
1911. A New Cestode from an African Bustard. Proc. U. S. Nat. Mus., 40: 637-647.

**ROSSETER, T. B.**

1890. Cysticercoïds parasitic in Cypris cinerea. Jour. Micr. Nat. Sci., 9: 241-247.
1891. Sur un cysticercoïde des Ostracodes, capable de se développer dans l'intestin du canard. Bull. soc. zool. France, 16: 224-229.
1892. On a New Cysticercus and a New Tapeworm. Journ. Queckett Micr. Club, 4: 361-366.
1897. On Experimental Infection of Ducks with Cysticercus coronula Mrazek (Rosseter), Cysticercus gracilis (von Linstow), Cysticercus tenuirostris (Hamann). Journ. Queckett Micr. Club, 6: 397-405.

**SCHMIDT, J. E.**

1894. Die Entwicklungsgeschichte und der anatomische Bau der Taenia anatina (Krabbe). Arch. Naturg., 1: 65-112.

**STILES, C. W.**

1896. Report upon the Present Knowledge of the Tapeworms of Poultry. Bull. Bur. An. Ind., 12; 78 pp.

**TOWER, W. L.**

1900. The Nervous System of the Cestode Monezia Expansa. Zool. Jahrb. Anat., 13: 359-384.



## EXPLANATION OF PLATES

Unless otherwise stated all drawing were made with the aid of a camera lucida.

## ABBREVIATIONS

<i>b</i> —bladder	<i>rs</i> —rostellar sac
<i>c</i> —cyst	<i>sg</i> —shell gland
<i>ca</i> —primitive cavity	<i>sr</i> —seminal receptacle
<i>cn</i> —connection of bladder with cyst	<i>sv</i> —seminal vesicle
<i>cp</i> —cirrus pouch	<i>t</i> —testes
<i>dex</i> —dorsal excretory canal	<i>u</i> —uterus
<i>ex</i> —excretory ring in scolex	<i>v</i> —vitelline duct
<i>o</i> —ovary	<i>va</i> —vagina
<i>oh</i> —onchospheric hooks	<i>vd</i> —vas deferens
<i>ov</i> —oviduct	<i>vex</i> —ventral excretory canal
<i>r</i> —rostellum	<i>y</i> —yolk gland

## PLATE V

## CHOANOTAENIA INFUNDIBULIFORMIS

- Fig. 1. Scolex much contracted. x40  
 Fig. 2. Scolex normal extension. x145  
 Fig. 3. Longitudinal section of scolex, showing rostellum and rostellar sac. x425  
 Fig. 4. Section of portion of sucker, showing hooklets. x425  
 Fig. 5. Section of portion of wall of scolex, showing hooklets. x425  
 Fig. 6. Longitudinal nerve tract, showing nerve cells with processes. x650

## PLATE VI

- Fig. 7. A, B, C, D. Embryos from mature proglottid. x425  
 Fig. 8. Hooks from rostellum of adult. x425

## CYSTICERCUS OF CHOANOTAENIA INFUNDIBULIFORMIS

- Fig. 9. Hooks from rostellum of cysticercus. x425  
 Fig. 10. Section through scolex, showing rostellum with hooks and rostellar sac. x425  
 Fig. 11. Section through scolex and cyst, showing suckers with hooklets, structure of cyst and primitive cavity between layers of cyst. x425  
 Fig. 12. Reconstruction of cysticercus with cyst and bladder or tail, showing scolex in cyst and onchospheric hooks in bladder. x145  
 Fig. 13. Section of wall of bladder, showing histological structure and peritoneum of host. x425

## PLATE VII

- Fig. 14. *Choanotaenia infundibuliformis*. Reconstruction of mature proglottid, showing reproductive organs, excretory vessels, and nerve. x145
- Fig. 15. *C. infundibuliformis*. Reconstruction of cirrus pouch showing cirrus and vas deferens, also part of vagina in connection with cloaca. x310
- Fig. 16. *C. infundibuliformis*. Reconstruction of female reproductive organs, showing part of ovary, yolk gland, shell gland, oviduct, vitelline duct, uterus, and connection of ducts with uterus and seminal receptacle. x310
- Fig. 17. *Davainea cesticillus*. Reconstruction of mature proglottid, showing reproductive organs and excretory vessels. x145
- Fig. 18. *Hymenolepis carioca*. Reconstruction of mature proglottids, showing reproductive organs from ventral view. x145

## PLATE VIII

- Fig. 19. Scolex of *Davainea tetragona*. x145
- Fig. 20. Hooks from rostellum of *D. tetragona*. x425
- Fig. 21. Hooks from suckers of *D. tetragona*. x425
- Fig. 22. Scolex of *Davainea echinobothrida*. x145
- Fig. 23. Hooks from rostellum of *D. echinobothrida*. x425
- Fig. 24. Hooks from suckers of *D. echinobothrida*. x425
- Fig. 25. Embryos of *D. echinobothrida*, showing capsule and fibrous gelatinous mass in which it is embedded. x425
- Fig. 26. Scolex of *Hymenolepis carioca*, after Ransom.
- Fig. 27. A, B, C, D. Embryos of *Hymenolepis carioca*, showing enveloping membranes. x425
- Fig. 28. Scolex of *Davainea cesticillus*. Free-hand drawing of living specimen well extended, showing rostellum.
- Fig. 29. Hooks from rostellum of *D. cesticillus*. x425
- Fig. 30. A, B, C, D. Embryos of *D. cesticillus*, showing enveloping membranes. x425

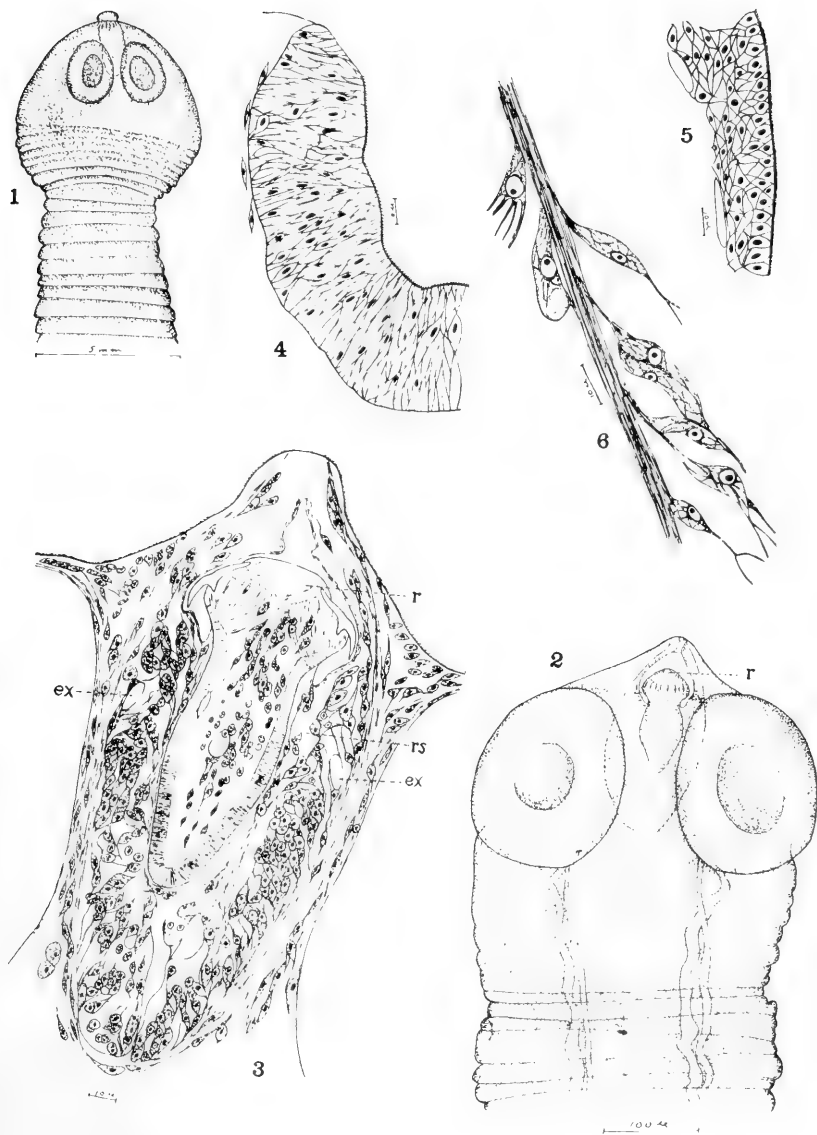


PLATE V



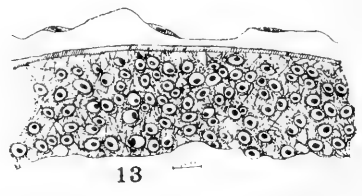
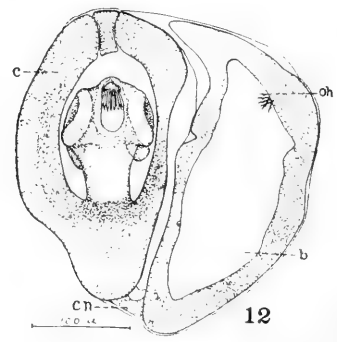
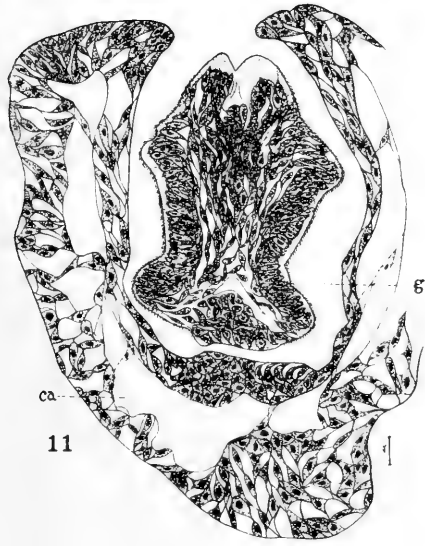
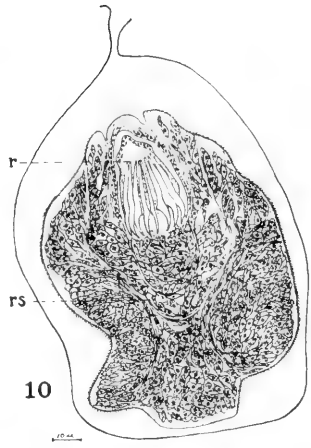
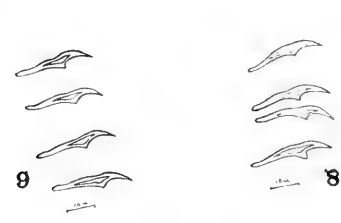
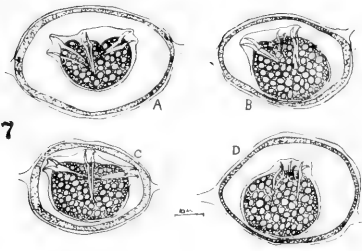


PLATE VI



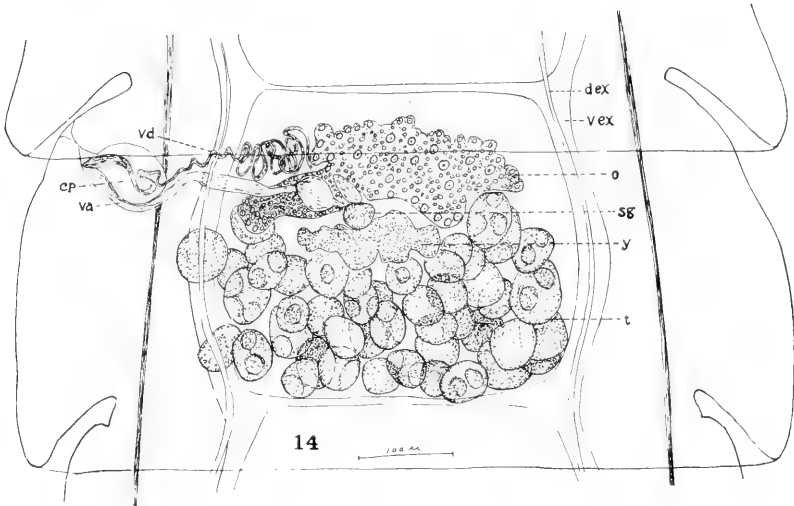
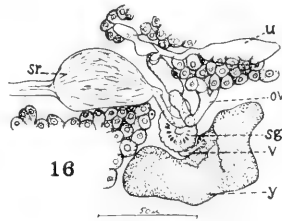
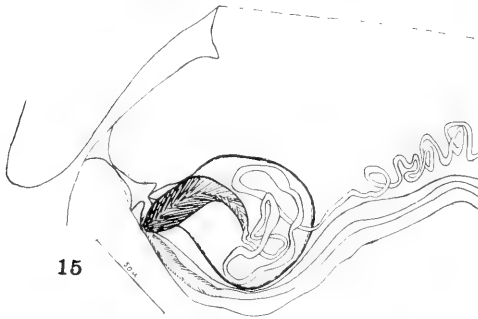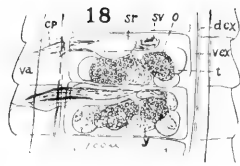
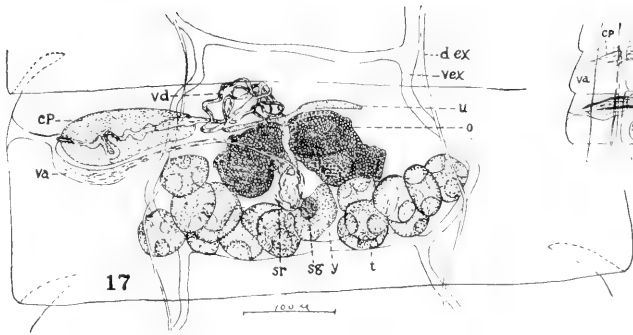


PLATE VII





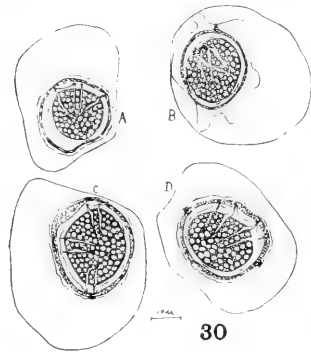
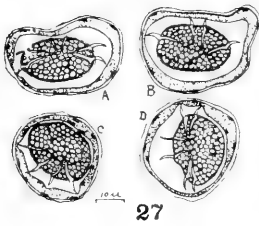
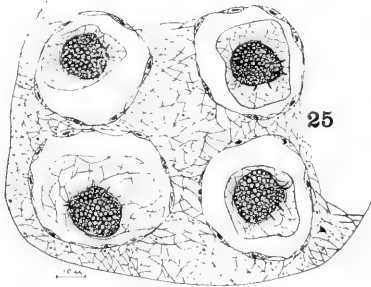
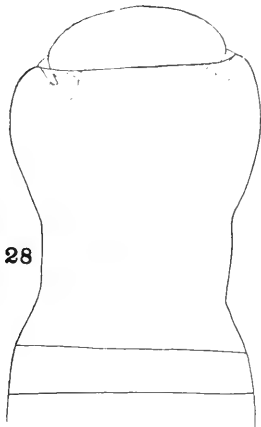

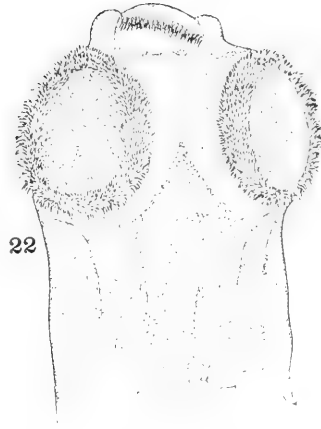
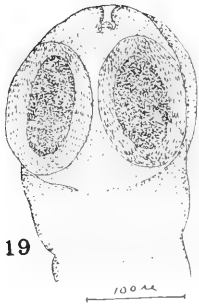


PLATE VIII







Contributions from the Zoological Laboratory of the University of Illinois,  
under the Direction of Henry B. Ward, No. 62.

# STUDIES ON THE TRANSMISSION AND PREVENTION OF CESTODE INFECTION IN CHICKENS

JOHN E. GUTBERLET, Carroll College, Waukesha, Wis.

INTRODUCTION. The problem of tapeworm infection in chickens has received but little attention in the United States. In fact it was entirely untouched until a few years ago when the subject was opened by Stiles (1896) and work was begun by Ransom (1900, 1902, 1904, 1909) on poultry and other birds. At the present time less than a dozen references constitutes the entire American literature on the subject. Five species of cestodes are known to infest chickens in various parts of the United States.

No work has been done on the life history of the forms existing in this country. However, studies have been carried on extensively with poultry cestodes in various other parts of the world, though as yet very little has been finally determined. In only one species of chicken cestode has the life cycle been demonstrated experimentally. That is *Davainca proglottina* (Davaine) for which Grassi and Rovelli (1889: 372; 1892: 30, 85) have shown that the intermediate host is a slug (*Limax cinereus*). This species of cestode has not as yet been reported in this country.

Chickens are supposed to become infested with another species through eating snails, a third through eating flies, and a fourth through eating earthworms. Piana (1881-1882) found in a snail (*Helix*) two cysticercoids which agree closely with the head of *Davainca tetragona* (Molin). No experiments were performed to demonstrate that the cysticercoid was the larval stage of that species and the only evidence of their connection is the similarity in form. Grassi and Rovelli (1892: 33, 87) found in flies cysticercoids which closely resembled *Choanotaenia infundibuliformis* and base their conclusion of identity on the structural similarity.

Grassi and Rovelli (1889: 372; 1892: 29) found in earthworms (*Allobophora foetida*) cysticercoids which they associated with the scolex of *Dicranotaenia sphenoides*, a chicken cestode not reported in this country. Here again the only evidence for regarding it to be the larval stage of this species is a general structural likeness. In no one of these three forms was the life cycle demonstrated experimentally. Such comparisons are not proof that the cysticercoids are intermediate stages of definite species, but only give a clue as to the probable life cycle.

In other kinds of poultry more has been done on the life histories of their cestodes. The life cycles of five species of duck cestodes have been demonstrated through experiment. Schmidt (1894) proved that *Drepanidotaenia anatina* (Krabbe) has its intermediate stage in a fresh-water crustacean (*Cypris ovata*). He fed large quantities of tapeworm eggs to the crustaceans and found that the larvae developed in two weeks during the summer. Rosseter (1891, 1892) has shown that a second duck cestode, *Echinocotylus Rosseteri* (Blanchard), has its intermediate stage in another small fresh-water crustacean (*Cypris cinereus*). He fed large numbers of the crustaceans to ducks which upon examination later yielded a large crop of tapeworms of the species named.

Rosseter (1897) also demonstrated experimentally the life histories of three other species of duck cestodes. He had discovered some cysticerci in crustaceans which he compared with the adult worms occurring in ducks and found that they agreed closely. He produced *Dicranotaenia coronula* in a duck by feeding it *Cypris cinerea*. *Drepanidotaenia gracilis* was introduced into the ducks through *Cypris cinerea* and *Cypris viriens*. *Drepanidotaenia tenuirostris* was likewise raised by feeding *Cyclops agilis*.

As in other cases the question of control of infection in chickens depends to a great extent upon the life history of the parasites. Little can be done to wipe out the disease until more is known of its source. Certain methods may be employed to check it, but as yet it has been impossible to prove the exact source of infection. Usually it is easiest to control such forms during the developmental stages.

This paper is the result of some investigations carried on to find out the life history of certain chicken tapeworms. Numerous experiments were tried on various insects and many observations made on the habits of the birds in the endeavor to ascertain where the cause of the infection was located. The habits of the birds are probably the chief factors to be dealt with in experiments of this kind. Certain insects that are common about the habitats of the birds are readily eaten. They are hence more likely to be intermediate hosts than those which are rare in these localities. Such factors have been taken into consideration and through experiment it has been shown that one cestode, *Choanotaenia infundibuliformis*, has its intermediate stage in the common house-fly.

The most of the material was collected, and the experimental

work was done on a farm at Hardy, Nebraska. A large amount of material was also collected at the poultry farm at the University of Illinois.

Thanks are due to Professor D. O. Barto, of the University of Illinois, for giving me the privilege of collecting material at the poultry farm. For other assistance I am indebted to my father and mother, William and Flora Gutberlet, for their untiring efforts to make this work a success by taking records and making collections of material at times of the year when they would not otherwise have been taken.

I wish to express my appreciation to Dr. Henry B. Ward, at whose suggestion this work was first taken up, for his helpful suggestions and criticisms during the preparation of this paper.

**METHODS OF TECHNIC.** In making collections of tapeworms the intestine of the bird was slit open under water and the contents removed by shaking gently. The worms are usually attached to the wall and can be easily seen and removed with the aid of a pair of needles. Those that are not attached sink to the bottom of the dish.

In removing the worms from the intestine it was found best to transfer them directly to fresh water. A weak saline solution was demonstrated to be harmful as the worms die in it in a very short time. Tower (1900: 362) found saline solution harmful to cattle cestodes (*Monezia*). In fresh water, the worms soon become well extended and remain alive and normal for twelve to fifteen hours, or even longer. The worms are best killed in a corrosive-acetic solution and preserved in 70% alcohol and glycerine. For study of structure and accurate diagnosis of species the worms were cut in sections from 5 to 10 microns in thickness, stained in Delafield's or Ehrlich's acid haematoxylin and destained in acid alcohol.

In order to use house-flies for experimental purposes one has to work out first, methods of keeping them alive. The flies used were kept for experiment in small cages. They demanded a great deal of attention because the slightest disturbance of conditions was harmful. They were fed most satisfactorily on blood, liver, and spleen. It was found that a fly could not live long without a constant supply of water in the cages. The cages had also to be placed in the sun for a few minutes each morning, and then kept in the shade for the rest of the day, but not in a cool place.



At the conclusion of the experiment the flies were killed, fixed in corrosive-acetic solution and preserved in 70% alcohol. The chitin covering of the body of the flies was punctured to allow these fluids to penetrate properly.

Large bottles proved very satisfactory as cages for beetles during the experiments. The bottles were fitted with glass or metal stoppers provided with pores for the passage of air. Leaves and a small amount of soil were placed in the bottom of the bottle. The beetles were killed and preserved like the flies, but before sectioning the chitin covering was removed by dissection.

**AMOUNT OF INFECTION.** The flock of chickens upon which these studies were carried on was so heavily infected with the tapeworm disease during certain seasons that it was rather unusual to find a bird that did not harbor at least a few of the parasites. The investigations extended over a period of two summers. Close observations were made during those seasons, and also at several other times during the year, to secure a record of the amount of infection during other seasons than the summer months.

The first summer (1912) about fifty chickens were examined for parasites. Eight of these were adults and in no case was there any infection. Ten young birds from six weeks to two months old were examined in June, but none of them were infected. The first infection of tapeworms for that year was detected on July 25. Between that date and September 9, thirty-two young birds were examined and every one showed some infection. In some it was slight, while in others it was very heavy. During this same period, between July 25 and September 9, some adult birds were examined but yielded no parasites.

During the summer of 1913 forty birds were examined between August 10 and September 18, with some infection in every bird. A few of these were adult birds which had only a few parasites. The young birds were more heavily infected, although the number of parasites varied with different birds. In one bird which was examined at the age of seven weeks, twenty-five tapeworms were found. Between June 17 and August 1, eight birds were examined and cestodes were present in every bird with the exception of one adult killed on June 24.

I have records of infection in the flock for January 1 and April 27, 1913, and for November 20, December 2, and December 26, 1913. There are five species of worms infesting the chickens in this place and further details are given in the table.

Between June 20 and August 1, 1913, examinations were made of about fifteen birds at Urbana, Ill. Some of these were from the poultry farm at the University of Illinois and others were from private yards of residents in this vicinity; in only one bird was there any trace of an infection. In that case there were a few fragments of worms which were in such a state of disintegration that they could not be preserved or determined. No further examinations for parasites were made in this locality until December 2, 1913, when it was discovered that the chickens at the poultry farm at the University of Illinois were badly infested. Several were examined and found to harbor *Davainea echinobothrida*, *Davainea cesticillus*, and *Hymenolepsis carioca*.

A general examination was made of the living birds at the poultry farm and it was discovered that symptoms of cestode disease were manifested by the great majority of the chickens, although the infection was apparently not heavy except in a small percentage of the flock.

In making examinations upon dead birds infested with *Davainea echinobothrida* it was found that large nodules were formed in the intestinal wall which is a characteristic pathologic effect of this particular spiny-suckered form. *Davainea cesticillus* seems to be almost universally present as there was hardly an infested bird examined in Nebraska or Illinois that did not harbor some of this species.

The following table shows the amount of infection and the number of worms occurring in each bird examined, both in Nebraska and Illinois:

DATE	LOCALITY	Age of host	No. of <i>D. cesticillus</i>	No. of <i>D. tetragona</i>	No. of <i>D. echinobothrida</i>	No. of <i>Hymeno. carioca</i>	No. of <i>Ch. infundibuliformis</i>
July 25, 1912	Hardy, Neb.	4 mo.	5				
" 29	"	4 mo.	2	8			
August 2	"	5 mo.	3				
" 7	"	5 mo.	3	15		20	2
" 8	"	5 mo.	10	25		10	
" 9	"	5 mo.	10	35			
" 10	"	5 mo.	5	15		5	2
" 11	"	5 mo.	7	10		3	
" 12	"	5 mo.	10	10		30	3
" 15	"	5 mo.	5	4			1
" 20	"	Adult					
" 20	"	5 mo.	3	15		3	1
" 21	"	5 mo.	15	10			
" 21	"	5 mo.	3	2			2
" 22	"	5 mo.	3	8			3

DATE	LOCALITY	Age of Host	No. of D. cestillus	No. of D. tetragona	No. of D. echinobothrida	No. of Hymenocarioca	No. of Ch. infundibuliformis	
" 23	"	5 mo.	3	3		2	2	
" 25	"	5 mo.	5	10		10		
" 27	"	5 mo	6	4			5	
" 29	"	Adult						
September 2	"	Adult						
" 4	"	6 mo.	5	20		10		
" 6	"	6 mo.	15	10			6	
" 7	Hardy	6 mo.	10	14			5	
" 8	"	6 mo.	4	10			2	
" 9	"	6 mo.	10	10		5		
January 2, 1913	"	Adult	3				5	
March 23	"	Adult						
" 25	"	Adult						
" 30	"	Adult						
April 27	"	Adult	10					
June 17	"	Adult						
" 24	"	Adult						
" 21	Urbana	2 yr.						
" 23	"	2 yr.						
" 28	"	2 yr.						
July 7, 17, 20	Hardy	4 mo.	infection, but records incomplete.					
August 10	"	4 mo.	5	10			15	
" 11	"	4 mo.	3					
" 15	"	4 mo.					3	
" 16	"	5 mo.	15	30		20	10	
" 17	"	5 mo.	25	30		5	8	
" 19	"	5 mo.	6	15			5	
" 20	"	5 mo.	6	6				
" 26	"	5 mo.		15	2			
" 26	"	5 mo.	20	25	8		10	
" 27	"	5 mo.	1	5	4			
" 28	"	5 mo.	2	10		10	5	
" 28	"	5 mo.	10	10			6	
" 30	Hardy	5 mo.	8	18			3	
September 2	"	Adult	3	12			4	
" 4	"	5 mo.	20	20				
" 6	"	7 wks.	17				8	
" 10	"	5 mo.	8			10	5	
" 10	"	5 mo.	15	25			4	
" 11	"	5 mo.	10	15			4	
" 12	"	5 mo.	25	35			15	
" 13	"	5 mo.	8	10	4		8	
" 15	"	6 mo.	10	10			5	
" 16	"	6 mo.	3	30				
" 17	"	6 mo.	20	10				
" 20	"	8 mo.	35	6			10	
December 2	Urbana	4 mo.	20		30			
" 5	"	4 mo.			3			
" 6	"	Adult	5			5		
" 9	"	6 mo.	6			6		
" 24	Knoxville, Ill	Adult	17	00	00	00	1	
" 26	Hardy	Adult	1	11			3	
January 1, 1914	"	Adult	3	2			5	

SYMPTOMS AND EFFECTS OF TAPEWORM INFECTION. A great deal has been written on the symptoms of this disease by various authors, but in every case they were unable to reach any definite conclusions on the subject. In my own study, which was extensive, I reached the following definite conclusions: The symptoms, while not really individual, vary to some extent with the different birds, with the age of the birds, and with the degree of infection. Some birds are affected by the disease much more than others and show symptoms and effects much more readily. Some birds that show no symptoms and appear in good health are heavily infested with the worms, while others showing severe effects and manifesting all the symptoms are not nearly as heavily infested. The age of the host is a factor of much importance for indicating the presence of an infection with the species I studied. Young, growing birds are affected much more than adults and show the symptoms more distinctly. Even a comparatively slight infection can be detected in a young bird a few weeks of age, while a heavy infection is very marked. Most adults manifest no external symptoms as far as appearance is concerned unless they are heavily infested. The degree of infection is another factor which is of importance in making a diagnosis for cestodes. Birds that harbor only a few worms show conditions which are quite different from those that possess a large number. Therefore the symptoms are rather variable.

Stiles (1896: 13) mentions some general principles for diagnosis, and Zurn (1882: 17) gives more fully some of the symptoms that may be taken as indications of the disease in the birds.

In general, one may say that a light infection can hardly be noticed and is apparently in no way harmful to the fowl. In cases suffering from a moderate to a heavy infection the conditions were found to be quite different. In the first place, birds that are moderately infested are apparently always hungry, having indeed ravenous appetites and seeming never to be able to get enough to eat. Secondly, they manifest a great desire for water, increasing in cases where the infection is heavy. Moreover, infected birds are greedy and it seems as if their hunger had caused them to lose control of themselves whenever there is a chance to obtain any food. Such birds are also restless, always moving about as if searching for something. This in part probably accounts for the fact that the fowls are poor in flesh and more or less in an emaciated con-

dition. They are never at ease on account of their restless attitude which is apparently due to nervousness. Normal exercise alone does not depress the condition of the bird, but rather the constant restlessness and uneasiness which is manifested by those that are infested.

The heavily infested chickens become emaciated and lose their color, the feathers become ruffled, and the plumage is not glossy as in the fowls that are free from the disease. Growing birds that were heavily infested, were found usually to be slender and quite poor in flesh, the head very thin and the comb pale. In cases of heavy infection the growing birds isolate themselves to some extent and often allow the wings to droop and hang at the sides. The sick birds, even though they isolate themselves, still manifest a great desire for food and water.

A slight infection is hardly to be detected in the droppings, but when it is heavy there is developed an irritation or inflammation of the intestinal epithelium, a kind of catarrh which results in a diarrhea, varying with the degree of infection. This irritation of the intestinal epithelium by the worms causes an abundant flow of mucus into the intestine. The mucous secretion is at first a clear, transparent semi-liquid, and sometimes slightly whitish. Worms which are slightly transparent are difficult to see, as they are imbedded in the mucus. Later the mucus takes on a brownish color which is due in part to slight hemorrhages of the epithelium caused by the irritation of the worms. This color of the mucus is retained until it is passed out with the feces so that the droppings of an infested bird have always a characteristic yellowish-brown color. This factor of coloration in the droppings is one that can nearly always be depended upon as a criterion of infection.

When the infection is heavy a gas is formed in the intestine which is noticeable in the droppings in the form of bubbles. These bubbles are present when the feces are first passed and remain in the semi-liquid droppings for some time. This is very characteristic in cases of heavy infection but is not noticeable at other times except in cases of extreme diarrhea, and then the gaseous formation is comparatively slight. In a flock that is heavily infested nearly every dropping detected about roosting or resting places shows the characteristic yellowish-brown color with a large number of small gas bubbles enclosed. The infested birds pass droppings often, though in small quantities.

Segments of the worms can usually be found when there is a moderately heavy infection, and eggs can nearly always be demonstrated by the aid of a microscope, but the latter method is not practical under all circumstances. When the above methods fail to show any signs of infection and an absolute diagnosis is desired it may be well to take a few of the birds that show some of the symptoms, kill them and make an examination of the contents of the intestine between the gizzard and caecum. Any infection which cannot be detected by the above methods is so slight that it is not harmful to the birds in any way, or is so recent that the cestodes are too small to be seen.

The best criteria for diagnosis are the emaciated condition of the birds, the great desire for food and water, and the marked diarrhea with the characteristic yellowish-brown color of the droppings; furthermore in cases of heavy infection segments of worms can usually be detected, though there is some degree of uncertainty in making gross examinations for the proglottids in the feces. The excretions from the kidneys are white in color and at times have somewhat the appearance of the tapeworm proglottides. This may at times be misleading to one who is inexperienced with this method of examination. The excretion from the kidneys can be readily distinguished from proglottids by placing the droppings in water and breaking up the mass. Proglottids have a definite shape and are firm, while the excretions break up into fine granules, or shreds which are easily disintegrated by shaking.

Some of the above symptoms for cestode infection are identical with those for nematodes: the emaciated, unthrifty condition, the ruffled, dull appearance of the feathers, and the more or less restless attitude of the bird. The feces, however, look quite different and often blood is passed with the droppings in cases of nematode infection. The nematodes produce hemorrhages in the intestine by boring into the epithelium.

Tapeworm infection is harmful according to the degree of infection. A slight infection does practically no harm to the bird, but when there is a heavy infection the condition is more serious. The intestinal inflammation or catarrh is quite a serious matter and in many cases may prove fatal. It brings on a more or less anaemic condition and the bird's general health is run down. Such a condition is suitable for the coming in of other diseases, since the fowl is unable to ward them off because of its weakened state

of health. Through these means the tapeworms are most harmful, as their effect works more or less indirectly with other diseases.

I have found instances where the worms were so numerous that they would form such a large compact mass in the intestine as to interfere with passage. These masses imbedded in a great quantity of mucus become lodged at the junction of the small and large intestines with the caeca.

One species, *Davainea echinobothrida*, produces nodules or ulcers in the intestinal wall which are often mistaken for other diseases. This has a more serious effect upon the chickens than some of the other species as it has more of a direct pathological effect.

Chickens infested with any of the species of common tapeworms devoured great quantities of food, but upon examination the intestines were usually found empty. It seems as if the food material after reaching the intestine rushes through rapidly on account of the large amount of mucus and the marked diarrhea. This does not allow the bird to obtain as much nourishment as it would otherwise. The cestodes of course absorb their nourishment from the chyme in the intestine. Furthermore, the excretions from the worms may also have some effect upon the general health of the bird, as some are without doubt resorbed into the system from the intestine.

More practical proof must be obtained by experimental study on the various effects and symptoms of infection in chickens before much can be definitely said on the subject. As yet there is but little known in regard to definite symptoms and effects except in a general way.

**METHODS OF CONTROL.** The subject of the control and treatment of tapeworm disease in chickens has not been studied extensively. There is need of more experimental data before much can be said concerning it. Several remedies, however, have been tried with some degree of success, although they do not seem practical when large numbers of birds are to be treated.

A practice general among poultry raisers is to isolate a sick bird and leave it to cure itself, or to kill it. Most poultry men do not take the trouble to treat a sick bird nor do they even try to find out the cause of its ailment, but simply say that it has "gone light." Such an expression covers a multitude of diseases prevalent among poultry. Birds that are heavily infested with worms

isolate themselves and become emaciated. They are also said to have "gone light."

As the first prerequisite for carrying on any sort of treatment for worm diseases, the infected birds must be isolated from the rest of the flock so that the latter can be kept free from contamination. The droppings from the sick birds must be cared for or destroyed in some way so that the embryos of the worms are killed and insects prevented from feeding on them. In general for any flock, preventive measures should be taken against infection of all kinds by keeping the surroundings clean and sanitary; all droppings around roosts should be collected often or subjected to such treatment as will render them harmless or inaccessible to insects. Wherever an infection is present, even if only slight, such preventive measures should be taken to eliminate all possibility of its further increase. One of the best is to collect the droppings about the coop daily and place them into vats or cans that are inaccessible to insects or worms; they are then treated with lime or some substance which destroys the embryos. Lime or ashes should be scattered over the droppings around the roosts and the resting places of the birds. This destroys the embryos and keeps insects from feeding upon the droppings. Furthermore, if the droppings are covered with lime and collected often it will prevent insects from breeding in them. House-flies especially, lay eggs in chicken manure if the droppings are not treated with lime.

Other features in the habitat of the birds should be kept sanitary; such are the feeding places and drinking vessels. Watering troughs should be so placed that the birds cannot get their feet into them, as they may carry in eggs or embryos of other parasitic worms (nematodes) which will reach the birds again through the water if the latter is allowed to stand in a filthy condition.

The location of poultry yards should be changed from time to time if possible, because if the same grounds are used from year to year some of the insects that may be the intermediate hosts of the tapeworms may become numerous and thus increase the possibility of infection. Embryos of parasites or germs of certain diseases remain on the premises from year to year, and if the yards are changed, more healthful conditions are produced for the birds.

In addition to destroying the eggs and embryos of parasites in the droppings, it is fully as important to destroy the adult insects and their breeding places. The life history of only one spe-



cies of tapeworm has been worked out in the United States, as is discussed elsewhere in this paper. This species is known to have its intermediate stage in the house-fly. House-flies breed commonly in bird or horse manure, or any decaying vegetable matter. The destruction of all such breeding places is a difficult matter and little can be done along that line or with the destruction of adult flies. However, fly traps\* can be placed over the windows of the chicken coop and many flies caught and killed.

According to Stiles (1896:18), the principal remedies that have been used for the removal of tapeworms from poultry are such drugs as extract of male fern, turpentine, powdered kamala, areca nut, pomegranate root bark, pumpkin seeds, and sulphate of copper. These have been experimented with to a certain extent and have been found to be satisfactory in some instances.

The experiments with these remedies have been worked out on individual birds. Each bird must be treated individually. While such methods of treatment are thorough, they are not practical for a poultry raiser who has an infection in a flock of several hundred birds. It would require handling each bird separately two or three times, and demand a considerable amount of time; too much to be practicable on account of the expense involved.

I tried experiments on a number of birds to see whether a more practical method could be found. It had been observed previously that hogs infected with worms could be freed from them by feeding the ashes from corncobs. The ashes contain a large amount of sodium and potassium carbonate. Lye is made from ashes and of course contains similar substances, together with sodium hydroxide.

The following experiment worked very successfully: Fifteen birds which showed symptoms of tapeworm infection were placed in a cage which was insect-proof and were given the following treatment; A gallon of a mixture of wheat and oats, to which was added a small tablespoonful of concentrated lye, was cooked slowly for about two hours and allowed to cool. The birds were fasted for about fifteen hours and were then given as much of the mixture as they would eat, with plenty of water. Twelve hours later one of the birds was killed and an examination of the small intestine was made. It was found that nearly all of the worms in

---

\*Such as described by F. C. Bishopp, Farmers' Bulletin No. 540, 1913.

the intestine were loose, the scolices being detached from the wall, and were also apparently dead. The rest of the birds were given a second dose twenty-four hours after the first. Many worms had passed with the droppings in from twenty-four to twenty-six hours after the first feeding. Most of the worms in these droppings were dead, but in all probability the embryos were still alive in the mature proglottids. Twelve hours after the second dose was given another bird was killed and it was found that only a few worms were left and all of these were detached and dead. The intestine was filled with a peculiar gray colored, slimy substance composed mainly of mucus. Many entire worms and fragments were passed with the droppings during the period of the feeding. The lye acted to some extent as a purgative.

The birds were given normal diet again, and in a few days they showed no symptoms of infection. Eight days after the second dose two more birds were killed and examinations made. One possessed a small fragment of a tapeworm and the other was entirely free.

The effects of such treatment upon the flock as a whole were shown later. While I was carrying on other investigations with chicken cestodes my father noticed that the birds were very heavily infested with worms. In an endeavor to free the birds of the worms and to improve their general condition he fed them a mixture of cooked grain and lye on July 15, unknown to me. As a result the entire flock of nearly four hundred birds was practically freed from the worms by a single application of the remedy. The cestodes were so thoroughly removed that there were not enough left to allow me to go on with my investigations and my observations on the worms were not taken up again until August 10, when the birds had become infested again and the parasites had grown to such size as to enable the continuance of my work.

This remedy is a very simple one and is practical. It has been known to many poultry raisers for some time, but they have neglected to use it, mainly on account of the fact that heretofore no definite evidence has ever been presented concerning its actual working possibilities. It may not, and in all probability will not, remove all the worms, but it does remove most of them so that they are not serious and can be controlled in the flock as a whole.

In a large flock the birds can be housed for the length of time required for the fast, then fed on the cooked grain and kept

in the house until after the effects of the second dose have passed off. During the time that they are confined the droppings should be collected often and lots of lime used about the coop and over the droppings to keep away the insects. In a flock the treatment would have to be repeated from time to time whenever the birds became infected again. Further experimental evidence must be obtained before much can be said in regard to details of this method of treatment, especially as to the amount of the alkali to be used. A large amount would be harmful to the intestinal mucosa, while a small amount would have little if any effect upon the parasites.

FEEDING EXPERIMENTS FOR INFECTION. Chickens in the vicinity of Hardy, Nebraska, were heavily infested with tapeworms, and young birds were found to be more heavily infested than the adults. This led to investigations concerning the reason for the difference in the infestation of the adult and young birds when they were together in the same environment and fed on the same diet.

The summer of 1913 was very dry in the locality which was a factor in keeping the numerous varieties of insects down to a minimum, because the drought interfered with their breeding. Upon observation it was found that only two kinds of insects were present in any abundance about the haunts of the birds. Those were the ground beetle *Tenebrio* and flies. The stable fly, *Stomoxys calcitrans*, which usually breeds in wet, decaying straw, was very scarce because its breeding places had dried up. The house flies were very abundant everywhere.

The reason why the adults should be only slightly infested with parasites, while the young and growing birds harbored so many, was then the subject for observation. The birds were watched in their haunts and their habits studied. It was soon noticed that the young birds, when in their resting places in the shade of a tree or a building, were busy the whole time pursuing flies and very often caught their prey, while the adults paid little or no attention to the flies. This led to the conclusion that flies might have something to do with the transmission of the worms to the birds.

With a view to testing this hypothesis, experiments were carried on with the worms that were most common in the birds. These species were *Davainea cesticillus*, *Davainea tetragona*, and *Choanotaenia infundibuliformis*.

Segments of these worms were teased apart so that the eggs or embryos were set free in a drop of water, and this was fed to flies

of the species: *Musca domestica*, *Stomoxys calcitrans*, and *Calliphora vomitaria*.

Only a few *Calliphora* could be obtained and these did not live long under experimental conditions. This species of fly does not frequent places where it would be likely to become the intermediate host of any of the chicken cestodes, as it always remains in cool, damp, and usually dark places, unless it can find carrion. However, on cool, dark, damp days it does appear in chicken yards, but its occurrence there is not frequent. Some *Stomoxys* were used, but in no case did they live long in captivity.

*Musca domestica* lived much longer than either of the others, even though it was difficult to keep them alive for a long period. After a great deal of experimentation it was found that they could be kept alive in a cage for twelve or thirteen days, and in one extreme case some were kept alive for twenty-one days. The flies in captivity were fed on blood, liver and spleen. These were found to be the best foods.

The oldest proglottids on the worm were usually taken for feeding to flies, and also some of the free segments in the intestine were used. The use of the oldest proglottids proved to be an error in the case of *Choanotaenia infundibuliformis*, because it was found later that in this species the oldest segments separate from the worm before they are entirely mature, but proglottids that have been free in the intestine for some time may be mature. The use of proglottids that were not entirely mature for feeding flies was an error in my experiments which may account for so few infections.

DAVAINEA CESTICILLUS. In a series of experiments 107 flies of the species *Musca domestica* were fed on the eggs from proglottids of *Davainea cesticillus*. Some were killed and preserved each day from the beginning of the experiment until the tenth day, when the remaining flies died, except in one case four were kept alive for twenty-one days. These were all sectioned with the exception of five, which were dissected. No stages of the cestodes were found in any of the flies when examined.

During the experiment microscopic examinations were made of a great number of the droppings of the flies and no eggs or embryos of the worms could be found in any case. It is certain that the flies got some of the eggs because they were numerous in the material that was fed to them. The flies would lap up all the water in which the eggs floated and would then suck on the fragments of

proglottids. In several instances when the flies were hungry it was observed that they would take small fragments of the proglottids between the labella of the labium and actually devour them. Since the eggs are microscopic in size it is practically certain that the flies got some of them.

Several *Calliphora* were fed on eggs from this species, but these flies lived for only two or three days.

Proglottids of this tapeworm were fed to a number of beetles of the species *Tenebrio melitor*. The beetles ate the segments readily. Some were killed at the end of one week, others at two weeks, and the rest at three weeks. These beetles were sectioned, but showed no developmental stage of cestodes.

DAVAINEA TETRAGONA. In experiments on this species 59 flies in all were used. Some of these were killed and preserved after from two to twelve days. The proglottids were broken up and the eggs set free in a drop of water. The flies lapped up the water with the eggs and afterwards sucked all of the moisture from the fragments of the proglottids. Therefore, it is very probable that the flies got some of the eggs. Microscopic examinations of the droppings of the flies showed no signs of eggs.

Material would pass through the flies in a few hours as was demonstrated by feeding them on blood. When the flies gorged themselves with blood they passed red droppings in from eight to ten or twelve hours. This indicated the length of time that it took material to pass through the alimentary canal. In this way the approximate time to make fecal examinations for the eggs was determined. However, examinations were made of the droppings after five or six hours as well as later and at regular intervals of two or three hours.

The flies were fed on eggs once or twice each day for three days. When they were fed once a day that was done in the morning, and when fed twice they were given one dose in the morning and the other at noon. On three occasions some flies were fed in the evening and fecal examinations were made the next morning and continued at intervals of two or three hours.

The flies were all sectioned and examined, but showed no stages of the cestodes in any instance.

Some *Calliphora* were fed upon the eggs of this species, but they did not live more than two or three days. Some beetles, *Tenebrio*, were fed on proglottids, but upon examination they showed nothing.

CHOANOTAENIA INFUNDIBULIFORMIS. Eggs of this species were fed to 88 flies of the species *Musca domestica*. Besides these some *Stomoxys calcitrans* were also fed, but these did not live long in captivity. The individuals of *Musca domestica* used in these experiments lived from two to seventeen days. Two flies lived for twelve days and four for seventeen days. The proglottids were broken up and fed to the flies in the same manner as in the other species mentioned. All of these flies were sectioned and examined. One fly preserved at the end of twelve days showed five cysticerci. These cysticerci agree very closely with the structure of the adult of this species, and the hooks are identical. This cysticercus is described in detail in another paper.

Grassi and Rovelli (1892: 33) found cysticerci in flies which they compared with this species. They found that there was a close agreement in structure between the cysticerci they discovered and the adult of *Choanotaenia infundibuliformis*. They therefore inferred that the larva they had was the intermediate stage of this species, but did not demonstrate experimentally its connection with the adult tapeworm.

During the process of my experiments I had hoped to be able to feed some chicks on flies that had been previously fed on tapeworm eggs, but as it was so difficult to keep the flies alive under experimental conditions such an experiment could not be carried out. However, another feeding experiment was tried with the following results: Six chicks were taken from the nest as soon as they were hatched and placed in a cage where they could get no insects and great care was taken during feeding so that no flies could enter. Flies (*Musca domestica*) were caught around the chicken roosts and fed to three of the chicks. The other three birds were used as a control and were given no flies. Fifty flies were fed to each of the three chicks. Three weeks after feeding, the chicks were killed and examined with the result that two were found to be infested with *Choanotaenia infundibuliformis*. One bird possessed six worms. These were of the same length, being 35 mm. long, and each one contained 103 proglottids. The other bird had one worm of the same species, but it was a little longer, 43 mm. and having 118 proglottids. This bird was fed on the flies three days before the one sheltering the six worms. The three birds which were used as a check on the experiments contained no worms when killed and examined.

These six birds were kept together in a cage and were fed on corn meal and bread crumbs. The three birds that were fed flies were caught and the insects were given to them from the hand.

A number of stable flies (*Stomoxys calcitrans*) were used in the experiments with this species of worm, but they would not live under experimental conditions for any length of time. They would usually die within 24 to 36 hours, except in one case when six lived for five days. They were sectioned, but nothing could be found.

On numerous occasions I have observed maggots in the droppings beneath the chicken roosts. Now, since house-flies are in the habit of breeding in such places, it seemed possible that infection might take place in the maggot stage of the flies. Experiments were then tried with the maggots of *Musca domestica* and *Stomoxys calcitrans*. Thirty *Musca domestica* maggots were fed on segments of three species of cestodes, *Davainea cesticillus*, *Davainea tetragona*, and *Choanotaenia infundibuliformis*. The maggots developed puparia in a day or two. Some were sectioned in the pupa stage. The rest developed into adults and were sectioned, a few were dissected, but only negative results were obtained. Fifty maggots of *Stomoxys calcitrans* were fed on proglottids of the same three species of tapeworms. The maggots went into the pupal stage within two or three days. Some were sectioned in the pupal stage. Most of them developed into adults and were sectioned while a few were dissected. No positive results were obtained from either pupal or adult stages.

From the foregoing it seems probable that flies are not the intermediate hosts for *Davainea cesticillus* and *Davainea tetragona*, as the experiments that I have carried on with them are extensive enough to appear conclusive. However, the small number of varieties of insects present in the locality seems to throw the burden upon the flies, since they were so abundant and observations show that they are taken and eaten by the chickens that are most heavily infested. The adult birds eat all other insects that are easy to catch, but since the flies are more difficult to take as prey they leave them alone. If the infection is direct, the adults would have fully as much chance as the young birds because they get food and water together and have the same environment.

In the case of *Choanotaenia infundibuliformis* it seems to be clear that the house-fly is the intermediate host. Grassi and Rovelli hold that it is the intermediate host on a purely structural basis. My experiments show that it is certainly an intermediate

host in some cases. Furthermore, feeding chicks on flies that were taken from about the chicken roosts and raising the cestodes make it probable that the house-flies are the intermediate hosts of this one species.

The reason why more flies were not infected by feeding on the eggs of this species was determined to be peculiar conditions in the maturing of the proglottid. At the time when the experiments were being carried on it was not known that the oldest proglottids separated from the worm before they are entirely mature. In the experiments the oldest proglottids on the worm were usually taken for feeding, though in some cases the free segments in the intestine were used. Since the flies were fed on eggs that were not entirely mature the embryos were digested. The free proglottids remain in the intestine of the bird for some time and in all probability mature there. Some such free proglottids were examined and found to contain mature embryos.

#### SUMMARY

1. The results of these experiments show that the intermediate (cysticercoid) stage of *Choanotaenia infundibuliformis* occurs in the common house-fly *Musca domestica*. The results were obtained by feeding flies on eggs of the tapeworm and raising cysticercoids in a fly; also by feeding chicks on flies and raising the worms in the birds. By morphological comparison of the cysticercoid and adult they are shown to be identical. Results from experiments by feeding flies on eggs from *Davainca cesticillus* and *Davainca tetragona* were negative.

2. The habits of the birds are important factors to be considered in experimental work for life history studies. Certain insects are found in great numbers around chicken houses and yards and are readily eaten by the birds. Flies are known to contain the larval stage of one species of cestode, and some other species of insects are to be considered as probable intermediate hosts for other species of cestodes.

3. The symptoms and effects of the infection from tapeworms vary with individual birds, age of birds, and the degree of infection. Birds infested with worms display an emaciated, unthrifty condition, an unnatural desire for food and water, and a marked diarrhea with droppings of a characteristic yellowish-brown color.

4. The control of tapeworm disease in chickens is in an unsettled condition. Little can be done until more is known concerning life histories of worms. Preventive measures are urged rather



than curative measures. Droppings should be cared for and treated with appropriate substances in order to prevent insects from feeding on them or developing in them. Experiments by giving lye with food to infested chickens showed satisfactory results in removing tapeworms.

5. The flocks of chickens that were studied showed at times a very heavy infection and nearly every bird examined harbored one or more species of worms. Five species were found in the chickens at Hardy, Nebraska, and three in the birds at the poultry farm at the University of Illinois. The species found in Nebraska are *Davainea cesticillus* (Molin), *Davainea tetragona* (Molin), *Davainea echinobothrida* (Megnin), *Hymenolepis carioeca* (Magalhaes), and *Choanotaenia infundibuliformis* (Goeze). At the poultry farm of the University the species *Davainea cesticillus* (Molin), *Davainea echinobothrida* (Megnin) and *Hymenolepis carioeca* (Magalhaes) were found.

6. A full description of the structure of these parasites has been published in the Transactions of The American Microscopical Society, Vol. 35, p. 23-44, Pl. 5-8.

—o—

BIBLIOGRAPHY

- GRASSI, B. B. and ROVELLI, G. 1889. Embryologische Forschungen an Cestoden. *Centralbl. f. Bakt. und Parasitenk.*, 5:370-377, 401-410.
1892. Ricerche embriologiche sui Cestodi. *Atti Accad. Gioenia di Sci. Nat. in Catania*, 4:1-108.
- PIANA, G. P. 1882. Di una nuova specie di Tenia del gallo domestico (*Taenia bothrioplitis*) e di una nuova cisticercio delle lumachelle terrestri (*Cysticercus bothrioplitis*). *Mem. Accad. Sci. Inst. Bologna*, 2:387-394.
- RANSOM, B. H. 1900. A new Avian Cestode—*Metroliasthes lucida*. *Trans. Amer. Micr. Soc.*, 21:213-226.
1902. On *Hymenolepis carioeca* (Magalhães) and *H. megalops* (Nitzsch) with Remarks on the Classification of the Group. *Trans. Amer. Micr. Soc.*, 23: 151-172.
1904. The Tapeworms of American Chickens and Turkeys. *Bur. An. Ind. Ann. Rpt.*, 21: 268-285.
1909. The Taenoid Cestodes of North American Birds. *Bull. U. S. Nat. Mus.*, 69: 1-141.
- ROSSETER, T. B. 1891. Sur un Cysticercioide des Ostracodes, capable de se développer dans l'intestin du Canard. *Bull. Soc. Zool. France*, 16: 224-229.
1892. On a New Cysticercus and a New Tapeworm. *Journ. Queckett Micr. Club*, 4: 361-366.
1897. On Experimental Infection of Ducks with *Cysticercus coronula* Mrazek (Rosseter), *Cysticercus gracilis* (von Linstow), *Cysticercus tenuirostris* (Hamann). *Journ. Queckett Micr. Club*, 6: 397-405.
- SCHMIDT, J. E. 1894. Die Entwicklungsgeschichte und der anatomische Bau der *Taenia anatina* (Krabbe). *Arch. f. Naturg.*, 1894, 1: 65-112.
- STILES, C. W. 1896. Report upon the Present Knowledge of the Tapeworms of Poultry. *Bur. An. Ind. Bull. No. 12*; 78 pp.
- TOWER, W. L. 1900. The Nervous System of the Cestode *Monezia Expansa*. *Zool. Jahrb.*, 13: 359-384.
- ZÜRN, F. A. 1882. Die Krankheiten des Hausgeflügels. 237 pp., 76 figs. Weimar.







## VITA

John Earl Gutberlet was born in Nebraska in March, 1887. He received his preparatory training in the high school at Hardy, Nebraska, and at Bethany Academy, Lindsborg, Kansas. He entered Bethany College, Lindsborg, Kansas, in 1905 and received the A. B. degree from that institution in 1909. During the year 1909-10 he was a graduate student and an assistant in the department of Zoology at the University of Colorado. He attended the summer session of the University of Colorado Biological Station in 1910. In the fall of 1910 he went to the University of Illinois where he accepted a position as assistant in the department of Zoology which he held until 1913. He received the A. M. degree from the University of Illinois in 1911. During the summer of 1911 he was engaged in study at the Marine Biological Station, La Jolla, California. He was elected to membership in the Illinois Chapter of Sigma Xi in 1912. He attended the summer session of the University of Illinois in 1913. During the year 1913-14 he held a fellowship in Zoology at the University of Illinois where he completed his work for the degree of Doctor of Philosophy in June, 1914.





LIBRARY OF CONGRESS



0 002 858 308 4