

OSTEOLOGY
OF THE
NORTH AMERICAN TETRAONIDÆ
AND
LANIUS LUDOVICIANUS EXCUBITORIDES.
BY
R. W. SHUFELDT,
1st LIEUT., MED. DEPT., U. S. A.

With the Compliments of
R. W. Sturtevant
3^d Mar. 1882

696
G285558
1881
Birds


AUTHOR'S EDITION.

DEPARTMENT OF THE INTERIOR.
UNITED STATES GEOLOGICAL AND GEOGRAPHICAL SURVEY.
F. V. HAYDEN, U. S. Geologist-in-Charge.

OSTEOLOGY
OF THE
NORTH AMERICAN TETRAONIDÆ.
BY
Dr. R. W. SHUFELDT, U. S. A.

EXTRACTED FROM THE BULLETIN OF THE SURVEY, Vol. VI, No. 2.

WASHINGTON, September 19, 1881.



598.61
1856

ART. XIII.—Osteology of the North American Tetraonidæ.

By R. W. Shufeldt, M. D., First Lieut. Med. Dept. U. S. A.

As far as the *Tetraonidæ* are represented in our avi-fauna, and the varieties are not few in number, there has been but little question among modern ornithologists as to the place they should occupy, and the manner in which they should be classified and arranged. In the writings of that distinguished naturalist, my friend Dr. Coues, we find him adhering to the excellent and natural division of the Family into the two sub-families, *Tetraoninæ*, the true Grouse, and *Odontophorinæ*, the Partridges, with their genera and species, truly stating, as he does so, that the inter-relation among the various representatives is so close that no violence is offered by the arrangement. Our labors have been confined principally to the study of the osteology of the Grouse, a complete collection of which we have before us, and in this memoir we will only occasionally refer to the osteological departures as observed in some of the Quails.

No country in the world can boast of a fairer collection of species of these noble birds than we find among the six North American genera, as seen in *Tetrao*, *Centrocerus*, *Pediæcetes*, *Cupidonia*, *Bonasa*, and *Lagopus*; and our Partridges yet exceed these in their brilliancy of plumage and oddity of some of their feathery decorations.

The anatomical peculiarities of the order *Gallinæ* has been the favorite theme of many an able writer, and we find Huxley, Owen, Gegenbaur, Coues, Parker, and others, in their several works, dwelling largely upon the osteology of these birds, ably exposing the observed characteristics of structure both by pen and pencil; but, as far as our knowledge extends, no one has as yet devoted himself to the production of a paper devoted exclusively to the osteology of the North American Grouse, such as the writer here proposes to undertake with every hope of success, aided as he has been by the kind assistance of many friends in different parts of the Union, in sending him valuable material in the way of representatives of the Family.

The author trusts that he may be allowed to carry out on some future occasion his present intention of devoting himself to the study of other systems of avian anatomy; in which event myology, the eye and ear, and respiratory apparatus, will all receive their due share of labor; but

in this monograph we will omit, as we have in former ones now published, any detailed description of the osseous elements of the ear, or the respiratory tube, small sesamoids, or such tendons as may ossify in the extremities. The hyoid as an arch of one of the cranial vertebræ evidently is not included in this category, and will in consequence receive the attention it undoubtedly deserves in its proper place.

The study of the bones entering into the cranial vertebræ has been initiated at a stage in the chick's life a few days after birth, and their relation to each other and their development carried up to the adult bird. It will be observed after a glance at the writer's drawings in Plate V that he has chosen the young of that grand old prairie-loving Grouse, *Centrocercus urophasianus*, as an example of the growth of the skull from the time above referred to in the *Tetraonina*.

In this plate the first three figures show respectively the skull of the young of the Sage Cock a few days after the parent has led it from the nest: 47 from above, 48 lateral view, with mandible, and 49 from below, the mandible removed.

Fig. 50 shows the bird in August of the same year, and Fig. 51 the disarticulated skull of the same, whereas in the next plate we observe the skull of an old cock of the same species that has, no doubt, trod the prairie for many a season. (Fig. 52).

In these birds the greatest amount of difference exists in point of size among the sexes and in individuals of various ages of the same sex; so we naturally find a corresponding amount of difference in the sizes of their crania.

Fig. 52 is the skull of an exceptionally large adult, ♂, chosen from a bevy of several hundred others, with a view of affording the reader the opportunity of seeing the proportions this Grouse may attain, as far as this part of its skeleton is concerned. This peculiarity seems to be confined to *Centrocercus*, and does not obtain with the other varieties, they seemingly arriving at maturity of growth at a much earlier period of their existence. *Tetrao obscurus* may form an exception to these remarks, but it is certain that it is not by any means so striking a characteristic in this bird. Another interesting point to be observed here, that no doubt has forced itself upon the reader since his inspection of the plates already introduced, is the unusual length of time that the original bony segments of this Grouse's head retain their individuality, over others of the class. This is indeed so, and in birds of one or two years of age, if we exclude the epencephalic arch of the occipital vertebra, it is not an unusual occurrence to be able to distinguish all the sutural boundaries among the remaining elements, and these appear to be persistent when applied to the nasals and the premaxillary bone of very old birds. We are all well aware that this rule holds good in the common barn-yard fowl.

Students of the works of that eminent anatomist and observer, Owen, will remember that in his *Comparative Anatomy and Physiology of*

Vertebrates he seems to accuse the *Struthionidæ* alone of this singular feature, or at least "those birds in which the power of flight is abrogated." Now, such of my readers as have had the opportunity of observing the flight of the "Cock of the Plains," after he has once been induced to take wing, will agree that there is anything save an abrogation of that avian privilege.

Crania of the North American *Tetraoninae* being placed on the horizontal plane as described in my monograph on the osteology of *Eremophila alpestris* (Bull. U. S. Geol. and Geogr. Surv. of the Terr., vol. vi., No. 1), we observe that their equilibrium is moderately stable, the anterior bearing point being the tip of the superior mandible, and the two posterior bearing points being the external facets upon the tympanics. The angles of the foramina magna average 70° while the centrum of the parietal vertebrae is the chief bone of what here must be the basi-cranii, and is found to be nearly in the horizontal plane: the neural arch of the occipital vertebrae being, as a whole, gently convex outwards and lying in nearly the same plane with the foramina magna.

*The Skull.**—So distinct do we find the hamal arch of the first cranial or occipital vertebra, and fulfilling such a diverse end, with its appendage the pectoral limb, in birds generally, that its description will be undertaken further on under the subject of the "scapular arch" and our attention be engaged at this point only with the neural or ependecephalic arch of this segment of the cranium.

The primoidal elements of this, the superior arch of the vertebra in question are seen to a greater or less extent *in situ* in the young and "bird of the year" of *Centrocercus* in Plate V, Figs. 47-50, and in the disarticulated skull of the same, Fig. 51, as *so*, *eo*, *bo*, and *po*, lettering respectively the essential elements "superoccipital," "exooccipital" (the parial bone and counterpart of this segment being intentionally omitted, as are the duplicates of other segments), "basiooccipital," and the conately developed process "paroccipital" of the neurapophyses.

In Sage Cocks the size of those figured in Plate V, Figs. 50 and 51, we find the neural spine of the first vertebra, *so*, to be a light, spongy bone, one and a half centimeters wide by about one-half of a centimeter deep—covered with a thin layer of compact substance. Its upper border displays in the median line a demi-lozenged shaped notch that when the bone meets the parietals, which latter have their posterior and inner corners deficient, forms in many birds of this age a "fontanelle." In younger individuals this diamond-shaped vacuity is always present, the "anterior fontanelle" being formed in them in a similar manner, though narrower and longer, between the frontals and parietals. The lower border of the superoccipital presents a smooth, angular depression, that in the articulated vertebra goes to complete the superior third of the foramen magnum.

* The authors plates and figures illustrating this paper are numbered in continuation with others of his published monographs.

The lateral bodies of this bone are cellular masses with several apertures opening forwards and outwards, the mastoids closing them in, in the completed cranium. On its outer surface near the inferior angles we observe two, one on either side, grooved foramina, leading upwards and inwards, to open into the lateral sinuses on the inner surface of the segment, nearer together. As age advances these canals contract, but still exist throughout life.

The basioccipital segment, *bo*, also is largely cancellous in structure, wedged shaped, having at its apex a long, rounded tubercle curving outwards and backwards, overhanging a slight depression beneath it. This tubercle in the complete vertebra forms the middle two-thirds of the occipital condyle, which, in the adult, is found below the foramen magnum, sessile, uniform in outline, with the rounded border below, and all indications of its original division into three parts obliterated.

The neurapophyses of this vertebra, termed the "exoccipitals" (Plate V, Fig. 51, *eo*), are each nearly as large as the neural spine; on their inner borders they present for examination the deeply-rounded margins to complete the foramen magnum, and immediately beneath, the minute tubercle jutting out that lends its assistance on either side to form the condyle of the occiput.

The outer angles, quadrate in outline, deflected slightly downwards, are the transverse processes of the vertebra, the "paroccipitals." The precondyloid foramina are also to be observed here, with one still more external, belonging to the group from which the eighth nerve makes its way from the cranium. The internal aspect of an exoccipital is a mass of open, irregular cells, that are closed in when this segment is approximated with the mastoid, superoccipital, and the "petrosal" (Fig. 51, 1), that odd-shaped and spongy bonelet which constitutes the capsule of the organ of hearing—and which has a foramen on its inner and smooth surface for the passage of the auditory nerve—forming, also, by a bending forwards of a part of this surface, and aided by the basi-sphenoid, the floor of the mesencephalic fossa on either side, while externally it shares in forming the entrance from without to the otocrane.

With the exception of the petrosal, the elements thus far described, when duly articulated, form the neural arch of the occipital vertebra, as already intimated above. The basioccipital, the centrum of this vertebra, by its larger extremity, and the exoccipitals with the connate diapophyses articulate with the basi-sphenoid in the basi-cranii below; the latter, with the superoccipital, meet the parietals and mastoids above and laterally. In old birds every trace, both sutural and otherwise, becomes completely obliterated as the osseous amalgamation progresses, though throughout the group a well-defined "superior line" limiting muscular attachment, indicates very nearly the terminating borders above, and sometimes, as in *Centrocercus*, a fainter indication exists in the vicinity of the union among the interested bones below. On either side of the condyle, to its outer aspect we observe in a slight

depression a group of usually four foramina—two external opening into the otocrane, one into the cranial cavity, and one leading through the basi-sphenoid to the base of the ‘sella turcica’ at the carotid openings; they transmit principally the eighth nerve and the internal jugular and branches.

In some of the very old individuals of the *Tetraoninae* quite a striking characteristic presents itself in the capaciousness of the opening to the otocrane, produced by a thin, wing-like expansion, recurved forwards, formed by the out-growing and union of the centrum of the second vertebra and the diapophysis of the first. This feature is not particularly noticeable in the *Odontophorinae*, nor in *Lagopus*, *Cupidonia*, and *Bonasa*, still less so in the Sharp-tailed Grouse, among the *Tetraoninae*, but quite marked in old males, especially in *Tetrao* and *Centrocercus* (Figs. 52, 74, 88, and 89). No very decided differences exist among the Grouse with regard to the foramen magnum and the occipital condyle; the former is universally of good size for its owner, subcircular, and without any encroachments upon its margins beyond the condyle. This latter, always sessile, occupies its usual position below the foramen, with its long axis placed horizontally, and so nearly approaching the typical haricot in form that one has no hesitancy in pronouncing it of a reniform outline. In all the Grouse, save *Tetrao* and *Centrocercus*, it slightly invades the marginal periphery of the great foramen of the occiput, and in all the excepted genera is more or less shortened transversely.

The second cranial segment constitutes the parietal vertebra, and its elements are shown in the same plate, Fig. 51, where indicators pass through its neural and hæmal arches, P. V and P. V¹: P. V as the mesencephalic arch, constituted in the complete cranium by the bones P, the parietal or neural spine, when linked with its fellow; *a. s.*, the alisphenoids, the neurapophyses; *m. s.*, the mastoids, the diapophyses; and *b. s.*, the basi-sphenoid, the centrum of the vertebra. The hæmal arch we see in the “hyoid,” which here shares the same fate of its analogue in the occipital vertebra, inasmuch as it is ununited to the superior arch by either osseous connection or by articulation, for in all living birds the hyoid, the well-known bony support of the tongue, depends entirely upon its muscular and ligamentous connections to retain its relations with the cranium. The manner in which the disjointed neural spine of the parietal vertebra goes to form the posterior fontanelle in the half-grown bird has already been sufficiently dwelt upon. The bone P, as detached in an individual of that age, is quadrilateral in outline, excessively spongy and light, owing to the paucity of compact substance over quite a large share of diploic tissue, which is chiefly deposited in a protuberance on its inner table, which protuberance, in union with the fellow of the opposite side of the complete cranial vault, forms two concave surfaces out of the remainder of the superficies, essential portions of the ep- and prosencephalic fossæ.

Superficially, these elements are smooth and convex, and in the adult, after consolidation, exhibit some faint evidence of a parietal eminence on either side, — more marked elevations, however, occurring in the spine of the vertebra beyond, immediately anterior to the suture termed in Anthropotomy the “coronal.” With the exceptions of the tympanomastoidal articulation and the connections between the mastoids and petrosals, the majority of the articulations of this vertebra in the mid-aged bird may be classed among the variety known and described in works upon human anatomy as the “squamosal,” — the parietals being bevelled above to accommodate themselves to the frontals.

The alisphenoids are separated from each other mesially by nearly half a centimeter; above they meet the frontals, below the basi-sphenoid, and laterally the mastoids, — the lower and outer angles almost reaching the cup-shaped articulation for the tympanics. This segment seems to ossify from its borders towards the centre, leaving a foramen that is eventually closed in. On its mid and lower border it presents for examination the half of the “foramen ovale,” which is completed by meeting the centrum of the vertebra. It is for the transmission of the trigeminal nerve into the orbital cavity. Laterally there is developed a quadrate apophysis (the parapophysis of the vertebra?), which joins with a similar, subsequently scale-like process coming from the mastoid, resulting in a foramen, cordate in outline above, elliptical below, between them, giving passage to the fibres of the temporal muscle, that is markedly characteristic of the *Tetraonidae*.

Below the point of union this apophysis is triangular, with its apex pointing forwards and downwards, flat, with its inner surface looking forwards, upwards, and inwards. Internally, the alisphenoid is deeply concave. (Plate VI, Fig. 52, and other skulls illustrating this paper).

The external appearance of the *mastoid* is well shown in Plate V, Fig. 50, and as *m. s.*, Fig. 51. Internally, the half-cells observed close in by the aid of similar excavations in the segments of the occipital vertebra, the acoustic capsule; and a double-concave surface, assists in forming cranial fossæ.

We now come to examine the ornithic characters of one of the most interesting segments of the bird-skull, the centrum of the parietal vertebra, well termed by most ornithotomists and general anatomists as the basi-sphenoid. At an early date in the life of the chick (*Centrocercus* and others) this bone becomes confluent with the centrum of the frontal vertebra beyond; this confluence takes place, if we may be allowed to differ with such high authority as Owen, who makes the rather sweeping assertion “that the pit for the pituitary body marks the boundary” (Comp. Anat. and Phys. of the Vert., vol. ii, p. 45) in the following manner, and the sutural trace is yet discernible in young birds of the Family under discussion (Plate V, Fig. 51). The *pre-sphenoid* lies beneath a tuberosus process projecting anteriorly from the latter bone, reaching *nearly* as far back as the carotid foramina. The com-

bined bones, the centra of the two mid-cranial vertebrae, thus constitute the compound bone *basi-pre-sphenoid* of comparative anatomists.

Viewed from above we discover, proceeding from before backwards, in the median line, 1. The upper aspect of the apophysis just mentioned, and immediately to its rear the deep "sella turcica" with the osseous canals of the carotids opening into one foramen at its base; 2. Two smooth surfaces, one on either side and a little laterally, for the optic chiasma to rest upon; 3. Another surface still more posteriorly for the mesencephalic fossa, being perforated by diminutive parial foramina; 4. A roughened open space for the articulation, with the head of the wedge-like basi-occipital. Anteriorly and at the same time laterally, broad and uneven borders for the alisphenoids, with their smooth groovelets of the foramen ovale, while back of these again, on either posterior angle, a concave wing-like expansion, the terminations of the Eustachian tubes, that add to the parietes of the entrance of the otocrane. Below and superiorly, at the base of the junction of the two bones, we find the carotid foramina, with a depression between them mesially, and still lower down, slightly protected by an attenuated offshoot from beneath, the separate apertures of the anterior and buccal entrances of the Eustachian tubes.

The remaining surface, unbroken in character, extending posteriorly, goes to complete the basi-cranii. The coaptation of the elements forming the neural arch of the parietal vertebra is shown in Plate V, Figs. 47-50, their amalgamation in the adult in Plate VI, Fig. 52.

The entire importance of the hæmal arch of this vertebra depends upon the bony support it affords the tongue, and the niche it fills in the chain of problems of Philosophical Anatomy. In a fine specimen of an adult *Lagopus leucurus*, kindly presented me by Mr. Robert B. McLeod, then residing in Leadville, Colo., we find the following characteristics presented to us for examination, and they extend with little deviation to all the members of the family. The hyoid arch consists of, in the specimen under consideration, seven bones. The confluent ceratohyals and glossohyal, which latter is largely completed anteriorly by cartilage, form one segment; the ceratohyals diverge from each other smartly behind, and at their point of meeting afford the facette for the transverse trochlea surface on the basi-hyal. This last bone, the second in order, measures half a centimeter in length, being enlarged at both extremities, flattened from above downwards, the anterior end being fashioned to fulfill the purpose already mentioned, while the posterior and larger extremity presents two facettes, looking backwards and outwards, to articulate with the hypobranchial elements of the thyro-hyals. The third segment also meets this compound articulation at this point, a short urohyal, it too being completed at its posterior extremity by cartilage. The hypo- and cerato-branchial elements of the thyro-hyals make angles with each other and curve upwards in conformity with the basi-cranii.

The sub-cylindrical hypo-branchials are one and a half centimetres long, and connected with the posterior elements by quite long and intervening piece of cartilage of the same calibre; the smaller cerato-branchials also taper off behind with the same material.

This arch in the *Tetraonidae* long remains almost entirely cartilaginous, the hypo-branchial elements alone being composed of bone, and a bird must be of quite an advanced age before he can boast of a complete osseous framework as forming a component part of his lingual apparatus.

The third cranial segment, now to be described, is the first of the series in the skull of any of the North American *Tetraonidae* in which one of the autogenous elements seems to be generated by osseous extension from continuous parts of the vertebra. The bone in the young and half-grown Grouse is absent, but is eventually replaced in a manner that will be discussed further on. We will ask the reader here, however, need any one doubt or be daunted because an element is missing? There may still be a greater modification in the ultimate segment; yet who would question the claim of these cranial arches to their being defined as vertebrae—distorted and expanded to meet certain required ends, as they are—on such grounds? Would it be the student who has faithfully carried his observations from the embryo vertebra from the mid-column of the fish, stage after stage, till he has almost unconsciously passed through the multifarious segments described in the adult piscine head, then any of our lizards—or a tortoise, to man himself? Such a one well knows that in every living creature that can vaunt of a vertebral column, that that column's most perfect, complete, and typical segments and arches are found at its centre, and not at its poles. There are ways and modes more difficult in nature of comprehension, as all her students and lovers are well aware, than the fact that the pygostyle at one extreme of the avian skeleton is composed of one or more vertebrae, and the beak, the hæmal spines of two more at the other!

The neural arch of the vertebra now to be defined is the prosencephalic—its hæmal arch the “mandibular,” as its hæmapophysis constitutes the lower jaw, termed “mandible” in avian skeletology.

The fusing of the centrum of this segment with the basi-sphenoid has already been elucidated; the rostrum thus formed is gently inclined upwards and forwards, grooved along its entire superior aspect, tapering to a sharp point anteriorly to receive the connate prefrontals in the bony gutter at its distal third. Beneath it displays towards its base the parial facets for the pterygoids and beyond the rounded surface for the palatine articulation.

The *orbito-sphenoids*, as the neurapophyses of this arch, are the elements whose absence has already been hinted at above.

The author has taken members of this family in sufficient numbers and ages to convince him of the fact that the rotund foramen for the exit of the optic nerve from the brain-case and the smaller aperture for the first pair above, seen in the adult skull, has been slowly formed by

osseous extension, chiefly from the ethmoid, frontals, and ali-sphenoids, and that the basi-sphenoid sends up on either side two delicate bony sprouts, that subsequently complete the periphery of the circular foramen for the oculomotorial nerve. This fact has been likewise carefully studied in the cranium of the common barn-yard fowl, and like conclusions arrived at. So that in Plate V. Fig. 51, this, as it occurs in some other birds, has been simply outlined and marked *os.*; in this same figure *Fr.* is the "frontal," *ps.* the prefrontal or centrum of the vertebra, and *x* the usual site for the postfrontal—this exogenous element, the diapophysis of the vertebra is not here found, its position being occupied by a depressed roughened surface for the squamous articulation of the mastoid. We have never personally examined any bird in our avi-fauna where this bone is seen independent. Descriptive ornithotomists, in their studies upon the skulls of *Rheidae* and *Struthionida* give the presence of this process as occurring free.

The neural spine of the frontal vertebra follows the example of the parietal in being completely bifidated in the younger specimens. As a whole it is perhaps the largest segment in the bird-skull—certainly as far as our Grouse and Partridges are concerned. Either half of its spine presents projecting anteriorly from the middle a flattened process, directed gently forwards, downwards, and outwards; that at its extremity is marked above by quite an extensive surface for one of the nasals, and below by another, against which the head of the ethmoid abuts. The concave surface below this process and the remaining hinder moiety forms the vault of the orbit. Another scale-like projection is thrown out posteriorly, deeply concave within, correspondingly convex without, to shield the prosencephalic lobes—the bones being joined. Huxley terms the pleurapophysis of the haemal arch of this segment the "quadrate"—the "os quadratum" of the older anatomists. Owen defined it as the *tympanic*, it being the homologue of a bone of the vertebral skull generally—it was the *os carré*, in birds, in the writings of the eminent Cuvier. The *tympanic* forms no exception here in the *Tetraonidæ* to birds of America generally, in being a free bone, of various shapes in divers families and genera. So symmetrical is it found to be in the Grouse, that little harm would be done, were such a step advisable, to appoint it as a type for the Class. The mastoidal and orbital arms are about of a length and calibre, the first being rather the larger, and is surmounted by a hemispherical articulating head for the cup on the lower border of the mastoid. The neck below the processes is moderately constricted before it expands to become the "mandibular" end, that has beneath, its transverse elliptical facet outwardly, the intervening notch and then the inner and smaller one, all for articulation with the mandible. The bone has likewise a surface to articulate with the pterygoid below the orbital process, and is always pneumatic. From the outer aspect of the mandibular extremity it supports its two appendages, the bony styles, termed "squamosal" and

“malar”—the first by a diminutive “ball and socket” joint articulated in the usual manner. The “malar,” as we know, is the mid-style of the “infraorbital bar”—the maxillary completing the connection anteriorly, and although upon superficial inspection of this striking ornithic feature of the lateral aspect of the skull, it seems to be firmly united in its schindylesial articulation, it simply requires ordinary maceration in the adult of any of the Grouse or Quails to have the three styles separate from each other and from their tympanic and intermaxillary connections.

The lower jaws of the *Tetraonina* are singularly alike in all their characteristics throughout the sub-family. The single bone is developed in the usual way by confluency of the “articular,” “surangular,” “angular,” and “splenial” elements posteriorly, and the outer moiety by the “dentary” element, the hæmal spine. (Plate V. See explanation of plates for the above-described bones.)

The mandible in the adult has a gentle and increasing curvature downwards from the interangular vacuity forwards. The curvatures at the extremities of the symphysial suture are both parabolic, the inner being the more open of the two. The interangular fenestra is a flattened ellipse, which has distinct sutural traces leading from it, indicating the borders of some of the original bits of bone of which it is composed.

The “coronoids” are but feebly developed and the articular ends not far below them; these latter have the usual pneumatic foramen at the ends of their in-pointed and blunt extremities, and sharp recurved processes behind, in a line with the rami of the jaw, which apophyses long remain in cartilage in immature birds. (Plate X, Fig. 71.)

On the lateral aspect of the bone, two muscular lines lead away from the coronoidal elevations. These last two mentioned features are universally characteristic of the *Tetraonidae*; they are strongly marked in *Lagopus*. (Plate XIII, Fig. 88.) Minute foramina are found above and below near the dentary margins, and two quite prominent, one beyond the ramal fenestra on the inner surface of the jaw; still another just anterior to a small tubercle below the coronoids on the same aspect. The inferior ramal borders are markedly smooth and rounded, as are the under surfaces of the articular ends where they originate in nearly the same plane.

The divergence of the ramal limbs of the mandible in *Odontophorina* is greater, owing to the greater width of the skull when compared with its length.

In some fine specimens of *Lophortyx Californicus*, generously furnished us by Mr. Charles A. Allen, of Nicasio, Marin County, California, we note the striking departure from the mandible in the Grouse in the absence of the interangular vacuity—this feature obtains, however, in the common Virginia Partridge and others. The deflection of the rami anteriorly is greater in these birds also, or at least more sudden, and so prominent are these ramal borders that the inner sides towards the posterior ends are converted into true fossæ.

Those interesting osseous and diminutive oblong plates, the *sclerotals*, present in so many of the class, are found here occupying their usual position. (Plate V, Fig. 51, 2, and Plate X, Fig. 75, in *Cupidonia*.) They number from thirteen to eighteen or twenty, and their function is so well known that it will not be dilated upon here. They differ principally in the amount of tenacity with which they retain their normal relation, after prolonged maceration. *Cupidonia* holds a high place here, and the fact seems to be due to the greater overlapping of the edges of these little affairs and the toughness, or perchance the thickness, of the internal and external sclerotic coats that cover them. Lately we saw in the case of *Sayornis nigricans* where these platelets were apparently confluent; no such condition ever occurs in the Grouse or Partridges.

The "lacrymal" (Plate V, Fig. 51, 3 and other figured skulls) is found on the anterior margin of the frontal, enjoying a free harmonial articulation that encroaches slightly on the nasal border. Each is a squamous, cordate lamella, with its larger end nearer the orbital cavity; this completes the bone in young birds, but in mature individuals it sends down a curved and delicate style with its point directed outwards, that encircles and gives support to the lacrymal duct on its passage to the rhinal cavity (*Centrocerus*).

We now come to examine into the last of the cranial vertebrae, and, in the family under consideration, the one most modified. It is the "nasal," and its neural arch the "rhinencephalic," the hamal, the "maxillary."

In the *Tetraonidæ* its centrum, the "vomer," is missing. We make this assertion boldly, for, after careful scrutiny in the embryo, we find no special ossification for that segment, nor can we appropriate honestly any part of the pre-sphenoid to compensate for the deficiency, and we are the more convinced of the fact after examining crania of birds of different ages. It is absent. Whether this be due to the foreshortened skull of the Grouse, with its long sphenoidal rostrum rendering any further extension superfluous, we cannot say. In the lengthened skull of any of the *Anatidæ*, where such a bone is imperatively called for, as a sub-interspinal partition, it is invariably present, and unusually prominent (Plate V, Fig. 51, *rr.* vomer, is merely outlined to indicate its position in other birds).

The neurapophyses of the arch are found in the connate *prefrontals*, the bone called "ethmoid" in androtomy. It here, in the young bird, is lodged in the outer third of the groove on the pre-sphenoid, rises columnar, sub-compressed laterally, leaning forwards at a gentle angle to expand above in a trihedral summit for the support of the frontals, nasals, and intermaxillary, a short process being projected backwards for the former. The posterior aspect of the column develops as the bird grows, the interorbital septum, reaching to, and perhaps aiding in, the formation of the exogenous orbito-sphenoids.

The *nasals*, or the divided neural spine of the arch, are squamous

lamella, twisted upon themselves in a manner to conform with the superior base of the beak, overlap the frontals as already defined, are separated from each other by the intermaxillary, throwing out below to meet this bone a sharp process, thus forming a broad elliptical boundary limiting the capacious osseous nares. In all adults of this family they are easily detached by maceration. These bones are well shown in Plate X, Figs. 71 and 73, in the cranium of *Cupidonia*, from an unusually fine bird sent with a number of others, for which our thanks are graciously tendered to Captain Richards Barnett, Medical Department United States Army. It will be observed that the bone becomes so attenuated in some specimens as to give rise to a foramen, as seen in the latter figure. The hæmal arch is cycled "maxillary," as its lower rib and spine constitute the major share of the superior mandible or *maxilla*. The pleurapophyses seen in the *palatines* are long, rib-like bones with their anterior ends much flattened from above downwards, to fit into a fissure on either side made for them in the intermaxillary below the maxillaries. Near their middles they curve moderately outwards to develop compressed heads at their posterior extremities, fitting into a notch in either pterygoid, and concave mesially for the rostrum of the basi-sphenoid.

At their inner thirds they send off thin sheets of bone that curve upwards, barely to touch the ramphosial process of the sphenoid, accompanying it as far as it extends distad, then sloping away on the ribs of the bones themselves. The hæmapophysial maxillaries are elements that seldom change their ornithic characters, and in *Tetraonide* seem to be reduced to their simple typical form—in completing the delicate infraorbital bar on the one hand—and just previous to becoming wedged into the premaxillary above the palatines, dispatching a bony offshoot on either side nearly to meet each other in the palatine fissure on the other.

The remaining pair of bones found at the inferior aspect of the birds' skull are the *pterygoids*. In the Grouse they are stumpy, subcompressed concerns, with half-twisted shafts, having broad concave surfaces for the facets on the rostrum, which are notched distally for the reception of the palatines. The articulation with the tympanics is equally extensive, monopolizing long, narrow facets beneath the orbital processes on those bones.

We have arrived finally at the point in our descriptive skeletology of the avian skull, where we have to deal with the anterior and ultimate hæmal spine, here fulfilling most important functions as the superior mandible, as it does throughout the class at large. In *Tetraonide*, as in the vast majority of birds, the *intermaxillary* or the "premaxillary" of some authors is of much stouter material than most other bones of the head, its use, being a very obvious reason for this. (Plate V, Fig. 51, N. *Pf. mx, i.mx.*)

From the moderately free fronto-maxillary and pseudo hinge-joint,

between the out-turned frontals, the culmen of this bone slopes by a gently increasing arc to the tip of the beak. This surface is rounded and split in two from the enlarged inner extremity to a point over the distal border of the nostril; this division lasts during life. The external nasal orifices are unusually large and sub-elliptical in outline. The head of the ethmoid shows in very young chicks, but is eventually covered by this bone, which also fills in snugly the internasal space (Plate X, Fig. 73).

The osseous maxillary tomia are even sharper than when they were capped with the horny integumental sheath that the entire bill wears during life; they are produced backwards on a triangular process of the bone below the shaft of the maxillaries, touching them in the Quails. A row of minute foramina encircle the beak anteriorly, where it is the thickest, though the segment is non-pneumatic. The general surface beneath is depressed below the tomial margins, though it is not very extensive, as the wide palatine fissure occupies a good part of the space, that terminates anteriorly in a U-shaped curve, opposite the outer nasal border. In the *Odontophorine* the curve of the culmen is more abrupt, and the frontals rise above, in some cases even jut over, the premaxillary. The nasal apertures are also very large and of a shorter elliptical outline; the palatine fissure is likewise narrower in comparison, a few of which differences are such as one would naturally look for in a bird of so near kin, and whose beak has been more than proportionately curtailed.

On removing the vault of the cranium in an adult female of *Centrocercus*, so as to obtain a free view of the brain-case, we discover the usual nervous and vascular foramina present at their most common sites, but beyond this we are more struck with the feebleness with which many of the salient points are developed, as compared with some of the other avian groups; we might sum it up by describing it as a lack of angularity and depth. It is true the various fossæ are well, though not strongly divided, the superior median crest is present but not very prominently developed, and the rhinencephalic fossa is barely conical. The section shows the greatest amount of deplotic tissue to be in the basi-sphenoid, and bones of the occiput, where for potent reasons such material is most urgently in demand.

In the study of the crania of the adult *Tetraonida* as an entirety we find among the most conspicuous features enlisting our interest the unusual number of bones that remain free in them. The skull can be so stripped of its outstanding segments that nothing remains save the cephalic casket with the interorbital septum. The rhinal chamber is strikingly open, due to the great external nasal passages, and all its internal structures, as the ethmo-turbinals, internasal septum, and floor being formed only in cartilage. A pocket existing in the extremity of the premaxillary, that fills in with a spongy osseous tissue during life, is observed in *Centrocercus*, which is solid in the *Odontophorina* and *Lago-*

pus—parial, subcircular pits placed side by side in like locality in *Tetrao obscurus*.

The orbits are more fortunate in the completeness of their bony enclosures—the heavy plate generously extended by the ethmoid to divide these cavities very rarely shows any deficiencies. Of all the crania before us *Tetrao obscurus* is the only delinquent in this respect, though no doubt this may occur in others. In it quite a vacuity exists near the middle of this septum. Anteriorly the prefrontal and frontal throw out laterally squamous septa of greater or less completeness, that divide these cavities from the common rhinal space. These plates may coalesce with the processes of the lacrymal, as a rare coincidence, and perchance meet the infraorbital style. The foramina for the passage of the optic nerves and the first pair are, as a rule, singularly circular and distinct, the minor apertures about them enjoying a like individuality. They are noted for their greater patentcy among the Partridges.

A separate canal is devoted to each olfactory nerve immediately below the orbital vaults, that usually at its outstart from the cranial end has a small opening between it and the one of the opposite side. About the entrance to the otoecane we notice principally a rounded, squamous plate thrown down from above by the mastoid, that is present in all the Grouse. Just below and within, this segment also develops a sharp spicula of bone, posterior to the tympanic articulation, that evidently serves the purpose of keeping this free ossicle in its socket in certain movements of the jaw.

Peculiarities of the floor of this cavity have already been described above; in specimens of *Tetrao canadensis*, carefully selected for me by Mr. William Brewster, of Cambridge, Mass., and forwarded to me by Prof. J. A. Allen, of the Museum of Comparative Zoology, also of Cambridge, to whom my grateful acknowledgments are due for so many like favors, we find, upon viewing the skull from below, the elevations or convexities due to these ellipsoidal and wing like formations, reminding one of their marked resemblance to the acoustic bullæ of the tympanic found among the crania of *Felidæ*.

The author in his various plates and figures believes he has given sufficient life size, as they all are, views of basal and superior aspects of the skulls of these birds, will not enter here into any needless details of measurements. The variation in size in this respect in *Centrocercus* has already been dwelt upon; it is not nearly so marked in other genera. The surface of the skulls above have a rough look caused by many minute depressions and groovelets, then running out to the margins of the orbits cause them in some to be finely serrated.

The Sharp-tailed Grouse is a unique exception to this, it being a bird of rather a delicate skull with smooth cranial superficies. All save *Centrocercus* possess rather depressed foreheads, apparently due more to a slight tilting upwards of the superior orbital peripheries. The lateral temporal fossæ are shallow and scarcely noticeable, the muscles they afford lodgment not being remarkable either for their size or strength.

Of the Vertebral Column.—In discussing the development and peculiarities of the vertebral column, we will still continue to adhere to *Centroceruus* as our model, explicitly stating names of other species when occasion requires a departure therefrom.

In examining the atlas and axis as they occur together in the chick a few days old, we find that the neuropophyses of the first have as yet failed to fairly meet above in the median line; though they may in some instances, as they undoubtedly do, soon touch each other. No ossific centre exists for an atlantal neural spine, as that process is not found upon this bone in any of the *Tetraonidæ*. Below the arch the interesting procedure is progressing in the appropriation of the centrum of this segment by the axis. The inferior extremities of the atlantal neuropophyses have inserted between them a circular ossicle whose plane is in the horizontal plane and on a level with the floor of the neural canal of the axis. This bonelet eventually becomes the "odontoid process" of the second vertebra. At this stage it is a little less than a millimeter in diameter, and in the adult occupying the same position remains a subsessile, and in comparison with the bulk of the bone it is attached to, an insignificant tubercle, though unquestionably fulfilling all the important functions required of it. In less than six weeks the odontoidal larceny is complete, and no trace remains to lead one to suspect how matters stood at the earlier date.

Immediately beneath and a little posterior to the primoidal and distinct centrum of the atlas, there is another, and still larger, free ossific centre, uniform in outline, concave above, surrounding the primitive odontoid apophysis with its long axis lying transversely; behind, and in contact with it, are two more very minute and elliptical ones placed side by side. The first of these unite with the atlas and latterly form the bony ring for the occipital condyle to revolve in, and the surface for the odontoid to move upon, and a notched lip of bone that projects from it behind, that subsequently develops—the remaining two, the anterior part of the body of the axis that bears the articulating surface for the first vertebra. In the full grown bird the postzygapophyses of the first vertebra projecting well to the rear look almost directly inward. They meet the prezygapophyses of the axis that face in a contrary direction and a little backwards. The articulating facet for the centrum of the axis is subelliptical, convex, of some size, and has in the segmented column the inferior and convex surface of the odontoid playing just above it, the superior and flat surface of the latter being confined by intervening and delicate ligament forming a part of the floor of the neural canal of this bone. In the axis of the adult the anterior part of the bone with the odontoid process, that was separately added, projects conspicuously forwards beyond the neural arch, and in birds of several months of age it can be distinctly discerned where the union was established between neuropophyses and centrum.

In the mature vertebra the neural canal is nearly circular. In the

centre of the bone, above, a knob-like tubercle acts as the neural spine, which has mesially and behind a deep pitlet for the insertion of the interspinous ligament. Anapophysial tubercles are found above the post-zygapophyses, which latter are of considerable size, concave, and faced downwards. The centrum of the axis is subcompressed from side to side and supports mesially, just anterior to the second vertebral articulation the first hypapophysis of the series. The first two segments of the vertebral column are non-pneumatic.

Vertebrae throughout the chain in the young chick invariably show the line of union between the centra and neuropophyses, but it is lost as soon as the birds come to be two or three months old. At this age, however, still very interesting points of development are strikingly visible in the third vertebra, which otherwise varies but slightly from the same bone in appearance as seen in the column of an old male, such as we have before us.

The neural spine, more compressed than in the axis, is nearer the middle of the vertebra, still deeply pitted for the interspinous ligament behind, and slightly so on its anterior margin. This characteristic becomes very faint among the long vertebrae in the middle of the neck, to be markedly reproduced as we approach the dorsals, the posterior depression always being by far the best defined. We find anapophysial tubercles still present in the third vertebra. These also exist throughout the cervical series, with more or less clearness; they form ridge-like lines upon the elongated segments of the mid-neck. The zygapophysial processes in general look upwards and inwards anteriorly, and *vice versa* behind—the fourth vertebra having in common with the one we are now describing an interzygapophysial bar, lending to these two segments that broad and solid appearance well known to ornithotomists, not possessed by any other of the cervicals. The neural canal in the third vertebra is nearly circular, which is also its form in the adult, becoming only moderately compressed from above downwards in the last three or four cervicals. Regarding the third vertebra from below, we observe that the articulating surface of the centrum for the axis to be quite concave and turned a little downwards. The processes that fall beneath the prezygapophyses form what would be a canal with its lateral margins; this groove, however, in the “bird of the year” is converted into the vertebral canal by an independent ossicle being placed over it on either side, and, being below the rest, it causes a broad shallow concavity to appear mesially and anteriorly.

These small bones have at the very outstart stumpy apophyses projecting backwards, and are the parapophyses of the vertebra—the projections they meet from above being the pleurapophyses, the groove they form mesially being the broad termination of the carotid canal.

The fourth vertebra has the same general appearance of the third, that we have just been describing; it is a little longer, however, and in both large pneumatic foramina are found laterally and beneath the diapoph-

yses. These apertures are found in the vertebral canal in the remainder of the cervicals. Again, in both, the bodies are rather compressed from side to side, and it is not until the bird has arrived at maturity that the hypapophyses are well seen in these two segments.

Now, taking up the cervicals from the fifth vertebra, we find certain characteristics holding good throughout the series, with certain gradual modifications. In the adult the neural spine in the fifth is prominent and placed anteriorly; it slowly subsides to the tenth, where it is mere tuberosous, nearer the middle of the bone, and bears evidence of having a posterior projection overhanging the depression for the interspinous ligament. This is the type to include the thirteenth, the projection being more and more prominent and slightly cleft behind; in the fourteenth and fifteenth it suddenly assumes the broad quadrate spine of the dorsal type. Returning to the fifth vertebra, we note another change in the lengthening of the postzygapophyses: the acme of this modification is seen to be in the sixth and seventh vertebrae. From these they gradually shorten again, while the anterior ones spread out with the diapophyses to assume the form of the consolidated ones in mid-dorsal column. This arrangement allows lozenge-shaped apertures to exist between the segments above, and subelliptical ones laterally, that become smaller and more circular above as the postzygapophyses shorten, and quite large laterally as they approach the point opposite where the brachial plexus is thrown off from the myelon.

In the adult and old Cock of the Plains we detect beneath, in the fifth vertebra, well anteriorly, a strongly developed quadrate hypapophysis. This process entirely disappears in the sixth, for in this segment the centrum of the bone, anteriorly on either side, just where the parapophyses meet the body mesiad, a tubercle commences to make its appearance, the apices slightly inclined towards each other. From the sixth to the tenth inclusive these apophyses become longer, approach each other below, but never meet so long as they have the "carotid canal," which they form between them. In the eleventh they seem to have not throughout their extent to form a hypapophysis on the exact site they occupy in the tenth, the tenth vertebra being the last cervical where there is any evidence of the carotid canal; hence from this method of formation Professor Owen is made to say (*Comp. Anat. and Phys. of Vertebrates*, vol. 11, p. 190), "In the Common Fowl each carotid * * * enters (ing) the canal formed by the hypapophyses."

In the completed twelfth vertebra of the mature bird we find this hypapophysis very large, with expanded extremity, and the parapophysis, on either side, sending down long subsquamous processes. In the thirteenth segment of the "bird of the year" the parapophyses begin to take on a change. This change develops in the adult still a perfect hypapophysis, but in the younger individual the parapophysial element begins to be notched anteriorly, a part favoring the pleurapophysis, a part the centrum, so that in the fourteenth vertebra of the adult the

hypapophysis is still present anteriorly with a tubercle developing on either side of it, with the parietes of the vertebral canal very much slenderer. In examining this segment in the younger bird we ascertain that the original ossicle is now a descending pleurapophysis meeting the parapophysis, a delicate and independent process, which, in the fifteenth and last cervical vertebra, constitutes a free rib, while the hypapophysis consists of a mid-process and a smaller nodule on either side. This beautiful metamorphosis can be thoroughly studied and easily comprehended in the cervical portion of the vertebral column in our *Cathartes aura*.

So that, as a partial recapitulation of the first fifteen segments, we find that they make up the "cervical portion" of the column. Their centra are universally subcompressed at their middles, they develop in the young bird parapophysial projections that eventually produce free ribs by the aid of the descending pleurapophyses, and their interarticulations, as far as their bodies are concerned, bear out the general ornithic law of being apparently proœlous on vertical section and opisthocœlous on horizontal section.

Backwards from the fifteenth the vertebral segments or the links of the chain take on a metamorphosis that is characteristic of the *Tetraonidae*. It consists in, in all the adults of the genera, a consolidation of the ensuing four vertebrae. The confluent bone thus formed constitutes the major part of the *dorsal* division of the spinal column and invariably supports free pleurapophyses (Plate VI, Fig. 55, *Centrocercus*, ad. ♂).

In *Centrocercus* these four vertebrae can easily be distinguished from each other until the bird is over a year old, but very soon after this all sutural traces are entirely obliterated and we have the segment as represented in the plate.

The neural spines become one long parallelogrammic plate, occasionally exhibiting a foramen or so at the site of the original interspinous spaces.

Its crest is rounded, but has no independent rim. Muscular fascia attached to it posteriorly often ossifies, leaving in the prepared skeleton flattened spiculae, on either side, directed backwards. The anterior aspect of this bone has all the necessary elements to meet the last free vertebra beyond it. The first pair of diapophyses are the shortest, the last pair the longest and most raised; these processes are more or less bound together by metapophysial offshoots of variously defined serrate margins, that allow interdiapophysial vacuities to exist. Below, and just anterior to the bases of the diapophyses, are the four subelliptical and concave facets of the capitula of the dorsal pleurapophyses. From their upper and posterior points sharp crests run beneath the transverse processes to meet the out-turned and cordate facets at their extremities for the tubercula of the ribs. At regular intervals, and nearly in a right line among the diapophyses, are the elliptical orifices for the transmission of the dorsal nerves.

Pneumatic foramina are found about the bases of the transverse processes, the most anterior one being of some size.

The centra of these amalgamated vertebræ are very much compressed from side to side. This compression has its due influence upon the form of the neural tube within, while the bone below is produced downwards into an excessively thin and sharp crest, which is still further extended into four inverted T-shaped hypapophyses of large size. They join each other beneath to a greater or less degree in many of the genera. This union more frequently takes place between the first and second, and the first is always upturned and flanged out laterally, a feature prominently reproduced in *Lagopus* and *Bonasa*. These winglike side extensions of the lower margins of the hypapophyses not infrequently are continued on two or three consecutive ones, and are sometimes the widest on the second.—*Tetrao*.

Both in the Grouse and Partridges we find a free vertebra inserted between the compound bone we have just been discussing and the first sacral vertebra. This segment we must consider as belonging to the dorsal series, although in *Cupidonia* and *Pediocetes* the upper and distal aspects of its diapophyses are more or less moulded to conform with the ilia. This bone is also figured in Plate VI, Fig 55, in conjunction with the other dorsals, with which it has all its characteristics in common, and such ones superadded as we might expect to find in a vertebra naturally disjointed in the middle of the column. It has the longest diapophyses of any of the series to which it belongs; facets for the tubercula and capitula of its own free pleurapophyses; a hypapophysis of no mean length that may or may not be expanded below.

Metapophysial spiculae on its transverse processes sometimes are so far produced as to reach vertebræ before and behind it.

This segment is likewise pneumatic.

There is a wonderful vein of regularity running through the dorsal pleurapophyses, hæmapophyses, and hæmal spine or sternum. As to the first pleurapophysis, or rather the first pair of these bones, we have already described them as they are found in the ultimate cervical. There we are aware it never reaches the sternum by the intervention of a sternal rib; that they are usually found to possess thoroughly developed heads and tubercles for the vertebra, their shafts being less flattened than the dorsal ribs, and only in *Lagopus* did we discover any epi-pleural appendages.

As far as our observations extend, the consolidated portion of the column of the dorsum has always consisted of four vertebræ, and consequently we find in this portion four pairs of movable dorsal pleurapophyses and one pair for the free dorsal vertebra, reckoning five altogether for this region. The first pair of dorsal vertebral ribs terminate in free extremities, which are usually in line with the inter-hæma-pleurapophysial articulations in old specimens, and as a rule support epi-pleural appendages, characteristic of the species to which the rib belongs.

In the *Tetraonidae*, following the general aphorism of the class, we observe a gradual dilation of the skeleton from the inter-coracoidal aperture towards the pelvic extremity of the body. To compensate, or rather what really gives rise to this, as far as the bird's osseous structure is concerned, among other things, is a lengthening of the diapophyses as we proceed in that direction. The ribs also become longer; the xiphoidal forks of the sternum flange outwards. So, too, we find a corresponding shrinking of the tubercula on the dorso-vertebral pleurapophyses, and a stretching of the correlative necks, so that the capitula may reach the facet intended for them on the vertebræ.

The vertebral ribs as seen in the Grouse are pneumatic, the foramina being found on the posterior aspect of these bones immediately below the tubercles, sheltered by the flattened bodies as they dilate in that region.

As in nearly all birds, these ribs are compressed from within outwards, and in *Centrocerus* are wider below the uncinæ processes, contracting as they meet their sternal ribs. In these birds, too, the epi-pleural appendages are firmly knit to the body of the rib—though in *Bonasa*, *Lagopus*, and *Tetrao* they may be easily detached, leaving behind them in each case a shallow concave facet. In the last dorsal rib this appendage is the smallest, and is directed upwards nearly parallel with the body of the rib, and sometimes (*Centrocerus*) the edge of its rib swells out to meet its apex above; and this may have been the method by which the unique and remarkably striking uncinæ appendages were formed in *Cupidonia*, a bird that constitutes itself an exception among the North American Grouse in this respect (Pl. XI, Figs. 79, 80), where not only the vertebral ribs are unusually broad, but their processes much more so, being great, odd, quadrate and compressed plates confluent with the body of the rib, and only rarely condescending to be weakened by the merest apophysis for a foramen to exist in them, as in Fig. 80. The Sharp-tailed Grouse appears to come next in approaching this state of affairs; it, too, invariably developing more or less expanded ribs. The only sacral pair of pleurapophyses conform to the general shape of the series to which they belong, and never support epi-pleural processes.

These bony protectors of the thoracic parietes were found to be exceedingly delicate in specimens of *Bonasa* kindly sent me by Leslie A. Lee, Esq., of Brunswick, Me.

Four hæmal ribs ascend from the costal borders of the sternum to meet the dorsal pleurapophyses in arthrodial articulations above the mid-horizontal plane of the bird's body. As is usual, their sternal ends are twisted so that the facets are situated transversely, while the upper extremities are broad and flat, particularly in *Cupidonia* and *Pediaccetes*.

The first pair are generally in advance of the others, and insert themselves higher up on the costal processes: The pneumatic foramina for these bones are to be found just above their transverse facets anteriorly. The extremities of the hæmapophyses of the sacral ribs meet the pos-

terior borders of the hæmal ribs of the last dorsal pair usually about the junction of their middle and lower thirds of the bodies of these bones.

The distal or upper extremities of these, the last pair of hæmaphyses, are sometimes very much expanded, and in a specimen of *Centrocercus*, ♀, a small bit of bone has been superadded, simulating an additional hæmal spine on either side, as if anticipating the descent of another pair of sacral ribs to protect this otherwise feebly guarded region of its owner's anatomy.

The short pair of xiphoidal processes overlap the ultimate sternal ribs of all the Grouse and Quails, on either side, as do the ilia the sacral pleurapophyses above.

The *Sternum*, in the North American *Tetraonidæ*, is developed from five points of ossification, and to these it seems to have added, later in life, or before the bone becomes one entire piece, an ossific centre at the extremity of each of the four lateral xiphoidal prolongations from which their subsequently dilated ends are produced. These later are easily to be demonstrated in the hæmal spine of *Centrocercus*, in the "bird of the year" (Plate VI, Figs. 53 and 56).

Fig. 53 represents the young of this last-named Grouse a day or so old, at which time all five of the primoidal points of development are eminently distinct. The "body" of the bone is nearly circular. The "keel," of which only the anterior part has as yet ossified, dips well down between the tender pectorals; the manubrium, now only in cartilage, has at this date no evidence of the foramen that later joins the coracoidal grooves. As to the rest, bands of delicate membranous tissue bind them loosely together. The sternum in a bird of several months' growth is shown in Fig. 56. Here the bone is rapidly assuming the shape it is destined to retain during life. The body and with it the keel is extending by generous deposition of bone tissue at its margins, principally at the mid-xiphoidal prolongation. The manubrium, still in cartilage, we find pierced at its base by the foramen just alluded to, and a rim of the same material runs about the anterior border of the *kyphosteon*, Fig. 56, 4, while a rapidly diminishing band also connects the elements known at this stage as the *pleurostemon*, *ib.*, 6, and the *metostemon*, *ib.*, 5. In cases where severe maceration is resorted to with this bone, in still older specimens, in which the sutures are not suspected, these parts will still separate about the original points of ultimate union.

On the reverse side of the bone shown in Fig. 56 we find that even at this stage it is deeply perforated by the pneumatic foramen at a point immediately over the carinal ridge.

In the adult the sternum is highly pneumatic, air having access to it through such apertures not only at this point but also in the costal borders between the sternal ribs, and by a single foramen in the groove, posterior to the manubrial process mesiad.

Thus it is that this bone is generated, and as an entirety we are well

aware that it represents the confluent hæmal spines of the free thoracic ribs, not developed in the order of a spine for a rib, completing the inverted hæmal arches separately, as in some vertebrates, which by their peculiar skeletal topography such niceties become feasible, but, as we have seen, and the fact is not new, by a fewer number of ossific centres, of necessity, due largely to idiosyncrasy of conformation as subservient to purpose, and a convergence of the inferior extremities of the several hæmapophyses to which, as a whole, it belongs.

In Plate VI, Figs. 52, 54, and 55 are all parts of the skeleton of the same bird—an old adult Sage Cock, *Centrocercus*—of which Fig. 54 is a view from below of the sternum.

It will be seen that it has a length of 14 centimetres, and other measurements can be easily obtained from it. We have never seen this bone any larger, and, as it is, it represents the maximum size the hæmal spine attains among North American Grouse. The bone is shown in other plates also, and their owners can be ascertained if the reader will kindly turn to the "Explanation of Plates" accompanying this paper.

The unique outline of the sternum of the *Galline* has long been known, many authors having both figured and described it, and we will say here that in the *Tetraonide* of our country no marked deviations are to be noted from the more common type.

Anteriorly the manubrium juts out as a quadrate process with rounded angles; its inferior margin is continuous with a line that runs down between the slightly prominent carinal ridges, to become continuous below with the anterior carinal margin.

Above, the general surface of the sternal body extends over it. A subcircular foramen, connecting the coracoidal grooves, pierces it at its base. The coracoidal furrow, thus becoming one groove, is biconvex, being depressed mesiad behind the manubrium, in which depression another pneumatic foramen usually occurs. Their upper and lower margins are produced slightly outwards, the inferior being the sharper of the two.

The "costal processes" are exceedingly prominent, being bent over anteriorly at their apices, which are rounded. Behind them are observed the limited "costal borders," exhibiting the four transverse facets for the sternal ribs and pneumatic foramina. The "carina" or keel affords the greatest amount of osseous surface of the entire bone, greatly exceeding the body. Its lower margin is a long convex curve outwards, and the "carinal angle" protrudes forwards nearly as far as the manubrium, causing the anterior margin of the keel to be markedly concave.

The "carinal ridge" is thickened and heavy superiorly, where it limits or rather constitutes the boundary of the bone in that direction. Below it spreads out, and is gradually lost, *within* the boundary of the carinal border proper.

"Subcostal" and "pectoral ridges" are nearly always well defined.

The *superior* and *inferior* xiphoidal processes are very characteristic

of the *Tetraonidæ*. They terminate by dilated extremities of nearly similar shapes, *Cupidonia* being an exception; the ends of the apophyses of the superior pair in this bird being rounded posteriorly (Plate XI, Fig. 82; see Plate XIII, Fig. 91, *Lagopus*, for the common pattern). These processes arise from a common stem, and their shafts are flat internally, with a raised ridge extending the entire length externally. The "body" of the sternum is, as a rule, very narrow, and notably concave anteriorly, becoming nearly flat behind, where it is produced beyond the keel for a greater or less distance.

The manner in which this part terminates varies in the different Grouse.

In *Centrocercus* it is nearly square across; in *Lagopus* roundly notched in the middle line, as it is in *Bonasa*; in *Tetrao canadensis* it is broadly cordate; while in *Tetrao obscurus*, *Cupidonia*, and *Pediocetes* it is distinctly cuneiform. The body is very narrow in *Bonasa*, approaching the *Odontophorina*, where it seems really to be nothing more than a good ribbon-like finish to the superior border of the keel. In these birds, too, we are struck with the double carinal margins anteriorly formed by the projecting ridges, and the long spicula-form costal processes that extend nearly half-way up the shafts of the coracoids.

So much do the sterni of the Grouse resemble one another in species of average size that it would puzzle one not a little to tell them apart if they were separated from the skeleton, and we were not allowed to examine them in connection with other diagnostic features of the osseous parts of the species to which they might belong.

Cupidonia and *Pediocetes* are particularly alike, but the former could be recognized by its superior xiphoidal processes, *Bonasa* by the narrow body, *Centrocercus* by its size in the larger specimens, and so on.

We will still continue to consider such of the vertebral column as is confluent in the old bird, or rather such vertebræ as become confluent and are more or less embraced by the ossa innominata, as the sacrum, and composed of sacral vertebræ, attempting to make no such divisions as Professor Huxley did, in his *Anatomy of Vertebrated Animals*, of this compound bone.

There are sixteen of these segments that are to be so reckoned in *Centrocercus*, but it is only in the "bird of the year" that they can be counted with anything like accuracy, and even then great care must be exercised, and various pelves examined and compared with the younger birds at different stages and ages.

The first sacral vertebra possesses free pleurapophyses, whose hamapophyses do not reach the costal borders of the sternum, but articulate in a manner to be described further on. Regarding the pelvis from below in *Centrocercus*, we note that the anterior four sacral vertebræ have their combined par- and diapophysial processes thrown out as braces against the expanded anterior iliac wings. After this the ilia change their form to accommodate themselves to the basin of the pelvis, which they

assist in inclosing, and with this change the succeeding vertebrae have their diapophyses much elevated to meet the internal iliac margins. This section consumes four additional vertebrae, the centra of which go to make up the latter moiety of the cavity for the "ventricular dilatation" of the myelon, and they show the double foramina on either side, one above another, for the separate exit of the motor and sensory roots of the sacral plexus.

A double row, *i. e.*, one on either side of subcircular vacuities, exists here also among the transverse processes (Plate XIII, Fig. 90, *Tetrao canadensis*, ♂). It is through this portion of the sacrum that we observe in the chick the greatest amount of firmness in sealing up of the neural tube above by the superior union of the engaged neuropophyses.

The remaining eight vertebrae become much compressed with expanded processes that rarely allow apertures to remain among them, forming an excellent mid-section to the broad and capacious pelvic cavity, with nearly all signs of its original formation obliterated on the outer and superior aspect.

The neural canal is distinctly circular as it enters the sacrum anteriorly, becoming only slightly flattened as it nears the coccyx. Above we find the neural spine confluent with the ilia anteriorly along its summit, and some additional bone deposited posteriorly in the way of their lateral plates, to bridge over the ample "ilio-neural" canals. Opposite the "gluteal ridges" the bones are yet firmly knit, but for the remaining part of the sacro-iliac suture the interested bones can be said only to snugly meet each other. *Cupidonia* alone has quite an interspace present (Plate XII, Figs. 83 and 84).

The sacral wedge is quite thoroughly permeated by air, which enters through foramina in the vertebrae in localities similarly situated to those described in speaking of the anterior part of the column.

In *Centrocerus* sometimes the first sacral vertebra bears a well-developed hypapophysis, and there may even be some evidence of this process on the second segment. The expanded extremities of these median processes are connected along their inferior margins by a delicate ligament of a firmer consistence than that membrane, which fills in the vacuities between the processes to which it is a limiting border. Now, it depends how far this ligament is conducted backwards as to how many of the anterior sacral vertebrae bear hypapophyses, as from its attachment to the hypapophysis (we have never seen it commence on the cervicals, though the directions assumed by their processes bear it out) of the first dorsal it completes a long shallow arc of an ellipse, in which the lower margins of the hypapophyses are found and assist to complete. This semi-osseous, semi-membranous, attenuated median plate dips down into the thoracic cavity in the living bird, for some little distance, as an interpneumonic septum.

The number of free caudal vertebrae in the adult Sage Cock is five, and to these is to be added the *pygostyle*. They all have pretty much

the same general appearance, differing principally in the length of their outstanding transverse processes. In this respect the first and second are about equal; in the third and fourth two or three millimetres are added on either side, with a roughened tuberosity above; while the fifth and last is in appearance and size very much like the first. These diapophyses are rounded at their extremities, and all slightly deflected. The centra are transversely elliptical and of good size. The neuropophyses arise from them to inclose a subcircular neural canal, which is roofed over by the bifid and clubbed terminations of the elements, that hook or lean forward (Plate IX, Fig. 66; Plate XIII, Fig. 91). We have never observed an hypapophysis upon any of them; and all the elements and processes, as always occurs in the coccygeal series, are more or less imperfectly developed.

The *pygostyle* is an acute subcompressed triangle with tuberos base. Anteriorly and above it exhibits a bifurcated process that simulates the crests of the series; below this a shallow facet, for articulation with the last caudal, and a feeble subconical depression to protect the termination of the myelon between the two. Behind it has, at its lower angle, a deep groove, with a heavy bony rim or margin that shows a constriction near its middle (Plate IX, Fig. 65). This formation is easily explained when we come to examine the development of this compound appendage in the chick of a day or so old. This will reveal the fact that the pygostyle is composed of *three* vertebrae, that are fused together, distorted and modified as the bird grows, so as to eventually result in the bone we have before us.

There is nothing more interesting to the student of comparative anatomy than to study the serial skeletons of birds of divers ages, demonstrating and elucidating such a point as this, that could not be brought to light in any other way.

We will now offer a few remarks upon the vertebral column, as applied to others of the *North American Tetraonidæ*.

Of all the specimens examined, representing all the genera, the number of distinctly free vertebrae between the skull and the ankylosed dorsals has been found to be invariably fifteen, the last one supporting movably-articulated pleurapophyses, that in *Lagopus*, at least, possess small epi-pleural appendages. This portion of the spinal column, then, will constitute the cervical division, and in it we note that the third and fourth segments have interzygopophysial bars present, becoming so broad in the quails that the foramina they give rise to are sometimes very minute.

The pleurapophyses become long and sharp in some and more conspicuous than in others; this applies particularly to *Cupidovia* and *Pediocetes*. The last cervical in the former has osseous spiculae leading backwards from its neural spine and postzygapophyses, as in the anterior dorsals. In the same vertebrae the hypapophyses become confluent to

form one broad process placed transversely with a mesial keel in front as the only indication of its original device.

The carotid canal seems to commence and terminate in the same vertebræ both in *Tetraoninae* and *Odontophorinae*.

Of the eminently characteristic dorsal bone little has to be said in addition to what has already been noted above. The number of vertebræ included in the ankylosis is never more nor less than four, and the first vertebral ribs have no hæmapophyses; so they never connect with the sternum, though they invariably bear uncinæ processes, and in many species contribute a good share toward the stability of the thoracic parietes. The metapophysial processes vary principally in their extent: in *Bonasa*, *Cupidonia*, and *Pediæcetes*. In several specimens they nearly cover the tops of the diapophysial arms. In *Lagopus* a narrow bar defines them, connecting the extremities of the transverse processes with comparatively few offshoots. In *Tetrao canadensis* the bone is very long and delicate. In *T. obscurus* it has the same general appearance as in *Centrocerus*. The hypapophyses develop after the common type, but often irregularly; they are found to be missing on the ultimate segment or rather the pelvic end of the bone in the Quails.

The free and last dorsal may or may not have a hypapophysis; we believe it never does in the *Odontophorinae*. It is overlapped by the ilia in *Cupidonia* and the Sharp-tailed Grouse. We find this to be a very marked feature in the last, and well marked among some of these birds sent me by Capt. James C. Merrill, Medical Department United States Army, from Fort Custer, Mont., at a time they were particularly acceptable, and when this erratic fowl became suddenly and unusually rare in many localities, so that the gift was reckoned at the time as more than valuable desiderata. As far as the sacral vertebræ are concerned, the same general plan seems to be carried out: sixteen seems to be the allotted number among the Grouse and, as a rule, among the Partridges. In these birds the sacrum, *i. e.*, the ankylosed sacral vertebræ, is much narrower, as is the entire pelvis, and much fewer perforations are to be seen among the dilated processes that go to meet the ossa innominata.

In *Cupidonia* and *Pediæcetes* the sacrum is very broad, conforming to a pelvis in these birds that will be described further on. We find in a specimen of *Tetrao canadensis*, for which we are greatly indebted to Mr. Manly Hardy, of Brewer, Me., where the sacro-iliac ankylosis is so perfect, and original land-marks so obscure, that one might easily imagine the pelvis in this individual as being developed from a very much fewer number of ossific centres. The caudal vertebræ number *five* in all the Grouse except *Cupidonia* and *Pediæcetes*, these birds each having distinctly *six* apiece. We would especially call the reader's attention to this fact, because when we come to discuss the pelvis of these two birds, and recapitulate general skeletal data, it will be found that, as far as osteological similarities are concerned, they come *very* near to each other. The coccygeal vertebræ, otherwise, in common with the pygostyle, show

very few differences worthy of record. In *Ortyx* and *Lophortyx* there are but four caudal vertebræ and the vomer is markedly acute and long. Occasionally the last segment is but feebly developed, as in *Lagopus*, where it may be a mere nodule; and in *Bonasa*, too, sometimes a sixth vertebræ can be found, but usually requires force to detach it from the pygostyle, and in our specimens seems to be one of those that originally formed that bone—though we do not deny in the face of such evidence that specimens of the Ruffed Grouse may be found that possess six of these vertebræ.

Of the Scapular Arch and the pectoral limb.—This arch, with its concomitant, could have, with all propriety, been described in connection with its vertebræ, but so distinct has it become, and so far removed in order to assist in carrying out such a notorious function as the bird's flight, that the author prefers to follow the general ruling of others by discussing it separately. Nothing could be more entertaining in the whole range of osteological research and study than the contemplation of the various avian shoulder girdles with their attached wing bones, particularly the former, as exemplifying the law of equilibrium between a bird's habits, the never-varying part it is to play in nature, and its skeleton or the framework that has been given it to carry that part out. This thought invariably enforces itself upon me in every instance after an examination of a collection of clavicles of different species of birds. It seems that there could not be an equipoise established anywhere in living nature more thoroughly compensatory than that 'twixt a bird's power and mode of flight, and its scapular arch and other bones about the chest—to meet it, more essentially the clavicles. See the broad, excessively pneumatic, yet robust, clavicular arch in any of the genus *Cathartes*, birds that sail aloft for hours apparently without fatigue, or the very similarly shaped arch in the Canada Goose, but in the latter for a very opposite style of sustained flight is non-pneumatic; the feeble and often ununited arch in *Sphocytio*, a bird with scarcely any pretensions to being a good flyer at all; in short one would, having a thorough knowledge of a bird's habits, be, in the vast majority of instances, able to guess very near as to the pattern of the furculum he would expect to find.

Now we have seen, in reviewing the skeletons of the Grouse, that in many points some of the species, if we disregard size, simulate each other very closely, as for instance in the various sterni and vertebræ. The clavicles of these birds form no exception to this rule, as far as general appearance goes. The common model is seen in Plate XII, Fig. 87, *Cupidonia*; but observe even here in these closely-related fowls how habit still tells upon skeletal characteristics. The broad, and not deep, pneumatic U-arch of *Cathartes* becomes the long non-pneumatic, almost acute, V-arch of the birds we are describing; so, in view of being familiar with the habits of the Sharp-tailed Grouse and Sage Cock, need one be surprised to find in the fourchette of the first a depth of 4

centimetres (omitting the inferior clavicular expansion), with an interspace of 2.5 centimetres separating the superior articulating extremities, as compared with the bone in the second, where the depth is 6.2 centimetres, and the interspace above only 1.7 centimetres.

The bones of this arch are easily taken apart by maceration, and as has already been hinted they resemble each other very closely among the genera. The posterior angle between *scapula* and *coracoid* averages for the species about 60° , and among the Grouse the distal end of the shoulder-blade is usually found to overhang the fourth dorsal pleurapophysis on either side; but in the California Quail these bones actually extend so far back as to overshadow the ilia for nearly a centimetre, they being proportionately narrow for their unusual length. This bone with the Grouse is only semi-pneumatic, its pneumaticity being confined to its coracoidal extremity, where the foramen is found in its usual site.

The blade is thin behind, becoming stouter as it nears the glenoid cavity, sharp along its inner border, rounded without, clubbed at its pelvic end, and turned gently outwards along its entire length. Anteriorly it contributes about one-third of the surface for the humeral joint, the coracoid the remaining two-thirds, while the acromial process within reaches forward barely to touch the clavicle, forming, as it does so, the usual interscapulo-coracoidal canal.

These bones are narrow in *Bonasa* and in *T. canadensis*, more curved in *Lagopus*, and very stout in *Centrocercus*, a good medium being seen in the Pinnated Grouse (Plate XII, Fig. 85).

The *coracoids* are quite stout bones, but devoid of any marked peculiarities; after leaving their sternal beds they extend upwards, forwards, and outwards, the furculum governing their distance apart at their upper ends. The glenoidal process is extensive, and rises nearly as high as the head of the bone; the clavicular process is faintly bifurcated, and curls over slightly towards the fellow of the opposite side. The shafts are compressed from before backwards, and soon dilate into broad expansions below; anteriorly one longitudinal muscular ridge marks the surface of the bone, while on the sternal aspect two or three very distinct ones occur. The inner angle of the dilated base nearly meets its fellow of the opposite side through the foramen, at the root of the manubrial process; from this corner outwards, for about two-thirds of the distance the surface is devoted to a curved articulating facet for the coracoidal groove, while the outer angle is tilted upwards and finished off by a distinctive little tubercle. On its posterior aspect, about the middle of the dilated part, a large, irregular pneumatic foramen is found in all the Grouse, but seems to be absent in the Partridges.

The position of the united clavicles, or the free acromial extensions of the scapulæ, is shown for *Lagopus* in my drawing in Fig. 91. Something has been said about this bone already; we will add, however, that the superior ends always terminate by rather tuberos enlargements, smooth internally, but uneven as applied to the clavicular processes of the

coracoids. The shafts are gently curved, of even calibre, and fall nearly directly downwards in some species, to be slightly expanded beneath in order to give better support for the large median dilatation below; this is triangular in outline, thickened in front, sharpened behind. In *Ortyx* this process is sometimes produced backwards, so as to nearly touch the sternum; this feature obtains, also, among some of the other Quails.

These bones are all well advanced in ossification in the young chick, but do not develop their distinctive markings until a bird is pretty well along in age; this applies more particularly to muscular lines on the shafts, the base of the coracoids, and the clubbed extremities of the scapula. In *Bonasa*, where we noticed how the body of the sternum was narrow like the Quails, we find also the median process of the united clavicles produced backwards towards that bone. This Grouse's skeleton, in fact, seems to have the greatest tendency Partridge-ward over any other of the North American *Tetraoninae*.

The free ossicle of the shoulder-joint, the *os humero-scapulare*, is not present in any of these birds; a firm piece of inelastic cartilage seems to supersede it and fulfill a like function.

The *humerus* (Plate VII, Fig. 57, H—Figs. 60, 61; also Plate X, Figs. 76, 77 of *Cupidonia*) of *Centrocercus* is so exceedingly regular that it could be well chosen as the type of that bone in all birds in which it is pneumatic. It is in due proportion for the size of the bird to which it belongs, possessing the usual sigmoidal curves from lateral and superior aspects (we describe the bone *in situ* in the closed wing) in graceful, though not decided, prominence. The head or proximal extremity, slightly bent anconad, displays the most usual points for examination about it; an extensive convex, smooth surface is seen for the glenoidal cavity, below it a deep notch, then the well-defined "ulnar crest" or lesser tuberosity curling over a large sub-elliptical pneumatic foramen, that is so patulous that the osseous trabeculae and net-work are plainly seen at its base. The radial crest encroaches but very little upon the shaft, is quite stout, and only at its summit shows any disposition to curve over palmad.

The shaft is smooth, markedly elliptical on section throughout its extent, and almost entirely devoid of any muscular markings or lines; it swells gently in the vertical plane as it approaches the distal end of the bone, upon which is placed the ordinary tubercles for articulation with radius and ulna. The inferior condyle, the internal of human anatomy, is the better developed of the two, and the ulnar tubercle is produced a little beyond the bone distally, while the oblique tubercle is brought down on the shaft. The olecranon fossa is rather shallow in the Grouse, being decidedly better shown among the Quails. There are no prominent points of difference in this bone among the *Tetraoninae*, except in regard to size; *Cupidonia*, which has rather a heavy skeleton any way, the humerus is moderately robust in accordance.

In *Odontophorinae* the same characteristics are to be seen; but we discover in addition at the proximal extremity of the bone, on its anconal

aspect between the greater and lesser tuberosities, a deep fossa that has a great resemblance to the pneumatic orifice externally, and of about the same dimensions, being only separated from that depression by a thin bony wall; it seems to be designed simply for muscular insertion, and has no communication with the general cavity of the hollow humeral shaft.

The *radius* and *ulna* are also singularly typical in their avian characteristics, as might have been looked for after our remarks upon the bone of the brachium; their principal difference lies in their being non-pneumatic, although they are hollow like all long bones.

In the right arm of *Lagopus leucurus*, which we have before us, carefully dried, in its position of rest, with all the ligaments still attached, *in situ*, we find the *radius* to be unusually straight, in fact almost in line between the oblique tubercle of the humerus and the bone it meets in the carpus. Its shaft is nearly cylindrical, and shows a muscular line, upon an otherwise smooth surface, that travels along its proximal two-thirds beneath. Distally it overlaps the cubit by a transversely dilated extremity to articulate with its carpal bone. The head of the *ulna* is large, and betrays the fact that it belongs to a bird of considerable power of flight; the olecranon process is a blunt, tuberos apophysis, slightly bent anconad; the greater and lesser sigmoidal cavities are distinct and fairly marked, particularly the former.

The shaft of the bone is more than twice the bulk of that of its companion, decidedly convex outwards, the curve being greatest at the junction of the proximal and middle thirds; it is elliptical on section, the major axis of the ellipse being vertical. The muscular lines of the ulna are but faintly developed, as are the row of minute tubercles for the bases of the quills of the secondaries.

Anteriorly the bone displays its usual trochlea head for its own carpal segment; this surface is bounded palmad by a sharp and even curve, convex distally, while the inner articulating surface beneath the expanded end of the radius is uneven and applied to the concavities and convexities of the free pair of carpal elements.

These bones among the Partridges and other Grouse, except in size, present to us no extraordinary departures from the description just given of *Lagopus*.

We do not believe there is a bird in our country that can offer us better facilities for the study of the bones of the carpus than the young of *Centrocercus urophasianus*. Anchylosis of the various segments involved is exceedingly tardy, and it is not at all necessary for the student of this joint, that has puzzled so many comparative anatomists and ornithotomists, to seek the primoidal ossicles in the very young chick, unless he desires to ascertain the points as regards priority of ossification of the carpal bones, a question we will evade here entirely, for these bones are quite distinct and easily detached in the bird at six weeks or more of age, such as we offer our reader in the plates.

In the old and mature Sage Cock, the carpus has the appearance of this joint, as it is seen in nearly all of the class where there are two free carpal bones, and the os magnum confluent with the proximal extremity of the metacarpus, and the mode of articulation is the same. This we know to be, first, a free, six-sided, uneven bone, the *scaphoid*, articulating chiefly with the distal extremity of the radius and the metacarpus. This is the *scapho-lunar* of my former papers, and we retain the application here; it is also the *radiale* of Prof. Edward S. Morse, who has made such positive advances in the elucidation of the tarsus and carpus in birds.

The second bone is the *cuneiform*, larger than the first, and engaged principally by the cubit, but having also a process and an articulating surface for the confluent carpal and metacarpals; this is the *ulnare* of Morse.

These are the two carpals that remain free during life.

We will now devote ourselves to the joint as observed in the bird at six weeks of age. We have no trouble in finding *scapho-lunar* and *cuneiform* whatever. At the summit of the second metacarpal there is found a concavo-convex segment, that is universally taken to be the *os magnum*, termed also *carpale* by Morse (Plate VII, Fig. 59, *om*). It articulates anteriorly with the upper end of the index metacarpal, covers the entire proximal extremity of the second, and nearly or quite meets another bone behind that is grasped by *cuneiform*; this is the *unciform* (Plate VII, Figs. 57 and 59, *z*). It has the appearance of being a detached and bulbous extension of the third metacarpal, and is about the size and shape of an ordinary grain of rice, having a shallow concavity on its anconal aspect.

There is yet one perfectly free and distinct bone to be observed; it is found on the inner aspect, very near the extremity of second metacarpal, just below os magnum; it nearly meets unciform, and articulates with the process of cuneiform behind. This little segment is flat and very nearly circular, being applied by one of its surfaces against the shaft of the metacarpal, and held in position by ligaments. This segment we do not find described by any author known to us, and here call it the *pisiform*. The manner in which it eventually joins the metacarpus and the conformation it gives to that bone in the adult are shown in Plate VII, Fig. 58, and it is marked 8 in Fig. 59 of the young Sage Cock. The metacarpal for the index digit is likewise detached, although even at this early date it begins to assume a likeness to the bone as found in the adult.

Medius and annularis metacarpals are also distinctly free, and their size and position faithfully portrayed in the figure alluded to above. The prominent process on the rear and upper third of the shaft of medius of the adult is now found only in cartilage in the younger individual. The rest of the bony part of the pinion is familiar to all of us; it consists, in the adult "Cock of the Plains," as in all Grouse and the

Odontophorina, of a trihedral phalanx for the first metacarpal, constituting the *index*; two more for the medius metacarpal, the superior joint or phalanx having the usual expanded blade, with the long free and pointed finger-bone below; and finally the smallest phalanx of all, freely attached to the distal end of the third metacarpal or annularis.

These bones are non-pneumatic, as are all the bones beyond the brachium in the *Tetraonida*.

Of the Pelvis and the Pelvic limb.—After what we have said and seen in regard to the dilatory manner in which originally primitive elements, in these birds ankylose, and only after the lapse of weeks condescend to amalgamate and form the confluent bones and cavities that occur in the major division of the Class, we must not be surprised to find the same routine and a like tardiness exhibited in the pelvic hæmal arch, or the pelvis, and its appendage the lower extremity.

A glance at the figures illustrating the condition of the bones in question, of birds from one to two months old, will convince us at once that the rule still obtains; in them we find the sutures among the ossa innominata still ununited, and the three bones of either side of the pelvis independent, and easily detached from each other about the cotyloid ring.

In the young chick of *Centrocercus* (Plate VIII, Fig. 62), the ilium is a scale-like bone that rests against the sacral vertebræ. The pre-acetabular portion is excessively thin and delicate, and at this period constitutes the longest and widest part of the bone; its border mesiad bears no vertebral impressions, but is sharp and brittle; the outer margin is slightly rounded; this condition increasing as we near the diminutive acetabulum, where it is the stoutest. The distal margin, imperceptibly continuous with the inner presents a convex curve anteriorly; the included surface viewed from above has a general concave aspect, especially near its central portion. As we proceed backwards, however, it gradually becomes convex, to rise over the region opposite the cotyloid ring to form the general convex surface of the post-acetabular portion.

The distal margin of the bone is nearly square across, and does not extend as far back as the ischium, the two being bound together at this age by cartilage, which has been removed in the plate. The outer and anterior margin of this division of the bone is rounded and fashioned to the cotyle, the anterior half of which it eventually forms. From this point it arches backwards over the future ischiatic foramen. The inner margin of the post-acetabular portion is rather more rounded than its anterior extension, and directly opposite the "ring" presents for examination the depressions of the transverse processes of the ninth and tenth sacral vertebræ in elongated and concave facettes. The ninth vertebra met the ilia first; so we may consider the ilia as the pleurapophyses of the ninth sacral vertebra, and the ischia and pubic elements as the hæmapophyses and divided hæmal spine, respectively, as associate parts of the same arch, which arch has been exaggerated to

meet a certain requisite need, the bony dorsal vault to shield the generative and urinary apparatuses and bear the pelvic limbs. This arch is so inclined that the remaining vertebrae soon, by their outgrowing apophyses, come in contact with it, ultimately fusing to develop the compound bone, usually termed sacrum. A good idea may be gained of the form of the ischium and os pubis by an inspection of Fig. 62, Plate VIII, at this stage of the bird's existence. For very obvious reasons the stoutest part of the ischiatic element surrounds the acetabulum; an inferior process, extending towards a similar one directed backwards by the ilium, grasps the head of the os pubis between them. From this point the ischium sends backwards a triangular thin plate, rounded behind, that is intermediate in length between ilium and pubis. This latter is satisfied to follow suit and direction by contributing a simple and diminutive spine. This crosses soon after the pubis has given its share to the cotylis, the obduratic notch of the ischium, converting, as the bones fuse, it into the obdurator foramen.

We give an additional figure in the Plate, 63, that exhibits the further advances of these elements towards maturity. The bird is now nearly two months old, and it will be seen that one after another the vertebrae impinge upon the iliac margins within. The ilia and ischia extend behind, including vertebra after vertebra, from a series that at this age might be easily taken for an extraordinary number of coccygeal segments. The head of the pubis at this time is entirely out of proportion with its rib-like extension, it having so spread and insinuated itself into the formation of the cotyloid ring as to form about one-fifth of its circumference. At this stage, too, the necessary cartilage begins to be thrown out to form the future anti-trochanter on the ilium.

So much for pelvic development; now let us examine this bony basin as it is seen in the full-grown representatives of the genera.

The manner in which the confluent sacral vertebrae meet the ossa innominata forming the ilio-neural canals and sacral sutures has already been defined above, so that here nothing more need be said of the mid-section of the pelvis taken as a whole. We give among the plates figures of the pelves of *Centrocerus*, *Tetrao canadensis*, *Lagopus*, and *Cupidonia* from the skeletons of the adult birds, and if the reader will compare the lateral views given of the Ptarmigan and the Sage Cock he will see how few the differences are that exist between the two birds. and the same may be said, we assure you, for its superior and inferior views; in fact in the case of *Lagopus* it may be stated that its pelvis in most instances is the perfect miniature of this bone found in *Centrocerus* in all respects. This applies, also, though not quite as strictly, to *Tetrao* and *Bonasa*. Of course certain minor differences are easily to be picked out, such as a greater fulness there, as slightly deeper depression here, and so on; still our plate of *Tetrao canadensis* represents the general pattern of the pelvis among all the North American Grouse, save *Pediocetes* and *Cupidonia*. In the superior aspect of this confluent bone

in a fine specimen of *Tetrao obscurus*, we find the pre-acetabular portions of the ilia very much depressed below the general surface of the bone, and quite concave. The convex anterior borders are embellished with a flattened rim that bounds them, often produced forwards as two median sharp-pointed processes. The post-acetabular surface is raised, and including the sacrum forms a gently convex surface; the "gluteal ridges" dividing these two regions commence with the anterior iliac borders and are conveyed clear round to form the posterior ones of the same bones, describing two great Ss, the lower and outer curves of which pass by the acetabular projections, points where in some birds they terminate.

Among the principal features to be noted in a lateral view is that the shaft of the pubis is in nearly all instances free from the ischium after quitting the cotylis and forming the elliptical obturator foramen. If it anchyloses with this bone at all it usually occurs just behind that orifice.

The ischium overlaps the pubis at two points—one quite broadly near its middle, and, again, by a process at its outer and inferior angle.

The "ischiatric foramen" is the largest vacuity of the group of three that here present themselves; its boundary is sub-elliptical, with its major axis depressed posteriorly if it were produced.

The cotyloid cavity, or ring rather, is markedly circular, both its internal and external margins, the former of which is not a little smaller, thus affording a very good and quite extensive surface for the head of the femur; the anti-trochanterian process or facet directed backwards is likewise ample, so that the femora are well supplied with articulating surfaces.

There seems to be among the Grouse a predisposition for the ilia to overhang the region of the ischiadic foramina; it is most successfully carried out in *Cupidonia*. Viewed from below, we are struck with the amount of room and space these combined bones inclose; the profundity of the pelvic basin. This is very much enhanced by broad reduplicatures of the ilia and ischia behind, and a general though even constriction of a prominent rounded border or rather ridge that extends from the fourth diapophysial abutment of the vertebra against the ilia on either side to the outer angles of the ischia. Within, too, we often find about and at the base of these iliac fossæ apertures for the entrance of air into these bones; such pneumatic foramina are also seen beyond the os pubis and below the cotylis on either aspect.

The pubic extremities never meet behind, though in many species they are very long and usually take the curve given them by the ischia just before leaving these bones. Their distal extremities are flattened in *Centrocercus* and generally more expanded than among the other varieties.

The pelvis of *Cupidonia* is so different from the general description we have just given that the author felt justified in giving to his reader two additional figures that present superior and lateral views of the bone in that bird; in comparing it with other figures given one cannot avoid

being struck with these marked departures from the common type. There is one other Grouse that affects this style of pelvis, and that is *Pediocetes*, and the attempt is not a bad one. The principal points wherein the Sharp-tailed Grouse has failed to make a perfect imitation of the unique pelvis of his ideal are, the ilia have failed to produce such ponderous overhanging lateral flaps, that nearly shut out from view the ischiadic foramen on either side. Again, these bones in *Pediocetes* meet the sacral vertebræ for their entire length internally; and in this bird, too, the pubic elements often unite all along the inferior borders of the ischia. This does not occur in the Pinnated Grouse; otherwise the bones are very similar and marked exceptions to the general pattern of the other members of this subfamily.

After examining a large number of the pelves of our Grouse, and noting their capacious cavities and great width from side to side, one cannot help but be surprised at the great change in outline, on turning to these bones as they are found among the Partridges.

As a rule in these birds, the pelvis is elongated and unusually narrow, though the drooping ischia behind give it additional depth in its more posterior parts; the pubic bones are turned up behind after they extend beyond the elements above them, and the lateral walls formed by the ilia are, just beyond the acetabula, almost vertical; in fact, one would almost suspect the pelvis of the common Virginia Partridge as belonging to the skeleton of some variety of Curlew, had he not been sure of the owner. This apparent departure from the more general model of this bone in Gallinaceous Fowls, however, is not nearly so decided in other varieties of the *Odontophorinae*, as for instance in *Lophortyx californicus*, and a very good drawing of the pelvis of this bird can be seen and studied, in Mr. T. C. Eyton's *Osteologia Avium*, London, 1867, Plate 22, figs. 1, 1, 1, 1; three of the figures here cited, however, are for the palatine bones, inferior view of sternum, and anterior and posterior views of the tarso-metatarsus. We have carefully compared the diameters of these representations with the skeletons of the species in question, and find them quite accurate.

The *femur* in the young chick of *Centrocercus* is less than demi-developed; above, the head is almost entirely cartilage, while below the condyles are very indistinct and the bone bears no signs of pneumaticity. In a few weeks, however, these points rapidly exhibit themselves: a rounded trochanterian ridge is thrown out; the head essays to assume its sphericity; the condyles become evident; the fibular groove appearing last of all and about the same time with the vascular foramen or medullary orifice at junction of upper and middle thirds. Regarding this bone in a fine old ♂ from *Cupidonia*, and comparing it with others, we find that it is remarkably well balanced in point of length and general development.

The trochanterian ridge is markedly prominent and arches over the articular facet for the ilium; the neck is distinct and makes an angle

of 45° with the shaft; the head is well formed, spherical, and in all Grouse seems to bear a double depression for the ligamentum teres. Anteriorly below the trochanterian eminence there is an extensive collection of pneumatic foramina. The "trochanter minor" never develops.

The shaft is smooth, bent slightly forwards; displays the usual muscular lines and the medullary orifice; it is nearly cylindrical on section about its middle, and before terminal expansion takes place. Below, the rotular channel is very evident, separating the prominent condyles; of these the external and lower one presents the usual fibular fissure; behind, the popliteal depression is well sunken, one of the muscular lines running into it, and often a foramen is found at its base. Slight fossæ are found laterally at the outer surfaces of the condylar enlargements, and sometimes a notch where shaft meets the internal one anteriorly. The bone is usually slenderer in *Bonasa*, *Pediacæctes*, and *Tetrao canadensis*.

Among the *Odontophorinae* the femur has the same general characteristics; it is, however, *non-pneumatic*, the double pit for the ligamentum teres is better marked, and the muscular lines are scarcely perceptible.

The *patella* is never absent in the *Tetraonide*, and occupies its usual position as a free bonelet protecting the anterior aspect of the knee-joint. It accommodates itself to the conformation of the rotular channel, having a flattened surface superiorly, a rounded border below, and a double surface behind, the most extensive aspect of which is applied to the side towards the internal condyle.

The proximal extremity of *tibia* in the young chick of *Centrocercus* has advanced so little toward assuming any of the definite characteristics of the full-grown bird, that, almost in self-defense, we take up for examination the bone from a skeleton of a bird of the same species several weeks older; here we discover the superior general condylar surface still capped with cartilage, and the borders confining it, as yet, but feebly produced. The most interesting point, by far, is the appearance of an unusually large epiphysis, if it may be so termed, fashioned to and resting upon the future location of the "rotular crest."

Why this bone should be here added we cannot, as far as our knowledge extends, exactly comprehend, for in the old and mature birds of any of the Grouse the epi-eneial crest is never very prominently produced, nor is it in any of their near kin. As age advances this segment becomes thoroughly confluent with the tibia, and leaves no trace of its early existence.

The head of the bone in the adult Sage Cock is a very substantial affair, with pro- and ecto-eneial ridges, that soon merge into the shaft, well produced; the latter ridge is usually dilated on its anterior aspect, and the rather extensive concavity between them is directly continuous with the shaft below.

The tibia never becomes pneumatic either in the Grouse or Quails, and in the former sections of its shaft are universally transversely

oval; the fibular ridge of the upper and outer third of this portion of the bone in *Centrocercus* is about 2 centimetres long, and appears to be little more than a raised and roughened line, the merest apology for an invitation to its delicate companion, the fibula, to ever form a lasting and inseparable bond of union with it, a contract which this free and independent little bone has never entered into, in any of the Grouse or the *Odontophorina*, notwithstanding the fact that they are destined to be the closest of associates their whole life through. Below the fibular ridge we find the nutrient foramen, but otherwise the tibial shaft is very straight and almost entirely devoid of any markings, at least to that point anteriorly, where the ascending groove coming from between the condyles impresses it, and that, with an increasing intensity to its termination over the intercondyloid notch; at this point a bony bridge is thrown across obliquely, the outer abutment of which is the lower (Plate IX. Fig. 69).

The most engaging points of interest so far as the tibia is concerned, (as many a young Grouse that long since has yielded up his life to the cause of ornithotomy can testify to) centre about the distal extremity of the bone. After careful examinations of the recently-killed subjects, dried skeletons, and carmine-stained specimens, the following results seem to be presented with greater or less distinctness in every case, and these results correspond very nearly with Professor Morse's invaluable investigations and studies: In the young of *Centrocercus*, several days after leaving the nest, we observe at the future site of the tibial condyles, encased in the then articular cartilage, on either side, a free reniform ossicle. These ossify to the surface in time, and the outer becomes the *fibulare*, the inner the *tibiale*; both are tarsal bones. It will take time and further research to decide definitely as to which is the os calcis, and which the astragalus. Above the former, and a little towards a mid-shaft position, there is yet another free ossicle; it is the *intermedium* of Morse. That it is another tarsal bone there can be no doubt, we believe, at this date; but before we decide upon its special homology we must satisfy ourselves by further research and dissection of the young at various stages of development in birds and other vertebrates where this bone constitutes a feature of the skeleton.

It soon fuses with the *tibiale*, and the latter with the *fibulare*, so that the faintest traces are alone discernible in the bird at two months of age (Plate IX, Fig. 67, E'), at which stage the subsequent bony span for tendinous confinement above them has not commenced to ossify.

In the adult the apex of the *intermedium* affords attachment to the oblique ligament that is attached higher up on the inner aspect of the shaft, that also holds some of the extensor tendons in position. The condyles in mature birds have an antero-posterior position at the extremity of the tibia; these are of a uniform outline, and the intercondyloid notch that separates them can boast of no particular depth until it arrives on the anterior aspect of the bone. Externally and laterally

almost within the limits of the outline of the outer condyle we find two tubercles, one above another; the lower is for ligamentous attachment, the upper is the remnant and only existing evidence of the lower extremity of the fibula. A similar tubercle is found on the opposite side corresponding to the lower one just described on the outer aspect.

The *fibula* is freely detached and never completely anchyloses with the tibia. Its proximal extremity is clubbed, enlarging very much as it rises above the condylar surface of its companion from the fibular ridge; it is laterally compressed and convex above at the summit. In many Grouse the attenuated remains of its extension below can be traced on the shaft of the tibia, which bone has nearly absorbed this third of its weaker associate.

In my papers upon the osteology of *Spheotyto* and *Eremophila* the old term of the "calcaneal" process was still retained for that prominent projection found at the superior and hinder end of the bone *tarso-metatarsus*. The older comparative anatomists gave it this name, probably, in view of the fact that this apophysis might eventually be proved to be the os calcis, but such advances have been instituted in the study of the avian tarsus, that we may say that this process is not in any way entitled to the term; it does not even come in contact with the primoidal element of that tarsal segment, so this appellation will here be abandoned, and as far as we are concerned such an error will receive no further encouragement in the way of ornithotomical recordation.

In the early life of the chick of the Grouse we have been discussing, the combined tarsals are surmounted by a third plate of cartilage, that subsequently ossifies, apparently by one centre. The bone thus formed, the *centrale*, we believe undoubtedly to represent either a single tarsal element or the connate bones of the second row.

At this age the metatarsals that combine to form the shaft of the tarso-metatarsus are still easily individualized, though well on the road toward permanent fusion. It will be observed that we still retain the term *tarso-metatarsus*, and we think justly so, as the compound bone of the mature bird has combined with it at least one of the tarsal bones. The tibia could with equal reason be termed the *tibio-tarsus*, and again the compound bone in manus, the *carpo-metacarpus*, but for obvious reasons such innovations are not always advisable.

We discover in *Centrocercus* and *Tetrao canadensis*—in that strong inelastic cartilage that is found at the back of the tarsal joint in all the Grouse, on the inner side—a concavo-convex free bone, nearly a centimetre long, in the Sage Cock, and two or three millimetres wide; this ossicle must be regarded only as a sesamoid, though it is nearly as large as the patella, and in no way as constituting one of the tarsal bones.

The posterior process, or the *tendinous process* (the "calcaneal" of the older authors), at the head of the combined metatarsals, is both vertically grooved and perforated for the passage of tendons; from its inner and posterior angle in many of the *Tetraonine* it sends down a thin plate

of bone that usually meets the shaft at junction of upper and middle thirds, occasionally running further down to become confluent with it in every instance; this feature is rarely present in the Quails. In *Centrocercus* and others the hinder aspect of the tarso-metatarsus is sharply marked by muscular ridges. The superior and articulating surface of this bone displays eminences and depressions fashioned to accommodate themselves to the condyles of the tibia; a tuberosity on the anterior margin in the articulated skeleton fits into the intercondyloid notch of the bone. Below this the shaft in front is scooped out, having at the base of the depression two small elliptical foramina, side by side, and to the inner side of its boundaries one or two pointed muscular tubercles. The distal and transversely expanded end of the bone presents the foramen for the anterior tibial artery, occupying its usual place, and the three trochlear apophyses for the toes, the middle one being the largest and on the lowest level. The two lateral ones, separated by wide notches from the former, are thrown but a limited distance to the rear, so that the concavity behind them is not peculiar for any great amount of depth.

The *os metatarsale accessorium* is situated rather high upon the shaft, and bears more than an ordinary semblance to a demi-phalanx, with its distal articular trochlea. As usual it is freely attached by ligaments.

The *internodes* are based upon the more common plan as applied to the avian foot; *i. e.*, in the order of the phalanges, from the first to the fourth, 2, 3, 4, 5 joints, and of such a pattern they are markedly typical, and justly equipoised for the size of the bird.

They possess the usual enlarged and bi-concave proximal extremities, with the distal and convex bi-trochlear ends, with a more or less subcylindrical shaft; the ungual joints being but moderately curved downwards.

There are but few or no striking differences to be noted as existing among the lower extremities of our *Tetraonidæ*.

The bones are very delicately fashioned in *Tetrao canadensis* and the Sharp-tailed Grouse; that is, the calibres of their shafts seem to be less as compared with their general lengths, but they belong, we must remember, to very trim little game birds, as contrasted with our heavy and ponderous old Sage Grouse of the western prairies. Our specimens of *Lagopus* and *Tetrao obscurus* do not show the bony extension from the *tendinous process* at the back of the *tarso-metatarsus*, apparently present in all the others and alluded to above—*Centrocercus* sometimes proving an exception—and this bone never normally develops a spur in any of our North American Grouse, as seen in birds of near kin.

Tendons of the anti-brachium and pinion are very prone to ossify, and one is quite constant on the anterior aspect of the metacarpus. This applies with still greater force to the lower limb, where it seems that every tendinous extension of the muscles of thigh and leg become bone for their entire lengths, then forking sometimes over the fore part of tarso-metatarsus as they branch to be distributed to the podium.

It may be found that *Bonasa* can claim normally six segments as rep-

representing the caudal vertebræ, and we have in our possession a pelvis of this bird where a rudimentary second sacral rib is evident, but this can only be regarded in the light of an anomaly.

Interesting osseous malformations are occasionally to be seen, but they are beyond the jurisdiction of this monograph to treat; nor will it be practicable to enter into the engaging subject of the differences between the pelvis in the male and female birds, but that such differences do exist there can be no reasonable doubt.

Did classification depend entirely upon *external* topography, appearance, and structure, the author would say that the *North American Tetraonine* as they now stand are well classified; but strip them of these characteristics, or, rather, permit them only to hold the subordinate place, allow specific habits to have no weight, and then from an osteological point of view, purely, we can perceive no good reason why *Pediaceetes* and *Cupidonia* should not be thrown into one and the same genus. As far as their skeletal framework is concerned they are singularly alike, and strikingly dissimilar from all the other genera; but as such changes will only be *generally* suggested and tolerated as our knowledge of ornithotomy increases, it must of necessity remain to be seen how the anatomy of the other systems of these two birds will support such a generic reduction.

FORT FETTERMAN, WYO., May 1, 1881.

EXPLANATION OF PLATES.

PLATE V.

FIG. 47.—Cranium of young *Centrocercus*, three or four days old, viewed from above.

FIG. 48.—The same; lateral view, with lower jaw added, showing articular element detached.

FIG. 49.—The same, viewed from below.

FIG. 50.—*Centrocercus*. Lateral view of skull of "bird of the year" four months old; the hyoid arch has been detached.

FIG. 51.—The same aged bird as in Fig. 50, showing the disarticulated segments of the four cranial vertebræ: OV, neural arch of the occipital vertebra (epencephalic arch), first of the skull; OV', its hæmal arch in outline (scapular arch); *so*, super-occipital; *eo*, exoccipital; *po*, the connate paroccipital; *bo*, basi-occipital; PV, neural arch of the parietal vertebra (mesencephalic arch), second of the skull; P. V.', its hæmal arch (the hyoidean); P, the parietal; *ms*, the mastoid; *as*, the alisphenoid; *bs*, the basi-sphenoid; *gh*, the glossohyal; *ch*, the ceratohyal; *bh*, the basi-hyal; *uh*, the urohyal; *hb* and *cb*, the hypo-branchial and cerato-branchial elements of the thyro-hyals, respectively; F. V., neural arch of the frontal vertebra (proencephalic arch), third of the skull; F. V.', its hæmal arch (the mandibular); Fr, the frontal; *x*, the site of the postfrontal in some of the class; *os*, the orbito-sphenoid in outline; *ps*, the basi-pre-sphenoid; Tp, the tympanic; *ar*, the articular; *S. an*, the surangular; *an*, the angular; *se*, the splenial element; and *de*, the dentary element; N. V., the neural arch of the nasal vertebra (rhinencephalic arch), the fourth and last in the skull; N. V.', its hæmal arch (the maxillary); N, the nasal; *Pf*, the prefrontal (ethmoid); *Vr*, vomer in out-

line, as it does not occur in this bird; *Pl*, palatine; *mx*, maxillary; *i. mx*, intermaxillary (or premaxillary); 1, the petrosal; 2, the sclerotals; 3, the lacrymal; *Pty*, the pterygoid, the diverging appendage of *Pl*, the palatine; *sq* and *ma*, the *squamosal* and *malar*, respectively, are diverging appendages of *Tr*, the tympanic.

PLATE VI.

FIG. 52.—Lateral view of skull of *Centrocercus*, adult ♂, hyoid arch removed. Figs. 54, 55, 58, 61, 64, 65, 66, 68, 69, and 70 are from the skeleton of the same specimen.

FIG. 53.—Sternum of the chick, three or four days old; *Centrocercus*.

FIG. 54.—Sternum of *Centrocercus*, viewed from below; adult ♂.

FIG. 55.—Dorsal vertebrae, lateral view, left side, from the same.

FIG. 56.—Sternum of *Centrocercus*, "bird of the year" (two months old), showing development of this bone: 4, *lophosteon*; 5, *metosteon*; 6, *pleurosteon*.

PLATE VII.

FIG. 57.—Right pectoral limb of *Centrocercus*, same bird as the sternum in Fig. 56 was taken from. *H*, humerus, palmar aspect; *r*, radius; *u*, ulna; *s*, scaphoid (radiale); *e*, cuneiform (ulnare); *z*, unciform; *d*, index digit; 9, third metacarpal (annularis); 9', second metacarpal (medius); *d'*, *d''*, phalanges of the second metacarpal; *d'''*, phalanx of the third metacarpal.

FIG. 58.—Left metacarpus of an adult *Centrocercus*.

FIG. 59.—Left metacarpus of the same bird as figured in 57, showing all the segments that go to make up the bone in Fig. 58: *om*, carpal or os magnum; *z*, unciform; 7, index or first metacarpal; 8, pisiform; 9', second metacarpal; 9, third metacarpal (annularis).

FIG. 60.—Left humerus (*Centrocercus*), taken from the same bird as in Fig. 57.

FIG. 61.—Left humerus, anconal aspect, *Centrocercus*; adult.

FIG. 62.—Ossa innominata, *Centrocercus*, three or four days old, showing how the pelvic bones form the acetabulum: *X*, ilium; *Y*, ischium; *Z*, os pubis.

FIG. 63.—Pelvis, same bird as in Fig. 57; *Centrocercus*; *X*, ilium; *Y*, ischium; *Z*, os pubis.

FIG. 64.—The perfect pelvis, lateral view, as in 62 and 63, of *Centrocercus*; adult ♂.

PLATE IX.

FIG. 65.—Posterior view of pygostyle, adult *Centrocercus*.

FIG. 66.—The same, left lateral view.

FIG. 67.—Pelvic limb, anterior view, *Centrocercus*, taken from same bird as in Fig. 57: *E*, *Epicnemial epiphysis* of the tibia; *E'*, the confluent tarsal bones found at the distal extremity of the tibia at this age, *tibiale* (astragalus), and *fibulare* (os calcis); *E''*, the *centrale*.

FIG. 68.—Left *tarso-metatarsus*, inside view, adult ♂, *Centrocercus*.

FIG. 69.—Anterior view of right tibia and fibula, from the same skeleton as 68.

FIG. 70.—Anterior view of right femur, same bird as shown in Figs. 68, 69.

PLATE X.

FIG. 71.—Right lateral view of skull of adult ♂ *Cupidonia cupido*.

FIG. 72.—Lower mandible from the same, viewed from above.

FIG. 73.—Skull from the same, lower jaw removed; seen from above.

FIG. 74.—The same from below.

FIG. 75.—Sclerotals, right eye from the same.

FIG. 76.—Right humerus, from the same, palmar aspect.

FIG. 77.—The same, anconal aspect.

PLATE XI.

FIG. 78.—Sacral vertebral rib with its hæmapophysis, left side; *w'*, the pleurapophysis, posterior view; *w*, the corresponding hæmapophysis.

FIG. 79.—Fifth pleurapophysis with its corresponding hæmapophysis attached; from the same bird, dorsal vertebræ, inside view.

FIG. 80.—Fourth pleurapophysis with its corresponding hæmapophysis attached; from the same bird, (*Cupidonia*), dorsal vertebræ, outside view.

FIG. 81.—Sternum from below; same bird.

FIG. 82.—Sternum, left lateral view; same bird (*Cupidonia cupido*).

PLATE XII.

FIG. 83.—Pelvis from above; same bird.

FIG. 84.—Pelvis, right lateral aspect; same bird.

FIG. 85.—Right scapula and coracoid, *in situ*; same bird.

FIG. 86.—Left coracoid, posterior view, from the scapular arch of the same bird.

FIG. 87.—Right lateral view of clavicles, from the scapular arch of the same bird; dotted lines show the outline viewing it from behind.

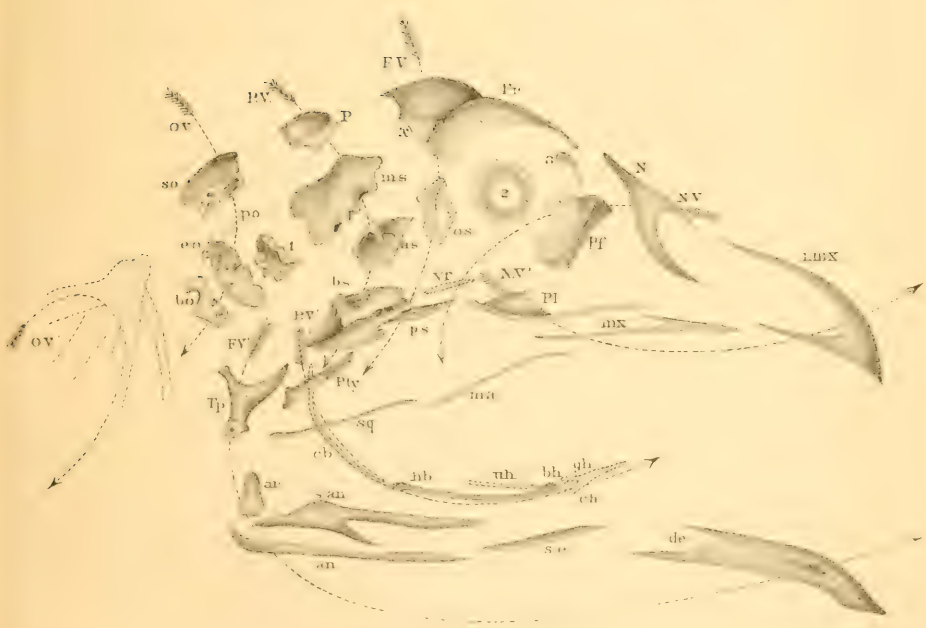
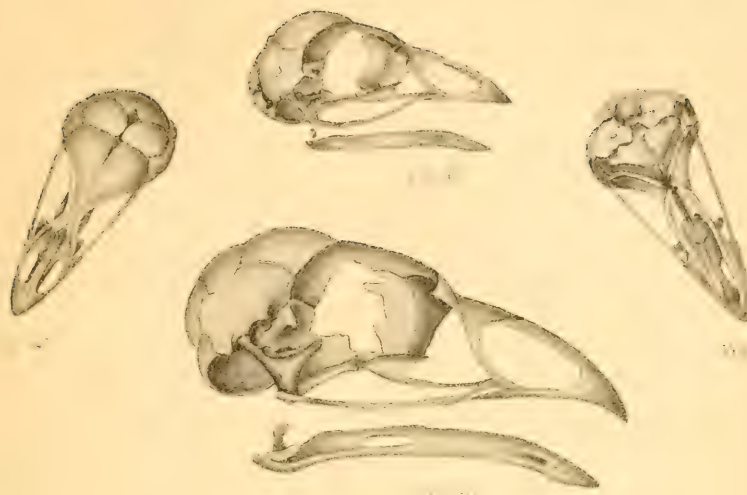PLATE XIII.

FIG. 88.—Right lateral view of skull of adult ♂ *Lagopus leucurus*; hyoid arch has been removed.

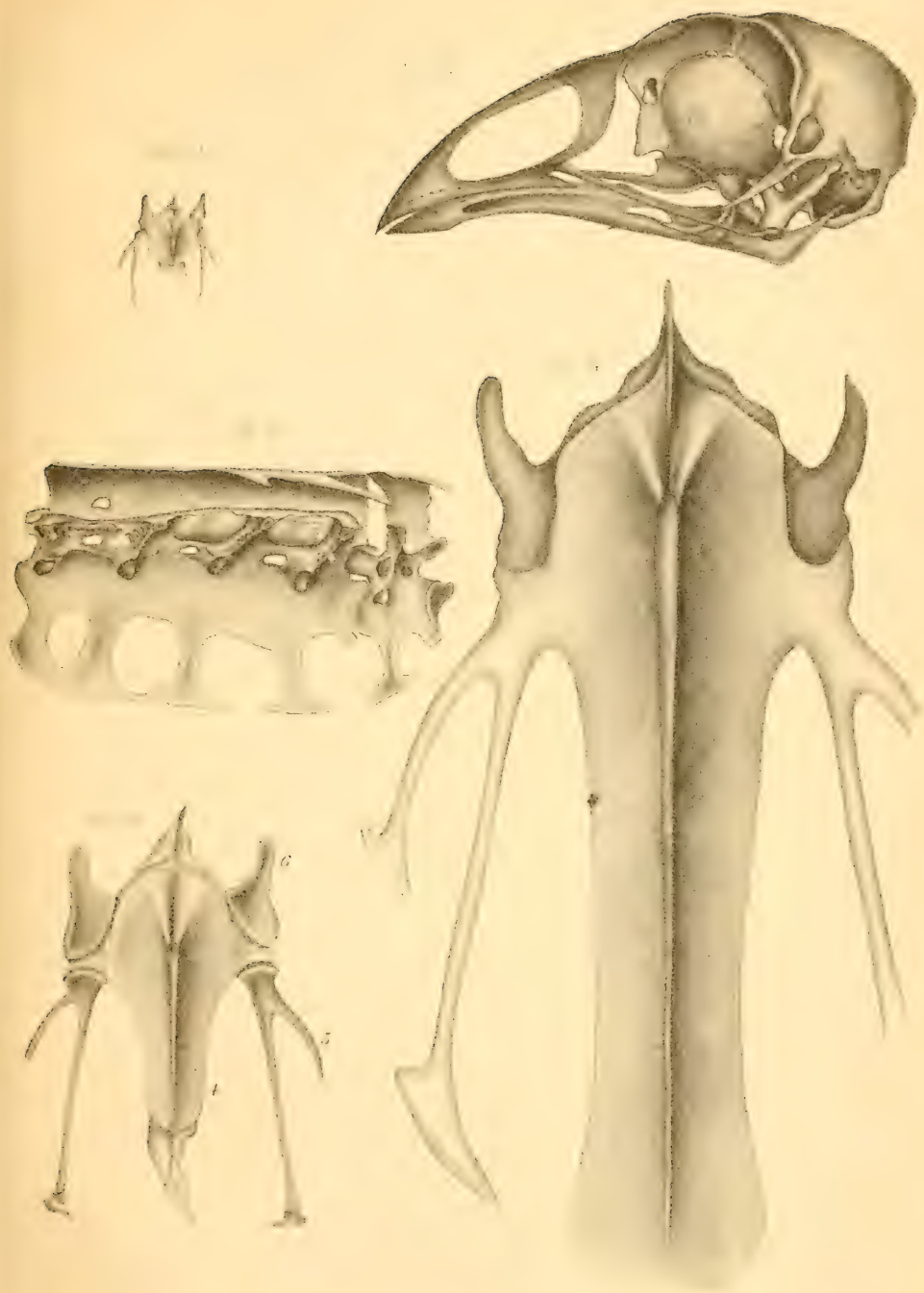
FIG. 89.—Cranium of *Pediocetes phasianellus*; lacrymal, nasal and intermaxillary still attached.

FIG. 90.—Pelvis, adult ♂ *Tetrao canadensis*, viewed from above.

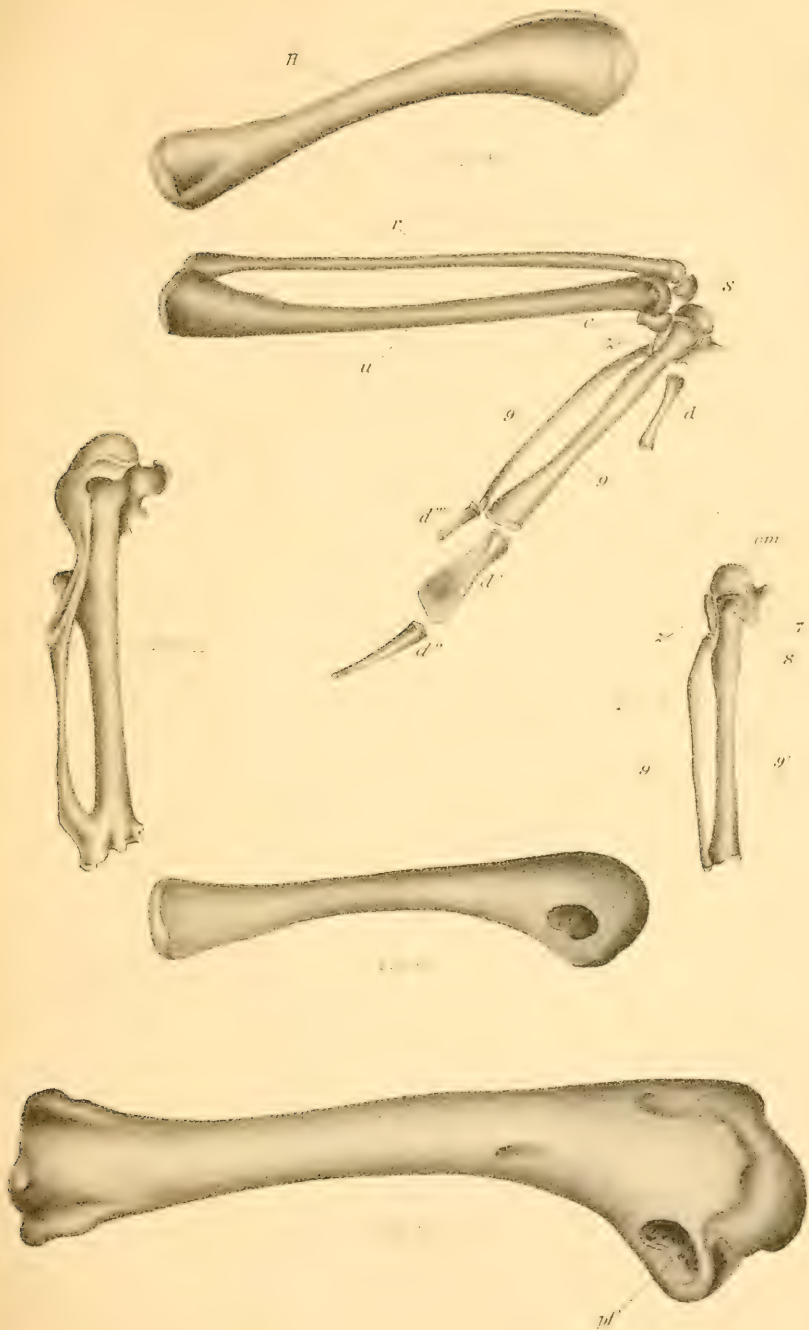FIG. 91.—Portion of skeleton of Ptarmigan, *Lagopus leucurus*, showing thoracic and pelvic bones *in situ*, with the scapular arch and caudal vertebræ. The last cervical vertebra still remains attached in order to show its free pleurapophysis.



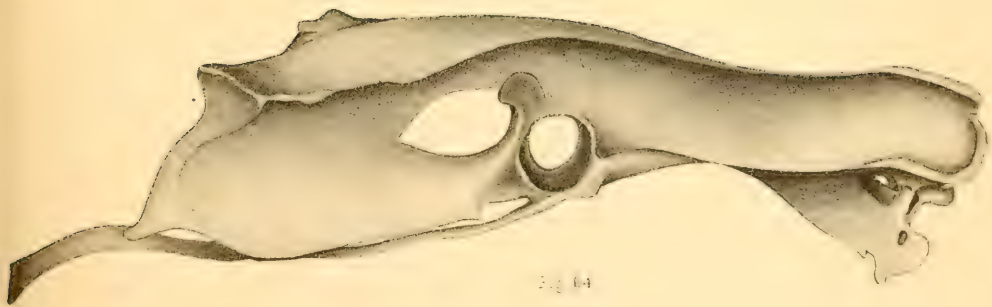
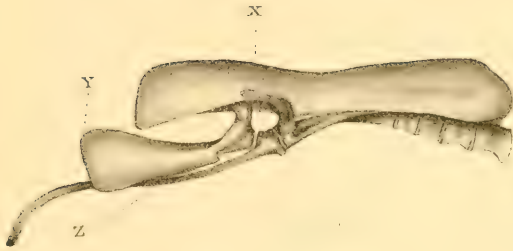
F. Sinclair & Son Lith.

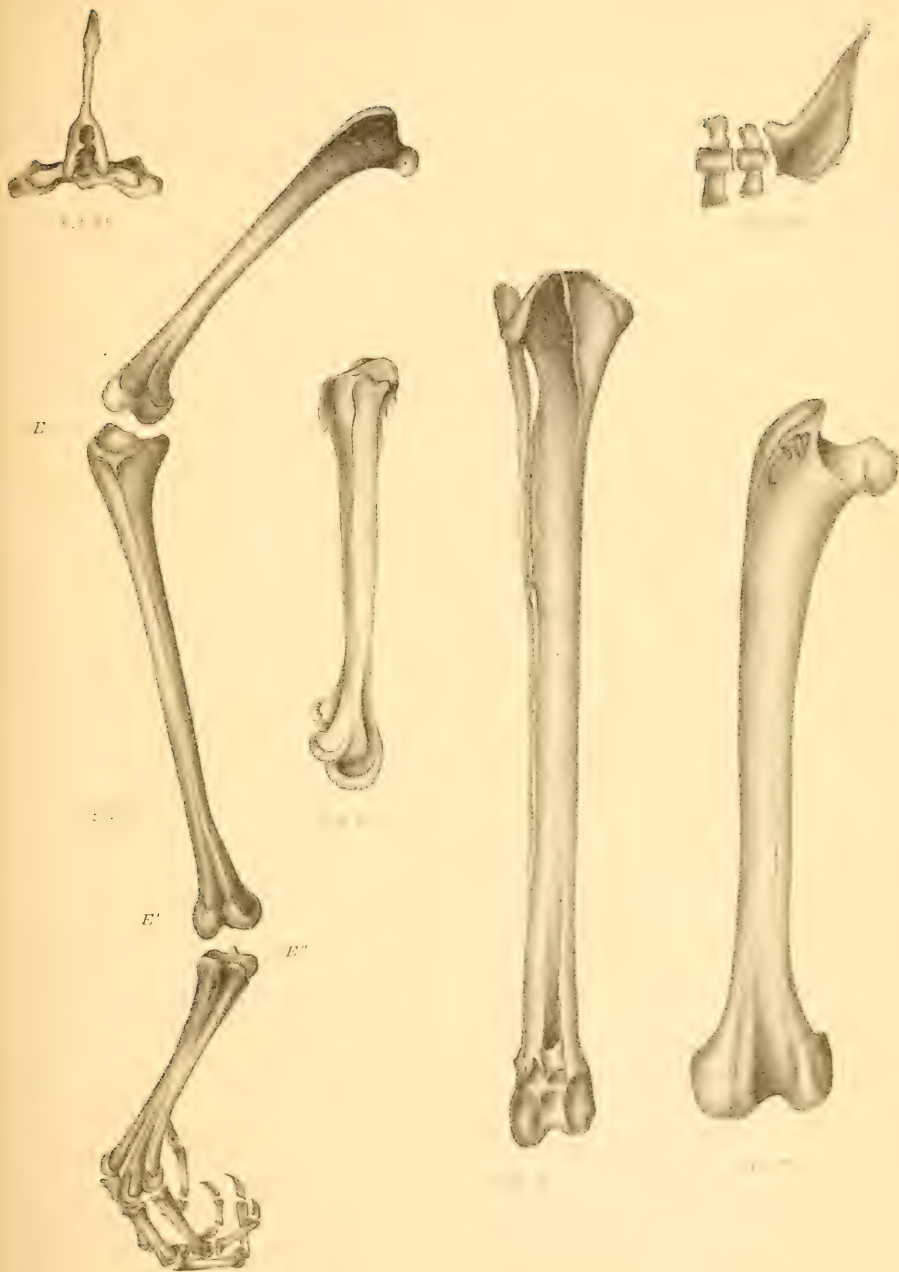

SHUFELDT ON THE OSTEOLOGY OF AMERICAN TETRAONIDÆ.

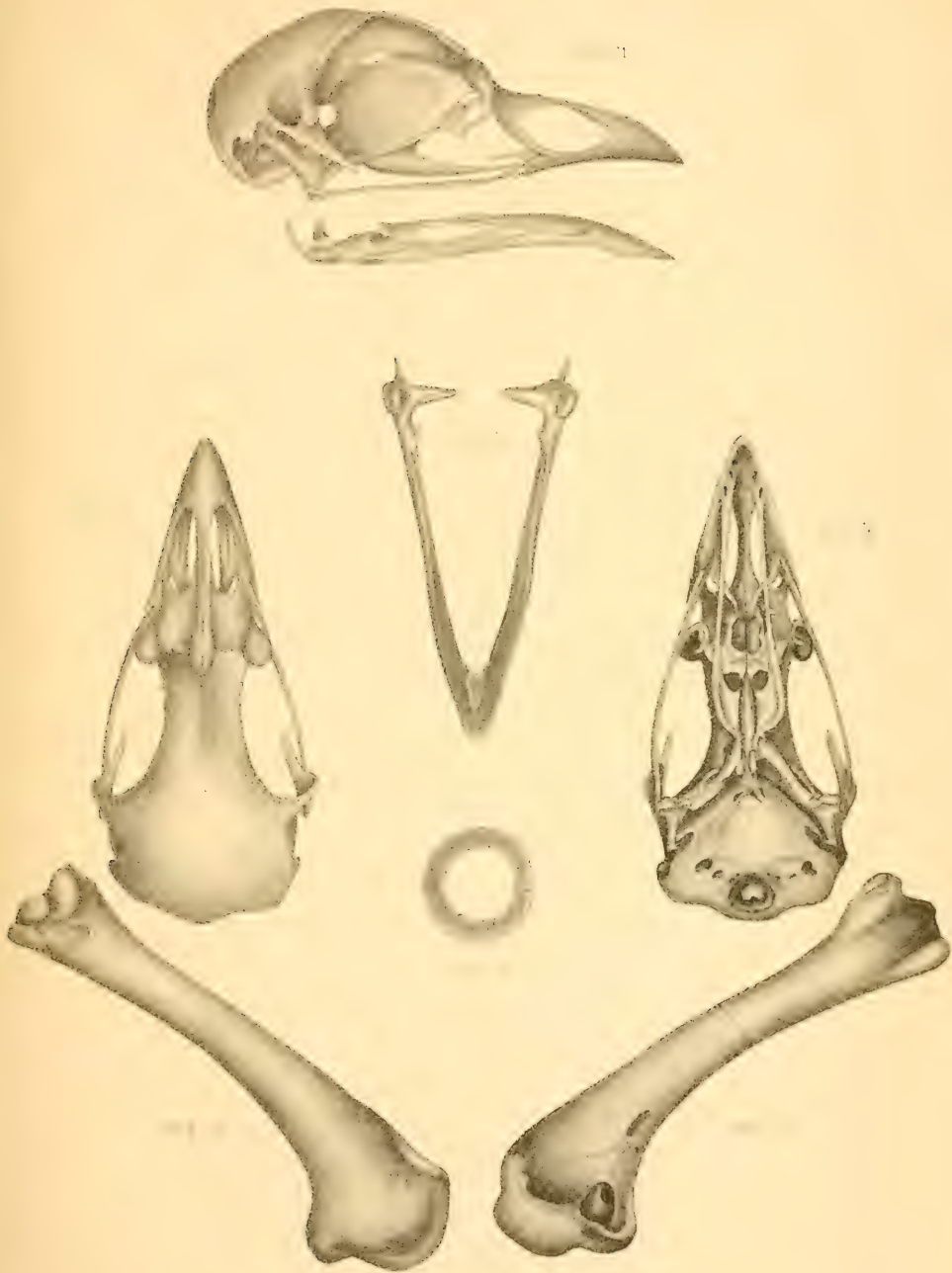


T. Sinclair & Co. Lith.

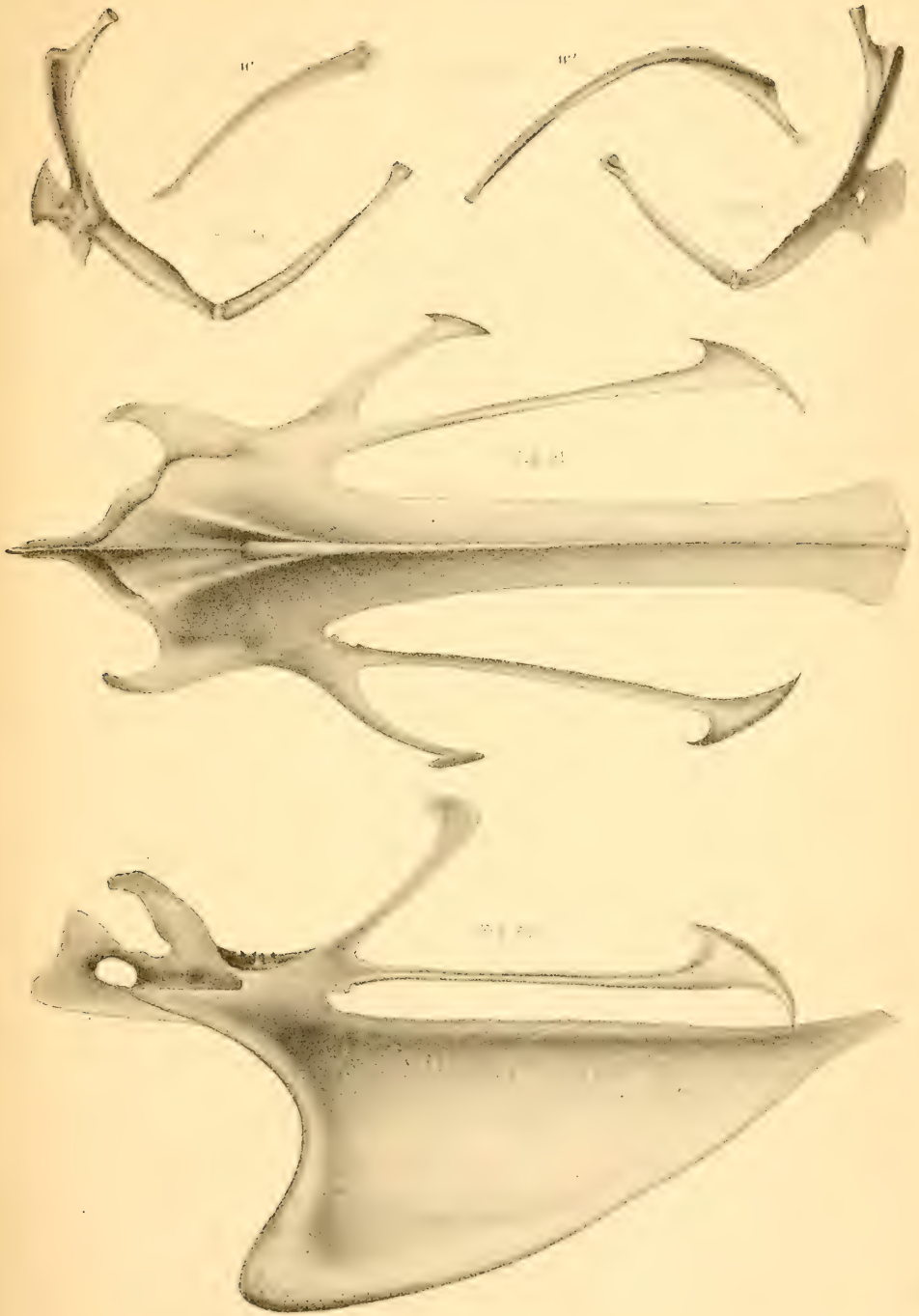






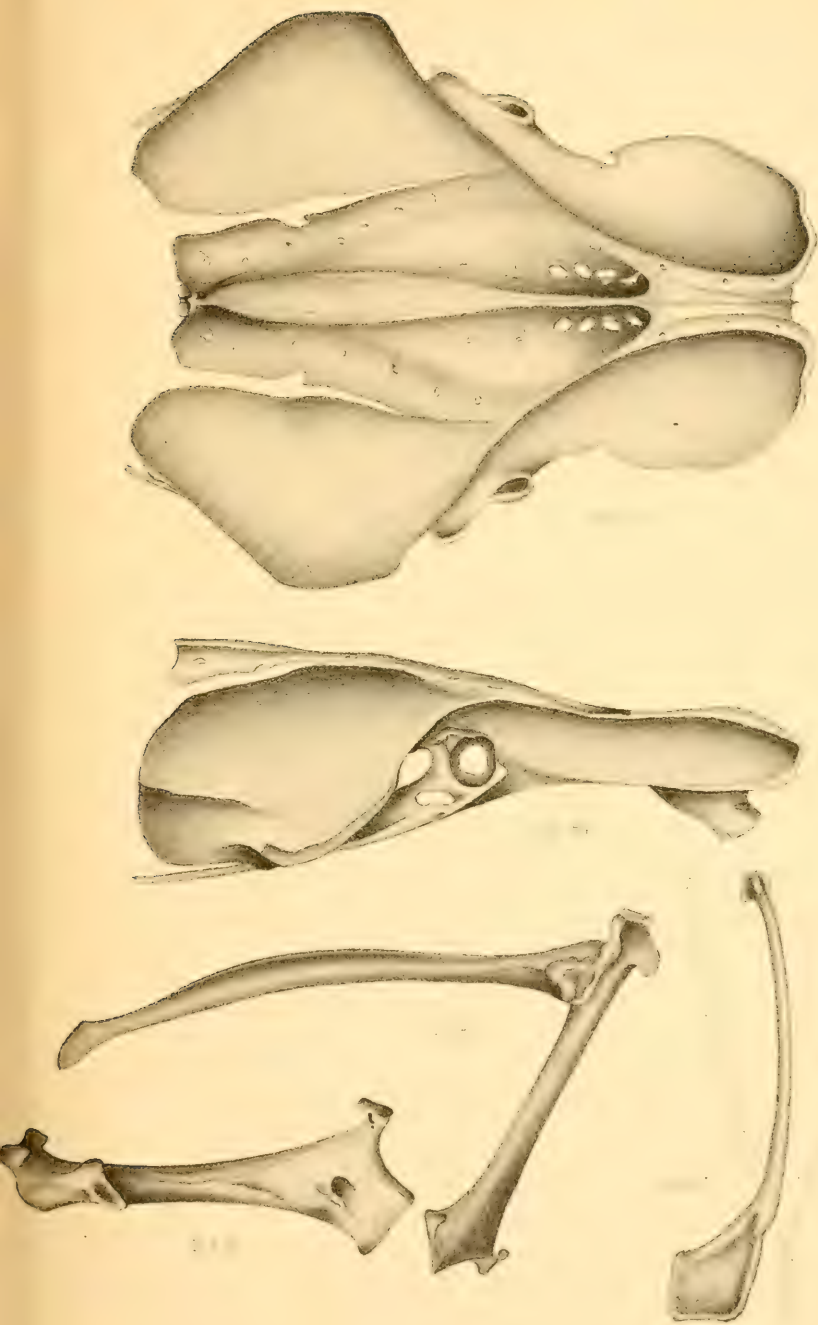


T. Sincfare & Son Lith.

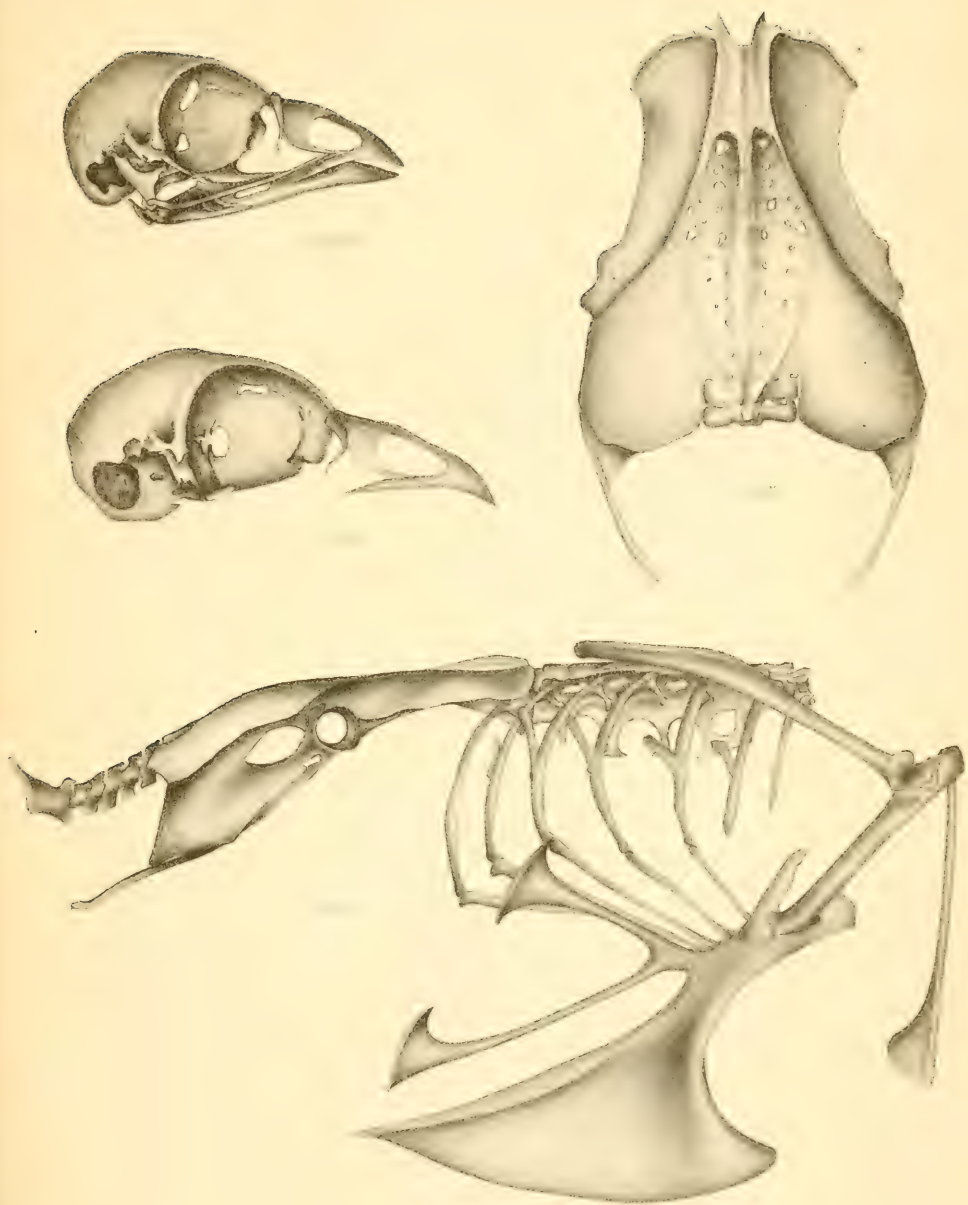


SHUFELDT ON THE OSTEOLOGY OF AMERICAN TETRAONIDÆ.

F. Sm. Jar & Son. L94.



F. Simlar & Son Lith.



T. Sinclair & Son, Lith.

AUTHOR'S EDITION.

DEPARTMENT OF THE INTERIOR.
UNITED STATES GEOLOGICAL AND GEOGRAPHICAL SURVEY.
F. V. HAYDEN, U. S. Geologist-in-Charge.

OSTEOLOGY
OF
LANIUS LUDOVICIANUS EXCUBITORIDES.

BY
Dr. R. W. SHUFELDT, U. S. A.

EXTRACTED FROM THE BULLETIN OF THE SURVEY, Vol. VI, No. 2.

WASHINGTON, September 19, 1881.



Art. XIV.—Osteology of *Lanius ludovicianus excubitorides*.

By R. W. Shufeldt, M. D., First Lieut. Med. Dept. U. S. Army.

Mr. Robert Ridgway, in his carefully prepared check-list of North American Birds (Bull. No. 21, Nomenclature of N. American Birds, chiefly contained in the U. S. Nat. Mus., Washington, D. C.), gives us the representatives of *Laniidae*, the species *borealis* and *ludovicianus*, with the two occidental varieties of the last, *robustus* and *excubitorides*, which latter form we have chosen as the subject of this paper to demonstrate the peculiarities of the skeleton of these interesting birds. The habits of the Shrikes are well known to all ornithologists, so one will not be surprised, after a view of Fig. 100, in the plate (where our subject has been made, by the aid of the dissecting knife and maceration, to exhibit one of the truest indices of his character), to find the large, semi-hawk-like skull surmounting the remainder of a bony frame-work, that might easily be mistaken as belonging to a Thrush or any other Oscine; but it is this very characteristic that individualizes these truly passerine-raptorial birds.

In the skull, divested of the lower jaw and hyoid arch in the adult, we find that ankylosis of the primoidal segments has been very thorough; outside of the bony parts of the sense capsules—the tympanic elements and the pterygoids are the sole escapers of this notorious feature in avian craniology—indeed, we discover in the skull of this species, before it has left the nest, that the primitive segments of the occipital vertebra are well advanced towards permanent union, especially about the condyle, traces of its formation being extremely difficult of discernment, and in the mature bird this hemispherical facet for the atlas is exceedingly diminutive, measuring only .5 of a millimeter in diameter. About the basi-cranii we find the usual foramina for the exit and entrance of vessels and nerves, and note in our examination that the anterior apertures of the Eustachian tubes are double, very small, and protected by an osseous lip from the basi-sphenoid. The foramen magnum is sub-circular and of medium size; together with the basi-cranii, it makes an angle with the horizontal plane of 25° , the anterior bearing point being the tip of the beak, and the two posterior bearing points being the internal facettes upon the tympanics. That part of the cranium above, formed by the frontals and parietals is very broad and smooth, and quite often

the sutural traces are easily made out, and in cases where maceration is persisted in, the coronal suture may gape—beyond, the interorbital region becomes slightly depressed. The pseudo fronto-maxillary articulation is denoted by a transverse line nearly a centimeter long, and is moderately flexible; the superior tips of the lacrymals form its lateral boundaries. The superior mandible is made up of the usual bones, it is very broad at its base, and gently deflected throughout; the nasal bones bound posteriorly on either side vacuities that lead into the rhinal chambers, but the true nostrils are found beyond these, as distinct elliptical apertures. It is, however, the horny integumental sheath that really gives to this bird's beak its peculiar raptorial aspect, for when stripped of this, the osseous tomia show no sign of notch or tooth beyond. Below, the palatine fissure is quite wide, and through its opening we discover that the ethmo-turbinals are more or less developed, together with a partial septum narium, and the space is further intruded upon by a sub-compressed and originally distinct vomer, that is bifurcated behind to receive the rostrum of the basi-pre-sphenoid, lodging a portion of the prefrontal in its fissure above.

The palatines have become amalgamated with the inter-maxillary anteriorly, and form, with the pterygoids, the usual joint on the rostrum of the sphenoid behind; they throw out sharp lateral apophyses that are directed backwards. The pterygoids are very much expanded at their mesial ends, their shafts being straight and delicate; and there are no pleurapophysial processes; they meet the tympanics in sub-circular heads, of no great size, just below the orbital processes. These latter elements possess very broad and twisted mastoid prolongations, with the usual double facet and intervening depression below; and the orbital apophyses are pointed at their extremities, sometimes slightly clubbed, being turned gently upwards. The segments composing the infraorbital bar have long since become one single bone, a slender style fulfilling its ordinary functions. A sub-elliptical sesamoid is found at its proximal end, between it and the tympanic. The orbital cavities are capacious, and well divided from the rhinal chambers by the broad, quadrate lacrymals on either side; their vaults are concavely arched, and their posterior walls quite extensive, looking almost directly forwards. The foramen for the exit of the first pair from the brain-case has run into one irregular aperture; but rarely joins, in the adult, with the elliptical foramina for the optic nerves below them. The orbital septum is never complete, a vacuity of greater or less extent occurring near the center of the plate. Laterally we observe shallow temporal fossæ above elongated openings to the otocrane, that look downwards, forwards, and outwards, standing out quite prominently from the side of the skull. The mastoids throw forwards and downwards horizontally flattened apophyses, which, by the aid of smaller ones from the alisphenoids, help it to guide the temporal muscles to their points of insertion. A moderately marked "cerebellar prominence" is found at

its usual site, above the foramen magnum behind; but we have never observed the foramina, caused by bone thinning, to occur on either side of it. In removing the cranial vault, we find the various fossæ unusually well defined, and bounded by sharp borders; the carotids enter by separate openings at the base of the "sella turcica," which latter has a deep notch, mesiad, in its posterior wall.

In the recent cranium, the internal and external tables are separated by an interspace of a millimeter or more, that is sparsely filled in by diploic tissue; but upon examining skulls that have been kept for a long time, and consequently become thoroughly dried, we cannot distinguish between the two tablets; the diploic tissue has entirely disappeared, and the whole roof is extremely attenuated and *flexible*. We are not prepared to explain how this remarkable change comes about.

The *hyoid arch* bears out its usual ornithic and oscine characteristics, and does not require any special description here, as the author intends to furnish a more elaborate description of the skull when he comes to touch upon the *Vireonidæ*; a faithful outline of this arch is given, however, from a superior view in Fig. 101 of the plate.

Before the young of this Shrike has left the nest the numerous elements of the lower jaw have become fused together, so that during maceration the two rami rarely separate at any other point except the symphysis between the dentary elements. In the old bird it is a stout and strong bone, with sharp-pointed extremity beyond, and deeply scooped-out articular ends posteriorly, with blunted processes behind, and up-turned ones looking towards each other, mesiad. Externally the "sides of the jaw" are concave for their posterior two-thirds, and exhibit the usual elliptic foramen (Fig. 102); while the superior ramal borders are rounded and rise into slight prominences at the junction of the outer and middle thirds. As to the sense capsules, we find that the sclerotals are well developed, and very accurately matched together; the usual ossicles of the organ of hearing likewise ossify.

There are thirteen vertebrae devoted to the cervical portion of the spine, and, although they make a faint attempt towards a raptorial appearance, they are more oscine in their character than anything else, and are not noted for the prominence of any of their outstanding processes; disregarding the atlas, the first four bear neural spines, this feature not showing itself again until we find it in the last two, the thirteenth possessing it as well developed as any of the dorsals. The post- and prezygapophyses are markedly short, thus bringing all the segments quite near together, giving considerable stability to this division of the column. The parapophyses are very delicate where they are produced anteriorly at mid-neck, and quite inconspicuous above; the first four and the last six vertebrae bear hypapophyses, they being three-pronged on the last two; this limits the carotid canal to the fifth, sixth, and seventh cervicals, unusually slight protection for this important arterial branch. The

vertebral canal commences in the tenth—*i. e.*, in this segment it is completely surrounded by bone, and continues its course through the axis; the last two or three vertebræ are very broad from side to side, the ultimate one bearing a free pair of pleurapophyses that have in their turn distinct uncinæ processes.

The neural tube as found in this section of the spine commences and terminates broadly and transversely elliptical, merging into the sub-circular as it nears its mid-portion at the middle of the neck; it is of considerable caliber throughout. The dorsal division of the spine has allotted to it five vertebræ, closely locked together, yet easily detached by ordinary maceration; their combined neural spines form one continuous quadrate crest. These are fastened together above by the "arrow-head" point that we have described in other papers. There is very little difference in the lengths of the transverse processes, from first to last, so we do not find much change in the processes of the ribs they sustain, as to length of pedicles and tubercula. Short metapophysial ridges are found above the diapophyses; they never seem to attain sufficient length to connect the vertebral segments, however.

The neural canal commences transversely elliptical, to terminate, much diminished in caliber, in the sub-circular form. In the first dorsal we find a thin quadrate lamina of bone, projecting downwards and forwards in the mesial plane, as a well-developed hypapophysis; the second supports the merest apology for this process, and the remaining dorsals have none at all, though by compression of the centra a low ridge presents itself along their middles, which is only faintly perceptible in the last. There is a free pair of ribs for each dorsal vertebra, and these are movably connected with the sternum by corresponding pairs of hæmapophyses, the whole structure and appearance being distinctly oscine in character. The pleurapophyses are very slender below and not markedly expanded above as they are in some other birds. Commencing with the last cervical rib, and continuing entirely through the dorsals, we find the series of epi-pleural appendages complete on either side, and freely articulated with the posterior borders of the ribs, with which they make an angle of about 45° , and attain sufficient length to overlap the rib in their immediate rear, though often in younger birds, and even some old ones, the last uncinæ process does not reach the free sacral rib. The sternal ribs are quite delicately fashioned, and support, as usual, anteriorly the transverse heads for articulation with the costal border of the sternum, while posteriorly we discern the moderately upturned and clubbed extremities with shallow facettes for the inferior ends of the vertebral ribs.

The *sternum* of the Loggerhead Shrike is almost or quite typically "cantorial" in its outlines, but only feebly pre-eminent in those features that stamp it as belonging to a bird of any great power of flight. The manubrium, directed upwards and forwards, springs from a solid base to become bifurcate at its anterior extremity and throw down a sharp border below, that becomes continuous with the carinal margin in

front; the coracoidal grooves pass round laterally well beneath the costal processes, and merge into each other, mesiad, their point of meeting being denoted by an elliptical depression, at the base of which we occasionally find a single pneumatic foramen. The costal processes rear themselves upwards, forwards, and outwards, being broad but thin laminae of bone, impressed upon their posterior margins by the five transverse facettes for the sternal ribs. The "body" is concave above, sloping to a shallow, osseous gutter, lying in the mesial plane directly over the keel; beyond, in this groove we observe a few scattered foramina for the admission of air to the more solid structures of this confluent hæmal spine. Behind, the bone is one-notched on either side, cutting out lateral processes with expanded posterior ends and a broad mid-xiphoidal portion—the direct continuation of the sternal body—(Fig. 92). The "carina" below averages about 7 millimeters at its deepest part; anteriorly it protudes as a rounded carinal angle, from which point its inferior boundary sweeps backwards by a gentle convex curve to terminate in a diminutive triangular space at the middle of the xiphoidal process beneath.

The sides of the keel present for examination well-defined subcostal, pectoral, and carinal ridges; the latter falls on either side from the base of the manubrial process to near the carinal angle, just within the border, and sometimes has a thickened backward branch starting from its lower end. The confluent pelvis, in common with the majority of passerine birds, has that strikingly angular outline, due largely to sharpened borders and outstanding spiny processes. There are ten vertebrae in its "sacrum," all unusually firmly fused together, vacuities only occasionally occurring among the diapophyses of the ultimate few, three or four at most. The pre-acetabular region of the ilia on either side is deeply concave, this concavity being carried up over the anti-trochanters to terminate in shallow grooves over the ischiatic foramina. The greater share of this surface looks almost directly outwards and only slightly upwards. The ilio-neural canals are divided by the confluent spines of the first four or five vertebrae, they vary in width in different individuals, and terminate at points opposite the cotyloid cavities, at which point the neural spine suddenly becomes compressed, or rather annihilated, and the sacrum sustains a flattened surface to the ultimate boundary of the bone. The post-acetabular regions are of about one-third the extent of the surfaces anterior to the cotyloid rings; they are produced behind in strong and clubbed processes, the outer margins of which are the terminations of the gluteal ridges or lines continuous with these ridges; these surfaces are convex and narrowed by the encroachment of the broad sacrum (Fig. 103).

Laterally the ilium overhangs the extensive and elliptical ischiatic foramen, which is bounded in front by the anti-trochanter, directed backwards and slightly outwards; the cotyloid ring is markedly circular and but little difference exists between the diameters of its inner and outer

peripheries. The obturator foramen is very small and varies in the figure of its outline, though generally assuming more or less the form of the ellipse; the broad and thin hinder blade of the ischium again dips down to meet the slender pubic shaft, just before its termination, to shut in an elongated spindle-shaped tendinal vacuity. (Fig. 100.)

Upon the ventral aspect of the pelvis, we note that the bone affords no shelter whatever for the important organs it incloses until we pass the fourth sacral segment and the very decided vertebral swelling to form the sinus rhomboidalis; it then drops into a deep depression on either side, whose concavities and convexities correspond with those described and attributed to the dorsal surfaces. The apophysial braces thrown out by the vertebrae are extremely slender, except in the cases of the first and fourth; the former segment bears a free pair of slender pleurapophyses, whose hæmapophyses articulate along the posterior border of the ultimate sternal ribs, as do some of the inferior so-called "costal cartilages" in anthropotomy, lacking the necessary length to arrive at the costal borders of the great ventral hæmal spine, constituting a common ornithic character. These sacral ribs rarely or never support uncinatæ processes.

Six segments are devoted, in this Shrike, to the coccygeal division of the column, exclusive of the pygostyle; they share the same fate, with their fellows and representatives in nearly all of the class Aves, in having many of their original vertebral components either rudimentary or entirely suppressed; the neural spines, hooking over each other, anteriorly, become more and more feebly developed as we proceed backwards; this order of things is just reversed when we come to examine the hypapophyses on the nether aspects. The neural canal that passes through them dwindles to mere capillary dimensions before reaching the "coccygeal vomer", into which bone it barely dares to enter.

The diapophyses of the caudal vertebrae are bent downwards, compressed horizontally, broad, and show but slight differences in length, before reaching the last one, in which they are shorter. The lamina of the pygostyle has the outline of an isosceles triangle, being truncate at its apex; the "body" below is of a substantial structure, barely dilated behind, and otherwise presenting the usual characteristics as found among the oscines.

The bones of the *scapular arch* are all free and independent of each other, the stability of their relative position depending upon strong ligaments in the living bird. The blade of the *scapula* is quite narrow, and, in the vast majority of cases, extends across the dorsal pleurapophyses, its distal end being obliquely truncate, from within, outwards; the blade-like portion is brought up in close juxtaposition with that portion of the bone that affords the scapular moiety of the glenoid fossa. Its acromial process is very short, owing to the fact that it has to proceed but a short way before it abuts against the much-expanded head of clavicle, on either side; it forms with the coracoid the usual ten-

dinal canal between the two bones. The head of the *coracoid* rears well above the glenoid cavity, in order to afford the required surface upon its mesial aspect for the broad clavicular extremity that rests against it; upon its opposite side it offers the usual surface to assist in completing the cavity for head of humerus. The shaft of the bone is very slender and cylindrical for its major part, and the wing-like extension, so broad in many birds, is here but a meager osseous scale attached to the side of the shaft, for its outer and lower half, becoming continuous with the formal dilatation of the bone below; for the sternal articulation, this is transversely concave and very narrow.

The minute pneumatic perforations of the scapulæ and coracoids occupy their usual sites back of the glenoid cavity, under the protection of the tendinal canal, at the heads of the bones. The united clavicles, or the *furculum*, inclines decidedly to the U-shaped variety (Figs. 94, 95); we have already alluded to the fact as how broad, yet compressed, their scapular ends are found to be; from these heads the shaft-like portions fall downward, with a gentle curve backward to meet and support the mesial and usual clavicular lamina, in birds where it is found, which here lies in that recess formed by the anterior and concave border of the carina of the sternum (Fig. 100).

Directing our attention again to the shoulder-joint we discover that this Shrike is another example of those birds in which that little peg-like ossicle, the *os humero-scapulare* is found, here attached by its usual ligaments to the upper and back part of the articulation and fulfilling its ordinary function. The *humerus* of *Lanius* bears the closest resemblance to that bone as found in many of the family *Turdidæ*—particularly does this apply to *Mimus polyglottus*, a bird the Shrike not unsuccessfully apes in point of external coloration.

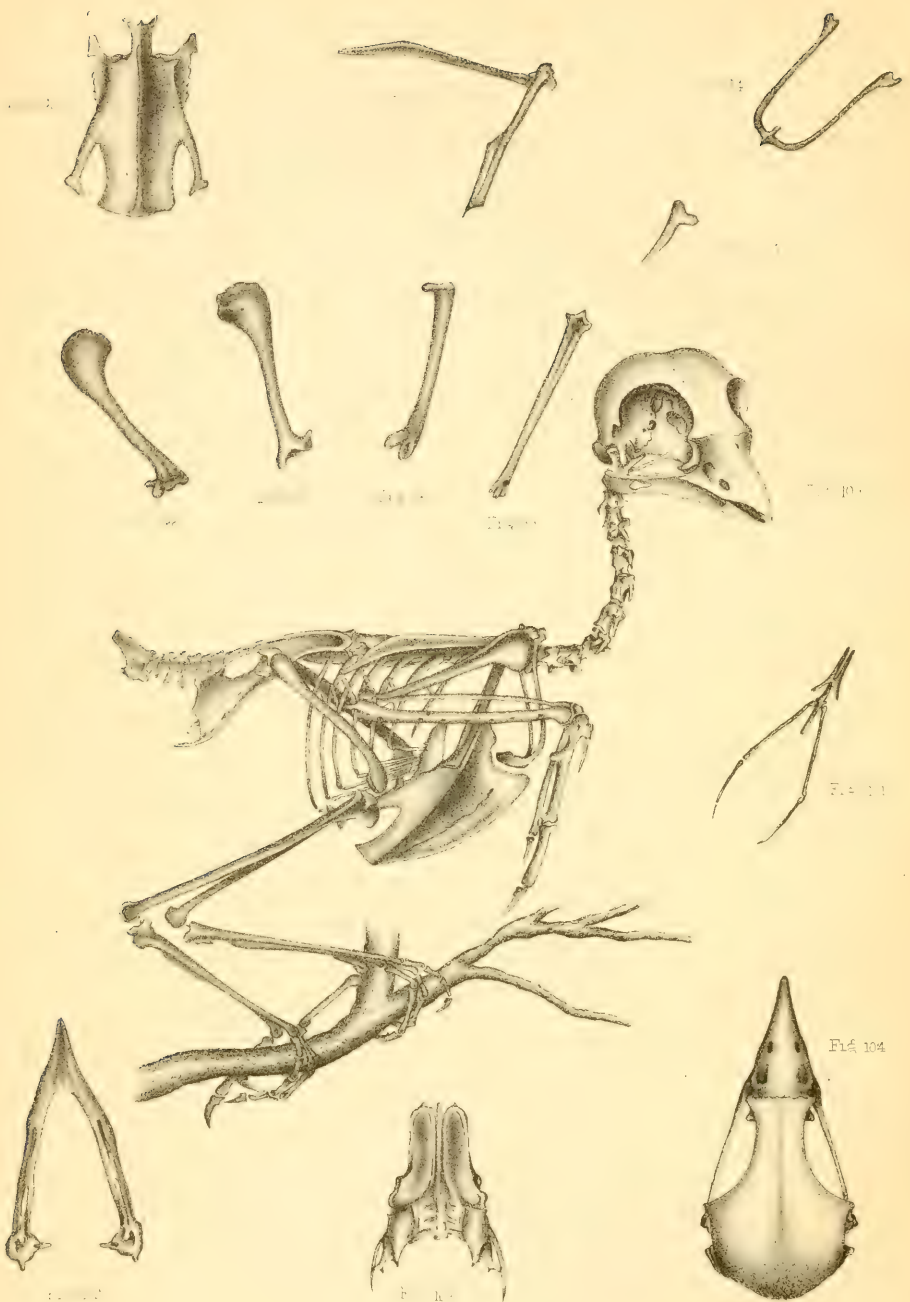The head, in most individuals, is well bent, anconal, and supports a short radial and not lofty crest, with the usual ulnar tuberosity overhanging an ample pneumatic fossa. The shaft is quite straight and nearly cylindrical, its distal and expanded extremity presenting quite a unique appearance (Figs. 96 and 97). The internal and external condyles are distinct processes, the former projecting almost directly backwards, the latter forwards and upwards; the olecranon fossa is likewise clearly defined, and on the palmar aspect we observe the oblique and ulnar facets unusually prominent. The humerus is the only bone of the pectoral limb that has air admitted to its interior, the bones of the anti-brachium and pinion lacking this rather rare prerogative.

The *ulna* is more than four times the bulk of the radius, being, as in most vertebrates, the main support of the forearm; there is scarcely any perceptible curvature along its well-balanced and cylindrical shaft, which presents a row of distinct little tubercles for the bases of the quills of the secondaries. Its proximal end presents for examination a prominent olecranon process, directed backwards, and the greater and lesser sigmoid cavities on its anconal aspect; the distal extremity is rather under

the average in point of eminence, but shows all the usual indentations and surfaces to accommodate this end of the bone to the wrist and radius. The *radius* differs principally in having a general curvature distributed along its subtriangular shaft, rather than having it confined to its proximal third, as in many birds; otherwise it presents its ordinary ornithic characteristics.

Among the mature birds representing the *Laniidae*, as in so many other families, the carpus is composed of the two free ossicles, the *cuneiform* and the *scapho-lunar*, which are here impressed by their usual articulating facettes, for the radial and ulna trochlae and the metacarpus, and although we have the young of this Shrike before us, the limits of this paper will not allow a critical description of this interesting and important region of the skeleton, that can only be obtained by careful study of the youngling.

The *manus* contains its customary complement of bonelets, as seen in the pinions of the major part of the class in general (Fig. 100); *medius* and *annularis* metacarpals are firmly united together, and with the short first metacarpal that bears the index; the broad phalanx of the second is concave upon its anterior aspect and supports below the distal joint of the hand; the smallest phalanx of all is freely attached to *annularis*, which latter metacarpal extends some little distance below its stouter fellow, the *medius*. The pelvic limb is non-pneumatic, and consists in the adults of the usual number of bones, the patella being present. The *femur*, less than 2.5 centimeters long, has no trochanter minor, and the larger process of this name is but feebly produced; the head, with its single depression for the ligamentum teres may justly be said to be at right angles with the cylindrical shaft, which latter is slightly convex forwards; the condyles are well developed and the outer one presents the usual fibular groove. The *tibia* presents nothing that differs in any marked extent from the oscines in general; it has no rotular process, but the pro- and ecto-enemial apophyses are well produced and turned slightly outwards; at its distal end we observe, anteriorly, the usual tendinal bony bridge for the extensor tendons. The *fibula* can be detached from the *tibia* by maceration, but its lower extremity spins out into a mere thread at the junction of mid and lower thirds of the latter bone. There are no free tarsal segments, and the same remarks apply here as we used in speaking of the wrist-joint above. The *tarso-metatarsus* (Fig. 99) is very delicately constructed below, while above it is stouter and presents immediately back of its head the process we have called *tendinous*, pierced by two pairs of foramina. A thin lamina of bone extends along its shaft behind. We observe that the *os metatarsale accessorium* is unusually large, as is the toe it supports; but otherwise the internodes are arranged upon the general plan of the oscine foot, which brings to our mind nothing of a raptorial type, except, perhaps, as we know the *bird*, the decided curvature of the hind claw, which is still further increased and lengthened when armed with its horny theca.



SHUFELDT ON THE OSTEOLOGY OF LANIUS LUDOVICIANUS EXCUBITORIDES.

EXPLANATION OF PLATE XIV.

- FIG. 92.—The sternum, from below.
FIG. 93.—Right scapula and coracoid, outer aspect.
FIG. 94.—Clavicular arch, from in front.
FIG. 95.—Head of clavicle, right limb, outer aspect.
FIG. 96.—Right humerus, palmar aspect.
FIG. 97.—The same, anconal aspect.
FIG. 98.—Right femur, posterior aspect.
FIG. 99.—Left tarso-metatarsus, anterior aspect.
FIG. 100.—Skeleton of adult ♂, *Lanius ludovicianus excubitorides*; the left free vertebral pleurapophyses and hæmapophyses and pectoral limb have been removed.
FIG. 101.—The hyoid arch, from above.
FIG. 102.—The lower mandible, from above.
FIG. 103.—The pelvis, from above.
FIG. 104.—Superior aspect of skull, the lower mandible having been removed.



SMITHSONIAN INSTITUTION LIBRARIES



3 9088 00670 1577