

Students Aids  
Series

UC-NRLF




B 4 139 579

Aids to Anatomy



Fagge

MEDICAL SCHOOL  
LIBRARY



Gift of  
ALICE F. MAXWELL, M.D.

Alice F. Maxwell  
University of California



Digitized by the Internet Archive  
in 2007 with funding from  
Microsoft Corporation

THE  
POCKET ANATOMY

SIXTH EDITION, REVISED AND EDITED

BY

C. H. FAGGE, M.B., M.S. LOND., F.R.C.S.

THIRTIETH THOUSAND

NEW YORK  
WILLIAM WOOD & COMPANY

MDCCCXCVIII

LC 1908-2

QM31  
F154  
1908

THE UNIVERSITY OF CHICAGO  
LIBRARY

## PREFACE

IN compiling this edition I have borrowed from Quain's 'Anatomy,' Cunningham's 'Text-book of Anatomy,' and Morris's 'Treatise of Anatomy.' It therefore seems that the old name of 'The Pocket Gray' no longer accurately describes this little volume, so on the advice of the publishers it has been altered to that of 'The Pocket Anatomy.'

The whole book has been carefully revised, and many descriptions have been changed, among which the chief is the substitution of Jonnesco's account of the iliac and pelvic colon and rectum for that of the sigmoid and rectum of previous editions.

C. H. FAGGE.

3, DEVONSHIRE PLACE,  
LONDON, W.

59547





# THE POCKET ANATOMY

## THE ARTICULATIONS.

### The Classification of Joints.

#### Synarthrosis (Immovable Joint).

*Varieties* :—

Sutura.

*Sub-varieties* :—

S. Dentata.

S. Serrata.

S. Limbosa.

S. Squamosa.

S. Harmonia.

Synchondrosis—may become a **Synostosis**.

Schindylesis.

Gomphosis.

#### Amphiarthrosis (allowing slight movement).

*Varieties* :—

Symphysis.

Syndesmosis.

#### Diarthrosis (Movable Joint).

*Varieties* :—

Arthrodia, or Gliding Joint.

Enarthrosis, or Ball-and-Socket Joint.

Ginglymus, or Hinge Joint.

Condylloid.

Reciprocal Reception, or Saddle Joint.

Trochoid, or Pivot Joint.

## ARTICULATIONS OF THE TRUNK.

### I.—ARTICULATIONS OF THE VERTEBRAL COLUMN.

- (A) Joints between the bodies which are amphiarthroses.  
(B) Joints between the neural arches by means of the

articular processes which are diarthroses of the arthro-dial variety.

(A) *The Ligaments of the Bodies.*

The **anterior common ligament**: a broad band of fibres, extending along front of bodies of vertebræ, from axis to sacrum. It consists of two sets of fibres, *superficial* and *deep*; the former extending between the bodies of two or more vertebræ, the latter only between adjacent vertebræ. The fibres are attached principally to the intervertebral substances.

The **posterior common ligament** is within the spinal canal, and extends along back of bodies of the vertebræ from axis to sacrum, being broad opposite the intervertebral discs, and narrow opposite the bodies, except in the neck, where it is as wide as the bodies. It is attached to the discs and contiguous parts of the bodies of the vertebræ.

The **intervertebral substances**, found between the vertebræ from axis to sacrum. The circumference of each consists of layers of oblique parallel fibres of white fibrous tissue, enclosing a central part of pulpy elastic material. They are thickest in the lumbar region, and they give the peculiar curves to the column by their differences in thickness.

(B) *The Ligaments of the Laminæ.*

The **ligamenta subflava** connect the laminæ of the vertebræ from the axis to the sacrum. Each ligament is attached to the anterior inferior edge of the lamina above, and to the posterior superior edge of the lamina below.

*The Ligaments of the Articular Processes.*

**Capsular ligaments** surround the articular processes, those in the cervical region being the loosest. Each is lined by a **synovial membrane**.

*The Ligaments of the Spinous Processes.*

The **interspinous ligaments** extend in all regions of the vertebral column between the spinous processes of the vertebræ, running from root to apex.

The **supraspinous ligament**: a fibrous cord, joining the tips of the vertebræ, and extending from the seventh cervical to the first sacral.

The **ligamentum nuchæ** continues the supraspinous ligament upwards. It consists of a *superficial* layer, extending from the spine of the seventh cervical to the external occipital protuberance, and a *deep* layer attached to the spines of the cervical vertebræ and the occipital crest.

*The Ligaments of the Transverse Processes.*

**Intertransverse ligaments** extend between the transverse

processes, often absent in the cervical, thin in the lumbar, but round and well marked in the dorsal region.

## II.—ARTICULATION OF ATLAS WITH AXIS.

The **atlo-axoid articulation** consists of four joints—(a) a pivot joint consisting of two parts, (i.) between odontoid process and anterior arch of atlas, and (ii.) between odontoid process and transverse ligament; (b) two arthro-dial, between the articular processes.

The **anterior atlo-axoid ligament** consists of a superficial and a deep part. The *superficial* part continues the anterior common ligament. It is attached above to the anterior tubercle of the atlas; and below to the body of the axis and base of the odontoid process. The *deep* part is broad, and reaches from the lower border of the anterior arch of atlas to the base of odontoid process and body of axis.

The **posterior atlo-axoid ligament**: a thin layer, connected above to the lower border of the posterior arch of atlas, and below to the upper edge of laminæ of axis, pierced by the second cervical nerve.

The **transverse ligament** keeps the odontoid process in its place; it is attached on each side to a tubercle on the inner surface of the superior auricular process of the atlas. A thin bundle of fibres passes upwards from the middle of the posterior surface to the basilar process, and a like process downwards to the body of the axis. These two processes, together with the transverse ligament, form the *cruciform* ligament.

**Capsular ligaments** as in ordinary vertebræ, but supplemented at the posterior and inner part by an accessory ligament passing downwards and inwards to the base of the odontoid process (*accessory atlo-axoid ligaments*).

**Synovial membranes**: besides those of capsular ligaments, two; one in front and one behind the odontoid process, the latter often communicating laterally with one of the occipito-atloid joints.

## III.—ARTICULATION OF ATLAS WITH OCCIPITAL BONE.

The **anterior occipito-atloid ligament** consists of a superficial and a deep part. The *superficial*, rounded, passes from the basilar process of the occiput to the anterior tubercle of the atlas. The *deep* part is broad, and attached above to the anterior edge of the foramen magnum, and below to the upper margin of anterior arch of atlas.

The posterior occipito-atloid ligament, thin and membranous, is attached above to posterior margin of foramen magnum; below, to upper border of posterior arch of atlas. (*Perforated on each side by vertebral artery and suboccipital or first cervical nerve.*)

The lateral occipito-atloid ligaments: one on each side; attached above to the jugular process of occiput, and below to the base of atlantal transverse process.

**Capsular ligaments** as in ordinary vertebræ.

#### IV.—LIGAMENTS BETWEEN THE AXIS AND OCCIPITAL BONE.

The occipito-axoid ligament (*apparatus ligamentosus colli*): a continuation of the posterior common ligament, connected above with basilar groove of occiput, and below to posterior surface of the body of axis.

The odontoid or check ligaments consist of two cords passing from the sides of the apex of the odontoid process to the rough surface on the inner side of each condyle of the occipital bone. In the interval between the two the *ligamentum suspensorium dentis* passes from the apex of the odontoid process to the anterior margin of the foramen magnum.

#### V.—TEMPORO-MAXILLARY ARTICULATION.

The condyle of the lower jaw articulates with the anterior part of the glenoid fossa, and with the eminentia articularis of the temporal bone, the joint being divided into an upper and a lower synovial cavity by an interarticular fibro-cartilage.

The external lateral ligament, attached above to tubercle and lower border of zygoma; below, to outer surface and posterior edge of neck of lower jaw.

The internal lateral ligament is attached above to the spinous process of the sphenoid, and below to the inner margin or lingula of the dental foramen of lower jaw.

The capsular ligament: thin and loose, attached above to the edge of anterior half of glenoid cavity and articular eminence; below, it surrounds neck of the condyle.

The interarticular fibro-cartilage has an oval shape; the upper surface is concavo-convex from before backwards, and slightly convex transversely; the lower surface is concave; the edge is attached to the capsule, and part of the external pterygoid muscle is inserted into its anterior margin.

**Synovial membranes**, two in number, one above and one below the fibro-cartilage; the upper being the larger.

The stylo-maxillary ligament: a band of fibrous tissue

extending from the styloid process to angle and posterior border of ramus of the jaw, which is derived from the deep cervical fascia (p. 26).

(*Stylo-hyoid ligament*: a fibrous cord extending from the styloid process to small cornu of hyoid bone).

#### VI.—ARTICULATION OF THE RIBS WITH THE VERTEBRÆ.

(a) *Articulations between the Heads of the Ribs and the Bodies of the Vertebrae.*

Arthrodial joints held together by the following ligaments:—

The **anterior costo-vertebral** or **stellate ligament** is composed of three fasciculi, which radiate from the anterior surface of the head of the rib. The *superior* fasciculus passes to the body of the vertebra above; the *inferior* fasciculus to the body of the vertebra below; the *middle* fasciculus to the intervertebral substance.

A **capsular ligament** surrounds articulation between the head of the rib and the articular surface formed by two vertebræ.

The **interarticular ligament** divides the joint into two parts, each of which has a separate *synovial membrane*. It passes between ridge on head of rib and intervertebral substance. (Absent in the 1st, 10th, 11th, and 12th ribs.)

(b) *Articulations of the Necks and Tubercles of the Ribs with the Transverse Processes of the Vertebrae.*

Arthrodial joints held together by the following ligaments:

The **anterior** or **superior costo-transverse ligament** passes from the upper border of neck of rib, to lower border of transverse process above. (Absent in 1st rib.)

The **middle costo-transverse** or **interosseous ligament**: a short thick band passing from the anterior surface of the transverse process to the posterior surface of neck of corresponding rib. (Rudimentary in 11th and 12th ribs.)

The **posterior costo-transverse ligament** passes from apex of transverse process to rough non-articular part of tubercle of rib. (Absent in 11th and 12th ribs.)

The **capsular ligament** surrounds articular surfaces, enclosing a small *synovial membrane*. (This articulation is absent in the 11th and 12th ribs.)

#### VII.—ARTICULATION OF THE UPPER SEVEN COSTAL CARTILAGES WITH THE STERNUM.

The **anterior chondro-sternal ligament**: a broad thin band, radiating from extremity of the rib cartilage to the sternum.

The *superior* fasciculi pass obliquely upwards, the *inferior* downwards, and the *middle* horizontally.

The **posterior chondro-sternal ligament** is an indistinct band of fibres radiating from the posterior surface of the inner end of the costal cartilage to the back of the sternum.

The **capsular ligament** surrounds the joint, and encloses a synovial membrane (In the 1st there is no synovial membrane; in the 2nd and 3rd there are 2, the joint being divided by an interarticular ligament passing between end of the costal cartilage and cartilage between adjacent pieces of the sternum. (The 4th, 5th, 6th, and 7th have one each.)

#### VIII.—ARTICULATIONS OF THE CARTILAGES OF THE RIBS WITH EACH OTHER.

The cartilages of the 6th, 7th, and 8th ribs articulate with each other by an oval-shaped facet, each having a capsule enclosing a synovial membrane.

#### IX.—ARTICULATIONS OF THE RIBS WITH THEIR CARTILAGES.

The costal end of each cartilage fits into a depression in the sternal end of the rib, and is bound down by periosteum.

#### X.—ARTICULATIONS OF THE STERNUM.

The 1st and 2nd pieces are united by a piece of cartilage, kept together by the following two ligaments:—

The **anterior intersternal ligament** consists of longitudinal fibres, which blend with the costo-sternal ligaments.

The **posterior intersternal ligament**: similar to the preceding, placed on the back of the sternum.

#### XI.—ARTICULATION OF THE PELVIS WITH THE SPINE.

The following ligaments connect the 5th lumbar vertebra with the sacrum, and are similar to the common vertebral ones:—

1. The continuations of the **anterior and posterior common ligaments**.

2. The **intervertebral substance** between the last lumbar vertebra and the sacrum.

3. The **ligamenta subflava** between the laminae of the last lumbar vertebra and the margins of upper opening of the sacral canal.

4. **Capsular ligaments**, between the articular processes.

5. **Interspinous and supraspinous ligaments**.

Besides these, there are the following special ligaments:

The **lumbo-sacral or sacro-vertebral ligament**: attached above to the front of tip of transverse process of the 5th

lumbar vertebra; below, to the outer border of the front of the lateral mass of the sacrum.

The **ilio-lumbar ligament** passes from the tip of transverse process of 5th lumbar vertebra, to the crest of ilium in front of sacro-iliac articulation.

## XII.—ARTICULATIONS OF THE PELVIS.

### (a) *Sacro-iliac Joint.*

The **sacro-iliac articulation** is an amphiarthrosis, formed between the lateral surfaces of the sacrum and ilium. The auricular or anterior parts of the articular surfaces are covered with cartilage, and connected by the two following ligaments:—

The **anterior sacro-iliac ligament**: small bands passing obliquely from sacrum to ilium on the anterior surface.

The **posterior sacro-iliac ligament** consists of strong interosseous bands passing chiefly downwards and inwards from the rough part of the ilium behind the cartilage, to the posterior part of the sacrum. There are two *superior*, passing from the 1st and 2nd transverse sacral tubercles, and one sometimes called the *oblique sacro-iliac* ligament, which reaches from the posterior superior iliac spine to the 3rd transverse sacral tubercle.

### (b) *Ligaments between the Sacrum and Ischium.*

The **great** (or *posterior*) **sacro-sciatic ligament**, attached by its base to the posterior inferior iliac spine, to the 4th and 5th transverse sacral tubercles, and to the lower part of the edge of the sacrum and coccyx; passes downwards, outwards, and forwards, to be attached to the inner edge of the ischial tuberosity and to the inner margin of the ramus, forming the *falciform* ligament.

The **small** (or *anterior*) **sacro-sciatic ligament**, attached by its apex to the spine of the ischium, and by its base to the lateral margin of the coccyx and sacrum.

**Foramina.**—Between the great sacro-sciatic ligament and the innominate bone is a space divided into two by the small sacro-sciatic ligament; the part above this ligament being the *great sacro-sciatic foramen*, and the part between the two ligaments the *small sacro-sciatic foramen*. The large foramen transmits pyriformis, together with superior gluteal, sciatic and internal pudic vessels, the superior gluteal, great and small sciatic, pudic and inferior gluteal nerves, and nerves to the obturator internus, quadratus, and gemelli. The small foramen transmits the obturator internus, whilst its nerve, together with the internal pudic vessels and pudic nerve, re-enters the pelvis by it.

*(c) Articulation of the Sacrum and Coccyx.*

Amphiarthrodial joint.

The **anterior sacro-coccygeal ligament**, very indistinct, passes from anterior surface of sacrum to that of the coccyx.

The **posterior sacro-coccygeal ligament** passes from the margin of the lower orifice of the sacral canal to the posterior surface of the coccyx.

**Interarticular ligaments** between the cornua. **Lateral ligaments**, passing from the lower lateral angle of sacrum to transverse process of 1st piece of coccyx.

A **fibro-cartilage** is placed between the sacrum and the coccyx.

*(d) Symphysis Pubis.*

Amphiarthrodial joint bound together by the following ligaments:—

The **anterior pubic ligament** consists of several layers of fibres crossing the symphysis horizontally in front.

The **posterior pubic ligament** resembles the anterior, but is much less distinct, and connects the bones posteriorly.

The **superior pubic ligament** connects the bones superiorly.

The **sub-pubic ligament**, forming the upper boundary of the pubic arch, is a thick triangular arch of fibres, attached above to the fibro-cartilage, and laterally to the rami.

The **fibro-cartilage** consists of two parts, one on each bone; the two are united in front, but posteriorly they are separated by a small cavity lined by a synovial membrane.

## ARTICULATIONS OF THE UPPER EXTREMITY.

## I.—STERNO-CLAVICULAR ARTICULATION.

An arthrodial joint between the inner end of the clavicle and the 1st piece of sternum and 1st costal cartilage, connected together by the following ligaments:

The **anterior sterno-clavicular ligament** is attached to upper and anterior part of the inner end of the clavicle, and to the upper and anterior part of the 1st piece of the sternum.

The **posterior sterno-clavicular ligament** passes between the inner end of the clavicle and the sternum on the posterior surface.

The **interclavicular ligament** passes along the top of the sternum from the inner end of one clavicle to the other.



The **costo-clavicular** or **rhomboid ligament**: a strong band of fibres passing backwards, upwards, and outwards from the upper surface of the sternal end of 1st costal cartilage, to a rough marking on the under surface of the inner end of the clavicle.

The **interarticular fibro-cartilage** is a nearly circular plate, thicker at the circumference than in the centre. It is attached above to the upper border of the clavicle, and below to the 1st costal cartilage at its junction with the sternum. There are two *synovial membranes*, one on each side of the cartilage.

## II.—SCAPULO-CLAVICULAR ARTICULATION.

(a) *Acromio-clavicular*, an arthrodial joint held together by the following ligaments:—

The **superior acromio-clavicular ligament** passes between the outer end of the clavicle and the upper surface of the acromion.

The **inferior acromio-clavicular ligament** covers the joint below, being attached to the clavicle internally, and the acromion externally.

An **interarticular fibro-cartilage**, rarely complete, usually occupies the upper half of the joint. When it is complete, there are two *synovial membranes*.

(b) The *coraco-clavicular ligaments* connect the clavicle and the coracoid process of the scapula; they are:—

The **trapezoid ligament** (the *anterior* and *external* one): attached below to the posterior half of the upper surface of the coracoid process, and above to the oblique line on the under service of the clavicle. It is in contact posteriorly with the conoid ligament.

The **conoid ligament** (the *posterior* and *internal* one) is attached above by its base, to the conoid tubercle on the inferior surface of the clavicle, and the contiguous part; by its apex to a rough depression at the base of the coracoid process.

## III.—PROPER SCAPULAR LIGAMENTS.

The **coraco-acromial ligament** passes over the shoulder-joint between the coracoid and acromion processes. Externally it is attached to the tip of the acromion, and internally to all the outer border of the coracoid process.

The **transverse** or **suprascapular ligament** stretches over the notch on the upper border of the scapula, and converts it into a foramen.

## IV.—THE SHOULDER-JOINT.

This joint between the head of the humerus and the glenoid cavity is an enarthrodial or ball-and-socket joint. The long tendon of the biceps acts as a ligament to this joint.

The **capsular ligament** is attached to the circumference of the glenoid cavity, and to the neck (anatomical) of the humerus. It is very loose, and permits free movement of the joint. There is generally an aperture on the inner side, through which a piece of the synovial pouch protrudes to form the bursa under the subscapularis.

The **coraco-humeral** or **accessory ligament** helps to strengthen the capsule; it is attached to the outer border and base of the coracoid process, and below to the neck of humerus, above great tuberosity, and it blends with the capsule at the margins of the bicipital groove.

**Gleno-humeral ligaments**, seen as three folds on inner aspect of joint:—

The **superior** or **Flood's ligament** passes along inner edge of biceps tendon from glenoid ligament to depression on lesser tuberosity at inner margin of the bicipital groove.

**Middle**: oblique, arises with superior, runs downwards forming lower margin of aperture for subscapularis bursa to lesser tuberosity.

The **inferior** or **Schlemm's ligament** passes from the lower part of the glenoid cavity to the neck of humerus on the inner side of the small tuberosity.

The **glenoid ligament** is a dense fibrous band attached to the edge of the glenoid cavity to deepen it, and is continuous with tendon of the long head of the biceps.

**Transverse** over bicipital groove.

A **synovial membrane** lines the joint, and protrudes to form the bursa under the subscapularis. It is reflected round the tendon of the biceps, and lines the bicipital groove.

**Subacromial bursa** beneath acromion and deltoid, and over supraspinatus and capsule.

## V.—THE ELBOW-JOINT.

The elbow is a ginglymus or hinge-joint, between the trochlear surface of the humerus and the greater sigmoid cavity of the ulna, combined with an arthrodial joint between the capitellum of the humerus and the upper end of the radius.

The **anterior ligament** is attached, above to the front of

the humerus just above the coronoid fossa ; and below to the coronoid process, and the front of orbicular ligament.

The **posterior ligament** is attached, above to the upper border of the olecranon fossa ; below, to the margin of the olecranon.

The **internal lateral ligament** is triangular in shape ; it is attached, above to the inner condyle of the humerus ; the fibres diverge as they descend, the *anterior* ones going to the inner margin of the coronoid process, the *posterior* to the inner margin of the olecranon.

The **external lateral ligament**, smaller than the preceding, is attached, above to a depression below the external condyle, and below to the orbicular ligament, some of the fibres being prolonged to the outer edge of the ulna.

The **synovial membrane** is very large, covering the articular surfaces of the humerus, ulna, and radius ; it also serves for the upper radio-ulnar articulation.

#### VI.—THE RADIO-ULNAR ARTICULATIONS.

##### (a) *Superior Radio-ulnar Articulation* (lateral ginglymus).

The **orbicular ligament** surrounds the head of the radius. It is attached to the two ends of the lesser sigmoid cavity, and is wider above than below. The *outer* surface is connected with the external lateral ligament. The internal surface is lined with synovial membrane continuous with that of the elbow-joint.

##### (b) *Middle Radio-ulnar Articulation*.

The **oblique or round ligament** is a fibrous cord passing downwards and outwards from the tubercle at the base of the coronoid process, to a little below the tubercle of the radius.

The **interosseous membrane** passes downwards and inwards (the opposite to the preceding) from the radius to the ulna ; it is attached to the interosseous border of each bone.

##### (c) *Inferior Radio-ulnar Articulation* (lateral ginglymus).

The **anterior radio-ulnar ligament** passes from the anterior edge of the radial sigmoid cavity to the anterior surface of the head of ulna.

The **posterior radio-ulnar ligament** extends similarly upon the posterior surface.

The **triangular fibro-cartilage** passes transversely beneath the lower end of the ulna, between its styloid process and the radius. Its apex is attached to the outer side of base of the styloid process of ulna, and the base to the edge of the radius between the sigmoid cavity and the lower articular surface.

The **synovial membrane** (*membrana sacciformis*) is very loose, and lines the contiguous surfaces of the radius and ulna, together with the upper surface of the triangular cartilage; sometimes communicates with the synovial sac of wrist-joint.

#### VII.—THE WRIST-JOINT.

The wrist-joint is a condyloid joint, formed by the lower end of the radius and the triangular fibro-cartilage above; and by the scaphoid, semilunar and cuneiform bones below. It is united by the following ligaments:—

The **external lateral ligament** passes from the tip of the styloid process of the radius to a depression on the outer surface of the scaphoid bone.

The **internal lateral ligament**, a fibrous cord, passes from the end of the styloid process of the ulna, and dividing into two, one part is attached to the pisiform bone, and the other to the inner side of the cuneiform bone.

The **anterior ligament**, broad and membranous, consists of three bundles of fibres, springing from the anterior edge of the lower end of radius, and the styloid process of the ulna; below it is fixed into the anterior surfaces of the scaphoid, semilunar and cuneiform bones, some fibres being continued to the os magnum.

The **posterior ligament**, weaker than the preceding, springs from the posterior margin of the lower end of the radius, and is attached to the dorsal surfaces of the scaphoid, semilunar, and cuneiform bones.

A **synovial membrane** lines the joint.

#### VIII.—ARTICULATIONS OF THE CARPUS.

*Articulations of the 1st Row of Carpal Bones*, the pisiform excepted (arthrodial).

The **dorsal ligaments** pass transversely between the scaphoid and semilunar, the semilunar and the cuneiform.

The **palmar ligaments** connect the bones similarly upon the anterior surface.

The **interosseous ligaments** (2) close the upper part of the intervals between the scaphoid and semilunar, the semilunar and cuneiform bones.

*Articulations of the 2nd Row of Carpal Bones* (arthrodial).

The **dorsal ligaments** (3) pass transversely from bone to bone as in the 1st row.

The **palmar ligaments** (3), similar to those of the 1st row

The **interosseous ligaments** (3) are thicker than those of the 1st row, and connect the os magnum and the trapezoid, the os magnum and the unciform bones and the trapezium and trapezoid.

*Articulations of the two Rows of Carpal Bones together.*

The **anterior or palmar ligaments** pass from the front of the 1st row to the palmar surface of the os magnum.

The **posterior or dorsal ligaments** are similarly placed upon the dorsal surface.

The **lateral ligaments**: the *external* connects the scaphoid and trapezium bones; the *internal* the cuneiform and unciform.

The **synovial membrane** is large; it lines the under surface of the bones of the 1st row, except the pisiform bone, and is reflected between their contiguous surfaces; it then passes between the bones of the 2nd row, and lines their contiguous surfaces, usually giving reflections between the carpal ends of the four inner metacarpal bones, and between the contiguous surfaces of the trapezium and 2nd metacarpal bone.

The **pisiform bone** is connected to the cuneiform by a thin capsule lined by a synovial membrane; and inferiorly to the unciform and 5th metacarpal bones.

The **anterior annular ligament** extends from the trapezium and scaphoid across to the unciform process and pisiform bone.

The **posterior annular ligament** extends from the outer border of lower end of radius, to inner side of cuneiform and pisiform bones.

#### IX.—CARPO-METACARPAL ARTICULATION.

*The Articulation of the Trapezium and 1st Metacarpal.*

Reciprocal reception joint.

The **capsular ligament**, thick and loose, passes from the upper end of the 1st metacarpal to the rough edge round the articular surface of the trapezium. It is lined by a separate synovial membrane.

*Articulations of the Carpus and the rest of the Metacarpus.*

The **dorsal ligaments** connect the carpal with the metacarpal bones on the posterior surface; each metacarpal receives two fasciculi, except the 5th, which has only one.

The **palmar ligaments** are similarly arranged on the anterior surface, except that the 3rd metacarpal has three fasciculi.

The **interosseous ligaments** connect the os magnum and unciform bones to the 3rd and 4th metacarpal bones.

The **synovial membrane** is continuous with that between the two rows of carpal bones, and has been described above.

*Articulations of the Metacarpal Bones with each other.*

The carpal ends are united by dorsal and palmar ligaments passing transversely.

The **interosseous ligaments** pass between the bones beneath the level of the articular facets. The *synovial membrane* is continuous with that between the two rows of carpal bones.

The **digital extremities** of the four inner metacarpals are connected by the *transverse metacarpal ligament*, which blends with the palmar surface of each metacarpo-phalangeal articulation.

## X.—METACARPO-PHALANGEAL ARTICULATIONS.

## Condyloid joint.

The **palmar ligament** is a thick plate of fibro-cartilage, attached to the head of the metacarpal bone and the base of the 1st phalanx: laterally it blends with the lateral ligaments.

The **lateral ligaments**, one on each side, attached above to the posterior tubercle and depression on the side of the head of the metacarpal bone, and below to the side of the 1st phalanx.

A synovial membrane lines the joint.

## XI.—ARTICULATIONS OF THE PHALANGES.

Each of these is a small ginglymus or hinge joint, connected by a *palmar* and *two lateral* ligaments, and lined by a synovial membrane.

## ARTICULATIONS OF THE LOWER LIMB.

## I.—THE HIP-JOINT.

This is an enarthrodial joint, formed by the head of the femur and the acetabulum. The ligaments are:—

The **capsular ligament**, very strong and fibrous, arises above from the rim of the acetabulum, just external to the cotyloid ligament, and from the transverse ligament as it bridges the cotyloid notch: below it is attached to the neck of the femur, in front to the anterior intertrochanteric line, superiorly to the root of the neck, and posteriorly to the middle of the neck of the bone, where many of its fibres are reflected upwards upon the neck as the *retinacula*. The fibres are circular and longitudinal. The circular are most distinct at the lower and posterior part, forming a collar at the lower and back part of the joint, known as the *zona orbicularis*. The longitudinal fibres form thick bands known as *accessory ligaments*. There is often an opening in front of the capsule for

a protrusion of the synovial membrane to form the bursa under the psoas.

The **ilio-femoral ligament** (*Y ligament of Bigelow*) is accessory to the capsule. It is attached above to the anterior inferior iliac spine, and below it bifurcates and is attached to the anterior intertrochanteric line at its outer and inner parts.

**Ischio-capsular ligament** (accessory), from ischium below acetabulum, to the circular fibres at the lower and back part of the capsule.

**Pubo-femoral ligament** (accessory) passes from the ilio-pectineal eminence to the rough tubercle in front of the trochanter minor.

The **ligamentum teres** passes from the depression on the head of the femur and spreads out to be attached to the margins of the rough depression at the bottom of the acetabulum. It consists of connective tissue and vessels, covered with a reflection of synovial membrane.

The **cotyloid ligament**, a dense fibro-cartilaginous rim, prismatic on section, is attached to the edge of the acetabulum, and to the transverse ligament.

The **transverse ligament** is a narrow band which crosses the cotyloid notch; the nutrient vessels to the joint pass under it.

The **synovial membrane** is single, and is reflected over the inner surface of the capsule on to the neck of the femur, thence over the ligamentum teres to the bottom of the acetabulum, where it loosely covers some fat. (Frequently communicates with bursa under ilio-psoas tendon.)

## II.—THE KNEE-JOINT.

This is a ginglymus, and is formed by the condyles of the femur, the head of the tibia, and the patella.

The **anterior** or **ligamentum patellæ** is the continuation of the tendon of the quadriceps extensor. Above it arises from the apex and rough marking on the lower and posterior surface of the patella; below it is attached to the lower part of the tubercle of the tibia. There is a bursa between the upper part of the tubercle and the ligament.

The **posterior ligament** (*ligamentum posticum Winslowii*), broad and thin, covers the back of the joint: it springs above from the femur above the condyles, and is attached below to the head of the tibia. From the semi-membranosus tendon it receives a strong expansion, which passes superficially from the inner tuberosity of the tibia to the inner side of the upper part of the outer condyle of the femur.

The **internal lateral ligament**, broad and flat, is attached above to the inner condyle of the femur; below to the margin of the inner tuberosity, and to the inner surface of the shaft of the tibia for  $1\frac{1}{2}$  inches.

The **long external lateral ligament**, a rounded cord, is attached above to the external condyle of the femur, and below to the external part of the head of the fibula, dividing the biceps tendon into two parts, a bursa intervening.

The **short external lateral ligament**, very indistinct, lies parallel and behind the preceding, attached above to the outer condyle of the femur, and below to the styloid process of the fibula.

The **capsular ligament**, thin, fills up the intervals between the special ligaments; it is attached to the margins of the articular surfaces of the bones, and blends with the fascia lata of the thigh: above it receives expansions from the vasti (*lateral patellar ligaments*).

*Interarticular Structures:—*

The **anterior or external crucial ligament** is attached to the depression in front of the spine of the tibia and to the external semilunar fibro-cartilage; it passes upwards, backwards, and outwards to the posterior part of the inner side of the external condyle of the femur.

The **posterior or internal crucial ligament** is attached to a depression behind the spine of the tibia, to the popliteal notch, and the posterior border of external semilunar fibro-cartilage, this latter slip being sometimes called the ligament of Wrisberg; it passes upwards, forwards, and inwards, the posterior fibres attached by side of oblique curve of inner condyle, the anterior ones to fore part of intercondylar fossa and to the anterior part of the outer surface of the inner condyle.

The **semilunar cartilages** are thicker at the circumferences than at the central margins, and serve to deepen the cavities for the head of the femur.

The **internal semilunar cartilage** is oval in shape, the antero-posterior diameter being the longer. Its anterior extremity is attached to the tibia *in front* of the anterior crucial ligament, and the posterior extremity *in front* of the posterior crucial ligament.

The **external semilunar cartilage** is nearly circular: its anterior extremity is attached to the tibia in front of the spine, the posterior extremity to the back of the spine.

In shape the cartilages may be described thus: the internal as a smaller segment of a larger circle, and the external as a larger segment of a smaller circle.



*Structures on the Head of the Tibia* in the middle line from before backwards:—

- |  |   |
|--|---|
| 1. Transverse ligament.                                | 5. The spine of tibia.                                  |
| 2. Anterior extremity of internal semilunar cartilage. | 6. Posterior extremity of external semilunar cartilage. |
| 3. Anterior crucial ligament.                          | 7. Posterior extremity of internal semilunar cartilage. |
| 4. Anterior extremity of external semilunar cartilage. | 8. Posterior crucial ligament.                          |

The **transverse ligament** is a band of fibres which passes between the anterior extremities of the semilunar cartilages.

The **coronary ligaments** bind down the circumferences of the semilunar cartilages to the head of the tibia.

The **synovial membrane** is the largest in the body. It extends 2 inches above the articular end of femur under the extensors; thence it passes over the crucial ligaments to the head of the tibia, where it covers both surfaces of the semilunar cartilages, and lastly it lines the capsule. It also gives a covering to the popliteus tendon, where it lies within the capsule, and usually communicates with a bursa under the inner tendon of the gastrocnemius and between this tendon and that of the semi-membranosus.

The **ligamentum mucosum** is a triangular fold of the synovial membrane, attached to the intercondyloid notch, and reaching to the patella.

The **ligamenta alaria** are two fringes of the synovial membrane, seen on either side of the ligamentum mucosum.

### III.—THE TIBIO-FIBULAR ARTICULATIONS.

(a) *The Superior Tibio-fibular Articulations* (arthrodial).

The **anterior superior ligament** passes from the head of the fibula upwards and inwards to the external tuberosity of the tibia.

The **posterior superior ligament** passes from the back part of the head of the fibula to the back part of the external tuberosity of the fibula.

A **synovial membrane** lines the joint.

(b) *The Middle Tibio-fibular Articulation* consists of the interosseous membrane, the fibres passing down from the tibia to the fibula, being attached to the interosseous ridges on the bones. Superiorly, there is an opening for the anterior tibial vessels; and inferiorly, one for the anterior peroneal vessels.

(c) *The Inferior Tibio-fibular Articulation.*

The **inferior interosseous ligament** passes between the contiguous rough surfaces of the tibia and fibula, and is continuous above with the interosseous membrane.

The **anterior ligament** is triangular in shape, and passes between the adjacent margins of the tibia and fibula.

The **posterior ligament** is similarly placed upon the posterior part of the articulation.

The **transverse or inferior ligament** lies deep to the preceding, passing transversely across the back of the joint, from the external malleolus nearly to the internal malleolus, and serves to deepen the ankle-joint.

The **synovial membrane** is continuous with that of the ankle-joint.

#### IV.—THE ANKLE-JOINT.

This is a ginglymus or hinge joint; the lower ends of the tibia and fibula embracing the upper articular surface of the astragalus.

The **anterior ligament**, broad and thin, is connected above with the edge of the articular surface of the tibia, and below with the margin of the superior articular surface of the astragalus.

The **posterior ligament** consists principally of transverse fibres, which blend above with the transverse ligament of the inferior tibio-fibular articulation, and are attached to the back part of the upper articular surface of the astragalus.

The **internal lateral or deltoid ligament** consists of two parts. The *superficial* part is attached by its apex to the internal malleolus, and by its base posteriorly to the inner side of the astragalus, the sustentaculi tali, and anteriorly to the tuberosity of the scaphoid, blending with the inferior calcaneo-scaphoid ligament. The *deep* part passes from the apex of the inner malleolus to the inner side of the astragalus.

The **external lateral ligament** consists of three bundles of fibres. The *anterior* slip passes between the front of the external malleolus and the side of the astragalus in front of the superior articular process. The *middle* passes from the apex of the outer malleolus to the middle of the outer side of the os calcis. The *posterior* is attached to the bone just behind the deep groove on the posterior part of the outer malleolus, running transversely inwards to a depression on the posterior surface of the astragalus.

The **synovial membrane** lines the inner surface of the ligaments, and is reflected on to the articular surfaces of the bones. It also lines the inferior tibio-fibular articulation.

## V.—ARTICULATIONS OF THE TARSUS.

These are arthrodial joints.

*Articulations between the Calcaneum and Astragalus.*

There are two articulations between the calcaneum and the astragalus: a posterior one, peculiar to the two bones, and an anterior one, common to them and the scaphoid bone; they are separated by the interosseous ligament.

The **external calcaneo-astragaloid ligament** passes from outer surface of the astragalus just below the external malleolus, to the outer surface of the os calcis.

The **posterior calcaneo-astragaloid ligament** connects the posterior parts of the two bones.

The **interosseous ligament** consists of a strong thick band passing from the groove between the articulating surfaces of the astragalus to a corresponding groove on the os calcis.

*Articulation between Calcaneum and Scaphoid.*

The **superior calcaneo-scaphoid ligament** arises from the groove between the astragalus and os calcis, being blended here with the internal calcaneo-cuboid ligament, and passes upwards and inwards to the outer side of the scaphoid bone.

The **inferior calcaneo-scaphoid** is a broad strong band passing from the anterior and inner end of the sustentaculum tali of the os calcis to the hollow on the under surface of the scaphoid bone. It supports the head of the astragalus, and its plantar surface is in contact with the tendon of the tibialis posticus.

*Articulation between the astragalus and scaphoid.* The only ligament is

The **superior astragalo-scaphoid**, passing from the neck of the astragalus to the upper surface of the scaphoid bone.

*Articulations between the Scaphoid, Cuboid, and Three Cuneiform Bones* are connected by the following ligaments:

**Dorsal ligaments**, which pass from one bone to the other.

**Plantar ligaments**, similarly arranged upon the sole.

**Interosseous ligaments** (4), strong fibres passing between the rough non-articulating surfaces of the bones.

*Articulation between Calcaneum and Cuboid.*

The **superior calcaneo-cuboid ligament** passes between the dorsal surfaces of the os calcis and cuboid bones.

The **internal calcaneo-cuboid** or **interosseous ligament** attached to a deep groove on the os calcis between it and the astragalus, here blending with the superior calcaneo-scaphoid ligament, and passing to the inner side of the cuboid bone.

The **Inferior ligaments** are two:—

The **long calcaneo-cuboid** (long plantar) ligament, attached

to the under surface of the os calcis in front of the tuberosities ; it passes to the posterior margin of the peroneal groove of the cuboid ; some of the fibres arch over the sheath of the tendon, and are attached to the bases of the 2nd, 3rd and 4th metatarsal bones.

The **short calcaneo-cuboid ligament** is more deeply placed , it reaches from the tubercle and depression on the under surface of the os calcis to the under surface of the cuboid behind the peroneal groove.

#### VI.—TARSO-METATARSAL ARTICULATIONS.

The metatarsal bones are connected to the tarsus by :—

**Dorsal ligaments**, one to each metatarsal bone from the tarsal bone it articulates with. The 2nd metatarsal has a slip from each cuneiform bone.

The **plantar ligaments**, disposed irregularly.

The **interosseous ligaments**, strong bands, three in number. The *internal* one passes from internal cuneiform to the 2nd metatarsal. The *middle* one passes between the external cuneiform and the 2nd metatarsal. The *external* connects the external cuneiform and the 3rd metatarsal.

The **synovial membranes** of the tarsus and metatarsus are six in number :—

One for the posterior calcaneo-astragaloid articulation.

One for the anterior calcaneo-astragaloid articulation and the scapho-astragaloid articulation.

One for the calcaneo-cuboid articulation.

One for the articulations of the scaphoid, and the three cuneiform bones ; the cuneiform bones with each other ; the external cuneiform and the cuboid ; and the middle and external cuneiform bones with the bases of the 2nd and 3rd metatarsal bones.

One between 1st metatarsal and internal cuneiform.

One for 4th and 5th metatarsal with cuboid.

#### VII.—ARTICULATIONS OF THE METATARSAL BONES WITH EACH OTHER.

The bases of the metatarsal bones are connected by *dorsal*, *plantar*, and *interosseous* ligaments.

The digital ends are united by the *transverse metatarsal ligament*, which on the plantar aspect connects the 1st metatarsal with the others (compare with hand).

#### VIII.—METATARSO-PHALANGEAL ARTICULATIONS.

These articulations are precisely similar to the corresponding parts of the hand.

## IX.—ARTICULATIONS OF THE PHALANGES.

The preceding remark equally applies to these articulations.

## THE MUSCLES.

*Explanation.*

The — dash divides the origin from the insertion.

Nervous supply is indicated by ( ) brackets.

Action of muscle is indicated by [ ] brackets, and if a muscle has two points on which it acts, A applies to action from origin on point of insertion, and B applies to action from insertion on point of origin.

F signifies that the attachment is fleshy.

T " " tendinous.

A " " aponeurotic.

A combination of any of these attachments may occur.

## MUSCLES AND FASCIÆ OF THE HEAD AND NECK.

The **superficial fascia** in the epicranial region and on the face is closely united to the skin, slightly developed, except between bellies of occipito-frontalis muscle. At the back part it becomes continuous with superficial fascia of posterior muscles of the neck, and descends laterally over the temporal fascia, where it envelops the external muscles of auricle, and the superficial temporal vessels and nerves. In the neck it is loose and fatty, as over rest of body.

## EPICRANIAL REGION.

**Occipito-frontalis**: *Frontal part*. Has no bony attachments, blends with orbicularis palpebrarum, pyramidalis nasi and corrugator supercillii(F)—epicranial aponeurosis(A) (Facial). *Occipital part*. Outer  $\frac{2}{3}$  superior curved occipital lines, mastoid processes(FR)—epicranial aponeurosis, which is attached behind to curved line between fleshy heads(A). (Posterior auricular branch of facial.) [*Frontal part* wrinkles forehead horizontally. *Occipital part* removes the wrinkles; acting alternately the two parts move scalp.]

Epicranial aponeurosis unites frontal and occipital muscles,

and is also attached to inner  $\frac{1}{3}$  of superior curved line of occipital behind. Laterally it is lost over temporal fascia, where it gives origin to *atrahens* and *attollens aurem*.

#### AURICULAR REGION.

**Atrahens aurem**: fore part of epicranial aponeurosis(F)—fore part of helix, and eminence on back of pinna, corresponding to the fossa of the antihelix(T) (Temporal branch of facial). [Very little; draws ear forward.]

**Attollens aurem**: epicranial aponeurosis(F)—cranial surface pinna, corresponding to fossa of antihelix(T) (Temporal branch of facial). [Very little; raises ears.]

**Retrahens aurem**: root of mastoid process(A)—lower part of cranial surface of concha(A) (Posterior auricular). [Very little; draws ear back.]

#### PALPEBRAL REGION.

**Orbicularis palpebrarum**: *Sphincter of eyelids. Orbital part.* Internal angular process of frontal, internal tarsal ligament, nasal process of superior maxilla(F). *Palpebral part.* Internal tarsal ligament(F)—external tarsal ligament(F) (Facial). *Ciliary part.* Marginal portion of preceding; lies along bases of eyelashes. [Closes eye; maintains apposition of eyelids to eyeball.]

**Tensor tarsi** (Horner's muscle): ridge of os lachrymalis(F)—joins with ciliary part of orbicularis internal to the punctum(F) (Facial). [Acting with orbicularis empties lachrymal sac.]

*Internal tarsal ligament* (tendo oculi) is attached to ridge on nasal process of superior maxilla in front of lachrymal groove, divides into two slips, each joining the inner end of the corresponding tarsal cartilage.

*External tarsal ligament*, connects the tarsal cartilages to outer part of orbit.

**Corrugator supercillii**: inner part of superciliary ridge of frontal(F)—under surface of orbicularis, opposite middle of orbital arch(F) (Facial). [Wrinkles forehead vertically.]

#### ORBITAL REGION.

**Levator palpebræ superioris**: inferior surface of small wing of sphenoid, anterior to foramen opticum and external to superior oblique(T)—anterior part of superior tarsal plate, also superiorly to join orbicularis and inferiorly to superior

fornix of conjunctiva(A) (Upper division of 3rd). [Raises upper eyelid.] The four recti arise from two common tendons—superior and inferior. Superior common tendon (ligament of Lockwood) rises above and outside optic foramen and gives origin to superior, internal and external recti (upper head). The inferior common tendon (ligament of Zinn) below and outside optic foramen goes to inferior, internal, and lower head of external recti.

**Rectus superior:** upper margin of optic foramen(τ)—sclerotic(τ) (Upper division of 3rd). [Rotates cornea upwards and inwards.]

**Rectus inferior:** margin of optic foramen(τ)—sclerotic(τ) (Lower division of 3rd). [Rotates cornea downwards and inwards.]

**Rectus internus:** optic foramen(τ)—sclerotic(τ) (Lower division of 3rd). [Rotates cornea inwards].

**Rectus externus:** *Upper head.* Optic foramen(τ). *Lower head.* Optic foramen and process of bone at the lower margin of sphenoidal fissure(τ)—sclerotic(τ) (6th). [Rotates cornea outwards.] *Between the two heads pass 3rd, 6th, nasal branch of 5th nerve and ophthalmic vein.*

**Obliquus superior:** inner part of optic foramen(τ)—passes through "pulley," thence reflected backwards and outwards between superior rectus and eyeball to be attached to sclerotic between superior and external recti (τ) (4th). [Rotates cornea downwards and outwards.] *The 4th nerve enters its upper surface.*

**Obliquus inferior:** depression on orbital plate of superior maxilla(F)—external surface of sclerotic under cover of external rectus(τ). (Lower division of 3rd). [Rotates cornea upwards and outwards.] *Passes outwards from origin beneath inferior rectus and between eyeball and external rectus to its insertion.*

#### NASAL REGION.

**Pyramidalis nasi:** occipito-frontalis(F)—compressor naris(A) (Facial). [Wrinkles skin over nose.]

**Compressor naris:** facial surface of superior maxilla by side of anterior nares(F)—its fellow of side(A) (Facial). [Closes anterior nares.]

**Levator labii superioris alæque nasi:** root of nasal process of superior maxilla(F)—1st slip, cartilage of ala; 2nd slip, orbicularis oris(F) (Facial). [Raises ala of nose and upper lip.]

**Depressor alæ nasi:** incisor fossa of superior maxilla(F)—septum and ala of nose(F) (Facial). [Very little; depresses ala.]

**Dilatator naris:** *Anterior slip.* Cartilage of ala(F)—inner border of integument of ala(F). *Posterior slip.* Nasal notch of superior maxilla(F)—inner border of integument of ala(F) (Facial). [Dilates anterior nares.]

#### SUPERIOR MAXILLARY REGION.

**Levator labii superioris:** superior maxilla and malar above infra-orbital foramen(F)—orbicularis oris(F) (Facial). [Raises upper lip.]

**Levator anguli oris:** canine fossa of superior maxilla, beneath infra-orbital foramen(F)—angle of mouth(F) (Facial). [Raises angle of mouth, as in smiling.]

**Zygomaticus major:** malar bone in front of zygoma(F)—angle of mouth(F) (Facial). [Raises angle of mouth.]

**Zygomaticus minor:** malar bone near maxillary suture(F)—angle of mouth(F) (Facial). [Raises angle of mouth.]

#### INFERIOR MAXILLARY REGION.

**Levator labii inferioris, vel levator menti:** incisor fossa of inferior maxilla(F)—integument of chin(F) (Facial). [Raises skin of chin.]

**Depressor labii inferioris, vel quadratus menti:** external oblique line of inferior maxilla from symphysis to mental foramen(F)—orbicularis oris(F) (Facial). [Draws down lower lip, everting it.]

**Depressor anguli oris, vel triangularis menti:** external oblique line of inferior maxilla(F)—angle of mouth(F) (Facial). [Depresses angle of mouth, as in crying.]

#### INTER-MAXILLARY REGION.

**Orbicularis oris:** *sphincter of mouth.* The *labial* part is free from attachment to bone, and forms red part of lips. The *outer* or *facial* part is connected with the muscles which converge to the angles of the mouth, and is attached in the upper lip to septum nasi and incisive fossa of superior maxilla, and in the lower lip to canine fossa of inferior maxilla(F) (Facial). [Closes oral fissure, producing radiating wrinkles.]

**Buccinator:** external surfaces of alveolar processes of superior and inferior maxillæ, as far forwards as 1st molar; pterygo-maxillary ligament(F)—angle of mouth where fibres decussate(F) (Facial). [Closes mouth, also prevents food collecting between teeth and lips; maintains tone of cheeks, as in whistling.]



The *pterygo-maxillary ligament* extends from the hamular process to the posterior edge of the mylo-hyoid ridge of inferior maxilla. It separates buccinator from superior constrictor of pharynx, giving origin to both.

**Risorius**: fascia covering masseter(F)—apex of depressor anguli oris(F) (Facial). [Draws angle of mouth back.] (*This muscle is part of the platysma of neck.*)

#### TEMPORO-MAXILLARY REGION.

**Masseter**: *Superficial part*. Malar process of superior maxilla. Anterior  $\frac{2}{3}$  of lower border of zygoma(TA)—angle and lower  $\frac{1}{3}$  of outer surface of ramus(F). *Deep part*. Posterior  $\frac{1}{3}$  lower border and inner surface of zygoma(F)—upper  $\frac{1}{2}$  of ramus and outer surface of coronoid process(F) (Inferior maxillary). [Muscle of mastication; elevates lower jaw and draws it forward.]

The *masseteric fascia*, a continuation of the deep cervical fascia, is attached above to the zygoma; continuing backwards it invests parotid gland (parotid fascia), from the deep surface of which the stylo-maxillary ligament proceeds.

**Temporal**: temporal fascia and fossa(F)—internal surface and fore part of coronoid process of inferior maxilla as far as last molar(AT) (Inferior maxillary). [Muscle of mastication, closing mouth; anterior fibres protrude jaw, posterior retract.]

The *temporal fascia* is attached above to the temporal ridge, and divides below into two layers, which are attached to inner and outer edges of superior border of zygoma. It covers the temporal muscle, and between the two layers are the temporal branch of temporo-malar nerve, and the orbital branch of superficial temporal artery.

#### PTERYGO-MAXILLARY REGION.

**External pterygoid**: pterygoid ridge and surface below on great wing of sphenoid, outer surface of external pterygoid plate(F)—pterygoid depression in front of neck of inferior maxilla and inter-articular fibro-cartilage of temporo-maxillary joint(F) (Inferior maxillary). [Muscle of mastication; both acting together protrude lower jaw: acting alternately cause grinding movements, each moving jaw to opposite side.]

*Between sphenoidal and pterygoid attachments, the internal maxillary artery dips down to reach spheno-maxillary fossa, and the buccal and anterior deep temporal nerves appear.*

**Internal pterygoid**: inner surface of external pterygoid plate, tuberosity of palate bone, and tuberosity of superior

maxilla(Ф)—angle and inner surface of ramus of inferior maxilla(ТА) (Inferior maxillary). [Muscle of mastication; elevates and draws lower jaw forward.]

*On muscle are inferior dental and gustatory nerves, internal maxillary and inferior dental arteries, and internal lateral ligament of jaw.*

#### SUPERFICIAL CERVICAL REGION.

**Platysma myoides** : clavicle and acromion, fascia covering deltoid, pectoralis major, and trapezius(Ф)—*Inner fibres*. Blend with opposite platysma. *Outer fibres*.—Lower jaw, prolonged to angle of mouth and cheek(Ф) (Facial). [Feeble depressor of jaw; moves skin of neck and maintains its contour.] *The higher fibres of this muscle form the risorius.*

**Sterno-cleido-mastoid** : *Inner head*. Upper and anterior part of 1st piece of sternum(τ). *Outer head*. Inner  $\frac{1}{3}$  of superior surface clavicle(Ф)—external surface of mastoid process from base to apex(τ), and outer  $\frac{2}{3}$  of superior curved line of the occiput(A) (Spinal accessory, Deep branch of 2nd cervical). [(A) Each side acting alone rotates face to opposite shoulder and bends neck to same side; (B) raises clavicle, and so aids forced inspiration.]

*Forms anterior boundary of posterior, and posterior boundary of anterior triangles of neck. Clavicular origin conceals* : anterior scalenus, omo-hyoid. *Sternal origin conceals* : depressors of hyoid bone, cervical lymphatic glands, great cervical vessels and pneumogastric nerve. *Union of two heads conceals* : middle scalenus, levator anguli scapulæ, cervical plexus. *Near insertion conceals* : splenius, trachelo-mastoid, digastric, occipital artery, part of parotid.

The **deep cervical fascia** is attached behind to the superior curved line of the occiput, to the ligamentum nuchæ and to the spine of 7th cervical vertebra.

It passes forwards enclosing the trapezius, and then over the posterior triangle as a single layer (where external jugular vein pierces it) until it reaches the posterior border of the sterno-mastoid, where it divides into two layers to enclose that muscle : in this area it is attached below to the clavicle. At the anterior border of the sterno-mastoid the two layers again blend together (except for about one inch above the sternum), and passing forwards, over the anterior triangle, it blends with the fascia of opposite side in the middle line.

Below where the two layers do not blend together, the anterior one is attached to the front of the upper part

of the sternum and to the interclavicular ligament, whilst the posterior one is connected to the posterior edge of the upper part of the same bone. A small interval (*Burn's space*) is thus left, triangular in vertical section with the base at upper border of the sternum, which contains some loose areolar tissue, some fat, and often a lymphatic gland, with the anterior jugular veins.

Superiorly this anterior layer passes over the parotid and masseter, forming the *parotid* and *masseteric* fascia, and is attached above and behind to the lower border of the zygoma, and below and in front to the lower edge of the body of the lower jaw.

From the posterior surface of the fascia covering the anterior triangle a septum passes inwards, separating the submaxillary and parotid glands, and forms the stylo-maxillary ligament.

*Processes given off from the deep cervical fascia.*

From the layer passing behind the sterno-mastoid there proceed:—

1. A layer which passes behind carotid vessels.
2. A layer which passes in front of carotid vessels.

These two layers blend together at the inner border of the carotid artery, forming the carotid sheath to enclose carotid artery, internal jugular, and pneumogastric nerve. The united layers pass upwards and inwards in front of the longus colli and behind the pharynx and œsophagus, to blend with like process from opposite side and form the *prevertebral* fascia.

This layer separates the prevertebral muscles from the pharyngeal fascia on the pharynx and œsophagus (retropharyngeal space continuous with the posterior mediastinum) and is prolonged laterally over the scaleni, brachial plexus, and subclavian vessels to help form the *axillary* sheath.

The cervical fascia is attached in the middle line to the symphysis menti, the hyoid bone, and the anterior edge of the upper border of the sternum.

3. A layer in *front* of thyroid body and trachea, but behind the sterno-hyoid and thyroid muscles, which joins with a corresponding process of the opposite side, and passing down to the root of the neck in front of the trachea and large vessels, blends with the fibrous layer of the pericardium.

4. A process to enclose the omo-hyoid tendon, which binds it down to the clavicle and first rib, blending with the costo-coracoid membrane.

## INFRA-HYOID REGION.

**Sterno-hyoid** : posterior surface of sternum, clavicle and intervening ligament (F)—lower border of body of hyoid bone (A) (1st, 2nd and 3rd cervical through ansa hypoglossi). [Depresses hyoid bone.]

**Sterno-thyroid** : posterior surface of sternum, cartilage of 1st rib(F)—oblique line on side of thyroid cartilage(F) (1st, 2nd and 3rd cervical through ansa hypoglossi). [Depresses thyroid cartilage.]

**Thyro-hyoid** : oblique line on side of thyroid cartilage(F)—internal half of greater cornu and outer part of body of hyoid bone(F) (1st and 2nd cervical). [Depresses hyoid on thyroid.]

**Omo-hyoid** : upper border of scapula behind notch, and transverse ligament(A)—lower part of body of hyoid bone(F) (1st, 2nd and 3rd cervical through ansa hypoglossi). [A depresses hyoid, B very feebly raises shoulder.]

*Consists of two bellies united by an intervening tendon. The tendon and posterior belly is bound down to clavicle and cartilage of 1st rib by a process of deep cervical fascia.*

## SUPRA-HYOID REGION.

**Digastric** : *Posterior belly.* Groove on internal surface of mastoid process(F). *Anterior belly.* Posterior surface of inferior maxilla, by side of symphysis(F)—intervening tendon (T), which is bound down to hyoid bone by process of deep cervical fascia (*anterior*, Mylo-hyoid of inferior dental; *posterior*, Facial). [With posterior belly fixed and hyoid bone depressed, it depresses mandible; with the lower jaw fixed, it raises hyoid.]

**Stylo-hyoid** : posterior aspect of styloid process near root(T)—body of hyoid bone at union of great cornu and body(T) (Facial). [Raises and draws back hyoid bone, and so tongue.] *Perforated by tendon of digastric.*

**Mylo-hyoid** : mylo-hyoid ridge on inner surface of inferior maxilla(F)—middle of body of hyoid bone(T), and joins fellow in median line(A) (Mylo-hyoid of inferior dental). [A raises and draws forwards hyoid under mandible; B depresses jaw.]

*Parts beneath the mylo-hyoid* : sublingual and part of submaxillary gland, with Wharton's duct; genio-hyoid, genio-hyo-glossus, hyo-glossus, stylo-glossus muscles, sublingual and ranine arteries; gustatory, and hypoglossal nerves; submaxillary ganglion.

**Genio-hyoid**: inferior genial tubercle on posterior surface of inferior maxilla near symphysis(τ)—middle of body of hyoid bone(ϕ) (1st and 2nd cervical). [Raises and draws forward hyoid.]

## LINGUAL REGION.

**Genio-hyo-glossus**: superior genial tubercle on posterior surface of inferior maxilla near symphysis(τ)—body of hyoid bone(ϕ) (posterior fibres): inferior surface of tongue from root to tip(ϕ) (anterior fibres) (Hypoglossal). [Raises tongue and hyoid bone, draws tongue forwards and protrudes it to opposite side.]

**Hyo-glossus**: side of body, from all great cornu of hyoid and from smaller cornu(ϕ)—back and side of tongue(ϕ) (Hypoglossal). [Depresses sides of tongue, making surface convex laterally.]

*Parts beneath hyo-glossus*: inferior lingualis, genio-hyo-glossus and middle constrictor muscles, lingual vessels, stylo-hyoid ligament, glosso-pharyngeal nerve.

**Stylo-glossus**: external surface of apex of styloid process and stylo-maxillary ligament(A)—dorsum and tip of tongue(ϕ) (Hypoglossal). [Draws tongue upwards and backwards, makes superior surface concave laterally.]

## PHARYNGEAL REGION.

**Inferior constrictor**: side of cricoid cartilage; oblique line on thyroid and surface behind it, inferior cornu of thyroid cartilage(ϕ)—fibrous *raphé* in posterior median line of pharynx(ϕ) (Pharyngeal plexus, External laryngeal, Recurrent laryngeal). [Squeezes food towards œsophagus in swallowing.]

**Middle constrictor**: great and small cornua of hyoid bone, stylo-hyoid ligament(ϕ)—fibrous *raphé* in posterior median line of pharynx(ϕ) (Pharyngeal plexus). [Squeezes food towards œsophagus in swallowing.] *Superior laryngeal vessels and internal laryngeal nerve pass between this muscle and the inferior, near origin.*

**Superior constrictor**: lower 3rd of posterior margin of internal pterygoid plate, hamular process, pterygo-maxillary ligament, posterior part of mylo-hyoid ridge of inferior maxilla, mucous membrane of mouth and side of tongue(ϕ)—fibrous *raphé* in posterior median line of pharynx(ϕ), and pharyngeal spine on basilar process(ϕ) (Pharyngeal plexus). [Squeezes food towards œsophagus in swallowing.] *Internal*

*carotid artery, pneumogastric and sympathetic nerves, middle constrictor and stylo-pharyngeus, etc., lie on outer surface.*

**Stylo-pharyngeus**: inner surface of base of styloid process(F)—pharynx and posterior border of thyroid cartilage(F) (Glosso-pharyngeal). [Raises pharynx over food in swallowing.] *Passes between external and internal carotid arteries.*

#### PALATAL REGION.

**Levator palati**: under surface of apex of petrous portion of temporal, lower margin of cartilage of Eustachian tube(T)—middle line of soft palate(F) (Pharyngeal plexus). [Raises palate, shutting off naso-pharynx.]

**Tensor vel circumflexus palati**: scaphoid fossa of sphenoid, outer side of Eustachian tube, spine of sphenoid(F) (*turns round hamular process*)—posterior border of hard palate, aponeurosis of soft palate(A) (Otic ganglion). [Raises and makes tense soft palate.]

**Azygos uvulæ**: posterior nasal spine of palate bone(F)—tip of uvula(F) (Pharyngeal plexus). [Shortens uvula.]

**Palato-glossus** (*anterior pillar of soft palate*): side and dorsum of tongue(F)—anterior and lateral surface of soft palate(F) (Pharyngeal plexus). [Tends to approximate back of tongue and soft palate.]

**Palato-pharyngeus** (*posterior pillar of soft palate*): *Anterior fibres* join opposite muscle at middle line lying between the levator and tensor. *Posterior fibres* join opposite fellow at middle line(F) (Pharyngeal plexus). **Salpingo-pharyngeus**: lower edge of cartilage of Eustachian tube—posterior border of thyroid cartilage, side of pharynx(F). [A raises pharynx; B will, with palato-glossus, shut off mouth from naso-pharynx.]

#### INTRA-LARYNGEAL REGION.

**Crico-thyroideus**: lower cornu and lower border of thyroid cartilage(F)—front and side of cricoid cartilage(F) (External laryngeal). [Rotates posterior part of cricoid downwards and backwards, and so makes vocal cords tense.]

**Thyro-arytenoideus**: lower half of receding angle of thyroid cartilage, crico-thyroid membrane(F).—Two sets of fibres. *Internal*, edge of vocal process(F)—*External*, outer surface of arytenoid cartilage(F) (Recurrent laryngeal). [Slackens vocal cords.]

**Crico-arytenoideus lateralis**: side of superior border of cricoid cartilage(F)—projection at external angle of base of arytenoid cartilage, and contiguous external surface(F) (Recurrent laryngeal). [Adducts cords.]

**Crico-arytenoideus posticus**: depression near ridge on posterior surface of cricoid cartilage(F)—projection at external angle of base of arytenoid cartilage(F) (Recurrent laryngeal). [Abducts cords.]

**Arytenoideus**: single muscle in the median line, fills up posterior concave surface of arytenoid cartilages. *Superficial* fibres pass from apex of one cartilage to base of other. *Deep* fibres pass between posterior surfaces of the cartilages (Recurrent laryngeal). [Approximates cords.]

#### ANTERIOR VERTEBRAL REGION.

**Rectus capitis anticus major**: four tendinous slips from anterior tubercles of transverse processes of 6th, 5th, 4th, 3rd cervical vertebræ(T)—basilar process of occipital(F) (1st, 2nd, 3rd and 4th cervical). [Flexes head and cervical spine.]

**Rectus capitis anticus minor**: root of transverse process and lateral mass of atlas(F)—basilar process of occipital(F) (1st cervical). [Flexes head.]

**Rectus lateralis**: superior surface of transverse process of atlas(F)—jugular process of occipital(F) (1st cervical). [Flexes head to same side.] *Highest intertransverse muscle.*

**Longus colli**: *Superior oblique part.* Anterior tubercles of transverse processes of 3rd, 4th, 5th cervical vertebræ(T)—tubercle on anterior arch of atlas(T). *Inferior oblique part.* Bodies of first three dorsal(F)—anterior tubercles of transverse processes of 5th and 6th cervical(T). *Vertical part.* Bodies of lower two cervical and upper three dorsal and transverse processes of 4th, 5th, 6th, 7th cervical vertebræ(FT)—bodies of 2nd, 3rd and 4th cervical vertebræ(T) (Cervical nerves). [Flexes cervical spine.]

#### LATERAL VERTEBRAL REGION.

**Scalenus anticus**: anterior tubercles of transverse processes of 3rd, 4th, 5th, 6th cervical vertebræ(T)—scalene tubercle on inner border and superior surface of 1st rib(T)—(Branches of lower cervical). [A raises ribs as in forced inspiration, B flexes spine and bends neck to same side.] *Phrenic nerve lies along anterior surface; subclavian artery passes behind at origin.*

**Scalenus medius**: posterior tubercles of transverse processes of lower six cervical vertebræ(T)—rough elevation on

superior border of 1st rib, behind groove for subclavian artery (F) (Branches of lower cervical). [A raises ribs as in forced inspiration, B flexes spine laterally.]

**Scalenus posticus**: posterior tubercles of transverse processes of lower two or three cervical vertebræ(τ)—superior border of 2nd rib(τ) (Branches of lower cervical). [A raises ribs, B flexes cervical spine laterally.]

#### POSTERIOR VERTEBRAL REGION.

**Rectus capitis posticus major**: spinous process of axis(τ)—outer  $\frac{1}{3}$  inferior curved line of occiput and bone below(F) (1st cervical, posterior primary division). [Extends head on spine.]

**Rectus capitis posticus minor**: posterior tubercle of neural arch of atlas(τ)—inner part of inferior curved line of occiput and bone between this and foramen magnum(F) (1st cervical, posterior primary division). [Extends head on spine.]

**Obliquus inferior**: spinous process of axis(F)—transverse process of atlas(τ) (1st cervical, posterior primary division). [Rotates face to same side.]

**Obliquus superior**: superior surface of transverse process of atlas(τ)—occipital bone, between the two curved lines(F) (1st cervical, posterior primary division). [Rotates face to opposite side.]

### MUSCLES AND FASCIÆ OF UPPER EXTREMITY.

#### ANTERIOR THORACIC REGION.

The deep fascia of the pectoral region covers the large pectoral muscle, is attached above to the clavicle, internally to the sternum, becoming continuous externally with fasciæ of shoulder, axilla, and lateral thoracic region.

The *costo-coracoid membrane*, continuous with the deep fascia of this part, is attached above to the clavicle so as to enclose the subclavius muscle; the posterior layer is continuous with the axillary sheath derived from the deep cervical fascia. The lower edge (costo-coracoid ligament) reaches from the 1st costal cartilage to the coracoid process, and passes downwards over pectoralis minor. It is pierced by cephalic vein, acromio-thoracic vessels, and external anterior thoracic nerve.

The *axillary fascia* is placed across the axilla; it is derived in front from the sheaths of the pectoral muscles, and joins, at the posterior border of the axilla, the sheaths of the latissimus dorsi and teres major.



**Pectoralis major** : *superiorly*, sternal half of clavicle(F) ; *internally*, front of sternum, cartilages of upper six ribs(F) ; *inferiorly* aponeurosis of external oblique muscle of abdomen(F) —outer ridge of bicipital groove of humerus( $\tau$ ) (External and internal anterior thoracic). [A adducts humerus, flexes shoulder; B raises ribs in forced inspiration.] *Anterior boundary of axilla, separated from the deltoid above by cephalic vein and branch of acromio-thoracic artery.*

**Pectoralis minor** : 3rd, 4th, and 5th ribs outside cartilages, aponeurosis over intercostal muscles(F)—anterior  $\frac{1}{2}$  of superior surface and inner border of coracoid process of scapula( $\tau$ ) (Internal anterior thoracic). [Draws scapula forwards and depresses it.] *Forms middle  $\frac{1}{3}$  of anterior axillary boundary, and conceals 2nd part of axillary artery.*

**Subclavius** : 1st rib at junction of bone and cartilage( $\tau$ )—groove on under surface of clavicle between the two tubercles(F) (Branch from 5th and 6th cervical). [Depresses clavicle.] *Encased by costo-coracoid sheath.*

#### LATERAL THORACIC REGION.

**Serratus magnus** : eight or nine digitations from as many ribs, the 1st digitation being attached to 1st and 2nd ribs; aponeurosis over intercostal muscles; lower four slips digitate with external oblique muscle of abdomen(F)—vertebral border of ventral surface of scapula; viz., 1st digitation from 1st and 2nd ribs to upper angle, from 2nd and 3rd ribs to base; the rest to inferior angle(F) (Posterior thoracic). [Draws scapula forwards, and by rotating inferior angle forwards and upwards, raises arm.]

#### ACROMIAL REGION.

The *deep fascia* over the shoulder conceals the back part of the deltoid and the infra-spinatus muscle, and is attached to the clavicle, acromion, and spine of scapula.

**Deltoid** : outer  $\frac{1}{3}$  anterior border of clavicle, anterior edge of acromion, all lower edge of spine of scapula(F)—rough deltoid impression on outer surface of humerus just above the middle( $\tau$ ) (Circumflex). [Abducts arm; anterior fibres flex shoulder, posterior extend.]

*Parts covered by deltoid* : head and neck of humerus; bursa between head of humerus and muscle; tendons of insertion of subscapularis, pectorales major and minor, teretes major and minor, latissimus dorsi, supra-spinatus, infra-spinatus. Origins of coraco-brachialis, biceps (two heads), triceps (long

and outer heads): capsular, coraco-acromial, humeral, clavicular, costo-coracoid (external part) ligaments; coracoid process: acromio-thoracic, supra-scapular, branch of superior profunda, and circumflex vessels; circumflex nerve.

#### ANTERIOR SCAPULAR REGION.

**Subscapularis**: all subscapular fossa, except at neck, angles, and inner border(F T A)—small tuberosity of humerus(T) and neck of humerus for one inch below(F) (Short subscapular and branch from lower subscapular). [Flexes and inwardly rotates shoulder-joint.] *Bursa placed between the tendon and root of coracoid process, communicating with shoulder-joint.*

#### POSTERIOR SCAPULAR REGION.

**Supra-spinatus**: supra-spinous fossa, except near neck of scapula; upper surface of spine, and fascia covering muscle(F)—upper of three facets upon great tuberosity of humerus(T) (Supra-scapular). [Abducts humerus.]

**Infra-spinatus**: infra-spinous fossa, except at neck, axillary border, and inferior angle; from inferior surface of spine of scapula, and fascia covering muscle(F)—middle of three facets on great tuberosity of humerus(T) (Suprascapular). [Extends and externally rotates shoulder-joint.]

**Teres minor**: from superior  $\frac{2}{3}$  of axillary border of dorsum of scapula, its investing fascia(F)—lowest of three facets upon great tuberosity of humerus(T), and bone below(F) (Circumflex; has a gangliform swelling on it). [Adducts and externally rotates humerus.] *Dorsal branch of subscapular artery bends backwards in front of this muscle to reach infra-spinous fossa.*

**Teres major**: from rough surface at inferior angle of dorsum of scapula, and axillary border for lower  $\frac{1}{3}$ , septum between it and teres minor(F)—inner edge of bicipital groove of humerus(T) (Lower subscapular). [Adducts and internally rotates humerus.] *A bursa is sometimes placed between tendon and humerus posteriorly, and between tendon and latissimus dorsi insertion anteriorly.*

#### ANTERIOR HUMERAL REGION.

The *deep fascia* of the arm is continuous with that of the shoulder, investing the muscles of this region. It gives off on either side an *intermuscular septum*, which is attached to the condyle and supra-condylar ridge.

**Coraco-brachialis**: apex of coracoid process of scapula, tendon of coracoid head of biceps(F)—rough ridge near middle

of inner surface of humerus; some of the upper fibres join a fibrous arch which is attached above to the small tuberosity( $\tau$ ) (Musculo-cutaneous). [Flexes and adducts shoulder-joint.]

*Brachial vessels to inner side.*

**Biceps** : *Long or glenoid head.* From scapula at upper border of glenoid cavity, and from glenoid ligament, within the shoulder-joint( $\tau$ ). *Short or coracoid head.* Apex of coracoid process of scapula( $\tau$ )—rough and hinder part of tubercle of radius( $\tau$ ) and fascia of forearm (Musculo-cutaneous). [Flexes shoulder, flexes elbow, supinates radius.] *A bursa is placed on the smooth and fore part of tubercle. Inner border, the guide to brachial vessels below middle of humerus. A broad band, the semilunar fascia, is given off from inner side of tendon opposite the elbow-joint, covering brachial artery and joining deep fascia of forearm.*

**Brachialis anticus** : lower half of outer and inner surfaces of shaft of humerus, embracing insertion of deltoid, all inner intermuscular septum, and upper part of outer intermuscular septum( $\tau$ )—rough surface in front of coronoid process of ulna( $\tau$ ) (Musculo-cutaneous, Musculo-spiral). [Flexes elbow.] *Brachial artery, median, musculo-spiral and musculo-cutaneous nerves lie on it.*

#### POSTERIOR HUMERAL REGION.

**Triceps** : *Long or middle head.* Depression on axillary border of scapula, close beneath glenoid cavity( $\tau$ ). *External head.* From root of great tuberosity to musculo-spiral groove on posterior surface of humerus( $\tau$ ). *Internal head.* Posterior surface of shaft of humerus, by side of and below musculo-spiral groove, internal and external intermuscular septa( $\tau$ )—posterior surface of olecranon process of ulna( $\tau$ ) (Musculo-spiral). [Extends and adducts shoulder, extends elbow.] *Bursa is placed between the tip of process and tendon.*

**Sub-anconeus** : by two fasciculi just above olecranon fossa of humerus( $\tau$ )—synovial sac of elbow-joint( $\tau$ ) (Musculo-spiral). [Raises synovial membrane out of olecranon fossa in extension of elbow.]

#### OF FOREARM—ANTERIOR. (a) *Superficial Layer.*

The *deep fascia* of the forearm, continuous above with fascia of arm, is attached posteriorly to subcutaneous edge of ulna, and invests the muscles in this region.

*Anterior annular ligament* (v. p. 13) is continuous by its upper border with the *deep fascia* of the forearm.

*Posterior annular ligament* (v. p. 13) is the thickened lower part of the posterior part of the deep fascia.

**Pronator radii teres:** *Humeral head.* Internal supra-condylar ridge of humerus, internal condyle of humerus by common flexor tendon. *Ulnar head.* Inner border of coronoid process of ulna, fascia and septum(F)—rough impression about middle of outer surface of radius(τ) (Median) 4, 7 [Flexes elbow and pronates forearm.] *Median nerve enters forearm between the two heads of origin.*

**Flexor carpi radialis:** common flexor tendon from internal condyle of humerus(τ), aponeurosis of forearm, intermuscular septa(F)—bases of palmar aspect of 2nd and 3rd metacarpal bones(τ) (Median) 6, 7 [Flexes elbow and wrist, abducts hand.] *External edge of muscle, guide to radial artery. Passes through groove in trapezium, and has special sheath externally under annular ligament.*

**Palmaris longus:** common flexor tendon from internal condyle of humerus(τ), aponeurosis of forearm(F), intermuscular septa(F)—Palmar fascia, and a slip to short muscles of thumb(τ) (Median) 8 [Flexes wrist, makes tense palmar fascia.] *Passes over annular ligament.*

**Flexor carpi ulnaris:** *Humeral head.* Common flexor tendon from internal condyle of humerus(τ). *Ulnar head.* Inner side of olecranon, upper  $\frac{2}{4}$  of posterior border of ulna(A)—Pisiform bone and prolonged to base of 5th metacarpal and hook of ulnariform bone(τ) (Ulnar) 9, 1 [Flexes elbow and wrist, adducts hand.] *Radial side of muscle, guide to ulnar artery. Ulnar nerve enters forearm between two heads of origin.*

**Flexor sublimis digitorum, vel perforatus:** *Humeral head.* Common flexor tendon from internal condyle of humerus(τ), internal lateral ligament(F), intermuscular septa(F). *Ulnar head.* Inner border of coronoid process of ulna. *Radial head.* Oblique line of radius below tubercle, and part of anterior border(A)—sides of middle phalanges of fingers, tendon being split for flexor profundus digitorum(τ) (Median) 10, 11 [Flexes elbow, wrist, carpal, metacarpal, and 1st interphalangeal joints.] *Tendons pass under annular ligament, in pairs, those of middle and ring-finger being anterior to those of index and little fingers.*

### (b) Deep Layer.

**Flexor profundus digitorum, vel perforans:** upper  $\frac{3}{4}$  of anterior and internal surfaces of shaft of ulna, upper  $\frac{3}{4}$  of ulnar half of interosseous membrane, aponeurosis from posterior border of ulna(F)—palmar surfaces of bases of last phalanges(τ). (*Inner*

*7.0.1*  
*half, Ulnar; Outer half, Anterior interosseous of median.)*  
 [Flexes wrist, metacarpal, phalangeal, and all interphalangeal joints.] *Tendons pass beneath annular ligament.*

**Flexor longus pollicis**: hollow on upper  $\frac{2}{3}$  of anterior surface of shaft of radius, outer  $\frac{1}{2}$  of interosseous membrane for same distance(F); base of coronoid process of ulna by a separate slip(F)—base of last phalanx of thumb(T) (Anterior interosseous)S<sub>1</sub> [Flexes wrist and all joints of thumb.] *Tendon passes beneath the annular ligament.*

**Pronator quadratus**: anterior surface and anterior border of shaft of ulna, for lower fourth(F)—for two inches into lower end of anterior surface and anterior border of radius(F) (Anterior interosseous)S<sub>1</sub> [Pronates radius.]

POSTERIOR. (a) *Superficial layer.*

**Supinator longus**: upper  $\frac{2}{3}$  external supra-condylar ridge of humerus, external intermuscular septum(F)—root of styloid process of radius(T) (Musculo-spiral). [Flexes elbow and pronates or supinates radius from extreme position to midway between pronation and supination.]

**Extensor carpi radialis longior**: lower  $\frac{1}{2}$  of external supra-condylar ridge of humerus, external intermuscular septum(F)—base of posterior surface of 2nd metacarpal(T) (Musculo-spiral). [Extends elbow, extends and abducts hand.] *Passes in groove, posterior to styloid process of radius.*

**Extensor carpi radialis breviar**: common extensor tendon from external condyle of humerus(T), external lateral ligament, intermuscular septum(F)—base of posterior surface of 3rd metacarpal(T) (Posterior interosseous). [Extends elbow and wrist, abducts hand.]

**Extensor communis digitorum**: common extensor tendon from external condyle of humerus(T); intermuscular septum(F)—dorsa of last two phalanges of fingers(T) (Posterior interosseous). [Extends wrists and all joints of carpus and fingers.] *The four tendons pass through a separate compartment of the posterior annular ligament with the extensor indicis. The tendons of the middle, ring, and little finger are connected by tendinous slips.*

**Extensor minimi digiti**: common extensor tendon from external condyle of humerus, deep fascia and intermuscular septum(T)—2nd and 3rd phalanges of little finger joining common expansion(T) (Posterior interosseous). [Extends wrist and all joints of little finger.] *Tendon passes through separate sheath of posterior annular ligament, below which it splits into two, the external one being united by a cross-piece with the tendon of common extensor going to little finger.*

**Extensor carpi ulnaris:** common extensor tendon from external condyle of humerus( $\tau$ ), intermuscular septum( $F$ ) by aponeurosis from upper  $\frac{2}{3}$  of posterior border of ulna( $A$ )—prominence on ulnar side of base of 5th metacarpal bone ( $\tau$ ) (Posterior interosseous). [Extends wrist, carpal joints and 5th metacarpo-phalangeal joint, adducts hand.] *Has separate sheath in posterior annular ligament.*

**Anconeus:** posterior surface of external condyle of humerus ( $\tau$ ) and deep fascia( $F$ )—outer side of olecranon, impression on upper  $\frac{1}{3}$  of posterior surface of ulna limited by oblique line( $F$ ) (Musculo-spiral). [Extends elbow.] *The recurrent interosseous vessels lie beneath this muscle.*

(b) *Deep Layer.*

**Supinator brevis:** external condyle, external lateral ligament of elbow-joint, orbicular ligament of radius, depression below lesser sigmoid cavity, external edge of ulna for 2 inches ( $F$ )—surrounds upper  $\frac{1}{3}$  of radius, is attached to all the neck, except at inner side, to the upper  $\frac{1}{3}$  of posterior, and upper  $\frac{1}{2}$  of external surfaces( $F$ ) (Posterior interosseous). [Extends elbow, supinates radius.]

**Extensor ossis metacarpi pollicis:** middle  $\frac{1}{3}$  of posterior surface of shaft of radius, special impression on superior and external part of posterior surface of ulna for same length, intervening interosseous membrane( $F$ )—dorsal aspect of base of 1st metacarpal (Posterior interosseous). [Extends 1st carpo-metacarpal joint abducts hand.] *The radial artery winds backwards beneath tendon near carpus.*

**Extensor brevis pollicis:** posterior surface of radius and interosseous membrane below preceding muscle for about  $1\frac{1}{2}$  inches( $F$ )—dorsal aspect of base of 1st phalanx of thumb ( $\tau$ ) (Posterior interosseous). [As preceding: also extends 1st metacarpo-phalangeal joint] *Goes through groove under posterior annular ligament with extensor ossis metacarpi pollicis.*

**Extensor longus pollicis:** posterior surface of ulna, on inner side and below extensor ossis metacarpi pollicis for 4 inches, interosseous membrane( $F$ )—dorsal aspect of base of last phalanx of thumb( $\tau$ ) (Posterior interosseous). [Extends wrist and all joints of thumb.] *Tendon goes through separate sheath of posterior annular ligament, and below is separated from other extensors of thumb by a triangular interval, which contains the radial artery.*

**Extensor indicis:** internal part of posterior surface of shaft of ulna for about 3 inches just below middle, and interosseous

**membrane(F)**—joins tendon of extensor communis digitorum to 2nd and 3rd phalanges of index-finger( $\tau$ ) (Posterior interosseous). [Extends wrist and all joints of index.]

#### THUMB, THENAR EMINENCE.

**Abductor pollicis**: ridge of trapezium, sometimes scaphoid, upper part of annular ligament(F)—outer side of base of 1st phalanx of thumb( $\tau$ ) (Median). [Abducts thumb.]

**Opponens pollicis**: anterior surface and ridge of trapezium, annular ligament(F)—whole length of radial border of shaft of 1st metacarpal(F) (Median). [Opposes thumb to palm.]

**Flexor brevis pollicis**: *Outer head*. Lower border of annular ligament—outer margin of the base of 1st phalanx of thumb (Median). *Inner head*. Inner side of base of 1st metacarpal bone—inner side of base of 1st phalanx of thumb (Ulnar). [Flexes metacarpo-phalangeal and 1st interphalangeal joint of thumb.] *A sesamoid bone developed in each tendon of insertion. Deep palmar arch of radial, issues from behind inner head.*

**Adductor obliquus pollicis**: sheath of flexor carpi radialis, anterior carpal ligaments, os magnum, bases of 2nd and 3rd metacarpal bones—inner side of base of 1st phalanx of thumb (Ulnar). [Adducts and flexes thumb.]

**Adductor transversus pollicis**: ridge on lower  $\frac{2}{3}$  of anterior surface of shaft of 3rd metacarpal(F)—ulnar side of base of 1st phalanx of thumb( $\tau$ ) (Ulnar). [Adducts and flexes thumb.]

#### LITTLE FINGER, HYPOTHENAR EMINENCE.

**Palmaris brevis**: annular ligament, palmar fascia(F)—skin on ulnar side of palm(F) (Ulnar). [Corrugates skin on ulnar side of palm.]

**Opponens minimi digiti**: process of unciform bone, lower part of annular ligament(F)—ulnar edge of 5th metacarpal(F) (Ulnar). [Opposes little finger to palm.]

**Flexor brevis minimi digiti**: tip of process of unciform, annular ligament(F)—ulnar side of base of 1st phalanx of little finger( $\tau$ ) (Ulnar). [Flexes little finger.]

**Abductor minimi digiti**: pisiform bone, tendon of flexor carpi ulnaris(F)—ulnar side of base of 1st phalanx of little finger( $\tau$ ) (Ulnar). [Abducts little finger.]

#### DEEP PALMAR REGION.

**Lumbricales (4)**: radial side of deep flexor tendons (2 inner from ulnar margins of 2nd and 3rd tendons also) (F)—radial

side of tendinous expansion on dorsa of 1st phalanges of fingers( $\tau$ ) (2 *outer* median, 2 *inner* ulnar). [Flex metacarpophalangeal and extend interphalangeal joints.]

**Interossei dorsales** (4): 1st muscle (*abductor indicis*). *Outer head*. From upper  $\frac{1}{2}$  of ulnar border of 1st metacarpal( $\mathbb{F}$ ). *Inner head*. Radial border of 2nd metacarpal( $\mathbb{F}$ ). The others from posterior part of lateral surfaces of both metacarpals, between which they lie—1st and 2nd muscles to radial side of 1st phalanx of index and middle fingers respectively, 3rd and 4th in similar manner to ulnar side of middle and ring fingers ( $\tau$ ). Each is inserted partly into base of 1st phalanx, and partly into expansion of common extensor on 1st phalanx( $\tau$ ) (Ulnar). [Abduct fingers from middle line of hand—*i.e.*, 3rd (middle) finger; also same action as lumbricales.]

**Interossei palmares** (3): 1st from ulnar side of 2nd metacarpal, 2nd and 3rd from radial sides of 4th and 5th metacarpals respectively( $\mathbb{F}$ )—1st phalanx of finger from which they arise and on the same side as the origin, and into extensor tendon expansion( $\tau$ ) (Ulnar). [Adduct fingers towards middle line, and same action as lumbricales.]

## MUSCLES AND FASCIÆ OF BODY.

### BACK, 1ST LAYER.

**Trapezius**: spinous processes of all dorsal and 7th cervical vertebræ, with supra-spinous ligaments, ligamentum nuchæ, inner  $\frac{1}{3}$ rd of superior curved line of occiput( $\tau$ )—outer  $\frac{1}{3}$ rd of posterior border of clavicle, superior edge of acromion, superior lip of posterior border of spine of scapula( $\mathbb{F}$ ), and rough impression on spine about 1 inch from root( $\tau$ ) (Spinal accessory, 3rd and 4th cervical by cervical plexus.) [A—Upper fibres draw scapula and clavicle upwards, lower fibres downwards, all backwards; B pulls head backwards, and also flexes to same side.] *Anterior margin forms posterior boundary of posterior triangle of neck.*

**Latissimus dorsi**: spinous processes of lower 6 dorsal, supra-spinous ligaments(A); from the posterior layer of the lumbar aponeurosis, by which it is attached to all the lumbar and sacral spines, and posterior  $\frac{1}{3}$  of outer edge of iliac crest, beyond this for 1 inch( $\mathbb{F}$ ), lower 3 or 4 ribs( $\mathbb{F}$ ), and occasionally a slip from angle of scapula—bottom of bicipital groove of humerus( $\tau$ ) (Long subscapular). [Draws arm down and backwards, rotating inwards.] *In the back the latissimus is posterior to*



*the teres major, but twisting upon itself it is inserted anteriorly to teres, and lowest fibres are inserted highest.*

#### BACK, 2ND LAYER.

**Levator anguli scapulæ:** posterior tubercles of transverse processes of upper three or four cervical vertebræ(τ)—vertebral border of scapula between spine and superior angle(ℱ) (5th cervical [nerve to rhomboidei] and deep branches from 3rd and 4th cervical). [Elevates scapula.] *Forms part of floor of posterior triangle of neck.*

**Rhomboideus minor:** ligamentum nuchæ, spinous processes of 7th cervical and 1st dorsal vertebræ(τ)—vertebral border of scapula, opposite root of spine(ℱ) (5th cervical). [Elevates and draws back scapula.]

**Rhomboideus major:** spines and supra-spinous ligaments of upper 4 or 5 dorsal vertebræ, below preceding(τ)—vertebral border of scapula between spine and inferior angle(ℱ) (5th cervical). [Elevates and draws back scapula.] *Sometimes the fibres end in a tendinous arch near the bone.*

#### BACK, 3RD LAYER.

**Serratus posticus superior:** ligamentum nuchæ, spinous processes of 7th cervical and two or three superior dorsal vertebræ, supra-spinous ligament(Λ)—upper borders and outer surfaces of 2nd, 3rd, 4th, and 5th ribs external to angle(ℱ) (External posterior branches of dorsal). [Elevates upper ribs.]

**Serratus posticus inferior:** spinous processes of 11th and 12th dorsal, and 1st and 2nd lumbar vertebræ, and from tendon of origin of latissimus dorsi and the fascia lumborum(Λ)—inferior borders of lower four ribs external to angle(ℱ) (External posterior branches of dorsal). [Draws lower ribs downwards and backwards, fixing them for diaphragm to act from.]

*The vertebral aponeurosis.* A thin membrane, attached to the spines of the dorsal vertebræ, and passing outwards to the angles of the ribs. Below it is joined to the upper edge of the inferior serratus and the tendon of latissimus, whilst above it passes beneath the superior serratus and splenius to become continuous with the deep fascia of the neck. It binds down the erector spinæ in the groove between the vertebral spines and the angles of the ribs.

**Splenius:** lower  $\frac{1}{2}$  of ligamentum nuchæ, spinous processes of 7th cervical and upper 6 dorsal vertebræ, supra-spinous

ligaments(A)—*Capitis*, apex and hinder border of mastoid process, outer  $\frac{1}{3}$  superior curved line of occiput( $\tau$ ); *Colli*, posterior tubercles of transverse processes of 1st, 2nd, and 3rd cervical vertebræ( $\tau$ ) (External posterior branches of cervical). [Extends spine and head; laterally flexes head and rotates face to the same side.]

#### BACK, 4TH LAYER.

**Erector spinæ:** *Outer mass.* Ilio-costalis, musculus accessorius, cervicalis ascendens. *Inner mass.* Longissimus dorsi, transversalis colli, trachelo-mastoid. [In all its parts extends spine.]

**Erector spinæ:** posterior  $\frac{1}{3}$ th inner lip of iliac crest, from the sacral transverse processes, and lower part of posterior surface of sacrum, from the sacral, lumbar and lower 3 dorsal spines, with supra-spinous ligaments( $\tau$ ). Divides opposite last rib into sacro-lumbalis and longissimus dorsi (External posterior branches of sacral and lumbar).

**Ilio-costalis:** erector spinæ( $\tau$ )—angles of lower 6 or 7 ribs ( $\tau$ ) (External posterior branches of lumbar and dorsal).

**Musculus accessorius:** angles of lower 6 ribs( $\tau$ )—angles of upper 6 ribs, and transverse process of 7th cervical( $\tau$ ) (External posterior branches of dorsal).

**Cervicalis ascendens:** angles of 3rd, 4th, 5th, and 6th ribs ( $\tau$ )—Posterior transverse tubercles of 6th, 5th, and 4th cervical vertebræ( $\tau$ ) (External posterior branches of cervical).

**Longissimus dorsi.** (*See erector spinæ, of which it forms nearly the whole of the inner mass.*)—*Internally.* Accessory processes of lumbar and transverse processes of dorsal vertebræ( $\tau$ )( $\tau$ ). *Externally.* Lumbar transverse processes( $\tau$ ), middle layer of fascia lumborum: to all the ribs except first two or three by fleshy processes between tubercle and angle( $\tau$ ) (External posterior branches of lumbar and dorsal).

**Transversalis colli:** transverse processes of upper 5 dorsal vertebræ( $\tau$ )—Posterior tubercles of transverse processes of 6th, 5th, 4th, 3rd, and 2nd cervical vertebræ( $\tau$ ) (External posterior branches of cervical).

**Trachelo-mastoideus:** transverse processes of upper 4 dorsal vertebræ( $\tau$ ), articular processes of 7th, 6th, 5th, and 4th cervical vertebræ( $\tau$ )—posterior edge of mastoid process ( $\tau$ ) (External posterior branches of cervical).

**Spinalis dorsi:** spinous processes of 11th and 12th dorsal and 1st and 2nd lumbar vertebræ( $\tau$ )( $\tau$ )—Spinous processes of

upper 4 or 8 dorsal vertebræ(τ) (External posterior branches of dorsal and lumbar).

**Complexus**: transverse processes of upper 6 dorsal and 7th cervical, articular processes of inferior 3 or 4 cervical, and spinous process of 7th cervical vertebræ(τ)—Impression between superior and inferior curved lines of occiput(ϕ) (Suboccipital, internal posterior branches of cervical). [Extends head, and rotates face to the opposite side.] *The inner part of this muscle is sometimes described as a separate muscle, called biventer cervicis.*

#### BACK, 5TH LAYER.

**Semi-spinalis dorsi**: transverse processes of 10th, 9th, 8th, 7th, and 6th dorsal vertebræ(τ)—Spinous processes of upper four dorsal and last two cervical vertebræ(τ) (Internal posterior branches of dorsal). [Extends spine.]

**Semi-spinalis colli**: transverse processes of upper 6 dorsal (ϕτ)—spinous processes of 2nd, 3rd, 4th, and 5th cervical vertebræ(τ) (Internal posterior branches of cervical). [Extends spine.]

**Multifidus spinæ**: back of sacrum as low as 4th sacral foramen; inner surface of posterior superior iliac spine, posterior sacro-iliac ligament, mammillary processes of lumbar, transverse processes of dorsal, articular processes of lower 5 cervical vertebræ(ϕτ)—spines and neural arches of vertebræ from 3rd sacral to 2nd cervical(ϕ) (Internal posterior branches of sacral, lumbar, dorsal and cervical). [Extends spine.] *Fills groove on either side of spinous processes of vertebræ.*

**Rotatores spinæ, vel dorsi** (eleven in number): tip and upper edge of transverse process of a dorsal vertebra(ϕ)—lower border of lamina of vertebra next above (A) (Internal posterior branches of dorsal). [Rotate spine.]

**Inter-spinales**: placed in pairs, one on each side of interspinous ligament between spinous processes (Internal posterior branches of cervical, dorsal, and lumbar). [Extend spine.] *These muscles are wanting between 1st and 2nd cervical, and all the dorsal except first and last two pairs.*

**Inter-transversales**: lie between transverse processes. *Cervical* (seven pairs, two sets). One set attached to anterior, the other to the posterior tubercles. *Dorsal*. Single sets, from three to six in number, attached to the processes of the lower vertebræ. *Lumbar*. Four in number, the lower ones filling up the spaces between processes entirely. A second set here pass between adjacent accessory processes. (Internal posterior branches of cervical, dorsal, and lumbar). [Laterally flex spine.]

## ABDOMINAL REGION.

**Obliquus abdominis externus:** eight digitations from inferior borders and outer surface of eight lower ribs, upper five digitating with serratus magnus, lower three with latissimus dorsi(F)—Anterior half of external lip of iliac crest, and aponeurosis in front of belly, which is attached to pubic spine and symphysis below(A), blends above with the fascia over the pectoralis major, and joins in the middle line with the opposite aponeurosis, forming the *linea alba*; the rest of the fibres forming *Poupart's* and *Gimbernat's ligaments* (A) (Lower intercostals, Ilio-hypogastric, and Ilio-inguinal). [Supports and compresses viscera, draws down lower ribs, and laterally flexes thorax.]

The *external abdominal ring* is an opening formed by a divergence of some of the lower fibres of the aponeurosis of the external oblique muscle; it is situated just above the crest of the pubes, and transmits spermatic cord in male and round ligament in female. *Boundaries*—*Below.* Pubic crest. *Above.* Arched fibres. *Laterally.* External and internal pillars; the external pillar is attached below to pubic spine, the internal pillar to pubic symphysis. The *intercolumnar fascia* passes between the pillars, and is prolonged downwards over the cord.

*Poupart's Ligament.* The part of the aponeurosis of the external oblique extending between anterior superior iliac spine and pubic spine. The inner attachment is prolonged along the pectineal line, forming *Gimbernat's ligament*, of which some fibres are again reflected upwards and inwards to *linea alba*, forming *triangular fascia*.

**Obliquus internus:** outer  $\frac{1}{2}$  of Poupart's ligament, anterior  $\frac{2}{3}$  middle lip of iliac crest, fascia lumborum between iliac crest and 12th rib(F)—inferior edges of cartilages of lower three ribs on posterior surface, aponeurosis blending with its fellow at *linea alba*; some of the lower fibres of the aponeurosis arch over spermatic cord, join tendon of transversalis just above pectineal line, forming the *conjoined tendon*, which is attached to pectineal line, and crest of pubes(r) (Lower intercostals, Ilio-hypogastric). [As externus.] *Aponeurosis forms sheath to encase the rectus except at lower fourth posteriorly.*

**Cremaster** (*peculiar to male*): middle of Poupart's ligament and internal oblique(F)—crest of os pubis(r) (Genito-crural). [Supports and raises testis.] *Fibres embedded in fascia (cremasteric) derived from internal oblique, covering cord and testis.*

**Transversalis:** outer  $\frac{1}{3}$  Poupart's ligament, anterior  $\frac{3}{4}$  inner lip iliac crest, inner surfaces of cartilages of lower six ribs(F)

fascia lumborum( $\tau$ )—lower fibres end in the *conjoined tendon*, inserted into pubes and pectineal line( $\tau$ ); rest of fibres terminate in an aponeurosis attached to linea alba(A) (Lower intercostals, Ilio-hypogastric, Ilio-inguinal). [Supports and compresses viscera.] *As low as midway between pubes and umbilicus, the aponeurosis is posterior to the rectus, but below this level it is anterior.*

*The Posterior aponeurosis of the Transversalis or fascia lumborum* is attached to the lower border of the last rib above, and to the ilio-lumbar ligament and posterior part of the iliac crest below. Tracing it towards the spine, it splits to enclose the quadratus, and becomes attached to the lumbar transverse processes. From the posterior of these layers a process is given off to the lumbar spines, enclosing the erector spinæ.

**Rectus abdominis**: pubic crest and symphysis( $\tau$ )—ensiform appendix, cartilages of 5th, 6th, and 7th ribs, bone and cartilage of 5th rib( $\text{FT}$ ) (Lower intercostals, Ilio-hypogastric). [Supports viscera, flexes spine, A drawing down thorax, B drawing up pelvis, as in climbing.] Traversed by three or four tendinous intersections, *lineæ transversæ*. *Sheath of rectus*. Aponeurosis of internal oblique splits at outer edge of muscle, one piece passing anteriorly, the other posteriorly. The posterior part is joined by aponeurosis of transversalis, and is deficient at lower fourth; the lower free border forms the *Fold of Douglas*. The anterior part blends with aponeurosis of the external oblique.

**Pyramidalis**: front of pubes and anterior pubic ligament( $\tau$ )—linea alba( $\tau$ ) midway between umbilicus and pubes (12th intercostal). [Makes linea alba tense.] *Enclosed in sheath of rectus, and frequently absent.*

**Quadratus lumborum**: *Anterior part*. Upper edge of transverse processes of 3rd, 4th and 5th lumbar vertebræ—inner  $\frac{1}{2}$  lower border 12th rib. *Posterior part*. Ilio-lumbar ligament, and inner lip of iliac crest for 2 inches external to it(A)—apices of transverse processes of upper four lumbar( $\tau$ ), inner  $\frac{1}{2}$  inferior border of 12th rib( $\text{F}$ ) (Anterior branches of lumbar). [Flexes spine laterally, draws down last rib and with its fellow extends spine.]

#### THORACIC REGION.

**Intercostales externi (II)**: outer lip of groove on inferior border of rib, from the tubercle to costal cartilage( $\text{F}$ )—outer edge of superior border of rib below( $\text{F}$ ) (Intercostals). [Elevate ribs and aid inspiration.] *Fibres run downwards and forwards.*

*The corresponding spaces between the rib cartilages are occupied by the anterior intercostal aponeurosis.*

**Intercostales interni (11)**: inner lip of groove on inferior border of rib, extending from angle to sternum(F)—inner edge of superior border of rib below (Intercostals). [Probably elevate ribs and aid inspiration.] *Fibres run downwards and backwards, but not so obliquely as the external muscles. The inner surface of each intercostal space between the tubercle and angle is occupied by the posterior intercostal aponeurosis. The intercostal vessels and nerve lie between the external and internal muscles.*

**Subcostales (10)**: inner surface of a rib, near angle(F)—inner surface of 1st, 2nd, or 3rd ribs below(F) (Intercostals). [Elevate ribs.]

**Triangularis sterni**: side of ensiform appendix and sternum, as high as 3rd intercostal space, posterior surfaces of cartilages of 7th, 6th, and 5th ribs(F)—posterior surfaces of 2nd, 3rd, 4th, 5th and 6th ribs at junction of bone and cartilage(TF) (Anterior branches of intercostals). [Draws down ribs.]

**Levatores costarum (12)**: apex and lower border of transverse processes of 7th cervical and upper 11 dorsal vertebræ (T)—superior border of rib below, extending from tubercle to angle(F) (Intercostals). [Raise ribs.]

#### DIAPHRAGMATIC REGION.

**Diaphragma**: posterior surface of ensiform appendix, internal surfaces of lower six costal cartilages(F), ligamenta arcuata (externa et interna) (A). Right crus, from bodies and intervertebral substances of 1st, 2nd, 3rd lumbar vertebræ(T). Left crus, from bodies and intervertebral substances of 1st and 2nd lumbar vertebræ(T)—central tendon (Phrenics). [Enlarges vertical diameter of thorax, so aids inspiration.] The *ligamentum arcuatum internum* arches over psoas, attached to body of 1st lumbar vertebra internally and to transverse process of 1st lumbar vertebra externally. The *ligamentum arcuatum externum* reaches from transverse process of 1st lumbar vertebra to lower border and apex of last rib, arching over quadratus.

*Openings.* **AORTIC(F)**: between the crura and spine, transmits aorta, thoracic duct, and vena azygos major. **ŒSOPHAGEAL(F)**: above and little to left of aortic, transmits œsophagus and pneumogastric nerves. **CAVAL(T)**: in the right leaflet of tendon, transmits vena cava inferior, which is inseparably united to it. In each crus there is a fissure for the three splanchnic nerves, the left one transmitting in addition

the vena azygos minor. The cord of the sympathetic perforates the outer part of the crus.

#### PERINEAL REGION.

*Superficial Fascia.* In the anterior half of the perineum this consists of two layers, the superficial fatty and the deep layer fibrous and well marked (fascia of Colles): the latter is attached to rami of pubes and ischium, and from ischial tuberosity to central point of perineum; here it joins the triangular ligament, by turning round the transversus perinei. It is continuous in front with the dartos, and from its deep surface there is a septum passing forwards to scrotum in the middle line.

*Triangular Ligament of the Urethra, or Deep Perineal Fascia,* consists of two layers. The *anterior* layer is attached to the symphysis and to rami of pubes and ischium on each side, and joins the superficial fascia where this curves over the transversus perinei. About an inch below the symphysis it is perforated by the urethra, and above this by the dorsal vein of the penis, and on either side of this opening the dorsal artery and nerve of penis are transmitted. The *posterior* layer consists of two lateral portions separated in the median line by the urethra, and continuous with the recto-vesical fascia in the middle line, which here invests the prostate; externally it joins the obturator fascia on the pubic and ischial rami, and is really the subpubic part of the parietal pelvic fascia.

*Parts between the two layers of the triangular ligament.* Subpubic ligament, dorsal vein of penis, membranous part of urethra, compressor urethræ. Cowper's glands and ducts. internal pudic arteries giving off branches to bulb, to glands of Cowper, and the artery to corpus cavernosum, and the dorsal nerves of penis.

**THE PELVIC FASCIA.** Lines muscles of pelvis and forms floor of outlet of pelvis. Consists of parietal and visceral layers.

*Parietal Layer. (a) The Obturator Fascia.* Covers inner surface of obturator internus. It is attached above to iliopectineal line, to oblique line on posterior surface of body of pubes from symphysis to upper part of thyroid foramen. Posteriorly it is attached to the anterior edge of the sacro-sciatic notch and large sacro-sciatic ligament, whilst below it is attached to the rami of pubis and ischium, and in front in the subpubic angle is continuous with the posterior layer of the triangular ligament. At the top of the thyroid foramen

the fascia joins the obturator membrane, its bony attachment being here interrupted, and forms thus the floor of the short canal which transmits the obturator vessels and nerve. The upper part of the fascia is in the pelvic cavity, and is lined by peritoneum, whilst the lower part forms the outer boundary of the ischio-rectal fossa, and encases the internal pudic vessels and pudic nerve as they pass forwards.

(b) *The Fascia of the Pyriformis* is the continuation of the obturator fascia to the sacrum, and lies anterior to the pyriformis and sacral plexus.

*Visceral Layer.* *The Recto-vesical Fascia* is attached in front to the posterior surface of the pubis, close to the obturator fascia, the origin of the levator ani intervening. Laterally it is attached to the obturator fascia along a line from the upper part of the thyroid foramen to the ischial spine, whilst behind it joins the lower part of the pyriformis fascia. From these attachments it passes downwards and inwards over the upper surface of the levator ani to the prostate, bladder and rectum, joining the fascia of the opposite side in front of the bladder, and between the bladder and the rectum, thus forming the floor of the pelvis. Along the attachment of the recto-vesical to the obturator fascia is a thickened band, the *white line* of the pelvic fascia.

*Processes from the recto-vesical fascia :—*

*Pubo-prostatic ligaments* or *anterior true ligaments of the bladder.* Narrow fasciculi, one on each side, passing from the back of the pubes to the front of the prostate and neck of the bladder.

*Lateral true ligaments of the bladder.* This is the anterior ligament prolonged laterally, and passes to the side of the prostate, and to the side of the bladder above the vesiculæ seminalis, enclosing the prostatic plexus, whilst posteriorly it is attached to the bladder between the vesiculæ, and is prolonged downwards over and enclosing them, being joined to a like process from the opposite side.

*Ligament of the rectum.* A piece of fascia descends from the ischium and is attached to the rectum on each side.

In the female the vagina receives a prolongation of the recto-vesical fascia corresponding to the prostatic sheath.

**Sphincter ani externus :** tip and back of coccyx and subcutaneous fatty layer on either side (TF)—central perineal tendon (F) (4th sacral and inferior hæmorrhoidal of pudic). [Closes anus.]

**Sphincter ani internus :** the involuntary muscular fibres of the large intestine thickened about  $\frac{1}{2}$  inch deep. [Closes anus.]



**Bulbo-cavernosus**, *vel* **accelerator**, *vel* **ejaculator urinæ**: central perineal tendon and *raphé*(F)—*Posterior fibres*. Under surface of triangular ligament(F). *Middle fibres* surround bulb and corpus spongiosum. *Anterior fibres*. Side of corpus cavernosum, and united with one on opposite side it encases dorsal vessels(A) (Deep perineal of pudic). [Compresses bulbous urethra, discharging its contents.]

**Erector penis**, *vel* **ischio-cavernosus**: internal surface of tuber ischii(TF)—internal and external surfaces of crus penis (T) (Deep perineal of pudic). [Compresses crus and produces erection.]

**Transversus perinæi**: internal surface of tuber ischii(T)—central perineal tendon(F) (Deep perineal of pudic). [Draws back and fixes central point of perineum.]

**Levator ani**: posterior surface of pubis near symphysis, spine of ischium, and between these two points from rectovesical fascia, along attachment of obturator fascia(T)—central perineal tendon, sides of rectum and coccyx(F) (Perineal of pudic and Anterior division of 4th sacral). [Supports pelvic viscera, compresses and raises lower part of rectum in defæcation.] *Forms floor of pelvic cavity.*

**Compressor** *vel* **constrictor urethræ**: internal surface of pubic arch, posterior surface of triangular ligament(A)—muscle of opposite side(T) (Deep perineal of pudic). [Constricts urethra and expels contents.] *Surrounds membranous portion of urethra.*

**Coccygeus**: upper part of ischial spine, small sacro-sciatic ligament(TF)—side and anterior surface of coccyx and last piece of sacrum(F) (Anterior division of 4th sacral). [Supports pelvic floor.]

*Note.*—In the female the perineal muscles are essentially the same: for erector penis, read *erector clitoridis*, inserted into side of clitoris. The *sphincter vaginæ*, corresponding to ejaculator urinæ, is attached to the central tendon of the perineum, and passing forwards on each side of the vagina—corpora cavernosa and body of clitoris.

## MUSCLES AND FASCIÆ OF LOWER EXTREMITY.

The FASCIA LATA of the thigh envelops the muscles and surrounds the limb. Above it is attached to the back of the sacrum and coccyx, to the iliac crest, to Poupart's ligament, pubic body and ramus, ischial tuberosity and ramus, and to the lower edge of the great sacro-sciatic ligament. The *ilio-tibial band* is a thickened part attached above to the iliac crest

and below to the head of the fibula and outer tuberosity of the tibia. The fascia lata is attached below to the head of the tibia and sides of the patella, being strengthened by aponeuroses from the vasti muscles. Behind the fascia passes across between the hamstring muscles, enclosing the popliteal space.

*The Saphenous Opening.* This is an aperture in the fascia lata in upper and inner part of the thigh, through which the internal saphenous vein passes. It is covered by the cribriform fascia. To describe it, the fascia is spoken of as consisting of two parts, of *pubic* portion on the inner side of the opening and continuous below with the *iliac* portion.

The *pubic* portion passes up over the pectineus, adductor longus and gracilis, and behind the femoral sheath, blending externally with sheath of psoas and attached internally to the pectineal line (Cooper's ligament) and to Gimbernat's ligament.

The *iliac* portion, on the outer side of the saphenous opening, and covering the femoral vessels, is attached externally to the iliac crest, Poupart's ligament, and pubic spine, joining here the pubic portion. From the pubic spine it passes down and out with a free margin, the *superior cornu* or *falciform process of Burns*, forming the outer margin of the saphenous opening, and becoming continuous below and internally with the pubic portion, the margin here being well defined and named the *inferior cornu*.

*Sheath of the Femoral Vessels.* The upper part of the sheath surrounding the femoral vessels is called the *crural sheath*, which is formed by a prolongation from the transversalis fascia in front, and from the fascia covering the iliacus behind. It is divided into three compartments, the outer containing the artery, the middle one the vein, and the inner one, or *crural canal*, a lymphatic gland.

The *crural canal*, the innermost compartment of the femoral sheath, is about  $\frac{1}{2}$  inch long, reaching from Gimbernat's ligament to the saphenous opening.

The upper opening of the crural canal is called the *crural ring*, which is on a level with Gimbernat's ligament, and is closed by a layer of sub-peritoneal fascia, the *septum crurale*.

*Boundaries of the crural ring :—*

*In front*, superficial (Poupart's ligament) and deep crural arches.

*Behind*, pubis, covered by pectineus ; pubic portion of fascia lata.

*Internally*, Gimbernat's ligament, conjoined tendon.

*Externally*, femoral vein.

The *deep crural arch* is a thickened bundle of fibres of the transversalis fascia, attached to Poupart's ligament outside the femoral vessels, and passing across the femoral sheath to the ilio-pectineal line behind Gimbernat's ligament.

## ILIAC REGION.

**Psoas magnus**: transverse processes and sides of bodies of all the lumbar and body of 12th dorsal vertebræ(F) (the fleshy fibres are only attached to upper and lower margins of bodies, and intervertebral substances, being connected by a tendinous arch between)—small trochanter of femur, receiving some fibres from the iliacus(T) (Branches from lumbar plexus). [A flexes thigh on trunk, and rotates femur outwards; B flexes trunk on thigh.]

**Psoas parvus**: bodies of 12th dorsal and 1st lumbar vertebræ and intervertebral disc(F)—ilio-pectineal line(T) (Branch from lumbar plexus). [Flexes lumbar spine.] *Frequently absent.*

**Iliacus**: upper half of iliac fossa, ilio-lumbar ligament, ala of sacrum, and capsule of hip-joint(F)—tendon of psoas, triangular surface anterior to and below the small trochanter (F) (Anterior crural). [A flexes hip-joint and rotates femur outwards; B flexes trunk on thigh.] *Passes beneath Poupart's ligament with the psoas.*

## ANTERIOR FEMORAL REGION.

**Tensor fasciæ femoris**: outer edge of iliac crest for one inch, anterior superior iliac spine, and half notch below it(A)—fascia lata (ilio-tibial band) about  $\frac{1}{3}$  down thigh, anterior to great trochanter(F) (Superior gluteal). [Makes fascia lata tense, rotates inwards, and abducts femur.]

**Sartorius**: anterior superior iliac spine and half notch below (A)—inner side of tibia, by side of tubercle, reaching by its upper edge as far back as internal lateral ligament(AT) (Middle cutaneous or special branch from anterior division of anterior crural). [Flexes hip and knee, abducts and rotates thigh out.] *Longest muscle of body, crosses thigh obliquely, forming outer boundary of Scarpa's triangle; lies over the roof of Hunter's canal; lower tendon pierced by patellar branch of long saphenous nerve.*

**Quadriceps extensor**—composed of:—

**Vastus externus**: upper half of shaft of femur, thus:—from base of neck, anterior and outer parts of base of great trochanter, and line from great trochanter to linea aspera, upper half of external lip of linea aspera, external intermuscular

septum(AF)—common extensor tendon, and slip to outer side of patella(τ) (Anterior crural).

**Vastus internus** : inner lip of linea aspera, lower part of spiral line, tendons of adductores longus and magnus(τA)—common tendon and inner side of patella(τ) (Anterior crural).

**Crureus** : upper  $\frac{3}{4}$  anterior and outer surfaces of shaft of femur, lower half external intermuscular septum(F)—common tendon(A) (Anterior crural).

**Rectus femoris** : 1st head. Anterior inferior iliac spine(τ). 2nd head. Groove above acetabulum(τ)—common extensor tendon into upper border of patella(τ) (Anterior crural).

THE COMMON EXTENSOR TENDON is inserted into the upper and lateral edges of the patella, very few fibres being prolonged over bone to help form the ligamentum patellæ. [Extends knee; rectus also flexes hip.]

**Subcrureus** : two slips from anterior surface of shaft of femur in lower fourth(F)—synovial sac of knee-joint(F) (Anterior crural). [Pulls up synovial expansion of knee-joint in extension.]

#### INTERNAL FEMORAL REGION.

**Gracilis** : internal margin of anterior surface of descending pubic ramus—inner side of tibia superior to semi-tendinosus, but inferior to backward prolongation of insertion of sartorius(τ) (Anterior branch of obturator). [Adducts thigh, flexes knee.]

**Pectineus** : ilio-pectineal line and triangular surface anterior to it(F)—posterior to small trochanter and upper half of line leading from it to linea aspera(τ) (Anterior crural, and Accessory obturator or Obturator). [Adducts thigh, flexes hip, rotates thigh out.]

**Adductor longus** : anterior surface of pubes below angle of crest and symphysis(τ)—inner lip of linea aspera(F) (Anterior division of obturator). [Adducts thigh, flexes hip, rotates thigh out.] *Forms internal boundary of Scarpa's triangle.*

**Adductor brevis** : body and ramus of pubis, extending from adductor longus to middle of ramus(FA)—behind pectineus into line leading from small trochanter to linea aspera(F) (Obturator, generally anterior branch). [Adducts thigh, flexes hip, rotates thigh out.] *Anterior division of obturator nerve placed in front and posterior part behind, the internal circumflex artery between upper border and obturator externus.*

**Adductor magnus** : pubic arch, from body of pubis to tuber ischii(A)—*Anterior part.* Line from great trochanter to linea aspera, inner lip of linea aspera, upper half of line leading

to inner condyle(F). *Posterior part.* Tubercle above inner condyle(T) (Posterior division of obturator, Great sciatic). [Adducts thigh; rotates thigh out; posterior fibres extend hip-joint.] *Between the two parts of the muscle there is an interval, the femoral opening, which transmits the femoral vessels.*

**HUNTER'S CANAL.** Extends from the apex of Scarpa's triangle to the opening in the adductor magnus, containing the superficial femoral vessels and long saphenous nerve. It is formed by aponeurotic fibres passing from the adductores magnus and longus to the vastus internus, and is covered by sartorius.

#### GLUTEAL REGION.

**Gluteus maximus:** external surface of ilium between superior curved line and posterior  $\frac{1}{3}$  of outer lip of crest, aponeurosis over erector spinæ, posterior surfaces of coccyx, and of last 2 pieces of sacrum, and great sacro-sciatic ligament(F)—gluteal ridge between linea aspera and great trochanter(AF), fascia lata(F) (Inferior gluteal). [A, extensor and rotator outwards of thigh; B, after stooping, extends trunk on thigh.]

*Parts beneath the gluteus maximus:* part of gluteus medius the pyriformis, superior and inferior gemelli, tendon of obturator internus, quadratus femoris, upper part of adductor magnus, origins of semi-membranosus, semi-tendinosus, and biceps and part of vastus externus. Superficial branch of gluteal artery and superior gluteal nerve, sciatic vessels, and great and small sciatic nerves, internal pudic vessels and pudic nerve, nerve to obturator internus, inferior gluteal nerve, branches of external and internal circumflex and 1st perforating arteries. Three bursæ, one over great trochanter, one over tuber ischii, one over vastus externus. Great sacro-sciatic ligament. Great trochanter and tuber ischii.

**Gluteus medius:** bone between iliac crest and superior curved line above, and middle curved line below, fascia(F)—outer surface of great trochanter from tip posteriorly to base anteriorly(F) (Superior gluteal). [Extends and abducts thigh: anterior fibres rotate thigh inwards, posterior outwards.] *Conceals gluteal vessels and nerve.*

**Gluteus minimus:** posterior surface of hip-bone between middle and inferior curved lines(F)—impression on anterior part of great trochanter(F) (Superior gluteal). [Abducts and rotates thigh inwards.]

**Pyriformis:** anterior surface of sacrum, from 2nd, 3rd, and 4th pieces between anterior foramina, upper margin of great sciatic notch, great sacro-sciatic ligament(F)—posterior part

of upper edge of great trochanter( $\tau$ ) (1st and 2nd Sacral). [Rotates the thigh outwards.] *Goes through great sacro-sciatic foramen.*

**Obturator internus** : posterior surfaces of pubic arch, obturator membrane, and ischium behind ; from great sciatic notch, fascia( $f$ )—front of upper border of great trochanter with the gemelli( $\tau$ ) (Sacral plexus). [External rotator of thigh.] *Passes through small sacro-sciatic foramen.*

The **obturator membrane** closes the thyroid foramen, except at the upper and outer part, where a canal is left for the obturator vessels and nerve.

**Gemellus superior** : outer surface of ischial spine( $f$ )—superior border of great trochanter anterior to the pyriformis with obturator internus( $\tau$ ) (Sacral plexus). [Rotates thigh outwards.]

**Gemellus inferior** : superior and outer border of tuber ischii( $f$ )—superior border of great trochanter with obturator internus( $\tau$ ) (Sacral plexus). [Rotates thigh outwards.]

**Obturator externus** : anterior half of outer surface of obturator membrane, rami of pubis and ischium( $f$ )—digital fossa at root of great trochanter( $\tau$ ) (Posterior division of obturator). [Rotates thigh outwards.]

**Quadratus femoris** : external border of tuber ischii( $f$ )—tubercle on posterior inter-trochanteric ridge, and downwards as far as insertion of adductor magnus( $f$ ) (Sacral plexus). [External rotator and adductor of thigh.]

#### POSTERIOR FEMORAL REGION.

**Biceps** : *Long head.* Lower and inner impression on tuber ischii, and great sacro-sciatic ligament( $\tau$ ). *Short head.* Outer lip of linea aspera in the lower half, upper part of line to external condyle, external inter-muscular septum( $f$ )—by two slips embracing the external lateral ligament upon the outer side of head of fibula( $\tau$ ) (Great sciatic). [Flexes knee and extends thigh, rotates leg outwards.] *Forms outer hamstring.*

**Semi-tendinosus** : lower and inner impression on tuber ischii with the biceps( $\tau$ ), tendon of biceps( $f$ )—upper part of internal surface of tibia, under cover of the sartorius( $\tau$ ) (Great sciatic). [Extends thigh, flexes knee, and rotates leg inwards.]

**Semi-membranosus** : upper and outer impression on the tuber ischii( $\tau$ )—(1) hinder part of lower lip of groove on internal tibial tuberosity( $\tau$ ) beneath internal lateral ligament—(2) forms principal part of posterior ligament of knee—(3) into fascia over popliteus (Great sciatic). [Extends thigh, flexes knee, and rotates leg inwards.]

## ANTERIOR TIBIO-FIBULAR REGION.

**Tibialis anticus**: external tuberosity and upper  $\frac{3}{4}$  of external surface of shaft of tibia, contiguous interosseous membrane, fascia and intermuscular septum(F)—inner surface of internal cuneiform; base of metatarsal bone of great toe(T) (Anterior tibial). [Flexes ankle and extends tarsal joints, adducts and inverts foot.] *Passes through innermost compartment of anterior annular ligament. Outer border conceals anterior tibial vessels.*

**Extensor proprius hallucis**: middle  $\frac{3}{4}$  of anterior surface of shaft of fibula, contiguous interosseous membrane(F)—base of last phalanx of great toe(T) (Anterior tibial). [Flexes ankle, extends tarsal joints and great toe.] *Anterior tibial vessels lie on the inner side, but the tendon crosses to inner side of vessels under anterior annular ligament.*

**Extensor longus digitorum**: external tuberosity of tibia, head and upper  $\frac{3}{4}$  of anterior surface of shaft of fibula, interosseous membrane(F)—by four tendons into the middle and last phalanges of four outer toes(T) (Anterior tibial). [Flexes ankle, extends joints of tarsus and toes.]

**Peroneus tertius**: lower  $\frac{1}{4}$  of anterior surface of shaft of fibula, interosseous membrane, intermuscular septum(F)—base of 5th metatarsal on dorsal surface(T) (Anterior tibial). [Flexes ankle and extends tarsal joints, everting the foot.]

## POSTERIOR TIBIO-FIBULAR REGION, SUPERFICIAL LAYER.

**Gastrocnemius**: *Inner head.* Impression on upper and posterior part of inner condyle(T), line above condyle(F). *Outer head.* Impression on external surface of outer condyle(T), upper and posterior part of condyle(F)—unites with tendon of soleus to form *tendo Achillis*, inserted into lower half of posterior surface of os calcis(T) (Internal popliteal). [Flexes knee and extends ankle.]

**Soleus**: posterior surface of head, and upper  $\frac{1}{3}$  of posterior surface of shaft of fibula, oblique line and middle  $\frac{1}{3}$  of internal border of tibia, fibrous arch over vessels(A)—*tendo Achillis* (Internal popliteal and posterior tibial). [Extends ankle.] *Posterior tibial vessels and nerve lie beneath.*

**Plantaris**: line above outer condyle, posterior ligament of knee-joint(F)—tuber calcis, with or by inner side of *tendo Achillis*(T) (Internal popliteal). [Flexes knee and extends ankle.] *Tendon, longest in body.*

## POSTERIOR TIBIO-FIBULAR REGION, DEEP LAYER.

The FASCIA of the leg invests the limb except where the inner surface of the tibia is subcutaneous; it is continuous above with the fascia lata of the thigh, and below with the annular ligaments of the ankle, being attached in front to the anterior and inner borders of the tibia, and to the antero- and postero-external borders of the fibula, forming intermuscular septa.

**Popliteus**: anterior half of impression on external surface of outer condyle(τ), posterior ligament of knee-joint(F)—triangular space on posterior surface of shaft of tibia above oblique line(F) (Internal popliteal). [Flexes knee and rotates leg inwards.] *Forms floor of popliteal space; arises in capsule of joint but outside synovial membrane.*

**Flexor longus hallucis**: lower  $\frac{2}{3}$  of posterior surface of shaft of fibula, intermuscular septum(F)—base of last phalanx of great toe(τ) (Posterior tibial). [Extends ankle, flexes tarsal joints and joints of great toe.] *Grooves astragalus.*

**Flexor longus digitorum**: inner part of posterior surface of shaft of tibia, from oblique line to 3 inches from lower end, aponeurosis over tibialis posticus(F)—four tendons, joined by flexor accessorius, passing through slits in tendons of flexor brevis digitorum, to bases of last phalanges of four outer toes (τ) (Posterior tibial). [Extends ankle, flexes joints of tarsus and four outer toes.]

**Tibialis posticus**: posterior surface of interosseous membrane except below, and aponeurosis superficial to muscle, external part of posterior surface of tibia from head to 2 inches from lower end, internal surface of shaft of fibula(F)—tubercle on scaphoid bone, slips to cuneiform, cuboid, bases of 2nd, 3rd, and 4th metatarsals, and sustentaculum tali(τ) (Posterior tibial). [Extends ankle, flexes and supports tarsal joints, inverts foot.]

## FIBULAR REGION.

**Peroneus longus**: upper  $\frac{2}{3}$  external surface of shaft of fibula, fascia, intermuscular septum(F)—outer part of plantar surface of internal cuneiform and of base of 1st metatarsal(τ) (Musculo-cutaneous). [Extends ankle-joint and everts foot.] *Winds round grooves behind external malleolus and outer border of cuboid bone.*

**Peroneus brevis**: lower  $\frac{2}{3}$  external surface shaft of fibula, intermuscular septum(F)—projection at base of 5th metatarsal(τ) (Musculo-cutaneous). [Extends ankle-joint and everts foot.]



THE ANTERIOR ANNULAR LIGAMENT consists of two parts. A *superior* or *vertical* part, attached to the anterior border of the tibia internally, and to the anterior border of the fibula externally, being continuous above with the fascia of the leg, and divided into two compartments, the internal one for the tibialis anticus tendon, which alone has a synovial sheath, the outer one for the extensor longus digitorum and peroneus tertius tendons. An *inferior* or *horizontal* part, which is attached externally to the upper surface of the os calcis, passes inwards across the foot and divides, the upper band being attached to the inner malleolus, the lower to the fascia over the foot. It contains three compartments, with separate synovial sacs, the internal one for the tibialis anticus tendon, the middle one for the extensor proprius hallucis tendon, and the external one for the extensor longus digitorum and peroneus tertius tendons.

THE INTERNAL ANNULAR LIGAMENT passes between the inner malleolus and the inner margin of the os calcis, being continuous above with the deep fascia, and below with the plantar fascia. It is divided into three compartments. The one next the malleolus transmits the tibialis posticus tendon, the next one the flexor longus digitorum, and the lowest, on the astragalus, the flexor longus hallucis. Between these last two canals the posterior tibial vessels and nerve pass under the ligament.

THE EXTERNAL ANNULAR LIGAMENT passes from the outer malleolus to the os calcis, binding down the peronei tendons.

THE PLANTAR FASCIA consists of a central and two lateral parts.

The *inner part* covers the abductor hallucis, and is continuous with the dorsal fascia.

The *outer part* covers the abductor minimi digiti, and extends from the external tubercle of the os calcis to the base of the 5th metatarsal.

The *central part* is attached behind to the internal tubercle of the os calcis, and, extending forwards, splits up into five parts at the heads of the metatarsal bones, one part passing to each of the toes.

#### FOOT, DORSAL REGION.

**Extensor brevis digitorum:** superior surface of os calcis in front of groove, anterior annular ligament(F)—four tendons, inner one to base of 1st phalanx of great toe, rest to outer side of tendons of long extensor to 2nd, 3rd, and 4th toes(T)

(Anterior tibial). [Extends toes and flexes tarsal joints.]  
*Inner tendon crosses dorsalis pedis artery.*

#### FOOT, PLANTAR REGION, 1ST LAYER.

**Abductor hallucis**: inner side of large tubercle on under surface of os calcis, plantar fascia, internal annular ligament (F)—inner side of base of 1st phalanx of great toe (T) (Internal plantar). [Abducts great toe.]

**Flexor brevis digitorum**: front part of inner tubercle of os calcis (T), plantar fascia (F), intermuscular septa (F)—four tendons, which on the 1st phalanx divide into two, allowing long flexor tendons to pass through; the slips then reunite and are inserted, again separating, into the sides of the bases to middle phalanges of four outer toes (T) (Internal plantar) [Flexes tarsal joints and first interphalangeal joint of toes.]

**Abductor minimi digiti**: outer tubercle and fore part of inner tubercle of os calcis, plantar fascia, intermuscular septa (F)—outer side of base of 1st phalanx of little toe (External plantar). [Abducts little toe.]

#### FOOT, PLANTAR REGION, 2ND LAYER.

**Flexor accessorius**: *Inner head.* Inner concave surface of os calcis (F). *Outer head.* Outer surface of os calcis in front of outer tubercle, long plantar ligament (T)—long flexor tendons (F) (External plantar). [Flexes toes, correcting obliquity of pull of the flexor longus digitorum.]

**Lumbricales**: long flexor tendons, from adjacent sides of two tendons, except most internal one, which arises from inner side of 1st flexor tendon (F)—inner sides of bases of 1st phalanx of four outer toes, and dorsal expansion of extensor tendon (T) (Internal plantar, 1st; External plantar, 2nd, 3rd, and 4th). [Flex metatarso-phalangeal and extend interphalangeal joints.]

#### FOOT, PLANTAR REGION, 3RD LAYER.

**Flexor brevis hallucis**: internal border of cuboid and adjacent part of external cuneiform (T), tendon of tibialis posticus (T)—outer and inner sides of base of 1st phalanx of great toe (T) (Internal plantar). [Flexes great toe and adducts it to middle line of foot.]

**Adductor obliquus hallucis**: bases of 2nd, 3rd, and 4th metatarsals, sheath of peroneus longus (F)—outer side of base of 1st phalanx of great toe (T) (External plantar). [Adducts great toe.]

**Adductor transversus pollicis**: capsules of metatarso-

phalangeal joints of three outer toes(F)—outer side of base of 1st phalanx of great toe (T) (External plantar). [Binds toes together and adducts great toe.]

**Flexor brevis minimi digiti** : base of 5th metatarsal, sheath of peroneus longus(F)—outer side of base of 1st phalanx of little toe(T) (External plantar). [Flexes metatarso-phalangeal joint of the little toe.]

#### FOOT, PLANTAR AND DORSAL INTEROSSEOUS REGION.

**Interossei dorsales** (4) : by two heads from adjacent sides of metatarsal bones(F)—side of and dorsal extensor expansion on 1st phalanx thus : the inner two go to 2nd toe, one on each side, outer two to outer sides of 3rd and 4th toes respectively(T) (External plantar). [Abduct from middle line of 2nd toe.]

**Interossei plantares** (3) : under and inner surfaces of three outer metatarsal bones(F)—inner side of base of 1st phalanx of same toes(T), and dorsal expansion on 1st phalanx(T) (External plantar). [Adduct to middle line of 2nd toe.]

## THE ARTERIES.

### ARTERIES OF HEAD AND NECK.

**THE SUBCLAVIAN ARTERIES.**—*Extent* : *Right*, from innominate opposite right sterno-clavicular articulation. *Left*, from transverse part of arch of aorta. Both pass into neck, arching outwards over pleura; lying on first rib, between scalenus anticus and medius, to end at outer border of it.

*Divisions* : The scalenus anticus, passing anteriorly to artery, is used to divide it into three parts, viz. :—

1st part, from origin of vessel to inner border of scalenus anticus.

2nd part, portion posterior to scalenus anticus.

3rd part, from outer edge of scalenus to external border of 1st rib.

## RELATIONS OF THE 1ST PART OF THE RIGHT SUBCLAVIAN.

<i>In Front.</i>		<i>Below.</i>	<i>Behind.</i>
Skin.	Internal jugular	Pleura. Recurrent laryngeal nerve.	Pleura. Recurrent laryngeal and cardiac branches of vagus.
Superficial fascia.	Vertebral		
Platysma.	Anterior jugular	}	}
Deep fascia.	Pneumogastric		
Sterno-mastoid	Sympathetic loop and superior cervical cardiac branch.	}	}
Sterno-hyoid			
Sterno-thyroid			
<i>Below and in Front.</i>			
Subclavian Commencement of innominate			Longus colli muscle.

## RELATIONS OF 1ST PART OF LEFT SUBCLAVIAN.

<i>In Front.</i>	<i>Inner Side.</i>	<i>Behind.</i>
Skin.	Left carotid.	Longus colli.
Superficial fascia.	Trachea.	Esophagus.
Manubrium sterni.	Esophagus.	Thoracic duct (below).
Platysma.	Thoracic duct	Inferior cervical ganglion.
Deep fascia.	Pneumogastric.	Cord of sympathetic.
Sterno-mastoid	Lower cardiac branches of sympathetic.	Pleura.
Sterno-hyoid	Left recurrent laryngeal nerve.	<i>Outer Side and Behind.</i>
Sterno-thyroid		Left lung.
Left common carotid artery.		Pleura.

## RELATIONS OF 2ND PART OF SUBCLAVIAN.

<i>In Front.</i>	<i>Behind.</i>	<i>Below</i>
Skin.	Pleura and lung.	Pleura.
Superficial fascia.		<i>Above.</i>
Platysma.		Brachial plexus.
Deep fascia.		
Sterno-mastoid (clavicular origin)		
Scalenus anticus		

## RELATIONS OF 3RD PART OF SUBCLAVIAN.

Contained in subclavian triangle, and enclosed in tube of deep cervical fascia.

	<i>In Front.</i>	<i>Below.</i>
Skin.	Supra-scapular artery.	1st rib.
Superficial fascia.	Clavicle.	
Descending cutaneous branches of cervical plexus.	Subclavius.	<i>Behind.</i>
Platysma.	Nerve to subclavius.	Scalenus medius.
Deep fascia.	<i>Above.</i>	Lowest brachial nerve trunk.
External jugular	Brachial plexus.	
Subclavian		
Branch from cephalic to external jugular		
Supra-scapular		
Transverse cervical		
Anterior jugular		

## BRANCHES FROM THE 1ST PART.

**VERTEBRAL:** from upper and back part. Passes upwards and backwards, behind inferior thyroid artery and internal jugular and vertebral veins, then between scalenus anticus and longus colli, to enter foramen in transverse process of 6th cervical vertebra. Ascends in corresponding foramina as far as axis, having vertebral vein in front, and cervical nerves behind. It then passes outwards and upwards, through foramen in atlas, and winds backwards and inwards in vertebral groove of atlas, lying on the floor of the suboccipital triangle, having the trunk of the 1st cervical nerve beneath it, and the posterior branch of same nerve crossing it behind. It pierces posterior occipito-atloid ligament and dura mater, and enters skull through foramen magnum. It then winds round bulb, passing between hypoglossal and anterior root of 1st cervical nerve to front of medulla, uniting with fellow, to form the basilar artery (p. 73), at the lower border of the pons.

*Cervical Branches:*—

**Lateral spinal:** each enters spinal canal through an intervertebral foramen, dividing into *posterior* to supply cord and membranes, and *anterior* to supply bodies of vertebræ.

**Muscular:** to deep cervical muscles.

*Cranial Branches:*—

**Posterior meningeal:** arises before vertebral pierces dura mater opposite foramen magnum, to falx cerebelli, and dura in posterior fossa

**Posterior spinal**: arises opposite posterior part of medulla, passes down back of cord behind roots of nerves, anastomising with spinal branches coming through intervertebral foramina.

**Anterior spinal**: given off near end of artery, descends in front of medulla, unites with opposite fellow just below foramen magnum to form a single artery, which is continued along the cord, anastomosing like the posterior artery; supplies pia mater and cord.

**Posterior inferior cerebellar**: arising near pons, passes backwards and outwards between roots of hypoglossal and then between spinal accessory and pneumogastric nerves, to reach under surface of cerebellum; divides into two branches, one continuing backwards in sulcus between two hemispheres, the other outwards to supply under surface of cerebellum; *anas.* superior cerebellar. Supplies hemisphere, vermiform process, and choroid plexus of 4th ventricle.

**Bulbar arteries** enter medulla.

**THYROID AXIS**: a short thick trunk from front of artery near scalenus anticus, quickly dividing into:—

**Inferior thyroid**: passes upwards on vertebral artery and under internal jugular vein; then inwards and downwards behind sheath of carotid and sympathetic (middle cervical ganglion), finally outwards and upwards to under part of thyroid body; *anas.* opposite fellow and superior thyroid.

*Branches*:—

**Ascending cervical**: arises as inferior thyroid turns behind carotid sheath, ascends parallel to phrenic nerve and between scalenus anticus and rectus anticus major, supplying them, the cord and its membranes.

**Inferior laryngeal**: upwards on trachea to back of larynx, with recurrent laryngeal nerve.

**Tracheal**: to trachea; *anas.* bronchial.

**Œsophageal**: to supply œsophagus.

**Thyroid**: to gland.

**Muscular**.

**Supra-scapular**: runs downwards at first, over scalenus anticus and phrenic nerve, crosses 3rd part of subclavian, then runs transversely outwards, behind and parallel to clavicle, to upper edge of scapula under cover of trapezius; inclining downwards with nerve to pass over transverse ligament on supra-scapular notch, enters supra-spinous fossa in contact with the bone beneath supra-spinatus, which it supplies. It then winds over neck of scapula to infra-spinous fossa; *anas.* with posterior scapular and dorsalis scapulæ.

*Branches* :—

*Muscular* : to neighbouring muscles, especially sterno-mastoid.

*Supra-acromial* : through trapezius to acromion ; *anas.* acromio-thoracic.

*Subscapular* : arises as suprascapular passes over notch ; *anas.* in subscapular fossa with posterior scapular and subscapular of axillary.

*Infra-spinous* : descends on neck of scapula to fossa ; *anas.* dorsal of subscapular and posterior scapular.

*Articular* : to shoulder-joint. *Nutrient* : to scapula.

**Transverse cervical** : over scaleni muscles, phrenic nerve, and brachial plexus, under omohyoid, to outer edge of levator anguli scapulæ, there dividing into :—

*Superficial cervical* : ascends beneath anterior edge of trapezius, supplying it together with glands, integuments and muscles of that region ; *anas.* superficial branch of arteria princeps cervicis.

*Posterior scapular* : backwards to superior angle of scapula beneath levator anguli scapulæ, then downwards along vertebral border of scapula under the rhomboids supplying surrounding muscles ; *anas.* supra-scapular, subscapular.

**INTERNAL MAMMARY** : from under surface of subclavian just below thyroid axis, runs down behind clavicle and subclavian vein to posterior surface of 1st costal cartilage, being crossed here by phrenic nerve ; downwards between pleura and costal cartilages, crossed by intercostal nerves and lying on triangularis sterni as far as the 6th space, there dividing into two terminal branches.

*Branches* :—

*Comes nervi phrenici (superior phrenic)* : arises high in chest, accompanies phrenic nerve between pleura and pericardium to diaphragm, supplying it ; *anas.* musculo-phrenic, inferior phrenic.

*Mediastinal* : to areolar tissue of anterior mediastinum and thymus gland.

*Pericardiac* : to upper part of pericardium.

*Sternal* : to triangularis sterni and sternum.

*Anterior Intercostal* : to upper five or six intercostal spaces, two in each space ; *anastomose* with aortic intercostal.

*Perforating* : perforate upper five or six intercostal spaces to supply pectoral muscles and mammary gland.

*Musculo-phrenic* : external of two terminal branches perforates diaphragm about 9th intercostal space, supplying diaphragm, and branches to lower intercostal spaces.

*Superior epigastric*: internal terminal branch passes behind 7th costal cartilage and pierces diaphragm, lies posterior to rectus within the sheath, terminating in that muscle; *anas.* deep epigastric of external iliac.

#### BRANCH FROM THE 2ND PART.

**SUPERIOR INTERCOSTAL**: from upper and back part behind scalenus anticus, bends backwards over pleural dome in front of neck of 1st rib to 1st and 2nd intercostal spaces, supplies small branches to cord and deep spinal muscles. On the neck of the 1st rib, the 1st intercostal nerve is external, and 1st thoracic ganglion of sympathetic, internal to artery.

*Branch*:—

**Deep cervical**: corresponds to posterior branch of an aortic intercostal; passes between transverse process of 7th cervical vertebra and 1st rib, ascending beneath complexus to axis; *anas.* vertebral, and deep branch of arteria princeps cervicis of occipital.

#### THE COMMON CAROTID ARTERY.

**THE COMMON CAROTID ARTERY**: *On the right side*, arises from the innominate, at its bifurcation behind the right sterno-clavicular articulation. *On the left side*, from the highest or transverse part of aortic arch, and is consequently longer than the right artery, and more deeply placed in the thorax at its origin. It ascends obliquely to the neck.

#### *Relations of the Left Common Carotid in the Thorax.*

	<i>In Front.</i>	<i>Behind.</i>	<i>Left Side.</i>
Skin.	Sterno-hyoid and	Trachea.	Left subclavian
Superficial fascia.	Sterno-thyroid	Œsophagus.	artery.
Deep fascia.	muscles.	Thoracic duct.	Left pneumogas-
Part of pectoralis	Left innominate	Left recurrent	tric and phrenic
major.	vein.	laryngeal	nerves.
1st piece of ster-	Thymus gland.	nerve.	Left pleura and
num.			lung.
		<i>Right Side.</i>	
		Innominate	
		artery.	

*Extent*.—In the neck the common carotid of either side extends from sterno-clavicular articulation to opposite upper border of thyroid cartilage, there dividing into external and internal carotids.

*Course*.—A line drawn from sterno-clavicular articulation, to point midway between mastoid process and angle of inferior maxilla.



*Relations of both Common Carotids in the Neck.*

Crossed about midway by omo-hyoid, and enclosed in same sheath of deep cervical fascia as internal jugular vein and pneumogastric nerve.

*Part below Superior Border of Omo-hyoid.*

<i>In Front.</i>		<i>Behind.</i>	<i>Inner Side.</i>
Skin.	Internal jugular (overlaps on left side) Superior and middle thyroid Anterior jugular Descendens and communicans hypoglossi.	Scalenus anticus.	Trachea.
Superficial fascia.		Longus colli.	Œsophagus.
Platysma.		Inferior thyroid artery. Vertebral artery. Sympathetic Recurrent laryngeal Pneumogastric	Recurrent laryngeal nerve.
Deep fascia.			Thyroid body.
Sterno-mastoid (sternal origin)			Superior thyroid artery.
Sterno-hyoid			
Sterno-thyroid			
Omo-hyoid			
		<i>Outer Side.</i>	
		Internal jugular.	
		Pneumogastric.	

*Part above Omo-hyoid.*

<i>In Front.</i>	<i>Behind.</i>	<i>Inner Side.</i>
Platysma.	Rectus capitis anticus major.	Larynx.
Deep fascia.	Pneumogastric nerve.	Pharynx.
Sterno-mastoid.	Sympathetic "	Superior thyroid artery.
Descendens hypoglossi.		<i>Outer Side.</i>
Sterno-mastoid branch of superior thyroid.		Internal jugular.

BRANCHES of the Common Carotid Artery. Terminal only, viz., external and internal carotid.

EXTERNAL CAROTID. *Extent.*—From bifurcation of common carotid opposite upper border of thyroid cartilage, to level of neck of condyle of inferior maxilla, there dividing into superficial temporal and internal maxillary.

*Course.*—Line of artery same as common carotid.

RELATIONS.

<i>Superficial.</i>	<i>Behind.</i>	<i>Inner Side.</i>
Skin.	Pharynx. Styloid process. Stylo-glossus. Stylo-pharyngeus. Glosso-pharyngeal nerve Internal carotid artery.	Pharynx.
Superficial fascia.		Ramus of jaw.
Platysma.		Stylo-maxillary ligament.
Deep fascia.		Parotid gland.
Sterno-mastoid	Superior laryngeal External laryngeal	Superior laryngeal External laryngeal
Digastric		
Stylo-hyoid		
Parotid gland.		

*Anterior Branches of External Carotid.*

**Superior thyroid** : given off just below great cornu of hyoid, curves downwards and forwards to thyroid body ; *anas.* fellow of opposite side, inferior thyroid.

*Branches :—*

**Muscular** : to muscles covering it. *Sterno-mastoid branch* passes downwards and outwards across sheath of common carotid, supplying sterno-mastoid and integument.

**Infra hyoid** : runs transversely inwards, along inferior border of hyoid ; *anas.* with opposite fellow.

**Superior laryngeal** : accompanies superior laryngeal nerve, pierces thyro-hyoid membrane, supplies muscles, glands, and mucous membrane of larynx ; *anas.* opposite fellow.

**Crico-thyroid** : crosses crico-thyroid membrane transversely ; *anas.* opposite fellow.

**Thyroid** : to upper and anterior part of gland.

**Lingual** : arises from anterior part of artery between superior thyroid and facial arteries, curves upwards and forwards on middle constrictor to tip of great cornu of hyoid, where it is crossed by hypoglossal nerve, thence forwards under hypoglossus muscle, digastric and stylo-hyoid, parallel with hypoglossal nerve, finally on genio-hyo-glossus upwards and forwards to tip of tongue as ranine.

*Branches :—*

**Supra-hyoid** : along superior border of hyoid, supplying muscles, etc. ; *anas.* opposite fellow.

**Dorsalis linguæ** : ascends to dorsum of tongue ; *anas.* opposite fellow, supplies mucous membrane, tonsil, epiglottis, soft palate, etc.

**Sublingual** : runs forwards and outwards to supply sublingual gland, adjacent muscles and mucous membrane.

**Ranine** : continuation of the lingual to tip of tongue, accompanies gustatory nerve ; *anas.* opposite fellow.

**Facial** : arises near angle of inferior maxilla, directed forwards and upwards beneath digastric and stylo-hyoid muscles in groove on deep surface of submaxillary gland to base of lower jaw, over which it ascends to face, being anterior to masseter muscle ; ascending to inner canthus, imbedded in levator labii superioris alæque nasi, where it takes name of angular, it rests successively upon lower jaw, buccinator, and levator anguli oris, with vein to outer side, and crossed by platysma, risorius, zygomaticus major, and sometimes by the levator labii superioris ; *anas.* ophthalmic

*Cervical Branches :—*

*Ascending or inferior palatine* : between stylo-glossus and stylo-pharyngeus to pharynx near border of internal pterygoid muscle ; after supplying muscles, tonsil, Eustachian tube, divides near levator palati into two branches, one going to supply soft palate, glands, etc., the other to tonsil ; *anas.* tonsillar and artery of opposite side.

*Tonsillar* : penetrates superior constrictor of pharynx to supply tonsil and root of tongue ; *anas.* ascending palatine.

*Submaxillary* (three or four) to supply submaxillary gland.

*Submental* : arises as artery turns round base of jaw, and runs forwards over mylo-hyoid, supplying it and digastric, then to symphysis, there dividing into *superficial*, which turns round chin ; *anas.* inferior labial and mental, and a *deep* branch perforates mylo-hyoid, supplying deep muscles ; *anas.* sublingual.

*Facial Branches :—*

*Muscular* : to masseter, buccinator, etc.

*Inferior labial* : runs beneath depressor anguli oris, to supply lower lip ; *anas.* inferior coronary, submental, mental.

*Inferior coronary* : arises near angle of mouth, tortuous course between mucous membrane of lower lip and orbicularis oris ; anastomoses with opposite fellow.

*Superior coronary* : arises with or near preceding, having corresponding course in upper lip ; anastomoses with opposite fellow, supplies a branch, *artery of septum*, to collumella of nose.

*Lateral nasal* : turns inwards beneath levator labii superioris alæque nasi to supply ala and dorsum of nose ; *anas.* opposite fellow, nasal of ophthalmic, and infra-orbital.

*Angular* : terminal branch ; anastomoses at inner canthus with nasal of ophthalmic.

*Posterior Branches of External Carotid :—*

*Occipital* : arising from the posterior part of artery, about opposite the facial, runs upwards and backwards beneath digastric, stylo-hyoid, sterno-mastoid, splenius, and trachelo-mastoid to interval between transverse process of atlas and mastoid process, then backwards in the occipital groove, and lying on rectus capitis lateralis, superior oblique and complexus ; lastly, piercing the trapezius near insertion, it ascends in company with the great occipital nerve to the back of scalp. Hypoglossal nerve hooks round it at origin, and the artery crosses in the neck the internal carotid artery, pneumogastric and spinal accessory nerves and internal jugular vein.

*Branches :—*

*Muscular* to digastric, stylo-hyoid ; *sterno-mastoid* branch to supply that muscle.

*Mastoid* : through mastoid foramen to dura mater.

*Posterior meningeal* : ascends, in company with internal jugular vein, through jugular foramen to dura mater in posterior fossa.

*Cervical (ramus princeps cervicis)* : at outer border of complexus ; descends at back of neck ; *superficial branch* passes beneath splenius, supplying it and the trapezius, *anas.* superficial cervical ; *deep branch*, goes beneath complexus, *anas.* vertebral, deep cervical of superior intercostal.

*Cranial* : to muscles and integuments of occiput ; *anas.* opposite fellow, posterior auricular and superficial temporal.

**Posterior auricular** : arises opposite apex of styloid process, ascends in parotid to groove between pinna and mastoid process, dividing into *anterior* or *auricular*, *anas.* posterior division of temporal ; and *posterior* or *mastoid*, *anas.* occipital. Joined near mastoid process by posterior auricular branch of the 7th nerve.

*Branches :—*

*Stylo-mastoid* : enters stylo-mastoid foramen, supplying tympanum, mastoid cells, etc.

*Auricular* : to posterior part of concha.

*Ascending branch of External Carotid :—*

**Ascending Pharyngeal** : smallest branch, arising half an inch above origin of trunk, ascends between internal carotid and pharynx to base of skull.

*Branches :—*

*Prevertebral* : to rectus anticus, 1st cervical ganglion, and 9th, 10th and 11th nerves, glands, etc.

*Pharyngeal* (three or four) : inwards to pharynx, supplying constrictors, Eustachian tube, and a *palatine* branch to soft palate and tonsil.

*Meningeal* : one through foramen jugulare, another through anterior condylar foramen, and a third through foramen lacerum medium to supply dura mater.

*Terminal Branches of External Carotid :—*

**Superficial temporal** : smaller of two terminal branches, continues in the line of external carotid. Imbedded at first in parotid, crosses over root of zygoma in front of auriculo-temporal nerve, upwards under skin for 2 inches, dividing into two terminal branches.

*Branches :—*

*Parotid* to gland.

*Transverse facial* : arises in parotid, accompanies transverse branches of facial nerve and parotid duct across face, lies above the duct, supplying muscles, glands, etc. ; *anas.* facial, infra-orbital.

*Middle temporal* : arises just above zygoma, perforates temporal fascia, supplying muscle ; *anas.* deep temporal.

*Orbital* (may come from middle temporal) : along zygoma between layers of temporal fascia to outer canthus.

*Anterior auricular* : to anterior portion of external ear ; *anas.* posterior auricular.

*Anterior temporal* : one of terminal branches, ascends over temporal fascia, supplying muscles, etc. ; *anas.* frontal, supra-orbital.

*Posterior temporal* : curves backwards over temporal fascia and inosculates with opposite fellow ; *anas.* posterior auricular, occipital.

*Internal maxillary* : larger of terminal branches, arises in parotid, at first (maxillary portion) curving forwards between jaw and internal lateral ligament, parallel with auriculo-temporal nerve and lying on internal pterygoid muscle and inferior dental nerve, then (pterygoid portion) forwards and outwards on outer (frequently on inner) surface of lower head of external pterygoid, finally (spheno-maxillary portion) enters spheno-maxillary fossa between two heads of origin of external pterygoid.

*Branches from Maxillary portion :—*

*Tympanic* : enters Glaserian fissure, supplies tympanum, and membrana tympani, generally gives off *deep auricular* to external auditory meatus ; *anas.* vidian, stylo-mastoid. (May come from middle meningeal.)

*Middle or great meningeal* : arises between internal lateral ligament and neck of condyle, passes between two roots of auriculo-temporal nerve, through foramen spinosum of the sphenoid, dividing on great wing of sphenoid into anterior and posterior branches ; *anterior* going to anterior inferior angle of parietal, *posterior* to squamous of temporal ; *anas.* opposite fellow, anterior and posterior meningeal. The trunk of the artery gives off *Gasserian*, to ganglion. *Petrosal* : enters hiatus Fallopii ; *anas.* stylo-mastoid of posterior auricular. *Orbital* : through sphenoidal fissure to orbit. *Temporal* : through foramen in bone to join branches from deep temporal.

*Small meningeal* : through foramen ovale, supplies Gasserian ganglion and dura mater. (Generally a branch of the middle meningeal.)

*Inferior dental*: descends with and behind inferior dental nerve through dental foramen on inner side of ramus of inferior maxilla, divides opposite 1st bicuspid into *incisor* and *mental*, the former going to incisor teeth; *anas.* opposite fellow: the latter comes out through mental foramen; *anas.* sub-mental, inferior labial, inferior coronary. *Mylo-hyoid branch* given off as artery enters dental foramen, runs in mylo-hyoid groove to muscle. *Lingual branch* accompanies lingual nerve.

*Branches from Pterygoid portion*:—

*Deep temporal* (2): anterior and posterior to temporal fossa between muscle and cranium; *anas.* other temporal, lachrymal through foramina in malar bone.

*Pterygoid*: to pterygoid muscles.

*Masseteric*: passes over sigmoid notch to deep surface of masseter; also supplies temporo-maxillary articulation.

*Buccal*: runs forward with buccal nerve between internal pterygoid and jaw to buccinator; *anas.* facial.

*Branches of Spheno-Maxillary Portion*:—

*Posterior superior dental, or alveolar*: given off as artery passes into spheno-maxillary fossa; descends on posterior aspect of maxilla with branch of superior maxillary nerve, enters posterior dental canals, supplying molars, bicuspids, antrum, gums, etc.

*Infra-orbital*: continuation of trunk, accompanies superior maxillary nerve through infra-orbital canal, appearing on face beneath levator labii superioris; *anas.* facial and buccal. In the canal it gives off branches to orbit, and an *anterior dental* branch goes with nerve to supply front teeth; *anas.* posterior dental. On the face it supplies lachrymal sac and inner canthus; *anas.* ophthalmic; and gives branches downwards; *anas.* transverse facial, buccal and facial.

*Descending, or superior palatine*: through posterior palatine canal with large palatine nerve, along hard palate, and through foramen of Stenson in anterior palatine fossa; *anas.* artery of septum from facial and naso-palatine.

*Vidian*: through vidian canal with nerve, supplies Eustachian tube and tympanum.

*Pterygo-palatine*: backwards through pterygo-palatine canal with pharyngeal nerve to upper part of pharynx.

*Nasal, or spheno-palatine*: enters spheno-palatine foramen, supplying posterior ethmoidal cells, etc. *Branch. Naso-palatine* or artery of septum, runs along vomer; *anas.* descending palatine.

INTERNAL CAROTID. *Extent*.—From superior border of

thyroid cartilage to Sylvian fissure of brain, there dividing into anterior and middle cerebral.

*Course.*—Extends directly upwards from common carotid to carotid canal of temporal bone; entering canal passes upwards, internal to and then above Eustachian tube, then forwards and inwards, then alongside of sella Turcica in the cavernous sinus, having the 6th nerve on the outer side; it turns upwards on inner side of anterior clinoid process, pierces dura mater, and divides between 2nd and 3rd cranial nerves at anterior perforated spot into branches. No branches given off from cervical part.

## RELATIONS IN THE NECK.

<i>Superficial.</i>	<i>Inner Side.</i>	<i>Behind.</i>
Skin.	Pharynx.	Internal jugular vein.
Superficial fascia.	Ascending pharyngeal artery.	Rectus capitis anticus major.
Platysma.	Superior and external laryngeal nerves.	Sympathetic.
Deep fascia.		Pneumogastric.
Sterno-mastoid.		
Parotid gland.		
External carotid.		
Digastric.		
Stylo-hyoid.		
Stylo-glossus.		
Stylo-pharyngeus.		
Occipital	} arteries.	
Posterior auricular		
Hypoglossal	} nerves.	
Glosso-pharyngeal		
Pharyngeal branch of vagus		
<i>Outer Side.</i>		
Internal jugular vein.		

*Branch from Petrous portion :—*

**Tympanic** : inconstant : through a foramen in carotid canal to tympanum ; *anas.* tympanic of internal maxillary and stylo-mastoid.

*Branches from Cavernous portion :—*

**Pituitary** : small branches to pituitary body, etc.

**Meningeal** : to dura mater in middle fossa.

**Ophthalmic** : arises at inner side of anterior clinoid process, enters orbit through optic foramen, external and below optic nerve ; it then crosses over nerve to inner angle of orbit to divide into two terminal branches, frontal and nasal.

*Branches arising outside Optic Nerve :—*

**Lachrymal** : accompanies lachrymal nerve over external rectus to lachrymal gland, gives off malar branches ; *anas.*

deep temporal and transverse facial. Branch sent back to *anas.* middle meningeal through sphenoid fissure

*Central of retina* : pierces optic nerve, runs in its substance to retina (*vide Eye*).

*Branches arising over Optic Nerve* :—

*Posterior ciliary* : divided into two sets. *Short* (10) perforate sclerotic and supply choroid. *Long* (2) pass forward between choroid and sclerotic; *anas.* anterior ciliary and supply iris and ciliary processes.

*Supra-orbital* : ascends with frontal nerve over muscles, etc., to supra-orbital foramen; passing out, ascends over frontal bone; *anas.* temporal, facial and frontal.

*Branches arising internal to Optic Nerve* :—

*Muscular, superior and inferior* : to muscles of orbit, give off *anterior ciliary* (6-8), which pierce sclerotic behind cornea.

*Ethmoidal* : *anterior* and *posterior* to ethmoidal cells, through anterior and posterior internal orbital canals respectively, supplying also dura mater, the anterior accompanying nasal nerve to skin of nose (*anterior nasal branch*).

*Palpebral* (2) : one for each lid, arise near pulley, form an arch in each lid, and supply lachrymal apparatus.

*Terminal Branches* :—

*Frontal* : turns upwards round inner margin of orbit; *anas.* supra-orbital.

*Nasal* : over tendo oculi to root of nose; *anas.* nasal and angular of facial.

*Branches from Cerebral Portion of Internal Carotid* :—

*Anterior cerebral* : arises at inner extremity of fissure of Sylvius, passes forwards in great longitudinal fissure. Opposite arteries united by *anterior communicating*. It then curves round fore part of corpus callosum, supplying offsets to corpus callosum, frontal and parieto-occipital sulci, and to anterior perforated spot.

*Middle cerebral* : largest offset, enters fissure of Sylvius, dividing into branches for external surface of hemisphere, and interior of brain, the latter entering anterior perforated spot. *Internal branches* : Caudate, thalamic, and lenticulo-striate. *External branches* : Frontal, parietal, parieto-temporal, and temporal.

*Posterior communicating* : from posterior part of artery, runs backwards; *anas.* posterior cerebral of basilar.

*Anterior choroid* : from back part of artery, passes backwards and outwards to enter descending horn of lateral ventricle, just beneath edge of middle lobe; supplies



hippocampus major, corpus fimbriatum, and choroid plexus.

**THE BASILAR ARTERY:** formed by union of the two vertebral arteries. *Extent*, from lower to upper border of pons, there dividing into posterior cerebrals.

*Branches* :—

**Transverse** (4 or 6): twigs to supply pons and *internal auditory*, an offset to internal ear, with auditory nerve.

**Anterior inferior cerebellar**: backwards to anterior part of inferior surface of cerebellum; *anas.* posterior inferior cerebellar of vertebral.

**Superior cerebellar**: arises near termination, to upper surface of cerebellum, winding round crus cerebri behind 3rd nerve; *anas.* opposite fellow, inferior cerebellar.

**Posterior cerebral** (2): one on each side, terminal of basilar, winds backwards round crus in front of 3rd nerve, passes upwards to under surface of posterior cerebral lobes, joined near crus by posterior communicating, and gives off :—*Postero-median* to posterior perforated spot; *Posterior choroid* to choroid plexus through transverse fissure; *Postero-lateral* to optic thalamus; *Cortical branches*: temporal, calcarine, parieto-occipital; *anas.* anterior and middle cerebral.

**CIRCLE OF WILLIS**: a name given to the anastomoses between the vertebral and internal carotid arteries at base of brain. The internal carotid sends forward the anterior cerebrals, which are connected by the anterior communicating. The basilar sends forwards the posterior cerebrals, which are joined to the carotid by the posterior communicating arteries.

## ARTERIES OF UPPER LIMB.

### THE AXILLARY ARTERY.

*Extent*.—From outer border of 1st rib to lower border of teres major insertion. Divided into three parts :—

**1ST PART.** *Extent*.—From outer border of 1st rib to upper border of pectoralis minor.

*Relations*.—*In front.* Pectoralis major, costo-coracoid membrane, cephalic vein, external anterior thoracic nerve, and branches of acromio-thoracic artery and vein.

*Behind.* 1st intercostal space and muscle, 1st serration of serratus magnus, posterior thoracic nerve.

*Inner side.* Internal anterior thoracic nerve and axillary vein. *Outer side.* Brachial plexus.

**2ND PART.** *Extent.*—From superior to inferior border of pectoralis minor.

*Relations.*—*In front.* Pectorales major and minor.

*Behind.* Subscapularis, posterior cord of plexus.

*Outer side.* Outer cord of plexus.

*Inner side.* Inner cord of plexus, separating artery from vein.

**3RD PART.** *Extent.*—From inferior border of pectoralis minor to lower border of teres major.

*Relations.*—*In front.* Pectoralis major, inner head of median and internal cutaneous nerves; below, skin and fasciæ.

*Behind.* Subscapularis, tendons of latissimus dorsi and teres major, musculo-spiral and circumflex nerves.

*Inner side.* Ulnar nerve, axillary vein, and lesser internal cutaneous nerve.

*Outer side.* Coraco-brachialis, median and musculo-cutaneous nerves.

*Branches:*—

**Superior thoracic** (1st part): arises opposite 1st intercostal space, supplies pectorales; *anas.* internal mammary, intercostals.

**Acromio-thoracic** (1st part): arises from front of artery just above pectoralis minor.

*Branches:*—

**Acromial:** supply and perforate deltoid; *anas.* branch of supra-scapular and posterior circumflex.

**Humeral:** accompanies cephalic vein; *anas.* anterior circumflex.

**Thoracic:** two or three branches to supply side of thorax; *anas.* intercostal.

**Clavicular:** one or two twigs to clavicle and subclavius.

**Long thoracic** (2nd part): passes downwards along inferior border of pectoralis minor to about 6th intercostal space, supplies pectorales and serratus magnus; *anas.* intercostal and other thoracic branches. *In female* gives branches to mammary gland: *external mammary.*

**Alar thoracic** (2nd part): supplies glands and fat of the axilla; not a constant separate branch.

**Subscapular** (3rd part): arises opposite lower border of subscapularis muscle, and courses with the long subscapular nerve to lower angle of scapula.

*Branch:*—

**Dorsalis scapulæ:** given off near origin to dorsum of scapula, passes backwards to the infraspinous fossa through triangular

interval, bounded above and internally by the subscapularis, below by teres major, and externally by the long head of the triceps. In the triangular interval it gives off ventral branches to subscapular fossa, and a *descending* branch which runs down between the two teres muscles to the angle. Supplies subscapularis, latissimus dorsi, teres major, serratus magnus; *anas.* supra-scapular and posterior scapular.

**Posterior circumflex** (3rd part): arises from back of artery opposite lower border of subscapularis, winds backwards through quadrilateral space, bounded above by the teres minor, below by the teres major, internally by the long head of the triceps, and externally by the neck of the humerus. Supplies deltoid, head of humerus, shoulder-joint, teres minor, and long head of triceps; *anas.* acromio - thoracic, anterior circumflex and superior profunda.

**Anterior circumflex** (3rd part): arises from outer side of artery, one branch ascends bicipital groove to shoulder-joint, another winds round surgical neck of humerus; *anas.* posterior circumflex.

#### THE BRACHIAL ARTERY.

*Extent.*—From lower border of teres major to half an inch below bend of elbow, runs along inner borders of coraco-brachialis and biceps, accompanied by venæ comites.

*Relations.*—*In front.* Integument, fascia, coraco-brachialis, biceps and bicipital fascia, median basilic vein. Crossed by median nerve at insertion of coraco-brachialis.

*Behind.* Long and inner heads of triceps, musculo-spiral nerve, superior profunda vessels, coraco-brachialis, brachialis anticus.

*Inner side.* Internal cutaneous nerve to about middle of arm, ulnar nerve to insertion of coraco-brachialis, median nerve from insertion of coraco-brachialis to elbow.

*Outer side.* Coraco-brachialis and biceps. Median nerve from origin of artery of insertion of coraco-brachialis.

*Branches* :—

**Superior profunda**: arises opposite lower border of teres major, winds backwards and outwards with musculo-spiral nerve in the groove to triceps; gives off anterior branch which pierces external intermuscular septum (*anas.* radial recurrent); and ends as posterior branch behind external condyle; *anas.* posterior circumflex, interosseous recurrent, anastomotic. Supplies triceps, anconeus.

**Nutrient**: arises about middle of humerus, and enters medullary foramen near insertion of coraco-brachialis.

**Inferior profunda:** arises opposite insertion of coraco-brachialis, accompanies ulnar nerve, pierces internal intermuscular septum; *anas.* posterior ulnar recurrent and anastomotic at elbow.

**Anastomotica magna:** arises 2 inches above elbow-joint, courses to hollow between olecranon and inner condyle of humerus; *anas.* inferior profunda, anterior and posterior ulnar recurrent, and a branch across the back of olecranon with superior profunda. Supplies elbow-joint.

**Muscular:** to coraco-brachialis, biceps, brachialis anticus.

#### THE RADIAL ARTERY.

*Extent.*—From bifurcation of the brachial to ending of the deep palmar arch of hand; accompanied by venæ comites.

*Relations in the forearm.*—*In front.* Integument, fascia, supinator longus.

*Behind.* Tendon of biceps, supinator brevis, pronator radii teres, flexores sublimis digitorum et longus pollicis, pronator quadratus, lower end of radius.

*Inner side.* Pronator radii teres, flexor carpi radialis.

*Outer side.* Supinator longus tendon, and for middle  $\frac{1}{3}$ rd, radial nerve.

The artery courses along inner border of supinator longus tendon to carpus, winds round carpus beneath extensors of thumb and radial nerve, lying on external lateral ligament of wrist, scaphoid and trapezium, enters palm of hand through the heads of the 1st dorsal interosseous muscle, forming deep palmar arch.

*Branches:*—

**Radial recurrent:** arises just below elbow, ascends to between brachialis anticus and supinator longus, supplying them and the elbow-joint; *anas.* superior profunda.

**Muscular:** to muscles attached to radial side of forearm.

**Superficial volar:** arises when the artery is about to wind round carpus, passes between muscles of ball of thumb; *anas.* with ulnar, completing superficial palmar arch.

**Anterior carpal:** arises near lower border of pronator quadratus, passes inwards under tendons; *anas.* anterior carpal of ulnar.

**Posterior carpal:** arises beneath extensor tendons of thumb; *anas.* posterior carpal of ulnar, forming posterior carpal arch, which gives off 2nd and 3rd *dorsal interosseous* to 3rd and 4th spaces; and *anas.* with superior perforating of deep arch, and at lower end of interosseous space gives off inferior perforating to join palmar digital arteries.

**Metacarpal (1st dorsal interosseous):** arises near or with the posterior carpal; *anas.* superior perforating of deep arch, digital of superficial arch; supplies adjoining sides of index and middle fingers.

**Dorsalis pollicis (2):** arising near base of 1st metacarpal, course along sides of dorsum of thumb.

**Dorsalis indicis:** courses along radial side of dorsum of index, supplying abductor indicis.

**Princeps pollicis:** arising as the artery enters palm, courses between 1st metacarpal and abductor obliquus pollicis to the base of 1st phalanx, where it divides into two terminal branches, which run along the sides of the palmar surface of thumb.

**Radialis indicis:** arising near the preceding, passes between 1st dorsal interosseous and adductor transversus pollicis to outer side of index-finger, sends a branch to superficial palmar arch; *anas.* digital of superficial arch.

**Deep palmar arch:** *Extent,* from upper end of 1st interosseous space to base of 5th metacarpal. It lies over the bases of the metacarpal bones, and terminates by inosculating with the deep branch of the ulnar.

*Branches:—*

*Recurrent:* to front of carpus; *anas.* carpal arteries.

**Palmar interossei (3):** in the three inner interosseous spaces join digital of superficial arch at cleft of fingers, and an offset from inner branch joins digital branch to inner side of 5th finger.

**Superior perforating:** pierce three inner dorsal interossei; *anas.* dorsal interosseous.

#### THE ULNAR ARTERY.

**Extent.**—From bifurcation of brachial to end in superficial palmar arch, coursing along outer side of flexor carpi ulnaris to the palm; accompanied by venæ comites.

**Relations in the forearm.**—*In front.* Pronator radii teres, flexor carpi radialis, palmaris longus, flexor sublimis, median nerve in upper half; lower half, overlapped by flexor carpi ulnaris tendon.

*Behind.* Brachialis anticus, flexor profundus digitorum.

*Inner side.* Flexor carpi ulnaris, the ulnar nerve in the lower  $\frac{2}{3}$ .

*Outer side.* Flexor sublimis digitorum.

Lies upon anterior annular ligament at wrist, external to the ulnar nerve and pisiform bone.

*Branches :—*

**Anterior ulnar recurrent :** arises near bifurcation of brachial, ascends between brachialis anticus and pronator radii teres, supplying them ; *anas.* inferior profunda, anastomotic.

**Posterior ulnar recurrent :** arising below the anterior, passes beneath flexor sublimis, ascends behind inner condyle, thence between heads of flexor carpi ulnaris, supplying joint and muscles around ; *anas.* inferior profunda, anastomotic.

**Common interosseous :** about half an inch long, arising just below radial tubercle, passes to interosseous membrane, there dividing into two terminal branches.

*Branches :—*

**Anterior interosseous :** passes down forearm, resting upon anterior surface of interosseous membrane, accompanied by and internal to interosseous branch of median nerve. At upper border of pronator quadratus one branch, the *anterior communicating*, goes downwards beneath quadratus to *anas.* with anterior carpal and deep arch : the other piercing interosseous membrane descends to back of carpus ; *anas.* posterior interosseous, posterior carpal of radial and ulnar. Supplies *nutrient* branches to radius and ulna, and branch to median nerve : *comes nervi mediani.*

**Posterior interosseous :** passes backwards between oblique ligament and interosseous membrane, and between supinator brevis and extensor ossis metacarpi pollicis, runs down back of forearm, lying internal to posterior interosseous nerve, between superficial and deep muscular layers as far as the wrist ; *anas.* posterior carpal of radial and ulnar, anterior interosseous.

*Branch :—*

**Posterior interosseous recurrent :** given off near origin, passes under anconeus to interval between olecranon and external condyle ; *anas.* superior profunda, anastomotic.

**Muscular :** to muscles on ulnar side of forearm.

**Anterior carpal :** courses beneath tendons of flexor profundus ; *anas.* anterior carpal of radial.

**Posterior carpal :** arises just above pisiform, winds back beneath flexor carpi ulnaris tendon, gives branch to inner side of 5th metacarpal, and then passes outwards to *anas.* with posterior carpal of radial, forming *posterior carpal arch* (*vide* Radial Artery).

**Superficial palmar arch :** continues the ulnar in the hand, lying immediately under palmar fascia and on digital nerves and flexor tendons. It turns outwards a little below the

anterior annular ligament, and, forming an arch with the convexity downwards, is directed to the thumb, where the arch becomes completed by joining the superficialis volæ, radialis indicis, or princeps pollicis. From the convex side of the arch it gives off four *digital* branches to supply three inner fingers and inner side of index-finger; *anas.* palmar interossei of deep arch, inferior perforating of dorsal interosseous.

The **deep branch of ulnar artery** or communicating branch is given off at commencement of arch, passes down with the deep branch of ulnar nerve between abductor and short flexor of little finger to complete deep palmar arch.

## ARTERIES OF BODY.

### THE AORTA.

Large main trunk of systemic arteries, situated partly in thorax and partly in abdomen, commences at left ventricle, arches over root of left lung, descends in front of vertebral column, through diaphragm into abdomen, ending opposite body of 4th lumbar vertebra by bifurcating into two common iliacs. Conveniently divided into three parts: *arch of aorta, descending thoracic aorta, abdominal aorta.*

**ARCH OF AORTA:** divided, according to the direction, into ascending and transverse portions. In the concavity of the arch are contained root of left lung, branching of pulmonary artery with ductus arteriosus, cardiac plexuses, left recurrent laryngeal nerve, œsophagus and thoracic duct.

**Ascending part:** *Extent and Course.*—Two inches in length. From base of left ventricle, opposite lower border of 3rd left costal cartilage, passing behind pulmonary artery, upwards and to the right, crossing the posterior surface of the sternum obliquely, and extending as high as superior border of 2nd right costal cartilage. At its root it presents three bulgings, the *sinuses of Valsalva*, and along the right side is a dilatation, the *great sinus of the aorta.*

*Relations.*—Is contained nearly completely in pericardium.

<i>In Front.</i>	<i>Behind.</i>	<i>Right Side.</i>	<i>Left Side.</i>
Pulmonary artery.	Left auricle.	Superior cava.	Pulmonary artery.
Right auricular appendix.	Right pulmonary vessels.	Right auricle.	
Pericardium.	Root of right lung.		
Right lung and pleura.			
Sternum.			

*Branches.*—Right and left coronary arteries distributed to heart (*vide* Heart).

**Transverse part**, which runs much more from before backwards than from right to left, so that relations in front are also to the left, and those behind to the right, commences at upper border of 2nd right costal cartilage, arching backwards over root of left lung, as far as inferior border of left side of body of 4th dorsal vertebra.

*Relations.*

<i>In Front and to Left.</i>	<i>Above.</i>	<i>Below.</i>	<i>Behind and to Right.</i>
Manubrium.	Left innominate vein.	Bifurcation of pulmonary artery.	Trachea.
Thymus.			Ductus arteriosus.
Left pleura and lung.		Left bronchus.	Œsophagus.
Left phrenic		Left recurrent laryngeal nerve.	Thoracic duct.
Inferior cardiac of left vagus	} Nerves.		Left recurrent laryngeal nerve.
Superior cardiac of left sympathetic			
Left vagus			
Left superior intercostal vein.			

*Branches* :—

*Innominate* ( $1\frac{1}{2}$  to 2 inches long): arises at commencement of transverse part, ascends to right beneath sternum, dividing opposite right sterno-clavicular articulation into *right common carotid* and *right subclavian* arteries (*vide* Arteries of Head and Neck, pp. 59 and 64).

*Relations of the Innominate.*—Lies behind manubrium and origins of right sterno-hyoid and sterno-thyroid muscles, thymus gland and left innominate and right inferior thyroid veins. Trachea at first behind, but above to left side, where artery lies on pleura. On the right side lie the right innominate vein and right phrenic nerve. On the left side, below is the left common carotid, above the trachea. The innominate occasionally gives off a branch, the *arteria thyroidea ima*, which passes in front of trachea to thyroid gland.

*Left common carotid* (*vide* Arteries of Head and Neck, p. 64).

THE DESCENDING THORACIC AORTA.

*Extent.*—From lower border of 4th dorsal vertebra (left side) to aortic opening in front of body of 12th dorsal vertebra.



*Course and Relations.*—Lies in posterior mediastinum; is at first to left of bodies of vertebræ, but afterwards lies in front of them.

*In front.* Root of left lung, pericardium and diaphragm, crossed by œsophagus at lower end.

*Behind.* Bodies of vertebræ and venæ azygoi minores, superior and inferior.

*Left side.* Left lung and pleura, œsophagus below.

*Right side.* Œsophagus above, thoracic duct, and vena azygos major: right lung and pleura.

*Branches:—*

**Bronchial:** supply structure of lungs. For the left lung two branches come off from front of aorta (superior and inferior). The artery supplying right lung arises either with or from superior left branch, or from first right aortic intercostal.

**Pericardial:** small twigs to posterior surface of pericardium.

**Œsophageal** (4 or 5): from front of aorta, running obliquely downwards to supply œsophagus; *anas.* with one another, inferior thyroid and coronary of stomach.

**Posterior mediastinal:** supply glands, etc., of posterior mediastinum.

**Intercostal** (9 pairs): arise from posterior part of aorta, run transversely outwards on bodies of vertebræ, and behind pleura to intercostal spaces. The right ones, crossing over front of spine, supply the bodies of vertebræ, and pass behind œsophagus, thoracic duct, and azygos veins. The arteries of both sides are crossed by sympathetic chain and its splanchnic branches. On reaching intercostal spaces, they divide into anterior and posterior branches; the *anterior* branch crosses the space obliquely upwards so as to get to lower border of the upper rib near the angle: at first it lies between external intercostal and fascia, subsequently between two intercostal muscles; *anas.* anterior intercostal of internal mammary, thoracic branches of axillary. Above the artery is a companion vein, and below the intercostal nerve. A branch, the *collateral intercostal*, is given off near the angle of the rib, which runs along the upper border of the lower rib; *anas.* anterior intercostal. Branches accompany the lateral cutaneous nerves of the thorax from the main trunks of the intercostals. The three lower branches pass forwards between muscles of abdominal wall; *anas.* epigastric and lumbar.

The *posterior* branch passes backwards between vertebra and superior costo-transverse ligament, sending inwards, *spinal* branch through intervertebral foramen to cord, membranes

and body of vertebra, and backwards, *muscular* branch which divides into inner and outer branches to muscles of back.

(The 1st and 2nd intercostal arteries come from the sub-clavian trunk, *vide* p. 64).

#### ABDOMINAL AORTA.

*Extent.*—From last dorsal vertebra to the left side of body of 4th lumbar vertebra, there dividing into common iliacs.

*Course and Relations.*—Enters abdomen between pillars of diaphragm, occupying middle line of spine, but near its bifurcations inclines to left side.

*In front, from above down.* Small omentum, stomach, solar plexus, pancreas, splenic vein, left renal vein, 3rd part of duodenum, root of mesentery, coils of small intestine, aortic plexus and peritoneum. It touches the pancreas and duodenum without any intervening peritoneum.

*Behind.* Bodies of upper 4 lumbar vertebræ, left lumbar veins, receptaculum chyli and thoracic duct. Embraced by crura of diaphragm above.

*On right side.* Vena cava inferior, thoracic duct, vena azygos major, and right semilunar ganglion.

*On left side.* Left semilunar ganglion, and left cord of sympathetic.

*Branches:—*

**Inferior phrenic (2):** arising close together immediately below diaphragm, pass on its under surface across crura, the left one passing behind œsophagus, the right one behind inferior vena cava.

*Branches:—*

*Internal:* to fore-part of diaphragm; *anas.* fellow, and superior and musculo-phrenic of internal mammary.

*External:* to outer side of muscle; *anas.* musculo-phrenic, lower intercostals.

*Superior capsular:* to supra-renal body.

**Cœliac axis:** arises between pillars of diaphragm, just above pancreas,  $\frac{1}{2}$  inch long, surrounded by solar plexus; divides into three visceral branches.

*Branches:—*

**CORONARY OF STOMACH:** smallest of three branches, directed upwards and to left side behind lesser sac of peritoneum to cardiac end of stomach; gives off a few *œsophageal* branches, then turns to right along lesser curvature, giving branches on each side to viscus, finally anastomoses with pyloric of hepatic.

**HEPATIC:** directed (to right) forwards and upwards between layers of small omentum, and anterior to *foramen of Winslow*.

to transverse fissure of liver, lying to left of common bile-duct and in front of vena portæ; at transverse fissure it divides into *right* and *left* hepatic, supplying corresponding lobes of the liver.

*Branches*:—

*Pyloric*: extends on lesser curvature of stomach running from right to left; *anas.* coronary.

*Gastro-duodenal*: passes behind 1st part of duodenum, divides at lower border into the two following branches:

*Right gastro-epiploic*: runs along great curvature of stomach from right to left, *anas.* with left gastro-epiploic of splenic, gives off branches upwards to viscus and downwards to omentum.

*Superior Pancreatico-duodenal*: runs between the 2nd part of duodenum and the pancreas down to *anas.* with inferior pancreatico-duodenal of superior mesenteric.

*Right Hepatic*, to right lobe of liver, giving off *Cystic*: to supply gall-bladder.

*Left Hepatic*, to left lobe, giving off branch to Spigelian lobe.

**SPLenic**: directed horizontally to left along upper border of pancreas, crossing the left kidney; reaches spleen by passing between two layers of lieno-renal ligament, and then gastric branches reach stomach between layers of gastro-splenic omentum: supplies spleen and partly stomach and pancreas. Very tortuous; divides near spleen into several terminal branches which enter hilum of that viscus.

*Branches*:—

*Pancreatic*: given off as artery runs along pancreas; one of them (*arteria pancreatica magna*) accompanies the duct, running from left to right.

*Left gastro-epiploic*: directed to right side between layers of great omentum, along great curvature of stomach. *Anastomoses* with right gastro-epiploic of hepatic.

*Gastric branches (vasa brevia)* (5 or 6): extend to left extremity of stomach to supply its coats.

**Supra-renal** or **middle capsular** (2) arises a little below cœliac axis; each runs transversely outwards over crus of diaphragm to supra-renal body; *anas.* superior capsular of phrenic and inferior capsular of renal.

**Superior mesenteric**: arises  $\frac{1}{4}$  inch below cœliac axis, passes forwards between pancreas and upper border of 3rd part of duodenum, crosses duodenum, and directed downwards and to the right between the layers of the mesentery, terminates in offsets to small intestine, cæcum and colon.

*Relations*.—*In front and above.* Pancreas and splenic vein.

*Behind.* Duodenum, 3rd part, and left renal vein. Surrounded by mesenteric plexus of nerves and accompanied by its vein, which lies anterior and to right.

*Branches :—*

*Inferior Pancreatico-duodenal*: directed from left to right along concave border of 3rd part of duodenum; *anas.* superior pancreatico-duodenal.

*Vasa intestini tenuis*: to supply jejunum and ileum, twelve or fifteen in number; spring from left convex side of artery; about 2 inches from origin they bifurcate, each division uniting with a neighbouring branch to form an arch, from which branches issue; these divide and communicate in the same way four or five times, the resultant branches proceeding directly to intestine.

*Ileo-colic*: from right side of artery down to cæcum, branching to supply head of colon. A *descending* branch to lower part of ileum. An *ascending* to ascending colon and *anas.* with right colic.

*Right colic* (often a branch of ileo-colic): from right side of trunk to middle of ascending colon, *ascending* branch *anas.* middle colic, *descending* branch *anas.* ileo-colic.

*Middle colic*: passing forward in transverse meso-colon from upper part of right side of artery, supplies transverse colon; *right* branch *anas.* right colic; *left* branch *anas.* on descending colon, with left colic of inferior mesenteric.

**Renal** (2): one from each side arising  $\frac{1}{2}$  inch below superior mesenteric, the right a little lower than the left one. Pass outwards to supply kidneys, the right one passing behind vena cava. Each divides near viscus into four or five branches, which enter it between vein and ureter. Is accompanied by plexus of nerves, supplies branches to suprarenal body (*inferior capsular*), ureter and fat around.

**Spermatic**: two small but very long arteries; arise just below renal, directed downwards and outwards behind peritoneum over psoas, crossing ureter and external iliac artery (the right one crosses also the inferior vena cava) to internal abdominal ring, thence accompanied by spermatic vein, spermatic plexus, and vas deferens, it passes along inguinal canal, and out of the external ring to the scrotum, where it divides into branches which enter the posterior surface of the testis; *anas.* artery of vas deferens and cremasteric.

In the female the artery is termed **ovarian**, and runs between layers of broad ligament of uterus, to ovary and round ligament.

**Inferior mesenteric**: arises on left side of aorta, about

1½ inches above bifurcation. Lies at first on left side of aorta, then crosses over left psoas, left common iliac and ureter, to back of rectum; supplies descending, iliac and pelvic parts of colon and rectum.

*Branches* :—

*Left colic* : directed upwards in front of left kidney, *ascending* branch *anas.* middle colic; *descending* branch supplies descending colon; *anas.* sigmoid and superior hæmorrhoidal.

*Sigmoid* : to iliac and pelvic colon; *anas.* left colic and superior hæmorrhoidal.

*Superior hæmorrhoidal* : continuation of inferior mesenteric trunk, passes behind rectum and divides in meso-rectum into two branches, which pass down, one on either side, to about 6 inches from anus, where they subdivide to supply pelvic colon and rectum; *anas.* sigmoid, middle and inferior hæmorrhoidals.

**Lumbar** (5 pairs) : arise from back of aorta, pass outwards, resting on body of corresponding vertebræ underneath sympathetic and psoas; the two upper pairs under crura of diaphragm; the right ones also under vena cava. Divide near transverse processes into :—

*Abdominal* : coursing outwards beneath quadratus (the first pair cross quadratus), to end between muscles of abdominal wall; *anas.* deep epigastric, internal mammary, intercostals, ilio-lumbar, circumflex iliac.

*Dorsal* : accompanies posterior primary branch of nerve, gives off *spinal* branch to supply meninges and cord; *anas.* intercostal.

**Middle sacral** : a small branch given off just at bifurcation courses over 5th lumbar vertebra and middle of sacrum to coccyx behind the left common iliac vein, *anas.* lateral sacral.

#### THE COMMON ILIAC ARTERY.

*Extent*.—From bifurcation of aorta, on body of 4th lumbar vertebra, to opposite lumbo-sacral articulation, there dividing into external and internal iliac. About 2 inches long.

*Relations*.—*In front*. Peritoneum, small intestines, ureter, branches of sympathetic.

*Differences between right and left artery*.—The *right* one is the longer, the aorta being on the left side of spine; on right side are inferior vena cava and right psoas. Companion vein at first behind, but to the right at upper part; left common iliac vein behind. The *left* one is crossed anteriorly by inferior mesenteric artery, the companion vein being below and internal.

*Collateral branches.*—None named, supplies peritoneum, psoas, ureters, and lymphatics. One of the renal, lumbar or ilio-lumbar vessels may come off from it.

#### THE INTERNAL ILIAC ARTERY.

*Extent.*—From bifurcation of common iliac opposite lumbo-sacral articulation to great sacro-sciatic notch, there dividing into *anterior* and *posterior* trunks.  $1\frac{1}{2}$  inches long.

*Relations :* *in front* peritoneum, crossed by ureter, ileum on right, pelvic colon on left : *behind* on inner border of psoas, internal iliac vein, lumbo-sacral cord and sacrum. Note that this artery lies inside parietal layer of pelvic fascia, which is pierced by all the parietal branches, *e.g.*, sciatic, gluteal.

From the extremity a partly obliterated artery, the hypogastric, extends forwards to side of bladder, between the layers of posterior false ligament. In the *fœtus* this vessel is nearly as large as the common iliac, ascends the wall of abdomen to umbilicus, passing thence to placenta; after birth the vessel becomes obliterated except  $1\frac{1}{2}$  inches at commencement.

*Branches from Anterior Trunk :*

**Superior vesical :** is the unobliterated part of hypogastric, extending from sacro-sciatic notch in posterior false ligament to side of bladder.

*Branches* supplied to side and upper part of bladder, and to ureter.

*Artery of vas deferens :* accompanies duct to *anas.* with spermatic.

**Middle vesical :** supplies side of bladder.

**Inferior vesical :** supplies base of bladder, side of prostate and vesiculæ seminales in the male.

**Middle hæmorrhoidal :** supplies lower part of rectum and in the female to vagina. May come off from inferior vesical; *anas.* superior hæmorrhoidal of inferior mesenteric, inferior hæmorrhoidal of internal pudic.

[**Uterine :** down to neck of uterus, passes inwards between layers of broad ligament to supply body of viscus, where it crosses the ureter superiorly and then divides into a large ascending branch to fundus and ovary, *anas.* ovarian; and small descending branch to vagina, *anas.* vaginal.]

**Vaginal :** corresponds to inferior vesical in male, supplies vagina, fundus of bladder, and lower part of rectum.]

**Obturator :** directed to groove in upper part of thyroid foramen, passing out of pelvis and dividing into two branches

at upper border of obturator externus. In pelvis it is placed between pelvic fascia and peritoneum, and just below obturator nerve. It lies beneath the horizontal pubic ramus with companion vein and nerve in canal, formed above by bone and below by obturator membrane.

*Branches within pelvis:—*

*Iliac*: enters iliac fossa, supplies iliacus and bone; *anas.* ilio-lumbar.

*Pubic*: ascends posterior surface of pubis; *anas.* opposite fellow, deep epigastric.

*Branches outside pelvis:—*

*Internal terminal*: curves inwards beneath obturator externus, supplies obturators, gracilis, and adductors; *anas.* internal circumflex, and external branch of obturator.

*External terminal*: passes downwards and outwards beneath obturator externus to ischial tuberosity, supplies obturators, hamstrings and hip-joint; *anas.* sciatic and internal branch of obturator.

**Internal Pudic:—**

*In the male.* Proceeds out of pelvis by great sacro-sciatic notch below pyriformis, winds round ischial spine, re-enters pelvis by small notch, passes within the obturator fascia on inner side of tuber ischii, courses along pubic arch, perforates the two layers of triangular ligament very obliquely, dividing on triangular ligament into dorsal of penis and artery of corpus cavernosum.

*Relations.*—In the pelvis, lies to outer side of rectum, in front of pyriformis and sacral plexus. In gluteal region is seen under gluteus maximus, on ischial spine, below pyriformis, external to pudic nerve, and internal to nerve to obturator internus. Thence, in company with vein and nerve, it is on external wall of ischio-rectal fossa, and internal to obturator internus. Beneath triangular ligament crossed by transverse perineal muscle.

*Branches:—*

*Inferior hæmorrhoidal*: arises just inside tuber ischii, piercing Alcock's canal, crosses transversely ischio-rectal fossa, supplies sphincter and levator ani; *anas.* middle hæmorrhoidal and opposite fellow.

*Superficial perineal*: arising half-way in ischio-rectal fossa, runs parallel to pubic arch, crossing transversus perinei, lying deep to Colles' fascia, between erector penis and accelerator urinæ, supplying them, together with scrotum; *anas.* superficial pudic of femoral.

*Transverse perineal*: arises from superficial perineal or from

trunk near it, courses transversely inwards, supplying integuments, etc.

*Artery of bulb*: arises near base of triangular ligament, as internal pudic artery lies between the two layers of triangular fascia, it then pierces anterior layer, reaching bulb  $\frac{1}{2}$  inch from base. Supplies a branch to Cowper's gland.

*Artery of corpus cavernosum*: lies between crus penis and pubic ramus. Enters crus and is distributed to corpus cavernosum.

*Dorsal artery of penis*: lies between crus and pubic ramus, through suspensory ligament, along dorsum of penis having the median dorsal vein inside and the nerve outside. It ends in the glans and prepuce.

*In the female*: the vessel is smaller and has similar course to that in male; the *superficial perineal* supplies labia pudendi. The *artery of bulb* supplies bulbus vestibuli. The terminal *dorsal* and *corpus cavernosum* arteries supply clitoris, being named *dorsalis* and *profunda clitoridis* respectively.

**Sciatic**: terminal branch of anterior trunk (*vide* Arteries of Lower Limb, p. 89).

*Branches from Posterior Trunk*:—

**Gluteal**: *vide* Arteries of Lower Limb (p. 90).

**Ilio-lumbar**: passes upwards, backwards, and outwards beneath psoas and obturator nerve, but anterior to lumbo-sacral cord; divides in iliac fossa into *ascending* or *lumbar* branch, supplying psoas, quadratus lumborum, and giving a *spinal* branch through foramen between 5th lumbar vertebra and the sacrum. *Transverse* or *iliac* ramifies in iliacus, supplies bone; *anas.* lumbar, deep circumflex iliac.

**Lateral sacral (2)**: *Superior*, the larger of the two distributed to upper part of sacrum, the *Inferior* to lower part of sacrum and coccyx; *anas.* middle sacral and opposite artery.

*Branches* (dorsal) are given off, which enter anterior sacral foramina for distribution on back of sacrum.

#### THE EXTERNAL ILIAC ARTERY.

**Extent**.—From bifurcation of common iliac opposite lumbo-sacral articulation to lower border of Poupart's ligament.

**Course**.—Lower  $\frac{3}{4}$  of line from  $\frac{3}{4}$  inch below and little to left of umbilicus, to point of Poupart's ligament midway between symphysis pubis and anterior superior iliac spine.

**Relations**.—Covered by peritoneum and sub-peritoneal fat, crossed by ureter and deep circumflex iliac vein, on the right by ileum, left by iliac colon. The spermatic vessels and genito-crural nerve lie on it for a short distance.



To *outer side*, psoas, except at termination, when it is behind. *Inner side*, vas deferens and lymphatic glands. The left vein is internal to its artery. The right one is at first internal, but at upper part beneath its artery.

*Branches* :—

**Deep epigastric** : from fore part of artery, just above Poupart's ligament, down to ligament, then upwards and inwards between peritoneum and fascia transversalis, being crossed externally by vas deferens near internal abdominal ring; pierces transversalis fascia, and then passes upwards behind rectus to enter sheath under semilunar fold of Douglas; terminates between rectus abdominis and sheath in anastomoses with superior epigastric branch of internal mammary and lower intercostals.

*Branches* :

**Cremasteric** : accompanies vas deferens, supplying cremaster; *anas.* spermatic, artery of vas deferens.

**Pubic** : ramifies behind pubis; *anas.* pubic of obturator.

**Muscular** : to rectus; *anas.* superficial epigastric.

**Deep circumflex iliac** : from outer side of artery, near Poupart's ligament, directed to anterior superior iliac spine, then on iliac crest, gradually piercing transversalis fascia and muscle and supplying iliacus, etc. ; *anas.* ilio-lumbar.

## ARTERIES OF LOWER LIMB.

### THE SCIATIC ARTERY.

Largest branch of internal iliac, except gluteal, passes out through lower part of great sacro-sciatic foramen, between pyriformis and superior gemellus, in company with great sciatic nerve and internal pudic artery, outside the pelvis it lies between the tuber ischii and great trochanter, under gluteus maximus, below which it ends in cutaneous branches to thigh.

*Branches* :—

*Within the pelvis.* **Muscular** to pyriformis, coccygeus and levator ani.

*Outside pelvis* :—

**Coccygeal branch** : pierces great sacro-sciatic ligament, inclined inwards, supplies gluteus maximus, integument, etc.

**Comes nervi ischiadici** : accompanies great sciatic nerve, finally enters the substance of it.

**Muscular** : branches to gluteus maximus and external rotators of thigh; *anas.* gluteal, internal circumflex.

**Anastomotie** : (1) to pit of great trochanter (*digital anastomosis*), supplies external rotators; *anas.* gluteal, ascending of internal circumflex, and (2) to *crucial anastomosis*; *anas.* first perforating, internal and external circumflex.

**Articular** : to capsule of hip-joint.

#### THE GLUTEAL ARTERY.

Largest branch of internal iliac, passes outwards between lumbo-sacral cord and 1st sacral nerve, escapes from pelvis above pyriformis, divides immediately into superficial and deep branches.

**Superficial branch** : runs between the two larger glutei, supplying gluteus maximus; *anas.* sciatic and internal circumflex.

**Deep branch** : goes between two smaller glutei, subdivides into two :—

*Superior division* : goes to anterior superior iliac spine; *anas.* circumflex iliacs, ascending branches of external circumflex.

*Inferior division* : supplies gluteal muscles, and descends to great trochanter; *anas.* external circumflex.

**Nutrient branch** : enters hip-bone just as artery emerges from pelvis.

#### THE FEMORAL ARTERY.

**Extent**.—From Poupart's ligament to the opening in the adductor magnus.

**Course**.—Thigh being abducted and rotated out, a line drawn from point midway between symphysis pubis and anterior superior iliac spine to most prominent part of internal condyle of femur, will in upper  $\frac{2}{3}$ rd give course.

**Relations**.—Superficial in upper  $\frac{1}{3}$ rd, being contained in Scarpa's triangle, more deeply placed in middle  $\frac{1}{3}$ rd (Hunter's canal). In first  $1\frac{1}{2}$  inches is enclosed in femoral sheath.

*In front*. Skin, superficial and deep fascia, internal cutaneous branch of anterior crural nerve, sartorius, long saphenous nerve, aponeurotic arch over Hunter's canal.

*Behind*. Psoas, profunda vessels, pectineus, adductor longus, femoral vein (at lower part of Scarpa's triangle, and in Hunter's canal), tendon of adductor magnus.

*Inner side*. Femoral vein (in Scarpa's space), adductor longus.

*Outer side*. Sartorius (in Scarpa's space), vastus internus, femoral vein gets to outer side near ending.

**Branches** :—

**Superficial epigastric** : arises  $\frac{1}{2}$  inch below Poupart's ligament, ascends through the saphenous opening to abdominal

wall, as high as umbilicus, in the fascia, *anas.* fellow of opposite side, superficial branches of deep epigastric.

**Superficial circumflex iliac:** arises near preceding, runs outwards to iliac crest, supplies glands, fasciæ, and integument, psoas and iliacus; *anas.* deep circumflex iliac, gluteal, external circumflex.

**Superior external pudic:** arises from inner side of artery  $\frac{1}{2}$  inch below Poupart's ligament, pierces cribriform fascia of saphenous opening, runs upwards to pubic spine, crosses external ring and spermatic cord, supplying integument of lower part of abdomen and external organs of generation; *anas.* internal pudic.

**Deep external pudic:** arises either separately or from a common trunk with the preceding, lies on pectineus, covered by fascia lata, which it pierces, and is distributed to scrotum in male and labium in female; *anas.* superficial perineal.

**Profunda femoris:** arises from outer and back part of artery, 1 or 2 inches below Poupart's ligament, and passing outwards and downwards rests in Scarpa's triangle upon the iliacus, then curving inwards, crosses psoas and pectineus behind the femoral artery, from which it is separated by the deep femoral vein, and lies subsequently upon adductores brevis and magnus, having the longus superficial to it. It ends in the lower third of thigh in a branch which perforates adductor magnus.

*Branches:—*

**External circumflex:** arises from the outer side of the profunda (sometimes from the femoral trunk), coursing under rectus and sartorius outwards through the divisions of the anterior crural nerve, dividing into:

(a) *Transverse* branches, piercing vastus externus just below great trochanter; *anas.* below trochanter with internal circumflex, first perforating branch of profunda, and sciatic (*crucial anastomosis*).

(b) *Ascending* pass beneath sartorius, rectus, and tensor fasciæ femoris; *anas.* with terminal of gluteal and deep circumflex iliac.

(c) *Descending* branches are distributed to the extensors of the thigh; *anas.* with superior articular arteries, a small offset passing, with the articular nerve from the nerve to vastus externus, to the knee-joint.

**Internal circumflex:** arises from the internal and back part of profunda, courses backwards between psoas and pectineus, and then below capsule of hip between obturator externus and adductor brevis, dividing at the small trochanter into two branches, one ascending deep to quadratus femoris to

the digital fossa of the great trochanter; *anas.* sciatic and gluteal; the other passes to the hamstrings, appears between adjacent borders of quadratus femoris and adductor magnus, gives off *muscular* branch at upper border of adductor brevis, which divides into superficial and deep branches to upper adductor muscles, the trunk of the artery then passes upwards and backwards; *anas.* first perforating, sciatic, and external circumflex (*crucial anastomosis*). An *articular* branch enters the joint through the notch in acetabulum.

*Perforating branches*: four in number, reach the back of thigh by perforating the adductor magnus, and end in the back of thigh:—

*First*, begins opposite lower border of pectineus, perforates adductores brevis and magnus, distributed to biceps and gluteus maximus; *anas.* sciatic, internal and external circumflex.

*Second*, comes off opposite middle of short adductor, perforating it and the magnus, distributed to hamstrings; a *nutrient* artery (passing upwards) is given off; *anas.* other perforating branches.

*Third*, arises at the lower border of adductor brevis, perforates magnus, as the second, ending in the biceps.

*Fourth*, or terminal branch, pierces adductor magnus near opening for femoral vessels, supplies short head of biceps; *anas.* popliteal and lower perforating.

**Muscular Branches**: two to seven in number, supplying sartorius and vastus internus.

**Anastomotic branch**: arises at the termination of the femoral, and courses in the line of the femoral to the internal condyle.

*Branches*:—

*Deep* branch, descends inner side of knee; *anas.* superior internal articular; gives off *external* branch, crosses the femur, supplying branches to knee-joint; *anas.* superior external articular, forming an arch above patella.

*Superficial* branch, accompanies long saphenous nerve to integument; *anas.* inferior internal articular.

#### THE POPLITEAL ARTERY.

*Extent*.—From the opening in the adductor magnus to lower border of popliteus, dividing into anterior and posterior tibial.

*Course*.—Upper part inclines from inner side of femur to middle of intercondylar space, thence occupying middle line of popliteal space.

*Relations.*—The part of artery in the popliteal space is partly covered by the semimembranosus, and below it is covered by the gastrocnemius and plantaris. It rests upon the femur, posterior ligament of knee-joint and popliteus. The vein lies to the outer side in the upper part, but crosses to the inner side near the termination. Superficial and slightly external to the artery is the internal popliteal nerve, in the upper part, but below it crosses to inner side. A small articular branch of the obturator nerve courses upon the artery.

*Branches* :—

**Muscular** : *Superior set* (3 or 4) : to lower end of hamstrings; *anas.* perforating of profunda, superior articular.

*Inferior set* or *sural* (2) : arise from the posterior part of artery opposite knee-joint, supply both heads of gastrocnemius, plantaris and soleus.

**Superficial** : accompanies external saphenous nerve to end in integuments.

**Superior articular** : *Internal*. Arises just above condyles of femur, courses transversely inwards beneath semimembranosus and tendon of adductor magnus to front of knee, ending in vastus internus and joint; *anas.* anastomotic and superior external articular.

*External*. Winds beneath biceps, perforates intermuscular septum; *anas.* descending branch of external circumflex, external of anastomotic and superior internal articular, forming an arch, inferior external articular; supplies joint by superficial and deep branches.

**Inferior articular** : *Internal*. Passes down on internal tuberosity of tibia, beneath inner head of gastrocnemius and internal lateral ligament; *anas.* opposite artery, superior internal articular, anterior tibial recurrent.

*External*. Courses outwards under outer head of gastrocnemius, plantaris and external lateral ligament; *anas.* in front with other articular branches, anterior tibial recurrent.

**Azygos articular** : arises opposite flexure of joint, pierces posterior ligament, supplying crucial ligaments and other structures in the joint.

#### THE ANTERIOR TIBIAL ARTERY.

*Extent.*—From division of popliteal artery at lower border of popliteus, to bend of ankle, where it becomes dorsalis pedis.

*Course.*—At first directed outwards and forwards, through two heads of origin of tibialis posticus, to reach anterior surface of interosseous membrane; thence a line drawn from

inner side of head of fibula to midway between the two malleoli will mark its course.

*Relations.*—Tibialis anticus to inner side, the extensor communis digitorum above, and the extensor proprius hallucis below upon its outer side, covered below by annular ligament and crossed by extensor proprius hallucis tendon, rests below upon the anterior surface of the tibia. It is accompanied by two venæ comites. Anterior tibial nerve lies at first on outer side, then becomes superficial, and below is on the outer side.

*Branches:*—

**Posterior Tibial Recurrent:** passes upwards deep to popliteus to back of knee.

**Superior Fibular:** passes over neck of fibula, through soleus, to peroneus longus.

**Anterior Tibial Recurrent:** arises as artery reaches anterior surface of interosseous membrane, passes in tibialis anticus to external and anterior surfaces of knee-joint; *anas.* articular of popliteal.

**Malleolar:** Two in number, arise just above ankle-joint, supplying it.

*Internal.* Passes beneath extensor longus hallucis and tibialis anticus tendons to inner malleolus; *anas.* branches of posterior tibial.

*External.* Passes outwards beneath extensor longus digitorum and peroneus tertius; *anas.* anterior peroneal, tarsal of dorsalis pedis.

**Muscular:** to surrounding muscles.

#### DORSAL ARTERY OF FOOT.

*Extent.*—From bend of ankle to posterior part of 1st interosseous space, ending by anastomosing with external plantar artery to form plantar arch after it has entered sole between heads of origin of 1st dorsal interosseous muscle.

*Relations.*—Lies between tendons of extensor proprius hallucis and extensor longus digitorum; near termination it is crossed by innermost tendon of extensor brevis digitorum. Bound down by fascia lying on astragalus, scaphoid, and middle cuneiform. Accompanied by two venæ comites. Anterior tibial nerve lies to outer side.

*Branches:*—

**Tarsal:** arises as artery crosses scaphoid, courses forwards and outwards beneath extensor brevis digitorum, supplying it, then backwards to cuboid; *anas.* external plantar, metatarsal, external malleolar, anterior peroneal.

**Metatarsal**: arises near bases of metatarsals, directed outwards in an arched direction, beneath short extensor of toes to outer side of foot, near bases of metatarsal bones; *anas. tarsal, external plantar*. From the convexity of arch proceed three dorsal *interosseous* branches to three outer metatarsal spaces. They supply the interossei and divide at cleft of toes into digital branches; the most external one supplies also outer side of little toe. Each interosseous artery communicates at the cleft of the toes with the plantar digitals by an *anterior perforating* branch, and at the back of the interosseous space with the plantar arch by a *posterior perforating* branch.

The **1st dorsal interosseous artery**: arises as *dorsalis pedis* is about to dip down into sole. It lies over dorsum of 1st interosseous space, and divides at cleft to supply contiguous sides of 1st and 2nd toes, having previously given off a branch to inner side of 1st toe.

**Plantar digital, or arteria magna hallucis**: arises in sole, passes forwards in 1st interosseous space to cleft, where it divides into two branches for contiguous sides of 1st and 2nd toes, having previously given off a branch of inner side of great toe.

#### THE POSTERIOR TIBIAL ARTERY.

*Extent*.—From lower border of popliteus to lower edge of internal annular ligament of ankle, there dividing into internal and external plantar, at a spot midway between internal malleolus and heel.

*Course*.—At first midway between tibia and fibula, afterwards approaches tibia and lies on it.

*Relations*.—Upper  $\frac{2}{3}$ rds covered by gastrocnemius and soleus. Lower  $\frac{1}{3}$ rd superficial between inner border of Tendo Achillis and inner border of tibia. Posterior tibial nerve is at first on inner side, but about 1 inch down crosses posteriorly to reach outer side. Has venæ comites, and lies on tibialis posticus, flexor longus digitorum, tibia, and back of ankle-joint.

*Relations of artery at inner malleolus*, from within outwards. Tibialis posticus and flexor longus digitorum tendons, vein, artery, vein, nerve, flexor longus hallucis tendon.

*Branches*:—

**Peroneal**: arises 1 inch from popliteus, courses obliquely to fibula, then along inner border of that bone, between origins of tibialis posticus and flexor longus hallucis, to lower part of interosseous membrane, where it gives off *anterior peroneal*,

and is continued as *posterior peroneal* over lower tibio-fibular articulation to outer side of external malleolus, where it ends by *anas.* with external plantar and tarsal. Covered in upper part by soleus and deep fascia, then by flexor longus hallucis. Beyond the malleolus it is superficial.

*Branches of peroneal :*

*Muscular :* to soleus, tibialis posticus, flexor longus hallucis, and peronei.

*Nutrient :* to the fibula, passes downwards.

*Anterior peroneal :* arises about 2 inches above external malleolus, pierces or passes below interosseous membrane, and under cover of peroneus tertius reaches front of outer malleolus and tarsus, supplying ankle-joint; *anas.* external malleolar, tarsal of dorsalis pedis, and terminal of peroneal.

*Communicating :* to join communicating of posterior tibial.

*Muscular :* to soleus, and deep muscles of back of leg.

*Nutrient :* to tibia, arises near origin of posterior tibial, largest of kind in body, passes downwards.

*Communicating :* arises 2 inches above inner malleolus, courses beneath flexor longus hallucis; *anas.* communicating of peroneal.

*Internal calcaneal :* arises near termination, pierces internal annular ligament with internal calcaneal nerve, to supply integument, fat of heel, and muscles on inner side of foot.

#### INTERNAL PLANTAR.

The smaller branch of the posterior tibial, directed forwards along inner border of foot as far as base of 1st metatarsal bone, thence along inner side of great toe to anastomose with inner digital branch, is covered at first by abductor hallucis, and subsequently becomes more superficial by lying between that muscle and the flexor brevis digitorum; it is accompanied by internal plantar nerve.

*Branches :—*

*Digital,* to clefts between four outer toes, joining digital branches from plantar arch.

*Cutaneous,* to inner side and sole of foot.

*Muscular.*

#### EXTERNAL PLANTAR.

From inner part of foot, beneath abductor hallucis, it runs with external plantar nerve, between flexor brevis digitorum and flexor accessorius, to base of fifth metatarsal; thence it



passes inwards, resting on the interosseous muscles and deep to flexor tendons and lumbricals to the back part of the 1st interosseous space, and anastomoses with *dorsalis pedis*, completing plantar arch.

The *plantar arch* is placed across the tarsal end of the metatarsus, and is accompanied by the deep branch of the external plantar nerve.

*Branches from the Plantar Arch* :—

**Recurrent** : small branches passing back to tarsal joints ; *anas.* branches of internal plantar.

**Posterior perforating** (3) : ascend to dorsum of foot through posterior part of three outermost interosseous spaces ; *anas.* interosseous of metatarsal.

**Digital** (4) : supply both sides of three outer toes and outer half of 2nd ; inner three bifurcate at the cleft of toes ; give off at point of division, *anterior* perforating to *anas.* with interosseous arteries of dorsum.

## THE VEINS.

### VEINS OF THE HEAD AND NECK.

**Cerebral** : noted for their thin coats, absence of muscular tissue and valves.

*Superior* (10 to 12 on each side) : lodged chiefly in sulci on cerebral surface, pass forwards and inwards to superior longitudinal sinus.

*Anterior inferior* : from under surface of anterior lobes ; terminate in cavernous sinus.

*Inferior lateral* (3 to 5) : terminate in lateral sinus.

*Inferior median* : from posterior lobe, etc., to straight sinus behind *venæ Galeni*.

**Venæ Galeni** (2, one from right, one from left lateral ventricle) : formed by *vena corporis striati* and *vena choroidea* ; pass backwards out of transverse fissure to unite and end in straight sinus.

**Cerebellar** : superior, inferior, and lateral sets ; the 1st open into straight, the 2nd into lateral, the 3rd into superior petrosal sinuses.

**Sinuses** (17 in number) : *Superior longitudinal* : begins at *crista Galli*, where it may communicate through foramen

cæcum with nasal veins, runs back in upper border of falx cerebri to torcular Herophili, usually joining right lateral sinus; receives superior cerebral, parietal and emissary veins. Intersected by fibrous bands, the chordæ Willisii; the lumen is triangular, and on either side lie the Pacchionian bodies.

*Inferior longitudinal*: along posterior  $\frac{2}{3}$  of free margin of falx cerebri to straight sinus.

*Straight*: is placed at junction of tentorium and falx cerebri, goes to torcular Herophili, ending usually in left lateral sinus; receives inferior longitudinal sinus, vena magna Galeni, inferior median cerebral, and superior cerebellar veins.

*Lateral* (2): from torcular Herophili to foramen lacerum posterius, empties into internal jugular vein, each receives superior petrosal and occipital sinuses, and mastoid vein: the right also receives the superior longitudinal and the left the straight sinus. Joins inferior petrosal sinus to form internal jugular vein below jugular foramen.

*Occipital* (2): smallest; from posterior margin of foramen magnum to torcular Herophili.

*Cavernous* (2): by side of sella turcica, passes from sphenoidal fissure to apex of petrous part of temporal. Receives ophthalmic veins which connect the angular vein with this sinus; also anterior inferior cerebral veins and sinus alæ parvæ. The ophthalmic veins are two in number: *superior*, the larger, accompanies artery; and *inferior*, running below optic nerve, is formed by lower ciliary and muscular branches, and communicates with pterygoid plexus; both pass through the sphenoidal fissure to empty into the cavernous sinus.

*Circular*: surrounds pituitary body, connects the cavernous sinuses.

*Inferior petrosal* (2): from termination of cavernous to internal jugular vein, lies over petro-occipital suture.

*Transverse*: connects the inferior petrosal sinuses across basilar process of occipital bone.

*Superior petrosal* (2): placed on superior border of petrous part of temporal, connecting lateral and cavernous sinuses; receives inferior lateral cerebral, and anterior lateral cerebellar veins.

*Sinus alæ parvæ* (*spheno-parietal*) receives some meningeal and inferior cerebral veins, and runs inwards along free margin of lesser wing of sphenoid to cavernous sinus.

**Veins of the diploë**: lodged in channels of the bones of the cranial vault. They are divided into *frontal*, joining the supra-orbital vein; *anterior temporal*, joining a deep temporal vein; *posterior temporal*, joining lateral sinus; and *occipital*, joining occipital vein or lateral sinus.

**Emissary veins** : small veins passing through foramina in the bones, and connecting the sinuses with the external veins of the head.

**Facial** : passes obliquely across side of face from inner canthus to anterior border of masseter, being the continuation of the angular vein from inner canthus of eye. Under the inferior maxilla near the angle it unites with a branch (communicating facial) from temporo-maxillary vein to form a short trunk (the common facial), which, crossing submaxillary gland, digastric and external carotid artery, empties into the internal jugular vein. Also communicates with ophthalmic (*vide* cavernous sinus).

The facial vein receives .. ..	}	angular	{	supra-orbital.	
				frontal.	
				palpebral (superior).	
				nasal.	
			inferior palpebral.		
			dorsal and lateral nasal.		
		anterior	internal	{	alveolar branches.
		maxillary (deep facial)	.. ..		infra-orbital.
					descending palatine.
					naso-palatine.
			Vidian.		
	labial	{	superior.		
			inferior.		
	buccal.				
	masseteric.				
	labial.				
	submental.				
	inferior palatine.				
	glandular (parotid and submaxillary).				
	part of temporo-maxillary.				

**Temporal** : from side and vertex of head, passes down over zygoma, there receiving the middle temporal vein; it then courses down between condyle of jaw and external auditory meatus into the substance of the parotid, where it joins the internal maxillary vein to form the temporo-maxillary trunk.

The temporal vein receives	}	anterior temporal.
		posterior temporal.
		middle temporal.
		parotid.
		anterior auricular.
		transverse facial.

**Internal maxillary:** is formed by branches corresponding with those of the internal maxillary artery. The branches form a plexus (pterygoid) placed between the pterygoid muscles. The trunk of the vein passes backwards with artery internal to neck of condyle to join temporal vein, and form temporo-maxillary trunk.

The pterygoid plexus is formed by .. .. .	}	middle meningeal (2). deep temporal. pterygoid. masseteric. infra-orbital. buccal. superior palatine. inferior dental. posterior dental. Vidian.
---	---	---

The pterygoid plexus communicates with the facial vein by the anterior internal maxillary vein (deep facial).

**Temporo-maxillary:** formed by union of temporal and internal maxillary veins; descends in parotid gland on external carotid artery and crossed by facial nerve, divides into two branches, one of which unites with the facial as the communicating facial, and the other receives the posterior auricular vein to form the trunk of the external jugular vein.

**Posterior auricular:** from plexus on side of head and back of ear, receives stylo-mastoid vein, and branches from external ear; joins into temporo-maxillary to form external jugular vein.

**Occipital:** from plexus at back part of vertex of skull, placed deeply between muscles of neck, and having on scalp same course as artery; it then passes deeply under complexus, over suboccipital triangle, where it communicates with vertebral, and passes on semispinalis into deep cervical vein; communicates with lateral sinus by *mastoid veins*.

**External jugular:** formed by junction of part of temporo-maxillary trunk and posterior auricular veins at angle of jaw in the substance of parotid. Descends beneath platysma over sterno-mastoid, pierces deep fascia near the clavicle to open into subclavian, or occasionally into the internal jugular. Has two pair of valves. Receives *posterior external jugular*, draining superficial region at back of neck, *supra-scapular*, *transverse cervical*, and frequently the *anterior jugular*.

**Anterior jugular:** drains integument and superficial muscles of anterior and middle regions of neck. Empties into subclavian or external jugular; communicates with fellow just

above the sternum, also with facial and external jugular veins.

**Internal jugular:** from jugular foramen, being formed by junction of lateral and inferior petrosal sinuses. Passes vertically down the side of neck, on the outer side of carotid artery, within the sheath, uniting with subclavian near the inner margin of the scalenus anticus to form the vena innominata. Usually crossed by spinal accessory and communicates hypoglossi nerves. One pair of valves placed  $\frac{3}{4}$  inch above termination.

The internal jugular vein receives .. ..	}	pharyngeal.
		lingual { dorsal of tongue.
		{ lingual venæ comites.
		{ ranine.
		common facial.
	}	superior thyroid { laryngeal.
		{ crico-thyroid.
		middle thyroid.

**Vertebral:** communicates with posterior spinal and occipital veins; drains occipital region and deep muscles of back of neck; enters foramen in transverse process of atlas, runs down behind artery through same foramina of the cervical vertebræ to 6th (or 7th), where it passes down to enter vena innominata. One pair valves guard its mouth.

The vertebral vein receives .. ..	}	muscular.
		spinal.
		anterior vertebral.
		deep cervical.
		1st intercostal.

**Deep cervical (posterior vertebral)** corresponds to profunda cervicis artery; lies deeply in neck; above receives occipital and ends in vertebral.

## VEINS OF THE UPPER EXTREMITY.

### A. SUPERFICIAL, LYING ON DEEP FASCIA.

**Anterior ulnar:** from the anterior and ulnar side of hand up along ulnar side of forearm to elbow-joint, to join the median basilic.

**Posterior ulnar:** from posterior ulnar border of hand and vein of little finger (*vena salvatella*), up along ulnar side of back of forearm to join median basilic just below the elbow-joint.

**Radial** : from dorsum of the thumb, radial side of index-finger and hand, along outer side of forearm to join median cephalic near bend of elbow, and form the cephalic vein.

**Median** : from palmar surface of hand up the middle of forearm communicating below the bend of elbow, with venæ comites of ulnar, and then divides into median cephalic and median basilic.

**Median basilic** : passes obliquely inwards over bicipital fascia, which separates it from the brachial artery. Empties into basilic.

**Median cephalic** : passes obliquely outwards from bend of elbow, between supinator longus and biceps. Empties into cephalic.

**Basilic** : formed by coalescence of anterior and posterior ulnar with the median basilic veins. Ascends on the inner side to middle of the arm, where it pierces deep fascia and joins brachial venæ comites to form axillary vein.

**Cephalic** : passes up between deltoid and pectoralis major, perforates deep fascia and costo-coracoid membrane, and opens into the axillary vein. It is occasionally connected with the external jugular by a branch over the clavicle (jugulo-cephalic).

**B. DEEP VEINS ACCOMPANYING THEIR RESPECTIVE ARTERIES AS VENÆ COMITES, INTERCOMMUNICATING WITH EACH OTHER, AND THE SUPERFICIAL VEINS FREQUENTLY.**

**Digital (2)** : empty into the superficial palmar.

**Palmar superficial (2)** : empty into ulnar and radial.

**Deep palmar** : empty into radial venæ comites.

**Interosseous (2)** : accompany the anterior and posterior interosseous arteries, commencing at the wrist, terminating in venæ comites of the ulnar.

**Comites radialis (2)** : form, with the ulnar, the comites of brachial.

**Comites ulnaris (2)** : with the radial, form comites of brachial.

**Comites brachialis (2)** : receiving veins corresponding to the branches of the brachial artery, empty into the axillary vein.

**Axillary (single)** : formed by junction of brachial veins with the basilic. Commences at lower border of the axillary space ; receives veins corresponding to branches of its artery, and terminates in the subclavian at outer border 1st rib. [Valves at inferior border of subscapularis, terminations of subscapular and cephalic veins.]

**Subclavian** : continuation of axillary, joins internal jugular vein behind the inner end of the clavicle to form vena

innominata. Separated from its artery by scalenus anticus muscle and phrenic nerve. Receives external and anterior jugular veins. [Valves just external to entrance of external jugular, or about 1 inch from its termination.]

VEINS OF THE BODY.

**Innominate** : two large trunks, placed one on each side of the neck, and formed by the junction of the internal jugular and subclavian veins of the corresponding side. They end by uniting to form the superior vena cava. No valves.

*The right innominate vein* is short (1 inch long), and, commencing behind the inner end of the clavicle, passes downwards to join left innominate at the inferior border of 1st right costal cartilage. Receives the right vertebral, right internal mammary, right inferior thyroid, and right superior intercostal veins. The right lymphatic duct opens at the angle of union of right subclavian and internal jugular veins.

*Relations* :—

*In Front.*

Right sterno-hyoid.  
Right sterno-thyroid.  
Clavicle.  
1st costal cartilage.  
Thymus.

*Behind.*

Right pleura and lung.

*Left Side.*

Innominate artery and right pneumogastric nerve.

*Right Side.*

Right lung and pleura.  
Right phrenic nerve.

*The left innominate* is 3 inches long, passes from left to right and downwards. The thoracic duct opens at the angle of union of the left subclavian and internal jugular veins.

**The left innominate vein receives**

{ left vertebral.  
left internal mammary.  
left inferior thyroid.  
left superior intercostal.  
thymic.  
mediastinal.  
pericardiac.

*Relations* :—

*In Front.*

First piece of sternum.  
Origin of left sterno-hyoid.  
Origin of left sterno-thyroid.  
Thymus gland.

*Below.*

Arch of aorta (transverse part).

*Behind.*

Innominate artery.  
Left carotid artery.  
Left subclavian artery.  
Left phrenic nerve.  
Left pneumogastric nerve.

**Internal mammary:** two with each artery, uniting in a single trunk, emptying into innominate veins.

**Inferior thyroid** (sometimes 3 or 4): from thyroid venous plexus, emptying into right and left innominate veins.

**Superior intercostal:** receives veins from 2nd and 3rd intercostal spaces. The *right* one passes down and enters the azygos major, the *left* passes forward across arch of aorta to left innominate vein, and receives the left bronchial vein.

**Vena cava superior:** 3 inches long, formed by the junction of the right and left innominate veins behind the junction of the 1st right costal cartilage with the sternum; passes down to the right auricle opposite upper border of 3rd right costal cartilage. The vena cava enters the pericardium about  $1\frac{1}{2}$  inches from its termination, and this part is covered with serous membrane except posteriorly. No valves. Receives pericardial and mediastinal veins, and just as it enters the pericardium the azygos major vein.

*Relations:—*

<i>Left Side.</i>	<i>In Front.</i>	<i>Right Side.</i>
Innominate artery, in upper part.	Pleura.	Pleura.
Ascending part of aortic arch, in lower part.	Thymus gland.	Right phrenic nerve.
	Costal cartilages and intercostal spaces.	
	Pericardium.	
	<i>Behind.</i>	
	Pleura.	
	Right bronchus.	
	Right pulmonary artery.	
	Upper right pulmonary vein.	
	Pericardium.	

**Azygos major:** commencing opposite 1st or 2nd lumbar vertebra by a branch from right lumbar veins, passes up through aortic opening in diaphragm to right of aorta, and along right side of column in front of right intercostal arteries to 3rd dorsal vertebra, where, arching over root of right lung, it empties into superior vena cava. Receives the ten lower right intercostal veins, venæ azygoi minores (superior and inferior), several œsophageal, mediastinal, and right bronchial veins. Imperfect valves, though its branches have complete ones.

**Azygos minor inferior:** commencing in lumbar region of left side from lumbar veins, or branches of renal, passes through left crus of diaphragm to 8th dorsal vertebra, there crossing behind aorta and thoracic duct to terminate in azygos major.



Receives three or four lower left intercostals; some œsophageal and mediastinal veins.

**Azygos minor superior**: formed by union of 4th, 5th, 6th, 7th, and 8th left intercostal veins; communicates above with superior intercostal vein, crosses 7th dorsal vertebra behind aorta and thoracic duct to end in vena azygos major.

**Bronchial**: from lungs; the right terminating in azygos major; the left in the left superior intercostal.

**SPINAL: Dorsi-spinales**; external to spinal canal, extend along whole length of back of spine, forming network, terminating in the vertebral (of neck), the intercostal (of thorax), lumbar and sacral veins.

**Meningo-rachidian**: situated between vertebra and dura mater, consisting of *longitudinales spinales anteriores*: whole length of anterior surface of vertebral canal, terminating in dorsi-spinal.

*Longitudinales spinales posteriores*: whole length of posterior surface of vertebral canal, terminating in dorsi-spinal.

Veins of the vertebræ: *Vena basis vertebrarum*: from bodies of vertebræ, terminating in anterior longitudinal.

Veins of the spinal cord: *Medulli-spinales*: cover cord, between pia and arachnoid, from sacrum to occiput; *anas.* freely with contiguous veins. No valves in any of the spinal veins.

**Iliaca externa, interna, and communis**: see Lower Extremity.

**Vena cava inferior**: formed by junction of the two common iliac veins in front and a little to the right of 5th lumbar vertebra, passes up on right side of aorta to posterior border of liver, where it becomes imbedded in a groove and receives the hepatic veins; thence it goes through special opening in diaphragm between middle and right leaflets, enters pericardium, and opens into lower and back part of right auricle, its orifice being protected by the Eustachian valve.

*Relations*:—

<i>In Front,</i>	<i>Behind.</i>	<i>Left Side.</i>
Mesentery.	Vertebral column.	Descending aorta
Transverse part of duodenum.	Right crus of diaphragm and psoas.	Right crus.
Pancreas.	Right renal	} arteries.
Foramen of Winslow.	Right lumbar	
Portal vein.	Right supra-renal	
Posterior surface of liver.	Right inferior phrenic	
Hepatic		
Right spermatic		} arteries.
Right colic		
Right common iliac		
Diaphragm.		

The inferior vena cava receives .. .. .	}	lumbar branches. right spermatic. (ovarian in female). right renal. left renal { left spermatic. left supra-renal. right supra-renal. inferior phrenic. hepatic.
--	---	--

**CARDIAC VEINS:** *Vena cordis magna*: from apex, up anterior interventricular groove to base of ventricles, curving to left side and back part of heart, empties into coronary sinus; guarded by two valves; receives posterior cardiac and left cardiac veins.

*Venæ cordis mediæ* (posterior cardiac): from apex up posterior interventricular groove, terminating in coronary sinus, guarded by valves.

*Venæ parvæ* (anterior veins): three or four small branches from anterior surface of right ventricle, emptying into lower part of right auricle.

*Venæ Thebesii*: drain muscular substance, opening into right auricle.

**Right or small coronary**: from back of right auricle and ventricle, runs in auriculo-ventricular groove to open in right end of coronary sinus.

**The coronary sinus**: is the part of the great cardiac vein which is placed in the left auriculo-ventricular groove. Is 1 inch in length, and opens in the right auricle, the opening being guarded by the Thebesian valve. Receives branches as above, and a small straight vein at the back of the left auricle, the oblique vein of Marshall, the remnant of the left superior vena cava of the fœtus.

**Pulmonary**: four in number; commence in capillary network upon the pulmonary alveoli, uniting to form a trunk for each lobe; the one of the middle lobe of the right lung unites with the one from the superior lobe, hence there are two veins from each side. No valves. Carry *arterial* blood and empty into the left auricle, the left veins crossing the descending thoracic aorta.

*Relations at the root of the lung*:—

*From Before Back.*

Vein.  
Artery.  
Bronchus.

*From Above Down.*

<i>Right Side.</i>	<i>Left Side.</i>
Bronchus.	Artery.
Artery.	Bronchus.
Vein.	Vein.

## THE PORTAL SYSTEM.

The veins of the portal system collect the blood from the digestive tract. They form a trunk, the **vena portæ**, which enters the liver and breaks up into small branches in its substance. The following veins form the portal system :—

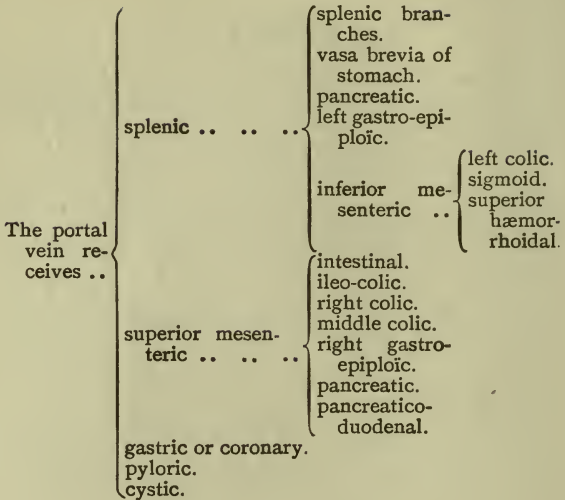
**Inferior mesenteric**: drains rectum, pelvic, iliac, and descending colon. It lies to the left of its artery, and passing behind transverse part of the duodenum and the pancreas, and over left kidney, opens into the splenic vein. (The hæmorrhoidal branches anastomose with the hæmorrhoidal branches of the internal iliac.)

**Superior mesenteric**: drains small intestines, cæcum, ascending and descending colon. It passes upwards in front and to right of superior mesenteric artery, in front of transverse part of duodenum, and behind neck of pancreas joins the splenic vein at the upper border of the pancreas to form the portal vein.

**Splenic**: commences in five or six tributaries in hilum of spleen; these unite to form a trunk which passes below splenic artery from left to right, behind upper border of pancreas, and in front of aorta; joins superior mesenteric at a right angle.

**The gastric or coronary**: a large vein accompanying coronary artery from right to left along lesser curvature of stomach to cardia, where it receives œsophageal tributaries, and, passing to right behind lesser sac, opens into the vena portæ.

**The vena portæ**: is formed by the union of the splenic and superior mesenteric veins in front of the right crus of diaphragm and inferior vena cava, and behind the neck of the pancreas. Passes up behind first part of duodenum and then between the layers of the small omentum, behind and between the common bile-duct and hepatic artery, the duct being placed on the right and artery on the left, to transverse fissure of liver; here it divides into right and left branches to corresponding lobes, and also gives an offset to the Spigelian lobe. Connected with the branch to the left lobe are in front the *obliterated umbilical vein* and behind the *ductus venosus*, the remains of a fetal connection with the inferior vena cava.



## VEINS OF THE LOWER EXTREMITY.

### SUPERFICIAL SET.

**Internal or long saphenous:** from plexus on dorsum and inner side of foot; ascends, in front of inner ankle, behind inner margin of tibia, accompanied by internal saphenous nerve; bends behind inner condyle of femur, ascends along inner side of thigh, through saphenous opening, empties into femoral  $1\frac{1}{2}$  inches below Poupart's ligament, where it receives *superficial circumflex iliac*, *superficial epigastric*, and *superficial external pudic*. Communicates with internal plantar, tibial, etc. Two to six valves.

**External or short saphenous:** from plexus on dorsum and outer side of foot, up behind outer ankle to median line of leg, accompanied by external saphenous nerve; empties into popliteal vein, between the heads of the gastrocnemius. Two valves, one near termination. Communicates with deep veins of foot.

DEEP SET.

**Posterior tibial:** two venæ comites, formed from *external* and *internal plantar*, joining with the *peroneal*. Course same as artery.

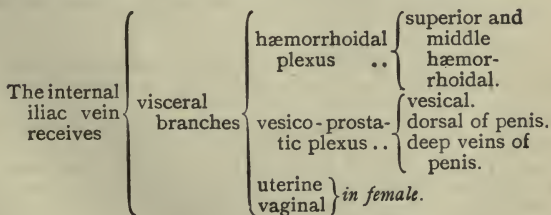
**Anterior tibial:** two venæ comites, continuation of *venæ dorsales pedis*, pierce interosseous membrane at upper part of leg, and form the popliteal vein, by junction with the *posterior tibial* veins, at the lower border of the popliteus muscle.

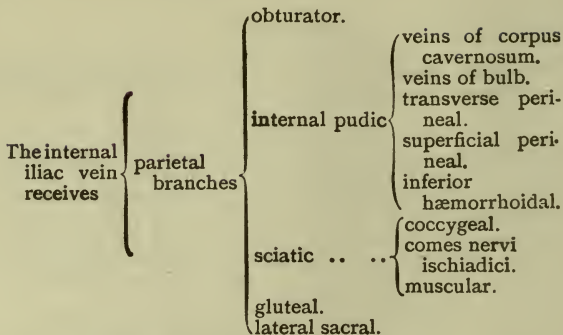
**Popliteal** (see anterior tibial): passes up to femoral aperture in adductor magnus, there becoming the femoral; receives *sural*, *articular*, and *external saphenous* veins. Four valves. Placed superficial to artery, which it crosses as it ascends, from within outwards.

**Femoral** (see above): passes from the opening in the adductor magnus up to Poupart's ligament, there becoming external iliac. Lies at first to outer side of artery, but higher up crosses behind to its inner side. Receives *muscular* branches, *profunda femoris*, and the *internal saphenous*. Four or five valves.

**External iliac** (see above): from Poupart's ligament to sacro-iliac synchondrosis, there uniting with the internal iliac to form common iliac. On *right* side, lies to inside of artery at first, but gradually passes behind it. On *left* side, altogether on inside of artery. Receives *deep epigastric* and *deep circumflex iliac*, and a *pubic* vein from the obturator.

**Internal iliac:** formed by the union of all of the venæ comites of the branches of the internal iliac artery, except the ilio-lumbar veins which open into the common iliac. It lies at first on the inner side, but finally gets behind the artery. It has no valves. The visceral veins opening into the internal iliac anastomose very freely and form a series of plexuses.





**Common iliac** (see external iliac): from base of sacrum to terminate on 5th lumbar vertebra, a little to the right of the middle line, where, with its fellow of opposite side, it forms vena cava inferior. The right vein is the shorter, and nearly vertical. Receives *ilio-lumbar* and sometimes *lateral sacral* veins. *Middle sacral* empties into left common iliac. No valves.

*Relations.*—*Right* vein passes behind, and then to right side of artery. *Left* vein is placed on inner side of left artery, and then passes behind right common iliac artery to join right vein, crossing middle sacral artery.

## THE ABSORBENT SYSTEM.

The **thoracic duct** receives the absorbents from both lower limbs, abdomen, except upper surface of liver, from left half of thorax, left upper limb, and left side of head and neck.

*Length.*—15 to 18 inches.

*Extent.*—From 2nd lumbar vertebra, where it commences by a dilatation, the *receptaculum chyli*, to junction of left internal jugular with left subclavian vein.

*Relations.*—The abdominal part is placed on the front of the body of the 2nd lumbar vertebra, behind and to the right side of the aorta and on the inner side of the right crus; it then enters the thorax through aortic opening, on the right side of aorta, lying between it and the vena azygos major, and passes upwards to right of aorta on right intercostal

vessels. Opposite the 4th dorsal vertebra it passes to the left behind aortic arch, and runs along the left side of the œsophagus, behind the left common carotid artery. At the level of the 7th cervical vertebra it turns outwards, and passing behind left internal jugular and crossing 1st part of left subclavian artery, arches over the apex of the left pleura to open at the angle of union of the left internal jugular and left subclavian veins.

The **right lymphatic duct**: receives the absorbents of the right limb, right side of chest, right half of head and neck, and upper surface of liver. It is about  $\frac{1}{2}$  inch long, and enters the venous system at the angle of union of the right internal jugular and right subclavian veins.

#### THE LYMPHATICS OF THE HEAD AND NECK.

**Suboccipital glands** (1 or 2): receive lymphatics from back of scalp, efferent vessels join superficial cervical glands.

**Mastoid glands** (2 or 3): receive lymphatics from back of ear and external auditory meatus, efferent vessels join superficial cervical glands.

**Parotid lymphatic glands** (3 or 4): one being placed just anterior to tragus. Receive lymphatics from temporal region, external auditory meatus and eyelids; efferent vessels pass to submaxillary and superficial cervical glands.

**Internal maxillary glands**: afferent vessels from temporal, nasal, zygomatic, and orbital fossæ, palate and upper part of pharynx; efferent vessels pass to superior deep cervical glands.

**Submaxillary lymphatic glands** (8 to 10): afferent vessels from face, floor of mouth, submaxillary and lingual glands; efferent vessels to cervical glands.

**Superficial cervical glands** (4 to 6): placed along the external jugular vein. Afferent vessels from external ear, skin of neck; efferent vessels to the deep cervical glands.

**Deep cervical glands** (20 to 30): glandulæ concatenatæ.

*Superior*: lie along internal jugular vein from division of common carotid to base of skull. Afferent vessels from internal maxillary and submaxillary glands, cranium, tongue, larynx, lower part of pharynx and thyroid body. Efferent vessels to inferior set.

*Inferior*: placed along lower part of internal jugular vein. Afferent vessels from other cervical glands and lower part of neck. Efferent vessels form a single trunk (*jugular lymphatic trunk*), opening into thoracic duct on left side, and into the right lymphatic duct on right side.

## THE LYMPHATICS OF THE UPPER LIMB.

The lymphatics of the arm are arranged in a superficial and a deep set which enter the axillary glands, except a few superficial which join the gland over the internal condyle.

There are two sets of lymphatic glands in the arm, viz., superficial and deep.

**The superficial lymphatic glands:** one or two above the internal condyle (epitrochlear).

**The deep lymphatic glands:** two or three on inner side of brachial artery.

**The axillary glands** (10 or 12): receive the lymphatics from the upper limb.

*Axillary set:* placed along axillary vessels, afferent vessels from limb.

*Pectoral set:* placed along long thoracic artery, afferent vessels from mamma and chest.

*Subscapular set:* placed along subscapular artery, afferent vessels from the back.

*Infra-clavicular set:* situated below the clavicle, in the hollow between pectoralis major and deltoid; afferent vessels from shoulder and efferent vessels from pectoral set.

## THE LYMPHATICS OF THE PELVIS AND ABDOMEN.

**External iliac glands** (6 to 10): lie along external iliac artery; afferent vessels from inguinal glands.

**Internal iliac glands:** placed along internal iliac artery; afferent vessels from pelvic viscera.

**Sacral glands:** placed in hollow of sacrum, receive lymphatics of rectum.

**Lymphatics of bladder:** placed near base of bladder; efferent vessels enter internal iliac glands.

**Lymphatics of uterus:** in the impregnated state enter internal iliac glands.

**Lumbar lymphatic glands:** *mesial* group, surround aorta and vena cava; afferent vessels from external and internal iliac, and sacral glands, lymphatics of kidney, supra-renal bodies, testicles (ovaries), etc. The *lateral* group lie behind psoas, and receive the deep lymphatics of the abdominal wall. The efferent vessels of the whole enter the thoracic duct.

**Mesenteric glands** (130 to 150): disposed around the trunk and branches of the superior mesenteric artery; efferent vessels go to the thoracic duct.

**Celiac glands** (16 to 20): surround coeliac axis. The afferent



vessels come from stomach, spleen, pancreas, and liver; the efferent vessels go to the thoracic duct.

#### THE LYMPHATICS OF THE THORAX.

**Sternal glands** (6 to 10): along internal mammary artery. The afferent vessels come from front of chest and abdominal walls, diaphragm and under part of mamma; the efferent vessels join anterior mediastinal glands and thoracic duct.

**Intercostal glands**: placed posteriorly on heads of ribs. The afferent vessels come from chest wall; the efferent open into the thoracic and right lymphatic ducts.

**Anterior mediastinal glands** (3 or 4): between pericardium and sternum. The afferent vessels come from lower sternal glands, upper surface of liver and diaphragm: the efferent vessels pass to thoracic and right lymphatic ducts.

**Superior mediastinal or cardiac glands** (8 to 10): placed in front of the arch of the aorta in the superior mediastinum. The afferent vessels come from the heart, pericardium and thymus gland; the efferent vessels unite in two or three trunks which open into the thoracic and right lymphatic ducts.

**Bronchial glands**: are placed behind and between the bronchi. The afferent vessels come from the lung; the efferent vessels join to open into the thoracic and right lymphatic ducts.

**Posterior mediastinal glands** (8 to 12): lie along descending thoracic aorta. The afferent vessels come from the œsophagus, pericardium, and diaphragm; the efferent vessels go to the thoracic duct.

#### THE LYMPHATICS OF THE LOWER LIMB.

The lymphatics of the lower limb are divided into a superficial and a deep set. The *superficial*, except a few which pass to the popliteal glands, go to the superficial inguinal glands. The *deep* lymphatics enter the deep inguinal glands.

**The popliteal glands** (4 or 5): are placed on the popliteal vessels. The afferent vessels come from the lymphatics of the leg; the efferent go to the inguinal glands.

**The superficial inguinal glands** (8 to 10):

*Oblique set*: lie along Poupart's ligament. The afferent vessels come from trunk, buttocks, anal canal, perineum, and external genitals, including membranous and spongy urethra in the male and lower third of vagina in female.

*Vertical or femoral set*: lie along the internal saphenous vein, and receive the superficial lymphatics of the limb. The efferent vessels of both sets join the deep glands.

The deep inguinal glands: surround the femoral vessels (a constant one in the crural canal). The afferent vessels come from the superficial inguinal glands and the deep lymphatics of the limb; the efferent vessels join the external iliac glands.

## THE SPINAL CORD.

The **spinal cord** is the part of the cerebro-spinal axis which occupies the spinal canal. In the adult it occupies about  $\frac{3}{8}$  of the length, but in the fœtus, before the third month, it extends the whole length of the canal.

*Extent.*—The spinal cord extends from the lower border of the foramen magnum, where it is continuous with the medulla oblongata above, to the lower border of the 1st lumbar vertebra, there terminating in a slender filament, the *filum terminale*.

### *Contents of the Neural Canal.*

Venus plexus between bone and dura mater.

Membranes { dura mater.  
arachnoid.  
pia mater, with ligamenta denticulata.

Cerebro-spinal fluid.

Spinal vessels { anterior spinal artery and vein.  
two posterior spinal arteries and veins.

Spinal cord, with anterior and posterior roots of nerves.

*Shape.*—In transverse section, nearly round, except at the enlargements, where it is more elliptical.

*Enlargements.*—Presents two enlargements. The upper or *cervical* extends from the upper limit of the cord downwards to the 1st or 2nd dorsal vertebra.

The lower or *lumbar* commences opposite the 10th dorsal vertebra; is largest at the 12th dorsal, and thence tapers, forming the *conus medullaris*, from the tip of which the *filum terminale* descends.

The *filum terminale* (central ligament of the cord): passes from the end of the *conus medullaris* downwards in the middle of the *cauda equina*; becomes closely invested with dura mater opposite the 1st or 2nd sacral vertebra, and blends with the periosteum at the lower end of the sacral canal.

It is a process of pia mater, containing in its upper half the continuation of the central canal of the cord, together with a little grey matter for a short distance. The lower half consists of connective-tissue, bloodvessels and medullated nerve-

fibres. The anterior spinal artery is continued along the front; it is a very slender vessel.

**The nerve-roots.**—Consist of anterior and posterior bundles, 31 pairs (see p. 158).

The *anterior* roots are arranged irregularly along the side of the cord; the *posterior* roots issue in a straight line along the postero-lateral groove. They are distinguished from the anterior roots by having a ganglion and by their larger size.

The nerve-roots pass outward to the intervertebral foramina, those in the upper part passing almost transversely; below they pass more obliquely, until in the lower part of the canal their course is vertical. The collected bundles of nerve-roots at the termination of the cord form the *cauda equina*.

#### FISSURES.

**Anterior median fissure:** along the anterior surface of the cord in the middle line. Extends into the substance of the cord for about a third of its thickness, but deeper below than in the upper part. Does not reach grey matter. Lined with pia mater.

**Posterior median fissure:** not a true fissure, and only contains a septum of pia mater. Reaches down to grey matter.

**Lateral fissures:** *Antero-lateral:* not a true fissure, but a line corresponding to origin of anterior nerve-roots.

*Postero-lateral:* corresponding to attachment of posterior nerve roots.

**Columns of the cord:**—

The cord being divided into two lateral halves by the median fissures, may again be subdivided into *anterior*, *lateral*, and *posterior* columns.

The *posterior* and *lateral* columns are separated by a groove or lateral sulcus, to which the posterior nerve-roots are attached.

The *anterior* and *lateral* columns are separated by the anterior roots of the nerves.

The *posterior column* is subdivided by a groove (only found in the upper part of the cord), a little outside the posterior median fissure, into two columns, the postero-mesial (of Goll) and the postero-lateral (of Burdach).

#### STRUCTURE OF THE SPINAL CORD.

The spinal cord in transverse section consists of white matter externally, and grey matter internally.

**The grey matter:** consists of a crescent-shaped portion in

each lateral half of the cord, united by an intervening process, the *posterior* or *grey commissure*.

Each crescent has two cornua, an *anterior*, thick and short, not reaching the surface of the cord; and a *posterior*, long and slender, reaching to the postero-lateral fissure, just before reaching which it becomes enlarged, *caput cornu*, and becomes less opaque (*substantia gelatinosa* of Rolando). The size of the grey crescents varies in different parts of the cord, being largest in the cervical and lumbar enlargements. In the upper dorsal region there is a projection of the grey matter on the outer side of the crescent between the anterior and posterior cornu, called the *intermedio-lateral tract* or *lateral cornu*.

**Central canal:** extends through the whole length of the cord in the middle of the posterior or grey commissure. It is lined with a spheroidal ciliated epithelium. Opens above into the floor of the 4th ventricle, and is continued below into the upper part of the *filum terminale*.

**The white matter:** encloses the grey matter in each lateral half of the cord, except where the posterior cornu comes to the surface. The portion of white matter between the posterior or grey commissure and the anterior median fissure constitutes the *anterior* or *white commissure*.

#### THE MEMBRANES OF THE SPINAL CORD.

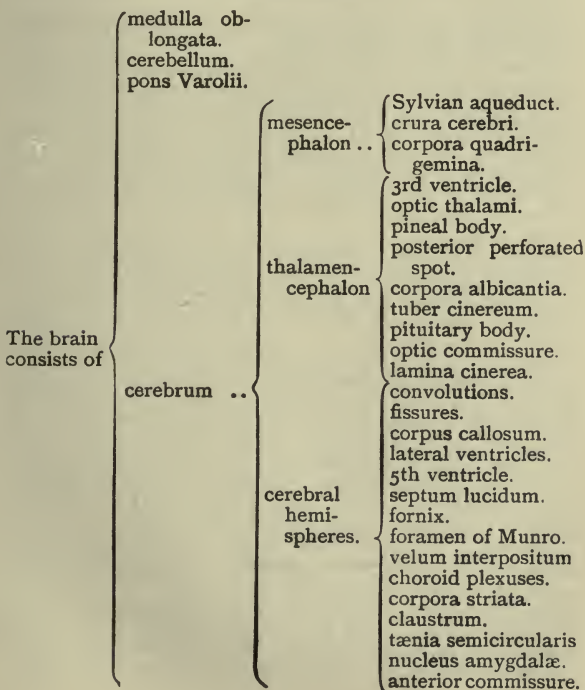
The DURA MATER is the most external membrane, and is continuous with that investing the brain; but it does not form the periosteum of the vertebræ, nor has it any sinuses, but is separated from the bones by areolar tissue and a plexus of veins. It is connected above with the edge of the foramen magnum; at the top of the sacrum it becomes impervious, and is continued as a slender cord to blend with the periosteum of the coccyx. This membrane gives sheaths to all the spinal nerves.

The PIA MATER is less vascular, thicker, and more fibrous than that investing the brain. It has an external fibrous layer of longitudinal bundles having a fold, the *linea splendens*, dipping into the anterior fissure, and a smaller one passing into the posterior fissure. The pia mater ends in a slender cord, the *filum terminale*, which is within the prolongation of the dura mater. A process of pia mater, the *ligamentum denticulatum*, passes outwards towards the dura, to which it is attached by twenty-two tooth-like processes situated between the origins of the spinal nerves; its pial origin is continuous, and lies between the anterior and posterior nerve-roots.

The ARACHNOID is placed outside the pia mater, and loosely

invests the cord. The subarachnoid space of the cord is large, and is imperfectly divided by the *ligamentum denticulatum*, into an anterior and a posterior portion. The posterior portion is further subdivided by the *septum posticum*, which passes from the posterior fissure backwards to the opposite part of the arachnoid, and contains the larger bloodvessels. Trabeculæ also pass between the nerve-roots and the inner surface of the arachnoid, and between the posterior nerve-roots and the *septum posticum*.

THE BRAIN.



## THE MEDULLA OBLONGATA, OR BULB.

*Extent.*—From the lower border of the foramen magnum to the lower border of the pons Varolii.

*Connections.*—Inferiorly it is connected with the spinal cord, superiorly it is continued into the pons, anteriorly it rests upon the basilar groove, and posteriorly it lies in a depression between the hemispheres of the cerebellum, called the vallecula, and here bounds the lower half of the floor of the 4th ventricle.

*Dimensions.*— $1\frac{1}{2}$  inches long; greatest breadth  $\frac{3}{4}$  inch.

*Shape.*—Pyramidal, with base at the pons, and apex at the spinal cord.

*Fissures.*—Anterior and posterior median fissures, continuous with those of the cord.

*Anterior median fissure:* terminates just below the pons in the *foramen cæcum*. The fibres of the anterior pyramids decussate at the lower part of the fissure, and partly interrupt it.

*Posterior median fissure:* continues up from the cord to about half-way up the medulla, where it widens out into the fossa rhomboidalis or floor of the 4th ventricle.

*Structure of the medulla.*—If the parts of the spinal cord are traced into the medulla, its structure will be easily understood.

*The line of the posterior roots* of the spinal nerves is continued by the upper bundles of the nerve-roots of the spinal accessory nerve, above this by the bundles of the vagus, and above this, again, by the bundles of the glosso-pharyngeal nerve.

The line of exit of these nerve-roots represents the postero-lateral groove of the spinal cord. As this line is traced upwards it turns ventrally outwards, so that about half-way up the medulla it appears upon the lateral surface, and in its upper part it lies close to the posterior margin of the *olivary body*, from which it is separated by a narrow groove.

The part behind these nerve-roots is termed the *posterior area of the medulla*, and corresponds to the posterior columns (postero-mesial and postero-lateral) of the cord.

*The line of the anterior roots* of the spinal nerves, when traced up into the medulla, deepens into a groove which is continued upwards nearly as far as the pons.

The bundles of the nerve-roots of the hypoglossal issue from this groove. The part of the medulla between this groove and the anterior median fissure is called the *anterior area*, and corresponds to the anterior column of the cord.

The part between the anterior and posterior areas—that is, the part between the line of issue of the nerve-roots of the spinal accessory, vagus, and glosso-pharyngeal nerves, and line of issue of the nerve-roots of the hypoglossal—is called the *lateral area*, and corresponds to the lateral column of the cord.

**Posterior area of the medulla.**—The postero-mesial column (of Goll) of the cord is continued up into the medulla as the *funiculus gracilis*, which expands as it approaches the 4th ventricle. This expansion is called the *clava*; and upon reaching the 4th ventricle the clavæ of opposite sides open out to form the lateral boundary of the ventricle in its lower part.

The postero-lateral column (of Burdach) of the cord is continued upwards into the medulla, where it expands slightly, and is called the *funiculus cuneatus*, which, on the same level with the clava, has an eminence, the *cuneate tubercle*.

Between the funiculus cuneatus and the line of origin of the nerve-roots of the spinal accessory, vagus, and glosso-pharyngeal, there appears in the lower part of the medulla a longitudinal prominence, the *funiculus of Rolando*, which broadens out above into the *tubercle of Rolando*. It is formed by the approach of the caput of the posterior cornu to the surface.

**The Restiform body.**—In the upper part of the medulla, a set of fibres issue from the anterior median fissure, pass transversely outwards over the anterior pyramid and olivary body, and, continuing transversely, cross over the funiculus of Rolando and the cuneate funiculus, to turn upwards on these. They are the *superficial arciform or arcuate fibres*, and are mainly derived from the gracile and cuneate nuclei of the same and opposite sides; joined to these, just above the tubercle of Rolando, are some transverse fibres which come from the lateral column, known as the *direct cerebellar tract*. These oblique fibres blend with the funiculus of Rolando, and with the superficial fibres of the funiculus gracilis and funiculus cuneatus, the whole forming the restiform body. Superiorly the restiform body diverges from its fellow and enters the cerebellum, of which it forms the inferior peduncle.

**Lateral area of the medulla.**—The lateral column of the cord, as continued into the medulla, consists of three sets of fibres. One set, the *crossed pyramidal tract*, crosses obliquely through the anterior column and across the anterior median fissure to the opposite side, where they form the greater part of the pyramid. A second set consists of the *direct cerebellar*

*tract* which join the restiform body, whilst the rest of the column passes upwards as far as the lower end of the olive which conceals it.

The *olivary body* is an oval prominence lying in the upper part of the medulla, between the pyramid and the restiform body. It is separated from the pons by a groove, which contains some of the external arcuate fibres.

On the inner side lie the nerve-roots of the hypoglossal; and on the outer side, but separated from it by a groove, the roots of the accessory, vagus, and glosso-pharyngeal nerves issue. Longitudinal fibres, prolonged from the lateral column, lie in the groove on the outer side of the olive, and occasionally a few bundles of longitudinal fibres are seen on the inner side. These, together with the arched fibres above and below, give it the appearance of being enclosed in a capsule.

The *fillet of the olivary body* is a small bundle of fibres derived from the capsule, and from the longitudinal fibres from the lateral tract. The fibres ascend in the crus cerebri.

**Anterior area of the medulla.**—Most of the fibres of the anterior columns of the cord are prolonged upwards deeply beneath the pyramids, but a bundle varying in size passes upwards on the outer side of the crossed portion of the lateral column (crossed pyramidal tract). These fibres form the *direct pyramidal tract*.

The **pyramids** are two oval prominences, broader above than below. They are placed one on each side of the anterior median fissure. They consist of two sets of fibres, the *outer* derived from the anterior column of the cord, the *inner* from the lateral column of the opposite side. The crossing of the two sets of these latter fibres constitutes the *decussation of the pyramids*.

The **fourth ventricle**. The central canal of the cord expands in the upper and posterior part of the medulla until opposite the middle peduncles of the cerebellum, where it again gradually narrows, and becomes continuous with the Sylvian aqueduct above. The floor or anterior (ventral) wall of the ventricle is thus diamond-shaped. The lower end has been compared in shape to a pen, and is hence termed the *calamus scriptorius*.

The **floor** in the lower half is formed by the upper part of the posterior surface of the medulla, and in the upper half by the back of pons Varolii.



*Structures on the floor.**Lower half.**Median groove.*

*Inferior fovea.*—A triangular pit on each side of the median groove near the *striæ acusticæ*, the apex being directed upwards. From the base two grooves pass downwards, one towards the *calamus scriptorius*, and the other towards the lateral boundary. Three areas are thus marked off in each lateral half of the medullary portion:—

1. *Trigonum hypoglossi*, next to median groove, subjacent to which is the hypoglossal nucleus.
2. *Trigonum vagi*, included between the two grooves passing from the fovea. Contains nucleus of *vagus* below, and nucleus of *glosso-pharyngeal* above.
3. *Trigonum acustici* (lower half), most external, contains chief part of auditory nucleus, forming part of acoustic tubercle.

*Upper half.**Median groove.*

*Superior fovea.*—A triangular depression in a line with the inferior fovea, dividing off each lateral half into three areas, viz. :—

1. *Fasciculus teres*, most internal, here raised into the *eminentia teres*, and continuous with the *trigonum hypoglossi* below.
2. *Locus cæruleus*, a depression extending from the superior fovea to the upper end of the ventricle, beneath which is some pigment, the *substantia nigra*.
3. *Tuberculum acusticum* (upper half).

Issuing from the median groove, and passing outwards on each side over the middle of the *tuberculum acusticum* are some white lines, the *striæ acusticæ*.

*Lateral recess.*—This is a lateral extension between the cerebellum and the medulla of the cavity of the ventricle at its widest part.

The roof: in the lower half is formed by *pia mater*, lined with epithelium. It has three apertures, one on each side in the lateral recess, and the third at the apex of the *calamus scriptorius*, the *foramen of Majendie*, by which the 4th ventricle communicates with the subarachnoid space.

On each side where the *pia mater* is attached laterally to

the ventricle it is thickened by white matter, and is termed the *ligula*; and at the apex of the calamus another thickening, the *obex*, occurs. Projecting from the roof on each side of the middle line is the choroid plexus.

In the upper half, the roof is formed by the converging superior peduncles of the cerebellum and the intermediate *superior medullary velum* or *valve of Vieussens*, continuous with the white matter of the cerebellum. Grey linear thickenings on the valve of Vieussens, continuous with the grey cerebellar cortex, constitute the *lingula*.

#### BOUNDARIES OF THE 4TH VENTRICLE.

	<i>Laterally.</i>	<i>Floor.</i>	<i>Roof.</i>
Below	{	Clavæ of funiculi graciles.	Medulla (below).
		Funiculi cuneati.	Pons (above).
Above	{	Restiform bodies.	Pia mater (below). Nodule of inferior vermi- form process.
		Superior peduncles of cerebellum.	Valve of Vieussens, and Superior peduncles of cerebellum (above).

#### Grey Matter of the Medulla.

##### 1. *Remains of grey matter of cord.*

(a) Grey tubercle of Rolando, from posterior cornu, appears in front of restiform body.

(b) Remains of grey commissure, part continued into vagus and auditory nuclei, and part into fasciculus teres.

(c) Remains of anterior cornu, intersected by white fibres, giving rise to the *formatio reticularis* of medulla.

##### 2. *Special deposits of grey matter.*

(a) Nucleus of hypoglossal.

(b) Nucleus for accessory part of spinal accessory.

(c) Nucleus of vagus, passing above, under auditory nucleus, into nucleus of glosso-pharyngeal.

(d) Nucleus of glosso-pharyngeal.

(e) Nucleus of auditory nerve.

(f) Corpus dentatum, or nucleus of the olivary body.

(g) Accessory olivary nucleus.

#### THE PONS VAROLII.

*Position.*—Placed above the medulla, below the *crura cerebri*, and between the lateral halves of the cerebellum.

*Dimensions.*—About  $1\frac{1}{2}$  inches long, and about 2 inches transversely.

*Anterior surface* is convex, grooved along the midline for the basilar artery; has transverse markings, and openings for the entrance of vessels.

*Posterior surface*: smaller than the anterior, and continuous with the posterior surface of the medulla; part of it forms the upper part of the floor of the 4th ventricle.

*Laterally*: transverse fibres pass outwards and backwards from it, forming the middle cerebellar peduncles.

*Upper border*: longer than the inferior, with a notch in the median line corresponding to the groove on the anterior surface.

*Lower border*: slightly arched, overlapping the upper part of the medulla.

**Structure**: Alternating layers of transverse and longitudinal fibres, with intermingled grey matter. The transverse fibres come from the middle peduncles of the cerebellum, and pass to the crura cerebri; the longitudinal are the continuation upwards of the fibres of the medulla.

Most anteriorly is a layer of transverse fibres of the middle peduncles; behind these, longitudinal fibres prolonged from the anterior pyramids of the medulla with intermingled transverse peduncular fibres. More posteriorly is a deep layer of transverse fibres, most marked at the lower part of the pons, where they form the *corpus trapezoides*, and behind these are longitudinal fibres prolonged from the formatio reticularis of the medulla, the lateral tract and the olivary fillet. A septum of commissural fibres exists at the posterior part of the pons.

*The grey matter of the pons.*—In addition to the grey matter scattered in the above-mentioned formatio reticularis are the following special deposits:—

(a) Superior olivary nucleus. Placed posteriorly near the outer side of the corpus trapezoides.

(b) Nucleus of the facial nerve. Lies in formatio reticularis, just behind superior olivary nucleus.

(c) Motor nucleus of the 5th nerve.

(d) Upper sensory nucleus of the 5th nerve, placed outside motor nucleus.

(e) Continuation upwards of principal auditory nucleus.

(f) Superior auditory nucleus, placed just outside principal nucleus.

(g) Accessory auditory nucleus.

(h) Nucleus of the 6th nerve, corresponding to the part of fasciculus teres, above the auditory *strixæ* (*vide* 4th ventricle).

## THE CEREBELLUM.

The cerebellum is contained in the occipital fossæ, being separated from the cerebrum above by the tentorium. It consists of two lateral hemispheres connected together by the *vermiform process*, which projects considerably upon the under surface, forming the *inferior vermiform process*; but on the upper surface only forms a slight ridge, the *superior vermiform process*, continuous with the hemispheres laterally.

The inferior surface of each hemisphere is convex, and between them there is a fossa, the *vallecula*, at the bottom of which the inferior vermiform process lies, and which is continuous posteriorly with a notch between the two hemispheres. The medulla is in contact with the anterior part of the vallecula, and the posterior part receives the falx cerebelli.

**Laminæ and fissures.** The surface of the cerebellum consists of *laminæ*, which are separated by sulci or fissures.

The *great horizontal fissure* divides each hemisphere into an upper and a lower part. It commences at the pons in front, and passes horizontally round the circumference to end at the notch behind.

**Lobes.** On the upper surface of the cerebellum are the following lobes:—

(a) *Central*: a small lobe, forming the anterior part of the superior vermiform process. It is continued forwards on to the valve of Vieussens, forming the *lingula* (*vide* roof of 4th ventricle, p. 122), and laterally on to each hemisphere by a winglike fold, the *ala*.

(b) *Lobus culminis*: the *culmen monticuli* forms the highest part of the superior vermis, and on each side is continuous with the anterior crescentic lobe of the lateral hemisphere; posteriorly the sulcus preclivalis separates it from—

(c) *Lobus clivi*: consists of the mesial *clivus monticuli*, connecting on either side the two *posterior crescentic lobes*, which are broad.

(d) *Lobus cacuminis*: behind the sulcus postclivalis, consists of a single folium of the superior vermis, *folium cacuminis*, connecting the large *postero-superior lobes* of the lateral hemisphere.

On the under surface of the cerebellum are the following lobes from before backwards :

(a) *Lobus noduli*, comprising the *nodule* of the inferior vermis and the *flocculus* of each side, with a delicate connecting white lamina, *inferior medullary velum*.

(b) *Lobus uvulæ*.—The *uvula* forms a considerable part of inferior vermis ; it is connected by a low ridge, the *furrowed band* crossing the sulcus vallecule, with the prominent *tonsil* or *amygdala*.

(c) *Lobus pyramidis*: the prominent mesial *pyramid* continuous laterally with the *biventral* lobes.

(d) *Lobus tubercis*: comprises the *tuber valvulæ*, which is the posterior part of the inferior vermis and the *postero-inferior lobes* of the lateral hemisphere; the latter is subdivided into *lobus gracilis* in front and *inferior semilunar lobe* behind.

#### STRUCTURE.

**White matter** : in each hemisphere there is a central white mass, containing in its middle a grey nucleus, the *corpus dentatum*.

The white centre sends processes into the laminæ, and is prolonged anteriorly into the crus cerebelli, which divides into three peduncles, viz. :—

*Superior peduncle* : passes to the base of the corpora quadrigemina and cerebrum.

Connecting the bases of the two superior peduncles is the valve of Vieussens.

*Middle peduncle* (the cerebellar commissure) : forms the transverse fibres of the pons.

*Inferior peduncle* : connects the cerebellum with the medulla and cord ; it passes downwards at the back of the medulla, forming the restiform body.

The white matter in the vermiform processes consists of a central part, projecting into the laminæ of the processes.

Anteriorly it is continued into the inferior medullary velum.

**Grey matter of the hemispheres** :

A *cortical layer* : forming a continuous covering of the cerebellum.

The *corpus dentatum*, or ganglion of the cerebellum, is a dentated capsule of grey matter enclosing white substance, situated in the middle of the white matter of the hemisphere. It is open at its anterior part, whence white fibres issue, passing to the superior peduncles and valve of Vieussens.

*Nucleus emboliformis*: covering hilum of corpus dentatum.

*Nucleus globosus*: placed on the inner side of the preceding, but at a lower level.

*Nucleus fastigii*: in the anterior part of the white centre of the vermiform process.

The arrangement of white and grey matter in the cerebellum gives on section an arborescent appearance, the *arbor vita*.

#### THE MESENCEPHALON.

The *Sylvian aqueduct* (iter a tertio ad quartum ventriculum) is about  $\frac{1}{2}$  inch long. Posteriorly it is continuous with the narrowed upper end of the 4th ventricle, and anteriorly it opens out into the 3rd ventricle. It has a ciliated epithelial lining, and outside this a layer of grey matter, both being continuous with corresponding parts of the 4th ventricle. Laterally and below are the *crura cerebri*, whilst posteriorly is the *lamina quadrigemina* bearing the *corpora quadrigemina*.

The grey matter of the aqueduct contains the nuclei of the 3rd and 4th nerves, and the upper nucleus of the 5th nerve.

The *crura cerebri* extend from the upper border of the pons, and, diverging, pass under the optic tract into the cerebral hemispheres. Between the *crura* is the *interpeduncular space*, containing the posterior perforated spot, the *corpora albicantia*, pituitary body, infundibulum, and the *tuber cinereum*. Near the angle of divergence the roots of the 3rd nerve issue from a groove on the inner side, which groove indicates the separation of the ventral part (*crusta* or *pes pedunculi*) from the dorsal portion (*tegmentum*) of the *crus*.

There is a layer of grey matter placed between the *pes pedunculi* and the *tegmentum*, known as the *substantia nigra* or *locus niger*.

The *pes*, or *crusta pedunculi*, consists of longitudinal white fibres, of which the middle third are continuous with the anterior pyramid of the medulla, and pass to the internal capsule.

The *tegmentum* consists of white longitudinal fibres and interspersed grey matter, continuous with the formatio reticularis of the medulla and pons, and passing above into the optic thalamus. Two more or less definite white longitudinal tracts are here passing upwards, the fillet and the superior cerebellar peduncle, which latter decussates with its fellow beneath the aqueduct.

The **corpora quadrigemina** are four small bodies placed in pairs, superior and inferior corpora quadrigemina.

*Relations* :—

<i>In Front.</i>	<i>Above.</i>	<i>Below.</i>
3rd ventricle. Posterior commissure.	Posterior border of corpus callosum.	Aqueduct of Sylvius.

The corpora quadrigemina of opposite sides are separated by a longitudinal groove, which is connected below with the superior medullary velum; the superior corpora quadrigemina are partly concealed by the overlying pineal gland. From the outer side of each corpus there proceeds a white tract, the *brachium*. The brachia from the inferior corpora go to the inner geniculate body, and the brachia from the superior bodies pass into the optic tract between the inner geniculate body on the one hand, and the optic thalamus and the external geniculate body on the other hand.

*Structure.*—The inferior bodies consist of a grey nucleus enclosed in a thin capsule of white fibres. The white fibres, separating the nuclei and the grey matter of the aqueduct, are derived from the fillet of the olivary body. The nuclei of each side are connected by commissural grey matter.

The superior bodies consist of a grey nucleus intersected by white longitudinal fibres.

#### THE THALAMENCEPHALON.

The **third ventricle** is the narrow space between the optic thalami, extending from the opening of the Sylvian aqueduct under the posterior commissure, to the foramen of Monro. It is much deeper in front than behind.

The third ventricle communicates above by the Y-shaped foramen of Monro with the lateral ventricles and behind with the 4th ventricle by the aqueduct of Sylvius.

*Boundaries :—*

<i>Roof.</i>	<i>Floor.</i>	<i>Laterally.</i>
Fornix.	Lamina cinerea.	Optic thalamus.
Velum interpositum with choroid plexus of 3rd ventricle.	Optic commissure.	Peduncles of pineal gland.
	Tuber cinereum.	
	Infundibulum.	<i>Anteriorly.</i>
	Corpora albicantia.	Pillars of fornix.
<i>Posteriorly.</i>	Posterior perforated spot.	Foramen of Monro.
Pineal gland.	Tegmenta of crura cerebri.	Anterior commissure.
Posterior commissure.		
Sylvian aqueduct.		

**Commissures :** the *anterior commissure* will be described with cerebral hemispheres.

The *posterior commissure*: is a commissural layer of white fibres connecting the two optic thalami posteriorly. It forms the posterior boundary of the 3rd ventricle, being placed just above the upper opening of the aqueduct of Sylvius, and beneath the pineal body.

The *middle or soft commissure*: a delicate band of grey matter passing between the optic thalami, near middle of ventricle.

The **optic thalami**. Two oblong masses of grey matter, covered with a thin layer of white fibres, the *stratum zonale*, and projecting above into the lateral ventricles.

*Upper surface*: there is a groove along this surface, running from behind obliquely forwards and inwards, which corresponds to the free lateral edge of the fornix and divides it into two pear-shaped pieces, the outer (ventricular area) having its base forwards and projecting in front, forming the *anterior tubercle*, and the inner (extra-ventricular area) having its base behind and to the inner side, which forms the *posterior tubercle* or *pulvinar*. This surface is separated from the *mesial*, or surface bounding the 3rd ventricle, by the peduncle of the pineal body; and between this and the pulvinar is a triangular depressed surface, the *trigonum habenulae*. This surface is partly covered by the fornix resting on the velum interpositum, and is separated externally from the caudate nucleus by the *tænia semicircularis*.

*Posterior extremity* is formed chiefly by the pulvinar. Below and outside this is the eminence of the *outer geniculate body*; and just below this is the *inner geniculate body*, the brachium from the superior corpus quadrigeminum passing between them.

*Under surface*: placed on the tegmentum of the crus.

*External surface*: fibres of the *crusta* (internal capsule) pass between this surface and the lenticular nucleus.



*Internal surface*: forms lateral wall of 3rd ventricle, and is covered by ependyma.

*Anterior extremity* (anterior tubercle): posterior boundary of foramen of Monro.

The **pineal body** is a cone-shaped body placed at the back of the 3rd ventricle, and overlying the superior quadrigeminal bodies. The 3rd ventricle projects backwards into its base or peduncle (pineal recess), which is thus divided into a dorsal part, connecting the pineal body on each side with the optic thalamus, and a ventral part, connecting it with the posterior commissure.

The **posterior perforated spot** is a depression containing grey matter placed at the base of the brain, in the angle of divergence of the crura. It is bounded by the corpora albicantia in front, and by the pons behind. The anterior part corresponds to the under portion of the floor of the 3rd ventricle, and is perforated for bloodvessels to the optic thalami.

The **corpora albicantia** are two small whitish bodies, placed in front of the posterior perforated spot and behind the tuber cinereum. They consist of grey matter covered with white fibres, derived from the anterior pillars of the fornix.

The **tuber cinereum** is an eminence of grey matter, situated in front of the corpora albicantia, and extending forwards to the optic tract. From its centre a tubular conical process of grey matter, the *infundibulum*, passes downwards and forwards to the posterior lobe of the pituitary body.

The **pituitary body** is a reddish-grey vascular mass lying in the sella turcica. It consists of two lobes, the anterior being the larger.

The **optic commissure** or **chiasma** is the union of the two optic tracts, and is placed in the middle line just in front of the tuber cinereum. From the anterior part the two optic nerves proceed.

*Decussation of the nerve fibres*.—When the fibres of the tract reach the commissure, they pass across for the most part to form the optic nerve of the opposite side, but a few pass directly into the nerve of the same side. The posterior fibres of the chiasma are described as simply passing between the two inner geniculate bodies.

The **lamina cinerea** is a layer of grey matter lying above the optic commissure, and passing from the extremity of the corpus callosum backwards to the tuber cinereum; laterally it is connected with the grey matter of the *anterior perforated spot*, which lies under the anterior end of the corpus callosum and is pierced by vessels.

## THE CEREBRAL HEMISPHERES.

The cerebral hemispheres form as a whole an oval mass, with the larger end backwards, and separated into two equal portions by the great longitudinal fissure. Each hemisphere presents three surfaces :

1. *Outer* : convex, occupying the vault of the cranium.
2. *Inner* : flat, forming one side of the longitudinal fissure.
3. *Under* : irregular, corresponding in shape to the anterior and middle fossæ, and to the upper surface of the tentorium. It has a deep cleft, the fissure of Sylvius, between the portions occupying the anterior and middle fossæ.

The surface of each hemisphere consists of grey matter, and is divided into convolutions or gyri by intervening sulci.

The **great longitudinal fissure** separates incompletely the two hemispheres, dividing them completely in front and behind ; but at the base near the middle they are united by the corpus callosum. The falx cerebri occupies the fissure.

The **transverse fissure of the cerebrum** is a cleft in the posterior part of the brain, which is seen when the velum interpositum and choroid plexuses of the lateral ventricles are removed. It extends from the tip of the descending cornu on one side, over the optic thalami, 3rd ventricle, and mesencephalon to the tip of the descending cornu on the other side.

*The FISSURES of the Hemispheres, or Interlobar Sulci.*

1. The **fissure of Sylvius** commences below at the outer side of the anterior perforated spot, passes upwards and outwards between the frontal and temporo-sphenoidal lobes, and divides into two branches, an *anterior* or *ascending*, the shorter, passing into the frontal lobe, and a *posterior* or *horizontal*, passing behind the island of Reil, upwards and backwards to about the middle of the outer surface of the hemisphere.

2. The **fissure of Rolando** commences at the longitudinal fissure near the vertex, passes downwards and forwards nearly as far as the division of the Sylvian fissure. It separates the parietal and frontal lobes.

3. The **parieto-occipital fissure** consists of two portions, an *internal* or *perpendicular* fissure, seen on the inner surface of the hemisphere, and an *external*, extending on the outer surface, between the parietal and occipital lobes, for about an inch.

4. The **calloso-marginal fissure** commences in front near the anterior perforated spot, and takes a course on the inner surface of the hemisphere about midway between the corpus callosum and the edge of the longitudinal fissure, ending a little behind the upper end of the fissure of Rolando.

5. The **collateral fissure** lies along the lower border of the uncinatè convolution ; it projects inwards and forms the

*eminentia collateralis* in the descending cornu of the lateral ventricle.

6. **Limiting sulcus of Reil**, round the island of Reil (p. 133).

#### THE LOBES.

The hemispheres are by the above fissures arbitrarily divided into seven lobes, viz.:—

1. *Frontal*: limited below by the Sylvian fissure, behind by the fissure of Rolando, internally by calloso-marginal fissure.

2. *Parietal*: limited in front by the fissure of Rolando, and behind by the parieto-occipital fissure; below by fissure of Sylvius continued backwards, and internally by calloso-marginal fissure.

3. *Occipital*: Bounded in front by the parieto-occipital fissure; forms the posterior part of the hemisphere.

4. *Temporo-sphenoidal*: occupies middle fossa at the base of the skull, being placed behind the Sylvian fissure, and below the parietal and occipital lobes, internally separated from limbic lobe by collateral fissure.

5. *Central or Island of Reil*: contained in the Sylvian fissure; triangular in shape.

6. *Limbic or falciform*: consists of callosal and uncinat gyri, bounded above and in front by calloso-marginal and below by collateral fissures.

7. *Olfactory*: lying on the under surface of the frontal lobe, sometimes termed the olfactory nerve.

**The frontal lobe**:—

*Convolution and sulci*:—

*On under surface*:—

The *tri-radiate* or *orbital sulcus* divides this surface into an inner, anterior, and posterior or outer orbital convolutions. On the inner convolution is the olfactory sulcus, which contains the *olfactory lobe*.

*On outer surface*:—

The *ascending frontal* or *precentral convolution* is bounded behind by the fissure of Rolando, round the lower end of which it joins the ascending parietal convolution; in front by the precentral sulcus.

The *longitudinal frontal convolutions* are three in number, *upper*, *middle*, and *inferior*; they occupy the rest of the outer surface and are separated from each other by two sulci, and from the ascending convolution by the precentral sulcus.

*On inner surface*:—

The *marginal convolution* extends along the edge of the longitudinal fissure. It commences at the anterior

perforated spot, and is limited below by the calloso-marginal sulcus, and behind by its upturned extremity.

## 2. The parietal lobe :—

*Convolutions and sulci :—*

*On outer surface :—*

The *intra-parietal sulcus* commences near posterior limb of Sylvian fissure, passes upwards parallel to the lower half of the fissure of Rolando, and then turns backwards to end near parieto-occipital fissure.

The *postcentral sulcus* continues the line of the vertical part of the intra-parietal sulcus.

The *ascending parietal convolution* is bounded in front by the fissure of Rolando, behind by the intra-parietal and postcentral fissures, below by the fissure of Sylvius, and above it joins the superior parietal convolution.

The *superior parietal convolution* is bounded by the post-central fissure in front, behind by the parieto-occipital fissure, round which it is connected to the superior occipital convolution by the *first annectant gyrus*.

*Inferior parietal* subdivided into :—

The *supra-marginal convolution*, bounded in front and above by the intra-parietal fissure, round the lower end of which it joins the ascending parietal convolution; behind by the posterior limb of the Sylvian fissure, round which it joins the superior temporo-sphenoidal convolution.

The *angular convolution* occupies the rest of the outer surface of the parietal lobe. Above is the superior parietal lobule, below the temporo-sphenoidal lobe, in front the supra-marginal gyrus, and behind the occipital lobe: it arches over the upturned end of the parallel sulcus, and is continuous with the second temporo-sphenoidal convolution. The *postparietal convolution* curves over the upturned second temporal sulcus, and is continued into the third temporo-sphenoidal convolution.

*On the inner surface :—*

The *quadrate lobule* lies anterior to the cuneate; it is bounded behind by the internal parieto-occipital fissure, and in front by the ascending terminal limb of the calloso-marginal sulcus.

## 3. The occipital lobe :—

*On outer surface* three convolutions, an *upper*, a *middle*, and an *inferior*, by two sulci.

The *superior occipital convolution* is connected anteriorly to the superior parietal lobule by the first annectant gyrus.

The *middle occipital convolution* joins the angular convolution by the second annectant gyrus, and to the middle temporo-sphenoidal convolution by the third annectant gyrus.

The *inferior occipital convolution* is connected to the inferior temporo-sphenoidal convolution by the fourth annectant gyrus.

*On inner surface :—*

The *cuneate lobule* is the area between the internal parieto-occipital and the calcarine fissures.

The *calcarine fissure* commences at the posterior part of the inner surface of the occipital lobe by a forked extremity; is joined about half-way by the internal parieto-occipital fissure, and ends near the posterior extremity of the corpus callosum.

*On under surface :—*

The *inferior occipito-temporal convolution* lies just below the collateral fissure, and extends from the apex of the temporo-sphenoidal lobe to the posterior part of the hemisphere, forming the under surface of both temporal and occipital lobes.

4. The **temporo-sphenoidal lobe** :—

*On outer surface :—*

The *superior temporo-sphenoidal* or *parallel sulcus* runs parallel to posterior limb of the Sylvian fissure.

The *middle temporo-sphenoidal sulcus* lies parallel to the superior.

The *superior temporo-sphenoidal convolution* (infra-marginal) is bounded above by posterior limb of Sylvian fissure, and continuous behind with supra-marginal convolution.

The *middle temporo-sphenoidal convolution* joins posteriorly the angular, and by the third annectant gyrus merges into the middle occipital convolution.

The *inferior temporo-sphenoidal convolution* joins the inferior occipital convolution by the fourth annectant gyrus.

*On under surface :—*

*Inferior occipito-temporal convolution* in its anterior part.

5. The **central lobe** or **island of Reil** lies in the fissure of Sylvius at the base of the brain. *Boundaries* : In front, the *anterior sulcus of Reil*, which separates it from the posterior orbital convolution. Superiorly, the *superior sulcus of Reil*, separating it from the gyri of the operculum, a collective name given to the portions of the inferior frontal, and lower ends of the ascending frontal and parietal convolutions which lie between the ascending and posterior limbs of the Sylvian fissure. Posteriorly, by the *posterior sulcus of Reil*, separating it from the temporo-sphenoidal lobe. It is divided by the central sulcus into an *anterior* part, which is subdivided into

three gyri breves, and a *posterior* part subdivided into two gyri longi.

6. The **limbic lobe** :

*On the inner surface* consists of :—

The *gyrus fornicatus* or *callosal convolution* lies beneath the marginal convolution, being separated from it by the callosomarginal sulcus. It commences near the anterior perforated spot, follows the curves of the corpus callosum, near the posterior end of which it becomes continuous with the uncinatè gyrus.

The *uncinatè convolution* (hippocampal) commences below the splenium of the corpus callosum; here the end of the calcarine fissure cuts into it, leaving a narrow *isthmus* connecting it with the callosal convolution. It runs forwards above the collateral fissure into the temporal lobe and ends as the *uncus*.

The *dentate sulcus* (hippocampal) lies along the upper border of the uncinatè convolution, and forms the hippocampus major in the descending cornu of the lateral ventricle.

The *dentate convolution* (fascia dentata) lies in the dentate fissure. It is formed by the superficial grey matter of the hemisphere, which here ends in a fringed margin.

7. The **olfactory lobe** extends from the anterior perforated spot as the *olfactory tract*, and ends in an enlargement, the *olfactory bulb*. It lies in the olfactory sulcus on the orbital surface of the frontal lobe. Posteriorly the tract bifurcates, the outer root passing across commencement of Sylvian fissure to the uncinatè convolution, and the inner one to the great longitudinal fissure to join the callosal convolution.

#### THE INTERIOR OF THE CEREBRUM.

The **centrum ovale minus** is the central white mass in each hemisphere seen on horizontal section, the section being made about  $\frac{1}{2}$  inch above the corpus callosum.

The **centrum ovale majus**, seen on section at the level of the corpus callosum, is the centrum ovale minus of each side, joined by the corpus callosum.

The **corpus callosum** lies at the bottom of the great longitudinal fissure. It is the great transverse commissure of the hemispheres, and consists principally of transverse fibres.

*Length*.—About 4 inches, extending to within  $1\frac{1}{2}$  inches of the anterior, and  $2\frac{1}{2}$  inches of the posterior extremities of the hemispheres.

*Shape*.—Broader behind than in front, thicker at each end

than at the middle, and thickest behind. It terminates posteriorly in a free, thickened border, the *splenium*; in front it curves down towards the base of the brain, the bend being known as the *genu*, and the reflected part as the *rostrum*.

*Raphé*: the longitudinal eminence along the centre of the upper surface.

*Nerves of Lancisi* (*striæ longitudinales*): longitudinal white fibres placed on each side of the raphé.

*Covered band of Reil*: longitudinal fibres outside the nerves of Lancisi, under cover of the convolution of the corpus callosum.

*Relations*.—Upper surface forms floor of great longitudinal fissure; under surface connected behind with the fornix, and in front of this with the *septum lucidum*. The extremity of the rostrum is connected centrally with the lamina cinerea, and laterally with two white bands, the *peduncles of the corpus callosum*, which pass backwards and outwards over the anterior perforated spot towards the Sylvian fissure to the anterior extremity of the temporal lobes. Traced upwards, these fibres are continuous with nerves of Lancisi. The corpus callosum roofs in the bodies and anterior cornua of the lateral ventricles.

The lateral ventricles are two in number, one in each hemisphere. They communicate below and in front with one another and with the 3rd ventricle by the foramen of Munro. Each ventricle consists of a body or central cavity, and three cornua, *anterior*, *posterior*, and *descending*.

*Relations of the body*:—

*Roof*.—Corpus callosum.

*Internal wall*.—Septum lucidum and the fornix.

*Floor*.—From before backwards.

1. Caudate nucleus of corpus striatum.
2. Tænia semicircularis.
3. Part of optic thalamus in front of choroid plexus.
4. Choroid plexus of lateral ventricle.
5. Fimbriated edge of the fornix.

The *anterior cornu* is the anterior end of the ventricle which curves outwards round the caudate nucleus.

*Relations*:—

<i>In Front.</i>	<i>Roof.</i>	<i>Floor and Externally.</i>	<i>Internally.</i>
Genu of corpus callosum.	Corpus callosum.	Caudate nucleus.	Septum lucidum.

The *posterior cornu* projects backwards and inwards into the occipital lobe.

*Relations :—*

<i>Roof and Outer Wall.</i>	<i>Floor.</i>	<i>Inner Wall.</i>	<i>At Junction of Posterior and Descending Cornua.</i>
Fibres of corpus callosum passing to temporo-sphenoidal lobe.	White substance of occipital lobe.	Hippocampus minor, formed by the calcarine sulcus, projecting inwards.	Eminentia collateralis, formed by the inward projection of the collateral sulcus.

The *descending cornu* passes at first backwards and outwards round the posterior part of the optic thalamus, then downwards, forwards and inwards.

*Relations :—*

<i>Roof.</i>	<i>Floor.</i>	<i>Inner Wall.</i>	<i>Outer Wall.</i>
Fibres of corpus callosum passing to temporo-sphenoidal lobe.	Hippocampus major.	Pia mater.	White substance of the hemisphere.
Amygdaloid tubercle.	Tænia hippocampi.		
Tail of caudate nucleus.	Choroid plexus.		
	Eminentia collateralis.		

The **hippocampus major** : a large white projection in the whole length of the floor of the descending cornu. It corresponds with the dentate sulcus. The anterior extremity becomes enlarged and indentated, forming the *pes hippocampi*.

*Tænia hippocampi* or *fimbria of the fornix* : a narrow white band prolonged from the posterior pillar of the fornix, and lying along the inner margin of the hippocampus major.

The **septum lucidum** is a double vertical partition between the lateral ventricles, attached to the fornix and rostrum below, and to the under surface of the body of the corpus callosum above. Between the layers is the 5th ventricle, a closed narrow space, having no connection with the other ventricles, and not lined by ependyma.

The **fornix** consists of two white longitudinal strata beneath the corpus callosum, separated in front and behind, forming the pillars, but joined in the middle, forming the body.

The *body* is triangular in shape, the base being placed posteriorly, and here connected with the corpus callosum. In front of this it is connected with the septum lucidum along its upper surface. The lateral margins are free, lying against the choroid plexus of the lateral ventricles. The under surface lies upon the velum interpositum.

The *anterior pillars* pass downwards, forming the anterior



boundary of the foramen of Monro, then through the grey matter on the outer side of the 3rd ventricle; and on reaching the base of the brain they make a half figure-of-eight turn, forming the white envelope of the corpora albicantia; they then ascend and pass into the anterior nucleus of the optic thalamus. The pillars receive near the foramen of Monro the fibres of the peduncles of the pineal gland, and those of the tænia semicircularis.

The *posterior pillars*: the two strata of the fornix diverge behind, being connected at first with the splenium of the corpus callosum; thence curving round the pulvinar they pass into the descending cornu, the outer fibres being lost on the hippocampus major, the inner ones forming the tænia hippocampi.

Between the diverging posterior pillars a portion of the splenium with transverse markings is exposed; this is known as the *lyra*.

The **foramen of Monro** is the interval between the anterior pillars of the fornix and the optic thalami. It is Y-shaped, the two limbs anteriorly communicating with the lateral ventricles on either side, and the junction of the two opening into the 3rd ventricle.

The **velum interpositum** is a triangular process of pia mater prolonged through the transverse fissure and lying over the 3rd ventricle and upper surfaces of the optic thalami. Its apex reaches the foramen of Monro, and the fornix lies upon its upper surface.

#### **Choroid plexuses :—**

*Of the lateral ventricles* are fringed vascular processes extending from the foramen of Monro to commencement of descending cornu, and attached along the lateral margins of the velum interpositum; thence each passes into the descending cornu, resting on the tænia hippocampi and hippocampus major, forming the *choroid plexus of the descending cornu*.

*Of the 3rd ventricle*: from the under surface of the velum interpositum there depend two vascular fringes, diverging behind, and forming the choroid plexus of 3rd ventricle.

**Veins of Galen**: two veins formed by junction of the vein of the corpus striatum and choroidal vein of each side, and running backwards between the layers of the velum interpositum, and uniting posteriorly into one trunk, which opens into the straight sinus.

The **corpora striata**, so called from their appearance on section, which displays alternate white and grey bands, are two in number, one in each hemisphere, and are sometimes termed the ganglia of the hemisphere. Each consists of an

ovoid mass of grey matter lying outside and in front of the optic thalamus. The largest part (*lenticular nucleus*) lies in the white matter of the hemisphere outside the lateral ventricle, and a smaller part (*caudate nucleus*) appears in the floor of that space.

The *caudate nucleus* is pear-shaped, with the larger end placed anteriorly, occupying the floor and outer wall of the anterior cornu; the narrow posterior part lying along the floor and outer wall of the lateral ventricle passes into the roof of the descending cornu, where it is joined by the *tænia semicircularis* to form the amygdaloid tubercle.

The *lenticular nucleus* lies outside and at a lower level than the caudate nucleus, from which it is separated by a layer of white fibres, the *internal capsule*. Outside the nucleus is another stratum of white fibres, the *external capsule*, and beyond this a thin lamina of grey matter called the *claustrum*, the outer surface of which lies next to the white substance of the island of Reil.

The *tænia semicircularis* is a narrow band of white fibres attached to the anterior pillar of the fornix in front, whence it passes backwards in the floor of the lateral ventricle, between the caudate nucleus and the optic thalamus; it then passes into the roof of the descending cornu, at the end of which it enters a mass of grey matter, the *nucleus amygdalæ*, continuous with the superficial grey matter at the apex of the temporo-sphenoidal lobe, and placed just under the lenticular nucleus.

The *anterior commissure* is a bundle of white fibres lying in the anterior part of the 3rd ventricle, in front of the anterior pillars of the fornix. The fibres go through the caudate nucleus, and, passing under the lenticular nucleus, ultimately enter the temporo-sphenoidal lobe.

#### SYNOPSIS OF COURSE OF FIBRES IN THE CENTRAL HEMISPHERES.

1. *Peduncular fibres*, connecting cord and cerebellum with cerebrum:—

- (a) *From crusta*, chiefly through internal capsule to convolutions.
- (b) *From tegmentum*, chiefly to optic thalamus; a part joins the inner capsule, and passes to occipital and temporo-sphenoidal lobes.

The peduncular fibres, in their course to the convolutions, are reinforced by fibres from the corpora striata and optic thalami.

2. **Transverse fibres**, connecting the two hemispheres :—
- (a) *Of corpus callosum.*
  - (b) *Anterior commissure.*
3. **Collateral fibres**, connecting different parts of the same hemisphere.
- (a) *Fornix.*
  - (b) *Tænia semicircularis.*
  - (c) *Nerves of Lancisi.*
  - (d) *Gyrus fornicatus*, the fibres of which are said to encircle the corpus callosum, near the middle line, meeting at the anterior perforated space.
  - (e) *Uncinate fasciculus*, a white bundle at the bottom of the Sylvian fissure, uniting the frontal and temporo-sphenoidal lobes.
  - (f) *Inferior longitudinal fasciculus*, a collection of fibres passing between temporo-sphenoidal and occipital lobes.
  - (g) *Association fibres*, passing between and connecting together the different convolutions.

#### THE MEMBRANES OF THE BRAIN, OR MENINGES.

The **DURA MATER**, the most external, is a dense fibrous membrane, which is closely attached to the bones of the skull, forming their internal periosteum. The inner surface is smooth, and covered with endothelium. It is continuous with the dura mater of the spinal cord through the foramen magnum. The fibrous part of the dura mater is divided into two layers, an outer, forming the periosteum, and an inner, lying under the endothelium, forming certain processes, and which, by its separation in certain situations, forms the *sinuses* (for sinuses of dura mater, *vide p. 97*). On the upper surface, near, and projecting into the longitudinal sinus, are the *Pacchionian bodies*, which are enlarged villi of the arachnoid projecting through the layers of dura mater.

*Processes of the dura mater* :—

The **falx cerebri** : placed vertically between the two hemispheres of the cerebrum, attached in front to the crista galli, behind to the upper surface of the tentorium, and between these above to middle line of internal surface of skull, while the lower border is concave and free. In relation with it are the superior and inferior longitudinal, and the straight sinuses.

The **tentorium cerebelli** is a crescentic fold of dura mater placed between the cerebrum and the cerebellum. It has an outer convex border, by which it is attached in front to the

posterior clinoid processes, superior edge of the petrous bone, and behind to the margins of the groove for the lateral sinus. The inner concave border is free posteriorly, and forms the opening through which the crura cerebri and the posterior cerebral arteries pass from the posterior into the middle cranial fossa; in front this border passes over the attached border, and is attached to the anterior clinoid processes. The tentorium is a tent-like process, highest above and in front, at its most anterior point of attachment of the falx cerebri by which the tentorium is suspended, and from this point descending on all sides. In relation to it are the lateral, superior petrosal, and straight sinuses.

The **falx cerebelli** reaches vertically from the tentorium to the foramen magnum, dividing the two hemispheres of the cerebellum. It is attached posteriorly to the vertical crest of the occiput, where it encloses the occipital sinus, and below to each side of the foramen magnum.

The **PIA MATER** consists of a delicate stroma supporting bloodvessels, and closely invests the brain, dipping into the sulci. At the transverse fissure it is prolonged into the lateral ventricles and over the 3rd ventricle, pushing the endothelial lining of those cavities in front of it, and forming the *velum interpositum* and choroid plexuses of the lateral and 3rd ventricles. It is prolonged over the roof of the 4th ventricle, sending inwards two vascular fringes, the choroid plexuses of that cavity.

The **ARACHNOID** is a thin membrane lying outside the pia mater, but is not so closely applied to the brain, as it passes over the sulci without dipping into them. Between the pia mater and the arachnoid is the *subarachnoid space*, containing the subarachnoid fluid. The space between the dura mater and arachnoid is now known as the *subdural space*.

The **subarachnoid space** is larger in some places than in others. The arachnoid stretches across between the two middle lobes at the base of the brain, forming the *cisterna basalis*, which lies anterior to the pons and reaches as far forward as the optic nerves. Beneath the cerebellum it forms in a like manner the *cisterna magna*, by stretching between the under surface of the cerebellum and the posterior surface of the medulla.

At the bottom of the longitudinal fissure the subarachnoid space is also large.

The subarachnoid space communicates with the cerebral ventricles by the *foramen of Majendie*, an opening into the

4th ventricle in the expansion of pia mater across the roof. There are two other openings through the pia mater, placed one on each side of the upper roots of the glosso-pharyngeal nerve, under the flocculus.

## THE NERVES.

### THE NERVES OF THE HEAD AND NECK.

#### THE CRANIAL NERVES, 12 pairs.

**1ST OR OLFACTORY.** *Course:* the olfactory tract passes forwards on the under surface of the frontal lobe near the longitudinal fissure, resting on cribriform plate and expanding anteriorly into olfactory bulb. There is an enlargement at the posterior part of the upper surface called the *olfactory tubercle*.

*Distribution.*—About twenty nerve filaments are given off from under surface of the *olfactory bulb* (p. 134), and pass downwards through ethmoidal foramina; they are divided into three sets to supply Schneiderian membrane of the nose; *inner* to septum, *middle* to roof of nose, *outer* to superior and middle turbinate bones.

*Special function.*—Smelling.

**2ND OR OPTIC.** *Origin,* from optic tract, which arises by two roots: *Outer*, from external geniculate body, optic thalamus and brachium of superior quadrigeminal body. *Inner*, from internal geniculate body.

*Course.*—Winds across outer and anterior surfaces of crus cerebri, uniting with fellow to form optic commissure, which is bounded in front by the lamina cinerea and behind by the tuber cinereum; the nerves separate at fore part of commissure, get ensheathed in arachnoid, and pass into orbit through optic foramen above and internal to ophthalmic artery; whilst passing through, each receives a tube of dura mater, which divides into two, the outer piece becoming orbital periosteum, and the inner, ensheathing the nerve, joins the sclerotic in front. The nerve pierces sclerotic and choroid coats of eyeball.

*Distribution.*—Expands to form innermost layer of retina.

*Special function.*—Nerve of sight.

**3RD OR MOTOR OCULI.** *Superficial origin:* inner side of crus cerebri, just in front of pons. *Deep origin:* floor of aqueduct of Sylvius.

*Course.*—Pierces dura mater to enter canal in outer wall of

cavernous sinus near posterior clinoid process, lying above and internal to 4th nerve. As it passes forwards to enter orbit through sphenoidal fissure, the 4th nerve and frontal branch of 5th cross externally and become superior to it. It divides into two branches in the fissure, which enter orbit between the heads of the external rectus, the nasal branch of the 5th lying between the two; whilst in cavernous sinus it communicates with cavernous plexus.

*Distribution.*—Superior branch supplies superior rectus and levator palpebræ superioris. Inferior divides into three, for internal rectus, for inferior rectus, and for inferior oblique, which latter gives off short or motor root to the lenticular ganglion, through which the 3rd nerve supplies the ciliary muscle and the sphincter fibres of the iris.

*Special function.*—Motor nerve of eyeball.

4TH OR TROCHLEAR. *Origin*—*Superficial*: valve of Vieussens, just behind corpora quadrigemina. *Deep*: floor of aqueduct of Sylvius.

*Course.*—Winds round outer surface of crus cerebri and pierces free border of tentorium; passes forwards in outer wall of cavernous sinus below 3rd, but enters orbit through sphenoidal fissure above and internal to the other nerves and external rectus.

*Distribution.*—Enters *orbital* surface of superior oblique.

*Special function.*—Motor nerve of superior oblique.

5TH OR TRIFACIAL. *Origin*—*Superficial*: from the side of the pons, by small motor and large sensory roots, the latter having a ganglion on it. *Deep*: **Sensory**: (a) floor of 4th ventricle; (b) (ascending root), posterior horn of grey matter of medulla, and upper part of cord. **Motor**: (a) floor of 4th ventricle; (b) (descending root), side of aqueduct of Sylvius.

*Course.*—The two roots pass forwards through oval opening in dura mater near apex of petrous bone, the sensory root entering the Gasserian ganglion, lodged on the apex of petrous part of temporal bone. The motor root passes under ganglion and is not connected with it, but goes through foramen ovale, uniting with the Inferior Maxillary division.

The **Gasserian ganglion**: lodged in a depression (Meckel's cave) near the apex of petrous part of temporal, gives off from its anterior edge the *ophthalmic*, *superior maxillary*, and *inferior maxillary* trunks. The two former are purely sensory; the last by joining small motor root becomes a mixed nerve.

**OPHTHALMIC** or 1st division of the 5th (sensory and smallest branch): courses along outer wall of cavernous sinus below 3rd and 4th nerves, to enter orbit through sphenoidal fissure.

In sinus communicates with cavernous plexus and third, fourth, and sixth nerves, and divides into three branches, two of which, frontal and lachrymal, enter orbit above external rectus, whilst the third or nasal passes between two heads of origin of that muscle, and between two divisions of 3rd nerve.

*Branches :—*

**Lachrymal** : passes along outer wall of orbit to under surface of lachrymal gland, communicates with orbital of superior maxillary, finally pierces palpebral fascia, and supplies skin of upper eyelid, inosculating with branches of facial.

**Frontal** : largest branch, enters orbit just outside 4th nerve, passes forward on levator palpebræ, and divides into :—

*Supra-trochlear* : directed forwards and inwards between pulley and supra-orbital notch ; distributed to forehead and communicates with infra-trochlear.

*Supra-orbital* : continuation of frontal, passes through notch, supplies palpebral filaments, and ends on forehead by dividing just outside orbit into two branches, of which the external is the larger. It supplies the scalp. Communicates with facial.

**Nasal** : enters orbit between the heads of the external rectus, passes forwards and inwards over optic nerve along inner side of orbit, through anterior ethmoidal foramen ; re-entering cranium, it passes down nasal slit by the side of the crista galli, dividing into two terminal branches, viz :—

*Internal* : supplying mucous membrane of the septum.

*External* : runs along groove on internal surface of nasal bone, then passes between bone and lateral cartilage to supply skin of ala, and tip of nose. Communicates with facial.

*Branches from nasal in the orbit :—*

**Ganglionic** : arises between heads of external rectus, passes along outer side of optic nerve, entering the posterior superior angle of lenticular ganglion, of which it forms the long or sensory root.

**Long ciliary** (2 or 3) pass along inner side of optic nerve, join some short ciliary branches from ganglion, and, piercing sclerotic, are distributed to ciliary body and iris.

**Infra-trochlear** : given off as nerve enters anterior ethmoidal foramen ; it passes to inner angle of orbit, communicating beneath ' pulley ' with the supra-trochlear of frontal. It supplies lachrymal sac, skin of eyelids and root of nose.

The LENTICULAR GANGLION is a small reddish-coloured body, placed between the optic nerve and the external rectus, at the back part of the orbit.

**Branches of communication or roots :—**

*Long or sensory root* : from the nasal of the ophthalmic, joins posterior superior angle.

*Short or motor root* : from the branch of the 3rd nerve supplying inferior oblique, joins posterior inferior angle.

*Sympathetic* : from the cavernous plexus, and frequently joined with the long or sensory root.

**Branches of distribution :—**

*Short Ciliary Nerves* : Ten or twelve given off in two bundles, large inferior and small superior. Pass forwards above and below optic nerve, with long ciliary of nasal. The branches subdivide and, piercing sclerotic, run in grooves on its internal surface to end in ciliary muscle and iris. The *circular fibres of the iris* and the *ciliary muscle* are innervated by the third nerve, the *radial fibres of the iris* by the sympathetic.

The SUPERIOR MAXILLARY NERVE (sensory) passes from the middle of the Gasserian ganglion through foramen rotundum, then across sphenomaxillary fossa to enter the infra-orbital canal, and here receives the name of *infra-orbital*. Emerging on the face from the infra-orbital foramen under the levator labii superioris, it divides into a number of branches, *nasal*, *palpebral* and *labial*, and joins with branches of the facial nerve to form the infra-orbital plexus.

*Branch in the Skull* :—

**Recurrent** : given off near origin to dura mater.

*Branches given off in the Sphenomaxillary fossa* :—

**Orbital or temporo-malar** : enters orbit by sphenomaxillary fissure and directly divides into :—

*Temporal* : passes along groove in outer wall of orbit, here communicating with the lachrymal : it then goes through a foramen in the malar bone, and, entering the temporal fossa, passes anterior to the temporal muscle : piercing the temporal aponeurosis, it becomes cutaneous, and inosculates with branches from the facial nerve.

*Malar* : passes to lower and outer angle of orbit, goes through malar foramen, and communicating with the facial becomes cutaneous.

**Spheno-palatine (2)** descend to Meckel's ganglion.

**Posterior superior dental** : comes off just before nerve enters canal, and divides into :—

*External branch* : passes downwards to the gums.

*Internal branch* : enters a canal in the superior maxilla, and runs along outer wall of antrum ; supplies the molar teeth and mucous membrane of the antrum. Communicates with middle superior dental.



*Branches arising within the infra-orbital canal :—*

**Middle and anterior superior dental :** descend in canals in anterior wall of antrum, and divide into branches.

The *anterior* supplies incisor and canine teeth.

The *middle* supplies the bicuspid teeth.

*Branches arising on the face :—*

**Inferior palpebral :** supplies integument of lower eyelid, communicating with facial, and malar of orbital.

**Nasal :** to integument of side of nose. Joins nasal of ophthalmic.

**Labial :** three or four branches to integument of upper lip.

The SPHENO-PALATINE OR MECKEL'S GANGLION is deeply placed in the spheno-maxillary fossa, near the spheno-palatine foramen.

*Roots :—*

*Motor* from the facial. (Large superficial petrosal nerve.)

*Sympathetic* from the carotid plexus. (Large deep petrosal nerve.) See Vidian nerve, p. 146.

*Sensory* from the superior maxillary. (Spheno-palatine nerves.)

*Branches of distribution :—*

**Ascending :** three or four small branches to the periosteum of the orbit.

**Descending :** mostly continuous with spheno-palatine of superior maxillary nerve.

The *anterior* or *large palatine nerve* passes through large posterior palatine canal to hard palate, there dividing into branches which run forward in grooves in the bone nearly to the incisor teeth, joining the naso-palatine nerve in the region of anterior palatine canal. It supplies the gums and mucous membrane of hard palate. Whilst in the posterior palatine canal it gives off the *inferior nasal branches* which supply mucous membrane on middle and inferior spongy bones.

The *posterior* or *small palatine nerve* enters smaller posterior palatine canal to supply mucous membrane of soft palate, uvula and tonsil.

The *external palatine nerve* passes through external palatine canal to the tonsil and soft palate.

**Internal.**

*Superior nasal* (4 or 5) through spheno-palatine foramen to supply the posterior and upper part of the superior meatus.

The *naso-palatine nerve* (nerve of Cotunnus) passes inwards through spheno-palatine foramen, crosses roof of nasal fossa to septum, on which it passes downwards and forwards with its fellow of the opposite side to the foramina of Scarpa in anterior palatine canal, the left nerve being anterior, and,

communicating with the large palatine nerve, ends in the gums of the incisor teeth. Branches are given to the mucous membrane over the septum.

**Posterior.**

The *Vidian nerve*, really formed by two roots of the ganglion, passes backwards through Vidian canal, here giving off the *upper posterior nasal branches* to the back part of the roof of the nose. On emerging from the canal it divides in the foramen lacerum medium into a *large deep petrosal nerve*, which joins the sympathetic on the carotid artery, and a *large superficial petrosal nerve*, which runs along a groove on the petrous bone to the hiatus Fallopii, and, passing into the Fallopian aqueduct, joins the geniculate ganglion on the facial nerve. As the motor root of Meckel's ganglion, it may be traced forwards from facial nerve.

The *pharyngeal nerve*, which may come off from the ganglion, or from the Vidian nerve, enters pterygo-palatine canal and ends in the mucous membrane of the palate, near the Eustachian tube.

The **INFERIOR MAXILLARY NERVE** is the largest of the three divisions of the 5th. The large sensory root comes from the inferior angle of the Gasserian ganglion, which root is joined on its deep aspect near or in the foramen ovale by the small motor root from the trunk of the 5th nerve. The united nerve leaves skull by foramen ovale, and immediately divides into anterior and posterior trunks.

*Branches from the trunk :—*

**Recurrent** : passes backwards with the middle meningeal artery, through foramen spinosum, to supply dura mater.

**Internal pterygoid** : to deep surface of internal pterygoid, connected near origin with otic ganglion.

*Branches from the anterior (small and chiefly motor) division :—*

**Masseteric** : passes outwards with posterior deep temporal nerve above external pterygoid, then over sigmoid notch with artery, to deep surface of masseter and gives twigs to temporo-maxillary joint.

**Deep temporal (3)** : *anterior*, from the buccal nerve, to supply front of temporal muscle; *middle*, passes above external pterygoid to deep part of temporal muscle; *posterior*, often united with masseteric nerve, to back part of temporal muscle.

**Buccal (sensory)** : comes out between heads of external pterygoid to reach buccinator, and is frequently joined to the anterior temporal and external pterygoid nerves; communicates with facial, and is distributed to mucous membrane and skin of cheek.

**External pterygoid** : to external pterygoid (generally given off from buccal).

*Branches from the posterior* (large and chiefly sensory) *division* :—

The **auriculo-temporal nerve** comes off by two roots, between which the middle meningeal artery passes; runs backwards under external pterygoid muscle, round temporo-maxillary capsular ligament, then upwards, with superficial temporal artery, beneath parotid to temporal fossa, where it becomes cutaneous, and lies posterior to superficial temporal artery.

*Branches of the Auriculo-temporal* :—

*Inferior auricular* : to ear below meatus.

*Superior auricular* : to integument of tragus, pinna, and to membrana tympani.

*Communicating* : to otic ganglion and facial.

*Superficial temporal* : to scalp with artery, joins temporal branches of facial.

*Parotid* : to gland.

*Temporo-maxillary* : to joint.

The **inferior dental nerve** passes down internal to external pterygoid muscle, and posterior to the lingual nerve; then between the ramus of jaw and internal lateral ligament, to the inferior dental foramen, along which canal it runs at first anterior and then above the dental artery. It supplies the molar and bicuspid teeth, and emerges at the mental foramen, having just previously divided into two branches, one of which (incisor) is continued in the bone, and the other (mental) is continued over the chin.

*Branch before entering the dental foramen* :—

*Mylo-hyoid* : descends in a groove on the inner side of ramus of jaw to outer side of mylo-hyoid muscle, supplying it and giving a branch to the anterior belly of the digastric.

*Branches given off in the dental canal* :—

*Dental* : to molars and bicuspid.

*Incisor* : to canine and incisors.

*Mental* : passes out of mental foramen, and divides into branches which supply integument of chin and lower lip, and communicate with the facial.

The **gustatory or lingual nerve** lies at first internal to the external pterygoid muscle; it then passes downwards in front of the inferior dental nerve, and is joined at an acute angle by the *chorda tympani* from the facial. Thence it passes downwards and forwards between internal pterygoid and ramus, over the superior constrictor of the pharynx and on the hyoglossus above the deep part of submaxillary gland, to the

side of the tongue, and, crossing Wharton's duct externally, is continued to the tip of the tongue.

*Branches* :—

*Communicating* : with inferior dental at commencement; with facial through chorda tympani; branches are sent also to submaxillary ganglion and the hypoglossal nerve.

*Distributory* : to mucous membrane of sides and tip of tongue, the gums and sublingual gland, the terminal branches supplying anterior  $\frac{3}{4}$  of mucous membrane of dorsum.

The SUBMAXILLARY GANGLION lies between the hyoglossus muscle and the deep part of the submaxillary gland.

*Roots* :—

*Motor and sensory* : the connecting branch from the lingual supplies sensory and motor from the facial, through the chorda tympani.

*Sympathetic* : from plexus round facial artery.

*Branches* :—

Five or six small twigs supply the submaxillary gland, the mucous membrane, and Wharton's duct.

The OTIC GANGLION (Arnold's) lies on the inner surface of the inferior maxillary nerve, close to the foramen ovale, and is connected with the commencement of the nerve to the internal pterygoid muscle.

*Roots* :—

*Motor and sensory* : from the inferior maxillary, by the branch to the internal pterygoid.

*Sympathetic* : from plexus on middle meningeal artery, which lies just behind it.

The *small superficial petrosal nerve* passes into the posterior part of the ganglion connecting it with the facial and glossopharyngeal nerves.

*Branches* :—

*Communicating* : to auriculo-temporal, and to chorda tympani.

*Muscular* : to the tensor tympani, and tensor palati.

## SYNOPSIS OF THE FIFTH NERVE.

### BRANCHES.

#### Ophthalmic.

*Recurrent.*

*Lachrymal :*

*Lachrymal.*

*Palpebral.*

**Ophthalmic (continued):**

*Frontal :*

Supra-orbital.  
Supra-trochlear

**Nasal :**

Ganglionic.  
Long ciliary.  
Infra-trochlear.  
Nasal, internal and external

**Superior Maxillary.**

*Recurrent.*

*Orbital :*

Malar.  
Temporal.

*Spheno-palatine.*

*Posterior superior dental.*

*Middle and anterior superior dental.*

*Infra-orbital.*

*Inferior palpebral.*

*Nasal.*

*Labial.*

**Inferior Maxillary.**

*Recurrent.*

*Internal pterygoid.*

*Anterior, small or motor part :*

*Deep temporal.*

*Masseteric.*

*Buccal (sensory).*

*External pterygoid.*

*Posterior, large or sensory part.*

*Auriculo-temporal :*

Auricular, inferior and superior.

Parotid.

Temporal, superficial.

Temporo-maxillary.

Communicating.

*Inferior dental :*

Mylo-hyoid (motor).

Dental.

Mental.

Incisor.

*Lingual :*

Communicating to inferior dental, sub-maxillary ganglion, and hypoglossal.

Distributory to tongue.

## GANGLIA IN CONNECTION WITH THE 5TH NERVE

**Lenticular Ganglion.***Roots :*

From nasal.

From 3rd nerve.

From sympathetic.

*Branch of Distribution :*

Short ciliary nerves.

**Meckel's Ganglion.***Roots :*

Facial.

Carotid plexus. } Vidian.

Superior maxillary.

*Internal Branches :*

Nasal.

Nasopalatine.

*Ascending :*

Orbital.

*Descending :*

Large palatine.

Small palatine.

External palatine.

*Posterior :*

Superior nasal.

Pharyngeal.

**Submaxillary Ganglion.***Roots :*

Lingual.

Chorda tympani.

Sympathetic.

*Distributory :*

To gland, etc.

**Otic Ganglion.***Roots :*

Inferior maxillary.

Sympathetic.

Small superficial petrosal.

*Branches :*

To auriculo-temporal.

Chorda tympani.

To Tensor tympani.

To Tensor palati.

The 6TH OR ABDUCENS OCULI. *Origin—Superficial*: from the sulcus between the pons and medulla, anterior to the anterior pyramid. *Deep*: floor of 4th ventricle beneath fasciculus teres.

*Course*.—Pierces dura mater on basilar process and grooves side of dorsum ephippii to reach cavernous sinus; lies to outer side of internal carotid, and below the other nerves. Enters orbit by sphenoidal fissure, between the heads of the external rectus, lying above ophthalmic vein.

*Distribution*.—External rectus (ocular surface).

*Relations*.—The following table shows how the nerves of the orbit change their position to one another. They lie from above down.

*In the Cavernous Sinus.*

*In the Sphenoidal Fissure.*

Third.	Fourth.	Frontal.	Lachrymal.	} Enter between the heads of external rectus.
Fourth.		(Above the muscles.)		
Fifth.		Superior division of 3rd		
Sixth.		Nasal branch of 5th		
		Inferior division of 3rd		
	Sixth			

The 7TH OR FACIAL. *Origin—Superficial*: from the pons, externally and posteriorly, on its ventral surface. *Deep*: floor of 4th ventricle, anterior and external to nucleus of 6th nerve.

*Course*.—Passes forwards and outwards to enter the internal auditory meatus; it lies upon a groove on the auditory nerve, with pars intermedia of Wrisberg between, and at the bottom of the meatus the latter joins the facial, which entering the aqueductus Fallopii, runs first outwards above and between cochlea and vestibule as far as hiatus Fallopii; then backwards in internal wall of tympanum, just above fenestra ovalis, at the bend presenting a swelling, the *geniculate ganglion*; and finally it passes downwards, to emerge from the bone at the stylo-mastoid foramen; it then passes outwards and forwards in the parotid, dividing behind the ramus of jaw into *temporo-facial* and *cervico-facial* branches, which further subdivide and intercommunicate, forming the *pes anserinus*.

*Communications*:—

In the meatus, with *auditory* and *pars intermedia*.

In the aqueduct, with *Meckel's ganglion* by large superficial petrosal; *otic ganglion* by small superficial petrosal; *plexus on middle meningeal* by external superficial petrosal.

At exit from foramen, with *pneumogastric, glosso-pharyngeal, carotid plexus, great auricular, auriculo-temporal.*

On the face, with the *three divisions on the 5th.*

*Branches within the Aqueduct:—*

**Communicating** from the geniculate ganglion to the auditory.

**Large superficial petrosal** passes from geniculate ganglion through hiatus Fallopii, then through foramen lacerum medium to Vidian canal, where it joins the large deep petrosal to form the Vidian nerve (*vide p. 146*).

**Communicating** with the small superficial petrosal nerve (*vide pp. 148 and 154*).

**External superficial petrosal**: from geniculate ganglion to plexus on middle meningeal artery.

**Tympanic**: to the stapedius.

**Chorda tympani**: given off just before exit from stylo-mastoid foramen, ascends to tympanum through *iter chordæ posterius*; it courses then between membrana tympani and base of pyramid, and between handle of malleus and long process of incus; it leaves tympanum by *iter chordæ anterioris*, and, passing through Huguier's canal, emerges at the inner end of the Glaserian fissure, then forwards between two pterygoids to join gustatory or lingual. It forms the sensory root of submaxillary ganglion, and ends in the tongue.

**Communicating** with the auricular branch (Arnold's nerve) of the pneumogastric.

*Branches given off at exit from Foramen:—*

**Posterior auricular**: passes up behind and between mastoid process and meatus, dividing into *auricular* to supply retrahens and attollens aurem, and *occipital* to posterior belly of occipito-frontalis; communicates with auricular of pneumogastric, great auricular, and small occipital.

**Stylo-hyoid**: to muscle.

**Digastric**: given off with former to supply posterior belly of digastric, communicates with glosso-pharyngeal.

*Branches on the Face:—*

Divides near ramus of inferior maxilla into temporo-facial and cervico-facial.

The **TEMPORO-FACIAL** crosses over external carotid and temporo-maxillary vein, communicating with auriculo-temporal and supplying pinna.

*Branches of the Temporo-facial:—*

**Temporal**: supply attrahens aurem, joining temporal of superior maxillary and auriculo-temporal of inferior maxillary; anterior branches supply orbicularis palpebrarum and



anterior belly of occipito-frontalis, joining lachrymal and supra-orbital nerves.

**Malar**: to supply eyelid muscles, and join supra-orbital.

**Infra-orbital**: *superficial*, to superficial muscles of the face, join infra-trochlear, and nasal (5th). *Deep*, to elevators of upper lip and angle of mouth, join infra-orbital of superior maxillary.

The **CERVICO-FACIAL** passes downwards and forwards in parotid, receiving communications from the great auricular nerve.

*Branches of the Cervico-facial*:—

**Buccal**: to buccinator and orbicularis oris; joins buccal of inferior maxillary.

**Supra-mandibular**: to muscles of lip and chin; join mental branch of inferior dental.

**Infra-mandibular**: perforates deep cervical fascia beneath lower jaw, to join superficial cervical and supply platysma.

The 8TH OR AUDITORY NERVE. *Origin*—*Superficial*: *Mesial Root*: between pons and restiform body. *Lateral Root*: floor of the 4th ventricle, by the striæ acusticæ. *Deep*—*both roots*: auditory nuclei in floor of 4th ventricle.

*Course*.—Passes round restiform body to posterior border of crus cerebelli with facial; it then enters the internal auditory meatus with the facial nerve, the latter lying in a groove on its upper surface, and divides at the bottom into *cochlear* and *vestibular* branches.

*Distribution*. — *Cochlear*, supplies cochlea, saccule and posterior semicircular canal; *vestibular*, to utricle and superior and external semicircular canals (*vide Ear*, p. 236).

The 9TH OR GLOSSO-PHARYNGEAL NERVE. *Origin*—*Superficial*: from the upper part of the medulla, in the groove between the olive and restiform body. *Deep*: floor of 4th ventricle.

*Course*.—Passes outwards over the flocculus to the jugular foramen. Leaves the skull with the pneumogastric and spinal accessory, but in a separate tube of dura mater and in front and external to them, being contained in a canal in the petrous part of the temporal bone. It presents near point of exit two ganglionic enlargements—the *jugular* and *petrous*. Issuing from the skull, the nerve passes downwards and outwards between the internal carotid artery and jugular vein, and then forwards over the internal carotid artery, downwards behind the muscles attached to the styloid process, to reach the lower border of the stylo-pharyngeus. Thence it

is inclined inwards on the middle constrictor beneath the hyo-glossus to the tongue, pharynx, and tonsil.

The **jugular ganglion**: the smaller of the two is situated at the upper part of the groove in the temporal bone through which the nerve passes. It involves only the outer side of the trunk of the nerve.

The **petrous ganglion** is placed in a depression on the inferior border of the petrous bone.

*Branches* :—

**Connecting**, from petrous ganglion :

- (a) To superior cervical ganglion of sympathetic.
- (b) To auricular of pneumogastric.
- (c) To ganglion of root of the pneumogastric.

**Tympanic** (Jacobson's nerve): arising from the petrous ganglion, enters a minute canal in the bone between jugular foramen and carotid canal to reach the inner wall of the tympanum; runs in a groove over the promontory, giving off several branches, and, after communicating with the facial, is continued forwards as the *small superficial petrosal nerve* (*vide* p. 148). This nerve pierces the petrous portion of the temporal to reach the middle fossa just external to the hiatus Fallopii, and, passing through the petro-sphenoidal suture, ends in the otic ganglion. It divides into six branches, which form the tympanic plexus on the promontory.

Three *branches of communication*, to the carotid plexus and small deep petrosal nerve, to the great superficial petrosal nerve, and to the otic ganglion respectively.

Three *branches of distribution*, to the fenestra ovalis, fenestra rotunda, and mucous membrane of the Eustachian tube respectively.

**Pharyngeal** (3 or 4): cross the internal carotid and join opposite the middle constrictor with pharyngeal of pneumogastric and sympathetic, to form pharyngeal plexus, supplying the mucous membrane of the pharynx.

**Communicating** with digastric branch of facial.

**Muscular**: to stylo-pharyngeus and mucous membrane of upper part of pharynx.

**Tonsillitic**: to the tonsil forming plexus, the circulus tonsillaris, and thence to fauces and soft palate.

**Lingual** (2): one branch distributed to the base supplying the circumvallate papillæ, the other to the posterior  $\frac{2}{3}$  of side of the tongue.

*Special functions*.—Nerve of sensation to the mucous membrane of pharynx, fauces and tonsil; of motion to stylo-pharyngeus muscle; and of taste of the tongue.

The 10TH NERVE—the PNEUMOGASTRIC or VAGUS. *Origin*—*Superficial* : sulcus, between restiform and olivary bodies. *Deep* : Trigonum vagi on floor of 4th ventricle.

*Course*.—Passes from origin over the flocculus to jugular foramen, through which it passes in same sheath with spinal accessory and behind the glosso-pharyngeal ; in the foramen it presents the ganglion of the root. Upon leaving the foramen, it is connected with the accessory part of the spinal accessory, and forms an enlargement, the ganglion of the trunk. The accessory part of the spinal accessory nerve passes over the ganglion, some fibres joining the trunk of the nerve, but the principal portions are continued into the pharyngeal and superior laryngeal branches. Thence the nerve passes down in the carotid sheath, behind and between the artery and vein, to the root of the neck, where its course on each side of the body becomes different.

The *right* nerve passes between 1st part of subclavian artery and subclavian vein, and down by side of trachea and behind right innominate vein to posterior part of the root of the right lung, forming the posterior pulmonary plexus ; thence proceed two cords, which run down on the œsophagus, communicate with nerve of opposite side (œsophageal plexus), join below into one trunk, which lies behind œsophagus, and passing through œsophageal orifice in diaphragm is distributed to the posterior surface of the stomach, joining solar and splenic plexuses.

The *left* nerve passes down between the left subclavian and carotid arteries, and behind the left innominate vein, where the left phrenic crosses it ; thence in front of the arch of aorta to posterior surface of root of left lung, forming the posterior pulmonary plexus ; then along the anterior surface of œsophagus through diaphragm, to be distributed on the anterior surface of stomach, and join left hepatic plexus.

*Connecting branches* :—

The ganglion of the root is connected to the spinal accessory, petrous ganglion of the glosso-pharyngeal and sympathetic nerves.

The ganglion of the trunk is connected with the hypoglossal, sympathetic, and loop between 1st and 2nd cervical nerves.

*Branches* :—

**Recurrent** : from the upper ganglion, passes backwards to the dura mater of the posterior fossa.

**Auricular** (Arnold's) : from the ganglion of the root, communicates with the petrous ganglion of the glosso-pharyngeal, and enters a foramen between the root of the styloid process

and jugular fossa. It passes through the temporal bone communicating with the facial, and emerges by the auricular fissure just behind the external auditory meatus. Finally it divides into two branches, to supply the back of the pinna, which inosculate with the posterior auricular of the facial.

**Pharyngeal**: principally formed by fibres from the accessory of spinal accessory, passes superficial to internal carotid artery to upper part of middle constrictor, where it joins branches from glosso-pharyngeal, superior laryngeal, and sympathetic to form the pharyngeal plexus.

**Superior laryngeal**: from the ganglion of the trunk, passes down behind internal carotid artery, where it divides into *external laryngeal nerve*, which communicates with pharyngeal plexus and upper cardiac of sympathetic, supplies the crico-thyroid and inferior constrictor muscle and *internal laryngeal nerve*, which passing through thyro-hyoid membrane, is distributed to the mucous membrane of the larynx, and communicates with a branch from the recurrent laryngeal.

**Inferior or recurrent laryngeal**: the *right* nerve arises in front of subclavian artery, winds back round it, and passes up behind common carotid and inferior thyroid arteries to right side of trachea. The *left* nerve arises on front of arch of aorta, round which it winds to the left of the ductus arteriosus and passes up by left side of trachea. Both nerves ascend in a groove between trachea and œsophagus, and enter larynx by passing under lower border of inferior constrictor muscle. The nerve supplies all the muscles of the larynx (except the crico-thyroid), the inferior constrictor, communicates with the internal branch of the superior laryngeal, and gives branches to the cardiac plexus, inferior cervical ganglion of the sympathetic, to the trachea, and to the œsophagus.

**Cervical cardiac (2 or 3)**: *Superior* are small; join cardiac of sympathetic. *Inferior*, one on either side, arise just above 1st rib; the *right* one passes by the side of innominate artery and joins deep cardiac plexus; the *left* one descends in front of the arch of the aorta, and joins superficial cardiac plexus.

**Thoracic cardiac**: *right* ones from the trunk of the nerve, end in deep cardiac plexus. *Left* ones arise from left recurrent laryngeal.

**Anterior pulmonary (2 or 3)**: to anterior part of root of lung, joining with sympathetic to form the anterior pulmonary plexus.

**Posterior pulmonary**: numerous, to posterior part of root of lung, which join branches from 2nd, 3rd, and 4th thoracic

ganglia of sympathetic, forming the posterior pulmonary plexus.

**Œsophageal:** to œsophagus, forming a plexus (plexus gulæ)

**Gastric:** the *right* nerve is distributed to posterior part of stomach, and ends in the solar, splenic and left renal plexuses. The *left* supplies the anterior surface and ends in the left hepatic plexus.

THE 11TH OR SPINAL ACCESSORY NERVE. *Origin*—*Superficial:* the *accessory* part from the lateral tract below vagus, the *spinal* part from the side of the cord as low down as the 5th cervical nerve. *Deep:* anterior horn of grey matter of medulla, and of cord as low as 5th cervical nerve.

*Course.*—The *accessory* part passes out of the jugular foramen close to the pneumogastric, and sends one or two branches to the ganglion of the root. It does not blend with the ganglion of the trunk, but joins vagus below. The principal part joins pharyngeal and superior laryngeal branches, but offsets are sent to the cardiac and inferior laryngeal branches. The *spinal* part enters skull through foramen magnum and passes to jugular foramen; it is enclosed in the same sheath of dura mater as the vagus. Issuing from the foramen, it passes downwards between internal carotid artery and internal jugular vein, and then backwards superficial to the internal jugular vein to upper part of sterno-mastoid, which it pierces, at the same time communicating with the branch to the muscle from the cervical plexus. Crossing the occipital part of the posterior triangle, it enters the under surface of the trapezius, where it joins with branches of the 3rd and 4th cervical nerves to form a plexus in the substance of the muscle.

*Distribution.*—Supplies sterno-mastoid and trapezius muscles.

THE 12TH OR HYPOGLOSSAL NERVE. *Origin*—*Superficial:* by ten or twelve filaments, from the groove between the olivary body and anterior pyramid. *Deep:* nucleus beneath trigonum hypoglossi in floor of 4th ventricle.

*Course.*—The nerve passes in two bundles through anterior condyloid foramen, then downwards and forwards between vagus and spinal accessory, between internal carotid artery and internal jugular vein to the lower border of the digastric muscle; curving round the occipital artery, it crosses the external carotid and lingual arteries, and passing between the mylo-hyoid and hyo-glossus muscles, ends by dividing into branches on the genio-hyo-glossus.

*Branches:*—

**Communicating.** To the ganglion of the trunk of pneumogastric

To the upper cervical ganglion of the sympathetic.  
 To the loop between 1st and 2nd cervical.  
 To the lingual branch from the pharyngeal plexus.  
 To the lingual of the 5th, on the hyo-glossus.

**Distributing :—**

**Descendens cervicis vel hypoglossi** : a slender branch, given off as the nerve hooks round occipital artery, passes down over carotid sheath, joining in a loop with branch from 2nd and 3rd cervical (communicans hypoglossi); from this loop muscular branches are given to sterno-hyoid, sterno-thyroid, and the two bellies of the omo-hyoid. *This branch, and those to thyro-hyoid and genio-hyoid, do not arise from hypoglossal nucleus, but are derived from communication above with 1st and 2nd cervical, and merely pass down with hypoglossal.*

**Thyro-hyoid** : passes round great cornu of hyoid bone to supply thyro-hyoid.

**Muscular** : to stylo-glossus, hyo-glossus, genio-hyoid, genio-hyo-glossus and intrinsic muscles of the tongue.

## THE SPINAL NERVES.

There are 31 pairs of spinal nerves, viz. : 8 cervical, 12 dorsal, 5 lumbar, 5 sacral, and 1 coccygeal. Each nerve arises from the spinal cord by an anterior (motor) and a posterior (sensory) root, the latter having a ganglion developed upon it. These roots join together in the intervertebral foramen, and upon issuing from it immediately split up again into two parts, the anterior and posterior primary divisions, each containing fibres from the two roots. The anterior primary divisions supply the parts in front of the spine, the posterior primary divisions the parts behind that column.

The posterior primary divisions of the spinal nerves are generally smaller than the anterior, and pass directly backwards, each quickly dividing into an *external* and an *internal* branch, to supply the muscles and integuments behind the spine. To this general rule there are a few exceptions, as posterior primary divisions of the 1st cervical, the 4th and 5th sacral, and the coccygeal nerves do not thus subdivide.

## THE CERVICAL NERVES.

### THE POSTERIOR PRIMARY DIVISIONS.

**The first cervical nerve.**—The posterior primary division of the 1st cervical or sub-occipital nerve passes backwards

beneath the vertebral artery on the posterior arch of atlas, and, entering the sub-occipital triangle, divides into branches to supply the inferior oblique, which branch communicates with the 2nd cervical nerve, the recti postici major and minor, the superior oblique, and the complexus.

With the exception of the sub-occipital nerve, the posterior primary divisions of the cervical nerves divide into:—

**External branches** : for the muscles behind the spine.

**Internal branches** are larger than the external branches, and, with the exception of that from the 2nd cervical nerve (*great occipital*), pass to spinous processes, supplying the muscles on their way, and become cutaneous. The branch from the 3rd cervical nerve supplies the integument at the base of the occiput (*third or least occipital*). The internal branches from the 6th, 7th, and 8th end in the muscles.

The *great occipital nerve* is the internal branch of the posterior primary division of the 2nd nerve. It passes through the complexus and trapezius, and ascends with the occipital artery to the back of the scalp, communicating with the small occipital nerve. It usually has an *auricular* branch.

#### THE ANTERIOR PRIMARY DIVISIONS.

The anterior primary divisions of the first four cervical nerves form the cervical plexus, and those of the lower four, with part of that of the 1st dorsal nerve, compose the brachial plexus.

The anterior primary divisions of the 1st and 2nd cervical nerves differ in form from the rest.

The anterior primary division of the **1st cervical nerve** passes outwards in the groove on the outer side of the upper articular process of the atlas, lying behind the vertebral artery, and giving a branch to the rectus lateralis and recti antici capitis major and minor. It joins the 2nd nerve, and communicates with the sympathetic on the vertebral artery, with the superior cervical ganglion, the pneumogastric, and with the hypoglossal nerves.

The **second cervical nerve**: the anterior primary division of this nerve winds forward outside the vertebral artery, and divides into an *ascending* part which joins the 1st cervical, and a *descending* part, which joins the 3rd cervical nerve.

The **Cervical Plexus** is formed by the union of the anterior primary divisions of the first four cervical nerves after each has communicated with the superior cervical ganglion. It is situated between the sterno-mastoid and the middle scalene muscles. Each nerve except the 1st divides into an *ascending*

*branch*, which connects it with the nerve above, and a *descending branch*, which joins it to the nerve below. From the loop between the 2nd and 3rd nerves cutaneous branches are given off to the head and neck, and from the union of the 3rd and 4th nerves superficial branches pass for the shoulder and chest, together with muscular and communicating branches.

**SUPERFICIAL ASCENDING BRANCHES :—**

**Superficial cervical nerve** : from loop between 2nd and 3rd nerves, passes forwards over the middle of the sterno-mastoid, perforates the cervical fascia, and divides beneath platysma into :—

*Ascending Branch* : accompanies external jugular vein, communicates with the facial, and becomes cutaneous, supplies front of upper half of neck.

*Descending* : supplies integument as low as sternum.

**Great auricular** : from 2nd and 3rd. Winds round margin of sterno-mastoid to reach parotid gland. Gives off :—

*Facial* : over parotid to integument of face.

*Auricular* : to back part of pinna; communicates with posterior auricular.

*Mastoid* : supplying skin over mastoid process, joining with posterior auricular of facial and small occipital.

**Small occipital** : from 2nd, ascends along posterior border of sterno-mastoid to scalp, lying between ear and occipital artery; supplies integument.

*Branch* :—

*Auricular* : supplies integument of cranial surface of auricle.

**SUPERFICIAL DESCENDING BRANCH** : from 3rd and 4th.

*Branches* :—

*Supra-sternal* : to integument as far as middle line.

*Supra-clavicular* : to integument over pectoral muscle, often pierces clavicle.

*Supra-acromial* : to integument of shoulder.

**DEEP BRANCHES (Internal) :—**

**Communicating** : from loop between 1st and 2nd, joins sympathetic, hypoglossal, and pneumogastric nerves.

*Communicans hypoglossi* : from 2nd and 3rd, form a loop with descendens hypoglossi in front of carotid vessels.

**Muscular** : to prevertebral muscles and through communications with hypoglossal to genio- and thyro-hyoid.

**Phrenic** : from 3rd and 4th, and a branch from the 5th; lies in front of scalenus anticus, descends inwards on it in front of subclavian artery to enter the chest, having crossed the internal mammary artery at origin, behind the subclavian vein. In the thorax it descends in front of the root of the



lung, being between the pericardium and the mediastinal pleura, to the diaphragm, which it perforates, and is distributed on its abdominal surface. The *right* nerve lies to right of right innominate vein and superior vena cava. The *left* nerve in the neck is crossed by the thoracic duct, and below crosses the arch of the aorta and left pneumogastric, and is longer than the right. Filaments from each supply the pericardium and pleura.

DEEP BRANCHES (External):—

**Communicating:** to spinal accessory in sterno-mastoid and trapezius muscles.

**Muscular:** to sterno-mastoid from the 2nd, levator anguli scapulæ from the 3rd and 4th, scalenus medius from the 3rd and 4th, and trapezius from the 3rd and 4th.

### NERVES OF THE UPPER EXTREMITY.

The BRACHIAL PLEXUS is formed by the union and subsequent division of the anterior primary divisions of the lower four cervical and part of anterior division of the 1st dorsal nerves. The 5th and 6th cervical communicate with the middle, and 7th and 8th with inferior cervical ganglia. The following is the usual method of union and redivision:—

The 5th and 6th cervical join together at outer border of the scalenus anticus to form an upper trunk.

The 7th cervical forms a middle trunk.

The 8th cervical and the 1st dorsal form a lower trunk.

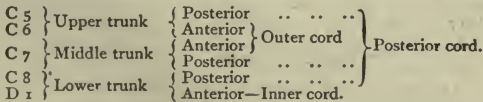
Each of these trunks then subdivides into an anterior and a posterior branch.

The anterior branches from the upper and middle trunks form the *upper* or *outer cord* of the plexus.

The anterior branch of the lower trunk forms the *lower* or *inner cord* of the plexus.

The posterior branches of all the trunks unite to form the *posterior* or *middle cord*.

The subjoined scheme will make this arrangement clear:—



The plexus lies between scalenus anticus and medius, and divides into branches for the upper limb below the pectoralis minor.

*Branches above the Clavicle :—*

**Muscular :** to the longus colli and scaleni.

*Nerve to the rhomboidei*, from the 5th cervical, passes through scalenus medius to the base of the scapula, then under levator anguli scapulæ, supplying it, and ending on the anterior surface of the rhomboid muscles.

*Nerve to the subclavius*, from the trunk formed by the 5th and 6th cervical, passes downwards in front of the 3rd part of the subclavian artery to the deep surface of the subclavius, often communicates with phrenic.

**Communicating :** from the 5th to join the phrenic on the scalenus anticus.

**Posterior thoracic, or external respiratory nerve of Bell :** from 5th, 6th and 7th, pierces scalenus medius and then descends behind the plexus and 1st part of axillary artery nearly to the lower border of the serratus magnus, which it supplies.

**Supra-scapular :** from the union of the 5th and 6th cervical, passes beneath trapezius to upper border of scapula, enters supra-spinous fossa through supra-scapular notch, gives off two branches to the supra-spinatus, and an articular one to the shoulder-joint ; thence it passes to the infra-spinous fossa, and ends in the infra-spinatus.

*Branches below the Clavicle :—*

The several nerves are given off as follows :—

<i>Outer Cord.</i>	<i>Inner Cord.</i>	<i>Posterior Cord.</i>
External anterior thoracic.	Internal anterior thoracic.	Subscapular.
Musculo-cutaneous.	Lesser internal cutaneous.	Circumflex.
Outer head of median.	Internal cutaneous.	Musculo-spiral.
	Ulnar.	
	Inner head of median.	

**External anterior thoracic (outer cord) :** crosses over axillary artery to under surface of the pectoralis major, in which it communicates with internal anterior thoracic.

**Internal anterior thoracic (inner cord) :** passes between axillary artery and vein to the two pectoral muscles.

**Subscapular :** three (posterior cord).

*Upper :* the smallest, perforates upper part of subscapularis.

*Lower :* ends in the teres major, having previously given a filament to the subscapularis.

*Middle or long :* runs along lower border of subscapularis with the subscapular vessels to supply the latissimus dorsi.

**Circumflex (posterior cord) :** passes backwards with posterior circumflex vessels at the lower border of the subscapularis, through quadrilateral space formed by teres major,

scapula, long head of the triceps and humerus, and, having given an *articular* branch to the shoulder-joint, divides into—

*Anterior branch* : winds round neck of the humerus, supplying deltoid and skin.

*Posterior branch* : gives a branch to *teres minor*, which has a gangliform swelling upon it ; also branches to deltoid and integument.

*Cutaneous* appears at posterior border of deltoid, supplies skin over lower  $\frac{2}{3}$  of muscle.

**Internal cutaneous** (inner cord) : lies in front of 3rd part of axillary artery, becomes cutaneous about middle of arm, and divides into two branches

*Anterior* : passes behind median basilic vein, supplies front of inner side of forearm as low as wrist.

*Posterior* : winds over internal condyle, supplying the back of inner side of forearm to about the middle.

**Lesser internal cutaneous** (nerve of Wrisberg) (inner cord) : lies to inner side of axillary vein, communicates with the intercosto-humeral, and then descends along inner side of brachial vessels to middle of the arm, where it becomes cutaneous and supplies integument of inner side as far as inner condyle. It communicates with the posterior branch of the larger internal cutaneous.

**Musculo-cutaneous** (outer cord) : perforates coraco-brachialis, passing to outer side of arm between biceps and brachialis anticus, supplying the three named muscles ; filaments also are given to the elbow-joint ; becomes cutaneous just above elbow, and, passing behind median cephalic vein, divides into—

*Anterior cutaneous branch* : passes along radial border of forearm, supplying ball of thumb and joining the radial.

*Posterior cutaneous branch* : supplies integument of lower 3rd of back of forearm on the radial side ; joins branches of radial and musculo-spiral (external cutaneous branch).

**Median** : arises by two roots, one from the outer cord, the other from the inner cord of the plexus, which crosses 3rd part of axillary artery to join the outer head. At first the nerve lies to the outer side of the axillary artery, but about the middle of the arm it crosses the brachial artery to reach the inner side ; it then passes between the two heads of the pronator radii *teres*, and is continued straight down the forearm upon the flexor profundus, and beneath the flexor sublimis ; at the wrist it lies between the tendons of the flexor sublimis and flexor carpi radialis. Passing beneath the annular ligament, it becomes somewhat

flattened, and divides into two parts to supply the outer  $3\frac{1}{2}$  fingers.

*Branches in the Forearm* :—

*Articular* : to elbow-joint.

*Muscular* : to pronator radii teres, flexor carpi radialis, palmaris longus, and flexor sublimis digitorum.

*Anterior interosseous* : is given off just below the elbow-joint. It passes down external to the anterior interosseous artery on the membrane, between the flexor profundus and flexor longus pollicis, to end in the deep surface of pronator quadratus. Supplies flexor longus pollicis, pronator quadratus, and outer half of flexor profundus digitorum.

*Palmar cutaneous* : pierces fascia just above angular ligament, ends in the integument of the palm, joining the palmar cutaneous of the ulnar nerve.

*Terminal branches in the Hand* :—

*Muscular to thumb* : supplies abductor, opponens, and outer head of flexor brevis pollicis.

*Digital* : five in number, supplying outer  $3\frac{1}{2}$  fingers. 1st and 2nd supply the thumb, 3rd to radial side of index finger also supplies 1st lumbrical; 4th supplies 2nd lumbrical and adjacent side of index and middle fingers; 5th supplies adjacent sides of ring and middle fingers, and joins a branch of the ulnar, giving sometimes a branch to the 3rd lumbrical.

**Ulnar** (inner cord) : passes down the inner side of axillary and brachial arteries to middle of arm; it then runs with inferior profunda artery through internal intermuscular septum to groove between olecranon and internal condyle. Thence it passes through the two heads of the flexor carpi ulnaris and descends under cover of that muscle, along ulnar side of forearm and internal to ulnar artery, as far as the pisiform bone; it then courses over the annular ligament external to that bone, and divides into superficial and deep palmar branches.

*Branches in the Forearm* :—

*Articular* : to elbow and wrist joints.

*Muscular* : to flexor carpi ulnaris and inner half of flexor profundus digitorum.

*Cutaneous* : arises near middle of forearm, and divides into: *superficial* to integument of forearm, and *palmar*, accompanies ulnar artery to hand, supplying the palm: joins the cutaneous of median.

*Dorsal cutaneous* : comes off about 3 inches above pisiform bone, winds round ulna beneath flexor carpi ulnaris, supplies inner side of little finger, and adjacent sides of ring and little fingers on the dorsal aspect.

*Palmar branches* :—

*Superficial* : supplies palmaris brevis, ends in two digital branches for inner  $1\frac{1}{2}$  fingers, the outer one communicating with the median.

*Deep* : accompanies deep palmar arch ; it supplies the small muscles of the 5th finger, and gives two branches to each interosseous space, one for each set of interossei ; branches are also given to the two inner lumbrical muscles. In the space between the thumb and index finger the nerve ends by supplying the adductor obliquus, adductor transversus, and inner head of the flexor brevis pollicis.

**Musculo-spiral** (posterior cord) : winds round between outer and inner heads of triceps in the musculo-spiral groove with superior profunda artery to the outer side of arm. Piercing the external intermuscular septum, it passes to the external condyle between the supinator longus and brachialis anticus, where it divides into radial and posterior interosseous nerves.

*Branches in the Arm* :—

*Muscular* : to the three heads of the triceps, to the anconeus, supinator longus, extensor carpi radialis longior, and brachialis anticus.

*Cutaneous* : *Internal*, comes off near axilla, supplies integument on back of arm to near olecranon. *External* (2), upper one perforates outer head of triceps, accompanies cephalic vein to elbow, supplying the integument of the lower half of arm in front. Lower one supplies integument of lower part of arm, and back part of radial side of forearm as far as the wrist.

*Terminal branches* :—

**Radial** : passes down by outer side of radial artery, under cover of the supinator longus, till within 3 inches of the lower end of the radius, where the nerve passes backwards beneath the tendon of the supinator longus, and, becoming cutaneous by piercing the fascia on outer side of forearm, divides into two branches :—

*External* : supplies ball and outer border of thumb, joining with the external cutaneous nerve.

*Internal* : joins a branch of the external cutaneous and dorsal of ulnar. It gives off four dorsal digital nerves, thus : 1st to inner side of thumb, 2nd to outer side of index, 3rd to adjacent sides of index and middle, 4th to adjacent sides of middle and ring fingers. It thus corresponds in its distribution with the median nerve.

**Posterior interosseous** : reaches the back of the forearm by piercing the supinator brevis ; there it passes between the superficial and deep layers of muscles to about middle of

forearm, where it passes deep to extensor longus pollicis to reach the interosseous membrane, on which it lies, as far as the wrist; it there ends in a gangliform enlargement, from which there are given off filaments to the ligaments, etc. Supplies supinator brevis, extensores carpi radialis brevior, communis digitorum, minimi digiti, carpi ulnaris, ossis metacarpi pollicis, longus and brevis pollicis, and indicis.

## NERVES OF THE TRUNK.

**DORSAL**: twelve in number. The 1st comes out between the 1st and 2nd dorsal vertebræ, and the greater part joins the brachial plexus. The last nerve emerges from between the 12th dorsal and 1st lumbar vertebræ. Each nerve at its exit from the intervertebral foramen divides into an anterior and posterior primary division. The 1st and 12th nerves, however, require a separate description.

The **POSTERIOR PRIMARY DIVISIONS**, or *dorsal branches*, pass backwards between the transverse processes and divide into external and internal branches, which emerge on either side of the middle division of the erector spinæ (longissimus dorsi), and supply the muscles of the back. *Cutaneous branches* are derived from each of these sets, the six upper ones coming from the internal branches and the six lower ones from the external branches.

The **ANTERIOR PRIMARY DIVISIONS**, or *intercostal nerves*, are twelve in number on each side; each communicates with the corresponding ganglion of the sympathetic chain.

The **UPPER six** pass forwards in the intercostal spaces below the vessels, lying at first between the pleura and external intercostal muscle, then between the external and internal intercostal muscles; after giving off the lateral cutaneous branches, they lie in the internal intercostal muscle, and then between that muscle and pleura, extending forwards to the sternum, and crossing the internal mammary artery, to end as the *anterior cutaneous nerves* of the thorax by perforating internal intercostal and pectoralis major.

*Branches*:—

*Lateral cutaneous*: given off midway between head of rib and sternum. The 1st intercostal nerve has generally no lateral cutaneous branch. Each branch, except that from the 2nd nerve, then pierces the external intercostal muscle, and divides into anterior and posterior branches, which supply the muscles, mammary gland, and integument.

The lateral cutaneous branch of the 2nd nerve, or *intercosto-*

*humeral*, has no anterior branch; the posterior branch crosses the axilla, joins the lesser internal cutaneous nerve, and supplies the integument of the inner side of the arm.

The LOWER six pass like the upper ones to the front of the intercostal spaces, thence between the internal oblique and transversalis to the sheath of the rectus, which they perforate, and terminate near the middle line as *anterior cutaneous* branches of the abdominal wall.

*Branches :—*

*Lateral cutaneous* : supply the integument of the abdomen, having anterior and posterior branches.

PECULIAR DORSAL NERVES: The 1st nerve: its *anterior primary division* is mostly consumed in the brachial plexus, but a small branch is given off to the 1st intercostal space, which has no lateral cutaneous branch. The 12th nerve does not lie in an intercostal space, but below the 12th rib in front of the quadratus lumborum; it then pierces the posterior aponeurosis of the transversalis, passing forwards between transversalis and internal oblique to end by perforating rectus; is remarkable for the large size of its *lateral cutaneous branch*, which does not divide, but, piercing internal and external obliques, passes over iliac crest and supplies skin over gluteal region as far down as great trochanter.

LUMBAR: five on each side. The ANTERIOR PRIMARY DIVISIONS increase in size from above downwards, and near their origin communicate with the sympathetic ganglia, the upper four forming the lumbar plexus; that of the 5th joins with the 1st sacral to form the *lumbo-sacral* cord. The POSTERIOR PRIMARY DIVISIONS pass backwards between the transverse processes and divide into internal and external branches. These are seen to be separated by the longissimus dorsi. The internal branches end in the muscles, and all the external give muscular branches; the upper three also give cutaneous branches to gluteal region.

## NERVES OF THE LOWER EXTREMITY.

LUMBAR PLEXUS: formed in the psoas by the communications of the anterior primary divisions of the four upper lumbar nerves in the following manner:—

The 1st gives off the ilio-hypogastric, the ilio-inguinal, a branch to the genito-crural, and a communicating branch to the 12th dorsal and 2nd lumbar.

The 2nd gives off branches to the genito-crural, and external

cutaneous, and a communicating branch to the 3rd, which also forms part of the anterior crural and obturator.

The 3rd gives off part of the external cutaneous, of the anterior crural, and of the obturator.

The 4th gives off a branch to the anterior crural, one to the obturator, and a communicating one to the 5th.

Muscular branches are also supplied to the psoas and quadratus lumborum.

#### BRANCHES OF THE LUMBAR PLEXUS.

**Ilio-hypogastric** : from 1st lumbar, appears at upper part of outer border of psoas, crosses quadratus lumborum to iliac crest, and, piercing the transversalis, divides into:—

*Iliac branch* : pierces two oblique muscles, crosses iliac crest behind lateral cutaneous of last dorsal to integument of buttock.

*Hypogastric branch* : pierces internal oblique and then external oblique aponeurosis above abdominal ring to integument of hypogastric region.

**Ilio-inguinal** : from 1st lumbar ; passes over quadratus lumborum and iliacus to iliac crest, pierces the transversalis and internal oblique ; it then accompanies the cord through canal and external ring, and is distributed to the integument of the groin and the scrotum.

**Genito-crural** : from 2nd lumbar, with a branch from 1st. Passes on the psoas to Poupart's ligament to divide into:—

*Genital branch* : crosses external iliac, enters inguinal canal through internal abdominal ring, accompanies spermatic cord, and supplies the cremaster muscle. In the female it accompanies the round ligament of the uterus.

*Crural branch* : passes beneath Poupart's ligament, perforates fascia on outer side of femoral artery, communicates with middle cutaneous nerve, supplies integument of upper and front of thigh.

**External cutaneous** : from loop between 2nd and 3rd lumbar ; perforates middle of outer border of psoas, and enters thigh just below anterior superior iliac spine, where it divides into:—

*Anterior branch* : contained at first in a tube of the fascia lata ; supplies outer part of anterior surface of thigh.

*Posterior branch* : supplies outer surface of thigh to the middle.

**Obturator** : from 2nd, 3rd, and 4th lumbar ; passes from inner border of psoas, near brim of pelvis and above obturator artery, but below external iliac, to canal in upper part of thyroid foramen. *In this canal* it divides into:—



*Anterior or superficial part*: descends in front of adductor brevis, behind pectineus and adductor longus; it supplies the hip-joint, gracilis, adductor longus, adductor brevis, femoral artery, and a branch to plexus near sartorius; rarely the pectineus; communicates with accessory obturator when this is present.

*Posterior or deep part*: passes through obturator externus and behind adductor brevis; it supplies a large branch to adductor magnus, and gives branches also to obturator externus, adductor brevis when this latter is not supplied by the anterior branch, and a branch along popliteal artery to knee-joint.

**Accessory obturator**: from 3rd and 4th lumbar or from obturator trunk; when present it passes down on inner side of psoas, over horizontal ramus of pubes, under pectineus, and supplies pectineus and hip-joint; communicates with the anterior branch of the obturator.

**Anterior crural**: from 3rd and 4th, and partly from the 2nd lumbar; emerges from lower part of outer border of psoas, and descends between that muscle and the iliacus, lying on the outer side of the iliac vessels. It supplies the *iliacus and femoral artery* whilst in the pelvis, and on emerging from it beneath Poupart's ligament, it divides into:—

**Anterior or superficial portion**: which gives off:—

*Middle cutaneous*: pierces fascia lata 3 inches below Poupart's ligament, dividing into two branches to supply the integument of the front of the thigh as far as the knee. Communicates with crural of genito-crural and internal cutaneous, and gives a branch to the sartorius.

*Internal cutaneous*: passes obliquely across to inner side of femoral artery, and divides into: *Anterior branch*: pierces fascia lata in lower  $\frac{1}{3}$  of thigh; supplies integument of the lower  $\frac{1}{3}$  of inner side of thigh; communicates near the knee with long saphenous. *Posterior branch*: passes down posterior border of sartorius to knee, giving branches to plexus near that muscle, and finally is distributed to integument of the leg; communicates in the thigh with the obturator and the internal saphenous nerves, forming in Hunter's canal a plexiform interlacement, the *subsartorial plexus*.

*Nerve to pectineus*: generally two, which pass inwards under femoral vessels to muscle.

*Nerves to sartorius*: given off with middle cutaneous.

*Plexus patellæ*: the patellar plexus is formed by communications between the anterior branch of the internal cutaneous, branches of the middle and external cutaneous nerves, together

with the patellar branch of the internal or long saphenous nerve.

**Deep or posterior part :** which gives off :—

*Internal or long saphenous :* accompanies, lying on outer side of, femoral vessels as far as Hunter's canal, where it crosses artery, and leaves it at opening in adductor magnus by passing inwards beneath sartorius. Here it becomes subcutaneous, and is continued with the internal saphenous vein along inner side of leg, behind inner border of tibia, and, passing in front of inner ankle, is distributed on inner side of foot as far as ball of great toe. In its course it gives off a branch to plexus under sartorius formed by obturator and internal cutaneous nerves, to patellar plexus, and below the knee to the integument on the anterior and inner surfaces of the leg.

*Muscular.*—*To the rectus*, which gives branch to hip-joint.

*To the vastus externus*, which gives an *articular* branch to the knee-joint, and accompanies descending branch of the external circumflex artery.

*To the vastus internus*, which gives off an *articular* branch to the knee-joint, and accompanies the deep branch of the anastomotica magna artery.

*To crureus*, two or three, the internal one supplying sub-crureus and knee-joint.

SACRAL NERVES, five in number. The roots of origin form the *cauda equina*, and in this region the posterior root ganglia are placed inside the spinal canal, though outside the dura mater. Each nerve divides into anterior and posterior primary branches.

The *posterior primary* branches of the upper four emerge from the posterior sacral foramina, the fifth at the lower end of the spinal canal; the upper three nerves divide into internal and external branches, the former supplying the multifidus spinæ, the latter the integument over sacrum, coccyx, and posterior gluteal region; the two lower nerves do not divide, and supply filaments to integument over coccyx, the 5th communicating with the coccygeal.

COCCYGEAL NERVE: this nerve divides into an *anterior* branch, which pierces sacro-sciatic ligament and coccygeus, supplies integument over coccyx, and communicates with the 5th sacral, forming part of ano-coccygeal plexus; and a *posterior*, to supply coccygeal integument.

The ANTERIOR PRIMARY BRANCHES decrease in size from above downwards. The upper four issue from the anterior sacral foramina, the 5th emerging between sacrum and coccyx. Each nerve communicates with the sympathetic. The first

three and part of the 4th nerves enter the sacral plexus, whilst the lower part of the 4th, the 5th, and the coccygeal nerve form a small plexus, ano-coccygeal, which lies on the pelvic surface of the coccygeus.

The **ano-coccygeal plexus** : formed as described above.

*Branches* :—

**Muscular** to :—

Coccygeus.

Levator ani.

Sphincter ani externus (usually called the perineal branch of the 4th sacral).

**Visceral**.

Vesical.

Rectal.

Vaginal (in female).

**Cutaneous** : *perforating cutaneous* of 4th sacral to integument over coccyx.

The **SACRAL PLEXUS** is formed by the lumbo-sacral cord (p. 167), anterior primary branches of the upper three and part of that of the 4th sacral nerves. Lies on anterior surface of pyriformis, behind the sciatic and internal pudic arteries.

*Branches* :—

**Muscular** : To pyriformis, from 1st and 2nd.

To obturator internus and gemellus superior, from 5th lumbar, 1st and 2nd sacral, emerges from pelvis through great sacro-sciatic foramen, winds over ischial spine outside the internal pudic artery, passes in through small sacro-sciatic foramen to inner surface of muscle, having first supplied superior gemellus.

To quadratus femoris and gemellus inferior, given off from lumbo-sacral cord and 1st sacral, passes anterior to gemelli and obturator internus tendon to anterior surface of quadratus, giving on its way a branch to gemellus inferior, and an articular branch to the hip-joint.

**Superior gluteal** : from lumbo-sacral cord and 1st sacral, passes out of great sacro-sciatic foramen, above the pyriformis, with the gluteal vessels ; divides into a *superior* branch, which passes between the two smaller glutei, supplying the medius, and an *inferior* branch, supplying the gluteus minimus and the tensor fasciæ femoris.

**Pudic** : comes off from the 2nd, 3rd, and 4th nerves, passes out of great sacro-sciatic notch between pyriformis and coccygeus internal to great sciatic nerve, winds over ischial

spine internal to pudic artery, and re-enters pelvis through the small notch lying on inner side of internal pudic artery; it then enters, with accompanying vessels, a sheath of the obturator fascia in the outer wall of the ischio-rectal fossa and divides into its three branches.

*Branches :—*

*Inferior hæmorrhoidal*: crosses ischio-rectal fossa to supply external sphincter, skin of anus; communicates with inferior pudendal of small sciatic and superficial perineal nerves.

*Perineal*: largest terminal branch, accompanies perineal artery, and divides into:

*Cutaneous or superficial perineal*, two in number: the *internal* passes with superficial perineal artery either under or over the transversus perinæi to supply the scrotum; the *external* gives a branch to the anus, and, piercing the deep layer of the superficial fascia, supplies the scrotum, joining the inferior pudendal.

*Muscular* branches supply transversus perinæi, erector penis, ejaculator urinæ, compressor urethræ, sphincter and levator ani.

*Nerve to bulb*: pierces ejaculator urinæ and supplies bulb.

*Dorsal nerve of the penis*: accompanies internal pudic artery between the layers of the triangular ligament lying on the outer side of the artery, pierces the anterior layer of the ligament, and the suspensory ligament to reach dorsum of penis, along which it runs as far as the glans, gives off many branches to supply the organ, and joins branches of the sympathetic. In the female this nerve is distributed to the clitoris.

*Inferior gluteal*: from the lumbo-sacral cord, 1st and 2nd sacral nerves; passes out of pelvis below the pyriformis, at the lower border of which it turns backwards, and, dividing into numerous branches, enters deep surface of gluteus maximus. Communicates near origin with the small sciatic.

*Small sciatic*: a cutaneous nerve to lower part of buttock and back of thigh; it comes off from 2nd and 3rd sacral nerves. It passes below the pyriformis with the sciatic artery, and runs down the back of the thigh beneath the gluteus maximus, and below this beneath the fascia lata, which it pierces in the popliteal space.

*Branches :—*

*Internal cutaneous*: to integument of upper and inner side of thigh: one larger one, the *inferior pudendal*, turns inwards over hamstrings, supplies scrotum, and joins the external superficial perineal nerve.

*External cutaneous* : winds round *gluteus maximus*, supplies the integument over lower part of buttock.

*Terminal* : to integument of thigh, popliteal region, and calf of leg.

**GREAT SCIATIC** : the largest nerve in the body, and is the main continuation of the sacral plexus, lies in pelvis on *pyriformis* ; it is derived from the lumbo-sacral cord, the 1st, 2nd, and 3rd sacral nerves. It passes out of pelvis below the *pyriformis*, and between the *tuber ischii* and great trochanter, resting upon the *gemelli*, *obturator internus*, *quadratus femoris*, and *adductor magnus*. It is at first external to the *biceps*, then between its two heads of origin, finally between it and *semi-membranosus*, and is accompanied by the sciatic artery, which supplies a branch to its substance (comes *nervi ischiadici*). At a variable distance between the sacral plexus and lower part of the thigh, but generally about the middle of the thigh, the nerve bifurcates into external and internal popliteal.

*Branches of the Trunk* :—

*Muscular* : given off under *biceps* to *semi-membranosus*, *semi-tendinosus*, both heads of *biceps*, and to the inner part of *adductor magnus*.

**INTERNAL POPLITEAL** : larger terminal branch, passes along middle of popliteal space to lower border of *popliteus*, where it gets the name of *posterior tibial* ; it is at first superficial to and outside the artery, but at the lower end of the space, under the *gastrocnemius*, crosses to the inner side.

*Branches* :—

**Articular** (3) : one accompanies each of the upper and lower internal articular arteries, the third the *azygos*.

*Muscular* : to the *gastrocnemius*, one for each head, the outer one supplying also the *plantaris*. To the *soleus* and to the *popliteus* ; the nerve to the latter turns round lower border of muscle and enters it upon its anterior surface.

**Tibial communicating** : passes down leg superficially between two heads of the *gastrocnemius*, pierces the deep fascia about middle of leg, there joining the *peroneal communicating* from the external popliteal, and is now known as the external or short saphenous nerve ; it then follows the course of the external saphenous vein round outer malleolus, and supplies integument of outer side of foot and little toe, communicating with the musculo-cutaneous on the dorsum.

**POSTERIOR TIBIAL** (continuation of internal popliteal) : begins at the lower border of the *popliteus*, and runs with

the posterior tibial vessels to interval between the external malleolus and heel, where it divides into external and internal plantar. It is at first inside the artery, but afterwards crosses to the outer side.

*Branches* :—

**Muscular** : to soleus, tibialis posticus, flexor longus digitorum, and flexor longus hallucis, the latter accompanying the peroneal artery.

**Internal calcanean** : pierces internal annular ligament, to supply integument of heel and inner side of sole of foot.

**Internal plantar** : larger terminal branch of the posterior tibial ; accompanies internal plantar artery along inner side of foot : the larger nerve thus accompanies the smaller artery. Corresponds in distribution to median nerve of hand. It passes between the abductor hallucis and flexor brevis digitorum to divide opposite the bases of the metatarsal bones into four branches, the outermost of which communicates with the external plantar.

*Branches* :—

*Cutaneous* : to sole of foot.

**Muscular** : to abductor hallucis and flexor brevis digitorum.

**Articular** : to tarsal and metatarsal articulations.

**Digital (4)** : the 1st supplies inner border of 1st toe and the flexor brevis hallucis, the 2nd supplies the adjacent sides of the 1st and 2nd toes and the 1st lumbrical, the 3rd supplies the adjacent sides of the 2nd and 3rd toes, and the 4th supplies the adjacent sides of the 3rd and 4th toes and joins a branch from the external plantar.

**External plantar** : passes across to outer side of foot with external plantar artery, supplying on its way the abductor minimi digiti and flexor accessorius ; at the outer border of the latter muscle it divides into two branches :—

**Superficial** : which divides into two digital nerves, one supplying the outer side of the little toe, the flexor brevis minimi digiti, and the two interossei of the 4th space ; the other supplies the adjacent sides of the 4th and 5th toes and communicates with the internal plantar.

**Deep or muscular** : accompanies deep part of external plantar artery, supplying the adductor obliquus hallucis, adductor transversus hallucis, three outer lumbricals and interossei of inner three spaces.

**EXTERNAL POPLITEAL OR PERONEAL** : passes along the popliteal space under cover of and inside biceps tendon, then over outer head of gastrocnemius to the fibula ;

1 inch below head of that bone it pierces the peroneus longus, and in that muscle divides into anterior tibial and musculo-cutaneous nerves.

*Branches* :—

**Articular** (2) : generally given off together, accompany superior and inferior external articular arteries.

**Cutaneous** : supply integument of back and outer side of leg in upper third.

**Peroneal or fibular communicating** : arises close to head of fibula and joins the tibial communicating, the two forming the short saphenous nerve.

**Anterior tibial** : passes to front of interosseous membrane by piercing extensor longus digitorum to reach outer side of anterior tibial artery, with which it descends to the ankle-joint, where it bifurcates into an internal and external branch ; it lies in middle  $\frac{1}{3}$  of leg, in front of artery, and in lowest  $\frac{1}{3}$ , again, outside it.

*Branches* :—

**Recurrent articular** : sends a branch to knee, which accompanies anterior tibial recurrent artery to joint.

**Muscular** : to tibialis anticus, extensor longus digitorum, peroneus tertius, and extensor proprius hallucis.

**External or tarsal** : passes outwards beneath the extensor brevis digitorum and becomes ganglionic, supplies the extensor brevis, and the articulations of the tarsus and metatarsus.

**Internal** : accompanies dorsalis pedis to 1st interosseous space, lying outside it, supplies adjacent sides of 1st and 2nd toes, communicating with the musculo-cutaneous.

**Musculo-cutaneous** : supplies peroneus longus and brevis, and dorsal integument of foot. It passes down between peronei and the long extensor of toes, piercing deep fascia at lower  $\frac{1}{3}$  of leg.

*Branches* :—

**Muscular** : to peroneus longus and peroneus brevis.

**Cutaneous** : to lower part of leg.

**Internal** : passes over ankle to inner side of 1st toe and adjacent sides of 2nd and 3rd toes, *communicates* with internal saphenous and anterior tibial nerves.

**External** : supplies adjoining sides of 3rd, 4th, and 5th toes ; *communicates* with short saphenous.

## SYMPATHETIC NERVES.

The sympathetic system consists of—

1. The great gangliated cords.
2. The prevertebral plexuses, and branches proceeding from them.

3. Ganglia of union with cranial nerves—viz., ophthalmic, sphenopalatine, otic, and submaxillary. These have been described with the 5th nerve.

#### THE GREAT GANGLIATED CORDS,

two in number, extend the whole length of the vertebral column. They consist of ganglia, united by intervening cords, and are placed partly in front and partly by the side of the vertebræ. Above they are connected with two plexuses entering the cranium, and below they join together in a loop over the coccyx. The parts of the cords are named according to the region they occupy—viz., cervical, dorsal, lumbar, and sacral. The cervical portion has three ganglia, whilst in the rest of its extent each cord contains ganglia equal in number to the vertebræ.

Each ganglion is connected with *the anterior primary division* of the corresponding spinal nerve by an afferent (white) filament, and an efferent (grey) connecting branch. The interganglionic cords are composed of white and grey fibres, the former being continuous with the filaments from the spinal nerves.

The **CERVICAL PART** of the gangliated cord lies behind the carotid sheath, just in front of the prevertebral muscles, and contains three ganglia.

1. The **SUPERIOR CERVICAL GANGLION** lies on the rectus capitis anticus major behind carotid sheath, opposite the 2nd and 3rd cervical vertebræ.

*Branches:—*

**Connecting** : with the anterior primary divisions of 1st, 2nd, 3rd, and 4th cervical nerves : with the ganglion of trunk and the ganglion of the root of the pneumogastric, with the hypoglossal, with the petrous ganglion of the glosso-pharyngeal.

**Pharyngeal nerves and plexus** : the pharyngeal nerves are given off from the front of the superior cervical ganglion, and pass forwards and downwards. They join with branches from the pneumogastric and glosso-pharyngeal nerves forming the pharyngeal plexus, which lies on the middle constrictor muscle. Branches from the plexus supply the constrictors, levator palati, palato-glossus, palato-pharyngeus, and azygos uvulæ muscles : the motor fibres are derived from the bulbar part of spinal accessory, and reach plexus through pharyngeal branch of vagus.

The **upper cardiac nerves** : the *right upper cardiac nerve* comes off by two roots from the upper cervical ganglion. It passes downwards behind the carotid sheath, but in front of the inferior thyroid artery and recurrent laryngeal nerve. It



then goes either behind or in front of the subclavian artery, and, coursing along the innominate, ends in the deep cardiac plexus behind the arch of the aorta. In the middle of the neck it communicates with the external laryngeal, lower down with the upper cardiac branches of the pneumogastric, in the thorax with the recurrent laryngeal, and with other sympathetic branches in its whole course.

The *left upper cardiac nerve* has the same connections in the neck as the right nerve. On entering the thorax, it passes along left common carotid artery, and, crossing the arch of the aorta, joins the superficial cardiac plexus.

**Branches to Vessels.**—Branches are given to the external carotid artery, which are prolonged to its branches.

**Ascending or carotid branch** lies behind internal carotid artery, enters carotid canal, and divides into:—

- (a) *External division*: distributed to internal carotid; communicates with tympanic branch of glossopharyngeal, and forms the carotid plexus.
- (b) *Internal division*: distributed over internal carotid artery, thus communicating with the external division, and prolonged to form the cavernous plexus.

The **carotid plexus** lies on the outer side of the internal carotid artery at its 2nd bend.

*Branches*:—

*Connecting*: to the 6th nerve and Gasserian ganglion.

The *large deep petrosal nerve* passes from the plexus through the hiatus Fallopii, to join the large superficial petrosal nerve at the Vidian canal, the junction of the two forming the Vidian nerve.

The *small deep petrosal nerve* passes backwards in a small canal in the processus cochleariformis, to join the tympanic plexus.

The **cavernous plexus** lies below and to the inner side of last bend of the internal carotid artery.

*Branches*:—

*Connecting*: to the 3rd, 4th, and ophthalmic division of 5th nerve.

*Ganglionic*: the sympathetic root of the ophthalmic or lenticular ganglion passes into the orbit. It is generally joined to the branch of the 3rd nerve supplying the inferior oblique.

*Pituitary*: to that body.

2. The **MIDDLE CERVICAL GANGLION** generally lies on the inferior thyrioid artery, opposite the 6th cervical vertebra.

*Branches*:—

*Connecting*: to the 5th and 6th cervical nerves.

**Thyroid**: to the thyroid body, communicating with external

and recurrent laryngeal nerves, and with the upper cardiac nerve from the superior ganglion.

**Middle or great cardiac nerve** : on the *right* side passes in front or behind subclavian artery to the front of the trachea, and joins the deep cardiac plexus. Communicates in the neck with the upper cardiac and recurrent laryngeal nerves. On the *left* side it lies between the left carotid and left subclavian arteries, and joins the deep cardiac plexus.

3. The **LOWER CERVICAL GANGLION** lies between the transverse process of the 7th cervical and the neck of the 1st rib, behind the vertebral artery, internal to the superior intercostal artery.

*Branches* :—

**Connecting** : to the 7th and 8th cervical nerves.

**Lower cardiac nerve** : passes behind the subclavian artery, joins recurrent laryngeal, and enters the deep cardiac plexus.

**Branches to vessels** : branches are given to form a plexus round the vertebral artery.

The **THORACIC PART** of the gangliated cord lies by the side of the vertebræ in a line corresponding to the heads of the ribs. The ganglia are usually twelve in number, and each communicates with the corresponding intercostal nerve.

*Branches of the upper 6 ganglia* are given off to the thoracic aorta, vertebræ, ligaments, and from the third and fourth to the posterior pulmonary plexus.

*Branches from the lower 6 ganglia* :—

The **great splanchnic nerve** : formed by the union of branches from the 6th, 7th, 8th, 9th, and 10th ganglia. It passes inwards over the bodies of the vertebræ, perforates the crus of the diaphragm, and ends in the semilunar ganglion.

The **small splanchnic nerve** comes from the 10th and 11th ganglia, passes with the great splanchnic nerve, and ends in the solar plexus.

The **smallest splanchnic nerve** comes from the 12th ganglion. It pierces the crus of the diaphragm, and ends in the renal plexus, and partly in the cœliac plexus.

The **LUMBAR PART** of the gangliated cord lies nearer the middle line than the thoracic on the bodies of the vertebræ.

Each ganglion communicates with the anterior division of a lumbar nerve by branches which pass under fibrous arches of psoas. The ganglia give off branches to the aorta, and other branches to form the hypogastric plexus.

The **SACRAL PART** of the gangliated cord lies to the inner side of the anterior sacral foramina, and is united with its opposite fellow at the lower end of the sacrum by a cord, in

the middle of which there is sometimes found a *coccygeal ganglion* or ganglion impar.

*Branches* are given from the ganglia to the pelvic plexus, and to the middle sacral plexus.

#### THE PREVERTEBRAL PLEXUSES OF THE SYMPATHETIC.

The **CARDIAC PLEXUS** lies against the aorta and pulmonary artery. It is divided into two parts, *superficial* and *deep*.

The **superficial cardiac plexus** lies in concavity of the arch of the aorta on the right of the ductus arteriosus. It is composed of the left upper cardiac nerve of the sympathetic, the lower cervical cardiac of the left vagus nerve, and branches from the deep plexus. In the plexus is the small *ganglion of Wrisberg*. The plexus gives branches to the anterior pulmonary plexus of the left side, and ends in the right coronary plexus which accompanies the right coronary artery.

The **deep cardiac plexus** lies between the arch of the aorta and the trachea. It consists of right and left halves united by branches. The right half lies above the right branch of the pulmonary artery; the left half lies on the left of the trachea, close to the ductus arteriosus.

*Afferent branches* :—

- a. All the cardiac branches from the cervical ganglia of the sympathetic, except the left upper nerve.
- b. All the cardiac of pneumogastriacs and recurrent laryngeals, except the lower cervical cardiac of the left vagus.

*Efferent branches from the right side* join the superficial cardiac plexus to form the right coronary plexus, and others are distributed to the right auricle.

*Efferent branches of the left side* mostly end in the left coronary plexus, which accompanies the left coronary artery, and in the superficial cardiac plexus.

The **SOLAR PLEXUS** is the largest prevertebral plexus. It lies behind the pancreas and inferior vena cava, in front of the aorta and crura of the diaphragm. It surrounds the origin of the celiac axis, extending laterally to the supra-renal bodies. It receives the large and small splanchnic nerves and part of the right pneumogastric. It contains several ganglia, and branches are given off from it to accompany the bloodvessels to the viscera, and to form secondary plexuses on these arteries.

The **semilunar ganglia**, one in each half of the solar plexus, lie on the inner side of the supra-renal bodies, the left one

lying behind inferior vena cava. The great splanchnic nerve enters its upper end.

The **diaphragmatic** or **phrenic plexus** accompanies the arteries to the diaphragm. On the right side near the suprarenal body is the *phrenic ganglion*, connecting together the phrenic nerves of the spinal and sympathetic systems.

The **supra-renal plexus** is derived from the solar plexus and the outer part of the semilunar ganglion. It is joined by branches of one of the splanchnic nerves.

The **renal plexus** is derived from the semilunar ganglion, and partly from the solar and aortic plexuses, and receives the smallest splanchnic nerve. It lies along the renal artery, and contains numerous small ganglia.

The **spermatic plexus** comes off from the renal and aortic plexuses.

The **cœliac plexus** is derived from the solar plexus. It surrounds the cœliac axis, and subdivides into:—

The *coronary plexus* accompanies coronary artery along the smaller curvature of the stomach, communicating with the pneumogastric nerves.

The *hepatic plexus* accompanies hepatic artery into the substance of the liver. Communicates with the left vagus, and the right supra-renal plexus. Gives off the *cystic*, *pyloric*, *right gastro-epiploic* and *pancreatico-duodenal* plexuses.

The *splenic plexus* accompanies splenic artery to the spleen, and is joined by the right pneumogastric. It gives off the *left gastro-epiploic* and *pancreatic* plexuses.

The **superior mesenteric plexus** accompanies superior mesenteric artery.

The **aortic plexus** lies on the anterior surface of the abdominal aorta. It gives off the *inferior mesenteric* and part of the *spermatic* plexuses. It ends in the hypogastric plexus.

The **HYPOGASTRIC PLEXUS** lies between the two common iliac arteries; it is formed by the terminations of the aortic plexus, together with branches from the lumbar ganglia. It divides below into two parts, which form the pelvic plexuses.

The **PELVIC PLEXUSES**: two in number. Each is composed of a division of the hypogastric plexus, joined with some branches from the 3rd and 4th sacral nerves and ganglia.

The following plexuses are derived from the pelvic plexuses:—

The **hæmorrhoidal plexus** to the rectum and anal canal.

The **vesical plexus** to the bladder, with secondary plexuses in the male to the vas deferens and to the vesiculæ seminales.

The prostatic plexus to the prostate gland, giving off the cavernous nerves of the penis.

(The vaginal plexus to the vagina.

The uterine plexus accompanying the uterine artery to the uterus.)

## THE ORGANS OF DIGESTION.

### THE TEETH.

**Temporary teeth** : the following is the dental formula for the temporary teeth, with the dates in months of their eruption :—

	Mo.	Mo.	Ca.	In.	In.	In.	In.	Ca.	Mo.	Mo.	
{	Upper ..	1	1	1	1	1	1	1	1	1	= 10
	Lower ..	1	1	1	1	1	1	1	1	1	= 10
		24	12	18	9	7	7	9	18	12	24 months.

**Permanent teeth** : subjoined is the dental formula for the permanent teeth, with the date in years of their eruption :—

	Wis.	Mo.	Mo.	Bi.	Bi.	Ca.	In.	In.	In.	In.	Ca.	Bi.	Bi.	Mo.	Mo.	Wis.	
{	Upper	1	1	1	1	1	1	1	1	1	1	1	1	1	1	1	= 16
	Lower	1	1	1	1	1	1	1	1	1	1	1	1	1	1	1	= 16
		18	12	6	10	9	11	8	7	7	8	11	9	10	6	12	18 years.

### THE TONGUE.

The tongue occupies the floor of the mouth ; its base is connected with the hyoid bone, the epiglottis, the pillars of the soft palate, and with the pharynx ; along its inferior surface the genio-glossus runs from base to tip, connecting it to the lower jaw and hyoid bone.

The mucous membrane on the under surface is smooth, forming in front a median fold, the *frænum linguæ* ; on the sides it is continuous with the mucous membrane of the mouth. On the dorsum there is a *raphé* along the middle line, which ends posteriorly in the *foramen cæcum*. Posteriorly the epiglottis is connected to the tongue by three glosso-epiglottic folds, the middle one being called the *frænum epiglottidis*. The anterior two-thirds of the dorsum of the tongue is covered with papillæ ; they are of three kinds :

The *circumvallate* papillæ (seven to ten) form a row on each side at the back of the tongue, meeting in the middle line thus, **Λ**, in front of the foramen cæcum.

The *fungiform* papillæ : found principally at the apex and on the sides.

The *filiform papillæ* are numerous, and are arranged in rows parallel to the circumvallate, but towards the tip of the tongue their direction becomes more transverse.

**Glands:** near the circumvallate papillæ are found numerous mucous glands, known as the lingual glands.

**THE MUSCLES OF THE TONGUE.**—The *extrinsic* muscles of the tongue are the hyo-glossus, genio-hyo-glossus, palato-glossus, and the stylo-glossus. These have been described (*vide* pp. 29 and 30).

The *intrinsic* muscles are entirely contained within the substance of the tongue, and are as follows:—

**The superior lingualis:** one on each side. Longitudinal fibres lying under the mucous membrane. It arises from the frænum epiglottidis, and from the fascia along the middle line; the fibres pass obliquely outwards, the anterior fibres being longitudinal, to the side of the tongue.

**The inferior lingualis (2)** is a bundle of muscular fibres running along the under surface of the tongue from base to tip. It lies between the genio-hyo-glossus and hyo-glossus muscles. It arises from the fascia at the base of the tongue, is joined anteriorly with some fibres of the stylo-glossus, and passes to the apex.

**Transverse fibres** form a horizontal layer of muscular fibres between the superior and inferior linguales. The fibres spring from the septum and pass outwards to the sides of the tongue.

**Vertical fibres** arise from dorsum, and mingle with transverse fibres.

**The septum** of the tongue is a vertical fibrous partition, extending, in the muscular portion, from the hyoid bone to the apex.

**Arteries:** lingual, tonsillar of facial.

**Nerves:** lingual or gustatory to anterior two-thirds; glosso-pharyngeal to side and posterior third; hypoglossal to muscles.

#### THE PALATE.

The **palate** forms the roof of the mouth, and consists of two parts—the front being the hard palate, and the back the soft palate.

The **hard palate** consists of the palatal processes of the superior maxillæ and palate-bones, together with the mucous membrane and the periosteum covering them. The descending palatine artery and anterior palatine nerve run forwards under cover of alveolus.

The **soft palate**, consisting of muscles, aponeurosis, vessels, nerves, etc., enclosed between two layers of mucous membrane, is attached in front to the posterior margin of the hard palate, the sides blending with the pharynx; from the middle of the posterior edge the *uvula* projects, and from the bases of this arch, on each side, there are two folds of mucous membrane enclosing muscular fibres—the *pillars*, anterior and posterior, between which the *tonsil* lies. The narrowed passage between the anterior pillars, leading from the mouth to the pharynx, is called the *isthmus faucium*.

The *aponeurosis* of the soft palate is attached to the posterior edge of the hard palate, is joined by the tendon of the tensor palati, and becomes lost between the muscles.

*Structure of the palate from before backwards:*

1. Oral mucous membrane and mucous glands.
2. Palato-glossus.
3. Aponeurosis.
4. Tensor palati.
5. Anterior fibres of palato-pharyngeus.
6. Levator palati.
7. Azygos uvulæ in middle line.
8. Posterior fibres of the palato-pharyngeus.
9. Mucous glands and pharyngeal mucous membrane.

The **tonsils** occupy the recesses between the pillars of the fauces, the anterior pillar being formed by the palato-glossus and the posterior by the palato-pharyngeus. On the outer side of each is the superior constrictor, and internally the buccal mucous membrane. Their arterial supply is large, from the ascending pharyngeal, ascending and descending palatine, tonsillar, and dorsalis linguæ arteries.

#### THE SALIVARY GLANDS.

The **PAROTID GLAND** is the largest, and lies between the external auditory meatus and mastoid process behind, and the vertical ramus of the jaw in front. Anteriorly, it overlaps the hinder part of the masseter.

*Boundaries:—*

<i>Externally.</i>	<i>Above.</i>	<i>Below.</i>	<i>Anteriorly and Below.</i>	<i>Behind.</i>
Skin.	Zygoma.	Line from angle of jaw to mastoid process.	Stylo-maxillary ligament.	External auditory meatus.
Platysma.		Posterior belly of digastric		Mastoid process.
Cervical fascia.				Sterno-mastoid.

The deep surface is irregular, and lies on the styloid process and its attached muscles, the internal jugular vein, the vagus, spinal accessory and hypoglossal nerves, and is divided into three lobes:—

The **glenoid lobe** fills up glenoid cavity behind Glaserian fissure.

The **pterygoid lobe** passes forwards internal to the ramus of the jaw between the external and internal pterygoid muscles.

The **carotid lobe** surrounds the styloid process, and lies between the external and internal carotid artery.

The **socia parotidis** is a separate lobe projecting from the anterior surface.

*Relations of the Socia Parotidis:—*

<i>Above.</i>	<i>Below.</i>	<i>Internally.</i>
Zygoma.	Duct.	Masseter.
	Cervico-facial division of facial nerve.	Transverse facial artery.

The duct (Stenson's) is 2 inches long; comes off from the anterior border and crosses the masseter to pierce the buccinator and buccal mucous membrane. Its opening in the mouth is opposite the 2nd upper molar tooth.

*Course of the duct:* line from bottom of lobule of ear to middle of upper lip. The transverse facial artery lies above the duct, and the buccal branches of the 7th nerve below.

The parotid gland is traversed by the following, of which the arteries lie deep and the nerves most superficial.

<i>Arteries.</i>	<i>Veins.</i>	<i>Nerves.</i>
External carotid.	Internal maxillary.	Facial.
Posterior auricular.	Temporal.	Auriculo-temporal.
Internal maxillary.	Temporo-maxillary.	Facial of great auricular.
Superficial temporal.		
Transverse facial.		

*Nerve supply of gland:* sympathetic and glosso-pharyngeal. The latter branch may be traced as follows: The tympanic (Jacobson) branch gives off small superficial petrosal, which passes through otic ganglion and joins the auriculo-temporal trunk, thus supplying the gland.

THE SUBMAXILLARY GLAND lies under cover of the body of the lower jaw.

**Superficial lobe:** separated by stylo-maxillary ligament from parotid, grooved above and behind by facial artery.



<i>Lies upon.</i>	<i>Superficial Coverings.</i>	<i>Below.</i>
Mylo-hyoid.	Platysma.	Tendon of
Stylo-hyoid.	Deep fascia.	digastric.
Hyo-glossus.	Facial vein.	

**Deep lobe** : passes with duct between mylo-hyoid and hyo-glossus.

The **duct of Wharton** : passes with deep lobe of gland beneath mylo-hyoid, resting on the hyo-glossus. At first the lingual nerve lies above the duct and the hypoglossal nerve below, but the duct, crossing over the nerve, passes upwards and forwards on genio-hyo-glossus to open on the papilla by the side of the frænum linguæ.

*Nerves* : sympathetic, and chorda tympani through submaxillary ganglion.

THE **SUBLINGUAL GLAND** occupies the sublingual fossa of lower jaw, lying under mucous membrane of floor of mouth, and having its anterior extremity close to the frænum. Below is the mylo-hyoid, and internally is the genio-hyo-glossus.

**Ducts of Rivini** (18 to 20) : open separately in the floor of the mouth. One larger one from the posterior part opens into or by the side of Wharton's duct, and is called the duct of Bartholin.

*Nerves* : sympathetic, and from chorda tympani through submaxillary ganglion.

#### THE PHARYNX.

The **Pharynx** is an oval musculo-membranous bag lying behind the nose, mouth, and larynx. It is about  $4\frac{1}{2}$  inches long, and extends from the base of the skull to the lower border of the cricoid cartilage in front, and to the lower border of the 5th cervical vertebra behind. It is widest opposite the hyoid bone. Behind, it is separated by a pre-vertebral layer of the deep cervical fascia from the longus colli and rectus capitis anticus muscles of each side. Below, it is continuous with the œsophagus.

*Attachments* :—

*Above* : under surface of body of sphenoid, under surface of petrous of temporal.

*In front* : internal pterygoid plate, pterygo-maxillary ligament, lower jaw, base of tongue, cornua of hyoid bone, and stylo-hyoid ligament; thyroid and cricoid cartilages, corresponding to attachments of constrictor muscles.

*Relations :—*

<i>Laterally.</i>		<i>Behind.</i>	<i>Below.</i>
Styloid process.		Longi colli.	Œsophagus
Stylo-hyoid.	} Muscles.	Recti capitis antici.	
Stylo-pharyngeus.		Upper 5 cervical	
Internal pterygoid.		vertebræ.	
Sterno-thyroid.		Prevertebral fascia.	
Sterno-hyoid.	} Arteries.		
Internal and common			
carotid.			
Ascending pharyngeal.			
Ascending palatine.	} Nerves.		
Tonsillar.			
Internal jugular vein.			
Glosso-pharyngeal.			
Pneumogastric.			
Sympathetic.			
Spinal accessory.			
Hypoglossal.			
Superior laryngeal.			
Thyroid gland.			

*Muscles* : inferior, middle and superior constrictors, stylo-pharyngeus, palato-pharyngeus, salpingo-pharyngeus. (*Vide* pp. 29 and 30.)

*Arteries* : Ascending pharyngeal ; pterygo-palatine ; ascending and descending palatine ; dorsalis linguæ ; tonsillar.

*Openings* : the *posterior nares* (2), placed in the upper part of the anterior wall ; *Eustachian tubes* (2), open one on each side at the upper part ; the *mouth*, situated just below the posterior nares ; the *laryngeal* and *œsophageal* openings.

The **pharyngeal wall** consists of 4 layers : (1) internally a striated squamous epithelium with submucous tissue ; (2) pharyngeal aponeurosis ; (3) muscular ; (4) an indistinct layer of fascia called the bucco-pharyngeal fascia, derived from the deep cervical fascia.

The **pharyngeal aponeurosis** forms the base of the walls of the pharynx, lying between the mucous membrane and the muscles. It is thin below, but strong above, where it fills in the space above the upper crescentic margin of the superior constrictor (sinus of Morgagni), over which the Eustachian tube passes. It is attached above to the body of the sphenoid and petrous portion of the temporal, being strengthened in the middle line by a process of fascia attached to the pharyngeal tubercle on the basilar part of the occipital bone. Inferiorly it becomes lost between the muscular and mucous strata.

THE ŒSOPHAGUS.

The Œsophagus extends from pharynx to stomach, and is 9 inches long. It begins at the lower border of cricoid cartilage opposite the 5th cervical vertebra, and ends opposite the 10th dorsal.

*Course and relations :—*

**In the neck :** passes downwards and to the left.

<i>In Front.</i>	<i>Behind.</i>	<i>Left Side.</i>		<i>Right Side.</i>
Trachea.	Vertebræ.	Left inferior thy-	} Arteries.	Right carotid.
Thyroid gland.	Left longus	roid.		Right recurrent
Left recurrent	colli muscle.	Left carotid.		laryngeal
laryngeal		Left subclavian.		nerve.
nerve.		Thoracic duct.		

**In the chest.**—*In the superior mediastinum* passes downwards to the right to reach middle line opposite 5th dorsal vertebra.

*In the posterior mediastinum :* passes forwards and downwards to the left, with the two pneumogastrics, which form a plexus on its surface; the left nerve is anterior, and the right is posterior.

<i>In Front.</i>	<i>Behind.</i>	<i>Left Side.</i>	<i>Right Side.</i>
Left carotid artery.	Longus colli.	Left subclavian	Right pleura.
Bifurcation of	Vertebræ.	artery.	Vena azygos
trachea.	Thoracic duct.	Left pneumogas-	major.
Right pulmonary	Venæ azygoi	tric nerve.	
artery.	minores.	Arch of aorta.	
Left bronchus.	Right intercostal	Thoracic aorta.	
Left recurrent laryn-	vessels.	Left pleura.	
geal nerve.	Aorta (below).		
Pericardium and left			
auricle.			
Diaphragm.			

**In the abdomen :** passes through œsophageal opening in diaphragm opposite the disc between the 9th and 10th dorsal vertebræ, to end at the cardiac opening of the stomach opposite the 10th dorsal vertebra.

THE STOMACH.

*Form :* conical, with base or fundus to left side; the upper border is concave, and is called the *lesser* curvature; the lower border is convex, and is named the *greater* curvature. The left extremity is known as the *fundus*, above and to the right of which is the *cardiac* orifice, and the right or small end is termed the *pyloric* extremity.

*Position* : occupies left hypochondriac and epigastric regions.

*Orifices* : *cardiac*, above, communicating with the œsophagus; *pyloric*, at the right extremity, passing into the duodenum.

*Dimensions* : 10 to 12 inches long; 4 to 5 inches in diameter at widest part.

*Relations* :—

*Left or cardiac end* : fixed by œsophagus and gastro-phrenic ligament to diaphragm, lying beneath the 7th left costal cartilage, 1 inch from sternum : it is connected with the spleen by the gastro-splenic omentum.

*Right or pyloric end* : reaches gall-bladder, touching under part of quadrate lobe of liver; is very movable, when stomach is empty is in mid-line on line midway between upper border of sternum and upper border of pubis, over 1st lumbar vertebra.

*Anterior surface*, which also looks upwards, is in contact with, from left to right, diaphragm, abdominal parietes (epigastric region), under surface of liver.

*Posterior surface* is separated from diaphragm, aorta, pancreas, spleen, left kidney, and supra-renal, transverse mesocolon and colon, by lesser sac of peritoneum.

*Superior border* : attached to liver by small omentum.

*Inferior border* : gives attachment to great omentum.

*ARTERIES*.—*Coronary* and *pyloric* run along lesser curvature; *right* and *left gastro-epiploic*, along inferior or greater curvature; *vasa brevia*, from the splenic to fundus.

*NERVES*.—*Right pneumogastric*, to posterior surface; *left pneumogastric*, to anterior surface; *sympathetic*, from the solar plexus to both surfaces.

## THE SMALL INTESTINES.

### THE DUODENUM.

*Length* : 8 to 10 inches.

*Shape* : horse-shoe, with the convexity to the right side, the concavity enclosing the head of the pancreas.

*Position* : occupies epigastric and umbilical regions.

Has no mesentery, and is only partially invested by peritoneum.

Divided into three parts.

*Relations* :—

**1st part** : 2 inches long; directed from pylorus upwards, backwards, and to the right, reaching the neck of the gall-

bladder. The 1st inch is invested with peritoneum, but the 2nd inch is covered in front only.

*In front.* Liver, gall-bladder.

*Behind.* Bile-duct, vena portæ, hepatic artery, gastro-duodenal artery.

*Below.* Head of pancreas.

**2nd part:**  $3\frac{1}{2}$  inches long; is vertical; passes from opposite neck of gall-bladder down to 3rd lumbar vertebra. Ducts of liver and pancreas enter this part. Covered in front by peritoneum.

*In front.* Transverse colon, liver and gall-bladder, small intestines.

*Behind.* Right kidney, supra-renal capsule, renal vessels, and inferior vena cava.

*Left side.* Head of pancreas, common bile-duct, and pancreatic duct.

*Right side.* Hepatic flexure of colon.

On the inner aspect,  $3\frac{1}{2}$  or 4 inches from the pylorus, is the *bile papilla*, on which is the orifice for both the common bile and pancreatic ducts.

**3rd part:** about  $4\frac{1}{2}$  inches long; passes from right to left across spine, ascending from 3rd to 2nd lumbar vertebra, ends in jejunum on left side of spinal column; lies below transverse meso-colon, and is covered in front by peritoneum, except where root of mesentery crosses it.

*In front.* Superior mesenteric vessels and plexus.

*Behind.* Aorta, inferior vena cava, crura of diaphragm, left psoas, and left renal vessels.

*Above.* Pancreas.

ARTERIES.—Pyloric, and superior pancreatico-duodenal of hepatic, inferior pancreatico-duodenal of superior mesenteric.

NERVES, from solar plexus.

#### THE JEJUNUM AND ILEUM.

The jejunum forms  $\frac{2}{3}$  of the rest of the small intestines, which are 23 feet long; commencing on the left side of the 2nd lumbar vertebra, it terminates in the ileum; it is wider, and its coats are thicker, more vascular, and of a deeper colour than the ileum.

The ileum consists of the remaining  $\frac{1}{3}$  of the small intestines, and terminates in the right iliac fossa by opening into the cæcum.

The ileum with the jejunum is suspended from the posterior abdominal wall by the mesentery (p. 196). The vessels are derived from the superior mesenteric artery, and the veins drain into the vein of the same name.

The following characteristics will serve to distinguish the three parts of the small intestines :

<i>Duodenum.</i>	<i>Jejunum.</i>	<i>Ileum.</i>
The largest part.	More vascular than ileum.	Villi, small.
Thickest coats.		Valvulæ conniventes,
Brunner's glands.	Valvulæ conniventes.	not present or only
Valvulæ conniventes.	Villi, well marked.	slightly.
No mesentery.		Peyer's patches.

### THE LARGE INTESTINE.

*Extent* : from the ileum to the anus. *Length* : 5 or 6 feet.

*Characteristics of Cæcum and Colon.*—Larger size, more fixed than the small intestine ; has appendices epiploïcæ. The longitudinal muscular fibres are arranged in three bands, which, being shorter than the other coats, cause sacculation.

The **cæcum** is a dilated pouch in which the large intestine commences, situated in the right iliac fossa, and completely covered by peritoneum ; at the lower, inner, and back part, and generally attached by a mesentery to the cæcum, is the *appendix vermiformis*, a blind tubular projection, about 3 inches long, and about the size of a large quill.

The *ileo-cæcal valve* lies on the left side of the cæcum ; is formed by the two inner coats of the ileum passing through the wall of the cæcum. The upper fold is horizontal, and called the ileo-colic. The lower is vertical, and termed the ileo-cæcal. The ridge on either side is called the *frænum*.

The **COLON** is divided into ascending, transverse, descending, iliac and pelvic.

The **ascending colon** extends from the cæcum to the under surface of the liver to the right of the gall-bladder, where it turns to the left, forming the *hepatic flexure*. It lies in the right lumbar and right hypochondriac regions. The peritoneum covers the anterior and lateral surfaces. Length, 8 inches.

*Relations.*—*In front.* The convolutions of the ileum.

*Behind.* Iliacus, quadratus lumborum, outer side of right kidney.

The **transverse colon** passes in the umbilical region from right to left, from the gall-bladder to the spleen. It forms an arch, convex anteriorly and below : *the transverse arch of the colon*. It is entirely surrounded by peritoneum, which is attached posteriorly to the spine, forming the meso-colon. Length, 20 inches.

*Relations.*—*Above.* Liver, gall-bladder, large curvature of stomach, lower end of spleen.

*Below.* Small intestines.

*Anteriorly.* Anterior layers of great omentum, anterior abdominal wall.

*Posteriorly.* Right kidney, 2nd part of duodenum, transverse meso-colon, pancreas, and small intestines.

The **descending colon** passes from the end of the transverse colon by a bend, *the splenic flexure*. Between the splenic flexure and the diaphragm, opposite the 10th left rib, is a fold of the peritoneum, the *costo-colic ligament*, which slings up the spleen. The gut then passes downwards to the left iliac crest, ending in the iliac colon. The peritoneum invests its anterior and lateral surfaces. Length, 4 to 6 inches.

*Relations.*—*Behind.* Left kidney, quadratus lumborum, and psoas.

*In front.* Small intestine.

*Inner side.* Outer border of left kidney.

The **iliac colon** is continuous with the descending colon at the left iliac crest, and ends at the inner border of the left psoas.

Peritoneum invests its anterior and lateral surfaces; it has no mesentery.

*Relations.*—*In front.* Small intestines; when distended, the anterior abdominal wall. *Behind.* Left ilio-psoas.

*Length.* 5 to 6 inches.

The **pelvic colon** extends from the inner border of the psoas to the level of the 3rd sacral vertebra.

*Length.* 16 or 17 inches; very variable. It has an extensive mesentery.

*Relations.*—Passing over left brim of pelvis, it crosses left external iliac vessels and left ureter, and passes to right margin of pelvis, resting on bladder in male and uterus in female; above lie coils of small intestine. It then turns back to mid-line on posterior wall of pelvis, and, forming a second bend, descends to end in the rectum.

The **rectum** :—

*Extent.*—From the 3rd sacral vertebra to the tip of the coccyx (5 to 6 inches long).

*Relations.*—It has peritoneum on the upper  $\frac{2}{3}$  of anterior surface only, and no mesentery.

*In front.* Recto-vesical pouch: triangular area at base of bladder, vesiculæ seminales, vasa deferentia, posterior surface of prostate (male), posterior wall of vagina (female).

*Behind.* Sacrum, coccyx, levatores ani.

*Laterally.* Pararectal fossa, below coccygeus.

The **anal canal** :—

*Extent.*—From the tip of the coccyx to anus (1 to 1½ inches long).

*Direction.* Downwards and backwards.

*Relations* :—

*In front.* Membranous part of the urethra, bulb of corpus

spongiosum (male), posterior wall of vagina, the perineum intervening (female).

*Laterally and behind.* Levatores ani, which, uniting, support it as in a sling. Internal and external sphincters. Ischio-rectal fossa.

## THE LIVER.

*Situation.*—Right and left hypochondriac and epigastric regions.

*Average weight.*—50 ounces.

*Upper surface.* Convex, covered by peritoneum; above is the diaphragm. It is divided into two unequal lobes (right and left) by a fold of peritoneum, called the *suspensory* or *broad ligament*. In relation with the diaphragm.

*Under surface.* Concave, and is in relation with the stomach, pylorus, duodenum, hepatic flexure, right kidney, and right supra-renal body; is covered with peritoneum, except where gall-bladder is attached, and at the transverse fissure, and at the fissure for ductus venosus, which give attachment to the lesser omentum.

*Posterior surface.* Is broad and round: connected to diaphragm over right lobe by the coronary ligament, between the two layers of which its surface is non-peritoneal. On this surface, opposite the 10th and 11th dorsal vertebræ, is the Spigelian lobe, which bounds the lesser sac in front. Right supra-renal capsule, inferior vena cava, aorta, œsophagus, and lesser peritoneal sac lie behind.

*Anterior surface.* Triangular, and marked by a notch opposite the attachment of the suspensory ligament. In relation with diaphragm and anterior abdominal wall.

*Right surface.* Convex and in relation with diaphragm.

The **LIGAMENTS** are five in number; four are composed of peritoneum, and are:—

The **suspensory, falciform, or broad** ligament, sickle-shaped, with the base forward. It is attached above to the diaphragm, extending on to the sheath of rectus as far as the umbilicus, and below from the notch in front, to the posterior edge of the liver. The inferior edge encloses the round ligament.

The **lateral ligaments**, right and left, extend from the sides of the diaphragm to the posterior border of the liver.

The **coronary ligament** is continuous with the lateral ligaments, and attaches the posterior surface of right lobe of the liver to the diaphragm.

The **round ligament** is the obliterated umbilical vein and ductus venosus contained within the posterior or free edge of the suspensory ligament.



**FISSURES :—**

The **longitudinal fissure** is occupied by the round ligament, and divides the organ into right and left lobes; it is separated into two parts by its union with the transverse fissure.

The *anterior* part or **umbilical fissure** contains the remains of the umbilical vein, and lies between the left lobe and the lobus quadratus. The *posterior* part or **fissure of the ductus venosus** lies between the left lobe and the lobus Spigelii, and contains the remains of the ductus venosus.

The **transverse or portal fissure** is placed at right angles to the longitudinal fissure, between the lobus quadratus and the lobus Spigelii, and lodges the hepatic ducts, artery, and portal vein, nerves and lymphatics. The artery lies between the duct in front, and the vein behind.

The **fissure for the inferior vena cava** is placed obliquely at the posterior margin of the liver, behind the gall-bladder, lying between the right lobe and the lobus Spigelii, and separated from the transverse fissure by the lobus caudatus. The hepatic veins enter the vena cava at the bottom of this fissure.

**LOBES :—**

**Right and left lobes** are separated from each other by the umbilical fissure on the under surface, and posteriorly by the fissure of the ductus venosus. The right is the larger, and contains the transverse fissure and fissure for the inferior vena cava; is subdivided into the three following lobes :—

The **lobus quadratus** : bounded by the umbilical and transverse fissures and the fossa of the gall-bladder.

The **lobus Spigelii** is on the posterior surface, and is the projection between fissures for the inferior vena cava and ductus venosus, behind the transverse fissure.

The **lobus caudatus** connects the preceding lobe with the main mass of the right lobe, and lies behind the transverse fissure.

**FOSSA :—**

The **fossa for the gall-bladder** lies on the under surface of the right lobe, parallel to the umbilical fissure, and separates the quadrate lobe from the main mass of the right lobe.

**THE GALL-BLADDER AND BILE-DUCTS.**

The **gall-bladder** is a conical bag placed in a fossa on the under surface of the right lobe of the liver. Its upper surface is attached to the liver, and its fundus and posterior surfaces are invested by peritoneum reflected from the adjacent surface of the liver.

*Relations.*—The body is in relation in front with the liver

and behind with the 1st part of duodenum, and the hepatic flexure of colon. The fundus is in contact with the parietes opposite the 9th right costal cartilage.

The **cystic duct** passes from the neck of the gall-bladder downwards, backwards, and to the left, to join the hepatic duct at the mouth of the portal fissure.

The **hepatic duct**, formed by union of ducts from right and left lobes, issues from the liver at the bottom of the transverse fissure. It joins the cystic duct, the two forming the *common bile-duct*. Its length is 1 inch, and it lies entirely within the portal fissure.

The **ductus communis choledochus** or **common bile-duct** results from the union of the hepatic and cystic ducts. It passes downwards in front of the foramen of Winslow in the layers of the gastro-hepatic omentum, having the vena porta behind, and the hepatic artery on the left. It then descends behind the 1st part of the duodenum, and, passing between the pancreas and 2nd part of the duodenum where it lies on the inferior vena cava, it enters the small intestine obliquely, a little below the middle of the descending part of the duodenum, by an opening on the biliary papilla (p. 189) common to it and the pancreatic duct. Length 3 inches.

*Vessels of the liver :—*

The **hepatic artery** from the cœliac axis enters the transverse fissure and divides into two branches for the right and left lobes. The right branch gives off the cystic branch to the gall-bladder.

The **portal vein**, having the hepatic artery on the left and in front, and the common bile-duct on the right, ascends between the layers of the gastro-hepatic omentum, in front of the foramen of Winslow, to the transverse fissure. The vessels, accompanied by nerves and lymphatics, are surrounded by areolar tissue, the *capsule of Glisson*, which passes with them into the liver.

The **hepatic veins** pass out of the liver at the bottom of the fissure of the inferior vena cava, immediately joining that vessel.

## THE PANCREAS.

*Length* : 6 to 8 inches. Consists of a body, enlarged to the right at its head, with which the body is connected by a narrow part or neck, and narrowed to the left, where it ends as the tail.

*Position.*—Placed in the epigastric and left hypochondriac regions, directed transversely across posterior wall of abdomen.

*Relations of the body :—*

*Upper surface.* Stomach and small omentum: covered by peritoneum.

*Posterior surface.* Aorta, crura of diaphragm, splenic vein, left kidney, left supra-renal body and left renal vessels.

*Upper border.* From right to left; coeliac axis, splenic artery.

*Inferior surface.* From right to left; duodeno-jejunal flexure, splenic flexure, and small intestines: covered by peritoneum.

*Left end or tail.* Touches lower part of internal surface of spleen.

*Right end or head.* Embraced by three parts of duodenum, from which it is partly separated, behind by common bile-duct, and in front by pancreatico-duodenal arteries. Is covered in front by transverse colon: the superior mesenteric vessels overlap the left end of the head, lying in a groove on the anterior surface. Behind are inferior vena cava and right renal vessels.

*Neck* lies on the 1st and 2nd lumbar vertebræ, from which it is separated by the crura of the diaphragm, superior mesenteric vessels, and portal vein.

*Duct* (canal of Wirsung): extends transversely from left to right, opens into 2nd part of the duodenum in common with the ductus communis choledochus.

*Arteries:* pancreatic of splenic, superior pancreatico-duodenal of hepatic, and inferior pancreatico-duodenal of superior mesenteric.

*Veins:* open into splenic and superior mesenteric.

*Nerves:* from the solar plexus.

## THE SPLEEN

situated in the left hypochondrium and epigastrium, is of an oblong, flattened form, the external surface being convex; on the inner surface is a vertical ridge dividing it into two parts, the posterior of which is applied to the outer surface of the left kidney, whilst the anterior receives the tail of the pancreas, and lies against the fundus of the stomach. Near this ridge is a fissure, *the hilum*, where the vessels enter. The anterior border is notched, and the inferior or basal surface is triangular, and rests on the costo-colic ligament (*vide* p. 191) and the splenic flexure. It is covered, except at the hilum, by peritoneum, which here passes forwards and inwards in a double line enclosing the vessels, as the gastro-splenic

omentum, to the fundus of the stomach: behind the hilum two layers pass on to the left kidney as *lienorenal* ligament.

*Relations.—External surface.* Diaphragm, which separates it from the 9th, 10th, and 11th left ribs and pleura.

*Internal surface. In front of the hilum.* Fundus of stomach. *Behind the hilum.* Left kidney, left supra-renal body. *Below the hilum.* Tail of pancreas.

*Inferior surface.* Costo-colic ligament and splenic flexure.

*Arteries:* Splenic.

*Nerves:* Branches from solar plexus of the sympathetic.

## THE PERITONEUM.

The **peritoneum** is the serous membrane of the abdominal cavity. It consists of a *parietal* layer lining the abdominal and pelvic walls, and a *visceral* layer reflected more or less over the contained organs. In the male it is a closed sac, but in the female the free extremities of the Fallopian tubes open into the cavity. The continuity of the peritoneum may be traced in the following manner.

Commencing at the middle line and passing horizontally, the peritoneum lines the right half of the abdominal wall, as far as the lumbar region, where it entirely surrounds the cæcum and vermiform appendix. It only invests the front and sides of the ascending colon, though occasionally the whole circumference of the gut is enclosed, a meso-colon being then formed. The peritoneum then passes inwards, covering the lower part of the anterior surface of the right kidney, the front of the 3rd part of duodenum, and goes downward over the front of the vessels of the small intestines, encloses the small intestines, and is reflected upwards on the posterior surface of the vessels to the spine, thus forming the *mesentery*. From the spine it may be traced to the left over the lower part of the anterior surface of the left kidney to the descending and iliac colon, and thence on to the abdominal parietes to the middle line. The descending and iliac colon is invested in a similar manner to the ascending.

The peritoneum of the pelvis is continuous with that of the abdominal cavity. It encloses completely the pelvic colon, and forms the *pelvic meso-colon*. It is applied to the front and sides, and lower down to the front only of the rectum, whence it is reflected in the male on to the base and upper part of the bladder, forming the *recto-vesical pouch*; this is bounded on each side by the peritoneum

reflected forwards from the sides of the rectum over the obliterated hypogastric artery and ureter, forming the *posterior false ligament* of the bladder.

From the apex of the bladder the peritoneum passes upwards on to the anterior abdominal wall, enclosing the remains of the urachus and constituting the *anterior false ligament* of the bladder; whilst laterally it is reflected from the bladder along the line of the obliterated hypogastric artery to the iliac fossa, forming the *lateral false ligaments* of that viscus. Where the obliterated hypogastric artery passes between the abdominal wall and the side of the bladder it raises the peritoneum into a fold, which separates two shallow fossæ, the *internal* and *external inguinal fossæ*, which correspond respectively to the internal and external abdominal rings.

In the female the peritoneum is reflected from the sides and front of the rectum to the upper part of the posterior wall of the vagina, and thence over posterior, upper, and anterior surfaces of the uterus to the bladder. Between the uterus and rectum is the *recto-vaginal* or *Douglas's pouch*, corresponding to the *recto-vesical* pouch in the male. The peritoneum passes off from the lateral margins of the uterus to the pelvic wall, forming the *broad ligaments*, in the upper border of which folds the Fallopian tubes run, the peritoneum being continuous with their open fimbriated extremities.

In the upper part of the abdomen the peritoneum is attached to the under surface of the diaphragm as far backwards as the posterior surface of the liver, and the œsophageal opening of the stomach. It is then reflected forwards on the upper surface of the liver, forming the ligaments of that organ; and passing round the anterior border it is applied to the under surface as far as the transverse fissure, where, meeting a peritoneal layer from the posterior surface (from the smaller sac), the two descend to the stomach to form the small or gastro-hepatic omentum. Tracing it to the right from the longitudinal fissure, it invests the gall-bladder, under surface of the right lobe, and the front of the 2nd part of the duodenum, passing to the anterior surface of the right kidney, where it becomes continuous with the part already traced. To the left of the longitudinal fissure the peritoneum covers the left lobe of the liver, and is reflected over the front of the cardiac end and fundus of the stomach, whence it passes off to invest the spleen, forming a reduplication, the *gastro-splenic omentum*. From the spleen it is continued over the anterior surface of the left kidney, forming the posterior

layer of the lieno-renal ligament, and over the descending colon to join the part already described.

Between the liver, stomach, and transverse colon is a diverticulum of the main peritoneal sac, which communicates with the larger peritoneal cavity through the *foramen of Winslow*. To understand the disposition of the layers one has only to imagine the smaller sac to have been invaginated through the foramen of Winslow inwards and behind the stomach, and the arrangement becomes clear.

*The two sacs traced vertically.*

From transverse fissure of liver, two layers pass:—

To small curvature of stomach.

Two layers separate, one passing in front and the other behind stomach, thus enclosing it.

Join together at great curvature, forming anterior layers of great omentum.

Pass down in front of and beyond transverse colon.

Bend upwards and backwards, and separate to enclose transverse colon; continue together to the posterior abdominal wall, until opposite the anterior border of the pancreas, where they part, one layer passing upwards, and the other downwards.

The *ascending layer* passes:—

Over upper surface of pancreas and posterior part of diaphragm.

Then on to posterior surface of liver to the transverse fissure.

The *descending layer* passes:—

Along superior mesenteric vessels, round jejunum and ileum, and back to spine, forming mesentery.

Downwards in front of spine, lower part of aorta and sacral promontory.

Over pelvic colon, forming pelvic meso-colon.

Forwards.

*Male.*—To bladder, forming recto-vesical pouch and posterior false ligaments.

*Female.*—To vagina and uterus, forming posterior ligaments of uterus and recto-vaginal pouch. Then over uterus to bladder, forming utero-vesical pouch and posterior vesical ligaments.

Over bladder to anterior abdominal wall, covering urachus and obliterated hypogastric arteries as far as umbilicus.

Over under surface of diaphragm.

Reflected over upper surface of liver.

Round anterior border of liver to under surface as far as transverse fissure.

*The two sacs traced horizontally, at the level of the foramen of Winslow.*

From falciform ligament of liver:—

Over anterior abdominal wall and diaphragm.

Over outer part of left kidney.

Reflected outwards behind splenic vessels to spleen, forming posterior layer of lieno-renal ligament.

Over spleen as far as hilum.

To stomach, forming anterior layer of gastro-splenic omentum.

Over anterior wall of stomach into anterior layer of gastro-hepatic omentum.

Turns round hepatic artery, forming anterior edge of foramen of Winslow (here the smaller sac commences).

Passing from right to left:—

Forms posterior layer of small omentum.

Over posterior surface of stomach.

Forms posterior layer of gastro-splenic omentum, reaching hilum of spleen.

Forms anterior layer of lieno-renal ligament.

Passing now from left to right:—

Continues over left kidney, aorta, and inferior vena cava, here forming posterior boundary of foramen of Winslow (here smaller sac ends, and large sac again commences).

Over right kidney to liver.

Over under-surface of liver to left border, round which it may be traced over anterior surface, to falciform ligament.

#### SYNOPSIS OF PROCESSES OF THE PERITONEUM.

**Omenta**—folds connected with the stomach.

*Lesser or Gastro-hepatic Omentum.*—From transverse fissure and fissure for ductus venosus on liver to small curvature of stomach and 1st part of duodenum. Right border free, forming anterior boundary of foramen of Winslow.

*Great or Gastro-colic Omentum.*—Formed, as shown above, by the passing downwards and then folding upwards of the two layers passing from stomach, and thus encloses the lower part of the cavity of the smaller sac of the peritoneum.

*Gastro-splenic Omentum.*—Passes from fundus of stomach to hilum of spleen, and contains the splenic vessels between its layers. Below it is continuous with the great omentum.

**Mesenteries**—folds connecting intestine to posterior abdominal wall.

*The Mesentery.*—Attached behind to left side of 2nd lumbar vertebra, passing downwards across vertebræ to right sacro-iliac synchondrosis. Contains superior mesenteric vessels, jejunum and ileum between its layers. The upper layer is continuous with inferior layer of transverse meso-colon, the lower layer with peritoneum on posterior abdominal wall.

*Transverse Meso-colon.*—Formed by junction of two ascending layers of great omentum after they have enclosed transverse colon; at the spine the two layers separate, as explained, into ascending and descending layers.

*Pelvic Meso-colon.*—A long process attached to brim of pelvis.

**Ligaments.**—The peritoneum, as explained, is reflected from the abdominal walls to viscera, forming ligaments.

*Ligaments of the Liver:*—

*Suspensory or Falciform.*—Sickle-shaped fold passing from anterior abdominal wall to upper and anterior surfaces of liver. The inferior free border contains obliterated umbilical vein or round ligament.

*Coronary.*—Connects right lobe to diaphragm; consists of two layers, the anterior being derived from greater sac, and the posterior from lesser sac.

*Lateral (2).*—These are the right and left ends of the coronary ligament.

*Ligaments (False) of the Bladder:*—

*Posterior False Ligaments (2).*—The edges of the recto-vesical pouch.

*Lateral False Ligaments (2).*—Reflection from sides of bladder.

*Superior False Ligament.*—Reflection from bladder to anterior abdominal wall along urachus.

*Ligaments of the Uterus:*—

*Broad Ligaments (2).*—Each passes from side of uterus to lateral pelvic wall: contains between its folds the round ligament, Fallopian tube, the ovary, and its ligament and branches of ovarian and uterine vessels.

*Anterior Ligaments (2).*—Margins of utero-vesical pouch.

*Posterior Ligaments (2).*—Margins of recto-vaginal pouch.

*Ligament of Spleen,* or lieno-renal ligament, passes from left kidney to spleen; the right or anterior layer is formed by the lesser sac, and the left or posterior by the larger one.



Costo-colic ligament (*vide* p. 191.)

The **foramen of Winslow** is the orifice behind the right free margin of the small omentum, by which the smaller peritoneal sac communicates with the general peritoneal cavity.

*Relations* :—

<i>In Front.</i>		<i>Behind.</i>	<i>Above.</i>	<i>Below.</i>
Hepatic artery. Portal vein. Common bile-duct.	}	Between the layers of the small omentum.	Inferior vena cava. Right crus of diaphragm.	Caudate lobe.  1st part of duodenum. Commence- ment of hepatic ar- tery.

## THE MEDIASTINA.

The **superior mediastinum** is the space above the pericardium extending upwards to the root of the neck.

*Boundaries* :—

*Above.* Superior aperture of the thorax.

*Below.* Plane passing from lower part of body of 4th dorsal vertebra, to the junction of the gladiolus and manubrium of sternum.

*In front.* Manubrium and origins of sterno-hyoid and sterno-thyroid muscles.

*Behind.* First four dorsal vertebræ, and lower ends of longi colli.

*Laterally.* The parietal or mediastinal pleura, passing back from posterior surface of sternum to vertebræ.

*Contents.* Trachea (lower end), œsophagus, thoracic duct, transverse part of arch of aorta, innominate artery, thoracic part of left carotid and subclavian arteries, innominate veins, upper part of superior vena cava, phrenic and pneumogastric nerves, left recurrent laryngeal and the cardiac nerves, lymphatic glands and remains of thymus gland.

The **anterior mediastinum** is the space between the two pleuræ in front of the pericardium; it is narrow above, but broader below.

*Boundaries* :—

*In front.* Sternum, with 5th, 6th, and part of 7th left costal cartilages, triangularis sterni, and left internal mammary vessels.

*Behind.* Pericardium.

*Laterally.* Pleura

*Contents.* Anterior mediastinal glands.

The **middle mediastinum** contains the pericardium with its contents, the phrenic nerves and accompanying vessels, the arch of the vena azygos major, the roots of the lungs and bronchial lymphatic glands.

The **posterior mediastinum** lies behind the pericardium.

*Boundaries:—*

*In front.* Pericardium and roots of lungs, and diaphragm (below).

*Behind.* Spinal column, from the lower border of the 4th dorsal to the 12th dorsal vertebra.

*Laterally.* Pleura.

*Below.* Diaphragm covered by pleura.

*Above.* Plane passing forwards from lower border of 4th dorsal vertebra.

*Contents.* Descending thoracic aorta and some of its right intercostal branches, œsophagus, pneumogastric and great splanchnic nerves, the three azygos veins, thoracic duct, and posterior mediastinal glands.

## THE HEART AND PERICARDIUM

### THE PERICARDIUM.

The pericardium is a fibro-serous membrane, containing the heart and the commencement of the great vessels. The *apex* points upwards and surrounds the ascending aorta, superior vena cava, and pulmonary artery for about 2 inches —*i.e.*, to the level of the lower border of the aortic arch. The *base* is fixed to the central tendon and adjoining muscular fibres of the diaphragm.

<i>In front.</i>	<i>Behind.</i>	<i>Laterally.</i>
Gladiolus.	Roots of lungs.	Pleura.
Left costal cartilages (4th to 7th).	Œsophagus.	Comes nervi phrenici vessels.
Remains of thymus gland.	Descending aorta.	Phrenic nerve.
Overlapped by both lungs and pleuræ.		

The serous layer of the pericardium lines the inner surface of the pericardium, and is continued on to the surface of the heart, being also prolonged over the vessels in the pericardium. The aorta and pulmonary artery are enclosed in one sheath, and it surrounds the ends of the four pulmonary veins, forming a pouch posteriorly between the veins of the right and left sides. The part of the superior vena cava within the pericardium is also invested by it.

The serous layer forms a reduplication above and in front of the root of the left lung, enclosing the fibrous remains of the left superior vena cava; it reaches from the left superior intercostal vein downwards to the side of the left auricle, where it joins the serous investment round the left upper pulmonary vein. This reduplication is known as the *vestigial fold* of Marshall.

#### THE HEART.

The heart is a hollow muscular organ enclosed in the pericardium, and having an irregular conical shape. It is attached at its base to the great bloodvessels, being otherwise free within the pericardial sac.

*Position.*—The heart is placed obliquely, the base being directed upwards, backwards, and to the right; the apex downwards, forwards, and to the left. The *apex* corresponds to a point in the 5th left intercostal space  $3\frac{1}{2}$  inches from the mid-line.

#### *The Limits of the Heart.*

*Superior.* Line from lower border of 2nd left, to upper border of 3rd right costal cartilage.

*Inferior.* Line from 7th right chondro-sternal articulation to apex.

*Right side.* Line drawn nearly vertically  $1\frac{1}{2}$  inches from mid-line of sternum, from upper to lower limit.

*Left side.* Line from lower border of 2nd left costal cartilage, 1 inch from sternum, downwards and to the left to apex.

#### *Position of the Valves.*

*Pulmonary.* Opposite upper border of 3rd left costal cartilage near sternum.

*Aortic.* Opposite left  $\frac{1}{2}$  of sternum, on level with lower border of 3rd costal cartilage.

*Tricuspid.* Opposite right  $\frac{1}{2}$  of sternum, on level with 4th intercostal space.

*Mitral.* Opposite junction of 4th left costal cartilage with sternum.

*Divisions.*—The heart is divided longitudinally by a septum into two halves, right and left, each of which is subdivided transversely into two cavities. Those four divisions are indicated on the heart's surface by grooves. Two longitudinal grooves, one situated on the anterior and the other on the posterior surface, indicate the lateral division, whilst a transverse furrow, the *auriculo-ventricular groove*, indicates its separation into auricles above the furrow and ventricles below it.

*The Circulation.*—The right auricle receives venous blood from the *venæ cavæ* and coronary sinus; thence it passes into the right ventricle, whence it is conveyed to the lungs by the pulmonary artery. After being oxygenized the blood passes into the left auricle by the pulmonary veins; thence it is conveyed into the left ventricle, and from there to the aorta, whence it passes through the body.

#### THE CAVITIES OF THE HEART.

The RIGHT AURICLE consists of a principal cavity and an appendix auriculæ.

The principal cavity, or *sinus venosus*, is of an irregular form.

The *appendix auriculæ* is a small muscular pouch projecting from the anterior and upper angle of the auricle overlapping the root of the pulmonary artery.

At the junction externally of the two cavities is seen a well-marked groove (*sulcus terminalis*), which on the interior appears as a ridge (*crista terminalis* of His).

*Openings in the sinus.*—*Superior vena cava*, in the upper and front part. *Inferior vena cava*, at the lower and back part of the auricle. Between the openings of the two *cavæ* is a muscular projection, the *tubercle of Lower*.

The *coronary sinus* opens between the inferior vena cava and the auriculo-ventricular opening.

*Foramina Thebesii* are the mouths of small cardiac veins.

The *auriculo-ventricular* opening is in front of the inferior cava.

*Openings of anterior cardiac veins* (2 or 3) from the surface of the right ventricle.

*Valves.*—The *Eustachian valve* is a semilunar fold of endocardium in front of the anterior margin of the inferior vena cava; passes upwards and to the left to anterior margin of *annulus ovalis*.

The *coronary valve*, or *valve of Thebesius*, protects the opening of the coronary sinus.

**Remnants of fetal structures.**—The *Fossa ovalis* is the remains of the foramen ovale on the lower and posterior part of the septum auricularum, just above and to the left of the opening of the inferior vena cava.

The *annulus ovalis* is the upper crescentic elevated margin of the fossa.

The *musculi pectinati* are the prominent muscular columns running over the surface of the appendix auriculæ.

The *endocardium* is smooth in the main part of the cavity, but irregular over the *musculi pectinati* of the auricular appendix.

The **RIGHT VENTRICLE** consists of a cavity, the upper and left angle of which is prolonged into a funnel-shaped canal, the *infundibulum* or *conus arteriosus*, leading to the pulmonary artery. On the wall (except in the infundibulum, which is smooth) are projections, *columnæ carneæ*, formed of muscular bundles, of which there are three varieties: the first are merely prominent ridges; the second are attached at the ends, being free in the middle; the third are the *musculi papillares*, which project inwards, and are attached by their bases to the wall of the ventricle, the other end being connected with the *chordæ tendineæ*, or cords attached to the flaps of the auriculo-ventricular valve.

The *tricuspid valve*, which guards the right auriculo-ventricular opening, consists of three cusps, formed by a reduplication of the endocardium, with some fibrous tissue enclosed. The bases of the flaps are attached to the fibrous ring of the auriculo-ventricular orifice, while to their free ends are attached the *chordæ tendineæ*.

*Position of cusps.* *Right one* against right wall of ventricle (marginal cusp). *Posterior one* between auriculo-ventricular opening and septum (septal cusp). *Left* between auriculo-ventricular and pulmonary orifices (infundibular cusp). The valve prevents regurgitation of blood into the auricle during the heart's contraction.

The opening of the *pulmonary artery* is at the summit of the funnel-shaped *infundibulum*, and is guarded by the pulmonary semilunar valves. The semilunar valves are three folds of the lining membrane, a right, left, and posterior, which guard the orifice of the pulmonary artery. The free margin of each has in its middle a small fibrous nodule, the *corpus Arantii*, and between each valve and the beginning of the pulmonary artery is a dilatation called the pulmonary sinus, or *sinus of*

*Valsalva.* The point corresponding externally to these valves is the upper border of the junction of the third left costal cartilage with the sternum.

The **LEFT AURICLE** consists of a principal cavity and an appendix auriculæ; the latter extends forwards and to the right side, projecting over the commencement of the pulmonary artery. Its interior presents *musculi pectinati* as on the right side.

**OPENINGS.**—The *pulmonary veins* (4) open into the cavity, two on either side.

The *auriculo-ventricular* opening is smaller than that on the right side.

On the septum may be seen a shallow depression, the remains of the *foramen ovale*.

The **LEFT VENTRICLE** is longer and more conical than the right, with its walls nearly three times as thick. The interior contains *columnæ carneæ*, *musculi papillares*, and *chordæ tendineæ*, as on the right side.

**OPENINGS.**—The *auriculo-ventricular* opening corresponds to the junction of 4th left costal cartilage with the sternum; it is closed by the *mitral valve*, which is attached to the circumference at the opening, similarly to the *tricuspid*. It consists of two flaps, the larger being anterior (*aortic cusp*).

The *aortic opening* is placed in front and to the right side of the preceding, and its position may be marked externally by a line drawn through left half of the sternum, on a level with the lower border of the 3rd left costal cartilage. The orifice is guarded by three semilunar valves, which are precisely similar to those on the pulmonary artery, the characteristics of which are, however, better marked; they are named from their position anterior, right posterior and left posterior.

The **endocardium** is the serous membrane lining the whole of the interior of the heart, and is continuous with the lining membrane of the bloodvessels.

The **coronary arteries** supply the substance of the heart.

The **right coronary artery** comes off from the anterior sinus of *Valsalva* (*aortic*), passes on the right side of the pulmonary artery, between it and the right appendix, then backwards along the right *auriculo-ventricular* groove as far as the posterior inter-ventricular groove, where it divides into two branches, one of which passes transversely in the left *auriculo-ventricular* groove and joins branch of left artery, whilst the other passes downwards in the posterior inter-ventricular groove to supply the ventricles and septum; *anas* descending branch of left artery.

The left coronary artery arises from the left posterior sinus of Valsalva. It passes behind and then to the left of the pulmonary artery, and divides it into two branches, one of which passes forwards and downwards in the anterior inter-ventricular groove, and the other to the left and backwards along the left auriculo-ventricular groove.

The cardiac veins return the blood from the muscular wall mainly through the coronary sinus into the right auricle (p. 106).

The nerves come from the cardiac plexuses.

## ORGANS OF VOICE AND RESPIRATION.

### THE LARYNX.

The larynx lies in the front and upper part of the neck, being placed below the tongue and hyoid bone and between the large vessels of the neck. It opens above into the pharynx and below into the trachea. It is subcutaneous in the middle line, being covered only by skin and cervical fascia; but laterally it is overlaid by the insertions of the sterno-hyoid and sterno-thyroid, by the thyro-hyoid and origin of the inferior constrictor. Is composed of cartilages held together by ligaments, and moved by muscles, the whole being lined with mucous membrane.

The cartilages of the larynx:—

The thyroid cartilage is the largest, consists of two wings or *alæ* united in front at an acute angle, and forming the projection known as the *pomum Adami*.

*Outer surface*: traversed by *oblique line*, passing upwards and backwards, giving attachment to sterno-thyroid and thyro-hyoid muscles, and below oblique line to inferior constrictor.

*Inner surface*: presents in the middle line at the junction of right and left ala, the *receding angle*, to which are attached the root of the epiglottis, the superior and inferior thyro-arytenoid ligaments, the thyro-arytenoidei and thyro-epiglottidei muscles.

*Superior border*: sinuous; connected to hyoid bone by thyro-hyoid membrane; the two meeting together anteriorly in the mid-line form notch above *pomum Adami*.

*Inferior border*: connected with upper border of cricoid by crico-thyroid membrane anteriorly, and by crico-thyroid muscle laterally.

*Posterior border*: thick and rounded, receives insertion of

stylo- and palato-pharyngei muscles, prolonged upwards into *superior cornu*, which passes upwards, backwards, and inwards, having lateral thyro-hyoid ligament attached to tip; and downwards into *inferior cornu*, shorter, passing downwards, forwards, and inwards, presenting on inner surface a small facet to articulate with cricoid.

The **cricoid cartilage**: shaped like signet ring, deep behind and shallow in front.

*Outer surface*: anterior half gives attachment to crico-thyroid muscles, and behind this to part of inferior constrictor. Posterior half, broad and thick, presents ridge in middle line for attachment of some longitudinal fibres of œsophagus; on each side of ridge, a depression giving attachment to the crico-arytenoideus posticus, and external to this a small facet for articulation with inferior cornu of thyroid.

*Inner surface*: smooth, lined with mucous membrane.

*Superior border*: inclines from the front, upwards and backwards, gives attachment anteriorly and laterally to crico-thyroid membrane and crico-arytenoideus lateralis. Presents posteriorly in mid-line a notch, on each side of which is a facet for articulation with arytenoid cartilage.

*Inferior border*: horizontal, connected with 1st ring of trachea by intervening membrane.

**Arytenoid cartilages**: are two small pyramidal cartilages, articulating with posterior part of upper border of cricoid.

*Antero-external surface*: convex and rough, receives attachment of thyro-arytenoideus muscle and false vocal cord. At upper end is a tubercle for superior thyro-arytenoid ligament, and below an oblique ridge.

*Posterior surface*: hollowed for attachment of arytenoideus muscle.

*Internal surface*: narrow and smooth, covered with mucous membrane.

*Base*: has concave facet on under surface for articulation with cricoid cartilage, and prolonged into three angles.

*External or muscular process*: short and prominent, gives attachment to lateral and posterior crico-arytenoid muscles.

*Anterior or vocal process*: long and pointed, gives attachment to true vocal cord.

*Internal*: rounded.

*Apex*: looks backwards and inwards, surmounted by the cartilage of Santorini.

**Cartilages of Santorini or cornicula laryngis**: two small cartilages of conical shape, each attached to the apex of an arytenoid cartilage, and giving attachment to the aryteno-epiglottidean fold.



**Cuneiform cartilages**, or cartilages of Wrisberg, are two small cartilages, one on each side, found in the aryteno-epiglottidean fold.

The **epiglottis** covers the superior aperture of the larynx; it is a leaf-shaped lamina of yellow fibro-cartilage.

*Apex*: attached to receding angle of thyroid by thyro-epiglottic ligament.

*Base*: broad, rounded, and free; directed upwards.

*Anterior surface*: covered in upper part by mucous membrane, which passes forwards as the three glosso-epiglottic folds to connect it with the tongue; below it is attached to the hyoid bone by hyo-epiglottic ligament.

*Posterior surface*: covered by mucous membrane, concave from side to side, concavo-convex from above downwards; the convex part is known as the *cushion* or *tubercle* of the epiglottis.

The **LIGAMENTS** of the larynx are:—

The **thyro-hyoid membrane**: passes from the upper border of the thyroid cartilage to the upper border of the posterior surface of the hyoid bone: between it and the posterior surface of the hyoid bone is a synovial bursa. It is pierced by the superior laryngeal vessels and internal laryngeal nerve of each side.

(The **lateral thyro-hyoid membrane** is the posterior edge of the preceding, passes from the superior cornu of the thyroid to the tip of the great cornu of the hyoid bone, in which is found a small cartilaginous nodule, the *cartilago triticea*.)

The **crico-thyroid membrane** connects the thyroid and cricoid cartilages. Consists of two parts:—

*Central*: thick, triangular, with base downwards, passing from lower border of thyroid to upper border of cricoid cartilage.

*Lateral*: thinner, passes from upper border of cricoid cartilage internally to ala of thyroid, ending in a free border, the true vocal cord, or inferior thyro-arytenoid ligament.

The **superior thyro-arytenoid ligaments** are attached anteriorly to the angle between the alæ of the thyroid cartilage, just below the epiglottis, and posteriorly to the anterior surface of the arytenoid cartilage. They lie within the mucous membrane, forming the false vocal cords.

The **inferior thyro-arytenoid ligaments** are attached anteriorly to the angle between the alæ of the thyroid cartilage, and posteriorly to the anterior process at the base of the arytenoid cartilage. The inner free edge, covered with mucous membrane, forms the true vocal cord, and below it is continuous with the lateral part of the crico-thyroid ligament.

**Capsular ligaments**, lined with synovial membrane, surround the articulations between the cricoid and inferior cornua of the thyroid, and also between the cricoid and two arytenoid cartilages.

The **hyo-epiglottic ligament** connects the lower part of the anterior surface of the epiglottis to the upper border of hyoid bone.

The **thyro-epiglottic ligament** connects the apex of the epiglottis to the upper part of the receding angle of the thyroid cartilage.

#### THE INTERIOR OF THE LARYNX.

The **cavity** of the larynx extends from the *superior* aperture to the lower border of the cricoid cartilage. The vocal cords form an imperfect diaphragm, dividing the cavity into two parts. The chink between the true vocal cords is the *glottis* or *rima glottidis*, which is the narrowest part of the larynx. The whole is lined by mucous membrane.

The **superior aperture** of the larynx is triangular in shape, with base directed forwards. In front is the epiglottis, behind are the summits of the arytenoid cartilages and cornicula, and, laterally, the aryteno-epiglottic folds pass between the lateral edges of the epiglottis backwards to the tips of the arytenoid cartilages and cornicula, enclosing the cuneiform cartilages.

The **superior or false vocal cords**, one on each side, are two folds of mucous membrane enclosing the superior thyro-arytenoid ligaments; each is placed above the corresponding ventricle.

The **inferior or true vocal cords**, one on each side, are attached in front to the receding angle of the thyroid cartilage, and behind to the anterior angle or vocal process at the base of the arytenoid cartilage. They are formed of mucous membrane, enclosing the inferior thyro-arytenoid ligaments.

The **ventricles** of the larynx are the fossæ between the false and true vocal cords; the anterior part of each ventricle is prolonged upwards between the false vocal cord and the ala of the thyroid cartilage into a pouch, the **sacculus laryngis**. The opening of the sacculus into the ventricle is narrow, and its cavity contains numerous small glands.

The **muscles** of the larynx have been described (*vide* pp. 30 and 31).

The **arteries** of the larynx are the laryngeal branches of the superior and inferior thyroid.

The nerves are the superior laryngeal, the inferior or recurrent laryngeal, and branches of the sympathetic of each side.

THE TRACHEA.

The trachea extends from the lower border of the larynx (opposite the lower border of 5th cervical vertebra) to the level of the disc between the 4th and 5th dorsal vertebrae, there dividing into the two bronchi. In length it measures  $4\frac{1}{2}$  inches.

*Relations in the Neck.*

<i>In front.</i>	<i>Laterally.</i>	<i>Behind.</i>
Skin.	Cervical fascia.	Œsophagus.
Superficial and deep fasciæ.	Common carotid artery.	
Anastomosis of anterior jugular veins.	Lateral lobe of thyroid gland.	
Sterno-hyoid } Muscles.	Inferior thyroid artery.	
Sterno-thyroid }	Recurrent laryngeal nerve.	
Isthmus of thyroid gland.		
Inferior thyroid veins.		

*In the Thorax.*

<i>In Front.</i>	<i>Right Side.</i>	<i>Left Side.</i>	<i>Posteriorly.</i>
Manubrium sterni.	Right pneumogastric nerve.	Left cardiac nerves.	Œsophagus.
Origin of sternomastoid.	Innominate artery.	Left pneumogastric nerve.	
Origins of sternothyroid and sternohyoid.	Pleura.	Left recurrent laryngeal nerve.	
Remains of thymus gland.		Aortic arch.	
Left innominate vein.		Left subclavian artery.	
Commencements of innominate and left carotid arteries.		Pleura.	
Arch of aorta.			
Deep cardiac plexus.			

The cartilages, from sixteen to twenty in number, are U-shaped, the anterior  $\frac{2}{3}$  or convex part being cartilage, the posterior  $\frac{1}{3}$  fibrous membrane.

The *right bronchus*, about 1 inch long, is shorter, more vertical in direction, and of larger calibre than the left. It passes from the trachea downwards and to the right on a level with the 5th dorsal vertebra to the root of the corresponding lung, lying at first above and then behind the right pulmonary artery. The superior vena cava and right phrenic nerve lie in front, and the vena azygos major arches forwards above it.

The *left bronchus* is nearly 2 inches long, and passes downwards and forwards under the arch of the aorta to the root of the left lung, joining it at the level of the upper border of 6th dorsal vertebra. Behind it are the œsophagus, thoracic duct, and descending aorta. It lies at first behind, and then below, the left pulmonary artery.

### THE LUNGS AND THE PLEURÆ.

The *lungs*, two in number, occupy the whole of the thorax except the mediastina (*vide* pp. 201 and 202), which separate them from each other. They are conical in shape, and are covered with pleura. Each lung is free except at the median part or root, where it is attached to the bloodvessels and bronchi.

The *pleuræ* are two serous sacs enclosing and investing the lungs. Each pleura consists of a visceral and parietal layer. The *visceral* portion covers the lung, and the *parietal* layer lines the inner surface of the chest walls, the upper surface of the diaphragm, and the sides of the pericardium. The visceral layer of each pleura becomes continuous with the parietal layer in front and behind the root of the lung; and below the root a fold, the *ligamentum latum pulmonis*, extends downwards along the inner surface of the lung to the diaphragm. The mediastina are formed by the visceral layers of each side approaching one another towards the median line.

The limits of the parietal pleuræ are as follows: each extends upwards into the neck, forming a dome-like process over the apex of the lung about 2 inches above the anterior end of the first rib; from this each pleura passes downwards and forwards to the posterior aspect of the sternoclavicular joint and meets its fellow in the mid-line at the manubrio-gladiolar articulation; they pass down together to level of 4th costal cartilages, where *right pleura* passes vertically to level of 7th right costal cartilage in mid-line; then outwards, crossing 9th rib in mid-axillary line; then downwards and backwards along 11th rib to reach spine at neck of

12th rib. Behind, it passes upwards on right side of bodies of vertebræ to apex. At level of 4th costal cartilage the *left pleura* arches outwards, leaving uncovered part of anterior surface of pericardium, and lying about  $\frac{3}{4}$  inch from the margin of sternum, to reach 7th left costal cartilage, below which it follows same line as on right, but is placed at a slightly lower level.

## THE LUNGS.

Each lung is cone-shaped, with the base downwards.

The *apex* projects upwards into the root of the neck behind the clavicle and anterior scalene muscle. Above the first rib, the first part of the subclavian artery lies in front, being separated from it by the pleura.

The *base* is concave, resting upon the diaphragm, and following the attachment of the midriff is placed lower externally and posteriorly than anteriorly.

The *outer surface* is convex, and corresponds to the chest wall.

The *inner surface* is concave, corresponding in part to the convex outer surface of the pericardium. It presents about its middle, and towards the posterior part, a slit, the *hilum pulmonis*, where the bronchi and vessels pass in to form the root.

The *anterior margin* is thin, and overlaps the pericardium, and presents on the left side a notch for the apex of the heart.

The *posterior margin* is rounded, and occupies the groove by the side of the vertebræ.

*Fissures and Lobes.*—The left lung is smaller and narrower than the right, and is divided into an upper and lower lobe by a fissure, which passes upwards and backwards from the anterior border nearly to the root. The right lung is larger and shorter than the left, and is divided into three lobes, upper, middle, and lower, by two fissures. One fissure passes obliquely from the outer surface upwards and inwards nearly to the root, and the second passes horizontally from the middle of the first, forwards to the anterior margin, cutting off a middle triangular lobe.

Each *root* consists of the corresponding bronchus, a branch of the pulmonary artery, two pulmonary veins, nutritive bronchial vessels, anterior and posterior pulmonary plexuses, lymphatic vessels and glands, all held together by areolar tissue, and covered by the pleura.

*Relations of the right root :—*

<i>In Front.</i>	<i>Behind.</i>	<i>Above.</i>	<i>Below.</i>
Right phrenic nerve.	Right pneumogastric nerve.	Vena azygos major.	Ligamentum latum pulmonis.
Superior vena cava.	Vena azygos major.		
Part of right auricle.			


*Relations of the left root :—*

<i>In Front.</i>	<i>Behind.</i>	<i>Above.</i>	<i>Below.</i>
Left phrenic nerve.	Descending thoracic aorta.	Arch of aorta.	Ligamentum latum pulmonis.
	Œsophagus.		
	Thoracic duct.		
	Left pneumogastric nerve.		

*Position of the constituents of the root :—*

From before backwards in each lung :—

Pulmonary veins.  
Pulmonary artery.  
Bronchus.



From above downwards :—

*Right side.*  
Bronchus.  
Pulmonary artery.  
Pulmonary veins.

*Left side.*  
Pulmonary artery.  
Bronchus.  
Pulmonary veins.

## THE PULMONARY ARTERY.

The pulmonary artery conveys venous blood from the right side of the heart to the lungs. It is 2 inches long, and commencing at the infundibulum of the right ventricle, is directed upwards in front of ascending part of aorta, and in same tube of pericardium, then passes upwards and backwards on left of ascending aorta to reach the concavity of the aortic arch, where it divides into right and left branches for the lungs. Near the bifurcation a fibrous cord, the *ligamentum arteriosum*, passes from the left branch to the under surface of the aorta. It is the remains of the *ductus arteriosus* in the foetus.

*Relations* (contained in same sheath of pericardium with ascending aorta) :—

<i>In Front.</i>	<i>Behind.</i>	<i>Above.</i>	<i>Laterally.</i>
Pericardium.	Ascending aorta.	Transverse aorta.	Coronary artery.
Left pleura and lung.	Left auricle.	Ligamentum arteriosum.	Auricular appendix.
			Ascending aorta (right side).

The right pulmonary artery is longer than the left, passes to the root of the right lung, behind the ascending aorta and superior vena cava, where it divides into three primary branches, one for each lobe.

The left pulmonary artery is connected at origin with arch of aorta by ligamentum arteriosum, and passes in front of the descending aorta and left bronchus to the root of the left lung, there dividing into two primary branches for the two lobes.

## DUCTLESS GLANDS ON THE TRACHEA.

### THE THYROID GLAND.

The thyroid gland is situated on the upper part of the trachea, and consists of two lateral lobes united at lower part by neck or isthmus, which lies over 2nd, 3rd, and 4th rings of trachea and is covered by skin, superficial and deep fasciæ, and anterior jugular veins.

Each lobe is conical, with smaller end upwards.

*Dimensions.* Vertical,  $1\frac{1}{2}$  inches; transverse,  $\frac{3}{4}$  inch; thick,  $\frac{1}{2}$  inch.

*Relations* :—

*Antero-external (convex), surface.* Deep cervical fascia, sternomastoid, sterno-thyroid, sterno-hyoid, and omo-hyoid muscles.

*Postero-internal (concave), surface.* Upper six rings of trachea, cricoid and thyroïd (below oblique line), crico-thyroid and inferior constrictor muscles, inferior thyroïd artery, recurrent laryngeal and external laryngeal nerves, œsophagus (on left side).

*Postero-external (convex) surface.* Sheath of carotid vessels.

*Vessels.* Arteries, superior and inferior thyroïd; veins, superior, middle, and inferior thyroïd.

### THE THYMUS GLAND.

The thymus gland attains its full size at two years, after which it gradually shrinks away. It is situated partly in the anterior mediastinum, and partly in the neck, reaching from level of 4th costal cartilage upwards on trachea as high as

lower border of thyroid gland. It consists of two lateral lobes with occasionally a middle connecting one.

*Relations in early life :—*

*Base.* Pericardium.

*Behind.* Trachea, pericardium, and great thoracic vessels.

*In front.* Sternum as low as 4th costal cartilages, origins of sterno-hyoid and sterno-thyroid muscles.

*Externally.* Pleura, sheath of carotid.

*Internally.* Opposite lobe and side of trachea.

## THE URINARY ORGANS.

### THE KIDNEYS.

The kidneys secrete the urine, and are situated for the most part in the hypochondriac and epigastric regions of the abdomen behind the peritoneum, extending from the 11th rib to within an inch of the crista ilii, the right being placed lower than the left, and lying slightly in the right lumbar and umbilical regions. The average length of each kidney is 4 inches, breadth 2 inches, and thickness 1 inch. Weight  $4\frac{1}{2}$  ounces.

*Relations.*—The relations of the two kidneys differ somewhat; each is placed so that its anterior surface looks outwards and the posterior inwards, the upper end being nearer the mid-line than the lower. Each kidney is covered partly on its anterior surface by peritoneum.

#### *Relations of the Right Kidney.*

##### *In front.*

Right lobe of liver.  
2nd part of duodenum.  
Hepatic flexure of colon.  
(Of which the last two areas are non-peritoneal.)

##### *Behind.*

Diaphragm.  
Quadratus lumborum.  
Psoas.  
Fasciæ covering these muscles.  
Anterior lamella of lumbar aponeurosis.  
Last dorsal.  
Ilio-hypogastric, } Nerves.  
ilio-inguinal, }  
1st lumbar artery.  
Pleura.  
Last intercostal space and 12th rib.



*Relations of the Left Kidney.**In front.*

Fundus of stomach.  
 Postero-internal surface of spleen.  
 Tail of pancreas.  
 Descending colon.  
 (Of which last two are non-peritoneal.)

*Behind.*

As on right, except that left kidney, lying rather higher, lies over 11th rib.

*Above* each kidney is the supra-renal body.

*Below* each kidney is the iliac crest.

The *external border* is convex, and is directed outwards and backwards.

The *internal border* is concave, directed well forwards, and at the centre is the fissure or *hilum*, where the vessels enter and the ureter leaves, lying from before backwards as follows: renal vein, renal artery, ureter.

Each kidney is connected with the bladder by a ureter, which serves to convey urine to the latter viscus; the top of each ureter is expanded, and forms the *pelvis of the kidney*, which is divided into three parts called *infundibula*, which are subdivided into about 12 *calyces*. Into these calyces small *papillæ* project, which are the apices of the *pyramids of Malpighi*. These latter form the medullary substance of the kidney, and are imbedded in the cortical substance, which encloses them completely except at the *papillæ*.

## SUPRA-RENAL CAPSULES.

These are ductless glands, resembling in shape a cocked hat, and which embrace the upper extremity of each kidney. The right usually has no peritoneum in front, but the left is covered in front by peritoneum, except where the pancreas crosses it.

*Relations:—*

*Anteriorly*—*Right*. Liver, inferior vena cava, and duodenum.  
*Left*. Stomach and lesser sac of peritoneum, pancreas and spleen.

*Posteriorly*. Diaphragm.

*Below*. Top of kidney.

## THE URETERS.

The **ureters** connect the kidneys with the bladder, forming the excretory ducts of the former, 12 to 14 inches long.

*Relations of the Ureter in the Abdomen.**Behind.*

Psoas.  
 Genito-crural nerve.  
 Common or external iliac  
 artery.

*In front.*

Peritoneum.  
 Colic vessels.  
 Spermatic vessels.  
 Ileum (right side).  
 Pelvic colon (left side).

The *right* ureter lies close to the outer side of the inferior vena cava.

*In the pelvis.*

*In the Male.*—Each ureter enters the fold of peritoneum limiting laterally the recto-vesical pouch (posterior false ligament of bladder) and reaches the base of the bladder, below which it runs downwards and forwards under the obliterated hypogastric artery, crossing the vas deferens externally; it reaches bladder 2 inches from its fellow and the same distance from prostate; finally it enters the interior of the bladder by passing very obliquely through its coats at the posterior angle of the base.

*In the Female.*—Passes in posterior false ligament of uterus, over side of cervix below uterine artery and lateral to upper part of vagina, to posterior part of base of bladder, and ends as in the male.

## THE BLADDER.

The bladder receives the urine from the kidneys by the ureters.

*Position.*—In *infancy* it lies partly in the abdomen. In the *adult* it lies in the pelvis behind the pubes; in the *male* in front of the rectum; in the *female* it is placed in front of the uterus and vagina.

*Differences in the sexes:* the female bladder is larger transversely.

The *apex* is connected to the umbilicus by the urachus and by the obliterated hypogastric arteries, the part posterior to the urachus being covered with peritoneum.

The *body* is uncovered anteriorly by peritoneum, and in front are the triangular ligament, the symphysis and body of the pubis, and pubo-prostatic ligaments. Superiorly it is covered by peritoneum in the upper part, and is in relation with the pelvic colon in the male, and uterus in the female, and with small intestines in both. Crossing

obliquely on each side of the bladder is the obliterated hypogastric artery, which marks the lateral limit of its peritoneal covering; the vas deferens crosses obliquely the lower part of the lateral surface along the inner side of the ureter and obliterated hypogastric artery.

The *base* or *fundus* is directed backwards and downwards.

*Relations of the Base.*

*In the Male.*

*In the Female.*

Rectum, from which it is separated by	{	<i>Above.</i>	Recto-vesical pouch of peri- toneum.	Pouch of Douglas. Cervix uteri and anterior vaginal wall.
		<i>Below.</i>	Recto-vesical fascia.	
		Vas deferentia and vesiculæ semin- ales.		

The *cervix* or neck of the bladder is the part continuous with the urethra, and is embraced in the male by the prostate.

**LIGAMENTS.**—There are two sets of ligaments of the bladder—true and false.

The **true ligaments** are two anterior and two posterior. These are formed of recto-vesical fascia, and are described on p. 48. The urachus is usually described as the 5th or superior true ligament.

The **false ligaments**, five in number, are formed of peritoneum; there are two posterior, two lateral, and an anterior, the latter covering the urachus. They have been described on p. 200.

*Interior of the Bladder.*—Upon the inner surface of the base of the bladder, just behind the urethral orifice, is a triangular smooth surface or *trigone*, with the apex looking forwards. It is bounded laterally by two ridges passing to the openings of the ureters, the posterior angles being formed by those openings, placed  $1\frac{1}{2}$  inches apart; at its apex there is an elevation, formed by the prostate, called the *uvula vesicæ*, which is  $1\frac{1}{2}$  inches from the ureters. The mucous membrane over the trigone is smooth, but everywhere else elevated upon the irregular muscular wall and is rugose.

## THE MALE ORGANS OF GENERATION.

## THE PROSTATE GLAND.

The prostate gland adjoins the neck of the bladder and surrounds the beginning of the urethra, which is placed nearer the anterior than the posterior surface of the gland. It is said to resemble a horse-chestnut in shape, with the apex directed downwards. It measures about  $1\frac{1}{2}$  inches across its base and  $1\frac{1}{4}$  inches in depth, and 1 inch from before backwards, and is held in position by the anterior true ligaments of the bladder.

The prostate is perforated from base to apex by the urethra, into which, as it lies in the gland, the common ejaculatory ducts open.

*Relations :—*

<i>Anterior or Pubic Surface.</i>	<i>Posterior Surface.</i>	<i>Base.</i>	<i>Apex.</i>
Symphysis pubis.	Rectum.	Surrounds bladder-neck.	Rests on upper layer of triangular ligament.
Anterior ligaments of bladder.	<i>Laterally.</i>	Vesiculæ seminales.	
Dorsal vein of penis.	Levator ani.	Vasa deferentia.	

The prostate is surrounded by a sheath derived from the recto-vesical fascia (*vide* p. 48) and by the prostatic plexus of veins, and is supported by the levator ani.

## COWPER'S GLANDS.

Cowper's glands are two small round bodies about the size of a pea, placed behind the membranous part of the urethra, between the two layers of the triangular ligament. Their ducts are about 1 inch long, and pass forwards, piercing anterior layer of triangular ligament, to open in the bulbous part of the urethra.

## THE PENIS.

The penis is divided into a root, body, and glans.

The *root* is connected to the pubic rami by two strong processes, the crura, and to the symphysis pubis by the suspensory ligament.

The *glans* forms the extremity; at its summit is the opening

of the urethra, the *meatus urinarius*; passing from the lower margin of this is a fold of mucous membrane continuous with the prepuce and called the *frenum præputii*. At the base of the glans is a projecting edge or *corona*, and behind that a constriction, the *cervix*. Sebaceous glands (of Tyson) are found on both. The integument of the penis, attached to the neck of the glans, is doubled upon itself, forming the *prepuce* or *foreskin*.

The *body* is the part between the root and the glans, the upper surface being the *dorsum*.

The *corpora cavernosa* form the greater part of the body of the penis; they are two cylindrical columns placed side by side, connected together for the anterior  $\frac{3}{4}$ ths, the *septum pectiniforme* intervening, but separated behind to form the two *crura*, which are attached to the inner margins of the ischial and pubic rami; anteriorly the *corpora cavernosa* fit into the base of the glans. There is a groove on the upper surface for the dorsal vein of the penis and another groove on the lower surface for the corpus spongiosum; the *corpora* are attached to the pubic symphysis by the suspensory ligament.

The *corpus spongiosum* commences at the triangular ligament by an enlargement, the *bulb*, and runs forward in the groove on the under surface of the *corpora cavernosa*, expanding over their extremities to form the *glans*. The *bulb* lies below the anterior or lower layer of the triangular ligament, and is embraced by the accelerator urinæ muscle. The urethra pierces the bulb near its upper surface, and then runs forward in the middle of the corpus spongiosum.

The URETHRA in the male extends from the neck of the bladder to the end of the penis, and has a length of from 6 to 8 inches. It is divided into three parts, according to the structures through which it passes.

(1) The *prostatic* portion passes through the prostate gland from base to apex; this part is  $1\frac{1}{4}$  inches long and spindle-shaped: in cross-section it is horseshoe-shaped, with the convexity forwards. On the posterior wall is a longitudinal ridge, the *verumontanum* or *caput gallinaginis*, and on each side of this promontory is a depression, the *prostatic sinus*, into which the prostatic ducts open. Towards the anterior part of the *verumontanum* is a depression, the *sinus pocularis*, *vesicula prostatica*, or *utricle*, upon the elevated edges of which the ejaculatory ducts open.

(2) The *membranous* portion extends from the apex of the prostate to the bulb, and is  $\frac{3}{4}$  inch long anteriorly, but only

$\frac{1}{2}$  inch posteriorly from the bulb projecting backwards; it is contained between the layers of the triangular ligament, and is surrounded by the compressor urethræ.

(3) The spongy portion is contained in the corpus spongiosum and occupies the rest of the canal, being from 4 to 6 inches long; the portion contained in the bulb is somewhat dilated, and the ducts of Cowper's glands open on the floor; the canal enlarges again just behind the meatus urinarius, which enlargement is named the *fossa navicularis*. The lumen of this part of the urethra is transverse, except at the meatus (its narrowest part), where it is vertical.

The floor of the urethra is sprinkled with *lacunæ*, which are the openings of the *glands of Littré*; one large one in the *fossa navicularis* is called the *lacuna magna*.

#### THE SCROTUM.

The scrotum contains the testicles and spermatic cords. It is divided in the middle line by a *raphé*; the left half is longer than the right, as the left testicle hangs down lower, the left spermatic cord being longer than its fellow.

*Coverings of the Testis in the Scrotum* :—

1. Skin.
2. Superficial fascia and dartos muscle.
3. Inter-columnar or spermatic fascia.
4. Cremaster muscle and fascia.
5. Infundibuliform fascia, continuous with the transversalis fascia.

6. Tunica vaginalis, consisting of a parietal and visceral layer, forms a closed sac. The visceral layer invests the body and epididymis of the testicle except behind, where the duct and vessels are attached; at its lateral reflection it is continuous with the parietal layer. It passes, on the outer side, a little between epididymis and body, forming the *digital fossa*.

#### THE SPERMATIC CORD.

The spermatic cord consists of the vas deferens with artery to the vas, spermatic artery and pampiniform plexus of veins forming spermatic vein above, sympathetic nerves, the cremasteric artery, the genital branch of the genito-crural nerve, lymphatics, together with some areolar tissue; it extends from the internal abdominal ring to the testis, passing in its course along the inguinal canal, from which it emerges by the external abdominal ring, and thence in front of the

pubes to the scrotum. The *vas deferens* is placed at the back of the cord, and may be recognised by its hard and cord-like feeling.

*Boundaries of the Inguinal or Spermatic Canal :—*

*Extent*:  $1\frac{1}{2}$  inches long, from the internal to the external abdominal ring

<i>Behind.</i>	<i>In Front.</i>	<i>Floor formed by</i>	<i>Roof formed by</i>
Peritoneum and fascia transversalis for whole length.	Internal oblique (outer third).	Meeting of Poupert's ligament and	Arched fibres of internal oblique and transversalis,
Conjoined tendon (inner two-thirds).	Aponeurosis of external oblique (for whole length).	fascia transversalis.	and apposition of layers of abdominal wall.
Triangular fascia.			

THE TESTES.

The testes are two glandular organs; each is suspended in the scrotum by the spermatic cord, which is attached to the posterior border. Each testis consists of two parts: the *body*, which is anterior, and the *epididymis*, placed posteriorly; to the lower end of this latter the duct or *vas deferens* is attached.

*Coverings of the Testis :—*

1. *Serous* or *tunica vaginalis* is derived from the peritoneum, and consists of two layers, the visceral and parietal.

2. *Fibrous* or *tunica albuginea* covers the body of the testicle, sending in a vertical septum the *mediastinum* or *corpus Highmori*: this latter gives off secondary processes or *septa*, which serve to separate the lobules of the testicle.

3. *Tunica vasculosa* consists of the bloodvessels, connected together with areolar tissue.

The *epididymis* is a long narrow body, consisting of three parts, viz.: a superior portion projecting forwards on the upper end of the body, the *head* or *globus major*; a lower, the *tail* or *globus minor*, with which the *vas deferens* is continuous; and between these two, the *body* or central portion. The *epididymis* consists of a duct 20 feet long, exceedingly convoluted, and bound together by areolar tissue; it receives the *coni vasculosi* at the upper part of the testicle.

The *body* of the testicle consists of numerous lobules of pyramidal shape, which are formed by trabeculæ, *mediastinum*, and *tunica albuginea*, the base of the lobule being directed to the circumference of the testis, and the apex towards the *mediastinum*. Each lobule contains one or more *tubuli seminiferi* held together by areolar tissue. Each tubule commences

near the base, in either a blind extremity or by anastomotic loops, becoming straighter near the apex; as they enter the mediastinum, they coalesce together to form twenty or thirty *tubuli recti*.

The *tubuli recti* or *vasa recta* pierce the mediastinum, interlace, and form the *rete testis*.

Above twelve to twenty tubules pass from the upper part of the rete as the *vasa efferentia*.

The *vasa efferentia* perforate tunica albuginea, being at first straight, then convoluted, and as the *coni vasculosi* form the globus major.

The coni open into the excretory duct at intervals (when unravelled) of about 3 inches.

The *vas deferens* commences at the lower part of the globus minor, and ascends along the inner side of the posterior part of the epididymis; thence it follows the spermatic cord through the inguinal canal and internal abdominal ring. Here it lies under the peritoneum and passes inwards, crossing to the inner side of the external iliac artery, and, entering the pelvis, arches over the superior surface of the bladder, crossing the obliterated hypogastric artery and ureter. At the base of the bladder it runs along the inner side of the vesiculæ seminales and loses its peritoneal covering, being separated from the rectum by the recto-vesical fascia, here becoming sacculated; narrowing again at the base of the prostate, it unites with the duct of the vesicula seminalis of the same side, and forms the *common ejaculatory duct*, which passes forwards through the prostate and opens on the lateral margin of the sinus pocularis into the prostatic urethra.

#### THE VESICULÆ SEMINALES.

The *vesiculæ seminales* are two sacculated pouches, placed between the base of the bladder in front and the rectum behind. They are pyramidal in shape, the posterior part being the wider; anteriorly they converge to enter the prostate near the middle line. The corresponding *vas deferens* lies on the inner side.

#### THE FEMALE ORGANS OF GENERATION.

The external organs of generation in the female are: the *mons veneris*, the *labia majora*, the *labia minora*, the *clitoris*, the *meatus urinarius*, and the orifice of the *vagina*. The term *vulva* includes the whole of these.



The *mons veneris* is the eminence in front of the pubes, covered with hair.

The *labia majora* are two prominent folds extending from the mons to the perineum. Externally they are covered with hair and integument, internally with mucous membrane; the labia are joined together anteriorly and posteriorly, forming commissures. A small transverse fold of mucous membrane is found in the posterior commissure called the *fourchette*; the space between this and the posterior commissure is known as the *fossa navicularis*.

The *labia minora* or *nymphæ* are two folds of mucous membrane, extending for  $1\frac{1}{2}$  inches downwards and outwards from the clitoris, finally losing themselves below in the *labia majora*. They surround the clitoris, the upper folds forming the *preputium clitoridis*, the lower ones, attached to the glands, being the *frænum*.

The *clitoris*, corresponding somewhat in structure to the penis, is placed just below the anterior commissure. It consists of two corpora cavernosa attached to the pubic rami by two crura; the free extremity or glans is formed by the corpus spongiosum. Between the *nymphæ*, and bounded anteriorly by the clitoris, is the *vestibule*, at the back part of which the *meatus urinarius* opens, being about 1 inch below the clitoris.

*The Bulb of the Vestibule*.—A mass of erectile tissue lying internal to the *nymphæ*, and resting on the inferior surface of the triangular ligament.

Below the meatus is the orifice of the vagina, closed more or less in the virgin by the *hymen*, which is a duplicature of mucous membrane, generally semilunar in shape. After its rupture small elevations, *caruncula myrtiformes*, only remain.

The *glands of Bartholin*, analogous to Cowper's glands in the male, are situated on each side near the entrance of the vagina, and their ducts open on the *nymphæ*, external to the hymen.

The *urethra* in the female is only  $1\frac{1}{2}$  inches long, and is embedded in the anterior wall of the vagina; it perforates the triangular ligament, as in the male. The *meatus urinarius*, the external orifice of the urethra, opens between the *nymphæ*, about an inch below and behind the clitoris.

The *vagina* is a dilatable canal, the axis of which is naturally transverse, extending from the vulva to the uterus; the anterior wall is about  $3\frac{1}{2}$  inches and the posterior wall  $4\frac{1}{2}$  inches long. The upper end widens to receive the neck of the uterus, which it meets at an angle anteriorly of about 90 degrees.

The relations are :—

<i>Anteriorly.</i>	<i>Posteriorly.</i>	<i>Laterally.</i>
Base of bladder.	Perineal body.	Broad ligament and ureter.
Urethra.	Rectum and anal canal.	Levator ani,
	Pouch of Douglas (upper inch).	Sphincter vaginæ.

There is a ridge or *raphé* along the middle of the inner surface of both the anterior and posterior walls. The walls likewise present many transverse ridges or *rugæ*. The lower end of the vagina is embraced by the sphincter vaginæ.

#### THE UTERUS.

The uterus or womb is a pear-shaped body, flattened from before backwards, placed in the pelvis between the bladder and rectum; superiorly it does not reach above the brim of the pelvis. The position corresponds to the pelvic axis. The uterus is covered by peritoneum behind, above, and in front except where it is attached to the base of the bladder; the peritoneum is reflected from off the sides to the pelvis, forming the *broad ligaments*. The average length of the uterus is 3 inches, breadth 2 inches, and thickness 1 inch, and it is, for the purpose of description, divided into three parts :—

(1) The *fundus* is the broad upper end of the body, projecting into the abdomen between the attachments of the Fallopian tubes.

(2) The *body* extends from the fundus to the neck, narrowing as it approaches the latter; at the junction of the fundus and body is an angle to which the Fallopian tube is attached; a little anteriorly to this the *round ligament* is connected, below and behind this the *ovarian ligament* is attached.

(3) The *neck* or *cervix uteri* is surrounded below by the vagina, into which it projects, forming a vaginal part, which presents a transverse opening, the *os uteri externum*, bounded by two thick lips, anterior and posterior, of which the anterior is the thicker and the posterior the longer. The part projecting into the vagina is called the *portio vaginalis*. The sulci in front of the anterior and behind the posterior lips are the *anterior* and *posterior fornices*, of which the posterior is much the deeper, and behind is in direct relation with peritoneum (pouch of Douglas).

The *cavity* of the uterus, flattened from before backwards, is triangular in shape, the superior angles leading to the

Fallopian tubes. Where the body joins the neck there is a constriction, the *os uteri internum*.

The **ligaments** are two anterior or utero-vesical, two posterior or recto-vaginal, and two lateral or broad ligaments, all formed of peritoneum.

The *broad ligaments* are formed of a double layer of peritoneum passing from the lateral margins of the uterus to the sides of the pelvis. Between the two layers of this ligament on each side are the Fallopian tube, the round ligament, the parovarium, the ovary and its ligament, uterine and ovarian vessels, nerves and lymphatics.

The *round ligament* is a cord placed between the layers of the broad ligament, extending from the superior angle of the uterus to the internal abdominal ring; thence it passes into the inguinal canal to lose itself in the labium. It is enclosed for some part of the way in peritoneum, which is known as the *canal of Nuck*.

#### THE APPENDAGES OF THE UTERUS.

The **Fallopian tubes** are two in number, placed in the upper margin of the broad ligament. Each tube measures about 4 inches in length. The cavity commences by a narrow orifice called the *ostium internum*, and terminates in a *fimbriated extremity*, which passes over the superior and posterior borders of the ovary, and is attached by the *fimbria ovarica* to the superior pole of the ovary.

The **ovaries** are two in number, and correspond to the testes in the male; they are of a flattened ovoid form, vertically placed in the posterior part of the broad ligament. By its anterior border the ovary is connected to the broad ligament, and by its lower pole to the uterus by a proper ligament, extending to the superior angle of the uterus, and called the *ligament of the ovary*. The lateral surfaces and posterior border are free. The superior pole and posterior border are embraced by the Fallopian tube; on its inner surface it is in relation with small intestine in Douglas' pouch, and externally lies in a peritoneal fossa between the external and internal iliac vessels as they diverge. The vessels enter the hilum at the attached anterior border.

The **parovarium** lies between the Fallopian tube and ovary, and is the remains of the Wolffian body.

## THE NOSE.

The organ of smell consists of an *anterior prominent part*, situated on the face, and composed of bones, cartilages, muscles, and integument, and two *nasal fossæ*.

The **cartilages of the nose** are five in number:—

The *upper lateral cartilages* (2): situated just below the free margins of the nasal bones. Each cartilage is triangular in shape; *anteriorly* it joins its fellow and the cartilage of the septum; *posteriorly* it is in connection with the nasal process of the superior maxilla, and *inferiorly* it joins the lower lateral cartilage.

The *lower lateral cartilages* (2) are peculiarly curved to form the nostrils, laterally and mesially, being open behind; *laterally* each cartilage is connected to the nasal process of the superior maxilla by fibrous membrane, in which are two or three sesamoid cartilages; *above* it joins the upper cartilage and the cartilage of the septum.

The *cartilage of the septum* is thicker at the edges than at the centre; its connections are: *anteriorly*, with the nasal bones, the two upper lateral cartilages and the lower lateral cartilages; *posteriorly*, with the perpendicular plate of the ethmoid; *inferiorly*, with the vomer and the palatal processes of the superior maxillæ.

The *nasal fossæ*, separated from each other by the *septum nasi*, open in front by the anterior nares and behind by the posterior nares. Each fossa may be described as possessing a roof, a floor, an inner and an outer wall.

The *roof* is formed by the nasal bones, the nasal spine of the frontal, the cribriform plate of the ethmoid, the under surface of the body of the sphenoid, alæ of the vomer, sphenoidal processes of the palate bones.

The *floor* consists of the palatal processes of the superior maxillæ and of the palate bones.

The *inner wall* is made up of the cartilage of the septum, the crest of the nasal bones, the nasal spine of the frontal, the perpendicular plate of the ethmoid, the vomer, the rostrum of the sphenoid, and the crests of the superior maxillary and palate bones.

The *outer wall* is formed by the nasal process of the superior maxilla, the lachrymal bone, the ethmoid, inner surface of the superior maxilla, the inferior turbinate bone, the vertical plate of the palate bone, and the internal pterygoid plate of the sphenoid.

**Meatuses** —The superior and middle turbinate processes of

the ethmoid and the inferior turbinate bone project inwards from the outer wall, dividing each fossa into a *superior*, a *middle*, and an *inferior* meatus.

*Openings* :—

*Superior meatus* : sphenoidal and posterior ethmoidal cells.

*Middle meatus* : anterior ethmoidal cells and frontal sinus, by a common orifice the infundibulum, and antrum of Highmore.

*Inferior meatus* : nasal duct.

The **septum** is the partition separating the two fossæ. It is formed by the perpendicular plate of the ethmoid, the vomer, crest of nasal bones, the nasal spine of the frontal, the rostrum of the sphenoid, the crests of the superior maxillary and palate bones, and the cartilage of the septum. The space between the anterior nares and the anterior edge of the cartilage of the septum is filled by membrane, the *columna nasi*.

The **anterior nares** are the anterior openings of the nasal fossæ. They are separated from each other by the *columna nasi*, and within the margin are arranged short stiff hairs, *vibrissæ*.

The **posterior nares** open backwards into the pharynx. They are oval in shape, being about 1 inch vertically and  $\frac{1}{2}$  inch transversely.

**Sinuses**.—The nasal fossæ communicate with the following sinuses in the neighbouring bones, the mucous membrane of the nose being continued into them :—

1. Sphenoidal sinus.
2. Posterior ethmoidal cells.
3. Anterior ethmoidal cells.
4. Frontal sinus.
5. Maxillary antrum.

The **mucous membrane** lining the cavity of the nose is called the Schneiderian membrane. It is continuous with that of the various sinuses communicating with the nasal fossæ, with the conjunctiva through the nasal duct and lachrymal canals, with the mucous membrane of the pharynx through the posterior nares, and with the skin of the face through the anterior nares. On the outer wall, as on the septum, the mucous membrane is inappreciably divided into an upper, olfactory, and a lower, respiratory, part; the *olfactory part* consists of the mucosa over the superior and upper part of the middle turbinated, the corresponding part of the septum and the roof of the nose; the remainder being *respiratory*.

The epithelium covering the surface consists of three varieties :—

1. *Stratified squamous*, in the region of the nostrils.
2. *Columnar*, in the olfactory region.
3. *Ciliated columnar*, in the respiratory region and the sinuses.

The vessels to the nose are the following arteries and veins: spheno-palatine, branches of descending palatine, and *arteria septi nasi* from facial. The nerves are: olfactory, nasal (first division 5th), naso-palatine, nasal branch of Vidian, nasal branch from anterior palatine and from Meckel's ganglion.

**The Olfactory Nerve.**—From the olfactory lobe there proceed about twenty branches through the cribriform plate of the ethmoid, which may be divided into three sets:—

1. *Inner*: pass along the grooves on the septum.
2. *Middle*: distributed to the roof.
3. *Outer*: passing to the upper turbinate bone, the anterior part of plain surface of the ethmoid and the middle turbinate bones.

## THE EAR.

The ear is divided, for the purpose of description, into three parts, external, middle, and internal.

### THE EXTERNAL EAR.

The **external ear** consists of the auricle or *pinna*, and the *external auditory meatus*.

The *pinna* is a plate of cartilage covered with integument, and attached to the commencement of the meatus; it has numerous ridges and depressions, as follows: the external rim is the *helix*, and anterior and parallel to it is another ridge, the *anti-helix*, which bifurcates above to enclose the *fossa of the anti-helix*; between the helix and anti-helix is the *fossa of the helix*. Anterior to the anti-helix is a depression, the *concha*; projecting backwards over the meatus is the *tragus*, and opposite to the latter is the *anti-tragus*. The lowest part of the pinna, which contains no cartilage, is called the *lobule*. It is controlled by three muscles (p. 22).

The **external auditory meatus** reaches from the bottom of the concha to the *membrana tympani*; it is  $1\frac{1}{2}$  inches long. It is arched slightly upwards, and is directed forwards and inwards; it is formed partly by cartilage and partly by bone. The outer or cartilaginous part is continuous with the pinna, and is about  $\frac{1}{2}$  inch long. The cartilage does not form a

complete tube, being deficient at the upper and back part, the interval being filled by fibrous tissue. One or two fissures (*fissures of Santorini*) partially traverse the tube. The inner or osseous part is longer than the preceding, and at its inner end there is a groove round the sides and floor for the insertion of the membrana tympani. In the cartilaginous part of the meatus are hairs and ceruminous glands, which latter secrete the ear-wax.

#### THE MIDDLE EAR OR TYMPANUM.

The tympanum is contained in the temporal bone. It communicates with the pharynx by the Eustachian tube, and is traversed by a chain of bones, which connect the membrana tympani with the internal ear.

The cavity of the tympanum is bounded *externally* by the meatus and membrana tympani, *internally* by the external surface of the internal ear, and it communicates posteriorly with the mastoid antrum.

The roof (*tęgmen tympani*) is formed by a thin plate of bone separating the tympanum from the middle fossa of the skull.

The floor is formed by the roof of the jugular fossa.

The outer wall is formed by the membrana tympani and the bone around it; the following fissures are seen:—

The *Glaserian fissure*: through which the processus gracilis of the malleus and tympanic branch of internal maxillary artery pass.

*Aperture of the iter chordę posterioris*: leading to a canal which opens into the aquęductus Fallopii.

*Aperture of the iter chordę anterioris*: leading to the canal of Huguier, and transmitting the chorda tympani.

The inner wall presents the following:—

The *fenestra ovalis*: leading into the vestibule, closed by a membrane and the base of the stapes.

The *ridge of the aquęductus Fallopii*: for the facial nerve placed just above the preceding; posteriorly it passes downwards and backwards on the mesial aspect of the large opening of the *aditus ad antrum*.

The *promontory*: placed below the fenestra ovalis, formed by the projection of the first turn of the cochlea.

The *fenestra rotunda* lies at the bottom of a funnel-shaped depression behind the promontory. It is closed by a membrane, the *secondary membrane of the tympanum of Scarpa*, which closes an aperture in the bone leading to the scala tympani of the cochlea.

The **posterior wall** presents above the large aperture of the *mastoid antrum* (*aditus ad antrum*) and below :

The *pyramid* which is placed just behind the fenestra ovalis ; it contains the stapedius, the tendon of which projects through the apex.

The **anterior wall** shows the following :—

The *canal for the tensor tympani*, opening just anteriorly to the fenestra ovalis.

The *processus cochleariformis* : a process of bone lying between and separating the canal for the tensor tympani and the Eustachian tube.

The *Eustachian tube* leads into the pharynx, is partly cartilaginous and partly osseous ; the internal or cartilaginous part is trumpet-shaped, and terminates in an oval opening at the side and upper part of the naso-pharynx. The osseous portion is placed along the angle of union of the squamous and petrous portions of the temporal bone, and is about  $\frac{1}{2}$  inch long. Below this a thin plate of bone separates the tympanum from the carotid canal.

The **membrana tympani** is the membrane which separates the external and middle ears. It is inserted into the groove in the osseous portion of the external meatus, and is placed obliquely across the opening, forming with the floor of the meatus an angle of  $45^\circ$ . It contains the handle of the malleus between its layers, which makes the membrane concave externally. There is a small notch in the upper and anterior part of the groove of insertion known as the *notch of Rivini*, which is closed by a loose portion of the membrane, the *membrana flaccida* of Shrapnell.

*Structure of the membrane, from without inwards* :—

1. Prolongation of skin of meatus.
2. Fibrous tissue or *membrana propria*.
3. Mucous membrane of the tympanum.

The **ossicles of the tympanum** are :—

1. The Malleus.
2. The Incus.
3. The Stapes.

The **malleus**, or hammer, consists of :—

The *head* : the thickened upper part, presenting on the posterior surface a facet for articulation with the body of the incus.

The *neck* : a constriction below the head.



The *handle*: a long tapering process passing downward, and attached by its outer side to the membrana tympani.

The *processus gracilis*: a slender spicule passing from the neck downwards and forwards into the Glaserian fissure.

The *processus brevis*: arises from the root of the handle and projects outwards to be attached to the membrana tympani by the anterior and posterior malleal folds which bound the notch of Rivini.

The *incus*, or anvil, consists of:—

The *body*: articulating in front by a saddle-shaped facet with the head of the malleus.

The *processus brevis*: attached to the margin of the mastoid aditus.

The *processus longus*: passes downwards, behind and parallel to the handle of the malleus. The tip projects inwards, and ends in the orbicular process, which articulates with the head of the stapes.

The *stapes* closely resembles a stirrup. It consists of:—

The *head*: looking outwards, and articulating with the orbicular process of the incus.

The *base*: fixed to the margins of the fenestra ovalis.

The *crura*: arising from a constricted part, the neck, pass inwards to the extremities of the base. The anterior crus is shorter and straighter than the posterior, and between the two a thin membrane is stretched.

The *ligaments* unite the chain of bones to the adjacent walls of the tympanum. They are:—

The *anterior ligament of the malleus*: passing between the root of the processus gracilis and the edge of the Glaserian fissure. This ligament was formerly described as a muscle passing from the malleus out of the Glaserian fissure, and termed the laxator tympani.

The *external ligament of the malleus*: passing between the processus brevis and notch of Rivini.

The *superior ligament of the malleus*: passing between the head of the malleus and the roof of the tympanum.

The *ligament of the incus*: passing between the processus brevis and the posterior wall of the tympanum.

The *annular ligament of the stapes* connects the base of the stapes with the edge of the fenestra ovalis.

The *muscles*:—

The *tensor tympani* arises from cartilage of the Eustachian tube, and from the bony canal in which it lies. The tendon turns round the end of the processus cochleariformis, and is inserted into the inner border of the handle of the malleus, near its root.

The *stapedius* is lodged in the aquæductus Fallopii and pyramid. The tendon issues from the apex of the pyramid, and is inserted in the posterior part of the neck of the stapes.

The *mastoid antrum* is a large recess placed behind and rather above the tympanum, with which it is connected by the large opening (*aditus*) before mentioned on the upper part of the posterior tympanic wall; it is developed with the tympanum and lined by a continuation of its mucous membrane. Into it open the mastoid pneumatic cells.

#### THE INTERNAL EAR OR LABYRINTH.

Within the internal ear are the terminal ramifications of the auditory nerve. The internal ear or labyrinth is divided into *osseous* and *membranous* parts, the former enclosing the latter. Within the membranous labyrinth is a fluid, the *endolymph*; and outside, between the membranous and osseous labyrinths, is a fluid, the *perilymph* or *liquor Cotunnii*.

The OSSEOUS LABYRINTH consists of the vestibule, the cochlea, and the semicircular canals.

The vestibule is the central part of the labyrinth. Its outer wall corresponds to the inner wall of the tympanum, and in it is the *fenestra ovalis*, closed by the base of the stapes; on its inner wall is a depression, the *fovea hemispherica*, perforated by several holes for the branches of the auditory nerve; behind this is a ridge, the *crista vestibuli*; and still further back is the internal opening of the *aqueduct of the vestibule*. On the roof is a depression, the *fovea hemi-elliptica*. At the posterior part are the five openings of the *semicircular canals*, and at the anterior part is the *apertura scalæ vestibuli*.

The *semicircular canals* are three arched osseous canals placed above and behind the vestibule, opening into that chamber by five rounded apertures, two adjacent canals having a common opening. Each canal forms about two-thirds of a circle, and presents at one end a dilated part, the *ampulla*. Two of the canals are vertical, and the third is horizontal.

The *superior canal* is vertical, and forms a projection on the upper surface of the petrous part of the temporal bone. The inner extremity joins the opening of the posterior canal.

The *posterior canal* is vertical, its upper end being joined to the lower opening of the superior canal.

The *horizontal* or *external canal* is the smallest of the three, and lies horizontally just above the level of the *fenestra ovalis*.

The *cochlea* is cone-shaped, with the base turned to the

internal meatus, and the apex opposite the canal for the tensor tympani, and consists of a tapering spiral canal of  $2\frac{1}{2}$  turns, with the inner wall formed by its axis or *modiolus* : the canal is divided into two scalæ by a partition of bone and membrane, the *lamina spiralis*. The enclosed arched extremity of the cochlea is called the *cupola*, and the first turn of the canal bulging into the tympanum forms the promontory. The *lamina spiralis ossea* ends at the apex of the cochlea in a small point, the *hamulus*, between which and the modiolus is a small opening, the *helicotrema*, by which the two scalæ communicate.

The *modiolus* is pierced by small canals for the passage of nerves, and one larger one, the *central canal of the modiolus*, passes from the base to the last half-turn of the cochlea. At the base of the lamina spiralis is a small canal, the *spiral canal of the modiolus*, which winds round the axis, and contains a spiral ganglionated cord, the *ganglion spirale*.

The scalæ are known respectively as the scala tympani and the scala vestibuli.

The *scala tympani* is the lower one ; it commences at the fenestra rotunda.

The *scala vestibuli* commences at the cavity of the vestibule, and communicates at the apex of the modiolus with the scala tympani, by the helicotrema.

The MEMBRANOUS LABYRINTH consists of sacs containing fluid (endolymph). The ramifications of the auditory nerve are distributed on the wall. These membranous sacs complete the septum between the scala tympani and the scala vestibuli, besides enclosing a third space, the *scala media* or membranous canal of the cochlea.

The membranous vestibule consists of two sacs, the *utricle* and the *sacculæ*.

The *utricle* or common sinus is larger than the sacculæ, and is situated in the posterior and upper part of the vestibule, being contained in the fovea hemi-elliptica. The apertures of the membranous semicircular canals open in the posterior part. At the anterior part is a thickened spot, the *macula acustica*, where the nerves enter. The interior contains, opposite the macula, attached to the wall, a small mass of calcareous grains, known as otoliths, otoconia, or ear sand. Below there is a canal, which, joined to a similar tube from the sacculæ, extends along the aqueduct of the vestibule, and ends in a dilated pouch, the *saccus endo-lymphaticus*.

The *sacculæ* is smaller and rounder than the utricle, and lies in the fovea hemispherica. Like the utricle, it contains

a macula and a collection of otoliths. Below there is a small canal, *canalis reuniens*, which connects it with the membranous canal of the cochlea.

The **membranous semicircular canals** are about one-third the size of the osseous ones, except at the ampullæ, where they dilate to nearly fill the bony canal. Each membranous canal is free on the convex surface, the concavity being fixed to the osseous canal. On the part of the internal surface of the ampulla, corresponding to the attachment to the bony canal, is a transverse projection, the *crista acustica*, in which some filaments of the auditory nerve end.

The **membranous cochlea** consists of a membranous tube divided into three parts—the *scala tympani*, *scala vestibuli*, and canal of the cochlea (*ductus cochlearis*), which latter contains the *organ of Corti*, to which the auditory nerve is chiefly distributed.

The *lamina spiralis ossea* partly divides the spiral canal into the *scala tympani* and *scala vestibuli*, the latter being superior. The septum is completed by the *membrana basilaris*, which is attached to the outer free edge of the *lamina spiralis ossea*, and passed outwards to the wall of the cochlea, where it is fixed to a thickening of the periosteum called the *spiral ligament*.

The canal of the cochlea contains the organ of Corti. It lies on the outer part of the *scala vestibuli*, and is separated from it by the *membrane of Reissner*, which passes from the *lamina spiralis* upwards and outwards to the roof of the *scala*. Thus a triangular piece is cut off, bounded internally by the membrane of Reissner, externally and above by the outer wall of the cochlea, and below by the basilar membrane. The canal of the cochlea is connected below with the saccule by the *canalis reuniens*, and above it terminates in a blind cone-shaped extremity, partly bounding the *helicotrema* and fixed to the cupola. The part of the *lamina spiralis* within the canal of the cochlea becomes thickened, and is called the *limbus*, and terminates in a concave border, the *sulcus spiralis*. The basilar membrane is attached to the lower margin of the *sulcus spiralis*.

**The Auditory Nerve.**—The auditory nerve divides in the internal auditory meatus into two branches, which perforate the cribriform plate, and are distributed to the cochlea and the vestibule.

The *superior* or vestibular branch supplies:—

1. The utricle.
2. The ampulla of the superior semicircular canal.
3. The ampulla of the horizontal semicircular canal.

The *inferior* or cochlear branch is distributed to :—

1. The cochlea.
2. The sacculæ.
3. The ampulla of the posterior semicircular canal.

**Nerves of the Cochlea.**—The branches of the auditory nerve destined for the cochlea perforate a number of foramina at the bottom of a spiral groove, the *tractus spiralis foraminulentus*, placed in the centre of the base of the cochlea. These foramina lead to small canals, which at first pass through the modiolus, and then radiate outwards between the bony layers of the lamina spiralis, so passing to the organ of Corti. In the centre of the tractus spiralis foraminulentus is a larger foramen leading to the central canal of the modiolus, and transmitting nerve filaments for the last half-turn of the cochlea.

## THE EYE AND ITS APPENDAGES.

### THE APPENDAGES OF THE EYE.

The **eye-brows** are two arched eminences over each orbit consisting of thickened integuments and muscles, surmounted by hairs.

The **eye-lids** are two movable folds, an upper and a lower, the upper one being more movable, which by their closure protect the eye from injury. When the eye-lids are open the angles of junction of the upper and lower lids are called respectively the *external* and the *internal canthus*. In the inner canthus the lids are separated by a small triangular area, the *lacus lachrymalis*, in which is seen a pink mass of fat and connective-tissue, the *caruncula lachrymalis*, and which is separated from the eye-ball by a vertical fold of conjunctiva, the *plica semilunaris*, a rudimentary third eye-lid; opposite the outer edge of the caruncle, on each lid, is the *lachrymal papilla*, which is pierced by the *punctum lachrymale*, the external opening of the lachrymal canal.

**Structure** from without inwards: skin, areolar tissue, orbicularis muscle (p. 22), tarsal plate, and palpebral ligament, Meibomian glands, and conjunctiva; the upper lid also contains the aponeurosis of the levator palpebræ, which is attached along the upper margin of the tarsal plate.

The **tarsal plates** are laminae of condensed connective-tissue found in each lid; the superior, the larger, is half oval

in shape, the lower a narrow oblong strip. In their substance are lodged the Meibomian follicles. Each tarsal plate is at its edge (except towards the ocular fissure, where it is free) continuous with the membranous sheet known as the palpebral ligament, while internally and externally it receives the tarsal ligaments (p. 22). The superior tarsal plate receives above the main insertion of the levator palpebræ superioris.

The palpebral ligaments form an incomplete diaphragm for the anterior orifice of the orbit; peripherally they are attached to orbital margin and centrally to edge of tarsal plates.

The conjunctiva is the membrane which forms the most posterior layer of both eye-lids, at the free edges of which it joins the skin. At the base of each eye-lid, where the structures enter its layers, the conjunctiva is reflected on to the eye-ball, the lines of reflection being known as the *fornices*, of which the superior is the deeper; into it some fibres of the levator palpebræ superioris are inserted. Over the eye-ball, where it covers the sclerotic, the conjunctiva is loosely connected, some connective-tissue and Tenon's capsule intervening; but at the corneo-sclerotic margin the conjunctiva is firmly adherent, covering the cornea as its anterior epithelial layer. The conjunctival sac has opening into it above the ducts of the lachrymal gland, and below the openings of the lachrymal canaliculi at the *puncta lachrymalia*.

The lachrymal gland occupies a depression in the supero-external angle of the orbit; the anterior margin is connected to the back part of the upper eye-lid. The ducts (12 or 14) open by apertures, placed in a row, on the inner surface of the upper lid.

The lachrymal canals commence at the *puncta lachrymalia*, which are the openings of the canaliculi, and, arching in the free edge of the lid, pass inwards to open into the *lachrymal sac*.

The lachrymal sac is placed in a groove formed by the lachrymal bone and the nasal process of the superior maxilla, being behind the tendo oculi, and in front of the tensor tarsi; it is the dilated upper end of the nasal duct.

The nasal duct, formed by the lachrymal, superior maxilla and inferior turbinal bones, leads from the lachrymal sac to the inferior meatus of the nose, where it opens, the aperture being partly guarded by a valve formed of the mucous membrane. It is about  $\frac{1}{2}$  inch long, and is directed downwards, and slightly outwards and backwards.

## THE EYE.

The eye-ball is contained within the orbit; its shape is spherical, with the segment of a smaller sphere, corresponding to the cornea, superimposed anteriorly.

The eye-ball consists of three coats enclosing three refractive media:

1st coat	..	...	...	} Sclerotic. Cornea. Choroid. Ciliary body. Iris. Retina.
2nd coat	...	---	...	
3rd coat	...	...	...	

The refractive media are:—

1. Aqueous humour.
2. Vitreous body.
3. The lens.

Covering the posterior  $\frac{5}{8}$  of the eye-ball is a layer of fascia, the *capsule of Tenon*, continuous posteriorly with the sclerotic at the entrance of the optic nerve, whilst anteriorly at the corneo-sclerotic junction it is connected with it by loose tissue only, and is pierced by the tendons of the muscles of the eye-ball. It is connected with the eye-ball only by delicate connective-tissue, the interval constituting an extensive lymph-space and forming a free socket in which the eye-ball glides.

The *sclerotic coat* is opaque and fibrous, and occupies the posterior  $\frac{5}{8}$  of the eye-ball, being continuous in front with the cornea, at the corneo-sclerotic junction.

The *outer surface* is white and smooth, receiving the insertions of the recti and obliqui muscles.

The *inner surface* is of a light-brown colour, due to a lining of pigmented connective-tissue, the *membrana fusca*, which is connected by fine filaments to the choroid coat. Between the sclerotic and choroid coats is a lymph-space transmitting branches of the ciliary vessels and nerves.

The optic nerve passes through the posterior part of the sclerotic, about  $\frac{1}{8}$  inch internal to the axis of the eye-ball, the point of perforation being called the *lamina cribrosa*. At its entrance, the outer sheath of the nerve blends with the sclerotic coat.

The sclerotic is thickest at its posterior part, gradually thinning until about  $\frac{1}{4}$  inch from the cornea, where it thickens again.

Close to the junction of the cornea with the sclerotic is a small circumferential lymph-space, called the *canal of Schlemm*.

The *bloodvessels* of the sclerotic are few in number, but near its junction with the cornea there is a vascular zone derived from the anterior ciliary branches of the ophthalmic artery.

The *cornea* is the anterior transparent part of the outer coat of the eye-ball, occupying about  $\frac{1}{8}$  of the circumference of the globe. It projects forward beyond the curvature of the sclerotic, being the segment of a smaller sphere. The posterior surface is concave, and projects further backwards than the anterior convex surface, being overlapped by the edge of the sclerotic; this surface forms the anterior boundary of the anterior chamber of the eye, containing the aqueous humour.

The cornea is clothed on its anterior convex surface by the conjunctiva, which here consists only of an epithelial layer.

At the circumference of the cornea some of the fibres which form its stroma are continued backwards and outwards into the choroid, sclerotic, and iris; those going to the iris are called the *ligamentum pectinatum iridis* or the *pillars of the iris*; they form an annular meshwork enclosing a series of lymph-spaces (spaces of Fontana) which communicate with the anterior chamber.

The *choroid coat* is situated between the sclerotic and the retina, and is the vascular tunic of the eye-ball. It is continued anteriorly into the iris, but before its junction it forms a number of projections, folding inwards, and arranged in a circle, known as the *ciliary processes*.

The choroid coat is thickest behind, where it is pierced by the optic nerve.

Externally it is connected to the sclerotic by loose connective-tissue traversed by vessels and nerves as before described. Internally it is covered by the pigmented cells of the retina.

The choroid consists of bloodvessels connected together by loose connective-tissue, and containing large branched and pigmented cells.

It is made up of two layers, an outer and an inner. The outer part contains the larger branches of the vessels. The arteries, the short posterior ciliary, pierce the sclerotic coat close to the optic nerve, pass forwards, and bend inwards to end in the inner layer.

The veins, *vasa vorticosa*, are external to the arteries and join together into four or five principal trunks, which pierce the sclerotic midway between the cornea and the optic nerve.

The inner coat, or *tunica Ruyschiana*, is formed by the



capillary endings of the vessels of the outer coat; they pass forwards to  $\frac{1}{4}$  inch from the cornea, joining those of the ciliary processes.

The **Ciliary Body** consists of the ciliary processes and the ciliary muscle.

The **ciliary processes** are of the same structure as the rest of the choroid. They are about seventy in number, and are placed in corresponding depressions upon the surface of the vitreous humour, and upon the suspensory ligament of the lens. The bloodvessels are derived from the anterior ciliary branches.

The **ciliary muscle** consists of two sets of involuntary muscular fibres, radiating and circular. (Nerve supply from 3rd cranial.)

The *radiating* arise by tendon from the sclerotic close to the junction with the cornea, between the spaces of Fontana and the canal of Schlemm, and are inserted into the choroid opposite the ciliary processes.

The *circular*: a zone of circular fibres internal to the radiating, at the base of the ciliary processes.

The **iris** is the coloured membrane suspended in the aqueous humour behind the cornea and in front of the lens. In the centre is an aperture, the *pupil*.

It is connected at its circumference to the choroid, being continuous with it; and anterior to this it is attached to the cornea by the pillars of the iris, or *ligamentum pectinatum*.

The anterior surface is coloured and marked by wavy lines converging towards the free edge of the pupil.

The posterior surface is darkly pigmented (*uvea*) and marked with folds prolonged from the ciliary processes.

The framework of the iris is a delicate stroma of connective-tissue, containing bloodvessels, nerves, pigment cells, and two groups of involuntary muscular fibres:—

The *sphincter*, a narrow band of fibres placed posteriorly close to the pupil (3rd nerve).

The *dilator*, commencing at the outer margin of the iris, with the fibres converging towards the pupil (sympathetic nerve).

The *bloodvessels* of the iris consist of the two long ciliary and the anterior ciliary arteries; the former pierce the sclerotic close to the optic nerve, and pass forwards in the lymph-space between the lamina fusca of the sclerotic and the lamina supra-choroidea of the choroid to enter the outer surface of the iris, having previously divided into two branches. They anastomose with the corresponding vessels of the opposite

side, and with those from the vascular zone of the sclerotic, formed by the anterior ciliary arteries. These form the *circulus iridis major*. Small branches from this circle converge towards the pupil, and freely anastomose with one another, forming the *circulus iridis minor*.

The veins follow the same arrangement as the arteries, and communicate with the canal of Schlemm.

The nerves of the choroid and iris are about fifteen in number, and are the *ciliary nerves*, from the lenticular ganglion and the nasal branch of the 5th; they follow very closely the course of the bloodvessels, and, reaching the ciliary body, form a plexus, sending twigs to the ciliary muscle, iris, and cornea.

The **retina** is the expanded termination of the optic nerve, and forms the innermost tunic of the eye. It reaches forwards nearly as far as the ciliary processes, where it ends in a saw-edged border, the *ora serrata*, and from this border there is prolonged a thin layer as far as the ciliary processes, which blends with the uvea of the iris. This prolongation contains no nerve-fibres, and is called the *pars ciliaris retinae*.

The *outer* surface is covered with uveal pigment-cells (formerly described as part of the choroid).

The *inner* surface contains:—

The *macula lutea*, or yellow spot, situated in the axis of the globe.

The *fovea centralis*, a depression in the preceding.

The *porus opticus*, or disc, about  $\frac{1}{10}$  inch to the inner side of the yellow spot, where the optic nerve enters, and from which its fibres radiate; coursing over the optic disc may be seen the central vessels of the retina.

*Bloodvessels of the retina*:—

The central artery of the retina passes through the optic nerve, and reaches the inner surface of the retina through the disc. It here divides into two branches, an ascending and descending, and each of these, again, into an outer or temporal division, and an inner or nasal.

The outer branches give small offsets to end in capillaries round the fovea. The rest of the branches are distributed, as capillaries, to the retina, as far as the ora serrata, but the smaller branches do not anastomose with one another or with any other vessels. The veins follow the same distribution as the arteries.

The **vitreous body** is a soft gelatinous substance occupying about  $\frac{2}{3}$  of the eye-ball. It supports the retina behind, and is hollowed out in front for the lens.

Between the retina and the vitreous, and enclosing the latter except in front, is a thin capsule, the *hyaloid membrane*.

This membrane passes forwards in front to the anterior part of the margin of the lens. It becomes stronger in this part, and is called the *zonule of Zinn*, the *zonula ciliaris*, or the *suspensory ligament of the lens*.

The zonule commences near the ciliary processes, and passes forwards to the front of the lens, and is attached in front to the lens capsule. In addition some fibres are attached to the extreme edge of the lens, and others become continuous with the posterior part of the capsule.

The interstices between these fibres are occupied by fluid, but after death they may be distended with air, and an appearance of a canal (*canal of Petit*) encircling the lens is produced.

Extending forwards from the optic disc through the vitreous, as far as the capsule of the lens, is the *canal of Stilling*, or *hyaloid canal*, which is the remains of a passage for a branch from the central artery of the retina in the fœtus.

The lens is a transparent bi-convex body enclosed in a transparent membrane, the lens capsule. It is in contact anteriorly with the iris; posteriorly it rests in a depression in the vitreous body, and it is surrounded by the suspensory ligament or zonule of Zinn. It is about  $\frac{1}{4}$  inch in diameter, and about  $\frac{1}{8}$  inch thick.

The lens capsule is the structureless membrane enclosing the lens, thick in front near its circumference, where it is strengthened by the fibres of the zonule, but very thin posteriorly.

The aqueous humour and the aqueous chambers.—The aqueous humour occupies the space between the anterior surface of the lens capsule and the posterior surface of the cornea.

The iris divides the chamber into two parts, known as the anterior and posterior chambers.

The anterior chamber is bounded in front by the cornea, behind by the iris, and opposite the pupil by the anterior part of the lens.

The posterior chamber is the triangular interval at the circumference of the lens between the ciliary processes, the iris, and the zonule of Zinn,

# INDEX

---

- ABDOMINAL** aorta, 82  
     ring, external, 44  
     internal, 223
- Abducens nerve, 151
- Abductor indicis muscle, 40  
     hallucis muscle, 58  
     minimi digiti muscle 39  
         pedis muscle,  
         58  
     pollicis muscle, 39
- Accessorius muscle, 58  
     ad sacro-lumbalem, 42
- Accessory obturator nerve, 169
- Acromio-clavicular articulation, 9
- Acromio-thoracic artery, 74
- Aditus ad antrum, 232
- Adductor brevis muscle, 52  
     obliquus hallucis muscle, 58  
     longus muscle, 52  
     magnus muscle, 52  
     obliquus pollicis muscle, 39  
     transversus hallucis muscle,  
     58  
     pollicis muscle,  
     39
- Alar ligaments of the knee, 17
- Ampulla, membranous, 235  
     of the semicircular canals,  
     234
- Amygdaloid lobe of cerebellum, 124
- Anastomotic artery of brachial, 76  
     femoral, 92
- Anconeus muscle, 38
- Angular artery, 67  
     vein, 99
- Ankle-joint, 18
- Annular ligament of ankle, anterior,  
     57  
     external, 57  
     internal, 57  
     of wrist, anterior,  
     13, 35  
     posterior,  
     13, 36
- Annulus ovalis, 205
- Anterior commissure of brain, 138
- Anti-helix, 230
- Anti-tragus, 230
- Aorta, 79
- Aorta, abdominal, 82  
     thoracic, 80
- Aortic arch, 79  
     opening, 46  
     plexus, 180  
     sinus, 79
- Aperture of the aorta, 46  
     inferior vena cava,  
     46  
     coronary arteries, 206  
     Eustachian tube, 232  
     for the femoral artery, 53  
     of the larynx, 210  
     nares, 186, 229  
     oesophagus, 187  
     pulmonary artery, 205  
     veins, 206
- Aponeurosis, epicranial, 21  
     of external oblique, 44  
     over femoral artery, 53  
     of internal oblique, 44  
     lumbar, 45  
     of the pharynx, 186  
     plantar, 57  
     of the soft palate, 183  
     temporal, 25  
     of the transversalis  
     muscle, 44  
     vertebral, 41
- Appendages of the eye, 237
- Appendix auriculæ, 200, 204, 206  
     vermiformis, 190
- Aqueduct of Sylvius, 126  
     of the vestibule, 234
- Aqueous humour, 243
- Arachnoid membrane of the brain, 140  
     of cord, 116
- Arbor vitæ cerebelli, 126
- Arch, crural or femoral, 50  
     of aorta, 79  
     of diaphragm, 46  
     palmar deep, 77  
     superficial, 78  
     plantar, 97
- Arciform fibres, 119
- Arteria acromialis thoracica, 74  
     anastomotica brachialis, 76  
     magna, 90  
     angularis faciei, 67

- Arter., aorta abdominalis, 82  
     thoracica, 80  
 articulares inferiores, 93  
     superiores, 93  
 articularis azygos, 93  
 auricularis posterior, 68  
 auditoria, 73  
 axillaris, 73  
 basilaris, 73  
 brachialis, 75  
 bronchiales, 81  
 buccalis, 70  
 capsularis inferior, 84  
     media, 83  
     superior, 82  
 carotis communis dextra, 64  
     sinistra, 64  
     externa, 65  
     interna, 73  
 carpi ulnaris anterior, 78  
     posterior, 78  
     radialis anterior, 76  
     posterior, 76  
 centralis retinae, 72  
 cerebelli inferior, 62  
     anterior, 73  
     superior, 73  
 cerebri anterior, 72  
     media, 72  
     posterior, 73  
 cervicalis ascendens, 62  
     profunda, 64  
 choroidea cerebri, 72  
 ciliares anteriores, 72  
     posteriores, 72  
 circumflexa anterior, 75  
     externa, 91  
     ilii interna, 89  
     superficialis, 91  
     interna, 91  
     posterior, 75  
 coeliaca, 82  
 colica dextra, 84  
     media, 84  
     sinistra, 84  
 comes nervi ischiadici, 89  
     phrenici, 63  
 communicans cerebri anterior,  
     72  
     posterior, 72  
     palmaris, 79  
     plantaris, 96  
 coronaria dextra, 206  
     labii inferioris, 67  
     superioris, 67  
     sinistra, 207  
     ventriculi, 82  
 corporis bulbosi, 88
- Arter., corporis cavernosi, 88  
 cremasterica, 89  
 crico-thyroidea, 66  
 cystica, 83  
 deferentialis, 86  
 dentalis anterior, 70  
     inferior, 70  
     superior, 70  
 diaphragmatica, 63, 82  
 digitales manûs, 79  
     pedis, 96, 97  
 dorsales pollicis, 77  
 dorsalis carpi radialis, 77  
     ulnaris, 78  
     hallucis, 95  
     indicis, 77  
     linguae, 66  
     pedis, 94  
     penis, 88  
     scapulæ, 74  
 epigastrica, 89  
     superficialis, 90  
 ethmoidalis anterior, 72  
     posterior, 72  
 facialis, 66  
 femoralis, 90  
 frontalis, 72  
 gastricæ, 83  
 gastro-duodenalis, 83  
     epiploica dextra, 83  
     sinistra, 83  
 glutea, 90  
 hæmorrhoidalis inferior, 87  
     media, 86  
     superior, 85  
 hepatica, 82  
 hyoidea lingualis, 66  
     thyroideæ, 66  
 hypogastrica, 86  
 ileo-colica, 84  
     lumbalis, 88  
 iliaca communis, 85  
     externa, 88  
     interna, 86  
 incisoria, 70  
 infra-orbitalis, 70  
     scapularis, 63  
 innominata, 80  
 intercostales anteriores, 63, 81  
     rami anteriores, 81  
     posteriores, 81  
 intercostalis superior, 64  
 interossea, 78  
     anterior, 78  
     posterior, 73  
 interosseæ manûs, 77  
     pedis, 95

- Arter., intestinales, 84  
   ischiadica, 89  
   labialis inferior, 67  
   lachrymalis, 71  
   laryngealis inferior, 62  
     superior, 66  
   lingualis, 66  
   lumbales, 85  
     rami anteriores, 85  
     posteriores, 85  
   malleolares, 94  
   mammaria, externa, 74  
     interna, 63  
   masseterica, 70  
   maxillaris interna, 69  
   mediana, 78  
   mediastinæ, 81  
   meningea media, 69  
     parva, 69  
   meningæ anteriores, 71  
     posteriores, 61  
   mesenterica inferior, 84  
     superior, 83  
   metacarpa radialis, 77  
     ulnaris, 78  
   metatarsæ, 95  
   musculo-phrenica, 63  
   mylo-hyoidea, 70  
   nasalis, 72  
     lateralis, 67  
     septi, 70  
   nutritia femoris, 92  
     humeri, 75  
     tibiæ, 96  
   obturatoria, 86  
   occipitalis, 67  
   œsophageales, 81  
   ophthalmica, 71  
   ovariana, 84  
   palatina inferior, 67  
     superior, 70  
   palmaris profunda, 77  
   palpebralis inferior, 72  
     superior, 72  
   pancreaticæ, 83  
   pancreatico-duodenalis, 83  
   perforantes femorales, 92  
     mammaria internæ, 63  
     manûs, 77  
     pedis, 95  
   pericardiæ, 81  
   perinæi superficialis, 87  
   peronea, 96  
     anterior, 96  
   pharyngea ascendens, 68  
   phrenicæ inferiores, 82  
     superiores, 63
- Arter., plantaris externa, 97  
     interna, 96  
   poplitea, 92  
   princeps cervicalis, 68  
     pollicis, 77  
   profunda cervicis, 64  
     femoris, 91  
     inferior, 76  
     superior, 75  
   pterygoideæ, 70  
   pterygo-palatina, 70  
   pudenda externa, 91  
     interna, 87  
   pulmonalis, 214  
     dextra, 215  
     sinistra, 215  
   pylorica, 83  
   radialis, 76  
     indicis, 77  
   ranina, 66  
   recurrens interossea posterior, 78  
     radialis, 76  
     tibialis, 97  
     ulnaris anterior, 78  
     posterior, 78  
   renales, 84  
   sacra-media, 85  
     lateralis, 88  
   scapularis posterior, 63  
   sciatica, 89  
   sigmoidea, 85  
   spermatica, 84  
   spheno-palatina, 70  
   spinales posteriores, 62  
   spinalis anterior, 62  
   splenica, 83  
   sterno-mastoidea, 66  
   stylo-mastoidea, 68  
   subclavia dextra, 59  
     sinistra, 59  
   sublingualis, 66  
   submentalîs, 67  
   subscapularis, 74  
   superficialis cervicalis, 63  
     perinæi, 88  
     volæ, 76  
   supra-orbitalis, 72  
     scapularis, 62  
   tarsæ, 94  
   temporales profundæ, 69  
   temporalis, anterior, 69  
     deep, 70  
     media, 69  
     posterior, 69  
     superficialis, 68  
   thoracica acromialis, 74  
     alaris, 74

- Arter., thoracica longa, 74  
 superior, 74  
 thyroidea ima, 80  
 inferior, 62  
 superior, 66  
 tibialis antica, 93  
 postica, 94  
 tonsillaris, 67  
 transversalis colli, 63  
 faciei, 69  
 perinaei, 87  
 pontis, 73  
 tympanica, 69, 71  
 ulnaris, 77  
 uterina, 86  
 vaginalis, 86  
 vertebralis, 61  
 vesicalis inferior, 86  
 media, 86  
 superior, 86  
 vidiana, 70
- Articular poplitea arteries, 93  
 nerves, 173, 174
- Articulation, acromio-clavicular, 9  
 astragalo-scaploid, 19  
 atlo-axoid, 3  
 of bones of the tympanum, 231  
 calcaneo-astragaloid, 19  
 cuboid, 19  
 scaphoid, 19  
 of carpal bones, 12  
 carpo-metacarpal, 13  
 of cervical vertebræ, 2  
 chondro-costal, 6  
 sternal, 5  
 of coccygeal bones, 8  
 coraco-clavicular, 9  
 of costal cartilages, 6  
 costo-clavicular, 9  
 vertebral, 5  
 crico-arytenoid, 208  
 thyroid, 209  
 of cuneiform bones, 19  
 cuneiform to cuboid, 19  
 to scaphoid, 19  
 of dorsal vertebræ, 3  
 femoro-tibial or knee, 15  
 humero - cubital or elbow, 10  
 ilio-femoral or hip, 14  
 of lower jaw, 4  
 of lumbar vertebræ, 2  
 of the metacarpal bones, 13  
 metacarpo - phalangeal, 14
- Articulation, metatarsal, 20  
 metatarso - phalangeal, 20  
 occipito-atloid, 3  
 axial, 4  
 os calcis to cuboid, 19  
 to scaphoid, 19  
 peroneo-tibial, 17  
 phalangeal of fingers, 14  
 of toes, 21  
 of pubic symphysis, 8  
 radio-carpal or wrist, 12  
 cubital inferior, 11  
 superior, 11  
 sacro-coccygeal, 8  
 iliac, 7  
 vertebral, 6  
 scaphoid to cuboid, 19  
 to cuneiform, 19  
 scapulo-humeral, 10  
 sterno-clavicular, 8  
 tarso-metatarsal, 20  
 temporo-maxillary, 4  
 of the thumb, 13  
 tibio-tarsal or ankle, 18  
 of vertebræ, 2
- Arcus externus diaphragmatis, 46  
 internus diaphragmatis, 46
- Aryteno-epiglottidean folds, 209
- Arytenoid cartilages, 208  
 muscle, 31
- Ascending cervical artery, 62  
 vein, 101  
 colon, 190  
 pharyngeal artery, 68  
 vein, 102
- Attollens aurem muscle, 22
- Attrahens aurem muscle, 22
- Auditory artery, 73  
 nerve, 153, 236  
 nucleus, 123
- Auricle of the ear, 230
- Auricles of the heart, 204  
 left, 206  
 right, 204
- Auricular artery, posterior, 68  
 nerve of vagus, 155  
 nerves, great, 160  
 inferior, 147  
 superior, 147  
 posterior, 152  
 vein, 100
- Auriculo-temporal nerve, 147  
 ventricular aperture, left, 206  
 ventricular aperture, right, 205

- Auricularis magnus nerve, 160  
 Axillary artery, 73  
     fascia, 32  
     vein, 102  
 Axis, cœliac, of artery, 82  
     of cochlea, 235  
     thyroid, 62  
 Azygos, artery, 93  
     veins, 104  
     uvulæ muscle, 30  
  
 Base of brain, 129  
 Basilar artery, 73  
     membrane, 237  
 Basilic vein, 102  
 Biceps femoris muscle, 54  
     flexor cubiti muscle, 35  
 Bicuspid teeth, 181  
 Bile ducts, 193  
 Biventral lobe, 125  
 Bladder, 218  
     interior of, 219  
     connections of, 219  
     ligaments of, 48, 191  
 Bones of the ear, 232  
 Brachial aponeurosis, 35  
     artery, 75  
     plexus, 161  
     veins, 102  
 Brachialis anticus muscle, 35  
 Brain, base of, 129  
     membranes of, 139  
 Broad uterine ligament, 227  
 Bronchial arteries, 81  
     glands, 113  
     veins, 105  
 Bronchus, left, 212  
     right, 212  
 Brunner's glands, 190  
 Buccal artery, 70  
     nerve, 146  
 Buccinator muscle, 24  
 Bulb of the urethra, 221  
     artery of, 88  
 Bulbus olfactorius, 141  
  
 Cæcum coli, 190  
     connections of, 190  
 Calamus scriptorius, 120  
 Calices of the kidney, 217  
 Calciform papillæ, 217  
 Canal, Hunter's, 53  
     of cochlea, 236  
     of Petit, 243  
     of spinal cord, 116  
     of Stilling, 243  
     of the tensor tympani, 232  
 Canine teeth, 181  
  
 Capsular arteries, inferior, 84  
     middle, 83  
     superior, 82  
     ligament of the hip, 14  
         knee, 16  
         shoulder, 10  
         thumb, 13  
 Capsule of crystalline lens, 243  
     of Glisson, 194  
     suprarenal, 217  
 Caput gallinaginis, 221  
 Cardiac nerve, inferior, 178  
     middle, 178  
     of pneumogastric, 156  
     superior, 176  
     plexus, 179  
     veins, 106  
 Carneæ columnæ, 199  
 Carotid artery, external, 65  
     internal, 73  
     left common, 64  
     right common, 64  
     plexus, 177  
 Carpal artery, radial anterior, 76  
     posterior, 76  
     ulnar anterior, 78  
     posterior, 78  
 Carpo-metacarpal articulation, 13  
 Cartilage, arytenoid, 208  
     cricoid, 208  
     cuneiform, 209  
     of the ear, 230  
     thyroid, 207  
     triangular of the nose,  
         228  
 Cartilages of the nose, 228  
     of Santorini, 208  
     of trachea, 211  
 Caruncula lachrymalis, 237  
 Carunculæ myrtiformes, 225  
 Cauda equina, 114  
 Cava inferior, 105  
     superior, 103  
 Cavernous body, 221  
     artery of, 88  
     plexus, 177  
     sinus, 98  
 Central artery of the retina, 72  
     passage of cochlea, 235  
     lobe of brain, 133  
 Centrum ovale cerebri, 134  
 Cephalic vein, 102  
 Cerebellar arteries, inferior, 62  
     superior, 73  
 Cerebellum, form of, 124  
     lobes of, 124  
     structure of, 125  
 Cerebral artery, anterior, 72



- Cerebral artery, middle, 72  
     posterior, 73  
 Cerebrum, division into lobes, 131  
     form of, 130  
     interior, 134  
     structure, 138  
 Cervical fascia, 26  
     ganglion, inferior, 178  
     middle, 177  
     superior, 176  
     glands, 111  
     nerves, anterior branches,  
         159  
         posterior branches,  
         159  
     plexus of nerves, 159  
     plexus of nerves, deep  
         branches, 161  
     plexus of nerves, superficial,  
         160  
 Cervicalis, ascendens artery, 62  
     muscle, 42  
     vein, 101  
     profunda artery, 64  
     vein, 101  
     superficialis nerve, 160  
 Cervico-facial nerve, 153  
 Cervix uteri, 226  
 Chamber of the eye, anterior, 243  
     posterior, 213  
 Check ligaments, 4  
 Chiasma of the optic nerves, 129  
 Chondro-costal articulations, 6  
     sternal articulations, 5  
 Chorda tympani nerve, 152  
 Chordæ tendineæ, 205  
 Chordæ vocales, 210  
 Chordæ Willisii, 98  
 Choroid arteries of the brain, 72  
     coat of the eye, 240  
     plexuses of the brain, 137  
     veins of the eye, 240  
         brain, 97  
 Ciliary arteries, 72  
     muscle, 241  
     processes of the choroid, 241  
     nerves of nasal, 143  
         of lenticular ganglion,  
         143  
 Circle of Willis, 73  
 Circular sinus, 98  
 Circumflex artery, anterior, 75  
     external, 91  
     internal, 91  
     posterior, 75  
     iliac artery, deep, 89  
         superficial, 91  
     nerve, 162  
 Clavicular cutaneous nerves, 160  
 Clitoris, 225  
 Coccygeal muscle, 49  
     nerve, 170  
 Cochlea, canal of, 236  
     nerves of, 237  
 Coeliac artery, 82  
     plexus, 180  
 Colic artery, left, 84  
     middle, 84  
     right, 84  
     veins, 108  
 Colon, 190, 101  
 Columnæ carneæ, 205  
 Columns of the cord, 115  
 Comes nervi ischiadici artery, 89  
     phrenici artery, 63  
 Commissure, anterior, 138  
     of the cerebellum, 125  
     of the cord, 116  
     great, 135  
     of the optic nerves, 129  
     posterior, 128  
     soft, 128  
 Commissural fibres of the medulla,  
     119  
 Communicating artery of anterior  
     cerebral, 72  
 Communicating artery of posterior  
     cerebral, 72  
 Communicating artery in the palm,  
     79  
 Communicating peroneal nerve, 175  
 Compressor muscle of the nose, 23  
     of the urethra, 49  
 Concha, 230  
 Conjoined tendon, 44  
 Conjunctiva, 238  
 Conoid ligament, 9  
 Constrictor muscle, inferior, 29  
     middle, 29  
     superior, 29  
 Conus arteriosus, 205  
     medullaris, 114  
 Convolution of the brain, 131  
     of hemisphere, 131  
     of longitudinal fissure,  
         132  
 Coraco-brachialis muscle, 34  
     clavicular articulation, 9  
     humeral ligament, 9  
 Cornea, 240  
 Cornicula laryngis, 210  
 Cornua of gray crescent, 116  
     of lateral ventricles, 135  
 Corona glandis, 221  
 Coronary vessels of the heart, 206  
     of the lips, 67

- Coronary artery of the stomach, 82  
 ligament of the liver, 192  
 plexus of the stomach, 180  
 plexus of the heart, 180  
 sinus, 106
- Corpora albicantia, 129  
 Arantii, 205  
 cavernosa, 221  
 geniculata, 128  
 olivaria, 120  
 quadrigemina, 127  
 restiformia, 119  
 striata, 137
- Corpus callosum, 134  
 dentatum cerebelli, 126  
 fimbriatum uteri, 227  
 geniculatum externum, 128  
 internum, 128  
 Highmori, 223  
 olivare, 120  
 spongiosum urethræ, 221  
 thyroideum, 215
- Corrugator supercilii muscle, 22
- Costo-clavicular ligament, 9  
 coracoid membrane, 32  
 transverse ligaments, 5
- Cotunnus, nerve of, 145
- Cotyloid ligament, 15
- Covered band of Reil, 135
- Cowper's glands, 220
- Cremaster muscle, 44
- Cremasteric artery, 89  
 fascia, 222
- Cribriform fascia, 50
- Crico-arytenoid articulation, 208  
 muscle, lateral, 31  
 posterior, 31  
 thyroid articulation, 208  
 membrane, 209  
 muscle, 30
- Cricoid cartilage, 209
- Crista vestibuli, 236
- Crucial ligaments, 16
- Crura cerebelli, 125  
 cerebri, 126  
 of the diaphragm, 46  
 of the fornix, 136, 137
- Crural arch, 50  
 deep, 51  
 canal, 50  
 nerve, 169  
 ring, 50  
 sheath, 50
- Cystic artery, 83  
 duct, 194  
 plexus of nerves, 180
- Decussation of the pyramids, 120
- Deep cervical artery, 64  
 crural arch, 51  
 transverse muscle of perinæum, 49
- Deferential artery, 86
- Deltoid ligament, 18  
 muscle, 33
- Dental artery, anterior, 70  
 inferior, 70  
 superior, 70
- Dental nerve, superior, 144, 145  
 inferior, 147  
 posterior, 144
- Dentate ligament, 117
- Depressor anguli oris muscle, 24  
 labii inferioris muscle, 24  
 alæ nasi muscle, 23
- Descendens hypoglossi nerve, 158
- Descending colon, 191
- Diaphragm, 46  
 arteries, 62, 83  
 plexus of, 180
- Digastric muscle, 28  
 nerve, 152
- Digital arteries of plantar, 97  
 of radial, 77  
 of ulnar, 79  
 nerves of median, 164  
 of plantar, 174  
 of radial, 165  
 of ulnar, 164
- Dilatator muscle of the nose, 24  
 of the pupil, 241
- Dorsal artery of the foot, 94  
 of the penis, 88  
 of the scapula, 74  
 of the tongue, 66  
 nerves, anterior branches, 159  
 posterior branches, 158  
 cutaneous of the hand, 164  
 of the penis, 172
- Dorsi-spinal veins, 105
- Douglas's fold, 45
- Ductus ad nasum, 239  
 arteriosus, 214  
 communis choledochus, 194  
 cysticus, 194  
 ejaculatorius, 224  
 hepaticus, 194  
 lymphaticus, 111  
 pancreaticus, 195  
 reuniens, 236  
 Riviniani, 185  
 Stenonis, 184  
 thoracicus, 110

- Ductus Whartonii, 185  
 Duodenum, connections, 188  
 Dura mater, 139  
     of the cord, 116
- Ear, external, 230  
     internal, 234  
 Eighth nerve, 153  
 Ejaculator urinæ muscle, 49  
 Elbow joint, 10  
 Eminentia collateralis, 136  
 Encephalon, 117  
 Endocardium, 205  
 Endolymph, 234  
 Epididymis, 223  
 Epigastric artery, 89  
     superficial, 90  
     veins, 109  
 Epiglottis, 210  
 Erector clitoridis muscle, 49  
     penis muscle, 49  
     spinæ muscle, 42  
 Ethmoidal arteries, 72  
 Eustachian tube, cartilaginous part, 232  
     osseous part, 232  
     valve, 204  
 Extensor carpi radialis brevior muscle, 37  
 Extensor carpi radialis longior muscle, 37  
     carpi ulnaris muscle, 38  
     digiti minimi muscle, 37  
 Extensor digitorum brevis muscle, 57  
     c o m m u n i s muscle, 37  
     l o n g u s pedis muscle, 55  
     indicis muscle, 38  
     ossis metacarpi muscle, 38  
     proprius hallucis muscle, 55  
     brevis pollicis muscle, 38  
     longus pollicis muscle, 38  
 External cutaneous nerves of arm, 163  
     of thigh, 168  
     saphenous nerve, 173  
     vein, 108
- Eye-ball, 239  
     brows, 237  
     lashes, 237  
     lids, 237  
     muscles of, 22  
     structure, 237
- Facial artery, 66  
     nerve, 151  
     vein, 99  
 Falciform ligament of the liver, 192  
     border of saphenous opening, 50
- Fallopian tube, 227  
 Falx cerebelli, 140  
     cerebri, 139  
 Fascia, axillary, 32  
     brachial, 35  
     cervical, deep, 26  
     costo-coracoid, 32  
     cremasteric, 222  
     cribriform, 501  
     of Colles, 47  
     of the forearm, 35  
     iliac, 50  
     intermuscular of the humerus, 34  
     of the thigh, 49  
     lata, 49  
     lumborum, 45  
     masseteric, 25  
     obturator, 47  
     of the leg, 56  
     of the pyriformis, 48  
     pelvic, 47  
     perinæal, deep, 47  
     superficial, 47  
     plantar, deep, 57  
     recto-vesical, 48  
     temporal, 25  
     transversalis, 222  
     triangularis, 44  
 Fasciculus teres, 121  
 Femoral artery, 90  
     vein, 109  
 Femoro-tibial articulation, 15  
 Fenestra ovalis, 231  
     rotunda, 232  
 Fibres of the cerebrum, 138  
     of the cerebellum, 124  
 Fifth nerve, 142  
     ventricle of brain, 136  
 Filiform papillæ, 182  
 Fillet of the olivary body, 120  
 Filum terminale, 114  
 First nerve, 141  
 Fissure, longitudinal, 130  
     parieto-occipital, 130  
     of Rolando, 130  
     of Sylvius, 130  
     transverse, 130  
 Fissures of Santorini, 231  
     of the cord, 115  
     of the cerebrum, 130  
 Flexor accessorius muscle, 58  
     brevis minimi digiti muscle, 39  
     pedis muscle, 59  
     carpi radialis muscle, 36  
     ulnaris muscle, 36  
     digitorum brevis pedis muscle, 58  
     longus pedis muscle, 56

- Flexor digitorum profundus muscle, 36  
     sublimis muscle, 36  
     hallucis longus muscle, 56  
     brevis muscle, 58  
     pollicis longus muscle, 37  
     brevis muscle, 39
- Flocculus cerebelli, 124
- Fold of Douglas, 45
- Follicles, Meibomian, 238
- Foramen of Monro, 137  
     for inferior vena cava, 45  
     of Winslow, 201  
     ovale, 206
- Foramina Thebesii, 204
- Fornix, 136
- Fossa navicular of the urethra, 221  
     of the pudendum, 225  
     ovalis, 205
- Fossæ of abdominal wall, 198
- Fourth nerve, 142  
     ventricle, 120
- Fovea centralis, 242  
     hemispherica, 234  
     hemi-elliptica, 234
- Foveæ of fourth ventricle, 121
- Frænum linguæ, 181  
     præputii, 221
- Frontal artery, 72  
     lobe, 131  
     nerve, 143  
     vein, 98
- Fungiform papillæ, 181
- Funiculus cuneatus, 119  
     gracilis, 119  
     of Rolando, 119
- Galen, veins of, 97, 137
- Gall bladder, 193
- Ganglia, cervical, inferior, 178  
     middle, 177  
     superior, 176  
     lumbar, 178  
     of spinal nerves, 158  
     sacral, 178  
     semilunar, 179  
     thoracic, 178
- Ganglion of the vagus, 155  
     Gasserian, 142  
     impar, 179  
     jugular, 154  
     lenticular, 143  
     Meckel's, 145  
     ophthalmic, 150  
     otic, 148  
     petrosal, 154  
     spheno-palatine, 145  
     submaxillary, 148
- Gastric arteries, 83
- Gastric plexus, 180  
     vein, 107
- Gastro-colic omentum, 199
- Epiploic arteries, 83  
     vein, 108  
     hepatic omentum, 199
- Gastrocnemius muscle, 55
- Gemellus inferior muscle, 54  
     superior muscle, 54
- Geniculate bodies, 128
- Genio-hyo-glossus muscle, 29  
     hyoid muscle, 29
- Genital organs, 220
- Genito-crural nerve, 168
- Gimbernat's ligament, 44
- Gland, lachrymal, 238  
     parotid, 183  
     pineal, 129  
     pituitary, 129  
     prostate, 220  
     sublingual, 185  
     submaxillary, 184
- Glands, axillary, 112  
     Bartholin's, 225  
     bronchial, 113  
     Brunner's, 190  
     cardiac, 113  
     cervical, 111  
     concatenate, 111  
     Cowper's, 220  
     inguinal, 113  
     intercostal, 113  
     intestinal, 112  
     lingual, 182  
     lumbar, 112  
     mediastinal, 113  
     Meibomian, 237  
     mesenteric, 112  
     oesophageal, 113  
     of Pacchioni, 139  
     pelvic, 112  
     Peyer's, 190  
     popliteal, 113  
     sternal, 113
- Glans of the clitoris, 225  
     of the penis, 220
- Glenoid ligament, 10
- Glisson's capsule, 194
- Globus major epididymis, 223  
     minor epididymis, 223
- Glosso-pharyngeal nerve, 153  
     nucleus, 122
- Glottis, 210
- Gluteal artery, 90  
     nerve, superior, 171  
     nerves, inferior, 171
- Gluteus maximus muscle, 53  
     medius muscle, 53

- Gluteus minimus muscle**, 53  
**Gracilis muscle**, 52  
**Grey commissure of the cord**, 116  
   *crest* of the cord, 115  
   *substance of the corpus striatum*, 137  
   *substance of the medulla oblongata*, 122  
   *substance of the third ventricle*, 128  
   *tubercle of Rolando*, 119  
**Great omentum**, 199  
**Gustatory nerve**, 147  
**Gyrus fornicatus**, 134  
  
**Hæmorrhoidal artery**, inferior, 87  
   middle, 86  
   superior, 85  
   *nerve*, inferior, 172  
   *plexus*, 180  
   *veins*, 109  
**Hamulus laminae spiralis**, 235  
**Heart**, 202  
**Helicotrema**, 235  
**Helix**, 230  
**Hepatic artery**, 82  
   *duct*, 194  
   *plexus*, 180  
   *veins*, 106  
**Hip-joint**, 14  
**Hippocampus major**, 136  
   *minor*, 136  
**Hunter's canal**, 53  
**Hyaloid membrane**, 243  
**Hymen**, 225  
**Hyo-glossus muscle**, 29  
**Hypogastric artery**, 86  
   *plexus of nerves*, 180  
**Hypoglossal nerve**, 157  
   *nucleus*, 128  
  
**Ileo-cæcal valve**, 190  
**Ileo-colic artery**, 84  
**Ileum**, 189  
**Iliac artery**, common, 85  
   *external*, 88  
   *internal*, 86  
   *colon*, 191  
   *fascia*, 50  
   *vein*, common, 110  
     *external*, 109  
     *internal*, 109  
**Iliacus muscle**, 51  
**Ilio-costalis muscle**, 42  
**Ilio-femoral articulation**, 15  
   *hypogastric nerve*, 168  
   *inguinal nerve*, 168  
   *lumbar artery*, 88  
  
**Incisor branch of nerve**, 147  
   *teeth*, 181  
**Incus**, 233  
**Inferior cornu of the lateral ventricle**, 135  
   *maxillary nerve*, 148  
**Infra-orbital artery**, 70  
   *nerves*, 144, 153  
   *vein*, 99  
   *scapular artery*, 63  
   *spinatus muscle*, 34  
   *trochlear nerve*, 143  
**Infundibulum of the brain**, 129  
**Inguinal canal**, 223  
   *glands*, 113  
**Innominate artery**, 80  
   *veins*, 103  
**Interarticular cartilage of the jaw**, 4  
   *of the hip*, 14  
   *of the knee*, 15  
   *of the ribs*, 5  
   *of the scapula*, 9  
   *sacro-iliac*, 7  
   *sterno-clavicular*, 8  
   *of the symphysis*, 8  
   *of the vertebræ*, 2  
   *of the wrist*, 12  
**Interclavicular ligament**, 8  
**Intercolumnar fascia**, 44 [81  
**Intercostal arteries**, anterior branches,  
   posterior branches,  
   *artery*, superior, 64 [81  
   *muscle*, external, 45  
     *internal*, 46  
   *nerves*, 166  
     *cutaneous anterior*, 166  
     *lateral*, 166  
   *veins*, superior, 104  
**Intercosto-humeral nerve**, 166  
**Intermuscular septa** of the arm, 34  
   *of the foot*, 57  
   *of the thigh*, 50  
**Internal cutaneous nerve of the arm**,  
   163  
   *of the thigh*,  
   169  
   *saphenous nerve*, 170  
   *vein*, 108  
**Interosseous arteries** of the foot, 95  
   *of the hand*, 77  
   *artery*, anterior, 78  
     posterior, 78  
   *ligament of the arm*, 11  
     *of the leg*, 17  
   *muscles of the foot*, 59  
     *of the hand*, 40  
   *nerve*, anterior, 164  
     posterior, 165

- Interspinal muscles, 43  
 Intertransverse muscles, 43  
 Intervertebral substances, 2  
 Intestinal arteries, 84  
 Intestine, large, 190  
     small, 188  
 Iris, 241  
     nerves of, 242  
     structure of, 241  
     vessels of, 241  
 Island of Reil, 133  
 Isthmus of the thyroid body, 215  
 Iter a tertio ad quartum ventriculum, 126  
  
 Jacobson's nerve, 154  
 Jejunum, 189  
 Joint, ankle, 18  
     elbow, 10  
     hip, 14  
     knee, 15  
     lower jaw, 4  
     shoulder, 10  
     thumb, 13  
     wrist, 12  
 Jugular ganglion, 154  
     vein, anterior, 100  
         external, 100  
         internal, 101  
  
 Kidney, 216  
     connections of, 216  
 Knee of the corpus callosum, 135  
     joint, 15  
  
 Labia pudendi externa, 225  
     interna, 225  
 Labial artery, inferior, 67  
 Labyrinth, 234  
     membranous, 235  
     osseous, 234  
 Lachrymal artery, 71  
     canals, 238  
     duct, 238  
     gland, 238  
     nerve, 143  
     sac, 238  
 Lacunæ of the urethra, 222  
 Lamina cinerea, 129  
     spiralis cochleæ, 235  
 Laminae of cerebellum, 124  
 Large intestine, connections, 190  
 Laryngeal arteries, 62, 66  
     nerve, external, 156  
         inferior, 156  
         superior, 156  
     pouch, 210  
 Larynx, 207  
     aperture of, 209  
     cartilages of, 207  
     interior of, 210  
     ligaments, 209  
     muscles, 30  
     nerves, 156  
     ventricle, 210  
     vessels, 62, 66  
 Lateral column of the medulla, 119  
     of the cord, 115  
     sinus, 98  
     ventricles, 135  
 Latissimus dorsi muscle, 40  
 Lens, 243  
 Lenticular ganglion, 143  
 Levator anguli oris muscle, 24  
     scapulæ muscle, 41  
     ani muscle, 49  
     labii superioris muscle, 24  
         alæque nasi,  
         muscle, 23  
     inferioris muscle, 24  
     palati muscle, 30  
     palpebræ superioris muscle,  
         22  
 Levatores costarum muscle, 46  
 Ligament of the lung, 212  
 Ligaments of the bladder, 48, 197  
     of the larynx, 209  
     of the ovary, 227  
     of the uterus, 227  
 Ligament, acromio-clavicular, 9  
     alar of the knee, 17  
     annular, anterior of the  
         ankle, 57  
         external of the  
         ankle, 57  
     anterior of the  
         wrist, 13  
     posterior of the  
         wrist, 13  
     anterior of ankle, 18  
         of elbow-joint, 10  
         of knee-joint, 16  
         of wrist-joint, 12  
         of carpus, 13  
     astragalo-scaploid, 19  
     atlo-axoid, anterior, 3  
         posterior, 3  
         transverse, 3  
     calcaneo-astragaloid, 19  
         cuboid, 19  
         scaploid, 19  
     capsular of the hip, 14  
         of the knee, 16  
         of the shoulder, 10  
         of the thumb, 13  
     carpal, dorsal, 12

- Ligament, carpal, palmar, 12**  
 carpo-metacarpal, 13  
 check, 4  
 common, anterior of vertebræ, 2  
 common, posterior, 2  
 conoid, 9  
 coraco-acromial, 9  
   clavicular, 9  
   humeral, 10  
**coronary, 17**  
**costo-clavicular, 9**  
 coracoid, 32  
 transverse, anterior, 5  
   middle, 5  
   posterior 5  
   vertebral, 5  
**cotyloid, 15**  
 crico-thyroid, 209  
 crucial, 16  
 deltoid, 18  
 dorsal of the carpus, 12  
 of Gimbernat, 44  
 glenoid, 10  
 ilio-femoral, 15  
   lumbar, 6  
**interarticular of the clavicle, 9**  
   of the hip, 15  
   of the jaw, 4  
   of the knee, 16  
   of the pubes, 8  
   of the ribs, 5  
**interclavicular, 8**  
**interosseous of astragalus and os calcis, 19**  
   of carpus, 13  
   of cuneiform bones, 19  
   of metacarpal bones, 13  
   of metatarsal bones, 20  
   of radius and ulna, 11  
   of the scaphoid and cuboid, 19  
   of the tibia and fibula, 17  
   inferior, of the tibia and fibula, 18  
**interspinous, 2**  
**intertransverse, 3**  
**intervertebral, 2**  
**ischio-capsular, 15**  
**lateral, external of the ankle, 18**  
   internal of the ankle, 18  
   external of the carpus, 13
- Ligament, lateral, internal of the carpus, 13**  
 external of the elbow, 11  
 internal of the elbow, 11  
 phalangeal of the foot, 20  
 phalangeal of the hand, 14  
 external of the jaw, 4  
 internal of the jaw, 4  
 external of the knee, 16  
 internal of the knee, 16  
 external of the wrist, 12  
 internal of the wrist, 12  
 long plantar, 19  
 lumbo-sacral, 6  
 metacarpal, dorsal, 13  
   palmar, 13  
 metacarpo-phalangeal, 14  
 metatarsal, dorsal, 20  
   plantar, 20  
 mucous, 17  
 obturator, 8  
 occipito-atloid, anterior, 3  
   lateral, 4  
   posterior, 4  
 occipito-axoid, 4  
 odontoid, 4  
 orbicular of the radius, 11  
 of the patella, 15  
 peroneo-tibial, 17  
 of Poupert, 44  
 posterior of carpus, 13  
   of elbow, 11  
   of knee, 15  
   of scapula, 9  
   of wrist, 12  
 proper of the scapula, 9  
 pubic, anterior, 8  
   posterior, 8  
   superior, 8  
 pubo-femoral, 15  
 radio-ulnar, 11  
 rhomboid, 9  
 round of the hip, 15  
 round of the radius and ulna, 11  
 sacro-coccygeal, anterior, 8  
   posterior,  
 sacro-iliac, anterior, 7

- Ligament, sacro-iliac, posterior, 7  
 sacro-sciatic, great, 7  
     small, 7  
 sacro-vertebral, 6  
 of the scapula, transverse, 9  
 sternal, anterior, 6  
     posterior, 6  
 sterno-clavicular, 8  
 stylo-hyoid, 5  
     maxillary, 4  
     sub-pubic, 8  
 supraspinous, 2  
 suspensory of penis, 220  
 tarso-metatarsal, dorsal, 20  
     plantar, 20  
 thyro-arytenoid, 209  
     epiglottidean, 210  
     hyoid, 209  
 tibio-fibular, 17  
 transverse of the atlas, 3  
     of the fingers, 14  
     of the hip, 15  
     of the knee, 17  
     of metacarpus, 14  
     of metatarsus, 20  
     of scapula, 9  
     trapezoid, 9  
 Ligament, triangular of the urethra, 49  
     of Winslow, posterior, 15  
 Ligamenta alaria, 17  
     subflava, 2  
 Ligamentum arcuatum, 46  
     denticulatum, 116  
     arteriosum, 215  
     latum pulmonis, 214  
     longum plantæ, 19  
     mucosum, 17  
     nuchæ, 2  
     patellæ, 15  
     posticum Winslowii, 15  
     spirale, 236  
     subflavum, 2  
     teres, 15  
 Limbus, 236  
 Linea alba, 44  
 Lineæ transversæ, 45  
 Lingual artery, 66  
     glands, 111  
     nerve, 147, 154  
     vein, 101  
 Linguales muscles, 182  
 Liquor Cotunnii, 234  
 Liver, 192  
     connections of, 192  
     ligaments, 192  
     vessels, 194  
 Lobes of the cerebellum, 124  
     of the cerebrum, 131  
     of the testis, 223  
     of the liver, 193  
 Lobus auris, 230  
     caudatus, 193  
     quadratus, 193  
     Spigelii, 193  
 Locus niger, 126  
     perforatus anticus, 129  
     posticus, 129  
 Longissimus dorsi muscle, 42  
 Longitudinal fibres of the brain, 135  
     fissure of the liver, 193  
     sinus, inferior, 98  
     superior, 97  
 Longus colli muscle, 31  
 Lumbar aponeurosis, 45  
     arteries, 85  
     anterior branches, 85  
     posterior branches, 85  
     ganglia, 178  
     glands, 112  
     nerves, anterior branches, 167  
     posterior branches, 167  
     plexus, 167  
     veins, 105  
 Lumbo-sacral nerve, 167  
 Lumbricales muscles of the foot, 58  
     of the hand, 39  
 Lungs, 212  
     connections, 213  
 Lymphatic duct, right, 111  
 Lymphatics of the arm, 112  
     of the axilla, 112  
     of the groin, 113  
     of the lungs, 113  
     of the mesentery, 112  
     of the neck, 111  
     of the pelvis, 112  
     of the popliteal space, 113  
     of the thorax, 113  
 Lyra, 137  
 Malleolar arteries, 94  
 Malleus, 232  
     muscles of, 233  
 Mammary artery, internal, 63  
 Masseter muscle, 25  
 Masseteric artery, 70  
     nerve, 146  
 Maxillary artery, internal, 69  
     nerve, inferior, 146.



- Maxillary nerve, superior, 144  
     vein, internal, 100  
 Meatus auditorius externus, 230  
     urinarius, 221, 225  
 Meatus of the nose, 228  
 Meckel's ganglion, 145  
 Median basilic vein, 102  
     cephalic vein, 102  
     nerve, 163  
     vein, 102  
 Mediastinal arteries, 81  
 Mediastinum of thorax, 201  
     of testis, 223  
 Medulla oblongata, 118  
     grey matter, 122  
     structure of, 118  
 Medullary substance of the kidney,  
     217  
 Medullary velum, inferior, 125  
     superior, 122  
 Meibomian follicles, 238  
 Membrana basilaris, 237  
     sacciformis, 12  
     tympani, 233  
 Membrane, hyaloid, 243  
     of the labyrinth, 235  
     obturator, 8  
     of Reissner, 236  
 Membranes of the brain, 139  
     of spinal cord, 116  
 Membranous labyrinth, 235  
     part of the cochlea,  
         236  
     part of the urethra, 221  
 Meningeal artery, anterior, 71  
     middle, 69  
     posterior, 61  
     small, 69  
 Mesenteric artery, inferior, 84  
     superior, 83  
     glands, 112  
     plexus, inferior, 180  
         superior, 180  
     vein, inferior, 107  
         superior, 107  
 Meso-cæcum, 200  
     colon, pelvic, 194  
         transverse, 200  
 Metacarpal arteries, 77, 78  
 Metatarsal artery, 95  
 Mitral valve, 206  
 Modiolus of the cochlea, 235  
 Molar teeth, 181  
 Mons Veneris, 225  
 Motor oculi nerve, 142  
 Mucous ligament, 17  
 Multifidus spinæ muscle, 43  
 Musculi papillares, 205  
 Musculi pectinati, 205  
 Musculo-cutaneous nerve of the arm,  
     163  
     phrenic artery, 63  
     spiral nerve, 165  
 Musc., abductor digiti minimi, 39  
     digiti minimi  
         pedis, 58  
         hallucis, 58  
         indicis, 40  
         pollicis, 39  
     accessorius pedis, 58  
     accessorius ad sacro-lumba-  
         lem, 42  
     adductor brevis, 52  
         obliquus hallucis,  
             58  
         longus, 52  
         magnus, 52  
         obliquus pollicis,  
             39  
             transver-  
                 sus, 39  
         transversus hallu-  
             cis, 58  
     anconeus, 38  
     arytenoideus, 31  
     attollens aurem, 22  
     attrahens aurem, 22  
     azygos uvulæ, 30  
     biceps femoris, 54  
         cubiti, 35  
     biventer cervicis, 43  
     brachialis anticus, 35  
     buccinator, 24  
     cervicalis ascendens, 41  
     ciliaris, 241  
     coccygeus, 49  
     complexus, 43  
     compressor naris, 23  
     constrictor, inferior, 29  
         medius, 29  
         superior, 29  
     coraco-brachialis, 34  
     corrugator supercilii, 22  
     cremastericus, 44  
     crico - arytenoideus latera-  
         lis, 31  
     crico - arytenoideus postie-  
         cus, 31  
     crico-thyroideus, 30  
     crureus, 52  
     deltoideus, 33  
     depressor anguli oris, 24  
     depressor labii inferioris,  
         24  
         alæ nasi, 23  
     diaphragma, 46

- Musc., digastricus, 28  
   dilatator naris, 24  
     pupillæ, 241  
   ejaculator urinæ, 49  
   erector clitoridis, 49  
     penis, 49  
     spinæ, 42  
   extensor carpi radialis  
     brevior, 37  
     carpi radialis  
       longior, 37  
     carpi ulnaris, 38  
     digitorum brevis  
       pedis, 57  
     digitorum com-  
       munis, 37  
     digitorum longus  
       pedis, 55  
     indicis, 38  
     minimi digiti, 37  
     ossis metacarpi pol-  
       licis, 38  
     proprius hallucis, 55  
     brevis pollicis,  
       38  
     longus pollicis,  
       38  
   flexor accessorius, 58  
     brevis digiti minimi,  
       39  
     brevis digiti minimi  
       pedis, 59  
     brevis hallucis, 58  
     brevis pollicis, 39  
     carpi radialis, 36  
       ulnaris, 36  
     digitorum brevis  
       pedis, 58  
     digitorum longus  
       pedis, 56  
     digitorum profundus,  
       36  
     digitorum sublimis,  
       36  
     hallucis longus, 56  
     pollicis longus, 37  
   gastrocnemius, 55  
   gemellus inferior, 54  
     superior, 54  
   genio-hyo-glossus, 29  
     hyoideus, 29  
   gluteus maximus, 53  
     medius, 53  
     minimus, 53  
   gracilis, 52  
   hyo-glossus, 29  
   iliacus, 51  
   ilio-costalis, 43
- Musc., infra-spinatus, 34  
   intercostales externi, 41  
     interni, 46  
   interossei manûs dorsales,  
     40  
   interossei manûs palmares,  
     40  
   interossei pedis dorsales, 59  
   interossei pedis plantares, 59  
   inter-spinales, 43  
   inter-transversales, 43  
   latissimus dorsi, 40  
   levator anguli oris, 24  
     scapulæ, 41  
     ani, 49  
     labii superioris, 24  
     labii superioris alæ-  
       que nasi, 23  
     palati, 30  
     palpebræ superioris,  
       22  
   levatores costarum, 46  
   linguales, 182  
   longissimus dorsi, 42  
   longus colli, 31  
   lumbricales manûs, 39  
     pedis, 58  
   massetericus, 25  
   multifidus spinæ, 43  
   mylo-hyoideus, 28  
   obliquus abdominis exter-  
     nus, 44  
   obliquus abdominis inter-  
     nus, 44  
   obliquus capitis inferior, 32  
     superior, 32  
     oculi inferior, 23  
     superior, 23  
   obturator externus, 54  
     internus, 54  
   occipito-frontalis, 21  
   omo-hyoideus, 28  
   opponens minimi digiti, 39  
     pollicis, 39  
   orbicularis oris, 24  
     palpebrarum, 22  
   palato-glossus, 30  
     pharyngeus, 30  
   palmaris brevis, 39  
     longus, 36  
   pectineus, 52  
   pectoralis major, 33  
     minor, 33  
   peroneus brevis, 56  
     longus, 56  
     tertius, 55  
   plantaris, 55  
   platysma myoides, 26

- Musc., popliteus, 56**  
 pronator, quadratus, 37  
     radii teres, 36  
 psoas magnus, 51  
     parvus, 51  
 pterigoideus externus, 25  
     internus, 25  
 pyramidalis abdominis, 45  
     nasi, 23  
 pyriformis, 53  
 quadratus femoris, 54  
     lumborum, 45  
 quadriceps extensor, 51  
 rectus abdominis, 45  
     capitis anticus major,  
     31  
     capitis anticus minor,  
     31  
     lateralis, 31  
     posticus major,  
     32  
     posticus minor,  
     32  
     femoris, 52  
     oculi externus, 23  
     inferior, 23  
     internus, 23  
     superior, 23  
 retrahens aurem, 22  
 rhomboideus major, 41  
     minor, 41  
 risorius, 25  
 rotatores dorsi, 43  
 salpingo-pharyngeus, 30  
 sartorius, 51  
 scalenus anticus, 31  
     medius, 31  
     posticus, 32  
 semi-membranosus, 54  
     spinalis colli, 43  
     dorsi, 43  
     tendinosus, 54  
 serratus magnus, 33  
     posticus inferior, 41  
     superior, 41  
 soleus, 55  
 sphincter ani externus, 48  
     internus, 48  
     pupillæ, 241  
     vaginæ, 49  
 spinalis dorsi, 42  
 splenius capitis, 41  
     colli, 42  
 stapedius, 234  
 sterno - cleido - mastoideus,  
 26  
     hyoideus, 28
- Musc., sterno-thyroideus, 28**  
 stylo-glossus, 29  
     hyoideus, 28  
     pharyngeus, 30  
 subanconeus, 35  
 subclavius, 33  
 subcostales, 46  
 subcrureus, 52  
 subscapularis, 34  
 supinator brevis, 38  
     longus, 37  
 supra-spinatus, 34  
 temporalis, 25  
 tensor palati, 30  
     tarsi, 22  
     tympani, 233  
     fasciæ femoris, 51  
 teres major, 34  
     minor, 34  
 thyro-arytenoideus, 30  
     hyoideus, 28  
 tibialis anticus, 55  
     posticus, 56  
 trachelo-mastoideus, 42  
 transversalis abdominis,  
 44  
     colli, 42  
 transversus perinæ, 49  
 trapezius, 40  
 triangularis sterni, 46  
 triceps extensor, 35  
 vastus externus, 51  
     internus, 52  
 zygomaticus major, 24  
     minor, 24
- Mylo-hyoid artery, 70**  
 muscle, 28  
 nerve, 147
- Nares, 229**
- Nasal artery, 72**  
 lateral, 67  
 cartilages, 228  
 duct, 238  
 fossæ, 228  
 nerve, 143
- Naso-palatine artery, 70**  
 nerve, 145
- Nerve of Jacobson, 154**  
 of Wrisberg, 163
- Nerve to the inferior gemellus and**  
 quadratus, 171  
 latissimus, 163  
 levator anguli scapulæ,  
 162  
 longus colli, 162  
 obturator internus, 171

- Nerve to the pectineus, 169  
 pterygoid, internal, 146  
 pyriformis, 171  
 rhomboid muscles, 162  
 scaleni, 162  
 serratus magnus, 163  
 subclavius, 162  
 superior gemellus, 171  
 tensor palati, 148  
 tympani, 148  
 fasciæ femoris, 172  
 teres major, 163  
 minor, 163  
 vastus externus, 170  
 internus, 170
- Nervous tunic of eyeball, 242
- Nerv., abducens, 151  
 accessorius obturatorius, 169  
 spinalis, 157  
 acromiales cutanei, 160  
 articularis poplitei, 173  
 articularis obturatorius, 169  
 auditorius, 153  
 auricularis inferior, 147  
 magnus, 160  
 pneumogastrici, 155  
 posterior, 152  
 auriculo-temporalis, 147  
 buccales, 146, 152  
 buccinatorius, 152  
 cardiacus inferior, 178  
 medius, 178  
 pneumogastrici, 156  
 superior, 176  
 cervicales nervi facialis, 153  
 rami anteriores, 159  
 posteriores, 159  
 cervicalis superficialis, 160  
 cervico-facialis, 153  
 chorda tympani, 152  
 ciliaris ganglii ophthalmici, 143  
 nasalis, 143  
 circumflexus, 162  
 claviculares cutanei, 160  
 coccygealis, 170  
 cochlearis, 237  
 communicans fibularis, 175  
 tibialis, 173  
 cruralis, 169  
 cutanei abdominis anteriores, 167  
 abdominis laterales, 167  
 cutaneus dorsalis manus, 164  
 externus brachialis, 163
- Nerv., cutaneus externus lumbalis, 168  
 externus musculo-spiralis, 165  
 infra-maxillar., 153  
 internus brachialis major, 163  
 internus brachialis minor, 163  
 internus femoris, 169  
 internus musculo-spiralis, 165  
 medius femoris, 169  
 musc. cutanei, 163  
 palmaris, 164  
 plantaris, 174  
 radialis, 165  
 supra-maxillar., 153
- dentales posteriores, 144  
 dentalis, superior, 144, 145  
 inferior, 147  
 descendens hypoglossi, 158  
 diaphragmaticus, 160, 180  
 ligastrius, 152  
 digitales mediani, 164  
 plantares, 170  
 radiales, 164  
 ulnares, 164
- dorsales, rami anteriores, 166  
 posteriores, 166
- dorsalis penis, 172  
 ulnaris, 164
- facialis, 151  
 frontalis, 143  
 genito-cruralis, 168  
 ramus femoralis, 168  
 ramus genitalis, 168
- glosso-pharyngeus, 153  
 glutei inferiores, 171  
 gluteus superior, 171  
 gustatorius, 147  
 hæmorrhoidalis inferior, 173  
 hepatici, 180  
 hypoglossalis, 157  
 ilio-hypogastricus, 168  
 inguinalis, 168
- incisorius, 147  
 infra-mandibularis facialis, 153  
 orbitales nervi facialis, 153  
 orbitalis, 144  
 trochlearis, 143
- intercostales, 166  
 intercosto-cutanei anteriores, 166  
 intercosto-cutanei laterales, 166  
 intercosto-humeralis, 166

- erv. interosseus anticus, 164  
     posticus, 165  
 ischiaticus magnus, 173  
     parvus, 172  
 labialis, 145  
 lachrymalis, 143  
 laryngeus externus, 156  
     inferior, 156  
     superior, 156  
 lingualis, 147, 154  
 tumbales rami anteriores, 167  
     posteriores, 167  
 lumbo-sacralis, 167  
 malaris nervi facialis, 153  
 massetericus, 146  
 maxillaris inferior, 146  
     superior, 144  
 medianus, 163  
 motor oculi, 142  
 musculo-cutaneus brachii, 163  
     cruris, 175  
     spiralis, 165  
 mylo-hyoideus, 147  
 nasalis, 143  
 naso-palatinus, 145  
 obturatorius, 168  
     articularis, 169  
 occipitalis major, 159  
     minor, 160  
 cesophageales, 157  
 olfactorius, 141, 230  
 ophthalmicus, 143  
 opticus, 141  
 orbitalis, 144  
 palatinus magnus, 145  
     externus, 145  
     minor, 145  
 palmaris cutaneus, 164  
     ulnaris profundus, 165  
     superficialis, 166  
 palpebrales, 145  
 patellaris, 170  
 perforans Casserii, 164  
 perinæales superficiales, 172  
 peronealis, 175  
 petrosus superficialis externus,  
     152  
 petrosus superficialis magnus,  
     152  
 petrosus superficialis parvus,  
     148  
 pharyngei, 154  
 pharyngeus, 146, 154, 156  
 phrenicus, 160  
 plantaris externus, 174  
     profundus, 174  
     internus, 174  
 pneumogastricus, 155
- Nerv., popliteus externus, 174  
     internus, 173  
 pterygoidei, 146  
 pudendus inferior, 171  
     internus, 171  
 pulmonares anteriores, 156  
     posteriores, 156  
 radialis, 165  
 recurrens articularis, 175  
 renales, 176  
 sacrales, rami anteriores, 170  
     posteriores, 170  
 saphenus externus, 174  
     internus, 170  
 sciaticus magnus, 173  
     parvus, 172  
 spermatici, 180  
 spheno-palati ii, 144  
 splanchnicus major, 178  
     minor, 178  
     minimus, 178  
 splenici, 180  
 stylo-hyoideus, 152  
 suboccipitalis, ramus anterior,  
     159  
 suboccipitalis, ramus pos-  
     terior, 158  
 subscapulares, 162  
 superficialis cordis dexter, 176  
     sinister, 177  
 supra-mandibularis nervi  
     facialis, 153  
 supra-orbitalis, 143  
     scapularis, 162  
     trochlearis, 143  
 sympathicus abdominis, 180  
     cervicis, 176  
     pelvis, 180  
     thoracis, 178  
 temporales nervi facialis, 152  
     profundi, 146  
     superficialis, 152  
 temporo-facialis, 152  
     malar, 144  
 thoracici anteriores, 162  
     laterales, 163  
 thoracicus posterior, 162  
 thyro-hyoideus, 158  
 tibialis anticus, 175  
     posticus, 173  
 trigeminus, 142  
 trochlearis, 142  
 tympanicus, 152, 154  
 ulnaris, 164  
 uterini, 181  
 vaginales, 181  
 Vidianus, 146
- Ninth nerve, 153

- Nodule, 125  
 Nose, cartilages, 228  
   cavity of, 228  
   meatuses of, 228  
 Nuclei of medulla oblongata, 122  
 Nucleus caudatus, 138  
   lenticularis, 138  
 Nutritious artery of femur, 92  
   of humerus, 75  
   of tibia, 96  
 Nymphæ, 225  
 Obliquus abdominis externus muscle, 44  
   internus muscle, 44  
   capitis inferior muscle, 32  
   superior muscle, 32  
   oculi inferior muscle, 23  
   superior muscle, 23  
 Obturator artery, 86  
   fascia, 47  
   membrane, 54  
   muscle, external, 54  
   internal, 54  
   nerve, 168  
 Occipital artery, 67  
   lobe, 131  
 Occipital vein, 100  
   sinus, 97  
   nerves, 159, 160  
 Occipito-atloid articulation, 3  
   ligaments, 3  
   axial ligaments, 3  
   frontalis muscle, 21  
 Odontoid ligaments, 4  
 Œsophagus, connections of, 187  
 Œsophageal arteries, 81  
   nerves, 157  
   opening of diaphragm, 46  
 Olfactory bulb, 134  
   nerve, 141  
 Olivary body, 120  
   fasciculus, 121  
 Omentum, great, 199  
   lesser, 199  
   splenic, 199  
 Omo-hyoid muscle, 28  
 Ophthalmic artery, 71  
   ganglion, 150  
   nerve, 143  
   veins, 98  
 Opponens minimi digiti muscle, 39  
   pollicis muscle, 39  
 Optic commissure, 129  
   nerve, 141  
   thalamus, 128  
   tract, 129  
 Ora serrata, 242  
 Orbicular ligament of the radius, 11  
 Orbicularis oris muscle, 24  
   palpebrarum muscle, 22  
 Organ of Corti, 236  
 Orifice of the urethra, 227  
   of the uterus, 227  
   of the vagina, 225  
 Ossicles of the tympanum, 232  
 Os uteri, externum, 226  
   internum, 227  
 Otic ganglion, 148  
 Otoliths, 236  
 Ovaries, 227  
 Palate, soft, 183  
 Palatine, arteries, superior, 70  
   artery, inferior, 67  
   nerve, external, 145  
   large, 145  
   small, 145  
 Palato-glossus muscle, 30  
   pharyngeus muscle, 30  
 Palmar arch, deep, 77  
   superficial, 78  
   nerve of the ulnar, deep, 164  
   superficial, 164  
   fascia, 36  
 Palmaris brevis muscle, 39  
   longus muscle, 36  
 Palpebræ, 237  
 Palpebral arteries, 72  
   ligament, 233  
 Pancreas, 194  
   connections, 194  
 Pancreatic arteries, 83  
   duct, 195  
 Pancreatico-duodenal arteries, 83  
 Papilla lachrymalis, 237  
 Papillæ of the tongue, 181  
 Parietal lobe, 132  
 Parotid gland, 183  
 Patellar nerve, 170  
   plexus, 169  
 Pectineus muscle, 52  
 Pectoralis major muscle, 33  
   minor muscle, 33  
 Peduncle of the cerebellum, inferior, 125  
 Peduncle of the cerebellum, middle, 125  
 Peduncle of the cerebellum, superior, 125  
 Peduncle of the cerebrum, 126  
   of the pineal body, 129  
 Peduncular fibres, 138  
 Pelvic colon, 191  
   fascia, 47  
   plexus, 180  
 Penis, 220  
 Perforating arteries, of femoral, 92  
   of internal mammary, 63

- Perforating arteries of the palm, 77  
     of the sole, 95  
 Perforans Casserii nerve, 164  
 Pericardium, 202  
 Perilymph, 234  
 Perinæal artery, superficial, 87  
     fascia, deep, 47  
     superficial, 47  
     nerves, superficial, 172  
 Peritoneum, 196  
     of female pelvis, 197  
     of male pelvis, 196  
 Peroneal artery, 96  
     anterior, 96  
     nerve, 171  
 Peroneus brevis muscle, 56  
     longus muscle, 56  
     tertius muscle, 55  
 Peroneo-tibial articulations, 17  
 Pes hippocampi, 136  
 Petrosal ganglion, 154  
     sinus, inferior, 98  
     superior, 98  
 Petrosal nerve, external, 152  
     large, 152  
     small, 148  
 Peyer's glands, 190  
 Pharyngeal ascending artery, 68  
     nerve, 154  
     vein, 101  
 Pharynx, 185  
     muscles of, 29  
     openings of, 186  
 Phrenic artery, 63, 82  
     nerve, 160  
 Pia mater of the brain, 140  
     of the cord, 116  
 Pigment cells of choroid, 240  
     of iris, 241  
 Pillars of the abdominal ring, 44  
     of the fornix, 136  
     of the iris, 240  
     of the soft palate, 183  
 Pineal body, 129  
 Pinna, or auricle of the ear, 230  
 Pituitary body, 129  
 Plantar arch, artery of the, 97  
     arteries, 96, 97  
     fascia, 57  
     ligament, long, 19  
     nerve, external, 174  
     internal, 174  
 Plantaris muscle, 55  
 Platysma myoides muscle, 26  
 Pleuræ, 212  
 Plexus, aortic, 180  
     brachial, 161  
     cardiac, superficial, 179  
     cardiac, deep, 179  
     carotid, 177  
     cavernous, 177  
     cervical, 159  
     choroides cerebri, 137  
     cæliac, 180  
     coronary, anterior, 180  
         posterior, 180  
         of the stomach,  
             180  
     diaphragmatic, 180  
     gulæ, 155  
     hæmorrhoidal, 180  
     hepatic, 180  
     hypogastric, 180  
     lumbar, 167  
     mesenteric, inferior, 180  
         superior, 180  
     œsophageal, 155  
     ovarian, 181  
     patellar, 169  
     pelvic, 180  
     pharyngeal, 176  
     prostatic, 181  
     pterygoid of veins, 100  
     pulmonary, anterior, 154  
         posterior, 157  
     renal, 180  
         supra, 180  
     sacral, 171  
     solar, 179  
     spermatic of nerves, 180  
         of veins, 106  
     splenic, 180  
     tympanic, 154, 177  
     uterine, 181  
     vaginal, 181  
     vesical, 180  
 Plica semilunaris, 237  
 Pneumogastric nerve, 155  
 Pomum Adami, 207  
 Pons Varolii, 122  
     structure of, 123  
 Popliteal artery, 92  
     glands, 113  
     nerve, external, 174  
     internal, 173  
     vein, 109  
 Popliteus muscle, 56  
 Portal vein, 107  
 Porus opticus, 242  
 Posterior commissure, 128  
     ligament of the knee,  
         15  
     pyramid, 120  
 Poupart's ligament, 44  
 Pouch, laryngeal, 210  
 Prepuce, 221

- Princeps cervicalis artery, 68  
     pollicis artery, 77  
 Processus cochleariformis, 232  
     vermiformis, 124  
 Profunda artery, inferior, 76  
     of the neck, 64  
     of the thigh, 91  
     superior, 75  
 Promontory, 231  
 Pronator quadratus muscle, 37  
     radii teres muscle, 36  
 Prostatic gland, 220  
     connections, 220  
     urethra, 221  
     sinuses, 221  
 Psoas magnus muscle, 51  
     parvus muscle, 51  
 Pterygoid arteries, 70  
     nerve, external, 146  
     internal, 146  
     plexus of veins, 100  
 Pterygoideus externus muscle, 25  
     internal muscle, 25  
 Pterygo-maxillary ligament, 25  
     palatine artery, 70  
 Pubo-prostatic ligaments, 48  
 Pudic arteries, external, 91  
     artery, internal, 87  
     nerve, internal, 171  
 Pulmonary artery, 214  
     nerves, 156  
     veins, 106  
 Pylorus, 187  
 Pyloric arteries, 83  
 Pyramid, anterior, 120  
     decussation of, 120  
     of the cerebellum, 125  
     of the tympanum, 232  
     posterior, 119  
 Pyramidal fibres of the medulla, 120  
     masses of kidney, 217  
 Pyramidalis abdominis muscle, 45  
     nasi muscle, 23  
 Pyramids of Malpighi, 217  
 Pyriformis muscle, 53  
  
 Quadratus femoris muscle, 54  
     lumborum muscle, 45  
  
 Radial artery, 76  
     nerve, 165  
     veins, 102  
 Radialis indicis artery, 77  
 Radio-carpal articulation, 12  
 Radio-ulnar articulations, 11  
 Ranine artery, 66  
     vein, 101  
 Raphé of the corpus callosum, 135  
     of the medulla, 118  
  
 Receptaculum chyli, 110  
 Recto-vesical fascia, 48  
     pouch, 197  
 Rectus abdominis muscle, 45  
     capitis anticus major muscle,  
         31  
         minor muscle,  
             31  
     lateralis muscle, 31  
     posticus major muscle,  
         32  
         minor muscle,  
             32  
     femoris muscle, 52  
     oculi externus muscle, 23  
     inferior muscle, 23  
     internus muscle, 23  
     superior muscle, 23  
 Rectum, connections of, in the  
     female, 191  
 Rectum, connections of, in the  
     male, 191  
 Recurrent interosseous artery, 78  
     radial, 76  
     tibial, 97  
     ulnar, anterior, 78  
         posterior, 78  
 Recurrent nerve of pneumogastric,  
     155  
 Recurrent nerve of the tibial, 175  
 Renal artery, 84  
     plexus, 180  
     vein, 106  
 Restiform body, 119  
 Rete testis, 224  
 Retina, 242  
 Retrahens aurem muscle, 22  
 Rhomboideus major muscle, 41  
     minor muscle, 41  
 Rima of the glottis, 210  
 Risorius muscle, 25  
 Root of the lung, 213  
 Rotatores dorsi muscles, 43  
 Round ligament of the hip-joint, 14  
     of the liver, 192  
     of the uterus, 227  
  
 Saccule of the ear, 235  
 Sacculus laryngis, 210  
     vestibuli, 235  
 Sacral artery, lateral, 88  
     middle, 85  
     ganglia, 180  
     nerves, anterior branches, 170  
         posterior branches,  
             170  
     plexus, 171  
 Sacro-coccygeal articulation, 8  
     iliac articulation, 7  
     vertebral articulation, 6



- Sacro-sciatic ligament, large, 7  
   small, 7  
 Salpingo-pharyngeus muscle, 30  
 Salvatella vein, 101  
 Saphenous vein, external, 108  
   internal, 108  
   opening, 50  
   nerve, external, 174  
   internal, 170  
 Sartorius muscle, 51  
 Scala tympani, 235  
   vestibuli, 235  
 Scalenus anticus muscle, 31  
   medius muscle, 31  
   posticus muscle, 32  
 Scapular artery, posterior, 63  
   ligaments, 9  
   muscles, 34  
 Scapulo-clavicular articulation, 9  
   humeral articulation, 10  
 Schneiderian membrane, 229  
 Sciatic artery, 89  
   nerve, large, 173  
   small, 172  
 Sclerotic coat of the eye, 239  
 Scrotum, 222  
 Second nerve, 141  
 Secondary membrane of the tympanum, 231  
 Semicircular canals, 234  
 Semilunar cartilages, 16  
   ganglia, 179  
   valves of aorta, 206  
   of pulmonary artery, 205  
 Semi-membranosus muscles, 54  
 Seminal ducts, 224  
 Seminiferous tubes, 223  
 Semi-spinalis coli muscle, 43  
   dorsi muscle, 43  
 Semi-tendinosus muscle, 54  
 Septum auricularum, 204  
   cochleæ, 236  
   crurale, 50  
   intermuscular, of the arm, 34  
   of the thigh, 49  
   lucidum, 136  
   nasi, 229  
   pectiniforme, 221  
   scroti, 222  
   of the tongue, 182  
   ventriculorum, 204  
 Serratus magnus muscle, 33  
   posticus inferior, 41  
   superior, 41  
 Seventh nerve, 151  
 Sheath of the rectus, 45  
 Shoulder-joint, 10  
 Sigmoid artery, 85  
 Sinus, cavernous, 98  
   circular, 98  
   coronary, 106  
   lateral, 98  
   longitudinal, inferior, 98  
   superior, 97  
   occipital, 98  
   petrosal, inferior, 98  
   superior, 98  
   pocularis, 221  
   prostaticus, 221  
   straight, of the skull, 98  
   transverse, 98  
   of Valsalva, 205  
 Sixth nerve, 151  
 Small intestine, 188  
   omentum, 199  
 Socia parotidis, 184  
 Soft commissure, 128  
 Soft palate, 183  
   muscles of, 30  
 Solar plexus, 179  
 Soleus muscle, 55  
 Spermatic artery, 84  
   cord, 222  
   plexus, 180  
   veins, 106  
 Spheno-palatine artery, 70  
   ganglion, 145  
   nerves, 144  
 Sphincter ani externus muscle, 48  
   internus muscle, 48  
   of the pupil, 241  
   vaginæ, 49  
 Spigelian lobe, 192  
 Spinal accessory nerve, 157  
   arteries, 61  
   cord, 114  
   membrane of, 116  
   structure, 115  
   nerves, 158  
   roots of, 158  
   veins, 105  
 Spinalis dorsi muscle, 42  
 Spiral tube of the cochlea, 235  
 Splanchnic nerve, large, 178  
   small, 178  
   smallest, 178  
 Spleen, 195  
   connections, 195  
 Splenic artery, 83  
   omentum, 199  
   plexus of nerves, 180  
   vein, 107

- Splenius capitis muscle, 41  
     colli muscle, 42  
 Spongy bones, 228  
     part of the urethra, 222  
 Stapedius muscle, 234  
 Stapes bone, 233  
 Stellate ligament, 5  
 Stenson's duct, 184  
 Sterno-clavicular articulation, 8  
     cleido-mastoid muscle, 26  
     hyoid muscle, 28  
     thyroid muscle, 28  
 Stomach, form and divisions, 187  
     connections of, 188  
 Straight sinus, 98  
 Striate body, 137  
 Stylo-glossus muscle, 29  
     hyoid ligament, 5  
     muscle, 28  
     nerve, 152  
     mastoid artery, 68  
     maxillary ligament, 25  
     pharyngeus muscle, 30  
 Subanconeus muscle, 35  
 Subarachnoid space, 140  
 Subclavian artery, left, 59  
     right, 59  
     vein, 103  
 Subclavius muscle, 33  
 Subcostales muscles, 46  
 Subcurreus muscle, 52  
 Subcutaneous malæ nerve, 144  
 Sublingual artery, 66  
     gland, 185  
 Submaxillary ganglion, 148  
     gland, 184  
 Submental artery, 67  
 Suboccipital nerve, anterior branch,  
     159  
 Suboccipital nerve, posterior branch,  
     158  
 Subpeduncular lobe, 124  
 Subpubic ligament, 8  
 Subscapular artery, 74  
     nerves, 162  
 Subscapularis muscle, 34  
 Sulci of brain, 131  
 Sulcus, longitudinal, of the liver, 193  
     spiralis, 236  
     transverse, 193  
 Superficialis cervicalis artery, 63  
     volæ artery, 76  
 Supinator radii brevis muscle, 38  
     longus muscle, 37  
 Supra-orbital artery, 72  
     nerve, 143  
     renal capsule, 217  
     plexus, 180  
 Supra-scapular artery, 62  
     nerve, 162  
     spinatus muscle, 34  
     trochlear nerve, 143  
 Suspensory ligament of the lens, 243  
     of the liver, 192  
     of the penis, 220  
 Sympathetic nerve in the abdomen,  
     180  
     in the head, 176  
     in the neck, 176  
     in the pelvis, 180  
     in the thorax, 178  
 Symphysis pubis, 8  
 Synarthrosis, 1  
 Tænia hippocampi, 136  
     semicircularis, 138  
 Tarsal artery, 94  
     plates, 237  
 Tarso-metatarsal articulations, 20  
 Teeth, 181  
 Tegmentum, 127  
 Temporal aponeurosis, 25  
     arteries, deep, 69  
     middle, 69  
     superficial, 68  
     fascia, 25  
     muscle, 25  
     nerves, deep, 146  
     superficial, 152  
     vein, 99  
 Temporo-fascial nerve, 152  
     malar nerve, 144  
     maxillary articulation, 4  
     sphenoidal lobe, 133  
 Tendo Achillis, 55  
     palpebrarum, 228  
 Tendon of quadriceps extensor  
     muscle, 52  
 Tensor fasciæ femoris muscle, 51  
     palati muscle, 30  
     tarsi muscle, 22  
     tympani muscle, 224  
 Tentorium cerebelli, 139  
 Teres major muscle, 34  
     minor muscle, 34  
 Testes, 223  
 Thalamus opticus, 128  
 Thebesian foramina, 204  
     valve, 205  
 Third nerve, 142  
     ventricle, 127  
 Thoracic duct, 110  
     ganglia, 178  
     acromial artery, 74  
     alar artery, 74  
     long artery, 74

- Thoracic superior artery, 74  
 Thymus body, 215  
 Thyro-arytenoid articulation, 209  
     ligaments, 209  
 Thyro-arytenoideus muscle, 30  
     epiglottidean ligament, 209  
     hyoid membrane, 209  
     muscle, 28  
     nerve, 158  
 Thyroid artery, inferior, 62  
     lowest, 80  
     superior, 66  
     axis, 62  
     body, 215  
     cartilage, 207  
     plexus of veins, 104  
     vein, inferior, 104  
     middle, 101  
     superior, 101  
 Tibial artery, anterior, 93  
     posterior, 94  
     nerve, anterior, 175  
     posterior, 173  
     veins, anterior, 109  
     posterior, 109  
 Tibialis anticus muscle, 55  
     posticus muscle, 56  
 Tibio-tarsal articulation, 19  
 Tongue, 181  
     muscles of, 29, 182  
 Tonsil, 183  
 Tonsillitic artery, 67  
 Torcular Herophili, 98  
 Trabeculæ carneæ, 205  
 Trachea, 211  
 Trachelo-mastoid muscle, 42  
 Tragus, 230  
 Transverse colon, 190  
     fissure of the cerebrum,  
         130  
         of the liver, 193  
     ligament of the acetabu-  
         lum, 14  
         of the atlas, 3  
         of the fingers,  
             14  
         of the knee, 17  
         of the meta-  
             carpus, 14  
         of the meta-  
             tarsus, 20  
         of the toes, 21  
     perineal artery, 87  
     sinus, 98  
     tarsal articulation, 20  
 Transversalis abdominis muscle, 44  
     cervicalis artery, 65  
     colli muscle, 42  
 Transversalis faciei artery, 69  
 Transversus perinæi muscle, 49  
 Trapezius muscle, 40  
 Trapezoid ligament, 9  
 Triangular cartilage of the nose,  
     228  
     fascia, 44  
     fibro-cartilage of wrist,  
         12  
     ligament of urethra, 49  
     surface of bladder, 219  
 Triangularis sterni muscle, 46  
 Triceps extensor cubiti muscle, 35  
 Tricuspid valve, 203  
 Trigeminal nerve, 142  
 Trigonum vesicæ, 219  
 Trochlear nerve, infra, 142  
     supra, 143  
 Tube of the cochlea, 235  
 Tuber cinereum, 129  
 Tubercle of Rolando, 119  
 Tubuli seminiferi, 223  
 Tunica albuginea testis, 223  
     Ruyschiana, 240  
     vaginalis, 223  
     vasculosa testis, 223  
 Turbinate bones, 228  
 Twelfth intercostal nerve, 167  
 Tympanic artery, 69, 71  
 Tympanum, 231  
 Ulnar artery, 77  
     nerve, 164  
     veins, 101  
         cutaneous anterior, 101  
         posterior, 101  
 Ureter, 217  
 Urethra, female, 225  
     orifice of, 225  
     male, interior, 221  
 Uterine arteries, 86  
     plexus of nerves, 181  
     veins and sinuses, 109  
 Uterus, 226  
     interior of, 226  
     ligaments of, 227  
     connections of, 226  
 Utricle of the ear, 235  
 Uvea iridis, 241  
 Uvula cerebelli, 125  
     palati, 183  
 Vagina, 225  
 Vaginal arteries, 86  
     plexus, 181  
     veins, 109  
 Vagus nerve, 155  
     nucleus, 122

- Vallecule, 124  
 Valve, Eustachian, 204  
   of cæcum, 125  
   mitral, 206  
   semilunar, 204  
   of Thebesius, 205  
   tricuspid, 205  
   of Vieussens, 124  
 Valvulæ conniventes, 185  
 Vas deferens, 223  
 Vasa brevia, 188  
   efferentia testis, 224  
   rete testis, 224  
   vorticosæ, 240  
 Vascular coat of eye, 240  
 Vastus externus muscle, 51  
   internus muscle, 52  
 Vein, alveolar, 99  
   angular, 99  
   ascending cervical, 101  
     lumbar, 104  
     pharyngeal, 102  
   auricular posterior, 100  
   axillary, 102  
   azygos, large, 104  
     small, 104  
     superior, 105  
   basilic, 102  
   brachial, 102  
   bronchial, left, 105  
     right, 105  
   cardiac, anterior, 106  
     great, 106  
     small, 106  
   cava, inferior, 105  
     superior, 103  
   cephalic, 102  
   cerebellar, 97  
   cerebral, 97  
   choroid, 97  
   ciliary, anterior, 98  
     posterior, 98  
   circumflex iliac, 108, 109  
   coronary of the heart, 106  
     of the stomach, 107  
   of the corpus striatum, 97  
   deep cervical, 101  
   dorsal of the penis, 109  
   dorsi-spinal, 105  
   emissary, 99  
   epigastric, deep, 109  
     superficial, 108  
   facial, 99  
   femoral, 109  
   frontal, 98  
   of Galen, 97  
   gastro-epiploic, 108  
   hæmorrhoidal, 109  
   hepatic, 106  
   iliac, common, 110  
     external, 109  
     internal, 109  
   infra-orbital, 99  
   innominate, 103  
   intercostal, 105  
     superior, left, 104  
     right, 104  
   jugular, anterior, 100  
     external, 100  
     internal, left, 101  
     right, 101  
   laryngeal, 101  
   lingual, 101  
   longitudinal of the spine, an-  
     terior, 105  
   lumbar, 105  
   mammary, internal, 104  
   maxillary, internal, 100  
   median of the arm, 102  
     basilic, 102  
     cephalic, 102  
   mesenteric, inferior, 107  
     superior, 107  
   occipital, 100  
   ophthalmic, 98  
   ovarian, 106  
   palpebral, inferior, 99  
     superior, 99  
   pancreatic, 108  
   perineal, superficial, 110  
   pharyngeal, 101  
   phrenic, inferior, 106  
   popliteal, 109  
   portal, 107  
   posterior, spinal plexus of, 105  
   profunda, of the thigh, 109  
   pterygoid plexus, 100  
   pudic external, 108  
     internal, 110  
   pulmonary, 106  
   radial cutaneous, 102  
   ranine, 101  
   renal, 106  
   sacral, lateral, 110  
     middle, 110  
   saphenous, external, 108  
     internal, 108  
   spermatic, 106  
   spinal, 105  
   splenic, 107  
   subclavian, 103  
   supra-orbital 99  
     renal, 106  
     scapular, 100  
   temporal, 99  
   thyroid, inferior, 104

- Vein, thyroid, middle, 101  
     superior, 101  
 tibial, anterior, 109  
     posterior, 109  
 transverse-cervical, 100  
 ulnar, 101  
     cutaneous, anterior, 101  
     posterior, 101  
 uterine, 109  
 vaginal, 109  
 of the vertebræ, 105  
 vertebral, 101  
 vesical, 109  
 Velum interpositum, 137  
 Vena cava, inferior, 105  
     superior, 104  
     portæ, 107  
 Ventricles of the brain, 127, 135  
     fifth, 136  
     fourth, 120  
     lateral, 135  
     third, 127  
     of the heart, 205  
         left, 206  
         right, 205  
     of the larynx, 210  
 Vermiform appendix, 190  
     processes, 124  
 Vertebral artery, 61  
     vein, 101  
 Verumontanum, 221  
 Vesica urinaria, 218  
 Vesical artery, inferior, 86  
     superior, 86  
     plexus of nerves, 180  
     of veins, 109  
 Vesicula prostatica, 221  
 Vesiculæ seminales, 224  
 Vestibule of the ear, 234  
     of the vulva, 225  
 Vestigial fold of the pericardium, 203  
 Vidian artery, 70  
     nerve, 146  
 Vitreous body, 242  
 Vocal cords, 210  
 Vulva, 224  
 Wharton's duct, 185  
 White commissure of the cord, 116  
 Winslow's foramen, 201  
 Wrisberg's nerve, 163  
 Wrist-joint, 12  
 Yellow spot of eye-ball, 242  
 Zygomaticus major muscle, 24  
     minor muscle, 24

THE END











UNIVERSITY OF CALIFORNIA  
MEDICAL CENTER LIBRARY

---

**THIS BOOK IS DUE ON THE LAST DATE  
STAMPED BELOW**

Books not returned on time are subject to a fine of 50c per volume after the third day overdue, increasing to \$1.00 per volume after the sixth day. Books not in demand may be renewed if application is made before expiration of loan period.

59547

