

















QUAIN'S ANATOMY.



2  
1  
Sept.  
QUAIN'S

# ELEMENTS OF ANATOMY /

*A. K. Fisher M.D.*  
EDITED BY

*Sept 28 1880*  
WILLIAM SHARPEY, M.D., LL.D., F.R.S. L. & E.,  
EMERITUS PROFESSOR OF ANATOMY AND PHYSIOLOGY IN UNIVERSITY COLLEGE, LONDON

ALLEN THOMSON, M.D., LL.D., F.R.S. L. & E.,  
PROFESSOR OF ANATOMY IN THE UNIVERSITY OF GLASGOW

AND

EDWARD ALBERT SCHÄFER  
ASSISTANT PROFESSOR OF PHYSIOLOGY IN UNIVERSITY COLLEGE, LONDON

IN TWO VOLUMES.

ILLUSTRATED BY UPWARDS OF 950 ENGRAVINGS ON WOOD.

VOL. I.

Eighth Edition.



NEW YORK  
WILLIAM WOOD AND CO., PUBLISHERS  
27 GREAT JONES STREET  
1878.



## ADVERTISEMENT

TO THE EIGHTH EDITION.



THE first four Editions of "Quain's Elements of Anatomy" were the work of the late Dr. Jones Quain; and it has been deemed advisable still to retain the title by which the book has been so long known, notwithstanding that in passing through the succeeding three Editions, and that which now appears, it has undergone alterations so extensive and fundamental that little of the original text now remains.

Of these later Editions, the fifth was brought out under the editorship of Professor Richard Quain and Dr. Sharpey; the sixth was edited by Dr. Sharpey and Professor Ellis, and the seventh by Dr. Sharpey and Dr. Allen Thomson, in association with Dr. Cleland, Professor of Anatomy in Queen's College, Galway, whose extensive and exact knowledge of the existing state of Anatomical Science was of much service throughout the work.

In the present Edition the distribution of the matter between the two volumes has been in some respects altered; and it is believed that the use of the book by students will be facilitated by the change.

The First Volume consists of the Special or Descriptive Anatomy of the Bones, Joints, Muscles, Vessels, and Nerves. It also includes the subject of Surgical Anatomy, which was formerly

treated of in a distinct chapter, originally written by Mr. Quain, but this is now incorporated, in substance at least, with the description of those Muscles and Bloodvessels to which it has special reference. It will be further noticed that the description of the Bones and Muscles has undergone considerable change, that in both of these sections a short account of the Morphology has been introduced, and that in that on the Muscles the varieties have been more fully described than in the previous Editions. The whole of this volume has been edited by Dr. Thomson, in association with Mr. David N. Knox, M.B., Demonstrator of Anatomy in the University of Glasgow, and assisted by Mr. H. Clarke in the description of the Bloodvessels, and by Dr. Gowers in that of the Cranial Nerves.

In the Second Volume the section on General Anatomy and the chapters on the Heart, the Respiratory, Vocal, Digestive, and Urinary Organs, and the Organs of the Senses, have been revised throughout, and in certain parts re-written by Dr. Sharpey, in association with Mr. Schäfer, by whom, it is right to state, the task has in large measure been performed. The Section on General Anatomy was completed and printed off in October, 1874. The account of the Brain and Spinal Cord has been carefully revised with especial regard to intimate structure, by Dr. Gowers, Assistant Physician to University College Hospital. Lastly, Dr. Thomson, who has revised the description of the Reproductive Organs, has contributed a chapter on Embryology, with which the second volume concludes. In this it has been his object to give, in such a form as is suited to an elementary work on Human Anatomy, a short general view of the Development of the Embryo, and of the Formation of the Membranes and the Placenta; and with this there is now brought together into one place the special history of the Development of the Several Organs of the Body which in the previous Edition was distributed throughout the work.

While due reference has been made to the leading authorities

on the different subjects treated of, many points have been re-investigated and new matter has been introduced from original observation.

A considerable number of new figures have been introduced into the present Edition, some having been substituted for former ones now withdrawn, others added as new illustrations. They are partly from original drawings, and partly electrotype copies of figures in other published works, for their courtesy in allowing copies of which the Editors have to thank the respective Authors and Publishers.

In the seventh Edition a large number of new figures were introduced, of which the originals were drawn by Dr. Allen Thomson, and by Mr. R. Tennant under his superintendence, and the engraving was executed by Mr. Stephen Miller of Glasgow. To these only a few have been added in the first volume of the present Edition. But in the General Anatomy and other parts of the Second Volume of the present Edition a considerable number of new figures have been added, the original drawings for which have been executed chiefly by Mr. Schäfer and Mr. Wesley, and the engravings by Mr. Pearson.

The Table of Contents and the Index, with the accompanying explanation of the derivation of terms, have been compiled by Dr. Alexander Henry.

*October, 1875.*





# CONTENTS.

## ELEMENTS OF ANATOMY.

	PAGE
INTRODUCTION . . . . .	1
Objects of Anatomy . . . . .	1
General and Descriptive Anatomy . . . . .	1
Plan of Organisation : Vertebrate Type . . . . .	2
Divisions of Descriptive Anatomy . . . . .	4

## DESCRIPTIVE OR SPECIAL ANATOMY.

	PAGE		PAGE
SECTION I.—OSTEOLOGY . . . . .	7	Inferior Turbinated Bones . . . . .	53
The Skeleton . . . . .	7	Inferior Maxillary Bone . . . . .	53
I. THE VERTEBRAL COLUMN . . . . .	9	Hyoid Bone . . . . .	55
Vertebræ . . . . .	9	THE SKULL AS A WHOLE . . . . .	56
General Characters . . . . .	9	The Sutures . . . . .	56
Groups of Vertebræ . . . . .	10	External Surface of the	
Cervical Vertebræ . . . . .	10	Skull . . . . .	58
Dorsal Vertebræ . . . . .	12	Interior of the Cranium . . . . .	62
Lumbar Vertebræ . . . . .	13	Nasal Cavities and Com-	
Sacral Vertebræ . . . . .	15	municating Air-Sinuses . . . . .	65
Coccygeal Vertebræ . . . . .	17	Ossification of the Bones of	
The Vertebral Column as a		the Head . . . . .	67
whole . . . . .	18	GENERAL MORPHOLOGY OF	
Ossification of the Vertebræ . . . . .	19	THE BONES OF THE HEAD . . . . .	73
General and Serial Homology of the Vertebræ . . . . .	22	Classified List of the Bones	
II. THE THORAX . . . . .		of the Head, and their	
The Sternum or Breast-Bone . . . . .	25	Typical Component	
The Ribs . . . . .	27	Parts . . . . .	74
The Costal Cartilages . . . . .	29	Various Forms of Skull . . . . .	77
The Thorax as a whole . . . . .	29	IV. BONES OF THE UPPER LIMB . . . . .	81
Ossification of the Ribs and		Scapula . . . . .	81
Sternum . . . . .	30	Clavicle . . . . .	84
III. THE BONES OF THE HEAD . . . . .	31	Humerus . . . . .	85
Occipital Bone . . . . .	31	Radius . . . . .	87
Parietal Bones . . . . .	34	Ulna . . . . .	88
Frontal Bone . . . . .	35	Carpus . . . . .	90
Temporal Bones . . . . .	37	Scaphoid Bone . . . . .	91
Sphenoid Bone . . . . .	41	Semilunar Bone . . . . .	91
Ethmoid Bone . . . . .	45	Cuneiform Bone . . . . .	91
Superior Maxillary Bones . . . . .	46	Pisiform Bone . . . . .	92
Palate Bones . . . . .	49	Trapezium Bone . . . . .	92
Vomer . . . . .	51	Trapezoid Bone . . . . .	92
Malar Bones . . . . .	51	Os Magnum . . . . .	92
Nasal Bones . . . . .	52	Unciform Bone . . . . .	93
Lachrymal Bones . . . . .	52	Metacarpus . . . . .	93
		Digital Phalanges . . . . .	94

	PAGE		PAGE
Ossification of the Bones of the Upper Limb . . .	95	ARTICULATIONS OF THE UPPER LIMB . . .	146
V. THE PELVIS AND LOWER LIMB . . .	100	The Scapulo-Clavicular Arch . . .	146
Innominate Bone . . .	100	Sterno-Clavicular Articulation . . .	146
Ilium . . .	101	Scapulo-Clavicular Articulation . . .	146
Os Pubis . . .	102	Ligaments of the Scapula . . .	148
Ischium . . .	103	Articulations of the Fore-Arm and Elbow . . .	150
The Pelvis . . .	104	Superior Radio-Ulnar Articulation . . .	150
Position of Pelvis . . .	105	Inferior Radio-Ulnar Articulation . . .	150
Differences according to Sex . . .	106	The Elbow-Joint . . .	152
Femur . . .	107	The Wrist-Joint and Articulations of the Hand . . .	154
Patella . . .	110	Radio-Carpal Articulation . . .	154
Tibia . . .	110	Carpal Articulations . . .	155
Fibula . . .	112	Carno-Metacarpal and Intermetacarpal Articulations . . .	157
Tarsus . . .	114	Metacarpo-Phalangeal and Interphalangeal Articulations . . .	158
Calcanem or Os Calcis . . .	114	ARTICULATIONS OF THE PELVIS . . .	159
Astragalus . . .	115	Articulation of the Pelvis with the last Lumbar Vertebra . . .	159
Scaphoid Bone . . .	115	Articulation of the Sacrum and Coccyx, and of the Pieces of the Coccyx . . .	160
Cuneiform Bones . . .	115	Sacro-Iliac Articulation . . .	161
Cuboid Bone . . .	116	ARTICULATIONS OF THE LOWER LIMB . . .	163
Metatarsus . . .	116	The Hip-Joint . . .	163
Phalanges . . .	117	The Knee-Joint . . .	166
The Bones of the Foot as a Whole . . .	117	Tibio-Fibular Articulations . . .	172
Ossification of the Bones of the Pelvis and Lower Limb . . .	118	The Ankle-Joint . . .	173
MORPHOLOGY OF THE BONES OF THE LIMBS . . .	122	Articulations of the Foot . . .	174
Relation to the Axial Skeleton . . .	122	Articulations of the Calcanem, Astragalus, and Scaphoid Bones . . .	174
Homological Comparison of Upper and Lower Limbs . . .	123	Calcanem-Cuboid Articulation . . .	176
Shoulder and Pelvic Girdles . . .	123	Articulations of the Scaphoid, Cuboid, and Cuneiform Bones . . .	177
Bones of the Limbs . . .	124	Articulation of the Tarsus with the Metatarsus . . .	179
Hand and Foot . . .	127	Metatarso-Phalangeal and Interphalangeal Articulations . . .	181
Table of the Homologous Bones in the Thoracic and Pelvic Limbs . . .	129	SECTION III.—MYOLOGY.	
Carpus and Tarsus . . .	129	THE MUSCLES IN GENERAL . . .	183
Scapula and Ilium . . .	129	FASCLE . . .	185
Adaptation of the Skeleton to the Erect Attitude . . .	129	MUSCLES AND FASCLE OF THE UPPER LIMB . . .	187
SECTION II.—ARTHROLOGY . . .	131	Between the Trunk and Upper Limb posteriorly . . .	187
THE ARTICULATIONS IN GENERAL . . .	131	Between the Trunk and Upper Limb anteriorly . . .	193
Various Forms of Joints . . .	131		
Various kinds of Movement . . .	132		
ARTICULATIONS OF THE TRUNK AND HEAD . . .	133		
Articulations of the Vertebral Column . . .	133		
Articulations of the Atlas, Axis, and Occipital Bone . . .	137		
Articulations of the Ribs . . .	140		
Temporo-Maxillary Articulation . . .	144		

PAGE	PAGE
Action of the Muscles between the Trunk and Upper Limb . . . . .	198
Muscles and Fasciæ of the Shoulder . . . . .	199
Muscles and Fasciæ of the Upper Arm . . . . .	205
Muscles and Fasciæ of the Fore-Arm . . . . .	208
Pronator and Flexor Muscles . . . . .	209
Supinator and Extensor Muscles . . . . .	215
Muscles of the Hand . . . . .	221
Muscles of the Thumb . . . . .	221
Muscles of the Little Finger . . . . .	222
Interosseous Muscles . . . . .	222
Action of the Muscles of the Fore-Arm and Hand . . . . .	224
<b>MUSCLES AND FASCIAE OF THE LOWER LIMB</b> . . . . .	226
Fasciæ of the Hip and Thigh . . . . .	226
Muscles of the Hip . . . . .	228
Posterior Femoral or Hamstring Muscles . . . . .	232
Anterior Muscles of the Thigh . . . . .	234
Internal Femoral or Adductor Muscles . . . . .	240
Action of the Muscles of the Hip and Thigh . . . . .	243
Muscles and Fasciæ of the Leg and Foot . . . . .	243
Anterior Region . . . . .	243
External Region . . . . .	248
Posterior Region . . . . .	248
The Plantar Fasciæ and Muscles . . . . .	255
First layer of Muscles . . . . .	256
Second layer . . . . .	257
Third layer . . . . .	257
Fourth layer . . . . .	258
Action of the Muscles of the Leg and Foot . . . . .	259
<b>MORPHOLOGY OF THE LIMB-MUSCLES</b> . . . . .	260
Table of Muscular Homologies in the Upper and Lower Limb . . . . .	262
<b>MUSCLES AND FASCIAE OF THE HEAD AND NECK</b> . . . . .	264
Epicranial Region . . . . .	264
Auricular Muscles . . . . .	265
Muscles of the Eyelids and Eyebrows . . . . .	265
Muscles of the Nose . . . . .	269
Muscles of the Lips and Mouth . . . . .	270
Muscles of the Orbit . . . . .	275
Muscles of Mastication . . . . .	278
Muscles between the Lower Jaw and the Hyoid Bone . . . . .	281
Muscles of the Pharynx and Soft Palate . . . . .	286
Subcutaneous Muscle of the Neck . . . . .	290
Muscles and Fasciæ of the Neck anteriorly . . . . .	291
Deep Lateral and Prevertebral Muscles of the Neck . . . . .	295
<b>MUSCLES AND FASCIAE OF THE TRUNK</b> . . . . .	297
Dorsal Muscles and Fasciæ . . . . .	297
Muscles of the Thorax . . . . .	306
Intercostal Muscles . . . . .	306
Diaphragm . . . . .	308
Movements of Respiration . . . . .	311
Muscles and Fasciæ of the Abdomen . . . . .	314
Lining Fascia of the Abdomen . . . . .	324
Muscles and Fasciæ of the Perinæum and Pelvis . . . . .	325
Fasciæ of the Perinæum . . . . .	325
Fasciæ of the Pelvis . . . . .	326
Muscles : A. in the Male . . . . .	327
B. in the Female . . . . .	331
<b>MORPHOLOGY OF THE FASCIAE AND MUSCLES OF THE TRUNK AND HEAD</b> . . . . .	332
<b>SURGICAL ANATOMY OF HERNIAE</b> . . . . .	335
Inguinal Hernia . . . . .	335
Femoral Hernia . . . . .	340
<b>SECTION IV.—ANGEIOLOGY.</b> . . . .	343
<b>BLOOD-VESSELS; ARTERIES AND VEINS</b> . . . . .	343
<b>PULMONARY ARTERIES AND VEINS</b> . . . . .	345
Pulmonary Artery . . . . .	345
Pulmonary Veins . . . . .	346
<b>THE SYSTEMIC ARTERIES</b> . . . . .	346
<b>AORTA</b> . . . . .	346
Arch of the Aorta . . . . .	346
Varieties of the Aorta and Pulmonary Arteries . . . . .	350
<b>BRANCHES OF THE ARCH OF THE AORTA</b> . . . . .	353
Coronary Arteries . . . . .	353
Innominate Artery . . . . .	355
Common Carotid Arteries . . . . .	356
Surgical Anatomy of the Common Carotid Artery . . . . .	360
External Carotid Artery . . . . .	360
Branches . . . . .	361
Internal Carotid Artery . . . . .	374
Branches . . . . .	375
Distribution of the Arteries in the Cerebrum . . . . .	378
Subclavian Arteries . . . . .	379
Branches . . . . .	383
Surgical Anatomy of the Subclavian Arteries . . . . .	392

	PAGE		PAGE
Axillary Artery . . . . .	394	Subclavian Vein . . . . .	489
Branches . . . . .	395	Azygos Veins . . . . .	489
Brachial Artery . . . . .	399	Veins of the Spine . . . . .	491
Branches . . . . .	401	INFERIOR VENA CAVA . . . . .	493
Surgical Anatomy of the		Veins of the Pelvis and	
Brachial Artery . . . . .	405	Lower Limb . . . . .	495
Ulnar Artery . . . . .	407	Superficial Veins of the	
Branches . . . . .	407	Lower Limb . . . . .	495
Superficial Palmar Arch . . . . .	411	Deep Veins of the Lower	
Radial Artery . . . . .	413	Limb . . . . .	496
Branches . . . . .	415	External Iliac Vein . . . . .	498
Deep Palmar Arch . . . . .	418	Internal Iliac Vein . . . . .	498
DESCENDING THORACIC AORTA . . . . .	419	Common Iliac Vein . . . . .	500
Branches to the Viscera . . . . .	420	PORTAL SYSTEM OF VEINS . . . . .	500
Parietal Branches to the		VEINS OF THE HEART . . . . .	503
Thorax . . . . .	420	THE ABSORBENT VESSELS . . . . .	504
ABDOMINAL AORTA . . . . .	422	Thoracic Duct . . . . .	504
A.—Visceral Branches of		Right Lymphatic Duct . . . . .	506
the Abdominal Aorta . . . . .	424	Lymphatics of the Lower	
B.—Parietal Branches of		Limb . . . . .	506
the Abdominal Aorta . . . . .	435	Lymphatics of the Abdomen	
Minute Anastomoses of the		and Pelvis . . . . .	508
Visceral and Parietal		Lymphatics of the Thorax . . . . .	512
Branches of the Abdo-		Lymphatics of the Upper	
minal Aorta . . . . .	436	Limb . . . . .	514
Middle Sacral Artery . . . . .	437	Lymphatics of the Head and	
Common Iliac Artery . . . . .	437	Neck . . . . .	516
Surgical Anatomy of the			
Common Iliac Artery . . . . .	439	SECTION V.—NEUROLOGY . . . . .	519
Internal Iliac Artery . . . . .	439	THE CEREBRO-SPINAL NERVES . . . . .	519
Hypogastric Artery . . . . .	440	I. CRANIAL NERVES . . . . .	519
Branches of the Internal		Connection with Ence-	
Iliac Artery . . . . .	440	phalon . . . . .	520
External Iliac Artery . . . . .	450	Mode of Exit from the	
Branches . . . . .	451	Cranium . . . . .	522
Surgical Anatomy of the		General Distribution . . . . .	523
Iliac Arteries . . . . .	453	Olfactory Nerve . . . . .	526
Femoral Artery . . . . .	453	Optic Nerve . . . . .	527
Branches . . . . .	456	Third Pair of Nerves . . . . .	528
Surgical Anatomy of the		Position of Nerves at the	
Femoral Artery . . . . .	461	Cavernous Sinus and as	
Popliteal Artery . . . . .	461	they enter the Orbit . . . . .	530
Branches . . . . .	461	Fourth Pair of Nerves . . . . .	530
Posterior Tibial Artery . . . . .	463	Fifth Pair of Nerves . . . . .	532
Branches . . . . .	464	Ophthalmic Division . . . . .	534
Plantar Arteries . . . . .	465	Ophthalmic Ganglion . . . . .	536
Anterior Tibial Artery . . . . .	468	Superior Maxillary Nerve . . . . .	537
Dorsal Artery of the Foot . . . . .	469	Spheno-Palatine Ganglion . . . . .	540
THE SYSTEMIC VEINS . . . . .	472	Inferior Maxillary Nerve . . . . .	542
SUPERIOR VENA CAVA . . . . .	472	Otic Ganglion . . . . .	546
Innominate or Brachio-		Submaxillary Ganglion . . . . .	547
Cephalic Veins . . . . .	473	Sixth Pair of Nerves . . . . .	547
Veins of the Head and		Seventh Pair of Nerves . . . . .	548
Neck . . . . .	475	Facial Nerve . . . . .	548
Venous Circulation with-		Auditory Nerve . . . . .	553
in the Cranium . . . . .	480	Eighth Pair of Nerves . . . . .	554
Cerebral Veins . . . . .	480	Glosso-Pharyngeal Nerve . . . . .	554
Cranial Sinuses . . . . .	481	Pneumo-Gastric Nerve . . . . .	556
Ophthalmic Vein . . . . .	484	Spinal Accessory Nerve . . . . .	564
Veins of the Diploë . . . . .	485	Ninth Pair of Nerves . . . . .	565
Veins of the Upper Limb . . . . .	485	II. SPINAL NERVES.	
Superficial Veins . . . . .	486	The Roots of the Spinal	
Deep Veins . . . . .	487	Nerves . . . . .	569
Axillary Vein . . . . .	488		

	PAGE		PAGE
Posterior Primary Divisions		Fourth Sacral Nerve . . . . .	608
of the Spinal Nerves . . . . .	571	Fifth Sacral Nerve . . . . .	608
The Suboccipital Nerve . . . . .	571	The Coccygeal Nerve . . . . .	608
Cervical Nerves . . . . .	573	The Sacral Plexus . . . . .	609
Dorsal Nerves . . . . .	574	Small Muscular	
Lumbar Nerves . . . . .	574	Branches . . . . .	612
Sacral Nerves . . . . .	574	The Pudic Nerve . . . . .	610
Coccygeal Nerves . . . . .	575	Small Sciatic Nerve . . . . .	613
Anterior Primary Divisions		Great Sciatic Nerve . . . . .	615
of the Spinal Nerves . . . . .	575	Internal Popliteal	
Cervical Nerves . . . . .	575	Nerve . . . . .	616
Suboccipital Nerve . . . . .	575	Posterior Tibial Nerve . . . . .	617
Second Cervical Nerve . . . . .	576	Internal Plantar	
The Cervical Plexus . . . . .	577	Nerve . . . . .	617
Superficial Ascending		External Plantar	
Branches . . . . .	577	Nerve . . . . .	619
Superficial Descending		External Popliteal	
Branches . . . . .	578	Nerve . . . . .	619
Deep Branches; In-		Anterior Tibial	
ternal Series . . . . .	578	Nerve . . . . .	621
Deep Branches; Exter-		SYNOPSIS OF THE CUTANEOUS	
nal Series . . . . .	580	DISTRIBUTION OF THE	
The Brachial Plexus . . . . .	582	CEREBRO-SPINAL NERVES . . . . .	622
Branches above the Clavicle . . . . .	582	SYNOPSIS OF THE MUSCULAR	
Branches below the Clavicle . . . . .	584	DISTRIBUTION OF THE	
Anterior Thoracic		CEREBRO-SPINAL NERVES . . . . .	624
Nerves . . . . .	584	III. SYMPATHETIC NERVES . . . . .	626
Subscapular Nerves . . . . .	584	Cervical Part of the Gang-	
Circumflex Nerve . . . . .	584	liated Cord . . . . .	628
Internal Cutaneous		Upper Cervical Ganglion	
Nerve . . . . .	585	Ascending Branch	
Musculo - Cutaneous		and Cervical Plex-	
Nerve . . . . .	587	uses . . . . .	628
Ulnar Nerve . . . . .	588	Pharyngeal Nerves	
Median Nerve . . . . .	590	and Plexus . . . . .	630
Musculo-Spiral Nerve . . . . .	592	Upper Cardiac Nerve	
Radial Nerve . . . . .	593	Branches to Blood-	
Posterior Interosseous		vessels . . . . .	632
Nerve . . . . .	594	Middle Cervical Gang-	
Dorsal Nerves . . . . .	595	lion . . . . .	632
First Dorsal Nerve . . . . .	595	Lower Cervical Gang-	
Upper or Pectoral In-		lion . . . . .	633
tercostal Nerves . . . . .	595	Thoracic Part of the Gang-	
Lower or Abdominal		liated Cord . . . . .	633
Intercostal Nerves . . . . .	597	Branches of the Ganglia	
Last Dorsal Nerve . . . . .	598	Lumbar Part of the Gang-	
Lumbar Nerves . . . . .	598	liated Cord . . . . .	636
The Lumbar Plexus . . . . .	598	Sacral Part of the Gang-	
Ilio - Hypogastric and		liated Cord . . . . .	636
Ilio - Inguinal Nerves . . . . .	600	Coccygeal Gland . . . . .	637
Genito-Crural Nerve . . . . .	601	The Great Plexuses of the	
External Cutaneous		Sympathetic . . . . .	638
Nerve . . . . .	602	Cardiac Plexus . . . . .	638
Obturator Nerve . . . . .	602	Solar or Epigastric	
Anterior Crural Nerve . . . . .	604	Plexus . . . . .	639
Fifth Lumbar Nerve . . . . .	607	Hypogastric Plexus . . . . .	641
Sacral and Coccygeal		Pelvic Plexus . . . . .	641
Nerves . . . . .	608	INDEX . . . . .	645



## CORRIGENDA AND ADDENDA.

- Page 26, line 6 from bottom, for "xyphisternum," read "xiphisternum."
- Page 69, line 6 from bottom, for "Opistotic," read "Opisthotic."
- Page 81. In third paragraph under Scapula, line 3, for "regular," read "oblique."
- Page 87. In paragraph under Varieties, line 7, for "completing," read "enclosing."
- Page 94. At the end of paragraph in small type, after "middle row," add "but this view is not generally adopted by anatomists."
- Page 99, line 13 from the bottom, for "epiphysis," read "epiphyses."
- Page 111, line 12, insert the word "crucial" before "spine."
- Page 129. In title of Table II, instead of "after Gegenbaur," read "modified from that of Gegenbaur."
- Page 158, line 17, omit "A. T."
- Page 172, line 26, for "relaxed," read "expanded."
- Page 175, line 17, for "lateral ligaments," read "internal lateral ligament."
- Page 176. In Figure 158, a posterior ligament is erroneously represented.
- Page 181, line 15 from the bottom, for "Interdigital," read "Interphalangeal."
- Page 186, line 16 from the bottom, for "rectinacula," read "retinacula."
- Page 220, line 4 from the bottom, insert a comma after "anconeus," and one after "supinator longus."
- Page 276, line 5 from the bottom, for "orbitis," read "orbitæ."
- Page 329, near middle, for "levator coccygei," read "levator coccygis."
- Page 343, at the top, for "ANGIOLOGY," read "ANGEOLOGY."
- Page 361, near the bottom, for "CARTOID," read "CAROTID."
- Page 375. In small print paragraph under "Branches," line 1, for "lachmyral," read "lachrymal."

• Concluded





The present edition (1878) is a reprint,  
without alteration, of the eighth edition, published in 1875.



# ELEMENTS OF ANATOMY.

---

---

## INTRODUCTION.

**Object of Anatomy.**—The object of Anatomy, in its most extended sense, is to ascertain and make known the Structure of Organised Bodies. But the science is divided into departments according to its subjects; such as, Human Anatomy, in which, as in the present work, the structure of man forms the principal subject; Comparative Anatomy, comprehending, as a whole or in various subdivisions, the study of the structure of different animals; and Vegetable Anatomy, comprehending the investigation of the structure of plants.

**Organs and Textures.**—On examining the structure of an organised body, we find that it is made up of members or organs, through means of which its functions are executed, such as the root, stem and leaves of a plant, and the heart, brain, stomach, and limbs of an animal; and farther, that these organs are themselves made up of certain constituent materials named tissues or textures, as the cellular, woody, and vascular tissues of the vegetable, or the osseous, muscular, connective, vascular, nervous, and other textures, which form the animal organs.

Most of the textures occur in more than one organ, and some of them indeed, as the connective and vascular, in nearly all, so that a multitude of organs, and these greatly diversified, are constructed out of a small number of constituent tissues, just as many different words are formed by the varied combination of a few letters; and parts of the body, differing widely in form, construction, and uses, may agree in the nature of their component materials. Again, as the same texture possesses the same essential characters in whatever organ or region it is found, it is obvious that the structure and properties of each tissue may be made the subject of investigation apart from the organs into whose formation it enters.

**General and Descriptive Anatomy.**—The foregoing considerations naturally point out to the anatomist a twofold line of study, and have led to the subdivision of anatomy into two branches, the one of which treats of the nature and general properties of the component textures of the body; the other treats of its several organs, members, and regions, describing the outward form and internal structure of the parts, their relative situation and mutual connection, and the successive conditions which they present in the progress of their formation or development. The former is usually named "General" Anatomy, or "Histology";\* the latter "Descriptive" or "Special" Anatomy.

\* From *ιστὸς*, a web.

Descriptive Anatomy may be treated of in two methods ; viz., the *Systematic* and the *Topographical*.

In the first or Systematic Anatomy, the several organs and parts of the body are considered in a systematic order, according to their structure, their connection with each other, and their relation to the purposes of life ; while in the second, or Topographical Anatomy, the parts are described in the order of their position or association in the same region of the body. The first method is best adapted for the elementary and complete study of the structure of organs, the second is more immediately useful in the study of particular regions in their relation to medicine and surgery. The object of the present work being mainly to serve as a guide for systematic study, the topographical details will be included under and combined with the general description of organs.

The anatomical description of any organ embraces the consideration of its form, size, position, connection and texture ; the whole of these comprising the structure of the organ. The adult or fully formed condition of the body is commonly assumed as the subject of this description ; but it is obvious that a consideration of the structure of the body and its organs in different stages of life is required to render the knowledge of their anatomy complete. The study of the origin and formation of organs in the embryo, known under the names of *Embryological Anatomy* or *Fœtal Development*, to which a separate chapter will be devoted in this work, is of peculiar importance in indicating the general relations of organic structure.

The study of anatomy may be viewed in two different aspects ; viz., the Physiological and the Morphological. In connection with the first, anatomy supplies the materials relating to structure from which an explanation is sought of the uses or functions of organs by the physiologist ; and for this purpose the study of Textural Anatomy is of particular service. In connection with the study of Morphology, Descriptive Anatomy investigates and combines the facts relating to structure and relations of organs, from which may be deduced general principles as to the construction of the human body or that of animals. In the determination of these general principles, or laws of Morphology, it is necessary to combine the knowledge of the anatomy of animals with that of man, and both of these with the study of development.

#### PLAN OF ORGANISATION.

**Vertebrate Type.**—The general plan of construction of the human body agrees closely with that which prevails in a certain number of animals, viz., mammals, birds, reptiles, amphibia, and fishes, and is known as the vertebrate type of organisation. The main feature of that type, and that from which its name is derived, belongs to the internal skeleton, and consists in the existence of a number of bones (or cartilaginous substitutes) termed vertebræ, which extend in a longitudinal series through the whole trunk of the body, and which by their more solid part, termed *centrum* or *body*, are so disposed as to form a pillar or axis, round which the rest of the parts are arranged with a certain conformity of structure. At one extremity of this pillar is situated the *head*, present-

ing in almost all the animals formed upon this type the character of increased development of its constituent parts: and at the other the *tail* in which an opposite character or that of diminution prevails: while on the sides of the main part or *trunk*, there project in relation with some of the vertebral elements two pairs of symmetrical *limbs* in two situations, which are determinate and similar in different animals.

The head and trunk contain the organs or viscera most important to life, such as the alimentary canal and the great central organs of the sanguiferous and nervous systems, while the limbs, from which such principal organs are absent, are less constant and differ more in the degree of their development among the various animals formed upon the vertebrate type. The whole body may thus be regarded as being formed of an *axial portion* consisting of the head and trunk, and of *appendicular portions* comprising the limbs. In man and the higher animals especially, the trunk presents a division into the neck, chest, abdomen, and pelvis.

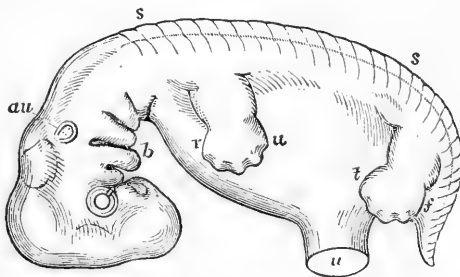
The vertebrate form of skeleton is invariably accompanied by a determinate and conformable disposition of the other most important organs of the body—as *first*, by the existence on the dorsal aspect of the vertebral axis of an elongated cavity or canal which contains the brain and spinal cord, or central organs of the nervous system; and *second*, by the existence on the ventral aspect of the vertebral axis of a larger cavity, the visceral cavity, in which are contained the principal viscera connected with nutrition, such as the alimentary canal, the heart and lungs, the great blood-vessels, and the urinary and genital organs.

The general disposition of the parts of the body and of the more important viscera in their relation to the vertebral axis are shown in the accompanying figures of the external form and longitudinal and transverse sections of the human embryo at an early period of its existence, when its structure resembles more closely that of the lower animals.

Fig. 1.—LATERAL VIEW OF THE HUMAN EMBRYO ABOUT SEVEN WEEKS OLD; THE VERTEBRAL AXIS PLACED HORIZONTALLY. MAGNIFIED ABOUT 7 DIAMETERS. (A.T.)

*s, s*, indications of the vertebral divisions along the line of the back; *r, u*, anterior or upper limb; *t, f*, posterior or lower limb; *u*, umbilical opening. In the cranial part the divisions of the brain are indicated, together with the eye, and *au*, the auditory vesicle; near *b*, the ventral plates of the head with the rudiments of the upper and lower jaws. These plates and the apertures between are represented in a state belonging to a somewhat earlier stage than the rest of the body.

Fig. 1.



**Segmented Character.**—The vertebrate type of organisation possesses, therefore, in the repetition of similar structural elements in a longitudinal series

a segmented character, especially in the axial portion of the body, and this segmentation affects more or less, not merely the skeletal parts of its structure, but also, to some extent, its other component organs.

Fig. 2.

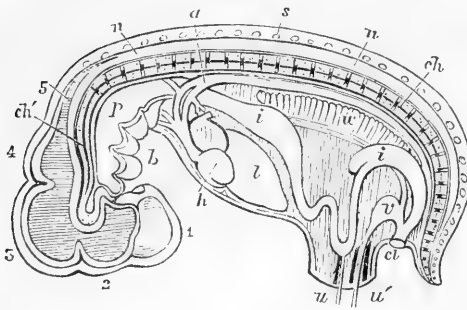


Fig. 2.—SEMIDIAGRAMMATIC VIEW OF A LONGITUDINAL SECTION OF THE EMBRYO REPRESENTED IN FIGURE 1; SHOWING THE RELATIONS OF THE PRINCIPAL SYSTEMS AND ORGANS TO EACH OTHER IN THE HORIZONTAL POSITION OF THE VERTEBRAL AXIS. (A. T.)

1, 2, 3, 4, 5, primary divisions of the brain in the cranial part of the neural canal; *n, n*, spinal cord in the vertebral part of the same; *s*, one of the spinous processes of the vertebrae

(4th dorsal); *ch*, chorda dorsalis running through the axis of the vertebral centra or bodies; *ch'*, the same extending into the base of the cranium; *a*, dorsal aorta; *p*, pharyngeal cavity; *i, i*, alimentary canal; *h*, ventricular part of the heart, from which the arterial bulb is seen joining the aorta by arches; *b*, branchial plates; *l*, liver; *v*, Wolffian body; *v*, urinary vesicle or allantois, joining the intestine in the cloaca; *u, u'*, umbilicus.

Fig. 3.

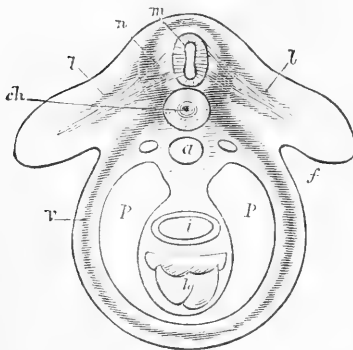


Fig. 3.—TRANSVERSE SECTION (DIAGRAMMATIC) OF THE TRUNK OF THE EMBRYO THROUGH THE ANTERIOR LIMBS. (A. T.)

*m*, spinal cord; *n*, neural or dorsal arch, including bone, muscle, skin, roots of the nerves, &c.; *ch*, chorda dorsalis, surrounded by the vertebral body or centrum; *v*, ventral or visceral arch, or wall of the body; *p, p*, pleuro-peritoneal cavity; *i*, alimentary canal; *h*, heart; *l, l*, the rudimentary limbs.

Fig. 4.

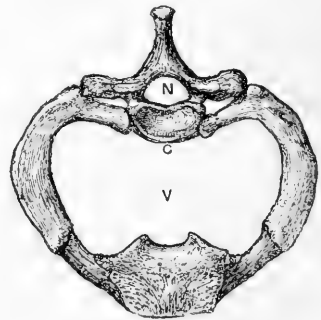


Fig. 4.—FIRST DORSAL VERTEBRA WITH THE FIRST RIB AND UPPER PART OF THE STERNUM, SEEN FROM ABOVE.  $\frac{1}{2}$

*C*, body or centrum; *N*, neural arch or vertebral ring; *V*, cavity of the chest, visceral cavity.

It is true that a segmented plan of construction is not restricted to vertebrate animals, but exists in several other classes of the animal kingdom, as is most conspicuously seen in the class Articulata, such as insects and crustacea. In these animals, however, there are many important deviations from the verte-

brate type of organisation, although there is an agreement in the repetition of parts of like structure in a longitudinal series; and it is unnecessary here to trace the correspondence between their structure and that of man.

In the human body, as in that of all vertebrate animals, the character of segmentation is most obvious in the osseous and nervous systems, so that the form and structure of the other systems seem to be in some measure moulded upon those of the skeleton and cerebro-spinal axis.

The trunk of the body more especially is formed of a series of parts or segments of similar structure sufficiently distinct in some of the systems, but more or less blended together in others. Such ideal segments of the body may be named *vertebral segments*, or *somatomes* (Goodsir). In the limbs, although in the earliest stages of their formation some segmental connection may be traced between them and the trunk, the repetition of vertebral elements is, in their more advanced state of growth greatly obscured by the modifications of form and structure they have undergone.

**Vertebrate Homology.**—A correspondence in the structure and connection of parts or organs constitutes what is now called anatomical *homology*, and the same term is frequently employed to designate anatomical correspondence of parts serially repeated in the same animal: but for this last or serial homology the modified term of *homotypy*, suggested by Owen, may with advantage be substituted. Thus, the arm-bone or humerus of man is homologous with the upper bone of the foreleg of a quadruped or of the wing of a bird, while it is properly homotypic with the thigh-bone of man himself or any other vertebrate animal. It has further been found convenient to express by the word *analogy* that kind of resemblance among the organs of animals which, though indicating similarity of function, and even in some respects of structure, is not rendered complete by anatomical relation and connection. This general resemblance may be very great; but it is of a different kind from that absolute identity which is implied by the term anatomical homology, which is intended to convey the idea of entire correspondence in fundamental structure, position, and connection of any organ, or set of organs, in relation to a general plan or type of construction of the organism, and which might be almost looked upon as synonymous with anatomical identity—a correspondence, too, which is conceived to be traceable through all the modifications, however great, which the form and structure of the organs may have undergone in the course of their development. Thus, the heart of a fish or amphibian, though very different in external form and internal arrangement, is strictly homologous with that of a mammal or of man; or, in other words, it is anatomically the corresponding organ. But the heart of the crustacean, though muscular in its structure, and fitted to propel the blood through the system, and thus *analogous* to the heart of a vertebrate animal, is not regarded as strictly homologous with it, because it differs in its anatomical relation to the rest of the organism, and cannot be referred to the same place in a general plan of structure.

**Symmetry of Form.**—A remarkable regularity of form pervades the organisation of certain parts of the body, especially the whole of the limbs, the head and neck, and the framework, at least, and external walls of the trunk of the body. Thus, if we conceive the body to be divided by a plane which passes from its dorsal to its ventral aspect (*mesial* plane), the two halves, in so far as regards the parts previously mentioned, correspond almost exactly with each other, excepting by their lateral transposition,—and the human body thus presents in a marked manner the character of *lateral symmetry*. There is, however, a departure from this symmetrical form in the developed condition of certain of the internal organs, such as the alimentary canal from the stomach downwards, the heart and first part of the great bloodvessels, the liver, spleen, and some other viscera, which are therefore styled the non-symmetrical parts or viscera.

But, while the parts on each side of the mesial plane are thus so far symmetrical, the same correspondence does not hold between parts situated in the dorsal and ventral regions, nor even between those placed in the cephalic and caudal extremities of the body. In the first, with the exception of the division of the ventrally-placed sternum into segments which often correspond to a certain number of the dorsal vertebræ, no such dorso-ventral symmetry exists: and in the

longitudinal axis of the trunk, as previously stated, the similarity between the cephalic and caudal parts is of a different and only a remote kind; that, viz., which is involved in the repetition in series of vertebral elements, which, though fundamentally similar, yet differ greatly in the form and development of their parts.

**Descriptive Terms.**—In the description of parts so numerous, so various in form, and so complex in their connections as those composing the human body, there is difficulty in finding terms which shall indicate with sufficient precision their actual position and their relation to the rest of the organism. This difficulty is farther increased by the exceptional erect attitude in which the trunk of the human body is placed as compared with the horizontal position in animals. Hence, a number of terms have long been in use in human anatomy which are understood in a technical or restricted sense. The *mesial plane*, for example, already referred to, is that by which the body might be divided into right and left lateral halves, and the *middle or median line* is that in which the mesial plane meets the surface of the body. The words *internal* and *external* are used to denote relative nearness to and distance from the mesial plane towards either side, and might therefore be replaced by *mesial* and *lateral*. The words *anterior* and *posterior*, *superior* and *inferior*, and several others indicating position, are employed in human anatomy strictly with reference to the erect posture of the body. But now that the more extended study of comparative anatomy and embryonic development is largely applied to the elucidation of the human structure, it is very desirable that descriptive terms should be sought which may without ambiguity indicate position and relation in the organism at once in man and animals.

Such terms as *dorsal* and *ventral*, *neural* and *visceral*, *cephalic* and *caudal*, *central* and *peripheral*, *proximal* and *distal*, *axial* and *appendicular*, *preaxial* and *postaxial*, are of this kind, and ought, whenever this may be done consistently with sufficient clearness of description, to take the place of those which are only applicable to the peculiar attitude of the human body, so as to bring the language of human and comparative anatomy as much as possible into conformity. In many instances, also, precision may be obtained by reference to certain fixed relations of parts, such as the *vertebral* and *sternal* aspects, the *radial* or *ulnar*, and the *tibial* or *fibular* borders, the *flexor* or *extensor* surfaces of the limbs, and similarly in other parts of the body.

#### DIVISIONS OF DESCRIPTIVE ANATOMY.

The systems and organs of the body to be described in this work may conveniently be brought under the following divisions, viz. :—

1. Osteology, the Bones.
2. Arthrology, the Joints.
3. Myology, the Voluntary Muscles, with the Fasciæ and Aponeuroses.
4. Angeiology, the Distribution of the Blood-vessels and Lymphatics.
5. Neurology, the Distribution of the Nerves.
6. Splanchnology, the Viscera, including—
  - a. The Brain and Spinal Cord.
  - b. The Organs of the Senses.
  - c. The Heart.
  - d. The Lungs and Organs of Respiration.
  - e. The Organs of Digestion with the Accessory Glands.
  - f. The Urinary Organs.
  - g. The Organs of Reproduction.

The integuments will be described in the part on General Anatomy.



# DESCRIPTIVE OR SPECIAL ANATOMY.

## OSTEOLOGY.

### THE SKELETON.

THE **Skeleton** or solid framework of the body is mainly formed of the bones, but is completed in some parts by the addition of cartilages. The bones are bound together by means of ligaments, and are so disposed as to support the softer parts, protect delicate organs, and give attachment to the muscles by which the different movements are executed.

In the lower animals the term skeleton has a wider signification than in man, comprehending two sets of parts, viz., 1st, those of the *endo-skeleton*, or the deeper osseous and cartilaginous framework which corresponds to the human skeleton; and 2nd, those of the *exo-skeleton*, or *dermal-skeleton*, comprising the integument and various hardened structures connected with it. All vertebrate animals possess an endo-skeleton; but in some of them the exo-skeleton attains greater proportions than in others, and is combined by means of hardened parts more fully with portions of the endo-skeleton. In almost all invertebrate animals the dermal or exo-skeleton alone exists.

In man, as in the higher vertebrates, the greater part of the endo-skeleton is formed of bone, a calcified animal tissue, which, when freed by putrefactive maceration from its fat and various soft adherent parts, and subsequently dried, is capable of remaining unchanged for a very long period of time. It is customary and convenient thus to study the bones chiefly in the macerated and dried state, that is, deprived of their accessory soft parts.

Certain accessory soft parts are connected with the bones: these consist chiefly of the external fibrous and vascular covering termed *periosteum*, and of the *medulla*, marrow or fat, which fills their larger internal cavities. The bones are permeated by blood-vessels, which supply materials for their nourishment, and they are provided also with absorbent vessels and with nerves in small quantity.

The **bony substance** or **osseous tissue** consists of an organised animal basis which is essentially fibrous in its structure, and is intimately combined with a large proportion of earthy and saline ingredients. The former gives tenacity, the latter hardness and rigidity to the osseous substance. The earthy and saline matter may be obtained separate by burning or calcination of bones in an open fire, and when this is done with sufficient care, these may be preserved in the form of the original bone. It constitutes about two-thirds of the weight of the dried substance of bone, and consists mainly of a tribasic phosphate of lime, or bone earth, together with about a fifth of carbonate of lime and smaller quantities of fluoride of calcium, chloride of sodium, and magnesian salts.<sup>5</sup>

The earthy ingredients and salts of bone may be removed by solution in hydrochloric acid, and there is thus obtained separately the

animal constituent or organised basis of the bone-tissue, which retains not only the general form, but also the minute structure of the original bone. This is a tough, flexible, and mainly fibrous substance, which is capable of being in great part resolved into gelatin by boiling.

The ends of the bones, when jointed moveably with others, are covered by a thin layer of dense permanent cartilage, called articular cartilage; and the adjacent bones are united together by fibrous ligaments which may be considered as continuous with the periosteum covering the rest of the bones. In some instances distinct bones are directly united by means of ligament or cartilage without any joint-cavity intervening. Thus the osseous system as a whole may be considered to be enveloped by a fibrous covering.

The bones are originally formed by a process termed **ossification** from soft substance. This process commences in the greater number of bones in cartilage; in some it begins in fibrous tissue or membrane; and in all instances the further growth of the bone substance takes place largely in the latter way. The deposit of bone begins generally at one spot, which is therefore called the original point or primary *centre* of ossification; but there are sometimes several of these from the first. In most bones, after considerable advance in growth by extension from the original centre, ossification occurs at comparatively later periods in one or more separate points, forming secondary or tertiary centres; and the portions of bones so formed, and remaining united to the main part for a time by intervening cartilage, are termed *epiphyses*. In many instances entire consolidation of the bone by the osseous union of the epiphyses does not take place till the full size has been attained, and this may be as late as the twenty-third or even the twenty-fifth year of life.

In their **outward form** the bones present much diversity, but have been reduced by anatomists to the following classes:—1. Long or cylindrical, such as the chief bones of the limbs. These consist of a body or shaft, cylindrical or prismatic in shape, and two extremities which are usually thicker than the shaft, and have smooth cartilaginous surfaces for articulation with neighbouring bones. The shaft is generally hollow and filled with marrow, by which sufficient size and strength are attained without undue increase of weight. 2. Tabular or flat bones, like the scapula, ilium, and the bones forming the roof and sides of the skull. 3. Short bones, which are more or less rounded or angular, as in the carpus and tarsus. 4. Irregular or mixed bones, mostly situated symmetrically across the median plane of the body, and often of a complex figure, such as the vertebræ.

In these differently shaped bones the osseous substance occurs in two forms, viz., the compact and the spongy. There is, however, no essential difference in structure or properties between these beyond that of thickness or thinness of the component material.

The surfaces of bones present various eminences, depressions, and other marks, to designate which the following terms are in common use. Any marked bony prominence is called a *process* or *apophysis*, the main part of the bone being sometimes named *diaphysis*; while processes originally ossified from a distinct centre are during their separate condition named *epiphyses*. A slender, sharp, or pointed eminence is named a *spine*, or *spinous process*; a blunt one a *tubercle*; a broad and rough one a *tuberosity*. The terms *crest*, *line*, and *ridge* are usually applied to a prominent border, or to an elevation running some way along the surface of a bone. A *head* (*caput*, *capitulum*, or *capitellum*) is a rounded process supported on a narrower part named the *neck* (*cervix*). The term *condyle*, some-

what variously applied by anatomists, is most frequently employed to denote an eminence bearing a flattened articular surface.

The cavities and depressions of bones are very various. An aperture or perforation, when short, is named a *foramen*; when continued some way as a passage it is termed a *canal* or *meatus*. A narrow slit is named a *fissure*, an open excavation or hollow in one or in several bones together is termed a *fossa*. This term is also sometimes applied to the socket of a joint, as in the *glenoid* or shallower, and the *cotyloid* or deeper form of joint cavity. *Sinus* and *antrum* are names applied to considerable cavities in the interior of certain bones. Besides these, various other terms are employed which do not require explanation, such as *notch*, (*incisura*) *groove*, *furrow*, (*sulcus*), &c.

**The number of bones** in the skeleton varies at different periods of life, some which are originally distinct becoming united together as the process of ossification advances. The following is a statement of the number usually reckoned as distinct in middle life :—

	Single bones.	Pairs.	Total.
The vertebral column . . . . .	26	...	26
The skull . . . . .	6	8	22
The hyoid bone . . . . .	1	...	1
The ribs and sternum . . . . .	1	12	25
The upper limbs . . . . .	...	32	64
The lower limbs . . . . .	...	31	62
	—	—	—
	34	83	200

Besides the bones included in the above enumeration, there exist likewise the small auditory ossicles, and various bones formed in tendons and called *sesamoid*, such as the patella, and those of the thumb and great toe, usually amounting to 8 pairs or 16 in all.

## I.—THE VERTEBRAL COLUMN.

The vertebral column is composed of a series of bones called *vertebræ*, which are united together, for the most part, by joints and elastic substance in such a manner that, although the amount of motion allowed between each pair is slight, the aggregate is sufficient to give the column very considerable flexibility. The *vertebræ* are originally thirty-three in number. Of these, the twenty-four upper remain separate in the adult, retaining their mobility, and are hence called *moveable* *vertebræ*. They are succeeded by five others, which rapidly diminish in size from above downwards, and which are united into one mass called the *sacrum*; beyond the *sacrum* are four dwindled terminal members of the series, which as age advances, likewise become more or less united, and form the *coccyx*. These sacral and coccygeal *vertebræ* have thus been called the *fixed* or *united* *vertebræ*.

**General characters of the *Vertebræ*.**—The general characters are best seen in the *vertebræ* placed near the middle of the column, of which the sixth dorsal *vertebra*, shown in Fig. 8, may serve as an example. Each has more or less the form of a ring, and presents for consideration a body, arch, and processes.

The *body* or *centrum* (Owen), is a short cylinder or disc, which forms the anterior part of the *vertebra*. Its superior and inferior surfaces are nearly flat. Its anterior aspect is convex from side to side, but slightly concave from above downwards. Its posterior surface forms part of the ring, and is slightly concave from side to side. These vertical surfaces

are pierced by numerous small foramina for the passage of blood-vessels, one or two of which foramina situated near the middle of the posterior surface are much larger than the others.

The *arch* consists of two symmetrical portions which spring, one on each side, from the posterior surface of the body, and meet in the middle line behind. The anterior part of each half, rounded and narrow, is called the *pedicle*; the posterior part is broad and flat, and is called the *lamina* (neurapophysis, Owen). The concavities on the upper and lower borders of the pedicles are named *notches*, and constitute by the apposition of those of contiguous vertebræ, the *intervertebral foramina*, a series of rounded apertures, which communicate with the vertebral canal, and transmit the spinal nerves and blood vessels.

The *spinous process* (neural spine, Ow.) projects backwards from the arch in the middle line. The *transverse processes* (diapophyses, Ow.), placed one on each side, project outwards from the anterior part of the arch. The *articular processes* (zygapophyses, Ow.), two superior and two inferior, project upwards and downwards from a point near the junction of pedicle and lamina. Their articular surfaces, coated with cartilage, in the superior pair look backwards, and in the inferior forwards, so that the former face the latter in adjoining vertebræ.

The *foramen* is bounded anteriorly by the body, posteriorly and laterally by the arch. The series of *rings* thus formed, united by ligaments, constitutes the *neural canal*, in which the spinal cord is contained.

*Texture.*—The bodies of the vertebræ are almost entirely composed of spongy substance, the surface being covered with only a thin layer of compact tissue. Venous canals, commencing at the larger foramina behind, traverse the cancellated structure. The arch and processes contain a much smaller proportion of spongy substance, being covered with compact tissue of considerable density in some places.

#### GROUPS OF VERTEBRÆ.

The vertebræ are divided into five groups, named from the regions which they occupy, *cervical*, *dorsal*, *lumbar*, *sacral*, and *coccygeal*.

**Cervical Vertebræ.**—These are seven in number. The first and second are so peculiar in form, as to require a separate description. The following characters belong to the five lower vertebræ.

Fig. 5.

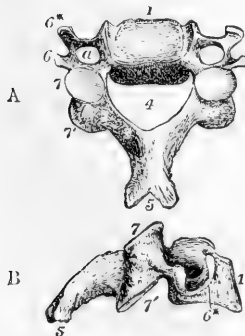


Fig. 5.—THIRD CERVICAL VERTEBRA. (A. T.)  $\frac{1}{2}$

A, from above and slightly from behind; B, from the side. 1, the body; behind *a*, the pedicle and inter-vertebral notch; 3, lamina; 4, vertebral ring, of a triangular form; 5, bifid spinous process; 6, 6\*, transverse process—6, posterior, 6\*, anterior tubercle; *a*, foramen in the transverse process transmitting the vertebral artery; 7, 7', articular processes—7, the superior, 7', the inferior.

The *body* is small and broader from side to side than from before backwards. Its superior surface is transversely concave from the upward projection of its lateral margins, and is sloped down anteriorly. The under surface on the contrary is rounded off at the sides, while its anterior margin forms a marked projection downwards.

The *laminae* are long and flat. The superior notches are deeper than the inferior.

The *spinous process* is short, horizontal, or only slightly depressed, and bifid; that of the seventh, however, is longer than the others, and terminates in a tubercle, which is readily felt below the skin, hence the name *vertebra prominens*, applied to this vertebra.

The lateral parts usually called *transverse processes* are short and bifid, presenting thus at their extremities two tubercles, anterior and posterior, which are named respectively by Owen, *parapophysis* and *diapophysis*. Each process is deeply grooved superiorly for the spinal nerves, and at its base is perforated vertically by a round foramen, through which in the upper six the vertebral artery and vein pass. It is united with the rest of the vertebra by two parts; by the posterior, at the place of junction of pedicle and lamina, like a dorsal transverse process; by the anterior, to the body of the vertebra, in the same line with the heads of the ribs. The transverse process of the seventh vertebra is large but not bifid, and only slightly grooved.

The *articular processes* are large and flat. Their articular surfaces are oblique, the superior, looking backwards, upwards and slightly inwards; the inferior forwards, downwards and slightly outwards.

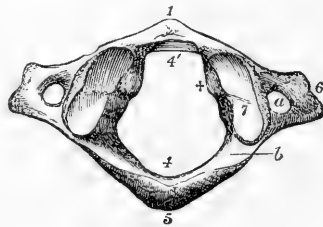
The *foramen* is triangular and larger than in the dorsal or lumbar vertebrae.

**The first Cervical Vertebra**, or *Atlas*, differs remarkably from the others, by the absence of a body and spinous process, having the form merely of a large ring with articular and transverse processes.

Fig. 6.—ATLAS VERTEBRA, FROM ABOVE. (A. T.)  $\frac{1}{2}$

1, the anterior arch, with a tubercle in front; 4, the posterior part of the ring, with 5, an indication of a spinous tubercle; 4', the anterior part of the ring, containing the odontoid process, and indicating in front of 4' the smooth surface on which the process moves in rotation; 6, the transverse process with a slight indication of division into two tubercles; 7, the condylar articular process; + inside it indicates the rounded tubercle to which the transverse ligament is attached; a, the foramen in the transverse process; b, the groove on the posterior arch for the vertebral artery.

Fig. 6.



The interior of the ring is wider posteriorly than anteriorly. Its posterior part corresponds to the foramina of the other vertebrae; its narrower anterior part is occupied by the odontoid process of the axis, and in the recent state is separated from the posterior by the transverse ligament. In front of the ring is the *anterior arch*, on the anterior aspect of which is a small tubercle, and on the posterior a smooth surface for articulation with the odontoid process. At the sides of the ring are the *lateral masses*, which are thick and strong, bearing the articular processes superiorly and inferiorly, and extending outwards into the transverse processes. The articular processes differ from those of other vertebrae in being situated in front of the places of exit of the nerves. The superior are oval, converging in front, with cartilaginous surfaces concave from before backwards, and looking upwards and inwards. At the inner margin of each is a smooth rounded tubercle, to which the transverse ligament is attached. The inferior articular

processes are smaller than the superior, flat, nearly circular, looking downwards and slightly inwards.

The *posterior arch* presents in the middle line a rough elevation, the rudiment of a spinous process. The rest of the arch is thick and round, but at its junction with the lateral masses, it is hollowed out superiorly, so as to form a smooth transverse groove, in which lie the vertebral artery and first spinal (sub-occipital) nerve. It is sometimes converted into a foramen by a small arch of bone, and corresponds to the notches of the other vertebræ.

The *transverse processes* are larger and project further outwards than those of the subjacent vertebræ. They are flattened from above downwards, and have the foramen for the vertebral artery at their roots. Their extremities are not bifid, but broad and rough.

**The Second Vertebra.**—*Axis* (vert. dentata) forms a pivot on which the head with the first vertebra rotates.

The body is characterised by the presence of a large blunt or tooth-like process called *odontoid* (proc. dentatus). This consists of an enlarged part termed the *head*, and a lower part or *neck*. It presents in front a smooth surface for articulation with the atlas, and behind a smooth groove to receive the transverse ligament. The lower surface

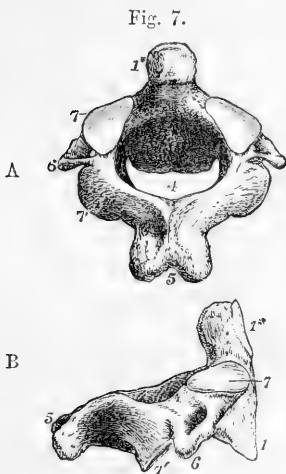


Fig. 7.—THE AXIS VERTEBRA. (A. T.)  $\frac{1}{2}$

A, seen from above and behind; B, seen from the right side. 1, the body; 4, the vertebral ring or foramen; 5, the spinous process, bifid and very large; 6, the transverse process; 7, the superior articular process; 7', the inferior oblique articular process; 1\* in A, is placed at the side of the odontoid process; in B, in front of it, marking the smooth surface of articulation with the anterior arch of the atlas.

of the body resembles that of the succeeding vertebræ. Its anterior surface presents a low median vertical ridge, with a depression on each side.

The superior *articular surfaces* placed like those of the atlas in front of the notch, lie close to the base of the odontoid process, partly on the body and partly on the arch of the vertebra. These surfaces look upwards and slightly outwards. The inferior articular processes are similar in form and position to those of the succeeding vertebræ.

The *spinous process* is very large, rough, deeply bifid, and grooved on its inferior surface. The *laminae* are very thick and strong.

The *transverse processes* are short and scarcely grooved and bifurcated. The foramen for the vertebral artery is inclined obliquely downwards and inwards.

**Dorsal Vertebrae.**—These are twelve in number, and support the ribs.

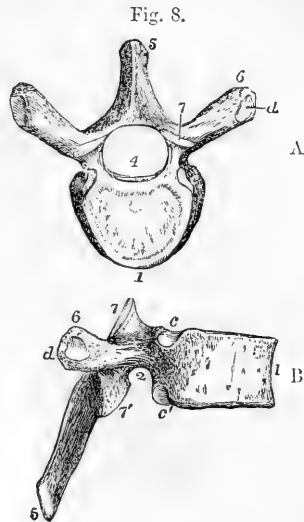
The body as seen from above is somewhat heart-shaped; its antero-posterior and transverse diameters are nearly equal.

It is specially characterised by the presence, at the place where it joins the arch, of depressed articular surfaces for the heads of ribs. In

the greater number of instances, there are two costal surfaces on each side,—one on the superior, the other on the inferior border,—so placed that each completes, with that of the adjacent vertebra, a cavity for the

Fig. 8.—SIXTH DORSAL VERTEBRÆ. (A. T.)  $\frac{1}{2}$

A, viewed from above; B, viewed from the right side. 1, the body; 2, the pedicle; 3, the lamina; 4, vertebral ring, nearly circular; 5, spinous process; 6, transverse process; 7, 7', superior and inferior articulating processes; c, c', superior and inferior facets on the body for the articulation of the head of the rib; d, facet, on the transverse process for the articulation of the tubercle of the rib.



head of one rib. The body of the first dorsal vertebra is, however, distinguished by having on each side, near its upper border, a complete articular surface for the head of the first rib, besides a smaller surface on the lower border for one facet of the second rib. On the bodies of the tenth, eleventh, and twelfth vertebrae, there is only one costal surface for the corresponding ribs; that on the tenth vertebra is usually complete, when there is necessarily no costal surface at the lower border of the ninth vertebra, but only one such surface, a demi-facet at its upper border for the ninth rib.

The *laminae* broad and flat are imbricated or sloped one pair over another like tiles on a roof. The superior notches are very shallow, the inferior comparatively deep.

The *spinous process*, described as bayonet-shaped, is three-sided, and terminates in a slight tubercle. It is longest and has the greatest downward inclination in those toward the middle of the series.

The *transverse processes* are directed outwards and backwards, and terminate in a rough tubercle which presents anteriorly a smooth surface for articulation with the tubercle of a rib. This articular surface is wanting on the eleventh and twelfth vertebrae. In several of the lowest vertebrae the extremity of the transverse process when looked at from behind presents three slight elevations, named the *external*, *internal*, and *inferior* tubercles. These are best marked on the twelfth vertebra, and correspond respectively to the transverse, mammillary, and accessory tubercles to be afterwards noticed on the lumbar vertebrae. (See Figs. 9 and 10, e, f, 6.)

The *articular processes* have their cartilaginous surfaces nearly vertical. Those of the superior processes look backwards, slightly upwards and outwards, those of the inferior look forwards, slightly downwards and inwards. But the superior articular processes of the first dorsal vertebra are similar to those of the cervical, and the inferior of the twelfth dorsal to those of the lumbar vertebrae.

The *foramen* is nearly circular, and is smaller than in the cervical or the lumbar region.

**Lumbar Vertebrae.**—These are five in number, larger than the

dorsal vertebræ, and distinguished by the absence of costal articular surfaces.

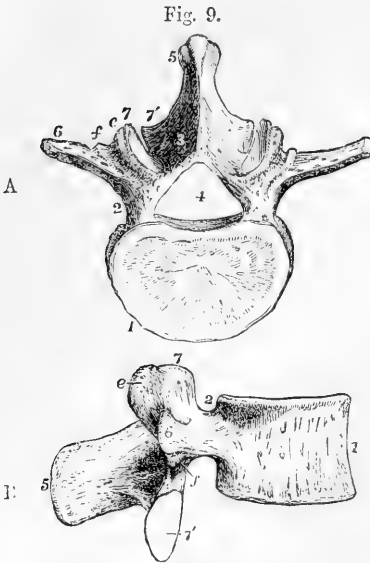


Fig. 9.—THIRD LUMBAR VERTEBRA. (A. T.)  $\frac{1}{2}$

A, from above; B, from the right side. 1, the body; 2, the pedicle and intervertebral notch; 3, the lamina; 4, the vertebral ring, somewhat triangular; 5, the spinous process; 6, transverse process; 7, 7', superior and inferior articular processes; e, the mammillary tubercle, apparently on the superior articular process; f, the accessory tubercle, between the articular and transverse processes.

The *body* has a greater diameter transversely than from before backwards, and viewed from above or below its surface presents a reniform outline. That of the fifth lumbar vertebra is considerably deeper in front than behind.

The *laminae* are shorter, deeper, and thicker than those of the dorsal vertebræ. The superior *notches* are shallow, the inferior deep.

The *spinous process* projects horizontally backwards. It has considerable breadth from above downwards, and is thickened and rough along its posterior edge.

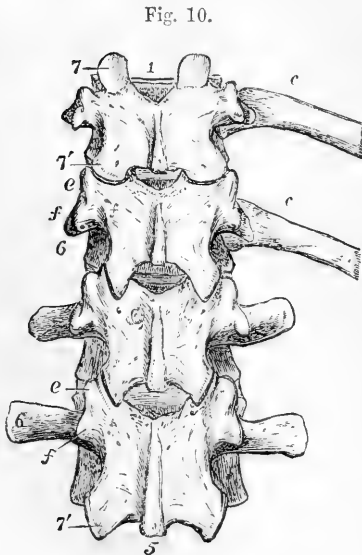


Fig. 10.—TWO LOWER DORSAL AND TWO UPPER LUMBAR VERTEBRÆ. (A. T.)  $\frac{1}{2}$

with portions of the eleventh and twelfth ribs of the right side: viewed from behind, chiefly to show the relations of the transverse processes and adjacent tubercles. 1, body of the eleventh dorsal vertebra; 5, spinous process of the second lumbar; 6, costal tubercle of the transverse process; 7, 7', superior and inferior articular processes; e, mammillary, and f, accessory tubercle; c, c, two ribs. These indications are placed only on the alternate vertebra to avoid crowding the figure.

The *transverse processes*, long and somewhat spatula-shaped, project directly outwards. Their extremities lie in series with the external tubercles of the lower dorsal transverse processes, and with the ribs. Behind each at its base is a small process pointing downwards, which corresponds to the inferior tubercles of the dorsal transverse processes, and is called the accessory process (anapophysis, Owen).



The *articular processes* are thick and strong. Their articular surfaces are vertical; those of the superior pair concave, look backwards and inwards, those of the inferior, convex, look forwards and outwards. The superior pair are further apart than the inferior, and embrace the inferior pair of the vertebra above them. From each superior articular process, a tubercle projects backwards, which corresponds to the internal tubercles of the dorsal transverse processes, and is called the *mammillary process* (metapophysis, Owen).

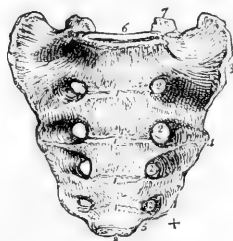
The *foramen* is large and triangular, or widely lozenge-shaped.

**Sacral Vertebræ.**—These by their union in the adult, form the *os sacrum*, but in youth they present the elements of five distinct vertebræ. The sacrum is placed below the last lumbar vertebra, and articulates laterally with the two *ossa innominata*, thus completing together with the coccyx the wall of the pelvis above and behind. The uppermost vertebra is the largest, those which follow become rapidly smaller and the fifth is rudimentary. Hence the sacrum has the form of a triangle with its base directed upwards. It is concave and smooth in front, convex and uneven behind. The direction of its surfaces is very oblique, its ventral aspect looking somewhat downwards, and forming above at the place where it joins the last lumbar vertebra, the projection termed *promontory*. The dorsal or posterior surface looks slightly upwards.

Fig. 11.—SACRUM OF THE MALE, VIEWED FROM BEFORE. †

1, 1, four transverse ridges, indicating the place of original separation of the bodies of the five sacral vertebræ; 2, anterior sacral foramina; 3, 4, lateral surface; 5, a notch which, with the coccyx, forms a passage for the fifth sacral nerve; 6, oval surface of the upper part of the sacrum for articulation with the body of the last lumbar vertebra; 7, superior articular processes; 8, inferior oval surface for articulation with the coccyx; +, inferior lateral angle.

Fig. 11.



The ventral surface is concave from above downwards, and slightly so from side to side. It is traversed horizontally by four ridges, which indicate the places of union of the bodies of the five vertebræ, and at the extremities of which are situated on each side four *foramina* called *anterior sacral*. These foramina widen externally into grooves, and diminish in size from above downwards.

The dorsal surface is convex, very uneven and somewhat narrower than the ventral. It presents along the median line four small eminences, the spinous processes, usually more or less connected, so as to form a ridge. Below the last spinous process is a triangular opening, the termination of the spinal canal, the lateral margins of which are formed by the imperfect laminae of the fifth sacral vertebra, and present a pair of tubercles, the *sacral cornua*, which project downwards, and articulate with the cornua or horns of the coccyx. On each side of the ridge of spines the surface is smooth and hollowed in the position of the united laminae, and beyond this surface are two rows of eminences, the inner of which corresponds to the articular and mammillary processes of the lumbar vertebræ, the outer to the transverse processes.

In the groove between the two rows are placed the four *posterior sacral foramina*, which are smaller than the anterior.

The part of the sacrum external to the foramina constitutes the *lateral mass*, and is broad and thick superiorly, but narrowed inferiorly. The outer aspect of the upper part presents in front a large uneven

Fig. 12.

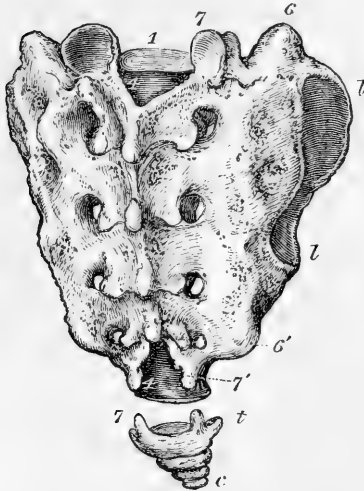


Fig. 12.—SACRUM AND COCCYX OF THE MALE VIEWED FROM BEHIND. (A. T.)  $\frac{1}{2}$

1, Body of the first sacral vertebra; 4, 4', sacral canal; and behind this, the series of four united laminae and spinous processes; 6, 6' line of tubercles corresponding to transverse processes; 7, 7', line of articular processes, with four adjacent posterior sacral foramina; l, l', auricular or iliac articular surface; in the coccyx, c, body of the last vertebra; t, transverse process; 7, cornu or superior articular process.

surface, covered in the recent state with cartilage, which articulates with the ilium, and is called from its shape the *auricular surface*: behind this it is rough and very uneven, for the attachment of ligaments. Lower down, the margin becomes narrowed and sinuous, terminating in the projection called the *inferior lateral angle*, below which the breadth of the bone is suddenly contracted so as to form a notch with the adjacent part of the coccyx.

The *base* or upper surface of the first vertebra bears considerable resemblance to the upper surface of the last lumbar. In the middle it presents the reniform surface of the body, behind which is the triangular aperture of the sacral canal, bounded by the depressed

Fig. 13.

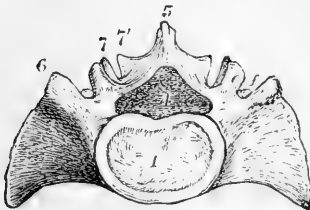


Fig. 13.—UPPER SURFACE OR BASE OF THE SACRUM OF A MALE. (A. T.)  $\frac{1}{2}$

1, the body; 4, the foramen, ring, or sacral canal; 5, the spinous process of the first sacral vertebra; 6, the part corresponding to a transverse process, in front of which is the large lateral mass; 7, 7' the superior and inferior articular processes; c, the mammillary tubercle; f, the accessory tubercle, slightly seen.

laminae. On each side of the aperture is an articular process, exactly resembling the superior process of a lumbar vertebra. In front of this is a groove which forms part of the last lumbar intervertebral foramen. The external portion of the base presents posteriorly an eminence corresponding to the lumbar transverse process, and in front of that a large smooth curved surface, continuous with the iliac fossa of the pelvis.

The lower end or *apex*, formed by the small inferior surface of the body of the fifth sacral vertebra, is transversely oval, and articulates with the coccyx.

The *sacral canal* is three-sided, curved with the bone, and gradually narrowed as it descends. It opens below on the posterior surface of the bone between the sacral cornua where the laminae of the last sacral vertebrae are imperfect. From this canal there pass outwards in the substance of the bone four pairs of intervertebral foramina, closed externally by the lateral masses, but opening on the surface by the anterior and posterior sacral foramina.

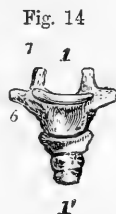*Differences in the sexes.*—The sacrum of the female is broader in proportion to its length than that of the male; it is also flatter, and usually inclines backwards from the direction of the lumbar vertebrae to a greater extent than in the male. But the curvature varies considerably in different skeletons.

*Varieties.*—The sacrum not unfrequently consists of six vertebrae, and sometimes, though rarely, of only four. Occasionally the bodies of the first and second vertebrae are not united, though complete union has taken place in every other part, or the first vertebra may present on one side the usual sacral form, while on the other it has the appearance of a lumbar vertebra, and is not united to the next (see fig. 21, 11, *V*), a peculiarity connected with the oblique form of pelvis. Instances also occur, in which it presents, on both sides, characters intermediate between those of sacral and lumbar vertebrae. The lower end of the sacral canal may be open to a greater extent than usual; it has even been found open throughout.

**Coccygeal vertebrae, or coccyx.**—These are very rudimentary vertebrae, commonly four, sometimes five, seldom only three in number. The first of the series is considerably broader than the others. It presents superiorly on the part corresponding to the body an oval concave surface which articulates with the lower end of the sacrum; two small processes, termed *cornua*, which project upwards from its posterior margin, connected by ligaments with the sacral cornua; and a short

Fig. 14.—FOUR COCCYGEAL VERTEBRÆ, SEEN FROM BEFORE.—FROM A MALE SUBJECT OF MIDDLE AGE (A. T). *J*.

The upper piece is separate from the second; the three lower are united together in one piece, and separated only by grooves. 1 above the middle or body of the first coccygeal vertebra; 1' below the fourth piece; 6, the transverse portion; 7, the superior articulating tubercle.

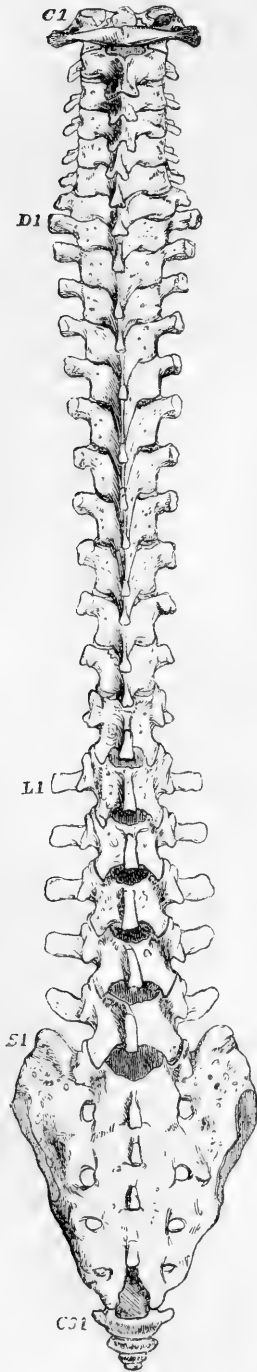


process, which projects from each side, and usually forms, with the inferior lateral angle of the sacrum, a notch for the fifth sacral nerve, but in some cases unites with that bone to form a fifth sacral foramen.

The remaining three coccygeal vertebrae are much smaller than the first, and correspond solely to vertebral bodies. When separate, the second piece presents an upper and lower flattened surface. The third and fourth pieces are mere rounded nodules. In middle life, the first piece is usually separate, while the three lower pieces are united into one, the original separation being indicated by transverse grooves.

In advanced life, the coccygeal vertebrae, having been previously joined into one bone, become also united to the sacrum. This union occurs at an earlier age and more frequently in the male than in the female, but it is subject to much variation.

Fig 15.

Fig. 15.—VERTEBRAL COLUMN OF AN ADULT MALE, SEEN FROM BEHIND (A. T.).  $\frac{1}{4}$ 

C 1 to above D 1, the seven cervical vertebrae; D 1 to above L 1, the twelve dorsal vertebrae; L 1 to above S 1, the five lumbar vertebrae; S 1 to above CO 1, the sacrum; CO 1, and below, the four coccygeal vertebrae. The transition in the form of the transverse processes and tubercles is well marked in this specimen.

#### The vertebral column as a whole.—

The vertebral column may be regarded as a central column upon which the other parts of the skeleton are arranged. Superiorly it supports the skull, laterally the ribs, through which also it receives the weight of the upper limbs, and near its lower extremity it rests upon the pelvic bones, by which it transmits the weight of the body to the lower limbs. It is a pillar of support to the rest of the skeleton, and protects the spinal cord by enclosing it in a bony canal. Its average length is about 28 inches.

When seen in profile the column presents four curves, directed alternately forwards and backwards,—forwards in the cervical and lumbar regions, backwards in the dorsal and sacral. The cervical and lumbar convexities are produced by the greater thickness of the anterior over the posterior parts of the intervertebral discs, and in the case of the latter also by the greater depth of the fifth lumbar body anteriorly, while in the dorsal and sacral concavities, the bodies of the vertebrae are thinner in front than behind. These curves are connected with the maintenance of the erect posture, and give to the column greater elasticity and security from injury than it would have were it perfectly straight. In the dorsal region also there is very frequently a slight degree of lateral curvature, the convexity of which, in most cases, is directed towards the right side, and is probably connected with the greater use made of the right than of the left arm.

Viewed in front, the bodies of the vertebrae are seen to become broader from the axis to the first dorsal, then slightly narrower to the fourth dorsal, and from that vertebra they gradually widen to the base of the sacrum. The width between the extremities of the transverse processes is considerable in the atlas; small in the axis, it

becomes greater as far as the first dorsal vertebra, thence it is again gradually contracted as far as the last dorsal, and becomes suddenly much greater in the lumbar region.

In a lateral view the antero-posterior diameter of the bodies increases in descending through the dorsal and lumbar regions.

Viewed from behind the spines occupy the middle line. On each side are the vertebral grooves, corresponding to the laminae, and bounded externally in the cervical and dorsal regions by the transverse processes, and in the lumbar by the mammillary processes. Along each groove is a series of spaces between the laminae, which, in the natural condition, are filled up by the yellow ligaments. The extent of these intervals is very trifling in the neck and in the greater part of the back; it increases in the lower third of the dorsal, and still more in the lumbar region. The interval between the occipital bone and the arch of the atlas is considerable, and so is that between the last lumbar vertebra and the sacrum.

Fig. 16.—THE VERTEBRAL COLUMN VIEWED FROM THE LEFT SIDE. (A. T.)  $\frac{1}{4}$

The letters and numbers indicate the several vertebrae. The antero-posterior curvatures of the column are shown, together with the shape and size of the bodies and intervertebral spaces, the form and transitions of the transverse and spinous processes, and the differences in the costal articulating surfaces.

OSSIFICATION OF THE VERTEBRÆ.

**The Vertebrae in general.**—The ossification of each vertebra proceeds in cartilage from three principal centres, one for the main part of the body, and one on each side for the arch and processes, together with a part on each side of the body. The lateral centres appear about the 7th week, that of the body very soon afterwards. From these centres the ossification extends gradually outwards, so as at last to form the greater part of the vertebra. That of the body does not pass, however, in the dorsal vertebrae, the place of articulation of the head of the rib, leaving on each side a portion of the body which is formed from the lateral centre,

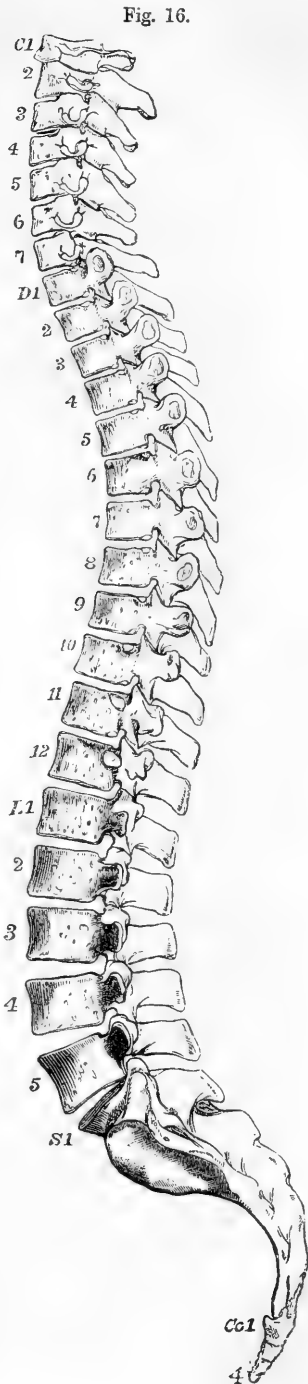


Fig. 16.

and is separated up to the third year by a narrow cartilaginous interval—the *neurocentral suture*. It would appear further, that while ossification in the centres of the arches commences first in the upper or cervical vertebrae, the osseous centres of the bodies appear earliest in the lower dorsal vertebrae.

At the time of birth most of the vertebrae consist of three osseous pieces, corresponding to the three original ossific centres. In the first year of infancy the osseous laminae of opposite sides become united in a number of the vertebrae, but not in all. The spinous processes, remaining cartilaginous for a time, are gradually completed by the growth of the cartilage and the extension of the bone into

Fig. 17.

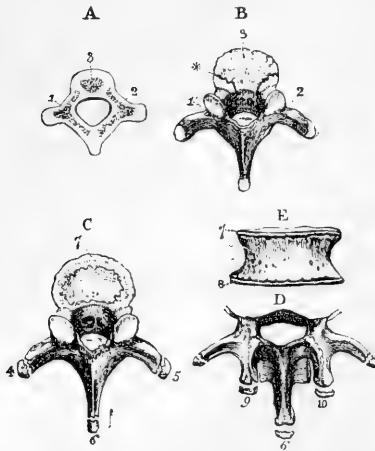


Fig. 17.—OSSIFICATION OF THE VERTEBRÆ. (R. QUAIN.)

A, foetal vertebra, showing the three primary centres of ossification; 1, 2, for the pedicles, laminae, and processes; 3, for the body.

B, dorsal vertebra from a child of two years; 1 & 2 are seen to have encroached upon the body at \* the neurocentral suture and into the articular and transverse processes, and to have united behind in the spinous process, leaving the ends cartilaginous.

C, dorsal vertebra at about sixteen or seventeen years, showing epiphyses on the transverse processes, 4 & 5, and spinous process, 6, and the upper epiphysal plate of the body, 7.

D & E, parts of a lumbar vertebra of about the same age, showing, in addition to the foregoing, 8, the lower epiphysal plate of the body; 9 & 10, the epiphyses of the mammillary tubercles.

them, and at the same time, by the ossific extension of the transverse processes and other parts, the vertebrae gradually attain to nearly their full size and shape about the age of puberty. At different periods subsequent to this, five sets of epiphyses, or supplementary centres of ossification, are added. Three of these are small portions of bone, placed on the tips of the spinous and transverse processes: the

Fig. 18.

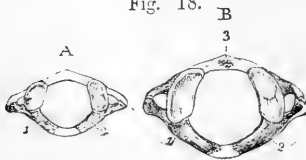


Fig. 18.—OSSIFICATION OF THE ATLAS. (R. QUAIN.)

A, before birth; 1 & 2, lateral centres of ossification; the anterior arch is cartilaginous.

B, in the first year; 1 & 2, as before; 3, ossific centre in the anterior arch.

Fig. 19.

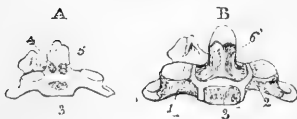

Fig. 19.—OSSIFICATION OF THE AXIS AS SEEN IN FRONT. (R. QUAIN.)

A, from a foetus of seven months; 3, the centre for the body; 4 & 5, two centres for the base of the odontoid process.

B, shortly after birth; 1 & 2 the lateral centres; 3, centre for the body; 4 & 5, the two centres for the odontoid process now united.

other two are thin circular plates, one on the upper, the other on the lower surface of the body, chiefly at its circumference. In the lumbar vertebrae two other epiphyses surmount the mammillary processes. The transverse process of the first lumbar vertebra is sometimes observed to be developed altogether from a separate centre. Most of the anterior divisions of the cervical transverse processes are ossified by the extension into them of osseous substance from the neighbouring posterior part of the process and from the arch; but that of the

seventh usually presents a separate osseous nucleus, and small nuclei have also been observed by Meckel in those of the second, fifth, and sixth vertebra. These epiphyses generally appear from the eighteenth to the twentieth year, and are not wholly united to the rest of the vertebra before the twenty-fifth year.

**The Atlas & Axis.**—The ossification of the atlas and axis differs considerably from that of the other vertebra. In the atlas, the body being absent, the anterior arch is formed by a strip of cartilage in which ossification, commencing by one or two centres, only appears in the course of the first year after birth. The neural arch, together with the processes, is formed from two lateral centres corresponding with those of the other vertebra, and which begin to ossify about the 7th or 8th week. Their union posteriorly occurs in the 3rd year, and is frequently preceded by the formation of a distinct spinal nucleus. Their union with the nucleus of the anterior arch does not take place till the 5th or 6th year.

In the axis the arch and processes are formed from two centres corresponding to those of the other vertebra, and appearing about the 7th or 8th week. Ossification begins in the body about the 6th month, from one or sometimes two centres, occupying the lower part of the common cartilage of the body and odontoid process. In the upper part of this cartilage, a little later, two collateral centres appear for the odontoid process; these soon unite into one, and become ossified to the body of the axis in the 3rd year. There is frequently also a distinct centre in the apex of the process. (Humphry.) This separate ossification of the odontoid process is important in connection with the view that it is the displaced body of the atlas.

**Sacral Vertebra.**—Each of the sacral vertebra presents three primary centres of ossification, one in the body and a pair in the arch. The centres of the bodies

Fig. 20

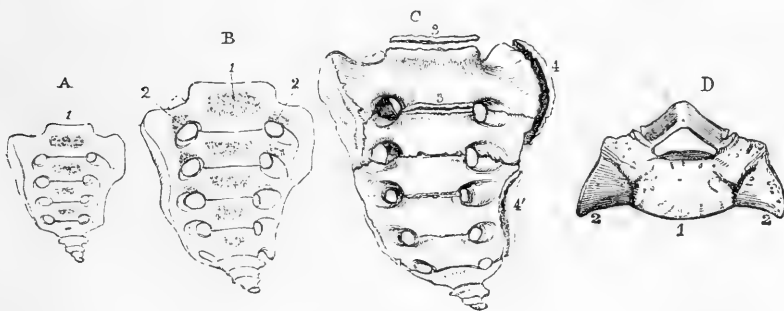


Fig. 20.—OSSIFICATION OF THE SACRUM. (R. QUAIN.)

A, sacrum of a fetus before six months, seen from the front, showing the ossific centre in the body of each vertebra, from 1 downwards.

B, at birth; 2, 2, additional centres for the lateral masses.

C, about twenty-three years; 3, 3, epiphysal plates still visible above and below the first vertebral body, the fissures still remaining between the first and second and the second and third lateral masses; 4, 4', lateral epiphysal plates.

D, upper surface of first sacral vertebra at four or five years, 1, and 2, as in A and B. (A.T.)

A & B, nearly full size; C, one-fourth; D, one-third.

of the first three vertebra appear about the 8th or 9th week, those of the two following vertebra somewhat later. The lamina begin to ossify about the 6th month, but the time of union with the bodies differs in the different vertebra; taking place as early as the 2nd year in the lowest, but not till the 5th or 6th year in the uppermost. In each of the first three vertebra, and sometimes only of two, the anterior part of the lateral masses on each side is formed from an additional nucleus which appears at the outer margin of the anterior sacral foramen from the 6th to the 8th month. These unite to the bodies later than the arches. In the case of the two lower vertebra, the lateral masses are formed by extension of ossification from the primary lateral nuclei. On the body of

each vertebra, epiphysial plates are formed after puberty, as in other vertebræ, and two flat irregular plates of bone are added to each lateral surface of the sacrum, the uppermost of which extends over the sides of the first two or three, while the lower connects the remaining two. These appear from the 18th to the 20th year, and are united about the 25th. The bodies of the sacral vertebræ are at first separated by intervertebral plates, but about the 18th year, in the case of the lower vertebræ, ossification begins to extend through these plates and the epiphyses, so as completely to unite the adjacent bodies. The ossific union of the first and second bodies does not take place till the 25th year or later. Previous to this, the lateral masses have coalesced nearly in the same order as the bodies.

The deficiency of the spine and dorsal part of the laminae usually existing in the fifth sacral vertebra, and not unfrequently extending to the fourth, but more rarely to the third, may be attributed in part to the non-extension of ossification in that direction: but such varieties of form, like many others to which the sacral vertebræ are subject, are probably intimately connected with the nature and development of the formative matrix of the bones. The more completely open state of the sacral canal posteriorly found in cases of spina-bifida is undoubtedly connected with early morbid changes interfering with the natural process of development.

**Coccygeal Vertebræ.**—Each of the coccygeal vertebræ is ossified from a distinct piece of cartilage, and usually from a single centre, but in the upper sometimes from two centres. Ossification commences in the first generally about the time of birth; in the second, from the 5th to the 10th year; in the third, some time before, and in the fourth, some time after puberty. The ossific union of the three lower coccygeal vertebræ occurs before middle life; their union with the first, and the union of this with the sacrum, belong to the later periods of life.

#### GENERAL AND SERIAL HOMOLOGY OF THE VERTEBRÆ.

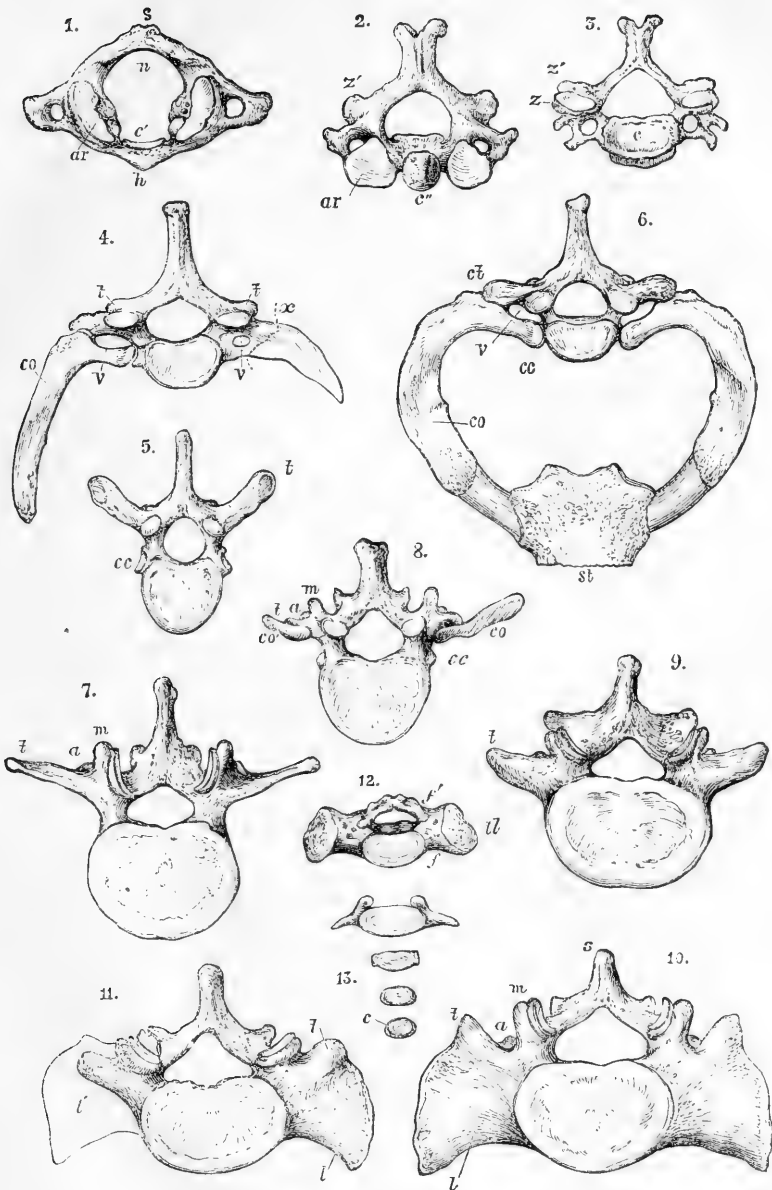
The study of the various forms presented by the parts of the vertebral column, and of its relation to the rest of the skeleton in man and animals, as also of its development in the fœtus, has led to the formation of the general views of homology referred to in the introduction. These views originated, in somewhat different forms, mainly with Oken, Carus, Geoffroy St. Hilaire, and Owen; and, with various modifications and extensions by more recent writers, as Goodsir, Huxley, Gegenbaur, St. George Mivart, and Flower, are now admitted by almost all anatomists, in some shape or other, as the basis of a morphological

Fig. 21.—VIEWS OF THE DIFFERENT VERTEBRÆ FROM ABOVE TO ILLUSTRATE THEIR HOMOLOGIES. (A. T.)

1, atlas; 2, axis; 3, sixth cervical; 4, seventh cervical with supernumerary ribs; 5, middle dorsal; 6, upper dorsal, with costal arch and sternum attached; 7, middle lumbar; 8, first lumbar with supernumerary ribs; 9, lower lumbar; 10, upper sacral; 11, upper sacral vertebra, presenting the lumbar form on the right side, as in the oblique pelvis; 12, fourth sacral vertebra in a young subject; 13, fourth coccygeal vertebra. In the several figures the parts are indicated by letters as follows, viz., in 1, *s*, spine; *n*, neural arch; *c'*, the space occupied by the processus dentatus, or displaced body; *h*, anterior or precentral arch; *ar*, superior articular process: in 2, *c''*, processus dentatus; *ar'*, superior articular process; *z'* inferior articular process: in 3, *c*, centrum or body; *z*, *z'*, superior and inferior articular processes: in 4, *t*, *t'*, transverse processes; *v*, *v'*, vertebrarterial foramina; *co*, moveable right supernumerary or cervical rib; *x*, with a dotted line marks the place where an anchylosed rib on the left side may be considered to be superadded to the transverse process (diapophysis and parapophysis) of the vertebra: in 5, *t*, transverse process with costo-transverse facet; *cc*, costo-central facet: in 6, *v*, vertebrarterial interval; *ct*, costo-transverse, and *cc*, costo-central articulations; *co*, first rib: in 7, *m*, mammillary, and *a*, accessory tubercles; *t*, transverse process: in 8, *co*, *co'*, left and right supernumerary ribs: in 10, *l*, the lateral mass: in 11, *l'*, place of the lateral mass, remaining undeveloped in this instance: in 12, *tl*, the transverse process and lateral mass which unite with the corresponding parts above; *f*, *f'*, anterior and posterior sacral foramina thus formed: in 13, *c*, the centrum or body, which alone remains in the last coccygeal vertebra.



Fig. 21.



doctrine of the construction of the skeleton. There is not, indeed, an entire agreement among anatomists with respect to some parts of this doctrine; but still there is such a general acknowledgment of both the zoological and serial homology of the parts composing the skeleton, that considerations of this kind

cannot be entirely omitted in a work on human anatomy. At the same time, it is obvious that the complicated nature of the subject, and the necessity for frequent reference to details of comparative anatomy for its elucidation make it impossible to enter fully into its consideration here, so that our remarks must be limited to those points in which the views of homology have the most immediate bearing upon the knowledge of human anatomy. The accompanying views of the several vertebræ and some of their varieties from above (in fig. 21) may assist the reader in comparing their forms.

1. The **series of centra or bodies**, surrounding the primary axis of the notochord, is complete in man, from the processus dentatus of the second vertebra to the caudal extremity. In the head it is ascertained to be prolonged into the basioccipital and basisphenoid parts of the base of the skull. It is apparently absent in the atlas, or rather the part corresponding to the centrum or body of that vertebra is united with the body of the axis in the odontoid process: while the anterior arch of the atlas belongs to a different series of parts, not yet accurately determined, perhaps to the precentral or subcentral parts or *hypapophyses*. The proofs of this view are derived mainly from, 1st, the remains of the notochord having been actually traced in the fœtus through the odontoid process (and not through the anterior arch of the atlas) into the basioccipital bone; 2nd, the separate ossification in cartilage of the odontoid process; and 3rd, the existence in some animals, as the ornithorhynchus and some reptiles, of a bone corresponding to the odontoid process, in a separate condition, without any other part representing the body of the atlas.

2. The **series of neural arches** is complete in the whole vertebral column of man, with the exception of the three lowest coccygeal vertebræ, and in part of the upper coccygeal and lowest sacral vertebræ. The neural spines are also complete in nearly the same vertebræ as the arches. The spine is absent or little developed in the atlas, bifid at its extremity in the next five cervical vertebræ, but simple in all the remaining vertebræ in which it is present.

3. The **articular processes, or zygapophyses**, superior and inferior (anterior and posterior in animals), correspond in their relations throughout the whole of the vertebræ in which they exist, with the exception of both of those of the atlas and the superior of the axis. In these last mentioned vertebræ the articular processes are not in the series of zygapophyses, being situated at the place of union of the pedicles with the bodies, or nearly in the place of the capitular articulation of the ribs with the vertebral bodies, and therefore anterior to the place of exit of the spinal nerves, instead of posterior to it as in the other vertebræ. In the sacral vertebræ the articular processes, existing as such in early life, come to be in the adult united by ankylosis. In the three lower coccygeal vertebræ they are absent.

4. It is in the comparison of the parts known in human anatomy under the general name of **transverse processes**, that the main difficulty of establishing homologies exists. In all the cervical vertebræ the processes so called are pierced by a vertebrarterial foramen, and the most of them have two tubercles. Those of the dorsal vertebræ are for the most part simple, but are articulated at two places with the ribs. At these two places are situated processes, sometimes projecting in animals to a considerable extent, which receive respectively the names of *diapophysis* and *parapophysis*; the first (diapophysis) being the tubercular or costo-transverse, the posterior or upper articulation of the rib; the second, or parapophysis, being the capitular or costo-central articulation, the lower or anterior, of the rib, placed close to the body but separated from it by the neuro-central suture. It is very generally admitted that the part in front of the vertebrarterial foramen of the cervical vertebræ corresponds in series to the first part of a rib; as is illustrated by the separate ossification of that piece of bone in the seventh cervical vertebra in man, and by the occasional occurrence of more fully developed cervical ribs in that situation.

The vascular passage in the dorsal region is between the neck of the rib and the vertebra. In the lumbar vertebræ the transverse processes are elongated laterally, and at their root two other processes become apparent, viz., the mammillary or *metapophysis*, looking upwards in man or forwards in animals, and the

accessory or *anapophysis*, directed downwards or backwards. Several circumstances in the anatomy both of the bones and muscles, as well as the form and position of occasional or supernumerary lumbar ribs, seem to indicate that the outer part of the lumbar transverse processes is serially homologous with the first part of the ribs, but so intimately combined with both diapophysis and parapophysis, and the part lying between them, as to leave no arterial passage; but a groove on the upper side is regarded by some as an indication of the place of separation. In the sacral part of the column still greater departure from the form of the transverse process of the upper vertebræ takes place by the large development and ossific union of the lateral parts. Throughout the whole five vertebræ recognised as sacral in man, this may be looked upon as occurring to some extent in portions of the bones which are serially homologous with the combined diapophysis and parapophysis; but in two at least, and perhaps in three of the upper sacral vertebræ, another lateral element appears to be interposed between that combined transverse process and the iliac surface of articulation, constituting the greater portion of the large lateral mass of the sacrum. This element is looked upon by some as serially homologous with part of a rib. (Retzius, Müller's "Archiv," 1849; Müller "Vergleich. Anat. der Myxinoiden;" Owen, "On the Archetype, &c., of the Vert. Skeleton;" Aug. Müller, Müller's "Archiv," 1853; Humphry, "Treatise on the Human Skeleton;" Goodsir, in "Edin. New Philos. Journ.," 1857; Cleland, in "Nat. Hist. Review," 1861 and 1863; Huxley, "Hunterian Lect. in Brit. Med. Journ.," 1869; St. George Mivart, in "Linn. Trans.," 1870, and "Elementary Anatomy," 1873; Flower, "Osteology of the Mammalia," 1870; Gegenbaur, "Grundzuge der Vergleich. Anat.," 1870.)

With the exception of the anterior arch of the atlas already referred to, there are no parts developed in the human skeleton which correspond with the *hypapophyses* which occur in connection with the vertebral column of animals, such as the "chevron" bones below the caudal vertebræ of cetacea, and the hæmal arches enclosing the main artery of fishes.

The similarity of some of the parts composing the skull to vertebræ, or the serial homology of the bones of the head and vertebræ, supposed by some anatomists to exist, will be referred to hereafter.

## II.—THE THORAX.

The thoracic part of the skeleton consists of the dorsal vertebræ already described, the sternum, the ribs, and the costal cartilages.

### THE STERNUM OR BREAST-BONE.

The sternum is situated in the median line at the fore part of the thorax. It is connected with the rest of the trunk by the cartilages of the first seven pairs of ribs, and gives attachment to the clavicles. It consists originally of six segments. The first of these usually remains distinct up to middle life, and is called the *manubrium* or *presternum*; the succeeding four are united into one in the adult, and form the *body*, or *mesosternum*: the sixth generally remains cartilaginous up to the period of puberty, and sometimes partially so even to advanced age, constituting the *ensiform process*, or *metasternum*: in middle life it is most frequently ossified and united by bone to the body.

The sternum is flattened from before backwards, and presents a slight vertical curve with the convexity in front. It is of unequal width, being broad at the upper part of the presternum, considerably narrower at the lower end of that portion and in the first segment of the mesosternum, somewhat wider near the lower end of that portion, and finally compressed and narrowed near the junction with the metasternum. It consists of light cancellated texture, with a thin covering of compact bone.

The *presternum* is the thickest part of the bone. Its anterior surface presents a slight median elevation, its posterior is smooth and

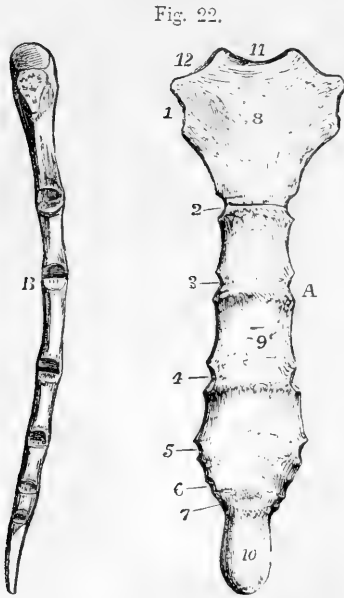


Fig. 22.

Fig. 22.—THE STERNUM OF A MIDDLE-AGED MAN. (A. T.)  $\frac{1}{3}$ 

A, from before, 1, 2, 3, 4, 5, 6, & 7, the articular surfaces for the corresponding costal cartilages; 8, manubrium or upper piece, still separate from the body; 9, middle of the body; 10, ensiform portion, osseous, and united to the body; 11, inter-clavicular notch; 12, articular notch for the clavicle.

B, the same sternum viewed from the right side, showing the general convexity of the bone forwards. The different facets of articulation of the clavicle and costal cartilages will be distinguished by their position in comparing the figure B. with A.

somewhat concave. Its upper border is divided into three deep notches; the middle one is named the *incisura semilunaris*, or *inter-clavicular notch*; the lateral ones form two depressed articular surfaces directed upwards and outwards, for articulation with the clavicles. Each lateral border presents superiorly close to the clavicular surface, a rough triangular surface, which unites with the cartilage of the first rib. Below this the bone slopes inwards, and at its inferior angle presents a small surface, which with a similar one on the mesosternum forms a notch for the cartilage of the second rib. The lower margin is straight and united by intervening cartilage to the upper margin of the mesosternum.

The *mesosternum* is marked on its anterior surface by three slight transverse elevations at the lines of junction of its four component parts. Its posterior surface is comparatively smooth. Each lateral margin presents five notches for the reception of costal cartilages, and a small surface superiorly, which, with the similar depression on the presternum, forms the notch for the second costal cartilage. The notches for the third, fourth, and fifth costal cartilages are opposite the lines of junction of the four segments of the body of the sternum; those of the sixth and seventh are placed close together on the sides of the inferior segment, that for the seventh being frequently completed by the ensiform cartilage. The lower part of the presternum is sometimes pierced in the middle line by a considerable hole.

The *metasternum*, ensiform process, or *xiphisternum*, is a thin spatula-like process projecting downwards between the cartilages of the seventh ribs. It is subject to frequent varieties of form; being sometimes bent forwards, sometimes backwards, often forked, and sometimes perforated.

The sternum is subject to many varieties. It is sometimes divided vertically in the whole or part of its length. It is not unfrequently much shorter than usual,

and indented at its lower part, as occurs especially from the pressure of the cobbler's last.

Two small nodules of bone, *ossa suprasternalia*, have been found in some rare cases at the sides of the incisura close to the clavicular notches, sometimes being united by bone, at others by ligament to the sternum. (Breschet, "Annales des Sciences Naturelles," 2nd series, v. 10, p. 91; and Luschka, "Die Halsrippen und die Ossa suprasternalia," Vienna, 1859.) Their position is indicated by the asterisks (\*\*) in figure 26, E. They derive an additional interest from the occurrence of suprasternal bones in some animals.

## THE RIBS.

The ribs (*costae*), twelve in number on each side, constitute a series of arched and highly elastic bones, which extend outwards and forwards from the vertebral column, and form the lateral walls of the thorax. Their anterior extremities give attachment to cartilaginous prolongations—the costal cartilages, the first seven pairs of which pass forward

Fig. 23.

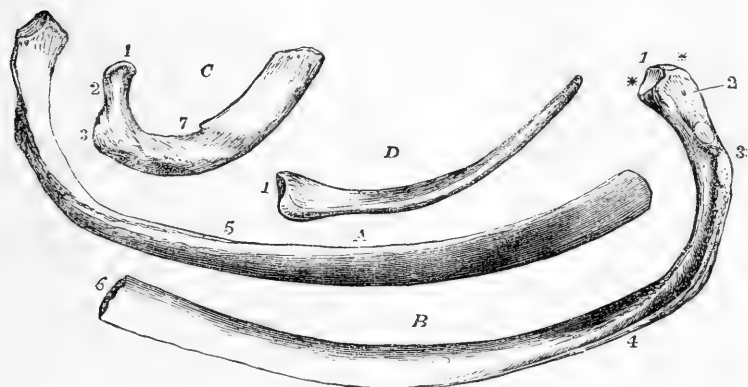


Fig. 23.—THE FIRST, SIXTH, AND TWELFTH RIBS OF THE RIGHT SIDE. (A. T.)  $\frac{1}{2}$

A, the sixth seen from above and the outer side; B, the same rib viewed from below and within; C, the first rib viewed from above and without; D, the twelfth rib viewed from above and within.

1, the head in C & D, the inter-vertebral ridge in B; \*\*, the costo-central facets; 2, the neck; 3, the tubercle, in B presenting the rough tubercle and the smooth facet for articulation with the transverse process; 4, the lower border with the ridge and subcostal groove; 5, the upper border; 6, the oval pit for the attachment of the costal cartilage; 7, in the first rib, C, the scalene tubercle or spine, and near it the smooth groove for the subclavian artery.

to the sternum. On this account the first seven pairs of ribs are called *sternal*, and the remaining five pairs *asternal* ribs. Of these asternal ribs each of the upper three has its cartilage attached along its superior border to the cartilage of the rib above it, while the last two being entirely free from such attachment are called *floating* ribs.

**General characters of the ribs.**—These are best marked in the ribs near the middle of the series. The posterior extremity is thickened, and is termed the *head* or *capitulum*; it presents a superior and an inferior oblique articular surface for articulation with the bodies of

two vertebræ, and, between them, a slight ridge, to which the inter-articular ligament is attached. At a little distance from the head, and separated from it by the slightly constricted *neck*, is the *tubercle*, which is directed backwards, and presents a smooth surface for articulation with the transverse process of the inferior of the two vertebræ with which the head is connected, and, outside that, a roughness marking the insertion of the posterior costo-transverse ligament. The whole extent beyond the tubercle constitutes the *body*. It is laterally compressed, and broader from above downwards towards the anterior extremity. Outside the tubercle, between it and the most convex part of the body, is a rough line, which corresponds to the outer border of the erector spinæ muscle, and marks the *angle*, so-called because at this point the rib takes a more sudden curve, its direction being now forwards and outwards. The inferior border presents on its inner aspect the *subcostal groove*, in which lie the intercostal vessels and nerve, and which is best marked opposite the angle, and disappears in front. The anterior extremity is hollowed at its tip into an oval pit, in which the costal cartilage is implanted.

*Inclination and Curves.*—There is a general inclination of the ribs downwards from the head to the anterior extremity, the slope being greatest between the head and angle. The curve of the ribs is more marked towards the back part than in front, especially near the angle. Besides the main curves now mentioned the rib is somewhat twisted on itself, so that while its surfaces are vertical behind, they are placed somewhat obliquely in front.

**Special characters of certain ribs.**—The ribs increase in length from the first to the eighth, and decrease from the ninth to the twelfth, so that the last is little longer, often even shorter, than the first. The first rib is the broadest, and after it the middle ones; the twelfth is the narrowest. The distance of the angle from the tubercle increases gradually from the second to the eleventh; in the first the angle coincides with the tubercle, in the last it is effaced.

The *first* rib is not twisted, and is so placed that its superficial and deep surfaces look respectively nearly upwards and downwards. The head is small, and presents a single articular surface. The neck is round and slender. It articulates with the body and transverse process of the first dorsal vertebra alone. On the superior surface are two very slight smooth depressions with an intervening rough mark, and a considerable rough surface behind. The rough surface marks the attachment of the scalenus medius muscle, the posterior depression the position of the subclavian artery, the anterior depression the subclavian vein; and the intervening slight elevation, frequently terminating in a sharp spine on the inner edge—the *scalene tubercle*—indicates the attachment of the scalenus anticus muscle.

The *second* rib, longer than the first, presents externally a prominent roughness which marks the attachment of the serratus magnus.

The *eleventh* and *twelfth* ribs have no groove on the inferior border, no articular facet on the tubercle, and only a single articulating surface on the head. The mark of the angle is scarcely perceptible on the eleventh, and is absent from the twelfth.

*Varieties.*—The number of the ribs is sometimes increased to thirteen on one or both sides. The supernumerary rib is most frequently very short, and is

usually formed in connection with the transverse process of the first lumbar vertebra, or occasionally with the seventh cervical: in the latter case the additional rib has usually a double attachment, viz., to the body and transverse process of the vertebra outside a vertebral foramen (see fig. 21, *f*, *r*, *v*, and *S*, *co*).

The **costal cartilages** unite the ribs to the sternum. Their breadth diminishes gradually from the first to the last, whilst their length increases as far as the seventh, after which they become gradually shorter. Their line of direction varies considerably. The first descends a little, the second is horizontal, and all the rest, except the last two, ascend more and more from the rib towards the sternum as they are situated lower down. The external or costal extremity, convex and uneven, is implanted into and united with the end of the corresponding rib. The internal extremities of the upper seven (except the first) are smaller than the external, somewhat pointed, and fit into the corresponding angular surfaces on the side of the sternum, with which they are articulated in synovial cavities. Each of the cartilages of the first three asternal ribs becomes slender towards its extremity, and is attached to the lower border of that which is next above it. The last two are pointed and unattached.

The first cartilage, which is directly united to the sternum without articular cavity, usually becomes more or less ossified in the adult male; and the others likewise exhibit a considerable tendency to ossify in advanced life. This tendency is not so great in the female, in whom costal respiration is generally more extended than in the male.

## THE THORAX AS A WHOLE.

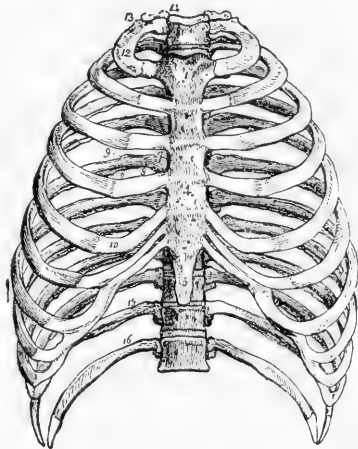
The bony thorax is of a somewhat conical shape, with convex walls.

Fig. 24.—FRONT VIEW OF THE THORAX, SHOWING THE STERNUM COSTAL CARTILAGES, RIBS, AND DORSAL VERTEBRÆ.  $\frac{1}{2}$

1, the manubrium, or first piece of the sternum; 2, is close to the place of union of the first costal cartilage; 3, the clavicular notch; 4, the middle of the body of the sternum; 5, the ensiform process; 6, the groove on the lower border of the ribs; 7, the vertebral end of the ribs; 8, the neck; 9, tubercle; 10, costal cartilage; 12, the first rib; 13, its tuberosity; 14, the first dorsal vertebra; 15, the eleventh; 16, the twelfth rib.

Its upper opening is contracted, and bounded by the first dorsal vertebra, the first pair of ribs, and the manubrium of the sternum. Its inferior margin slopes downwards and backwards on each side from the ensiform cartilage to the twelfth rib. Its longitudinal axis is directed upwards and somewhat backwards. Its transverse diameter, at its widest part, greatly exceeds that from before backwards. The latter is shortened in the middle line by the projection of the vertebral column,

Fig. 24.



but on each side of the column a considerable extension of the cavity is produced by the backward direction of the posterior parts of the ribs, and thus the weight of the body is thrown further back and is more equally distributed round the vertebral column. At the same time a broad furrow is produced between the spines of the vertebræ and the angles of the ribs, in which are placed the *erectores spinæ* muscles.

The intercostal spaces are eleven in number, somewhat wider above than below, and varying in width with the elevation or depression of the ribs.

OSSIFICATION OF THE RIBS AND STERNUM.

The ossification of the ribs begins in cartilage posteriorly about the eighth week, and extends rapidly forwards, so as to reach the permanent cartilage about

Fig. 25.



Fig. 25.—ONE OF THE MIDDLE RIBS ABOUT EIGHTEEN OR TWENTY YEARS OF AGE. (R. QUAIN.)

1, the principal piece or body; 2, the epiphysis of the head; 3, that of the tubercle.

the fourth month. Subperiosteal ossification contributes largely to their subsequent growth. After puberty the centres of two small epiphyses appear in the cartilage of the head and tubercle. These become united with the main bone before the twenty-fifth year.

The ossification of the sternum begins about the sixth month, and usually by

Fig. 26.

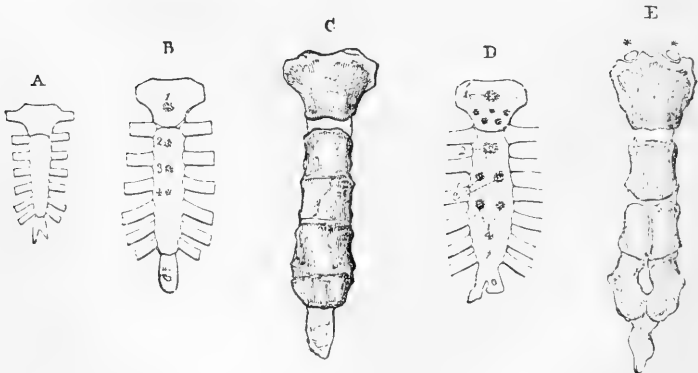


Fig. 26.—OSSIFICATION OF THE STERNUM. (R. QUAIN.)

A, the cartilaginous sternum before the middle of fetal life.  
 B, the sternum of a child at birth. 1, 2, 3, & 4, mark the commencing ossific nuclei for the manubrium and three upper pieces of the body.  
 C, the sternum soon after puberty, showing cartilage between the manubrium and



body, and imperfect union of the first, second, and third pieces of the body, while the third and fourth are united.

D, example of a sternum at birth with an unusual number of ossific centres, six in the manubrium, 1', which is very uncommon; two pairs in the lower pieces of the body 3' & 4', which is not unusual; 2, the single centre of the first piece of the body.

E, example of the perforated sternum, which probably depends upon the imperfect union of the pairs of ossific nuclei shown in D in the lower part of the body; this figure also shows two episternal bones or granules, \* \*. C, and E, are reduced below the size of nature.

a single centre in the presternum. - The next centre appears at the seventh month in the upper segment of the mesosternum, and ossification follows in the next two segments shortly before birth. In the lower segments, ossification begins in the first year or later, and in the metasternum not before the sixth year, and often much later. In the presternum occasionally two centres of ossification appear, one above the other. In the upper segment of the mesosternum the centre is most commonly single, but in each of the following segments there are frequently two placed one on each side of the middle line. The lower segments of the mesosternum unite together after puberty, but the upper one often remains separate till after the twenty-fifth year. The metasternum is united to the mesosternum in middle life, the presternum in more advanced life. The bony parts formed from the lateral centres of the lower segments of the mesosternum, as well as of the metasternum, not unfrequently remain separate for a considerable time, and occasionally, by defect of ossification or non-union across the middle line, have a permanent median aperture in the bone—the so-called *foramen sternale*. The metasternum is sometimes bifid, and in rare cases the mesosternum has been found divided to a greater or less extent from below upwards, constituting the malformation of *fissura sterni*, and connected in some instances with *ectopia cordis*. (See the case of E. Groux, described by Allen Thomson in the Glasgow Med. Journal, 1858.)

### III.—THE BONES OF THE HEAD.

The skull, comprising the bones of the head, is of a spheroidal figure, compressed on the sides, broader behind than before, and supported on the vertebral column. All its bones, with the exception of the lower jaw, are almost immovably united together by lines and narrow surfaces, more or less uneven, termed *sutures*. The skull is divided by anatomists into two parts, the *cranium* and the *face*. The cranium protects the brain; the face surrounds the mouth and nasal passages, and completes with the cranium the orbits or cavities for the eyes. The cranium is composed of eight bones, viz.: the *occipital*, two *parietal*, the *frontal*, two *temporal*, the *sphenoid*, and the *ethmoid*. The face is composed of fourteen bones, of which twelve are in pairs, viz.: the *superior maxillary*, *malar*, *nasal*, *palate*, *lachrymal*, and *inferior turbinated bones*; and two single, viz., the *vomer*, and the *inferior maxilla*. There is also suspended by ligaments from the under surface of the cranium, the hyoid bone, which may be classed with the bones of the head.

#### THE OCCIPITAL BONE

The occipital bone is situated at the lower and back part of the cranium. In general form it is rhomboidal, and through its lower and anterior part passes a large oval foramen, forming the communication between the cranium and spinal canal. The portion of the bone behind the foramen is *tabular*, the narrower part in front forms a thick mass named *basilar process*, and the parts on the sides of the foramen, bearing

the condyles or articulating processes by which the head is supported on the first vertebra, are the *condylar portions*.

Fig. 27.

5

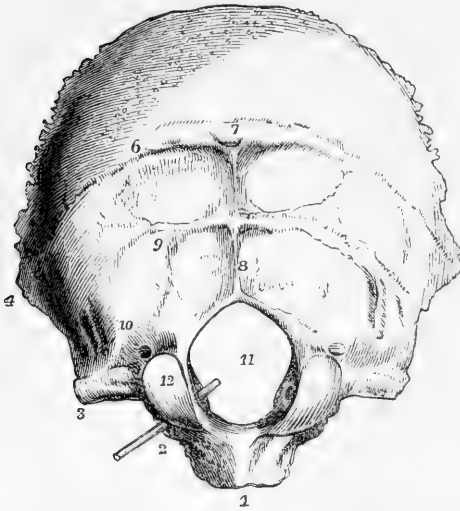


Fig. 27. — OCCIPITAL BONE FROM BELOW AND BEHIND, SHOWING THE EXTERNAL SURFACE. (A. T.)  $\frac{1}{2}$

1, basilar process; 2, condyloid portion, the probe marks the anterior condylar foramen; 3, jugular or transverse process; 4, external or lateral angle; 5, superior angle; 6, superior curved line; 7, external or posterior occipital protuberance; 7, 8, external occipital crest; 9, inferior curved line; 10, groove and ridge connected with the attachment of the superior oblique muscle; 11, foramen magnum; 12, articular condyle; immediately above it the posterior condylar foramen.

the parietal bones in the lamodoidal suture. By its two inferior

The two superior borders are deeply serrated, and are articulated with

Fig. 28.

5

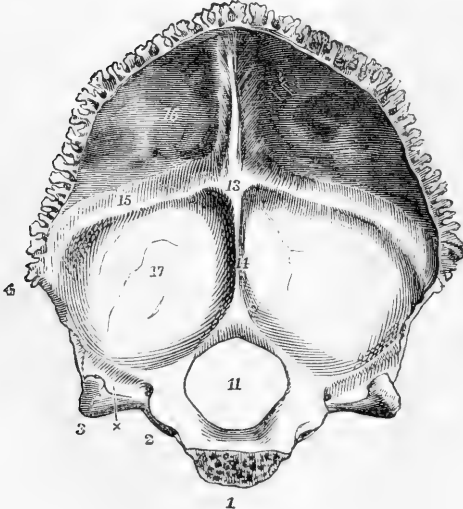


Fig. 28. — OCCIPITAL BONE FROM BEFORE, SHOWING THE INTERNAL SURFACE. (A. T.)  $\frac{1}{2}$

1, basilar process sawn through at the place of union with the sphenoid bone; 2, condylar portion; 3, jugular or transverse process; x, between 2 & 3, the sigmoid groove of the lateral sinus and the jugular notch; 4, external or lateral angle; 5, superior angle; 1 to 3, the edge of articulation with the petrous bone; 3 to 4, with the mastoid bone; 4 to 5 with the parietal bone; 11, foramen magnum; 13, internal occipital protuberance and groove of the torcular Herophili; 14, inferior spine; 15, groove of the lateral sinus; from 5 to 13, groove of the superior longitudinal sinus; 16, cerebral fossa; 17, cerebellar fossa.

borders, which are uneven but not deeply serrated, it articulates with the mastoid and petrous portions of the

temporal bone, while the extremity of its basilar process is united to the body of the sphenoid, in the young condition by cartilage, but after the age of twenty years by continuous osseous substance. The rhomboidal form generally given by the meeting of these borders at the four angles is not unfrequently somewhat changed to the octagonal, by the greater or less projection of subordinate obtuse angles between the upper and lateral, and between the lateral and lower angles.

The **tabular portion**, or **supra-occipital**, on its *posterior surface* presents a rough prominence, the *external occipital protuberance*, arching outwards from which, on each side, is the *superior occipital ridge* or *curved line*, which divides the surface into two parts, the upper, covered by the hairy scalp, convex and uniform; the lower, uneven, and marked by the impressions of the muscles of the neck which are attached to it. This lower surface is divided into two lateral portions by a median ridge called the *external occipital crest* or *spine*, and each of these portions is again divided into an upper and a lower surface by the *inferior curved line* or *ridge*, which, after extending some distance outwards, is met by a ridge and groove passing from before backwards. These surfaces mark the attachments of the rectus capitis posterior major and minor, and of the obliquus capitis superior muscles.

The *deep surface* of the bone is marked by two smooth ridges which cross one another, one extending from the upper angle to the great foramen, and the other transversely from one lateral angle to the other, and at the point of intersection of these ridges is the *internal occipital protuberance*. Separated by these ridges are four hollows, the *superior* and *inferior occipital fossae*, which lodge respectively the posterior cerebral and the cerebellar lobes. The superior and transverse ridges are grooved in the course of the longitudinal and lateral venous sinuses respectively. The wider space where those grooves meet at the internal occipital protuberance receives the torcular Herophili. The inferior ridge is single, and is named the internal occipital crest or spine. The margins of the tabular portion are deeply serrated above the lateral angles for articulation with the parietal bones; below that level, they unite with the mastoid portions of the temporal bones.

The **condylar portions** or **ex-occipitals**, bear the articulating condyles on their lower part, close to the margin of the foramen magnum in its anterior half. The condyles are elliptical and converge in front: their surfaces are convex from behind forwards and from side to side, and slightly everted. Their inner borders are rough, and receive the insertion of the odontoid ligaments of the axis. In front, and to the inside of the condyles, are the anterior condyloid foramina, which pass forwards and outwards from the interior of the cranium, and transmit the hypoglossal nerves. Behind the condyles are two pits, containing usually the posterior condyloid foramina; each of these gives passage to a vein, but they vary greatly in size and are often absent on one or both sides. Externally to the condyle, on each side, is a portion of bone, which is placed over the transverse process of the atlas, continuous posteriorly with the tabular part, and anteriorly having a free excavated margin, the *jugular notch*, which contributes, with a notch in the temporal bone, to form the *foramen lacerum jugulare*; its external extremity projects into the angle between the mastoid and petrous portions of the temporal bone, and is called the *jugular eminence*. This process presents inferiorly a rough elevation, which gives attach-

ment to the rectus capitis lateralis muscle ; and superiorly a deep groove for the lateral sinus before it terminates in the jugular notch.

The **basilar process**, or **basio-occipital**, projects forwards and upwards into the middle of the base of the skull. It increases in thickness and diminishes in breadth towards its extremity. Inferiorly it gives attachment to the rectus capitis anticus major and minor muscles and the fibrous band of the pharynx. Its superior surface presents a smooth depression, the basilar groove, which supports the medulla oblongata, and close to each lateral margin a slight grooved mark, which indicates the place of the inferior petrosal sinus.

#### THE PARIETAL BONES.

The **parietal bones** form a considerable part of the roof of the skull. They have the shape of quadrilateral plates, convex externally, concave internally. They are a little broader above than below, and the anterior inferior angle is the most projecting. They articulate with each other in the middle line, with the frontal bone anteriorly, the occipital posteriorly, and the temporal and sphenoid below.

On the *outer surface*, near its middle, a more marked convexity exists forming the *parietal eminence*. Below this is a curved line,

Fig. 29.

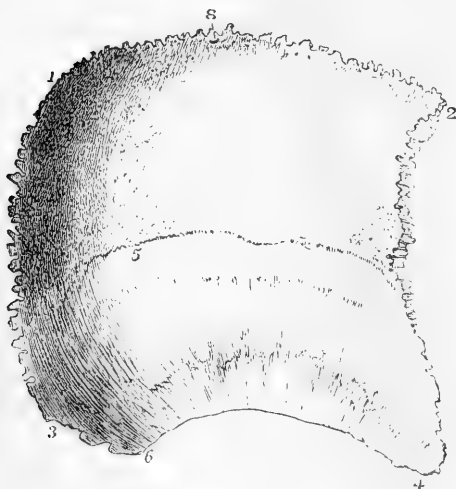


Fig. 29.—EXTERNAL SURFACE OF THE RIGHT PARIETAL BONE. (A. T.)  $\frac{1}{2}$

1, posterior superior angle ; 2, anterior superior angle ; 3, posterior inferior angle ; 4, anterior inferior angle, articulating with the great wing of the sphenoid bone ; from 1 to 2, superior border in the sagittal suture ; from 2 to 4, anterior border in the coronal suture ; from 1 to 3, posterior border in the lambdoidal suture ; from 4 to 6, margin of the squamous suture ; from 3 to 6, the additamentum suturæ squamosæ ; 5, the temporal or semicircular line above which is the parietal eminence ; 8, parietal foramen.

the parietal part of the temporal ridge, bounding a surface

somewhat flatter than the rest, *planum temporale*, which forms part of the temporal fossa. Near the posterior and upper angle, is the small *parietal foramen*.

The concave inner surface is marked by shallow depressions corresponding with the convolutions of the brain, and by narrower furrows branching upwards and backwards from the lower border for the middle meningeal vessels. The largest of these grooves running from the anterior inferior angle is sometimes converted into a canal for a short distance. A slight depression along the inner part of the superior border, forms with the one of the opposite side, the groove of the

longitudinal sinus; and a depression at the posterior inferior angle forms a small part of the groove of the lateral sinus. Near the upper

Fig. 30.—THE PARIETAL BONE FROM THE INSIDE. (A.T.)  $\frac{1}{2}$

1, 2, 3, 4, 6, & 8, indicate the same parts as in the last figure: between 1 & 2 the half groove of the superior longitudinal sinus; 3', groove of the lateral sinus; 7, the ramified grooves of the meningeal vessels; above this groove is converted into a canal; 9, the irregular pits for the glandulæ Pacchionii.

border there are in most skulls, but particularly in those of old persons, small irregular pits, *foveæ glandulares*, lodging the so-named glandulæ Pacchionii.

*Borders.*—The anterior, superior, and posterior borders are deeply serrated. The inferior border presents in the greater part of its extent a sharp or squamous edge, with a slightly fluted surface directed outwards and overlapped at its anterior extremity by the great wing of the sphenoid, and behind that by the squamous part of the temporal bone; its posterior part is serrated, and articulates with the mastoid portion of the temporal. The anterior border is slightly overlapped by the frontal bone above, but overlaps the edge of that bone inferiorly.

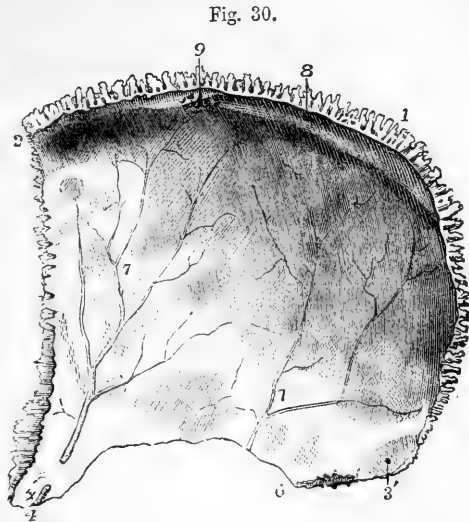


Fig. 30.

#### THE FRONTAL BONE

The **frontal bone**, arching upwards and backwards from above the orbits, forms the fore part of the cranium. It likewise presents inferiorly two thin horizontal laminæ, the *orbital plates*, which form the roofs of the orbits and are separated by a mesial excavation, the *incisura ethmoidalis*.

The frontal is articulated with twelve bones, viz., posteriorly with the parietals and sphenoid; outside the orbits with the malars; and between the orbits, from before backwards, with the nasal, superior maxillary, lachrymal, and ethmoid bones.

**Anterior surface.**—The part forming the greatest convexity of the forehead on each side is called the *frontal eminence*. It is separated by a slight depression below from the *superciliary ridge*, a curved elevation of varying prominence immediately above the margin of the orbit. Between the superciliary ridges is the surface called *glabella*. The margin of the orbit, the *orbital arch*, is most defined towards its outer part; it presents towards its inner third the *supraorbital notch*, sometimes converted into a foramen, which transmits the supraorbital nerve and artery. The extremities of the orbital arch point downwards, and

form the *internal* and *external angular processes*. The internal is but slightly marked; the external is strong and projecting, and articulates with the malar bone. The temporal ridge springs from the external

Fig. 31.

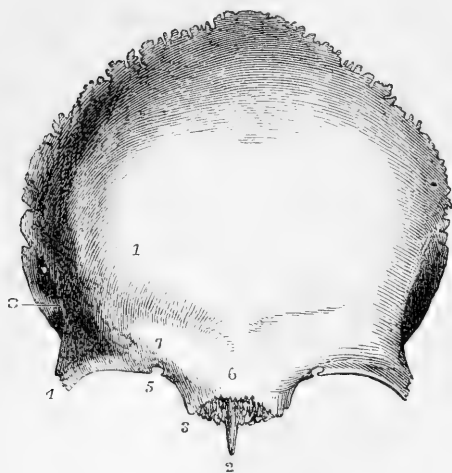

Fig. 31.—FRONTAL BONE FROM BEFORE, SHOWING ITS EXTERNAL SURFACE. (A. T.)  $\frac{1}{2}$

1, frontal eminence; 2, nasal spine, and above this the serrated surface for articulation of the nasal and superior maxillary bones; 3 to 4, supra-orbital edge—3, internal, and 4, external angular process; 5, supra-orbital notch or foramen; 6, glabella; 7, superciliary eminence and ridge; 8, temporal ridge, and behind this a part of the temporal fossa.

process, and arches upwards and backwards to be continued on the parietal bone: it separates the temporal from the frontal part of the outer surface of the bone.

**Inferior surface.**—The orbital surfaces are somewhat triangular, their internal margins being parallel, while the external are directed backwards and inwards. Close to the external angular process is the *fossa lachrymalis*, which lodges the lachrymal gland; and close to the internal angular process is a small impression where the pulley of the trochlearis muscle is attached. Between the orbits in front is the serrated surface which articulates with the superior maxillary and nasal bones, and in the middle line a sharp process of variable length, the *nasal spine*, descends between the latter bones and the central plate of the ethmoid. Between the incisura ethmoidalis and the inner margin of the orbit is an irregular surface occupied with depressions forming the roofs of cells in the ethmoid bone. Traversing this surface are two grooves, which complete, with the ethmoid, the *anterior* and *posterior internal orbital foramina*. The anterior groove transmits the nasal twig of the ophthalmic nerve and the anterior ethmoidal vessels; the other, the posterior ethmoidal vessels. Further forward, on each side of the nasal spine, is the larger opening of the *frontal sinus*, a cavity which extends within the bone for a variable distance behind the superciliary ridges. Outside and behind the orbital surface, there is a large serrated triangular area which articulates with the great wing of the sphenoid.

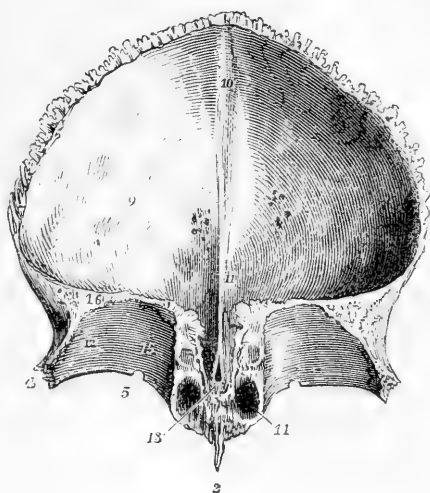
**Cerebral surface.**—This surface forms a large concavity, except over the roofs of the orbits, which are slightly convex. Upon it are seen the impressions of the cerebral convolutions, which, with the intervening ridges, are strongly marked over the orbits. A groove, the *sulcus frontalis*, lodging the longitudinal sinus, descends from the middle of the upper margin of the bone, and is succeeded by the *crista frontalis*, a ridge which runs down to the lower margin. A small foramen, usually formed in part by the central plate of the ethmoid, is

situated at its base; it is known as the *foramen cæcum*, and transmits a minute vein from the nasal fossæ. The upper and greater part of the

Fig. 32.—THE FRONTAL BONE FROM BEHIND AND BELOW, SHOWING THE INTERNAL CEREBRAL SURFACE AND THE ROOF OF THE ORBITS. (A. T.)  $\frac{1}{2}$

2, 4, and 5, as in the preceding figure; 9, internal or cerebral surface, slightly marked by cerebral convolutions and glandular pits; 10, groove of the superior longitudinal sinus, ending below in, 11, the internal frontal crest, which leads down to, 13, the foramen cæcum; 12, the orbital plate, the number is placed in the depression for the lachrymal gland; 14, the opening of the frontal sinus; 15, placed on the roof of the orbit internally, is near the opening of the anterior ethmoidal or internal orbital foramen.

Fig. 32.



edge encompassing the cerebral surface of the bone is deeply serrated, and articulates with the parietal bones in the coronal suture; the lower transverse part is thin and uneven, and articulates with the greater and lesser wings of the sphenoid in the transverse suture. The adult frontal bone is sometimes divided into two parts by a median suture, the *frontal* suture which may be regarded as the persistence of the original foetal condition.

#### THE TEMPORAL BONE.

The **temporal bone** (*os temporis*) takes part in the construction of the side and base of the skull, and contains in its interior the organ of hearing. It is usually described in three parts, viz., an expanded anterior and superior part, the *squamous* portion with the zygomatic process, a thicker posterior portion, the *mastoid*, and below and between these the *petrous* portion, a three-sided pyramid, exhibiting at its base externally the aperture of the ear, and projecting forwards and inwards into the base of the skull. With these is combined in the adult the styloid process or bone.

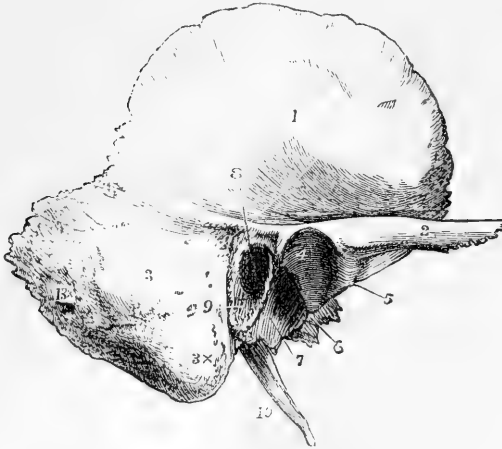It articulates superiorly and internally with the occipital bone, superiorly with the parietal, anteriorly with the sphenoid, by the zygomatic process with the malar, and by the glenoid cavity with the inferior maxillary bone.

The **squamous portion**, or squamo-zygomatic, extends forwards and upwards from its connection with the other portions, and presents superiorly an arched border which describes about two-thirds of a circle.

The *inner surface* is marked by cerebral impressions, and by meningeal grooves. At its upper border, the outer table is prolonged considerably beyond the inner, forming a thin scale with the fluted surface looking

inwards and overlapping the corresponding bevelled edge of the parietal bone. But in front the border is thicker, looks directly forwards, and is serrated for articulation with the great wing of the sphenoid bone.

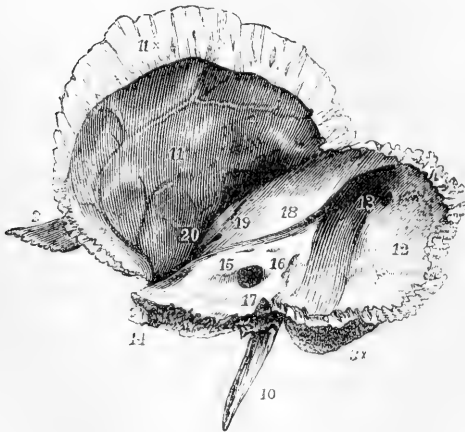
Fig. 33.

Fig. 33.—RIGHT TEMPORAL BONE FROM THE OUTSIDE. (A. T.)  $\frac{2}{3}$ 

1, the external surface of the squamous part; 2, the zygoma; 3, the mastoid part; 3 x, the mastoid process; 4, the articular part of the glenoid fossa; 5, the articular eminence at the root of the zygoma, and above it the tubercle; 6, fissure of Glaser; 7, the tympanic plate forming the posterior non-articular part of the glenoid fossa, terminating behind in the vaginal process; 8, the meatus auditorius externus; 9, the auditory process; 10, the styloid process; 13 x, the mastoid foramen.

The *outer surface* is in its greatest extent vertical, with a slight convexity, and forms part of the temporal fossa. From its lowest part a long process, the zygoma, takes origin.

Fig. 34.

Fig. 34.—THE RIGHT TEMPORAL BONE FROM THE INNER SIDE. (A. T.)  $\frac{2}{3}$ 

The indications where marked are the same as in the preceding figure. 11, the inner or cerebral surface of the squamous portion; 11 x, the squamous edge, 12, inner surface of the mastoid portion; 13, the sigmoid groove of the lateral sinus—the figure is placed at its upper part, and close to the mastoid foramen; 14, the apex of the petrous bone; 15, the meatus auditorius internus; 16, the scale of bone covering the aqueduct of the vestibule; 17, is above the aqueduct of the cochlea; 18, the superior petrosal groove; 19, the eminence of the superior semicircular canal; 20, the hiatus Fallopii.

The *zygoma*, or zygomatic process, is connected with the lower and outer part of the squamous portion, and is of considerable breadth at its base, which projects outwards. It then becomes narrower, and is



twisted on itself so as to present an outer and inner surface, and a sharp upper and lower border. The superior margin is thinner, and prolonged further forward than the inferior. The bevelled extremity is serrated, and articulates with the malar bone. At its base the zygomatic process presents two roots. The *anterior* root is a broad convex ridge, directed inwards. The *posterior* root passes backwards, and is divided into two parts, of which one turns inwards in front of the meatus externus, while the other, gradually subsiding, is continued backwards over that opening, and marks behind it the line of union of the squamous and mastoid portions of the bone. At the point of division of the two roots is a slight *tubercle*, which gives attachment to the external lateral ligament of the lower jaw. Between the two roots is the *glenoid fossa*, a depression elongated from without inwards, and which, together with the cylindrical elevation formed by the anterior root of the zygoma in front of it, is coated with cartilage, and forms the concavo-convex surface which articulates with the lower jaw. The fissure of Glaser separates this articular part of the glenoid fossa from the remaining part behind, which is formed by the tympanic plate of the petrous division of the temporal bone, and lodges a part of the parotid gland.

The **mastoid portion** is rough externally for the attachment of muscles, and is prolonged downwards behind the aperture of the ear into a nipple-shaped projection—the *mastoid process*. This process has on its inner side a deep groove, the *digastric fossa*, which gives attachment to the digastric muscle; and internal to that is the slight *occipital groove*, for the occipital artery. The internal surface of the mastoid portion is marked by a deep sigmoid depression, which is part of the groove of the lateral sinus. A passage for a vein, of very variable size, the *mastoid foramen*, usually pierces the bone near its posterior margin, and opens into the groove.

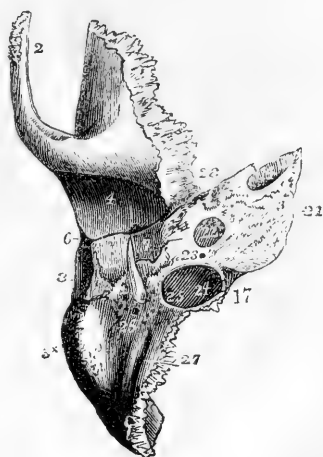
Fig. 35.—THE RIGHT TEMPORAL BONE FROM BELOW. (A. T.)  $\frac{2}{3}$

The indications where marked are the same as in the preceding figures. 14, is at the apex of the petrous bone in the upper opening of the carotid canal; 17, aqueduct of the cochlea; 21, lower rough surface of the petrous bone; 22, the lower opening of the carotid canal; 23, the small foramen of Jacobson's nerve; 24, the jugular depression, and within it, 25, the foramen of Arnold's nerve; 26, stylo-mastoid foramen—the figure is placed in the anterior part of the digastric groove; 27, groove of the occipital artery; 28, place of the anterior opening of the osseous Eustachian canal.

The **petrous portion** is named from its hardness. It contains the organ of hearing. It forms a three-sided pyramid, with its base directed outwards, one surface looking downwards, and the other two turned towards the interior of the skull.

*Inferior surface, base, and apex.*—At the base is the aperture of the

Fig. 35.



ear. It forms a short canal, the *meatus auditorius externus*, directed inwards and a little forwards, narrower in the middle than at its extremities, and leading into the cavity of the *tympanum*, part of which is seen from the exterior in the macerated bone. It is bounded superiorly by the posterior root of the zygoma, and in the remainder of its circumference chiefly by the *external auditory process*, a curved uneven border, to which the cartilage of the ear is attached. This process is the thickened outer extremity of the *tympanic plate*, a lamina one surface of which forms the anterior wall of the external auditory meatus and the tympanum, while the other looks towards the glenoid fossa. The upper margin of the tympanic plate is separated from the glenoid fossa by the *fissure of Glaser*, while its lower margin descends as a sharp edge, the *raginal process*, which partly surrounds the front of the styloid process at its base. The *styloid process* is long and tapering, and is directed downwards and forwards. It is placed in front of the digastric fossa, and has immediately behind it the foramen which forms the outlet of the canal of the facial nerve, named *stylo-mastoid* from its position between the styloid and mastoid processes. A smooth rounded and deep depression, the *jugular fossa*, lies internal to the styloid process; it is close to the posterior margin of the bone, and completes with the jugular notch of the occipital bone the foramen lacerum posterius. In front and a little to the inside of the jugular fossa is the *carotid foramen*, the inferior extremity of the carotid canal; and internal to the carotid foramen is a rough surface which gives attachment to the levator palati muscle, and is continued into the rough inner extremity, or *apex* of the petrous bone. The *carotid canal* ascends at first perpendicularly, then turns horizontally forwards and inwards, and emerges at the apex, close to the anterior margin. It transmits the internal carotid artery. In the angle between the petrous and squamous portions of the bone is the anterior opening of the *Eustachian canal*.

The *posterior surface* looks backwards and inwards, and forms part of the posterior fossa in the base of the skull. It presents a large orifice leading into a short canal which is directed outwards, the *meatus auditorius internus*. This canal is terminated by a plate of bone, the *lamina cribrosa*, presenting in the lower part small apertures through which the divisions of the auditory nerve pass, while in its upper part is the commencement of the canal called *aqueduct of Fallopius*, which transmits the facial nerve. This canal takes a somewhat circuitous course through the petrous bone, passing outwards and backwards over the labyrinth of the ear, and then downwards to terminate at the stylo-mastoid foramen.

The *anterior or upper surface* looks upwards and forwards, and forms part of the middle fossa in the base of the skull. A depression near the apex marks the position of the Gasserian ganglion. A narrow groove runs obliquely backwards and outwards to a foramen named the *hiatus Fallopii*, which leads to the aqueduct of Fallopius, and transmits the large superficial petrosal nerve. Farther back is a rounded eminence, indicating the situation of the superior semicircular canal.

The *superior border* is grooved for the superior petrosal sinus. The *anterior border* is very short, and forms at its junction with the squamous part an angle in which is situated the orifice of the *Eustachian canal*, the osseous portion of a tube of the same name, which leads from the pharynx to the tympanum; and above this, partially

separated from it by a thin lamella, the *processus cochleariformis*, is a small passage which lodges the tensor tympani muscle. The *posterior border* articulates with the basilar process of the occipital bone, and bounds the foramen lacerum posterius.

**Small Foramina.**—The opening of the *aqueductus vestibuli* is a narrow fissure, covered by a depressed scale of bone, and situated on the posterior surface of the petrous bone, about three lines behind the internal auditory meatus; that of the *aqueductus cochleæ* is a small foramen, beginning in a three-sided wider depression in the posterior margin, directly below the internal auditory meatus. In the plate between the jugular fossa and the carotid canal is the foramen by which the nerve of Jacobson passes to the tympanum. In the ascending part of the carotid canal is the minute foramen for the tympanic branch of the carotid plexus. In the jugular fossa are a groove and foramen for the auricular branch of the vagus nerve; and parallel to the hiatus Fallopii, close to the canal for the tensor tympani muscle, are a groove and foramen for the small superficial petrosal nerve.

The description of the small bones of the ear with the tympanum and internal ear, will be found in the chapter on the Organs of the Senses.

#### THE SPHENOID BONE.

The **sphenoid**, or wedge-shaped bone, is placed across the base of the skull, near its middle. It enters into the formation of the cavity of the cranium, the orbits, and the posterior nares. It is of very irregular shape, and consists of a central part or *body*, a pair of lateral expan-

Fig. 36.

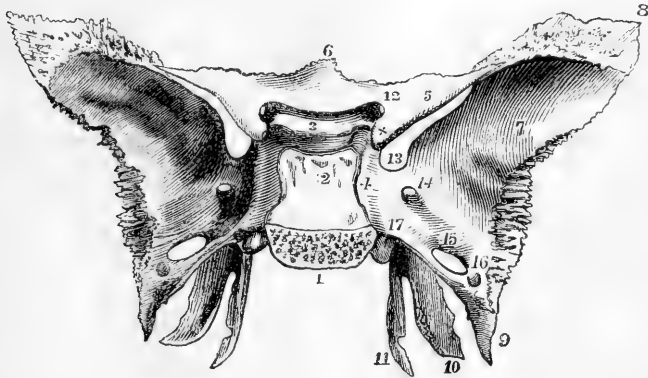


Fig. 36.—THE SPHENOID BONE FROM ABOVE AND BEHIND. (A. T.)  $\frac{2}{3}$

1, the basilar surface, sawn separate from the occipital bone; 2, Dorsum sellæ, or inclined surface of the body terminating superiorly in the two posterior clinoid processes; 3, is placed on the olivary eminence or process, and between it and 2 is the sella turcica, or pituitary fossa; in front of 3 is the transverse groove of the optic commissure; 4, the side of the body with the sigmoid groove of the internal carotid artery and cavernous sinus; 5, the lesser wing; x, the anterior clinoid process; 6, the ethmoid spine; 7, the cerebral surface of the greater wing; 8, the upper angle of the greater wing, which articulates with the parietal bone; 9, the spinous process; 10, the external, and 11, the internal pterygoid process; 11, is placed opposite the hamular process and groove for the tendon of the tensor palati muscle; 12, the optic foramen, 13, the sphenoidal fissure or foramen lacerum orbitale; 14, the foramen rotundum; 15, the foramen ovale; 16, the foramen spinosum; 17, is placed above the posterior opening of the pterygoid or Vidian foramen.

sions called the *great wings*, a pair of smaller horizontal processes in front, called the *small wings*, and a pair which project downwards, the *pterygoid processes*.

The sphenoid is articulated with all the seven other bones of the cranium and with five of those of the face, viz., posteriorly with the occipital and with the petrous portions of the temporals, anteriorly with the ethmoid, frontal, and malars, laterally with the squamous portion of the temporals, the parietals and frontals, and inferiorly with the vomer and palate bones.

The **body**.—Posteriorly the body of the sphenoid is solid, but anteriorly it is hollowed out into two large cavities, the sphenoidal sinuses, separated by a thin mesial lamina and opening into the upper part of the nasal fossa by two rounded apertures. The *superior surface* presents in the middle a deep pit, the *pituitary fossa*, or *sella turcica*, which lodges the pituitary body. In front of the fossa, separated from it by a shallow transverse groove, is a narrow portion of bone on a level with the optic foramina, the *olivary process*, (tuberculum sellæ—Henle), on which rests the commissure of the optic nerves; and in front of this is a surface on a slightly higher level, continuous with the superior surfaces of the small wings, and having a slight projection forwards of its anterior border, which articulates with the cribriform plate of the ethmoid, and is called the *ethmoidal spine*. Behind the pituitary fossa is a prominent lamella, the *dorsum sellæ*, the posterior surface of which is sloped upwards and forwards in continuation of the basilar groove of the occipital bone. The angles of this lamella project over the fossa, and are called the *posterior clinoid processes*. On each side of the body the surface descends obliquely to a considerably lower level than the fossa; it presents close to the margin of the fossa a superficial curved groove directed from behind forwards, marking the course of the internal carotid artery. At the bottom of this groove, and in the angle between the body and the great wing, there projects the small ridge of bone termed *lingula sphenoidalis*.

The *posterior surface* is flat, and is united to the basilar process of the occipital bone, in early life by cartilage, but in adult age by continuous bony substance.

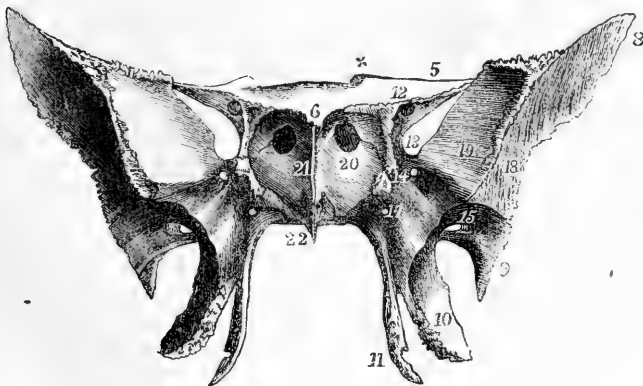
The *anterior surface* presents in the middle line the *sphenoidal crest*, a thin projecting edge which extends downwards from the ethmoidal spine and terminates in the *rostrum*, a sharp bony prominence projecting vertically between the anterior and inferior surfaces. The sphenoidal crest articulates with the central plate of the ethmoid; the rostrum is inserted between the alæ of the vomer.

The **sphenoidal spongy bones** (*cornua sphenoidalia*, *bones of Bertin*), form a considerable part of the anterior wall of the body of the sphenoid, including the foramen of each sinus. These bones have a triangular form, with the apex directed downwards, and are in the adult usually incorporated with the sphenoid, but as explained in the account of their development, they are originally distinct. They are frequently united by earlier or stronger ankylosis with the ethmoid or palate bones, so as to come away, at least in part, with either of these in disarticulation of the skull, and thus lay open the sphenoidal sinuses. A small portion of these bones sometimes appears on the inner wall of the orbit, between the ethmoid, frontal, sphenoid, and palate bones (Cleland in Trans. of Roy. Soc. for 1862).

The **great wings**, *alæ majores*, project outwards and upwards from the sides of the body. The back part of each is placed horizontally, and occupies the angle between the petrous and squamous portions of the temporal bone; from its pointed extremity it sends downwards a short and sharp projection, the *spinous process*. The upper and fore part is vertical, and three-sided, lying between the cranial cavity, the orbit, and the temporal fossa. The *cerebral surface* of the great wing is concave, and forms part of the middle fossa of the base of the cranium. The *external surface* (temporo-zygomatic) is divided by a ridge into an inferior part, which looks downwards into the zygomatic fossa, and an elongated superior part, looking outwards, which forms a part of the temporal fossa. The *anterior surface* looks forwards and inwards, and consists of a quadrilateral *orbital* portion, which forms the back part of the external wall of the orbit, and of a smaller inferior portion which overhangs the pterygoid process, looks into the sphenomaxillary fossa, and is perforated by the foramen rotundum. The external margins between the cerebral and external surfaces articulate with the temporal and parietal bones; anteriorly, the margin between the orbital and external surfaces articulates with the malar bone. The margin below this forms the upper part of the posterior boundary of the pterygomaxillary fissure; internally, the cerebral and orbital surfaces come into contact at the outer border of the sphenoidal fissure; and superiorly, the cerebral, orbital, and external surfaces surround the triangular area which articulates with the frontal bone.

The **small wings**, *alæ minores* (*wings of Ingrassias*), extend nearly horizontally outwards from the fore part of the superior surface of the body. The extremity of each is slender and pointed, and comes very close to, but not into actual contact with, the great wing. The superior surface forms part of the anterior fossa of the base of the cranium, the inferior overhangs the sphenoidal fissure and the back of the orbit.

Fig. 37.

Fig. 37.—THE SPHENOID BONE FROM BEFORE. (A. T.)  $\frac{2}{3}$ 

The indications where marked are the same as in the preceding figure. 17, marks the anterior opening of the Vidian foramen or canal; 18, the external or temporal surface of the great wing; 19, its orbital surface; 20, the sphenoidal turbinated or spongy bone; above 20, the opening into the sphenoidal sinus; 21, the sphenoidal spine; 22, the rostrum, and above 22, the inverted laminae, which fit with the edges of the vomer.

The anterior border, thin and serrated, articulates with the orbital plate of the frontal bone. The posterior border is prominent and free, and forms the boundary between the anterior and middle cranial fossæ, terminating internally in a smooth rounded knob, the anterior clinoid process. Below and to the inside of this is the optic foramen.

The **pterygoid processes** project downwards and slightly forwards, between the body and the great wings. Each consists of two plates united in front and diverging behind, so as to enclose between them the *pterygoid fossa*. The *external pterygoid plate*, broader than the internal, lies in a plane extending backwards and outwards; its outer surface bounds the zygomatic fossa, and gives attachment to the external pterygoid muscle. The internal pterygoid muscle arises from its inner surface. The *internal pterygoid plate* is longer and narrower than the external, and is prolonged into the slender hook-like or *hamular process*, round which in a groove plays the tendon of the tensor palati muscle. At its base, the internal plate turns inwards beneath the body, from which its extremity remains distinct as a slightly raised edge, which articulates with the everted margin of the vomer; and externally to this it is marked by a small groove, which contributes with the palate bone to form the *pterygo-palatine canal*. The interval between the lower ends of the pterygoid plates is occupied by the pyramidal process of the palate bone. At the base of the internal pterygoid process is a slight depression, distinguished as the *navicular fossa*, which gives attachment to the tensor palati muscle.

**Fissures and foramina.**—Each lateral half of the bone presents a fissure, four foramina, and a canal. The *sphenoidal fissure* is the obliquely placed elongated interval between the great and the small wing; it is closed externally by the frontal bone, so as to form the *foramen lacerum orbitale*; it opens into the orbit, and transmits the third, fourth, and sixth nerves, the ophthalmic division of the fifth nerve, and the ophthalmic vein. Above and to the inside of it is the *optic foramen*, which is inclined outwards and forwards from the side of the olivary process, pierces the base of the small wing, and transmits the optic nerve and the ophthalmic artery. The *foramen rotundum* is directed forwards through the great wing, below the sphenoidal fissure; it opens immediately below the level of the orbit, and transmits the superior maxillary division of the fifth nerve. The *foramen ovale* is large, placed behind and a little external to the foramen rotundum, near the posterior margin of the great wing; it is directed downwards, and transmits the inferior maxillary division of the fifth nerve. The *foramen spinosum* is a small foramen piercing the great wing, near its posterior angle, and transmits the middle meningeal vessels.

The *Vidian* or *pterygoid canal*, passes through the bone horizontally from before backwards at the base of the internal pterygoid plate; it opens anteriorly into the speno-maxillary fossa, and posteriorly into the foramen lacerum medium, and transmits the Vidian nerve and vessels.

**Varieties.**—Spicula of bone sometimes connect the anterior clinoid process with the pituitary fossa and with the posterior clinoid process. The outer pterygoid plate is sometimes connected by a bridge of bone or of ligament with the spinous process. The foramen ovale and foramen spinosum are frequently incomplete at the posterior margin of the bone.

## ETHMOID BONE

The **ethmoid**, or sieve-like bone, projects downwards from between the orbital plates of the frontal bone, and enters into the formation of the cranium, the orbits, and the nasal fossæ. It is of a cuboid figure. It is exceedingly light for its size, being composed of very thin plates of bone forming in part irregular cells. It consists of a *central vertical plate*, and of two *lateral masses*, the *ethmo-turbinals*, united at their superior extremities by the horizontal *cribriform lamella*.

It articulates with thirteen bones; the frontal, sphenoid and vomer, the nasal, lachrymal, superior maxillary, palatal, and inferior turbinated bones.

The **vertical plate** lies in the mesial plane, and forms the upper part of the septum of the nose. Its superior margin appears in the cranial cavity, above the cribriform lamella, in the form of a ridge

Fig. 38.—THE ETHMOID BONE. (A. T.)  $\frac{2}{3}$

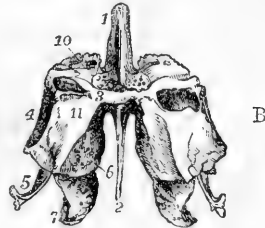
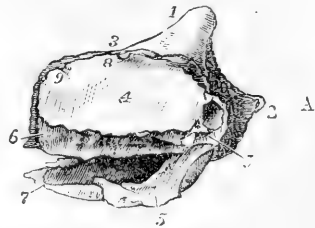
A, from the right side. 1, crista galli; 2, vertical plate; 3, cribriform plate and foramina; 4, orbital plate or os planum; 5, 5, the uncinate process; 6, the superior, and 7, the inferior turbinated bone; 8, the anterior, and 9, the posterior ethmoidal groove or foramen.

B, the ethmoid bone from behind. The indications where marked are the same as in A. 10, the lateral or cellular part of the bone; 11, its posterior surface of union with the sphenoidal turbinated and palate bones.

which rises anteriorly into a thick process, the *crista galli*, to which the falx cerebri is attached. The anterior margin of the crista galli is vertical and broad, usually presenting a groove, which completes the foramen cæcum of the frontal bone. Below the level of the cribriform lamella, the anterior margin of the vertical plate articulates with the nasal spine of the frontal and occasionally with the nasal bones. The inferior margin articulates in front, and sometimes even in its whole extent, with the septal cartilage of the nose; and in its posterior half, in the adult, it is more or less completely joined by osseous union on one or both sides to the two plates or alæ of the vomer. The posterior margin is very thin, and is united to the crest of the sphenoid. This plate presents superiorly a number of grooves and minute canals leading from the foramina of the cribriform lamella, for the transmission of the olfactory nerves.

The **lateral masses** enclose a number of spaces of irregular form, arranged in two sets, the *anterior* and *posterior ethmoidal cells*, which in the recent state are lined with prolongations of the mucous membrane of the nose. On the *external aspect* of each lateral mass is a thin, smooth lamina, of a quadrilateral form, the *orbital plate* or *os planum*, which closes in the ethmoidal cells, and forms a consider-

Fig. 38.



able part of the inner wall of the orbit. The orbital plate articulates in front with the lachrymal, behind with the sphenoid, above with the frontal, and below with the orbital surfaces of the superior maxillary and palate bones. In front of the orbital plate the lateral mass extends forwards, under cover of the lachrymal bone; and from this part descends the *uncinate* process, a long thin lamella which curves downwards, outwards and backwards, forming part of the inner wall of the maxillary sinus, and articulating at its extremity with the inferior turbinated bone.

The *internal aspect* of each lateral mass forms part of the external wall of the nasal fossa, and consists of a thin, uneven plate, connected above with the cribriform lamella, and exhibiting a number of canals and grooves for branches of the olfactory nerve. It is divided at its back part by a channel, directed forwards and upwards from its posterior margin to about its middle. This is called the *superior meatus of the nose*, and communicates with the posterior ethmoidal cells. The short margin which overhangs this channel constitutes the *superior turbinated process* or *spongy bone*. Below this is a slightly folded margin of greater extent, free in front and behind, the *inferior turbinated process* or *middle spongy bone*, which overhangs the *middle meatus of the nose*. From the front of the middle meatus a passage, the *infundibulum*, is prolonged upwards and forwards through the anterior ethmoidal cells, into the frontal sinus.

In the separate ethmoid bone the cells are open posteriorly and superiorly, but when the bone is in connection with the rest of the cranium these cells are closed, above by the frontal bone, and behind by the sphenoidal spongy bones. In the superior margin are two grooves, which complete with the frontal bone the internal orbital foramina.

The **cribriform lamella** corresponds in size to the incisura ethmoidalis of the frontal bone which it occupies. At the sides of the crista it is depressed into two grooves which lodge the olfactory bulbs; and it is pierced by numerous foramina, for transmission of the filaments of the olfactory nerves. The foramina which lie along the middle of each groove, are simple perforations; the internal and external sets are longer, and are the orifices of small canals which subdivide as they descend on the vertical plate and lateral masses. At the anterior extremity is a small fissure at each side of the crista galli, close to its base, and externally to this a foramen, connected usually by a slight groove with the anterior internal orbital foramen, which transmits the nasal branch of the ophthalmic nerve.

#### THE SUPERIOR MAXILLARY BONE.

The **upper jaw**, *maxilla superior*, is one of the principal bones of the face; it supports all the teeth of the upper range, and takes part in the formation of the hard palate, the floor of the orbit, and the floor and lateral wall of the nasal cavity. It presents inferiorly a thick ridge, the alveolar process, containing the sockets or alveoli for the roots of the teeth, and a horizontal palate plate; externally, a convex surface corresponding with the anterior and lateral parts of the face; superiorly, an ascending or nasal process and an orbital plate; and internally, a nasal surface, opening from which is a large cavity or sinus,



hollowed out beneath the orbital plate in the body of the bone. The superior maxillary bone articulates with its fellow, with the nasal, frontal, lachrymal, ethmoid, palate, malar, vomer, and inferior turbinated bones, and with the nasal cartilages.

The *alveolar border* or process, thick and arched, is hollowed out into sockets or *alveoli*, corresponding in number, form, and depth to the roots of the teeth, which are fixed in them.

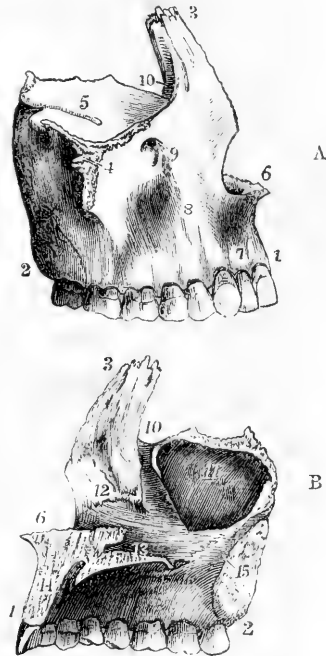
The *palate plate*, along with that of the opposite side, forms about three-fourths of the hard palate. Its superior surface is smooth and concave from side to side; its inferior surface is vaulted and rough, and is marked laterally with grooves for nerves and vessels, which reach the palate through the posterior palatine canal. Its posterior extremity falls short of that of the alveolar arch and body of the bone, and articulates with the horizontal process of the palate bone, which completes the hard palate. The mesial border rises into a serrated vertical ridge, which, with its fellow, constitutes in front the *nasal*

Fig. 39.—SUPERIOR MAXILLARY BONE OF THE RIGHT SIDE. (A. T.)  $\frac{1}{2}$

Fig. 39.

A, from the outside; B, from the inside.

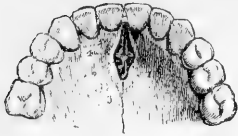1 to 2, alveolar process or arch—1 at the middle incisor tooth, 2 marks the tuberosity, and above it, in A, the posterior dental foramina; 3, the nasal or ascending process; 4, malar tuberosity or process; 5, orbital plate or process; 6, placed in front of the nasal notch marks the nasal crest terminating in the nasal spine; 7, the incisor or myrtiliform fossa; 8, is in front of the canine fossa; 9, the infra-orbital foramen, and below 5, the infra-orbital groove and canal; 10, groove of the nasal or lachrymal duct; 11, antrum maxillare, or maxillary sinus; 12, marks the oblique ridge for the attachment of the inferior turbinated bone; 13, is placed above the palate plate; from 13 to 6, the vomeric and nasal crest; from 13 to 14, the anterior palatine foramen; 15, placed on the surface of articulation of the body with the palate bone, points to the groove of the palato-maxillary canal. These figures also exhibit a full set of the upper teeth of one side as they occur in middle life.



*crest*—a grooved elevation which supports the extremity of the vomer and the septal cartilage, and is prolonged forwards into the *nasal spine*. This ridge is interrupted at its anterior part by a canal, the *incisor foramen*, which is completed on its mesial side by a slender lamina passing from the anterior to the posterior border. Each incisor foramen widens out below into a larger hollow, which when placed in apposition with that of the opposite side, completes a mesial aperture, the *anterior palatine foramen*. Viewed from below, this aperture may be seen to be divided into four smaller foramina, two of which, placed laterally, are the incisor foramina, called also *foramina of Stenson*, while the other two, placed in the middle line, one before, the other behind,

are distinguished as the *foramina of Scarpa*. The whole communication between the nose and the palate may be designated collectively as the *anterior palatine canal*.

Fig. 40.

Fig. 40.—FRONT PART OF THE PALATE AND ALVEOLAR ARCH OF AN ADULT.  $\frac{2}{3}$ 

Showing the lower opening of the anterior palatine or incisor foramen. 1, 2, are placed on the palate plates of the two superior maxillary bones; 3, anterior palatine foramen, in which is seen a partial division into four openings—the two lateral, with lines pointing to them from 1 and 2, are the incisor foramina (foramina of Stenson); the anterior and posterior, indicated by 3 and 4, are the naso-palatine, or foramina of Scarpa.

The terms *incisor foramen* and *anterior palatine canal* are often used convertibly and vaguely to express what has been above defined as the anterior palatine canal, or its inferior opening. According to the definitions here given, *incisor foramen* has the same meaning in human as in comparative anatomy, while anterior palatine canal is restricted to an appearance which presents itself only in man and a few animals. The lamina passing backwards from before each incisor foramen corresponds to the mesial palatine process of the intermaxillary bone in other animals, e.g. the carnivora: while the incisor foramina are those which are seen largely developed in those animals, and are the remains of a primitive communication between the nose and mouth. The foramina of Scarpa lie in the suture between the laminae referred to. They transmit the naso-palatine nerves; the nerve of the right side occupying, according to Scarpa, the posterior one, which is usually largest, and that of the left side, the anterior: but they are very inconstant. (Scarpa, *Annot. Anatom.*, lib. ii. cap. 5.)

The *external surface* is divided into an anterior and a posterior part by the *malar process*, a prominence situated above the first molar tooth, and presenting a large triangular roughness for articulation with the malar bone. The anterior portion is deeply notched at its internal margin for the opening of the anterior nares. It is marked by a prominence corresponding to the position of the fang of the canine tooth; and internal to this is a slight depression, the *incisor* or *myrtiform fossa*; while between it and the malar process is the deeper *canine fossa*, in which arise the levator anguli oris and compressor nasi muscles. Above the canine fossa, immediately below the margin of the orbit, is the *infra-orbital foramen*, which transmits the superior maxillary nerve. The posterior portion looks partly into the zygomatic, partly into the pterygo-maxillary fossa. It exhibits a rough convexity, the *tuberosity*, projecting backwards, and is perforated by a number of foramina transmitting the superior dental nerves and arteries.

The *nasal process* projects upwards from the anterior and internal part of the bone. Its internal surface, towards its summit, is rough for articulation with the lateral mass of the ethmoid; its anterior border is rough for articulation with the nasal bone, and its summit serrated for articulation with the frontal. Posteriorly it articulates by a linear edge with the lachrymal bone; and external to this it presents a well-marked groove for the lachrymal sac, the *lachrymal groove*, which is continued downwards on the inner surface of the bone, between this process and the orbital plate, and with the lachrymal and inferior turbinated bones forms the nasal canal.

The *nasal surface* presents an oblique rough line or ridge beneath the

ascending process, for articulation with the inferior turbinated bone, and behind that process the lachrymal groove. Behind the lachrymal groove is the large opening into the sinus; behind the sinus the surface is rough for articulation with the palate-bone; and traversing the lower part of this roughness is a smooth groove, passing downwards and forwards from the posterior margin, and completing with the palate bone the posterior palatine or palato-maxillary canal.

The *orbital surface* extends from the margin of the orbit to the spheno-maxillary fissure, and is bounded externally by the surface for the malar bone, and internally by the lachrymal groove and a rough edge which articulates with the lachrymal, ethmoid, and palate bones. A groove commences in its posterior border, and leads forwards into a complete canal, the *infraorbital*, which opens anteriorly at the infra-orbital foramen.

The *maxillary sinus*, or *antrum of Highmore* is a large cavity lying above the molar teeth and below the orbital plate, lined in the fresh state by mucous membrane, and communicating with the middle meatus of the nose. Its orifice is considerably diminished by contiguous bones, viz., by the uncinatè process of the ethmoid, the inferior turbinated bone, and the palate bone.

THE PALATE BONE.

The palate bone forms the back part of the hard palate, and the lateral wall of the nose between the superior maxillary bone and the internal pterygoid process. It consists of a horizontal and a vertical plate united at a right angle, and of three processes, viz., the

Fig. 41.—THE PALATE BONE OF THE RIGHT SIDE.  
(A. T.)  $\frac{2}{3}$

A, from the outside and behind; B, from the inside.

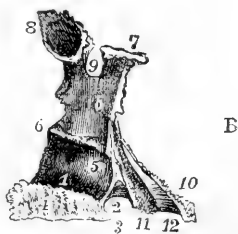
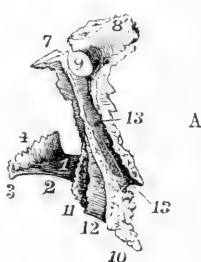
1, the upper surface of the palatine plate; 2, its posterior curved border or palatine arch; 3, posterior nasal or palatine spine; 4, the rough surface of adjacent articulation rising superiorly into the vomeric crest in A; 5, 5, the nasal process; 6, the ridge or shelf supporting the inferior turbinated bone; 7, the sphenoidal process; 8, in B, the orbital process, showing a cellular cavity; 8', in A, its orbital surface; 9, the sphenopalatine notch; 10, 11, 12, the pyramidal process—10, rough surface of union with the external pterygoid plate, 11, with the internal plate, and 12, the inter-ptyergoid smooth surface; 13, 13, groove of the palato-maxillary or posterior palatine canal.

pyramidal process, extending outwards and backwards from the junction of the horizontal and vertical plates, and the orbital and sphenoidal processes, surmounting the vertical plate.

The palate bone articulates with its fellow, and with the superior maxillary, ethmoid, sphenoid, vomer, and inferior turbinated bone.

The *horizontal* or *palate plate* presents posteriorly a thin free border, forming the limit of the hard palate, and

Fig. 41.



giving attachment to the soft palate or velum : anteriorly it articulates with the palate plate of the superior maxillary bone, and internally by a thick serrated border with its fellow of the opposite side, forming with it a ridge or crest for articulation with the vomer, continuous with that of the superior maxillaries; externally, at its junction with the vertical plate, it is grooved by the extremity of the posterior palatine canal. Its superior surface is smooth, and forms the back part of the floor of the nasal cavity; its inferior surface is rough, and is marked near its posterior border by a transverse ridge which gives attachment to the tendinous fibres of the tensor palati muscle.

The *vertical plate* is very thin. Its internal or nasal surface is divided into two parts, corresponding to the middle and inferior meatus of the nose, by a nearly horizontal ridge which articulates with the inferior turbinated bone. The external surface is smooth, and at its upper part forms the internal wall of the sphenomaxillary fossa, while the lower part is hollowed into a deep groove, completing with the superior maxillary the *posterior palatine canal*, which transmits the large descending palatine nerve and vessels. In front of this canal the external surface is in contact with the internal surface of the maxillary bone and the inner side of the antrum; behind the canal it articulates inferiorly with the hinder border of the maxilla, superiorly with the inner surface of the pterygoid process.

The *pyramidal process* or *tuberosity* fits into the cleft between the pterygoid plates. It presents posteriorly a triangular surface which is smooth and grooved, and completes the pterygoid fossa; on its sides it is rough for articulation with the borders of the pterygoid plates. Inferiorly, close to its connection with the horizontal plate, are two small foramina, the *posterior* and *external small palatine* foramina, the extremities of two minute canals which transmit the smaller palatine nerves; the external one is the smaller and is inconstant.

The *orbital process* surmounts the anterior margin of the vertical plate. It is somewhat pyramidal in shape, and has five surfaces, two of which, the superior and external, are free, and the rest articulated. The superior surface forms the posterior angle of the floor of the orbit; the external looks into the sphenomaxillary fossa, the anterior articulates with the maxillary, the internal with the ethmoid, and the posterior, which is small and only exists towards the extremity of the process, articulates with the sphenoidal spongy bone.

The orbital surface is frequently found enlarged from the union with the palate bone of a portion of bone ossifying from a separate centre, usually united with the ethmoid or sphenoid, and already described with the sphenoidal spongy bone (p. 40).

The *sphenoidal process* curves upwards, inwards, and backwards from the posterior part of the vertical plate. Its superior or external surface is in contact with the sphenoidal spongy bone and the base of the internal pterygoid plate, and is grooved for the completion of the pterygo-palatine canal; its internal or under surface looks to the posterior nares; and at its base a third surface looks forwards and outwards into the sphenomaxillary fossa. Its inner extremity is in contact with the wing of the vomer.

The *sphenopalatine* foramen is formed in greatest part by the deep notch between the orbital and sphenoidal processes, and is completed above by the sphenoidal spongy bone. It leads from the sphenoid

maxillary fossa into the nasal cavity, and transmits the internal nerves from Meckel's ganglion and the nasal branch of the internal maxillary artery.

THE VOMER.

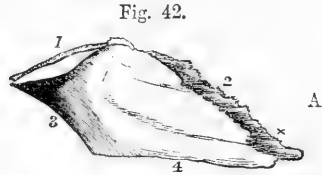
The vomer is a thin mesial bone, irregularly quadrilateral, and placed vertically between the nasal fossæ. It articulates with the sphenoid, ethmoid, palate, and maxillary bones, and with the septal cartilage of the nose. It usually becomes united by ankylosis, at an early age, to other bones.

The lower and back part of the vomer forms a thin *mesial plate*, while the upper and anterior part consists of two *alæ*, rising on each side of a mesial groove, in which lies the septal cartilage of the nose. The *alæ* posteriorly are thick and expanded, and form the bifid posterior extremity of the bone, which rests beneath the sphenoid. The superior border of each *alæ* articulates edge to edge with the lamella projecting inwards at the base of the internal pterygoid plate, and

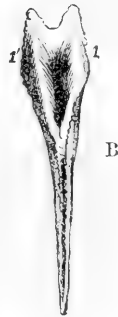Fig. 42.—THE VOMER (A. T.)  $\frac{3}{8}$

A, from the right side ; B, from above.

1, 1', the upper everted edges, or *alæ* on each side of the hollow which receives the rostrum of the sphenoid ; 2, the anterior or ethmoid border, grooved to receive the septal cartilage of the nose, and prolonged at x into a process which rests upon the nasal crest ; 3, the posterior or free border ; 4, the inferior or maxillary and palatine border.



the sphenoidal process of the palate bone, while the cavity between the *alæ* receives the rostrum of the sphenoid ; the anterior border, sloping downwards and forwards, in contact with the septal cartilage, is free in the inferior part, and is united superiorly by ankylosis on one or both sides with the central plate of the ethmoid. The anterior extremity of the vomer forms a short vertical plate which fits in behind the nasal crest of the maxillaries, and from the upper end of which a process projects forwards in the groove of the crest, while from its lower end a point projects downwards between the incisor foramina. The inferior border articulates with the ridge or crest which rises from the palate plates of the maxillary and palate bones. The posterior border, thin, smooth, and unattached, separates the posterior nares.

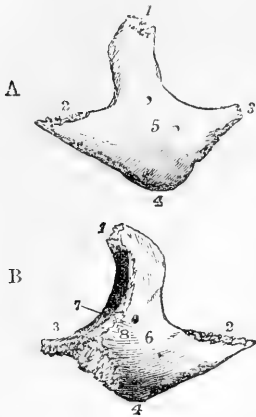


THE MALAR BONE.

The malar bone forms the most prominent part of the cheek, and divides the orbit from the temporal fossa. It articulates by a broad serrated surface near its anterior inferior angle with the malar process of the superior maxillary bone, by a slender posterior process with the zygoma, by a superior process with the frontal, and, continuously with that, by the margin of its deep plate with the great wing of the sphenoid bone. Between its sphenoidal and maxillary articulations a small portion of free margin generally intervenes, which closes the anterior

extremity of the speno-maxillary fissure. The facial surface is convex, and pierced by one or more *malar foramina*, which pass through from

Fig. 43.

Fig. 43.—RIGHT MALAR BONE. (A. T.)  $\frac{3}{4}$ 

A, from the outside ; B, from the inside.

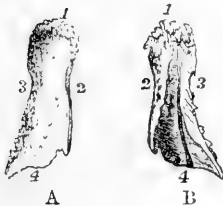
1, superior or frontal angle and serrated edge ; 2, posterior or external angle and serrated surface for the zygoma ; 3, anterior or internal angle ; 4, inferior angle ; from 1 to 2, the temporal border ; from 1 to 3, the orbital border ; from 1 to 8, edge of articulation with the frontal and sphenoid bones ; at 8, the notch usually terminating the speno-maxillary fissure ; from 2 to 4, the masseteric rough border ; between 8, 3, and 4, the triangular serrated surface for articulation with the superior maxillary bone ; 5, the external surface ; 6, the deep or posterior surface ; 5 and 6, are placed near the foramina for the temporo-malar nerves ; 7, the orbital surface, with the orbito-malar foramen.

the orbital surface and transmit a small nerve and vessels. The orbital surface is concave from above downwards, and enters into the formation of the outer wall and floor of the orbit. The posterior surface is concave from side to side, and looks into the temporal and zygomatic fossæ ; it is also pierced by a small foramen.

#### THE NASAL BONE.

The nasal bones form the bridge of the nose. They are thick and narrow above, but gradually become wider and thinner below. The superior border of each is serrated, and articulates with the frontal bone ; the inferior supports the lateral nasal cartilage ; the external edge articulates with the ascending process of the superior maxillary bone ; and the internal with its fellow, with the nasal spine of the

Fig. 44.

Fig. 44.—RIGHT NASAL BONE. (A. T.)  $\frac{3}{4}$ 

A, from the front ; B, from behind.

1, upper or frontal serrated border ; 2, internal border for adjacent articulation ; 3, external or superior maxillary border ; 4, lower free border ; in B, 4 is placed at the lower end of the groove for the nasal nerve.

frontal bone, and frequently with the perpendicular plate of the ethmoid. The anterior surface, concave at its upper part, convex in the rest of its extent, presents a minute vascular foramen ; the posterior or nasal surface is marked by a groove for the passage of the nasal nerve.

#### THE LACHRYMAL BONE.

The lachrymal bone, or *os unguis*, is a thin scale of bone placed at the anterior and inner part of the orbit. It articulates superiorly with the frontal bone, posteriorly with the orbital plate of the ethmoid ; anteriorly it presents a longitudinal or vertical groove, and articulates with the ascending process of the superior maxillary bone, completing

with it the groove for the lachrymal sac ; inferiorly it articulates in its greatest extent with the orbital plate of the superior maxillary bone, while its anterior grooved part projects downwards, taking part in the

Fig. 45.—RIGHT LACHRYMAL BONE, FROM THE OUTSIDE. (A. T.)  $\frac{2}{3}$

1, upper or frontal border ; 2, the orbital surface ; 3, lachrymal groove ; 4, the hooked process which meets the inferior turbinated bone.

Fig. 45.



formation of the lachrymal canal, and terminates in a pointed extremity, *hamulus lachrymalis*, which fits into an angle between the superior maxillary and inferior turbinated bone. The inner surface looks superiorly to the anterior ethmoidal cells, and inferiorly to the middle meatus of the nose.

THE INFERIOR TURBINATED BONE.

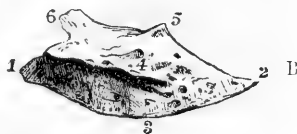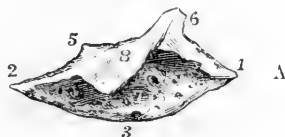
The inferior turbinated, *maxillo-turbinal*, or spongy bone, is a slender lamina, attached by one margin from before backwards along the lateral wall of the nose, and projecting into the nasal cavity, so as to divide the middle from the inferior meatus. It is slightly convoluted, its convexity looking inwards, and its free margin being dependent, slightly thickened, and rolled upon itself. The attached margin articulates anteriorly with the oblique ridge below the nasal process of the superior maxillary bone, and ascends abruptly to form the lachrymal process and complete the lachrymal canal and articulate with the lachrymal bone ; behind this it is folded downwards in the maxillary process, forming part of the inner wall of the antrum below the

Fig. 46.—THE INFERIOR TURBINATED BONE OF THE RIGHT SIDE. (A. T.)  $\frac{2}{3}$

Fig. 46.

A, from the outside ; B, from the inside.

1, anterior angle ; 2, posterior angle ; 1, 3, 2, inferior free border ; 4, internal convex surface ; 5, part of the bone articulating with the uncinate process of the ethmoid ; 6, portion articulating with the lachrymal ; 7, the outer concave surface ; 8, the maxillary process or plate deflected from the upper border, which, by union with the superior maxillary, forms a part of the inner wall of the maxillary sinus.



entrance into that cavity ; above and behind this, it presents a small projection which articulates with the uncinate process of the ethmoid, and posteriorly it is attached to the horizontal ridge on the vertical plate of the palate bone.

This bone is marked by horizontal grooves and canals for vessels and nerves, but not, as the turbinal parts of the ethmoid are, with vertical grooves for the olfactory nerve.

THE INFERIOR MAXILLARY BONE.

The inferior maxilla, mandible, or lower jaw, is the thickest and strongest bone of the face, and moves on the rest of the skull by means

of a pair of articular surfaces or condyles. It has the shape of an inverted arch bent forwards upon itself, and consists of a middle larger and horizontal part—the body, and of two rami or ascending branches.

The *body* is marked in the middle by a vertical ridge, indicating the original division of the bone into two lateral parts, and thence named the *symphysis*. The superior or *alveolar* border is hollowed out into sockets for the teeth. The inferior border, thicker anteriorly than beneath the ramus, is slightly everted in front, constituting the chin, or *mentum*, a prominence peculiar to the human skull. On the outer surface, on each side of the symphysis, below the incisor teeth, is a shallow depression, the *incisor fossa*, which gives origin to the levator menti muscle, and, more externally, the *labial* or *mental foramen*, which transmits the branches of the inferior dental nerve and artery. From beneath the mental foramen an elevation, the *external oblique line*, extends upwards and outwards to the anterior border of the ramus. The deep surface is marked, on each side of the symphysis, along the inferior margin, by an oval depression, indicating the anterior attachment of the digastric muscles, and above them by two pairs of

Fig. 47.

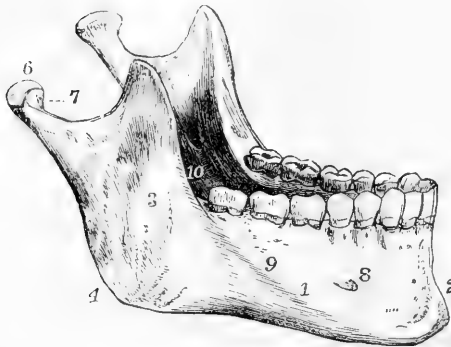


Fig. 47.—THE INFERIOR MAXILLARY BONE, FROM THE RIGHT SIDE AND ABOVE. (A. T.)  $\frac{1}{2}$

1, the body; 2, the symphysis; 3, the ramus; 4, the angle, near it the oblique ridges marked by the attachment of the masseter muscle; 5, the coronoid process; 6, the condyle or articular head; 7, placed in the sigmoid notch, points to the front of the neck; 8, the mental foramen; 9, the external oblique ridge; 10, the inferior dental foramen and mylo-hyoid groove of the left side. This figure represents a full set of the teeth of the lower jaw in

middle life. (See also, for the view of the inner surface of the lower jaw, figure 54, the vertical section of the skull.)

prominent tubercles, *spinæ mentales*, placed closely together, giving attachment, the upper pair to the genio-hyo glossi, and the lower to the genio-hyoidei muscles. An oblique prominent line, the *mylo-hyoidean ridge*, leading from beneath the *spinæ mentales*, upwards and outwards to the ramus, gives attachment to the mylo-hyoideus muscle. Above this line is a smooth depression for the sublingual gland, and beneath and external to it another for the submaxillary gland.

The *ramus* is thinner than the body of the bone. Its posterior border in meeting the line of the base forms the angle of the jaw. The external surface is flat and uneven, and towards the angle stronger ridges mark the place of attachment of the masseter muscle. The internal surface presents at its middle the *inferior dental foramen*, leading into the *dental canal*, which lodges the dental nerve and vessels. Passing



down from the sharp inferior margin of this foramen is the *mylo-hyoid groove* (occasionally a canal for a short space), marking the passage of the mylo-hyoid nerve with an accompanying artery and vein. Behind this, inside the angle, is a marked roughness for the internal pterygoid muscle.

Each ramus is surmounted by two processes, the condyle and the coronoid, which are separated by a deep excavation, the *sigmoid notch*. The *condyle* is continued upwards from the posterior part of the ramus. It is supported by a constricted portion, the *neck*, which presents anteriorly a depression, into which the external pterygoid muscle is inserted. The condyle is a transversely elongated convex articular process, whose major axis is directed obliquely, so that if prolonged it would meet with that of its fellow near the anterior margin of the foramen magnum. The *coronoid process* is continued vertically upwards in front, from the anterior margin of the ramus. It is pointed, and gives attachment by its margin and inner aspect to the temporal muscle. At its base, in front, is a groove, to which the buccinator muscle is attached.

The anterior margin of the ramus is placed at nearly a right angle to the alveolar border. The angle of the jaw, which is the meeting of the posterior border of the ramus with the base, is in the adult usually about  $120^\circ$ ; in infancy it is as great as  $140^\circ$  or more; in strongly developed jaws it may be diminished to  $110^\circ$  or less; and in old and toothless jaws it is increased. These changes are connected with a variety of circumstances, among which may be noticed,—the development of the temporary and permanent teeth, the absorption of the alveolar arch after the loss of the teeth in advanced age, the elongation of the face and upper jaw towards adult life, and the varying state of development of the masseter muscles at different periods.

#### THE HYOID BONE.

The hyoid bone, or *os linguae*, is situated at the base of the tongue, and may be felt between the chin and the thyroid cartilage. It is shaped like the letter U, and consists of a body and two pairs of cornua. It is suspended from the tips of the styloid processes of the temporal bones by a pair of slender bands, the *stylo-hyoid ligaments*, which in most animals usually form distinct bones. Though belonging rather to the neck than to the cranium or face, it may properly be considered in this place.

Fig. 48.—THE HYOID BONE, FROM BEFORE. 3

1, the prominent part of the body; 2, the great cornu; 3, the lesser cornu.

Fig. 48.



The *body*, or central piece, *basi-hyal*, is compressed from before backwards, and lies in a plane, directed downwards and forwards. Its anterior surface is convex, and marked in the middle by a vertical ridge, on each side of which are depressions for the attachment of muscles. Its posterior surface is concave, and is directed towards the epiglottis.

The *great cornua*, *thyro-hyals*, project backwards from the sides of the body, and end in rounded extremities.

The *small cornua*, or *cornicula*, *cerato-hyals*, short and conical, project upwards and backwards from the place of junction of the body with the great cornua, and give attachment at their extremities to the stylo-

hyoid ligaments. They continue for a long time movable, as the cartilage which connects them remains unossified till an advanced period of life.

## THE SKULL AS A WHOLE.

### THE SUTURES.

With the exception of the lower jaw, which is articulated movably with the temporal bone, all the bones of the skull are closely fitted together by more or less uneven edges or surfaces. To those articulations which are markedly serrated the name of *suture* is given.

The sutures of the skull are best named from the bones between which they lie, as, for example, occipito-parietal, occipito-mastoid, fronto-ethmoid, parieto-sphenoid, &c. The arch of the skull is inter-

Fig. 49.

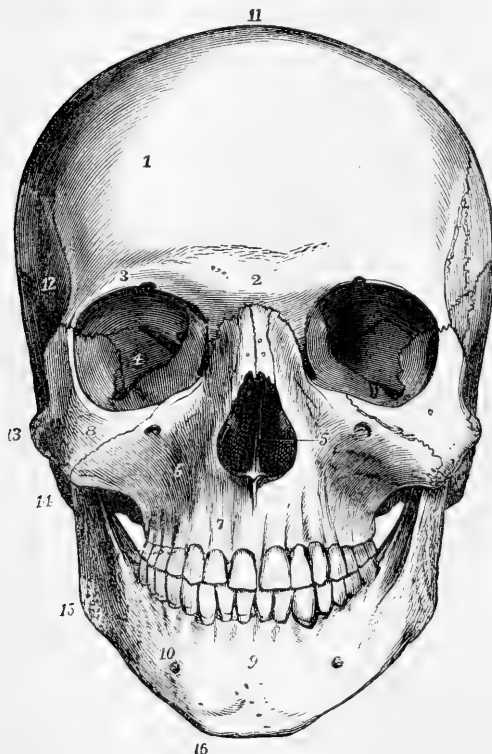


Fig. 49.—FRONT VIEW OF MALE SKULL AT ABOUT TWENTY YEARS. (A. T.)  $\frac{1}{2}$

1, frontal eminence; 2, glabella, between the superciliary eminences, and above the transverse suture of union with the nasal and superior maxillary bones; 3, supra-orbital ridge near the supra-orbital notch; 4, in the orbit on the orbital plate of the sphenoid bone, between the foramen lacerum orbitale and the sphenomaxillary fissure; 5, the anterior opening of the nares, within which are seen in shadow the nasal crest of the superior maxillary bones, the vertical plate of the ethmoid bone, and on each side the turbinated bones; 6, superior maxillary bone at the canine fossa—above the figure is the infra-orbital foramen; 7, myrtiform, or incisive fossa; 8, malar bone; 9, symphysis menti and median ridge; 10, body of the lower jaw, above the outer oblique ridge and the mental foramen; 11, vertex, near the coronal suture; 12, temporal fossa; 13, zygoma; 14, mastoid process; 15, angle of the jaw; 16, mental

angle. In this skull there are fourteen teeth in each jaw, the wisdom teeth having not yet appeared.

sected superiorly by three great serrated sutures, two of which, placed transversely, correspond to the anterior and posterior margins of the parietal bones, while the third passes between them in the middle line. On each side also an irregular longitudinal line of suture runs from the

malar to the occipital bone, bounded by the frontal and parietal bones above, and the malar, sphenoid, and temporal bones below.

The *fronto-parietal*, or *coronal suture*, connects the frontal and the two parietal bones. It commences at each side, about an inch behind the external orbital process of the frontal bone, above the great wing of the sphenoid, and mounts upwards and backwards to the vertex. It presents the most marked dentations in the middle of each lateral half; at the summit the serrated surface is oblique, the frontal bone overlapping the parietal, while similarly at the lower part the parietal overlaps the frontal.

The *occipito-parietal*, or *lambdaoidal suture*, between the occipital and parietal bone, inclines downwards and outwards on each side and has somewhat of the form of the Greek letter  $\Lambda$ . The *occipito-mastoid suture* is in continuation with it.

Fig. 50.

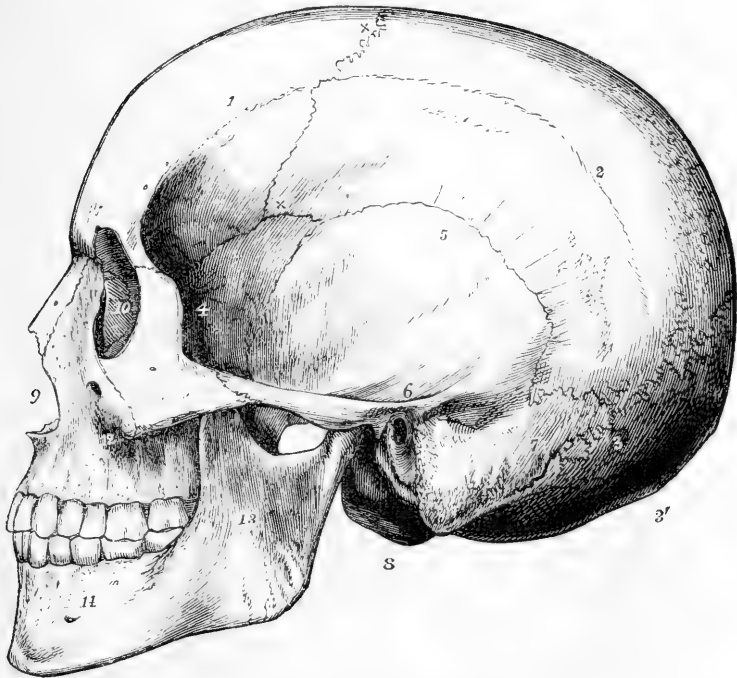


Fig. 50.—LATERAL VIEW OF THE SKULL REPRESENTED IN FIGURE 49. (A. T.)  $\frac{1}{2}$

1, frontal bone; 2, parietal bone at the temporal ridge; x x, coronal suture; 3, on the occipital bone at the lower end of the lambdaoidal suture, near its meeting with the occipito-mastoid and parieto-mastoid sutures; 3', external or posterior occipital protuberance; 4, great wing of the sphenoid bone; 5, squamous part of the temporal bone; 6, the same at the root of the zygoma, immediately over the meatus auditorius externus; 7, mastoid portion of the temporal bone, in front of which is the mastoid process; 8, the left condyle of the occipital bone; 9, the anterior opening of the nares; 10, on the lachrymal bone in the inner wall of the orbit; 11, malar bone, near its junction with the zygoma; 12, superior maxillary bone behind the canine fossa; 13, ramus of the lower jaw; 14, body of the lower jaw, near the mental foramen.

The *interparietal*, or *sagittal suture*, connects the two parietal bones: it is continued in children, and occasionally in adults, by a suture between the two halves of the frontal bone, the *frontal suture*. In the much elongated forms of skull the sagittal suture is often found partially or wholly obliterated by ossification.

The *temporo-parietal suture* consists of two very distinct parts, the *squamous suture*, arched in direction, in which the scale-like margin of the squamous portion of the temporal bone overlays the similar margin of the parietal, and the *parieto-mastoid suture*, which is thick and serrated.

The *spheno-parietal suture*, between the parietal bone and great wing of the sphenoid, is about half an inch in extent. It is absent only in very rare cases, and then the frontal and temporal bones come into contact.

The name of *transverse* has by some anatomists been given to the series of sutures which unite the facial and orbital margins of the frontal to other bones, as the malar, sphenoid, ethmoid, lachrymal, maxillary, and nasal. The lines of union between the other bones, though more or less serrated, have not received any special designation, but may be named from the bones between which they run, as for example, petro-occipital, petro-sphenoid, inter-maxillary, palatopterygoid, &c.

**Ossa Triquetra.**—Separate pieces of bone are found in many skulls, interposed between the cranial bones. They are called *ossa triquetra*, *ossa Wormii*, *ossa suturarum*, &c. They are of irregular form, with margins adapted to the character of the sutures in which they are situated. They are most frequently found in the occipito-parietal suture, where they occur sometimes in great numbers, more or less symmetrically arranged; in other instances, one or several bones of considerable size may occupy the place of the superior part of the occipital, and may correspond to the interparietal bone of some animals. They are much less frequently found in the other sutures.

#### EXTERNAL SURFACE OF THE SKULL.

The external surface of the skull may be conveniently divided into superior, inferior, anterior, and lateral regions.

The **superior region**, extending from the supra-orbital ridges in front to the superior curved line of the occipital bone behind, and bounded laterally by the temporal ridges, is smooth and convex, covered only by the integument and by the muscular fibres and fascia of the occipito-frontalis muscle. It is of an oval form, broader in the parietal than the frontal region, flattened in front, and projecting somewhat in the middle behind. There is also a slight projection from the general curve at each of the frontal and parietal eminences.

The **anterior region** of the skull, below the forehead, presents the openings into the orbits, bounded by the frontal, malar, and superior maxillary bones; and between the orbits, the bridge of the nose, formed by the nasal bones and ascending processes of the superior maxillaries. Below the nasal bones is the nasal aperture, of an inverted heart shape: its thin margin gives attachment to the nasal cartilages, and projects forwards in the middle line below as the nasal spine. Below the nasal aperture are the incisor fossæ of the upper jaw; below the orbits are the canine fossæ; and external to the canine fossæ are prominences of the cheeks, formed by the anterior inferior parts of the malar bones. The lower jaw completes the skeleton of the face.

The foramina in this region, on each side, are the supra-orbital foramen or notch in the superior margin of the orbit, the infra-orbital foramen below the inferior margin of the orbit, the mental foramen of the lower jaw, and the small irregular foramina of the malar bone.

The **orbits** are pyramidal fossæ, irregularly quadrilateral, with their bases directed forwards and slightly outwards, their inner walls being nearly parallel, and their outer walls diverging so as to be nearly at right angles to each other. The roof of each orbit is formed by the

Fig. 51.

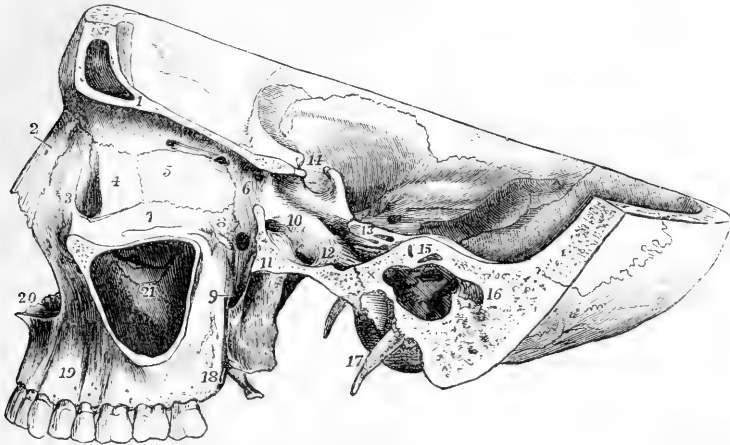


Fig. 51.—SECTION OF MALE SKULL OF MIDDLE AGE, IN TWO PLANES, ONE PASSING VERTICALLY THROUGH THE LEFT ORBIT, THE OTHER OBLIQUELY FROM BEHIND THE ORBIT, BACKWARDS AND OUTWARDS, THROUGH THE TYMPANUM AND MASTOID PROCESS. (A. T.)  $\frac{1}{2}$

1, section of the frontal bone in the roof of the orbit ; 2, left nasal bone ; 3, nasal process of the superior maxillary bone ; 4, left lacrimal bone, and in front the lacrimal groove ; 5, placed on the os planum of the ethmoid bone, below the anterior ethmoidal foramen ; 6, is placed below the root of the lesser wing of the sphenoid bone, between the optic foramen and the posterior ethmoidal foramen, and in front of the foramen lacerum orbitale ; 7, orbital plate of the superior maxillary bone inside the infra-orbital groove ; 8, on the orbital plate of the palate bone, in front of and above the spheno-palatine foramen and spheno-maxillary fossa ; 9, the upper extremity of the posterior palatine canal ; 10, the cranial opening of the foramen rotundum—its anterior opening is seen in the spheno-maxillary fossa ; 11, section of the great wing of the sphenoid bone outside the foramen ovale, and in the fossa near it the anterior opening of the Vidian canal ; 12, placed between the spinous and oval foramina ; 13, on the anterior surface of the petrous bone, near the apex. In front of the figure is seen the sigmoid groove of the internal carotid artery, and below the figure and externally the hiatus Fallopii ; 14, the pituitary fossa, with the anterior and posterior clinoid processes ; 15, section of the petrous bone above the labyrinth ; two of the semicircular canals are opened ; immediately below is the tympanum. The inner wall is seen with the promontory, fenestra ovalis and pyramid in shadow ; forwards near  $\times$ , the tympanic opening of the Eustachian canal, and backwards, below 16, the opening into the mastoid cells ; 17, left styloid process—that of the right side is seen in perspective below the skull, close by the occipital condyle ; 18, tuberosity of the superior maxilla ; 19, canine fossa ; 20, nasal notch and anterior nasal spine ; 21, inner wall of the antrum seen by the removal of its outer wall ; above the figure is the maxillary process of the inferior turbinated bone, and over that an irregular fissure, viz., the opening of the antrum into the middle meatus of the nose, and above that the uncinatè process of the ethmoid bone.

orbital process of the frontal and the small wing of the sphenoid bone; the floor by the orbital processes of the malar and superior maxillary bones, and by the small orbital surface of the palate bone at the back part; the inner wall by the ascending process of the superior maxillary, the lachrymal, the ethmoid, the sphenoid, and sometimes the palate bone; and the outer wall by the orbital surfaces of the malar bone and great wing of the sphenoid. The *sphenoidal fissure* (foramen lacerum orbitale), at its inner extremity, occupies the apex of the orbit, while its outer and narrower part lies between the roof and the external wall. The foramen opticum is internal and superior to the sphenoidal fissure. In the angle between the external wall and the floor is the *spheno-maxillary fissure*, bounded by the sphenoid, palate, superior maxillary, and malar bones, and leading into the spheno-maxillary fossa at its back part, and the zygomatic fossa at its fore part. Passing forwards from the margin of the spheno-maxillary fissure is the commencement of the infra-orbital canal, grooving the posterior part of the floor of the orbit. On the inner wall in front is the lachrymal groove, formed by the superior maxillary and lachrymal bones, and leading into the nasal duct: further back, between the ethmoid and frontal bones, are the anterior and posterior ethmoidal foramina; on the roof at its anterior margin, is the supra-orbital foramen or notch; within the external angular process is the fossa for the lachrymal gland; and in the outer wall are one or two minute foramina which perforate the malar bone.

The **lateral region** of the skull presents in a horizontal line from behind forwards the mastoid process, the external auditory meatus, the glenoid fossa, with the condyle of the lower jaw, and the *zygomatic or malar arch*, formed by the zygomatic process of the temporal bone and the posterior part of the malar. When the head of the lower jaw is in the glenoid cavity, the coronoid process lies internal to the malar arch. The upper part of the space bridged over by this arch is called the *temporal fossa*, the lower part the *zygomatic fossa*, the line of division being the rough ridge which divides the external surface of the great wing of the sphenoid bone into an upper and lower portion. The temporal fossa is occupied by the temporal muscle; it is bounded superiorly by the temporal ridge; and the frontal, parietal, sphenoid and malar bones take part in its formation. The zygomatic fossa is occupied in part by the external pterygoid muscle; its wall is formed internally by the external pterygoid plate, superiorly by the lower part of the great wing of the sphenoid bone, and anteriorly by the superior maxillary. Inferiorly the external pterygoid plate comes nearly into contact with the superior maxillary bone, but is almost always separated from it by a thin portion of the pyramidal process of the palate bone; superiorly, it is divided from it by the *pterygo-maxillary fissure*, a vertical opening, which leads into the spheno-maxillary fossa, and which is continued above into the outer extremity of the horizontal spheno-maxillary fissure opening into the orbit.

The *spheno-maxillary fossa* is the space which lies in the angle between the pterygo-maxillary fissure and the inner part of the spheno-maxillary fissure. It is bounded posteriorly by the external pterygoid process and lower part of the anterior surface of the great wing of the sphenoid bone, anteriorly by the superior maxillary bone, and internally by the vertical plate of the palate bone. Into this narrow space five

foramina open, *viz.*, on the posterior wall, the foramen rotundum, the Vidian canal, and, between the sphenoidal process of the palate bone and the root of the internal pterygoid plate, the pterygo-palatine canal; on the inner wall, the spheno-palatine foramen formed by the palate bone and a small part of the sphenoidal spongy bone, and opening into the nasal cavity; and inferiorly, the posterior palatine canal, which leads down to the palate between the palatal and superior maxillary bones.

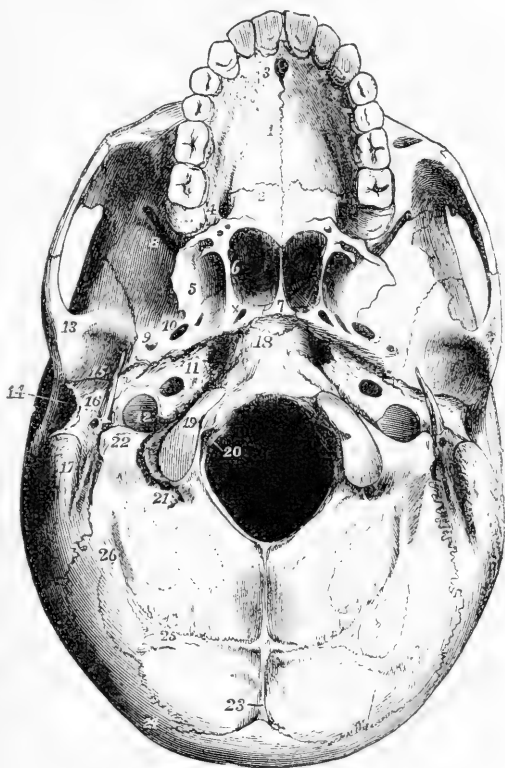
The **external base of the skull**, excluding the lower jaw, is divisible into three parts, anterior, middle, and posterior.

The *anterior division* consists of the palate and the alveolar arch. It is traversed longitudinally by a mesial suture, and transversely by that

Fig. 52.—EXTERNAL BASIS OF THE SKULL SHOWN IN FIGURE 49. (A. T.)  $\frac{1}{2}$

Fig. 52

1, palatine plate of the superior maxillary bone near the mesial suture; 2, palatine plate of the palate bone below the palato-maxillary suture; 3, the anterior palatine foramen; 4, is placed outside the posterior palatine foramen, inside the tuberosity of the superior maxilla, and in front of the smaller posterior palatine foramina, in the pyramidal process of the palate bone; 5, inner surface of the external pterygoid plate of the sphenoid bone; 6, is placed within the posterior opening of the left nasal fossa on the internal pterygoid plate; 7, the vomer; x, the posterior opening of the pterygo-palatine canal in front of the foramen lacerum anterius; 8, sphenomaxillary fissure leading into the orbit; 9, foramen spinosum; 10, foramen ovale; 11, placed on the apex of the petrous bone, between the foramen lacerum anterius and the inferior opening of the carotid canal; 12, the jugular fossa of the temporal bone, and foramen lacerum posterius; 13,



on the articular eminence of the inner root of the zygoma; 14, meatus auditorius externus; 15, glenoid fossa in front of the fissure of Glaser; 16, tympanic plate or posterior part of the glenoid fossa, close to the styloid process, below which is seen the stylo-mastoid foramen; 17, mastoid process, and to its inside the digastric and occipital grooves; 18, basilar process of the occipital bone, and in front of the mark of the still incomplete union with the body of the sphenoid bone; 19, condyle of the occipital bone; 20, is placed in the foramen magnum, and points to the lower opening of the anterior condylar foramen; 21, posterior condylar foramen; 22, jugular process of the occipital bone, and to its inner side the jugular notch; 23, external occipital spine running down from the protuberance; 24, superior curved line of the occipital bone; 25, inferior curved line; 26, groove and ridge of insertion of obliquus capitis superior muscle.

between the maxillary and palate bones. Anteriorly, in the middle line, is the anterior palatine foramen, with the four smaller foramina contained within it; posteriorly, on each side, at the base of the alveolar arch, is the posterior palatine foramen, and externally and posteriorly to that, the posterior and external small palatine foramina. The palate is surrounded in front and on the sides by the alveolar arch bearing the teeth of the upper jaw.

The *middle division* extends back to the front of the foramen magnum. Its central portion has been called the *guttural fossa*. In the middle line is the basilar process of the occipital bone, and in front of that the body of the sphenoid bone, covered anteriorly by the extremity of the vomer. On each side, the petrous portion of the temporal bone reaches as far forwards as the extremity of the basilar process; and between the petrous and squamous portions of the temporal is the back part of the great wing of the sphenoid bone. Between this division of the base of the skull and the palate are the *posterior nares*, separated by the vomer, and bounded above by the body of the sphenoid bone, below by the horizontal plates of the palate bones, and on the sides by the internal pterygoid processes. Between the pterygoid plates is the pterygoid fossa; and placed in an oblique line backwards and outwards from this are the foramen ovale, foramen spinosum, and processus spinosus; while behind and parallel to these is a *groove for the Eustachian tube*, formed by the margins of the sphenoid bone and pars petrosa, leading into the Eustachian orifice, and in a line with the fissure of Glaser. Between the apex of the pars petrosa, the basilar process, and the sphenoid bone, is the *foramen lacerum medium*, on the external wall of which opens the carotid canal, and on the anterior the Vidian canal; it is closed inferiorly by a plate of cartilage, and its area is crossed by the internal carotid artery and the Vidian nerve. Behind the pars petrosa, and bounded posteriorly by the jugular fossa of the occipital bone, is the *foramen jugulare*, or *foramen lacerum posterius*: it is divided into a large rounded part situated externally and posteriorly, bounded in front by the jugular fossa of the temporal bone, and occupied by the jugular vein; and a narrow angular part situated anteriorly and internally, bounded by a portion of the pars petrosa distinct from the jugular fossa, and transmitting the eighth pair of cranial nerves. These two parts are sometimes separated by a spiculum of bone. In front of this is the carotid foramen, on its outside is the stylo-mastoid foramen and styloid process, and internal to it is the anterior condyloid foramen.

The *posterior division* presents on each side of the foramen magnum, from within outwards, the occipital condyle, the rough surface for the rectus capitis lateralis muscle, the occipital groove of the temporal bone, the digastric fossa, and the mastoid process. Behind the foramen magnum is the tabular part of the occipital bone, with its ridges and muscular impressions.

#### THE INTERIOR OF THE CRANIUM.

The walls of the cranium consist of two layers of compact bony substance, the *outer* and *inner tables*, and an intervening cancellated substance, called *diploe*. The inner or *vitreous* table, has a smooth, close-grained, shining appearance, is hard and brittle, and presents



irregular digitate impressions corresponding to the convolutions of the brain. The thinnest portions of the cranial wall are the cribriform plate of the ethmoid and the orbital plates of the frontal bone, in both of which the diploe is entirely absent; the bone is also thin and compact in the middle part of the inferior occipital fossæ, and in the squama and glenoid fossa of the temporal.

The upper part of the cranial cavity consists of a single vaulted dome formed by the frontal, parietal, and occipital bones. It is marked by the superior longitudinal grooves, by shallow cerebral impressions, by small ramified meningeal grooves, and by Pacchionian fossæ of varying depth. The lower part or *internal basis* of the skull is divided into three fossæ, named anterior, middle, and posterior.

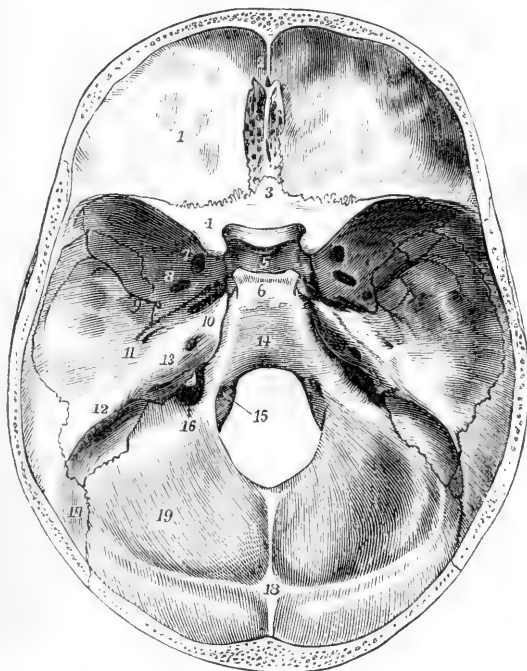
The **anterior fossa**, formed by the orbital plates of the frontal bone, the small wing of the sphenoid, and the cribriform plate of the ethmoid, supports the anterior lobes of the brain. It sinks into a hollow at the

Fig. 53. — INTERNAL BASIS OF THE SKULL. (A. T.)  $\frac{1}{2}$

1, anterior fossa and roof of the orbit, as formed by the frontal bone, marked by impressions of cerebral convolutions; between 2 and 3, the foramen cæcum, crista galli and cribriform plate of ethmoid; 3, ethmoidal spine of the sphenoid; 4, lesser wing of sphenoid terminating posteriorly in the anterior clinoid process, inside which is the optic foramen; 5, placed in the pituitary fossa, behind the olivary eminence and transverse groove of the optic commissure; 6, dorsum sellæ, terminating in the posterior clinoid processes, and to the side of these the groove of the internal carotid artery; 7, foramen rotundum, in front of which, but not seen in the figure, is the foramen

lacerum orbitale; 8, foramen ovale; 9, foramen spinosum; 10, on the ridge of the petrous bone, near its apex, and to the inside of the hollow occupied by the Gasserian ganglion; in front of this is the foramen lacerum medium; 11, in front of the eminence of the superior semicircular canal of the labyrinth, and behind the hiatus Fallopii; 12, the prominent ridge of the petrous bone, marked by the superior petrosal groove; 13, the posterior surface of the petrous bone—to the inside, the meatus auditorius internus, behind, the scale of bone covering the aqueduct of the vestibule; 14, basilar groove; 15, anterior condylar foramen; 16, jugular part of the foramen lacerum posterius; 17, groove of the lateral sinus; 18, internal occipital protuberance, and running down from it the internal occipital spine; between 17 and 18, the upper part of the groove of the lateral sinus, between 17 and 16, the lower part; 19, cerebellar fossa.

Fig. 53.



cribriform plate of the ethmoid where it is pierced by numerous small foramina and rises to a convexity over the orbits. The foramen cæcum is situated in front of the crista galli of the ethmoid bone.

The **middle fossa**, on a lower level than the anterior, presents a mesial and two lateral parts. The mesial part is small, being formed by the olivary process and sella turcica of the sphenoid bone, and limited be-

Fig. 54.

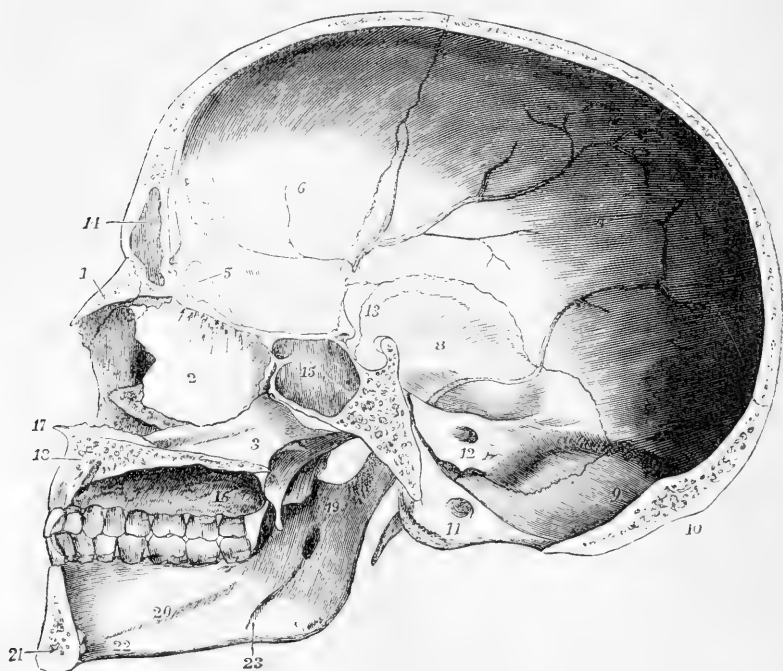


Fig. 54.—ANTERO-POSTERIOR VERTICAL SECTION OF THE ADULT SKULL A LITTLE TO THE LEFT OF THE MIDDLE LINE. (A. T.)  $\frac{1}{2}$

1, basal bone ; 2, perpendicular plate of the ethmoid bone, with olfactory foramina and grooves at its upper part ; 3, vomer ; 4, nasal process of the right superior maxillary bone, forming part of the wall of the right nasal fossa ; below this, the anterior extremity of the right inferior turbinate bone overhanging  $\times$ , which is the right inferior meatus of the nose ; 5, crista galli ; 6, inner surface of the frontal bone ; 7, of the parietal bone ; 8, squamous part of the temporal ; 9, on the occipital bone below the internal occipital protuberance ; 10, external occipital protuberance ; 11, on the condylar process below the anterior condylar foramen ; 12, on the posterior surface of the petrous bone below the meatus auditorius internus ; between 9 and 12, the groove of the right lateral sinus ; 13, placed above the sella turcica ; 14, part of the left frontal sinus ; 15, part of the left sphenoidal sinus, the figure being placed on the septum of the sinuses ; 16, hard palate and alveolar arch—the figure is placed near the lower opening of the posterior palatine canal, and the grooves which extend forwards from it ; 17, anterior nasal spine ; 18, section of the left superior maxillary bone, and near the place to which the line points, the section of the lower part of the anterior palatine canal ; 19, on the inner surface of the ramus of the lower jaw, below the sigmoid notch, and above the inferior dental foramen ; 20, inner surface of the body of the jaw on the mylo-hyoid ridge ; 21, surface of section of the lower jaw to the left of the symphysis, and behind the symphysis, and between 21 and 22, the mental spines ; 23, groove for the mylo-hyoid nerve.

hind by the dorsum sellæ. The lateral part on each side, formed by the great wing of the sphenoid, the squamous part, and the anterior surface of the petrous part of the temporal, lodges the temporal lobe of the brain. The foramina of the middle fossa are the foramen opticum, the sphenoidal fissure, foramen rotundum, foramen ovale, foramen spinosum, foramen lacerum anterius, and hiatus Fallopii.

The **posterior fossa**, deeper and larger than the others, extends back to the occipital protuberance, and lodges the cerebellum and medulla oblongata. The occipital bone and the petrous and mastoid portions of the temporal bone take part in its formation. In the posterior surface of the pars petrosa, which limits this fossa anteriorly on each side, is the internal auditory meatus; lower down is the foramen lacerum posterius; between that and the foramen magnum is the anterior condylar foramen.

*Grooves for Bloodvessels.*—The groove of the middle meningeal artery commences at the foramen spinosum of the sphenoid bone, and ramifies principally on the squamous portion of the temporal bone and on the parietal. The groove of the internal carotid artery lies on the side of the body of the sphenoid bone, and terminates inside the anterior clinoid process. The groove of the superior longitudinal sinus, commencing at the foramen cœcum, passes backwards in the middle line of the roof of the skull, and terminates at the internal occipital protuberance. From that point the grooves of the lateral sinuses pass outwards on the occipital bone, cross the posterior inferior angles of the parietal bones, descend on the mastoid portions of the temporal bones, run inwards again on the occipital, and turn forwards to terminate at the jugular foramen. The groove of the inferior petrosal sinus lies between the petrous portion of the temporal bone and the basilar process; that of the superior petrosal sinus extends along the superior angular edge of the petrous portion.

#### THE NASAL CAVITIES AND COMMUNICATING AIR SINUSES.

The **nasal cavities**, or fossæ, are placed one at each side of a median vertical septum. They open in front and behind by the anterior and posterior nares already described, and communicate by foramina with the sinuses of the frontal, ethmoid, sphenoid, and superior maxillary bones. Their vertical extent, as well as that from before backwards, is considerable, but their transverse width is very limited, especially in the upper part.

The *internal wall*, or *septum narium*, is formed principally by the central plate of the ethmoid bone, the vomer, the frontal spine, the rostrum of the sphenoid bone, and the crests of the maxillary and palate bones. It presents a great angular deficiency in front, which in the recent state is filled up by the septal cartilage. In very many cases it deviates from the middle line, and more frequently to the left than to the right side.

The *roof* is horizontal in its middle part, but sloped downwards before and behind. The middle part is formed by the cribriform plate of the ethmoid bone, the fore part by the frontal and nasal bones, and the back part by the sphenoidal spongy bone.

The *floor*, formed of the palate plates of the maxillary and palate bones, is smooth, and concave from side to side. Towards its anterior extremity is the superior orifice of the incisor canal.

The *external wall* is the most extensive. The bones which take part in its formation are the nasal, superior maxillary, ethmoid, inferior spongy, and palate bones, and the internal pterygoid plates. The superior and inferior turbinated parts of the ethmoid bone (ethmo-turbinal bone), and the inferior spongy bone (maxillo-turbinal), project-

Fig. 55.

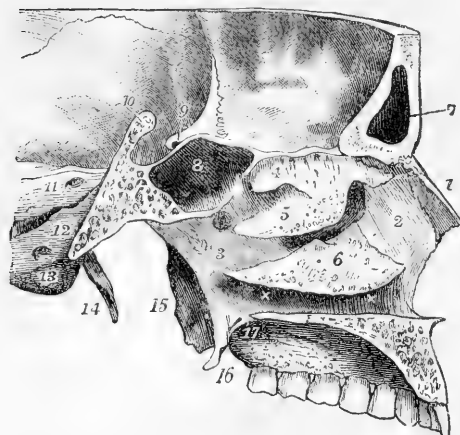


Fig. 55.—VERTICAL ANTERO-POSTERIOR SECTION OF A PART OF THE CRANIUM, SHOWING THE OUTER WALL OF THE LEFT NASAL FOSSA, &c. (A. T.)  $\frac{1}{2}$

1, nasal bone; 2, nasal process of the superior maxillary bone; 3, ascending plate of the palate bone; 4, superior turbinate bone of the ethmoid—below it the superior meatus, behind it the opening into the left sphenoidal sinus; 5, the middle turbinate bone—below it the middle meatus, into which opens the maxillary sinus; superiorly and anteriorly, is the common opening of the infundibulum and anterior ethmoidal cells; behind it, and above 3, the sphenopalatine foramen; 6, the inferior turbinate bone—below it the

inferior meatus  $\times \times$ ; below these marks the section of the palatine plates of the left palate and superior maxillary bones; 7, the left frontal sinus; 8, the left sphenoidal sinus; 9, the left optic foramen in the root of the lesser wing of the sphenoid, and anterior clinoid process; 10, the ridge of the dorsum sellae divided; and between 9 and 10, the sella turcica; 11, the posterior surface of the petrous bone, close to the internal auditory meatus; 12, the basilar process of the occipital bone, close to the foramen lacerum posterius; 13, below the anterior condyloid foramen; 14, left styloid process; 15, external, and 16, internal pterygoid processes; 17, posterior palatine canal and grooves.

ing inwards, overhang the three divisions of the nasal fossæ, called *meatus*. The *superior meatus*, very short, is placed between the superior and inferior turbinated parts of the ethmoid bone; into it open anteriorly the posterior ethmoidal cells, and posteriorly the sphenopalatine foramen and sphenoidal sinus. The *middle meatus*, the space between the inferior turbinate part of the ethmoid and the inferior spongy bone, communicates at its fore part by means of the infundibulum, with the anterior ethmoidal cells, and with the frontal sinus, while in its middle is the opening of the maxillary sinus. The *inferior meatus*, longer than the others, lies between the inferior spongy bone and the floor of the nasal cavity; in its fore part is the orifice of the nasal duct and the anterior palatine canal.

The **air sinuses** are hollows within the ethmoid, frontal, sphenoid, and maxillary bones, which communicate with the nasal cavities by narrow orifices. With the exception of the maxillary sinus these cavities are absent in early youth. The *maxillary sinus* begins to be formed about the fourth month of foetal life; the frontal, ethmoidal, and sphenoidal first appear during childhood, but remain of small size up to the time of puberty, when they undergo a great enlargement. In advanced life they all increase in size by absorption of the cancellated

tissue in their vicinity. The *ethmoidal sinuses* consist of several irregular spaces occupying the lateral masses of the ethmoid bone. The *anterior* open into the infundibulum, the *posterior* into the superior meatus. The *frontal sinuses* are placed between the outer and inner tables of the frontal bone over the roof of the nose. They extend outwards from behind the glabella to a variable distance over the orbit, being separated from each other by a thin bony septum. They open into the middle meatus of the nose through the infundibula. The *sphenoidal sinuses* occupy the anterior part of the body of the sphenoid bone, being formed in connection with the sphenoidal spongy bones. They are separated by a median septum, and open anteriorly behind and above the superior meatus of the nose.

The *maxillary sinus* is of an irregular pyramidal form; its apex points to the malar tuberosity; its inner wall, which separates it from the nasal cavity, is formed by the maxillary, palate, and inferior turbinated bones, and the uncinatè process of the ethmoid; its other sides are formed by the superior maxillary bone, an irregular gap or deficiency being left between the uncinatè process and the inferior turbinated bone, by which the sinus opens into the middle meatus. The alveolus of one of the molar teeth generally forms a marked projection in the floor of the sinus, at its outer part.

#### OSSIFICATION OF THE BONES OF THE HEAD.

Some of these bones originate in cartilage, and others in membrane, or unchondrified formative tissue.

To the first set belong chiefly the bones of the base of the cranium, viz., the occipital, sphenoid, ethmoid, petro-mastoid, and inferior turbinated, together with the small bones of the ear, the styloid process, and hyoid bone. All the other bones of the cranium and face originate in membrane or formative tissue. The parts of the bones which are median or central—the basi-occipital, basi-sphenoid, pre-sphenoid, and mesethmoid—arise either from one median centre each, or from more numerous centres, which coalesce into one at an early period. The other bones or their parts are all in pairs, although some of them, as the frontal, ex-occipital, ethmo-turbinal, alisphenoid, orbito-sphenoid, and lower jaw finally coalesce with each other or with a median portion.

In the tabular bones ossification usually spreads outwards from certain centres, and the marginal portions, in the earlier stages, present more or less the form of radiated fibres or spicula. The sutured edges, and especially the angles of the bones, are incomplete, the bones being united together at their margins by fibrous tissue. The diploe and sinuses are at first absent, some of the latter arising early in life, and others being formed at a comparatively late but variable period.

The **occipital** bone. This bone at birth, and for some time afterwards, consists of four separate pieces—a basilar, a tabular, and two condylar parts, united together by intervening cartilage. The lines of junction of the basilar and condylar parts pass through the condyles near their anterior extremities; those of the condylar and tabular parts extend outwards from the posterior margin of the foramen magnum. The basilar and condylar parts arise each from one osseous nucleus, which appears from the seventh to the eighth week. A few days earlier there appear in the tabular part usually four nuclei, placed in pairs above and below the occipital protuberance. These nuclei speedily unite to form a single thin tabular mass. Four fissures, however, remain, two median and two lateral running in from the margins of the bone, and marking the limits of the original pieces. These fissures, especially the lateral, sometimes remain visible for several years, simulating fractures. The largest *ossa Wormii*, when symmetrical, may arise from the persistence of the upper and lateral fissures. The osseous union of the

condylar and tabular parts, beginning in the second or third, is completed in the fourth year; that of the basilar and condylar parts, beginning in the third or fourth, is completed in the fifth or sixth year. The basi-occipital is united to

Fig. 56. B

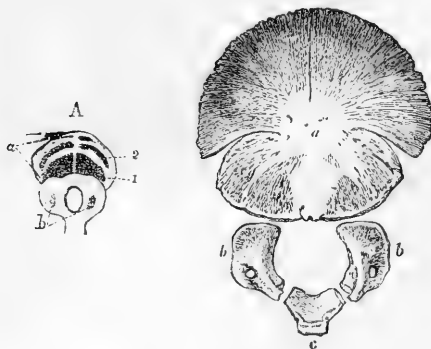


Fig. 56.—OSSIFICATION OF THE OCCIPITAL BONE (R. Quain).

A, in a fetus of 10 weeks (from Meckel, Archiv, vol. i. tab. vi.); *a*, upper or tabular part; 1 & 2, lower and upper pairs of ossific centres in it; *b*, lower part or basilar and condylar portions: ossific centres are seen in the condylar portions.

B, occipital bone of a child at birth; *a*, upper or tabular part, in which the four centres have become united into one, leaving fissures between them; *b, b*, the ossified condylar portions; *c*, the basilar portion.

the basi-sphenoid by intervening cartilage up to the twentieth year, after which ossific union begins and is completed in one or two years.

The **parietal** bone is ossified from a single nucleus, which appears in the parietal eminence about the seventh or eighth week. The eminence is very conspicuous in the young bone, and gives a marked character to the form of the skull for a number of years in early life.

The **frontal** bone is ossified from two nuclei which appear one on each side above the orbital arch, about the seventh week. At birth the bone consists of

Fig. 57.

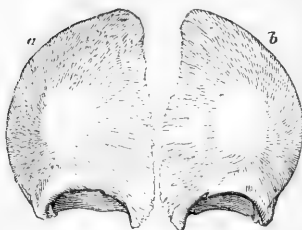


Fig. 57.—FRONTAL BONE OF A FÆTUS SHORTLY BEFORE BIRTH (R. Quain).

*a* & *b* indicate the two separate portions of the bone, in each of which the radiation of bony spicula from the frontal eminence is seen.

two separate lateral portions, which unite by a vertical median suture during the first year. This *frontal suture* usually becomes obliterated by osseous union taking place from below upwards, during the second year, though not infrequently

it persists throughout life. The frontal sinuses appear during the first year, and go on increasing in size up to old age.

The **Fontanelles**. These are membranous intervals between the incomplete angles of the parietal and neighbouring bones, in some of which movements of the soft wall of the cranium may be observed in connection with variations in the state of the circulation and respiration. They are four in number, two median, anterior and posterior, and two lateral. The *anterior* fontanelle, situated between the anterior superior angle of the parietal bones and the superior angles of the ununited halves of the frontal bone, is quadrangular in form, and remains open for some time after birth. The *posterior* fontanelle, situated between the posterior superior angles of the parietal bones and the superior angle of the occipital bone, is triangular in shape. It is filled up before birth, but the edges of the bones, being united by membrane only, are still freely movable upon each other. The *lateral* fontanelles, small and of irregular form, are situated opposite

the posterior inferior angles of the parietal bones. The fontanelles are gradually

Fig. 58.—SKULL OF A CHILD AT BIRTH, SEEN FROM ABOVE (from Leishman).  $\frac{1}{3}$

*a*, superior fontanelle; *p*, posterior fontanelle; *b*, *b*, parietal eminences; for the lateral fontanelles, see fig. 65, p. 77.

filled up by the extension of ossification into the membranes which occupy them from neighbouring bones, thus completing the angles of the bones and forming the sutures. The closure, especially of the posterior and lateral, is further assisted by the frequent development of Wormian bones in these situations. All traces of these unossified spaces disappear before the age of four years.

The temporal bone in respect of its state of ossification in the later stages of foetal life, consists of three pieces, the squamo-zygomatic, petro-mastoid, and tympanic. The *squamo-zygomatic* is ossified from a single nucleus, which appears in the lower part of the squamosal about the seventh or eighth

Fig. 58.

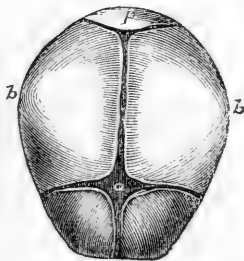


Fig. 59.—SEPARATE PARTS OF THE TEMPORAL BONE OF A CHILD AT BIRTH (R. Quain).

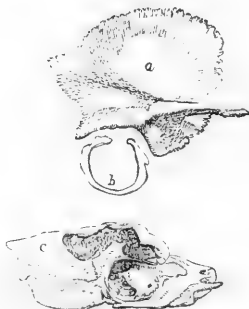*a*, squamo-zygomatic; *b*, the tympanic bone, forming an imperfect ring, open superiorly; *c*, the petro-mastoid part; *c* being placed on the mastoid part: part of the cavity shown in shade is the tympanum.

week. From this point ossification extends upwards into the squamosal, and outwards into the zygoma. During the third month an osseous nucleus appears in the lower part of the external membranous wall of the tympanum, and extends upwards as a slender arch, forming the *tympanic ring*, an imperfect circle, open superiorly, and which encloses the tympanic membrane. Before birth the extremities of this ring become united with the squamo-zygomatic.

**Petro-mastoid or periotic.** The ossification of this part of the temporal bone does not begin so soon as that of the other parts. It is only towards the end of the fifth month and in the course of the sixth (according to Kölliker and Huxley) that the bony parts of the internal ear begin to appear in the cartilage which precedes them. These parts arise, at least in the case of the labyrinth, from numerous minute bony deposits; some, however, soon coalescing. The first osseous nuclei appear at the end of the fifth month on the anterior surface of the petro-mastoid over the cochlea, and shortly afterwards one or two nuclei appear on the posterior surface in connection with the formation of the semi-circular canals. These different nuclei soon unite, and ossification extends outwards into the mastoid portion. According to Huxley the principal ossific centres come to be disposed so as to form three portions, which may be distinguished by the following names applied to them respectively by him, viz.: 1, *Prootic*, including most of the labyrinth and upper part of the petrous bone, together with part of the mastoid; 2, *Opisthotic*, comprehending mainly the lower part of the petrous bone, with the fenestra rotunda and half of the fenestra ovalis; and 3, *Epiotic*, corresponding to the lower part of the mastoid.

At birth the petro-mastoid is separated from the squamosal by a thin plate of intervening cartilage, bony union taking place during the first year; the mastoid portion also is quite flat, the glenoid fossa shallow, the articular eminence scarcely

Fig. 59.



to be seen, and the styloid process cartilaginous. After birth the external auditory meatus is gradually formed, superiorly by the arching outwards of the united squamous and petro-mastoid portions, and inferiorly and laterally by the development of the *tympanic plate*, a lamina developed from the outer surface of the tympanic ring, and which becomes united behind with the petro-mastoid, but is separated in front by the fissure of Glaser from the squamosal. The mastoid process is developed about the second year, but air-cells are not formed till near puberty. About puberty also ossification begins in the styloid process, but osseous union with the temporal only takes place in adult life.

The **sphenoid** bone presents in infancy traces of a natural division into a posterior or *postsphenoid* part, to which the sella turcica and great wings belong, and an anterior or *presphenoid* part, to which belong the body in front of the olivary process and the small wings,—a division which is found in many animals complete and persistent through life. The first osseous nuclei of the postsphenoid division appear about the eighth week in the great wings, one on each side, between the foramen rotundum and foramen ovale, and spread thence outwards into the wing and downwards into the external pterygoid process. About the same time also two granules appear in the postsphenoid part of the body, placed side by side in the sella turcica; these unite about the fourth month, and after their union two others appear, from which are formed the lingulae, inside which are placed the carotid grooves. The internal pterygoid processes, corresponding to the pterygoid bones of animals, are ossified from distinct nuclei, which appear in the fourth month; they unite with the external pterygoid processes in the fifth or sixth month.

Fig. 60.

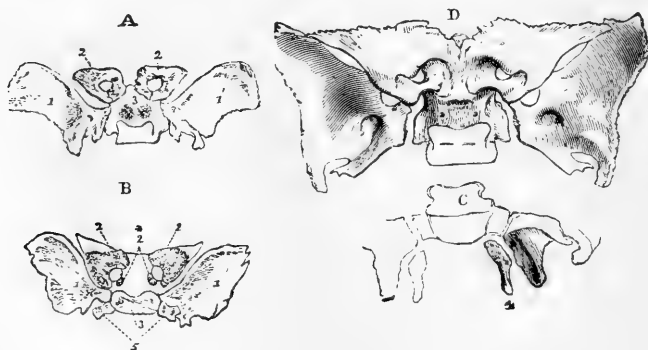


Fig. 60.—OSSIFICATION OF THE SPHENOID BONE (R. Quain).

A, sphenoid bone from a foetus of three months, seen from above; 1, 1', the greater wings ossified; 2, 2', the lesser wings, in which the ossification has encircled the optic foramen, and a small suture is distinguishable at its posterior and inner side; 3, two round granules of bones in the body below the sella turcica, the rest being cartilaginous.

B, copied from Meckel (Archiv, vol. i. tab. vi. fig. 23), and stated to be from a foetus of six months; 2\*, additional nuclei for the lesser wings; 5, separate lateral processes of the body: the other indications are the same as in A.

C, sketch of the back part of the bone shown in A; 4, the internal pterygoid processes still separate.

D, the sphenoid at the usual period of birth. The great wings are still separate. The anterior sphenoid is now joined to the body, and the internal pterygoid processes (not seen in the figure) are united to the external.

The great wings are united to the body in the first year. In the presphenoid division the first pair of nuclei appear in the eighth or ninth week outside the optic foramina, and extend by their growth into the small wings: another pair of granules appear on the inner sides of the foramina, and the presphenoid por-



tion of the body either results from the union of these, or is an independent growth. The presphenoid is united to the body of the postsphenoid from the seventh to the eighth month. The line of union is indicated for some time by a hole filled with cartilage, round above, and opening inferiorly into a wide notch, which is recognisable for several years after birth. The body of the presphenoid is for a year or two broad and rounded inferiorly, but becomes gradually narrower and more prominent: it is separated at first by a layer of fibro-cartilage from the sphenoidal spongy bones.

The *sphenoidal spongy bones* seldom appear till after birth, and are united to the body at the age of puberty. Each is in early life a hollow pyramid formed by the union of three separate laminae, viz., an inferior, an external, and a superior: the inferior lamina forms the greater part of what can be distinguished in the adult; the external is that to which the orbital portion belongs; while the superior lamina, forming the inner wall and roof of the original sphenoidal sinus, becomes, as the sinus expands, partly absorbed and partly united to the attenuated body of the pre-sphenoid, which is ultimately reduced to the thin septum sphenoidale and the rostrum.

In the *ethmoid* bone ossification commences in the fourth or fifth month, by the appearance of a nucleus in the orbital plates of the lateral masses gradually extending into the turbinated bones. During the first year the vertical and cribriform plates are ossified from a single nucleus, which, spreading outwards, unites with the lateral masses about the beginning of the second year. The ethmoidal cells are not formed till the fourth or fifth year.

The *superior maxillary* commences to ossify immediately after the lower maxilla and the clavicle from several nuclei, the earliest of which appears in the

Fig. 61.

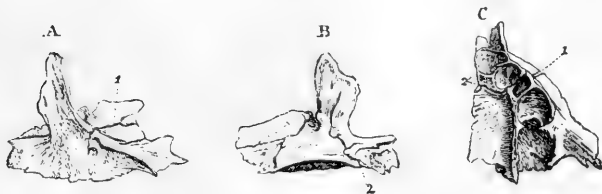

Fig. 61.—DIFFERENT VIEWS OF THE SUPERIOR MAXILLARY BONE OF A FETUS OF FOUR OR FIVE MONTHS (R. Quain).

A, external surface; a fissure, 1, is seen extending through the orbit into the infra-orbital foramen.

B, the internal surface; the incisor fissure, 2, extends from the foramen upwards through the horizontal plate and some way into the nasal process.

C, the bone from below, showing the imperfect alveoli and the incisor fissure, 2', 1, which crosses the palatine plate, between the second and third alveolus, and passes through the outer part of the bone.

alveolar arch about the sixth or seventh week. Its early growth has not yet been sufficiently studied. Béclard (Meckel's Archiv, vi. p. 432) states that it consists at first of five pieces, viz.: 1, an alveolar arch; 2, a palatal part; 3, an orbital and malar; 4, a nasal and facial; 5, an incisor part. This, however, does not appear to be a constant arrangement. By the end of the third month these pieces have united together: at the same time two ridges are seen prolonged downwards from the lower surface of the alveolar arch, forming the *dental groove*. Before birth this groove is divided into alveoli by partitions which arise from its floor. The antrum begins as a shallow depression, formed before birth on the inner surface of the bone. This deepens and extends outwards, gradually separating the orbital and palate portions of the bone, which at birth are very close together.

In all young subjects, and sometimes even in the adult, there is a fissure—the *incisor fissure*—passing outwards from the incisor foramen to the alveolar

border, in front of the canine socket. The part in front of this fissure—namely, that which bears the incisor teeth—forms in all mammals except man a separate bone, the *intermaxillary* or *premaxillary*; and anatomists have therefore sought with great care for proofs of its original independence in the human subject, but it does not appear that even in the earliest stages of development it has been seen by any one entirely unattached to the rest of the bone, or that its line of suture has been traced upon the facial surface. On the other hand, in cases of completely cleft palate, the bones supporting the incisor teeth are placed on a projecting portion of bone corresponding to the premaxillary, which is articulated to the fore part of the vomer, and is entirely detached from the superior maxillary bones.

The **palate** bone is ossified from a single centre, which appears in the seventh or eighth week at the angle between its horizontal and ascending parts.

The **vomer** is ossified from a single nucleus appearing at the upper part about the eighth week. From this nucleus two laminae are developed, which, passing down

Fig. 62.



Fig. 62.—THE FŒTAL VOMER NEAR THE TIME OF BIRTH (R. Quain).

1 & 2 show the two plates of which the bone consists, and which are united behind and below.

on either side of the middle line, embrace the septal cartilage. These laminae gradually undergo increased union from behind forwards till the age of puberty, thus forming a mesial plate, with only a groove remaining on its anterior and superior margins.

The **nasal** and **lachrymal** bones are each ossified from a single centre, which appears about the eighth week.

The **malar** bone has been generally described as being ossified from a single nucleus, but more recently it has been observed to be double in the human fœtus of two months, and it remains composed of two parts in some quadrumana through life. (Canestrini in *Ann. d. Soc. d. Natur. in Modena*, 1867; Darwin, on the Descent of Man, vol. i. p. 124.)

The **inferior turbinated** bone is ossified from a single centre, which only appears in the fifth month.

The **inferior maxilla** begins to ossify before any other bone except the clavicle. It consists of two similar lateral parts, which are still separate at birth.

Fig. 63.

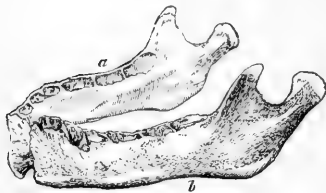


Fig. 63.—THE INFERIOR MAXILLA OF A CHILD AT BIRTH (R. Quain).

*a* & *b* indicate the two portions separate at the symphysis.

The ossific matter is at first deposited in fibrous tissue, surrounding the cartilage of Meckel externally, and at a later period cartilage participates in the ossification. Some observers admit only a single ossific centre for each side (Nesbitt and Meckel); while, according to others, in addition to the main piece there are separate nuclei for the coronoid process, the condyle, the angle, and the inner side of the alveolus (Spix), or only for some of these parts (Kerckringius, Béclard, Cruveilhier). The dental canal is at first a simple open groove; but by a gradually deepening, and by the growth of a thin lamina of bone upon the inner side of the body of the jaw, it is converted into a channel at the bottom of the dental groove. This lamina also forms the inner wall of the dental groove, in which, as in the upper jaw, the alveoli are formed by the subsequent growth of partitions. At birth the coronoid process is large, the neck of the condyle short and bent backwards, the ramus also very short and oblique, the angle at

which it joins the body of the jaw being about  $150^{\circ}$ . During the first year osseous union takes place at the symphysis between the segments of the jaw. In this and subsequent years the body becomes deeper, thicker, and longer, the ramus and the neck of the condyle lengthen, and the angle at which the ramus joins the body becomes less obtuse, till in the adult it is nearly a right angle. In old age, consequent upon the loss of the teeth and the absorption of the alveolar margin, the body becomes shallower, and the angle is again increased.

The hyoid bone has five points of ossification—one for the body, and one for each of its great and small cornua. The ossification begins in the great cornua and body in the last month of foetal life. Ossification of the small cornua begins in the first year, but osseous union with the body only occurs after middle life. The stylo-hyoid ligaments are occasionally ossified in some part of their extent.

#### GENERAL MORPHOLOGY OF THE BONES OF THE HEAD.

The circumstances which contribute most to modify the form of the human skull and the condition of its component bones, as compared with that of animals, are—1st, the proportionally large size of the brain and the corresponding expansion of the cranial bones which enclose it; 2nd, the smaller development of the face as a whole, and especially of the jaws, which brings the facial bones almost entirely under the fore part of the brain-case, instead of in front of it, as occurs in all animals, with the partial exception of the anthropoid apes; and 3rd, the adaptation of the human skeleton to the erect posture, which, as regards the head, is attended with the sudden bend of the basicranial axis at a considerable angle upon the line of the erect vertebral column; and along with this the advance of the occipito-vertebral articulation to such an extent as to make the head nearly balanced on the upper extremity of the spine. The downward openings of the nostrils, the forward aspect of the orbits and eyes, the nearly vertical forehead, and more or less oval-shaped face, are accompaniments of these human peculiarities in the form of the head, which, together with those already mentioned, strongly contrast with the smaller cranium and its strong crests of bone, the larger projecting face and jaws, and the other characteristic features of the skull in most animals.

As regards the condition of the individual bones, it is further to be remarked that there is generally in the human skull a more complete consolidation or bony union of the osseous elements than in animals, so that the whole number of bones forming the cranium and face is least in man. Thus, to mention only some of the most marked examples of this difference among mammals; the frontal bone and the lower jaw frequently divided into two lateral portions; the premaxillary very generally a separate bone from the maxillary; the presphenoid in many separate from the postsphenoid; the interparietal from the occipital; the reduction in size of the squamosal, and its occasional separation from the petrous; the increase in the proportions of the tympanic portion or bulla; and the very frequent development of bony elements connecting the hyoid bone directly with the skull. It is also worthy of observation that some of the conditions now referred to as permanent in animals exist as transitory stages of development in the foetus of man.

**Homologies.**—It would be out of place in this work to enter at any length into the consideration of the homologies of the bones of the human skull,—a subject which would require a minute reference to embryology and a wide range of comparative anatomy. But as it may be useful at least to show the bearing of such homological views on human anatomy, there has been introduced here a diagrammatic figure of the bones of the foetal head (see fig. 64) and a table of their nomenclature, in which an attempt is made to indicate the morphological relations of the several bones to each other and to those of quadrupeds, and an explanation is given of the signification of some of the terms applied by comparative anatomists to these bones in connection with the names usually given to them in works on human anatomy. For fuller information on this subject the reader is referred to the works of Owen, Goodsir, Huxley, Flower, St. George Mivart, and others already quoted.

CLASSIFIED LIST OF THE BONES OF THE HEAD AND THEIR  
TYPICAL COMPONENT PARTS\* :—

1. BONES FORMING THE CRANIO-FACIAL AXIS.

**Mesethmoid**; Vertical plate of the ethmoid bone, including the cartilaginous nasal septum, which is partially enclosed by

**Vomeric**; The Vomer.

**Presphenoid**; Anterior part of the body of the sphenoid bone.

**Basisphenoid**; Posterior part of the body of the sphenoid bone, including the sella turcica.

**Basioccipital**; Basilar process of the occipital bone.

2. UPPER OR NEURAL ARCHES, FORMING LATERAL AND UPPER WALLS  
OF THE CRANIAL CAVITY.

**Nasals**; The nasal bones.

**Orbito-sphenoids**; The lesser wings of the sphenoid bone.

**Frontals**; United in the single frontal.

**Alisphenoids**; Great wings of the sphenoid bone with the external pterygoid plates.

**Parietals**; The parietal bones.

**Exoccipitals**; Condylloid portions of the occipital bone.

**Supraoccipital**; Tabular part.

**Interparietal**, of some animals, corresponds to the upper part of the foregoing.

The temporal bones interposed between the occipitals and sphenoids consist of

**Periotics**, or petro-mastoid bones; The petrous and mastoid portions of the temporal bone; the first including the labyrinth and meatus auditorius internus.

**Squamosals**, or squamo-zygomatic; The squamous part of the temporal bone with the zygoma, including the articular surface of the lower jaw.

**Tympanics**; The tympanic ring and auditory process with the postglenoid part of the temporal bone.

3. LOWER OR VISCERAL ARCHES COMPLETING THE FACE AND  
ENCLOSING THE NOSE, MOUTH, AND PHARYNX.

**Ethmo-turbinals**; The lateral masses with the upper and lower turbinated bones of the ethmoid, and the cribriform plates.

**Lachrymals**; The lachrymal bones.

**Maxillo-turbinals**; The inferior turbinated bones.

**Premaxillary**, or intermaxillary; The incisor part of the superior maxillary bones.

**Pterygoids**; The internal pterygoid plates.

**Palatals**; The palate bones.

**Maxillæ**; The superior maxillary bones, excepting the incisor part.

**Malars**; The malar bones.

**Malleus, Incus, and Stapes**; The ossicula auditus or malleus, incus, and stapes.

**Mandibles**; United in the inferior maxilla or lower jaw.

**Stylo-hyals** with **Tympano-hyals** (of Flower); The styloid process of the temporal bone.

**Epi-hyals**; The stylo-hyoid ligaments.

**Cerato-hyals**; The upper or lesser cornua of the hyoid bone.

**Basi-hyals**; The body of the hyoid bone.

**Thyro-hyals**; The great cornua of the hyoid bone.

**Branchial Arches**; These follow the preceding, but are only temporary foetal structures in man and all vertebrate animals, except amphibia and fishes.

\* The names first given, and printed in block type, are those received in comparative anatomy; those usually employed in human anatomy follow, and are printed in common type.

The general correspondence between the bones of the head in man and animals, implied in the names given to them in the foregoing table, is so well ascertained, and, in most instances, so obvious, that it is unnecessary to say more than that it is very generally acknowledged by comparative anatomists, and that it is chiefly

Fig. 64.

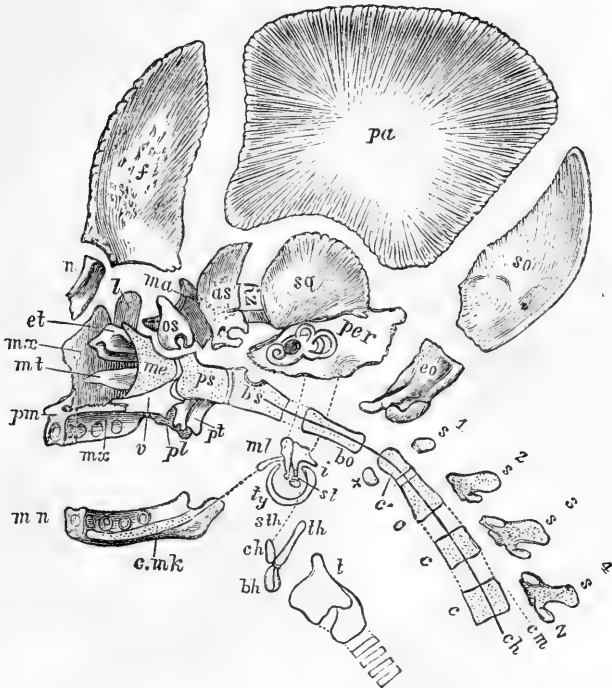


Fig. 64.—DIAGRAMMATIC VIEW OF THE BONES IN THE RIGHT HALF OF A FETAL SKULL FROM THE INSIDE. (A. T.)

In this figure the bones have been slightly separated and displaced so as to bring the whole into one view: *f*, frontal; *pa*, parietal; *so*, supra-occipital; *n*, nasal; *l*, lacrimal; *ma*, malar; *os*, orbito-sphenoid; *as*, ali-sphenoid; *sq*, squamosal; *zy*, zygomatic; *per*, petro-mastoid; *eo*, exoccipital; *et*, ethmoturbinal; *mx*, maxilla; *mt*, maxillo-turbinal; *pm*, premaxillary; *me*, mesethmoid; *v*, vomer; *pl*, palatal; *pt*, pterygoid; *ps*, presphenoid; *bs*, basisphenoid; *bo*, basioccipital; *c*, bodies of 2nd, 3rd, and 4th cervical vertebrae; *c'*, odontoid process; *x*, anterior arch of atlas; *s*, spinous process of 1st, 2nd, 3rd, and 4th cervical vertebrae; *cm*, neural or medullary canal; *ch*, a line indicating the position of the notochord passing through the vertebral bodies into base of the cranium, *bs*; *ty*, tympanic ring, along with *ml*, *i*, and *st*, displaced from its connection with *per*; *ml*, malleus; *c.m.k*, cartilage of Meckel; *mn*, lower jaw or mandible; *i*, incus; *st*, stapes; *sth*, stylo-hyal; *ch*, cerato-hyal (lesser cornu); *th*, thyro-hyal (greater cornu); *bh*, basi-hyal (body of hyoid).

on some points connected with the earliest condition, and the homological comparison of a few of the bones, that differences of opinion continue to exist.

Besides the general evidence in favour of the homologies of these bones which has been drawn from the study of their form, position and connections, strong confirmation of these views is also obtained from their relations to other organs. Among these, from the remarkable constancy of their relations, the passage of the nerves out of the cranium is one of the most important. Thus, the nerves

belonging to the principal organs of the senses pass into their sense capsules as follows, viz.: *a*, the olfactory through the cribriform plate developed in connection with the ethmo-turbinal; *b*, the optic through the inner part of the orbito-sphenoid; *c*, the auditory directly into the petiotic; *d*, the motor nerves of the eyeball and its muscles, with the ophthalmic division of the trifacial, between the orbito-sphenoid and ali-sphenoid; *e*, the second and third divisions of the trifacial through the inner part of the ali-sphenoid; *f*, the facial by its descending division through the meatus internus, the so-called aqueduct of Fallopius and the stylo-mastoid foramen, and by the Vidian nerve, through the pterygoid foramen; *g*, the glosso-pharyngeal, pneumogastric, and spinal-accessory nerves between the petrosal and exoccipital; and the hypoglossal nerve through the condylar foramen of the exoccipital. The internal carotid artery, it may be further stated, enters the cranium by a canal separated from the foramen lacerum medium or space between the petrous, basi-occipital, and basi-sphenoid; and the jugular vein issues by the fore part of the foramen lacerum posterius.

A general review of the relations of the bones of the head leads to the conclusion that they may be looked upon as consisting mainly of three sets of parts, viz.: 1st, **Basal or central parts**, forming a series prolonged forwards in the line of the vertebral axis, and constituting a cranio-facial axis; 2nd, **Lateral superior arches**, enclosing the brain or much-expanded medullary centre; and 3rd, **Lateral inferior arches**, enclosing, in part at least, the visceral cavity as represented by the nose, mouth, and pharynx. Together with the foregoing are associated two other sets of elements, viz., 1st, the **Sense capsules or cavities**, which are interposed between other bones, and are connected with the lodgment of the higher organs of sense, the nose, eye, and ear; and in the case of the nose, but more especially of the ear, the capsules are formed of special and complex bony apparatus; and 2nd, **Superadded or investing bones**, which are extraneous to the more fundamental osseous elements.

**Vertebrate theory of the skull.**—It is mainly this relation of a superior neural arch and an inferior visceral arch to parts of the skull which are central or basicranial, notwithstanding the great expansion of the one and the limited nature of the other, which has made it a favourite view of many anatomists to compare the plan of construction of the skull to that of a series of vertebrae, from the time when the idea of a vertebrate theory of the skull first occurred to Goethe in 1791, and was subsequently, though independently, conceived and worked out by Oken, and first published by him in 1807. This theory, however, has undergone various modifications in the hands of the successive comparative anatomists by whom it has been supported; while others of distinction have refused to admit the validity of the grounds on which it has been framed. More recent researches, and especially those of W. K. Parker, have thrown much new light on the subject.

The osseous segments which have hitherto been most frequently regarded by anatomists as representing central vertebral elements in the head correspond with the four basicranial bones distinguished in the preceding table, viz., the occipital, basisphenoid, presphenoid, and mesethmoid; the vomer being merely an investment of the last. The upper or neural arches connected respectively with these as supra are as follows, viz., with the first or basioccipital, the exoccipital and supraoccipital surrounding the foramen magnum, and in which few refuse to recognise something of the vertebral character; 2nd, with the basisphenoid, the alisphenoid and parietal, to which the temporal seems also to contribute a part; 3rd, with the presphenoid, the orbito-sphenoid and frontal; and 4th, with the mesethmoid, also the frontal and the nasal, if the latter bone be included in the number of superior arches. The lower or visceral arches are less easily referred to their respective centra. But if, leaving aside the more precise determination of their morphological relations which may result from a full study of embryology, we regard chiefly their form and connections after the bones have attained their osseous condition, the following elements may be enumerated in an order from before backwards, including the investing or superimposed bones along with those of the arches, viz.: 1st, the premaxillary; 2nd, the pterygo-maxillary, including the palate; 3rd, the mandibular, including the cartilage of Meckel and the malleus; 4th, the upper or cerato-hyoid, including the incus

and stapes (according to Huxley and Parker); and 5th, the lower or thyro-hyoid; following which, 6th, &c., are the branchial plates, which, though never attaining even the cartilaginous condition in the foetus of man and the higher animals, yet give indications of the tendency to the continuation backwards of visceral arches in the region between the head and the trunk.

The origin of the walls of the cranial cavity from the same embryonic elements as the vertebræ, and the prolongation of the notochord of the embryo into the substance of the basioccipital and part of the basisphenoid bones, are of themselves strong arguments in support of the central character of these two osseous elements. But, on the other hand, it is to be remarked that the notochord does not reach the region of the sella turcica, but is directed towards the dorsum sellæ, and thus leaves a part of the basisphenoid and the whole of the presphenoid and mesethmoid unoccupied by any true central or vertebral axis. And according to Parker's views the last-named parts, arising in the trabeculæ cranii, are originally double, and only secondarily become mesial and single. Further, it is contended that there is not, as occurs throughout the whole of the vertebral column, any primary division of the formative cartilage marking out four or even two of these centres of the basis of the skull, and it is only after ossification has begun separately in each that the divisions between them become apparent.

The similarity of construction, then, implied in the vertebrate theory of the skull belongs chiefly to the region of the occipital bone; and while it may be admitted that in other parts of the skull further forward there are circumstances of correspondence with the vertebrate plan, yet in these there are also differences, and we must therefore await the fuller and more certain determination of several homological points, at present involved in doubt, before any general theory of cranial morphology worthy of general adoption can be framed. (See especially W. K. Parker's paper on the "Structure and Development of the Skull in the Pig," *Phil. Trans.*, 1873; and in addition to the works previously referred to, Cleland, "On the Relations of the Vomer," &c., *Trans. Roy. Soc.*, 1862; Spix, "Cephalogenesis," 1815; Hallman, "Die Vergleich. Anat. des Schläfenbeins," 1837.

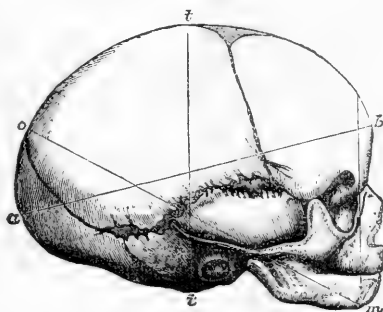
#### THE VARIOUS FORMS OF THE SKULL.

**I. Differences according to Age.**—In the earlier stages of its development the posterior part of the cranium bears a very large proportion to the anterior part: so much so, that in the second month of foetal life the line of the tentorium cerebelli is vertical to the basis cranii, and divides the cranial cavity almost

Fig. 65.—LATERAL VIEW OF THE CHILD'S HEAD AT BIRTH (from Leishman).  $\frac{1}{2}$

This figure shows the peculiarly elongated form of the skull in the child, and the small proportion which the facial bears to the cranial part, and also the interval left between the parietal, occipital, and temporal bones sometimes called lateral fontanelles. The lines indicate the various diameters.

Fig. 65.



equally into two parts. The parietal region then increases rapidly in volume, along with the increased development of the cerebral hemispheres; the frontal region next augments; and again, in the latter part of foetal life, the occipital region increases as the cerebrum extends backwards (Cleland). At the time of birth the parietal region has reached its largest development in proportion to the occipital and frontal regions. The greatest frontal breadth is then smaller in proportion to that between the parietal eminences than afterwards. In the

first years of childhood the superior parts of the cranium grow more rapidly than the base. Thus, in the frontal region, the upper part of the frontal bone grows more rapidly than its orbital processes, giving the prominent appearance of the frontal eminences peculiar to children. The face at birth scarcely reaches an eighth of the bulk of the rest of the head, while in the adult it is at least a half (Froriep, "Characteristik des Kopfes nach dem Entwicklungsgesetz desselben, 1845"). At the same time that the face increases in bulk, the lower part of the forehead is brought forward by elongation of the anterior cranial fossa, and on the approach of adult age, especially in the male, it becomes still more prominent by the expansion of the frontal sinuses. The face becomes elongated in the progress of growth, partly by increased height of the nasal fossæ and adjacent air-sinuses, partly by the growth of the teeth and the enlargement of the alveolar arches of the jaws. In old age the proportion of the face to the cranium is diminished by the loss of the teeth and absorption of the alveolar portions of the jaws. In consequence of this the upper jaw retreats, while in the lower jaw the same cause gives, especially when the mouth is closed, a greater seeming prominence to the chin.

**II. Sexual Differences.**—The female skull is, in general, smaller, lighter, and smoother than that of the male; it is less marked by muscular prominences, and has also the frontal sinus less developed. The face is smaller in proportion to the cranium, the jaws narrower, and the frontal and occipital regions less capacious in proportion to the parietal. (Huschke.) The female skull resembles the young skull more than that of the adult male; but it must also be admitted that it is often impossible to determine the sex by the appearance or form of a skull.

**III. National Differences.**—That characteristic forms of skull are presented by the various races of men has probably been long known, but was first distinctly pointed out by Camper. Subsequently the investigations of Blumenbach established the connection between the study of these forms and ethnology, which since his time has been maintained and greatly extended. The extent, nature and constancy, however, of the ethnical differences of skulls are subjects open to discussion. But, although many skulls are to be met with which fail to exhibit the common characteristics of the race to which they belong, or which present peculiarities similar to those of nations considerably removed from them, yet, it must be admitted, that there are certain forms of skull highly distinctive of the principal varieties of mankind, and often even distinguishable in nations inhabiting countries not far removed from one another. Great differences occur with respect to size in the skulls of different nations. Among the smallest skulls may be mentioned those of the Hindoo, the ancient Peruvian, and the Bosjesman; among the most massive those of the Scandinavian, the Caffre, and the Maori. Various characters are found belonging to the skulls of rude tribes, which serve to distinguish them from those of civilised nations. Among those characters may be mentioned,—a depressed appearance between the middle line of the calvarium and the temporal ridges, both of which stand out prominently, making the roof of the skull seem like a house top; a greater width of the zygomatic arches, and of the anterior nares; greater length and strength of the jaws, together with projection forwards of the incisors, so that the teeth of the upper meet those of the lower jaw at an angle, instead of both sets being nearly perpendicular, as in cultivated nations. Elongation of the face downwards may be regarded as a specially human characteristic connected with the use of voice and speech, but projection of the jaws forwards is only advantageous for the seizure of food, and gives an appearance of approach to the still further projected form of the jaws in the lower animals, particularly when accompanied, as it often is, by deficient development and receding form of the chin.

The average horizontal circumference of the British male cranium, taken one inch above the orbits, is about 21 inches, varying however frequently between 20 and 22; the antero-posterior diameter is about  $7\frac{1}{4}$  inches, and the greatest transverse (parietal) diameter is about  $5\frac{3}{4}$  inches. The average height of the skull from the plane of the foramen magnum to the vertex is about  $5\frac{1}{4}$  inches. The average capacity of the well-formed British male cranium may be stated at from 90 to 95 cubic inches, varying in extremes from about 70 to 120. That



of the female is from 80 to 90 cubic inches. As contrasting with this more developed condition may be mentioned the cranial capacity of the Australian, which averages from 70 to 80 cubic inches, and not unfrequently falls as low as 65 cubic inches. (See on this subject the further details under Size of the Brain.)

**Measurement and Classification of Differences.**—The estimation of differences in the form and size of skulls by a simple and accurate method is not easily accomplished, and their suitable arrangement and nomenclature is still more difficult.

The method proposed by Camper, in which the degree of projection of the face as compared with the cranium is measured by the "facial angle," formed by the meeting of a line descending from the most projecting part of the forehead in front of the upper incisor teeth with another carried backwards from the anterior nasal spine at the level of the external auditory meatus, fails to take cognizance of the size of the cranium and many important features of difference, and is subject to various sources of fallacy from partial variations which do not affect the whole character of the skull.

The "occipital" angle of Daubenton, which varies with the direction of the plane of the foramen magnum of the occipital bone, is mainly an indication of the attitude of the head in relation to the vertebral column. In man this plane looks downwards and forwards, in the anthropoid apes downwards and backwards, and in most quadrupeds nearly directly backwards, so as in them to bring the basicranial and the vertebral axis almost into the same line.

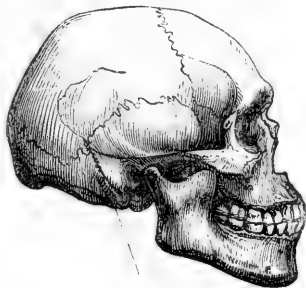The method of Blumenbach by the "norma verticalis," or perpendicular view from above, when combined with measurements, gives important information as to the size and form of the cranium, and the extent to which the zygomatic arches and jaws project beyond or are concealed by the cranial walls, and when combined with the lateral and front views of the head, as in the estimations of Pritchard, may give sufficiently clear views of the form of the cranium and face, their more or less oval form, and the degree of orthognathism or prognathism.

The more recent classification of skulls by Retzius, in which cranial form and facial relation are both taken into account, is at once simple and comprehensive. In this system all those skulls in which the transverse diameter of the cranium bears to the longitudinal the proportion of 80 per cent. or above it are ranked as Brachycephalic, wide or short skulls, and those in which the proportion is lower than 80 per cent. are placed in the Dolichocephalic group, narrow or long skulls; and under each of these primary divisions is established a subordinate one founded on the relation of the face to the cranium, under the names of the orthognathous and prognathous forms. Thus, the usual British skull and that of the natives of Western Europe belong to the orthognathous dolichocephalic type; the African negro and Australian to the prognathous dolichocephalic; the Selavonic nations are examples of the orthognathous brachycephalic, and the Mongolians of the prognathous brachycephalic type.

For an approximate determination of the form and size of skulls it may be sufficient to ascertain the principal dimensions by external measurements in the horizontal, transverse and vertical diameters of the cranium, and in the vertical and transverse diameters of the face, and to measure the capacity of the cranium by means of suitable material introduced into its cavity: and it will add greatly to the value of these measurements if other dimensions are ascertained by measurements between different fixed points of the skull.

But for the full description of all the varieties which occur, and the minuter appreciation of the relations of the several parts, a more elaborate system of measurement must be carried out. Considerable attention has in recent times

Fig. 66.

Fig. 66.—PROGNATHOUS SKULL OF A NATIVE AUSTRALIAN (Carpenter).  $\frac{1}{4}$

been given to this subject, on the Continent by Carus, V. Baer, R. Wagner, Virchow, Welcher, Huschke, Lucae and others, and in this country by Busk, Huxley, Cleland, and Barnard Davies. From the researches of these authors the general conclusion may be drawn, that external measurements alone are insufficient to supply all the information required as to the form and relations of the parts of the skull, and that it is necessary to combine with them numerous measurements which can only be made in the skull opened by a mesial vertical section. The observations of Virchow, Huxley, and Cleland have also shown the

Fig. 67.

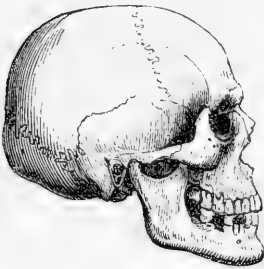


Fig. 68.

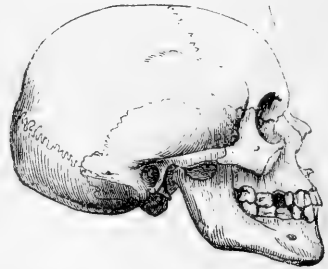


Fig. 67.—SKULL OF EUROPEAN TENDING TOWARDS THE BRACHYCEPHALIC FORM (Carpenter).  $\frac{1}{4}$

Fig. 68.—STRONGLY DOLICHOCEPHALIC SKULL OF EUROPEAN (Carpenter).  $\frac{1}{4}$

importance which is to be attached to the relations of the basi-cranial axis as a very uniform standard of reference for comparing the direction and dimensions of other parts. Without going into farther detail here, it may be mentioned that the angle formed by the basiscranial axis with the line of the cribriform plate, the "ethmo-cranial" angle of Huxley, and nearly the "saddle-angle" of Virchow, is about  $140^\circ$  in British and Western European skulls, diminishing in the highest forms, and opening out in the lower, till in quadrupeds the two lines run almost into one; and that the "premaxillary" angle of Huxley, between the anterior extremity of the basiscranial axis and the front of the incisor ridge of the upper jaw, gives a reliable estimate of the degree of facial projection; varying in different skulls from  $83^\circ$  to  $110^\circ$ , so that the angle above  $95^\circ$  is indicative of prognathism, below it of orthognathism. (On the foregoing subject consult, in addition to the works of Camper, Cuvier, Blumenbach, Lawrence, Carpenter, and other authors quoted, the following: viz., Transl. of the Memoir of Retzius in the Brit. and For. Med. Chir. Review, 1860; Owen, in Trans. Zool. Soc., vol. iv., 1851; Busk's papers in Trans. Ethnol. Soc. Lond., vol. i., 1861, and Journ. of Anthropol. Inst., vol. iii.; Huxley's Lect. "Man's Place in Nature," and in Journ. of Anat. and Physiol., vols. i. and ii.; Thurnam and Davies, "Crania Britannica," and Davies, "Thesaurus Craniorum," 1867; Cleland's Memoir in Philos. Trans., 1869; as also Virchow, in his work on the "Development of the Cranial Basis," 1857, and in Germ. Quart. Mag., Nov. 1871; Huschke, Schädel, Hirn, and Seele, &c., 1854; and Lucae, Zur Morphol. der Rassenschädel, 1861-64.)

**IV. Irregularities of Form.**—The most frequent irregularity in the form of the skull is want of symmetry. This sometimes occurs in a marked degree, and there is probably no skull perfectly symmetrical. The condition which has been observed to co-exist most frequently with irregular forms of skull is *synostosis*, or premature obliteration of certain of the sutures. The cranial bones increase in size principally at their margins; and when a suture is prematurely obliterated the growth of the skull in the direction at right angles to the line of suture may be supposed to be checked, and increased growth in other directions may take place to supply the defect: but this condition is not constant (see Huxley, *loc. cit.*; Virchow, "Gesammelte Abhandlungen," 1856; J. Barnard Davies,

"On Synostotic Crania," 1865; W. Turner, "On Cranial Deformities," in Nat. Hist. Review, 1864.) Another series of irregular forms of skull is that produced by pressure artificially applied in early life, and is best exemplified from among those American tribes who compress the heads of their children by means of an apparatus of boards and bandages: it is also illustrated in a slighter degree by individual instances in which undue pressure has been employed unintentionally. (Gosse, "Essai sur les Déformations artificielles du Crane," 1855.) Posthumous distortions likewise occur in long-buried skulls, subjected to the combined influence of pressure and moisture. (Wilson, "Prehistoric Annals of Scotland.")

#### IV.—BONES OF THE UPPER LIMB.

The upper limb consists of the shoulder, the arm, *brachium*, the forearm, *antibrachium*, and the hand, *manus*. The bones of the shoulder are the scapula and clavicle, which together form the pectoral arch or *shoulder girdle*; in the arm is the humerus; in the forearm are the radius and ulna; and in the hand three groups of bones, the carpus, metacarpus, and digital phalanges.

##### SCAPULA.

This bone is placed upon the upper and back part of the thorax, occupies the space from the second to the seventh rib, and forms the posterior part of the shoulder-girdle. It is not attached directly to the trunk, but is articulated with the outer end of the clavicle, and from it is suspended the humerus in the shoulder-joint.

It is an irregular flat bone of a triangular form, its surfaces are anterior and posterior, its borders superior, internal, and external, and its angles superior, inferior, and external.

The *anterior surface* presents a shallow concavity, the *fossa subscapularis* or *venter*, occupied by the subscapularis muscle, and marked by ~~regular~~ prominent lines converging upwards and outwards, which give attachment to the tendinous intersections of that muscle. Separated from this concavity, there are several smaller flat spaces; one is a triangular surface in front of the superior angle, another is a smaller surface at the inferior angle, and these, together with a rough line running close to the posterior border and uniting them, give attachment to the serratus magnus muscle.

The *posterior surface* or *dorsum* is divided by the *spine* into two unequal parts, the superior and smaller of which is called *fossa supraspinata*, the inferior *fossa infraspinata*. The supraspinous fossa is occupied by the supraspinatus muscle. The infraspinous fossa, much larger than the preceding, presents in the middle a convexity corresponding to the concavity of the venter, and outside this a concavity bounded by the prominent external border. It is marked near the inner border by short lines, corresponding to tendinous septa of the infraspinatus muscle, and is occupied by that muscle in the greater part of its extent. Adjacent to the external border, in its middle third, is a narrow interval giving attachment to the *teres minor muscle*; and beneath this, extending over the inferior angle, is a raised oval surface, from which the *teres major* arises. These spaces are separated from that of the *infraspinatus* muscle by a rough line, which gives attachment to an aponeurotic septum.

The *spine* of the scapula is a massive plate of bone projecting backwards from the dorsum, and curving slightly upwards. It extends outwards and a little upwards from the internal border near its upper

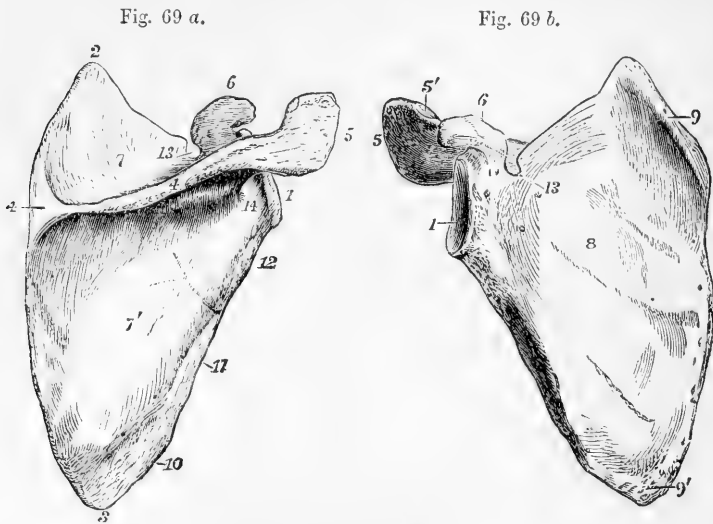


Fig. 69 a.—RIGHT SCAPULA FROM BEHIND. (A. T.)  $\frac{1}{3}$

1, glenoid head; 2, superior angle; 3, inferior angle; 4, spine; 4, at the base, triangular smooth surface of the spine; 5, acromion; 6, coracoid process; 7, supra-spinous fossa; 7', infraspinous fossa; 1 to 2, superior border; 2 to 3, posterior border or base; 1 to 3, external or inferior border; 10, is opposite the oval surface of origin of the *teres major* muscle; 11, the oblique groove where the *teres minor* muscle rises; 12, the rough ridge where the long head of the *triceps* rises; 13, supra-scapular notch; 14, is below the great scapular notch.

Fig. 69 b.—RIGHT SCAPULA FROM BEFORE. (A. T.)  $\frac{1}{3}$

1, 5, 6, and 13, as in fig. 69; 5' articular facet on the acromion for the clavicle; 8, subscapular fossa; 9, long, narrow surface, and 9', triangular rough surface, separated from the subscapular fossa and giving attachment to the upper and lower parts of the *serratus magnus* muscle.

fourth, towards the middle of the neck of the scapula, and becoming gradually elevated towards its external extremity, it turns forwards and is continued into the acromion process. The upper and lower surfaces are smooth, concave, of a triangular form, and form part respectively of the supra-spinous and infra-spinous fossae. It presents two unattached borders, the most prominent of which is subcutaneous and arises from the internal border of the bone by a smooth, flat, triangular surface, over which the tendon of the inferior part of the *trapezius* muscle glides, as it passes to be inserted into a rough thickening beyond. In the rest of its extent this border is rough, broad, and serpentine, giving attachment by its superior margin to the *trapezius*, and by its inferior to the *deltoid* muscle. The anterior or external border, short, smooth, and concave, arises near the neck of the scapula, and is continuous with the under surface of the acromion, surrounding thus the *great scapular notch* between the spine and the neck of the bone.

The *acromion process*, projecting outwards and forwards from the extremity of the spine over the glenoid cavity, forms the summit of the shoulder. It is an expanded process, compressed from above downwards. Its superior surface, rough and subcutaneous, is continuous with the prominent border of the spine; its inferior surface, smooth and concave, is continuous with the superior surface and external border of the spine. On its internal border anteriorly is a narrow oval surface for articulation with the clavicle.

The *glenoid cavity* is a slightly concave surface, looking outwards and forwards. It is pyriform in shape, with the narrow end uppermost, and gently incurved in front. Its rim is flattened, and in the recent state, it is covered by a fibrous band, the glenoid ligament, which deepens its concavity; at its upper extremity is a slight roughness, marking the attachment of the long head of the biceps muscle.

The *neck*, supporting the glenoid cavity, is most distinct posteriorly, where it forms with the spine the *great scapular notch* or *groove*, leading from the supraspinous to the infraspinous fossa. The line of the neck, as described by anatomists, passes superiorly between the glenoid cavity and the coracoid process, but that of the part described as neck by surgeons passes internal to the coracoid process.

The *coracoid process*, thick, strong, and hook-like, rises for a short distance almost vertically from the superior border of the bone, above the glenoid cavity, and then bending at a right angle, is directed forwards and outwards. Its superior surface, towards the base, is rough and uneven, giving origin to the coraco-clavicular ligaments; on its outer border is attached the coraco-acromial ligament, at its extremity the coraco-brachialis muscle and short head of the biceps, and on the inner edge the pectoralis minor.

The *borders* or *costæ* of the scapula are three in number. The *superior* border is the shortest; it extends from the superior angle outwards and downwards to the coracoid process, at the base of which it presents a rounded *suprascapular notch*, which is converted into a foramen by a ligament or occasionally by a spiculum of bone, and is traversed by the suprascapular nerve. The *external, axillary, or inferior* border presents at its upper part, beneath the glenoid cavity, a rough ridge, above an inch long, to which the long head of the triceps muscle is attached: below this there is usually a slight groove, where the dorsal branch of the subscapular artery passes backwards: and at its lower extremity the border is thick, and rounded over into the space from which the *teres major* muscle arises. The *internal or posterior* border, called also the base, is the longest of the three, and is divisible into three parts, viz., a short one opposite the triangular surface of origin of the prominent border of the spine, and the portions above and below that space, both of which incline outwards as they recede from the spine. The upper part gives attachment to the levator anguli scapulae muscle, the middle to the rhomboideus minor, and the lower to the rhomboideus major muscle.

*Texture.*—The triangular part of the scapula is in great part thin and translucent, and contains little cancellated tissue. The neck, the coracoid and acromion processes, the prominent border of the spine, and the part near the inferior angle, derive their greater thickness and strength from increased thickness of the compact bony substance in some parts, and from cancellated tissue in others. A vascular foramen

usually pierces the inferior surface of the spine, and others are to be found on the anterior surface of the bone, near the neck.

#### THE CLAVICLE.

The clavicle or collar-bone extends transversely outwards, with an inclination backwards, from the summit of the sternum to the acromion process of the scapula, and connects the upper limb with the trunk.

It is curved somewhat like an italic *f*: the convexity of the internal curve is directed forwards, and extends over two-thirds of the length of the bone; that of the outer curve looks backwards, and is most marked near the outer fourth of the bone.

The clavicle, towards its scapular end, is compressed and broad from above downwards, but in the extent of its inner curve it is more or less prismatic or cylindrical. In its description, four surfaces of the shaft may be distinguished, together with the two extremities.

Fig. 70.

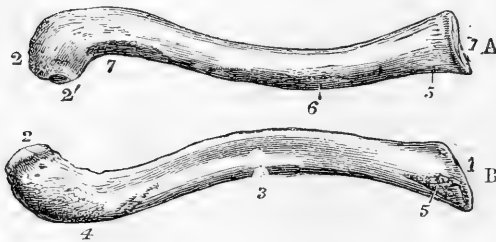


Fig. 70.—THE RIGHT CLAVICLE. (A. T.)  $\frac{1}{3}$

A, from above; B, from below.

1, sternal end; 2, acromial end; 2', small facet for articulation with the acromion; 3, groove on the lower surface for the subclavius muscle; 4, rough elevation at the place of attachment of the coraco-clavicular ligaments; 5, rough depression at the place of attachment

of the costo-clavicular or rhomboid ligament; 6, in front, the mark of the attachment of the pectoralis major; 7, that of the deltoid muscle.

The *superior surface* is broadest in its outer part; it is principally subcutaneous, but near the inner extremity presents a slight roughness, marking the clavicular attachment of the sterno-cleido-mastoid muscle. The *anterior surface* opposite the outer curve is a mere rough border, from which the deltoid muscle takes origin, but in the inner half of its extent is broadened out into an uneven space more or less distinctly separated from the inferior surface, and giving attachment to the pectoralis major muscle. The *posterior surface* is broadest at the inner extremity, and smooth in the whole extent of the internal curvature; but towards its outer extremity it forms a narrow rough border which separates it from the superior surface, and gives attachment to the trapezius muscle. On the *inferior surface* an elongated roughness near the scapular extremity marks the attachment of the coraco-clavicular ligaments; extending inwards from this, over the middle third of the bone, is a groove in which the subclavius muscle is inserted; and near the sternal end is a smaller rough depression, to which the costo-clavicular ligament is attached. On this surface also is found the opening of a small nutritious foramen.

The *sternal end* is the thickest part of the clavicle. It presents a somewhat triangular concavo-convex surface, with its most prominent

angle directed downwards and backwards. The *scapular end* is broad and flat, and articulates by a small oval surface with the acromion.

*Texture*.—The interior of the clavicle contains coarse cancellated tissue in its whole extent. Towards the middle of the shaft the spaces widen out, and unite so as to form an irregular medullary cavity.

## THE HUMERUS.

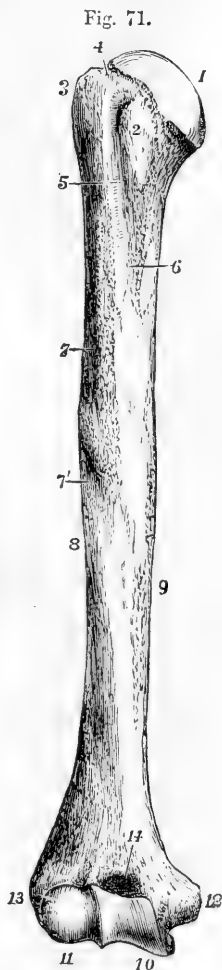
The humerus or arm-bone extends from the scapula to the bones of the forearm, with both of which it is articulated. It hangs nearly vertically from the shoulder, with an inclination inwards towards the lower end. It is divisible into a superior extremity, including the head, neck, and greater and smaller tuberosities; the shaft; and the inferior extremity, including the external and internal condylar eminences, and the inferior articular surface. In general form it is subcylindrical and slightly twisted.

Fig. 71.—RIGHT HUMERUS FROM BEFORE. (A. T.)  $\frac{1}{3}$

1, the articular head; 2, lesser tuberosity; 3, greater tuberosity; 4, neck; 5, bicipital groove; 6, inner bicipital ridge, and mark of the attachment of the latissimus dorsi and teres major muscles; 7, outer bicipital ridge, and rough surface of insertion of the pectoralis major, running down into 7', the triangular mark of the insertion of the deltoid; 8, spiral groove; 9, inner ridge of the humerus; 10, trochlear articular surface; 11, capitellum, or radial condyle; 12, epitrochlear or internal condylar eminence; 13, capitellar or external condylar eminence; 14, coronoid depression or fossa.

The *superior extremity* is the thickest part of the bone. The *head* is a large hemispherical articular elevation, directed inwards, upwards, and somewhat backwards. The *neck* as described by anatomists, is the ring of bone which supports the head; inferiorly, it passes into the shaft; superiorly, it is a mere groove between the head and the great tuberosity. The *great tuberosity* is a thick projection, continued upwards from the external part of the shaft, and reaching nearly to the level of the upper margin of the head; it is surmounted by three flat surfaces, the uppermost of which gives attachment to the *supraspinatus* muscle, the lowest to the *teres minor*, and the intermediate one to the *infraspinatus* muscle. Separated from the great tuberosity by the commencement of the bicipital groove, the *small tuberosity*, rounded and prominent, looks directly forwards and gives attachment to the *subscapularis* muscle.

The *shaft* or *body*, thick and cylindrical superiorly, becomes expanded transversely, and somewhat three-sided inferiorly. It is divided into



anterior and posterior faces by lateral lines, slightly marked in the upper and middle parts, but more prominent in the lower, where they pass into the condylar ridges. Superiorly on its anterior aspect is the

Fig. 72.



bicipital groove, so named from lodging the long tendon of the biceps muscle: this groove, commencing between the tuberosities, descends with an inclination inwards, and is bounded by two rough ridges, the external and most prominent of which gives attachment to the pectoralis major muscle, the internal to the latissimus dorsi and teres major. Towards the middle of the shaft, on the inner lateral line, is a rough linear mark where the coraco-brachialis muscle is inserted, and lower down there is a medullary foramen directed downwards into the interior of the bone. On the external part of the shaft, near its middle, in a line anteriorly with the external bicipital ridge, is a large, rough, and uneven surface, of a triangular shape, the impression of the deltoid muscle. Below this the external bicipital ridge is continued into a smooth elevation which, descending on the front of the shaft to the inferior extremity, separates an external from an internal surface, while at the sides two sharp edges, the external and internal condylar ridges spring from the eminences of the same name and ascend for some distance, separating the anterior from the flat posterior surface. About the middle of the shaft externally, a broad depression, the spiral groove, winds downwards and forwards, limited above by the deltoid impression and below by the external condylar ridge, and lodges the musculo-spiral nerve and the accompanying artery.

Fig. 72.—RIGHT HUMERUS FROM BEHIND. (A. T.)  $\frac{1}{3}$ 

1, 3, 8, & 10, the same as in Fig. 71; 15, is placed above the olecranon fossa.

The inferior extremity is much enlarged laterally, flattened from before backwards, and is curved slightly forwards. Projecting on either side are the external and internal condylar eminences (the condyles of most authors, epicondyle and epitrochlea of Chaussier), the internal of which is much more prominent than the external, and is slightly inclined backwards. The inferior articular surface is divided by a ridge into two parts. The external part, articulated with the radius, consists of a rounded eminence directed forwards, called the capitellum, and a groove internal to it; it does not extend to the posterior surface. The internal part, the trochlea, articulates with the ulna, and extends completely round from the anterior to the posterior surface of the bone; it is grooved down the middle like the surface of a pulley, and is somewhat broader behind than in front; anteriorly, its margins are inclined downwards and inwards; posteriorly, upwards and outwards, and so that, seen from behind, it lies in the middle part



of the bone. Anteriorly, the internal margin of the trochlea is the most prominent, and widens below into a convexity parallel to the groove; posteriorly, the external margin is most prominent. Above the trochlea posteriorly is a large and deep pit, the *olecranon fossa*, which receives the olecranon process of the ulna in extension of the forearm; and above it anteriorly, separated from the olecranon fossa only by a thin lamina of bone, is the much smaller *coronoid fossa*, which receives the coronoid process in flexion. Above the capitellum is a shallow depression, into which the head of the radius is pressed in complete flexion.

*Varieties.*—A small hook-like process, with its point directed downwards, is not unfrequently found in front of the internal condylar ridge, the *supracondyloid process*. From its extremity, a fibrous band, giving origin to the pronator radii teres muscle, passes to the internal condylar eminence, and through the arch thus formed passes the median nerve, accompanied frequently by the brachial artery, or by a large branch rising from it. This process represents a portion of the bone ~~completing~~ <sup>occluding</sup> a foramen in carnivorous animals. (See Struthers, Edin. Med. Journ., 1848; Gruber. "Canalis supracondyloideus humeri," Mem. de l'Acad. Imp. de St. Petersburg, 1859, p. 57.) The thin plate between the olecranon and coronoid fossæ is sometimes perforated.

#### THE RADIUS.\*

The radius is the external of the two bones of the forearm, and extends from the humerus to the carpus. It articulates with the humerus, the ulna, the scaphoid, and the semilunar bones.

The *head*, or superior extremity, is disc-shaped, with a smooth vertical margin. It presents on its summit a depression, which articulates with the capitellum of the humerus, and is surrounded by a convex part, broadest internally where it glides upon the groove internal to the capitellum. The smooth, short, cylindrical surface of the vertical margin, likewise broadest internally, rolls in the small sigmoid cavity of the ulna, and within the orbicular ligament. The head is supported on a constricted portion, named the *neck*.

The *shaft* or *body* is slightly curved, with the convexity directed outwards and backwards. On its internal aspect superiorly, where it is continuous with the neck, is the *bicipital tuberosity*, to the posterior border of which is attached the tendon of the biceps muscle. Below the bicipital tuberosity the shaft presents three sides, the external of which is rounded into the others by smooth convex margins, while the anterior and posterior surfaces are separated by an acute internal margin, which gives attachment to the interosseous ligament. The *external surface* is convex transversely as well as longitudinally; it is marked near the middle by an oval rough part, about one inch and a half long, which gives insertion to the pronator radii teres. The *anterior surface* is marked in its upper part by an oblique ridge, below which is a shallow longitudinal groove for the flexor longus pollicis; inferiorly it is expanded, and presents a flat impression corresponding with the pronator quadratus; and above the middle is the foramen for the medullary vessels, directed upwards into the bone. The *posterior surface* presents slight oblique impressions of the extensor muscles of the thumb.

The *lower extremity* of the radius, broad and thick, and somewhat

\* In anatomical description the forearm is supposed to be placed in supination, with the thumb directed outwards and the palm of the hand looking forwards.

quadrilateral, presents inferiorly a large surface, which articulates with the carpus, and internally a small one, which articulates with the ulna. The carpal articular surface, slightly concave, is divided by a line into a quadrilateral internal part, which articulates with the semilunar bone, and a triangular external part, which articulates with the scaphoid bone. The ulnar articular surface is placed at a right angle with the inferior surface; it is concave from before backwards, forming a *semi-lunar cavity*, in which the rounded lower end of the ulna plays. At the external angle of the inferior surface a part projecting downwards, called the *styloid process*, gives attachment to the external lateral ligament of the wrist joint, while the anterior and posterior margins are

Fig. 73.



Fig. 74.

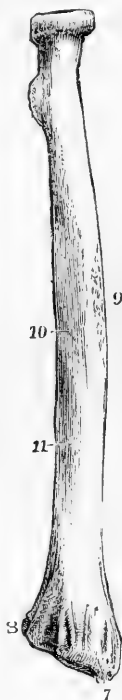


Fig. 73.—RIGHT RADIUS FROM BEFORE.

Fig. 74.—RIGHT RADIUS FROM BEHIND. (A. T.)  $\frac{1}{2}$ 

1, head, showing the hollow above for the humerus, and the vertical surface surrounding it for the ulnar articulation; 2, the neck; 3, the tubercle; 4, is opposite to the oblique line; 5, interosseous ridge; the shaded part near 5 marks the slight hollow in which the flexor longus pollicis muscle lies; 6, carpal articular surface; 7, styloid process; 8, the articular hollow for the lower end of the ulna; 9, mark of the attachment of the pronator radii teres; 10 and 11, oblique impressions of the extensor longus digitorum and extensor ossis metacarpi pollicis; between 7 and 8, dorsal grooves for the tendons of the extensor muscles.

likewise rough and prominent for other ligaments. On its external posterior aspects the inferior extremity of the radius is marked by grooves, which transmit the extensor tendons. Thus, on the external border, is a flat groove directed downwards and forwards, which lodges the extensor ossis metacarpi and extensor primi internodii pollicis; and on the posterior surface are three grooves, the middle one of which, oblique and narrow, and with prominent borders, lodges the extensor secundi internodii pollicis; while of the two others, which are broad and shallow, the external, subdivided by a slight mark, gives passage to the extensores carpi radiales longior and bre-

vior, and the internal transmits the extensor communis digitorum and extensor indicis.

#### THE ULNA.

The ulna is the internal of the two bones of the forearm. It is longer than the radius by the extent of the olecranon process. It is inclined downwards and outwards from the humerus in such a direction that a straight line passing from the great tuberosity of the humerus downwards through the capitellum would touch the lower end of the ulna.

The ulna articulates with the humerus and the radius: in the

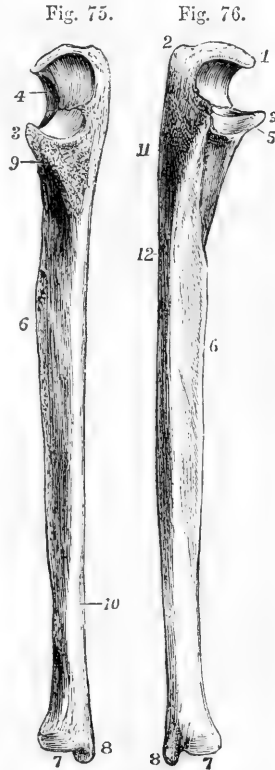
natural skeleton it is not in contact with the carpal bones, being separated from the cuneiform bone by an interarticular fibro-cartilage.

The *superior extremity* is of large size, and presents for articulation with the humerus a large articular surface, the *great sigmoid cavity*, which looks forwards and is bounded in its posterior and upper part by the olecranon, a thick process continued upwards from the shaft, and in its lower part by the coronoid process, which projects forwards. The great sigmoid cavity is concave from above downwards, and is convex from side to side, being traversed by a vertical ridge. The part external to this ridge is broad and convex above, while the part internal to the ridge is broad and concave below: a slight constriction, and

Fig. 75.—RIGHT ULNA FROM BEFORE.

Fig. 76.—RIGHT ULNA FROM BEHIND. (A. T.)  $\frac{1}{3}$

1, point or beak of the olecranon; 2, tuberosity of the olecranon; 3, end of the coronoid process; 4, great sigmoid articular surface; 5, lesser sigmoid cavity, and below it the surface for the supinator brevis muscle; 6, interosseous ridge; 7, lower extremity or head; 8, styloid process; 9, rough surface of insertion of the brachialis anticus muscle; below 10, the oblique line marking the attachment of the pronator quadratus muscle; 11, triangular surface for the anconeus muscle; 12, upper part of the posterior border, to the right of which the depressions for the long extensor muscles of the fingers occupy the posterior surface.



sometimes a notch or division occurs across the middle of the cavity. Continuous with the great is the *small sigmoid cavity*, a small articular surface on the outer side of the base of the coronoid process, slightly concave from before backwards, and articulating with the cylindrical part of the head of the radius. Superiorly the *olecranon* is broad and uneven, terminating in front in an acute process or beak, which overhangs the great sigmoid cavity, and which in extension of the elbow passes into the olecranon fossa of the humerus, and behind in a rectangular prominence or tuberosity, which forms the point of the elbow, and gives attachment to the triceps extensor muscle. The posterior surface of the olecranon is subcutaneous and continuous with the posterior margin of the shaft of the ulna. The extremity of the *coronoid process* is sharp and prominent, and is received during flexion into the coronoid fossa of the humerus: its superior surface forms part of the surface of the great sigmoid cavity; the inferior surface rises gradually from the anterior surface of the bone, and is covered by a large triangular roughness which gives insertion to the brachialis anticus muscle.

The *body* or *shaft* in the upper three-fourths of its extent is three-

sided, and presents a slight curve with the convexity backwards, but near the lower extremity it is slender, straight and cylindrical. The *anterior surface* is grooved in the upper half, where the flexor profundus muscle takes origin; and at its lower end has an oblique line to which the pronator quadratus is attached. Placed near the upper third is a foramen for vessels, directed upwards into the medullary cavity. The *internal surface* is smooth, and somewhat depressed superiorly on the side of the olecranon, where it gives attachment to the flexor profundus muscle, while inferiorly it is subcutaneous. The *posterior surface*, more uneven, looks outwards and backwards; an oblique ridge descending from behind the small sigmoid cavity, limits superiorly a triangular area, which extends over the outer side of the olecranon and gives attachment to the anconeus muscle; immediately below the small sigmoid cavity is a short space looking directly outwards, to which the supinator brevis is attached: while the remaining and largest part of this surface is slightly impressed by the extensor muscles. Of the three *margins*, the anterior and posterior are rounded, and for the most part smooth; the external is sharp, and gives attachment to the interosseous ligament.

The *inferior extremity* presents a rounded articular head; and on the internal aspect of the head a short cylindrical projection, the *styloid process*, which descends in a line with the inner and posterior surface of the shaft, and gives attachment to the internal lateral ligament of the wrist joint. The *head* presents two aspects, of which one, flattened and circular in form, looks towards the wrist joint; whilst the other, narrow and cylindrical, looks outwards, and is received into the semilunar cavity in the contiguous border of the radius. The head and the styloid process are separated posteriorly by a groove, which is traversed by the tendon of the extensor carpi ulnaris; and inferiorly by a depression, into which the triangular fibro-cartilage which intervenes between the ulna and the carpus is inserted.

#### THE CARPUS.

The carpus is composed of eight short bones, which are disposed in

Fig. 77.

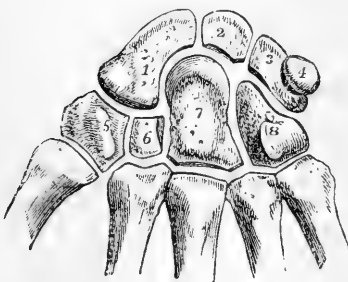


Fig. 77.—SEMI-DIAGRAMMATIC VIEW OF THE RIGHT CARPUS AND PART OF THE METACARPAL BONES, FROM BEFORE, THE CARPAL BONES BEING SLIGHTLY SEPARATED TO SHOW THE GENERAL MODE OF THEIR CONNECTION WITH EACH OTHER. (A. T.)  $\frac{3}{4}$

1, scaphoid bone; 2, semilunar, presenting, as often occurs, a small surface of articulation with the unciform bone; 3, cuneiform; 4, pisiform; 5, trapezium, the figure is placed upon the ridge, to the inside of which is the groove for the tendon of flexor carpi radialis; 6, trapezoid; 7, os magnum, the figure is placed on the tuberosity; 8, unciform, the figure is

placed on the unciform process. The articulation of the os magnum with the fourth metacarpal bone is represented somewhat too large.

two ranges, four in each range. Enumerated from the radial to the ulnar side, the bones which constitute the first or superior range are

named scaphoid, semilunar, cuneiform, and pisiform; those of the second or inferior range, trapezium, trapezoid, os magnum, and unciform.

The dorsal surface of the carpus is convex, the palmar is concave from side to side, the concavity being bounded by four prominences, one at the outer and one at the inner extremity of each range. The anterior annular ligament is stretched across the carpus between these prominences, so as to form a canal for the transmission of the flexor tendons.

The superior surfaces of the scaphoid, semilunar, and cuneiform bones form, when in apposition, a continuous convexity which corresponds with the concavity presented by the radius and the interarticular cartilage, while the pisiform bone is attached in front of the cuneiform, with which alone it articulates. The line of articulation between the superior and inferior ranges is concavo-convex from side to side, the trapezium, trapezoid and os magnum bounding a cavity which lodges the external part of the scaphoid, and the os magnum and unciform rising up in a convexity, which is received into a hollow formed by the scaphoid, semilunar, and cuneiform bones.

The **scaphoid** bone, the largest and most external of the first row of carpal bones, is of a curved form, and lies with its longest axis directed outwards and downwards. Its superior surface, convex and smooth for articulation with the radius, is inclined backwards, so that the posterior surface of the bone is not so deep as the anterior. The internal surface narrow from above downwards, articulates with the semilunar bone. The outer extremity, rough superiorly for the attachment of ligaments, presents inferiorly an articular convexity, which occupies the hollow formed by the upper surfaces of the trapezium and trapezoid bones, and is continuous with a large concave surface extending over the rest of the inferior aspect of the bone, and articulating with the os magnum. The fore part of the outer extremity of the scaphoid bone projects forwards, forming one of the tubercles to which the anterior annular ligament is attached. The scaphoid articulates with five bones, viz., the radius, the semilunar, trapezium, trapezoid, and os magnum.

The **semilunar** bone, irregularly cubic, is named from the crescentic concavity from before backwards of its inferior surface, which rests on the head of the os magnum, and frequently also by a bevelled edge slightly on the unciform bone. Its external surface is vertical, and articulates with the scaphoid bone; its internal surface looks downwards and inwards, is much deeper and narrower than the external, and articulates with the cuneiform. The convex superior surface, which articulates with the radius, is inclined, like that of the scaphoid, more backwards than forwards and hence the anterior surface is deeper than the posterior. The semilunar articulates with five bones, viz., the radius scaphoid, cuneiform, os magnum, and unciform.

The **cuneiform** bone is somewhat wedge-shaped, its internal extremity, rough for ligaments, forming the blunt narrow end of the wedge. Superiorly it presents an articular surface, which glides upon the triangular cartilage interposed between it and the ulna; externally it articulates with the semilunar bone, and inferiorly with the unciform, by means of a surface which is concavo-convex from without inwards. Its anterior surface is distinguished from the posterior by a smooth

circular facet on its outer half, which articulates with the pisiform bone. The cuneiform articulates with three bones, viz., the semilunar, pisiform, and unciform.

The **pisiform** bone lies on a plane anterior to the other bones of the carpus. Posteriorly it possesses an articular surface, which rests on the cuneiform bone. The mass of the bone is so inclined from this surface downwards and outwards, that the pisiform bone of one hand is distinguishable from that of the other.

The **trapezium** bone is the most external of the second row of carpal bones. It presents a rhombic form when seen in its dorsal or palmar aspect, and has its most prominent angle directed downwards.

Fig. 78.

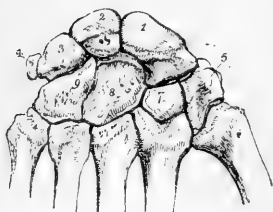


Fig. 78.—DORSAL VIEW OF THE CARPUS, WITH A PORTION OF EACH OF THE METACARPAL BONES.  $\frac{1}{2}$

1, scaphoid ; 2, semilunar ; 3, cuneiform ; 4, pisiform ; 5, trapezium ; 7, trapezoid ; 8, os magnum ; 9, unciform.

Its anterior surface is marked by a vertical groove traversed by the tendon of the flexor carpi radialis muscle, and external to the groove by a ridge, or tubercle, one of the four prominences which give attachment to the anterior annular ligament. Of the internal sides of the rhomb, the superior articulates with the scaphoid bone, the inferior with the trapezoid bone, and by a small facet close to the inferior angle also with the second metacarpal bone. Of the external sides the superior is rough, and the inferior presents a smooth surface, convex from behind forwards, and concave from without inwards, which articulates with the metacarpal bone of the thumb, and is separated by a rough line at the inferior angle from the surface for the second metacarpal bone. The trapezium articulates with four bones, viz., the scaphoid, trapezoid, and first and second metacarpals.

The **trapezoid** bone is considerably smaller than the trapezium. Its longest diameter is from before backwards. Its posterior surface, which is pentagonal, is much larger than the anterior. The external inferior angle of the anterior surface is distinguished by being prolonged a little backwards between the trapezium and second metacarpal bone. The superior surface articulates with the scaphoid bone ; the external with the trapezium ; the internal with the os magnum ; and the inferior by a large surface convex from side to side with the second metacarpal bone. The trapezoid articulates with four bones, viz., the scaphoid, trapezium, os magnum, and second metacarpal bone.

The **os magnum** is the largest of the carpal bones. In form it is elongated vertically, rectangular inferiorly, rounded superiorly. The articular surface of the superior extremity or *head* is prolonged on the outer, but not on the inner side, and is continued further down behind than in front. A *neck* is formed beneath by depressions on the anterior and posterior surfaces. The anterior surface of the bone is much narrower than the posterior. The posterior surface projects downwards at its internal inferior angle. On the outer side beneath the surface for the scaphoid is a short surface for the trapezoid bone ; and on the inner side is a vertically elongated surface which articulates with

the unciform bone. Inferiorly this bone articulates by three distinct surfaces, of which the middle is much the largest, with the second, third, and fourth metacarpal bones. The os magnum articulates with seven bones, viz., the scaphoid, semilunar, trapezoid, unciform, and second, third, and fourth metacarpal bones.

The **unciform** bone is readily distinguished by the large process projecting forwards and curved slightly outwards on its anterior surface. Seen from the front or behind, it has a triangular form. Its external surface is vertical, and articulates with the os magnum; its inferior surface is divided into two facets which articulate with the fourth and fifth metacarpal bones; its superior surface, meeting the cuneiform, is concavo-convex, inclines upwards and outwards towards the head of the os magnum, and is separated internally by a rough border from the inferior surface. The unciform articulates with five bones, viz., the os magnum, semilunar, cuneiform, and fourth and fifth metacarpal bones.

#### THE METACARPUS.

The metacarpus, the part of the hand which supports the fingers, consists of five shafted bones, diverging slightly from each other, and which are numbered from without inwards.

Fig. 79.—THE RIGHT HAND FROM BEFORE.  
(A. T.)  $\frac{1}{3}$

*s*, scaphoid bone; *l*, semilunar; *c*, cuneiform; *p*, pisiform; *t*, trapezium; next it the trapezoid, not lettered; next the os magnum, also not lettered; *u*, unciform.

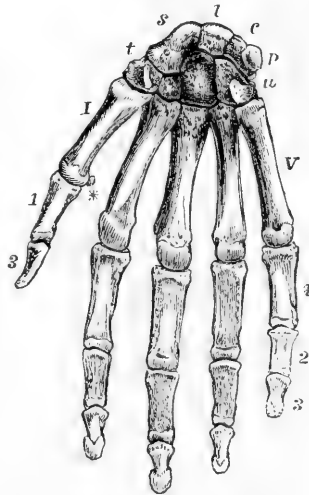
I to V, the metacarpal bones; 1, 3, first and second phalanges of the thumb; 1, 2, 3, the first, second, and third phalanges of the little finger, and similarly for the other three fingers, not marked; \* one of the sesamoid bones of the thumb seen sideways.

The metacarpal bones are placed in a segment of an arch transversely, and being at the same time slightly curved, longitudinally they present a concavity directed forwards. They are terminated at their carpal extremities by expanded portions of different forms, and at the digital ends by large rounded heads.

The first metacarpal bone is thicker and shorter than the others. Of the remaining bones the third is the longest and thickest, the second, fourth, and fifth decreasing regularly in length, according to their position from without inwards.

The *shaft* of the first metacarpal bone is somewhat compressed from before backwards, flat behind, and transversely convex in front. The shafts of the others are prismatic, presenting a broad surface towards the back of the hand, and towards the palm a rounded margin between the two lateral surfaces. They are most slender immediately beyond the carpal extremity, and become gradually thicker towards the head. They present on their dorsal surfaces each a triangular subcutaneous

Fig. 79.

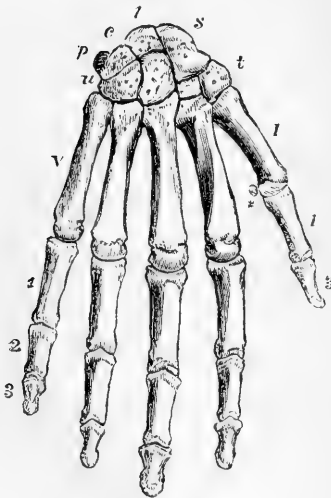


area, bounded by lines which, proceeding from the sides of the head, pass upwards and converge in the second, third, and fourth metacarpal bones opposite the middle of the carpal extremity, and in the fifth towards its inner side.

The *heads* or *digital extremities* articulate with the proximal phalanges. Their smooth, rounded surfaces are broader, and extend further on the palmar than on the dorsal aspect of the bones; and on the sides present hollows and elevations for the attachment of ligaments.

The *carpal extremity* presents distinctive peculiarities in each metacarpal bone. That of the first has only one articular surface, concave from before backwards, and convex from side to side, which articulates with the trapezium; and posteriorly a rough prominence, to which the extensor ossis metacarpi pollicis is attached. The second presents a transversely concave surface which receives the trapezoid bone; on the radial side it articulates by a small facet on its posterior part with the trapezium, on the ulnar side with the third metacarpal bone, and by a narrow facet wedged between the third metacarpal and trapezoid bones, with the os magnum. The third bone articulates superiorly with the os magnum, and on the sides with the contiguous metacarpal bones: at its posterior and outer angle it forms a projection upwards. The fourth articulates principally with the unciform bone above, but also by a narrow facet with the os magnum; on its radial side are two small surfaces, and on the ulnar side one, for articulation with the adjacent metacarpal bones. The fifth articulates superiorly with the unciform bone by means of a concave surface inclined slightly outwards, and externally with the fourth metacarpal bone, while on its ulnar side it presents a rough and prominent tuberosity.

Fig. 80.



From the proximal position of its epiphysis, the metacarpal bone of the thumb has been considered by Winslow and some other anatomists, as a phalanx of the first row, and the bone which it supports a phalanx of the middle row. But this view is not generally adopted by Anatomists.

Fig. 80.—RIGHT HAND SEEN FROM BEHIND.  
(A. T.)  $\frac{1}{3}$

The indications are the same as in the preceding figure.

#### THE DIGITAL PHALANGES.

The digital phalanges, or *internodia*, are fourteen in number; three for each finger, except the thumb, which has only two.

Those of the *first row* are slightly curved like the metacarpal bones. Their dorsal surfaces are smooth and transversely convex; the palmar are flat from side to side, and bounded by rough margins, which give insertion to the fibrous sheaths of the flexor tendons. Their proximal extremities are thick, and articulate each by a transversely oval concave surface with the corresponding metacarpal bone. Their distal extremities, smaller and



more compressed antero-posteriorly, are divided by a shallow groove into two condyles.

Those of the *middle row* are four in number. Smaller than those of the preceding set, they resemble them in form, with this difference, that their proximal extremities present, on the articular surface a slight middle elevation and two lateral depressions, adapted to articulate with the condyles of the first phalanges.

The *terminal* or *ungual* phalanges, five in number, have proximal extremities similar to those of the middle row, but with a rough depression in front, where the flexor tendons are inserted. They taper towards their somewhat flattened and expanded free extremities, which are rough and raised round the margins and upon the palmar aspect in the unguis process.

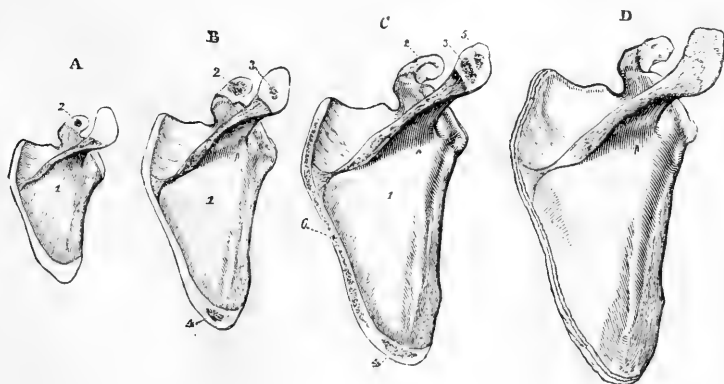
**SESAMOID BONES.**—A pair of sesamoid bones is placed in the palmar wall of the metacarpo-phalangeal articulation of the thumb; and similar nodules, single or double, are sometimes found in the corresponding joint of one or more of the other fingers, most frequently of the index and little fingers.

OSSIFICATION OF THE BONES OF THE UPPER LIMB

With the exception of the clavicle, all the bones of the upper limb begin to ossify from cartilage.

The *scapula* is ossified from a single osseous nucleus for the body, and additional centres for the coracoid process, acromion, base, and lower angle. The

Fig. 81.



1 year.      15 or 16 years.      17 or 18 years.      22 years.

Fig. 81.—OSSIFICATION OF THE SCAPULA (R. Quain).

A, about one year. 1, shows the large spreading ossification, from the primary centre. 2, the commencing nucleus in the coracoid process.

B, about fifteen or sixteen years. The coracoid process (represented as too little ossified in the figure) is now partially united at its base; a nucleus, 3, has appeared in the acromion, and another, 4, at the lower angle.

C, male scapula at seventeen or eighteen years; a second point, 5, has appeared in the acromion, and ossification has advanced into the ridge of the base, 6.

D, the scapula of a man of about twenty-two years of age; the acromion and the ridge of the base are still separate. B, C, and D, are about the fourth of the natural size.

nucleus for the body appears a little behind the glenoid cavity about the 7th or 8th week. Around this centre is formed a triangular plate of bone, from near the upper margin of which about the 3rd month the spine appears as a slight ridge. At birth the coracoid and acromion process, the base and inferior angle, the edges of the spine and of the glenoid cavity are cartilaginous. The nucleus of the coracoid process is especially worthy of attention, both because it appears in the first year, while the other supplementary nuclei are formed only after puberty, and because, although reduced to a mere epiphysis in mammals, it forms a distinct and sometimes large bone in other vertebrate animals. The coracoid process is united to the body about the age of puberty. The acromion process is cartilaginous till the 14th or 16th year, when two distinct nuclei appear. These soon coalesce and form an epiphysis which is united to the spine from the 22nd to the 25th year. The cartilage of the base, which it may be noticed corresponds

Fig. 82.

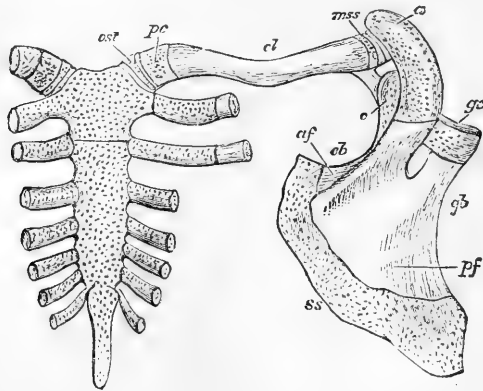


Fig. 82.—POSTERIOR ASPECT OF THE STERNUM AND RIGHT SHOULDER GIRDLE FROM A FETUS OF ABOUT FOUR MONTHS (Flower after Parker).  $1\frac{1}{2}$

The dotted parts are cartilaginous; *ost*, omosternum, afterwards becoming the inter-articular fibro-cartilage; *pc*, precoracoid of Parker; *a*, acromion; *cl*, shaft of clavicle; *mss*, mesoscapular segment of Parker; *c*, coracoid; *gc*, glenoid cavity; *gb*, glenoid border; *cb*, coracoid border; *af*, anterior or supraspinous fossa; *pf*, posterior or infraspinous fossa; *ss*, suprascapular border.

to a more largely developed permanent cartilage or bone found in many animals, becomes the seat of ossification about the 16th to the 18th year, by the appearance of a nucleus at the inferior angle, and thereafter of a line of osseous deposit extending upwards throughout its length. The epiphysis thus formed, together with an epiphysal lamina which occasionally forms the border of the glenoid cavity, are united to the body about the 25th year.

Fig. 83.



Fig. 83.—OSSIFICATION OF THE CLAVICLE (R. Quain).

*a*, the clavicle of a fetus at birth, osseous in the shaft, 1, and cartilaginous at both ends.

*b*, clavicle of a man of about twenty-three years of age; the shaft, 1, fully ossified to the acromial end; the sternal epiphysis, 2, is represented rather thicker than natural.

The clavicle begins to ossify before any other bone in the body. Its ossification commences before the deposition of cartilage in connection with it, but afterwards progresses in cartilage as well as in fibrous substance. It is formed

from two separate centres, the one appearing about the 6th week, for the shaft and acromial end, the other appearing about the 18th to the 20th year for an epiphysis at the sternal end. The epiphysis is united to the shaft about the 25th year.

In the humerus an ossific nucleus appears near the middle of the shaft in the 8th week. It gradually extends, until at birth only the ends of the bone are cartilaginous. About the beginning of the 2nd year the nucleus of the head appears, and during the 3rd year that for the great tuberosity. The lesser tuberosity is either ossified from a distinct nucleus which appears in the 5th year, or by extension of ossification from the great tuberosity. These nuclei unite together about the 5th year to form an epiphysis, which is not united to the shaft till the 20th year. In the cartilage of the lower end of the bone four separate nuclei are seen, the first appearing in the capitellum in the 3rd year,

Fig. 84.

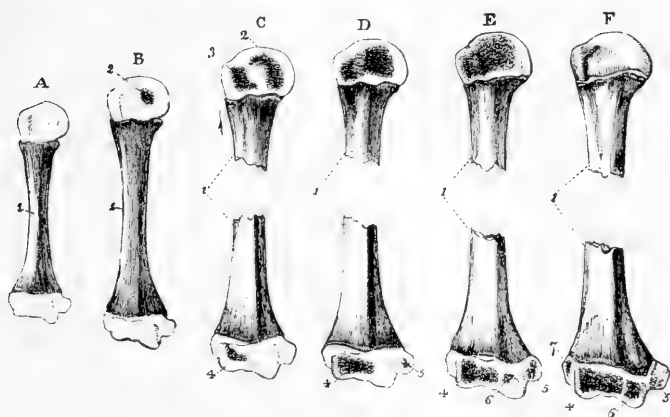


Fig. 84.—OSSIFICATION OF THE HUMERUS (R. Quain).

A, from a full grown fœtus ; B, at two years ; C, in the third year ; D, at the beginning of the fifth year ; E, at about the twelfth year ; F, at the age of puberty.

1, the primary centre for the shaft ; 2, nucleus for the articular head ; 3, that for the great tuberosity ; 4, for the radial condyle and adjacent part of the trochlea ; 5, for the inner or trochlear eminence ; 6, for the inner part of the trochlea ; 7, for the external or capitellar eminence. In this and the following figures the more advanced bones are shown on a smaller scale than the earlier ones.

The nucleus of the internal condylar eminence appears in the 5th year, that of the trochlea in the 11th or 12th year, and that of the external condylar eminence in the 13th or 14th year. The nucleus of the internal condylar eminence forms a distinct epiphysis which unites with the shaft in the 18th year ; the other three nuclei coalesce to form an epiphysis, which is united to the shaft in the 16th or 17th year.

The radius is developed from an osseous nucleus, which appears in the middle of the shaft in the 8th week, and from an epiphysial nucleus in each extremity which only appear some time after birth. The nucleus in the carpal extremity appears at the end of the 2nd year, while that of the head is not seen till the 5th or 6th year. The superior epiphysis and shaft unite about the 17th or 18th year ; the inferior epiphysis and shaft unite about the 20th year.

The ulna is ossified similarly to the radius, but ossification begins a few days later. The nucleus of the shaft appears about the 8th week, that of the carpal

extremity in the 4th or 5th year. The upper extremity is formed chiefly in connection with the shaft, except the point of the olecranon where a small

Fig. 85.

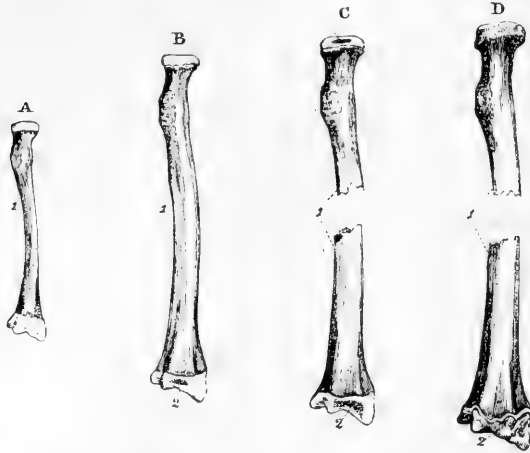


Fig. 85.—OSSIFICATION OF THE RADIUS (R. Quain).

A, the radius of a full-grown foetus ; B, at about two years of age ; C, at five years ; D, at about eighteen years.

1, the primary piece or shaft ; 2, the ossific point of the lower or carpal epiphysis ; 3, that of the upper end. In D, the upper epiphysis is united to the shaft, while the lower epiphysis is still separate.

Fig. 86.

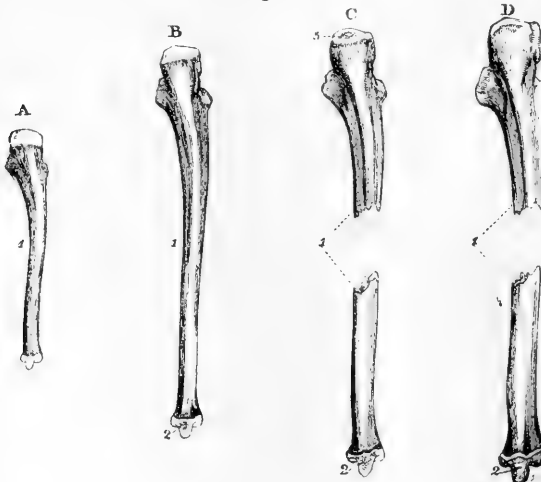


Fig. 86.—OSSIFICATION OF THE ULNA. (R. Quain).

A, the ulna of a child at birth ; B, the ulna of a child at the end of the fourth year ; C, of a boy of about twelve years of age ; D, the ulna of a male of about nineteen or twenty years.

1, the primary piece of the shaft ; 2, the nucleus of the lower epiphysis ; 3, the nucleus of the upper epiphysis. In D, the upper epiphysis is united to the shaft, while the lower one is still separate.

epiphysis is formed from a distinct nucleus which appears in the 10th year. This epiphysis is united to the shaft about the 17th year, while the inferior epiphysis is only united to the shaft about the 20th year.

Fig. 87.

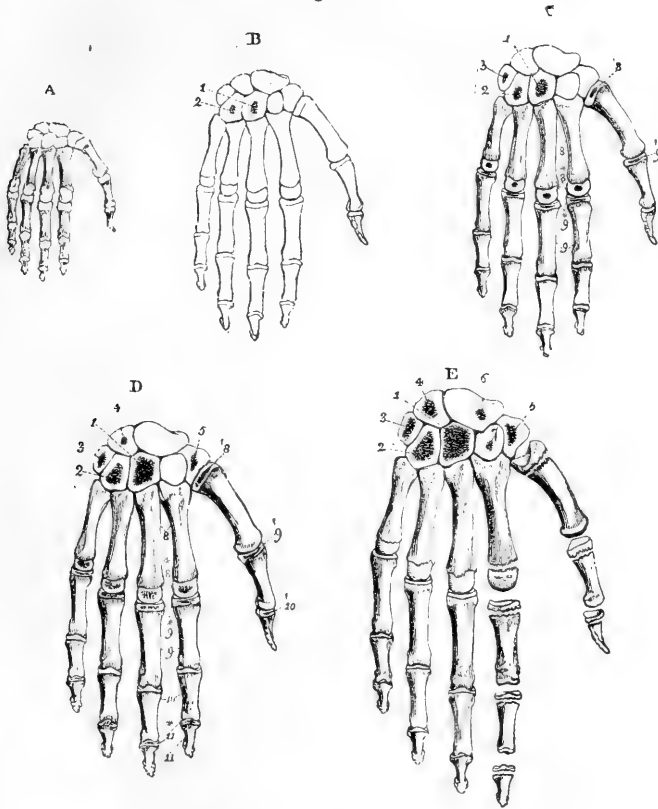


Fig. 87—OSSIFICATION OF THE BONES OF THE HAND.

A, represents the state of the bones and cartilages at the period of birth. The carpus is entirely cartilaginous. Each of the metacarpal bones and digital phalanges has its shaft ossified.

B, the state of the bones in a child at the end of the first year; the os magnum and unciform bone have begun to ossify.

C, the condition about the third year. Centres of ossification are seen in the cuneiform and in the proximal epiphyses of the first and the distal epiphyses of the other four metacarpal bones, and in the proximal epiphyses of the first row of phalanges.

D, the condition at the fifth year. Centres have been formed in the trapezium, and later in the semilunar bone, and in the middle and distal phalanges: (the figure does not show them distinctly in the middle phalanges.)

E, the condition at about the ninth year. Centres have been formed in the scaphoid and trapezoid bones, and the more developed epiphyses of the metacarpal bones and phalanges are shown in the first and second digits separately.

1, os magnum; 2, unciform; 3, cuneiform; 4, semilunar; 5, trapezium; 6, scaphoid; 7, trapezoid; 8, metacarpal bones, the principal pieces; 8\*, four metacarpal epiphyses; 8', that of the thumb; 9, the first range of phalanges; 9\*, their epiphyses; 9', that of the thumb; 10, second range of phalanges; 10', epiphyses of terminal phalanx of thumb, 11, terminal range of phalanges of the fingers; 11\*, their epiphyses.

From what is stated above it appears that in the bones of the arm and forearm the epiphyses which meet at the elbow-joint begin to ossify later, and unite with their shafts earlier, than those at the opposite ends of the bones, while in the bones of the thigh and leg the epiphyses at the knee-joint are the soonest to ossify and the latest to unite with their shafts. In the bones of the arm and forearm the nutrient foramina are directed towards the elbow; in those of the thigh and leg they are directed away from the knee. Thus in each bone the epiphysis of the extremity towards which the nutrient foramen is directed is the first to be united to the shaft.

The **carpus** is entirely cartilaginous at birth. Each carpal bone is ossified from a single nucleus. The nucleus of the *os magnum* appears in the first year; that of the *unciform* in the first or second year; that of the *cuneiform* in the third year; those of the *trapezium* and *semilunar* bones in the fifth year; that of the *scaphoid* in the sixth or seventh year; that of the *trapezoid* in the seventh or eighth year; and that of the *pisiform* in the twelfth year.

The **Metacarpal bones** and **Phalanges** are usually formed each from a principal centre for the shafts and one epiphysis. The ossification of the shafts begins about the eighth or ninth week. In the four inner metacarpal bones the epiphysis is at the distal extremity, while in the metacarpal bone of the thumb and in the phalanges it is placed at the proximal extremity. In many instances, however, as was known to Albinus, and has been more fully shown by Allen Thomson (*Jour. of Anat.*, 1869), there is also a distal epiphysis visible in the first metacarpal bone at the age of seven or eight years, and there are even traces of a proximal epiphysis in the second metacarpal. In the seal and some other animals there are always two epiphyses in these bones. The epiphyses begin to be ossified from the third to the fifth year, and are united to their respective shafts about the twentieth year.

## V.—THE PELVIS AND LOWER LIMB.

The divisions of the lower limb are the haunch or hip, thigh, leg, and foot. In the haunch is the innominate bone, which enters into the formation of the pelvis; in the thigh is the femur; in the leg the tibia and fibula; and at the knee a large sesamoid bone, the patella. The foot is composed of three parts; the tarsus, metatarsus, and phalanges.

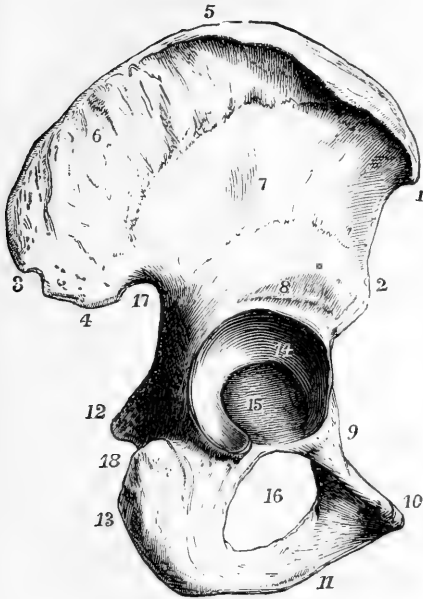
### THE INNOMINATE BONE.

The innominate bone, *os coxae*, or *pelvic bone*, with its neighbour of the opposite side and the addition of the sacrum and coccyx, forms the pelvis; it transmits the weight of the body to the lower limb. In form it is constricted in the middle and expanded above and below, and is so bent upon itself that the anterior margin of the upper part looks outwards, while the lower part is directed inwards. On the external aspect of the constricted portion is the *acetabulum*, a cavity which articulates with the femur, and perforating the inferior expansion is a large opening, the *obturator foramen*. The superior wider part of the bone forms part of the abdominal wall: the inferior enters into the formation of the true pelvis. The innominate bone articulates with its fellow of the opposite side, with the sacrum, and with the femur.

In the description of this bone it is convenient to recognise as distinct the three parts of it which are separated in early life, viz., the

*ilium, os pubis* and *ischium*. These three portions meet at the acetabulum, in the formation of which they all take part; and the *os pubis* and *ischium* also meet on the inner side of the obturator foramen.

Fig. 88.

Fig. 88.—RIGHT OS INNOMINATUM FROM THE DORSAL ASPECT. (A. T.)  $\frac{1}{2}$ 

1, anterior superior; 2, anterior inferior spinous process; 3, posterior superior; 4, posterior inferior spinous process; 5, crest of the ilium; 6, surface occupied by the *gluteus medius* muscle above the superior curved line; above 3 and 4 is a rough surface to which the *gluteus maximus* is attached; 7, surface between the superior and inferior curved lines occupied by the *gluteus minimus*; 8, groove above the acetabulum for the posterior tendon of the *rectus femoris*; 9, superior ramus of the *pubis*, and *pectineal eminence*; 10, crest and spinous process of the *pubis*; 11, place of meeting of the descending ramus of the *pubis* with the ascending ramus of the *ischium*; 12, spine; and 13, tuberosity of the *ischium*; 14, cartilaginous surface of the acetabulum; 15, synovial depression and pit for the round ligament; 16, thyroid or obturator foramen; 17, greater, and 18, lesser sciatic notches.

The **ilium** constitutes the superior expanded portion of the bone, and forms a part of the wall of the acetabulum by its inferior extremity. Above the acetabulum it is limited anteriorly and posteriorly by margins which diverge at right angles one from the other, and superiorly by an arched thick and extensive border, 5, the *crista ili*. The *crest* is curved like the letter *f*, the anterior extremity pointing slightly inwards and the posterior outwards; its surface is broadest in its anterior and posterior thirds, it is rough for the attachment of muscles, and on it may be distinguished an external and internal lip and an intermediate space. The anterior extremity of the crest forms a projection forwards called the *anterior superior spine of the ilium*, and, separated from it by a concave border, and placed immediately above the acetabulum, is another eminence called the *anterior inferior spine*: the projecting posterior extremity of the crest forms the *posterior superior spine*, and separated from it by a notch is the *posterior inferior spine*, below which the posterior border of the bone is hollowed out into the *great sciatic notch*. The external surface, or *dorsum* of the ilium, concavo-convex from behind forwards, presents, close to the posterior extremity of the crest, a roughness of some extent, to which the *gluteus maximus* muscle is attached, and is traversed by two rough arched lines, one of which, the *superior curved line*, beginning in front, at the upper border of the bone, about an inch and a half from its

anterior extremity, arches backwards to the upper part of the great sciatic notch, while the other, *the inferior curved line*, shorter and less strongly marked, extends from the space between the anterior spinous processes to the middle of the great sciatic notch. The curved space between the crest and the superior curved line, broad behind and pointed in front, gives attachment to the gluteus medius muscle, while that between the two curved lines gives attachment to the gluteus minimus. The internal surface of the ilium is divided into three parts. The anterior of these, the largest, is called the *iliac fossa*; it is concave and smooth, and towards the middle of it the bone is very thin. The posterior part is subdivided, presenting inferiorly, for cartilaginous articulation with the sacrum, the smooth but uneven *auricular surface*, broad in front and extending to the posterior inferior spine behind; and superiorly a more uneven and rough surface for the attachment of ligaments. The third part, entering into the formation of the true pelvis, is not distinguished by any mark in the adult from the ischium and os pubis; it is separated from the iliac fossa by a smooth border, the *iliac portion of the ilio-pectineal line*, which extends from the auricular surface to the pubic spine.

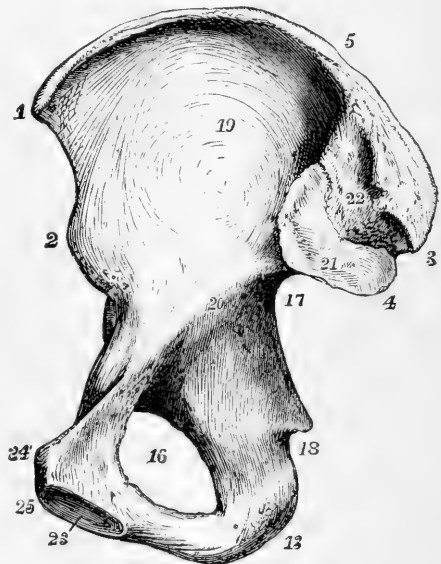
Fig. 89.—RIGHT OS INNOMINATUM,  
FROM THE INNER OR PELVIC  
SURFACE. (A. T.)  $\frac{1}{3}$

1, 2, 3, 4, 5, 16, 17, and 18, indicate the same parts as in the preceding figure; 19, iliac fossa; 20, ilio-pectineal line; 21, auricular cartilaginous sacro-iliac surface; 22, rough tuberculated surface for the posterior sacro-iliac ligaments; 23, oval surface of the symphysis pubis; 24, spinous process; 25, angle of the os pubis; between 24 and 25, the crest; between 17 and 20, the pelvic surface of the ilium.

The **os pubis** forms the anterior wall of the pelvis, and bounds the obturator foramen in the upper half of its extent. At its outer and upper extremity it forms a part of the acetabulum; at its inner extremity it presents an elongated oval surface, articulating by fibro

cartilage with the bone of the opposite side, its junction with which is called the *symphysis pubis*. The part which passes downwards and outwards below the symphysis is called the *inferior* or *descending ramus*, the upper part is called the *superior* or *ascending ramus*, and the flat portion between the rami may be distinguished as the *body*. The deep or pelvic surface of the os pubis is smooth; the outer surface is roughened near the symphysis by the attachments of muscles. At the superior extremity of the symphysis is the *angle* of the pubis, and extending outwards from this, on the superior border, is the

Fig. 89.





rough *crest*, terminating in the projecting *spine*. The descending ramus is flat from before backwards; the superior or ascending ramus becomes prismatic, and increases in thickness as it passes upwards and outwards, and between its posterior and superior surfaces there is prolonged outwards from the spine a ridge which is the pubic portion of the *ilio-pectineal line*. The surface in front of this line is covered by the pectineus muscle; the inferior surface of the ramus presents a deep groove for the obturator vessels and nerve directed from behind forwards and inwards. On the superior surface above the acetabulum there is a slight elevation, the *ilio-pectineal eminence*, marking the place of junction of the os pubis and ilium.

The **ischium** forms the posterior and inferior part of the os innominatum, and bounds the obturator foramen in the lower half of its extent. Superiorly it forms about two-fifths of the acetabulum, inferiorly it is enlarged in a thick projection, the *tuberosity*, and this part, diminishing in size, is continued forwards into the *ramus*. On its posterior border, behind the acetabulum, a sharp process, the *spine*, projecting with an inclination inwards, forms the inferior limit of the *great sciatic notch*, and is separated from the tuberosity by a short interval, the *small sciatic notch*, against the smooth margin of which glides the tendon of the obturator internus muscle. In front of this, on the external surface, a horizontal groove, occupied by the tendon of the obturator externus muscle, lies between the inferior margin of the acetabulum and the tuberosity. The tuberosity, which is the part on which the body rests in the sitting posture, presents a rough surface continuous with the internal margin of the ramus, and on which may be distinguished four impressions, viz., on its upper and broad part two slight hollows, which are placed side by side, the external corresponding to the attachment of the semimembranosus muscle, and the internal to the conjoined origin of the biceps and semitendinosus; and inferiorly two elongated rough elevations, likewise side by side, the external giving attachment to the adductor magnus muscle, and the internal to the great sacro-sciatic ligament: there is likewise along the outer margin a rough elevated line, marking the place of origin of the quadratus femoris muscle. The ramus of the ischium is flattened like the descending ramus of the pubis, with which it is continuous on the inner side of the obturator foramen.

The *acetabulum* is a *cotyloid* or cup-shaped cavity, looking outwards, downwards, and forwards, and surrounded in the greater part of its circumference by an elevated margin, which is most prominent at the posterior and upper part; while at the opposite side, close to the obturator foramen, it is deficient, forming the *notch* or *incisura*. Its lateral and upper parts present a broad bent ribbon-like smooth surface, which articulates with the head of the femur, and in the recent state is coated with cartilage, but the lower part of the cup and the region of the notch are depressed below the level of the articular surface, lodge a mass of fat, and have no cartilaginous coating. Rather more than two-fifths of the acetabulum are formed from the ischium, less than two-fifths from the ilium, and the remainder from the os pubis. The iliac portion of the articular surface is the largest, the pubic the smallest: the non-articular surface belongs chiefly to the ischium.

The *obturator* or *thyroid* foramen, also called *foramen ovale*, is internal and inferior to the acetabulum. In the male it is nearly oval, with the

long diameter directed downwards and outwards; in the female it is more triangular, or narrowed at its lower part. In the recent state it is closed by a fibrous membrane, except in the neighbourhood of the groove in its upper margin.

### THE PELVIS.

The ossa innominata with the sacrum and coccyx form the osseous walls of the pelvis.

Fig. 90.

Fig. 90.

ADULT MALE PELVIS  
SEEN FROM BEFORE,  
IN THE ERECT AT-  
TITUDE OF THE  
BODY. (A. T.)  $\frac{1}{4}$

1, 2, anterior ex-  
tremities of the  
crests of the ilia in  
front of the widest  
transverse diameter  
of the upper or false  
pelvis; 3, 4, aceta-  
bula; 5, 5, obturator  
foramina; 6, sub-  
pubic angle or arch.

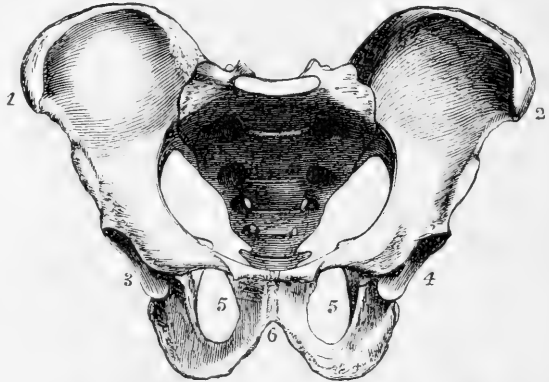
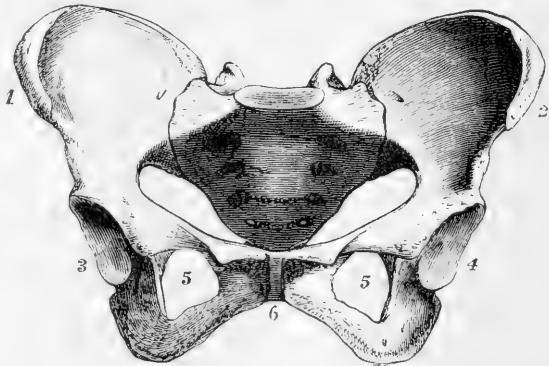


Fig. 91.

Fig. 91.

ADULT FEMALE PEL-  
VIS (A. T.)  $\frac{1}{4}$

Similarly placed with  
that shown in the  
preceding figure, and  
illustrating by com-  
parison with it, the  
principal differences  
between the male and  
female pelvis. The  
numbers indicate the  
same parts as in the  
preceding figure.



This part of the skeleton may be considered as divided into two parts by a plane passing through the upper border of the symphysis pubis, the sacral promontory, and the ilio-pectineal lines. The circle thus completed constitutes the *brim* or *inlet* of the lower or *true pelvis*; the space above it, between the iliac fossæ, belongs really to the abdomen, but has been called the upper or *false pelvis*. The inferior circumference, or *outlet* of the pelvis, presents three large bony eminences, the coccyx and the tuberosities of the ischia. Between the tuberosities of the ischia in front is the *sub-pubic arch*, which bounds an angular space extending forwards to the symphysis, and is formed by the descending rami of the ossa pubis and the ascending rami of the ischia. The

interval between the sacrum and coccyx and the ischium on each side is bridged over in the recent state by the sacro-sciatic ligaments, which therefore assist in bounding the outlet of the pelvis.

**Position of the Pelvis.**—In the erect attitude of the body, the pelvis is so inclined that the plane of the brim of the true pelvis forms an angle with the horizontal, which varies in different individuals from

Fig. 92.

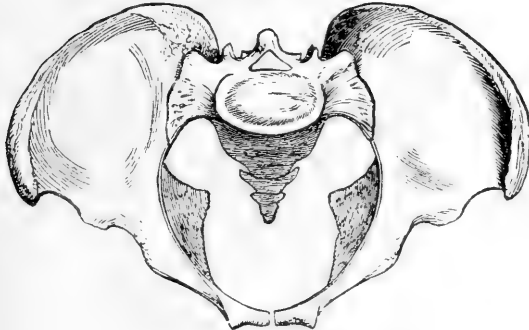
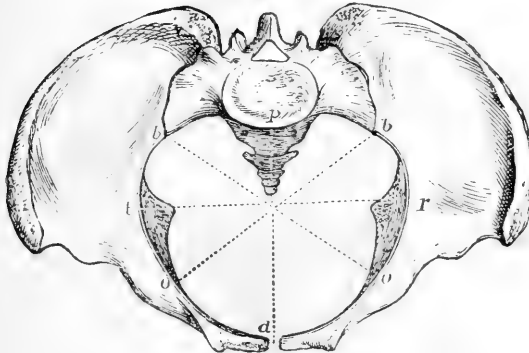


Fig. 93.



Figs. 92 &amp; 93.

SKETCHES OF THE MALE AND FEMALE PELVIS AS SEEN FROM ABOVE AND IN FRONT. (A. T.)

In fig. 90 of the female pelvis the lines are shown in which the dimensions of the pelvis are usually measured at the brim.

*a, p*, antero-posterior or conjugate diameter ;  
*t, r*, transverse or widest diameter ; *o, b*, oblique diameters.

In the original specimens, which were selected as giving the full average dimensions, the following were the measurements in inches :—

Antero-posterior diameter—female,  $4\frac{1}{2}$  ; male, 4. Transverse diameter—female  $5\frac{1}{4}$  ; male,  $4\frac{1}{2}$ . Oblique diameter—female, 5 ; male,  $4\frac{1}{4}$ .

$60^{\circ}$  to  $65^{\circ}$ . The base of the sacrum was found by Nägele in a large number

of well-formed female bodies to be about  $3\frac{1}{4}$  inches above the upper margin of the symphysis pubis ; the level of the top of the coccyx he found varying from 22 lines above the apex of the pubic arch to 9 lines below the same point, and on an average to be 7 or 8 lines above it (Nägele, "Das weibliche Becken," &c., Karlsruhe, 1825 ; Wood, article "Pelvis" in the Cyclopædia of Anatomy and Physiology). The pelvic aspect of the sacrum, near its base, looks much more downwards than forwards, hence the sacrum appears at first sight to occupy the position of the keystone of an arch ; but being in reality broader at its pelvic than on its dorsal aspect, it is a keystone inverted, or having its broad end lowest, and is supported in its place chiefly by cartilage and ligaments, but also to a slight extent by the inward projection of the anterior margin of the iliac articular surface. The line of pressure of the weight of the body on the sacrum is directed downwards towards the symphysis pubis, and the resistance of the head of the thighbone on each side is directed upwards and inwards.

The *axis of the pelvis* is the name given to a line drawn at right angles to the planes of the brim, cavity and outlet, through their

Fig. 94.—VERTICAL MEDIAN SECTION OF A FEMALE PELVIS (reduced from Nägele's figure).  $\frac{1}{3}$

1, symphysis pubis; 2, promontory of the sacrum; 3, coccygeal bones; 4, anterior superior spine of ilium; 5, tuberosity of ischium; 6, spine of ischium (the obturator foramen is not represented so pointed below as it generally is in females). The vertical and horizontal lines in the lower part of the figure will assist the eye in judging of the degree of inclination of the pelvis, as illustrated by the next figure.

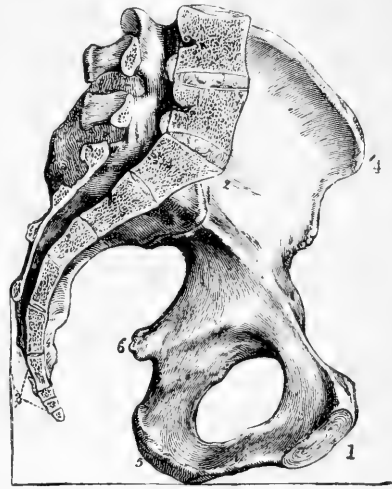


Fig. 94.

central points. The posterior wall, formed by the sacrum and coccyx, being about five inches long and concave, while

the anterior wall at the symphysis pubis is only one and a half or two inches long. The axis is curved; it is directed at the inlet upwards and forwards towards the umbilicus, and at the outlet downwards and a little forwards.

Fig. 95.—SKETCH OF PART OF THE PRECEDING FIGURE, SHOWING THE INCLINATION OF THE BRIM OF THE PELVIS AND ITS AXIS IN THE ERECT POSTURE.  $\frac{1}{3}$

*a, b*, line of inclination of the brim of the true pelvis from above the symphysis pubis to the promontory of the sacrum; *c, f*, a line inclining backwards and upwards, touching the lower edge of the symphysis pubis and point of the coccyx; *e, d*, axis of the brim at right angles to the plane of the brim; *d, h, g*, curved axis of the cavity and outlet.

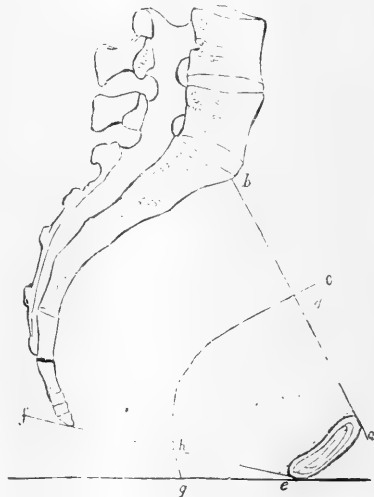

Fig. 95.

#### Differences according

to Sex.—The size and form of the pelvis differ remarkably in the two sexes. In the female the constituent bones are more slender and less marked with muscular impressions;

the perpendicular depth is less, and the breadth and capacity greater; the ilia are more expanded than in the male; the inlet of the true

pelvis is more nearly circular, the sacral promontory projecting less into it; the sacrum is flatter and broader; the depth of the symphysis pubis is less, the pubic arch is much wider, and the space between the tuberosities of the ischia greater.

The average dimensions of the pelvis, as measured in a number of full-sized males and females, may be stated as follow, in inches:—

	MALE.			FEMALE.		
	Brim.	Cavity.	Outlet.	Brim.	Cavity.	Outlet.
Distance between the widest part of the crests of the ilia . . .	10 to 11			10½ to 11		
Distance between the anterior superior spines of the ilia . . .	9½ to 10			10 — 10½		
Distance between the front of symphysis pubis and the sacral spines . . .	6½ — 7			6½ — 7½		
<b>TRUE PELVIS.</b>						
Transverse diameter . . . . .	4½	4½	3½	5¼	5	4¾
Oblique diameter . . . . .	4½	4½	4	5	5¼	4¾
Antero-posterior diameter . . . .	4	4½	3¼	4½	5¼	5

## THE FEMUR.

The femur or thigh bone, the largest bone of the skeleton, is situated between the os innominatum and the tibia. In the erect position of the body it inclines inwards and slightly backwards as it descends, so as to approach inferiorly its fellow of the opposite side, and to have its upper end a little in advance of the lower. It is divisible into a superior extremity, including the head and neck and two eminences called trochanters, the shaft, and an inferior extremity expanded into an external and an internal condyle.

At the *superior extremity* of the bone, the *neck*, surmounted by the head, extends inwards, upwards, and slightly forwards, being set upon the shaft at an angle of about 125° or 130°. The neck has a constricted appearance, and its diameter from before backwards is less than in the vertical direction, in which last greater strength is required to sustain the weight of the body. It is shorter superiorly than inferiorly, and the anterior surface is shorter than the posterior. The *head* forms more than half a sphere, and is covered with cartilage in the fresh state. Behind and below its central point is a small depression, which gives attachment to the round ligament of the hip joint.

The *trochanter major* is a thick truncated process prolonged upwards in a line with the external surface of the shaft. In front it is marked by the insertion of the gluteus minimus; externally an oblique line directed downwards and forwards indicates the inferior border of the insertion of the gluteus medius muscle, and lower down a horizontal line, continued upwards in front of the trochanter, marks the upper limit of the vastus externus. Internally at its base, and rather behind the neck, is the *trochanteric* or *digital fossa*, which gives attachment to the obturator and gemelli muscles. The posterior border of the great trochanter is prominent, and continued into a smooth elevation, the

*posterior intertrochanteric line*, which passes downwards and inwards to

Fig. 96.—FEMUR OF A MALE FROM BEFORE.

Fig. 96.

(A. T.)  $\frac{1}{3}$

1, shaft; 2, head; 3, neck; 4, great trochanter; 5, small trochanter; 6, anterior inter-trochanteric line; 7, internal articular condyle; 8, external articular condyle; 9, internal tuberosity; 10, external tuberosity; 11, the patella articular surface; above it, 12, the flat part of the femur sometimes called the suprapatellar surface; 13, the depression for the tendon of the popliteus muscle.

the small trochanter, and limits the neck posteriorly. The *small trochanter*, a conical rounded eminence, projects from the posterior and inner aspect of the bone, and gives attachment to the tendon of the psoas and iliacus muscles. The *anterior intertrochanteric line* is a rough ridge limiting the neck in front between the two trochanters; it indicates the superior border of the crureus and vastus internus muscles, and is continuous beneath the great trochanter with the line which limits the vastus externus.

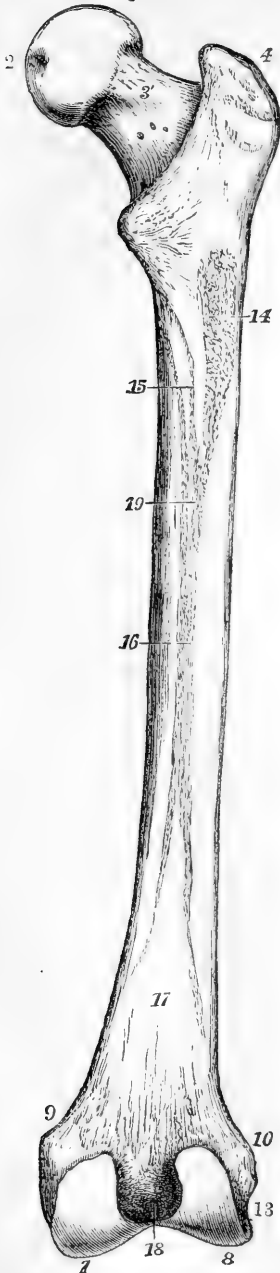
The *shaft* is slightly arched from above downwards, with the convexity forwards. It is expanded at its upper and lower ends. Towards the centre it is nearly cylindrical, but with an inclination to the prismatic form. Its anterior and lateral surfaces, smooth and uniform, are covered by the crureus and vasti muscles. The elevation which separates the anterior from the internal surface is at the upper part strongly marked and inclined forwards, giving the appearance to the bone as if the forward inclination of the neck were produced by a twisting outwards of the upper end of the shaft. The lateral surfaces in the middle of their extent approach one another behind, being only separated by the *linea aspera*. The *linea aspera* is a prominent ridge, extending along the central third of the shaft posteriorly, and bifurcating above and below. It inclines slightly inwards in the middle, so as to make the external surface of the shaft seem concave in that



part. It presents two sharp margins and a flat interval. The external divi-

Fig. 97.

Fig. 97.—FEMUR OF A MALE FROM BEHIND  
(A. T.)  $\frac{1}{3}$



4, 5, 7, 8, 9, 10, and 13, the same as in the preceding figure; 2', pit on the head for the round ligament of the hip-joint; 3', the back of the neck, showing a slight groove of the obturator externus muscle as it passes over the capsular ligament and neck; between 4 and 5, the posterior intertrochanteric ridge; 14, rough impression of the attachment of the gluteus maximus muscle in the upper and outer continuation of the linea aspera; 15, two lines running up towards the lesser trochanter from the linea aspera, marking the attachments of the adductor brevis and pectineus muscles; 16, flat elevated surface of the linea aspera; 17, flat triangular popliteal surface between the lower divisions of the linea aspera; 18, intercondylar notch; 19, foramen for the nutritive or medullary vessels.

sion of its superior bifurcation passes up to the great trochanter, and in its course is strongly marked where the gluteus maximus is attached; the internal division terminates in front of the small trochanter. The inferior divisions terminate at the tuberosities of the condyles, and enclose between them a flat triangular surface of bone, which is free from muscular attachments, and forms the floor of the upper part of the popliteal space. Towards the superior part of the linea aspera is the foramen for the medullary vessels, directed upwards into the bone.

The *inferior extremity* presents two rounded eminences, the *condyles*, united anteriorly, but separated posteriorly by a deep *intercondylar fossa* or *notch*. Their greatest prominence is directed backwards, and their curve, as it increases towards that part, may be compared to that of a partially uncoiled piece of watch-spring. The external condyle is the broader and more prominent in front; the internal is the longer and more prominent inferiorly. One large articular surface, coated continuously with cartilage, extends over both condyles, but, opposite the front of the intercondylar fossa, it is divided by two slight linear depressions into three parts, an elevated surface on each side

of the fossa for articulation with the tibia; and a grooved anterior surface

for the patella. The patellar surface is of a trochlear form, being marked by a vertical hollow and two prominent ridges; the external portion of this surface is more prominent, and rises higher than the internal. The tibial surfaces are nearly parallel, except in front, where the internal turns obliquely outwards to reach the patellar surface. Above the condyles are two rough tuberosities, one on each side of the bone, which give attachment to the external and internal lateral ligaments of the knee-joint. Between the external tuberosity and the back part of the external condyle is a smooth groove directed downwards and forwards, and ending anteriorly in a pit, in which the popliteus muscle takes origin.

*In the female* the angle made by the neck of the femur with the shaft is less obtuse than in the male; and from the greater width of the pelvis, and the shortness of the limbs, the convergence of the thigh bones inferiorly is more apparent.

*In advanced age* the neck comes to be placed at a less obtuse angle than in middle life, and at last may almost assume a rectangular position in regard to the shaft. (See Holden's Osteology.)

#### THE PATELLA.

The patella, *rotula*, or knee-pan, is situated at the front of the knee joint, is attached inferiorly by a ligament or tendon to the tibia, and

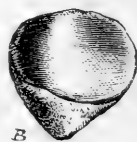Fig. 98.—RIGHT PATELLA. (A. T.)  $\frac{1}{2}$

A from before; B, from behind.

Both views show the lower extremity pointing slightly inwards; the posterior view shows the articular cartilaginous surface, divided by an elevated ridge into a smaller internal and a larger external part.

may be considered as a sesamoid bone developed in the tendon of the quadriceps extensor cruris. It is compressed from before backwards, and has the form of a triangle with the apex below. Its anterior surface is subcutaneous; the superior border is broad, and gives attachment to the extensor muscles; its inferior angle, together with a rough depression on its deep aspect, gives attachment to the ligamentum patellæ. The deep surface, except at the inferior angle, is coated with cartilage for articulation with the femur, and is divided by a vertical elevation into two parts, the external of which, the larger, is transversely concave, while the internal is convex.

Fig. 98.



#### THE TIBIA.

The tibia, or shin bone, is, next to the femur, the longest bone in the skeleton. It is the anterior and inner of the two bones of the leg, and alone communicates the weight of the trunk to the foot. It articulates with the femur, fibula, and astragalus.

The *superior extremity* is thick and expanded, broader from side to side than from before backwards, and slightly hollowed posteriorly. On its superior aspect are placed two slightly concave articular surfaces, which sustain the femur. These are the *condylar surfaces*; they



are oval in form, the external being wider transversely, and the internal longer from before backwards. Between them is an irregular interval, depressed in front and behind, where it gives attach-

Fig. 99.

Fig. 99.—RIGHT TIBIA FROM BEFORE. (A. T.)  $\frac{1}{2}$ 

1, shaft, and shin or anterior border ; 2, inner tuberosity ; 3, outer tuberosity ; 4, inner, and 5, outer, condylar articular surface ; 6, crucial spine, with fossa at its root in front ; 7, anterior tuberosity ; 8, lower articular surface for astragalus ; 9, malleolus internus.

ment to the crucial ligaments and semilunar cartilages of the knee joint, and elevated in the middle, where is formed the <sup>crucial</sup> spine. The summit of the spine presents two prominent tubercles, formed by the prolongation upwards on its sides of the margins of the condylar portions ; the outer being turned slightly forwards, and the inner slightly backwards. On the sides of the upper extremity of the bone are two rounded eminences, the *external* and *internal tuberosities* ; the outer one of these, somewhat smaller than the other, is marked posteriorly by a flat surface which articulates with the fibula, while the inner presents a groove for the insertion of the semi-membranosus muscle. Lower down, in front, is situated the *anterior tuberosity* or *tubercle*, rough inferiorly, where it gives attachment to the ligamentum patellæ, and smooth above, where it is covered by a synovial bursa.

The *shaft* of the tibia is three-sided, and diminishes in size as it descends for about two-thirds of its length, but increases somewhat towards its lower extremity. The *internal surface* is convex and subcutaneous, except at the upper part where it is crossed by the tendons of the sartorius, gracilis, and semitendinosus muscles. It is separated from the external surface by a sharp subcutaneous, slightly sinuous *crest*, the shin ridge, which descends from the anterior tuberosity, and is smoothed away in the inferior third of the bone. The *external surface* is slightly hollowed in the larger part of its extent,

where it gives origin to the tibialis anticus muscle ; but beneath the point where the crest disappears it turns forwards, becomes convex, and is covered by the extensor tendons. The *posterior surface* is traversed obliquely in its upper third by the *popliteal line*—a rough mark which extends upwards and outwards to the external tuberosity, giving attachment to the soleus muscle, and separating a triangular area, in which the popliteus muscle lies, from the space below, which gives origin to the flexor longus digitorum and tibialis posticus. The posterior surface is

separated from the internal by a smooth rounded border, and from the external by a sharp ridge, inclined forwards above, to which the interosseous membrane is attached. Near the popliteal line is a large me-

Fig. 100.—RIGHT TIBIA FROM BEHIND. (A. T.)  $\frac{1}{3}$

6, and 9, as in the preceding figure; 2', groove behind the internal tuberosity for the tendon of the semi-membranosus muscle; 10, inclined articular facet below and behind the outer tuberosity for the head of the fibula; 11, oblique line of tibia, above which is the triangular popliteal surface; 12, nutritious foramen directed downwards; 13, triangular rough surface for the lower interosseous ligament, and small cartilaginous surface below it for articulation with the fibula; 14, below a slight groove marking the place of the flexor longus pollicis muscle; 15, below the groove of the tendons of the flexor communis digitorum and tibialis posticus muscles.

dullary foramen, directed downwards into the interior of the bone.

The *inferior extremity*, much smaller than the superior, is expanded transversely, and projects downwards on its inner side, so as to form a thick process, the *internal malleolus*. Inferiorly it presents for articulation with the astragalus a cartilaginous surface, which is quadrilateral, concave from before backwards, and having its posterior border narrower and projecting farther downwards than the anterior; internally the cartilaginous surface is continued down in a vertical direction upon the internal malleolus, clothing its outer surface somewhat more deeply in front than behind. The external surface, slightly concave, is rough superiorly for ligament, and smooth below for articulation with the fibula. The posterior surface of the internal malleolus is marked by a double groove for the tendons of the tibialis posticus and flexor longus digitorum, and more externally by a slight depression where the flexor longus pollicis lies; the inner surface of the malleolus is subcutaneous.

The tibia is slightly twisted, so that when the internal malleolus is directed inwards, the internal tuberosity is inclined backwards.

#### THE FIBULA.

The fibula, or *peroneal bone*, is situated at the outer side of the leg: it is nearly equal to the tibia in length, but is much more slender. Its inferior extremity is placed a little in advance of the superior; and its shaft is slightly curved, so as to have the convexity directed backwards, and, in the lower half, slightly inwards towards the tibia.



The *superior extremity*, or *head*, somewhat expanded, presents a small oval cartilaginous surface looking upwards and inwards, which articulates with the external tuberosity of the tibia, and externally to this a

Fig. 101.—RIGHT FIBULA FROM THE OUTSIDE AND BEFORE. (A. T.)  $\frac{1}{3}$

1, shaft showing the oblique grooves of the peronei muscles on the outer anterior surface; 2, head; 3, its projection, giving insertion to the tendon of the biceps femoris; 4, malleolus externus or lower end, the figure is placed opposite its anterior or oblique edge; above this is seen the triangular subcutaneous surface of the bone.

Fig. 102.—RIGHT FIBULA FROM THE INSIDE AND BEHIND. (A. T.)  $\frac{1}{3}$

5, the oblique surface of articulation with the tibia superiorly; 6, points to the internal or interosseous ridge; 7, the triangular rough surface for the lower interosseous ligament; 8, the external malleolar surface for articulation with the astragalus; 9, groove behind the malleolus externus for the tendons of the peronei muscles; at a little distance below 6, the nutritious foramen.

rough prominence directed upwards, to which the tendon of the biceps muscle is attached: its external surface is subcutaneous; the rest is rough for ligaments.

The *inferior extremity*, or *external malleolus*, is larger than the head of the bone, and longer and more prominent than the internal malleolus; internally it forms the outer limit of the ankle joint, and presents a triangular smooth surface for articulation with the astragalus, bounded posteriorly by a rough depression where the transverse ligament is attached: its anterior border, after projecting rather abruptly forwards, slopes downwards and backwards; its posterior border presents a shallow groove traversed by the tendons of the peronei muscles; while externally it is convex and subcutaneous, and a triangular subcutaneous surface is continued up from it for an inch or two on the shaft.

The *shaft* is irregularly three-sided and twisted. One surface, from which the peronei muscles take origin, looks forward at the commencement, then turning outwards and backwards, is continued behind the subcutaneous space of the lower end to the groove behind the malleolus. Another surface, looking backwards in the upper half of its extent, winds inwards and terminates above the articular surface of the malleolus; near its upper end this surface is rough, giving attachment to the soleus muscle, and in the rest of its extent it is occupied by the flexor longus pollicis. The remaining part of the surface of the bone, internal, turns forward inferiorly, and terminates on the anterior margin of the malleolus; it is divided by a longitudinal line,

Fig. 101. Fig. 102.



the interosseous ridge, into a posterior and upper part, which gives origin to the tibialis posticus, and an anterior and lower part, from which arise the long extensors of the toes and the peroneus tertius, the interosseous membrane being attached to the line between these surfaces. About the middle of the posterior surface is the medullary foramen directed downwards into the bone.

#### THE TARSUS.

The tarsus is composed of seven bones, viz., the calcaneum, astragalus, cuboid, scaphoid, and three cuneiform.

The **calcaneum**, or *os calcis*, is the largest bone of the foot. Projecting downwards and backwards, it forms the heel. Above it articulates with the astragalus, and in front with the cuboid bone. Its principal axis extends forwards and outwards from its posterior extremity to the cuboid bone.

The large posterior extremity, or *tuber calcis*, presents inferiorly two *tubercles*, which rest upon the ground, and the internal of which is the larger: the rest of its surface, looking backwards, is divided into a lower

Fig. 103.

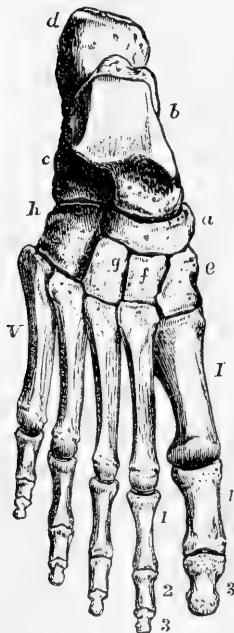


Fig. 103.—RIGHT FOOT, VIEWED FROM ABOVE, SHOWING ITS DORSAL ASPECT. (A. T.)  $\frac{1}{2}$

*a*, scaphoid bone; *b*, astragalus; *c*, os calcis; *d*, its great tuberosity; *e*, internal or first cuneiform; *f*, middle cuneiform; *g*, external cuneiform; *h*, cuboid bone. I to V, the series of metatarsal bones; 1, 3, first and terminal phalanges of the great toe; 1, 2, 3, first, second, and terminal phalanges of the second toe.

part, which receives the attachment of the tendo Achillis, and an upper part smooth and less prominent, separated from that tendon by a synovial bursa. The part in front of the tuber forms a slightly constricted *neck*. The internal surface of the bone, traversed by the plantar vessels and nerves and the flexor tendons, is deeply concave, and its concavity is surmounted in front by a flattened process, the *sustentaculum tali*, which projects inwards near the anterior extremity of the bone in a line with its upper surface, and presents inferiorly a groove occupied by the tendon of the flexor longus pollicis. The superior surface presents two articular facets for the astragalus: the anterior of these is placed over the sustentaculum, and is flat; the other, external and posterior to this, and larger, is separated from it by a rough

furrow, giving attachment to the interosseous ligament, and is convex from without inwards and backwards. In front of this latter facet is a rough depression, from which the extensor brevis digitorum takes origin. The anterior extremity articulates by a surface slightly concave in the vertical and convex in the transverse direction, with the cuboid bone, and internal to this, in front of the sustentaculum

tali, it gives attachment to the inferior calcaneo-scapoid ligament. The inferior surface, projecting in a rough *anterior tubercle*, gives attachment to the calcaneo-cuboid ligaments. The external surface is subcutaneous, and on the whole smooth, but presents in its fore-part a slight ridge, and below it, superficial grooves traversed by the tendons of the peronei muscles.

The **astragalus**, or *talus*, irregular in form, receives the weight of the body from the leg. It articulates with the tibia and fibula above, the os calcis below, and the scaphoid in front. Its longest axis is directed forwards and inwards. Its convex anterior extremity is called the *head*, and the circular groove behind it the *neck*. The superior articular sur-

Fig. 104.—RIGHT FOOT VIEWED FROM BELOW, SHOWING THE PLANTAR ASPECT. (A. T.)  $\frac{1}{3}$

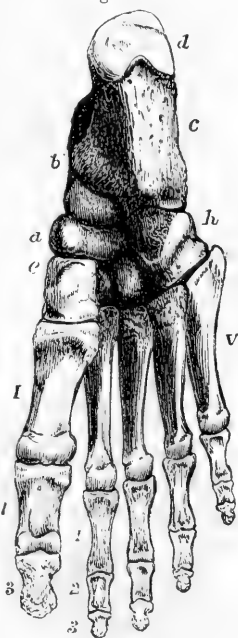
The indications are the same as in the preceding figure; the middle and external cuneiform bones are not lettered; the sesamoid bones are not represented; they will be seen in the view of the articulations of the foot.

face, placed behind the neck, consists of a middle and two lateral parts. The middle part, looking upwards to the tibia, is convex from before backwards, broader in front than behind, with its outer margin higher and longer than the inner, and curved, while the inner is straight. The inner lateral part is narrow, and articulates with the internal malleolus; the outer lateral part, much deeper, articulates with the external malleolus. Inferiorly, there are two smooth surfaces, which articulate with the calcaneum. The posterior of these, the larger, concave from within outwards and forwards, is separated by a rough depression for the interosseous ligament from the flat anterior surface, which rests on the sustentaculum tali. The anterior margin of this surface is continuous with the rounded surface of the head, which articulates with the scaphoid bone. The posterior border of the bone lies behind the sustentaculum tali, and like that process, is grooved by the tendon of the flexor longus pollicis.

The **scaphoid** or *navicular* bone is placed at the inner side of the foot between the astragalus and cuneiform bones. It is short from behind forwards, and broad from side to side. It presents posteriorly an articular concavity for the head of the astragalus, and anteriorly a convex surface divided by two lines converging below, into three facets which articulate respectively with the three cuneiform bones. On its outer side, in some instances, is a small smooth surface, by which it is articulated to the cuboid bone. Its superior and inferior surfaces are rough, and on its inner border, directed downwards, is a prominent *tubercle* to which the tendon of the tibialis posticus muscle is attached.

The **cuneiform**, or wedge-shaped bones, three in number, are distinguished numerically according to their order from within outwards. They intervene between the scaphoid bone and the three inner metatarsa.

Fig. 104.



bones, and present anteriorly and posteriorly smooth surfaces for articulation with those bones. The first or internal cuneiform bone is the largest ; it is narrow above, and thick and rough towards the sole ; its dorsal surface looks inwards and upwards, and is marked by an oblique descending groove, in which the tendon of the tibialis anticus lies ; its external surface, concave and rough inferiorly, is smooth and articular above. The second and third, or middle and external, cuneiform bones present each a quadrangular surface superiorly, and a narrower rough edge below, contributing thus to form the transverse arch of the foot. The proximal ends of the three bones are in the same transverse line ; but as the middle bone is shortest, the internal and external project forwards, so as to articulate laterally not only with the sides of that bone, but also with the base of the second metatarsal bone, which is inserted between them. The outer side of the third cuneiform articulates by a smooth flat surface with the cuboid, and by a small narrow facet (sometimes absent) with the fourth metatarsal bone.

The **cuboid** bone is situated at the outer side of the foot, between the calcaneum and the fourth and fifth metatarsal bones. It deviates from the cuboid form and becomes rather pyramidal, by the sloping of four of its surfaces towards the smaller external border. The posterior cartilaginous surface articulates with the os calcis : the anterior surface, also covered with cartilage, is divided into an internal quadrilateral and an external triangular facet, articulating with the fourth and fifth metatarsal bones. On the internal aspect, in the middle, and touching its superior border, is a smooth surface, which articulates with the external cuneiform bone, and behind this, in some instances, a smaller surface articulating with the scaphoid, while the remainder is rough for ligaments. The external border presents a smooth vertical groove, in which the tendon of the peroneus longus lies ; and the inferior surface is traversed obliquely near its anterior margin by a continuation of the same groove ; behind this there is a thick ridge, which, with the rest of the inferior surface, gives attachment to the calcaneo-cuboid ligaments. The superior surface, looking outwards and upwards, is on the whole even, but rather rough.

#### THE METATARSUS.

The five **metatarsal** bones are distinguished by numbers, according to their position from within outwards.

They resemble the metacarpal bones of the hand in being shafted bones, slightly convex from behind forwards on the dorsal aspect, and having irregularly shaped proximal extremities, three-sided shafts, and rounded heads which articulate with the phalanges. The first metatarsal bone is much thicker and more massive, though shorter than any of the rest. The others diminish in length from the second to the fifth.

The *proximal extremities* resemble those of the metacarpal bones exactly as regards the number of bones with which each articulates. The first articulates with one bone, the internal cuneiform ; the second with four bones, viz., the three cuneiform and the third metatarsal ; the third with three bones, viz., the external cuneiform and the adjacent metatarsals ; the fourth with four bones, viz., the cuboid, external cuneiform, and the adjacent metatarsals ; the fifth with two bones, viz., the cuboid and the fourth metatarsal. The fourth, however, is sometimes con-

nected with only three bones, its facet for articulation with the external cuneiform being absent. The tarsal extremity of the first metatarsal bone presents a slightly concave articular surface, and is broad below and narrow above. That of the fifth presents externally a large rough tuberosity which projects beyond the other bones at the outer side of the foot; and the line of its articulation with the cuboid bone is so oblique that, if prolonged inwards, it would reach the digital end of the first metatarsal bone. The tarsal ends of the remaining three bones are broad and flat above, rough and narrower below, and by their wedge-like form assist in producing the transverse arch of the foot.

The *shafts* present in the greater part of their extent a prominent border looking upwards, which in the middle three projects between the dorsal interosseous muscles on each side.

The *heads*, or distal ends are smaller than the proximal, and are marked on their sides by depressions and tubercles. Their articular surfaces, smooth and convex, are prolonged on the inferior aspect, where they terminate in bifid margins. That of the first metatarsal bone presents inferiorly a ridge in the middle, with grooved depressions placed one on each side and corresponding to the position of the sesamoid bones.

#### THE PHALANGES.

The **phalanges** of the toes correspond so nearly in general conformation with those of the fingers that it will only be necessary in this place to state the points in which they differ from the latter.

The phalanges of the four outer toes are much smaller than the corresponding phalanges of the hand; but those of the great toe are larger than those of the thumb. The shafts of the first row of phalanges in the four outer toes are compressed laterally and narrowed in the middle; those of the second row, more especially the fourth and fifth, are very short, and consist of little beyond what is necessary to unite their articular extremities. The last two phalanges of the little toe are in adults not unfrequently connected by bone into one piece.

**SESAMOID BONES.**—Two sesamoid bones lie side by side in the plantar wall of the first metatarso-phalangeal joint, and glide in the grooves on the head of the first metatarsal bone. Small sesamoid bones sometimes occur in the corresponding joints of the other toes.

#### THE BONES OF THE FOOT AS A WHOLE.

The foot is narrowest at the heel, and as it passes forwards becomes broader as far as the heads of the metatarsal bones. The posterior extremity of the calcaneum is inclined slightly inwards. The astragalus, overhanging the sustentaculum tali, inclines inwards from the calcaneum so much that its external superior border is directly over the middle line of the calcaneum, and hence the internal malleolus appears more prominent than the external. The foot is arched from behind forwards, the posterior pier of the arch being formed by the heel, the anterior by the balls of the toes. The arch, indeed, may be considered as double in front, with a common support behind. The internal division of the arch is that which bears the greater part of the weight of the body, and is most raised from the ground; it consists of the calcaneum in its posterior two-thirds, the scaphoid and cuneiform bones, and the three inner toes; the outer arch is formed by the calcaneum in its

whole length, the cuboid bone, and the fourth and fifth toes, a great part of which rests upon the ground in standing. Besides being arched longitudinally, the foot presents likewise a transverse arch formed behind by the cuboid and three cuneiform bones, and in front by the metatarsal bones.

#### OSSIFICATION OF THE BONES OF THE PELVIS AND LOWER LIMB.

**Os innominatum.**—The innominate bone is formed from the three principal pieces previously mentioned, viz., the ilium, ischium, and os pubis, and from various others of an epiphysial nature. Ossification commences in the cartilage of the ilium a little later than in other large bones, bone beginning to be deposited above the sciatic notch in the 8th or 9th week. This is followed by similar deposits in the thick part of the ischium below the acetabulum in the 3rd month, and in the ascending ramus of the pubis in the 4th or 5th month. At

Fig. 105.

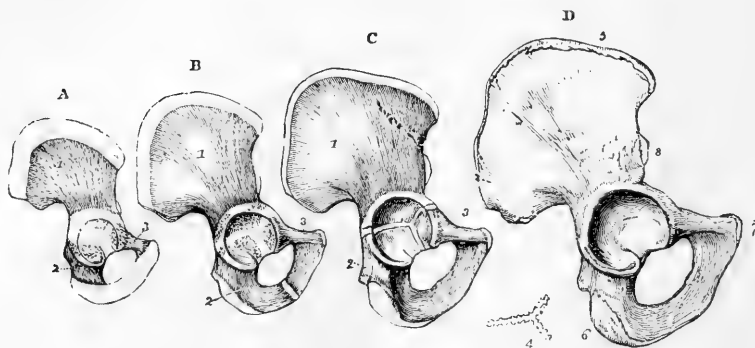


Fig. 105.—OSSIFICATION OF THE OS INNOMINATUM (R. Quain).

A, the condition of the bone at birth. Bone has spread from three nuclei into the ilium, ischium, and pubis, which meet in the cartilage of the acetabulum.

B, from a child under six years of age. The rami of the ischium and pubis are farther ossified, but still separate.

C, a bone of two or three years later, in which the rami are united.

D, the bone of the right side from a person of about twenty years. Union has taken place in the acetabulum, and the additional epiphyses are seen in the crest of the ilium, the anterior inferior spine, the ischial tuberosity, and the margin of the symphysis pubis.

In A, B and C, 1, ilium ; 2, ischium ; 3, pubis ; below D, 4, separated x-shaped piece formed of several fragments which begin to ossify about the 14th year, and often unite into this form before the completion of the acetabulum ; 5, epiphysis of the crest ; 6, that of the tuberosity of the ischium ; 7, that of the symphysis pubis ; 8, that of the anterior inferior spine of the ilium.

birth the greater part of the acetabulum, the crest of the ilium, the tuberosity and ramus of the ischium, the body and descending ramus of the pubis are still cartilaginous ; ossification, however, from the three primary centres has extended into the margin of the acetabulum. In the 7th or 8th year the rami of the ischium and pubis become completely united by bone. The parts which meet in the acetabulum are still separated by a tri-radiate strip of cartilage, which from its shape has been called the Y cartilage. This cartilage begins to be ossified from one or more centres about the age of puberty, and the intermediate bone or epiphysis so formed is united to the neighbouring parts about the 17th or 18th year. Epiphyses are likewise formed in the cartilage of the crest of the



ilium, the tuberosity of the ischium, the anterior inferior spine of the ilium, and the symphysis pubis. These begin to ossify soon after puberty, and unite with the main bone from the 23rd to the 25th year.

The *pelvis* of the foetus and young child is of very small capacity proportionally to the size of the body, and those viscera which are afterwards contained for the most part in the true pelvis occupy a part of the abdominal cavity. The inclination of the pelvis is considerably greater in early life than in the adult.

The **femur** is developed from one principal ossific centre for the shaft which appears in the 7th week, and from four epiphyses, the centres for which appear in the following order ;—A single nucleus for the lower extremity appears several weeks before birth, one for the head appears in the 1st year, one for the

Fig. 106.

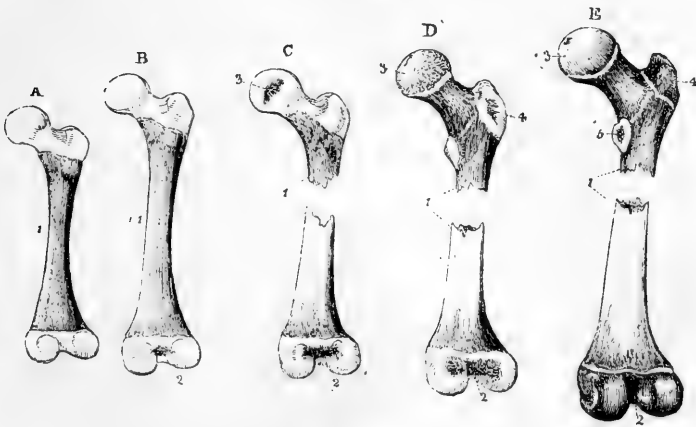


Fig. 106.—OSSIFICATION OF THE FEMUR (R. Quain.)

A, from a foetus under eight months ; the body is osseous, both ends are cartilaginous.

B, from a child at birth, showing a nucleus in the lower epiphysis.

C, from a child of about a year old, showing a nucleus in the articular head.

D, at the fifth or sixth year. Ossification has extended from the shaft into the neck, and a nucleus has appeared in the great trochanter.

E, near the age of puberty, showing more complete ossification and a nucleus in the lesser trochanter.

1, shaft ; 2, lower extremity ; 3, head ; 4, great trochanter ; 5, small trochanter.

C, D, & E are represented considerably, A and B very little, under the natural size.

great trochanter in the 4th year, and one for the small trochanter in the 13th or 14th year. These epiphyses become united to the shaft in an order the reverse of that of their appearance. The small trochanter is united about the 17th year, the great trochanter about the 18th year, the head from the 18th to the 19th year, and the lower extremity soon after the 20th year. The neck of the femur is formed by extension of ossification from the shaft

The **patella** is formed in the 3rd month by a deposit of cartilage in the tendon of the quadriceps extensor cruris muscle. In this cartilage ossification begins from a single centre during the third year, and is completed about the age of puberty.

The **tibia and fibula** each present, besides the principal centre of ossification for the shaft, a superior and an inferior epiphysis. In the tibia the centre for the shaft appears in the 7th week ; that for the upper extremity, including the anterior and lateral tuberosities, appears most frequently before, but sometimes after birth ; and that for the inferior extremity and internal malleolus appears

Fig. 107.

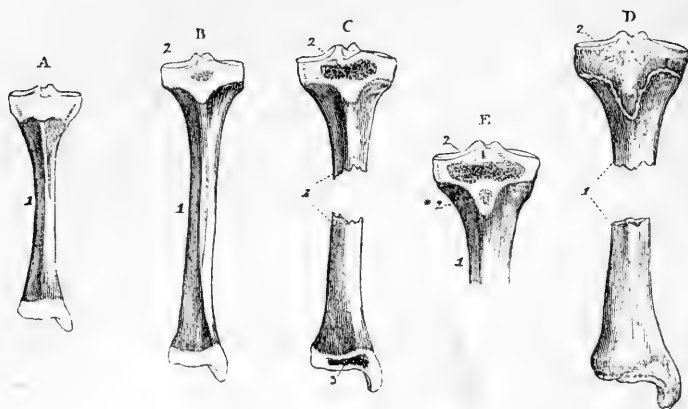


Fig. 107.—OSSIFICATION OF THE TIBIA (R. Quain).

A, from a fetus some weeks before birth; the shaft is ossified; the ends are cartilaginous.

B, from a child at birth, showing the commencement of a nucleus in the upper epiphysis.

C, at the third year, showing the nucleus of the lower epiphysis.

D, at about eighteen or twenty years, showing the united condition of the lower epiphysis, while the upper remains separate. The upper epiphysis is seen to include the anterior tuberosity.

E shows an example of a separate centre for the anterior tuberosity.

1, shaft; 2, superior epiphysis; 2\*, separate centre for the anterior tuberosity; 3, inferior epiphysis.

Fig. 108.

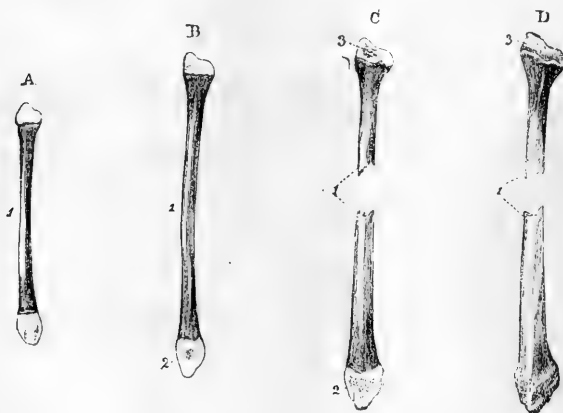


Fig. 108.—OSSIFICATION OF THE FIBULA (R. Quain).

A, from a child at birth. The shaft ossified; the ends cartilaginous.

B, from a child of two years, showing a nucleus in the lower epiphysis.

C, from a child of about four years, showing the nucleus of the upper epiphysis; the lower ought to have been shown as more advanced.

D, from a person of about twenty years, in which the lower end is complete, but the upper epiphysis is still separate.

1, shaft; 2, lower epiphysis; 3, upper epiphysis.

Fig. 109.




Fig. 109.—OSSIFICATION OF THE BONES OF THE FOOT (R. Quain).

A, right foot of a fetus of six months. The metatarsal bones and digital phalanges have each their shafts ossified from their primary centres; the tarsus is wholly cartilaginous, excepting the os calcis, in which the nucleus of bone has just appeared.

B, foot of a fœtus of from seven to eight months. The astragalus shows an osseous nucleus.

C, from a child at birth; the cuboid has begun to ossify.

D, about a year old, showing a nucleus begun in the external cuneiform.

E, in the third year; ossification has reached the internal cuneiform.

F, between three and four years old, showing ossification in the middle cuneiform and scaphoid bones, and in the epiphyses of the metatarsal bones and phalanges.

G, about the age of puberty. Ossification is nearly complete in the tarsal bones; an epiphysis has been formed on the tuberosity of the os calcis, and the epiphyses of the metatarsal bones and phalanges are shown separate.

1, nucleus of the os calcis; 1\* in G, the epiphysis of the os calcis; 2, nucleus of the astragalus; 3, of the cuboid; 4, of the external cuneiform; 5, of the internal cuneiform; 6, of the scaphoid; 7, of the middle cuneiform; 8, metatarsal bones; 8\*, distal epiphyses of the four metatarsal bones; 8', proximal epiphyses of the first; 9, first range of digital phalanges; 9\*, proximal epiphyses of the four outer of these phalanges; 9', that of the first phalanx of the great toe; 10, second range of phalanges; 10\*, the epiphyses of these phalanges; 10', epiphysis of the terminal phalanx of the great toe; 11, four terminal phalanges; 11\*, their epiphyses.

in the 2nd year. The anterior tuberosity is occasionally formed from a separate centre. The lower epiphysis and shaft unite in the 18th or 19th year, the upper epiphysis and shaft unite in the 21st or 22nd year. In the fibula the centre for the shaft appears rather later than in the tibia; that for the lower extremity appears in the 2nd year, and that for the upper, unlike that of the tibia, not till the 3rd or 4th year. The lower epiphysis and shaft unite about the 21st year, the upper epiphysis and shaft unite about the 24th year.

The *tarsal bones* are ossified in cartilage each from a single nucleus, with the exception of the os calcis, which in addition to its proper osseous centre, has an epiphysis upon the upper part of its posterior extremity. The principal nucleus of the os calcis appears in the 6th month of foetal life; its epiphysis begins to be ossified in the 10th year, and is united to the tuberosity in the 15th or 16th year. The nucleus of the astragalus appears in the 7th month; that of the cuboid at birth; that of the external cuneiform in the 1st year; that of the internal cuneiform in the 3rd year; that of the middle cuneiform in the 4th year; and that of the scaphoid in the 4th or 5th year.

The *metatarsal bones and phalanges* agree respectively with the corresponding bones in the hand, in the mode of their ossification. Each bone is formed from a principal piece and one epiphysis; and while in the four outer metatarsal bones the epiphysis is at the distal extremity, in the metatarsal bone of the great toe and in the phalanges it is placed at the proximal extremity. In the first metatarsal bone there is also to be observed, as in the first metacarpal (see ossification of that bone), a tendency to the formation of a second or distal epiphysis. (A. Thomson.) In the metatarsal bones the nuclei of the shafts appear in the 8th or 9th week. The epiphyses appear from the 3rd to the 8th year, and unite with the shafts from the 18th to the 20th year. The nuclei of the shafts of the phalanges appear in the 9th or 10th week. The epiphyses appear from the 8th to the 10th year, and unite with the shafts from the 19th to the 21st year.

#### MORPHOLOGY OF THE BONES OF THE LIMBS.

**Relation to the Axial Skeleton.**—Anatomists have generally agreed to look upon the relation which the bones of the limbs bear to the rest of the skeleton as that of appendages to the trunk, hence their distinction as *appendicular* parts of the *axial* skeleton; and most are also disposed to regard these appendages as similar radiations or extensions from one or more of the vertebral segments in two determinate situations of the trunk. But opinions are still divided as to the typical number of the vertebral somatomes which are involved, and as to the exact nature of the parts which form the radiations. The existence in both of a supporting arch in relations somewhat resembling those of pleurapophyses or ribs, and the division of this arch at the joints of the limbs (shoulder and hip joints) into an upper or dorsal and a lower or ventral section is easily recognised; the dorsal being firmly attached to the side of the sacrum in the lower limb, while in the upper, the ventral part of the arch abuts on the sternum. But it does not appear to be yet determined, even in the case of the pelvic arch, what is the exact nature of the lateral mass of the sacrum, and in both limbs it is still doubtful what is the precise homological relation of the arch to the vertebræ. The fact, however, that a quinquifid division of the peripheral parts of both limbs is constant in man and a certain number of animals, and that in no animals above fishes is there a greater number of elements than five, while in many animals some of the elements may be absent or abortive, together with the remarkably regular passage of a certain number of spinal nerves from the trunk to the limb, of which five are of considerable size in man and those animals possessing the limb elements complete, appears favourable to the view that both limbs have prolonged into them the elements of five vertebral segments, and it is generally held that these elements follow each other in a similar order in the two limbs from the cephalic to the caudal part of the vertebral axis, so that the pollex and radial elements occupy the cephalic side of the upper, while the hallux and tibia take the same place in the lower limb. (See Owen "On the Nature of Limbs," Goodsir "On the Morphological Constitution of Limbs," in Edin. New Philos. Journ., 1857.)

**Homological Comparison of Upper and Lower Limbs.**—A certain anatomical correspondence between the upper and lower limbs, which is apparent to common observation, is admitted in even a fuller degree by most scientific anatomists as the result of a careful comparison of the form, structure, and relations of their bones, as well as of their other parts. But very different views have been taken of the nature and extent of the comparison which may be made between them. Thus Vicq d'Azyr compared the bones of the upper limb of one side of the body to the bones of the lower limb of the other; and Bourguery and Cruveilhier regarded the upper end of the tibia as homologous with that of the ulna, while they compare its lower end to that of the radius. But all such fanciful views have now yielded to the fuller appreciation of homological correspondence which has resulted from a more careful comparison of structure in a wide series of animals, and the study of their transformations in embryonic development; and thus the general conclusion has been formed, that the thoracic and pelvic limbs are constructed on the same general type in man and animals, both as regards the attaching girdles of the shoulder and pelvis, and in the three several sections of which each limb is composed. There are, however, certain modifications of that general plan, leading to considerable differences in the form, size, and number of the individual parts in different animals, which appear to be in a great measure related to the different uses to which the upper and lower limbs are respectively applied; as, for example, in the upper limb of man, the breadth of the shoulders, caused by the interposition of the clavicle, the greater extent of motion in the shoulder joint, the eversion of the humerus, and the forward flexed attitude of the elbow-joint, the arrangements for pronation and supination by rotation of the radius and hand, and the opposability of the thumb, all have reference to the freedom, versatility, and precision of the movements of the upper limb as an organ of prehension and touch; while in the lower limb, the comparatively fixed condition and arched form of the pelvic girdle, the greater strength of the bones, the close-fitting of the hip-joint, the inversion of the femur, the backward flexure of the knee-joint, the arched form of the foot, and non-opposability of the great toe, have all manifest relation to the support of the trunk and pelvis, and their movements upon the lower limbs. In the lower animals, greater modifications in the form of both limbs are to be observed, obviously adapted to their different functions in each case.

Without attempting to follow out this subject by any detailed reference to comparative anatomy or development, it may be useful to state here shortly the more probable conclusions which have been formed by the most recent inquirers with respect to the homological correspondence of the several parts of the upper and lower limbs.\*

**Shoulder and Pelvic Girdles.** With respect to the attaching bones of the two limbs, it is generally held that the blade of the scapula corresponds with the ilium, each of them forming the dorsal section of their respective arches; and the greatest difference between them consisting in the scapula being entirely free from bony articulation with the vertebral column, and capable therefore of considerable motion, while the ilium is firmly jointed to the lateral mass of the sacrum. The ventral part of the shoulder-girdle, completed by the articulation of the clavicles with the sternum, presents no doubt at first sight some similarity to the meeting of the ossa pubis at the symphysis; and thus at one time the clavicle and the pubis were looked upon as homologous bones. But the fuller knowledge of comparative anatomy has more recently led to the adoption of a different view, according to which it appears more probable that the pubis represents rather the epicoracoid bone of the Monotremata and of Reptiles, while, as before believed, the coracoid process of man, originally separate, and typically a distinct bone, is represented in the pelvic girdle by the ischium. Thus, then, it appears that the clavicle is not repeated in the lower limb girdle; and in the place of the very imperfect coracoid process of man and most mammals, there

\* It is right to mention that, while in the comparison here given most British and European authors coincide, opinions widely different from these are held by several comparative anatomists of distinction in America, among whom may be mentioned Agassiz, Wyman, Wilder, and Coues.

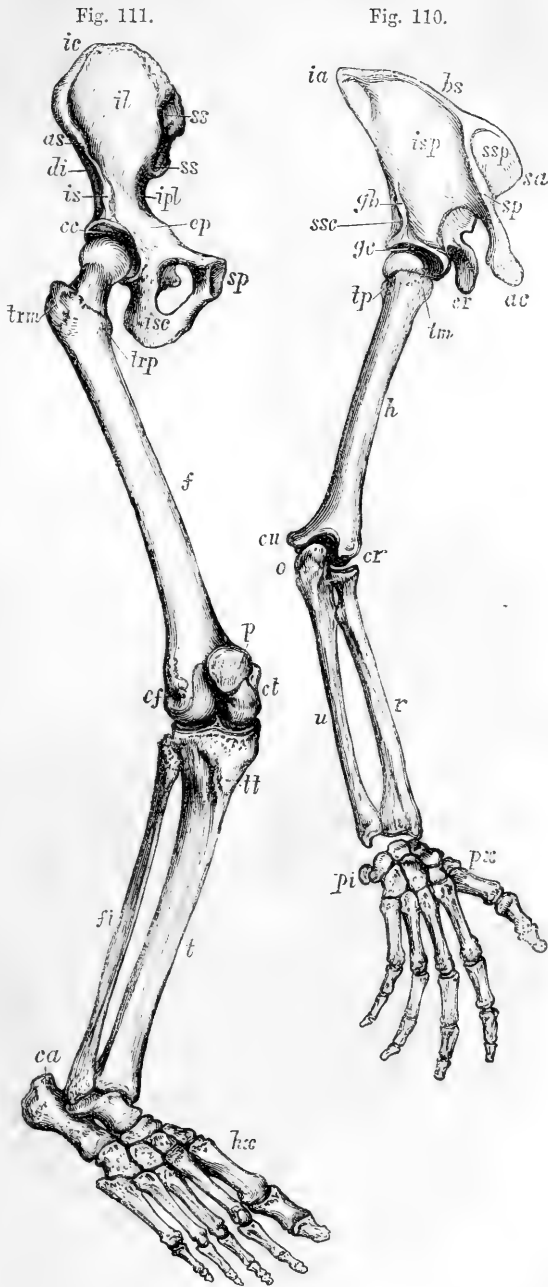
exists in the lower limb a double ventral branch (pubis and ischium) most probably corresponding morphologically to the epicoracoid and coracoid of the Monotremata and Reptiles. The clavicle has, indeed, by some been held to be represented by Poupart's ligament, but it seems on the whole more probable that there is no exact homologue of the clavicular arch in the lower limb. The marsupial bone of the pouched mammals does not represent the clavicle, but lies in the situation of the upper or mesial pillar of the external inguinal aperture.

With regard to the comparison to be established between the individual parts of the scapula and ilium, still greater difficulty prevails than in the general determinations before mentioned. When looked at only in man, the iliac fossa appears at first sight to be the most obvious representative of the subscapular fossa; while the dorsum ilii seems to contain within its limits parts corresponding to both the supra- and infraspinal fossæ. But when our observation extends to a series of different animals, this view loses its apparent probability, and a different mode of comparison is forced upon us. It then appears obvious that the iliac fossa does not at least correspond to the subscapular; but the full determination of the homologies of the different parts of the scapula and ilium, is one of the most difficult parts of this intricate subject. Two different views have lately been brought forward, the one supported by Flower, according to which the scapula and ilium are supposed to have undergone rotation with reference to the axis of the limbs in different directions, the scapula backwards, the ilium forwards, in such a manner that the prescapular fossa (supraspinous of man) corresponds to the sacral surface of the ilium, the postscapular (infraspinous of man) to the iliac fossa or surface, and the subscapular to the gluteal. (See Flower's "Osteology of the Mammalia," and "On the Correspondence between parts composing the shoulder and the pelvic girdle of the Mammalia," *Journ. of Anat.*, vol. iv., 1870.) According to the other view maintained by Humphry, the prescapular and iliac fossæ are regarded as homologous, and the postscapular fossa as corresponding with the dorsum ilii or gluteal surface, the subscapular surface being represented by the sacral and the true pelvic surfaces of the ilium. (Humphry, "Comparison of the Shoulder Bones and Muscles with the Pelvic Bones and Muscles," *Journ. of Anat.*, vol. v. : see also Mivart, in *Linn. Soc. Trans.* 1866, and Rolleston, in the same, 1869). In the more developed forms of the scapula and ilium, in which the muscular fossæ are of large extent, it is almost impossible to trace the relations now referred to; but in the comparison of the simple forms of these bones which belong to some animals with those of others throughout the series, resemblances are perceived which give to the views of Flower the greatest share of probability. In such simpler forms of scapula and ilium these bones may be described as three-sided prismatic rods, in which an internal surface is separated from two external surfaces by anterior and posterior ridges, and the two external surfaces are divided by an external ridge which descends from the dorsal extremity of the bones to the cavity of the joints. It is in this external ridge, glenoid in the scapula and cotyloid in the ilium, and which includes in both the attachment of the great extensor muscle of the limb, that the key to the homologies of the bones is probably to be found. Further observations, especially on the disposition of the muscles, are necessary to determine this question satisfactorily.

**Bones of the Limbs.**—In making the comparison of the bones composing the limbs themselves, it may be proper to revert to the simpler relations subsisting between the limbs and the trunk or vertebral axis of the body in earlier embryonic life, and to remind the reader that there is a determinate and similar position in which the elements of the limb-forming parts are developed from the side of the vertebral stem or trunk (Humphry). In the very earliest stage, while the embryo still occupies the prone position in the blastoderm, the limbs may be said to bud out laterally from the dorsal plates as flattish semilunar flaps, so that they present a dorsal and a ventral surface, coinciding with these respective surfaces of the trunk: but in the next stage, when the limbs come to be folded against the body in the ventral direction, although the original relation to the trunk is undisturbed, their axes have now come to lie nearly perpendicularly to the transverse plane of the vertebral axis, and the position of the limbs is such that in each there is one border which looks towards the head, and another which looks

Figs. 110 & 111.—SKETCH OF THE BONES OF THE THORACIC AND PELVIC LIMBS SO PLACED AS TO SHOW CORRESPONDING PARTS IN BOTH. (A. T.)  $\frac{1}{2}$

The preaxial borders of both limbs are towards the reader's right hand, and the dorsal or true extensor surfaces are shown throughout the whole extent of the limbs. The somewhat artificial representation given in these figures cannot be obtained from a single view of the specimens in one position, but it is easily brought out by slightly shifting the bones or changing the point of view. The humeral tuberosities are separated so as to show them on the borders of the bone. Fig. 110, Thoracic Limb; *ssp*, supraspinous or preacromioclavicular fossa; *isp*, infraspinous or postacromioclavicular fossa; *ssc*, a small part of subscapular fossa; *bs*, base of scapula; *sa*, superior angle; *ia*, inferior angle; *sp*, spine; *ac*, acromion; *cr*, coracoid process; *gb*, glenoid border with place of attachment of triceps muscle; *gc*, glenoid cavity; *h*, humerus, preaxial border; *tm*, large or preaxial tuberosity; *tp*, small or postaxial tuberosity; *cr*, radial condyle; *cu*, ulnar condyle; *r*, radius; *u*, ulna; *o*, olecranon; *px*, pollex side; *pi*, pisiform and postaxial side of hand. Fig. 111, Pelvic Limb: *ss*, sacral surface of ilium; *il*, iliac fossa; *di*, a small part of dorsum ilii or gluteal surface; *ic*, crest of ilium; *as*, anterior superior iliac spine; *ipb*, iliopectineal line; *ep*, pectineal eminence; *is*, inferior spine and attachment of rectus muscle; *cc*, cotyloid cavity; *sp*, symphysis pubis; *isc*, ischium; *f*, femur, its preaxial border; *trp*, lesser or preaxial trochanter; *trm*, greater or postaxial trochanter; *ct*, tibial condyle; *cf*, fibular condyle; *p*, patella; *t*, tibia; *tt*, tibial tuberosity; *fi*, fibula; *hx*, hallux; *ca*, calcaneal tuberosity.



towards the tail. To these borders of the limbs, Huxley and Flower have given the names of preaxial and postaxial respectively, as indicating their position before and behind the axis of the limbs. When at a somewhat later stage of development, the divisions of the limbs make their appearance, and more especially when the quinquid division of the digits in the hand and foot becomes perceptible, it is obvious that the thumb and radius in the one limb, and the great toe and tibia in the other, occupy corresponding cephalic and preaxial situations; and it is not difficult to trace from these the corresponding relations of the parts in the upper division of the limbs; and thus the radial condyle of the humerus with the great tuberosity are preaxial, while the lesser tuberosity, ulnar condyle, ulna, and little finger are postaxial. In the lower limb, the lesser trochanter, internal condyle, tibia and great toe are preaxial, while the great trochanter, external condyle, fibula, and lesser toe, are postaxial. And at the same time the dorsal or extensor surface of the limbs becomes external, and the ventral or flexor surface becomes internal.

Fig. 112.

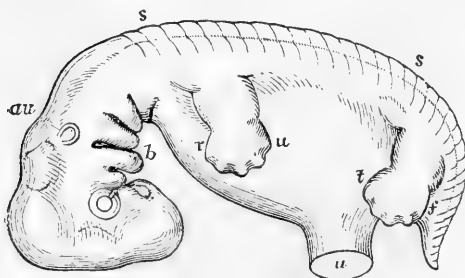


Fig. 112.—LATERAL VIEW OF THE HUMAN EMBRYO OF ABOUT SEVEN WEEKS, SHOWING THE RUDIMENTARY LIMBS IN THEIR SECOND POSITION. (A. T.) MAGNIFIED 7 DIAMETERS.

*r*, preaxial or radial and pollex border of the thoracic limb; *u*, its postaxial or ulnar and little finger border; *t*, preaxial or tibial and hallux border of the pelvic limb; *f*, its postaxial or fibular and little toe border.

Very soon, however, in the higher animals and in man, farther changes operate in bringing about the permanent form. First, there is the eversion of the humerus so as to place the radial condyle outwards, and the inversion of the femur so as to place the tibial condyle inwards. In the upper limb of man, the radius being in semipronation, no material change occurs in the position of the hand, the thumb hanging naturally forward; but in animals, destined to rest on the palmar aspect of the hand or digits, important changes occur in the position of the radius by which, as this bone is brought forward upon the humerus, and its lower end carried inwards, the manus or its elements are placed permanently in the prone position, with the first or radial digit inwards. In the foot no such change is required, as already by the internal rotation of the femur at its upper part, the conditions for plantar support have been secured, and the first or tibial digit is on the inner side. Further, in man, as the body attains its full development, both limbs are extended in a line parallel to the axis of the trunk, the upper dropping loosely from the shoulder-joint with the greatest freedom of motion; the lower more closely articulated in the hip-joint, and suited to give firm support to the body in the erect posture.

It is proper to mention here a very ingenious view of the homologies of the limbs which has been suggested by Martins, according to which the humerus is to be regarded as virtually twisted upon itself to the extent of  $90^\circ$  at the neck, and  $90^\circ$  more from that part downwards, or to the extent of  $180^\circ$  in its whole length. By this torsion, Martins accounts for the deviation of the external condyle of the humerus from the original or typical position which he considers to remain in the femur, and thus he endeavours to show, and it must be admitted with some appearance of probability, how, by supposing the humerus to be untwisted, an exact correspondence of the surfaces and borders can be established between the humerus and femur. Gegenbaur has adopted this view, and has added some facts in illustration of it. (Ch. Martins, "Nouv.



Compar. des Membres Pelviens et Thoraciques, &c., déduite de la Torsion de l'Humerus," Mem. de l'Acad. de Montpellier, tom. iii., 1857. Gegenbaur, "On the Torsion of the Humerus," in Jenaischen Zeitsch. and Annal. des Sciences Nat., iv., p. 50.) But it is easy to show by reference to the embryonic condition, that the outward displacement of the lower end of the humerus in the progress of its formation, does not exceed 90°.

Martins has also proposed the view, that in order to compare the lower leg with the fore-arm, it is necessary to look upon the upper part of the tibia (corresponding in the main to the radius), as including, or having had transferred to it as it were, the olecranon process and upper part of the ulna; and he thus accounts for the attachment of the great extensor tendon of the leg to the tibia through the patella, which, according to his scheme, represents the olecranon instead of to the fibula. Ingenious as these views undoubtedly are, they are liable to considerable objections on embryological grounds, and though not to be rejected altogether, cannot be considered as supplying the key to the explanation of the homologies of the limbs.

**Hand and Foot.**—The similarity of the digital and metacarpal bones of the hand with those of the foot in number, form, and connections is so great that the homological correspondence of these bones is immediately recognised. The main differences between them consist in the greater general length of the digits of the hand, and the opposability of the thumb to the other fingers through its mobility at the carpo-metacarpal articulation.—conditions which are peculiarly characteristic of man, and do not exist in the same form or degree in any of the lower animals.

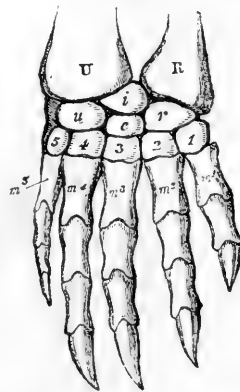
Fig. 113.—DORSAL SURFACE OF THE RIGHT MANUS OF A WATER TORTOISE. (Flower after Gegenbaur.)

R, radius; U, ulna; *r*, radiale; *i*, intermedium; *u*, ulnare; *c*, centrale; 1—5, five carpal bones of the distal row; *m*<sup>1</sup>—*m*<sup>5</sup>, five metacarpals.

Between the carpus and tarsus there is also considerable general similarity, especially in the bones of the distal series; but in those of the proximal row there are some differences which may be referred to here at greater length. There can, indeed, be no doubt as to the homological correspondence of the trapezium, trapezoid and magnum with the internal, middle and external cuneiform bones of the tarsus respectively, nor of the unciform with the cuboid bone; and all the more in the case of the last two bones, that it is found that in the *Chelonia* and some other reptiles and amphibia, the second series of carpal and tarsal bones are increased to five by the division of the unciform of the hand and cuboid of the foot into two each; thus giving one carpal or tarsal bone for articulation with each of the five metacarpal or metatarsal bones.

Upon the homologies of the proximal series of bones, new light has been thrown by the researches of Gegenbaur. ("Untersuch. zur Vergleich. Anat. &c., Carpus und Tarsus," Leipzig, 1864.) In the simplest and most constant form of this series in the carpus, he distinguishes typically three bones, viz., a *radial*, an *intermediate*, and an *ulnar*, corresponding respectively to the scaphoid, lunar and cuneiform bones of human anatomy. The pisiform he regards as an osseous element developed in the tendon of a muscle (flexor carpi ulnaris), and therefore not holding the same rank in the series as the other bones, but constituting an *ulnar sesamoid*. In the foot Gegenbaur shows that the *astragalus* corresponds to the united scaphoid and lunar of the hand, or to the proximal parts at least of these bones. But in some mammals (*Simiæ* and *Rodentia*), as well as in reptiles and amphibia, another bone has long been known

Fig. 113.



to exist, interposed between the bones of the proximal and distal rows, and more immediately between the scaphoid and lunar and the trapezium and trapezoid. This bone is termed the *os centrale*, and several circumstances appear to indicate that it most frequently corresponds to a part of one of the proximal bones. In the carnivora and some other mammals, the scaphoid and lunar are united in the adult into one bone, the *scapho-lunar*, and Flower has observed, that in the young dog there is frequently, but not invariably, a separate ossification in the distal part of the scapho-lunar corresponding in position and relations with the *os centrale* of other animals (Flower, Journ. of Anat., vol. iv., 1870); and a similar

Fig. 114.

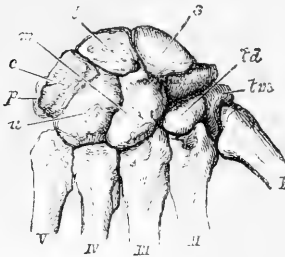


Fig. 115.

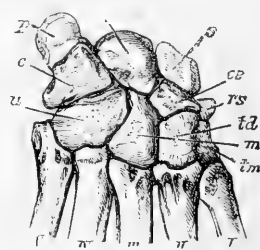


Fig. 114.—DORSAL SURFACE OF THE RIGHT CARPUS OF MAN (Flower).  $\frac{1}{2}$

s, scaphoid; l, lunar; c, cuneiform; p, pisiform; tm, trapezium; td, trapezoid; m, magnum; u, unciform; I—V, five metacarpals.

Fig. 115.—DORSAL SURFACE OF THE CARPUS OF A BABOON (Flower).

s, scaphoid; l, lunar; c, cuneiform; p, pisiform; tm, trapezium; td, trapezoid; m, magnum; u, unciform; rs, radial sesamoid; ce, *os centrale*; I—V, five metacarpals.

observation has been made in the carpus of the young lion by Wilder (1873). But in both of these animals in the adult this piece of bone has become completely ossified, so as to form one with the scapho-lunar. It seems probable that in some animals a central bone may be derived from the separation of the proximal part of the *os magnum*.

The determination of the homology of the navicular bone of the tarsus is not yet fully made out, but it seems most probable that this bone corresponds not to any single or entire bone of the carpus, but rather to the *os centrale*, together with a detached portion of the scaphoid.

In some animals there is a tenth separate bone of the carpus, which seems most nearly to correspond to the tuberosity of the scaphoid: this constitutes the typical *radial sesamoid* of Gegenbaur, and the navicular bone of the tarsus may perhaps correspond to this along with the *os centrale*. It is interesting to remark that this bone is sometimes found separate in the human hand. (See W. Grüber, Struthers, Turner, and others, in Journ. of Anat., and Mivart "On the Appendicular Skeleton of the Primates" in Philos. Trans. 1867.)

The *os calcis* is generally believed to correspond most nearly with the cuneiform of the carpus, and by some it has been held to include the pisiform,—a view not participated in by Gegenbaur, but of the truth of which any one will be convinced by the inspection of the hand and foot of the bear. It is deserving of remark that in the young of that animal, the much enlarged pisiform possesses an epiphysis of its own, exactly similar to the one known as existing on the tuberosity of the calcaneum,—a fact observable also in other animals, and which of itself refutes the view taken by some that the pisiform corresponds to the epiphysis of the calcaneal tuberosity. (Allen Thomson.)

The following tables present a synoptical view of the corresponding or homologous bones or other parts in the thoracic and pelvic limbs.

I.—TABLE OF THE HOMOLOGOUS BONES IN THE THORACIC AND PELVIC LIMBS

THORACIC LIMB.	PELVIC LIMB.
Scapula . . . . .	Ilium.
Precoracoid . . . . .	Pubis.
Coracoid . . . . .	Ischium.
Glenoid cavity . . . . .	Cotyloid cavity.
Clavicle . . . . .	<i>Absent.</i>
Humerus . . . . .	Femur.
Great tuberosity . . . . .	Lesser trochanter.
Small tuberosity . . . . .	Great trochanter.
External condyle . . . . .	Internal condyle.
Radius . . . . .	Tibia.
Ulna . . . . .	Fibula.
Carpus . . . . .	Tarsus.
Metacarpus . . . . .	Metatarsus.
Pollex . . . . .	Hallux.
Digital phalanges . . . . .	Digital phalanges.

II.—TABLE OF THE HOMOLOGOUS BONES OF THE CARPUS AND TARSUS  
*Modified from that of (GEGENBAUR).*

CARPUS.		TARSUS.	
<i>Typical Names.</i>	<i>Names in Human Anatomy.</i>	<i>Typical Names.</i>	
Radiale . . . . .	Scaphoid . . . . .	Astragalus . . . . .	{ Tibiale.
Intermedium . . . . .	Lunar . . . . .		{ Intermedium.
Ulnare . . . . .	Cuneiform . . . . .	Os calcis . . . . .	{ Fibulare . . . . .
Ulnare sesamoideum . . . . .	Pisiform . . . . .		{ Fibulare sesa- moideum . . . . .
Centrale . . . . .	(part of scaphd. or other bone) . . . . .	Navicular . . . . .	{ (Centrale) . . . . .
Radiale sesamoideum . . . . .	(part of scaphoid) . . . . .		{ (Tibiale sesamoi- deum) . . . . .
Carpale I. . . . .	Trapezium . . . . .	Int. Cuneiform . . . . .	Tarsale I.
— II. . . . .	Trapezoid . . . . .	Mid. Cuneif. . . . .	— II.
— III. . . . .	Magnum . . . . .	Ext. Cuneif. . . . .	— III.
— IV. . . . .	Unciform . . . . .	Cuboid . . . . .	{ — IV. — V.
— V. . . . .			

III.—TABLE OF THE HOMOLOGOUS PARTS OF THE SCAPULA AND ILIUM  
 (ACCORDING TO FLOWER).

SCAPULA.	ILIUM.
Suprascapular fossa . . . . .	Sacral and true pelvic surface.
Infrascapular fossa . . . . .	Iliac fossa.
Subscapular fossa . . . . .	Gluteal or dorsal surface.
Base . . . . .	Iliac crest.
Spine and acromion . . . . .	Ilio-pectineal line and eminence.
Superior angle . . . . .	Posterior superior spine.
Inferior angle . . . . .	Anterior superior spine.
Superior border . . . . .	Posterior or ischial border.
External or glenoid border . . . . .	Anterior or cotyloid border.

ADAPTATION OF THE SKELETON TO THE ERECT ATTITUDE.

The axial skeleton of man is, for the purposes of station and progression raised more fully to the vertical position than is the case in any animal; and along with this the lower limbs are extended in lines parallel to the axis of the trunk. The feet rest on the ground by the contact of the heel and the balls of the toes, the centre of gravity of the body falling within the basis of support. For the maintenance of this attitude, the constant action of the muscles passing

over the ankle-joint is more immediately necessary. But at the knee and hip-joint, it is mainly by the mechanism of the ligaments and other parts of the joints, and less directly by muscular action, that the erect attitude is maintained, as will be more fully shown in the description of the different articulations.

There are, besides, many peculiarities in the construction of the body, and especially of the skeleton, which are associated with the assumption of the erect posture, and although many of them have been noticed in the description of the several sets of bones, it may still be useful to recapitulate them briefly in this place.

It may first be remarked that the full development of these peculiarities belongs to the adult condition. In the infant, while still unable to walk, the large proportional size of the head, amounting to nearly a fifth of the whole body, the comparative straightness of the vertebral column, or absence of the curves which characterise the spine of the adult, the shortness of the lower limbs, and incompleteness of their structures, all contribute to render the assumption of the erect attitude by the child, for a time, difficult and insecure. Thus the middle distance between the vertex of the head and the foot in a child is situated somewhat above the umbilicus, while in the adult it is generally at the upper border of the pubis, or even lower in some part of the symphysis. In the child also, from the large dimensions of the head and upper part of the body, the centre of gravity is carried to a considerably higher point than in the adult.

The skull of man differs from that of animals in being nearly balanced on the vertebral column, the condyles of the occipital bone being brought forward to near the middle of the base, by the comparative shortness of that part of the skull which lies in front of the foramen magnum, and the projection backwards of that which lies behind it. In animals the skull hangs forwards, as it were, from the extremity of the column, and is sustained by the elastic ligamentum nuchæ, represented in man by a comparatively feeble structure which passes between the external occipital protuberance, and the spinous processes of the cervical vertebra.

The spinal column, by its pyramidal form, is fitted to sustain the weight which bears down upon its lower part, and by means of its different curvatures possesses elasticity and strength combined, and allows considerable range of motion to the trunk, without removal of the centre of gravity from within its base. The strong and expanded sacrum is the immediate means of transferring the weight of the trunk to the ossa innominata and lower limbs.

The pelvis is of peculiar breadth in man, presenting an upper and lower arch which meet at the hip-joints, and is so inclined that a vertical line descending from the centre of gravity of the body is in a plane slightly behind the centres of motion of the hip-joints. The breadth of the pelvis enables the balance to be more easily maintained in lateral movements of the body by compensating inclinations of different parts to opposite sides of the basis of support, and the long neck of the femur gives an advantageous insertion to the muscles by which the balance of the body is principally preserved. The os innominatum is mainly distinguished from the same bone in animals by the breadth of its iliac portion, which gives support to the abdominal viscera, and attachment to the greatly developed iliac and gluteal muscles.

The lower limbs are remarkable for their length and strength. The femur is greatly elongated, its length considerably exceeding that of the tibia,—a condition which is requisite not only to give a sufficient extent of stride, but also to enable the body to be balanced in different degrees and varieties of stooping. The foot of man alone among animals has an arched instep, and it likewise presents a great breadth of sole. The great toe is distinguished by its full development, and especially from that of the quadrumana, by its want of opposability, being constructed, not for grasping, but for supporting the weight of the body, and giving spring to the step.

While stability and strength are thus provided in the lower limbs, mobility and lightness are secured in the upper. This is apparent on comparison of the shoulder, elbow, and wrist, with the hip, knee, and ankle. In the hand, also, the movable phalanges are as long as the carpal and metacarpal bones taken together, while in the foot they are not a third of the length of the tarsal and metatarsal bones.

## SECTION II.—ARTHROLOGY.

## THE ARTICULATIONS IN GENERAL.

**VARIOUS FORMS OF JOINTS.**—The name of articulation, synonymous with joint, is given in descriptive anatomy to the connection subsisting in the recent skeleton between any of its denser component parts, whether bones or cartilages. In most instances some softer intervening substance lies between the bones, uniting them together, or clothing the surfaces which are opposed; but the manner in which the several pieces of the skeleton are thus connected, varies to a great degree both as to the nature of the uniting substances, and the extent of movement which they allow. In some instances, as in the cranial bones, the closeness of the apposition, the unevenness of the fitting surfaces or edges, and the small amount and dense nature of the intervening substance (periosteum), admit of little or no perceptible movement. In other instances of continuous union the extremities of the bones are placed at such a distance, and the intervening substance (ligament or cartilage) is so yielding, that bending or other movements may take place. But in the greater number of articulations the apposed surfaces of bone are not united either directly or mediately with each other, but are free, and covered with plates of smooth cartilage, the surfaces of which fit accurately together, while the bones are held together by ligamentous structures placed in the vicinity of the joints. In such articulations the bones are capable of gliding or moving upon each other, the extent and directions of such movements varying with the shape of the opposed cartilaginous surfaces, and the form and attachments of the ligamentous and other bands which unite them. It is upon distinctions such as those now adverted to that the various kinds of joints or articulations have been brought under the three classes of Synarthrosis, Amphiarthrosis, and Diarthrosis.

**Synarthrosis** means direct or immediate union, and comprehends the joints with little or no motion. It is found chiefly in the various forms of suture by which the bones of the head, excepting the lower jaw, are united. The *suture* is *serrated* or *dentated* when the contiguous margins of the bones are subdivided or broken up into projecting points and recesses by which they fit very closely to one another, as in the borders of most of the tabular bones of the cranium. The *squamous* or scaly suture is that in which, as in the union of the temporal with the parietal bone, the edges are thinned and bevelled, so that one overlaps the other to a considerable extent.

The *harmonic* suture or *harmonia* is the term employed to denote simple apposition of comparatively smooth surfaces or edges, as in the case of the two superior maxillary bones; and the term *schindylesis* is applied to that kind of union in which one bone is received into a groove in another, as occurs between the rostrum of the sphenoid bone and the vomer. The impaction of the roots of the teeth in their sockets has likewise been reckoned among the articulations, though with doubtful propriety, and has been designated by the term *gomphosis*.

**Amphiarthrosis** means the mixed articulation, or that in which there is mediate union by some intervening substance, with partial mobility. The articulations between the bodies of the vertebræ, that between the two ossa pubis at the symphysis, and that between the two first pieces of the sternum, may be taken as examples of this mode of connection. Some of the joints of this kind pass on the one hand into synarthrosis, and on the other into diarthrosis.

**Diarthrosis** includes the complete joints, with synovial cavities separating the surfaces of the articular bones, and is attended with considerable yet varying degrees of mobility. In this form of joint, plates of cartilage cover the articular parts of the bones and present within the joint free surfaces of remarkable smoothness, and these surfaces are further lubricated by the synovial fluid secreted from the delicate membrane which lines the fibrous coverings and all other parts of the articulating cavity except the cartilage. This membrane is continuous with the margin of the articular cartilages, and along with them completely encloses the joint cavity. The bones are further held together by fibrous tissue in the various forms of ligaments, such as membranous capsules, flat bands, or rounded cords. These ligaments, it is true, are not so tight as to maintain the bones in close contact in all positions of the joint, but are rather tightened in some positions and relaxed in others, so that they may be looked upon chiefly as controllers of movements. The bones are likewise held together in diarthrodial joints, by atmospheric pressure, and by the surrounding muscles. Certain forms of diarthrodial joint have received special names. The term *ginglymus* is used to distinguish a hinge joint, or one which admits only of flexion and extension, like the elbow, knee and ankle. *Euarthrosis* (Cruveilhier) is the ball-and-socket form of joint, like the shoulder and hip, allowing motion in every direction. *Arthrodia* is a joint with nearly flat surfaces, which admits of gliding movement merely, as in the articulations of the carpus, tarsus, and articular processes of the vertebræ.

**VARIOUS KINDS OF MOVEMENT.**—The various movements of the bones in diarthrodial joints are distinguished by different terms according to their directions, viz., angular movement, circumduction, rotation, and gliding; but it is proper to remark that although different kinds of movement, answering to these several terms, may readily be recognised, yet they are rarely of only one kind in any joint, but rather several kinds of movement are frequently combined, and they also run into one another in great variety.

**Angular movement** is movement in such a manner as to increase or diminish the angle between two bones, so that they shall lie more or less nearly in a straight line. The different kinds of angular movement are designated by different terms according to the directions in which they take place with reference to the limb or body: thus *flexion* and *extension* indicate angular movements, which have the effect of bending or straightening parts upon one another or upon the trunk of the body: *adduction* and *abduction* indicate angular movement to and from the mesial plane of the body, or, when fingers and toes are referred to, these terms may be used to denote movement to and from the middle line of the hand or foot.

*Coaptation* is a form of angular movement, in which, as in the movement of the patella on the femur the articular surface of one bone travels over that of another, so as to bring different parts of the surfaces successively into contact in

the manner of a wheel rolling on the ground, this movement being usually accompanied by a certain amount of gliding.

**Circumduction** is the movement performed when the shaft of a long bone or a part of a limb describes a cone, the apex of which is placed in the joint at or near one extremity of the bone, while the sides and base of the cone are described by the rest of the moving part.

**Rotation** signifies movement of a bone round its axis without any great change of situation.

**Gliding** is applied to that kind of movement in which the surfaces of adjacent bones are displaced without any accompanying angular or rotatory motion, as in the movement of flat surfaces over each other in some of the carpal and tarsal articulations, or in the movement of advance and retreat of the lower jaw.

In the various joints provided with synovial cavities, the cartilaginous surfaces of the bones are so formed as usually to be in close apposition or contact; but in certain positions they are not entirely so, and there are even instances in which the separation of the surfaces must be considerable, as in the case of the patella, in some positions of the knee. In these cases the vacuity is filled up by folds of the synovial membrane, or by fatty processes connected with it.

## ARTICULATIONS OF THE TRUNK AND HEAD.

### ARTICULATIONS OF THE VERTEBRAL COLUMN.

The moveable vertebræ are connected together by elastic discs interposed between the bodies; by synovial joints between the articulating processes; and by ligaments.

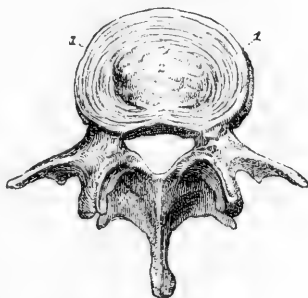
The **intervertebral discs** are plates of composite structure placed between the bodies of the vertebræ from the axis to the sacrum. Each is composed of a fibro-laminar part externally, and of a pulpy substance in the centre.

Fig. 116.—A LUMBAR VERTEBRA, SEEN FROM ABOVE, WITH PART OF THE INTERVERTEBRAL DISC ADHERING TO THE BODY.  $\frac{1}{2}$

1, 1, the concentric arrangement of the fibrous laminae; 2, the central soft cartilaginous or gelatinous substance.

The laminar part forms more than half of the mass, and consists of concentric laminae of fibro-cartilage and fibrous tissue alternating one with another. These laminae are not quite vertical, for if a vertical section of a disc be made, a certain number of the layers nearest to the circumference of the disc will be seen bulging outwards, while others situated more deeply and less closely compacted together are convex towards the centre; and when the spine is bent in any direction, the curves of the different layers are augmented on the side towards which the column is inclined. The individual layers consist chiefly of fibres extending obliquely between the vertebræ and firmly

Fig. 116.



attached to both; the direction of the fibres being reversed in each successive layer. Some of the fibres also are nearly horizontal. The central part of the fibro-cartilage is a pulpy and elastic material which, when the pressure which confines it is taken off by cutting through the intervertebral substance, rises up so as to assume a conical form. It is then seen to be of a lobate structure, and, examined under the microscope, exhibits a finely fibrous and homogeneous matrix, with numerous spherical and elliptical cells, some of them resembling cartilage-corpuseles, others larger and of various appearance.

It is now generally admitted that the pulp of the intervertebral disc is a persistent part of the chorda dorsalis; homologous, therefore, with those larger vestiges of the chorda dorsalis which occupy the biconical cavities between the bodies of the vertebræ in fishes. According to Luschka, there is present in each disc a synovial cavity, and the lobes of the pulp are synovial villi, similar to those which are to be found in the knee and shoulder joints, but of larger size, and occupying the whole cavity; and it is worthy of notice that in like manner secondary cavities, developed within the chorda dorsalis, are found in the intervertebral substance in many fishes. (Luschka, "Die Halbgelenke des Menschlichen Körpers," Berlin, 1858, p. 84.)

A thin cartilaginous layer, incomplete towards the circumference, covers the surfaces of the vertebræ and gives attachment to the discs. Excluding from consideration the first two vertebræ, between which it

Fig. 117.

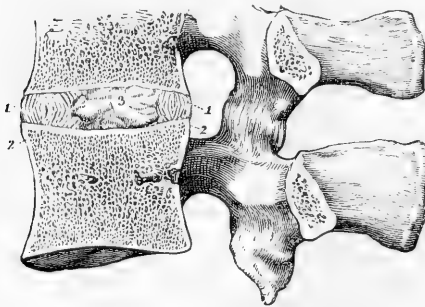


Fig. 117.—VERTICAL ANTERO-POSTERIOR SECTION THROUGH TWO LUMBAR VERTEBRÆ, SHOWING THE ARRANGEMENT OF THE INTERVERTEBRAL DISC.  $\frac{3}{3}$

1, 1, the fibrous oblique bands, which are curved outward; 2, those which are curved inward; 3, the central soft cartilaginous or gelatinous substance: the capsule of the joint between the articular processes is represented.

does not exist, the intervertebral material forms in length about a fourth of the movable part of the column. The dorsal part of the column has, in comparison with its length, a much smaller proportion than the cervical or lumbar parts.

The discs in the cervical and lumbar regions are thicker in front than behind, and it has been determined that the convexity of those portions of the column is due to them much more than to the bodies of the vertebræ, while the arching of the dorsal portion, on the contrary, is rather owing to the shape of the bones. (W. and E. Weber, "Mechanik der menschl. Werkzeuge," p. 90, et seq., Göttingen, 1836.)

The **anterior common ligament** is a strong band of fibres, which is placed on the front of the bodies of the vertebræ, and reaches from the axis to the first bone of the sacrum, becoming broader as it descends. It consists of longitudinal fibres which are dense, firm, and well marked. The superficial fibres extend from a given vertebra to the fourth or fifth below it; the fibres beneath these pass over the bodies of several verte-



bræ; whilst the deeper ones pass only between adjacent vertebræ. The band is thicker towards the middle of the bodies of the vertebræ than at their margins, or over the intervertebral cartilages; by which means the transverse depressions of the bodies are filled up, and the surface of the column rendered more even. The fibres adhere more closely to the margins of the bones than to the middle of their bodies, and still more

Fig. 118.—THE 5TH, 6TH, 7TH, 8TH AND 9TH DORSAL VERTEBRÆ, WITH A PART OF THE 6TH, 7TH, AND 8TH RIBS, FROM THE RIGHT SIDE AND FRONT. (A. T.)  $\frac{1}{3}$

1 to 2, the anterior common ligament of the bodies of the vertebræ; at + +, a portion of the ligament is removed so as to expose the intervertebral plate between the 8th and 9th vertebræ, in which the diagonal fibres of the external lamina of the intervertebral disc are represented. (The further description of this figure will be found at p. 141.)

closely to the intervertebral cartilages. Upon the sides of the bodies there are some fibres which are thin and scattered, and reach from one bone to another.

The **posterior common ligament** is situated within the spinal canal, and is attached to the posterior surface of the bodies of the vertebræ; it extends from the axis to the sacrum. At its upper extremity it is continuous with the apparatus ligamentosus. It is smooth, shining, and broader at the upper than at the lower part of the spine.

Fig. 119.—THE BODIES OF THREE LUMBAR VERTEBRÆ, SEEN FROM BEHIND, WITH THE POSTERIOR COMMON LIGAMENT.  $\frac{1}{3}$

The arches have been removed by cutting through the pedicles. The narrowing of the posterior common ligament opposite the middle of each body, and its greater width and attachments opposite the intervertebral discs, are represented.

In the neck it extends quite across the bodies of the vertebræ, but in the back and loins it is broader opposite the intervertebral cartilages than at the middle of the bodies, so that its margins present a series of points or dentations with intervening concave spaces. It adheres firmly to the fibro-cartilages and to the contiguous margins of the bodies of the vertebræ, but it is separated from the middle of the bodies by the transverse parts of the large venous plexus. Between the ligament and the prolongation of the dura mater which lines the canal, some loose connective tissue is interposed.

Fig. 118.

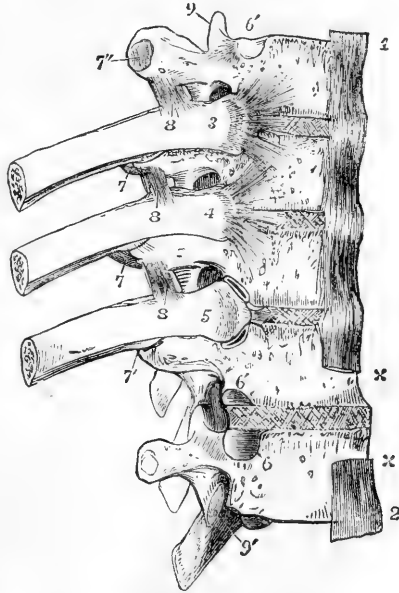
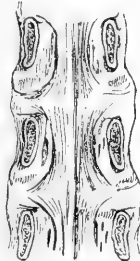


Fig. 119.



The **joints of the articulating processes** present each a synovial cavity surrounded by an irregular fibrous capsule. The fibrous bands

Fig. 120.

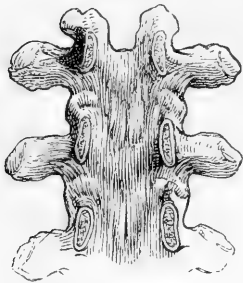


Fig. 120.—THE ARCHES OF THREE DORSAL VERTEBRÆ, SEEN FROM BEFORE.  $\frac{1}{3}$

The bodies of the vertebræ have been removed by sawing through the pedicles, to show the articular capsules and the ligamenta subflava.

of these capsules are longer and looser in the cervical than in the dorsal and lumbar regions.

The **ligamenta subflava** are ligaments consisting of yellow elastic tissue, which connect the laminae of the vertebræ. Their fibres are nearly vertical, and are attached superiorly to the anterior surface of the

lamina of one vertebra near its inferior margin, and inferiorly to the upper margin and part of the posterior surface of the lamina of the

Fig. 121.

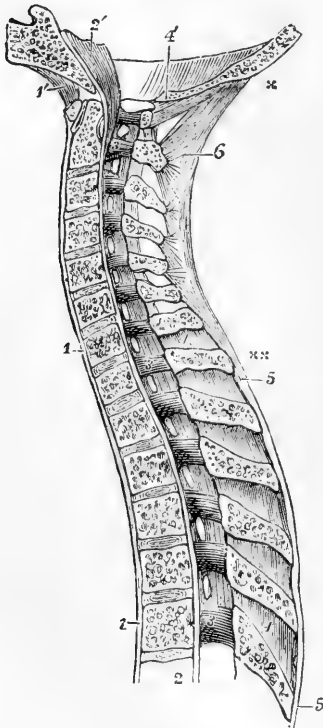


Fig. 121.—ANTERO-POSTERIOR VERTICAL SECTION OF THE UPPER PART OF THE VERTEBRAL COLUMN, AND PART OF THE OCCIPITAL BONE, SHOWING THE ARTICULATIONS. (A. T. after Arnold.)

1, 1, anterior common ligament of the bodies of the vertebræ; 1', anterior atlanto-occipital ligament; 2, from this figure upwards the posterior common ligament of the bodies; 2', the continuation of the preceding or apparatus ligamentosus lying on the basilar process of the occipital bone; 3, 3, 3, these figures are placed on the inside of the arches of the 2nd cervical and 1st and 6th dorsal vertebræ; the ligamenta subflava are to be seen stretching between the laminae; 4, 4, placed upon two of the interspinous ligaments; 4', divided edge of the occipital bone behind the foramen magnum, and below it, the posterior occipito-atlantal ligament; 5, 5, supraspinous ligaments; 6, ligamentum nuchæ; +, its upper extremity at the occipital tuberosity; ++, its lower extremity terminating in the supraspinous ligaments of the upper dorsal vertebræ.

vertebra beneath. They are most distinctly seen when the arches are detached from the bodies of the vertebræ, and they are viewed from the front. Posteriorly they appear short, and in the dorsal region are concealed by the prominent inferior margins of the laminae and the roots of the spines. Their outer margins are close to the

articulating processes; their inner margins are thickened and in contact with each other beneath the root of the spinous process.

The ligamenta subflava do not exist between the occiput and the

atlas, nor between the latter and the axis; common fibrous membrane supplies their place in these two spaces, constituting posterior occipito-atlantal and atlanto-axial ligaments.

The **interspinous ligaments**, thin and rather membranous, have an attachment extending from the root to near the summit of each spinous process, and connect the inferior border of one with the superior border of that next below it. They are best seen in the lumbar region, and are least developed in the neck.

The **supraspinous ligaments** consist of small compressed bundles of longitudinal fibres, which connect the summits of the spinous processes, and form a continuous chain from the seventh cervical vertebra to the spine of the sacrum. The superficial fibres pass down from a given vertebra to the third or fourth below it; those more deeply seated reach only from one to the next, or the second below it.

The **ligamentum nuchæ** is the continuation upwards of the supraspinous ligament. It is, in the human subject, a thin intermuscular septum of elastic and white fibrous tissue, the most superficial part of which extends from the spine of the seventh cervical vertebra to the occipital protuberance, while the deeper fibres, springing from the same origin, pass to the occipital spine, and the spines of the six upper vertebrae. It is the representative of a strong elastic structure which suspends the head in the lower animals.

The **intertransverse ligaments** are unimportant bands extending between the transverse processes. In the lumbar regions they are membranous, in the dorsal region they are rounded bundles intimately connected with the muscles of the back; and in the neck they are usually reduced to a few irregular fibres, which may in some instances be wanting.

**Movements.**—The movements of flexion and extension of the vertebral column are freely allowed in the cervical and lumbar regions, but in the dorsal are limited by the small amount of intervertebral substance and the imbrication of the laminae. The greatest bending backwards is permitted in the cervical, the greatest bending forwards in the lumbar region, especially between the fourth and fifth lumbar vertebrae. Movements in other directions are limited chiefly by the articular processes. In the dorsal region the articular surfaces of each vertebra lie in the arc of a circle whose centre is in front of the vertebrae, and round this centre a considerable degree of rotation is permitted. In the lumbar region, the centre of the circle in which the articular surfaces lie is placed behind, so that rotation is prevented; the articular processes, however, fit sufficiently loosely to permit of lateral flexion, and by combination of this with antero-posterior flexion, some degree of circumduction is produced. The articular surfaces of the cervical vertebrae, being oblique and placed in nearly the same transverse plane, allow neither pure rotation nor pure lateral flexion. They permit, besides forward and backward motion, only one other, which is rotatory round an oblique axis—the inferior articulating process of one side gliding upwards and forwards on the opposing surface, and that of the other side gliding downwards and backwards, by which a combination of lateral flexion and rotation is obtained.

#### ARTICULATIONS OF THE ATLAS, AXIS, AND OCCIPITAL BONE.

The atlas, axis, and occipital bone are connected by articular surfaces and ligaments, without the presence of intervertebral discs.

Two pairs of **synovial articulations**, surrounded by capsular ligaments, connect the lateral masses of the atlas with the superior

articular surfaces of the axis and with the condyles of the occipital bone. The atlanto-axial capsule is strengthened behind by an accessory ligament, directed downwards and inwards to the body of the axis near the base of the odontoid process.

The **transverse ligament of the atlas** is a strong and thick band, which extends across the ring of the atlas, and retains the odontoid process in its place. It is attached on each side to the tubercle below the inner border of the superior articulating process. It is arched backwards behind the odontoid process, and is broadened out in the middle line. From the middle of its posterior surface a short thin bundle of fibres passes down to be attached to the body of the axis, whilst another passes up to the basilar process. These form, with the transverse portion, the figure of a cross, and serve to bind the occiput to the first two vertebræ; from this arrangement is derived the term *cruciform*, which is sometimes applied to the transverse ligament and its appendages together.

Fig. 122.

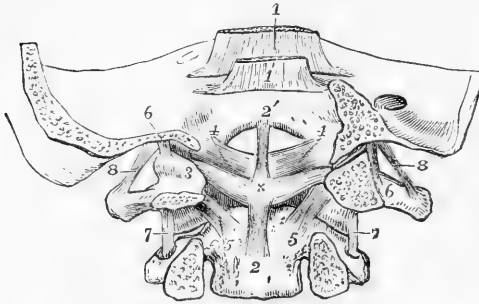


Fig. 122.—TRANSVERSE VERTICAL SECTION OF THE LOWER PART OF THE OCCIPITAL BONE, AND THE TWO UPPER VERTEBRÆ BEHIND THE ARTICULATIONS (A. T. after Arnold).  $\frac{1}{2}$

1, 1, apparatus ligamentosus turned up on the occipital bone; 2, 2', vertical part, and 3, 3', transverse or principal part of the cruciform ligament; x, neck of the odontoid process; 4, 4', the alar or lateral odontoid ligaments; 5, 5, the accessory ligaments of the

atlanto-axial capsules; 6, 6, part of the capsular ligaments of the condylar articulations; 7, 7, capsular ligaments of the atlanto-axial articulations; 8, 8, intertransverse ligaments between the occiput and atlas.

Two **synovial membranes** are placed one in front and another behind the odontoid process; the first of these is situated between the

Fig. 123.

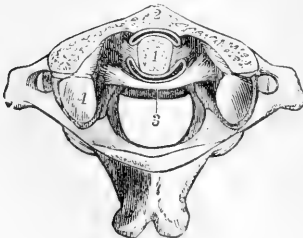


Fig. 123.—HORIZONTAL SECTION THROUGH THE ODONTO-ATLANTAL ARTICULATION. (A. T.)  $\frac{1}{2}$

1, cut surface of the odontoid process; 2, cut surface of the anterior arch of the atlas; 3, transverse ligament; between 1 and 2, the anterior synovial cavity, and between 1 and 3, the posterior synovial cavity of the articulation; 4, is placed on the back part of the left superior articular process of the atlas; the anterior part of this process, and that of the other side, have been partly removed by the section. For the sake of distinctness, the synovial spaces are represented somewhat wider than natural.

process and the anterior arch of the atlas, the other between the process and the transverse ligament.

The **lateral or alar odontoid ligaments** are two thick and very strong bundles of fibres, which extend from the sides of the summit of the odontoid process outwards and a little upwards to be implanted into the rough depression on the inner side of each condyle of the occipital bone, and into a small part of the margin of the foramen magnum. Some of the fibres of the two ligaments are continuous across the middle line.

Fig. 124.

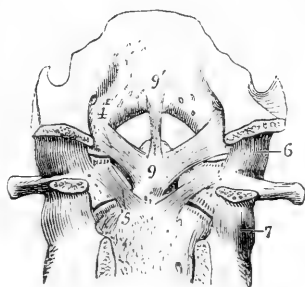


Fig. 124.—TRANSVERSE SECTION SIMILAR TO THAT REPRESENTED IN FIG. 122, THE CRUCIFORM LIGAMENTS HAVING BEEN REMOVED. (A. T.)

4, alar odontoid ligament ; 5, accessory atlanto-axial ligament ; 6, 7, capsular ligaments of the occipito-atlantal and the atlanto-axial articulations ; 9, head of the odontoid process ; 9, 9', middle odontoid ligament.

Fig. 125.

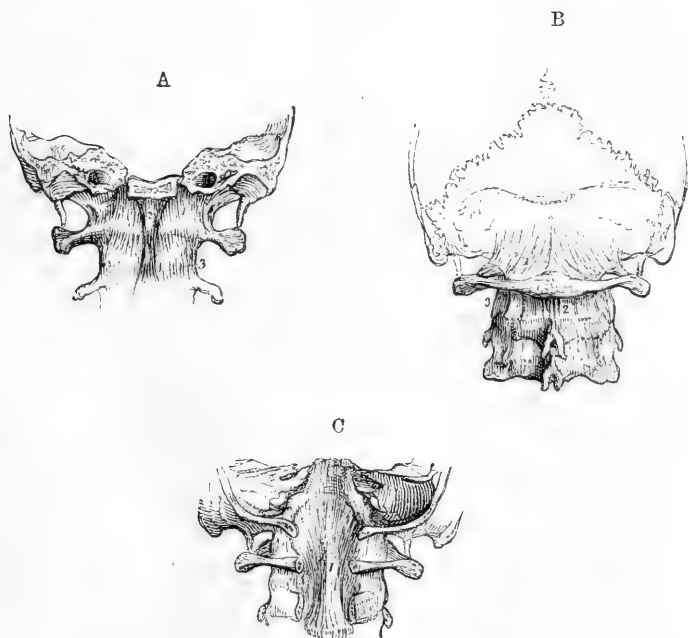


Fig. 125.—THE LIGAMENTOUS STRUCTURES WHICH SURROUND THE ARTICULATIONS OF THE OCCIPUT AND TWO UPPER VERTEBRE.  $\frac{1}{2}$

A, the lower part of the skull sawn transversely through the basilar process, with the atlas and axis, viewed from before. 1, the anterior occipito-atlantal ligament ; 2, the accessory occipito-atlantal ligament ; 3, the anterior atlanto-axial ligament.

B, the lower part of the skull, with three adjacent vertebrae, viewed from behind. 1, the posterior occipito-atlantal ligament ; 2, the posterior atlanto-axial ligament.

C, the occipital bone sawn transversely through the foramen magnum, and a part of the arches of the atlas and axis removed posteriorly, so as to show the apparatus ligamentosus.

The *ligamentum suspensorium dentis* or **middle odontoid ligament** consists of fibres which pass directly upwards from the summit of the odontoid process to the margin of the foramen magnum.

The **occipito-axial ligament** sometimes called *apparatus ligamentosus colli*, is the continuation upwards of the posterior common ligament, and by its breadth covers the cruciform and odontoid ligaments. It is attached above in the basilar groove, and below to the body of the axis.

The **anterior occipito-atlantal ligament** extends from the anterior border of the occipital foramen, between the condyles, to the anterior arch of the atlas. It is thin, broad, and membranous; but in the median line it is strengthened by an *accessory* ligament, thick and round, placed in front of it, which is sometimes described as the commencement of the anterior common ligament.

The **anterior atlanto-axial ligament**, likewise thin and membranous, except in the middle, where it is considerably thickened, extends from the anterior arch of the atlas to the body of the axis.

The **posterior occipito-atlantal ligament**, thin and membranous, is attached superiorly to all that part of the margin of the occipital foramen which is behind the condyles, and inferiorly to the adjacent border of the arch of the atlas. It is partly blended with the dura mater.

The **posterior atlanto-axial ligament**, similar to the preceding, connects the neural arch of the atlas with that of the axis, in the absence of ligamentum subflavum.

**Movements.**—The atlanto-axial articulation is so constructed that the head, together with the atlas, is rotated on the axis; the odontoid process serving as a pivot. The rotation is limited by the check ligaments. The occipito-atlantal articulation takes no part in rotation, but allows the head to be freely raised or depressed upon the vertebral column. When the atlas is placed symmetrically over the axis, it is seen that the opposing articular surfaces, instead of fitting one to the other, come very slightly into contact, the surface of the axis being inclined too little outwards, and presenting an antero-posterior convexity, to which there is no corresponding concavity presented by the atlas; but a slight rotation brings the bones into a stable position, in which the anterior half of one articular surface of the axis and the posterior half of the other, are laid closely against the atlas. It will also be found that a small amount of oblique motion between the atlas and occipital bone is permitted, by which the anterior half of one condyle and the posterior part of the other may be rested together on the atlas, and that that is the position of greatest stability. This oblique position is that into which the bones are brought when there is any lateral flexure of the column, as is the case in the most natural and easy attitudes.

#### ARTICULATIONS OF THE RIBS.

The articulations of the ribs may be divided into three sets, costo-central, costo-transverse, and costo-sternal.

The **COSTO-CENTRAL ARTICULATION** unites the head of the rib, in most instances, with the bodies of two vertebræ by two distinct synovial joints, supported by ligaments as follows.

The **anterior costo-central ligament**, *radiated* or *stellate*, consists of three bundles, of which the middle one passes horizontally forwards upon the corresponding intervertebral fibro-cartilage, the superior ascends to the body of the vertebra above it, and the inferior descends

to that below. In the first, eleventh, and twelfth ribs, this ligament is inserted into only one vertebral body, and into no fibro-cartilage.

Fig. 126.—THE 5TH, 6TH, 7TH, 8TH, AND 9TH DORSAL VERTEBRÆ, WITH PARTS OF THE 6TH, 7TH AND 8TH RIBS, FROM THE RIGHT SIDE AND FRONT. (A. T.)  $\frac{1}{2}$

The 9th rib has been removed to show the articular surfaces of the vertebrae corresponding to it; 3 & 4, the heads of the 6th and 7th ribs, from which the stellate ligaments are seen spreading over the two adjacent vertebral bodies and intervertebral substance; 5, the head of the 8th rib, from which the stellate ligament has been removed, so as to expose the upper and lower synovial cavities, and between them the interarticular ligament; 6, lower, and 6', upper facet of the costo-central articulation; 7, posterior costo-transverse ligament; 7', the costo-transverse synovial cavity; 7'', the costo-transverse articular facet; 8, superior costo-transverse ligament; 9, superior articular process of the 5th vertebra; 9', inferior of the 9th.

The **interarticular ligament** is a thin and short band of fibres, which passes transversely from the ridge separating the two articular surfaces on the head of the rib to the intervertebral substance, and divides the articu-

Fig. 126.

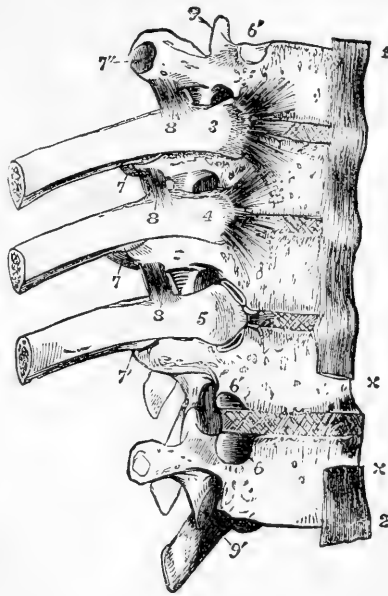


Fig. 127.—FIVE DORSAL VERTEBRÆ, WITH PORTIONS OF THE CORRESPONDING RIBS.  $\frac{1}{4}$

1 and 2 are placed on the laminae of the vertebrae close to the interspinous ligaments; 3, ligamentum subflavum; 4, anterior costo-transverse ligament; 5, posterior costo-transverse ligament.

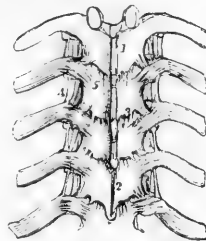
lation into two parts, each lined by a separate synovial membrane. The ligament does not exist in the articulations of the first, eleventh, or twelfth ribs, as these ribs are each attached to only one vertebral body by a single synovial joint.

The **COSTO-TRANSVERSE ARTICULATION** unites the tubercle and neck of the rib to the corresponding transverse process by a synovial joint and ligaments, and by a longer ligament to the transverse process of the vertebra above.

The **posterior costo-transverse ligament** is a distinct band extending outwards from the posterior part of the summit of the transverse process to the rough external part of the tubercle of the rib.

The **middle or interosseous costo-transverse ligament**, consists of a series of short parallel fibres, which unite the neck of the rib to the anterior surface of the contiguous transverse process. These

Fig. 127.



fibres are seen on removing by horizontal section a portion of the rib and transverse process, and forcibly drawing the one from the other.

Fig. 128.

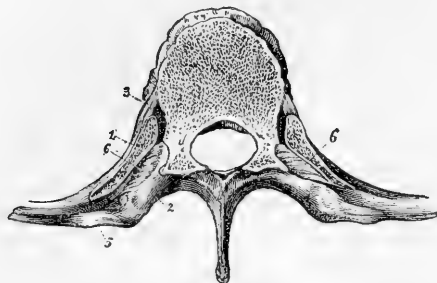


Fig. 128.—HORIZONTAL SECTION OF A DORSAL VERTEBRA, WITH THE ADJACENT PORTIONS OF TWO RIBS.  $\frac{2}{3}$

1, the rib; 2, transverse process; 3, anterior costo-central ligament; 5, posterior costo-transverse ligament; 6, interosseous or middle costo-transverse ligament.

The **superior costo-transverse ligament**, *anterior* or *long*, consists of fasciculi of fibres, passing from the neck of the rib

obliquely upwards and outwards to the lower margin of the transverse process next above it. It does not exist in the articulation of the first rib.

There are no synovial joints, but only posterior costo-transverse ligaments, between the two lowest ribs and the transverse processes.

The **COSTO-STERNAL ARTICULATIONS**, situated between the anterior extremities of the cartilages of the sternal ribs, and the corresponding fossæ in the margins of the sternum, consist of small synovial capsules covered and supported by *anterior*, *posterior*, *upper* and *lower ligaments*. The anterior ligamentous fibres are thin, scattered, and radiated, passing from the extremity of the cartilage to the anterior surface of the sternum, where they interlace with those of the opposite side, and are blended with the aponeurosis of the pectoralis major muscle; the posterior fibres are similarly disposed, but not so thick or numerous, and connect the thoracic surfaces of the same parts; the upper and lower ligamentous fibres are inconsiderable, and are placed above and below the joint. *Synovial cavities* are interposed between the end of the cartilage of each true rib (excepting the first) and the sternum, that of the seventh is single; the others are usually divided into an upper and lower cavity by interarticular fibres attached to the end of the cartilage and to the sternum. The cartilage of the first rib is almost always directly united to the sternum.

A thin fasciculus of fibres connecting the cartilage of the seventh rib, and sometimes likewise that of the sixth, with the xiphoid cartilage, is called the *costo-xiphoid ligament*.

**Articulation of the cartilages one with another.**—The cartilages of some of the ribs, viz., from the sixth to the ninth, have a part of their adjacent borders smoothed into articular surfaces, which are held in connection by ligamentous fibres, lined by synovial membranes. Some of the articular surfaces are occasionally found to be wanting.

**Connection of the ribs with their cartilages.**—The external extremities of the cartilages are fixed into the oval depressions on the ends of the ribs, and the union receives support from the periosteum.

**Ligaments of the sternum.**—The manubrium, body, and xiphoid process of the sternum, so long as they are not united by bone, are connected by intervening cartilage, and by anterior and posterior ligaments, which have chiefly a longitudinal direction. The whole sternum

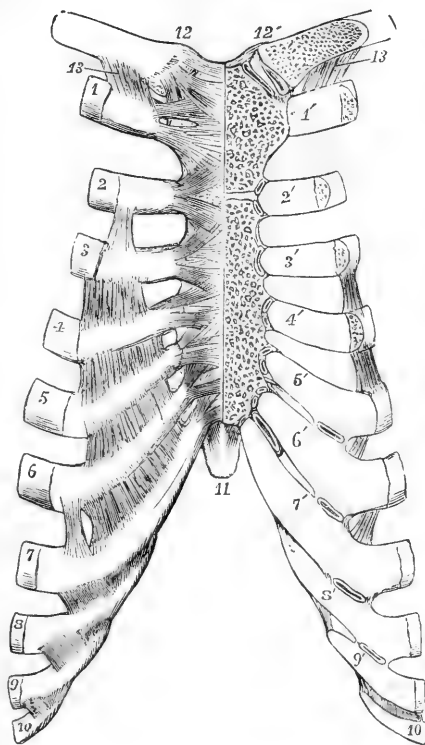


is much strengthened by thick periosteum, and by the radiating bands of the costo-sternal ligaments already mentioned.

Fig. 129.—ARTICULATIONS OF THE STERNUM, CLAVICLE, AND RIBS, AS SEEN FROM BEFORE. (A. T., after Arnold.)  $\frac{1}{3}$

On the right of the middle line the anterior ligaments are shown; on the left side, the front parts of the clavicle, sternum and costal cartilages have been removed so as to display the articular cavities. 1 to 10, the anterior extremities of the ribs from the first to the tenth inclusive, on the right side; 1' to 10', the costal cartilages of the left side from the first to the tenth; at 1', the direct union of the first costal cartilage with the sternum is shown; at the sternal ends of the cartilages marked 2' to 6', the small double synovial cavities are shown opened; between the costal cartilages on the right side, ligamentous bands are shown stretching over the intercostal spaces; and on the left side, by a section, small synovial cavities are shown between the adjacent edges of the intercostal cartilages from the 5th to the 9th; on the front of the right half of the sternum the radiating anterior costo-sternal ligaments are shown; 11, the ensiform process; 12, 12', the inter-clavicular ligament; and below 12, the anterior sterno-clavicular ligament; below 12', the sterno-clavicular articulation is opened, showing the interarticular fibro-cartilage and double synovial cavity; 13, the costo-clavicular or rhomboid ligament.

Fig. 129.



**Movements of the Ribs.**—Each rib is capable of a certain amount of elevation and depression, and of rotation on an axis passing between its vertebral and sternal ends. The heads of the ribs are, however, bound down by the interarticular ligaments so tightly as to prevent any gliding motion at the attachments of those ligaments, which may therefore be regarded as the fixed points round which the ribs are moved. When the vertebral column is bent forwards, the ribs are depressed; and when the column is rotated, the ribs of that side towards which the upper part of the trunk is turned are raised, and those of the other side correspondingly depressed. The movement of the tubercle of the rib on the transverse process is of a gliding description, in the circumference of a circle of which the head of the rib is the centre; and as the plane in which the opposed surfaces of the costo-transverse articulation in most instances lie looks upwards and backwards, the ribs are moved backwards as well as upwards in inspiration, and forwards and downwards in expiration. The combined movements of the thoracic walls in respiration will be described along with the actions of the intercostal muscles. It is sufficient at present to state that the elevation and rotation of the ribs in inspiration are the main causes of the antero-posterior and transverse enlargement of the chest. The angular movement is greatest in the upper and least in the lowest ribs.

## TEMPO-MAXILLARY ARTICULATION.

The lower jaw articulates by its condyle on each side with the smooth surface of the temporal bone, extending over the part of the glenoid

Fig. 130.

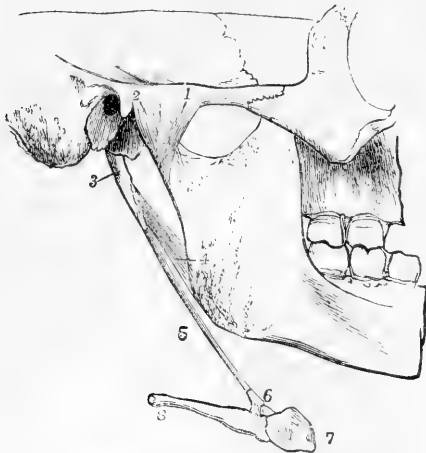


Fig. 130.—A PORTION OF THE SKULL WITH THE LOWER JAW AND HYOID BONE, SEEN FROM THE RIGHT AND OUTER SIDE. (A. T., after Arnold.)  $\frac{1}{2}$

1, the external lateral ligament; 2, a part of the capsule of the joint; 3, styloid process; 4, stylo-maxillary ligament; 5, stylo-hyoid ligament; 6, lesser cornu of the hyoid bone with some short ligaments attaching it to the body and great cornu; 7, the body; 8, the great cornu.

fossa in front of the Glaserian fissure and the anterior root of the zygoma. The joint is divided by an interarticular fibro-cartilage into an upper and a lower synovial cavity.

The **external lateral ligament** is a short fasciculus of fibres, attached above to the external surface and the tubercle of the zygoma;

Fig. 131.

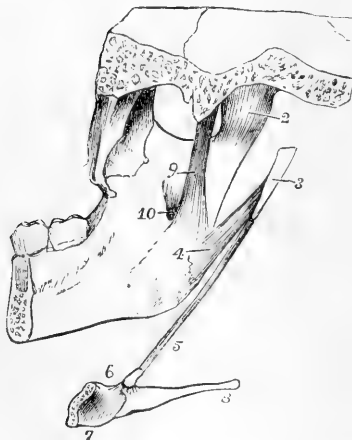


Fig. 131.—A PORTION OF THE SKULL AND LOWER JAW WITH HALF THE HYOID BONE, SEEN FROM THE INSIDE. (A. T.)  $\frac{1}{3}$

The numbers are the same as in Fig. 130; 3, the styloid process, detached from the skull; 7, the posterior and inner surface of the right half of the body of the hyoid bone; 9, the internal lateral ligament of the temporo-maxillary joint; 10, the upper opening of the inferior dental canal.

and below, to the external surface and posterior border of the neck of the lower jaw, its fibres being directed downwards and backwards. Thin and short additional ligamentous fibres cover the synovial membrane in front and on the inside, forming an irregular capsule round the joint.

The **internal lateral ligament**, thin, loose, and elongated, lies at some distance from the joint. It extends from the spinous process of the sphenoid bone downwards and a little forwards, to be attached to the inner border of the inferior dental foramen. Between it and the lower jaw are placed the external pterygoid muscle, the internal maxillary artery, and the inferior dental nerve. It has no immediate

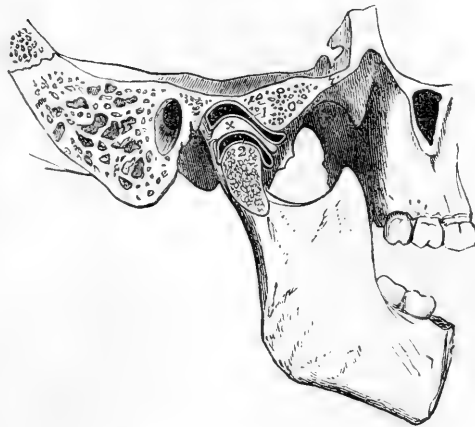
connection with the joint, and by some anatomists is not recognised as a ligament.

The **interarticular fibro-cartilage** is a thin plate placed between the articular surfaces of the bones. It is of an oval form, broadest transversely, thickest posteriorly, and thinnest at its centre, where it is sometimes perforated. The inferior surface, which is in contact with the condyle, is concave; the superior is concavo-convex from before backwards, conforming with the articular surface of the temporal bone. Its circumference is connected at the outside with the external lateral ligament, and anteriorly with the external pterygoid muscle.

**Synovial Membranes.**—The synovial membrane which lies between

Fig. 132.—ANTERO-POSTERIOR SECTION OF THE TEMPORO-MAXILLARY ARTICULATION OF THE RIGHT SIDE. (A. T.)  $\frac{1}{3}$

Fig. 132.



1, is placed close to the articular eminence, and points to the superior synovial cavity of the joint; 2, is placed close to the articular surface of the head of the lower jaw, and points to the inferior synovial cavity of the joint; x, is placed on the thicker posterior portion of the interarticular fibro-cartilage.

the interarticular fibro-cartilage and the glenoid cavity is larger and looser than that which is interposed between the fibro-cartilage and the condyle of the jaw. When the fibro-cartilage is perforated, the upper and lower synovial cavities necessarily communicate with each other.

The **stylo-maxillary ligament** is the name given to a strong thickened band of fibres connected with the cervical fascia extending from near the point of the styloid process to the posterior border of the ramus of the jaw, where it is inserted between the masseter and internal pterygoid muscles. It separates the parotid from the submaxillary gland.

It may be proper also to mention in this place the **stylo-hyoid ligament**, a thin fibrous cord, which extends from the point of the styloid process to the lesser cornu of the hyoid bone, and serves to suspend that bone from the styloid process. A considerable portion of the stylo-hyoid ligament is sometimes converted into bone in the human subject, and in many animals it is naturally osseous, constituting the *epihyal bone*.

**Movements.**—The jaw is capable of movements of elevation and depression, of some degree of lateral displacement, and of protraction and retraction; but it is to be observed that when the jaw is depressed, as in opening the mouth, the condyle advances from the glenoid cavity so as to be placed on the articular eminence in front of it. The movements which take place in the superior and

inferior compartments of the joint are of different kinds. In the upper the fibro-cartilage glides backwards and forwards on the temporal bone; in the lower compartment the condyle rotates on a transverse axis against the fibro-cartilage. In opening the mouth the two movements are combined: the jaw and fibro-cartilage together move forwards and rest on the convex root of the zygoma, while at the same time the condyle revolves on the fibro-cartilage. When the lower incisors are protruded beyond those of the upper jaw, the movement is confined chiefly to the upper articulation; and when the same movement is alternately performed in the joints of opposite sides a horizontal, circular, or grinding motion is produced. The fibres of the external lateral ligament remain tight in opening the mouth, owing to the descent of the condyle when it passes forwards on the articular eminence.

## ARTICULATIONS OF THE UPPER LIMB.

### THE SCAPULO-CLAVICULAR ARCH.

The supporting arch of the upper limb has only one point of attachment to the skeleton of the trunk, namely, that at the sterno-clavicular articulation; the scapula being connected with the trunk only by muscles.

The clavicle articulates at its inner end with the first bone of the sternum, and is connected by ligaments to its fellow of the opposite side and to the first rib. At its outer end it is united to the scapula.

**STERNO-CLAVICULAR ARTICULATION.**—The articular surface of the inner end of the clavicle is considerably larger than the opposing surface of the sternum. Between the two bones an interarticular fibro-cartilage is interposed.

The **anterior sterno-clavicular ligament**, broad and consisting of parallel fibres, passes from the inner extremity of the clavicle in front, downwards and inwards, upon the anterior surface of the sternum.

The **posterior sterno-clavicular ligament**, on the posterior aspect of the joint, is of similar conformation to the anterior ligament, but is not so broad or strongly marked.

The **interclavicular ligament** is a dense fasciculus of fibres passing over the sternal ends of both clavicles. It dips downwards in the middle, where it is attached to the interclavicular notch of the sternum.

The **interarticular fibro-cartilage**, nearly circular in its form, and thicker above and at its margins than at the centre, is interposed between the articulating surfaces of the sternum and clavicle. Towards its upper part it is attached to the inner and upper part of the clavicle, and at its lower edge to the cartilage of the first rib. In the latter situation it is thin and prolonged outwards, beneath the inferior border of the clavicle.

**Synovial membranes.**—In this articulation, as in that of the lower jaw, there are two cavities lined by synovial membrane, one on each side of the interarticular fibro-cartilage.

The **costo-clavicular** or **rhomboid ligament** does not properly form part of the sterno-clavicular articulation; yet it contributes materially to retain the clavicle in its situation. It is attached inferiorly to the cartilage of the first rib near its sternal end, and passes obliquely backwards and upwards, to be fixed to a rough depression at the under surface of the clavicle near the sternal end.

**SCAPULO-CLAVICULAR ARTICULATIONS.**—At its outer end the clavicle articulates with the acromion and coracoid processes of the scapula.

The **acromio-clavicular articulation** is a synovial joint uniting the outer extremity of the clavicle with the inner edge of the acromion. It is supported above by a thick and broad *superior ligament*, and below by an *inferior ligament* which is not so strong. An *interarticular fibro-cartilage* is frequently present, but is sometimes wanting. It is wedge-shaped, attached by its base to the superior ligament, and only partially separates the small oval articular surfaces.

Fig. 133.

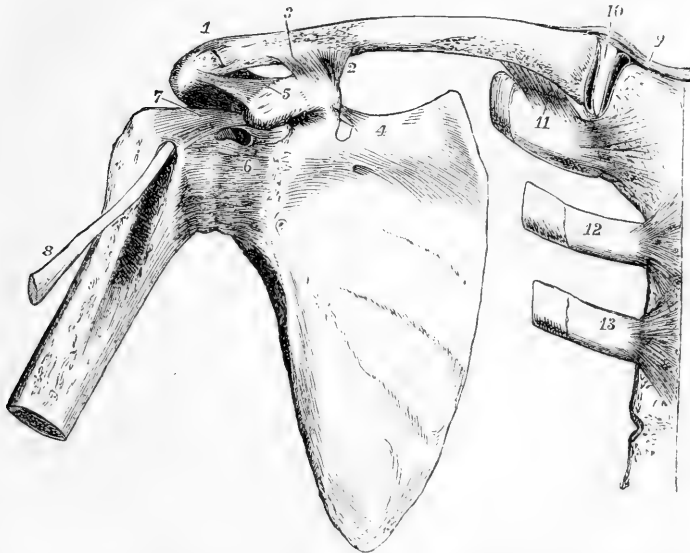


Fig. 133.—VIEW FROM BEFORE OF THE ARTICULATIONS OF THE SHOULDER BONES.  
(A. T.)  $\frac{1}{3}$

1, acromio-clavicular articulation ; 2, conoid, and 3, trapezoid part of the coraco-clavicular ligament ; 4, near the suprascapular ligament ; 5, on the coracoid process, points to the coraco-acromial ligament ; 6, the capsular ligament of the shoulder joint ; 7, the coraco-humeral ligament ; above 6, an aperture in the capsular ligament through which the tendon of the subscapularis muscle passes ; 8, tendon of the glenoid head of the biceps muscle ; 9, right half of the interclavicular ligament ; 10, interarticular fibro-cartilage of the sternoclavicular articulation ; 11, the costo-clavicular ligament ; 12 and 13, the cartilage and small part of the second and third ribs attached by their anterior costo-sternal ligaments.

The **coraco-clavicular ligament**, which connects the clavicle with the coracoid process of the scapula, is divisible into two parts. The *conoid ligament*, which is the posterior or internal fasciculus, broad above, narrow below, is attached inferiorly to the inner part of the root of the coracoid process, and superiorly to the conoid tubercle of the clavicle : its fibres are directed backwards and upwards. The *trapezoid ligament*, the anterior or external fasciculus, slopes upwards, backwards, and outwards from the inner border of the coracoid process to an oblique line extending outwards from the conoid tubercle, on which it is

inserted into the clavicle. In the angle between the conoid and trapezoid ligaments there is frequently present a synovial bursa.

**Movements.**—The movements allowed at the clavicular articulations are limited, not so much by the forms of the articular surfaces, as by the costo-clavicular and coraco-clavicular ligaments, and the position of the thoracic wall. When the clavicle is forcibly depressed, as in lifting a heavy weight, it presses upon the first rib, its sternal end rises, and the interarticular cartilage and inter-clavicular ligament are put upon the stretch. When the shoulders are drawn backwards and downwards the angle between the clavicle and the upper border of the scapula is increased by the descent of the scapular arch on the conical wall of the thorax. In raising and depressing the arm to its full extent, there is not only vertical movement at the shoulder joint, but also movement at the sterno-clavicular and acromio-clavicular articulations.

**LIGAMENTS OF THE SCAPULA.**—There are two ligaments which stretch from one part of the scapula to another. 1. The **coracoid or suprascapular ligament** is a thin, flat band of fibres, attached by its extremities to the opposite margins of the notch at the root of the coracoid process, which it thus converts into a foramen for the transmission of the supra-scapular nerve, the corresponding artery most commonly passing above it. This ligament is frequently converted into bone. 2. The **coraco-acromial ligament**, broad, firm, and triangular, is attached by its broader extremity to the outer edge of the coracoid process, and by the narrower to the tip of the acromion. Its inferior surface looks downwards upon the shoulder joint, the superior is covered by the deltoid muscle. It completes the arch formed by the coracoid and acromion processes, and gives protection to the shoulder joint.

#### THE SHOULDER JOINT.

In this articulation the large and hemispherical head of the humerus is opposed to the much smaller surface of the glenoid cavity of the scapula. The bones are retained in position, not by the direct tension of ligaments, which would restrict too much the movements of the joint, but by surrounding muscles and atmospheric pressure.

Fig. 134.

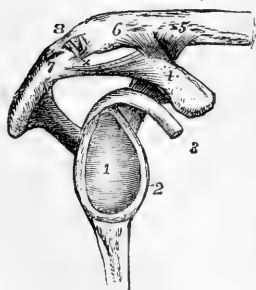


Fig. 134.—VIEW OF THE GLENOID CAVITY AND LIGAMENTS BETWEEN THE SCAPULA AND CLAVICLE OF THE RIGHT SIDE.  $\frac{1}{3}$

1, glenoid fossa, its cartilaginous surface; 2, the glenoid ligament or fibrous border; 3, the tendon of the biceps muscle seen in connection with the upper part of the glenoid fossa and ligament; 4, upper surface of the coracoid process; 5 and 6, on the adjacent part of the clavicle; 4 to 5, the conoid; 4 to 6, the trapezoid portion of the coraco-clavicular ligament; 7, the apex of the acromion process; 4 to 7, the coraco-acromial ligament; 8, the acromio-clavicular articulation, which is represented as open anteriorly, showing a wedge-shaped interarticular cartilage attached above to the superior acromio-clavicular ligament; x, the inferior acromio-clavicular ligament.

The **capsular ligament** is attached to the scapula round the margin of the glenoid cavity, and to the humerus at the place where the neck springs from the tuberosities and shaft. It extends furthest

down the humerus on the internal or inferior aspect, and is strongest on the superior aspect. It is so lax that the humerus separates from the glenoid cavity as soon as its muscular connections are detached. Superiorly and posteriorly the capsule is strengthened by the tendons of the *supraspinatus*, *infraspinatus*, and *teres minor* muscles, which are intimately connected with it as they pass over it to reach the great tuberosity of the humerus. Anteriorly the tendon of the *subscapularis* muscle comes into direct contact with the synovial membrane, which is prolonged upon it through an oval opening. The insertion of the capsule is likewise interrupted opposite the bicipital groove, to give passage to the long tendon of the *biceps* muscle.

The **coraco-humeral**, or accessory ligament, is a broad bundle of fibres extending obliquely over the upper and outer part of the articulation; it is attached to the root of the coracoid process, and thence descends towards the greater tuberosity of the humerus, intimately connected with the capsule. A few fibres of the coraco-humeral ligament project into the joint, and are inserted into the inner and upper part of the bicipital groove; these have been called the *gleno-humeral* ligament, and are supposed to correspond with the *ligamentum teres* of the hip joint.

Fig. 135.

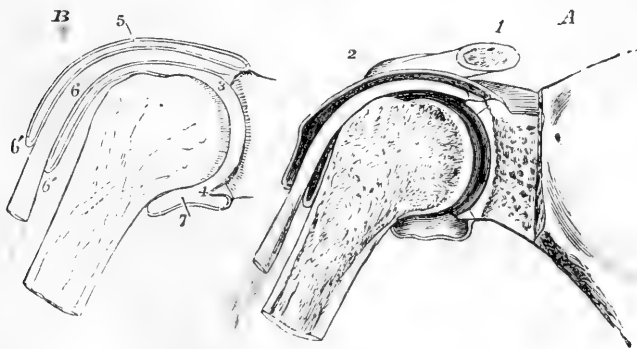


Fig. 135.—A SECTION THROUGH THE SHOULDER-JOINT, TENDON OF THE BICEPS AND BICIPITAL GROOVE, SHOWING SOMEWHAT DIAGRAMMATICALLY THE SYNOVIAL CAVITY OF THE JOINT, &c. (A. T.)  $\frac{1}{3}$

B, OUTLINE OF THE SAME, TO SHOW THE REFLECTION OF THE SYNOVIAL MEMBRANE OVER THE TENDON.

1, outer part of the clavicle; 2, the acromial end; 3, the cavity of the shoulder-joint close to the upper part of the glenoid head, where there are seen the section of the cartilages on the head of the humerus and in the glenoid cavity of the scapula, the glenoid ligament and the origin of the tendon of the *biceps* muscle; 4, the glenoid ligament in the lower part of the cavity; 5, the upper part of the capsular ligament and synovial membrane; 6, the tendon of the *biceps* as it passes out of the joint into the bicipital groove; 6', the tubular prolongation of the synovial membrane round the tendon; 7, the reflection of the synovial membrane on the humerus within the lower part of the capsular ligament.

The **glenoid ligament** is a firm fibrous band, about two lines thick which is fixed to the edge of the glenoid fossa, and thus deepens

the cavity. The upper part of it is connected with the tendon of the long head of the biceps muscle, which is also fixed into the upper part of the glenoid fossa, within the capsule of the joint.

The **synovial membrane** is reflected uninterruptedly from the margin of the glenoid cavity on the inner surface of the fibrous capsule to the humerus, but its form is complicated by its relation to the tendons of the biceps and subscapularis muscles. The long tendon of the biceps muscle traversing the joint in its course from the upper border of the glenoid cavity to the bicipital groove, is enclosed in a tubular sheath, formed by an offset or process of the synovial membrane, which is continued down upon it beyond the fibrous capsule into the bicipital groove, and is thence reflected upwards upon it to its origin, where it again becomes continuous with the synovial membrane of the capsule in such a manner as to preserve the integrity of the membrane. The bursal prolongation of the synovial membrane on the tendon of the subscapularis muscle is of variable extent, sometimes scarcely existing, sometimes forming a considerable pouch on the venter of the scapula.

**Subacromial Bursa.**—Superficial to the muscles covering the top of the joint is a considerable bursa mucosa, by means of which the contiguous surfaces of the coracoid and acromion processes, and of the coraco-acromial ligament and deltoid muscle, are lubricated, so as to facilitate the movements of the subjacent head of the humerus.

**Movements.**—Great freedom of movement of the humerus in every direction is admitted at the shoulder-joint; but superiorly and posteriorly the extent of the movement is somewhat limited by the margin of the acromion. When the arm is raised the great tuberosity of the humerus becomes locked against the acromion as soon as the position is reached in which the limb lies at right angles to the trunk, and all further elevation is accomplished by movements in the sterno-clavicular and acromio-clavicular articulations. The arch formed by the acromion, the coracoid process, and the deltoid ligament, lined by the sub-acromial bursa, forms a sort of secondary socket in which the extremity of the humerus, covered by the tendons inserted into the great tuberosity, revolves, and against which it is pressed when the weight of the body is made to rest upon the arms.

#### ARTICULATIONS OF THE FOREARM AND ELBOW.

The bones of the forearm are united by a superior and an inferior articulation and an interosseous membrane.

In the **SUPERIOR RADIO-ULNAR ARTICULATION** the head of the radius is connected with the small sigmoid cavity of the ulna by the **annular** or **orbicular ligament**. This ligament is a strong band of fibres attached to the ulna in front and behind, at the extremities of the small sigmoid cavity, and forming four-fifths of a ring which encircles the head of the radius and binds it firmly in its situation. The external lateral ligament of the elbow is inserted into its outer surface; its deep surface is smooth, and is lined by the synovial membrane of the elbow-joint.

**THE INFERIOR RADIO-ULNAR ARTICULATION.**—The connection between the semilunar surface of the radius and the lower end of the ulna is effected by means of a fibro-cartilage, a synovial membrane, and some scattered ligamentous fibres in front and behind. The **triangular fibro-**



**cartilage** is a thick plate attached by its base to a ridge separating the carpal from the ulnar articulating surface of the radius; and by its

Fig. 136.—THE UPPER PART OF THE ULNA, WITH THE ORBICULAR LIGAMENT OF THE RADIUS.  $\frac{1}{2}$

1, upper division of the sigmoid surface on the olecranon; 2, extremity of the coronoid process; 3, orbicular ligament.

apex to a depression at the root of the styloid process of the ulna, and to the side of that process. Its upper surface looks towards the ulna, its lower towards the cuneiform bone, and it separates the inferior radio-ulnar articulation from the wrist-joint. The **synovial membrane**, sometimes called from its looseness *membrana sacciformis*, extends upwards between the radius and ulna, and horizontally inwards between the ulna and triangular fibro-cartilage. When the fibro-cartilage is perforated, as is occasionally the case, this synovial cavity communicates with that of the wrist-joint.

The **interosseous membrane** or **ligament** of the forearm is a thin,

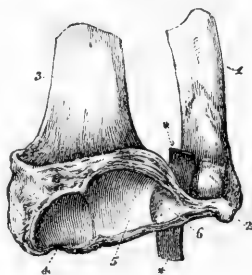
Fig. 136.

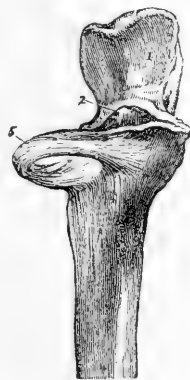

Fig. 137.—THE LOWER PARTS OF THE RADIUS AND ULNA, WITH THE TRIANGULAR FIBRO-CARTILAGE CONNECTING THEM.  $\frac{2}{3}$

1, ulna; 2, its styloid process; 3, radius; 4, articular surface for the scaphoid bone; 5, that for the semilunar bone; 6, lower surface of the triangular fibro-cartilage; \*\*, a piece of whalebone passed between the fibro-cartilage and the ulna.

Fig. 137.



flat, fibrous membrane, the direction of whose fibres is for the most part obliquely downwards and inwards, from the interosseous ridge of the radius to that of the ulna. Its superior border is placed about an inch below the tubercle of the radius, leaving an open space above (*hiatus interosseus*) through which the posterior interosseous vessels pass. This space is diminished in size by the **round or oblique ligament**, a thin, narrow fasciculus of fibres extending obliquely downwards and outwards from the coronoid process, to be attached to the radius about half an inch below the tubercle. Other small bundles of fibres, having the same direction as the round ligament, are often to be found at intervals, decussating with the fibres of the interosseous ligament on its posterior surface.

**Movement of the Radius on the Ulna.**—The disposition of the annular ligament allows the head of the radius to rotate freely within it, while the lower end of the radius, bound by the triangular fibro-cartilage to the styloid process of the ulna, has a freedom of circumduction round that point, by which the hand is brought into the prone or the supine position. Thus in pronation and supination the radius describes a part of a cone, the axis of which

extends from the centre of the head of the radius to the styloid process of the ulna.

Fig. 133.

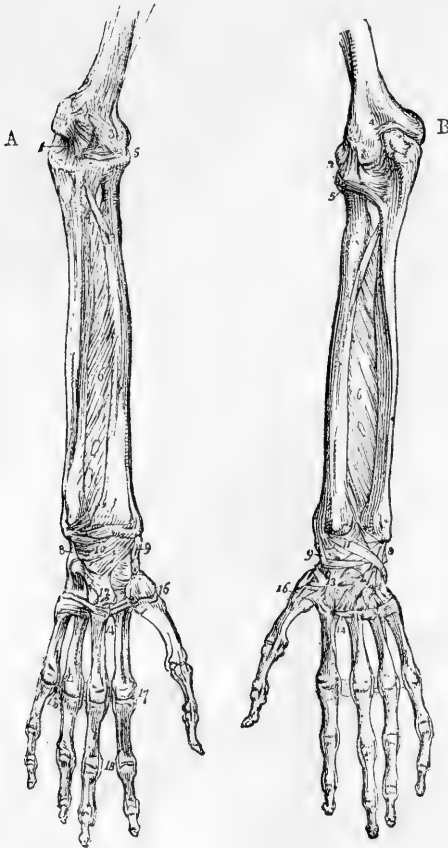


Fig. 133.—A, FRONT, AND B, BACK VIEW OF THE ARTICULATIONS OF THE FOREARM, WRIST AND HAND.  $\frac{1}{2}$

1, the internal lateral ligament of the elbow-joint; 2, the external lateral; 3, the anterior; 4, the posterior; 5, orbicular ligament of the radius; 6, interosseous membrane; 7, oblique or round ligament; 8, internal lateral ligament of the wrist; 9, external; 10, anterior; 11, posterior; 12, palmar, and 13, dorsal carpo-metacarpal ligaments; 14, ligaments connecting metacarpal bones; 15, transverse metacarpal ligament; 16, carpo-metacarpal ligament of the thumb; 17, lateral ligaments connecting the phalangeal with the metacarpal bones; 18, lateral ligaments of the phalanges.

#### THE ELBOW-JOINT.

The lower extremity of the humerus is in contact with the ulna and radius at the elbow, and forms with them a hinge-joint. The greater sigmoid cavity of the ulna articulates with the trochlea of the humerus, so as to admit of flexion

and extension only; while the cup-shaped depression on the head of the radius is fitted to turn freely on the rounded capitulum. These bones are united principally by lateral ligaments.

The **internal lateral ligament**, composed of diverging and radiating fibres, is divisible into an anterior and a posterior part. The anterior part radiates from the front of the internal condylar eminence of the humerus, and is inserted into the coronoid process, along the inner margin of the sigmoid cavity. The posterior part, of the same triangular form, passes from the under and back part of the condylar eminence downwards to the inner border of the olecranon; and some fibres are connected with a small transverse band, which passes over the notch between the olecranon and the coronoid process.

The **external lateral ligament**, intimately connected with the tendinous attachment of the extensor muscles, is shorter and much

Fig. 139.

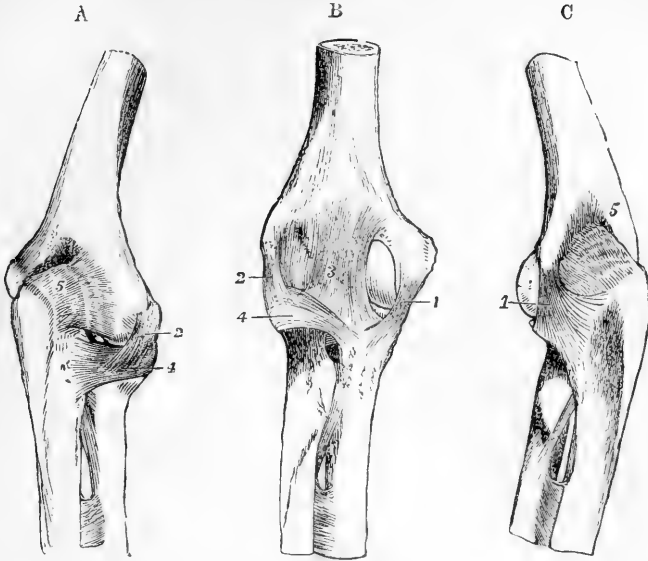


Fig. 139.—LIGAMENTS OF THE ELBOW-JOINT. (A. T.)

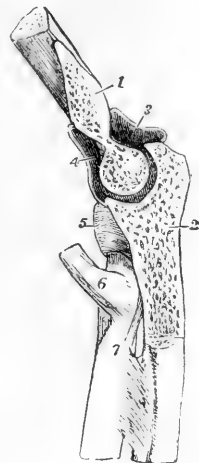A, from the outer side and behind ; B, from the front ; C, from the inner side and behind. 1, internal lateral ligament ; 2, external lateral ; 3, the middle strongest part of the anterior ligament ; 4, orbicular ligament ; 5, posterior, represented as wrinkled from relaxation in extension. In these figures the round ligament and upper part of the interosseous membrane are also represented below the elbow-joint.

narrower than the internal. It is attached superiorly to the external condylar eminence of the humerus, and inferiorly becomes blended with the annular ligament of the radius, some of its hinder fibres being prolonged to the external margin of the ulna.

Fig. 140.

Fig. 140.—VERTICAL ANTERO-POSTERIOR SECTION OF THE ELBOW-JOINT THROUGH THE GREATER SIGMOID CAVITY OF THE ULNA AND CORRESPONDING TROCHLEAR SURFACE OF THE HUMERUS. (A. T.)

1, cut surface of the humerus ; 2, that of the ulna ; 3, posterior part, and 4, anterior part of the synovial cavity of the joint ; 5, orbicular ligament enclosing the head of the radius ; 6, tendon of the biceps muscle at its insertion into the tuberosity ; 7, is at the lower end of the round ligament.



The **anterior ligament** consists of a thin sheet of fibres, strongest in its middle part, extending downwards from above the coronoid pit of the humerus to the coronoid process of the ulna and the orbicular ligament.

The **posterior ligament** is comparatively thin and weak, and consists of loose and irregular fibres passing transversely across the olecranon fossa of the humerus, and from the sides of that fossa to the

olecranon process, thus completing the capsule of the joint behind.

The **synovial membrane** extends upwards on the humerus so far as to line the fossæ for the coronoid and olecranon processes, and is loose and vascular in the latter positions. It is also prolonged round the neck of the radius, and lines the annular ligament.

**Movements.**—Flexion and extension are the only movements which can take place between the humerus and ulna; and these are limited by the locking of the coronoid and olecranon processes in the respective fossæ of the humerus which receive them. The path of motion is in a nearly vertical plane, with a direction slightly outwards. The inner lip of the trochlea being prominent below, forms an expansion which corresponds to an inward projection of the coronoid part of the ulnar surface, and is only brought into use in flexion; and the outer lip of the trochlea, being everted at the upper and back part, forms a surface which is only in use in complete extension, and which then corresponds to a surface on the outer aspect of the olecranon, which comes into contact with no other part of the humerus. In flexion and extension the radius moves by its cup-shaped head upon the capitulum, and on the groove between that process and the trochlea, by a ridge internal to the cup. It is most completely in contact with the humerus in the position of semi-flexion and semi-pronation. In full extension and supination, the anterior margin of the head of the radius is barely in contact with the inferior surface of the capitulum. In full flexion the margin of the head of the radius rests against the pit above the capitulum.

#### THE WRIST-JOINT AND ARTICULATIONS OF THE HAND.

THE RADIO-CARPAL ARTICULATION, or wrist-joint, is formed between the radius and triangular fibro-cartilage above, and the scaphoid, semilunar and cuneiform bones below. The superior surface, concave both transversely and from before backwards, is subdivided by linear elevations into three parts corresponding to the three bones below, the innermost part being formed by the fibro-cartilage. The inferior surface, convex in both directions, is prolonged further down upon the carpal bones behind than in front.

The **internal lateral ligament** is a rounded cord passing directly downwards from the extremity of the styloid process of the ulna, to the cuneiform bone; it also sends some fibres to the anterior annular ligament and the pisiform bone.

The **external lateral ligament** extends from the styloid process of the radius to a rough surface on the outer side of the scaphoid bone, some of its fibres being prolonged to the trapezium, and also to the anterior annular ligament of the wrist.

The **anterior ligament**, broad and membranous, consists partly of fibres which have a nearly transverse direction, partly of others which diverge as they descend from the anterior border of the radius to the scaphoid, semilunar, and cuneiform bones; some of them are continued to the os magnum.

The **posterior ligament** extends obliquely downwards and inwards, from the extremity of the radius, to the posterior surface of the first row of the carpal bones, especially the cuneiform bone; its fibres are prolonged some distance on the surface of the carpal bones.

The **synovial membrane** is reflected from the radius and the triangular fibro-cartilage, on the surrounding ligaments, and, after lining these, passes to the margins of the opposed surface of the carpal bones.

**THE CARPAL ARTICULATIONS.**—The bones of the carpus, the pisiform excepted, are so arranged in two rows, that while only slight movement can take place between the members of each row, a considerable amount of movement is possible between the two rows. The surface presented by the first row to the second is concave both transversely and from before backwards in the greater part of its extent, but at its outer side it is bounded by the convex part of the scaphoid bone. The opposing surface of the second row is concavo-convex from without inwards, the concavity being formed by the trapezium and trapezoid, the convexity by the os magnum and unciform bone.

Fig. 141.

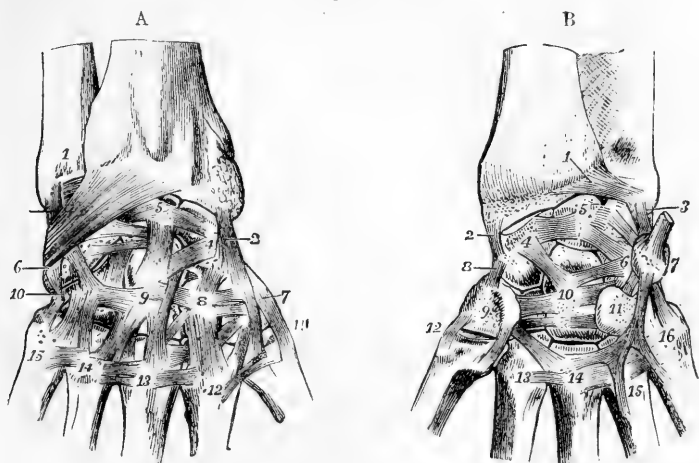


Fig. 141, A.—DORSAL VIEW OF THE DEEPER LIGAMENTS OF THE WRIST-JOINT, AND OF THE CARPAL AND CARPO-METACARPAL ARTICULATIONS. (A. T., after Arnold).  $\frac{1}{2}$

1, lower part of the ulna; 2, external lateral ligament of the wrist-joint; 3, internal; near it descending obliquely to 6, from the radius, the dorsal radio-carpal ligament; 4 to 5, transverse dorsal ligaments of the first row; 4, is on the scaphoid; 5, on the semilunar bone; 6, cuneiform bone, with the attachment of the dorsal radio-carpal ligament; 7, trapezium; 8, trapezoid; 9, os magnum; 10, unciform; 11 to 15, first to fifth metacarpal bones; 7 to 8, 8 to 9, and 9 to 10, transverse dorsal ligaments of the second row of carpal bones; 4 to 8, 4 to 9, 5 to 9, and others, dorsal ligaments between the first and second row; 8 to 12, 9 to 13, and others, dorsal ligaments from the second row to the metacarpal bones; between the metacarpal bones, from 11 to 15, the dorsal inter-metacarpal ligaments.

Fig. 141, B.—PALMAR VIEW OF THE LIGAMENTS OF THE WRIST-JOINT, AND OF THE CARPAL AND CARPO-METACARPAL ARTICULATIONS. (A. T.)  $\frac{1}{2}$

The anterior radio-carpal ligament has been removed: 1, anterior ligament of the lower radio-ulnar articulation; 2, external, and 3, internal lateral ligament of the wrist-joint; 4, scaphoid bone; 5, semilunar; 6, cuneiform; 7, pisiform, with the tendon of flexor carpi ulnaris attached: 4 to 5, and 5 to 6, palmar transverse ligaments of the first row; 8, external lateral ligament between the first and second row of carpal bones; 9, trapezium (the trapezoid is not numbered); 10, os magnum; 11, hooked process of the unciform bone, 9 to 10, 10 to 11, and others, transverse palmar ligaments of the second row; 4 to 10, and 6 to 10, some of the palmar ligaments uniting the two rows, converging on the os magnum; 7 to 11, ligament from the pisiform bone to the unciform process; 7 to 16, ligament from the pisiform to the fifth metacarpal bone; 12, external ligament of the first carpo-metacarpal articulation, the internal of which is also shown; 13, 14, 15, 16, the proximal ends of the second to the fifth metacarpal bones, on which the palmar transverse, and on three of them, a set of piso-metacarpal ligaments are shown.

The **two rows of carpal bones** are united by dorsal, palmar, and lateral ligaments. The *lateral ligaments* are placed one at the radial, the other at the ulnar border of the carpus; the former connects the scaphoid bone with the trapezium, the latter the cuneiform with the unciform. The *dorsal ligaments* consist of fibres passing in various directions; the *palmar ligaments* are chiefly composed of fibres converging towards the os magnum.

The **bones of the first row**, the pisiform bones excepted, are united by interosseous and by dorsal and palmar ligaments. The *interosseous* ligaments, placed on the sides of the semilunar bone on a level with its superior surface, connect it with the scaphoid and cuneiform bones, thus completing the inferior wall of the radio-carpal joint. The *dorsal* and *palmar* ligaments, each two in number, extend transversely on the dorsal and palmar surfaces from the scaphoid bone to the semilunar, and from the semilunar to the cuneiform.

The **bones of the second row** are connected by similar means. The *dorsal* and *palmar* ligaments, each three in number, pass transversely between the contiguous bones. The *interosseous ligaments* are generally three (but sometimes only two) in number, a strong ligament being placed between the os magnum and unciform bones, another between the trapezoid and trapezium, and a slender ligament between the os magnum and trapezoid. A small interosseous ligament is also sometimes found between the os magnum and the scaphoid. (Fig. 142.)

The **synovial cavity** of the carpal articulations is extensive and complicated. Passing between the two rows of carpal bones, it sends

Fig. 142.

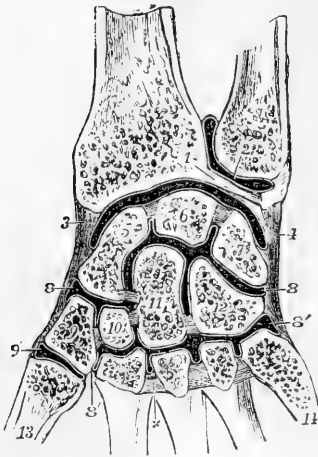


Fig. 142.—TRANSVERSE SECTION OF THE SYNOVIAL CAVITIES OF THE INFERIOR RADIO-ULNAR, RADIO-CARPAL, INTERCARPAL, AND CARPO-METACARPAL ARTICULATIONS. (A. T.)

1, points to the triangular fibro-cartilage below the ulna; 2, placed on the ulna, points to the cavity of the sacciform synovial membrane; 3, external lateral, and 4, internal lateral ligament, and between them the synovial cavity of the wrist; 5, scaphoid bone; 6, semilunar; 7, cuneiform; 8, 8, upper portion, and 8', 8', lower portion of the general synovial cavity of the intercarpal and carpo-metacarpal articulations; between 5 and 6, and 6 and 7, the interosseous ligaments are seen separating the carpal articular cavity from the wrist-joint; between the four carpal bones of the lower row, and between the magnum and scaphoid, the interosseous ligaments are also shown; the upper division of the synovial cavity communicates with the lower between 10 and 11, and between 11 and 12; x, marks one of the three interosseous metacarpal ligaments; 9', separate synovial cavity of the first

carpo-metacarpal articulation; 13, first, and 14, fifth, metacarpal bone.

NOTE. It is to be observed that in this figure, and in others of a like kind which represent the joint-cavities, the white or black lines indicating the synovial membranes are, for the sake of clearness, generally represented as passing over the surfaces of the articular cartilages, although this is not the case in nature. These lines therefore must be held to represent merely the whole continuity of the articular, or, as they are often called, the synovial surfaces.

likewise two processes between the three bones of the first row, and three between the four bones of the second. It is further continued downwards into the inner four carpo-metacarpal and three intermetacarpal articulations. In some rare cases there is continuity with the synovial membrane of the wrist-joint, by deficiency of one of the interosseous ligaments between the carpal bones.

The **pisiform bone** is articulated by a fibrous capsule and synovial membrane with the cuneiform bone. Inferiorly it is united by two strong ligaments with the unciform and fifth metacarpal bones, and is sometimes also connected with other metacarpal bones; superiorly it receives the tendon of the flexor carpi ulnaris muscle. The synovial cavity is usually distinct, but sometimes communicates with that of the radio-carpal articulation.

The **anterior annular ligament** of the wrist is a strong and thick band, which extends from the prominences made by the trapezium and scaphoid bone on the radial side of the carpus, directly across to the pisiform bone and unciform process, and converts the transverse arch of the carpus into a ring through which the flexor tendons of the digits pass into the hand.

The **posterior annular ligament**, placed at the back of the wrist, is only a thickened part of the aponeurosis of the forearm. It extends from the lower part of the radius, at its outer border, to the inner part of the cuneiform and pisiform bones and serves to bind down the extensor tendons.

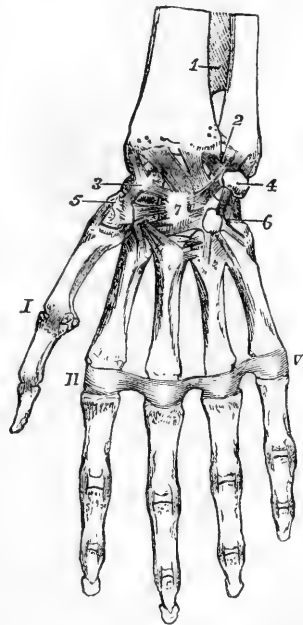
#### CARPO-METACARPAL AND INTERMETACARPAL ARTICULATIONS

Fig. 143.—GENERAL VIEW OF THE ARTICULATIONS OF THE WRIST AND HAND FROM BEFORE.  $\frac{3}{4}$

1, lower part of the interosseous membrane; 2, and from that point across the lower end of the radius, the palmar radio-carpal ligaments; 3, scaphoid bone; 4, pisiform; 5, trapezium; 6, unciform; 7, os magnum, with most of the deeper ligaments uniting these bones; I, first metacarpophalangeal articulation with its external lateral ligament; II to V, transverse metacarpal ligament: in the several phalangeal articulations the lateral ligaments are shown; in the first the external only is visible.

The **four inner metacarpal bones** are bound together at their distal extremities by thin fibres passing between them on their palmar aspect, and constituting the *transverse ligament*. At their proximal extremities they are united to one another and to the carpal bones in articulations, the common synovial lining of which is derived from that of the carpal joint. In these articulations the four metacarpal bones are bound together by three *dorsal*, and three *palmar*, and by strong *interosseous* ligaments. There are also *dorsal* ligaments uniting these metacarpal bones with the carpus, each having two such ligaments expect

Fig. 143.



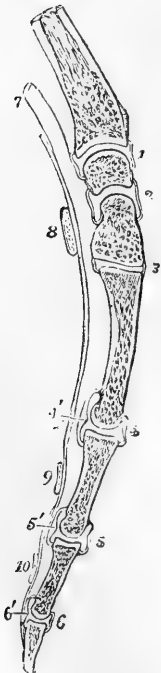
the fifth. Thus to the second, or that of the forefinger, a thin fasciculus of fibres passes from the trapezium, and another from the trapezoid bone; the third receives one from the trapezoid, and from the os magnum; the fourth from the os magnum and also from the unciform; but the fifth is connected with the unciform only. The *palmar* ligaments are not so well defined; there is a single band to each bone, except that of the little finger. There is likewise an interosseous band in one part of the carpo-metacarpal articulation, connecting the lower and contiguous angles of the os magnum and unciform to the adjacent angle of the third metacarpal bone. This ligament is usually surrounded by a part of the general synovial membrane, but sometimes it separates the cavity between the unciform and two inner metacarpal bones from the rest of the joint.

The **first metacarpal bone** is unconnected with the others, and is articulated with the trapezium by an external and an internal ligament, a capsular investment, and a distinct synovial membrane.

#### METACARPO-PHALANGEAL AND INTERPHALANGEAL ARTICULATIONS.

The rounded head of each of the last four metacarpal bones, being received into the slight hollow in the extremity of the first phalanx, is maintained in its position by two lateral ligaments, an anterior ligament, and a synovial membrane.

Fig. 144.



The **lateral ligaments** consist of strong fasciculi of fibres, on each side of the joint, from the metacarpal bone to the contiguous extremity of the phalanx. The direction of the fibres is downwards and forwards.

Fig. 144.—LONGITUDINAL ANTERO-POSTERIOR SECTION THROUGH THE LOWER PART OF THE RADIUS, SEMILUNAR BONE, OS MAGNUM, METACARPAL BONE AND PHALANGES OF THE MIDDLE FINGER, TO SHOW THE SHAPE OF THE ARTICULAR SURFACES AND SYNOVIAL CAVITIES BETWEEN THESE SEVERAL BONES. (A. T.)  $\frac{1}{3}$

1, synovial cavity of the wrist-joint; 2, intercarpal cavity; 3, carpo-metacarpal cavity; 4, metacarpo-phalangeal cavity; 5 and 6, phalangeal cavities; 4', 5', and 6', the palmar fibro-cartilaginous plates which are attached to the base of the several phalanges; 7, indicates the place of the tendons of the long flexor muscles; 8, a transverse section of the anterior annular ligament; 9 and 10, transverse retinacula, or vaginal ligaments of the flexor tendons on the first and second phalanges.

The **anterior** or **palmar ligament**, or rather **fibrous plate**, occupies the interval between the lateral ligaments on the palmar aspect of each joint; it is a thick and dense fibro-cartilaginous structure, which is firmly united to the phalanx but loosely adherent to the metacarpal bone. It is continuous at each side with the lateral ligament, so that the three form one undivided structure which covers the joint, except on the dorsal aspect. Its palmar surface is grooved for the flexor tendon, whose sheath is connected to it at each side; the other surface, looking to the interior of the joint, is lined by the synovial membrane, and



supports the head of the metacarpal bone. In the joint of the thumb there are two sesamoid bones, one situated at each side, which are connected with its ligaments.

A **synovial membrane** is present in each joint, and invests the surface of the ligaments which connect the bones.

The *interphalangeal articulations* are formed on the same plan as that which obtains in the articulations between the bases of the proximal phalanges with the metacarpal bones.

**Movements of the Wrist and Fingers.**—In the radio-carpal and common carpal articulations, there is allowed not only flexion and extension, but a certain amount of lateral bending. The superior articular surfaces of both ranges of carpal bones being prolonged further on the dorsal than on the palmar aspect, over-extension is allowed in both joints to some degree. In over-extension the opposing surfaces are most perfectly adapted to each other; in flexion they are least so. The kind of movement which is allowed between the carpal and metacarpal bones is best illustrated by placing the hand in such a position that the weight of the body is rested upon the open palm. The metacarpal range, which naturally is concave towards the palm, is flattened; and the interosseous and palmar metacarpal ligaments are thus tightened, while a slight separation of the opposed surfaces of the bones takes place; so also the palmar carpo-metacarpal ligaments are tightened, and both palmar and interosseous ligaments of the second range of carpal bones. The convex part of the os magnum and unciform bone, fitted in these circumstances into the concavity of the first range, is a little wider than the part usually in contact with it; and thus, while the bones of the first range are separated from the palmar side, those of the second range are pressed still more apart from the distal aspect. The whole arrangement secures elasticity. The fourth and fifth metacarpal bones, being more movable at their carpal articulation than the second and third, bend forward very distinctly in shutting the hand, thus rendering the palm more hollow, and bringing the tips of the fingers more closely together. At the phalangeal articulations the only movements allowed are flexion and extension, while over-extension is prevented by the ligamentous structures in front of the joints. At the metacarpo-phalangeal articulations abduction and adduction are allowed chiefly in the extended position. In the articulation of the metacarpal bone of the thumb with the trapezium every movement is allowed except rotation, which is prevented by the shape of the articular surfaces.

## ARTICULATIONS OF THE PELVIS.

**ARTICULATION OF THE PELVIS WITH THE LAST LUMBAR VERTEBRA.**—The fifth lumbar is united to the first sacral vertebra by anterior and posterior ligaments of the body, capsular ligaments of the articular processes, ligamenta subflava of the arch, interspinous ligaments, and by an intervertebral plate, all of which are similar to those between the vertebræ above. It is also attached to the pelvis by two other ligaments, as follows.

The **sacro-vertebral ligament** extends obliquely from the tip of the transverse process of the last lumbar vertebra downwards to the depressed lateral part of the base of the sacrum; its form is triangular, and its fibres diverge as they descend, some of them joining the anterior sacro-iliac ligament.

The **ilio-lumbar ligament** is extended horizontally between the summit of the transverse process of the last lumbar vertebra and the iliac crest of the innominate bone; it is inserted into the latter at the

back part of the iliac fossa, where its fibres expand somewhat, so as to give it a triangular form.

**ARTICULATION OF THE SACRUM AND COCCYX, AND OF THE PIECES OF THE COCCYX.**—These articulations are effected by an **anterior ligament**, consisting of irregular fibres placed in front of the bones, a prolongation of the anterior common ligament of the vertebræ; by a **posterior ligament** more strongly marked, the fibres of which descend upon the bones of the coccyx from the margin of the inferior orifice of the sacral canal; by fibrous bands extending between the cornua of the sacrum and coccyx; and by **intervertebral discs** between the contiguous surfaces of the bones.

A distinct cavity is stated by Cruveilhier ("Anatomie descriptive," tom. i. p. 305. Paris, 1862), to be present in the centre of the disc in those cases in which the coccyx is freely moveable. This is in conformity with the more recent observations of Luschka on the other intervertebral discs. In the male, after middle life, the union between the sacrum and coccyx, and between the pieces of the latter, is usually ossific. In the female this change does not generally

Fig. 145.

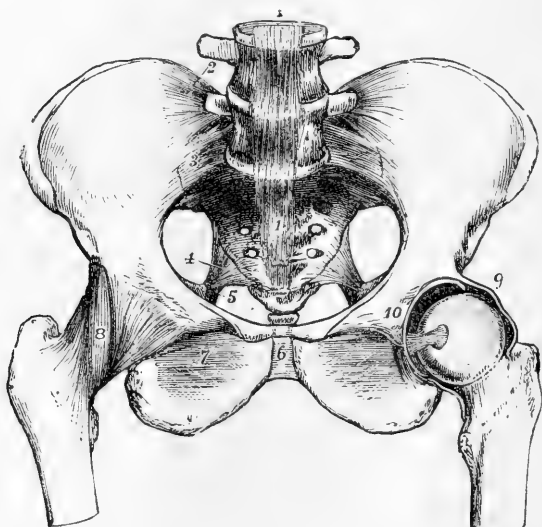


Fig. 145.—ARTICULATIONS OF THE PELVIS AND HIP-JOINT, SEEN FROM BEFORE. THE ANTERIOR HALF OF THE CAPSULAR LIGAMENT OF THE LEFT HIP-JOINT HAS BEEN REMOVED, AND THE FEMUR ROTATED OUTWARDS. (A. T.)  $\frac{1}{4}$

1, 1, anterior common ligament of the bodies of the vertebrae passing down to the front of the sacrum and coccyx; 2, ilio-lumbar ligament; 3, anterior sacro-iliac ligament; between 2 and 3, on the right side, the sacro-vertebral ligament is shown, but not with sufficient distinctness; 4, placed in the great sacro-sciatic foramen, points to the lesser sacro-sciatic ligament; 5, a portion of the great sciatic ligament; 6, the anterior ligament of the symphysis pubis; 7, the obturator membrane; 8, the capsular ligament of hip-joint: the figure is placed on its ilio-femoral band; 9, the upper part of the divided capsular ligament of the left hip-joint near the place of its attachment to the border of the acetabulum; 10, placed on the os pubis of the left side above the transverse ligament of the acetabular notch. The head of the femur is withdrawn partially from the socket, so as to show the round ligament stretched from the transverse ligament.

occur till a more advanced age ; the pieces of the coccyx uniting one to another in the first place, and the joint between the sacrum and coccyx not ossifying till old age. The mobility seems to increase during pregnancy.

THE SACRO-ILIAC ARTICULATION, often named the *sacro-iliac synchondrosis*, is formed between the auricular surfaces of the sacrum and ilium, which are bound together by a plate of cartilage, and by strong ligaments (see fig. 148).

The **auricular cartilaginous plate** unites the bones with great firmness. When the ilium and sacrum are forcibly torn asunder, this plate usually separates into two layers, one of which adheres to the surface of each bone. In some instances a small cavity naturally exists between these two plates of cartilage, and in advanced life small spaces containing glairy fluid are liable to be formed between them. Even when separate in part, however, these plates are very closely applied, and admit only a limited amount of movement. The cavity of this articulation becomes more apparent, and the ligaments somewhat looser before parturition.

The **posterior sacro-iliac ligament** consists of a large number of strong irregular fibres extending across the interval between the pos-

Fig. 146.

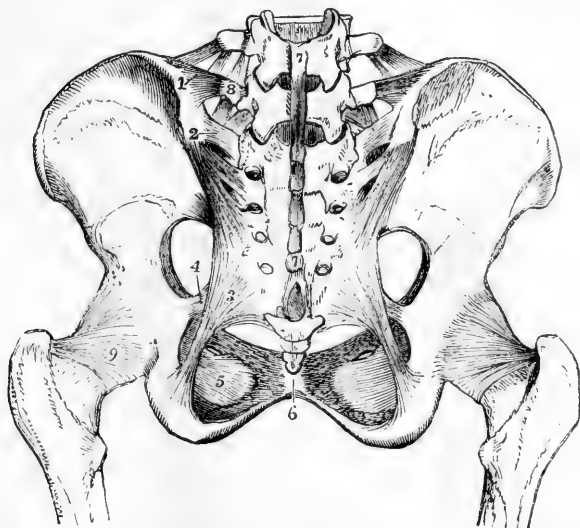


Fig. 146.—LIGAMENTS OF THE PELVIS AND HIP-JOINT. SEEN FROM BEHIND, FROM A FEMALE SUBJECT. (A. T.)  $\frac{1}{4}$

1, ilio-lumbar ligament : above it the last lumbar intertransverse ligament ; 2, posterior sacro-iliac ligaments, the short and the oblique ; 3, great sacro-sciatic ligament ; 4, lesser sacro-sciatic ligament ; 5, obturator membrane ; 6, posterior ligament of symphysis pubis ; 7, 7, continuation of supraspinous ligaments from the lower lumbar vertebrae over the sacral spines ; 8, transverse process of last lumbar vertebra, to which from above is seen descending the last intertransverse ligament, and from below ascending the sacro-vertebral ligament ; 9, posterior surface of the capsular ligament of the hip-joint. The posterior ligaments passing between the sacrum and coccyx are also partially shown.

terior rough portion of the lateral surface of the sacrum and that part of the ilium which projects beyond the dorsum of the sacrum. A superficial band extending downwards from the posterior superior iliac spine to the third or fourth piece of the sacrum, in a direction different from the other fibres, is distinguished as the *oblique sacro-iliac ligament*.

The **anterior sacro-iliac ligament** consists of thin irregular fibres passing between the sacrum and os innominatum on their pelvic surfaces.

**THE SACRO-SCIATIC LIGAMENTS.**—The **posterior, or great sacro-sciatic ligament**, broad and triangular, assists in closing the lower aperture of the pelvis. Its base is attached to the postero-inferior iliac spine and to the side of the sacrum and coccyx; whilst its apex is fixed along the inner surface of the ischial tuberosity, where it expands somewhat, and sends upwards and forwards along the margin of the ischial ramus a *falciform process*, the border of which is continuous with, and forms the inferior attachment of, the obturator fascia.

The **anterior, or small sacro-sciatic ligament**, much shorter and thinner than the preceding one, in front of which it lies, is also triangular in form, and is attached by its base to the side of the sacrum and coccyx, where its fibres are blended with those of the great ligament; and, by its apex, to the spine of the ischium.

**Foramina.** Between the upper border of the great sacro-sciatic ligament and the innominate bone, is a large space subdivided by the small sacro-sciatic ligament. The part which lies above this ligament is a large oval opening, named the *great sacro-sciatic foramen*. It transmits the pyriform muscle and the gluteal and sciatic vessels and nerves. The part between the greater and lesser sacro-sciatic liga-

Fig. 147.

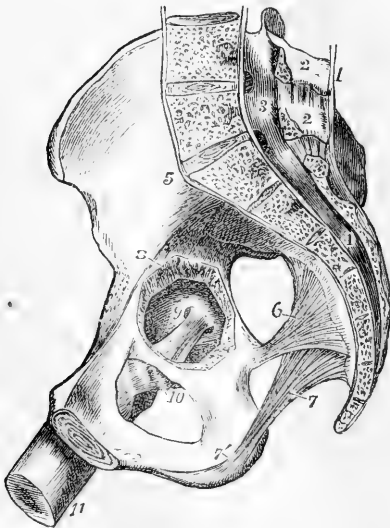

Fig. 147.—RIGHT HALF OF A FEMALE PELVIS, SEEN FROM THE INNER SIDE. (A. T.) ?

1, supraspinous ligaments descending to the sacrum from 2, 2, the lumbar spinous processes; 3, 4, the lumbar and sacral spinal canal, with its periosteal lining; 5, placed on the ilium above the anterior sacro-iliac ligament; 6, placed in the great sacro-sciatic foramen, points to the lesser sacro-sciatic ligament; 7, greater sacro-sciatic ligament, with 7', its continuation over the inner border of the tuberosity of the ischium; 8, a portion of the wall of the cotyloid cavity, removed so as to give a view from the inside of the head of the femur; 9, the round ligament put upon the stretch, the femur being partially flexed and adducted; 10, the inner part of the capsular ligament relaxed; 11, the shaft of the femur.

ments, much smaller in size, and bounded in front by the smooth surface between the spine and tuberosity of the ischium, is the *small sacro-sciatic foramen*,

through which pass the obturator internus muscle and the internal pudic vessels and nerve.

The **pubic articulation**, or *symphysis pubis*, is the connection of the pubic bones in front, and is effected by fibro-cartilaginous plates and ligaments. The adjacent surfaces of bone are each coated with cartilage, and to this is attached the fibro-cartilage which unites them. The *fibro-cartilage* is thicker and stronger in front than behind, and generally contains a synovial cavity towards the upper and back part of the joint. The ligaments are named *anterior*, *posterior*, *superior*, and *inferior*. The anterior pubic ligament consists of irregular fibres passing obliquely across from bone to bone in front of the symphysis. The superior and posterior ligaments consist of only a few fibres on the upper and back part of the articulation. The inferior or subpubic ligament, thick and triangular, is attached to the rami of the pubic bones, giving smoothness and roundness to the subpubic angle, and forming part of the outlet of the pelvis.

The **obturator membrane**, or *ligament*, is a fibrous septum attached to the border of the thyroid foramen, which it closes, except at the upper and outer part of its circumference, where a small oval canal is left for the obturator vessels and nerve. The membrane is fixed accurately to the bony margin at the upper and outer sides of the foramen, and to the posterior surface at the inner side. The obturator muscles are attached to its surfaces.

**Movements.**—In ordinary circumstances there is very little movement allowed between the bones of the pelvis. In the erect posture the sacrum is thrown so much backwards that none of the advantage of the key-stone of an arch is obtained by the tapering of its form from base to apex. It is only by the sinuosities of its auricular surfaces that it directly presses on the hip-bones; and as the width of the bone rather diminishes at the upper or ligamentous part, the principal strain is borne by the posterior sacro-iliac ligaments, from which the sacrum is in great measure suspended (see fig. 148). The space which might be gained by the small amount of movement which is allowed between the bones of the pelvis in the ordinary state is increased during parturition in this way, that the lower part of the sacrum being pressed backwards, the wider part of the wedge formed by this bone is forced farther between the ossa innominata, so as to separate them to a greater degree, and thus to increase the capacity of the pelvis. During pregnancy, also, a slight amount of separation may occur at the symphysis pubis from relaxation of the connecting parts. (See Wood, article "Pelvis" in "Cyclopæd. of Anat. and Physiol.;" Zaglas, in Monthly Journ. of Med. Science, 1851; J. M. Duncan, in Dublin Quart. Journ. of Med. Science, 1854, and Edin. Med. Journ. 1855; Struthers, "Anat. Observ.")

## ARTICULATIONS OF THE LOWER LIMB.

### THE HIP-JOINT.

This is a large ball and socket joint, in which the globular head of the femur is received into the acetabulum or cotyloid cavity of the innominate bone. The articular surface of the acetabulum is formed by a broad ribband-shaped cartilage occupying the upper and outer part, and folded round a depression which, extending from the notch, is hollowed out in the bottom of the cavity, and is occupied by delicate adipose tissue covered with synovial membrane, the so-called synovial or Haversian gland. The articular surface of the femur presents a little beneath its centre a pit in which the round ligament is attached,

Fig. 148.

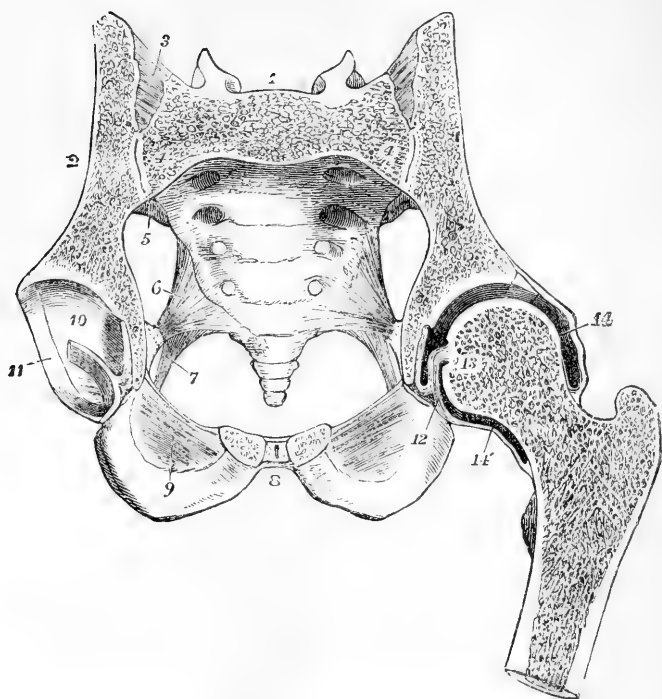


Fig. 148—TRANSVERSE OBLIQUE SECTION OF THE PELVIS AND HIP-JOINT, CUTTING THE FIRST SACRAL VERTEBRA AND THE SYMPHYSIS PUBIS IN THEIR MIDDLE, FROM A MALE SUBJECT OF ABOUT NINETEEN YEARS OF AGE. (A. T.)  $\frac{1}{3}$

1, the first sacral vertebra ; 2, the divided ilium ; 3, the posterior sacro-iliac ligaments ; 4, 4, the sacro-iliac synchondrosis, with a slight separation between the two plates of cartilage ; 5, the anterior sacro-iliac ligament ; 6, the lesser sacro-sciatic ligament ; 7, greater sacro-sciatic ligament ; 8, placed in front of the symphysis pubis, in the cut surface of which the small median cavity, the adjacent fibro-cartilaginous plates, and the anterior and posterior ligamentous fibres are shown ; 9, the lower part of the obturator membrane ; 10, the cartilaginous surface of the cotyloid cavity, through the middle of which the incision passes transversely, dividing the round ligament and the synovial fat of the depression ; 11, the cotyloid ligament ; 12, the round ligament connected with the transverse part of the cotyloid ligament ; 13, placed on the cut surface of the head of the left femur near the depression where the round ligament is attached ; 14, 14', the upper and lower parts of the capsular ligament and synovial capsule.

The **cotyloid ligament** forms a thick fibro-cartilaginous ring round the margin of the acetabulum, increasing the depth of its cavity, and bridging over the deficiency in its border. Its external surface is in contact with the capsular ligament, the internal closely embraces the head of the femur, and both are covered by the synovial membrane. Its fibres do not run parallel to the circumference of the cotyloid cavity, but pass obliquely from without inwards over its margin, one extremity being attached to the outer, the other to the inner surface.

At the cotyloid notch the fibres of the ligament are continued from

side to side, so as to render the circumference complete, and deeper transverse fibres are superadded, from which circumstance, as well as from being stretched across from one margin of the notch to the other, this part is called the *transverse ligament*. Beneath it an interval is left for the admission of the articular vessels.

The **interarticular** or **round ligament** (ligamentum teres) is a strong fasciculus surrounded by synovial membrane, implanted by one extremity, which is round, into the fossa in the head of the femur; by the other, which is broad, flat, and bifid, into the margins of the cotyloid notch, where its fibres become blended with those of the transverse ligament. It rests on the fat in the depression of the acetabulum.

The **capsular ligament** or **membrane** surrounding the joint is attached superiorly to the margin of the cotyloid cavity, and inferiorly to the neck of the femur. At its cotyloid attachment the capsule arises, above and behind, from the bony margin outside the attachment of the cotyloid ligament, having its inner surface in close contact with that ligament; in front it arises from the outer aspect of the cotyloid ligament near its base, and at the notch it is similarly attached to the transverse ligament. At its femoral attachment the capsule extends anteriorly to the intertrochanteric line, superiorly to the root of the great trochanter, posteriorly and inferiorly to the junction of the middle and external thirds of the neck. The fibres of which the capsule consists run in two directions, circularly and longitudinally. The circular fibres are found in the middle of the lower wall of the capsule, gathered into a thick broad band (*Zona orbicularis*, Henle,) which as it extends upwards spreads out so as to form a tolerably even layer over the front and upper part of the joint. Behind, these fibres again form a band which for about a finger's breadth next the neck of the femur complete the capsule. The circular fibres are embedded to some extent in the longitudinal fibres, except posteriorly, where the latter are almost absent, being represented by a few scattered fibres which support the synovial membrane, and attach the circular fibres to the neck of the bone. In other parts of the capsule the longitudinal fibres form thick bands, certain of which from their greater size and strength are distinguished as accessory ligaments. The chief of these are formed on the anterior and superior aspects of the capsule. The *ilio-femoral* ligament consists of two diverging bands of fibres, which arise from the anterior inferior iliac spine, and pass obliquely downwards over the front of the joint. The inner of these bands passes almost vertically to the root of the small trochanter; the outer to the upper end of the anterior intertrochanteric line. In the triangular space thus left between the bands, the deeper fibres of the capsule are seen. On the superior aspect of the joint the outer band of the ilio-femoral ligament is joined by another band of fibres (*ilio-trochanteric*) which is attached to the ilium, above the origin of the long head of the rectus femoris muscle, and to the root of the great trochanter on its anterior aspect. To the under surface of the capsule, a broad and strong band of fibres (*ischio-capsular*) passes from the furrow on the ischium below the acetabulum to end in the circular fibres. In front and below may be also found a number of scattered fibrous bundles, which converge to the capsule from the ilio-pectineal eminence, from the margin of the obturator foramen, and from the obturator membrane, and to which Henle has given the name of *pubo-femoral* ligament. Besides these the capsule receives other strength-

ening bands from the tendons of neighbouring muscles, in front from the ilio-psoas, above from the long head of the rectus femoris, behind from the gluteus minimus, and below from the obturator externus.

From the inside of the capsule the inner layers of fibres are reflected upwards from their insertion upon the neck of the femur to the articular cartilage, forming a surface partly level and partly raised into longitudinal folds called *retinacula* (Henle).

The **synovial membrane** of the joint is reflected from the neck of the femur to the inner surface of the capsule, thence to the inner surface of the cotyloid ligament and to the pad of fat in the bottom of the acetabulum, from which it is further prolonged as a tubular investment upon the round ligament. It frequently communicates through an opening in the anterior wall of the capsule, with a synovial bursa placed beneath the tendon of the ilio-psoas muscle.

**Movements.**—The movements allowed at the hip-joint are extension, flexion, abduction, adduction, circumduction, and rotation. Extension is limited by the anterior fibres of the capsular ligament, and the ilio-femoral band: flexion is limited only by the contact of the neck of the femur with the acetabulum. Abduction is controlled by the pubo-femoral bands, and by the lower part of the capsule; adduction by the ilio-trochanteric band and by the upper part of the capsule. The round ligament is put upon the stretch when the thigh is partially flexed and adducted; it therefore resists dislocation upwards and backwards on the *dorsum ili*, which is, notwithstanding its presence, the most frequent kind of displacement. The round ligament is also put upon the stretch in the position of flexion and external rotation. The swinging antero-posterior movement of the femur, as in walking or running, is effected by rotation of the head of the bone in the hip-joint. In the erect attitude, as a vertical line passing through the centre of gravity of the trunk falls behind the centres of rotation in the hip-joints, the pelvis tends to fall backwards by over extension of the hip-joints, but as this is prevented by the tightening of the capsule in front, the maintenance of the erect attitude, without muscular effort, is partly due to this mechanism of the hip-joint.

#### THE KNEE-JOINT.

The articular surfaces of this complicated joint are the condyles of the femur and tibia, with fibro-cartilages interposed, the articulating surface of the patella, and the patellar surface of the femur. The action is mainly that of a hinge-joint. The joint is strengthened superficially by fibrous coverings derived from the muscular tendons and aponeuroses. The ligaments which have received special names are the following.

The **internal lateral ligament**, long and flat, connects the internal tuberosity of the femur with the inner tuberosity and the hinder border of the tibia, on the shaft of which it descends for some distance. Superiorly its deep surface rests on the articular synovial membrane; in the middle it is attached to the internal semilunar cartilage; and below the head of the tibia the anterior slip of insertion of the semimembranosus muscle passes between the ligament and the bone.

The **external lateral ligament** is a rounded cord, which extends from the external tuberosity of the femur to the head of the fibula. Its internal surface corresponds with the tendon of the popliteus muscle and the inferior external articular vessels. The tendon of the biceps flexor cruris muscle is frequently divided into two by this ligament, and between the ligament and the tendon there is a synovial bursa. Further



back is another band, the *short external lateral ligament*, the arrangement of which is more variable; it is often connected with the tendon of the popliteus muscle, and occasionally terminates in the capsular membrane.

The **posterior ligament** is a flat fasciculus of fibres passing from behind the inner tuberosity of the tibia upwards and outwards to the external condyle of the femur, and is in part continuous at its inner end with the tendon of the semimembranosus muscle.

Fig. 149.

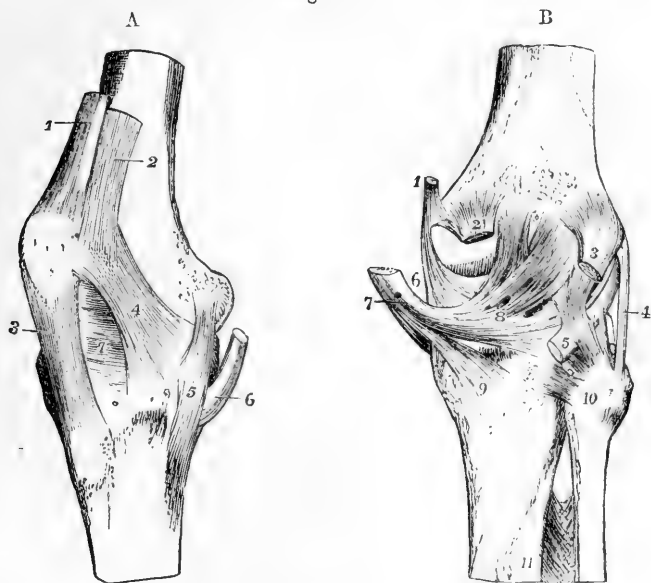


Fig. 149, A.—RIGHT KNEE-JOINT, FROM THE INSIDE AND ANTERIORLY. (A. T.)  $\frac{1}{3}$

1, tendon of the rectus muscle near its insertion into the patella; 2, insertion of the vastus internus into the rectus tendon and side of the patella; 3, ligamentum patellæ descending to the anterior tuberosity of the tibia; 4, capsular fibres forming a lateral ligament of the patella prolonged in part from the insertion of the vastus internus downwards towards the inner tuberosity of the tibia; 5, internal lateral ligament; 6, tendon of the semimembranosus muscle. (After Arnold.)

Fig. 149, B.—KNEE-JOINT FROM BEHIND. (A. T.)

1, insertion of the tendon of adductor magnus; 2, origin of the inner head of the gastrocnemius muscle; 3, outer head of the same; 4, cord-like external lateral ligament; 5, tendon of the popliteus muscle: a ligament descending from behind the outer condyle of the femur is seen attached to this tendon below, and another descending from the tendon is attached to the head of the fibula, constituting the short external lateral ligament; 6, part of internal lateral ligament; 7, tendon of the semimembranosus muscle; 8, posterior ligament of Winslow, spreading outwards from the tendon; 9, expansion of the popliteal fascia downwards from the same, represented as cut short; 10, on the head of fibula, marks the posterior superior tibio-fibular ligament; 11, upper part of the interosseous ligament, with the foramen above it for the anterior tibial artery.

The **ligamentum patellæ** is a strong flat tendinous band, attached superiorly to the lower extremity of the patella, and the depression beneath its articular surface, and inferiorly to the anterior tubercle of

the tibia. Between the tibia and the ligament, near its insertion, is placed a synovial bursa. If the patella be considered a sesamoid bone, this ligament may be regarded as part of the tendon of the rectus femoris muscle.

The **crucial ligaments**, placed in the centre of the joint, pass from the sides of the intercondylar fossa to the spaces in front of and behind the spine of the tibia. They decussate somewhat like the lines of the letter X. The *anterior* or *external ligament* is fixed by its lower

Fig. 150.

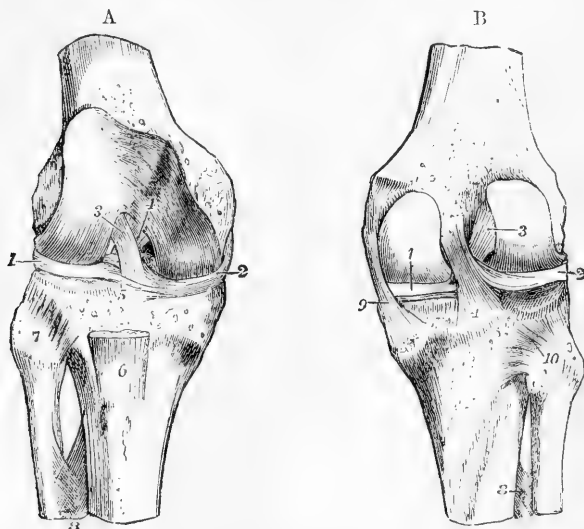


Fig. 150, A.—THE KNEE-JOINT, OPENED FROM BEFORE, TO SHOW THE CRUCIAL LIGAMENTS AND SEMILUNAR CARTILAGES. (A. T.)  $\frac{1}{2}$

1, external, and 2, internal semilunar cartilage; 3, on the outer condylar surface of the femur, points to the anterior crucial ligament; 4, placed on the elevated line separating the patellar from the inner condylar surface of the femur, points to the posterior crucial ligament; 5, transverse ligament of the semilunar cartilages; 6, part of the ligamentum patellæ; 7, on the head of the fibula, points to the superior anterior tibio-fibular ligament; 8, upper part of the interosseous membrane, showing the perforation for the anterior tibial artery.

Fig. 150, B.—THE KNEE-JOINT, OPENED FROM BEHIND, SO AS TO EXPOSE THE CRUCIAL LIGAMENTS AND SEMILUNAR CARTILAGES. (A. T.)  $\frac{1}{2}$

1, internal semilunar cartilage; 2, external semilunar cartilage; 3, anterior crucial ligament; 4, posterior crucial ligament: farther up is seen its accessory band joining the external semilunar cartilage; 8, upper part of the interosseous membrane; 9, internal lateral ligament; 10, placed on the head of the fibula, points to the posterior superior tibio-fibular ligament; between the head of the fibula and the external semilunar cartilage (2) is seen the synovial surface of the tibia, upon which the semilunar cartilage descends in flexion, and where a communication sometimes takes place between the synovial cavities of the knee-joint and the tibio-fibular articulation.

extremity to the inner part of the pit before the spine of the tibia, and by its upper extremity it is inserted into the inner and hinder part of the external condyle of the femur; hence its direction is upwards, backwards, and outwards. The *posterior* or *internal ligament* is at-

tached inferiorly to the back of the pit behind the tibial spine, and superiorly to the fore part of the intercondylar hollow, as well as slightly to the side of the inner condyle of the femur; its fibres are directed upwards and a little forwards.

The **semilunar cartilages** are two crescent-shaped interarticular fibro-cartilages, placed on the articulating surfaces of the head of the tibia, and interposed between these and the condyles of the femur. They have each a synovial surface above and below, and a convex border, which is thick, while the concave border is thinned to a fine edge, and the part of the articular surface of the tibia within the concave border of each cartilage is left uncovered. At their extremities they are fibrous, and are firmly fixed to the head of the tibia, whilst by the circumference they are connected with the fibrous capsule of the joint.

Fig. 151.—VIEW OF THE INTERARTICULAR FIBRO-CARTILAGES OF THE RIGHT KNEE-JOINT, FROM ABOVE, WITH THE CRUCIAL LIGAMENTS DIVIDED, AND THE LIGAMENTUM PATELLE TURNED FORWARDS. (A. T.)  $\frac{1}{2}$

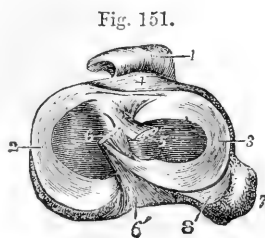


Fig. 151.

1, ligamentum patellæ; 2, the inner fibro-cartilage; 3, the outer one; 4, the anterior tuberosity of the tibia in front of the transverse ligament; 5, the cut end of the anterior crucial ligament directed obliquely towards the outer side and backwards; 6, the cut end of the posterior crucial ligament, from which fibres are seen descending to the outer fibro-cartilage; 6', tibial attachment of the posterior crucial ligament; 7, the head of the fibula; 8, the synovial surface of the tibia, which extends for some way downwards towards the tibio-fibular synovial sac, with which it is sometimes continuous.

The **internal semilunar cartilage** forms nearly a semicircle; its anterior cornu is small and pointed, and is inserted into an impression at the fore and outer part of the internal articular surface of the tibia; its posterior end is attached to the inner edge of the hollow behind the spine, and is in relation with the posterior crucial ligament.

The **external semilunar cartilage** forms more than three-fourths of a circle; its two cornua, fixed, one before, the other between the points of the spine of the tibia, are so close at their insertion that they may be said to be interposed between the attachments of the internal semilunar plate. Its external border is in contact behind with the tendon of the popliteus muscle, and is therefore separated by this from the fibrous capsule. From this fibro-cartilage a ligamentous band ascends, to be attached to the inner condyle of the femur in connection either in front or behind with the posterior crucial ligament (*accessory band of the posterior crucial ligament*).

**Transverse ligament.**—Towards the front of the joint the convex borders of the interarticular fibro-cartilages are connected by a slight transverse band, which receives this name. Its thickness varies much in different bodies.

**Capsular membrane.**—Under this name is described the fibrous tissue which invests the joint in the intervals between the stronger bands which have been named ligaments. It is incomplete, not extending underneath the tendons of the extensor muscles. Between the sides

of the patella and the femur it consists of fibres connected with the insertion of the vasti muscles and with the fascia lata, and thus forms the structures, uniting the patella to the tibia, which have been called *lateral patellar ligaments*; posteriorly it covers the condyles of the femur beneath the gastrocnemius muscle. In this last situation it is thin, and a sesamoid bone is often found in connection with it in the outer, less frequently in the inner head of the muscle.

The **synovial membrane** is the largest in the body. Traced downwards from the femur on either side of the joint, it may be followed from the capsule to the upper surface of the semilunar cartilages, round the free borders of those structures to their inferior surfaces, and thence to the tibia. The crucial ligaments are invested in front by a reflected

Fig. 152.

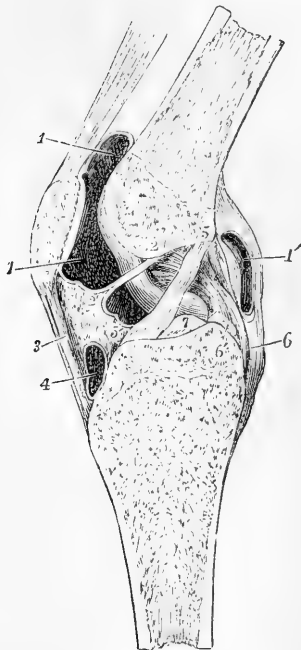


Fig. 152.—VERTICAL ANTERO-POSTERIOR SECTION OF THE LEFT KNEE-JOINT, SEEN FROM THE OUTER OR LEFT SIDE. (A. T.)  $\frac{1}{3}$

The section is made somewhat obliquely a little to the outside of the middle, so as to preserve entire the crucial ligaments with their attachments: it is from a young subject of eighteen or nineteen years. 1, 1, the upper portion of the synovial cavity extending upwards between the extensor tendons and the femur; 1', an aperture made into the posterior portion of the synovial cavity; 2, 2', ligamentum mucosum; 3, ligamentum patellae; 2, 3, the subpatellar synovial fatty cushion; 4, bursa above the insertion of the ligamentum patellae into the anterior tibial tuberosity; 5, 5', the anterior crucial ligament; 5', points also to the internal semilunar cartilage within the joint; 6, lower part of the posterior crucial ligament, the upper part of which is towards 2; 6', the accessory band joining the external semilunar cartilage, which is cut short; 7, the spine of the tibia.

portion of the membrane continued forwards from the posterior wall of the joint. Between the tibia and patella the synovial membrane lies upon a large pad or cushion of fat, on the surface of which it forms two lateral folds (*alar ligaments*) which fit into the space between the tibia, patella and femur, while from the middle of the pad it sends backwards a tapering process, the *ligamentum mucosum*, through the joint to the front of the intercondylar fossa. Above the patella the synovial membrane extends upwards some distance, forming a large pouch between the extensor tendons and the femur.

**Movements, &c.**—In order to explain the nature of the movements, it is necessary to state some considerations with regard to the relations of the several parts of the knee-joint to each other. The knee-joint may be regarded as consisting of three articulations conjoined, viz., that between the patella and femur, and two others, one between each condyle of the femur and the tibia. In most mammals the synovial membranes of those three joints are either completely distinct or communicate with each other by only small openings; and this sometimes occurs in Man. In the human subject the ligamentum mucosum is an

indication of the original separation of the synovial membranes of the inner and outer joints, and the crucial ligaments may be looked upon as the external and internal lateral ligaments of those two joints respectively. Each portion of the articular surface of the femur belongs either to one or other of the three component joints of the knee, and no part is common to any two of them. On a well-marked femur, the inferior limits of the patellar surface are quite distinguishable; the line which separates this surface from the outer tibial joint passing directly between it and the condyle, and that which separates it from the inner joint being continued backwards, so as to cut off from the rest of the inner condyle a narrow tract at the side of the intercondylar fossa.

Fig. 153.

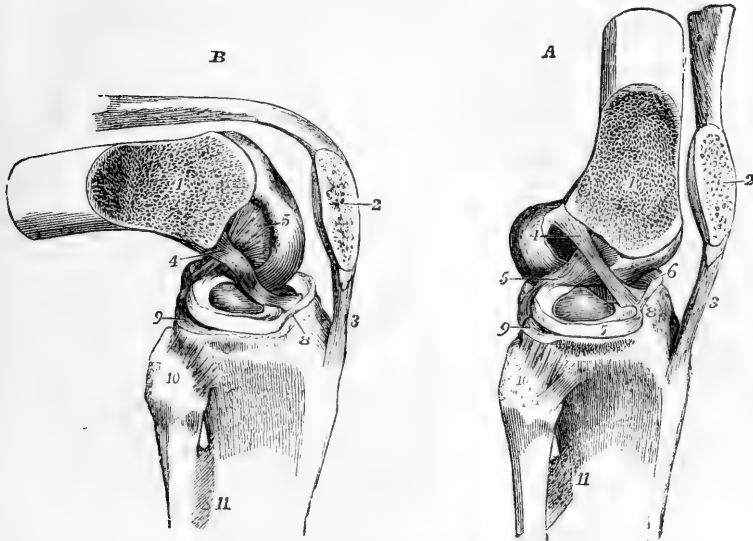


Fig. 153.—THE SUPERFICIAL PARTS OF THE KNEE-JOINT REMOVED, AND THE EXTERNAL CONDYLE OF THE FEMUR SAWN OFF OBLIQUELY, TOGETHER WITH HALF THE PATELLA, SO AS TO EXPOSE BOTH THE CRUCIAL LIGAMENTS TOGETHER. (A. T.)  $\frac{1}{3}$

In A, the parts are in the position of extension, in B, that of flexion, the figures being designed to show the different state of tension of the crucial ligaments in these positions. 1, sawn surface of the femur; 2, sawn surface of the patella; 3, ligamentum patellæ; 4, anterior or external crucial ligament, tense in A, and relaxed in B; 5, posterior or internal crucial ligament, relaxed in A, tense in B; 6, internal, and 7, external semilunar cartilage; 8, transverse ligament; 9, articular surface of the tibia, extending behind the external semilunar cartilage; 10, on the head of the fibula, points to the anterior superior tibio-peroneal ligament; 11, upper part of the interosseous membrane.

The movement of the patella on the femur is one partly of gliding, partly of coaptation. This is illustrated by a careful examination of the articular surface of the patella, which is not uniformly curved from above downwards, as it would be, were the movement one of gliding only, but exhibits on each side of the vertical ridge three very slightly depressed surfaces, separated by two slight transverse elevations, and along the inner margin a seventh area, upon which the transverse lines do not encroach (Goodsir.) When the knee is extended, and the patella drawn upwards by the extensor muscles, the two inferior facets of the patella are in contact with the upper margin of the femoral surface; in semiflexion the middle facets only are in contact with the femur; in greater flexion, the superior parts of the patella are in contact with the lower part of

the femoral surface; and in extreme flexion the patella, which has been gradually turned outwards by the increasing prominence of the inner condyle, rests by its innermost facet on the outer margin of that condyle. The articulation between each condyle and the opposed almost flat surface of the tibia, while resembling, is not exactly a hinge joint, and extension and flexion, the movements of which it is capable, are produced by a combination of gliding, rolling, and rotation. If the condyles of the femur be examined as they rest upon the tibia in the flexed position of the joint, it will be seen that the inner condyle is longer than the outer, and that its anterior portion inclines obliquely outwards, to reach the patellar surface. In the movement of extension the condyles move parallel to one another, both gliding and rolling until extension is nearly completed, and then, the anterior part of the rolling surface of the external condyle having already come into contact with the tibia, the inner condyle continues to glide backwards, bringing its oblique anterior part into contact with the tibia, so that the bone is rotated inwards on the tibia, and over-extension is prevented, not merely by the tightness of the ligaments, but by the femur being pressed up against the tibial spine. In complete extension the lateral ligaments and the external crucial ligament are tight, while the posterior crucial ligament is relaxed; in flexion, the posterior crucial ligament only is tightened, the others being relaxed. In extension of the joint no rotation of the leg is possible; in the flexed condition a considerable amount is allowed. The semilunar cartilages being loosely attached to the head of the tibia, move forwards in extension and backwards in flexion of the joint; and further, as the condyles rolling upon the tibia present to the condylar surfaces of that bone portions having different curvatures, each cartilage, like a moveable wedge, is contracted round the condyle during flexion of the joint and ~~relaxed~~ <sup>expanded</sup> during extension. In extension of the knee, as the weight of the body keeps the bones in their position, the extensor muscles are relaxed, the patella drops down from its position in contact with the femur, and the ligamentum mucosum then comes into play, supporting the synovial membrane and fat below the patella. As the line of the centre of gravity of the body in the erect attitude descends in front of the axis of motion of the knee-joint, there is a tendency to over extension of the joint, which is resisted by the tension of the two lateral and the posterior ligaments, as well as of the anterior crucial, and thus the maintenance of the erect attitude without muscular effort is partly due to the mechanism of the knee-joint. (See Meyer, *op. cit.*; Goodsir, "Anatomical Memoirs," vol. ii. pp. 220, 231; Langer, "Sitzungsber d. Acad. der Wissensch. Wien," 1858; Henke, "Zeitschr. für rat. Med.," v. viii., 1859.)

#### TIBIO-FIBULAR ARTICULATIONS.

The tibia and fibula are connected at their upper and lower extremities by synovial articulations, and their shafts are united by an interosseous membrane.

**Upper tibio-fibular articulation.**—The superior extremities of the bones present two flat oval articular surfaces, retained in close contact by an *anterior* and a *posterior superior tibio-fibular ligament*, both of which pass upwards and inwards from the head of the fibula to the external tuberosity of the tibia. The synovial membrane which lines this joint not unfrequently communicates posteriorly with that of the knee.

The **interosseous membrane** or **ligament**, which connects the shafts of the tibia and fibula, passes between the external ridge of the tibia and the ridge on the inner surface of the fibula, and is composed for the most part of parallel fibres running outwards and downwards, only a few fibres crossing them in a different direction. The membrane is broader above than below, and presents superiorly an elongated opening for the transmission of the anterior tibial vessels, and inferiorly

a small aperture for the passage of the anterior branches of the peroneal vessels.

Fig. 154.—ARTICULATIONS OF THE KNEE, LEG AND ANKLE, SEEN FROM BEFORE.  $\frac{1}{2}$

1, superior anterior tibio-fibular ligament; 2, interosseous membrane; 3, the anterior inferior tibio-fibular ligament; 4, internal lateral ligament of the ankle-joint; 5, middle vertical part (calcaneo-fibular) of the external lateral ligament of the ankle-joint; 6, anterior part (talo-fibular) of the same; 7, anterior ligament of the ankle-joint.

**Lower tibio-fibular articulation.**—The inferior extremities of the tibia and fibula are in contact by surfaces which for the most part are rough and bound together by ligament, but near their lower edges are smooth and covered by cartilage. The tibial surface is concave, the fibular convex; but the lower edges of both surfaces are straight. The strong short fibres which pass directly between the opposed surfaces form the *inferior interosseous ligament*. The *anterior ligament* is a flat band of fibres, extended obliquely over the lower part of the bones, the direction of its fibres being downwards from the tibia to the fibula. The *posterior ligament*, somewhat triangular, is similarly disposed behind the articulation; its outer surface is covered by the peronei muscles. The *transverse ligament*, longer and narrower than the preceding, is placed immediately below it; its fibres are horizontal, and extend from the external malleolus to the contiguous part and hinder border of the articular surface of the tibia; it closes the interval between the bones.

The *synovial cavity* lying between the small articular surfaces is an extension of that of the ankle-joint.

#### THE ANKLE-JOINT.

In this articulation, which is a hinge joint, the inferior extremi-

Fig. 155.—THE LOWER TIBIO-FIBULAR ARTICULATION AND ANKLE-JOINT, FROM BEHIND.

1, inferior posterior tibio-fibular ligament; 2, transverse ligament; 3, posterior fibres of the internal lateral ligament of the ankle-joint; 4, middle, and 5, posterior part of the external lateral ligament of the ankle-joint; 6, posterior talo-calcaneal ligament.

ties of the tibia and fibula are united so as to present a three-sided hollow, which embraces the astragalus, and renders lateral movement impossible when the ligaments are tense.

The **internal lateral** or **deltoid ligament** is a flat fasciculus of fibres, much broader at the lower than at the upper part. One extremity is attached to the groove on the inferior border of the internal

Fig. 154.

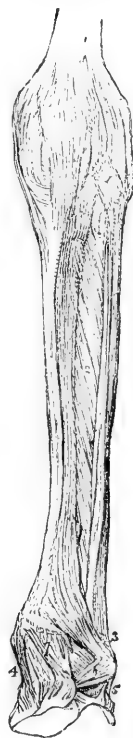
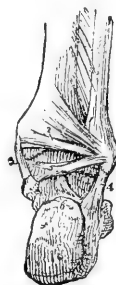
Fig. 155.



malleolus ; the other, to the inner side of the astragalus, the os calcis, and the scaphoid bone, as well as to the inferior calcaneo-scaphoid ligament.

The **external lateral ligament** consists of three distinct bands separated by intervals and disposed in different directions. 1. The *middle* band descends from the extremity of the fibula, and is inserted into the middle of the external surface of the os calcis. 2. The *anterior* band passes obliquely forwards and inwards from the fore part of the outer malleolus to a part of the astragalus in front of its external malleolar surface ; it is the shortest of the three. 3. The *posterior* band, the strongest of the three, passes almost horizontally inwards from the pit on the inner and back part of the malleolus to the posterior surface of the astragalus.

Fig. 156.

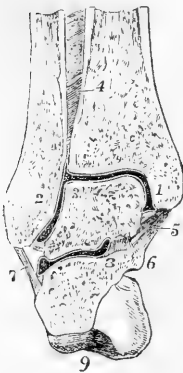


Fig. 156.—TRANSVERSE-VERTICAL SECTION OF THE RIGHT ANKLE-JOINT NEAR ITS MIDDLE, AND OF THE POSTERIOR TALO-CALCANEAL ARTICULATION, SO AS TO SHOW THE SHAPE OF THE ARTICULAR SURFACES AND CAVITIES, VIEWED FROM BEFORE. (A. T.)  $\frac{1}{2}$

1, internal, 2, external malleolus ; 3, placed on the astragalus at the angle between its superior and its external malleolar surfaces ; 4, interosseous tibio-fibular ligament ; 5, internal lateral ligament of the ankle-joint ; 6, sustentaculum tali ; 7, calcaneo-fibular or middle part of the external lateral ligament ; 8, inner part of the interosseous calcaneo-talar ligament ; 9, great tuberosity of the calcaneum : between the tibia, fibula and astragalus, the synovial cavity is indicated by the dark space enclosed by a white line ; between the astragalus and os calcis a section of the posterior calcaneo-talar synovial cavity is shown.

The **anterior and posterior ligaments** are merely scattered fibres in front of and behind the joint ; those of the posterior ligament are weak and principally transverse.

The **synovial membrane** of the ankle-joint extends upwards by a small process which lines the inferior peroneo-tibial articulation.

**Movements.**—The movements of the ankle-joint are mainly those of flexion and extension of the foot, the directions of those movements being principally determined by the shape of the articular surfaces. The external border of the superior cartilaginous surface of the astragalus is curved, and longer than the internal border, and hence extension of the ankle-joint is accompanied with a slight inward movement of the toes. The horizontal surfaces of both the tibia and astragalus are broader in front than behind ; hence in complete extension of the ankle the narrow part of the astragalus is brought into the widest part of the space between the malleoli, and a certain amount of lateral motion is allowed, whereas in complete flexion, as when the weight of the body, with completely bended knees, is supported on the toes, the broad part of the surface of the astragalus is pushed back into the narrowest part of the space, and the inferior extremity of the fibula is pressed upon, so as to stretch the ligaments between it and the tibia, and thus to prevent lateral movement of the joint, and give it at the same time a certain amount of spring. There appears to be no other movement between the tibia and fibula ; these bones being bound together at their lower ends with remarkable firmness.

#### ARTICULATIONS OF THE FOOT.

#### ARTICULATIONS OF THE CALCANEUM, ASTRAGALUS, AND SCAPHOID



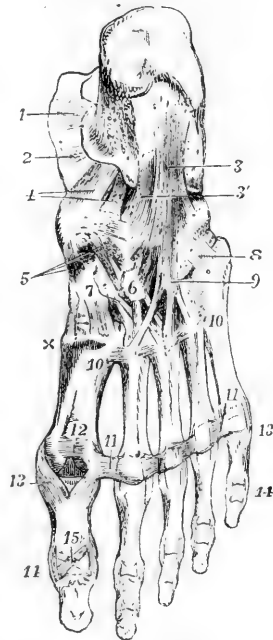
**BONES ONE WITH ANOTHER.**—The astragalus is connected with the calcaneum by two synovial articulations, viz., by a posterior one peculiar to those two bones, and by an anterior one common to them with the scaphoid bone. The following are the principal parts requiring description.

**Astragalo-calcaneal ligaments.**—The *interosseous ligament*, broad and strong, passes vertically downwards from the groove between the anterior and posterior articular surfaces of the astragalus to the similar groove between the corresponding articular surfaces of the calcaneum. A membranous *posterior ligament* connects the posterior border of the astragalus with the upper surface of the calcaneum; its fibres are oblique and very short. There is also an *external ligament*, consisting of a slight fasciculus of fibres, which descends perpendicularly from the outer surface of the astragalus to the outer side of the calcaneum, parallel with the middle division of the external lateral ligament of the ankle-joint. It may be further observed, that those portions of the lateral ligaments of the ankle-joint which pass down over the astragalus to the os calcis assist in uniting these two bones.

Fig. 157.—LIGAMENTS OF THE FOOT, SEEN FROM BELOW. (A. T.)  $\frac{1}{3}$

1 and 2, portions of the internal lateral ligament of the ankle-joint; 3, calcaneo-cuboid or long plantar ligament; 3', deep or short part of the same; 4, plantar calcaneo-scaphoid ligament; 5, three scaphoido-cuneiform ligaments of the internal, middle and external cuneiform bones; 6, is placed upon the external cuneiform bone, towards which is seen coming from behind a cuboido-cuneiform ligament; 7, is placed upon the internal cuneiform bone; from 6 and 7, are seen passing downwards the plantar-cunco-metatarsal ligaments; x, part of the first dorsal cunco-metatarsal ligament; 8 and 9, ligamentous fibres prolonged from the cuboid bone and sheath of the peroneus longus muscle upon the outer metatarsal bones; 10, 10, between these figures the posterior intermetatarsal (or transverse) ligaments; 11, 11, anterior transverse metatarsal ligament, continued across the four metatarsal spaces; 12, intersesamoid ligament; 13, 13, between these figures are seen the five pairs of internal and external lateral metatarso-digital ligaments; 14, 14, between these figures are seen the five pairs of internal and external lateral digital (phalangeal) ligaments of the first series; those of the second series have no figure placed to mark them; 15, inferior ligament of the phalangeal articulation of the great toe.

Fig. 157.



**Calcaneo-scaphoid ligaments.**—The calcaneum and scaphoid bone are not in contact, but they are connected by two ligaments. The *inferior* or *plantar* ligament, much the larger of the two, is a broad band which passes forwards and inwards from the fore part of the calcaneum (sustentaculum tali) to the inferior surface of the scaphoid bone. It is in contact inferiorly with the tendon of the tibialis posterior muscle, while superiorly it forms the floor of the articular cavity which receives the head of the astragalus, and is lined by synovial membrane. The *external, dorsal, or interosseous ligament*, forms the external boundary

of the cavity just mentioned, and lies deeply at the anterior part of the fossa (*sinus pedis*), between the astragalus and os calcis. Its fibres, very short, are directed from behind forwards between the contiguous extremities of the bones. They are attached posteriorly to a ridge of the os calcis that separates the articular surfaces for the astragalus and os cuboides, and anteriorly to the outer side of the scaphoid bone.

The **talo-scaphoid** or **astragal-scaphoid ligament**, a membranous band of fibres situated on the dorsum of the foot, extends obliquely forwards from the anterior extremity of the astragalus to the superior surface of the scaphoid bone, and completes the capsule of the calcaneo-talo-scaphoid joint, formed in the rest of its extent by the plantar and external calcaneo-scaphoid ligaments.

Two **synovial membranes** line the articulations of the calcaneum and scaphoid with the astragalus, one belonging to the calcaneo-talar joint, and another to the calcaneo-talo-scaphoid articulation.

**CALCaneo-CUBOID ARTICULATION.**—The calcaneum is united to the cuboid bone by a synovial joint and ligaments.

The **inferior ligament** consists of two distinct fasciculi of fibres, of which one is superficial, the other deep-seated. The superficial parts called the **long plantar ligament**, is the longest of the tarsal ligaments. Its fibres, attached behind to the inferior surface of the calcaneum as far as the anterior tubercle, pass forwards, and are attached in greater part to the tuberosity on the under surface of the cuboid bone; some of them are continued onwards, and terminate at the bases of the

Fig. 158.

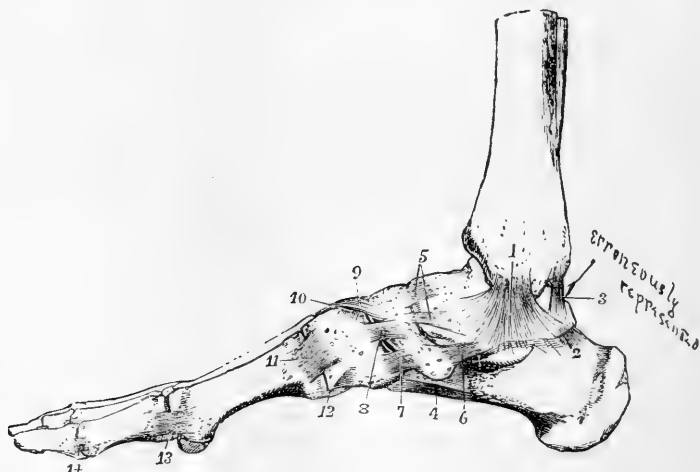


Fig. 158.—LIGAMENTS OF THE FOOT, FROM THE INNER SIDE. (A. T.)  $\frac{1}{3}$

1, internal lateral ligament of the ankle; ×, in front of the sustentaculum tali, showing part of the internal lateral ligament descending upon it; 2, posterior talo-calcaneal ligament; 3, posterior ligament of the ankle-joint; 4, part of the long and short calcaneo-cuboid ligaments seen from the inside; 5, two superior astragal-scaphoid or talo-scaphoid ligaments; 6, internal talo-scaphoid ligaments; 7, internal scapho-cuneiform (first); 8, dorsal or superior cuneiform; 9, scapho-cuneiform (second); 10, intercuneiform, or transverse dorsal cuneiform, between the first and second cuneiform bones; 11, internal or first tarso-metatarsal ligament; 12, inferior first tarso-metatarsal; 13, internal lateral metatarso-phalangeal; the internal sesamoid bone is seen below; 14, internal lateral interphalangeal ligament of the first toe.

third and fourth metatarsal bones, after covering the tendon of the peroneus longus muscle. The **short** or **deep-seated plantar ligament** lies close to the bones, being separated from the superficial part by some cellular tissue. Its breadth is considerable, its length scarcely an inch. One extremity is attached to the calcaneum in front of the long ligament, the other, somewhat expanded, to the under surface of the cuboid bone, internal to the tuberosity.

The **dorsal** or **superior ligament** is a flat band of fibres which connects the anterior and upper surface of the calcaneum with the adjacent part of the cuboid bone.

The **internal** or **interosseous ligament** is placed deeply in the hollow between the astragalus and os calcis, and is closely connected with the external calcaneo-scaploid ligament.

A separate *synovial membrane* lines this joint.

ARTICULATIONS OF THE SCAPHOID, CUBOID, AND CUNEIFORM BONES, ONE WITH ANOTHER.—**Scapho-Cuboid Articulation.**—The *scaphoid* and *cuboid bones* are connected by a *dorsal ligament*, composed of short

Fig. 159.

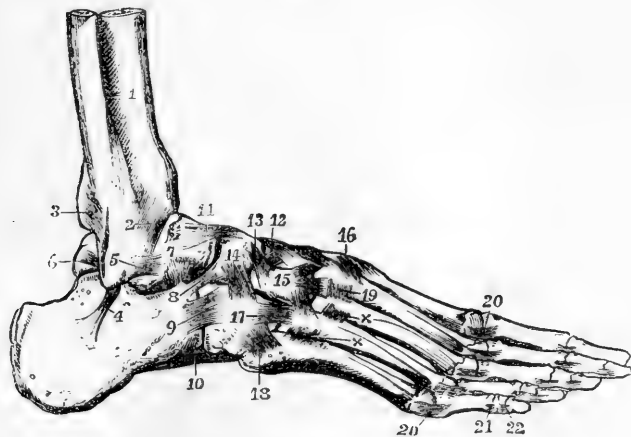


Fig. 159.—LIGAMENTS OF THE FOOT, FROM THE OUTSIDE AND DORSAL ASPECT. (A.T.)  $\frac{1}{2}$

1, lower part of the interosseous membrane; 2, lower anterior tibio-peroneal ligament; 3, lower posterior tibio-peroneal ligament; 4, middle part of the external lateral ligament of the ankle-joint, passing to the calcaneum; 5, anterior part of the external lateral ligament of the ankle-joint, passing to the astragalus; below the last ligament the external calcaneo-talar ligament has not been represented in this figure; 6, posterior part of the external lateral ligament of the ankle-joint, passing to the astragalus; 7, is placed above the interosseous calcaneo-talar ligament; 8, dorsal calcaneo-scaploid; 9, dorsal calcaneo-cuboid; 10, part of the long plantar or calcaneo-cuboid; 11, superior talo-scaploid; 12 and 13, second and third scapho-cuneiform, and between them one of the intercuneiform ligaments; 14, superior scapho-cuboid; 15, placed on the external cuneiform bone, points to the cuneo-metatarsal ligaments from that bone to the second, third, and fourth metatarsal bones; 16, cuneo-metatarsal ligament, from the first cuneiform to the second metatarsal bone; between 12 and 16, are seen the cuneo-metatarsal ligaments which converge from the three cuneiform bones on the second metatarsal; 17, cubo-metatarsal ligament passing to the fourth metatarsal bone; 18, that to the fifth, 19 and  $\times$ , dorsal intermetatarsal ligaments; 20, lateral metatarso-digital; 21, 22, lateral digital.

thin fibres, extending obliquely between the two bones ; a *plantar*, consisting of transverse fibres ; and an *interosseous ligament*, which intervenes between their contiguous surfaces. When the bones touch, which is not always the case, they present two small articulating surfaces, which are covered with cartilage and have between them an offset of the adjacent synovial membrane.

**Scapho-Cuneiform Articulation.**—The *scaphoid* and the *cuneiform bones* are held together by dorsal ligaments. It will be recollected that the scaphoid articulates with the three cuneiform bones by the smooth faces on its anterior surface. The *dorsal ligaments*, three in number, pass from the upper surface of the scaphoid to the first, second, and third cuneiform bones, into which they are respectively inserted. *Plantar bands* are similarly disposed on the under surface of the bones, but these are continuous with, or offsets from, the tendon of the *tibialis posticus* muscle.

**Cubo-cuneiform Articulation.**—The *cuboid* and the *external cuneiform bones* are connected by a *dorsal ligament*, which is a thin fasciculus of transverse fibres ; a *plantar ligament*, whose fibres are also transverse and rather indistinct ; and a bundle of *interosseous* fibres. Between

Fig. 160.

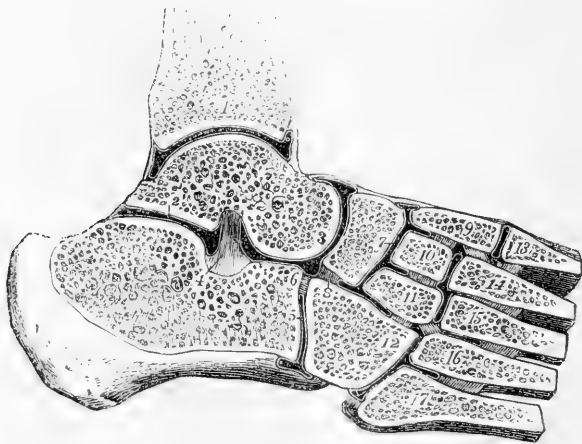


Fig. 160.—THE SYNOVIAL CAVITIES OF THE ANKLE-JOINT AND THE TARSAI AND TARSO-METATARSAL ARTICULATIONS, IN SECTION. (A. T.)  $\frac{1}{2}$

The section has been carried obliquely upwards and inwards across the foot, and vertically through the upper part of the astragalus and the tibia. 1, cut surface of the tibia above the ankle-joint ; 2, placed on the astragalus above the posterior calcaneo-talar synovial cavity ; 3, on the head of the astragalus close to the common calcaneo-talo-scaphoid synovial cavity ; 4, interosseous calcaneo-talar ligament ; 5, on the anterior edge of the calcaneum, points to the calcaneo-cuboid synovial cavity ; 6, interosseous calcaneo-cuboid ligament ; 7, on the scaphoid bone, marks the common scapho-cuneiform and intercuneiform synovial cavity ; 8, on the cuboid bone, points to the interosseous scapho-cuboid ligament ; 9, internal, 10, middle, 11, external cuneiform bones ; 12, cuboid : between these several bones the interosseous ligaments are shown ; from 13 to 17, are the metatarsal bones, with the interosseous ligaments between them ; between 9 and 14, the interosseous ligament from the internal cuneiform to the second metatarsal bone ; 11 and 16, the interosseous ligament from the external cuneiform to the fourth metatarsal bone : there are also shown in this figure, the synovial cavity of the first tarso-metatarsal articulation, that between the middle and external cuneiform bones and the second and third metatarsal ; and that between the cuboid and the fourth and fifth metatarsal bones.

the two bones a distinct articulation is formed by cartilaginous surfaces ; it is provided sometimes with a separate synovial membrane, at others with an offset from that which belongs to the scapho-cuneiform articulation.

The **three cuneiform bones** are connected by transverse *dorsal ligaments* and strong *interosseous* fibres ; the latter being their most efficient uniting structures. A transverse plantar ligament exists only between the two innermost bones. The articulations between these bones are lined by offsets from the synovial membrane of the joint between them and the scaphoid bone.

**ARTICULATION OF THE TARSUS WITH THE METATARSUS.**—The four anterior bones of the tarsus, viz., the three cuneiform and the cuboid, articulate with the metatarsal bones ; and as the first and third cuneiform bones project beyond the middle one, and the third cuneiform beyond the cuboid bone, the anterior surface of the tarsus is very irregular. The first metatarsal bone articulates with the internal cuneiform ; the second is wedged in between the first and third cuneiform, and rests against the second ; the third metatarsal bone articulates with the extremity of the external cuneiform ; and the last two with the cuboid bone, the fourth having also an attachment to the external cuneiform. The articulations are furnished with synovial membranes, and the bones are held in contact by dorsal, plantar, and interosseous ligaments.

The **dorsal tarso-metatarsal** ligaments are flat thin bands of parallel fibres, which pass from behind forwards, connecting the contiguous extremities of the bones before mentioned. Thus the first metatarsal bone receives a broad thin band from the corresponding cuneiform bone ; the second receives three, which converge to its upper surface, one passing from each cuneiform bone ; the third has one from the external cuneiform bone ; and, finally, the last two are bound by a fasciculus from each to the cuboid bone, and by fibres to the external cuneiform from the fourth metatarsal bone. The **plantar** ligaments are less regular ; the bands of the first and second toes are more strongly marked than the corresponding ligaments on the dorsal surface ; and those of the fourth and fifth toes, which are merely a few scattered fibres passing to the cuboid, receive support from the sheath of the peroneus longus muscle. Ligamentous bands stretch in an oblique or transverse direction from the internal cuneiform to the second and third metatarsal bones, and from the external cuneiform to the fifth metatarsal.

The **interosseous** ligaments run obliquely between the bones, and from their strength and deep position oppose great resistance to the knife in separating the metatarsus from the tarsus. *a.* The *internal* and largest of these extends from the outer side of the first cuneiform bone, to the neighbouring side of the second metatarsal, close to the articular surface. *b.* The *external* interosseous ligament separates the articulation of the fourth and fifth metatarsal bones from the rest. It connects the outer side of the external cuneiform bone to the same side of the third, and very strongly to the inner side of the fourth metatarsal. *c.* Occasionally some fibres, of less strength and importance than the preceding, are observable on the outer side of the second metatarsal bone, connecting it to the middle cuneiform.

The interosseous ligaments are found to vary somewhat in their connections from those here stated, being sometimes attached at once to the contiguous sides of two tarsal and two metatarsal bones. Attention was first particularly directed to these ligaments by M. Lisfranc, in connection with the amputation of the foot through the tarso-metatarsal articulation. See "Manuel des Opérations Chirurgicales," &c. Par J. Coster. 3rd edit. Paris, 1829.

**Synovial membranes.**—There are three synovial membranes in this irregular series of articulations. *a.* One belongs to the internal cuneiform and the first metatarsal bone: the joint formed between these two bones is altogether separate and out of the range of the rest. *b.* A second synovial membrane is placed between the cuboid and the fourth and fifth metatarsal bones; this is isolated on the inner side by the external interosseous ligament. *c.* The third or middle one is placed between the middle and external cuneiform and the second and third metatarsal bones, and is prolonged between the two last-named bones, as well as sometimes between the third and fourth metatarsal bones. The disposition of this last synovial membrane is subject to variation.

**Metatarsal Articulations.**—The metatarsal bones are bound together at their tarsal and digital ends; very firmly in the former, and loosely in the latter situation.

The tarsal ends of the four outer bones articulate with each other, having lateral cartilaginous surfaces and provided with synovial membrane, and are connected by dorsal, plantar, and interosseous ligaments. The

Fig. 161.

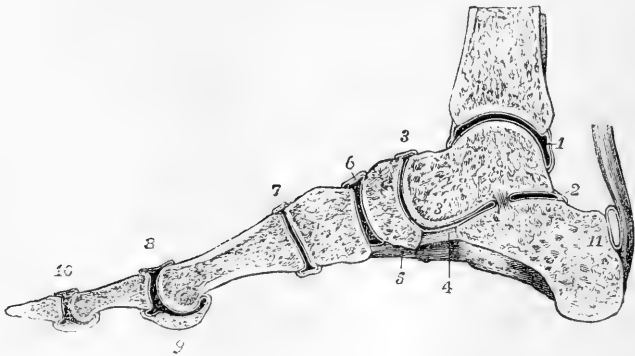


FIG. 161.—VERTICAL ANTERO-POSTERIOR SECTION OF THE ANKLE-JOINT AND ARTICULATIONS OF THE FOOT, A LITTLE TO THE INSIDE OF THE MIDDLE OF THE GREAT TOE OF THE RIGHT FOOT. (A. T.)  $\frac{1}{2}$

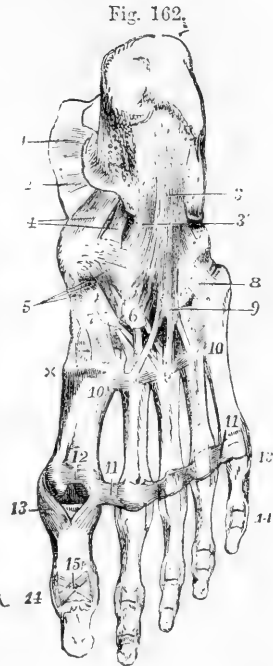
1, the synovial cavity of the ankle-joint; 2, the posterior talo-calcaneal articulation; 3, placed above the talo-scapoid articulation; 3', on the astragalus above the anterior talo-calcaneal articulation, which is continuous with the preceding: the interosseous ligament is seen separating 2 from 3'; 4, the inferior calcaneo-scapoid ligament; 5, part of the calcaneo-cuboid or long plantar ligament; 6, the scapho-cuneiform articulation; 7, the first cuneo-metatarsal articulation; 8, the first metatarso-phalangeal articulation; 9, section of the inner sesamoid bone; 10, the phalangeal articulation; 11, placed on the calcaneum, indicates the bursa between the upper part of the tuberosity of that bone and the tendo Achillis.

*dorsal* and *plantar* ligaments are short transverse bands stretching across the five metatarsal bones from one to another. The *interosseous* fibres, lying deeply between the bones, occupy the rough parts of their lateral surfaces: they are of considerable strength and firmness. The intermetatarsal articular cavities are lined with *synovial membrane*, which in each is continued forwards from that lining the joints formed between the bases of these bones and the tarsus. The first and second metatarsal bones do not articulate laterally with each other.

**Transverse metatarsal ligament.**—The digital extremities or heads of the metatarsal bones are loosely connected by a transverse band, which is identical in its arrangement with the corresponding structure in the hand, with this exception, that it is attached to the great toe, whereas in the hand the transverse metatarsal ligament does not reach the thumb.

Fig. 162.—LIGAMENTS OF THE FOOT, SEEN FROM BELOW. (A. T.)  $\frac{1}{2}$

1 and 2, portions of the internal lateral ligament of the ankle-joint; 3, calcaneo-cuboid or long plantar ligament; 3', deep or short part of the same; 4, plantar calcaneo-scaphoid ligament; 5, three scapho-cuneiform ligaments of the internal, middle and external cuneiform bones; 6, is placed upon the external cuneiform bone, towards which is seen coming from behind a cubo-cuneiform ligament; 7, is placed upon the internal cuneiform bone; from 6 and 7, are seen passing downwards the plantar cuneo-metatarsal ligaments; x, part of the first dorsal cuneo-metatarsal ligament; 8 and 9, ligamentous fibres prolonged from the cuboid bone and sheath of the peroneus longus muscle upon the outer metatarsal bones; 10, 10, between these figures, the posterior intermetatarsal (or transverse) ligaments; 11, 11, anterior transverse metatarsal ligament, continued across the four metatarsal spaces; 12, intersesamoid ligament; 13, 13, between these figures are seen the five pairs of internal and external lateral metatarso-digital ligaments; 14, 14, between these figures are seen the five pairs of internal and external lateral digital (phalangeal) ligaments of the first series; those of the second series have no figure placed to mark them; 15, inferior ligament of the phalangeal articulation of the great toe.



**METATARSO-DIGITAL AND INTERDIGITAL ARTICULATIONS.**—The heads of the metatarsal bones are connected with the small concave articular surfaces of the first phalanges by two lateral ligaments, an inferior ligament, to which sesamoid plates are united by scattered fibres, and a synovial membrane,—all which are closely similar to those which belong to the corresponding parts of the hand. In the first metatarso-digital articulation the sesamoid plate is divided into two parts, which are fully ossified, forming the sesamoid bones. These are held together by strong transverse ligamentous fibres, and being provided with cartilaginous surfaces, move upon the corresponding grooved cartilaginous surfaces of the first metatarsal bone.

The articulations of the phalanges with one another are also constructed on the same plan as those of the superior extremity. In each, the bones are held in contact by two lateral ligaments and an inferior

ligament or fibrous plate ; and each of the cavities is lined by a synovial membrane.

**Movements.**—In the mechanism of the foot three arches are distinguishable, two of them longitudinal and one transverse ; all of them capable of being flattened somewhat by pressure from above, thus securing elasticity. The inner arch is formed by the os calcis, astragalus, scaphoid, and three cuneiform bones, together with the three inner toes, the head of the astragalus being the key-stone, and is supported by the inferior calcaneo-scaphoid ligament. The outer arch is formed by the os calcis, cuboid bone, and two outer toes, and is supported by the strong inferior calcaneo-cuboid ligaments. Thus the calcaneo-scaphoid and calcaneo-cuboid ligaments are stretched by the whole weight of the body bearing down upon the arch, and prevent the too great flattening of the instep ; an action in which they are assisted, however, by the plantar aponeurosis. The transverse arching of the foot is most marked in the line of the tarso-metatarsal articulations, and is maintained by the wedge-shape of the bones and by the plantar ligaments. The weight of the body, falling upon the balls of the toes when the heel is raised, tends to spread out the metatarsal bones at their distal extremities, and to flatten the transverse arch, which recovers its position when the pressure is removed. Between the astragalus and the calcaneum only one kind of motion is possible, the centre of which is the interosseous astragalo-calcaneal ligament, and is of such a nature, that when the posterior part of the os calcis slides inwards and upwards beneath the astragalus, its cuboid extremity moves downwards and outwards. A certain amount of gliding movement is also allowed between the tarsal and metatarsal bones, and that most considerably between the cuboid bone and outer toes. Thus it happens that if the foot is bent up against the leg, and then is gradually extended by force applied to the toes, as by the action of the flexores digitorum muscles, the first part of the movement is accomplished at the ankle, and consists of extension, with only a slight inward turning of the toes ; further extension is accomplished by movement between the calcaneum and astragalus, and is accompanied by depression of the outer edge of the foot ; and after that a little more extension, accompanied by more considerable depression of the outer edge of the foot, is effected at the tarso-metatarsal articulations. The direction of the movement of extension of the toes at the metatarso-phalangeal articulations is upwards and outwards, so that although the great toe is in a line with the inner edge of the foot when resting on the ground, it is no longer so when over-extended.



## SECTION III.—MYOLOGY.

## THE MUSCLES IN GENERAL.

UNDER this section will be brought the description of the Voluntary Muscles, and along with it that of the Fasciæ and Aponeuroses by which they are invested.

The voluntary muscles are for the most part placed in close relation with the Endo-skeleton, being attached to the bones or other hard parts, and moving these in different directions by their contractions. There are, however, some muscles which may be looked upon as belonging to the cutaneous system, or Exo-skeleton, and there are a few others which are connected with the viscera at the places where parts of these reach the surface of the body. The muscles are all symmetrical, and, with the exception of the sphincters and one or two others, are in pairs.

The number of voluntary muscles to which distinct names have been given in the systems of Albinus and Sœmmering, which are mainly followed in this work, amounts to about 240, there being some variation above or below that number according as certain muscular parts are regarded as separate and independent muscles or only as portions of others. They naturally fall under the following four great divisions, and in the numerical proportions stated under each, viz. :—

A. In the axial part of the body.

1. The muscles of the head and neck = 75.

2. The muscles of the vertebral column and trunk = 51.

B. In the limbs.

3. The muscles of the upper limb = 58.

4. The muscles of the lower limb = 59.

In the detailed description of the muscles, however, while the foregoing general divisions will be followed, it may be expedient occasionally to deviate from the strictly systematic arrangement, in so far as may conduce to facility in study and convenience in dissection.

Each muscle constitutes a separate organ, composed chiefly of a mass of the contractile fibrous tissue which is called muscular, and of other tissues and parts which may be regarded as accessory. Thus the muscular fibres are connected together in bundles or fasciuli (*see* General Anatomy), and these fasciuli are again embedded in and united together by a quantity of connective tissue, forming the *perimysium*, and the whole muscle is usually enclosed in an external sheath of the same material. Many of the muscles are connected at their more or less tapering extremities with tendons by which they are attached to the bones or hard parts; and tendinous bands frequently run to a considerable length either on the surface of a muscle or between its fibres. There is indeed great variety in the relation of the muscular and tendinous portions, but few muscles are entirely destitute of some tendinous element in their composition.

Further, blood-vessels are largely distributed in the substance of a muscle, carrying the materials necessary for its nourishment and chemicovital changes, and there are also lymphatic vessels, as in other vascular parts of the body. Nerves are ramified through every muscle, by which the muscular contractions are called forth and a low degree of sensibility is conferred upon the muscular substance.

The muscles vary much in their individual forms. Some are broad and

thin, others are more or less elongated straps, and others are cylindrical or fusiform masses of various thickness; hence some of the various names applied to them, such as long and short, square, round, rhomboid, &c. Not unfrequently two or more muscular parts run into one, as in the bicipital, tricipital, or quadricipital forms. In other instances muscles, beginning as single masses, become divided, at their remote ends, into two or more muscular tendinous slips. A division of a muscle into two parts by an intermediate tendon gives the form called digastric or biventral, and there are some muscles in which a greater number of parts are thus separated by what have been called tendinous inscriptions.

In the description of the muscles it is customary to state the attachments of their opposite ends under the names of *origin* and *insertion*; the first term being usually applied to the more fixed, or in the case of the limbs the proximal extremity, and the second to the more movable or remote attachment; but it is to be observed, that it is often difficult to lay down a rule for the correct use of these terms, and that in the great majority of instances it is of importance to consider the action of a muscle as it may affect the motions of the parts attached not to one only but to both of its extremities.

The study of the actions of the muscles either singly or in groups, though strictly a physiological subject, cannot be separated from their anatomical description. With respect to this the following general principles ought to be kept in view. 1st. That the force exerted by any muscle during its contraction is in proportion to the *number* of muscular elements or fibres composing the muscle. 2nd. That the extent of motion, in so far as it merely depends on the shortening of the fibres of the muscle, is in proportion to the *length* of the fibres. And 3rd. That the direction of the force produced by a contracting muscle is in the line of the axis of the whole muscle if it run straight between its opposite points of attachment, but in the line of the portion attached to the moving part if the muscle or its tendon be bent in its course. In most instances of such deflection from the straight course the muscles or their tendons run in loops or in grooves somewhat after the manner of a pulley. The loops are either fibrous or cartilaginous. In the pulley-like disposition of tendons running over bones, there are frequently fibrous or cartilaginous or bony nodules developed at the place of angular bending of the tendons. The name *sesamoid*, originally given to the small bones developed in some of the digital tendons, has been applied generally to all similar intratendinous structures.

It is further to be observed that the direction in which the muscular fibres or fasciculi run in a muscle is very frequently not that of the axis of the muscle, nor do the muscular fasciculi in the great majority of instances extend from end to end in a muscle. On the contrary, the muscular fibres and fasciculi are much oftener comparatively short, and are attached within the length of the muscle to prolongations of the main tendons or to other tendinous bands which intersect its substance; and thus the muscular fibres run into these tendinous parts with various degrees of obliquity to the axis of the muscle.

The muscular flesh forms a large proportion of the weight of the whole body. This proportion has been carefully determined by measurements recently published by Dr. G. v. Liebig (Archiv. fur Anat. u. Physiol. 1874, p. 96), from whose tables the following is calculated

for a man of 150 lbs. weight : skeleton, 27 lbs. ; muscles, 63 lbs. ; viscera (with skin, fat, blood, &c.), 60 lbs.

**General Morphology.**—It cannot be doubted that the disposition of the muscles, as a whole and in groups, originally bears a close relation to the plan of vertebrate organization in the skeleton. This is very perceptible in the earlier stages of foetal development and in the lowest vertebrate animals. In fishes especially, and partly in amphibia, the muscles present a remarkable degree of vertebrate segmentation, the greater part of the muscles of the trunk being subdivided into zones, or *myotomes*, by partitions or *sclerotomes*, partly bony and partly cartilaginous or membranous, which extend transversely through the walls of the trunk, and which correspond in number and position with the vertebral and costal segments. In the higher animals and in man, together with the greater specialization of muscles in connection with the development of limbs, great deviations from the primitive muscular type in the trunk have occurred, and it becomes extremely difficult to trace the morphological relations of the rest of the muscles in the axial part of the body. It is indeed only in the deeper muscles of the vertebral column and of the ribs that the vertebrate subdivision and relation remain in any degree apparent. In the more superficial muscles, and more especially in the muscles of the limbs, where the direction of the fibres is generally outwards from the trunk, portions of the myotomes run together so as to form muscles of greater or less length, and in which all appearance of vertebrate division is effaced. In their more general relations also to the trunk of the body two sets of the muscles may be distinguished as *epaxial* and *hypaxial* (episkeletal and hyposkeletal of Huxley), according as they lie above or below the embryonic vertebral axis and the plane of its lateral extension. The *hypaxial* muscles, comparatively little developed in man, comprise chiefly the prevertebral muscles of the neck with the psoas and pyriformis. Of the *epaxial* muscles a *dorso-lateral* division consists mainly of the long and short erector muscles of the spine and head ; while a *ventro-lateral* division consists both of such ventral longitudinal muscles as genio-hyoid, sterno-hyoid, and recti abdominis, and of the lateral, obliquely directed, sterno-mastoid, scalene, intercostal, and abdominal muscles. The muscles of the limbs are also primarily derived from this great ventro-lateral muscle. They may be distinguished as *extrinsic* when attached partly to the limbs and partly to the trunk, and as *intrinsic* when wholly attached to the bones of the limbs and their arches.

To these morphological relations further reference will hereafter be made under the several large divisions of the muscles. (See Humphry, "Observations in Myology," &c., 1872, and in various papers in the Journ. of Anat. ; Huxley, "Anat. of Verteb. Animals," and Mivart, "Lessons in Elementary Anatomy.")

**Varieties.**—It follows from what has been stated above, that homologous correspondence can be traced between the individual muscles and groups of muscles of man and those of animals. But as the form and attachments of the muscles are subject to very great variations in different animals, as well as to occasional varieties in the same species, the determination of the special homologies is attended in many cases with great difficulty, and is still very imperfect. Many varieties have also been observed in the human body, and it is interesting to notice that these varieties are found to reappear generally in the same form, or in modifications of it which indicate relations to a typical or fundamental structure ; and that many of them are thus more or less repetitions of forms known to exist in different species of the lower animals. (Consult John Wood in Proceedings of Roy. Soc. 1864-7, and Turner and others in Journ. of Anat. & Physiol. ; Macalister's Instructive Catalogue of Muscular Anomalies, in Trans. Roy. Irish Acad., 1872, and other papers ; Hallet, in Edin. Med. Journ., 1845 ; Wenzel Gruber, in Mem. of the Petersburg Acad.)

#### FASCIAE.

The term *Fascia* is applied to parts presenting a membranous disposition of reticulated or felted fibrous tissue. These structures have usually been distinguished as the *superficial* and the *deep* ; the former consisting of looser and finer material, and passing by their slenderer

kinds into the looser varieties of connective tissue; while the latter, denser in character, frequently exhibit more or less regular arrangements of strong white fibres, giving them a shining appearance, and are often termed *aponeuroses*.

**Superficial Fascia.**—Under this name, or as *subcutaneous fascia*, is described the layer of loose tissue of varying density, which is placed immediately below the skin, all over the body. It is the web which contains the subcutaneous fat, the *panniculus adiposus*, and in some regions superficial muscles, as the *panniculus carnosus*. From the subcutaneous tissue of the eyelids, however, as well as from that of the penis and scrotum, adipose matter is entirely absent. Beneath the fatty layer of the superficial fascia, which is immediately subcutaneous, there is generally another layer of the same structure, comparatively devoid of adipose tissue, in which the trunks of the subcutaneous vessels and nerves are found. When the subcutaneous fat becomes absorbed, the stroma in which it was deposited is still left, and its meshes approach one another, so that in lean subjects a more fibrous condition of the superficial fascia is found than in others.

**Deep Fasciæ and Aponeuroses.**—Under the name of deep fascia is comprehended that stronger layer of fibrous or connective tissue which, lying close to the muscles, invests them, or dips between them, and forms a nearly continuous covering of the body beneath the superficial fascia. It is chiefly to the stronger parts of this fascia that the name of aponeuroses has been given. Those covering the muscles have been named *aponeuroses of investment* (Bichat), to distinguish them from proper tendinous expansions, or *aponeuroses of insertion*, of muscles. This distinction, however, is far from being universally applicable: aponeuroses of insertion are often continued into aponeuroses of investment, as in the instance of the *gluteus maximus*, or into softer fascia, as at the lateral parts of the occipito-frontal aponeurosis. The principal aponeuroses of investment are those which incase the muscles of the limbs, binding them down in a common sheath, and connected in various places by septa with the bones. They are characteristic of the limbs, there being no structure entirely corresponding to them in the rest of the body. Parts of the deep fasciæ in the vicinity of the larger joints as at the wrist and ankle, become strengthened into tight transverse bands, which serve to hold the tendons close to the bones, and hence receive the name of *retrinaacula*.

**Synovial Sacs and Sheaths: Bursa Mucosa.**—In various situations where the tendons of muscles pass over the prominences of bones, or run in fibrous sheaths, synovial cavities exist, either of a vesicular or tubular form, thus forming the *synovial bursa* or *sheaths*. In many such instances a true synovial membrane appears to cover the adjacent surfaces, and diminishes their friction in moving on each other. In other places less defined spaces exist in the connective tissue between parts of the tendons or fasciæ, and occasionally between parts of the skin and the harder or more prominent structures on which they lie. In some of these subcutaneous bursæ a distinct synovial membrane cannot be found; but there are probably gradations of transition between these bursal spaces and those which are lined by synovial membrane. Some of the synovial sacs and sheaths of tendons in the vicinity of joints communicate freely with the articular cavities. (See *Gen. Anat.*, vol. ii. p. 201.)

## I.—MUSCLES AND FASCIAE OF THE UPPER LIMB.

A certain number of muscles situated superficially on the trunk pass to the bones of the shoulder and humerus, so as to attach the upper limb to the body. These muscles, from their position, form a division of the muscles of the trunk, but considered with reference to their destination and action they may be held as belonging to the upper limbs, and will therefore be so described in the present section. The muscles referred to are, posteriorly, the trapezius, latissimus dorsi, the rhomboidei, and levator anguli scapulæ; and, anteriorly, the two pectoral muscles, the subclavius, and the serratus magnus. Along with these might also be included the clavicular part of the sterno-cleido-mastoid muscle and the omohyoid; but as these last have important relations with parts situated in the neck, they are more conveniently described among the muscles of that region.

## I. BETWEEN THE TRUNK AND THE UPPER LIMB POSTERIORLY.

**FASCIAE.**—The **superficial fascia** covering the muscles which pass from the trunk to the shoulder and upper limb posteriorly forms a layer of considerable strength with embedded fat lying below the skin: it is continuous with that of the neck above, that of the axilla and breast in front, and that of the abdomen and hips below.

The **deep fascia** of the back forms a dense fibrous layer closely investing the superficial muscles to which it furnishes sheaths: at the outer margins of the trapezius and latissimus dorsi muscles it is continuous with the deep fasciæ of the neck, breast, axilla, and abdomen, and turns round beneath the edges of the muscles so as to complete their sheaths and separate them from the subjacent layer of muscles. It is attached to the skeleton along the line of the spines of the vertebræ, and dorsum of the sacrum, to the occipital bone, the spine of the scapula, and the crest of the ilium.

In the loins there is a strong, flat, shining tendinous structure called the *lumbar aponeurosis*, to which the latissimus dorsi and other muscles are attached posteriorly; but this will be most conveniently described along with the muscles of the back.

**MUSCLES.**—The **trapezius** muscle (*cucullaris*) arises by a thin aponeurosis from the protuberance of the occipital bone, and the inner third of its superior curved line, from the ligamentum nuchæ, and from the spines of the last cervical and all the dorsal vertebræ, as well as from the supraspinous ligaments. From this extended line of origin the fibres converge to their insertion: the superior fibres, descending and turning forwards in the neck, are inserted into the external third of the clavicle at its posterior border; the succeeding fibres pass transversely to the inner border of the acromion process and upper border of the spine of the scapula, while the inferior fibres, ascending obliquely, terminate in a flat tendon which glides over the triangular area at the base of the spine of the scapula, and is inserted into the rough mark at the root of the spine. The greater part of the line of origin presents only a small admixture of tendinous fibres, but opposite the seventh cervical

Fig. 163.

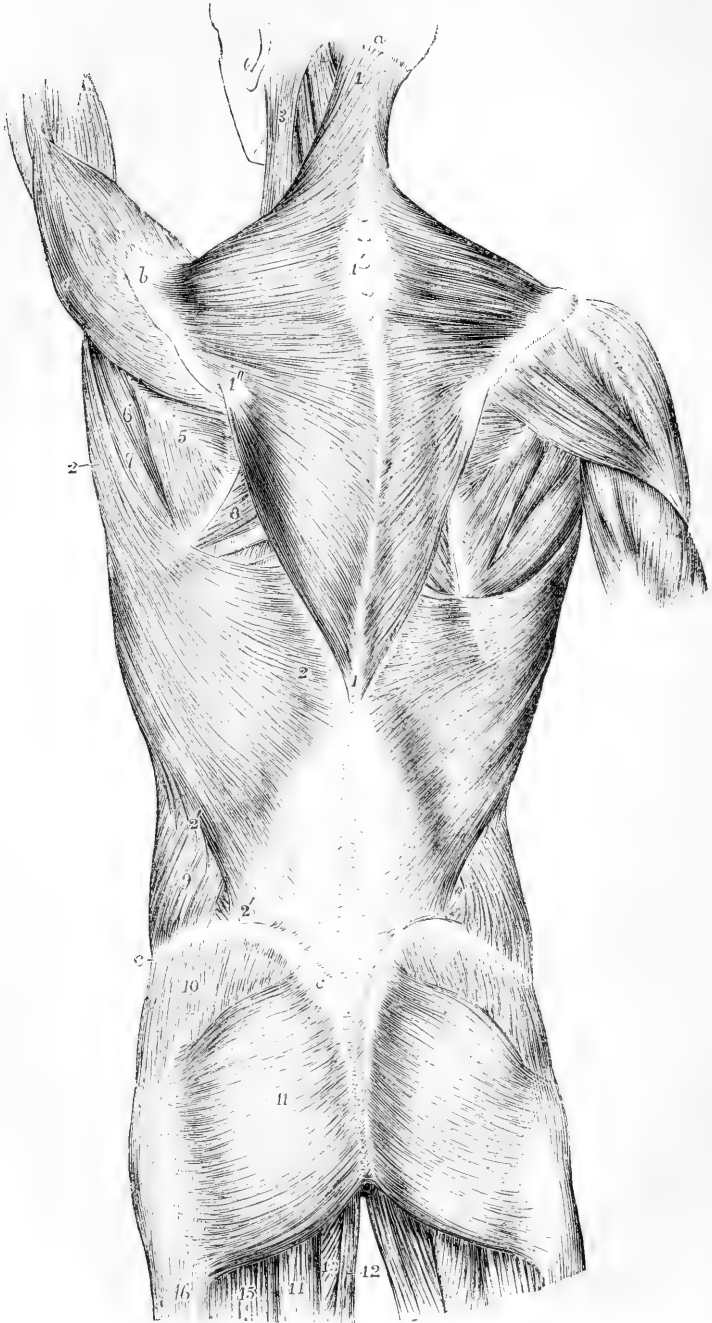


Fig. 163.—SUPERFICIAL MUSCLES OF THE TRUNK, SHOULDER AND HIP, VIEWED FROM BEHIND. (A. T.)  $\frac{1}{2}$

$\alpha$ , external occipital protuberance;  $\delta$ , acromion of the scapula;  $c$ , crest of the ilium; 1, trapezius; 1', oval tendon of the two muscles in the upper dorsal and lower cervical region; 1'', triangular tendon of insertion; 2, latissimus dorsi; 2', 2'', its costal origins and its direct origin from the crest of the ilium; 1, 2',  $c$ , the posterior layer of the lumbar aponeurosis; 3, sterno-mastoid; 4, deltoid; 5, infraspinatus; 6, teres minor; 7, teres major; 8, rhomboideus major; below this on the left side is seen a triangular space bounded by the rhomboid, trapezius, and latissimus dorsi muscles, in which a part of the seventh rib may be felt; on the left side, the arm and shoulder being elevated, the space is enlarged so as to show a part of the sixth and seventh ribs; 9, back part of the external oblique muscle of the abdomen; between 9 and 2', a small part of the internal oblique; 10, part of the gluteus medius covered by the fascia lata; 11, gluteus maximus; 12, gracilis; 13, small part of the adductor magnus; 14, semitendinosus; 15, biceps; 16, fascia lata covering the vastus externus.

spine, and for the distance of several vertebræ above and below that point, a flat tendon extends outwards, widest at the middle of the space and narrowing towards the upper and lower ends, so that the aponeuroses of the two muscles taken together have an elliptical form. The fibres of origin from the occipital bone have little or no tendinous lustre. The muscles of the two sides have together the form of a four-sided figure, or shawl or cowl, pointing downwards: hence the name of cucullaris which has been given to it.

*Relations.*—The trapezius is superficial in its whole extent: it covers the splenius, the greater part of the complexus above the splenius, the levator anguli scapulae, the rhomboidei, the supraspinatus, and small portions of the infraspinatus, latissimus dorsi, and lumbar aponeurosis. The spinal accessory nerve, and the superficial cervical artery, pass into it from its deep surface.

*Varieties.*—The trapezius is subject to considerable variations in its attachments: it is not unfrequently shorter than above described, and the number of dorsal vertebræ with which it is connected is sometimes diminished to six or seven, or even fewer. Its occipital attachment is occasionally wanting; and sometimes a separation exists between its cervical and dorsal portions, in the same manner as in some of the rodent animals. These varieties affect either one or both sides.

The **latissimus dorsi** muscle arises by tendinous fibres from the spinous processes of the six or seven lowest dorsal vertebræ, and from the posterior layer of the lumbar aponeurosis, through the medium of which it is attached to the lumbar and upper sacral spines and back part of the iliac crest; it also arises by fleshy fibres for an inch or more from the iliac crest in front of the outer margin of the lumbar aponeurosis, and from the last three or four ribs by narrow fleshy slips which inter-digitate with the attachments of the external oblique muscle of the abdomen. The fibres at the upper part are the shortest, and pass almost horizontally outwards over the lower angle of the scapula, from which they generally receive a small slip of fleshy fibres; those lower down become longer and pass more obliquely upwards; finally, those which are attached to the ribs ascend almost vertically. By this convergence the fibres of the muscle come to form a narrow band of some thickness, which, accompanying the teres major towards the axilla, winds round the lower and outer border of that muscle so as finally to be placed in front of it. It terminates in a flat tendon of about two inches in length, which is adherent at its lower border to that of the teres major, but is again detached from it previous to its insertion, a synovial bursa intervening between them. The tendon is attached to the

Fig. 164.



Fig. 164.—SUPERFICIAL VIEW OF THE MUSCLES OF THE TRUNK, SHOULDER AND HIP. (After Bourguery.) (A. T.)  $\frac{1}{2}$

o, occipital protuberance; C, transverse process of the atlas; D, first dorsal vertebra; L, first lumbar vertebra; S, first piece of the sacrum; Co, first piece of the coccyx; a, acromion; b, base of the scapula; i, crest of the ilium; 1, upper and back part of the sternomastoid muscle; 2, splenius, levator anguli scapulae, and other deep muscles; 3, 3', upper and lower ends of the line of origin of the trapezius muscle; 3'', triangular tendon attached to the inner end of the spine of the scapula; +, half of the oval tendon belonging to the two trapezius muscles in the lower cervical and upper dorsal region; 4, 4', latissimus dorsi; 4'', line along which the latissimus dorsi takes origin from the lumbar fascia; 5, infraspinatus; 6, teres minor; 7, teres major; 8, deltoid; 9, external oblique muscle of the abdomen; 10, gluteus medius, covered by the aponeurosis of the fascia lata; 11, 11', line of origin of the gluteus maximus from the posterior part of ilium to the coccyx; 11'', its insertion into the fascia lata over the trochanter major; 11''', a part of its insertion into the femur; 12, biceps; 13, semitendinosus; 14, adductor magnus; 15, gracilis.

floor of the bicipital groove of the humerus, a little higher than the insertion of the teres major. From this twisting of the muscle upon itself, the anterior surface of the tendon is continuous with the posterior surface of the rest of the muscle.

*Relations.* — The latissimus dorsi is subcutaneous, except at its origin from the dorsal vertebra, where it is covered by the trapezius, and at its insertion, where it dips into the axilla. It rests on part of the rhomboideus major and infraspinatus, on the teres major, serratus posticus inferior, vertebral aponeurosis, external intercostal muscles, and the posterior borders of the external and internal oblique muscles.



Between the adjacent borders of the latissimus dorsi, trapezius, and rhomboideus major, there is left, when the scapula is drawn forward, a triangular area in which a portion of one or two ribs and of an intercostal space becomes superficial; this is taken advantage of for the purpose of auscultation.

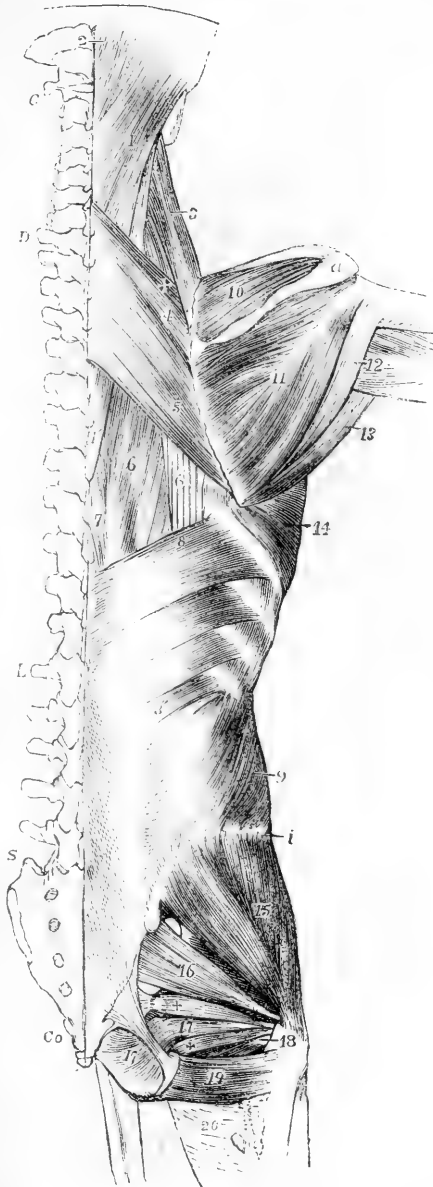
Fig. 165.

Fig. 165.—DEEPER VIEW OF THE MUSCLES OF THE TRUNK, SHOULDER AND HIP. (After Bourguery.) (A. T.)  $\frac{1}{2}$

The trapezius, latissimus dorsi, deltoid, gluteus maximus and external oblique muscles have been removed. The bones are lettered as in the preceding figure.

1, splenius capitis and splenius colli; 1', lower end of splenius colli; 2, complexus near its insertion; 3, levator anguli scapulae; 4, rhomboideus minor; above it +, a part of the serratus posticus superior; 5, rhomboideus major; 6, part of the longissimus dorsi; 6', part of the tendons of insertion of the sacro-lumbalis; 7, part of the spinalis dorsi; 8, upper, and 8', lower part of the serratus posticus inferior; 9, obliquus abdominis internus; 10, supraspinatus; 11, infraspinatus; 12, placed upon the long head of the triceps, points to the teres minor; 13, teres major; 14, serratus magnus; 15, gluteus medius; 16, pyriformis; 17, portion of the obturator internus; + and +, superior and inferior gemelli; 17', the intra-pelvic portion of obturator internus; 18, the tendon of the obturator externus passing to its insertion; 19, quadratus femoris; 20, upper part of the adductor magnus.

*Varieties.*—The number of dorsal vertebrae to which the latissimus dorsi is attached varies from four to seven or eight, and the number of the costal attachments is also inconstant, being frequently diminished and more rarely increased. Muscular bands (*axillary arches*) are sometimes seen to stretch from the border of this muscle across the axilla to its anterior part, where they terminate variously, in the tendon of the greater pectoral, in the coraco-brachialis muscle, the biceps, or in the fascia. There is also occasionally a slip of attachment to the scapular part of the triceps.



The **rhomboideus minor**, a comparatively narrow muscle, arises from the spinous processes of the seventh cervical and first dorsal vertebræ and from the ligamentum nuchæ. It inclines downwards and outwards, and is inserted into the base of the scapula opposite the triangular surface at the commencement of the spine.

The **rhomboideus major**, much broader than the preceding muscle, lies immediately below and in contact with it. It arises from the spinous processes of the four or five upper dorsal vertebræ and their interspinous ligaments, and is inserted into that part of the base of the scapula which is included between the spine and inferior angle. A considerable part of the attachment at the insertion is only by firm connective tissue, and the most of the fibres, instead of being fixed directly to the bone, end in a tendon which is connected to the scapula near the lower angle; in consequence of this arrangement, the muscle may, in part, be separated from the bone without division of its muscular or tendinous fibres, and must therefore act most immediately on the lower angle.

*Relations.*—The greater part of the rhomboidei muscles is covered by the trapezius, a small angular portion only of the rhomboideus major being subcutaneous in the interval between the trapezius and latissimus dorsi; the extent of this portion varies with the position of the scapula, being increased when the arm and shoulder are raised from the side. The rhomboidei cover the greater part of the serratus posticus superior, and the posterior scapular artery descends on their deep surface.

*Varieties.*—Both rhomboid muscles are liable to variations in the extent of their vertebral and scapular attachments. An additional muscle has been observed running close and parallel to the upper border of the minor, from the scapula to the occipital bone, and has been called *rhomboideus occipitalis* after a similar muscle occurring in some animals.

The **levator anguli scapulæ** arises by slightly tendinous slips from the posterior tubercles of the transverse processes of the four or five upper cervical vertebræ, between the attachments of the splenius and scaleni muscles, and forms an elongated fleshy mass which is inserted into the base of the scapula from the spine to the superior angle.

*Varieties.*—The number of vertebral attachments of the levator anguli scapulæ is subject to some variation. A slip has been observed to extend to it from the occipital or from the mastoid process of the temporal bone (Theile), and from the second rib (Meckel). It often appears as a divided muscle, the parts connected with the several vertebræ remaining separate, even to the place of insertion. It is occasionally connected by slips with the trapezius, scalene, or serrated muscles. In quadrupeds it is united with the serratus magnus, so as to form a single muscle.

*Nerves of the preceding muscles.*—The trapezius muscle receives its nerves from the spinal accessory which enters it on the deep surface, after being joined by branches from the third and fourth cervical nerves, from these nerves directly, and probably also from the posterior branches of the cervical and dorsal spinal nerves as they pierce it. The latissimus dorsi is chiefly supplied by the long subscapular nerve of the brachial plexus, but may also receive twigs from the dorsal and lumbar nerves which pass through it. The nerves of the rhomboid muscles proceed in one or sometimes two branches from the fifth cervical, and the levator scapulæ is supplied from the third, and sometimes also from the fifth, cervical nerves.

## II. BETWEEN THE TRUNK AND THE UPPER LIMB ANTERIORLY.

**FASCIA.**—The **superficial fascia** of the pectoral region encloses the mammary gland, covering it both in front and behind, and sending strong septa in between its lobes. Processes likewise extend forwards from the fascial investment of the gland, between the masses of fat, to the skin and nipple, thus affording support to the gland.

The **deep fascia** of the pectoral region is continuous with that of the neck both before and behind the clavicle, and with the similar structure spreading over the shoulder and thorax. As belonging to the deep fascia there may be specially noticed the *costo-coracoid membrane*, which is a distinct layer of firm fascia, attached superiorly to the clavicle and giving a firm covering to the subclavius muscle. Its strong lower margin, distinguished sometimes as the *costo-coracoid ligament*, extends from the coracoid process to the first rib at the origin of the subclavius muscle. The deep fascia, continued from this structure inferiorly, is narrowed like a funnel, and becomes thinner as it descends upon the surface of the axillary vessels, forming the anterior part of the sheath of those vessels, while the posterior part is formed by a deep process of the cervical fascia.

The **axillary fascia** is a strong membrane stretched across the axilla, and so disposed as to maintain the skin in position over that hollow. Beneath the pectoralis major muscle is a layer of fascia attached to the chest in front of the costo-coracoid membrane: it divides into two layers to enclose the pectoralis minor, and, these reuniting, it continues to pass outwards as a strong membrane between the pectoralis minor and short head of the biceps muscle; lower down it is joined by the fascia covering the pectoralis major, which is folded round the margin of that muscle, and, thus strengthened, it slopes outwards and backwards to the inferior border of the scapula, where it is joined by the sheaths of the latissimus dorsi and teres major muscles. In the deepest part of the axilla the fascia is perforated by numerous blood-vessels and lymphatics. At the outer side occupied by the large vessels and nerves of the limb, it is continuous with the sheath of the vessels and with the aponeurosis of the arm. The density of this fascia offers a considerable obstacle to the progress of axillary abscesses to the surface.

**MUSCLES.**—The **pectoralis major** muscle arises from the anterior and lower surface of the sternal half of the clavicle; from the anterior surface of the sternum; from the cartilages of the second to the sixth ribs, and also the bony part of the sixth rib; and from the aponeurosis of the external oblique muscle of the abdomen. Its fibres form a thick mass, and converge to be inserted by a tendon of considerable breadth into the outer bicipital ridge of the humerus. At the axillary border the muscular fasciculi, especially those of the pectoral part, are folded backwards, so that the lower fibres successively disappear from view, and the insertion into the humerus takes place by a broad flat tendon which is doubled upon itself in two close parallel lines, open above and connected below. The clavicular fasciculi are for the most part inserted on the outer surface of the anterior fold of the tendon, but they are also continued by independent tendon directly to the humerus. The posterior fold of the pectoral tendon is usually considerably broader than the anterior, and thus its line of attachment rises higher on the humerus.

Fig. 166.

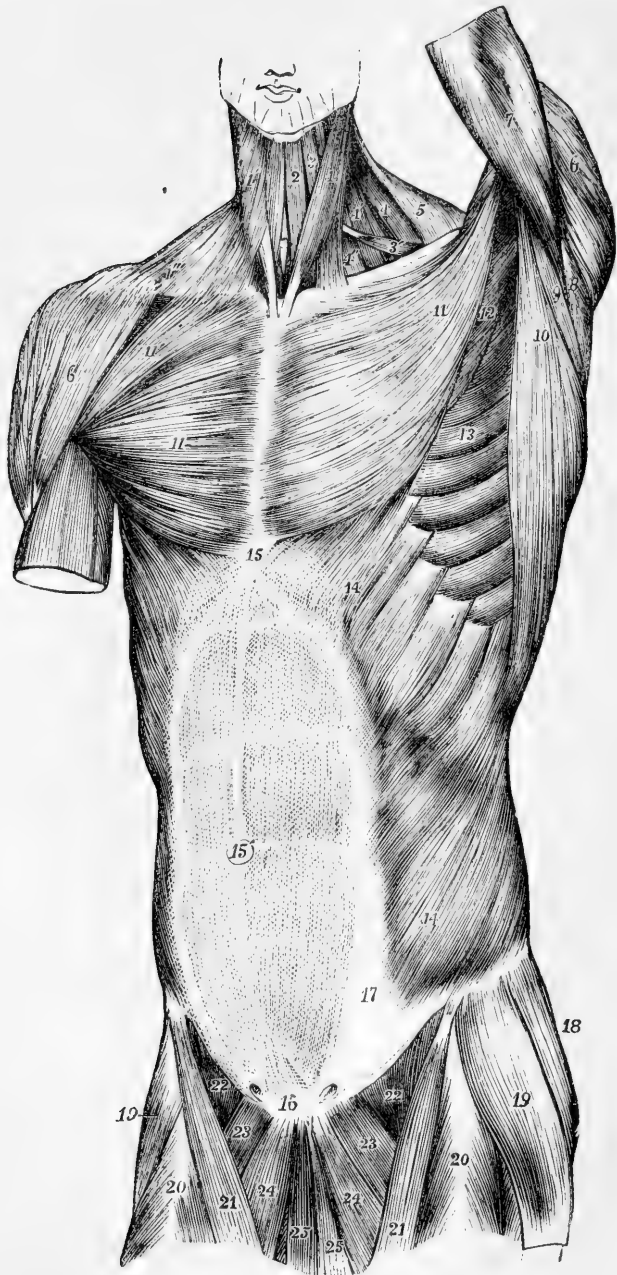


Fig. 166.—SUPERFICIAL VIEW OF THE MUSCLES OF THE TRUNK, FROM BEFORE. (A.T.)<sub>5</sub>  
 1, sterno-mastoid of the left side ; 1', 1', platysma myoides of the right side ; 2, sterno-

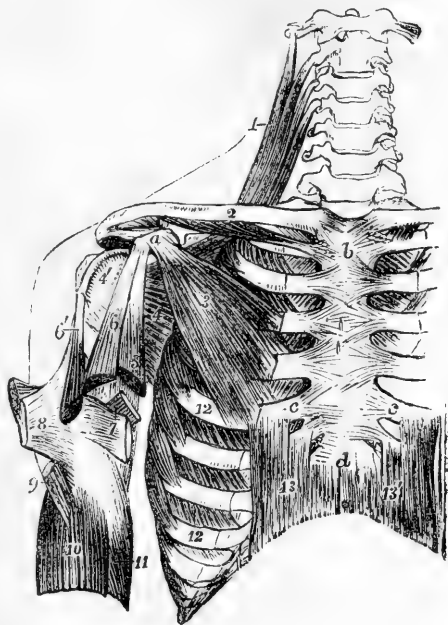
hyoid ; 3, upper, 3', lower belly of the omo-hyoid ; 4, levator anguli scapulæ ; 4', 4'', scalene muscles ; 5, anterior part of the trapezius ; 6, deltoid ; 7, upper part of the triceps brachii in the left arm ; 8, teres minor ; 9, teres major ; 10, latissimus dorsi ; 11 pectoralis major ; 11', on the right side its clavicular portion ; 12, part of the pectoralis minor ; 13, serratus magnus ; 14, external oblique muscle of the abdomen ; 15, placed on the xiphoid cartilage at the upper end of the linea alba ; 15', is placed on the umbilicus ; 16, is placed over the symphysis pubis, and at the lower end of the linea alba, above 16, the pyramidal muscles are seen through the abdominal aponeurosis ; 15 to 17, the linea semilunaris at the outside of the rectus muscle, the transverse tendinous lines of which are seen through the abdominal aponeurosis ; 18, part of the gluteus medius ; 19, tensor vaginæ femoris ; 20, rectus femoris ; 21, sartorius ; 22, femoral part of the iliacus and psoas ; 23, pectineus ; 24, adductor longus ; 25, gracilis. On each side of 16, the external abdominal ring is indicated.

It is further prolonged upwards by a slip which runs over the bicipital groove to the great tuberosity, and gives an offset to the head of the humerus. The lower or doubled end of the tendon is closely united with the insertion of the deltoid, and a slip is prolonged from its inferior margin to the fascia of the arm.

Fig. 167.—VIEW OF SOME OF THE DEEPER MUSCLES OF THE SHOULDER AND TRUNK, FROM BEFORE. (A.T.)  $\frac{1}{2}$

On the right side the pectoralis major and external oblique muscles have been removed. *a*, coracoid process of scapula ; *b*, manubrium of sternum ; *c, c*, cartilages of the fifth ribs ; *d*, ensiform portion of the sternum ; 1, upper part of the levator anguli scapulæ muscle ; 2, on the middle of the clavicle, points to the subclavius muscle ; 3, pectoralis minor ; 4, subscapularis ; 4', its insertion into the lesser tuberosity of the humerus ; 5, coraco-brachialis cut short ; 6, coracoid, and 6' glenoid head of the biceps brachii, both cut short near the place where they unite into one muscle ; 7, on the tendon of the latissimus dorsi, points by a line to the tendon of the teres major, both cut short and passing to their insertion inside the bicipital groove ; 8, folded tendon of the pectoralis major ; 9, insertion of the deltoid ; 10, brachialis anticus, embracing the insertion

Fig. 167.



of the deltoid ; 11, part of the inner head of the triceps, the middle head of which is seen passing behind the tendons of the latissimus and teres ; 12, 12, on the fifth and eighth ribs, point to the insertion of the serratus magnus ; 13, 13', recti abdominis.

*Relations.*—The folded inferior border of the pectoralis major forms the anterior margin of the axilla ; the superior runs parallel with that of the deltoid muscle, from which it is separated only by a slight interval which becomes wider towards the clavicle, and in which run the cephalic vein and the humeral branch of the acromio-thoracic artery. The anterior surface is subcutaneous in the greater part of its extent being covered only by some of the fibres of the

platysma myoides and by the mamma. The posterior surface rests chiefly on the pectoralis minor, and with that muscle forms the anterior wall of the axilla.

*Varieties.*—The more important varieties of this muscle consist in the greater or less extent of its attachments to the ribs or sternum, and the greater or less union or separation of its clavicular, sternal, and costal parts. The clavicular part has occasionally been observed to be absent, or to be incorporated completely with the deltoid. The tendinous and fleshy fibres of origin of opposite sides sometimes meet and even decussate in front of the sternum. In some instances additional muscular slips take origin from the aponeurosis of the external oblique muscle, and in others the lower part of the muscle presents considerable deficiency. Sometimes also slips connect the great pectoral with the biceps muscle. The slips of connection with the latissimus dorsi have already been noticed.

As closely related to the great pectoral muscle there may be noticed here the muscular band which has been observed by Wood, Struthers, Macalister, and others, passing from a fascial origin over some of the lower true and upper false ribs to a very variable tendinous or aponeurotic insertion at some place along the inner border of the arm, or even as far down as the inner condyle of the humerus, and which has been named *chondro-epitrochlearis*.

The **pectoralis minor** muscle arises from the upper margins and external surfaces of three ribs near their cartilages—usually the third, fourth, and fifth—and from the neighbouring parts of the intercostal aponeurosis. Its fibres converge to a narrow tendon, which is inserted into the anterior half of the inner border and upper surface of the coracoid process, in contact with the conjoined origin of the coracobrachialis and biceps muscles.

*Relations.*—This muscle is covered by the pectoralis major, and forms a part of the anterior wall of the axilla. It crosses the axillary artery and brachial plexus of nerves. When the arm is much raised a portion of the muscle may be seen below the outer margin of the pectoralis major.

*Varieties.*—The pectoralis minor is sometimes found split up or subdivided into as many pieces as it has of costal attachments. The place and number of the costal slips are subject to slight variation. The tendon of insertion is not unfrequently detached from the coracoid process, and carried on by the coraco-acromial ligament to the acromion process or some other neighbouring part.

The **subclavius** muscle arises by a short thick tendon from the first costal arch at the junction of the rib and cartilage, close to the costo-clavicular ligament. From this tendon its fibres pass outwards and upwards, forming a rounded belly, which is inserted into the groove along the inferior surface of the clavicle, extending as far as the recess between the conoid and trapezoid parts of the coraco-clavicular ligament.

*Relations.*—The subclavius is covered in front by the costo-coracoid fascia, and is placed immediately over the axillary vessels and nerves.

*Varieties.*—The subclavius is sometimes found to be without any attachment to the clavicle, being inserted into the root of the coracoid process; or it may have a double insertion, the upper into the clavicle, the lower into the coracoid process.

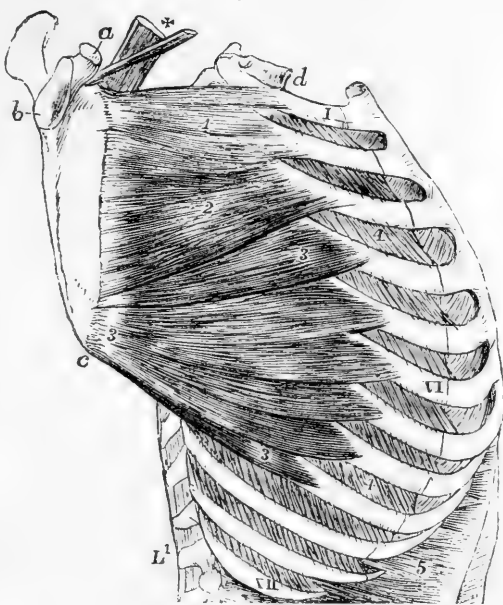
The **serratus magnus** muscle, placed upon the upper and lateral part of the thorax, between the ribs and the scapula, is attached anteriorly by nine fleshy angular slips to the first eight or sometimes nine ribs, two of these being connected with the second rib; it also derives some fibres from the aponeurosis covering the upper intercostal spaces. Posteriorly, the muscle, considerably narrowed, is attached to the line in front of the base of the scapula, and at the upper and lower angles of the bone into the flat surfaces which are excluded from the fossa of the subscapular muscle. The fibres are arranged in three sets,

thus:—*a*, those from the first and second digitations form a thick bundle which terminates on the flat area in front of the upper angle of

Fig. 168.—LATERAL VIEW OF THE TRUNK, SHOWING THE SERRATUS MAGNUS MUSCLE. (A. T.) }

Fig. 168.

*a*, coracoid process of the scapula; *b*, glenoid cavity; *c*, lower angle; *d*, first dorsal vertebra; 1, VI, XII, the first, sixth, and twelfth ribs; 1, upper portion of the serratus magnus attached to the first and second ribs; 2, second or middle portion attached chiefly to the third rib; 3, lower or fan-shaped portion attached to the ribs from the fourth to the ninth; 4, external intercostal muscle; 5, costal origins of the transversalis abdominis; +, scapular extremities of the levator scapulae and omohyoid muscles.



the scapula; *b*, those of the third and fourth digitations, but especially the first of these, which is the inferior digitation of the second rib, spread out into a triangular layer, the thinnest part of the muscle, and are attached along the line in front of the base of the scapula, extending from the place of insertion of the preceding part nearly to the lower angle of the bone; *c*, the remaining five or six digitations converge in the form of a fan, and terminate posteriorly in a thick mass, which is attached to the flat surface in front of the lower angle of the scapula.

*Relations.*—By its deep surface, the serratus magnus rests on the upper ribs, the intercostal muscles, and part of the serratus posticus superior. Its outer surface is in contact posteriorly with the subscapular and latissimus dorsi muscles, and forms anteriorly the internal wall of the axilla, being subcutaneous in the lower part of its extent.

*Varieties.*—Not unfrequently the lowest slip of the muscle extends to the tenth rib: in other instances the number of costal slips is diminished, occasionally by the suppression of the first, but oftener by the absence of some of the lower digitations, so that the muscle does not pass lower than the seventh rib. The muscle has been observed divided into three parts: sometimes the middle part is absent; and in various instances the serratus has been observed united partially with the levator scapulae, the external intercostals, or the external oblique. With the levator scapulae it forms one muscle in many mammals.

*Nerves.*—The nerves which supply the anterior muscles passing from the trunk to the upper limb are all derived from parts of the brachial plexus. The nerve of the subclavius is a small twig from a loop between the fifth and sixth cervical nerves. The large nerve of the serratus magnus, called posterior thoracic, proceeds from the same nerves and pierces the middle scalene muscle. The nerves of the pectoral muscles, named anterior thoracic, are in two

sets, internal and external, proceeding respectively from the inner and outer divisions of the plexus, the outer supplying the great pectoral muscle, the inner both it and the lesser pectoral.

**Actions of the muscles passing between the Trunk and Upper Limb.**— Considered with reference to the movements of the limb upon the trunk, the upper part of the trapezius, the levator scapulæ and the rhomboid muscles are elevators of the shoulder; the lower part of the trapezius, the pectoralis minor, and the subclavius are depressors; the serratus magnus as a whole carries forward the base of the scapula, and the rhomboidei draw it back; the latissimus dorsi and pectoralis major depress the humerus and carry it towards the middle line, behind or in front, according as the one or other muscle is in action.

More particularly, the superior fibres of the *trapezius* elevate the clavicle; the middle fibres acting on the acromion have also some elevating action, but tend rather to carry back the scapula towards the spine; the inferior part of the muscle acting upon the spine of the scapula would of itself depress that bone while it carried it inwards towards the dorsal spines, but acting in concert with the upper two-thirds of the muscle, a rotation is produced in the scapula round a central point, in such a manner that while the whole bone, and more especially the acromion, is raised and carried towards the dorsal spines, the upper angle of the scapula is somewhat depressed and carried inwards, while the lower angle is carried outwards and elevated.

The *levator anguli scapulæ* and *rhomboidei* elevate the superior angle and base of the scapula, thus counteracting in some degree the rotating action of the trapezius. In this manner, when the trapezius, levator, and rhomboid muscles act together, the scapula is raised without rotation, and its base is carried at the same time inwards towards the dorsal spines.

The *subclavius* depresses the clavicle, and may also act as a support to the sterno-clavicular articulation.

The *pectoralis minor* draws the coracoid process downwards and forwards, and tends to throw the lower angle of the scapula backwards.

The *serratus magnus* muscle, by withdrawing the base of the scapula from the spinal column, enables the arm when raised from the shoulder to be still farther outstretched, as in the movement termed extension in fencing. It comes powerfully into action in all movements of pushing; it likewise combines with the trapezius in rotating the scapula. In forced inspiration, the scapula being fixed by the muscles which attach it to the trunk posteriorly and superiorly, the serratus magnus assists in dilating the chest by raising and expanding the ribs.

The *latissimus dorsi* carries the elevated arm downwards and backwards, rotating it at the same time inwards, so as to make the palm look backwards, thus accomplishing such a movement as is made by the arm in swimming. By passing over the angle of the scapula it binds that process to the trunk, preventing its projection backwards; and by being folded round the outer border of the scapula, it limits the projection outwards of the same angle when the arm is raised.

The *pectoralis major* muscle, while it combines with the latissimus dorsi in depressing the humerus from the raised position, opposes that muscle by drawing the limb forwards. It is placed upon the stretch when the arms are thrown backwards, and is most shortened when they are folded across the chest. In the remarkable case of Groux, affected with congenital cleft sternum, when the shoulders were fixed backwards, the action of the great pectoral muscles tended to separate the two segments of the sternum, and increased the space in which the motions of the heart could be observed through the integuments.

Considered as acting on the trunk from the upper limb in a fixed condition, these muscles all tend to draw the trunk of the body towards the limb, as in climbing, or other like efforts. The latissimus dorsi muscles, if acting on both sides, carry the body upwards and forwards, as in the use of crutches. The pectorales and latissimus dorsi are also muscles of forced inspiration, tending to raise and expand the ribs, more especially when the shoulders are fixed and the arms are elevated. The upper parts of both trapezii acting on the occipital bone aid the sterno-mastoid muscle in throwing forward the chin; and if one muscle only acts, it aids in rotating the head.



## MUSCLES AND FASCÆ OF THE SHOULDER.

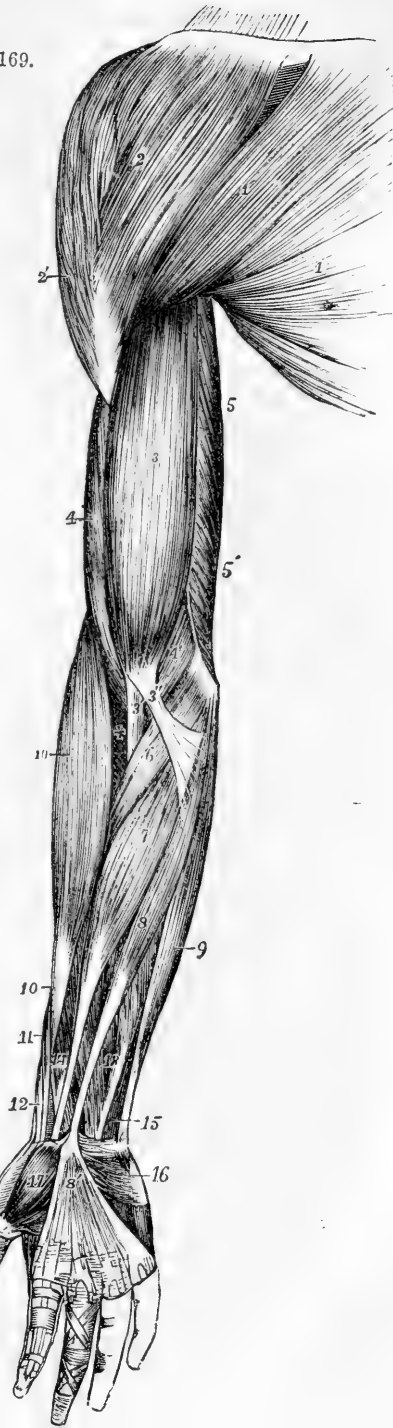
**FASCÆ.**—The **deep fascia** binds together the muscles of the shoulder with considerable firmness, and over the back part of the deltoid and infraspinatus muscles assumes a tendinous appearance. A strong and somewhat isolated portion, bound down to the posterior and axillary margins of the scapula, covers the infraspinatus and teres minor muscles as far as they are left uncovered by the deltoid muscle. On reaching the posterior border of the deltoid muscle, this aponeurosis divides into two layers, of which the deeper is continued beneath the deltoid to the shoulder-joint, and the more superficial forms a thin aponeurotic covering of that muscle, becoming more and more slender as it passes forwards, and is attached to the lower border of the spine.

Fig. 169.—SUPERFICIAL MUSCLES OF THE SHOULDER AND UPPER LIMB, FROM BEFORE. (A. T.)  $\frac{1}{5}$

1, pectoralis major; 1', its clavicular portion; 2, deltoid, its clavicular part; 2', its acromial part; 3, biceps brachii; 3', its tendon of insertion; 3'', its aponeurotic slip; 4, brachialis anticus; 4', its inner and lower portion; 5, inner head of the triceps; 5', lower part of the same, seen arising from behind the intermuscular septum. The explanation of the remaining references will be found in the description of fig. 179.

**MUSCLES.**—The **deltoid muscle** is of a triangular form and coarsely fasciculated, and extends from the most prominent part of the shoulder down a third of

Fig. 169.



the upper arm. It takes origin in an extended line which may be divided into three portions, viz., an anterior from the front of the external third of the clavicle, a middle from the outer edge and point of the acromion, and a posterior from the lower border of the spine of the scapula as far back as the triangular surface at its inner end. The fasciculi from these several parts converge as they descend, and are inserted by a strong thick tendon into the deltoid impression, a triangular rough surface above the middle of the humerus, on its outer side.

The three parts, composing the deltoid muscle, differ somewhat in the disposition of the muscular fasciculi and the tendons. The anterior and posterior portions are composed of long fibres which, arising directly from the clavicle and spine of the scapula, are inserted into the outer surface of the marginal parts of the inferior tendon. In the acromial portion, while some of the muscular fibres spring directly from the bone, yet most of them arise in a penniform manner from the sides of three or, more frequently, four tendinous septa, which pass downwards into the substance of the muscle. These oblique fibres, running nearly parallel to each other, are inserted in a similar manner into the sides of two, or more frequently three, septa which pass from below upwards and alternate with the upper septa. The oblique fibres, from the outside of the first and fourth upper septa are inserted into the marginal parts of the main tendon. There are besides wedge-shaped bundles of muscular fibres, rising directly from the acromion in the intervals between the penniform bundles, which, are inserted into the tips of the lower tendinous septa, and others which springing from the ends of the upper tendinous septa, are directly inserted into the humerus between the lower septa. The main tendon of insertion spreads from below upwards for some distance on the deep surface of the muscle.

*Relations.*—At the posterior border of the deltoid, the aponeurosis covering the infraspinatus muscle divides into two thin layers, of which one covers the muscle superficially, and the other lines its deep surface. At its anterior border this muscle is in contact with the pectoralis major, the cephalic vein lying between them. In immediate contact with the deep surface is the large bursa, which separates this muscle and the acromion from the shoulder joint and the muscles supporting it. The deltoid muscle covers the origins of the biceps, coracobrachialis, and long head of the triceps, and the insertions of the subscapularis, supraspinatus, infraspinatus and teres minor muscles, as also the circumflex vessels and nerve.

*Varieties.*—The deltoid muscle is not subject to great varieties. One of the commonest is a greater degree of subdivision of its parts than usual. Another is the continuation into it of fibres from the trapezius, as in animals wanting the clavicle. Occasionally its anterior part is closely united with the great pectoral muscle. Its insertion varies sometimes in extent. A remarkable prolongation of its tendon on the radial border of the forearm, as far as the insertion of the supinator longus, seems to repeat the tensor plicae alaris of the bird. (Macalister).

The **supraspinatus** muscle arises from the whole of the supraspinous fossa of the scapula to within a short distance of the neck of the bone, and from an aponeurosis by which it is covered. Its fibres converge beneath the acromion to a tendon, which adheres to the capsule of the shoulder-joint, and to the tendon of the infraspinatus muscle, and is inserted into the upper of the three facets on the great tuberosity of the humerus.

The **infraspinatus** muscle is of a triangular form, and occupies the greater part of the infraspinous fossa. It arises from the fascia covering it, from the under surface of the spine, and from the dorsal surface of the scapula in the fossa, except those parts at the lower angle and along the external border, to which the teres muscles are attached. The fibres converge to a tendon, which, concealed at first within the substance of the muscle, is inserted into the middle facet of the great tuberosity of the humerus.

*Relations.*—The supraspinatus muscle is covered by the trapezius and the acromion process. The suprascapular nerve and artery pass beneath it.

The infraspinatus muscle is bound down by the aponeurosis which superiorly and externally divides so as to enclose the deltoid muscle. It is covered by the deltoid at its upper and outer part, and by the trapezius at its upper and inner part, by the latissimus dorsi at its lower angle, and in the intermediate portion it remains superficial.

*Varieties.*—The infraspinatus muscle is sometimes very closely united with the teres minor. The supraspinatus is very constant in its form and attachments.

The **teres minor** muscle is placed along the outer border of the infraspinatus, and is intimately connected with that muscle. It arises by

a series of fibres from a narrow obliquely grooved surface on the dorsum of the scapula close to the axillary border, and from aponeurotic septa between it and the infraspinatus and teres major muscles, and is inserted by tendon into the greater tuberosity of the humerus, immediately below the infraspinatus.

Fig. 170.

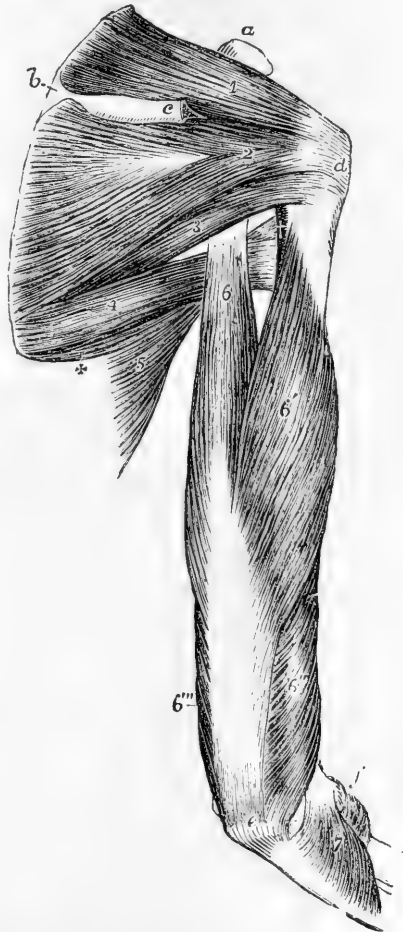

Fig. 170. — MUSCLES OF THE RIGHT SHOULDER AND ARM, SEEN FROM BEHIND. (A. T.)  $\frac{1}{4}$

The acromion process and a part of the spine of the scapula, with the deltoid muscle, have been removed. *a*, coracoid process; *b*, triangular surface at the commencement of the spine; *c*, is close to the cut portion of the spine; *d*, greater tuberosity; *e*, olecranon of the ulna; *f*, is close to the external condylar eminence and head of the radius; 1, supraspinatus muscle; 2, infraspinatus; 3, teres minor; below the figure is the triangular space; 4, teres major; 5, part of latissimus dorsi; +, slip from the inferior angle of the scapula; †, on the edge of the humerus, points to the tendon of the latissimus dorsi and the quadrangular space; 6, scapular head of the triceps, passing above between the teres major and minor; 6', outer head; 6'', part of the muscle rising below the spiral groove, continuous with the inner head; 6''', part of the inner head; 7, anconeus.

tus, and by fleshy fibres into the bone for a short distance lower down.

*Relations.*—This muscle is crossed behind by the deltoid, and in front is in relation with the long head of the triceps, and the capsule of the shoulder-joint.

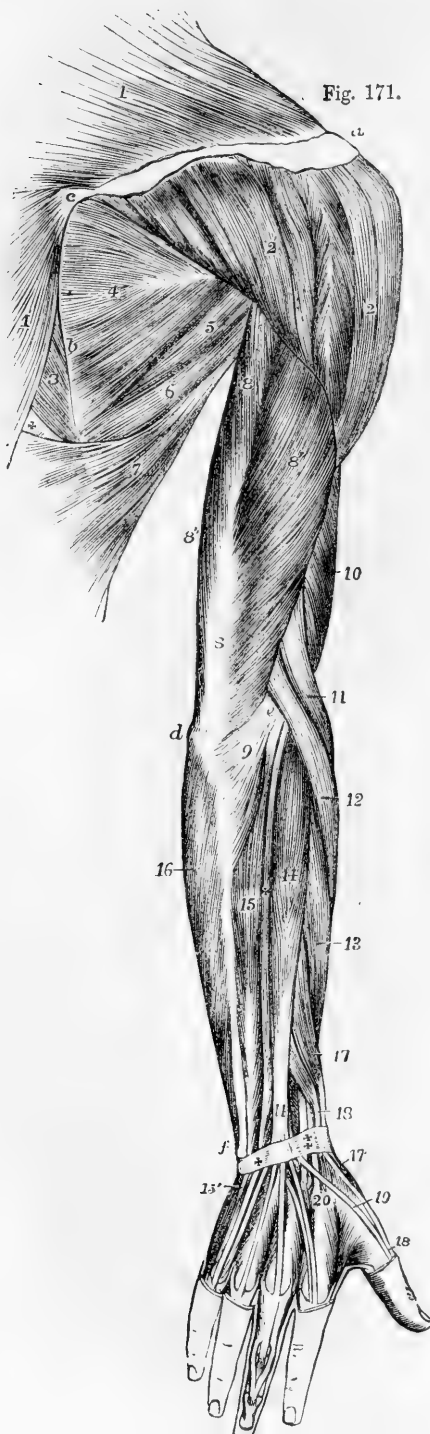


Fig. 171.

The dorsal scapular artery passes between it and the bone. At its lower border is the *teres major* separated in part by the long head of the *triceps*. A bursa is sometimes found between the tendon and the bone.

Fig. 171.—SUPERFICIAL MUSCLES OF THE SHOULDER AND UPPER LIMB, SEEN FROM BEHIND. (A. T.)  $\frac{1}{5}$

*a*, acromion; *b*, base of the scapula; *c*, tendon of the *trapezius* muscle over the triangular surface of the spine of the scapula; *d*, olecranon of the ulna; *e*, external condylar eminence; *f*, lower end of the ulna; 1, *trapezius*; 2, acromial part of *deltoid*; 2', the part of the same muscle rising from the spine of the scapula; 3, *rhomboides major*; 4, *infraspinatus*; 5, *teres minor*; 6, *teres major*; 7, *latissimus dorsi*; +, space between the *trapezius*, *rhomboid* and *latissimus* muscles; 8, *triceps extensor cubiti*; 8', its outer head; 8'', part of its inner head; 9, *anconeus*; 10, part of the *brachialis anticus*; 11, *supinator longus*; 12, *extensor carpi radialis longior*. The explanation of the remaining references will be found in the description of fig. 182.

The **teres major** muscle arises from the flat oval surface on the dorsum of the scapula near its inferior angle, slightly from the axillary border of the bone, and from the septa interposed between it and the *teres minor* and *infraspinatus*. It is inserted by a flat tendon about two inches wide, into the inner border of the bicipital groove of the humerus, behind and in contact with the tendon of the *latissimus dorsi*, to which it is adherent for a short space. Close to the insertion, however, the tendons of these muscles are separated by a small bursa. The fibres of the muscle are longitudinal.

*Relations.*—Posteriorly this muscle is covered at its lower part by the latissimus dorsi, and at its upper part it is crossed by the long head of the triceps. The outer side is surrounded obliquely by the latissimus dorsi; and the anterior surface is concealed in the upper part of its extent by the tendon of that muscle. The inner border of the muscle forms the margin of a triangular space, of which the other sides are the upper part of the humerus, and the axillary border of the scapula, covered before by the subscapular and behind by the teres minor muscles; this triangle is divided by the long head of the triceps into a superior or external quadrilateral, and an inferior or internal, triangular compartment. Through the quadrilateral space pass backwards the posterior circumflex vessels and the circumflex nerve; and in the triangular subdivision the dorsal branch of the subscapular artery passes round the margin of the scapula into the infraspinous fossa.

*Varieties.*—The teres major muscle is sometimes found connected with the fasciculi of the latissimus dorsi arising from the same part of the scapula. A slip from this muscle has also been observed descending upon the fascia of the upper arm externally.

The **subscapularis** muscle arises partly by muscular and partly by tendinous fibres from the venter of the scapula, with the exception of the neck of the bone and the spaces occupied by the serratus magnus; its fibres unite into a broad tendon which perforates the capsular ligament of the shoulder-joint, and is inserted into the small tuberosity of the humerus. Some fleshy fibres also are directly inserted into the bone for a short distance lower down. Three or four tendinous septa, attached to the ridges of the subscapular fossa, pass outwards in the origin of the muscle; and others are prolonged inwards from the tendon of insertion.

*Relations.*—The tendon of the subscapularis is incorporated with the capsule of the shoulder-joint, and between its upper and posterior surface, the coracoid process, and the neck of the scapula is a bursa usually communicating with that joint. There is also sometimes a bursa intervening between the anterior surface of the muscle and the origin of the biceps and coraco-brachialis muscles. Anteriorly the muscle is in contact at its origin with the serratus magnus, and is covered at its insertion by the coraco-brachialis and biceps, while, in the interval between, it forms part of the posterior wall of the axilla.

*Varieties.*—The varieties hitherto observed in this muscle are not considerable. A small additional muscle, of somewhat variable form, has been described by different authors, as passing from the surface of the subscapularis over the capsular ligament, but without piercing it, to be inserted into or near the inner margin of the bicipital groove, the *subscapulo-capsularis* of Wenzel Gruber.

**Nerves of the Shoulder Muscles.**—The supraspinatus and infraspinatus muscles receive their nerves from the suprascapular branch which proceeds from the upper loop of the brachial plexus, and therefore from the fifth and sixth cervical nerves. The other muscles of this group are all supplied with nerves from the posterior division of the plexus, as follows: the deltoid and teres minor from the circumflex nerve, the teres major and the subscapularis from the middle and short subscapular nerves.

**Actions of the Shoulder Muscles.**—The deltoid muscle raises the arm from the side as far as the structure of the shoulder-joint permits, viz., till it is at right angles with the trunk. Further elevation of the upper limb is effected chiefly by the trapezius; and it may be remarked that the insertion of that muscle corresponds exactly in extent to the origin of the deltoid, so that the two muscles may be considered continuous in structure as well as in action. The anterior fibres of the deltoid combine with the pectoralis major to draw the humerus forwards; the posterior assist in drawing it backwards. The supraspinatus, infraspinatus, and subscapularis muscles being placed more closely round the joint, when acting in concert with the deltoid, probably give steadiness and precision, while the deltoid gives the main elevating force to the movement. The supraspinatus simply elevates: the infraspinatus and subscapularis carry the arm backwards or for-

wards when it is raised, and rotate it outwards or inwards when hanging by the side. The *teres major* rotates the raised humerus inwards, the *teres minor* outwards: acting together, they assist in depressing the arm. The deltoid muscle superficially, and the supra- and infraspinatus muscles, the *teres minor* and *subscapularis*, more deeply, afford important protection to the shoulder-joint, and by their tension prevent displacement of the head of the humerus.

#### MUSCLES AND FASCIAE OF THE UPPER ARM.

**FASCIAE.**—The **aponeurosis of the arm** is composed chiefly of transverse fibres, held together by others having an oblique or longitudinal direction; it is thin over the biceps muscle, stronger where it covers the triceps, and particularly dense as it approaches the outer and inner condylar eminences of the humerus. It is pierced on the inner side of the limb by the basilic vein, below the middle of the arm. It is attached to the shaft and condylar eminences of the humerus by the two processes next to be described.

The **external and internal intermuscular septa** are two fibrous partitions which bind the aponeurosis of the arm to the humerus, and with which the neighbouring muscles of the arm are intimately connected. The external intermuscular septum extends upwards from the outer condylar eminence along the outer lateral ridge to the insertion of the deltoid, from which it receives tendinous fibres. It is pierced from behind forwards by the musculo-spiral nerve and superior profunda artery. The internal septum, much stronger, extends along the ridge from the inner condylar eminence to the insertion of the coracobrachialis muscle. It is traversed from before backwards by the ulnar nerve, and by the inferior profunda and anastomotic arteries.

At the bend of the elbow the aponeurosis is closely connected with the periosteum covering the condylar eminences of the humerus and the olecranon process of the ulna; and it is strengthened by tendinous fibres sent from the triceps and biceps muscles.

**MUSCLES.**—The **coraco-brachialis** muscle, elongated in form, arises from the tip of the coracoid process of the scapula, between the pectoralis minor and the short head of the biceps, with which latter it is for a short distance conjoined by an intermediate tendon. The lower part of the muscle is directly inserted into the inner border of the humerus near its middle, in a linear impression of from two to three inches in length, between the origin of the triceps and the brachialis anticus. Higher up its fibres are found inserted into a tendinous band which is prolonged upwards to the head of the humerus, forming a sling over the latissimus dorsi.

**Relations.**—This muscle is usually pierced by the musculo-cutaneous nerve; its outer border is in contact with the biceps muscle, and its inner with the brachial artery, by which it is crossed obliquely near its insertion. It lies in front of the tendons of the subscapularis, latissimus dorsi, and *teres major*, and is covered by the deltoid and pectoralis major muscles.

**Varieties.**—This muscle has been shown by various authors to be subject to considerable varieties, which seem to indicate, according to Wood, that it consists typically of three parts; viz., 1, a superior short one rising from the coracoid process, or near it, and running over the capsular ligament, to be inserted close below the small tuberosity of the humerus; 2, a second corresponding most nearly to that usually described in human anatomy, of middle size, and placed between the first and third; 3, a third which is the longest and most superficially placed, and descends to the inner condyle, or near it, and in many instances is

inserted into a supracondylar process. The middle division of the muscle is most constant in man : but is generally accompanied by a part of the third ; the musculo-cutaneous nerve passing between them. The first and third constitute the most marked varieties in man, and all three are found in various forms and degrees of development in different animals. The internal brachial ligament of Struthers is a fibrous band connected with the inferior part of this muscle. (John Wood, on Hum. Musc. Variations, &c., Journ. of Anat. vol. i. p. 45.)

Fig. 172.—DEEP VIEW OF THE MUSCLES OF THE RIGHT SHOULDER AND ARM, FROM BEFORE. (A. T.)  $\frac{1}{4}$

*a, b*, outer half of the divided clavicle ; *c*, coracoid process ; *d*, upper, and *e*, lower triangular space left at the upper and lower angles of the scapula on its anterior surface to which the serratus magnus is attached ; *f*, great tuberosity of the humerus ; *g*, surface of the humerus below the bicipital groove ; *h*, outer, and *i*, inner condylar eminence of the humerus ; 1, cut coracoid head, and 1', cut glenoid tendon of the biceps muscle ; 2, folded tendon of insertion of the pectoralis major, of which one portion is seen running up to the bicipital groove ; 3, lower cut end of the deltoid ; 4, coraco-brachialis ; 5, subscapularis ; 5', its insertion into the lesser tuberosity ; 6, teres major ; 6', its insertion behind and below the latissimus dorsi ; 7, part of the latissimus dorsi ; +, slip from the inferior angle of the scapula ; 7', insertion of the tendon, after winding round the teres major, in front of and higher than that muscle ; 8, 8', brachialis anticus ; 9, long head of the triceps, at the upper part seen in the interval between the teres major and subscapularis muscles ; 9', inner head ; 10, flexor communis digitorum profundus ; 11, tendon of insertion of the biceps.



Fig. 172.

The **biceps flexor cubiti** muscle has two heads of origin : one of these, the internal or short head, arises conjointly with the coraco-brachialis from the coracoid process of the scapula by a tendon which is soon continued into muscle ; the other, the long head, arises by a rounded tendon from the upper border of the glenoid fossa and glenoid ligament, within the capsule of the shoulder-joint, and this tendon, passing over the head of the humerus, leaves the joint by the bicipital groove, gradually enlarging into the fleshy head as it descends. The two muscular heads, lying side by side, then unite to form an elongated and thick belly, occupying the middle and lower part of the arm : a

little above the bend of the elbow, the muscle suddenly becomes narrower, and is continued into the flat rounded tendon of insertion. This tendon, slightly twisted upon itself as it descends, is inserted into the rough posterior margin of the tuberosity of the radius, gliding on the anterior smooth surface of that process by the intervention of a synovial bursa. From the inner side of the lower part of the muscle and tendon a strong flat aponeurotic band, called the *semilunar fascia*, passes downwards and inwards, and becomes blended with the deep fascia of the forearm over the pronator radii teres.

*Relations.*—Concealed above by the deltoid and pectoralis major muscles, the biceps forms in the rest of its extent the prominence of the front of the arm. It rests in its upper part on the humerus, and in its lower on the brachialis anticus, and by its inner margin is in contact in its upper half with the coraco-brachialis, in its lower with the brachial artery. Its inferior tendon is in contact with the supinator brevis, and the fibrous expansion or semilunar fascia is stretched across the brachial artery and median nerve.

*Varieties.*—The biceps is one of the most variable muscles in the body. Among the most frequent of its varieties are, 1st, the greater than usual separation of its glenoid and coracoid portions, and 2nd, the increase in the number of its heads of origin. The last occurs most frequently by a slip which forms a third head arising from the humerus, in more or less close connection with the brachialis anticus and the insertion of the coraco-brachialis, and being inserted into the under surface of the semilunar fascia so as to form a tensor of that fascia: this head lies generally on the outer side of the brachial artery, and has sometimes been found covering it. A muscular band has also been observed extending downwards from the biceps to the intermuscular septum over the inner condyle of the humerus, and passing over the brachial artery. (R. Quain, "The Anatomy of the Arteries," &c., p. 270, pl. 57.) A third head has also been observed passing from the outside of the humerus (brachio-radialis of W. Gruber), and sometimes from the bicipital groove, or great tuberosity. Occasionally the long head does not reach the glenoid part of the bone, but stops short in the bicipital groove.

The **brachialis anticus** muscle arises from the lower half of the anterior surface of the humerus. At the upper part of its origin it embraces the insertion of the deltoid by two angular fleshy processes; it extends downwards to the capsule of the elbow-joint, and inwards to the internal supracondylar ridge and the intermuscular septum in its whole extent; on its outer side it is separated from the external ridge and septum in the greater part of its length by the supinator longus, and only arises from it for a short distance at its upper end. It is closely adherent to the ligament in front of the elbow-joint, and terminates below in a thick mass which is inserted into the rough triangular surface on the front of the coronoid process of the ulna.

*Relations.*—This muscle lies immediately behind and projects at each side of the biceps. It supports the brachial artery and median nerve. Fibres have been found to pass inwards from it, over the brachial artery, to the internal intermuscular septum.

*Varieties.*—This muscle is subject to considerable variation. The most frequent of these consist in its subdivision into two or sometimes more parts; its union with neighbouring muscles, such as supinator longus, pronator teres or biceps; insertion of a slip from it into the semilunar fascia; and occasionally into the radius.

The **triceps extensor cubiti** muscle occupies the whole posterior brachial region. It consists superiorly of three portions or heads which are united lower down in a common mass, the tendon of which is inserted into the posterior and upper part of the olecranon, a bursa inter-



vening between the tendon and the most prominent part of the process. The *middle* or *long head* arises from the lower part of the glenoid cavity and an adjoining rough portion of the outer border of the scapula, by a tendon which spreads over the sides of the muscular structure proceeding from it. This head forms the middle and superficial part of the common mass, presenting a long flat tendon on its posterior surface inferiorly. The *external head* takes origin by tendinous and fleshy fibres along a line extending from the insertion of the teres minor, downwards on the outer border of the humerus, as low as the musculo-spiral groove, and from an aponeurotic arch, formed by the external intermuscular septum, as it crosses the upper part of the groove: its fibres, which are comparatively short, descend obliquely to be inserted into the tendon of the middle part. The *internal* or *deep head*, the shortest of the three, arises from the whole posterior surface of the humerus, beginning on the external aspect below the musculo-spiral groove, and on the inner aspect of the arm reaching by a pointed process as high as the insertion of the teres major: it also rises from the internal intermuscular septum in all its length, and from the inferior portion of the external septum. Some of its lower fibres are inserted immediately into the olecranon, but the greater part of them join the deep surface of the common tendon. No muscular fibres arise from the musculo-spiral groove itself.

*Relations.*—The long head of the triceps lies between the two teres muscles above, and is in contact with the capsule of the shoulder-joint. The musculo-spiral nerve, and the superior profunda artery, are deeply imbedded in the muscle, and in the musculo-spiral groove, pass between the inner and outer heads.

*Varieties.*—The most frequent varieties of the triceps muscles are the following, viz. :—1, an additional or fourth head arising from the inner part of the humerus, above or near the inner head; and 2, a slip of connection between the triceps and the latissimus dorsi, corresponding with the *dorsi-epitrochlearis* or *accessorius tricipiti* which is common among quadrumana, and exists in many other mammals. The *epitrochleo-anconeus* of Wenzel Gruber is a small muscle observed by that author, Wood, and others, rising from behind the inner condyle, and inserted into the olecranon.

*Subanconeus.*—On removing the triceps from the lower part of the humerus, some muscular fibres will be found passing from that part of the bone to the capsule of the elbow-joint. These fibres, which are analogous to the subcrureus in the lower limb, have been described as distinct from the triceps under the name subanconeus.

The **anconeus** muscle, although placed chiefly below the elbow and in the forearm, is intimately connected with the triceps, and may be most appropriately associated in description with that muscle. It arises by a narrow tendon from the extremity of the outer condylar eminence of the humerus, at the posterior aspect. From this the fibres diverge from one another, the upper being transverse, the rest passing downwards with increasing degrees of obliquity, and are inserted into the olecranon on its radial aspect, and into the adjacent impression on the upper third of the shaft of the ulna. Its superior fibres are parallel to the lowest fibres of the internal head of the triceps, and are generally in contact with them.

*Relations.*—This muscle is subcutaneous in its whole extent. Its deep surface is in contact with the synovial membrane and external ligaments of the elbow-joint.

*Varieties.*—The anconeus varies chiefly in being more or less united to the triceps or the extensor carpi ulnaris.

**Nerves of the Brachial Muscles.**—The three anterior flexor muscles are all supplied from the musculo-cutaneous nerve: the brachialis anticus, however, receives also a small twig from the musculo-spiral nerve. The triceps and anconeus receive their nerves entirely from the musculo-spiral.

**Actions.**—The biceps muscle raises the arm at the shoulder and flexes the elbow-joint; the short head of the biceps draws the arm inwards as well as upwards, as does also the coraco-brachialis. If the biceps be called into action when the hand is in pronation, its first effect, from its insertion into the back part of the tuberosity of the radius, is to produce supination of the forearm. The biceps also makes tense the fascia of the forearm. The brachialis anticus is a simple flexor of the elbow. The external and internal heads of the triceps and the anconeus muscle, are simple extensors of the elbow joint; the long head, while it assists extension, also tends to depress the arm on the scapula.

#### MUSCLES AND FASCIÆ OF THE FOREARM.

**FASCIÆ.**—The **superficial fascia** of the forearm is most distinct opposite the bend of the elbow, where the superficial veins contained within its laminae are numerous and large. In the palm of the hand, on the contrary, the subcutaneous tissue forms a firm connecting medium between the skin and a strong aponeurosis named the palmar fascia: it consists of a network of fibres passing between those two structures, dividing the subcutaneous fat into small granular masses, and preventing the skin from shifting to any considerable extent.

The **aponeurosis** of the forearm, like that of the arm, is composed principally of circular fibres, strengthened, however, by longitudinal and oblique fibres descending from the condylar eminences of the humerus, from the olecranon, and from the semilunar fascia of the biceps muscle. It is attached along the subcutaneous margin of the ulna, and may be conveniently divided into an anterior and a posterior part.

The *anterior part* of the aponeurosis of the forearm is much weaker than the membrane on the posterior aspect of the limb. It is continued below into the anterior annular ligament of the wrist. In the hollow immediately below the bend of the elbow, it presents a small oval aperture for the transmission of a short communicating branch between the superficial and the deep veins of the forearm. It increases in density towards the hand; and a little above the wrist affords a sheath to the tendon of the long palmar muscle, which passes over the annular ligament to be inserted into the narrow end of the palmar fascia. Several white lines seen on the surface of the fascia mark the positions of the septa between the origins of the muscles descending from the inner condylar eminence, which are continuous with it. Between the superficial and the deep flexor muscles, another layer of fascia is stretched from side to side; it is stronger below than above, where it generally consists of little more than thin connective tissue.

The *anterior annular ligament* of the carpus, previously described at p. 157, is continuous at its upper margin with the fascia of the forearm, and receives some fibres from the tendon of the flexor carpi ulnaris: the lower margin is connected with a deep part of the palmar fascia, and gives origin in part to most of the short muscles of the thumb and little finger. This structure may be considered in some measure as a deep thickened portion of the fascia of the wrist.

The *posterior portion* of the aponeurosis of the forearm, much thicker

than the anterior, is intimately connected with the strong septa between the several superficial muscles, and sends off transversely a thin membrane to separate the superficial from the deeper group of muscles. Approaching the back of the wrist, the transverse fibres increase in number and strength, and these, being stretched somewhat obliquely from the outer margin of the radius on one side to the cuneiform and pisiform bones and the palmar fascia on the other, constitute the *posterior annular ligament* of the carpus. This structure is attached not only to the points now indicated, but is likewise connected to the several longitudinal ridges on the posterior surface of the radius, and thus converts the intermediate grooves into fibro-osseous canals to lodge the tendons of the extensor muscles. There are six separate spaces so enclosed, and each is lined by a distinct synovial sac. The outermost space corresponds with the groove on the outer side of the radius, and gives passage to the extensores ossis metacarpi and primi internodii pollicis, the next three, placed on the back of the radius, give passage respectively to the two radial carpal extensors, the extensor secundi internodii pollicis, and the common extensor of the fingers, with the extensor indicis accompanying it; between the radius and ulna is the compartment for the extensor minimi digiti; and resting in the groove on the back of the ulna is that for the extensor carpi ulnaris.

#### PRONATOR AND FLEXOR MUSCLES.

The eight muscles on the front and inner part of the fore arm are disposed in two sets, five being superficial, the others more deeply seated.

The **SUPERFICIAL LAYER** of muscles comprehends the pronator radii teres, flexor carpi radialis, palmaris longus, flexor carpi ulnaris, and flexor digitorum sublimis. These five muscles are intimately united at their origin from the inner condyle, to which they are attached by a common tendon which gives fibres to each, and also sends septa between them.

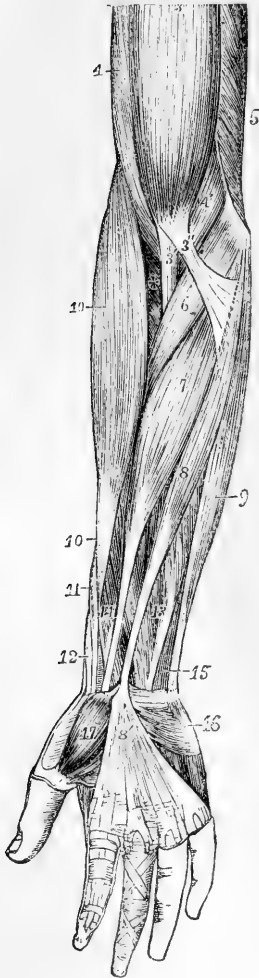
The **pronator radii teres** muscle, the most external of the group, arises by two distinct heads; one, large and superficial, is derived from the upper part of the inner condylar eminence of the humerus, and from the common tendon above mentioned; also from the fascia and the inter-muscular septum of the forearm. The second head, a thin fasciculus deeply placed, comes from the inner margin of the coronoid process, and joins the other at an acute angle. The fleshy belly thus formed proceeds outwards and downwards, and ends in a flat tendon which turns over the radius, and is inserted into a rough surface at the middle of the outer side of that bone.

*Relations.*—The pronator teres is placed superficially in the greater part of its extent; but towards its insertion it is crossed by the radial artery and nerve, and the supinator longus muscle. The ulnar border is in contact with the flexor carpi radialis and palmaris longus: the radial border forms the inner boundary of the angular space at the bend of the arm, in which are placed the brachial artery, the median nerve, and the tendon of the biceps muscle. The pronator teres covers the flexor sublimis digitorum; the ulnar artery passes behind the whole muscle, and the median nerve between its two heads.

*Varieties.*—The coronoid head is sometimes absent. In other cases the muscle is prolonged further than usual by a slip rising from the intermuscular septum above the inner condylar eminence of the humerus, or from the supracondylar process when that is present. This peculiarity is sometimes associated with a

change in the direction of the brachial artery. An additional head of origin from the biceps or from the brachialis anticus has also been observed.

Fig. 173.

Fig. 173.—SUPERFICIAL MUSCLES OF THE FOREARM AND HAND, SEEN FROM THE FRONT. (A. T.)  $\frac{1}{2}$ 

3, biceps flexor cubiti; 3', its tendon of insertion; 3'', its aponeurotic slip; 4, brachialis anticus; 4', its inner and lower portion; 5', lower part of the triceps, seen arising from behind the intermuscular septum; 6, pronator radii teres; 7, flexor carpi radialis; 8, palmaris longus, passing at 8' into the palmar aponeurosis; 9, flexor carpi ulnaris; 10, supinator longus; between 10 and 3, +, supinator brevis; 11, extensor ossis metacarpi pollicis; 12, extensor primi internodii; 13, lower part of the flexor digitorum sublimis; 14, flexor longus pollicis; 15, small part of the flexor digitorum profundus; 16, palmaris brevis, lying on the muscles of the little finger; 17, abductor pollicis.

The **flexor carpi radialis** muscle arises from the inner condyle by the common tendon, from the fascia of the forearm, and from the intermuscular septa placed between it and the pronator teres on one side, the palmaris longus on the other, and the flexor sublimis posteriorly. The fleshy fibres end a little below the middle of the forearm in a flat tendon, which occupies a special compartment in the outer part of the anterior annular ligament of the wrist, and running through a groove in the os trapezium, to which it is bound by a thin fibrous sheath lined by a synovial membrane, is inserted into the base of the second metacarpal bone.

*Relations.*—In the lower half of the forearm the radial artery is placed to the outer side of the tendon.

*Varieties.*—At its origin this muscle has been observed connected by an additional slip with the tendon of the biceps or semilunar fascia, or with the coronoid process of the ulna. Its insertion has been found frequently displaced, as into the trapezium, or into the third and even the fourth metacarpal bone as well as the second.

The **palmaris longus**, the smallest muscle of this group, is placed between the flexores carpi radialis and ulnaris, resting on the flexor sublimis: it arises from the inner condyle and the intermuscular septa, forming a small muscular belly, which soon ends in a long slender tendon, inserted into the palmar fascia near the middle of the wrist, and sometimes sending a slip to the short muscles of the thumb.

*Varieties.*—This is one of the most variable muscles in the body. It is wanting to the extent of about ten per cent. of the bodies examined. It is subject to many variations of form; e.g., the muscular fibres may occupy the middle of the muscle, which then commences and ends by an elongated tendon; or the mus-

cular structure may be placed towards the lower end, the upper part being tendinous. Occasionally there are two long palmar muscles, one having the ordinary shape, while the other has one of the forms above referred to. Occasionally its origin passes up to the triceps muscle. Its insertion below is also subject to great variation. The most remarkable peculiarity is that in which a small muscle, a second palmaris longus, placed nearer to the inner border of the forearm than the usual muscle, covers the ulnar artery for some space above the carpus, and terminates sometimes in the annular ligament or in the fascia, and frequently in the short muscles of the little finger.

The **flexor carpi ulnaris**, the innermost muscle of the superficial group, arises by two heads, one of which is attached tendinously to the inner condylar eminence of the humerus, the other to the inner side of the olecranon, and to the posterior border of the ulnar for two-thirds of its length, by an aponeurosis which is inseparably connected with the investing aponeurosis of the limb. The muscular fibres descending from this long line of origin, terminate in a tendon, which descends along the anterior margin of the muscle, and is inserted into the pisiform bone: this tendon is prolonged, by means of ligamentous structures, to the fifth metacarpal and unciform bones, as well as to the annular ligament and muscles of the little finger.

*Relations.*—This muscle rests on the flexor profundus digitorum. The ulnar nerve passes down into the forearm in the interval between the two heads, and is then covered by the muscle; for the middle part of its course the ulnar artery is also covered by it, and in the lower part of the forearm, the nerve and artery, emerging from behind the muscle, lie on its radial side. The posterior ulnar recurrent artery passes between its two heads of origin.

The **flexor digitorum sublimis vel perforatus**, the superficial flexor of the fingers, is a broad flat muscle placed behind the preceding muscles. It arises from the inner condyle by the common tendon, and the fibrous septa common to it and the other muscles; from the internal lateral ligament; from the anterior surface of the coronoid process at the inner side; and by a thin flat portion from the oblique line and part of the anterior border of the radius. It is divided inferiorly into four tendons, which pass to be inserted into the second phalanx of each of the four inner digits. These tendons pass under the annular ligament of the wrist in pairs, one in front of the other; the anterior pair consisting of those for the middle and ring fingers, the posterior of those for the index and little fingers. That for the little finger is smaller than the others.

In the palm of the hand the tendons diverge, and each, accompanied by a tendon of the flexor profundus, enters a fibrous sheath which binds both tendons down to the palmar surface of the phalanges. Opposite the first phalanx the tendon of the flexor sublimis divides into two parts, which fold closely round the tendon of the deep flexor, and are reunited by their margins behind it: the two portions of the tendon thereafter separating, pass to be inserted one on each side into a ridge at the middle of the lateral border of the second phalanx. A large *synovial bursa* loosely invests the tendons of both the superficial and deep flexors of the fingers behind the annular ligament, extending downwards into the palm of the hand. In the little finger it approaches the synovial lining of the sheath, and in the thumb it usually communicates with it.

The *sheaths of the flexor tendons*, by which they are bound down to

the fingers, are formed opposite the first and second phalanges by strong tendinous bands of transverse fibres (ligamenta vaginalia) attached to the rough margins of the palmar surfaces of the phalanges. Opposite the joints, flexion is secured by the substitution for those bands of a thin membrane, strengthened by oblique decussating fibres. The tendinous sheath has a synovial lining, which is simple in front, but poste-

Fig. 174.

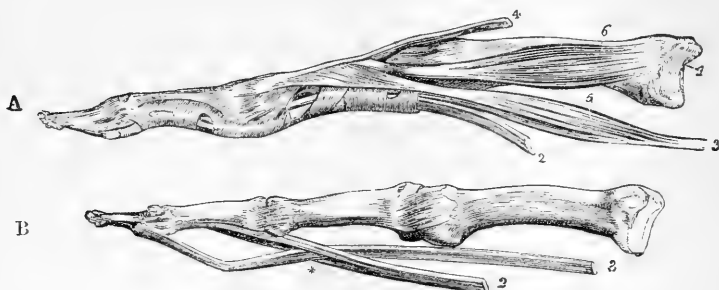


Fig. 174.—BONES OF TWO FINGERS, WITH THE INSERTIONS OF THE TENDONS.  $\frac{1}{2}$

In A, the tendons of the flexor muscles are bound to the finger by the fibrous sheaths. In B, the bands have been removed, as well as the synovial capsules and vincula accessoria; 1, metacarpal bone; 2, tendon of the flexor sublimis; 3, tendon of the flexor profundus; \*, perforation of the sublimis by the profundus tendon; 4, tendon of the extensor digitorum communis; 5, one of the lumbricales muscles; 6, one of the interosseous muscles.

riorly dips between the tendons. A few slender and loose bands (vincula accessoria tendinum) extend from the floor of the sheath to the deep surface of both tendons. Behind each tendon, near its insertion, is a short membranous structure (ligamentum breve) which fixes the tendon to the front of the phalanx situated above that into which it is inserted.

*Relations.*—Superiorly, the flexor sublimis is concealed by the other muscles of the superficial set, and is crossed near its radial origin by the radial artery; it rests on the flexor pollicis longus and flexor profundus, separated from the latter by the median nerve and the ulnar artery. In the palm of the hand, its tendons are covered by the palmar fascia, the superficial palmar arterial arch, and the branches of the median nerve; and they lie in front of the accompanying tendons of the flexor profundus.

*Varieties.*—The radial origin of the flexor sublimis is sometimes wanting. The body of the muscle is occasionally subdivided, so that each of the four tendons has a distinct muscular belly: this happens most frequently with the radial and the little finger part. The tendon to the little finger has been observed to be absent.

In connection with this muscle may be mentioned an additional small muscle, the *radio-carpalis*, which has been seen by many anatomists, rising from the outer border of the radius usually above the pronator quadratus, and very variably inserted below, into the trapezium magnum, or some other part of the carpus; and in other cases into one or other of the metacarpal bones.

A muscular slip is frequently given from this muscle to the flexor profundus, or to the flexor longus pollicis.

The DEEP-SEATED MUSCLES, on the anterior surface of the forearm, are the flexor profundus, flexor pollicis longus, and pronator quadratus.

The **flexor profundus digitorum**, or **flexor perforans**, a large and thick muscle, arises from the hollow at the inner side of the olecranon; from the inner and anterior surfaces of the ulna for three-fourths of its length; from the ulnar half of the interosseous ligament for the same distance; and from the aponeurosis attaching the flexor carpi ulnaris to the ulna. It divides inferiorly into four tendons, only one of which, that for the index finger, is distinct from the others above the wrist—the rest being connected together as far as the palm. In the palm the tendons, as they diverge, give origin to the lumbricales muscles. In front of the fingers they are bound to the first and second phalanges in the sheath common to them with the perforated tendons by the vaginal ligaments. Opposite the first phalanx, the tendon of each finger passes through the opening formed for its transmission in the tendon of the flexor sublimis, and is inserted into the base of the last phalanx.

Fig. 175.

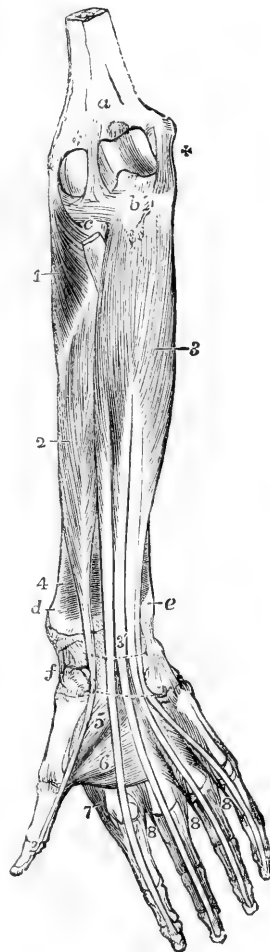


Fig. 175.—DEEP ANTERIOR MUSCLES OF THE FOREARM. (A. T.)  $\frac{1}{2}$

The superficial muscles of the forearm and hand, together with the lumbricales, have been removed, and the place of the anterior annular ligament of the carpus is marked by two dotted lines. *a*, surface of the humerus above the coronoid fossa; *b*, rough surface of the ulna, into which the brachialis anticus is inserted; *c*, head of the radius covered by the orbicular ligament, and between this and *a*, the anterior ligament of the elbow-joint; +, the internal lateral ligament; *d*, the lower end of the radius; *e*, that of the ulna; *f*, the scaphoid and trapezium bones; 1, supinator radii brevis; 2, flexor longus pollicis; 3, flexor digitorum profundus; 3', its four tendons, where they are about to pass under the annular ligament; 4, pronator quadratus on the lower part of the radius; 5, deep head of flexor brevis pollicis; 6, adductor pollicis; 7, first dorsal interosseous muscle; 8, in the second space, is placed between the first palmar and the second dorsal interosseous muscles; in the third space, between the third dorsal and the second palmar; in the fourth space, between the fourth dorsal and the third palmar. (For the lumbricales muscles, see Figs. 174 and 180.)

**Relations.**—The upper extremity of this muscle embraces the insertion of the brachialis anticus. On its surface lie the median nerve and the ulnar artery and nerve. The external border is parallel with the flexor longus pollicis, from which it is separated, on the interosseous membrane, by the anterior interosseous vessels and nerve. The tendons are covered by the synovial sacs, which have been mentioned in connection with the flexor sublimis.

The **lumbricales** muscles are four tapering fleshy fasciculi, passing from the tendons of the flexor profundus to the first digital phalanges. Each muscle rises by fleshy fibres from the outer or radial border of one

of the deep flexor tendons, and in the case of the two inner muscles also from the ulnar border of the second and third, and proceeding forwards to the radial sides of the fingers, each is inserted into an expansion of the extensor tendon on the dorsal aspect of the metacarpal phalanx of the finger.

*Varieties.*—The flexor profundus often presents varieties in its origin, deriving fibres from the radius in some instances, a distinct slip from the coronoid process of the ulnar in others, and more rarely from the inner condyle of the humerus. It is not unfrequently connected with the flexor sublimis, or with the flexor longus pollicis. The distinct slip from the coronoid process constitutes in numerous cases an accessory or supplemental muscle which joins very variously one or more of the perforating tendons.

The varieties of the lumbricales muscles are of frequent occurrence. Their number is sometimes diminished to three, and in rare instances is increased to five or six. The destination of one or two of them is often changed, and one finger (most frequently the third or fourth) has sometimes two inserted into it. Lastly, one muscle may be inserted into two fingers. The fourth has been observed to take the place of the fourth perforating tendon of the flexor profundus.

The **flexor longus pollicis** muscle, placed side by side with the flexor profundus digitorum, arises from the anterior grooved surface of the radius from the oblique line to the edge of the pronator quadratus; it arises also from the adjacent part of the interosseous ligament, and sometimes by a rounded fleshy and tendinous slip, distinct from the rest of the muscle, from the inner part of the coronoid process. The muscle ends in a tendon which passes behind the annular ligament of the wrist close to the trapezium, turns outwards between the two heads of the flexor brevis and between the sesamoid bones, and, entering a canal similar to those of the other flexor tendons, is finally inserted into the base of the second phalanx of the thumb.

*Varieties.*—A very common variety in this muscle (in two-fifths of subjects dissected by Macalister) is the existence of a second or accessory tendon for the thumb: this may arise from the flexor sublimis, the coronoid process, or sometimes as far up as the internal condyle. The flexor longus pollicis is also sometimes connected by a slip with the flexor sublimis or profundus, or the pronator teres. A tendon of insertion into the index finger has also been observed.

The **pronator quadratus**, placed close to the bones behind the last two muscles, arises from the anterior and inner surfaces of the ulnar for about two inches above its carpal extremity; its fibres cross the lower part of the forearm, some transversely and others obliquely, and they are inserted for an equal distance into the fore part of the radius.

*Varieties.*—The pronator quadratus is subject to varieties, chiefly as follows:—  
1. It may be entirely absent, but this is rare; 2, it is subdivided into two layers, or occasionally into three; 3, it extends farther upwards on the bones of the forearm than usual; 4, it is prolonged downwards on the carpus, in some cases as a radio-carpal, and in others as an ulno-carpal muscle (Macalister, Journ. of Anat., vol. v., W. Grüber, loc. cit.).

**Nerves.**—The muscles of the pronator and flexor group receive their nerves in great part from the median; only one muscle being wholly supplied from the ulnar nerve. The branches from the median are distributed to the muscles in two groups, one to the superficial and another to the deep set. From these the anterior interosseous is a distinct branch, which accompanies the anterior interosseous vessels in front of the interosseous ligament, and ends in the pronator



quadratus. Only one half of the flexor profundus digitorum is supplied with nerves from the median, the other half, together with the whole of the flexor carpi ulnaris receives twigs from the ulnar nerve.

## SUPINATOR AND EXTENSOR MUSCLES.

The muscles of this group are, like those of the front of the forearm, divided into a superficial and a deep layer.

The SUPERFICIAL MUSCLES are six in number, viz., the supinator longus, the extensores carpi radiales longior and brevior, the extensor communis digitorum, extensor minimi digiti, and extensor carpi ulnaris.

The **supinator radii longus** muscle arises from the upper two-thirds of the external ridge of the humerus, and the external inter-muscular septum. Its fibres form a thin fleshy mass which descends upon the anterior and outer border of the forearm, about the middle of which they end in a flat tendon, which is inserted into the external border of the radius, near the base of the styloid process.

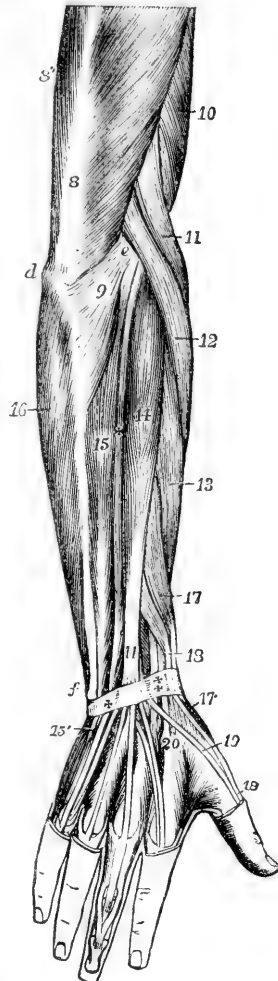
Fig. 176.—SUPERFICIAL MUSCLES OF THE FOREARM AND HAND, SEEN FROM BEHIND. (A. T.)  $\frac{1}{2}$

*d*, olecranon; *e*, external condylar eminence; *f*, lower end of the ulnar; *8*, main tendon of the triceps extensor cubiti; *8'*, its inner head; *9*, anconeus; *10*, part of brachialis anticus; *11*, supinator longus; *12*, extensor carpi radialis longior; *13*, ——— brevior; *14*, extensor communis digitorum; *15*, extensor carpi ulnaris; *15'*, its insertion into the fifth metacarpal bone; *+*, between *14* and *15*, extensor minimi digiti; *16*, origin of the flexor carpi ulnaris by an aponeurosis from the back of the ulna; *17*, extensor ossis metacarpi pollicis; *17'*, its insertion into the first metacarpal bone; *18*, extensor primi internodii pollicis; *18'*, its insertion into the first phalanx; *+* and  $\ddagger$ , posterior annular ligament of the carpus or retinaculum of the extensor tendons; at  $\ddagger$ , the tendons of the long and short radial extensors; at *+*, the tendon of the extensor minimi digiti; *19*, tendon of the extensor secundi internodii; *20*, is placed on the proximal end of the second metacarpal bone, close to the insertion of the radial extensors of the carpus: in the hand, the dorsal interossei muscles are shown, and on the middle finger the insertion of the extensor tendons.

*Relations.*—This muscle is covered only by skin and fascia, except at its insertion, where two of the extensor tendons of the thumb lie superficial to it. Above, the brachialis anticus is in contact with its inner surface and the radial extensors of the carpus are beneath it. It forms the outer boundary of the triangular space at the bend of the elbow, and in the forearm it rests upon the supinator brevis, flexor sublimis digitorum, pronator teres, radial artery, musculo-spiral and radial nerves.

*Varieties.*—These are neither great nor numerous in this muscle. One of the

Fig. 176.



commonest is the division of the tendon or lower part of the muscle into two or sometimes three slips, which are inserted either together or at some distance from each other. The supinator longus may also be connected to some of the neighbouring muscles, especially at its origin.

The **extensor carpi radialis longior** muscle arises from the lower part of the external condylar ridge of the humerus, and from the intermuscular septum. Its muscular belly ends at the meeting of the upper and middle thirds of the forearm in a flat tendon, which passes, conjointly with that of the following muscle, over the lower end of the radius in the outermost of the two broad grooves on the posterior surface of that bone, and is inserted into the base of the second metacarpal bone. A small bursa lies beneath the tendon at its insertion.

The **extensor carpi radialis brevior** muscle arises from the outer condylar eminence of the humerus by a tendon common to it and the other extensor muscles, from the intervening fibrous septa, from a superficial tendinous expansion, and from the external lateral ligament of the elbow-joint. Its muscular belly ends in a flat tendon, which descends with that of the extensor longior, passes through the same groove of the radius with it, and is inserted into the base of the metacarpal bone of the middle finger. A bursa is placed between this muscle and the supinator brevis, and a smaller one between the tendon and the metacarpal bone.

*Relations.*—Of the two foregoing muscles the extensor longus is the most superficial. The extensor brevis covers the supinator brevis and the insertion of the pronator radii teres. The tendons of these muscles and that of the supinator longus are crossed obliquely by the extensors of the metacarpal bone and first phalanx of the thumb.

*Varieties.*—The two foregoing muscles are subject to a similar variation in being, one or other of them, split up into two or sometimes three tendons previous to insertion; the tendons of either muscle being inserted into both the second and third metacarpal bones: occasionally a slip passes also to the fourth metacarpal bone.

An additional muscle, called *extensor carpi radialis accessorius* by Mr. Wood, is of frequent occurrence, rising from the radius below the extensor carpi radialis longior, and running through the same groove behind the radius at the wrist, it is inserted most frequently into the metacarpal bone of the thumb, but sometimes into the abductor pollicis, first dorsal interosseous muscle or other part.

The **extensor communis digitorum** muscle, placed between the extensor carpi radialis brevior and the extensor minimi digiti, arises from the outer condylar eminence by a tendon common to it and the other superficial extensor muscles, also from the fascia of the forearm, and the septa between it and the adjoining muscles. Somewhat below the middle of the forearm the muscular part ends in four tendons, which pass between the posterior annular ligament of the wrist and the innermost broad groove on the back of the radius, and diverge as they proceed along the carpus and metacarpus to reach the fingers. Here each is increased by tendinous fibres derived from the lumbricales and interosseous muscles forming a fibrous expansion, which covers the back of the first and second digital phalanges, and terminates upon the third phalanx. It is attached to the second and third phalanges in the following manner. Opposite the first bone the tendon divides into three fasciculi; the central one is much thinner than the others, and is inserted into the base of the second phalanx; the two lateral parts, continuing

onwards, are joined together towards the middle or fore part of the second phalanx, and, having passed beyond this, are inserted into the last phalanx. On the index and little fingers the tendons are joined before their division, by the special extensor tendons of those digits.

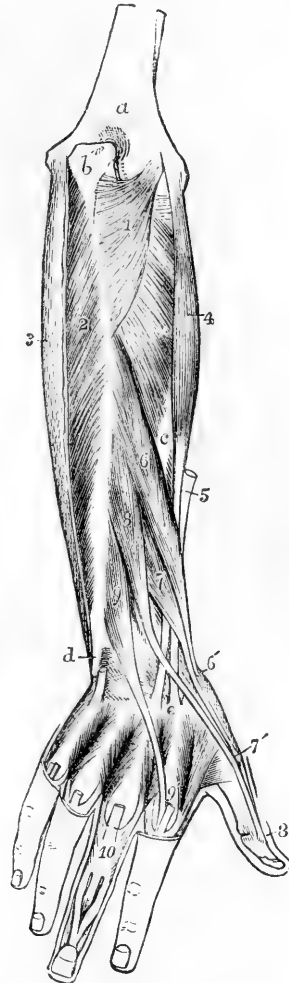Fig. 177.—DEEP POSTERIOR MUSCLES OF THE FOREARM. (A. T.)  $\frac{1}{4}$

*a*, posterior surface of the humerus; *b*, olecranon; *c*, radius; *d*, lower part of the ulnar, grooved for the tendon of the extensor carpi ulnaris; *e*, base of the second metacarpal bone; 1, anconeus; 2, flexor digitorum profundus, exposed by the removal of the aponeurotic tendon of 3, the flexor carpi ulnaris; +, supinator brevis; 4, extensor carpi radialis brevis, and 5, the cut tendon of the extensor carpi radialis longior; *e*, their insertion into the second and third metacarpal bones; 6, extensor ossis metacarpi pollicis; 6', its insertion into the first metacarpal bone; 7, extensor primi internodii pollicis; 7', its insertion into the base of the first phalanx; 8, extensor secundi internodii pollicis; 8', its insertion into the base of the last phalanx; 9, extensor indicis; 9', its junction with the tendon of the common extensor, which is cut short; in the metacarpal spaces the four dorsal interossei muscles are represented, the tendons of the common extensor having been removed; and at 10, the insertion of the second and third dorsal interossei, by a triangular expansion, into the tendon of the extensor communis, as well as the mode of insertion of that tendon into the middle and last phalanges, are shown.

On the back of the hand the tendon of the ring-finger gives off two processes, one on each side, the lateral vincula, which pass obliquely downwards to join the tendons of the middle and little fingers: in consequence of this arrangement it follows that, if those two fingers be flexed, the tendon of the ring-finger is held downwards, and it becomes impossible to extend that finger by the action of the muscle. The tendon of the index-finger is only united to that of the middle finger by a loose transverse, semi-transparent band of fibres, and is free in its action. A synovial membrane invests the tendons of this muscle as they pass under the annular ligament.

*Varieties.*—The varieties of the extensor communis digitorum resolve themselves chiefly into the following, viz., 1st, the occasional deficiency of one or more of the tendons of insertion, and, 2nd, more frequently an increase in their number. This last goes in some instances to the extent of doubling the tendon to each of the fingers, and even to tripling it to one or two of them. More frequently, however, the increase of number of the tendons is limited to the index or little finger alone. The muscular substance is also liable to be divided more deeply than usual into distinct portions for a part or the whole of its length.

Fig. 177.



The **extensor minimi digiti** is a slender muscle which is placed between the extensor communis digitorum and the extensor carpi ulnaris, and arises by means of a thin tendon in common with the extensor communis. The tendon in which it ends occupies a groove between the radius and ulna, passing through a special compartment in the annular ligament, and joins the fourth digital tendon of the common extensor.

*Varieties.*—This muscle, like that preceding, and the same occurs in the indicator muscle afterwards described, is subject to an increase in the number of its tendons of insertion, and in a large proportion of the cases the additional tendon is inserted into the ring-finger. The entire absence of the muscle has also been observed. In the case of the indicator, the additional tendon is most frequently inserted into the middle finger, constituting the extensor medii, which is sometimes separate in the whole length of the muscle.

The **extensor carpi ulnaris**, the most internal of the muscles descending on the back of the forearm, arises from the external condylar eminence of the humerus by the common tendon and prolongation of that structure; from the posterior border of the ulna, below the anconeus, for about the middle third; and from the fascia of the forearm. The muscular fibres derived from these sources incline somewhat inwards, and end in a tendon, which runs through a special groove in the carpal end of the ulna and a separate sheath in the annular ligament, and is inserted into the base of the metacarpal bone of the little finger on its posterior aspect.

*Varieties.*—This muscle is frequently connected with the short abductor minimi digiti. It also sometimes sends a prolongation to the extensor tendons on the back of the little finger, which has been named ulnaris quinti.

The DEEP-SEATED MUSCLES on the back of the forearm are five in number, the supinator brevis, the three extensors of the thumb, and the extensor of the index-finger.

The **supinator radii brevis** muscle arises from the external lateral ligament of the elbow-joint, and from the annular ligament of the radius; also from a rough depression below the sigmoid cavity of the ulna, and from the outer border of that bone for two inches. The fibres of the muscle, derived from these points of attachment, as well as from a tendinous expansion on the surface, pass obliquely round the upper part of the radius, covering it closely except at the inner side, and are inserted into that bone for rather more than a third of its length, passing down to the upper margin of the insertion of the pronator teres. It is pierced by the posterior interosseous nerve.

*Varieties.*—This muscle is subject to more or less division at the place of passage of the posterior interosseous nerve, and occasionally the insertion of an accessory slip takes place into the biceps tendon or tuberosity of the radius. A set of short fibres passing round the upper part of the radius has received the name of tensor ligamenti orbicularis anterior (W. Grüber, Cruveilhier).

The **extensor ossis metacarpi pollicis** muscle (abductor longus pollicis,—Alb.) arises from an elongated depression on the radial side of the posterior surface of the ulna below the origin of the supinator brevis, from a similar extent of surface of the radius below the insertion of the same muscle, and from the interosseous membrane between. Thence descending obliquely outwards, it ends in a tendon, which passes, in company with the extensor primi internodii pollicis, through

the groove on the outer border of the lower extremity of the radius, and is inserted in the base of the metacarpal bone of the thumb.

*Relations.*—The upper part of this muscle is concealed by the common extensor, but it becomes superficial beneath, and together with the next muscle crosses the tendons of the radial extensors of the carpus, conceals the insertion of the supinator longus, and, beneath the extremity of the radius, crosses the radial artery.

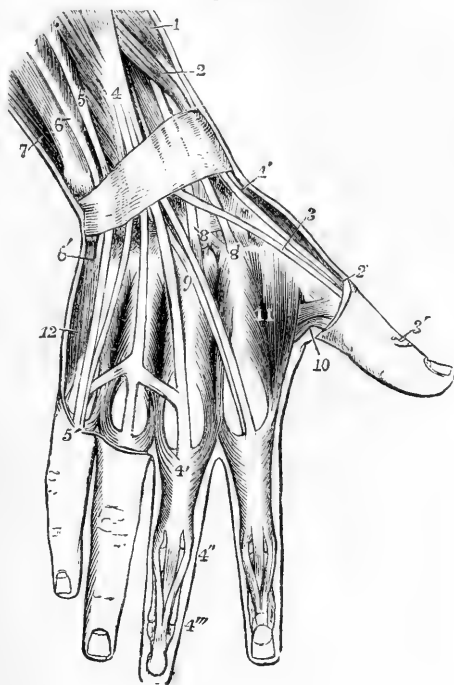
The **extensor primi internodii pollicis** muscle lies close to the lower border of the extensor ossis metacarpi, and is much smaller than that muscle ; it arises from the interosseous ligament and the radius near the middle of the forearm ; its tendon accompanies that of the extensor ossis metacarpi through the same compartment of the annular ligament, and passes on to be inserted into the proximal end of the first phalanx.

The **extensor secundi internodii pollicis** muscle, much larger than the extensor primi internodii, which it overlaps, arises immediately below the extensor ossis metacarpi from the shaft of the ulna for two or three inches and from the interosseous ligament at its lower end for about

Fig. 178.—SUPERFICIAL MUSCLES AND TENDONS ON THE BACK OF THE WRIST AND HAND (after Bourguery).  $\frac{1}{3}$

The posterior annular ligament of the wrist is represented. 1, extensor ossis metacarpi pollicis ; 1', its insertion ; 2, extensor primi internodii pollicis ; 2', its insertion ; 3, 3', tendon of the extensor secundi internodii pollicis ; 4, extensor communis digitorum ; 4', tendon to the middle finger, receiving the insertion of the second and third dorsal interossei ; 4", division of the tendon into three portions, of which the median is inserted into the second phalanx, the two lateral passing on to be inserted into the terminal phalanx ; the union of the tendons of the third, fourth, and fifth fingers is shown ; 5, extensor minimi digiti ; 5', its junction with the slip of the common extensor ; 6, placed on the lower end of the ulna, points to the extensor carpi ulnaris ; 6', insertion of this muscle into the base of the fifth metacarpal bone ; 7, part of the flexor carpi ulnaris ; 8, placed on the os magnum, points to the insertion of the extensor carpi radialis brevis ; 8', placed on the base of the second metacarpal bone, points to the insertion of the extensor carpi radialis longior ; 9, tendon of the extensor indicis ; 10, small part of the adductor pollicis, and deep head of the flexor brevis pollicis ; 11, first dorsal interosseous or abductor indicis : in the other three interosseous spaces are seen in succession, from the radial side inwards, the insertion of the first palmar, second dorsal, third dorsal, second palmar, fourth dorsal, and third palmar interossei muscles ; 12, abductor minimi digiti.

Fig. 178.



an incn. Its fibres end in a tendon, which occupies the narrow oblique groove in the middle of the posterior surface of the carpal end of the radius, and is bound down in a separate compartment of the annular ligament; it is inserted into the base of the terminal phalanx of the thumb.

*Relations.*—The groove which lodges the radial extensors of the carpus intervenes between those which lodge the tendon of this muscle and the tendons of the other extensors of the thumb.

*Varieties.*—The extensor muscles of the thumb are subject to considerable variations, and if all the three muscles be included they seem to occur as often as in one out of every six subjects dissected. The most common occur in the extensor ossis metacarpi, and consist in more or less cleavage of the muscle or its tendon into separate parts. The insertion of the distinct tendons takes place either doubly into the first metacarpal bone, or in part into the trapezium, or into the abductor or opponens pollicis muscles. The extensor primi internodii is sometimes absent, being, as it were, fused with the extensor ossis metacarpi, in other cases it is more or less united with the extensor secundi internodii pollicis. A frequent variety, representing a muscle normally existing in the dog and many carnivora, is formed by the interposition of an additional extensor between the indicator and the extensor secundi internodii pollicis, with a double tendon and insertion into both fingers.

The **extensor indicis** or indicator muscle arises from the lower end of the posterior surface of the ulna for three or four inches. The tendon passes with the common extensor through a compartment of the annular ligament, comes in contact with the tendon from that muscle destined for the index-finger, and unites with it to form the expansion already described.

Fig. 179.

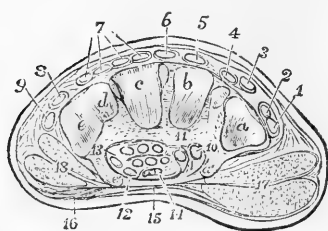


Fig. 179.—TRANSVERSE SECTION OF THE RIGHT HAND BETWEEN THE CARPUS AND METACARPUS. (A. T.)  $\frac{1}{2}$

*a, b, c, d, e*, articular surfaces of the trapezium, trapezoid, and unciform bones; *a'*, palmar ridge of the trapezium; *e'*, unciform process; between *a'* and *e'*, the cut edge of the annular ligament, a process towards the trapezium at 11, by which the tendon of the flexor carpi radialis is enclosed in the groove of the trapezium; 1, tendon of the extensor ossis metacarpi pollicis; 2, extensor primi internodii; 3, extensor secundi internodii; 4, extensor indicis;

5 and 6, long and short radial extensors of the carpus; 7, the four divisions of the tendon of the common extensor of the fingers; 8, extensor minimi digiti; 9, extensor carpi ulnaris; 10, flexor carpi radialis; 11, flexor longus pollicis; 12, the first on the ulnar side of the tendons of the flexor sublimis digitorum; 13, the same of the flexor profundus; 14, the median nerve; 15, the palmar aponeurosis stretched across the annular ligament; 16, palmaris brevis; 17, muscles of the ball of the thumb; 18, muscles of the little finger.

*Varieties.*—A short additional extensor of one or more of the fingers has been observed as an occasional variety by various anatomists since Albinus, and who named it extensor brevis in the case of the index-finger with which it is most frequently connected. But it appears from later observations to vary considerably both in its origin, which may be from the radius or from a carpal or metacarpal bone, and in its insertion which may be into only one or into two or more of the fingers; thus forming an extensor brevis digitorum.

*Nerves.*—The anconeus, supinator longus, and extensor carpi radialis longior receive branches directly from the musculo-spiral nerve; the short radial extensor, the ulnar extensor of the carpus, and the common extensor of the fingers, with that of the little finger, are supplied from the radial division, while the supinator

brevis and the four deeper extensor muscles receive branches from the interosseous nerve.

### MUSCLES OF THE HAND.

Besides the tendons of the long muscles and the lumbricales already described, there are placed in the hand one superficial muscle called *palmaris brevis*, the short muscles of the thumb and little finger, and the interossei muscles.

Fig. 180.—MUSCLES AND TENDONS OF THE PALMAR ASPECT OF THE HAND.  $\frac{1}{4}$

Portions of the tendons of the superficial flexor have been cut away to show those of the deep flexor and the lumbricales. 1, tendon of the flexor carpi radialis, cut short; 2, tendon of the flexor carpi ulnaris, inserted into the pisiform bone; 3, anterior annular ligament of the carpus; 4, abductor pollicis; 5, opponens pollicis; 6, 6, flexor brevis; 7, adductor pollicis; 8, abductor minimi digiti; 9, flexor brevis minimi digiti; 10, lumbricales, passing to their insertion on the radial side of the four fingers.

The *palmaris brevis* is a thin flat subcutaneous muscle, which arises from the inner margin of the palmar fascia and annular ligament; its fibres proceed transversely inwards, and are inserted into the skin along the inner border of the palm.

*Relations.*—The *palmaris brevis* crosses the muscles of the little finger and covers the ulnar artery and nerve. It is subject to considerable variation in its breadth and thickness, consisting sometimes of only a few scattered fibres.

Fig. 181.—DEEP MUSCLES OF THE PALM OF THE HAND.  $\frac{1}{2}$

The abductor pollicis and abductor minimi digiti, together with the anterior annular ligament and the long flexor tendons in the palm have been removed; in the fore-finger the tendons of both the superficial and deep flexors remain; in the other fingers the tendons of the superficial flexor have been removed. 1, pronator quadratus muscle; 2, opponens pollicis; 3, flexor brevis pollicis; 4, adductor pollicis; 5, opponens minimi digiti; 6, unciform bone; 7, 8, interosseous muscles.

**MUSCLES OF THE THUMB.**—The fleshy mass which forms the *thenar eminence*, or ball of the thumb, consists of four muscles.

The *abductor pollicis* muscle (abductor brevis pollicis, —Alb.), superficial and flat, arises from the annular ligament and from the ridge of the os trapezium, and proceeding outwards and forwards, is inserted

Fig. 180.

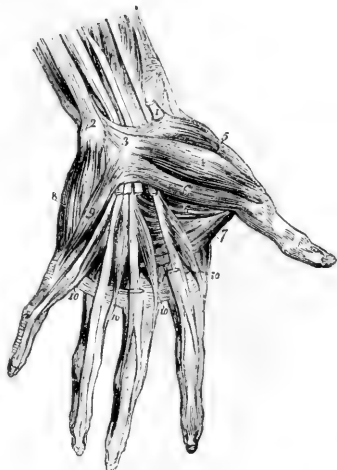
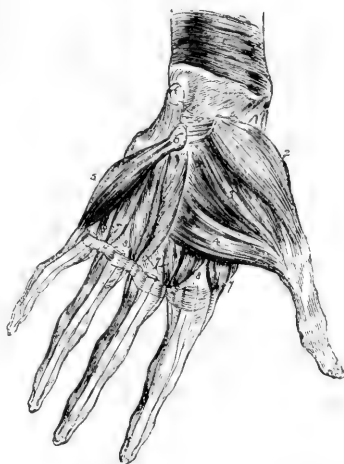

Fig. 181.



by a tendon into the radial border of the first phalanx of the thumb at its base.

The **opponens pollicis** muscle, placed behind the abductor, arises from the annular ligament and from the os trapezium and its ridge, and is inserted into the whole length of the metacarpal bone of the thumb at the radial border.

The **flexor brevis pollicis** muscle arises by two heads, a superficial and a deep. The superficial head is attached to the outer two-thirds of the annular ligament and to the trapezium: the deep head is attached to the os trapezoides and os magnum, to the sheath of the flexor carpi radialis, and to the sheath of the flexor carpi radialis, and to the bases of the second and third metacarpal bones. From the superficial and deep heads of origin two strong masses of fibres proceed, which, becoming tendinous, are inserted into the sides of the base of the first phalanx of the thumb; the outer head is also joined by a considerable fasciculus from the deeper origin; the inner head is inserted conjointly with the adductor pollicis. In each of the tendons of insertion a sesamoid bone is developed, which plays over the grooved surface of the first metacarpal bone. The tendon of the long flexor lies between the heads of origin, and grooves the surface of the muscle as it passes between the tendons of insertion.

The **adductor pollicis** muscle arises from the middle two-thirds of the palmar surface of the third metacarpal bone, and is inserted into the base of the first phalanx of the thumb along with the inner tendon of the short flexor.

**MUSCLES OF THE LITTLE FINGER.**—The fleshy mass at the inner border of the hand (*hypothenar eminence*) consists of three muscles passing to the little finger.

The **abductor minimi digiti** muscle arises by tendinous fibres from the pisiform bone and the inserted tendon of the flexor carpi ulnaris, and is inserted into the base of the first phalanx of the little finger on the ulnar border.

The **flexor brevis minimi digiti**, separated at its origin from the abductor muscle by a small interval through which pass the deep palmar branch of the ulnar nerve and the communicating branch of the ulnar artery, arises from the front of the annular ligament, and from a tip of the hooked process of the unciform bone, and is inserted into the base of the first phalanx of the little finger, in connection with the preceding muscle. This muscle is sometimes absent, or becomes incorporated with the abductor.

The **opponens minimi digiti** muscle arises from the annular ligament and the unciform process, and is inserted into the ulnar border of the fifth metacarpal bone in all its length.

The **INTEROSSEOUS MUSCLES** occupy the intervals between the metacarpal bones. They are seven in number, all of them more or less visible from the palmar aspect, and they are divided into two sets, viz. those which are best seen on the dorsal aspect of the metacarpus, and those which are seen only in the palm. Their disposition is most easily understood by reference to their action.

The **dorsal interossei** muscles withdraw the fingers from the middle line of the hand; they are four in number, each occupying one of the spaces between the metacarpal bones, and are numbered from without inwards. Each muscle arises from both the metacarpal bones



between which it is placed, but most extensively from that supporting the finger upon which it acts, and the fibres converge pennately

Fig. 182.

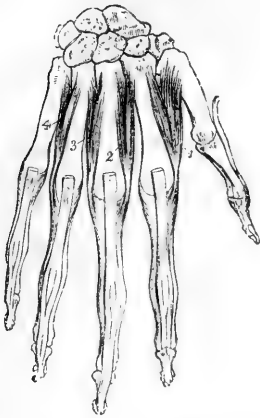


Fig. 183.

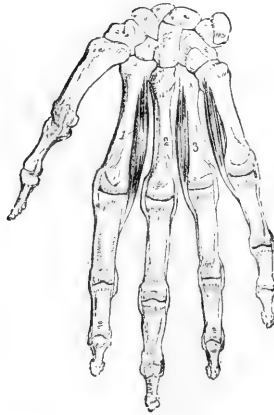

Fig. 182.—THE RIGHT HAND FROM BEHIND, SHOWING THE DORSAL INTEROSSEOUS MUSCLES.  $\frac{2}{3}$

The tendons of the extensor muscles have been removed as far as the distal ends of the metacarpal bones. 1, 2, 3, and 4, the dorsal interossei muscles, in order from the radial side inwards; their expanded insertion in connection with the extensor tendons, is shown upon the first phalanges.

Fig. 183.—THE RIGHT HAND FROM BEFORE, SHOWING THE PALMAR INTEROSSEI MUSCLES.  $\frac{2}{3}$

1, 2, 3, refer to the first, second, and third palmar interosseous muscles.

to a common tendon in the middle. Each terminates in a tendon, which is inserted partly into the base of the first phalanx, and partly into the tendon of the common extensor muscle on the dorsum of the same part of the finger. Two dorsal interossei are inserted into the middle finger and draw it to either side; of the remaining muscles one passes to the radial side of the index-finger, and the other to the ulnar side of the ring-finger; they withdraw those fingers from the middle line of the hand.

The *first* dorsal interosseous muscle or *abductor indicis* is larger than the others; its outer and larger head of origin arises from the proximal half of the ulnar border of the first metacarpal bone, the inner is attached to the whole length of the second metacarpal bone, and between these heads there is left superiorly an interval wider than in the other dorsal interosseous muscles.

*Relations.*—Between the heads of the abductor indicis the radial artery passes forwards to the palm of the hand; between those of the other dorsal interossei small perforating arterial branches are transmitted.

The three **palmar interossei** muscles are adductors, drawing the index, ring, and little fingers towards the middle line of the hand. They are visible only from the palmar aspect of the hand, each one arising from the concave part of the body of the metacarpal bone of the finger on which it acts: they terminate, like the dorsal muscles, in small

tendons inserted partly into the base of the first phalanx at the side, and partly into the extensor tendon. The first palmar interosseous muscle belongs to the ulnar side of the index-finger: the others are placed on the radial sides of the ring and little fingers.

**Varieties in the short muscles of the hand.**—The palmaris brevis varies greatly in the strength of its muscular fibres, and somewhat also in their length and direction. It is sometimes entirely absent (in the proportion of one in forty-five out of six hundred dissections by Macalister). It is also sometimes found running into the flexor minimi digiti.

The abductor pollicis (brevis) muscle is frequently found divided into an outer and an inner part,—a condition described by Soemmerring as normal; and accessory slips have been observed connected with it,—in some instances proceeding from the styloid process (Cruveilhier and Turner), and in others from the opponens pollicis (Macalister).

The flexor brevis pollicis is a variable muscle, especially in its deeper belly, a part of which shows a tendency to run more or less in connection with the adductor pollicis; and in the same manner the latter muscle is subject to variation in its breadth of origin and extent in inverse proportion to those of the flexor brevis (Dursy in Henle and Pfeifer's Zeitsch. 1853).

The abductor minimi digiti is found in some cases partially divided into two or even into three slips, and in others to be united with the flexor brevis.

The opponens muscles are subject to varieties chiefly affecting their extent, and the degree of their union with or separation from the neighbouring muscles.

The interossei muscles present some variations but not of any great magnitude. They are occasionally double in one or more of the spaces, and sometimes, though rarely, a palmar interosseous has been observed in the first space (Heale and Wood). The arrangement which usually exists in the foot, and which is peculiar to man, has also been observed to occur in the hand.

**Nerves of the muscles of the hand.**—The median nerve supplies branches to the abductor pollicis, the flexor brevis and opponens immediately below the annular ligament, and to the two first lumbricales muscles from the first and second digital collateral nerves respectively. The ulnar nerve, besides giving a twig to the palmaris brevis, furnishes by its deep palmar division branches to the two internal lumbricales, all the interossei, the adductor, and the deep head of the flexor brevis pollicis muscles.

#### ACTIONS OF THE MUSCLES OF THE FOREARM AND HAND.

The muscles of the forearm may be distinguished according to their actions as pronators and supinators, flexors and extensors of the wrist, and long flexors and extensors of the fingers; those of the hand are flexors and extensors, adductors, abductors and opposers of the fingers; the terms adduction and abduction being here used with reference to the middle of the hand.

*Pronation* is mainly effected by the pronator teres and pronator quadratus: the flexor carpi radialis also contributes slightly to this movement. The pronator teres is fitted to flex the elbow when pronation has been completed, or when it is prevented by antagonistic muscles.

*Supination* is effected principally by the supinator brevis, the supinator longus only partially accomplishing this action. The latter muscle is principally a flexor of the elbow, acting, however, only after that movement has been begun by other muscles. By the successive and alternating action, however, of the pronators and supinators and of the flexors and extensors of the carpus, a more complete rotation of the hand is produced, so that the ulna as well as the radius moves round a fixed axis which is nearly in the line of the middle finger, as may be well seen in the use of a corkscrew or other like movements. When still more extensive movements of this kind are effected, they are accompanied by rotation of the whole limb at the shoulder-joint.

*Flexion of the wrist* is produced by the radial and ulnar flexors of the carpus, and is aided by the flexors of the fingers when the action of those muscles on

the fingers is either completed or is opposed by any resistance, as when the over-extended hand is pressed against a surface in pushing, or in the support of the body.

*Extension of the wrist*, in a similar manner, is accomplished not only by the three muscles specially devoted to that function, but also by the extensors of the fingers.

To ensure the efficient action of the long extensor and flexor muscles of the fingers it is necessary that there should be simultaneous action of the flexors and extensors of the wrist respectively; for the wrist-joint must be fixed backwards by its extensors in order that the long flexors of the fingers may act, and the wrist must be fixed forwards by its flexors in order that the long extensors may act upon the fingers.

The *flexor communis digitorum sublimis* and the *flexor profundus* bend respectively the second and the third phalanges of the fingers, while the *extensor communis* extends the first phalanx. The four *lumbricales*, on the other hand, and the seven *interossei* muscles have a double action, in consequence of their insertion into the lateral expansions of the extensor tendons, and of some of the interossei directly into the first phalanges. This action consists first, in the flexion of the fingers at the metacarpo-phalangeal articulations, and second, in extension of the second and third phalanges. The lumbricales and interossei, therefore, are antagonists to both the long flexors and to the long extensor. This partial and combined action of the long and short muscles upon the fingers, of which the movements made in forming the hair-stroke in writing may be taken as an example, has been well known for a considerable time, especially as regards the lumbricales, but it has recently been confirmed and elucidated as regards the interossei by the electro-physiological experiments and pathological observations of Duchenne, whose interesting work as quoted below,\* may be advantageously consulted on this and other muscular movements.

With respect to the *interossei*, it is further to be observed that, besides being flexors of the first and extensors of the second and third phalanges in the manner previously stated, they severally exercise an abducting or adducting action on certain fingers, or direct them away from or towards the middle line of the hand, according to the places of their respective insertions: and thus the four dorsal interossei are abductors of the index, middle and ring fingers, and the three palmar interossei are adductors of the index, fourth and fifth fingers respectively.

When the thumb is opposed to the other fingers, the metacarpal bone is drawn forwards, chiefly by the *opponens*, the *adductor*, and the *flexor brevis* muscles. The precise action of the *adductor* is to draw the thumb forwards. The *extensor ossis metacarpi* is entirely an abductor, as indicated by the name given to it by Albinus. The *extensor primi internodii* likewise is an abductor as well as an extensor of the first phalanx. The *extensor secundi internodii* extends both phalanges and also draws the metacarpal bone backwards. The *adductor* and the inner fibres of the *flexor brevis* adduct the thumb. A combination of the actions of the different muscles in succession produces circumduction.

The little finger is withdrawn from the others by its *abductor*, as the ring-finger is withdrawn from the middle finger by the fourth dorsal interosseous muscle; and the *abductor* acting with the long flexors, likewise assists the *flexor brevis* in keeping the first phalanx firmly down in grasping.

While the *palmaris longus* has the effect of tightening the palmar fascia, the *palmaris brevis* assists in deepening the hollow of the hand by raising the integument on the inner side, so as to increase the hypothenar prominence.

\* Dr. D. B. Duchenne, "Physiologie des Mouvements, &c.," Paris, 1867.

## II.—MUSCLES AND FASCIÆ OF THE LOWER LIMB.

The muscles which pass between the trunk and the lower limb, viz., the psoas, pyriformis, coccygeus, and part of the gluteus maximus, are so few in number and so intimately connected with others belonging strictly to the limb, that it is unnecessary to describe them as a distinct group, as has been done in the case of the more numerous and considerable muscles which attach the upper limb to the trunk.

### FASCIÆ OF THE HIP AND THIGH.

The **superficial fascia** of the lower limb is similar to and continuous with that of other parts of the body. Over the gluteal region it is very thick, and assists in forming the prominence of the buttock. On the front of the thigh it is readily divisible into two layers. Of these the subcutaneous passes freely over Poupart's ligament, and is continuous with the subcutaneous layer of the abdominal fascia; internally it passes into the tunica dartos of the scrotum and superficial fascia of the perinæum. The deeper layer is separated from the subcutaneous by the superficial vessels and lymphatics, and is continuous superiorly and internally with the deeper layer of the superficial fascia of the abdomen. It is firmly bound down to Poupart's ligament, to the front of the fascia lata of the thigh at its upper part, and to the body and ramus of the pubis. It also covers in and partially fills up the saphenous opening of the fascia lata, where from its being perforated by numerous small foramina for the passage of blood-vessels and lymphatics, it receives the name of *cribriform fascia*. It is a very thin membrane, and does not contain much fat. It gradually disappears by becoming incorporated with the fascia lata about three inches below the groin.

The **deep fascia** or **fascia lata** of the thigh is a thin but strong aponeurotic membrane, consisting of white shining fibrous tissue, quite devoid of fat, and forming a continuous sheath round the limb. It is attached superiorly to the posterior surface of the sacrum and coccyx, to the crest of the ilium, to Poupart's ligament, to the body and ramus of the pubis, and to the ramus and tuberosity of the ischium. In the gluteal region it descends on the surface of the gluteus medius muscle, as far as the upper border of the gluteus maximus, where it divides into two layers, one of which passes on the superficial, the other on the deep surface of that muscle. After encasing the muscle, the layers unite at its lower and external borders. Over the great trochanter, where the layers unite externally, and where also the fascia is much thickened, the upper fibres of the muscle are inserted between the layers. This thickened portion of the fascia may be traced downwards on the outside of the thigh, from the crest of the ilium to the outer tuberosity of the tibia, and to the head of the fibula. This *ilio-tibial band* consists of dense glistening parallel fibres, and about the junction of the upper and middle thirds of the thigh it receives the insertion of the tensor vaginæ femoris muscle. On the rest of the thigh the fascia lata varies in thickness. It is thinnest in the upper and inner part of the thigh, where it covers the adductor muscles. Near the knee it is considerably strengthened by tendinous expansions given off from the lower parts of the extensor and flexor muscles of the knee-joint.

In front of the thigh, a little below and external to the inner end of

Poupart's ligament, is placed the *saphenous opening*, an aperture in the fascia lata through which the internal saphenous vein passes to join the femoral vein, and which receives special attention from its being the place of exit of femoral hernia. The outer part of this opening lies in front of the femoral artery, and is bounded externally by a crescentic margin, the *falciform border*, which crosses the surface of the infundibuliform sheath of the femoral vessels. This margin in the middle of its extent is continued into looser tissue, but superiorly and inferiorly it ends in two more distinct incurved extremities, the *superior* and *inferior cornua*. The inferior cornu, the most completely defined part of the margin, lies in the angle between the internal saphenous and the femoral veins, below their junction; while the superior cornu forms a larger curve, the inner extremity of which, often called *femoral ligament*, passing completely to the inner side of the femoral sheath, is attached to the front of Gimbernat's ligament.

It is customary to call the parts of the fascia lata which are placed external and internal to the saphenous opening the *iliac* and *pubic portions*. The iliac portion is intimately connected above with Poupart's ligament, as well as with the fascia transversalis and deep layer of the superficial fascia of the abdomen, and internally forms the falciform margin of the saphenous opening; the pubic portion, attached superiorly to the pectineal line, passes on its outer side deeply behind the sheath of the vessels, with which it is connected, and is continued into the fasciæ between the muscles.

The fascia lata is perforated in many places by foramina, which allow the passage of the cutaneous nerves and blood-vessels.

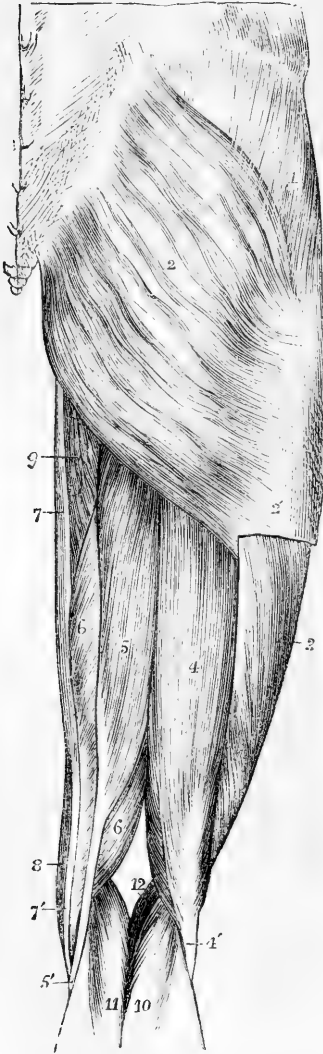
The fascia lata has various deep processes. One of these, leaving the main fascia at the insertion of the tensor vaginæ femoris muscle, passes upwards within that muscle as a strong flat band on the surface of the vastus externus, and is attached superiorly to the ilium above the origin of the posterior head of the rectus femoris. Two processes, the *external* and *internal intermuscular septa*, bind the fascia to the femur in the lower part of the thigh: the external septum, situated between the vastus externus muscle and the short head of the biceps, is inserted into the linea aspera from the lower border of the tendon of the gluteus maximus to the outer condyle of the bone: the internal septum, which is much thinner, is inserted into the femur between the vastus internus and the adductor muscles.

*Sheath of the Femoral Vessels.*—The femoral vessels are surrounded by an investment of fascia, which in its upper part is particularly distinct, and receives the name of the *crural sheath*. This sheath, commencing at the deep crural arch, is continuous with the fascia transversalis and fascia iliaca of the cavity of the abdomen. Its outer border descends in contact with the artery, while its inner border is inclined outwards from the margin of Gimbernat's ligament, and comes in contact with the vein at the distance of less than an inch lower down: the sheath is therefore funnel-shaped. It is divided into three compartments, separated by thin septa: the outermost contains the artery, the middle one the vein, and the innermost forms a space occupied at its upper end by the crural ring, and in which there is generally a lymphatic gland and some fat. Through this passage femoral hernia descends, and on this account it has been named the *crural canal*. (See later, the special account of Hernia.)

## MUSCLES OF THE HIP.

The muscles of this region are the three glutei, the piriformis, the obturator internus with the gemelli, the obturator externus, and the quadratus femoris.

Fig. 184.

Fig. 184.—SUPERFICIAL MUSCLES OF THE HIP AND THIGH, SEEN FROM BEHIND. A. T.  $\frac{1}{2}$ 

1, gluteus medius, covered by the fascia lata; 2, middle of the gluteus maximus; 2', placed on the fascia lata below the place where the gluteus maximus is inserted into it, and above the insertion of the muscle into the femur; 3, vastus externus; 4, biceps flexor cruris; 4', tendon of the biceps, receiving on its outer side the oblique fibres of the short head; 5, 5', semitendinosus; 6, semimembranosus; 7, 7', gracilis; 8, sartorius; 9, adductor magnus; 10, outer, and 11, inner head of the gastrocnemius; 12, placed in the popliteal space, points to the origin of the plantaris.

The **gluteus maximus** is a very large and coarsely fasciculated muscle, somewhat quadrilateral in shape, which arises from the posterior fifth of the iliac crest, and from the adjacent rough surface of the ilium; from the posterior surface of the last piece of the sacrum; from the side of the coccyx; from the great sacro-sciatic ligament; and between the sacrum and the ilium, from the aponeurosis of the muscles of the back. Thence it passes downwards and outwards; the fibres of its lower third are inserted into an elongated rough impression, extending from the base of the great trochanter to the linea aspera; and those of the upper two-thirds into a thickened portion of the fascia lata of the thigh over the great trochanter; a few of the lowest fibres also terminate in the fascia.

*Relations.*—The lower border of the muscle lies in the fold of the nates. The deep surface rests on the gluteus medius and piriformis muscles, the tendon of the obturator internus, with the two gemelli, the quadratus femoris, a small portion of the adductor magnus, the great trochanter, the ischial tuberosity, and the origin of the

hamstring muscles; it covers also the sciatic artery and nerves as they emerge from the pelvis below the piriformis, the superficial branch of the gluteal artery passing out above that muscle, and the pudic artery and nerve lying behind the spine of the ischium.

Between the tendon of the muscle and the great trochanter of the femur, are

placed two or three synovial bursæ, or a single multilocular bursa of large size, a bursa is also situated between the muscle and the tendon of the vastus externus, and another separates it from the tuber ischii.

The great size of the gluteus maximus and the consequent prominence of the buttock, is a characteristic of man as compared with those animals which most nearly approach him in general structure.

*Varieties.*—This muscle varies chiefly in the extent of its origin; it may obtain a high fascial slip from the lumbar aponeurosis, or it may be attached only to the last two sacral vertebræ. It may also be considerably subdivided. Thus it has been seen wholly or partly bilaminar (Tiedemann, Macalister); or with a separate muscle, constituting in animals the agitator caudæ attached to the coccyx and lowest part of the sacrum (Macalister).

The **gluteus medius** muscle, covered partly by the gluteus maximus, partly by the fascia lata, arises from the surface of the dorsum ilii above the superior curved line, and in front of the gluteus maximus, from the strong fibres of the fascia lata, covering its outer surface. The muscular fibres converge as they descend, the anterior fibres passing obliquely backwards, the posterior fibres obliquely forwards, and terminate in a fan-shaped tendon, which is inserted into an oblique line directed downwards and forwards on the outer surface of the great trochanter. The tendon is separated by a small bursa from the upper part of the trochanter.

*Relations.*—Between this muscle and the gluteus minimus are the gluteal nerve and deep branches of the gluteal artery. At its anterior and inferior border its fibres are parallel to and united with those of the gluteus minimus. This border also is in contact with the tensor vaginae femoris. The posterior border is in contact with the pyriformis, being separated by the gluteal vessels and nerves.

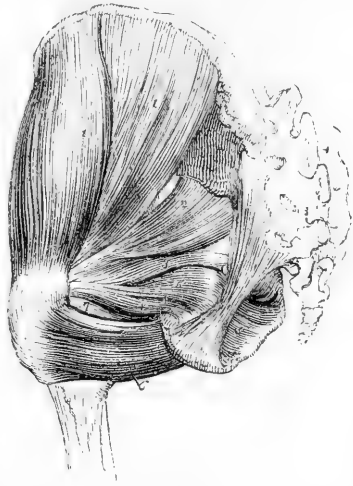*Varieties.*—The gluteus medius has been found bilaminar by Henle. It may be united posteriorly by a tendinous slip to the tendon of the pyriformis, or the two tendons may be separated by a bursa (the bursa of Loder). This last condition occurs once in every fifteen subjects (Macalister).

Fig. 185.—DEEP MUSCLES OF THE HIP ON THE LEFT SIDE, FROM BEHIND.  $\frac{1}{4}$

The gluteus maximus, and the muscles of the thigh have been removed. 1, gluteus medius; 2, pyriformis; 3, gemellus superior; 4, gemellus inferior; 5, obturator internus, seen partially within the pelvis, and, after issuing by the lesser sciatic notch, between the gemelli muscles; 6, quadratus femoris; 7, tendon of the obturator externus between the gemellus inferior and quadratus.

The **gluteus minimus**, covered by the preceding muscle, arises from the whole space on the dorsum ilii between the superior and inferior curved lines. The fibres, converging as they descend, terminate in an aponeurotic tendon on the outer surface of the muscle, which becoming narrowed is inserted into an impression on the anterior border of the great trochanter. The tendon is bound down to the prominence of the trochanter by a strong fibrous band which joins

Fig. 185.



it from the upper margin of the capsule of the hip-joint. A synovial bursa is interposed between the tendon and the trochanter.

*Relations.*—The anterior border of the muscle is in contact with that of the *gluteus medius*; its deep surface with the capsule of the hip joint, the *dorsum ilii*, and the posterior head of the *rectus femoris*: its outer surface is covered by the *gluteus medius*, *gluteal vessels* and *nerves*; and its posterior border is covered by the *pyriformis* muscle.

*Varieties.*—This muscle may be divided into an anterior and a posterior part, or it may send detached slips to the hip joint, to the *pyriformis*, to the *gemellus superior*, or to the outer part of the origin of the *vastus externus* (Macalister).

The **pyriformis** muscle arises within the pelvis by three fleshy digitations from the second, third, and fourth divisions of the sacrum, between the anterior sacral foramina, slightly from the deep surface of the iliac bone, near the sacro-sciatic notch, and from the sacro-sciatic ligament. The muscle passes out of the pelvis by the great sacro-sciatic notch, and is inserted by a rounded tendon into the upper border of the great trochanter, being bound down for some distance from the point of its final insertion to the subjacent tendon of the *obturator internus* and *gemelli* muscles.

*Relations.*—The *pyriformis* muscle, after escaping from the pelvis, is in contact by its upper border with the *gluteus medius* and *minimus*, the *gluteal vessels* and *nerve* intervening; and by its lower border with the *superior gemellus* muscle, the *sciatic vessels* and *nerves*, which emerge beneath it, lying between; its outer surface is covered by the *gluteus maximus*, and its deep surface is in contact with the capsule of the hip joint.

*Varieties.*—This muscle is frequently found to be pierced by the great sciatic nerve or by its external popliteal branch, and is thus divided more or less completely into two parts. It may be united with the *gluteus medius*, *superior gemellus*, or *obturator internus*. It may have only one or two sacral attachments, or again its tendon may be inserted into the hip joint. Its entire absence has also been noted.

The **obturator internus** muscle, in great part lodged within the pelvis, arises from the deep surface of the obturator membrane; from the fibrous arch which completes the canal for the obturator vessels and nerves; from the bone surrounding the obturator foramen, extending downwards to the outlet, backwards as far as the sciatic notch, and upwards to the brim of the pelvis; a few fibres also arise from the obturator fascia, which is in contact with the deep surface of the muscle. Its fibres converging as they proceed backwards from this origin, the muscle emerges from the pelvis by the small sacro-sciatic foramen, gliding over the trochlear surface of the ischium, and is directed outwards, to be inserted, in connection with the *gemelli*, into the upper part of the digital fossa of the great trochanter. The tendon, occupying the surface of the muscle which is towards the bone, is folded together into four or five plaits which lie side by side as they turn over the trochlear groove: their motion in that groove is facilitated by a synovial bursa, which is inflected over them, and by a thin coating of cartilage on the trochlear surface of the bone. Another bursa, of much smaller size, elongated and narrow, is placed between the tendon and the fibrous capsule of the hip-joint. These bursæ are sometimes continuous with one another.

*Relations.*—The deep surface of the pelvic portion is in contact with the deep pelvic fascia and near its lower border with the *pubic vessels* and *nerve*. The outer surface is in contact with the bones and obturator membrane. At its upper



border the obturator vessels and nerve pass through the obturator foramen. The extra-pelvic portion lies between the gemelli and in contact with the ischium and capsule of the hip joint. It is covered by the great sacro-sciatic ligament, the sciatic vessels and nerves, and by the gluteus maximus.

The **gemelli** (gemini) are two small narrow muscles, consisting chiefly of fleshy fibres extended horizontally at each side of the tendon of the obturator internus; and they are named from their position above and below the tendon. The *gemellus superior*, which is usually the smaller muscle, arises from the ischial spine; the *gemellus inferior* takes origin from the upper and back part of the tuberosity of the ischium. Passing outwards, they join the tendon of the internal obturator muscle, covering and concealing it more or less, and along with it are inserted into the digital fossa of the trochanter. Some of their fibres, especially from the superior gemellus, run obliquely into the tendon of the obturator.

*Relations.*—The superior gemellus is placed immediately below the pyriformis; the inferior gemellus is above the quadratus femoris, and at its insertion is close to the tendon of the obturator externus muscle. These muscles may be regarded as portions of the obturator internus arising externally to the pelvis.

*Varieties.*—The gemellus superior is often very small, and in some cases is altogether absent. The gemellus inferior has also been found absent, but more rarely than the upper muscle.

The **quadratus femoris** muscle, of an oblong shape, arises from the external border of the tuber ischii, and, proceeding horizontally outwards, is inserted into the greater part of the *linea quadrati* on the posterior surface of the great trochanter of the femur.

*Relations.*—Superiorly this muscle is close to the inferior gemellus. Its inferior border is in contact, at its origin, with the descending fibres of the adductor magnus, and at its insertion with the superior or horizontal fibres. It conceals the outer part of the obturator externus, and also the lesser trochanter, which is separated from it by a small bursa.

*Varieties.*—It may be entirely absent and replaced by an enlarged gemellus inferior.

The **obturator externus** muscle arises from the outer surface of the anterior two-thirds of the obturator membrane, from the outer surface of the body of the pubis, and from the rami of the pubis and ischium; its fibres extend horizontally outwards and backwards, converging to a tendon which is directed along the groove between the acetabulum and the tuberosity of the ischium, in contact at the same time with the under and hinder surfaces of the neck of the femur to be inserted into the trochanteric fossa below the obturator internus and gemelli.

*Relations.*—The deep surface of the muscle is in contact with the obturator membrane, while the obturator vessels and nerves pass over its upper border. Its anterior surface is covered by the upper borders of the pectineus, adductor brevis, and adductor magnus; in the groove beneath the acetabulum it is in contact with the lower and posterior parts of the capsule of the femur, and close to its insertion it is concealed by the quadratus femoris.

*Nerves.*—The gluteus maximus is mainly supplied by the small sciatic nerve, but also receives at its upper part a separate branch from the sacral plexus. The gluteus medius and minimus are supplied by the gluteal nerve. The pyriformis, gemelli, obturator internus, and quadratus femoris receive special branches from the sacral plexus. The obturator externus is supplied by the obturator nerve.

**Actions.**—The *gluteus maximus* muscle is the chief extensor of the hip-joint. By means of it the bent thigh is brought into a line with the body. It is not in action in the ordinary movements of walking or in standing on level ground, but it is so in ascending an incline or a stair, and in the exercises of leaping or dancing, and in rising from the sitting posture. Its most powerful action, and that in connection with which it is so largely developed in the human subject, is to extend the trunk upon the thigh when bent forward. The muscle acts also as an adductor and external rotator of the limb. But although the full contraction of the *glutei maximi* is required to bring the body into the erect posture, it is not necessary for its maintenance when complete, that being effected chiefly by the tension of certain ligaments and fasciæ passing over the joints, while the body is so poised that the centre of gravity of the trunk is placed slightly behind the vertical plane passing through the middle of the hip-joints. The *gluteus medius* and *minimus* are powerful abductors of the thigh, and along with the tensor *vaginæ femoris*, come principally into action in supporting the body on one limb, and in the rotation of the pelvis on the two limbs alternately which takes place in walking. Their anterior fibres draw forwards the great trochanter, and rotate the limb inwards, while the posterior part produces outward rotation.

The *pyriformis*, *obturator internus*, *gemelli* and *quadratus femoris* muscles support the hip-joint posteriorly, and rotate the limb outwards. These muscles may also act as extensors when the thigh is strongly flexed.

The *obturator externus*, besides being an external rotator, is also a flexor and adductor of the thigh, as is the case in the uppermost of the two limbs when we cross the knees in sitting. It supports the hip-joint posteriorly and inferiorly.

#### POSTERIOR FEMORAL OR HAMSTRING MUSCLES.

At the back of the thigh are three long flexor muscles of the knee-joint; viz., the biceps, semitendinosus, and semimembranosus.

The **biceps flexor cruris** muscle consists of two parts, arising one from the hip-bone, the other from the femur, which unite inferiorly to terminate on the fibula. The *long head* arises by a tendon common to it and the semitendinosus from the most prominent part of the ischial tuberosity; the *short head* arises from the outer lip of the *linea aspera* in its whole extent, from the upper part of the line leading thence to the outer condyle, and from a part of the adjacent external intermuscular septum. The muscular fibres from both heads end in a common tendon, which is inserted into the head of the fibula by two portions, one on each side of the external lateral ligament of the knee-joint. Some of the fibres of the tendon, passing forwards and downwards, are inserted into the front of the tibia, and others passing backwards strengthen the fascia of the leg.

**Relations.**—The origin of the biceps is covered by the *gluteus maximus*, the rest of the muscle is subcutaneous. It rests upon the head of the semimembranosus, the great sciatic nerve, and the adductor magnus; its inner border is in contact with the semi-tendinosus and at its lower end it forms the upper and outer boundary of the popliteal space.

**Varieties.**—The short head may be absent, or there may be an additional long head arising from the tuber ischii, or from the *linea aspera*, or from the inner condylar ridge of the femur, or from various other parts. A slip has been found passing from the long head to the tendo Achillis (Otto).

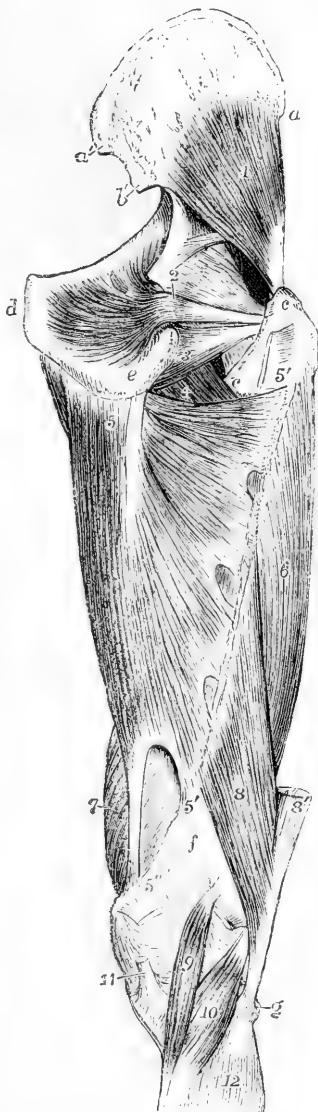
The **semitendinosus** muscle, closely united at its origin with the biceps, arises from the tuberosity of the ischium, and from the tendon common to it with the biceps, for about three inches; it descends on the back of the thigh, and terminates below the middle in a long, rounded, and slender tendon, which passes along the inner side of the

popliteal space, resting on the semimembranosus, and curves forwards to be inserted in an expanded form into the upper part of the tibia at its inner side. There the tendon is on the same plane with, but below that of the gracilis, both being under cover of the sartorius. A thin oblique tendinous intersection traverses the muscle about the middle.

Fig. 186.

Fig. 186.—DEEP MUSCLES OF THE RIGHT HIP AND THIGH, FROM BEHIND. (A.T.)  $\frac{1}{2}$

*a*, anterior, *a'*, posterior superior spine of the ilium; *b'*, posterior inferior spine; *c*, *c*, great and small trochanter; *d*, symphysis pubis; *e*, tuberosity of the ischium; *f*, popliteal surface of the femur; *g*, head of the fibula; 1, gluteus minimus; 2, obturator internus: the gemelli muscles have been removed; 3, obturator externus; 4, small part of the back of the pectineus and adductor brevis; 5, origin of the adductor magnus from the lower part of the ischial tuberosity; 5', 5', line of insertion of this muscle on the linea aspera, in which are seen three arched tendinous intervals for the passage of the perforating vessels; 5'', tendon of insertion into the inner tuberosity of the femur; between the lower 5' and 5'', the interval through which the femoral vessels pass into the popliteal space; the upper 5' is placed upon the cut end of the quadratus femoris; 6, vastus externus; 7, vastus internus; 8, femoral head of the biceps femoris: the lower part is represented as passing too far inwards; 8', its ischial head, cut short; 9, plantaris muscle: at its upper end the outer head of the gastrocnemius; the figure 5'', is upon the cut inner head; 10, popliteus, cut short below; 11, tendon of the semimembranosus; 12, upper part of the soleus.



The **semimembranosus** muscle arises from the tuberosity of the ischium, above and to the outside of the origin of the biceps and semitendinosus, by a strong flattened tendon, two or three inches long, which, as it descends in front of the common tendon of those two muscles, passes to their inner side. The muscle presents inferiorly a thick fleshy belly, ending in a short flattened tendon, which is inserted in three parts: the principal part turns forwards and is inserted into a well-marked groove on the inner tuberosity of the tibia, beneath the internal lateral ligament of the knee-joint, some of its fibres joining that ligament; a second part, passing downwards and outwards, expands in the aponeurosis over the popliteus muscle; and the remaining fibres are directed upwards and outwards, and blend with the posterior ligament of the knee-joint,

of which they may be said to form a considerable portion. The muscle consists of numerous short fibres extending obliquely between two aponeurotic expansions, which are continued upwards and downwards on the opposite sides of the muscle for three fourths of its length from the superior and inferior tendons.

*Relations.*—The inferior tendon of the semimembranosus muscle is separated from the tendon of the inner head of the gastrocnemius by a large bursa. The muscle rests on the adductor magnus.

The hamstring muscles descend in contact with one another, being bound down by the fascia lata; but inferiorly they diverge, the biceps passing to the outside, and the semimembranosus and semitendinosus to the inner side of the knee, forming the superior borders of a diamond-shaped hollow at the back of the knee—the popliteal space. The great sciatic nerve is concealed by them while they are in contact, and its principal division, the internal popliteal, lies in contact with the semimembranosus muscle in the popliteal space, while the smaller or external popliteal division runs along the edge of the biceps muscle.

*Varieties.*—The semimembranosus muscle has been found absent; again it has been found double or it may have its origin for the most part from the great sciatic ligament.

*Nerves.*—The hamstring muscles are all supplied with branches from the great sciatic nerve.

*Actions.*—The *hamstring muscles* extend the hip and flex the knee. It is to be observed, however, that in ordinary circumstances these movements take place together, and that therefore it is by the occurrence of simultaneous action of other muscles that it is determined whether flexion of the one or extension of the other will occur.

The *short head* of the *biceps* is the only flexor of the knee which passes over that joint alone. The action of the whole muscle produces external rotation of the leg.

#### ANTERIOR MUSCLES OF THE THIGH.

The **ILIO-PSOAS** muscle, the great flexor of the hip-joint, is divisible into two parts, a broad outer part, the iliacus, and an elongated inner part, the psoas magnus, which are inserted together into the small trochanter.

The **iliacus** muscle arises from the iliac fossa of the innominate bone, and from the anterior border of the same, likewise from the base of the sacrum, the ilio-lumbar ligament, and the capsule of the hip-joint. Its fibres converging, as they pass downwards and inwards, are inserted for the most part into the tendon of the psoas muscle; while some are prolonged to a special triangular impression on the upper part of the femur, in front of and below the small trochanter.

*Relations.*—Above Poupart's ligament this muscle is covered by the iliac fascia, the external iliac artery, the ilio-inguinal and external cutaneous nerves. Outside the pelvis it lies on the capsule of the hip-joint; in front of it lie the anterior crural nerves; at its outer border are the origins of the sartorius and rectus femoris muscles, and at its inner is the psoas.

*Variety.*—The chief variety consists in the presence of the *iliacus minor* or *ilio-capsularis*, a small detached portion of the iliacus major. It arises from the anterior inferior spine of the ilium, and is inserted into the anterior intertrochanteric line of the femur. It is closely united to the front of the capsule of the hip-joint.

The **psoas magnus** muscle arises by five fleshy slips from the anterior surface and lower margin of the transverse processes of the lumbar vertebræ near their bases; also from the bodies of the last dorsal and

all the lumbar vertebræ in the following manner:—Each slip takes origin from an intervertebral disc, and from the contiguous margins of the bodies of two vertebræ, the highest being attached to the neighbouring margins of the last dorsal and first lumbar vertebræ, and the lowest to the fourth and fifth lumbar vertebræ with the intervertebral substance between them. These attachments are connected by thin tendinous arches extending over the middle of each vertebra, covering the lumbar vessels and communicating branches of the sympathetic nerve, and giving origin to other muscular fibres. The various bundles of fibres speedily unite to form a thick elongated muscle, which runs along the brim of the pelvis, and emerging from the abdomen beneath Poupart's ligament is inserted into the small trochanter of the femur by means of a tendon, which is placed at first within the substance of the muscle, and afterwards at its outer side, receiving in this manner the fibres of the iliacus as well as those of the psoas.

*Relations.*—The psoas muscle, at its superior extremity, passes behind the diaphragm, below the arch of the ligamentum arcuatum internum. Posteriorly it is in contact with the quadratus lumborum muscle and the os innominatum. Resting on its inner border along the margin of the pelvis, is the external iliac artery, and deeply in the substance of the muscle is the lumbar plexus of nerves. The ilio-inguinal and external cutaneous nerves cross the iliacus muscle, and the anterior crural nerve descends on the tendon of the psoas. The iliac fascia extends over the surface of the whole ilio-psoas muscle in the abdomen. After emerging from the abdomen beneath Poupart's ligament, and turning over the brim of the pelvis, the tendon of the psoas rests on the capsule of the hip-joint, on which it glides by means of a large synovial bursa, which occasionally communicates with the interior of the joint; its outer margin is in contact with the rectus muscle, and its inner margin is separated from the pectineus by the internal circumflex artery.

*Variety.*—The *psoas parvus*, an occasional muscle, placed on the surface of the psoas magnus, arises from the bodies of the last dorsal and first lumbar vertebræ, and from the fibro-cartilage between them, and soon ends in a flat tendon, which passes along the front and the inner side of the psoas magnus, to be inserted into the ilio-pectineal line and eminence. This muscle, although it is well developed and constant in animals, is most frequently absent in the human subject. It was found in only one of twenty bodies examined by Theile with special reference to its existence. When present, it is liable to many changes in the place of origin; thus, it may be connected only with the first lumbar vertebra, or with the second and the intervertebral substance above it, and it has been observed to commence by two parts or heads separated by an interval.

The *tensor vaginæ femoris*, or ilio-aponeurotic muscle of the thigh, arises by muscular and tendinous fibres from the external surface of the iliac crest close to its fore-part, and from part of the notch between the two anterior iliac spines, external to the attachment of the sartorius; and passing downwards and a little outwards it is inserted between two laminae of the fascia lata, from three to four inches below the great trochanter of the femur. The outer of these laminae is continued upwards on the muscle in its whole extent, being part of the general investment of the limb, the deeper is connected above with the origin of the rectus muscle, and with the fibres attaching the gluteus minimus to the hip-joint. The part of the fascia, made tense by the action of the muscle, forms a strong tendinous band, which descends to the outer surface of the anterior tuberosity of the tibia.

*Relations.*—This muscle lies upon the anterior border of the gluteus minimus, the upper parts of the rectus femoris and vastus externus muscles, and the

ascending branches of the external circumflex artery. At its origin it lies between the sartorius and anterior border of the gluteus medius muscles.

Fig. 187.

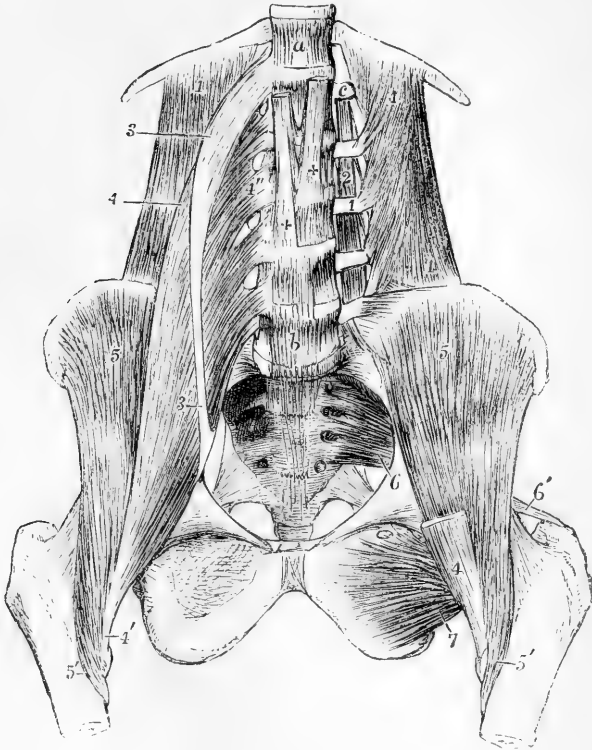


Fig. 187.—DEEP DISSECTION OF THE MUSCLES OF THE ABDOMEN AND PELVIS. (A. T.)  $\frac{1}{2}$

*a*, twelfth dorsal vertebra; *b*, fifth lumbar vertebra; *c*, transverse process of the first lumbar vertebra; 1, quadratus lumborum muscle; on the left side, its fibres of origin from the transverse processes of the lumbar vertebrae are shown by the removal of the psoas muscles; 2, placed upon one of the intertransversales muscles of the left side; 3, the upper part of the psoas parvus, drawn somewhat to the outer side; 3', the insertion of its tendon into the brim of the pelvis; 4, the upper part of the psoas magnus; 4'', one of the origins of the muscle; 4''', the insertion of the muscle into the lesser trochanter of the femur; 5, iliacus shown fully on the left side by the removal of the psoas muscles; 5'', insertion of the iliacus muscle into a line below the trochanter minor; 6, piriformis muscle of the left side rising within the pelvis from the sacrum; 6'', insertion of its tendon into the summit of the great trochanter; 7, the obturator externus seen from before on the left side; ++, the right and left crura of the diaphragm on the front of the upper lumbar vertebrae.

The **sartorius** muscle is very long, narrow, and ribbon-shaped, and presents the longest fibres of all the muscles of the body: it arises by a short tendon from the anterior superior spinous process of the ilium, and from a small part of the anterior margin of that bone immediately below, and, passing downwards and inwards across the front of the thigh, is inserted by an expanded aponeurosis into the inner side of the tibia, near to the tubercle, and for about an inch below it.

*Relations.*—In this long course the muscle is directed over the anterior part of the thigh, obliquely inwards in the upper third, and vertically at the inner aspect of the limb as far as the knee; below this it turns obliquely forwards to its place of attachment. The tendon of insertion, broad and expanded, covers the tendons of the gracilis and semitendinosus (a synovial bursa being interposed), and gives off one expansion which strengthens the capsule of the knee-joint by becoming incorporated with it, and another which blends with the fascia of the leg.

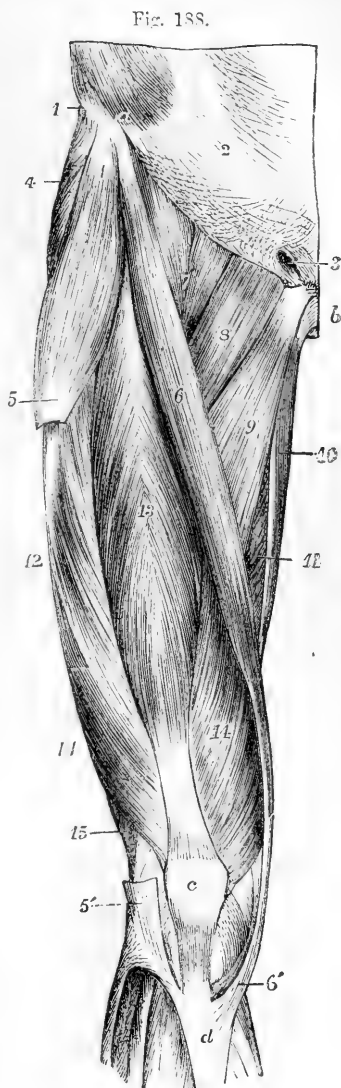
Fig. 188.—SUPERFICIAL MUSCLES OF THE FRONT OF THE THIGH. (A. T.)  $\frac{1}{2}$

*a*, anterior part of the crest of the ilium; *b*, symphysis pubis; *c*, patella; *d*, the anterior tuberosity of the tibia; 1, the insertion of the external oblique muscle into the iliac crest; 2, its aponeurosis at the linea semilunaris; 3, the external abdominal ring; 4, the gluteus medius; 5, tensor vaginae femoris at the place of its insertion into a portion of the fascia lata, which has been removed between 5 and 5', which latter part is seen descending to be attached to the tibia and fibula; 6, the sartorius; 6', the insertion of the sartorius; 7, psoas and iliacus conjoined; 8, pectineus; 9, adductor longus; 10, gracilis; 11, part of the adductor magnus; 12, vastus externus; 13, rectus femoris; 14, vastus internus; 14', its continuation on the outer side below; 15, the biceps flexor cruris.

The sartorius is covered only by the fascia lata and the integument. It passes over the iliacus and rectus femoris muscles, the anterior crural nerve and femoral vessels, the pectineus, the adductor longus, adductor magnus, vastus internus and semitendinosus muscles. The inner border of this muscle and the most projecting part of the adductor longus form the sides, and Poupart's ligament forms the base, of a triangular space in the upper third of the thigh, through the middle of which the femoral artery passes. This usually receives the name of Scarpa's triangle.

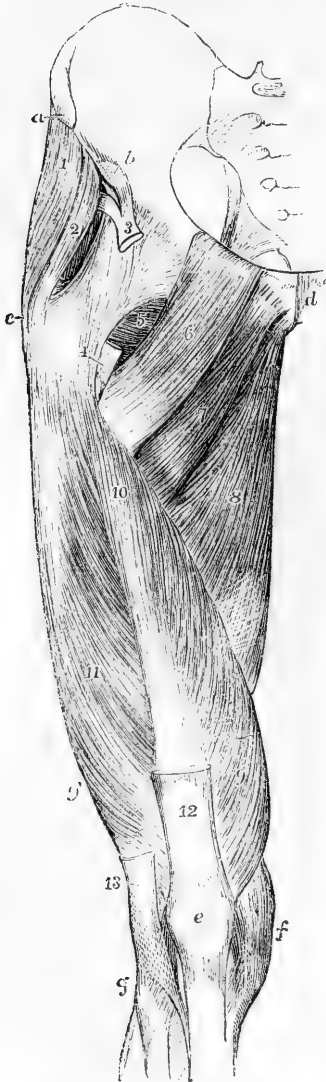
*Varieties*—The sartorius has frequently been found divided into two parts similarly attached; or the lower muscle is inserted into the femur or into the tendon of the normal one. The tendon of insertion has been found to end in the fascia lata or in the capsule of the knee-joint. Total absence of the muscle has also been noted.

The **quadriceps extensor cruris**, the extensor muscle of the knee, is divisible into four parts, one of which, the rectus femoris, descends from the hip-bone and remains distinct, while the other three,



distinguished one from the other only by the arrangement of their fibres, cover the whole of the anterior and lateral surfaces of the thigh-bone, from which they arise.

Fig. 189.

Fig. 189.—DEEP MUSCLES OF THE FRONT OF THE THIGH. (A. T.)  $\frac{1}{2}$ 

*a*, anterior superior, and *b*, anterior inferior spinous process of the ilium; *c*, outer and upper part of the great trochanter; *d*, symphysis pubis; *e*, patella; *f*, inner side of the knee-joint and internal lateral ligament; *g*, head of the fibula; 1, the gluteus medius; 2, the gluteus minimus; 3, tendon of the rectus, dividing above into its two portions; 4, points to the cut tendon of insertion of the ilio-psoas muscle; 5, part of the obturator externus and quadratus femoris; 6, pectineus; 7, part of the adductor brevis; 8, adductor magnus; 9, vastus internus; 9', its continuation down on the outer side; 10, crureus; 11, vastus externus; 12, tendon of the rectus; 13, lower part of the slip of the fascia lata by which the tensor vaginae femoris is inserted into the tibia and fibula.

*a*. The **rectus femoris** muscle extended in a straight line from the pelvis to the patella, arises by two tendons, one of which is attached to the anterior inferior spinous process of the ilium, and the other united to the first within an inch of that point, takes origin from the groove on the dorsum ili above the brim of the acetabulum. From the prolongation of the tendon so formed the muscular fibres arise pennately, and, turning outwards and backwards as they descend, are inserted in a similar manner into the tendon below, the superior tendon being prolonged on the anterior, the inferior tendon on the posterior surface of the muscle. The inferior tendon forms a broad band inserted into the upper surface of the patella.

*Relations*.—Superiorly this muscle is covered by the tensor vaginae femoris, iliacus, and sartorius muscles; further down it is covered only by fascia. The acetabular tendon lies beneath the gluteus minimus. The muscle rests upon the capsular

ligament of the hip-joint, the insertion of the ilio-psoas, the crureus, and parts of the vasti muscles. Behind it also pass the external circumflex artery and a part of the anterior crural nerve.

*b*. The **vastus externus** arises by an extensive aponeurosis attached



to the base of the great trochanter in front, and to a ridge on its outer side; to the line extending from the great trochanter to the linea aspera and to the outer border of the linea aspera itself in its upper half; the aponeurosis being prolonged on the outer surface of the muscle, also gives origin to numerous muscular fibres. The muscle forms a somewhat rhomboidal mass of considerable thickness, and descends obliquely inwards and forwards on the outer surface of the vastus internus to be inserted by a broad flat tendon into the tendon of the rectus muscle and the patella.

*Relations.*—This muscle forms the large mass on the outer and upper part of the thigh. Its deep surface rests on the vastus internus: its outer surface is covered by the fascia lata and by the aponeurotic insertions of the gluteus maximus and tensor vaginae femoris. Anteriorly it is in contact with the rectus femoris and external circumflex arteries.

*c* and *d*. The muscles usually described as **vastus internus** and **crureus** are inseparably united and form the inner or deep head of the common extensor. The fibres of this head may, however, be easily separated into a superficial and a deep set. The superficial fibres form a continuous lamina or *mantle* (Henle) arching over the front and both sides of the shaft of the femur, and completely enclosing the deeper fibres which are only seen on cutting through the mantle. These fibres of the mantle descend in different directions, the middle or anterior fibres, while arching forwards being nearly parallel to the femur, and the lateral fibres being more oblique; this obliquity increases towards the lower part of the muscle, where the fibres are nearly horizontal. The anterior fibres arise from the middle of the anterior intertrochanteric line; the inner lateral fibres arise from the line running from the anterior intertrochanteric line in front of the small trochanter to join the inner line leading to the linea aspera, from the lower half of that inner line, from the inner lip of the linea aspera, and from the internal intermuscular septum. The line of origin of the outer lateral fibres runs from the anterior intertrochanteric line obliquely across the front of, and down the outer surface of the shaft of the femur, immediately in front of, and closely connected with the origin of the vastus externus. The lower lateral fibres on the outside of the limb reach considerably beyond the lower border of the vastus externus, taking origin from the outer lip of the linea aspera and from the external intermuscular septum. From this extensive origin the fibres converge to the under surface and margins of a flat tendon which runs upwards for the most part on the surface of the anterior fibres. This tendon becomes incorporated inferiorly with the tendons of the rectus femoris and vastus externus, and so becomes attached to the upper and lateral margins of the patella. Many of the lowest lateral fibres on both sides are also attached directly to the sides of the patella and to the fascia lata at the sides of the knee-joint.

The deep set of fibres, for which the name of *crureus* may be still retained, arises from the anterior aspect only of the shaft of the femur for about its middle two-thirds, the upper part of the origin being separated by a slight interval from the origin of the superficial fibres, and the lower part reaching to within three inches of the patellar surface. These fibres pass obliquely downwards and forwards to be

inserted into the posterior surface of the tendon belonging to the superficial fibres. On either side of the origin of this part of the muscle there is a longitudinal band of the lateral surface of the femur from which no muscular fibres arise: this band varies somewhat in breadth in different subjects, and it is also broader on the inner aspect of the shaft than on the outer.

*Relations.*—On its anterior surface this muscular mass is in contact with the rectus femoris and sartorius muscles and the anterior crural nerve. At its inner border run the femoral artery and vein, and the muscle is in contact with the iliacus, adductor longus, and adductor magnus, being firmly united to the last two by the aponeurotic fibres which form Hunter's canal. On its outer surface lies the vastus externus.

The **subcrureus** is a small band of muscular fibres, which extends from the lower part of the anterior surface of the femur to the upper part of the synovial membrane of the knee-joint, on which it ends in scattered fibres.

*Relations.*—This little muscle is placed beneath the crureus muscle, and in some cases it is united with that muscular mass. It is not unfrequently double, or consists of two separate bundles.

*Varieties.*—The parts of the quadriceps muscle are not liable to many anomalies. The rectus has been found with an additional origin from the anterior superior spine of the ilium; or, again, its acetabular origin may be wanting. The vasti muscles are sometimes bilaminar, as is seen also normally in many birds.

*Nerves.*—The psoas muscle is supplied by small branches from the lumbar plexus. The iliacus, quadriceps extensor cruris and sartorius are supplied by the anterior crural nerve, and the tensor vaginæ femoris by the superior gluteal nerve.

*Actions.*—The *ilio-psoas* muscle, the flexor of the hip-joint, bends the thigh on the body, or the body on the thigh, according as either of these is the more fixed. It also produces considerable rotation outwards.

The *tensor vaginæ femoris* assists the action of the other muscles by making tense the fascia lata. It aids the gluteus medius and minimus in rotating the limb inwards, but its action in this respect is exactly opposed by the upper fibres of the gluteus maximus, along with which it acts as an abductor of the limb, and is considered by Meyer (op. cit. p. 222) to be an extensor of the knee.

The *sartorius* produces the flexion of the hip and knee-joints, accompanied by abduction. It has been supposed to be the muscle principally concerned in producing the posture assumed by the tailor in sitting, and hence its name; but Duchenne denies that this is its special action.

The *quadriceps extensor femoris* extends the knee-joint; but its action is not requisite for the maintenance of the erect attitude, the knee-joint remaining in complete extension without muscular aid while the foot is firmly planted on the ground. This may be tested by the fact that the patella of a person standing with the knee extended will be found to lie quite loosely, but will become at once fixed when it is attempted to lift the foot.

The *rectus femoris* flexes the hip and extends the knee: it acts mainly from its anterior head of origin when the thigh is fully extended, and the posterior head is alone tense when the thigh is bent.

#### INTERNAL FEMORAL OR ADDUCTOR MUSCLES.

The **gracilis** or **adductor gracilis** muscle, long and slender, arises by a thin tendon from the inner margin of the pubic bone, along the lower half of the symphysis and the upper part of the pubic arch. The lower tendon, which is at first round, is inserted by a flattened and

expanded portion into the inner side of the tibia, on the same plane with but higher than the semitendinosus, and under the expanded tendon of the sartorius.

*Relations.*—This thin muscle is covered by the fascia lata, except in a small part inferiorly, where it is overlapped by the sartorius; the deep surface rests against the adductor brevis, adductor magnus, semimembranosus, and the internal lateral ligament of the knee-joint. A bursa separates it from that ligament.

The **pectineus** muscle, flat and somewhat quadrangular, arises from the pectineal line, and from the surface of bone in front of it, between the iliopectineal eminence and the pubic spine. Inclining outwards and backwards as it descends, it is inserted by a flat tendon into the femur behind the small trochanter, and into the upper part of the line which connects the linea aspera of the femur with that prominence.

*Relations.*—The pectineus is in contact, by its anterior surface, with the fascia lata and the femoral vessels; by the posterior surface, with the obturator vessels and nerve, and the external obturator and adductor brevis muscles. By the outer border it touches the psoas magnus; by the inner border, the adductor longus.

*Varieties.*—The pectineus is frequently divided into two parts, which are separate superiorly and have their nerves from different sources, viz., the inner from the obturator and the outer from the anterior crural nerve. This division occurs naturally in many animals.

The **adductor longus**, a flat triangular muscle, internal to the pectineus, and lying in the same plane, arises by a short tendon from the body of the pubes below the crest and near the angle, and is inserted into the inner margin of the linea aspera between the vastus internus and the adductor magnus.

*Relations.*—This muscle is covered by the fascia lata, the sartorius, and the femoral vessels; the posterior surface rests superiorly on the adductor brevis, and inferiorly on the adductor magnus. Externally it is separated by a small interval from the pectineus, and internally it is in apposition with the gracilis. It forms the inner boundary of Scarpa's triangle.

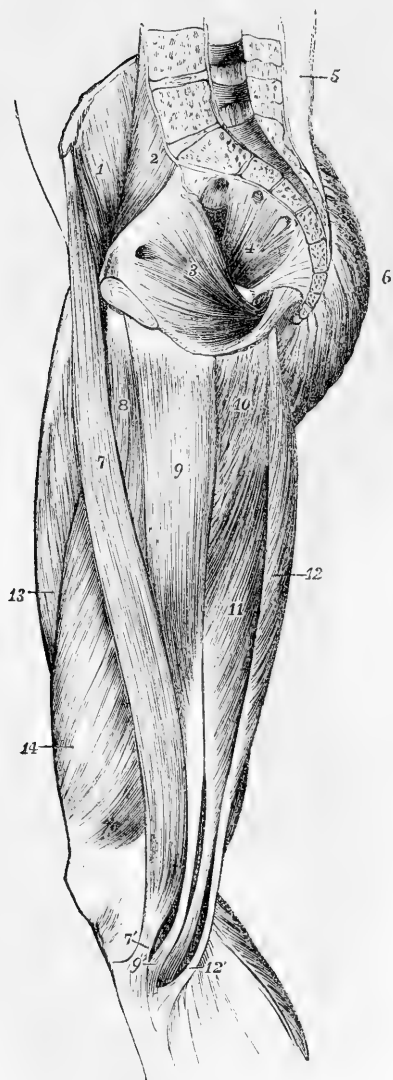
The **adductor brevis**, thick above and broad below, arises by a narrow origin, about two inches deep, in contact with that of the gracilis, from the anterior surface of the body, and the descending ramus of the pubes; directed obliquely backwards and outwards, it is inserted by a flat tendon into the whole of the oblique line leading from the small trochanter of the femur to the linea aspera, immediately behind the insertion of the pectineus.

*Relations.*—The adductor brevis is concealed at its origin by the adductor longus and at its insertion in part by the pectineus; it is crossed by the superficial division of the obturator nerve, and by the profunda femoris artery; it rests on the adductor magnus and deep division of the obturator nerve, and by its deep surface is in contact superiorly with the obturator externus, the internal circumflex artery passing between.

The **adductor magnus** muscle arises from the lower part of the body of the pubis external to the origin of the adductor brevis, from the rami of the pubis and ischium, and from the tuberosity of the ischium near the pubic arch. The muscular fibres diverge from their origin, somewhat like the ribs of a fan from their central pivot: those from the pubis, shorter than the rest, pass transversely outwards, and are

inserted into the lower part of the linea quadrati, and into the line prolonged from the linea aspera to the great trochanter; others pass with increasing degrees of obliquity downwards and outwards, to be

Fig. 190.



inserted into the whole length of the linea aspera, and into the line prolonged from it to the inner condyle for about an inch; finally, the posterior fibres which arise from the ischial tuberosity, descend almost vertically, forming the inner border of the muscle, and terminate in a narrow tendon, which is inserted into the tuberosity of the inner condyle of the femur.

Fig. 190.—MUSCLES OF THE INNER SIDE OF THE THIGH AND INTERIOR OF THE PELVIS. (A. T.)  $\frac{1}{2}$

1, iliacus; 2, psoas magnus; 3, obturator internus, with its fibres converging towards the lesser sciatic foramen; 4, pyriformis, with three heads of origin, and its fibres converging towards the great sciatic foramen; 5, lumbar aponeurosis covering the erector spinae muscle; 6, gluteus maximus; 7, sartorius, 7', its tendon inserted below the tuberosity of the tibia; 8, adductor longus; 9, gracilis, 9', its insertion passing below that of the sartorius; 10, part of the adductor magnus; 11, semimembranosus; 12, semitendinosus, 12', its insertion, and between 9' and 12', the tendon of the semimembranosus passing to its insertion in the inner tuberosity of the tibia.

Along the femoral attachment the insertion is interrupted by three or more tendinous arches through which pass the perforating arteries, and below the level of the inferior bifurcation of the linea aspera, between the tendinous and fleshy portions of the insertion of the muscle, an interval is left for the transmission of the femoral vessels backwards into the popliteal space. Extending upwards from the opening for the femoral ves-

sels, is an aponeurotic membrane which consists of transverse fibres passing from the surface of the vastus internus to the adductor magnus and adductor longus muscles. It becomes thinner as it ascends, and encloses a three-sided passage called *Hunter's canal*, which contains

the femoral artery and vein, together with the internal saphenous nerve.

*Relations.*—This muscle is in contact in front with the long and short adductors, the vastus internus, the obturator nerve, and the profunda artery, behind with the hamstring muscles, gluteus maximus, and great sciatic nerve, internally with the gracilis muscle, superiorly with the obturator externus and quadratus femoris muscles, and along the line of attachment to the femur it is pierced by the femoral and perforating arteries.

*Varieties.*—The adductor muscles are so closely related that their varieties may be conveniently considered together. The *pectineus* has been found double, as already stated. It has also been seen attached to the capsule of the hip-joint, or even inserted into it. The *adductor longus* may be double, or it may extend as far as the knee with its tendon of insertion inseparable from that of the adductor magnus. The *adductor brevis* is frequently found divided into two or three parts, or it may be incorporated with the adductor magnus. The *adductor magnus* varies in the degree of its segmentation. Its condylar part has been found quite distinct from the rest of the muscle. The upper transverse part is so frequently divided from the rest by the superior profunda artery, that it is looked upon by some anatomists as a special muscle, being called the *adductor minimus* (Henle, Günther, Macalister). On the other hand, the muscle has been found undivided, and its upper part completely united to the quadratus femoris (Macalister).

*Nerves.*—The adductor muscles as a whole are supplied by the obturator nerve, but the adductor magnus likewise receives a branch from the great sciatic, and the outer part of the pectineus sometimes has a branch from the anterior crural.

*Actions.*—The *gracilis* acts as an adductor of the limb. The gracilis, semitendinosus, semimembranosus, and sartorius muscles, together with the popliteus, all rotate the leg inwards at the knee-joint; the latter muscle acting chiefly in the flexed state of the knee.

The *pectineus* is partly a flexor and partly an adductor.

The *adductores magnus, longus, and brevis*, adduct the thigh, and, along with their opponents the gluteus medius and minimus, and with the gluteus maximus, balance the body on the femur in walking.

The *ilio-psoas* and the *adductor* muscles, together with the pectineus, being all inserted at the back part of the femur, tend to rotate the thigh outwards at the same time that they produce their adducting and flexing actions. The advantage of this preponderance of rotators outwards over rotators inwards becomes apparent by reference to the movements which take place in walking. When a step is taken, the pelvis is drawn forwards on that side on which the foot has been advanced, which involves a considerable *rotation of the pelvis backwards* at the other hip-joint, by the action of the muscles of the opposite limb.

## MUSCLES AND FASCIAE OF THE LEG AND FOOT.

### ANTERIOR REGION.

**FASCLE.**—The **aponeurosis of the leg** is particularly dense in the upper and fore part, and is strengthened by fibres from the tendons of the biceps externally, and the sartorius, gracilis, and semimembranosus internally. Behind, over the popliteal space, it consists of strong transverse fibres, which bind together the muscles of the outer and inner sides, and is perforated at the lower part of the space by the external saphenous vein; lower down it becomes much thinner over the gastrocnemius muscle. The fascia is adherent to the periosteum

covering the head, the spine and the posterior margin of the tibia, the head of the fibula, and the outer and inner malleoli; and it invests the leg completely except at the inner surface of the tibia. From its deep surface intermuscular septa are prolonged inwards between the muscles on the anterior and outer aspects of the leg, and afford attachment along with the upper part of the fascia itself to some of their fibres.

Beneath the gastrocnemius and soleus muscles on the back of the leg, a deep layer of fascia is stretched from side to side, binding down the deeper muscles firmly in the hollow between the tibia and fibula. Where covered by the soleus and gastrocnemius, this fascia is weak, but it becomes stronger as it escapes from under cover of those muscles and approaches the malleoli.

Below the ankle the deep fascia of the leg becomes continuous with that of the foot. In front, and on the sides of that joint, it is strengthened by broad bands of fibres, which are called annular ligaments. These serve as retinacula, confining the tendons in their natural positions.

The **anterior annular ligament** includes two structures, one placed on the lower part of the leg, the other opposite the bend of the ankle. The *upper band*, *ligamentum transversum cruris* (Henle), of considerable breadth, stretches from the lower end of the fibula to the lower end of the tibia, and binds down the vertical portion of the extensor tendons as they turn forwards to the foot: the sheath for the tendon of the tibialis anticus is distinct from the others. The *lower band*, *ligamentum cruciatum cruris* (Henle), presents superficially the appearance of the letter  $\sphericalangle$  placed thus upon its side, being single in its outer half, and usually divided into two branches internally. The outer portion consists of a strong loop of fibres arising from the fore part of the os calcis, completely surrounding the peroneus tertius and extensor longus digitorum muscles, and inserted into the fore part of the os calcis, deep in the hollow between that bone and the astragalus. Less regular is the arrangement of the bands which pass from the extremity of the loop to the inside of the foot: the strongest and most constant band passes superficial to the extensor pollicis and on the deep surface of the tibialis anticus muscle, only a few fibres passing superficial to the latter; while another band, lower down, after crossing both those tendons, is inserted into the lower side of the foot in front of the ankle.

The **internal annular ligament** crosses the space between the inner ankle and the heel through which the tendons of the flexor muscles run. Its upper border, continuous with the fascia of the leg (more especially the intermuscular layer), is very imperfectly defined; and its lower border, giving origin to many fibres of the abductor pollicis, is but little more distinct. Its anterior extremity is attached to the inner malleolus, and its posterior is inserted into the inner surface of the calcaneum; but between these two points it arches over several osseous grooves so as to form canals for the passage of tendons. The first canal (next to the malleolus) contains the tendon of the tibialis posticus, and the second that of the flexor longus digitorum, each being provided with a synovial lining. Then follows a wider space for the passage of the posterior tibial vessels and nerve. Lastly, a fourth canal upon the astragalus, lined like the first two by a synovial bursa, transmits the tendon of the flexor longus pollicis.

The **external annular ligament** extends from the point of the

outer malleolus to the outer surface of the calcaneum, and keeps in place the tendons of the long and short peronei muscles. The tendons are close together, and are surrounded by one synovial sac.

The **dorsal fascia of the foot** is reduced to a thin membrane prolonged from the anterior annular ligament over the extensor tendons. Beneath it, deeper layers of fasciæ are placed over the short extensor of the toes and the interossei muscles.

**MUSCLES.**—Between the tibia and fibula, and on the front of the leg, are placed four muscles—the tibialis anticus, extensor proprius pollicis, extensor longus digitorum, and peroneus tertius; and on the dorsum of the foot one muscle only arises,—the extensor brevis digitorum.

The **tibialis anticus** arises from the external tuberosity of the tibia, and about two-thirds of the outer surface of that bone; from a small portion of the adjoining interosseous ligament; from the strong fascia of the leg; and from an aponeurotic septum placed between it and the extensor longus digitorum. The tendon glides in a synovial sheath beneath the anterior annular ligament, and is inserted into the inner and lower part of the internal cuneiform and the contiguous extremity of the first metatarsal bone, dividing slightly into two slips as it descends.

*Relations.*—This muscle is entirely covered by the aponeurosis of the leg. It rests upon the outer surface of the tibia, and the interosseous ligament. Its outer surface is in contact above with the extensor longus digitorum, and lower down with the extensor proprius pollicis; it also conceals the anterior tibial vessels and nerve. Its tendon passes over the lower end of the tibia, the ankle-joint, and the inner surface of the tarsus.

*Varieties.*—In cases of talipes the tendon of this muscle has been found split into two, one half going to the usual place of insertion, the other to the astragalus or first metatarsal; the whole tendon has also been seen inserted into the plantar fascia. The *tibio-fasciæ anticus* is a small muscle described by Wood, arising from the lower third of the anterior edge of the tibia over the tibialis anticus and inserted into the annular ligament and deep tibial fascia. It may also exist as a tendinous slip from the tibialis anticus.

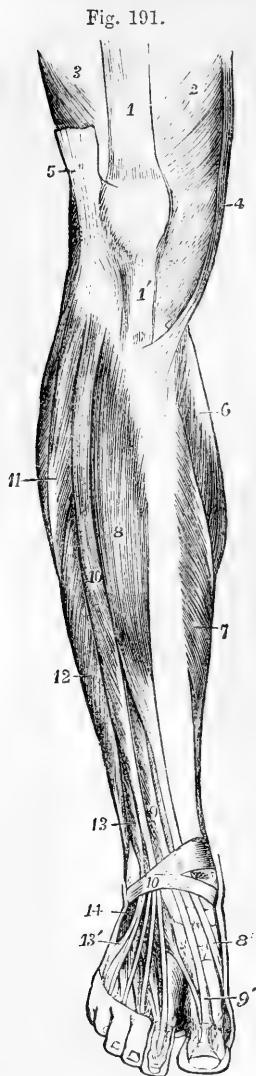
The **extensor proprius pollicis pedis** muscle, or extensor hallucis, placed between the tibialis anticus and the extensor longus digitorum, arises from the middle three-fifths of the anterior narrow part of the inner surface of the fibula, and from the contiguous portion of the interosseous ligament. Its tendon passes through a distinct compartment in the lower portion of the annular ligament in and along the dorsum of the foot, to be inserted into the base of the terminal phalanx of the great toe. A delicate expansion given off from the tendon on each side spreads over the joint between the metatarsal bone and the first phalanx.

*Relations.*—This muscle is partly concealed by those between which it is placed. It lies external to the anterior tibial artery in the leg, but crosses in front of that vessel at the bend of the ankle, and is internal to it on the foot.

*Varieties.*—The *extensor ossis metatarsi pollicis* is a small muscle, sometimes found as a slip from the extensor proprius, or from the tibialis anticus, or from the extensor communis digitorum; or it may be a distinct muscle arising close to the extensor proprius, and traversing the same compartment of the annular ligament with that muscle.

The *extensor primi internodii pollicis*, another occasional muscle is nearly always an offshoot from the extensor proprius, though it has been found separate. It was seen by Wood in one half of the subjects examined by him.

The **extensor longus digitorum pedis** arises from the external tuberosity of the tibia; from the head and the anterior narrowed part



of the inner surface of the fibula in front of the interosseus membrane, for about three-fourths of its length; from a small part of the interosseus ligament at its upper part; also from the aponeurotic septa intervening between it and the muscles on each side, and from the fascia of the leg. The tendon divides into four slips, which descend through the lower part of the annular ligament, in the same sheath as the peroneus tertius, and on the dorsum of the foot pass respectively to the four outer toes. The three inner tendons are each joined at the outer side, on the first phalanx, by a tendon from the extensor brevis digitorum. All the four tendons are continued into expansions, which are joined on the first phalanx by tendinous processes from the lumbricales and interossei muscles; they divide into three parts, their middle fibres being inserted into the second phalanx, while their lateral parts unite together and are inserted on the third, in a manner exactly similar to the arrangement of the extensor tendons of the fingers.

Fig. 191.—MUSCLES OF THE LEG AND FOOT FROM BEFORE. (A. T.)  $\frac{1}{2}$

1, tendon of the rectus femoris; 1', ligamentum patellæ; 2, vastus externus; 3, vastus internus; 4, sartorius; 5, fascia lata cut near the place of its insertion at the knee; 6, inner head of the gastrocnemius; 7, inner part of the soleus; 8, tibialis anticus; 8', its tendon near the insertion; 9, extensor longus pollicis; 9', its tendon; 10, extensor communis digitorum longus; 10', anterior annular ligament; 11, peroneus longus; 12, peroneus brevis; 13, peroneus tertius; 13', its tendon at its insertion; 14, origin of the extensor communis digitorum brevis, the first head of which is seen passing to the great toe near the line from 9'.

*Relations.*—It is in contact internally with the tibialis anticus and extensor proprius pollicis, and externally with the peronei muscles. It rests upon the external tuberosity of the tibia, the anterior surface of the fibula, the lower end of the tibia, the front of the ankle-joint, and the extensor

brevis digitorum. The anterior tibial nerve passes obliquely beneath its upper part.

*Varieties.*—This muscle varies considerably in the mode and place of insertion of its various tendons. The tendons to the second and fifth toes may be found doubled, or extra slips are frequently given off from one or more tendons to their corresponding metatarsal bones or to the short extensor, or to one of the interossei muscles.

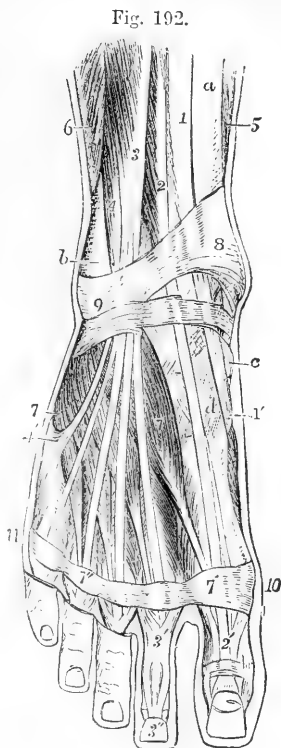
The **peroneus tertius** muscle arises below the extensor longus



digitorum, from the lower fourth of the inner surface of the fibula, from the lower part of the interosseus membrane, and from the intermuscular septum which connects it on the outer side with the peroneus brevis. Its tendon is inserted into the upper surface of the base of the fifth metatarsal bone.

Fig. 192.—SUPERFICIAL MUSCLES AND TENDONS ON THE DORSUM OF THE FOOT AND LOWER PART OF THE FRONT OF THE LEG (after Bourguery).  $\frac{1}{3}$

*a*, the tibia; *b*, the fibula; *c*, the scaphoid bone; *d*, internal cuneiform bone; 1, the tibialis anticus muscle; 1', its tendon descending in the groove of the internal cuneiform bone; 2, extensor longus pollicis; 2', its expansion on the dorsum of the great toe; 3, extensor communis digitorum dividing into its four tendons for the toes; 3', its expansion, and 3'', final insertion (upon the second toe); 4, peroneus tertius; 4', its expanded insertion on the base of the fifth metatarsal bone; 5, soleus; 6, peroneus brevis; 7, extensor brevis digitorum; 7', 7'', placed on the transverse band of aponeurosis, marks the first and fourth tendons of the extensor brevis muscle passing to join those of the long extensor; 8, 9, part of anterior annular ligament, and ligamentum cruciatum; between 8 and *c*, the slings enclosing the extensor longus pollicis and tibialis anticus; below 9, the outer part of the ligamentum cruciatum enclosing the tendons of the extensor communis and peroneus tertius; 10, 11, dorsal transverse metatarsal band of aponeurosis.



*Relations.*—It is placed to the outer side of the long extensor of the toes, with which it is usually united at its origin, and it passes through the same compartment of the annular ligament with that muscle.

*Varieties.*—The peroneus tertius is sometimes as large as the extensor longus digitorum; it has been observed to terminate on the fourth metatarsal bone; and it is sometimes altogether wanting.

The **extensor brevis digitorum pedis** arises from the outer surface of the os calcis in front of the groove for the peroneus brevis muscle, and from the lower band of the anterior annular ligament. It divides into four tapering slips each of which terminates in a tendon; the first or most internal of these, sometimes reckoned as a distinct muscle, is inserted separately into the dorsal surface of the first phalanx of the great toe near its tarsal extremity; and the other three become severally united to the outer border of the extensor tendons proceeding to the three next toes.

*Relations.*—It crosses the dorsum of the foot somewhat obliquely, resting on the tarsus and metatarsus, and lying beneath the tendons of the peroneus tertius and long extensor of the toes. Its inner tendon also crosses the dorsalis pedis artery and the anterior tibial nerve.

*Varieties.*—The tendons of this muscle vary considerably both as to number and position, they may be reduced to two, or one of them may be doubled. The inner part of the muscle very commonly forms a distinct *extensor brevis hallucis* being separate at its origin from the rest of the muscle; this is regarded by Henle as the normal arrangement.

**Nerves.**—All the muscles in front of the leg, together with the *extensor brevis digitorum*, are supplied by the anterior tibial nerve.

#### EXTERNAL REGION.

The **peroneus longus** muscle arises from the head of the fibula, and from the upper two-thirds of the external surface of that bone ; from the fascia of the leg ; and from the intermuscular septa on either side. It ends above the ankle in a tendon which passes downwards behind that of the *peroneus brevis* in the hollow behind the external malleolus, and in the same sheath of the external annular ligament with it ; it then inclines forwards over the outer margin of the foot, and enters the groove on the lower surface of the cuboid bone, proceeding inwards and forwards to be inserted into the lower part of the internal cuneiform and the tarsal end of the first metatarsal bone : an offset is continued from it to the base of the second metatarsal bone.

**Relations.**—At its origin the *peroneus longus* lies between the *extensor communis digitorum* in front and the *soleus* and *flexor longus pollicis* behind ; in the lower part of the leg it lies behind the *peroneus brevis*. Beneath the external annular ligament the tendons of both peronei are surrounded by the same synovial sheath. In the sole of the foot the tendon of the *peroneus longus* lies in a fibrous sheath formed by the long plantar ligament, and is enclosed by a tubular sheath of synovial membrane. A small sesamoid cartilage is sometimes found in that part of the tendon which lies in the groove of the cuboid.

The **peroneus brevis** arises from the lower two-thirds of the external surface of the fibula, internal to the *peroneus longus*, and from the intermuscular septa on either side. Its tendon passes behind the external malleolus, and inclining forwards, is inserted into the projection at the base of the fifth metatarsal bone.

**Relations.**—In front it is in contact with the *extensor longus digitorum* and the *peroneus tertius*, and behind with the *peroneus longus* and *flexor longus pollicis*. Behind the malleolus it is enclosed in the same fibrous and synovial sheaths with the tendon of the *peroneus longus*, but over the calcaneum it traverses a separate sheath above that for the *peroneus longus*, but lined by an offset of the same synovial membrane.

**Varieties.**—The following are the most common :—The *peroneus accessorius* (Henle) arises from the fibula between the *peroneus longus brevis* and joins the tendon of the former in the sole of the foot. The *peroneus quinti digiti* arises from the lower fourth of the fibula under the *peroneus brevis*, and is inserted into the aponeurosis on the upper surface of the little toe ; or it may arise from the tendon of the *peroneus brevis* itself. (Hallet, Wood, Macalister.) *Peroneus quartus* (Otto) arises from the back of the fibula, between the *peroneus brevis* and the *flexor pollicis*, and is inserted into a tubercle on the os calcis, behind the tendons of the peroneal muscles. (Macalister.)

**Nerves.**—The *peroneus longus* and *brevis* are supplied by the musculo-cutaneous branch of the popliteal nerve.

#### POSTERIOR REGION.

The muscles at the back of the leg consist of a superficial group inserted into the extremity of the calcaneum, and a deeper group covered in by a deep fascia and descending to the sole.

The SUPERFICIAL GROUP consists of three muscles ; two of them, placed one on the surface of the other, are of large size, the *gastrocnemius* and *soleus*, form the bulk of the calf of the leg, and are inserted into the heel by a common tendon—the tendo Achillis ; the third, a small muscle, the *plantaris*, descends between the other two.

The **gastrocnemius** muscle arises by two thick tendinous heads from the condyles of the femur, and ends below in the tendo Achillis. The

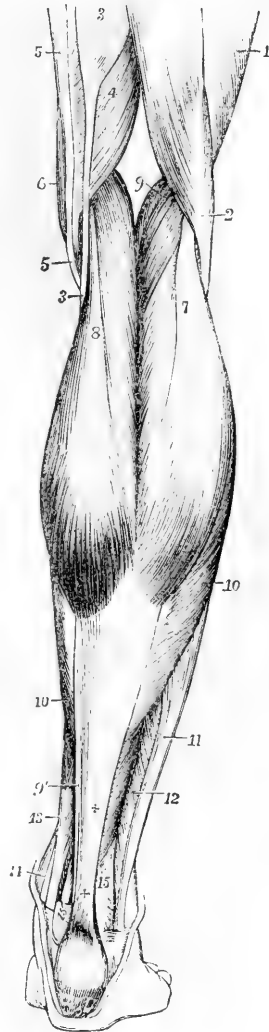
Fig. 193.—SUPERFICIAL MUSCLES OF THE LEG, SEEN FROM BEHIND (after Bourguery).  $\frac{1}{2}$

1, lower outer part of the vastus muscle; 2, biceps flexor cruris; 3, semitendinosus; 4, semimembranosus; 5, gracilis; 6, sartorius; 7, outer, and 8, inner head of the gastrocnemius; 9, placed in the popliteal space, points to the plantaris; 9', its thin tendon inside the tendo Achillis; 10, the fibres of the soleus descending to the flat tendon, which joining with that of the gastrocnemius, forms ++ the tendo Achillis; 11, peroneus longus; 12, peroneus brevis; 13, flexor longus digitorum; 14, tibialis posticus; 15, is placed on the lower part of the fibula, and points to the lower fibres of the flexor longus pollicis, the tendon of which is seen descending over the tibia at 15'.

outer tendon of origin is attached to a depression on the outer side of the external condyle, above the groove for the popliteus muscle, and also to the upper and back part of the same condyle. The inner tendon is attached in a horizontal line to an impression above the back part of the internal condyle, and to a small part of the ridge running to the *linea aspera*. The muscular fibres descending from the two heads remain separated by a vertical groove on the surface, but those next the middle meet at an angle on a tendinous structure below. The fibres of the superior tendons spread out upon the surface of the muscle; the inferior tendon lies on the deep surface of the muscular mass, and is continued upwards in a thin aponeurosis with parallel fibres, which glide against the soleus: between the superficial tendon of each head and the deep common tendon, the greater number of the muscular fibres run obliquely downwards and forwards. The lower edge of each muscular part presents a convexity downwards; the inner descending furthest. A synovial bursa, usually communicating with the knee-joint, lies beneath the inner head of origin, and separates it from the tendon of the semimembranosus muscle. In the outer head a sesamoid fibrocartilage is sometimes met with over the outer condyle of the femur, which is occasionally found ossified.

*Relations.*—The heads of the gastrocnemius muscle form the inferior boundaries of the popliteal space, and are placed between the hamstring muscles: the peroneal nerve is lodged between the external head and the biceps. The gastrocnemius conceals the popliteus, plantaris and soleus muscles, with the popliteal

Fig. 193



vessels and internal popliteal nerve. The short saphenous vein is placed on its surface, in the interval between its two parts.

*Varieties.*—The gastrocnemius is, in some cases, joined by a bundle of muscular fibres, which arises separately from the femur above one of the condyles. This bundle has been observed passing between the popliteal artery and vein (R. Quain, *op. cit.*, plate 80, figs. 4 and 5).

Fig. 194.

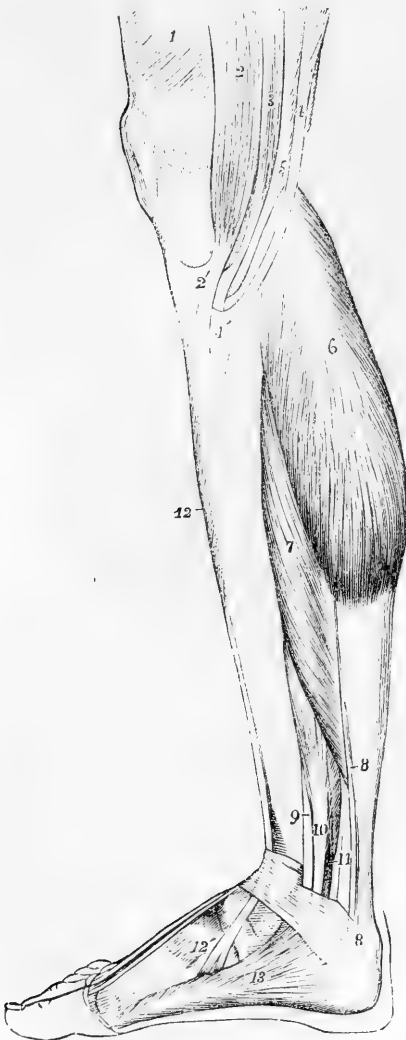


Fig. 194.—SUPERFICIAL MUSCLES OF THE LEG, SEEN FROM THE INNER SIDE (after Bourguery).  $\frac{1}{2}$

1, vastus internus; 2, sartorius; 2', its tendon, spreading on the inner upper part of the tibia; 3, gracilis; 4, semitendinosus; 4', its insertion; and between 2' and 4', that of the gracilis; 5, semimembranosus; 6, inner head of the gastrocnemius; 7, soleus; 8, 8', placed upon the tendo Achillis, point to the small tendon of the plantaris descending on the inner side; 9, small part of the tendon of the tibialis posticus; 10, flexor communis digitorum; 11, flexor longus pollicis; 12, tibialis anticus; 12', its tendon of insertion; 13, abductor pollicis.

The **soleus** muscle arises externally from the posterior surface of the head and upper third of the shaft of the fibula; internally from the oblique line which gives insertion to the popliteus, and from the posterior edge of the tibia about three inches below that line; and between the tibia and fibula, from a tendinous band which arches over the posterior tibial vessels and nerve. Inferiorly, the muscular fibres descend upon the tendo Achillis considerably further than those of the gastrocnemius. The posterior surface presents a thin covering of longitudinal aponeurotic fibres continued up from the tendon below, and gliding on the similar tendinous surface of the gastrocnemius muscle. On the deep surface the edges of

two membranous tendons, the other edges of which look towards the middle line of the muscle, imbedded in its substance, are seen descending from the tibial and fibular origins: the fibres from the deep aspects of those tendons are directed obliquely inwards to a tendinous

septum which divides the muscle into lateral halves; while those from their superficial aspects pass with similar obliquity to the flat tendon on the surface of the muscle, the fibres placed at the sides forming the lateral borders and part of the deep surface of the muscles. Thus the soleus is composed entirely of short oblique fibres of from one to two inches in length.

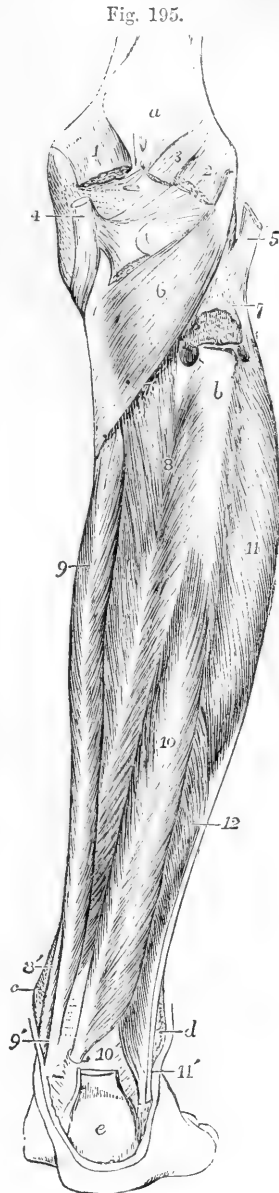
Fig. 195.—DEEP POSTERIOR MUSCLES OF THE LEG. (A. T.)  $\frac{1}{4}$

*a*, popliteal surface of the femur; *b*, bare surface of the upper fourth of the fibula, from which the soleus muscle has been removed; *c*, malleolus internus; *d*, malleolus externus; *e*, tuberosity of the os calcis, with a part of the tendo Achillis inserted into it, and the plantaris on its inner side; 1, inner head of the gastrocnemius cut short at its origin; 2, outer head; 3, plantaris; 4, tendon of the semimembranosus muscle near its insertion, seen spreading in three portions, viz., to the inside of the tibia, towards the popliteal fascia, and towards the ligamentum posticum; 5, tendon of the biceps inserted into the head of the fibula; 6, popliteus muscle; 7, upper part of the origin of the soleus from the fibula, cut short; 7', line of its tibial origin; between these figures is seen the perforation in the upper part of the interosseous membrane; 8, tibialis posticus; 8', its tendon, passing between the flexor digitorum communis and the tibia; 9, flexor digitorum communis; 9', its tendon, with that of the tibialis posticus, passing behind the malleolus internus; 10, flexor longus pollicis; 10', placed beside its tendon, where it passes over the tibia and astragalus; 11, peroneus longus; 11', its tendon behind that of the peroneus brevis, passing down behind the malleolus externus; 12, peroneus brevis.

*Relations.*—The soleus rests upon the flexor longus pollicis, flexor longus digitorum, and tibialis posticus muscles, together with the posterior tibial vessels and nerve, from which, however, it is separated by the deep aponeurosis.

*Varieties.*—To the soleus an accessory portion is occasionally added at its lower and inner part; this usually ends on the inner side of the tendo Achillis, but it sometimes forms a tendon, attached separately to the os calcis.

The **tendo Achillis**, the thickest and strongest tendon in the body, is formed by the union of the flat tendon of the gastrocnemius with the thicker and more rounded tendon of the soleus. It is from three to four inches long below the point where the muscular fibres of the soleus cease to be attached to it. It is inserted inferiorly into the back part of the tuberosity of the os calcis. A synovial bursa is interposed between the upper part of the tuberosity of the os calcis and the tendon.



The **plantaris** muscle arises from the femur immediately above the external condyle, and from the posterior ligament of the knee-joint; its muscular part is from three to four inches in length, and terminates in a long delicate tendon, which inclines inwards between the gastrocnemius and soleus, and, running along the inner border of the tendo Achillis, is inserted not far from it into the posterior part of the calcaneum.

*Varieties.*—The plantaris varies in its mode of termination; it is sometimes enclosed in the lower part of the tendo Achillis; and, in other cases, it ends in the internal annular ligament, which binds down the tendons and vessels behind the inner malleolus. It is not unfrequently absent altogether. This muscle, which is little developed and almost vestigial in man, is sometimes of large size in animals, and in some is continued forward in the sole of the foot as a part of the flexor muscles of the toes.

The DEEP GROUP of posterior muscles of the leg is in close contact with the bones; it consists of the popliteus, flexor longus digitorum, flexor longus pollicis, and tibialis posticus.

The **popliteus**, an oblique muscle placed below the knee, arises by a thick tendon, about an inch in length, from the fore part of the popliteal groove on the outer surface of the external condyle of the femur, within the external lateral ligament and capsule of the knee-joint; it is in contact with the external semilunar cartilage, and receives additional fibres from the posterior ligament of the joint. The muscular fibres diverge as they pass downwards, and are inserted into the triangular surface of the tibia above the posterior oblique line.

The tendon of the popliteus muscle occupies the groove on the outside of the femur in flexion only.

*Relations.*—The popliteus is bound down by an aponeurosis, principally derived from the tendon of the semimembranosus muscle. The plantaris and gastrocnemius muscle, the popliteal vessels and internal popliteal nerve lie upon its posterior surface.

The three remaining muscles of this group are bound down together by a deep fascia, which extends between the tibia and fibula, and separates them from the soleus.

The **flexor longus digitorum pedis** muscle, or **flexor perforans**, arises from the posterior surface of the tibia, in a space extending from the oblique line to within three inches of the inner ankle; it likewise arises in connection with the flexor longus pollicis, by aponeurotic fibres, which pass over the surface of the tibialis posticus. Its tendon descends in a groove behind the internal malleolus, lying on that of the tibialis posticus, and invested by a distinct fibrous and synovial sheath; it is then directed under the arch of the os calcis, obliquely forwards and outwards, into the sole of the foot, crossing the tendon of the flexor longus pollicis inferiorly, and connected with it by a tendinous slip; it then divides into four parts, which pass forwards to be inserted into the terminal phalanges of the four smaller toes. Each digital tendon enters a fibrous sheath on the toe to which it belongs, perforates the corresponding tendon of the flexor brevis digitorum, and is invested with synovial membrane, and connected by vincula accessoria to the phalanges; the whole arrangement being essentially the same as that which has been already described in the fingers.

*Relations.*—It rests upon the tibia and upon the inner surface of the tibialis posticus, the tendon of which it also crosses about two inches above the ankle.

It is covered at the upper part by the soleus and inferiorly by the aponeurosis of the leg. Upon it also lie the posterior tibial vessels and nerve.

*Varieties.*—A second head of origin has not unfrequently been found. This may arise from the outer tuberosity of the tibia, or from the fibula, or from the fascia of the leg. This second head has been seen joining the accessorius or even replacing it (Otto). Gies describes an accessory slip from the tibialis anticus, which joined the flexor digitorum at the ankle. A *flexor digiti secundi proprius* was found by Bahnsen, arising from the back of the tibia.

Fig. 196.—SECOND LAYER OF PLANTAR MUSCLES.

1, tendon of the flexor longus pollicis muscle, emerging behind from its sheath below the sustentaculum tali, and passing deeper than, 2, the tendons of the deep common flexor; 3, two heads of the flexor accessorius; 4, the four lumbricales; 5, tendon of the flexor brevis cut short and seen splitting to allow the passage through it of the tendon of the long flexor; 6, flexor brevis pollicis; 7, flexor brevis minimi digiti; there is also represented on the outer side of the foot the tendon of the peroneus longus winding round the cuboid bone.

Intimately connected with the tendon of the flexor longus digitorum are the flexor accessorius and the lumbricales muscles, which, although they occupy the foot, may be most conveniently described in this place.

The **flexor accessorius** arises by two heads, the internal and larger of which is fleshy, and is attached to the inner surface of the calcaneum, while the external, flat, narrow, and tendinous, is attached to the plantar surface of the calcaneum a little in front of the external tubercle, and to the ligamentum longum plantæ. These origins united form a muscular mass which is inserted into the external border and upper and lower surfaces of the tendon of the flexor longus digitorum.

The **lumbricales** muscles, four in number, arise from the tendons of the flexor longus digitorum at their point of division, each being, with the exception of the most internal, attached to two tendons. They pass forward to the inner sides of the four outer toes, each muscle ending in a tendon, which is inserted into the expansion of the extensor tendon on the dorsum of the first phalanx of the toe.

*Relations.*—In the sole of the foot the tendons of the flexor longus digitorum, together with the flexor accessorius and the lumbricales, are covered below by the flexor brevis digitorum; the plantar nerves and hinder part of the external plantar artery being placed between. These tendons, with their additional muscles, conceal the adductor pollicis, the tendon of the flexor longus pollicis, the transversus pedis, the interossei muscles, and the plantar arterial arch.

The **flexor longus pollicis pedis**, or flexor hallucis muscle, arises from the lower two-thirds of the posterior surface of the fibula, except for an inch at its lowest part; from the intermuscular septum between it and the peronei; and from the aponeurosis common to it and the flexor longus digitorum, which covers the tibialis posticus. The muscular fibres, passing obliquely backwards and downwards, end in a tendon on the posterior surface of the muscle. This tendon traverses a groove on the lower end of the tibia, at the back of the astragalus and

Fig. 193.



the under surface of the sustentaculum tali, being bound down to those bones by fibrous and synovial sheaths. Thence passing forwards and inwards, in the sole of the foot, it gives off a tendinous slip to the tendon of the flexor longus digitorum, by which it is crossed, and proceeds in a fibrous sheath over the first phalanx of the great toe to be inserted into the base of the terminal phalanx.

*Relations.*—This muscle is concealed for the most part by the soleus, a small part only at the outer side of the tendo Achillis being covered by the fascia of the leg. Externally it is in contact with the peronei, and internally with the tibialis posticus. It rests upon the fibula and conceals the peroneal vessels. Below the ankle the tendon of this muscle is separated from that of the flexor longus digitorum by an interval of more than half an inch, in which are placed the posterior tibial vessels and nerves. In the sole it is covered by the plantar fascia and abductor pollicis muscle; it is also crossed by the plantar vessels and nerves, and the tendon of the long flexor of the toes. It rests upon the flexor brevis pollicis.

*Varieties.*—This muscle is liable to very few variations, but the mode of union of its tendon with that of the flexor longus digitorum is exceedingly variable. According to Turner, in no two subjects is it exactly similar. In almost every case the slip of union comes from the flexor pollicis, though in about one-sixth of the cases an additional slip proceeds from the flexor digitorum to the flexor pollicis (Turner, Wood). Complete separation of the tendons is very rare. This slip from the flexor pollicis most frequently passes to the second and third toes but it may pass to the second only, or to all the four outer toes.

The *peroneo-calcaneus internus* is a small muscle described by Macalister as the probable homotype of the pronator quadratus of the arm. It arises below the flexor longus pollicis from an oblique line on the back of the fibula, behind the external malleolus, passes over the sustentaculum tali in the groove with the flexor pollicis, to be inserted into a tubercle of the os calcis (Muscular Anomalies, p. 125).

Fig. 197.

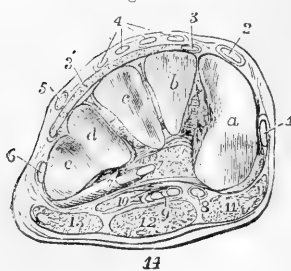


Fig. 197.—TRANSVERSE SECTION OF THE RIGHT FOOT BETWEEN THE TARSUS AND METATARSUS.

A. T.  $\frac{1}{2}$ 

*a, b, c*, articular metatarsal surface of the internal, middle, and external cuneiform bones; *d* and *e*, the surfaces of the cuboid bone for the fourth and fifth metatarsal bones; between these bones are seen the strong interosseous and plantar ligaments which bind them together; 1, slip of the tendon of the tibialis anticus, which passes on to its insertion on the first metatarsal bone; 2, tendon of the extensor longus pollicis; 3, slip of the extensor brevis digitorum to the great toe; 3', remainder of the extensor brevis digitorum; 4, four slips of the extensor communis digitorum longus; 5, peroneus

tertius; 6, peroneus brevis; 7, peroneus longus cut obliquely where it is emerging from its sheath below the cuboid bone; 8, tendon of the flexor longus pollicis; 9, tendon of the flexor communis digitorum longus, with the slip of union from the flexor pollicis; 10, flexor accessorius; 11, abductor pollicis; 12, flexor brevis digitorum; 13, abductor minimi digiti.

The **tibialis posticus** muscle, placed between the two long flexor muscles, arises from the whole interosseous membrane except for two inches at the lower end, and from the adjacent surfaces of the tibia and fibula, the tibial attachment extending from the superior tibio-fibular articulation to a point at a lower level than that of the flexor longus digitorum, and the attachment to the fibula extending along the three middle fifths of that bone; it also arises from the aponeurosis derived



from the adjacent muscles, which covers it. The muscular fibres end in a strong flat tendon, which, passing between the tibia and the long flexor of the toes, turns forwards in a groove beneath the internal malleolus, and is inserted into the tuberosity of the scaphoid bone.

From its insertion, offsets of the tendon are prolonged forwards to all the cuneiform bones, to the os cuboides, and to the bases of the second, third, and fourth metatarsal bones; and one thin process is directed backwards to the sustentaculum tali. The tendon is covered by a synovial membrane behind the malleolus. Close to its insertion, where it lies against the astragalus, it contains a sesamoid fibro-cartilage, which is occasionally converted into bone.

*Relations.*—The tibialis posticus is concealed in great part by the aponeurosis prolonged over it from the muscles on either side. Superiorly, where it is not covered by these muscles, it supports the posterior tibial and peroneal vessels.

*Varieties.*—These are rare. Several anatomists have described an occasional muscle, which arises from the back of the tibia below the flexor digitorum, and is inserted into the capsule of the ankle-joint or into the ligamentum cruciatum. This is the tensor of the capsule of the ankle-joint of Henle and Linhart, or the tibialis secundus of Bahnsen.

*Nerves.*—The gastrocnemius, plantaris, soleus, and popliteus, are supplied with branches from the internal popliteal nerve. The flexor longus digitorum, flexor longus pollicis and tibialis posticus derive their nerves from the posterior tibial.

#### THE PLANTAR FASCIA AND MUSCLES.

The **superficial fascia** of the sole of the foot resembles that of the palm of the hand. It forms a thick cushion, especially over bony prominences, and consists mainly of small lobules of fatty tissue bound down by numerous fibrous bands which pass vertically from the skin to the deep fascia.

The **deep plantar fascia**, which is remarkably strong, is composed of dense white glistening fibres, the greater number of which are arranged in a longitudinal direction, and extend from the under surface of the os calcis forwards to the heads of the metatarsal bones. It presents a central and two lateral portions, clearly marked off from each other by two strong intermuscular septa, indicated on the surface by grooves. The *inner* portion, thinner and looser than the others, invests the abductor pollicis, and is often partly removed with the skin in dissection. It is continuous round the inner border of the foot with the dorsal fascia and with the internal angular ligament. The *outer* part covers the abductor minimi digiti, and is much stronger, particularly between the outer tubercle of the calcaneum and the base of the fifth metatarsal bone, between which points it forms a strong ligament. It is continuous round the outer border of the foot with the dorsal fascia, and sends a thin prolongation forwards over the insertion of the abductor and the short flexor of the little toe. The *central portion*, like the corresponding part of the palmar fascia, is narrow behind, and becomes wider and thinner towards the toes. At the back, where it is thickest, the fascia is attached to the inner tubercle on the under surface of the calcaneum immediately behind the origin of the flexor brevis digitorum, with which muscle it is closely connected. Nearly opposite the middle of the metatarsal bones, this fascia, becoming broader and thinner as it advances, begins to divide into five processes, one for each of the toes; and from this point forwards to the base of the toes, numerous strong

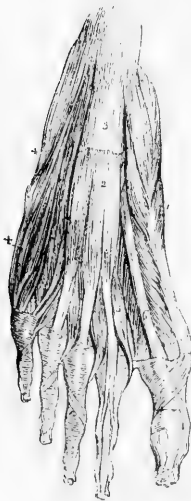
transverse fibres are superadded, which bind the processes together, and connect them closely with the skin. Near the articulation of the toes with the metatarsal bones, each of the five processes divides, to permit the passage of the flexor tendons; and the two bundles of fibres resulting from the division of each process, after strengthening the sheath of the tendons over which they pass, are attached to the sides of the metatarsal bone, and are blended with the transverse ligament uniting those bones. From the point of splitting of each process, as in the hand, fibrous bands are continued forwards to the skin in the divisions between the toes.

The two *intermuscular septa* which lie between the middle and lateral portions of the plantar fascia pass deeply into the sole of the foot; they separate the flexor brevis digitorum from the abductor pollicis on the inner side, and from the abductor minimi digiti on the outer side, and give partial origin to each of these muscles.

In the sole of the foot as in the palm of the hand there is a band of transverse fibres across the roots of the digits, placed immediately beneath the skin, and connected with the subjacent sheaths of the tendons. The digital nerves and vessels are covered by this structure, which receives the name of *transverse ligament* of the toes.

**SHORT PLANTAR MUSCLES.**—These muscles may most conveniently be described in layers, as they are found in the course of a dissection. The *first*, or superficial layer includes the common flexor of the toes, and the abductors of the great and little toes. The *second* layer consists of the flexor accessorius and the lumbricales, the *third* layer of the deep plantar muscles of the great and little toes, and the *fourth* layer of the dorsal and plantar interossei.

Fig. 198.

Fig. 198.—FIRST LAYER OF PLANTAR MUSCLES, AS SEEN ON THE REMOVAL OF THE PLANTAR FASCIA.  $\frac{1}{4}$ 

1, abductor pollicis; 2, flexor brevis digitorum; on the second toe the sheath is opened so as to show the tendon of the flexor brevis perforated by that of the flexor longus; on the other toes the transverse and oblique crossing fibres of the sheath are shown; 3, strongest portion of the plantar aponeurosis left upon the surface of the flexor brevis, near the os calcis; 4, abductor minimi digiti; 5, the lumbricales muscles; 6, tendon of the flexor longus hallucis muscle.

**FIRST LAYER OF MUSCLES.**—The **flexor brevis digitorum**, or **flexor perforatus**, arises by a small pointed and tendinous attachment from the inner part of the greater tuberosity of the calcaneum, from the deep surface of the plantar fascia for about two inches forwards, and from the intermuscular septum on each side. The muscle terminates in four slender tendons, inserted into the second phalanx of each of the four outer toes. Each tendon prior to its insertion divides and gives passage between its parts to the tendon of the long flexor, in a manner precisely similar to the arrangement of the tendons of the flexor sublimis and flexor profundus muscles of the hand.

*Relations.*—This muscle lies between the abductor pollicis and abductor minimi

digiti, and is covered by the plantar fascia, which adheres very closely to the posterior part of its surface, and gives origin there to some of its fibres; it conceals the flexor accessorius, with the tendons of the flexor longus digitorum, the lumbricales, and the plantar vessels and nerves.

*Varieties.*—This muscle has been seen with only three tendons, that for the little toe being absent; or with five tendons, two to the second toe. The slip to the little toe frequently arises as a small fusiform muscle from the side of the long flexor tendon, or from the flexor accessorius; or it may arise by two heads, one from the long flexor, the other from the inner tubercle of the os calcis.

The **abductor pollicis pedis** muscle arises from the inner part of the larger protuberance of the calcaneum, from the internal annular ligament and the tendinous and fibrous structures on the inner border of the foot as far forwards as the internal cuneiform bone, from the septum between it and the flexor brevis digitorum, and from the plantar fascia covering it. The fleshy fibres end in a tendon, which, after uniting with the internal head of the flexor brevis pollicis, is inserted into the inner border of the base of the first phalanx of the great toe.

*Relations.*—It is covered by the thin internal division of the plantar fascia. Its deep surface is in contact with the tendons of the tibialis anticus and posticus, and of the long flexor muscles, with the flexor brevis pollicis, and with the plantar vessels and nerves.

*Varieties.*—The abductor pollicis sometimes sends a slip to the base of the first phalanx of the second toe. Another slip is occasionally given to the skin of the ball of the great toe.

The **abductor minimi digiti** muscle has a wide origin behind, from the front of both tubercles on the under surface of the os calcis, from the external intermuscular septum, and from the deep surface of the process of the plantar fascia which extends from the external tubercle to the base of the fifth metatarsal bone. The fleshy fibres end in a tendon, which after sliding along a smooth impression on the inferior surface of the base of the fifth metatarsal bone, is inserted into the external surface of the base of the first phalanx of the little toe.

*Relations.*—This muscle is covered by the plantar fascia. Its deep surface is in contact with the external head of the flexor accessorius, the ligamentum longum plante, the peroneus longus, and the flexor brevis minimi digiti.

*Variety.*—The *abductor ossis metatarsi minimi digiti* is an occasional muscle which arises from the external tubercle of the os calcis, and is inserted into the spur-like process of the fifth metatarsal bone beneath the outer margin of the plantar fascia. It may be adherent to the abductor minimi digiti, and it has been seen inserted into the middle or even the anterior part of the metatarsal bone. It was first described as a human muscle by Wood, and it occurs nearly once in every two subjects. (Wood, Macalister.)

**THE SECOND LAYER OF MUSCLES.**—The **flexor accessorius** and the **lumbricales** muscles composing this layer, have been already described (p. 253) with the tendons of the long flexor muscles, with which they are intimately associated.

**THE THIRD LAYER OF MUSCLES.**—The **flexor brevis pollicis pedis** arises by a flat tendinous process from the inner border of the cuboid bone and from the fibrous band sent to the cuneiform bones from the tendon of the tibialis posticus. The muscle is single and pointed behind, but in front it divides so as to form two muscular bellies which are inserted by tendons one into the inner border of the base of the first phalanx in union with the abductor pollicis, the other into the outer border in union with the adductor.

*Relations.*—The tendon of the flexor longus pollicis runs in the interval between the heads of the short flexor. A sesamoid bone is developed in connection with each tendon of the short flexor.

Fig. 199.



Fig. 199.—THIRD LAYER OF PLANTAR MUSCLES.

1, flexor brevis pollicis ; 2, adductor pollicis ; 3, transversus pedis ; 4, flexor brevis minimi digiti ; 5, 5, part of the third and fourth dorsal interossei ; 6, 6, the second and third plantar interossei ; 7, tendon of the peroneus longus passing round the cuboid bone to enter its groove ; 8, long plantar ligament passing forwards to the ridge of the cuboid bones and spreading over the groove of the peroneus tendon.

The **adductor pollicis pedis**, placed obliquely in the sole of the foot, and forming a thick fleshy mass, arises from the tarsal extremities of the third and fourth metatarsal bones, and from the sheath of the peroneus longus muscle ; narrowing as it passes forwards, it is inserted, conjointly with the external head of the flexor brevis pollicis, into the base of the first phalanx of the great toe.

*Relations.*—At its inner side it is connected with the flexor brevis pollicis ; its deep surface rests upon the second, third, and fourth metatarsal bones and the intervening interosseous muscles. The external plantar artery and nerve pass inwards beneath its outer border.

*Variety.*—The *opponens hallucis* is a muscle frequently found. It usually comes off as a slip from the adductor, and is inserted into the metatarsal bone of the great toe. It occurs in some apes. (Macalister.)

The **transversus pedis** consists of narrow fasciculi of fleshy fibres, placed transversely under cover of the flexor tendons, and arising from the inner lateral metatarso-phalangeal ligaments of the four outer toes. The fibres of the muscle pass transversely inwards, and are inserted in union with the adductor pollicis into the first phalanx of the great toe.

*Relations.*—Superficially it is crossed by the flexor tendons and by the digital nerves ; its deep surface rests upon the heads of the second, third, and fourth metatarsal bones, the interossei muscles and the digital vessels.

*Variety.*—The slip from the little toe is frequently absent : absence of other slips of the entire muscle has also been recorded. (Boehmer.)

The **flexor brevis minimi digiti** arises by tendinous fibres from the base of the fifth metatarsal bone, and from the sheath of the peroneus longus, and terminates in a tendon which is inserted into the base and external border of the first phalanx of the little toe.

*Relations.*—It is covered partly by the abductor minimi digiti, partly by the plantar fascia. It rests upon the fifth metatarsal bone, and its tendon blends at its insertion with the inferior metatarso-phalangeal ligament.

*Variety.*—The *opponens minimi digiti* is a small additional muscle frequently found at the inner border of the flexor brevis, of which, indeed, it would seem to be a slip. It is always united to the flexor brevis for some distance from its origin, but is inserted separately into the inner side of the anterior half of the fifth metatarsal bone.

THE FOURTH LAYER OF MUSCLES.—The **interosseous muscles** of the foot, like those of the hand, are seven in number, three plantar and four dorsal ; the plantar interossei are visible only from the under side :

the dorsal muscles are visible both from above and below. Two muscles are found in each space, except the innermost, in which there is only one.

Fig. 200, A.—THE DORSAL INTEROSSEOUS MUSCLES FROM ABOVE.  $\frac{1}{2}$

1, 2, 3, 4, the several dorsal interosseous muscles: the final insertion of the extensor tendons into the phalanges of the toes is also shown in this figure.

B.—THE PLANTAR INTEROSSEOUS MUSCLES FROM BELOW.

1, 2, 3, the three plantar interossei; this figure also shows the long and short plantar ligaments, and the insertion of the tendon of the peroneus longus muscle into the first metatarsal bone.

The *dorsal* interossei lie one in each interspace. Each muscle arises by two heads from the adjacent sides of two metatarsal bones; their muscular fibres are attached pennately on the two sides of a central tendon which is inserted partly into the dorsal surface of the first phalanx and partly into the extensor aponeurosis of the toe to which each belongs. The first two are inserted one on each side of the second toe; the third and fourth are severally inserted on the outer sides of the third and fourth toes. At the proximal ends of each muscle there is an interval between the two origins giving passage to perforating arteries as in the hand.

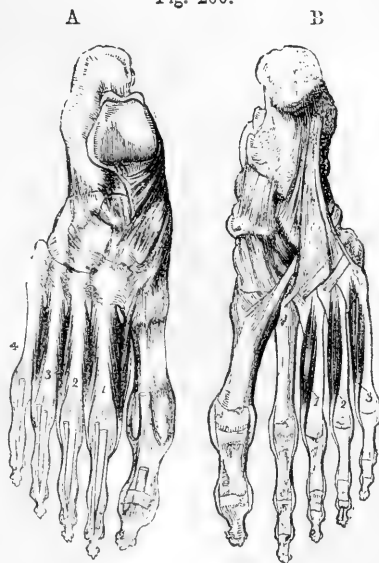The *plantar* interossei arise from the inner and under surfaces of the third, fourth, and fifth metatarsal bones, and are severally inserted in a manner similar to the dorsal interossei, partly into the inner sides of the first phalanges of the third, fourth, and fifth toes, and partly into the extensor tendons of these toes.

**Nerves.**—The flexor brevis digitorum, the abductor, the flexor brevis pollicis, and the two inner lumbricales, are supplied by the internal plantar nerve; all the other plantar muscles, including the flexor accessorius and the interossei, are supplied by the external plantar nerve.

**Actions of the Muscles of the Leg and Foot.**—There is only one muscle of the leg, viz., the *popliteus*, which acts on the knee-joint alone. Its principal action is that of a rotator inwards of the lower leg; and it is interesting to observe that, while inward rotation of the leg at the knee-joint occurs only in flexion, it is in that position only that the tendon of the popliteus lies in its groove on the femur.

It may here be observed that owing to the difference in the direction of the bend at the ankle, as compared with that at the wrist-joint, some confusion is apt to arise in the description of the action of the muscles of the leg upon the foot. As it is obvious from morphological considerations, that the anterior surface of the leg and the dorsal surface of the foot belong to the general *extensor* surface of the limb, corresponding with the back of the forearm and the dorsum of the hand; and that the back of the leg and the sole of the foot belong in the same way to the general *flexor* surface corresponding with the front of the fore-

Fig. 200.



arm and the palm of the hand, the foot being in a position of over-extension, it follows that the muscles on the anterior aspect of the leg are really extensors, and that their action in moving the foot so as to approximate the toes to the front of the leg merely increases the over-extension; while, on the other hand, the muscles on the posterior aspect of the leg are really flexors, and their action in straightening the ankle-joint is to reduce merely this over-extension by an opposite movement of flexion. Nevertheless, it has been customary to apply the name of flexion to the action of raising the foot on the front of the leg, and that of extension to its depression. In the following description the usual terms are employed.

The *gastrocnemius* muscle acts both as a flexor of the knee and an extensor of the ankle-joint. When the anterior muscles of the leg fix the ankle-joint, it is fitted to act as a flexor of the knee; when the knee is fixed either by being placed in complete extension or by the sustained action of the extensor muscles, the *gastrocnemius* acts entirely on the foot, and combines with the *soleus* in lifting the heel from the ground, and in raising the body on the toes.

The *tibialis anticus* and *peroneus tertius* are flexors of the foot; the *tibialis posticus* and *peroneus longus* and *brevis* are extensors. The two tibial muscles acting together, raise the inner border of the foot, and draw it inwards. The three peronei muscles raise the outer border of the foot and draw it outwards. The *peroneus longus*, in crossing the foot inferiorly, strengthens the transverse arch formed by the metatarsal bones and anterior range of tarsal bones; especially when that arch is pressed upon by the weight of the body falling on the balls of the toes, as in stooping with bended knees.

The *flexor* and *extensor muscles* of the toes, including the *lumbricales* and *interossei*, act like the corresponding muscles in the hand. The direction of the *flexor longus digitorum* is, however, modified by the *flexor accessorius*, so as to bring its line of action into the direction of the middle of the foot and of the short flexor. The *flexor accessorius* and tendon of the long flexor muscles, likewise assist the short flexor and the plantar aponeurosis in maintaining the arch of the foot.

## MORPHOLOGY OF THE LIMB-MUSCLES.

It has already been mentioned (p. 185) that the muscles of the limbs and limb girdles are primarily derived mainly from the ventro-lateral division of the epaxial set of muscles. In the case of the upper limbs there are no muscles of hypaxial origin, but in the lower limb there are at least two muscles which may be regarded as prolongations outwards from the hypaxial set, one passing to its inner and anterior (preaxial) aspect (*psaos*), the other to its posterior and outer (postaxial) aspect (*pyriformis*). These two muscles are consequently without homologues in the upper limbs. As each limb begins bud-like to project from the side of the embryo, it may be supposed to receive an enveloping sheath of muscle from the side of the body (Humphry). This sheath is at first a simple infundibulum, but it gradually extends in length with the growth of the limb, and becomes segmented, *pari passu*, with the segmentation of the hard parts. The deeper fibres of the sheath are restricted to passing from one segment to the next, while the superficial fibres are frequently found to pass over one segment altogether, to the more distal parts. Humphry holds that of the three layers into which the trunk portion of the ventro-lateral muscle divides, two layers may be traced into its appendicular segments, corresponding respectively to the external oblique and superficial portion of the internal oblique layers. In the upper limb, from the greater freedom of movement of the girdle, and from its more superficial position, the first segment of the muscular sheath is longer, and its constituent parts more easily recognised, than in the case of the trunk-girdle muscles of the lower limb, which are not differentiated to the same extent from the trunk muscles. Traced to the shoulder-girdle, the superficial layer of trunk-limb muscles is found to divide into three principal masses. Anteriorly are the pectorals; superiorly and posteriorly are the cleido-mastoid and trapezius, the latter being continued to the bone of the forearm as the deltoid; and inferiorly and posteriorly the *latissimus dorsi*. Beneath the trapezius are the rhomboids.

and on the deeper surface of the latissimus dorsi are its occasional scapular portion and the teres major, all of which are formed in the deeper parts of this layer. The muscles of this layer are frequently found to some extent united together either as varieties in man, or as regular structures among some of the lower animals, and it is interesting to note that most of the varieties hitherto described, seem to be reversions so far towards a uniform type. Thus in Lepidosiren, the pectoralis major and latissimus dorsi are blended together at their margins, so as to form one continuous muscle; and in man the frequently recurring axillary arches or loops of muscular fibres which pass from one muscle to the other across the axillary space may point to an imperfectly segmented condition. Again, the pectoralis major is always united in man with the superficial fibres of the external oblique, but in the cryptobranch it is continuous with it in its entire thickness. The cleido-mastoid, which in man is in close relation with the clavicular portion of the pectoralis major, being only separated from it by the clavicle runs with the anterior part of the trapezius into the deltoid in those animals in which the clavicle is deficient, forming a mastoido-humeral muscle.

The trunk-limb muscles of the deep layer, form a much less complete layer than those of the superficial. They are attached to the shoulder-girdle in two sets. In front of the glenoid cavity, and attached to the coracoid, is the costocoracoid muscle (in man called subclavius from its more common place of attachment); and behind the glenoid cavity, attached to the scapula, are the costo-scapular muscles, comprising the serratus magnus, and the levator scapulae. Besides these there is the slender omo-hyoid from the front of the hyoidean arch to the upper border of the scapula.

In the lower limb the ventro-appendicular muscles are represented for the most part by the oblique abdominal muscles, only those muscles which pass over the girdle to the limb being found distinct. The gluteus maximus most closely represents the latissimus dorsi, and is similarly inserted into the postaxial border of the limb. The pectoralis corresponds most nearly with the gracilis, and the trapezio-deltoid with the anterior part of the external oblique and pectineus. The gracilis and pectineus arise near each other, and are inserted into the preaxial border of the limb. The pectineus, however, seems to consist of two parts, of which the inner may be related to subclavius, and the outer to great pectoral and deltoid.

All the other muscles of the limbs are *intrinsic*, and in their relation to the several segments are arranged in groups which may in the main be compared homologically with each other. These groups are situated chiefly on the ventral and dorsal aspects, or on the preaxial and postaxial borders of the limbs, and the muscles of which they are composed are respectively flexors and extensors, or protractors and retractors.

In attempting, however, to institute a homological comparison between the individual muscles of the various segments in the two limbs, it will be necessary to bear in mind, first, the great difference in the attitude of the bones of the proximal segments, the flexor surface in the upper limb being thrown forwards as if by an outward twist, and in the lower limb the flexor surface being turned backwards as if by an inward twist of the proximal segments; and further, the preponderance in the second segment of the lower limb of the preaxial bone (tibia) over the postaxial (fibula) as opposed to the greater development of the upper end of the postaxial bone of the arm (ulna) over the preaxial (radius). These differences are apt to lead to confusion and difficulty, inasmuch as the insertions of homologous muscles are in some cases very different in the two limbs. In such cases the determination of the homologies may be greatly assisted by the observation of the more constant origins. For example, the great extensor of the forearm is inserted into the postaxial ulna, while in the leg the quadriceps is inserted into the preaxial tibia; and yet few will doubt the justness of the homological comparison between them.

In the distal segments of both limbs the muscles, though more numerous, become shorter and more uniform in their disposition, and hence the homology becomes more apparent between the muscles of the hand and foot, than in those situated nearer the root of the limbs.

From what has been said it appears that considerable difficulty still prevails in the determination of the muscular homologies of the upper and lower limbs, especially in their proximal segments and attachment to the trunk, and the comparison of these muscles cannot, therefore, be minutely followed out. But the following table may be useful to the student of human anatomy, as presenting what appear to be the most probable views of the muscular relations in the upper and lower limbs, and as indicating the bearing upon such views of some facts in comparative anatomy as well as of some of the varieties mentioned in the previous description of the individual muscles. (Upon this subject consult the works of Humphry, Mivart, Rolleston and Huxley, previously quoted in the Osteology.)

### TABLE OF MUSCULAR HOMOLOGIES IN THE UPPER AND LOWER LIMBS.

#### I. MUSCLES PASSING FROM TRUNK TO LIMBS OR THEIR GIRDLES,

<i>Upper Limb.*</i>	<i>Lower Limb.</i>
1. Trapezius . . . . .	1. Lumbar aponeurosis, &c.
1a. Cleido-mastoid and sterno-mastoid } 1b. Rhomboids . . . . . }	1a, b. External oblique.
2. Levator scapulae } 2a. Serratus magnus } . . . . .	2, 2a { Internal oblique. Transversalis. Quadratus Lumborum.
3. Latissimus dorsi } 3a. Teres major } . . . . .	{ 3. Gluteus maximus. 3a. Tensor vaginae femoris.
4. Pectoralis major . . . . .	4. Gracilis. Part of pectineus?
4a. Pectoralis minor . . . . .	4a. Coccygeus.?
4b. Subclavius (second pectoral of birds, Rolleston) . . . . .	{ 4b. Inner or deep head of Pectineus, supplied by obturator nerve (Rolleston)?
5. Omohyoid . . . . .	5.?

#### II. MUSCLES PASSING MAINLY FROM GIRDLE TO LIMB.

6. Deltoid { 6a. Scapular part . . . . . 6b. Clavicular part . . . . . }	{ 6a. Sartorius. 6b. Pectineus, outer head supplied by anterior crural nerve (Rolleston).
7. Supra spinatus . . . . .	7. Obturator internus?
7a. Infra spinatus . . . . .	7a. Iliacus.
7b. Teres minor . . . . .	7b. <i>Iliacus minor</i> (Luschka).
8. Subscapularis . . . . .	8. { Gluteus medius. Gluteus minimus.
9. Coraco-brachialis . . . . . a, b, c. <i>Upper, middle and lower</i> parts . . . . . }	9a, b, c. Three adductors, with perhaps obturator externus.
10. Biceps flexor cubiti . . . . . a. Scapular head . . . . . b. Coracoid head . . . . . c. <i>Humeral head</i> . . . . . }	{ 10a, b. { Ischial head of Biceps femoris. Semi-membranosus. Semi-tendinosus. 10c. Femoral head of Biceps femoris.
10d. Brachialis Anticus . . . . .	
11. Triceps extensor cubiti . . . . . a. Scapular head . . . . . b. External humeral head . . . . . c. Internal humeral head . . . . .	11. Quadriceps extensor cruris. a. Rectus femoris. b. Vastus externus. { Vastus internus. Crureus.

\* The numbers affixed to the several muscles in the two columns are intended merely as a means of facilitating the reference from one to the other, the upper limb being taken as the standard of comparison. The names of muscles printed in italics are those of varieties more or less frequently found in human anatomy.



III. MUSCLES PASSING OVER ELBOW AND KNEE JOINTS AND ACTING ON THE RELATIVE POSITION OF THE BONES OF THE FOREARM AND LOWER LEG.

<i>Upper Limb.</i>	<i>Lower Limb.</i>
11. Supinator radii longus . . .	11. ?
12. Supinator radii brevis . . .	12. ?
13. Pronator radii teres . . .	13. Popliteus.
14. Pronator quadratus . . .	14. <i>Peroneo-calcaneus internus</i> (Macalister.)

IV. MUSCLES PASSING OVER WRIST AND ANKLE JOINTS.

A. *To the carpus and metacarpus or to the tarsus and metatarsus.*

15. Extensor carpi radialis longior . . .	} 15. Tibialis anticus.
15a. Extensor carpi radialis brevior . . .	
15b. Extensor ossis metacarpi pollicis . . .	
16. Extensor carpi ulnaris . . .	16. Peroneus tertius.
17. Flexor carpi radialis . . .	17. Tibialis posticus.
18. Flexor carpi ulnaris . . .	18. Peroneus brevis, and in part muscles of the calf.
19. ?	19. Peroneus longus.

B. *To the digital phalanges.*

20. Extensor com. digit. longus . . .	20. Extensor com. digit. long.
20a. Extensor secundi internod. poll. . .	20a. Extensor long. hallucis.
21a. Extensor primi internod. poll. . .	21a. First slip of ext. brevis digit.
21b. Extensor indicis . . .	21b. Second slip of ext. brevis digit.
21c. Extensor minimi digiti . . .	21c. <i>Occasional slip of peroneus tertius.</i>
22. Flexor digitorum profundus . . .	22. Flexor digitorum longus.
22a. Flexor longus pollicis . . .	22a. Flexor longus hallucis.
23. Flexor digitorum sublimis . . .	23. Flexor digitorum brevis.
24. Palmaris longus. . . . .	24. Plantaris, and flexors ?

V. MUSCLES CONFINED TO THE HAND AND FOOT.

25. { Tendons of extensores secundi } internodii pollicis, indicis, and minimi digiti . . . . .	25. Extensor communis digitorum brevis.
26. Abductor pollicis . . . . .	26. Abductor hallucis.
27. Flexor brevis pollicis, inner head a. outer head . . . . .	27. Flexor brevis hallucis. 27a. Adductor hallucis obliquus.
27b. Opponens pollicis . . . . .	27b. <i>Opponens hallucis.</i>
28. Adductor pollicis . . . . .	28. Transversus pedis.
29. Tendons of flexor profundus digi- torum . . . . .	29. Flexor communis digitorum brevis.
30. Palmaris brevis . . . . .	30. ?
31. Abductor minimi digiti . . . . .	31. Abductor quinti digiti.
32. Flexor brevis minimi digiti . . . . .	32. Flexor brevis quinti digiti.
33. Opponens minimi digiti . . . . .	33. <i>Opponens quinti digiti.</i>
34. Interossei, dorsal and palmar a. Radialis secundi digiti (dors.) b. Ulnaris sec. dig. (palm.) . . . . . c. Radialis medii (dors.) . . . . . d. Ulnaris medii (dors.) . . . . . e. Radialis quarti (palm.) . . . . . f. Ulnaris quarti (dors.) . . . . . g. Radialis quinti (palm.) . . . . .	34. Interossei, dorsal and palmar. a. Tibialis secundi digiti (dors.) b. Fibularis sec. dig. (dors.) c. Tibialis tertii (plant.) d. Fibularis tertii (dors.) e. Tibialis quarti (plant.) f. Fibularis quarti (dors.) g. Tibialis quinti (plant.)
35. Lumbricales quatuor, radiales sec. tert. quart. et quint. digit. . . . .	35. Lumbricales quatuor, tibiales sec tert. quart. et quint. digit.

## III. MUSCLES AND FASCIAE OF THE HEAD AND NECK.

## EPICRANIAL REGION.

**FASCIA.**—The **superficial fascia** is little developed on the head and neck generally, and is in great measure blended with structures described under other names. A layer of considerable firmness, however, intervenes between the aponeurosis of the occipito-frontalis muscle and the skin, uniting them together: from the surface of the occipital part of the muscle it becomes continuous with a superficial covering of the posterior muscles of the neck, and on each side of the epicranial aponeurosis it descends over the temporal fascia, and contains between its laminae the external muscles of the ear, with the superficial temporal vessels and nerves.

**MUSCLES.**—Under the title of **occipito-frontalis** muscle are comprehended the occipital and frontal muscles, united together by a thin aponeurosis which extends over and covers the upper part of the cranium.

The **occipitalis** muscle, thin and subcutaneous, is attached inferiorly by short tendinous fibres to the external two-thirds, sometimes less, of the superior curved line of the occipital bone, and to the mastoid portion of the temporal bone, immediately above the attachment of the sterno-mastoid muscle. Its fleshy fibres, from one to two inches in length, are directed upwards, and terminate in distinct tendinous fibres, continuous with the epicranial aponeurosis. The interval between the muscles of opposite sides is occupied by the aponeurosis.

The **frontalis** muscle, larger and of a paler colour than the occipitalis, arises superiorly in a convex line from the epicranial aponeurosis, while inferiorly its innermost fibres are continuous with the pyramidalis nasi muscle; some take attachment to the internal angular process of the frontal bone, and the others are blended with the corrugator supercillii and with the orbicularis palpebrarum as far as the outer side of the orbit. The fibres are nearly vertical, running slightly inwards; the margins of the right and left muscles are united for a short distance above the root of the nose, but are separated by an angular interval superiorly.

The **epicranial** or **occipito-frontal aponeurosis** extends over the upper surface of the cranium uniformly from side to side, without division. Posteriorly it is attached to the occipitales muscles, and to the protuberance and superior curved lines of the occipital bone, and anteriorly it terminates in the frontales muscles, while laterally it presents no distinct margin, but below the temporal ridge becomes thinner and less aponeurotic, and gives attachment to the superior and anterior auricular muscles. Its fibres are chiefly longitudinal, and are most distinctly tendinous where they give attachment to the occipitales muscles. Its outer surface is firmly bound to the skin by an abundant network of connective tissue, constituting the so-called superficial fascia, by the meshes of which the subcutaneous fat is divided into granules; while its deep surface glides upon the subjacent pericranium, to which it is loosely attached by a delicate connective tissue devoid of fat.

*Varieties.*—Both parts of the occipito-frontalis muscle are subject to variation in their fulness or extent, and in their places of attachment. The occipitalis sometimes approaches the middle line, and is occasionally broken up into separate

parts. The frontalis has been found to send slips of attachment to the frontal; nasal, or superior maxillary bones, and occasionally to the tendo oculi or to the upper end of the levator labii superioris alæque nasi.

A pair of symmetrical muscular slips is very frequently observed extending outwards from the occipital protuberance, generally on the surface of the trapezius, but sometimes underlying that muscle, and inserted variously into the posterior auricular or sterno-mastoid muscles, or into the outer part of the occipital bone. This pair of muscular slips has received the name of *transversus nuchæ*.

**Actions.**—By the contraction of the combined occipito-frontales muscles, the scalp is drawn backwards, and the eyebrows elevated; by the contraction of the frontales muscles alone, the eyebrows are elevated, the scalp pulled forwards, and the skin of the forehead thrown into transverse wrinkles; by the contraction of the occipitales muscles alone, the scalp is drawn backwards; and by the alternate action of the occipitales and frontales muscles the scalp is moved backwards and forwards. In the majority of persons, however, there is only a partial control over the action of these muscles, limited to the elevation of the eyebrows and horizontal wrinkling of the forehead.

#### AURICULAR MUSCLES

Besides minute bundles of muscular fibres which pass from one part of the auricle to another, and which will be most conveniently described along with that structure, there are attached to the external ear three larger, but still very slightly developed, muscles, which serve to move it as a whole.

The **auricularis superior** or **attollens auriculam**, the largest of the three, arises in the temporal region of the head from the epicranial aponeurosis. Its fibres are extremely delicate, and converge from a wide surface to be inserted by a compressed tendon into the cartilage of the ear at the upper and anterior part of the helix and upper part of the concha.

The **auricularis anterior** or **attrahens auriculam**, scarcely separated from the preceding muscle, is pale and indistinct, and is attached to the thin lateral prolongation of the epicranial aponeurosis, from which it passes backwards to be inserted into the fore part of the helix.

The **auricularis posterior** or **retrahens auriculam** muscle, consists of two or three fasciculi, which arise from the mastoid process by short aponeurotic fibres, and are inserted into the back part of the concha. The fibres are deeper in colour and more distinctly marked than in either of the other auricular muscles.

**Varieties.**—Of the auricular muscles the posterior and the anterior are subject to greater varieties than the superior, but all vary somewhat in the extent of their development, the posterior more frequently by an increase in the number of its slips, the anterior by a diminution of the volume and distinctness of its fibres. The posterior fibres of the attollens have been observed continued back into the occipitalis.

**Actions.**—The three auricular muscles respectively draw the pinna of the ear upwards, backwards, and forwards. In the majority of persons their action is not directly under voluntary control.

#### MUSCLES OF THE EYELIDS AND EYEBROWS.

These are four in number—namely, the orbicularis palpebrarum and tensor tarsi, the levator palpebræ superioris, and the corrugator supercilii.

The **orbicularis palpebrarum** is a thin elliptical muscle closely adherent to the skin, surrounding the fissure between the eyelids and covering their surface, and spreading for some distance outwards on the temple, upwards on the forehead, and downwards on the cheek. The

Fig. 201.

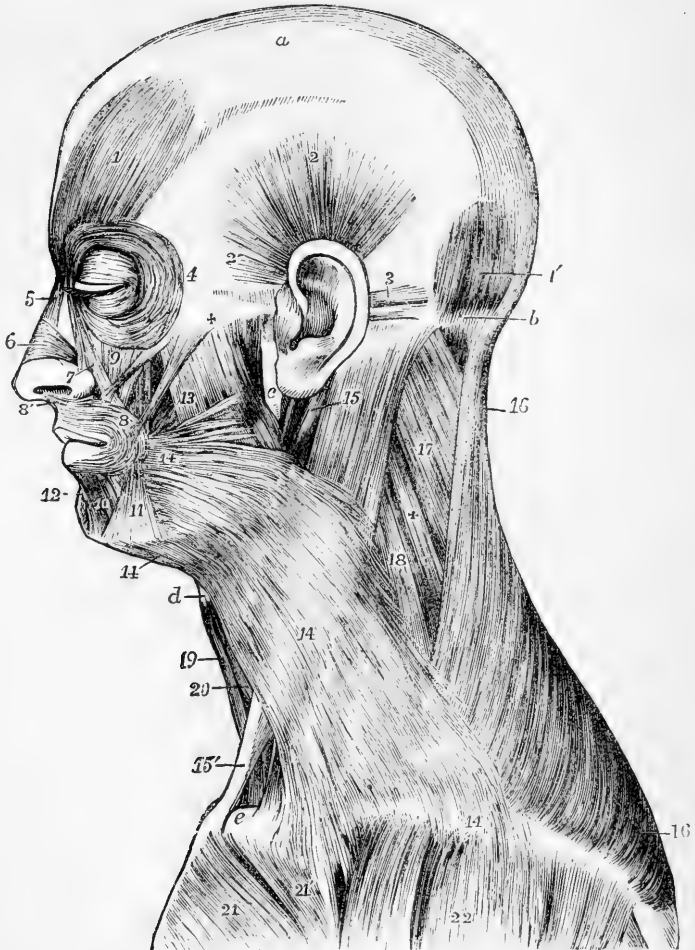


Fig. 201.—SUPERFICIAL VIEW OF THE MUSCLES ON THE LEFT SIDE OF THE HEAD AND NECK (slightly altered from Bourguery). (A. T.)  $\frac{1}{3}$

*a*, epicranial aponeurosis; *b*, superior curved line of the occipital bone; *c*, ramus of the lower jaw; *d*, lower edge of the hyoid bone; *e*, sternal end of the clavicle. 1, frontal, and 1', occipital part of the occipito-frontalis muscle; 2, superior auricular muscle; 2', anterior auricular; 3, posterior auricular in two fasciculi; 4, margin of the orbicularis palpebrarum; 5, pyramidalis nasi; 6, triangularis nasi; 7, levator labii superioris alaeque nasi; 8, orbicularis oris; 8', its attachment to the columella nasi, or depressor nasi; 9, levator labii superioris, and close by it, zygomaticus minor; between + and 8, zygomaticus major; and between the zygomatici, in shadow, is seen a portion of the levator anguli oris; 10, quadratus menti or depressor labii inferioris,

11, triangularis oris or depressor anguli oris ; 12, levator menti ; 13, on the masseter, is immediately above the risorius or upper horizontal fibres of the platysma myoides, and a line from it points to the buccinator ; 14, platysma myoides ; 15, on the upper part of the sterno-mastoid, points by a line to the posterior belly of the digastric muscle ; 15', the sternal tendon of the sterno-mastoid, a part of its clavicular portion is seen near *c* ; 16, trapezius ; 17, splenius capitis ; +, splenius colli ; 18, levator scapulæ ; 19, sterno-hyoid ; 20, omo-hyoid ; 21, pectoralis major, its pectoral part ; 21', its clavicular part ; 22, deltoid.

fibres form neary concentre curves, and are attached by their extremities at the inner angle of the orbit ; 1st, to the edges and anterior surface of the tendo palpebrarum ; 2nd, to the srface of the nasal process of the superior maxilla, near the anterior margin of the lachrymal groove ; and 3rd, to the internal angular process of the frontal bone.

*Relations.*—The *palpebral* portion of the muscle consists of thin, pæŕ and slightly curved fibres situated in the eyelids, and which conceal the tarsal cartilages and the insertion of the levator palpebræ superioris ; the *orbicular* portion, more largely developed, rests on the cheek and margin of the orbit. Superiorly this muscle conceals the corrugator supercilii, with which and the occipito-frontalis it is intimately connected ; inferiorly it covers the origin of the elevators of the upper lip, part of the common elevator of the lip and nose, and the lachrymal sac ; and externally it lies upon a part of the temporal fascia.

The *tendon* of the orbicularis muscle (tendo palpebrarum), at the inner commissure of the eyelids, is a small white cord which is often obscured by the fibres of the muscle, but is rendered apparent by drawing the lids outwards. This tendon is about two lines in length, and half a line in breadth, and is attached to the anterior margin of the lachrymal groove ; thence it runs horizontally outwards to the inner commissure of the eyelids, where it divides into two thin fibrous lamellæ, which diverge, and terminate on the tarsal cartilages. One surface of the tendon is subcutaneous ; the other crosses the lachrymal sac a little above the centre, and from it a thin but firm fascia is given off, which spreads over the lachrymal sac, and adheres to the margins of the groove which lodges it.

The **tensor tarsi**—(musculus sacci lachrymalis, Horner)—consists of very thin fibres resting on the fascia just mentioned. It is only a deep portion of the inner marginal fibres of the ciliary part of the orbicularis muscle : two slips, one from each eyelid, passing behind the lachrymal canals, unite on the hinder surface of the lachrymal sac before reaching their attachment on the posterior margin of the lachrymal g oove.

The **corrugator supercilii** is a small, deeply-coloured muscle, narrower below than above, placed at the inner side of the eyebrow. It arises from the inner extremity of the superciliary ridge of the frontal bone ; thence its fibres proceed outwards and a little upwards, and end, at the middle of the orbital arch, by becoming blended with those of the orbicularis and occipito-frontalis muscles.

*Relations.*—This muscle crosses the supratrochlear branch of the ophthalmic nerve and the accompanying vessels, as they emerge from the orbit. It rests upon the frontal bone and is covered by the orbicularis and occipito-frontalis muscles.

The **levator palpebræ superioris** occupies the upper part of the orbit. Its tendon only is seen in the dissection of the upper eyelid, in which it forms a broad fibrous expansion which curves downwards, and is

Fig. 202.

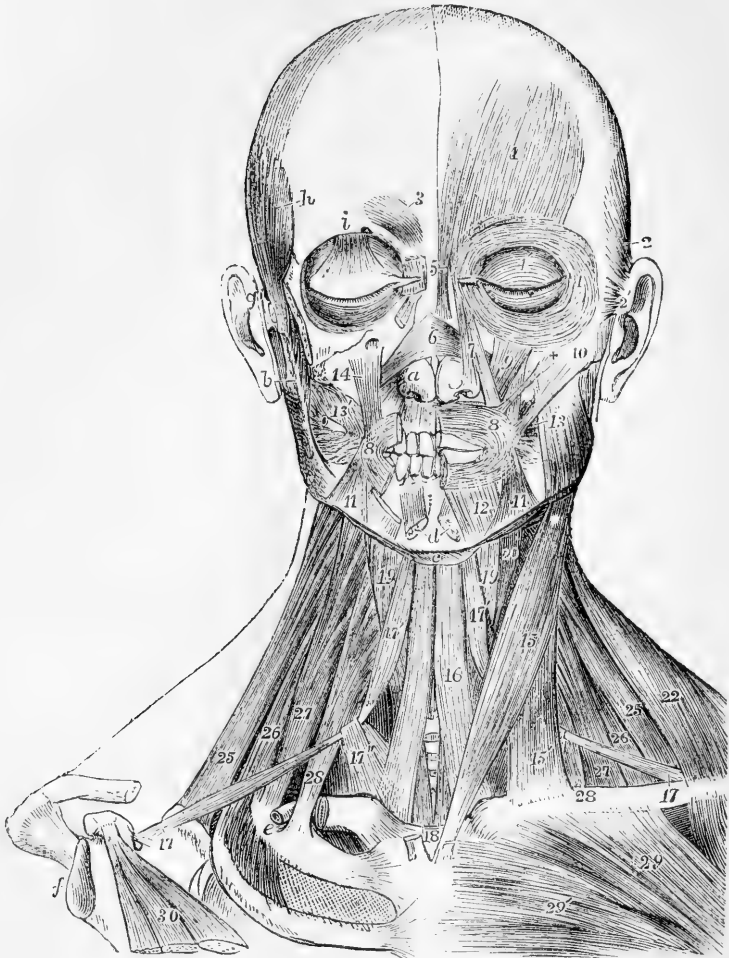


Fig. 202.—SUPERFICIAL AND DEEP VIEW OF THE MUSCLES OF THE HEAD AND NECK, FROM BEFORE (altered from Bourguery). (A. T.)  $\frac{1}{2}$

On the left side, the platysma alone has been removed ; on the right side, portions of the zygomatic arch and the clavicle, the superficial muscles of the cranium and face, the masseter, trapezius, sterno-mastoid and pectoralis major muscles have been removed ; *a*, right alar cartilage of the nose ; *b*, upon the lobe of the right ear, points to the coronoid process of the lower jaw ; *c*, the body of the hyoid bone ; *d*, symphysis of the lower jaw ; *e*, upon the subclavian groove of the first rib, lying in which is the cut end of the subclavian artery ; *f*, the glenoid cavity of the scapula ; *g*, the right zygomatic arch separated from the malar bone ; *h*, upon the temporal ridge of the frontal bone ; *i*, above the supra-orbital ridge ; 1, frontalis muscle ; 2, superior auricular ; 2', insertion of the anterior auricular ; 3, corrugator supercilii ; 4, orbital portion of the orbicularis palpebrarum ; 4', palpebral portion ; below *i*, the expanded insertion of levator palpebre superioris in the eyelid ; 5, pyramidalis nasi ; 6, insertion of the triangulares nasi on the dorsum of the nose ; 7, levator labii superioris alaeque nasi ; 8, orbicularis oris of the left side ; 8', outer part of the same on the right side, the inner part being removed ; 9, levator labii superioris ; +, zygomaticus minor ; 10, zygomaticus major ; 11, depressor anguli oris ;

12, depressor labii inferioris ; *d*, points to the cut ends of the levatores menti ; 13, placed on the left masseter, points to the buccinator ; 13', buccinator, of the right side, a portion of the parotid duct passing through the muscle ; 14, levator anguli oris, seen also on the left side behind the zygomaticus minor. The remaining references will be given under the muscles of the neck.

inserted under cover of the orbicularis muscle into the anterior surface of the tarsal cartilage. It will be described along with the muscles of the orbit.

*Varieties.*—The muscles of this group are not subject to great variation. The external fibres of the orbicularis palpebrarum sometimes extend farther than usual, and take more intimate attachment to the corrugator supercilii, or blend with the zygomaticus minor or levator labii superioris. The tensor tarsi is not unfrequently divided into two parts.

*Actions.*—The orbicularis palpebrarum closes the eyelids. In the ordinary closure of the eye, it is chiefly the upper lid which moves, being depressed by the superior half of the palpebral part of the muscle ; but in forcible closure both eyelids move, and not only come together, but are drawn towards the nose, at the same time that the eyebrows are drawn downwards and inwards, and the neighbouring skin of the face thrown into wrinkles, the whole fibres of the orbicularis being thus contracted and drawn towards the tendo palpebrarum. In these circumstances the fibres which form the tensor tarsi, being contracted like the others, compress the lachrymal sac, and prevent the introduction into it of the lachrymal secretion from the conjunctiva. The corrugator muscles draw the skin of the forehead downwards and inwards, producing longitudinal furrows, as in frowning. The upper eyelid is supported by the levator palpebrae, and droops when that muscle is paralysed. On the other hand, paralysis of the orbicularis is attended by an inability to close the eyelids.

#### MUSCLES OF THE NOSE.

Under this head may be conveniently grouped not only the compressor naris and smaller muscles which act upon the nose alone, but also the pyramidalis nasi which acts on the forehead, and the common levator of the nose and lip.

The **pyramidalis nasi**, continuous with the innermost fibres of the frontalis muscle, extends downwards from the root of the nose, over the upper part of it, and terminates by a tendinous expansion in connection with the compressor naris muscle. The muscles of opposite sides, united superiorly, diverge slightly as they descend.

The **compressor naris**, a thin triangular muscle, arises narrow and fleshy from the canine fossa in the superior maxillary bone, and proceeding inwards, gradually expands into a thin aponeurosis, which is partly blended with that of the corresponding muscle of the opposite side, and with the pyramidalis nasi, and is partly attached to the cartilage of the nose. It is concealed at its origin by the proper levator of the lip, and is crossed by the common levator.

The **levator labii superioris** *alæque nasi*, the common levator of the lip and nose, lies along the side of the nose, extending from the inner margin of the orbit to the upper lip. It arises by a pointed process from the upper extremity of the nasal process of the superior maxillary bone, and, as it descends, separates into two fasciculi ; one of these, much smaller than the other, becomes attached to the wing of the nose, whilst the other is prolonged to the upper lip, where it is blended with the orbicularis and the special levator muscle. It is

subcutaneous, except at its origin, where the orbicularis palpebrarum overlaps it a little.

Fig. 203.

Fig. 203.—MUSCLES OF THE SIDE OF THE NOSE AND UPPER LIP.  $\frac{2}{3}$ 

1, pyramidalis nasi; 2, levator labii superioris alæque nasi; 3, compressor naris or triangularis; 4, levator proprius alæ nasi anterior; 5, levator proprius alæ nasi posterior or dilatator; 6, depressor alæ nasi; 7, orbicularis oris; 7\*, naso-labialis.

The **depressor alæ nasi** is a small flat muscle which arises from the superior incisor fossa, and is inserted into the septum and posterior part of the ala of the nose. The external fibres curve forwards and downwards to the ala.

Besides the muscles above described there are other irregular and often indistinct fibres which cover the small alar cartilages of the nose. Of these the following may be distinguished.

The **levator proprius alæ nasi posterior**, or **dilatator naris posterior**, is attached to the margin of the ascending process of the superior maxillary bone and the smaller (sesamoid) cartilages of the ala nasi on the one hand, and to the skin on the other. Another set of fibres, the **levator proprius alæ nasi anterior**, or **dilatator naris anterior**, is interposed between the cartilage of the aperture of the nose and skin, to both of which it is attached. The **musculus anomalus** of Albinus is a longitudinal muscular slip of more than an inch in length, lying beneath the common elevator of the lip and ala of the nose, connected by the lower end with the origin of the compressor naris, and attached exclusively to the superior maxillary bone.

*Varieties.*—The compressor naris is sometimes very slightly developed, or even reduced to an aponeurotic condition. The dilators and depressor of the nostril are also subject to considerable variations in strength and in the mode of their attachment.

*Actions.*—The pyramidalis nasi muscle, being continuous with the frontalis, is the means of giving that muscle a more fixed attachment to the dorsum of the nose, and assists in drawing down the integument of the forehead, and in producing wrinkles across the root of the nose; it probably acts also as an opponent to the compressor naris muscle. The compressor naris, acting along with its fellow of the other side, depresses the cartilaginous part of the nose, and to some extent also compresses the alæ together. The actions of the other muscles are sufficiently indicated by their names; the dilatation of the alæ is perceptible in natural inspiration, and is well marked in dyspnœa.

#### MUSCLES OF THE LIPS AND MOUTH.

Around the orifice of the mouth are situated an orbicular muscle with concentric fibres, and numerous other muscles, whose fibres converge towards the aperture, viz., superiorly the common elevator of the lip and nose already described, the proper elevator of the upper lip, the elevator of the angle of the mouth and the zygomatic muscles, laterally the risorius and buccinator muscles, and, inferiorly, the depressor of



the angle of the mouth and that of the lower lip ; and lastly, acting indirectly on the lower lip, the levator menti.

The **orbicularis oris** muscle, or **sphincter oris**, consists of labial and facial parts. The *labial* or *marginal part* occupies the red part of the lips, and forms a slightly convex fasciculus of pale fine fibres which are free from bony attachment, and can be traced from one lip to another round the corner of the mouth. The *facial part*, thinner and wider than the other, blends by its outer border with the several contiguous muscles that converge to the mouth, and more particularly with the buccinator muscle, the fibres of which are continuous with the deeper part of the orbicularis. Besides those fibres it has others, *musculi incisivi* (Henle), that are attached to the subjacent cartilage and bone ; viz., in the upper lip two bundles for each half ; and in the lower lip one for each. In the upper lip the outer slip, thin and weak, passes downwards, and is attached opposite the incisor teeth, close to the alveolar edge of the upper jaw-bone ; while the other, thick and pointed, passes upwards and is fixed to the septum of the nose. In the lower lip the reinforcing fasciculus arises from the surface of the lower jaw, near the root of the canine tooth, and external to the levator labii inferioris, and passing directly outwards towards the angle of the mouth, its fibres blend with the rest of the muscle.

*Relations.*—The skin of the lips is closely connected to the inner part of the orbicularis oris muscle, whilst over the outer part fatty tissue is interposed between them. The deep surface is in contact with the mucous membrane and the labial glands, as well as with the coronary arterial arch in each lip.

The **levator labii superioris proprius** muscle arises from the superior maxillary bone immediately above the infraorbital foramen, and from the adjoining surface of the malar bone ; it passes downwards and a little inwards to be blended with the orbicularis and other muscular fibres in the upper lip.

*Relations.*—At its origin this muscle is overlapped by the orbicularis palpebrarum, but its lower part is subcutaneous ; it partly conceals the levator anguli oris and the compressor naris, and beneath it the infraorbital vessels and nerve emerge from the canal of that name.

*Varieties.*—This muscle is frequently united with the levator lab. sup. alæque nasi. It is also commonly seen arising by two heads, the outer being attached to the malar bone, or coming as a slip from the orbicularis palpebrarum.

The **levator anguli oris**, or **musculus caninus**, arises in the canine fossa immediately below the infraorbital foramen, inclines downwards and slightly outwards, and is inserted into the angle of the mouth, where it becomes blended with the fibres of the orbicularis, zygomatici and depressor anguli oris.

*Relations.*—At its origin this muscle is concealed by the proper elevator of the upper lip ; its anterior surface supports the infraorbital nerve and artery, which separate it from the preceding muscle ; the posterior surface lies on the superior maxilla and the orbicularis and buccinator muscles, with which and the depressor anguli oris the fibres are blended.

The **ZYGOMATICI** are two narrow and subcutaneous fasciculi of muscular fibres, extending obliquely from the most prominent part of the cheek to the angle of the mouth, one being thicker and longer than the other.

The **zygomaticus minor**, a very small muscle, arises from the anterior and inferior part of the malar bone, and inclines downwards and forwards to terminate by joining the outer margin of the levator labii superioris; sometimes near the origin of that muscle. It lies internal to the zygomaticus major, but distinct from it in its whole length.

The **zygomaticus major**, placed externally to the smaller muscle of the same name, arises from the malar bone near the zygomatic suture, from which it descends to the angle of the mouth, where it is continued into the orbicularis and depressor anguli oris.

*Varieties.*—The zygomaticus minor is frequently absent; or it may fall short of the mouth, and be inserted into the fascia of the cheek. It may arise wholly or in part from the orbicularis palpebrarum; it has also been observed joined to the zygomaticus major, or to the levator labii superioris, or even to the outer fibres of the frontalis (Eustachius). It has frequently been found double.

The zygomaticus major has also been found double, or it may be double merely at its origin. Sometimes it arises from the masseteric fascia below the zygoma. (Macalister.)

The **risorius**, or smiling muscle (Santorini), is generally regarded as a part of the platysma myoides. It consists of some very thin fasciculi, which commence in the fascia over the masseter, or on the parotid gland, and, extending transversely inwards in the fat of the cheek, join the orbicularis and depressor anguli oris at the angle of the mouth.

*Varieties.*—The risorius has been seen to arise from the integument over the upper end of the sterno-mastoid (Hallet); from the zygoma (McWhinnie); from the external ear (Albinus); and from the fascia over the mastoid process (Macalister). It was found double and even triple by Santorini.

The lower and lateral part of the face receives a superficial muscular covering from the facial part of the **platysma myoides**, which is incorporated with the muscles of the angle of the mouth and lower lip, and passes along with the superficial fascia over the base of the jaw into the cervical portion of the muscle; while the anterior portion of the cervical platysma, continuous externally with the facial, takes firm attachment to the base of the jaw for a length of two inches or more external to the symphysis.

The **buccinator** muscle consists of a flat and thin but strong set of fibres in contact with the mucous membrane, and forming a considerable part of the wall of the mouth. It is attached by its upper and lower margins to the outer surface of the alveolar parts of the maxillary bones, opposite the molar teeth, and by its posterior margin to the *pterygo-maxillary ligament*, a narrow band of tendinous fibres, which extends from the internal pterygoid plate to the mylohyoid ridge of the lower jaw close to the last molar tooth, and is placed between the buccinator muscle and the superior constrictor of the pharynx. From these points the fibres of the muscle are directed forwards, approaching each other, so that the muscle is narrowed and proportionally thickened near the angle of the mouth, where it becomes incorporated with the orbicularis. The fibres near the middle of the muscle cross each other, those from above passing into the lower lip, and those from below into the upper one; but the higher and lower fibres are directed into the corresponding lip without decussation.

*Relations.*—The buccinator is covered and supported by a thin fascia, which is closely adherent to the muscular fibres; and is overlapped by the triangulans

Fig. 204.

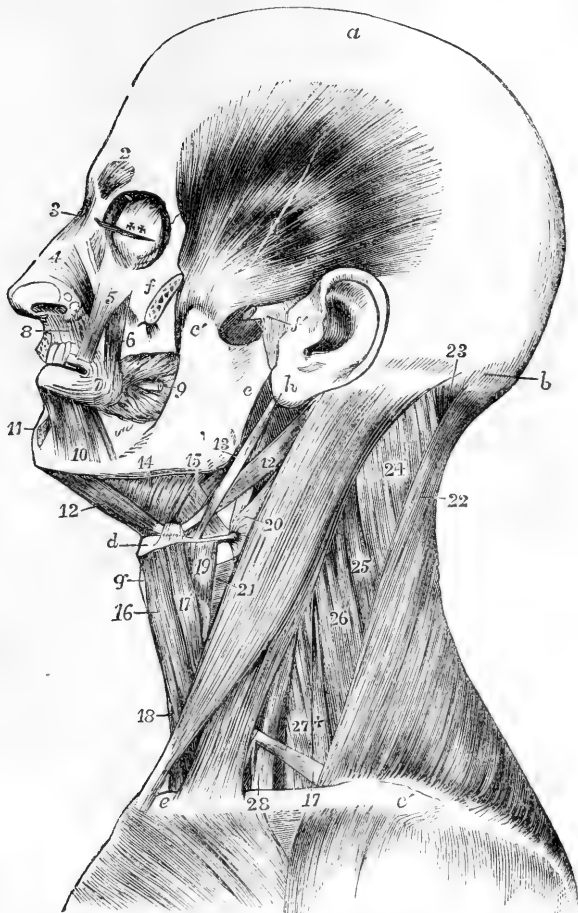


Fig. 204.—DEEP VIEW OF THE MUSCLES OF THE LEFT SIDE OF THE HEAD AND NECK (modified from Bourguery). (A. T.)  $\frac{1}{2}$

*a*, vertex of the head; *b*, superior curved line of the occipital bone; *c*, ramus of the lower jaw; *c'*, its coronoid process; *d*, body of the hyoid bone; *e*, sternal end of the clavicle; *e'*, acromial end; *f*, malar bone divided to show the insertion of the temporal muscle; *f'*, divided zygoma, and external lateral ligament of the jaw; *g*, thyroid cartilage; *h*, placed on the lobe of the auricle, points to the styloid process; *l*, temporal muscle; *2*, corrugator supercilii; *3*, pyramidalis nasi; *4*, lateral cartilage of the nose covered by the triangularis nasi; *5*, levator labii superioris proprius; *6*, levator anguli oris; *7*, outer part of the orbicularis oris, the part below the nose has been removed; *8*, depressor alae nasi; *9*, points to the buccinator muscle, through which the parotid duct is seen passing; *10*, quadratus menti; *11*, levator menti; *12*, *12*, anterior and posterior bellies of the digastric; *13*, stylo-hyoid muscle; *14*, mylo-hyoid; *15*, hyo-glossus, between which and *13*, is seen a part of the stylo-glossus; *16*, sterno-hyoid; *17*, on the clavicle, indicates the lower, and *17'*, the upper belly of the omohyoid; *18*, sterno-thyroid; *19*, thyro-hyoid; *20*, *21*, on the sterno-mastoid muscle, point, the first to the middle, the second to the lower constrictor of the pharynx; *22*, trapezius; *23*, upper part of the complexus; *24*, splenius capitis; *25*, splenius colli; *26*, levator scapulae; *27*, middle scalenus; *+*, posterior scalenus; *28*, anterior scalenus.

oris, by the terminal fibres of the platysma myoides, and by the masseter and zygomatici, from which it is separated by a quantity of soft adipose tissue of a peculiar character. Opposite the second molar tooth of the upper jaw, its fibres give passage to the duct of the parotid gland.

The **depressor anguli oris**, or **triangularis oris** muscle, is broad at its origin from the external oblique line of the lower jaw; passing upwards it is collected into a narrower bundle, which is inserted into the orbicularis at the angle of the mouth.

*Relations.*—This muscle is covered by the skin, and at its insertion, by the zygomaticus major, under which its fibres pass; it conceals part of the buccinator and of the depressor of the lower lip.

*Variety.*—The *transversalis menti* (Santorini) is a small band of muscular fibres sometimes found arising from the inner border of the depressor, and curving downwards and inwards below the chin towards the mesial line of the neck.

The **depressor labii inferioris**, or **quadratus menti** muscle, arises from the lower jaw by a line of attachment extending from near the symphysis to a little beyond the mental foramen; thence it ascends with an inward inclination, unites with its fellow, and blending with the orbicularis oris is inserted into the lower lip. Its fibres are intermixed with much adipose matter.

The **levator labii inferioris**, or **levator menti** muscle, arises by a narrow head from the incisor pit of the lower jaw, and, expanding in a nearly vertical plane, is directed downwards, and slightly forwards and inwards, between the depressors of the lower lip, to the integument of the chin.

*Nerves.*—All the superficial muscles of the face previously described receive their motor nerves from one source, viz., the facial motor, or portio dura of the seventh pair, twigs from this widely distributed nerve being sent even into the occipitalis muscle. The expression of the passions by the varying state of the skin of the forehead and eyebrows, the eyelids, nostrils and mouth, the closure of the eyelids, the dilatation of the nostrils in breathing, and the movements of the lips in the prehension of food and otherwise, together with the movements of the scalp and external ear, when they are possible,—are all under the influence of the facial nerve, which has thus been reckoned as a nerve of respiration and expression.

*Actions.*—The orbicularis oris acting alone draws the lips together in both the vertical and transverse directions. Acting in conjunction with the buccinators it closes the lips, while at the same time they are elongated transversely. Its facial portion acting alone projects the lips. The labial portion, when acting in concert with the converging muscles, tightens the lips, one or both, against the teeth. The convergent muscles each draw their oral points of insertion in a direction corresponding to that of their muscular fibres. The common elevator of the lip and nose and the upper part of the orbicularis oris act on both the upper lip and the ala of the nose together—the one elevating the other depressing them. When the cheeks are distended with air, and the aperture of the lips narrowed, it is by the action of the buccinator that the forced expulsion of the air is effected and regulated. The levator menti not only draws upwards the integument of the chin, but it also protrudes the lower lip, as in pouting. The muscles attached to the angles of the mouth are, along with others of the face, intimately connected with the expression of the passions: those which pass downwards not only raise the upper lip, but also push upwards the cheek, and thus elevate the margin of the lower eyelid, as in mirth: and those which descend from the angle of the mouth depress that part, as in grief. (On the action of the facial muscles may be consulted, more especially, Sir Charles Bell, "Anatomy and Philosophy of Expression," and Duchène, "Mécanisme de la Physionomie Humaine," Paris, 1862, and "Physiol. des Mouvements," &c., 1867.)

## MUSCLES OF THE ORBIT.

In this group will be described seven muscles, namely, the elevator of the upper eyelid before referred to, and six muscles of the eyeball, viz., the four straight and the two oblique muscles. Of these muscles, the inferior oblique alone is confined to the fore part of the orbit; all the others take their origin at its back part, and pass longitudinally forwards to their insertion in front.

The **levator palpebræ superioris** is a slender muscle, which arises, pointed and tendinous, above and in front of the margin of the optic foramen, and, passing forwards over the eyeball, ends in a fibrous expansion inserted into the anterior surface of the tarsal cartilage of the upper eyelid.

*Relations.*—Between this muscle and the roof of the orbit are situated the fourth and frontal nerves and the supraorbital vessels, and beneath it are the superior rectus muscle and the globe of the eye. In the lid, it is placed behind the palpebral ligament, close to the membrana conjunctiva.

The four straight muscles of the eye surround at their origin the optic nerve, and, passing forwards from that point, are inserted into the front of the globe of the eye at four opposite equidistant parts, by delicate expanded tendons which become blended into one at their termination.

The **superior rectus** arises close in front of the foramen opticum, and beneath the levator palpebræ; the **inferior rectus**, **internal rectus**, and **external rectus** are united in a common tendinous attachment around the circumference of the optic foramen, except above. But the external rectus differs from the others in having two heads of origin: the upper head unites with that of the superior rectus, the second head arises from the common tendon and from a bony point on the lower margin of the sphenoidal fissure close to its wider inner end; and intermediate fibres proceed from a fibrous band between the heads of origin. The four recti thus attached posteriorly, pass forwards, one above, one below, and one on each side of the eyeball, becoming flattened as they lie in contact with it, and are inserted by short membranous tendons into the fore part of the sclerotic coat, at an average distance of four lines from the margin of the cornea.

In length and breadth there are some differences among these muscles. The external rectus exceeds the internal one in length. On the other hand, the internal rectus is the broadest, and the superior the narrowest of all. Between the heads of the external rectus is a narrow interval, which gives transmission to the third and sixth nerves and the nasal branch of the fifth nerve, with the ophthalmic vein.

The **superior oblique** or **trochlearis** is a narrow elongated muscle, placed at the upper and inner part of the orbit, internally to the levator palpebræ. It arises about a line in front of the inner part of the optic foramen; thence it proceeds towards the internal angle of the orbit, and terminates in a round tendon which passes through a fibro-cartilaginous ring or pulley (trochlea) attached to the fovea trochlearis of the frontal bone; it is there reflected outwards and backwards, and passes between the eye and the superior rectus to be inserted into the sclerotic coat midway between the superior and external recti muscles, nearly equidistant from the cornea and the entrance of the optic

nerve. A synovial sheath lines the contiguous surfaces of the tendon and pulley.

*Relations.*—This muscle is covered by the roof of the orbit, the fourth nerve entering its upper surface; and beneath it lie the nasal nerve and the internal rectus muscle.

Fig. 205.

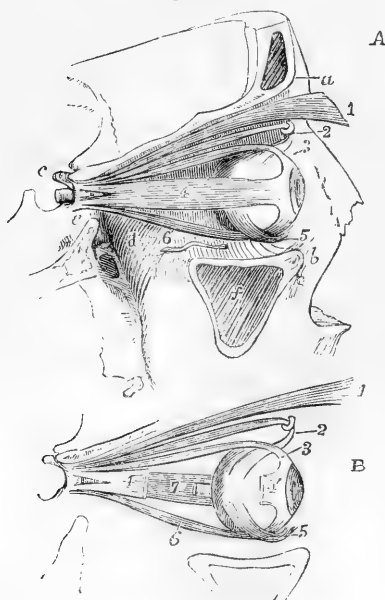


Fig. 205.—A VIEW OF THE MUSCLES OF THE RIGHT ORBIT, FROM THE OUTSIDE, THE OUTER WALL HAVING BEEN REMOVED. (A. T.)  $\frac{1}{2}$

B, EXPLANATORY SKETCH OF THE SAME MUSCLES.

*a*, supraorbital ridge; *b*, lower margin of the orbit formed by the superior maxillary bone; *c*, anterior clinoid process; *d*, posterior part of the floor of the orbit above the speno-maxillary fossa; *e*, side of the body of the sphenoid bone below the optic foramen and sphenoidal fissure; *f*, sinus maxillaris; 1, levator palpebrae superioris, near its insertion; 2, pulley and tendon of the superior oblique muscle; 3, tendon of the superior rectus muscle at its insertion upon the eyeball; 4, in A, external rectus; 4', in B, tendon of insertion of the same muscle, a part of which has been removed; the double origin of the muscle is shown at the apex of the orbit; 5, the inferior oblique muscle crossing the eyeball below the inferior rectus; 6, the inferior rectus; 7, in B, the inside of the internal rectus, seen in consequence of the removal of a part of the external rectus, and near it, the end of the optic nerve cut short close to the place of its entrance into the eyeball.

The **inferior oblique** is the only muscle of the eye which does not take origin at the apex of the orbit. It arises from a minute depression in the orbital plate of the superior maxillary bone, just within the anterior margin of the orbit, and close to the external border of the lachrymal groove. The muscle inclines outwards and backwards between the inferior rectus and the floor of the orbit, and ends in a tendinous expansion, which passes between the external rectus and the eyeball, to be inserted on the external and posterior aspect of the globe.

*Varieties.*—The levator palpebrae sometimes gives off a slip from its inner border, which passes to be inserted into the trochlea, forming the *tensor trochleae* of Budge. A slip of a similar nature was described by Albinus as a case of doubling of the levator palpebrae, and by Mollinetti as a fifth rectus. The levator palpebrae has been seen entirely wanting (Macalister).

The rectus externus may have its two heads separate to their insertion, thus forming a double rectus (Albinus). Macalister has twice noted the absence of the outer head.

The *transversus orbitae* (Bochdalek) consists of an arching slip of muscular fibres passing from the anterior and superior portion of the os planum across the upper surface of the eyeball to the outer wall of the orbit. It is probably, as Macalister suggests, a displaced deep slip of the palpebral fibres of the orbicularis palpebrarum.

**Nerves.**—Five of the muscles of the orbit, viz., levator palpebræ superioris, the superior, internal, and inferior recti and the inferior oblique, are under the influence of the third pair or common oculo-motor nerve; the external rectus is supplied by the sixth pair, or abducent ocular, and the superior oblique by the fourth pair, or trochlear nerve. From what is stated hereafter as to the action of the muscles, it will appear that in all the consentaneous movements of direction of the two eyes muscles are in action which receive their motor nerves from two different sources.

**Actions.**—The levator palpebræ superioris is, as its name implies, simply an elevator of the upper eyelid, acting in this as the antagonist of the upper palpebral part of the orbicularis muscle.

The eyeball is so situated in the structures which surround it in the orbit that it is capable of free motion on a central fixed point: but it does not appear to shift its place as a whole within the orbit, nor to undergo perceptible change of form from the action of the muscles. The position of the point round which the movements of the eyeball take place is nearly in the centre of curvature of the posterior wall, and from half a line to a line behind the middle of the antero-posterior axis of the eyeball.

The movements of the eyeball may be conveniently reduced to four kinds, viz., 1, simple lateral movements in a horizontal plane; 2, simple movements of elevation or depression; 3, oblique movements of elevation or depression, and 4, movements of rotation. In the first two kinds the vertical meridian of the eye is not subject to any change of inclination; in the third kind the movements of direction are accompanied by a small amount of rotation or inclination of the vertical meridian to one or other side; and in the fourth kind, when simple, the whole movement is one of inclination of the vertical meridian. These movements however, unless perhaps the first, are seldom simple, but more frequently different kinds are combined together. The three first kinds constitute the various movements of direction by which the visual axis is turned within certain limits to various points in space; the extent of motion being about  $90^\circ$  in the vertical and  $100^\circ$  in the horizontal direction. Simple movements of rotation do not appear to occur to any considerable extent, and it has been ascertained by experiment that they do not, as was supposed by Hueck and others, maintain the eyeballs in a fixed position during inclined movements of the head.

In these different movements the six muscles of the eyeball may advantageously be considered as acting in three pairs. 1st. In the horizontal movements the internal and external recti muscles are the sole agents, the one acting as an adductor and the other as an abductor; and this movement they effect without any rotation, their line of action being exactly in the horizontal plane of the eyeball. 2nd. It is different with the superior and inferior recti; for while these muscles undoubtedly are respectively the most direct elevators and depressors of the cornea, they have both a tendency, from the line of their action being to the inside of the centre of motion of the eyeball, to produce inward direction with a small amount of rotation. This tendency is corrected by the association of the oblique muscles in all upward and downward movements; the inferior oblique being associated with the superior, and the superior oblique with the inferior rectus muscle. The simple action of the superior oblique muscle, when the eye is directed straight forward, is to produce a movement of the cornea downwards and outwards, that of the inferior oblique to direct the cornea upwards and outwards, and in both with a certain amount of rotation, though in different directions in the two cases. But these movements caused by the oblique muscles are precisely those which are required to neutralise the inward direction and rotatory movements produced by the superior or the inferior rectus, and accordingly, by the combined action of the superior rectus and the inferior oblique muscles a straight upward movement is effected, while a similar effect in the downward direction results from the combined action of the inferior rectus and superior oblique muscles.

It has been further shown that in all the oblique movements of direction a combination takes place of the action of the oblique with that of the recti muscles. Here, however, two recti muscles are in action and are associated with one oblique muscle; as, for example, in the upward and inward direction, the

superior and internal recti with the inferior oblique; and in the downward and inward direction the inferior and internal recti with the superior oblique. And the same is true of the upward and outward and downward and outward movements of direction; for in all these movements the action of the oblique muscles is necessary to control or supplement the rotatory tendency of the recti muscles; and in the consentaneous movements of the two eyes the whole six muscles must co-operate in both eyes to produce that perfect agreement in their movements of direction and convergence which is required for perfect vision.

It is unnecessary here to enter into the detail of the modifications of these actions of the muscles which must accompany changes in the various consentaneous movements of the eyes, as, for example, in the convergence which is associated with the adjustment of the eyes to near and distant vision. (Consult G. Johnston in article "Orbit," of Cyclopæd. of Anat. and Physiol., Jacob in Dublin Med. Press, 1841; John S. Wells, in the Ophthalmic Hosp. Reports, vol. ii. 1859-60; Von Graefe, in Archiv für Ophthalmologie, vol. i. p. 1; and other works of that author, and of Alfred Graefe, and other Ophthalmologists, especially those on Strabismus. Also Helmholtz in his Physiological Optics.)

**Fasciæ of the Orbit.**—The space within the orbit which is not occupied by the eyeball and its muscles, or other parts belonging to it, is completely filled with soft fat and delicate yielding connective tissue. In various places this last is condensed into layers of slender fasciæ of various degrees of strength. One layer of this structure forming the capsule of Tenon, surrounds the eyeball on every side except in front, where it is reflected on the inside of the conjunctiva and eyelids, and this layer is so loosely connected with the surrounding parts that it seems to serve all the purposes of a synovial membrane in the ball and socket-like disposition of the globe of the eye in its padding. The various muscles pierce this capsule at a short distance from the place of their insertion into the sclerotic. From the capsule of Tenon, septa of fascial connective tissue spread outwards mainly in the direction of the recti muscles, all of which receive delicate investments from the structure; a layer also spreads between the muscles and the periosteal lining of the orbit. In two places these septa of fascia are of greater strength than elsewhere, viz., on the inside towards the lachrymal sac and eyelids, and on the outside towards the margin of the orbit, where it is united with the external ligament of the palpebræ and the periosteum.

In several parts of these fascial structures, more especially in those last mentioned, plain or unstriped muscular fibres have been detected, and these, together with the elastic connective tissue are conceived to act in restoring the position of parts after the action of the voluntary muscles is over. These involuntary muscles are under the influence of the cervical sympathetic nerves. (See Henle's Anatomie d. Mensch., vol. ii., and Merckel in the Handbuch der Gesammt. Augenheilkunde, 1st part, 1874; H. Müller, Sitzungsber. d. Würzburg. Gesellsch. 1858, and Turner, Nat. Hist. Rev., 1862; Cruveilhier, Traité d'Anatomie, &c.)

#### MUSCLES OF MASTICATION.

The masseter, temporal, and two pterygoid muscles form a group of muscles of mastication, which may be properly considered together.

The **masseteric fascia** is a continuation upwards of the deep fascia of the neck over the masseter muscle. It is firmly bound down to the outer surface of the muscle, and is attached superiorly to the zygoma. Posteriorly it closely invests the parotid gland (*fascia parotidea*); it likewise sends upwards a process on the posterior and deep surfaces of the parotid gland; and a strong band of this process, the *stylo-maxillary ligament*, extending from the angle of the jaw to the styloid process, separates the parotid and submaxillary glands.

The **masseter** is a thick quadrate muscle, whose fibres form two portions differing in size and direction. The *superficial* part, obliquely four-sided in form, arises from the lower border of the malar bone in the anterior two-thirds of the zygomatic arch, chiefly by thick tendons



projecting down between the muscular fasciculi, to which they afford an extensive surface of origin : its fibres proceed downwards and a little backwards to be inserted into the lower half of the ramus of the jaw, extending as far as the angle. The *deep* part of the muscle, of a triangular form, consists of fibres which are much shorter than those of the superficial part, and are directed downwards and forwards. They arise from the posterior third of the lower border and from all the deep surface of the zygomatic arch, and, becoming united with the superficial part, are inserted into the upper half of the ramus of the jaw, including the coronoid process : only the upper and back part of this portion of the muscle is left uncovered by the superficial portion.

*Relations.*—The external surface of the masseter muscle is covered for the most part only by the skin and fascia ; it is, however, overlapped behind by the parotid gland, and crossed by its duct ; the branches of the facial nerve and the transverse facial artery also rest upon it. Its inner surface is towards the buccinator, from which it is separated by soft adipose tissue ; it is in close contact with the ramus of the jaw, and covers a nerve and vessels which enter it over the sigmoid notch of that bone.

The **temporal fascia** is a dense white shining aponeurotic structure, which covers the temporal muscle above the zygoma, and gives attachment to some of its fibres of origin. It is attached superiorly to the posterior border of the malar bone and to the temporal ridge on the frontal, parietal, and temporal bones ; while inferiorly, where it is separated by a quantity of fat into two layers, it is attached to the zygoma, the superficial layer to the outer surface, and the deep layer to the inner surface of that process. This dense fascia is separated from the integuments by the layer of thin membrane descending from the epicranial aponeurosis, and by the auricular muscles ; and from the temporal muscle below, by a layer of fat.

The **temporal** muscle is fan-shaped, and arises from the whole surface of the temporal fossa, with the exception of the anterior or malar wall, and from the deep surface of the temporal fascia, as it passes down over it to the zygoma ; some of its posterior fibres arising from this fascia blend with the deep fibres of the masseter muscle. The direction of the anterior fibres is nearly vertical, that of the middle fibres oblique, and that of the posterior fibres at first horizontal. The fibres converge as they descend, and all terminate in a tendon, which, emerging from the interior of the muscle, is implanted into the inner surface and anterior border of the coronoid process of the lower jaw-bone, as far down as the union of the body and ramus of the jaw.

*Relations.*—The upper part of the muscle is closely covered by the temporal fascia ; the lower and anterior part is imbedded in fat continuous with that which lies between the masseter and buccinator muscles ; the insertion of the tendon is mainly concealed by the lower jaw. Between the muscle and the bone of the temporal fossa are the deep temporal arteries and nerves, which penetrate its substance. In contact with the deep surface of the muscle near its insertion the buccal nerve descends, and at the posterior border of the insertion the masseteric nerve and artery emerge.

The **internal pterygoid** muscle arises from the pterygoid fossa ; its fibres, tendinous and fleshy, being attached mostly to the inner surface of the external pterygoid plate, and that portion of the tuberosity of the palate-bone which is situated between the pterygoid plates. Thence it is inclined downwards, with a direction backwards and outwards, and

is inserted into the angle and the inner surface of the ramus of the jaw as high as the dental foramen.

*Relations.*—The internal pterygoid muscle is placed on the inner side of the ramus of the jaw, somewhat in the same manner as the masseter lies on the outside. Between the external surface of the muscle and the ramus of the maxilla are the internal lateral ligament and the internal maxillary vessels, with the dental artery and nerve; and at its upper part the muscle is crossed by the external pterygoid muscle. Its inner surface is in contact, whilst in the pterygoid groove, with the tensor palati muscle, and lower down with the superior constrictor of the pharynx.

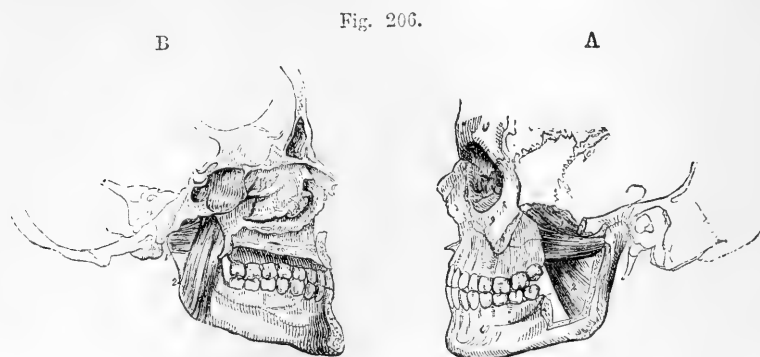


Fig. 206.—VIEWS OF THE PTERYGOID MUSCLES—A, FROM THE OUTER SIDE; B, FROM THE INNER SIDE.  $\frac{1}{4}$

1, external pterygoid; 2, internal pterygoid—the outer surface in A, the inner surface in B.

The **external pterygoid** muscle, occupying the zygomatic fossa, arises by two fleshy heads placed close together, the superior of which is attached to that part of the external surface of the great wing of the sphenoid bone which looks into the zygomatic fossa, and to the ridge which separates that surface from the temporal fossa; while the inferior, which is larger, is attached to the outer surface of the external pterygoid plate, and to the tuberosities of the palate and upper maxillary bones. The fibres from both heads pass backwards, and converge to be inserted into the fore part of the neck of the condyle of the lower jaw, and into the interarticular fibro-cartilage of the temporo-maxillary articulation.

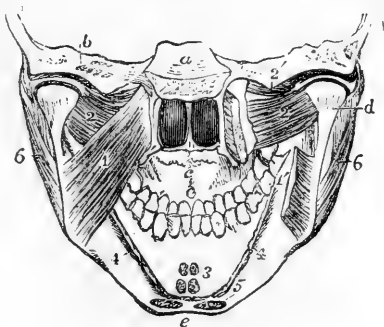
*Relations.*—The internal maxillary artery is usually placed on the outer surface of this muscle, passing thence between the heads of origin; while the buccal nerve issues from between those heads. The deep surface rests against the upper part of the internal pterygoid muscle, whose direction it crosses, also the internal lateral ligament of the lower jaw, the inferior maxillary nerve, and the middle meningeal artery. The upper border is in contact with the great wing of the sphenoid bone, and is crossed by the deep temporal nerve and arteries.

*Varieties.*—The *pterygoides proprius* (Henle). This is nearly a vertical slip, which passes from the crest of the great wing of the sphenoid to the tuberosity of the palate bone or to the posterior margin of the external pterygoid plate. In some cases reported by Mr. Wagstaffe (*Journ. of Anat.* vol. v., p. 281), in which this slip was present, the maxillary head of the external pterygoid was absent, and some of the ordinary fibres arose from those vertical bands. Another form

of this muscle has been described by Macalister, as passing superficial to the external pterygoid to be inserted into the tuberosity of the maxillary bone.

Fig. 207.—VIEW OF THE LOWER PART OF THE SKULL AND FACE, FROM BEHIND, TO SHOW THE ATTACHMENTS OF THE PTERYGOID AND SOME OTHER MUSCLES (modified from Bourger). (A. T.)  $\frac{1}{3}$

Fig. 207.



*a*, placed above the basi-sphenoid bone, below which are seen the posterior nares and palate; *b*, transverse section through the temporal bone; *c*, roof of the mouth; *d*, back of the head and neck of the lower jaw, above which are seen the synovial cavities of the joint divided by the interarticular fibro-cartilage; *e*, placed below the symphysis menti; 1, on the left internal pterygoid muscle; 1', on the right side, the lower part of the same muscle, of which the middle portion has been removed to show the external pterygoid; 2, the lower thick portion of the external pterygoid; 2', on the right side points to the upper smaller portion of the muscle, attached in part to the interarticular plate; 3, small portions of the genio-hyoid and genio-hyo-glossus muscles cut short at their attachment to the genial tubercles; 4, the attachment of the mylo-hyoid muscle cut short; 5, the attachment at the side of the symphysis of the anterior belly of the digastric muscle; 6, the masseter muscle descending to the angle of the jaw.

**Nerves.**—The four muscles above described receive their motor nerves from one source, viz., the external muscular branches of the fifth pair, which may be traced to the lesser or motor root of that nerve. These nerves are named from the muscles they respectively supply. There are usually two branches to the temporal, and one to each of the other muscles.

**Actions.**—The masseter, temporal, and internal pterygoid muscles are elevators of the lower jaw, and generally act in concert, bringing the lower teeth forcibly into contact with the upper. The opposite movement of depressing the jaw, not being opposed by any resisting obstacle, requires less force, and is effected by muscles of much smaller size, the principal of which is the digastric muscle hereafter described. The external pterygoid muscle, having the great body of its fibres nearly horizontal, draws forwards the condyle of the jaw, and, when the muscles of both sides act together, the lower jaw is protracted so as to make the lower incisor teeth project beyond the upper; but their more usual mode of action is alternately on the two sides, as in the grinding movement of the molar teeth, in which the horizontal movements of the external pterygoids are associated with the elevating actions of the other muscles. The masseter and internal pterygoid muscles assist in protracting the jaw; the temporal alone is a retractor. The two pterygoid muscles of one side, in advancing one condyle of the jaw, necessarily throw the teeth towards the opposite side.

#### MUSCLES BETWEEN THE LOWER JAW AND THE HYOID BONE.

The **digastric** muscle, extending from the temporal bone to the lower jaw, consists of two elongated muscular bellies united by an intervening rounded tendon. The posterior belly, longer than the anterior, arises from the digastric groove of the temporal bone, and is directed downwards, forwards, and inwards: the anterior is attached to a rough depression situated on the lower border of the lower jaw, close to the symphysis menti; it is less tapering than the posterior belly, and is directed downwards and backwards. The intervening

tendon is connected with the body and great cornu of the os hyoides by a broad band of aponeurotic fibres in the form of a loop, and lined with synovial membrane, and by the fleshy fibres of the stylo-hyoid muscle, through which the tendon passes.

*Relations.*—The anterior belly, placed immediately beneath the deep cervical fascia, rests on the mylo-hyoid muscle; it is connected with its fellow of the opposite side by dense fascia, and occasionally is united by muscular fibres to it or to the mylo-hyoid muscle.

The posterior belly is covered by the mastoid process and the muscles arising from that bone, and crosses the external carotid artery, and the internal jugular vein.

Fig. 208.

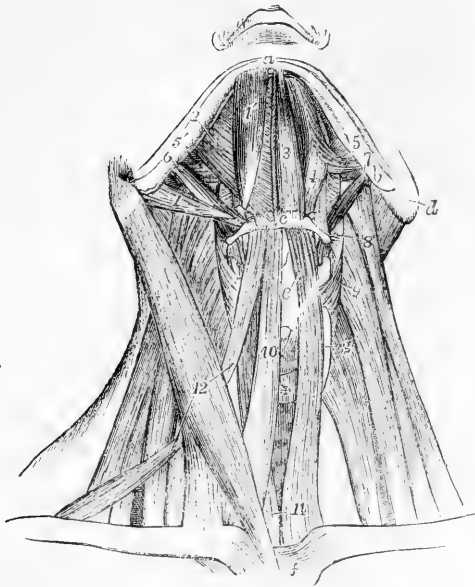


Fig. 208.—VIEW OF THE SUB-MAXILLARY MUSCLES AND THE DEPRESSORS OF THE HYOID BONE AND LARYNX, FROM BEFORE. (A. T.)  $\frac{1}{3}$

On the right side, the platysma alone has been removed; on the left side both the bellies of the digastric, the stylo-hyoid, the mylo-hyoid, the sterno-hyoid, and omo-hyoid muscles have been removed: *a*, symphysis; *b*, angle of the lower jaw; *c*, middle of the body of the hyoid bone; *d*, mastoid process; *e*, placed on the front of the thyroid cartilage, points to the thyro-hyoid muscle; *f*, upper part of the sternum; *g*, lateral lobe, and +, isthmus of the thyroid gland; above +, the front of the cricoid cartilage covered by the crico-thyoid muscle; 1, posterior belly; 1', anterior belly of right digastric muscle; 2, right mylo-hyoid; 3, left genio-hyoid; 4, hyo-glossus; 5, stylo-glossus; 5', a portion

of it seen on the right side; 6, stylo-hyoid of the right side; 7, stylo-pharyngeus of the left side; 8, placed on the levator scapulae, points to the left middle constrictor of the pharynx; 9, placed on the middle scalenus, points to the left inferior constrictor; 10, right sterno-hyoid; 11, placed on the left sterno-thyroid, points also to the lower part of the right muscle; 12, placed on the right sterno-mastoid, points to the upper and lower bellies of the right omo-hyoid.

*Varieties.*—The digastric muscle is subject to many variations. The posterior belly may receive an accessory slip from the styloid process (Wood), or from the angle of the lower jaw (Henle). It has been seen arising from the styloid process. Rarely the muscle is monogastric, the posterior belly alone being present and being inserted into the ramus of the jaw (McWhinnie). The anterior belly is frequently divided into two or more parts, one or even two of which may cross the middle line and decussate with similar slips from the muscle of the opposite side; or a slip sometimes passes to the median raphé of the mylo-hyoid, with which and its fellow of the opposite side it becomes incorporated. The tendon of the digastric has been seen in front of, or more rarely behind the stylo-hyoid instead of passing through it.

The *mento-hyoid* (Macalister) is an occasional mesial slip found passing

from the body of the os hyoides to the chin. It sometimes consists of two parallel bands, and Macalister suggests that it may be a differentiated portion of the platysma.

The **stylo-hyoid** muscle lies close to the posterior belly of the digastric muscle, being a little behind and beneath it. It arises from the outside of the middle of the styloid process of the temporal bone, and inclines downwards and forwards, to be inserted into the os hyoides at the union of the great cornu with the body. Its fibres are usually divided into two fasciculi near its insertion, for the transmission of the tendon of the digastric muscle.

*Relations.*—The upper part of the stylo-hyoid muscle lies deeply, being covered by the sterno-mastoid and digastric muscles, and by part of the parotid gland; the middle crosses the external carotid artery; the insertion is comparatively superficial.

*Varieties.*—This muscle is sometimes wanting; occasionally a second is present (stylo-hyoides alter.—Alb.) The position too may be varied—it has been found to the inner side of the external carotid artery instead of over that vessel. ("The Anatomy and Operative Surgery of the Arteries," by R. Quain, plate 12, fig. 5. Macalister, Journal of Anat., vol. v., p. 28.)

The **mylo-hyoid** muscle arises from the mylo-hyoid ridge along the inner surface of the lower jaw, extending from the last molar tooth to the symphysis. The posterior fibres are inserted into the body of the

Fig. 209.—A, THE LOWER JAW AND HYOID BONE, FROM BELOW, WITH THE MYLO-HYOID MUSCLES ATTACHED.

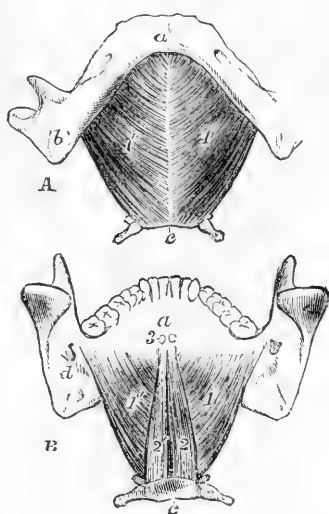
B, THE SAME FROM BEHIND, WITH THE MYLO-HYOID AND GENIO-HYOID MUSCLES ATTACHED. (A. T.)  $\frac{1}{3}$

*a*, the symphysis; *b*, the angle of the lower jaw; *c*, the lower border of the body of the hyoid bone; *d*, in B, the inferior dental foramen and upper end of the mylo-hyoid ridge; 1, 1', the mylo-hyoid muscles; 2, 2', the genio-hyoid muscles from above; 3, the cut ends of the attachment of the genio-glossi muscles to the superior genial spines.

os hyoides; the rest, proceeding parallel to the fibres behind, and becoming gradually shorter, join at an angle with those of the corresponding muscle, forming with them a sort of raphé along the middle line, from the symphysis of the jaw to the os hyoides. Thus the two muscles together form a floor below the anterior part of the mouth (*diaphragma oris* of Meyer).

*Relations.*—The lower surface of the mylo-hyoid muscle is covered by the digastric muscle, the submaxillary gland, and the submental vessels and nerve. The deep surface which looks upwards and inwards, is in contact with the genio-hyoides and part of the hyo-glossus and stylo-glossus muscles, the ninth and gustatory nerves, the sublingual gland, and the duct of the submaxillary gland. The posterior border alone is free and unattached, and behind it the duct of the submaxillary gland turns, in passing to the mouth.

Fig. 209.



*Varieties.*—This muscle may be inseparably united with, and even upon one side replaced by the anterior belly of the digastric. It frequently receives an accessory slip from one of the other hyoid muscles, as the sterno-hyoid, omohyoid, or stylo-hyoid.

The **genio-hyoid** is a narrow muscle arising from the inferior of the two genial tubercles behind the symphysis of the jaw, and inserted into the anterior surface of the body of the hyoid bone.

*Relations.*—It is in contact above with the lower border of the genio-glossus muscle, and below with the mylo-hyoid and with its fellow in the middle line.

*Nerves.*—The muscles of this group receive their motor nerves from various sources, viz., the anterior belly of the digastric and the mylo-hyoid from the mylo-hyoid branch of the inferior maxillary division of the fifth nerve, and the posterior belly of the digastric and the stylo-hyoid from the facial nerve near the place of its exit from the stylo-mastoid foramen. The genio-hyoid receives its motor nerve from the hypoglossal.

*Actions.*—The genio-hyoid and mylo-hyoid muscles draw the hyoid bone upwards and forwards, as happens in the first stage of deglutition. The stylo-hyoid muscles draw it upwards and backwards, and come into action in raising the pitch of the voice. The anterior belly of the digastric muscle acts by itself like the genio-hyoid and the posterior half like the stylo-hyoid; but when both bellies act together they are capable of producing two

movements, in one of which, when the lower jaw is fixed, the hyoid bone is elevated, and in the other, when the hyoid bone is held downwards by the depressing muscles, the lower jaw is depressed.

Fig. 210.

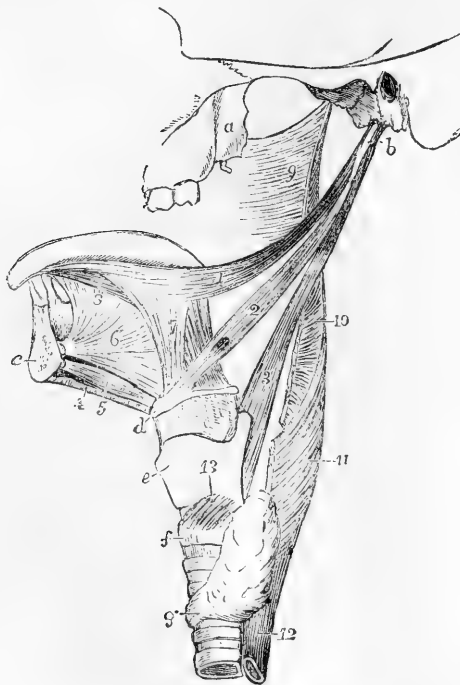


Fig. 210.—MUSCLES OF THE TONGUE, PHARYNX, &c., OF THE LEFT SIDE. (A. T.)  $\frac{1}{2}$

*a*, external pterygoid process; *b*, styloid process; *c*, section of the symphysis of the lower jaw; *d*, front of the body of the hyoid bone; *e*, thyroid cartilage; *f*, cricoid cartilage; between *d* and *e*, the thyro-hyoid membrane and ligament; *g*, isthmus of the thyroid gland; 1, stylo-glossus muscle; 2, stylo-hyoid; 3, stylo-pharyngeus; 4, cut edge of the mylo-hyoid; 5, genio-hyoid; 6, genio-hyo-glossus; 7, hyo-glossus; 8, lingualis inferior; 9, part of the superior constrictor of the pharynx; 10, back part of the middle constrictor; 11, inferior constrictor; 12, upper part of the œsophagus; 13, crico-thyroid muscle.

#### MUSCLES OF THE TONGUE.

The tongue is a muscular organ attached posteriorly to the hyoid bone, and inferiorly to the lower jaw. It is composed partly of fibres

peculiar to itself—the *intrinsic* muscles, which will be noticed along with the tongue; and partly of muscles arising from neighbouring parts—the *extrinsic* muscles about to be described.

The **genio-glossus** or **genio-hyo-glossus** muscle is fan-shaped, and is placed vertically in contact with its fellow in the mesial plane. It arises by a short tendon from the superior genial tubercle behind the symphysis of the jaw: from this its fibres diverge, to be inserted, the inferior, for the most part, into the body of the hyoid bone, and a few into the side of the pharynx; the superior into the tip of the tongue; and the intermediate fibres into the whole length of the tongue spreading outwards in its substance.

*Relations.*—The external surface is in contact with the lingualis inferior, hyo-glossus and stylo-glossus muscles, the sublingual gland, the ranine vessels, and the nerves of the tongue, and its lower border with the genio-hyoid muscle.

*Varieties.*—Occasional slips of this muscle have been noticed passing to the epiglottis (Luschka), or to the pharynx (Winslow), or to the stylo-hyoid ligament (Sömmerring). It has also been found united anteriorly with the genio-hyoid muscle.

The **hyo-glossus** is a flat quadrate muscle, arising from the whole length of the great cornu, from the lateral part of the body, and from

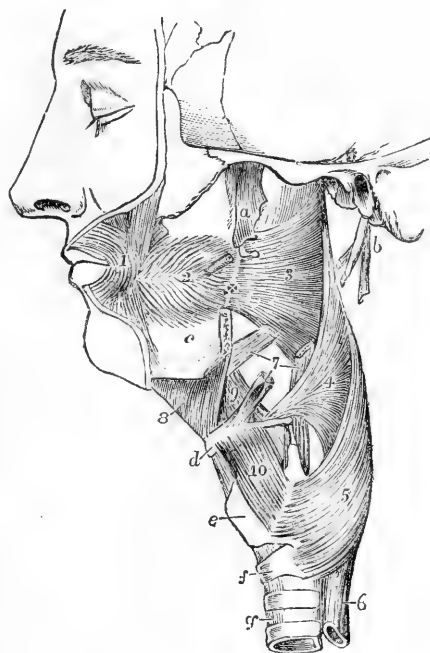
Fig. 211.—DEEP MUSCLES OF THE CHEEK, PHARYNX, &c. (modified from Cloquet). (A. T.)  $\frac{1}{2}$

The pharynx has been distended by stuffing. *a*, external pterygoid process; *b*, styloid process, with short portions of the three styloid muscles attached; *c*, body of the lower jaw, which has been divided at the place where the pterygo-maxillary ligament + is attached; *d*, body of the hyoid bone; *e*, thyroid cartilage; *f*, cricoid cartilage; *g*, trachea; 1, outer part of the orbicularis oris muscle; 2, buccinator; 3, superior constrictor of the pharynx; 4, middle constrictor; 5, inferior constrictor; 6, œsophagus; 7, points by three lines to the lower parts of the stylo-glossus, stylo-hyoid, and stylo-pharyngeus muscles respectively; 8, mylo-hyoid; 9, hyo-glossus, of which a small part is removed posteriorly to show the attachment of the middle constrictor; 10, thyro-hyoid.

the small cornu of the hyoid bone; it passes upwards to be inserted into the side of the tongue, blending with the stylo-glossus and palato-glossus muscles.

*Relations.*—The hyo-glossus is concealed by the digastric, stylo-hyoid and mylo-hyoid muscles, except at its posterior inferior angle: the deep part of the submaxillary gland rests on its surface, and it is crossed from below upwards by

Fig. 211.



the hypoglossal nerve, the Whartonian duct, and the gustatory nerve. It covers the genio-glossus and the origin of the middle constrictor of the pharynx, together with the lingual artery and glosso-pharyngeal nerve.

*Variety.*—*Triticeo-glossus* (Bochdalek). This is a small muscle which arises from the cartilago triticea in the posterior thyro-hyoid ligament, and passes upwards and forwards to enter the tongue along with the posterior part of the hyo-glossus. It always lies behind the lingual artery.

The **stylo-glossus**, the shortest of the three muscles which spring from the styloid process, arises from that process not far from its point, and from the stylo-maxillary ligament, to which in some cases the greater number of its fibres are attached by a thin aponeurosis: passing forwards and slightly downwards, it is inserted along the side and under part of the tongue as far as the tip, its fibres decussating, and becoming blended with those of the hyo-glossus and palato-glossus muscles.

*Relations.*—This muscle lies deeply beneath the parotid gland, and is crossed by the gustatory nerve.

*Varieties.*—The *mylo-glossus* (Wood) is a small accessory slip, which usually comes from the angle of the lower jaw, but has also been seen coming from the stylo-maxillary ligament. Occasionally the whole muscle arises from one of these points. A very rare origin has been noted by Gruber from the external meatus. Albinus and Böhmer have noted entire absence of the muscle, and various anatomists have seen it double.

*Nerves.*—The muscles of this group are all supplied with branches from the hypoglossal or motor linguæ nerve.

*Actions.*—The genio-glossus muscle has a complicated action, one part protruding and another retracting the tongue, while a third depresses the middle portion of the organ. Protrusion is effected by contraction of its posterior, and retraction by contraction of its anterior fibres, while the middle part, or nearly the whole muscle, acts as a depressor. In deglutition the stylo-glossus muscle raises the side of the tongue spasmodically backwards and upwards, while the hyo-glossus opposes that action. In other circumstances the first muscle assists in forming a hollow, and the second a convexity on the dorsum of the tongue.

#### MUSCLES OF THE PHARYNX AND SOFT PALATE.

THE PHARYNX, the dilated upper part of the alimentary tube, extending from the base of the skull to the œsophagus, presents at the sides and back a continuous wall, in great part formed and supported by distinct muscles resting posteriorly on the vertebral column, and is open in front towards the nasal cavity, the mouth, and the larynx.

The **CONSTRICATORS OF THE PHARYNX** are three thin expanded muscles which invest the pharyngeal wall, overlapping one another from below upwards, so that the lowest is most superficial.

The **inferior constrictor** muscle arises from the side of the cricoid cartilage, and from the oblique lateral ridge and upper and lower borders of the thyroid cartilage, and curves backwards, expanding as it proceeds, and unites with its fellow in the middle line behind the pharynx. The direction of the inferior fibres is horizontal, concealing and overlapping the commencement of the œsophagus; the rest ascend with increasing degrees of obliquity, and cover the lower part of the middle constrictor.

*Relations.*—This muscle lies in contact posteriorly with the cervical vertebrae and the longus colli muscle; its outer surface is related to the side of the larynx,

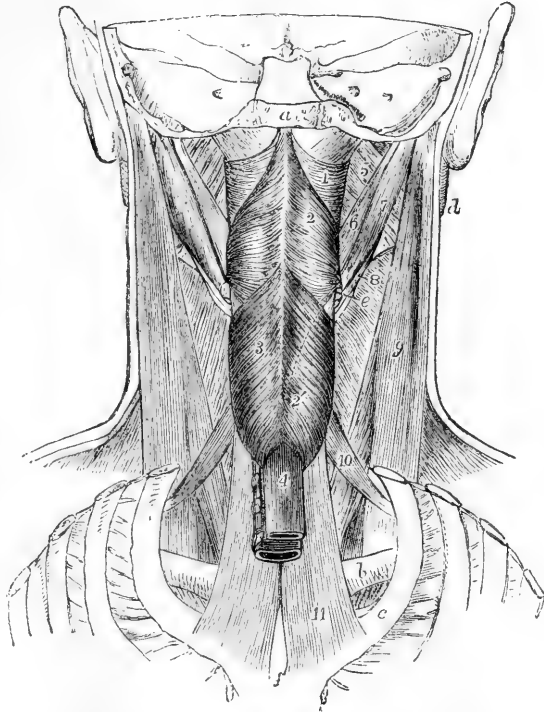


the thyroid body, the carotid artery, and the sterno-thyroid muscle; and from this last, where the two muscles meet on the thyroid cartilage, some fibres are continued into the constrictor. By its inner surface it is related to the middle constrictor, the stylo-pharyngeus, the palato-pharyngeus, and the mucous membrane of the pharynx. The two laryngeal nerves pass inwards to the larynx, close respectively to the upper and lower margins of this constrictor—the upper being interposed between it and the middle constrictor, the lower between it and the œsophagus.

Fig. 212.—VIEW OF THE MUSCLES OF THE PHARYNX, &C., FROM BEHIND (after Bourguery).  $\frac{1}{2}$

The back part of the skull, the vertebral column and back parts of the ribs are removed. *a*, cut surface of the basilar process; *b*, the clavicle; *c*, the first rib; *d*, the ramus of the lower jaw; *e*, posterior extremity of the great cornu of the hyoid bone; *f*, posterior surface of the manubrium of the sternum; 1, superior constrictor muscle of the pharynx; above it the fibrous membrane which closes the pharynx; 2, middle constrictor; 2', a dotted line, indicating the direction of the lower part of the muscle; 3, the inferior constrictor; 4, œsophagus; 5, internal pterygoid; 6, stylo-glossus; 7, posterior belly of the digastric; 8, a portion of the stylo-hyoid surrounding the tendon of the digastric; 9, sterno-mastoid; 10, upper belly of the omo-hyoid; 11, sterno-thyroid muscle (represented somewhat too broad).

Fig. 212.



The **middle constrictor** muscle arises from the upper surface of the cornua of the os hyoides, and from the stylo-hyoid ligament: its fibres, diverging greatly, pass back to the middle line of the pharynx behind, the lowest fibres inclining downwards, beneath the inferior constrictor, the highest ascending and overlapping the superior constrictor, and the intermediate fibres running transversely.

*Relations.*—This muscle is separated from the superior constrictor by the stylo-pharyngeus muscle and the glosso-pharyngeal nerve, while between its origin and that of the inferior constrictor the superior laryngeal nerve pierces the thyro-hyoid membrane.

*Varieties.*—Fibres of the middle constrictor have been observed to arise from the body of the os hyoides and the thyro-hyoid ligament, (*syndesmo-pharyngeus*

of Douglas), and a slip is frequently continued into it from the genio-hyo-glossus muscle. The two middle constrictors have been found connected behind to the base of the skull by muscular fibres or by a fibrous band (Albinus).

The **superior constrictor** arises by fibres attached in series from below upwards, to the side of the tongue, to the mucous membrane of the mouth, to the extremity of the mylo-hyoid ridge of the jaw, to the pterygo-maxillary ligament, and to the lower third of the posterior border of the internal pterygoid plate. The fibres curve backwards, and are mostly blended with those of the corresponding muscle along the middle line, a few ending posteriorly in the aponeurosis which fixes the pharynx to the base of the skull. The upper margin curves round the levator palati and the Eustachian tube; and the space intervening between this concave margin of the constrictor and the base of the skull is closed by fibrous membrane.

*Relations.*—In contact with the outer surface of this muscle are the internal carotid artery, the eighth and other large nerves, the middle constrictor, which overlaps a considerable portion, and the stylo-pharyngeus, which descends to the pharynx between the two constrictors. It conceals the palato-pharyngeus and the tonsil, and is lined by mucous membrane. It is united to the buccinator muscle anteriorly by the pterygo-maxillary ligament.

*Variety.*—The *azygos pharyngis* (Meckel) is a small mesial slip about half an inch in length, lying behind the upper and middle constrictors. It arises from the pharyngeal spine on the under surface of the basilar process of the occipital bone, and is inserted into the median raphe of the pharynx.

The **stylo-pharyngeus**, larger and longer than the other styloid muscles, arises from the inner surface of the styloid process, near the root, and proceeding downwards and inwards to the side of the pharynx, passes under cover of the middle constrictor muscle, where it detaches some fibres to the constrictors, and, gradually expanding, is connected with the palato-pharyngeus muscle, and ends in the superior and posterior borders of the thyroid cartilage.

*Relations.*—The external surface of this muscle is, in the upper part of its extent, in contact with the styloid process, the stylo-hyoideus muscle, and the external carotid artery; in the lower, with the middle constrictor of the pharynx. Internally it rests on the internal carotid artery and jugular vein; and lower down on the mucous membrane of the pharynx. The glosso-pharyngeal nerve is close to the muscle, and crosses over it in turning forwards to the tongue.

*Varieties.*—The *cephalo-pharyngeus* (Sandifort) is a small occasional muscle which usually arises from the vaginal process of the temporal bone, but sometimes also from the spine of the sphenoid or from the angle of the petrous bone (Macalister); in its course it is separated from the stylo-pharyngeus by the glosso-pharyngeal nerve, and it is finally lost below the inferior constrictor of the pharynx.

The *salpingo-pharyngeus* (Santorini), arising by a tendon from the Eustachian tube, descends in the interior of the pharynx towards its back part, and, after joining with the palato-pharyngeus, is lost in the muscular structure of the cavity.

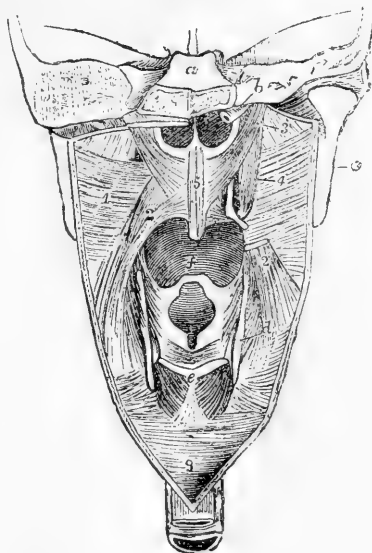
THE **SOFT PALATE** (*velum pendulum palati*) is a movable curtain, continued backwards from the hard palate. It presents posteriorly a free pendulous margin, prolonged in the middle into a conical process, the *uvula*, and at each side into two prominent curved folds, the anterior of which, the *anterior pillar* of the fauces, descends to the side of the tongue, while the posterior fold, the *posterior pillar* of the fauces, runs downwards and backwards into the pharynx; between the two is

lodged the tonsil. The constricted passage between the anterior pillars, leading from the mouth to the pharynx, is called the *isthmus* of the

Fig. 213.—DIAGRAMMATIC VIEW OF THE MUSCLES OF THE PHARYNX, &C., FROM BEHIND. (A. T.)  $\frac{1}{2}$

The posterior wall of the pharynx has been divided by a vertical incision in the middle line, and the cut edges drawn to the side so as to expose the nasal, buccal, and laryngeal openings; *a*, is above the cut surface of the basi-occipital bone, and below that are the posterior nares; *b*, cartilage of the left Eustachian tube; *c*, back of the ramus of the lower jaw; *d*, posterior border of the thyroid cartilage; *e*, upper part of the cricoid cartilage; *f*, base of the tongue above the epiglottis; *g*, lower end of the pharynx leading into the gullet; 1, superior constrictor of the pharynx seen from within, and part of the middle constrictor; 2, palato-pharyngeus; 2', the lower part of the same muscle, on the right side; 3, placed on the internal pterygoid muscle, points to the levator palati; 4, the right circumflexus palati muscle winding round the hamular process; 5, the azygos uvulæ; above *e*, the transverse arytenoid, and below it on each side the posterior crico-arytenoid muscle.

Fig. 213.



fauces. The soft palate is acted on by five pairs of elongated muscles, two superior, one intermediate, and two inferior.

The **palato-glossus** muscle, or **constrictor isthmi faucium**, occupies the anterior pillar of the fauces. Superiorly it is anterior to all the other muscles of the velum, and its fibres are continuous with those of its fellow of the opposite side; inferiorly, it is lost on the side of the tongue.

The **palato-pharyngeus** muscle, occupying the posterior pillar of the pharynx, arises in the soft palate by fibres connected with those of the opposite side, and passing partly above and partly below the levator palati and azygos muscles. As the muscle descends it becomes greatly expanded, and its fibres are found extended from the posterior cornu of the thyroid cartilage, back to the middle line of the pharynx posteriorly.

The **azygos uvulæ** muscle (Morgagni), so called from having been supposed to be a single muscle, consists of two slips, which arise, one on each side of the middle line, from the tendinous structure of the soft palate, and, sometimes, from the spine of the palate plate, and descend into the uvula. The two slips are separated by a slight interval above, and unite as they descend.

The **levator palati** muscle arises from the extremity of the petrous portion of the temporal bone, in front of the orifice of the carotid canal, and from the cartilaginous part of the Eustachian tube. Approaching the middle line as it passes downwards and forwards, it is inserted aponeurotically into the posterior part of the soft palate, and

meets its neighbour of the opposite side. In its upper part it is placed above the concave margin of the superior constrictor.

The **circumflexus** or **tensor palati** arises from the navicular fossa at the root of the internal pterygoid plate, from the outer side of the Eustachian tube, from the spine of the sphenoid, and the edge of the tympanic plate of the temporal bone. It descends perpendicularly, resting on the internal pterygoid plate, between it and the internal pterygoid muscle, and ends in a tendon which, turning round the hamular process, where a synovial bursæ smooths its passage, extends horizontally inwards, and terminates in the forepart of the aponeurosis of the soft palate and the under surface of the palate bone.

**Nerves.**—The muscles of this group receive their nerves from various sources, some of which are not yet sufficiently determined. The stylo-pharyngeus receives a branch from the glosso-pharyngeal; the constrictors are supplied from the same and from the pharyngeal plexus. The tensor palati receives a branch from the otic ganglion of the fifth nerve, the levator palati and azygos uvulæ from the facial through the petrosal nerve of the Vidian, and the palato-glossus and palato-pharyngeus from the palatine branches of Meckel's ganglion.

**Actions.**—The muscles of the pharynx and soft palate are so arranged as to accomplish, in conjunction with those of the tongue and hyoid bone, the action of deglutition—that is to say, the propulsion of food into the œsophagus without any portion being permitted to pass into the nasal cavity or larynx. while the tongue near the fauces is thrown upwards and backwards by the stylo-glossi muscles, and the larynx is drawn upwards and forwards under it by muscles attached to the hyoid-bone, and by the stylo-pharyngeus muscle, so as to be both closed by the epiglottis and overlapped by the tongue, the palato-glossi muscles constrict the fauces and shut off the bolus from the mouth. The soft palate is raised and made tense by its superior muscles; the palato-pharyngei, being approximated, nearly touch one another (the uvula lying in the small interval between them), and prevent the passage of the food towards the upper part of the pharynx or the posterior nares, while at the same time they form an inclined surface for its guidance into the lower part of the pharynx. The food being thus thrown into the grasp of the constrictors of the pharynx, those muscles contract from above downwards and force it into the tube of the gullet below. The Eustachian tube, according to most anatomists, is opened during deglutition by the contraction of the levator palati and salpingo-pharyngeus muscles. It should, however, be mentioned that a different view is taken by Cleland, who holds—and with him, to some extent, Luschka agrees—that the tube is closed during deglutition by the thickening which takes place during the contraction of the levator palati, pressing up the membranous floor of the canal against the firm upper and outer wall, so as completely to obliterate the opening. The salpingo-pharyngeus, when present, assists the palato-pharyngeus and superior constrictor in elevating the pharynx. (See Journ. of Anat., vol. iii., p. 97.)

#### SUBCUTANEOUS MUSCLE OF THE NECK.

The **platysma myoides** is a pale-coloured thin sheet of muscular fibres, superficial to the deep cervical fascia, and extending over the front and sides of the neck and lower portions of the side of the face. Its fibres rise by thin bands from the clavicle and acromion, and from the fascia covering the upper part of the deltoid, pectoral, and trapezius muscles: thence they proceed upwards and inwards over the clavicle and the side of the neck, gradually narrowing and approaching the muscles of the opposite side. The greater number of the fibres are inserted into the outer surface of the lower jaw from the symphysis to the attachment of the masseter; the inner fibres mingle with those of

the opposite platysma in front of the symphysis, and even cross from the one side to the other below the chin, those of the right side overlapping those of the left; and the posterior fibres are prolonged upon the side of the face as far as the angle of the mouth, blending with the *triangularis oris* and *orbicularis oris* muscles. The uppermost fibres (*risorius*, Santorini) have been already described.

*Varieties.*—The muscular fibres of the platysma sometimes extend upwards on the face and downwards on the neck, shoulder and breast further than usual; and they occasionally take attachment to the clavicle. This muscle is the representative in man of a subcutaneous group of muscles, the *panniculus carnosus*, largely developed in most mammals, by which very varied movements of the skin and some superficial parts may be given, as, for example, when the horse communicates a rapid motion to the skin to free itself from insects, or the dog shakes off the water after swimming, or the hedgehog elevates its spines.

*Nerves.*—The platysma receives its principal motor nerves from the descending branches of the facial, but as this unites with the superficial cervical nerve it may also be influenced through some of the spinal nerves.

*Action.*—The platysma, being much less developed in man than in animals has a comparatively limited action in the human subject; it raises the skin of the neck into longitudinal wrinkles; it also assists in drawing the angle of the jaw downwards and outwards, and protects parts more deeply situated in the neck. It is contracted in sudden fear, and assists in the expression of this emotion.

#### MUSCLES AND FASCIAE OF THE NECK ANTERIORLY.

*FASCIAE.*—The **deep cervical fascia** passes forwards from the anterior border of the trapezius muscle over the sides and front of the neck beneath the platysma myoides. Posteriorly it is continuous with the layers of connective tissue with which the trapezius and deeper muscles are invested; it extends over the posterior triangle of the neck, viz., the space bounded by the trapezius and sterno-mastoid muscles and the clavicle: at the posterior border of the sterno-mastoid it divides into two layers, which form an investment for that muscle; these unite again at the anterior border into a membrane which passes forwards across the middle line, and covers the area bounded by the middle line, the border of the jaw, and the sterno-mastoid muscle, and called the anterior triangle. In the posterior triangle the fascia is attached inferiorly to the clavicle, and near that bone is perforated by the external jugular vein, which in the previous part of its course lies superficial to the membrane. In the anterior triangle it is bound superiorly to the base of the jaw in front, and further back is continued over the masseter muscle (*masseteric fascia*), and the parotid gland (*parotid fascia*) to the zygoma.

In front the fascia is attached to the hyoid bone, and becoming stronger as it descends, it splits, a little below the level of the thyroid body into two distinct layers. Of these the more superficial and weaker, running along the sterno-mastoid muscles, is fixed to the sternum and the interclavicular ligament; whilst the stronger layer, lying under the former, and closely covering the sterno-hyoid and sterno-thyroid muscles, is attached to the deeper surface of that bone. These layers materially assist in closing the cavity of the chest behind the sternum superiorly: between them there exists a quantity of loose connective tissue and fat, and sometimes a small lymphatic gland.

Continuous with the deeper of those two layers, a fascia is found

in the posterior triangle, investing the posterior belly of the omo-hyoid muscle, and binding it down to the clavicle and first rib, where this structure is connected with the costo-coracoid membrane. Still deeper in the anterior triangle the fascia passes behind the depressor muscles of the larynx, investing the thyroid body, and extending thence on the trachea and large vessels at the root of the neck down to the fibrous layer of the pericardium.

Continuous with the deep processes of the cervical fascia is the *common sheath of the large cervical blood vessels*, an envelope of fascia enclosing the carotid artery and jugular vein with the pneumogastric nerve. A thin fibrous septum intervenes between the artery and vein, thus completing a separate sheath for each.

The layer of fascia descending on the prevertebral muscles, and intervening between them and the pharynx and œsophagus, is called the *prevertebral fascia*.

**MUSCLES.**—The **sterno-cleido-mastoid** or **sterno-mastoid** muscle is attached inferiorly in two parts to the anterior surface of the sternum and the inner third of the clavicle. The sternal attachment is thick and rounded, tendinous in front and fleshy behind. The clavicular portion, separated from the sternal by a narrow interval, is flat, and is composed of fleshy and tendinous fibres. Those two portions become blended together about the middle of the neck into a thick and prominent muscle, which, extending upwards and backwards, is attached superiorly to the anterior border and external surface of the mastoid process, and from thence backwards into a rough ridge of the temporal bone, and by a thin aponeurosis into the outer part of the superior curved line of the occipital bone. The sterno-mastoid muscle divides the quadrilateral space on each side of the neck into two great triangles.

*Relations.*—This muscle is covered for more than the middle three-fifths of its extent by the platysma. It is also crossed by the external jugular vein, and by the ascending superficial branches of the cervical plexus of nerves. It rests on part of the sterno-hyoid and sterno-thyroid muscles, and crosses the omo-hyoid muscle; in the middle part of the neck it covers the cervical plexus and the great cervical vessels, and in the upper part, the digastric and stylo-hyoid muscles: it is pierced by the spinal accessory nerve.

*Varieties.*—The sterno-cleido-mastoid is occasionally described as two muscles, under the names sterno-mastoid and cleido-mastoid. Normally the fibres of the clavicular part run upwards for some distance behind and inside those of the sternal part before finally blending with them, and sometimes they are separated at the root of the neck by a considerable interval which is occupied by connective tissue. The muscle varies much in breadth at the lower end, the variation being due altogether to the clavicular part, which is sometimes as narrow as the sternal tendon, while in other instances it extends for three inches along the clavicle. This part of the muscle may likewise, when broader than usual, be divided into several slips separated by intervals near the clavicle. A band of muscular fibres has, in a few instances, been found reaching from the trapezius to this muscle over the subclavian artery; and the margins of the two muscles have been observed in contact. In animals without a clavicle the cleido-mastoid muscle is continued into the clavicular part of the great pectoral muscle, thus forming a *mastoido-humeral* muscle.

The four following muscles may be classed together as a group of **DEPRESSORS OF THE HYOID BONE AND LARYNX**.

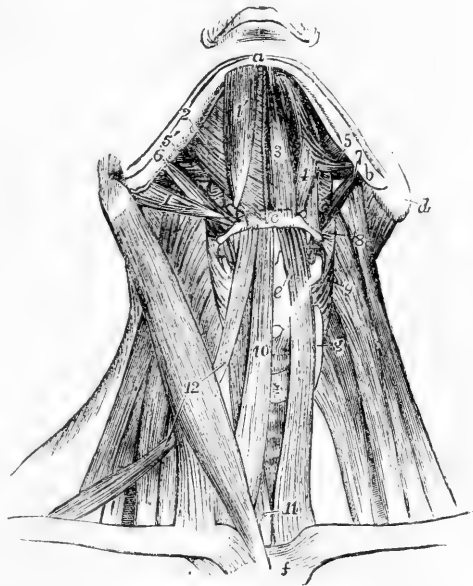The **sterno-hyoid** muscle, a flat band of longitudinal fibres, arises variously, from the sternum and the posterior sterno-clavicular ligament, from the clavicle and that ligament, or from the clavicle only, and

occasionally, to a small extent, from the cartilage of the first rib. It is inserted into the lower border of the body of the hyoid bone.

*Relations.*—The muscle is concealed below by the sternum and the sterno-mastoid muscle, higher up by the skin and fascia only; it lies on the sterno-thyroid and thyro-hyoid muscles, which it partly covers. The inner border approaches that of the corresponding muscle towards the middle of its extent, but is separated from it by a slight interval superiorly, and by a larger interval near the sternum; the outer margin is in contact with the omo-hyoid near the os hyoides. The muscular fibres are, in many cases, interrupted by a transverse tendinous intersection.

Fig. 214.—VIEW OF THE SUBMAXILLARY MUSCLES AND THE DEPRESSORS OF THE HYOID BONE AND LARYNX, FROM BEFORE. (After Bourguery).  $\frac{1}{3}$

Fig. 214.



(For the explanation of the references in the upper part of the figure, see p. 282). *c*, body of the hyoid bone; *d*, mastoid process; *e*, placed on the front of the thyroid cartilage, points to the thyro-hyoid muscle; *f*, upper part of the sternum; *g*, lateral lobe of the thyroid gland; +, its isthmus, above which is the crico-thyroid muscle covered by the crico-thyroid muscle; 8, placed on the levator scapulae, points to the left middle constrictor of the pharynx; 9, placed on the middle scalenus, points to the left inferior constrictor; 10, right sterno-hyoid; 11, placed on the left sterno-thyroid, points also to the lower part of the right muscle; 12, placed on the right sterno-mastoid, points to the upper and lower bellies of the right omo-hyoid.

The **sterno-thyroid**, broader and shorter than the preceding muscle, behind which it lies, arises from the thoracic surface of the first part of the sternum, lower down and more internally than the sterno-hyoid muscle, and ascends, diverging a little from its fellow, to be inserted into the oblique line on the ala of the thyroid cartilage.

*Relations.*—The greater part of its anterior surface is concealed by the sternum and the sterno-hyoid muscle, as well as by the sterno-mastoid. By its deep surface it rests on the innominate vein, the lower part of the common carotid artery, the trachea, and the thyroid body. The inner margin is contiguous to the muscle of the other side in the lower part of the neck. The median incision in the operation of tracheotomy is made between the two muscles.

*Varieties.*—This muscle is sometimes partly crossed by transverse or oblique tendinous lines. At the upper extremity a few fibres are often found to blend with the thyro-hyoid muscle or with the inferior constrictor of the pharynx.

The **thyro-hyoid** muscle is continued upwards from the preceding; it arises from the oblique line on the ala of the thyroid cartilage, and

is inserted into the lower border of the body and great cornu of the hyoid bone, near the place where these unite.

*Relations.*—This muscle is concealed by the sterno-hyoid and omo-hyoid, and rests on the ala of the thyroid cartilage, and on the thyro-hyoid membrane. Between that membrane and the muscle, the superior laryngeal nerve and artery are placed before entering the larynx.

The **omo-hyoid** is a long ribbon-shaped muscle, consisting of two bellies united by an intervening tendon. It arises from the upper border of the scapula, near the suprascapular notch, and occasionally from the ligament which crosses the notch. Thence it extends forwards and only slightly upwards, across the root of the neck, till it passes beneath the sterno-mastoid muscle, and then, curving rapidly, it ascends nearly vertically, to be inserted into the lower border of the body of the hyoid bone. The tendon which divides the muscle is placed beneath the sterno-mastoid muscle, and varies much in length and form in different bodies. The tendon is enclosed within the deep cervical fascia, which, after forming a sort of sheath for it, is prolonged downwards, and becomes attached to the sternum and the cartilage of the first rib; and by this means, as also by fascia investing the posterior belly and descending to the clavicle, the muscle is maintained in its curved position.

*Relations.*—At its scapular origin the muscle is covered by the trapezius, in the middle of its course by the sterno-mastoid, and at its upper part by the platysma; it crosses the scaleni muscles, the cervical nerves, the sheath of the common carotid artery and jugular vein, and the sterno-thyroid and thyro-hyoid muscles.

*Varieties.*—The muscle occasionally is attached to the clavicle instead of the scapula, arising from the former bone about its middle, and in such cases the posterior belly is absent. One instance has been recorded (R. Quain) in which the posterior belly alone was present, and was connected to the hyoid bone by a band of fascia. The muscle has likewise been observed double, one slip being attached to the clavicle and the other to the normal place of origin from the scapula.

*Nerves.*—The sterno-mastoid receives its motor nerves from the spinal accessory, which in the substance of the muscle is reinforced by union with branches from the second and third cervical nerves. The infra-hyoid muscles receive their motor nerves mainly from the hypo-glossal, the thyro-hyoid by a direct branch from the trunk of the nerve, the rest from the descendens noni, and in part from it in combination with the communicating branches from the second and third cervical nerves.

*Actions.*—The sterno-cleido-mastoid muscles acting together bend forwards the head and neck towards the sternum. When the muscle of one side only is in action, the head, while it is slightly flexed, is inclined laterally to the side on which the muscle contracts, and rotation is produced, by which the face, and especially the chin, is directed towards the opposite side. This is the attitude in wry-neck, produced by the unequal action of the muscles of the two sides.

While the sterno-hyoid and omo-hyoid muscles act only as depressors of the hyoid bone, the sterno-thyroid muscle, being a direct depressor of the thyroid cartilage, may also draw down the hyoid bone when it acts in conjunction with the thyro-hyoid, the latter muscle elevating the larynx when the hyoid bone is fixed. When, in the act of swallowing, the hyoid bone and thyroid cartilage have passed suddenly upwards and forwards, their original position is restored by the action of the infra-hyoid muscles. In the utterance of low notes the larynx and hyoid bone descend below the natural level, in the direction of the sternal muscles; while in the utterance of high notes there is little elevation of the



hyoid bone, but the larynx is raised by the action of the thyro-hyoid muscles. During deglutition the action of the thyro-hyoid muscles, by approximating the thyroid cartilage and hyoid bone, facilitates the descent of the epiglottis on the superior aperture of the larynx.

#### DEEP LATERAL AND PREVERTEBRAL MUSCLES OF THE NECK

The **SCALENI** muscles form a group of strong muscular columns, which are usually three in number, but sometimes only two. All of them are subdivided superiorly into musculo-tendinous slips, corresponding in number with their vertebral attachments.

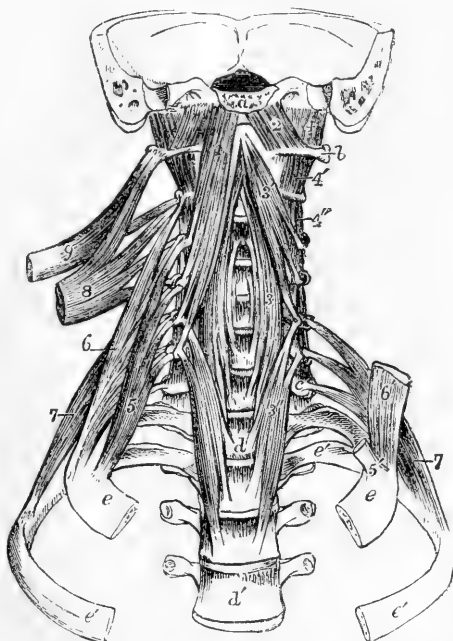
The **anterior scalenus** muscle is attached superiorly to the anterior tubercles of the transverse processes of the third, fourth, fifth, and sixth cervical vertebrae, and inferiorly by a thick flattened tendon to the scalene tubercle, a rough part of the inner border and upper surface of the first rib in front of the subclavian groove.

*Relations.*—This muscle is placed deeply: in its lower part it is crossed by the posterior belly of the omo-hyoid muscle, and in its whole length it is traversed by the phrenic nerve passing obliquely from above downwards and inwards. The subclavian vein and artery pass respectively in front and behind its inferior attachment. The nerves of the brachial plexus emerge from behind its outer border above the subclavian artery. The *rectus capitis anticus major* arises on its inner side, the ascending cervical branch of the inferior thyroid artery lies in the groove between that muscle and the scalenus, and in front is the internal jugular vein.

Fig. 215.—THE DEEP LATERAL AND PREVERTEBRAL MUSCLES OF THE NECK FROM BEFORE. (A. T.)  $\frac{1}{2}$

Fig. 215.

*a*, cut surface of the basilar process; *b*, transverse process of the atlas; *c*, transverse process of the seventh cervical vertebra; *d*, body of the first, *d'*, of the fourth dorsal vertebra; *e*, first, and *e'*, second rib; 1, *rectus capitis anticus major* muscle; 2, *rectus capitis anticus minor*; 3, middle part, 3', upper part, and 3'', lower part of the *longus colli*; 4, *rectus lateralis*; 4', first pair, and 4'', second pair of *intertransversales*; 5, *scalenus anticus* of the right side; 5', the tendon of attachment to the first rib on the left side; 6, *scalenus medius*; 6', lower portion of the corresponding muscle of the left side; 7, *scalenus posticus*, its superior attachments shown upon the left side; 8, upper part of the *levator scapulae* drawn out from its vertebral attachments; 9, *splenius colli*, shown in the same manner.



The **scalenus medius** is attached superiorly to the posterior tubercles

of the transverse processes of the last six cervical vertebræ; and inferiorly to a rough elevation on the first rib, extending for an inch and a half forwards from the tubercle.

*Relations.*—In front of this muscle, between it and the anterior scalenus, are the cervical nerves and the subclavian artery; behind it are the posterior scalenus and levator anguli scapulæ muscles.

*Varieties.*—This muscle sometimes arises from the transverse processes of all the cervical vertebræ. It takes the place of the first levator costæ.

The **scalenus posticus**, smaller than the other scaleni muscles, is attached above by two or three small tendons to the transverse processes of as many of the lowest cervical vertebræ, and inferiorly by an aponeurotic tendon to the second rib, between its tubercle and angle, in front of the attachment of the second levator costæ.

*Relations.*—This muscle is partly covered by the middle scalene muscle, and is in contact by its posterior surface with the levator costæ and cervicalis ascendens muscle.

*Varieties.*—The scaleni muscles are subject to some amount of variation, both in the number of their points of attachment, and in the arrangement of their fibres. A slip from the scalenus anticus sometimes passes behind the subclavian artery.

The **PREVERTEBRAL** muscles of the cervical region consist of three, of which two pass to the head from the upper vertebræ, viz., the recti capitis antici major and minor, and the third is confined to vertebral attachments, the longus colli. Along with these the rectus capitis lateralis muscle may also be described in this place.

The **rectus capitis anticus major** muscle arises by tendinous slips from the anterior tubercles of the transverse processes of the third, fourth, fifth, and sixth cervical vertebræ: it is inserted into the basilar process of the occipital bone, a little in front of the foramen magnum. The muscles of opposite sides converge as they ascend, and their mesial fibres are longest.

*Relations.*—The anterior surface of the rectus capitis anticus major supports the pharynx, the sympathetic and vagus nerves, and the great cervical vessels. The posterior surface rests upon part of the longus colli and the rectus anticus minor.

The **rectus capitis anticus minor**, under cover of the preceding muscle, arises from the anterior arch of the atlas, and slightly from the root of its transverse process; it is inserted into the basilar process, between the margin of the foramen magnum and the preceding muscle, half an inch from its fellow.

The **rectus capitis lateralis** is a short thick muscle arising from the upper surface of the anterior division of the transverse process of the atlas, and inserted into the rough surface beneath the jugular eminence of the occipital bone. It completes the series of intertransversales muscles, which are described along with the deep posterior muscles of the neck.

*Relations.*—The anterior surface of this muscle is in contact with the internal jugular vein, the posterior with the vertebral artery.

The **longus colli** muscle rests on the front of the vertebral column from the atlas to the third dorsal vertebra: it consists of three sets of fibres, of which two are oblique, and one vertical. *a.* The superior

oblique portion arises, by a narrow tendinous process, from the anterior tubercle of the body of the atlas, and is inserted into the fore part of the transverse processes of the third, fourth, and fifth cervical vertebræ. *b.* The inferior oblique, the smallest part of the muscle, extends obliquely downwards and inwards from the transverse processes of the fifth and sixth cervical to the bodies of the first two or three dorsal vertebræ. *c.* The vertical part, connected by its extremities with the other divisions, is attached superiorly to the bodies of the second, third, and fourth cervical vertebræ, and inferiorly to the bodies of the three lower cervical and two or three upper dorsal vertebræ.

*Relations.*—By its anterior surface this muscle is in contact with the pharynx and œsophagus, the great vessels of the neck contained in their sheath, the sympathetic and recurrent laryngeal nerves, and the inferior thyroid artery. Behind, it rests upon the vertebræ.

*Nerves.*—The rectus capitis anticus major and minor are supplied by branches from the upper cervical nerves; the longus colli and scaleni by branches of the lower cervical nerves.

*Actions.*—The scalene muscles, when the vertebral column is fixed, act as elevators of the ribs, and by many are considered as constant aids in the movement of inspiration. They may also act as lateral flexors of the neck when the ribs are fixed. The longus colli muscle is chiefly a flexor of the vertebral column. The recti muscles are capable of producing some degree of flexion of the head, and from the obliquity of their fibres may probably, when acting on one side, also give rise to slight rotation.

#### IV.—MUSCLES AND FASCIÆ OF THE TRUNK.

The muscles passing between the trunk and the upper limb having been already described, those which belong exclusively to the trunk itself will now be treated of under the three divisions of, 1. Dorsal muscles, extending throughout the whole length; 2. Thoracic muscles, including the diaphragm; and 3. Abdominal and Perineal muscles.

##### I.—DORSAL MUSCLES AND FASCIÆ.

The muscles to be described under the above head, taken as a whole, occupy the vertebral groove or hollow between the line of vertebral spines and the prominences formed by the mastoid processes, the transverse cervical processes, the most projecting parts of the ribs, and the crest of the ilium, and they extend from the superior curved line of the occipital bone to the lower part of the sacrum. Some of them are small and are limited to certain parts of the extensive region now referred to; others extend either continuously or by the serial repetition of similar short fasciculi, throughout the greater part of it. These muscles, together with those in the same region which belong more properly to the upper limb, have been frequently described as constituting six successive layers; but the limits of several of these layers are ill-defined, and it will be sufficient for the purpose of description to arrange the muscles falling properly within the present section, according to the main characteristics of their form and position, in the following groups: viz., *a*, the posterior serrati muscles; *b*, the splenius and long erectors of the spine; *c*, the complexus and transverso-spinales; *d*, the interspinales and intertransversales; *e*, the

short cranio-vertebral muscles. Of these muscles those included in the first two groups may be considered as having their fibres passing outwards from the middle; those in the third group as having their fibres passing inwards; those of the fourth group as having their fibres passing in a nearly vertical direction; and those of the fifth group, confined to the upper part of the vertebral column and to the head, may be looked upon as combining some examples of the others.

**SERRATI MUSCLES.**—The **serratus posticus superior** is a thin flat muscle, which arises from the lower part of the ligamentum nuchæ and from the spines of the last cervical and two or three upper dorsal vertebræ by a thin aponeurotic tendon forming about a third of the length of the muscle; it is inserted by four fleshy digitations into the second, third, fourth, and fifth ribs, a little beyond their angles. It is directed obliquely downwards and outwards, resting on the deep muscles and the angles of the ribs. The muscle is covered, excepting at its superior border, by the rhomboid and levator anguli scapulæ muscles.

Fig. 216.

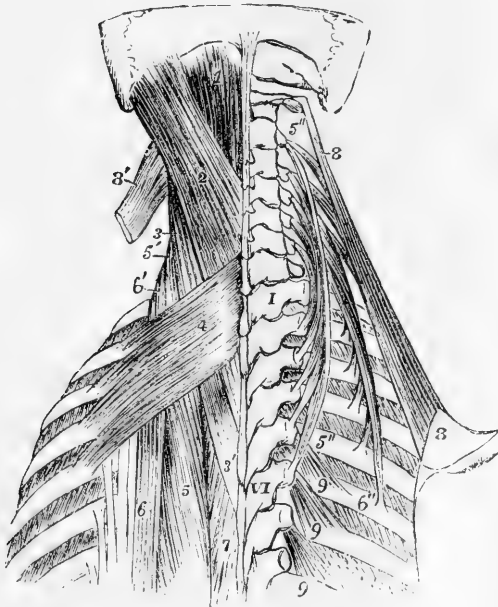


Fig. 216.—DORSAL MUSCLES OF THE UPPER PART OF THE TRUNK. (A. T.).  $\frac{1}{4}$

I, first; VI, sixth dorsal vertebra, 1, upper part of the complexus muscle; 2, splenius capitis; 3, 3', splenius colli; 4, serratus posticus superior; 5, upper part of the longissimus dorsi; 5', the same continued up on the left side into the transversalis cervicis; 5'', 5'', on the right side, the transversalis cervicis spread out from its attachments; 6, upper insertions of the sacro-lumbalis and accessorius; 6', the same continued up on the left side into the cervicalis ascendens; 6'', lower end of the latter muscle of the right side spread out from its attachments; 7, small part of the spinalis dorsi; 8, right levator anguli scapulæ; 8', on the left side, its upper part divided; 9, three of the levatores costarum on the right side.

The **serratus posticus inferior**, broader and stronger than the preceding muscle, passes outwards and upwards to the four lowest ribs; it arises, by a thin aponeurotic membrane from the posterior layer of the lumbar aponeurosis, and is inserted by four fleshy digitations into the lower borders of the last four ribs. The uppermost of those digitations is very broad, and covers in part the second; the last, varying in size with the length of the twelfth rib, is entirely concealed by the rest of the muscle (see fig. 165, p. 191). The serratus inferior is covered by

the latissimus dorsi, and its aponeurotic part is firmly united for some distance with the tendon of that muscle.

**Actions.**—The serratus posticus superior elevates the upper ribs, and is therefore to be regarded as a muscle of inspiration. The serratus inferior acts directly as a depressor of the lower ribs, and may aid either in expiration or inspiration; in expiration by acting in concert with the muscles which depress the higher ribs; in inspiration by fixing the lower ribs and giving firmness to the origin of the diaphragm.

The **vertebral aponeurosis** is situated on the same plane as the serratus posticus inferior, and consists of a thin lamella which separates the muscles belonging to the shoulder and arm from those which support the spine and head. Its fibres are for the most part transverse; some however are longitudinal. Above, it passes beneath the superior serratus; below, it is connected with the tendons of the latissimus and inferior serratus muscles, and in being stretched from the spinous processes outwards across the vertebral groove, it helps to enclose the angular space in which are lodged the long extensor muscles.

**DORSAL AND LUMBAR FASCIAE.**—Under the name of **lumbar fascia** or **aponeurosis** it has been customary to describe three layers of strong fibrous substance sheathing the erector spinæ and quadratus lumborum muscles. The deeper parts of this structure, to which by some the name of lumbar fascia is restricted, will be described along with the abdominal muscles, with which they are chiefly connected. The *superficial* or *posterior* layer is that through which the latissimus dorsi and serratus posticus inferior muscles are attached to the spines of the dorsal, lumbar and sacral vertebræ and to the crest of the ilium. This layer, which is of considerable strength, extends outwards beyond the origin of the latissimus and serratus inferior, and being closely united with the middle layer, binds down firmly the erectores spinæ muscles: it is by some described as the lower part of the vertebral aponeurosis, with which it is continuous, by others it has been named the aponeurosis of the latissimus dorsi.

The **SPLIENIUS** muscle is so named from its having the form of a strap, which binds down the parts lying under it. It is attached superiorly in part to the cervical vertebræ, in part to the skull, and is described accordingly under two names.

*a.* The **splenius colli** is attached inferiorly to the spinous processes of the third, fourth, fifth, and sixth dorsal vertebræ, and superiorly along with the slips of the levator anguli scapulæ to the transverse processes of the first two or three cervical vertebræ.

*b.* The **splenius capitis**, broader and thicker than the preceding, arises from the spines of the seventh cervical and two upper dorsal vertebræ, and from the ligamentum nuchæ as high as the third cervical vertebræ. It is inserted into the lower and back part of the mastoid process, and into the outer part of the superior curved line of the occipital bone.

**Relations.**—The splenius is covered by the trapezius, the rhomboid, and the serratus posticus superior; and at its attachment to the occipital bone by the sterno-mastoid. It conceals, in part, the complexus and trachelo-mastoid.

**ERECTOR SPINÆ.**—This muscle may either be regarded as one large composite muscle, or as consisting of seven distinct muscles. Viewed as one muscle it may be conveniently considered as formed of three

columns, of which the inner, or that next the spine, is comparatively slender; the middle and outer columns are much thicker, and consist each of three divisions which have received separate names.

The erector spinæ takes origin inferiorly as a common mass, the outer part of which is muscular, while the inner and larger part is tendinous. The muscular portion arises from the posterior fifth of the crest of the ilium; the tendinous portion arises from the back part of the ilium, the lower and back part of the sacrum, and the sacral and lumbar spines; it is inseparably united below with the lumbar aponeurosis, and is prolonged upwards on the surface of the muscular part, concealing the multifidus spinæ. The division of the larger part into the external and middle columns takes place below the level of the last rib.

The three parts of the outer columns are—

*a.* The **ilio-costalis** (Theile) or **sacro-lumbalis**, the main muscle of the outer column, is fleshy inferiorly, springing from that part of the common origin which proceeds from the crest of the ilium; it ends in a series of tendons which incline slightly outwards, and are inserted one into each of the six or seven lowest ribs at their angles.

*b.* The **musculus accessorius ad ilio-costalem** (**ad sacro-lumbalem**) is a continuation upwards of the preceding muscle. It arises by flat tendons from the upper margins of the lower six ribs, internal to the tendons of the ilio-costalis, and ends superiorly by continuing the series of those tendons to the angles of the upper ribs.

*c.* The **cervicalis ascendens** consists of slips in serial continuation with those of the musculus accessorius, taking origin from four or five of the highest ribs, and inserted into the transverse processes of three cervical vertebræ, usually the fourth, fifth, and sixth. Its insertions are intimately connected with those of the transversalis cervicis.

The middle column consists of

*d.* The **longissimus dorsi** muscle. This muscle is both larger and longer than the ilio-costalis, its original fibres passing as high as the first dorsal vertebræ. Internally it is closely connected on the surface with the spinalis dorsi, from the lower part of which it generally receives one or more tendinous slips. When those slips and the tendons of origin from the lumbar spines are cut through, the inner surface of the muscle can be brought into view. The longissimus dorsi presents two series of insertions. The inner row of insertions is a series of rounded tendons attached to the inferior tubercles of all the transverse processes of the dorsal, and the accessory processes of the lumbar vertebræ. The outer insertions form a series of thin fleshy processes which are attached in the dorsal region to the nine or ten lowest ribs, between their tubercles and angles, and in the lumbar region to the whole length of the transverse processes, and beyond these to the lumbar fascia connected with them.

*e.* The **transversalis cervicis** muscle prolongs upwards the column of fibres of the longissimus dorsi. It arises from the internal tubercles of the transverse processes of the four or five highest dorsal vertebræ, and occasionally the last cervical, and is inserted into the posterior tubercles of the transverse processes of five cervical vertebræ from the second to the sixth inclusive. It always receives a slip of the original fibres of the longissimus dorsi.

*f.* The **trachelo-mastoid** muscle, which may be regarded as the

continuation of the longissimus dorsi to the head, arises in close connection with the transversalis cervicis from the upper dorsal transverse processes, and also from behind the articular processes of the three or four lowest cervical vertebræ, and, forming a thin flat muscle, passes to be inserted into the posterior margin of the mastoid process, under cover of the splenius and sterno-mastoid muscles. It is the only muscle which lies between the splenius and complexus, and the only portion of the erector spinæ concealed by the former.

7. The **spinalis dorsi** is a long narrow muscle placed at the inner side of the longissimus dorsi, and closely connected with it. It forms the innermost column of the erector spinæ. It arises by several tendons from the spines of the first two lumbar, and the two lowest dorsal vertebræ, and is inserted into from four to eight of the higher dorsal spines. It adheres closely to the semispinalis muscle upon which it lies.

**Actions:**—The splenii and trachelo-mastoid muscles of both sides acting together draw backwards the head and upper cervical vertebræ: when the muscles of one side alone act, the extension is accompanied by lateral flexion and rotation, especially of the head on the axis.

When the greater part of the erector muscles of the spine are in action on both sides, they bend backwards the vertebral column and trunk; and these muscles co-operate powerfully in almost every great muscular effort of the body or limbs. Their power to straighten the back from the bent condition, as measured by the muscular dynamometer, varies in adults of medium strength from 200 lbs. to 400 lbs. By the action of the erector muscles of one side a certain amount of lateral flexion and of rotation, which is greatest in the chest, accompanies the extension. A certain amount of extension or erection of the spine, as previously stated, accompanies inspiration; but if the spine be fixed, some of the erector muscles may also, by their costal attachments, depress the ribs, and thus assist in expiration.

**COMPLEXUS AND TRANSVERSO-SPINALES.**—The muscles of the complicated group comprising the complexus, semispinalis, multifidus and rotatores spinæ, present the feature in common of ascending with an inward inclination, and are thus distinguished from those last described. The most superficial, the complexus, not usually included in this group, but obviously resembling the others, has the longest and most vertical fibres, but is the shortest in its whole extent, being limited to the upper dorsal and the cervical region; the muscle beneath it, the semispinalis, occupies the greater part of both these regions: while the multifidus spinæ, extending from the sacrum to the axis, has the shortest and most oblique fibres.

The **complexus** muscle arises by tendinous points from the transverse processes of the seven highest dorsal and the lowest cervical vertebræ, and from the articular processes of four and sometimes five other cervical vertebræ, together with the capsular ligament uniting them; and it is inserted into the large internal impression between the two curved lines of the occipital bone. It is narrower above than below, and its inner margin in the neck is in contact with the ligamentum nuchæ. Above its middle the muscle is partly intersected by a tendon. This portion of the muscle is often described separately, under the name of *biventer cervicis*: its fibres are also frequently connected by a tendinous slip with one or two of the spinous processes belonging to the last cervical or first dorsal vertebræ.





gissimus; 7, ilio-costalis drawn slightly inwards to show the slips of insertion into the lumbar fascia and the various ribs; inside the costal insertions are seen the origins of the accessorius; 7', the ascendens cervicis continued upwards from the accessorius; 8, spinalis dorsi. On the right side, 6, marks, in the lumbar region, the insertions of the longissimus dorsi into the upper four transverse processes (the insertion into the accessory processes not being shown); in the dorsal region the narrower tendons of insertion into the lower part of the dorsal transverse processes (the six lower only are represented); 6', the series of insertions into nine ribs; 7, the ilio-costalis drawn outwards; 7', placed between the lowest costal insertion of the ilio-costalis and the lowest origin of the accessorius; 7'', extension of the ascendens cervicis from the fifth rib towards the neck; 9, 9, semi-spinalis colli; 10, 10, semi-spinalis dorsi; 11, 11, lower dorsal and lumbar parts of the multifidus spinæ, which appears again above the semi-spinalis colli, over the upper 9; 12, levatores costarum, long and short; 13, in the upper part of the figure, points by four lines to the rectus capitis posticus minor, rectus major, obliquus superior, and obliquus inferior muscles.

*Relations.*—The complexus muscle is covered by the splenius, except at its lowest origins from the dorsal vertebræ and at the internal portion of its upper extremity; the trachelo-mastoid and transversalis cervicis rest upon its series of origins, and the semispinalis colli, the posterior recti, and the obliqui capitis, together with the deep cervical artery, are concealed by it.

The **semispinalis** muscle consists of fibres extending from transverse processes to spines, each bundle crossing over about five vertebræ. It is described in two parts.

*a.* The *semispinalis colli* is the part under cover of the complexus. It arises from the internal tubercles of the upper four or five dorsal transverse processes, and is inserted into the spines of the cervical vertebræ from the second to the fifth inclusive being thickest at its insertion into the second vertebra.

*b.* The *semispinalis dorsi*, not covered by the complexus, consists of narrow muscular bundles interposed between tendons of considerable length, and forms an elongated thin stratum, especially towards its lower border. It arises from the transverse processes of the dorsal vertebræ from the tenth to the fifth inclusive, and is inserted into the spines of the last two cervical and first four dorsal vertebræ.

The **multifidus spinæ** muscle reaches from the sacrum to the axis vertebra, passing up under cover of the semispinalis, and is much more largely developed towards the lower than at the upper end of the column. In the sacral region the fibres arise from the deep surface of the tendinous origin of the erector spinæ, from the groove on the back of the sacrum as low as the fourth foramen, from the inner part of the posterior extremity of the iliac crest, and from the ligaments between that bone and the sacrum; in the lumbar region they take origin from the mammillary processes; in the dorsal region from the transverse processes; and in the neck from the articular processes of the four lower cervical vertebræ. From these several points the muscular bundles ascend obliquely, to be inserted into the laminæ of the vertebræ, and into the spines from their bases nearly to their extremities. The fibres from each point of origin are fixed to several vertebræ, some being inserted into the side of the spinous process next above, and others ascending more and more vertically as high as the fourth from the place of origin; the longer fibres from one origin overlapping those from the origin next above.

The **rotatores spinæ** are eleven pairs of small muscles, which may be regarded as the deepest fibres of the multifidus spinæ in the dorsal

region, and are distinguished by being more nearly horizontal than the rest. Each arises from the upper and back part of the transverse process, and is inserted into the vertebra next above, at the inferior margin and on part of the surface of the lamina, as far as the root of the spinous process.

**INTERTRANSVERSALES.**—The **intertransversales** are short muscles passing nearly vertically from vertebra to vertebra between the transverse processes. They are most developed in the cervical, and least in the dorsal region. Beneath each cervical transverse process there are two such muscles, one descending from the anterior, and another from the posterior part of the process. In the lumbar region there are likewise two sets: one set, the *intertransversales laterales*, lie between the transverse processes, and are in series with the levatores costarum; the other set, *intertransversales mediales* or *interaccessorii*, pass from the accessory process of one vertebra to the mammillary process of the next, and are in series with the intertransversales of the dorsal region

Fig. 218.

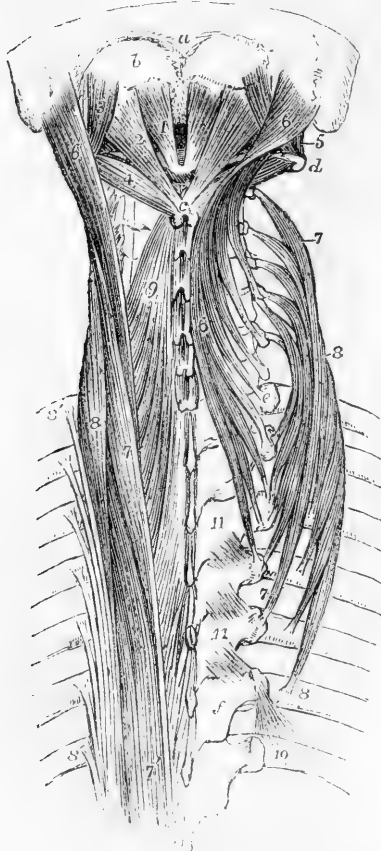


Fig. 218.—VIEW OF THE DEEP POSTERIOR MUSCLES OF THE UPPER PART OF THE VERTEBRAL COLUMN. (A. T.) 3

*a*, posterior occipital protuberance; *b*, surface between the superior and inferior curved lines on which the complexus is inserted; *c*, spinous process of the axis vertebra; *d*, transverse process of the atlas; *e*, transverse process of the first dorsal vertebra; *f*, lamina of the sixth dorsal vertebra; 1, rectus capitis posterior minor muscle; 2, rectus capitis posterior major; 3, obliquus superior; 4, obliquus inferior; 5, rectus capitis lateralis; 6, trachelo-mastoid, the muscle of the right side turned inwards and its slips of attachment to the dorsal and cervical transverse processes separated from each other; 7, transversalis cervicis, the figures are placed near the extreme ends of the muscle on the right side; 7', on the left side, longissimus dorsi; 8, cervicalis ascendens, the muscle of the right side is spread out; 8', on the left side, the seven upper tendinous insertions of the iliocostalis and accessorius muscles; 9, upper part of the semispinalis colli of the left side; 10, placed on the seventh rib of the right side close to the insertion of its levator costae muscle; 11, 11, three rotatores vertebrarum between the third and sixth dorsal vertebrae.

**INTERSPINALES.**—The **interspinales** are short vertical fasciculi of fleshy fibres, placed in pairs between the spinous processes of the contiguous vertebrae. They are best marked in the neck, where they are

connected one to each of the two parts into which the spinous process is divided. In the dorsal part of the column only a few are met with, and these are not constant.

*Varieties.*—The *spinalis cervicis* consists of a few irregular bundles of fibres, of greater length than the preceding muscles, placed close to the ligamentum nuchæ: they arise by two or more heads from the spines of the fifth and sixth cervical and sometimes other neighbouring vertebrae, and are inserted into the spine of the axis, and occasionally into the two vertebrae next below it. This muscle is sometimes wanting. (See Henle and Heidenbeck, in Müller's "Archiv," 1837.)

The name *sacro-coccygeus posticus*, or *extensor coccygis*, has been given to slender fibres occasionally found extending from the lower end of the sacrum to the coccyx, and representing the extensor of the caudal vertebrae of other animals. (Günther and Milde, "Chirurgische Muskellehre," quoted by Theile, "Sömmerring vom Baue," &c.)

**SHORT POSTERIOR CRANIO-VERTEBRAL MUSCLES.**—The **rectus capitis posticus major** muscle arises by a narrow tendon from the spinous process of the axis, and expanding as it passes upwards and outwards, is inserted into and beneath the outer part of the inferior curved line of the occipital bone. Its insertion is inside and below that of the superior oblique muscle.

The **rectus capitis posticus minor** muscle arises from the posterior arch of the atlas by the side of the tubercle, and expands as it passes to be inserted into the inferior curved line of the occipital bone, and the rough surface between that and the foramen magnum.

The **obliquus capitis inferior**, the strongest of the muscles now under consideration, arises from the spinous process of the axis, between the origin of the rectus posticus major and the insertion of the semi-spinalis colli, and is inserted into the extremity of the transverse process of the atlas.

The **obliquus capitis superior**, smaller than the preceding muscle, arises from the upper surface of the transverse process of the atlas, inclines from thence obliquely upwards and backwards, increasing somewhat as it ascends, and is inserted into a groove situated externally to the inferior curved line of the occipital bone.

*Relations.*—The two oblique muscles with the rectus major, form the sides of a small triangular space, in the area of which the posterior primary branch of the sub-occipital nerve and the vertebral artery will be found.

*Nerves.*—All the muscles of the back which are unconnected with the upper limb, viz., the posterior serrati, splenius, complexus, erector spinae, and the muscles more deeply seated are supplied by the posterior primary branches of the spinal nerves.

*Actions.*—The transverso-spinales muscles, including the complexus, are essentially extensors of the head and vertebral column; and the movements produced by them vary according as the muscles of one side or both are in action, in a manner similar to that already pointed out in regard to the erector muscles.

The interspinales and intertransversales muscles approximate the vertebrae between which they pass, and thus may act as extensors and lateral flexors respectively of the portion of the vertebral column in which they are situated.

Of the four muscles last described, two—the rectus minor and superior oblique—act principally by drawing the head backwards, that being the chief movement allowed between the atlas and occipital bone; while the principal action of the rectus posticus major and the inferior oblique, when acting on one side, is to rotate the atlas and skull upon the axis.

## MUSCLES OF THE THORAX.

The muscles of the thoracic wall are the intercostales, levatores costarum, subcostales, and triangularis sterni, and along with these the diaphragm intervening between the thorax and abdomen may conveniently be grouped.

The **INTERCOSTAL MUSCLES** consist of two thin layers of oblique short muscular fibres filling up the intercostal spaces : these layers are named respectively the external and internal muscles.

Fig. 219.

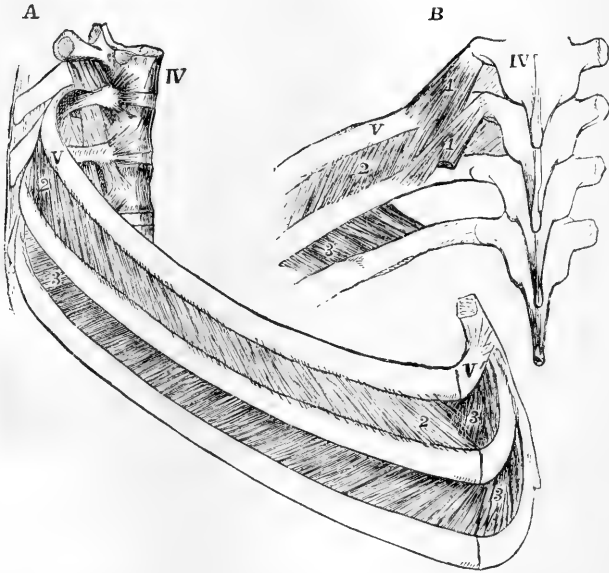


Fig. 219.—VIEW OF SEVERAL OF THE MIDDLE DORSAL VERTEBRÆ AND RIBS, TO SHOW THE INTERCOSTAL MUSCLES (after Cloquet). (A. T.)  $\frac{1}{2}$

A, from the side ; B, from behind.

IV, the fourth dorsal vertebra ; V, V, the fifth rib and its cartilage ; 1, 1, the levatores costarum muscles, short and long ; 2, the external intercostal muscles ; 3, the internal intercostal layer shown, in the lower of the two spaces represented, by the removal of the lower of the external layer, and seen in A in the upper space, in front of the external layer : the deficiency of the internal layer towards the vertebral column is shown in B.

The **external intercostal** muscles, consisting of muscular with some tendinous fibres intermixed, are directed obliquely downwards and forwards from one rib to another. Their extent for the most part is from the tubercles of the ribs, nearly to the outer end of the cartilages ; but in the two lowest intervals they reach forwards to the ends of the spaces. Thin tendinous fibres, having the same direction as the external intercostal muscles, are continued forwards between the costal cartilages, from the points where the muscles cease, to the sternum, and there cover the internal intercostals.

The **internal intercostal** muscles, placed deeper than the preceding, are attached to the inner margins of the ribs and their cartilages.

Commencing at the anterior extremities of the cartilages of the ribs, they extend as far back as a point within the angles of those bones. The fibres incline downwards and backwards, crossing those of the external intercostals; they are, however, somewhat shorter and less oblique in their direction.

*Relations.*—The internal are separated from the external intercostal muscles at the back of the spaces by the intercostal vessels and nerves; they are lined internally by the pleura.

Fig. 220.

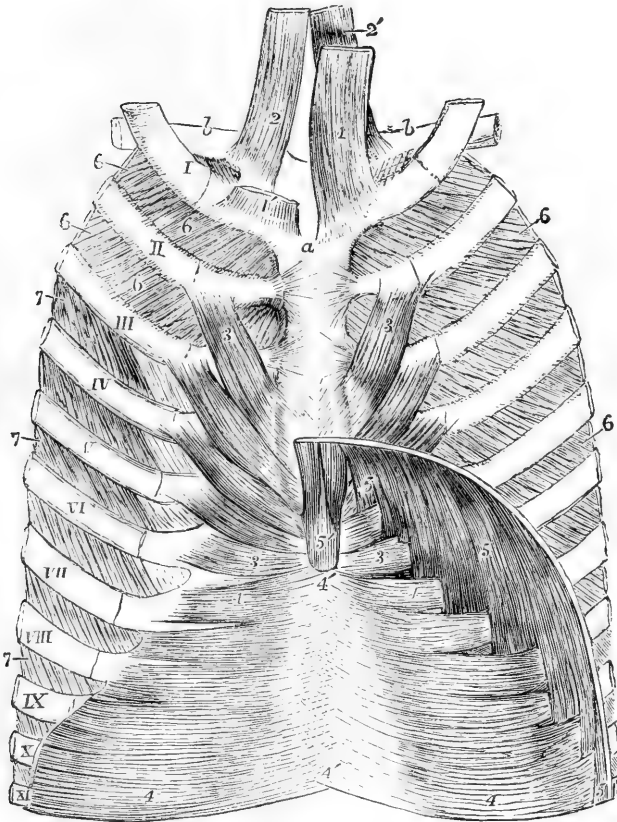


Fig. 220.—VIEW OF THE DEEP MUSCLES OF THE ANTERIOR WALL OF THE THORAX, SEEN FROM BEHIND (modified from Luschka). (A. T.)  $\frac{1}{3}$

*a*, back of the manubrium of the sternum; *b*, clavicles; I to XI, the anterior parts of eleven ribs and costal cartilages; 1, 1', sterno-thyroid muscles, that of the right side being cut short to show more fully the next muscle; 2, 2', the sterno-hyoids; 3, triangularis sterni; 4, upper part of transversalis abdominis united in 4', 4', the back of the linea alba; 5, attachments of the diaphragm to the lower ribs (the twelfth not represented in the figure), indigitating with those of the transversalis; 5', the two slips to the ensiform process; 6, internal layer of intercostal muscles extending to the sternum, shown in all the spaces on the right side, but only in the two uppermost of the left side; 7, in the lower spaces of the left side, indicates the external layer of intercostal muscles exposed by removing the internal layer.

The **levatoros costarum**, twelve on each side, arise from the tips of the transverse processes of the seventh cervical and eleven highest dorsal vertebræ. Corresponding in direction with the external intercostal muscles, on which they lie, they pass downwards and outwards, spreading as they descend, and each is inserted into the outer surface of the rib belonging to the vertebra below that from which it springs. The levator muscles belonging to the lower ribs present some longer additional fibres which, passing over a rib, are inserted into the next one below; these fibres are sometimes distinguished as *levatoros costarum longiores*.

*Relations.*—The levatoros costarum lie in series superiorly with the scaleni medius and posticus, and inferiorly with the lateral lumbar intertransverse muscles.

The **subcostal** muscles are small bundles lying on the inner aspect of the thoracic wall, close to the surface of the internal intercostals, and chiefly in the neighbourhood of the angles of the ribs. They follow the same direction as the internal intercostal muscles, but their fibres extend over one or two intercostal spaces. They are most constant on the lower ribs (see fig. 221).

The **triangularis sterni**, a thin stratum of muscular and tendinous fibres placed within the thorax, behind the costal cartilages, arises from the deep surface of the ensiform process of the lower part of the body of the sternum, and of the cartilages of one or two of the lower true ribs. Its fibres pass outward and upwards in a diverging manner, the lowest being horizontal, the middle oblique, and the upper becoming more and more nearly vertical; they are inserted by separate slips into the cartilages of the true ribs from the sixth to the second inclusive, on the lower border and inner surface of each, at the junction with the bony part. At the lower margin the fibres are in the same plane with those of the transversalis abdominis, of which the triangularis sterni muscle is a continuation upwards.

*Relations.*—The internal mammary artery and veins pass between its anterior surface and the costal cartilages; the pleura is in contact with its deep surface.

*Varieties.*—The triangularis sterni is subject to much variation as to its extent and points of attachment in different bodies, and even on the opposite sides of the same body. The subcostales also vary greatly in their extent in different subjects.

The *rectus sternalis*, or *sternalis brutorum*, is an elongated muscle, of nearly the same length as the sternum, frequently seen lying in front and parallel to the outer margin of that bone, and over the inner part of the pectoral muscle. It is fleshy in the middle and tendinous at both ends; it is attached superiorly to the sternum in connection with the tendon of the sterno-mastoid, and inferiorly it is connected with the rectus abdominis muscle. It is rarely present on both sides. It represents a muscle which is constant in some animals.

#### THE DIAPHRAGM.

The **diaphragm**, or **midriff**, forms a musculo-tendinous partition between the abdominal and thoracic cavities. It consists of muscular fibres which arch upwards as they converge from the circumference of the visceral cavity to a tendinous structure in the centre, and it is perforated by the various structures which pass from the thorax to the abdomen.

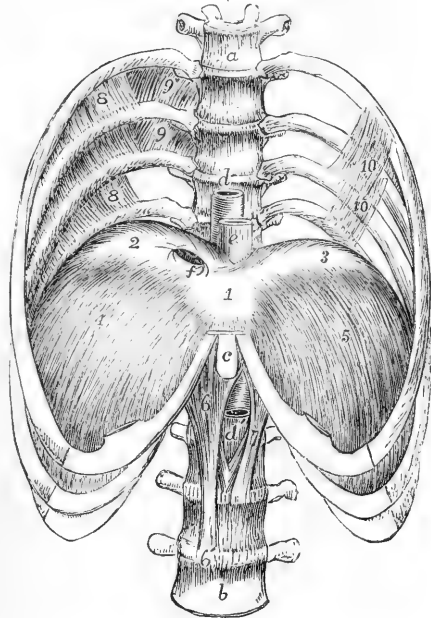
The fibres arise from the bodies of several of the upper lumbar vertebræ by two thick crura ; from two arches on each side external to the bodies of the vertebræ, called ligamenta arcuata ; and from the ensiform cartilage and the cartilages of the six lower ribs.

*a.* The *crura* arise by tendinous fibres aggregated into two bundles, from the first, second, and third lumbar vertebræ, and the interposed fibro-cartilages on the right side, and from the first and second vertebræ on the left side. The tendons of both crura curve forwards and upwards so as to enclose the aorta in an arch between them and the bodies of the vertebræ ; their inner margins are united behind, so that they form a nearly complete fibrous ring or oval loop round that vessel. The muscular fibres of the crura, springing from those tendons in thick bundles, on each side of the aorta, diverge as they pass upwards to the central aponeurosis. The innermost fibres on each side decussate with those of the side opposite, those of the right usually lying anterior to those of the left, and, curving upwards, limit an opening for the transmission of the œsophagus, before ending in the central aponeurosis.

Fig. 221.—THE LOWER HALF OF THE THORAX, WITH FOUR LUMBAR VERTEBRÆ, SHOWING THE DIAPHRAGM FROM BEFORE (modified from Luschka). (A. T.)  $\frac{1}{4}$

*a*, sixth dorsal vertebra ; *b*, fourth lumbar vertebra ; *c*, ensiform process of the sternum ; *d*, the aorta descending in front of the lower dorsal vertebræ ; *d'*, the aorta emerging in the abdomen below the arch formed by the meeting of the pillars of the diaphragm ; *e*, the œsophagus descending through its aperture in the diaphragm ; *f*, opening in the tendon of the diaphragm for the inferior vena cava ; 1, central, 2, right, and 3, left division of the trefoil tendon of the diaphragm ; 4, right, and 5, left muscular part, descending from the margins of the tendon to be attached to the ribs ; 6, the right, and 7, the left crus or pillar of the muscle ; 8, to 8', in the three upper intercostal spaces of the right side the internal layer of intercostal muscles interrupted towards the vertebral column, where in the two upper spaces the external layer, 9, 9, is seen ; 10, 10, on the left side, subcostal muscles.

Fig. 221.



*b.* The *ligamentum arcuatum internum* is a fibrous band which extends from the body to the transverse process of the first lumbar vertebra, and sometimes also to that of the second, and arches over the upper part of the psoas muscle. The *ligamentum arcuatum externum* extends outwards from the transverse process of the first lumbar

vertebra to the last rib, arching over the front of the quadratus lumborum: it is the upper part of the fascia covering that muscle, somewhat increased in thickness. From both ligamenta arcuata diaphragmatic muscular fibres take their origin, and are directed upwards to the posterior part of the tendinous centre.

Fig. 222.

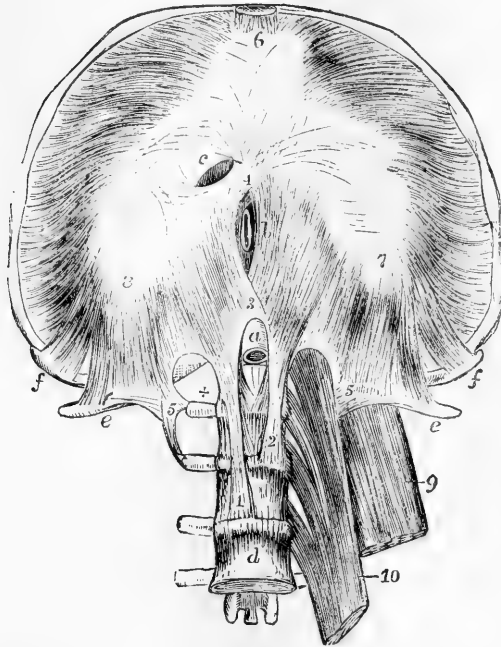


Fig. 222.—VIEW OF THE DIAPHRAGM, FROM BELOW. (A. T.)  $\frac{1}{2}$

In the preparation from which this figure is drawn, the lower ribs and sternum are thrown upwards so as to expose and stretch the lower surface of the diaphragm, and the four upper lumbar vertebræ have been exposed by the removal of all the muscles on the right side, and the dissection of the psoas magnus and quadratus lumborum on the left side. *a*, the aorta emerging in the abdomen from between the pillars on the first lumbar vertebra; *b*, the œsophagus, in its aperture between the muscular crura, represented too far to the right; *c*, the aperture for the vena cava inferior situated at the place of union of the middle and right divisions of the trefoil tendon; *d*, the body of the fourth lumbar vertebra; *e, e*, the twelfth ribs near their extremities; *f, f*, the ends of the eleventh

ribs; *1*, the tendinous part of the right crus; *2*, the left; *3*, the tendinous arch formed by their union over the aorta, above which the decussation of muscular fibres is seen; *4*, second decussation of muscular fibres in front of the œsophageal opening; *5*, on the right side, placed near the end of the transverse process of the first lumbar vertebra, towards which, arching from above and from within, over the +, is seen the ligamentum arcuatum internum; and from which, passing towards *e*, is seen the ligamentum arcuatum externum; *5'*, on the left side, is in a similar position, but here the quadratus lumborum muscle is seen descending from the twelfth rib behind the ligamentum arcuatum externum, and the upper part of the psoas muscle is within the ligamentum arcuatum internum; *6*, the middle division of the trefoil tendon, from which in front pass the slips of attachment of the diaphragm to the ensiform process; *7*, the left, and *8*, the right divisions of the trefoil tendon; from the outer and anterior margins of these the costal slips of the muscle are seen diverging, and from the posterior border of the tendon the slips of origin proceeding from the ligamenta arcuata and the tendinous arch of the crura; *9*, part of the quadratus lumborum; *10*, part of the psoas muscle.

*c*. The fibres arising from the cartilages of the six lower ribs form a series of serrated slips interdigitating with the attachments of the transversalis abdominis muscle. They sometimes arise also in part from the osseous ribs. The fibres proceeding from the ensiform cartilage form a narrow slip, sometimes divided into two, on each side of which there occurs an interval, in which the lining membranes of the thorax and



abdomen are separated only by a small quantity of loose connective tissue. The anterior fibres of the diaphragm are much the shortest. The fibres of the sternal and costal slips, after being united, rise in an arched and converging manner to be inserted into the anterior and external margins of the central tendon.

*d. The central tendon*—*trefoil or cordiform tendon*, is a strong aponeurosis, forming the central and highest part of the diaphragm. It is elongated from side to side, and consists of three *lobes* or *alæ*, partly separated by indentations. The right lobe is the largest; and the left, which is elongated and narrow, is the smallest of the three. The central tendon is surrounded on every side by the muscular portion of the diaphragm, the fibres of which are directly continuous with those of the tendon. The tendinous fibres cross one another, and are interwoven in various directions.

*Foramina*.—There are in the diaphragm three large perforations for the passage respectively of the aorta, the œsophagus, and the vena cava, besides some smaller holes or fissures which are less regular.—*a.* The foramen for the aorta (*hiatus aorticus*), placed in front of the vertebrae, is bounded by tendinous fibres of the crura as already described. Besides the aorta, this opening transmits the thoracic duct, and generally also the vena azygos. *b.* The foramen for the œsophagus, higher and farther forward than the preceding, as well as a little to its left, is separated from that opening by the decussating fibres of the crura. It is oval in form, and is generally entirely surrounded by muscular fibres; in some rare cases, however, a small part, the anterior margin, is found to be tendinous, being formed by the margin of the central tendon. *c.* The opening for the vena cava (*foramen quadratum*) is placed in the highest part of the diaphragm, in the tendinous centre at the junction of the right and middle *alæ*, posteriorly. Its form is somewhat quadrangular; and it is bounded by fasciculi of tendinous fibres running parallel with its sides. Besides the foregoing large foramina there are small perforations through the crura for the sympathetic and splanchnic nerves on both sides, and for the vena azygos minor on the left side. Moreover, the larger azygos vein often takes its course through the right crus.

*Relations*.—The upper or thoracic surface of the diaphragm is highly arched. Its posterior and lateral fibres, ascending from their connection with the lower margin of the thorax, are for a considerable extent placed close to the ribs, the lungs, especially in their collapsed condition, not descending so far as their attachments. The vault of the diaphragm rises higher on the right than on the left side. On the right side in the dead body it rises to the level of the fifth rib at the sternum, and on the left side only as high as the sixth. This difference has relation to the great size and firmness of the liver on the right side. It is covered superiorly by the pleura and the pericardium; the fibrous layer of the latter membrane blending with the tendinous centre, as well as with the fascia covering its muscular substance. The lower surface, of a deeply concave form, is lined by the peritoneum, and has in apposition with it the liver, the stomach, the pancreas and spleen, and the kidneys.

*Nerves*.—The intercostals, subcostals, levatores costarum and triangularis sterni are supplied by the intercostal nerves. The diaphragm is supplied by the phrenic nerves from the fourth and fifth cervical nerves, and likewise by sympathetic filaments from the plexuses round the phrenic arteries.

*Actions*.—*Movements of Respiration*.—The mechanical act of respiration

consists of two sets of movements, viz., those of inspiration and of expiration, in which air is successively drawn into the lungs and expelled from them by the alternate increase and diminution of the thoracic cavity. The changes in the capacity of the thorax are effected by the expansion and contraction of its lateral walls, called *costal respiration*, and by the depression and elevation of the floor of the cavity, through contraction and relaxation of the diaphragm, called *abdominal respiration*. These two movements are normally combined in the act of respiration, but in different circumstances one of them is resorted to more than another. Thus, abdominal respiration is most employed in the male, costal respiration most in the female.

*Inspiration.*—The study of the movements of the thoracic walls in respiration presents considerable difficulty from the complexity of these movements, and from the impossibility of perfectly imitating in the dead body the mechanical conditions under which they occur in life. On the prepared skeleton, by raising and depressing the sternum the ribs may be moved upwards and downwards nearly parallel to one another; the first rib moving as freely as the others. But during life several causes combine to make the first rib more fixed than those which follow: as for example, the weight of the upper extremity, and the strain of the intercostal muscles and ribs beneath. The movements of the thoracic walls in respiration are as follows: 1st. The antero-posterior diameter is increased by a forward movement of the sternum with the attached ribs and cartilages; the lower end of the sternum is raised and advanced, while the upper end, which in easy respiration is at rest, or nearly so, is only raised in full inspiration. 2nd. The lateral diameter of the thorax is increased by the elevation and the rotation of the ribs; the first of these movements bringing larger costal arches to a level occupied in expiration by smaller arches above them; and the second, by the rotation of the ribs round an axis extending from their vertebral extremities to the sternum, which everts the lower edge of the ribs, and increases the width of their arch outwards. 3rd. The capacity of the thorax, transversely and antero-posteriorly, is increased by the elastic bending of the ribs, as well as the opening of the angle between the ribs and their cartilages, produced by the resistance of the sternum and weight of the limbs to the forward and upward motion of the extremities of the cartilages, and by the inclination backwards given to the middle ribs in their upward movement by the oblique direction of the plane of the costo-transverse articular surfaces. 4th. The vertical diameter of the thoracic cavity is increased by the descent of the platform of the diaphragm forming its floor; but as any considerable elevation of the ribs would tend to diminish the capacity of the thorax in inspiration, the lowest ribs are drawn backwards and outwards rather than raised. Lastly, it may be remarked, that extension of the vertebral column is an important agent in respiration, for when the column is bent forwards, the ribs are pressed together in the concavity of the curve, and, conversely, when the column is extended the ribs are separated.

*Action of the Intercostal Muscles.*—The manner in which these muscles act has been a subject of controversy from an early time, and is not yet thoroughly determined. Among those who look upon the intercostal muscles as active in respiration, all are agreed that the external muscles are elevators of the ribs, and therefore muscles of inspiration. According to one view, defended by Haller, the external and internal layers have a common action, the decussating fibres acting in the direction of the diagonal between them; while according to another view, that of Hamberger, the external intercostal muscles are admitted to be elevators, but the whole internal are held to be depressors of the ribs. More recently these views have been modified by Hutchinson to the extent of admitting that the external intercostal muscles, and the parts of the internal intercostals placed between the costal cartilages, elevate the ribs, and that the lateral portions of the internal intercostals act as depressors. This view is illustrated mechanically, and supposed by some to be demonstrated, by means of a mechanism of rods and elastic bands imitating the conditions of the ribs. But the ribs differ from such rods in respect that they are not straight or rigid bars, and are not free at either end, but are deeply curved, and have the greatest extent of

motion in the middle of their arch ; and in the living subject, the ribs, in their elevation, both rotate upon their axis and bend upon themselves, instead of describing a simple upward and downward movement like the bars, so that it is impossible to draw any certain conclusion from such imperfect imitations of the mechanism. On the whole, the deficiency of the external intercostal muscles in front and of the internal behind, in which situations they would have acted as depressors, seems to point to a combined action of the muscles as elevators of the ribs in the manner maintained by Haller. This view is farther supported by the result of experiments on the galvanic stimulation of the intercostal muscles. Thus Duchenne found (*Physiol. des Mouvements, &c., p. 647*) that the direct galvanic stimulation of the external intercostal muscles throughout the fifth space caused the lower ribs to rise ; towards the upper, and likewise that the stimulation of the internal intercostal muscles in the intercartilaginous part of the space also caused the lower rib to rise, and he farther found that when the galvanic stimulus was so strong as to reach the intercostal nerve, and throw the whole of the internal as well as the external intercostal muscles into action, the lower ribs were still elevated. These results received additional confirmation from the pathological observation that in cases of paralysis of the diaphragm and the auxiliary muscles of inspiration the ribs were raised by the sole action of the intercostal muscles, and that in other cases in which the intercostal muscles were paralysed, while the diaphragm retained its power, the expansion of the upper ribs was entirely abolished.

Among the more recent anatomical writers, Henle inclines to Haller's view ; Luschka refers to Budge's experiments on the muscles of living animals, as proving that the internal intercostal muscles elevate the ribs (Budge, "*Lehrbuch der Physiologie des Menschen,*" Weimar, 1860, p. 79).

The levatores costarum have a similar action with the posterior fibres of the external intercostal muscles, and ought therefore to be ranked among the agents of inspiration. The scalena muscles also are usually believed to contribute, even in normal and quiet inspiration, to the support and elevation of the first and second ribs and it is obvious that the serratus posticus superior must have a similar effect on those upper ribs to which it is attached.

The action of the diaphragm is more easily understood than that of the intercostal muscles. By its contraction and descent its convexity is diminished, the abdominal viscera are pressed downwards, and the thorax expanded vertically. The fibres arising from the lowest ribs, being directed nearly vertically upwards from their costal attachments, must tend to pull those ribs upwards. Duchenne has shown that the contraction of the diaphragm by itself elevates and expands the lower ribs, but only so long as the vault of the muscle is supported by the abdominal viscera, for when they are removed it no longer has that action (*op. cit. p. 620*). The serratus posticus inferior and quadratus lumborum muscles, by opposing the diaphragm, and thus giving it a fixed point on which to descend, become assistant muscles of inspiration. The anterior fibres of the diaphragm being directed more horizontally towards the central tendon, oppose the forward motion of the sternum ; hence the sternum becomes arched in patients long subject to asthma. (Hutchinson, Article "*Thorax,*" in Todd's "*Cyclopædia of Anatomy and Physiology ;*" Meyer, "*Physiologische Anatomie.*")

In more forcible inspiration, and more especially in severe attacks of dyspnoea, there are called into play other powerful muscles, to secure the inspiratory action of which a fixed attachment must be provided by the support and elevation of the shoulder and arm ; among these may be enumerated the serratus magnus and pectoralis minor, acting from the shoulder, and the pectoralis major and latissimus dorsi, acting from the raised arm, which together produce expansion and elevation of the ribs.

*Expiration.*—In normal and quiet expiration the diminution of the capacity of the chest is mainly, if not wholly due to the return of the walls of the chest to the condition of rest, in consequence of their own elastic re-action, and of the elasticity and weight of the viscera and other parts displaced by inspiration ; the lungs themselves, after distension by air, exert considerable elastic force, and no doubt the ribs and their cartilages react strongly by their elastic

return from the elevated and bent condition into which they had been thrown by the inspiratory forces. In more forcible acts of expiration, in muscular efforts of the limbs and trunk, and in efforts of expulsion from the thoracic and abdominal cavities, all the muscles which tend to depress the ribs, and those which compress the abdominal cavity, concur in powerful action to empty the lungs, to fix the trunk, and to expel the contents of the abdominal viscera. (See further, "Action of the Abdominal Muscles.")

### MUSCLES AND FASCIÆ OF THE ABDOMEN.

**FASCIÆ.**—The **superficial fascia** of the abdomen is usually described as consisting of two layers. One of these, the *subcutaneous layer*, corresponds in its general features with the areolar subcutaneous tissue of other parts of the body, and contains embedded in it a very variable and often large quantity of fat. The other, or *deeper layer*, is of a denser and more membranous structure, contains a considerable amount of yellow elastic tissue in its substance, and is united by intervening fibres, in some places very closely, to the aponeurosis of the external oblique muscle. These two layers are both continuous with the superficial fascia on other parts of the trunk: they can be dissected as distinct layers only on the fore part of the abdomen, and are separated in a more marked manner in the lower part of its wall, where subcutaneous vessels, such as the superficial epigastric and circumflex iliac, lie between them. The deep or elastic layer of the superficial fascia is bound down by a thin but dense intervening layer of fibrous tissue to the aponeurosis of the external oblique muscle in two places more particularly, viz., along the linea alba from the umbilicus to the pubis, and in the whole length of Poupart's ligament. At the lower part of the linea alba it sends fibrous and elastic processes towards the dorsum of the penis, which form its so-called suspensory ligaments. By its close union to Poupart's ligament, it comes into relation with the fascia lata of the thigh, which is also united to that structure: but in the neighbourhood of the external inguinal aperture it remains free, and is prolonged downwards over the spermatic cord to the scrotum. The subcutaneous layer, losing its fat, is combined with the deeper layer as they both pass to the scrotum; and here the united layer acquires a reddish brown colour, and undergoing a modification in structure by being mingled largely with involuntary muscular fibres, constitutes the *dartos tunic* of the scrotum. Some involuntary muscular fibres also exist in the altered superficial fascia which covers the penis. This covering, on leaving the scrotum posteriorly, becomes continuous with the superficial fascia of the perinæum.

The parts of the superficial fascia here described have received minute attention from surgical anatomists, because of their close relation to the seat of hernial tumours; the adhesion of the fascia to Poupart's ligament, and its disposition over the inguinal aperture, spermatic cord, and scrotum, while they prevent the descent upon the thigh of matter which has been effused beneath the fascia, cause it rather to spread upwards upon the abdomen or to take its course downwards upon the scrotum.

The deep layer of the abdominal fascia is also interesting, as corresponding with the *tunica abdominalis*, a strong membrane consisting almost entirely of yellow elastic tissue, which exists in animals, as may be well seen in the horse or ox, and which contributes to the support of the viscera.

**MUSCLES.**—The muscular wall of the abdomen is formed for the most

part on each side, of three layers of muscle, the fibres of which run in different directions ; those of the two most superficial layers being oblique, and those of the innermost layer being transverse. In front those three layers of muscle are replaced by tendinous expansions, which meet in the middle line ; on either side of that line the fibres of the recti muscles extend in a vertical direction between the tendinous layers, supported usually at the lower end by the pyramidales muscles. Posteriorly the wall is formed in part by aponeurosis, and in part by muscles of which the fibres are chiefly vertical, viz., the muscles of the back, and in front of them the quadratus lumborum.

Fig. 223.

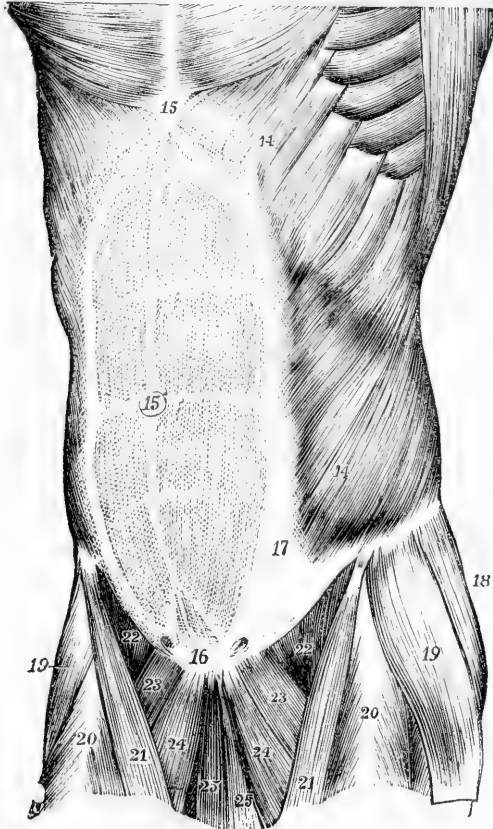


Fig. 223.—SUPERFICIAL VIEW OF THE MUSCLES OF THE ABDOMEN, FROM BEFORE.  
(A. T.)  $\frac{1}{3}$

14, external oblique muscle ; 15, is placed on the ensiform cartilage at the upper end of the linea alba ; 15', umbilicus ; 16, symphysis pubis at the lower end of the linea alba ; above 16, the pyramidales muscles are seen shining through the abdominal aponeurosis ; from the upper 14 to 17, the linea semilunaris ; between this line and the linea alba are seen the transverse lines of the rectus muscle ; above 22, the curved margin of Poupart's ligament ; on either side of 16, the external abdominal ring is indicated.

The **abdominis externus obliquus** muscle arises from the outer

surface of the eight inferior ribs, by slips arranged in a serrated series, four or five of them meeting with origins of the serratus magnus, and three or four with origins of the latissimus dorsi. The slips of these two sets of muscles alternate with each other, as the tips of the fingers of one hand may be made to fit in between those of the other, and hence they are said to interdigitate, and are termed digitations. The lower and upper digitations of the external oblique are connected with the ribs near their cartilages, the others are attached to the ribs at some distance from their extremities; the lowest digitation generally embraces the point of the twelfth rib. The fleshy fibres from the last ribs pass down in nearly a vertical direction to be inserted into the external margin of the crest of the ilium for about the anterior half of its length; all the rest incline downwards and forwards, and terminate in tendinous fibres, which form the broad aponeurosis by which the muscle is inserted.

The *aponeurosis* of the external oblique muscle, wider at the lower than at the upper part, and larger than that of either of the subjacent abdominal muscles, extends inwards towards the middle line in front; at some distance from this, but farther out above than below, it becomes inseparably united with the aponeurosis beneath, and forms a part of the sheath of the rectus muscle in the whole extent of the space from the ensiform cartilage to the symphysis pubis. The upper part of the aponeurosis is connected externally with the larger pectoral muscle. Its lower fibres are closely aggregated together, and extend across from the anterior superior iliac spine to the spine of the pubis, in the form of a broad band, which is called *Poupart's ligament*. This band is curved at the middle and outer parts, the convexity of the curve being directed towards the thigh, a form which is given to it by its connection with the fascia lata of the limb.

Above the crest of the pubis the fibres of the aponeurosis, separating from the inner part of Poupart's ligament, leave between them an oblique opening, the *superficial* or *external abdominal ring*, through which passes the spermatic cord in the male and the round ligament in the female. The direction of this opening is upwards and outwards, its base being formed by the pubic crest, and its sides by the two sets of diverging fibres called the *pillars*. The upper or internal pillar is attached to the anterior surface of the symphysis pubis, interlacing with the corresponding fibres of the opposite side; the lower or external pillar is formed by Poupart's ligament, near its attachment to the spine of the pubic bone. The inner pillar is flat and straight, but the outer, especially near its attachment to the pubis, is thick and triangular. The innermost fibres of the outer pillar are continued over the crest of the pubis and beneath the spermatic cord in a thin somewhat fan-shaped layer called the *triangular fascia*, which, curving upwards and inwards, passes behind the base of the inner pillar to interlace with the fibres of the opposite side.

A portion of the aponeurosis, which is reflected backwards and outwards along the pectineal line from the attachment of Poupart's ligament to the spine of the pubis, constitutes a small triangular process with a curved external border, not far distant from the femoral ring. This receives the name of *Gimbernat's ligament*. Some curved fibres, directed across the diverging pillars and uniting them together, are named *intercolumnar*. A few of these, descending upon the spermatic

cord from the margin of the opening, are prolonged upon that structure as a delicate fascia, named *intercolumnar fascia*. The intercolumnar fibres may be regarded as the lowest of a series of tendinous fibres, which cross the aponeurosis of the external oblique muscle somewhat obliquely over a considerable extent of its surface, and the strongest of which proceed from near the superior spine of the ilium and upper part of Poupart's ligament.

*Varieties.*—This muscle chiefly varies in respect to the number of attachments to the ribs, the slips from the eighth and ninth ribs being occasionally double, while those from the eleventh and twelfth are sometimes wanting. Besides the usual slip to the pectoralis major, a slip is sometimes found to the serratus magnus. The muscle has also been found double, the deeper portion passing from the three lowest ribs to the crest of the ilium. (Macalister.)

The **obliquus abdominis internus** muscle, placed under cover of the external oblique, arises by fleshy fibres from the external half or two-thirds of the deep surface of Poupart's ligament, from the iliac crest for two-thirds of its length, and by some fibres from the posterior aponeurosis of the transversalis muscle, in the angle between the crest of the ilium and the outer margin of the erector spinæ muscle. From those attachments the fibres, spreading somewhat, pass to be inserted as follows: the most posterior fibres pass upwards and forwards to the lower margins of the cartilages of the last four ribs, where they are inserted in the same plane with the internal intercostal muscles; those arising further forwards from the crest of the ilium pass, the upper more obliquely, and the rest more horizontally, forwards to end in an aponeurosis in front of the abdomen; those from the front part of the crest extend horizontally inwards to the same aponeurosis; while the fibres from Poupart's ligament, usually paler than the rest, arch downwards and inwards over the spermatic cord, or the round ligament of the uterus, and end in tendinous fibres common to them and the lower part of the transversalis muscle, and hence known as the *conjoined tendon* of these muscles; through the medium of this tendon they are attached to the front of the pubis, and for some distance along the pectineal line, behind and to the outside of Gimbernat's ligament. The spermatic cord and round ligament pass under the arched lower border of the internal oblique and transversalis muscles through the internal or deep abdominal ring,

The *aponeurosis* of the internal oblique may be regarded as the expanded tendon of the muscle continued forwards and inwards: it extends from the margin of the thorax to the pubis, and is wider at the upper than at the lower end. At the outer border of the rectus muscle this structure divides into two layers, one passing before, the other behind, that muscle; and the two reunite at its inner border, so as to enclose it in a sheath. The anterior layer, as already mentioned, becomes inseparably united with the aponeurosis of the external oblique muscle, and the posterior layer is similarly incorporated with that of the transversalis. The upper border of the posterior lamina is attached to the margins of the seventh and eighth ribs, as well as to the ensiform cartilage. This division, however, of the aponeurosis into layers stops short a little above half way between the umbilicus and the pubis, the aponeurosis below that level remaining undivided, and along with that of the transversalis muscle to which it is united, passing wholly in front

of the rectus muscle. The deficiency thus resulting in the posterior wall of the sheath of the rectus muscle is marked superiorly by a well-defined lunated edge, whose concavity looks downwards towards the pubis—the *semilunar fold of Douglas*.

Fig. 224.

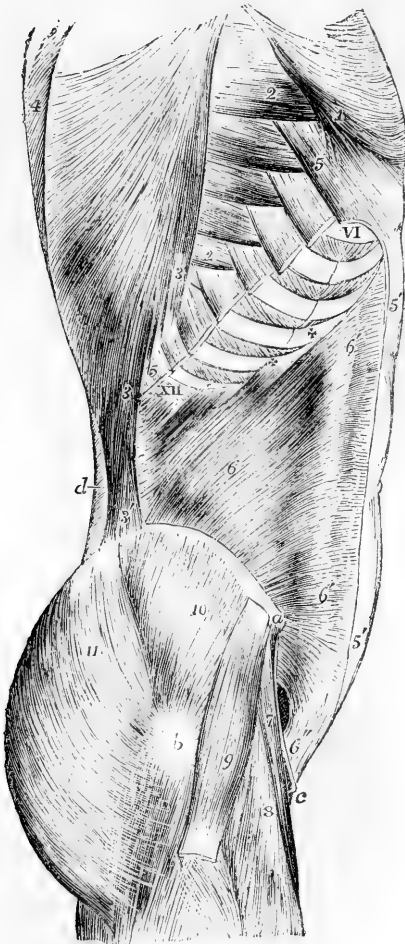

Fig. 224.—LATERAL VIEW OF THE MUSCLES OF THE ABDOMEN AND TRUNK, THE INTERNAL OBLIQUE MUSCLE HAVING BEEN EXPOSED BY THE REMOVAL OF THE EXTERNAL OBLIQUE (modified from Henle). (A. T.)  $\frac{1}{2}$

*a*, anterior superior spinous process of the ilium; *b*, trochanter major; *c*, spine of pubes; *d*, lumbar fascia; VI to XII, the sixth to the twelfth ribs; 1, lower part of the great pectoral muscle, where it is attached to the external oblique muscle; 2, 2, lower digitations of the serratus magnus from the fourth to the eighth ribs; 3, lower costal attachments of the latissimus dorsi; 3', its iliac attachment; 4, trapezius; 5, divided attachments of the external oblique, left in connection with the ribs; 5', aponeurosis of the external oblique divided in front of the rectus, where it joins the sheath; 6, internal oblique at its middle; 6', 6', line where it divides to form the sheath of the rectus; + + + XII, its attachment to the four lowest ribs; 6'', the conjoined tendon, and above, and to the outside, the internal inguinal aperture; 7, sartorius; 8, rectus femoris; 9, tensor vaginae femoris; 10, gluteus medius; 11, gluteus maximus.

*Varieties*.—A fibrous inscription is frequently seen in the upper part of this muscle prolonged forward

from the point of the tenth rib, and a slender cartilaginous slip perfectly separate from that of the rib has been seen lying in this inscription. (Henle.) An inscription opposite the eleventh rib is described by Macalister.

The **cremaster**, a muscle peculiar to the male, consists of fibres lying in series with those of the lower border of the internal oblique muscle. It presents an external and an internal attachment. The external attachment is to the inner end of Poupart's ligament, and there its fibres are continuous with those of the internal oblique muscle;

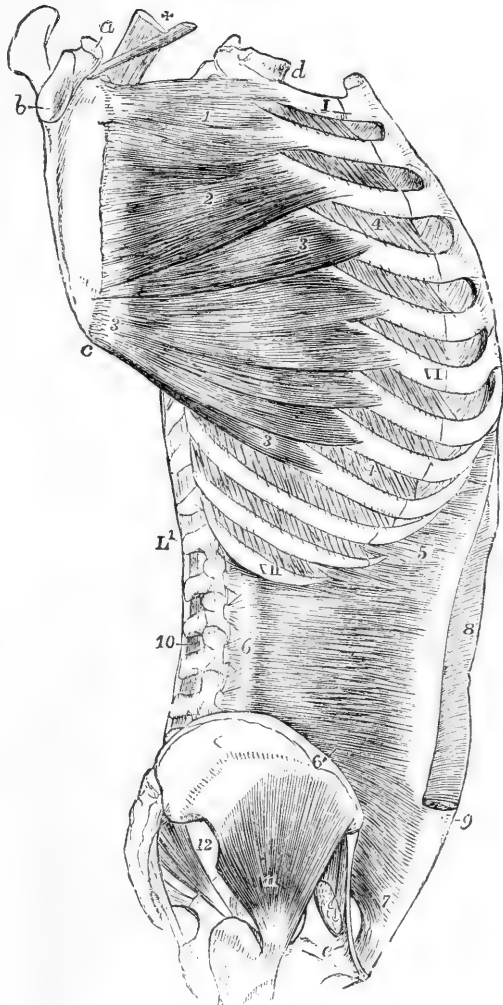


the internal attachment, smaller and less constant, is by means of a tendinous band to the spine and crest of the pubis, close to the insertion of the internal oblique muscle. The superior fibres of the muscle

Fig. 225.—LATERAL VIEW OF THE TRUNK, GIVING A DEEP VIEW OF THE SERRATUS MAGNUS AND TRANSVERSALIS ABDOMINIS MUSCLES. (A. T.)  $\frac{1}{2}$

The serratus magnus is stretched out by the scapula being drawn away from the ribs. *a*, coracoid process of the scapula; *b*, glenoid cavity; *c*, lower angle; *d*, first dorsal vertebra; *e*, placed on the os pubis, point to the insertion of Gimbernat's ligament; I, VI, XII, the first, sixth, and twelfth ribs; L', first lumbar vertebra; 1, upper portion of the serratus magnus attached to the first and second ribs; 2, second or middle portion attached to the second and third ribs; 3, lower or fan-shaped portion attached to the ribs from the fourth to the ninth; 4, the external intercostal muscles; 5, upper costal origins of the transversalis abdominis; 6, origins of the muscles from the transverse processes of the lumbar vertebrae by the lumbar aponeurosis; 6', part rising from the crest of the ilium; 7, lower portion rising from the upper half of Poupart's ligament, and passing over the internal inguinal aperture; 8, the sheath of the rectus muscle opened in its upper part by removing the aponeurosis of the oblique muscles; 9, the same in its lower part left entire at the place where the tendons pass entirely in front of the rectus muscle; 10, the interspinales muscles of the lumbar vertebrae; 11, gluteus minimus; 12, pyriformis.

Fig. 225.



extend between those attachments in a series of successively longer loops, descending in front of the spermatic cord, a few of them reaching as low as the level of the testicle: the remaining fibres, the greatest number of which descend from the outer attachment, and a few from the inner, spread out inferiorly and are embedded in the substance of a

fascia, termed *cremasteric*, which adheres to the fascia propria of the testicle. Sometimes the only fibres developed are a bundle descending from the outer attachment.

In the female there may be almost constantly detected a small bundle of fibres descending on the round ligament of the uterus, which correspond with the last-mentioned fibres of the cremaster muscle of the male.

The **transversalis abdominis** muscle, subjacent to the internal oblique, arises from the inner surface of the cartilages of the six lower ribs; from a strong aponeurosis attached to the lumbar vertebræ; from the inner margin of the crest of the ilium in the anterior two-thirds of its extent, and from the iliac third of Poupart's ligament. The greater part of the fibres have a horizontal direction, and extend forwards to a broad aponeurosis in front; the lowest fibres curve downwards like those of the internal oblique, and are inserted into the front of the pubis and into the pectineal line, through the medium of the conjoined tendon already described as common to this muscle and the internal oblique.

The *anterior aponeurosis* of the transversalis muscle commences in the greater part of its extent at the distance of about an inch from the outer border of the rectus muscle; but at its upper extremity it is much narrower, and there the muscular fibres of opposite sides approach nearly to the middle line behind the recti muscles. It becomes united with the posterior layer of the aponeurosis of the internal oblique forming the posterior wall of the rectus sheath, and inferiorly, where that aponeurosis passes entirely in front of the rectus muscle, it passes likewise in front of that muscle.

The *posterior aponeurosis* of the transversalis muscle extends backwards between the last rib and the iliac crest, and opposite the outer border of the erector spinæ muscle, becomes continuous with the lumbar aponeurosis.

*Varieties.*—The transversalis has been found fused with the internal oblique (Soemmering); or entirely absent (Macalister). The spermatic cord has been seen to pierce its lower border (Guthrie).

The **rectus abdominis** is a long flat muscle, consisting of vertical fibres, situated at the fore part of the abdomen, within a tendinous sheath, formed in the manner already described in the account of the aponeurosis of the internal oblique muscle; it is separated from the muscle of the other side by a narrow interval, which is occupied by a dense fibrous structure, the *linea alba* afterwards described. It arises from the upper margin of the pubis by a flat tendon consisting of two parts, of which the internal is much the smaller, and is connected with the ligaments covering the pubic symphysis, while the external one is fixed to the pubic crest. Expanding and becoming thinner at the upper end, the muscle is inserted into the cartilages of three ribs, the fifth, sixth, and seventh, usually by three distinct parts of unequal size. Some fibres also are generally found attached to the ensiform cartilage.

The fibres of the rectus muscle are interrupted by three or more irregular tendinous intersections, named *lineæ transversæ*. The three which are most constant are placed, one opposite the umbilicus, another on a level with the ensiform cartilage, and the third intermediately between them: and these generally run across the whole muscle.

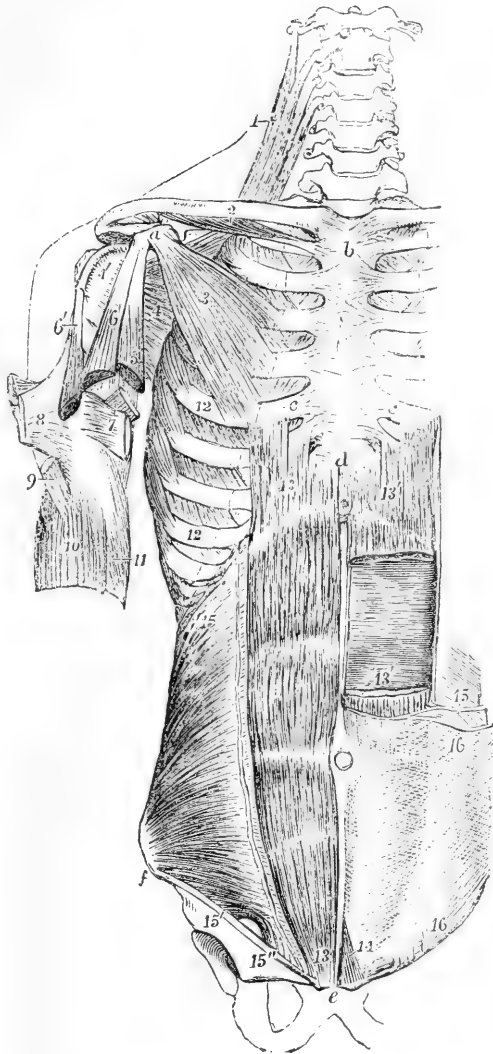
When one or two additional transverse lines occur, they are usually incomplete; one of them is very generally placed below the umbilicus, the

Fig. 226.—DEEP MUSCLES OF THE FOREPART OF THE TRUNK AND SHOULDER. (A. T.)  $\frac{1}{2}$

Fig. 226.

For the explanation of the references in the upper part of the figure see p. 195.

*c, c*, cartilages of the fifth ribs; *d*, ensiform portion of the sternum; *e*, symphysis pubis; *f*, anterior superior iliac spine; 12, insertion of the serratus magnus on the ribs; 13, on the right side, the rectus abdominis; on the left side 13', 13', the divided ends of the same muscle, a portion being removed; 14, points to the pyramidalis muscle exposed on the left side; 15, on the right side, the internal oblique muscle; 15', origin of its lower fibres from the deep surface of Poupart's ligament; 15'', conjoined tendon of the internal oblique and transversalis, descending to the pectineal line; between 15' and 15'', the internal inguinal aperture; 15, on the left side, cut edge of the internal oblique, shown diagrammatically, to indicate the manner in which its tendon splits to form the sheath of the rectus muscle; 16, the tendon or aponeurosis of the external oblique muscle, uniting in front with the sheath of the rectus.



position of the other is variable. The intersections do not usually penetrate the whole thickness of the muscle, but are confined chiefly to its anterior

fibres, and are firmly united to the anterior wall of the sheath of the muscle, while the posterior surface of the muscle has no attachment to the sheath.

of some of the lower animals; they are rather vestiges of the septa between the original vertebral myotomes. They sometimes extend outwards from the rectus, and penetrate partially into the internal oblique.

The **pyramidalis** is a small muscle resting on the lower part of the rectus. It arises from the front of the pubis and the ligaments of the symphysis, and becoming narrow as it ascends over the lower third of the interval between the umbilicus and pubis, is inserted into the *linea alba*.

*Relations.*—The pyramidalis is covered in front by the aponeurosis of the other muscles, and rests posteriorly on the rectus, the size of the lower part of which is augmented when the pyramidalis is wanting.

*Varieties.*—This muscle is often absent on one or both sides: in some instances it has been found to be double. It occasionally exceeds the length above stated.

The *linea alba* is a white fibrous structure, extended perpendicularly downwards in the middle line from the ensiform cartilage to the pubis. This tendinous band is formed by the union of the aponeuroses of the two oblique and the transverse muscles, the tendinous fibres being continued in a decussating manner from one side to the other. Some longitudinal fibres are distinguishable towards its lower end. It is broader superiorly than inferiorly, and a little below the middle is widened out into a circular flat space, in the centre of which is situated the cicatrix of the *umbilicus*.

The *lineae semilunares* are the two curved linear spaces on the surface of the abdomen, placed externally to the outer margins of the recti muscles. They are produced by the union of the aponeurotic tendons of the oblique and transversalis muscles, and they correspond on their inner side to the outer margin of the sheath of the rectus.

The **quadratus lumborum** is an irregularly quadrilateral muscle, slightly broader below than above, placed between the last rib and the crest of the ilium, close to the vertebral column. It is divisible into two parts. One of these, arising by fleshy and tendinous fibres from the ilio-lumbar ligament, and from the iliac crest for several inches near the place where that ligament is attached, is inserted into the inferior border of the last rib for about half its length, and by four tendinous slips into the transverse processes of the four superior lumbar vertebrae. Another series of fibres, arising by two or three tendinous slips from as many of the inferior transverse processes at their upper margins, passes in front of those inserted into the same processes, and joins with the part of the muscle attached to the rib.

*Relations.*—This muscle is placed between the middle and deepest layer of the lumbar aponeurosis, and its inner part is covered in front by the psoas muscle.

*Varieties.*—The number of the points of insertion of this muscle to the vertebrae, and the extent of its connection with the last rib, vary in different instances. It is sometimes attached to the body or transverse process of the last dorsal vertebra.

**ACTIONS.**—The abdominal muscles not only form a great part of the wall to enclose and support the abdominal viscera, but by their contractions are capable of acting successively on those viscera, on the thorax, and on the pelvis. When the pelvis and thorax are fixed, the abdominal muscles constrict the cavity and compress the viscera, particularly if the diaphragm be fixed or be made to descend at the same time, as occurs in vomiting and in the expulsion of the fœtus, the fœces, and the urine.

If the vertebral column be fixed, these muscles press up the diaphragm through the abdominal viscera, draw down the ribs, and contract the lower border of the thorax, and so contribute to expiration; but if the vertebral column be not fixed, the thorax will be bent directly forwards, when the muscles of both sides act, or rotated to either side, should they act alternately.

Fig. 227.

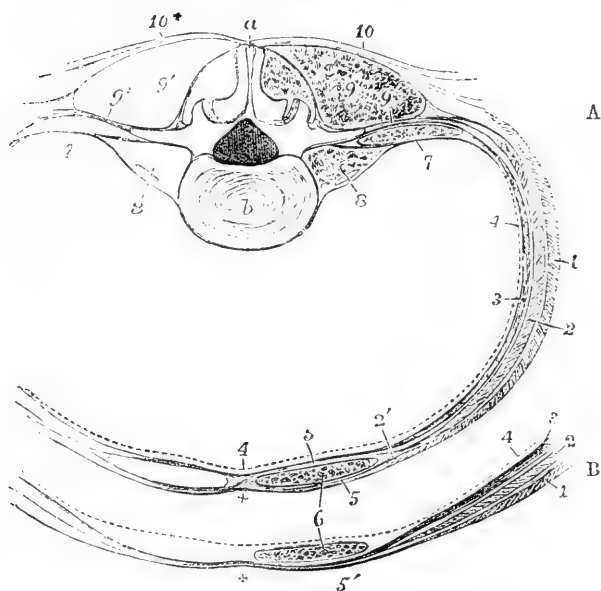


Fig. 227.—DIAGRAM OF A TRANSVERSE SECTION OF THE WALL OF THE ABDOMEN, TO SHOW THE CONNECTIONS OF THE LUMBAR AND ABDOMINAL APONEUROSIS, AND THE SHEATH OF THE RECTUS MUSCLE. (A. T.)  $\frac{1}{4}$

A, at the level of the third lumbar vertebra; B, the fore part, at a few inches above the pubes.

*a*, spinous process of the third lumbar vertebra; *b*, body; 1, external oblique muscle; 2, internal oblique; 3, transversalis; 4, a dotted line to mark the position of the fascia lining the abdomen; 5, 5, in A, the anterior and posterior parts of the sheath of the rectus, formed by the aponeurosis of the internal oblique splitting at its outer edge 2'; 6, the rectus abdominis; 7, innermost layer of the aponeurosis, covering in front the quadratus lumborum, and passing to the root of the transverse process; 8, the psoas magnus and parvus muscles; 9, the erectores spinæ muscles; 9+, the middle layer of the lumbar aponeurosis passing to the extremity of the transverse process; 10, 10+, the posterior layer of the lumbar aponeurosis, connected with the latissimus dorsi and serratus inferior: in A, at the sheath of the rectus, the aponeurosis of the external oblique is seen to unite in front with the sheath, while that of the transversalis is seen uniting with it behind: in B, the section is taken below the semilunar fold of Douglas, where all the tendons pass in front of the rectus as at 5'; the + near this, and in a similar place in A, marks the middle line, and the place of the union of the several aponeuroses in the linea alba.

If the thorax be fixed, the abdominal muscles may be made to act on the pelvis; thus, in the action of climbing, the trunk and arms being elevated and fixed, the pelvis is drawn upwards, either directly or to one side, as a preparatory step to the elevation of the lower limbs.

The attachment of the tendinous intersections of the rectus muscle to the

anterior wall of its sheath, causes the formation of corresponding transverse folds during its contraction, and may enable the separate parts of the muscle to act on different portions of the abdominal wall. The pyramidalis muscle strengthens the inferior part of the rectus.

**LINING FASCIA OF THE ABDOMEN.**—On the inner surface of the wall of the abdomen is a membranous structure which lines the visceral aspect of the deepest stratum of muscles; it is divisible into two principal parts, the fascia transversalis and fascia iliaca.

The **fascia transversalis** is named from its position on the deep surface of the transversalis muscle. It is strongest in the lower part of the abdomen, where the muscular and tendinous support is somewhat weaker. Followed upwards from this situation, the transversalis fascia becomes gradually less strong, and beyond the margin of the ribs it forms a thin covering for the under surface of the diaphragm. Along the inner surface of the iliac crest, between the iliacus and transversalis muscles, the fascia is attached to the periosteum. For about two inches inwards from the anterior superior iliac spine, it is closely connected with the posterior surface of Poupart's ligament, and is there directly continuous with the fascia iliaca. At this place also, and to the same extent it is attached to the fascia lata. About midway between the iliac spine and the pubis, the external iliac artery and vein, as they pass out into the thigh, intervene between the fascia transversalis and the fascia iliaca, and from this point to the edge of Gimbernat's ligament the fascia transversalis is prolonged downwards under the crural arch, and over the artery and vein, forming the anterior portion of the funnel-shaped femoral sheath. As this prolongation of the fascia passes under Poupart's ligament, it is strengthened by a dense band of fibres (the deep crural arch) which arches over the vessels, and is inserted into the pubic crest and pectineal line behind the conjoined tendon of the transversalis and internal oblique. It includes beneath it, internal to the vessels, a space between Gimbernat's ligament and the vein, sufficiently large to admit the point of the little finger; this is called the *crural ring*, and is the space through which femoral hernia descends. About half way between the anterior superior iliac spine and the symphysis pubis, and about half an inch above Poupart's ligament, the spermatic cord in the male, or the round ligament in the female, pierces the fascia transversalis. The opening thus made is called the *internal* or *deep abdominal ring*; the fascia above and internal to it is thin, but below and external to it is firm and thick, and forms a distinct crescentic margin, over which the cord or round ligament passes; from the borders of the opening a delicate funnel-shaped covering, the *infundibuliform fascia*, is prolonged downwards on the emerging structure, and forms in cases of oblique hernia one of the coverings of the tumour.

The **fascia iliaca**, stronger than the fascia transversalis, lines the back part of the abdominal cavity, and covers the iliacus and psoas muscles. The densest portion of its fibres is stretched transversely from the iliac crest, over the margin of the psoas muscle to the brim of the pelvis, where it is intimately blended with the periosteum. Superiorly, this membrane, becoming much weaker, is connected internally with the sacrum, and by small and distinct processes with the intervertebral substances and the neighbouring margins of the lumbar vertebrae; and finally it becomes blended with the fascia which covers the diaphragm and forms the ligamentum arcuatum externum. The external iliac

vessels lie in front of this part of the iliac fascia. To the outer side of those vessels, the fascia turns forwards to be connected with Poupart's ligament and the fascia transversalis, as already described; to the inner side of the femoral vein it is attached to the ilio-pectineal line, along with the fascia lata; and between these two points, namely, behind the femoral vessels, it continues downwards over the margin of the pelvis, forming the back part of the sheath of those vessels.

The psoas parvus is closely connected with the iliac fascia, by means of an expansion of its tendon.

At the back part of the abdomen there is also a thin but strong fascia covering the quadratus lumborum muscle and forming the **anterior layer** of the **lumbar aponeurosis**. It is attached at the outer border of the quadratus to the middle layer of the aponeurosis, and at its inner border to the roots of the transverse processes of the lumbar vertebræ. Superiorly it forms two strong bands, the ligamenta arcuata of the diaphragm already described, and inferiorly it is attached to the crest of the ilium.

The **middle layer** of the **lumbar aponeurosis** consists of strong fibrous bundles which are attached to the posterior layer at the outer margin of the erector spinæ. It intervenes between that muscle and the quadratus, and is attached internally by three or four slips to the tips of the lumbar transverse processes. It gives origin at its outer part to the middle fibres of the transversalis abdominis muscle.

#### MUSCLES AND FASCIÆ OF THE PERINÆUM AND PELVIS.

**FASCIÆ OF THE PERINÆUM—Superficial Fascia.**—In the posterior half of the perinæum the subcutaneous fat is continued deeply into the ischio-rectal fossa, the pyramidal space intervening between the obturator fascia and the levator ani muscle. In the anterior half of the perinæum, beneath the subcutaneous fat, is placed a special layer of fascia, continuous with the dartos, the *proper superficial perineal fascia*, sometimes called *fascia of Colles*. This fascia is bound down on each side to the margin of the pubic arch as far back as the ischial tuberosity; posteriorly, along a line from the ischial tuberosity to the central point of the perinæum, it turns round the posterior margin of the transversus perinæi muscle to join the subpubic fascia, to be presently described. From its deep surface likewise, an incomplete septum in the middle line dips down to the urethra and passes forwards into the scrotum. It thus happens that air blown in beneath the proper perineal fascia on one side passes forwards and distends the scrotum to a certain extent on that side; it may then penetrate to the other also, and if injected with sufficient force may reach the front of the abdomen, and travel upwards beneath the superficial fascia; but it neither passes backwards to the posterior half of the perinæum nor down upon the thighs. The same course is followed by urine or matter extravasated beneath the proper perineal fascia.

The **deep perineal** or **subpubic fascia** is stretched across the pubic arch on the deep surface of the crura of the penis and the bulb of the urethra. It consists of two distinct layers of strong fibrous membrane, separated by intervening structures. The *anterior layer*, or *triangular ligament of the urethra*, attached to the inferior margin of the

symphysis pubis and to the rami of the pubic and ischial bones, and extending in the middle line back to the central point of the perinaeum, is perforated about an inch from the symphysis by the urethra, immediately before its expansion into the bulb, and above and in front of this by the dorsal vein of the penis in the middle line, and by the pudic arteries and nerves on each side. At its posterior and inferior extremity it is connected with the deep layer, and with the recurved margin of the perineal fascia. Between the two layers of the subpubic fascia are placed the membranous portion of the urethra, the deep transverse and constrictor muscles of the urethra, and Cowper's glands, together with the pudic arteries and nerves and the arteries of the bulb. The *posterior* or *deep layer* consists of a right and left lateral half, which are separated in the middle line by the urethra close to the neck of the prostate, and are continued into the capsule of that gland. This layer of fascia is superficial to the anterior fibres of the levator ani muscle, which lie between it and the pelvic fascia, and is connected with a thin web of areolar tissue which extends backwards on the surface of the levator ani muscle, and is distinguished as the *anal fascia*.

In the female the subpubic fascia is divided in the middle by the vagina.

**FASCIA OF THE PELVIS.**—The fascia lining the pelvis is described in three parts, viz., the upper part, or undivided pelvic fascia, and the two lower—the recto-vesical fascia, and the obturator fascia. The first of these is divided into the other two at the level of a white band of fibres, stretched from the lower part of the symphysis pubis to the spine of the ischium. The space between those two fasciæ is occupied by the levator ani and the fat and other contents of the ischio-rectal fossa.

*a.* The **pelvic fascia** is attached at the side superiorly for a short space to the brim of the pelvis, but in front of the line of its osseous attachment it inclines downwards towards the lower part of the symphysis pubis, following the margin of the obturator internus muscle. Anterior to the spine of the ischium, it lies between the obturator internus and the peritoneum, and at the back part of the pelvis is continued as a thin membrane over the pyriformis muscle and the sacral nerves, and is perforated by branches of the internal iliac artery and vein.

*b.* The **recto-vesical fascia** is the direct continuation of the pelvic fascia downwards and inwards to the viscera, below the level of the white line previously mentioned; it descends, immediately in contact with the inner surface of the levator ani muscle, to the prostate gland, the urinary bladder, and the rectum. On reaching those organs it spreads over them, and to some extent encases them. Close to the symphysis pubis, a short band is directed backwards above the prostate gland, to the bladder, with which it is intimately connected. A similar band exists at the opposite side of the symphysis pubis, and the two are separated by a narrow depression, in which the dorsal veins of the penis lie, after entering the pelvis. The bands in question are named the *anterior true ligaments of the urinary bladder*. At the place where it is reflected inwards to the side of the bladder, the recto-vesical fascia forms the *lateral true vesical ligament*. At the side of the bladder and prostate, the fascia gives a prolongation forwards on the veins which cover the prostate, and is firmly adherent to the capsule of



that organ, except at its base, where an angular furrow, occupied by large veins, exists between the prostate and bladder. Into this furrow the incision for lithotomy ought not to extend, on account of the danger from wounding the veins and from the infiltration of urine. A portion of the recto-vesical fascia invests the vesiculæ seminales, and is extended across between the bladder and the rectum; continuing into the membrane of the opposite side, it supports the bladder, and separates that organ from the intestine. On the rectum the fascia is also reflected upwards and downwards, gradually degenerating into a thin membrane over the surface of the bowel, as it likewise does on the bladder.

c. The **obturator fascia** is a membrane stretched over the lower part of the surface of the obturator internus muscle within the pelvis. It is connected superiorly with the white band before referred to, which consists indeed of its superior fibres, and it is attached in the rest of its circumference to the rami of the pubis and ischium, the ischial tuberosity, and the greater or lesser sacro-sciatic ligaments. It lines the inner surface of the obturator internus muscle and presents between its fibres a canal, which contains the internal pubic artery and nerve in their course to the perinæum.

The obturator fascia is sometimes included in the description of the pelvic fascia, while the recto-vesical is considered as an offset from it. It will be found, however, on dissection, that the recto-vesical fascia is always most directly continuous with the pelvic fascia, and that the obturator fascia is only loosely connected with it. Indeed, the fibres of the levator ani muscle in most cases pass upwards to some extent beyond the white line, and thus separate the obturator from the pelvic fascia.

The *ischio-rectal fossa* is a pyramidal space occupied by subcutaneous fat. It is bounded externally by the obturator fascia, posteriorly by the gluteus maximus muscle and great sacro-sciatic ligament, and internally by the recto-vesical fascia; anteriorly, its base is limited by the margins of the perineal and the subpubic fasciæ.

In the female, the pelvic fascia is connected with the vagina in the same manner as with the other pelvic organs.

MUSCLES.—The muscles of the perinæum differ somewhat in the two sexes, and must therefore be separately described in each. In both sexes they may be divided into two groups, according as they are more immediately connected with the lower orifice of the alimentary canal or with the genito-urinary outlet. In both groups superficial and deep muscles are to be distinguished.

A.—IN THE MALE.—a. ANAL MUSCLES.—The **internal or circular sphincter** is a thick ring of unstriped muscle connected with the lowest circular fibres of the rectum, which will fall more naturally to be described along with the anatomy of that organ.

The **superficial or external sphincter** muscle is a thin layer of fibres placed immediately beneath the skin surrounding the margin of the anus. It is elliptical in form, about half an inch in breadth on each side of the anus, and is attached posteriorly by a small tendon to the tip and back of the coccyx; passing forwards on each side of the anus, it becomes blended anteriorly with the transverse and the bulbo-cavernosus muscles at the *central point of the perinæum*, a name given to the depressed root situated in the male between the anus and the bulb of the urethra, and in the female between the anus and vulva.

The **levator ani** arises in front from the posterior surface of the pubis, near the symphysis and midway between its upper and lower

Fig. 228.

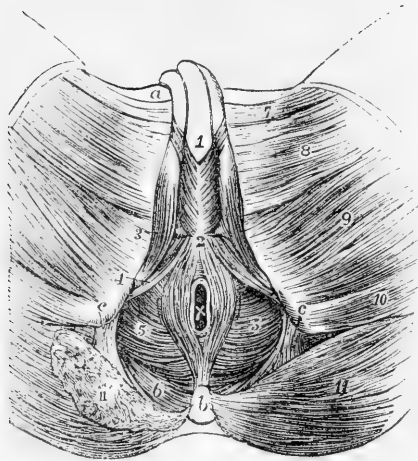


Fig. 228. — SUPERFICIAL VIEW OF THE MUSCLES OF THE PERINÆUM IN THE MALE (modified from Bourguery). (A. T.)  $\frac{1}{4}$

*a*, crest of the pubis; *b*, coccyx; *c*, placed on the tuberosity of the ischium, points by the line to the greater sacro-sciatic ligament; *x*, the anus; 1, placed on the spongy body of the urethra in front of the bulbo-cavernosus muscles; 2, the central point of the perinæum; 3, ischio-cavernosus; 4, transversus perinæi; 5, levator ani; from 2 to *b*, elliptical sphincter of the anus; surrounding *x*, is the circular sphincter; 6, coccygeus muscle; 7, adductor longus; 8, gracilis; 9, adductor magnus; 10, semitendinosus and biceps; 11, on the left side, the gluteus maximus entire; 11', the same cut on the right side, so as to expose a part of the coccygeus muscle.

borders; behind from the spine of the ischium, and between those points from the pelvic fascia along the line of attachment of the obturator fascia. Some of its fibres are also traceable upwards in the substance of the pelvic fascia above the level of the obturator. From this extensive origin the fibres of the levator proceed downwards and inwards towards the middle line of the floor of the pelvis. Its posterior fasciculi are inserted upon the side of the lower end of the coccyx; the bundles immediately in front of the coccyx unite in a median raphe with those of the opposite sides as far forward as the margin of the anus; the middle and larger portion of the muscle is prolonged upon the lower part of the rectum, where it is connected with the fibres of the external sphincter, and slightly with those of the internal; and lastly, the anterior muscular bundles pass between the rectum and the genito-urinary passages, and, descending upon the side of the prostate, unite beneath the neck of the bladder, the prostate, and the neighbouring part of the urethra, with corresponding fibres from the muscle of the opposite side, and blend also with those of the external sphincter and deep transverse perineal muscles.

The anterior portion of the levator ani, which arises from the ramus of the pubis, close to the symphysis and above the pubic arch, and also from the adjacent fasciæ, is sometimes separated at its origin by areolar tissue from the rest of the muscle. From this circumstance, and from its connection with the prostate gland, it was described by Santorini, and since by Albinus and Sæmmerring, as a distinct muscle, under the name of the *levator prostatae*. Its fibres pass backwards parallel with the middle line.

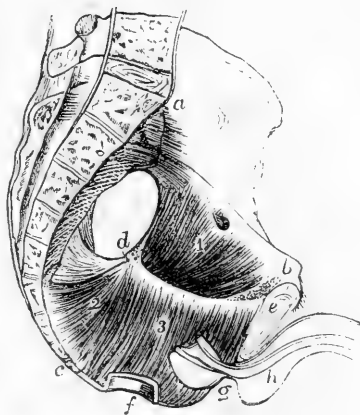
*Relations.*—The upper or pelvic surface of the levator ani is in contact with the recto-vesical fascia, the capsule of the prostate, and the lower end of the

rectum. The under or perineal surface, invested by the thin anal fascia, is covered by the fat which occupies the ischio-rectal fossa. The posterior border is continuous with the coccygeus.

Fig. 229. — LEFT HALF OF THE MALE PELVIS, TO SHOW THE LEVATOR ANI AND COCCYGEUS MUSCLES (after Cloquet).  $\frac{1}{2}$

*a*, the promontory of the sacrum; *b*, the crest of the pubis; *c*, the last bone of the coccyx; *d*, the spine of the ischium; *e*, the symphysis pubis; *f*, a small portion of the anal part of the rectum; *g*, half the prostate gland; *h*, half the bulb and a portion of the penis; 1, upper part of the obturator internus muscle exposed by removing from within it the pelvic fascia; 2, coccygeus muscle, and above it and between it and *d*, the sacro-sciatic ligaments; 3, inner surface of the levator ani; the white line extending between *d* and *e*, shows the place of its origin from the fascia of the pelvis; below is shown the descent of the fibres to the anus, and to the portions of the perineum before and behind it.

Fig. 229.



The **coccygeus** or **levator coccygeus** muscle is composed of fleshy and tendinous fibres, forming a thin, flat, and triangular sheet, which arises by its apex from the spine of the ischium and the lesser sciatic ligament, and is attached along its base to the border of the coccyx and the lower part of the sacrum. The fibres of this muscle diverge as they approach the middle line, while those of the levator ani rather converge as they descend.

*Relations.*—The internal or pelvic surface of this muscle assists in supporting the rectum: its external or under surface rests on the front of the sacro-sciatic ligaments, and on the gluteus maximus muscle.

The levatores ani and coccygei muscles together have been named somewhat appropriately by Meyer, the pelvic diaphragm.

*Varieties.*—The coccygeus is sometimes inserted into the side of the sacrum instead of the coccyx. A few muscular fibres have been found extending from the lower part of the sacrum to the coccyx, both in front and behind. The anterior slip is described by Von Behr and others as *curvator*, and the posterior as *extensor coccygis*. (See Macalister, *Musc. Anomalies*, p. 66.)

**b. GENITO-URINARY MUSCLES.**—Covered by the special fascia of the perineum are three muscles, placed superficially—the superficial transverse, the ischio-cavernosus, and the bulbo-cavernosus; while, situated more deeply between the superficial and deep layers of the subpubic fascia, are the deep transverse muscle and the constrictor of the urethra—sometimes described as one muscle under the name of compressor of the urethra.

The **transversus perinæi** muscle arises from the inner surface of the pubic arch, near the ischial tuberosity, and is directed obliquely forwards and inwards to unite with the muscle of the opposite side, as well as with the sphincter ani and bulbo-cavernosus at the central point of the perineum. It lies immediately in front of the line where the perineal dips back to join the subpubic fascia.

*Varieties.*—It is sometimes absent, and at other times one or more small muscular slips are found lying on the same plane with it, in front or behind.

The **ischio-cavernosus**, or erector penis muscle, embracing the crus penis, arises from the inner part of the tuber ischii, behind the extremity of the crus penis, and from the pubic arch along the inner and outer sides of the crus. From this origin the fleshy fibres are directed forwards to a tendinous expansion which is spread over the lower surface of the crus penis, and is inserted into the under and outer surfaces of that body towards the fore part.

*Varieties.*—Houston has described (Dublin Hosp., Reports, vol. v.), under the name of *compressores venæ dorsalis penis*, two slips of muscle, separated from the erectors penis on each side by an interval, though apparently belonging to them. They are said to arise from the pubic arch, above the origin of the erector muscles and the crura of the penis, and, passing upwards and forwards, are inserted above the dorsal vein, by joining each other in the middle line. These muscles, which are well developed in the dog and several other animals, are by no means constant in the human subject.

The **bulbo-cavernosus** or **ejaculator urinæ**, may be considered as a single muscle, consisting of two symmetrical parts.

The fleshy fibres of the muscle take origin behind from the central tendon of the perinæum, and from a median tendinous raphé interposed between the two halves of the muscle. The larger number of the fibres are directed round the bulb and the adjoining part of the corpus spongiosum urethræ, and join above that body with those from the opposite side by a strong aponeurosis. At the fore part, a portion of the muscle passes over the sides of the corpus cavernosum, and is attached to that body in front of the erector penis: from its insertion a tendinous offset is said to be prolonged over the dorsal vessels of the penis (Kobelt). The posterior fibres, shorter than the anterior, are inserted into the front of the triangular ligament.

The fibres which invest the most prominent part of the bulb are more or less distinct from those contiguous to them, and have been described by Kobelt as forming a separate muscle, to which he has given the name *compressor hæmiphæriam bulbi*. The fibres of this muscular slip are connected by a small tendon, above the urethra, with the corresponding part of the opposite side.

The **deep transversus perinæi** muscle is a thin rather inconstant fasciculus which, arising from the margin of the pubic arch, is directed inwards and meets with its fellow of the opposite side behind the bulb, at the central point of the perinæum. Its fibres conceal Cowper's gland.

The **constrictor urethræ** muscle consists of a number of transverse fibres extending across the arch of the pubis, some of them above and others below the membranous portion of the urethra, and closely embracing it. In some bodies a tendinous raphé, placed over the middle of the urinary canal, separates each stratum into lateral halves.

*Relations.*—This muscle rests in contact with the deep layer of the triangular ligament, which separates it from the anterior fibres of the levator ani.

**Circular fibres** of Santorini (*stratum internum circulare*, Müller).—Beneath the transverse muscle just described is a series of circular involuntary muscular fibres, entirely surrounding the membranous part

of the urethra: these are continuous behind with the circular fibres of the prostate, and are referred to in the description of that body. (See Structure of the Prostate.)

Fig. 230.—POSTERIOR VIEW OF THE PUBES WITH PART OF THE BLADDER AND URETHRA ATTACHED (from Santorini).  $\frac{1}{2}$

1, body; 2, rami of the pubes; 3, obturator internus muscle; 5, portion of the fundus and neck of the bladder laid open; 6, the prostate gland; 7, transverse fibres of the compressor urethrae muscle, passing above the urethra; 8, similar fibres passing beneath that canal.

*Varieties.*—A *pubo-urethral* muscle was described by James Wilson (Medico-Chirurgical Trans., London, vol. i. p. 176), and is sometimes referred to as Wilson's muscle, but has not been recognised as a separate muscle by succeeding anatomists. An unstriped *pubo-vesical* band has been described, descending from the back of the symphysis to the neck of the bladder (Luschka).

*Nerves.*—The muscles of the urethra and penis are supplied by the inferior hæmorrhoidal branch of the pudic nerve; the levator and sphincter ani by the inferior hæmorrhoidal and by the fourth and fifth sacral and by the coccygeal nerves; and the coccygeus muscle by the three last-named nerves.

*Actions.*—The *sphincters* of the anus cause by their contraction occlusion of that aperture. The contraction of the external is usually maintained involuntarily, though it may be rendered firmer by an act of the will; that of the internal is wholly involuntary.

The *levator ani* and *coccygeus* elevate the lower part of the rectum and invert its anal border, after the protrusion and eversion which accompany defecation.

The *transversi* acting together draw backwards and fix the central point of the perinæum, thus assisting to give a base of support to the ejaculator muscle.

The *erector penis* serves to compress the crus penis and thus assist in producing or at least in maintaining the erection of the penis.

The *ejaculator urinae* compresses the bulb and the adjoining part of the corpus spongiosum of the urethra, so as to eject forcibly any fluid lodged in the canal. It comes into action near the end of the process of micturition, when its contraction is mainly a voluntary act, and in the emission of the semen when it is involuntary.

The *constrictor urethrae* and the *circular* involuntary muscles diminish the calibre of the urethra and expel its contents; their fibres contract near the end of micturition, so as to assist the ejaculator in clearing the canal.

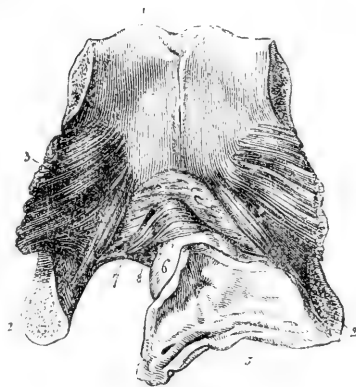
**B.—IN THE FEMALE.**—In the female the anterior fibres of the *levator ani* embrace the vagina as they do the prostate in the male.

The *transversus perinæi* and the *sphincter ani* are arranged nearly in the same manner as in the male.

The *erector clitoridis* differs from the erector penis of the male by its smaller size alone.

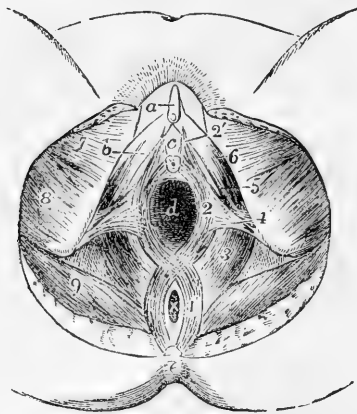
The *sphincter vaginae* is attached behind to the central point of the perinæum, in common with the sphincter ani and transversus perinæi muscles; its fibres open out to surround the vaginal orifice and vestibule, closely embracing on the outer side the two bulbs of the vesti-

Fig. 230.



bule; again approaching each other in front, they become narrow, and

Fig. 231.

Fig. 231.—MUSCLES OF THE PERINEUM IN THE FEMALE. (A. T.)  $\frac{1}{4}$ 

*a*, clitoris; *b*, crus clitoridis; *c*, is placed in the vestibule above the orifice of the urethra; *d*, vagina; *x*, anus; *e*, coccyx; 1, external sphincter ani muscle; 2, sphincter vaginae; 2', a few of its fibres prolonged to the clitoris; 3, levator ani; 4, on the left ischial tuberosity, points to the transversus perinaei (the inner fibres of this muscle are represented too far forwards in the figure); 5, 6, ischio-cavernosus; 7, gracilis; 8, adductor magnus and semi-tendinosus, &c.; 9, gluteus maximus.

are inserted upon the corpora cavernosa of the clitoris, a fasciculus crossing over these and including the vena dorsalis. The two halves of this elliptical muscle appear to correspond strictly to those of the bulbo-cavernosus muscle in the male.

A **deep transverse** muscle, corresponding to part of the constrictor urethrae of the male, has been described as resting on the pubic surface of the female urethra.

#### THE MORPHOLOGY OF THE FASCIAE AND MUSCLES OF THE TRUNK AND HEAD.

**Fasciæ.**—There is a general correspondence in the relation of the deep fascia to the skeleton and masses of the trunk muscles throughout vertebrate animals. In its simplest and lowest form the general investing fascia is prolonged from the surface towards the skeleton in four places, viz., two median, which have been called respectively the *neural* and *hæmal* septa, and two lateral, one on each side, running towards the transverse processes of the vertebrae. The layers of the hæmal septum are in close contact in the caudal region, but they are separated and somewhat complicated in the rest of the trunk by the interposition of the visceral cavity between them.

In man and the higher animals the dorsal part of the general investing fascia is represented by the tendinous attachments of the trapezius, latissimus dorsi, and serrati postici muscles, and by the vertebral aponeurosis and deep temporal fascia, while the deep fascia of the side and front of the trunk, neck, and head and the aponeurotic sheath of the limbs correspond with its ventral portion. The neural septum remains as the median fascial interval of the dorsal spinal muscles, ligamentum nuchæ, &c. The hæmal septum partly constitutes the linea alba, and is elsewhere separated into two as an investment of the visceral cavity, forming the transversalis, iliac, and pelvic fasciæ. The lateral septum, which is strongly developed in fishes and amphibia, is only seen at all clearly in the middle layer of the lumbar aponeurosis of man and the higher animals, being in them situated much nearer the dorsal than the ventral aspect of the body. This difference of position is coincident with the greater development of the ventro-lateral muscles and the limbs in the higher than in the lower vertebrates.

**Muscles.**—The *dorso-lateral* muscle consists of fibres which more than any others retain their original segmented character and longitudinal direction. It is represented in man by the mass of muscles, the chief of which is the erector spinae, which lies in the vertebral groove of the back, and which, arising from the lower vertebrae, splits up as it passes forwards to be inserted into other vertebrae, the ribs and the skull. It may be divided into three sets of muscles, characterized by the different direction of their fibres. The *first* set consist of those which run

for the most part in a longitudinal direction, as from spine to spine, in spinalis and interspinales; from transverse process to transverse process in longissimus dorsi and intertransversales; or from rib to rib in ilio-costalis. The *second* set consist of muscular fibres directed more or less obliquely upwards and outwards from spines to transverse processes, as in splenius capitis and colli, rectus posticus major and obliquus inferior. The *third* set are also oblique, but they are directed upwards and inwards from transverse processes to spine, as in complexus, semi-spinalis, multifidus, and obliquus superior; and from transverse processes to laminae, as in rotatores costarum.

In the posterior part of the trunk in tailed animals this dorsal series of muscles is continued backwards without interruption as the superior caudal muscles, and in man an occasional muscle is sometimes found developed as an extensor coccygis; but as a general rule owing to the very slight development of the caudal vertebræ, and the large size of the pelvic girdle, the dorso-lateral muscles do not in man extend beyond the upper part of the sacrum.

Anteriorly this muscle is prolonged to the side of the head, where it forms the group of temporal, pterygoids, masseter, and probably the orbital muscles. The connection between these muscles and the dorsal muscles is well seen in the Tailed-Batrachians, where the fibres of the dorsal muscle are directly continuous with those of the temporal. In man this continuity is interrupted by the ossification of the temporal ridge and root of the zygoma.

The *ventro-lateral* muscle, while equally simple in the lowest vertebrates with the dorso-lateral, presents in the higher animals much greater complexity both of form and attachments. As regards its general relation to the vertebral axis of the body it may be divided into two portions, which are usually quite distinct from each other.

The first or deeper portion is that to which the name of *hypaxial* may most properly be applied. It consists of fibres which lie for the most part immediately under the bodies of the vertebræ and attached to them. They may also spread round the internal surface of the walls of the visceral cavity of the body, and may even, as in the diaphragm and levator ani, spread across that cavity, forming one or more muscular partitions. Posteriorly this set of muscles is prolonged on the under surface of the tail, as the most deeply situated layer, corresponding to an occasional muscle in man, the curvator coccygis. In man, also, two prolongations are sent outwards on the hind limb, one on its preaxial border, the psoas, the other on its postaxial, the pyriformis. Passing forwards, we find belonging to the same group, the subvertebral muscles, represented in man by the subcostals, but which in birds, serpents, &c., are very largely developed as the retrahentes costarum and the levatores costarum interni; also the various diaphragms, including the post-cardiac or midriff, and the pelvic or levator ani. In this list, also, should be placed the triangularis sterni, or, as it is called by some, the subcostalis anterior.

In front of the thorax these hypaxial muscles are prolonged in two sub-divisions, of which the upper forms the recti antici and longus colli, and the lower includes the muscles which connect together the various parts of the hyobranchial arches and jaws, and invest the buccal and pharyngeal cavities; the chief of these being the hyoid and styloid muscles, the digastric, or at least its posterior belly, the lingual muscles, the buccinator and palatal muscles, and the constrictors of the pharynx.

The second or more superficial portion of the ventro-lateral muscle may be distinguished as *paraxial* (Mivart). It arises in connection with the transverse processes of the vertebræ, from their lower surfaces and tips and from the lateral septa and general fascial investment. It thus at its place of attachment to the vertebral axis separates the epaxial from the hypaxial sets of muscles. It is further distinguished by the disposition which certain of its sclerotomes show to ossification in the ribs and the limb-girdles. These paraxial muscular bundles form the superficial layer of muscles on the ventral surface of the tails of fishes, &c., and almost the entire thickness of the muscular layer which bounds the visceral cavity of all vertebrates. Their connection with the alimentary canal is limited to its extremities where they form the external sphincters.

According to the direction of its fibres the trunk portion of this muscular mass may be divided into two groups of muscles, a *ventral* with longitudinally directed fibres and a *lateral* with more or less obliquely directed fibres.

The *ventral* group is represented in man by the rectus abdominis, rectus thoracis (an occasional muscle), and the sterno-mastoid, and repeats more closely the simple segmented condition of the dorsal muscle than is the case with the lateral fibres. In fishes the oblique fibres are almost entirely wanting, and in the lower vertebrates generally they are less developed than the longitudinal. On the other hand in the higher forms, as in man, the oblique fibres are the more important, the longitudinal fibres being in certain places (thorax) absent altogether, or only occasionally present as rectus thoracis. Again, the connection of the rectus thoracis with the sterno-mastoid is but rarely seen in man. In some animals, as *Lepidosiren*, the oblique fibres are directly continuous with the longitudinal, but in man greater differentiation exists, for the lateral muscles are merely prolonged forwards as strong aponeuroses which form a fibrous sheath for the rectus on each side of the middle line. In man these longitudinal fibres have little or no connection with the muscles of the limbs, but in *Urodelans* they are continued outwards upon the ventral aspect of each limb as part of the pectoralis major and gracilis.

Longitudinal fibres are also found in the pyramidalis, a small rudimentary muscle in man, but which in marsupials and monotremes is extremely large; they are also found, but rarely, in man between the lateral oblique muscles forming a *lateral rectus*, which consists of a few fibres running between the lower ribs and the ilium. Posteriorly again the longitudinal direction is maintained by certain fibres of the quadratus lumborum.

The *lateral* group of trunk muscles, distinguished by the oblique direction of their fibres, is divisible usually into three or it may be into four layers. In the lowest vertebrates this stratification does not occur, but in the higher animals it is coincident with the differentiation of separate muscles. Of these layers three are very constant in their relations and extent, but the fourth, which is the most superficial, though very constantly found, is on the whole only a partial layer. In man these layers are represented, the first three by the abdominal muscles, the external and internal oblique and transversalis respectively, and the fourth by the platysma myoides, the facial, auricular and epicranial muscles.

The transverse or deepest of these layers is represented by the transversalis muscle, and according to Humphry and others by the triangularis sterni and the subcostals, which, however, have already been described as belonging more properly to the hypaxial set of muscles.

The internal oblique is in series with the internal intercostals, levatores costarum, anterior cervical and lateral lumbar intertransversales, and scaleni muscles. It is also in most direct connection with the quadratus lumborum. Posteriorly this layer furnishes the ischio-caudal (occasionally found in man), the erector penis, compressor urethrae, and transversus perinaei. Laterally it gives the costo-scapular muscles, serratus magnus and levator scapulae, and the costo-coracoid, or subclavius, to the shoulder girdle.

The external oblique layer is prolonged upwards upon the side of the chest, and outwards upon the fore limb as pectorales major and minor, latissimus dorsi, and between the limb and the head, as cleido-mastoid and trapezius.

The fourth layer, corresponding to the panniculus carnosus of animals, seems to be mainly developed from the cutaneous surface of the last or external oblique layer; it is also developed in close connection with the skin and fascial investment. In man this layer extends only upon the surface of the head and neck, and very slightly over the shoulder. It forms the subcutaneous colli or platysma myoides, and those slight continuations downwards which are found upon the surface of the pectoral and deltoid muscles. On the surface of the head this forms the epicranial muscles, with the intervening aponeurosis, the auricular and the facial muscles, except the orbicularis palpebrarum. All these muscles are attached to bone usually by one end only, the other being attached to the skin or to the cartilage of some moveable structure, but in some cases they may reach to the deeper structures by both ends. Portions of this layer in animals



may blend with or even take the place of parts of the subjacent muscles, or they may be enormously developed as compared with the other layers, or lastly, the whole layer may be aborted. (See the works of Humphry and Mivart, as quoted at p. 185.)

### THE SURGICAL ANATOMY OF HERNIÆ.

In connection with the description of the fasciæ and muscles forming the walls of the abdomen, it is desirable to introduce a short account of the anatomical relations of the various kinds of abdominal herniæ. These hernial protrusions are chiefly of three kinds, *inguinal*, *femoral*, and *umbilical*. The last-named, however, which occurs at the umbilicus, inasmuch as it presents relations by no means intricate, need not be more than mentioned in an anatomical work. An inguinal hernia following the course of the spermatic cord from the cavity of the abdomen, and a femoral hernia coming through the crural canal at the inner side of the femoral vessels, have important anatomical relations which must be studied with the greatest attention.

#### INGUINAL HERNIA.

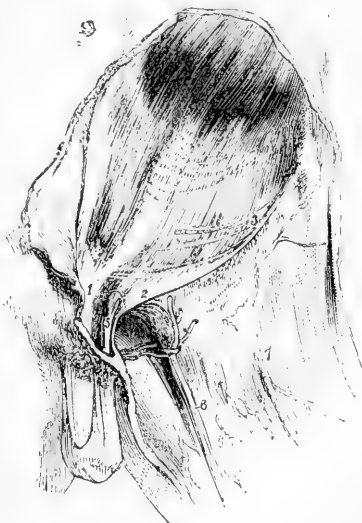The **inguinal canal**, through which the spermatic cord passes from the cavity of the abdomen to the testis, and through which an inguinal hernia also passes, begins at the internal abdominal ring, and ends at the external one. It is oblique in its direction, being parallel with and immediately above the inner half of Poupart's ligament; and it measures two inches in length. The external ring is immediately over the crest of the pubis, and the internal is opposite the middle of Poupart's ligament. In front the canal is bounded by the aponeurosis of the external oblique muscle in its whole length, and at the outer end by the fleshy part of the internal oblique also; behind it, is the fascia transversalis,

Fig. 232.—THE APONEUROSIS OF THE EXTERNAL OBLIQUE MUSCLE AND THE FASCIA LATA.

1, the internal pillar of the abdominal ring; 2, the external pillar of the same (Poupart's ligament); 3, transverse fibres of the aponeurosis; 4, pubic part of the fascia lata; 5, the spermatic cord; 6, the long saphenous vein; 7, outer part of the fascia lata.

together with, towards the inner end, the conjoined tendon of the two deeper abdominal muscles. Above, the canal is bounded by the arching lower borders of the internal oblique and transversalis muscles, while below, it is supported by the broad surface of Poupart's ligament, which separates it from the sheath of the large blood-vessels descending to the thigh, and from the femoral canal at the inner side of

Fig. 232.



those vessels. The deep epigastric artery is close to the inner border of the internal ring, and the femoral vessels are beneath it, and rather to its inner side.

Fig. 233.

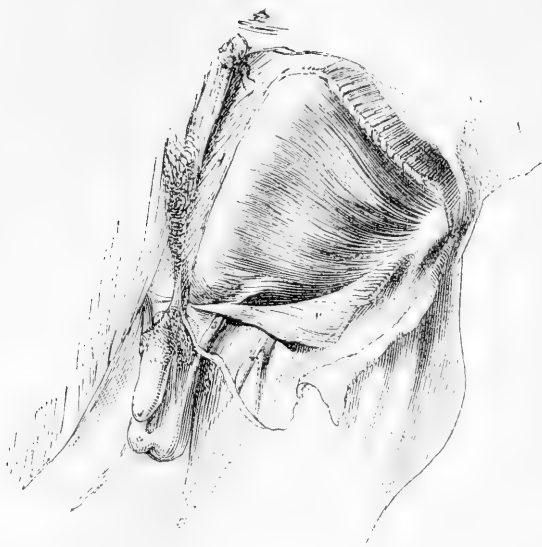


Fig. 233.—DEEPER DISSECTION OF THE ABDOMINAL WALL IN THE GROIN.

The aponeurosis of the external oblique muscle having been divided and turned down, the internal oblique is brought into view with the spermatic cord escaping beneath its lower edge; 1, aponeurosis of the external oblique; 1', lower part of the same turned down; 2, internal oblique muscle; 3, spermatic cord; 4, saphenous vein.

The spermatic cord, which occupies the inguinal canal, is composed of the arteries, veins, lymphatics, nerves, and excretory duct (vas deferens) of the testis, together with a quantity of loose areolar tissue mixed up with those parts.

The coverings given from the constituent parts of the abdominal wall to the spermatic cord, besides the integuments, are, from the external ring a prolongation of the intercolumnar or spermatic fascia; the cremasteric muscle and fascia from the lower border of the internal oblique muscle, and a thin, funnel-shaped prolongation of the transversalis fascia from the edge of the inner ring (infundibuliform fascia). Lastly, on the inside of the abdominal walls is the peritoneum, and a thin layer of areolar tissue lying between the peritoneum and fascia transversalis, and usually containing a small quantity of sub-peritoneal fat.

**VARIETIES OF INGUINAL HERNIÆ.**—Two principal forms of inguinal hernia are described which are distinguished according to the part of the canal in which they first enter, as well as by the position which they bear with respect to the epigastric artery. Thus, when the hernia takes the course of the inguinal canal from its commencement, it is named *oblique*, because of the direction of the canal, or *external*, from the position which its neck bears with respect to the epigastric artery. On the other hand, when the protruded part, without following the

Fig. 234.

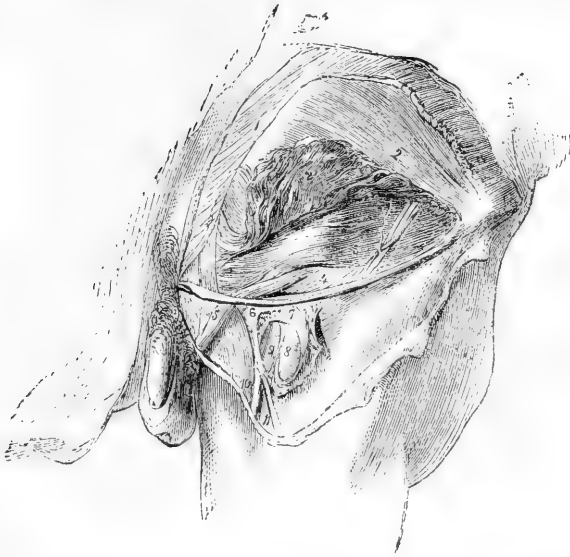

Fig. 234.—THE INGUINAL CANAL AND FEMORAL SHEATH FULLY EXPOSED.

The lower part of the external oblique has been removed (with the exception of Poupart's ligament), a portion of the internal oblique raised, and the transversalis muscle and fascia brought into view. The femoral artery and vein are seen to a small extent, the fascia lata having been turned aside and the sheath of blood-vessels laid open. 1, external oblique muscle; 2, internal oblique; 2', part of same turned up; 3, transversalis muscle. Upon the last-named muscle is seen a branch of the circumflex iliac artery, with its companion veins; 4, transversalis fascia; 5, spermatic cord covered with the infundibuliform fascia. 6, upper angle of the iliac part of fascia lata; 7, the sheath of the femoral vessels; 8, femoral artery; 9, femoral vein; 10, saphenous vein; 11, a vein joining it.

length of the canal, passes at once through its posterior wall at a point opposite the external abdominal ring, the hernia is named, from its course, *direct*, or, from its relation to the epigastric artery, *internal*.

**Oblique inguinal hernia.**—In the common form of this hernia the protruded viscus carries before it a covering of peritoneum (the *sac* of the hernia), derived from the outer fossa of that serous membrane; and, in passing along the inguinal canal to the scrotum, it is successively clothed with the coverings given to the spermatic cord from the abdominal parietes. The hernia and its sac lie directly in front of the vessels of the spermatic cord, and do not extend below the testis, even when the disease is of long standing.

When the hernia does not extend beyond the inguinal canal, it is distinguished by the name *bubonocœle*: and when it reaches the scrotum, it is commonly named from that circumstance *scrotal* hernia.

There are two other varieties of oblique inguinal hernia, in which the peculiarity depends on the condition of the process of peritoneum that accompanies the testis when this organ is moved from the abdomen. In ordinary circumstances the part of the peritoneum connected immediately with the testis, becomes separated after birth from the general cavity of that serous

membrane by the obliteration of the intervening canal; and the hernial protrusion occurring after such obliteration has been completed, carries with it a distinct serous investment—the sac. But if this process of obliteration should not take place, and if a hernia should be formed, the protruded part is then received into the cavity of the tunica vaginalis testis, which serves in the place of its sac. In this case the hernia is named *congenital* (hernia tunicæ vaginalis, —Cooper). It is thus designated, because the condition necessary for its formation only exists normally about the time of birth; but the same kind of

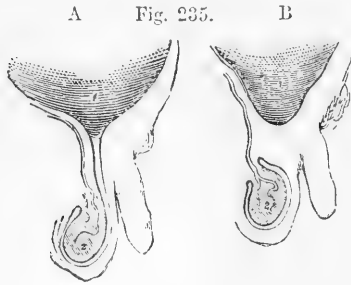


Fig. 235.—DIAGRAM OF A PART OF THE PERITONEUM AND THE TUNICA VAGINALIS TESTIS.

In the first, A, the serous investment of the testis is seen to be continuous with the peritoneum; while in the second, B, the two membranes are shown distinct from each other. 1, the peritoneal cavity; 2, the testis.

hernia is occasionally found to be first formed in the adult, obviously in consequence of the tunica vaginalis remaining unclosed, and still continuous with the peritoneum. The congenital hernia, should it reach the scrotum, passes below the testis; and, this organ being embedded in the protruded viscus, a careful examination is necessary in order to detect its position. This peculiarity serves to distinguish the congenital from the ordinary form of the disease.

To the second variety of inguinal hernia, in which the distinguishing character depends on the state of the tunica vaginalis testis, the name *infantile* has been applied (Hey). The hernia in this case is covered with a distinct sac, which is again invested by the upper end of the tunica vaginalis. The relative position of the two serous membranes (the hernial sac and the tunica vaginalis) may be accounted for by supposing the hernia to descend when the process of the peritoneum, which accompanies the testis from the abdomen, has been merely closed at the upper end, but not obliterated for any length. Hence during an operation in such a case, the hernial sac is met with only after another serous bag (the tunica vaginalis testis) has been divided. The peculiarity here described has been repeatedly found present in the recently formed herniæ of grown persons. The term *infantile*, therefore, like congenital, has reference to the condition of certain parts, rather than to the period of life at which the disease is first formed.

*In the female*, oblique inguinal hernia follows the course of the round ligament of the uterus along the inguinal canal, in the same manner as in the male it follows the spermatic cord. After escaping from the external abdominal ring, the hernia lodges in the labium pudendi. The coverings are the same as those in the male body, with the exception of the cremaster, which does not exist in the female: but it occasionally happens that some fibres of the internal oblique muscle are drawn down over this hernia in loops, so as to have the appearance of a cremaster (Cloquet).

A strictly congenital inguinal hernia may occur in the female, the protruded parts being received into the little diverticulum of the peritoneum (canal of Nuck), which sometimes extends into the inguinal canal with the round ligament. But as this process of the peritoneum, in such circumstances, would probably not differ in any respect from the ordinary sac, there are no means of distinguishing a congenital hernia in the female body.

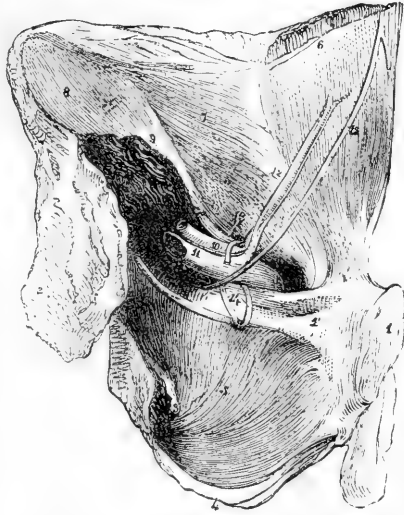**Direct inguinal hernia** (internal: ventro-inguinal).—Instead of

following the whole course of the inguinal canal, in the manner of the hernia above described, the viscus in this case is protruded from the

Fig. 236.—INTERNAL VIEW OF THE VESSELS RELATED TO THE GROIN.

A portion of the wall of the abdomen and pelvis of the left side, seen from behind. 1, symphysis of the pubis; 2, irregular surface of the hip-bone separated from the sacrum; 3, ischial spine; 4, ischial tuberosity; 5, obturator internus; 6, rectus, covered with an elongation from 7, fascia transversalis; 8, fascia iliaca covering the iliacus muscle; 9, psoas magnus cut; 10, iliac artery; 11, iliac vein; 12, epigastric artery and its two accompanying veins; 13, vessels of the spermatic cord, entering the abdominal wall at the internal ring the vas deferens joining them from below; 14, two obturator veins; 15, the obliterated umbilical artery.

Fig. 236.

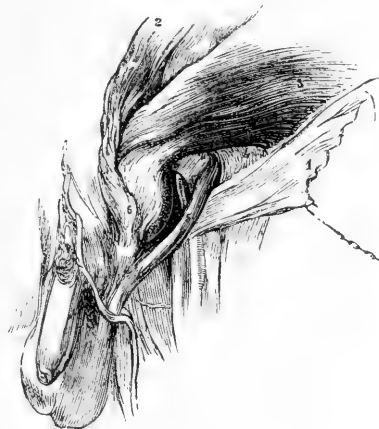

abdomen to the groin directly through the lower end of the canal, at the external abdominal ring. At the part of the abdominal wall through which the direct inguinal hernia finds its way, there is recognised on its posterior aspect a triangular interval,

Fig. 237.—A DIRECT INGUINAL HERNIA ON THE LEFT SIDE, COVERED BY THE CONJOINED TENDON OF THE INTERNAL OBLIQUE AND TRANSVERSALIS MUSCLES.

1, aponeurosis of the external oblique; 2, internal oblique turned up; 3, transversalis muscle; 4, fascia transversalis; 5, spermatic cord; 6, the hernia. A small part of the epigastric artery is seen through an opening made in the transversalis fascia.

Fig. 237.



the sides of which are formed by the epigastric artery, and the margin of the rectus muscle, and the base by Poupart's ligament. It is commonly named the triangle of Hesselbach. Through this space the hernia is protruded, carrying before it a sac from the fossa of the peritoneum internal to the obliterated hypogastric artery; and it is in general forced onwards directly into the external abdominal ring.

The coverings of this hernia, taking them in the order which they are successively applied to the protruded viscus, are the following:—

The peritoneal sac and the subserous membrane which adheres to it, the fascia transversalis, the conjoined tendon of the internal oblique

Fig. 238.

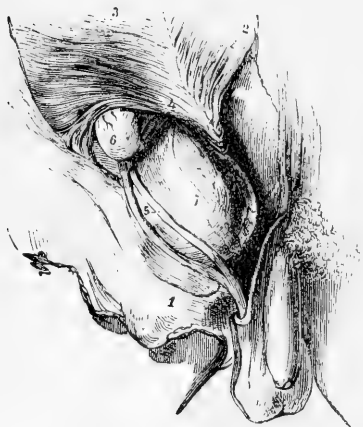

Fig. 238.—A SMALL OBLIQUE AND A DIRECT INGUINAL HERNIA, ON THE RIGHT SIDE.

1, tendon of the external oblique turned down; 2, internal oblique turned up; 3, transversalis; 4, on its tendon above a part of the epigastric artery, which has been exposed by dividing the fascia transversalis; 5, the spermatic cord (its vessels separated); 6, a bubonocele; 7, direct hernia protruded at the conjoined tendon of the two deeper muscles, and covered by a prolongation of the fascia transversalis.

and transverse muscles, and the intercolumnar (external spermatic) fascia derived from the margin of the external abdominal ring, together with the superficial fascia and skin. With regard to the conjoined tendon the hernia may be covered by it, or may pass through an opening in its fibres, or may escape beneath it.

The spermatic cord is commonly placed behind the outer part of the hernia. The hernial sac is not, however, in contact with the vessels of the cord. The investments given from the fascia transversalis to those vessels and to the hernia respectively, are interposed.

But the point at which the internal inguinal hernia passes through the triangle of Hesselbach is subject to some variation. Instead of pushing directly through the external abdominal ring (the most frequent position), the hernia occasionally enters the inguinal canal nearer to the epigastric artery, and, passing through a portion of the canal to reach the external ring, has therefore a certain degree of obliquity. This form of hernia is frequently called *internal oblique* inguinal. Direct inguinal hernia is very rarely met with in the *female*. In the single case observed by Richard Quain as well as in the few cases found recorded in books, the hernia though not inconsiderable in size was still covered by the tendon of the external oblique muscle.

#### FEMORAL HERNIA.

A femoral hernia leaves the abdomen at the groin, passing beneath the lower margin of the broad abdominal muscles, and over the anterior border of the hip-bone immediately at the inner side of the large femoral blood-vessels. It takes its course through the innermost compartment of the sheath of the femoral vessels till it reaches the saphenous opening, when it turns forwards through the opening towards the front of the thigh, and is even bent upwards in the groin.

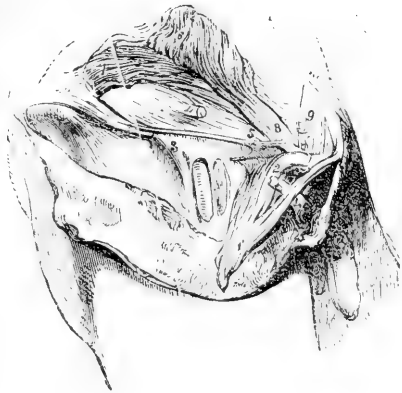The femoral sheath is a somewhat funnel-shaped structure embracing the upper parts of the femoral artery and vein. It is wide superiorly, but embraces the vessels closely below. It is formed by the lining fasciæ of the abdomen, the transversalis fascia being in front, and the iliac fascia behind. On removing its anterior wall the sheath

is found to be divided into three compartments, by fibrous septa; the outer compartment containing the femoral artery, the middle, the

Fig. 239.—THE GROIN OF THE RIGHT SIDE DISSECTED SO AS TO DISPLAY THE DEEP FEMORAL ARCH.

1, the outer part of the femoral arch; 1', part of the tendon of the external oblique muscle, with external inguinal ring, projecting through which is seen a portion of the spermatic cord cut; 2, the femoral arch at its insertion into the spine of the pubis, and to the outer side the fibres of Gimbernat's ligament; 3, the outer part of the femoral sheath; 4, the spermatic cord; 5, the deep femoral arch—its inner end, where it is fixed to the pubis; 6, internal oblique muscle; 7, transversalis; below this the transversalis fascia continued into the femoral sheath under the deep femoral arch; 8, conjoined tendon of the internal oblique and transversalis muscles; 9, a band of tendinous fibres directed upwards behind the external abdominal ring.

Fig. 239.



femoral vein, and the inner being occupied merely by lymphatic vessels, a gland, and some fat. This inner compartment is about half an inch long, and from its being the passage through which the hernia descends, has been called the *femoral* or *crural* canal. The upper extremity of the canal presents a rounded aperture towards the cavity of the abdomen, usually of sufficient size to admit the point of the forefinger; its size, however, varies in different persons, and it is larger in the female than in the male. This aperture is called the femoral ring, and is covered when viewed from the inside by peritoneum, and beneath that by the subperitoneal connective tissue, which here forms the *crural septum* (Cloquet). On three sides the ring is bounded by very unyielding structures. In front are the femoral arches, the superficial being formed by Poupart's ligament, and the deep by a strong bundle of fibres, which, springing from the under surface of Poupart's ligament outside the femoral vessels, extends across the forepart of the femoral sheath and widening at its inner end, is fixed to the pectineal line behind Gimbernat's ligament. Behind the ring is the hip-bone covered by the pectineus muscle and the pubic layer of the fascia lata; on the outer side lies the external iliac vein, but covered with its sheath; and on the inner side are several layers of fibrous structure connected with the pectineal line—namely, Gimbernat's ligament, the conjoined tendon of the two deeper abdominal muscles, and the fascia transversalis, with the deep femoral arch. The last-mentioned structures—those bounding the ring at the inner side—present respectively a more or less sharp margin towards the opening.

**Relations to blood-vessels.**—Besides the femoral vein, the position of which has been already stated, the epigastric artery is closely connected with the ring, lying above its outer side. It not unfrequently happens that an aberrant obturator artery descends into the

pelvis at the outer side of the ring, or immediately behind it; and in some rare cases that vessel passes over the ring to its inner side. An obturator vein also has occasionally the same course; and small branches of the epigastric artery will be generally found ramifying on the posterior aspect of Gimbernat's ligament. In the male the spermatic vessels are separated from the canal only by the femoral arch.

Fig. 240.

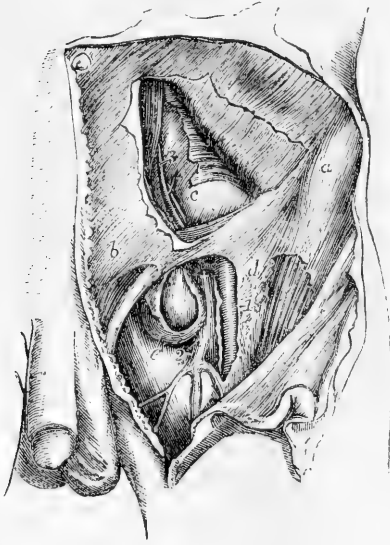


Fig. 240.—VIEW OF THE RELATIONS OF THE VESSELS OF THE GROIN TO A FEMORAL HERNIA, &c. (from R. Quain). †

In the upper part of the figure a portion of the flat muscles of the abdomen has been removed, displaying in part the transversalis fascia and peritoneal lining of the abdomen; in the lower the fascia lata of the thigh is in part removed and the sheath of the femoral vessels opened: the sac of the femoral hernial tumour has also been opened.

*a*, anterior superior spinous process of the ilium; *b*, aponeurosis of the external oblique muscle above the external inguinal aperture; *c*, the abdominal peritoneum and fascia transversalis; *d*, the iliac portion of the fascia lata near the saphenous opening; *e*, sac of the femoral hernia; 1, points to the femoral artery; 2, femoral vein at the place where it is joined by the saphenous vein; 3, epigastric artery and vein passing up towards the back of the rectus muscle; +, placed upon the upper part of the femoral vein, close below the common trunk of the

epigastric and an aberrant obturator artery; the latter artery is seen in this case to pass close to the vein and between it and the neck of the hernial tumour.

**Descent of the hernia.**—When a femoral hernia is being formed, the protruded part is at first vertical in its course; but at the lower end of the canal it bends forward at the saphenous opening, and, as it increases in size, ascends over the iliac part of the fascia lata and the femoral arch. Within the canal the hernia is very small, being constricted by the unyielding structures which form that passage; but when it has passed beyond the saphenous opening, it enlarges in the loose fatty layers of the groin; and, as the tumour increases, it extends outwards in the groin towards the iliac spine of the hip-bone.

**Coverings of the hernia.**—The coverings of a femoral hernia in order from within outwards are, the peritoneum (which forms the sac); the septum crurale and the sheath of the femoral vessels. These two structures combined constitute a single very thin covering, known as the fascia propria of the hernia (Cooper). It sometimes happens that the hernia is protruded through an opening in the sheath, which therefore in that event does not contribute to form the fascia propria. Lastly the hernia is covered by the cribriform fascia, covering the saphenous opening; the superficial fascia and skin.



## SECTION IV.—**ANGIOLOGY**,

### OR, DESCRIPTION OF THE BLOOD-VESSELS AND ABSORBENT VESSELS.

THE vascular system, as a whole, comprehends two sets of vessels, viz., those carrying blood and those carrying lymph or chyle. The first, constituting the sanguiferous system, includes the heart or central propelling organ and the peripheral channels for the blood, viz., the arteries, capillaries and veins. The absorbent system includes the smaller and larger lymphatic and lacteal vessels, together with the lymphatic and mesenteric glands with which many of these vessels are connected. The descriptive anatomy of the heart is given along with that of the thoracic viscera in the second volume: the account of the minute structure of the blood-vessels and of the lymphatic vessels and glands will be found in the part of the same volume which treats of the General Anatomy. Under the present division, therefore, will be brought only the descriptive anatomy of the principal blood-vessels and absorbent vessels.

#### 1.—BLOOD-VESSELS. ARTERIES AND VEINS.

The descriptive anatomy of the blood-vessels includes an account of their form, position, mode of division, distribution, anastomosis with each other, and relation to other parts. Seeing, however, that the blood-vessels are subject to frequent variations, while the most constant forms and modes of distribution are described as the normal, it will be necessary also to make frequent reference to the more important varieties which have been observed.

The varieties of blood-vessels may consist either of a deviation from the usual size of the channels or from their usual position and their connection with other vessels. Thus, they may be described as consisting in differences of origin from the main stem, or from a branch, or from quite another source than that which is the most common or usual. But some varieties are so common that it becomes doubtful which form is to be described as normal.

Many of the vascular varieties are not only compatible with life, but cause no disturbance whatever in the performance of the ordinary functions of the body. Others are of such a nature as to be compatible only with the conditions of the circulation subsisting during foetal or intra-uterine life, and therefore prove fatal at birth. Some are of considerable interest from their frequency, and others from their existing in situations which are liable to diseases requiring surgical operations.

Many vascular varieties repeat forms which are natural in different species among the lower animals; others are obviously due to the persistence of early foetal forms of distribution; and not a few are explicable on the supposition of abnormal enlargement or diminution of naturally existing vessels.

Fig. 241

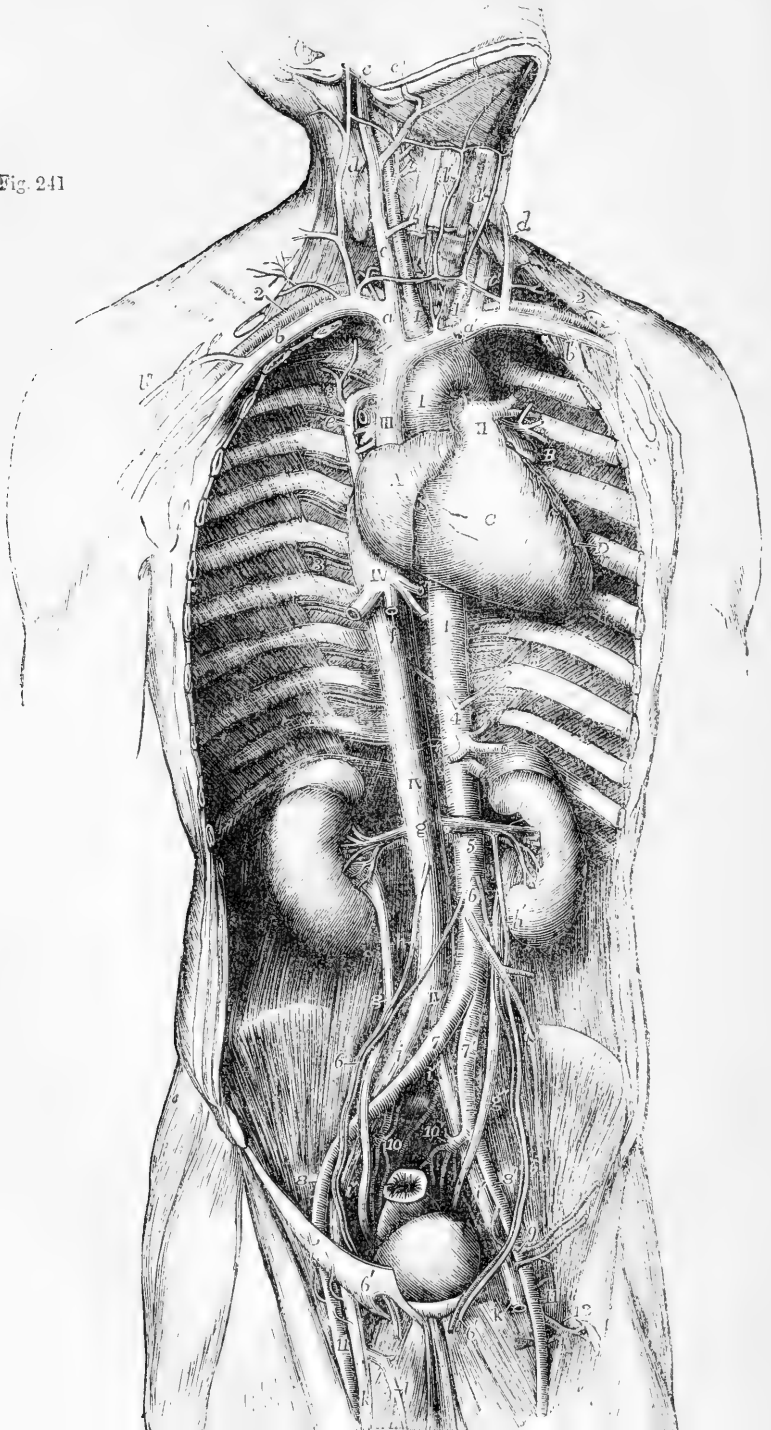


Fig. 241.—GENERAL VIEW OF THE HEART AND BLOOD-VESSELS, FROM BEFORE AND FROM THE RIGHT SIDE IN A MALE ADULT.  $\frac{1}{4}$

A, Right auricle; B, left auricular appendix; C, right ventricle; D, part of the left ventricle; I, aortic arch, and descending aorta; II, trunk of the pulmonary artery dividing into its right and left branches, and connected to the aorta by the cord of the ductus arteriosus; III, vena cava superior; IV, vena cava inferior.

1, innominate artery and right carotid; 1', left carotid; 2, right and left subclavian arteries; 3, intercostal vessels; 4, inferior diaphragmatic arteries; below 4, the cœliac axis and superior mesenteric artery; 5, renal arteries; 6, 6', the spermatic arteries; below 6, the inferior mesenteric; 7, 7', right and left common iliac arteries; 8, 8', external iliac arteries; 9, left epigastric and circumflex iliac arteries; 10, 10', internal iliac arteries; and between these two figures, the middle sacral artery; 11, femoral arteries; 2, profunda femoris artery of the left side.

a, right brachio-cephalic vein; a', the left; b, b', right and left subclavian veins; b'', the cephalic vein of the right arm; c, c', internal jugular veins; c'', right facial vein joining the internal jugular; d, external jugular veins formed by the posterior auricular and temporal; d', anterior jugular veins with the transverse joining the external jugular; e, azygos vein passing over the root of the right lung; f, the hepatic veins; g, origin of the renal veins; to the sides are seen the kidney and the suprarenal bodies; g', right, g'', left ureter; h, right spermatic vein; h', the left, joining the left renal vein; i, i, common iliac veins; i', i'', external iliac veins; k, femoral veins; l, saphenous vein of the right side.

For fuller information on the natural and abnormal distribution of the blood-vessels, the reader may consult the works of Haller and Tiedemann, and more especially the "Anatomy of the Arteries," by Richard Quain, 1844; the third volume of Henle's "Systematic Work," 1868, in which a connected view of the varieties is given; and other special treatises.

The sanguiferous system consists of two great divisions, comprehended in the lesser or pulmonic and the greater or systemic circulations. To the former belong the pulmonary arteries and veins, which will be first described.

## PULMONARY ARTERIES AND VEINS.

### PULMONARY ARTERY.

The main pulmonary artery is a short wide vessel, which carries the dark blood from the right side of the heart to the lungs. It arises from the infundibulum or conus arteriosus of the right ventricle, and passes for the space of nearly two inches upwards, and at the same time backwards and to the left side, to reach the concavity of the aortic arch, where it divides into two branches—the right and left pulmonary arteries. The mode of attachment of the main pulmonary artery to the base of the ventricle has already been fully noticed. At each side of its commencement is the corresponding coronary artery springing from the aorta, and close to its side are the two auricular appendages. It is at first in front of the aorta and conceals the origin of that vessel; but higher up, where it lies in front of the left auricle, it passes to the left side of the ascending aorta, and is finally placed beneath the middle part of the arch. The pulmonary artery and the aorta are united together by connective tissue and by the serous layer of the pericardium, which for the space of about two inches forms a single tube around both vessels. Rather to the left of its point of bifurcation it is connected to the under side of the aortic arch by means of a short fibrous cord, which passes obliquely upwards, backwards, and to the left. This

is the remains of the *ductus arteriosus*, a large vessel peculiar to the fœtus, which has been already described.

The **right pulmonary artery**, longer and somewhat larger than the left, runs almost transversely outwards behind the ascending aorta and the superior vena cava into the root of the right lung, where it immediately begins to divide in the usual manner of arteries.

The **left pulmonary artery**, shorter than the right, passes horizontally in front of the descending aorta and left bronchus into the root of the left lung, to undergo its ramification.

The right and left pulmonary arteries, at the root of the lung, both lie in front of the bronchus and behind the veins. On the right side the bronchus is highest and the veins lowest, while on the left side the bronchus sinks to a level between the artery and veins.

#### PULMONARY VEINS.

The pulmonary veins are four short venous trunks which convey the red blood back from the lungs to the left side of the heart, and which are found, two on each side, in the root of the corresponding lung. The two veins of the *right* side, which are longer than those of the left, pass below the right pulmonary artery, and behind the superior vena cava, the right auricle, and the aorta, to enter the left auricle. Not unfrequently a third smaller vein exists on the right side in connection with the third lobe of the right lung. The two *left* pulmonary veins run a shorter course to reach the auricle, passing in front of the aorta. The distribution of the pulmonary capillaries is exclusively to the membrane lining the air cells of the lungs.

The varieties of the pulmonary arteries will be referred to along with those of the aorta.

### SYSTEMIC ARTERIES.

#### THE AORTA.

The aorta, the large main trunk of the systemic arteries, is situated partly within the thorax and partly in the abdomen. It commences at the left ventricle of the heart, and after arching over the root of the left lung, descends in front of the vertebral column, and passing through the diaphragm into the abdominal cavity, ends opposite the fourth lumbar vertebra, by dividing into the right and left common iliac arteries. In this course the aorta forms a continuous undivided trunk, which gradually diminishes in size from its commencement to its termination, and gives off larger or smaller branches at various points. Different parts of the vessel have received particular names, derived from their position or direction. The short curved part, which reaches from the ventricle of the heart to the side of the third dorsal vertebra, is named the *arch*; the straight part, which extends from that vertebra to the diaphragm, is called the *thoracic aorta*; and the remainder of the vessel, down to its bifurcation, is designated the *abdominal aorta*.

#### ARCH OF THE AORTA.

The arch of the aorta commences at the upper part of the base of the left ventricle of the heart, behind the pulmonary artery. At first it passes upwards and to the right side, somewhat in the direction of the heart itself, and crosses obliquely behind the sternum, approach-

ing at the same time more nearly to that bone. Having gained the level of the upper border of the second costal cartilage of the right side,

Fig. 242, A. — THE AORTA FROM BEFORE, WITH THE ORIGINS OF ITS PRINCIPAL BRANCHES (R. Quain).  $\frac{1}{4}$

Fig. 242.

1, the aorta at the place where it has been separated from the left ventricle, showing the semilunar valves in a closed condition, the sinuses of Valsalva, and the origin of the right and left coronary arteries; 2, the ascending part of the arch, with the dilatation termed sinus; 3, the third part of the arch; 4, innominate artery; 5, left carotid; 6, left subclavian; 7, concavity of the middle part of the arch; and farther down the aorta, 7, 7, indicate two out of the series of intercostal and lumbar arteries: the oesophageal arteries are also seen rising from the front of the thoracic aorta; 8, 8, right and left renal arteries; 9, 9, right and left common iliac arteries; 10, middle sacral artery; 11, one of the inferior diaphragmatic arteries; +, the coeliac axis; 12, the gastric artery; 13, the hepatic; 14, the splenic; 15, superior mesenteric; 16, inferior mesenteric; 17, 17, right and left spermatic arteries.

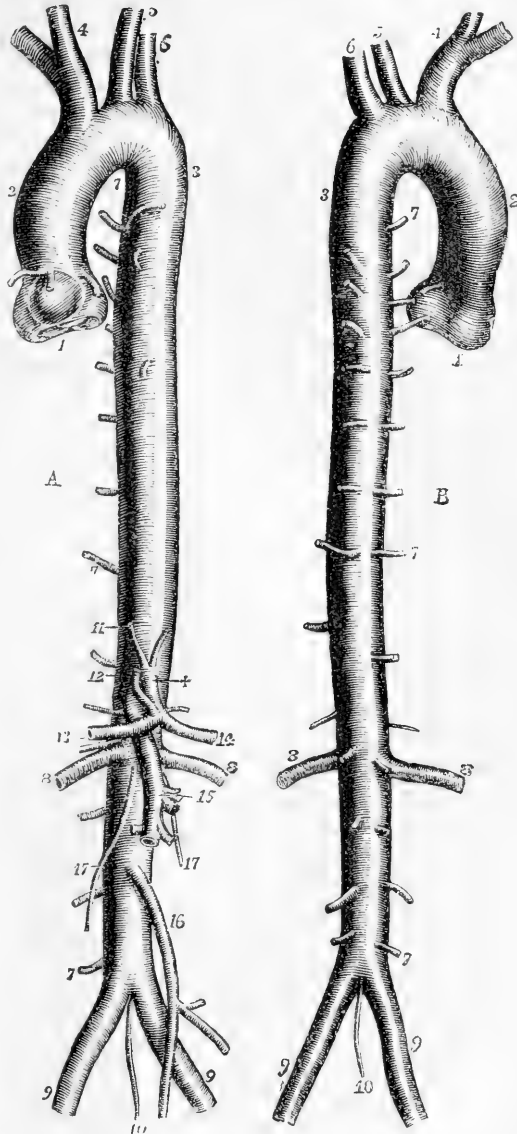


Fig. 242, B. — THE SAME AORTA FROM BEHIND. (R. Quain).  $\frac{1}{4}$

The numbers have the same signification as in A. The origin of the right and left intercostal arteries close to each other from near the middle line of the posterior wall of the aorta is shown.

the vessel alters its course, and is directed upwards, backwards, and to the left side, then directly backwards, in contact with the trachea, to the left side of the body of the second dorsal vertebra. Arrived at that point,

it bends downwards, inclining, at the same time, a little towards the middle line; and at the lower border of the body of the fourth dorsal vertebra, on its left side, the arch terminates in the descending portion of the vessel. Near the base of the heart the aorta is larger than elsewhere, and presents externally three small bulgings of nearly equal size, corresponding with the dilatations which form the *sinuses of Valsalva* or *sinuses of the aortic valves*, described with the heart. Two of these sinuses are placed anteriorly and one posteriorly, and in the two anterior sinuses are seen the orifices of the two coronary arteries of the heart, the first branches given off by the aorta.

From the difference in the direction and connections of different portions of the arch it is described as consisting of an *ascending*, a *transverse*, and a *descending* portion.

The *ascending* portion of the arch of the aorta is placed at its commencement behind the sternum, on a level with the lower border of the third costal cartilage of the left side: and it rises as high as the upper border of the second costal cartilage of the right side. Its length is about two inches or two inches and a quarter; and its direction is curved. In most cases there exists along the right side a dilatation, named the *great sinus of the aorta*. This dilatation varies in size in different bodies, and occasionally is not to be detected.

This portion of the aortic arch is for the greater part of its length enclosed in the same sheath of pericardium with the pulmonary artery in such a manner that both vessels are covered by the serous membrane, except where they are in contact with each other.

At its commencement the ascending part of the arch is in contact anteriorly with the pulmonary artery, and with the right auricular appendage; but, further up, the aorta passes to the right side and the pulmonary artery to the left, and thus the aorta comes into view. It then approaches very near to the sternum, from which it is separated only by the pericardium, by some connective tissue, and by the remains of the thymus gland lodged in the mediastinal space; the descending vena cava lies on the right side, and the pulmonary artery passes backwards on the left; while behind are placed the structures forming the root of the right lung.

The second or *transverse* part of the arch is covered on the left side by the left pleura and lung, and is placed immediately in front and to the left of the trachea, the œsophagus and the thoracic duct. The upper border of the transverse part of the arch has in contact with it the left innominate vein; and from it are given off the large arteries (innominate, left carotid, and left subclavian), which are furnished to the head and the upper limbs. The lower or concave border overhangs the bifurcation of the pulmonary artery, and is connected with the left branch of that artery by the remains of the ductus arteriosus. This part of the arch is crossed in front by the left pneumogastric phrenic and superficial cardiac nerves; and the recurrent laryngeal branch of the pneumogastric turns upwards beneath and behind it.

The *descending* portion of the arch rests against the left side of the body of the third and fourth dorsal vertebra, and is covered by the left pleura and the root of the left lung. To the right side of this part of the arch is the œsophagus with the thoracic duct.

BRANCHES.—The branches given off from the arch of the aorta are five in number. Two of these, named the coronary arteries of the

Fig. 243.—VIEW OF THE THORACIC AND UPPER PART OF THE ABDOMINAL AORTA, SHOWING THEIR PRINCIPAL RELATIONS (A. T.)  $\frac{1}{4}$

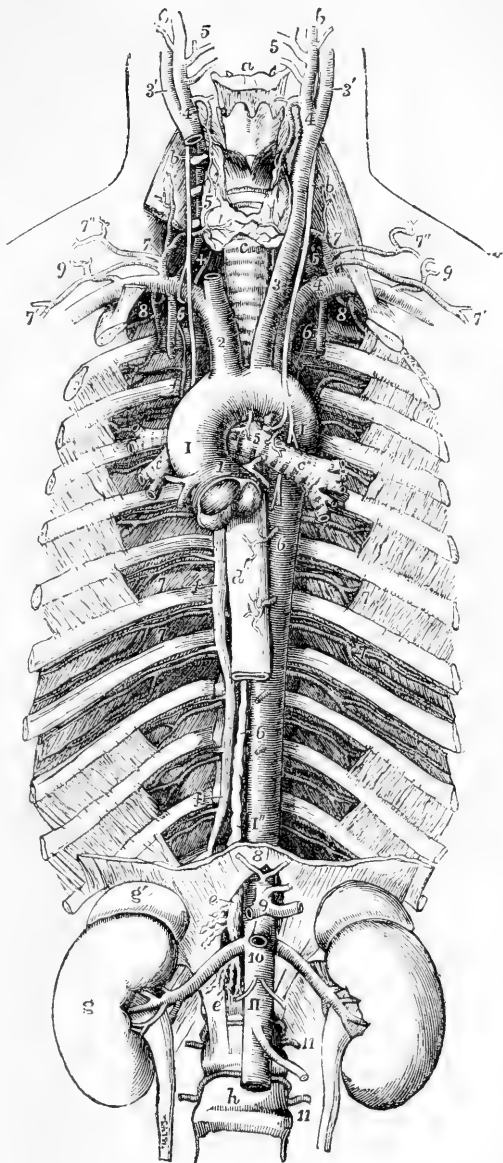
Fig. 243.

*a*, the hyoid bone; *b*, placed on the anterior scalene muscles, points to the upper part of the pneumogastric nerves; *c*, the trachea below the isthmus of the thyroid gland, and lower down the same letter is on the left bronchus; *c'*, one of the divisions of the right bronchus emerging from behind the aorta; in the hollow of the aortic arch, above 5, are seen the cord of the ductus arteriosus cut short, and the left recurrent nerve passing below the arch; +, is placed on the right side between the recurrent nerve and the vertebral artery as they pass upwards; *d*, the œsophagus; *e*, upon the right crus of the diaphragm, and farther down *e'*, mark the receptaculum chyli of the thoracic duct, and its commencement by the lumbar plexus of lymphatic vessels and efferent mesenteric lacteal vessels; *f*, on the third, seventh, and eleventh ribs, points to the vena azygos and superior intercostal veins of the right side; *g*, kidney; *g'*, suprarenal body; *h*, body of the fourth lumbar vertebra.

*I*, sinus of the aortic arch or ascending part of the arch: below this the semilunar valves are seen closed and distended by injection; *I'*, posterior part of the arch, upon which the left pneumo-gastric nerve is seen descending; *I''*, descending thoracic part of the aorta; *II*, abdominal aorta emerging from between the crura of the diaphragm.

Branches of the arch and thoracic aorta; 1, right and left coronary arteries; 2, innominate; 3, left carotid; 4, left subclavian; 5, bronchial arteries; 6, 6, œsophageal arteries: the lower figure points by a line to the thoracic duct; 7, intercostal arteries, marked in the sixth and seventh intercostal spaces.

Branches of the abdominal aorta; 8, inferior diaphragmatic arteries cut short; 9, celiac axis with the gastric, splenic, and hepatic arteries cut short; 10, placed on the



aorta below the superior mesenteric artery (cut short) and the origin of the renal arteries; a little below this the origin of the spermatic arteries; below *II*, the inferior mesenteric artery, 11, 11, two of the lumbar arteries.

heart, comparatively small, arise from the two anterior sinuses of Valsalva, and are distributed to the walls of the heart. The other three are large primitive trunks, which supply the head and neck, the upper limbs, and, in part, the thorax, and usually arise from the middle or highest part of the arch, in the following order:—first, the *innominate* or *brachio-cephalic* artery; second, the *left carotid*; and, third, the *left subclavian* artery. The origin of the left carotid artery is usually somewhat nearer to the innominate artery than it is to the subclavian artery of its own side.

**Varieties.**—It will be proper in this place to refer to the varieties which affect the whole aorta, as well as to those of the pulmonary arteries. The former may be distinguished, according as they occur in the whole length of the vessel, or belong to one or other of its parts, those which are very frequent in the arch being especially deserving of notice. These last are of peculiar interest, but as the full explanation of their mode of formation is connected with the history of foetal development, the reader is referred to the chapter on that subject for elucidation of the present outline of the nature of the varieties which is introduced in this place.

1. The *Aorta* may vary in its position and extent. Thus the height to which the arch rises in the upper part of the chest is found to be subject to variation to the extent frequently of from one to two vertebral spaces; more rarely to a greater extent, so that while in some instances the summit of the arch has been on a level with the top of the sternum, in other cases it has been as low as the fourth or fifth dorsal vertebra.

The distance to which the aorta extends downwards depends on the seat of its division into the common iliac trunks, which frequently varies to the extent of one of the lumbar vertebrae, so that the place of division may be as low down as on the fifth, or as high up as on the third. In other rarer cases the division occurs still higher.

The position of the aorta with reference to the middle line or vertebral column is also subject to some variation, but such deviation to the side is more frequently the result of pathological changes than of congenital malformation.

A very remarkable malformation of the aorta consists in the greater or less division of the vessel through a part or the whole of its channel into two closely united tubes, by a median septum running through the cylindrical tube from before backwards, or slanting from side to side, as in the cases observed by Craveilhier, Vrolik, Schröder Van der Kolk, and Allen Thomson, which when not due to pathological changes may admit of explanation on the supposition of the fusion of the original double embryonic aorta having remained incomplete.

2. The *Varieties of the Stems*, or main trunks of the aorta and pulmonary artery, are intimately connected and usually associated with malformations of the heart, and frequently with the persistence of the ductus arteriosus. These first parts of the two great arteries, specially enclosed by the pericardium, are derived from the arterial bulb of the foetal heart, and are liable to variations which may be traced to deviations from the natural mode of their septal division, and of their union with the left or right ventricles of the heart respectively. Thus these two arterial trunks may be transposed, or each one may be connected with the ventricle to which it does not naturally belong, *i.e.*, the pulmonary artery with the left, and the aorta with the right ventricle. Or the arterial trunks may communicate together more or less freely by deficiency of the septum between them. Or one of the vessels may be nearly or entirely obliterated; while the other, from unnatural openings left between them, serves as the channel for the stream of blood belonging to both vessels. Or the aorta and pulmonary arteries may be entirely united in one simple stem in connection with a simple heart similar to that of fishes.



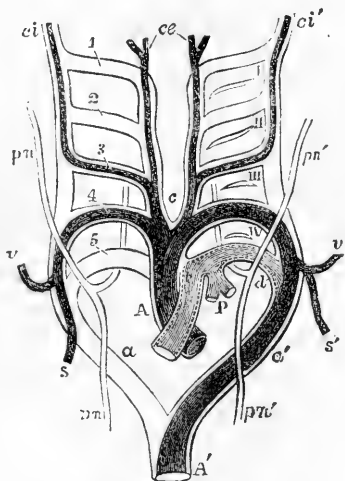
3. The *Varieties in the Aortic Arch* itself, along with which must be included those of the ductus arteriosus, are intimately connected with the mode of development of the fourth and fifth fetal branchial arteries. The natural aortic arch of man, and of all mammalia, is a left one produced by the persistence and development of the fourth left branchial arch: in birds it is the right arch which forms the permanent aorta; and in reptiles both the right and left fourth arches remain patent.

Here it may be proper to call attention to the *complete lateral transposition, i. e.*, from right to left and *vice versa*, which affects the aortic arch and pulmonary vessels, as well as the other parts of the heart, when transposed with or without the transposition of other viscera. Several cases of this kind have been accurately recorded by various observers, and are usually unattended with any disturbance of the functions or otherwise unnatural condition of structure. There is, in fact, only a change of position, which may be best described by comparing it to that in which the natural parts would appear if viewed by reflection from a mirror. Although this transposition gives rise to no perceptible lesion of function, yet from the direction of the apex of the heart towards the right, and other differences from the natural position, its existence is capable of being ascertained during life.

Fig. 244.—DIAGRAM OF THE FETAL AORTIC ARCHES, SHOWING THEIR TRANSFORMATIONS INTO THE PERMANENT VESSELS OF THE MAMMAL (after Rathke). A.T.

A, to the right of the primitive arterial bulb, now divided into aortic and pulmonary stems, the latter in front; *a*, the right, *a'*, the left aortic roots; *A'*, the descending aorta; on the right side, the double outlines, 1, 2, 3, 4, 5, indicate the five primitive branchial vascular arches; on the left side, I, II, III, IV, mark the seat of the four branchial or pharyngeal clefts; *c*, the place of division of the aortic arches into two anteriorly, between the common carotid arteries; *ce*, the permanent external carotids; *ci*, the right, *ci'*, the left internal carotids; *s*, the right, *s'*, the left subclavians; *v*, the right, *v'*, the left vertebrals; the fourth right arch forms the innominate trunk, and passes on to *v* and *s*, the right vertebral and subclavian arteries; the fourth left arch passes to *a'* as permanent aortic arch; *P*, pulmonary arteries springing from the fifth left arch, which at *d* is continued into the left aortic root as ductus arteriosus; *pn*, right, *pn'*, left pneumogastric nerves. The permanent systemic arteries are represented in deep shade.

Fig. 244.



The aortic arch has been observed *completely double* in two remarkable cases, known as those of Malacarne and Hommel, and various less complete cases of a similar kind have been observed. Hommel's case admits of being explained on the supposition simply of both the right and left fourth branchial arches having remained pervious, and undergone equal development. The pulmonary artery was situated to the left of the main aortic stem; the right and left aortic arches embraced closely the trachea and gullet in a ring, and each arch gave rise to a common carotid and subclavian artery in the order now mentioned. Malacarne's case is different, and seems to have been complicated with some remarkable abnormal mode of development of the arterial stem. The two arches, as in Hommel's case, embraced the trachea and gullet, but they divided close to the heart, so as to receive the pulmonary stem between them; and each gave rise to a subclavian, an external, and an internal carotid artery, in the order now stated,

which cannot be explained by what is as yet known of the modes of development of the branchial vascular arches.

The existence of a *right aortic arch*, that is, one passing to the right of the trachea and gullet, instead of the usual left arch, is easily explained on the supposition of the fourth right branchial arch having been developed instead of the left; and accordingly there are instances of this variety, in which no other deviation from the natural condition of the parts exists, beyond what proceeds from the change of side taken by the aortic arch, leading to the innominate or brachio-cephalic artery being a left one, or furnishing the left subclavian and carotid arteries, and the succeeding vessels being the right carotid and right subclavian. The recurrent laryngeal nerve forms its sling on the right side, round the aortic arch, and on the left round the arch of the subclavian artery.

Under the same division as the foregoing might also be brought those remarkable and numerous cases of varieties in the mode of closure of the ductus arteriosus and of its union with the aortic root or other vessels; but these and other modifications of the variations of the arches may best fall under the next division.

4. Varieties of the *posterior part of the arch and ductus arteriosus* belong properly to the changes occurring in connection with the posterior embryonic aortic roots.

One of the most frequent varieties of this group is that of the subclavian artery (of the right side, when the aortic arch is left or normal) rising, as it has been described, from the back part of the arch, or fourth in the series of vessels proceeding from it, but which, according to embryological elucidation, would be more correctly designated as the subclavian artery formed in connection with one of the posterior aortic roots; the natural anterior root and arch being abnormally closed. In such cases the subclavian artery takes its course behind the trachea and gullet to reach its subsequent natural place as it passes between the scalene muscles and over the first rib.

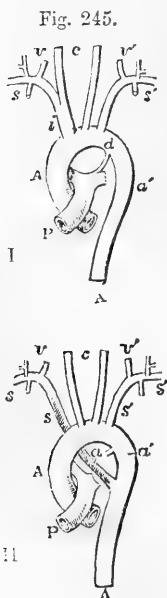


Fig. 245.—DIAGRAM OF THE NATURAL ORIGIN OF VESSELS FROM THE AORTIC ARCH AS COMPARED WITH THE DISPLACED SUBCLAVIAN ARTERY.

(I). The normal disposition; (II), the right subclavian artery displaced or proceeding from the right aortic root. A, A, ascending and descending parts of the thoracic aorta; P, pulmonary stem; d, ductus arteriosus; a, right aortic root or its remains; a', left aortic root; c, common carotid arteries; i, innominate artery; s, right, and s', left subclavian arteries; v, right, and v', left vertebral arteries.

A similar variety may occur in an instance of right aortic arch, in which case it is the left subclavian artery which takes the abnormal course. In both examples of this variety, the anterior part of the subclavian arch being absent, the inferior laryngeal nerve is not recurrent, but passes directly to the larynx, without being drawn down as a sling or loop by the subclavian artery.

There are also many instances of transitions or gradations between these cases and the completely double aortic arch. See a paper on "Varieties of the Arch of the Aorta," by Turner, in *Brit. and For. Med. Chir. Review*, 1863, and "Description of a Case of Right Aortic Arch," by Allen Thomson, in *Glasg. Med. Journ.* 1862, in which such cases are more fully explained, and also the works of Henle, Hyrtl and Struthers.

In some of the instances of aberrant subclavian artery of the kind now referred to, the vertebral artery is detached from the subclavian, and rises directly from the arch of the aorta.

Under the same division may be brought those numerous varieties in the closure of the ductus arteriosus and its union with the aorta or other vessels.

which have been observed; the greater number of which it will be understood, from the nature of the change in the circulation which takes place at birth, are only compatible with intra-uterine life. Such are those cases in which the pulmonary artery leads through the ductus arteriosus, or fifth branchial arch of the left side into the descending aorta; while the aortic arch itself is completely separated by a constriction or even a complete closure of its tube from the descending part of the aorta. It is remarkable, however, that in some rare cases of the kind now referred to, life has been prolonged after birth, and the ductus arteriosus having become closed, probably gradually, the descending aorta has come to receive a full supply of blood from enlarged anastomosing vessels (internal mammary, intercostal, &c.) passing between the vessels which rise from the arch and those connected with the descending aorta.

Along with the same division may also be classed the series of converse cases, in which the pulmonary arch being closed anteriorly, the pulmonary vessels have received their supply of blood from the descending aorta. Such examples of the origin of the pulmonary arteries from the aorta, as they have been styled, and examples of the origin of the left, or in most rare cases of the right subclavian artery from the ductus arteriosus or from one of the pulmonary arteries, are explicable by reference to the same group of developmental phenomena.

5. The varieties in the *number and position* of the *vessels springing from the arch* of the aorta are extremely numerous; some very frequent, others comparatively rare. These vessels may be all collected into one trunk, or they may rise separately from the aorta to the number of six. In the rare case of one trunk, we may suppose the anterior aortic roots to be combined so as to collect all the branches proceeding from them together, as naturally occurs in what is called the anterior aorta of the horse.

The cases of two vessels from the arch may be of two kinds; one, which is the commonest of all the varieties of the aortic vessels, in which the left carotid is united with the innominate artery into a common stem: and the other, comparatively rare, in which there are two innominate or brachio-cephalic trunks, as in birds.

Three is the normal number of branches rising separately from the arch in man, and apes, and some other mammals. There is, however, a rarer form of variety in which the number is the same, and in which, as occurs naturally in some cetacea, the subclavians are both separate vessels, and the two carotids spring from a common stem in the interval between them.

The commonest form of the condition in which there are four vessels rising from the aortic arch, is that in which the sessile left vertebral artery rises between the left carotid and subclavian arteries. A rarer form is that in which the vessels rising from the arch are successively the right subclavian, the right carotid, the left carotid, and the left subclavian arteries.

The number of five arteries proceeds from the division of the innominate into subclavian and carotid, together with separate origin of the left vertebral artery.

In the case of six vessels proceeding from the single arch, of which there is an instance described, the vessels were in the following order, which is that which might be anticipated from the mode of development, viz., right subclavian, vertebral and carotid, left carotid, vertebral and subclavian arteries.

There are, however, many other varieties and modifications of those already mentioned, for which the fuller works already quoted may be referred to.

#### BRANCHES OF THE ARCH OF THE AORTA.

The **coronary arteries** are two small vessels, named right and left, which arise from the root of the aorta in the upper parts of the two anterior of the three sinuses of Valsalva, on a level with the margins of the semilunar valves.

The *right coronary artery* about the size of a crow's quill, runs obliquely in the auriculo-ventricular groove towards the right side, and thence along the posterior aspect of the heart, until it reaches the line of

separation between the two ventricles, where it divides into two branches. The smaller of these continues transversely in the groove between the left auricle and ventricle, approaching the termination of the transverse branch of the left coronary artery; while the other branch runs longitudinally downwards along the posterior wall of the septum between the ventricles, giving branches to each ventricle and to the septum between them.

In its course the right coronary artery gives, besides the offsets already noticed, small branches to the right auricle and ventricle, and also to the first part of the pulmonary artery. Along the right border of the ventricle a rather large branch usually descends towards the apex of the heart, and gives offsets, in its progress, to the anterior and posterior surfaces of the ventricle.

Fig. 246.

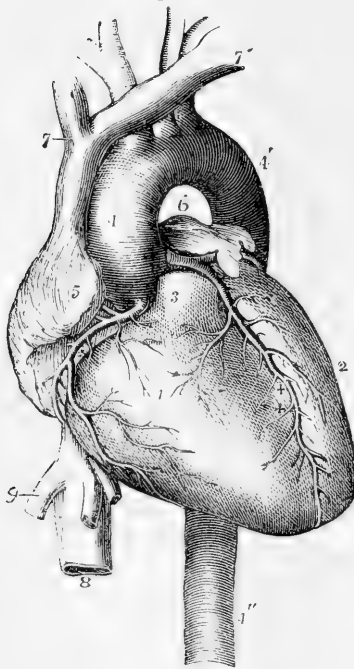


Fig. 246.—VIEW OF THE HEART AND CORONARY ARTERIES FROM BEFORE (R. Quain).  $\frac{1}{3}$

The pulmonary artery has been cut short close to its origin in order to show the first part of the aorta. 1, anterior part of the right ventricle; 2, left ventricle; 3, root of the pulmonary artery; 4, ascending part of the arch of the aorta; 4', the posterior or descending part of the arch; between these is seen the transverse or middle part from which the brachio-cephalic arteries take their origin; 4'', the descending aorta; 5, the appendix and anterior part of the right auricle; 6, those of the left auricle; 7, the right, and 7', the left innominate or brachio-cephalic veins joining to form the vena cava superior; 8, the inferior vena cava below the diaphragm; 9, one of the large hepatic veins; +, placed in the right auriculo-ventricular groove, points to the right or posterior coronary artery; ++, placed in the anterior interventricular groove, points to the left or anterior coronary artery.

The *left coronary artery* is rather smaller than the preceding, and arises from the left anterior sinus of Valsalva. It passes behind and then to the left side of the pulmonary artery, appearing between that vessel and the left auricular

appendage. At first it descends obliquely towards the anterior interventricular sulcus, where it divides into two branches. Of these, one pursues a transverse direction, turning outwards and to the left side in the groove between the left ventricle and auricle, and approaching at the posterior aspect of the heart the transverse branch of the right coronary artery; the other branch, much the larger, descends on the anterior surface of the heart along the line of the interventricular groove, to the right of the apex.

The left coronary artery supplies some small branches at its commencement to the pulmonary artery, to the coats of the aorta, and to

the left auricular appendage ; its two branches also furnish throughout their course smaller offsets, which supply the left auricle, both ventricles, and the interventricular septum.

It has been customary to describe the transverse branches of the coronary arteries as anastomosing in the left atriculo-ventricular sulcus, and the descending branches as anastomosing near the apex of the heart, and this description was never doubted till it was found by Hyrtl, as the result of separate injection of these vessels, that the branches of one coronary artery cannot be injected with material introduced into the other. (Nat. Hist. Review, 1861, p. 321.)

**Varieties.**—The coronary arteries have been observed in a few instances to commence by a common trunk, from which they diverged and proceeded to their usual destination. The existence of three coronary arteries is not a very rare occurrence, the third being small, and arising close by one of the others. Meckel, in one instance, observed four, the supplementary vessels appearing like branches of one of the coronary arteries transferred to the aorta.

### THE INNOMINATE ARTERY.

The innominate, or brachio-cephalic artery, the largest of the vessels which proceed from the arch of the aorta, arises from the commencement of the transverse portion of the arch, before the left carotid artery. From this point the vessel ascends obliquely towards the right, until it arrives opposite the sterno-clavicular articulation of that side, nearly on a level with the upper margin of the clavicle, where it divides into the right subclavian and the right carotid artery. The place of bifurcation would, in most cases, be reached by a probe passed backwards through the cellular interval between the sternal and clavicular portions of the sterno-mastoid muscle. The length of the innominate artery is very variable, but usually ranges from an inch and a half to two inches.

This artery, lying for the most part within the thorax, is placed behind the first bone of the sternum, from which it is separated by the sterno-hyoid and sterno-thyroid muscles, and a little lower down by the left innominate vein, which crosses the artery at its root. The lower part of the innominate artery lies in front of the trachea, which it crosses obliquely : on its left side is the left carotid artery, with the thymus gland or its remains ; and to the right is the corresponding brachio-cephalic vein and the pleura.

No branches usually arise from this vessel.

**Varieties.**—The length of the innominate artery sometimes exceeds two inches, and occasionally it measures only one inch or less. Its place of division is a point of surgical interest, inasmuch as upon it in a great measure depends the accessibility of the innominate in the neck, and the length of the right subclavian artery. It has sometimes been found dividing at a considerable distance above the clavicle, and sometimes, but less frequently, below it. Though usually destitute of branches, this vessel has been observed to supply a thyroid branch, the *thyroidea ima*, and sometimes a thymic branch, or a bronchial, which descends in front of the trachea.

The *thyroidea ima* is an occasional artery. When present, it usually arises (as already stated) from the innominate trunk, but in some instances it has been observed to come from the right common carotid artery, or from the aorta itself. More rarely it arises from the right internal mammary, or the right subclavian. It is of very different size in different bodies, and compensates in various degrees for deficiencies or absence of the other thyroid arteries. It ascends to its destination in front of the trachea, and its presence might therefore complicate the operation of tracheotomy.

## COMMON CAROTID ARTERIES.

POSITION AND RELATIONS—DIFFERENCE ON THE TWO SIDES.—The common carotid arteries of the right and left sides of the body are nearly similar in their course and position whilst they are in the neck; but

Fig. 247.

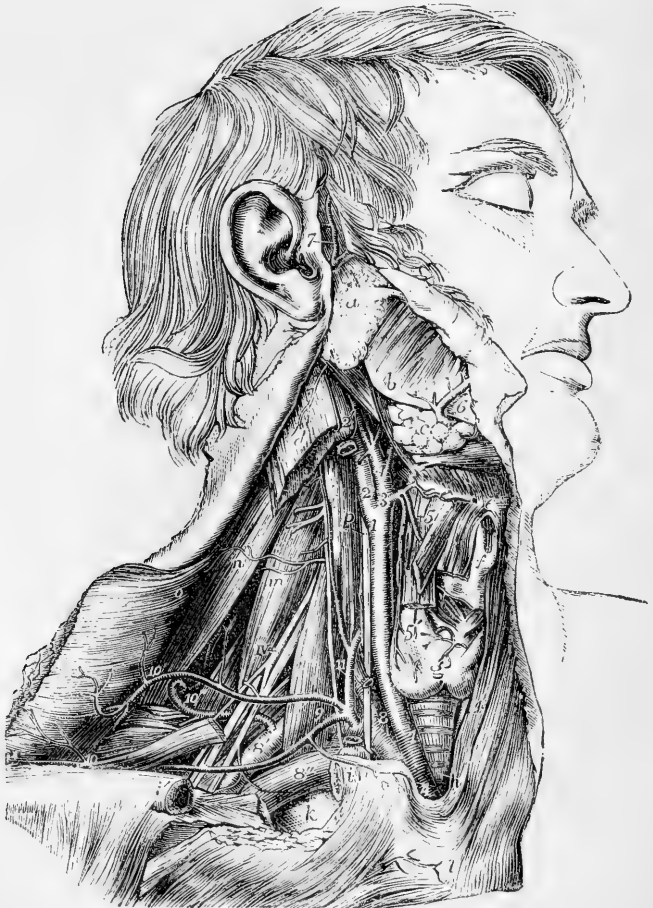

Fig. 247.—VIEW OF THE RIGHT COMMON CAROTID AND SUBCLAVIAN ARTERIES, WITH THE ORIGIN OF THEIR BRANCHES AND THEIR RELATIONS (R. Quain).  $\frac{1}{2}$

The sterno-mastoid, sterno-thyroid, sterno-hyoid, and omo-hyoid muscles have been removed, the trapezius has been detached from the outer part of the clavicle and turned backwards, and the inner part of the clavicle has been removed: *a*, parotid gland near the place where the duct of Stenson leaves it; *b*, angle of the jaw and masseter muscle; *c*, submaxillary gland, enclosed between the digastric and stylo-hyoid muscles; *d*, divided upper part of the sterno-mastoid muscle; *e*, front of the hyoid bone; *f*, thyroid cartilage; *g*, isthmus of the thyroid gland; *h*, the trachea; *i*, *i'*, the sawn ends of the clavicle, the portion between them having been removed; *k*, the first rib; *l*, front of the sternum; *m*, scalenus medius; *n*, levator anguli scapulae; *o*, deep surface of the trapezius; *p*, on the longus colli muscle, pointing to the pneumogastric nerve; IV, the uppermost of the nerves of the brachial plexus;  $\Delta$ , the innominate artery; 1, right common carotid artery;

1', placed on the left sterno-thyroid muscle, points to a part of the left common carotid ; 2, internal carotid ; 2', upper part of the internal jugular vein, which has been removed between *i*, and 2' ; 3, and 4, external carotid ; 3 is placed at the origin of the superior thyroid artery ; 4, at that of the lingual ; farther up the vessel may be seen the separation of the sterno-mastoid twig and the facial and occipital branches from the main vessel ; 5, is placed on the thyro-hyoid muscle between the hyoid and laryngeal branches of 5', the superior thyroid artery ; 6, the facial artery passing over the base of the jaw ; 7, the superficial temporal artery ; 8, the first part, 8', the third part of the subclavian artery ; 8'', the subclavian vein separated from the artery by the scalenus anticus muscle ; 9, is placed on the scalenus anticus muscle in the angle between the transversalis colli and suprascapular branches of the thyroid axis ; 10, outer part of the suprascapular artery ; 10', transverse cervical branches passing into the deep surface of the trapezius ; 10'', the posterior scapular artery, rising directly from the third part of the subclavian artery ; 11, on the scalenus anticus muscle, points to the inferior thyroid artery near the place where the ascending cervical artery of the neck is given off ; the phrenic nerve lies on the muscle to the outside of the figure at *i*, the suprasternal twig of the suprascapular artery is shown.

they differ materially in their place of origin, and consequently in their length and position, at their commencement. On the right side the carotid artery commences at the root of the neck behind the upper part of the sterno-clavicular articulation, at the bifurcation of the innominate artery ; but on the left side the carotid arises within the thorax, from the highest part of the arch of the aorta, very near the origin of the innominate artery.

The left carotid is thus as a whole longer than the right, and its first part is placed at some depth within the thorax. While within the thorax, the left carotid ascends obliquely behind and at some distance from the upper piece of the sternum and the muscles (sterno-hyoid and sterno-thyroid) connected with that part of the bone ; it is covered in front by the remains of the thymus gland, and is crossed by the left innominate vein. This part of the artery lies in front of the trachea, and of the œsophagus, which, at the root of the neck, deviates a little to the left side ; the thoracic duct is also behind it. The left carotid artery here lies between the innominate and the left subclavian arteries, and the vagus nerve is to its outer side.

In the neck the common carotid artery of either side reaches from behind the sterno-clavicular articulation to the level of the upper border of the thyroid cartilage, where it divides into two great branches, of which one is distributed to the cranium and face, and the other to the brain and eye. These divisions have, from their destination, been named respectively the *external* and *internal carotid arteries*.

The oblique course taken by the common carotid artery along the side of the neck is indicated by a line drawn from the sterno-clavicular articulation to a point midway between the angle of the jaw and the mastoid process of the temporal bone. At the root of the neck, the arteries of opposite sides are separated from each other only by a narrow interval, corresponding with the width of the trachea ; but, as they ascend, they are separated by a much larger interval, corresponding with the breadth of the pharynx and larynx. The carotid arteries have the appearance of being placed farther back at the upper than at the lower part of the neck, owing to the forward projection of the larynx above.

The common carotid artery is enclosed, together with the internal jugular vein and the vagus nerve, in a common sheath, which is continuous with the deep cervical fascia ; the nerve, artery and vein are, however, each contained in a separate fibrous investment

within the sheath. The artery is deeply placed at the lower part of the neck, but is comparatively superficial towards its upper end. It is covered below by the sterno-mastoid, sterno-hyoid, and sterno-thyroid muscles, in addition to the platysma and the layers of fascia between and beneath the muscles; and it is crossed opposite or near the lower margin of the cricoid cartilage by the omo-hyoid muscle. From this point upwards to its bifurcation, the vessel is covered by the sterno-mastoid, by the platysma and fascia, and by the common integument; and lies in a triangular space bounded by the sterno-mastoid, the omo-hyoid, and the digastric muscles.

Posteriorly, the artery is supported by the cervical vertebræ, the longus colli and rectus capitis anticus muscles intervening. Hence the flow of blood through it may be commanded by pressure directed backwards against the vertebral column. The inferior thyroid artery crosses behind the carotid sheath.

On the inner side the vessel is in contact with the trachea, the thyroid body (which often overlaps the artery), the larynx, and the pharynx. Along its outer side are placed the internal jugular vein and the vagus nerve.

*Relation to veins.*—The *internal jugular vein* is close to the artery at the upper part of the neck, but, in approaching the thorax, the veins of both sides incline to the right, and hence that of the right side is separated from the artery by an angular interval, while that of the left side approaches the artery, and even lies in front of it at the lower part of the neck.

Crossing over the upper part of the common carotid artery to join with the jugular vein, are two or more *superior thyroid veins*, which occasionally form a sort of plexus over the artery. A *middle thyroid vein* not unfrequently crosses the artery about half way up the neck.

The *anterior jugular vein*, where it turns outwards under the sterno-mastoid muscle to join the subclavian, crosses the lower part of the artery. This vein is generally of small size, but occasionally is rather large, and is placed nearly over the carotid artery along the neck.

*Relation to nerves.*—The descending branch of the hypoglossal nerve, *descendens noni*, usually rests, together with the branches of cervical nerves which join it, on the fore part of the sheath of the carotid artery, and crosses it from the outer to the inner side: in some instances this branch descends within the sheath between the carotid artery and jugular vein. The *vagus nerve* lies within the sheath of the vessels between the artery and vein posteriorly: it was in one case observed to descend over the artery. The *sympathetic nerve* is placed along the back of the sheath, between it and the vertebral muscles, and the *recurrent laryngeal nerve* crosses inwards behind the lower part of the sheath.

The common carotid artery usually gives off no branch, and therefore continues of equal size in its whole length, except at its bifurcation, where a slight enlargement is observable.

*Varieties.—Origin.*—The *right carotid artery* occasionally arises directly from the aorta, or in conjunction with the left carotid. When it arises from the aorta, it is usually the first vessel from the arch, the subclavian being displaced; but it has been found to occupy the second place,—the right subclavian, or, very rarely, the left carotid being the first.

The place at which the right carotid artery commences varies with the point



of bifurcation of the innominate artery. A change from the usual position on a level with the upper border of the clavicle was found by R. Quain in the propor-

Fig. 248.



Fig. 248.—DISSECTION OF THE RIGHT SIDE OF THE NECK TO SHOW THE CAROTID AND SUBCLAVIAN ARTERIES, &c. (from R. Quain).  $\frac{1}{2}$

*a*, angle of the jaw and masseter muscle; *b*, parotid gland; +, the posterior belly of the digastric muscle; *c*, submaxillary gland; *d*, mylohyoid muscle below the anterior belly of the digastric muscle; *e*, upper belly of the omohyoid muscle; *e'*, lower belly; *f*, sternohyoid muscle; *g*, sternothyroid; 1, upon the sterno-mastoid muscle, points by a line to the upper part of the common carotid artery; 2, upon the scalenus anticus muscle, points to the third part of subclavian artery; 3, upon the scalenus medius, points to the superficial transverse cervical artery crossing the axillary nerves; 4, points to the posterior scapular artery, passing under the levator scapulae muscle; 5, placed upon the clavicle, points to the suprascapular artery; 6, external carotid artery; 6', internal carotid artery; 7, upon the thyro-hyoid muscle, points to the superior thyroid artery giving superiorly its hyoid branch; 8, is placed upon the hyo-glossus muscle within the arch of the lingual artery; 9, placed on the stylo-hyoid muscle, indicates the facial artery; 10, origin of the occipital artery, from the root of which the small sterno-mastoid artery is given off; between the occipital and the facial arteries, +, upon the posterior belly of the digastric muscle, points to the continuation of the external carotid artery before entering the parotid gland.

tion of about one case in eight and a half of those observed by him ; and it was found to occur more frequently above than below that point.

The *left carotid artery* varies in its *origin* much more frequently than the right. In the greater number of its deviations from the ordinary place of origin, this artery arises from, or in conjunction with the innominate artery ; and in those cases in which the right subclavian is a separate branch of the aorta, the two carotids most frequently arise by a common trunk.

In cases of transposition, or of right aortic arch without other abnormality, the left common carotid springs from a left innominate artery, which is the first vessel to rise from the arch, and the right carotid is the second vessel.

*Place of division.*—This often deviates somewhat from its usual position ; it does so more frequently in an upward than in a downward direction. It is often as high as the os hyoides, and occasionally much higher. It is found from time to time opposite the middle of the larynx, and, in rare instances, opposite the lower margin of the cricoid cartilage, or even lower. One case was observed by Morgagni, in which the carotid artery, measuring one inch and a half in length, divided at the root of the neck. (“*De Sedibus et Causis Morborum.*” Epist. 29, Art. 20.) The common carotid artery has been found, as a very rare occurrence, to ascend in the neck *without dividing* into its two usual terminal branches ; the internal carotid artery being altogether wanting.

In two recorded cases the common carotid artery was absent, the external and internal carotids arising directly from the arch of the aorta.

*Relation to nerves.*—In one case the pneumogastric nerve was observed to descend in front of the artery.

*Occasional branches.*—The common carotid artery sometimes gives origin at its upper part to the superior thyroid artery, and, in some rare cases, to a laryngeal or an inferior thyroid branch ; also, in a few instances, to the vertebral artery.

#### SURGICAL ANATOMY OF THE COMMON CAROTID ARTERY.

As the common carotid does not in ordinary cases furnish any branch, a ligature can be applied to any part of the vessel except immediately at its commencement and termination. It is usually tied either immediately above or below the omo-hyoid muscle, the operation above the muscle being preferred if possible because here the artery is more superficial, and is at the same time free from the difficulties offered by the muscles lower down, and by the superior thyroid veins, if the artery be secured near its bifurcation. An incision three inches long is made from the level of the hyoid bone downwards along the inner margin of the sterno-mastoid muscle.

Before dividing the integument it is well to ascertain whether the anterior jugular vein be in the line of incision. The sterno-mastoid is slightly everted, and the anterior belly of the omo-hyoid displayed, which last is then raised and turned inwards. On the front of the sheath of the vessels may now be seen the descendens noni nerve. The sheath is to be opened over the artery near the trachea in order to avoid the internal jugular vein, and it is best to insert the aneurism needle conveying the ligature on the outer side of the artery, for thus the vein and the pneumogastric nerve will be most effectually avoided. Should the internal jugular vein lie in front of the artery, as it sometimes does on the left side, and especially at the lower part of the neck on that side, it will be a source of much difficulty in completing the operation, and much caution will be required in passing the aneurism needle with the ligature about the artery. Should the operation be performed at the lower part of the neck, some fibres of the muscles will require to be cut across in order to lay the artery bare with facility ; and the necessity for this step increases in approaching towards the clavicle.

#### EXTERNAL CAROTID ARTERY.

*FORM AND POSITION.*—The external carotid artery, distributed mainly to the face and to the walls of the cranium, is smaller than the internal carotid in young persons : but the two are nearly of equal size in

adults. It reaches from the point of division of the common carotid, opposite the upper margin of the thyroid cartilage, to the neck of the condyle of the lower jaw-bone, or a little lower, and there divides into its two terminal branches, the temporal and the internal maxillary. It diminishes rapidly as it ascends, owing to the number and size of the branches which spring from it.

At first the external carotid lies nearer to the middle line of the body than the internal carotid; but it soon becomes superficial to that artery, at the same time curving slightly forwards as it ascends to its place of division. At its origin this artery is concealed by the sterno-mastoid muscle, emerging from beneath which, it is covered only by the platysma myoides and the fascia, and traverses the upper part of a triangular intermuscular space bounded by the sterno-mastoid, omohyoid and digastric muscles; it then becomes deeply placed, passing beneath the stylo-hyoid and digastric muscles, and finally becoming embedded in the substance of the parotid gland. In the lower part of its course it is in contact with the pharynx and hyoid bone; further up it is separated by a portion of the parotid gland from the back of the ramus of the lower jaw, and rests upon the styloid process and the stylo-pharyngeus muscle, which, with the glosso-pharyngeal nerve, are interposed between it and the internal carotid artery.

*Relation to veins.*—This artery has usually no companion vein, though it may be crossed superficially by small branches of the contiguous veins; but, when the internal maxillary vein joins the deep instead of the superficial jugular, it accompanies the external carotid.

*Relation to nerves.*—Close to the digastric muscle the external carotid artery is crossed by the *hypoglossal nerve*, and at a short distance from its upper end, in the substance of the parotid gland, by the *facial nerve*. The *glosso-pharyngeal nerve* lies between it and the internal carotid; and the *superior laryngeal nerve* is under both vessels.

**BRANCHES.**—The branches of the external carotid artery are eight in number, viz., three directed forwards, the superior thyroid, the lingual, and the facial; two directed backwards, the occipital and posterior auricular; and three extending upwards, the ascending pharyngeal branch, together with the temporal and internal maxillary, the two terminal branches into which the artery divides.

In addition to the principal branches here enumerated, the external carotid gives off small offsets to the parotid gland.

**Varieties.**—The peculiarities in the origin of this vessel have been noticed along with those of the common carotid artery. The branches are not unfrequently crowded together on the main stem, near the commencement, or at a higher point. Occasionally they take origin at regular distances in the whole length of the vessel. The usual number of branches may be diminished by the association with another artery of one of the ordinary branches, or by the union into a single trunk of two or three branches which are usually derived separately from the main artery: so also the number may be augmented by the transfer to this vessel of some branch not ordinarily derived from it, or by the addition of some unusual branch. There is frequently present a small distinct branch for the sterno-mastoid muscle, which bends outwards over the hypoglossal nerve.

CAROTID  
BRANCHES OF THE EXTERNAL CAROTID ARTERY.

**1. Superior Thyroid Artery.**—This, the first of the anterior set of branches, is given off close to the commencement of the external carotid,

immediately below the great cornu of the hyoid bone. From this point the artery curves forwards and downwards to the upper margin of the thyroid cartilage; it then descends a short distance beneath the omohyoid, sterno-hyoid, and sterno-thyroid muscles, furnishing offsets to those muscles; and, reaching the anterior surface of the thyroid body,

Fig. 240.

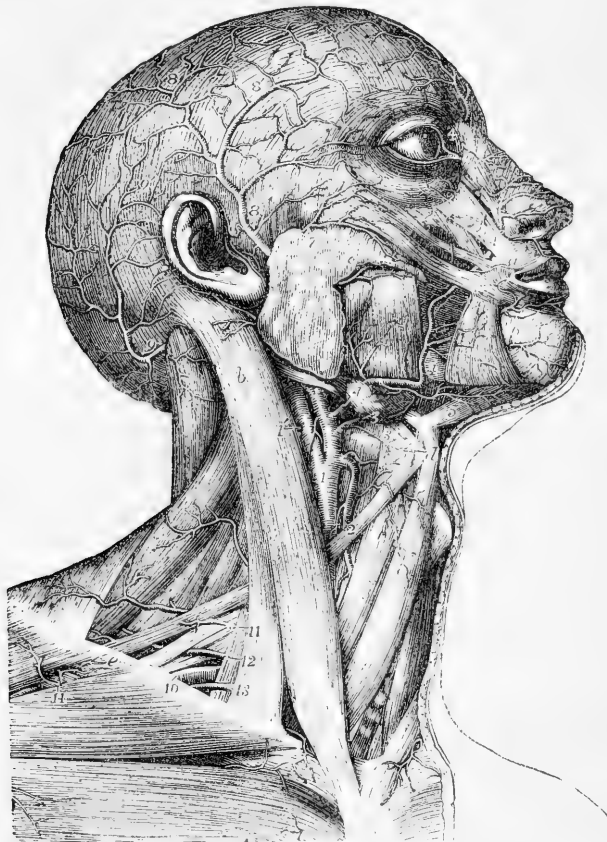


Fig. 240.—SUPERFICIAL VIEW OF THE ARTERIES OF THE HEAD AND NECK (reduced from Tiedemann).  $\frac{1}{3}$

*a*, orbicularis oris; *b*, sterno-mastoid; *c*, parotid gland near its duct; *d*, body of the hyoid bone; *e*, the clavicle; 1, trunk of the common carotid artery near its division into the external and internal carotid arteries: 1', the internal carotid; 2, placed on the upper belly of the omohyoid muscle, points to the superior thyroid artery; 3, lingual artery and its hyoid branch; 4, placed on the submaxillary gland at the place where the facial artery is sunk in the gland, and again where the artery turns over the lower jaw; 4', termination of the facial artery by division into the angular and lateral nasal branches; 5, submental branch; 6, inferior labial branches; 7, transverse facial branch of the superficial temporal; 8, superficial temporal, passing over the zygoma and distributed by 8', 8'', its anterior and posterior divisions on the surface of the cranium; 9, occipital artery rising upon the cranium; 9', its distribution and anastomosis with the temporal and posterior auricular arteries; 10, outer part of the subclavian artery; 11, superficial cervical, and 12, posterior scapular arteries; 13, suprascapular artery; 14, acromio-thoracic branches of the axillary artery.

distributes branches to its substance, and communicates freely with the branches of the inferior thyroid artery.

**Branches.**—Besides the branches furnished to the muscles which cover it, and to the thyroid body, together with some to the lowest constrictor of the pharynx, the superior thyroid furnishes the following offsets, which have received distinctive names :—

(a) The *hyoid*, a small branch, running transversely inwards immediately below the os hyoides, and assisting to supply the soft parts connected with that bone. This little artery sometimes unites, across the middle line, with its fellow from the opposite side.

(b) A *superficial descending* or *sterno-mastoid* branch, which passes downwards a short distance over the sheath of the large cervical vessels, and ramifies in the sterno-mastoid and the muscles attached to the thyroid cartilage, as well as in the platysma and neighbouring integuments. The position of this branch with respect to the sheath of the carotid artery is the only circumstance which gives it interest. This branch frequently arises directly from the external carotid.

(c) The *laryngeal* branch, or *superior laryngeal artery*, proceeding inwards in company with the superior laryngeal nerve, and piercing the thyro-hyoid membrane. Before entering the larynx this branch is covered by the thyro-hyoid muscle. On reaching the interior of the larynx, it ramifies in the small muscles, the glands, and the mucous membrane of that organ.

(d) The *crico-thyroid*, a small branch, to be noticed on account of its position rather than its size. It crosses the membrane connecting the thyroid and cricoid cartilages, and communicates with a similar branch from the other side : hence it may be a source of hæmorrhage in the operation of laryngotomy.

**Varieties.**—*Size.*—The superior thyroid artery is frequently much larger, and, on the other hand, it may be smaller than usual. In either case the deviation from the accustomed size is accompanied by an opposite alteration in other thyroid arteries. It has been seen extremely small, ending in branches to the sterno-mastoid muscle and the larynx. (See the observations on the inferior thyroid artery.)

*Origin.*—The superior thyroid is often transferred to the upper part of the common carotid artery ; and it has been seen conjoined with the lingual branch, or with that and the facial branch of the external carotid.

There are sometimes two superior thyroid arteries.

*Branches.*—The *hyoid* branch is frequently very small, or absent. The *laryngeal* branch arises not infrequently from the external carotid artery, and likewise, but rarely, from the common carotid. Examples have occurred of this branch being of very large size, and terminating in the thyroid body. The laryngeal artery occasionally enters the larynx through a foramen in the thyroid cartilage, and it has likewise been observed to pass inwards below the cartilage.

**2. Lingual Artery.**—The lingual artery arises from the inner side of the external carotid, between the origins of the superior thyroid and facial arteries. Curving upwards and inwards, it reaches the upper margin of the hyoid bone, behind the tip of its great cornu ; it then passes forwards under cover of the hyo-glossus muscle, resting at first on the middle constrictor of the pharynx, and afterwards on the genio-hyo-glossus muscle, in contact with which it ascends almost perpendicularly to reach the under surface of the tongue, and there makes its final turn forwards to the tip of that organ, receiving the name of *ranine* artery.

At the posterior border of the hyo-glossus muscle, the hypoglossal nerve crosses the artery, and passes forwards on a lower level, superficial to the muscle.

**Branches.**—(a) The *hyoid* branch runs along the upper border of the hyoid bone, and supplies the contiguous muscles and skin.

(b) The *dorsal artery of the tongue*, which is often replaced by several smaller branches. It arises from the deep portion of the lingual artery, beneath the hyoglossus muscle, and ascends to supply the upper part, or dorsum, and the substance of the tongue, ramifying as far back as the epiglottis.

(c) The *sublingual branch*. Taking origin at the anterior margin of the hyoglossus, this branch turns slightly outwards, under cover of the mylo-hyoid muscle, and between this and the sublingual gland. It supplies the substance of the gland, and gives branches to the mylo-hyoid and other muscles connected with the maxillary bone. Small branches are also distributed to the mucous membrane of the mouth, and the inside of the gums.

(d) The *ranine artery*, which may be considered from its size and direction the continuation of the lingual artery. It runs forwards beneath the tongue, giving numerous branches as it proceeds, covered by the mucous membrane, and resting on the genio-hyo-glossus muscle. Having reached the tip of the tongue, it has been said to anastomose with the corresponding artery of the other side; but this is denied by Hyrtl. In the last part of its course it lies quite superficially at the side of the frænum.

**Varieties.**—The origin of the lingual artery sometimes takes place from a trunk common to it and the facial artery. It is occasionally joined with the superior thyroid. The *hyoid branch* is often deficient; and it appears that this branch varies in size inversely with the hyoid branch of the superior thyroid. The *sublingual branch* varies in size. It is sometimes derived from the facial artery, and then perforates the mylo-hyoid muscle. The lingual artery has been seen to give off as unusual branches, the submental and ascending palatine.

**3. Facial Artery.**—The facial artery, taking origin a little above the lingual artery, is first directed obliquely forwards and upwards beneath the base of the maxillary bone; then changing its direction, it passes upwards over the base of the lower maxilla, in front of the masseter muscle. Commencing here its course upon the face, it is directed forwards, near to the angle of the mouth, and ascends to the inner canthus of the eye, where it ends by anastomosing with the ophthalmic artery. In its whole course the artery is tortuous, a circumstance connected with the great mobility of the parts on which it rests.

In the neck, the facial artery, immediately after its origin, which is comparatively superficial, being covered only by the platysma and fascia, is crossed by the digastric and stylo-hyoid muscles, and is then concealed in the substance of the submaxillary gland. Emerging from the gland, it turns over the border of the jaw, covered by the platysma: here the pulsation of the artery is easily felt, and the circulation through it may be readily controlled by pressure against the bone. In its progress over the face, it is covered successively by the platysma and the zygomatic muscles, and rests upon the buccinator, the levator anguli oris, and the levator labii superioris.

The *facial vein* is separated by a considerable interval from the artery on the face. It takes nearly a straight course upwards, instead of inclining forwards near the angle of the mouth, and it is not so tortuous as the artery.

Branches of the *facial nerve* cross the vessel; and the *infraorbital nerve* is beneath it, separated by the fibres of the elevator of the upper lip.

**A. Cervical branches.**—The following branches are derived from the facial artery below the lower jaw:—

(a) The *inferior or ascending palatine artery*, a branch which ascends between the stylo-glossus and stylo-pharyngeus muscles, and reaches the pharynx close to the border of the internal pterygoid muscle. After having given small branches

to the tonsil, the styloid muscles, and the Eustachian tube, this artery divides near the levator palati muscle into two branches, one of which follows the course of the circumflexus palati muscle, and is distributed to the soft palate and its glands, while the other penetrates to the tonsil, and ramifies upon it with the branch to be next described.—The place of this artery upon the palate is often taken by the ascending pharyngeal.

(b) The *tonsillar* branch ascends along the side of the pharynx, and penetrating the superior constrictor of the pharynx, terminates in small vessels upon the tonsil and the side of the tongue near its root.

(c) The *glandular* branches, a numerous series which enter the substance of the submaxillary gland, whilst the facial artery is in contact with it; and some of which are prolonged upon the side of the tongue.

(d) The *submental* branch, the largest arising from the facial in the neck. Leaving the artery near the point at which it turns upwards to the face, it runs forwards below the base of the maxillary bone on the surface of the mylohyoid muscle and subjacent to the digastric. Giving branches in its course to the submaxillary gland and the muscles attached to the jaw, and anastomosing with the sublingual artery, it approaches the symphysis of the chin and divides into two branches; one of these running more superficially than the other, passes between the depressor muscle of the lower lip and the skin, supplying both; while the other dips between that muscle and the bone, and ramifies in the substance of the lip, communicating with the inferior labial and mental branches.

**B. Facial branches.**—Of the branches derived from the facial artery upon the side of the face, some are directed outwards to the muscles, as to the masseter and buccinator, and require only to be indicated. The larger branches are directed inwards, and are as follows:—

(a) The *inferior labial* branch. This arises soon after the facial artery has turned over the lower border of the maxilla, and running forward beneath the depressor anguli oris, distributes branches to the skin and muscles of the lower lip, anastomosing with the inferior coronary and submental branches, and with the inferior dental branch of the internal maxillary artery.

(b) The *coronary artery* of the lower lip. Arising near the angle of the mouth, as often in conjunction with the superior coronary as from the facial separately, this branch penetrates the muscular fibres surrounding the orifice of the mouth, takes a transverse and tortuous course between those fibres and the mucous membrane of the lip, and inosculates with the corresponding artery of the opposite side. Small twigs from it ascend to supply the orbicular and depressor muscles, the glands, and other structures of the lower lip; whilst others descend towards the chin, and communicate there with other branches.

(c) The *coronary artery* of the upper lip. Larger and more tortuous than the preceding branch, with which it often arises, this vessel runs across between the muscles and mucous membranes of the upper lip, and inosculates with its fellow of the opposite side. In addition to supplying the whole thickness of the upper lip, it gives two or three small branches to the nose. One of these, named the *artery of the septum*, runs along the lower border of the septum nasi, on which it ramifies as far as the point of the nose; another reaches the ala of the nose.

(d) The *lateral nasal artery*. This branch turns inwards to the side of the nose beneath the common elevator of the nose and lip, and sends branches to the ala and the dorsum of the nose. It anastomoses with the nasal branch of the ophthalmic, with the artery of the septum nasi, and with the infra-orbital artery.

(e) *Angular artery*. Under this name is recognised the terminal part of the facial artery, which inosculates at the inner side of the orbit with a terminal branch of the ophthalmic artery.

Communication between the superficial and deep branches of the external carotid is established by the anastomoses of the facial artery with the infra-orbital, buccal, inferior dental, and nasal branches of the internal maxillary; and between the external and the internal carotids by the anastomosis of the facial with the ophthalmic arteries.

**Varieties.**—*Origin.*—The facial artery not unfrequently arises by a common trunk with the lingual. Occasionally it arises above its usual position, and then descends beneath the angle of the jaw to assume its ordinary course.

*Size.*—This artery varies much in size, and in the extent to which it is distributed. It has been observed, very rarely, however, to end as the submental, not reaching the side of the face; in some cases it supplies the face only as high as the lower lip. The deficiency of the facial artery is most frequently compensated for by an enlargement of the nasal branches of the ophthalmic at the inner side of the orbit; occasionally by branches from the transverse facial or internal maxillary arteries.

*Branches.*—The *ascending palatine* artery is in some instances transferred to the external carotid. This branch varies in size and the extent to which it reaches. Not unfrequently it is expended without furnishing any branch to the soft palate. When it is thus reduced in size, the pharyngeal artery takes its place on the soft palate.

The *tonsillar* branch is not unfrequently altogether wanting.

The *submental* branch has been observed to take its rise from the lingual artery. On the other hand, the facial artery, instead of the lingual, has been found to furnish the branch which supplies the sublingual gland.

**4. Occipital Artery.**—The occipital artery, arising from the posterior part of the external carotid, usually opposite the facial or a little higher up, is directed upwards and backwards, beneath the posterior belly of the digastric muscle, to the interval between the transverse process of the atlas and the mastoid process of the temporal bone. From that point it turns horizontally backwards along the skull in the occipital groove of the temporal bone, internal to the mastoid process and the sterno-mastoid, splenius, digastric and trachelo-mastoid muscles, and resting on the superior oblique and complexus muscles. Lastly, changing its direction a second time, and piercing the cranial attachment of the trapezius, it ascends beneath the integument on the back of the head accompanied by the great occipital nerve, and divides into numerous branches upon the upper and back part of the cranium. While in the neck, the occipital artery crosses over the internal carotid artery, the vagus, and spinal accessory nerves, and the internal jugular vein; and the hypoglossal nerve turns from behind over it at its origin.

**Branches.**—(a) Small *muscular* offsets to the digastric and stylo-hyoid muscles, and one of larger size to the sterno-mastoid. This last is so regular a branch that it is known as the *sterno-mastoid* branch.

(b) An *auricular* branch to the back part of the concha of the ear, and two or three other muscular branches to the splenius and trachelo-mastoid.

(c) The *meningeal* branch. This runs up with the internal jugular vein, enters the skull through the foramen jugulare, and ramifies in the dura mater of the posterior fossa of the base of the skull.

(d) The *cervical* branch, *ramus cervicalis princeps*. To the upper and back part of the neck the occipital artery furnishes a branch thus designated. Descending a short way, this vessel divides into a superficial and a deep branch. The former ramifies beneath the splenius, sending offsets through that muscle to the trapezius; while the deep branch passes beneath the complexus, and anastomoses with branches of the vertebral artery, and with the deep cervical artery. The size of this branch varies very much.

(e) The *superficial* or *cranial* branches. These pursue a tortuous course between the integument and the occipito-frontalis muscle; and in proceeding upwards on the skull they separate into diverging branches, which communicate with the branches of the opposite artery, as well as with those of the posterior auricular artery, and of the temporal artery at the vertex and side of the skull.

A small twig, the *mastoid* branch, enters the skull through the mastoid foramen, and ramifies in the dura mater.



**Varieties.**—*Origin.*—The occipital artery is occasionally derived from the internal carotid, and from the ascending cervical branch of the inferior thyroid—an offset of the subclavian artery.

*Course.*—The occipital artery sometimes passes outside the trachelo-mastoid instead of internal to it. The chief portion of the vessel was found, in one instance, to pass over the sterno-mastoid muscle, only a small artery being placed in the usual position. The artery has, in a few instances, been seen to turn backwards below the transverse process of the atlas.

*Branches.*—The posterior auricular and the pharyngeal arteries sometimes take origin from the occipital.

**5. Posterior Auricular Artery.**—The posterior auricular artery, a small vessel, arises from the external carotid a little higher up than the occipital. It ascends under cover of the parotid gland, and resting on the styloid process of the temporal bone, reaches the angle formed by the cartilage of the ear with the mastoid process. It is crossed by the portio dura of the seventh nerve. Somewhat above the mastoid portion of the temporal bone it divides into two sets of branches, of which one set inclines forwards to anastomose with the posterior branch of the temporal artery, and the other backwards towards the occiput, on which it communicates with the occipital artery.

**Branches.**—The following are the branches of this artery:—

(a) Small branches to the parotid gland and the digastric muscle.

(b) The *stylo-mastoid* branch. This twig enters the foramen of the same name in the temporal bone; on reaching the tympanum, it divides into delicate vessels, which pass, some to the mastoid cells, others to the labyrinth. One branch is constantly found in young bodies to form, with the tympanic branch of the internal maxillary artery which enters the fissure of Glaser, a vascular circle around the auditory meatus, from which delicate offsets ramify upon the membrana tympani. This small tympanic branch sometimes arises from the occipital artery.

(c) *Auricular branches.*—As it passes the back of the ear, the auricular artery gives one or two branches which supply the posterior surface of the concha, and turn over the margin, or perforate the substance of the auricle to gain the anterior surface.

**Varieties.**—The posterior auricular artery is frequently very small, and has been seen to end in the stylo-mastoid branch. It is often a branch of the occipital.

**6. Temporal Artery.**—The temporal artery, one of the two branches into which the external carotid artery finally divides a little below the condyle of the lower jaw, continues upwards in the direction of the main trunk, whilst the other branch (the internal maxillary) curves forwards under cover of the jaw. The temporal artery is at first imbedded in the substance of the parotid gland, in the interval between the meatus of the ear and the condyle of the lower jaw. Thence it ascends over the root of the zygoma, against which it may readily be compressed. From this point onwards, it lies close beneath the skin, upon the temporal fascia; and, about two inches above the zygoma, divides into two branches, which again subdivide and ramify beneath the integument on the side and upper part of the head.

**Branches.**—Besides several small offsets to the parotid gland, some branches to the articulation of the lower jaw, and one or two to the masseter muscle, the temporal artery gives off the following branches:

(a) The *transverse* artery of the face. This branch arises whilst the temporal

Fig. 250.

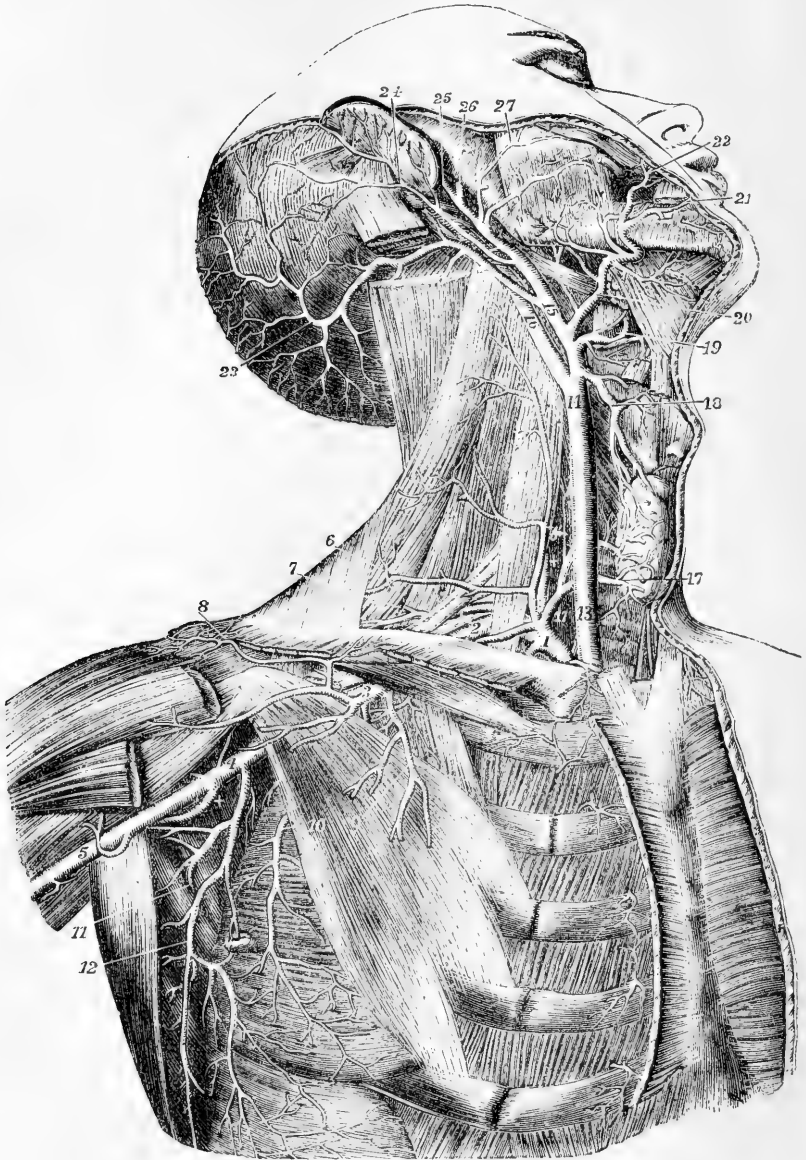


Fig. 250.—DEEP VIEW OF THE CAROTID, SUBCLAVIAN, AND AXILLARY ARTERIES (from Tiedemann.)  $\frac{1}{3}$

The great pectoral, the sterno-mastoid, and the sterno-hyoid and sterno-thyroid muscles have been removed; the front part of the deltoid has been divided near the clavicle; the greater part of the digastric muscle has been removed, and the upper part of the splenius capitis and trachelo-mastoid divided near the mastoid process. For the explanation of the references from 1 to 12, see p. 396. *Carotid Artery and its Branches.*—13, lower part, and 14, upper part of the right common carotid artery; 15, trunk of the

external carotid artery ; 16, trunk of the internal carotid artery ; 17, 17, inside the thyroid axis of the subclavian artery, and on the inferior thyroid artery where it is distributed in the gland ; 18, superior thyroid artery, anastomosing in the gland with the inferior thyroid ; 19, lingual artery, brought into view by the removal of the lower part of the hyo-glossus muscle ; 20, facial artery, giving off the palatine, tonsillitic and submental ; 21, inferior labial ; 22, coronary artery ; 23, occipital artery ; 24, posterior auricular artery ; 25, superficial temporal artery ; 26, internal maxillary artery ; 27, transverse facial, given off in this instance directly by the external carotid artery.

artery is deeply seated in the parotid gland, through the substance of which it runs nearly horizontally forwards ; getting between the parotid duct and the zygoma, it rests on the masseter muscle, and is accompanied by one or two transverse branches of the facial nerve. It gives small vessels to the parotid gland, the masseter muscle, and the neighbouring integument ; and divides into three or four branches, which are distributed to the side of the face, anastomosing with the infra-orbital and facial arteries.

(b) The *middle temporal* branch. This arises close above the zygoma, and immediately perforating the temporal fascia, sends branches to the temporal muscle, which communicate with the deep temporal branches of the internal maxillary artery. An offset from this artery runs to the outer angle of the orbit, where it gives branches to the orbicularis palpebrarum muscle.

(c) The *anterior auricular* branches, two or more in number, superior and inferior. These branches arise above the middle temporal. They are distributed to the fore-part of the pinna, the lobe of the ear, and a part of the external meatus, anastomosing with the ramifications of the posterior auricular artery.

(d) The *anterior temporal* branch, one of the two terminal branches of the temporal artery. This vessel inclines forwards as it ascends over the temporal fascia, and ramifies extensively upon the forehead, supplying the orbicular and occipito-frontal muscles, the pericranium, and the skin, and communicating with the supra-orbital and frontal branches of the ophthalmic artery. On the upper part of the cranium the branches of this artery are directed from before backwards. When it is desired to take blood from the temporal artery, the anterior temporal branch is selected for the operation.

(e) The *posterior temporal* branch. This is usually larger than the anterior, passes back on the side of the head, above the ear, and over the temporal fascia ; its branches ramify freely in the coverings of the cranium, both upwards to the vertex, where they communicate with the corresponding vessel of the opposite side, and backwards to join with the occipital and posterior auricular arteries.

**Varieties.**—The *temporal artery* is frequently tortuous, especially in aged persons. Occasionally a large unusual branch runs forward above the zygoma, to the upper part of the orbit. The temporal artery sometimes joins with the ophthalmic and furnishes large frontal arteries.

The *anterior temporal* branch is sometimes larger than the posterior, and passing backwards over the vertex of the head, communicates with the occipital.

The *transverse artery of the face* varies in size ; occasionally it is much larger than usual, and takes the place of a defective facial artery. In some instances the transverse artery arises directly from the external carotid.

**7. Internal Maxillary Artery.**—The internal maxillary or deep facial artery, the larger of the two terminal branches of the external carotid, is concealed by the parotid gland at its origin below the condyle of the jaw ; it curves horizontally forwards between the jaw and the internal lateral ligament of the temporo-maxillary joint, then passes obliquely forwards and upwards on the outer surface of the external pterygoid muscle (not unfrequently beneath and within it), and opposite the interval between the two heads of that muscle, bends inwards to the sphenomaxillary fossa, where it ends by division into a number of branches.

To facilitate the arrangement of its numerous branches, this artery may be considered in three parts, viz. : 1, the part between the jaw and internal lateral ligament ; 2, the part in contact with the external pterygoid muscle ; and, 3, the part in the spheno-maxillary fossa.

A. **Branches of the first part.**—The branches of the first part of the artery all pass through the bony foramina.

(a) The *tympanic branch*, of small size and variable in origin, passes deeply behind the articulation of the lower jaw, and enters the fissure of Glaser, supplying the laxator tympani muscle, and the tympanic cavity, where it ramifies

Fig. 251.

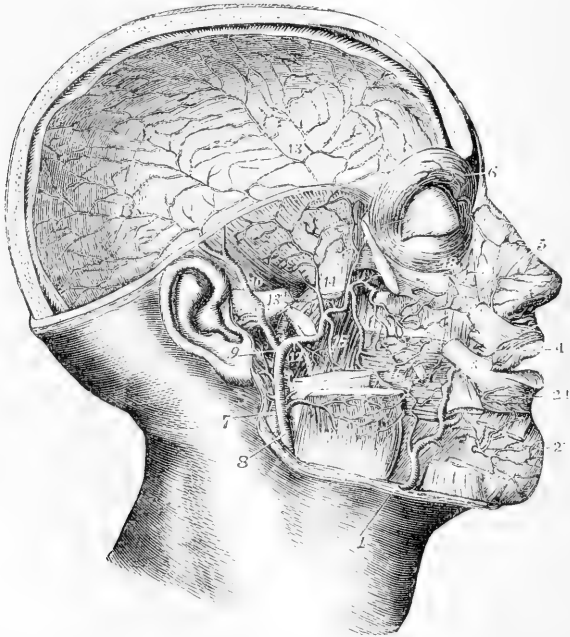


Fig. 251.—DEEP DISSECTION OF THE HEAD AND FACE, TO SHOW THE INTERNAL MAXILLARY ARTERY AND ITS BRANCHES (from Tiedemann).  $\frac{1}{2}$

The right half of the calvarium, the zygomatic arch, and the upper half of the ramus of the lower jaw, with the external pterygoid muscle, have been removed ; some of the superficial muscles of the face have been divided, and the internal pterygoid and buccinator muscles are exposed : 1, facial artery, rising over the edge of the lower jaw ; 2, inferior labial branches ; 2', deep mental branch of the inferior dental artery ; 3, facial artery continued ; 4, superior coronary of the facial ; 5, lateral nasal ; 6, frontal branch of the ophthalmic artery, giving descending twigs to communicate with the angular branch of the facial and with the dorsal nasal ; 7, internal carotid artery ; 8, external carotid artery at the place where it passes through the parotid gland, which has been removed ; 9, division of the external carotid artery into superficial, temporal and internal maxillary arteries ; 10, superficial temporal ; 11, masseteric branch of the external carotid artery ; 12, the trunk of the internal maxillary artery, at the origin of its inferior dental branch ; 13, on the root of the zygoma, points to the middle meningeal branch, and on the dura mater above, to its distribution ; 14, on the lower part of the temporal muscle separated from the coronoid process of the jaw, is between the deep temporal branches of the artery ; 15, pterygoid branches ; 16, buccal artery ; 17, posterior superior dental, and deepest part of the internal maxillary artery where it enters the spheno-maxillary fossa ; 18, branches of the infraorbital artery issuing upon the face.

upon the membrana tympani. It anastomoses in the tympanum with the stylo-mastoid and Vidian arteries.

(b) The *middle* or *great meningeal* artery, by far the largest of the arteries which supply the dura mater, passes directly upwards under cover of the external pterygoid muscle, between the two roots of the auriculo-temporal nerve, and enters the skull by the spinous foramen of the sphenoid bone. Within the cranium, it ascends to the anterior inferior angle of the parietal bone, and divides into numerous branches, which ramify in deep arborescent grooves on the inner surface of the bones some passing upwards over the parietal bone, as high as the vertex, and others backwards even to the occipital bone.

Immediately on entering the cranium the meningeal artery gives minute branches to the ganglion of the fifth nerve and to the dura mater near the sella turcica, and a small twig which enters the hiatus Fallopii, and anastomoses with the stylo-mastoid branch of the posterior auricular artery. It also inosculates with branches of the ophthalmic artery.

The middle meningeal artery is accompanied by two veins.

(c) The *small meningeal* artery, usually arising from the preceding branch, enters the skull through the foramen ovale, to supply the dura mater in the middle fossa.

(d) The *inferior dental* artery, passing downwards, enters the dental canal along with the inferior dental nerve, and subsequently escapes on the face by the mental foramen. As it enters the canal, it gives off the *mylo-hyoid* branch, which, with the nerve bearing the same name, runs in a groove on the inner surface of the jaw, below the dental foramen, and ramifies on the under surface of the mylo-hyoid muscle. In its course through the bone, the inferior dental artery gives off small offsets, which ascend to enter the minute apertures in the extremities of the fangs of the teeth, and supply the pulp of each; before emerging at the mental foramen, it sends forwards a branch which supplies the incisor teeth and inosculates with its fellow of the opposite side. The terminal or facial branches anastomose with the inferior coronary and submental arteries.

**B.—Branches of the second part.**—The branches of this part are chiefly distributed to muscles.

(a) The *deep temporal* branches, two in number (anterior and posterior), ascending between the temporal muscle and the cranium, supply that muscle, and anastomose with the branches of the other temporal arteries, and with minute branches of the lachrymal artery, through small foramina in the malar bone.

(b) The *pterygoid* branches, small, short offsets, irregular in number and origin, are distributed to the pterygoid muscles.

(c) The *masseteric* is a small but regular branch which passes from within outwards, above the sigmoid notch of the lower maxillary bone, to the deep surface of the masseter muscle. It is often joined at its origin with the posterior temporal branch.

(d) The *buccal* branch runs obliquely forwards upon the buccinator muscle with the buccal nerve; it is distributed to that and other muscles of the cheek, and anastomoses with the branches of the facial artery.

**C.—Branches of the third part.**—These branches, like those of the first series, enter bony foramina or canals.

(a) The *alveolar* or *superior maxillary* branch, arising near the tuberosity of the maxillary bone, frequently in common with the infra-orbital branch, runs tortuously forwards upon the surface of the upper jaw, and gives off the *superior dental* and other branches which enter the foramina of the tuberosity, and supply the pulps of the upper molar and bicuspid teeth, besides ramifying in the lining membrane of the maxillary sinus. Other small branches supply the gums.

(b) The *infra-orbital* artery runs horizontally forwards into the infra-orbital canal, and having traversed that canal along with the superior maxillary nerve, emerges upon the face at the infra-orbital foramen.

Whilst still in the canal, it sends upwards into the orbit small branches, which enter the inferior rectus and the inferior oblique muscles of the eye and the lachrymal gland, and others downwards to supply the front teeth. On the face it

gives branches upwards, to the lachrymal sac and inner angle of the orbit, anastomosing with the nasal branches of the ophthalmic and facial arteries, and sends other branches downwards, beneath the levator labii superioris, which join the ramifications of the transverse facial, buccal, and superior coronary arteries.

(c) The *descending or superior palatine* artery descends perpendicularly through

Fig. 252.

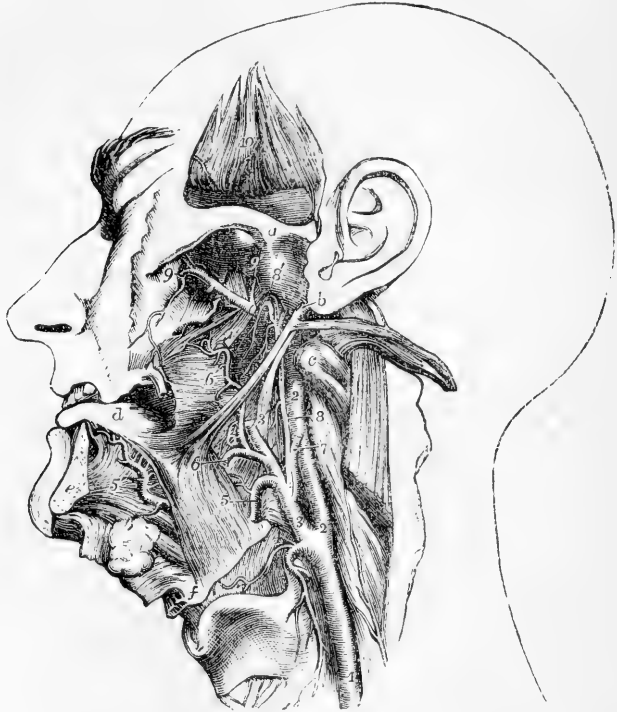

Fig. 252.—DEEP VIEW OF THE LINGUAL AND PHARYNGEAL ARTERIES (from R. Quain).  $\frac{1}{3}$

The lower jaw has been removed, and the tongue drawn forwards between the teeth; the external pterygoid muscle has been removed, and the temporal muscle has been turned up from within the zygoma; *a*, the root of the zygoma, above the glenoid cavity; *b*, placed on the lobe of the ear, points by a line to the styloid process, from which the stylo-glossus and stylo-pharyngeus are seen passing downwards and forwards, and the stylo-hyoid detached from the hyoid bone is thrown backwards with the digastric muscle; *c*, transverse process of the atlas; *d*, upper surface of the tongue; *e*, sawn surface of the symphysis of the lower jaw; *f*, the angle of the hyoid bone; 1, left common carotid artery; 2, internal carotid artery; 3, external carotid artery; 3', placed on the stylo-pharyngeus muscle, points by a line to the upper part of the external carotid artery divided where it enters the parotid gland; 4, superior thyroid artery, its laryngeal branch passing upon the thyro-hyoid membrane; 5, lingual artery about to pass within the hyo-glossus muscle; 5', placed on the genio-hyo-glossus, points to the continuation of the lingual artery as the ramus; 6, the trunk of the facial artery cut short; 6', its tonsillar and pharyngeal branches; 7, occipital artery cut short; 8, ascending pharyngeal artery; 8', its upper part turning down upon the pharynx; 9, internal maxillary artery as it passes into the sphenomaxillary fossa, and gives the posterior dental and the infra-orbital arteries; 9', middle meningeal artery; 10, placed on the deep surface of the temporal artery, which is turned up and shows some cut branches of the deep temporal arteries.

the posterior palatine canal, with the palatine nerve, and runs along the hard palate. In front it ends in a small vessel which ascends through the incisor foramen, and anastomoses with the artery of the septum. While descending in the canal, this artery sends off twigs through the bone, which communicate on the soft palate with the ascending palatine branch of the facial artery.

(d) The *Vidian* branch traverses the Vidian canal with the nerve of the same name; it is distributed to the Eustachian tube and the top of the pharynx, and sends a small vessel into the tympanum.

(e) The *pterygo-palatine*, a very small branch, passes backwards through the pterygo-palatine canal to reach the top of the pharynx, to which, and to the Eustachian tube and sphenoidal cells, it is distributed.

(f) The *nasal* or *spheno-palatine* artery enters the spheno-palatine foramen, and divides into two or three branches, some of which may ramify extensively over the spongy bones, while others supply the posterior ethmoidal cells and the antrum. One long branch, the *artery of the septum*, runs forwards along the septum nasi, ends in a small vessel which enters the incisor foramen, and inosculates with the descending palatine artery.

**Varieties.**—*Origin.*—The internal maxillary artery is very constant in its place of origin. It has, however, been seen to arise from the facial.

*Course.*—The artery often passes under cover of the external pterygoid muscle, crossing the inferior maxillary division of the fifth nerve. It has likewise been observed to issue from under cover of the external pterygoid by piercing the middle of that muscle. When the artery is placed beneath the muscle, it has been found lodged in a notch in the posterior margin of the external pterygoid plate, and bound down by fibrous structure.

*Branches.*—The *middle meningeal* artery occasionally furnishes the lachrymal artery (usually an offset of the ophthalmic), it has also been seen to give off the ophthalmic itself, and on the other hand the ophthalmic has been seen to give off the middle meningeal, peculiarities which may be looked on as resulting from the enlargement of an ordinary anastomosing branch. (Curnow, *Journ. of Anat.*, vol. viii., p. 155. Krause. Blandin.)

In a case in which the internal carotid artery was wanting, two tortuous branches from the internal maxillary entered the skull by the foramen rotundum and foramen ovale, to supply its place. (Quain, "On the Arteries," p. 13, fig. 8.)

**8. Ascending Pharyngeal Artery.**—This artery, long and slender, the smallest branch of the external carotid which has received a distinctive designation, arises most commonly from half an inch to an inch above the origin of the external carotid; and in its straight course upwards rests on the rectus capitis anticus, close to the surface of the pharynx, between it and the internal carotid artery, and is thus directed up towards the base of the skull.

**Branches.**—These are very small, and may be divided into three sets, viz., those to the pharynx; a set directed outwards; and meningeal branches.

(a) The *pharyngeal* branches pass inwards, for the most part to the pharynx. One or two small and variable branches ramify in the middle and inferior constrictor muscles. Higher up than these is a larger and more regular branch, which runs upon the upper constrictor, and sends small ramifications to the Eustachian tube, and to the soft palate and tonsil.

The last mentioned, or *palatine* branch, is sometimes of considerable size, and supplies the soft palate, taking the place of the inferior palatine branch of the facial artery, which in such cases is small. It divides into an anterior and a posterior twig, both of which anastomose with their fellows of the opposite side in the middle line.

(b) The *external* branches, small and irregular, are distributed to the rectus anticus muscle, the first cervical ganglion of the sympathetic nerve, some of the cerebral nerves as they issue from the skull, and to lymphatic glands. Some

of them anastomose with the ascending cervical branch of the subclavian artery.

(c) The *meningeal* branches are terminal twigs, which pass through the foramen lacerum posticum and anterior condylar foramen, to end in the dura mater.

**Varieties.**—This artery varies greatly in its place of origin from the carotid. It occasionally springs from the occipital or internal carotid, and, in a few instances, it has been seen double.

#### INTERNAL CAROTID ARTERY.

The internal carotid artery is distributed to the brain, to the eye with its appendages, and in part to the forehead. It extends directly upwards from the termination of the common carotid artery, opposite the upper border of the thyroid cartilage, to the carotid foramen of the temporal bone. Entering the cranial cavity through the carotid canal, it crosses the foramen lacerum medium, and turning upwards on the side of the sphenoid bone, it passes forward on the carotid groove of that bone. Thence it turns abruptly upwards on the inner side of the anterior clinoid process, and divides opposite the inner end of the Sylvian fissure of the brain, into the anterior and middle cerebral arteries.

*In the neck,* the internal carotid artery varies in length according to the height of the division of the common carotid. It rests on the rectus anticus major muscle, and has the pharynx and tonsil on its inner side. The internal jugular vein is in contact with it as far as the base of the skull, lying on its superficial and posterior aspect: and placed more deeply behind it are the vagus nerve and main trunk of the sympathetic. At its commencement the artery is covered only by the sterno-mastoid muscle, by the platysma myoides, and by fascia, and lies to the outer side of the external carotid. It soon, however, becomes concealed by the parotid gland, and lies internal and posterior to the external carotid trunk, and is crossed first by the occipital artery, and by the hypoglossal nerve and the digastric and stylo-hyoid muscles, three structures which lie superficial to both carotid arteries; and higher up, by the stylo-glossus and stylo-pharyngeus muscles, and the glosso-pharyngeal nerve, which, together with, in some cases, the pharyngeal branch of the vagus nerve, pass forwards between the external and internal carotid arteries.

*Within the cranium,* the internal carotid artery has a very tortuous course, curving forwards and inwards within the carotid canal, then turning upwards to reach the sphenoid bone, on which it is at first directed horizontally forwards, and afterwards resumes the vertical position on the inner side of the anterior clinoid process. In this part of its course the artery is accompanied by the carotid and cavernous plexuses of the sympathetic nerve. After leaving the carotid canal, it lies in the floor of the cavernous sinus, and in contact with it externally are the nerves which pass through the sphenoidal fissure. Opposite the anterior clinoid process it pierces the layer of dura mater which forms the roof of the sinus, and becomes invested with arachnoid membrane.

**Varieties.**—In very rare cases of abnormal arrangement of the arch of the aorta, the internal carotid artery has arisen as a primary trunk. A few examples of its entire absence are recorded.



## BRANCHES OF THE INTERNAL CAROTID ARTERY

In the neck the internal carotid artery gives usually no branch. While within the carotid canal it sends a small offset to the tympanum, which anastomoses with the tympanic and stylo-mastoid arteries. Within the cavernous sinus some small branches proceed from it to supply the walls of the sinus and the adjacent dura mater.

Opposite the anterior clinoid process, the internal carotid gives off the *ophthalmic* artery; and at the Sylvian fissure of the brain, before dividing into the *anterior* and *middle cerebral* arteries, it gives off or is joined by the *posterior communicating* artery, a slender anastomotic branch which unites the internal carotid with the posterior cerebral branch of the basilar artery.

**1. Ophthalmic Artery.**—This artery, arising from the internal carotid artery by the side of the anterior clinoid process, enters the orbit by the foramen opticum, below and to the outer side of the optic nerve. It soon changes its direction, passing over the nerve to reach the inner wall of the orbit, along which it runs forwards, and terminates in branches which ramify on the forehead and side of the nose.

**Branches.**—(a) The *lacrimal* <sup>*tympanic*</sup> artery, arising on the outer side of the optic nerve, passes forwards along the upper border of the external rectus muscle to the lachrymal gland, in which the greater number of its branches are distributed. Some of the branches pass onwards to the eyelids and conjunctiva, joining with other palpebral branches; and one or two delicate *malar* branches pierce the malar bone and reach the temporal fossa, where they join branches from the deep temporal arteries. The lachrymal artery has also branches of communication through the sphenoidal fissure with small offsets from the middle meningeal artery.

(b) The *central artery of the retina*, a very small vessel, pierces the sheath and substance of the optic nerve about a quarter of an inch behind its junction with the eyeball, and runs imbedded within it to the retina, in which it ramifies in minute branches. In the fetus, a very delicate vessel passes forwards through the vitreous humour, to reach the posterior surface of the capsule of the crystalline lens.

(c) The *supraorbital* branch ascends above the muscles, and coursing forwards to the supraorbital notch, in company with the frontal nerve, terminates on the forehead. It distributes branches to the eyelids, and communicates with the temporal artery.

(d) The *ciliary* arteries are divisible into three sets, viz., short, long, and anterior ciliary. The *short* ciliary arteries, varying from twelve to fifteen in number, enclose the optic nerve as they pass forwards to reach the posterior aspect of the sclerotic coat, which they pierce, and enter the eyeball about a line or two from the entrance of the optic nerve. The *long* ciliary arteries, two in number, also enter the back of the eyeball, and then pass forwards, one on each side, between the choroid and sclerotic coats, as far as the ciliary ligament, where they divide into branches. The *anterior* ciliary arteries are derived from some of the muscular branches; they form a vascular circle around the fore part of the eyeball, and then pierce the sclerotic within a line or two of the margin of the cornea. All these ciliary arteries anastomose together within the eyeball, their distribution in which will be particularly described with the anatomy of the eyeball.

(e) The *muscular* branches, subject to much variety, usually arranged in an upper and lower set, supply the muscles of the orbit.

(f) The *ethmoidal* branches are two in number, a *posterior* and an *anterior*. They pass through the posterior and anterior internal orbital foramina, the latter in company with the nasal branch of the ophthalmic nerve; and both

arteries having furnished branches to the ethmoidal cells, enter the skull, supply the adjacent dura mater, and send branches through the cribriform lamella to the nose.

Fig. 253.

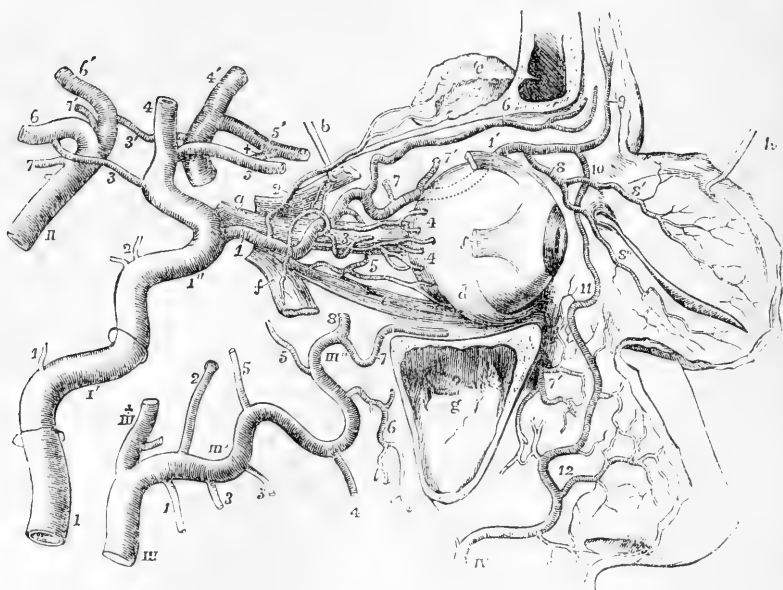


Fig. 253.—SEMIDIAGRAMMATIC VIEW OF THE ARTERIES OF THE ORBIT AND NEIGHBOURING PARTS, WITH THEIR BRANCHES AND ANASTOMOSES (founded on Hirschfeld and Leveillé, with additions). (A. T.)

The outer wall of the orbit has been removed, the sinus maxillaris is laid open, the eyelids are turned forwards, and the external and superior recti, and the superior oblique muscles have been partially removed. *a*, optic nerve; *b*, hook, holding up the posterior part of the superior rectus muscle, the anterior part of which is left attached to the eyeball; *c*, lachrymal gland, thrown up on the frontal bone; *d*, insertion of the inferior oblique muscle; *e*, inferior rectus; *f, f*, anterior and posterior portions of the divided external rectus; *g*, maxillary sinus; *h*, hook, holding up the eyelids, of which the deep surface is exhibited.

I, internal carotid artery below the inferior aperture of the carotid canal of the temporal bone, which is indicated higher up by a ring surrounding the artery; 1', the part of the artery situated within the temporal bone, a second ring indicating the place of the upper aperture of the temporal canal; 1'', the part of the artery situated upon the sphenoid bone; upon this artery, 1, twig to the mastoid cells and tympanum; 2, twigs in the cavernous sinus; 3, communicating branches to the posterior cerebral; 4, middle cerebral; 5, anterior cerebral.

II, basilar artery; upon this artery, 6, posterior cerebral; 7, superior cerebellar: the accented numbers, 3', 4', 5', 6', 7', indicate, on the left side, the arteries already named under the same numbers on the right side, and with these and the anterior communicating branch marked by +, complete the Circle of Willis.

III, upper part of the external carotid artery dividing into III x, the superficial temporal, and III', the internal maxillary artery; upon the latter artery, 1, inferior dental branch; 2, middle meningeal; 3, 3, masseteric and pterygoid branches; 4, buccal; 5, 5, anterior and posterior deep temporal; 6, posterior superior dental; 7, infraorbital; 7', branches of the same issuing upon the face; 8, part of the internal maxillary, which passes into the spheno-maxillary fossa.

IV, facial artery, terminating at 11, in the angular, and giving off, at 12, the lateral nasal branches, and others which communicate with the infraorbital.

In the orbit the following numbers indicate the ophthalmic artery and its branches: 1,

the ophthalmic artery at its origin from the internal carotid; 1', the same artery continued on the upper and inner side of the orbit; 2, lachrymal branch; 3, central artery of the retina; 4, some of the ciliary arteries; 5, 5', upper and lower muscular branches; 6, supraorbital; 7, 7', posterior and anterior ethmoidal arteries; 8, palpebral; 8', 8'', its superior and inferior divisions; 9, frontal; 10, nasal, communicating with the angular of the facial.

(g) The two *palpebral* branches, *superior* and *inferior*, arise near the front of the orbit, usually together, but soon diverge, one lying above, the other below the tendon of the orbicularis muscle at the inner angle of the eye; they form arches, one in each lid, which lie between the orbicularis muscle and tarsal cartilage, and send branches to the caruncula lachrymalis and the lachrymal sac.

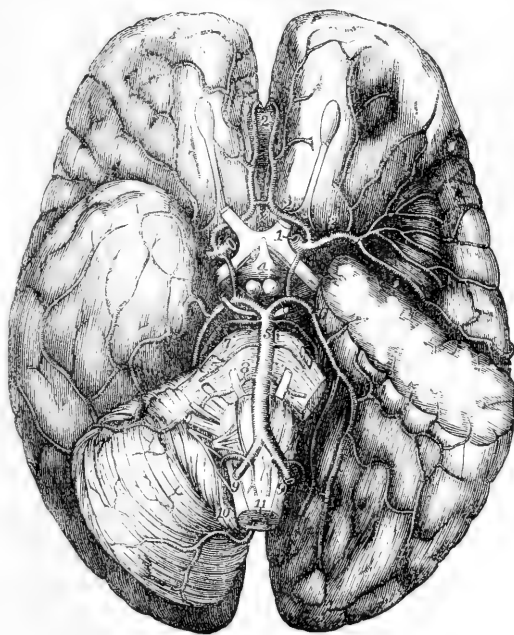
(h) The *nasal* branch courses forwards above the tendon of the orbicularis muscle to the root of the nose, where it ramifies, maintaining a free communication with the nasal and angular branches of the facial artery.

(i) The *frontal* branch runs close to the preceding, but on reaching the margin of the orbit turns upwards on the forehead, where it anastomoses with the supra-orbital artery.

## 2. Cerebral Arteries.—The terminal branches of the internal

Fig. 254.—VIEW OF THE DISTRIBUTION OF THE BRANCHES OF THE INTERNAL CAROTID AND VERTEBRAL ARTERIES TO THE LOWER PARTS OF THE BRAIN (altered from Hirschfeld and Leveillé). (A. T.)  $\frac{1}{2}$

Fig. 254.



On the left side of the brain a portion of the middle lobe of the cerebrum has been removed so as to open up the fissure of Sylvius and expose the convolutions of the island of Reil; and the left half of the cerebellum has been removed to show the lower surface of the posterior cerebral lobe. 1, placed on the optic commissure, points to the divided stem of the left internal carotid artery where its cerebral distribution begins; 2, anterior cerebral branch, exposed fully by the removal of a portion of the left optic nerve; 2', placed on the knee or anterior bend of the corpus callosum between its two arteries; x, placed on the lamina cinerea in front of the optic commissure, marks the anterior communicating artery; 3, middle cerebral artery, passing into the fissure of Sylvius and distributing its branches over the convolutions of the island of Reil and others beyond; 4, placed between the infundibulum and the corpora albicantia, points by a line to the left posterior communicating artery; 5, basilar artery; 6, posterior cerebral artery, its distribution exposed on the left side by the removal of half of the cerebellum; 7, placed on the pons Varolii, points to the right superior cerebellar artery; 8, anterior inferior cerebellar artery; between 7, and 8, one of the largest of the transverse branches of the basilar artery; 9, 9, right and left vertebral arteries; 10, posterior inferior cerebellar arteries; 11, anterior spinal arteries.

carotid artery supply the anterior and greater part of the pia mater and brain.

The *anterior cerebral*, commencing at the subdivision of the internal carotid at the inner end of the fissure of Sylvius, turns forwards towards the middle line to reach the longitudinal fissure between the anterior lobes of the cerebral hemisphere, and is connected with the vessel of the opposite side by the *anterior communicating artery*, a branch not more than two lines in length. The two anterior cerebral arteries, lying close together, in the next place turn round the anterior border of the corpus callosum, run backwards on its upper surface, concealed by the cerebral hemispheres, and end by anastomosing with the posterior cerebral arteries. In their course they give numerous branches to the olfactory lobes and optic nerves, the under surface of the anterior lobes, the third ventricles, corpus callosum and inner surface of the hemisphere.

The *middle cerebral* artery, larger than the anterior, inclines obliquely outwards, taking the course of the fissure of Sylvius; within this it divides into several branches, which ramify in the pia mater investing the surfaces of the anterior and middle lobes of the brain, and join with the branches of both the anterior and posterior cerebral arteries. Numerous small branches, without ramifying in the pia mater, turn upwards at once, and enter the brain at the anterior perforated spot, through which they reach the corpus striatum.

One or two *choroid* arteries, which sometimes arise directly from the internal carotid, passing backwards, enter the fissure between the middle lobe and the crus cerebri, to reach the descending cornu of the lateral ventricle, in which they are distributed to the choroid plexus.

**Varieties.**—In rare instances, the anterior cerebral arteries have united into a single trunk, like the basilar artery behind, and have again divided into a right and left artery. The anterior communicating artery is frequently double.

Frequently the posterior cerebral artery of one side arises by an enlarged posterior communicating artery from the internal carotid, and is connected only by a slender vessel with the basilar.

**Circle of Willis.**—A remarkable anastomosis exists between the branches of the vertebral and internal carotid arteries within the cranium, by which the circulation in the brain may be equalised, and any irregularity which might arise from the obliteration of one, or even two of the vessels, may speedily be remedied by a corresponding enlargement of the others. This anastomosis, known as the *circle of Willis*, results from a series of communications between the following branches. The anterior cerebral arteries are connected together, as already mentioned, in the longitudinal fissure by the anterior communicating artery. The right and left internal carotids, the trunks from which the anterior cerebral arteries arise, are united by the posterior communicating arteries to the posterior cerebral arteries, which arise behind from a single trunk—the basilar artery. Within or opposite to the area of this vascular circle are the following parts of the encephalon, viz., the commissure of the optic nerves, lamina cinerea, infundibulum and tuber cinereum, corpora albicantia, posterior perforated spot with part of the crus cerebri, and the origin of the third pair of nerves.

**Distribution of the Arteries in the Cerebrum.**—The recent researches of Duret and Heubner have thrown some additional light on the circulation in

the brain. According to these authors, the three great arteries which go to the cerebrum—the anterior, middle, and posterior cerebral—give origin to two very distinct systems of vessels. The first of these, consisting of branches given off by the arteries immediately after they leave the circle of Willis, is destined to the great central ganglia, and is called the *central system of arteries*; the other ramifies in the pia mater, and is distributed to the grey matter of the convolutions and the subjacent white matter; it is called the *cortical system of arteries*. These two systems are to a great extent independent of each other, the vessels which connect them being few in number, and of almost capillary minuteness. Moreover, not only are the two systems thus distinct, but the branches of the several arteries are also limited in their distribution to certain well-defined areas, and their communications are few and small, and occur only at the periphery of their respective areas of distribution, so as to render the areas practically independent territories. The same remark applies, in less degree, however, to the secondary, and even tertiary division of these arteries.

The *anterior cerebral* has a very limited central distribution, giving only a few small branches (and these liable to much variation as to size and number) to the anterior extremity of the corpus striatum. Its cortical branches are three in number: the first being distributed to the two internal orbital convolutions; the second to the anterior extremity of the marginal convolution, to the superior, and to the anterior portion of the middle frontal convolutions on the outer surface; the third to the inner surface of the hemisphere as far as the extremity of the calloso-marginal fissure; the fourth to the quadrate lobule; and from this last branch the artery of the corpus callosum is given off.

The *middle cerebral* immediately after leaving the internal carotid gives off a number of small vessels which pass directly upwards, parallel to each other, into the foramina of the anterior perforated space, and enter the base of the corpus striatum. They are distributed to the two extraventricular nuclei (grey nucleus and lenticular nucleus) of that body, to the posterior part of the nucleus candatus and the portion which borders upon the optic thalamus. The main trunk of the middle cerebral passes upwards and outwards in the fissure of Sylvius until it reaches the island of Reil, on the surface of which it divides into four branches. The first branch is limited in its distribution to the outer part of the orbital surface and the adjacent inferior frontal convolution; the second branch supplies the posterior part of the middle frontal, and the chief part of the ascending frontal convolution; the third branch passes in the fissure of Rolando to the rest of the ascending frontal and to the ascending parietal convolution and to the anterior part of the superior parietal lobule; and the fourth, lying in the posterior branch of the fissure of Sylvius, supplies the inferior parietal lobule, and the superior temporo-sphenoidal convolution.

The *posterior cerebral* arteries (the origin and course of which are described at p. 386) gives off a number of twigs in the posterior perforated spot, and others as it passes round the crus, both of which sets pass into the thalami optici, *crura cerebri* and *corpora quadrigemina*. The cortical branches are three in number: the first is distributed to the anterior part of the uncinat gyrus and its immediate vicinity; the second branch supplies the posterior part of the uncinat gyrus and the lower part of the temporo-sphenoidal lobe; the third, lying in the calcarine fissure, supplies the occipital lobe on its inner and outer surfaces. (H. Duret, in *Archives de Physiol.* 1874; Heubner, in *Centralblatt für die Med. Wissensch.* 1872.)

### SUBCLAVIAN ARTERIES.

The subclavian artery is only the commencing portion of a long trunk which forms the main artery of the upper limb, and which is artificially divided for purposes of description into three parts, named the subclavian, axillary, and brachial arteries.

The subclavian artery, arising on the right side from the extremity of the innominate stem, and on the left from the arch of the aorta, passes a short way up into the neck, arches outwards over the pleura.

and rests between the scalenus anticus and scalenus medius muscles on the first rib. At the outer border of the first rib it ceases to be called subclavian, and is continued into the axillary artery.

Each subclavian artery is conveniently divided into three parts,—the *first* part extending from the origin of the vessel to the inner border of the anterior scalenus muscle; the *second* consisting of the portion of the vessel situated behind that muscle; and the *third* reaching outwards to the external border of the first rib. In examining each of these portions in detail, it will be necessary in the first part to give separate descriptions for the right and the left sides, as there is a material difference in the origin, course, and relations of the two vessels.

THE FIRST PART OF THE RIGHT SUBCLAVIAN ARTERY commences close to the trachea, at the division of the innominate artery, behind the upper part of the sterno-clavicular articulation, and ends at the inner margin of the anterior scalenus muscle. Separating from the carotid artery, it arches upwards and outwards, and ascends above the level of the clavicle to an extent which varies in different cases. It is deeply placed, being covered by the platysma, the sterno-mastoid, the sterno-hyoid, and sterno-thyroid muscles, and the deep cervical fascia. It is in contact with the pleura inferiorly, and is separated by an interval from the longus colli muscle behind.

*Relation to Veins.*—The *subclavian* vein lies lower than the artery, close under the clavicle. In its course to join this vein, the *internal jugular* passes in front of the artery near the scalenus muscle, as do also, nearer the middle line, the *anterior jugular* and *vertebral* veins.

*Relation to Nerves.*—The *vagus* nerve passes in front of the artery on the inner side of the internal jugular vein, and its *recurrent laryngeal* branch, turning round below the artery, ascends behind. Some cardiac branches of the *sympathetic* nerve pass down over the artery, while the main trunk passes behind.

THE FIRST PART OF THE LEFT SUBCLAVIAN ARTERY arises from the upper surface of the arch of the aorta, at the left end of its transverse portion, and ascends to the margin of the first rib, behind the insertion of the anterior scalenus muscle. It is, therefore, longer than the first part of the right subclavian, and ascends at first almost vertically out of the chest, instead of arching, like that vessel, outwards across the neck. It is at first overlapped by the left lung, and is covered in front and on the left side by the pleura; it rests on the longus colli muscle, and lies, for a short space, in front of the œsophagus (here deviating to the left side), and the thoracic duct. To the inner or right side of the vessel are situated the left carotid artery and the trachea, and further up the œsophagus and the thoracic duct.

*Relation to Veins.*—The internal jugular vein is immediately before the artery, where it turns outwards from the thorax, close to the scalenus muscle; and the left innominate vein is likewise anterior to it.

*Relation to Nerves.*—The *pneumogastric* nerve is anterior to the first part of the left subclavian artery, and parallel with it, the recurrent branch on this side turning round below the arch of the aorta. The *phrenic* nerve descends over the artery along the inner margin of the scalenus muscle, immediately outside the thyroid axis. The *cardiac* nerves of the left side, descending from the neck, are close to the artery.

THE SECOND PART OF THE SUBCLAVIAN ARTERY, the short portion con-

cealed by the anterior scalenus muscle, forms the highest part of the arch described by the vessel across the neck. Somewhat less deeply

Fig. 255.



Fig. 255.—VIEW OF THE RIGHT COMMON CAROTID AND SUBCLAVIAN ARTERIES, WITH THE ORIGINS OF THEIR BRANCHES AND THEIR RELATIONS (R. Quain).  $\frac{1}{3}$

For the explanation of the references in the upper part of this figure, see p. 356. The following explanation relates to the subclavian artery and its branches: 8, the first part, 8', the third part, of the arch of the subclavian artery; 8'', the subclavian vein, shown by the removal of a portion of the clavicle; 9, is placed on the scalenus anticus muscle in the angle between the transverse cervical and suprascapular branches of the thyroid axis; 10, outer part of the suprascapular artery; 10', transverse cervical branches passing into the deep surface of the trapezius; 10'', the posterior scapular artery, represented as rising directly from the third part of the subclavian artery, and passing through the axillary plexus of nerves and under the levator anguli scapulæ; 11, on the scalenus anticus muscle, points to the inferior thyroid artery, near the place where the ascending cervical artery is given off; the phrenic nerve lies on the muscle to the outside; 7, the supra-sternal twig of the suprascapular artery.

placed than the first part, it is covered by the platysma and the sternomastoid muscle, with layers of the cervical fascia. Behind, it rests against the middle scalenus muscle; and below, it lies on the pleura.

*Relation to Veins and Nerves.*—The subclavian vein is lower than the artery, and is separated from it by the anterior scalenus muscle. The phrenic nerve, which descends obliquely inwards over that muscle, usually crosses the first part of the subclavian artery of the left side close to the muscle, while on the right side, not having quite reached the margin of the muscle at the level of the artery, it is usually separated by the muscle from the second part of the artery.

THE THIRD PART OF THE SUBCLAVIAN ARTERY lies in a small triangular space, the sides of which are formed by the omo-hyoid muscle and clavicle, and the base by the anterior scalenus muscle; the omo-hyoid is in some instances immediately over the artery. The subclavian artery is nearer to the surface here than elsewhere, being covered only by the platysma and layers of the cervical fascia, but towards its termination it becomes deeper, sinking under the clavicle and the subclavius muscle.

*Relation to Veins.*—The subclavian vein continues to be anterior to, and lower than the artery. The *external jugular* vein lies over the artery, and receives on the outer side from the shoulder the two veins which accompany the supra-scapular and transverse cervical arteries. The veins in some cases form a sort of plexus over the artery.

*Relation to Nerves.*—Above the vessel are placed the large *brachial* nerves, the lowest cord formed by the union of the last cervical and the first dorsal nerve being behind and in contact with it. The small nerve of the *subclavius* muscle passes down over the artery, and the space which lodges the artery is crossed in front by the superficial descending (clavicular) branches from the *cervical* plexus of nerves.

BRANCHES.—Four branches are usually described as arising from each subclavian artery. Of these, three, namely, the *vertebral*, the *internal mammary*, and the *thyroid axis*, generally spring close together from the first part of the artery, near the inner side of the anterior scalenus muscle; while the fourth branch, the *superior intercostal*, is usually found internal to that muscle on the left side, but arising under cover of it, from the second part of the artery on the right.

The vertebral artery springs from the upper and back part of the subclavian, and ascends in the neck to reach the interior of the skull; the internal mammary proceeds from the lower side of the vessel, and descends into the fore part of the chest and abdomen; the thyroid axis arises from the front of the artery, and divides into three branches, one of which, the inferior thyroid, is distributed in the fore part of the neck, whilst the other two, the suprascapular and the transverse cervical, pass outwards across the neck to the shoulder; lastly, the superior intercostal and deep cervical arise by a common stem from the back part of the artery, and pass into the upper part of the thoracic wall and the posterior muscles of the neck. The deep cervical is reckoned by some writers as a fifth branch of the subclavian artery, but it usually rises in common with the superior intercostal artery.

Another branch, in the great majority of instances, arises from the third part of the artery. This is the posterior scapular artery, a branch which otherwise is derived from the transverse cervical, one of the divisions of the thyroid axis.



**Varieties.**—The variations in origin of the subclavian arteries have been considered along with the peculiarities of the arch of the aorta.

**Course.**—The height to which these vessels reach in the neck is liable to some variation. Most commonly the artery crosses the neck a little higher than the clavicle, but it is sometimes, especially on the right side, placed as high as an inch or even an inch and a half above the level of that bone. Occasionally the subclavian artery perforates the anterior scalenus muscle, and in a few rare cases it has been seen altogether in front of the muscle, and close to the subclavian vein. That vein has been also seen to pass with the artery behind the scalenus muscle.

**Branches.**—Besides the variation in the position of the branches already referred to, it may be noticed that, in a few cases, one or more of the three first branches have been found moved inwards from their usual position, or outwards to another division of the subclavian. Sometimes two, and much more rarely three branches arise from the third part of the vessel.

#### BRANCHES OF THE SUBCLAVIAN ARTERY.

**1. Vertebral Artery.**—The vertebral artery, which is usually the first and largest branch of the subclavian, arises from the upper and back part of that vessel, and passing upwards and a little backwards, enters the transverse foramen of the sixth cervical vertebra—not unfrequently that of one of the higher vertebrae. The vessel then ascends in a vertical direction through the series of foramina of the transverse processes, as far as to the upper border of the axis; thence it inclines outwards to reach the corresponding foramen of the atlas, and after passing through that aperture winds backwards and inwards in the groove on the neural arch of that vertebra, and, piercing the dura mater, enters the skull through the foramen magnum. Finally, it proceeds upwards and forwards, and turning round from the side to the front of the medulla oblongata on the basilar process of the occipital bone, unites with the vessel of the opposite side, at the lower border of the pons Varolii, to form the *basilar* artery.

At its commencement, the vertebral artery lies behind the internal jugular vein, and on approaching the vertebrae passes between the longus colli and the scalenus anticus muscle. On the left side, the thoracic duct in ascending crosses in front of the vessel from within outwards.

While within the foramina of the cervical vertebrae, the artery is accompanied by a plexus of the sympathetic nerves and by the vertebral vein, which, as the vessels issue from the foramen of the sixth vertebra, is in front of the artery: the cervical nerves as they emerge from the intervertebral foramina lie behind it. The suboccipital nerve passes out beneath it, where it lies on the groove of the atlas, and at that point the artery is covered by the superior oblique muscle.

Within the skull it turns round the side of the medulla oblongata, between the origin of the hypoglossal nerve and the anterior root of the sub-occipital, and then lies between the anterior surface of the medulla and the basilar process of the occipital bone.

#### **Branches.**—A. Cervical Branches:

(a) In the neck, the vertebral artery sends off at different points of its course several small branches named *lateral spinal* arteries. Each of these entering the spinal canal through an intervertebral foramen divides into two branches; one

passes along the roots of the spinal nerves, supplying the spinal cord and its membranes, and anastomoses with the other spinal arteries; the other branch ramifies on the back part of the bodies of the vertebrae in the same manner as similar branches derived from the intercostal and lumbar arteries.

(b) *Muscular* branches of variable size are distributed to the deep-seated cervical muscles.

#### B. Cranial branches :

(a) The *posterior meningeal* artery is a small branch which arises opposite the foramen magnum, and ramifies between the dura mater and the bone in the occipital fossa, and upon the falx cerebelli. There are sometimes two of these small vessels.

(b) The *posterior spinal* artery, arising at an obtuse angle from the vertebral, inclines backwards round the medulla oblongata to reach the back part of the spinal cord; aided by reinforcements from small arteries which ascend upon the cervical and dorsal nerves through the intervertebral foramina, it may be traced along the cord, lying behind the roots of the nerves, as a minute tortuous vessel, or rather a series of little inosculating vessels, as far as the second lumbar vertebra, where it terminates in ramifications on the cauda equina.

Fig. 256.

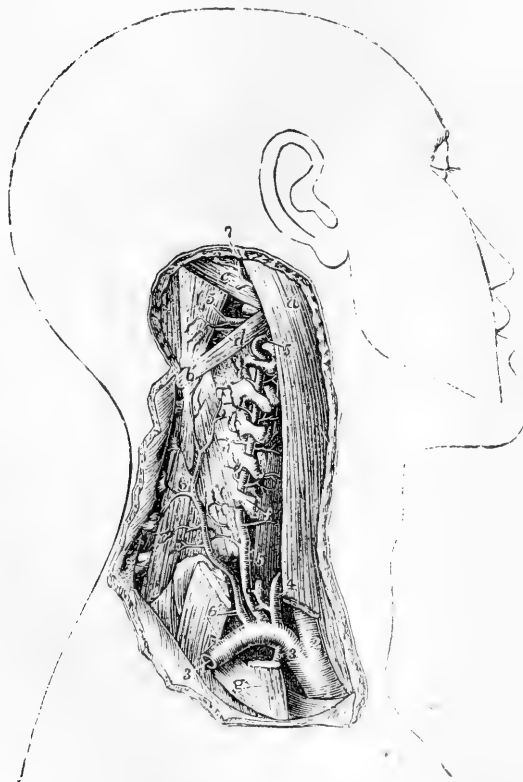


Fig. 256. — DEEP DISSECTION OF THE SUBCLAVIAN ARTERY ON THE RIGHT SIDE, SHOWING THE ORIGIN AND COURSE OF THE VERTEBRAL ARTERY (from Tiedemann).  $\frac{1}{2}$

*a*, Upper part of the sterno-mastoid muscle, its clavicular part divided below; *b*, spinous process of the axis; *c*, superior oblique muscle; *d*, placed on the inferior oblique muscle, points by a line to the posterior arch of the atlas vertebra; *e*, semispinalis colli; *f*, placed on the longus colli, points to the transverse process of the sixth cervical vertebra; *g*, on the first rib, points to the scalenus anticus muscle cut near its attachment; 1, innominate artery; 2, right common carotid; 3, right subclavian; below it, the origin of the internal mammary artery; above it, 4, the thyroid axis, its branches cut short; 5, vertebral artery, passing up through the canal of the transverse processes and giving branches to the muscles; 5', placed

on the rectus major, points to its horizontal part on the arch of the atlas; 6, placed on the lower part of the divided scalenus medius, points to the trunk of the deep cervical artery; 7, occipital artery emerging from below the sterno-mastoid and other muscles attached to the mastoid process.

(c) The *anterior spinal artery*, somewhat larger than the preceding, arises near the end of the vertebral artery, and descends obliquely in front of the medulla oblongata. Immediately below the foramen magnum, it unites with the corresponding vessel of the opposite side, so as to form a single trunk, which descends a short distance only along the middle line in front of the spinal cord, forming the upper part or commencement of the anterior median artery of the cord. This anterior spinal branch of the vertebral artery supplies therefore only the upper part of the cord; the remainder being provided with a series of small arteries, which are derived in the neck from the vertebral and inferior thyroid arteries, in the back from the intercostals, and below this from the lumbar, ilio-lumbar, and lateral sacral arteries. These small vessels enter the spinal canal at irregular intervals through the intervertebral foramina, and, passing along the roots of the nerves, communicate with each other along the middle line by means of ascending and descending branches; so that, by a succession of anastomoses, a very slender single vessel, of varying thickness, named the *anterior median artery*, appears to extend from the one end to the other of the cord. This vessel, or chain of inosculating vessels, supplies the pia mater and the substance of the cord—some entering the anterior median fissure. At the lower end of the spinal cord it sends branches downwards on the cauda equina.

On a part of the spinal cord near the lower end, and in front of the posterior roots of the nerves, may be found another small artery, about equal in size to the anterior spinal.

(d) The *posterior inferior cerebellar artery*, the largest of the branches, arises from the vertebral near the pons, and sometimes from the basilar artery: it turns backwards and outwards, between the hypoglossal and pneumogastric nerves, over the restiform body and near the side of the opening of the fourth ventricle to reach the under surface of the cerebellum. Here, running backwards between the inferior vermiform process and the hemisphere, it divides into two branches: one of which continues backwards in the sulcus between the hemispheres; while the other, turning outwards, ramifies on the under surface of the cerebellum as far as its outer border, over which the ultimate divisions of each branch anastomose with those of the superior cerebellar arteries. This artery partly supplies the hemisphere and the vermiform process, and gives branches to the choroid plexus of the fourth ventricle.

**Varieties.**—*Origin.*—The right vertebral artery has been seen to arise from the common carotid of the same side, in some of those cases in which the right subclavian has been given as a separate vessel from the posterior part of the aorta. In very rare instances, the right vertebral artery arises from the aorta.

The left vertebral artery is not unfrequently derived from the aorta, in which case it generally arises between the left carotid and subclavian arteries, but sometimes it is the last of the branches from the arch.

The left vertebral artery in a few instances, and the right vertebral in one, have been found to arise by more than a single root; and an example of three roots to a vertebral artery has been placed on record. (R. Quain, plate 24, fig. 2.) Two roots may proceed from the subclavian artery, or one from the subclavian and one from the aorta.

*Course.*—Instead of entering the foramen of the sixth vertebra, the vertebral artery of one side not unfrequently enters higher up, through the foramen of the fifth, or fourth, or more rarely of the third vertebra, or even, according to several anatomists, of the second. On the other hand, the vertebral artery has been seen to enter the foramen of the seventh vertebra.

*Branches.*—In the neck, the vertebral artery has been found, though very rarely, to give branches which are usually derived from the subclavian, such as the superior intercostal and the inferior thyroid.

The **basilar** artery the single trunk formed by the junction of the right and left vertebral arteries in the middle line, extends from the posterior to the anterior border of the pons Varolii, along the median groove of which it lies under cover of the arachnoid. The length of this artery is therefore about equal to that of the pons, at the anterior border of

which it divides into two terminal branches, the posterior arteries of the cerebrum.

**Branches.**—Besides numerous small branches to the substance of the pons, the basilar artery gives off the following :—

(a) The *transverse* arteries, several on each side, pass directly outwards. One, the *artery of the auditory nerve*, accompanies that nerve into the internal auditory meatus and labyrinth of the ear.

(b) The *anterior inferior cerebellar* arteries pass backwards, one on each side, to the anterior part of the under surface of the cerebellum, anastomosing with the inferior cerebellar branches of the vertebral arteries.

(c) The *superior cerebellar* arteries arise so close to the bifurcation of the basilar, that this artery is described by several anatomists as dividing into four branches. Each one turns backwards and outwards immediately behind the third nerve, and entering the groove between the pons Varolii and the crus cerebri, turns round the latter, close to the fourth nerve, to reach the upper surface of the cerebellum, where it divides into branches. Of these some extend outwards, and one or more backwards along the superior vermiform process, to reach the circumference of the cerebellum, where they anastomose with the branches of the inferior cerebellar arteries: while others run inwards to supply the vermiform process and the valve of Vieussens, and in part the velum interpositum.

The **posterior cerebral** artery on each side, resulting from the division of the basilar, passes outwards, parallel to the superior cerebellar artery, and separated from it at its origin by the third nerve, which comes forwards between the two vessels. It turns backwards round the crus cerebri, and then runs outwards and upwards on the under surface of the posterior lobe of the cerebrum, passing near the posterior extremity of the corpus callosum. It divides beneath the posterior lobe into many branches, which ramify upon the under, median, and outer surfaces, and anastomose with the other cerebral arteries.

**Branches.**—Immediately after its origin the posterior cerebral artery gives off numerous small parallel branches, which perforate the substance of the brain between the crura, at the point which is called from this circumstance the posterior perforated spot. As it turns backwards, a short distance from its origin, this artery is joined by the *posterior communicating artery*, and in this way contributes as already described (p. 363) to form the circle of Willis. Lastly, the posterior cerebral gives origin to a small branch, the *posterior choroid*, which, arising external to the junction of the communicating artery, turns backwards over the crus cerebri and the tubercula quadrigemina, supplying these with branches, and ending in the velum interpositum and choroid plexus, in the interior of the brain.

**Varieties.**—The basilar artery is originally formed by the coalescence of two separate vertebral arteries, and traces of a septum are sometimes found in its interior. (Davy, "Researches," &c., vol. i. p. 301.) The occurrence of a perforation of the vessel, which has also been observed, may be likewise attributed to the incomplete fusion of the two arteries.

The posterior cerebral artery is occasionally given off on one side from the internal carotid artery.

2.—**Thyroid axis.**—The thyroid axis springs from the fore part of the subclavian artery, close to the inner side of the anterior scalenus muscle. It is a short thick trunk, and receives the name of "axis," because, at a line or two from its origin, it divides into branches, which diverge in different directions, viz., the inferior or ascending thyroid, the suprascapular, and a third branch, which is either the transverse

cervical, or one of the branches into which that artery, when present, divides, viz., the superficial cervical.

**Varieties.**—The thyroid axis has been known to arise beyond the scalenus anticus muscle. It may be associated at its origin with another branch; thus, it sometimes give origin to the internal mammary, and has been known to give origin to the vertebral, superior intercostal, or deep cervical arteries.

A. The **inferior thyroid** artery passes directly upwards, resting on the longus colli muscle, and after a short course bends inwards and downwards behind the sheath of the large cervical vessels, and also behind the sympathetic nerve (the middle cervical ganglion of which, when present, often rests upon this vessel). The artery then makes another curve in the opposite direction, and is distributed to the under part of the thyroid body. Its branches communicate freely with those of the superior thyroid artery, and with the corresponding artery of the other side.

**Branches.**—(a) The *ascending cervical* branch arises at the point where the inferior thyroid turns inwards behind the carotid artery; it proceeds upwards, close to the phrenic nerve, on the line of separation between the scalenus anticus and rectus anticus major, giving *muscular* branches to both, and a few which pass transversely outwards across the neck. These muscular branches communicate with others sent outwards from the vertebral artery. To the spinal canal the ascending cervical artery sends one or two branches (*spinal branches*), which enter the intervertebral foramina along the cervical nerves, and assist in supplying the bodies of the vertebræ, and the spinal cord and its membranes.

(b) A *laryngeal* branch of irregular size is usually supplied by the inferior thyroid artery; it ascends on the trachea and the back of the larynx, and is distributed to the muscles and mucous membrane in that situation.

(c) *Tracheal* branches ramify over the trachea, and anastomose below with the bronchial arteries.

(d) *Œsophageal* branches are given off, and one or more descend upon the trachea into the chest.

**Varieties.**—*Origin.*—The inferior thyroid artery occasionally arises as an independent branch from the subclavian artery, and rarely from the common carotid or the vertebral. Instances have occurred—very rarely, however—of the presence of two inferior thyroid arteries, one passing over the common carotid artery.

The *ascending cervical artery* is occasionally derived from the subclavian or from one of the branches of that vessel, as from the transverse cervical or the suprascapular, or from a trunk common to those two arteries. It is sometimes much larger than usual, and takes the place of the occipital artery. A branch from it not unfrequently compensates for the small size of the deep cervical artery.

B. The **suprascapular** artery (transverse scapular, or transverse humeral), a smaller vessel than the transverse cervical arises almost constantly from the thyroid axis, and runs from within outwards deeply at the root of the neck. At first it descends obliquely towards the clavicle, resting upon the scalenus anticus, and covered by the sternomastoid muscle; it then crosses the subclavian artery, and continues transversely outwards behind and parallel with the clavicle and subclavius muscle, and below the posterior half of the omo-hyoid muscle. Approaching the upper margin of the scapula, under cover of the trapezius muscle, it inclines downwards with the suprascapular nerve towards the suprascapular notch. At this point the nerve usually passes beneath the ligament stretched across the notch,

while the artery more frequently turns over to it to enter the supra-spinous fossa, where, lying close to the bone, it gives off branches which ramify in the fossa beneath the supraspinatus muscle, and sends a small

Fig. 257.

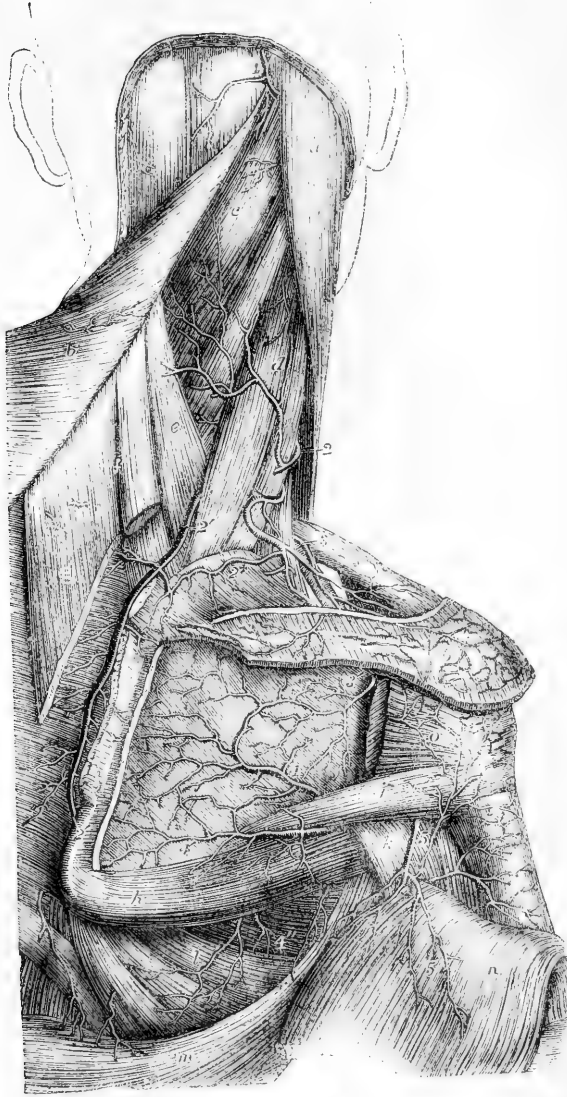


Fig. 257.—VIEW OF THE ANASTOMOSES OF ARTERIES ON THE SHOULDER AND DORSUM OF THE SCAPULA (from Tiedemann).  $\frac{1}{2}$

*a*, sterno-mastoid muscle; *b*, trapezius turned towards the left side; *c*, splenius capitis, and below it splenius colli; *d*, levator anguli scapulae; *e*, serratus posticus superior; *f*, rhomboideus minor, and *g*, rhomboideus major, divided from the base of the scapula; *h*, teres major; *i*, teres minor; *k*, scapular head of the triceps brachii; *l*, serratus magnus; *m*, latissimus dorsi; *n*, deep surface of the deltoid muscle turned down; *o*, portion of the infraspinatus muscle attached to the great tuberosity of the humerus, the rest having been removed from the infraspinous fossa; 1, occipital artery appearing between the trapezius and sterno-mastoid muscles; 2, superficial cervical branch of the transverse cervical artery; 2', 2'', posterior scapular artery; 2 +, its supra-spinous branch; 3, supra-scapular artery; 3', the same after passing through the scapular notch into the infraspinous fossa, where it anastomoses with 4, the dorsal

branch of the subscapular artery; 4', inferior scapular branch of the subscapular; 4'', some of the descending thoracic branches of the subscapular artery; 5, posterior circumflex artery emerging from the quadrangular space, and sending branches upwards on the shoulder-joint, round the humerus, and downwards into the deltoid muscle; 6, anastomosis of the acromial branches of the supra-scapular with the acromio-thoracic artery.

communicating branch into the subscapular fossa, and is itself continued down into the infraspinous fossa.

**Branches.**—*Muscular* branches are given by the suprascapular artery to the sterno-mastoid and other neighbouring muscles.

(b) The *supra-acromial* branch passes obliquely forwards through the attachment of the trapezius to reach the cutaneous surface of the acromion, on which it ramifies, anastomosing with offsets from the acromio-thoracic artery.

(c) A small *subscapular* branch, given off as the artery passes over the notch, anastomoses with the posterior scapular and subscapular arteries in the subscapular fossa and substance of the subscapularis muscle.

(d) An *infraspinous* branch is continued from the suprascapular artery, and descending close upon the neck of the scapula, between the glenoid cavity and the spine of that bone, joins with the dorsal branch of the subscapular artery.

(e) Branches enter the bone and shoulder joint.

**Varieties.**—The suprascapular artery has in some cases been observed to spring directly from the subclavian, or to arise from that vessel by a common trunk with the transverse cervical, or more rarely with the internal mammary. It has also been found to proceed from the axillary artery, and from the subscapular branch of that vessel.

C. The **transverse cervical** artery, the third branch of the thyroid axis, passes outwards a short distance above the clavicle, and therefore higher than the suprascapular artery. It crosses over the scaleni muscles and the brachial plexus, sometimes passing between the nerves of the latter, and is crossed by the omo-hyoid muscle. Beneath the anterior margin of the trapezius, and near the outer edge of the levator anguli scapulæ, it divides into two branches, the superficial cervical and the posterior scapular.

The *superficial cervical* artery ascends beneath the anterior border of the trapezius, and distributes branches to that muscle, the levator anguli scapulæ, and sterno-mastoid muscles, as well as to the cervical glands and the integuments in the intervals between those muscles. When the posterior scapular arises separately from the subclavian, the name superficial cervical may be given to the whole remaining part of the transverse cervical artery.

The *posterior scapular* artery, whether arising from the transverse cervical artery or directly from the subclavian, passes backwards to the upper angle of the scapula, under cover of the levator anguli scapulæ, and then changing its direction, runs downwards beneath the rhomboidei muscles, as far as the inferior angle of that bone. It anastomoses freely on both surfaces of the scapula with the divisions of the suprascapular and subscapular arteries; and supplies branches to the rhomboidei, serratus magnus, and latissimus dorsi muscles, communicating at the same time with the posterior muscular branches of some of the intercostal arteries.

**Varieties.**—Not only does the transverse cervical branch of the thyroid axis present the variation of being nearly as often the superficial cervical alone as of comprising also the posterior scapular artery, but it occasionally happens that the vessel derived from the thyroid axis is very small, and represents only in part the superficial cervical artery; whilst a large vessel arising from the third part of the subclavian divides near the levator anguli scapulæ into two branches, of which one ascends and represents the remaining and larger portion of the superficial cervical artery, while the other forms the posterior scapular.

The transverse cervical artery is sometimes derived directly from the subclavian, beneath or even beyond the scalenus anticus muscle. The transverse cervical sometimes gives off the ascending cervical artery.

When the *superficial cervical* is separated from the posterior scapular, it sometimes arises from other sources than the thyroid axis, as from the suprascapular or the subclavian artery.

Fig. 258.

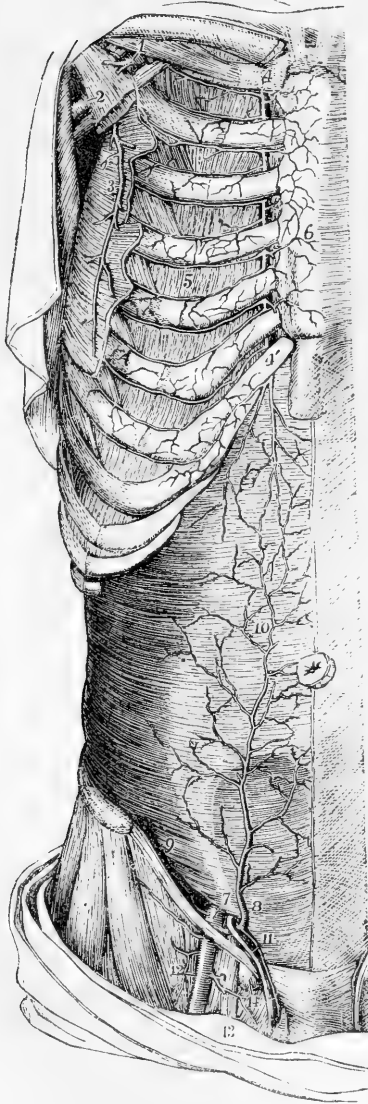

Fig. 258.—DISSECTION OF THE RIGHT SIDE OF THE ANTERIOR THORACIC AND ABDOMINAL WALL, TO SHOW THE ANASTOMOSES OF THE INTERNAL MAMMARY, INTERCOSTAL, AND EPIGASTRIC VESSELS (slightly altered from Tiedemann), (A. T.)  $\frac{1}{4}$

The pectoral part of the serratus magnus, the external and internal oblique, and the rectus abdominis muscles, have been removed; 1, upon the subclavius muscle, points to the first part of the axillary artery above the pectoralis minor muscle, giving rise to the acromio-thoracic artery, which is cut short; 2, upon the pectoralis minor, points to the lower part of the axillary artery and vein; 3, the long thoracic artery; 4, on the cartilage of the first rib, marks the upper part of the internal mammary artery; 4', the lower part of the same artery giving its abdominal branch behind the cartilage of the seventh rib; 5, in the fourth intercostal space, marks the anastomosis of the internal mammary and intercostal arteries; 6, anterior branches of the internal mammary artery ramifying over the front of the sternum; 7, on the transversalis muscle immediately above the internal inguinal aperture, points to the last part of the external iliac artery, from which are seen rising, 8, the deep epigastric artery, and 9, the deep circumflex iliac; 10, the anastomosis of the epigastric with the abdominal branch of the internal mammary artery; 11, the spermatic cord and spermatic twig of the epigastric artery; 12, the femoral artery; 13, the femoral vein; 14, a lymphatic gland closing the femoral ring.

### 3.—Internal Mammary Artery.

The internal mammary artery, remarkable for its length and the number of its branches, arises from the under side of the subclavian, opposite the thyroid axis. It runs forwards and downwards behind the clavicle to the inner surface of the cartilage of the first rib, lying between this and the sac of the pleura: from

this point it inclines a little inwards, and then descends vertically behind the costal cartilages, a short distance from the border of the sternum, as far as to the interval between the sixth and seventh cartilages, where it ends by dividing into two branches. One of the



branches into which the artery divides, musculo-phrenic, inclines outwards along the margin of the thorax; while the other, under the name of superior epigastric, continues onwards to the abdomen in the original direction of the trunk. The internal mammary artery is covered at its origin by the internal jugular and subclavian veins, and is crossed in front by the phrenic nerve. In the chest it has the costal cartilages and the internal intercostal muscles in front, and lies at first upon the pleura; but lower down it is separated from the pleura by the triangularis sterni muscle. This artery has two companion veins, which are united into a single trunk at the upper part of the chest.

**Branches.**—The branches of this artery are numerous, and are distributed chiefly to the walls of the chest and abdomen.

(a) The *superior phrenic* or *comes nervi phrenici*, a very slender but long branch, arises high in the chest, and descends with the phrenic nerve between the pleura and the pericardium, to the diaphragm, in which it is distributed, anastomosing with offsets from the musculo-phrenic and with the inferior phrenic arteries from the abdominal aorta.

(b) The *mediastinal* or *thymic* branches, of very small size, ramify in the loose connective tissue of the mediastinal space, and supply the thymus body or its remains. *Pericardiac* branches are given off directly to the upper part of the pericardium, the lower part of which receives some from the musculo-phrenic division. Branches named *sternal* are also supplied to the triangularis sterni muscle, and to both surfaces of the sternum.

(c) The *anterior intercostal arteries*, two in each space, arise from the internal mammary, either separately, or by a trunk common to the two, which soon divides. The arteries pass outwards, at first between the pleura and the internal intercostal muscles, and afterwards between the two layers of intercostals; they lie, one near the upper and one near the lower rib, in each of the upper five or six intercostal spaces, and inosculate with the corresponding intercostal branches derived from the aortic intercostals. These branches supply the intercostal and pectoral muscles, and give some offsets to the mamma and integument.

(d) The *anterior* or *perforating* branches pass forwards from the internal mammary artery through from four to six intercostal spaces, and turning outwards ramify partly in the pectoralis major, and partly in the integument on the front of the chest. Those placed nearest to the mammary gland supply that organ, and in the female they are of comparatively large size, especially during lactation. Some offsets ramify on the sternum.

(e) The *musculo-phrenic* artery, the outer of the two branches into which the internal mammary artery divides, inclines downwards and outwards behind the cartilages of the false ribs, perforating the attachment of the diaphragm at the eighth or ninth rib, and becoming gradually reduced in size as it reaches the last intercostal space. It gives branches backwards into the diaphragm; others, which pass outwards to form the anterior intercostals of each space, and are disposed precisely like those which are derived higher up from the main internal mammary; and some which descend into the abdominal muscles.

(f) The *abdominal branch* or *superior epigastric artery* of the internal mammary, descending into the wall of the abdomen, lies behind the rectus, between the muscle and its sheath; and afterwards, entering the muscle, terminates in its substance, at the same time anastomosing with the epigastric artery. It also supplies twigs to the broad muscles of the belly, to the skin, and to the diaphragm; and one runs forwards upon the side and front of the xiphoid cartilage, where it anastomoses with that of the opposite side.

**Varieties.**—The internal mammary is occasionally found connected at its origin with the thyroid axis, or with the scapular arteries—these being detached from the thyroid. It occasionally springs from the second or third part of the subclavian artery (the latter being the more frequent position of the two). In very rare instances it has been found arising from the axillary, the innominate, or the aorta.

An unusual branch, of considerable size, occasionally comes off from it, and passes downwards and outwards, crossing several of the ribs, on their inner surface, in contact with the pleura. The internal mammary artery may likewise furnish a bronchial branch.

**4.—Superior Intercostal Artery.**—This artery generally arises from the upper and back part of the subclavian, behind the anterior scalenus muscle on the right side, and immediately at the inner side of the muscle on the left side. Taking its course backwards, it speedily gives off the deep cervical branch (*profunda cervicis*), and bending backwards and downwards in front of the neck of the first rib, ends in one or two intercostal spaces: on the right side it more frequently descends into the second space than on the left side. On the neck of the first rib, the artery is situated on the outer side of the first dorsal ganglion of the sympathetic nerve.

**Branches.**—Besides giving off the deep cervical artery, the superior intercostal gives branches to the first and second intercostal spaces. The branch to the first space is similar in course and distribution to the aortic intercostals: that to the second space usually joins with one from the first aortic intercostal. A small offset is likewise sent backwards, through the first space, to the posterior spinal muscles, and also a small one through the corresponding intervertebral foramen to the spinal cord and its membranes.

**Varieties.**—*Origin.*—The superior intercostal artery has been found, in a few instances, to proceed from the vertebral artery or from the thyroid axis.

*Course.*—It has been observed to pass between the necks of one or two ribs and the corresponding transverse processes of the dorsal vertebræ; and a case has been recorded in which, after arising from the vertebral artery, it descended through the intertransverse foramen of the last cervical vertebra, and then continued, as in the instances just mentioned, between the necks of the ribs and the contiguous transverse processes of the vertebræ of the back. (Quain on the Arteries, plate 22, fig. 5.) The intercostal artery is sometimes, though very rarely, wanting.

The **deep cervical** artery, often described as a separate branch of the subclavian artery, arises in most cases from the superior intercostal. Resembling the posterior branch of an aortic intercostal artery, it generally passes backwards in the interval between the transverse process of the last cervical vertebra and the first rib, to reach the posterior aspect of the neck. Here it ascends in the interval between the transverse and spinous processes, as high as the second vertebra, under cover of the complexus muscle, between this and the semi-spinalis colli. Some of the branches communicate with those given outwards by the vertebral artery, whilst others ascend to anastomose with the cervical branch of the occipital artery.

**Varieties.**—*Origin.*—The deep cervical artery sometimes arises from the subclavian, and more rarely from the posterior scapular. It is not unfrequently supplemented by a branch turning backwards from the ascending cervical artery beneath the transverse process of the third cervical vertebra, or by another branch from the superior intercostal, or, in some instances, by a twig from the posterior scapular or inferior thyroid arteries.

*Course.*—This artery occasionally passes back between the sixth and seventh cervical vertebræ, and sometimes between the first and second dorsal, or even below the second. It has been seen to pass between the first rib and the transverse process which supports it.

#### SURGICAL ANATOMY OF THE SUBCLAVIAN ARTERIES

The depth of the subclavian artery, its intimate and varying connections with

important parts, and the large size of its branches, render operations on this vessel peculiarly difficult.

The third division of the artery, situated beyond the anterior scalenus muscle is the part which is most favourably circumstanced for the application of a ligature. Here the vessel is nearest to the surface, and most remote from the origin of the large branches. The subclavian artery is generally most easy of access above the clavicle while the parts are in their natural position, but when they are displaced by an aneurism in the axilla, the clavicle may be so much elevated by the tumour, as to be placed in front of the vessel, or even above it; and such a condition may require special modifications of the operation.

In the operation of passing a ligature round the third part of the subclavian artery, an incision is to be made a little above the most prominent or convex part of the clavicle, opposite the place where the vessel lies, and parallel with it. By drawing the integument downwards over the clavicle, the parts covering the bone may be divided with freedom.

Along with the integument, the platysma and several nerves are divided in this incision, but no vessel is endangered, except in those rare cases in which the cephalic vein or the external jugular crosses over the clavicle. It will, in most cases, be an advantage to add a short vertical incision, directed downwards to the middle of the horizontal one. Should the sterno-mastoid muscle be broad at its lower end, or should the interval between that muscle and the trapezius be insufficient for the farther steps of the operation, a portion of the former muscle, or even of both muscles, must be divided.

The external jugular vein, joined by the veins from the shoulder, is usually over the artery, and it must be held aside, or it may be necessary to divide it. If divided, the lower end of the vessel requires the application of a ligature as well as the upper one, in consequence of the reflux of blood from the subclavian vein. The omo-hyoid muscle will also be turned aside if necessary. At this stage of the operation, in the usual position of the clavicle, the first rib is the best guide to the vessel. At this place the brachial nerves are close to the vessel, so that great care must be exercised in passing the ligature round the artery. But if it is found necessary to raise greatly the outer end of the clavicle, then it will, in many cases, be more easy to place the ligature on the artery inside the insertion of the scalenus muscle, or even behind that muscle. Above the first rib, the situation of the vessel may be ascertained by means of the brachial nerves and the scalenus muscle; and, before the membrane covering them is divided, the position of these structures may be ascertained by the cord-like feel of the nerves, and the smooth, flat form of the muscle.

With reference also to the choice of the exact place at which the ligature is to be passed round this part of the artery, it should always be borne in mind that a very considerable branch may be given off from the main artery, immediately beyond the scalenus muscle, or at some other part of the vessel. This branch is most frequently one corresponding to the posterior scapular; but in rarer cases may be the superficial cervical or suprascapular.

The *second division of the subclavian artery*, or that situated behind the scalenus anticus muscle, is the part which rises highest in the neck, and on this account it may be advantageously selected for the application of a ligature when the vessel is difficult of access beyond the muscle. The chief objection to operating on this part of the artery arises from the contiguity of the large branches. Care is necessary in dividing the scalenus muscle to avoid the phrenic nerve and the internal jugular vein. Moreover, the fact of the close apposition of the subclavian artery with the pleura, except where it rests on the rib, must be borne in mind.

Difficulties also arise from the occurrence of an unusual position of the artery, as when it passes through the substance of the anterior scalenus, or when it is in front of that muscle; but such cases are of very rare occurrence.

The *first part* of the subclavian artery on the left side may be said to be inaccessible for the application of a ligature, in consequence of its depth and its close connection with the lung and other important structures, such as the internal jugular and left innominate veins.

On the right side, though deeply placed and closely connected with important parts, the first division of the subclavian artery may be tied without extreme difficulty. But inasmuch as the length of the vessel, between its three large branches on the one hand, and the common carotid on the other, ordinarily measures no more than an inch, and often less; the success of the operation is somewhat doubtful.

In order to place a ligature on the portion of the right subclavian artery here referred to, it is necessary to divide by horizontal incisions the three muscles which cover it, together with the layers of fascia between and beneath them. While the muscles are being divided, a branch of the suprascapular artery will probably require to be secured. In the farther steps of the operation, the exact relations of the artery to the internal jugular vein, the vagus nerve, and the pleura, are to be well kept in view.

It is to be remembered also that the right subclavian artery is occasionally somewhat more deeply placed than usual in the first part of its course; as in certain cases of variation, when it springs from the back part of the aortic arch, or, more frequently, when it merely separates from the innominate behind the carotid.

#### AXILLARY ARTERY.

The axillary artery is that part of the artery of the upper limb which extends from the outer border of the first rib to the lower margin of the tendons of the latissimus dorsi and teres major muscles. In this course it passes through the axilla, and its direction varies with the position of the limb, being curved downwards, or upwards, or being straight, according as the arm hangs by the side, or is elevated, or extended.

In front, the axillary artery is covered by the pectoralis major muscle, behind which it is crossed by the pectoralis minor. It may be conveniently divided into three parts: the first part lying internal to the pectoralis minor muscle, the second part being behind that muscle, and the third part beyond it.

In the *first part* of its course the vessel has the first intercostal space, and the first slip of the serratus magnus muscle with the posterior thoracic nerve on its inner side, and is covered by the costo-coracoid membrane, which, attached above to the clavicle, is continued below into a common sheath investing the artery and vein, which is completed behind by a prolongation of the deep cervical fascia. In this part of its course the artery is placed with the trunks of the brachial plexus above and behind it, and the axillary vein in front of it and somewhat nearer the thorax: it is also crossed by the cephalic and acromio-thoracic veins as they dip down to terminate in the axillary vein.

In the *second part* of its course, behind the pectoralis minor, the axillary artery is completely surrounded by the trunks of the brachial plexus, and is crossed in front by one of the roots of the median nerve: the vein is on the thoracic side of the artery, separated from it by nerves.

In the *third part* of its course, beyond the pectoralis minor, the axillary artery rests on the subscapular muscle and the insertions of the latissimus dorsi and teres major, while to the outer side is the coracobrachialis muscle. The axillary vein is still on the thoracic side, but sometimes the venæ comites, by whose union it is formed, are continued up to this level, one on each side of the artery. The main branches resulting from the division of the brachial plexus of nerves are disposed behind and on each side of this part of the artery, as

follows, viz., behind it, the circumflex and musculo-spiral; to its inner side, the ulnar and the two internal cutaneous; to the outer side, the external cutaneous and median. The external cutaneous and the circumflex nerves leave the artery in the axilla, and at the lower part of the axilla median nerve is often before the vessel; in an operation, that nerve might serve as a guide to the position of the artery, for it could be distinguished from the other large nerves (ulnar and musculo-spiral) by the circumstance of its being the nearest to the pectoral muscle. Beyond the border of the pectoralis major, the artery is covered only by the skin and fascia on the inner side; and here the flow of blood may be controlled by pressure of the finger directed outwards against the humerus.

#### BRANCHES OF THE AXILLARY ARTERY.

The branches of the axillary artery consist of the *external thoracic* branches furnished to the muscles of the chest, the *subscapular* branch to the shoulder, and the *anterior* and *posterior circumflex* branches to the upper part of the arm. The branches are not constant in their number, size, or mode of origin.

1. The **short thoracic** artery (*thoracica suprema*), a branch of inconsiderable size, arises at a point internal to the pectoralis minor muscle, and inclines downwards and inwards across the first two intercostal spaces, anastomosing with the internal mammary and intercostal branches contained in them, and terminates between the pectoral muscles.

2. The **acromio-thoracic axis** (*art. thoracica humeraria*), of considerable size, and by far the most constant of the thoracic branches of the axillary, arises from its forepart at the inner border of the pectoralis minor muscle, and soon divides into branches which take different directions.

(a) The *acromial* branches pass partly to the deltoid muscle and partly to the upper surface of the acromion, and anastomose with the suprascapular and posterior circumflex arteries.

(b) The *humeral* branch passes down in the interval between the pectoralis major and deltoid muscles, and is distributed to their margins; it is accompanied by the cephalic vein.

(c) The *thoracic* branches are distributed to the serratus magnus and pectoral muscles, and anastomose with the other thoracic arteries.

(d) The *clavicular* branch, very small, passes inwards to the subclavius muscle.

3. The **long thoracic** or **external mammary** artery is directed downwards and inwards, along the lower border of the pectoralis minor, and is distributed to the mamma, and to the serratus and pectoral muscles, and anastomoses with the external branches of the intercostal arteries.

4. The **alar thoracic** branch is a very small vessel and not constant, being frequently wanting, and having its place supplied by branches from the thoracic and subscapular arteries. It is distributed to the lymphatic glands and the fatty tissue in the axilla.

5. **Subscapular Artery.**—This branch, the largest given off by the axillary artery, arises close to the lower border of the subscapular muscle, along which it proceeds downwards and backwards, towards

Fig. 259.

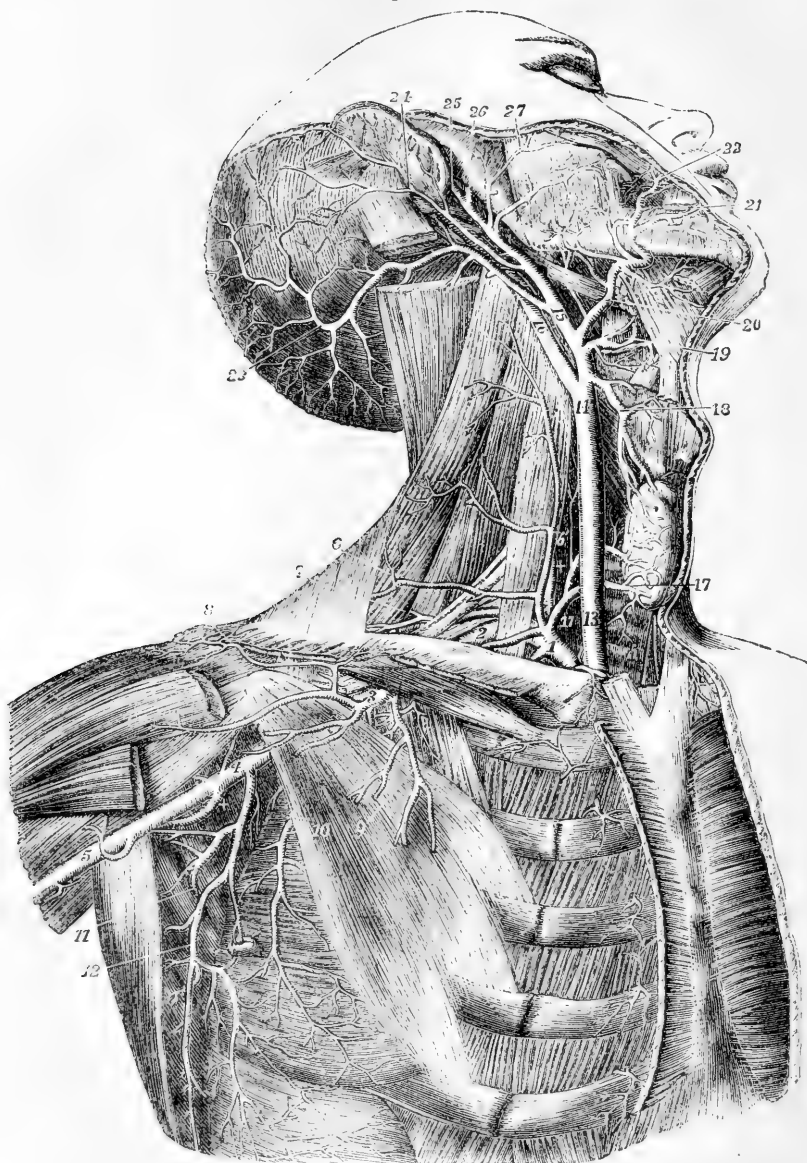


Fig. 259.—DEEP VIEW OF THE CAROTID, SUBCLAVIAN, AND AXILLARY ARTERIES (from Tiedemann).  $\frac{1}{3}$

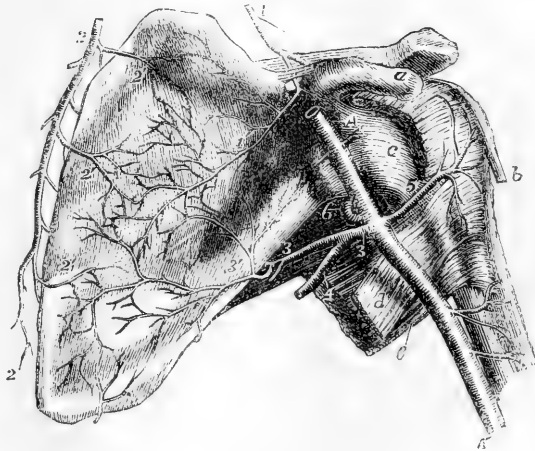
The great pectoral, the sterno-mastoid, and the sterno-hyoid and sterno thyroid muscles have been removed; the front part of the deltoid has been divided near the clavicle: the greater part of the digastric muscle has been removed, and the upper part of the splenius capitis and trachelo-mastoid divided near the mastoid process. *Subclavian Artery and its Branches.*—1, First or inner part of the subclavian artery giving rise to the thyrocervical trunk and internal mammary, and also to +, the vertebral artery; 2, third part of the

subclavian artery outside the scalenus anticus muscle ; 3, first part of the axillary artery giving rise to the acromio-thoracic, short thoracic, &c. ; 4, third part of the axillary artery giving rise to the subscapular, circumflex, &c. ; 5, commencement of the brachial artery ; 6, superficial transverse cervical artery ; 6', placed on the scalenus anticus muscle, marks the ascending cervical branch ; 7, posterior scapular artery arising from the subclavian artery behind the scalenus anticus muscle ; 8, acromial branches of the acromio-thoracic ; 9, pectoral branches of the same ; 10, long thoracic artery outside the pectoralis minor muscle ; +, posterior circumflex branch of the axillary artery (the anterior circumflex is seen rising from the opposite side of the same part of the axillary trunk ; 11, subscapular artery passing between the subscapularis and teres minor muscles to proceed to the lower angle and dorsum of the scapula ; 12, thoracic descending branch of the subscapular artery. For the explanation of the references 13 to 27, to the carotid artery and its branches see p. 368.

the inferior angle of the scapula, accompanied by the long subscapular nerve ; and it terminates in branches to the subscapularis, serratus magnus, teres major, and latissimus dorsi muscles. It soon becomes considerably diminished in size, owing to its giving off a large branch to the dorsum of the scapula. Its final ramifications anastomose with one another and with the branches of the posterior scapular artery.

Fig. 260.—VIEW OF THE ARTERIES WHICH RAMIFY AND ANASTOMOSE ON THE VENTRAL SURFACE OF THE SCAPULA, AND OF THE ANTERIOR CIRCUMFLEX ARTERY (from R. Quain).  $\frac{1}{2}$

Fig. 260.



a, coracoid process ; b, tendon of the long head of the biceps muscle ; c, the front of the capsular ligament of the shoulder-joint ; d, tendon of the latissimus dorsi muscle ; e, teres major ; l, supra-scapular artery descending to the supra-scapular notch, over the ligament of which

the larger part of the artery passes into the supraspinous fossa ; A, A', the axillary and brachial artery ; 1', its subscapular branch passing through the notch and ramifying in the subscapular fossa ; 2, 2, posterior scapular artery descending parallel to the base of the scapula ; 2', its subscapular branches ; 3, main stem of the subscapular artery at its origin from the axillary and continuation towards the dorsum of the scapula ; 3', the branch to the ventral surface of the scapula proceeding to anastomose with the subscapular branches of the supra-scapular and posterior scapular arteries ; 4, descending or thoracic branch of the subscapular artery ; 5, anterior circumflex artery ; 6, posterior circumflex passing back through the quadrilateral muscular space.

The *dorsal* branch (*dorsalis scapulae*) turns back from the subscapular artery, about an inch and a half from its origin, and is sometimes larger than the continuation of the vessel. Descending along the lower border of the scapula, it passes through the interval bounded internally by the subscapularis and teres minor, externally by the latissimus dorsi and teres major, and superiorly by the long head of the triceps muscle ; and,

turning closely round the border of the scapula, which is frequently grooved to receive it, passes between the teres minor and the bone, and ramifies in the infraspinous fossa, where it anastomoses with the suprascapular and posterior scapular arteries.

**Branches.**—The dorsalis scapulae gives off,—(a) *ventral* branches, slender vessels which ramify in the subscapular fossa between the subscapular muscle and the bone, and anastomose with twigs from the suprascapular and posterior scapular arteries; (b) branches to the teres muscles, and particularly a twig which descends between their origins; (c) terminal branches in the infraspinous fossa.

6. The **posterior circumflex** artery, a considerable vessel but smaller than the subscapular, arises opposite the lower border of the subscapular muscle, below the subscapular artery, and is directed backwards in company with the circumflex nerve, passing through the space between the teres muscles, the humerus, and the long head of the triceps muscle, and therefore separated by the long head of the triceps from the subscapular artery. It winds round the humerus, and terminates by ramifying in the deltoid muscle and on the shoulder-joint, and by anastomosing with the anterior circumflex and suprascapular arteries, as well as with the acromio-thoracic.

7. The **anterior circumflex** artery, much smaller than the posterior circumflex, arises nearly opposite to it or lower down, and from the outer side of the axillary artery. It passes from within outwards and forwards, under the inner head of the biceps and the coraco-brachialis muscle, resting on the fore part of the humerus, until it reaches the bicipital groove. There it divides into two branches, one of which ascends in the groove with the long head of the biceps, to the head of the bone and the capsule of the joint; the other continues outwards, and anastomoses with the posterior circumflex branch.

**Varieties.**—The most important variety in the trunk of the axillary artery consists in its giving off a much larger branch than usual,—an arrangement which has been observed in the proportion of one out of every ten cases. In one set of cases, this large branch is continued as one of the arteries of the fore-arm; most frequently the radial (about one in 33), sometimes the ulnar (1 in 72), and, rarely, the interosseous artery (1 in 506: R. Quain). In another set of cases, the large branch gives origin to the subscapular, the two circumflex, and the two profunda arteries of the arm; but sometimes only one of the circumflex, or only one of the deep humeral arteries, arises from it. In the second class of cases the divisions of the brachial plexus of nerves surround the common trunk of the branches instead of the main vessel. This disposition may with probability be explained by supposing that the trunk of the branches was originally the brachial artery, but that in early life it had become obstructed below, and that there had become developed in its place, as an apparent brachial artery for the supply of the lower portions of the limb, a vas aberrans, such as is sometimes seen arising from the brachial artery, and uniting with one of its branches.

The superior thoracic artery is so frequently given off by the acromio-thoracic, that some anatomists have described that as the normal arrangement, giving the common trunk the name of *thoracic axis*. The long thoracic artery often rises from the acromio-thoracic, or is replaced by enlargement of the normal branches of that artery, and not unfrequently is given off by the subscapular.

The dorsalis scapulae sometimes springs directly from the axillary artery.

The posterior circumflex artery is sometimes removed from the axillary to the superior profunda branch of the brachial, in which case it ascends behind the tendons of the latissimus dorsi and teres major. In another class of cases not quite so numerous, the posterior circumflex gives off one or more branches usually derived from other sources: as for example (placing them in the order of frequency), the anterior circumflex, the superior profunda, the dorsal scapular,



the anterior circumflex and superior profunda together, or some other rarer combination of those vessels. The posterior circumflex is sometimes double; and so is the anterior, but more seldom.

#### SURGICAL ANATOMY OF THE AXILLARY ARTERY.

This artery is usually tied in the third part of its course. The limb having been carried away from the chest, an incision three inches long is made about midway between the folds of the axilla and in the direction of the axis of the limb. On cutting through the deep fascia, the vein, artery and brachial nerves are exposed. The vein is internal, and the artery is partly surrounded by the nerves. The ligature is passed from within outwards. In the rest of its course the artery is so deeply placed and in such close relations with the vein and nerves that an operation on the third part of the subclavian is both easier and more successful.

#### BRACHIAL ARTERY.

The brachial or humeral artery, the continuation of the axillary,

Fig. 261.

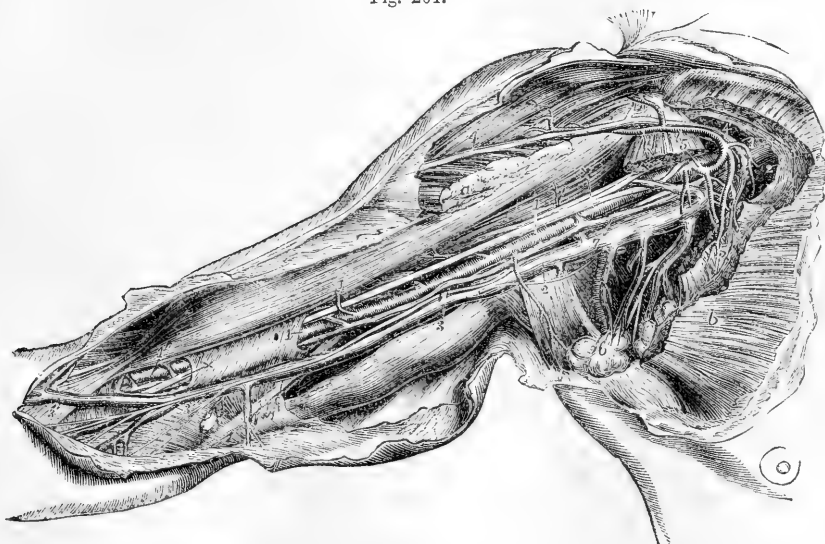

Fig. 261.—DISSECTION OF THE AXILLA AND INSIDE OF THE ARM TO SHOW THE AXILLARY AND BRACHIAL VESSELS (from R. Quain)  $\frac{1}{4}$

The greater and lesser pectoral muscles have been divided so as to expose the axillary vessels: *a*, the inserted portion of the pectoralis major; *b*, the pectoral portion; 1, 1, axillary artery; +, +, the median nerve formed by the two portions of the plexus which surround the artery; 1', placed on a part of the sheath of the brachial vessels, and 1'', on the lower part of the biceps muscle, points to the brachial artery surrounded by its venæ comites; 2, 2, axillary vein; 3, 3, the basilic vein; the upper figure is placed on the triceps muscle, the lower on the fascia near the junction of the ulnar vein: on the basilic vein are seen the ramifications of the internal cutaneous nerve; 4, on the deltoid, and 4', near the clavicular part of the great pectoral muscle, mark the cephalic vein joining the acromio-thoracic and through it the axillary vein; 5, 5, placed on the divided portions of the pectoralis minor, point to the origin and branches of the acromio-thoracic artery; 6, placed on a group of axillary glands, indicates the alar thoracic and subscapular vessels; 7, placed on the trunk of the axillary vein, points to one of the venæ comites of the brachial vein, which being joined by the other higher up passes into the axillary vein; the ulnar nerve is seen passing from below the basilic vein towards the inner condyle; near 1, placed on the coraco-brachialis muscle, is seen the musculo-cutaneous nerve before it passes through that muscle; near 2, placed on the tendon of the latissimus dorsi muscle, a portion of the nerve of Wrisberg.

extends from the lower border of the posterior fold of the axilla, to about a finger's breadth below the bend of the elbow, or to a point opposite the neck of the radius, where it divides into the radial and ulnar arteries. The vessel gradually inclines from the inner side to the fore part of the limb, lying in the depression along the inner border of the coraco-brachialis and biceps muscles; and its direction may be marked out by a line drawn from midway between the folds of the axilla to the middle point between the condyles of the humerus. To command the flow of blood through the artery at its upper part, pressure should be directed outwards, while over the lower end of the vessel the pressure should be made from before backwards.

The brachial artery lies beneath the integument and fascia of the arm as far as the bend of the elbow, where it sinks deeply in the interval between the pronator teres and supinator longus muscles, and is covered by the semilunar fascia, a fibrous expansion given from the tendon of the biceps to the fascia of the forearm. It rests at first on the long head of the triceps muscle, the musculo-spiral nerve, and the superior profunda artery intervening; it then inclines forwards over the insertion of the coraco-brachialis muscle, and lies thence to its termination on the brachialis anticus. At its outer side it is in apposition first with the coraco-brachialis, and afterwards and for the greater part of its length with the biceps, the inner border of one or both muscles sometimes slightly overlapping it.

Fig. 262.

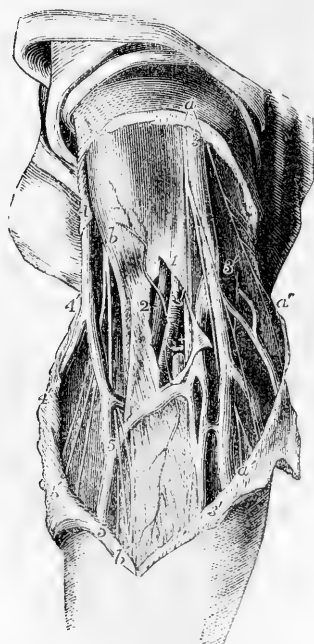

Fig. 262.—SUPERFICIAL DISSECTION OF THE BLOOD-VESSELS AND NERVES AT THE BEND OF THE ARM (from R. Quain).

*a*, two branches of the internal cutaneous nerve; *a' a''*, the descending twigs of the same nerve; *b*, placed over the biceps near its insertion and close to the external cutaneous nerve; *b'*, anterior twigs of the same nerve accompanying the median vein; *1*, placed on the fascia of the arm near the bend of the arm, above the place where it has been opened to show the lower part of the brachial artery with its venæ comites, of which one is entire, marked *2*, and the other has been divided; *+*, is placed between the artery and the median nerve; *3*, basilic vein; *3'*, *3''*, ulnar veins; *4*, cephalic vein; *4'*, radial vein; *5*, *5'*, median vein; *3', 5'*, median basilic vein; *4', 5'*, median cephalic vein.

*Relation to Veins.*—Venæ comites are in close contact with the brachial artery, short transverse branches of communication passing from one to another, so as at many points to encircle it. Superficial to the aponeurosis, the basilic vein is placed over or to the inner side of the artery in the lower half or more, or in the whole length of its course, according the level at which the vein dips down to join the venæ comites; and at the bend of the elbow the median basilic vein crosses over the artery, the aponeurotic insertion of the biceps lying between them.

*Relation to Nerves.*—The median nerve descends in contact with the artery, lying on its outer side at the axilla, directly in front of it below the middle of the arm, and on the inner side at the elbow. Of the other large branches of the brachial plexus which are closely connected with the axillary artery, none continue in the immediate neighbourhood of the brachial artery along the arm. The external cutaneous and circumflex separate at once from the vessel in the axilla, the musculo-spiral soon turns backwards in the musculo-spiral groove, and the internal cutaneous and ulnar nerves descend vertically on the inner side of the limb.

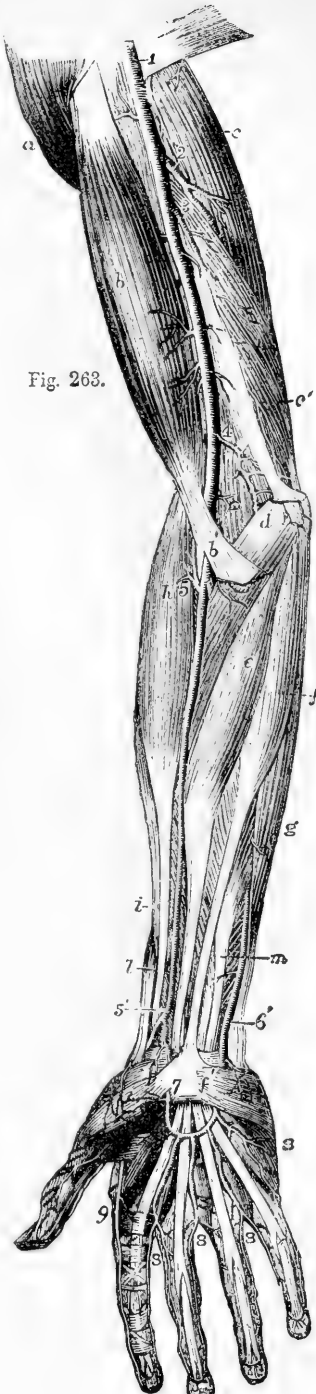

Fig. 263.

Fig. 263.—SUPERFICIAL VIEW OF THE ARTERIES OF THE FRONT OF THE FORE-ARM, AND HAND (from Tiedemann).  $\frac{1}{4}$

a, deltoid muscle ; b, biceps ; b', its semilunar fascia ; c, scapular head of the triceps ; c', its internal head ; d, pronator radii teres ; e, flexor carpi radialis ; f, palmaris longus ; f', its tendon spreading in the upper part of the palmar fascia, from which, on the inner side, the palmaris brevis muscle is seen rising ; g, flexor carpi ulnaris ; h, supinator radii longus ; i, extensor carpi radialis longior ; l, extensor ossis metacarpi pollicis ; m, flexor digitorum sublimis ; 1, placed on the tendon of the latissimus dorsi, the lower part of the axillary artery, continued into the brachial ; 2, superior profunda ; 3, inferior profunda ; 4, anastomotic ; 5, near the division of the brachial artery into ulnar and radial, points to the origin of the recurrent radial artery ; 5', lower part of the radial artery, where it gives off the superficialis volæ, and turns round the wrist ; 6', the lower part of the ulnar artery, near the place where it passes down to form the superficial palmar arch ; 7, the superficialis volæ, which joins it ; 8, 8, 8, 8, first, second, third, and fourth digital branches of the superficial arch to the inside of the little finger, adjacent sides of the 4th and 5th, 3rd and 4th, and 2nd and 3rd fingers ; 9, radialis indicis ; on the thumb are seen the two branches of the princeps pollicis artery.

*BRANCHES.*—The brachial artery gives some small *muscular* branches, which are directed outwards and backwards to the coraco-brachialis, biceps, and brachialis anticus ; and the following larger branches which incline inwards :—

(a) The **superior profunda** artery arises from the inner and back part of the brachial, just below the border of the *teres major*, and inclines inwards and backwards, to reach the interval between the outer and inner heads of the *triceps* muscle. Accompanied by the musculo-spiral nerve, it winds round the back of the humerus, in the spiral groove, under cover of the *triceps*, and perforating the external intermuscular septum, reaches the external and anterior aspect of the bone. There the artery lies deeply in the interval between the *brachialis anticus* and *supinator longus* muscles, considerably diminished in size by having given off several branches, and descends to the elbow, where it anastomoses with the recurrent branch of the radial artery.

*Branches.*—The superior profunda gives off branches in its first part to the deltoid, coraco-brachialis, and *triceps*; and many to the last-named muscle, whilst it is between it and the bone. In this position it also gives one long branch, which descends perpendicularly between the muscle and the bone to the back part of the elbow-joint on the outer side, where it anastomoses with the interosseous recurrent branch; and another which anastomoses on the inner side with the ulnar recurrent and the anastomotic or the inferior profunda.

(b) The **inferior profunda** artery of small size, arises from the brachial artery a little below the middle of the arm, and is directed to the back part of the inner condyle of the humerus. Descending in company with the ulnar nerve, it pierces the intermuscular septum, then lies on the inner surface of the *triceps* muscle, to which it gives branches, and entering the interval between the olecranon and inner condyle, it terminates by inosculating with the posterior recurrent branch of the ulnar artery, and with the anastomotic branch of the brachial.

(c) The **nutrient** artery of the shaft of the humerus is a small branch given off by the brachial about the middle of the arm, or by one of its collateral branches. It inclines downwards, enters the oblique canal in the humerus near the insertion of the coraco-brachialis muscle, and is distributed in the interior of the bone.

(d) The **anastomotic** artery is a very constant branch of moderate size. Arising from the brachial artery about two inches above the bend of the arm, it is directed transversely inwards on the *brachialis anticus* muscle, above the inner condyle of the humerus, and, after perforating the intermuscular septum, turns outwards behind the humerus, between the bone and the *triceps* muscle, and forms with the superior profunda an arch across the humerus, immediately above the olecranon fossa (*arcus dorsalis humeri posticus*,—Haller). In front of the humerus the anastomotic artery furnishes a branch which ramifies in the *pronator teres*, and anastomoses with the anterior ulnar recurrent branch. Behind the inner condyle another offset joins with the posterior ulnar recurrent, and behind the humerus several branches are given to the joint and the muscle.

*Varieties.*—From their comparative frequency, and surgical interest, the peculiarities of the brachial artery, especially those which affect its trunk, deserve particular attention.

*Course.*—The brachial artery sometimes lies in front of the median nerve, instead of behind it.

The brachial artery has been seen, though rarely, to descend, accompanied by the median nerve, towards the inner condyle of the humerus, and regain its usual position at the bend of the elbow by passing forwards underneath a fibrous

arch, from which the pronator teres in those cases arises, and which descends to the inner condyle from the occasional prominence called the supra-condylar

Fig. 264.—DISSECTION OF THE RIGHT ARM, SHOWING AN EXAMPLE OF HIGH SEPARATION OF THE RADIAL ARTERY FROM THE BRACHIAL, AND AN ENLARGED MEDIAN ARTERY IN THE FORE-ARM (from Tiedemann).  $\frac{1}{4}$

1, on the tendon of the latissimus dorsi, points to the upper part of the brachial artery; 2, the brachial artery after giving off the radial; 3, the radial rising in the upper third of the arm and descending in its usual situation in the fore-arm; 3', its superficial volar branch; 4, the ulnar artery in its usual course, forming at 5, the superficial palmar arch, from which three of the palmar digital arteries and the princeps pollicis take origin; the radial supplying the branches to the index finger and one side of the middle finger; 6, the superior profunda branch of the brachial artery; 7, muscular branches; 8, anastomotic; 9, recurrent radial; 10, anterior interosseous giving an unusually large median branch which descends over the wrist to unite with the superficial palmar arch.

process. Sometimes this disposition occurs without the development of any bony prominence.

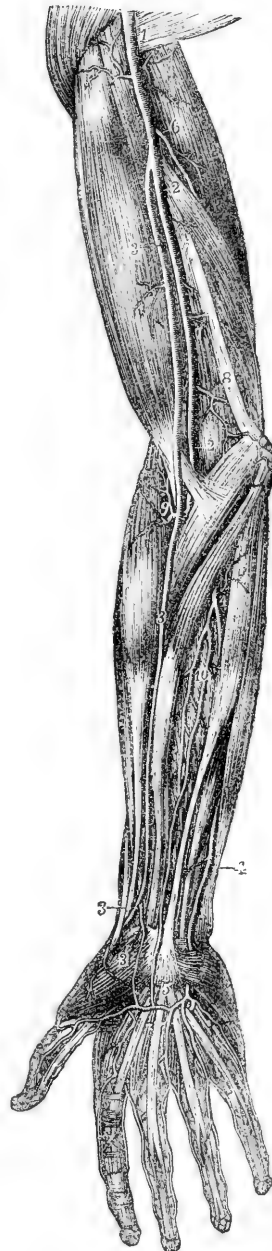As an extremely rare condition, the artery has been found divided into two vessels near its commencement, the artery being single above and below.

In a very few cases the three arteries of the fore arm, radial, ulnar, and interosseous, have arisen together from the end of the brachial trunk, at the usual distance below the elbow.

*High division.*—The most frequent change from the ordinary arrangement of the brachial artery is connected with its division into terminal branches.

Out of 481 examples recorded by Richard Quain from observations made, some on the right and some on the left side of the body, the vessel was found in 386 to divide at its usual position, a little below the elbow-joint. In one case only (and that complicated by another peculiarity, viz., the existence of a *vas aberrans* proceeding from the axillary to the radial), was the place of division lower than usual, being between two and three inches lower than the elbow-joint. In 64 cases the brachial artery divided *above* the usual point, at various heights upwards to the lower border of the axilla. The branch prematurely separated from the rest of the trunk in an early division, is, in the proportion of nearly three cases out of four,

Fig. 264.



the radial artery; sometimes the ulnar is the branch given off; that is to say, a branch corresponding to the ulnar in its distribution below the middle of the fore-arm separates from a trunk which afterwards divides into the normal radial artery and the interosseous of the fore-arm, which last is normally derived from the ulnar artery. Rarely the interosseous of the fore-arm, or a *vas aberrans*, is the branch given off. In one instance found in the dissecting room of Glasgow University, the posterior interosseous artery of the fore-arm was thus given off.

In all cases of the high origin of one or other of the arteries of the fore-arm, the extent in which the two vessels thus formed run separately must vary according to the height at which the main artery divides. The point of division in the entire number of cases, without reference to the particular branch given off, is most frequently in the upper, less so in the lower, and least so in the middle third of the arm. But the early division of the main artery of the upper limb may, as mentioned in connection with the varieties of the axillary artery, take place within the axilla, in which case it follows that the brachial portion of the vessel is replaced, throughout its whole extent, by two separate trunks. In 94 cases out of 481 observed by R. Quain, or about one in five, there were two arteries instead of one in some part of the arm.

*The position of the two arteries*, in these cases, is also of much surgical interest. Usually they are close together, and occupy the ordinary position of the brachial artery; but it has been noticed that the *radial* artery, when thus given off in the arm, often arises from the inner side of the brachial, then runs parallel with the larger vessel (the brachial or ulnar-interosseous), and crosses over it, sometimes suddenly, opposite the bend of the elbow, still covered by the fascia. It has also been found, in a considerable number of instances, to perforate the fascia, and run immediately under the skin, near the bend of the elbow.

When the *ulnar* is the branch given off high from the brachial, it often inclines from the position of the brachial, at the lower part of the arm, towards the inner condyle of the humerus. This vessel generally lies beneath the fascia as it descends, and superficial to the flexor muscles. It is occasionally placed between the integuments and the fascia; and in a single instance was found beneath the muscles. In one instance occurring in the dissecting-room of the Glasgow University, the ulnar artery given off from the humeral at the middle of the arm was observed to descend superficially behind the inner condyle.

The *interosseous*, after arising from the axillary or brachial artery, is commonly situated behind the main artery, and, on reaching the bend of the elbow, passes deeply between the muscles, to assume its usual position in the fore-arm.

Lastly, when the radial has arisen high in the arm, the residuary portion of the brachial (*ulnar-interosseous*) has occasionally been observed descending, accompanied by the median nerve, along the intermuscular septum towards the inner condyle of the humerus, as far as the origin of the pronator teres (which in the case recorded was found broader than usual), whence it turned forwards under cover of the muscle, to gain the usual position at the middle of the bend of the elbow.

The two arteries taking the place of the brachial are in some instances connected near the bend of the arm by an intervening trunk, which proceeds from the larger (or ulnar-interosseous) artery to the radial or the radial recurrent, and varies somewhat in its size, form, and course. More rarely the two unusual arteries are actually *re-united*.

The *aberrant arteries*, "*vasa aberrantia*," alluded to above, are long slender vessels, which arise either from the brachial or the axillary artery, and end by joining one of the arteries of the fore-arm, or one of their branches. In eight cases out of nine, observed by Quain, this unusual vessel joined the radial; in the remaining case it joined the radial recurrent, which arose irregularly from the ulnar artery. Very rarely the aberrant vessel joins the ulnar. This peculiarity may be regarded, perhaps, as an approach to that condition in which there is division of the brachial artery and subsequent connection of its two parts by an intervening branch.

In most cases of the high division of the brachial arteries the condition of the

vessels is not the same in the right and left arms. In 61 bodies in which the high division existed, it occurred only on one side in 43; on both sides, in different positions, in 13; and on both sides, in the same position, in the remaining 5.

Fig. 265.—ABERRANT ARTERY, SEPARATING FROM THE BRACHIAL AT THE MIDDLE OF THE ARM, PASSING WITH THE MEDIAN NERVE THROUGH THE INTERNAL INTERMUSCULAR SEPTUM, AND JOINING FARTHER DOWN THE REGULAR ULNAR (from R. Quain).  $\frac{1}{4}$

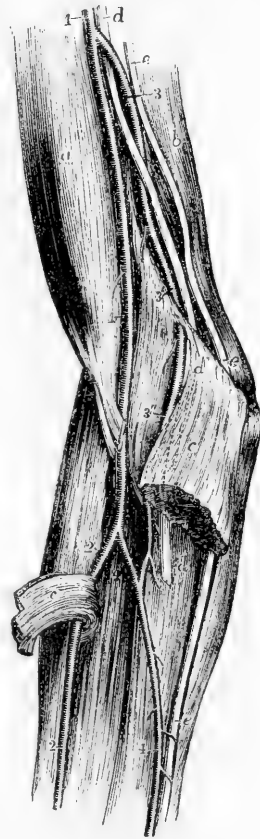*a*, biceps muscle; *b*, triceps; *c*, *c*, divided pronator teres; *d*, *d*, *d'*, median nerve, diverted from its usual course, and passing with the aberrant artery through the internal intermuscular septum; *e*, *e*, *e*, ulnar nerve in its usual course; 1, brachial artery, giving off an aberrant artery at the middle of the arm; 2, the usual radial artery; 3, aberrant artery, with the median nerve twining round it, passing at 3', through the internal intermuscular septum; 3'', the same farther down, and communicating at 4' with the first part of the normal ulnar artery, 4, given off from the brachial.

*Branches.*—It has been already mentioned that the *superior profunda* may give origin to the posterior circumflex artery, and that its own origin is sometimes transferred to a branch arising from the axillary artery.

The *inferior profunda* is likewise occasionally absent, and on that account has not been recognised by some anatomists as a regular branch of the brachial artery.

The *anastomotic* artery is sometimes much reduced in size, and in that case the *inferior profunda* takes its place behind the humerus.

Fig. 265.



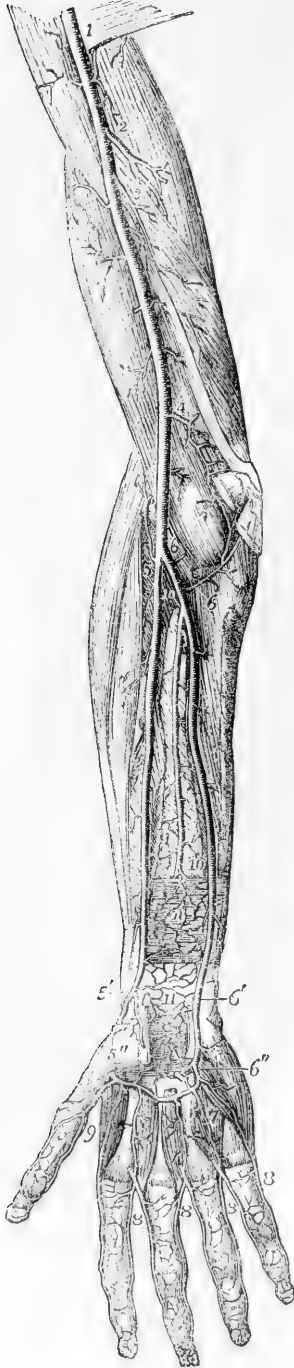#### SURGICAL ANATOMY OF THE BRACHIAL ARTERY.

The brachial artery may be easily reached for the application of a ligature in any part of its course. In the middle third of the arm its position on the inside of the biceps muscle, where its pulsation may be felt, is a sufficient guide for the incision. From the thinness of the parts covering the artery, however, and the proximity of superficial veins, especially the basilic, the integuments and fascia must be divided with caution. When the fascia has been cut through the median nerve generally comes into view, as it lies in front of the artery. Occasionally it is found necessary to divide some muscular fibres before the artery is reached.

In the lower third of the arm, the median nerve being placed to the inner side, the artery is more fully exposed after division of the fascia, but here care is necessary in passing the ligature round the artery, to avoid the *venæ comites* or their communicating cross branches, which cling very closely to the artery.

From the very frequent occurrence of varieties in the mode of division of the brachial artery into the vessels derived from it, the surgeon must be prepared for many deviations from the usual position of the parts, and especially for the presence of two arteries in place of one in the lower third of the brachial region. In such cases the two arteries are most frequently close together and nearly parallel, and it will be easy to tie both vessels, should this be rendered necessary by the nature of the injury for which the operation is performed. But, as will be seen from what has previously been said of the abnormal forms of the brachial artery,

Fig. 266.



the position of one or both the vessels may be subject to very considerable variation in different instances; and in some of these, while one of the vessels is near the usual position, the other may be at some distance, as for example when it is bound down to the inner condylar line of the humerus.

Fig. 266.—DEEP ANTERIOR VIEW OF THE ARTERIES OF THE ARM, FORE-ARM, AND HAND (from Tiedemann). 4

The biceps brachii, the pronator teres and muscles rising from the inner condyle, the supinator longus, the lower part of the flexor longus pollicis and flexor profundus digitorum, the anterior annular ligament of the carpus and the muscles of the ball of the thumb, have been removed; *n*, pronator quadratus muscle; 1, lower part of the axillary artery continued into the brachial; 2, superior profunda branch; 3, inferior profunda; 4, anastomotic; 5, upper part of the radial artery and radial recurrent; 5', lower part of the radial artery giving off the superficialis volæ branch; 5'', the radial artery emerging from between the heads of the abductor indicis muscle; 6, 6, the upper part of the ulnar artery with the anterior and posterior ulnar recurrent branches; 6', the ulnar artery approaching the wrist and descending into the superficial palmar arch which has been cut short; 6'', the deep branch of the ulnar artery uniting with the deep palmar arch; 7 (marked only on one), three interosseous branches from the deep palmar arch joining the palmar digital arteries 8, 8, 8, which have been cut away from their origin from the superficial arch to near their division into the collateral digital arteries; the ulnar collateral of the little finger is represented as rising in this instance from the deep ulnar artery; 9, placed between the princeps pollicis and radialis indicis branches of the radial artery; 10, lower part of the anterior interosseous artery passing behind the pronator quadratus muscle; 11, anastomosis of the anterior carpal branches of the radial and ulnar arteries with recurrent branches from the deep palmar arch.

At the bend of the arm the brachial artery is exposed to the risk of injury from the operation of venesection, for which the median basilic vein is most commonly selected. This vein lies often exactly in front of the artery, the semilunar fascia being stretched between them. Instances are on record in which the artery has been wounded by the lancet transfixing the vein and fascia, and a communication has thus been established between the vein and artery. On this account the incision into the vein must be made with due care, and indeed the median cephalic, if of sufficient size, may be selected for venesection.



## ULNAR ARTERY.

The ulnar artery, the larger of the two vessels into which the brachial divides, extends along the inner side of the fore-arm into the palm of the hand, where, joining a branch of the radial, opposite the muscles of the thumb, it forms the superficial palmar arch. In this course it inclines at first downwards and inwards, describing a slight curve, the convexity of which is directed inwards, and passes under cover of the superficial muscles arising from the inner condyle of the humerus, viz., the pronator teres, flexor carpi radialis, palmaris longus, and flexor sublimis, until it reaches the flexor carpi ulnaris near the junction of the upper with the middle third of the fore-arm; at this point the artery comes into contact with the ulnar nerve, which was previously separated from it by a considerable interval, and changing its direction, descends vertically with the nerve towards the inner border of the palm of the hand. Descending along the radial border of the tendon of the flexor ulnaris muscle, the ulnar artery reaches the outer or radial side of the pisiform bone, where, still accompanied by the nerve, it passes over the cutaneous surface of the anterior annular ligament of the wrist into the palm of the hand. Its disposition in the hand will be separately described.

In the first half of its course through the fore-arm, the artery is deep seated, being covered by the muscles arising from the inner condyle of the humerus which have been already enumerated. About the middle of the fore-arm it is overlapped by the fleshy part of the flexor carpi ulnaris; but below that, it becomes more superficial, being overlaid by the tendon of the muscle, and covered by the skin, the fascia of the fore-arm, and a thin layer of membrane by which the vessel is bound down to the muscle beneath. At first the ulnar artery lies on the insertion of the brachialis anticus into the coronoid process of the ulna; then on the flexor profundus in the rest of the fore-arm, and lastly, on the annular ligament of the carpus. Below the point at which it emerges from under the flexor carpi ulnaris (or a little below the middle of the fore-arm), the tendon of that muscle is on its inner or ulnar side.

*Relation to Nerves.*—The *median nerve* lies immediately on the inner side of the ulnar artery at its origin, but being directed down the middle of the fore-arm it soon passes over the vessel, separated from it at the point of crossing by the deep head of the pronator teres muscle. As the *ulnar nerve* descends behind the inner condyle of the humerus, it is removed from the ulnar artery by a considerable interval at the upper part of the fore-arm; but as the vessel inclines inwards, it approaches the nerve, and is accompanied by it in the lower half of its course—the nerve lying close to its inner side. A small branch of the ulnar nerve descends upon the lower part of the vessel.

*Relation to Veins.*—Two veins (*venæ comites*) accompany the ulnar artery, and are frequently united by branches crossing it.

**BRANCHES.**—The ulnar artery gives off in the fore-arm the anterior and posterior recurrent, the interosseous, and several muscular branches. At the wrist it gives off the anterior and posterior carpal branches.

The **anterior ulnar recurrent** artery, a small branch, arches inwards and upwards from the upper part of the ulnar artery, in front of the inner condyle, running on the brachialis anticus muscle, and covered by

the pronator teres, both of which muscles it partly supplies. On reaching the front of the condyle, it anastomoses with the inferior profunda and anastomotic branches of the brachial.

The **posterior ulnar recurrent** artery, larger than the preceding, comes off lower down; but not unfrequently the two vessels arise by a short common trunk. The posterior recurrent runs inwards and backwards beneath the flexor sublimis, and then ascends behind the inner condyle. In the interval between that process and the olecranon it lies beneath the flexor carpi ulnaris, and passing between the heads of that muscle along the ulnar nerve, supplies branches to the muscles, to the elbow joint, and to the nerve itself. This branch communicates with the inferior profunda, the anastomotic, and, over the olecranon, likewise with the interosseous recurrent.

Fig. 267.

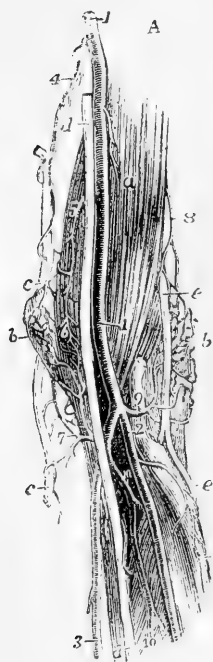


Fig. 267.—VIEW OF THE ANASTOMOSES OF ARTERIES NEAR THE ELBOW-JOINT: A, FROM BEFORE; B, FROM BEHIND (from R. Quain).  $\frac{1}{4}$

A. *a*, brachialis anticus muscle; *b*, external condylar eminence covered by the supinator radii brevis and the anastomoses of the superior profunda and radial recurrent arteries; *c*, ulnar nerve; *d*, median nerve; *e*, musculo-spiral nerve; *f*, its posterior interosseous branch; its radial branch is cut short; *g*, oblique line of the radius; 1, brachial artery; 2, radial artery; 3, ulnar artery; 4, inferior profunda; 5, anastomotic; 6, anterior ulnar recurrent anastomosing with the anterior descending branches of the anastomotic; 7, posterior ulnar recurrent passing up behind the inner condylar eminence to anastomose with the inferior profunda and posterior branch of the anastomotic; 8, spiral branch of the superior profunda; 9, placed on the tendon of the biceps muscle, points to the radial recurrent artery; 10, 10, interosseous artery and its anterior branch.

B. *a*, a part of the brachialis anticus muscle; *b*, external lateral ligament of the elbow-joint; *c*, ulnar nerve; *d*, a small part of the musculo-spiral nerve; 1, superior profunda artery; 2, its branch to the triceps muscle; 3, its spiral branch to the outer condyle; 4, its anastomosis with the recurrent radial artery; 5, recurrent of the posterior interosseous artery, passing up to anastomose with the preceding and with the anastomotic, behind the joint; 6, inferior profunda; 7, posterior branch of the anastomotic artery; 8, anastomosis of the anastomotic and inferior profunda with the superior profunda and the posterior interosseous recurrent; 9, posterior ulnar recurrent artery passing up in the groove of the ulnar nerve to anastomose with the inferior profunda and anastomotic.

The **interosseous** or **common interosseous** artery, the next, and the largest branch of the ulnar, is a trunk of considerable size, about

an inch in length, which arises below the bicipital tuberosity of the radius, beneath the flexor sublimis, and passes backwards to reach the upper border of the interosseous ligament, where it divides into the *anterior* and *posterior* interosseous arteries.

The *anterior interosseous* descends upon the anterior surface of the interosseous ligament, accompanied by the interosseous branch of the median nerve and venæ comites, and overlapped by the contiguous borders of the flexor profundus digitorum and flexor longus pollicis muscles. It continues its course directly downwards as far as the upper border of the pronator quadratus muscle, then pierces the interosseous ligament, and descends to the back of the carpus.

The anterior interosseous artery gives off the following branches :—

(a) The artery of the median nerve, or the *median artery*, a long slender branch, which accompanies the median nerve and sends offsets into its substance. This artery is sometimes much enlarged, and in that case it presents several peculiarities to be hereafter noticed.

(b) *Muscular* branches to the flexor profundus, flexor longus pollicis, and pronator quadratus muscles.

(c) The *nutrient* arteries of the shafts of the radius and ulna, which diverging from one another, enter the oblique foramina in those bones to be distributed to the medullary membrane in their interior.

(d) An *anterior inosculating* branch, given off before the artery pierces the interosseous membrane, and descending beneath the pronator quadratus muscle to anastomose with the anterior carpal arteries.

(e) *Terminal* twigs inosculating with the posterior carpal arteries.

The *posterior interosseous* artery passes backwards through the interval left between the oblique ligament and the upper border of the interosseous ligament, and continuing its course downwards along the fore-arm, between the superficial and deep layers of extensor muscles, gives branches to them, and reaches the carpus considerably diminished in size.

In addition to muscular branches, it gives off the following :—

(a) The *posterior interosseous recurrent*, which passes directly upwards, covered by the anconeus, to reach the interval between the olecranon and external condyle; at which place it divides into several offsets which anastomose with the superior profunda and the posterior ulnar recurrent.

(b) *Terminal* branches, which anastomose with the posterior or terminal branch of the anterior interosseous artery, and with the carpal branches of the radial and ulnar arteries.

**Muscular Branches** of the ulnar artery are distributed to the muscles in the course of the vessel along the fore-arm : some of these perforate the interosseous ligament to reach the extensor muscles.

The **posterior ulnar carpal** branch, of variable size, arises a little above the pisiform bone, and winding back under the tendon of the flexor carpi ulnaris, reaches the dorsal surface of the carpus beneath the extensor tendons.

Its branches are the following :—

(a) A branch anastomoses with the posterior carpal artery derived from the radial, so as to form the *posterior carpal arch*, and from this arch are derived the *second* and *third dorsal interosseous arteries*, which descend on the spaces between the third and fourth and the fourth and fifth metacarpal bones, and are reinforced at the upper ends of those spaces by anastomoses with the posterior perforating branches of the deep palmar arch.

(b) A branch runs along the metacarpal bone of the little finger. Sometimes.

this *metacarpal branch* arises as a separate vessel, the posterior carpal being then very small.

Fig. 268.

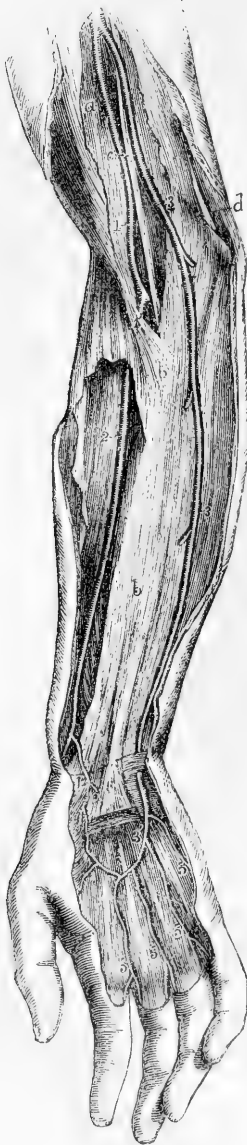

Fig. 268.—ABNORMAL SUPERFICIAL ULNAR ARTERY RISING HIGHER THAN USUAL FROM THE BRACHIAL (from R. Quain, and from a preparation in Allen Thomson's collection). †

*a*, biceps muscle covered by the deep brachial fascia; *b*, the same fascia in the fore-arm, which has been opened in a considerable extent to show the radial artery subjacent to it; *c*, median nerve; *d*, ulnar nerve; 1 on the biceps muscle, points to the brachial artery after having given off an ulnar artery higher up, and dividing at 1', into the radial artery and a deep vessel corresponding to the interosseous and a part of the usual ulnar; 2, on the supinator longus muscle, points to the radial artery; 3, 3, artery which is given off by the brachial in the arm, and which descending upon the fascia takes the place of the ulna at the wrist; 3', the same continued into the superficial palmar arch, giving off digital branches nearly in the usual manner, and joined by a branch from the radial, 4, the superficial volar; 5, digital branches.

The **anterior ulnar carpal branch** is a very small artery, which runs on the anterior surface of the carpus beneath the flexor profundus, anastomoses with a similar offset from the radial artery, and supplies the carpal bones and articulations.

**Varieties.**—*Origin.*—In the whole number of cases observed by Richard Quain, the ulnar artery was found to deviate from its usual mode of *origin*, nearly in the proportion of one in thirteen. The brachial artery was, more frequently than the axillary, the source from which it sprang; indeed, the examples of its origin from the main trunk at different parts appeared to decrease in number in proportion as the place of origin was higher up the artery. In one case of high origin of the ulnar artery the vessel was connected with the brachial opposite the elbow-joint by means of a transverse branch (Gruber, Reich. Arch., 1871). See, on this subject, the description of the varieties of the axillary and brachial arteries.

*Course.*—The *position* of the ulnar artery in the fore-arm is more frequently altered than that of the radial.

In cases of high origin, it almost invariably descends over the muscles arising from the inner condyle of the humerus, only one exception to this rule having been met with. (R. Quain, plate 36, fig. 2.) In one instance where it took this course it divided just below the elbow into a superficial and deep branch (Gruber, loc. cit.).

Most commonly it is covered by the fascia of the fore-arm; but cases also occur in which the vessel rests on the fascia, and either continues in that position or becomes subaponeurotic lower down, while the vessel thus disposed is distributed after the manner of the normal ulnar artery. The vessel from which

the high ulnar separates is afterwards divided into the radial artery and the interosseous, the last of which is usually derived from the ulnar; it appears therefore probable that the abnormal arrangement results from early obstruction of the ulnar artery below the origin of the interosseous, and the development of a superficial vas aberrans, which unites the portion of vessel below the obstruction with the axillary or brachial trunk. The interosseous artery in such cases of abnormality thus comprises not only the ordinary interosseous branch, but likewise the portion of ulnar artery above the obstruction; and, in accordance with this view, we find that the recurrent branches are derived from it.

As to *size*, the ulnar artery presents some peculiarities which, being accompanied by deviations of an opposite and compensating character in the radial artery, will be noticed with that vessel.

*Branches.*—The *anterior and posterior ulnar recurrent branches* frequently arise by a common trunk. One or both have been seen to arise from the brachial artery.

The *anterior and posterior interosseous* arteries are occasionally given separately from the ulnar. The common interosseous trunk has been found to arise above its ordinary situation, taking origin from the brachial, and even (but more rarely) from the axillary artery. The anterior interosseous presents some striking varieties of excess in its branches, usually connected with a deficiency in the radial or ulnar arteries: the most important of these is enlargement of the median branch.

*Median artery.*—The branch accompanying the median nerve is sometimes much enlarged, and in such cases may be regarded as a reinforcing vessel. It is generally a branch of the anterior interosseous, but sometimes of the ulnar; and more rarely a median branch has been met with descending from the brachial artery. Accompanying the median nerve beneath the annular ligament into the palm of the hand, the median artery ends most frequently by joining the superficial palmar arch, sometimes by forming digital branches. In other cases by joining digital branches given from other sources.

#### SUPERFICIAL PALMAR ARCH.

The superficial palmar arch or artery is the continuation of the ulnar artery into the hand. Changing its course near the lower border of the annular ligament, this artery turns obliquely outwards across the palm of the hand towards the middle of the museles of the thumb, where it terminates by inosculating with the superficial volar branch of the radial artery. In its course across the hand, the palmar artery describes a curve, having its convexity directed towards the fingers, and extending downwards somewhat lower than a line on a level with the phalangeal articulation of the thumb.

The superficial palmar artery rests at its commencement on the annular ligament of the wrist, and slightly on the short muscles of the little finger; then on the tendons of the superficial flexor of the fingers, and the divisions of the median and ulnar nerves, the latter nerve accompanying the vessel for a short distance. It is covered towards the ulnar border of the hand by the palmaris brevis, and afterwards by the palmar fascia and the integument.

*BRANCHES.*—The branches given off by the superficial palmar arch, which are generally numerous, are as follow.

(a) The **deep or communicating** branch arises from the ulnar artery at the commencement of the palmar arch a little beyond the pisiform bone, sinks deeply between the flexor brevis and the abductor of the little finger, and inosculates with the palmar termination of the radial artery, thereby completing the deep palmar arch.

(b) Small **recurrent** branches, following a retrograde course towards

the annular ligament, are given off from the upper or concave side of the palmar arch.

(c) The **digital** branches, usually four in number, proceed downwards from the convexity of the palmar arch to supply both sides of the three inner fingers, and the ulnar side of the fore finger. The *first digital* branch inclines inwards to the ulnar border of the hand, and, after giving minute offsets to the muscles of the little finger, runs along the inner margin of its phalanges. The *second* runs along the fourth metacarpal space, and at the root of the fingers divides into two branches, which proceed along the contiguous borders of the ring and little fingers. The *third* is similarly distributed to the ring and middle fingers; and the *fourth* to the latter and the index fingers. The thumb and the radial side of the index finger are supplied from the radial artery.

Fig. 269.

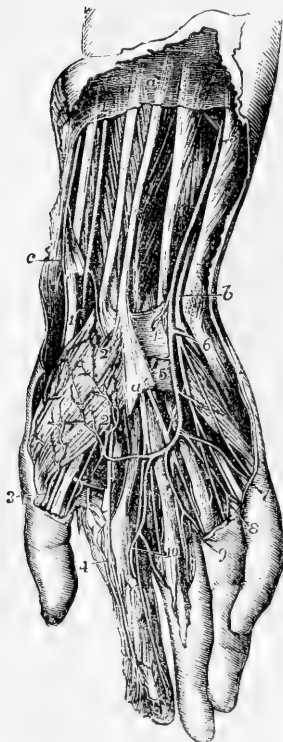


Fig. 269.—SUPERFICIAL DISSECTION OF THE LOWER PART OF THE FOREARM AND THE HAND, SHOWING THE RADIAL AND ULNAR ARTERIES, THE SUPERFICIAL PALMAR ARCH, AND THE ACCOMPANYING NERVES (from R. Quain).  $\frac{1}{2}$

*a*, placed on the deep fascia of the forearm, between the tendons of the palmaris longus and flexor carpi radialis muscles; *b*, points by a line crossing the pisiform bone to the ulnar nerve; *c*, points to the styloid process of the radius and twigs of the radial nerve; 1, radial artery lying on the flexor longus pollicis; 1', the radial artery passing behind the tendons of the extensor ossis metacarpi pollicis and extensor primi internodii pollicis; 2, superficialis volæ branch piercing the short muscles of the thumb and emerging below to join the superficial palmar arch; 3, external branch of the princeps pollicis; 4, radialis indicis; a branch from the superficial arch is seen joining the internal branch of the princeps pollicis; 5, ulnar artery lying upon the flexor digitorum profundus; 5', the same descending on the anterior annular ligament to form the superficial palmar arch; 6, deep branch of the ulnar artery passing between the abductor and flexor minimi digiti to join the deep arch, accompanied by the deep branch of the ulnar nerve; 7, branch of the superficial arch to the ulnar side of the little finger; 8, division of the common branch to the 4th and 5th fingers; 9, the same to the 3rd and 4th fingers; 10, the same to the 2nd and 3rd fingers; 7 and 8, are accompanied by the digital branches of the ulnar nerve, and 3, 4, 9, and 10, by the branches of the median nerve.

The digital arteries are placed at first superficial to the tendons, and then they lie between them, accompanied by the digital nerves as far as the clefts of the fingers, where they are joined by the anterior interosseous arteries, branches of the deep arch. On the sides of the fingers, each artery lies beneath the corresponding nerve, and gives branches which supply the sheaths of the tendons and the joints, some of them anastomosing across the front of the bones with similar branches from the opposite side. At about the middle of the last phalanx, the two branches for each finger converge and form an arch,

from which proceed numerous small offsets to supply the matrix of the nail and all the structures at the tip of the finger.

[The varieties observed in the branches of the superficial palmar arch will be noticed after the description of the deep arteries of the hand.]

### RADIAL ARTERY.

The radial artery appears by its direction to be the continuation of the brachial, although it does not equal the ulnar in size. It extends along the front of the fore-arm as far as the lower end of the radius, below which it turns round the outer border of the wrist, and descends to the back of the space between the metacarpal bones of the thumb and fore finger: there it passes forwards into the palm of the hand, and crosses towards the inner side, so as to form the deep palmar arch. In consequence of the changes in its course, the direction and connections of the radial artery may be separately described in the forearm, on the wrist, and in the hand.

*In the forearm* the radial artery, commencing at the point of bifurcation of the brachial opposite the neck of the radius, descends at first somewhat obliquely outwards in a line with the brachial artery, and then nearly vertically along the outer part of the front of the forearm to the styloid process of the radius. Its course may be indicated by a line drawn from the middle of the bend of the elbow to the narrow interval between the trapezium bone and the tendons of the extensors of the thumb, which can be readily felt on the outer border of the wrist.

The radial artery is nearer to the surface than the ulnar, and is covered only by the common integument and fascia, except where it is overlapped by the fleshy part of the supinator longus, which must be drawn aside in order to bring the vessel into view. At first it is in contact with the tendon of the biceps, and is supported by the fatty tissue contained in the hollow in the front of the elbow, which separates it from the short supinator muscle. It then rests in succession on the insertion of the pronator teres, the thin radial origin of the flexor sublimis, the flexor pollicis longus, the pronator quadratus, and the lower end of the radius. It is at this last point that the pulse is usually felt during life. To the inner side of this vessel lie the pronator teres in the upper part of its course, and the flexor carpi radialis in the remainder; and on the outer side, in its whole course along the fore-arm, is the supinator longus muscle.

*Relation to Veins.*—The artery is accompanied by venæ comites, which have the usual arrangement of those veins.

*Relation to Nerves.*—The radial branch of the musculo-spiral nerve is placed on the outer side of the artery in the middle third of its course. At the elbow that nerve is separated from the artery by a considerable interval; and towards the lower end of the fore-arm it turns backwards beneath the tendon of the supinator longus, to reach the dorsal aspect of the limb, and thus loses all connection with the artery. Some filaments of the *external cutaneous* nerve pierce the fascia to reach the lower part of the artery, which they accompany to the back of the carpus.

*At the wrist* the radial artery turns outwards between the styloid process of the radius and the carpus, beneath the tendons of the

Fig. 270.

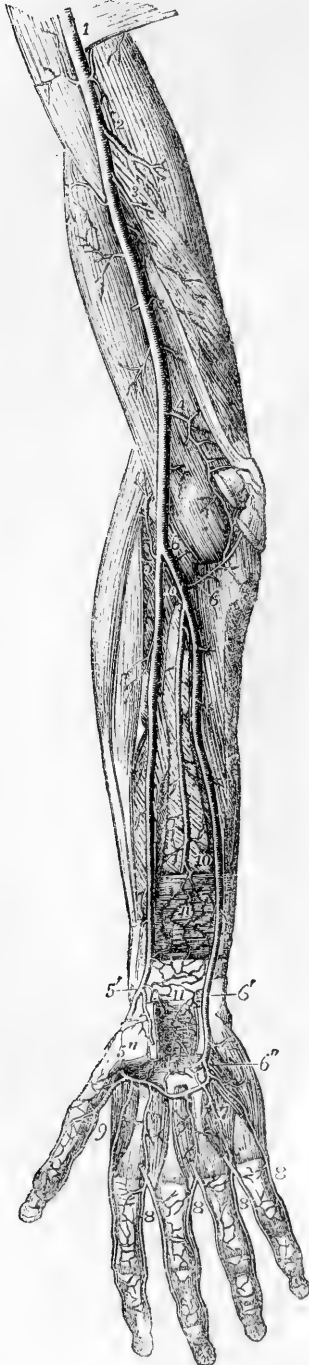

Fig. 270.—DEEP ANTERIOR VIEW OF THE ARTERIES OF THE ARM, FOREARM, AND HAND (from Tiedemann). 4

The biceps brachii, the pronator teres and muscles rising from the inner condyle, the supinator longus, the lower part of the flexor longus pollicis and flexor profundus digitorum, the anterior annular ligament of the carpus and the muscles of the ball of the thumb, have been removed; *n*, pronator quadratus muscle; 1, lower part of the axillary artery continued into the brachial; 2, superior profunda branch; 3, inferior profunda; 4, anastomotic; 5, upper part of the radial artery and radial recurrent; 5', lower part of the radial artery, giving off the superficialis volæ branch; 5'', the radial artery emerging from between the heads of the abductor indicis muscle; 6, 6, the upper part of the ulnar artery with the anterior and posterior ulnar recurrent branches; 6', the ulnar artery approaching the wrist and descending into the superficial palmar arch which has been cut short; 6'', the deep branch of the ulnar artery uniting with the deep palmar arch; 7 (marked only on one), three interosseous branches from the deep palmar arch joining the palmar digital arteries 8, 8, 8, which have been cut away from their origin from the superficial arch to near their division into the collateral digital arteries; the ulnar collateral of the little finger is represented as rising in this instance from the deep ulnar artery; 9, placed between the princeps pollicis and radialis indicis branches of the radial artery; 10, lower part of the anterior interosseous artery passing behind the pronator quadratus muscle; 11, anastomosis of the anterior carpal branches of the radial and ulnar arteries with recurrent branches from the deep palmar arch.

extensors of the metacarpal bone and first phalanx of the thumb, and upon the external lateral ligament of the wrist-joint, to reach the back of the carpus. It then runs downwards for a short distance, is crossed by the tendon of the extensor of the second phalanx of the thumb, and reaching the upper end of the space between the first and second metacarpal bones, turns forwards into the palm of the hand, by passing between the heads of the first dorsal interosseous muscle.

As it turns round below the end of the radius the artery is deep-seated, but afterwards comes nearer to the surface. It is accompanied by two veins and by some filaments of the external cutaneous nerve, and is crossed by subcutaneous veins and by filaments of the radial nerve.



Fig. 271.—ARTERIES OF THE OUTER AND BACK PART OF THE ARM AND HAND, SUPERFICIAL VIEW (from Tiedemann).  $\frac{1}{4}$

*a*, deltoid muscle; *b*, external humeral head of triceps; *c*, biceps brachii; *d*, brachialis anticus; *e*, supinator longus; *f*, extensor carpi radialis longior; *g*, brevior; *h*, extensor communis digitorum and extensor minimi digiti; *i*, extensor carpi ulnaris; *k*, anconeus; *l*, flexor carpi ulnaris; *m*, extensor ossis metacarpi pollicis; *n*, extensor primi internodii pollicis; *o*, tendon of the extensor secundi internodii pollicis; 1, 1, branches of superior profunda artery appearing between the triceps and brachialis anticus, and descending on the outer supracondylar eminence to anastomose with the branches of the recurrent radial artery; 2, above the posterior annular ligament points to the posterior carpal branch of the anterior interosseous artery; 3, posterior carpal branch of the ulnar artery; 4, radial artery taking its course between the outer lateral ligament of the wrist-joint and the tendons of the extensor muscles before passing near 5, between the two heads of the abductor indicis; beneath the extensor tendons is seen the posterior carpal arch, giving the third and fourth dorsal interosseous arteries; 6, the inner dorsal artery of the thumb; 7, the outer dorsal artery of the index finger, and between 7, and 7', the remaining dorsal digital vessels in the spaces between the heads of the metacarpal bones, near their communications with the palmar digital vessels.

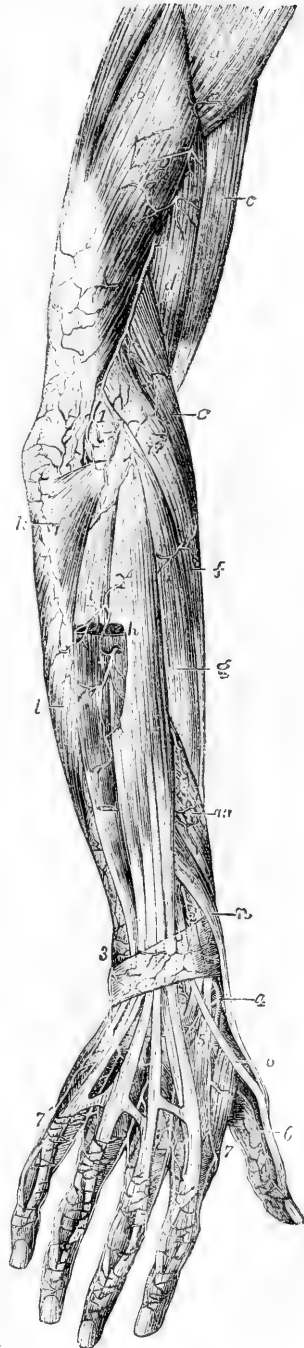
**BRANCHES.**—The branches of the radial artery may be arranged according as they are given off in the fore-arm, on the wrist, and in the hand.

**A.** The branches which arise from the radial in the fore-arm are the radial recurrent, the muscular branches, the anterior carpal, and the superficial volar.

The **radial recurrent** artery, which varies much in size, arches upwards from the radial soon after its origin, running between the branches of the musculo-spiral nerve. It first lies on the supinator brevis, and then on the brachialis anticus, being covered by the supinator longus. In front of the outer condyle, and in the interval between the two last muscles, it anastomoses with the terminal branches of the superior profunda.

From the lower or convex side of this artery are given off several branches; one, of considerable size, to the supinator and extensor muscles, and some beneath the latter to anastomose with the posterior interosseous branches. It also supplies the supinator brevis, and brachialis anticus in part.

Fig. 271.



The **anterior radial carpal** is a small branch which arises from the radial artery, near the lower border of the pronator quadratus, and runs inwards in front of the radius. It anastomoses with the anterior ulnar carpal artery, so as to form an arch above and in front of the radio-carpal articulation, from which branches descend to supply the joints at the wrist.

The **superficial volar** (*ramus superficialis volæ*), arising from the radial artery, near the place where it leaves the front of the fore-arm, passes onwards into the hand. In size it is variable; in most instances it is very small, and ends in the muscles of the thumb; but in others it attains considerable size, and crossing those muscles, terminates by inosculating with the radial extremity of the superficial palmar arch, which it thus completes.

Several unnamed **muscular** branches are given by this part of the artery to the muscles on the fore part of the arm.

B. The branches which arise from the radial artery behind the wrist are, the posterior carpal, the metacarpal, the dorsal arteries of the thumb, and the dorsal artery of the index finger.

Fig. 272.

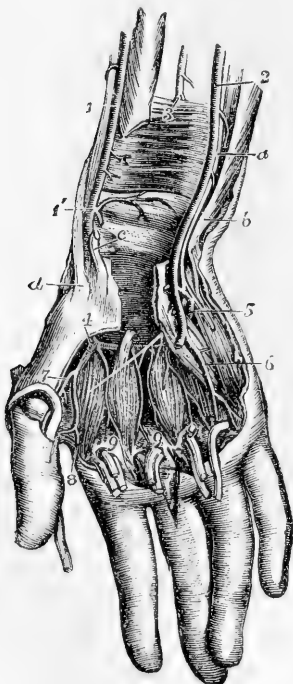


Fig. 272.—DEEP VIEW OF THE ARTERIES OF THE WRIST AND HAND, FROM BEFORE (from R. Quain).  $\frac{1}{3}$

The anterior annular ligament of the carpus has been divided and the lower parts of the common flexors and flexor of the thumb have been removed; portions of these tendons are represented as turned down upon the fingers with parts of the lumbricales muscles; the superficial palmar artery is removed, and the interossei muscles are exposed. *a*, ulnar nerve; *b*, tendon of the flexor carpi ulnaris muscle; *c*, tendon of the flexor carpi radialis; *d*, inserted tendon of the extensor ossis metacarpi pollicis; 1, radial artery; 1', its lower part giving off the anterior carpal and superficial volar branches; 2, ulnar artery; 3, anterior interosseous artery before passing behind the pronator quadratus muscle; 4, radial artery, appearing deeply in the palm between the first and second metacarpal bones and passing into the deep palmar arch; 5, deep branch of the ulnar artery dipping between the abductor and flexor brevis minimi digiti to join the deep arch and accompanied by the deep branch of the ulnar nerve; 6, a palmar digital artery, rising from the first part of the superficial palmar arch; 7, the princeps pollicis, and 8, the radialis indicis arteries rising from the radial artery; 9, 9, 9, interosseous branches of the deep palmar arch proceeding down on the interosseous muscles to join the palmar digital arteries from the superficial arch.

(*a*) The **posterior radial carpal** is a small but constant branch. It arises beneath the extensor tendons of the thumb, and running inwards on the back of the carpus anastomoses with the posterior ulnar carpal branch, completing the arch from which spring the dorsal interosseous arteries of the third and fourth spaces. It anastomoses, also, with the terminal branch of the anterior interosseous of the fore-arm.

(b) The **first dorsal interosseous** or **metacarpal** branch arises beneath the extensor tendons of the thumb, frequently in common with the posterior carpal branch, passes to the interval between the second and third metacarpal bones, communicates with the corresponding perforating branch of the deep palmar arch, and, descending on the second dorsal interosseous muscle, anastomoses with the palmar digital branch at its division between the fingers.

(c) The **dorsal arteries of the thumb**, two small branches, arising separately or together opposite the head of the metacarpal bone, run upon the dorsal aspect of the bones of the thumb, one at the radial, the other at the ulnar border.

(d) The **dorsal artery of the index finger**, a very small branch, arises lower down than the preceding, and sending branches to the abductor indicis, runs along the radial side of the back of the index finger.

c. The branches derived from the radial after it has entered the hand, are, the great artery of the thumb, the radial branch of the index finger, and the large terminal branch, which forms the deep palmar arch.

(a) The **large artery of the thumb** (*arteria princeps pollicis*,—Hallér) arises from the radial, where it is about to turn inwards across the palm of the hand. It descends in front of the abductor indicis, between the metacarpal bone of the thumb and the muscles covering it, to the space between the lower ends of the flexor brevis pollicis. At that point, and beneath the tendon of the long flexor, it divides into two *collateral branches*, which course along the borders of the phalanges, on their palmar aspect, and unite in front of the last phalanx, to form an arch similar in arrangement to that on the other fingers.

(b) The **radial branch for the index finger** generally arises close to the large artery of the thumb; but though constantly found, it varies in size and in its mode of origin. It descends between the abductor indicis and adductor pollicis muscles, and continues along the radial border of the index finger, forming the radial collateral branch of that finger, and anastomosing in the usual manner on the last phalanx with the ulnar collateral branch derived from the superficial palmar arch.

**Varieties.**—*Origin.*—In the observations of Richard Quain, the radial artery was found to arise higher up than usual in nearly one case in eight.

*Course.*—The radial artery more rarely deviates from its usual position along the fore-arm than the ulnar. It has been found lying upon the fibrous expansion from the tendon of the biceps, and over the fascia of the fore-arm, instead of beneath those structures. This vessel has been also observed on the surface of the long supinator, instead of on the inner border of that muscle. In turning round the wrist, it has been seen passing over the extensor tendons of the thumb, instead of within them. As was previously stated (p. 404), the vasa aberrantia occasionally derived from the brachial or axillary arteries most commonly end by joining the radial, or one of its branches.

*Branches.*—The radial *recurrent* is sometimes very large, or it may be replaced by several separate branches. When the radial itself arises high up, the recurrent artery usually comes from the residual brachial trunk, or sometimes from the ulnar artery, or more rarely from the interosseous. When given from the brachial trunk, the radial recurrent has been found crossing beneath the tendon of the biceps.

The *superficial volar* branch is small in a considerable number of cases, and is lost in the short muscles of the thumb, without forming any connection with the palmar arch, or with any of the digital arteries. In some instances in which it is

enlarged, it furnishes one or two digital branches, and along with this the anastomosis with the superficial arch may be absent. The superficial volar branch occasionally arises as much as an inch and a half higher than usual.

The *first dorsal interosseous* branch (metacarpal), which descends on the second *interosseous* space to the cleft between the index and middle fingers, is not unfrequently so large as to furnish the collateral digital branch to each of those fingers.

The *carpal* and *interosseous* (metacarpal) branches of the radial are sometimes small, their place being supplied by the perforating offset of the anterior interosseous, apparently by an enlargement of the ordinary anastomosis between them.

The radial artery very frequently gives off a communicating branch to the superficial arch, near the lower border of the adductor pollicis.

Fig 273.

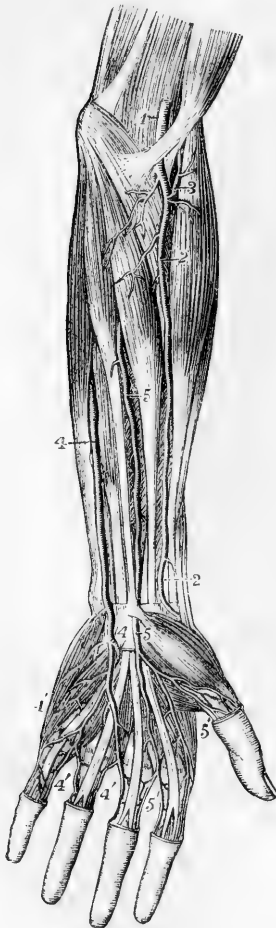


Fig. 273.—DISSECTION OF THE LEFT ARM, SHOWING AN ENLARGED MEDIAN ARTERY WHICH REPLACES THE RADIAL AND ULNAR ARTERIES IN THE SUPPLY OF PALMAR DIGITAL ARTERIES TO HALF THE FINGERS (from Tiedemann).  $\frac{1}{4}$

1, lower part of the brachial artery; 2, radial artery, not giving any superficial volar branch; 3, recurrent radial branch; 4, ulnar artery passing superficially over the wrist and supplying at 4', digital arteries to half the hand; 5, the enlarged median artery passing in front of the annular ligament of the carpus, and supplying 5', digital vessels to the outer half of the hand.

#### DEEP PALMAR ARCH.

The deep palmar arch, the continuation of the radial artery, commences at the upper end of the first interosseous space between the heads of the abductor indicis, turns transversely across the palm towards the fourth metacarpal bone, and inosculates with the communicating branch of the ulnar artery. The convexity of the arch thus formed is directed downwards. It rests on the interosseous muscles and on the metacarpal bones immediately below their carpal extremities, and is covered by the flexor brevis pollicis, the flexor tendons of the fingers, and the muscles of the little finger. It is nearer to the carpus than the superficial arch, and differs from it in retaining its size almost undiminished. It is in part accompanied by the deep branch of the ulnar nerve, which runs from the inner end of the arch outwards.

**Branches.**—(a) The *recurrent branches* (rami retrogradi,—Haller), from the upper concave side, ascend and anastomose with the branches from the anterior carpal arch.

(b) The *superior perforating branches*, three in number, pass backwards through the upper extremities of the last three interosseous spaces to inosculate with the dorsal interosseous arteries.

(c) The *palmar interosseous* arteries, usually three in number, but very liable to variation, lie in front of the interosseous spaces, supply the muscles there, and anastomose at the clefts of the fingers with the digital branches from the superficial arch.

It is by an enlargement of these small vessels that the deep palmar arch sometimes supplies the corresponding digital arteries in the absence of those usually derived from the superficial arch.

**Varieties of the Arteries of the Hand.**—The arteries of the hand frequently vary from their usual mode of distribution.

(a) By far the larger number of deviations consist of a deficiency in either the radial or ulnar system of arteries, accompanied by a corresponding increase in the other; and it may be observed that the defect is much more commonly on the part of the superficial, and the increase on the part of the deep set.

(b) In the second and smaller class of variations a deficiency in one or other of the two systems is supplied, either by the enlargement of branches which descend in front of the limb, as the superficial volar (from the radial), or the median artery (from the anterior interosseous, as shown in fig. 273), or by the enlargement of a metacarpal branch (from the radial) on the back of the hand.

In illustration of these general remarks, the following modes of arrangement of the vessels may be mentioned:—

In the greater number of cases the superficial palmar arch is diminished, and gives off fewer digital branches than usual. Generally only one branch is wanting, viz., that which supplies the adjacent sides of the fore and middle fingers; but sometimes two or three branches are absent, or even all four, as when the ulnar artery, after giving branches to the short muscles of the little finger, ends in the deep palmar arch. In the last-mentioned case, which is rare, it is obvious that the superficial arch is altogether wanting.

These various deficiencies in the superficial palmar arch and its branches are usually compensated for by an enlargement of the deep arch, the palmar interosseous branches of which, being increased in size, divide at the clefts of the fingers, and form such collateral digital branches as are not derived from the usual source. But a defective superficial arch may, as before mentioned, be reinforced from other vessels, viz., from the superficial volar, from an enlarged median artery, or from a large metacarpal branch.

It sometimes, but more rarely, happens, that the radial system of vessels is deficient; in which case the superficial arch (which belongs to the ulnar system) may supply all the digital arteries to the thumb and fingers, or one of these may be derived from the superficial volar, the median, or the radial interosseous artery.

## DESCENDING THORACIC AORTA.

From the point at which its arch is considered to terminate—the lower margin of the third dorsal vertebra, the aorta descends along the fore part of the spine to the fourth lumbar vertebra, where it divides into the common iliac arteries. The direction of this part of the vessel is not vertical, for as it follows the bend of the spine, upon which it rests, it is necessarily concave forwards in the dorsal region, and convex forwards in the lumbar. Again, as its commencement is at the left side of the bodies of the vertebræ, and its termination also inclined a little to the left, whilst about the last dorsal vertebra the vessel is nearly in the middle line, there is produced another slight curve, the convexity of which is to the right side. Within the thorax, where the offsets are small, the aorta diminishes only slightly in size; in the abdomen the diminution is considerable, in consequence of large branches being furnished to the viscera of that cavity.

That part of the descending aorta which is situated in the thorax, is

called the **THORACIC AORTA**; it extends from the lower border of the third dorsal vertebra on the left side, to the opening between the crura of the diaphragm in front of the last dorsal vertebra. It lies in the back part of the interpleural space or posterior mediastinum, being placed before the spine and behind the root of the left lung and the pericardium: on the left side it is in contact with the corresponding pleura and lung, and close on the right side are the azygos vein, the thoracic duct, and the œsophagus. The œsophagus, however, towards the lower part of the thorax, is in front of the artery, and near the diaphragm gets somewhat to the left side. The left or small azygos vein crosses behind the thoracic aorta.

The *branches* derived from the thoracic aorta are numerous, but small. They are distributed to the walls of the thorax, and to the viscera contained within it—the latter being much the smaller and least numerous branches.

#### A. BRANCHES TO THE VISCERA :—

The **pericardiac branches** are some very small and irregular vessels which pass forwards and ramify on the pericardium.

The **bronchial arteries** are the proper nutritive arteries of the substance of the lung: they accompany the bronchial tubes in their ramifications through that organ, and they also supply the bronchial glands, and in part the œsophagus. These vessels vary frequently in number, and in their mode of origin. The bronchial artery of the right side arises from the first aortic intercostal artery, or by a common trunk with the left bronchial artery from the thoracic aorta; on the left side there are generally two bronchial arteries, both of which arise from the thoracic aorta, one near the commencement of that trunk, and the other, named inferior bronchial, lower down. Each artery is usually directed to the back part of the corresponding bronchus, along which it runs, dividing and subdividing with the successive bronchial ramifications in the substance of the lung.

**Varieties.**—The place of origin of the bronchial arteries is liable to much variation. The artery of the right side has been found to arise singly from the aorta, from the internal mammary, or from the inferior thyroid. The bronchial arteries of the two sides have been seen to arise by a common trunk from the subclavian. (Haller.) Two common trunks, each furnishing a branch to the right and left lungs, have been observed in a single case to descend into the thorax after arising, one from the internal mammary, and the other from the superior intercostal artery. (R. Quain, pl. 26, f. 5.) In some cases they arise from the under surface of the arch, instead of from the thoracic aorta. Instances occur of two distinct bronchial arteries for each lung.

The **œsophageal arteries** are variable in size and number. There are usually four or five, which arise from the fore part or right side of the aorta, and run obliquely downwards upon the œsophagus, supplying its coats.

Their lower branches anastomose with the ascending offsets of the coronary artery of the stomach and with the phrenic artery, while their upper branches communicate with those of the inferior thyroid artery.

**Posterior mediastinal branches** of the aorta, small and irregular, supply the glands and loose tissue of the posterior mediastinum.

#### B. PARIETAL BRANCHES TO THE THORAX.

The **intercostal arteries** arise from the posterior part of the aorta,

and run outwards upon the bodies of the vertebræ, to reach the intercostal spaces. They are usually ten in number—the upper intercostal

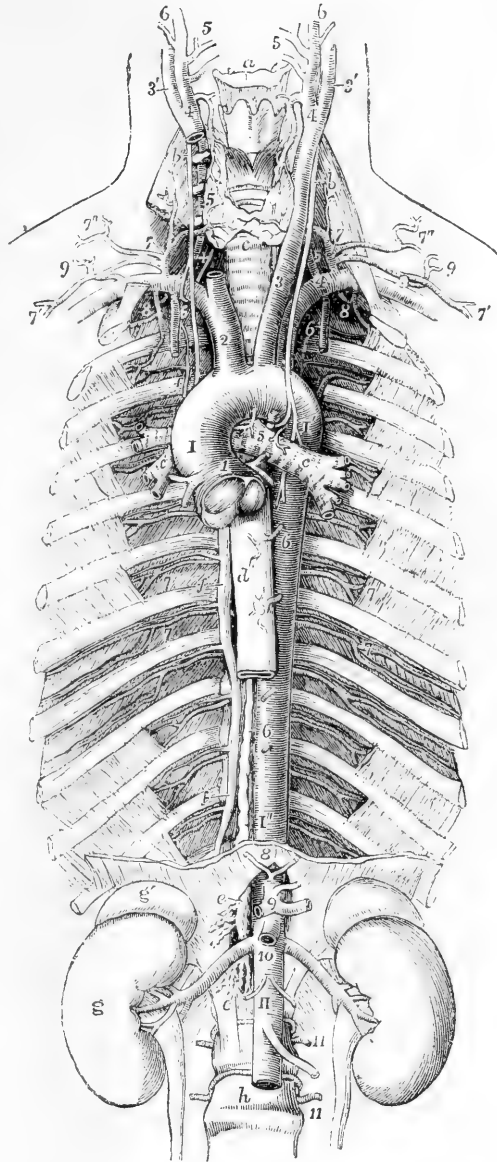
Fig. 274.—VIEW OF THE THORACIC AND UPPER PART OF THE ABDOMINAL AORTA, &c.  $\frac{1}{4}$

For the general description of this figure, see p. 349. The following numbers indicate the branches of the aorta; 1, placed between the origins of the right and left coronary arteries; 2, innominate; 3, left carotid; 4, left subclavian; 5, bronchial; 6, 6, œsophageal; 7, 7, intercostal arteries (sixth and seventh); 8, inferior phrenic; 9, cœliac axis; 10, below the superior mesenteric and opposite the origin of the renal arteries; 11, two of the lumbar arteries.

space, and occasionally also the second, being supplied by the superior intercostal branch of the subclavian artery. Owing to the position of the aorta to the left side of the spine, the right aortic intercostals cross over the front of the vertebræ, furnishing small branches to their interior, and are longer than the arteries of the left side. The vessels of both sides pass outwards behind the pleura, and are crossed by the sympathetic nerve: those of the right side also pass behind the œsophagus, the thoracic duct, and the azygos vein.

In each intercostal space the artery, passing outwards more horizontally than the ribs, crosses the space obliquely, so as to gain the lower border of the upper rib near its angle. It lies upon the deep

Fig. 274.



surface of the external intercostal muscle, and in the back of the space is separated from the pleura by a fascia only, but further outwards it lies between the two layers of intercostal muscles. Extending forwards in contact with the rib above, it finally anastomoses with one of the anterior intercostal branches derived from the internal mammary artery, and with the thoracic branches of the axillary artery.

The first of the aortic intercostal arteries has an anastomosis with the superior intercostal proceeding from the subclavian artery; and the last three are prolonged into the abdominal muscles, where they communicate with the epigastric artery in front, with the phrenic arteries at the side, and with the lumbar branches of the abdominal aorta lower down.

Each intercostal artery is accompanied, as it runs outwards between the ribs, by a corresponding vein, and by one of the dorsal nerves; the vein usually being uppermost, and the artery next below it.

**Branches.**—(a) The *posterior or dorsal* branch of each intercostal artery passes backwards to the inner side of the anterior costo-transverse ligament, along with the posterior branch of the corresponding spinal nerve; and, having furnished an offset to the spinal canal, reaches the muscles of the back, and divides into an internal and an external branch. The internal branch is directed towards the spinous processes, on or through the multifidus spinæ, and ramifies in the muscles and the skin. The external branch turns outwards under the longissimus dorsi, and is distributed between that muscle and the sacro-lumbalis; some twigs reach the superficial muscles and the integuments.

The *spinal* branches of the aortic intercostal arteries are distributed partly to the cord and its membranes, and partly to the bones, in the same manner as the spinal branches of the lumbar arteries, to the description of which the reader is referred.

(b) The *collateral intercostal* branch, long and slender, arises near the place where the main trunk comes in contact with the upper rib of the space, and inclining downwards approaches the border of the lower rib, supplying the bone and the intercostal muscles, and anastomosing in front with an anterior intercostal branch of the internal mammary artery. There are thus in each intercostal space two terminal branches of the intercostal arteries communicating with the branches of the internal mammary.

**Varieties.**—The number of the intercostal arteries is subject to much variation: the third, fourth, and fifth vessels may be entirely absent upon one side, the corresponding spaces being supplied from neighbouring arteries. Two arteries frequently arise from the aorta by a single stem. In this way the first lumbar artery is sometimes conjoined with the twelfth intercostal (Henle).

## ABDOMINAL AORTA.

The aorta, after having passed the diaphragm, is thus named. It commences on the front of the last dorsal vertebra, and terminates

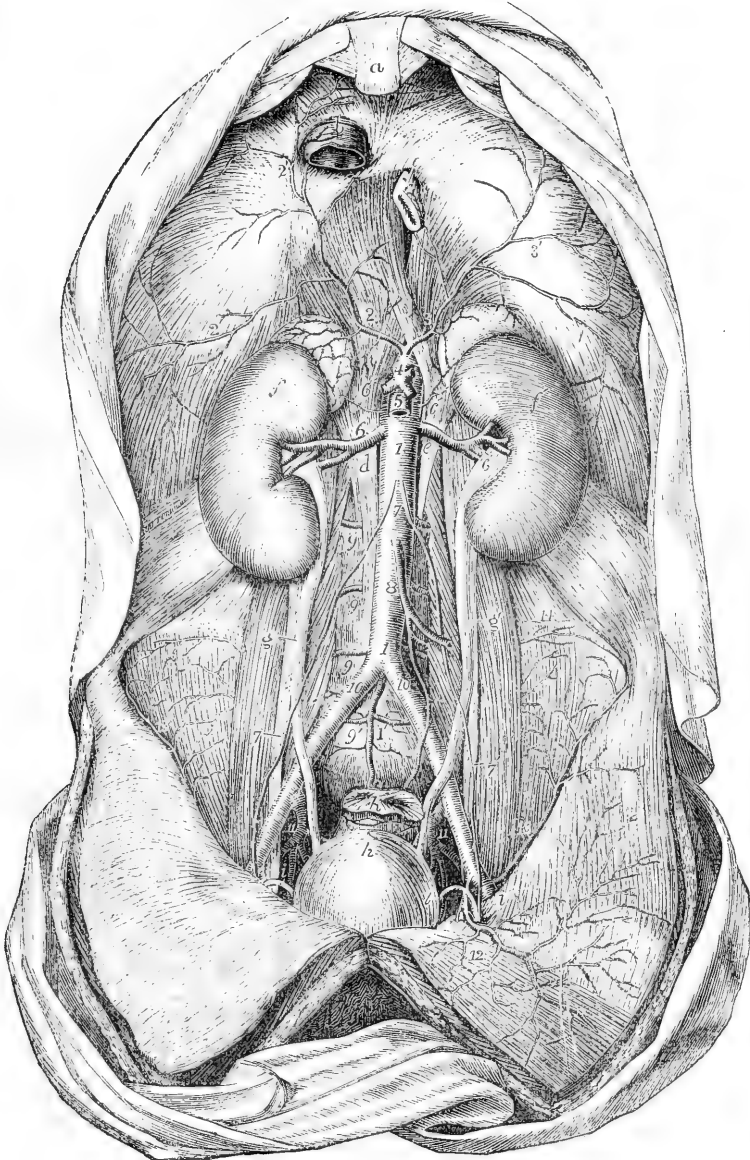
Fig. 275.—VIEW OF THE ABDOMINAL AORTA AND ITS PRINCIPAL BRANCHES (from Tiedemann). †

*a*, ensiform portion of the sternum; *b*, vena cava inferior passing through the tendon of the diaphragm; *c*, the œsophagus passing through the muscular portion; *d* and *e*, tendinous parts of the right and left crura; *f*, *f'*, the right and left kidneys with their suprarenal bodies; *g*, *g'*, the ureters; *h*, the upper part of the urinary bladder; *i*, *i'*, the right and left vasa deferentia passing up from the bladder to the internal inguinal apertures; *k*, the rectum, divided and tied near its upper part; 1, 1, the abdominal aorta; 1', the middle sacral artery; 2, 2', the right, 3, 3', the left inferior phrenic arteries, represented as arising by a short common stem from the front of the aorta immediately below the meeting of the crura of the diaphragm; 4, the trunk of the cœliac axis; 5, the superior mesenteric artery; 6, 6, the renal arteries; 6', 6', the suprarenal arteries arising partly



from the aorta and partly from the inferior phrenic; 7, placed on the front of the aorta below the origin of the spermatic arteries; 7, 7', placed on the psoas muscles, point to the right and left spermatic arteries as they descend to the internal inguinal apertures; 8, inferior mesenteric artery; 9, lumbar arteries, of which the lowest is here represented as proceeding from the middle sacral artery; 10, common iliac arteries; 11, between the external and internal iliac arteries; 12, left epigastric artery; 13, circumflex iliac; 14, branches of the ilio-lumbar.

Fig. 275



below by dividing into two trunks, named the common iliac arteries. The bifurcation usually takes place about half way down the body of the fourth lumbar vertebra, a little to the left of the middle line; a point which is nearly on a level with a line drawn from the one crista ili to the other, and opposite the left side of the umbilicus.

The anterior surface of the abdominal aorta is successively in apposition with the pancreas and the splenic vein, the left renal vein, the third portion of the duodenum, and the peritoneum. The vena cava lies along its right side, the right crus of the diaphragm being interposed at the upper part of the abdomen; close to the same side are the thoracic duct and the azygos vein, which are placed between the aorta and the right crus of the diaphragm. The aorta is also covered in front by meshes of nerves derived from the sympathetic, and numerous lymphatic vessels and glands.

**BRANCHES.**—The abdominal aorta gives numerous branches, which may be divided into two sets, viz., those which supply the viscera, and those which are distributed to the walls of the abdomen. The former consists of the cœliac artery, the superior mesenteric, the inferior mesenteric, the capsular, the renal, and the spermatic arteries; whilst in the latter are included the phrenic, the lumbar, and the middle sacral arteries. The first three of the visceral branches are single arteries.

**Varieties.**—*Place of Division.*—In more than three-fourths of a considerable number of cases, the aorta divided either upon the fourth lumbar vertebra, or upon the intervertebral disc below it; in one case out of nine it was below, and in about one out of eleven above the spot thus indicated. In ten bodies out of every thirteen, the division of the great artery took place within half an inch above or below the level of the iliac crest; and it occurred more frequently below than above the fourth intervertebral space. (R. Quain, op. cit. p. 415.) An instance of bifurcation immediately below the origin of the right renal artery is recorded by Haller (Disputat. Anatom. t. vi. p. 781.)

*Unusual Branch.*—A very remarkable case is recorded of the existence of a large pulmonary branch which arose from the abdominal aorta, close to the cœliac artery, and after passing upwards through the œsophageal opening in the diaphragm, divided into two branches, which were distributed to the lungs near their bases. (Referred to by R. Quain in his work "On the Arteries," p. 416.)

#### A.—VISCERAL BRANCHES OF THE ABDOMINAL AORTA.

The **CÆLIAC ARTERY** or **AXIS**, a short and wide vessel, arises from the aorta close to the margin of the diaphragm. It is directed forwards nearly horizontally, and is not more than half an inch long. It is behind the small omentum, and lies close to the left side of the lobulus Spigelii of the liver, and above the pancreas, the two semilunar ganglia being contiguous to it, one on each side. This artery divides into three branches, viz., the coronary artery of the stomach, the hepatic and the splenic, which separate simultaneously from the end of the artery like radii from an axis.

**Varieties.**—The *cœliac axis* is occasionally partly covered at its origin by the diaphragm. It may be longer than usual, in which case its branches are not given off together; or it may be entirely wanting, the coronary, hepatic, and splenic arteries arising separately from the aorta. In some cases the cœliac artery gives off only two branches at its division (the coronary and the splenic), the hepatic being supplied from another source. Rarely, it gives more than three branches

to the viscera, the additional vessel being a second coronary, or a separate gastro-duodenal artery. One or both phrenic arteries are sometimes derived from this trunk. Cases have been met with in which a connection existed between the cœliac axis and the superior mesenteric artery close to their origin.

1. The **coronary artery of the stomach**, the smallest of the three visceral branches derived from the cœliac artery, inclining upwards and to the left side, reaches the cardiac orifice of the stomach, and then proceeding along the smaller curvature of the stomach, from left to right, gives branches to both sides of that viscus and inosculates with the pyloric branch of the hepatic artery.

Where it first reaches the stomach, this artery sends upwards *œsophageal branches*, which anastomose with the aortic œsophageal arteries. The branches to the stomach descending on the fore and back part of the organ, anastomose with branches from the arterial arch on the great curvature.

**Varieties.**—The coronary artery of the stomach is sometimes given off directly from the aorta: and is occasionally replaced by two separate vessels. It sometimes furnishes an additional hepatic artery.

2. The **hepatic artery** is in the adult intermediate in size between the coronary and splenic arteries, but, in the fœtus, it is the largest of the three. The main part of this vessel inclines upwards and to the right side, between the layers of the small omentum, and in front of the foramen of Winslow, towards the transverse fissure of the liver; and in this course it lies upon the vena portæ and to the left of the bile-duct.

Near the transverse fissure of the liver, the hepatic artery divides into right and left branches, which supply the corresponding lobes of that organ. The *left*, the smaller division, lying in front of the vena portæ, diverges at an acute angle from the other branch, and turns outwards to reach the left extremity of the transverse fissure of the liver, where it enters that organ.

The *right* branch inclines outwards to the right extremity of the transverse fissure, and divides into two or three branches before entering the liver. The ramifications of the hepatic artery in the liver accompany the divisions of the venæ portæ and hepatic ducts.

**BRANCHES.**—The named branches of the hepatic artery are as follow.

(a) The *pyloric* artery, coming in contact with the stomach at the upper border of the pylorus, extends from right to left along the smaller curvature and inosculates with the coronary artery. It is sometimes a branch of the gastro-duodenal.

(b) The *gastro-duodenal* artery, of considerable size, separating from the hepatic artery before that vessel ascends in the small omentum, descends behind the duodenum, near the pylorus, and reaches the lower border of the stomach; there it gives off the superior pancreatico-duodenal branch, and its remaining part, which receives the name of right gastro-epiploic, runs from right to left along the great curvature of the stomach, between the layers of the great omentum, and finally inosculates with the left gastro-epiploic derived from the splenic artery.

The *gastro-epiploic* artery gives branches upwards to both surfaces of the stomach, and long slender vessels downwards to the omentum.

Fig. 276.

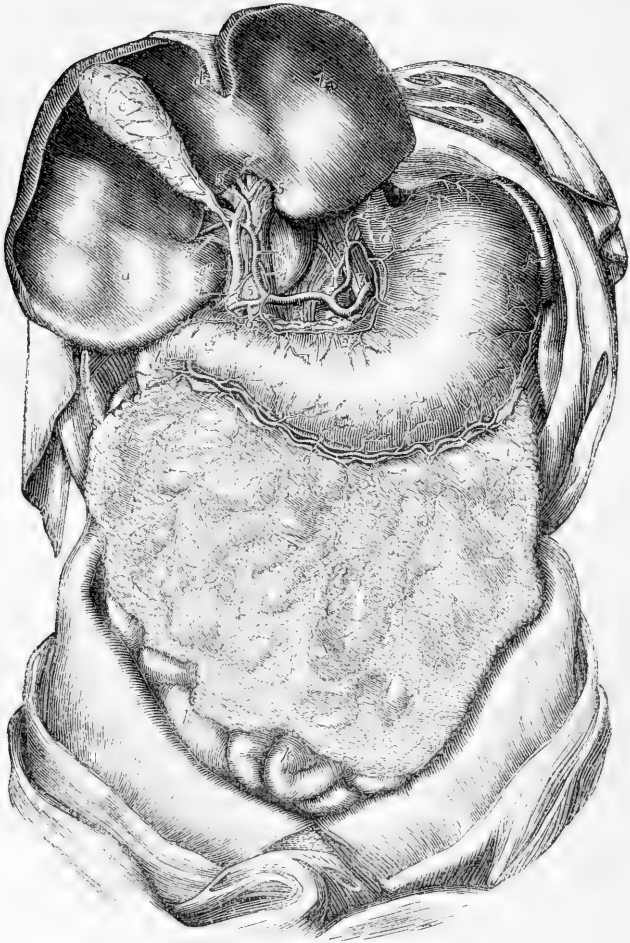


Fig. 276.—THE ARTERIES OF THE STOMACH, LIVER, AND OMENTUM  
(from Tiedemann).  $\frac{1}{4}$

The liver is turned up so as to show its lower surface with the portal fissure, and the vessels and ducts entering it. *a*, the right lobe of the liver; *b*, the left lobe; *c*, the gall-bladder; *c'*, the biliary or hepatic ducts; *c''*, the ductus communis choledochus; *d*, the front of the antero-posterior fissure and the round ligament; *e*, the cardiac orifice of the stomach; *f*, on the great curvature of the stomach near its cardiac end, points to the spleen; *g*, the pylorus; *h*, the duodenum; *i*, the great omentum; *k*, some of the small intestines in the lower part of the abdomen; 1, upon the trunk of the abdominal aorta below the root of the inferior phrenic arteries, and above the coeliac axis; 2, placed on the meeting of the crura of the diaphragm, the coronary artery of the stomach; 2', the same artery proceeding round the small curvature of the stomach and ending by anastomosis with the superior pyloric; 3, the main hepatic artery, continued at 3' as proper hepatic artery to the liver; 4, superior pyloric artery; 4', another pyloric branch; 5, placed on the main trunk of the vena portæ at the place where the hepatic artery and ductus communis choledochus are in front of it; 5', branches of the vena portæ in the

transverse fissure; 6, gastro-duodenal artery; 6', its continuation as the right gastro-epiploic; 7, on the left crus of the diaphragm, the splenic artery; 8, its left gastro-epiploic branch proceeding round the great curvature of the stomach to communicate with the right gastro-epiploic artery; both of these vessels are seen giving long epiploic as well as gastric branches.

The *superior pancreatico-duodenal* branch descends along the inner margin of the duodenum, between it and the pancreas, and, after furnishing several branches to both these organs, anastomoses with the inferior pancreatico-duodenal from the superior mesenteric artery.

(c) The *cystic* artery, given off by the right hepatic when crossing behind the cystic duct, turns upwards and forwards upon the neck of the gall-bladder, and divides into two smaller branches, of which one ramifies between the coats on the depending surface, the other between the bladder and the liver.

**Varieties.**—The hepatic artery sometimes arises from the superior mesenteric artery, or from the aorta itself. Accessory hepatic arteries are often met with,

Fig. 277.

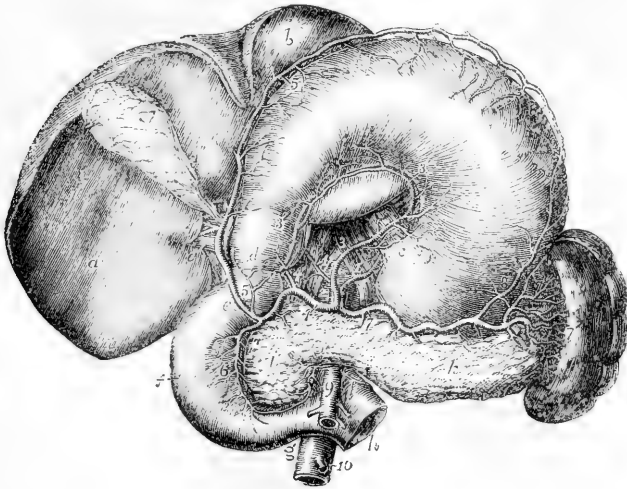


Fig. 277.—THE ARTERIES OF THE STOMACH, DUODENUM, PANCREAS, AND SPLEEN (from Tiedemann).  $\frac{1}{2}$

The stomach and liver are turned upwards so as to show their lower surface. The jejunum is divided at its commencement. *a*, lower surface of the right lobe of the liver; *b*, left lobe; *c*, cardiac orifice of the stomach; *d*, pylorus; *e*, first part, *f*, second or descending part, and *g*, third or lower part of the duodenum; *h*, commencement of the jejunum emerging from behind the superior mesenteric artery; *i*, the head, and *k*, the body of the pancreas; *l*, the spleen; 1, 1, right and left inferior phrenic arteries passing from the aorta upon the crura of the diaphragm; 2, placed on the aorta close to the celiac axis; 3, 3', the coronary artery; 4, common hepatic; 4', its right branch; 4'', cystic branch; 5, gastro-duodenal giving the inferior pyloric; 5, on the great curvature of the stomach, the right gastro-epiploic; 6, superior pancreatico-duodenal; 7, common splenic; 7', proper splenic; 7'', one of the vasa brevia to the stomach; 8, 8, left gastro-epiploic artery uniting with the right on the great curvature of the stomach; 9, trunk of the superior mesenteric artery, giving off the inferior pancreatico-duodenal; 10, inferior mesenteric.

usually coming from the coronary artery of the stomach. The hepatic artery has been found to furnish a phrenic branch.

3. The **splenic artery**, in the adult the largest branch of the cœliac axis, supplies the spleen, and in part the stomach and pancreas. It is directed horizontally towards the left side. Waving and often tortuous in its course, it passes, together with the splenic vein which is below it, behind the upper border of the pancreas, and divides near the spleen into several branches. The largest of these enter the fissure in that organ, and are distributed to its substance; three or four are reflected towards the bulging end of the stomach, upon which they ramify.

**Branches.**—(a) *Pancreatic* branches, variable in size and number, are given off whilst the artery is passing along the pancreas, the middle and left part of which they supply with vessels. One of larger size not unfrequently runs from left to right in the direction of the pancreatic duct, and is called *pancreatica magna*.

(b) The *splenic* branches are the proper terminal branches of the artery; they are five or six, or even more, in number, and vary in length and size; they enter the spleen by the hilus or fissure in its concave surface, and ramify within that organ.

(c) The *short gastric* branches (*vasa brevia*) vary from five to seven in number; they are directed from left to right, some issuing from the trunk of the splenic artery, others from its terminal branches: they reach the left extremity of the stomach, where they divide and spread out between the coats, communicating with the coronary and left gastro-epiploic arteries.

(d) The left *gastro-epiploic* artery runs from left to right along the great curvature of the stomach, supplying branches to both surfaces of the stomach and to the omentum on the left side, and anastomoses with the right gastro-epiploic branch from the hepatic artery.

The **superior mesenteric**, an artery of large size, supplies the whole of the small intestine beyond the duodenum, and half of the great intestine. It arises from the fore part of the aorta, a little below the cœliac axis. For a short space this artery is covered by the pancreas; on emerging from below that gland it descends in front of the duodenum near the end, and is thence continued between the layers of the mesentery. The splenic vein crosses over its root. In the mesentery the artery at first passes downwards and to the left side, but afterwards turns towards the right iliac fossa, opposite to which it anastomoses with its own ileo-colic branch.

**BRANCHES.**—(a) The *inferior pancreatico-duodenal*, given off under cover of the pancreas, runs along the concave border of the duodenum, and joins with the superior pancreatico-duodenal artery.

(b) The *rami intestini tenuis*, or intestinal branches, supplying the jejunum and ileum, spring from the convex or left side of the vessel. They are usually twelve or more in number, and are all included between the layers of the mesentery. They run parallel to one another for some distance, and then divide into two branches, each of which forms an arch with the neighbouring branch. From the first set of arches, other branches issue, which divide and communicate in the same way, until finally, after forming four or five such tiers of arches, each smaller than the other, the ultimate divisions of the vessels proceed directly to the intestine, spreading upon both sides, and ramifying in its coats.

Fig. 278.

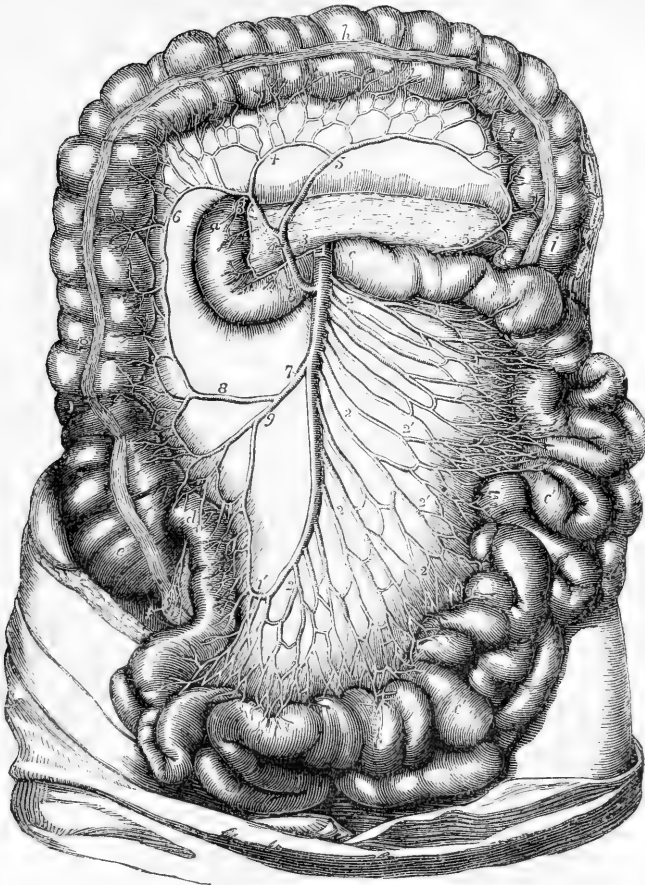


Fig. 278.—THE SUPERIOR MESENTERIC ARTERY AND ITS BRANCHES  
(from Tiedemann). †

The transverse arch of the colon is turned upwards; the transverse meso-colon is dissected so as to expose the duodenum and pancreas at its root; the small intestines are thrown towards the left side; *a*, the descending part of the duodenum; *b*, the lower part; *c*, the commencement of the jejunum; *c'*, *c'*, the jejunum and ileum; *d*, the termination of the ileum in the caput cæcum coli; *e*, the cæcum; *f*, the vermiform process; *g*, the ascending colon; *h*, the transverse arch; *i*, the descending colon; *k*, the pancreas; *1*, the trunk of the superior mesenteric artery; *1'*, the termination of that vessel where it loops round into a branch of the ileo-colic artery; *2*, *2*, the intestinal branches; *2'*, *2'*, their loops in the mesentery; *3*, inferior pancreatico-duodenal branch passing to *3'*, to unite with the branch from the gastro-duodenal; *4*, the middle colic branch; *5*, its left colic branch passing at *5'* to unite with the branch of the left colic of the inferior mesenteric; *6*, its right branch; *7*, right colic and ileo-colic arteries in one trunk; *8*, right colic, uniting by a loop with the middle colic; *9*, the ileo-colic, uniting with the end of the superior mesenteric artery.

(*c*) The *colic* branches arise from the right or concave side of the artery, and are usually three in number.

1. The *ileo-colic* artery, the first in order from below upwards, inclines downwards and to the right side, towards the ileo-colic valve, near which it divides into two branches: one of these descends to inosculate with the termination of the mesenteric artery itself, and to form an arch, from the convexity of which branches proceed to supply the junction of the small with the large intestine, and the cæcum and its appendix; the other division ascends and inosculates with the next mentioned branch. The ileo-colic artery is not always distinct from the termination of the superior mesenteric.

2. The *right colic* artery passes transversely towards the right side, beneath the peritoneum, to the middle of the ascending colon, opposite to which it divides into two branches, of which one descends to communicate with the ileo-colic artery, whilst the other ascends to join in an arch with the middle colic. This artery and the ileo-colic often arise by a common trunk.

3. The *middle colic* artery passes upwards between the layers of the mesocolon towards the transverse colon, and divides in a manner exactly similar to that of the vessels just noticed. One of its branches inclines to the right, where it inosculates with the preceding vessel; the other descends to the left side, and maintains a similar communication with the left colic branch, derived from the inferior mesenteric artery. From the arches of inosculation thus formed, small branches pass to the colon for the supply of its coats.

Those branches of the superior mesenteric artery which supply the ascending colon have a layer of peritoneum only on their anterior aspect: the others lie between two strata.

**Varieties.**—The number of the branches of this artery, both intestinal and colic, is by no means constant. It also frequently gives off accessory branches to the neighbouring viscera; of these that to the liver is the most common. It may replace the gastro-duodenal or its chief branch, the right epiploic (Henle), or it may give accessory pancreatic and splenic branches (Hyrtl). It has also been seen to give off the left colic and superior hæmorrhoidal arteries when the inferior mesenteric was absent (Fleischmann). A rare anomaly is the presence of an omphalo-mesenteric artery, arising either from the main stem or from one of the branches of the superior mesenteric. In one case it ran direct to the umbilicus where it gave a branch to the urachus (Haller). In another it reached the anterior wall of the abdomen rather below the umbilicus, and after giving a branch to the rectus, which anastomosed with the deep epigastric, it terminated by winding round the ligamentum teres, and forming a capillary network on the suspensory ligament of the liver (Hyrtl).

**Inferior mesenteric artery.**—This artery, much smaller than the superior mesenteric, supplies the lower half of the colon, and the greater part of the rectum. It arises from the aorta, between one and two inches above the bifurcation of that trunk.

The inferior mesenteric artery inclines to the left side in the direction of the left iliac fossa, from which point it descends between the layers of the mesorectum into the pelvis, and, under the name of *superior hæmorrhoidal* artery, runs down behind the rectum. It lies at first close to the aorta, on its left side, and then crosses over the left common iliac artery.

**BRANCHES.**—(a) The *left colic* artery is directed to the left side behind the peritoneum, and across the left kidney to reach the descend-



ing colon. It divides into two branches, and forms a series of arches in the same way as the colic vessels of the opposite side. One of

Fig. 279.

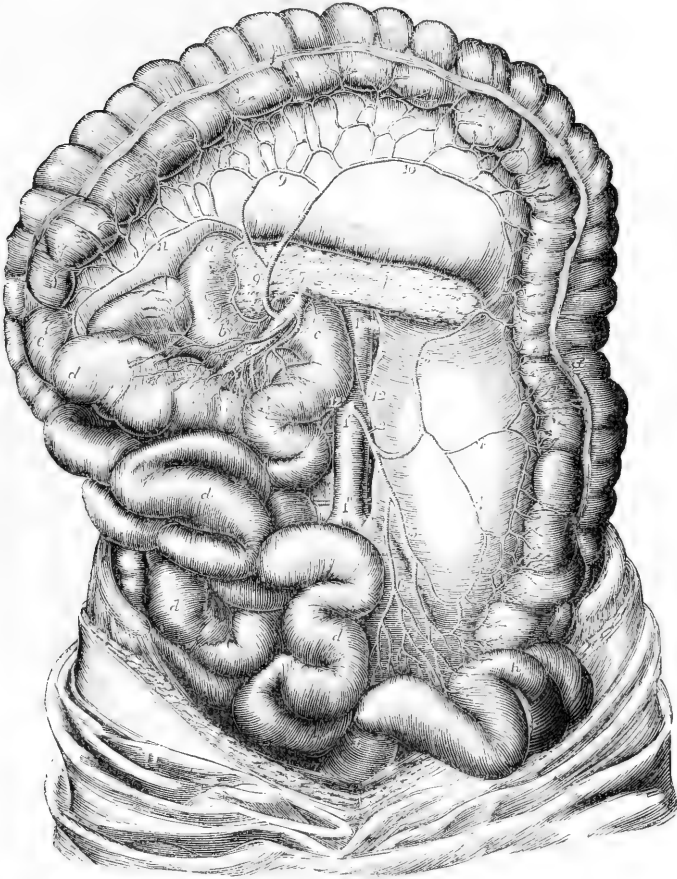


Fig. 279.—THE INFERIOR MESENTERIC ARTERY WITH ITS DISTRIBUTION AND COMMUNICATIONS (from Tiedemann). †

The small intestines with the superior mesenteric artery are turned towards the right side, the pancreas is exposed, and the large intestine is stretched out : *a*, *b*, the duodenum ; *c*, the commencement of the jejunum ; *d*, the small intestine ; *e*, the ascending colon ; *f*, the transverse colon ; *g*, the descending colon ; *h*, the sigmoid flexure ; *i*, the commencement of the rectum ; *k*, the pancreas ; *l*, placed on the trunk of the abdominal aorta at the origin of the renal arteries ; *l'*, on the same at the origin of the inferior mesenteric ; *l''*, near the division into common iliac arteries ; *2*, inferior mesenteric, giving off the left colic ; *3*, ascending branch of the left colic ; *4*, branches to the descending colon ; *5*, the sigmoid branch ; *6*, the superior hæmorrhoidal branch ; *7*, the trunk of the superior mesenteric issuing from behind the pancreas ; *8*, some of its intestinal branches ; *9*, the middle colic artery ; *10*, its left branch forming a loop of communication with the left colic ; *11*, its right branch ; *12*, the spermatic arteries.

these two branches passes upwards along the colon, and inosculates with the descending branch of the middle colic; whilst the other descends towards the sigmoid flexure, and anastomoses with the sigmoid artery.

(b) The *sigmoid* artery runs obliquely downwards to the sigmoid flexure of the colon, where it divides into branches; some of which incline upwards and form arches with the preceding vessel, while others turn downwards to the rectum and anastomose with the following branch. Instead of a single sigmoid artery, two or three branches are sometimes present.

(c) The *superior hæmorrhoidal* artery, the continuation of the inferior mesenteric, passes downwards over the common iliac artery and vein into the pelvis behind the rectum, lying at first in the meso-rectum, and then divides into two branches which extend one on each side of the intestine toward the lower end. About five inches from the anus these subdivide into branches, about a line in diameter, which pierce the muscular coat two inches lower down. In the intestine, these arteries, about seven in number, and placed at regular distances from each other, descend between the mucous and muscular coats to the end of the gut, where they communicate in loops opposite the internal sphincter, and end by anastomosing with the middle and inferior hæmorrhoidal arteries.

**Varieties.**—Absence of this artery has been noted, its branches being given off by the superior mesenteric. It has also been found supplying accessory branches to the liver and kidneys.

**Anastomoses on the intestinal tube.**—The arteries distributed to the alimentary canal communicate freely with each other over the whole length of that tube. The arteries of the great intestine derived from the two mesenteric arteries, form a range of vascular arches along the colon and rectum, at the lower end of which they anastomose with the middle and inferior hæmorrhoidal arteries, given from the internal iliac and pudic arteries. The branches from the left side of the superior mesenteric form another series of arches along the small intestine, which is connected with the former by the ileo-colic artery. Farther, a branch of the superior mesenteric joins upon the duodenum with the superior pancreatico-duodenal artery. The latter, at its commencement, is in a manner continuous with the pyloric artery; and so likewise, through the coronary artery of the stomach and its ascending branches, a similar connection is formed with the œsophageal arteries, even up to the pharynx.

The **suprarenal** or **capsular** arteries are two very small vessels which arise from the aorta on a level with the superior mesenteric artery, and incline obliquely outwards upon the crura of the diaphragm to reach the suprarenal capsules, to which bodies they are distributed, anastomosing at the same time with the upper and lower capsular branches derived respectively from the phrenic and the renal arteries. In the fetus these arteries are of large size.

**Varieties.**—This middle suprarenal artery is often very small, its place being supplied by the superior and inferior suprarenals. The middle suprarenal sometimes gives off the spermatic artery. This occurs usually on the left, but it also occurs, though rarely, on the right side (Henle).

The **renal** or **emulgent** arteries, of large diameter in proportion to the size of the organs which they supply, arise from the sides of the

aorta, about half an inch below the superior mesenteric artery, that of the right side being rather lower down than that of the left. Each is directed outwards, so as to form nearly a right angle with the aorta. In consequence of the position of the aorta upon the spine, the right renal artery has to run a somewhat longer course than the left, in order to reach the kidney. The artery of the right side crosses behind the vena cava, and both right and left arteries are overlapped by the accompanying renal veins. Previously to reaching the concave border of the kidney, each artery divides into four or five branches, the greater number of which usually lie intermediate between the vein in front and the pelvis of the kidney behind. These branches, after having passed deeply into the fissure of the kidney, subdivide and are distributed in the gland, in the manner described in the account of the structure of that organ.

**Branches.**—The renal artery, before passing into the glandular substance, furnishes a small branch to the suprarenal capsule, a second to the ureter, and several others which ramify in the connective tissue and fat behind the kidney.

**Varieties.**—The renal artery may be replaced by two, three, four, or even five branches; and the greatest difference as to the origin of these vessels is found to exist even on opposite sides of the same body. As they usually arise in succession from the aorta itself, it would seem as if the deviation were merely an increased degree of that in which the renal artery divides into branches sooner than usual after its origin. In some cases a renal artery has been seen to proceed from the common iliac; and in one case, described by Eustachius, from the internal iliac. Portal found in one instance the right and left renal arteries arising by a common trunk from the fore part of the aorta. In another case, one of several arteries arose from the front of the aorta at its bifurcation; or from the left common iliac at its origin.

The branches of the renal artery, instead of entering at the hilus, sometimes reach and penetrate the gland near its upper end, or on its anterior surface. The right renal artery has been seen to cross the vena cava in front instead of behind. Supernumerary branches are also frequently found. The most common are, the diaphragmatic from the inferior suprarenal; a hepatic branch from the right renal; branches to the small and large intestines; the middle suprarenal; the spermatic, and various lumbar arteries. Lastly, cases occur, though very rarely, in which one of the renal arteries is wanting.

**Spermatic and ovarian arteries.**—The spermatic arteries, two small and very long vessels, arise close together from the fore part of the aorta a little below the renal arteries. Each artery is directed downwards and outwards, resting on the psoas muscle; it crosses obliquely the ureter and, afterwards, the external iliac artery, and turns forward to the internal abdominal ring. There it comes into contact with the vas deferens, and, separating from the peritoneum, passes with the other constituents of the spermatic cord along the inguinal canal, and descends to the scrotum, where it becomes tortuous, and reaching the back part of the testis anastomoses with the artery of the vas deferens, and finally divides into branches which pierce the fibrous capsule of the testis.

In the female, the ovarian arteries, corresponding to the spermatic arteries in the male, are shorter than these vessels, and do not pass out of the abdominal cavity. The origin, direction, and connections of the ovarian artery in the first part of its course are the same as in the male; but at the margin of the pelvis it inclines inwards, and running tortu-

Fig. 280.

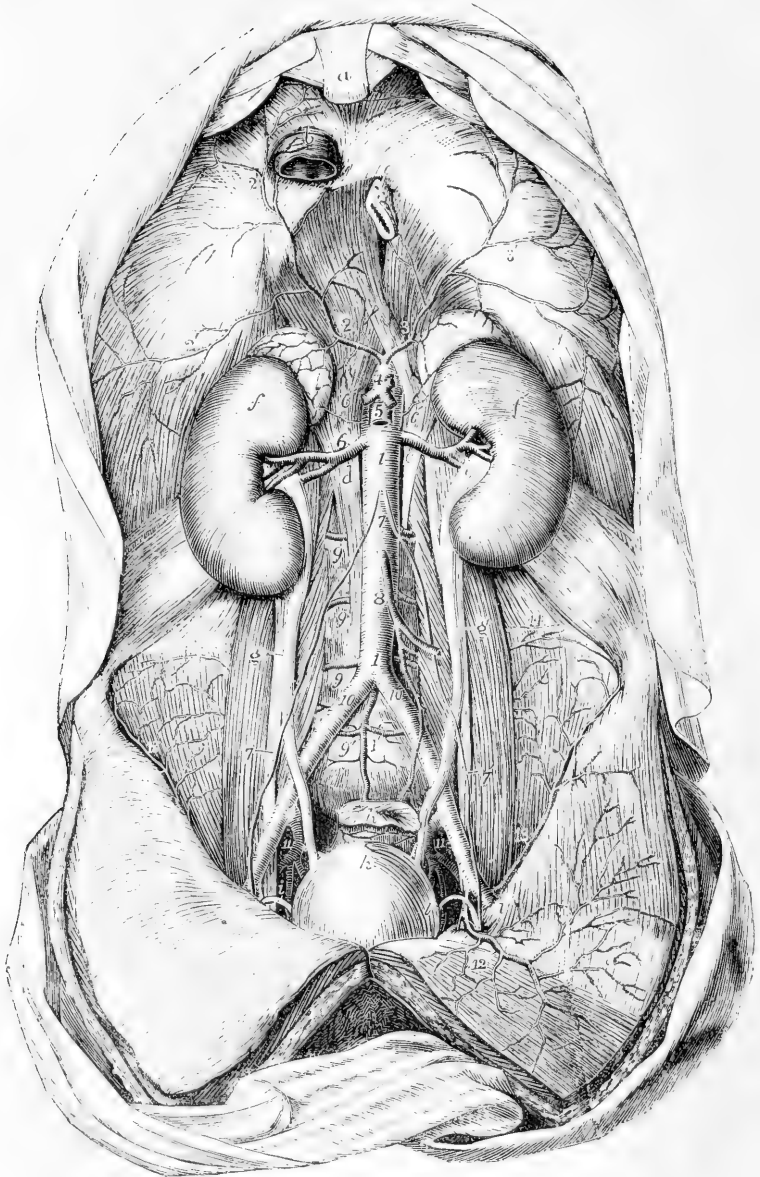


Fig. 280.—VIEW OF THE ABDOMINAL AORTA AND ITS PRINCIPAL BRANCHES  
(from Tiedemann).  $\frac{1}{4}$

For the detailed description of this figure, see p. 422; 6, renal arteries; 6', suprarenal arteries arising from the aorta; other suprarenal arteries are seen proceeding from the inferior phrenic; 7, placed on the abdominal aorta below the origin of the spermatic arteries; 7', lower down the same arteries descending on the psoas muscles and crossing the ureters, that on the left side entering the internal inguinal

aperture along with the vas deferens (*i*) ; 8, inferior mesenteric artery ; 9, lumbar arteries ; 9', the lowest lumbar artery rising in this instance from the middle sacral (1') ; 10, 10', right and left common iliac arteries ; 11, 11, placed between the external and internal iliac arteries on each side ; 12, left epigastric artery ; 13, circumflex iliac artery.

ously between the layers of the broad ligament of the uterus, is guided to the attached margin of the ovary, which it supplies with branches. Some small offsets can be also traced along the round ligament into the inguinal canal, and others along the Fallopian tube : one, continuing inwards towards the uterus, joins with the uterine artery.

In early foetal life the spermatic and ovarian arteries are short, as the testes and the ovaries are at first placed close to the kidneys, but the arteries become lengthened as these organs descend to their ultimate positions.

**Varieties.**—The *spermatic* arteries occasionally arise by a common trunk. Two spermatic arteries are not unfrequently met with on one side ; both of these usually arise from the aorta, though sometimes one is a branch from the renal artery. A case has occurred of three arteries on one side,—two from the aorta and the third from the renal.

#### B.—PARIETAL BRANCHES OF THE ABDOMINAL AORTA.

**Inferior phrenic arteries.**—The phrenic arteries are two small vessels, which spring from the aorta, either close together or by a short common trunk, on a level with the under surface of the diaphragm. When they arise separately from each other, one is frequently derived from the cœliac artery close to its origin, and the other from the aorta immediately above. They soon diverge from each other, and, passing across the crura of the diaphragm, incline upwards and outwards upon its under surface ; the artery of the left side passing behind the œsophagus, whilst that of the right side passes behind the vena cava. Before reaching the central tendon of the diaphragm, each of the arteries divides into two branches, of which one runs forwards towards the anterior margin of the thorax, and anastomoses with the musculophrenic branch of the internal mammary artery, while the other pursues a transverse direction towards the side of the thorax, and communicates with the terminations of the intercostal arteries.

**Branches.**—Each phrenic artery gives small branches (superior capsular) to the suprarenal capsule of its own side ; the left artery sends some branches to the œsophagus, whilst the artery of the right side gives off small vessels which reach the termination of the vena cava. Small offsets descend to the liver between the layers of the peritoneum.

**Varieties.**—The *phrenic* arteries are found to vary greatly in their mode of origin, but these deviations seem to have little influence on their course and distribution. In the first place they may arise either separately, or by a common trunk : and it would appear that the latter mode of origin is nearly as frequent as the former. When the two arteries are joined at their origin, the common trunk arises most frequently from the aorta ; though, sometimes, it springs from the cœliac axis. When arising separately, the phrenic arteries are given off sometimes from the aorta, more frequently from the cœliac axis, and occasionally from the renal ; but it most commonly happens that the artery of the right side is derived from one, and that of the left side from another of these sources. An additional phrenic artery (derived from the left hepatic) has been met with.

In only one out of thirty-six cases observed by R. Quain did the phrenic arteries

arise in the mode ordinarily described; viz., as two separate vessels from the abdominal aorta. (Op. cit. p. 417.)

**Lumbar arteries.**—The lumbar arteries resemble the intercostal arteries, not only in their mode of origin, but also in a great measure in the manner of their distribution. They arise from the back part of the aorta, and are usually four in number on each side. They pass outwards, each resting on the body of the corresponding lumbar vertebra, from the first to the fourth, and soon dip deeply under the psoas muscle. The two upper arteries are likewise under the pillars of the diaphragm; and those on the right side are covered by the vena cava. At the interval between the transverse processes, each lumbar artery divides into an *abdominal* and a *dorsal* branch.

**Branches.**—(a) The *abdominal* branch of each lumbar artery runs outwards behind the quadratus lumborum,—the lowest of these branches not unfrequently in front of that muscle. Continuing outwards between the abdominal muscles, the artery ramifies in their substance, and maintains communications with branches of the epigastric and internal mammary in front, with the terminal branches of the intercostals above, and with those of the ilio-lumbar and circumflex iliac arteries below.

(b) The *dorsal* branch of each lumbar artery, like the corresponding branch of the intercostal arteries, gives off, immediately after its origin, an offset, named *spinal*, which enters the spinal canal. The dorsal branch then proceeding backwards with the posterior primary branch of the corresponding lumbar nerve between the transverse processes of the vertebrae, divides into smaller vessels, which are distributed to the muscles and integuments of the back.

(c) The *spinal branch* enters the spinal canal through the intervertebral foramen, and, having given an offset which runs along the nerves to the dura mater and cauda equina, it communicates with the other spinal arteries, and divides into two branches, which are distributed to the bones in the following manner:—one curves upwards on the back part of the body of the vertebra above, near to the root of the pedicle, whilst the other descends in a similar manner on the vertebra below; and each communicates with a corresponding branch from the neighbouring spinal artery. As this arrangement prevails on both sides and throughout the whole length of the spine, there is formed a double series of arterial arches behind the bodies of the vertebrae, the convexities of which are turned towards each other. From the arches on opposite sides offsets are directed inwards at intervals to reinforce a median longitudinal vessel, which extends along the spine like the single artery on the front of the spinal cord. The arches are moreover joined together across the bodies of the vertebrae by transverse branches.

From this interlacement of vessels, numerous ramifications are distributed to the periosteum and the bones.

**Varieties.**—The *lumbar* arteries of opposite sides, instead of taking their origin separately from the aorta, occasionally commence by a common trunk, whose branches pass out laterally, and continue their course in the ordinary way. Two arteries of the same side are sometimes conjoined at their origin. On the last lumbar vertebra, the place of a lumbar artery is often taken by a branch from the middle sacral artery, and the ilio-lumbar compensates for the absence of the lumbar vessel amongst the muscles.

#### MINUTE ANASTOMOSES OF THE VISCERAL AND PARIETAL BRANCHES OF THE ABDOMINAL AORTA.

The existence of minute anastomoses between some of the visceral branches of the abdominal aorta and those supplying the wall of the cavity has been recognised by several anatomists, and various examples have been noticed in the previous description. These communications have been more distinctly proved and

their nature elucidated by W. Turner in a series of experimental injections, made with a view to their detection. ("Brit. and For. Med. Chirug. Review," July, 1863.)

These anastomoses constitute a well-marked vascular plexus, situated in the subperitoneal tissue, which Turner calls the *subperitoneal arterial plexus*. It occupies the lumbar region from the diaphragm downwards into the iliac regions and pelvis, and establishes communication between the parietal vessels and those of the viscera, chiefly, though not exclusively, through branches of the arteries of those viscera which are situated behind the peritoneum. It belongs to the renal and suprarenal arteries, those of the pancreas and duodenum, the cæcum, and the ascending and descending parts of the colon. It extends also to the vessels of the rectum, and to the spermatic arteries in their descent through the abdomen, and into the inguinal canal and scrotum.

In these situations it was found that the injected material (coloured gelatine) when thrown into the vessels of the viscus, so as to fill them completely, extended through the subperitoneal plexus in various ways, so as to reach one or other set of parietal vessels, such as the lumbar, ilio-lumbar, circumflex iliac, lower intercostal, and epigastric arteries; and in the pelvis, the middle and lateral sacral arteries; and in the scrotum, the superficial pudic and perineal arteries.

The more direct inoculations of the hæmorrhoidal arteries on the rectum with the inferior hæmorrhoidal branches of the pubic artery are well known, and the importance of these and other similar anastomoses, as well as the more extensive and minute anastomosing plexus investigated by Turner, is obvious, with reference not merely to the nutrition of the subperitoneal tissue, but also to the debated question of the influence exerted by local superficial blood-letting on the state of the vessels of the deeper viscera.

**Middle sacral artery.**—The middle sacral artery, the last of the branches of the abdominal aorta, is a small vessel about the size of a crowquill, which arises from the extremity of the aorta just at the bifurcation. From this point the artery proceeds downwards upon the last lumbar vertebra and over the middle of the sacrum, as far as the coccyx, where it forms small arches of anastomosis with the lateral sacral arteries.

**Branches.**—From its anterior surface some small branches come forward within the fold of the meso-rectum, and ramify upon the posterior surface of the intestine; and on each side others spread out upon the sacrum, and anastomose with the lateral sacral arteries, occasionally sending small offsets into the anterior sacral foramina.

**Varieties.**—The middle sacral artery sometimes deviates a little to the side. It may proceed, not from the bifurcation of the aorta, but from one of the common iliac arteries, usually from that of the left side. This artery represents the caudal prolongation of the aorta of animals.

#### COMMON ILIAC ARTERIES.

The common iliac arteries, commencing at the bifurcation of the aorta, pass downwards and outwards, diverging from each other, and divide opposite the lumbo-sacral articulation into the internal and external iliac arteries.

The common iliac arteries measure usually about two inches in length. Both are covered by the peritoneum and the intestines, and are crossed by the ureters near their point of division, as well as by the branches of the sympathetic nerve which are directed towards the hypogastric plexus. They rest on the bodies of the vertebrae, and come into contact with the psoas muscle.

The common iliac artery of the right side is separated from the front of the last lumbar vertebra, the two common iliac veins being interposed. The artery of the left side is crossed by the branches of the inferior mesenteric vessels.

*Relation to Veins.*—The left iliac vein, supported on the last lumbar vertebra, lies to the inner side of, and below the left artery. On the right side there are three veins in proximity to the artery; the right iliac vein lying behind the lower part of the vessel, the left iliac vein

Fig. 281.

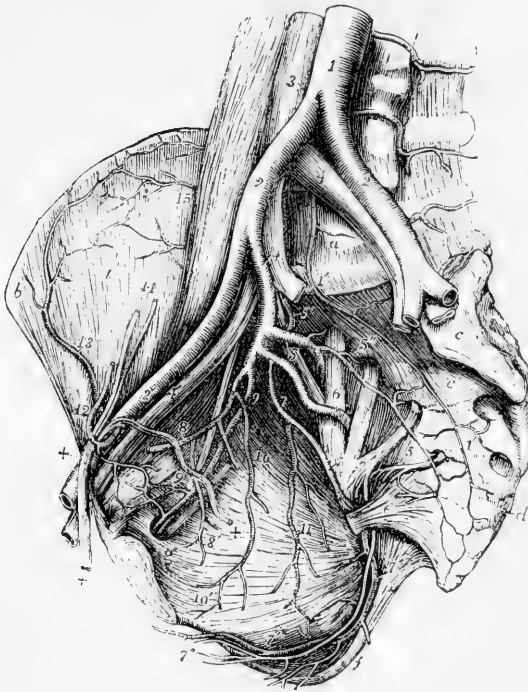


Fig. 281.—VIEW OF THE RIGHT SIDE OF A MALE PELVIS SHOWING THE EXTERNAL AND INTERNAL ILIAC ARTERIES AND THEIR BRANCHES. (A.T.)  $\frac{1}{2}$

The viscera of the pelvis have been removed as well as the internal iliac veins: the larger nerves have been retained. *a*, body of the fifth lumbar vertebra; *b*, anterior and superior spine of the right ilium; *c*, left auricular surface of the sacrum; *c'*, third piece of the sacrum; *d*, first piece of the coccyx; *e*, short sacro-sciatic ligament; *f*, tuberosity of the ischium covered internally by the great sacro-sciatic ligament; *g*, obturator foramen; *i*, iliacus muscle; 1, abdominal aorta; 1', middle sacral artery; 2, 2, common iliac arteries; 2', right external iliac; 3, vena cava inferior; 4, 4, common iliac veins; the

number on the right points by a line to the right internal iliac artery; 4', right external iliac vein; 5, placed on the lumbo-sacral nervous trunk, points to the posterior division of the internal iliac artery giving off the gluteal; 5', ilio-lumbar artery; 5'', lateral sacral artery with branches passing into the anterior sacral foramina; 6, placed on the anterior division of the first sacral nerve, points to the sciatic artery coming from the anterior division of the internal iliac; 7, pudic artery; 7', the same artery passing behind the spine of the ischium, and proceeding within the ischium and obturator internus muscle, accompanied by the pudic nerve towards the perineum; towards *f*, inferior hæmorrhoidal branches are given off; 7'', superficial perineal artery and nerve; 8, hypogastric artery, with the obliterated remains of the umbilical artery cut short, and 8', superior vesical branches rising from it; 9, obturator artery with the corresponding nerve and vein; 9', the pubic twigs which anastomose with descending twigs of the epigastric artery; 10, inferior vesical; 11, middle hæmorrhoidal vessels rising in this instance from the pudic; 12, epigastric artery winding to the inside of +, +, the vas deferens and spermatic cord; 13, circumflex iliac artery; 14, spermatic artery and vein divided superiorly; 15, twigs of the ilio-lumbar artery proceeding to anastomose with the circumflex iliac.



crossing behind it, and the vena cava, resulting from the union of the two others, being on the right side of the artery at its upper end.

**Varieties.**—*The place of division* of these arteries is subject to great variety. In two thirds of a large number of cases, it ranged between the middle of the last lumbar vertebra and the upper margin of the sacrum; in one case out of eight it was above, and in one case out of six it was below that space. Most frequently the left artery was found to divide lower down than the right. (R. Quain.)

*The length* varies in most instances between an inch and a half and three inches, but it has been seen in some rare cases less than half an inch, and as long as four inches and a half. In one instance recorded by Cruveilhier, ("Anat. descript." v. iii., p. 186,) the right common iliac artery was wanting, and the internal and external vessels of that side arose as distinct branches from the aorta.

*Branches.*—The common iliac artery often gives off a small unnamed branch to the lymphatic glands, the ureter or the psoas muscle, and sometimes even a larger branch—a renal artery, a lumbar, or the ilio-lumbar.

#### SURGICAL ANATOMY OF THE COMMON ILIAC ARTERY.

The common iliac artery may be reached in an operation by dividing the abdominal muscles in the iliac region. The incision may be made, beginning above the middle of Poupart's ligament, and running parallel with that structure towards the anterior superior spine of the ilium, thence curving for two inches towards the umbilicus. In cutting through the muscles, care is to be taken of the deep epigastric and circumflex iliac arteries, and especially of the peritoneum, which, with the subperitoneal fascia and the adherent ureter, are to be carefully stripped from the iliac and psoas muscles till the artery is reached. The delicate sheath is then scraped through and the ligature applied.

#### INTERNAL ILIAC ARTERY.

The internal iliac artery (art. hypogastrica,) extends from the bifurcation of the common iliac artery towards the sacro-sciatic foramen, near which it divides into branches. It is usually about an inch and a half in length, and is smaller than the external iliac in the adult, but the reverse in the fœtus. At its origin, the artery lies near the inner border of the psoas muscle: lower down, it rests against part of the pyriform muscle. Behind it are situated the internal iliac vein, and the communicating branch which passes from the lumbar to the sacral plexus of nerves: in front it is crossed by the ureter, which separates it from the peritoneum.

**BRANCHES.**—The branches of the internal iliac artery, though constant and regular in their general distribution, vary much in their origin. They arise, in most instances, from two principal divisions of the parent trunk, of which one is anterior to the other. From the *anterior division* arise the superior vesical (connected with the pervious portion of the fœtal hypogastric artery), the inferior vesical, middle hæmorrhoidal, obturator, internal pudic, and sciatic arteries, and also, in the female, the uterine and the vaginal arteries. The *posterior division* gives off the gluteal, the ilio-lumbar, and the lateral sacral arteries.

**Varieties.**—*Length.*—The internal iliac artery has been found as short as half an inch, and sometimes as long as three inches, but it is not often less than

an inch in length. An instance has been observed in which this vessel was absent, and its branches were derived from a bend of the external iliac artery down into the pelvis (Preparation in Univ. Coll. Mus., London). The lengths of the common iliac and internal iliac arteries bear an inverse proportion to each other—the internal iliac being long when the common iliac is short, and *vice versa*. Moreover, when the common iliac is short, the internal iliac (arising higher than usual) is placed for some distance above the brim of the pelvis, and descends by the side of the external iliac to reach that cavity.

The *place of division* of the internal iliac into its branches varies between the upper margin of the sacrum and the upper border of the sacro-sciatic foramen.

*Branches.*—Sometimes all the branches of the internal iliac artery arise without the previous separation of that vessel into two portions.

In more than a fourth of R. Quain's cases a branch, corresponding usually to the ilio-lumbar artery, arose before the subdivision of the main trunk.

**Hypogastric Artery.**—*In the fetus*, the internal iliac artery, retaining almost the full size of the common iliac, curves forwards from that artery to the side of the urinary bladder, and ascends on the anterior wall of the abdomen to the umbilicus. There the vessels of opposite sides come into contact with one another, and with the umbilical vein, and coiling spirally round that vein in the umbilical cord, they proceed to the placenta. To that part of the artery which is placed within the abdomen, the term *hypogastric* is applied; the remaining portion, passing onwards through the umbilicus to the placenta, being the proper *umbilical* artery. After the cessation of the placental circulation at birth, the two hypogastric arteries become impervious from the side of the bladder upwards to the umbilicus, and are converted into fibrous cords. These two cords, being shorter than the part of the peritoneum on which they rest, cause a fold of the serous membrane to project inwards; and thus are formed two fossæ (external and internal fossæ of the peritoneum) on each side of the abdomen, in one or other of which the projection of a direct inguinal hernia takes place. The part of the artery intervening between its origin and the side of the bladder remains pervious, although proportionally much reduced in size, and forms the trunk of the superior vesical artery.

#### BRANCHES OF INTERNAL ILIAC ARTERY.

The **superior vesical** artery is, at its commencement, that part of the hypogastric artery in the *fœtus* which remains pervious after the changes that take place subsequently to birth. It extends from the anterior division of the internal iliac to the side of the bladder.

**Branches.**—(a) It distributes numerous branches to the upper part and sides of the bladder.

(b) The *artery of the vas deferens*, arising from one of the lowest of these, is a slender artery which reaches the vas deferens, and accompanies that duct in its course through the spermatic cord to the back of the testicle, where it anastomoses with the spermatic artery.

(c) Other small branches ramify on the lower end of the ureter.

The **inferior vesical** artery (vesico-prostatic), derived usually from the anterior division of the internal iliac, is directed downwards to the lower part of the bladder, where it ends in branches which are distributed to the base of the bladder, to the side of the prostate, and to the vesiculæ seminales. One offset, to be presently described, descends upon the rectum.

The branches upon the prostate communicate more or less freely upon that body with the corresponding vessels of the opposite side, and, according to Haller, with the perineal arteries.

Small twigs of this vessel also run towards the subpubic arch, and in instances

of deficient pudic arteries replace one or more of their branches, as will be more fully noticed under those arteries.

Besides the superior and inferior vesical arteries, other smaller branches will be found to reach the bladder, and usually one slender vessel which is distributed particularly to the under surface of the vesiculæ seminales.

Fig. 282.

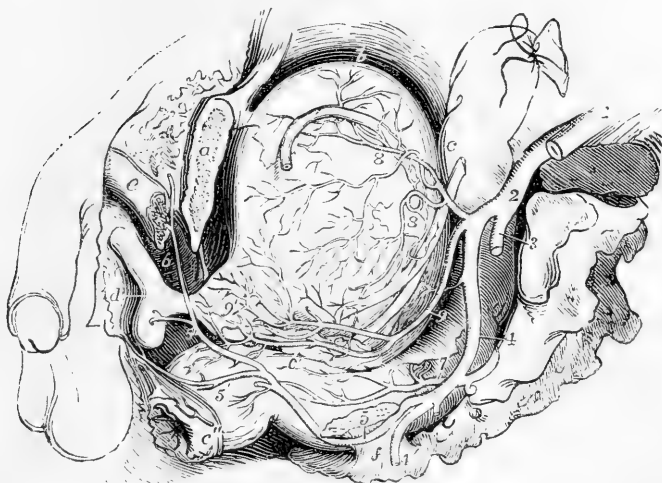


Fig. 282.—VIEW OF THE VISCERA OF THE MALE PELVIS FROM THE LEFT SIDE, SHOWING THE VISCERAL AND PUDIC ARTERIES (from R. Quain).  $\frac{1}{2}$

*a*, the os pubis divided a little to the left of the symphysis; *b*, placed close to the upper part of the urinary bladder, upon which lies the vas deferens; *c*, placed on the upper part of the rectum, near the left ureter; *c'*, at the junction of the middle and lower parts of the rectum points to the vesicula seminalis; *c''*, the anus; *d*, the urethral bulb; *e*, the crus penis divided; *f*, the short sacro-sciatic ligament attached to the spine of the ischium; 1, common iliac artery; 2, internal iliac artery; 3, gluteal artery cut short; 4, common trunk of the sciatic and pudic arteries; 4', sciatic artery cut as it is passing out of the great sacro-sciatic foramen; 5, placed on the divided surface of the ischium near the spine, points to the pudic artery as it is about to re-enter the pelvis by the lesser sacro-sciatic foramen; 5', the superficial perineal branches of the pudic; 5'', the pudic artery, proceeding to give the artery of the bulb, and passing on to give 6, the artery of the crus penis and the dorsal artery of the penis; 7, placed on the middle part of the rectum, points to the descending branches of the superior hæmorrhoidal artery; 8, the superior and middle vesical arteries; 9, the inferior vesical artery, of considerable size in this instance, giving branches to the bladder, the vesicula seminalis, the rectum (middle hæmorrhoidal), and 9', to the prostate gland.

**Middle hæmorrhoidal artery.**—This branch is usually supplied to the rectum by the inferior vesical artery, but sometimes proceeds from other sources. It anastomoses with the branches of the other hæmorrhoidal arteries.

The **uterine artery** is directed downwards from the anterior division of the internal iliac artery towards the neck of the uterus. Insinuating itself between the layers of the broad ligament, it passes upwards on the side of the uterus, pursuing an exceedingly tortuous course, and sends off numerous branches, which enter the substance of that organ.

This artery supplies small branches to the bladder and the ureter; and, near its termination, communicates with an offset directed inwards from the ovarian artery.

**Vaginal artery.**—The vagina derives its arteries principally from a branch which corresponds with the inferior vesical in the male. The *vaginal* artery descends and ramifies upon the vagina, at the same time sending some offsets to the lower part of the bladder over the neck, and others to the contiguous part of the rectum.

Fig. 283.

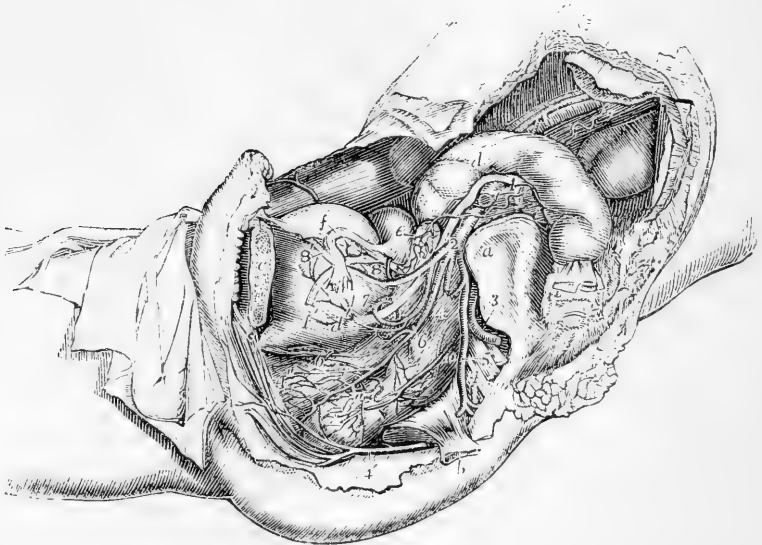


Fig. 283.—VIEW OF THE DISTRIBUTION OF THE ARTERIES TO THE VISCERA OF THE FEMALE PELVIS, AS SEEN ON THE REMOVAL OF THE LEFT OS INNOMINATUM, &c. (from R. Quain).  $\frac{1}{4}$

*a*, the left auricular surface of the sacrum; *b*, the spine of the ischium with the short sacro-sciatic ligament; *c*, the os pubis divided a little to the left of the symphysis; *d*, placed upon the sigmoid part of the colon, and *d'* on the lower part of the urinary bladder, point to the ureter; *e*, on the upper part of the body of the uterus, points by a line to the left ovary; *f*, on the upper part of the bladder, points to the left Fallopian tube; *f'*, round ligament of the uterus; 1, left external iliac artery cut short; 2, left internal iliac artery; 3, gluteal artery cut short; 4, 4, left pudic artery from which a part has been removed; 4', the same artery after it has re-entered the pelvis proceeding towards the muscles of the perinæum, clitoris, &c.; 5, placed on the sacral nerves, points to the sciatic artery; 6, 6', inferior vesical and vaginal arteries; 6'', branches from these to the rectum; 7, uterine artery much coiled; 8, the superior vesical, and 8', the remains of the hypogastric artery; 9, 9, the left ovarian artery, descending from the aorta, and emerging from below the peritoneum; 10, the superior hæmorrhoidal artery spreading over the left side of the rectum.

The **obturator artery**, while it usually arises from the anterior division of the internal iliac artery, is sometimes derived from its posterior division. The artery is directed forwards along the inside of the pelvis to reach the groove at the upper part of the thyroid foramen. By this aperture it passes out of the pelvis, and immediately divides into its

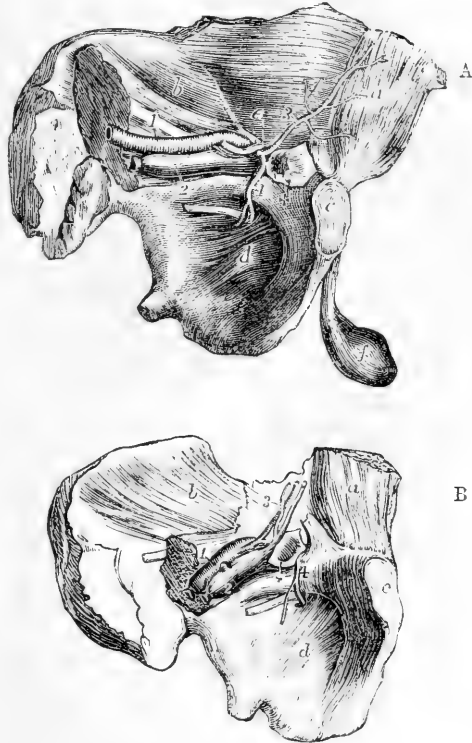
terminal branches. In its course through the pelvis, the artery is placed between the pelvic fascia and the peritoneum, a little below the obturator nerve. Beneath the pubis it lies with its accompanying vein and nerve in an oblique canal, formed partly by a groove in the bone, and partly by fibrous tissue, after passing through which it divides immediately into an external and an internal branch, which are deeply placed behind the external obturator muscle.

**Branches.**—(a) *Within the pelvis*, besides others of smaller size, the obturator artery often supplies a branch to the iliac fossa and muscle, and one which runs backwards upon the urinary bladder.

(b) *Anastomotic vessels*, which may be called *pubic*, are given off by the obturator artery as it is about to escape from the pelvis: these vessels ramify on the back of the pubis, and communicate behind the bone and the attachments of the abdominal muscles, with small offsets from the epigastric artery. These anastomosing branches lie to the inner side of the crural ring.

Fig. 234, A. and B.—VIEWS OF THE LEFT WALL OF THE PELVIS, WITH THE ATTACHED ABDOMINAL MUSCLES FROM THE INSIDE, SHOWING DIFFERENT POSITIONS OF THE ABERRANT OBTURATOR ARTERIES (from R. Quain).  $\frac{1}{4}$

Fig. 234.



In A, a case is represented in which the aberrant artery passes to the outside of a femoral hernia; in B, an instance is shown in which it surrounds the neck of the sac.

*a*, posterior surface of the rectus muscle; *b*, iliacus internus muscle; *c*, symphysis pubis; *d*, obturator membrane; *e*, placed on the fascia transversalis, points to the vas deferens passing through the internal inguinal aperture; *f*, the testicle; +, the neck of a femoral hernial sac; 1, the external iliac artery; 2, the external iliac vein; below 2, the obturator nerve; 3, the deep epigastric artery; 4, aberrant obturator artery, arising from the epigastric.

(c) The *internal terminal* branch curves inwards beneath the obturator externus, close to the inner margin of the thyroid foramen, and furnishes branches to the obturator muscles, the gracilis, and the adductor muscles.

(d) The *external terminal* branch has a similar arrangement near the outer margin of the thyroid foramen; it descends as far as the ischial tuberosity, and supplies the obturator muscles, and the upper ends of the long muscles which are attached to that tuberosity. This branch usually sends off a small artery, which enters the hip-joint through the cotyloid notch, and ramifies in the synovial fatty tissue, and along the round ligament as far as the head of the femur,

The two terminal branches of the obturator artery communicate with each other near the lower margin of the obturator ligament, and anastomose with branches of the internal circumflex artery. The external branch also communicates with offsets from the sciatic artery near the tuber ischii.

**Varieties.**—The obturator artery frequently has its origin transferred to the commencement of the epigastric artery, and sometimes to the external iliac at its termination.

In 361 cases observed by R. Quain, the origin of the obturator artery varied as follows. In the proportion of 2 cases out of 3, it arose from the internal iliac: in 1 case out of  $3\frac{1}{2}$ , from the epigastric: in a very small number of cases (about 1 in 72), it arose by two roots from both the above-named vessels; and in about the same proportion, from the external iliac artery.

Sometimes the obturator artery arises from the epigastric on both sides of the same body, but in the majority of instances, this mode of origin of the vessel is met with only on one side.

When the obturator artery arises from the epigastric, it turns backwards into the pelvis to reach the canal at the upper part of the thyroid foramen; and in this course it is necessarily close to the crural ring, the opening situated at the inner side of the external iliac vein, through which hernial protrusions descend from the abdomen into the thigh. In the greater number of instances the artery springs from near the root of the epigastric, and is directed backwards close to the iliac vein, and therefore lies to the outer side of the femoral ring; but in other instances, arising from the epigastric artery higher up, it occasionally crosses over the ring, and curves to its inner side. It is when it takes this last course that the obturator artery is liable to be wounded in the operation for dividing the stricture in a femoral hernia.

The anastomosis which normally exists between the obturator artery and the epigastric explains the nature of the change which takes place when the origin of the obturator artery is transferred from the one place to the other. In such cases one of the anastomosing vessels may be supposed to have become enlarged, and the posterior or proper root of the obturator artery to have remained undeveloped or to have been obliterated in a proportionate degree.

The **internal pudic artery** is a branch of considerable size (smaller in the female than in the male), which is distributed to the external generative organs. The following description of this artery has reference to its arrangement in the male; its distribution in the female will be noticed separately.

The pudic artery arises from the anterior division of the internal iliac, sometimes by a trunk common to it and the sciatic artery. Proceeding downwards, it emerges from the pelvis along with the sciatic artery, through the great sacro-sciatic foramen, and continuing in a uniformly curved course, it re-enters the pelvis by the small sacro-sciatic foramen, immediately below the ischial spine, and passes forward on the inner side of the tuber ischii, in the substance of the obturator fascia.

Distant at first from the lower margin of the ischial tuberosity an inch or an inch and a half, it approaches the surface at the inner margin of the pubic arch, and lies subjacent to the triangular ligament or superficial layer of the subpubic fascia. Finally, piercing this fascia, it divides below the subpubic arch into the dorsal artery of the penis and the artery of the corpus cavernosum.

In the first part of its course, whilst within the pelvis, the pudic artery lies to the outer side of the rectum, and in front of the pyriformis muscle and the sacral nerves. Thence onwards it is accompanied by the pudic nerve and vein. On the ischial spine it is covered by the gluteus maximus muscle close to its origin. In the obturator fascia it

lies externally to the ischio-rectal fossa and internally to the obturator internus muscle, and beneath the triangular ligament it is crossed by the deep transverse perineal muscle.

**Branches.**—(a) The *inferior* or *external hæmorrhoidal* arteries, two or three in number, incline inwards from the pudic artery as it passes outside the ischio-rectal fossa above the tuber ischii. These small vessels run across the ischio-rectal fossa through the fat in that space, and are distributed to the sphincter and levator ani muscles, and to the parts surrounding the anus.

(b) The *superficial perineal* artery, a long, slender, but regular vessel, supplies

Fig. 285.

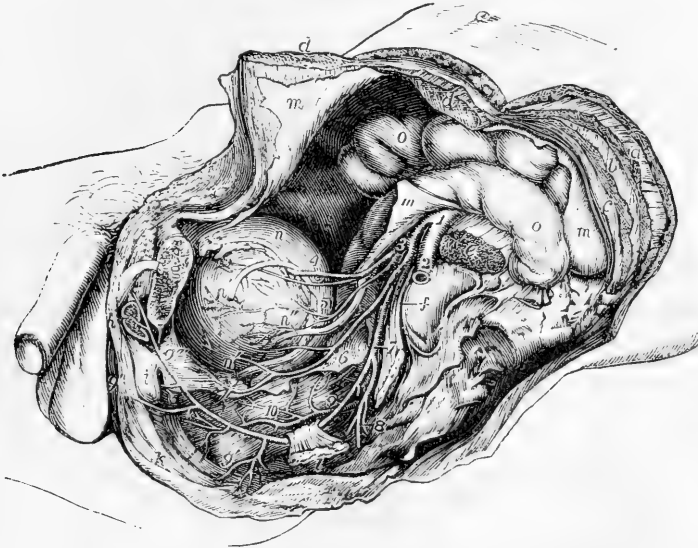


FIG. 285.—VIEW OF THE DISTRIBUTION OF THE ARTERIES TO THE VISCERA OF THE MALE PELVIS, AS SEEN ON THE REMOVAL OF THE LEFT OS INNOMINATUM, &c. (from R. Quain).  $\frac{1}{4}$

*a*, left external oblique muscle of the abdomen divided; *b*, internal oblique; *c*, transversalis; *d, d*, the parts of the divided rectus muscle; *e*, psoas magnus muscle divided; *f*, placed on the left auricular surface of the sacrum, points by a line to the sacral plexus of nerves; *g*, placed on the os pubis, sawn through a little to the left of the symphysis, points to the divided spermatic cord; *h*, the cut root of the crus penis; *i*, the bulb of the urethra; *k*, external sphincter ani muscle; *l*, spine of the ischium, to which is attached the short sacro-sciatic ligament; *m*, the parietal peritoneum; *n*, the upper part of the urinary bladder; *n', n'*, the left vas deferens descending towards the vesicula seminalis; *n''*, the ureter; *o*, the intestines; 1, the common iliac at the place of its division into external and internal iliac arteries; 2, left external iliac artery; 3, internal iliac; 4, obliterated hypogastric artery, over which the vas deferens is seen passing, with the superior vesical artery below it; 5, middle vesical artery; 6, inferior vesical artery, giving branches to the bladder, and descending on the prostate gland and to the back of the pubis; 7, placed on the sacral plexus, points to the common trunk of the pudic and sciatic arteries; close above 7, the gluteal artery is seen cut short; 8, sciatic artery cut short as it is escaping from the pelvis; 9, placed on the rectum, points to the pudic artery as it is about to pass behind the spine of the ischium; 9', on the lower part of the rectum, points to the inferior hæmorrhoidal branches; 9'', on the perineum, indicates the superficial perineal branches; 9''', placed on the prostate gland, marks the pudic artery as it gives off the arteries of the bulb and of the crus penis; 10, placed on the middle part of the rectum, indicates the superior hæmorrhoidal arteries as they descend upon that viscus.

the scrotum and the upper part of the perinæum. Given off from the pudic artery in front of the hæmorrhoidal branches, it turns upwards parallel with the pubic arch, crosses the transverse muscle of the perinæum, and runs forwards under cover of the superficial fascia, between the erector penis and accelerator urinæ muscles, supplying both. In this course the artery gradually becomes superficial, and is finally distributed to the skin of the scrotum and the dartos. It not unfrequently gives off the following branch.

Fig. 286.

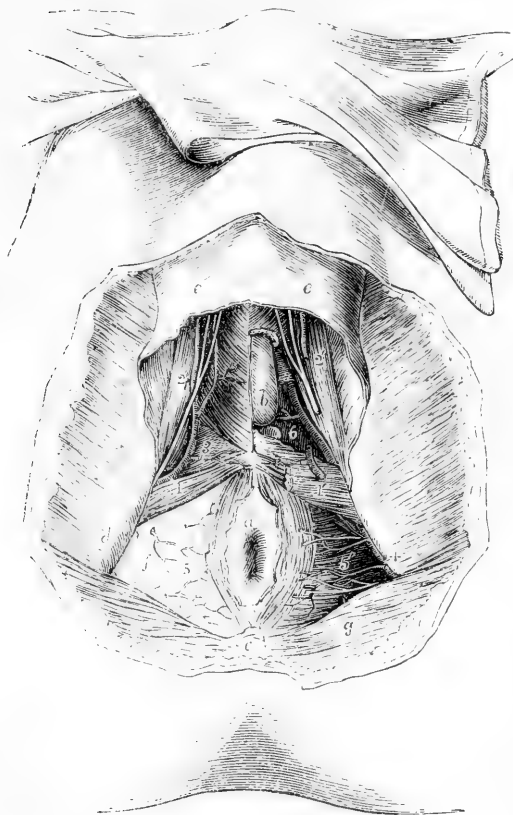


Fig. 286.—DISSECTION OF THE PERINEUM IN A YOUNG MALE SUBJECT SHOWING THE BLOOD-VESSELS, &c. (A.T.)  $\frac{1}{2}$

This drawing is made from a preparation upon a modification of the plan of R. Quain's 61st and 62nd Plates. The right side shows a superficial, the left a deeper view.

*a*, the anus, with a part of the integument surrounding it; *b*, left half of the bulb of the urethra exposed by the removal of a part of the bulbo-cavernosus muscle; *c*, coccyx; *d*, right tuberosity of the ischium; *e*, *e*, superficial perineal fascia passing forward upon the scrotum; *f*, right ischio-rectal fossa, from which the fat and fascia have not been removed; *g*, gluteus maximus muscle; *l*, placed on the right transversus perinæi muscle, points to the superficial perineal artery as it emerges in front (in this case) of the muscle; *l'*, placed on the left side on the surface of the triangular ligament near its reflection into the superficial fascia, points to the superficial perineal artery cut short; *2*, on the right ischio-cavernosus muscle,

points to the superficial perineal arteries and nerves passing forward; *2'*, the same on the left side, the vessels and nerves having been divided there; *3*, on the triangular ligament of the right side points to the transverse perineal branch of the superficial perineal artery; *4*, on the left tuberosity of the ischium, points to the pudic artery deep in the ischio-rectal fossa; *5*, *5'*, the inferior hæmorrhoidal branches of the pudic arteries and nerves; *6*, on the left side, placed in a recess from which the triangular ligament or anterior layer of the subpubic fascia has been removed to show the continuation of the pudic artery, its branch to the bulb, and one of Cowper's glands.

(*c*) The *transverse perineal* artery, a very small vessel, is frequently a branch of the preceding, but in some instances arises from the pudic artery. It crosses the perinæum, and terminates in small branches which are distributed to the



transverse muscle, and to the parts between the anus and the bulb of the urethra.

(d) The artery of the bulb is, surgically considered, an important vessel. It is very short; arising from the pudic between the layers of the sub-pubic fascia, and passing transversely inwards, this artery reaches the bulb a little in front of the central point of the perinaeum, and ramifies in the erectile tissue. It gives a branch to Cowper's gland.

(e) The artery of the *corpus cavernosum* (*profunda penis*), one of the terminal branches of the internal pudic, runs a short distance between the crus penis and the ramus of the pubis, and then continuing forward penetrates the crus, and ramifies in the *corpus cavernosum*.

(f) The dorsal artery of the penis runs between the crus and the pubic symphysis: having pierced the suspensory ligament, it continues along the dorsum of the penis immediately beneath the skin, and parallel with the dorsal vein, as well as with the corresponding artery of the opposite side. It supplies the integument of the penis, and the fibrous sheath of the *corpus cavernosum*, anastomosing with the deep arteries; and, near the corona glandis, divides into branches, which supply the glans and the prepuce.

**Varieties.**—*Origin.* The pudic artery is sometimes small, or it is defective in one or two, or even three of its usual branches, which, in those circumstances, are supplied by a supplemental vessel, the *accessory pudic*. The defect most frequently met with is that in which the pudic ends as the artery of the bulb, whilst the arteries of the *corpus cavernosum* and the dorsum of the penis are derived from the accessory pudic. But all the three arteries of the penis may be supplied by the accessory pudic, the pudic itself ending as the superficial perineal. A single accessory pudic has been found to supply both cavernous arteries, whilst the pudic of the right side gave both dorsal arteries. On the other hand, cases have occurred in which only a single branch was furnished by the accessory artery, either to take the place of an ordinary branch altogether wanting, or to supplement one of the branches which was diminutive in size.

The *accessory pudic* generally arises from the pudic itself, before the passage of that vessel from the sacro-sciatic foramen, and descends within the pelvis, and along the lower part of the urinary bladder. It lies on the upper part of the prostate gland, or it may be, for a short space, likewise on the posterior margin, and then proceeding forwards above the membranous part of the urethra, reaches the perinaeum, by piercing the fascia of the sub-pubic arch.

The accessory pudic sometimes arises from other branches of the internal iliac artery, and is not unfrequently connected with the prostatic or some other branch of the inferior vesical artery. A vessel having a similar distribution may spring from the external iliac, through an irregular obturator, or through the epigastric artery.

*Branches.*—The artery of the bulb is sometimes small, sometimes wanting on one side, and occasionally it is double. But a more important deviation from the common condition is one sometimes met with, in which the vessel, arising earlier, and crossing the perinaeum farther back than usual, reaches the bulb from behind. In such a case there is considerable risk of dividing the artery in performing the lateral operation for stone. On the other hand, when this small vessel arises from an accessory pudic artery, it lies more forward than usual, and out of danger in case of operation.

The dorsal artery of the penis has been observed to arise from the deep femoral artery and to pass obliquely upwards and inwards to reach the root of the penis. Tiedemann gives a drawing of this variety.

**The pudic artery in the female.**—In the female this vessel is much smaller than in the male. Its course is similar, and it gives the following branches.

The *superficial perineal* branch is distributed to the labia pudendi. The artery of the bulb supplies the mass of erectile tissue above and at the sides of the entrance of the vagina, named the bulb of the vagina; whilst the two terminal branches, corresponding to the artery of the

corpus cavernosum and the dorsal artery of the penis, are distributed to the clitoris, and are named the *profunda* and *dorsal* arteries.

The **sciatic artery**, the largest branch of the internal iliac trunk, excepting the gluteal, is distributed to the muscles on the back of the pelvis. It descends upon the pelvic surface of the pyriformis muscle and the sacral plexus of nerves; and turning backwards beneath the border of that muscle, it passes between it and the superior gemellus, and thus escapes from the pelvis, along with the great sciatic nerve and the pudic artery, at the lower part of the great sciatic foramen. Outside the pelvis, this artery lies in the interval between the tuber ischii and the great trochanter, covered by the gluteus maximus.

**Branches.**—The sciatic artery gives off several branches to the external rotator muscles of the thigh, on which it lies, and to the great gluteus by which it is concealed. Two others have received special names, viz., the following:—

(a) The *coccygeal*, inclines inwards, and piercing the great sacro-sciatic ligament, reaches the posterior surface of the coccyx, and ramifies in the fat and skin about that bone.

(b) The *comes nervi ischiadici* runs downwards, accompanying the sciatic nerve, along which it sends a slender vessel.

Some of the branches of this artery are distributed to the capsule of the hip-joint; whilst others, after supplying the contiguous muscles, anastomose with the gluteal, the internal circumflex, and the superior perforating arteries in the upper part of the long flexor muscles of the thigh.

The **gluteal artery**, the largest branch of the internal iliac, is distributed to the muscles on the outside of the pelvis. It inclines downwards to the great sacro-sciatic foramen, and escaping from the cavity of the pelvis, between the contiguous borders of the middle gluteal and the pyriform muscles, divides immediately into a superficial and a deep branch.

**Branches.**—(a) The *superficial* branch running between the gluteus maximus and gluteus medius, divides into ramifications which are most copiously distributed to the gluteus maximus, and anastomose with the sciatic and posterior sacral arteries.

(b) The *deep* branch, situated between the gluteus medius and gluteus minimus, runs in an arched direction forwards, and divides into two other branches. One of these, the superior branch, follows the upper border of the gluteus minimus beneath the middle gluteal muscle and the tensor of the fascia lata, towards the anterior iliac spine, and, after having freely supplied the muscles between which it passes, anastomoses with the circumflex iliac and the ascending branches of the external circumflex arteries. The second or inferior branch descends towards the great trochanter, supplies the gluteal muscles, and anastomoses with the external circumflex and the sciatic arteries.

(c) A *nutrient* branch enters the ilium at the place where the artery emerges from the pelvis.

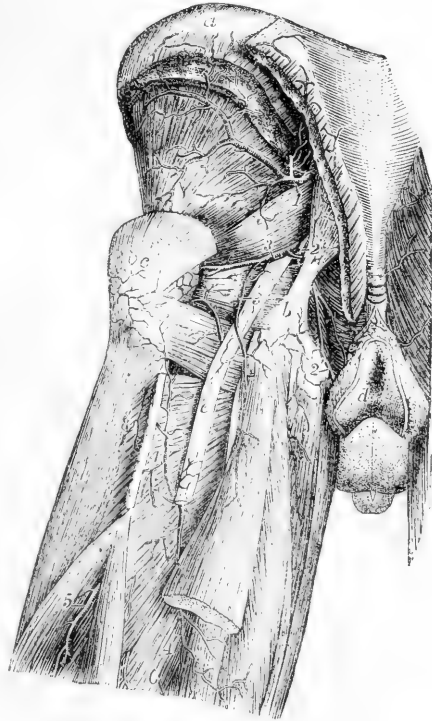
The **ilio-lumbar** artery resembles in a great measure one of the lumbar arteries. It passes outwards beneath the psoas muscle and the external iliac vessels, to reach the margin of the iliac fossa, where it separates into a *lumbar* and an *iliac* division. The first of these ramifies in the psoas and quadratus muscles, communicating with the last lumbar artery, and furnishing branches to the vertebral canal. The second or *iliac* division, turning downwards and outwards, either in the iliacus muscle or between it and the bone, anastomoses with the circumflex iliac artery, and even with the external branches of the epigastric.

**Varieties.**—The ilio-lumbar artery sometimes arises from the internal iliac above the division of that trunk; and more rarely from the common iliac. The iliac and lumbar portions sometimes arise separately from the parent trunk.

Fig. 237.—ARTERIES OF THE BACK OF THE PELVIS AND UPPER PART OF THE THIGH (from Tiedemann).  $\frac{1}{4}$

*a*, crest of the ilium; *b*, tuberosity of the ischium and lower attachment of the great sacro-sciatic ligament; *c*, great trochanter; *d*, integument round the anus; *e*, great sciatic nerve; 1, trunk of the gluteal artery as it issues from the great sacro-sciatic foramen, the superficial branches cut short, the deep arch seen passing round on the upper part of the gluteus minimus muscle; 2, placed on the great sacro-sciatic ligament, points to the pudic artery at the place where it winds over the back of the spine of the ischium; 2', the continuation of the artery towards the perineum on the inside of the tuberosity and ramus of the ischium; 3, 3, the sciatic artery, the upper figure placed on the pyriformis muscle, the lower on the great sciatic nerve; 4, 4', first perforating branch of the femoral anastomosing with the posterior branch of the internal circumflex artery, which appears between the quadratus and the abductor muscles; 5 and 6, part of the second and third perforating arteries.

Fig. 237.



When the lowest of the lumbar arteries is wanting it is replaced by a branch from the ilio-lumbar, which is increased in size, and by a small offset from the middle sacral artery.

The **lateral sacral** arteries are usually two in number on each side, though occasionally they are united into one. The two arteries arise close together from the posterior division of the internal iliac. One is distributed upon the upper, and the other upon the lower part of the sacrum.

Both arteries pass downwards, at the same time inclining somewhat inwards, in front of the pyriform muscle and the sacral nerves, which they supply with twigs, and reach the inner side of the anterior sacral foramina. Continuing to descend, the lower one approaches the middle line, and anastomoses with the middle sacral artery.

**Branches.**—The lateral sacral arteries give off a series of branches which enter the anterior sacral foramina. Each of these, after having furnished within the foramen a spinal branch, which ramifies on the bones and membranes in the interior of the sacral canal, escapes by the corresponding posterior sacral foramen, and is distributed upon the dorsal surface of the sacrum to the skin and muscles.

## EXTERNAL ILIAC ARTERY.

The external of the two arteries resulting from the division of the common iliac forms a large continuous trunk, which extends downwards in the limb as far as the lower border of the popliteus muscle, but, for convenience of description, it is named in successive parts of its course external iliac, femoral and popliteal.

The external iliac artery, larger than the internal iliac, is placed within the abdomen, and extends from the division of the common iliac to the lower border of Poupart's ligament, where the vessel enters the thigh, and is named femoral. Descending obliquely outwards, its course through the abdominal cavity may be marked by a line drawn from the left side of the umbilicus to a point midway between the anterior superior spinous process of the ilium and the symphysis pubis. This line would also indicate the direction of the common iliac artery, of which the external iliac is the direct continuation.

Fig. 288.

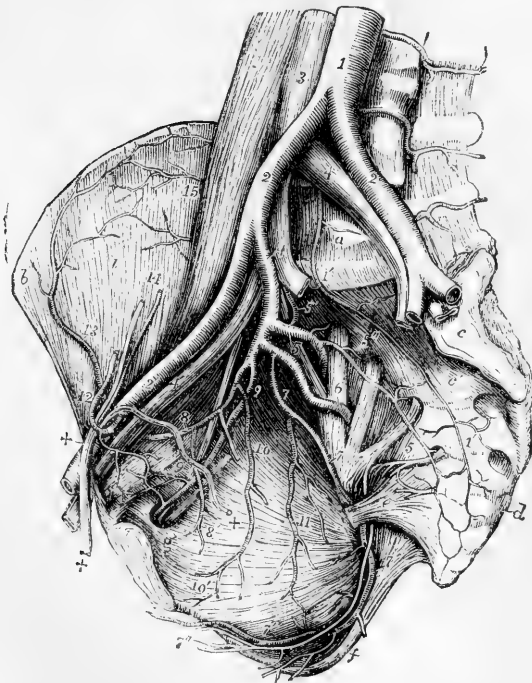


Fig. 288.—VIEW OF THE PRINCIPAL ARTERIES OF A MALE PELVIS. (A.T.)  $\frac{1}{2}$

For the detailed description of this figure see p. 438.

2', the right external iliac artery, accompanied by the corresponding vein 4', passing below into the femoral vessel under Poupart's ligament; 12, epigastric artery winding to the inside of +, +, the spermatic cord; the epigastric artery is cut short superiorly; 13, circumflex iliac artery anastomosing with 15, branches of the ilio-lumbar; 14, spermatic artery and vein descending to join the spermatic cord; +, within the pelvis, the vas deferens descending from the cord towards the bladder.

The vessel is covered by the peritoneum and intestines. It lies along the upper margin of the true pelvis, resting upon the inner border of the psoas muscle. The artery, however, is separated from the muscle by the fascia iliaca, to which it is bound, together with the external iliac vein, by the sub-peritoneal tissue.

*Relation to Veins, &c.*—The external iliac vein lies at first behind the artery with an inclination to the inner side; but, as both vessels approach Poupart's ligament at the fore part of the pelvis, the vein is on the same plane with the artery and quite to the inner side, being borne

forwards by the bone. At a short distance from its lower end the artery is crossed by the circumflex iliac vein.

Fig. 289.—VIEW OF THE DISTRIBUTION AND ANASTOMOSIS OF THE DEEP EPIGASTRIC AND INTERNAL MAMMARY ARTERIES (from Tiedemann). †

For the detailed description of this figure, see p. 390.

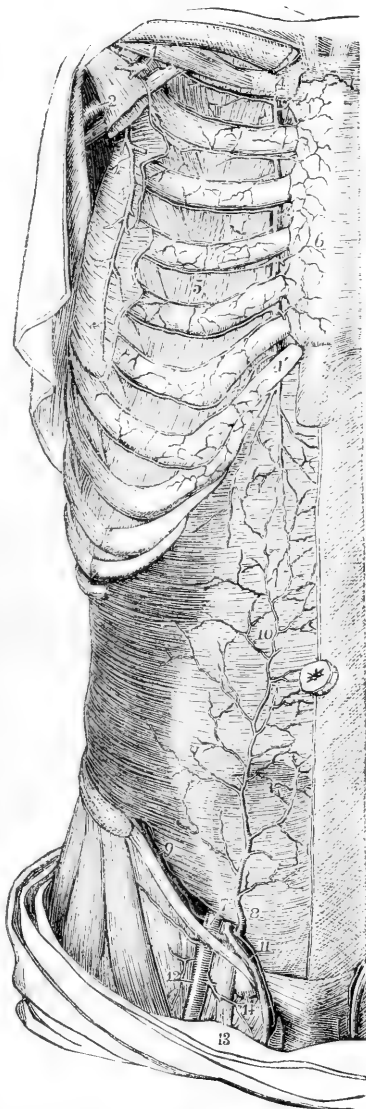7, placed on the transversalis muscle above the internal inguinal aperture, points to the last part of the external iliac artery at the place where it gives origin to 8, the epigastric and 9, the circumflex iliac artery; 10, anastomosis of the epigastric artery and the abdominal branch of the internal mammary in and behind the rectus muscle; 11, the spermatic cord receiving the cremasteric branch from the epigastric artery; 12, femoral artery; 13, femoral vein; 14, a lymphatic gland closing the femoral ring.

Large *lymphatic glands* are found resting upon the front and inner side of the vessel; and the spermatic vessels descend upon it near its termination. A branch of the *genito-crural nerve* crosses it just above Poupart's ligament.

**BRANCHES.**—The external iliac artery supplies some small branches to the psoas muscle and the neighbouring lymphatic glands, and, close to its termination, two other branches of considerable size, named the epigastric and the circumflex iliac, which are distributed to the walls of the abdomen.

1. **The deep epigastric artery** (inferior epigastric) arises from the fore part of the external iliac artery, usually a few lines above Poupart's ligament. It first inclines downwards, so as to get on a level with the ligament, and then passes obliquely upwards and inwards between the fascia transversalis and the peritoneum, to reach the rectus muscle of the abdomen. It ascends almost vertically behind the rectus, and rising within the sheath is placed between it and the muscle, and terminates at some distance above the umbilicus in offsets which ramify in the substance of the muscle and anastomose with the terminal branches of the internal mammary and inferior intercostal arteries.

Fig. 289



The epigastric artery is accompanied by two *veins*, which unite into a single trunk before ending in the external iliac vein.

In its course upwards from Poupart's ligament to the rectus muscle, the artery passes close to the inner side of the internal abdominal ring; and the vas deferens, entering through the ring, turns behind the artery in descending into the pelvis.

**Branches.**—These are small but numerous.

(a) The *cremasteric* artery, a slender branch, accompanies the spermatic cord, and, supplying the cremaster muscle and other coverings of the cord, anastomoses with the spermatic artery.

(b) Several *muscular* branches arise from each side of the epigastric artery, ramify in the rectus muscle, and communicate with the branches of the lumbar and circumflex iliac arteries.

(c) *Superficial* branches perforate the abdominal muscles, and join beneath the skin with branches of the superficial epigastric artery.

(d) The *pubic* is a small branch, which ramifies behind the pubes, and communicates by means of one or more descending twigs with a similar branch from the obturator artery

Fig. 290.

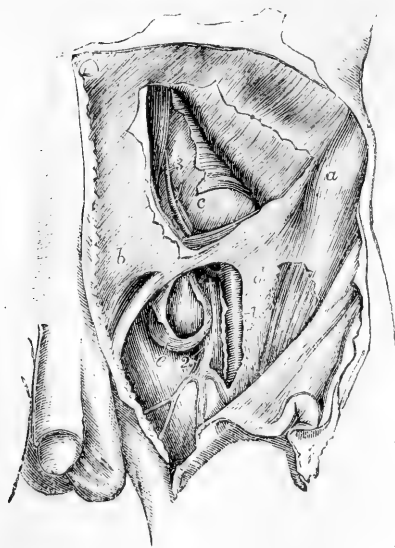


Fig. 290.—VIEW OF THE RELATION OF THE VESSELS OF THE GROIN TO A FEMORAL HERNIA, &c. (from R. Quain). †

In the upper part of the figure a portion of the flat muscles of the abdomen has been removed, displaying in part the transversalis fascia and peritoneum; in the lower the fascia lata of the thigh is in part removed and the sheath of the femoral vessels opened.

*a*, anterior superior spinous process of the ilium; *b*, aponeurosis of the external oblique muscle; *c*, the peritoneum and fascia transversalis; *d*, the iliac portion of the fascia lata near the saphenic opening; *e*, sac of a femoral hernia opened; 1, femoral artery; 2, femoral vein at the place where it is joined by the saphena vein; 3, deep epigastric artery and vein; †, placed upon the upper part of the femoral vein close below the common trunk of the epigastric and an aberrant obturator artery; the latter artery is seen in this case to pass close to the vein between it and the neck of the hernial tumour.

2. The **deep circumflex iliac** artery, smaller than the preceding vessel, arises from the outer side of the iliac artery near Poupart's ligament, and is directed outwards behind that band to the anterior superior iliac spine. Following thence the crest of the hip-bone, the artery gives branches to the iliacus and abdominal muscles, and anastomoses with the ilio-lumbar artery. In its course outwards, this artery lies in front of the transversalis fascia, at the junction of this with the fascia iliaca.

Two *veins* accompany the circumflex iliac artery; these unite below

into a single vessel, which crosses the external iliac artery about an inch above Poupart's ligament, and enters the external iliac vein.

**Branch.**—The *muscular* branch is given off near the iliac crest, and ascends on the fore-part of the abdomen between the transversalis and internal oblique muscles: having supplied those muscles, it anastomoses with the lumbar and epigastric arteries. This branch varies much in size, and is occasionally replaced by several smaller muscular offsets.

**Varieties.**—*Size.*—The external iliac artery is much diminished in those rare cases in which the principal blood-vessel of the lower limb is continued from the sciatic branch of the internal iliac, and ends in the muscles of the front of the thigh, taking the place of the profunda.

**Branches.**—The usual number of two principal branches of the external iliac artery may be increased by the separation of the circumflex iliac into two branches, or by the addition of a branch usually derived from another source, such as the internal circumflex artery of the thigh or the obturator artery.

The *deep epigastric* artery occasionally arises higher than usual, as at an inch and a half, or even two inches and a half, above Poupart's ligament; and it has been seen to arise below that ligament from the femoral, or from the deep femoral artery. The epigastric frequently furnishes the obturator artery as already described; and two examples are recorded in which the epigastric artery arose from an obturator furnished by the internal iliac artery. (Monro, "Morbid Anatomy of the Human Gullet," &c., p. 427. A. K. Hesselbach, "Die sicherste Art des Bruchschchnittes," &c.) In a single instance the epigastric artery was represented by two branches, one arising from the external iliac, and the other from the internal iliac artery. (Lauth, in "Velpeau's Médecine Opératoire," v. ii., p. 452.) Some combinations of the epigastric with the internal circumflex, or with the circumflex iliac, or with both those vessels, have been noticed.

The *deep circumflex iliac* artery sometimes deviates from its ordinary position, —arising at a distance not exceeding an inch above Poupart's ligament. Deviations in the opposite direction are more rarely met with; it has in a few cases been observed to arise below the ligament, from the femoral artery.

#### SURGICAL ANATOMY OF THE ILIAC ARTERIES.

The *external iliac* artery is usually tied about midway between the origins of the internal iliac and of the deep epigastric arteries. It is reached by a curved incision about three and a half inches long, made through the abdominal muscles an inch above and parallel to Poupart's ligament. After dividing the transversalis fascia, the peritoneum (to which the spermatic vessels adhere) is raised, and the artery is found at the margin of the pelvis, running along the inner border of the psoas muscle. The vein is close to the artery, but on its inner and posterior aspect. In order to pass the ligature, it is necessary to divide the thin subserous membrane which binds the vessel down to the fascia iliaca.

The *internal iliac* artery is reached by a similar but somewhat longer incision. The steps of the operation are the same, but owing to the shortness of the vessel, and the greater depth at which it is placed, the operation itself is more difficult.

#### FEMORAL ARTERY.

The femoral artery is that portion of the artery of the lower limb which lies in the upper two-thirds of the thigh,—its limits being marked above by Poupart's ligament, and below by the opening in the great adductor muscle, after passing through which, the artery receives the name of popliteal.

A general indication of the direction of the femoral artery over the fore-part and inner side of the thigh is given by a line reaching from a point midway between the anterior superior iliac spine and the symphysis of the pubes above to the inner side of the internal condyle of the femur below. At the upper part of the thigh, it lies along the middle of a depression between the muscles covering the femur on the

Fig. 291.

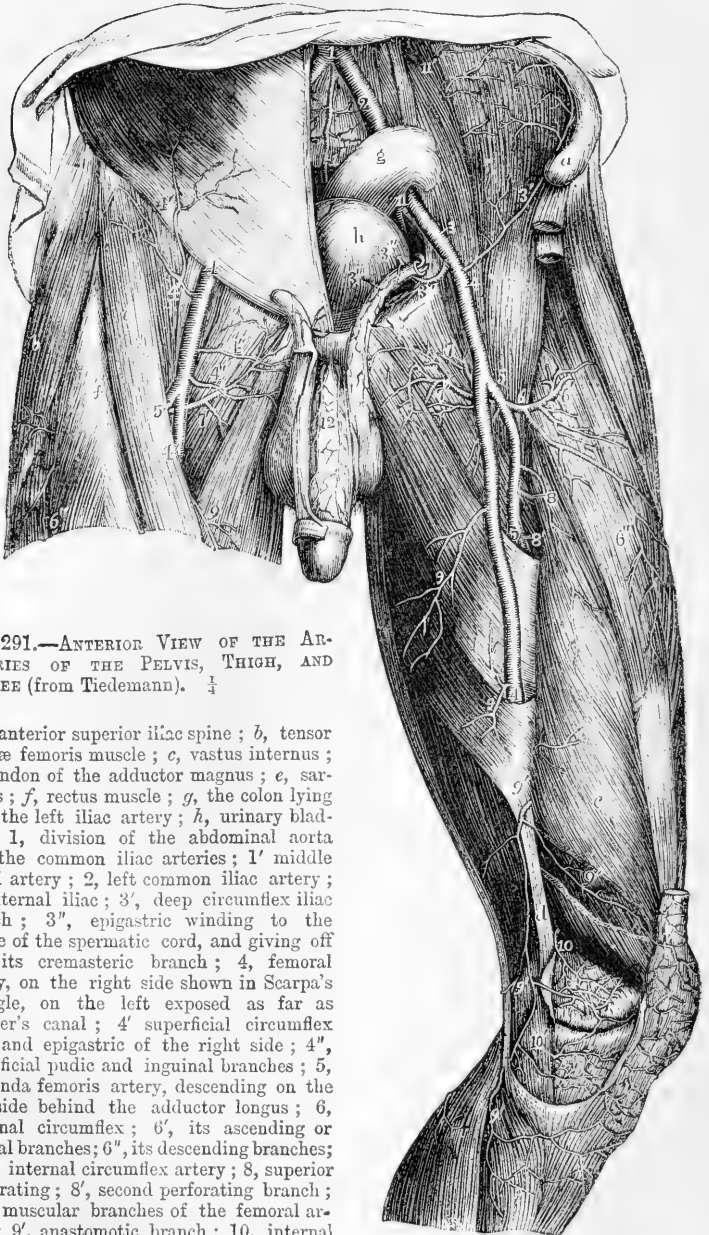


Fig. 291.—ANTERIOR VIEW OF THE ARTERIES OF THE PELVIS, THIGH, AND KNEE (from Tiedemann). †

*a*, anterior superior iliac spine; *b*, tensor vaginae femoris muscle; *c*, vastus internus; *d*, tendon of the adductor magnus; *e*, sartorius; *f*, rectus muscle; *g*, the colon lying upon the left iliac artery; *h*, urinary bladder; *1*, division of the abdominal aorta into the common iliac arteries; *1'* middle sacral artery; *2*, left common iliac artery; *3*, external iliac; *3'*, deep circumflex iliac branch; *3''*, epigastric winding to the inside of the spermatic cord, and giving off *3'''*, its cremasteric branch; *4*, femoral artery, on the right side shown in Scarpa's triangle, on the left exposed as far as Hunter's canal; *4'* superficial circumflex iliac and epigastric of the right side; *4''*, superficial pudic and inguinal branches; *5*, profunda femoris artery, descending on the left side behind the adductor longus; *6*, external circumflex; *6'*, its ascending or gluteal branches; *6''*, its descending branches; *7*, *7'*, internal circumflex artery; *8*, superior perforating; *8''*, second perforating branch; *9*, *9'*, muscular branches of the femoral artery; *9''*, anastomotic branch; *10*, internal superior articular branch of the popliteal; *10'*, inferior branch.

outer side, and the adductor muscles on the inner side of the limb, and which is known by the name of Scarpa's triangle. In this situation



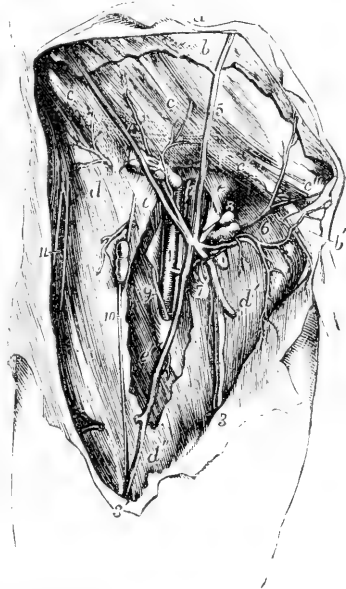
the beating of the artery may be felt, and the circulation through the vessel may be most easily controlled by pressure. Below the upper third of the thigh it is crossed by the sartorius muscle, the upper and inner border of which forms the outer wall of the triangle, and which conceals the vessel in the remainder of its course. In the first part of its course the femoral artery is covered only by the skin and fascia lata, and by the crural sheath which invests both the artery and vein. In the lower part of its course it is deeply placed, being covered not only by the sartorius muscle, but by a dense stratum of fibrous structure, which stretches across from the tendons of the long and great adductors to the vastus internus muscle, and encloses the space called *Hunter's canal*, in which the vessels lie.

The artery rests successively upon the following parts. First, upon the psoas muscle, by which it is separated from the margin of the pelvis and the capsule of the hip-joint; next it is placed in front of the pectineus muscle, the deep femoral artery and vein being interposed; afterwards, it lies upon the long adductor muscle; and lastly, upon the tendon of the great adductor, the femoral vein being placed between the tendon and the artery. At the lower part of its course, it has immediately on its outer side the vastus internus muscle, which intervenes between it and the inner side of the femur.

Fig. 202.—VIEW OF THE FEMORAL VESSELS, WITH THEIR SMALLER SUPERFICIAL BRANCHES IN THE RIGHT GROIN (from R. Quain).  $\frac{1}{4}$

$\alpha$ , the integument of the abdomen;  $b$ , the superficial abdominal fascia;  $b'$ , the part descending on the spermatic cord;  $c, c$ , the aponeurosis of the external oblique muscle;  $c'$ , the same near the external abdominal ring;  $c''$ , the inner pillar of the ring;  $d$ , the iliac part of the fascia lata;  $d'$ , the pubic part;  $e, e$ , the sheath of the femoral vessels laid open, the upper letter is immediately over the crural aperture;  $e'$ , sartorius muscle partially exposed; 1, femoral artery, having 2, the femoral vein to its inner side, and the septum of the sheath shown between the two vessels; 3, the principal saphenous vein; 3', its anterior branches; 4, the superficial circumflex iliac vein and arterial branches to the glands of the groin; 5, the superficial epigastric vein; 6, the external pudic arteries and veins; 7 to 8, some of the lower inguinal glands receiving twigs from the vessels; 9, internal, 10, middle, and 11, external cutaneous nerves.

Fig. 202.



At the groin the artery, after having passed over the margin of the pelvis, is placed slightly in front of or internal to the head of the femur; and at its lower end, the vessel lies close to the inner side of the shaft of the bone; but in the intervening space, in consequence of the projection of the neck and shaft of the femur outwards, while the artery holds a straight course, it is separated from the bone by a considerable interval.

*Relation to Veins.*—The femoral vein is very close to the artery, both being enclosed in the same sheath, and separated from each other only by a thin partition of fibrous membrane. At the groin the vein lies in the same plane as the artery, and on the inner side; but gradually inclining backwards, it is placed behind it at the lower end of Scarpa's space, and afterwards gets somewhat to the outer side. The deep femoral vein, near its termination, crosses behind the femoral artery; and the long saphenous vein, as it ascends on the fore part of the limb, lies to the inner side; but it not unfrequently happens that a superficial vein of considerable size ascends for some space directly over the artery.

*Relation to Nerves.*—At the groin the *anterior crural* nerve lies a little to the outer side of the femoral artery (about a quarter of an inch), separated from the vessel by some fibres of the psoas muscle and by the sheath and fascia. Lower down in the thigh, the *long saphenous* nerve accompanies the artery until this vessel perforates the adductor magnus. There are likewise small cutaneous nerves which cross the artery.

**BRANCHES.**—The femoral artery gives off the following branches:—some small and superficial, which are distributed to the integument and glands of the groin and ramify on the lower part of the abdomen, viz., the external pudic (superior and inferior), the superficial epigastric, and the superficial circumflex iliac; the great nutrient artery of the muscles of the thigh, named the deep femoral; several muscular branches; and lastly, the anastomotic artery, which descends on the inner side of the knee-joint.

The portion of the femoral artery extending from its commencement to the origin of the deep femoral, a part varying from an inch to two inches in length, is sometimes distinguished by surgical writers as the *common femoral*, and described as dividing into the *superficial* and *deep* femoral arteries.

The **external pudic** arteries arise either separately or by a common trunk from the inner side of the femoral artery. The *superior*, the more superficial branch, courses upwards and inwards to the pubic spine, crosses the external abdominal ring, passing in the male over the spermatic cord, and is distributed to the integuments on the lower part of the abdomen, and on the external organs of generation. The *inferior* branch, more deeply seated, extends inwards, resting on the pectineus muscle, and covered by the fascia lata, which it pierces on reaching the inner border of the thigh, and is distributed to the scrotum in the male, or to the labium in the female, its branches inosculating with those of the superficial perineal artery.

The **superficial epigastric** artery, arising from the femoral vessel, about half an inch below Poupart's ligament, passes forwards through the fascia lata, and runs upwards on the abdomen in the superficial fascia covering the external oblique muscle. Its branches, ascending nearly as high as the umbilicus, anastomose with superficial branches of the epigastric and internal mammary arteries.

The **superficial circumflex iliac** artery runs outwards in the direction of Poupart's ligament towards the iliac spine, across the psoas and iliacus muscles: to both of these it gives small branches, as also

some others which pierce the fascia lata; it is distributed to the integument.

All the preceding arteries give small branches to the lymphatic glands in the groin.

Fig. 293.—DEEP VIEW OF THE FEMORAL ARTERY AND ITS BRANCHES ON THE LEFT SIDE (from R. Quain).  $\frac{1}{2}$

The sartorius muscle has been removed in part, so as to expose the artery in the middle third of the thigh. *a*, the anterior superior iliac spine; *b*, the aponeurosis of the external oblique muscle near the outer abdominal ring, *c*, rectus femoris muscle; *d*, abductor longus; *e*, fibrous sheath of Hunter's canal covering the artery; 1, femoral artery; 1', femoral vein divided and tied close below Poupart's ligament; 2, profunda femoris artery; 3, anterior crural nerves, the figure lies between two superficial epigastric branches; 3', superficial circumflex iliac artery; 4, internal circumflex branch; 5, superficial pudic branches; 6, external circumflex branch, with its ascending transverse and descending branches separating from it; 6', twigs to the rectus muscle; 7, branches to the vastus internus muscle; 8 and 9, some of the muscular branches of the femoral; +, origin of the superior perforating artery.

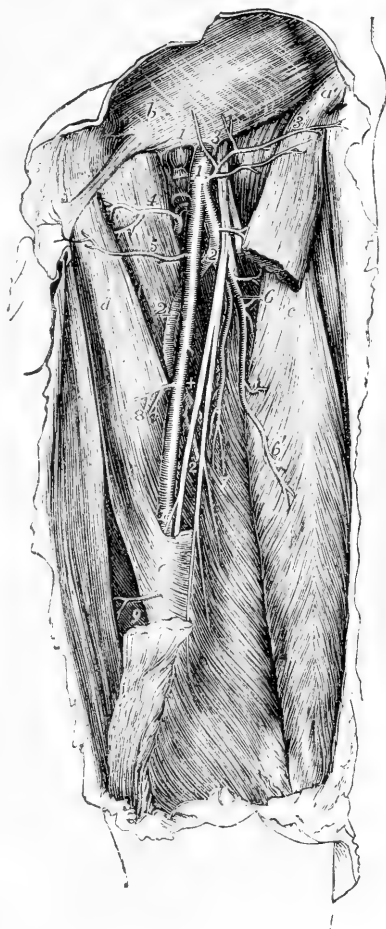


Fig. 293.

### The deep femoral artery

—(*profunda femoris*) the principal nutrient vessel of the thigh, is an artery of considerable calibre, being nearly equal in size to the continuation of the femoral after the origin of this great branch. It usually arises from the outer and back part of the femoral artery, about an inch and a half below Poupart's ligament. At its commencement, it inclines outwards in front of the iliacus muscle, to such an extent as to be visible for a short distance external to the femoral artery; it then runs downwards and backwards behind that vessel, and passing between the long and great adductor muscles near their femoral attachments, divides into terminal branches, which pierce the great adductor, and ramify in the muscles at the back and outer part of the thigh.

This artery lies successively in front of the iliacus, pectineus, adductor brevis and adductor magnus muscles. The femoral and profunda veins

and the long adductor muscle are interposed between it and the femoral trunk.

The named branches of the deep femoral artery are the external and the internal circumflex, and the perforating arteries.

1. The *external circumflex* artery, a branch of considerable size, arises from the outer side of the profunda near its origin, and passing outwards for a short distance beneath the sartorius and rectus muscles, and through the divisions of the anterior crural nerve, divides into three sets of branches.

(a) *Transverse* branches pass outwards over the crureus muscle, pierce the vastus externus, so as to get between it and the femur, just below the great trochanter, and reach the back part of the thigh, where they anastomose with the internal circumflex and the perforating branches of the deep femoral, and with the gluteal and sciatic branches of the internal iliac.

(b) *Ascending* branches, directed upwards beneath the sartorius and rectus, and afterwards under the tensor muscle of the fascia lata, communicate with the terminal branches of the gluteal, and with some of the external descending branches of the circumflex iliac artery.

(c) *Descending* branches incline outwards and downwards upon the extensor muscles of the knee, covered by the rectus muscle. They are usually three or four in number, some being of considerable size; most of them are distributed to the muscles on the fore-part of the thigh, but one or two can be traced beneath the vastus externus muscle as far as the knee, where they anastomose with the arterial branches surrounding that joint.

2. The *internal circumflex* artery, smaller than the external circumflex, arises close to that branch from the inner and hinder part of the deep femoral artery, and is directed backwards between the pectineus and the psoas muscle to the inner side of the femur. On reaching the tendon of the external obturator, along which the vessel passes to the back of the thigh, it divides into two principal branches.

(a) The *ascending* branch is distributed partly to the adductor brevis and gracilis, and partly to the external obturator muscle, near which it anastomoses with the obturator artery.

(b) The *transverse* branch passes backwards above the small trochanter, and appears on the back of the limb, between the quadratus femoris and great adductor muscles, where it supplies the hamstring muscles, and anastomoses with the sciatic artery and with the superior perforating branches of the deep femoral artery.

(c) An *articular* vessel, arising from the transverse branch opposite the hip-joint, enters the joint through the notch in the acetabulum, beneath the transverse ligament, and supplies the adipose tissue and the synovial membrane in that articulation. Some offsets are guided to the head of the femur by the round ligament. In some instances the articular branch is derived from the obturator artery; and sometimes the joint receives a branch from both sources.

3. The *perforating* arteries (perforantes) are branches which reach the back of the thigh by perforating the adductor brevis and adductor magnus muscles; they are four in number, including the terminal branch of the parent vessel.

(a) The *first perforating* artery passes backwards below the pectineus muscle, through the fibres of the adductor brevis and magnus, and is distributed to both these adductor muscles, to the biceps and great gluteal muscle, and communicates with the sciatic and internal circumflex arteries.

(b) The *second perforating* artery, considerably larger than the first, passes through the adductor brevis and magnus; after which it divides into ascending

and descending branches, which ramify in the hamstring muscles, and communicate with the other perforating branches: an offset from it, named the *nutrient artery* of the femur, enters the medullary foramen of that bone.

Fig. 294.

Fig. 294.—POSTERIOR VIEW OF THE ARTERIES OF THE PELVIS, THIGH, AND POPLITEAL SPACE (from Tiedemann).

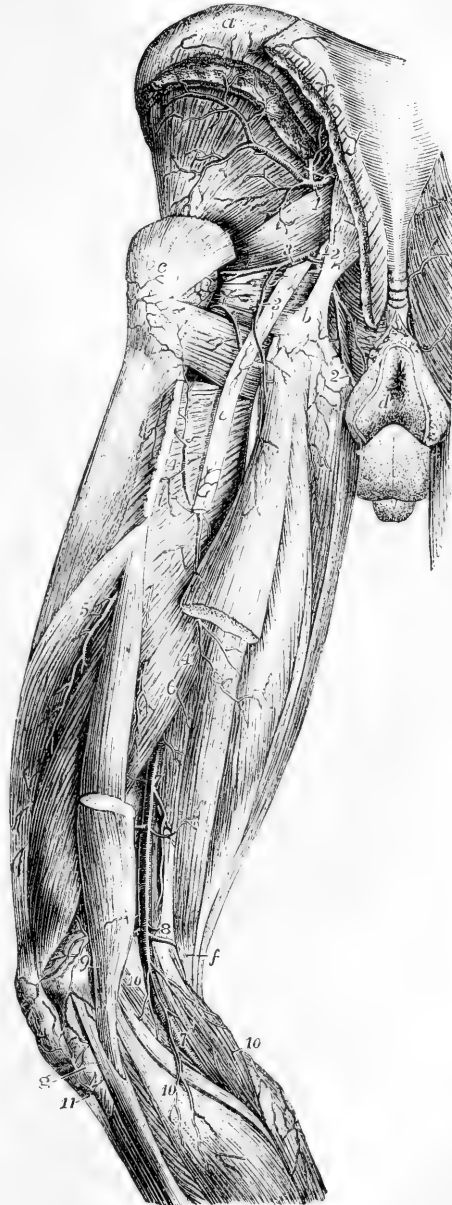*a*, the iliac crest; *b*, the great sacro-sciatic ligament attached to the tuberosity of the ischium; *c*, great trochanter; *d*, the integument close to the anus; *e*, great sciatic nerve; *f*, the line from this letter crosses the tendons of the inner hamstring muscles; *g*, head of the fibula; 1, gluteal artery; 2, pudic; 3, sciatic artery, giving its branches to the short external rotator muscles, to the sciatic nerve, and to the upper part of the long flexor muscles; 4, first perforating artery; 4', its branches to the flexor muscles; 5, branches of the second perforating; 6, branches of the third perforating; 7, popliteal artery, near this the origin of the superior muscular branches; 8, placed on the tendon of the adductor magnus, near the origin of the superior articular branches; 9, the anastomosis of the external superior articular with other branches; 10, the sural branches; 11, the recurrent of the anterior tibial artery.

(*c*) The *third perforating artery* pierces the adductor magnus muscle, below the insertion of the adductor longus, and is distributed in a manner similar to the second perforating artery.

(*d*) The *fourth perforating artery*, the termination of the deep femoral artery, passing backwards close to the *linea aspera*, is distributed to the short head of the biceps and to the other hamstring muscles, and communicates with branches of the popliteal artery, and with the lower perforating arteries.

#### Muscular branches.—

In its course along the thigh, the femoral artery gives off several branches to the contiguous



muscles. They vary in number from two to seven. They supply the sartorius and the vastus internus with other muscles which are close to the femoral artery: their size appears to bear an inverse proportion to that of the descending branches of the external circumflex artery.

**Anastomotic artery.**—This branch arises from the femoral artery when in Hunter's canal. It pierces the anterior wall of that canal and descends upon the tendon of the adductor magnus to the inner condyle of the femur, giving off several branches, and covered by some of the fibres of the vastus internus muscle; it finally anastomoses with the internal articular arteries, and with the recurrent branch of the anterior tibial artery. It gives off the following branches.

(a) A *superficial* branch accompanies the long saphenous nerve beneath the sartorius muscle to the integument on the inner side of the knee.

(b) The *external* branch, arising from the lower part of the vessel, crosses over the femur, supplies offsets to the knee-joint, and forms an arch a little above the articular surface, by anastomosing with the superior external articular artery.

**Varieties of the Femoral Artery and Branches.**—*Trunk.*—Four instances have been recorded of division of the femoral artery below the origin of the profunda into two vessels, which subsequently were reunited near the opening of the adductor magnus so as to form a single popliteal artery. In all these cases, the arrangement of the vessels appears to have been similar. To one of them (that first observed) special interest is attached, inasmuch as it was met with in a patient operated upon for popliteal aneurism. (This case was treated by Charles Bell, and recorded in "The London Medical and Physical Journal," vol. lvi. p. 134. London, 1826.)

The femoral artery is occasionally replaced at the back of the thigh by a trunk continuous with the internal iliac. Having passed from the pelvis through the large sacro-sciatic notch, this trunk accompanies the great sciatic nerve along the back of the thigh to the popliteal space, where its connections and termination become similar to those of the vessel presenting the usual arrangement. Four examples of this deviation from the common state of the blood-vessel have been recorded. Reference is made to these in a Paper in vol. 36 of the Medico-Chirurgical Transactions, giving an account of a specimen of remarkable deformity of the lower limbs of a man in whom the artery was so transposed on both sides.

*Branches.*—The *deep femoral* is occasionally given off from the inner side of the parent trunk, and more rarely from the back part of the vessel. Occasionally it arises at a distance of less than an inch, and sometimes of more than two inches, below Poupart's ligament. It was even found by Richard Quain arising, in one instance, above Poupart's ligament, and in another four inches below it; but in the latter instance the internal and external circumflex arteries did not arise from the profunda.

The *external circumflex* branch sometimes arises directly from the femoral artery; or it may be represented by two branches, of which, in most cases, one proceeds from the femoral, and one from the deep femoral: both branches, however, have been seen to arise from the deep femoral, and much more rarely, both from the femoral artery.

The *internal circumflex* branch may be transferred to the femoral artery above the origin of the profunda. Examples have also been met with in which the internal circumflex arose from the epigastric, from the circumflex iliac, or from the external iliac artery.

Many occasional branches have been seen arising from the femoral, as the deep epigastric or an aberrant obturator; more rarely an ilio-lumbar or a dorsalis penis, an accessory profunda femoris, or an accessory external circumflex. The *great saphenous* artery is an occasional vessel of some magnitude. It arises, when present, either above or below the origin of the profunda, and running at first between the vastus internus and adductor magnus, it pierces Hunter's canal to

reach the inner aspect of the knee and accompanies the long saphenous vein to the internal malleolus (Henle).

#### SURGICAL ANATOMY OF THE FEMORAL ARTERY.

The femoral artery may be tied in two parts of its course, either at the apex of Scarpa's triangle or in Hunter's canal. The former situation is that usually preferred by surgeons, owing to the superficial position of the vessel, and its freedom from large branches. An incision about three and a half inches long is made in the direction of the vessel, and so that the centre of the incision shall be about four and a half inches below the middle of Poupart's ligament. The integument and fascia lata are cut through at once, and the sartorius muscle exposed. The inner edge of that muscle is to be raised and turned outwards, and the sheath of the artery scraped through. The femoral vein is close behind the artery and only separated by a thin fibrous partition, and the long saphenous nerve is to its outer side. The needle bearing the ligature is to be passed from within outwards, its point being kept close to the artery.

To reach the artery in Hunter's canal a much longer incision is needed, owing to the greater depth of the vessel. The integuments are cut through over the inner border of the sartorius muscle, which here lies directly in front of the artery, avoiding at the same time the long saphenous vein. The fibrous structure stretching over the vessels is then to be cut through and the artery exposed. The ligature is passed as in the previous operation.

#### POPLITEAL ARTERY.

The popliteal artery placed at the back of the knee-joint extends along the lower third of the thigh and the upper part of the leg, reaching from the opening in the great adductor to the lower border of the popliteus muscle. It is continuous above with the femoral, and divides at the lower end into the anterior and posterior tibial arteries.

This artery at first inclines from the inner side of the limb to reach a point behind the middle of the knee-joint, and thence continues to descend vertically to its lower end. Lying deeply in its whole course, it is covered for some distance at its upper end by the semimembranosus muscle; a little above the knee it is placed in the popliteal space; inferiorly it is covered for a considerable distance by the gastrocnemius muscle; and at its termination by the upper margin of the soleus muscle.

At first the artery lies close to the inner side of the femur; in descending, it is separated by an interval from the flat or somewhat hollowed triangular surface at the lower end of the bone; it then rests on the posterior ligament of the knee-joint, and afterwards on the popliteus muscle.

*Relation to Veins.*—The popliteal vein lies close to the artery, behind and somewhat to the outer side till near its termination, where it crosses the artery and is placed somewhat on the inner side. The vein is frequently double along the lower part of the artery, and, more rarely, also at the upper part. The short saphenous vein, ascending into the popliteal space over the gastrocnemius muscle, approaches the artery as it is about to terminate in the popliteal vein.

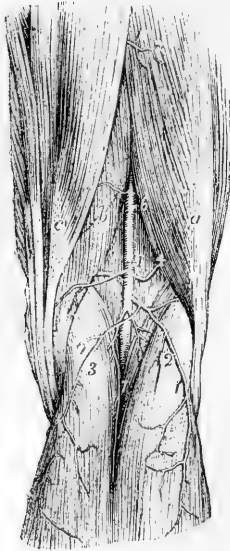
*Relation to the Nerve.*—The *internal popliteal* nerve lies at first to the outer side of the artery, but much nearer to the surface than the vessel: the nerve afterwards crosses over the artery, and is placed behind and to the inner side below the joint.

**BRANCHES.**—The branches of the popliteal artery may be arranged in two sets, viz., the muscular and the articular.

1. The **muscular** branches are divided into a superior and an inferior group.

(a) The *superior* branches, three or four in number, are distributed to the lower ends of the hamstring muscles, as also to the vasti muscles, and anastomose with the perforating and articular arteries.

Fig. 295.

Fig. 295.—VIEW OF THE POPLITEAL ARTERY AND ITS BRANCHES IN THE RIGHT LEG (from Tiedemann).  $\frac{1}{2}$ 

*a*, biceps muscle; *b*, semi-membranosus; *c*, semi-tendinosus; 1, the popliteal artery; 2, 3, the superficial sural branches; 4, the outer, 5, the inner superior articular branch; 6, the superior muscular; 7, the inferior muscular or deep sural branches.

(b) The *inferior muscular branches, or sural arteries*, usually two in number, and of considerable size, arise from the back of the popliteal artery, opposite the knee-joint, and enter, one the outer and the other the inner head of the gastrocnemius muscle, which they supply, as well as the fleshy part of the plantaris muscle.

Over the surface of the gastrocnemius will be found at each side, and in the middle of the limb, slender branches, which descend a considerable distance along the calf of the leg, and end in the integument. These small vessels (superficial sural) arise separately from the popliteal artery, or from some of its branches.

2. The **articular arteries**. Two of these pass off nearly at right angles from the popliteal artery, one to each side, above the flexure of the joint, whilst two have a similar arrange-

ment below it, and a fifth passes from behind into the centre of the joint.

(a) The *upper internal articular artery* winds round the femur just above the inner condyle; and, passing under the tendon of the great adductor and the vastus internus, divides into two branches; one of these, comparatively superficial, enters the substance of the vastus, and inosculates with the anastomotic branch of the femoral, and with the lower internal articular artery. The other branch runs close to the femur, ramifies upon it, and also on the knee-joint, and communicates with the upper external articular artery.

(b) The *upper external articular artery* passes outwards a little above the outer condyle of the femur, under cover of the biceps muscle, and, after perforating the intermuscular septum, divides into a superficial and a deep branch. The latter, lying close upon the femur, spreads branches upon it and the articulation, and communicates with the preceding vessel, with the anastomotic of the femoral, and with the lower external articular artery; the superficial branch descends through the vastus to the patella, anastomosing with other branches and assisting in the supply of the joint.

(c) The *lower internal articular artery* passes downwards below the internal tuberosity of the tibia, lying between the bone and the internal lateral ligament; its branches ramify on the front and inner part of the joint, as far as the patella and its ligament.

(d) The *lower external articular artery* takes its course outwards, under cover of the outer head of the gastrocnemius in the first instance, and afterwards under the external lateral ligament of the knee and the tendon of the biceps muscle, passing above the head of the fibula. Having reached the fore part of the joint, it divides near the patella into branches, some of which communicate with the lower articular artery of the opposite side, and with the recurrent



branch from the anterior tibial; whilst others ascend, and anastomose with the upper articular arteries.

(e) The *middle or azygos articular artery* is a small branch which arises opposite the flexure of the joint, and, piercing the posterior ligament, supplies the crucial ligaments and other structures within the articulation.

Fig. 296.—ANTERIOR VIEW OF THE DEEP ARTERIAL BRANCHES SURROUNDING THE KNEE-JOINT AND THEIR ANASTOMOSES (from Tiedemann).  $\frac{1}{4}$

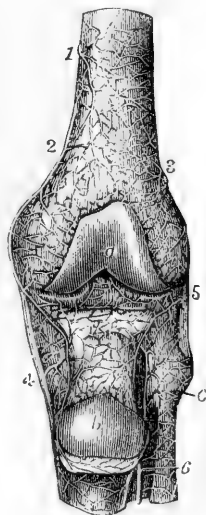
*a*, the patellar articular surface of the femur; *b*, the posterior surface of the patella which, with the ligamentum patellæ, has been turned down; *c*, the head of the fibula; 1 and 2, branches of the internal superior articular branch of the popliteal ramifying on the periosteum, and anastomosing with the external superior articular branch 3, and with other arteries within and below the joint; 4, branches of the internal inferior articular; 5, external inferior articular; 6, recurrent of the anterior tibial artery.

**Varieties.**—Deviations from the ordinary condition of the popliteal artery are not frequently met with. The principal departure from the ordinary arrangement consists in its high division into terminal branches. Such an early division has been found to take place most frequently opposite the flexure of the knee-joint, and not higher.

In a few instances, the popliteal artery has been seen to divide into the anterior tibial and peroneal arteries—the posterior tibial being small or absent. In a single case, the popliteal artery was found to divide at once into three terminal vessels, viz., the peroneal and the anterior and posterior tibial arteries.

The *azygos articular* branch frequently arises from one of the other articular branches, especially from the upper and external branch. There are sometimes several small middle articular branches.

Fig. 296.



### POSTERIOR TIBIAL ARTERY.

The posterior tibial artery is situated along the back part of the leg, between the superficial and deep layers of muscles, and is firmly bound down to the deep muscles by the fascia which covers them. It extends from the lower border of the popliteus muscle, where it is continuous with the popliteal artery, down to the inner side of the calcaneum, where it terminates beneath the origin of the abductor pollicis muscle by dividing into the external and internal plantar arteries.

Placed at its origin opposite the interval between the tibia and fibula, it approaches the inner side of the leg as it descends, and lies behind the tibia; at its lower end it is placed midway between the inner malleolus and the prominence of the heel. Very deeply seated at the upper part, where it is covered by the fleshy portion of the gastrocnemius and soleus muscles, it becomes comparatively superficial towards the lower part, being there covered only by the integument and two layers of fascia, and by the annular ligament behind the inner malleolus. It lies successively upon the tibialis posticus, the flexor longus digitorum, and, at its lower end, directly on the tibia and the ankle-joint. Behind the ankle, the tendons of the tibialis posticus and flexor longus digitorum lie between the artery and the internal

malleolus; whilst the tendon of the flexor longus pollicis is to the outer side of the artery.

*Relation to the Veins and Nerve.*—The posterior tibial artery, like the other arteries below the knee, is accompanied by two *venæ comites*. The *posterior tibial nerve* is at first on the inner side of the artery, but in the greater part of its course the nerve is close to the outer side of the vessel.

Fig. 297.

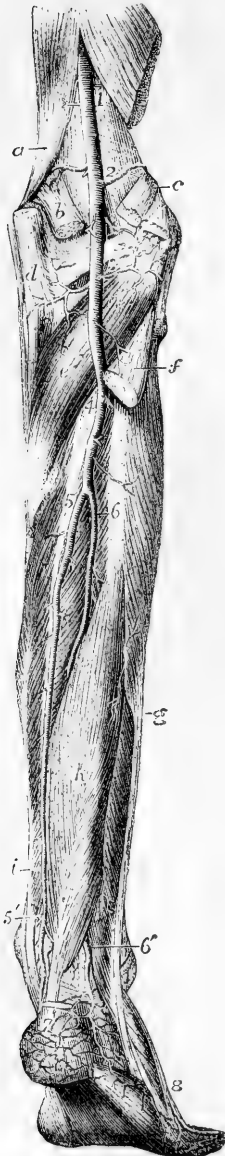


Fig. 297.—DEEP POSTERIOR VIEW OF THE ARTERIES OF THE LEG (from Tiedemann).  $\frac{1}{4}$

*a*, lower part of the adductor magnus muscle; *b*, origin of the inner head of the gastrocnemius; outer head and plantaris; *d*, tendon of the semimembranosus muscle; *e*, popliteus; *f*, upper part of the soleus divided below its origin from the head of the fibula; *g*, peroneus longus; *h*, flexor longus pollicis; *i*, flexor communis digitorum; 1, upper part of the popliteal artery; 2, origin of the superior articular branches; 3, origin of the inferior articular branches; the middle or azygos branch is seen between these numbers; 4, division of the popliteal artery into anterior and posterior tibial arteries; 5, 5', posterior tibial; 6, peroneal artery; 6', its continuation as posterior peroneal; between 5' and 6', the communicating branch; 7, calcaneal branches; 8, external branches of the metatarsal of the dorsalis pedis artery.

**BRANCHES.**—The posterior tibial artery furnishes numerous small branches, and one large branch—the peroneal artery.

**Small Branches.**—(*a*) Several *muscular* branches arise from the posterior tibial artery, and are distributed principally to the deep-seated muscles in its neighbourhood, besides one or two of considerable size to the inner part of the *solcus* muscle.

(*b*) The *nutrient artery* of the tibia, which is the largest of its kind in the body, arises from the posterior tibial artery near its commencement, and, after giving small branches to the muscles, enters the nutrient foramen in the bone, and ramifies on the medullary membrane. This vessel not unfrequently arises from the anterior tibial artery.

(*c*) A *communicating* branch from the peroneal artery, passing transversely, joins the posterior tibial about two inches above the ankle-joint.

The **peroneal** artery lies deeply along the back part of the leg, close to the fibula. Arising from the posterior tibial artery about an inch below the lower border of the popliteus muscle, it inclines at first obliquely towards the fibula, and then descends nearly perpendicularly along that bone and behind the outer ankle, to reach the side of the os calcis. In

the upper part of its course, this artery is covered by the soleus muscle and the deep fascia, and afterwards by the flexor longus pollicis, which is placed over it as far as the outer

malleolus; below this point, the vessel is covered only by the common integument and the fascia. The peroneal artery rests at first against the upper part of the tibialis posticus muscle, and afterwards in the greater part of its course, it is surrounded by fibres of the flexor longus pollicis, lying close inside the projecting posterior ridge of the fibula. Descending beyond the outer malleolus, it terminates in branches on the outer surface and back of the os calcis.

**Branches.**—(a) *Muscular* branches from the upper part of the peroneal artery pass to the soleus, the tibialis posticus, the flexor longus pollicis, and the peronei muscles.

(b) A *nutrient* artery enters the fibula.

(c) The *anterior peroneal* artery arises about two inches above the outer malleolus, and, immediately piercing the interosseous membrane, descends along the front of the fibula, covered by the peroneus tertius muscle, and, dividing into branches, reaches the outer ankle, and anastomoses with the external malleolar branch of the anterior tibial artery. It supplies vessels to the ankle-joint, and ramifies on the front and outer side of the tarsus, inosculating more or less freely with the tarsal arteries.

(d) The *terminal* branches anastomose with the external malleolar and with the tarsal arteries on the outer side of the foot; and behind the os calcis with ramifications of the posterior tibial artery.

(e) The *communicating* branch, lying close behind the tibia, about two inches from its lower end, is a transverse branch situated close to the bones, which connects the peroneal with the posterior tibial artery.

**Varieties.**—The *posterior tibial* artery, as well as the anterior tibial, is lengthened in those instances in which the popliteal artery divides higher up than usual. Not unfrequently the posterior tibial artery is diminished in size, and is subsequently reinforced either by a transverse branch from the peroneal in the lower part of the leg, or, in rare instances, by two transverse vessels, one crossing close to the bone, and the other over the deep muscles. In other instances the posterior tibial may exist only as a short muscular trunk in the upper part of the leg, while an enlarged peroneal artery takes its place from above the ankle downwards into the foot.

The *peroneal* artery has been found to arise lower down than usual, about three inches below the popliteus muscle; and, on the contrary, it sometimes commences higher up from the posterior tibial, or even from the popliteal artery itself. In some cases of high division of the popliteal artery, the peroneal artery is transferred to the anterior tibial. It more frequently exceeds than falls short of the ordinary dimensions, being enlarged to reinforce the posterior tibial. In those rare instances in which it is lost before reaching the lower part of the leg, a branch of the posterior tibial takes its place. The anterior peroneal branch is sometimes enlarged to compensate for the small size of the anterior tibial artery in the lower part of the leg, or to supply the place of that artery on the dorsum of the foot; or it may be absent and be replaced by the anterior tibial. In a singular case, recorded by Otto, the peroneal artery was wholly wanting.

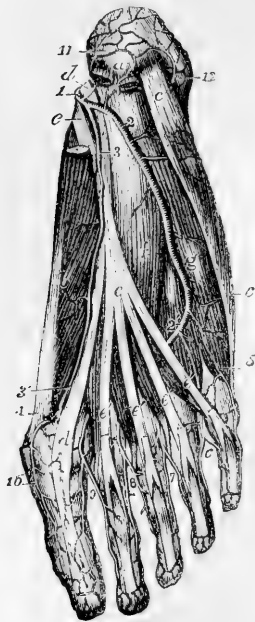
#### PLANTAR ARTERIES.

The **external** and **internal plantar** arteries are the branches into which the posterior tibial divides in the hollow of the calcaneum, where it is covered by the origin of the abductor pollicis.

The **internal plantar** artery, much smaller than the external, is directed forwards, along the inner side of the foot. Placed at first under cover of the abductor pollicis, it passes forwards in the groove between that muscle and the short flexor of the toes, near the line separating the middle from the inner portion of the plantar fascia, and on reaching the extremity of the first metatarsal bone, considerably

diminished in size, it terminates by running along the inner border of the great toe, anastomosing with the digital branches.

Fig. 298.

Fig. 298.—SUPERFICIAL VIEW OF THE ARTERIES IN THE SOLE OF THE RIGHT FOOT (from Tiedemann).  $\frac{1}{2}$ 

*a*, tuberosity of the calcaneum close to the origin of the flexor brevis digitorum (cut short) and the abductor pollicis, of which a part is removed, to show the plantar arteries; *b*, abductor pollicis; *c*, abductor minimi digiti; *d*, tendon of the flexor pollicis longus; *e*, tendon of the flexor communis longus; *e'*, its four slips, close to the lumbricales muscles, passing on to perforate the tendons of the flexor brevis; *f*, flexor accessorius; *g*, flexor brevis minimi digiti: 1, posterior tibial dividing into the plantar arteries; 2, 2', external plantar; 3, internal plantar; 3', the same passing forward to communicate with 4, the digital branch for the great toe, derived from the dorsal artery of the foot; 5, first digital or external plantar branch to the fifth toe; 6, placed in the angle of division of the second plantar digital artery, between the fourth and fifth toes; 7, the third plantar digital artery dividing similarly between the third and fourth toes; 8, the fourth plantar digital artery dividing similarly between the second and third toes; 9, the plantar digital artery dividing similarly between the first and second toes; 10, internal plantar artery of the great toe; 11, calcaneal branches of the plantar arteries, anastomosing with 12, the calcaneal branches of the posterior peroneal artery.

**Branches.**—The internal plantar artery gives off numerous small twigs, which may be distinguished in sets as follows:—(*a*) muscular branches to the abductor pollicis and flexor brevis digitorum; (*b*) offsets which incline towards the inner border of the foot, and communicate with branches of the dorsal arteries; and (*c*) cutaneous offsets which appear in the furrow between the middle and inner portions of the plantar fascia.

The **external plantar** artery, of considerable size, at first inclines outwards and then forwards, to reach the base of the fifth metatarsal bone: it then turns obliquely inwards across the foot, to gain the interval between the bases of the first and second metatarsal bones, where it joins, by a communicating branch, with the dorsal artery of the foot; and thus is completed the *plantar arch*, the convexity of which is turned forward. At first the artery is placed, together with the external plantar nerve, between the calcaneum and the abductor pollicis; further on it lies between the flexor brevis digitorum and flexor accessorius. As it turns forwards it lies in the interval between the short flexor of the toes and the abductor of the little toe, being placed along the line separating the middle from the external portion of the plantar fascia, and covered by that membrane. The remainder of the artery, which turns inwards and forms the plantar arch, is placed deeply against the interosseous muscles, and is covered by the flexors of the toes and the lumbricales muscles.

**Branches.**—*A.* In its course to the fifth metacarpal bone the external plantar artery gives off (*a*) branches to the skin of the heel; (*b*) numerous muscular branches; (*c*) small offsets which run outwards over the border of the foot, and

anastomose with the dorsal arteries; and (*d*) others which appear in the furrow between the middle and outer divisions of the plantar fascia.

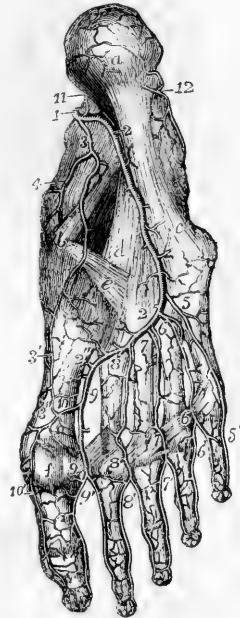B. From the plantar arch are given off the following more important branches.

(*a*) The posterior perforating branches, three in number, pass upwards through the back part of the three outer interosseous spaces, between the heads of the dorsal interosseous muscles, and on reaching the dorsum of the foot inosculate with the interosseous branches of the metatarsal artery.

Fig. 299.—DEEP VIEW OF THE ARTERIES IN THE SOLE OF THE RIGHT FOOT (from Tiedemann).  $\frac{1}{3}$

Fig. 299.

All the muscles have been removed. *a*, the calcaneal tuberosity; *b*, the scaphoid bone and end of the calcaneo-scaphoid ligament; *c*, to *a*, calcaneo-cuboid ligament; *d*, its deep part; *e*, scaphoido-cuneiform ligament; *f*, one of the sesamoid bones of the great toe; 1, posterior tibial artery dividing into the plantar arteries; 2, 2', external plantar artery; 2'', deep plantar arch terminating by communication with the dorsal artery of the foot; 3, 3', internal plantar artery; 3'', its communication with the internal digital of the great toe; 4, branches of the internal plantar to the inside of the foot; 5, 5', first digital or external plantar branch of the fifth toe; 6, second plantar digital artery; 6', interval of the division of the same between the fourth and fifth toes; 7, third plantar digital; 7', its distribution to the third and fourth toes; 8, fourth plantar digital; 8', its distribution to the second and third toes; 9, fifth plantar digital; 9', its distribution to the first and second toes; 10, internal plantar digital branch of the great toe; at the upper numbers, 6, 7, and 8, the posterior perforating branches of the interosseous arteries are partially indicated; at 2'', the large communication between the plantar arch and the dorsalis pedis artery; above 6', 7', and 8', are situated the anterior perforating arteries, not represented in the figure; 11, and 12, calcaneal branches of the plantar and posterior peroneal arteries.



(*b*) The digital branches are four in number. The first digital branch inclines outwards from the outermost part of the plantar arch, opposite the end of the fourth metatarsal space, crosses under cover of the abductor minimi digiti, and runs along the outer border of the phalanges of the little toe. The second digital branch passes forwards along the fourth metatarsal space, and near the cleft between the fourth and fifth toes divides into two vessels, which course along the contiguous borders of those toes, and end on the last phalanges. The third digital branch is similarly disposed of on the fourth and third toes. The fourth ends in like manner on the third and second toes.

The digital artery which supplies the opposed sides of the first and second toes, and that which runs on the inner side of the first toe, arise deeply between the first and second metatarsal bones, usually from that part of the arch which is formed by the end of the dorsal artery of the foot.

Thus, as in the fingers, collateral arteries pass along the sides of the flexor surface of each of the toes. Near the base of the last phalanx these inosculate so as to form an arch, from the convexity of which minute vessels pass forwards to the extremity of the toe, and to the matrix of the nail.

(*c*) An anterior perforating branch is sent upwards by each of the digital arteries of the three outer interspaces near its bifurcation, to communicate with the corresponding digital branch of the metatarsal artery of the dorsum of the foot.

Varieties.—The posterior perforating branches, which are usually very small

vessels, are sometimes enlarged, and furnish the interosseous arteries on the upper surface of the foot; the metatarsal branch of the dorsal artery, from which the interosseous arteries are usually derived, being in that case very small.

Fig. 300.

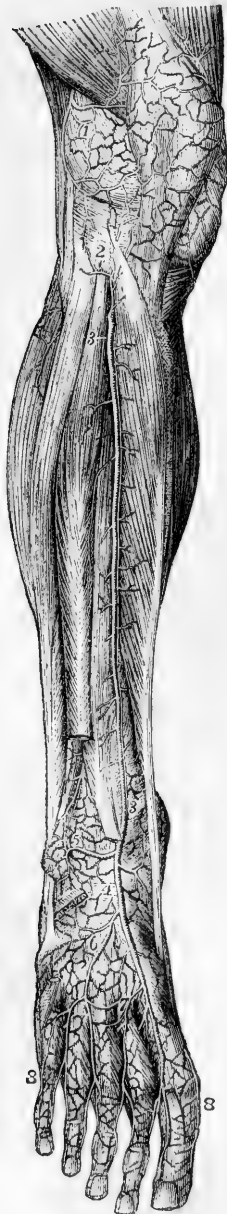

Fig. 300.—ANTERIOR VIEW OF THE ARTERIES OF THE LEG AND DORSUM OF THE FOOT (from Tiedemann).  $\frac{1}{4}$

The tibialis anticus muscle is drawn towards the inner side so as to bring the anterior tibial artery into view; the extensor proprius pollicis, the long common extensor of the toes, and the peroneus tertius muscles in their lower part, and the whole of the extensor communis brevis, have been removed. 1, external superior articular branch of the popliteal artery, ramifying on the parts surrounding the knee, and anastomosing with the other articular branches and with 2, the recurrent branch of the anterior tibial artery; 3, 3, anterior tibial, giving off muscular branches on each side; 4, dorsal artery of the foot; 5, external anterior malleolar artery coming off from the anterior tibial, and anastomosing with the anterior peroneal artery which is seen descending upon the lower part of the fibula: the internal malleolar is represented proceeding from the other side of the anterior tibial artery; 6, the tarsal branch of the dorsal artery, represented in this instance as larger than usual and furnishing some of the branches of the next artery; 7, the metatarsal branch, giving off the dorsal interosseous arteries: (in the first interosseous space the dorsal artery of the foot is seen to give off the anastomosing branch which unites with the deep plantar arch;) between 8, and 8, the collateral branches of the dorsal digital arteries.

#### ANTERIOR TIBIAL ARTERY.

The anterior tibial artery, placed along the fore part of the leg, is at first deeply seated, but gradually approaches nearer to the surface as it descends. It extends from the division of the popliteal artery to the bend of the ankle; whence it is afterwards prolonged to the interval between the first and second metatarsal bones, under the name of *dorsal artery* of the foot.

The anterior tibial artery is at first directed forwards to reach the anterior surface of the interosseous ligament, passing through the divided upper end of the tibialis posticus, and through the interval left unoccupied by the interosseous ligament. It then extends obliquely downwards to the middle of the ankle-joint, in a direction which may be nearly indicated by a line drawn from the inner side of the head of the fibula to midway between the two malleoli. Lying with the tibialis anticus on its inner side, and having

the extensor communis digitorum and, lower down, the extensor proprius pollicis on its outer side, the vessel is

deeply placed at the upper part of the leg, where those muscles are fleshy; but it is comparatively superficial below, between their tendons, and comes forward upon the tibia. At the bend of the ankle it is covered by the annular ligament, and is crossed from without inwards by the tendon of the extensor proprius pollicis. In its oblique course downwards the anterior tibial artery lies at first close to the interosseous ligament, and is then at a considerable distance from the spine of the tibia; but in descending it gradually approaches that ridge, and towards the lower part of the leg is supported on the anterior surface of the bone.

*Relation to Veins and Nerves.*—The anterior tibial artery is accompanied by two veins (*venæ comites*). The *anterior tibial nerve*, coming from the outer side of the head of the fibula, approaches the artery at some distance below the place where the vessel appears in front of the interosseous ligament. Lower down, the nerve for the most part lies in front of the artery, but often changes its position from the one side of the vessel to the other.

**Branches.**—Besides numerous small muscular branches, the anterior tibial artery furnishes the following.

(a) The *recurrent artery*, given off as soon as the anterior tibial reaches the front of the leg, ascends through the fibres of the *tibialis anticus*, and, ramifying on the outside and front of the knee-joint, anastomoses with the inferior articular and other branches of the popliteal artery.

(b) The *malleolar arteries*, two in number, external and internal, are given off near the ankle-joint, but are very variable in size and mode of origin. The *internal* branch passes beneath the tendon of the *tibialis anticus* to the inner ankle, and communicates with branches of the posterior tibial artery. The *external* branch passes outwards under the tendon of the common extensor of the toes, and anastomoses with the anterior division of the peroneal artery, and also with some ascending or recurrent branches from the tarsal branch of the dorsal artery of the foot.—These malleolar arteries supply articular branches to the neighbouring joints.

#### DORSAL ARTERY OF THE FOOT.

The dorsal artery of the foot (*dorsalis pedis*), the continuation of the anterior tibial artery, extends from the termination of that vessel at the bend of the ankle, to the posterior end of the first metatarsal space. At this spot it divides into two branches, of which one proceeds forwards in the first interosseous space, whilst the other dips into the sole of the foot, and terminates by inosculating with the plantar arch. The dorsal artery of the foot lies in the interval between the tendon of the proper extensor of the great toe, and that of the long extensor of the other toes; and is covered by a deep layer of fascia, which binds it to the parts beneath. Near its end it is crossed by the innermost tendon of the short extensor of the toes.

Two veins accompany this artery; the anterior tibial nerve lies on its outer side.

**BRANCHES.**—The principal branches of the dorsal artery of the foot are directed outwards and forwards upon the tarsus and metatarsus, and are named accordingly. Some small offsets also run obliquely inwards, and ramify upon the inner side of the foot.

(a) The **tarsal** branch arises from the artery usually where it crosses the scaphoid bone, but its point of origin varies in different instances.

It inclines forwards and outwards upon the tarsal bones covered by the short extensor muscle of the toes, then curving backwards towards the cuboid bone, divides into branches which take different directions over the tarsus.

Fig. 301.



Fig. 301.—ANTERIOR VIEW OF THE ARTERIES OF THE LEG AND DORSUM OF THE FOOT (from Tiedemann). 4

The *tibialis anticus* muscle is drawn towards the inner side so as to bring the anterior tibial artery into view, the *extensor proprius pollicis*, the long common extensor of the toes, and the *peroneus tertius* muscles in their lower part, and the whole of the *extensor communis brevis*, have been removed. 1, external superior articular branch of the popliteal artery, ramifying on the parts surrounding the knee; and anastomosing with the other articular branches, and with 2, the recurrent branch of the anterior tibial artery; 3, 3, anterior tibial, giving off muscular branches on each side; 4, dorsal artery of the foot; 5, external anterior malleolar artery coming off from the anterior tibial and anastomosing with the anterior peroneal artery which is seen descending upon the lower part of the fibula; the internal malleolar is represented proceeding from the other side of the anterior tibial artery; 6, the tarsal branch of the dorsal artery, represented in this instance as larger than usual and furnishing some of the branches of the next artery; 7, the metatarsal branch, giving off the dorsal interosseous arteries; (in the first interosseous space the dorsal artery of the foot is seen to give off the anastomosing branch which unites with the deep plantar arch;) between 8 and 8, the collateral branches of the dorsal digital arteries.

Its branches supply the *extensor brevis digitorum* muscle and the tarsal joints, and anastomose with the external plantar, the metatarsal, the external malleolar, and the peroneal arteries.

(b) The **metatarsal** artery arises farther forwards than the preceding vessel, and is directed outwards like it, beneath the short extensor muscle. Sometimes there are two metatarsal arteries, the second being of smaller size; and not unfrequently, when there is but a single vessel of this name, it arises in common with the tarsal artery. Its direction is necessarily influenced by these circumstances; being oblique when it arises far back, and almost transverse when its origin is situated farther forwards than usual. It anastomoses with the tarsal and external plantar arteries, and gives off interosseous branches.

The three *interosseous* branches are small straight vessels which pass forwards along the three outer interosseous spaces, resting upon the dorsal interosseous muscles. Somewhat behind the clefts between the toes each divides into two branches, which run forward along the contiguous borders of the corresponding toes, forming their dorsal collateral

arteries.



branches. Moreover, from the outermost of these interosseous arteries a small branch is given off, which gains the outer border of the little toe, and forms its external collateral branch. These arteries communicate with the plantar arch opposite the fore part of the interosseous spaces, by means of the *anterior perforating* branches, and at the back part of the interosseous spaces, by the *posterior perforating* branches.

(c) The **dorsal artery of the great toe (dorsalis hallucis)** is continued forwards from the dorsal artery of the foot at the point where it dips down to the sole. This branch runs along the outer surface of the first metatarsal bone, and furnishes the small *dorsal digital* vessels of the great toe and adjacent side of the second toe.

(d) The **plantar digital branch of the first space** is given off from the dorsal artery between the heads of the first interosseous muscle, near the inosculation with the plantar arch, and passing forwards divides into two smaller branches which proceed along the contiguous sides of the first and second toe.

(e) The **plantar digital branch for the inner side of the great toe** crosses beneath the first metatarsal bone, and runs along the inner side of the great toe on its plantar surface.

**Varieties of the Anterior Tibial Artery.**—*Origin.*—In cases of early division of the popliteal artery, the place of origin of the anterior tibial is necessarily higher up than usual, being sometimes found as high as the bend of the knee-joint. In some of these cases (the posterior tibial artery being small or wanting), the anterior tibial is conjoined with the peroneal artery. When the anterior tibial arises higher than usual, the additional upper part of the vessel has been seen resting on the posterior surface of the popliteus muscle, and it has been likewise found between that muscle and the bone.

*Course.*—The anterior tibial artery, having its usual place of origin, has been found to deviate outwards towards the margin of the fibula in its course along the front of the leg, and then to return to its ordinary position beneath the annular ligament in front of the ankle-joint. This artery has been also noticed by Pelletan and by Velpeau to approach the surface at the middle of the leg, and to continue downwards from that point, covered only by the fascia and integument. Velpeau states that he found the artery to reach the fore part of the leg by passing round the outer side of the fibula. (Pelletan, "Clinique Chirurgicale," &c., p. 101 : Paris, 1810. Velpeau, "Nouveaux Elémens de Médecine Opératoire," &c., t. i., pp. 137 and 537 : Paris, 1837.)

*Size.*—This vessel more frequently undergoes a diminution than an increase of size.

It may be defective in various degrees. Thus the dorsal branch of the foot may fail to give off digital branches to the great and second toes, which may be then derived from the internal plantar division of the posterior tibial. In a farther degree of diminution the anterior tibial ends in front of the ankle or at the lower part of the leg; its place being then taken by the anterior division of the peroneal artery, which supplies the dorsal artery of the foot; the two vessels (anterior tibial and anterior peroneal) being either connected together or separate.

Two cases are mentioned by Allan Burns, in which the anterior tibial artery was altogether wanting, its place in the leg being supplied by perforating branches from the posterior tibial artery, and on the dorsum of the foot by the anterior peroneal artery.

The dorsal artery of the foot is occasionally larger than usual; in that case compensating for a defective condition of the internal plantar branch from the posterior tibial artery.

This artery has been repeatedly found to be curved outwards between its commencement at the lower border of the annular ligament and its termination in the first interosseous space.

## THE SYSTEMIC VEINS.

The systemic veins commence by small branches which receive the blood from the capillaries throughout the body, and unite to form larger vessels, which end at last by pouring their contents into the right auricle of the heart through two large venous trunks, the superior and inferior venæ cavæ. The blood which nourishes the substance of the heart itself, is also returned by the coronary veins to the right auricle.

The veins, however, which bring back the blood from the stomach, intestines, spleen, and pancreas, have an exceptional destination, not conveying the blood directly to the heart, but joining to form a single trunk—the portal vein, which ramifies after the manner of an artery in the substance of the liver, and carries the blood within it to the capillaries of that organ. From these the blood passes into the ultimate twigs of the hepatic veins, and is conveyed by these veins into the inferior vena cava. The veins thus passing to the liver constitute the *portal system*.

The anastomoses of veins are much larger and more numerous than those of arteries. The veins of many parts of the body consist of a subcutaneous and a deep set, which have very frequent communications with each other. In some parts of the body, chiefly in the limbs and at the surface, the veins are provided with valves, whilst in others no valves exist.

The systemic veins are naturally divisible into two groups: firstly, those from which the blood is carried to the heart by the superior vena cava, viz., the veins of the head and neck and upper limbs, together with those of the spine and a part of the walls of the thorax and abdomen, with which may be associated also the veins of the heart; and secondly, those from which the blood is carried to the heart by the inferior vena cava, viz., the veins of the lower limbs, the lower part of the trunk, and the abdominal viscera. (For a general representation of the venous system, see fig. 240, at p. 344.)

## SUPERIOR VENA CAVA.

The superior vena cava conveys to the heart the blood which is returned from the head, the neck, the upper limbs, and the thorax. It is formed by the union of the right and left brachio-cephalic veins. It extends from a little below the cartilage of the first rib on the right side of the sternum to the base of the heart, where it opens into the right auricle. Its course is slightly curved, the convexity of the curve being turned to the right side. It has no valves. At about an inch and a half above its termination, it is invested by the fibrous layer of the pericardium, the serous membrane being reflected over it. The upper vena cava lies immediately in front of the right pulmonary vessels, and between the right lung and the aorta, which partly overlap it. It receives several small veins from the pericardium and the mediastinum; and lastly, it is joined by the right azygos vein, immediately above the place where it becomes invested by the pericardium.

**Varieties.**—In several instances, the two innominate veins, which usually join to form the vena cava superior, have been seen to open separately into the right auricle. This peculiarity is explained by reference to the development of

the parts, and will be more fully referred to at p. 485, in connection with the description of the great cardiac vein. The superior vena cava in one case has been seen to be joined by one of the pulmonary veins (Meckel). In several cases two superior venæ cavæ have been found, a right and a left, the left always opening into the left auricle, and in one case being joined by a pulmonary vein. (Hyrſl, Gruber, Luschka.)

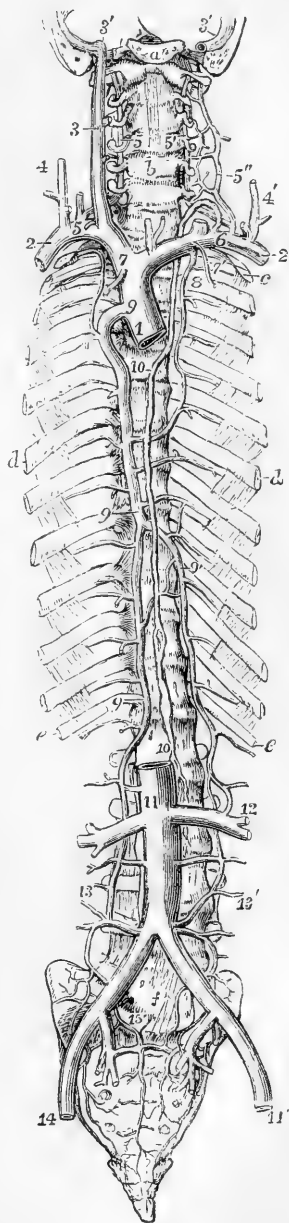
Fig. 302.

Fig. 302.—SKETCH OF THE PRINCIPAL VENOUS TRUNKS, TOGETHER WITH THE THORACIC DUCT.  $\frac{1}{2}$

*a*, the basilar process of the occipital bone, through which and the temporal bones a transverse incision has been made so as to lay open the jugular foramen on both sides; *b*, the fifth cervical vertebra; *c*, the first rib; *d*, the sixth; *e*, the twelfth; *f*, the fifth lumbar vertebra; 1, vena cava superior divided at the place of its entrance into the right auricle; 2, right, 2', left subclavian veins; 3, right internal jugular vein; 3', 3', lower part of the lateral sinuses of the dura mater; that of the right side shows at its junction with the jugular vein the bulb which lies in the jugular depression of the temporal bone; 4, right, and 4', left external jugular veins; 5, right, and 5', left vertebral veins, anastomosing with 5'', external vertebral veins, before joining the subclavian veins; 6, placed on left subclavian vein below the opening of the last, and of the thoracic duct; below *b*, the inferior thyroid veins; 7, 7', the internal mammary veins; 8, the left superior intercostal vein joining the left brachio-cephalic vein, and anastomosing below with intercostal veins which join the trunk of the azygos; the right superior intercostal vein is seen joining the azygos vein; 9, main or right azygos vein; 9', the left azygos, represented here as crossing the vertebral column on the eighth vertebra; 10, the thoracic duct; 11, trunk of the inferior vena cava at the place of junction of the renal veins; the vena cava is seen dividing on the fourth lumbar vertebra into the two common iliac veins; 12, the union of the left azygos vein with the left renal vein; 13, on the right side, the commencement of the right azygos vein in the lumbar region, joined by several lumbar veins; 13', the commencement of the azygos vein of the left side, joining similar veins on that side; 14, 14', the external iliac veins; 15, placed on the promontory of the sacrum, points on either side to the prolongation of the lower branches of the right and left lumbar veins into the pelvis, and their union with sacral and other branches of the internal iliac veins.

#### INNOMINATE OR BRACHIO-CEPHALIC VEINS.

The blood returned from the upper limbs through the subclavian veins, and from the head and neck by the jugular veins, is poured into two trunks, named the brachio-cephalic or innominate veins.



These vessels, resulting from

the union of the subclavian with the internal jugular vein at each side, commence opposite the inner ends of the clavicles, and terminate a little below the cartilage of the first rib on the right side, where, by uniting, they form the upper vena cava. The right vein is very short, and nearly vertical in its direction; it is in apposition, on the right side, with the pleura and the upper part of the right lung. The vein of the left side, about three times longer than the right vein, pursues a course from left to right, at the same time inclining somewhat downwards: it crosses behind the upper part of the first bone of the sternum, separated from it by the sterno-hyoid and sterno-thyroid muscles, and by the thymus gland or its remains; it lies in front of the three primary branches given off from the arch of the aorta, and rests upon the highest part of the arch. The innominate veins have no valves.

**LATERAL TRIBUTARIES.**—(a) The **inferior thyroid** veins emerge from a venous plexus situated on the thyroid body—those of opposite sides communicating by small branches across the trachea. The vein of the left side descends in front of the trachea, behind the sterno-thyroid muscles, and ends in the left brachio-cephalic or innominate vein: that of the right side inclines outwards in some degree, and opens into the corresponding brachio-cephalic vein, or into the angle of union between it and the vessel of the opposite side. In their course these veins receive inferior laryngeal and tracheal branches.

(b) The **internal mammary** veins follow exactly the course of the arteries of the same name—two veins accompanying each of the arteries. The two companion veins of the artery arise by small branches, derived from the fore part of the walls of the abdomen, where they anastomose with the epigastric veins; from thence proceeding upwards between the cartilages of the ribs and the pleura, they receive the *anterior intercostal* veins which correspond with the branches of the internal mammary artery, together with some small *diaphragmatic*, *thymic*, and *mediastinal* veins, and these finally uniting into a single trunk, each vein terminates in the brachio-cephalic of its own side.

(c.) The **superior intercostal** veins.—The right superior intercostal vein receives the blood from the first two or three spaces, communicating with the vessel in the space next below, and opens into the innominate trunk of the same side, or into the vena cava. Frequently the veins at the right side, corresponding with the superior intercostal artery, pass downwards separately, to open into the azygos vein, as that vessel arches forwards to join the upper vena cava: the separate vein thus formed is inferior in size to that on the left side. The *left* superior intercostal vein varies in length in different persons, being small when the azygos minor is large, and *vice versâ*. Usually it receives the veins from the three or four upper spaces, and is then directed forwards over the left side of the spinal column and the aorta to open into the left innominate vein. It receives in its course the left bronchial vein. The left vein is sometimes directed downwards to join an azygos vein on its own side.

A small fibrous cord is frequently found joining the trunk of the superior intercostal vein with the coronary sinus of the heart. This is the remains of the left duct of Cuvier, a foetal structure to be afterwards described.

## VEINS OF THE HEAD AND NECK.

The blood returning from the head and neck flows on each side into two principal veins, the external and internal jugular. The veins of the head and neck have generally no valves. The external jugular vein is provided with a valve at its entrance into the subclavian vein, and in most cases with another about the middle of its course: and the internal jugular is also furnished with valves near its junction with the subclavian. These valves, however, are not sufficient to stop the regurgitation of the blood, or the passage of injections from below upwards.

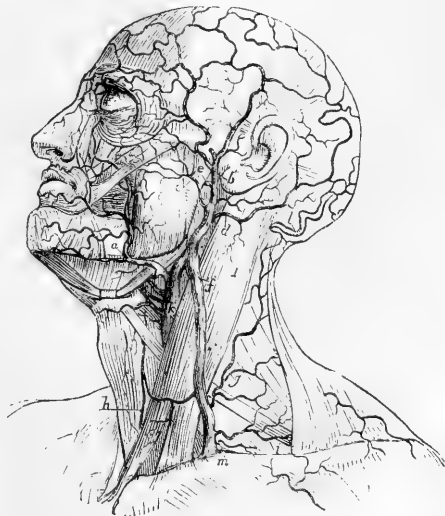The veins on the exterior of the cranium and face converge and unite, so as to form two trunks, the facial and the temporal veins.

The **facial** vein lies obliquely along the side of the face, extending from the inner margin of the orbit downwards and outwards to the anterior border of the masseter muscle. Resting on the same plane as the facial artery, but farther back, and less tortuous, it has very nearly the same relations to contiguous parts. It commences at the side of the root of the nose by a vein formed by the junction of branches from the forehead, eyebrow, and nose, and increases by receiving others during its course. Below the jaw it inclines outwards and backwards, covered by the cervical fascia and the platysma muscle: and soon unites with a large branch of communication derived from the temporal vein, to form the *temporo-maxillary* or *common facial* vein, a short vessel of considerable size, which joins obliquely the trunk of the internal jugular.

Fig. 303.—VIEW OF THE SUPERFICIAL VEINS OF THE HEAD AND NECK.

Fig. 303.

1. sterno-mastoid muscle; *a*, facial vein; *b*, temporal vein; *c*, transverse facial; *d*, posterior auricular; *e*, internal maxillary vein; *f*, external jugular vein; *g*, posterior external jugular; *h*, anterior jugular; *i*, posterior scapular and suprascapular veins; *k*, internal jugular vein; *l*, occipital vein; *m*, subclavian vein; above the inner side of the orbit are shown the frontal and supra-orbital veins, and their descending branches to anastomose with the angular or terminal branch of the facial vein.



**Tributaries.**—(*a*) The *frontal* vein commences on the roof of the skull by branches, which descend obliquely inwards upon the forehead, maintaining communications in their course with the anterior branches of the temporal vein. It descends vertically, parallel with the corresponding vessel of the opposite side, with which it is connected by transverse branches, and ends in the angular vein. In some instances the veins of the two sides unite and form a short trunk, which again divides into two branches at the root of the nose. As it descends from the

forehead, the frontal vein receives a branch from the eyebrow, and some, of smaller size, from the nose and upper eyelid.

(b) The *supra-orbital vein* (v. *supercilii*) runs inwards in the direction of the eyebrow, covered by the occipito-frontalis muscle. Its branches are connected externally with those of the external palpebral and superficial temporal veins : in its course it receives branches from the contiguous muscles and integument, and at the inner angle of the orbit inclines downwards to terminate in the frontal vein.

(c) The *angular vein*, formed by the junction of the supra-orbital and frontal veins, is perceptible beneath the skin as it runs obliquely downwards and outwards near the inner margin of the orbit, resting against the side of the nose at its root. This vessel receives on the inner side the *nasal veins*, which pass upwards obliquely to join it from the side and ridge of the nose ; whilst some small *superior palpebral veins* open into it from the opposite direction. On a level with the lower margin of the orbit it becomes continuous with the facial vein.

(d) The *inferior palpebral veins*, two or three in number, are derived from the lower eyelid, from the outer side of the orbit, and from the cheek. They pass in a direction obliquely inwards above the zygomatic muscle, and then turn beneath it previously to their termination.

(e) *Communicating branches* from the pterygoid plexus (deep facial, anterior internal maxillary) and also some branches proceeding from the orbit, furnished by the *infra-orbital* of the internal maxillary vein, join the facial on a level with the angle of the mouth.

(f) *Labial, buccal, masseteric and mental branches* join the facial below the angle of the mouth.

(g) The *ranine vein* is a small vessel which lies along the under surface of the tongue, close to the frenum linguæ, in apposition with the artery of the same name : its course is backwards and outwards, between the mylo-hyoid and hyoglossus muscles, to open into the facial vein, or sometimes into the lingual.

(h) The *submental vein*, larger than the preceding, commences below the chin ; it receives branches from the submaxillary gland, and from the mylo-hyoid muscle, and, keeping close under cover of the margin of the jaw-bone, joins the facial vein ; but in some instances it enters the lingual or superior thyroid vein.

(i) *Submaxillary branches* from the gland join the facial vein either separately or united into one trunk.

(j) The *palatine vein* returns the blood from the plexus surrounding the tonsil and from the soft palate ; it passes downwards, deeply seated by the side of the pharynx, to join one of the preceding veins, or terminate in the facial separately.

The **temporal vein**, a vessel of considerable size, descends in front of the external auditory tube, reaching from the zygoma, upon which it rests, to the angle of the jaw. It results from the union of branches which are spread out upon the side of the head, some superficially, and others deeply seated. The *superficial branches* commence upon the arch of the skull, where they communicate with the ramifications of the frontal and occipital veins, as well as with those of the corresponding vein of the opposite side. Descending on the surface of the temporal fascia, they converge ; those from the fore part inclining a little backwards, while the posterior branches run forwards over the ear ; and the two sets joining together above the zygoma form the trunk of the temporal vein. The deeper branches, arising in the substance of the temporal muscle, unite to form a vein of some size, called the *middle temporal*, to distinguish it from branches still more deeply placed, and which open into the internal maxillary vein. The middle temporal vein falls into the common temporal trunk at its commencement above the zygoma. The temporal vein gradually sinks into the

substance of the parotid gland as it descends behind the ramus of the jaw. Beneath the angle of that bone, it divides into two vessels, one of which turns backwards, and forms the commencement of the external jugular vein, while the other communicates with the facial vein near its termination.

**Tributaries.**—These are numerous :—(a) *parotid* branches from the parotid gland ; (b) *articular*, from the articulation of the jaw ; (c) *anterior auricular* veins from the external ear ; (d) the *transverse facial*, a branch of considerable size, corresponding with the transverse facial artery ; (e) the *posterior auricular* directed forwards from behind, and joined by the stylo-mastoid vein ; and (f) the *internal maxillary* vein, a large vessel, which requires more particular description.

The **internal maxillary** vein corresponds somewhat in direction and position with the artery of the same name, and receives branches from the neighbouring parts, most of which are the venæ comites of the corresponding divisions of the internal maxillary artery. Thus three or four *deep temporal* branches descend from the temporal muscle ; others come from the pterygoid, masseter, and buccinator muscles. The middle *meningeal* veins and some *palatine* veins also end in the internal maxillary ; and lastly, branches from the surface of the upper jaw—*superior dental*, and another, of large size, from the lower jaw, emerging from the dental foramen—*inferior dental*. These different branches form a plexus of veins, named *pterygoid plexus*, which is placed in the lower part of the temporal fossa, between the temporal and the external pterygoid muscle, and in part between the pterygoid muscles. It communicates in front with the facial vein, and above, with the cavernous sinus by branches through the base of the skull. From this plexus proceed one or two short trunks, which join nearly at right angles with the temporal vein.

The *facial communicating* vein, extending between the temporal vein at the angle of the jaw and the facial vein, a little in front of it, is a short trunk, usually the larger of the two into which the temporal vein divides, and placed nearly transversely, so as to allow the flow of blood either from the temporal into the internal jugular vein, or from the facial into the external jugular.

**External Jugular Vein.**—This vein commences on a level with the angle of the lower maxilla, at the end of the temporal vein, and descends perpendicularly between the platysma and fascia, crossing the sterno-mastoid muscle. In consequence of the oblique direction of that muscle, the vein gets to its outer border, and continues behind it down to the lower part of the neck, where it pierces the fascia to terminate either as a single trunk, or by two or three branches in the subclavian vein. It is provided with a valve at its lower end, and in most cases with another about the middle of its course.

**Tributaries.**—The external jugular vein receives some large branches from behind, and superficial branches from the fore part of the neck. The largest branches are the following.

(a) The *posterior* branch, lying at first between the splenius and trapezius muscles, passes down at the outside of the jugular vein, and below the middle of the neck opens into that vessel.

(b) The *suprascapular* and *posterior scapular* veins, corresponding to the arteries of the same name, pass transversely inwards to join the external jugular vein close to its termination.

Fig. 304.

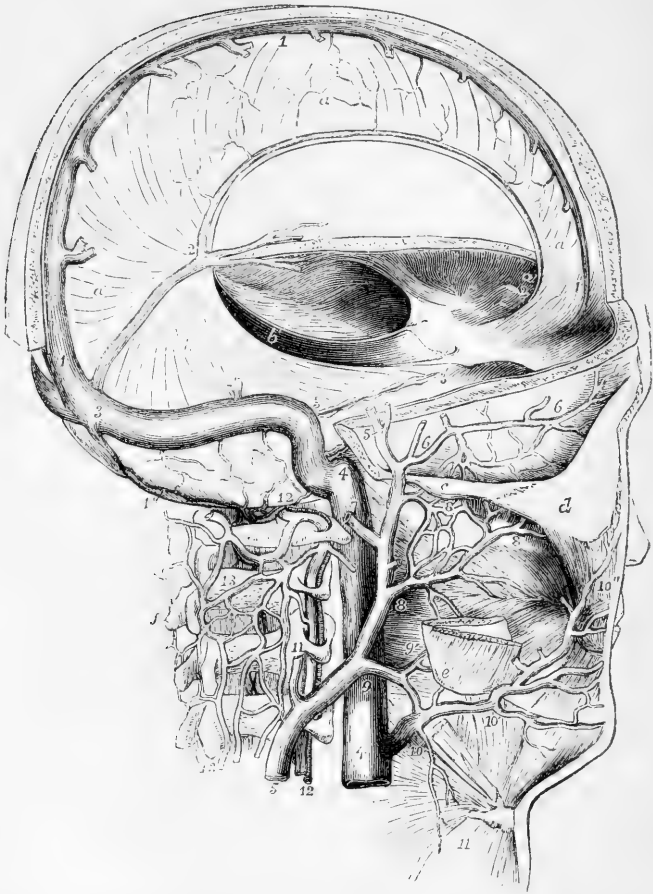


Fig. 304.—DIAGRAMMATIC VIEW OF THE SINUSES OF THE DURA MATER AND SOME OF THE DEEP VEINS OF THE NECK AND HEAD (modified from Cloquet and other sources). (A. T.)  $\frac{1}{2}$

The greater part of the calvarium has been removed; but an arched strip has been kept in the fore and upper part of the region of the superior longitudinal sinus. The occiput has been entirely removed so as to expose the lateral sinus and its termination in the jugular vein. *a*, the falx cerebri; *b, b'*, the tentorium cerebelli; *c*, zygomatic arch; *d*, malar bone; *e*, angle of the jaw; *f*, spinous process of the axis vertebra; 1, superior longitudinal sinus; 2, inferior longitudinal sinus; 2, 3, straight sinus; 2', internal veins of the brain (veins of Galen); 3, lateral sinus, descending to 4, the commencement of the internal jugular vein; 3', superior petrosal sinus; 4, 4, the internal jugular vein; 5, 5, superficial temporal vein, leading into the external jugular vein; 6, middle temporal; 7, posterior auricular; 8, internal maxillary; 8', pterygoid plexus and communications with the deep temporal veins; 9, communicating branch between the facial, temporal, and external jugular; 9', pharyngeal branches; 10, facial vein; 10', submental branch; 10'', continuation of the facial into the angular; 11, an occasional branch from the neck; 12, vertebral vein and artery; 13, external spinal veins forming a plexus over the vertebral arches; 14, occipital sinus communicating above the atlas with the spinal plexus.



The **anterior jugular** vein arises from the convergence of some superficial branches in the submaxillary region. This vessel lies along the fore part of the neck, sometimes near the sterno-mastoid muscle, and either terminates by inclining outwards to join the external jugular vein, or, after giving to it a branch of communication, sinks beneath the sterno-mastoid muscle, and ends in the subclavian vein. The lower ends of the two anterior jugular veins are frequently united by a transverse branch placed behind the sterno-mastoid muscles and top of the sternum.

**Varieties.**—The external jugular vein is very variable in size. It is frequently very small, and may be absent altogether. It is sometimes joined by the cephalic vein of the arm, or by a jugulo-cephalic branch of that vein running up over the clavicle. The external jugular vein has also been seen to descend in front of the clavicle, and pass through the infra-clavicular fossa, to join the subclavian vein beneath the clavicle. The anterior jugular vein is likewise very variable.

**Internal Jugular Veins.**—These veins, receiving the blood from the brain and cranial cavity, are continuous at their upper extremities with the lateral sinuses within the cranium, and terminate inferiorly in the innominate or brachio-cephalic veins. The commencement of each internal jugular vein at the wide part (*jugular fossa*) of the foramen jugulare, is somewhat enlarged, and has been named the *sinus* or *gulf* of the internal jugular vein. Beneath the skull, the vein is supported by the rectus lateralis muscle, and lies close to the outer side of the internal carotid artery, as far as the cornu of the os hyoides. It is joined at this point by the common facial vein, and becomes considerably enlarged; it then descends parallel with the common carotid artery, lying at its outer side and enclosed in the same sheath, together with the vagus nerve. At the root of the neck it joins nearly at a right angle with the subclavian vein, and so forms the innominate or brachio-cephalic vein. Close to the lower termination of the jugular, or from half an inch to an inch above it, is placed a double valve as in other veins. (Struthers, "Anat. and Phys. Observ.," p. 173.)

**Tributaries.**—Previously to its junction with the facial vein, the internal jugular receives the lingual, pharyngeal, and occipital veins; one or more of which, however, very frequently end in the common facial trunk.

(a) The *lingual* vein begins at the side and upper surface of the tongue, and passes backwards, receiving branches from the sublingual gland; occasionally the ranine vein joins it, and sometimes also the pharyngeal.

(b) The *pharyngeal* vein commences at the back and sides of the pharynx, and sometimes ends in the superior thyroid vein, and at other times in the lingual, or separately in the internal jugular vein.

(c) The *occipital* vein, corresponding in course and distribution with the occipital artery, communicates with a plexus of veins upon the occiput, and terminates occasionally in the external jugular vein, but more frequently in the internal.

(d) The *common facial* vein has been already described.

(e) The *laryngeal* vein receives branches from the larynx through the thyro-hyoid membrane, and opens into the internal jugular, the common facial, or sometimes into the superior thyroid vein.

(f) The *superior thyroid* vein commences by branches in the thyroid body, in company with those of the superior thyroid artery, and runs transversely outwards.

(g) The *middle thyroid vein*, likewise derived from the thyroid body, is placed lower than the superior thyroid.

#### VENOUS CIRCULATION WITHIN THE CRANIUM.

The part of the venous system contained within the skull consists of veins properly so called, and of certain channels called *sinuses*, which receive the blood from those veins, and conduct it to the internal jugular veins. The sinuses alluded to are spaces left between the layers of the *dura mater*, the fibrous covering of the brain.

#### CEREBRAL VEINS.

The veins of the brain are divisible into those which ramify upon its surface, and those which are placed within its ventricles.

Fig. 305.

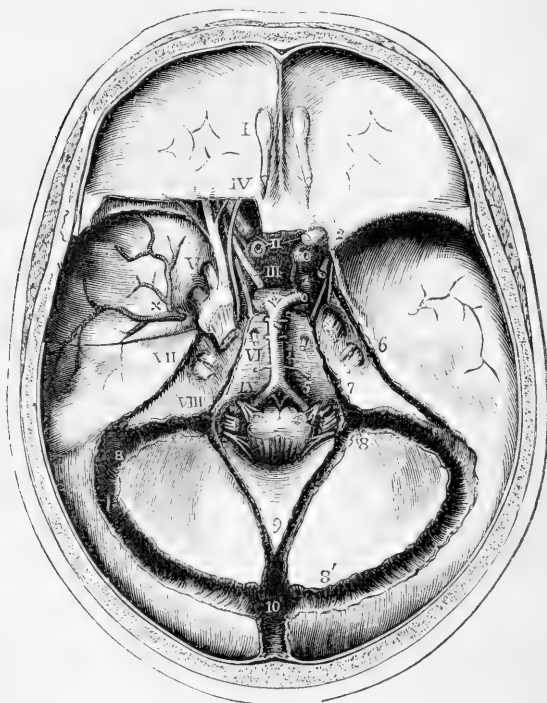


Fig. 305.—INTERNAL VIEW OF THE BASE OF THE SKULL, SHOWING THE SINUSES OF THE DURA MATER, &c. (A. T.)  $\frac{1}{2}$

The sinuses of the *dura mater* have been opened, a small portion of the roof of the orbit has been removed posteriorly on the left side, and the *dura mater* has been dissected so as to bring into view the arteries at the base of the skull, the venous sinuses and the trunks of the cranial nerves.

I., the olfactory bulb ; II., the optic nerves ; III., placed on the pituitary body, indicates the third nerve ; IV., the trochlear nerve ; V., placed opposite to the middle of the three divisions of the fifth nerve ; VI., the sixth nerve ; VII., the facial and auditory nerves ; VIII., placed opposite to the three portions of the eighth pair ; IX., the

hypoglossal nerve ; 1, the right internal carotid artery as it makes its turn in the cavernous sinus in the groove of the sphenoid bone ; 2, its ophthalmic branch proceeding into the orbit, below and to the outside of the optic nerve ; 3, division of the basilar artery into the two posterior cerebral arteries, one of which is represented on the right side as giving off the communicating artery to the internal carotid ; 4, basilar artery ; 5, vertebral arteries giving off the anterior spinal ; ×, great meningeal vessels spreading upwards from the foramen spinosum ; 6, superior petrosal sinus ; 7, inferior petrosal running back into the lower part of the lateral sinus ; 8, termination of the lateral sinus in the internal jugular vein, and continuation of the lateral sinus ; 8', commencement of the lateral sinus ; 9, occipital sinuses ; 10, torcular Herophili, and below that number in the figure, the superior longitudinal sinus.

The **superficial veins** upon the upper surface of the hemispheres are for the most part lodged in the tortuous sulci between the convolutions ; but some run over the convexity of the convolutions. Their general direction is towards the middle line ; and on reaching the margin of the longitudinal fissure between the hemispheres, they receive branches from the flat mesial surface of the hemispheres, and becoming invested by tubular sheaths of arachnoid membrane, incline obliquely forwards and open in that direction into the superior longitudinal sinus.

The veins upon the sides and under surface of the brain are directed outwards, to open into the lateral and other sinuses at each side.

The **deep veins** of the brain commence by branches within the ventricles of that organ. Thus, upon the surface of the corpus striatum several small venous branches are seen, which for the most part converge to form a slender vein which runs along the groove between the corpus striatum and optic thalamus, and opens into one of the veins of the choroid plexus. The minute veins of the choroid plexus pass backwards, and incline towards the middle line from each side, so as to form, by their union, two veins—*venæ Galeni*. These, lying parallel, run directly backwards, enclosed within the velum interpositum, and escape from the interior by passing through the great transverse fissure of the brain between the under surface of the corpus callosum and the corpora quadrigemina. In this way they reach the anterior margin of the tentorium cerebelli, at its place of union with the falx cerebri, where they terminate by entering the straight sinus.

The *veins of the cerebellum* are disposed in two sets. Those of the upper surface incline inwards and forwards for the most part, and run upon the upper vermiform process, over which they ascend a little to reach the straight sinus, in which they terminate ; some, farther forward, open into the veins of Galen. Those at the under surface run transversely outwards, and pour their contents into the occipital and the lateral sinuses.

#### Cranial Sinuses.

The **venous sinuses** within the cranial cavity admit of being divided into two sets, viz., those placed in the prominent folds of the dura mater, and those situated in the base of the skull.

The form and size of the sinuses are various. All of them are lined by a continuation of the internal membrane of the veins, the dura mater serving as a substitute for the other coats.

The sinuses which are contained in the several processes or folds of

the dura mater converge to a common point, which corresponds with the internal occipital protuberance, and is called the **confluence of the sinuses** or **torcular Herophili**. The form of the torcular is very irregular. Five or six apertures open into it: viz., one from the longitudinal, and one from the straight sinus; two from the right and left lateral sinuses; and one or two from the posterior occipital sinuses.

Fig. 306.

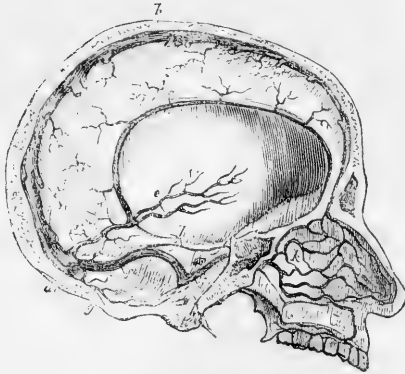


Fig. 306.—SKETCH OF THE INTERNAL VEINS OF THE CRANIUM AND NOSE.  $\frac{1}{4}$

*a*, torcular Herophili; *b*, superior longitudinal sinus of the dura mater; *c*, inferior longitudinal sinus; *d*, straight sinus; *e*, internal veins of the brain, or veins of Galen; *g*, occipital sinus; *h*, superior petrosal sinus; *i*, inferior petrosal sinus; *k*, nasal veins on the septum; some of which superiorly form the commencement of the superior longitudinal sinus, and others lower down pass out by the sphenopalatine foramen.

#### The superior longitudinal sinus (s. falciformis)

superior), commencing at the crista galli, extends from before backwards, in the upper border of the falx cerebri, gradually increasing in size as it proceeds. It is three-sided, and is crossed obliquely at the inferior angle by several bands, the *chordæ Willisii*. The veins from the cerebral surface open into this sinus chiefly towards the back part; and in such a way that the apertures of the greater number of them are directed from behind forwards, contrary to the direction of the current within it. The longitudinal sinus communicates with the veins on the outside of the occipital bone, by a branch (one of the "emissary veins," Santorini) which passes through a hole in the parietal bone.

The **inferior longitudinal sinus** (s. falciformis inferior) is very small, and has so much of a cylindrical form, that it is sometimes named *inferior longitudinal vein*. Placed in the inferior concave border of the falx cerebri, it runs from before backwards, and opens into the straight sinus on reaching the anterior margin of the tentorium cerebelli. It receives branches from the surface of the falx cerebri, and sometimes from the flat surface of the hemispheres.

The **straight sinus** (s. tentorii) runs backwards in the base of the falx cerebri, gradually widening as it approaches the torcular Herophili, in which it terminates. Besides the inferior longitudinal sinus, the venæ Galeni and the superior veins of the cerebellum open into it.

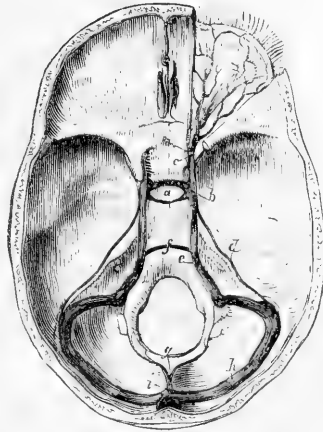
The **lateral sinuses** (s. transversi) are of considerable size. Their direction conforms to that of the groove marked along the inner surface of the occipital and other bones, and extending from opposite the internal occipital protuberance to the foramen jugulare. The sinus of the right side is usually larger than that of the left; both commence at the torcular Herophili, and terminate in the jugular veins. The lateral sinuses receive the blood transmitted from both the longitudinal sinuses,

from the straight and occipital sinuses, from the veins upon the sides and base of the brain, from those on the under surface of the cerebellum, and from some of the veins of the diploë. The petrosal sinuses also join the lateral sinus on each side : and two *emissary* veins connect these with the veins at the back of the head and neck.

Fig. 307.—SKETCH OF THE VENOUS SINUSES IN THE BASE OF THE CRANIUM, WITH THE OPHTHALMIC VEIN.

*a*, sella turcica and circular sinus ; *b*, cavernous sinus receiving *c*, the ophthalmic vein ; *d*, superior petrosal ; *e*, inferior petrosal sinus ; *f*, transverse sinus ; *g*, occipital ; *h*, lateral ; *i*, termination of the superior longitudinal in the torcular Herophili.

Fig. 307.



The **posterior occipital sinus** is sometimes a single canal, at other times double, as if composed of two compartments. It lies along the attached border of the falx cerebelli, extending from the posterior margin of the foramen magnum to the confluence of the sinuses. It communicates in front with the posterior spinal plexuses of veins.

The sinuses placed at the base of the skull are as follows, taking them in their order from before backwards.

The **circular sinus** has the form of a ring, and is placed superficially in the substance of the dura mater round the pituitary body ; it receives the blood from the minute veins of the pituitary body and communicates at each side with the cavernous sinus. Sometimes it is only partially developed, the part in front of the gland being that usually present ; sometimes, however, it is behind the gland.

The **cavernous sinuses**, placed one on each side of the body of the sphenoid bone, over the roots of the great wings, and stretching from the sphenoidal fissure to the apex of the petrous portion of the temporal bones, are of considerable size, and of very irregular form. Each receives the ophthalmic vein at its fore part, and communicates internally with the circular sinus, and posteriorly with the petrosal sinuses. In the wall of each, separated by the lining membrane from the cavity of the sinus, pass forward the third, fourth, and sixth cranial nerves, the ophthalmic division of the fifth nerve, and the internal carotid artery.

The **superior petrosal sinus** is a narrow canal running along the upper margin of the petrous part of the temporal bone. Commencing at the back part of the cavernous sinus, it is directed outwards and backwards in the attached margin of the tentorium cerebelli ; and, descending a little, ends in the lateral sinus where this lies upon the temporal bone.

The **inferior petrosal sinus**, wider than the upper, passes downwards and backwards along the lower margin of the petrous bone, between this and the basilar process of the occipital bone. It opens into the lateral sinus near its termination, or into the internal jugular vein.

The **anterior occipital** or **transverse sinus** (sinus basilaris) is placed at the fore part of the basilar process of the occipital bone, so as to establish a transverse communication between the two inferior petrosal sinuses.

#### OPHTHALMIC VEIN.

The **ophthalmic vein** opens into the cavernous sinus. Its branches are distributed in the different structures contained within the orbit, in company with the branches of the ophthalmic artery : some small ramifications arise from the eyelids, whilst others communicate with the angular branch of the facial vein ; and those which accompany the supraorbital artery have similar connections with the veins upon the forehead. All these branches, together with others arising from the lachrymal gland, from the different muscles, from the ethmoidal cells, and from the globe of the eye, severally named

Fig. 308.

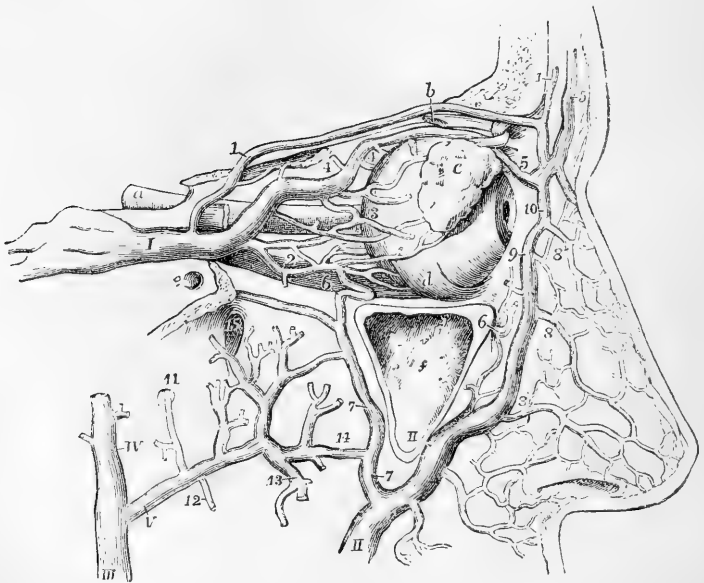


Fig. 308.—SKETCH OF THE OPTHALMIC VEIN, AND OF ITS DISTRIBUTION AND COMMUNICATION WITH OTHER VEINS (altered from Hirschfeld and Leveillé. A. T.)

The orbit is opened from the outer side and the dissection is similar to that for displaying the ophthalmic artery (Fig. 253, p. 376) ; *a*, the optic nerve before it enters the optic foramen ; *b*, the superior oblique muscle divided a little way behind its pulley ; *c*, the lachrymal gland lying upon the eyeball ; *d*, the insertion of the inferior oblique muscle ; *e*, foramen rotundum ; *f*, sinus maxillaris, opened externally : I, the ophthalmic vein joining the cavernous sinus ; 1, supraorbital branch ; 2, muscular and lachrymal branches ; 3, ciliary ; 4, anterior and posterior nasal or ethmoid ; 5, frontal ; 6, infraorbital ; II, facial vein ; 7, communication with the internal maxillary ; 8, external nasal ; 9, angular, communicating at 10, with the frontal and supraorbital ; III, external jugular vein commencing at the junction of IV, the temporal, and V, the internal maxillary veins ; 11, meningeal branch ; 12, inferior dental ; 13, muscular ; 14, communication between the facial, malar and infraorbital ; 15, placed in the spheno-maxillary fossa above branches connected with the pterygoid plexus.

according to the arterial branches which they accompany, join to form a short single trunk, which leaves the orbit by the inner part of the sphenoidal fissure, where it is placed between the heads of the external rectus muscle, and terminates in the cavernous sinus.

**Varieties.**—Not unfrequently one of the frontal veins is much larger than the others, and descending vertically near the middle of the forehead, joins the facial and a branch of the ophthalmic vein on one side of the root of the nose.

## VEINS OF THE DIPLOË.

The **veins of the diploë** of the cranial bones are only to be seen after the pericranium is detached, and the external table of the skull carefully removed by means of a file. Lodged in canals hollowed in the substance of the bones, their branches form an irregular network, from which a few larger vessels issue. These are directed downwards at different parts of the cranium, and terminate, partly in the veins on the outer surface of the bones, and partly in the sinuses at the base of the skull.

Fig. 309.—VEINS OF THE DIPLOË OF THE CRANIAL BONES (after Breschet).  $\frac{1}{3}$

The external table has been removed from the greater part of the calvarium so as to expose the diploë and the veins which have been injected. 1, a single frontal vein; 2, 3, the anterior temporal vein of the right side; 4, the posterior temporal; 5, the occipital vein of the diploë.

According to Breschet there are four such veins on each half of the cranium, viz., a frontal, an occipital, and two temporal.

The *frontal* is small, and issues by an aperture at the supra-orbital notch to join the vein in that situation. There is often only one frontal vein present.

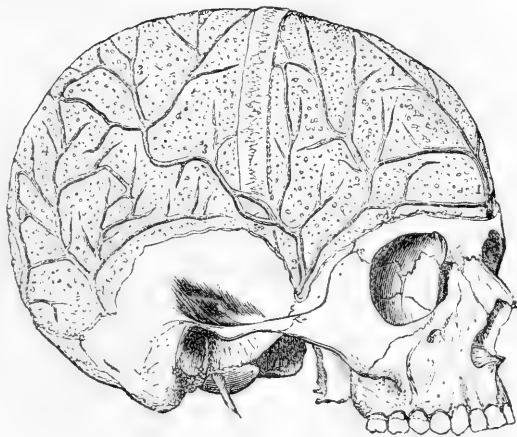
The *temporal* are distinguished as anterior and posterior. The anterior is contained chiefly in the frontal bone, but may extend also into the parietal, and opens into the temporal vein, after escaping by an aperture in the great wing of the sphenoid. The posterior ramifies in the parietal bone, and passes through an aperture at the lower and hinder angle of that bone to the lateral sinus.

The *occipital* is the largest of all; and leaves the occipital bone opposite the inferior curved line to open, either internally or externally, into the occipital sinus or the occipital vein. Its ramifications are confined especially to the occipital bone.

## VEINS OF THE UPPER LIMB.

The veins of the upper limb are divisible into two sets, the superficial, and the deep-seated. Both sets are provided with valves, and

Fig. 309.



these are more numerous in the deep than in the subcutaneous veins. Valves are constantly to be found at the entrance of branches in the main vessels.

#### SUPERFICIAL VEINS OF THE UPPER LIMB.

The superficial veins of the upper limb are much larger than the deep; they lie between the skin and the fascia. At the upper part of

Fig. 310.

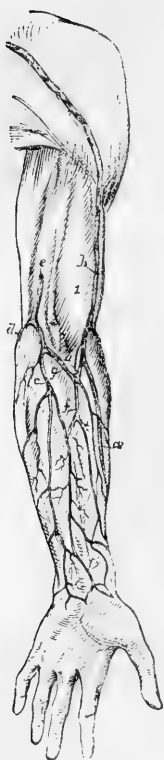


Fig. 310.—SKETCH OF THE SUPERFICIAL VEINS OF THE ARM AND FOREARM FROM BEFORE.  $\frac{1}{2}$

1, biceps muscle; *a*, radial veins; *b*, cephalic vein; *c*, ulnar veins; *d*, some of the posterior ulnar veins; *e*, basilic vein dipping below the fascia; *f*, median vein; *g*, median basilic; *h*, median cephalic.

the forearm they are most frequently collected into three trunks, the *radial*, *ulnar*, and *median* veins. At the bend of the elbow the median vein divides into an outer and an inner vessel, named respectively *median cephalic* and *median basilic*, one of which joins with the radial to form the *cephalic* vein, while the other joins with the ulnar to form the *basilic*. The two principal cutaneous veins of the forearm, the radial and the ulnar, commence on the dorsal surface of the hand, by a sort of plexus, formed by the convergence of numerous small veins, which proceed from the dorsal surfaces of the fingers.

The **radial cutaneous** vein commences by branches upon the dorsal surface of the thumb and fore finger. These ascend over the outer border of the wrist, and form by their union a large vessel, which passes along the radial border of the forearm, receiving numerous branches from the anterior and posterior surfaces. At the bend of the arm, in the groove external to the biceps muscle, it unites with the median-cephalic division of the median vein, to form the cephalic vein.

The **cephalic** vein ascends along the outer border of the biceps muscle in the interval between the great pectoral and deltoid muscles, and finally, dipping in between those muscles, terminates in the axillary vein, between the coracoid process and the clavicle.

The **ulnar cutaneous** veins are two in number, one on the front, the other on the back part of the forearm. The *posterior* ulnar cutaneous vein, begins on the back of the hand by branches, which unite to form a vein placed over the fourth metacarpal space, and called by some of the older anatomists "vena salvatella." This proceeds along the ulnar border of the forearm on the posterior aspect, and, below the bend of the elbow, turns forwards to join the *anterior* ulnar cutaneous vein, which ascends from the anterior surface of the wrist. At the bend of the elbow, the common ulnar cutaneous unites with the median basilic division of the median to form the basilic vein.



The **basilic** vein, usually of considerable size, ascending along the inner border of the biceps muscle, in front of the brachial artery, passes through the fascia below the middle of the arm, and finally unites with one of the venæ comites of that vessel, or with the axillary vein, which it chiefly forms.

Fig. 311.—VIEW OF THE SUPERFICIAL VEINS AT THE BEND OF THE ARM (from R. Quain).  $\frac{1}{3}$

The full description of this figure will be found at p. 400. The following numbers indicate the veins:—At 1 and 2, the fascia is opened in front of the brachial artery and its accompanying veins; the inner vena comes, marked 1, has been divided, the outer marked 2, is entire; +, the median nerve; 3, the basilic vein; 3', the ulnar veins; 4, the cephalic vein; 4', one of the radial veins; 5, the median vein: 5 to 4', median cephalic; 5 to 3', median basilic.

The **median cutaneous** vein results from the union, on the anterior part of the forearm, of several branches. It is a short trunk of variable length, which ascends between the ulnar and radial cutaneous veins on the front of the forearm, and terminates beneath the hollow in front of the elbow by dividing into the median basilic and median cephalic branches, which diverge upwards from each other. Close to its bifurcation it receives a short branch, the *deep median vein*, which pierces the fascia to meet it, and forms a communication between it and the deep veins accompanying the arteries.

The **median basilic** vein, inclining inwards to join the basilic vein, passes in front of the brachial artery, from which it is separated by the fibrous expansion given by the tendon of the biceps muscle to the fascia covering the flexor muscles; it is crossed by branches of the internal cutaneous nerve.

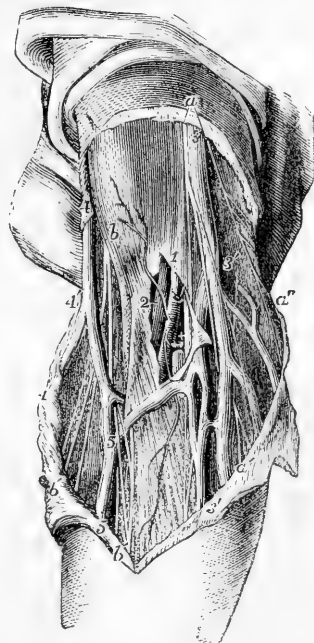
The **median cephalic** vein, directed outwards, unites with the cephalic vein. Branches of the external cutaneous nerve descend behind it.

**Varieties.**—The cephalic vein frequently terminates in the external jugular instead of the axillary vein; usually running up over the clavicle, but sometimes below that bone. In one case it passed below the clavicle but sent a branch over, which also opened into the external jugular, and thus formed a venous ring round the clavicle (Nuhn). In other cases the cephalic is merely united to the external jugular by a communicating branch (*jugulo-cephalic*) which runs up over the clavicle. In two cases which occurred in the dissecting-room of Glasgow University, winter, 1872-73, this jugulo-cephalic branch instead of passing over the clavicle passed right through the bone, accompanied in one of the cases by a small artery.

DEEP VEINS OF THE UPPER LIMB.

The brachial artery and its various branches in the arm, forearm,

Fig. 311



and hand, are each accompanied by two veins, named *venæ comites*. These companion veins lie one on each side of the corresponding artery, and are connected with each other at intervals by short cross branches, which in some places closely surround the artery. Their distribution so nearly corresponds with that of the arteries, that they need not be more particularly described.

The **brachial veins**, or **companion veins** of the brachial artery, terminate at the lower margin of the subscapularis muscle by joining the axillary vein; not unfrequently, however, one of them will be found to come forward and unite with the basilic, which soon after becomes continuous with the axillary vein.

Between the several veins of the upper limb numerous communications exist in their whole course. Thus, those which lie beneath the integument are connected to each other by branches in the hand and forearm. Not only are the veins in each pair of *venæ comites* united by short transverse vessels crossing the artery which they accompany, but also those attending different arteries have frequent connections with each other. Lastly, the subcutaneous and the deep veins communicate freely, especially in the neighbourhood of joints. This general anastomosis ensures the continuance of the circulation during muscular action in the frequent and varied motions of the limb.

#### AXILLARY VEIN.

The **axillary vein** collects all the blood returning from the upper limb: its size is very considerable, and it is the highest of the veins of the

Fig 312.

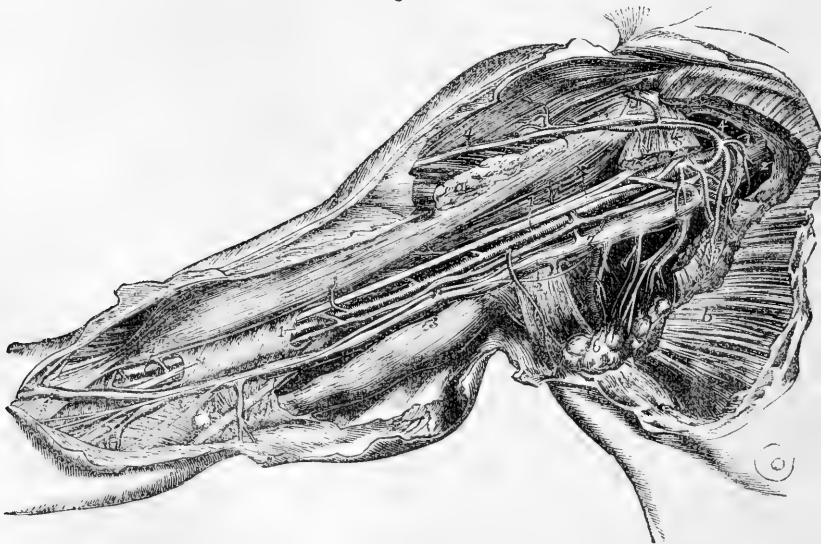

Fig. 312.—VIEW OF THE BLOOD-VESSELS OF THE RIGHT AXILLA AND ARM FROM THE INNER SIDE (from R. Quain).  $\frac{1}{4}$

The detailed description of this figure will be found at p. 399. The following numbers indicate the principal veins:—2, the axillary vein; 3, basilic vein; 3', median basilic; 4, 4', cephalic vein joining the acromial thoracic and axillary; 6, alar-thoracic and subscapular; 7, one of the brachial veins.

upper limb in which valves are constantly found. It extends, like the corresponding artery, from the lower border of the axilla to the outer margin of the first rib; it is covered by the pectoral muscles and the costo-coracoid membrane, and is placed to the inner side of the axillary artery. It is continuous below with the basilic vein of the arm, either alone or in conjunction with one of the deep brachial veins.

**Tributaries.**—The axillary vein receives the subcutaneous veins of the arm, viz. the basilic at its commencement, the cephalic towards its termination; and between these the companion veins of the brachial artery; it is also joined by the several veins corresponding with the branches of the axillary artery, viz., the two *circumflex* and the *subscapular* veins from the shoulder, the *alar* vein from the axilla, and the *inferior*, *superior*, and *acromio-thoracic* veins from the side of the chest.

#### SUBCLAVIAN VEIN.

The **subclavian vein** is the continuation of the axillary, but is not like it constantly provided with valves, although a pair may often be found near its termination (Struthers, loc. cit.). It extends from the outer margin of the first rib to the inner end of the clavicle, behind which it terminates by joining with the internal jugular vein to form the innominate or brachio-cephalic vein. The subclavian vein crosses over the first rib and behind the clavicle, not reaching so high up in the neck as the subclavian artery; it is covered by the clavicle, and by the subclavius and sterno-mastoid muscles, and lies on a plane anterior to the artery, from which, while resting on the rib, it is separated by the scalenus anticus muscle and the phrenic nerve.

**Tributaries.**—(a) The *external* and *anterior jugular* veins open into the subclavian vein on the outer side of the scalenus anticus muscle.

(b) The *vertebral vein*, commencing in branches which proceed from the pericranium and the deep muscles lying behind the foramen magnum of the occipital bone, passes outwards and downwards to reach the foramen in the transverse process of the atlas. Through this foramen, and through the canal formed by the corresponding foramina of the other cervical vertebrae, the vein descends with the vertebral artery. Emerging at the foramen in the sixth vertebra, it runs forwards and downwards to join the subclavian vein close to its termination: a small branch sometimes descends through the foramen in the seventh vertebra, and opens separately into the subclavian. The vertebral vein is joined in its course by several branches from the neighbouring muscles; also, immediately before its termination, by a branch corresponding with the deep cervical artery; and in the same situation by another branch of considerable size, which descends in front of the bodies and transverse processes of the vertebrae of the neck, and may be termed the external vertebral vein. It communicates frequently with the spinal veins in the neck, both those on the outer side, and those in the interior of the spinal canal.

**Varieties.**—The subclavian vein has been seen to pass behind the scalenus anticus muscle along with the artery (Henle). In another case the vein and artery changed places with relation to the muscle. The vein has been seen several times to pass between the subclavius muscle and the clavicle (Luschka). Instead of being the continuation of a single axillary vein, the subclavian vein is sometimes made up by the union of two brachial veins (Henle); or it may receive as unusual branches a bronchial vein (Weber), or a superficialis colli inferior vein (Hyrtl).

#### AZYGOS VEINS.

The azygos veins are longitudinal vessels formed by the union of the veins corresponding to the arteries of the intercostal spaces, and

are placed on the sides of the spine. In the lower part of the thorax

Fig. 313.

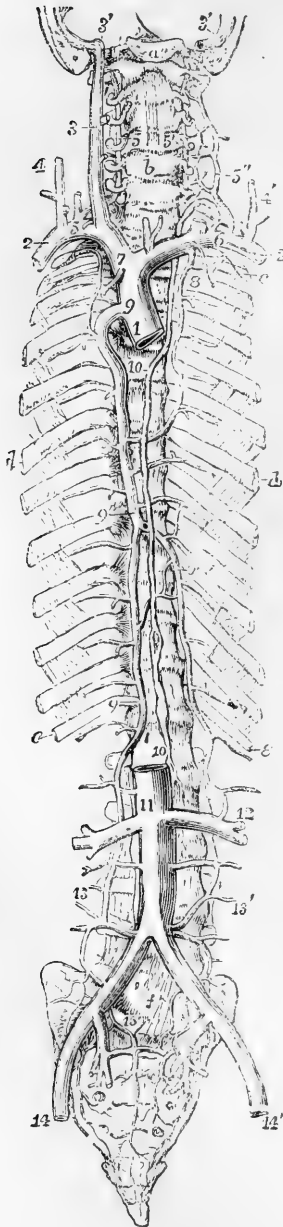


Fig. 313.—SKETCH OF THE PRINCIPAL SYSTEMIC VENOUS TRUNKS, THE AZYGOS, AND INTERCOSTAL VEINS.

For the detailed description of this figure see p. 473. The following indications relate to the accompanying part of the text:—8', the left superior intercostal veins (the number is omitted on the right side); 9, the main trunk of the azygos vein; the uppermost number marks its junction with the superior cava, the lowest its passage into the abdomen; 9', the left or hemiazygos; 10, thoracic duct; 11, inferior vena cava; 12, the union of a branch of the left azygos with the left renal vein; 13, 13', the right and left azygos veins continued down into the abdomen, and joining some of the lumbar veins; 15, union of lumbar, ilio-lumbar, and sacral veins.

the two veins of opposite sides are disposed symmetrically, but higher up the blood gathered from some of the veins of the left side is poured into the trunk on the right, which becomes enlarged and unsymmetrical, and has on that account received the name of *main* or *right azygos*, while the united lower veins from the corresponding parts on the left side constitute the *small* or *left azygos*.

The **right azygos** vein (*vena azygos major*) generally commences below by branches from the lumbar veins (ascending lumbar) of the right side, and sometimes from the renal vein; but not unfrequently it receives a small branch from the inferior cava, where that vessel turns forwards to reach its opening in the diaphragm. Passing from the abdomen into the thorax through the aortic opening in the diaphragm, or to the outer side of that opening through the fibres of the right crus, the azygos vein ascends on the bodies of the dorsal vertebrae, until it arrives opposite the root of the right lung, over which it arches forwards, and then opens into the upper vena cava, immediately above the point at which that vessel is invested by the pericardium. When passing through the opening in the diaphragm, this vein is accompanied by the thoracic duct, both being situated on the right side of the aorta. In the thorax, maintaining the same position with respect to the duct and the œso-

phagus, it passes in front of the intercostal arteries, and is covered by

the pleura. It is joined by the several veins which accompany the aortic intercostal arteries of the right side; and, at about the sixth or seventh dorsal vertebra, by the left or smaller azygos vein. It is also joined by several œsophageal and other small veins, and near its termination by the bronchial vein of the right lung; and it is generally connected with the right superior intercostal vein. As it communicates below with the vena cava inferior through one of the branches of that large vein, while it terminates above in the vena cava superior, it forms a connection between those two vessels. A few valves of imperfect formation have been found in the azygos vein; its branches (intercostal veins) are provided with distinct valves.

On the left side of the chest the veins of the three or four upper intercostal spaces are usually united into one trunk, forming the left superior intercostal vein, which (as already mentioned) is most frequently united with the left innominate vein, but sometimes is connected with the main azygos vein.

Of the remaining left intercostal veins, one or two, generally about the fifth and sixth, pass directly into the azygos; while the lowest in greater number unite almost constantly into one trunk, forming the left or small azygos, which crosses to join the main azygos in the neighbourhood of the seventh dorsal vertebra. There is frequently union between these three sets of veins or their intercostal branches, so that a part of one may be replaced by another, and the relative size of the veins may be subject to considerable variation.

The **left lower** or **small azygos vein** (vena hemiazygos) commences from one of the lumbar veins (ascending lumbar), or from the left renal vein, and, having entered the thorax with the aorta, or through the left crus of the diaphragm, ascends upon the spine in front of the left intercostal arteries, receiving the lower intercostal veins of the left side; and passing behind the aorta, it opens into the right azygos vein, opposite the sixth or seventh dorsal vertebra.

**Varieties.**—The azygos vein has been seen to receive the lower vena cava, and, in such cases, is of course extremely large. An example of this variety exists in the Anatomical Museum of Glasgow University. In one instance, Meckel found the azygos ending in the subclavian vein.

All the intercostal veins of the left side have been observed in some instances to join a single vein, which ended in the left innominate; the arrangement corresponding with that on the right side of the body.

The **bronchial** veins return the blood employed in the nutrition of the lungs. Their course corresponds with that of the bronchi, which support them as they pass towards the root of the lungs. The bronchial vein of the right side opens into the trunk of the azygos vein near its termination, that of the opposite side ends in the superior intercostal vein.

#### VEINS OF THE SPINE.

The spinal veins form plexuses of closely anastomosing vessels along the whole length of the spinal column. They have no valves.

The veins within and upon the spinal column may be distinguished into the following sets: *a.* The dorsal, placed deeply in the vertebral grooves, and resting upon the spines and arches of the vertebræ: *b.* The veins lodged within the bodies of the vertebræ: *c.* The anterior longitudinal, two long series of veins, or rather venous plexuses, extend

behind the bodies of the vertebræ in the whole length of the canal : 7. The posterior longitudinal veins, situated within the canal on the fore part of the arches of the vertebræ : *e*. The veins of the spinal cord. There are likewise branches of communication, some of which connect all the other sets together, and some which bring them into connection with the general venous system. (Breschet, "Essai sur les Veines du Rachis," 4to; "Traité Anatomique sur le Système Veineux," fol., 1829; Cloquet, "Traité d'Anatomie descriptive," &c.)

*a*.—The **dorsal veins**. The blood from the muscles and integument along the back of the spine is returned by a series of short veins, which ramify upon the arches and spinous processes of the vertebræ. They run forwards close to the spinous processes, and on reaching the interval between the arches of the vertebræ, pierce the ligamenta subflava, and terminate in a venous plexus within the canal. Towards the outer part of the intervertebral grooves other veins arise, which pass obliquely forwards, through the intertransverse spaces, in company with the posterior branches of the lumbar and intercostal arteries, and open into the veins which accompany those vessels.

Fig. 314.

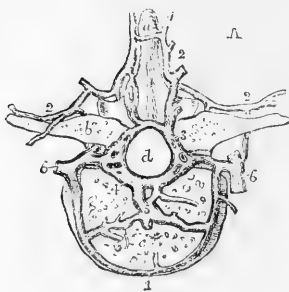
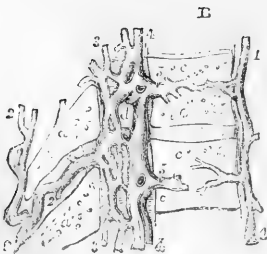


Fig. 314, A and B.—HORIZONTAL AND VERTICAL SECTIONS OF THE LOWER DORSAL VERTEBRÆ, SHOWING THE EXTERNAL AND INTERNAL VEINS OF THE SPINE (after Breschet).  $\frac{3}{4}$

*a*, spinous process; *b*, transverse process; *c*, body; *d*, spinal canal; 1, anterior external veins of the body; 2, posterior external veins of the vertebral column communicating with the internal and forming a plexus over the laminae and processes; 3, the posterior, and 4, the anterior internal plexus of veins of the vertebral canal; 5, the internal veins of the body joining the internal spinal veins; 6, the lateral veins, which are joined by the internal and external spinal veins, and themselves unite with the intercostal.



*b*.—The **veins of the bodies of the vertebræ** (*venæ basis vertebrarum*, —Dupuytren) are comparatively large vessels contained in the canals within the bodies of the vertebræ; the arteries which accompany them being very small. They anastomose on the front of the bones with some of the superficial veins; and the trunk of each, having reached the spinal canal through the foramen in the posterior surface of the body of

the vertebra, divides into two branches, which diverge and terminate in the large spinal veins behind the bodies of the vertebræ.

*c*.—The **anterior longitudinal spinal veins**.—The blood collected by the different vessels here described is poured into two large veins, or rather tortuous venous canals, which extend, one on each side, along the whole length of the spinal canal behind the bodies of the vertebræ. These vessels (the great spinal veins of Breschet) are alternately constricted and enlarged, the constricted points corresponding with the intervertebral foramina, where they are drawn forwards, and bound

down by the branches of communication which pass outwards. In some parts the veins are double, or even triple, so as to form a plexus, and occasionally they are altogether interrupted. In the thoracic region their communicating branches open into the intercostal veins, in the loins into the lumbar veins, in the neck for the most part into the vertebral.

*d.* The **posterior longitudinal spinal veins** are a complex interlacement of tortuous veins along the inner or anterior surface of the arches of the vertebræ. In the lower part of the canal this interlacement of veins is not so close as in the upper portion, where it usually conceals (if the injection has been successful) the whole surface of the dura mater. These veins converge to the intervertebral foramina, and join by rather small vessels with the intercostal veins.

*c.*—The **veins of the spinal cord** (Breschet) ramify upon the cord and its nerves, enclosed within the sheath formed by the dura mater. Though they communicate with the other spinal veins, they are not injected with them, even when the injecting process is most successful. Very small, long, and tortuous, they run upon both surfaces of the cord, and form a diffused network. They become larger, for the most part, as they ascend, but near the base of the skull they are smaller than in the lumbar region. They communicate freely with the spinal veins and plexuses, by means of branches which accompany the nerves towards the intervertebral foramina. Near the base of the skull they unite to form two or three small trunks, which communicate by transverse branches with the vertebral veins, and terminate in the inferior cerebellar veins, or in the petrosal sinuses.

From a consideration of the connection and arrangement of the different parts of these complex veins, it would appear that the main currents of the blood in each part flow through them horizontally. The dorsal veins pour their blood into the longitudinal plexus on the inner surface of the arches of the vertebræ; thence it is collected, at each of the intervertebral foramina, by two or three small converging branches, which open into some of the veins outside the vertebral column in front, viz., into the lumbar, azygos, and cervical veins. Into these, also, the contents of the great spinal veins are conveyed by the short communicating branches already noticed.

#### INFERIOR VENA CAVA.

The lower or ascending vena cava returns the blood from the lower limbs, and from the viscera of the pelvis and abdomen. It commences at the junction of the two common iliac veins on the side of the fifth lumbar vertebra, and thence ascends along the right side of the aorta, as far as the posterior border of the liver; it there becomes lodged in a groove in that organ, and inclines forwards to reach the opening in the diaphragm appropriated to it, and after being enclosed in a fold of the pericardium, terminates in the right auricle of the heart. A large valve is situated at its entrance into the auricle, named the valve of Eustachius, which, however, as explained in the description of the heart, is only a vestige of a foetal structure, variable in size, and without influence in preventing reflux of the blood.

**TRIBUTARIES.**—Besides the common iliac veins, the inferior vena cava receives the following.

*a.*—The **middle sacral vein**, taking its course upwards on the front of the sacrum, opens into the left common iliac vein, or into the commencement of the vena cava.

*b.*—The **lumbar veins** correspond in number with the arteries of the same name: they commence by small *posterior* branches in the muscles of the back; and by others from the walls of the abdomen, where they communicate with the epigastric and other veins in the neighbourhood. Having reached the spine, they receive branches from the *spinal* plexuses, and proceed forward upon the bodies of the vertebræ, behind the psoas muscle: those on the left side passing behind the aorta, terminate in the back of the vena cava. Some of these veins are frequently found to unite into a single trunk before their termination. The lumbar veins of the same side communicate with each other by branches which cross in front of the transverse processes. Not unfrequently a branch of this description is met with called the *ascending lumbar vein*, which connects more or less completely the common iliac vein, the ilio-lumbar and lumbar veins, and the azygos vein.

*c.*—The **spermatic veins**, proceeding upwards from the testicle and forming part of the constituents of the spermatic cord, enter the abdomen, and ascend on the psoas muscle behind the peritoneum. Below the abdominal ring there are numerous convoluted branches forming the *spermatic plexus* (plexus pampiniformis). These branches gradually unite and form a single vessel, which opens on the right side into the lower vena cava, and on the left into the renal vein. The spermatic veins sometimes bifurcate before their termination, each division opening separately; in this case the veins of the right side may be found communicating with the vena cava and the renal vein.

In the female the **ovarian veins** have the same general course as the ovarian arteries; they form a plexus near the ovary (ovarian or pampiniform plexus) in the broad ligament, and communicate with the uterine plexus.

Valves exist in the spermatic veins in man (Monro); and in exceptional cases they have been also seen in the ovarian veins (Theile).

*d.*—The **renal or emulgent veins** are short but of very considerable size. That of the left side is longer than that of the right, and passes in front of the aorta. They join the vena cava at nearly a right angle. The renal veins usually receive branches from the suprarenal capsules; the left has also opening into it the spermatic vein of the same side. A valve is usually found at the orifice of the left spermatic vein, or in the renal vein within a quarter of an inch from the orifice of the spermatic. (Rivington, Journ. of Anat. Vol. VII., p. 163.)

*e.*—The **capsular or suprarenal veins**, though actually small, are, relatively to the organs from which they arise, of considerable size. On the right side the vein ends in the vena cava, and on the left in the renal or phrenic vein.

*f.*—The **phrenic veins** follow exactly the course of the arteries supplied to the diaphragm by the abdominal aorta.

*g.*—The **hepatic veins** return from the liver the blood sent to that organ by the portal vein and hepatic artery. They converge to the groove in which the inferior vena cava lies, and pass at once obliquely into that vein. There are usually three sets of hepatic veins proceeding to this common point: those from the right and left lobes are



oblique in their direction, those from the middle of the liver and the lobule of Spigelius have an intermediate position and course. The hepatic veins have no valves; but, owing to their oblique entrance into the vena cava, a semi-lunar fold is seen at the lower border of the orifice of each vein.

*Varieties.*—The lower vena cava presents some occasional deviations from its ordinary condition, which may be briefly noticed.

In the lower part of its course it is sometimes placed to the left side of the aorta, and, after receiving the left renal vein, resumes its ordinary position by crossing over the great artery. Less frequently, the vena cava is placed altogether on the left side, and is continued upwards to the heart, without any change in its direction; this occurs in cases of transposition of the thoracic and abdominal viscera and of the great vessels.

In a more numerous class of cases, the left common iliac vein, instead of joining the right in its usual position, is connected with it only by a small branch, and then ascends on the left side of the aorta. After receiving the left renal vein, it crosses over the aorta, and terminates by uniting with the common iliac vein of the right side. In these cases, the vena cava inferior can be said to exist only at the upper part of the abdomen, and below this point there is a vein on each side of the aorta.

Lastly, the lower vena cava, instead of ending in the right auricle of the heart, has been seen to join the right azygos vein, which is then very large so that the blood from the lower, as well as from the upper part of the body, is returned to the heart through the upper vena cava. In this case, the hepatic veins do not join the lower cava, but pass directly into the right auricle, at the usual place of termination of the great vein. (Specimen in Glasgow University Museum.)

The left renal vein has been seen to cross behind the aorta.

In a remarkable case, observed by Rothe, one of the hepatic veins ended, not in the lower cava, nor in the right auricle, but in the right ventricle of the heart, its orifice being guarded by valves. (Act. Acad. Joseph. Med. Chir. Vindobonensis, t. i. p. 233, tab. 5. Vindobonæ, 1788.)

## VEINS OF THE LOWER LIMB AND PELVIS.

The veins of the lower limb are divisible into two sets, those of the one being deeply seated, those of the other running in the superficial fascia. All the veins of the lower limb, as high as the femoral venous trunk, are provided with valves, and these are more numerous than in the veins of the upper limb. The deep veins have more valves than the subcutaneous set.

### SUPERFICIAL VEINS OF THE LOWER LIMB.

Immediately beneath the integument, on the dorsum of the foot, there exists a network of veins forming an arch, from which issue two principal trunks, which are named the internal or long and the external or short saphenous veins.

The **internal or long saphenous vein** extends from the ankle to within an inch and a half of Poupart's ligament. Taking rise from the plexus of veins on the dorsum of the foot, it passes upwards in front of the inner ankle, and along the inner border of the tibia, accompanied by the internal saphenous nerve. It inclines a little backwards as it passes the inner condyle of the femur, and ascending along the inner and fore part of the thigh, it terminates in the femoral vein, at the *saphenous opening* in the fascia lata, through which it passes.

In the leg it communicates with the deep veins accompanying the

anterior and posterior tibial arteries, and in the thigh one or more branches pass between it and the femoral vein. This long vein has a variable number of valves. Sometimes six have been counted; in other cases only four or even two. It contains more in its course through the thigh than in the leg.

Fig. 315.

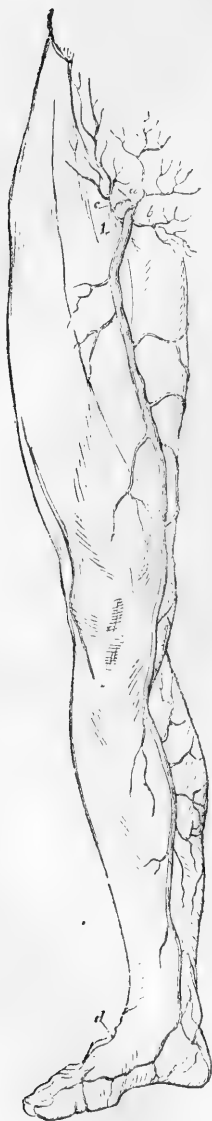

Fig. 315.—SUPERFICIAL VEINS OF THE FRONT AND INNER SIDE OF THE LOWER LIMB.

1, the saphenous aperture of the fascia lata; *a*, superficial epigastric vein; *b*, external pudic; *c*, superficial circumflex iliac; *d*, external or short saphenous beginning on the dorsum of the foot (see Fig. 316).

**Tributaries.**—The long saphenous vein is joined in its course by numerous cutaneous vessels. Close to its termination it receives, besides a considerable anterior branch, the *superficial epigastric*, *external pudic*, and *superficial circumflex iliac* veins corresponding severally to arterial branches of the same name.

It is also usually joined near its termination by a posterior branch of considerable size, coming from the posterior and inner part of the thigh.

The **external** or **short saphenous vein** proceeds from branches, which arise along the outer side of the dorsum of the foot. It passes behind the outer ankle, and ascends the leg along the border of the tendo Achillis and on the belly of the gastrocnemius muscle, accompanied by the external saphenous nerve; running upwards between the heads of the gastrocnemius, it unites with the popliteal vein. Opposite the ankle and along the leg it communicates with the deep veins: and it receives superficial accessory veins from the outer part of the foot and the back of the leg.

**Variety.**—The short saphenous vein sometimes issues from the popliteal space, and winding round the inside of the thigh, opens into the long saphenous vein.

#### THE DEEP VEINS OF THE LOWER LIMB.

The deep veins accompany the arteries and their branches, following exactly their distribution. Those below the knee, being for the most part disposed in pairs, and presenting the disposition described in the corresponding veins of the upper limb, are named the **venæ comites** of the vessels with which they are associated. The **venæ comites** of the arteries of the leg, namely, the **anterior** and **posterior tibial** veins (the latter having previously received the **peroneal**), unite near the lower border of the popliteus muscle, and form by their junction the popliteal vein. The valves of the deep veins of the leg are very numerous,—ten or twelve being sometimes found between the heel and the knee.

The **popliteal vein**, thus formed, receives smaller branches corresponding with the articular and muscular arteries, and the larger branch named the external saphenous vein. In its course through the ham, the popliteal vein is placed at first internally to the popliteal artery, then behind, and lastly to the outer side of it, but always posteriorly and between it and the nerve. Thus situated, it passes up through the aperture in the adductor magnus, and becomes continuous with the femoral vein.

**Varieties.**—The union of the veins which form the popliteal is often farther up than usual, and the lower part of the artery is accompanied by two veins. This arrangement in some rare cases extends to the entire length of the artery.

Fig. 316.

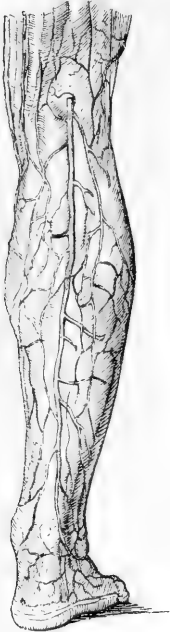

Fig. 316.—OUTLINE OF THE POSTERIOR OR SHORT SAPHENOUS VEIN.

The vein, commencing on the dorsum and outside of the foot, is seen to pass up behind the outer ankle and to dip beneath the fascia in the popliteal space.

Fig. 317.

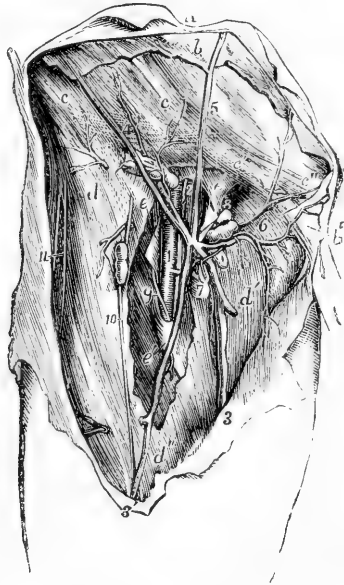


Fig. 317.—VIEW OF THE VEINS OF THE GROIN AND NEIGHBOURING PARTS (from R. Quain). 4

The full description of this figure will be found at p. 455. The following numbers indicate the veins :—2, the femoral vein ; 3, the large or internal saphenous vein ; 3', anterior saphenous ; 4, superficial circumflex veins with twigs to the inguinal glands ; 5, superficial epigastric ; 6, superficial pudic.

The **femoral vein** extends, like the artery which it accompanies, through the upper two-thirds of the thigh, and terminates at Poupart's ligament in the external iliac vein. Placed at first outside the artery, it gradually inclines inwards behind it; and on reaching Poupart's ligament, lies on the inner side, on the same plane with the artery, and separated from it only by a slight partition of the membranous sheath,

by which they are both invested. In the lower part of its course, the vein receives all the branches which accompany the offsets of the chief artery. In the upper part, the deep femoral vein opens into it, having first received all the branches from muscles supplied by the deep femoral artery. Near its termination the femoral vein is joined by the internal saphenous vein.

**Varieties.**—The femoral vein occasionally pursues a course different from that of the artery along the thigh. Extending upwards from the popliteal space, the vein in such cases perforates the adductor magnus above the ordinary position, and, joining with the deep femoral vein, first approaches the femoral artery at the groin. The same vein is sometimes double in a small part, or more rarely in almost its whole length.

#### EXTERNAL ILIAC VEIN.

The external iliac vein is the continuation of the femoral vein from Poupart's ligament to the junction of the internal iliac vein, in the neighbourhood of the sacro-iliac articulation. It is at first internal to the artery, and on the left side it continues in that position, but on the right side it gradually inclines somewhat behind the artery. It does not possess valves.

**Tributaries.**—Near its commencement at Poupart's ligament, the external iliac vein receives the *circumflex iliac* and the *epigastric* veins.

#### INTERNAL ILIAC VEIN.

The internal iliac vein is formed by the union of branches which accompany the corresponding branches of the internal iliac artery. The umbilical vein of the fetus, however, which in the cord accompanies the corresponding arteries, diverges from these arteries within the body, and passes upwards to the liver. The internal iliac vein lies behind the corresponding artery in front of the sacro-iliac articulation, and, after a short course upwards to the margin of the pelvis, joins with the external iliac vein to form the common iliac. No valves are found in the trunk of the internal iliac vein, but they exist in its branches.

**TRIBUTARIES.**—The tributaries of the internal iliac vein correspond in general to the various branches of the internal iliac artery, with the exception that the internal pudic vein does not receive the main supply of blood from the dorsal vein of the penis. The visceral veins are remarkable for their size and frequent anastomoses, and have been described as forming a series of plexuses, severally named the *vesical*, *prostatic*, *hæmorrhoidal*, *uterine*, and *vaginal*.

The **vesical plexus** consists of vessels which ramify over the whole of the bladder external to its muscular coat, being particularly large and numerous towards the base of the organ, where they are closely connected with the prostatic and hæmorrhoidal plexuses in the male, and with the vaginal plexus in the female.

The **prostatic plexus** receives two large vessels, one at each side, the divisions of the dorsal vein of the penis. These, coursing downwards and backwards on the sides of the prostate gland, expand into a close network at the base of the gland, which is quite encircled by it.

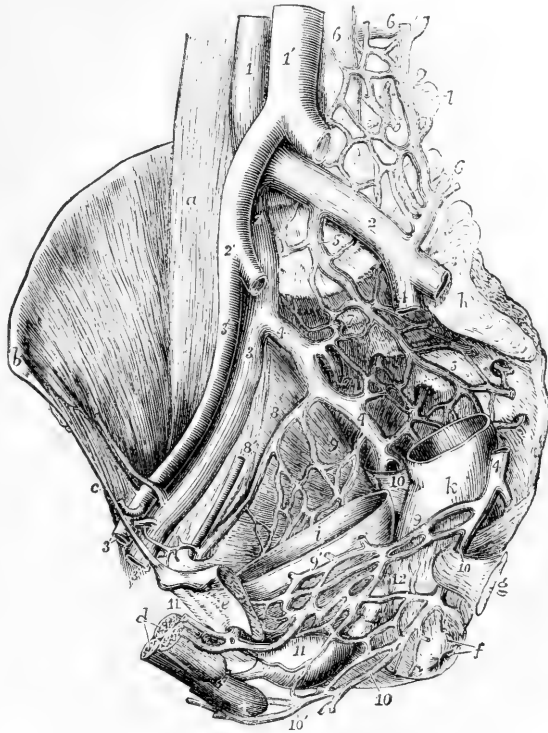
The **hæmorrhoidal plexus** consists of enlarged and copiously anastomosing veins in the walls of the lower part of the rectum, imme-

diately underneath the mucous membrane. From it proceed superior, middle, and inferior hæmorrhoidal veins accompanying the arteries of the same name, and it communicates freely with the plexuses in front of it. The superior hæmorrhoidal vein being a branch belonging to the portal system, the hæmorrhoidal plexus forms a very direct communication between the portal and general venous systems.

Fig. 318.—INTERNAL VIEW OF THE MALE PELVIS FROM THE LEFT SIDE, TO SHOW THE PRINCIPAL VEINS. (A. T.)  $\frac{1}{2}$

The greater part of the os innominatum and pelvic wall of the left side, and the upper parts of the rectum and urinary bladder, have been removed: the left common iliac and the right internal iliac arteries, and the left external and internal iliac veins, have been cut short. *a*, the right psoas magnus muscle; *b*, the anterior superior iliac spine; *c*, Poupart's ligament; *d*, the cavernous and spongy body of the penis divided near the root; +, the spongy body of the bulb, above which the membranous part of the urethra, the prostate, &c.; *e*, the left os pubis close to the symphysis; *f*, the anus; *g*, the spine of the ischium with the short sacro-sciatic ligament; *h*, auricular sacro-iliac surface; *i*, interior of the urinary bladder; *k*, exterior of the rectum; *l*, transverse process of the fourth lumbar vertebra; 1, lower part of the vena cava inferior; 1', abdominal aorta; 2, common iliac veins; 2', right common iliac artery; 3, external iliac veins; 3', external iliac artery; 4, internal iliac veins, that of the right side entire, that of the left divided and in great part removed; 5, middle and other veins of the sacral plexus; 6, ilio-lumbar and lumbar veins; 7, right gluteal and upper lateral sacral veins; 8, 8', obturator vein and artery of the right side; 9, pelvic plexus of veins of the right side; 9', that of the left side connected with the lower vesical plexus; 10, placed on the right side on the short sacro-sciatic ligament immediately below the division of the internal iliac vein into the pudic and sciatic veins: on the left side, below 4, the sciatic vein is cut short; 10, lower down, the pudic vein; 10', the perineal veins; 11, placed on the prostate among the lower vesical veins, into one of which the left dorsal vein of the penis, 11, is seen to pass; 12, placed on the lower part of the rectum, may indicate the plexus of hæmorrhoidal veins.

Fig. 318



The **vaginal plexus**, surrounding the vagina principally in its lower part, communicates freely with the hæmorrhoidal and vesical plexuses.

The **uterine plexus** pours its blood in greatest part into the ovarian veins, and is not considerable except in pregnancy.

The **dorsal vein of the penis** commences by branches which issue from the glans penis, and form in the first instance two veins, one at each side of the middle line, in the dorsal groove of the penis. These receive branches from the spongy body of the penis, and some superficial veins which accompany the external pudic arteries, and proceeding backwards unite and form a short trunk which enters the pelvis beneath the subpubic ligament. Here it divides into two branches, which are directed obliquely downwards over the prostate and the neck of the bladder, and are united with the prostatic plexus.

#### COMMON ILIAC VEIN.

The common iliac vein is formed by the confluence of the external and internal iliac veins. Extending from the sacro-iliac articulation upwards to near the junction of the fifth with the fourth lumbar vertebra, at a point a little to the right of the middle line, the two common iliac veins unite to form the lower or ascending vena cava. The right vein is shorter than the left, and is nearly vertical in its direction. The right vein is placed behind, and then to the outer side of its artery; whilst the left vein is to the inner side of the left common iliac artery, and then passes behind the right. These veins are destitute of valves.

#### THE PORTAL SYSTEM OF VEINS.

The portal vein differs from other veins of the body in being subdivided into branches at both its extremities. The branches of origin, by the union of which it may be said to be formed, are the veins of the chylipoietic viscera, viz., the stomach, intestine, pancreas, and spleen; the other branches, or those of distribution, ramifying after the manner of an artery in the substance of the liver, convey to the capillaries of that organ the blood collected in the main trunk. This blood, together with that of the hepatic artery, after having served for the secretion of the bile and the nourishment of the liver, is withdrawn from that organ by the hepatic veins, and carried by them into the vena cava inferior.

The **portal vein** or **vena portæ** is about three inches in length. Commencing at the junction of the splenic and superior mesenteric veins, it passes upwards and a little to the right to reach the transverse fissure of the liver. It is placed close behind the hepatic artery and the bile-duct: and is surrounded by the filaments of the hepatic plexus of nerves, together with numerous lymphatics. All these are imbedded in loose connective tissue, and enclosed within the layers of the small omentum. Within the transverse fissure it is somewhat enlarged, and is there named *sinus of the portal vein*.

Near the right end of the transverse fissure, the vena portæ divides into two branches. That of the *right* side enters directly the substance of the corresponding lobe of the liver, and spreads out into branches, each of which is accompanied by an offset of the hepatic artery and of the hepatic duct. The *left* branch, which is smaller, but necessarily longer, passes across to gain the left end of the transverse fissure, where it enters the liver and ramifies like the preceding branch.

**TRIBUTARIES.**—The principal branches which by their union contribute to form the vena portæ are the coronary vein of the stomach, the superior mesenteric, and the splenic veins. The cystic vein is also sometimes a lateral tributary of the portal vein, but more frequently proceeds from its right branch.

Fig. 319.—VIEW OF THE PRINCIPAL BRANCHES OF THE VENA PORTE.  $\frac{1}{6}$

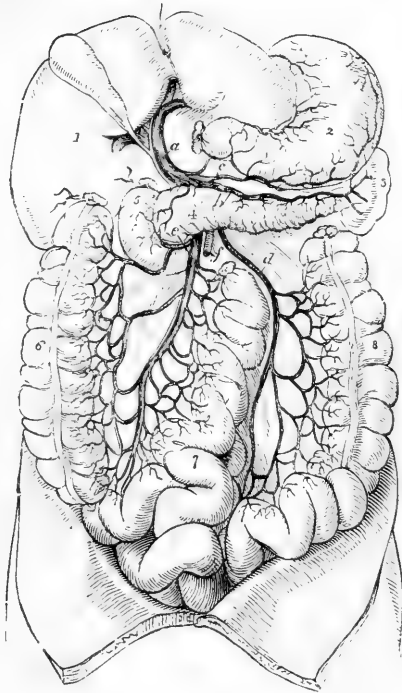
1, lower surface of the right lobe of the liver; 2, stomach; 3, spleen; 4, pancreas; 5, duodenum; 6, ascending colon; 7, small intestines; 8, descending colon; *a*, vena portæ dividing in the transverse fissure of the liver; *b*, splenic vein; *c*, right gastro-epiploic; *d*, inferior mesenteric; *e*, superior mesenteric vein; *f*, superior mesenteric artery.

The **coronary** vein of the stomach lies parallel with the artery of the same name. Its size is inconsiderable, and its direction transverse from the cardiac end of the stomach along the small curvature. On reaching the latter point it turns downwards, and opens into the trunk of the vena portæ.

The **splenic** vein, a vessel of very considerable size, returns the blood not only from the spleen, but also from the pancreas, the duodenum, the greater part of the stomach and omentum, the descending colon, and part of the rectum. It commences by five or six branches, which issue separately from the fissure of the spleen, and soon join to form a single vessel. It is directed from left to right beneath the pancreas, in company with the splenic artery, below which it is placed. On reaching the front of the spine it joins the superior mesenteric vein, nearly at a right angle. It receives *gastric* branches (*vasa brevia*) from the left extremity of the stomach, the *left gastro-epiploic* vein, some *pancreatic* and *duodenal* branches, and also the inferior mesenteric vein.

The **superior mesenteric** vein lies to the right side, and somewhat in front of the artery of the same name. The distribution of its branches corresponds with that of the superior mesenteric artery, and it returns the blood from the several parts supplied by that vessel, viz., from the small intestine, and from the ascending and transverse parts of the colon. The trunk, formed by the union of its several branches, inclines upwards and to the right side, passing in front of the duodenum

Fig. 319.



and behind the pancreas, where it joins with the splenic vein to form the vena portæ.

Fig. 320.

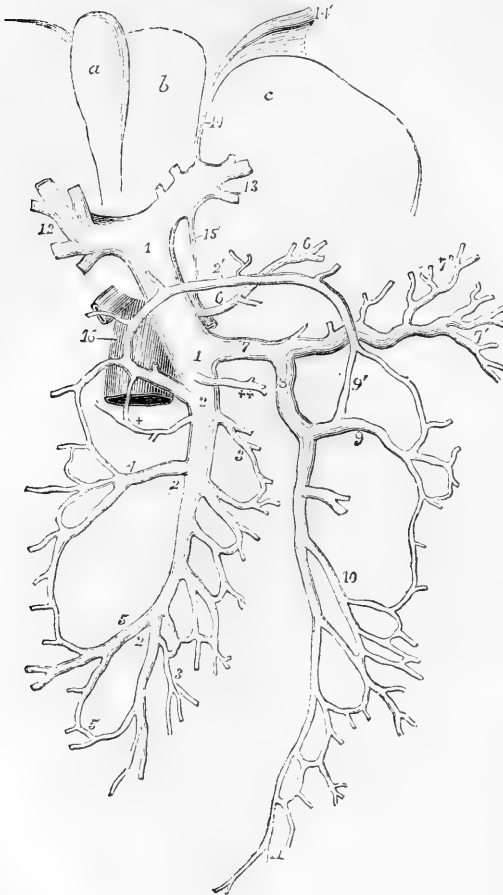


Fig. 320. — DIAGRAMMATIC OUTLINE OF THE PORTAL VEIN AND ITS RELATION TO THE LIVER, &c. (A. T.)  $\frac{1}{4}$

The liver is supposed to be turned upwards so as to present a portion of its under surface. *a*, gall-bladder; *b*, square lobe; *c*, left lobe; 1, trunk of the vena portæ; 2, great or superior mesenteric vein; 2', its middle colic branch, forming loops of communication between the right and left colic veins; 3, intestinal branches; +, small pancreatico-duodenal branch; 4, right colic branch; 5, ileocolic; 6, coronary vein of the stomach; + +, right gastro-epiploic; 7, splenic vein; 7', its branches to the spleen; 7'', its branches to the stomach; 8, inferior mesenteric vein; 9, left colic branch; 9', its communication with the middle colic; 10, sigmoid; 11, superior hæmorrhoidal; 12, the right, and 13, the left division of the vena portæ in the transverse fissure of the liver; 14, the obliterated cord of the umbilical vein; 15, the obliterated cord of the ductus venosus; 16, part of vena cava inferior.

The branches of the **inferior mesenteric** vein correspond with the ramifications of the artery of the same name. They commence at the lower part of the rectum in the hæmorrhoidal plexus, and unite into a single vessel near the sigmoid flexure of the colon. From this point the vein proceeds upwards and inwards along the lumbar region, behind the peritoneum, crossing between the transverse mesocolon and the spine, or farther to the left, and then passing beneath and behind the pancreas, it reaches the splenic vein in which it terminates.

**Varieties.**—In some cases the umbilical vein remains in some degree pervious from the point where it joins the left portal branch, up to the inner surface of the rectus muscle, and is joined in the latter situation by a branch of the deep epigastric vein, thus establishing a communication between the external iliac and portal veins. This communicating branch, according to Luschka, is normal,



and is described by him under the name of *vena parumbilicalis*. (Champneys, "Journ. of Anat.," vol. vi., p. 416).

### VEINS OF THE HEART.

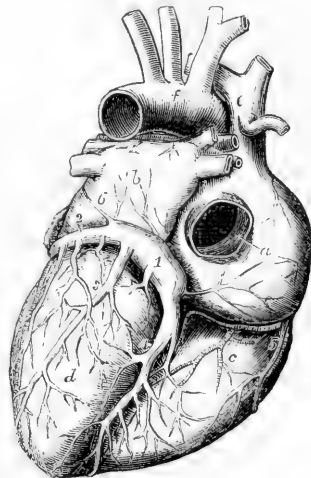
The greater number of the cardiac veins are collected into a large common trunk which pours its blood into the posterior part of the right auricle, in the angle between the inferior vena cava and the right auriculo-ventricular orifice. The terminal part of this vein is considerably dilated, and is named the coronary sinus. The principal veins leading into it are named the great, the posterior, and the anterior coronary veins. Among these the first alone deserves the name of coronary, as it surrounds the heart in the left auriculo-ventricular groove.

Besides the larger cardiac veins which join the great coronary sinus, there are also small separate veins (*venæ minimæ cordis*), which open directly into the right auricle, especially along its right border. The openings of these veins, as well as some depressions which do not admit veins, have been named *foramina Thebesii*.

Fig. 321. — VIEW OF THE ADULT HEART, FROM BEHIND, TO SHOW THE CORONARY VEINS. (A. T.)  $\frac{1}{2}$

*a*, placed on the back of the right auricle, points to the Eustachian valve seen within the opening of the inferior vena cava; *b*, the back of the left auricle; *c*, the right ventricle; *d*, left ventricle; *e*, vena cava superior; *f*, arch of the aorta; 1, sinus of the great coronary vein; 2, great coronary vein turning round the heart in the auriculo-ventricular groove; 3, 4, posterior branches; 5, one of the small right cardiac veins passing directly into the right auricle; 6, the vestige of the left superior vena cava proceeding over the left auricle downwards to join the coronary sinus.

Fig. 321.



The veins of the heart are without valves excepting at their terminations.

The **great cardiac** vein (*vena cordis magna*) is a vessel of considerable size, and from the way in which it coils round the left side of the base of the heart, or rather of the ventricle, it may be named "coronary." Its chief branch runs along the groove upon the fore part of the heart, corresponding with the septum of the ventricles. Commencing at the apex of the heart, it gradually increases in size as it approaches the base of the ventricles, and then inclining backwards and to the left side in the groove between the left auricle and ventricle, ends in the coronary sinus: a valve of two segments closes its aperture in the sinus. In this course it receives branches from the ventricles, especially from the left, and also from the left auricle: and as it passes round the thick margin of the left ventricle, it receives a vein of some size which ascends to join it.

The **posterior cardiac** veins ascend on the back of the ventricles, especially on the left, and open into the coronary sinus by four or more

valved orifices. One of these, larger than the rest, (middle or posterior cardiac vein), ascends along the groove between the ventricles upon the posterior surface of the heart. It commences by small branches at the apex of the heart, which communicate with those of the preceding vein, and then ascends to the base, receiving branches from the substance of both ventricles.

The **small** or **anterior cardiac** veins (*venæ cordis parvæ*) are several small branches, which commence upon the anterior surface of the right ventricle, and passing upwards and outwards, open separately into the right auricle, after having crossed over the groove between it and the ventricle.

The **coronary sinus** is about an inch in length, and is placed at the back of the heart in the transverse groove between the left auricle and ventricle, where it is covered by the muscular fibres of the auricle. At one end it is joined by a small vein from the right side, and opens into the right auricle beneath the Thebesian valve; at the other, it receives the large coronary vein, and a small straight vein directed obliquely along the back of the left auricle; whilst between those points other veins enter it from the back of the heart. All the veins joining it, except the small oblique vein, are provided with more or less complete valves at their terminations.

The coronary sinus, together with the small oblique vein above referred to, considered with reference to their early fetal condition and certain malformations to which they are subject along with other neighbouring veins, may be looked upon rather as the persistent terminal parts of a typically distinct left superior vena cava, than as simply the main stem of the cardiac veins. The explanation of this will be found in the description of the development of these veins.

## 2.—THE ABSORBENT VESSELS.

The absorbent vessels are divisible physiologically into two sets;—the *lacteals*, which convey the chyle from the alimentary canal to the thoracic duct; and the *lymphatics*, which take up the lymph from all the other parts of the body, and return it into the venous system. Anatomically considered, however, the lacteals are not different from the lymphatics, and may be regarded as the absorbents of the mucous membrane of the intestine. The larger lacteals and lymphatics are provided with numerous valves, which give them, when distended, a somewhat moniliform appearance; and both are connected in their course with *lacteal* or *lymphatic* glands.

The general anatomy of the absorbents having been elsewhere detailed, only their course and position remain to be here described. They are gathered into a right and a left trunk, which open into the angles of union of the subclavian and internal jugular veins. The large vessel of the left side traversing the thorax is named the *thoracic duct*: it receives not only the lymphatics of its own side of the head and arm, and the most of those of the trunk, but likewise the lymphatics of both lower limbs, and the whole of the lacteals. The vessel of the right side is named the *right lymphatic duct*, and receives the lymphatics only of that side of the head and neck and upper part of the trunk.

### THE THORACIC DUCT.

The thoracic duct is the common trunk which receives the absorbents from both the lower limbs, from the abdominal viscera (except part of

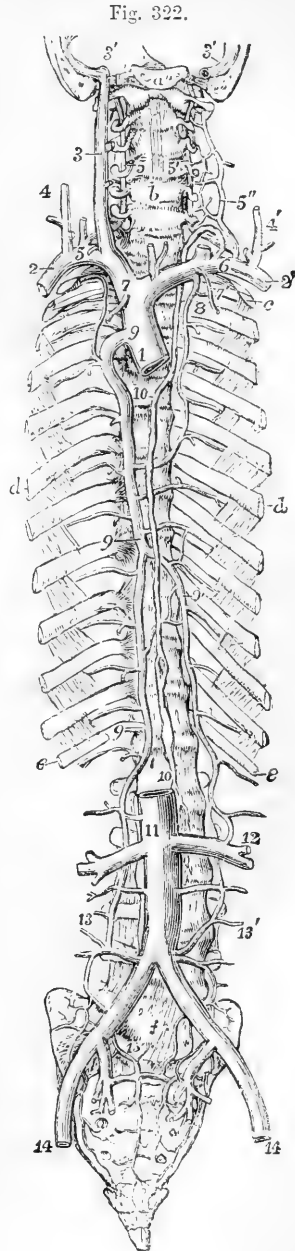
the upper surface of the liver), and from the walls of the abdomen, from the left side of the thorax, left lung, left side of the heart, and left upper limb, and from the left side of the head and neck. It is from fifteen to eighteen inches long in the adult, and extends usually from the second lumbar vertebra to the root of the neck. Its commencement, however, is often as low as the third lumbar vertebra; and in some cases as high as the first lumbar, or even the last dorsal vertebra. Here there is usually a dilatation of the duct, of variable size, which is called *receptaculum chyli* (Pecquet), and is the common place of junction of the lymphatics from the lower limb with the trunks of the lacteal vessels.

Fig. 322.—SKETCH OF THE THORACIC DUCT WITH THE PRINCIPAL SYSTEMIC VEINS. (A. T.)

The full description of this figure will be found at p. 473.

10, 10, indicate the thoracic duct; the lower number is close to the receptaculum chyli, the upper is on the fourth dorsal vertebra, above which the duct inclines to the left; 6, on the left subclavian vein, marks the termination of the duct in the angle of union of the subclavian and internal jugular veins; 5, on the right subclavian vein, indicates the similar termination of the right lymphatic trunk.

The lower part of the thoracic duct is generally wider than the rest, being about three lines in diameter; it lies at first to the right side of or behind the aorta; it then ascends on the right side of that vessel, in contact with the right crus of the diaphragm, to the thorax, where it is placed at first upon the front of the dorsal vertebræ, between the aorta and the azygos vein. The duct ascends, gradually inclining to the left, and at the same time diminishing slightly in size, until it reaches the third dorsal vertebra, where, passing behind the arch of the aorta, it comes into contact with the œsophagus, lying between the left side of that tube and the pleura. Continuing its course into the neck to the level of the upper border of the seventh cervical vertebra, it changes its direction and turns forwards, at the same time arching downwards and outwards so as to



describe a curve over the apex of the pleura, and then terminates on the outer side of the internal jugular vein, in the angle formed by the union of that vein with the subclavian. The diminution in the size of the duct as it ascends is such that at the fifth dorsal vertebra it is often only two lines in diameter, but above this point it again enlarges. The duct is generally waving and tortuous in its course, and is constricted at intervals so as to give it a varicose appearance.

The thoracic duct has numerous double valves at short intervals throughout its whole course, the constrictions of their attachments giving a nodulated appearance to the vessel. They are more numerous in the upper part of the duct. At the termination of the duct in the veins there is a valve of two segments, so placed as to allow the contents of the duct freely to pass into the veins, but which effectually prevents the reflux of either chyle or blood into the duct.

**Varieties.**—The thoracic duct is not always a single trunk throughout its whole extent; it frequently divides opposite the seventh or eighth dorsal vertebra into two trunks, which soon join again; sometimes it separates for a short distance into three divisions, which afterwards unite, and enclose between them spaces or islets. Cruikshank in one case found the duct double in its entire length; "in another triple, or nearly so." In the neck, the thoracic duct often divides into two or three branches, which in some instances terminate separately in the great veins, but in other cases unite first into a common trunk. In a case of right aortic arch the thoracic duct has been observed to end in the veins of the right side (A. Thomson). Dr. Morrison Watson describes a case in which without transposition of the viscera, or any change in the disposition of the branches of the aorta, the thoracic duct terminated in the veins of the right side, and no trace of a left lymphatic duct could be discovered. ("Journ. of Anat.," vol. vi., p. 427.) In the lower animals, the termination of the thoracic duct in the veins of the right side as well as of the left is not uncommon.

#### THE RIGHT LYMPHATIC DUCT.

The right lymphatic duct is a short vessel, about a line or a little more in diameter, and about a quarter or half an inch in length, which receives the lymph from the absorbents of the right upper limb, the right side of the head and neck, the right side of the chest, the right lung, and the right half of the heart, and from part of the upper surface of the liver. It enters obliquely into the receding angle formed by the union of the right subclavian and internal jugular veins, where its orifice is guarded by a double valve.

#### LYMPHATICS OF THE LOWER LIMB.

The lymphatics of the lower limb are arranged in a superficial and a deep series. Those of the superficial series, together with the superficial lymphatics of the lower half of the trunk, converge to the superficial inguinal glands; with the exception of a few which dip into the popliteal space. Those of the deep series converge to the deep inguinal glands.

The **popliteal lymphatic glands**, usually very small, and four or five in number, surround the popliteal vessels, and are imbedded in a quantity of loose fat. They receive from below the deep lymphatics of the leg, and those which accompany the short saphenous vein; and

from them proceed efferent vessels, which ascend with the femoral artery to the groin.

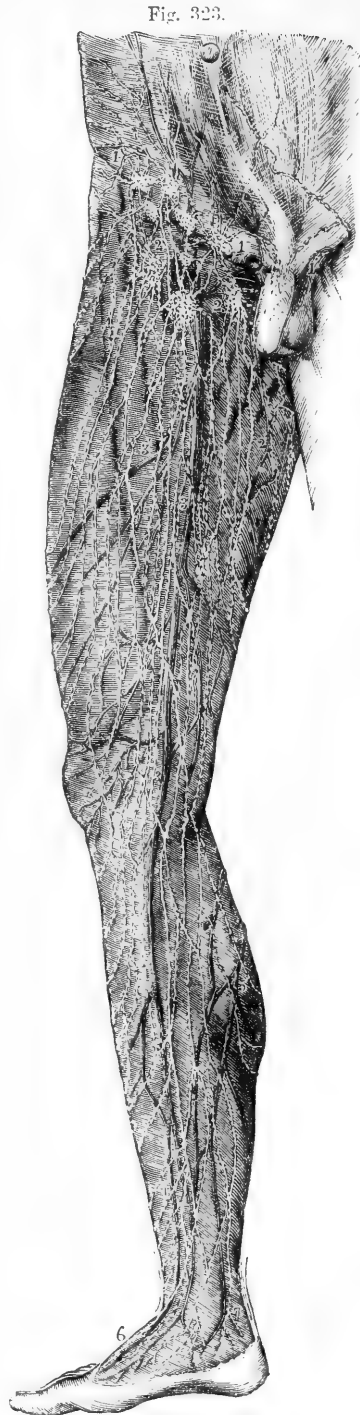Fig. 323.—VIEW OF THE SUPERFICIAL LYMPHATIC VESSELS AND GLANDS OF THE LOWER LIMB, AS SEEN FROM THE FRONT AND INNER SIDE (founded on Mascagni and others). (A. T.)  $\frac{1}{2}$

1, 1, upper inguinal glands receiving the lower abdominal, the inguinal, penal, and scrotal lymphatic vessels ; 2, 2, femoral or lower inguinal glands, receiving the anterior, internal, and external femoral lymphatic vessels ; 2', the internal lymphatic vessels ; 3, 3, large plexus of lymphatic vessels in the course of the saphenous veins ; 4, the same descending upon the leg ; 5, posterior lymphatics of the calf of the leg ; 6, lymphatic vessels of the dorsum of the foot ; 7, those of the heel and inner ankle.

The **superficial inguinal glands** vary much in number, amounting on an average to eight or ten : they are divisible into a superior or oblique and an inferior or vertical set. The oblique glands lie in the line of Poupart's ligament and receive lymphatics from the integuments of the trunk and genital organs, together with a few from the upper and outer part of the limb : the vertical glands surround the upper part of the long saphenous vein, and extend two or three inches downwards along the course of that vessel ; they receive the greater number of the lymphatics which ascend from the limb. The efferent vessels of the superficial inguinal glands perforate the fascia, come into connection with those situated deeply, pass into the abdomen by the side of the blood-vessels, and being connected with a chain of lymphatics which lie along the external iliac artery, terminate in the lumbar glands.

The **deep-seated inguinal glands** are placed beneath the others, and surround the femoral artery and vein.

The **superficial lymphatics of the lower limb** arise in two sets, one from the inner part of the dor-



sum and sole of the foot, the other from the outer. The *inner* vessels follow a similar course to that of the internal saphenous vein: passing partly in front and partly behind the inner ankle, they ascend along the inner side of the knee and front of the thigh, and terminate in the superficial inguinal glands. The *outer* vessels, ascending from the outer side of the foot, pass in great part obliquely across the popliteal space to join the inner set above the knee; in part they reach the inner set by crossing in front of the tibia; and a small number of them accompanying the external saphenous vein, dip down between the heads of the gastrocnemius muscle, and end in the popliteal glands. From the middle line of the back of the thigh lymphatics pass round on both sides to reach the inguinal glands. (Mascagni, "Vasorum Lymph. Historia," 1787.)

The **deep-seated lymphatics of the lower limb** are associated in their whole course with the deep blood-vessels. In the leg they consist of three divisions, namely, anterior tibial, posterior tibial and peroneal. Neither these nor the superficial absorbents pass through any lymphatic gland in the leg, unless it be those lymphatics which accompany the anterior tibial artery, near which a small gland is sometimes found on the front of the interosseous ligament, above the middle of the leg. The several sets of deep lymphatics in the leg enter the lymphatic glands situated in the popliteal space. The efferent vessels from those glands are joined by other lymphatics in contact with the branches of the femoral artery, and enter the deep inguinal glands. Other deep lymphatics, derived from the muscles of the gluteal region, and many proceeding from the adductor muscles of the thigh, enter the cavity of the pelvis in company with the gluteal, sciatic, and obturator arteries, and pass through a series of glands situated in the neighbourhood of the internal and common iliac arteries.

The **superficial lymphatics of the lower half of the trunk** converge to the superficial inguinal glands, the direction of some of them being indicated by the superficial circumflex iliac and epigastric, and the external pudic arteries. Externally they converge to the groin from the gluteal region and from the lower part of the back, those from the back crossing others which pass upwards to the axillary glands. Anteriorly they descend from the greater part of the surface of the abdomen, crossing and mingling above the umbilicus with vessels which ascend towards the axillary glands.

The **superficial lymphatics of the penis** usually form three vessels, two being placed at the sides and the other on the dorsum of the organ. Commencing in the prepuce and beneath the mucous lining of the urethra, they pass backwards, unite on the dorsum penis, and, again subdividing, send branches on each side to the oblique inguinal glands. The *deep-seated* lymphatics of the penis pass under the pubic arch, and end in the glands on the internal iliac artery.

The **lymphatics of the scrotum** pass to the superficial inguinal glands along the course of the external pudic arteries.

The lymphatics of the external generative organs in the female present a disposition similar to that existing in the male.

#### LYMPHATICS OF THE ABDOMEN AND PELVIS.

The **external iliac lymphatic glands**, from six to ten or more in

number, clustering round the external iliac artery, receive the efferent vessels from both deep and superficial inguinal glands.

The **internal iliac lymphatic glands**, a numerous series placed on the internal iliac artery, and the **sacral glands**, placed in the hollow of the sacrum, receive the lymphatics from the pelvic viscera and parietes.

The **lumbar lymphatic glands** are very large and numerous ; they are placed in front of the lumbar vertebræ, around the aorta and vena cava. To these proceed the efferent vessels of the glands already mentioned, as well as those which accompany several of the branches of the abdominal aorta.

The efferent absorbent vessels which proceed from the lumbar glands progressively increase in size, while their number diminishes, and at length they unite into a few trunks, which, with those of the lacteals, form the origin of the thoracic duct.

The **deep lymphatics of the abdominal wall** in part pass along the circumflex iliac and epigastric arteries, to the external iliac glands ; the greater number are directed backwards with the ilio-lumbar and lumbar arteries, and, being joined by the lymphatics from the muscles of the back, pass behind the psoas muscle to the vertebral column, where they enter the lumbar glands.

The **lacteals** (*vasa lactea, chyliifera*) commence in the coats of the intestines by a very close plexus, and extend to the thoracic duct, in which they all terminate : they are far more numerous in the small than in the large intestine, so that they abound in the mesentery, and particularly in that of the jejunum and ileum. Two series of absorbent vessels are found along the tube of the intestine, having different positions and directions : those nearest to the outer surface of the intestine run longitudinally in the course of the canal, lying beneath the peritoneal coat, whilst others, placed more deeply between the muscular and mucous coats, run transversely round the intestine, and are directed thence with the arteries and veins along the mesentery, enclosed between the two layers of the peritoneum. (Cruikshank, "Anatomy of the Absorbent Vessels," p. 162.) Sometimes the more superficial absorbents of the intestine are named lymphatics, to distinguish them from the deep set which absorb the chyle from the cavity of the intestine. According to Teichmann ("Das Saugader-system," 1861, p. 75), the two plexuses have no capillary anastomoses, but communicate only through valved vessels : this they do freely. The lacteals, having entered the mesentery, take the course of the blood-vessels, and pass through successive sets of numerous mesenteric lymphatic glands.

The **mesenteric glands** vary in number from a hundred and thirty to a hundred and fifty ; and in the healthy state are seldom larger than an almond. They are most numerous in that part of the mesentery which corresponds with the jejunum ; and they seldom occur nearer to the attached border of the intestine than two inches. Small glands in limited numbers are also disseminated irregularly between the folds of the peritoneum connected with the large intestines.

Having passed through these glands, the lacteals gradually unite as they approach the attached border of the mesentery, and so become diminished in number but increased in size, until at length, near the root of the superior mesenteric artery, only two or three trunks remain,

Fig. 324.

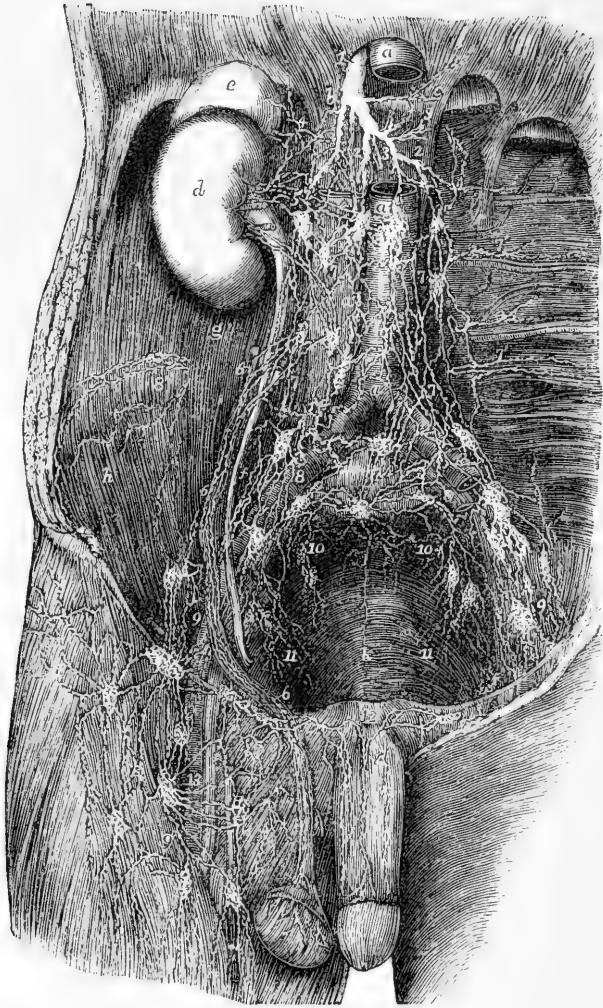


Fig. 324.—PRINCIPAL LYMPHATIC VESSELS AND GLANDS OF THE ABDOMEN AND PELVIS  
(modified from Mascagni). †

*a*, the abdominal aorta, the upper part of it having been removed to show the deepest lumbar plexuses of lymphatics; *a'*, the vena cava inferior; *b*, the right; *c*, the left crus of the diaphragm; *d*, the right kidney; *e*, the suprarenal body; *f*, the ureter; *g*, the psoas muscle; *h*, the iliacus; *k*, the lower part of the sacrum within the pelvis; 1, the commencement of the thoracic duct; 2, 3, 2, the largest of the lymphatic and lacteal trunks which join the thoracic duct, the hepatic, splenic, gastric, &c.; 4, the suprarenal lymphatics; 5, the renal, joining some of the lumbar plexus; 6, the spermatic; 7, the lumbar lymphatic vessels and glands; 7', some of the lymphatics of the loins; 8, those surrounding the common iliac vessels, and proceeding from the lymphatics of the pelvis and lower limb; 8', lymphatics of the abdominal wall; 9, the external iliac; 10, the internal iliac receiving those from the sacrum, walls of the pelvis, and at 11, and at *k*, those from the viscera (bladder and rectum); 12, lymphatics of the dorsum of the penis passing to those of the groin; 13, the deep femoral lymphatics and glands.



which end in the thoracic duct. Sometimes, however, six or seven of these vessels open separately into the commencement of the duct. Those from the descending colon and its sigmoid flexure usually join some of the lumbar lymphatics, or turn upwards and open by a separate trunk into the lower end of the thoracic duct.

The **lymphatics of the stomach**, like those of the intestines, are placed, some beneath the peritoneal coat, and others between the muscular and mucous coats. Following the direction of the blood-vessels, they become arranged into three sets. Those of one set accompany the coronary vessels, and receiving, as they run from left to right, branches from both surfaces of the organ, turned backwards near the pylorus, to join some of the larger trunks. Another series, from the left end of the stomach, follow the vasa brevia, and unite with the lymphatics of the spleen: whilst those of the third set, guided by the right gastro-epiploic vessels, incline from left to right along the great curvature of the stomach, from which they pass backwards, and at the root of the mesentery, terminate in one of the principal efferent *lacteal* vessels.

The **lymphatics of the rectum**, likewise in two strata, are frequently of considerable size: immediately after leaving the intestine, some of them pass through small glands which lie contiguous to it; finally, they enter the lymphatic glands situated in the hollow of the sacrum, or those higher up in the loins. At the anus, their capillary network is continuous with that of the cutaneous lymphatics.

The **lymphatics of the spleen** are placed, some immediately under its peritoneal covering, others in the substance of the organ. Both sets converge to the inner side of the spleen, come into contact with the blood-vessels, and, accompanying these, pass through a series of small glands, and terminate in the larger lymphatics of the digestive organs.

Lymphatics emerge from the *pancreas* at different points, and join those derived from the spleen.

The **lymphatics of the liver** are divisible into three principal sets, according as they are placed upon its upper or its under surface, or are spread through its substance with the blood-vessels.

The lymphatic vessels on the *upper surface of the liver* incline towards particular points, and so become distinguishable into groups, of which four are usually enumerated. 1. From the middle of this surface five or six branches run towards the falciform ligament, and, being directed forwards on this membrane, they unite to form a large trunk, which passes upwards between two slips of the attachment of the diaphragm, behind the ensiform cartilage. Having reached the interpleural space behind the sternum, they ascend through a chain of lymphatic glands found upon the internal mammary blood-vessels. 2. The second group consists of vessels which incline outwards towards the right lateral ligament, opposite to which they unite into one or two larger lymphatics; these pierce the diaphragm, and run forwards upon its upper surface to join the preceding set of vessels behind the sternum. In some cases, however, instead of passing into the thorax, they turn inwards on reaching the back part of the liver, and, running upon the crus of the diaphragm, open into the thoracic duct close to its commencement. 3. Another set of lymphatics is found upon the left lobe of the liver; the vessels of which it is composed, after reaching the

left lateral ligament pierce the diaphragm, and, turning forwards, end in the anterior glands of the mediastinum. 4. Finally, along the fore part of the liver some vessels will be observed to turn downwards and join those placed upon the under surface.

The *under* surface of the liver is covered by an open network of lymphatic vessels. On the right lobe they are directed over and under the gall-bladder to the transverse fissure, where some join the deep lymphatics; whilst others, passing through some scattered lymphatic glands, are guided by the hepatic artery to the right side of the aorta, where they terminate in the thoracic duct. Branches also proceed to the concave border of the stomach, between the folds of the small omentum, to join with the coronary lymphatics of that organ.

The *deep lymphatics of the liver* accompany the branches of the portal vein in the substance of the organ, and pass out of the gland by the transverse fissure. After communicating with the superficial lymphatics, and also with those of the stomach, they pass backwards, and join, at the side of the cœliac artery, with one of the large *lacteal* trunks previously to its termination in the thoracic duct.

The **lymphatics of the kidney** likewise consist of a deep and a superficial set. Those placed upon the surface of the organ are comparatively small; they unite at the hilus of the kidney with other lymphatics from the substance of the gland, and then pass inwards to the lumbar lymphatic glands. The lymphatics of the *suprarenal capsules* unite with those of the kidney. The lymphatic vessels of the *ureter* are numerous; they communicate with those of the kidney and bladder, and for the most part terminate by union with the former.

The **lymphatics of the bladder**, taking rise from the entire surface of that organ, enter the glands placed near the internal iliac artery; with these are associated the lymphatics of the prostate gland and vesiculæ seminales.

The **lymphatics of the uterus**, in the unimpregnated state of the organ, are small, but during the period of gestation they are greatly enlarged. Issuing from the entire substance of the uterus, the greater number descend, together with those of the vagina, and pass backwards to enter the glands upon the internal iliac artery; thus following the course of the principal uterine blood-vessels. Others, proceeding from the upper end of the uterus, run outwards in the folds of peritoneum which constitute the broad ligaments, and join the lymphatics derived from the ovaries and Fallopian tubes. The conjoined vessels then ascend with the ovarian arteries, near the origin of which they terminate in the lymphatic vessels and glands placed on the aorta and vena cava.

The **lymphatics of the testicle** commence in the substance of the gland, and upon the surface of the tunica vaginalis. Collected into several large trunks, they ascend with the other constituents of the spermatic cord, pass through the inguinal canal, and accompany the spermatic vessels in the abdomen to enter some of the lumbar lymphatic glands.

#### LYMPHATICS OF THE THORAX.

The **lymphatic glands of the thorax**.—Along the course of the internal mammary blood-vessels there are placed six or seven small glands, through which pass the lymphatics situated behind the sternum;

they may be named the *anterior mediastinal* glands. Between the intercostal muscles and in the line of the heads of the ribs on the side of the spine is a set of glands, named *intercostal*, which receive the lymphatics from the thoracic parietes and the pleura; their efferent ducts communicate freely with each other and open into the thoracic duct. Three or four *cardiac* lymphatic glands lie behind the aortic arch, and one before it: and another cluster, varying from fifteen to twenty in number, is found along the œsophagus, constituting the *œsophageal glands*. The *bronchial glands*, ten or twelve in number, are

Fig. 325.—LYMPHATIC VESSELS OF THE HEAD AND NECK AND OF THE UPPER PART OF THE TRUNK (from Mascagni).  $\frac{1}{2}$

The chest and pericardium have been opened on the left side, and the left mamma detached and thrown outwards over the left arm, so as to expose a great part of its deep surface.

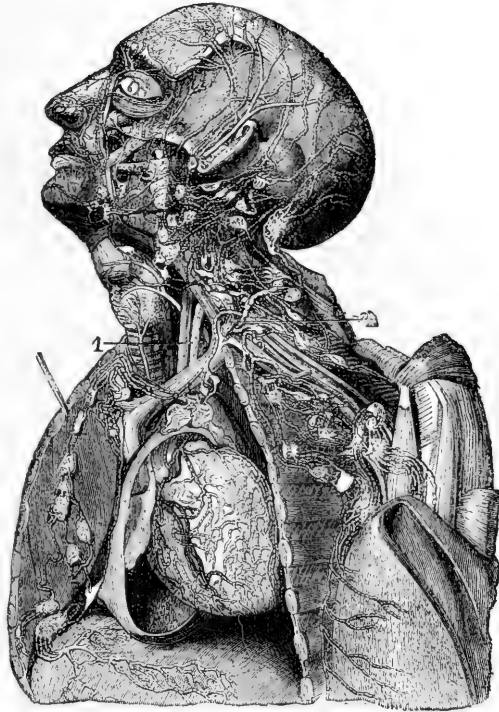
The principal lymphatic vessels and glands are shown on the side of the head and face, and in the neck, axilla, and mediastinum. Between the left internal jugular vein and the common carotid artery, the upper ascending part of the thoracic duct marked 1, and above this, and descending to 2, the arch and last part of the duct. The termination of the upper lymphatics of the diaphragm in the mediastinal glands, as well as the cardiac and the deep mammary lymphatics, are also shown.

of much larger size than those just mentioned.

The largest of these occupy the interval between the right and left bronchi at their divergence, whilst others of smaller size rest upon the first divisions of these tubes for a short distance within the lungs. In early infancy their colour is pale red; towards puberty, we find them verging to grey, and studded with dark spots; at a more advanced age they are frequently very dark or almost black. In chronic diseases of the lungs they sometimes become enlarged and indurated, so as to press on the air-tubes and cause much irritation. They are frequently the seat of tuberculous deposits.

The **deep lymphatics of the thoracic walls** are divisible into two sets, the sternal and the intercostal. The *sternal* lymphatics, commencing in the muscles of the abdomen, ascend between the fibres of the diaphragm at its attachment to the ensiform cartilage, and continue

Fig. 325.



upwards behind the costal cartilages to terminate on the left side in the thoracic duct, and on the opposite side in the right lymphatic duct. They receive branches from the upper surface of the liver, and small branches from the anterior parts of the intercostal spaces. The *intercostal* lymphatics, passing backwards in each intercostal space, receive, as they approach the spine, branches coming forward through the intertransverse space, and enter the intercostal glands, through the efferent ducts of which their contents are poured on both sides of the body into the thoracic duct.

The **lymphatics of the lungs**, like those of other organs, form two sets, one being superficial, the other deep-seated. Those at the surface run beneath the pleura, where they form a network by their anastomoses. Their number is considerable, but they are sometimes difficult of demonstration. The deep lymphatics run with the pulmonary blood-vessels. Both superficial and deep lymphatics converge to the root of the lung, and terminate in the bronchial glands. From these, two or three trunks issue, which ascend along the trachea to the root of the neck, and terminate on the left side in the thoracic duct, and on the right in one of the right lymphatic trunks.

The **lymphatics of the heart** follow the coronary arteries and veins from the apex of the organ towards the base, where they communicate with each other, and those of each side are gathered into one trunk. The trunk from the *right side*, running upwards over the aortic arch between the innominate and left carotid arteries to reach the trachea, ascends to the root of the neck, and terminates in the right lymphatic duct. The vessel from the left side proceeding along the pulmonary artery to its bifurcation, passes through some lymphatic glands behind the arch of the aorta, and ascends at the side of the trachea to terminate in the thoracic duct.

The **lymphatics of the œsophagus**, unlike those of the rest of the alimentary canal, form only one layer, which lies internal to the muscular coat. They are connected with glands in the neighbourhood, and after having communicated by anastomoses with the lymphatics of the lungs, at and near the roots of those organs, they terminate in the thoracic duct.

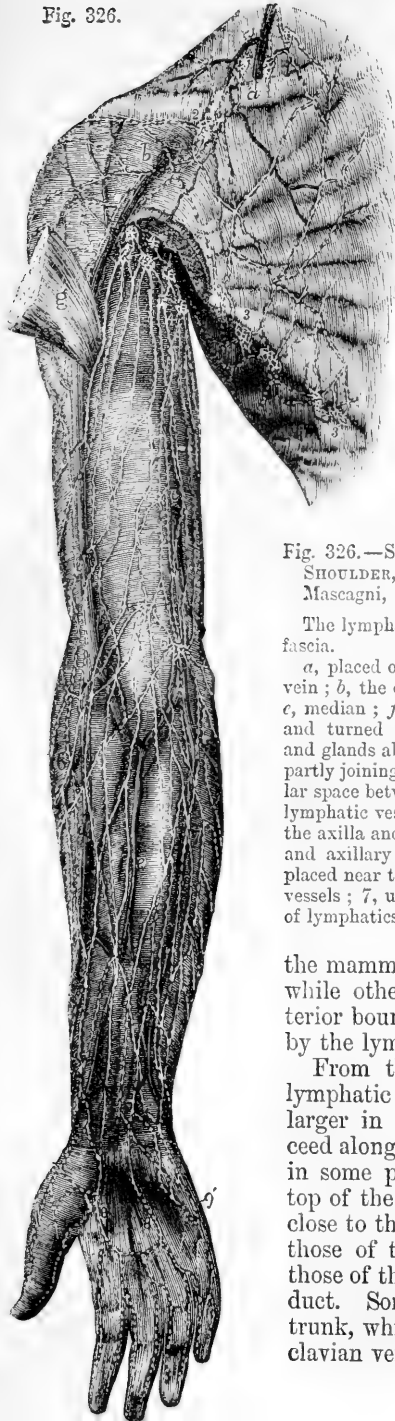
The **lymphatics of the thymus gland** are numerous. According to Astley Cooper, two large vessels proceed downwards from them on each cornu, and terminate in the jugular veins by one or more orifices on each side. (Anatomy of the Thymus Gland, p. 14.)

#### LYMPHATICS OF THE UPPER LIMB.

In the upper limb, as in the lower, the lymphatics are arranged in a deep and a superficial set. These two sets of vessels, together with the lymphatics of the surface of the greater part of the back, and those of the mamma and pectoral muscles, converge to the axillary glands.

The lymphatic glands found in the upper limb below the axilla are neither large nor numerous; a few, however, are found in the course of the brachial artery, and even of the arteries of the forearm; and one or more small glands are found in connection with the superficial

Fig. 326.



lymphatics, lying near the commencement of the basilic vein, a little above and in front of the inner condyle of the humerus.

The **axillary glands** are generally ten or twelve in number : they vary, however, considerably in their number as well as in their size, in different individuals ; they are mostly placed along the axillary vessels, and receive the lymphatics which ascend from the limb ; but a few also lie further forwards on the serratus magnus near the external mammary artery, and beneath the pectoral muscles, and receive the lymphatics from

Fig. 326.—SUPERFICIAL LYMPHATICS OF THE BREAST, SHOULDER, AND UPPER LIMB, FROM BEFORE (after Mascagni, A. T.)  $\frac{1}{2}$

The lymphatics are represented as lying upon the deep fascia.

*a*, placed on the clavicle, points to the external jugular vein ; *b*, the cephalic vein ; *c*, the basilic vein ; *d*, radial ; *e*, median ; *f*, ulnar vein ; *g*, great pectoral muscle cut and turned outwards ; 1, superficial lymphatic vessels and glands above the clavicle ; 2, those below the clavicle partly joining the foregoing and dipping into the triangular space between the deltoid and pectoral muscles ; 3, lymphatic vessels and glands placed along the border of the axilla and great pectoral muscle ; 4, upper brachial and axillary glands and vessels ; 5, two small glands placed near the bend of the arm ; 6, radial lymphatic vessels ; 7, ulnar lymphatic vessels ; 8, 8, palmar arch of lymphatics ; 9, 9', outer and inner sets of vessels.

the mamma and muscular walls of the chest ; while others incline downwards at the posterior boundary of the axilla, and are joined by the lymphatics from the back.

From the glands of the axilla efferent lymphatic vessels, fewer in number, but larger in size than the afferent vessels, proceed along the course of the subclavian artery, in some parts twining round it. From the top of the thorax they ascend into the neck, close to the subclavian vein, and terminate—those of the left side in the thoracic duct, those of the right side in the right lymphatic duct. Sometimes they unite into a single trunk, which opens separately into the subclavian vein near its termination.

The **superficial lymphatics of the upper limb** are usually described as forming two divisions corresponding with the superficial veins on the outer and inner borders. On the front of the limb they arise from an arch formed in the palm of the hand by the union of two lymphatic vessels proceeding from each finger: becoming more numerous in the forearm, they are found thickly set over its surface, whence they pass upwards in the arm; the inner vessels in a straight direction, and those placed further outwards inclining gradually inwards over the biceps muscle to reach the axillary glands. On the back of the hand also two lymphatics proceed from each finger; and from the copious network on the back of the forearm vessels pass over the radial margin, and in greater number round the ulnar side to join those in front. The lymphatic vessels in the front of the upper arm are also joined by others which pass round each side of the limb, and by some which descend from the shoulder.

The **deep lymphatics of the upper limb** correspond with the deep blood-vessels. In the forearm they consist, therefore, of three sets, associated respectively with the radial, ulnar, and interosseous arteries and veins. In their progress upwards some of them have communication near the wrist with the superficial lymphatics; and some of them enter the glands which lie by the side of the brachial artery near the bend of the elbow. They all terminate in the glands of the axilla.

The **superficial lymphatics of the chest** consist of branches running under cover of the pectoral muscles, and of subcutaneous vessels, twigs of which are continued from those on the abdominal wall as low as the umbilicus, decussating with the vessels which converge to the inguinal glands.

The **superficial lymphatics of the back** converge to the axillary glands from its various regions; from the neck over the surface of the trapezius muscle, from the posterior part of the deltoid, and from the whole dorsal and lumbar regions as low as the crest of the ilium; the branches decussating inferiorly with vessels leading to the inguinal glands, and likewise crossing the middle line so as to decussate with branches of the opposite side. (Mascagni, Tab. xxii., xxiii., xxiv.)

#### LYMPHATICS OF THE HEAD AND NECK.

The lymphatic glands found on different parts of the head and face are few and small: those in the *neck*, on the contrary, are comparatively very large and numerous.

The **cervical glands** are placed chiefly on the sides of the neck, and are divisible into a superficial and a deep series. Of the former, some lie beneath the base of the inferior maxillary bone; the remainder, arranged along the course of the external jugular vein, exist in greatest number in the angular space behind the lower end of the sterno-mastoid muscle, where that vein enters the subclavian vein: at this point the cervical glands approach and are connected with the glands of the axilla. The *deep cervical* glands are placed along the carotid artery and internal jugular vein, extending downwards on the sheath of those vessels as far as the thorax.

The lymphatic vessels of the cranium and face, together with those of the tongue, pharynx, larynx and other parts of the neck, pass into the

cervical glands. From these glands efferent vessels issue, which progressively diminish in number during their descent, and unite into two

Fig. 327.

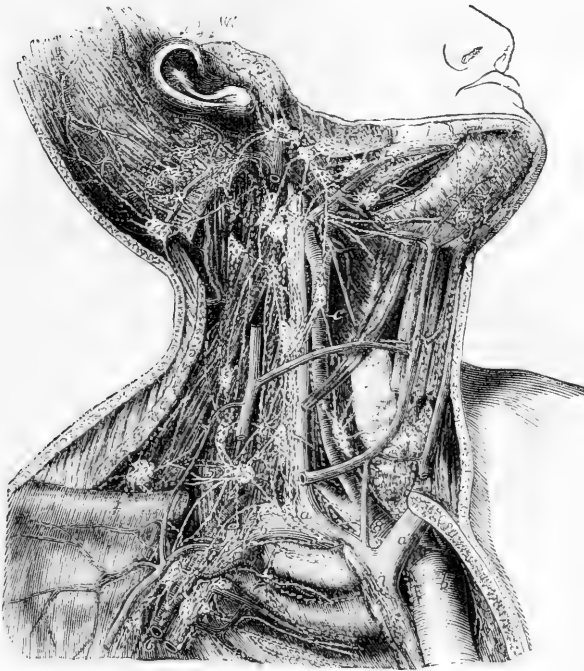


Fig. 327.—PRINCIPAL LYMPHATIC VESSELS AND GLANDS OF THE HEAD AND NECK ON THE RIGHT SIDE (after Bourguery in part).  $\frac{1}{2}$

The inner half of the right clavicle and part of the sternum have been removed so as to expose the arch of the aorta, and the innominate artery and veins: the posterior belly of the omohyoid muscle is removed: and the sterno-mastoid, sterno-hyoid, and sterno-thyroid muscles, and a part of the external jugular vein have been divided so as to expose the deeper parts.

*a*, the right innominate vein at the place where it is joined by the principal lymphatic trunk; *a'*, the left vein; *b*, arch of the aorta; *c*, common carotid artery; *d*, thyroid gland crossed by the anterior jugular vein; *e*, cut surface of the sternum; *f*, outer part of the clavicle; 1, submaxillary lymphatic vessels; 1', sublingual; 2, temporal, facial and parotid; 3, occipital and posterior auricular; 4, deep or descending cervical close to the great vessels; 5, transverse cervical; 6, deep pectoral and axillary; 7, on the vena cava superior, some of the right mediastinal; 8, on the innominate artery, some of the deeper cardiac and bronchial; to these last are seen descending some of the lymphatics from the thyroid gland and lower part of the neck.

trunks, of which the left one ends in the thoracic duct, and the other in the right lymphatic duct: sometimes, however, the main cervical lymphatic vessel terminates separately at the junction of the subclavian and internal jugular veins, or in one of those veins immediately before their union.

The **lymphatics of the cranium** consist of a temporal and an occipital set. Those of the *temporal* set descend in front of the ear,

some of the vessels passing through one or two glands usually found near the zygoma, whilst others enter those situated on the parotid gland; all of them terminate in the lymphatic glands of the neck. The cranial lymphatics of the *occipital* set, accompanying the occipital artery, descend to the glands situated behind the ear, on and near the mastoid process of the temporal bone, and hence join the superficial lymphatics of the neck.

Within the cranial cavity, lymphatic vessels have been demonstrated in the pia mater and in the arachnoid membrane. Distinct vessels have not been traced in the dura mater, nor have they been shown in the substance of the brain. The trunks of those derived from the pia mater pass out of the skull with the veins.

In the substance of the brain and spinal cord, according to the observations of Robin and of His, *perivascular spaces* or *canals* surround all the bloodvessels, even to their capillary ramifications, and are in communication with similar spaces and lymphatic vessels in the pia mater, and, according to Axel Key and Retzius, they may be injected from the subarachnoid spaces. The delicate walls of these perivascular canals agree in their histological character with those of the capillary lymphatic vessels, and their cavity is filled with a clear lymph-like fluid, containing numerous lymph corpuscles (Robin, in *Journ. de la Physiol.*, 1859, p. 537; and His, in *Zeitsch. fur Wissensch. Zool.*, vol. xv. p. 127. See also Vol. II. p. 572, of this work.)

The **superficial lymphatics of the face**, more numerous than those of the cranium, descend obliquely in the course of the facial vein, and join the submaxillary glands, from six to ten in number, which are placed beneath the base of the lower maxillary bone; a few of them in their descent pass through some glands situated on the buccinator muscle. The *deep* lymphatics of the *face*, derived from those of the temporal fossa and the cavities of the nose, mouth, and orbit, proceed outwards in the course of the internal maxillary vein; and, having reached the angle of the jaw, they enter the glands in that neighbourhood.



## SECTION V.—NEUROLOGY.

THE nervous system consists of central and peripheral parts. To the first belong those large masses of nervous substance forming the brain and spinal cord, or great cerebro-spinal centre; and to the second belong the various nervous cords, cerebro-spinal and sympathetic, which are distributed in different parts of the body. Along with these the nervous system also includes the organs of the external senses and the ganglia.

The description of the cerebro-spinal centre and of the organs of the senses will be given in the Second Volume. The present section includes the descriptive anatomy of the cerebro-spinal and sympathetic nerves, and of the ganglia connected with them.

## THE CEREBRO-SPINAL NERVES.

The nerves directly connected with the great cerebro-spinal centre constitute a series of symmetrical pairs, of which a certain number issue from the cranium through different foramina or apertures in its base, and are thence strictly named *cranial*. The next following nerve passes out between the occipital bone and the first vertebra, and the remaining thirty nerves all issue below the corresponding vertebral pieces of the spine. The first is sometimes distinguished by the name of suboccipital, but to the whole series of thirty-one nerves the name of *spinal* is usually given.

## CRANIAL NERVES.

The cranial nerves, besides being distinguished by numbers in the order of their passage through the dura mater lining the cranium, have likewise received other names, according to the place or mode of their distribution, or their functions.

The number of the cranial nerves has been variously stated as nine or as twelve by Willis and Sæmmerring respectively. Of the nine pairs of cranial nerves distinguished by Willis, or twelve as enumerated by Sæmmerring, the first six and the last correspond, but the seventh of Willis is divided into two by Sæmmerring, viz., the seventh and the eighth pairs, or the facial and the auditory nerves, while the eighth of Willis falls, in the more modern arrangement, into three distinct nerves, the ninth, tenth, and eleventh, or the glosso-pharyngeal, pneumogastric and spinal accessory nerves, as in the following table:—

WILLIS.	SCÈMMERRING.	OTHER NAMES.
First pair of nerves . . .	First pair of nerves . . .	Olfactory nerves.
Second " . . .	Second " . . .	Optic.
Third " . . .	Third " . . .	Common oculo-motor.
Fourth " . . .	Fourth " . . .	Pathetic or trochlear.
Fifth " . . .	Fifth " . . .	Trifacial or trigeminal.
Sixth " . . .	Sixth " . . .	Abducent ocular.
Seventh " { portio dura . . .	Seventh " . . .	Facial motor
" { portio mollis . . .	Eighth " . . .	Auditory.
Eighth " { n. vagus . . .	{ Ninth " . . .	Glosso-pharyngeal.
" { n.accessorius . . .	{ Tenth " . . .	Pneumo-gastric.
Ninth " . . .	Eleventh " . . .	Spinal accessory.
	Twelfth " . . .	Hypoglossal or lingual motor.

The arrangement of Sæmmerring is on the whole the preferable one ; but as the plan of Willis has long been in general use, it cannot be entirely abandoned.

**Connection with the encephalon.**—The roots of the cranial nerves may be traced for some depth into the substance of the encephalon, a circumstance which has led to the distinction of the *deep* and the *superficial* origin, by which latter is understood the place at which the nerve appears to be attached to the surface of the encephalon.

Fig. 328.

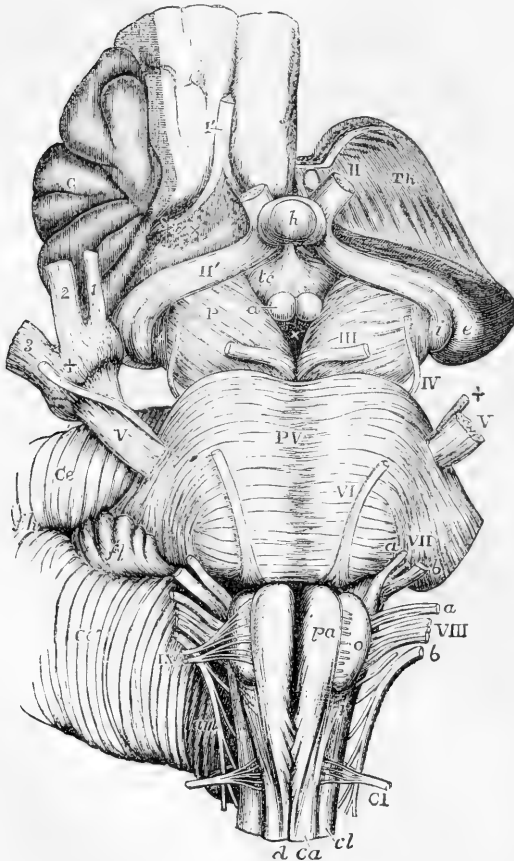


Fig. 328. — VIEW FROM BELOW OF THE CONNECTION OF THE PRINCIPAL NERVES WITH THE BRAIN. (A. T.)

The full description of this figure will be found at p. 534 of vol. ii. The following references apply to the roots of the nerves ; I', the right olfactory tract divided near its middle ; II, the left optic nerve springing from the commissure which is concealed by the pituitary body ; II', the right optic tract ; the left tract is seen passing back into *i* and *c*, the internal and external corpora geniculata ; III, the left oculomotor nerve ; IV, the trochlear ; V, V, the large roots of the trifacial nerves ; +, the lesser roots, the + of the right side is placed on the Gasserian ganglion ; 1, the ophthalmic ; 2, the superior maxillary, and 3, the inferior maxillary nerves ; VI, the left abducent nerve ; VII, *a*, *b*, the facial and auditory nerves ; *a*, VIII, the glosso-pharyngeal, pneumo-gastric, and spinal accessory nerves ; IX, the right hypoglossal nerve ; at *o*, on the left side, the rootlets are seen cut short ; CI, the left suboccipital or first cervical nerve.

The *superficial origin* of these nerves is quite obvious. The first pair are attached to the under surface of the frontal lobes, the second to the posterior portion of the optic thalami, the third to the crura cerebri, the fourth to the valve of Vieussens, the fifth to the sides of the pons, and the remainder to the medulla oblongata.

The *deep connection* or origin of these nerves is still in some cases a matter of considerable uncertainty. Where they can be followed, the fibres may be traced to, and probably in part arise from, certain collections of grey substance termed "nuclei." These nuclei are further connected by other fibres with each other and with the cerebral hemispheres. The deep origin of the first or olfactory nerves is still doubtful; the second pair are connected chiefly with the optic thalami and corpora quadrigemina; the third and fourth with a nucleus deeply placed beneath the corpora quadrigemina; the remainder with a continuous series of collections of grey matter which lie beneath the floor of the fourth ventricle and in the central part of the medulla oblongata, around the central canal, as low down as the decussation of the pyramids.

Fig. 329.

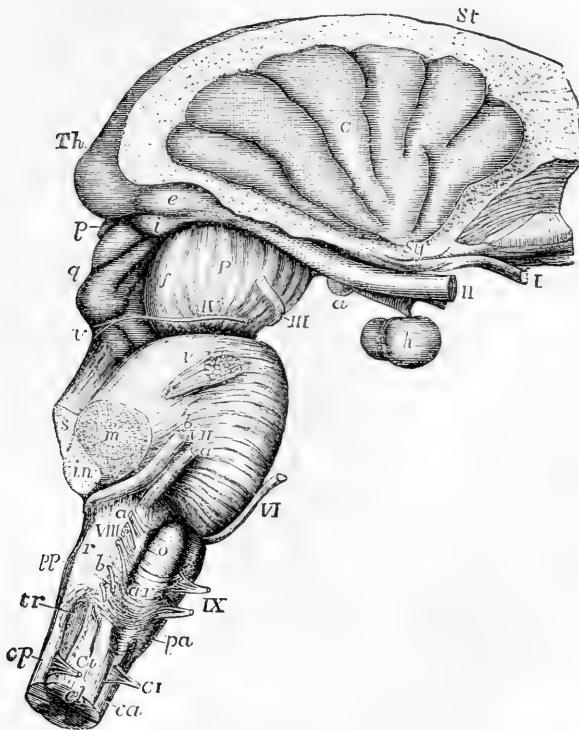


Fig. 329.—LATERAL VIEW OF THE CONNECTION OF THE PRINCIPAL NERVES WITH THE BRAIN. (A. T.)

The full description of this figure will be found at p. 550, vol. ii. The following references apply to the roots of the nerves: I, the right olfactory tract cut near its middle; II, the optic nerves immediately in front of the commissure; the right optic tract is seen passing back to the thalamus (*Th*), corpora geniculata (*i, e*), and corpora quadrigemina (*q*); III, the right oculo-motor nerve; IV, the trochlear nerve rising at *v*, from near the valve of Vieussens; V, the trifacial nerve; VI, the abducent ocular; *a, VII, b*, the facial and auditory nerves, and between them the pars intermedia; *a, VIII, b*, the roots of the glosso-pharyngeal, pneumo-gastric, and spinal accessory nerves; IX, the hypoglossal nerve; C I, the separate anterior and posterior roots of the suboccipital nerve.

**Mode of exit from the cranium.**—Each of the cranial nerves in leaving the cranial cavity passes through a foramen or tubular prolongation of the dura mater: some of these nerves or their main divisions are contained in distinct foramina of the cranium, others are

Fig. 330.

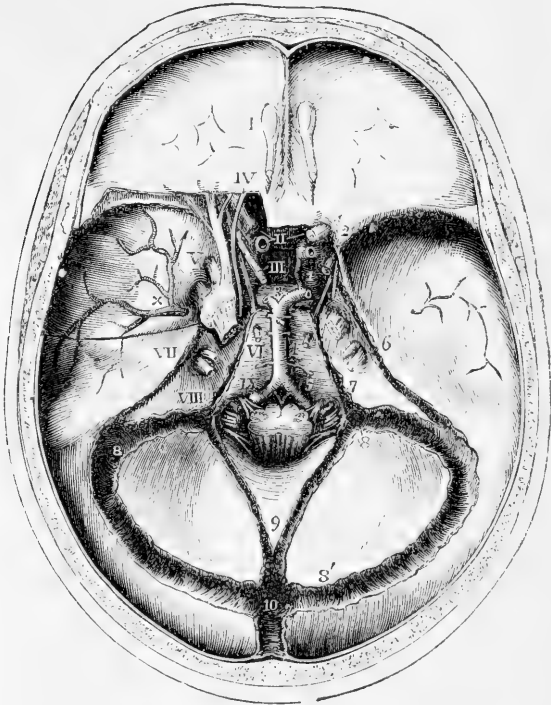


Fig. 330.—INTERNAL VIEW OF THE BASE OF THE SKULL, SHOWING THE PLACES OF EXIT OF THE CRANIAL NERVES. (A. T.)  $\frac{1}{2}$

The dura mater is left in great part within the base of the skull: the tentorium is removed and the venous sinuses are opened. On the left side a small portion of the roof of the orbit has been removed to show the relation of certain nerves at the cavernous sinus and in the sphenoidal fissure. The roots of the several cranial nerves have been divided at a short distance inside the foramina of the dura mater through which they respectively pass. I, the bulb of the olfactory nerve lying over the cribriform plate of the ethmoid bone; II, the optic nerves; that of the left side cut short; III, placed on the pituitary body, indicates the common oculo-motor nerve: IV, the trochlear nerve; V, is placed on the left side opposite to the middle of the three divisions of the trigeminal, which, together with the ganglion and greater root, have been exposed by opening up the dura mater; on the right side the greater root is seen; VI, placed below the foramen of exit of the abducent ocular; VII, placed on the upper part of the petrous bone opposite the entrance of the facial and auditory nerves into the meatus auditorius internus; VIII, placed on the petrous bone outside the jugular foramen opposite the place of exit of the three divisions of the eighth pair of nerves; IX, placed upon the basilar part of the occipital bone in front of the hypoglossal nerve as it passes through the anterior condylar foramen. On the left side of the cavernous sinus, the third, fourth, and ophthalmic division of the fifth nerves are seen keeping towards the outer side, while the sixth nerve is deeper and close to the internal carotid artery. The explanation of the remaining references in this figure will be found at p. 480.

grouped together in one foramen. The numerous small olfactory nerves descend into the nose through the cribriform plate of the ethmoid bone; the optic nerve pierces the root of the lesser wing of the sphenoid bone; the third, fourth, and sixth nerves, with the ophthalmic division of the fifth nerve, pass through the sphenoidal fissure; the superior maxillary and inferior maxillary divisions of the fifth pass respectively through the foramen rotundum and foramen ovale of the great wing of the sphenoid; the facial and auditory nerves pierce the petrous bone; the glossopharyngeal, pneumogastric, and spinal accessory nerves descend in separate canals of the dura mater through the anterior part of the jugular foramen between the petrous and occipital bones; and the hypoglossal nerve passes through the anterior condylar foramen of the occipital bone.

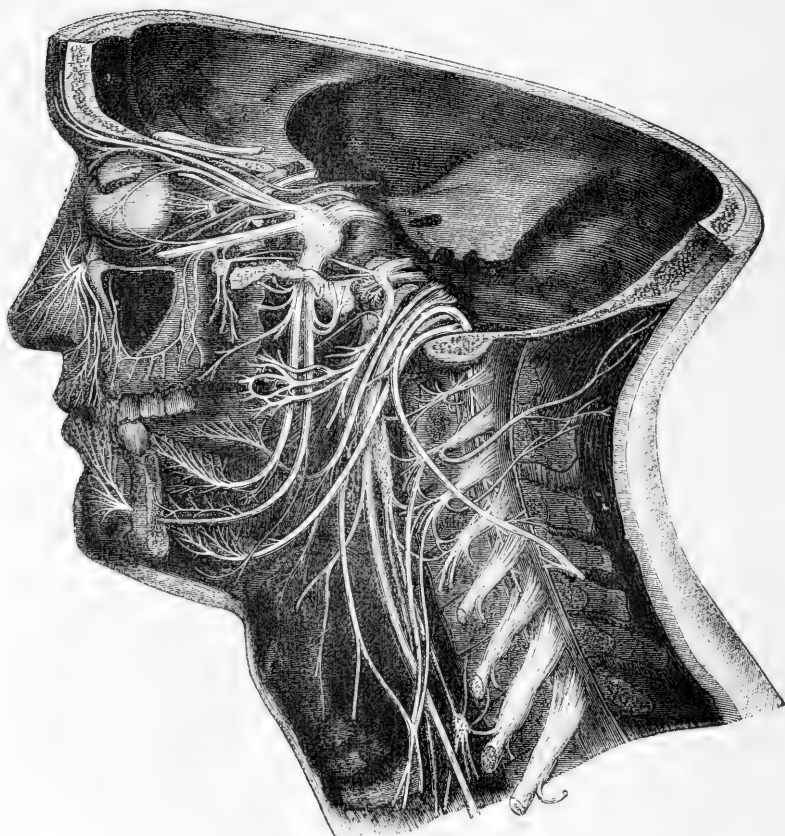
**General distribution.**—The greater number of the cranial nerves are entirely confined in their distribution within the limits of the head; as in the case of the first six pairs and the auditory nerve. Of these, the olfactory, optic, and auditory are restricted to their respective organs of sense: while the third, fourth, and sixth are exclusively motor nerves in connection with the external and internal muscles of the eyeball and the elevator of the upper eyelid. In the remaining nerve, the fifth or trifacial, all the fibres derived from the greater root, and connected with the Gasserian ganglion, are entirely sensory in their function, and constitute the whole of the first and second and the greater part of the third division of the nerve: but the last of these divisions has associated with it the fibres of the lesser or motor root, so as to become in some degree a compound nerve. As a nerve of sensation the trifacial occupies in its distribution the greater part of the head superficially and deeply, excepting the interior of the cranium and that part of the scalp which is situated in the region behind a perpendicular line passing through the external auditory meatus. The muscular distribution of the inferior division of the fifth nerve is chiefly to the muscles of mastication.

Of the remaining nerves, the facial and hypoglossal, both exclusively motor in function, are almost entirely cephalic in their distribution; the facial nerve giving fibres to all the superficial and a few of the deeper muscles of the head and face; and the ninth or hypoglossal supplying the muscles of the tongue. Of the facial, however, a small branch joins one of the cervical nerves in the platysma myoides; and of the ninth, the descending branch supplies in part the muscles of the neck which depress the hyoid bone and larynx.

Of the three parts of the eighth pair, ranked as cranial nerves in consequence of their passing through one of the foramina of the cranium, two, the pneumogastric and spinal accessory, have only a very limited distribution in the head, and furnish nerves in much greater proportion to organs situated in the neck and thorax. The first of these, after giving a small branch to the ear-passages, and supplying nerves to the larynx and pharynx, the trachea, gullet, the lungs and heart, extends into the abdominal cavity as the principal nerve of the stomach. The other, the spinal accessory, which is partially united with the glossopharyngeal and pneumogastric near their origin and thus furnishes some of their motor fibres, is entirely a motor nerve, and is distributed in the sterno-mastoid and trapezius muscles. The glosso-pharyngeal nerve is more strictly confined to the head, supplying branches to the tongue, pharynx, and part of the ear passages.

Fig. 331.—A. SEMIDIAGRAMMATIC VIEW OF A DEEP DISSECTION OF THE CRANIAL NERVES ON THE LEFT SIDE OF THE HEAD (from various authors and from nature). B. EXPLANATORY OUTLINE OF THE SAME. A. T.  $\frac{1}{2}$

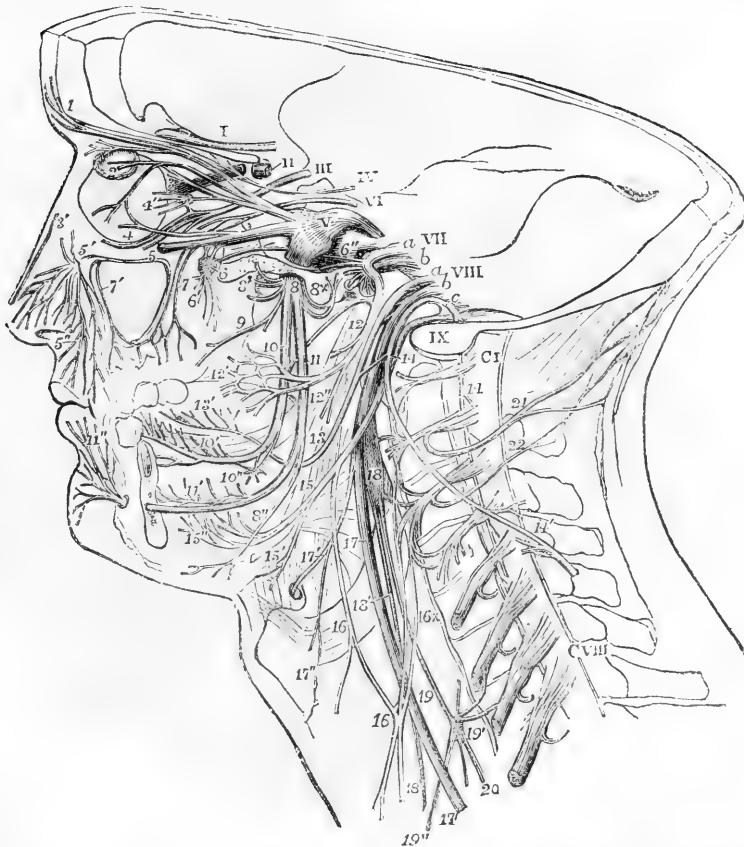Fig. 331, A.



The Roman numerals from I to IX indicate the roots of the several cranial nerves as they lie in or near their foramina of exit. V, is upon the great root of the fifth with the ganglion in front; *a* and *b*, in connection with VII, indicate respectively the facial and auditory nerves; *a*, *b*, and *c*, in connection with VIII, point respectively to the glosso-pharyngeal, pneumo-gastric, and spinal accessory nerves: C I, the suboccipital or first cervical nerve; C VIII, the eighth. The branches or distributed parts of the nerves are marked as follows, viz.:—1, frontal branch of the fifth; 2, lachrymal passing into the gland; 3, nasal passing towards the internal orbital foramen and giving the long twig to the ciliary ganglion (4'); 3', external branch of the internal nasal nerve; 4, lower branch of the third or oculo-motor nerve; 5, the superior maxillary division of the fifth passing into the infraorbital canal; 5', its issue at the infraorbital foramen and distribution as inferior palpebral, lateral nasal, and superior labial nerves (5''); 6, ganglion of Meckel and Vidian nerve passing back from it; 6', palatine and other nerves descending from it; 6'', superior petrosal nerve; 7, posterior superior dental nerves; 7', placed in the antrum maxillare, which has been opened, points to the anterior superior dental nerves; 8, inferior maxillary division of the fifth immediately below the foramen ovale; 8', some of the muscular branches coming from it; 8+, the anterior auricular branch cut short, and above it the small petrosal nerve to join the facial nerve; 9, buccal and internal pterygoid; 10, lingual or gustatory nerve; 10', its distribution to the side and front

of the tongue and to the sublingual glands; 10", the submaxillary ganglion connected with the gustatory nerve; below 10, the chorda tympani passing back from the gustatory to join the facial nerve above 12; 11, inferior dental nerve; 11', the same nerve and part

Fig. 351, B.



of its dental distribution exposed by removal of the jaw; 11", termination of the same as mental and inferior labial nerves; 12, the twigs of the facial nerve to the posterior belly of the digastric and to the stylo-hyoid muscle immediately after its exit from the stylo-mastoid foramen; 12', the temporo-facial division of the facial; 12'', the cervico-facial division; 13, the trunk of the glosso-pharyngeal passing round the stylo-pharyngeus muscle after giving pharyngeal and muscular branches; 13', its distribution on the side and back part of the tongue; 14, the spinal accessory nerve, at the place where it crosses the ninth and gives a communicating branch to the pneumo-gastric and glosso-pharyngeal nerves; 14', the same nerve after having passed through the sterno-mastoid muscle uniting with branches from the cervical nerves; 15, ninth nerve; 15', its twig to the thyro-hyoid muscle; 15'', its distribution in the muscles of the tongue; 16, descendens noni nerve giving a direct branch to the upper belly of the omo-hyoid muscle, and receiving the communicating branches 16+ from the cervical nerve; 17, pneumo-gastric nerve; 17', its superior laryngeal branch; 17'', external laryngeal twig; 18, superior cervical ganglion of the sympathetic nerve, uniting with the upper cervical nerves, and giving at 18' the superficial cardiac nerve; 19, the trunk of the sympathetic; 19', the middle cervical ganglion, uniting with some of the cervical nerves, and giving 19'', the large middle cardiac nerve; 20, continuation of the sympathetic nerve down the neck; 21, great occipital nerve; 22, third occipital.

On the preceding two pages, Fig. 331 is introduced in illustration of the general view of the distribution above given. In this figure the cranium and orbit have been opened up to the depth of the several foramina through which the nerves pass. The greater part of the lower jaw has also been removed on the left side, and the tongue, pharynx, and larynx are partially in view. The occipital bone has been divided by an incision passing down from the occipital tuberosity and through the condyle to the left of the foramen magnum. The cervical vertebræ have been divided to the left of the middle, and the sheath of the spinal cord opened so as to expose the roots of the cervical nerves.

#### OLFACTORY NERVE.

The first or olfactory nerve, as it is usually termed, or *tract*, as it has been more correctly designated, is the special nerve of the sense of smell. It lies on the under (orbital) surface of the frontal lobe of the cerebrum, lodged in a sulcus (olfactory sulcus) to the outer side of and parallel to the longitudinal median fissure. In front the tract swells into an oval enlargement, the *olfactory bulb*, which lies in the same sulcus, and from which small nerves descend, through the cribriform plate, into the nose. The olfactory tract and bulb contain a considerable quantity of grey matter, and, in respect of structure, connections, and development, are to be regarded rather as constituent parts of the cerebrum than as a true nerve,—the true peripheral olfactory nerves taking origin from the lower surface of the bulb. In accordance, however, with the most common practice in anatomical works, the nerve will be here described as arising at the commencement of the tract in the brain. A fuller description of the tract and bulb will be found in the account of the cerebrum (Vol. ii., pp. 536 and 562).

**Surface attachment.**—At its posterior extremity the olfactory tract widens out and is attached to the under surface of the frontal lobe, in front of the anterior perforated space, by means of three roots, named external, middle and internal, which pass in different directions.

The *external* or *long* root consists of a band of medullary fibres, which passes, in the form of a white streak, outwards and backwards along the anterior margin of the perforated space, towards the posterior border of the Sylvian fissure, where it disappears.

The *middle* or *grey* root (tuber olfactorium) is of a pyramidal shape, and consists of grey matter on the surface, which is prolonged from that of the adjacent part of the anterior lobe and of the perforated space. Within it there are white fibres, which are sometimes described as alone constituting the middle root.

The *internal root* (short root, Scarpa), which cannot always be demonstrated, is composed of white fibres which may be traced from the inner and posterior part of the anterior lobe.

**Deep origin.**—This is still doubtful. The outer root has been traced by different observers to the island of Reil, the optic thalamus (Valentin), and to a nucleus in the substance of the temporo-sphenoidal lobe in front of the anterior extremity of the hippocampus (Rolando, Luys, Foville. This agrees also with Ferrier's experimental localisation of the sense of smell in the monkey). The fibres of the inner root have been thought to be connected with the anterior extremity of the gyrus fornicatus, or to cross over to the opposite hemisphere. The fibres of the middle root have been said by some to join those of the inner root, by others to be connected with the corpus striatum.



**Distribution.**—The olfactory nerve is exclusively distributed to the nasal fossæ.

From the under surface of the olfactory bulb about twenty branches proceed through the holes in the cribriform plate of the ethmoid bone, each invested by tubular prolongations of the membranes of the brain. These tubes of membrane vary in the extent to which they are continued on the branches: the offsets of the dura mater sheathe the filaments, and join the periosteum lining the nose; those of the pia mater and arachnoid become blended with the neurilemma of the nerves.

Fig. 332.

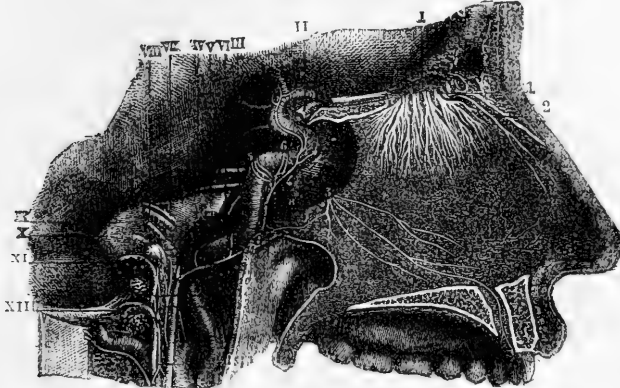


Fig. 332. DISTRIBUTION OF THE OLFACTORY NERVES ON THE SEPTUM OF THE NOSE (from Sappey after Hirschfeld and Leveillé).  $\frac{3}{4}$

The septum is exposed and the anterior palatine canal opened on the right side. I, placed above, points to the olfactory bulb, and the remaining Roman numbers to the roots of the several cranial nerves; 1, the small olfactory nerves as they pass through the cribriform plate; 2, internal or septal twig of the nasal branch of the ophthalmic nerve; 3, naso-palatine nerves. (See fig. 339 for a view of the distribution of the olfactory nerves on the outer wall of the nasal fossa.)

The branches are arranged in three sets. Those of the inner set, lodged for some distance in grooves on the surface of the bone, ramify in the pituitary membrane of the septum; the outer set extend to the upper two spongy bones and the smooth surface of the ethmoid bone in front of these; and the middle set, which are very short, are confined to the roof of the nose. The distribution of the olfactory nerve is confined to the upper part of the nasal fossa; none of the branches reach the lower spongy bone.—(See Anatomy of the Nose.)

#### OPTIC NERVE.

The second pair or optic nerves of the two sides meet each other at the optic commissure (chiasma), where they partially decussate. From this point they may be traced backwards round the crura cerebri, under the name of the optic tracts.

**Surface attachment.**—Each optic tract arises from the posterior part of the optic thalamus and the corpora geniculata. As it leaves the under part of the thalamus, it makes a sudden bend forwards and then runs obliquely across the under surface of the cerebral peduncle,

in the form of a flattened band, which is attached by its anterior surface to the peduncle; after this, becoming more nearly cylindrical, it adheres to the tuber cinereum, from which, and from the lamina cinerea, it is said to receive an accession of fibres, and thus reaches the optic commissure.

**Deep origin.**—The fibres may be traced into the substance of the optic thalamus and the corpora geniculata, and to the anterior of the corpora quadrigemina. The fibres which come from the anterior corpus quadrigeminum arise from the cells of that body. Those connected with the internal and external corpus geniculatum are in part connected with the cells of those bodies, in part pass through them to reach the optic thalamus. The fibres which pass into the thalamus beneath the inner corpus geniculatum, between it and the crus (and have been described as a middle root of the tract), arise, according to Meynert, from the cells of the lower stratum of the thalamus. The fibres which arise in the base are derived from the lamina cinerea and also from a “basal optic ganglion,” which lies on the outer side of the tuber cinereum, and sends fibres to the optic nerve of the same side.

**Course and distribution.**—In the *commissure*, or *chiasma*, the nerve fibres of the two sides undergo a partial decussation. The outer fibres of each tract continue onwards to the eye of the same side: the inner fibres cross over to the opposite side; and fibres have been described as running from one optic tract to the other along the posterior part of the commissure, while others pass between the two optic nerves in its anterior part (Mayo). The outer fibres of each tract which do not decussate are much less numerous than those which cross to the opposite side. The decussating fibres are arranged in alternate layers.

The view before stated is that most commonly given as to the structure of the commissure; but it is right to state that its accuracy has been called in question by several observers who hold, both on anatomical and physiological grounds, that all the fibres from one tract cross into the optic nerve of the opposite side. The point appears to be still undecided. In many fishes the optic nerves do not unite in a commissure but merely cross, each to the side opposite to that of its origin. (See Waller, Proc. Roy. Soc. vol. viii, Biesiadecki, Wien. Sitzungsab. 1861, p. 86, and Michel, Archiv für Ophthalm. 1873, p. 59.)

In front of the commissure, the nerve diverges from its fellow and acquires greater firmness. It enters the foramen opticum, by which it reaches the orbit.

Within the orbit it forms a cylindrical trunk, thick and strong, with a uniform surface. On dissection it is seen to consist of a number of separate bundles of nerve fibres, imbedded in tough fibrous tissue prolonged from the dura mater, and perforated in the centre by the small arteria centralis retinae, which passes into it soon after it enters the orbit. It is surrounded by the recti muscles, and, entering the eyeball posteriorly a little to the inside of its middle, it pierces the sclerotic and choroid coats, and expands in the retina.—(See the Anatomy of the Eye.)

### THIRD PAIR OF NERVES.

This nerve, the common motor nerve of the eyeball (*motorius oculi*), gives branches to all the muscles of the orbit, with the exception of the superior oblique and external rectus.

**Surface attachment.**—The nerve is attached to the inner surface of the crus cerebri in the interpeduncular space, immediately in front of the pons. Each nerve consists of a number of funiculi which arise in an oblique line from the surface.

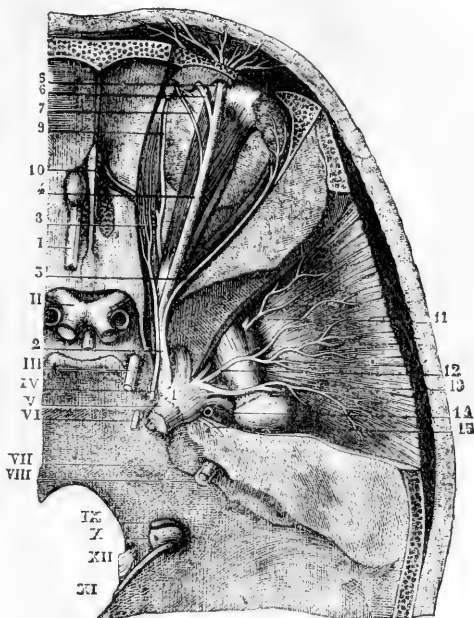
**Deep origin.**—The fibres, diverging, pass backwards through the substance of the crus, some through the locus niger, some through the tegmental nucleus, to reach the grey matter in which the majority of them end. This is a collection of large multipolar nerve-cells, lying on each side close to the middle line, beneath the thick layer of grey matter which forms the floor of the aqueduct of Sylvius, and below the corpora quadrigemina. The anterior portion of the nucleus, beneath the anterior of the corpora quadrigemina, is that in which the fibres of the third nerve end, the posterior portion giving origin to some of the fibres of the fourth nerve.

A few fibres are said to run downwards in the pons, among its longitudinal fibres.

Fig. 333.—VIEW FROM ABOVE OF THE UPPERMOST NERVES OF THE ORBIT, THE GASSERIAN GANGLION, &c. (from Sappey after Hirschfeld and Leveillé).

Fig. 333.

I, the olfactory tract passing forwards into the bulb; II, the commissure of the optic nerves; III, the oculo-motor; IV, the trochlear nerve; V, the greater root of the fifth nerve, a small portion of the lesser root is seen below it; VI, the sixth nerve; VII, facial; VIII, auditory; IX, glosso-pharyngeal; X, pneumo-gastric; XI, spinal accessory; XII, hypoglossal; 1, the Gasserian ganglion; 2, ophthalmic nerve; 3, lachrymal branch; 4, frontal; 5, external frontal or supraorbital; 6, internal frontal; 7, supra-trochlear branch; 8, nasal nerve; 9, infratrochlear branch; 10, internal nasal passing through the internal orbital foramen; 11, anterior deep temporal proceeding from the buccal nerve; 12, middle deep temporal; 13, posterior deep temporal arising from the masseteric; 14, origin of the temporo-auricular; 15, great superficial petrosal nerve.



**Course and distribution.**—Cylindrical and firm, like the other motor nerves, the third nerve, quitting the investment of the arachnoid membrane, pierces the inner layer of the dura mater close to the posterior clinoid process, and proceeds towards the sphenoidal fissure, lying in the external fibrous boundary of the cavernous sinus.

The third nerve divides near the orbit into two parts, which are continued into that cavity between the heads of the external rectus muscle,

and are separated one from the other by the nasal branch of the ophthalmic nerve.

The *upper*, the smaller part, is directed inwards over the optic nerve to the superior rectus muscle of the eye and the elevator of the eyelid, to both of which muscles it furnishes branches.

The *lower* and larger portion of the nerve separates into three branches; of these one reaches the inner rectus; another the lower rectus; and the third, the longest of the three, runs onwards between the lower and the outer rectus, and terminates below the ball of the eye in the inferior oblique muscle. The last-mentioned branch is connected with the lower part of the lenticular ganglion by a short thick cord, and gives two filaments to the lower rectus muscle.

The several branches of the third nerve enter the muscles to which they are distributed on the surface which in each is turned towards the eyeball.

**Varieties.**—A branch of the third nerve has been found supplying the external rectus in a case in which the sixth nerve was wanting (Generali, quoted by Henle). The branch to the inferior oblique muscle was seen by Arnold to pass through the lower part of the lenticular ganglion; and by Henle to pierce the inferior rectus.

In the outer wall of the sinus the third nerve is said to be connected with the first division of the fifth nerve, and with the cavernous plexus of the sympathetic.

**POSITION OF CERTAIN NERVES AT THE CAVERNOUS SINUS, AND AS THEY ENTER THE ORBIT.**—There are several nerves, besides the third, placed close together at the cavernous sinus, and entering the orbit through the sphenoidal fissure. To avoid repetition hereafter, the relative positions of these nerves may now be described. The nerves thus associated are the third, the fourth, the ophthalmic divisions of the fifth, and the sixth.

*At the cavernous sinus.*—In the dura mater which bounds the cavernous sinus on the outer side, the third and fourth nerves and the ophthalmic division of the fifth are placed, as regards one another, in their numerical order both from above downwards and from within outwards. The sixth nerve is placed separately from the others close to the carotid artery, on the floor of the sinus and internally to the fifth nerve. Near the sphenoidal fissure, through which they enter the orbit, the relative position of the nerves is changed, the sixth nerve being here close to the rest, and their number is augmented by the division of the third and the ophthalmic nerves—the former into two, the latter into three parts.

*In the sphenoidal fissure.*—The fourth and the frontal and lachrymal branches of the fifth, which are here higher than the rest, lie on the same level, the fourth being the nearest to the inner side, and enter the orbit above the muscles. The remaining nerves pass between the heads of the outer rectus muscle, in the following order from above downwards; the upper division of the third, the nasal branch of the fifth, the lower division of the third, and, lowest of all, the sixth.

#### FOURTH PAIR OF NERVES.

The fourth (nervus trochlearis, n. patheticus) is the smallest of the cranial nerves, and is distributed entirely to the upper oblique muscle of the orbit.

**Surface attachment.**—Each nerve appears at the outer side of the

crus cerebri immediately in front of the pons. Each nerve may be traced backwards round the peduncle to a place below the corpora quadrigemina where it arises from the upper part of the valve of Vieussens.

**Deep origin.**—Entering the substance of the valve the fibres of each nerve separate into three groups, which follow different directions.

1. The fibres of an anterior group pass obliquely forwards and upwards in the wall of the aqueduct of Sylvius to end in the posterior part of the nucleus beneath the floor of the aqueduct, which is common to the third and fourth nerves.

2. Other descending fibres pass down on the outer side of the locus ceruleus to the neighbourhood of the nucleus of the fifth nerve.

3. The fibres of a third group pass transversely inwards in the substance of the velum, decussating with those of the opposite side, and join the ascending or descending fibres of the opposite nerve

Fig. 334.—VIEW FROM ABOVE OF THE MOTOR NERVES OF THE EYEBALL AND ITS MUSCLES (after Hirschfeld and Leveillé, altered.) (A. T.)

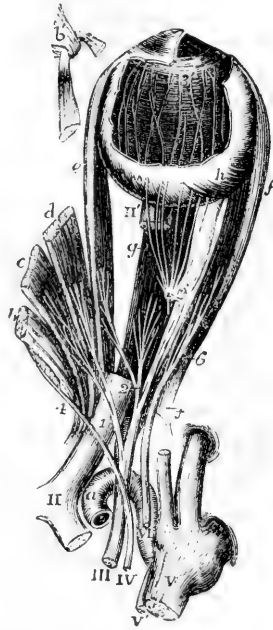
The ophthalmic division of the fifth pair has been cut short: the attachment of the muscles round the optic nerve has been opened up, and the three upper muscles turned towards the inner side, their anterior parts being removed; a part of the optic nerve is cut away to show the inferior rectus: and a part of the sclerotic coat and cornea is dissected off showing the iris, zona ciliaris, and choroid coat, with the ciliary nerves.

*a*, the upper part of the internal carotid artery emerging from the cavernous sinus; *b*, the superior oblique muscle; *b'*, its anterior part passing through the pulley; *c*, the levator palpebræ superioris; *d*, the superior rectus; *e*, the internal rectus; *f*, the external rectus; *f'*, its upper tendon turned down; *g*, the inferior rectus; *h*, insertion of the inferior oblique muscle.

II, the commissure of the optic nerve; II', part of the optic nerve entering the eyeball; III, the common oculo-motor; IV, the fourth or trochlear nerve; V, the greater root of the trigeminus; V', the smaller or motor root; VI, the abducent nerve; 1, the upper division of the third nerve separating from the lower and giving twigs to the levator palpebræ and superior rectus; 2, the branches of the lower division supplying the internal and inferior recti muscles; 3, the long branch of the same nerve proceeding forward to the inferior oblique muscle, and close to the number 3, the short thick branch to the ciliary ganglion: this ganglion is also shown, receiving from behind the slender twig from the nasal nerve, which has been cut short, and giving forward some of its ciliary nerves, which pierce the sclerotic coat; 3', marks the termination of some of these nerves in the ciliary muscle and iris after having passed between the sclerotic and choroid coats; 4, the distribution of the trochlear nerve to the upper surface of the superior oblique muscle; 6, the abducent nerve passing into the external rectus.

**Course and distribution.**—From the remoteness of its place of origin, the part of this nerve within the skull is longer than that of any other cranial nerve. It enters an aperture in the free border of the tentorium, outside that for the third nerve, and near the posterior

Fig. 334.



clinoid process. Continuing onwards through the outer wall of the cavernous sinus, the fourth nerve enters the orbit by the sphenoidal fissure, and above the muscles. Its position with reference to other nerves in this part of its course has been already described.

In the orbit, the fourth nerve inclines inwards above the muscles, and enters finally the upper oblique muscle at its orbital surface.

While in its fibrous canal in the outer wall of the sinus, the fourth nerve is joined by filaments of the sympathetic, and not unfrequently is blended with the ophthalmic division of the fifth. Bidder states that three or more small filaments of this nerve extend to the tentorium as far as the lateral sinus; and has figured one as joining the sympathetic on the carotid artery. (Neurologische Beobachtungen, von F. H. Bidder. Dorpat, 1836.)

#### FIFTH PAIR OF NERVES.

The fifth, or trifacial nerve (nerv. trigeminus), the largest cranial nerve, resembles a spinal nerve, in respect that it consists of a motor and a sensory part, and that the sensory fibres pass through a ganglion while the motor do not. Its sensory division, which is much the larger, imparts common sensibility to the face and the fore part of the head, as well as to the eye, the nose, the ear, and the mouth; and endows the fore part of the tongue with the powers of both touch and taste. The motor root supplies chiefly the muscles of mastication.

**Surface attachment.**—The nerve arises from the side of the pons Varolii, where the transverse fibres of the latter are prolonged into the middle crus cerebelli, considerably nearer to the upper than to the lower border of the pons. The smaller root is at first concealed by the larger, and is placed a little higher up, there being often two or three cross fibres of the pons between them. On separating the two roots, the lesser one is seen to consist of a very few funiculi. In the larger root the funiculi are numerous, amounting sometimes to nearly a hundred.

**Deep origin.**—The fibres of the *large root* pass backwards inwards and slightly downwards as a compact bundle, towards the outer part of the floor of the fourth ventricle. The chief nucleus, in which most of the fibres end, is situated to the outer side of the trunk, and consists of a collection of nerve cells, continuous below with the grey tubercle of Rolando (caput cornu posterioris). The cells are small and arranged in clusters, separated by the delicate fasciculi of origin of the nerve. In front of this nucleus a number of *descending fibres* pass down, mingled with grey matter, to the lower part of the medulla oblongata.

Some fibres of the nerve are said to join the middle peduncle of the cerebellum; others pass inwards beneath the floor of the fourth ventricle, decussate at the raphé, and (according to Meynert) ascend on the opposite side of the medulla.

The *small root* passes in a curve, with the convexity forwards, to reach the neighbourhood of the nucleus of the larger root. Its fibres arise from a group of large nerve cells, situated close to the outer angle of the fourth ventricle, to the inner side of the fibres of the nerve. A prolongation from this nucleus extends down the medulla, as far as the olivary bodies, receding from the surface, and to it, below, some fibres of origin of the facial nerve are traced.

**Course.**—The roots of the fifth nerve, after emerging from the surface of the encephalon, are directed forwards, side by side, to the middle fossa of the skull, through a recess in the dura mater on the

summit of the petrous part of the temporal bone. Here the larger root alters in appearance : its bundles of fibres diverge and enter the Gasserian ganglion. The fasciculi divide and unite in the expanded part of the nerve, so as to form a plexiform network. The smaller root passes inside and beneath the ganglion, without its nerve-fibres being incorporated in any way with it, and joins outside the skull the lowest of the three trunks which issue from the ganglion.

Fig. 335.—GENERAL PLAN OF THE BRANCHES OF THE FIFTH PAIR (after a sketch by Charles Bell).  $\frac{1}{4}$

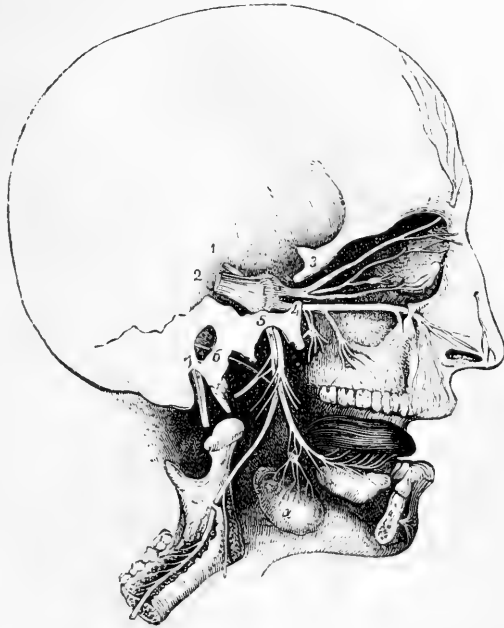
1, lesser root of the fifth pair ; 2, greater root passing forwards into the Gasserian ganglion ; 3, placed on the bone above the ophthalmic nerve, which is seen dividing into the supra-orbital, lachrymal, and nasal branches, the latter connected with the ophthalmic ganglion ; 4, placed on the bone close to the foramen rotundum, marks the superior maxillary division, which is connected below with the sphenopalatine ganglion, and passes forwards to the infraorbital foramen ; 5, placed on the bone over the foramen ovale, marks the submaxillary nerve, giving off the anterior auricular and muscular branches, and continued by the inferior dental to the lower jaw, and by the gustatory

to the tongue ; a, the submaxillary gland, the submaxillary ganglion placed above it in connection with the gustatory nerve ; 6, the chorda tympani ; 7, the facial nerve issuing from the stylo-mastoid foramen.

The *ganglion of the fifth nerve* or *Gasserian ganglion* (ganglion semilunare), occupies a depression on the upper part of the petrous portion of the temporal bone, near the apex, and is somewhat crescentic in form, the convexity being turned forwards. It is flattened and striated on the surface. On its inner side the ganglion is joined by filaments from the carotid plexus of the sympathetic nerve, and, according to some anatomists, it furnishes from its back part filaments to the dura mater.

**Distribution.**—From the fore part, or convex border of the Gasserian ganglion, proceed the three large divisions of the nerve. The highest (first or ophthalmic trunk) enters the orbit ; the second, the upper maxillary nerve, is continued forwards to the face, below the orbit ; and the third, the lower maxillary nerve, is distributed chiefly to the external ear, the tongue, the lower teeth, and the muscles of mastication. The first two trunks proceed exclusively from the ganglion

Fig. 335.



and are entirely sensory, while the third or inferior maxillary trunk, receiving a considerable part from the ganglion, has associated with it also the whole of the fibres of the motor root, and thus distributes both motor and sensory branches.

#### I.—OPHTHALMIC NERVE.

The ophthalmic nerve, or first division of the fifth nerve, the smallest of the three offsets from the Gasserian ganglion, is somewhat flattened, about an inch in length, and is directed forwards and upwards to the sphenoidal fissure, where it ends in branches which pass through the orbit to the surface of the head and to the nasal fossæ. In the skull it is contained in the process of the dura mater bounding externally the cavernous sinus, and is joined by filaments from the cavernous plexus of the sympathetic: according to Arnold, it gives recurrent branches to the tentorium cerebelli. It also frequently communicates by a considerable branch with the fourth nerve.

**BRANCHES.**—Near the orbit the ophthalmic nerve furnishes from its inner side the nasal branch, and then divides into the frontal and lachrymal branches. These branches are transmitted separately through the sphenoidal fissure, and are continued through the orbit (after supplying some filaments to the eye and the lachrymal gland) to their final distribution in the nose, the eyelids and the muscles and integument of the forehead.

**Lachrymal branch.**—The lachrymal branch is external to the frontal at its origin, and is contained in a separate tube of dura mater. In the orbit it passes along the outer part, above the muscles, to the outer and upper angle of the cavity. Near the lachrymal gland, the nerve has a connecting filament with the orbital branch of the superior maxillary nerve; and when in close apposition with the gland, it gives many filaments to that body and to the conjunctiva. Finally, the lachrymal nerve penetrates the palpebral ligament externally, and ends in the upper eyelid, the terminal ramifications being joined by twigs from the facial nerve.

**Varieties.**—Turner records a case in which on one side the lachrymal nerve was absent, and the gland was supplied by a twig from the orbital branch of the superior maxillary; on the other side the lachrymal was small, and was supplemented by a branch from the orbital. (*Journal of Anat.*, vol. vi. p. 101.)

In consequence of the junction which occurs between the ophthalmic trunk of the fifth and the fourth nerve, the lachrymal branch sometimes appears to be derived from both these nerves. Swan considers this the usual condition of the lachrymal nerve. (“A demonstration of the Nerves of the Human Body,” page 36. London, 1834.)

**Frontal branch.**—The frontal branch, the largest division of the ophthalmic, lies, like the preceding nerve, above the muscles in the orbit, being situated between the elevator of the upper eyelid and the periosteum. About midway forwards in the orbit, the nerve divides into two branches, supratrochlear and supraorbital.

*a.* The *supratrochlear branch* (internal frontal) is prolonged to the inner angle of the orbit, close to the point at which the pulley of the upper oblique muscle is fixed to the orbit. Here it gives downwards a filament to connect it with the infratrochlear branch of the nasal nerve, and issues from the cavity between the orbicular muscle of the lids and the bone. In this position filaments are distributed to the upper eyelid.



The nerve next pierces the orbicularis palpebrarum and occipito-frontalis muscles, furnishing twigs to these muscles and the corrugator supercilii, and after ascending on the forehead, ramifies in the integument.

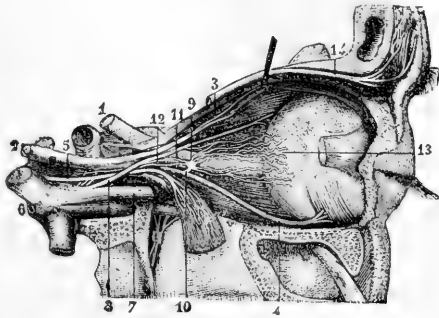
b. The *supraorbital branch* (external frontal) passes through the supraorbital notch to the forehead, and ends in muscular, cutaneous, and pericranial branches; while in the notch it distributes *palpebral* filaments to the upper eyelid.

The *muscular branches* referred to are comparatively small, and supply the corrugator of the eyebrow, the occipito-frontalis, and the orbicular muscle of the eyelids, joining the facial nerve in the last muscle. The *cutaneous branches*, among which two (outer and inner) may be noticed as the principal, are placed at first beneath the occipito-frontalis. The outer one, the larger, perforates the tendinous expansion of the muscle, and ramifies in the scalp as far back as the lambdoidal suture. The inner branch reaches the surface sooner than the preceding nerve, and ends in the integument over the parietal bone. The *pericranial branches* arise from the cutaneous nerve beneath the muscle, and end in the pericranium covering the frontal and parietal bones.

Fig. 336.—NERVES OF THE ORBIT FROM THE OUTER SIDE (from Sappey after Hirschfeld and Leveillé).  $\frac{3}{4}$

The external rectus muscle has been divided and turned down: 1, the optic nerve; 2, the trunk of the third nerve; 3, its upper division passing into the levator palpebræ and superior rectus; 4, its long lower branch to the inferior oblique muscle; 5, the sixth or abducent nerve joined by twigs from the sympathetic; 6, the Gasserian ganglion; 7, ophthalmic nerve; 8, its nasal branch; 9, the ophthalmic ganglion; 10, its short or motor root; 11, long sensory root from the nasal nerve; 12, sympathetic twig from the carotid plexus; 13, ciliary nerves passing into the eyeball; 14, frontal branch of the ophthalmic nerve.

Fig. 336.



**Nasal branch.**—The nasal branch (oculo-nasalis), separating from its parent trunk in the wall of the cavernous sinus, enters the orbit between the heads of the outer rectus. It then inclines inwards over the optic nerve, beneath the elevator of the upper eyelid and the superior rectus muscle, to the inner wall of the orbit, through which it passes by the anterior internal orbital foramen. In this oblique course across the orbit it furnishes a single filament to the ophthalmic ganglion, two or three (long ciliary) directly to the eyeball; and, at the inner side of the cavity, a considerable branch (infratrochlear), which issues from the orbit at the fore part.

On leaving the orbit the nasal nerve is directed transversely inwards to the upper surface of the cribriform plate of the ethmoid bone, and passing forwards in a groove at its outer edge, within the cranium, descends by a special aperture, close to the crista galli at the fore part of the plate, to the roof of the nasal fossa, where it divides into two branches, one of which (external or superficial nasal) reaches the integument of the side of the nose, and the other (ramus septi) ramifies in the pituitary membrane.

a. The *branch to the ophthalmic ganglion* (*radix longa ganglii ciliaris*), very slender, and about half an inch long, arises generally between the heads of the external rectus: it lies on the outer side of the optic nerve, and enters the upper and back part of the ophthalmic ganglion, constituting its *long root*.

This small branch is sometimes joined by a filament from the cavernous plexus of the sympathetic, or from the upper branch of the third nerve.

b. The *long ciliary nerves*, two or three in number, are situated on the inner side of the optic nerve; they join one or more of the nerves from the ophthalmic ganglion (*short ciliary*), and after perforating the sclerotic coat of the eye, are continued between it and the choroid to the ciliary muscle, the cornea, and the iris.

c. The *infratrochlear branch* runs forwards along the inner side of the orbit below the superior oblique muscle, and parallel to the supratrochlear nerve, from which it receives, near the pulley of that muscle, a filament of connection. The branch is then continued below the pulley to the inner angle of the eye, and ends in filaments which supply the orbicular muscle of the lids, the caruncula, and the lachrymal sac, as well as the integument of the eyelids and side of the nose.

In the cavity of the nose the nasal nerve ends by dividing into the following branches.

d. The *branch to the nasal septum* extends to the lower part of the partition between the nasal fossæ, supplying the pituitary membrane near the fore part of the septum.

e. The *superficial branch* (*externus seu lateralis*) descends in a groove on the inner surface of the nasal bone; and after leaving the nasal cavity between that bone and the lateral cartilage of the nose, it is directed downwards to the tip of the nose, beneath the compressor naris muscle. While within the nasal fossa, this branch gives two or three filaments to the fore part of its outer wall, which extend as far as the lower spongy bone. The cutaneous part is joined by a filament of the facial nerve.

**Varieties.**—The frontal may give off a long slender accessory infra-trochlear (Turner, loc. cit.). Branches of the nasal have been described as entering the levator palpebræ superioris. Luschka describes, also, a *spheno-ethmoidal* branch of the nasal, which passes through the posterior ethmoidal foramen and ramifies in the mucous membrane of the sphenoidal sinus, and of the posterior ethmoidal cells.

**SUMMARY.**—The first division of the fifth nerve is altogether sensory in function. It furnishes branches to the ball of the eye and the lachrymal gland; to the mucous membrane of the nose and eyelids; to the integument of the nose, the upper eyelid, the forehead, and the upper part of the hairy scalp; and to the muscles above the middle of the circumference of the orbit. Some of the cutaneous and muscular filaments join branches of the facial nerve, and the nerve itself communicates with the sympathetic.

### Ophthalmic Ganglion.

There are four small ganglia connected with the divisions of the fifth nerve: the ophthalmic ganglion with the first, Meekel's ganglion with the second, and the otic and submaxillary ganglia with the third. These ganglia, besides receiving branches from the sensory part of the fifth, are each connected with a motor nerve from the third, the fifth, or the facial, and with twigs from the sympathetic; and the nerves thus joining the ganglia are named their roots.

The *ophthalmic* or *lenticular* ganglion (*gang. semilunare, vel ciliare*) serves as a centre for the supply of nerves—motor, sensory, and sympathetic—to the eyeball. It is a small reddish body, compressed laterally and somewhat four-sided. It is situated at the back of the orbit,

between the outer rectus muscle and the optic nerve, and generally in contact with the ophthalmic artery; it is joined behind by branches from the fifth, the third, and the sympathetic nerves; while from its fore part proceed the ciliary nerves to the eyeball.

**UNION OF THE GANGLION WITH NERVES: ITS ROOTS.**—The posterior border of the ganglion receives three nerves. One of these, the *long root*, a slender filament from the nasal branch of the ophthalmic trunk, joins the upper part of this border. Another branch, the *short root*, much thicker and shorter than the preceding, and sometimes divided into two parts, is derived from the branch of the third nerve to the inferior oblique muscle, and is connected with the lower part of the ganglion. The *third root* is a very small nerve which emanates from the cavernous plexus of the sympathetic, and reaches the ganglion with the long upper root: these two nerves are sometimes conjoined before reaching the ganglion. Other roots have been assigned to the ganglion. (Valentin, in Müller's Archiv. for 1840.) The ganglion is sometimes very small, probably from the nerve cells being distributed along the nerves which are connected with it.

**BRANCHES OF THE GANGLION.**—From the fore part of the ganglion arise ten or twelve delicate filaments—the *short ciliary nerves*. These nerves are disposed in two fasciculi, arising from the upper and lower angles of the ganglion, and they run forwards, one set above, the other below the optic nerve, the latter being the more numerous. They are accompanied by filaments from the nasal nerve (long ciliary), with which some are joined. Having entered the eyeball by apertures in the back part of the sclerotic coat, the nerves are lodged in grooves on its inner surface; and at the ciliary muscle, which they pierce (some filaments supplying it and the cornea), they turn inwards and ramify in the iris.

## II. SUPERIOR MAXILLARY NERVE.

The superior maxillary nerve, or second division of the fifth cranial nerve, is intermediate in size between the ophthalmic and the inferior maxillary trunks.

It commences at the middle of the Gasserian ganglion, and, passing horizontally forwards, soon leaves the skull by the foramen rotundum of the sphenoid bone. The nerve then crosses the speno-maxillary fossa, and enters the infraorbital canal of the upper maxilla, by which it is conducted to the face. After emerging from the infraorbital foramen, it terminates beneath the elevator of the upper lip in branches, which spread out to the side of the nose, the eyelid, and the upper lip.

**BRANCHES.**—Near its origin a recurrent branch passes to the dura mater and middle meningeal artery. In the speno-maxillary fossa a temporo-malar branch ascends from the superior maxillary nerve to the orbit, and two speno-palatine branches descend to join Meckel's ganglion. Whilst the nerve is in contact with the upper maxilla, it furnishes two posterior dental branches on the tuberosity of the bone, and an anterior dental branch at the fore part. On the face are the terminal branches already indicated.

**Orbital branch.**—The orbital or temporo-malar branch, a small cutaneous nerve, enters the orbit by the speno-maxillary fissure, and divides into two branches (temporal and malar), which pierce the malar bone, and are distributed to the temple and the prominent part of the cheek.

*a.* The *temporal branch* is contained in an osseous groove or canal in the outer wall of the orbit, and leaves this cavity by a foramen in the malar bone. When about to traverse the bone, it is joined by a communicating filament (in some cases, by two filaments) from the lachrymal nerve. The nerve is then inclined upwards in the temporal fossa between the bone and the temporal muscle, and perforating the aponeurosis over the muscle an inch above the zygoma, ends in cutaneous filaments over the temple. The cutaneous ramifications are united with the facial nerve, and sometimes with the auriculo-temporal branch of the third division of the fifth.

*b.* The *malar branch* lies at first in the loose fat in the lower angle of the orbit, and is continued to the face through a foramen in the fore part of the malar bone, where it is frequently divided into two filaments. It is distributed to the skin over the malar bone. In the prominent part of the cheek this nerve communicates with the facial nerve.

Fig. 337.

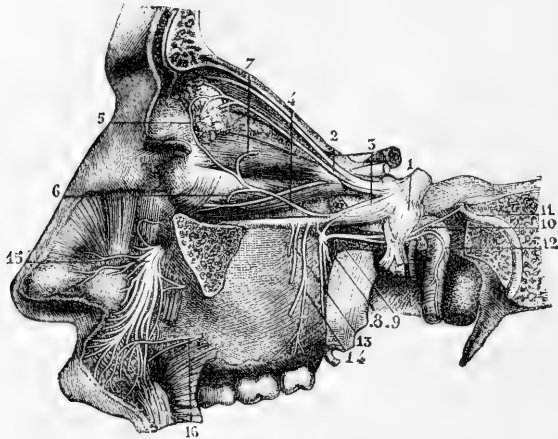


Fig. 337.—SUPERIOR MAXILLARY NERVE AND SOME OF THE ORBITAL NERVES (from Sappey after Hirschfeld and Leveillé). <sup>3</sup>

1, the Gasserian ganglion; 2, lachrymal branch of the ophthalmic nerve; 3, trunk of the superior maxillary nerve; 4, its orbital branch, joining, at 5, the palpebral twig of the lachrymal; 6, origin of its malar twig; 7, its temporal twig; 8, sphenopalatine ganglion; 9, Vidian nerve; 10, its upper branch or great superficial petrosal nerve proceeding to join the facial nerve (11); 12, union of the lower branch of the Vidian nerve with the carotid branch of the sympathetic; 13, 14, posterior dental nerves; 15, terminal branches of the infraorbital nerves ramifying on the side of the nose and upper lip; 16, a branch of the facial uniting with some of the twigs of the infraorbital.

**Posterior dental branches.**—The posterior dental branches, two in number, are directed downwards and outwards over the back part and tuberosity of the maxillary bone.

One of the branches enters a canal in the bone by which it is conducted to the teeth, and gives forwards a communicating filament to the anterior dental nerve. It ends in filaments to the molar teeth and the lining membrane of the maxillary sinus, and near the teeth joins a second time with the anterior dental nerve.

The *anterior* of the two branches, lying on the surface of the bone, is distributed to the gums of the upper jaw and to the buccinator muscle.

**Anterior dental branch.**—The anterior dental branch, leaving the trunk of the nerve at a varying distance behind its exit from the infra-orbital foramen, enters a special canal in front of the antrum of Highmore. In this canal it receives the communicating filament from the posterior dental nerve, and divides into two branches, which furnish offsets for the front teeth.

(a) The *inner* branch supplies the incisor and canine teeth. Filaments from this nerve enter the lower meatus of the nose, and end in the membrane covering the lower spongy bone. Also above the root of the canine tooth, it unites with a branch of the posterior nasal nerve from Meckel's ganglion, and forms with it a small thickening, the *ganglion of Bochdalek*, from which branches are described as descending to the alveolar process and gums of the incisor and canine teeth. (See Hyrtl's *Lehrbuch*, p. 804.) It is probable, however, that this enlargement contains no nerve cells, and is a minute plexus rather than an actual ganglion.

(b) The *outer* branch gives filaments to the bicuspid teeth, and is connected with the posterior dental nerve.

**Infraorbital branches.**—The infraorbital branches, large and numerous, spring from the end of the superior maxillary nerve beneath the elevator muscle of the upper lip, and are divisible into palpebral, nasal, and labial sets.

Fig. 338.

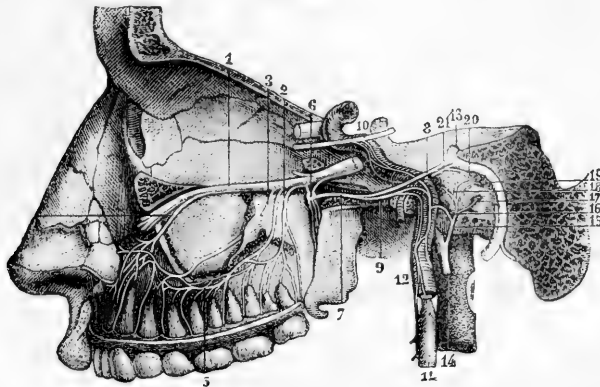


Fig. 338.—DEEP VIEW OF THE SPHENO-PALATINE GANGLION, AND ITS CONNECTIONS WITH OTHER NERVES, &c. (from Sappey after Hirschfeld and Leveillé). 3

1, superior maxillary nerve; 2, posterior superior dental; 3, second posterior dental branch; 4, anterior dental; 5, union of these nerves; 6, sphenopalatine ganglion; 7, Vidian nerve; 8, its great superficial petrosal branch; 9, its carotid branch; 10, a part of the sixth nerve, receiving twigs from the carotid plexus of the sympathetic; 11, superior cervical sympathetic ganglion; 12, its carotid branch; 13, trunk of the facial nerve near the knee or bend at the hiatus Fallopii; 14, glosso-pharyngeal nerve; 15, anastomosing branch of Jacobson; 16, twig uniting it to the sympathetic; 17, filament to the fenestra rotunda; 18, filament to the Eustachian tube; 19, filament to the fenestra ovalis; 20, external deep petrosal nerve uniting with the lesser superficial petrosal; 21, internal deep petrosal twig uniting with the great superficial petrosal.

a. The *palpebral branch* (there are sometimes two branches) turns upwards to the lower eyelid in a groove or canal of the bone, and supplies the orbicular muscle; it ends in filaments which are distributed to the eyelid in its entire breadth. At the outer angle of the eyelids this nerve is connected with the facial nerve.

b. The *nasal branches*, directed inwards to the muscles and integument of the side of the nose, communicate with the cutaneous branch of the nasal nerve.

c. The *labial*, the largest of the terminal branches of the upper maxillary

nerve, and three or four in number, are continued downwards beneath the proper elevator of the upper lip. Ramifying as they descend, these nerves are distributed to the integument, the mucous membrane of the mouth, the labial glands, and the muscles of the upper lip.

Near the orbit the infraorbital branches of the superior maxillary nerve are joined by considerable branches of the facial nerve, the union between the two being named *infraorbital plexus*.

### Spheno-Palatine Ganglion.

The spheno-palatine ganglion, frequently named Meckel's or the nasal ganglion, is deeply placed in the spheno-maxillary fossa, close to the spheno-palatine foramen. It receives the two spheno-palatine branches which descend together from the superior maxillary nerve as it crosses the top of the fossa. It is of greyish colour, triangular in form, and convex on the outer surface. Its diameter is about the fifth of an inch. The grey or ganglionic substance does not involve all the fibres of the spheno-palatine branches of the upper maxillary nerve, but is placed at the back part, at the point of junction of the sympathetic or deep branch of the Vidian, so that the spheno-palatine nerves proceeding to the nose and palate pass to their destination without being incorporated with the ganglionic mass.

Branches proceed from the ganglion upwards to the orbit, downwards to the palate, inwards to the nose, and backwards through the Vidian and pterygo-palatine canals.

ASCENDING BRANCHES.—These consist of three or more very small twigs, which reach the orbit by the spheno-maxillary fissure, and are distributed to the periosteum.

Bock describes a branch ascending from the ganglion to the sixth nerve; Tiedemann, one to the lower angle of the ophthalmic ganglion. The filaments described by Hirzel as ascending to the optic nerve, most probably join the ciliary twigs which surround that nerve.

DESCENDING BRANCHES.—These are three in number,—the large, the small, and the external palatine nerves, and are continued chiefly from the spheno-palatine branches of the superior maxillary. They are distributed to the tonsil, the hard and soft palate, the gums, and the mucous membrane of the nose.

*a.* The *larger* or *anterior palatine* nerve descends in the palato-maxillary canal, and divides in the roof of the mouth into branches, which are received into grooves in the hard palate, and extend forwards nearly to the incisor teeth. In the mouth it supplies the gums, the glands, and the mucous membrane of the hard palate, and joins in front with the naso-palatine nerve. When entering its canal, this palatine nerve gives a nasal branch which ramifies in the middle and lower spongy bones; and a little before leaving the canal, another branch is supplied to the membrane covering the lower spongy bone: these are *inferior nasal branches*. Opposite the lower spongy bone springs a small branch, which is continued to the soft palate in a separate canal behind the trunk of the nerve.

*b.* The *smaller* or *posterior palatine* branch, arising near the preceding nerve, enters with a small artery the lesser palatine canal, and is conducted to the soft palate, the tonsil, and the uvula. According to Meckel, it supplies the levator palati muscle.

*c.* The *external palatine* nerve, the smallest of the series, courses between the upper maxilla and the external pterygoid muscle, and enters the external palatine canal between the maxillary bone and the pterygoid process of the palate bone. At its exit from the canal it gives inwards a branch to the uvula, and outwards another to the tonsil and palate. Occasionally this nerve is altogether wanting.

**INTERNAL BRANCHES.**—These consist of the naso-palatine, and the upper and interior nasal, which ramify in the lining membrane of the nasal fossæ and adjoining sinuses.

The *upper nasal* are very small branches, and enter the back part of the nasal fossa by the spheno-palatine foramen. Some are prolonged to the upper and posterior part of the septum, and the remainder ramify in the membrane covering the upper two spongy bones, and in that lining the posterior ethmoid cells. A branch, as has been already stated, forms a connection in the wall of the maxillary sinus, above the eye-tooth, with the anterior dental nerve.

The *naso-palatine nerve*, nerve of Cotunnus (Scarpa), long and slender, leaves the inner side of the ganglion with the preceding branches, and after crossing the roof of the nasal fossa is directed downwards and forwards on the septum nasi towards the anterior palatine canal, situated between the periosteum and the pituitary membrane. The nerves of opposite sides descend to the palate through the mesial subdivisions of the canal, called the foramina of Scarpa, the nerve of the right side usually behind that of the left. In the lower common foramen the two naso-palatine nerves are connected with each other in a fine plexus; and they end in several filaments, which are distributed to the papillæ behind the incisor teeth, and communicate with the great palatine nerve. In its course along the septum, small filaments are furnished from the naso-palatine nerve to the pituitary membrane. (See fig. 402. This nerve was discovered independently by John Hunter and Cotunnus; see Hunter's "Observations on certain parts of the Animal Economy;" and Scarpa, "Annotations Anatomica," lib. ii.)

**POSTERIOR BRANCHES.**—The branches directed backwards from the spheno-palatine ganglion are the Vidian and pharyngeal nerves.

The *Vidian nerve* arises from the back part of the ganglion, which seems to

Fig. 339.

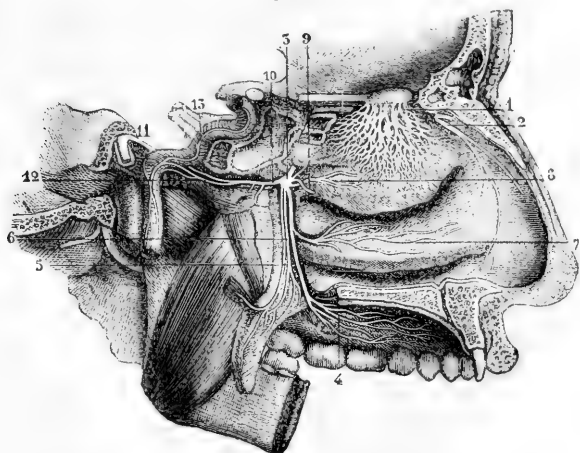


Fig. 339.—NERVES OF THE NOSE AND OF THE SPHENO-PALATINE GANGLION FROM THE INNER SIDE (from Sappey after Hirschfeld and Leveillé). 3

1, network of the branches of the olfactory nerve descending upon the membrane covering the superior and middle turbinated bones; 2, external twig of the ethmoidal branch of the nasal nerve; 3, spheno-palatine ganglion; 4, ramification of the anterior division of the palatine nerves; 5, posterior, and 6, middle divisions of the palatine nerves; 7, branch to the membrane on the lower turbinated bone; 8, branch to the superior and middle turbinated bones; 9, naso-palatine branch to the septum cut short; 10, Vidian nerve; 11, its great superficial petrosal branch; 12, its carotid branch; 13, the sympathetic nerves ascending on the internal carotid artery.

be prolonged into it, passes backwards through the Vidian canal, and after emerging from this divides in the substance of the fibro-cartilage, which fills the foramen lacerum medium, into two branches: one of these, the superficial petrosal, joins the facial nerve, while the other, the carotid branch, communicates with the sympathetic. Whilst the Vidian nerve is in its canal, it gives inwards some small *nasal* branches, which supply the membrane of the back part of the roof of the nose and septum, as well as the membrane covering the end of the Eustachian tube.

The *large superficial petrosal branch* of the Vidian nerve, entering the cranium on the outer side of the carotid artery and beneath the Gasserian ganglion, is directed backwards in a groove on the petrous portion of the temporal bone to the hiatus Fallopii, and is thus conducted to the aqueductus Fallopii, where it joins the gangliform enlargement of the facial nerve.

The *carotid or sympathetic portion* of the Vidian nerve, shorter than the other, is of a reddish colour and softer texture: it is directed backwards, and on the outer side of the carotid artery ends in the filaments of the sympathetic surrounding that vessel.

In accordance with the view taken of the ganglia connected with the fifth nerve (p. 536), the superficial petrosal and carotid parts of the Vidian nerve may be regarded as the motor and sympathetic roots respectively of the sphenopalatine ganglion; the sphenopalatine being its sensory root.

The *pharyngeal nerve* is inconsiderable in size, and, instead of emanating directly from the ganglion, is frequently derived altogether from the Vidian. This branch, when a separate nerve, springs from the back of the ganglion, enters the pterygo-palatine canal with an artery, and is lost in the lining membrane of the pharynx behind the Eustachian tube.

**SUMMARY.**—The superior maxillary nerve, with Meckel's ganglion, supplies the integument above the zygomatic arch, and that of the lower eyelid, the side of the nose, and the upper lip; the upper teeth, the lining membrane of the nose; the membrane of the upper part of the pharynx, of the antrum of Highmore, and of the posterior ethmoidal cells; the soft palate, tonsil, and uvula, and the glandular and mucous structures of the roof of the mouth.

### III.—INFERIOR MAXILLARY NERVE.

The lower maxillary nerve, the third and largest division of the fifth nerve, is made up of two portions, unequal in size, the larger being derived from the Gasserian ganglion, and the smaller being the slender motor root of the fifth nerve. These two parts leave the skull by the foramen ovale in the sphenoid bone, and unite immediately after their exit. A few lines beneath the base of the skull, and under cover of the external pterygoid muscle, the nerve separates into two primary divisions, one of which is higher in position and smaller than the other.

The *small, anterior, or upper portion*, chiefly motor, terminates in branches to the temporal, masseter, buccinator, and pterygoid muscles. The *larger or lower portion*, chiefly sensory, divides into the auriculo-temporal, lingual or gustatory, and inferior dental branches; it likewise supplies the mylo-hyoid muscle, and the anterior belly of the digastric. The branch to the internal pterygoid muscle, with which also are connected those proceeding from the otic ganglion to the tensors of the palate and tympanum, is sometimes counted as a part of the larger division, but is more correctly regarded as arising from the undivided trunk.

**Deep temporal, masseteric and pterygoid branches.**—The *deep temporal branches*, two in number, *anterior* and *posterior*, pass outwards above the external pterygoid muscle, close to the bone, and run upwards, one near the front, and the other near the back of the



temporal fossa, beneath the temporal muscle in the substance of which they are distributed. (See fig. 340.)

The anterior branch is frequently joined with the buccal nerve, and sometimes with the other deep temporal branch.

The *masseteric branch* likewise passes above the external pterygoid muscle, and is directed nearly horizontally outwards, through the sigmoid notch of the lower jaw to the posterior border of the masseter muscle, which it enters on the deep surface. It gives a filament or two to the articulation of the jaw, and occasionally furnishes a branch to the temporal muscle.

The *external pterygoid branch*, is most frequently derived from the buccal nerve. It is sometimes a separate offset from the smaller portion of the lower maxillary nerve.

The nerve of the *internal pterygoid* muscle is closely connected at its origin with the otic ganglion, and enters the inner or deep surface of the muscle.

The **buccal nerve** pierces the substance of the external pterygoid muscle, and courses downwards and forwards to the face, in close contact with the deep surface of the temporal muscle at its insertion. It furnishes a branch to the external pterygoid muscle as it pierces it, and on emerging gives two or three ascending branches to the temporal muscle. It divides into two principal branches, an *upper* and a *lower*, which communicate with the facial nerve in a plexus round the facial vein, and are distributed to the integument, the buccinator muscle, and the mucous membrane. It is chiefly a sensory nerve.

**Varieties.**—The buccal nerve is sometimes replaced by a branch of the infra-orbital (Henle). It has been seen to arise as a branch of the inferior dental, being given off from that nerve within the dental canal, and emerging close to the alveolar border of the bone (Turner, Nat. Hist. Review, 1864, p. 612). Gaillet (quoted by Henle) describes it as arising directly from the Gasserian ganglion, and piercing the base of the skull by a special foramen between the round and oval foramina.

**Auriculo-temporal nerve.**—The auriculo-temporal nerve takes its origin close to the foramen ovale. It often commences by two roots, between which may be placed the middle meningeal artery. It is directed at first backwards, beneath the external pterygoid muscle, to the inner side of the articulation of the jaw; then changing its course, it turns upwards between the ear and the joint, covered by the parotid gland; and emerging from this place, it finally divides into two temporal branches which ascend towards the top of the head.

(a) *Communicating branches.*—There are commonly two branches which pass forward round the external carotid artery, and join the facial nerve. Filaments to the otic ganglion arise near the beginning of the nerve.

(b) *Parotid branches* are given from the nerve while it is covered by the gland.

(c) *Auricular branches.*—These are two in number. The *lower* of the two, arising behind the articulation of the jaw, distributes branches to the ear below the external meatus; and sends other filaments round the internal maxillary artery to join the sympathetic nerve; the *upper branch*, leaving the nerve in front of the ear, is distributed in the integument covering the tragus and the pinna above the external auditory meatus. Both are confined to the outer surface of the ear.

(d) *Branches to the meatus auditorius.*—These, two in number, spring from the point of connection of the facial and auriculo-temporal nerves, and enter the interior of the auditory meatus between the osseous and cartilaginous parts. One of them sends a branch to the membrana tympani.

(e) *Articular branch.*—The nerve to the temporo-maxillary articulation comes from one of the preceding branches, or directly from the auriculo-temporal nerve.

(f) *Temporal branches.*—One of these, the smaller and *posterior* of the two, distributes filaments to the *atrahens auriculam* muscle, the upper part of the pinna and the integument above it. The anterior temporal branch extends with the superficial temporal artery to the top of the head, and ends in the integument. It is often united with the temporal branch of the upper maxillary nerve. Meckel mentions a communication between this branch and the occipital nerve.

**Lingual Nerve.**—The lingual branch (or gustatory nerve), descends under cover of the external pterygoid muscle, lying to the inner side and in front of the dental nerve, and sometimes united to it by a cord which crosses over the internal maxillary artery. It is there joined at

Fig. 340.

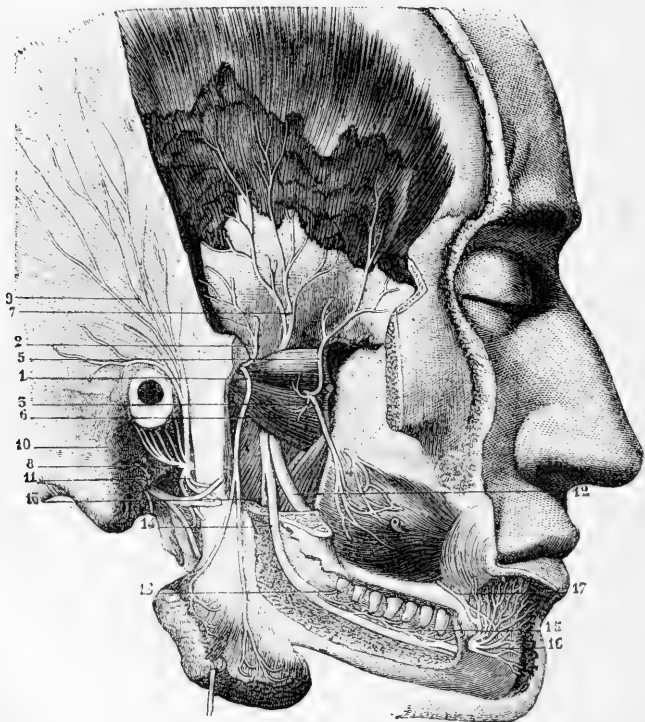


Fig. 340.—VIEW OF THE BRANCHES OF THE INFERIOR MAXILLARY NERVE FROM THE OUTER SIDE (from Sappey after Hirschfeld and Leveillé). 3

The zygoma and ramus of the jaw have been removed, and the outer plate of the jaw taken off, so as to open up the dental canal; the lower part of the temporal muscle has been dissected off the bone, and the masseter muscle turned down.

1, Masseteric branch, descending to the deep surface of the muscle; 2, a twig to the temporal muscle; 3, anterior, and 7, posterior deep temporal nerves; 3, buccal; 4, its union with the facial; 6, filaments given by the buccal to the external pterygoid muscle; 8, auriculo-temporal nerve; 9, its temporal branches; 10, its anterior auricular branches; 11, its union with the facial; 12, gustatory or lingual nerve; 13, mylo-hyoid nerve; 14, inferior dental nerve; 15, its twigs supplied to the teeth; 16, mental branches; 17, branch of the facial uniting with the mental.

an acute angle by the *chorda tympani*, a small branch connected with the facial nerve, which descends from the inner end of the Glaserian fissure. It then passes between the internal pterygoid muscle and the lower maxilla, and is inclined obliquely inwards to the side of the tongue, over the upper constrictor of the pharynx, (where this muscle is attached to the maxillary bone,) and above the deep portion of the submaxillary gland. Lastly, the nerve crosses Wharton's duct, and is continued along the side of the tongue to the apex, in contact with the mucous membrane of the mouth.

(a) *Communicating branches* are given to the submaxillary ganglion, at the place where the nerve is in contact with the submaxillary gland. Others form a plexus with branches of the hypoglossal nerve at the inner border of the hypoglossus muscle.

(b) *Branches to the mucous membrane* of the mouth are given from the nerve at the side of the tongue, and supply also the gums. Some delicate filaments are likewise distributed to the substance of the sublingual gland.

(c) The *lingual* or terminal branches perforate the muscular structure of the tongue, and divide into filaments, which are continued almost vertically upwards to the conical and fungiform papillæ. Near the tip of the tongue the branches of the gustatory and hypoglossal nerves are united.

**Inferior Dental Nerve.**—The inferior dental nerve is the largest of the three branches of the lower maxillary nerve. It descends under cover of the external pterygoid muscle, behind and to the outer side of the gustatory nerve, and, passing between the ramus of the jaw and the internal lateral ligament of the temporo-maxillary articulation, enters the inferior dental canal. In company with the dental artery, it proceeds along this canal, and supplies branches to the teeth. At the mental foramen it bifurcates; one part, the incisor branch, being continued onwards within the bone to the middle line, while the other, the much larger labial branch, escapes by the foramen to the face.

When about to enter the foramen on the inner surface of the ramus of the jaw, the inferior dental nerve gives off the slender mylo-hyoid branch.

(a) The *mylo-hyoid branch* is lodged in a groove on the inner surface of the ramus of the maxillary bone, in which it is confined by fibrous membrane, and is distributed to the lower or cutaneous surface of the mylo-hyoideus and to the anterior belly of the digastric muscle. This nerve may be traced back within the sheath of the inferior dental to the motor portion of the inferior maxillary nerve.

(b) The *dental branches* supplied to the molar and bicuspid teeth correspond to the number of the fangs of those teeth. Each branch enters the minute foramen in the extremity of a fang, and terminates in the pulp of the tooth. Not unfrequently a collateral branch supplies twigs to several teeth.

(c) The *incisor branch* has the same direction as the trunk of the nerve: it extends to the middle line from the point of origin of the labial branch, and supplies nerves to the canine and incisor teeth.

(d) The *labial or mental branch* emerging from the bone by the foramen on the outer surface, divides beneath the depressor of the angle of the mouth into two parts.

One of these, the outer division, communicating with the facial nerve, supplies the depressor anguli oris and orbicularis oris muscles, and the integument of the chin.

The inner portion, the larger of the two, ascends to the lower lip beneath the depressor labii inferioris muscle, to which it gives filaments: the greater number of the branches end on the inner and outer surfaces of the lip. These inner branches assist only slightly in forming the plexus of union with the facial nerve.

**Varieties.**—The lingual has been observed to form a single trunk with the inferior dental as far as the dental foramen. The inferior dental sometimes has one or two accessory roots from other divisions of the inferior maxillary. The most common of these is one which arises from the stem of the inferior maxil-

lary near the origin of the nerve for the external pterygoid muscle, and which, from its being occasionally separate from the rest of the inferior dental nerve till after it enters the dental canal, has been called the *lesser inferior dental* (Sappolini, "Omodei Annali," 1869). The mylo-hyoid frequently gives off a small branch, which pierces the mylo-hyoid muscle and joins the lingual nerve. This anastomosis is said by Sappey to be constant.

### Otic Ganglion.

The otic ganglion, or ganglion of Arnold, of a reddish-grey colour, is situated on the deep surface of the lower maxillary trunk, nearly at the point of junction of the motor fasciculus with that nerve, and around the origin of the internal pterygoid branch. Its inner surface is close to the cartilaginous part of the Eustachian tube and the circumflexus palati muscle; and behind it is the middle meningeal artery.

*Connection with nerves—roots.*—The ganglion is connected with the lower maxillary nerve, especially with the branch furnished to the internal pterygoid muscle, and with the auriculo-temporal nerve, and thus obtains motor and sensory roots; it is brought into connection with the sympathetic by a filament from the plexus on the middle meningeal artery. It likewise receives the *small superficial petrosal* nerve, which emerges from the petrous bone by the small foramen internal to the canal of the tensor tympani muscle, and reaches the exterior of the skull by piercing the sphenoid bone close to the foramen spinosum. By this nerve the ganglion forms a communication with the glosso-pharyngeal and facial nerves.

*Branches.*—Two small nerves are distributed to muscles—one to the tensor of the membrane of the tympanum, the other to the circumflexus or tensor palati.

Fig. 341.

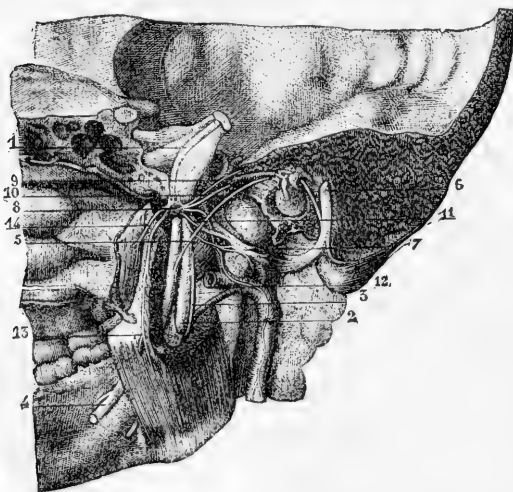


Fig. 341.—OTIC GANGLION AND ITS CONNECTIONS FROM THE INSIDE (from Sappey after Arnold).

This figure exhibits a view of the lateral portion of the skull with a part of the nasal fossa and lower jaw of the right side; the petrous bone has been removed so as to show the inner surface of the membrana tympani and the canal of the facial nerve.

1, smaller motor root of the fifth nerve passing down on the inside of the Gasserian ganglion to unite with the inferior maxillary division; 2, inferior dental nerve entering the canal of the lower jaw; 3, mylo-hyoid

branch, seen also farther down emerging in front of the internal pterygoid muscle; 4, lingual or gustatory nerve; 5, chorda tympani; 6, facial nerve in its canal; 7, auriculo-temporal nerve, enclosing in its loop of origin the middle meningeal artery; 8, otic ganglion; 9, small superficial petrosal nerve joining the ganglion; 10, branch to the tensor tympani muscle; 11, twig connecting the ganglion with the temporo-auricular nerve; 12, twig to the ganglion from the sympathetic nerves on the meningeal artery; 13, branch to the internal pterygoid muscle; 14, branch to the tensor palati muscle.

### Submaxillary Ganglion.

The submaxillary or lingual ganglion is placed above the deep portion of the submaxillary gland, and is connected by filaments with the lingual nerve. It is about the size of the ophthalmic ganglion, and triangular or fusiform in shape. By the upper part or base it receives branches from nerves which may be regarded as its roots, whilst from the lower part proceed the filaments which are distributed from the ganglion.

*Connection with nerves—roots.*—This ganglion receives filaments from the lingual nerve, and likewise, at its back part, a root which apparently comes from the lingual nerve, but is in reality derived from the chorda tympani, which is prolonged downwards in the sheath of the lingual nerve. It receives also small twigs from the sympathetic filaments on the facial artery.

**BRANCHES.**—Some nerves, five or six in number, radiate to the substance of the submaxillary gland. Others from the fore part of the ganglion, longer and larger than the preceding, end in the mucous membrane of the mouth, and in Wharton's duct.

According to Meckel ("De quinto pare," &c.), a branch occasionally descends in front of the hyo-glossus muscle, and after joining with one from the hypoglossal nerve, ends in the genio-hyo glossus muscle.

It may be noticed that while the branches from the otic ganglion pass exclusively to muscles, the submaxillary ganglion gives no muscular offsets.

**SUMMARY.**—Cutaneous filaments of the inferior maxillary nerve ramify on the side of the head, and the external ear, in the auditory passage, the lower lip, and the lower part of the face; sensory branches are supplied by it to the greater part of the tongue; and branches are furnished to the mucous membrane of the mouth, the lower teeth and gums, the salivary glands, and the articulation of the lower jaw.

This nerve supplies the muscles of mastication, viz., the masseter, temporal, and two pterygoid; also the buccinator, the mylo-hyoid, and the anterior belly of the digastric; and from the otic ganglion proceed the branches to the circumflexus palati and tensor tympani muscles.

### SIXTH PAIR OF NERVES.

**Surface Attachment.**—The sixth cranial nerve (abducens) motor oculi externus, takes its apparent origin from between the pyramidal body and the pons Varolii by means of a larger and a smaller bundle. It is connected with the pyramid, and to a small extent with the pons also.

**Deep origin.**—The fibres pass backwards and a little upwards through the fibres of the pons, parallel with the raphe, to reach a column of large nerve cells situated beneath the eminentia teres. The same nucleus gives origin to a large number of the fibres of the facial nerve, and is termed the common nucleus of the facial and sixth nerves.

**Course and Distribution.**—The nerve enters the dura mater behind the dorsum sellæ, and passing forwards in the floor of the cavernous sinus, close to the outer side of the carotid artery, enters the orbit through the sphenoidal fissure, between the heads of the external rectus muscle, and is entirely distributed to that muscle, piercing it on the ocular surface. In entering the orbit between the heads of the

external rectus muscle, it is beneath the other nerves, but above the ophthalmic vein. While passing along the internal carotid artery in the cavernous sinus, it is joined by several filaments of the sympathetic from the carotid plexus. According to Bock it is joined in the orbit by a filament from Meckel's ganglion.—("Beschreibung des Fünften Nervenpaares." 1817.)

**Varieties.**—Absence upon one side has been recorded, its place being supplied by a branch from the third nerve. (Generali.)

#### SEVENTH PAIR OF NERVES.

In the seventh cranial nerve of Willis are comprised two nerves having a distinct origin, distribution, and function. One of these, the facial, is the motor nerve of the face; the other, the auditory, is the special nerve of the organ of hearing. Both enter the internal auditory meatus in the temporal bone, but they are soon separated from each other. The facial nerve being the firmer of the two, was termed the portio dura, the other being called the portio mollis.

#### FACIAL NERVE.

**Surface attachment.**—The facial nerves appear, on each side, at the inferior margin of the pons, and in a line with the roots of the fifth pair. Each nerve emerges from the medulla oblongata, in the outer part of the depression between the olivary body and the diverging restiform body (inferior peduncle of cerebellum), and is often firmly adherent, as a flattened band, to the lower edge and even for a short distance to the upper surface of the pons. On its outer side is the auditory nerve. A separate fasciculus of the facial nerve (*intermediate part*) is sometimes attached to both auditory and facial nerves.

**Deep origin.**—The fibres of the facial nerve course backwards, inwards, and a little upwards to reach the outer side of the column of nerve-cells, which lies beneath the eminentia teres (common nucleus of sixth and facial nerves). In it many of the fibres end. A few pass inwards, and cross at the raphe to the opposite side of the medulla. Other fibres ascend to the upper extremity of the nucleus, around which they turn, and descend, as a compact bundle, on its inner side. These fibres finally radiate forwards and outwards to the column of nerve-cells, prolonged downwards from the motor nucleus of the fifth nerve, and also to the superior olivary body.

**Course.**—The facial nerve is inclined outwards with the auditory nerve, from its place of origin, to the internal auditory meatus. The facial lies in a groove on the auditory nerve, and the two are united in the auditory meatus by one or two small filaments. At the bottom of the meatus the facial nerve enters the aqueduct of Fallopius, and follows the windings of that canal to the lower surface of the skull. The nerve passes through the temporal bone at first almost horizontally outwards, between the cochlea and vestibule; on reaching the inner wall of the tympanum it is turned suddenly backwards above the fenestra ovalis towards the pyramid. At the place where it bends, the nerve presents a reddish *gangliform enlargement*, sometimes called the *geniculate ganglion*, which marks the place of junction of several nerves. Opposite the pyramid it is arched downwards behind the tympanum to the stylo-mastoid foramen, by which it leaves the osseous canal. It is then continued forwards through the substance of the parotid gland,

and separates in the gland, behind the ramus of the lower maxilla, into two primary divisions, the temporo-facial and the cervico-facial, from which numerous branches spread out over the side of the head, the face, and the upper part of the neck, forming what is known as the "pes anserinus."

**Distribution.**—Within the temporal bone the facial is connected with several other nerves by separate branches; and immediately after issuing from the stylo-mastoid foramen, it gives off three small branches, viz., the posterior auricular, digastric, and stylo-hyoid.

Fig. 342.—THE FACIAL NERVE EXPOSED IN ITS CANAL, WITH ITS CONNECTING BRANCHES, &c. (from Sappey after Hirschfeld and Levicillé). 3

The mastoid and a part of the petrous bone have been divided nearly vertically, and the canal of the facial nerve opened in its whole extent from the meatus internus to the stylo-mastoid foramen. The Vidian canal has also been opened from the outside. 1, facial nerve in the horizontal part of the commencement of the canal; 2, its second part turning backwards; 3, its vertical portion; 4, the nerve at its exit from the stylo-mastoid foramen; 5, geniculate ganglion; 6, large superficial petrosal nerve passing from this ganglion to the sphenopalatine ganglion, and joined by the small internal petrosal branch; 7, sphenopalatine ganglion; 8, small superficial petrosal nerve; 9, chorda tympani; 10, posterior auricular branch cut short at its origin; 11, branch for the digastric muscle; 12, branch for the stylo-hyoid muscle; 13, twig to the stylo-glossus muscle uniting with muscular branches of the glosso-pharyngeal nerve (14 and 15).

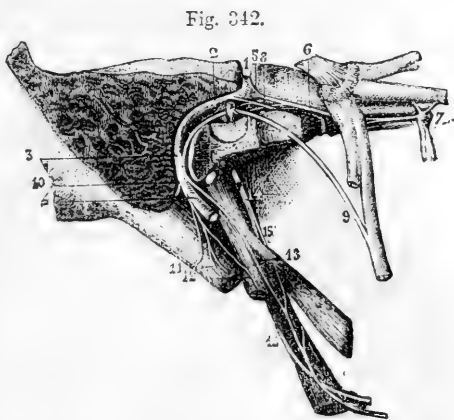


Fig. 342.

**Connecting Branches.**—*Filaments of union with the auditory nerve.*—In the meatus auditorius one or two minute filaments pass between the facial and the trunk of the auditory nerve.

*Nerves connected with the gangliform enlargement.*—About two lines from the beginning of the aqueduct of Fallopius, where the facial nerve swells into the gangliform enlargement, it is joined by the large superficial petrosal branch from the Vidian nerve. This ganglion likewise receives a small branch from the small superficial petrosal nerve which unites the otic ganglion with the tympanic nerve of Jacobson. The nerve beyond the ganglion receives the external superficial petrosal nerve (Bidder), which is furnished by the sympathetic accompanying the middle meningeal artery, and enters the temporal bone by a canal external to that traversed by the small superficial petrosal.

**Chorda Tympani and Nerve to the Stapedius.**—The nerve named chorda tympani leaves the trunk of the facial while within its canal, and crosses the tympanum to join the lingual branch of the fifth, along which it is conducted towards the tongue. It enters the back part of the tympanic cavity through a short canal emerging below the level of the pyramid, close to the ring of bone giving attachment to the membrane of the tympanum; and being invested by the mucous lining of the cavity, it is directed forwards across the membrana tympani and the handle of the malleus, to an aperture at the inner end of the Glaserian fissure. It then passes downwards and forwards, under cover of the external pterygoid muscle, and uniting with the lingual nerve at an acute angle,

descends in close contact with it, and is partly distributed to the submaxillary ganglion and partly blended with the lingual nerve in its distribution to the tongue. As this nerve crosses the tympanum, it is said to supply a twig to the laxator tympani muscle.

The nerve to the *stapedius* muscle arises from the trunk of the facial opposite the pyramid, and passes obliquely inwards to the fleshy belly of the muscle.

Fig. 343.

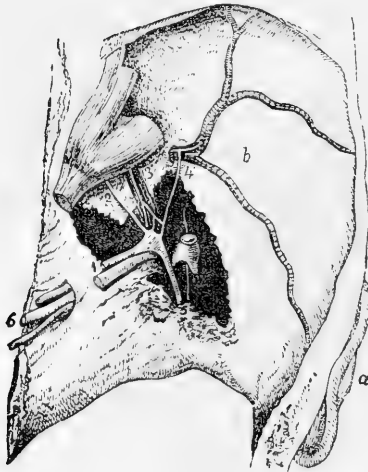


Fig. 343.—GENICULATE GANGLION OF THE FACIAL NERVE AND ITS CONNECTIONS FROM ABOVE (from Bidder).

The dissection is made in the middle fossa of the skull on the right side; the temporal bone being removed so as to open the meatus internus, hiatus Fallopii, and a part of the canal of the facial nerve, together with the cavity of the tympanum. *a*, the external ear; *b*, middle fossa of the skull with the meningeal artery ramifying in it; 1, facial and auditory nerves in the meatus auditorius internus; 2, large superficial petrosal nerve; 3, small superficial petrosal nerve lying over the tensor tympani muscle; 4, the external superficial petrosal joining sympathetic twigs on the meningeal artery; 5, facial and chorda tympani; 6, nerves of the eighth pair.

The chorda tympani is regarded by some anatomists as a continuation of the great superficial petrosal nerve. According to Owen, in the

horse and calf, the portio dura being less dense in structure, the Vidian branch of the fifth may be distinctly seen crossing the nerve after penetrating its sheath, and separating into many filaments, with which filaments of the seventh nerve are blended, while a ganglion is formed by the superaddition of grey matter; and the chorda tympani is continued partly from this ganglion, partly from the portio dura. (Hunter's Collected Works, vol. iv., p. 194, note.)

**Posterior auricular branch.**—This branch arises close to the stylo-mastoid foramen. In front of the mastoid process, it divides into an auricular and an occipital portion, and is connected with the great auricular nerve of the cervical plexus. It is said to be joined by the auricular branch of the pneumo-gastric nerve.

*a.* The *auricular division* supplies filaments to the retrahent muscle of the ear, and ends in the integument on the posterior aspect of the auricle.

*b.* The *occipital branch* is directed backwards beneath the small occipital nerve (from the cervical plexus) to the posterior part of the occipito-frontalis muscle; it lies close to the bone, and besides supplying the muscle, gives upwards filaments to the integument.

**Digastric and stylo-hyoid branches.**—The digastric branch arises in common with that for the stylo-hyoid muscle, and is divided into numerous filaments, which enter the digastric muscle: one of these sometimes perforates the digastric, and joins the glosso-pharyngeal nerve near the base of the skull.

The stylo-hyoid branch, long and slender, is directed inwards from



the digastric branch to the muscle from which it is named. This nerve is connected with the plexus of the sympathetic on the external carotid artery.

**TEMPORO-FACIAL DIVISION.**—The temporo-facial, the larger of the two primary divisions into which the main trunk of the facial nerve separates, is directed forwards through the parotid gland. Its ramifications and connections with other nerves form a network over the side of the face, extending as high as the temple and as low as the mouth. Its branches are arranged in temporal, malar, and infraorbital sets.

(a) The *temporal branches* ascend over the zygoma to the side of the head. Some end in the anterior muscle of the auricle and the integument of the temple, and communicate with the temporal branch of the upper maxillary nerve near the ear, as well as with (according to Meckel) the auriculo-temporal branch of the lower maxillary nerve. Other branches enter the occipito-frontalis, the orbicularis palpebrarum, and the corrugator supercilii muscles, and join offsets from the supraorbital branch of the ophthalmic nerve.

(b) The *malar branches* cross the malar bone to reach the outer side of the orbit, and supply the orbicular muscle. Some filaments are distributed to both the upper and lower eyelids: those in the upper eyelid join filaments from the lachrymal and supraorbital nerves; and those in the lower lid are connected with filaments from the upper maxillary nerve. Filaments from this part of the facial nerve communicate with the malar branch of the upper maxillary nerve.

(c) The *infraorbital branches*, of larger size than the other branches, are almost horizontal in direction, and are distributed between the orbit and mouth. They supply the buccinator and orbicularis oris muscles, the elevators of the upper lip and angle of the mouth, and likewise the integument. Numerous communications take place with the fifth nerve. Beneath the elevator of the upper lip these nerves are united in a plexus with the branches of the upper maxillary nerve; on the side of the nose they communicate with the nasal, and at the inner angle of the orbit with the infratrochlear nerve. The lower branches of this set are connected with those of the cervico-facial division.

Near its commencement the temporo-facial division of the facial is connected with the auriculo-temporal nerve of the fifth, by one or two branches of considerable size which turn round the external carotid artery; and it gives some filaments to the tragus of the outer ear.

**CERVICO-FACIAL DIVISION.**—This division of the facial nerve is directed obliquely through the parotid gland towards the angle of the lower jaw, and gives branches to the face, below those of the preceding division, and to the upper part of the neck. The branches are named buccal, supramaxillary, and inframaxillary. In the gland, this division of the facial nerve is joined by filaments of the great auricular nerve of the cervical plexus, and offsets from it penetrate the substance of the gland.

(a) The *buccal branches* are directed across the masseter muscle to the angle of the mouth; supplying the muscles, they communicate with the temporo-facial division, and on the buccinator muscle join with filaments of the buccal branch of the lower maxillary nerve.

(b) The *supramaxillary branch*, sometimes double, gives an offset over the side of the maxilla to the angle of the mouth, and is then directed inwards, beneath the depressor of the angle of the mouth, to the muscles and integument between the lip and chin; it joins with the labial branch of the lower dental nerve.

(c) The *inframaxillary branches* (r. subcutanei colli) perforate the deep cervical fascia, and, placed beneath the platysma muscle, form arches across the side of the neck as low as the hyoid bone. Some branches join the superficial cervical nerve beneath the platysma, others enter that muscle, and a few perforate it to end in the integument.

**SUMMARY.**—The facial nerve is the motor nerve of the face. It is distributed to most of the muscles of the ear, and to the muscles of the

Fig. 344.

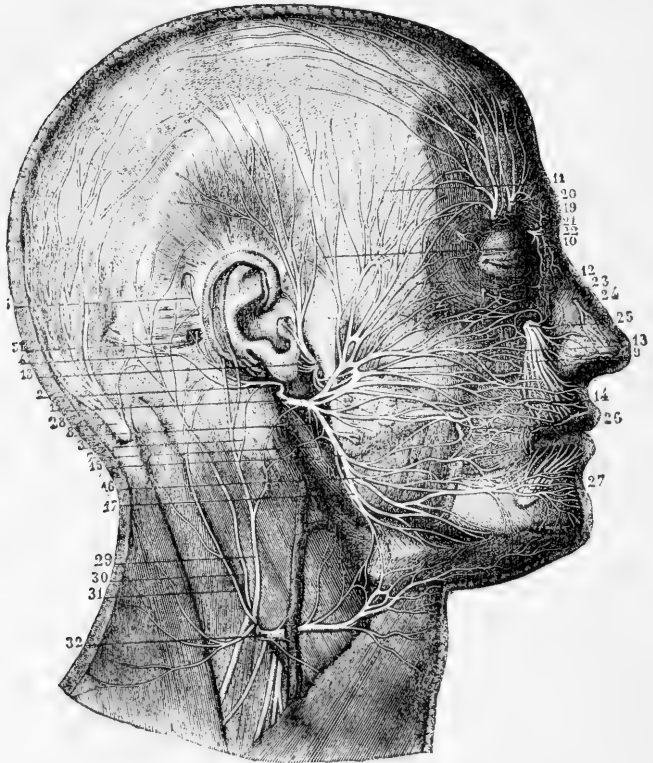


Fig. 344.—SUPERFICIAL DISTRIBUTION OF THE FACIAL, TRIGEMINAL, AND OTHER NERVES OF THE HEAD (from Sappey after Hirschfeld and Leveillé). 3

*a, References to the Facial Nerve.*—1, trunk of the facial nerve after its exit from the stylo-mastoid foramen; 2, posterior auricular branch; 3, filament of the great auricular nerve uniting with the foregoing; 4, twig to the occipitalis muscle; 5, twig to the posterior auricular muscle; 6, twig to the superior auricular muscle; 7, branch to the digastric; 8, that to the stylo-hyoid muscle; 9, superior or temporo-facial division of the pes anserinus; 10, temporal branches; 11, frontal; 12, palpebral or orbital; 13, nasal or infraorbital; 14, buccal; 15, inferior or cervico-facial division of the nerve; 16, labial and mental branches; 17, cervical branches.

*b, References to the Fifth Nerve.*—18, temporo-auricular nerve (of the inferior maxillary nerve) uniting with the facial, giving anterior auricular and parotid branches, and ascending to the temporal region; 19, external frontal or supra-orbital nerve; 20, internal frontal; 21, palpebral twigs of the lachrymal; 22, temporal branches of the infratrochlear; 23, malar twig of the orbito-malar; 24, external nasal twig of the ethmoidal; 25, infraorbital nerve; 26, buccal nerve uniting with branches of the facial; 27, labial and mental branches of the inferior dental nerve.

*c, Cervical Nerves.*—28, great occipital nerve from the second cervical; 29, great auricular nerve from the cervical plexus; 30, lesser occipital; 31, another branch with a similar distribution; 32, superficial cervical, uniting by several twigs with the facial.

scalp; to those of the mouth, nose, and eyelids; and to the cutaneous muscle of the neck (platysma). It likewise supplies branches to the integument of the ear, to that of the side and back of the head, as well as to that of the face and the upper part of the neck.

This nerve is connected freely with the three divisions of the fifth nerve, and with the submaxillary and sphenopalatine ganglia; with the glosso-pharyngeal and pneumo-gastric nerves: with the auditory, and with parts of the sympathetic and the spinal nerves.

**Varieties.**—The chorda tympani has been found more or less separate from the trunk of the lingual nerve, and in these cases it is very easy to trace the distribution of its terminal branches. Thus, in a case reported by Embleton (*Journ. of Anat.*, vol. vi., p. 217), the chorda applied itself to the inferior dental nerve, which it only left a line or two above the dental canal, and, passing on, divided into branches to the submaxillary and sublingual glands, and to the lingual nerve.

#### AUDI. ORY NERVE.

The auditory nerve, or portio mollis of the seventh pair, is the special nerve of the organ of hearing, and is distributed exclusively to the internal ear.

**Surface attachment.**—The auditory nerves appear at the lower border of the pons, on the outer side of and close to the facial nerves. They are also connected with the lower edge of the pons opposite the restiform body, from the inner side or middle of which they emerge.

**Deep origin.**—The fibres of the nerve divide into two nearly equal parts, of which one, *posterior*, winds round the restiform body, while the other, *anterior*, passes through its substance. The chief nucleus of the nerve (inner nucleus) forms a convex prominence in the outer portion of the lower half of the floor of the fourth ventricle. Its transverse section is triangular, and it is composed of small, round, oval and triangular cells. The posterior portion of the auditory nerve, winding round the restiform body (with which it is connected), reaches the outer part of this nucleus. The anterior division passes through the substance of the inferior peduncle of the cerebellum towards the apex of the inner nucleus. A few of its fibres join the inner nucleus; the majority, however, turn outwards to a network of cells and fibres in the posterior portion of the restiform body (outer nucleus, Lockhart Clarke) to the outer side of the inner nucleus. Some of the fibres of this division turn outwards along the restiform body to reach the cerebellum, where they have been traced to the superior vermiform process. Both portions of the auditory nerve contain many nerve-cells: in the posterior portion they constitute a pyriform swelling at the anterior edge of the restiform body.

**Course.**—As the auditory nerve is inclined outwards from its connection with the medulla oblongata to gain the internal auditory meatus, it is in contact with the facial nerve, being only separated from it in part by a small artery destined for the internal ear. Within the meatus the two nerves are connected to each other by one or two small filaments. Finally the auditory nerve bifurcates in the meatus: one division, piercing the anterior part of the cribriform lamina, is distributed to the cochlea; the other, piercing the posterior half of the lamina, enters the vestibule of the internal ear. The distribution of these branches will be described with the ear.

## EIGHTH PAIR OF NERVES.

The eighth pair is composed of three distinct nerves—the glosso-pharyngeal, pneumo-gastric, and spinal accessory, which leave the skull through the anterior and inner division of the foramen lacerum posticum, to the inner side and in front of the internal jugular vein. Two of these nerves, the glosso-pharyngeal and pneumo-gastric, are attached to the medulla oblongata in the same line, and resemble one another somewhat in their distribution, for both are distributed to the first part of the alimentary canal. The other, the spinal accessory, takes its origin chiefly from the spinal cord, and is mainly distributed to muscles; but it gives fibres to the first two nerves by its communicating branch.

## I.—GLOSSO-PHARYNGEAL NERVE.

The glosso-pharyngeal nerve is destined, as the name implies, for the tongue and pharynx.

**Surface attachment.**—The nerve arises from the surface of the restiform body of the medulla by five or six roots, arranged in a vertical line, the highest being contiguous to the facial and auditory nerves, the lowest to the highest roots of the pneumogastric.

**Deep origin.**—The fibres pass inwards and backwards through the substance of the medulla, to reach the nucleus, a small column of large nerve-cells placed deeply beneath the lower part of the floor of the fourth ventricle, between the highest part of the vagal nucleus and the lower part of the inner auditory nucleus.

Fig. 345.

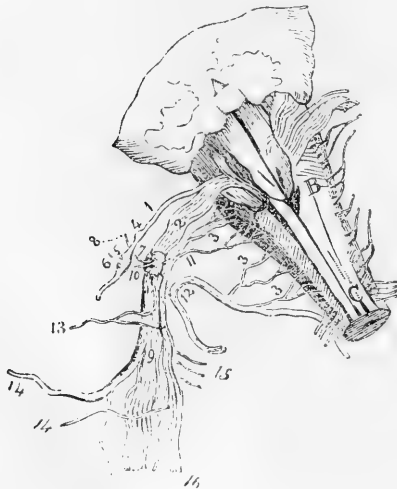


Fig. 345. — DIAGRAMMATIC SKETCH FROM BEHIND OF THE ROOTS OF THE NERVES OF THE EIGHTH PAIR, WITH THEIR GANGLIA AND COMMUNICATIONS (from Bendz).

A, part of the cerebellum above the fourth ventricle; B, medulla oblongata; C, posterior columns of the spinal cord; 1, root of the glosso-pharyngeal nerve; 2, roots of the pneumo-gastric; 3, 3, 3, roots of the spinal accessory, the uppermost number indicating the filaments intermediate between the spinal accessory and pneumo-gastric; 4, jugular ganglion of the glosso-pharyngeal; 5, petrosal ganglion; 6, tympanic branch; 7, ganglion of the root of the pneumo-gastric; 8, auricular branch; 9, long ganglion on the trunk of the pneumo-gastric; 10, branch from the upper ganglion to the petrosal ganglion of the glosso-pharyngeal; 11, inner portion of the spinal accessory; 12, outer portion; 13, pharyngeal branch of the pneumo-gastric; 14, superior laryngeal branch; 15, twigs connected with the sympathetic; 16, fasciculus of the spinal accessory

prolonged with the pneumo-gastric.

**Course and distribution.**—Directed outwards from its place of origin over the flocculus to the foramen jugulare, it leaves the skull with the pneumo-gastric and spinal accessory nerves, but in a separate tube of dura mater. In passing through the foramen, somewhat in

front of the others, this nerve is contained in a groove, or in a canal in the lower border of the petrous portion of the temporal bone, and presents, successively, two ganglionic enlargements,—the jugular ganglion, and the petrous ganglion.

After leaving the skull, the glosso-pharyngeal nerve appears between the internal carotid artery and the jugular vein, and is directed downwards over the carotid artery and beneath the styloid process and the muscles connected with it, to the lower border of the stylo-pharyngeus muscle. Here, changing its direction, the nerve curves inwards to the tongue, on the stylo-pharyngeus and the middle constrictor muscle of the pharynx, above the upper laryngeal nerve; and, passing beneath the hyo-glossus muscle, ends in branches for the pharynx, the tonsil, and the tongue.

The **jugular ganglion**, the smaller of the two ganglia of the glosso-pharyngeal nerve, is situated at the upper part of the osseous groove in which the nerve is laid during its passage through the jugular foramen. Its length is from half a line to a line, and the breadth from half to three-fourths of a line. It is placed on the outer side of the trunk of the nerve, and involves only a part of the fibres,—a small fasciculus passing over the ganglion, and joining the nerve below it.

Fig. 346.—SKETCH OF THE TYMPANIC BRANCH OF THE GLOSSO-PHARYNGEAL NERVE, AND ITS CONNECTIONS (from Breschet).

A, squamous part of the left temporal bone; B, petrous part; C, inferior maxillary nerve; D, internal carotid artery; *a*, tensor tympani muscle; 1, carotid plexus; 2, otic ganglion; 3, glosso-pharyngeal nerve; 4, tympanic nerve; 5, twigs to the carotid plexus; 6, twig to fenestra rotunda; 7, twig to fenestra ovalis; 8, junction with the large superficial petrosal nerve; 9, small superficial petrosal; 10, twig to the tensor tympani muscle; 11, facial nerve; 12, chorda tympani; 13, petrous ganglion of the glosso-pharyngeal; 14, twig to the membrane of the Eustachian tube.

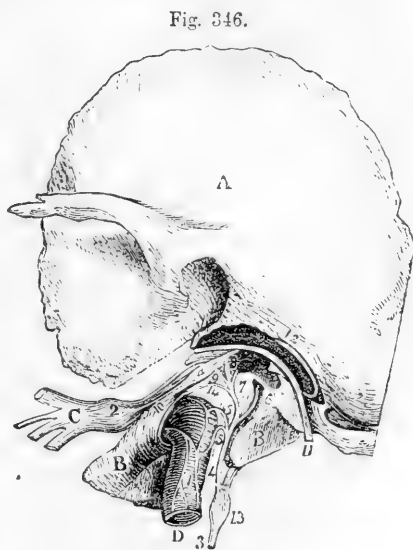

Fig. 346.

The **petrous ganglion** is contained in a hollow in the lower border of the petrous part of the temporal bone (receptaculum ganglioli petrosi), and measures about three lines in length. This ganglion includes all the filaments of the nerve, and resembles the gangliform enlargement of the facial nerve. From it arise the small branches by which the glosso-pharyngeal is connected with other nerves at the base of the skull; these are the tympanic nerve, and the branches which join the pneumo-gastric and sympathetic.

**Connecting branches, and tympanic branch.**—From the petrous ganglion spring three small connecting filaments. One passes to the auricular branch of the pneumo-gastric, one to the upper ganglion of the sympathetic or *vice versâ*,

and a third to the ganglion of the root of the pneumo-gastric nerve. The last is not constant.

There is sometimes likewise a filament from the digastric branch of the facial nerve, which, piercing the digastric muscle, joins the glosso-pharyngeal nerve below the petrous ganglion.

The *tympanic branch* (nerve of Jacobson) arises from the petrous ganglion, and is conducted to the tympanum by a special canal, the orifice of which is in the ridge of bone between the jugular fossa and the carotid foramen. On the inner wall of the tympanum the nerve joins with a twig from the sympathetic forming a plexus (tympanic), and distributes filaments to the membrane lining the tympanum and the Eustachian tube, as well as one to the fenestra rotunda, and another to the fenestra ovalis.

From the tympanic nerve are given three *connecting branches*, by which it communicates with other nerves; and which occupy channels given off from the osseous canal through which the nerve enters the tympanum. One branch enters the carotid canal and joins with the sympathetic on the carotid artery. A second is united to the large superficial petrosal nerve, as this lies in the hiatus Fallopii. And the third is directed upwards, beneath the canal for the tensor tympani muscle, towards the surface of the petrous portion of the temporal bone, where it becomes the *small petrosal nerve*; and under this name it is continued to the exterior of the skull through a small aperture in the sphenoid and temporal bones, to end in the otic ganglion. As this petrosal nerve passes the gangliform enlargement of the facial, it has a connecting filament with that enlargement, which is by some considered its principal posterior termination.

Jacobson described an interior or internal branch from the tympanic nerve to the spheno-palatine ganglion.

**Branches distributed in the neck.**—The *carotid branches* course along the internal carotid artery, and unite with the pharyngeal branch of the pneumo-gastric, and with branches of the sympathetic nerve.

The *pharyngeal branches*, three or four in number, unite opposite the middle constrictor of the pharynx with branches of the pneumo-gastric and sympathetic to form the *pharyngeal plexus*. Nerves to the mucous membrane of the pharynx perforate the muscles, and extend upwards to the base of the tongue and the epiglottis, and downwards nearly to the hyoid bone.

The *muscular branches* are given to the stylo-pharyngeus and constrictor muscles.

*Tonsillic branches.*—When the glosso-pharyngeal nerve is near the tonsil, some branches are distributed on that body in a kind of plexus (circulus tonsillaris). From these nerve offsets are sent to the soft palate and the isthmus of the fauces.

*Lingual branches.*—The glosso-pharyngeal nerve divides into two parts at the border of the tongue. One turns to the upper surface of the tongue, supplying the mucous membrane at its base; the other perforates the muscular structure, and ends in the mucous membrane on the lateral part of the tongue. Some filaments enter the circumvallate papillæ.

**Variety.**—In one case a branch from the glosso-pharyngeal supplied the mylo-hyoid muscle and the anterior belly of the digastric, the normal mylo-hyoid nerve being wanting. (Guy's Hosp. Reports, vol. xiv., p. 436.)

**SUMMARY.**—The glosso-pharyngeal nerve distributes branches to the mucous membrane of the tongue, pharynx, tympanum, and Eustachian tube. The muscles supplied by it are some of those of the pharynx and base of the tongue. It is connected with the following nerves, viz., the lower maxillary division of the fifth, the facial, the pneumo-gastric (the trunk and branches of this nerve), and the sympathetic.

## II.—PNEUMO-GASTRIC NERVE.

The pneumo-gastric nerve (nervus vagus, par vagum) has the longest course of any of the cranial nerves. It extends through the neck and the cavity of the chest to the upper part of the abdomen; and it

supplies nerves to the organs of voice and respiration, to the alimentary canal as far as the stomach, and to the heart.

**Surface attachment.**—This nerve arises from the restiform body of the medulla, by twelve or fifteen fine roots, beneath and in a line with the roots of the glosso-pharyngeal nerves.

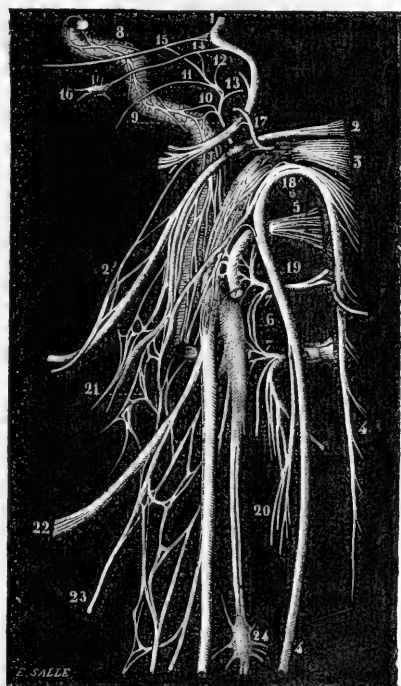
**Deep origin.**—The fibres pass inwards and backwards through the medulla to a column of nerve-cells beneath the lowest part of the floor of the fourth ventricle, where they cause a prominence on the surface. At the point of the calamus scriptorius the nuclei are in contact in the middle line, but a little higher up they are separated by the nuclei of the hypoglossal nerve.

**Course and distribution.**—The filaments by which this nerve springs from the medulla oblongata close below those of the glosso-pharyngeal nerve are arranged in a flat fasciculus, which is directed outwards with that nerve, across the flocculus to the jugular foramen.

Fig. 347.—DIAGRAM OF THE ROOTS AND ANASTOMOSING BRANCHES OF THE NERVES OF THE EIGHTH PAIR AND NEIGHBOURING NERVES (from Sappey after Hirschfeld and Leveillé).

Fig. 347.

1, facial nerve; 2, glosso-pharyngeal with the petrous ganglion represented; 2', connection of the digastric branch of the facial nerve with the glosso-pharyngeal nerve; 3, pneumo-gastric, with both its ganglia represented; 4, spinal accessory; 5, hypoglossal; 6, superior cervical ganglion of the sympathetic; 7, loop of union between the two first cervical nerves; 8, carotid branch of the sympathetic; 9, nerve of Jacobson (tympenic), given off from the petrous ganglion; 10, its filaments to the sympathetic; 11, twig to the Eustachian tube; 12, twig to the fenestra ovalis; 13, twig to the fenestra rotunda; 14, twig of union with the small superficial petrosal; 15, twig of union with the large superficial petrosal; 16, otic ganglion; 17, branch of the jugular fossa, giving a filament to the petrous ganglion; 18, union of the spinal accessory with the pneumo-gastric; 19, union of the hypoglossal with the first cervical nerve; 20, union between the sterno-mastoid branch of the spinal accessory and that of the second cervical nerve; 21, pharyngeal plexus; 22, superior laryngeal nerve; 23, external laryngeal; 24, middle cervical ganglion of the sympathetic.



In passing through the opening at the base of the skull the pneumo-gastric nerve is contained in the same sheath of dura mater, and surrounded by the same tube of arachnoid membrane as the spinal accessory nerve; but it is separated from the glosso-pharyngeal nerve by a process of membrane. In the foramen the filaments of the nerve

become aggregated together ; and it here presents a ganglionic enlargement, distinguished as the *ganglion of the root* of the pneumo-gastric. After its passage through the foramen, it is joined by the accessory

Fig. 348.

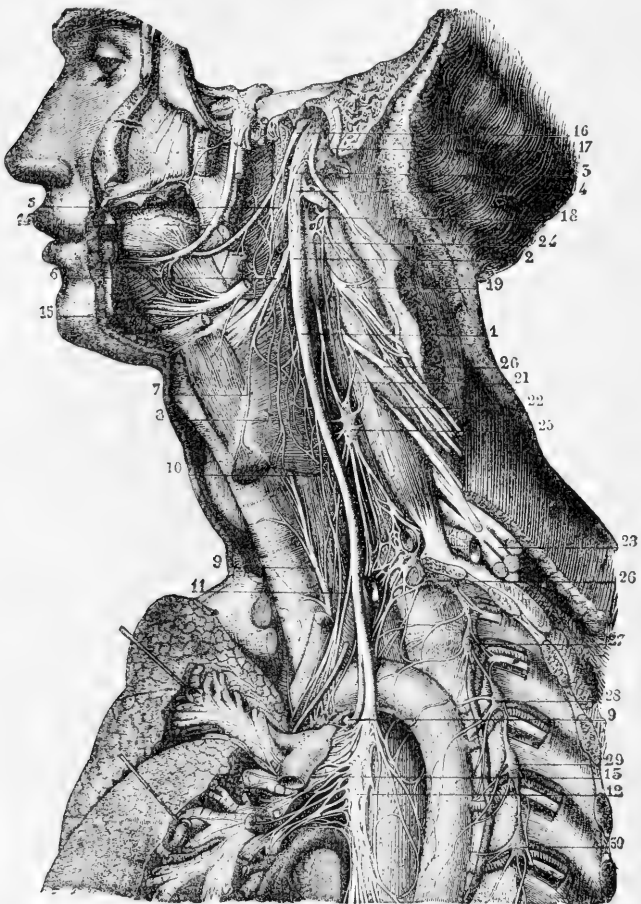


Fig. 348.—VIEW OF THE NERVES OF THE EIGHTH PAIR, THEIR DISTRIBUTION AND CONNECTION ON THE LEFT SIDE (from Sappey after Hirschfeld and Leveillé).  $\frac{1}{3}$

1, pneumo-gastric nerve in the neck ; 2, ganglion of its trunk ; 3, its union with the spinal accessory ; 4, its union with the hypoglossal ; 5, pharyngeal branch ; 6, superior laryngeal nerve ; 7, external laryngeal ; 8, laryngeal plexus ; 9, inferior or recurrent laryngeal ; 10, superior cardiac branch ; 11, middle cardiac ; 12, plexiform part of the nerve in the thorax ; 13, posterior pulmonary plexus ; 14, lingual or gustatory nerve of the inferior maxillary ; 15, hypoglossal, passing into the muscles of the tongue, giving its thyro-hyoid branch, uniting with twigs of the lingual ; 16, glosso-pharyngeal nerve ; 17, spinal accessory nerve, uniting by its inner branch with the pneumo-gastric, and by its outer, passing into the sterno-mastoid muscle ; 18, second cervical nerve ; 19, third ; 20, fourth ; 21, origin of the phrenic nerve ; 22, 23, fifth, sixth, seventh, and eighth cervical nerves, forming with the first dorsal the brachial plexus ; 24, superior cervical ganglion of the sympathetic ; 25, middle cervical ganglion ; 26, inferior cervical ganglion united with the first dorsal ganglion ; 27, 28, 29, 30, second, third, fourth, and fifth dorsal ganglia.



part of the spinal accessory nerve, and a second ganglion is formed upon it, *the ganglion of the trunk* of the nerve. Several communications are at the same time established with the surrounding nerves.

The **upper ganglion**, or **ganglion of the root** of the pneumo-gastric nerve, situated in the foramen jugulare, is of a greyish colour, nearly spherical, and about two lines in diameter; it has filaments connecting it with other nerves, viz., with the facial, the petrous ganglion of the glosso-pharyngeal, the spinal accessory, and the sympathetic.

The **lower ganglion**, or **ganglion of the trunk** of the pneumo-gastric nerve, is placed about half an inch beyond the preceding. Occupying the trunk of the nerve outside the skull, it is of a flattened cylindrical form and reddish colour, and measures about ten lines in length and two in breadth. The ganglion does not include all the fibres of the nerve; the fasciculus, which is sent from the spinal accessory to join the vagus, is the part not involved in the ganglionic substance. It communicates with the hypoglossal, the spinal, and the sympathetic nerves.

The pneumo-gastric nerve descends in the neck, between and concealed by the internal jugular vein and the internal carotid artery, and afterwards similarly between that vein and the common carotid artery, being enclosed along with them in the sheath of the vessels. As they enter the thorax, the nerves of the right and left side present some points of difference, of which the following are the most important.

*On the right side* the nerve crosses over the first part of the right subclavian artery, at the root of the neck, and its recurrent laryngeal branch turns backwards and upwards round that vessel. The nerve then enters the thorax behind the right innominate vein, and descends on the side of the trachea to the back of the root of the lung, where it spreads out in the posterior pulmonary plexus. It emerges from this plexus in the form of two cords, which are directed to the œsophagus, and by their union and subdivision on it form, with similar branches of the left side, the œsophageal plexus. Near the lower part of the thorax, the branches of the nerve, which have thus interchanged fibres with the nerve of the left side, are gathered again into a single trunk, which, descending on the back of the œsophagus, is spread out on the posterior or inferior surface of the stomach.

*On the left side* the pneumo-gastric nerve, entering the thorax between the left carotid and subclavian arteries and behind the left innominate vein, lies further forwards than the right nerve, and crosses over the arch of the aorta, while its recurrent laryngeal branch turns up behind the arch. It then passes behind the root of the left lung, and, emerging from the posterior pulmonary plexus, is distributed like its fellow on the œsophagus. Inferiorly, it forms a single trunk in front of the œsophagus, and is spread out on the anterior or superior surface of the stomach.

There are various circumstances in the distribution of the pneumo-gastric nerves which at first sight appear anomalous, but which are explained by reference to the process of development. The recurrent direction of the inferior laryngeal branches in all probability arises from the extreme shortness or rather absence of the neck in the embryo at first, and from the branchial arterial arches having originally occupied a position at a higher level than the parts in which those branches are ultimately distributed, and having dragged them down as it

were in the descent of the heart from the neck to the thorax. The recurrent direction may therefore be accepted as evidence of the development of those nerves before the occurrence of that descent. The passage of one recurrent laryngeal nerve round the subclavian artery, and of the other round the aorta, arises from the originally symmetrical disposition in which the innominate and subclavian arteries on the right side and the arch of the aorta on the left are derived from corresponding arches. The supply of the back of the stomach by the right pneumo-gastric nerve, and of the front by the left nerve, is connected with the originally symmetrical condition of the alimentary canal, and the turning over of the stomach on its right side in its subsequent growth.

**BRANCHES.**—Some of its branches serve to connect the pneumo-gastric with other nerves, and others are distributed to the muscular substance or the mucous lining of the organs which the nerve supplies. The principal connecting branches of this nerve are derived from the ganglia. In the different stages of its course branches are supplied to various organs as follows. In the jugular foramen, a branch is given to the ear; in the neck, branches are furnished successively to the pharynx, the larynx, and the heart; and in the thorax, additional branches are distributed to the heart, as well as to the lungs and the œsophagus. Terminal branches in the abdomen are distributed to the stomach, liver, and other organs.

**Connecting branches and auricular branch.**—*Connections between the upper ganglion of the vagus nerve and the spinal accessory, glosso-pharyngeal and sympathetic nerves.*—The connection with the spinal accessory is effected by one or two filaments. The filament to the petrous ganglion of the glosso-pharyngeal is directed transversely; it is not always present. The communication with the sympathetic is established by means of the ascending branch of the upper cervical ganglion.

The *auricular branch* is continued to the outer ear. Arising from the ganglion of the root, this branch is joined by a filament from the glosso-pharyngeal nerve, and then turns backwards along the outer boundary of the jugular foramen to an opening near the styloid process. Next, it traverses the substance of the temporal bone, crosses the aqueduct of Fallopius about two lines from the lower end, and, reaching the surface between the mastoid process and the external auditory meatus, is distributed to the integument of the back of the ear. On the surface it joins with a twig from the posterior auricular branch of the facial nerves.

*Connections of the second ganglion with the hypoglossal, sympathetic, and spinal nerves.*—This ganglion is connected by filaments with the trunk of the hypoglossal, with the upper cervical ganglion of the sympathetic, and with the loop formed between the first two cervical nerves.

**Pharyngeal branch.**—The pharyngeal branch arises from the upper part of the ganglion of the trunk of the nerve. In its progress inwards to the pharynx this nerve crosses in some cases over, in others under, the internal carotid artery; and it divides into branches, which, conjointly with others derived from the glosso-pharyngeal, the superior laryngeal, and the sympathetic nerves, form a plexus (*pharyngeal*) behind the middle constrictor of the pharynx. From the plexus branches are given to the muscular structure, and to the mucous membrane of the pharynx. As the pharyngeal nerve crosses the carotid artery, it joins filaments which the glosso-pharyngeal distributes on the same vessel.—There is sometimes a second pharyngeal branch.

**Superior pharyngeal branch.**—This nerve springs from the middle of the ganglion of the trunk of the pneumo-gastric nerve. It is directed

inwards to the larynx beneath the internal carotid artery, and divides beneath that vessel into two branches, distinguished as external and internal laryngeal, both of which ramify in the structures of the larynx.

The *external laryngeal* branch, the smaller of the two divisions, gives backwards, at the side of the pharynx, filaments to the pharyngeal plexus and the lower constrictor muscle; and it is finally prolonged beneath the muscles on the side of the larynx to the crico-thyroid muscle in which it ends. In the neck this branch joins the upper cardiac nerve of the sympathetic.

The *internal laryngeal* branch is continued to the interval between the hyoid bone and the thyroid cartilage, where it perforates the thyro-hyoid membrane with the laryngeal branch of the superior thyroid artery, and distributes filaments to the mucous membrane: some of these are directed upwards in the aryteno-epiglottidean fold of mucous membrane to the base of the tongue, the epiglottis, and the epiglottidean glands; while others are reflected downwards in the lining membrane of the larynx, extending to the corda vocalis, on the inner side of the laryngeal pouch. A slender communicating branch to the recurrent laryngeal nerve descends beneath the lateral part of the thyroid cartilage. A branch enters the arytenoid muscle, some filaments of which seem to end in the muscle, while others proceed through it to the mucous membrane.

**Recurrent laryngeal branch.**—The recurrent or inferior laryngeal branch of the vagus nerve, as the name expresses, has a reflex course to the larynx.

The nerve on the *right side* arises at the top of the thorax, winds round the subclavian artery, and passes beneath the common carotid and inferior thyroid arteries in its course towards the trachea. On the *left side* the recurrent nerve is bent round, below and behind the arch of the aorta, immediately beyond the point where the obliterated ductus arteriosus is connected with the arch, and is thence continued upwards to the trachea.

Each nerve in its course to the larynx is placed between the trachea and œsophagus, supplying branches to both tubes; and each, while making its turn round the artery, gives nerves to the deep cardiac plexus. At the lower part of the cricoid cartilage the recurrent nerve distributes branches to supply all the special muscles of the larynx, except the crico-thyroid muscle, which is supplied from the upper laryngeal nerve. It likewise gives a few offsets to the mucous membrane, and a single communicating filament which joins the long branch of the upper laryngeal nerve beneath the side of the thyroid cartilage.

**Cardiac branches.**—Branches to the heart are given off by the pneumo-gastric nerve both in the neck and in the thorax.

The *cervical cardiac* branches arise at both the upper and the lower part of the neck. The *upper branches* are small, and join the cardiac nerves of the sympathetic. The *lower*, a single branch, arises as the pneumo-gastric nerve is about to enter the chest. On the right side this branch lies by the side of the innominate artery, and joins one of the cardiac nerves destined for the deep cardiac plexus; it gives some filaments to the coats of the aorta. The branch of the left side crosses the arch of the aorta, and ends in the superficial cardiac plexus.

The *thoracic cardiac* branches of the right side leave the trunk of the pneumo-gastric as this nerve lies by the side of the trachea, and some

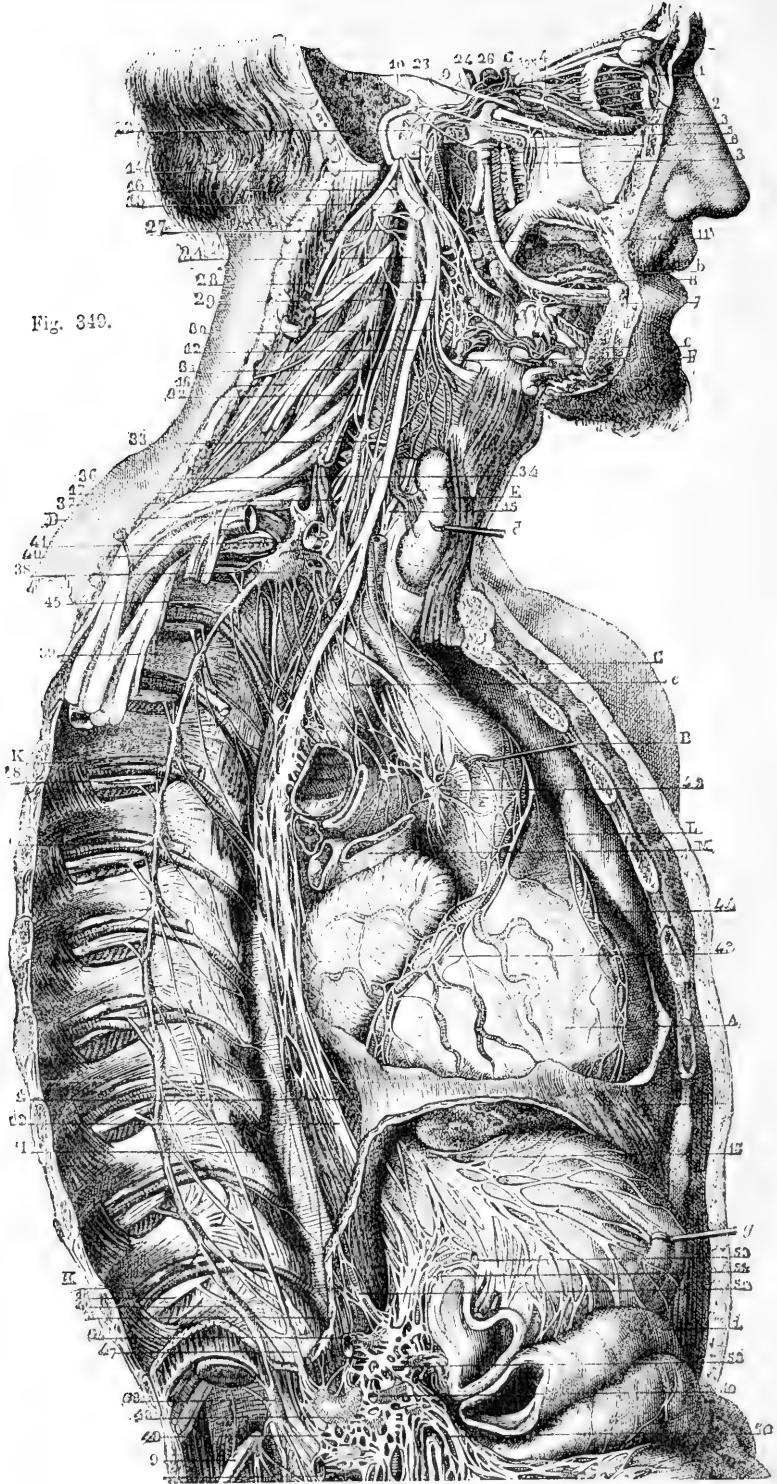


Fig. 340.

Fig. 349.—VIEW OF THE DISTRIBUTION AND CONNECTIONS OF THE PNEUMOGASTRIC AND SYMPATHETIC NERVES ON THE RIGHT SIDE (after Hirschfeld and Leveillé). §

*a*, lachrymal gland; *b*, sublingual gland; *c*, submaxillary gland and facial artery; *d*, thyroid gland, pulled forwards by a hook; *e*, trachea, below which is the right bronchus cut across; *f*, the gullet; *g*, the stomach, divided near the pylorus; *i*, transverse colon, with some folds of the intestines below.

A, heart, slightly turned aside to show the cardiac plexus, &c.; B, aortic arch, drawn forward by a hook; C, innominate artery; D, subclavian artery, of which a portion has been removed to show the sympathetic ganglia; E, inferior thyroid artery; F, a divided part of the external carotid artery, upon which runs a nervous plexus; G, internal carotid emerging from its canal superiorly; H, thoracic aorta; K, intercostal vein; L, pulmonary trunk, the right branch cut; M, superior vena cava; O, intercostal artery.

1, ciliary nerves of the eyeball; 2, branch of the oculo-motor to the inferior oblique muscle, connected with the ophthalmic ganglion; 3, 3, 3, the three principal divisions of the trifacial nerve; 4, ophthalmic ganglion; 5, sphenopalatine; 6, otic; 7, submaxillary; 8, sublingual; 9, sixth nerve; 10, facial in its canal, uniting with the sphenopalatine and otic ganglia; 11, glosso-pharyngeal; 12, right pneumogastric; 13, left pneumogastric spreading on the anterior surface of the stomach; 14, spinal accessory; 15, hypoglossal; 16, lower nerve of the cervical plexus; 17, middle nerve of the brachial plexus; 18, intercostal nerves; 21, superior cervical ganglion of the sympathetic, connected with, 22, the tympanic nerve of Jacobson; 23, carotid branch of the Vidian nerve; 24, cavernous plexus; 25, ophthalmic twig; 26, filament to the pituitary gland; 27, union with the upper cervical nerves; 28, points to the pneumogastric nerve, close to the pharyngeal and carotid branches; 29, points to the superior laryngeal nerve, close to the pharyngeal and inter-carotid plexuses; 30, laryngeal branch joining the laryngeal plexus; 31, great sympathetic nerve; 32, superior cardiac nerve; 33, middle cervical ganglion; 34, twig connecting the ganglion with, 35, the recurrent; 36, middle cardiac nerve; 37, great sympathetic nerve; 38, inferior cervical ganglion; below 37, branches from the ganglion, passing round the subclavian and vertebral arteries; 39, the line from this number crosses the nerves proceeding from the brachial plexus; 40, sympathetic twigs surrounding the axillary artery; 41, branch of union with the first intercostal nerve; the line from the letter *e*, pointing to the trachea, crosses the superior, middle, and inferior cardiac nerves; 42, cardiac plexus and ganglion; 43, 44, right and left coronary plexuses; 45, 46, thoracic portion of the great sympathetic nerve and ganglia showing their connections with the intercostal nerves; 47, great splanchnic nerve; 48, semilunar ganglion; 49, lesser splanchnic; 50, solar plexus; 51, union with the pneumogastric nerve; 52, diaphragmatic plexus and ganglion; 53, coronary plexus; 54, hepatic; 55, splenic; 56, superior mesenteric; 57, renal plexus.

are also derived from the first part of the recurrent branch: they pass inwards on the air-tube, and end in the deep cardiac plexus. The corresponding branches of the left side come from the left recurrent laryngeal nerve.

**Pulmonary branches.**—Two sets of pulmonary branches are distributed from the pneumogastric nerve to the lung; and they reach the root of the lung, one on its fore part, the other on its posterior aspect. The *anterior* pulmonary nerves, two or three in number, are of small size. They join with filaments of the sympathetic ramifying on the pulmonary artery, and with these nerves constitute the *anterior pulmonary plexus*. Behind the root of the lung the pneumogastric nerve becomes flattened, and gives several branches of much larger size than the anterior branches, which, with filaments derived from the second, third, and fourth thoracic ganglia of the sympathetic, form the *posterior pulmonary plexus*. Offsets from this plexus extend along the ramifications of the air-tube through the substance of the lung.

**Œsophageal branches.**—The œsophagus within the thorax receives branches from the pneumogastric nerves, both above and below the pulmonary branches. The lower branches are the larger, and are derived from the *œsophageal plexus*, formed by connecting cords between

the nerves of the right and left sides, while they lie in contact with the œsophagus.

**Gastric branches.**—The branches distributed to the stomach (*gastric nerves*) are the terminal branches of both pneumogastric nerves. The nerve of the left side, on arriving in front of the œsophagus, opposite the cardiac orifice of the stomach, divides into many branches: the largest of these extend over the fore part of the stomach; others lie along its small curvature, and unite with branches of the right nerve and the sympathetic; and some filaments are continued between the layers of the small omentum to the hepatic plexus. The right pneumogastric nerve descends on the back of the gullet to the stomach, and distributes branches to the posterior surface of the organ: a part of this nerve is continued from the stomach to the left side of the cœliac plexus, and to the splenic plexus of the sympathetic.

**Varieties.**—The pneumogastric nerve of the right side has been found in front of the sheath of the great cervical vessels (Quain). In several instances the origin of the descendens noni has been transferred to the trunk of the pneumogastric. Turner, who has recorded such cases, mentions also one in which the entire trunk of the hypoglossal nerve was intimately connected with the pneumogastric as low as the posterior belly of the digastric muscle. The superior laryngeal nerve has frequently been seen to give branches to the thyro-hyoid and sterno-hyoid muscles (Meckel, Reid, Cloquet, Krause). The recurrent laryngeal in rare cases supplies the crico-thyroid muscle (Reid). This nerve also, in those cases in which the right subclavian artery arises from the left side of the aortic arch, passes directly inwards to the larynx in the neck, and is not hooked downwards towards the thorax by the subclavian. This abnormality is explained developmentally by the origin of the subclavian from the right aortic root posteriorly, and by the closure of the fourth branchial arch, as well as of the fifth, upon the right side.

**SUMMARY.**—The pneumogastric nerves supply branches to the upper part of the alimentary canal, viz., the pharynx, œsophagus, and stomach with the liver and spleen; and to the respiratory passages, namely, the larynx, trachea, and its divisions in the lungs. These nerves give branches likewise to the heart and great vessels by means of their communication with the cardiac plexus. Each pneumogastric nerve is connected with the following cranial nerves—the spinal accessory, glosso-pharyngeal, facial, and hypoglossal: also, with some spinal nerves; and with the sympathetic in the neck, thorax, and abdomen.

### III. SPINAL ACCESSORY NERVE.

The spinal nerve accessory to the vagus, or, as it is shortly named, the spinal accessory nerve, consists of two parts: one (accessory) joins the trunk of the pneumogastric; the other (spinal) ends in branches to the sterno-mastoid and trapezius muscles.

**Surface attachment.**—The accessory nerve arises by a series of roots, the upper of which are attached to the side of the medulla below those of the pneumogastric, while the remainder arise from the lateral column of the cervical portion of the cord as low down as the sixth or seventh pair of nerves. The lowest spinal roots are attached to the middle of the lateral column; the highest spinal roots arise close to the posterior nerve roots.

**Deep origin.**—The upper roots pass inwards to a nucleus which lies, on each side, at the back of and close to the central canal. It contains large nerve-cells, and is continuous, above, with the column of

cells giving origin to the pneumogastric nerve. The lower or spinal roots pass through the lateral column of the cord, and enter the grey substance midway between the anterior and posterior cornua. They then curve forwards into the anterior horn, and are believed to be connected with its large nerve-cells, especially with the outer group.

**Course and distribution.**—The *internal or accessory part*, the smaller of the two, joins in the foramen of exit the ganglion on the root of the pneumogastric, by two or three filaments; and having passed from the skull, blends with the trunk of the pneumogastric beyond its second ganglion, as already said.

It is stated by Bendz that a filament is given from the spinal accessory to the pharyngeal nerve above the place of junction with the pneumogastric, and the fibrils of the same nerve have been traced into each of the muscular offsets of the pneumogastric nerve. (Bendz, "Tract. de connexu inter nerv. vag. et acces." 1836.)

The *external portion* of the nerve communicates with the accessory part in the foramen jugulare. After issuing from the foramen, the nerve is directed backwards in front of the internal jugular vein, and perforates the sterno-mastoid muscle, supplying this with branches, and joining amongst the fleshy fibres with branches of the cervical plexus. Descending in the next place across the neck behind the sterno-mastoid, the nerve passes beneath the trapezius muscle. Here it forms a kind of plexus with branches of the third and fourth cervical nerves, and distributes filaments to the trapezius, which extend nearly to the lower edge of the muscle.

**Varieties.**—The spinal accessory nerve frequently passes behind the internal jugular vein. It has also been found to pass behind the sterno-mastoid muscle without piercing it (Turner, Nat. Hist. Review, 1864).

#### NINTH PAIR OF NERVES.

The hypoglossal or ninth cranial nerve is the motor nerve of the tongue, and in part of some of the muscles of the neck.

**Surface attachment.**—The nerve arises, by a series of fine roots, from the furrow between the anterior pyramid of the medulla and the olivary body.

**Deep origin.**—The bundles of fibres pass backwards, through the inner part of the olivary body, to reach their nucleus, a column of large branching nerve-cells lying in front of and close to the central canal, as low as the decussation of the pyramids. Above, where the canal opens into the floor of the fourth ventricle, the nucleus comes to the surface, causing a prominence close to the middle line, a little above the point of the calamus scriptorius.

**Course and distribution.**—The filaments by which this nerve arises from the medulla oblongata are collected into two bundles, which converge to the anterior condylar foramen of the occipital bone. Each bundle of filaments perforates the dura mater separately within the foramen, and the two are joined after they have passed through it.

After leaving the cranium, this nerve descends almost vertically to the lower border of the digastric muscle, where, changing its course, it is directed forwards above the hyoid bone to the under part of the tongue. It lies at first very deeply with the vagus nerve, to which it is connected; but passing between the internal carotid artery and the jugular vein, it curves forwards round the occipital artery, and then

crosses over the external carotid below the digastric muscle. Above the hyoid bone it is crossed by the lower part of the stylo-hyoid muscle and posterior belly of the digastric, and rests on the hyo-glossus muscle. At the anterior border of the hyo-glossus it is connected with the gustatory nerve, and is continued in the fibres of the genio-hyo-glossus muscle beneath the tongue to the tip, distributing branches upwards to the muscular substance.

The principal BRANCHES of this nerve are distributed to the muscles ascending to the larynx and hyoid bone, and to those of the tongue ; a few serve to connect it with some of the neighbouring nerves.

Fig. 350

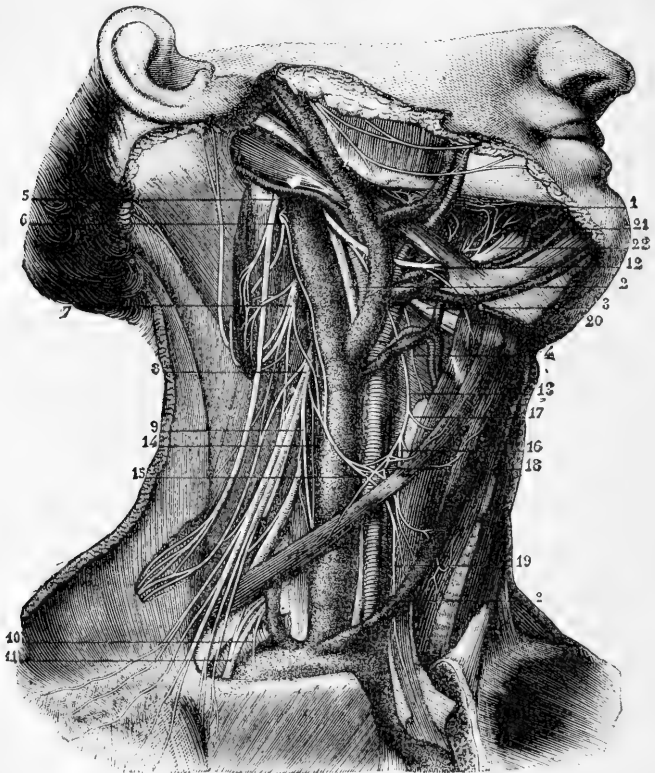


Fig. 350.—VIEW OF THE DISTRIBUTION OF THE SPINAL ACCESSORY AND HYPOGLOSSAL NERVES (from Sappey after Hirschfeld and Leveillé).  $\frac{1}{2}$

1, lingual nerve ; 2, pneumogastric nerve ; 3, superior laryngeal (represented too large) ; 4, external laryngeal branch ; 5, spinal accessory ; 6, second cervical ; 7, third ; 8, fourth ; 9, origin of the phrenic nerve ; 10, origin of the branch to the subclavius muscle ; 11, anterior thoracic nerves ; 12, hypoglossal nerve ; 13, its descending branch ; 14, communicating branch from the cervical nerves ; 15, 16, 18, 19, descending branches from the plexiform union of these nerves to the sterno-hyoid, sterno-thyroid, and omo-hyoid muscles ; 17, branch from the descendens noni to the upper belly of the omo-hyoid muscle ; 20, branch from the hypoglossal nerve to the thyro-hyoid muscle ; 21, communicating twigs from the hypoglossal to the lingual nerve ; 22, terminal distribution of the hypoglossal to the muscles of the tongue.



**Connecting branches.**—*Connection with the pneumogastric.*—Close to the skull the hypoglossal nerve is connected with the second ganglion of the pneumogastric by separate filaments, or in some instances the two nerves are united so as to form one mass.

*Union with the sympathetic and first two spinal nerves.*—Opposite the first cervical vertebra the nerve communicates by several twigs with the upper cervical ganglion of the sympathetic, and with the loop uniting the first two spinal nerves in front of the atlas.

**Descending branch of the ninth nerve.**—This branch (*r. descendens noni*) leaves the ninth nerve where this turns round the occipital artery, or, sometimes, higher up. It passes downwards on the surface of the sheath of the carotid vessels, gradually crossing from the outer to the inner side, gives a branch to the anterior belly of the omo-hyoid muscle, and joins about the middle of the neck in a loop with one or two branches from the second and third cervical nerves, forming the *ansa hypoglossi*. The concavity of this loop is turned upwards; and the connection between the nerves is effected by means of two or more interlacing filaments, which enclose an irregularly shaped space. From this interlacement of the nerves, filaments are continued backwards to the posterior belly of the omo-hyoid, and downwards to the sterno-hyoid and sterno-thyroid muscles. Occasionally a filament is continued to the chest, where it joins the cardiac and phrenic nerves.

**Muscular branches.**—The branch to the thyro-hyoid muscle is a separate twig given off from the hypoglossal nerve as it approaches the hyoid bone.

The nerve supplies branches to the hyo-glossus, genio-hyoid, and genio-hyo-glossus muscles as it becomes contiguous to each, and, when arrived close to the middle of the tongue in company with the ranine artery, gives off several long slender branches, which pass upwards into the substance of the organ. Some filaments join with others proceeding from the gustatory nerve.

**Varieties.**—In animals the ninth nerve not unfrequently possesses a posterior root furnished with a ganglion, in the same manner as that of a spinal nerve.

It is not uncommon to find the descending branch of the ninth nerve within the sheath of the large cervical vessels and in such cases it is placed either over or under the vein. This nerve in some cases appears to be derived either altogether from the pneumogastric, or from both the pneumogastric and hypoglossal nerves. There is every reason, however, to believe that these varieties in origin are only apparent, arising from the temporary adhesion of the filaments of this branch to those of the pneumogastric. It is probable, moreover, that the *descendens noni* has little if any real origin from the hypoglossal nerve: Luschka states, as the result of numerous researches on the human subject, that the *descendens noni* usually contains no filaments from the hypoglossal, but is a branch from the first and second cervical, temporarily associated with the ninth nerve; and this quite agrees with the circumstance that in some animals the nerves supplied to those muscles to which the *descendens noni* of the human subject is distributed come from the cervical plexus.

A branch is described as uniting with its fellow of the opposite side in the substance of the genio-hyoid muscle, or between it and the genio-glossus. This loop, as also the *ansa hypoglossi*, is recommended by Hyrtl as a particularly favourable example for the observation of nerve-fibres returning to the nervous centres without distribution, to which he gives the name of "nerves without ends." ("Nat. Hist. Review," Jan. 1862.) It was observed by Cruveilhier that in the *ansa hypoglossi* an interchange of fibres takes place, so that a filament of the cervical spinal nerve is directed upwards along the branch of the hypoglossal, and *vice versa*

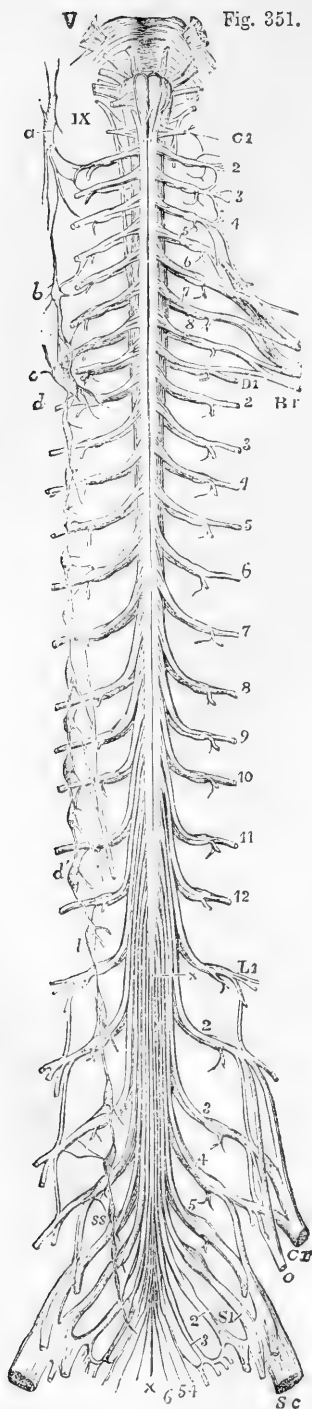


Fig. 351.

Fig. 351.—DIAGRAMMATIC OUTLINE OF THE ROOTS AND FIRST PART OF THE SPINAL NERVES, TOGETHER WITH THE SYMPATHETIC TRUNK OF ONE SIDE. (A. T.)  $\frac{1}{4}$

The view is taken from before. In the upper part of the figure the pons Varolii and medulla oblongata are represented, and from V to IX, the roots of the several cranial nerves from the trifacial to the hypoglossal are indicated. On the left side C 1 is placed opposite the first cervical or suboccipital nerve; and the numbers 2 to 8 following below indicate the corresponding cervical nerves; Br, indicates the brachial plexus; D 1, is placed opposite the intercostal part of the first dorsal nerve, and the numbers 2 to 12 following mark the corresponding dorsal nerves; L 1, the first lumbar nerve, and the numbers 2 to 5, following indicate the remaining lumbar nerves; Cr, the anterior crural, and *o*, the obturator nerve; S 1, the first sacral, and the following numbers 2 to 5, the remaining sacral nerves; 6, the coccygeal nerve; Sc, the great sciatic nerve; +, +, the filum terminale of the cord.

On the right side of the figure the following letters indicate parts of the sympathetic nerves; viz., *a*, the superior cervical ganglion communicating with the upper cervical spinal nerves and continued below in the great sympathetic cord; *b*, the middle cervical ganglion; *c*, *d*, the lower cervical ganglion united with the first dorsal; *d'*, the eleventh dorsal ganglion; from the fifth to the ninth dorsal ganglion the origins of the great splanchnic nerve are shown; *l*, the lowest dorsal or upper lumbar ganglion; *ss*, the upper sacral ganglion. In the whole extent of the sympathetic cord, the twigs of union with the spinal nerves are shown.

**SUMMARY.**—The hypoglossal nerve supplies, either alone or in union with branches of the spinal nerves, all the muscles connected with the os hyoides, including those of the tongue, with the exception of the digastric, stylo-hyoid, mylo-hyoid and the middle constrictor of the pharynx. It also supplies the sterno-thyroid muscle.

It is connected with the following nerves, viz., pneumo-gastric, lingual, three upper cervical nerves, and the sympathetic.

## B. SPINAL NERVES.

The spinal nerves are characterised by their origin from the spinal cord, and their direct transmission outwards from the spinal canal in the intervals between the vertebræ. Taken together, these nerves consist of thirty-one pairs;

and, according to the region in which they issue from the spinal canal, they are named cervical, dorsal, lumbar, sacral, and coccygeal.

By universal usage each pair of nerves in the dorsal, lumbar, and sacral regions is named in correspondence with the vertebra beneath which it emerges. Of the remaining eight pairs of nerves between the cranium and the first dorsal nerve, the uppermost is placed above the atlas, and the second and following nerves below the seven cervical vertebræ in succession. These eight pairs are usually reckoned as eight cervical nerves, but the first is also distinguished by the name of sub-occipital nerve. The nerves of the thirty-first pair emerge from the lower end of the sacral canal, pass below the first vertebra of the coccyx, and are named coccygeal.

Although the plan of counting eight cervical nerves is continued in this work for the sake of convenience, it being that which is most frequently followed, it is by no means intended to represent this method as the best or as scientifically correct. The plan of Willis, who reckoned the sub-occipital as a cranial nerve, had at least the advantage that it made the numbers of the remaining seven cervical nerves correspond each with the vertebra beneath which it emerged, as do the dorsal, lumbar and sacral nerves; and if the sub-occipital nerve, while recognised as the first spinal nerve, were to be kept distinct from the seven which succeed, a more uniform system of nomenclature would be arrived at than that which is at present in most common use.

**Varieties.**—Sometimes an additional coccygeal nerve exists. Among seven cases which appear to have been examined with great care, Professor Schlemm ("Observat. Neurologicæ," Berolini, 1834) found two coccygeal nerves on each side in one instance, and on one side in another case. In all the rest there was only a single coccygeal nerve on each side.

#### THE ROOTS OF THE SPINAL NERVES.

Each spinal nerve springs from the spinal cord by two roots which approach one another as they quit the spinal canal, and join in the corresponding intervertebral foramen into a single cord; and each cord so formed separates immediately into two divisions, one of which is destined for parts in front of the spine, the others for parts behind it.

**Structure.**—The *posterior roots* of the nerves are distinguished from the anterior roots by their greater size, as well as by the greater thickness of the fasciculi of which they are composed. Each spinal nerve is furnished with a ganglion situated on the posterior root: but the first cervical or sub-occipital nerve is in some cases without one. The size of the ganglion is in proportion to that of the nerve on which it is formed.

The ganglia are in general placed in the intervertebral foramina, immediately beyond the points at which the roots perforate the dura mater lining the spinal canal. The first and second cervical nerves, however, which leave the spinal canal, over the laminae of the vertebræ, have their ganglia opposite those parts. The ganglia of the sacral nerves are contained in the spinal canal, that of the last nerve being occasionally at some distance from the point at which the nerve issues. The ganglion of the coccygeal nerve is placed within the canal in the sac of dura mater, and at a variable distance from the origin of the nerve.

The fibres of the posterior root of the nerve divide into two bundles as they approach the ganglion, and the inner extremity of the oval-shaped ganglion is sometimes bilobate, the lobes corresponding to the two bundles of fibres.

The *anterior roots* of the spinal nerves are, as will be inferred from what has been already stated, the smaller of the two; they are devoid of ganglionic enlargement, and their fibres are collected into two bundles near the intervertebral ganglion, as in the posterior root.

**Size.**—The roots of the upper *cervical nerves* are smaller than those of the lower nerves, the first being much the smallest. The posterior roots of these nerves exceed the anterior in size more than in the other spinal nerves, and they are likewise composed of fasciculi which are considerably larger than those of the anterior roots.

Fig. 352. — DIFFERENT VIEWS OF A PORTION OF THE SPINAL CORD FROM THE CERVICAL REGION WITH THE ROOTS OF THE NERVES. Slightly enlarged. (A. T.)

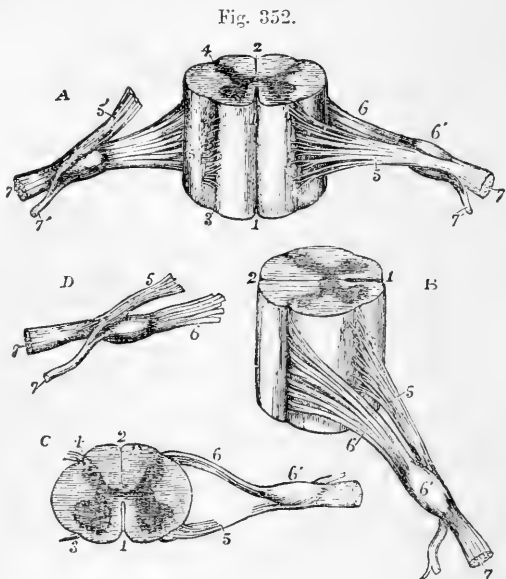
In A, the anterior surface of the specimen is shown, the anterior nerve-root of the right side being divided; in B, a view of the right side is given; in C, the upper surface is shown; in D, the nerve-roots and ganglion are shown from below. 1, the anterior median fissure; 2, posterior median fissure; 3, anterior lateral depression, over which the anterior nerve-roots are seen to spread; 4, posterior lateral groove, into which the posterior roots are seen to sink; 5, anterior roots passing the ganglion; 5', in A. the anterior root divided;

6, the posterior roots, the fibres of which enter the ganglion, 6'; 7, the united or compound nerve; 7', the posterior primary branch seen in A and D to be derived in part from the anterior and in part from the posterior root.

The roots of the *dorsal nerves*, exception being made of the first, which resembles the lowest cervical nerves and is associated with them in a part of its distribution, are of small size, and vary but slightly, or not at all, from the second to the last. The fasciculi of both roots are thinly strewn over the spinal cord, and are slender, those of the posterior exceeding in thickness those of the anterior root in only a small degree.

The roots of the lower *lumbar*, and of the upper *sacral nerves*, are the largest of all the spinal nerves; those of the lowest sacral and of the coccygeal nerve are, on the other hand, the slenderest. All these nerves are crowded together round the lower end of the cord. Of these nerves the anterior roots are the smaller, but the disproportion between the anterior and posterior roots is not so great as in the cervical nerves.

**Length of the nerves in the spinal canal.**—The place at which the roots of the upper cervical nerves are connected with the



spinal cord being nearly opposite the foramina by which they respectively leave the canal, these roots are comparatively short. But the distance between the two points referred to is gradually augmented from nerve to nerve downwards, so that the place of origin of the lower cervical nerves is the breadth of at least one vertebra, and that of the lower dorsal nerves about the breadth of two vertebræ above the foramina by which they respectively emerge from the canal. Moreover, as the spinal cord extends no farther than the first lumbar vertebra, the length of the roots of the lumbar, sacral and coccygeal nerves increases rapidly from nerve to nerve, and in each case may be estimated by the distance of the foramen of exit from the extremity of the cord. Owing to their length, and the appearance they present in connection with the spinal cord, the aggregation of the roots of the nerves last referred to has been named the "cauda equina."

The *direction* the roots take within the canal requires brief notice. The first cervical nerve is directed horizontally outwards. The roots of the lower cervical and dorsal nerves at first descend over the spinal cord, held in contact with it by the arachnoid, till they arrive opposite the several intervertebral foramina, where they are directed horizontally outwards. The nerves of the cauda equina run in the direction of the spinal canal.

**Division of the nerves.**—The two roots of each of the spinal nerves unite immediately beyond the ganglion, and the trunk thus formed separates, as already mentioned, into two divisions, an anterior and a posterior, which are called primary branches or divisions.

In the detailed description of the spinal nerves which follows, we shall begin with their posterior primary divisions, calling attention first to certain characters common to the whole of them, and afterwards stating separately the arrangement peculiar to each group of nerves (cervical, dorsal, &c.)

#### POSTERIOR PRIMARY DIVISIONS OF THE SPINAL NERVES.

The posterior divisions of the spinal nerves are, with few exceptions, smaller than those given to the fore part of the body. Springing from the trunk which results from the union of the roots of the nerve in the intervertebral foramen, or frequently by separate fasciculi from each of the roots, each turns backwards at once, and soon divides into two parts, distinguished as *external* and *internal*, distributed to the muscles and the integument behind the spine. The first cervical, the fourth and fifth sacral and the coccygeal nerve are the only nerves the posterior divisions of which do not separate into external and internal branches.

**THE SUB-OCCIPITAL NERVE.**—The posterior division of the sub-occipital nerve, which is the larger of the two primary divisions, emerging over the arch of the atlas, between this and the vertebral artery, enters the space bounded by the larger rectus and the two oblique muscles, and divides into branches for the surrounding muscles.

*a.* One branch descends to the lower oblique muscle and gives a filament, through or over the fibres of that muscle, to join the second cervical nerve.

*b.* Another ascends over the larger rectus muscle, supplying it and the smaller rectus.

*c.* A third enters the upper oblique muscle.

*d.* A fourth sinks into the complexus, where that muscle covers the nerve and its branches.

Fig. 353.

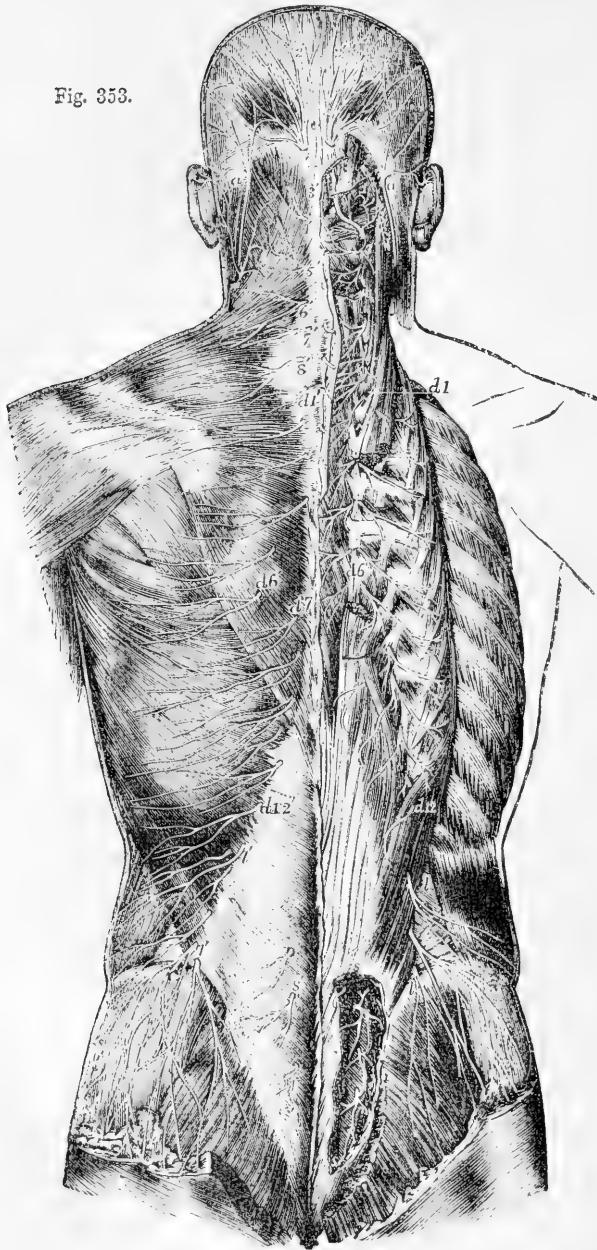


Fig. 353.—SUPERFICIAL AND DEEP DISTRIBUTION OF THE POSTERIOR PRIMARY DIVISIONS OF THE SPINAL NERVES (after Hirschfeld and Leveillé).  $\frac{1}{2}$

On the left side the cutaneous branches are represented as lying upon the superficial layer of muscles; on the right side, the superficial muscles having been removed, the

splenius and complexus have been divided in the neck, and the erector spinæ separated and partially removed in the back, so as to expose the deep issue of the nerves.

*a, a*, lesser occipital nerve from the cervical plexus; 1, external muscular branches of the first cervical nerve and union by a loop with the second; 2, placed on the rectus capitis posticus major, marks the great occipital nerve passing round the short muscles and piercing the complexus; the external branch is seen to the outside; 2', cranial distribution of the great occipital; 3, external branch of the posterior primary division of the third nerve; 3', its internal branch, or third occipital nerve; 4, 5, 6, 7, 8, internal branches of the several corresponding nerves on the left side; the external branches of these nerves proceeding to muscles are displayed on the right side: *d 1* to *d 6*, and thence to *d 12*, external muscular branches of the posterior primary divisions of the twelve dorsal nerves on the right side; *d 1'*, to *d 6'*, the internal cutaneous branches of the six upper dorsal nerves on the left side; *d 7'* to *d 12'*, cutaneous branches of the six lower dorsal nerves from the external branches; *l, l*, external branches of the posterior primary branches of several lumbar nerves on the right side piercing the muscles, the lower descending over the gluteal region; *l', l'*, the same more superficially on the left side; *s, s*, on the right side, the issue and union by loops of the posterior primary divisions of four sacral nerves; *s', s'*, some of these distributed to the skin on the left side.

A *cutaneous branch* is occasionally given to the back of the head; it accompanies the occipital artery, and is connected beneath the integument with the great and small occipital nerves.

**CERVICAL NERVES** (*excepting the sub-occipital*). — The **external branches** give only muscular offsets, and are distributed to the splenius and the slender muscles prolonged to the neck from the erector spinæ, viz., the cervicalis ascendens, and the transversalis colli with the trachelo-mastoid. That of the second nerve is the largest of the series of external branches, and is often united to the corresponding branch of the third; it supplies the complexus muscle which covers it, and ends in the splenius and trachelo-mastoid muscles.

The **internal branches**, larger than the external, are differently disposed at the upper and the lower parts of the neck. That of the second cervical nerve is named, from its size and destination, the *great occipital*, and requires separate notice. The rest are directed inwards to the spinous processes of the vertebræ. Those derived from the third, fourth, and fifth nerves pass over the semispinalis and beneath the complexus muscle, and, having reached the spines of the vertebræ, turn transversely outwards and are distributed in the integument over the trapezius muscle. From the cutaneous branch of the third nerve a branch passes upwards to the integument on the lower part of the occiput, lying at the inner side of the great occipital nerve, and is sometimes called third occipital nerve.

Between the inner branches of the first three cervical nerves, beneath the complexus, there are frequently communicating fasciculi; and this communication Cruveilhier has designated as "the posterior cervical plexus."

The internal branches from the lowest three cervical nerves are placed beneath the semispinalis muscle, and end in the muscular structure, without furnishing (except occasionally the sixth) any offset to the skin. These three nerves are the smallest of the series.

The *great occipital nerve* is directed upwards on the lower oblique muscle, and is transmitted to the surface through the complexus and trapezius muscles, giving twigs to the complexus. Ascending with the occipital artery, it divides into branches which radiate over the occipital part of the occipito-frontalis muscle, some appearing to enter the muscle, and others joining the smaller occipital nerve.

An *auricular branch* is sometimes supplied to the back of the ear by the **great occipital nerve**.

**DORSAL NERVES.**—The **external branches** increase in size from above downwards. They are directed through or beneath the longissimus dorsi to the space between that muscle and the ilio-costalis and accessorius; they supply both those muscles, together with the small muscles continued upwards from the erector spinæ to the neck, and also the levatores costarum. The lower five or six nerves give cutaneous twigs, which are transmitted to the integument in a line with the angles of the ribs.

The **internal branches** of the upper six dorsal nerves appear in the interval between the multifidus spinæ and the semispinalis dorsi; they supply those muscles, and become cutaneous by the side of the spinous processes of the vertebræ. The cutaneous branch of the second nerve, and sometimes others, reach as far as the scapula. The internal branches of the lower six dorsal nerves are placed between the multifidus spinæ and longissimus dorsi, and end in the multifidus without giving branches to the integument. Where cutaneous nerves are supplied by the internal branches, there are none from the external branches of the same nerve, and *vice versâ*.

**LUMBAR NERVES.**—The **external branches** enter the erector spinæ, and give filaments to the intertransverse muscles. From the upper three, cutaneous nerves are supplied; and from the last, a fasciculus descends to the corresponding branch of the first sacral nerve. The *cutaneous nerves* given from the external branches of the first three lumbar nerves, pierce the fleshy part of the ilio-costalis, and the aponeurosis of the latissimus dorsi: they cross the iliac crest near the edge of the erector spinæ, and terminate in the integument of the gluteal region. One or more of the filaments may be traced as far as the great trochanter of the femur.

The **internal branches** wind backwards in grooves close to the articular processes of the vertebræ, and sink into the multifidus spinæ muscle.

**SACRAL NERVES.**—The posterior division of the nerves, except the last, issue from the sacrum through its posterior foramina. The first three are covered at their exit from the bone by the multifidus spinæ muscle, and bifurcate like the posterior trunks of the other spinal nerves; but the remaining two, which continue below that muscle, have a peculiar arrangement, and require separate examination.

The **internal branches** of the first three sacral nerves are small, and are lost in the multifidus spinæ muscle.

The **external branches** of the same nerves are united with one another, and with the last lumbar and fourth sacral nerves, so as to form a series of anastomotic loops on the upper part of the sacrum. These branches are then directed outwards to the cutaneous or posterior surface of the great sacro-sciatic ligament, where, covered by the gluteus maximus muscle, they form a second series of loops, and end in cutaneous nerves. These pierce the great gluteus muscle in the direction of a line from the posterior iliac spine to the tip of the coccyx. They are commonly three in number—one is near the innominate bone, another opposite the sacrum, and the third about midway between the other two. All are directed outwards over the great gluteal muscle.

In six dissections by Ellis this arrangement was found to be the most frequent. The variations to which it is liable are these:—the first nerve may not take part in the formation of the second series of loops, and the fourth may be associated with them.



The posterior divisions of the *last two sacral nerves* are smaller than those above them, and are not divided into external and internal branches. They are connected with each other by a loop on the back of the sacrum, and the lowest is joined in a similar manner with the coccygeal nerve; one or two small filaments from these sacral nerves are distributed behind the coccyx.

**COCYGEAL NERVE.**—The posterior division of the coccygeal nerve is very small, and separates from the anterior primary portion of the nerve in the sacral canal. It is joined by a communicating filament from the last sacral nerve, and ends in the fibrous structure covering the posterior surface of the coccyx.

### ANTERIOR PRIMARY DIVISIONS OF THE SPINAL NERVES.

The anterior primary divisions of the spinal nerves are distributed to the parts of the body situated in front of the vertebral column, including the limbs. They are, for the most part, considerably larger than the posterior divisions.

The anterior division of each spinal nerve is connected by one or two slender filaments with the sympathetic. Those of the cervical, lumbar, and sacral nerves form plexuses of various forms; but those of the dorsal nerves remain for the most part separate from one another.

#### CERVICAL NERVES.

The anterior divisions of the four upper cervical nerves form the cervical plexus. They appear at the side of the neck between the scalenus medius and rectus anticus major muscles. They are each connected by a communicating filament with the first cervical ganglion of the sympathetic nerve, or with the cord connecting that ganglion with the second.

The anterior divisions of the four lower cervical nerves, larger than those of the upper four, appear between the scaleni muscles, and, together with that of the first dorsal, go to form the brachial plexus. They are each connected by a filament with one of the two lower cervical ganglia of the sympathetic, or with the plexus on the vertebral artery.

The anterior divisions of the first and second nerves require a notice separately from the description of the nerves of the cervical plexus.

#### SUB-OCCIPITAL NERVE.

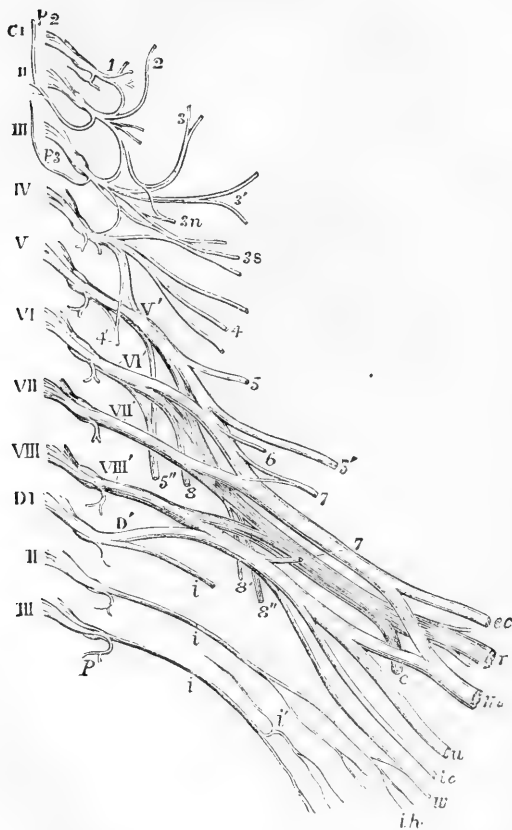
The anterior primary division of the first nerve runs forwards in a groove on the atlas, and bends downwards in front of the transverse process of that vertebra to join the second nerve. In this course forwards it lies beneath the vertebral artery, and at the inner side of the rectus lateralis muscle, to which it gives a branch. As it crosses the foramen in the transverse process of the atlas, the nerve is joined by a filament from the sympathetic; and from the loop which it makes in front of the transverse process, branches are supplied to the two anterior recti muscles. Short filaments connect this part of the nerve with the pneumo-gastric, the hypoglossal, and the sympathetic nerves.

Valentin notices filaments distributed to the articulation of the occipital bone with the atlas, and to the mastoid process of the temporal bone.

## SECOND CERVICAL NERVE.

The anterior division of the second cervical nerve, beginning between the arches of the first two vertebrae, is directed forwards between their transverse processes, being placed outside the vertebral artery, and beneath the intertransverse and other muscles fixed to those processes. In front of the intertransverse muscles, the nerve divides into an ascending part, which joins the first cervical nerve, and a descending part to the third.

Fig. 354.

Fig. 354. — DIAGRAMMATIC OUTLINE OF THE CERVICAL AND BRACHIAL PLEXUSES. (A. T.)  $\frac{1}{3}$ 

The nerves are separated from the spinal cord at their origin and are supposed to be viewed from before. C1, is placed opposite the roots of the first cervical or sub-occipital nerve, and the Roman numbers in succession from II, to VIII, opposite the roots of the corresponding cervical nerves; D1, is placed opposite to the roots of the first dorsal nerve, and II, and III, opposite the second and third nerves; the origin of the posterior primary branch is shown in all the nerves: of these *p* 2, indicates the great occipital from the second, and *p* 3, the smallest occipital nerve from the third. *Cervical plexus*: 1, anterior primary branch of the first cervical nerve and loop of union with the second nerve; 2, lesser occipital nerve proceeding in this case from the second cervical nerve, more frequently from the second and third; 3, great auricular nerve from the second and third; 3', superficial cervical nerve from the third; 3 *n*, communicating branches to the descendens noni from

the second and third; 3 *s*, communicating to the spinal accessory from the second, third, and fourth; 4, supraclavicular and supra-acromial descending nerves: the loops or arches of communication between the four upper cervical nerves, and between the fourth and fifth, are shown; 4', the phrenic nerve springing from the fourth and fifth nerves. *Brachial plexus*: V', to VIII', and D', the five roots of the brachial plexus; 5, the rhomboid nerve; 5', suprascapular; 5'', posterior thoracic; 6, nerve to the subclavius muscle; 7, 7', inner and outer anterior thoracic nerves; 8, 8', 8'', upper and lower subscapular nerves. In the larger nerves proceeding to the shoulder and arm from the plexus, those of the anterior division are represented of a lighter shade, those belonging to the posterior division darker; *ec*, external cutaneous or musculo-cutaneous; *m*, median; *u*, ulnar, *ic*, internal cutaneous; *w*, nerve of Wrisberg; *r*, musculo-spiral; *c*, circumflex; *i*, intercostal nerves; *i'*, lateral branch of the same; *ih*, intercosto-humeral nerves.

## CERVICAL PLEXUS.

The cervical plexus is formed by the anterior divisions of the first four cervical nerves, and distributes branches to some of the muscles of the neck, and to a portion of the integument of the head and neck. It is placed opposite the first four vertebræ, beneath the sterno-mastoid muscle, and rests against the middle scalenus muscle and the levator anguli scapulæ. The disposition of the nerves in the plexus is easily recognised. Each nerve, except the first, branches into an ascending and a descending part: and these are united in communicating loops with the contiguous nerves. From the union of the second and third nerves, superficial branches are supplied to the head and neck; and from the junction of the third with the fourth, arise the cutaneous nerves of the shoulder and chest. Muscular and communicating branches spring from the same nerves.

The BRANCHES of the plexus may be separated into two sets—a superficial and deep; the superficial consisting of those which ramify over the cervical fascia, supplying the integument and some also the platysma; the deep comprising branches which are distributed for the most part to the muscles. The superficial nerves may be subdivided into ascending and descending; the deep nerves into an internal and external series.

## SUPERFICIAL ASCENDING BRANCHES.

**Superficial cervical nerve.**—This nerve takes origin from the second and third cervical nerves, turns forward over the sterno-mastoid muscle about the middle, and, after perforating the cervical fascia, divides beneath the platysma myoides into two branches, which are distributed to the anterior and lateral parts of the neck.

*a.* The *upper branch* gives an ascending twig which accompanies the external jugular vein, and communicates freely with the facial nerve (cervico-facial division); it is then transmitted through the platysma to the surface, supplying that muscle, and ramifies in the integument of the upper half of the front of the neck, filaments reaching as high as the lower maxilla.

*b.* The *lower branch* likewise pierces the platysma, and is distributed below the preceding, its filaments extending in front as low as the sternum.

The superficial cervical nerve may arise from the plexus in the form of two or more distinct branches. Thus Valentin describes three superficial cervical nerves, which he names superior, middle, and inferior. (“Sömmerring v. Bau,” &c.)

While the superficial cervical nerve ramifies over the platysma myoides, the facial nerve is beneath the muscle. According to Valentin many anastomotic arches are formed on the side of the neck between those two nerves, as well as between the branches of the former, one with another

**Great auricular nerve.**—This nerve winds round the outer border of the sterno-mastoid, and is directed obliquely upwards beneath the platysma myoides, between the muscle and the deep fascia of the neck, to the lobe of the ear. Here the nerve gives a few small branches to the face, and ends in the auricular and mastoid branches.

*a.* The *auricular branches* are directed to the back of the external ear, on which they ramify, and are connected with twigs derived from the facial nerve. One of these branches reaches the outer surface of the ear by a fissure between the antihelix and the concha. A few filaments are supplied likewise to the outer part of the lobule.

*b.* The *mastoid branch* is united to the posterior auricular branch of the facial nerve, and ascends over the mastoid process to the integument behind the ear.

*c.* The *facial branches* of the great auricular nerve, which extend to the integuments of the face, are distributed over the parotid gland. Some slender filaments penetrate deeply through the substance of the gland, and communicate with the facial nerve.

**Small occipital nerve.**—The smaller occipital nerve varies in size, and is sometimes double. It springs from the second cervical nerve, and is directed almost vertically to the head along the posterior border of the sterno-mastoid muscle. Having perforated the deep fascia near the cranium, the small occipital nerve is continued upwards between the ear and the great occipital nerve, and ends in cutaneous filaments which extend upwards in the scalp; it communicates with branches from the larger occipital nerve, as well as with the posterior auricular branch of the facial. It appears to supply sometimes the occipito-frontalis muscle.

The *auricular branch* is distributed to the upper part of the ear on the posterior aspect, and to the elevator muscle of the auricle. This auricular branch is an offset from the great occipital nerve when the small occipital is of less size than usual.

## II. SUPERFICIAL DESCENDING BRANCHES.

**Supraclavicular nerves.**—The descending series of the superficial nerves are thus named. There are two of these nerves, or, in some cases, a greater number. They arise from the third and fourth cervical nerves, and descend in the interval between the sterno-mastoid and the trapezius muscles. As they approach the clavicle, the nerves are augmented to three or more in number, and are recognised as internal, middle, and posterior.

*a.* The *internal* (suprasternal) branch, which is much smaller than the rest, ramifies over the inner half of the clavicle, and terminates near the sternum.

*b.* The *middle branch* (supraclavicular), lying opposite the interval between the pectoral and deltoid muscles, distributes some twigs over the fore part of the deltoid, and others over the pectoral muscle. The latter join the small cutaneous branches of the intercostal nerves.

*c.* The *external* or *posterior branch* (supra-acromial) is directed outwards over the acromion, and the clavicular attachment of the trapezius muscle, and ends in the integument of the outer and back part of the shoulder.

## III. DEEP BRANCHES : INNER SERIES.

**Connecting branches.**—The cervical plexus is connected near the base of the skull with the trunks of the pneumo-gastric, hypoglossal, and sympathetic nerves, by means of filaments intervening between those nerves and the loop formed by the first two cervical nerves in front of the atlas (p. 560).

**Muscular branches.**—*Branches to the anterior recti muscles* proceed from the cervical nerves close to the vertebrae, including the loop between the first two of these nerves.

*Two branches to the ansa hypoglossi*, one from the second, the other from the third cervical nerve, descend over or under the internal jugular vein, to form a loop of communication with the ramus descendens noni, and aid in the supply of the muscles below the hyoid bone (p. 567).

**Phrenic nerve.**—The diaphragmatic or phrenic nerve passes down through the lower part of the neck and the thorax to its destination.

It commences from the fourth cervical nerve, and receives usually a fasciculus from the fifth. As it descends in the neck, the nerve is inclined inwards over the anterior scalenus muscle; and near the chest

Fig. 355.

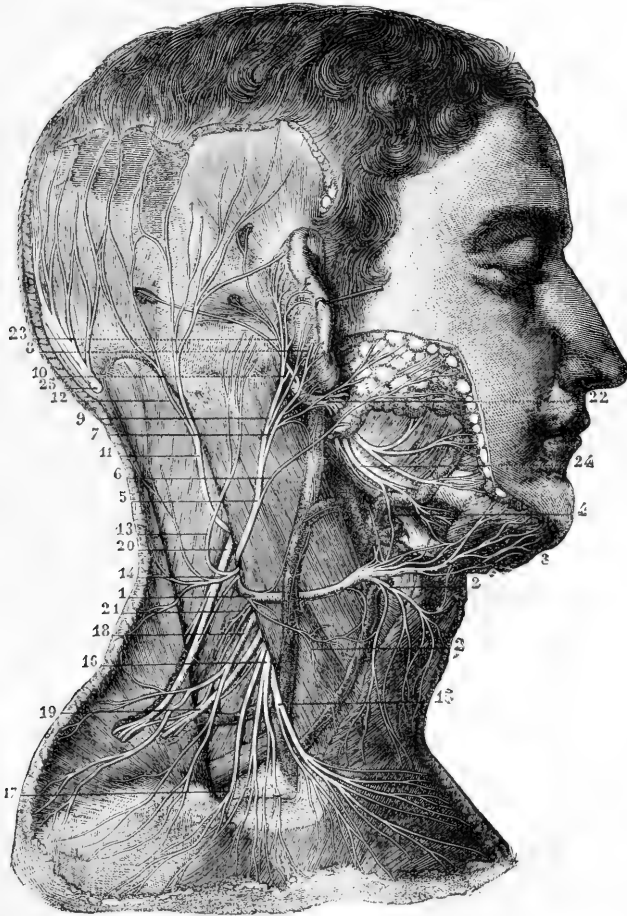


Fig. 355.—VIEW OF THE SUPERFICIAL DISTRIBUTION OF THE NERVES PROCEEDING FROM THE CERVICAL PLEXUS (from Sappey after Hirschfeld and Leveillé).  $\frac{1}{3}$

1, superficial cervical nerve; 2, 2, descending branches of the same; 3, ascending branches; 4, twigs uniting with the facial; 5, great auricular nerve; 6, its parotid branch; 7, its external auricular branch; 8, twig of the same which pierces the auricle to pass to its outer surface; 9, branch to the deep surface of the pinna; 10, its union with the posterior auricular of the facial nerve; 11, small occipital nerve; 12, its branch which unites with the great occipital nerve; 13, a mastoid branch or second small occipital; 14, twigs from this to the back of the neck; 15, 16, supraclavicular nerves; 17, 18, supra-acromial nerves; 19, branch of the cervical nerves passing into the trapezius muscle; 20, spinal accessory distributed to the same and receiving a uniting branch from the cervical nerves; 21, branch to the levator scapulae; 22, trunk of the facial nerve; 23, its posterior auricular branch passing into the occipital and posterior and superior auricular muscles; 24, its cervico-facial branches.

it is joined by a filament of the sympathetic, and sometimes also by another filament derived from the fifth and sixth cervical nerves.

As it enters the thorax each phrenic nerve is placed between the subclavian artery and vein, and crosses over the internal mammary artery near the root. It then takes nearly a straight direction, in front of the root of the lung on each side, and along the side of the pericardium,—between this and the mediastinal part of the pleura. Near the diaphragm it divides into branches, which separately penetrate the fibres of that muscle, and then diverging from each other, are distributed on the under surface.

The *right nerve* is placed more deeply than the left, and is at first directed along the outer side of the right innominate vein, and the descending vena cava.

The *nerve of the left side* is a little longer than that of the right, in consequence of the oblique position of the pericardium round which it winds, and also because of the diaphragm being lower on this than on the opposite side. This nerve crosses in front of the arch of the aorta and the pulmonary artery before reaching the pericardium.

Besides the terminal *branches* supplied to the diaphragm, each phrenic nerve gives filaments to the pleura and pericardium; and receives sometimes an offset from the union of the descendens noni with the cervical nerves. Swan notices this union as occurring only on the left side. Luschka describes twigs from the lower part of the nerve to the peritoneum, the inferior cava, and the right auricle of the heart.

One or two filaments of the nerve of the right side join in a small ganglion with branches to the diaphragm which are derived from the solar plexus of the sympathetic; and from the ganglion twigs are given to the suprarenal capsule, the hepatic plexus, and the lower vena cava. On the left side there is a junction between the phrenic and the sympathetic nerves near the œsophageal and aortic openings in the diaphragm, but without the appearance of a ganglion.

#### IV. DEEP BRANCHES: EXTERNAL SERIES.

**Muscular branches.**—The sterno-mastoid receives a branch from the second cervical nerve. Two branches proceed from the third nerve to the levator anguli scapulæ; and from the third and fourth cervical nerves, as they leave the spinal canal, branches are given to the middle scalenus muscle. Further, the trapezius has branches prolonged to it; and thus, like the sterno-mastoid, this muscle receives nerves from both the spinal accessory and the cervical plexus.

*Connection with the spinal accessory nerve.*—In the substance of the sterno-mastoid muscle, this nerve is connected with the branches of the cervical plexus furnished to that muscle. It is also connected with the branches distributed to the trapezius—the union between the nerves being beneath the muscle, and having the appearance of a plexus; and with another branch of the cervical plexus in the interval between the two muscles.

**SUMMARY OF THE CERVICAL PLEXUS.**—From the cervical plexus are distributed cutaneous nerves to the back of the head, to part of the ear and face, to the anterior half of the neck, and to the upper part of the trunk. The muscles supplied with nerves from the plexus are the sterno-mastoid, the platysma, and the lower hyoid muscles in part; the anterior recti capitis, the levator anguli scapulæ, the trapezius, the scalenus medius, and the diaphragm. By means of its branches

the plexus communicates with the pneumo-gastric, spinal accessory, hypoglossal, and sympathetic nerves.

Fig. 356.

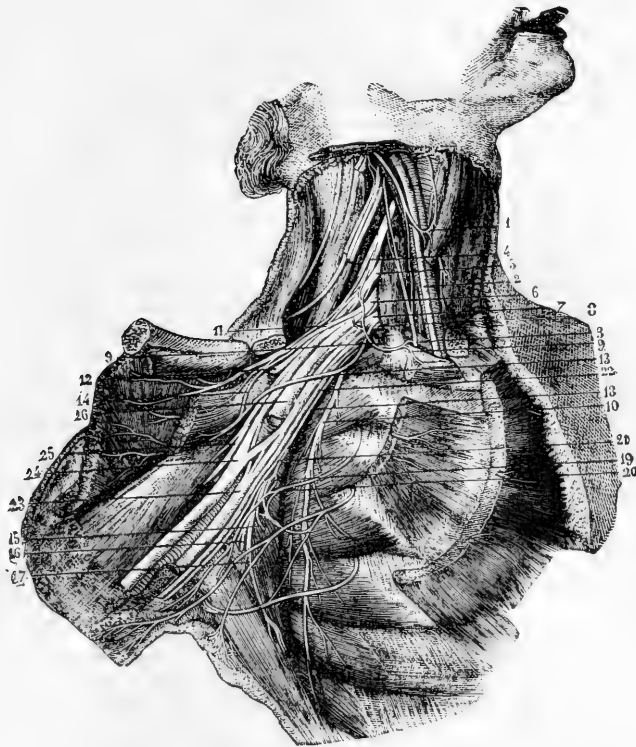


Fig. 356.—DEEP DISSECTION OF THE AXILLA, SHOWING THE BRACHIAL PLEXUS AND NEIGHBOURING NERVES (from Sappey after Hirschfeld and Leveillé).  $\frac{1}{4}$

The clavicle has been sawn through near its sternal end, and is turned aside with the muscles attached to it; the subclavius and the greater and lesser pectoral muscles have been removed from the front of the axilla. 1, loop of union between the descendens noni and a branch of the cervical plexus; 2, pneumo-gastric; 3, phrenic passing down to the inner side of the scalenus anticus muscle; 4, anterior primary division of the fifth cervical nerve; 5, the same of the sixth; 6, 7, the same of the seventh and eighth cervical nerves; 8, the same of the first dorsal nerve; 9, 9, branch from the plexus to the subclavius muscle, communicating with the phrenic nerve; 10, posterior thoracic nerve distributed to the serratus magnus; 11, upper anterior thoracic nerve passing into the great pectoral muscle; 13, lower anterior thoracic distributed to the lesser pectoral; 14, twig of communication between these two nerves; 12, suprascapular nerve passing through the suprascapular notch; 15, lower of the two subscapular nerves; 16, nerve of the teres major; 17, long subscapular, or nerve of the latissimus dorsi; 18, accessory of the internal cutaneous nerve; 19, union of the accessory cutaneous with the second and third intercostal nerves; 20, lateral branch of the second intercostal; 21, second internal cutaneous or nerve of Wrisberg; 22, internal cutaneous nerve; 23, the ulnar nerve to the inside of the axillary artery, passing behind the vein, and having, in this case, a union with the upper division of the plexus; 24, the median nerve immediately below the place where its two roots embrace the artery, which is divided above this place; 25, the musculo-cutaneous nerve passing into the coraco-brachialis muscle; 26, the musculo-spiral nerve passing behind the divided brachial artery.

## BRACHIAL PLEXUS.

This large plexus, from which the nerves of the upper limbs are supplied, is formed by the union of the anterior trunks of the four lower cervical and first dorsal nerves; and it further receives a fasciculus from the lowest of the nerves (fourth), which goes to form the cervical plexus. The plexus extends from the lower part of the neck to the axillary space, and terminates opposite the coracoid process of the scapula in large nerves for the supply of the limb.

The manner in which the nerves are disposed in the plexus is liable to some variation, but the following may be regarded as the arrangement most frequently met with. The fifth and sixth cervical join together at the outer border of the scalenus medius to form an upper trunk; similarly the eighth cervical and first dorsal unite together between the scaleni muscles to form a lower trunk, while the seventh cervical remains single, forming a middle trunk.

Soon after passing the outer border of the scaleni muscles each primary trunk divides so as to form an anterior and a posterior branch. The anterior branches of the upper and middle trunks unite together to form what is called the *upper or outer cord* of the plexus; the anterior branch of the lower trunk forms by itself the *lower or inner cord* of the plexus, and the posterior branches of all three trunks unite together to form the *middle or posterior cord*. The cords thus formed lie side by side in the fore part of the plexus, and external to the first part of the axillary vessels, but lower down they are placed, one on the outer side of the axillary artery, one on the inner side, and one behind that vessel, and are continued into the principal nerves for the arm.

**Varieties.**—Instead of three primary trunks, only two are found in a great number of instances. This arises from the frequent union of the seventh nerve with the trunk formed by the fifth and sixth nerves, which takes place at the outer border of the scaleni muscles. The fasciculi which unite to form the posterior cord are generally separated at a higher level than the formation of the two other cords, but they are also frequently given off as low as the clavicle, or even farther down. As regards position, the fifth and sixth nerves or the fifth alone not unfrequently pierce the upper fibres of the anterior scalenus muscle; the fifth nerve has even been found to pass altogether in front of that muscle. (Turner, Nat. Hist. Review, 1864. and Journ. of Anat., 1872; Henle, Systematic Anatomy, vol. iii.; Lucas, Guy's Hosp. Reports, 1875, &c.)

**BRANCHES.**—The branches proceeding from the plexus are numerous, and may be conveniently divided into two classes—viz., those that arise above the clavicle, and those that take origin below the bone.

## BRANCHES ABOVE THE CLAVICLE.

Above the clavicle there arise from the trunks of the brachial plexus, the posterior thoracic and suprascapular nerves, a nerve for the rhomboid muscles, another for the subclavius, irregular branches for the scaleni and longus colli, and a branch to join the phrenic nerve.

**Small muscular branches.**—The branches for the *scaleni and longus colli muscles* spring in an irregular manner from the lower cervical nerves close to their place of emergence from the vertebral foramina.

The branch for the *rhomboid muscles* arises from the fifth nerve, and is directed backwards to the base of the scapula through the fibres of the middle scalenus



and beneath the levator anguli scapulæ. It is distributed to the deep surface of the rhomboid muscles, and gives sometimes a branch to the levator scapulæ.

The nerve of the *subclavius muscle*, of small size, arises from the front of the cord which results from the union of the fifth and sixth cervical nerves. It is directed over the outer part of the subclavian artery to the deep surface of the subclavius muscle. This small nerve is commonly connected with the phrenic nerve in the neck or in the chest, by means of a slender filament.

Branch to join the *phrenic nerve*.—This small and short branch is an offset from the fifth cervical nerve; it joins the phrenic nerve on the anterior scalenus muscle.

Fig. 357. — DISTRIBUTION OF THE SUPRASCAPULAR AND CIRCUMFLEX NERVES (from Hirschfeld and Leviellé).  $\frac{1}{2}$

*a*, the scalenus medius and posticus muscles; *b*, levator anguli scapulæ; *c*, acromion; *d*, deltoid muscle, of which the back part has been detached from the scapula and in part removed; *e*, rhomboid muscle; *f*, teres major; *g*, latissimus dorsi; 1, the brachial plexus of nerves as seen from behind; 1', the nerve of the levator scapulæ and rhomboid muscles; 2, placed on the clavicle, marks the suprascapular nerve; 3, its branch to the supraspinatus muscle;

4, branch to the infraspinatus; 5, placed on the back of the humerus below the insertion of the teres minor, marks the circumflex nerve passing out of the quadrangular interval; 6, its branch to the teres minor muscle; 7, branches to the deep surface of the deltoid; 8, cutaneous branch to the back of the shoulder.

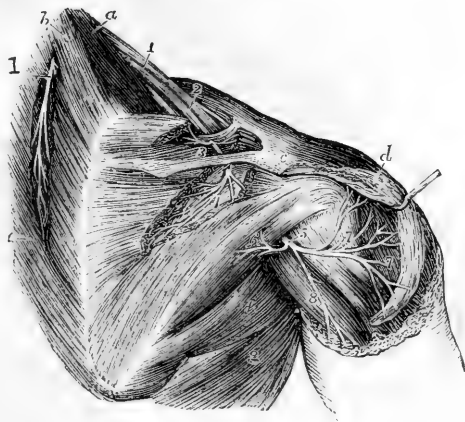
**Posterior thoracic nerve.**—The posterior thoracic nerve (nerve of the serratus magnus; external respiratory of Bell) is formed in the substance of the middle scalenus muscle by two roots, one from the fifth and another from the sixth nerve, and reaches the surface of the scalenus lower than the nerve of the rhomboid muscles, with which it is often connected. It descends behind the brachial plexus on the outer surface of the serratus magnus, nearly to the lower border of that muscle, supplying it with numerous branches.

**Suprascapular nerve.**—The suprascapular nerve arises from the back of the cord formed by the union of the fifth and sixth nerves, and bends beneath the trapezius to the upper border of the scapula, where it passes between the muscles and the bone. Entering the supraspinous fossa of the scapula, through the suprascapular notch (beneath the ligament which crosses the notch), the suprascapular nerve supplies two branches to the supraspinatus, one near the upper, the other near the lower part of the muscle, and it then descends through the great scapular notch into the lower fossa, where it ends in the infraspinatus muscle.

**Articular branches.**—In the upper fossa of the scapula, a slender *articular filament* is given to the shoulder-joint, and in the lower fossa other twigs of the nerve enter the same joint and the substance of the scapula.

**Varieties.**—The communicating branch to the phrenic nerve has been seen to pass down into the thorax over the subclavian artery and even over the vein before joining with the phrenic. The posterior thoracic nerve sometimes gets an additional branch from the seventh cervical, and Lucas has recorded three

Fig. 357.



instances in which it received a fourth branch or root from the eighth cervical. Its highest root from the fifth cervical nerve is frequently united at its origin with the nerve to the rhomboids.

#### BRANCHES BELOW THE CLAVICLE.

The several nerves now to be described are derived from the three great cords of the plexus in the following order.

From the upper or outer cord,—the external of the two anterior thoracic nerves, the musculo-cutaneous, and the outer root of the median

From the lower or inner cord,—the inner of the two anterior thoracic, the nerve of Wrisberg, the internal cutaneous, the ulnar, and the inner root of the median.

From the posterior cord,—the subscapular nerves, the circumflex, and the musculo-spiral.

If the fasciculi of which the principal nerves are composed be followed through the plexus, they may be traced to those of the spinal nerves which in the subjoined table are named along with each trunk. The higher numbers refer to the cervical nerves, the unit to the dorsal nerve:—

Subscapular from . . . . .	} 5.6.7.8.	Ulnar . . . . . 8.1. or 7.8.1.
Circumflex . . . . .		
Musculo-spiral . . . . .	} 5.6.7.	Small internal cutaneous } 8.1.
External cutaneous . . . . .		
Median . . . . .	5.6.7.8.1.	inner 8.1.

**Anterior thoracic nerves.**—The anterior thoracic nerves, two in number, supply the pectoral muscles.

The *external*, or more superficial branch, arising from the outer cord, crosses inwards over the axillary artery, and terminates in the great pectoral muscle.

The *internal*, or deeper branch, springing from the inner cord, comes forwards between the axillary artery and vein to the small pectoral muscle, and is joined by a branch from the external. This nerve presents a plexiform division beneath the small pectoral muscle, and supplies branches to it and the larger pectoral muscle. The two nerves are connected by a filament which forms a loop over the artery, at the inner side.

**Subscapular nerves.**—These nerves, three in number, take origin from the posterior cord of the plexus.

The *upper* nerve, the smallest of the subscapular nerves, penetrates the upper part of the subscapular muscle. The *middle* nerve gives a branch to the subscapularis at its axillary border, and ends in the teres major muscle. There is sometimes a distinct nerve for the last-named muscle.

The *long subscapular* nerve, the largest of the three, runs along the lower border of the subscapular muscle to the latissimus dorsi, to which it is distributed.

**Circumflex nerve.**—The circumflex nerve gives both muscular and cutaneous nerves to the shoulder. Springing from the posterior cord, this nerve is at first placed behind the axillary artery, but at the lower border of the subscapular muscle it is inclined backwards with the posterior circumflex artery, in the space between the scapula and teres major muscle above the long head of the triceps, and separates into an

upper and a lower branch, which are distributed to the deltoid and teres minor muscles, the integument of the shoulder, and the shoulder-joint

Fig. 358.—DISTRIBUTION OF THE POSTERIOR CUTANEOUS NERVES OF THE SHOULDER AND ARM (after Hirschfel and Leveillé).  $\frac{1}{2}$

1, supra-acromial branches of the cervical nerves descending on the deltoid muscle; 2, ascending or reflected, and 2', descending cutaneous branches of the circumflex nerve; 3, inferior external cutaneous of the musculo-spiral nerve; 4, external and posterior cutaneous branches of the musculo-cutaneous nerve to the forearm; 5, internal cutaneous of the musculo-spiral; 6, intercosto-humeral branches; 7, twigs of the nerve of Wrisberg; 8, upper posterior branch of the internal cutaneous nerve; 9, lower branch of the same.

a. The *upper portion* winds round the upper part of the humerus, extending to the anterior border of the deltoid muscle, to which it is distributed. One or two *cutaneous filaments*, penetrating between the muscular fibres, are bent downwards and supply the integument over the lower part of the muscle.

b. The *lower branch* supplies offsets to the back part of the deltoid, and furnishes the nerve to the teres minor, which is remarkable in presenting a gangliform enlargement. It then turns round the posterior border of the deltoid below the middle, and ramifies in the integument, over the lower two-thirds of that muscle, one branch extending to the integument over the long end of the triceps muscle.

c. An *articular filament* for the shoulder-joint arises near the commencement of the nerve, and enters the capsular ligament below the subscapular muscle

**Varieties.**—In two instances Turner has described a branch of the circumflex nerve which supplies the teres major. (Journ. of Anat. vol. vi., p. 104.)

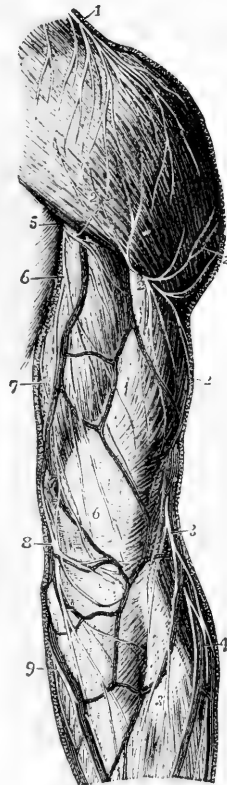
**Internal cutaneous nerve.**—At its origin from the inner cord of the brachial plexus, this nerve is placed on the inner side of the axillary artery. It becomes cutaneous about the middle of the arm, and after perforating the fascia, or, in some cases, before doing so, is divided into two parts; one destined for the anterior, the other for the posterior surface of the forearm.

a. The *anterior branch* crosses at the bend of the elbow behind (in some cases over) the median basilic vein, and distributes filaments in front of the forearm, as far as the wrist; one of these is, in some instances, joined with a cutaneous branch of the ulnar nerve.

b. The *posterior branch* inclines obliquely downwards at the inner side of the basilic vein, and winding to the back of the forearm, over the prominence of the internal condyle of the humerus, extends somewhat below the middle of the forearm. Above the elbow this branch is connected with the smaller internal cutaneous nerve (nerve of Wrisberg), and afterwards communicates with the outer portion of the internal cutaneous, and, according to Swan, with the dorsal branch of the ulnar nerve.

c. A branch to the *integument of the arm* pierces the fascia near the axilla, and

Fig. 358.



reaches to the elbow, or nearly so, distributing filaments outwards over the biceps muscle. This branch is often connected with the intercosto-humeral nerve.

Fig. 359.

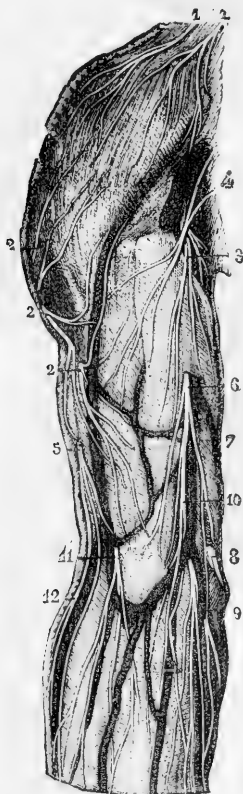

Fig. 360.

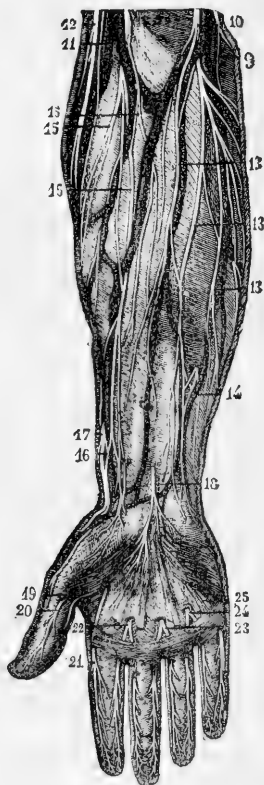

Fig. 359.—ANTERIOR CUTANEOUS NERVES OF THE SHOULDER AND ARM (from Sappey after Hirschfeld and Leveillé).  $\frac{1}{2}$

1, 1, supraclavicular and supra-acromial nerves from the cervical plexus; 2, 2, 2, cutaneous branches of the circumflex nerve; 3, 4, upper branches of the internal cutaneous nerve; 5, superior external cutaneous branch of the musculospiral; 6, internal cutaneous nerve piercing the deep fascia; 7, posterior branch; 8, communicating twig with one of the anterior branches; 9, 10, anterior branches of this nerve, some turning round the median basilic and ulnar veins; 11, musculo-cutaneous nerve descending over the median cephalic vein; 12, inferior cutaneous branch of the musculospiral nerve.

Fig. 360.—ANTERIOR CUTANEOUS NERVES OF THE FOREARM AND HAND (from Sappey after Hirschfeld and Leveillé).  $\frac{1}{2}$

9, 10, 13, distribution of the anterior branches of the internal cutaneous nerve; 14, union of one of these with a twig of the ulnar nerve; 12, inferior cutaneous branch of the musculospiral nerve; 11, 15, distribution of the external cutaneous nerve; 16, union of one of its branches with 17, the terminal branch of the radial nerve; 18, palmar cutaneous branch of the median nerve; 19, 20, internal and external collateral branches to the thumb from the median nerve; 21, external collateral to the index finger; 22, 23, collateral branches to the index, middle and fourth fingers; 24, 25, collateral branches from the ulnar nerve to the fourth and fifth fingers; the network of communicating twigs formed by the terminal branches of these cutaneous nerves is represented at the extremities of the fingers.

**Small internal cutaneous nerve.**—The smaller internal cutaneous nerve, or nerve of Wrisberg, destined for the supply of the integument of the lower half of the upper arm on the inner and posterior aspect, commonly arises from the inner cord of the brachial plexus in union with the larger internal cutaneous and ulnar nerves. In the axilla it lies close to the axillary vein, but it soon appears on the inner side of that vessel, and communicates with the intercosto-humeral nerve. It then descends along the inner side of the brachial vessels to about the middle of the arm, where it pierces the fascia, and its filaments are thence continued to the interval between the internal condyle of the humerus and the olecranon.

**Branches.**—In the lower third of the arm, branches of this small nerve are directed almost horizontally to the integument on the posterior aspect; and the nerve ends at the elbow by dividing into several filaments, some of which are directed forwards over the inner condyle of the humerus, while others are prolonged downwards behind the olecranon.

*Connection with the intercosto-humeral nerve.*—This connection presents much variety in different cases:—in some, there are two or more intercommunications, forming a kind of plexus on the posterior boundary of the axillary space; in others, the intercosto-humeral nerve is of larger size than usual, and takes the place of the nerve of Wrisberg, only receiving in the axilla a small filament from the brachial plexus, and this small communicating filament represents in such cases the nerve of Wrisberg.

**Musculo-cutaneous nerve.**—The musculo-cutaneous or external cutaneous nerve is deeply placed between the muscles as far as the elbow, and below that point is immediately under the integument. Arising from the brachial plexus opposite the small pectoral muscle, it perforates the coraco-brachialis muscle, and, passing obliquely across the arm between the biceps and brachialis anticus muscles, reaches the outer side of the biceps a little above the elbow. Here it perforates the fascia, and nearly opposite the elbow-joint it passes behind the median-cephalic vein, and, inclining outwards, divides into two branches which supply the integument on the outer side of the forearm, one on the anterior, the other on the posterior aspect.

#### A. BRANCHES IN THE ARM:—

*a.* A branch to the coraco-brachialis and short head of the biceps is given off before the nerve pierces the former muscle; and other filaments are furnished to the coraco-brachialis, while the nerve lies among its fibres.

*b.* Branches to the biceps and brachialis anticus are given off while the nerve is between those muscles.

*c.* Small filaments are given to the humerus and elbow-joint.

#### B. BRANCHES IN THE FOREARM:—

*a.* The *anterior branch* descends near the radial border of the forearm. It is placed in front of the radial artery near the wrist, and distributes some filaments over the ball of the thumb. Piercing the fascia, it accompanies the artery to the back part of the carpus. This part of the nerve is connected at the wrist with a branch of the radial nerve.

*b.* The *posterior branch* is directed outwards to the back of the forearm, and ramifies in the integument of the lower third, extending as far as the wrist. It communicates with a branch of the radial nerve, and with the external cutaneous branch of the musculo-spiral nerve.

**SUMMARY.**—The musculo-cutaneous nerve supplies the coraco-brachialis, biceps, and brachialis anticus muscles, and the integument

on the outer side of the forearm. Communications are established between it and the radial and the external cutaneous branch of the musculo-spiral.

**Varieties.**—In some cases it does not perforate the coraco-brachialis muscle. It is frequently found to communicate by a cross branch with, or to be an offset of the median nerve; and in the latter case, the coraco-brachialis muscle receives a separate branch from the brachial plexus, which may be explained thus,—that the main part of the musculo-cutaneous nerve, instead of piercing the coraco-brachialis muscle, remains adherent to the outer root and trunk of the median.

**Ulnar nerve.**—The ulnar nerve, the largest branch of the inner cord of the brachial plexus, descends on the inner side of the artery of the limb as far as the middle of the arm, then turns backwards through the internal intermuscular septum with the inferior profunda artery, to reach the interval between the olecranon and the inner condyle of the humerus. From the axilla to this place it is covered only by the fascia, and it may be felt through the integument a little above the elbow. It here passes between the two heads of the flexor carpi ulnaris, and it remains concealed by that muscle as far as the middle of the forearm; it thence extends in a straight course along the outer margin of the muscle, between it and the ulnar artery, to the outer side of the pisiform bone. Above the wrist it gives off a large dorsal branch to the hand, and continuing onwards it enters the palm on the surface of the annular ligament, and divides into muscular and cutaneous branches.

The ulnar nerve usually gives off no branches in the upper arm.

#### A. BRANCHES IN THE FOREARM:—

*a. Articular filaments* are given to the elbow-joint as the nerve passes behind it. Some filaments are also given to the wrist-joint.

*b. Muscular branches.*—One branch enters the upper part of the flexor carpi ulnaris, and another supplies the two inner divisions of the deep flexor of the fingers.

*c. Cutaneous branches to the forearm.*—These two small nerves arise about the middle of the forearm by a common trunk. One pierces the fascia, and turning downward, joins a branch of the internal cutaneous nerve. This branch is often absent. The second, a *palmar branch*, lies on the ulnar artery, which it accompanies to the hand. This little nerve gives filaments around the vessel, and ramifies in the integument of the hand, joining in some cases with other cutaneous offsets of the ulnar or median nerve.

*d. Dorsal branch to the hand*—This large offset, leaving the trunk of the ulnar nerve two or three inches above the wrist, winds backwards beneath the flexor carpi ulnaris and divides into branches; one of these ramifies on the inner side of the little finger, another divides to supply the contiguous sides of that finger and the ring finger, while a third joins on the back of the metacarpus with the branch of the radial nerve which supplies the contiguous sides of the ring and middle finger. The several posterior digital nerves, now described, are united with twigs directed backwards from the anterior digital nerves of the same fingers.

#### B. PALMAR BRANCHES:—

*a. The deep branch* separates from the trunk beyond the annular ligament, and, dipping down through the muscles of the little finger in company with the deep branch of the ulnar artery, it follows the course of the deep palmar arch across the hand. It supplies the short muscles of the little finger as it pierces them; and as it lies across the metacarpal bone, it distributes two branches to each

Fig. 361.

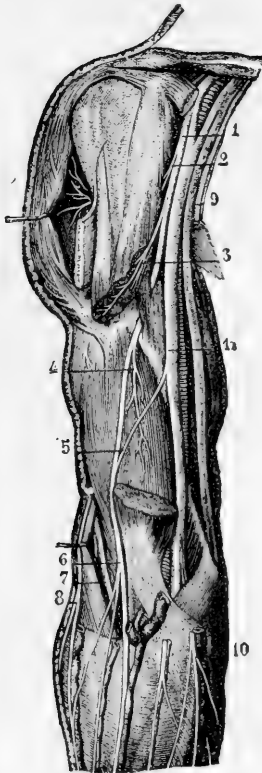


Fig. 362.

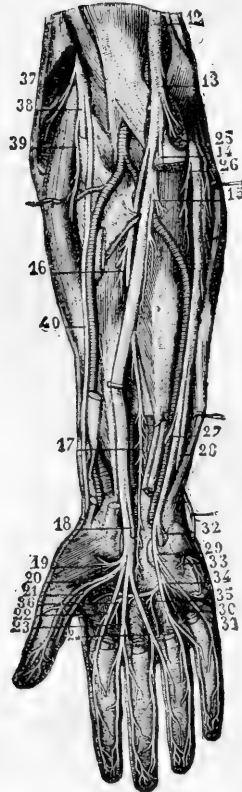


Fig. 361.—DEEP VIEW OF THE ANTERIOR NERVES OF THE SHOULDER AND ARM (from Sappey after Hirschfeld and Leveillé).  $\frac{1}{2}$

1, musculo-cutaneous nerve; 2, its twig to the coraco-brachialis muscle; 3, its branch to the biceps; 4, its branch to the brachialis anticus; 5, twig of union with the median nerve (a variety); 6, continuation of the nerve in its cutaneous distribution; 7, musculo-spiral nerve in the interval between the brachialis anticus and supinator longus; 8, inferior external cutaneous branch of the musculo-spiral; 9, the internal cutaneous and small internal cutaneous nerves divided; 10, anterior branch of the internal cutaneous; 11, median nerve; to the inside the ulnar nerve is crossed by the line from 11.

Fig. 362.—DEEP VIEW OF THE ANTERIOR NERVES OF THE FOREARM AND HAND (from Sappey after Hirschfeld and Leveillé).  $\frac{1}{2}$

12, the median nerve; 13, its branches to the pronator teres; 14, branch to the superficial flexor muscles, which have been removed; 15, branch to the flexor digitorum profundus; 16, branch to the flexor longus pollicis; 17, anterior interosseous branch; 18, cutaneous palmar branch cut short; 19, branches to the short muscles of the thumb; 20, 21, collateral branches to the thumb; 22, 23, 24, collateral branches to the second, third, and fourth fingers; 25, branch given by the ulnar nerve to the flexor carpi ulnaris; 26, branch to the flexor digitorum profundus; 27, cutaneous communicating twig; 28, dorsal branch of the ulnar; 29, superficial palmar branch; 30, 31, collateral branches to the fourth and fifth fingers; 32, deep palmar branch; 33, its branch to the short muscles of the little finger; 34, 35, 36, twigs given by the deep branch of the ulnar to the third and fourth lumbricales, all the interossei, and the adductor pollicis.

interosseous space—one for the palmar, the other for the dorsal interosseous muscle, and supplies filaments to the two innermost lumbricales muscles. Opposite the space between the thumb and the index finger the nerve ends in branches to the adductor pollicis, and the inner head of the flexor brevis pollicis.

*b.* The remaining part of the nerve supplies a branch to the palmaris brevis muscle and small twigs to the integument, and divides into two digital branches.

*Digital nerves.*—One of these belongs to the ulnar side of the little finger. The other is connected in the palm of the hand with a digital branch of the median nerve, and at the cleft between the little and ring fingers, divides into the collateral nerves for these fingers. The terminal disposition of the digital branches on the fingers is the same as that of the median nerve, to be presently described.

**SUMMARY.**—The ulnar nerve gives cutaneous filaments to the lower part of the forearm (to a small extent), and to the hand on its palmar and dorsal aspects. It supplies the following muscles, viz., the ulnar flexor of the carpus, the deep flexor of the fingers (its inner half), the short muscles of the little finger with the palmaris brevis, the interosseous muscles of the hand, the two internal lumbricales, the adductor pollicis and the inner half of the flexor brevis pollicis. Lastly, it contributes to the nervous supply of the elbow and wrist joints.

**Varieties.**—When the occasional epitrochleo-anconeus muscle is present, it receives a branch from the ulnar in the upper arm (Henle). From the same part of the nerve also small branches have been found entering the inner head of the triceps. In three instances, Gruber has found the nerve descending in front of the inner condyle instead of behind. A case has been recorded in which the ulnar nerve supplied also two branches to the flexor sublimis digitorum (Turner, "Nat. Hist. Review," 1864). The usual anastomosis between the digital branches of the median and ulnar nerves is sometimes wanting (Henle).

**Median nerve.**—The median nerve arises by two roots, one from the outer, the other from the inner cord of the brachial plexus. Commencing by the union of these roots in front or on the outer side of the axillary artery, the nerve descends in contact with the brachial artery, gradually passing inwards over it, and near the elbow is at the inner side of the vessel. Crossing the bend of the arm it passes beneath the pronator radii teres, separated by the deep slip of that muscle from the ulnar artery, and continues straight down the front of the forearm, between the flexor sublimis digitorum and flexor profundus. Arrived near the wrist it lies beneath the fascia, between the tendons of the flexor sublimis and that of the flexor carpi radialis. It then enters the palm behind the annular ligament, and rests on the flexor tendons. Somewhat enlarged, and of a slightly reddish colour, it here separates into two parts of nearly equal size. One of these (the external) supplies some of the short muscles of the thumb, and gives digital branches to the thumb and the index finger; the second portion supplies the middle finger, and in part the index and ring fingers.

The median nerve gives no branch to the upper arm.

#### A. BRANCHES IN THE FOREARM :—

In the forearm the median nerve supplies muscular branches, and, near the wrist, a single cutaneous filament. All the muscles on the front of the forearm (pronators and flexors), except the flexor carpi



ulnaris and part of the deep flexor of the fingers, are supplied from this nerve.

*a.* The branches, for the superficial muscles are separate twigs given off from the nerve below or near the elbow-joint, but the branch furnished to the pronator teres often arises above the joint.

*b.* *Anterior interosseous nerve.*—This is the longest branch of the median nerve, and it supplies the deeper muscles of the forearm. Commencing at the upper part of the forearm, beneath the superficial flexor of the fingers, it passes downwards with the anterior interosseous artery on the interosseous membrane, and between the long flexor of the thumb and the deep flexor of the fingers, to the pronator quadratus muscle, in which it ends.

*c.* The *cutaneous palmar branch* pierces the fascia of the forearm close to the annular ligament, and descending over that ligament, ends in the integument of the palm about the middle: being connected by a twig with the cutaneous palmar branch of the ulnar nerve. It distributes some filaments over the ball of the thumb, which communicate with twigs of the radial or the external cutaneous nerve.

## B. BRANCHES IN THE HAND:—

*a.* *Branch to muscles of the thumb.*—This short nerve subdivides into branches for the abductor, the opponens, and the outer head of the flexor brevis pollicis muscle.

*b.* *Digital nerves.*—These are five in number, and belong to the thumb, and the fingers as far as the outer side of the ring-finger. As they approach the clefts between the fingers, they are close to the integument in the intervals between the longitudinal divisions of the palmar fascia.

The *first* and *second* nerves lie along the sides of the thumb; and the former (the outer one) is connected with the radial nerve upon the ball of the thumb.

The *third* destined for the radial side of the index finger, gives a muscular branch to the first or most external lumbricalis muscle.

The *fourth* supplies the second lumbricalis, and divides into branches for the adjacent sides of the index and middle fingers.

The *fifth*, the most internal of the digital nerves, is connected by a crossing-twig with the ulnar nerve, and divides to furnish branches to the adjacent sides of the ring and middle fingers.

Fig. 362\*.—DISTRIBUTION OF THE DIGITAL NERVES (from Hirschfeld and Leveillé).  $\frac{1}{2}$

1, palmar collateral nerve; 2, its final palmar distribution; 3, its dorsal or ungual distribution, and between these numbers the network of terminal filaments; 4, collateral dorsal nerve; 5, uniting twigs passing between the dorsal and palmar digital nerves.

Each digital nerve divides at the end of the finger into two branches, one of which supplies the ball on the fore part of the finger; the other ramifies in the pulp beneath the nail. Branches pass from each nerve forwards and backwards to the integument of the finger; and one larger than the rest inclines backwards by the side of the first phalanx of the finger, and, after joining the dorsal digital nerve, ends in the integument over the last phalanx.

**SUMMARY.**—The median nerve gives cutaneous branches to the palm, and to three and a half fingers. It supplies the pronator muscles, the flexors of the carpus and the long flexors of the fingers (except the ulnar flexor of the carpus, and part of the deep flexor of the fingers), likewise the outer set of the short muscles of the thumb, and two lumbricales.

Fig. 362\*.



Some similarity will be observed between the course and distribution of the median and ulnar nerves. Neither gives any offset in the arm. Together they supply all the muscles in front of the forearm and in the hand, and together they supply the skin of the palmar surface of the hand, and impart tactile sensibility to all the fingers.

**Varieties.**—One or both heads of the median may be double, and the outer head may pass behind instead of in front of the brachial artery. (Turner.) The whole nerve has frequently been seen passing behind the brachial artery. (Turner, Gruber.) Gruber has also noticed one case in which the nerve entered the forearm after passing completely over the pronator teres muscle.

**Musculo-spiral nerve.**—The musculo-spiral nerve, the largest offset from the brachial plexus, occupies chiefly the back part of the limb, and supplies nerves to the extensor muscles, as well as to the skin.

Arising behind the axillary vessels from the posterior cord of the brachial plexus, of which it is the principal continuation and the only one prolonged into the arm, it soon turns backwards into the musculo-spiral groove, and, accompanied by the superior profunda artery, proceeds along that groove, between the humerus and the triceps muscle, to the outer side of the limb. It then pierces the external intermuscular septum, and descends in the interval between the supinator longus and the brachialis anticus muscle to the level of the outer condyle of the humerus, where it ends by dividing into the radial and posterior interosseous nerves. Of these, the radial is altogether a cutaneous nerve, and the posterior interosseous is the muscular nerve of the back of the forearm.

The branches of the musculo-spiral nerve may be classified according as they arise on the inner side of the humerus, behind that bone, or on the outer side.

#### A. INTERNAL BRANCHES :—

*a.* *Muscular branches* for the inner and middle heads of the triceps. That for the inner portion of the muscle is long and slender; it lies by the side of the ulnar nerve, and reaches as far as the lower third of the upper arm. One branch, previously noticed by authors, but more particularly described by Krause, is named by him the *ulnar collateral* branch. It arises opposite the outer border of the latissimus dorsi tendon, and descends within the sheath of the ulnar nerve, through the internal intermuscular septum, and is distributed to the short inferior fibres of the triceps (Reichert and Du Bois Reymond's Archiv, 1864).

*b.* The *internal cutaneous* branch of the musculo-spiral nerve, commonly united in origin with the preceding, winds backwards beneath the intercosto-humeral nerve, and after supplying filaments to the skin, ends about two inches from the olecranon; in some instances extending as far as the olecranon. This nerve is accompanied by a small cutaneous artery.

#### B. POSTERIOR BRANCHES :—

These consist of a fasciculus of *muscular branches* which supply the outer head of the triceps muscle and the anconeus. The *branch* of the *anconeus* is slender, and remarkable for its length; it descends in the substance of the triceps to reach its destination.

#### C. EXTERNAL BRANCHES :—

*a.* The *muscular branches* supply the supinator longus, extensor carpi radialis longior, (the extensor carpi radialis brevior receiving its nerve from the posterior interosseous,) and frequently give a small branch to the brachialis anticus.

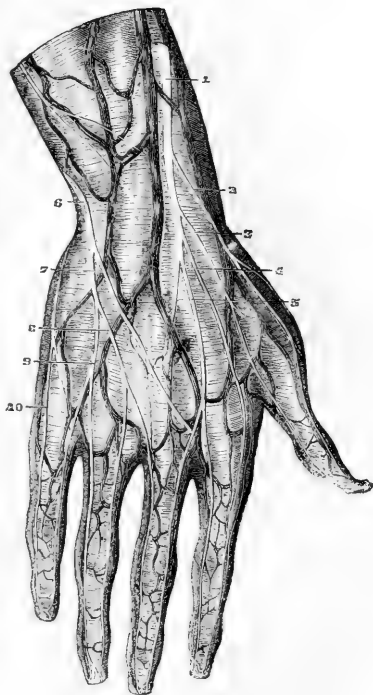
(b) The *external cutaneous branches*, two in number, arise where the nerve pierces the external intermuscular septum.

The *upper branch*, the smaller of the two, is directed downwards to the fore part of the elbow, along the cephalic vein, and distributes filaments to the lower half of the upper arm on the anterior aspect. The *lower branch* extends as far as the wrist, distributing offsets to the lower half of the arm, and to the forearm, on their posterior aspect, and is connected near the wrist with a branch of the external cutaneous nerve.

Fig. 363.

Fig. 363.—DORSAL CUTANEOUS NERVES OF THE HAND.  $\frac{1}{3}$ 

The distribution delineated in this figure is not the most common, there being a larger than usual branch of the ulnar nerve: 1, the radial nerve descending beside the principal radial cutaneous vein; 2 and 3, dorsal branches to the two sides of the thumb; 4, branch to the radial side of the forefinger; 5, branch to the forefinger and middle finger, communicating with one from the ulnar nerve; 6, the posterior branch of the ulnar nerve; 7, communicating twig; 8, collateral branch to the middle and ring fingers; 9, collateral branch to the ring and little fingers; 10, branch to the inner side of the hand and little finger.



**Radial nerve.**—The radial nerve, continuing straight down from the musculo-spiral, is concealed by the long supinator muscle, and lies a little to the outer side of the radial artery. This position beneath the supinator is retained to about three inches from the lower end of the radius, where the nerve turns backwards beneath the tendon of the muscle, and becomes subcutaneous. It then separates into two branches, which ramify in the integument on the dorsal aspect of the thumb and the next two fingers in the following manner.

(a) The *external branch* extends to the radial side of the thumb, and is joined by an offset of the external cutaneous nerve. It distributes filaments over the ball of the thumb.

(b) The *internal portion* communicates with a branch of the external cutaneous nerve on the back of the forearm, and divides into digital branches; *one* running along the ulnar side of the thumb, a *second* on the radial side of the index finger, a *third* dividing to supply the adjacent sides of the index and middle fingers, while a *fourth* joins with an offset from the dorsal branch of the ulnar, and along with it forms a branch for the supply of the contiguous sides of the middle and ring fingers. These branches communicate on the sides of the fingers with the palmar digital nerves.

Sometimes the interspace between the middle and ring fingers is entirely supplied by the radial, and at other times entirely by the ulnar nerve.

**Posterior interosseous nerve.**—This nerve, the larger of the two divisions of the musculo-spiral nerve, winds to the back of the forearm through the fibres of the supinator brevis muscle, and is prolonged between the deep and superficial layers of the extensor muscles to the interosseous membrane, which it approaches about the middle of the forearm.

Fig. 364.

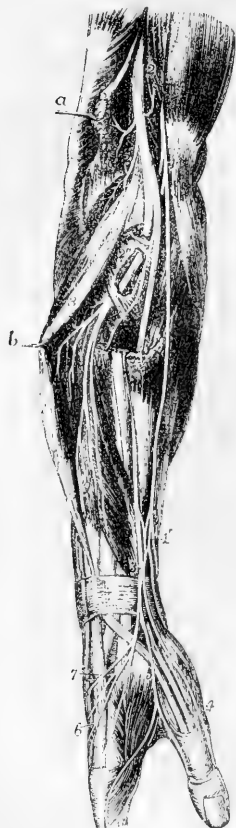

Fig. 364.—VIEW OF THE RADIAL SIDE OF THE FOREARM, SHOWING THE FINAL DISTRIBUTION OF THE MUSCULO-SPIRAL NERVE (after Hirschfeld and Leveillé).  $\frac{1}{4}$

The supinator longus, and extensores carpi radiales longior and brevior have been divided, and their upper parts removed; the extensor communis digitorum is pulled backwards by a hook, and the supinator brevis has been partially dissected to show the posterior interosseous nerve passing through it.

1, placed upon the tendon of the biceps muscle, points to the musculo-cutaneous nerve; 1', near the wrist, the lower part of this nerve and its plexus of union with the radial nerve; 2, trunk of the musculo-spiral nerve emerging from between the brachialis anticus, on which the number is placed, and the supinator longus muscle; 2', its muscular twigs to the long supinator and long radial extensor of the carpus; 2'', the posterior interosseous nerve passing through the substance of the supinator brevis; 3, placed upon the cut lower portion of the supinator longus, and lower down the radial nerve; 4, the external collateral nerve of the thumb; 5, the common collateral of the fore-finger and thumb; 6, the common collateral of the fore-finger and middle finger; 7, the twig of union with the dorsal branch of the ulnar nerve; 8, placed upon the common extensor of the fingers, the muscular branches of the posterior interosseous nerve to the long extensor muscles; 9, upon the extensor secundi internodii pollicis, the branches to the short extensor muscles.

Much diminished in size by the separation of numerous branches for the muscles, the nerve lies at the lower part of the forearm beneath the extensor of the last phalanx of the thumb and the tendons of the common extensor of the fingers, and terminates on the back of the carpus in a gangliform enlargement, from which filaments are given to the adjoining ligaments and articulations.

The *branches* of the interosseous nerve enter the surrounding muscles, viz., the extensor carpi radialis brevior and supinator brevis, the superficial layer of the extensor muscles, except the anconeus, and the deep layer of the same muscles:—that is to say, the nerve supplies the supinators, and the extensors of the carpus and fingers, with the exception of the supinator longus and the extensor carpi radialis longior.

**SUMMARY.**—The musculo-spiral nerve distributes its branches to the extensor muscles of the elbow-joint exclusively, with the exception of a filament to the brachialis anticus, which, however, receives its principal nerves from another source. Before separating into its two large divisions, the nerve gives branches to two muscles of the forearm, viz., the long supinator, and the long radial extensor of the carpus. The

posterior interosseous division distributes nerves to the remaining muscles on the outer and back part of the forearm, except the anconeus (previously supplied), viz., to the short supinator and the extensors.

Cutaneous nerves are distributed, from the trunk of the nerve and its radial division, to the lower part of the upper arm, to the forearm, and to the hand—on the posterior and outer aspect of each.

**Varieties.**—The dorsal branch of the radial nerve sometimes supplies the whole of the back of the hand and fingers. In a single case recorded by Turner the posterior interosseous did not form the so-called ganglion behind the carpus, but passed down to supply the adjacent sides of the index and middle fingers.

### DORSAL NERVES.

These nerves are twelve in number, and, with the exception of the larger part of the first of them, which joins the brachial plexus, they are distributed to the walls of the thorax and abdomen. Eleven of the nerves so distributed are termed intercostal, and the twelfth is situated below the last rib. The cords connecting them with the sympathetic nerve, placed close to the vertebræ, are very short.

The anterior divisions of these nerves pass separately to their destination, without forming any plexus by the connection or interlacement of their fibres, and in this respect they differ from those of the other spinal nerves. From the intervertebral foramina they are directed transversely across the trunk, and nearly parallel one to another. The upper six nerves, with the exception of the first, are confined to the parietes of the thorax; while the lower six nerves are continued from the intercostal spaces to the muscles and integument of the anterior wall of the abdomen.

### FIRST DORSAL NERVE.

The greater part of the anterior division of this nerve ascends over the neck of the first rib and the first intercostal artery to enter into the brachial plexus. The remaining portion of the nerve is continued as the *first intercostal*, a small branch which courses along the first intercostal space, in the manner of the other intercostal nerves, but has usually no lateral cutaneous branch, and may also want the anterior cutaneous.

### UPPER OR PECTORAL INTERCOSTAL NERVES.

In their course to the fore part of the chest, these nerves accompany the intercostal blood-vessels. After a short space they pass between the internal and external intercostal muscles, supplying them with twigs, and, about midway between the vertebræ and the sternum, give off the lateral cutaneous branches. The nerves, greatly diminished, are now continued forwards amid the fibres of the internal intercostal muscles as far as the costal cartilages, where they come into contact with the pleura. In approaching the sternum, they cross the internal mammary artery and the fibres of the *triangularis sterni* muscle. Finally, these nerves pierce the internal intercostal muscle and the

Fig. 365.

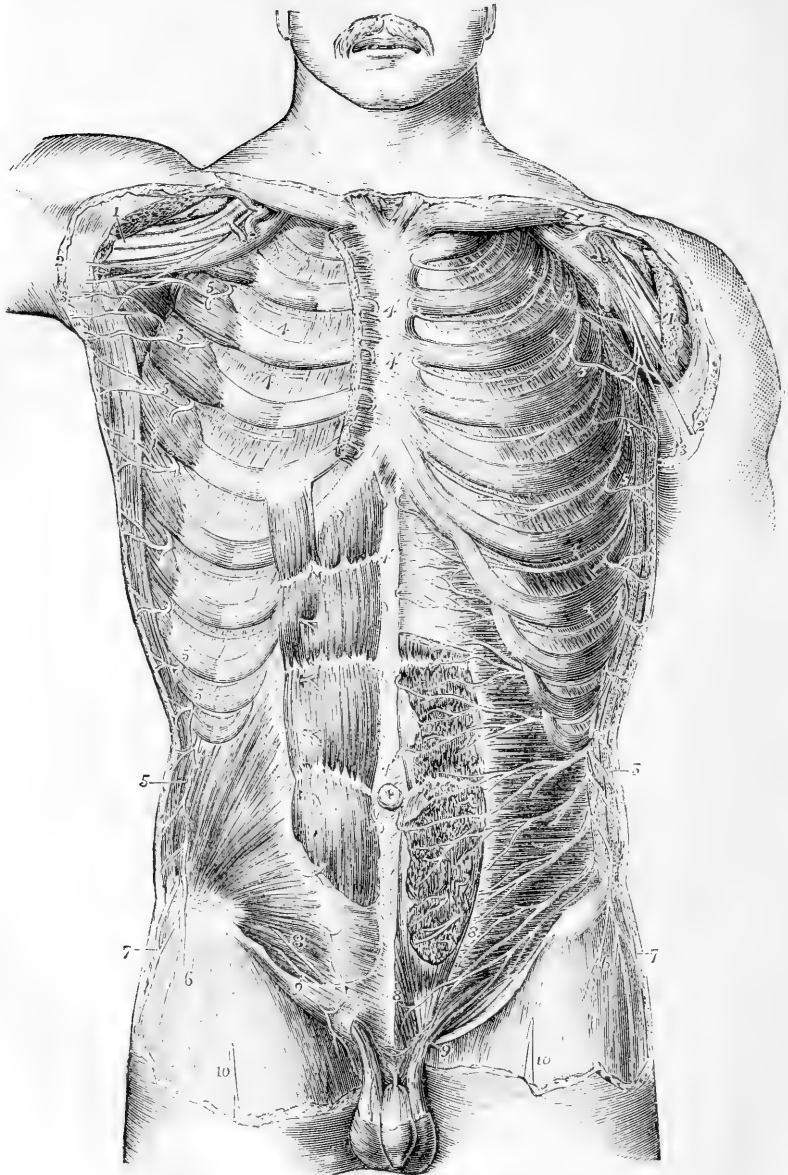


Fig. 365.—VIEW OF THE ANTERIOR DIVISIONS OF THE DORSAL AND SOME OF THE OTHER SPINAL NERVES FROM BEFORE (from Hirschfeld and Leveillé).  $\frac{1}{4}$

The pectoralis major and minor muscles have been removed ; on the right side the rectus abdominis and internal oblique muscles are shown, on the left side the anterior part of the rectus is cut away, and the transversalis is exposed.

1, the median and other nerves of the brachial plexus ; 2, the internal cutaneous ;

3, the nerve of Wrisberg ; 4, the intercostal nerves continued forwards to 4', their anterior cutaneous twigs ; 5, the lateral cutaneous branches of these nerves ; 6, cutaneous branch of the last dorsal spinal nerve ; 7, the iliac twig of the ilio-hypogastric branch of the first lumbar nerve ; 8, termination of the ilio-hypogastric ; 9, the ilio-inguinal ; 10, the middle cutaneous of the thigh.

greater pectoral, and end in the integument of the breast, receiving the name of the anterior cutaneous nerves of the thorax.

At the anterior part of the chest some of the muscular twigs cross the cartilages of the ribs, passing from one intercostal space to another.

(a) The **lateral cutaneous nerves of the thorax** pierce the external intercostal and serratus magnus muscles, in a line a little behind the pectoral border of the axilla. The first intercostal usually gives no lateral branch or only a slender twig to the axilla, but, when that of the second nerve is unusually small, it is supplemented by that of the first. The branch from the second intercostal is named intercosto-humeral, and requires separate description. Each of the remaining lateral cutaneous nerves divides into two branches, which reach the integument at a short distance from each other, and are named anterior and posterior.

The *anterior branches* are continued forwards over the border of the great pectoral muscle. Several reach the mammary gland and the nipple ; and from the lower nerves twigs are supplied to the digitations of the external oblique muscle of the abdomen.

The *posterior branches* turn backwards to the integument over the scapula and the latissimus dorsi muscle. The branch from the third nerve ramifies in the axilla, and a few filaments reach the arm.

The *intercosto-humeral* nerve, the lateral cutaneous branch of the second intercostal nerve, corresponds with the posterior of the two divisions of the succeeding lateral cutaneous branches, the anterior being commonly wanting. It crosses the axillary space to reach the arm, and is connected in the axilla with an offset of the nerve of Wrisberg. Penetrating the fascia it becomes subcutaneous, and ramifies in the integument of the upper half of the arm, on the inner and posterior aspect ; a few filaments reach the integument over the scapula. The branches of this nerve cross over the internal cutaneous offset of the musculospiral, and a communication is established between the two nerves. The size of the intercosto-humeral nerve, and the extent of its distribution, are in the inverse proportion to the size of the other cutaneous nerves of the upper arm, especially the nerve of Wrisberg.

(b) The **anterior cutaneous nerves of the thorax**, which are the terminal twigs of the intercostal nerves, are reflected outwards in the integument over the great pectoral muscle. The branch from the second nerve is connected with the superclavicular and the lateral cutaneous nerves ; those from the third and fourth nerves are distributed to the mammary gland.

#### LOWER OR ABDOMINAL INTERCOSTAL NERVES.

The lower intercostal nerves are continued from the anterior ends of the intercostal spaces, between the internal oblique and the transverse muscle of the abdomen, to the outer edge of the rectus. Perforating the sheath, they enter the substance of that muscle, and afterwards terminate in small cutaneous branches (anterior cutaneous).

(a) The **lateral cutaneous nerves of the abdomen** pass to the integument through the external intercostal and external oblique muscles, in a line with the corresponding nerves on the thorax, and divide in the same manner into anterior and posterior branches.

The *anterior branches* are the larger, and are directed inwards in the superficial fascia, with small cutaneous arteries, nearly to the edge of the rectus muscle.

The *posterior branches* bend backwards over the latissimus dorsi muscle.

(b) The **anterior cutaneous nerves of the abdomen** become subcutaneous near the linea alba, accompanying the small perforating arteries. Their number and position are very uncertain. They are directed outwards towards the lateral cutaneous nerves. A second set is described by Cruveilhier as existing at the outer edge of the rectus muscle.

#### LAST DORSAL NERVE.

The anterior primary division of this nerve is below the last rib, and is contained altogether in the abdominal wall. The nerve has the general course and distribution of the others between the internal oblique and transversalis, but, before taking its place between those muscles, it passes in front of the upper part of the quadratus lumborum, and pierces the posterior aponeurosis of the transverse muscle. This nerve is connected by offsets with the nerve above, and occasionally with the ilio-hypogastric branch of the lumbar plexus. Near the spine it sometimes communicates with the first lumbar nerve by means of a small cord in the substance of the quadratus lumborum.

The **lateral cutaneous branch** of the last dorsal nerve, passing through both oblique muscles, is directed downwards over the iliac crest to the integument, covering the fore part of the gluteal region and the upper and outer part of the thigh, some filaments reaching as far as the great trochanter of the femur.

#### LUMBAR NERVES.

The anterior divisions of the lumbar nerves increase in size from the first to the fifth; and all, except the fifth, which passes down to join the sacral nerves, are connected together by communicating loops, so as to form the lumbar plexus. On leaving the intervertebral foramina these nerves are connected by filaments with the sympathetic nerve, these filaments being longer than those connected with other spinal nerves, in consequence of the position of the lumbar sympathetic ganglia on the fore part of the bodies of the vertebræ. In the same situation are furnished small twigs to the psoas and quadratus lumborum muscles.

#### LUMBAR PLEXUS.

The lumbar plexus is formed by the communications between the anterior primary divisions of the four upper lumbar nerves. It is placed in the substance of the psoas muscle, in front of the transverse processes of the corresponding vertebræ. Above, the plexus is narrow, and is sometimes connected with the last dorsal nerve by a small offset from that nerve, named dorsi-lumbar; below it is wider, and is joined to the sacral plexus by means of a branch given by the fourth lumbar nerve to the fifth.

The arrangement of the plexus may be thus stated. The first nerve gives off the ilio-hypogastric and ilio-inguinal nerves, and sends downwards a communicating branch to the second nerve. The second furnishes the greater part of the genito-crural and external cutaneous nerves, and gives a connecting branch to the third, from which some of the fibres of the anterior crural and obturator nerves are derived. From the third nerve, besides the descending branch to the fourth,

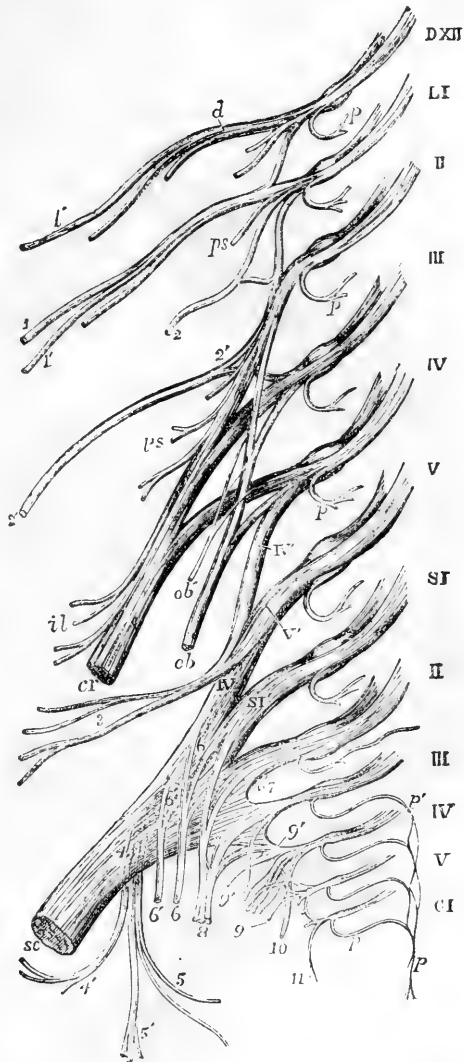


two branches proceed; one of these, the larger, forms part of the anterior crural nerve; the other, a part of the obturator nerve. The fourth nerve gives two branches, which serve to complete the obturator

Fig. 366. — DIAGRAMMATIC OUTLINE OF THE LUMBAR AND SACRAL PLEXUSES WITH THE PRINCIPAL NERVES ARISING FROM THEM.  $\frac{1}{2}$

D, XII, placed opposite the divided roots of the last dorsal nerve; L, I to V, opposite the roots of the five lumbar nerves: the loops uniting the anterior primary divisions of these nerves together, and the first with the twelfth dorsal are shown; S, I to V, and C, I, the same in the sacral and coccygeal nerves; *p*, placed on some of the nerves marks the posterior primary divisions cut short; *p*, *p'* the plexus formed by the union of the posterior branches of the third, fourth, and fifth sacral and the coccygeal nerves; *d*, the abdominal continuation of the last dorsal nerve, from which *d'* the iliac cutaneous branch arises; *l*, *l'*, the ilio-hypogastric and ilio-inguinal branches of the first lumbar nerve; *2*, the genitocrural rising by a loop from the first and second lumbar; *2'*, external cutaneous of the thigh rising by a loop from the second and third; *ps*, branches to the psoas muscle along the lumbar plexus; *cr*, anterior crural nerve from the second, third, and fourth lumbar; *il*, branches to the iliacus; *ob*, obturator nerve from the second, third, and fourth lumbar nerves; *ob*, accessory obturator; *IV*, *V*, loop from the fourth and fifth lumbar, forming the lumbo-sacral cord; *3*, superior gluteal nerve; *sc*, sacral plexus ending in the great sciatic nerve; *4*, lesser sciatic nerve rising from the plexus posteriorly; *4'*, inferior gluteal branches; *5*, inferior pudendal; *5'*, posterior cutaneous of the thigh and leg; *6*, *6*, branches to the obturator internus and gemellus superior; *6'*, *6'*, branches to the gemellus inferior, quadratus and hip-joint; *7*, twigs to the pyriformis; *8*, *8*, pudic nerve from the first, second, third, and fourth sacral; *9*, visceral branches; *9'*, twig to the levator ani; *10*, cutaneous from the fourth, which passes round the lower border of the gluteus maximus; *11*, coccygeal branches.

Fig. 366.



and anterior crural nerves, and a connecting branch to the fifth nerve.

The BRANCHES of this plexus form two sets, which are distributed, one to the lower part of the wall of the abdomen, the other to the fore part and inner side of the lower limb. In the former set are the ilio-hypogastric and ilio-inguinal nerves, and part of the genito-crural; and to the latter belong the remaining part of the genito-crural nerve, the external cutaneous, the obturator, and the anterior crural nerves.

### Ilio-hypogastric and ilio-inguinal nerves.

These nerves are the upper two branches from the lumbar plexus; they are both derived from the first lumbar nerve, and have a nearly similar distribution. They become subcutaneous by passing between the broad muscles of the abdomen, and through the outer one, and end in the integument of the groin and scrotum in the male, and the labia pudendi in the female, as well as in the integument covering the gluteal muscles. The extent of distribution of the one is inversely proportional to that of the other.

The **ilio-hypogastric** nerve, emerging from the upper part of the psoas muscle at the outer border, runs obliquely over the quadratus lumborum to the iliac crest, and there perforating the transverse muscle of the abdomen, gets between that muscle and the internal oblique, and divides into an iliac and hypogastric branch.

(a) The *iliac branch* pierces the attachment of both oblique muscles, immediately above the iliac crest, and is lost in the integument over the gluteal muscles, behind the distribution of the lateral cutaneous branch of the last dorsal nerve.

(b) The *hypogastric* or *abdominal* branch passes on between the transverse and internal oblique muscles, and is connected with the ilio-inguinal nerve near the iliac crest. It then perforates the internal oblique muscle, and, piercing the aponeurosis of the external oblique, a little above the superficial inguinal opening, is distributed to the skin of the abdomen above the pubes.

The size of the iliac branch of this nerve varies inversely with that of the lateral cutaneous branch of the twelfth dorsal. The hypogastric branch is not unfrequently joined with the last dorsal nerve between the muscles, near the crest of the innominate bone.

The **ilio-inguinal** nerve, smaller than the preceding, supplies the integument of the groin. Descending obliquely outwards over the quadratus lumborum, it crosses the fibres of the iliacus muscle, being placed lower down than the ilio-hypogastric: it then perforates the transverse muscle further forwards than the ilio-hypogastric; communicating with that nerve between the abdominal muscles. Then piercing the internal oblique muscle, it descends in the inguinal canal, and emerging at the superficial inguinal ring, is distributed to the skin upon the groin, as well as to that upon the scrotum and penis in the male, or the labium pudendi in the female, communicating with the inferior pudendal nerve. In its progress this nerve furnishes branches to the internal oblique muscle.

**Varieties.**—The ilio-inguinal nerve occasionally arises from the loop connecting the first and second lumbar nerves. It is sometimes small, and ends near the iliac crest by joining the ilio-hypogastric nerve; in which case the latter gives

off an inguinal branch having a similar course and distribution to the ilio-inguinal nerve, the place of which it supplies.

### Genito-crural nerve.

The genito-crural nerve belongs partly to the external genital organs and partly to the thigh. It is derived chiefly from the

Fig. 367.

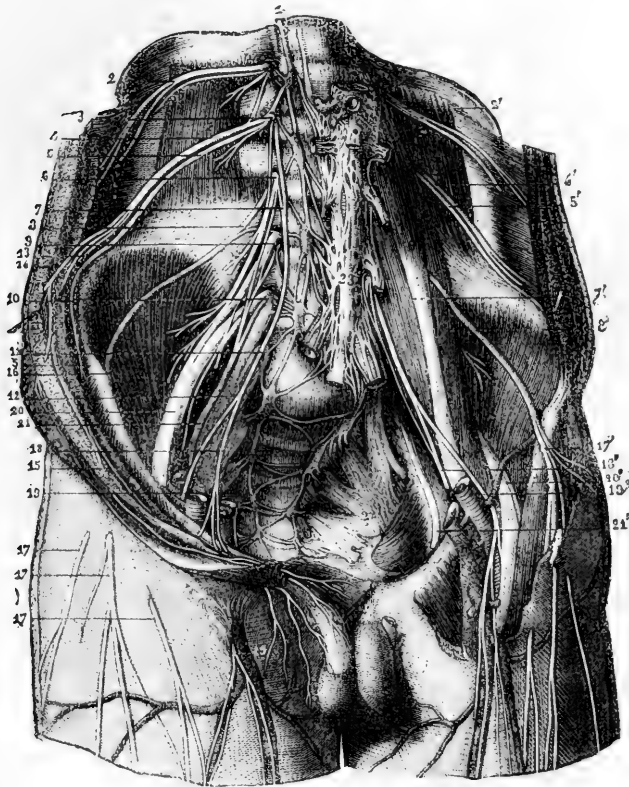


Fig. 367.—VIEW FROM BEFORE OF THE ANTERIOR BRANCHES OF THE LUMBAR AND SACRAL NERVES WITH THE PLEXUSES (from Sappey, after Hirschfeld and Leveillé). 4

1, lumbar cord of the great sympathetic nerve ; 2, 2', anterior primary division of the twelfth dorsal nerve ; 3, first lumbar ; 4, 4', ilio-inguinal branch of this nerve ; 5, 5', ilio-hypogastric branch ; 6, second lumbar nerve ; 7, 7', genito-crural nerve rising from the first and second lumbar ; 8, 8', external cutaneous nerve of the thigh ; 9, third lumbar nerve ; 10, fourth ; 11, fifth ; 12, lumbo-sacral trunk ; 13, iliac branch of the ilio-inguinal ; 14, its abdominal branch ; 15, its genital branch ; 16, external cutaneous nerve of the right side passing out of the pelvis under Poupart's ligament ; 17, 17', cutaneous ramifications of this nerve ; 17, the same nerve exposed on the left side ; 18, 18', genital branch of the genito-crural ; 19, its crural branch on the right side becoming cutaneous ; 19', the same on the left side exposed as it descends in front of the femoral artery ; 20, anterior crural nerve ; 21, 21', obturator nerve ; 22, left sciatic plexus ; 23, aortic plexus of the sympathetic nerve connected superiorly with the other pre-aortic plexuses and the lumbar ganglia, and inferiorly with the superior plexus.

second lumbar nerve, but receives also a few fibres from the connecting cord between that and the first nerve. The nerve descends obliquely through the psoas muscle, and afterwards on its fore part, towards Poupart's ligament, dividing at a variable height into an internal or genital, and an external or crural branch. It often bifurcates close to its origin from the plexus, in which case its two branches perforate the psoas muscle in different places.

(a) The *genital branch* (external spermatic, Schmidt) lies upon or near the external iliac artery, and sends filaments along that vessel; then perforating the transversalis fascia, it passes through the inguinal canal with the spermatic cord, and is lost upon the cremaster muscle. In the female it accompanies the round ligament of the uterus.

(b) The *crural branch* (lumbo-inguinal nerve, Schmidt) descends upon the psoas muscle beneath Poupart's ligament into the thigh. Immediately below that ligament, and at the outer side of the femoral artery, it pierces the fascia lata, and supplies the skin on the upper part of the thigh, communicating with the middle cutaneous branch of the anterior crural nerve. Whilst it is passing beneath Poupart's ligament, some filaments are prolonged from this nerve on the femoral artery. It is stated by Schmidt, that when the crural branch of the genito-crural nerve is large, and commences near the plexus, he has observed it to give a muscular branch to the lower border of the internal oblique and transversalis muscles.

#### External cutaneous nerve.

This nerve, commencing from the loop formed between the second and third lumbar nerves, on emerging from the outer border of the psoas muscle, crosses the iliacus muscle below the ilio-inguinal nerve, and passing beneath Poupart's ligament, reaches the thigh beneath the anterior superior iliac spine, where it divides into an anterior and a posterior branch distributed to the integument of the outer side of the hip and thigh.

(a) The *posterior branch* perforates the fascia lata and subdivides into two or three others, which turn backwards and supply the skin upon the outer surface of the limb, from the upper border of the hip-bone nearly to the middle of the thigh. The highest among them are crossed by the cutaneous branches from the last dorsal nerve.

(b) An *anterior branch*, the continuation of the nerve, is at first contained in a sheath or canal formed in the substance of the fascia lata; but, about four inches below Poupart's ligament, it enters the subcutaneous fatty tissue, and is distributed along the outer part of the front of the thigh, ending near the knee. The principal offsets spring from its outer side. In some cases, this branch reaches quite down to the knee, and communicates there with the internal saphenous nerve.

#### Obturator nerve.

The obturator nerve is distributed to the adductor muscles of the thigh, and to the hip and knee-joints. It arises from the lumbar plexus by two roots, one from the third and the other from the fourth lumbar nerve. Having emerged from the inner border of the psoas muscle, opposite to the brim of the pelvis, it runs along the side of the pelvic cavity, above the obturator vessels, as far as the opening in the upper part of the thyroid foramen, through which it escapes from the pelvis into the thigh. Here it immediately divides into an

anterior and a posterior branch, which are separated from one another by the short adductor muscle.

A.—The ANTERIOR PORTION communicates with the accessory obturator nerve, when that nerve is present, and descends in front of the adductor brevis and behind the pectineus and adductor longus muscles. It gives branches as follows.

(a) An *articular branch* to the hip-joint arises near the thyroid membrane.

(b) *Muscular branches* are given to the gracilis and adductor longus muscles, and occasionally also others to the adductor brevis and pectineus.

(c) The *terminal twig* turns outwards upon the femoral artery, and surrounds that vessel with small filaments.

(d) An offset at the lower border of the adductor longus communicates beneath the fascia with the internal cutaneous branch of the anterior crural nerve, and with a branch of the internal saphenous nerve, forming a sort of *plexus*.

Fig. 368.—THE LUMBAR PLEXUS FROM BEFORE, WITH THE DISTRIBUTION OF SOME OF ITS NERVES (slightly altered from Schmidt).  $\frac{1}{2}$

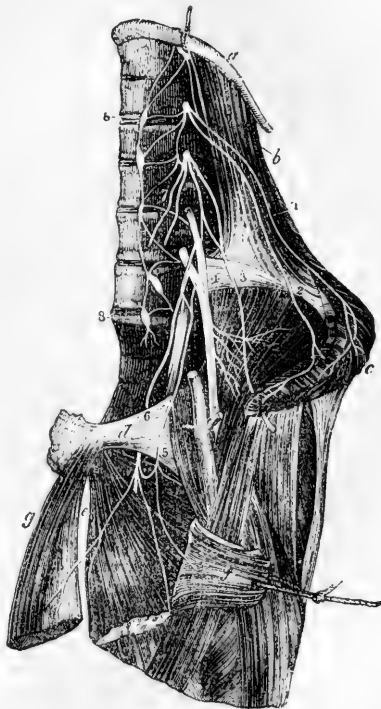
*a*, the last rib; *b*, quadratus lumborum muscle; *c*, oblique and transverse muscles cut near the crest of the ilium and turned down; *d*, pubes; *e*, adductor brevis muscle; *f*, pectineus divided and turned outwards; *g*, adductor longus; 1, ilio-hypogastric nerve; 2, ilio-inguinal; 3, external cutaneous; 4, anterior crural; 5, accessory obturator; 6, obturator united with the accessory by a loop round the pubes; 7, genito-crural in two branches cut short near their origin; 8, 8, lumbar portion of the gangliated sympathetic cord.

B.—The POSTERIOR or DEEP part of the obturator nerve, having passed through some fibres of the external obturator muscle, crosses behind the short adductor to the fore part of the adductor magnus, where it divides into many branches, all of which enter those muscles, excepting one which is prolonged downwards to the knee-joint.

(a) The *muscular branches* supply the external obturator and the great adductor muscle, with the short adductor also when this muscle receives no branch from the anterior division of the nerve.

(b) The *articular branch* for the knee rests at first on the adductor magnus, but perforates the lower fibres of that muscle, and thus reaches the upper part of the popliteal space. Supported by the popliteal artery, and sending filaments around that vessel, the nerve then descends to the back of the knee-joint, and enters the articulation through the posterior ligament. (Thomson, "London Med. and Surg. Journal," No. xcvi.)

Fig. 368.



**Varieties.**—*Occasional cutaneous nerve.*—In some instances the communicating branch described is larger than usual, and descends along the posterior border of the sartorius to the inner side of the knee, where it perforates the fascia, communicates with the internal saphenous nerve, and extends down the inner side of the limb, supplying the skin as low as the middle of the leg.

When this cutaneous branch of the obturator nerve is present, the internal cutaneous branch of the anterior crural nerve is small, the size of the two nerves bearing an inverse proportion to each other.

*Accessory obturator nerve.*—The accessory obturator nerve, a small and inconstant nerve, arising from the obturator nerve near its upper end, or separately from the same nerves of the plexus, descends along the inner border of the psoas muscle, over the pubic bone, and, passing behind the pectineus muscle, ends by dividing into several branches. Of these one joins the anterior branch of the obturator nerve; another penetrates the pectineus on the under surface; whilst a third enters the hip-joint with the articular artery.

This nerve is sometimes smaller than usual, and ends in filaments which perforate the capsule of the hip-joint. When it is altogether wanting, the hip-joint receives branches from the obturator nerve.

**SUMMARY.**—The obturator nerve and accessory obturator give branches to the hip and knee joints, also to the adductor muscles of the thigh, and, in some cases, to the pectineus. Occasionally a cutaneous branch descends to the inner side of the thigh, and to the inner and upper part of the leg.

#### Anterior crural nerve.

This nerve is the largest branch of the lumbar plexus, and is derived principally from the third and fourth lumbar nerves, but in part also from the second. Emerging from the outer border of the psoas muscle, near its lower part, it descends into the thigh in the groove between that muscle and the iliacus, and, therefore, to the outside of the femoral blood-vessels. It now becomes flattened out and divides into two parts, one of which is cutaneous, while the other is distributed to muscles.

**BRANCHES OF THE TRUNK.**—The branches given from the anterior crural nerve within the abdomen are few and of small size.

(a) The *iliacus* receives three or four small branches, which are directed outwards from the nerve to the fore part of the muscle.

(b) The *nerve of the femoral artery* is a small branch which divides into numerous filaments upon the upper part of that vessel. It sometimes arises lower down than usual in the thigh. It may, on the other hand, be found to take origin above the ordinary position; and in this case it proceeds from the middle cutaneous nerve, when that branch springs from or near the lumbar plexus. In either case its ultimate distribution is the same as that already described.

**TERMINAL BRANCHES.**—From the principal or terminal divisions of the nerve the remaining branches take their rise as follows.

From the *superficial division* cutaneous branches are given to the fore part of the thigh, and to the inner side of the leg. They are the middle and internal cutaneous nerves, and the internal saphenous nerve. One of the muscles, the sartorius, receives its nerves from this group.

The *deep branches* supply the muscles on the fore part of the thigh, and also the pectineus muscle. The branch to the pectineus, however, sometimes arises from the superficial part of the trunk.

**A. Muscular branches.**—The branch to the *pectineus* muscle crosses inwards behind the femoral vessels, and enters the muscle on the anterior aspect.



part of the femoral artery. It divides either in front of that vessel, or at the inner side, into two branches (one anterior, the other internal), which pierce the fascia separately. Before dividing, this nerve gives off two or three cutaneous twigs, which accompany the upper part of the long saphenous vein. The highest of these perforates the fascia near the saphenous opening, and reaches down to the middle of the thigh. The others appear beneath the skin lower down by the side of the vein; one, larger than the rest, passes through the fascia about the middle of the thigh, and extends to the knee. In some instances, these small branches spring directly from the anterior crural nerve, and they often communicate with each other.

Fig. 370.

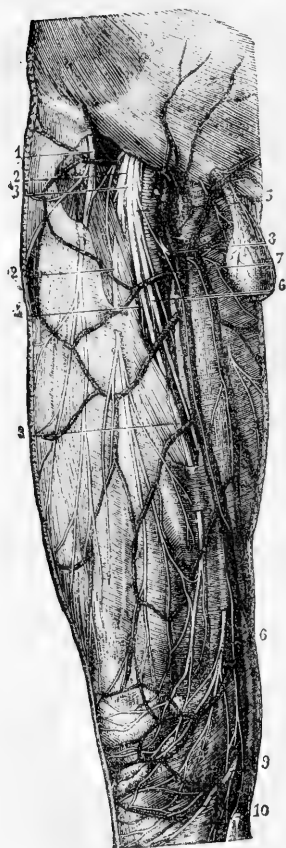


Fig. 370.—CUTANEOUS NERVES OF THE ANTERIOR AND INNER PART OF THE THIGH (from Sappey after Hirschfeld and Leveillé).  $\frac{1}{2}$

1, external cutaneous nerve; 2, 2, middle cutaneous branch of the anterior crural passing through the sartorius muscle and the fascia; 3, 3, anterior division of the internal cutaneous; 4, filament to the sartorius; 5, inner or posterior division of the internal cutaneous; 6, its superficial branch to the inside of the knee after perforating the fascia; 7, deep or communicating branch; 8, superficial branch of the musculo-cutaneous of the crural; 9, patellar branch of the internal saphenous nerve; 10, continuation of the saphenous down the leg.

The *anterior terminal branch*, descending in a straight line to the knee, perforates the fascia lata in the lower part of the thigh; it afterwards runs down near the intermuscular septum, giving off filaments on each side to the skin, and is finally directed over the patella to the outer side of the knee. It communicates above the joint with a branch of the long saphenous nerve; and sometimes it takes the place of the branch usually given by the latter to the integument over the patella.

This branch of the internal cutaneous nerve sometimes lies above the fascia in its whole length. It occasionally gives off a cutaneous filament, which accompanies the long saphenous vein, and in some cases it communicates with the branch to be next described.

The *inner branch* of the internal cutaneous nerve, descending along the posterior border of the sartorius muscle, perforates the fascia lata at the inner side of the knee, and communicates by a small branch with the internal saphenous nerve, which here descends in front of it. It gives some cutaneous filaments to the lower part of the thigh on the inner side, and is distributed to the skin upon the inner

side of the leg. Whilst beneath the fascia, this branch of the internal cutaneous nerve joins in an interlacement with offsets of the obturator nerve below the middle of the thigh, and with the branch of the saphenous nerve nearer the knee.

**D. Internal saphenous nerve.**—The internal or long saphenous nerve is the largest of the cutaneous branches of the anterior crural nerve. In some cases it arises in connection with one of the deep or muscular branches.

This nerve is deeply placed as far as the knee, and is subcutaneous in the rest



of its course. In the thigh it accompanies the femoral vessels, lying at first somewhat to their outer side, but lower down approaching close to them, and passing beneath the same aponeurosis. When the vessels pass through the opening in the adductor muscle into the popliteal space, the saphenous nerve separates from them, and is continued downwards beneath the sartorius muscle to the inner side of the knee; where, having first given off, as it lies near the inner condyle of the femur, a branch which is distributed over the front of the patella, it becomes subcutaneous by piercing the fascia between the tendons of the sartorius and gracilis muscles.

The nerve then accompanies the saphenous vein along the inner side of the leg, and passing in front of the ankle is distributed to the inner side of the foot. In the leg it is connected with the internal cutaneous nerve.

The distribution of the branches is as follows.

A *communicating branch* is given off about the middle of the thigh to join in the interlacement formed beneath the fascia lata by this nerve and branches of the obturator and internal cutaneous nerves. After it has left the aponeurotic covering of the femoral vessels, the internal saphenous nerve has, in some cases, a further connection with one or other of the nerves just referred to.

The *branch to the integument in front of the patella* perforates the sartorius muscle and the fascia lata; and, having received a communicating offset from the internal cutaneous nerve, spreads out upon the fore part of the knee; and, by uniting with branches of the middle and external cutaneous nerves, forms a plexus—plexus patellæ.

A branch to the inner ankle is given off in the lower third of the leg, and descends along the margin of the tibia, and some small filaments pierce the tarsal ligaments.

**SUMMARY.**—The anterior crural nerve is distributed to the skin upon the fore part and inner side of the thigh, commencing below the termination of the ilio-inguinal and genito-crural nerves. It furnishes also a cutaneous nerve to the inner side of the leg and foot. All the muscles on the front and outer side of the thigh receive their nerves from the anterior crural, and the pectineus is also in part supplied by this nerve, and in part by the obturator. The tensor muscle of the fascia lata is supplied from a different source, viz., the superior gluteal nerve. Lastly, two branches are given from the anterior crural nerve to the knee-joint

#### FIFTH LUMBAR NERVE.

The anterior branch of the fifth lumbar nerve, having received a fasciculus from the nerve next above it, descends to join the first sacral nerve, and forms part of the sacral plexus. The cord resulting from the union of the fifth with a part of the fourth nerve, is named the *lumbo-sacral* nerve.

**Superior Gluteal Nerve.**—Before joining the first sacral nerve the lumbo-sacral cord gives off from behind the superior gluteal nerve; this offset leaves the pelvis through the large sacro-sciatic foramen, above the pyriformis muscle, and divides like the gluteal artery into two branches, which are distributed chiefly to the smaller gluteal muscles and tensor of the fascia lata.

(a) The *upper* branch runs with the gluteal artery along the origin of the gluteus minimus, and is lost in it and in the gluteus medius.

(b) The *lower* branch crosses over the middle of the gluteus minimus between this and the gluteus medius, and supplying filaments to both those muscles, is continued forwards, and terminates in the tensor muscle of the fascia lata.

## SACRAL AND COCCYGEAL NERVES.

The anterior divisions of the first four sacral nerves emerge from the spinal canal by the anterior sacral foramina, and the fifth passes out between the sacrum and coccyx.

The first two sacral nerves are large, and of nearly equal size; the others diminish rapidly, and the fifth is exceedingly slender. Like the anterior divisions of the other spinal nerves, those of the sacral nerves communicate with the sympathetic: the communicating cords are very short, as the sympathetic ganglia are close to the inner margin of the foramina of the sacrum.

The first three nerves and part of the fourth contribute to form the sacral plexus. The fifth has no share in the plexus,—it ends on the back of the coccyx. As the description of the fourth and fifth sacral nerves and of the coccygeal will occupy only a short space, these three nerves may be noticed first, before the other nerves and the numerous branches to which they give rise are described.

## THE FOURTH SACRAL NERVE.

Only one part of the anterior division of this nerve joins the sacral plexus; the remainder, which is nearly half the nerve, supplies branches to the viscera and muscles of the pelvis, and sends downwards a connecting filament to the fifth nerve.

(a) The *visceral branches* of the fourth sacral nerve are directed forwards to the lower part of the bladder, and communicate freely with branches from the sympathetic nerve. Offsets are distributed to the neighbouring viscera, according to the sex. They will be described with the pelvic portion of the sympathetic nerve. The foregoing branches are, in some instances, furnished by the third sacral nerve instead of the fourth, and not unfrequently from both of these nerves.

(b) Of the *muscular branches*, one supplies the *levator ani*, piercing that muscle on the pelvic surface; another enters the *coccygeus*, whilst a third ends in the *external sphincter* muscle of the rectum. The last branch, after passing either through the coccygeus, or between it and the levator ani, reaches the perinaeum, and is distributed likewise to the integuments between the anus and the coccyx.

## THE FIFTH SACRAL NERVE.

The anterior branch of this, the lowest sacral nerve, comes forwards through the coccygeus muscle opposite the junction of the sacrum with the first coccygeal vertebra; it then descends upon the coccygeus nearly to the tip of the coccyx, where it turns backwards through the fibres of that muscle, and ends in the integument upon the posterior and lateral aspect of the bone.

As soon as this nerve appears in front of the bone (in the pelvis) it is joined by the descending filament from the fourth nerve, and lower down by the small anterior division of the coccygeal nerve. It supplies small filaments to the coccygeus muscle.

## THE COCCYGEAL NERVE.

The anterior branch of the coccygeal, or, as it is sometimes named, the sixth sacral nerve, is a very small filament. It escapes from the

spinal canal by the terminal opening, pierces the sacro-sciatic ligament and the coccygeus muscle, and, being joined upon the side of the coccyx with the fifth sacral nerve, partakes in the distribution of that nerve.

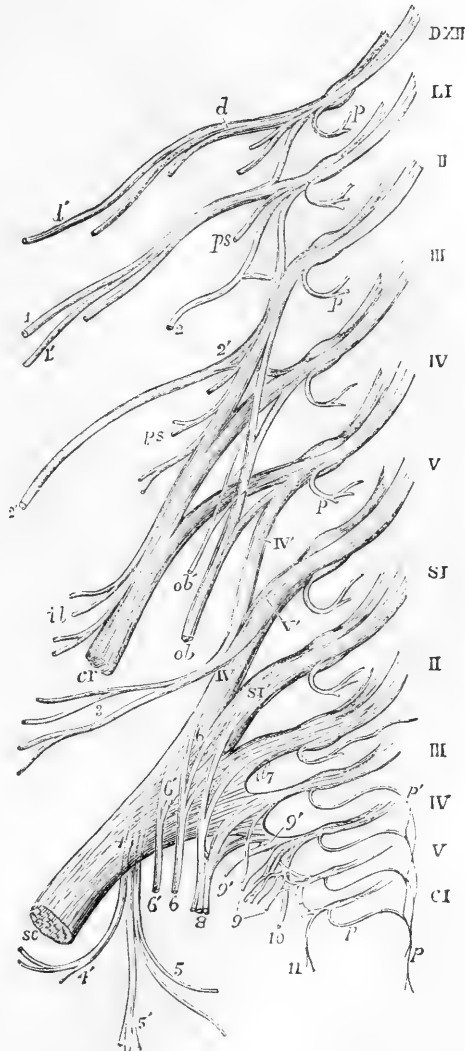
THE SACRAL PLEXUS.

The lumbo-sacral cord (resulting as before described from the junction

Fig. 371. — DIAGRAMMATIC OUTLINE OF THE LUMBAR AND SACRAL PLEXUSES WITH THE PRINCIPAL NERVES ARISING FROM THEM. (A.T.)

The references to the nerves of the lumbar plexus will be found at p. 599. IV', V', loop from the anterior primary branches of the fourth and fifth lumbar nerves, forming the lumbo-sacral cord; 3, superior gluteal nerve; SC, sacral plexus ending in the great sciatic nerve; 4, lesser sciatic nerve, rising from the plexus posteriorly; 4', inferior gluteal branches; 5, inferior pudendal; 5', posterior cutaneous of the thigh and leg; 6, 6, branches to the obturator internus and gemellus superior; 6', 6', branches to the gemellus inferior, quadratus and hip-joint; 7, twigs to the pyriformis; 8, 8, pudic from the first, second, third, and fourth sacral; 9, visceral branches; 9', twig to the levator ani; 10, cutaneous from the fourth, which passes round the lower border of the gluteus maximus; 11, coccygeal branches.

Fig. 371.



of the fifth and part of the fourth lumbar nerves), the anterior divisions of the first three sacral nerves, and part of the fourth, unite to form this plexus. Its construction differs from that of the other spinal nervous plexuses in this respect, that the several constituent nerves entering into it unite into one broad flat cord. To the place of union the nerves proceed in different

directions, that of the upper ones being obliquely downwards, while

that of the lower is nearly horizontal ; and, as a consequence of this difference, they diminish in length from the first to the last. The sacral plexus rests on the anterior surface of the pyriform muscle, opposite the side of the sacrum, and escaping through the great sacro-sciatic foramen, ends in the great sciatic nerve.

BRANCHES.—The sacral plexus gives rise to the great sciatic nerve, and to various smaller branches ; viz., the pudic nerve, the small sciatic nerve, and branches to the obturator internus, pyriformis, gemelli, and quadratus femoris muscles.

### Small Muscular branches.

*a.* To the *pyriformis muscle*, one or more branches are given, either from the plexus or from the upper sacral nerves before they reach the plexus.

*b.* The *nerve of the internal obturator muscle* arises from the part of the plexus formed by the union of the lumbo-sacral and the first sacral nerves. It turns over the ischial spine of the hip-bone with the pudic vessels, and is then directed forwards through the small sacro-sciatic foramen to reach the inner surface of the obturator muscle.

*c.* To the *levator ani* one or more twigs proceed from the lower part of the plexus.

*d.* The *superior gemellus* receives a small branch, which arises from the lower part of the plexus.

*e.* The small nerve which supplies the *lower gemellus* and *quadratus femoris* muscles springs from the lower part of the plexus. Concealed at first by the great sciatic nerve, it passes beneath the gemelli and the tendon of the internal obturator,—between those muscles and the capsule of the hip-joint,—and reaches the deep (anterior) surface of the quadratus. It furnishes a small articular filament to the back part of the hip-joint.

### The Pudic Nerve.

This nerve, arising from the lower part of the sacral plexus, turns over the spine of the ischium, and then passes forwards through the small sacro-sciatic foramen, where it usually gives off the inferior hæmorrhoidal branch. It is next directed along the outer part of the ischio-rectal fossa, in a sheath of the obturator fascia, along with the pudic vessels, and divides into two terminal branches, the perineal nerve and the dorsal nerve of the penis.

*A.*—The *perineal nerve*, the lower and much the larger of the two divisions of the pudic nerve, lies below the pudic artery, and is expended in superficial and muscular branches.

*a.* The *superficial perineal* branches are two in number, anterior and posterior. The *posterior* branch, which first separates from the perineal nerve, reaching the back part of the ischio-rectal fossa, gives filaments inwards to the skin in front of the anus, and turns forwards in company with the anterior branch to reach the scrotum. The *anterior* branch descends to the fore part of the ischio-rectal fossa ; and, passing forwards with the superficial perineal artery, ramifies in the skin on the fore part of the scrotum and on the penis. This branch sends small twigs to the levator ani muscle. The superficial perineal nerves are accompanied to the scrotum by the inferior pudendal branch of the small sciatic nerve. The three branches are sometimes named *long scrotal nerves*.

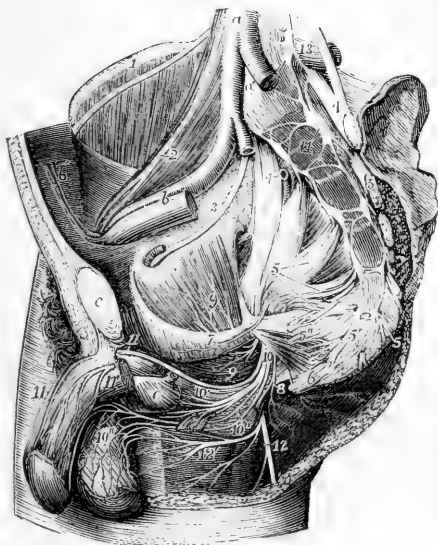
In the female, both the superficial perineal branches terminate in the external labium pudendi.

*b.* The *muscular branches* generally arise by a single trunk, which is directed inwards under cover of the transversalis perinæi muscle, and divides into offsets which are distributed to the transversalis perinæi, erector penis, accelerator urinæ, and compressor urethræ.

c. Slender filaments are sent inwards to the corpus spongiosum urethræ; some of these, before penetrating the erectile tissue, run a considerable distance over its surface.

Fig. 372.—RIGHT SIDE OF THE INTERIOR OF THE MALE PELVIS, WITH THE PRINCIPAL NERVES DISPLAYED (after Hirschfeld and Leveillé).  $\frac{1}{4}$

Fig. 372.



The left wall has been removed as far as the sacrum behind and the symphysis pubis in front; the viscera and the lower part of the levator ani have been removed; *a*, the lower part of the aorta; *a'*, placed on the fifth lumbar vertebra, between the two common iliac arteries, of which the left is cut short; *b*, the right external iliac artery and vein; *c*, the symphysis pubis; *d*, the divided pyriformis muscle, close to the left auricular surface of the sacrum; *e*, bulb of the urethra covered by the accelerator urinæ muscle; the membranous part of the urethra cut short is seen passing into it; 1, placed on the crest of the ilium, points to the external cutaneous nerve of the thigh passing over the iliacus muscle; 2, placed on the psoas muscle, points to the genito-crural nerve; 3, obturator nerve; 4, 4, placed on the lumbo-sacral cords; that of the right side points to the gluteal artery cut short; 4', the superior gluteal nerve; 5, placed on the inside of the right sacral plexus, points by four lines to the anterior divisions of the four upper sacral nerves, which, with the lumbo-sacral cord, unite in the plexus; 5', placed on the fifth piece of the sacrum, points to the fifth sacral nerve; 5'', the visceral branches proceeding from the third and fourth sacral nerves; 6, placed on the lower part of the coccyx, below the coccygeal nerves; 7, placed on the line of division of the pelvic fascia, points to the nerve of the levator ani muscle; 8, placed at the lower border of the great sacro-sciatic ligament, points to the cutaneous nerves of the anus; 9, nerve of the obturator internus; 10', the pudic nerve; 10'', is placed above the muscular branches of the perineal nerve; 10''', the anterior and posterior superficial perineal nerves, and on the scrotum the distribution of these nerves and the inferior pudendal nerve; 11, the right dorsal nerve of the penis; 11', the nerve on the left crus penis which is cut short; 12, the continuation of the lesser sciatic nerve on the back of the thigh; 12', the inferior pudendal branch; 13, placed on the transverse process of the fifth lumbar vertebra, marks the lowest lumbar sympathetic ganglion; 14, placed on the body of the first piece of the sacrum, points to the upper sacral sympathetic ganglia; between 14 and 6, are seen the remaining ganglia and sympathetic nervous cords, as well as their union with the sacral and coccygeal nerves, and at 6, the lowest ganglion or ganglion impar.

B.—The dorsal nerve of the penis, the upper division of the pudic nerve, accompanies the pudic artery in its course between the layers of the deep perineal or subpubic fascia, and afterwards through the suspensory ligament, to reach the dorsum of the penis, along which it passes as far as the glands, where it divides into filaments for the supply of that part. On the penis, this nerve is joined by branches of the sympathetic system, and it sends outwards numerous offsets to the integument on the upper surface and sides of the organ, including the prepuce. One large branch penetrates the corpus cavernosum penis.

In the female the dorsal nerve of the clitoris is much smaller than the corresponding branch in the male ; it is similarly distributed.

C.—The *inferior hæmorrhoidal* nerve arises from the pudic nerve at the back of the pelvis, or it may come directly from the sacral plexus, and be transmitted through the small sacro-sciatic foramen to its distribution in the lower end of the rectum.

Fig. 373.

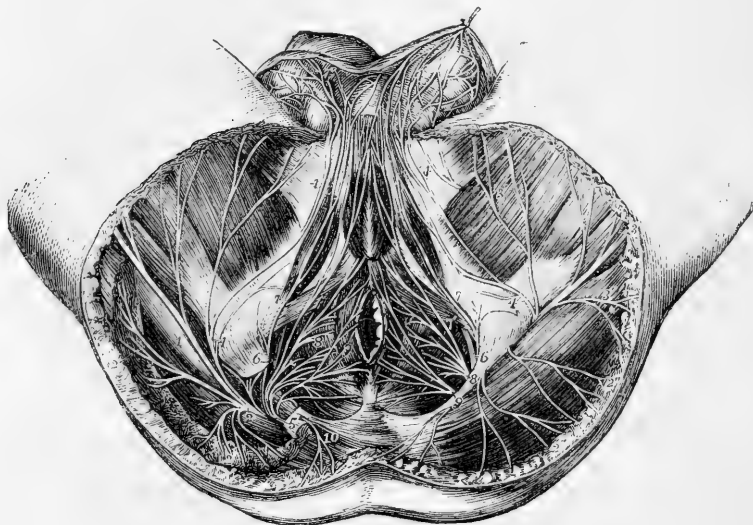


Fig. 373.—DISSECTION OF THE PERINEUM OF THE MALE TO SHOW THE DISTRIBUTION OF THE PUDIC AND OTHER NERVES (after Hirschfeld and Leveillé).  $\frac{1}{4}$

On the right side a part of the gluteus maximus muscle and the great sacro-sciatic ligament have been removed to show the descent of the nerves from the great sacro-sciatic foramen. 1, great sciatic nerve of the right side ; 2, lesser sciatic nerve ; 2', its muscular branches to the gluteus maximus (right side) ; 2'', cutaneous branches to the buttock (left side) ; 3, continuation of the nerve as posterior middle cutaneous of the thigh ; 3, internal and external cutaneous branches ; 4, 4, inferior pudendal branch ; 4', network of this and the perineal nerves on the scrotum ; 5, right pudic nerve ; 6, superior branch or nerve to the penis ; 7, the external superficial perineal branch ; 7', the internal superficial perineal branch ; 8, musculo-bulbal branches ; 9, hæmorrhoidal or cutaneous anal branches ; 10, cutaneous branch of the fourth sacral nerve.

Some of the branches of this nerve end in the external sphincter and in the adjacent skin of the anus ; others reach the skin in front of that part, and communicate with the inferior pudendal branch of the small sciatic nerve, and with the superficial perineal nerves.

**SUMMARY.**—The pudic nerve supplies the perinæum, the penis, and part of the scrotum, also the urethral and anal muscles in the male ; and the clitoris, labia, and other corresponding parts in the female. It communicates with the inferior pudendal branch of the small sciatic nerve.

### Small Sciatic Nerve.

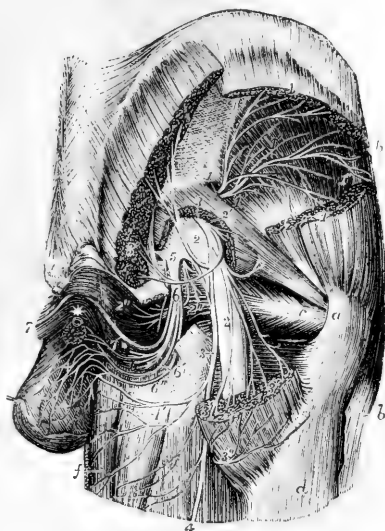
The small sciatic nerve (*nervus ischiadicus minor*) is chiefly a cutaneous nerve, supplying the integument of the lower part of the buttock, the back of the thigh, and upper part of the calf of the leg; it furnishes also branches to one muscle—the *gluteus maximus*.

This nerve is formed by the union of two or more nervous cords, derived from the lower and back part of the sacral plexus. Arising below the *pyriform* muscle, it descends beneath the *gluteus maximus*, and at the lower border of that muscle comes into contact with the *fascia lata*. Continuing its course downwards along the back of the limb, it perforates the *fascia* a little below the knee.

Fig. 374.—DEEP NERVES IN THE GLUTEAL AND INFERIOR PUDENDAL REGIONS (after Hirschfeld and Leveillé). †

Fig. 374.

*a*, back part of the great trochanter; *b*, *tensor vaginae femoris* muscle; *c*, tendon of the *obturator internus* muscle near its insertion; *d*, upper part of the *vastus externus*; *e*, *coccyx*; *f*, *gracilis* muscle; between *f* and *d*, the *adductor magnus*, *semitendinosus*, and *biceps* muscles; \* placed at the meeting of the *crura penis* above the *urethra*; 1, placed upon the *ilium* close above the *sacro-sciatic notch*, marks the *superior gluteal nerve*, and on the divided parts of the *gluteus medius* muscle, the *superior branch* of the nerve; 1', on the surface of the *gluteus minimus* muscle, the *inferior branch* of the nerve; 1'', branch of the nerve to the *tensor vaginae femoris*; 2, *sacral plexus* and *great sciatic nerve*; 2', *muscular twig* from the plexus to the *pyriformis*; 2'', *muscular branches* to the *gemellus superior* and *obturator internus*; 3, *lesser sciatic nerve*; 3', placed on the upper and lower parts of the divided *gluteus maximus*, the *inferior gluteal muscular branches* of the *lesser sciatic nerve*; 3'', the *cutaneous branches* of the same nerve winding round the lower border of the *gluteus maximus*; 4, the *continuation* of the *lesser sciatic nerve* as *posterior cutaneous nerve* of the thigh; 4', *inferior pudendal branch* of the *lesser sciatic*; 5, placed on the lower part of the *sacral plexus*, points to the *origin* of the *pubic nerve*; 6, its *perineal division* with its *muscular branches*; 6', *anterior or superior superficial perineal branch*; 6'', *posterior or inferior superficial perineal branch*; + +, *distribution* of these nerves and the *inferior pudendal* on the *scrotum*; 7, *dorsal nerve* of the *penis*.



*a*, back part of the great trochanter; *b*, *tensor vaginae femoris* muscle; *c*, tendon of the *obturator internus* muscle near its insertion; *d*, upper part of the *vastus externus*; *e*, *coccyx*; *f*, *gracilis* muscle; between *f* and *d*, the *adductor magnus*, *semitendinosus*, and *biceps* muscles; \* placed at the meeting of the *crura penis* above the *urethra*; 1, placed upon the *ilium* close above the *sacro-sciatic notch*, marks the *superior gluteal nerve*, and on the divided parts of the *gluteus medius* muscle, the *superior branch* of the nerve; 1', on the surface of the *gluteus minimus* muscle, the *inferior branch* of the nerve; 1'', branch of the nerve to the *tensor vaginae femoris*; 2, *sacral plexus* and *great sciatic nerve*; 2', *muscular twig* from the plexus to the *pyriformis*; 2'', *muscular branches* to the *gemellus superior* and *obturator internus*; 3, *lesser sciatic nerve*; 3', placed on the upper and lower parts of the divided *gluteus maximus*, the *inferior gluteal muscular branches* of the *lesser sciatic nerve*; 3'', the *cutaneous branches* of the same nerve winding round the lower border of the *gluteus maximus*; 4, the *continuation* of the *lesser sciatic nerve* as *posterior cutaneous nerve* of the thigh; 4', *inferior pudendal branch* of the *lesser sciatic*; 5, placed on the lower part of the *sacral plexus*, points to the *origin* of the *pubic nerve*; 6, its *perineal division* with its *muscular branches*; 6', *anterior or superior superficial perineal branch*; 6'', *posterior or inferior superficial perineal branch*; + +, *distribution* of these nerves and the *inferior pudendal* on the *scrotum*; 7, *dorsal nerve* of the *penis*.

**BRANCHES.**—A. The *inferior gluteal* branches, given off under the *gluteus maximus*, supply the lower part of that muscle.—A distinct gluteal branch commonly proceeds from the *sacral plexus* to the upper part of the muscle.

B. The *cutaneous branches* of the nerve principally emerge from beneath the lower border of the *gluteus maximus*, arranged in an external and an internal set. Others appear lower down.

*a*. The *internal* are mostly distributed to the skin of the inner side of the thigh at the upper part. One branch, however, which is much larger than the rest, is distinguished as the *inferior pudendal*.

The *inferior pudendal* branch turns forwards below the ischial tuberosity to reach the perineum. Its filaments then extend forwards to the front and outer part of the scrotum, and communicate with one of the superficial perineal nerves.

Fig. 375.

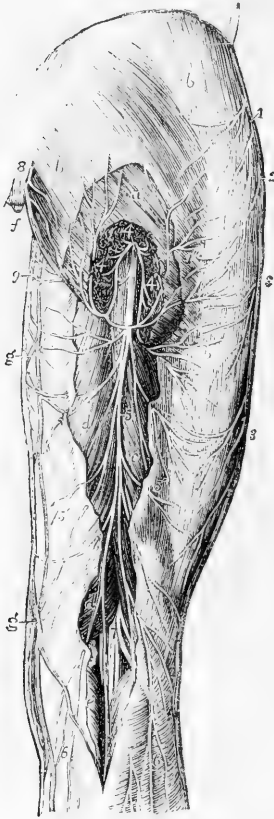


Fig. 376.



Fig. 375.—POSTERIOR CUTANEOUS NERVES OF THE HIP AND THIGH  
(after Hirschfeld and Leveillé).  $\frac{1}{2}$

*a*, gluteus maximus muscle partially uncovered by the removal of a part of the fascia lata, and divided at its inferior part to show the lesser sciatic nerve; *b*, fascia lata over the glutei muscles and the outer part of the hip; *c*, *d*, part of the semitendinosus, biceps, and semimembranosus muscles exposed by the removal of the fascia; *e*, gastrocnemius; *f*, coccyx; *g*, internal branches of the saphena vein; 1, iliac cutaneous branches of the ilio-inguinal and ilio-hypogastric nerves; 2, cutaneous iliac branches of the last intercostal; 3, posterior twigs of the external cutaneous nerve of the thigh; 4, lesser sciatic nerve issuing from below the gluteus maximus muscle; 4', its muscular branches; 4'', its cutaneous gluteal branches; 5, posterior middle cutaneous continued from the lesser sciatic; 5', 5'', its inner and outer branches spreading on the fascia of the thigh; 6, 6', its terminal branches descending on the calf of the leg; 7, posterior tibial and fibular nerves separating in the popliteal space; 8, lower posterior divisions of the sacral and coccygeal nerves; 9, inferior pudendal nerve.

Fig. 376.—DEEP POSTERIOR NERVES OF THE HIP AND THIGH.

(after Hirschfeld and Leveillé).  $\frac{1}{2}$

*a*, gluteus medius muscle; *b*, gluteus maximus; *c*, piriformis; *d*, placed on the



trochanter major, points to the tendon of the obturator internus; *e*, upper part of the femoral head of the biceps; *f*, semitendinosus; *g*, semimembranosus; *h*, gastrocnemius; *i*, popliteal artery; 1, placed on the gluteus minimus muscle, points to the superior gluteal nerves; 2, inferior gluteal branches of the lesser sciatic; 3, placed on the greater sacro-sciatic ligament, points to the pudic nerve; 3', its farther course; 4, inferior pudendal; 5, placed on the upper divided part of the semitendinosus and biceps, points to the posterior middle cutaneous nerve of the thigh; 6, great sciatic nerve, 6', 6', some of its muscular branches to the flexors; 7, internal popliteal nerve; 7', its muscular or sural branches; 8, external popliteal nerve; 8', its external cutaneous branch; 9, communicating tibial; 9', communicating peroneal branch to the external saphenous nerve.

In the female, the inferior pudendal branch is distributed to the external labium pudendi.

*b.* The *external* cutaneous branches, two or three in number, turn upwards in a retrograde course to the skin over the lower and outer part of the great gluteal muscle. In some instances one takes a different course, descending and ramifying in the integuments on the outer side of the thigh nearly to the middle.

*c.* Of the *lower branches* some small cutaneous filaments pierce the fascia of the thigh above the popliteal space. One of these, arising somewhat above the knee-joint, is prolonged over the popliteal region to the upper part of the leg.

Of the *terminal twigs*, perforating the fascia lata opposite the lower part of the popliteal space, one accompanies the short saphenous vein beyond the middle of the leg, and others pass into the integument covering the inner and outer heads of the gastrocnemius muscle. Its terminal cutaneous branches communicate with the short saphenous nerve.

### Great Sciatic Nerve.

The great sciatic nerve (*nervus ischiadicus major*), the largest nerve in the body, supplies the muscles at the back of the thigh, and by its branches of continuation gives nerves to all the muscles below the knee and to the greater part of the integument of the leg and foot. The several joints of the lower limb receive filaments from it and its branches.

This large nerve is continued from the lower end of the sacral plexus. It escapes from the pelvis through the great sacro-sciatic foramen, below the pyriformis muscle, and reaches down below the middle of the thigh, where it separates into two large divisions, named the *internal* and *external popliteal* nerves. At first it lies in the hollow between the great trochanter and the ischial tuberosity, covered by the gluteus maximus and resting on the gemelli, obturator internus, and quadratus femoris muscles, in company with the small sciatic nerve and the sciatic artery, and receiving from that artery a branch which runs for some distance in its substance. Lower down it rests on the adductor magnus, and is covered behind by the long head of the biceps muscle.

The bifurcation of the sciatic nerve may take place at any point intermediate between the sacral plexus and the lower part of the thigh; and, occasionally, it is found to occur even within the pelvis, a portion of the pyriformis muscle being interposed between the two great divisions of the nerve.

**BRANCHES OF THE TRUNK.**—In its course downwards, the great sciatic nerve supplies offsets to some contiguous parts, viz., to the hip-joint, and to the muscles at the back of the thigh.

*a.* The *articular branches* are derived from the upper end of the nerve, and enter the capsular ligament of the hip-joint, on the posterior aspect. They sometimes arise from the sacral plexus,

*b.* The *muscular branches* are given off under cover of the biceps muscle; they supply the flexors of the leg, viz., the biceps, semitendinosus, and semimembranosus. A branch is likewise given to the adductor magnus.

**Internal Popliteal Nerve.**—The internal popliteal nerve, the larger of the two divisions of the great sciatic nerve, following the same direction as the parent trunk, continues along the middle of the popliteal space to the lower border of the popliteus muscle, beneath which point the continuation of the trunk receives the name of *posterior tibial*. The internal popliteal nerve lies at first at a considerable distance from the popliteal artery, at the outer side and nearer to the surface; but, from the knee-joint downwards, the nerve, continuing a straight course, is close behind the artery, and then crosses it rather to the inner side.

Fig. 377.

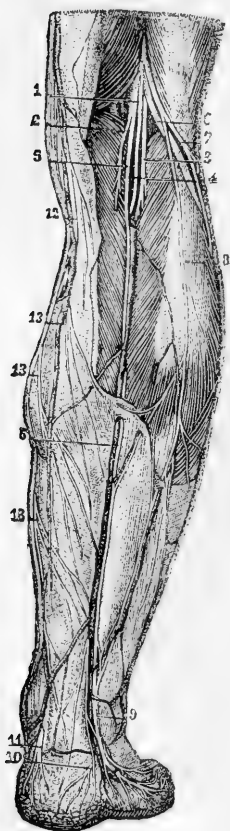


Fig. 377.—POSTERIOR CUTANEOUS NERVES OF THE LEG (from Sappey after Hirschfeld and Leveillé).

1, internal popliteal division of the great sciatic nerve; 2, branch to the internal part of the gastrocnemius muscle; 3, 4, branches to the external part and plantaris; 5, communicating branch to the external saphenous nerve; 6, external popliteal nerve; 7, cutaneous branch; 8, communicating branch descending to unite with that from the internal popliteal in, 9, the external saphenous nerve; 10, calcaneal branch from this nerve; 11, calcaneal and plantar cutaneous branches from the posterior tibial nerve; 12, internal saphenous nerve; 13, posterior branches of this nerve.

**BRANCHES.**—The internal popliteal nerve supplies branches to the knee-joint and to the muscles of the calf of the leg, and also part of a cutaneous branch, the external or short saphenous nerve.

**Articular Nerves.**—The *articular branches* are generally three in number; two of these accompany the upper and lower articular arteries of the inner side of the knee-joint, the third follows the middle or azygos artery. These nerves pierce the ligamentous tissue of the joint.—The upper one is often wanting.

**Muscular Branches.**—The muscular branches of the internal popliteal nerve arise behind the knee-joint, while the nerve is between the heads

of the gastrocnemius muscle.

*a.* The nerves to the *gastrocnemius* consist of two branches, which separate, one to supply each part of the muscle.

*b.* The small nerve of the *plantaris* muscle is derived from the outer of the branches just described, or directly from the main trunk (internal popliteal).

*c.* The *soleus* receives a branch of considerable size, which enters the muscle on the posterior aspect after descending to it in front of the gastrocnemius.

*d.* The nerve of the *popliteus* muscle lies deeper than the preceding branches, and arises somewhat below the joint; it descends along the outer side of the popliteal vessels, and, after turning beneath the lower border of the muscle, enters the deep or anterior surface.

**External or short saphenous nerve.**—The cutaneous branch of the internal popliteal nerve (ramus communicans tibialis) descends along the leg beneath the fascia, resting on the gastrocnemius, in the furrow between the heads near the muscle, to about midway between the knee and the foot. Here it perforates the fascia, and a little lower down is usually joined by a branch from the external popliteal nerve (communicans peronei). After receiving this communicating branch, the external saphenous nerve descends beneath the integument near the outer side of the tendo Achillis in company with the short saphenous vein, and turns forwards beneath the outer malleolus to end in the skin at the side of the foot and on the little toe. On the dorsum of the foot this nerve communicates with the musculo-cutaneous nerve.

In many cases, the external saphenous nerve supplies the outer side of the fourth toe, as well as the little toe. The union between the saphenous nerve and the branch of the external popliteal nerve occurs in some cases higher than usual, occasionally even at or close to the popliteal space. It sometimes happens that the communication between the nerves is altogether wanting; in which case the cutaneous nerve to the foot is generally continued from the branch of the internal popliteal nerve.

**Posterior Tibial Nerve.**—The internal popliteal nerve receives the name of posterior tibial at the lower margin of the popliteus muscle. It passes down the leg with the posterior tibial artery, lying for a short distance at the inner side of the vessel and afterwards at the outer side; the artery inclining inwards from its origin while the nerve continues its straight course. In the interval between the inner malleolus and the heel, it divides into the two plantar nerves (internal and external). The posterior tibial nerve, like the accompanying vessels, is covered at first by the muscles of the calf of the leg, afterwards only by the integument and fascia, and it rests upon the deep-seated muscles.

**LATERAL BRANCHES.**—The deep muscles on the back of the leg and the integument of the sole of the foot receive branches from the posterior tibial nerve in its course along the leg.

*a.* The muscular branches emanate from the upper part of the nerve, either separately or by a common trunk; and one is distributed to each of the deep muscles, viz., the tibialis posticus, the long flexor of the toes, and the long flexor of the great toe. The branch which supplies the last-named muscle runs along the peroneal artery before penetrating the muscle.

*b.* A *calcaneo-plantar cutaneous* branch is furnished from the posterior tibial nerve; the plantar part perforates the internal annular ligament, and ramifies in the integument at the inner side of the sole of the foot, and beneath the heel.

**Internal Plantar Nerve.**—The internal plantar, the larger of the two nerves to the sole of the foot, into which the posterior tibial divides, accompanies the internal or smaller plantar artery, and supplies nerves to both sides of the three inner toes, and to one side of the fourth. From the point at which it separates from the posterior tibial nerve, it is directed forwards under cover of the first part of the abductor of the great toe, and passing between that muscle and the short flexor of the toes, it gives off the internal cutaneous branch for the great toe, and divides opposite the middle of the foot into three digital branches. The outermost of these branches communicates with the external plantar nerve.

*a.* Small *muscular* branches are supplied to the abductor pollicis and flexor brevis digitorum.

*b.* Small *plantar cutaneous* branches perforate the plantar fascia to ramify in the integument of the sole of the foot.

*c.* The *digital branches* are named numerically from within outwards: the three outer pass from under cover of the plantar fascia near the clefts between the toes. The first or innermost branch continues single, but the other three bifurcate to supply the adjacent sides of two toes. These branches require separate notice.

The *first* digital branch is that destined for the inner side of the great toe; it becomes subcutaneous farther back than the others, and sends off a branch to the *flexor brevis pollicis*.

Fig. 378.

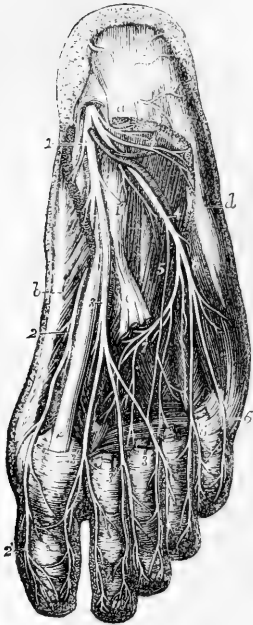


Fig. 378.—SUPERFICIAL AND DEEP DISTRIBUTION OF THE PLANTAR NERVES (after Hirschfeld and Leveillé, slightly modified). (A. T.)  $\frac{1}{3}$

The flexor communis brevis, the abductor pollicis and abductor minimi digiti, a part of the tendons of the flexor communis longus, together with the lumbricales muscles, have been removed so as to bring into view the transversus and interossei in the middle of the foot.

*a.*, upon the posterior extremity of the flexor communis brevis, near which, descending over the heel, are seen ramifications of the calcaneal branch of the posterior tibial nerve; *b.*, abductor pollicis; *c.*, tendon of the flexor communis longus divided close to the place where it is joined by the flexor accessorius; *d.*, abductor minimi digiti; *e.*, tendon of the flexor longus pollicis between the two portions of the flexor brevis pollicis; 1, internal plantar nerve giving some twigs to the abductor pollicis, and 1', a branch to the flexor communis brevis, cut as it lies on the accessorius; 2, inner branch of the internal plantar nerve giving branches to the abductor pollicis, flexor brevis pollicis, and forming, 2', the internal cutaneous of the great toe; 3, continuation of the internal plantar nerve, dividing subsequently into three branches, which form, 3', 3', 3'', the collateral plantar cutaneous nerves of the first and second, second and third, and third and fourth toes; 4, the external plantar nerve; 4', its branch to the abductor minimi digiti; 5, twig of union between the plantar nerves; 6, superficial branch of the external plantar nerve; subsequently dividing into 6', 6'', the collateral cutaneous nerves of

the fourth and fifth toes and the external nerve of the fifth; 7, deep branch of the external plantar nerve giving twigs to the adductor pollicis, the interossei, the transversalis, and to the third and fourth lumbricales muscles.

The *second* branch having reached the interval between the first and second metatarsal bones, furnishes a small twig to the *first lumbricalis* muscle, and bifurcates behind the cleft between the great toe and the second to supply their contiguous sides.

The *third* digital branch, corresponding with the second interosseous space, gives a slender filament to the *second lumbricalis* muscle, and divides in a manner similar to that of the second branch into two offsets for the sides of the second and third toes.

The *fourth* digital branch distributed to the adjacent sides of the third and fourth toes, receives a communicating branch from the external plantar nerve.

Along the sides of the toes, cutaneous and articular filaments are given from

these digital nerves ; and, opposite the unguis phalanx, each sends a dorsal branch to the pulp beneath the nail, and then runs on to the ball of the toe, where it is distributed like the nerves of the fingers.

**External Plantar Nerve.**—The external plantar nerve completes the supply of digital nerves to the toes, furnishing branches to the little toe and half the fourth : it also gives a deep branch of considerable size, which is distributed to several of the short muscles in the sole of the foot. There is thus a great resemblance between the distribution of this nerve in the foot and that of the ulnar nerve in the hand.

The external plantar nerve runs obliquely forwards towards the outer side of the foot, along with the external plantar artery, between the flexor brevis digitorum and the flexor accessorius, as far as the interval between the former muscle and the abductor of the little toe. Here it divides into a superficial and a deep branch, having previously furnished offsets to the *flexor accessorius* and the *abductor minimi digiti*.

*a.* The *superficial portion* separates into two digital branches, which have the same general arrangement as the digital branches of the internal plantar nerve. They are distributed thus.

*Digital branches.*—One of the digital branches continues undivided, and runs along the outer side of the little toe : it is smaller than the other, and pierces the plantar fascia further back. The *short flexor muscle of the little toe*, and occasionally one or two *interosseous* muscles of the fourth metatarsal space receive branches from this nerve.

The larger digital branch communicates with an offset from the internal plantar nerve, and bifurcates near the cleft between the fourth and fifth toes to supply one side of each.

*b.* The *deep or muscular branch* of the external plantar nerve dips into the sole of the foot with the external plantar artery, under cover of the tendons of the flexor muscles and the adductor pollicis, and terminates in numerous branches for the following muscles :—all the *interossei* (dorsal and plantar) except occasionally one or both of those in the fourth space, the two outer *lumbricales*, the *adductor pollicis*, and the *transversalis pedis*.

**SUMMARY OF THE INTERNAL POPLITEAL NERVE.**—This nerve supplies all the muscles of the back of the leg and sole of the foot, and the integument of the plantar aspect of the toes, the sole of the foot, and in part that of the leg.

**External Popliteal Nerve.**—This nerve descends obliquely along the outer side of the popliteal space, lying close to the biceps muscle. Continuing downwards over the outer part of the gastrocnemius muscle (between it and the biceps) below the head of the fibula, the nerve turns round that bone, passing between it and the peroneus longus muscle, and then divides into the *anterior tibial* and the *musculo-cutaneous* nerves.

**LATERAL BRANCHES.**—Some articular and cutaneous branches are derived from the external popliteal nerve before its final division.

**Articular nerves.**—The articular branches are conducted to the outer side of the capsular ligament of the knee-joint by the upper and lower articular arteries of that side. They sometimes arise together, and the upper one occasionally springs from the great sciatic nerve before the bifurcation.

From the place of division of the external popliteal nerve, a *recurrent articular* nerve ascends through the tibialis anticus muscle with the recurrent artery to reach the fore part of the knee-joint.

**Cutaneous nerves.**—The cutaneous branches, two or three in number, supply the skin on the back part and outer side of the leg.

Fig. 379.

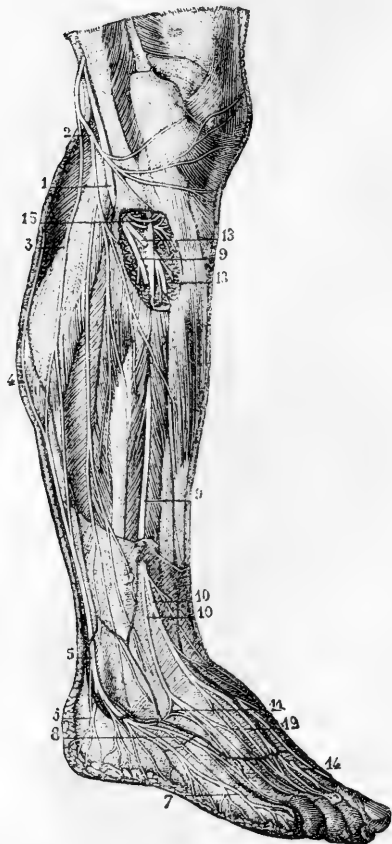


Fig. 379.—CUTANEOUS NERVES OF THE OUTER SIDE OF THE LEG AND FOOT (from Sappey after Hirschfeld and Leveillé).  $\frac{1}{2}$

1, external popliteal nerve; 2, its external cutaneous branch; 3, communicating branch which unites with 4, that from the internal popliteal, in 5, the external saphenous nerve; 6, calcaneal branch of the external saphenous; 7, external dorsal digital branch to the fifth toe; 8, collateral dorsal digital branch of the fourth and fifth toes; 9, musculo-cutaneous nerve; 10, its cutaneous branches; 11, loop of union with the external saphenous; 12, union between its outer and inner branches; 13, anterior tibial nerve, shown by the removal of a part of the muscles, and giving muscular branches superiorly; 14, its terminal branch emerging in the space between the first and second toes, where it gives the collateral dorsal digital branches to their adjacent sides; 15, branches to the peronei muscles.

The *peroneal communicating branch* (r. communicans fibularis), which joins the short saphenous nerve below the middle of the back of the leg, is the largest of these nerves. In some instances, it continues a separate branch and its cutaneous filaments reach down to the heel or on to the outside of the foot.

Another cutaneous branch extends along the outer side of the leg to the middle or lower part, sending offshoots both backwards and forwards.

**Musculo-Cutaneous Nerve.**—The musculo-cutaneous (peroneal) nerve descends between the peronei muscles and the long extensor of the toes, and reaches the surface by perforating the fascia in the lower part of the leg on the anterior aspect. It then divides into two branches, distinguished as external and internal, which proceed to the toes. The two branches sometimes perforate the fascia at a different height.

(a) *Muscular branches* are given to the peroneus longus and peroneus brevis.

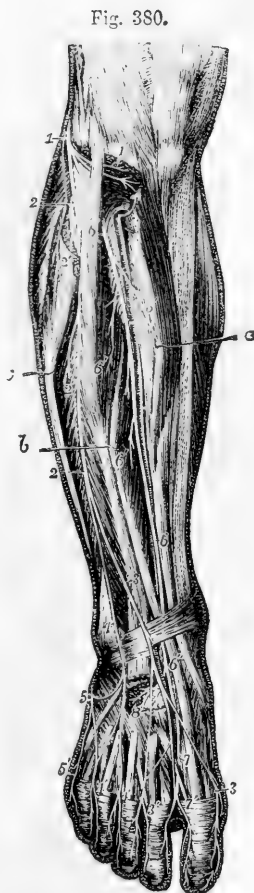
(b) *Cutaneous branches* given off before the final division are distributed to the lower part of the leg.

(c) The *internal branch* of the musculo-cutaneous nerve, passing forwards along the dorsum of the foot, furnishes one branch to the inner side of the great toe, and others to the contiguous sides of the second and third toes. It gives other offshoots, which extend over the inner ankle and side of the foot. This nerve communicates with the long saphenous nerve on the inner side of the foot, and with the anterior tibial nerve between the first and second toes.

(d) The *external branch*, larger than the internal one, descends over the foot towards the fourth toe, which, together with the contiguous borders of the third and fifth toes, it supplies with branches. Cutaneous nerves, derived from this branch, spread over the outer ankle and the outer side of the foot, where they are connected with the short saphenous nerve.

Fig. 380. — VIEW OF THE DISTRIBUTION OF THE BRANCHES OF THE EXTERNAL POPLITEAL NERVE IN THE FRONT OF THE LEG AND DORSUM OF THE FOOT (after Hirschfeld and Leveillé).

The upper part of the peroneus longus muscle has been removed, the tibialis anticus, the long extensor of the great toe and the peroneus longus have been drawn separate in the leg by hooks marked *a*, *b*, and *c*, and the tendons of the extensor muscles have been removed in the dorsum of the foot, to show the deeper seated nerves; 1, the external popliteal or peroneal nerve winding round the other part of the fibula; 1', its recurrent articular branches exposed by the dissection of the upper part of the tibialis anticus muscle; 2, 2, the musculo-cutaneous nerve; 2', 2', twigs to the long and short peroneal muscles; 3, internal branch of the musculo-cutaneous nerve; 3', 3', its dorsal digital branches to the inside of the great toe, and to the adjacent sides of the second and third toes; 4, the external branch; 4', 4', its dorsal digital branches to the adjacent sides of the third and fourth toes, and in part to the space between the fourth and fifth toes; 5, the external saphenous nerve descending on the outer border of the foot, and uniting at two places with the outer branch of the musculo-cutaneous; 5', its branch to the outer side of the fifth toe; 6, placed on the upper part of the extensor communis digitorum, marks the anterior tibial nerve passing beneath the muscles; 6, placed further down on the tendon of the tibialis anticus, points to the nerve as it crosses to the inside of the anterior tibial artery; 6', its muscular branches in the leg; 6'', on the tendon of the extensor longus pollicis points to the anterior tibial nerve after it has passed into the foot behind that tendon; 7, its inner branch uniting with a twig of the musculo-cutaneous, and giving the dorsal digital nerves to the adjacent sides of the first and second toes; 8, distribution of its outer branch to the extensor brevis digitorum and tarsal articulations.



The dorsal digital nerves are continued on to the last phalanges of the toes.

The number of toes supplied by each of the two divisions of the musculo-cutaneous nerve is liable to vary; together these nerves commonly supply all the toes on the dorsal aspect, excepting the outer side of the little toe, which receives a branch from the short saphenous nerve, and the adjacent sides of the great toe and the second toe, to which the anterior tibial nerve is distributed: with this latter branch, however, it generally communicates.

**Anterior Tibial Nerve.**—The anterior tibial (interosseous nerve), commencing between the fibula and the peroneus longus, inclines obliquely beneath the long extensor of the toes to the fore part of the interosseous membrane, and there comes into contact with the anterior tibial vessels, and with those vessels it descends to the front of the ankle-joint, where it divides into an external and an internal branch.

The nerve first reaches the outer side of the anterior tibial artery, above the middle of the leg; and, after crossing in front of that vessel once or oftener, lies to the outer side of it at the bend of the ankle.

(a) *Muscular branches*.—In its course along the leg, the anterior tibial nerve gives slender filaments to the muscles between which it is placed, namely, the tibialis anticus, the long extensor of the toes, and the special extensor of the great toe.

(b) The *external branch* of the anterior tibial nerve turns outwards over the tarsus beneath the short extensor of the toes; and, having become enlarged (like the posterior interosseous nerve on the wrist) terminates in branches which supply the short extensor muscle, and likewise the articulations of the foot.

(c) The *internal branch*, continuing onwards in the direction of the anterior tibial nerve, accompanies the dorsal artery of the foot to the first interosseous space, and ends in two branches, which supply the integument on the neighbouring sides of the great toe and the second toe on their dorsal aspect. It communicates with the internal division of the musculo-cutaneous nerve.

**SUMMARY OF THE EXTERNAL POPLITEAL NERVE.**—This nerve supplies, besides articular branches to the knee, ankle, and foot, the peronei muscles, extensor muscles of the foot, also the integument of the front of the leg and dorsum of the foot. It gives the ramus communicans fibularis to the short saphenous branch of the internal popliteal nerve, and communicates with the long saphenous nerve.

#### SYNOPSIS OF THE CUTANEOUS DISTRIBUTION OF THE CEREBRO-SPINAL NERVES.

**1. In the Head.**—The *face and head in front of the ear* are supplied with sensory nerves from the fifth cranial nerve. The ophthalmic division supplies branches to the forehead, upper eyelid, and dorsum of the nose. The superior maxillary division supplies the cheek, ala of the nose, upper lip, lower eyelid, and the region behind the eye, over the temporal fascia. The inferior maxillary division supplies the chin and lower lip, the pinna of the ear on its outer side, and the integument in front of the ear and upwards to the vertex of the head.

The *head, behind the ear*, is mainly supplied by the great occipital branch of the posterior division of the second spinal nerve, but above the occipital protuberance there is also distributed the branch from the posterior division of the third spinal nerve; and, in front of the area of the great occipital nerve, is a space supplied by anterior divisions of spinal nerves, viz., the back of the pinna of the ear, together with the integument behind and that in front over the parotid gland, which are supplied by the great auricular nerve; while between the area of that nerve and the great occipital the small occipital nerve intervenes. The auricular branch of the pneumo-gastric nerve also is distributed on the back of the ear.

**2. In the Trunk.**—The *posterior divisions of the spinal nerves* supply an area extending on the back from the vertex of the skull to the buttock. This area is narrow in the neck; it is spread out over the back of the scapula; and on the buttock the distribution of the lumbar nerves extends to the trochanters.

The *area supplied by the cervical plexus*, besides extending upwards, as already mentioned, on the lateral part of the skull, stretches over the



front and sides of the neck, and the upper part of the shoulder and breast.

The *area of the anterior divisions of the dorsal and first lumbar nerves* meets superiorly with that of the cervical plexus, and posteriorly with that of the posterior divisions of dorsal and lumbar nerves. It passes down over the haunch and along by the outer part of Poupart's ligament, and includes part of the scrotum and a small portion of the integument of the thigh internal to the saphenous opening.

The *perinæum* and *penis* are supplied by the pudic nerve; the *scrotum* by branches of the pudic, inferior pudendal, and ilio-inguinal nerves.

**3. In the Upper limb.**—The *shoulder*, supplied superiorly by the cervical plexus, receives its cutaneous nerves inferiorly as far as the insertion of the deltoid from the circumflex nerve.

The *arm* internally is supplied by the intercosto-humeral nerve and the nerve of Wrisberg. The inner and anterior part is supplied by the internal cutaneous nerve; and the posterior and outer part by the internal and external branches of the musculo-spiral nerve.

The *forearm*, anteriorly and on the outer side, is supplied by the external cutaneous; on its outer and posterior aspect, superiorly by the external cutaneous branches of the musculo-spiral, and inferiorly by the radial branch of the same nerve. On the inner side, both in front and behind, is the internal cutaneous nerve, and inferiorly are branches of the ulnar.

On the *back of the hand* are the radial and ulnar nerves, the radial supplying about three fingers and a half or less, and the ulnar one and a half or more.

On the *front of the hand*, the median nerve supplies three fingers and a half, and the ulnar one and a half. In the *palm* is a branch of the median given off above the wrist. On the *ball of the thumb* are branches of the musculo-cutaneous, median, and radial nerves.

**4. In the Lower limb.**—The *buttock* is supplied from above by the cutaneous branches of the posterior divisions of the lumbar nerves, with the ilio-hypogastric and lateral branches of the last dorsal nerves; internally by the posterior divisions of the sacral nerves; externally by the posterior branch of the external cutaneous nerve proceeding from the front; and inferiorly by branches of the small sciatic nerve proceeding from below.

The *thigh* is supplied externally by the external cutaneous nerve; posteriorly, and in the upper half of its inner aspect, by the small sciatic; anteriorly, and in the lower half of the inner aspect, by the middle and internal cutaneous.

The *leg* is supplied posteriorly by the small sciatic and short saphenous nerves; internally by the long saphenous and branches of the internal cutaneous of the thigh; and outside and in front by cutaneous branches of the external popliteal nerve and by its musculo-cutaneous branch.

On the *dorsum of the foot* are the branches of the musculo-cutaneous, supplying all the toes with the exception of the adjacent sides of the first and second, which are supplied by the anterior tibial, and the outer side of the little toe, which, with the outer side of the foot, is supplied by the short saphenous nerve. The long saphenous is the cutaneous nerve on the inner side of the foot.

The *sole of the foot* is supplied by the plantar nerves. The internal plantar nerve gives branches to three toes and a half; the external to the remaining one toe and a half.

### SYNOPSIS OF THE MUSCULAR DISTRIBUTION OF THE CEREBRO-SPINAL NERVES.

#### 1. To Muscles of the Head and Fore Part of the Neck.

The *muscles of the orbit* are mostly supplied by the third cranial nerve—the superior division of that nerve being distributed to the levator palpebræ and the superior rectus muscles; and the inferior division to the inferior and internal recti and the inferior oblique. The superior oblique muscle is supplied by the fourth nerve, the external rectus by the sixth; while the tensor tarsi has no special nerve apart from those of the orbicularis palpebrarum, which are derived from the facial.

The *superficial muscles of the face and scalp*, which are associated in their action as a group of muscles of expression, together with the buccinator muscle, are supplied by the portio dura of the seventh cranial nerve; the retrahens auriculam and occipitalis muscles being supplied by its posterior auricular branch.

The *deep muscles of the face*, employed in mastication, viz., the temporal, masseter, and two pterygoid muscles are supplied by the inferior maxillary division of the fifth cranial nerve.

*Muscles above the hyoid bone.*—The mylo-hyoid muscle and anterior belly of the digastric are supplied by a special branch of the inferior maxillary division of the fifth cranial nerve; the posterior belly of the digastric muscle, and the stylo-hyoid, are supplied by branches of the portio dura. The genio-hyoid and the muscles of the tongue receive their nervous supply from the hypoglossal nerve.

The *muscles ascending to the hyoid bone and larynx*, viz., the sternohyoid, omo-hyoid, and sterno-thyroid, are supplied from the ramus descendens noni and its loop with the cervical plexus, while the thyro-hyoid muscle receives a separate twig from the ninth nerve.

*The larynx, pharynx, and soft palate.*—The crico-thyroid muscle is supplied by the external laryngeal branch of the pneumo-gastric nerve, and the other intrinsic muscles of the larynx by the recurrent laryngeal. The muscles of the pharynx are supplied principally by the pharyngeal branch of the pneumo-gastric; the stylo-pharyngeus, however, is supplied by the glosso-pharyngeal nerve. Of the muscles of the soft palate unconnected with the tongue or pharynx, the tensor palati receives its nerve from the otic ganglion (which also supplies the tensor tympani); the levator palati gets a twig (Meckel) from the posterior palatine branch of the spheno-palatine ganglion, and the azygos uvulæ is probably supplied from the same source.

#### 2. To Muscles belonging exclusively to the Trunk, and Muscles ascending to the Skull.

All those *muscles of the back* which are unconnected with the upper limb, viz., the posterior serrati, the splenius, complexus, erector spinæ, and the muscles more deeply placed, receive their supply from the posterior divisions of the spinal nerves.

The *sterno-mastoïd* is supplied by the spinal accessory nerve and a twig of the cervical plexus coming from the second cervical nerve.

The *rectus capitis anticus major* and *minor* are supplied by twigs from the upper cervical nerves; the *longus colli* and *scaleni* muscles by twigs from the lower cervical nerves.

The *muscles of the chest*, viz., the intercostals, subcostals, levatores costarum, and triangularis sterni, are supplied by the intercostal nerves.

The *obliqui*, *transversus*, and *rectus* of the abdomen are supplied by the lower intercostal nerves; and the oblique and transverse muscles also get branches from the ilio-inguinal and ilio-hypogastric nerves. The *cremaster* muscle is supplied by the genital branch of the genito-crural nerve.

The *quadratus lumborum* (like the *psaos*) receives small branches from the lumbar nerves before they form the plexus.

The *diaphragm* receives the phrenic nerves from the fourth and fifth cervical nerves, and likewise sympathetic filaments from the plexuses round the phrenic arteries.

The *muscles of the urethra and penis* are supplied by the pudic nerve; the *levator ani* and *sphincter ani* by the pudic and by the fourth and fifth sacral and coccygeal nerves; and the *coccygeus* muscle by the three last-named nerves.

**3. To muscles attaching the upper limb to the trunk.**—The *trapezius* and the *sterno-cleido-mastoïd* receive the distribution of the *spinal accessory* nerve, and, in union with it, filaments from the cervical plexus.

The *latissimus dorsi* receives the long subscapular nerve.

The *rhomboidei* are supplied by a special branch from the anterior division of the fifth cervical nerve.

The *levator anguli scapule* is supplied by branches from the anterior division of the third cervical nerve, and sometimes partly also by the branch to the rhomboid muscles.

The *serratus magnus* has a special nerve, the posterior thoracic, derived from the fifth and sixth cervical nerves.

The *subclavius* receives a special branch from the place of union of the fifth and sixth cervical nerves.

The *pectorales* are supplied by the anterior thoracic branches of the brachial plexus, the larger muscle receiving filaments from both these nerves, and the smaller from the inner only.

**4. To muscles of the upper limb.**—*Muscles of the shoulder.*—The *supraspinatus* and *infraspinatus* are supplied by the suprascapular nerve; the *subscapularis* by the two smaller subscapular nerves; the *teres major* by the second subscapular, and the *deltoid* and *teres minor* by the *circumflex* nerve.

*Posterior muscles of the arm and forearm.*—The *triceps*, *anconeus*, *supinator longus*, and *extensor carpi radialis longior* are supplied by direct branches of the musculo-spiral nerve; while the *extensor carpi radialis brevior* and the other *extensor* muscles in the forearm receive their branches from the posterior interosseous division of that nerve.

*Anterior muscles of the arm and forearm.*—The *coraco-brachialis*, *biceps*, and *brachialis anticus* are supplied by the musculo-cutaneous nerve; the *brachialis anticus* likewise generally receives a twig from

the musculo-spiral nerve. The muscles in front of the forearm are supplied by the median nerve, with the exception of the flexor carpi ulnaris and the ulnar half of the flexor profundus digitorum, which are supplied by the ulnar nerve, and the supinator longus, which is supplied by the musculo-spiral.

*Muscles of the hand.*—The abductor and opponens pollicis, the outer half of the flexor brevis pollicis, and the two outer lumbricales muscles, are supplied by the median nerve: all the other muscles receive their nerves from the ulnar.

**5. To muscles of the lower limb.**—*Posterior muscles of the hip and thigh.*—The gluteus maximus is mainly supplied by the small sciatic nerve, and receives at its upper part a separate branch from the sacral plexus. The gluteus medius and minimus, together with the tensor vaginae femoris, are supplied by the gluteal nerve. The pyriformis, gemelli, obturator internus, and quadratus femoris receive special branches from the sacral plexus. The hamstring muscles are supplied by branches from the great sciatic nerve.

*Anterior and internal muscles of the thigh.*—The psoas muscle is supplied by separate twigs from the lumbar nerves. The iliacus, quadriceps extensor femoris, and sartorius are supplied by the anterior crural nerve. The adductor muscles, the obturator externus and the pectineus, are supplied by the obturator nerve, but the adductor magnus likewise receives a branch from the great sciatic, and the pectineus sometimes has a branch from the anterior crural.

*Anterior muscles of the leg and foot.*—The muscles in front of the leg, together with the extensor brevis digitorum, are supplied by the anterior tibial nerve.

The *peroneus longus* and *brevis* are supplied by the musculo-cutaneous nerve.

*Posterior muscles of the leg.*—The gastrocnemius, plantaris, soleus, and popliteus are supplied by branches from the internal popliteal nerve; the deep muscles, viz., the flexor longus digitorum, flexor longus pollicis, and tibialis posticus, derive their nerves from the posterior tibial.

*Plantar muscles.*—The flexor brevis digitorum, the abductor and flexor brevis pollicis, and the two inner lumbricales, are supplied by the internal plantar nerve; all the others, including the flexor accessorius and interossei, are supplied by the external plantar nerve.

### III. SYMPATHETIC NERVES.

The nerves of the sympathetic system are distributed in general to all the internal viscera, and to the coats of the blood-vessels. Some organs, however, receive their nerves also from the cerebro-spinal system, as the lungs, the heart, and the upper and lower parts of the alimentary canal.

This division of the nervous system consists of a somewhat complicated collection of ganglia, cords and plexuses, the parts of which may, for convenience, be classified in three groups, viz., the principal gangliated cords, the great prevertebral plexuses with the nerves proceeding from them, and the ganglia of union with cranial nerves.

The **great gangliated cords** consist of two series, in each of which

the ganglia are connected by intervening cords. These cords are placed symmetrically in front of the vertebral column, and extend from the base of the skull to the coccyx. Superiorly they are connected with plexuses which enter the cranial cavity, while inferiorly they converge on the sacrum, and terminate in a single ganglion on the coccyx. The several portions of the cords are distinguished as cervical, dorsal, lumbar, and sacral, and in each of these parts the ganglia are equal in number, or nearly so, to the vertebræ on which they lie, except in the neck, where there are only three.

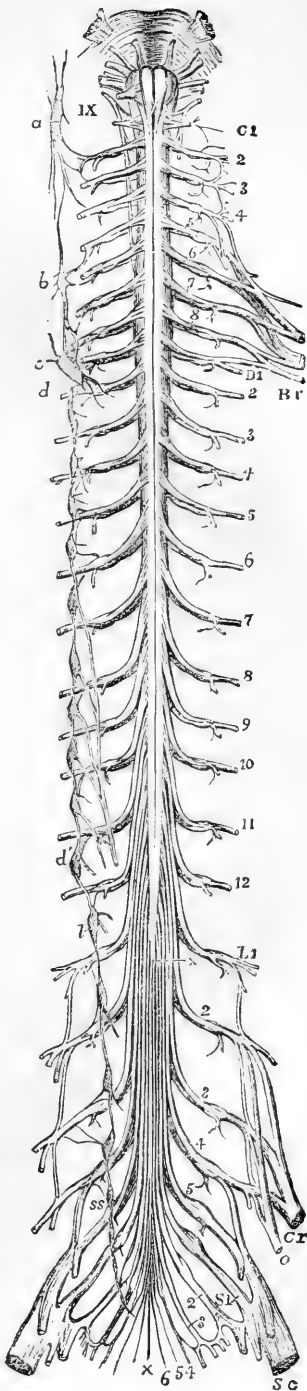
Fig. 381.—DIAGRAMMATIC OUTLINE OF THE SYMPATHETIC CORD OF ONE SIDE IN CONNECTION WITH THE SPINAL NERVES.

The full description of this figure will be found at p. 568.

On the right side the following letters indicate parts of the sympathetic nerves, viz. *a*, the superior cervical ganglion, communicating with the upper cervical spinal nerves and continued below into the great sympathetic cord; *b*, the middle cervical ganglion; *c*, *d*, the lower cervical ganglion united with the first dorsal; *d'*, the eleventh dorsal ganglion; from the fifth to the ninth dorsal ganglia the origins of the great splanchnic nerve are shown; *l*, the lowest dorsal or upper lumbar ganglion; *ss*, the upper sacral ganglion. In the whole extent of the sympathetic cord, the twigs of union with the spinal nerves are shown.

*Connection of the gangliated cords with the cerebro-spinal system.*—The ganglia are severally connected with the spinal nerves in their neighbourhood by means of short filaments; each connecting filament consisting of a white and a grey portion, the former of which may be considered as proceeding from the spinal nerve to the ganglion, the latter from the ganglion to the spinal nerve. At its upper end the gangliated cord communicates likewise with certain cranial nerves. The main cords intervening between the ganglia, like the smaller filaments connecting the ganglia with the spinal nerves, are composed of a grey and a white part, the white being continuous with the fibres of the spinal nerves prolonged to the ganglia.

s s 2



The **great prevertebral plexuses** comprise three large aggregations of nerves, or nerves and ganglia situated in front of the spine, and occupying respectively the thorax, the abdomen, and the pelvis. They are single and median, and are named respectively the cardiac, the solar, and the hypogastric plexus. These plexuses receive branches from both the gangliated cords above noticed, and they constitute centres from which the viscera are supplied with nerves.

The **cranial ganglia** of the sympathetic are the ophthalmic, sphenopalatine, submaxillary, and otic, which, being intimately united with the fifth cranial nerve, have already been described along with that nerve. They are also more or less directly connected with the upper end of the sympathetic gangliated cords; but it will be unnecessary to give any special description of them in this place.

#### THE CERVICAL PART OF THE GANGLIATED CORD.

In the neck, each gangliated cord is deeply placed behind the sheath of the great cervical blood-vessels, and in contact with the muscles which immediately cover the fore part of the vertebral column. It comprises three ganglia, the first of which is placed near the base of the skull, the second in the lower part of the neck, and the third immediately above the head of the first rib.

#### THE UPPER CERVICAL GANGLION.

This is the largest ganglion of the great sympathetic cord. It is continued superiorly into an ascending branch, and tapers below into the connecting cord, so as to present usually a fusiform shape; but there is considerable variety in this respect in different cases, the ganglion being occasionally broader than usual, and sometimes constricted at intervals. It has the reddish-grey colour characteristic of the ganglia of the sympathetic system. It is placed on the larger rectus muscle, opposite the second and third cervical vertebræ, and behind the internal carotid artery.

*Connection with spinal nerves.*—At its outer side the superior cervical ganglion is connected with the first four spinal nerves, by means of slender cords, which have the structure pointed out in the general description as being common to the series.

The circumstance of this ganglion being connected with so many as four spinal nerves, together with its occasionally constricted appearance, is favourable to the view that it may be regarded as consisting of several ganglia which have coalesced.

*Connection with cranial nerves.*—Small twigs connect the ganglion or its cranial cord with the second ganglion of the pneumo-gastric, and with the ninth cranial nerve, near the base of the skull; and another branch, which is directed upwards from the ganglion, divides at the base of the skull into two filaments, one of which ends in the second (petrosal) ganglion of the glosso-pharyngeal nerve; while the other, entering the jugular foramen, joins the ganglion of the root of the pneumo-gastric.

Besides the branches connecting it with cranial and spinal nerves, the first cervical ganglion gives off also the ascending branch, the upper cardiac nerve, pharyngeal nerves, and branches to blood-vessels.

1. ASCENDING BRANCH AND CRANIAL PLEXUSES.—The **ascending**

**branch** of the first cervical ganglion is soft in texture and of a reddish tint, seeming to be in some degree a prolongation of the ganglion itself. In its course to the skull, it is concealed by the internal carotid artery, with which it enters the carotid canal in the temporal bone, and it is then divided into two parts, which are placed one on the outer, the other on the inner side of the vessel.

The *external division* distributes filaments to the internal carotid artery, and, after communicating by means of other filaments with the internal division of the cord, forms the *carotid plexus*.

Fig. 382.

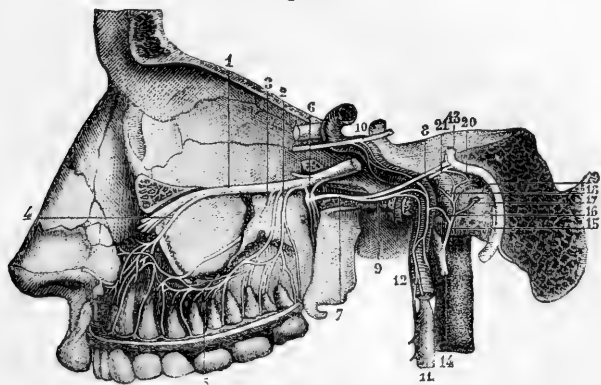


Fig. 382.—CONNECTIONS OF THE SYMPATHETIC NERVE THROUGH ITS CAROTID BRANCH WITH SOME OF THE CRANIAL NERVES.

The full description of this figure will be found at p. 539. The following numbers refer to sympathetic nerves and their connections:—6, spheno-palatine ganglion; 7, Vidian nerve; 9, its carotid branch; 10, a part of the sixth nerve, receiving twigs from the carotid plexus of the sympathetic; 11, superior cervical sympathetic ganglion; 12, its prolongation in the carotid branch; 15, anastomosing nerve of Jacobson; 16, twig uniting it to the sympathetic.

The *inner division*, rather the smaller of the two, supplies filaments to the carotid artery, and goes to form the *cavernous plexus*. The terminal parts of these divisions of the cranial cord are prolonged on the trunk of the internal carotid, and extend to the cerebral and ophthalmic arteries, around which they form secondary plexuses, those on the cerebral artery ascending to the pia mater. One minute plexus enters the eye-ball with the central artery of the retina.

It was stated by Ribes (*Mem. de la Société Méd. d'Emulation*, tom. viii, p. 606.) that the cranial prolongations of the sympathetic nerve from the two sides coalesce with one another on the anterior communicating artery,—a small ganglion or a plexus being formed at the point of junction; but this connection has not been satisfactorily made out by other observers.

**Carotid plexus.**—The carotid plexus, situated on the outer side of the internal carotid artery at its second bend (reckoning from below), or between the second and third bends, joins the fifth and sixth cranial nerves, and gives many filaments to the vessel on which it lies.

**Branches.**—(a) The connection with the *sixth nerve* is established by means of one or two filaments of considerable size, which are supplied to that nerve where it lies by the side of the internal carotid artery.

(b) The filaments connected with the *Gasserian ganglion* of the fifth nerve proceed sometimes from the carotid plexus, at others from the cavernous.

(c) The *deep branch* of the Vidian nerve passes backwards to the carotid plexus, and after leaving the Vidian canal, lies in the cartilaginous substance which closes the foramen lacerum medium. Valentin describes nerves as furnished to the dura mater from the carotid plexus.

**Cavernous plexus.**—The cavernous plexus, named from its position in the sinus of the same name, is placed below and rather to the inner side of the highest turn of the internal carotid artery. Besides giving branches on the artery, it communicates with the third, the fourth, and the ophthalmic division of the fifth cranial nerves.

**Branches.**—(a) The filament which joins the *third nerve* comes into connection with it close to the point of division of that nerve.

(b) The branch to the *fourth nerve*, which may be derived from either the cavernous or the carotid plexus, joins the nerve where it lies in the wall of the cavernous sinus.

(c) The filaments connected with the *ophthalmic trunk* of the *fifth nerve* are supplied to its inner surface. One of them is continued forwards to the lenticular ganglion, either in connection with or distinct from the nasal nerve.

2. PHARYNGEAL NERVES AND PLEXUS.—These nerves arise from the inner part of the ganglion, and are directed obliquely inwards to the side of the pharynx. Opposite the middle constrictor muscle they unite with branches of the pneumogastric and glosso-pharyngeal nerves; and by their union with those nerves the **pharyngeal plexus** is formed. Branches emanating from the plexus are distributed to the muscles and mucous membrane of the pharynx.

3. UPPER CARDIAC NERVE.—Each of the cervical ganglia of the sympathetic furnishes a cardiac branch, the three being named respectively the upper, middle, and lower cardiac nerves.

These branches are continued singly, or in connection, to the large prevertebral centre (cardiac plexus) of the thorax. Their size varies considerably, and where one branch is smaller than common, another will be found to be increased in size, as if to compensate for the defect. There are some differences in the disposition of the nerves of the right and left sides.

The **upper cardiac nerve** (n. cardiacus superficialis) of the **right side** proceeds from two or more branches of the ganglion, with, in some instances, an offset from the cord connecting the first two ganglia. In its course down the neck the nerve lies behind the carotid sheath, in contact with the longus colli muscle; and it is placed in front of the lower thyroid artery and the recurrent laryngeal nerve. Entering the thorax, it passes in some cases before, in others behind the subclavian artery, and is directed along the innominate artery to the back part of the arch of the aorta, where it ends in the deep cardiac plexus, a few small filaments continuing also to the front of the great vessel. Some branches accompany the inferior thyroid artery to be distributed to the thyroid body.

In its course downwards this cardiac nerve is repeatedly connected with other branches of the sympathetic, and with the pneumo-gastric nerve. Thus about the middle of the neck it is joined by some filaments from the external laryngeal nerve; and, rather lower down, by one or more filaments from the trunk of the pneumo-gastric nerve; lastly, on entering the chest, it joins with the recurrent laryngeal.



**Variety.**—Instead of passing to the thorax in the manner described, the superior cardiac nerve may join the cardiac branch furnished from one of the other cervical ganglia. Scarpa describes this as the common disposition of the nerve; but Cruveilhier (*Anat. Descript.*, t. iv.) states that he has not in any case found the cardiac nerves to correspond exactly with the figures of the “*Tabulæ Neurologiæ.*”

The upper cardiac nerve of the left side has, while in the neck, the same course and connections as that of the right side. But within

Fig. 383.

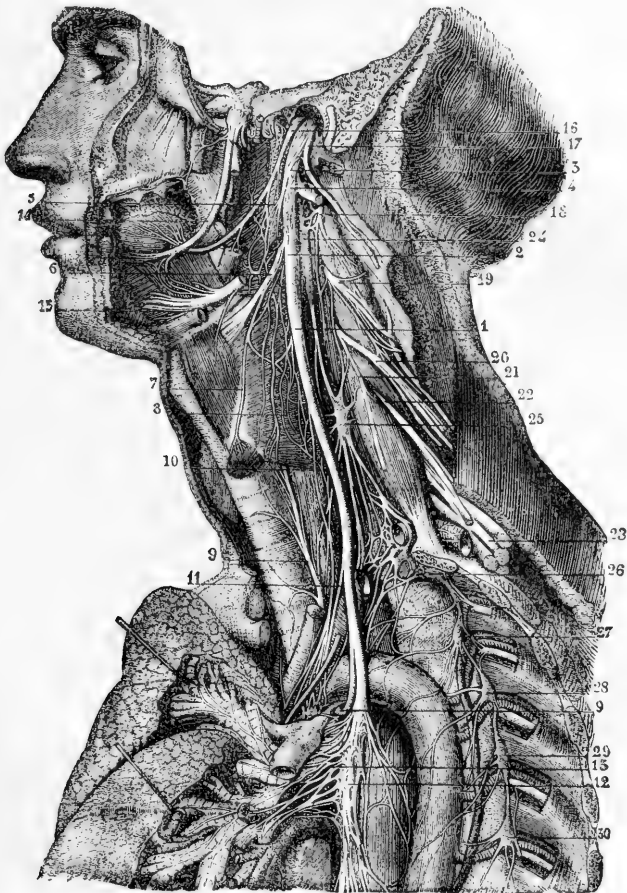


Fig. 383.—CONNECTIONS OF THE CERVICAL AND UPPER DORSAL SYMPATHETIC GANGLIA AND NERVES ON THE LEFT SIDE.

The full description of this figure will be found at p. 558. The following numbers refer to the sympathetic ganglia and nerves, and those immediately connected with them:—5, pharyngeal plexus; 8, laryngeal plexus; 13, pulmonary plexus; and to the reader's left, above the pulmonary artery, a part of the cardiac plexus; 24, superior cervical ganglion of the sympathetic; 25, middle cervical ganglion; 26, inferior cervical ganglion united with the first dorsal ganglion; 27, 28, 29, 30, second, third, fourth, and fifth dorsal ganglia.

the chest it follows the left carotid artery to the arch of the aorta, and ends in some instances in the superficial cardiac plexus, while in others it joins the deep plexus; and accordingly it passes either in front of or behind the arch of the aorta.

4. BRANCHES TO BLOOD-VESSELS.—The nerves which ramify on the arteries (*nervi molles*) spring from the front of the ganglion, and twine round the trunk of the carotid artery. They are also prolonged on the branches of the external carotid, and form slender plexuses upon them.

**Communications with other nerves.**—From the plexus on the facial artery is derived the filament which joins the submaxillary ganglion; and, from that on the middle meningeal artery, twigs have been described as extending to the otic ganglion, as well as to the gangliform enlargement of the facial nerve. Lastly, a communication is established between the plexus on the carotid artery and the digastric branch of the facial nerve.

**Varieties.**—Small ganglia are occasionally found on some of the vascular plexuses, close to the origin of the vessels with which they are associated. Thus lingual, temporal, and pharyngeal ganglia have been described; and besides these there is a larger body, the ganglion intercaroticum, placed on the inner side of the angle of division of the common carotid artery. This body, long known to anatomists as a ganglion, has been stated by Luschka to have a structure very different from the nervous ganglia in general, and has been named by him the “*glandula intercarotica*.”

It is described by him as presenting principally a follicular structure, similar to that of the *glandula coccygea*, which he had previously discovered. It appears, however, from the researches of Julius Arnold, that the follicular appearances observed by Luschka, both in this instance and in the coccygeal gland, were produced by arterial glomeruli seen in section; and that the ganglion intercaroticum consists of numbers of those glomeruli gathered into several larger masses, and of dense plexuses of nerves surrounding respectively the glomeruli, the masses, and the whole structure. Within those plexuses nerve-cells are scattered, but not in very great number. The ganglion is usually about one-fourth of an inch long; but, according to Luschka, may be divided into small separate masses, and thus escape attention, or be supposed to be absent.—(Luschka, “*Anat. d. Menschen*,” vol. i. 1862; and Julius Arnold, in “*Virchow's Archiv*,” June, 1865.)

#### MIDDLE CERVICAL GANGLION.

The middle ganglion (*ganglion thyroideum*), much the smallest of the cervical ganglia, is placed on or near the inferior thyroid artery. It is usually connected with the fifth and sixth spinal nerves, but in a somewhat variable manner. It gives off thyroid branches and the middle cardiac nerve.

**Thyroid branches.**—From the inner side of the ganglion some twigs proceed along the inferior thyroid artery to the thyroid body, where they join the recurrent laryngeal and the external laryngeal nerves. Whilst on the artery, these branches communicate with the upper cardiac nerve.

**The middle cardiac nerve** (*nervus cardiacus profundus v. magnus*) of the *right side* is prolonged to the chest behind the sheath of the common carotid artery, and either in front of or behind the subclavian artery. In the chest it lies on the trachea, where it is joined by filaments of the recurrent laryngeal nerve, and it ends in the right side of the deep cardiac plexus. While in the neck, the nerve communicates with the upper cardiac nerve and the recurrent branch of the pneumogastric.

On the *left side*, the middle cardiac nerve enters the chest between the left carotid and subclavian arteries, and joins the left side of the deep cardiac plexus.

When the middle cervical ganglion is small, the middle cardiac nerve may be found to be an offset of the inter-ganglionic cord.

#### LOWER CERVICAL GANGLION.

The lower or third cervical ganglion is irregular in shape, usually somewhat flattened and round or semilunar, and is frequently united in part to the first thoracic ganglion. Placed in a hollow between the transverse process of the last cervical vertebra and the neck of the first rib, it is concealed by the vertebral artery. It is connected by short communicating cords with the two lowest cervical nerves. Numerous branches are given off from it, among which the largest is the lower cardiac nerve.

**The lower cardiac nerve**, issuing from the third cervical ganglion or from the first thoracic, inclines inwards on the *right side*, behind the subclavian artery, and terminates in the cardiac plexus behind the arch of the aorta. It communicates with the middle cardiac and recurrent laryngeal nerves behind the subclavian artery.

On the *left side*, the lower cardiac often becomes blended with the middle cardiac nerve, and the cord resulting from their union terminates in the deep cardiac plexus.

**Branches to blood-vessels.**—From the lowest cervical and first dorsal ganglia a few slender branches ascend along the vertebral artery in its osseous canal, forming a plexus round the vessel by their inter-communications, and supplying it with offsets. This plexus is connected with the cervical spinal nerves as far upwards as the fourth.

One or two branches frequently pass from the lower cervical ganglion to the first dorsal ganglion in front of the subclavian artery, forming loops round the vessel (*ansæ Vieussenii*), and supplying it with small offsets.

#### THORACIC PART OF THE GANGLIATED CORD.

In the thorax the gangliated cord is placed towards the side of the spinal column, in a line passing over the heads of the ribs. It is covered by the pleura, and crosses the intercostal blood-vessels.

Opposite the head of each rib the cord usually presents a ganglion, so that there are commonly twelve of these; but, from the occasional coalescence of two, the number varies slightly. The first ganglion when distinct is larger than the rest, and is of an elongated form; but it is often blended with the lower cervical ganglion. The rest are small, generally oval, but very various in form.

*Connection with the spinal nerves.*—The branches of connection between the spinal nerves and the ganglia of the sympathetic are usually two in number for each ganglion; one of these generally resembling the spinal nerve in structure, the other more similar to the sympathetic nerve.

#### BRANCHES OF THE GANGLIA.

The branches furnished by the *first five or six ganglia* are small, and are distributed in a great measure to the thoracic aorta, the vertebræ,

Fig. 334.

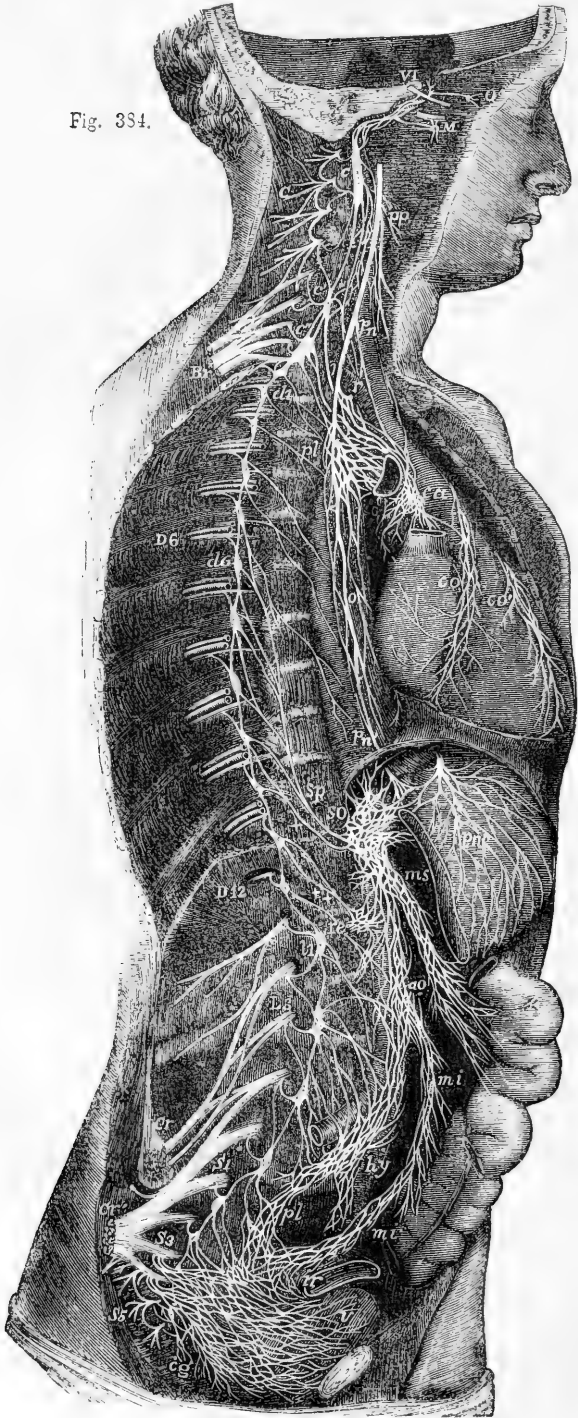


Fig. 334.—DIAGRAMMATIC VIEW OF THE SYMPATHETIC CORD OF THE RIGHT SIDE, SHOWING ITS CONNECTIONS WITH THE PRINCIPAL CEREBRO-SPINAL NERVES AND THE MAIN PNEAORTIC PLEXUSES.  $\frac{1}{4}$

*Cerebro-spinal Nerves.*—VI, a portion of the sixth cranial nerve as it passes through the cavernous sinus, receiving two twigs from the carotid plexus of the sympathetic nerve; O, ophthalmic ganglion connected by a twig with the carotid plexus; M, connection of the sphenopalatine ganglion by the Vidian nerve with the carotid plexus; C, cervical plexus; Br, brachial plexus; D 6, sixth intercostal nerve; D 12, twelfth; L 3, third lumbar nerve; S 1, first sacral nerve; S 3, third; S 5, fifth; Cr, anterior crural nerve; Cr', great sciatic; *pn*, pneumo-gastric nerve in the lower part of the neck; *r*, recurrent nerve winding round the subclavian artery.

*Sympathetic Cord*—*c*, superior cervical ganglion; *c'*, second or middle; *c''*, inferior; from each of these ganglia cardiac nerves (all deep on this side) are seen descending to the cardiac plexus; *d* 1, placed immediately below the first dorsal sympathetic ganglion; *d* 6, is opposite the sixth; *l* 1, first lumbar ganglion; *c* *g*, the terminal or coccygeal ganglion.

*Pneurotic and Visceral Plexuses.*—*p* *p*, pharyngeal, and, lower down, laryngeal plexus; *p* *l*, posterior pulmonary plexus spreading from the pneumo-gastric on the back of the right bronchus; *c* *a*, on the aorta, the cardiac plexus, towards which, in addition to the cardiac nerves from the three cervical sympathetic ganglia, other branches are seen descending from the pneumo-gastric and recurrent nerves; *c* *o*, right or posterior, and *c* *o'*, left or anterior coronary plexus; *o*, oesophageal plexus in long meshes on the gullet; *s* *p*, great splanchnic nerve formed by branches from the fifth, sixth, seventh, eighth, and ninth dorsal ganglia; +, small splanchnic from the ninth and tenth; ++, smallest or third splanchnic from the eleventh: the first and second of these are shown joining the solar plexus, *s* *o*; the third descending to the renal plexus, *r* *e*; connecting branches between the solar plexus and the pneumo-gastric nerves are also represented; *p* *n'*, above the place where the right pneumo-gastric passes to the lower or posterior surface of the stomach; *p* *n''*, the left distributed on the anterior or upper surface of the cardiac portion of the organ: from the solar plexus large branches are seen surrounding the arteries of the coeliac axis, and descending to *m* *s*, the superior mesenteric plexus; opposite to this is an indication of the suprarenal plexus; below *r* *e* (the renal plexus), the spermatic plexus is also indicated; *a* *o*, on the front of the aorta, marks the aortic plexus, formed by nerves descending from the solar and superior mesenteric plexuses and from the lumbar ganglia; *m* *i*, the inferior mesenteric plexus surrounding the corresponding artery; *h* *y*, hypogastric plexus placed between the common iliac vessels, connected above with the aortic plexus, receiving nerves from the lower lumbar ganglia, and dividing below into the right and left pelvic or inferior hypogastric plexuses; *p* *l*, the right pelvic plexus; from this the nerves descending are joined by those from the plexus on the superior hæmorrhoidal vessels, *m* *i'*, by sympathetic nerves from the sacral ganglia, and by numerous visceral nerves from the third and fourth sacral spinal nerves, and there are thus formed the rectal, vesical, and other plexuses, which ramify upon the viscera from behind forwards, and from below upwards, as towards *i* *r*, and *v*, the rectum and bladder.

and ligaments. Several of these branches enter the posterior pulmonary plexus.

The branches furnished by the *lower six or seven ganglia* unite into three cords on each side, which pass down to join plexuses in the abdomen, and are distinguished as the great, the small, and the smallest splanchnic nerve.

**The Great Splanchnic Nerve.**—This nerve is formed by the union of small cords (roots) given off by the thoracic ganglia from the fifth or sixth to the ninth or tenth inclusive. By careful examination of specimens after immersion in acetic or diluted nitric acid, small filaments may be traced from the splanchnic roots upwards as far as the third ganglion, or even as far as the first (Beck, in the "Philosophical Transactions," Part 2, for 1846).

Gradually augmented by the successive addition of the several roots, the cord descends obliquely inwards over the bodies of the dorsal vertebrae; and, after perforating the crus of the diaphragm at a variable

point, terminates in the semilunar ganglion, frequently sending some filaments to the renal plexus and the suprarenal body.

The splanchnic nerve is remarkable from its white colour and firmness, which are owing to the preponderance of the spinal nerve-fibres in its composition.

**Varieties.**—In the chest the great splanchnic nerve is not unfrequently divided into parts, and forms a plexus with the small splanchnic nerve. Occasionally also a small ganglion (ganglion splanchnicum) is formed on it over the last dorsal vertebra, or the last but one; and when it presents a plexiform arrangement, several small ganglia have been observed on its divisions.

In eight instances out of a large number of bodies, Wrisberg observed a fourth splanchnic nerve (*nervus splanchnicus supremus*). It is described as formed by offsets from the cardiac nerves, and from the lower cervical as well as some of the upper thoracic ganglia. (*“Observ. Anatom. de Nerv. Viscerum particula prima,”* p. 25, sect. 3.)

**Small Splanchnic Nerve.**—The small or second splanchnic nerve springs from the tenth and eleventh ganglia, or from the neighbouring part of the cord. It passes along with the preceding nerve, or separately through the diaphragm, and ends in the cœliac plexus. In the chest this nerve often communicates with the large splanchnic nerve; and in some instances it furnishes filaments to the renal plexus, especially if the lowest splanchnic nerve is very small or wanting.

**Smallest Splanchnic Nerve.**—This nerve (*nerv. renalis posterior*—Walter) arises from the twelfth thoracic ganglion, and communicates sometimes with the nerve last described. After piercing the diaphragm, it ends in the renal plexus, and in the inferior part of the cœliac plexus.

#### LUMBAR PART OF THE GANGLIATED CORD.

In the lumbar region the two gangliated cords approach one another more nearly than in the thorax. They are placed before the bodies of the vertebræ, each lying along the inner margin of the psoas muscle; and that of the right side is partly covered by the vena cava.

The ganglia are small, and of an oval shape. They are commonly four in number, but occasionally, when their number is diminished, they are of larger size.

*Connection with spinal nerves.*—In consequence of the greater distance at which the lumbar ganglia are placed from the intervertebral foramina the branches of connection with the spinal nerves are longer than in other parts of the gangliated cord. There are generally two connecting branches for each ganglion, but the number is not so uniform as it is in the chest; nor are those belonging to any one ganglion connected always with the same spinal nerve. The connecting branches accompany the lumbar arteries, and, as they cross the bodies of the vertebræ, are covered by the fibrous bands which give origin to the larger psoas muscle.

**BRANCHES.**—The branches of these ganglia are uncertain in their number. Some join a plexus on the aorta; others descending go to form the hypogastric plexus. Several filaments are distributed to the vertebræ and the ligaments connecting them.

#### SACRAL PART OF THE GANGLIATED CORD.

Over the sacrum the gangliated cord of the sympathetic nerve is much diminished in size, and gives but few branches to the viscera.

Its position on the front of the sacrum is along the inner side of the anterior sacral foramina; and like the two series of those foramina, the two cords approach one another in their progress downwards. The upper end of each is connected with the last lumbar ganglion by a single or a double interganglionic cord; and at the lower end they are connected by means of a loop with a single median ganglion, *ganglion impar*, placed on the fore part of the coccyx. The sacral ganglia are usually five in number; but the variation both in size and number is more marked in these than in the thoracic or lumbar ganglia.

*Connection with spinal nerves.*—From the proximity of the sacral ganglia to the spinal nerves at their emergence from the foramina, the communicating branches are very short: there are usually two for each ganglion, and these are in some cases connected with different sacral nerves. The coccygeal nerve communicates with the last sacral, or the coccygeal ganglion.

*BRANCHES.*—The branches proceeding from the sacral ganglia are much smaller than those from other ganglia of the cord. They are for the most part expended on the front of the sacrum, and join the corresponding branches from the opposite side. Some filaments from one or two of the first ganglia enter the hypogastric plexus, while others go to form a plexus on the middle sacral artery. From the loop connecting the two cords on which the coccygeal ganglion is formed, filaments are given to the coccyx and the ligaments about it, and to the coccygeal gland.

### Coccygeal Gland.

Under this name has been described by Luschka a minute structure, which has since received the attention of a number of writers. It is usually, according to Luschka, of the size of a lentil, and sometimes as large as a small pea; its colour is reddish grey; its surface lobulated; and it occupies a hollow at the tip of the coccyx, between the tendons attached to that part. It receives terminal twigs of the middle sacral artery and minute filaments from the *ganglion impar*. It consists of an aggregation of grains or lobules, which in some instances remain separate one from another. These lobules are principally composed of thick-walled cavities of vesicular and tubular appearance, described by Luschka and subsequent writers as closed follicles filled with cellular contents, but recently demonstrated by Julius Arnold to be clumps of dilated and tortuous small arteries, with thickened muscular and epithelial coats. Nerve-cells are found scattered in the stroma of the organ.

The coccygeal gland is a structure evidently of a similar nature to the *ganglion intercaroticum*, the principal differences apparently being, that the glomeruli of the *ganglion intercaroticum* are produced principally by the convolution and ramification of arterial twigs, while in the coccygeal gland there is dilation of the branches and thickening of their walls; and that the nervous element is more developed in the *intercarotid ganglion* than in the coccygeal gland. Arnold, with Luschka, appears inclined to consider both structures as allied in nature to the suprarenal capsules. According to Arnold, there is always a number of small grape-like appendages on the coccygeal part of the middle sacral artery, microscopic in size, but similar in nature to the lobules of which the coccygeal gland is composed. (Luschka, "Der Hirnanhang und die Steissdrüse des Menschen." Berlin, 1860. Also "Anat. d. Mensch.," vol. ii, part 2, p. 187. Julius Arnold in Virchow's "Archiv," March, 1865.)

### THE GREAT PLEXUSES OF THE SYMPATHETIC.

Under this head may be included certain large plexuses of nerves placed further forwards in the visceral cavity than the gangliated cords, and furnishing branches to the viscera. The principal of these plexuses are the cardiac, the solar, and the hypogastric with the pelvic plexuses prolonged from it. They are composed of assemblages of nerves, or of nerves and ganglia, and from them smaller plexuses are derived.

#### CARDIAC PLEXUS.

This plexus receives the cardiac branches of the cervical ganglia and those of the pneumo-gastric nerves, and from it proceed the nerves which supply the heart, besides some offsets which contribute to the nervous supply of the lungs. It lies upon the aorta and pulmonary artery, where these vessels are in contact, and in its network are distinguished two parts, the superficial and the deep cardiac plexuses, the deep plexus being seen behind the vessels, and the superficial more in front, but both being closely connected. The branches pass from these plexuses chiefly forward in two bundles, accompanying the coronary arteries.

**Superficial Cardiac Plexus.**—The superficial cardiac plexus lies in the concavity of the arch of the aorta, in front of the right branch of the pulmonary artery. In it the superficial or first cardiac nerve of the sympathetic of the left side terminates, either wholly or in part, together with the lower cardiac branch of the left pneumo-gastric nerve, and in some cases also that of the right side. In the superficial plexus a small ganglion, the *ganglion of Wisberg*, is frequently found at the point of union of the nerves. Besides ending in the anterior coronary plexus, the superficial cardiac plexus furnishes laterally filaments along the pulmonary artery to the anterior pulmonary plexus of the left side.

**Deep Cardiac Plexus.**—The deep cardiac plexus, much larger than the superficial one, is placed behind the arch of the aorta, between it and the end of the trachea, and above the point of division of the pulmonary artery.

This plexus receives all the cardiac branches of the cervical ganglia of the sympathetic nerve, except the first or superficial cardiac nerve of the left side. It likewise receives the cardiac nerves furnished by the vagus and by the recurrent laryngeal branch of that nerve, with the exception of the left lower cardiac nerve.

Of the branches from the *right side* of the plexus, the greater number descend in front of the right pulmonary artery, and join branches from the superficial part in the formation of the anterior coronary plexus, while the rest, passing behind the right pulmonary artery, are distributed to the right auricle of the heart, and a few filaments are continued into the posterior coronary plexus.

On the *left side*, a few branches pass forwards by the side of the ductus arteriosus to join the superficial cardiac plexus; but the great majority end in the posterior coronary plexus.

The deep cardiac plexus sends filaments to the anterior pulmonary plexus on each side.

**Coronary Plexuses.**—The *anterior coronary plexus*, formed at first from the fibres of the superficial cardiac plexus, passes forwards between the aorta and



pulmonary artery, and having received an accession of fibres from the deep cardiac plexus follows the course of the left or anterior coronary artery.

The *posterior coronary plexus*, derived chiefly from the left part of the deep cardiac plexus, but joined by nerves from the right portion of that plexus surrounding the branches of the right coronary artery accompanies them to the back of the heart.

Nervous filaments ramify in great number under the lining membrane of the heart. They are not so easily distinguished in man as in some animals. In the heart of the calf or the lamb they are distinctly seen without dissection, running in lines which cross obliquely the muscular fibres. Remak was the first to observe that these branches are furnished with small ganglia, both on the surface and in the muscular substance. (Müller's "Archiv," 1844.) For a description of the Ganglia and Nerves of the Heart from original observations, see I. Bell Pettigrew, "Physiol. of the Circulation," &c., 1874, p. 293.

#### SOLAR OR EPIGASTRIC PLEXUS.

The solar or epigastric plexus, which is the largest of the prevertebral centres, is placed at the upper part of the abdomen, behind the stomach, and in front of the aorta and the pillars of the diaphragm. Surrounding the origin of the cœliac axis and the upper mesenteric artery, it occupies the interval between the suprarenal bodies, and extends downwards as far as the pancreas. The plexus consists of nervous cords, with several ganglia of various sizes connected with them. The large splanchnic nerves on both sides, and some branches of the pneumogastric, terminate in it. The branches given off from it are very numerous, and accompany the arteries to the principal viscera of the abdomen, constituting so many secondary plexuses on the vessels. The diaphragmatic, cœliac, mesenteric, and other plexuses are recognised, which follow the corresponding arteries.

**Semilunar ganglia.**—The solar plexus contains, as already mentioned, several ganglia; and by the presence of these bodies, and their size, it is distinguished from the other prevertebral plexuses. The two principal ganglionic masses, named *semilunar*, though they have often little of the form the name implies, occupy the upper and outer part of the plexus, one on each side, and are placed close to the suprarenal bodies by the side of the cœliac and the superior mesenteric arteries. At the upper end, which is expanded, each ganglion receives the great splanchnic nerve.

**Diaphragmatic Plexus.**—The nerves (inferior diaphragmatic) composing this plexus are derived from the upper part of the semilunar ganglion, and are larger on the right than on the left side. Accompanying the arteries along the lower surface of the diaphragm, the nerves sink into the substance of the muscle. They furnish some filaments to the suprarenal body, and join with the spinal phrenic nerves.

At the right side, on the under surface of the diaphragm, and near the suprarenal body, there is a small ganglion, (*ganglion diaphragmaticum*.) which marks the junction between the phrenic nerves of the spinal and sympathetic systems. From this small ganglion filaments are distributed to the vena cava, the suprarenal body, and the hepatic plexus. On the left side the ganglion is wanting, but some filaments are prolonged to the hepatic plexus.

**Suprarenal Plexus.**—The suprarenal nerves issue from the solar plexus and the outer part of the semilunar ganglion, a few filaments being added from the diaphragmatic nerve. They are short, but numerous in comparison with the size of the body which they supply: they enter the upper and inner parts of the suprarenal capsule. These nerves are continuous below with the renal plexus. The plexus is joined by branches from one of the splanchnic nerves, and presents a ganglion (*gangl. splanchnico-suprarenale*), where it is connected

with those branches. The plexus and ganglion are smaller on the left than on the right side.

**Renal Plexus.**—The nerves forming the renal plexus, fifteen or twenty in number, emanate for the most part from the outer part of the semilunar ganglion; but some are added from the solar and aortic plexuses. Moreover, filaments from the smallest splanchnic nerve, and occasionally from the other splanchnic nerves, terminate in the renal plexus. In their course along the renal artery, ganglia of different sizes are formed on these nerves. Lastly, dividing with the branching of the vessel, the nerves follow the renal arteries into the substance of the kidney. On the right side some filaments are furnished to the vena cava, behind which the plexus passes with the renal artery; and others go to form the spermatic plexus.

**Spermatic Plexus.**—This small plexus commences in the renal, but receives in its course along the spermatic artery an accession from the aortic plexus. Continuing downwards to the testis, the spermatic nerves are connected with others which accompany the vas deferens and its artery from the pelvis.

In the female, the plexus, like the artery, is distributed to the ovary and the uterus.

**Cœliac Plexus.**—This plexus is of large size, and is derived from the fore part of the great epigastric plexus. It surrounds the cœliac axis in a kind of membranous sheath, and subdivides, with the artery, into coronary, hepatic, and splenic plexuses, the branches of which form communications corresponding with the arches of the arterial anastomosis. The plexus receives offsets from one or more of the splanchnic nerves, and on the left side a branch from the pneumogastric nerve is continued into it. (Swan.)

The *coronary plexus* is placed with its artery along the small curvature of the stomach, and unites with the nerves which accompany the pyloric artery, as well as with branches of the pneumogastric nerves. The nerves of this plexus enter the coats of the stomach, after running a short distance beneath the peritoneum.

The *hepatic plexus*, the largest of the three divisions of the cœliac plexus, ascends with the hepatic vessels and the bile-duct, and, entering the substance of the liver, ramifies on the branches of the vena portæ and the hepatic artery. Offsets from the left pneumogastric and diaphragmatic nerves join the hepatic plexus at the left side of the vessels. From this plexus filaments are furnished to the right suprarenal plexus, as well as other secondary plexuses which follow the branches of the hepatic artery. Thus there is a *cystic* plexus to the gall-bladder; and there are *pyloric*, *gastro-epiploic*, and *gastro-duodenal* plexuses, which unite with coronary, splenic, and mesenteric nerves.

The *splenic plexus*, continued on the splenic artery and its branches into the substance of the spleen, is reinforced at its beginning by branches from the left semilunar ganglion, and by a filament from the right vagus nerve. It furnishes the *left gastro-epiploic* and *pancreatic* plexuses, which course along the corresponding branches of the splenic artery, and, like the vessels, are distributed to the stomach and pancreas.

**Superior Mesenteric Plexus.**—The plexus accompanying the superior mesenteric artery, whiter in colour and firmer than either of the preceding offsets of the solar plexus envelopes the artery in a membraniform sheath, and receives a prolongation from the junction of the right pneumogastric nerve with the cœliac plexus. Near the root of the artery, ganglionic masses (gangl. meseraica) occur in connection with the nerves of this plexus.

The offsets of the plexus are in name and distribution the same as the vessels. In their progress to the intestine some of the nerves quit the arteries which first supported them, and are directed forwards in the intervals between the vessels. As they proceed they divide, and unite with lateral branches, like the arteries, but without the same regularity: they finally pass upon the intestine along the line of attachment of the mesentery.

**The Aortic Plexus.**—The aortic or intermesenteric plexus, placed along the abdominal aorta, and occupying the interval between the origin of the superior and inferior mesenteric arteries, consists, for the most, of two lateral portions,

connected with the semilunar ganglia and renal plexuses, which are extended on the sides of the aorta, and which meet in several larger communicating branches over the middle of that vessel. It is joined by branches from some of the lumbar ganglia, and presents not unfrequently one or more distinct ganglionic enlargements towards its centre.

The aortic plexus furnishes the inferior mesenteric plexus and part of the spermatic, gives some filaments to the lower vena cava, and ends below in the hypogastric plexus.

**Inferior Mesenteric Plexus.**—This plexus is derived principally from the left lateral part of the aortic plexus, and closely surrounds with a network the inferior mesenteric artery. It distributes nerves to the left or descending part and the sigmoid flexure of the colon, and assists in supplying the rectum. The nerves of this plexus, like those of the superior mesenteric plexus, are firm in texture and of a whitish colour.

The highest branches (those on the left colic artery) are connected with the last branches (middle colic) of the superior mesenteric plexus, while others in the pelvis unite with offsets derived from the pelvic plexus.

#### HYPOGASTRIC PLEXUS.

The hypogastric plexus, the assemblage of nerves destined for the supply of the viscera of the pelvis, lies invested in a sheath of dense connective tissue, in the interval between the two common iliac arteries. It is formed by eight or ten nerves on each side, which descend from the aortic plexus, receiving considerable branches from the lumbar ganglia, and, after crossing the common iliac artery, interlace in the form of a flat plexiform mass placed in front of the lowest lumbar vertebra. The plexus contains no distinct ganglia. At the lower end it divides into two parts, which are directed forwards, one to each side of the pelvic viscera, and form the pelvic plexuses.

#### PELVIC PLEXUS.

The pelvic or inferior hypogastric plexuses, one on each side, are placed in the lower part of the pelvic cavity by the side of the rectum, and of the vagina in the female. The nerves, prolonged from the hypogastric plexus, enter into repeated communications as they descend, and form at the points of connection small knots, which contain a little ganglionic matter. After descending some way, they become united with branches of the spinal nerves, as well as with a few offsets of the sacral ganglia, and the union of all constitutes the pelvic plexus. The spinal branches, which enter into the plexus, are furnished from the third and fourth sacral nerves, especially the third; and filaments are likewise added from the first and second sacral nerves. Small ganglia are formed at the places of union of the spinal nerves, as well as elsewhere in the plexus (plexus gangliosus—Tiedemann).

From the plexus so constituted, numerous nerves are distributed to the pelvic viscera. They correspond with the branches of the internal iliac artery, and vary with the sex; thus, besides hæmorrhoidal and vesical nerves, which are common to both sexes, there are nerves special to each:—namely, in the male for the prostate, vesicula seminalis, and vas deferens; in the female, for the vagina, uterus, ovary, and Fallopian tube.

The nerves distributed to the urinary bladder and the vagina contain a larger proportion of spinal nerves than those furnished to the other pelvic viscera.

**Inferior Hæmorrhoidal Nerves.**—These slender nerves proceed from the back part of the pelvic plexus. They join with the nerves (superior hæmorrhoidal) which descend with the inferior mesenteric artery, and penetrate the coats of the rectum.

**Vesical Plexus.**—The nerves of the urinary bladder are very numerous. They are directed from the anterior part of the pelvic plexus to the side and lower part of the bladder. At first these nerves accompany the vesical blood vessels, but afterwards they leave the vessels, and subdivide into minute branches before perforating the muscular coat of the organ. Secondary plexuses are given in the male to the *vas deferens* and the *vesicula seminalis*.

The *nerves of the vas deferens* ramify round that tube, and communicate in the spermatic cord with the nerves of the spermatic plexus. Those furnished to the *vesicula seminalis* form an interlacement on the vesicula, and some branches penetrate its substance. Other filaments from the prostatic nerves reach the same structure.

**Prostatic Plexus.**—The nerves of this plexus are of considerable size, and pass onwards between the prostate gland and the levator ani. Some are furnished to the prostate and to the *vesicula seminalis*; and the plexus is then continued forwards to supply the erectile substance of the penis, where its nerves are named “cavernous.”

*Cavernous nerves* of the penis.—These are very slender, and difficult to dissect. Continuing from the prostatic plexus they pass onwards, beneath the arch of the pubes, and through the muscular structure connected with the membranous part of the urethra, to the dorsum of the penis. At the anterior margin of the levator ani muscle the cavernous nerves are joined by some short filaments from the pudic nerve. After distributing twigs to the fore part of the prostate, these nerves divide into branches for the erectile substance of the penis, as follows:—

*Small cavernous nerves* (Müller), which perforate the fibrous covering of the corpus cavernosum near the root of the penis, and end in the erectile substance.

The *large cavernous nerve*, which extends forward on the dorsum of the penis, and dividing, gives filaments that penetrate the corpus cavernosum, and pass with or near the cavernous artery (*art. profunda penis*). As it continues onwards, this nerve joins with the dorsal branch of the pudic nerve about the middle of the penis, and is distributed to the corpus cavernosum. Branches from the foregoing nerves reach the corpus spongiosum urethræ. (Müller, “*Ueber die organischen Nerven der erectilen männlichen Geschlechtsorgane*,” &c. Berlin, 1836.)

**Nerves of the Ovary.**—The ovary is supplied chiefly from the plexus prolonged on the ovarian artery from the abdomen; but it receives another offset from the uterine nerves.

**Vaginal Plexus.**—The nerves furnished to the vagina leave the lower part of the pelvic plexus—that part with which the spinal nerves are more particularly combined. They are distributed to the vagina without previously entering into a plexiform arrangement; and they end in the erectile tissue on the lower and anterior part, and in the mucous membrane.

**Nerves of the Uterus.**—These nerves are given more immediately from the lateral fasciculus prolonged to the pelvic plexus from the hypogastric plexus, above the point of connection with the sacral nerves.

Separating opposite the neck of the uterus, they are directed upwards with the blood-vessels along the side of this organ, between the layers of its broad ligament. Some very slender filaments form round the arteries a plexus, in which minute ganglia are found scattered at intervals, and these nerves continue their course in the substance of the organ in connection with the blood-vessels. But the larger part of the nerves soon leave the vessels ; and after dividing repeatedly, without communicating with each other and without forming any gangliform enlargements, sink into the substance of the uterus, penetrating for the most part its neck and the lower part of its body. One branch, continued directly from the common hypogastric plexus, reaches the body of the uterus above the rest ; and a nerve from the same source ascends to the Fallopian tube. Lastly, the fundus of the uterus often receives a branch from the ovarian nerve. (Fr. Tiedemann, *Tab. Nerv. Uteri*, Heidelberg, 1823 ; Robert Lee, in *Phil. Trans*, 1841, 1842, 1846, and 1849 ; and Snow Beck, in *Phil. Trans.*, 1846, part ii. See also F. Frankenhäuser, *Die Nerven der Gebärmutter*, 1867.)

The *nerves of the gravid uterus* have been frequently investigated, with a view to discover if they become enlarged along with the increase in size of the organ. It is ascertained that the increase which takes place is confined, for the most part to the thickening of the fibrous envelopes of the nerves ; but it appears also, from the researches of Kilian, that fibres furnished with a medullary sheath, which in the unimpregnated state of the uterus lose that sheath as they proceed to their distribution, in the impregnated condition of the uterus continue to be surrounded with it as they run between the muscular fibres. (Farre, in *Supplement of Cyclopædia of Anat. and Phys.*, "Uterus and Appendages.")



## INDEX TO VOLUME I.

- ABDOMEN** (*abdo*, I hide), fascia of, lining, 324  
     superficial, 314  
     lymphatics of, 508  
     muscles of, 314  
     nerves of, 625  
**Abdominal aorta**, 422  
     artery (internal mammary), 391  
         (lumbar), 436  
     nerve (hypogastric), 600  
     ring, external or superficial, 316  
         internal or deep, 324  
**Abducent** (*ab*, from; *duco*, I lead), nerves, 519, 547  
**Abduction**, 132  
**Abductor**. *See* MUSCLES.  
**Aberrant arteries**, 403, 404  
**Accessorius ad ilio-costalem**, 300  
**Accessory artery**, pudic, 447  
     nerve, obturator, 604  
         spinal, 564  
         process of lumbar vertebrae, 14, 25  
**Acetabulum** (a vessel for holding vinegar), 100, 103  
**Acromial artery**, 395  
**Acromio-clavicular articulation**, 147  
**Acromion** (*ἄκρον*, a summit; *ἄμος*, top of the shoulder), 83  
     ossification of, 96  
**Acromio-thoracic artery**, 395  
     vein, 489  
**Adduction** (*ad*, to; *duco*, I lead), 132  
**Adductor**. *See* MUSCLES.  
**Age**, difference in, form of skull, 77  
**Air-sinuses in bones of head**, 66  
**Alæ of diaphragm**, 311  
     of sphenoid bone, 43  
     of vomer, 51  
**Alar ligaments of knee**, 170  
     odontoid, 139  
     thoracic artery, 395  
     vein, 489  
**Alisphenoid bones**, 74  
**Alveolar artery**, 371  
**Alveoli** (*alveolus*, a small hollow vessel), of lower jaw, 54  
     upper jaw, 47  
**Amphiarthrosis** (*ἀμφι*, on both sides, intermediate; *ἄρθρον*, a joint), 132  
**Anal fascia**, 326  
     muscles, 327, 331  
     nerves, 626  
**Analogy of organs**, 5  
**Anapophysis** (*ἀνά*, upon; *apophysis*), 14, 25  
**Anastomoses** (*ἀνά*, through; *στόμα*, a mouth), of branches of abdominal aorta, 436  
**Anastomotoc artery**, of arm, 402  
     pubic, 443  
     of thigh, 460  
**Anatomy** (*ἀνά*, apart; *τέμνω*, I cut), embryological, 2  
     general and descriptive, 1  
     morphological and physiological, 2  
     Object of, 1  
     systematic and topographical, 2  
**Anconeus** (*ἄγκών*, the elbow), 207  
**Angiology** (*ἀγγείων*, a vessel; *λόγος*, discourse), 343  
**Angle**, ethmo-cranial, 80  
     facial, 79  
     occipital, 80  
     premaxillary, 80  
     saddle, 80  
**Angular artery**, 365  
     movement, 132  
     processes of frontal bone, 36  
     vein, 476  
**Ankle-joint**, ligaments of, 173  
     annular, 244  
     movements of, 174  
     muscles passing over, 263  
**Annular** (*annulus*, a ring) ligament of ankle, 244  
     of radio-ulnar articulation, 150  
     of wrist, 157, 208, 209  
**Ansa** (a loop) hypoglossi, 567, 578  
**Anse Vieussenii**, 633  
**Antibrachium** (*ἀντί*, opposite; *brachium*), 81  
**Antrum** (a cavern), 9  
     of Highmore, 49  
**AORTA** (perhaps from *αἶρω*, I take up or carry), 346  
     abdominal, 422  
     branches of, parietal, 435

AORTA—*continued*.

- abdominal, branches of, visceral, 424
  - anastomoses of visceral and parietal branches of, 436
  - varieties of, 424
- arch of, 346
  - branches of, 348, 353
  - varieties of, 351
- foramen in diaphragm for, 311
- thoracic, descending, 419
  - branches of, 420
  - varieties of, 350
- Aortic plexus, 640
- Aponeurosis (*ἀπό*, from ; *νεῦρον*, a string, a tendon), 186
  - of arm, 204
  - of diaphragm, 311
  - epicranial, 264
  - of external oblique muscle, 316
    - fore-arm, 208
    - internal oblique muscle, 317
    - leg, 243
  - lumbar, 187, 299, 325
  - occipito-frontal, 264
  - of transversalis muscle, 320
  - vertebral, 299
- Apophysis (*ἀπό*, from ; *φύω*, I grow), 8
- Apparatus ligamentosus colli, 140
- Appendicular portions of body, 3, 122
- Aqueduct (*aqueductus*, a conduit) of Fallopius, 40
- Aqueductus cochleæ, 41
  - vestibuli, 41
- Arch of aorta, 346. *See* AORTA.
  - carpal, posterior, 409
  - crural or femoral, 341
    - deep, 324, 341
  - malar, 60
  - orbital, 35
  - palmar, superficial, 411
    - deep, 419
  - plantar, 466
  - scapulo-clavicular, ligaments of, 146
  - subpubic, 104
  - of a vertebra, 10
  - zygomatic, 60
- Arches, axillary, 191
  - lateral, of skull, 76
  - neural, of head, 74, 76
    - of vertebrae, 24
  - visceral, of head, 74, 76
- Arcus dorsalis humeri posticus, 402
- Arm, aponeurosis of, 204
  - arteries of, 399
  - bones of, 81
  - fasciæ of, 204
  - lymphatics of, 515
  - muscles of, 204
  - nerves of, cutaneous, 623
    - muscular, 208, 625
  - veins of, 485
- Arnold, ganglion of, 546
- ARTERIA comes nervi ischiadici, 448
- comes nervi phrenici, 391

ARTERIA—*continued*.

- dorsalis pedis, 469
- dorsalis scapulæ, 397
- hypogastrica, 439
- pancreatica magna, 428
- princeps pollicis, 417
- profunda femoris, 457
- profunda penis, 447
- thoracica humeraria, 395
  - suprema, 395
- thyroidea ima, 355
- ARTERIES (*ἀρτηρία*, from *ἀρτήρ*, that by which anything is suspended; originally applied to the windpipe, by which the lungs might be said to be suspended, *τραχεῖα ἀρτηρία*, *arteria aspera*, afterwards to the arteries, at one time supposed, like the windpipe, to contain air. Another less probable derivation is from *ἀήρ*, air; *τηρέω*, I keep), Descriptive Anatomy of, 343
- ARTERIES or ARTERY, abdominal, of internal mammary, 391
  - of lumbar arteries, 436
- aberrant, in arm, 403, 404
- accessory pudic, 447
- aeromial, 395
- aeromio-thoracic, 395
- alar thoracic, 395
- alveolar, 371
- anastomotic, of arm, 402
  - pubic, 443
  - of thigh, 460
- angular, of face, 365
- articular, of hip, 458
  - of knee, 462
- of auditory nerve, 386
- auricular, anterior, 369
  - posterior, 367
- auricular (occipital); 366
- axillary, 394
  - surgical anatomy of, 399
  - varieties of, 398
- azygos articular, 463
- basilar, 383, 385
- brachial, 399
  - surgical anatomy of, 405
  - varieties of, 402
- brachio-cephalic, 355
  - varieties of, 353, 355
- bronchial, 420
- buccal, 371
- of bulb, 447
- capsular, 432
- carotid, common, 356
  - surgical anatomy of, 360
  - varieties of, 358
- external, 360
  - varieties of, 361
- internal, 374
- carpal, anterior radial, 416
  - ulnar, 410
  - posterior radial, 416
  - ulnar, 409



ARTERY—*continued.*

- central, of retina, 375
- cerebellar, anterior inferior, 386
  - posterior inferior, 385
  - superior, 386
- cerebral, 377
  - anterior, 378, 379
  - distribution of, 378
  - middle, 378, 379
  - posterior, 379, 386
- cervical, ascending, 387
  - deep, 392
  - of occipital, 366
  - superficial, 389
  - transverse, 389
- choroid, 378
  - posterior, 386
- ciliary, 375
- circumflex, of arm, anterior, 398
  - posterior, 398
- iliac, deep, 452
  - superficial, 456
- of thigh, external, 458
  - internal, 458
- clavicular, 395
- of clitoris, 448
- coccygeal, 448
- coeliac, 424
- colic, left, 430
  - middle, 430
  - right, 430
- communicating, of brain, anterior, 378
  - posterior, 386
  - of palm, 411
- coronary of heart, 353
  - of lips, 365
  - of stomach, 425
- of corpus cavernosum, 447
- cranial, 366
- cremasteric, 452
- crico-thyroid, 363
- cystic, 427
- dental, inferior, 371
  - superior, 371
- digital, of foot, 467, 471
  - of hand, 412
- dorsal, of foot, 469
  - of fore-finger, 417
  - of great toe, 471
  - of lumbar, 436
  - of penis, 447
  - of scapula, 397
  - of thumb, 417
  - of tongue, 364
- emulgent, 432
- epigastric, deep or inferior, 451
  - relation to femoral hernia, 341
  - to inguinal hernia, 336
  - superficial, 456
  - superior, 391
  - varieties of, 453
- ethmoidal, 375
- facial, 364
- femoral, 453

ARTERY—*continued.*

- femoral, relation to hernia, 341
  - surgical anatomy of, 461
  - varieties of, 460
  - deep, 457
- frontal, 377
- gastric, short, 428
- gastro-duodenal, 425
- gastro-epiploic, left, 428
  - right, 425
- gluteal, 448
- hæmorrhoidal, inferior or external, 445
  - middle, 441
  - superior, 430, 432
- of hand, varieties of, 419
- hepatic, 425
- humeral, 399
  - of acromio-thoracic, 395
  - transverse, 387
- hyoid (lingual), 363
  - (thyroid), 363
- hypogastric, 440
- ileo-colic, 430
- iliac, common, 437
  - surgical anatomy of, 439
  - varieties of, 439
  - external, 450
    - surgical anatomy of, 453
    - varieties of, 453
  - internal, 439
    - in fetus, 440
    - surgical anatomy of, 453
- ilio-lumbar, 448
- of index-finger, radial, 417
- infra-orbital, 371
- infraspinous, 389
- innominate, 355
  - varieties of, 353, 355
- intercostal, aortic, 420
  - anterior of internal mammary, 391
    - superior, 392
- interosseous, of arm, 408
  - anterior, 409
  - posterior, 409
- of foot, 470
- of hand, dorsal, 409, 417
  - palmar, 419
- intestinal, 428
- labial, inferior, 365
- lachrymal, 375
- laryngeal, of inferior thyroid, 387
  - of superior thyroid, 363
- lingual, 363
- lumbar, 436
- malar, 375
- malleolar, 469
- mammary, external, 395
  - internal, 390
- masseteric, 371
- mastoid, 366
- maxillary, internal, 369
  - varieties of, 373
  - superior, 371

ARTERY—*continued.*

- median, 409
  - varieties of, 411
  - anterior, 385
- mediastinal, 391
  - posterior, 420
- meningeal, of ascending pharyngeal, 374
  - middle or great, 371
  - of occipital, 366
  - posterior, 384
  - small, 371
- mesenteric, inferior, 430
  - superior, 428
- metacarpal, 417
  - of little finger, 409
- metatarsal, 470
- musculo-phrenic, 391
- mylo-hyoid, 371
- nasal, of internal maxillary, 373
  - lateral, 365
  - of ophthalmic, 377
  - of septum, 365
- nutrient, of femur, 459
  - of fibula, 465
  - humerus, 402
  - ilium, 448
  - radius, 409
  - tibia, 464
  - ulna, 409
- obturator, 442
  - relation to femoral hernia, 341
  - varieties of, 444
- occipital, 366
- oesophageal, of aorta, 420
  - of coronary artery, 425
  - of inferior thyroid, 387
- ophthalmic, 375
- ovarian, 433
- palatine, inferior or ascending, 364
  - superior or descending, 372
  - of pharyngeal, 373
- palmar, superficial, 411
  - deep, 418
- palpebral, 377
- pancreatic, 428
- pancreatico-duodenal, inferior, 428
  - superior, 427
- perforating, of foot, 467, 471
  - of hand, 419
  - of thigh, 458
  - of thorax, 391
- pericardiac, 391, 420
- perineal, superficial, 445
  - in female, 447
  - transverse, 446
- peroneal, 464
  - anterior, 465
- pharyngeal, ascending, 373
- phrenic, inferior, 435
  - superior, 391
- plantar, internal, 465
  - external, 466
- popliteal, 461
- profunda, of arm, inferior, 402

ARTERY—*continued.*

- profunda, of arm, superior, 402
  - of penis, 447
  - of thigh, 457
- pterygoid, 371
- pterygo-palatine, 373
- pubic, of epigastric, 452
  - of obturator, 443
- pubic accessory, 447
  - external, 456
  - internal, 444
  - in female, 447
- pulmonary, 345
  - varieties of, 350, 353
- pyloric, 425
- radial, 413
  - varieties of, 417
  - of index-finger, 417
- ranine, 364
- recurrent, of deep palmar arch, 418
  - interosseous posterior, 409
  - radial, 415
  - of superficial palmar arch, 411
  - tibial, 469
  - ulnar, anterior, 407
  - posterior, 408
- renal, 432
- sacral, middle, 437
  - lateral, 449
- scapular, posterior, 389
- sciatic, 448
- sigmoid, 432
- spermatic, 433
- spheno-palatine, 373
- spinal, anterior, 385
  - of intercostals, 422
  - of inferior thyroid, 387
  - lateral, 383
  - of lumbar, 436
  - posterior, 384
- splenic, 428
- sternal, 391
- sterno-mastoid (occipital), 366
  - (superior thyroid), 363
- stylo-mastoid, 367
- subclavian, 379
  - surgical anatomy of, 392
  - varieties of, 352, 383
- sublingual, 364
- submental, 365
- subscapular, 395
  - of suprascapular, 389
- supra-acromial, 389
- supra-orbital, 375
- suprarenal, 432
- suprascapular, 387
- sural, 462
- tarsal, 469
- temporal, 367
  - anterior, 369
  - deep, 371
  - middle, 369
  - posterior, 369
- thoracic, acromial, 395

ARTERY—*continued.*

- thoracic alar, 395
    - long, 395
    - short, 395
  - of thumb, dorsal, 417
    - large, 417
  - thymic, 391
  - thyroid, inferior, 387
    - superior, 361
  - tibial, anterior, 468
    - varieties of, 471
    - posterior, 463
    - varieties of, 465
  - tonsillar, 365
  - tracheal, 387
  - transverse, of basilar, 386
    - cervical, 389
    - of face, 367
    - humeral or scapular, 387
    - perineal, 446
  - tympanic, 370
  - ulnar, 407
    - varieties of, 410
  - umbilical, 440
  - uterine, 441
  - vaginal, 442
  - of vas deferens, 440
  - vertebral, 383
    - varieties of, 385
  - vesical, inferior, 440
    - superior, 440
  - vesico-prostatic, 440
  - Vidian, 373
    - volar, superficial, 416
  - Arthrodia (ἄρθρον, a joint), 132
  - Arthrology (ἄρθρον, a joint; λόγος, a discourse), 131
  - Articular (*articulus*, diminutive of *artus*, a joint) nerve. *See* NERVES
    - artery of hip, 458
    - of knee, 462
    - processes of vertebrae, 10
    - homology of, 24
- ARTICULATIONS** (*articulus*, a joint), 131
- acromio-clavicular, 147
  - of ankle, 173
  - of astragalus, 174
  - of atlas and axis, 137
  - calcaneo-cuboid, 176
  - of calcaneum, 174
  - carpal, 155
  - carpo-metacarpal, 157
  - classification of, 131
  - of coccyx, 160
  - costo-central, 140
  - costo-sternal, 142
  - costo-transverse, 141
  - cubo-cuneiform, 178
  - of elbow, 152
    - foot, 174
    - fore-arm, 150
    - hand, 154
    - hip, 163
  - interphalangeal of hand, 159
  - of knee, 166

ARTICULATIONS—*continued.*

- of lower limb, 163
  - metacarpal, 157
  - metacarpo-phalangeal, 158
  - metatarsal, 180
  - metatarso-digital, 181
  - modes of, 131
  - movements of, 132
  - of pelvis, 159
  - pubic, 163
  - radio-carpal, 154
  - radio-ulnar, superior, 150
    - inferior, 150
  - of ribs, 140
  - sacro-coecygeal, 160
  - sacro-iliac, 161
  - sacro-vertebral, 159
  - of sacrum and coccyx, 160
  - scapho-cuboid, 177
  - scapho-cuneiform, 178
  - of scaphoid bone, 175, 177
  - scapulo-clavicular, 146
  - of shoulder, 148
  - sterno-clavicular, 146
  - tarsal, 174
  - tarsometatarsal, 179
  - temporo-maxillary, 144
  - tibio-fibular, 172
  - of trunk and head, 133
  - of upper limb, 146
    - vertebral column, 133
- Asternal (ἀ, neg.; στήρρον, the breast) ribs, 27
- Astragalo-calcaneal ligament, 175
- Astragalo-scaphoid ligament, 176
- Astragalus (ἀστράγαλος, the ankle-bone, or a die, the astragali of the sheep having been used as dice by the ancients), 115
- articulation of, 174
  - homology of, 127, 129
  - ossification of, 122
- Atlanto-axial ligaments, 140
- Atlas, 11
- ligaments of, 137
  - ossification of, 21
- Attollens (*attollo*, I raise up) auriculam muscle, 265
- Attrahens (*ad*, to; *traho*, I draw) auriculam muscle, 265
- Auditory meatus, 40
- nerve, 548, 553
  - process, 40
- Auricular arteries, 366, 367, 369
- muscles, 265
  - nerves. *See* NERVES.
  - surface of ilium, 102
  - surface of sacrum, 16, 161
  - veins, 477
- Auriculo-temporal nerve, 543
- Axial portion of body, 3
- skeleton, relation of limbs to, 123
- Axillary arches, 191
- artery, 394
  - fascia, 193

Axillary—*continued*.

lymphatic glands, 515  
vein, 488

## Axis (vertebra), 12

ossification of, 21  
ligaments of, 137

cœliac, 424  
of pelvis, 106  
thoracic, 398  
thyroid, 386

Azygos (*ἄζυγος*, single) artery, 463

pharyngis muscle, 288  
uvule muscle, 289  
veins, 489

## BACK, fasciæ and muscles of, 297

lymphatics of, 516  
nerves of, cutaneous, 622  
muscular, 624

## Basal optic ganglion, 528

Basilar (*basis*, a base) artery, 383, 385

process of occipital bone, 31, 34  
sinus, 484.

Basilic vein (*βασιλικός*, royal; this vein having been supposed by the old physicians to be connected with the liver and spleen, which they termed basilic viscera), 487

## Basi-hyals, 55, 74

## Basi-occipital bone, 34, 76

## Basi-sphenoid bone, 76

## Bertin, bones of, 42

Biceps (*bis*, twice; *caput*, a head) muscle, of arm, 205

of leg, 232

## Bicipital groove of humerus, 86

tuberosity of radius, 87

Biventer (*bis*, twice; *venter*, a belly), cervicis muscle, 301

## Bladder, urinary, ligaments of, true, 326

lymphatics of, 512  
nerves of, 642

## BLOOD-VESSELS, description of, 343

*See* ARTERIES and VEINS, also under the several organs for blood-vessels belonging to them

## Blumenbach's norma verticalis, 79

## Bochdalek's ganglion, 539

## BONES, Descriptive Anatomy of, 7

astragalus, 115, 122  
atlas, 11, 21  
axis, 12, 21  
of Bertin, 42  
calcaneum, or os calcis, 114, 122  
carpal, 90, 100  
clavicle, 84, 96  
coccyx, 17, 22  
cuboid, 116, 122  
cuneiform, of carpus, 91, 100  
tarsus, 115, 122  
ethmoid, 45, 71  
femur, 107, 119  
fibula, 112, 119  
frontal, 35, 68  
of head, 31

BONES—*continued*.

of head, homologies of, 73  
ossification of, 67

humerus, 85, 97

hyoid, 55, 73

ilium, 101, 118

innominate, 100, 118

ischium, 103, 118

lachrymal, 52, 72

of limbs, homological comparison of, 123

morphology of, 122

of lower limb, 100

ossification of, 119

magnum, 92, 100

malar, 51, 72

maxillary, inferior, 53, 72

maxillary, superior, 47, 71

metacarpal, 93, 100

metatarsal, 116, 122

nasal, 52, 72

navicular of tarsus, 115, 122

number of, 9

occipital, 31, 67

palate, 49, 72

parietal, 34, 68

patella, 110, 119

pelvic, 100, 104

ossification of, 118

phalangeal, of hand, 94, 100

foot, 117, 122

pisiform, 92, 100

pubic, 102, 118

radius, 87, 97

ribs, 27

ossification of, 30

sacrum, 15, 21

scaphoid, of carpus, 91, 100

tarsus, 115, 122

scapula, 81, 95

semilunar, 91, 100

sesamoid, in hand, 95

in foot, 117

sphenoid, 41, 70

spongy, ethmoidal, 46

inferior, 53

middle, 46

sphenoidal, 42, 71

sternum, 25

ossification of, 30

tarsal, 114, 122

temporal, 37, 69

tibia, 110, 119

trapezium, 92, 100

trapezoid, 92, 100

triquetral, 58

turbinated inferior, 53, 72

ulna, 88, 97

of upper limb, 81

ossification of, 95

uneiform, 93, 100

vertebra dentata, 12

prominens, 11

vertebra, 9

homology of, 22

- BONES—continued.**  
vertebræ, ossification of, 19  
vomer, 51, 72  
Wormian, 58
- Brachial artery, 399. *See* ARTERY .  
muscles, 204  
plexus, 582  
vein, 488
- Brachialis anticus muscle, 206
- Brachio-cephalic (*brachium*, the arm ;  
*κεφαλή*, the head) artery, 355  
vein, 473
- Brachio-radialis* muscle, 206
- Brachium (arm), 81
- Brachycephalic (*βραχύς*, short ; *κεφαλή*,  
the head) skulls, 79
- Branchial arches, 74
- British skulls, measurements of, 78
- Bronchial (*βρόγχος*, the windpipe) artery,  
420  
lymphatic glands, 513  
veins, 491
- Bubonocele (*βουβών*, the groin ; *κήλη*, a  
tumour), 337
- Buccal (*bucca*, the mouth) artery, 371  
nerves, 543, 551  
vein, 476
- Buccinator (*buccina*, a trumpet) muscle,  
272
- Bulb, olfactory, 526  
of urethra, artery of, 447
- Bulbo-cavernosus muscle, 330
- Bursæ, synovial, or bursæ mucosæ,  
186
- Buttock, nerves of, 623
- CALCaneo-CUBOID** articulation, 176
- Calcaneo-fibular ligament, 174
- Calcaneo-scapoid ligaments, 175
- Calcaneo-talar (*calcaneum* ; *talus*, the  
astragalus) ligament, 174
- Calcaneum (belonging to the heel, from  
*calx*, the heel). *See* Os Calcis
- Camper's facial angle, 79
- Canal, of bone, 8  
carotid, 40  
crural or femoral, 227, 341  
dental, 54  
Eustachian, 40  
Hunter's, 455  
infra-orbital, 49, 60  
inguinal, 335  
nasal, 48  
neural, 10  
palatine, 48, 50, 61  
pterygoid, 44  
pterygo-palatine, 44, 61  
sacral, 17  
Vidian, 44, 61
- Canals, perivascular, 518
- Canine fossa, 48, 58
- Caninus muscle, 271
- Capitellum (dim. of *caput*, a head), 8  
of humerus, 86
- Capitulum (dim. of *caput*, a head), 8
- Capitulum—*continued.*  
of rib, 27
- Capsular artery, 432  
ligament of hip, 165  
of knee, 169  
of shoulder, 148  
vein, 194
- Caput (a head) of bone, 8
- Caput cornu posterioris, 532
- Cardiac (*καρδία*, the heart) ganglia, 639  
lymphatic glands, 513  
nerves, of pneumogastric, 561  
of sympathetic, 631, 632,  
633  
plexus, 638  
veins, 503
- Carotid (*καρωτίδες αρτηρίαι*, from *καρῶν*,  
I cause sleep : also said to be  
from *κάρα*, the head ; *οὖς*, the ear)  
artery, common, 356  
external, 360  
internal, 374  
canal, 40  
foramen, 40, 62  
nerves, 542, 556  
plexuses, 629
- Carpal (*καρπός*, the wrist) arteries, 409,  
410, 416  
articulations, 155
- Carpo-metacarpal articulation, 157
- Carpus (*καρπός*, the wrist), bones of, 90  
homology of, 127  
ossification of, 100  
compared with tarsus, 127  
ligaments of, 155, 208, 209
- Cartilages of ribs, 29  
connections of, 142  
*See* Fibro-cartilage.
- Cauda equina (horse's tail), 571
- Cavernous nerves of penis, 642  
plexus, 629, 630  
sinus, 483  
position of nerves in, 530
- Cavities, nasal, 65
- Cavity, cotyloid, 9, 103  
cranial, 62  
glenoid, 9, 83  
semilunar of radius, 88  
sigmoid of ulna, 89
- Cells, ethmoidal, 45, 67
- Central artery of retina, 375  
tendon of diaphragm, 311
- Centrum of vertebræ, 9, 24
- Cephalic (*κεφαλή*, the head) vein, so  
called from having been supposed  
by the old physicians to be con-  
nected with the head, 486
- Cephalo-pharyngeus (*κεφαλή*, the head ;  
*φάρυγξ*, pharynx) muscle, 288
- Cerato-hyals (*κέρας*, a horn : *hyoid bone*),  
55, 76
- Cerebellum, arteries of, 385, 386  
veins of, 481
- Cerebral arteries, 377, 386  
distribution of, 378

- Cerebral—*continued*.  
veins, 480
- Cervical (*cervix*, a neck) arteries, 366,  
387, 389, 392  
fascia, 291  
ganglia, 628, 632, 633  
lymphatic glands, 516  
nerves, 573, 575  
plexus, 573, 577  
vertebrae, 10
- Cervicalis ascendens muscle, 300
- Cervico-facial division of facial nerve, 551
- Cervix (neck) of bone, 8
- Cheeks, 58
- Chest. *See* Thorax
- Chiasma (χιάσμα, I mark with the letter  
X; crossing or decussation) of  
optic tracts, 528
- Child, characters of skeleton in, 130
- Chorda dorsalis, 134  
tympani, 545, 549
- Chordæ Willisii, 482
- Choroid artery, 378  
posterior, 386  
plexus, 481
- Chyliferous (*chylus*, chyle; *fero*, I carry)  
vessels, 509
- Ciliary (*cilium*, an eyelash) arteries,  
375  
ganglion, 536  
nerves, 535, 536
- Circle of Willis, 378
- Circular muscle of Santorini, 330  
sinus, 483
- Circulus tonsillaris, 556
- Circumduction (*circum*, about; *duco*, I  
lead), 132
- Circumflex (*circum*, around; *flecto*, I  
bend) artery, of arm, 398  
iliac, 452, 456  
of thigh, 458  
nerve, 584  
vein, iliac, 496, 498  
of shoulder, 489
- Circumflexus (*circum*, around; *flecto*, I  
bend) palati muscle, 290
- Clavicle (*clavicula*, dim. of *clavis*, a  
key), 84  
homology of, 123  
ligaments of, 146  
ossification of, 96
- Clavicular artery, 395
- Cleido-mastoid (κλείς, a key, or the cla-  
vicle; *mastoid* process) muscle,  
292
- Clinoid (κλίση, a bed; *εἶδος*, shape) pro-  
cesses, 42
- Clitoris (perhaps from κλείω, I enclose),  
artery of, 448
- Coaptation (*con*, together; *apto*, I fit),  
132
- Coccygeal (*coccyx*) artery, 448  
gland, 637  
nerves, anterior, 606  
posterior, 575
- Coccygeus (*coccyx*) muscle, 329
- Coccyx (κόκυξ, a cuckoo), 9, 17  
articulation of, 160  
ossification of, 22
- Cochleariform (*cochleare*, a spoon; *forma*,  
shape) process, 41
- Cœliac (κοιλία, the abdomen) artery or  
axis, 424  
plexus, 640
- Colic (κῶλον, the colon or large intestine)  
arteries, 430
- Collar-bone, 84
- Colles, fascia of, 325
- Comes (a companion; pl. *comites*), nervi  
ischiadici, 448  
nervi phrenici, 391
- Commissure (*con*, together; *mitto*, I  
send) optic, 528
- Communicating arteries of brain, 378,  
386  
of palm, 411
- Complexus muscle, 301
- Compressor hemisphærum bulbi, 330  
naris, 269
- Compressores venæ dorsalis penis, 330
- Condylar foramen, anterior, 33, 62, 65  
posterior, 33  
surfaces of tibia, 110
- Condyle (κόνδυλος, a knuckle), 8
- Condyles of femur, 109  
of humerus, 86  
of lower jaw, 55  
of occipital bone, 32, 33, 62
- Congenital hernia, 338
- Conoid (κῶνος, a cone; *εἶδος*, shape) liga-  
ment, 147
- Constrictor muscles of pharynx, 286  
isthmi faucium, 289  
urethræ, 330
- Coraco-acromial ligament, 148
- Coraco-brachialis muscle, 204
- Coraco-clavicular ligament, 147
- Coraco-humeral ligament, 149
- Coracoid (κόραξ, a raven; *εἶδος*, shape)  
ligament, 148  
process of scapula, 83
- Cordiform (*cor*, the heart; *forma*, shape)  
tendon of diaphragm, 311
- Cornicula (*corniculum*, dim. of *cornu*, a  
horn) of hyoid bone, 55
- Cornua of coccyx, 17  
of fascia lata, 227  
of hyoid bone, 55  
sacral, 15  
sphenoidalia, 42
- Coronal suture, 57
- Coronary arteries of heart, 353  
lips, 365  
stomach, 425  
plexus of heart, 638  
of stomach, 640  
sinus, 504  
veins of heart, 503  
of stomach, 501
- Coronoid fossa of humerus, 87

- Coronoid—*continued*.  
 process of lower jaw, 55  
 of ulna, 89
- Corpus cavernosum, artery of, 447
- Corrugator supercilii muscle, 267
- Costæ or ribs, 27  
 of scapula, 83
- Costal cartilages, 29
- Costo-central articulation, 140
- Costo-clavicular ligament, 146
- Costo-coracoid membrane and ligament,  
 193  
 muscle, 261
- Costo-sternal articulations, 142
- Costo-transverse articulation, 141
- Costo-xiphoid ligaments, 142
- Cotunnus, nerve of, 541
- Cotyloid (κοτύλη, a cup; εἶδος, shape)  
 cavity, 9  
 of pelvis, 103  
 ligament, 164
- CRANIAL NERVES. *See* NERVES, CRA-  
 NIAL.
- Cranial arteries, 366  
 cavity, 62  
 ganglia, 628  
 plexus, 628  
 sinuses, 481
- Cranio-facial axis, bones forming, 74
- Cranio-vertebral muscles, 305
- Cranium (κρανίον, the skull), 31. *See*  
 Skull.  
 lymphatics of, 517  
 venous circulation in, 480
- Cremaster (κρεμάω, I suspend), 318
- Cremasteric artery, 452  
 fascia, 320
- Crest of bone, 8  
 external occipital, 33  
 nasal, 47  
 of ilium, 101  
 of os pubis, 103  
 sphenoidal, 42
- Cribriform (cribrum, a sieve; forma,  
 shape) fascia, 226  
 lamella of ethmoid bone, 46  
 of temporal bone, 40
- Crico-thyroid artery, 363
- Crista frontalis, 36  
 galli (cock's comb), 45  
 illi, 101
- Crucial (cruz, a cross) ligaments, 168
- Cruciform ligament, 138
- Crura of diaphragm, 309
- Crural (crus, a leg) arch, 324, 341  
 canal, 227, 341  
 nerve, 602, 604  
 ring, 324  
 septum, 341  
 sheath, 227
- Crureus muscle, 239
- Cubo-cuneiform articulation, 178
- Cuboid (κύβος, a cube; εἶδος, shape)  
 bone, 116  
 homology of, 127
- Cuboid bone—*continued*.  
 ligaments of, 176, 177  
 ossification of, 122
- Cucullaris (cucullus, a hood) muscle,  
 187
- Cuneiform (cuneus, a wedge; forma,  
 shape) bones of foot, 115  
 homology of, 129  
 ligaments of, 179  
 ossification of, 122  
 of hand, 91  
 homology of, 127  
 ossification of, 100
- Curvator coccygis muscle, 329
- Cutaneous nerve. *See* NERVES.
- Cylindrical bones, 8
- Cystic (κύστις, a bladder) artery, 427  
 plexus, 640  
 veins, 501
- DARTOS (δαρτός, the skin of scrotum;  
 δέρω, I flay), 314
- Daubenton's occipital angle, 79
- Deltoid (δέλτα, the letter Δ, or delta;  
 εἶδος, shape) ligament, 173  
 muscle, 199
- Dental artery, 371  
 canal, 54  
 foramen, 54  
 groove, 71  
 nerves, anterior, 539  
 inferior, 545  
 posterior, 538  
 veins, 477
- Dentated suture, 131
- Depressor alæ nasi, 470  
 anguli oris, 274  
 labii inferioris, 274
- Dermal (δέρμα, skin) skeleton, 7
- Descendens noni nerve, 567
- Diaphragm (διά, between; φράσσω, I  
 fence) 308  
 action of, 313  
 pelvic, 329
- Diaphragma oris, 283
- Diaphragmatic nerve, 578  
 plexus, 639  
 veins, 474
- Diaphysis (διά, between; φύω, I grow), 8
- Diapophysis (διά, apart; apophysis), 10,  
 24  
 of cervical vertebra, 11
- Diarthrosis (διά, between; ἄρθρον, a joint),  
 132
- Digastric (δῖς, twice; γαστήρ, a belly)  
 fossa, 39, 62  
 muscle, 281  
 nerve, 550
- Digital arteries of foot, 467, 471  
 of hand, 412  
 fossa of femur, 107  
 nerves in foot, 618, 619, 620,  
 623  
 in hand, 590, 591, 593, 623  
 phalanges, 94

- Dilatator naris, 270  
 Diploë (διπλός, double), 62  
   veins of, 485  
 Dolichocephalic (δολιχός, long; κεφαλή, the head) skulls, 79  
 Dorsal artery. *See* ARTERY.  
   fascia, 299  
   of foot, 245  
   ligaments. *See* LIGAMENT  
   muscles, 297  
   nerves of foot, 623  
   of hand, 588, 623  
   of penis, 611  
   spinal, 574, 593  
   veins of penis, 500  
   spinal, 492  
   vertebrae, 12  
 Dorsi-lumbar (*dorsum*, the back; *lumbus*, the loin) nerve, 598  
*Dorsi-epitrochlearis muscle*, 207  
 Dorso-lateral muscles, 185, 332  
 Dorsum sellæ (back of the saddle), 42  
 Douglas, semilunar fold of, 318  
 Duodenal veins, 501  
 Duret's researches in the arteries of the brain, 378
- EAR, muscles of, 265  
 Ejaculator urinæ muscle, 330  
 Elbow-joint, 152  
   ligaments of, 152  
   movements of, 154  
   nerves of, 588  
 Eminence, frontal, 35  
   illio-pectineal, 103  
   jugular, 33  
   parietal, 34  
 Eminences of bones, 8  
   condylar of humerus, 86  
 Emulgent (*emulgeo*, I milk or drain out), arteries, 432  
   veins, 494  
 Enarthrosis (ἐν, in; ἄρθρον, a joint), 132  
 Endoskeleton (ἐνδον, within; *skeleton*), 7  
 Ensiform (*ensis*, a sword; *forma*, shape), process of sternum, 26, 26  
 Epaxial (ἐπί, on; *avis*) muscles, 185, 260  
 Epicondyle (ἐπί, on; *condyle*), 86  
 Epieranial (ἐπί, on; κρανίον, the skull) muscles, 264  
 Epigastric (ἐπί, on; γαστήρ, the stomach) artery. *See* ARTERY.  
   plexus, 639  
   veins, 496, 498  
 Epiphyal (ἐπί, on; *hyoid* bone) bones, 74  
   145  
 Epiotic (ἐπί, on; οὖς, gen. ὠτός, the ear) centre, 69  
 Epiphysis (ἐπί, on; φύω, I grow), 8  
 Episkeletal (ἐπί, on; *skeleton*) muscles, 185  
 Epitrochlea (ἐπί, on; *trochlea*), 86  
*Epitrochleo-anconicus muscle*, 207
- Erect attitude, adaptation of skeleton to, 122  
 Erector clitoridis, 331  
   penis, 330  
   spinæ, 299  
 Ethno-cranial angle, 80  
 Ethmoid (ἕθμος, a sieve; εἶδος, shape) bone, 45  
   ossification of, 71  
 Ethmoidal artery, 375  
   cells or sinuses, 45, 67  
   spine, 42  
 Ethmo-turbinals, 45, 74  
 Eustachian canal, 40  
   tube, 62  
 Exoccipitals, 33, 74  
 Exoskeleton (ἔξω, without; *skeleton*), 7  
 Expiration, physiology of, 313  
 Extension, 132  
 Extensor muscles of hand and fingers, 216, 220  
   of foot and toes, 245  
 Extrinsic (*extrinsecus*, outward) muscles, 185  
 Eyeball, movements of, 277  
 Eyelids and eyebrows, muscles of, 265  
   nerves of, cutaneous, 622  
   muscular, 624
- FACÆ, lymphatics of, 518  
   muscles of, 274  
   nerves of, cutaneous, 622  
   muscular, 624  
   veins of, 475, 477  
 Facial angle, 79  
   artery, 364  
   nerves, 548, 578  
   vein, 475  
 Falciform (*fulx*, a sickle or scythe; *forma*, shape) border of fascia lata, 277  
   process, 162  
   sinus, 482  
 Fallopius, aqueduct of, 40  
   hiatus of, 40  
 FASCIA (a band), 185  
   abdominal, 314, 324  
   anal, 326  
   of arm, 204  
   axillary, 193  
   cervical, deep, 291  
   of Colles, 325  
   cremasteric, 320  
   cribriform, 225  
   deep, 186  
   dorsal, 299  
   of foot, 245  
   of fore-arm, 208  
   hand, 208, 209  
   head and neck, 264  
   hip and thigh, 226  
   iliac, 324  
   infundibuliform, 324, 336  
   intercolumnar, 317  
   lata (broad fascia), 226  
   of leg, 243



- FASCIA**—*continued*.  
of lower limb, 226  
lumbar, 299  
masseteric, 278, 291  
obturator, 327  
of orbit, 278  
parotid, 291  
of pectoral region, 193  
pelvic, 326  
perineal, 325  
plantar, 255  
prevertebral, 292  
propria, femoral, 342  
recto-vesical, 326  
of shoulder, 199  
subpubic, 325  
superficial or subcutaneous, 186  
temporal, 279  
of thigh, 226  
transversalis, 324  
triangular, 316  
of trunk, anterior, 193  
    posterior, 187  
    homologies of, 332  
of upper limb, 187
- Fauces** (the throat), isthmus of, 289  
pillars of, 288
- Femoral** (*femur*, the thigh) artery, 453  
*See* ARTERY  
canal, 227, 341  
hernia, 340  
ligament, 227  
muscles, anterior, 234  
    internal, 240  
    posterior, 232  
ring, 341  
vein, 497  
vessels, sheath of, 227
- Femur**, 107  
compared with humerus, 126  
ossification of, 119
- Fibro-cartilage**, intervertebral, 133  
of knee, 169  
of lower jaw, 145  
pubic, 163  
radio-ulnar, 150  
scapulo-clavicular, 147  
sterno-clavicular, 146
- Fibula** (a brace, a clasp), 112  
ligaments of, 172  
ossification of, 119
- Fingers**, bones of, 94  
ossification of, 100  
muscles of, 221
- Tissue** of bone, 9  
of Glaser, 39, 40  
incisor, 71  
pterygo-maxillary, 60  
sphenoidal, 44, 60, 65  
    position of nerves in, 530  
spheno-maxillary, 60
- Flat** bones, 8
- Flexion**, 132
- Flexor** muscles of foot and toes, 252-258  
of hand and fingers, 211-214, 22
- Floating** ribs, 27
- Flower**, homologous parts of scapula and  
ilium, 129
- Foetal** development, 2
- Fontanelles** (*fons*, a fountain), 68
- Foot**, arteries of, dorsal, 469  
    plantar, 465  
articulations of, 174  
bones of, 114, 117  
    compared with hand, 129  
    ossification of, 112  
fascia of, 245, 255  
muscles of, 256, 263  
nerves of, cutaneous, 623, 624  
    muscular, 626
- Foramen** (*foro*. I pierce) of bone, 9  
caecum of frontal bone, 37, 64  
carotid, 40, 62  
dental, inferior, 54  
incisor, 47  
infraorbital, 48, 59  
jugulare, 62  
labial, 54  
lacerum anterius, 65  
    jugulare, 33  
    medium, 62  
    orbitale, 44  
    posterius, 62, 65  
magnum, 31, 62, 65  
mastoid, 39  
mental, 54, 59  
obturator, 100, 103  
occipital, 31, 65  
opticum, 44, 60, 65  
ovale of pelvis, 100, 103  
ovale of sphenoid, 44, 62, 65  
palatine, anterior, 47, 62  
    posterior, 62  
parietal, 34  
quadratum, 311  
rotundum, 44, 61, 65  
sacro-sciatic, great and small, 162  
spheno-palatine, 50, 61  
spinousum, 44, 62, 65  
sternale, 31  
stylo-mastoid, 40, 62  
supraorbital, 35, 59, 60  
thyroid, 100, 103  
of a vertebra, 10
- Foramina**, condylar, anterior, 33, 62, 65  
    posterior, 33  
of diaphragm, 311  
of ethmoid bone, 60  
intervertebral, 10  
malar, 52, 59  
orbital, anterior and posterior in-  
ternal, 36  
palatine, small, 50, 62  
sacral, anterior, 15  
    posterior, 16  
of Scarpa, 48  
of Stenson, 47
- Fore-arm**, aponeurosis of, 208  
arteries of, 407  
articulations of, 150

- Fore-arm—*continued*.  
 bones of, 87  
   compared with leg, 126  
   ossification of, 97  
 fascia of, 208  
 muscles of, 208  
 nerves of, cutaneous, 623  
   muscular, 625  
 Form, symmetry of, 5  
 Fossa of bone, 9  
   canine, 48, 58.  
   coronoid, 87  
   digastric, 39, 62  
   digital, 107  
   glenoid, 39, 60  
   guttural, 62  
   iliac, 102  
   incisor of upper jaw, 48, 58  
     of lower jaw, 54  
   infraspinata, 81  
   intercondylar, 109  
   ischio-rectal, 327  
   jugular, 40  
   lachrymalis, 36, 60  
   myrtiform, 48  
   navicular, 44  
   olecranon, 87  
   pituitary, 42  
   pterygoid, 44  
   spheno-maxillary, 60  
   subscapularis, 81  
   supraspinata, 81  
   temporal, 60  
   trochanteric, 107  
   zygomatic, 60  
 Fossæ, nasal, 65  
   occipital, superior and inferior, 33  
   of skull, internal, 63  
 Foveæ (pl. of *fovea*, a pit or depression),  
   glandulares, 35  
 Frontal (*frons*, the forehead) artery, 377  
   bone, 35, 74  
   ossification of, 68  
   eminence, 35  
   nerve, 534, 535  
   sinus, 36, 67  
   suture, 37, 58, 68  
   vein, 475  
     of diploë, 485  
 Frontalis muscle, 264  
 Fronto-parietal suture, 57  
 Furrow of bone, 9
- GANGLIA, of cardiac nerves, 639  
 cranial, 628  
 of glosso-pharyngeal nerve, 555  
 lumbar, 636  
 meseraica, 640  
 of pneumo-gastric nerve, 559  
 sacral, 637  
 semilunar, 639  
 of spinal nerves, 569  
   sympathetic nerves, 626  
 thoracic, 633
- Gangliated cord, sympathetic, 626  
 cervical part, 628  
 connections with cerebro-spinal sys-  
 tem, 627  
 lumbar part, 636  
 sacral part, 636  
 thoracic part, 633
- GANGLION, Arnold's, 546  
 basal optic, 528  
 Bochdalek's, 539  
 cervical, lower, 633  
   middle, 632  
   upper, 628  
 ciliare, 536  
 diaphragmaticum, 639  
 on facial nerve, 548, 549  
 of fifth pair, or Gasserian, 533  
 geniculate, 548  
 impar, 637  
 intercaroticum, 632  
 jugular, 555  
 lenticular, 536  
 Meckel's, 540  
 nasal, 540  
 ophthalmic, 536  
 otic, 546  
 petrous, 555  
 semilunare (Gasserian), 533  
 semilunare (ophthalmic or lenti-  
 cular), 536  
 spheno-palatine, 540  
 splanchnico-suprarenale, 639  
 submaxillary, 547  
 thyroideum, 632  
 of Wisberg, 638
- Gasserian ganglion, 533  
 Gastric (*γαστήρ*, the stomach) artery, 428  
 nerve, 564  
 Gastrocnemius (*γαστήρ*, the belly; *κνήμη*,  
 the leg) muscle, 249  
 Gastro-duodenal (*γαστήρ*, the stomach;  
*duodenum*) artery, 425  
 plexus, 640  
 Gastro-epiploic (*γαστήρ*, the stomach;  
*ἐπίπλοον*, the omentum) arteries,  
 425, 428  
 plexus, 640  
 vein, 501
- Gegenbaur, homologies of carpus and  
 tarsus, 127, 129  
 Gemelli (twin) muscles, 231  
 Geniculate ganglion, 548  
 Genial (*γένειον*, the chin) tubercles, 284  
 Genio-glossus (*γένειον*, the chin; *γλῶσσα*,  
 the tongue) muscle, 285  
 Genio-hyo-glossus (*γένειον*, the chin;  
*ὑοειδής*, *hyoid* bone; *γλῶσσα*, the  
 tongue) muscle, 285  
 Genio-hyoid (*γένειον*, the chin; *ὑοειδής*,  
*hyoid* bone) muscle, 284  
 Genital nerve, 602  
 Genito-crural nerve, 601  
 Genito-urinary muscles, 329  
 Gimbernat's ligament, 316  
 Ginglymus (*γίγγλυμος*, a hinge), 132

Girdles, shoulder and pelvic, comparison of, 123  
 Glabella (dim. of *glabra*, fem. of *glaber*, smooth), 35  
 Glands, Lymphatic. See Lymphatic Glands.  
 Glaser, fissure of, 39, 40  
 Glenoid (γλήνη, a shallow pit of a bone; εἶδος, shape) cavity, 9  
     of scapula, 83  
     fossa of temporal bone, 39, 60  
     ligament, 149  
 Gliding, 133  
 Glosso-pharyngeal (γλωσσα, the tongue; φάρυγξ, the pharynx) nerve, 554  
     ganglia of, 555  
 Gluteal artery, 448  
     nerve, inferior, 613  
     superior, 607  
 Glutei (γλουτός, the buttock) muscles, 228  
 Gomphosis (γόμφος, a nail), 131  
 Gracilis (slender) muscle, 240  
 Groove, bicipital, 86  
     of bone, 9  
     dental, 71  
     for Eustachian tube, 62  
     lachrymal, 48, 60  
     mylo-hyoid, 55  
     occipital, 39  
     scapular, 83  
     spiral, 86  
     subcostal, 28  
 Gustatory (*gusto*, I taste) nerve, 544  
 Guttural (*guttur*, the throat) fossa, 62  
 HÆMAL (αἷμα, blood) septum, 332  
 Hæmorrhoidal (αἷμα, blood; ῥέω, I flow)  
     artery, inferior, 445  
     middle, 441,  
     superior, 430, 432  
     nerves, inferior (pudic), 612  
         (sympathetic), 642  
     superior, 642  
     plexus, 498  
 Hamstring muscles, 232  
 Hamular process, of sphenoid bone, 44  
 Hamulus (dim. of *hamus*, a hook)  
     lachrymalis, 53  
 Hand, arteries of, 411, 415  
     varieties of, 419  
     articulations of, 154  
     bones of, 90  
         ossification of, 100  
     compared with foot, 127  
     fasciæ of, 208, 209  
     muscles of, 221, 263  
         action and varieties of, 224  
     nerves of, cutaneous, 623  
         muscular, 626  
 Harmonia (ἀρμόζω, I fit together), 131  
 Haunch, 100  
 Head, bones of, 31  
     homologies of, 73

Head—*continued*.  
     bones of, morphology of, 73  
         ossification of, 67  
     nerves of, cutaneous, 622  
         muscular, 624  
     typical component parts of, 74  
 Head of a bone, 8  
 Head and neck, fasciæ and muscles of, 264  
     lymphatics of, 516  
     veins of, 475  
 Heart, arteries of, 353  
     lymphatics of, 514  
     nerves of, 561, 650, 632, 638  
     veins of, 503  
 Heel, 114  
 Hepatic (ἥπαρ, the liver) artery, 425  
     plexus, 640  
     veins, 494  
 Hernia (ἔρνος, a branch), congenital, 338  
     femoral, 340  
     infantile, 338  
     inguinal, 335  
         direct or internal, 338  
             in female, 340  
         oblique or external, 337  
             in female, 338  
         varieties of, 336  
     scrotal, 337  
     surgical anatomy of, 335  
     tunicæ vaginalis, 338  
     umbilical, 335  
     ventro-inguinal, 338  
 Hesselbach, triangle of, 339, 340  
 Hiatus (an opening, from *hio*, v. n., I open)  
     aorticus, 311  
     Fallopian, 40  
     interosseus, 151  
 Highmore, antrum of, 49  
 Hip-joint, 163  
     ligaments of, 164  
     movements of, 166  
     muscles of, 228  
     nerves of, 603, 604, 615, 624  
 Hip and thigh, fascia of, 226  
 Histology (ιστός, a web; λόγος, discourse), 1  
 Homologies of bones of head, 73  
     carpus and tarsus, Gegenbaur's table, 129  
     fasciæ and muscles of trunk and head, 332  
     hand and foot, 127  
     muscles of limbs, 262  
     scapula and ilium, Flower's table, 129  
     shoulder and pelvic girdles, 123  
     upper and lower limbs, 123, 124, 129  
     vertebræ, 22  
 Homology (ὁμός, the same; λόγος, proportion), 5  
 Homotypy (ὁμός, the same; τύπος, a type or model), 5

- Humeral artery, 399  
     of acromio-thoracic, 395  
     transverse, 387  
 Humerus (the shoulder), 85  
     compared with femur, 126  
     ossification of, 97  
 Hunter's canal, 455  
 Hyoglossus (*ὀσείδης*, *hyoid* bone; *γλώσσα*, tongue) muscle, 285  
 Hyoid arteries, 363  
 Hyoid (*υ*, the letter *upsilon*; *ε. os*, shape) bone, 55  
     ossification of, 73  
 Hypapophysis (*ὑπό*, under; *apophysis*), 24, 25  
 Hypaxial (*ὑπό*, under; *axis*) muscles, 185, 333  
 Hypogastric (*ὑπό*, under; *γαστήρ*, the stomach) artery, 440  
     nerve, 600  
     plexus, 641  
 Hypoglossal (*ὑπό*, under; *γλώσσα*, the tongue) nerve, 565  
 Hyposkeletal (*ὑπό*, under; *skeleton*) muscles, 185  
 Hypothenar (*ὑπό*, under; *θέναρ*, the palm), eminence, 222  
  
 ILEO-COLIC artery, 430  
 Iliac artery, common, 437  
     external, 450  
     internal, 439  
     fascia, 324  
     fossa, 102  
     lymphatic glands, 508  
     nerves, 600  
     portions of fascia lata, 227  
     veins, 498  
 Iliacus (*ἰλία*, the flank) muscle), 234  
 Ilio-aponeurotic muscle, 235  
 Ilio-capsularis muscle, 234  
 Ilio-costalis muscle, 300  
 Ilio-femoral ligament, 165  
 Ilio-hypogastric nerve, 600  
 Ilio-inguinal nerve, 600  
 Ilio-lumbar artery, 448  
     ligament, 159  
 Ilio-pectineal eminence, 103  
     line, 102  
 Ilio-psoas muscle, 234  
 Ilio-tibial band, 226  
 Ilio-trochanteric ligament, 165  
 Ilium (*ἰλία*, the flanks), 101  
     homology of, 123, 124, 129  
     ossification of, 118  
 Incisor foramen, 47  
     fissure, 71  
     fossa, lower jaw, 54  
     upper jaw, 48, 58  
     nerve, 545  
 Incisura (notch), 9  
     of acetabulum, 103  
     ethmoidalis, 35  
     semilunaris, of sternum, 26  
 Incus (an anvil), 74  
  
 Indicator muscle, 220  
 Infantile hernia, 338  
 Inframaxillary nerve, 551  
 Infraorbital artery, 371  
     canal, 49, 60  
     foramen, 48, 59  
     nerves, 539, 551  
     plexus, 540  
     veins, 476  
 Infraspinata fossa, 81  
 Infraspinatus muscle, 200  
 Infraspinous artery, 389  
 Infratrochlear nerves, 535, 536  
 Infundibuliform fascia, 324, 336  
 Infundibulum (funnel) of ethmoid bone, 46  
 Ingrassias, wings of, 43  
 Inguinal (*ἰνγυέν*, the groin), canal, 335  
     hernia, 335. *See* Hernia  
     lymphatic glands, 507  
 Innominate artery, 355  
     bone, 100  
     ossification of, 118  
     veins, 473  
 Insertion of muscles, 184  
 Inspiration, movements of, 312  
 Interaccessorii muscles, 304  
 Interarticular fibro-cartilages and ligaments. *See* the various joints  
 Intercarotid ganglion, 632  
 Interclavicular notch, 26  
     ligament, 146  
 Intercolumnar fascia, 317  
 Intercondylar fossa, 109  
 Intercostal arteries, 391, 392, 420  
     lymphatics, 513, 514  
     muscles, 306  
     actions of, 312  
     nerves, 593, 597  
     veins, 474  
 Intercosto-humeral nerve, 597  
 Intermaxillary bone, 72, 74  
 Intermetacarpal articulations, 157  
 Intermuscular septa. *See* Septa.  
 Internodia (*inter*, between; *nodus*, knot), 94  
 Interossei muscles of hand, 222  
     of foot, 258  
 Interosseous arteries of arm, 408  
     of foot, 470  
     of hand, 409, 417, 419  
     ligament. *See* LIGAMENTS.  
     nerves, 591, 594, 621  
 Interparietal bones, 74  
     suture, 58  
 Interphalangeal articulations, hand, 159  
     toes, 181  
 Interspinales muscles, 304  
 Interspinous ligaments, 137  
 Intertransversales muscles, 304  
 Intertransverse ligaments, 137  
 Intertrochanteric line, 108  
 Intervertebral discs, 133, 160  
     foramina, 10

- Intrinsic muscles, 185, 261  
 Irregular or mixed bones, 8  
 Ischio-capsular ligament, 165  
 Ischio-cavernosus muscle, 330  
 Ischio-rectal fossa, 327  
 Ischium (*ἰσχίον*, the hip), 103  
   homology of, 123  
   ossification of, 118  
 Isthmus of the fauces, 289
- JACOBSON'S nerve, 556  
 Jaw, lower, 53, 74  
   articulation of, 144  
   muscles of, 281  
     action of, 284  
   ossification of, 72  
   upper, 46  
     ossification of, 71
- Joint, ankle, 173  
 elbow, 152  
 hip, 163  
 knee, 166  
 shoulder, 148  
 wrist, 154
- See ARTICULATION  
 Joints, motions of bones in, 134  
   various forms of, 131
- Jugular eminence, 33  
 foramen, 62  
 fossa, 40  
 ganglion, 555  
 notch, 33  
 veins, 477, 479, 489
- Jugulo-cephalic vein, 487
- KIDNEY, lymphatics of, 512  
 Knee-joint, 166  
   ligaments of, 166  
   movements of, 171  
   nerves of, 603, 605, 616, 619  
 Knee-pan, 110
- LABIAL artery, 365  
   foramen, 54  
   nerve of inferior dental, 545  
   infraorbital, 539  
   veins, 476
- Lachrymal artery, 375  
 bone, 52, 74  
   ossification of, 72  
   fossa, 36, 60  
   groove, 48, 60  
   nerve, 534
- Lacteals (*lac*, milk), 509  
 Lambdoidal ( $\Lambda$ , the letter *lambda*;  $\epsilon\lambda\delta\omicron\varsigma$ ,  
   shape) suture, 57  
 Lamella, cribriform, 45, 46  
 Lamina of a vertebra, 10  
   cribrosa of temporal bone, 40  
 Laminae or plates of vertebrae, 10, 11,  
   13, 14  
 Laryngeal arteries, 363, 387  
   nerves, 561, 624  
   veins, 479  
 Latissimus dorsi muscle, 189
- Leg, aponeurosis of, 243  
 articulations of, 172  
   bones of, 110, 112  
   muscles of, anterior, 243  
     external, 248  
     posterior, 248  
   nerves of, cutaneous, 623  
     muscular, 626
- Lenticular (dim. from *lens*) ganglion,  
 536
- Levator. See MUSCLES  
 Ligamenta arcuata, 309  
   subflava, 136  
   vaginalia, 212
- LIGAMENTS (*ligo*, I bind), acromio-clavi-  
 cular, 147  
 alar, 170  
 alar odontoid, 139  
 of ankle, 173  
   annular, 244  
 astragalo-calcaneal, 175  
 astragalo-scaphoid, 176  
 atlanto-axial, 140  
 of atlas, transverse, 138  
 of bladder, true, 326  
 calcaneo-cuboid, 176  
 calcaneo-fibular, 174  
 calcaneo-scaphoid, 175  
 carpal, 156  
   annular, 208, 209  
 carpo-metacarpal, 157  
 of coccyx, 160  
 conoid, 147  
 coraco-acromial, 148  
 coraco-clavicular, 147  
 coraco-humeral, 149  
 coracoid, 148  
 costo-central, anterior, 140  
 costo-clavicular, 146  
 costo-coracoid, 193  
 costo-sternal, 142  
 costo-transverse, 141  
 costo-xiphoid, 142  
 cotyloid, 164  
 crucial, 168  
 cruciform, 138  
 cubo-cuneiform, 178  
 of cuboid bone, 176, 177  
 of cuneiform bones, 179  
 deltoid, 173  
 of elbow, 152  
 femoral, 227  
 of foot, 174  
 of forearm, 150  
 Gimbernat's, 316  
 glenoid, 149  
 of hand, 154  
 of hip-joint, 163  
 ilio-femoral, 165  
 ilio-lumbar, 159  
 ilio-trochanteric, 165  
 interclavicular, 146  
 interspinous, 137  
 intertransverse, 137  
 ischio-capsular, 165

LIGAMENTS—*continued.*

of knee-joint, 166  
of lower limb, 163  
metacarpal, 157  
    of thumb, 158  
metacarpophalangeal, 158  
metatarsal, 180  
    transverse, 181  
metatarso-digital, 181  
obturator, 163  
occipito-atlantal, 140  
occipito-axial, 140  
odontoid, alar, 139  
    middle, 140  
orbicular, 150  
palmar, 156, 157, 158  
of patella, 167  
    lateral, 170  
of pelvis, 159  
of phalanges, fingers, 159  
    toes, 181  
Poupart's, 316  
pterygo-maxillary, 272  
pubic, 163  
pubo-femoral, 165  
radiated, of ribs, 140  
radio-carpal, 154  
radio-ulnar, 150  
rhomboid, 146  
of ribs, 140  
round, radio-ulnar, 151  
    of hip, 165  
sacro coccygeal, 160  
sacro-iliac, 161  
sacro-sciatic, 162  
sacro-vertebral, 159  
scapho-cuboid, 177  
scapho-cuneiform, 178  
of scapula, 148  
scapulo-clavicular, 146  
of shoulder-joint, 148  
stellate, 140  
of sternum, 142  
sterno-clavicular, 146  
stylo-hyoid, 55, 145  
stylo-maxillary, 145, 278  
subpubic, 163  
suprascapular, 148  
supraspinous, 137  
suspensory of penis, 314  
talo-scaphoid, 176  
tarsal, 174  
tarso-metatarsal, 179  
temporo-maxillary, 144  
tibio-fibular, 172  
transverse of atlas, 138  
    of acetabulum, 165  
    metacarpal, 157  
    metatarsal, 181  
    of toes, 256  
trapezoid, 147  
of upper limb, 146  
of urethra, triangular, 323  
vertebral, 133  
of wrist, 154

Ligamentum arcuatum externum, 309  
arcuatum internum, 309  
breve (of fingers), 212  
cruciatum cruris, 244  
mucosum, 170  
nuchæ, 137  
patellæ, 167  
suspensorium dentis (of the odontoid process), 140  
teres of hip-joint, 165  
transversum cruris, 244  
Limb, lower, articulations of, 163  
    bones of, 100  
        ossification of, 118  
    fasciæ of, 226  
    lymphatics of, 506  
    muscles of, 226, 263  
    nerves of, cutaneous, 623  
        muscular, 626  
    veins of, 495  
upper, articulations of, 146  
    bones of, 81  
        ossification of, 95  
    fasciæ of, 187  
    lymphatics of, 514  
    muscles of, 187, 262  
    nerves of, cutaneous, 623  
        muscular, 625  
    veins of, 485  
Limbs, distinctive characters of, in man, 130  
    homological comparison of, 122  
    homologous bones, tables of, 129  
    homology of muscles of, 262  
    morphology of bones of, 122  
        of muscles, 260  
    relation to axial skeleton, 122  
Line, curved of ilium, 101, 102  
    occipital, 33  
    ilio-pectineal, 102, 103  
    intertrochanteric, 108  
    oblique of lower jaw, 54  
    popliteal, 111  
Linea alba, 322  
    aspera, 108  
Lineæ semilunares, 322  
    transversæ, 320  
Lingual artery, 363  
    nerve, of fifth, 544  
        of glosso-pharyngeal, 556  
    vein, 479  
Lingula sphenoidalis, 42  
Lips, muscles of, 270  
Liver, lymphatics of, 511  
Long or cylindrical bones, 8  
Longissimus dorsi muscle, 300  
Longus colli muscle, 296  
Longitudinal sinuses, superior and inferior, 482  
Lumbar aponeurosis or fascia, 187, 299  
    arteries, 436  
    ganglia, 636  
    lymphatic glands, 509  
    nerves, anterior division of, 558

- Lumbar—*continued*.  
 nerves, posterior, 574  
   fifth, 607  
 plexus, 598  
 veins, 494  
 vertebrae, 13  
 Lumbo-inguinal nerve, 603  
 Lumbo-sacral nerve, 607  
 Lumbricales (*lumbricus*, an earthworm)  
   muscles, of foot, 253  
     of hand, 213  
 Lungs, lymphatics of, 514  
 Lymphatic duct, right, 504, 506  
   glands, 504  
     axillary, 515  
     bronchial, 513  
     cardiac, 513  
     cervical, 516  
     iliac, 508, 509  
     inguinal, 507  
     intercostal, 513  
     lumbar, 509  
     mediastinal, 513  
     mesenteric, 509  
     oesophageal, 513  
     popliteal, 506  
     sacral, 509  
     of thorax, 512  
 LYMPHATICS, Descriptive Anatomy of,  
   504  
   of abdomen and pelvis, 508, 509  
     back, 516  
     bladder, 512  
     cranium, 517  
     face, 518  
     head and neck, 516  
     heart, 514  
   intercostal, 514  
   of kidneys, 512  
     limb, lower, 506  
       deep, 508  
       superficial, 507  
     upper, 514  
       superficial, 516  
       deep, 516  
     liver, 511  
     lungs, 514  
   occipital, 517  
   of oesophagus, 514  
     pancreas, 511  
     penis, 508  
     pia mater, 518  
     rectum, 511  
     scrotum, 508  
     spleen, 511  
   sternal, 513  
   of stomach, 511  
     suprarenal capsules, 512  
   temporal, 517  
   of testicle, 512  
     thorax, 512, 513  
     thymus gland, 514  
     trunk, lower half, 508  
     ureter, 512  
     uterus, 512
- MALAR (*mala*, the cheek) arch, 60  
 arteries, 375  
 bone, 51, 74  
   ossification of, 72  
 foramina, 52, 59  
 nerve, of facial, 551  
   of orbital, 538  
 process, 48  
 Malleolar (*malleolus*, the ankle) arteries,  
   469  
 Malleolus (dim. of *malleus*, a hammer ;  
 the ankle), external, 113  
   internal, 112  
 Mammary ( *mamma*, the breast) artery,  
   external, 395  
   internal, 390  
   vein, internal, 474  
 Mammillary (*mammilla*, a nipple) pro-  
   cesses of vertebrae, 15, 24  
 Mandible, 53, 74  
 Manubrium (a handle) of sternum, 25  
 Marrow of bone, 7  
 Martins on homologies of limbs, 126  
 Masseter (*μαστώμαι*, I chew) muscle, 278  
 Masseteric (*masseter*) artery, 371  
   fascia, 278, 291  
   nerve, 543  
   vein, 476  
 Mastication, muscles of, 278  
 Mastoid (*μαστός*, a nipple ; *είδος*, form)  
   artery, 366  
   foramen, 39  
   portion of temporal bone, 37, 39  
   process, 39  
 Mastoido-humeral muscle, 292  
 Maxillary (*maxilla*, a jaw) artery, in-  
   ternal, 369, 373  
   superior, 371  
   bone. *See* Jaw.  
   nerve, inferior, 533, 542  
   superior, 533, 537  
   sinus, 49, 66, 67  
   vein, internal, 477  
 Maxillo-turbinal bone, 53, 74  
 Meatus (*meo*, I pass), 9  
   auditorius, 40  
   of nose, 46, 66  
 Meckel's ganglion, 540  
 Median artery, 409, 411  
   anterior, 385  
   basilic (*βασιλικός*, royal) vein, 487  
   cephalic (*κεφαλή*, the head) vein,  
     487  
   cutaneous vein, 487  
   line, 6  
   nerve, 590  
   vein, deep, 487  
 Mediastinal arteries, 391, 420  
   lymphatic glands, 513  
   veins, 474  
 Medulla (marrow) of bones, 7  
 Membrana sacciformis, 151  
 Membrane, costo-coracoid, 193  
 Meningeal arteries. *See* ARTERY.  
   vein, middle, 477

Mental (*mentum*, the chin) foramen, 54,  
59  
nerve, 545  
vein, 476

*Mento-hyoid muscle*, 282

Mesenteric (*μέσος*, middle; *έντερον*, intestine) artery, inferior, 430  
superior, 428  
glands, 509  
plexus, inferior, 641  
superior, 640  
veins, inferior, 502  
superior, 501

Mesial (*μέσος*, middle) plane, 5, 6

Mesosternum (*μέσος*, middle; *στέρνον*, the chest), 25, 26

Metacarpal arteries, 409, 417

Metacarpo-phalangeal articulations, 158

Metacarpus (*μετά*, beyond; *καρπός*, the wrist), 93  
articulations of, 157  
ossification of, 100

Metaphysis (*μετά*, beyond; *αποφύσις*), 15, 24

Metasternum (*μετά*, beyond; *στέρνον*, the chest), 25, 26

Metatarsal artery, 470  
articulations, 180

Metatarso-digital articulations, 181

Metatarsus (*μετά*, beyond; *ταρσός*, the instep), 116  
ossification of, 122

Midriff (Sax. *midd*, middle; *hrif*, the belly), 308

Morphology (*μορφή*, form; *λόγος*, discourse), 2  
of bones of head, 73  
of limbs, 122  
of fasciæ of trunk and head, 332  
of muscles of limbs, 260  
of trunk and head, 332

Motorius oculi nerve, 528

Mouth, muscles of, 270

Movement, various kinds of, 132

Movements of ankle-joint, 174  
clavicular, 148  
of elbow, 154  
foot and toes, 182  
hip, 166  
knee, 170  
lower jaw, 145  
occipito-vertebral, 140  
of patella on femur, 171  
of pelvis, 163  
radius on ulna, 151  
ribs, 143  
shoulder, 150  
vertebral column, 137  
wrist and fingers, 159

Multifidus (*multus*, many; *findo*, I cleave) spine muscle, 303

MUSCLES, Descriptive Anatomy of, 183  
*abductor brevis pollicis*, 221  
*abductor indicis*, 223  
*abductor longus pollicis*, 218

## MUSCLES—continued.

*abductor minimi digiti* (hand), 222  
*minimi digiti* (foot), 257  
ossis metacarpi minimi digiti (hand), 257  
pollicis (hand), 221  
pollicis pedis, 257

accessorius ad ilio-costalem, 300

*abductor brevis*, 241  
gracilis, 240  
longus, 241  
magnus, 241  
*minimus*, 243  
pollicis manus, 222  
pollicis pedis, 258

anconeus, 207  
anomalus, 270

attollens auriculam, 265

attractans auriculam, 265

auricularis, superior, anterior, et posterior, 265

azygos pharyngis, 288  
uvulæ, 289

biceps flexor cruris, 232  
flexor cubiti, 205

biventer cervicis, 301

brachialis anticus, 206  
*brachio-radialis*, 206

buccinator, 272

bulbo-cavernosus, 330

caninus, 271

cephalo-pharyngeus, 288

cervicalis ascendens, 300

circular of Santorini, 330

circumflexus palati, 290

coccygeus, 329  
complexus, 301  
*compressor hemisphæricam bulbi*, 330  
*compressor naris*, 269  
*compressores venæ dorsalis penis*, 330

constrictor of pharynx, inferior, 286  
middle, 287  
superior, 288  
isthmi faucium, 289  
urethræ, 330

coraco-brachialis, 204

corrugator supercilii, 267

cremaster, 318

crureus, 239

euocularis (like a hood), 187

*curvator coccygis*, 329

deltoid, 199

depressor alæ nasi, 270  
anguli oris, 274  
labii inferioris, 274

diaphragm, 308. See DIAPHRAGM.

diaphragma oris, 283

digastric, 281

dilatator naris anterior, 270  
naris posterior, 270

*dorsi-epitrochlearis*, 207

ejaculator urinæ, 330

*epitrochleo-anconeus*, 207

erector clitoridis, 331  
penis, 330



MUSCLES—*continued.*

- erector spinæ, 299  
 extensor brevis digitorum pedis, 247  
   *brevis hallucis*, 247  
   carpi radialis brevior, 216  
   carpi radialis longior, 216  
   carpi ulnaris, 218  
   *coccygis*, 305, 329  
   communis digitorum, 216  
   indicis, 220  
   longus digitorum pedis, 246  
   *minimi digiti*, 218  
   ossis metacarpi pollicis  
     (hand), 218  
     (foot), 245  
   primi internodii pollicis, 219  
     (foot), 245  
   proprius pollicis, 245  
   secundi internodii pollicis  
     (hand), 219  
 flexor accessorius, 253  
   brevis digitorum pedis, 256  
   brevis minimi digiti (hand), 222  
   brevis minimi digiti pedis (foot),  
     258  
   brevis pollicis manûs, 222  
   brevis pollicis pedis, 257  
   carpi radialis, 210  
   carpi ulnaris, 211  
   *digiti secundi proprius* (foot),  
     253  
   digitorum profundus, 213  
   digitorum sublimis, 211  
   longus digitorum pedis, 252  
   longus pollicis manûs, 214  
   longus pollicis pedis, 253  
   perforans digitorum manûs, 213  
   perforans digitorum pedis, 252  
   perforatus digitorum manûs, 211  
   perforatus digitorum pedis, 256  
 frontalis, 264  
 gastrocnemius, 249  
 gemelli, 231  
 genio-glossus, 285  
 genio-hyo-glossus, 285  
 genio-hyoid, 284  
 gluteus maximus, 228  
   medius, 228  
   minimus, 229  
 gracilis, 240  
 hyo-glossus, 285  
 iliacus, 234  
   *iliacus minor*, 234  
 ilio-aponeurotic, 235  
 ilio-capsularis, 234  
 ilio-costalis, 300  
 ilio-psoas, 234  
 incisivi, 271  
 indicator, 220  
 infraspinatus, 200  
 intercostal, external, 306  
   internal, 306  
   action of, 312  
 interossei, of hand, 222  
   of foot, 258

MUSCLES—*continued.*

- interspinales, 304  
 intertransversales, 304  
 ischio-cavernosus, 330  
 latissimus dorsi, 189  
 levator anguli oris, 271  
   anguli scapulae, 192  
   ani, 328, 331  
   coccygis, 329  
   labii inferioris, 274  
   labii superioris proprius, 271  
   labii superioris alæque nasi, 269  
   menti, 274  
   palati, 289  
   palpebrae superioris, 267, 275  
   proprius alæ nasi anterior,  
     270  
   proprius alæ nasi posterior, 270  
   *prostata*, 328  
 levatores costarum, 308  
   *longiores costarum*, 308  
 longissimus dorsi, 300  
 longus colli, 296  
 lumbricales (worm-shaped muscles),  
   of hand, 213  
   of foot, 253  
 masseter, 278  
 mastoïdo-humeral, 292  
 mento-hyoid, 282  
 multifidus spinæ, 303  
 mylo-glossus, 286  
 mylo-hyoid, 283  
 oblique, of eye, inferior, 277  
   superior, 275  
 obliquus abdominis externus, 315  
   internus, 317  
   capitis inferior, 305  
   superior, 305  
 obturator externus, 231  
   internus, 230  
 occipitalis, 264  
 occipito-frontalis, 264  
 omo-hyoid, 294  
 opponens hallucis, 258  
   *minimi digiti* (foot), 258  
 opponens minimi digiti (hand), 222  
   pollicis, 222  
 orbicularis oris, 271  
   palpebrarum, 266  
 palato-glossus, 289  
 palato-pharyngeus, 289  
 palmaris brevis, 221  
   longus, 210  
 pectineus, 241  
 pectoralis major, 193  
   minor, 196  
*peronco-calcaneus internus*, 254  
 peroneus brevis, 248  
   longus, 248  
   tertius, 246  
*peroneus accessorius*, 248  
   *quartus*, 248  
   *quinti digiti*, 248  
 plantar, 255  
 plantaris, 252

MUSCLES—*continued.*

- platysma myoides, 272, 290  
 popliteus, 252  
 pronator radii quadratus, 214  
   radii teres, 209  
 psoas magnus, 234  
   *parvus*, 235  
 pterygoid external, 280  
   internal, 279  
*pterygoideus proprius*, 280  
*pubo-urethral*, 331  
*pubo-vesical*, 331  
 pyramidalis abdominis, 322  
 pyramidalis nasi, 269  
 pyriformis, 230  
 quadratus femoris, 231  
   lumborum, 322  
   menti, 274  
 quadriceps extensor cruris, 237  
*radio-carpalis*, 212  
 recti of eye, 275  
 rectus abdominis, 320  
   capitis anticus major, 296  
   capitis anticus minor, 296  
   capitis lateralis, 296  
   capitis posticus major, 305  
   capitis posticus minor, 305  
   femoris, 238  
*rectus sternalis*, 308  
 retrahens auriculam, 265  
 rhomboideus major, 192  
   minor, 192  
*rhomboideus occipitalis*, 192  
 risorius (smiling muscle), 272  
 rotatores spine, 303  
*sacci lachrymalis*, 267  
*sacro-coccygeus posticus*, 305  
 sacro-lumbalis, 300  
 salpingo-pharyngeus, 288  
 Santorini's, circular, 330  
   risorius, 272  
 sartorius, 236  
 scalenus anterior, 295  
   medius, 295  
   posticus, 296  
 semimembranosus, 233  
 semispinalis colli, 303  
   dorsi, 303  
 semitendinosus, 232  
 serratus magnus, 196  
   posticus inferior, 298  
   posticus superior, 298  
 soleus, 250  
 sphincter ani, external or superficial, 327  
   internal or circular, 327  
   oris, 271  
   vaginae, 331  
*spinalis cervicis*, 305  
*spinalis dorsi*, 301  
 splenius capitis, 299  
   colli, 299  
*sternalis brutorum*, 308  
 sterno-cleido-mastoid, 292  
 sterno-hyoid, 292

MUSCLES—*continued.*

- sterno-thyroid, 293  
 stylo-glossus, 286  
 stylo-hyoid, 283  
*stylo-hyoidæus alter*, 283  
 stylo-pharyngeus, 288  
 subanconeus, 207  
 subclavius, 196  
 subcostal, 308  
 suberureus, 240  
 subscapularis, 203  
*subscapulo-capsularis*, 203  
 supinator radii brevis, 218  
   longus, 215  
 supraspinatus, 200  
*syndesmo-pharyngeus*, 287  
 temporal, 279  
 tensor palati, 290  
   tarsi, 267  
   vaginae femoris, 235  
*tensor trochlae*, 276  
 teres major, 200  
   minor, 201  
 thyro-hyoid, 293  
 tibialis anticus, 245  
   posticus, 254  
   *secundus*, 255  
*tibio-fascialis anticus*, 245  
 trachelo-mastoid, 300  
 transversalis abdominis, 320  
   cervicis, 300  
*transversalis menti*, 274  
 transversus pedis, 258  
   perinaei, 329, 330, 331  
*transversus nuchæ*, 265  
   *orbitæ*, 276  
 trapezius, 187  
 triangularis oris, 274  
   sterni, 308  
 triceps extensor cubiti, 206  
 triticeo-glossus, 286  
 trochlearis, 275  
 vastus externus, 238  
   internus, 239  
*Wilson's*, 331  
 zygomaticus major, 272  
   minor, 272
- MUSCLES of abdomen, 314  
   action of, 322  
   anal, 327  
   of arm, upper, 204  
     action of, 208  
   auricular, 265  
   of back, 297  
     action of, 305  
   cranio-vertebral, short posterior, 305  
   dorso-lateral (morphol.), 332  
   epicranial, 264  
     action of, 265  
   of eyelids and eyebrows, 265  
     action of, 269  
   femoral, anterior, 234  
     action of, 240  
   internal, 240  
     action of, 243

MUSCLES—*continued.*

- femoral, posterior, 232
  - action of, 234
- of foot, 256
  - action of, 259
- of forearm, 208
  - action of, 224
- genito-urinary, 329
- hamstring, 232
- of hand, 221, 263
  - action of, 224
  - varieties of, 224
- of head and neck, 264
- of hip, 228
  - action of, 232
- of hyoid bone, 281
  - action of, 284
- hypaxial (morphol.), 185, 333
- lateral (morphol.), 334
- of leg and foot, anterior, 243
  - external, 248
  - posterior, 248
  - action of, 259
- of limb, lower, 226, 263
  - upper, 187, 262
- of limbs, morphology of, 260
  - table of homologies of, 262
- of little finger, 222
- of lips and mouth, 270
  - action of, 274
- of mastication, 278
  - action of, 281
- of neck, anterior, 291
  - action of, 294
  - lateral and prevertebral, 295
    - action of, 297
- of nose, 269
  - action of, 270
- of orbit, 275
  - action of, 277
- of palate, 288
  - action of, 290
- paraxial (morphol.), 333
- of perinaeum, 327
  - action of, 331
- of pharynx, 286
  - action of, 290
- plantar, short, 256
- prevertebral, 296
- pronators and flexors, 209
  - action of, 224
- of shoulder, 199
  - action of, 203
- supinators and extensors, 215
  - action of, 224
- of thigh, 232
- of thorax, 306
  - action of, 311
- of thumb, 221
  - action of, 225
- of tongue, 284
  - action of, 286
- of trunk and upper limb, anterior, 193
  - posterior, 187
  - action of, 198

MUSCLES—*continued.*

- ventral (morphol.), 334
  - ventro-lateral (morphol.), 185, 260, 333
  - Musculo-cutaneous nerve of arm, 587
    - of leg, 619
  - Musculo-phrenic (*musculus*, muscle; *φρήν*, the diaphragm) artery, 391
  - Musculo-spiral nerve, 592
  - Mylo-glossus (*μύλη*, a mill, the jaw; *γλῶσσα*, the tongue), muscle, 286
  - Mylo-hyoid (*μύλη*, a mill, the jaw; *hyoid* bone) artery, 371
  - Mylo-hyoid groove, 55
    - muscle, 283
    - nerve, 545
    - ridge, 54
  - Myoides. *See* Platysma.
  - Myology (*μῦς*, a muscle; *λόγος*, discourse), 183
  - Myotome (*μῦς*, a muscle; *τέμνω*, I divide), 185
  - Myrtiform (*μύρτον*, a myrtle-berry; *forma*, shape) fossa, 48
- NARES (nostrils), 48, 58
  - posterior, 62
  - septum of, 65
- Nasal (*nasus*, the nose), aperture, 58
  - arteries, 365, 373, 377
  - bone, 52, 74
    - ossification of, 72
  - canal, 48
  - fosse, or cavities, 65
  - ganglion, 540
  - nerves. *See* NERVES
  - process, 48
  - spine, 36, 47
  - vein, 476
- Naso-palatine nerve, 541
- National differences in skull, 78
- Navicular (*navicula*, a small ship or boat) bone of foot, 115
  - homology of, 128
  - fossa, 44
- Neck, of a bone, 8
- Neck, fasciæ of, 291
  - muscles, anterior, 291, 292
    - lateral and prevertebral, 295
  - veins of, 475
- NERVES, Descriptive Anatomy of, 519
  - abdominal of ilio-hypogastric, 600
  - abducent, 519, 547
  - accessory, spinal, 564
    - obturator, 604
  - articular of elbow-joint, 588
    - of hip-joint, 603, 604, 615
    - knee, 603, 605, 616, 619
    - shoulder-joint, 583, 585
    - temporo-maxillary joint, 544
    - wrist, 588
  - auditory, 548, 553
  - auricular, of auriculo-temporal, 543
    - great, 577

NERVES—*continued.*

- auricular, posterior, 550
  - of pneumogastric, 560
  - of great occipital, 573
  - of small occipital, 578
- auriculo-temporal, 543
- buccal of facial, 551
  - of inferior maxillary, 543
- cardiac, lower, 633
  - middle, 632
  - of pneumogastric, 561
  - upper, 631
- carotid of petrous ganglion, 556
  - of Vidian, 542
- cavernous of penis, 642
- cervical, divisions of, anterior, 575
  - posterior, 573
    - second, 576
    - superficial, 577
- cervico-facial, 551
- chorda tympani, 545, 549
- ciliary, long, 535, 536
  - short, 536
- circumflex of arm, 584
- coccygeal, divisions of, anterior, 606
  - posterior, 575
- of Cotunnus, 541
- crural, anterior, 604
  - summary of, 607
  - of genito-crural, 602
- cutaneous, of abdomen, 597
  - calcaneo-plantar, 617
  - external, of arm, 593
    - of lumbar plexus, 602
    - musculo-spiral, 593
  - internal, of arm, 585
    - small, 587
    - musculo-spiral, 592
    - of thigh, 605
  - lateral, of last dorsal, 598
  - middle, of thigh, 605
  - of obturator, 604
  - of small sciatic, 613
  - of thoracic, anterior, 597
    - lateral, 597
- dental, anterior, 539
  - inferior, 545
  - lesser inferior, 546
  - posterior, 538
- descendens noni, 567
- diaphragmatic, 578
- digastric, 550
- digital, in hand, of median, 591
  - of radial, 593
  - of ulnar, 590
- in foot, external plantar, 619
  - internal plantar, 618
  - musculo-cutaneous, 620
- dorsal, divisions of, anterior, 593
  - posterior, 574
    - first, 593
    - of hand, 588
    - last, 598
    - of penis, 611
- dorsi-lumbar, 598

NERVES—*continued.*

- facial, 548
  - summary of, 552
  - of great auricular, 578
- of femoral artery, 604
- frontal, 534
  - external, 535
  - internal, 534
- gastric, 564
- genital, 602
- genito-crural, 601
- glosso-pharyngeal, 554
  - summary of, 556
- gluteal, inferior, 613
  - superior, 607
- gustatory, 544
- haemorrhoidal, inferior, 612, 642
  - superior, 642
- hypogastric, 600
- hypoglossal, 565
  - summary of, 568
- iliac, 600
- ilio-hypogastric, 600
- ilio-inguinal, 600
- incisor, 545
- inframaxillary, 551
- infra-orbital, 539
  - of facial, 551
- infratrochlear, 535, 536
- intercostal, first, 593
  - lower or abdominal, 597
  - upper or pectoral, 593
- intercosto-humeral, 597
- interosseous, of arm, anterior, 591
  - posterior, 594
    - of leg, 621
- Jacobson's, 556
- labial, of inferior dental, 545
  - of infraorbital, 539
- lacrimal, 534
- laryngeal, external, 561
  - internal, 561
  - recurrent, 561
- lingual, of fifth, 544
  - glosso-pharyngeal, 556
- lumbar, divisions of, posterior, 574
  - anterior, 588
    - fifth, 607
  - lumbo-inguinal, 603
  - lumbo-sacral, 607
  - malar, of facial, 551
    - of orbital, 538
  - masseteric, 543
  - mastoid, 578
  - maxillary, inferior, 542
    - summary of, 547
    - superior, 533, 537
    - summary of, 542
- median, 590
  - summary of, 591
- mental, 545
- motor of eye, common, 528
  - external, 547
- musculo-cutaneous of arm, 587
  - leg, 619

NERVES—*continued.*

- musculo-spiral, 592
  - summary of, 594
- mylo-hyoid, 545
- nasal, 535
  - external or superficial, 535
  - of infraorbital, 539
  - inferior, 540
  - upper, 541
  - of Vidian, 542
- naso-palatine, 541
- obturator, 602
  - accessory, 604
- occipital (of facial), 550
  - great, 573
  - small, 578
- oculo-motor, 519
- oesophageal, 563
- olfactory, 526
- ophthalmic, 533, 534
  - summary of, 536
- optic, 527
- orbital, 537
- palatine, anterior or larger, 540
  - external, 540
  - posterior or smaller, 540
- palmar, of median, 591
  - of ulnar, 588
- palpebral, 539
- parotid, 543
- pathetic, 519
- perineal, 610
- peroneal, 620
  - communicating, 620
- petrosal, superficial, large, 542
  - external, 549
  - small, 546, 556
- pharyngeal of pneumogastric, 560
  - of glosso-pharyngeal, 556
  - of spheno-palatine ganglion, 541, 542
  - of sympathetic, 630
- phrenic, 578
- plantar, cutaneous, 618
  - external, 619
  - internal, 617
- pneumogastric, 556
  - summary of, 564
- popliteal, external, 615, 619
  - summary of, 622
  - internal, 615, 616
  - summary of, 619
- portio dura, 548
  - mollis, 548, 553
- pterygoid, external, 543
  - internal, 543
- pudendal, inferior, 614
- pubic, 610
- pulmonary, of pneumogastric, 563
- radial, 593
- renal, 640
- respiratory, external, 583
- sacral, divisions of, anterior, 608
  - posterior, 574
  - fifth, 608

NERVES—*continued.*

- sacral, fourth, 608
  - saphenous, internal, or long, 606
    - external, or short, 617
  - sciatic, great, 615
    - small, 613
  - scrotal, long, 610
  - spermatic, external, 602
  - spinal, 568. *See* NERVES, SPINAL.
    - accessory, 564
  - splanchnic, great, 635
    - small, 636
    - smallest, 636
  - stylo-hyoid, 550
  - suboccipital, 571, 575
  - subscapular, 584
  - supra-acromial, 578
  - supraclavicular, 578
  - supramaxillary, 551
  - supraorbital, 535
  - suprascapular, 553
  - suprasternal, 578
  - supratrochlear, 534
  - temporal, of auriculo-temporal, 544
    - deep, 542
    - of facial, 551
    - of orbital, 537, 538
  - temporo-facial, 551
    - malar, 537
  - thoracic, anterior, 584
    - posterior, 583
  - thyroid, 632
  - tibial, anterior, 619, 621
    - posterior, 617
  - tonsillitic, 556
  - trifacial, 532
  - trochlear, 519
  - tympanic, 556
  - ulnar, 588
    - summary of, 590
    - collateral, 592
    - Vidian, 541
    - of Wrisberg, 587
- NERVES, CRANIAL, classification of, 519
- connections with encephalon, 520
  - general distribution of, 523
  - first pair, or olfactory, 526
  - second pair, or optic, 527
  - third pair, 528
  - fourth pair, 530
  - fifth pair, 532
    - ophthalmic, 534
    - superior maxillary, 537
    - inferior maxillary, 542
  - sixth pair, 547
  - seventh pair, 548
    - facial, 548
    - auditory, 553
  - eighth pair, glosso-pharyngeal, 554
    - pneumogastric, 556
    - spinal accessory, 564
  - ninth pair, 565
- NERVES, SPINAL, 568
- divisions of, anterior, 575
  - posterior, 571

**NERVES, SPINAL**—*continued*.  
 length of, in spinal canal, 570  
 roots of, 569

**NERVES, SYMPATHETIC**, descriptive  
 Anatomy of, 626  
 ganglia of. *See* GANGLION  
 gangliated cords of, 626  
   cervical part, 628  
   lumbar part, 636  
   sacral part, 636  
   thoracic part, 633  
 plexuses of, 638. *See* PLEXUSES

**NERVES of abdomen**, muscular, 625  
 of arm, cutaneous, 623  
   muscular, 208, 625  
 of back, cutaneous, 622  
   muscular, 624  
 of bladder, 642  
 of buttock, cutaneous, 623  
   muscular, 626  
 of eyelids and eyebrows, cutaneous,  
   622  
   muscular, 528, 530, 547, 624  
 of face, cutaneous, 622  
   muscular, 274, 624  
 of foot, cutaneous, 623, 624  
   muscular, 259, 626  
 of forearm, cutaneous, 623  
   muscular, 214, 221, 625  
 of hand, cutaneous, 623  
   muscular, 224, 626  
 of head, cutaneous, 622  
   muscular, 624  
 of heart, 561, 630, 632, 638  
 of hip, muscular, 284, 624  
 of larynx, 561, 624  
 of leg, cutaneous, 623,  
   muscular, 248, 255, 626  
 of limb, lower, cutaneous, 623  
   muscular, 626  
   upper, cutaneous, 623  
   muscular, 625  
 of lips, cutaneous, 622  
 of lungs, 563  
 of muscles of mastication, 626  
 of muscles between trunk and upper  
   limb, 192, 197, 625  
 of neck, cutaneous, 622  
   muscular, 294, 297, 624, 625  
 of nose, cutaneous, 622  
 of œsophagus, 553  
 of orbit, muscular, 277, 624  
 of ovary, 642  
 of palate, muscular, 290, 624  
 of penis, 623, 642  
 of perinaeum, cutaneous, 623  
   muscular, 331, 625  
 of pharynx, 290, 561, 624, 630  
 of scrotum, 623  
 of shoulder, cutaneous, 623  
   muscular, 203, 625  
 of thigh, cutaneous, 623  
   muscular, 234, 240, 243, 626  
 of thorax, muscular, 311, 625  
 of thumb muscular, 625

**NERVES**—*continued*.  
 of tongue, 286, 624  
 of trunk, cutaneous, 622  
   muscular, 624  
 of uterus, 642  
 of vagina, 642  
 of vas deferens, 642  
 of vesicula seminalis, 642

**Nervus abducens**, 547  
 cardiacus profundus, seu magnus,  
   632  
 cardiacus superficialis, 630  
 ischiadicus major, 615  
 ischiadicus minor, 613  
 motor oculi externus, 547  
 motorius oculi, 528  
 oculo-nasalis, 535  
 patheticus, 530  
 renalis posterior, 636  
 splanchnicus supremus, 636  
 trigeminus, 532  
 trochlearis, 530  
 vagus (wandering nerve), 556

**Neural** (*νεῦρον*, a nerve), arches of cra-  
 nium, 76  
 of vertebrae, 24  
 canal, 10  
 septum, 332  
 spines of vertebrae, 10

**Neurapophysis** (*νεῦρον*, a nerve; *απορρη-  
 σις*), 10

**Neurocentral suture**, 20

**Neurology** (*νεῦρον*, a nerve; *λόγος*, dis-  
 course), 519

**Norma verticalis** (vertical rule), 79

**Nose**, arteries of, 365, 373, 377  
 cavities or fosse ol, 65  
 meatus of, 46, 66  
 muscles of, 269  
 nerves of, 535, 539, 541, 542, 622  
 septum of, 65  
 veins of, 476

**Notch of acetabulum**, 103  
 of bone, 9  
 interclavicular, 26  
 intercondylar, 109  
 jugular, 33  
 sacro-sciatic, 101, 103  
 scapular, 82  
 sigmoid, 55  
 supraorbital, 35  
 suprascapular, 83

**Notches of vertebrae**, 10

**Nuclei of cranial nerves**, 521

**Nutrient artery of femur**, 459  
 fibula, 465  
 humerus, 402  
 ilium, 448  
 radius, 409  
 tibia, 464  
 ulna, 409

**OBLIQUE inguinal hernia**, 337  
 muscles of eye, inferior, 277  
   superior, 275

- Obliquus abdominis externus, 315  
     internus, 317  
     capitis, 305  
 Obturator (*obturro*, I stop up) artery, 442  
     relation to hernia, 341  
     fascia, 327  
     foramen, 100, 103  
     membrane or ligament, 163  
     muscles, 230, 231  
     nerve, 602  
         accessory, 604  
 Occipital (*occiput*, the back of the head)  
     angle, 79  
     artery, 366  
     bone, 31  
         articulations of, 137, 140  
         ossification of, 67  
     crest, 33  
     foramen, 31, 65  
     fossæ, 33  
     groove, 39  
     lymphatics, 517  
     nerve, of facial, 550  
         great, 573  
         small, 578  
     protuberances, 33  
     ridge, 33  
     sinus, anterior, 484  
         posterior, 481  
     vein, 479  
         of diploë, 481  
 Occipitalis muscle, 264  
 Occipito-atlantal ligaments, 140  
 Occipito-axial ligaments, 140  
 Occipito-frontal aponeurosis, 264  
 Occipito-frontalis muscle, 264  
 Occipito-mastoid suture, 57  
 Occipito-parietal suture, 57  
 Oculo-motor nerve, 519  
 Odontoid (*ὀδύς*, gen. *ὀδόντος*, a tooth;  
     *ὀδός*, shape) ligament, 139, 140  
     process of the axis, 12, 21  
 Œsophageal arteries, 387, 420, 425  
     lymphatic glands, 513  
     nerves, 563  
     plexus, 563  
 Œsophagus, foramen for in diaphragm,  
     311  
     lymphatics of, 514  
 Olecranon (*ὠλένη*, the elbow; *κράνος*, a  
     helmet), 89  
     fossa of, 87  
 Olfactory nerve, 526  
 Olivary process, 42  
 Omo-hyoid (*ὠμος*, the shoulder; *hyoid*  
     bone) muscle, 294  
 Ophthalmic (*ὀφθαλμός*, an eye) artery,  
     375  
     ganglion, 536  
     nerve, 533, 534  
     vein, 484  
 Opisthotic (*ὀπισθεν*, behind; *ὀς*, gen.  
     *ὠτός*, the ear), portion of temporal  
     bone, 69  
 Opponens muscle, thumb, 222  
 Opponens—*continued*.  
     muscle, toe, 258  
 Optic foramen, 44, 60, 65  
     nerve or tract, 527  
 Orbicular ligament, 150  
 Orbicularis oris, 271  
     palpebrarum, 266  
 Orbital arch, 35  
     bones, 74  
     foramina, 36  
     nerve, 537  
     plate of ethmoid bone, 45  
     process of palate bone, 50  
 Orbito-sphenoid bone, 74  
 Orbits (*orbita*, a circle), 59  
     fasciæ of, 278  
     muscles of, 275, 277  
     nerves passing into, 550  
 Organs and textures, 1  
 Origin of muscles, 184  
 Orthognathous (*ὀρθός*, upright; *γνάθος*, a  
     jaw) skulls, 79  
 Os calcis, 114  
     articulations of, 174  
     homology of, 128  
     ossification of, 122  
         centrale, 128  
         coxæ (the bone of the hip), 100  
         linguæ, 55  
         magnum, 92  
             ossification of, 100  
         planum, 45  
         pubis, 102  
             homology of, 123  
             ossification of, 122  
         unguis, 52  
 Ossa suprasternalia (bones above the  
     sternum), 27  
 Ossa triquetra (triangular bones), 58  
 Ossa Wormii, 58, 67  
 Osseous (*os*, a bone) tissue, 7  
 Ossification, 8  
     of bones of head, 67  
     of pelvis and lower limb, 118  
     of upper limb, 95  
     of ribs and sternum, 30  
     of vertebrae, 19  
 Osteology (*ὀστέον*, a bone; *λόγος*, dis-  
     course), 7  
 Otic (*ὠς*, gen. *ὠτός*, the ear) ganglion,  
     546  
 Ovarian artery, 433  
     nerves, 642  
     plexus, 494  
     vein, 494  
 PALATAL bones, 74  
 Palate bone, 49  
     ossification of, 72  
     hard, 47, 49  
     muscles of soft, 288  
     plate of superior maxilla, 47  
     soft, 288  
 Palatine arteries, 364, 372, 373  
     canal, 48, 61

- Palatine—*continued*.  
 foramina, 47, 48, 50, 62  
 nerves, 54<sup>o</sup>  
 veins, 476, 477
- Palato-glossus muscle, 289
- Palato-pharyngeus muscle, 289
- Palmar arches, 411, 418  
 ligaments, carpal, 156  
 carpo-metacarpal, 157  
 metacarpal, 158  
 nerves, of median, 591  
 of ulnar, 588
- Palmaris muscle, brevis, 221  
 longus, 210
- Palpebral artery, 377  
 nerve, 539  
 vein, 476
- Pampiniform (*pampinus*, a tendril;  
*forma*, shape), plexus, 494
- Pancreas, lymphatics of, 511
- Pancreatic artery, 428  
 plexus, 640  
 vein, 501
- Pancreatico-duodenal arteries, 427, 428
- Panniculus adiposus, 186  
 carnosus, 186, 291
- Par vagum, 556
- Parapophysis (*παρά*, beside; *epophysis*),  
 11, 24
- Paraxial (*παρά*, beside; *axis*) muscles,  
 333
- Parietal bone, 34  
 ossification of, 68  
 foramen, 34
- Parieto-mastoid suture, 58
- Parotid fascia, 291  
 nerve, 543  
 vein, 477
- Patella (a dish or plate), 110  
 ligament of, 167  
 lateral, 170  
 movement of  $\delta\eta$  femur, 171  
 ossification of, 119
- Patellar plexus, 607
- Pathetic nerve, 519
- Pectineus muscle, 241
- Pectoral region, fascia of, 193
- Pectoralis major muscle, 193  
 minor, 196
- Pedicles of vertebrae, 10
- Pelvic fascia, 326  
 girdle, 123  
 plexus, 641
- Pelvic and thoracic limbs, homologous  
 bones in, 129
- Pelvis (a basin), 100, 104  
 articulations of, 159  
 axis of, 106  
 brim of, 104  
 compared with shoulder, 123  
 differences in the sexes, 106  
 dimensions of, 107  
 distinctive characters of in man, 130  
 fasciae of, 326  
 lower or true, 104
- Pelvis—*continued*.  
 lymphatics of, 508  
 ossification of, 118  
 position of, 105  
 upper or false, 104
- Penis, dorsal artery of, 447  
 nerve of, 611  
 vein of, 500  
 lymphatics of, 508  
 muscles of, 264  
 nerves of, 623, 625, 642
- Perforans muscle, in hand, 213  
 in foot, 252
- Perforating arteries of foot, 467, 471  
 of hand, 419  
 of thigh, 458  
 of thorax, 391
- Perforatus muscle, of hand, 211  
 of foot, 256
- Pericardiac arteries, 391, 420
- Pericranium (*περί*, about; *κρανιον*, the  
 skull), 264
- Perimysium (*περί*, around; *μῦς*, a  
 muscle), 183
- Perinæum (*περί*, about; *ναίω*, I am  
 situated), fascia of, 325  
 muscles of, 327  
 in female, 331  
 nerves of, cutaneous, 623  
 muscular, 331, 625
- Perineal artery, superficial, 445, 447  
 transverse, 446  
 fascia, 325  
 nerve, 610
- Periotic (*περί*, about; *οἶς*, gen. *ωτός*, the  
 ear) portion of temporal bone, 69,  
 74
- Periosteum (*περί*, about; *ὀστέον*, a bone),  
 7
- Perivascular spaces or canals, 518
- Peroneal (*περόνη*, the pin of a buckle,  
 the fibula) arteries, 464, 465  
 bone, 112  
 nerve, 620  
 vein, 496
- Peronei muscles, 246, 248
- Peroneo-calcaneus internus muscle*, 254
- Petro-mastoid portion of temporal bone,  
 69, 74
- Petrosal nerves, large, 542  
 external, 549  
 small, 546, 556  
 sinuses, 485
- Petrous (*πέτρα*, a rock) ganglion, 555  
 portion of the temporal bone, 37, 39
- Phalanges (*φάλαγξ*, a rank of soldiers) of  
 fingers, 94  
 articulations of, 159  
 ossification of, 100  
 of toes, 117  
 articulations of, 181  
 ossification of, 122
- Pharyngeal artery, 373  
 nerve, of glosso-pharyngeal, 556  
 of pneumogastric, 560



- Pharyngeal—*continued*  
 nerve, of sphenopalatine ganglion,  
   541, 542  
   of sympathetic, 630  
 plexus, 556, 560, 630  
 vein, 479
- Pharynx (*φάρυγξ*) muscles of, 286  
 nerves of, 624
- Phrenic (*φρήν*, the diaphragm) artery,  
 inferior, 435  
 superior, 391  
 nerve, 578  
 vein, 494
- Pia mater, lymphatics of, 518
- Pillars of abdominal ring, 316  
 fauces, 288
- Pisiform (*πίσιον*, a pea; *forma*, shape)  
 bone, 92  
 articulation of, 157  
 ossification of, 100
- Pituitary (*πιτυίτα*, phlegm or mucus)  
 fossa, 42
- Plane, mesial, 5, 6
- Plantar (*πλάντα*, the sole of the foot) ar-  
 teries, 465, 466  
 fascia, 255  
 muscles, 255  
 nerves, 617, 618, 619
- Plantaris muscle, 252
- Planum temporale (temporal plane), 34
- Plate, mesial, of vomer, 51  
 orbital of frontal bone, 35  
   of ethmoid, 45  
 palate, of palate bone, 49  
 of superior maxilla, 47  
 pterygoid, internal and external,  
   44  
 tympanic, 40  
 vertical of ethmoid, 45
- Platysma myoides (*πλάτυσμα*, a plate,  
 from *πλατύνω*, I extend; *μῦς*, a  
 muscle; *εἶδος*, shape), 272, 290
- Plexus, subperitoneal arterial, 437
- PLEXUSES of nerves, aortic, 640  
 brachial, 582  
 cardiac, 638  
 carotid, 629  
 cavernous, 629, 630  
 cervical, 577  
   summary of, 580  
   posterior, 573  
 celiac, 640  
 coronary, of heart, 638  
   of stomach, 640  
 cranial, 628  
 cystic, 640  
 diaphragmatic, 639  
 epigastric, 639  
 gangliosus, 641  
 gastro-duodenal, 640  
 gastro-epiploic, 640  
 hepatic, 640  
 hypogastric, 641  
   inferior, 641  
 infraorbital, 540
- PLEXUSES—*continued*.  
 intermesenteric, 640  
 lumbar, 598  
 mesenteric, inferior, 641  
   superior, 640  
 œsophageal, 563  
 pancreatic, 640  
 patellar, 607  
 pelvic, 641  
 pharyngeal, 556, 560, 630  
 preaortic, 635  
 prevertebral, 687  
 prostatic, 642  
 pulmonary, 563  
 pyloric, 640  
 renal, 640  
 sacral, 609  
 solar, 639  
 spermatic, 640  
 splenic, 640  
 suprarenal, 639  
 tympanic, 556  
 vaginal, 642  
 vesical, 642
- PLEXUSES of veins, choroid, 481  
 hæmorrhoidal, 498  
 ovarian, 494  
 pampiniform, 494  
 prostatic, 498  
 pterygoid, 477  
 spermatic, 494  
 uterine, 500  
 vaginal, 499  
 vertebral, 493  
 vesical, 498
- Pneumogastric (*πνεύμων*, the lung;  
*γαστήρ*, the stomach) nerve, 556
- Popliteal artery, 461  
 line, 111  
 lymphatic glands, 506  
 nerves, 615, 616, 619  
 vein, 497
- Popliteus muscle, 252
- Portal vein, 500
- Portio dura, 548  
 mollis, 548, 553
- Postaxial (*post*, behind; *axis*) borders of  
 limbs, 126
- Postspenoid bone, 70
- Poupart's ligament, 316
- Preaortic plexus, 635
- Preaxial (*præ*, before; *axis*) borders of  
 limbs, 126
- Premaxillary angle, 80  
 bone, 72, 74
- Presphenoid bone, 70
- Pressure, effects of on skull, 81
- Presternum (*præ*, before; *sternum*), 25,  
 26
- Prevertebral fascia, 292  
 muscles of neck, 296  
 plexus, 687
- Process of bone, 8  
 acromion, 83  
 alveolar, of superior maxilla, 46

- Process—*continued*.  
 angular, of frontal bone, 36  
 auditory, external, 40  
 basilar, 31, 34  
 clinoid, posterior, 42  
 coracoid, 83  
 coronoid of lower jaw, 55  
   of ulna, 89  
 ensiform, 25  
 falciform, 162  
 hamular, 44  
 malar, 48  
 mastoid, 39  
 nasal, 48  
 odontoid, 12, 21  
 olivary, 42  
 orbital, of palate bone, 50  
 pterygoid, 42, 44  
 pyramidal, 50  
 sphenoidal, 50  
 spinous, of sphenoid bone, 43  
 styloid, of temporal bone, 40, 62  
   of radius, 88  
   of ulna, 90  
 supracondyloid, 87  
 turbinated, superior and inferior,  
   46  
 uncinatè, 46  
 vaginal, 40  
 zygomatic, 38
- Processes, accessory, of lumbar verte-  
 bræ, 14, 25  
 mammillary, of lumbar vertebræ,  
 15, 24  
 of vertebræ, articular, 10, 11, 12,  
 13, 15  
   spinous, 10, 11, 12, 13, 14  
   transverse, 10, 11, 12, 13, 14  
   serial relations of, 24
- Processus cochleariformis (spoon-shaped  
 process), 41
- Profunda artery of arm, 402  
   of penis, 447  
   of thigh, 457
- Prognathous (*πρό*, forward; *γνάθος*, a  
 jaw) skulls, 79
- Promontory of sacrum, 15
- Pronation and pronator (*pronus*, having  
 the face downward), 224
- Pronator and flexor muscles, 209  
   nerves of, 214
- Pronator quadratus, 214  
   teres, 209
- Prootic (*πρό*, before; *οὖς*, gen. *ὠτός*, the  
 ear) centre, 69
- Prostatic plexus (nerves), 642  
   (veins), 498
- Protuberance, occipital, external, 33  
   internal, 33
- Psoas (*ψάα*, the loin) muscles, 234, 235
- Pterygoid (*πτερυξ*, a wing; *εἶδος*, shape)  
 arteries, 371  
 bones, 74  
 canal, 44  
 fossa, 44
- Pterygoid—*continued*.  
 muscles, 279, 280  
 nerves, 543  
 plates, 44  
 plexus, 477  
 processes, 42, 44
- Pterygoideus proprius muscle*, 280
- Pterygo-maxillary fissure, 60  
 ligament, 272
- Pterygo-palatine artery, 373  
 canal, 44, 61
- Pubic arteries, 443, 452  
 articulation, 163  
 bone. *See* Os Pubis  
 portion of fascia lata, 227
- Pubo-femoral ligament, 165
- Pubo-urethral muscle*, 331
- Pubo-vesical muscle*, 331
- Pudendal nerve, inferior, 614
- Pudic artery, accessory, 447  
   external, 456  
   internal, 444  
   in female, 447  
 nerve, 610  
 vein, 496
- Pulmonary artery, 345  
   varieties of, 350, 353  
 nerve of pneumogastric, 563  
 plexuses, 563  
 veins, 346
- Pyloric artery, 425  
 plexus, 640
- Pyramidal process of palate bone, 50
- Pyramidalis abdominis, 322  
 nasi, 269
- Pyriformis (*pyrus*, a pear; *forma*, shape)  
 muscle, 230
- QUADRATUS femoris, 231  
 lumborum, 322  
 menti, 274
- Quadriceps extensor muscle, 237
- RADIAL artery, 413  
   varieties of, 417  
 nerve, 593  
 vein, 486
- Radiated ligament, 140
- Radio-carpal articulation, 154
- Radio-carpalis muscle*, 212
- Radio-ulnar articulations, 150
- Radius (a ray, or the spoke of a wheel),  
 87  
 movement of on ulna, 151  
 ossification of, 97
- Radix longa ganglii ciliaris, 536
- Ramus (a branch; *pl. rami*) of ischium,  
 103  
 of lower jaw, 54  
 of pubic bone, 102  
 cervicalis princeps (art.), 366  
 communicans peronei (nerve), 617  
 tibialis (nerve), 617  
 descendens noni (nerve), 567  
 oculo-nasalis (nerve), 535

- Ramus—*continued*.  
 superficialis volæ (art.), 416
- Rami intestini tenuis (art.), 428  
 retrogradi (art.), 418
- Ranine (*rana*, a frog; also a swelling under the tongue) artery, 364  
 vein, 476
- Receptaculum chyli, 505  
 ganglii petrosi, 555
- Recti muscles of head, anterior, 296  
 posterior, 305  
 of eye, 275
- Recto-vesical fascia, 326
- Rectum, lymphatics of, 511
- Rectus abdominis, 320  
 femoris, 238  
 sternalis, 308
- Recurrent arteries. *See* ARTERY  
 laryngeal nerve, 561
- Renal (*ren*, the kidney) artery, 432  
 plexus, 640  
 vein, 494
- Respiration, movements of, 311
- Respiratory nerve, external, 583
- Retinacula (restraining bands) of tendons, 186
- Retrahens auriculum muscle, 265
- Retzius's classification of skulls, 79
- Rhomboid (*ῥόμβος*, a rhomb, or equilateral four-sided figure with oblique angles; *ῆδος*, shape) ligaments, 146
- Rhomboidæus muscle, major and minor, 192
- Ribs, 27  
 articulations of, 140  
 cartilages of, 29  
 ossification of, 30  
 movements of, 143
- Ridge of bone, 8  
 superciliary, 35  
 mylo-hyoidean, 54  
 occipital, 33
- Ridges, condylar, 86
- Ring, abdominal, external or superficial, 316  
 internal, or deep, 324  
 crural, 324
- Risorius (*rideo*, I laugh) muscle, 272
- Rostrum (a beak) of sphenoid bone, 42
- Rotation, 133
- Rotatores spinæ, 303
- Rotula (dim. of *rota*, a wheel), 110
- SACRAL (*sacrum*) arteries, middle, 437  
 lateral, 449  
 canal, 17  
 cornua, 15  
 foramina, 15, 16  
 lymphatic glands, 509  
 nerves, division of, anterior, 608  
 posterior, 574  
 fourth and fifth, 608  
 plexus, 609  
 vein, middle, 494
- Sacro-coccygean articulation, 160
- Sacro-coccygeus posticus* muscle, 305
- Sacro-iliac articulation, 161
- Sacro-lumbalis muscle, 300
- Sacro-sciatic foramina, 162  
 ligaments, 162  
 notches, 103
- Sacro-vertebral articulation, 159
- Sacrum (*os sacrum*, the sacred bone: because formerly offered in sacrifices), 9, 15  
 articulations of, 160  
 ossification of, 21  
 varieties of, 17
- Saddle-angle of skull, 80
- Sagittal (*sagitta*, an arrow) suture, 58
- Salpingo-pharyngeus (*σάλπιγγξ*, a trumpet; *φάρυγξ*, the pharynx) muscle, 288
- Santorini's muscle, circular, 330  
 risorius, 272
- Saphenous (*σαφηνής*, manifest) nerve,  
 external, 617  
 internal, 606  
 opening, 495  
 vein, long, 495  
 short, 496
- Sartorius (*sartor*, a tailor) muscle, 236
- Scalene tubercle, 28
- Scalenus (*σκαληνός*, with unequal sides) muscles, 295, 296
- Scapho-cuboid articulation, 177
- Scapho-cuneiform articulation, 178
- Scaphoid (*σκάφη*, a skiff or boat; *ῆδος*, shape) bone of foot, 115  
 articulation of, 175, 177  
 ossification of, 122  
 bone of hand, 91  
 ossification of, 100
- Scapho-lunar bone, 128
- Scapula, 81  
 compared with ilium, 124  
 ligaments of, 146, 148  
 ossification of, 95
- Scapular artery, 389  
 notch, 82  
 vein, posterior, 477
- Scapulo-clavicular articulation, 146
- Scarpa's foramina, 48  
 triangle, 454
- Schindylesis (*σχινωδύλεω*, I split), 131
- Sciatic (*ισχίον*, the hip) artery, 448  
 nerve, great, 615  
 small, 613  
 notches, 101, 103
- Sclerotome (*σκληρός*, hard; *τέμνω*, I cut), 185
- Scrotal hernia, 337  
 nerve, long, 610
- Serotum (a hide), lymphatics of, 508  
 nerves of, 623
- Segmentation of muscles, 185
- Segmented character of vertebrate skeleton, 3
- Segments, vertebral, 5
- Sella Turcica (Turkish saddle), 42
- Semilunar bone, 91

- Semilunar—*continued*.  
 bone, ossification of, 100  
 cartilages of knee, 169  
 cavity of radius, 88  
 ganglia of sympathetic, 639
- Semimembranosus muscle, 233
- Semispinalis muscle, 303
- Semitendinosus muscle, 232
- Sense capsules or cavities, 76
- Septa, neural and hæmal, 332  
 intermuscular, of arm, 204  
 foot, 256  
 forearm, 208  
 leg, 244  
 thigh, 277
- Septum (a partition, from *sepio*, I hedge in), crural, 341  
 narium, 65
- Serial homology of vertebræ, 22
- Serrated (*serra*, a saw) suture, 131
- Serratus muscle, magnus, 196  
 posticus, 298
- Sesamoid (*σῆσαμον*, a kind of small grain; *εἶδος*, shape) bones, 9  
 of fingers, 95  
 radial, 128  
 of toes, 117  
 ulnar, 127
- Sexual differences in skull, 78  
 in pelvis, 106  
 in femur, 110
- Sheath, crural, 227
- Shin-bone, 110
- Shoulder, articulation of, 148  
 compared with pelvis, 123  
 fascia of, 199  
 ligaments of, 148  
 muscles of, 199  
 nerves of, cutaneous, 623  
 muscular, 203, 625
- Sigmoid (G, a form of the letter *σίγμα*, *sigma*; *εἶδος*, shape) artery, 432  
 cavity of ulna, 89  
 notch, lower jaw, 55
- Sinus (a hollow) of aorta, 348  
 basilar, 484  
 of bone, 9  
 cavernous, 483  
 nerves in, 530  
 circular, 483  
 coronary, of heart, 504  
 falciformis inferior, 482  
 superior, 482  
 frontal, 36, 67  
 of jugular vein, 479  
 lateral, 482  
 longitudinal, inferior, 482  
 longitudinal, superior, 482  
 maxillary, 49, 67  
 occipital, anterior, 484  
 posterior, 483  
 pedis, 176  
 petrosal, inferior, 483  
 superior, 483  
 of portal vein, 500
- Sinus—*continued*.  
 straight, 482  
 tentorii, 482  
 transverse, 482, 484
- Sinuses, air, in bones of head, 66  
 ethmoidal, 45, 67  
 sphenoidal, 42, 67  
 of Valsalva, 348  
 venous, of cranium, 481
- SKELETON (*σκέλλω*, I dry), 2, 7  
 adapted to erect attitude, 123  
 axial, relation of bones of limbs to, 122
- SKULL, anterior region of, 58  
 as a whole, 56  
 base of, external, 61  
 internal, 63  
 bones of, 31  
 difference from animals, 130  
 differences in from age, 77  
 nation, 78  
 sex, 78  
 external surface, 58  
 forms of, 77  
 irregular, 80  
 fosse of, 63  
 grooves for blood-vessels in, 65  
 homologies of, 73  
 interior of, 62  
 lateral region of, 60  
 morphology of, 73  
 ossification of bones of, 67  
 superior region of, 58  
 sutures of, 56  
 vertebrate theory of, 76
- Stæmmerring's classification of cranial nerves, 519
- Solar (*sol*, the sun) plexus, 639
- Soleus (*solea*, a sandal, or sole of a shoe, also a sole fish) muscle, 250
- Somatome (*σῶμα*, a body; *τέμνω*, I cut), 5
- Spermatic artery, 433  
 cord, 336  
 nerve, external, 602  
 plexus (nerves), 640  
 (veins), 494  
 vein, 494
- Sphenoid (*σφήν*, a wedge; *εἶδος*, shape) bone, 41  
 ossification of, 70
- Sphenoidal crest, 42  
 fissure, 44, 60, 65  
 position of nerves in, 530  
 process of palate bone, 50  
 sinus, 42, 67  
 spongy bones, 42, 71
- Spheno-maxillary fissure, 60  
 fossa, 60
- Spheno-palatine artery, 373  
 foramen, 50, 61  
 ganglion, 540
- Spheno-parietal, suture, 58
- Sphincter (*σφιγγω*, I bind) ani, external, 327  
 internal, 327

- Sphincter—*continued*.  
 oris, 271  
 vaginæ, 331
- Spina bifida, 22
- Spinæ mentales, 54
- Spinal accessory nerve, 564
- arteries, 383. *See* ARTERIES  
 cord, veins of, 493  
 nerves, 568. *See* NERVES  
 veins, 491  
   anterior longitudinal, 492  
   posterior longitudinal, 493
- Spinalis cervicis, 395
- dorsi, 391
- Spine. *See* Vertebral Column
- Spine of bone, 8
- ethmoidal, 42
- of ilium, anterior and posterior, 101  
   ischium, 103
- nasal, 36, 47
- neural, 10
- occipital, 33
- of os pubis, 103  
   scapula, 81, 82  
   tibia, 103
- Spinous processes of vertebræ, 10  
 of sphenoid bone, 43
- Splanchnic nerve, great, 635  
 small, 636
- Spleen, lymphatics of, 511
- Splenic artery, 428  
 plexus, 640  
 vein, 501
- Splenius (*splenium*, a pad) muscle, 299
- Spongy bones, ethmoidal, 46, 66  
 inferior, 50, 53, 66, 74  
 sphenoidal, 42  
 ossification of, 71
- Squamosals, 74
- Squamous (*squama*, a scale) portion of  
 temporal bone, 37  
 suture, 58, 131
- Squamo-zygomatic centre, 69
- Stellate ligament, 140
- Stenson, foramina of, 47
- Sternal artery, 391  
 lymphatics, 513  
 ribs, 27
- Sternalis brutorum* muscle, 308
- Sterno-clavicular articulation, 146
- Sterno-cleido mastoid muscle, 292
- Sterno-hyoid muscle, 292
- Sterno-mastoid arteries, 363, 366
- Sterno-thyroid muscle, 293
- Sternum (*στέρον*, the breast or chest),  
 25  
 ligaments of, 142  
 ossification of, 30
- Stomach, lymphatics of, 511
- Straight sinus, 482
- Stratum internum circulare, 330
- Stylo-glossus muscle, 286
- Stylo-hyoid ligament, 55, 145  
 muscle, 283  
 nerve, 550
- Styloid (*στυλος*, a style or pen; *είδος*,  
 shape) process of radius, 88  
 of temporal bone, 40  
 of ulna, 90
- Stylo-mastoid artery, 367  
 foramen, 40, 62
- Stylo-maxillary ligament, 145, 278
- Stylo-pharyngeus muscle, 288
- Subacromial bursa, 140
- Subanconeus muscle, 207
- Subclavian artery, 379  
 branches of, 382  
 surgical anatomy of, 392  
 varieties of, 352, 353  
 vein, 489
- Subclavius muscle, 196
- Subcostal groove, 28  
 muscles, 308
- Subcreureus muscle, 240
- Subcutaneous fasciæ, 186
- Sublingual artery, 364
- Submaxillary ganglion, 547  
 vein, 476
- Submental artery, 365  
 vein, 476
- Suboccipital nerve, 571, 575
- Subperitoneal arterial plexus, 437
- Subpubic arch, 104  
 fascia, 325  
 ligament, 163
- Subscapular arteries, 389, 395  
 nerve, 584  
 vein, 489
- Subscapularis fossa, 81  
 muscle, 203
- Subscapulo-capsularis* muscle, 203
- Suleus of bone, 9  
 frontalis, 36  
 olfactory, 526
- Superciliary ridge, 35
- Superficial fascia, 186
- Supination (*supinus*, lying on the back),  
 224
- Supinator and extensor muscles, 215  
 nerves of, 220
- Supinator brevis, 218  
 longus, 215
- Supra-acromial artery, 389  
 nerve, 578
- Supraclavicular nerve, 578
- Supracondyloid process, 87
- Supramaxillary nerve, 551
- Supra-occipital bone, 33
- Supraorbital artery, 375  
 foramen, 35, 59, 60  
 nerve, 535  
 vein, 476
- Suprarenal capsules, lymphatics of,  
 512  
 artery, 432  
 plexus, 639  
 vein, 494
- Suprascapular artery, 387  
 ligament, 148  
 nerve, 553

- Suprascapular—*continued*.  
 notch, 83  
 vein, 477
- Supraspinatus muscle, 200
- Supraspinous fossa, 81  
 ligaments, 137
- Suprasternal nerve, 578
- Supratrochlear nerve, 534
- Sural (*suræ*, the calf) arteries, 462
- Surgical anatomy of arteries, axillary, 399  
 brachial, 405  
 carotid, common, 360  
 iliac, common, 439  
   external, 453  
   internal, 453  
 femoral, 461  
 subclavian, 392  
 of hernia, femoral, 340  
 inguinal, 335
- Suspensory ligament of penis, 314
- Sustentaculum tali (the support of the astragalus), 114
- Sutures (*sutura*, a seam), forms of, 131  
 coronal, 57  
 frontal, 37  
 fronto-parietal, 57  
 interparietal, 58  
 lambdoidal, 57  
 neuro-central, 20  
 occipito-mastoid, 57  
 occipito-parietal, 57  
 parieto-mastoid, 58  
 sagittal, 58  
 spheno-parietal, 58  
 squamous, 58  
 temporo-parietal, 58  
 transverse, 58
- Symmetry of form, 5
- Sympathetic nerve, 626. *See* NERVE,  
 SYMPATHETIC
- Symphysis (*σύν*, with, together; *φύω*, I grow) of lower jaw, 54  
 pubis, 102, 163
- Synarthrosis (*σύν*, with, together; *ἄρθρον*, a joint), 131
- Synchondrosis (*σύν*, with, together; *χόνδρος*, cartilage), sacro-iliac, 161
- Syndesmo-pharyngeus muscle*, 287
- Synostosis (*σύν*, with, together; *ὀστέον*, a bone), 80
- Synovial bursæ, or sheaths, 186  
 of ankle, 174  
 of atlas, 137  
 of axis, 138  
 carpal, 157  
 costo-central, 140  
 costo-sternal, 142  
 of elbow-joint, 154  
 of flexors of fingers, 211  
 of hip, 166  
 of knee-joint, 170  
 metacarpal, 159  
 metatarsal, 181  
 radio-carpal, 154
- Synovial bursæ—*continued*.  
 radio-ulnar, 151  
 of ribs, 140, 142  
 of shoulder-joint, 150  
 sterno-clavicular, 146  
 tarsal, 176, 177  
 tarso-metatarsal, 180  
 of temporo-maxillary articulation, 145  
 tibio-fibular, 173  
 of vertebrae, articulating, 136
- Systemic arteries, 346  
 veins, 472
- TABLES of skull, 62
- Tabular bones, 8  
 portion of occipital bone, 33
- Talo-scaphoid (*talus*, the astragalus; *scaphoid*) ligament, 176
- Talus (a die), 115. *See* Astragalus
- Tarsal (*tarsus*) artery, 469  
 articulations, 174
- Tarso-metatarsal articulations, 179
- Tarsus (*ταρσός*, the upper surface of the foot), 114  
 homologies of, 127  
 ligaments of, 174  
 movements of, 182  
 ossification of, 122
- Temporal (*tempora*, the temples) artery, 367  
 anterior, 369  
 deep, 371  
 middle, 369  
 posterior, 369  
 varieties of, 369
- bone, 37  
 ossification of, 69
- fascia, 279  
 fossa, 60  
 lymphatics, 517  
 muscle, 279
- nerve, of auriculo-temporal, 544  
 deep, 542  
 of facial, 551  
 of orbital, 537, 538
- vein, 476  
 deep, 477  
 of diploë, 481
- Temporo-facial nerve, 551
- Temporo-malar nerve, 537
- Temporo-maxillary articulation, 144  
 vein, 475
- Temporo-parietal suture, 58
- Tendo Achillis (tendon of Achilles) 251  
 palpebrarum, 267
- Tendon, central or cordiform, of diaphragm, 311  
 conjoined, of abdominal muscles, 317
- Tensor palati, 290  
 tarsi, 267  
 trochleæ, 276  
 vaginae femoris, 235
- Teres major, 200  
 minor, 201
- Terms, descriptive, 6

- Testis, lymphatics of, 512**  
**Thenar** (*θέναρ*, the palm of the hand) prominence, 221  
**Thigh, bone of, 107**  
   fasciæ of, 226  
   muscles of, anterior, 234  
     internal, 240  
     posterior, 232  
   nerves of, cutaneous, 623  
     muscular, 234, 240, 243, 626  
**Thoracic** (*thorax*): aorta, 419  
   arteries, 395  
   axis, 398  
   duct, 504  
   ganglia, 633  
   nerves, anterior, 584  
     posterior, 583  
   veins, 489  
**Thorax** (*θώραξ*, a breast-plate), 25  
   as a whole, 29  
   lymphatics of, 512, 513  
   muscles of, 306  
**Thumb, arteries of, 417**  
   muscles of, 221  
**Thymic** (*thymus* gland) arteries, 391  
   vein, 474  
**Thyinus gland, lymphatics of, 514**  
**Thyro-hyals, 55, 74**  
**Thyro-hyoid muscles, 293**  
**Thyroid artery, inferior, 387**  
   superior, 361  
   axis, 386  
   foramen, 100, 103  
   nerves, 632  
   veins, 474, 479, 480  
**Tibia** (a pipe or flute, from its supposed resemblance), 110  
   homology of, 127, 129  
   ossification of, 119  
**Tibial artery, anterior, 468, 471**  
   posterior, 463  
   nerve, anterior, 619, 621  
   posterior, 617  
   vein, 496  
**Tibialis anticus, 245**  
   posticus, 254  
   *secundus*, 255  
*Tibio-fascialis anticus muscle, 245*  
**Tibio-fibular articulations, 172, 173**  
**Toe, great, muscles of, 257**  
**Toes, bones of, 117**  
   movements of, 182  
   muscles of, 256  
   transverse ligament of, 256  
**Tongue, muscles of, 284**  
   nerves of, 286, 624  
**Tonsillar artery, 365**  
**Tonsillitic nerve, 556**  
**Torcular** (a wine or oil-press) Herophili, 482  
**Tracheal artery, 387**  
**Trachelo-mastoid** (*τράχηλος*, the neck, *mastoid*) muscle, 300  
**Tract, olfactory, 526**  
   optic, 527  
**Transversalis fascia, 324**  
   muscle, abdominis, 320  
     cervicis, 300  
     menti, 274  
**Transverse arteries. See ARTERY**  
   ligament *See* LIGAMENT.  
   processes of vertebrae, 10, 24  
   sinus, 484  
*Transversus nuchæ, 265*  
   *orbitæ, 276*  
**Transversus pedis, 258**  
   perinæi, 329, 330, 331  
**Trapezium** (*τραπεζίον*, a geometrical figure, dim. of *τράπεζα*, a table or board), 192  
   ossification of, 100  
**Trapezius muscle, 187**  
**Trapezoid bone, 92**  
   ossification of, 100  
   ligament, 340  
**Triangle of Hesselbach, 339**  
   Scarpa's, 454  
**Triangularis oris, 274**  
   sterni, 308  
**Triceps** (three-headed) muscle, 206  
**Trifacial nerve, 532.**  
**Trochanter** (*τροχάντηρ*, *τροχάινω*, words implying turning) major, 107  
   minor, 108  
**Trochanteric fossa, 107**  
**Trochlea** (*τροχίλια*, a pulley) of humerus, 86  
   of orbit, 275  
**Trochlear nerve, 519**  
**Trochlearis muscle, 275**  
**Trunk, articulations of, 133**  
   fasciæ of, anterior, 193  
     posterior, 187  
     morphology of, 332  
   lymphatics of, 508  
   muscles of, abdominal, 314  
     dorsal, 297  
     perineal, 325  
     thoracic, 306  
     morphology of, 332  
   nerves of, cutaneous, 622  
     muscular, 624  
**Tuber calcis, 114**  
   olfactorium, 526  
**Tubercle of bone, 8**  
   of os calcis, 114  
   ribs, 28  
   scaphoid bone, 115  
   tibia, 111  
   zygoma, 39  
**Tuberculum sellæ, 42**  
**Tuberosity of bone, 8**  
   of humerus, 85  
   bicipital, 87  
   of ischium, 103  
     palate bone, 50  
     superior maxillary bone, 48  
   tibia, 111  
**Tunica abdominalis, 314**  
   vaginalis, hernia in, 333

- Turbinated (coiled, from *turbo*, a whirl) bones. See Spongy bones
- Tympanic (*tympanum*, the drum of the ear) artery, 370
- bones, 74
- nerve, 556
- plate, 40, 70
- ring, 69
- Tympano-hyal bones, 74
- ULNA (*ὠλένη*, the elbow), 89
- compared with bones of leg, 127
- ossification of, 97
- Ulnar artery, 407
- varieties of, 410
- nerve, 588
- collateral, 592
- veins, 486
- Umbilical artery, 440
- Umbilicus, cicatrix of, 322
- Unciform (*uncus*, a hook; *forma*, shape) bone, 93
- Uncinate (*uncus*, a hook) process of ethmoid bone, 46
- Ungual (*unguis*, a nail) phalanges, 95
- Ureter (*ὀυρέω*, I pass urine), lymphatics of, 512
- Urethra (*ὄστρον*, urine), ligament of, triangular, 325
- Uterine artery, 441
- plexus, 500
- Uterus (womb), lymphatics of, 512
- nerves of, 642
- Uvula (dim. of *uva*), 288
- muscle of, 289
- VAGINA, nerves of, 642
- Vaginal artery, 442
- plexus, 642
- process, 40
- Valsalva, sinuses of, 348
- Vas deferens, artery of, 440
- nerves of, 642
- Vasa aberrantia, brachial, 404
- brevia of the stomach, arteries, 428
- veins, 501
- chylifera or lactea, 509
- Vastus muscle, externus, 238
- internus, 239
- Veins, pulmonary, 346
- VEINS, Systemic, Descriptive Anatomy of, 472
- acromial thoracic, 489
- alar, 489
- angular, 476
- auricular anterior, 477
- posterior, 477
- axillary, 488
- azygos, 489
- left or small, 491
- right, 490
- basilic, 487
- brachial, 488
- brachio-cephalic, 473
- bronchial, 491
- VEINS—*continued.*
- buccal, 476
- capsular, 494
- cardiac, 503
- great, 503
- posterior, 503
- small or anterior, 504
- cephalic, 486
- of cerebellum, 481
- cerebral, 480
- of choroid plexus, 481
- circumflex iliac, deep, 498
- superficial, 496
- of shoulder, 489
- coronary, of heart, 503
- stomach, 501
- of cranium, 480. See Sinuses.
- cystic, 501
- dental, inferior, 477
- superior, 477
- diaphragmatic, 474
- of diploë, 485
- dorsal, spinal, 492
- of penis, 500
- duodenal, 501
- emulgent, 494
- epigastric, 498
- superficial, 496
- facial, 475
- common, 475
- communicating, 477
- transverse, 477
- femoral, 497
- frontal, 475
- of diploë, 485
- of Galen, 481
- gastric, 501
- gastro-epiploic, 501
- of head and neck, 475
- heart, 503
- hepatic, 494
- iliac, external, 498
- internal, 491
- common, 500
- infraorbital, 476
- innominate, 473
- intercostal, anterior, 474
- superior, 474
- jugular, anterior, 479
- external, 477, 489
- internal, 479
- jugulo-cephalic, 487
- labial, 476
- laryngeal, 479
- lingual, 479
- of lower limb and pelvis, 495
- deep, 496
- superficial, 495
- lumbar, 494
- ascending, 494
- mammary, internal, 474
- masseteric, 476
- maxillary, internal, 477
- median basilic, 487
- cephalic, 487



VEINS—*continued.*

- median cutaneous, 487
  - mediastinal, 474
  - meningeal, middle, 477
  - mental, 476
  - mesenteric, inferior, 502
    - superior, 501
  - nasal, 476
  - occipital, 479
    - of diploë, 481
  - ophthalmic, 484
  - ovarian, 494
  - palatine, 476, 477
  - palpebral, inferior, 476
    - superior, 476
  - pancreatic, 501
  - parotid, 477
  - peroneal, 496
  - pharyngeal, 479
  - phrenic, 494
  - popliteal, 497
  - portal, 500
    - sinus of, 500
  - pubic, external, 496
  - radial cutaneous, 486
  - ranine, 476
  - renal, 494
  - sacral, middle, 494
  - saphenous, long, or internal, 495
    - short, or external, 496
  - scapular, posterior, 477
  - spermatic, 494
  - spinal, 491
    - anterior longitudinal, 492
    - posterior longitudinal, 493
  - of spinal cord, 493
  - splenic, 501
  - subclavian, 489
  - submaxillary, 476
  - submental, 476
  - subscapular, 489
  - supraorbital, 476
  - suprarenal, 494
  - suprascapular, 477
  - temporal, 476
    - deep, 477
    - middle, 476
    - of diploë, 481
  - temporo-maxillary, 475
  - thoracic, inferior and superior, 489
  - thymic, 474
  - thyroid, superior, 479
    - middle, 480
    - inferior, 474
  - tibial, 496
  - ulnar, cutaneous, 486
    - deep, 467
  - of upper limb, 485
    - deep, 487
    - superficial, 486
  - of vertebræ (bodies), 492
  - vertebral, 489
- Veins, plexuses of. *See* PLEXUSES
- Velum pendulum palati, 288
- Vena azygos major, 491

Vena—*continued.*

- cava, 493
  - inferior, 493
    - opening in diaphragm for, 311
    - varieties of, 495
    - superior, 472
  - cordis magna, 503
  - hemiazygos, 491
  - parumbilicalis, 503
  - portæ, 500
    - tributaries of, 501
  - salvatella, 486
- Venæ basis vertebrarum, 492
  - comites vel satellites (companion or satellite veins), 488, 496
  - cordis minimæ, 503
    - parvæ, 504
  - Galenî (veins of Galen), 481
- Venesection, caution regarding, 406
- Venter (belly) of scapula, 81
- Ventral (*venter*, a belly) muscles, 334
- Ventro-lateral muscles, 185, 260, 333
- Ventro-inguinal (*venter*, the belly, *inguen*, the groin) hernia, 338
- Vertebra dentata, 12
  - prominens, 11
- VERTEBRÆ, 9
  - cervical, 10
    - first and second, 11
  - coccygeal, 17
  - dorsal, 12
    - fixed or united, 9
    - general characters of, 9
    - groups of, 10
    - homology of, 22
    - lumbar, 13
    - movable, 9
    - number of, 9
    - ossification of, 19
    - sacral, 15
    - veins of bodies of, 492
- Vertebral aponeurosis, 299
  - artery, 383
  - column, 9
    - as a whole, 18
    - articulations of, 133
    - in child and in adult, 130
    - curves of, 18
    - movements of, 137
    - ossification of, 19
    - veins of, 489
  - plexus, 493
  - segments, 5
- Vertebrate homology, 5
  - theory of skull, 76
  - type of skeleton, 2
- Vesical arteries, 449
  - ligaments, 326
  - plexus, nerves, 642
  - veins, 498
- Vesico-prostatic artery, 440
- Vesicula seminalis, nerves of, 642
- Vessels. *See* ARTERIES, VEINS, and LYMPHATICS

- Vidian artery, 373  
 canal, 44, 61  
 nerve, 604
- Vincula accessoria tendinum, 212
- Vitreous (*vitrum*, glass) table of skull, 62
- Volar (*vola*, the palm of the hand)  
 artery, superficial, 416
- Vomer (a ploughshare), 51  
 ossification of, 72
- WILLIS, classification of cranial nerves,  
 519  
 circle of, 378
- Wilson's muscle, 331
- Wings of sphenoid bone, 43
- Wormian bones, 58
- Wrisberg, ganglion of, 638  
 nerve of, 587
- Wrist, articulation of, 154  
 extension of, 225  
 flexion of, 224  
 movements of, 159  
 nerves of, 588
- XIPHISTERNUM (*ξίφος*, a sword; *στέρνον*,  
 the breast, 26
- ZONA orbicularis, 165
- Zygapophyses (*ζυγ*, root of *ζεύγνυμι*, I  
 yoke, or join together; *apophysis*),  
 10, 24
- Zygoma (a cross-bar, or bolt, from root  
 above given), 38
- Zygomatic arch, 60  
 fossa, 60
- Zygomatici muscles, 272

END OF VOLUME I.















9/1993

SMITHSONIAN INSTITUTION LIBRARIES



3 9088 00563 8929